

HOPKINS (W.B.) *al*

A MONTHLY REVIEW OF NUTRITIONAL SCIENCE AND PRACTICE

L. S. PILCHER, A.M., M.D.
OF CHICAGO, ILL.
FREDERICK TREVES, F.R.C.S.
OF CHICAGO, ILL.

J. WILLIAM WHITE, M.D.
OF CHICAGO, ILL.
WILLIAM MACEWEN, M.D.
OF CHICAGO, ILL.

TABLE OF CONTENTS.

[illegible]

UNIVERSITY OF PENNSYLVANIA PRESS
PHILADELPHIA, PA.

Great Britain: Cassell and Company, London.

25.00 a Year in Advance. One Order a Year in Advance
Single Copies, Two Shillings

APRIL, 1895

A PRELIMINARY NOTE ON A NEW METHOD OF CORRECTING
INVETERATE TALÍPES VARUS BY THE ARTIFICIAL
PRODUCTION OF POTT'S FRACTURE
DEFORMITY.

BY W. BARTON HOPKINS, M.D.,
OF PHILADELPHIA.

presented by the author —





A PRELIMINARY NOTE ON A NEW METHOD OF
CORRECTING INVETERATE TALIPES VARUS
BY THE ARTIFICIAL PRODUCTION OF
POTT'S FRACTURE DEFORMITY.

By W. BARTON HOPKINS, M.D.,

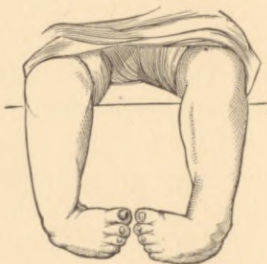
OF PHILADELPHIA.

TWO years ago it occurred to me that a badly-treated Pott's fracture, in a case of talipes varus, would tend to correct the varus. That almost every characteristic of the one had its counterpart in the other. The flat foot, the rotation outward, the strain upon the internal lateral ligament, the outward deflection of the plane of the ankle-joint seen after Pott's fracture, and the exaggerated arch of the foot, the rotation inward, the strain upon the external lateral ligament, and the deflection inward of the plane of the ankle-joint of varus offered an opportunity to obtain a resultant of deformity and injury by artificially causing the deformity which follows fracture of the fibula just above the ankle.

The objections that would naturally appear to such a measure—(1) that a limb so treated would always be functionally weak, because deformity after Pott's fracture is apt to impair the strength of the ankle-joint; (2) that a cure so effected would not be permanent, but that the deformity would relapse after a time on the one hand, or, on the other, that a condition of valgus might ensue from over-correction—are, I think, unfounded.

The weakness in Pott's fracture deformity depends primarily upon the line of weight being directed inside the axis of support, the vertical axis of the leg having lost its normal relation to the foot. The internal lateral ligament of the ankle-joint is consequently strained and the arch of the instep broken down. If, therefore, a foot whose weakness depends upon the line of its superincumbent weight being directed to a point to its outer side,

as in talipes varus, is made to occupy a normal position in relation to the axis of weight, it matters not if the malleolar mortise has been widened and the astragalus somewhat tilted in its socket. Any subsequent tendency to stretching of the internal lateral ligament of the ankle-joint, and to flattening of the exaggerated arch of the foot, would tend still further to open out the inbent tarsus by stretching the contracted ligaments of its inner and lower side and by gradually removing the inward bevel existing in all or some of its articular surfaces. In November, 1892, selecting an inveterate case of talipes varus in a boy of four years of age, one in which tenotomy of tendons and fasciæ and the continuous use of a properly-applied brace had failed to effect a cure, the following operation was done at the Episcopal Hospital: An incision two inches long was carried down upon the fibula to

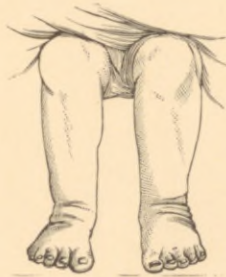

Double talipes varus before operation (from a photograph).

within half an inch of the external malleolus. The fibula having been exposed, five-eighths of an inch of its shaft was resected, the sections being made with a fine saw. Forcible abduction of the foot almost corrected the deformity and closed the hiatus between the fragments to within perhaps one-sixteenth of an inch, and they were held in apposition by three or four turns of silk-worm gut carried through minute drill-holes in lower and upper fragments. The wound was dressed in the ordinary way, and the limb was placed upon an internal metal splint. The wound gave no trouble, union being almost primary, and the child walked, four months after the operation, squarely upon the sole of his foot.

Two other operations were performed simultaneously upon a girl, twenty-three months old, at the Episcopal Hospital, on

November 17, 1894. The deformity in this case is shown in the accompanying illustration. The details of both operations were similar. After tenotomy of the tendo Achillis, though the equinus element was almost absent, an incision two inches long was carried down to within half an inch of the external malleolus. The fibula, having been stripped of periosteum, was prepared out and three-eighths of an inch of its shaft excised with cutting forceps, the lower section being three-fourths of an inch above the lower end of the bone. Forcible abduction of the foot brought the sole beneath and a little beyond. A few strands of drainage were placed in the wound, the limb was dressed antiseptically and placed upon an internal straight splint. A plaster-of-Paris dressing was applied fourteen days later, when



The same case immediately after operation (also from a photograph).

a scanty serous oozing had ceased and the wounds were healed. The child showed no inflammatory reaction after the operation; indeed, none was to be expected, for the shaft of the fibula was not more than an eighth of an inch in diameter. As shown well in the photograph, the deformity was somewhat over-corrected, and the deep folds of integument testify to the extent of shortening of the outer aspect of the limb.

Though, as stated in the title of this note, this operation is designed for *inveterate* cases of varus, *i.e.*, cases where tenotomy and force have failed to correct the deformity, the fact that no after-treatment by either the employment of braces or by manipulation is necessary, would seem to render it applicable to many cases not to be classed as *inveterate*, but occurring in children whose

parents cannot afford, or will not take the time or pains necessary to, a prolonged course of treatment. Apart from this, the operation is, as a surgical procedure, trifling in importance when compared with any of the tarsal resections or osteotomies which are practised. It involves little or no risk and causes no mutilation of the foot. Osteotomy of the lower end of the tibia for varus is intended to correct the deformity upon principles which govern other osteotomies and operates in an entirely different manner from the procedure just described.

