

White (J. W.)

A CASE

OF

SUPPOSED DISLOCATION OF THE TENDON OF THE LONG
HEAD OF THE BICEPS MUSCLE.

BY

J. WILLIAM WHITE, M.D.,

SURGEON TO THE PHILADELPHIA HOSPITAL, ASSISTANT SURGEON TO THE
UNIVERSITY HOSPITAL;

DEMONSTRATOR OF SURGERY AND LECTURER ON OPERATIVE SURGERY AND VENEREAL
DISEASES IN THE UNIVERSITY OF PENNSYLVANIA;

FELLOW OF THE AMERICAN SURGICAL ASSOCIATION AND OF THE
PHILADELPHIA ACADEMY OF SURGERY, ETC.



Reprinted from the
American Journal of the Medical Sciences for January, 1884.

PHILADELPHIA:
COLLINS, PRINTER, 705 JAYNE STREET.
1884.

A CASE
OF
SUPPOSED DISLOCATION OF THE TENDON OF THE LONG
HEAD OF THE BICEPS MUSCLE.

BY
J. WILLIAM WHITE, M.D.,
SURGEON TO THE PHILADELPHIA HOSPITAL, ASSISTANT SURGEON TO THE
UNIVERSITY HOSPITAL;
DEMONSTRATOR OF SURGERY AND LECTURER ON OPERATIVE SURGERY AND VENEREAL
DISEASES IN THE UNIVERSITY OF PENNSYLVANIA;
FELLOW OF THE AMERICAN SURGICAL ASSOCIATION AND OF THE
PHILADELPHIA ACADEMY OF SURGERY, ETC.

Reprinted from the
American Journal of the Medical Sciences for January, 1884.

PHILADELPHIA:
COLLINS, PRINTER, 705 JAYNE STREET.
1884.

A CASE

OF

SUPPOSED DISLOCATION OF THE TENDON OF THE LONG HEAD OF THE BICEPS MUSCLE.¹

BEFORE proceeding to a description of the case which, by reason of its apparent rarity, it has seemed worth while to bring to the attention of the profession, it may be profitable, possibly not uninteresting, to review the history of the few other cases in which this same accident, luxation of the tendon of the long head of the biceps muscle, was supposed to have occurred.

The earliest mention of it in surgical literature seems to have been made in the first quarter of the last century, or thereabouts.

In the edition of the *Myotomia Reformata* of William Cowper, published thirteen years after his death by Richard Mead, at London, in 1724, appears the following description :—²

“ An extraordinary Case, relating to this Muscle, has more than once happened in our Practice. Particularly a Woman, three days before she consulted us, had (as she suspected) dislocated her Shoulder-Bone, by wringing of Linen Clothes after washing (which is commonly done, to express the Water), adding that, in straining her arms in that Action, she sensibly felt something (as she thought) slip out of its place on her Shoulder. After examining the Part, we were well satisfied that there was no Dislocation; but observing a Depressure on the external part of the Deltoid Muscle, and finding the two inferior Tendons of this Bicipital Muscle rigid, and the *Cubit* thereby denied its due Extension, we suspected that the external tendinous Beginning (before taken notice of) was slipped out of its Chancel on the head of the *Os Humeri*; but finding the part at that time

¹ Read before the Philadelphia Academy of Surgery, Dec. 3, 1883.

² An Anatomical Treatise on the Muscles of the Human Body. Illustrated with Figures after the Life. By the late Mr. William Cowper (p. 75).

somewhat inflamed, we advised her to an emollient Application, and to give her Arm rest till the next day, at which time we found our Conjecture true; for by turning the whole arm to and fro, the Tendon readily slipped into its place, she recovering the use of the Part immediately."

Monteggia² (*Institutione Chirurgice*, t. v. 179) describes the case

Of an aged woman, who fell, receiving a severe shock to the shoulder, followed by an acute pain which only ceased after she had felt "something" which was displaced return to its proper position. Afterwards she had a recurrence of this symptom from very trivial causes. Each time that she felt anew the localized pain, she would rest the hand of that side upon the shoulder of another person, and with the arm in that position, she felt the tendon of the long head of the biceps return to its position, and the pain disappeared.

Mr. William Bromfield, Surgeon to her Majesty's Household, and to St. George's Hospital, in his *Chirurgical Observations and Cases* (London, 1773), says (p. 76):—

"I dare say many surgeons have seen a lameness in the shoulder from almost a similar cause, that is, the tendon of the *biceps* muscle, which runs in the excavated groove in the head of the *os brachii*, having by some turn of the limb, slipped out of the *sulcus*, and resting on one of the little exuberances of the upper part of the channel, till it returned, has occasioned, not only an immobility of the joint, but most violent pains. When the case is known, the reduction is very easy, for the cubit being bent the muscle is relaxed, and while an assistant holding the lower extremity of the *os brachii*, moves the head thereof, sometimes inward, sometimes outward in the *acetabulum scapulae*; the operator with his fingers will easily replace it, and the patient presently becomes perfectly easy."

In the one hundred years which have elapsed since worthy Mr. Bromfield thus confidently expressed his views upon this subject, but very few if any cases have been reported, which on examination seem to belong beyond question to the class of injuries which he here describes.

The case of Mr. John Soden, of Bath, communicated to the Royal Medical and Chirurgical Society of London, July 6, 1841, by Richard Partridge, Esq., is the one which has excited most comment, as the symp-

¹ Mangetus, who died in 1742, at the advanced age of ninety, in his *Theatrum Anatomicum*, published at Geneva in 1717 (subsequent to the first edition of Mr. Cowper's treatise on the muscles), quotes the above case (pp. 39 and 40), together with some remarks on the "two inferior tendons" of the biceps, and on their relation to the operation of phlebotomy, all of which he translates, without the alteration of a word, into the scholarly Latin in which his work is written. He gives Mr. Cowper full credit, as is apparent from his opening sentence (see foot-note to page 53), in which he speaks of him as "Accuratissimus Anatomicus," etc.

Mr. Henry Hancock (*Provincial Medical and Surgical Journal*, 1844, vol. viii. p. 507), quoting the case of Mangetus (whom he calls Magnetus) from the *Encyclopædie Méthodique*, and that of Cowper from an edition published in 1737 by Albinus, at Leyden, very unjustly observes that these "two cases," as he calls them, so closely resemble each other that there can be little if any doubt that the one is an unacknowledged and pirated version of the other; and as Cowper is known to have appropriated Bidloo's anatomical plates, he suggests that he would not hesitate long in appropriating another man's case. An excellent illustration of the danger of quoting at second-hand!

² Quoted by Jarjavay, *Gazette Hebdomadaire*, May 24, 1867, p. 325.

toms during life were in this instance supposed to be explained by the result of the autopsy:—

A man aged 59, while falling backwards, placed his arm behind him and received the whole weight of his body on the right elbow. Acute pain in the shoulder was immediately experienced, and the man supposed that he had suffered either a fracture or dislocation, but, finding that he could raise the arm over his head, he felt reassured.

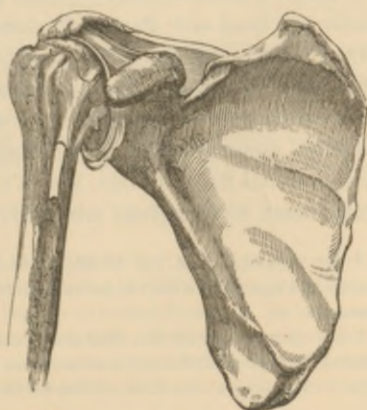
The next morning the joint was greatly swollen, tender to the touch, and painful on very slight motion. A severe sprain was diagnosed and antiphlogistic measures adopted, but at the end of three weeks the tenderness in front of the joint and pain on certain movements of the limb were scarcely less than on the day after the occurrence of the accident. Another careful examination was then made. On comparing the joint with its fellow, now that the swelling had subsided, a marked difference was observable between their respective outlines. The injured joint was manifestly out of drawing, without presenting any glaring deformity. When the man stood erect, with his arms dependent, the distinction was very manifest, but difficult to define. There was a slight flattening on the outer and posterior part of the joint, and the head of the bone looked as though it were drawn up higher in the glenoid cavity than it should be. Examination verified this appearance in two ways: 1st. On moving the limb, with one hand placed on the shoulder, a crepitating sensation was experienced under the fingers, simulating a fracture, but in reality, caused by the friction of the head of the humerus against the acromion. 2d. On attempting abduction, you found that the arm could not be raised beyond a very acute angle with the body, from the upper edge of the great tubercle coming in contact with the tip of the acromion. The head of the bone was unduly prominent in front, almost to the amount of a partial dislocation.

For all useful purposes the arm was powerless. The smallest weights could not be raised on account of the severe pain induced by any exercise of the biceps, which was described as very acute and extending through the whole course of the muscle, but felt chiefly at its extremities, the lower with the upper. When not excited by muscular action it was referred to the front of the joint and confined to the space between the coracoid process and the head of the humerus, which was marked by some puffy swelling. The patient being of a rheumatic habit, inflammatory action of that character was soon established in the joint, so that the peculiar symptoms of the injury were masked by those of general articular inflammation, which added greatly to the man's suffering and to the difficulty of diagnosis.

The patient found most relief from the elbow being well supported and placed close to the side, with pressure by a soft pad firmly applied against the deltoid muscle.

All this occurred in the month of May, 1839. In November of the same year the patient died of compound fracture of the skull, and an opportunity for an autopsy was afforded.

On examining the joint the accident was found to be a dislocation of the long head of the biceps from its groove, unaccompanied by any other injury (Fig. 1). The tendon was entire and lying inclosed in its sheath on the lesser tubercle of the humerus; the capsule was but slightly ruptured; the joint exhibited extensive traces of inflammation; the synovial membrane was vascular and coated with lymph; recent adhesions were stretched between different parts of its surface, and ulceration had commenced on the carti-



lage covering the humerus where it came in contact with the under surface of the acromion; the capsule was thickened and adherent, and in time probably ankylosis of the joint would have taken place.

In his remarks on this interesting case, Mr. Soden endeavours to explain the phenomena by attributing to the long head of the biceps the function of a capsular muscle. He remarks that the altered position of the bone must have been dependent on the displacement of the tendon, as the injury was uncomplicated; and continues: The head of the humerus is said to owe the security of its position rather to the combined action of the capsular muscles than to the ligamentous attachments of the humerus to the scapula; and the tendon is vaguely described as strengthening the joint, and in that respect having an analogy to the ligamentum teres of the femur. The capsular muscles may be considered as having their origin from the upper three-fourths of the circumference of a circle; they then converge towards its centre, represented by the head of the humerus, into the upper, anterior, and posterior parts of which they are inserted. In the lower segment of this circle there is a gap (the axilla) not occupied by muscles. As the head of the bone rolls on an almost flat surface, its position is entirely under the control of the capsular muscles; it follows, therefore, that to enable the bone to maintain its equilibrium these muscles should exactly antagonize each other or the head of the humerus would be drawn to the side of the preponderating muscle. The necessity of a muscle from the ribs to the humerus, to counteract the upper capsular muscles, is probably superseded by the singular course of the long head of the biceps. We can thus understand why, when the tendon is ruptured or displaced, the head of the bone should rise upwards and forwards—a precisely opposite direction to that in which the tendon would, when *in situ*, tend to direct it.

This case and Mr. Soden's remarks have been quoted by almost every writer on the subject since their publication. Bransby Cooper, in his edition of Sir Astley Cooper's Treatise on Fractures and Dislocations of the Joints (London, 1842), quotes it almost in full with seeming approval under the head of "Partial Dislocation upwards of the Shoulder-joint."¹ Mr. Pirrie under the same caption gives in his treatise on surgery an abstract of the case. He adds that in the museum of the Medico-Chirurgical Society of Aberdeen there is a preparation of an unreduced dislocation upwards which in all respects very closely agrees with the description and figure of Mr. Soden's case. The criticisms of other writers in this case will be given presently.²

¹ See Agnew, vol. ii. pp. 55-56, on those cases of so-called partial dislocation forwards and upwards, which he believes to be impossible, without fracture of the coracoid process.

² The second case of Mr. Soden was one of forward dislocation of the humerus attended with great difficulty in reduction. The patient died in a few days from internal injuries received at the time of the accident, and the autopsy disclosed the fact that

Dr. James S. Green reports a case (*Virginia Medical Monthly*, vol. iv. p. 106) of supposed luxation of the tendon occurring during muscular action. It was thought that in this case the tendon was preternaturally mobile (see *supra*, case of Monteggia), at least after the first of a series of accidents which took place as follows:—

In November, the patient, a large corpulent woman, aged 52 years, fell on a slippery step, injuring her shoulder. She was taken home in a carriage, on getting out of which she fell again and felt something—"the bone"—return to its place, upon which she was relieved. Ten weeks later, while attempting to drive a bird into its cage, striking at it over head with a newspaper, she was seized with violent pain in the same shoulder, and the arm fell to her side. The next day she had the following symptoms: Exquisite tenderness on the anterior and inner surface of the shoulder, over a space about a finger's width and finger's length in extent; abduction of the arm gave great pain; movement of the arm backward, either passively or by means of the latissimus dorsi, gave rise to the same pain which extended along the tract of the musculo-cutaneous nerve. This pain was constantly present as far as the external condyle of the humerus. Active flexion of the forearm upon the arm, to less than a right angle, gave most acute pain at the shoulder.

There were no symptoms of fracture or of scapulo-humeral displacement.

Partial relief from pain was obtained by keeping the arm close to the body and elevating it by a sling and bandage.

Ten days later, in an effort to save herself from another fall, she suddenly threw the injured arm upward and backward, when she "felt something return to its place with a snap," accompanied by agonizing pain. After this the symptoms all gradually disappeared.

From the study of the mode by which this spontaneous reduction took place, and of the symptoms of the case, Dr. Green recommends in the treatment of such cases, flexion of forearm, rotation of the hand outward, and the use of a sling.

Mr. G. W. Callender, in an article on Dislocations of Muscles and their Treatment (*The British Medical Journal*, July 13, 1878), wrote:—

"Perhaps of all tendons, those which have been most under notice are the biceps of the arm, and the conjoined tendon, which, through the patella, comes occasionally to be dislocated from the front surface of the femur. There is Dr. Hamilton's case of supposed dislocation of the biceps tendon; and in our London museums there are specimens showing displacement of the tendon of this muscle. It is not long since a woman was under our notice in Sitwell ward, who suffered from a hurt of this nature. I am very sorry we could do but little for her; but we did not see her until long after the first occurrence of her trouble. This woman had great pain with her hurt. The shoulder seemed to droop forward, and she shrank from using the biceps, and, indeed, from moving the joint. The tendon lay on the inner side of its groove, and by pressing against it so as to push it outwards, and by rotating the arm inwards, it would slip back into the groove, but only to slip out again, when the pain, which had been for the time relieved, was again felt. Of course continued rest was tried in the hope that the tendon would be resheathed in its groove, but it was not so; and the conclusion we came to was that the groove had become in part filled up, probably, by fibrous tissue;

the tendon had escaped and had slipped completely over the head of the bone, lying at the inner and posterior part of the joint.

No symptoms are mentioned except that the dislocation was "very high up." The difficulty in reduction was attributed to the complication of the injury to the biceps. "The inferences from the former case would lead us to expect that, had the tendon been *in situ*, it would have aided in the return of the bone; but its influence being removed the influence of the upper capsular muscles became doubled, and twice the amount of force was consequently required to overcome it."

or that the tendon could not lie and act in it without some binding down by a sheath; and as such ensheathing did not follow the reduction, the leader worked out so soon as any strain was brought to bear on it."

Laugier, Chirurgien de l'Hôpital Necker, has recorded (*Archives Générales de Médecine*, 2d series, vol. v. pp. 65, 66, 67) a case of "incomplete luxation of the head of the humerus upwards and forwards behind the coracoid apophysis,

In which, some days after an accident which was at first taken for a sprain of the shoulder, he found a slight depression beneath the acromion, a prominence of the head of the bone anteriorly, a shortening of the arm to the extent of five or six lines, and a difficulty in abduction of the humerus, the movement being accompanied by an equal movement of the scapula. There had been at no time the signs of a fracture or dislocation. Attempts at reduction were made, but were unsuccessful."

Mr. Alfred Mercer (*Buffalo Med. and Surg. Journal*, vol. xiv. p. 641) relates the following case:—

"Mrs. B., a well-developed woman, of full habit, aged fifty-six, seven years since was thrown from a carriage, dislocating her right shoulder, which was reduced a short time after the accident, but the shoulder was painful, and tender to the touch, and almost useless for months after. She could carry the arm forwards and backwards, but could not raise it from the side, or carry the hand behind her, or raise it to her head for fourteen months. She has gradually gained better use of her arm, but now, July, 1858, she cannot raise her elbow from the side more than half-way to a horizontal position without assistance; but with assistance the arm may be carried into any position without pain or resistance. Measurement shows no appreciable difference in the size or length of the arm or size of the shoulder; but the point of the shoulder is still tender to the touch, is prominent in front, and correspondingly flattened behind. The head of the humerus appears to rest against the outside of the coracoid process, but the fulness of habit obscures the diagnosis compared with the other cases. Several doctors at different times have examined the shoulder; some have said it was not properly reduced, and advised a suit for malpractice.

"I examined the shoulder again in November last; it presented the same general appearance, although the patient was much thinner in flesh, from recent sickness. Some six weeks previous to this examination, in a sudden and thoughtless effort to raise the arm above the head, the muscles unexpectedly obeyed the will; since which time she has had perfect use of it, though the deformity still remains. She thinks she felt or heard a snap when the arm went up, but it was followed by no pain, soreness, or swelling."

There can be no doubt, we think, adds Dr. F. H. Hamilton, that in this case, at least, the deformity and maiming were due, in a great measure, to a displacement of the long head of the biceps.

Mr. Henry Hancock, Surgeon to Charing Cross Hospital, wrote as follows (*loc. cit.*) in reference to this dislocation, but describes no particular case:—

"The principal signs of this accident are pain and tenderness in front of the joint, corresponding to the bicipital groove; acute pain in the course of the biceps, when it is thrown into action, the pain being referred more particularly to its two extremities; the patient is unable to raise his hand to his head, or his arm beyond an acute angle from his body; the appearance of the shoulder is somewhat altered, the head of the humerus being drawn upwards, and more forward than natural, lying close beneath the acromion process, while the posterior and external part of the joint is somewhat flattened. When we consider how much

in appearance these accidents resemble partial dislocations of the humerus upward and forward, we can entertain but little doubt that they have frequently been mistaken for them." "I am not aware of any particular symptom by which we can be guided with any certainty as to when the tendon is dislocated inward, or when outward; but, as a result of my experiments, I should imagine that it is more frequently dislocated inward than outward, the inclination of the head of the humerus, and the greater projection of the large tubercle being unfavourable to the latter displacement."

These clinical cases were long ago supplemented, and were supposed to be confirmed by the reports of dissections in which dislocation of the tendon of the biceps was found associated with other pathological conditions of the shoulder-joint. For example, in the *Medical Gazette* for May 24, 1835, Mr. John Gregory Smith reported seven cases of injury of the shoulder-joint as observed in the dissecting-room. The pathological changes which have any bearing on the present paper, may be enumerated as follows, it being understood, of course, that no clinical histories were obtainable:—

CASE I. The bursa beneath the deltoid was much enlarged and thickened, and communicated with the general cavity of the joint by a large, irregular opening. The tendons of the scapular muscles were completely detached from the greater and lesser tuberosities. The tendon of the long head of the biceps had been torn away from the upper part of the glenoid cavity, and entirely withdrawn from the joint; it was found to be firmly attached to the anterior margin of the bicipital groove. The head of the humerus moved freely in all directions on the glenoid surface of the scapula.

CASE II. Sub-deltoid bursa as above; tendon of subscapularis detached; tendon of long head of biceps ruptured; attached to margin of bicipital groove.

CASE III. Tendons completely torn from greater tuberosity; that of subscapularis partially detached; tendon of long head of biceps torn; attached to bicipital groove.

CASE IV. Bursa beneath deltoid as above; tendons of subscapularis and supra-spinatus detached; tendon of long head of biceps torn from the upper part of the glenoid cavity; attached to bicipital groove; the portion of the belly of the biceps pertaining to the long head was remarkably short, the short head being unusually developed.

CASE V. Sub-deltoid bursa as above; partial separation and detachment of the supra-spinatus and subscapularis muscles from the larger and lesser tubercles; tendon of the biceps torn.

CASE VI. Bursa as above; tendon of subscapularis and supra-spinatus detached; fibres of infra-spinatus and teres minor appear to have suffered severe tension; tendon of the long head of the biceps displaced from its groove, but not separated from its origin; it lay loose in the inner part of the cavity of the joint; the capsular ligament had been much stretched and readily allowed the head of the humerus to be displaced so as to rest upon the inner margin of the glenoid cavity.

CASE VII. Bursa very large, parietes thickened, separated from cavity of joint by a thick layer of lymph. Head of bone freely movable, and easily drawn to inferior margin of glenoid cavity; tendon of subscapularis detached; tendons of supra- and infra-spinatus attached, but the fibres of these muscles had evidently been much stretched; tendon of the long head of the biceps permanently displaced from the bicipital groove, and lying at the inner and lower part of the joint, playing over a smooth part of the lesser tubercle.¹

¹ Cases VI. and VII. represent the two shoulder-joints of one individual, as did also Cases IV. and V.

Mr. Edward Stanley, in the *London Medical Gazette* for 1829 (vol. iii. p. 12), wrote :—

“ In two instances I have found, upon dissection, the tendon of the biceps separated from the edge of the glenoid cavity, and firmly adherent to the margin of the bicipital groove; but there was no other unusual appearance of the parts, either in or about the joint. In a third instance, I found the tendon of the biceps dislocated from its groove, and resting upon the great tuberosity of the humerus. A membranous sheath attached to the humerus, and extending around the tendon, confined it in its new situation. This sheath was polished on its internal surface, it seemed for the purpose of facilitating the play of the tendon, and its formation may be presumed to have been analogous to that of the capsule inclosing the ends of a fractured bone.”

These cases will suffice as examples of this sort of evidence, that obtained at autopsies and unassociated with clinical histories. They, as well as their predecessors, have met with scant mercy at the hand of their critics.

Pouteau, who believed that he had established the occasional dislocation of muscles from their aponeurotic sheaths, asks himself (*Mélanges de Chirurgie*, p. 433) if it is possible for tendons to become thus displaced, and, after some expression of doubt, declares that he is forced to the conclusion that, during the energetic contraction of muscles, the tendons themselves would break rather than their sheaths.

Mons. J. F. Jarjavay, Professeur à la Faculté de Médecine, chirurgien de l'hôpital Beaujon, etc., published in 1867 (*Gazette Hebdomadaire*, Nos. 21 and 23) a paper on this subject. After alluding to the cases of Bromfeild, Cowper, Monteggia, Stanley, Smith, and Soden, he sums up, not altogether correctly, the symptoms observed by the first three of them as follows :—

An acute pain in the point of the shoulder during a violent twist of the arm; a sensation of displacement in that region, giving rise to the belief on the part of the patient that a luxation of the humerus has occurred; a greater or less difficulty in the movements of the scapulo-humeral articulation; a variable degree of inflammation; a well-pronounced bruit heard on moving the arm; rigidity of the biceps with flexion of the elbow; a sensation of reduction following movements of rotation imparted to the head of the humerus. This group of symptoms, he says, has led the authors in question to diagnose a luxation of the biceps tendon, but he considers the proof of such a lesion to be entirely wanting. He adds that there is no doubt, however, that patients present themselves after violent strains of the shoulder, with acute pain and immobility of the joint, with a sensation of fatigue about the lower portion of the biceps, with a feeling of something displaced, and with a marked bruit produced by rotating the arm, but that these phenomena are due to a lesion altogether different from luxation of the tendon. In proof of this he reports five cases of injury of the shoulder which may be summarized as follows :—

CASE I. A man, aged 25 years, in order to carry a heavy bag of sand on his left shoulder, steadied it with his right hand passed behind and above his head. While he was raising it into this position he felt a sudden pain at the point of the shoulder, and the arm became powerless and fell suddenly by the side of the trunk. Three days later he presented the following symptoms: Slight swelling of the right shoulder; forearm flexed on arm; immobility produced by the pain of movement; pain over lower portion of the biceps on which the skin above the elbow is tense; pain in extending the forearm. He could carry the arm feebly forward, backward, and inward, but abduction to a slight extent caused severe pain. Rotation of the humerus with the arm at the side was noiseless, with the arm abducted until it was horizontal was associated with a species of *claquement*, which could be plainly heard by the surgeon and his assistants. If

the arm were then abandoned it would fall to the side with a sudden pain and noise resembling the reduction of a luxation. The same phenomena could be reproduced repeatedly. If, during the rotation of the humerus held horizontally, an assistant pressed downwards its upper extremity, the noise ceased.

All these symptoms greatly diminished in a few days under the use of cold lotion and a sling. Nine days after the accident the sling was discarded and movements of the arm were good.

CASE II. A man, 56 years of age, while drawing powerfully on a corkscrew, had an acute pain in the shoulder. Eight days afterwards, when he was first seen, he had painful abduction, creaking on rotation, etc. (as in Case I.), flexion of the forearm, etc. No swelling or tenderness. Nearly well in three days.

CASE III. A woman, 47 years of age, fell and twisted her right arm, producing a sharp pain in the shoulder. The symptoms were the same as the above. No pain except during abduction, when it was acute and associated with the creaking noise. She returned to her work quite well in three days.

CASE IV. A man, 28 years of age, fell on his right hand, wrenching his shoulder. The same symptoms followed—moderate swelling of the shoulder, but no deformity and no ecchymosis. Four days later all the swelling had disappeared and much of the pain. In three weeks he was entirely cured.

CASE V. A man, 27 years of age, and entirely without any history of traumatism, presented himself with a swollen reddened shoulder, with painful rotation of humerus, a slight creaking, etc. A puncture beneath the tip of the acromion was followed by the escape of about two teaspoonfuls of clear serum. This was repeated two or three times—other treatment was applied, and the patient was almost well in six weeks.

These cases have the following characteristics which distinguish them, according to M. Jarjavay, from other injuries about the shoulder, and which establish the fact that they were not due to a luxation of the bicipital tendon. 1. They were all produced—except Case V.—by a twist of the arm. 2. The seat of the pain (as in the cases of Cowper, Bromfeild, and Monteggia) was at the external aspect of the point of the shoulder, on a line with the tip of the acromion. 3. The long tendon of the biceps is at least two and a half centimetres within this point. 4. The pain and the noise are synchronous, and are manifested only at the moment when the arm is carried into abduction, and is sufficiently elevated for the great tuberosity to glide under the tip of the acromion, or is rotated, while in that position. 5. Case V. shows that an acute hygroma of the sub-acromial bursa may produce all these symptoms. 6. If we examine this bursa we find that movements of tension distend or crumple up its walls; if the deltoid muscle is detached from its insertion and turned upwards over the acromion and clavicle, and the humerus is abducted, it will be seen that the walls of this bursa are folded upon themselves, and form a pad or cushion beneath the tip of the acromion, and that at the moment the humerus reaches the horizontal, the tuberosity glides under the acromion, pushing these folds of the bursa before it.

Bearing these clinical and anatomical facts in mind, M. Jarjavay comes to the following conclusions, which refer to his own cases and to those of Cowper, Bromfeild, and Monteggia.¹

¹ Those of Stanley and Gregory Smith observed post mortem only, he attributes to previous luxation. As to that of Soden he agrees entirely with Malgaigne, whom he quotes.

1. Simple luxation of the long tendon of the biceps muscle does not exist, or at least has never been demonstrated.

2. The lesion which has been considered to be a luxation of this tendon, has its seat in the sub-acromial serous sac.

3. This lesion is an inflammatory enlargement, caused by contusion or laceration of this sac, or by hypertrophy, with induration of its walls and fibrous transformation of its cellular partitions, consecutive to inflammation.

4. Its symptoms are the following: Sensation of displacement at the time of the accident; swelling of the shoulder; pain preventing movements of the arm, principally those of abduction; forearm flexed upon the arm, and consequent rigidity of the biceps muscle and a feeling of uneasiness in the front of the elbow; increase of pain, and bruit below the acromion when the arm is raised and abducted, and the greater tuberosity is made to glide under this apophysis (the bruit is a crackling sound, and gives the sensation of a reduction of something displaced; it is reproduced whenever the bone maintained in a horizontal position is rotated); relief of pain, and restoration of the movements of the arm after rest; habitual persistence of the crackling bruit, even when the pain is no longer felt, and the movements are free.

Malgaigne (*Traité des Fractures et des Luxations*, Paris, 1855, t. ii. pp. 565-66-67) makes the following criticism upon Mr. Soden's cases, prefacing it with a few remarks upon the so-called upward luxation, which are so pertinent to the case I am about to describe, that I translate them also:—

It is not rare to observe in *scapulargies*, which have become chronic, a *sub-luxation upward and forward*, which has acquired a certain importance on account of the mistakes to which it has given rise. I have shown many examples of it at my clinics. The humeral head is elevated until it is almost in contact with the acromion, and is carried forward against the external border of the coracoid process; there is found, in consequence, a slight depression under the acromion, shortening of the arm and limitation of its movements. It is really this condition, unless I am mistaken, which M. Laugier has described as an incomplete upwards and forwards luxation, produced by traumatism. (See p. 22.) His patient, after a twist of the shoulder, had pain and swelling. M. Laugier, after a careful examination, diagnosed at first only a sprain. At the end of twelve days, however, the swelling had largely disappeared, and he then perceived that the head of the bone was prominent at the front and inner side of the joint near the coracoid process, and was somewhat elevated, the arm being shortened five or six lines.¹ M. Avard has observed a displacement of the same character, dating back thirty-one years, and following a fall upon the shoulder. The head occupied the space included between the coracoid, the acromion, and the glenoid cavity, into which it could not be brought again. The arm was shortened from eight to ten millimetres; abduction was arrested at 30° by the impinging of the great tuberosity upon the point of the acromion, and all the movements of the joint were greatly restricted.²

That which deceived these two observers was the traumatic cause of the affection; I have myself for a long time sought to explain their observations by a traumatic lesion. J. Soden, in England, having been able to study an analogous case with the scalpel, came to the conclusion that it was a luxation of the long tendon of the biceps. His patient, after a fall on the elbow, felt a sharp pain in the shoulder, and fearing a fracture or a luxation, was only reassured by finding that he could raise the arm above his head. The next day the shoulder was swollen, and elevation of the arm had become impossible. Soden was called in, found no displacement, and treated the case as a sprain. Finally, at the end of three weeks, the swelling having subsided, it was found that the head of the humerus was unnaturally prominent in front and above. There was still pain in the joint, and elevation of the arm appeared to be prevented by contact between

¹ Arch. Gén. de Méd., 1834, t. v. p. 65.

² Revue Méd.-Chir., 1878, t. iv. p. 282.

the great tuberosity and the acromion. Five months later the patient died of a head injury. *The joint showed numerous traces of inflammation, the synovial membrane was unduly vascular and covered with lymph; there were recent adhesions between different points of its surface; the cartilage of the humeral head, where it was in contact with the lower surface of the acromion, was ulcerated; the capsule was thickened and adherent.*¹ Finally, the tendon of the biceps was displaced from its groove without other lesion.

A figure accompanying this description (see Fig. 1) seems to complete it. The head is actually elevated in the glenoid cavity; at the inferior portion of which a little space is left empty. The tendon occupying the greater part of its sheath, has simply dilated it above, in such a manner as to deviate a little in the direction of the lesser tuberosity. A deviation to that extent is not necessarily traumatic; and besides it would not explain the ascension of the humerus, which can readily be accounted for by the pathological retraction of the ligaments. On the other hand, this ascension might well have been the determining cause of the deviation of the tendon, forced to slip forwards in order to reach its glenoidal insertion by the shortest path. I have seen and shown at my clinic, many cases of the same character, and have come to a definite conclusion in reference to them. There has never been a traumatic luxation of the tendon of the biceps, otherwise than as a complication of a fracture or luxation; there cannot be a traumatic luxation which holds the head at the external side of the coracoid process; but there is a pathological sub-luxation of the humerus, due to articular inflammation and to retraction of ligaments, favoured, perhaps, by mal-position, or improperly applied dressings.

The criticisms of Mr. Robert Adams on the case of Mr. Soden, in his article on Abnormal Conditions of the Shoulder-Joint (*Cyclopædia of Anatomy and Physiology*, vol. iv. p. 595), seem to me worthy of great consideration. He had previously shown: 1. That one of the commonest conditions in chronic rheumatic arthritis of the shoulder-joint was atrophy or degeneration of the bicipital tendon which was often absent from the joint. 2. That in these cases the humerus has a very general tendency to pass upward towards the coraco-acromial vault, and that besides the removal of the biceps tendon the superior part of the capsular ligament is also observed to be deficient. 3. That these changes, as demonstrated in autopsies, frequently affect *both* shoulder-joints (see Cases VI. and VII. of Mr. Smith); but are described by writers, who (with the one exception of Mr. Soden), knew nothing of the clinical histories of their cases, as "rupture of the tendon of the biceps," an accident in the highest degree unlikely to occur symmetrically. 4. That so long as the long tendon of the biceps remains in its state of integrity, arching over the head of the bone, and then passing in a perpendicular line down along the humerus, the head of this bone cannot be partially elevated above its normal situation, nor even drawn inwards or backwards by either of the great muscles which form the anterior or posterior walls of the axilla; but that when the long tendon of the biceps is destroyed or dislocated, then the head of the humerus may be moved in whatever direction the inclination of the new plane formed by the altered surface of the glenoid cavity may give, or the muscles may draw it in. 5. He had given also the results of a post-mortem examination in a case of chronic rheumatic disease in a patient of Mr. Robert

¹ The Italics are Malgaigne's.

Smith, in which there was no history of accident. The head of the humerus was displaced upwards; the capsular ligament was deficient superiorly; the tendon of the biceps was perfect, but was thrown off the head of the bone inwards;¹ and, 6. Had given in addition the details of an autopsy in which almost the same displacement of the head of the humerus and tendon of the biceps, as in Mr. Soden's case, were found in *both* shoulder-joints, associated with the ordinary anatomical characters of chronic rheumatic arthritis.

Examining Mr. Soden's case in the light of these facts, it is important to observe: 1. That the patient was a man 59 years of age, "of a rheumatic habit," and that "inflammatory action of that character was soon established in the joint," etc. 2. That he at first supposed he had either a fracture or dislocation, but, finding that "he could raise the arm over his head," he felt reassured, and tried to resume his work. It would appear to us, says Mr. Adams, that if the tendon of the biceps were accidentally dislocated, the patient would not be able, immediately after the accident, to raise his arm over his head. 3. That the first symptoms were simply those of an inflammatory character, or, as Mr. Soden then supposed, of a severe sprain. 4. That the later symptoms; the flattening of the outer and posterior part of the joint; the elevation of the head of the bone; the crepitation, the pain along the biceps, the difficulty in abduction, the prominence of the head of the bone in front, all belong to an early stage of chronic rheumatic arthritis of the shoulder. 5. Dr. Macdowell (who examined the specimen for Mr. Adams) reported to him that "the head of the humerus is considerably enlarged, and that the long tendon of the biceps, which has been dislocated internally, is in a state of atrophy."

The criticism directed against the clinical aspects of these cases has been strongly reinforced by observations on disease of the shoulder-joint, particularly chronic rheumatic arthritis, which showed that many cases of dislocated tendon, discovered post mortem, and supposed to be the result of injury, were really due to disease.

Dr. Knox, of Edinburgh (quoted by Callaway), seems to have been the first person to notice a morbid condition of the tendon of the biceps. He found in the dissecting-room four cases in which the tendon had more or less disappeared, in one case altogether. In the others it was reduced to a few cellular and fibrous-looking threads, which could be traced with difficulty.

¹ "The great peculiarity in this case, Dr. Smith thought, consisted in the circumstance that the tendon of the biceps was not, as it usually is in cases of this chronic disease, absorbed, but was in a perfect state of integrity, as to structure. This tendon having been thrown off the head of the humerus and displaced inwardly, its normal function to restrain the ascent of the humerus through the medium of its muscular connection was as much annulled as if it had been removed altogether, as it usually is under the influence of this chronic disease."

Mr. Hargraves reported (*Edinburgh Journal*, 1837), a case of "partial dislocation" of the humerus in which the biceps tendon was ruptured. Sir Astley Cooper's case has already been referred to. In this the tendon was thought to have been ruptured, but to have again united. Mr. Calaway thinks (op. cit., p. 151), that he must have meant "united to the capsule of the joint."

Mr. Stanley (*Medical Gazette*, vol. iii. p. 12), says that in one instance he found the tendon of the biceps dislocated from its groove and resting on the great tuberosity of the humerus. A specimen (No. 55) in the museum of St. Bartholomew's Hospital is an example of dislocation (Calaway, op. cit., p. 145).¹

Mr. Canton (*London Med. Gazette*, 1879, vol. viii., 3d series, p. 958) reports a case of chronic rheumatic arthritis of the right shoulder, in which the long tendon of the biceps was flattened and expanded, "permitting the head of the humerus to shift upward and thereby to articulate with the under surface of the acromion process."

Among the most important papers bearing upon this subject with which I am familiar, are those published by Dr. Robert W. Smith, Professor of Surgery in the University of Dublin (*The Dublin Quarterly Journal of Medical Sciences*, 1853, vol. xv. pp. 1, 343), under the title "Observations upon Chronic Rheumatic Arthritis of the Shoulder."

Having detailed the pathological appearances of this disease, and illustrated them by a case of his own, he proceeds to review the various cases which have from time to time been recorded in surgical literature as instances of rupture or dislocation of the biceps tendon, partial luxation of the humerus upwards, etc., beginning with Mr. John Gregory Smith's series of cases (see p. 23). He says:—

"It would be difficult to lay before the reader any more striking examples of the anatomical characters of chronic rheumatic arthritis of the shoulder than those furnished by the preceding group of cases, gratuitously described by the author (for their history was unknown) as instances of the effects of accidental violence. The absorption of a portion of the capsule; the detachment of the tendons of the capsular muscles from the tubercle of the humerus; the separation of the acromion into two portions; the ivory-like deposit upon the surface of the bones; the loss of the tendon of the biceps; its adhesions to the bicipital groove; *its displacement inwards from the summit of the humerus*; the osseous nodules about the tubercles; the conversion of these processes into articular surfaces; the enlargement of the capsule; the symmetrical development of the disease,² etc. etc., are elucidated in the clearest manner by this series of specimens."

¹ Mr. Stanley found that in a case which he supposed to be rupture of the biceps tendon, the slightest movement of the elbow backwards was followed by acute pain, precisely in the situation where the tendon of the biceps turns over the head of the humerus. There was also effusion of blood into the subcutaneous cellular tissue, but confined to the tract of the biceps tendon. In a similar case occurring in the practice of Mr. Normald it was observed that "the effort of bending the forearm was attended with a peculiar spasmodic and vibrating movement of that part of the biceps from which the long head is continued, and which was distinctly felt by the hand placed against the arm."

² Cases 4 and 5 occurred in the same person, as did also Cases 6 and 7.

Professor Fergusson's statement that partial luxation of the head of the humerus upward occurs pretty frequently, his opinion being grounded upon phenomena observed in the dissecting-room (see p. 34), he believes to be erroneous, and attributes it to the same cause: "In the remarks which he has made upon the subject, he has unknowingly described many of the leading features of chronic rheumatic arthritis of the shoulder, although he looks upon them as resulting from accident." Mr. Hilton's case¹ (*Guy's Hospital Reports*, vol. v.) and Mr. Alfred Smee's² (*The Lancet*, 1845, vol. i. p. 323) are interpreted by him in the same manner. He disposes similarly of the cases of Mr. Barron³ (*London Med. Gazette*, vol. xx. p. 554), of Dr. Knox (*Ibid.*, vol. i.), of Mr. Stanley (*Ibid.*, vol. iii.), of Sandefort (*Museum Anatomicum*, vol. iv., tab. cli.), of Mr. Callaway (see p. 35), and of Sir Astley Cooper (see p. 20), all of which were reported as partial dislocation of the shoulder upwards, or as instances of rupture or dislocation of the bicipital tendon, and all of which, as he clearly shows, presented marked evidence of chronic arthritis. In none of them was there any satisfactory clinical history, the diagnosis having been founded, chiefly if not entirely, on post-mortem appearances.

Of Soden's case he says:—

"It has been clearly demonstrated that the fall alluded to in the history of the case had only this much to do with the partial displacement upwards of the head of the humerus which succeeded to it, that this accident became the starting-point of an inflammatory action of a rheumatic character, under the influence of which the head of the bone became elevated to the acromion process and the tendon of the biceps displaced."

He then describes the case of an elderly female, who had for many years suffered from chronic rheumatic arthritis of the right shoulder-joint, which, after death, was examined by him. The head of the humerus was displaced upwards, and the tendon of the biceps, perfect as to structure, crossed the inner instead of the upper surface of the head, the cartilage of which was abraded. The case of Charles Mailly, recorded by

¹ Dislocation downwards of the humerus into the axilla, associated with rupture of the tendon of the biceps.

² Dissection of a partial dislocation of the shoulder upwards. There was detachment of the biceps tendon from the edge of the glenoid cavity. Mr. Smee says: "Regarding the total alteration in the joint, arising from the injury, as a whole, we find that the shoulder-joint was converted into a double joint, one joint existing between the head of the bone and the glenoid cavity, the other between the great tuberosity and the under surface of the acromion." After study of the case he comes to the following conclusions: "First, that the tendon of the biceps is sufficient alone to keep the head of the bone from rising from its situation, or, at any rate, contributes principally to that object. Secondly, that the supra- and infra-spinati have no influence in drawing the head of the humerus under the acromion, as it was drawn into that situation when these muscles were divided."

³ Detachment of the biceps tendon from the glenoid cavity. Mr. Barron and Mr. Pilcher met with this condition frequently in dissecting-rooms, especially in aged females.

Mr. Adams (see page 27), illustrates the same displacements of the head of the humerus and of the tendon, occurring in *both* shoulder-joints (as in Cases VI. and VII. of Mr. J. G. Smith's series).

He continues :—

“The remarkable elevation of the head of the humerus to which the name of ‘partial luxation upwards’ has been given has invariably been ascribed to the destruction or displacement of the tendon of the biceps, not only by those who look upon it as the result of external injury, but also by those who, in my opinion, correctly refer it to the effects of chronic rheumatic arthritis. Mr. Adams, for instance, observes that ‘the effects of the loss of the tendon of the biceps are such that the head of the humerus is at once elevated by the deltoid and kept habitually pressed up against the under surface of the acromion.’¹ The correctness of this opinion certainly admits of being questioned, and I am inclined to believe that in the cases under consideration the cause has been mistaken for the effect. I do not mean to say that the accidental rupture or displacement of the biceps in a healthy shoulder-joint would *not* be followed by the elevation of the head of the humerus, but I suspect that in cases of partial luxation upwards resulting from the rheumatic disease in question the sequence of events is different from that observed by authors. I believe that in these cases the elevation of the head of the humerus occurs at a comparatively early period of the disease, and is a gradual process, and that the displacement is not in any instance sudden, as might be expected to happen were it consequent upon the rupture or dislocation of the tendon.”

He believes the sequence of phenomena is as follows : Spastic contraction of the muscles under rheumatic irritation of the joint ; elevation of the head of the bone ; pressure against the tendon of the biceps ; displacement inwards of the tendon which slips over the smooth globular head of the humerus until the tension is somewhat relieved ; later should the tendon not atrophy under pressure the extra-capsular portion may become implicated, and will be found crossing the lesser tubercle.

Dr. Smith concludes his elaborate paper as follows :—

“A long and careful consideration of the subject discussed in the preceding pages leads me to believe that the occurrence of partial dislocation of the head of the humerus upwards, as an immediate result of rupture or displacement of the tendon of the biceps muscle from accidental violence, has not been anatomically demonstrated ; that all the cases accompanied by dissections that have hitherto been published, as examples of the luxation in question, resulting from injuries to the tendon, have, in reality, been instances of the effects of chronic rheumatic arthritis ; and that the morbid conditions which in them have been regarded as affording the clearest evidence of the joint having at some former period suffered from external violence, are among the most constant effects of this disease.”

Dr. A. G. Gerster, of New York, in an article on Subcutaneous Injuries of the Biceps Brachii (*New York Medical Journal*, 1878, vol. xxvii. p. 487), refers to injuries and dislocations of the tendon of the muscle, as follows :—

¹ Mr. Canton also, in his description of a case of this disease, brought under the notice of the Westminster Medical Society, and in which the tendon was divided into four or five slips, remarks that “this condition of the tendon had permitted the head of the humerus to shift upwards, and thereby to articulate with the under part of the acromion process.”

"There are cases where the tendon of the long head is but partially lacerated, or in which it is intact, its sheath only being injured. These changes have been for a long time the diagnostic stumbling-blocks of many surgeons. The changes in the outward shape of the shoulder are very slight indeed in these cases; you find, perhaps, a scarcely noticeable synovial effusion in the joint, sometimes an ecchymotic streak in the front of the shoulder; but the functional disturbance is very marked, in fact it seems to be out of proportion with the visible anatomical changes. The patient is unable to use his arm, and endeavours with earnest care to keep it in the same well-flexed condition as if the humerus were broken.

"Passive extension, as well as flexion, of the pronated forearm, causes some pain, active extension and flexion in the same position possible, but a good deal more painful; active flexion of the forearm in supination quite impossible. By pressing the finger tips against various points of the humerus, palpation along the bicipital sulcus, especially between the two tubercles, elicits marked signs of distress."

Dr. Gerster then quotes the case of a carpenter, æt. thirty-ve, who fell down a staircase and "struck the ground heavily" (how, it is not said); he instantly felt something snap, followed by a stinging pain in his left shoulder; swelling rapidly ensued, and ecchymosis along the course of the bicipital tendon. A week after the accident active and passive extension were possible, but somewhat painful; passive flexion the same; active flexion in pronation difficult, but possible; active flexion in supination absolutely impossible; even the attempt producing intense pain at the upper bicipital region. Ecchymosis, which before was marked, almost gone. Since even most careful palpation could not prove breach of continuity of the tendon, or signs of dislocation in the shoulder-joint, the diagnosis was: laceration of the tendon, and the corresponding part of the sheath of the long head of the biceps. The arm was restored to usefulness by the use of a simple sling.

After narrating the views of the older surgeons, and mentioning Mr. Soden's case, and Malgaigne's opinion thereof (see p. 26), he continues:—

"So much is true, that no surgeon ever saw the said tendon in *statu luxationis*, and that those who made a diagnosis of dislocation concluded a *posteriori* from conditions consequent upon, or found after, a supposed dislocation."

He then directs his argument against the probability of inward or outward rotation of the arm forcing the tendon from its sheath without either disrupting or causing a luxation of the joint, but says nothing as to the possible effect of direct force. His conclusions are:—

"First, that the luxation of the long head of the biceps never was observed on the living subject in its uncomplicated form, and that its existence is very doubtful, although conventionally accepted by and reprinted in older manuals of different surgeons. Second, in cases presenting compound injuries of the joint and its osseous components, accompanied by rupture of the articular capsule, the inevitable displacement of the tendon is not of much consequence as to the whole injury, and therefore cannot be ranked as a pathological phenomenon of independent standing."

Von Pitha writes as follows (*Handbuch der Chirurgie*, Bd. 4, Abth. 2, p. 46: Luxation der Bicepssehne und Ruptur desselben):—

"Besides the previously mentioned luxation of the biceps tendon upon the tuberosity (as a complication of luxation of the humerus) an uncomplicated dislocation of this tendon has been described by Monteggia, Bromfield (*sic*), and Stanley, occurring during violent exertion, or through sudden inward rotation of the humerus. It is not apparent how in such a manner the biceps tendon is to be lifted out of its sulcus upon the great tuberosity, a dislocation in the way of which stand the insertion of the capsular ligament and of the tendon of the supra-spinatus. The diagnosis has often been made erroneously on the basis of the subjective symptoms, referred to the neighbourhood of the bicipital groove and on the associated disturbance of function. A crackling noise produced by raising the arm has been given as an important symptom. This is, however, poorly adapted to show a luxation of the tendon, as in that case the noise could only be produced by a rapid drawing back (spontaneous reposition) of the tendon from the great tuberosity with the sulcus, which would be accompanied by an instant relief to the patient; while, on the contrary, in the supposed injury the pain is increased during the production of the noise."

He then states that Jarjavay has elucidated this matter, and refers to his paper (see p. 24), adding that, moreover, no one has ever felt a luxated tendon on the great tuberosity¹ or been able to replace it. The trouble requires no manœuvres for the purpose of reposition, but disappears of itself under rest, and cold fomentation of the shoulder, with the arm in a sling.

He believes that although this "mysteriöse luxation der bicepssehne als selbständige dislocation auf das tuberc. majus," thus appears in its true light that other injuries of the tendon of the long head of the biceps are well grounded, instancing its rupture and its separation from its scapular insertion.

Volkman (*Handbuch der Chirurgie*, Bd. 2, Abd. 2, p. 874. Luxationen der muskeln und Sehnen), after detailing the symptoms described by Cowper, Bromfield, and Monteggia, says that it is well known that similar symptoms present themselves in relation to other joints, and depend upon conditions entirely different from injuries or luxations of tendons. He alludes to Jarjavay's cases, and their implicit acceptance by Von Pitha, and to the fact that Chassaignac also denies the occurrence of this luxation, adding, that it seems to him, that these authors go too far. He mentions a case recorded by Cloquet, in which a man was able at will to dislocate the biceps tendon either inwards or outwards.

"Autopsies have not thus far shown the existence of an *uncomplicated* luxation of the tendon, i. e., one not associated with luxation of the shoulder. The oft-quoted case of Soden is inconclusive. In future cases of this supposed injury in the living, there will be necessary a much more precise local examination with especial reference to the function of the biceps."

The views in regard to this accident of the other writers whom I have been able to consult, may be readily summarized.

Agnew (*The Principles and Practice of Surgery*, vol. iii. p. 394), says:—

"Though I have seen a number of supposed luxations of the long tendon of the flexor biceps cubiti muscle, yet in only one case, that of a patient of Dr. J. William White, were the evidences of the displacement unequivocal."

¹ Why he insists upon it being on the great tuberosity is not apparent.

Gross (*A System of Surgery*, vol. i. p. 1161), says:—

“The nature of the lesion is always obscure, and, therefore, very apt to be overlooked, or to be mistaken for fracture, sprain, or dislocation of the shoulder. The most reliable symptoms are, inability to flex the arm from loss of power in the biceps, and pain at the seat of the injury, either alone, or in conjunction with more or less prominence of the head of the humerus.”

Mr. Flower (*Holmes's System of Surgery*, vol. i. p. 841), says:—

“In the opinion of the last-named surgeon (Dr. R. Adams, of Dublin), the reported cases of dislocation of the long tendon of the biceps with partial displacement of the head of the humerus upwards, are also to be classed as the effects of disease, and not of injury; but the proof of this appears to me not quite so satisfactory as in the former cases.”¹

Prof. Andrews, of Chicago (*International Encyclopædia of Surgery*, vol. iii. p. 670), dismisses the subject thus:—

“Dislocation of the long head of the biceps from the bicipital groove sometimes causes a puzzling deformity after a successful reduction, or even when there has been no luxation. Without being ruptured, this tendon is not certainly known ever to have been dislocated, although commonly so stated by old authors.”

Ashhurst (*Principles and Practice of Surgery*, p. 287), says:—

“Under this head (partial dislocation) has been described an injury which appears to consist in a rupture or displacement of the long head of the biceps muscle, allowing the head of the humerus to project anteriorly.” He adds in a foot-note: “This inward displacement of the biceps tendon, which Soden and others have considered traumatic, is believed by Canton to be due to the existence of chronic rheumatic arthritis, which may or may not have been the result of injury.”

Hamilton (*Fractures and Dislocations*, p. 614), speaking of partial dislocation of the humerus, says:—

“It is quite probable that a majority of these accidents were examples of rupture or displacement of the tendon of the long head of the biceps muscle.” “I have seen one example, in which the tendon of the biceps suddenly resumed its position after the lapse of several days, and the prominence of the head of the humerus at once disappeared.” “If a displacement of the tendon necessarily causes a displacement of the head of the humerus, it might seem proper to infer that a rupture of the tendon would do the same. The only example of rupture of the tendon which has come under my observation does not confirm this view.”

Sir William Fergusson (*A System of Practical Surgery*, Philadelphia, 1853, p. 201), says:—

“That this tendon is displaced in the luxations forwards or backwards (or, perhaps, to speak more correctly, that the head of the bone in such instances is displaced from the tendon), there can be little doubt; *I have seen the change more than once in the dissecting-room.*”

Nancrede (Article on Injuries and Diseases of the Bursæ, *Internat. Encyc. of Surg.*, vol. ii. p. 709), says:—

“It is quite probable that the so-called luxation of the long head of the biceps is really due to chronic bursitis of this sac,² for all the symptoms attributed to that

¹ The cases referred to are those in which, like those of J. G. Smith, Stanley, Cooper, and Fergusson, without history of injury, the tendon was found on dissection to be torn or absent. He attributes the majority of these to “chronic rheumatic arthritis,” resulting in disorganization and destruction of the intra-capsular portion of the tendon.

² The sub-deltoid bursa.

lesion are present in such an inflammation with others which are irreconcilable with the existence of any displacement of the tendon."

Mr. Thomas Callaway (*A Dissertation on Dislocation and Fracture of the Clavicle and Shoulder-Joint*, London, 1849, p. 143) thinks that the accident which is usually described as a partial dislocation of the humerus forwards results from either dislocation or rupture of the long head of the biceps muscle. He describes the cases of Knox, Stanley, and Soden, and then discusses the possibility of distinguishing between a dislocation and rupture of the tendon, premising that he fears that there are but

"few distinctive signs which would materially help us in our diagnosis. Rupture of the tendon usually takes place in old persons in whom the powers of nutrition have begun to fail. It is a milder accident than dislocation. It usually takes place midway between the glenoid cavity and the anatomical neck of the humerus. The capsule of the joint is not ruptured, hence there is but little effusion, and the subsequent inflammation is not severe."

A writer in the *Real Encyclopædia*, vol. xii. p. 451, says:—

"Luxations of tendons, since the confident observations of W. Cowper and Monteggia, have been met with frequently only in the case of a few tendons. Indeed, that of the tendon of the long head of the biceps is contradicted, and has been characterized once (Jarjavay) as a supposed contusion of the sub-acromial bursa; in another case, as the result of a chronic rheumatic arthritis. (Adams.)"

Mr. Wharton Hood (*On Bone-Setting*, p. 37), says:—

"Displacement of a tendon is certainly of more frequent occurrence than is usually supposed; and, excluding several cases where the symptoms were unmistakable, I have seen numerous others operated upon in which the alteration in the appearance of the joint immediately afterwards, could only be accounted for by this explanation of the injury."

The author of the article on Tendons, in the *Nouv. Dict. de Méd. et Ch.*, vol. xxxv. p. 185, merely alludes to the subject as follows:—

"The luxation of tendons was absolutely denied by Cl. Pouteau, but its possibility was demonstrated by Monteggia, in 1803. Before him, however, William Cowper had recorded the case of a woman who had dislocated the long portion of the biceps in wringing linen."

C. Hueter says (*Grundriss der Chirurgie*, vol. ii. p. 735):—

"It may be remarked that, following the lead of Cowper, Monteggia, and others, a traumatic luxation of the long tendon of the biceps has been accepted by some. P. Vogt is very properly of the opinion that these luxations are only a portion of the injury in case of fracture of the tubercles, or of dislocations of the shoulder, and cannot well arise independently."

Mr. Frederick Treves says (*Surgical Applied Anatomy*, p. 191):—

"In certain violent wrenches of the limb the tendon may slip from its groove and be displaced to one or other side, usually to the inner side. In these cases, also, the head is drawn up under the acromion, and is prominent in front, while abduction is rendered less free than normal, owing to the great tuberosity being sooner brought in contact with the acromion."

Mr. George Murray Humphrey says (*A Treatise on the Human Skeleton*, p. 415):—

"I quite agree with the writer in the *Cyclopædia of Anatomy*, that many of the specimens in which the biceps tendon stops short in the bicipital groove, or

becomes lost in the capsule of the joint, are to be attributed, not to rupture of the tendon, but to the continued effects of chronic rheumatism originating in an accident or commencing spontaneously."

We find thus, in studying the literature of the subject, and I believe that the foregoing represents about all of importance which relates directly to it, that the recorded evidence of the occurrence of dislocation of the tendon of the long head of the biceps muscle may be divided into two general classes: 1. The reports of clinical cases in which certain symptoms were referred by the writers to this displacement, but in which its existence was not otherwise confirmed.

2. The reports of cases in which the tendon of the biceps was found luxated at an autopsy, or during a dissection, but in many of which no clinical history was obtainable.

Mr. Soden's case seems to be the only one which belongs to both classes, and must be considered separately.

Under the first class may be placed the cases of Cowper, Monteggia, Bromfeild, Green, Callender, Mercer, and Hancock. The first three of these, as we have seen, have been assigned by Jarjavay to the category of contusions of the sub-acromial bursa, and with some show of reason. Without entering into a discussion which, on account of the meagreness of the clinical premises, would probably be fruitless, I may call attention to the fact that he does not explain satisfactorily certain symptoms which are stated positively by these writers to have existed and are entitled to as much credence as any other portion of their very careless reports. In the case of Cowper there was said to be "a depressure of the deltoid muscle," and "the two inferior tendons of the biceps"¹ were on the stretch. The difficulty was immediately removed by forcible rotation of the arm. Bromfeild describes the same method of reduction by rotation and the same result of speedy relief, while in Monteggia's case the tendon was said to return to its place and the pain to disappear, while the hand of the injured side was "upon the shoulder of another person," or in the very position which, according to Jarjavay, by making pressure on the inflamed bursa, should excite the most acute pain. The bursitis, which no doubt existed in his own cases, does not account for the depression of the deltoid, the stretching of the "lower tendons" of the biceps, or the sudden relief afforded during rotation. The true character of these cases will doubtless always remain undetermined for lack of sufficient evidence; but, whatever they may have been, it seems evident to me that they are not satisfactorily explained by Jarjavay.

Dr. Green's case can hardly be considered as conclusive, but the mode of disappearance of the trouble was certainly suggestive of a spontaneously reduced luxation of the tendon. Every other symptom can be explained on the theory of lesion of the subacromial bursa, the attachment

¹ The tendon of insertion into the radius, and the bicipital fascia.

of which over the bicipital groove to the sheath of the tendon would account for the pain felt in the shoulder on flexion of the forearm.

Mr. Callender states positively that in his case the tendon could be felt in its unnatural position, and could be replaced, but not retained in its groove. This would be evidence of a very high order if the tendon of the long head of the biceps were a structure easily recognized by palpation through the overlying tissues, but as any one can verify in his own person it is not. If Mr. Callender had stated that he recognized the bicipital groove—a distinct depression, with well-marked, prominent bony walls, having sharp edges—his assertion would have carried much greater weight.

Mercer's case I have only included out of deference to the high authority of Prof. Hamilton, who, as it seems to me, on very insufficient grounds classes it as an instance of luxation of the tendon. It was at any rate not an uncomplicated case, as the original injury was a dislocation of the shoulder, and it may therefore be dismissed without further consideration.

Hancock describes the symptoms of displacement of the tendon in much detail; but as far as I can learn does not seem, himself, ever to have seen a case.

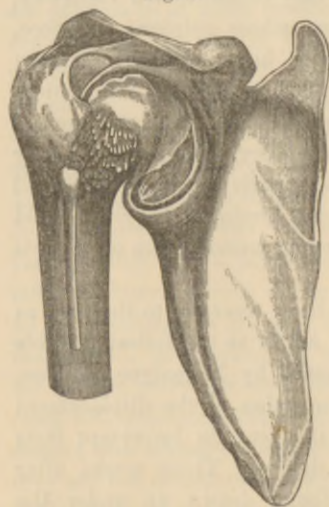
Among those authors, who in a general way admit the existence of the luxation and describe certain symptoms as associated with it, but who do not state that they have ever met with it, may be mentioned Callaway, Gross, Ashhurst, Flower, Hood, and others, whose opinions therefore, though always worthy of respectful consideration, have not in this instance the weight which would attach to them if founded on personal observation.

The second group of cases in which the luxation was found at autopsies includes those of Gregory Smith, Knox, Stanley, Hargraves, Astley Cooper, and Fergusson, which have been so clearly shown to be in all probability examples of changes in the joint produced by rheumatoid arthritis, and not by traumatism, that no further consideration of them is necessary.

In discussing the case of Soden, which I have reserved to the last, as being by far the most important, I wish to admit to the fullest possible extent the weight of the arguments advanced by Malgaigne, Adams, and Smith in favour of the pathological causation of the displacement of the tendon. It seems to me, however, that certain important facts remain unexplained in the light of this theory. Three weeks after the accident the head of the bone was found drawn up under the acromion and unnaturally prominent in front; abduction was impossible; flexion of the forearm intensely painful, etc. Although the patient is stated to have been "of rheumatic habit," there is no mention made of any previous trouble with the shoulder, and it seems hardly probable that these marked changes occurred solely as a result of a rheumatic inflamma-

tion of the joint of three weeks' duration. They may partly have been due to a bursitis such as is described by Jarjavay, which would account for the crepitation, painful abduction, puffy swelling over the front of the joint, etc. etc., and which, it would be necessary to suppose was prevented from subsiding, as in Jarjavay's cases, in two, three, or four days, by the super-vention of the rheumatic inflammation. But even admitting the plausibility of this theory, it hardly seems to me that it is in perfect accord with the result of the autopsy. I refer here especially to the *degree* of displacement of the tendon as compared with the duration of the supposed chronic rheumatic arthritis and with the slight and certainly doubtful concomitant changes in the joint. The rheumatoid inflammation was believed to date its origin from the fall which the patient had in May, 1839. He died in November, 1839, six months later, and the tendon was found, not only displaced as to its intra-articular portion, but *out of the bicipital groove*. Now, it is evident that viewing the progress of the case in the light of the theory of Messrs. Smith and Adams, that while displacement of the upper part of the tendon over the smooth rounded head of the humerus might be expected to occur early in the disease, on the other hand, detachment of the tendon from the firm fibrous prolongation of the capsule and the synovial membrane which holds it in its groove must necessarily be a much later phenomenon. The amount of pressure required for this purpose either must

Fig. 2.



be very great when it is done suddenly, or must be distributed over a long period of time before it can produce the necessary weakening and disintegration of structure.

The accompanying cut, which represents the right shoulder-joint in the case of Chas. Mailly, reported by Mr. Adams, as parallel with that of Mr. Soden, illustrates the point to which I refer (Fig. 2). It will be seen that while the intra-capsular portion of the tendon is dislocated inwards, the displacement does not extend beyond the summit of the bicipital groove, in which the rest of the tendon lies.

And yet this patient had been ill for seven years or more, and bedridden for five years; and the joint was extensively diseased. The left shoulder-joint was symmetrically affected, particularly as regarded the tendon of the biceps.

Mr. Adams himself says, in regard to the condition of the joint in Soden's case:—

"As to the anatomical examination of the joint, it will be recollected that the disease had been only six months established, and, therefore, that the more striking results of chronic rheumatic disease should be found was not to be expected. Those which were noticed, however, were such as might be supposed to represent the anatomical character of chronic rheumatic arthritis of the shoulder at an early stage."

It would appear, therefore, that, although the case cannot be considered as it originally was, as demonstrating beyond a doubt the possibility of the accident, on the other hand, it cannot be summarily dismissed as one of the many instances of *post hoc ergo propter hoc* reasoning, which have led to the mistaking of lesions due to chronic arthritis for those caused by traumatism.

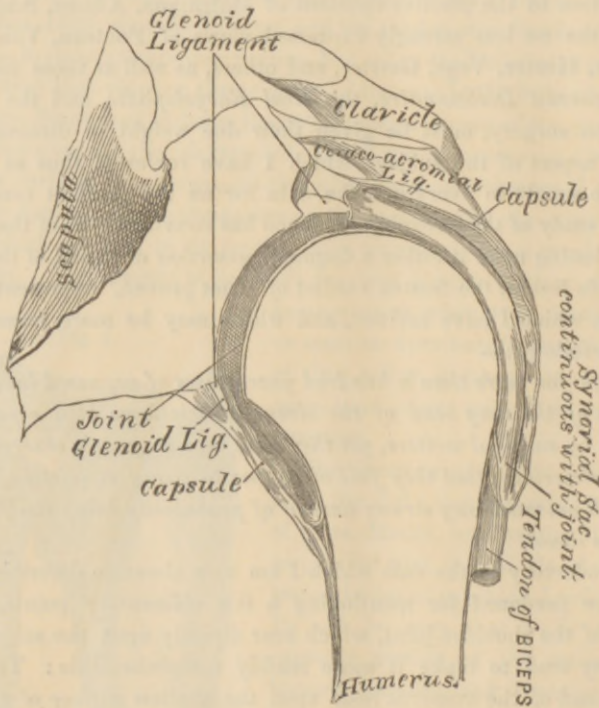
In addition to the positive opinions of Malgaigne, Adams, Smith, and Jarjavay, the no less strongly expressed views of Pouteau, Von Pitha, Volkmann, Hueter, Vogt, Gerster, and others, as well as those contained in the *Nouveau Dictionnaire*, the *Real Encyclopädie*, and the various treatises on surgery, must be given their due weight in discussing the historical aspect of the subject, which I have reviewed thus at length, in order to supply to every one the data for an independent conclusion. A careful study of the foregoing evidence has convinced me of the impropriety of basing upon it either a dogmatic assertion or denial of the existence of this lesion, the Scotch verdict of "not proven," representing the opinion at which I have arrived, and which may be more formally expressed as follows:—

Although for more than a hundred years cases of supposed luxation of the tendon of the long head of the biceps muscle have been reported or alluded to by surgical writers, yet they have been so poorly observed or so carelessly described, that they fail altogether to carry conviction, the one case which possesses any strong element of probability being itself open to reasonable doubt.

As introductory to the case which I am now about to describe, I may perhaps be pardoned for mentioning a few elementary points, in the anatomy of the shoulder-joint, which bear directly upon the subject, and which may tend to make it more readily comprehensible: The large rounded head of the humerus rests upon the shallow surface of the comparatively small glenoid cavity, which is not more than one-third the size of the former. The depth of the cavity is, however, somewhat increased by a narrow fibro-cartilaginous rim, the glenoid ligament. Overhanging this cavity is a vaulted arch formed by the coraco-acromial ligament, uniting the two processes from which it takes its name. Arising from the margin of the glenoid cavity, embracing loosely the head and anatomical neck of the humerus, and extending down to be attached below the tuberosities, is the capsular ligament, which has been described as "a sac having two apertures, of which the lower is by far the larger." This sac is so loose and capacious that it could contain a body nearly twice as large

as the head of the humerus ; it gives no aid in maintaining the latter in contact with the glenoid cavity, and does not appreciably limit its movements. With its fibres are intermingled those of the tendons of insertion of the supra- and infra-spinatus and subscapularis muscles, which materially add to its strength. It is also reinforced in front and within by the tendon of the long head of the biceps which arises from the summit of the glenoid cavity, where its fibres are intimately blended with the glenoid ligament, and passes directly over the top of the head of the humerus within the capsule (Fig. 3), and then down exactly in front of the joint

Fig. 3.



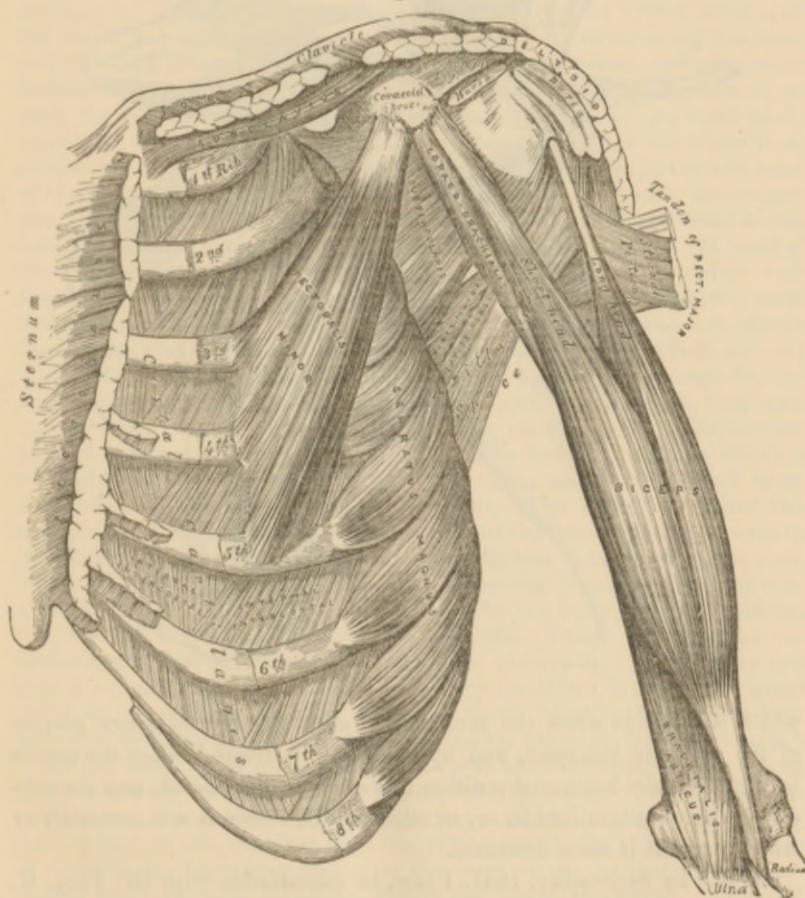
in the sulcus—the bicipital groove—between the greater and lesser tuberosities. A prolongation of the capsular ligament, and within that another of the synovial membrane, cover the tendon at this point, and convert the groove into a canal. This is strengthened externally by the insertion of the tendon of the pectoralis major into its outer lip.

The bicipital tendon, however, at least when the forearm is fixed, would manifestly have a tendency to draw downwards the head of the humerus, and certainly cannot be considered as holding it in its articular cavity. This is effected chiefly by atmospheric pressure, aided greatly, however, by

the action of the deltoid, the clavicular fibres of the great pectoral, and the supra-spinatus, all of which muscles act to great mechanical advantage as direct elevators. The arm is turned outward by the action of the muscles inserted into the greater tuberosity, the supra- and infra-spinatus and teres minor; it is rotated inwards by the subscapularis assisted by the sternal fibres of the pectoralis major; it is abducted, or drawn directly out from the side by the deltoid, assisted by the supra-spinatus. It is then lowered by the latissimus dorsi and teres major muscles.

Between the outer and anterior portion of the capsular ligament and the under surface of the deltoid muscle is situated a large bursa (Fig. 4),

Fig. 4.

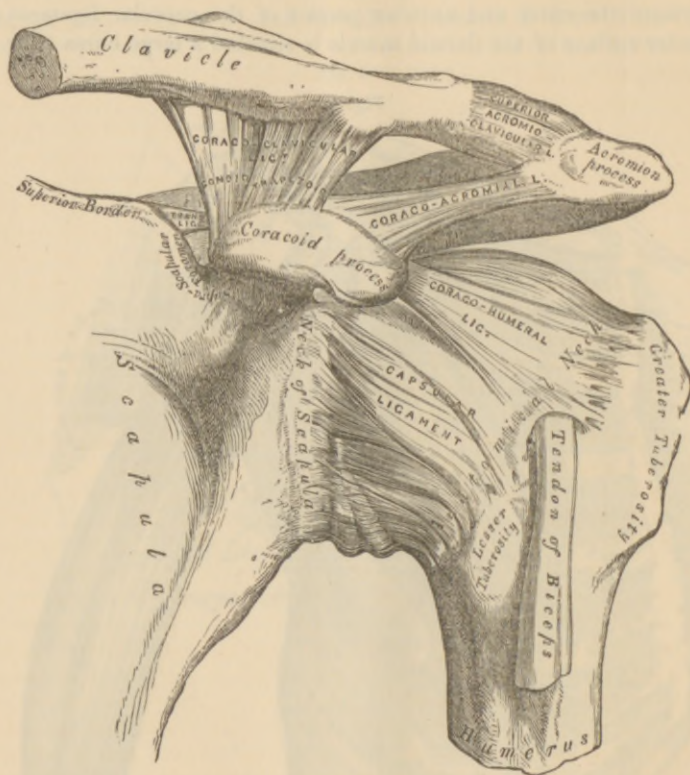


which, by reducing friction, facilitates the movements of abduction and rotation. The lower wall of this bursa is attached by some strong connective tissue fibres to the underlying parts; including the fibrous sheath

of the bicipital tendon. Its upper wall is attached to the under surface of the deltoid muscle. Another bursa lies beneath the subscapularis muscle, and almost invariably communicates with the general synovial cavity of the joint.

Between the lower surface of the acromion and the upper surface of the head of the humerus there exists normally a considerable interval (Fig. 5),

Fig. 5.



which is occupied when the arm hangs by the side by the upper portion of the capsular ligament, and by some fibrous tissue;¹ when the arm is brought into the horizontal position this space is diminished, and the sub-deltoid bursa glides into it, or, in other words, becomes sub-acromial, by which name it is often described.

CASE. In September, 1881, I saw, in consultation with Dr. Thos. K. Reed, of Atlantic City, New Jersey, the following case:—

¹ A case of paralysis of the deltoid is recorded by Nannoni, in which four fingers could be lodged between the humeral head and the acromial vault. Paulet, *Traité d'Anatomie Topographique*, p. 677

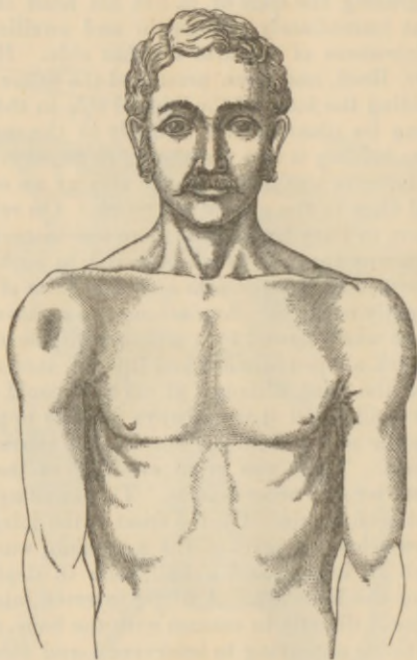
T. W., a carpenter, aged 37, previously healthy in every respect, while ascending a ladder, with his arms full of tools, lost his balance, and fell backward from a height of six or eight feet. While falling he made an effort to save himself, and so far succeeded as to effect a semi-rotation of the head and trunk, which brought the right anterior surface of the body into the most dependent position. His fall was arrested by a porch about fifteen inches in height, upon which the front of his right shoulder struck, his right ear just grazing the edge of it, but his head escaping all other injury. There was immediately acute pain and swelling over the right shoulder, with helplessness of the arm on that side. He was seen in a few minutes by Dr. Reed, and then presented the following phenomena: He was sitting, holding the hand of the injured side in the left hand, palm upward, and turning its ulnar border strongly in the same direction, or, in other words, was holding it in a position of external rotation, or forced supination. The forearm was flexed on the arm at an obtuse angle, and the elbow was held close to the side of the trunk. On releasing the hand and allowing the arm to hang by the side there was instant and irresistible rotation of the humerus inward, which occurred to such an extent as to turn the palmar surface of the forearm and the palm of the hand backward, and even slightly outward. Any attempt to remove the elbow from contact with the side was followed by a seeming displacement of the head of the humerus, which slipped forward and inward, increasing the projection on the front of the joint, although at no time could the head of the bone be felt in the axilla, and it was always possible to place the hand of the injured side on the sound shoulder, keeping the elbow in contact with the front of the chest. There was great swelling of the shoulder, most marked over its anterior and outer aspects. This swelling was soft, almost fluctuating, and not ecchymotic. On the front of the joint, about one and a half to two inches below the level of the acromion, was an oval depression, about an inch in length, and a half inch in depth, its long axis parallel with that of the humerus. A finger inserted into this depression seemed to come almost directly in contact with the bone, nothing but skin and subcutaneous tissue appearing to intervene; and these seemed to be bound down tightly at this particular point. The patient described the condition as the skin having "grown fast" to the bone. There was sharp lancinating pain in the shoulder on the slightest movement of the arm, which was preternaturally mobile. On removing the elbow from the side a creak or "squeak" could be plainly heard by the bystanders, resembling, but moister than, the sound of true crepitus. There was a slight but undoubted depression beneath the acromion externally. An axillary pad and a handkerchief so applied as to carry the elbow inward gave great relief to the patient, although he still suffered considerable pain, which persisted in varying, but gradually decreasing, intensity for some weeks.

At the time of my visit, about two weeks after the accident, the above symptoms were noted, and, in addition, the following: The vertical circumference of the shoulder, although there was still some swelling, was half an inch to one inch less than that of the sound side (Fig. 6). A line of ecchymosis, beginning about on the level of the axillary border, extended down the arm, following closely the line of the biceps. This had made its appearance three or four days after the injury. It persisted for some weeks, gradually finding its way down the radial side of the forearm almost to the wrist.

When the forearm was extended upon the arm, a painful degree of

tension was produced along the line of the biceps, the border of which muscle became plainly evident beneath the skin; this pain extended to the point of insertion in the radius and was described by the patient as even running down to the wrist. Flexion of the forearm was possible with difficulty, the movement being tremulous and void of force;

Fig. 6.

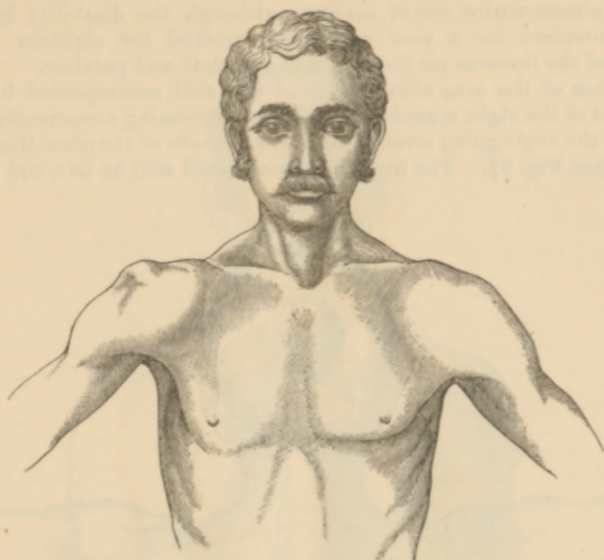


it was associated with a sharp pain over the head of the humerus. Flexion of the supinated forearm was much more painful than flexion during pronation. In the former case the sensation described by the patient was one of "dragging" over the head of the humerus. The oblong or oval depression over the head of the bone (Fig. 6) had, with the subsidence of the swelling, become more rounded in appearance, but was still very distinctly marked. At this point, and for a little distance above and below it, a longitudinal furrow could be plainly felt in the bone which seemed to correspond accurately with the situation of the bicipital groove. This furrow was empty. To its inner side could be felt indistinctly a round movable body, rolling slightly beneath the fingers, and thought at the time to be the bicipital tendon. Neither this nor the groove could be felt on the sound shoulder. All attempts at replacement were futile.

On elevating the arm, it was seen that the scapula moved largely with the humerus, the acromion became prominent on the summit of the shoulder (Fig. 7), and the axilla of the injured side as compared with that of the sound side was greatly lengthened (Fig. 8). The angle of the scapula on the injured side, when the arm was raised above the head, was carried out quite to or a little beyond the side of the chest.

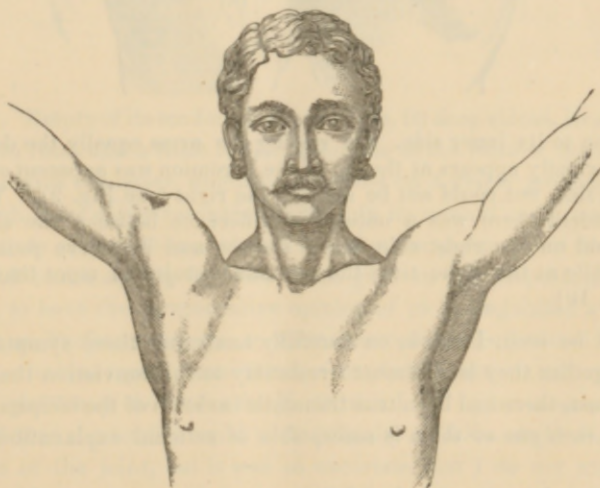
The slight depression immediately below the tip of the acromion still existed, with considerable fulness over the upper, front, and inner aspects

Fig. 7.



of the joint, apparently due to an abnormal projection of the head of the humerus in that region. There was slight shortening on measurement from

Fig. 8.



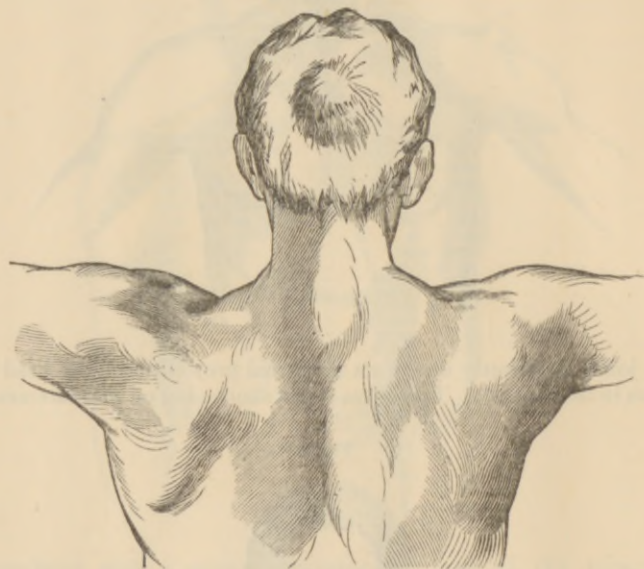the acromion to the external condyle, but not more than half an inch, possibly a little less. The tendency to spontaneous rotation of the arm was

still felt, but was much less noticeable. The arm was very mobile, and the head of the bone could be rotated freely in every direction. There was no history of rheumatism in the patient himself or in his family.

In October, 1883, the patient was again seen and examined. He had regained almost entire use of his arm, although the disability had been almost complete for a year and quite marked for eighteen months. Flexion of the forearm on the arm was complete and painless.

Elevation of the arm above the head was still accompanied by undue movement of the right scapula, the acromion becoming unnaturally prominent and the angle going somewhat nearer the side of the chest than on the left side (see Fig. 9). The bicipital groove could still be felt, and possibly

Fig. 9.



the tendon to its inner side. On raising the arms equally the depression which normally appears at the tip of the acromion was apparent on the left or sound side, but could not be seen on the right (see Fig. 9). With the arms pendent there was a noticeable difference between the shoulders, the deltoid on the right side being shorter and its curve rounder and fuller, while at the same time the acromion projected more than normal (see Fig. 10).

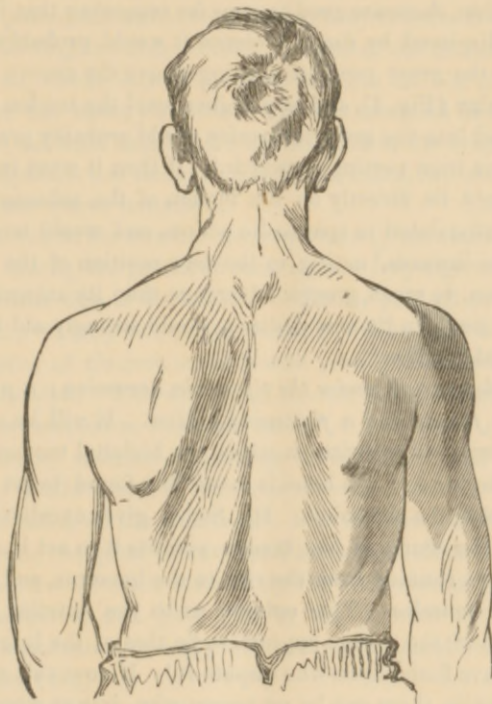
It will be seen, I think, on carefully analyzing these symptoms, that taken together they lead almost irresistibly to the conviction that, in this case at least, there had been true traumatic luxation of the bicipital tendon, and that each one of them is susceptible of rational explanation on this theory.

They may be enumerated as follows:—

1. *The recognition of the bicipital groove, empty.* This, which was the symptom on which the original diagnosis was founded, is perhaps the

most important of the group, as, if its existence be admitted, it is absolutely pathognomonic. In very thin persons the groove may be felt through the anterior fibres of the deltoid which overlies it; in muscular persons not

Fig. 10



so readily. Empty of its tendon its sharp edges, its deep sulcus, its situation precisely in front and a little to the inner side of the head of the bone, its movement with the latter, might be expected on *à priori* grounds to render it much more easily recognizable than in its normal condition.

It certainly seemed to me, when I first saw the patient, that it could be readily and unmistakably felt, but I am glad in this respect, as well as in others, to have the corroborative opinion of so distinguished a surgical anatomist as Professor Agnew, to whom the case was submitted for criticism, and who was equally convinced of the facts above stated.

2. *Recognition of the tendon itself.* Of this I was by no means positive. It seemed that the tendon could with difficulty be felt a slight distance to the inside of the joint, but it was so uncertain that I do not attach any weight to this symptom, which was of but doubtful value.

3. *Inward rotation of the arm.* This was very peculiar, and could only be simulated, as far as I know, by that which is said to occur after frac-

ture of the great tuberosity in which the external rotators, the supra- and infra-spinatus and teres minor being rendered powerless the arm is turned inwards by the subscapularis assisted by the sternal fibres of the pectoralis major. Something analogous to this took place, I believe, in this case. Although, as I have said, there was no conclusive evidence as to the position of the tendon, there are good reasons for supposing that in any case in which it was displaced by direct violence it would probably go inwards. The tendon of the great pectoral arching above the groove and inserted into its outer edge (Fig. 4), and at a higher level the tendon of the supra-spinatus inserted into the great tuberosity would probably prevent it in the majority of cases from passing outwards.¹ If then it went in the opposite direction it would lie directly on the tendon of the subscapularis, which would thus be stimulated to spasmodic action, and would tend strongly to rotate the bone inwards,² acting in the new position of the bone, as will presently be seen, to much greater advantage than its antagonists. Then too the tendon itself, in its new position, would strongly aid in the movement of internal rotation.³

4. *A slight depression under the tip of the acromion; a prominence of the shoulder in front; and a flattening behind.* It will be observed that in cases of rheumatoid arthritis in which the bicipital tendon is atrophied or displaced, the head of the bone is invariably found to be elevated and to lie just beneath the acromion. Mr. Soden gives excellent reasons for supposing that the course of the tendon permits it to act in the place of a capsular muscle running from the ribs to the humerus, and opposing the upper capsular muscles. This opinion as to the function of the intra-capsular portion of the tendon appears to be that of the large majority of surgeons. I have found none who dispute it.⁴ If now, this tendon is displaced by violence, there can be no reason why, just as when it is dislo-

¹ "In its course between the tubercles it plays upon the inner rather than the outer one." Humphry, op. cit., p. 414.

² Duchenne (*Physiologie des Mouvements*, p. 84) describes the subscapularis as the great anterior—or internal—rotator of the humerus.

³ See Humphry, op. cit., p. 414. "By its pressure upon the inner tubercle the tendon prevents undue rotation of the head of the humerus outward," *et seq.*

⁴ "It strengthens the upper part of the articular cavity, and prevents the head of the humerus from being pressed up against the acromion process when the deltoid contracts." Gray, p. 310. "The biceps tendon strengthens the upper part of the joint . . . and prevents the head of the bone from being pulled too closely upwards under the acromion." Treves, op. cit., p. 191. "Several purposes are served by the peculiar course and disposition of this tendon. It strengthens the capsule at the upper part, and assists to prevent the head of the humerus being pressed against the acromion by the contraction of the deltoid and other muscles." Humphry on the Skeleton, p. 414. "The biceps tendon tends to prevent the head of the humerus being pulled too closely upward against the under surface of the acromion." Henry Morris, *Anatomy of the Joints*, p. 218. "Its evident function is to apply the humeral head to the glenoid cavity and to prevent its displacement in shocks directed from below upward." Paulet, op. cit., p. 678.

cated from disease, the powerful deltoid, aided by the supra-spinatus¹ and the clavicular fibres of the pectoralis major, should not draw it up into close proximity to the acromion, and this seems to be what occurred in the present case, the bone at the same time being drawn inward by the sternal fibres of the pectoralis major, and by the latissimus dorsi and teres major, all of which are placed somewhat on the stretch by this elevation of the humerus. This drawing inwards permits, in spite of the elevation of the head of the humerus, of the little depression beneath the tip of the acromion. While on the one hand, also, the origin and insertion of the supra-spinatus, an active external rotator, are approximated, the origin and insertion of the subscapularis are removed from each other, favouring strongly the internal rotation above described.

5. *Diminution in the vertical circumference of the shoulder.* That this existed even during the period of swelling was very significant. It is just the reverse of the sign of dislocation, originally pointed out by Mr. Callaway, and was evidently due to the elevation of the head of the humerus.

6. *Shortening of the arm as measured from the tip of the acromion to the external condyle.* This should, of course, in the absence of symptoms of fracture, be referred to the same cause.

7. *Elevation of shoulder, tilting up of acromion, and elongation and narrowing of axilla when the arm was carried upwards.* This was also due to the elevation of the humerus. The muscles which constitute the axillary borders, the great pectoral and latissimus, already on the stretch, as has been said, were made more so by the abduction of the arm, became tense and elongated, and gave rise to the peculiar appearance of the axilla which contrasted strongly with the easy natural curves of that on the sound side. (Fig. 8.)

The tilting up of the acromion was due to the presence of the head of the humerus just beneath its tip, the two bones impinging on the injured side when they formed a large obtuse angle, while on the other side they hardly touched until the arm was lifted a little above the head, or had at least attained a horizontal position.

This symptom (as will be seen by reference to Figs. 9 and 10) persisted, though to a less degree, two years after the accident. To the same cause—elevation of the humerus—are due the shortened deltoid, the unnaturally rounded outline of the shoulder, the lessened vertical circumference, the absence during elevation of the arm of the normal dimple found at the tip of the acromion superiorly, and the slight tilting of the scapula, all of which appearances are admirably shown in the same cuts.

8. *The peculiar depression situated over the bicipital groove.* Unless the "depression in the deltoid muscle" described by Cowper, referred to a

¹ Duchenne (op. cit., p. 75) says that this elevating action of the supra-spinatus is much more energetic and important than is generally supposed.

similar appearance, I can find no mention of any such exact phenomenon in surgical writings, either in connection with this or any other injury of the shoulder-joint. I believe it to have been probably caused in one of the following ways, the last of which I am inclined to favour, though it does not appear that anatomical considerations alone enable us exactly to determine the point :—

1. The tendon in its displacement from the groove may have dragged with it a portion of the inner edge of the subdeltoid bursa attached to its sheath, and through its medium, put on the stretch and tied down some of the fibres of the deltoid muscle itself. The injury being followed, just as in a bad sprain, by rapid and extensive synovial effusion, involving not only the bursæ but the general cavity of the joint, this swelling manifested itself wherever the capsule and the bursæ permitted of distension. Over the region of the groove, however, they were drawn so tightly and were so tense by reason of their connection with the sheath of the tendon that swelling could not occur. (The succeeding symptom, No. 9, will explain my reason for thinking that this sheath was put greatly on the stretch, but not lacerated.) The drawing of the muscular fibre with them would account for the ease with which at the bottom of this dimple the bicipital groove could be felt, covered apparently with little else than skin. The chief objection to this view lies in the fact that the subdeltoid connective tissue, though exceptionally very dense and firm, is, as a rule, loose and yielding, and would probably stretch considerably without materially displacing the muscle itself. 2. There may have been rupture with retraction of some of the fibres of the deltoid muscle directly over the seat of injury. 3. The bursal and synovial swelling pushed before it, and slightly separated the adjacent edges of the deltoid and pectoralis major muscles, leaving the interspace over the line of the groove, without superjacent muscular tissue. The larger size of the bursa *external* to the groove,¹ and the greater freedom from tension of the capsule and synovial membrane at that point—the tendon having been presumably displaced inward—would account for a greater proportionate displacement outward of the anterior edge of the deltoid, giving the depression the appearance of being somewhat external to the normal situation of the groove between that muscle and the pectoralis major.

Examination of the dissected shoulder shows that a line drawn from a little within the tip of the acromion directly down over the front of the joint, will at a point below the head of the bone intersect the bicipital groove and the intermuscular fissure in question, or will at the furthest be a few lines outside of that fissure. Now it must be remembered that in this case the deltoid was markedly shortened, and its anterior edge consequently displaced upward, so that the peculiar depression and the part of

¹ See Morris, *op. cit.*, p. 221.

the interspace overlying the bicipital groove were in the same general locality.

It is well known that the synovial swelling which sometimes makes its appearance in the groove between the pectoralis major and the deltoid muscles during the course of a synovitis may be distinctly bilobed from pressure of the unyielding biceps tendon, then *in situ*, and this resembles more closely the symptom under consideration than any other development associated with disease or injury of this joint.¹

While, therefore, I do not deny the possibility of the depression having been caused in one of the two preceding ways, I think on anatomical grounds that the latter explanation is the most probable, though I do not pretend to consider it as indubitable.

9. *The line of ecchymosis following and strictly limited to the course of the biceps muscle.* This was most marked and characteristic, appearing only some days after the injury, and slowly gravitating down the arm in the line of the sheath of the muscle. It might occur, of course, in a fracture between the tuberosities extending into the bicipital groove, or it might follow a rupture of the tendon. If the sheath of the tendon were torn the ecchymosis would possibly be less strictly limited to the area of the muscle.

10. *A creak or "squeak," heard distinctly on carrying the elbow away from the side.* This was thought at the time to be due to the play of the tendon in its new position, but it is more probable that it was caused by the accompanying bursitis. To elicit it it was not necessary to take the arm more than a few inches from the side of the chest, but then it must be remembered that the head of the bone was already high up beneath the acromion, and that the bursa was largely distended, so that compression of the latter between the humerus and the acromion would begin very early in the movement of abduction. This noise was not heard on *flexion* of the elbow, another fact which renders it probable that its origin was bursal and not tendineal. It was not to be confounded with true crepitus, which could at no time be elicited.

11. *Flexion of the forearm on the arm was painful, the pain being sharp, lancinating, and felt at the front of the shoulder; flexion during supination was much more painful than flexion during pronation.* The existence of pain during flexion of the forearm can readily be understood. The reason for the difference between pronation and supination may best be explained by the following article by C. Hueter,² which I trans-

¹ Lorsqu'une collection liquide s'amasse dans la synoviale, le gonflement qui en résulte arrondit le moignon de l'épaule et en fait disparaître les saillies extérieures; mais le tendon du biceps se trouvant de plus en plus distendu, coupe, pour ainsi dire, la tumeur en deux, de sorte que celle-ci semble être bilobée. Il est clair que si la collection liquide est située en dehors de l'articulation, on n'y observera rien de semblable." Paulet, op. cit., p. 678.

² Zur Diagnose der verletzungen des M. Biceps Brachii. Archiv für Klinische Chirurgie, 1864, Bd. 5, s. 321.

cribe somewhat fully on account of the important bearing of the symptom to which it relates.

A student suddenly felt, while fencing, a severe pain in the upper third of the forearm exactly corresponding to the long head of the biceps; thenceforth he had on account of this severe pain, which manifested itself at every attempt at motion, lost the ability to bend the forearm actively while it was supinated. But on the contrary, when the forearm was in pronation, active flexion was easy and painless. This particular symptom in an injury which certainly must have been associated with a lesion in the course of the long head of the biceps or with a rupture of the muscular fibres, or with an injury of the sheath of the tendon, was to me especially striking, because theoretically I had believed, on the contrary, that we should expect a marked pain on flexing the pronated forearm. It is well known that when the forearm is pronated, the points of origin and insertion of the biceps are further apart than in supination, its muscular fibres being also stretched to a greater degree.¹ A contraction of these must on that account, in this position, so much the more draw apart from each other the already separated fibres or much more strongly drag the tendon against the wounded sheath.

Nevertheless, the elucidation of the symptoms becomes very easy if we sufficiently consider the physiological action of the biceps. In the pronated forearm, the radius crosses the course of the ulna in such a manner that it can be supported in the movement of flexion of the latter; the moving forces which have their *points d'appui* in the ulna can, by the motion of the pronated forearm under these favourable circumstances, move the radius in the direction of flexion with very slight exertion. In supination both bones lie next to each other, and on that account the mechanical relations become so unfavourable for their common flexion that the contraction of the brachialis internus² is no longer sufficient for the completion of this motion. At least one feels on flexion of the supinated forearm, even although there is nothing to overcome but gravity, that the biceps swells. But in the pronated forearm, flexion is not only possible through the unaided action of the brachialis internus, but this flexion is well known to be, as a rule, exclusively completed through this muscle. If one then, with moderate force, completely flexes the pronated forearm, it may easily be felt that the belly of the biceps muscle remains soft and flabby. In a similar complete flexion of the supinated forearm, there may be plainly felt, on the contrary, a contraction of the biceps, and by measuring the circumference of the arm at its middle, there is found in the latter instance an increased circumference of several lines. In very energetic movements the biceps muscle also contracts in flexion of the pronated forearm, but there always remains noticeable, in a similarly strong complete flexion of the supinated forearm, a striking difference in the tension of the muscle. Clearly a contraction of

¹ Gerster translates this: "The tendon of the biceps is stretched to its full length in supination, in pronation it is wound around the radius." (Op. cit., p. 498.) "The sentence in the original is as follows: Bekanntlich sind bei pronirtem Vorderarm die Insertionspunkte des M. biceps weiter von einander entfernt, als bei Supination, seine Muskelfasern, also in höherem Grade gespannt; eine Contraction derselben muss deshalb in dieser Stellung die getrennten Fasern um so mehr auseinander-zerren, oder die Sehne gegen die verletzte Scheide um so kräftiger andrängen."

² Brachialis anticus.

the biceps in the pronated forearm must always next occasion a movement of supination; *i. e.*, the tendon rolled around the neck of the radius must be unrolled before its flexing action can take place, and therefore we are accustomed in movements of moderate force not to set that muscle in action. In powerful movements, however, its contraction is not superfluous; its supinating action must then become equalized through the contraction of the pronators. In supination the action of the biceps is indispensable, both on account of the above-mentioned unfavourable position of the two bones of the forearm and also because the muscles which can largely aid in flexion of the forearm, especially the pronator teres and the flexor carpi radialis, have at the same time a pronating action, and therefore cannot contract.

The above described symptom, which led me to a consideration of the facts detailed, makes it clear that in flexion of the pronated forearm, the biceps muscle is not usually brought into action, and on that account a separation of its injured fibres does not occur during this movement. We have also in this symptom a means of diagnosing injuries of the biceps in doubtful cases.

12. *When extension of the forearm was attempted, a tense line along the edge of the biceps could be both felt and seen.* The cause of this is obvious.¹

13. *The pain felt over the joint was also felt along the line of the biceps as far as its insertion, and the patient still has a "drawing" sensation over that region.* The explanation of this is to be found in the fact that Mr. Hilton long ago called attention to:—

"That the same trunks of nerves, the branches of which supply the groups of muscles moving any joint, furnish also a distribution of nerves to the skin over the same muscles and their insertions, and that the interior of the joint receives its nerves from the same source."²

14. *The arm was preternaturally mobile for some time after the accident.* The support of the tendon being withdrawn, this was to be expected.³ It is important, however, to note that at no time was there any approach to ankylosis, which might have been suspected from the tilting of the

¹ The stretching of the "two inferior tendons" of the biceps, described by Cowper and Mangetus, will be remembered. This expression, which does not occur in modern anatomical or surgical writings, is explained by the following passage from the *Theatrum Anatomicum* of Mangetus (Geneva, 1717, p. 39), and clearly refers to the bicipital fascia and to the radial tendon of insertion: "Accuratissimus Anatomicus, Guillelmus (sic) Cowper super Musculo Bicipite, seu potius ejus tendine, hæc observat. Tendo hic duplex est, ejusque pars exterior, quæ tenuis est, transit oblique super Musculum Pronatorem Radii Teretem & instar membranæ se se expandens, jungitur Membranæ Musculorum Communi, quæ omnes externos Carpi ac Digitorum Musculos complectitur. Altera vero robustior multo ac rotunda in superiori Radii capite inseritur. Duplex autem, addit, tendinosa hujus musculi terminatio (quamvis à nullò autore, quod sciam, observato fuerit) est admodum evidens, & à nobis primùm conspecta ante aliquot annos," etc. For the original, see Cowper, *op. cit.*, pp. 74, 75.

² "By its passage along the bicipital groove it assists to render the head of the humerus steady in the various movements of the arm and forearm." Humphry, *op. cit.*, p. 413. See also Cloquet, *Anatomie Descriptive*, p. 199.

shoulder and the appearance of the axilla. The head of the bone was always freely movable with no trace of adhesion.

15. *The position of the patient after the accident.* This was markedly different from that seen after fracture of the clavicle, dislocation of the humerus, etc. No attempt was made to support the humerus, as in those cases, by the hand placed under the elbow. The effort was obviously directed to overcome: (1) the internal rotation of the humerus; and (2) the drawing inwards of the head of the bone; and for these objects the hand was held strongly with its ulnar border upward, and the elbow was brought in front of the chest.

16. *The character of the force producing the difficulty.* This was peculiar in the fact that the *front* part of the shoulder struck first, the height of the piazza protecting the head from injury. It was, as will be evident on careful thought, just such a blow as might be expected to produce the injury in question, the force coming evidently from above and outside, and striking just in the region of the tendon; the biceps at the time was probably relaxed, though this is a matter of conjecture.

These symptoms, as I have said, seem to me collectively to constitute very strong evidence in favour of the existence in this case of a luxation of the tendon, but a few words may be added in regard to diagnosis.

From *chronic rheumatic arthritis*, the entire absence of rheumatic history, the cause and the progress of the case sufficiently separate it, all the diagnostic symptoms coming on in a healthy joint within a few moments of the accident. Those which remained after the subsidence of the swelling and traumatic inflammation were evidently due to the new position of the head of the bone and not to any arthritic process.

From uncomplicated *subdeltoid bursitis*, it might be diagnosed by the elevation of the head of the bone, the accompanying changes in the shape and size of the shoulder, and all the symptoms referable to the biceps muscle itself; *i. e.*, the ecchymotic line, the difference in flexion between pronation and supination, etc. The much greater severity of the accident also constitutes a marked point of distinction. It will be noticed that two of Jarjavay's patients were nearly or quite well in three days, one in nine days, one in three weeks, and the other in six weeks, in the latter instance in spite of very meddlesome treatment.

These symptoms also differentiate it from *fractures* near the joint, the only one of which that at all resembles it being *fracture of the greater tuberosity*. In a supposed case of this injury, Gurlt¹ noted the symptoms as extreme passive mobility at the shoulder, complete loss of voluntary outward rotation, and partial loss of voluntary elevation of the arm; crepitation could be elicited by vigorous rotation. There is to this extent a superficial resemblance between the cases, but it goes no further, all the

¹ Quoted by Stimson—*Treatise on Fractures*—p. 363.

other symptoms noted in my case being absent or at least undescribed. In the cases of Mayo (quoted by Bransby Cooper) there was flattening of the deltoid, and abduction, instead of increasing the deformity, which resembled a luxation, caused its disappearance. In the cases of R. W. Smith¹ there was probably a concomitant luxation; the transverse diameter of the shoulder was apparently much increased.

In Stimson's case,² voluntary abduction was possible; there was demonstrable separation between the two tuberosities, the lesser one moving with the shaft of the humerus; there was crepitus, and the shoulder presented no deformity, except general swelling. In my case the entire head of the humerus could always be felt to move with the shaft, there was no crepitus, the transverse diameter of the shoulder, if changed at all, was lessened, certainly not increased; the groove felt in front of the head of the bone was perfectly fixed. If it had been a line of fracture or separation between the two tuberosities, the outer lip should have been more or less mobile. The symptoms directly referable to the biceps muscle complete the diagnosis.

From *dislocation of the humerus* it could readily be distinguished by the preternatural mobility, the presence of the head of the bone in or above the glenoid cavity, the ability to place the hand on the opposite shoulder, the diminished circumference of the injured shoulder, etc.

In all of these cases there are to be mentioned, in addition, the *peculiar* symptoms of the case, the recognition of the groove, the depression in front of the shoulder, the line of ecchymosis, the early movement of the scapula during abduction, the inward rotation of the arm, the difference between flexion in pronation and that in supination, etc. etc.

The condition with which it is most likely to be confounded is *rupture of the biceps tendon*, apparently a more frequent accident.

As might be expected, several of the symptoms coincide. The painful flexion, the difference between pronation and supination, the sharp pain at the shoulder-joint, the approximation between the head of the humerus and the acromion,³ etc. etc., are all present. There is, in addition, however, in the large majority of the reported cases of rupture, a larger ecchymotic swelling coming on almost immediately; no mention has been made of the peculiar depression; or of the internal rotation of the arm; or of the line of tension along the edge of the biceps; the accident has invariably been caused by violent muscular action, not by direct force; and there is also in most of the cases of rupture⁴ a history of the sudden appearance on the front of the arm of a more or less firm tumour, consisting of the con-

¹ Fractures in the Vicinity of Joints, p. 176.

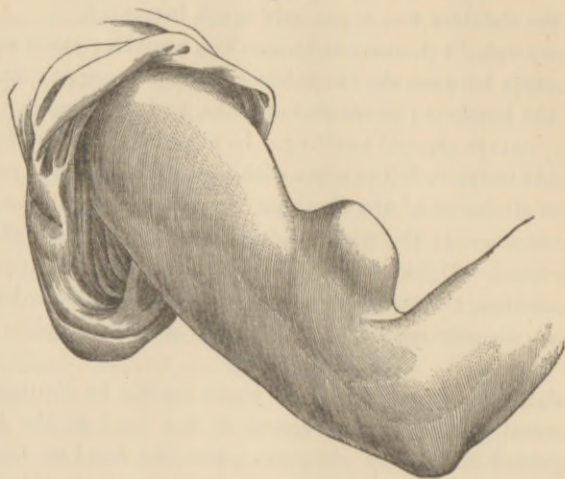
² Op. cit., p. 364. See also, Hamilton, p. 240; Agnew, vol. i. p. 881.

³ Hancock, op. cit., p. 509.

⁴ Gerster, op. cit., p. 496; Hamilton, op. cit., p. 616; Hancock, op. cit., p. 532; Stokes, Lancet, 1842-3, vol. ii. pp. 621, Humphry, op. cit., p. 415, etc. etc.

tracted belly of the muscle. In other cases, the whole muscle is flabby and relaxed. As I have said, these cases are comparatively numerous; they may as a class be illustrated by the accompanying cut (Fig. 11),

Fig. 11.



taken from a case reported by Dr. Hopkins (*Med. Times*, March 24, 1883), in which, during violent muscular exertion in a man 55 years of age, who had had for several months a chronic rheumatic trouble of the shoulder, something was suddenly felt to snap, and there was pain with partial loss of power in the arm. He was disabled for but a short time. The deformity, five weeks later, is figured in the cut, and was thus described: "The mass of muscle stood out prominently. Its upper border, irregular in outline and somewhat nodular, terminated abruptly in the depression which exists just below the inferior margin of the deltoid. The hard nodulated condition at this point was evidently caused by the contraction of unresisted muscular fibres on themselves, and on their tendinous coverings. The position of the muscle was changed, being below the middle of the arm rather than slightly above, as in health. The tendon of the short head could be clearly traced almost up to its origin at the coracoid process of the scapula, while that of the long head could not be felt to react at all beneath the fingers during forcible flexion and extension of the forearm, as it ordinarily can be."

It is possible that the case which I have thus related may be susceptible of some other interpretation; it is not one about which it would be judicious to dogmatize; surgical experience is amply convincing of the inevitable uncertainty which hangs about changes occurring beneath the skin, and especially in the neighbourhood of joints; surgical literature shows, and very aptly in this particular instance, that phenomena which at one time or to one mind seem susceptible of but one interpretation, at another

period or to other observers assume a widely different aspect. Yet the symptoms in this case, taken as a group, and viewed from the theory that an uncomplicated luxation of the tendon of the long head of the biceps took place, certainly seem sufficiently consistent with one another and with the facts of anatomy and physiology, to justify me in placing them in this shape before the profession.

222 S. 16TH ST., PHILADELPHIA.

