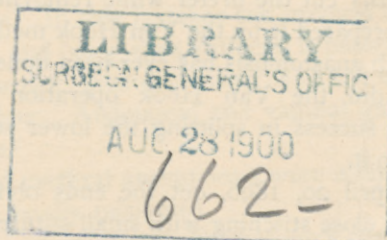


Noble (Geo. H.)

[Reprinted from the AMERICAN GYNÆCOLOGICAL AND OBSTETRICAL JOURNAL for August, 1899. Copyright, 1899, by J. D. EMMET, M.D.]



### URETERAL ANASTOMOSIS.\*

BY GEORGE H. NOBLE, M.D., ATLANTA, GA.

To facilitate analysis this subject has been divided into two classes, viz.: ureteral anastomosis and ureteral implantation. The first embraces all end-to-end and end-to-side union of the ureter; the second, transplantation of the ureter and burying of its extremity into the bladder or other hollow viscera of the abdomen. These expressions have been selected on account of their simplicity, which makes them fittingly applicable.

Prior to 1886 I find no record of success in work of this kind. In that year, however, Schopf cut a ureter in removing a cyst of the broad ligament. He made a successful end-to-end union with fine silk sutures, displaying originality and ability in successfully coping with so formidable an accident.

Four years later, 1890, Hochenegg made a resection of the ureter in doing a hysterectomy for cancer, but happily joined the ends. His patient had a fatal hæmorrhage on the twentieth day.

In 1891-92 Fritsch followed with a successful case. The next year Kelly mistook the ureter for an enlarged vein, ligated and severed it, but united it end-to-side, after Van Hook's method, thus doing the first successful case in America.

Cushing followed in 1893, but using a deficiency of sutures (three), had leakage. His patient subsequently recovered.

Taufer did two cases, 1893 and 1894. The first was cut in removing intraligamentous cyst; the second was severed by mistaking a bluish tumefaction for a tumor. He united them end-to-end on a seg-

\* Read before Southern Surgical and Gynæcological Association, at Memphis, Tenn., December, 1898.



ment of catheter to which a string was attached for the purpose of removing it before tying the last three sutures.

Emmet (B.) cut the ureter while removing a tumor in the lumbar region, and prepared it by the Van Hook method. This is the highest point at which anastomosis has ever been done.

Doherty did the Van Hook operation in 1895.(?) Robinson (Mayo) had success in splitting the lower segment and invaginating the upper into it.

Bovée, April 20, 1896, cut the ends obliquely and made careful coaptation by close stitching with small sutures. Over these he introduced longer ones to relieve the tension.

July 2, 1898, the writer ligated the ureter with the ovarian vessels and Fallopian tube in a case of large extraperitonæal fibroma. This was the very first ligature applied in doing the hysterectomy. The bladder end was split about three-eighths of an inch, as much of the mucous membrane as could be drawn out was cut away; then the upper or kidney end of the ureter was invaginated into it, using a mattress suture for the purpose. The split was then closed with fine sutures, making a snugly fitting cuff around the opposing end, with no muscosa intervening. Small silk was used to stitch the raw edge of the inferior segment around and to the sides of the upper section. A peritonæal cuff was thrown around the joint thus made, and the ureter buried behind the peritonæum. The entire work was conducted with the aid of a ureteral catheter, which had been introduced through the ureter into the bladder and drawn out of the urethra with a pair of forceps. The upper end was passed into the kidney end of the ureter. This served a great purpose, the entire manipulation being greatly facilitated by it. It also prevented obstruction of the ureter by crowding down the cut end of the musosa just below the line of union. This woman suffered from absorption of pus for a number of weeks from double pyosalpinx, was emaciated and thoroughly septic. Her temperature just before going upon the table was  $103^{\circ}$ , and had been running equally as high for the time she had been in the hospital, and perhaps longer. Her pulse was 130 per minute, weak, and thready. Thus this anastomosis was done with unfavorable conditions, but with success.

In October, 1898, the writer did a successful resection of the left ureter in a case of extraperitonæal extension of sarcoma of the ovary. About one and a half inches of the duct was removed and ends united as above, the peritonæum being stripped from the entire left half of the pelvis. The bladder was separated from the upper portion of the



vagina and the horizontal rami of the pubic bones and drawn up to the left ileopectinal line to cover over or bury the ureter, and there fastened with silk sutures. In this instance the ureteral catheter was introduced on the stylet, and being thus stiffened it passed directly out of the urethra from the ureter, thus dispensing with the use of forceps to fish it out of the bladder. Abdominal and vaginal gauze drains were employed; no leakage.

The twelve cases of urethral anastomosis were ultimately successful. One had leakage, but finally recovered.

Schopf's case lived seven weeks; Hochenegg's died on the twenty-first day, but the autopsies proved both cases to have had successful union of the cut ureters.

The twelve cases were what I have termed primary operations—that is, the ducts were repaired at the time of the injury. Secondary operations for anastomosis are impracticable on account of shrinkage of the distal end, which naturally follows disuse of that segment; therefore, no operations of this character have been accounted.

Theoretically, Van Hook's operation is the simplest and safest, but



Fig. 1.—Simple end-to-end or butt union.

it is difficult to execute in a normal ureter. It also requires about a half-inch more in length of the ureter than the end-splitting, as done by Robinson and modified by the writer, or that of oblique union, after Bovée. The only case of leakage reported was one of simple end-to-end or butt union; all the invaginations, whether end-to-end or end-to-side, made perfect recoveries. Any of them may be greatly facilitated by the use of the catheter, as it steadies the delicate duct, and it gives to this work that which the "hollow keck" of Thomas Bryan or the Murphy button gave to intestinal anastomosis. Invagination is less likely to result in leakage than the end-to-end union, whether transverse or oblique. There seems to be no common method of operating applicable to all cases, the conditions existing in one may so modify its requirements that the method used in it would not apply to another or simpler one; it is, therefore, useless to attempt to draw hard-and-fast rules, but to incline to the general principles to be obtained; thus, there are several features necessary to success aside from thorough asepsis.



First, perfect coaptation or invagination; this must be done in such a way that no mucous membrane can slip between the two ends of the ureter. Second, the urethral artery should be preserved in its continuity to the ends of the ureter. Serious injury to this vessel will cause the ureter to perish beyond the point where it ceases to receive its blood-supply. Dr. Kelly reports a fistula following a very careful dissection of some malignant glands off the ureter with catheter introduced, saying he must have cut the ureter. The chances are that in the dissection the ureteral artery was injured, consequently the ureter sloughed, for it was not at all probable that it was injured when so prominent and clearly outlined as it is made by the catheter. The ends of the ureter, therefore, should be cut back to the point where the artery is intact, lest underdiminished blood-supply and tension should cause it to slough. Third, all strain and tension must be relieved. Should union occur by first intention, the parts will separate as soon as the sutures cut out or release them, as will be seen later on. Fourth, there must be no obstruction to the flow of urine.

*Implantation.*—There have been seventeen cases of implantation of



Fig. 2.—Ends obliquely joined. After Bovée.

the ureter into the bladder and one into the pelvis of the kidney. This operation is more recent than that of anastomosis by six years. Baumm did the first in 1892, making the sacrococcygeal incision. His case had double ureter with congenital fistula. Navaro, in 1893, cut a displaced ureter, but stitched it into the bladder. His case had leakage, but ultimately recovered. Krug, 1894, did the first American implantation. He cut the ureter in an abdominal hysterectomy for carcinoma uteri. Penrose published in 1894 (private communication says 1893) his case of resection of an inch of the ureter for carcinoma uteri.

Westermarck, May 2, 1894, did the sacrococcygeal operation, resecting the ureter and stitching the same into the bladder. Abbe's case, August, 1894, was not a true implantation. He attempted to remove a foul pouch or abscess, but finding the ureter involved, desisted, stitching it to this diverticulum of the bladder. Krouse, in the summer of 1894, did the secondary operation for fistula following vaginal hysterectomy. He used tension sutures, bringing them out of the



urethra. Kelley did implantation in October, 1894. Boldt, October 10, 1895, did the secondary operation for fistula, leaving the catheter in the ureter to give it support.

December, 1895, Baldy inadvertently lacerated a ureter in removing a tubo-ovarian mass involving an inflamed and softened broad ligament. He implanted the ureter into the bladder and, releasing the viscus from its attachment to the horizontal rami of the pubic bone, tacked it to the pelvic wall at the ileopectinal line (private communication). Polk, January 26, 1896, resected the right ureter in an abdominal hysterectomy for cancer. He made the implantation, but had leakage. His case ultimately recovered, but subsequently died of cancer. He secured the specimen, which showed a contraction of the ureteral outlet and hydro-ureter.

January, 1896, the writer did the implantation for severed ureter. It was included in the ligature of the left ovarian artery. This is the

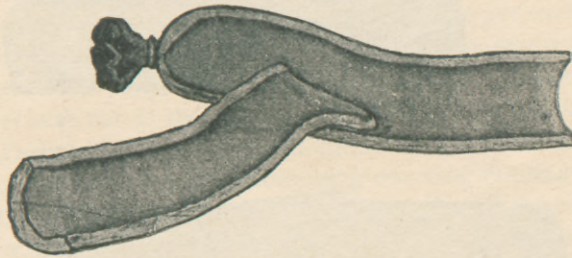


Fig. 3.—The Principle of Van Hook's operation.

fourth instance in which the ureter was displaced to this extreme point and tied with the ovarian vessels. O. Witzel, spring of 1896, did the secondary operation for fistula, transplanting the ureter extraperitoneal by a more direct or shorter route.

Anna M. Fullerton had a case of double ureter in which both were severed and implanted successfully, March 10, 1897.

Kelley, January 26, 1897, did Fritsch's operation, but failed on account of supervening pyelonephritis. At another time he endeavored to operate for fistula, and in order to determine which ureter was injured, catheterized, and, finding an obstruction, concluded that that side was injured, but it proved to be a strictured condition instead of a severed ureter, so he cut the wrong one in operating the second time upon the same case, and then had resulting two fistulæ instead of one. Later, they were relieved by a vaginal operation.



Fürth, 1897, cut the right ureter in abdominal hysterectomy for large fibroid tumor, but succeeded in implanting it into the bladder. The ureter was hidden in a mass of varicose veins and included in the ligature that secured them.

One other case was mentioned by H. T. Hanks (in discussion), but as it has not been published he could send me no data (private communication).

These have been divided into primary and secondary operations for the purpose of better consideration. In the first class (those that were repaired at the time of the injury) there were nine cases with one failure, and one case of leakage which finally recovered, thus giving an ultimate success of eight cases, or nearly 89 per cent. This one failure was due to tension exerted upon the ureter. The ninth day, when the bladder was allowed to fill with urine and assume its normally globular

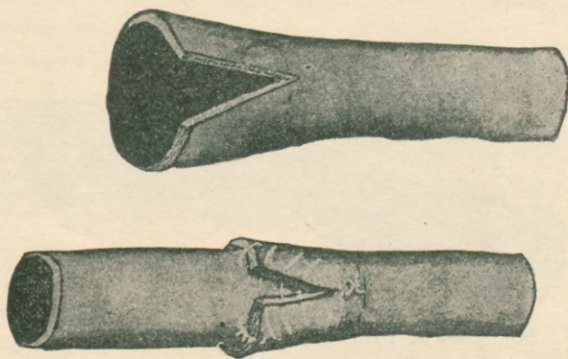


Fig. 4.—End splitting and invagination employed by the writer.

shape, it pulled away from the ureter and caused leakage. The bladder in this case had been stripped from its attachment to the horizontal rami of the pubic bones and the upper portion of the vagina and anchored to the side of the pelvis. Everything went on well till the day above mentioned, when the removal of the permanent catheter caused this unhappy result. Thus there is some danger of failure in the released or displaced bladder. It is not a safe measure when it does not entirely relieve the tension upon the ureter. In such circumstances prolonged catheterization is needful. These results show a very high percentage of success.

The primary operation is easy of execution, so that if the ureter is long enough for implantation, and yet not cut too low in the pelvis for ureteral anastomosis, implantation should be the elect of one who has



had no experience in the work, though anastomosis gives the best results in skilful hands.

There were eight secondary operations for implantation, resulting in three with leakage; six ultimate recoveries, and two complete failures giving a percentage of 75 per cent., which is a remarkable showing for this very trying kind of surgery. Two were "partial success," but ultimately recovered. The secondary operation is a much more formidable undertaking. The peri-ureteritis, exudate, scar tissue, and false passages render the work one of exceeding difficulty, as every available centimeter of the ureter must be preserved. Difficult dissection may cause one to desist and cut the tube too short for implantation. The skilful hand of Kelly has had two failures, and he abandoned the operation in two other cases. According to his experience, there is an uncertainty in the reliability of the catheter as a guide, he fearing to use it in the fistulous opening lest infection of the ureter and kidneys result from it. He attempted to make a diagnosis of the ureter involved by searching out a healthy or uninjured one per urethram, but, encountering an obstacle in the ureter about the base of the broad ligament, he concluded that it must be the injured one. Accordingly, the wrong ureter was cut in the operation and engrafted into the bladder, but failed. Perhaps filiform bougies might have prevented this error; or if he had not been satisfied with examining one side, but had also examined the other, he would then have discovered that obstruction existed in both, in which case the filiform might have been called into use for the purpose of differentiation. The urethral catheter, though dangerous, is a valuable aid to diagnosis, and is invaluable in this class of work, but should be used by skilful hands and with strict aseptic precaution, as death has followed its introduction into a fistula.

The details of fixing the ureter into the bladder varied so greatly that it is difficult to make a comparison of the relative merits of each. When tension sutures were used, or the ureter split and stitched to the bladder at the sides of the incision, no leakage occurred. In cases where the character of sutures are not mentioned, there are three with leakage. Krouse brought threads out of the ureter to prevent the strain from dragging on the bladder, while Boldt let the catheter remain to give the ureter support. So it is difficult to draw a satisfactory conclusion. Perhaps preference should be given to the Van Hook method. Drainage is useless when the work is well done, unless there is some tension upon the ureter, when it will aid in fistula formation and saving the life of the patient in case of failure. It should be gauze freely applied and brought through the vagina. In anastomosis of the



ureter high up it should be inserted above the pelvic brim. With drainage there is a liability of infecting the sutures, so it should not be placed directly upon them, but in close proximity. It is, however, a misfortune that prompts its use, for if coaptation is good, no strain upon the ureter and no infection in the wound, it is unnecessary and is liable to encourage failure by permitting infection. It was used in six of the seventeen cases of implantation, and leakage occurred in four of them. In no case where drainage was omitted has leakage occurred. It does not follow that gauze drainage is the cause of all failures, but the percentage is so great it cannot be passed without notice. Upon the other hand, no operator is apt to drain if he feels satisfied with his work. So it is presumed the drainage cases were bad ones.

Stricture of the cut end does occur, as has been shown by Polk's specimen. Cystoscopic examinations have been made in many cases, and no tendency to stricture reported. But such examinations are not thoroughly reliable. Doubtless Polk's case would have shown no tendency to stricture if it had been examined by the cystoscope, but when removed from the body the stricture and hydro-ureter were self-evident facts. To prevent this, either splitting the duct or obliquely cutting the end will suffice. Perhaps the latter is better, on account of the tendency of the split to close by granulation. But little harm can come from strictures thus formed unless they are exceedingly tight, for in ordinary conditions the urine is secreted so slowly that very small apertures will suffice for its escape. While the urine enters the bladder by hydrostatic force as well as by contraction of the ureter, this force may be overcome by complete obstruction temporarily existing in or at the ends of the ureters. Excessive distention of the bladder alone will not suffice to create this condition; it necessitates some adjuvant which is not infrequently found in kinking of the ureter from adhesions or fixation by exudate thrown out in the process of inflammation. When existing, this condition of affairs will fix or hold immobile a section of the ureter, while the lower extremity may be drawn upward, producing an acute angle and obstructing the flow of urine at the point of fixation. Again, hydro-ureter follows compression by malignant growths in the broad ligaments. The writer saw double hydro-ureter produced by obstruction of the patulous ends of the ureters in a case of loss of the base of the bladder (vesico-vaginal fistula). Intra-abdominal pressure crowded the upper portions of the bladder into the fistula, effectually shutting off the escape of urine from the ureter.

With the exception of two instances the ureter was buried extra-peritonæally, which no doubt is the safest method. In one case the



total operation was extraperitonæal; it failed, however, on account of death from pyelonephritis (Kelly). This method (Fritsch's) is the ideal for the secondary operation of implantation, the only objection being the exposure of the iliac vessels to the danger of an infected wound in case the operator should be unfortunate. In clean wounds it does not appear to add any material risks to strip these vessels of fatty tissue and peritonæum, for several times in removing enormous extraperitonæal tumors I have exposed the external and internal iliac vessels their full length without injury.

In addition to the above there was one implantation into the pelvis of the kidney, the highest point at which ureteral surgery can be done. This case will be recognized as the brilliant resection of a strictured upper extremity of a ureter by Küster. Though the primary result was not a complete success, on account of leakage, he effected a cure by subsequently closing the fistula.

Of the total number of operations (thirty), including Küster's, there were three failures, or 10 per cent., which is a remarkably good showing in such new work, especially of an organ that a decade ago was considered beyond the reach of the surgeon's skill. This estimate is fair, for there can have been but a few operations not reported, unless failure has dampened the ardor of the operators; but silence of this character does not pertain to this operation alone. These figures, so far as statistics go, are as good as any, for the work has been confined to skilful hands and honest men.

Success has nearly banished the practice of nephrectomy in injuries of the ureter, as those of you who have advocated it six years ago at Louisville show by your radical change of views. The merits of each case must decide the operation best fitted for its repair. If a primary operation, the point at which the ureter is cut will probably decide it. High injuries preclude implantation and tend to make anastomosis easy; those inflicted at a point very low down or close to the bladder render anastomosis difficult and favor implantation. Between these there is a line of demarcation not well defined that will allow of some latitude of selection, so that the operation easiest to accomplish should be done. When a long section has been removed it renders it either impracticable or the problem a vexed one. Fortunately, such cases must be rare, for the disposition of the proximal ureter then becomes a serious question. Intestinal implantation has its dangers and discomforts. Skin implantation means all the distress of repulsive fistula, though it affords ample time for reflection. Switching it across to the opposite ureter is probably practicable only when there is



## IMPLANTATION INTO BLADDER

Operator.	Date.	Bibliography.	Cause.	Primary or Secondary.	Incision.	Operation.	Extra- or Intra-perit.	Drainage.	Leakage.	Result.	Remarks.
1 Baum.	1892.	Centralbl. für Gynäk., 1892, No. 17, p. 336.	Congenital double ureter fistula.	Primary.	Sacro-coccygeal.	Stitched in bladder.	Extra-perit.	None.	None.	Success.	.....
2 Navaro.	1892.	Ibid., No. 27, 1893.	Vag. hyst.	Secondary.	Abd. into perit.	Stitched to incision in bladder.	Intra-perit.	Gauze, abd.	None.	Partial success. Final success.	Length of bladder incision, 1½ centimetres.
3 Krug, F.	Spring, 1894.	Amer. Gynec. and Obstet. Journ., N.Y., 1894, pp. 495-497.	Abd. hyst. fibroid displaced ureter.	Primary.	Abd. into perit.	Stitched in bladder; end of ureter split; bladder closed by superimposed layers of sutures.	.....	None.	None.	Success.	Length of bladder incision, 1½ centimetres.
4 Penrose, C. B. July, 1893.	Spring, 1894.	Med. News, Phila., April 28, 1894, p. 470.	Abd. hyst. carcinoma uteri.	Primary.	Abd. into perit.	Abd. hyst.; resected about an inch of left ureter. Van Hook's method.	.....	None.	None.	Success.	.....
5 Wistermark, F.	May 2, 1894.	Centralbl. für Gynäk., 1895, Vol. 7, p. xix.	Sacro-coccyg. cyst; carcinoma uterus and ureter.	Primary.	Sacro-coccygeal.	After hyst.; resection ureter; stitched in bladder.	Extra-perit.	Gauze.	None.	Success.	.....
6 Abbe.	Aug., 1894.	Ann. Surg., August 1894, p. 183.	Lacerated while operating on abscess.	Secondary.	Kraske.	Failed to remove pouch, so anastomosed ureter into it.	Extra-perit.	.....	None.	Success.	.....
7 Krause.	Summer 1894.	Centralbl. für Chirurg., 1895, No. 9, p. 220.	Vag. hyst. fistula.	Secondary.	Abd. into perit.	Implantation into bladder; tension threads drawn out through urethra.	.....	.....	None.	Success.	.....



8 Kelly.	Oct., 1894.	Bull. Johns Hopkins Hospital, Feb., 1895.	Vag. hyst. fistula.	Second-ary.	Abd. into perit.	Van Hook. Ureter short; bladder loosened from peritoneal attachments; under surface of ureter split.	Intra-perit.	Gauze.	None.	Success.	.....
9 Boldt.	Oct. 10, 1895.	Amer. Journ. Obstet., N.Y., 1896, Vol. xxxiii, p. 884.	Vag. hyst. fistula.	Second-ary.	Abd. into perit.	Catheter inserted through fistula, ureter dissected and implanted in bladder; catheter <i>in situ</i> , and projecting through urethra.	Extra-perit.	.....	None.	Success.	Three stitches. Boldt also had long fistulous track from brim pelvis—nephrectomy.
10 Baldy.	Dec., 1895.	Amer. Journ. Obstet., 1896, No. 3, Vol. xxxiii.	Divided ureter in encysted cleaving tubo-ovarian mass in which bd. ligament destroyed by inflam. process.	Prim-ary.	Abd. into perit.	Implantation into bladder; two lateral sutures, ureter to bladder; bladder tacked to pelvic wall at ilio-pectoneal line ( <i>d</i> ).	Extra-perit.	Glass.	None.	Success.	Length of bladder incision, 1 in. Bladder released from peritoneal attachments. (Private communication.)
11 Polk.	Jan. 26, 1896.	Amer. Gyn. and Obstet. Journ., Feb., 1892, No. 2.	Abd. hyst. carcinoma uterus and ureter.	Prim-ary.	Abd. into perit.	Resect. r. ureter for 1 in.; implantation.	.....	Gauze.	Leakage.	Partial success. Final bladder insertion.	Constriction shown pt.-mort. one year after at bladder insertion.
12 Noble, G. H.	Jan., 1896.	Grady Hosp., Atlanta.	Abd. hyst. displaced ureter; ligated with ovarian ends.	Prim-ary.	Abd. into perit.	Implantation by forceps through urethra; 3 inches resected; ureter too short; bladder released; Kelly method.	Extra-perit.	Gauze, abd. and vag.	None.	.....	Ninth day bladder allowed to fill up with urine; ureter pulled out; urinary infection; uræmia, etc.



## IMPLANTATION INTO BLADDER.—Continued.

Operator.	Date.	Bibliography.	Cause.	Primary or Secondary.	Incision.	Operation.	Extra- or Intra-perit.	Drainage.	Leakage.	Result.	Remarks.
13 Witzel, O.	Spring, 1896.	Kelly's Gyn.	.....	Secondary.	Abd. into perit.	Ureter transferred to side of pelvis above ilio-pectoneal line to shorten route; end cut oblique; segment of ureter buried in bladder wall.	Extra-perit.	.....	None.	Success.	.....
14 Fullerton, Anna M.	Mar. 10, 1897.	Kelly's Gyn. and Amer. Gyn. and Obstet. Journ.	Abd. hyst. fibroid; displaced ureter; double; cut a little below Fallopian tube.	Primary.	Abd. into perit.	Double ureter; both ends implanted into the incision in bladder.	Extra-perit.	.....	None.	Success.	Double ureter; both transplanted.
15 Füh, R.	1897.	Inaug. Diss., Strassburg, 1898. Graepfner, 1898. Centralbl. für Gynäk., July 16, 1898.	Abd. hyst. cut r. u. on post surface of large myoma, tumor ligated in bundle of veins.	Primary.	Abd. into perit.	Implantation into bladder.	Extra-perit.	None.	None.	Success.	.....
16 Kelly.	Jan. 26, 1898.	Amer. Gyn. and Obstet. Journ., June, 1898, pp. 739, 740.	Fistula.	Secondary.	Inguinal. Fritsch.	Inguinal incision; extra-peritoneal; peritoneum lacerated in two places; pyeloneph. ureter split on dorsum; gauze in bladder removed and new drain put in vagina.	Extra-perit.	Gauze accidentally forced through bladder.	None.	Failure.	Pyelonephritis.



17 Kelly.	Not given.	Ibid.	Abd. hyst. carcinoma; injured ureter and fistula; catheter in ureter.	Secondary.	Abd. into perit.	Attempted to implant ureter, but cut the wrong one on account of stricture or obstruction to catheter; too weak to operate on other ureter.	.....	None.	Leakage.	Failure.	Having cut the wrong ureter, and that failing, two fistulae were thus formed; this case was afterward closed by vaginal operation.
IMPLANTATION INTO PELVIS OF KIDNEY.											
1 Kuster.	1892.	Archiv für klin. Chir., 1892, xlv, Heft 4, p. 850.	Fistula after lumbar nephro-ectomy; vesicle anuria.	Primary.	Lumbar.	Resection of strictured portion of ureter close to pelvis of kidney and implantation of ureters in same.	Extra-perit.	.....	Leakage. 4 mos. subsequent op. for fistula	Success.	This is the highest point at which repair of the ureter has ever been done.
URETERAL ANASTOMOSIS.											
1 Schopf.	June 2, 1886.	Allgemeine Wiener Med. Zeitsch., 1886; b. I. dis- Centralbl. für Gynäk., No. 39, 1887.	Cut in removing cyst; b. I. dis- placed ureter.	Primary.	Abdominal.	Ends fastened and united by 8 sutures through all but mucosa.	Extra.	None.	None.	Success.	Eight stitches. Died of tuberculosis seven weeks later.
2 Hochenegg.	Feb. 9, 1890.	Wiener klin. Wochens., 1893, vi, pp. 740-755, 812, 864.	Cancer of uterus.	Primary.	Abdominal.	Resected left ureter and bladder; ends of ureter sutured end to end; bladder closed; twentieth day hæmorrhage.	Extra.	None.	None.	Died 20th day hæmorrhage.	At autopsy ureter intact, and this case seems to be classed as a success.



UTERINE ANASTOMOSIS.—Continued.

Operator.	Date.	Bibliography.	Cause.	Primary or Second-ary.	Incision.	Operation.	Extra- or Intra-perit.	Drain- age.	Leak- age.	Result.	Remarks.
3 Fritsch.	1891-1892.	Ueber die gyn- äko logischen Operationen des Jahrgangs, 1891-92. Berlin, 1895, 8vo., p. 287.	Operation of tumor of abdomen.	Prim- ary.	Abdom- inal.	Stitched ends with fine intestinal sutures.	Extra.	.....	None.	Success.	.....
4 Kelly.	May 1, 1892-1893.	Bull. Johns Hopkins Hos- pital, 1893, iv, p. 89.	Hysteromyo- metomy, mis- took ureter for large vein.	Prim- ary.	Abdom- inal.	Van Hook's anasto- mosis.	Extra.	Gauze.	None.	Success.	.....
5 Cushing.	1893.	Ann. Gynec. and Pediatrics, 1893, vi, p. 277.	Intralig. my- oma dis- placed ure- ter.	Prim- ary.	Abdom- inal.	Ends united; two silk one catgut suture.	.....	.....	Leak- age for two weeks.	Success.	Patient well two years later.
6 Tauffer.	1893.	Pest med. Chir. Presse, Buda- pest, 1893.	Cut intralig- amentous cyst.	Prim- ary.	Abdom- inal.	End to end on seg- ment of catheter No. 8, which was re- moved before trying last three stitches.	.....	Vaginal and glass abdom.	None.	Success.	.....
7 Tauffer.	1894.	Archiv für Gynäk., 1894, Band xlv, Hefte 3, p. 231.	Extra-perit. tumor; bluish mass mistaken for tumor and incised.	Prim- ary.	Abdom- inal.	Operation as above.	.....	Same.	.....	Success.	.....
8 Emmet, B.	Nov. 22, 1894.	Amer. Journ. of Obst., 1895, xxxi, pp. 449-464.	Cut in re- moval of tu- mor in lum- bar region.	Prim- ary.	Lumbar.	Van Hook method.	.....	None.	.....	Success.	Highest point at which anasto- mosis has been done.



9	Doherty.	1895.	Van Hook in Journ. Amer. Med. Assoc., 1895, xxv, 843.	Cut in abdominal section.	Prim-ary.	Abdom-inal.	Van Hook.	.....	.....	Success.	.....
10	Robson (Mayo).	1896.	Internat. Med. Annual, 1896, p. 602.	Extra-peritomyoma; removed 2 in. of ureter.	Prim-ary.	Abdom-inal.	Splitting lower end, invaginating.	.....	.....	Success.	.....
11	Bovée.	Apr. 20, 1896.	Reprint Ann. of Surgery, Jan., 1897.	Tubo-ovarian abscess; ureter caught in ligature of ovarian vessels on right.	Prim-ary.	Abdom-inal.	End cut obliquely and ditch closed with fine silk and tension sutures over these.	.....	.....	Success.	.....
12	Noble, G. H.	July 2, 1898.	Grady Hospital.	Displaced ureter ligated and cut with ovarian vessels, Fallopian tube right side; very large intralig. fibroid.	Prim-ary.	Abdom-inal.	End to end; split lower end, pushed down mucosa, and inserted kidney, end stitched over split and made peritoneal cuff; all done on urethral catheter. Patient in extreme condition, having had for weeks high temp. and feeble pulse. At time of operation pulse 160.	Extra.	None.	Success.	Multiple fibroid extra-perito. or intra-lig.; emaciated; contin'd high temp.; feeble, rapid pulse; temp. 103° just before operat'n; pulse went up during operat'n to 160 at time of anastomosis; urethral catheter kept in 12 hours.
13	Noble, G. H.	Oct., 1898.	P. I.	Resect. left ureter, sarcoma intra-lig. of left ovary.	Prim-ary.	Abdom-inal.	End to end as above. Peritoneum stripped from pelvis to above brim and from sacrum tumor dissect'd down behind vagina to floor of pelvis and around outer side and behind rectum and sigmoid; iliac vessels laid bare in operation.	.....	None.	Success.	Malignant.



coexisting dilatation or hydro-ureter, as the forcible introduction of a tube larger than the ampulla, into which it is to go, is liable to obstruct the flow of urine from above the point of anastomosis. This might be overcome by giving the ureter to be transplanted an upward turn and anastomosing it to the wider portion of its fellow at the pelvis of the kidneys, or into the latter cavity, even if a lumbar incision is required. Implantation into the bladder will be requisite when the ureter is cut low down and in secondary operations for injuries of the inferior extremity of the ureter, for the cut-off portion becomes occluded or shrunken so that anastomosis into it is impracticable.

It will be observed that the consideration of other ureteral operations have been studiously avoided; many of them teem with brilliancy, such as the removal of foreign bodies and excision of the ureter. Of the first, Hall, of Cincinnati, claims the honor of one of these operations; in the latter Kelly has done brilliant work, being the first to remove the entire ureter in long sections, Reynier having done his by piecemeal. Vaginal operations are too numerous to mention, and do not come within the scope of this paper, the conditions being such that they are not applied to the same class of cases.

A noticeable feature is that with three exceptions each operator had but one case. Tauffer had two. The writer three, with one failure. Kelly published four, with two failures.

---

*Dr. George Henry Noble.*

*Private Infirmary,  
131 & 133 S. Pryor Street.*

*Atlanta, Ga.*