# HUMAN ANATOMY.

AN

# INTRODUCTION

TO THE

# STUDY OF HUMAN ANATOMY.

By JAMES PAXTON,

MEMBER OF THE ROYAL COLLEGE OF SURGEONS, HONORARY MEMBER OF THE ASHMOLEAN SOCIETY, AND AUTHOR OF NOTES AND ILLUSTRATIONS TO PALEY'S NATURAL THEOLOGY.

IN TWO VOLUMES, WITH ILLUSTRATIONS.

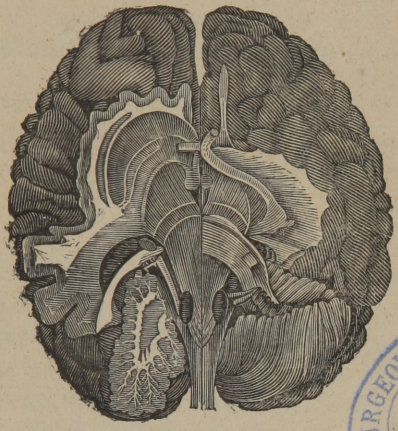

Formative fibres of the Brain. See page 134.

SURGEON GEN'L'S OFFICE LIBRARY

## VOLUME II.

SECOND AMERICAN EDITION, WITH ADDITIONS,

By WINSLOW LEWIS, Jr. M. D.

DEMONSTRATOR OF ANATOMY TO THE MEDICAL DEPARTMENT OF HARVARD UNIVERSITY.

SURGEON GEN'L'S OFFICE 100136. LIBRARY

BOSTON:

WILLIAM D. TICKNOR,

Corner of Washington and School Streets.

M DCCC XXXV.

1835

Entered according to Act of Congress in the year 1835,
By William D. Ticknor,
In the Clerk's office of the District Court of Massachusetts.

QS
P342i
1835
v.2

BOSTON:
TUTTLE AND WEEKS, PRINTERS,
No. 8, School Street.

# CONTENTS.

CONTINUATION OF ARTICLE V.—VASCULAR SYSTEM.

## CHAPTER II.


| | Page. |
|---|---|
| Of the Veins in General, | 1 |
| Structure of Veins, | 2 |
| General Department of the Venous System, | 4 |
| Veins which form the superior vena cava, | 4 |
| Veins which give rise to the external jugular, | 4 |
| Veins which give rise to the internal jugular, | 5 |
| Veins forming the subclavian veins, | 7 |
| Superior vena cava, | 11 |
| Veins forming the inferior vena cava, | 13 |
| Veins forming the internal iliac vein, | 15 |
| Common iliac veins, | 15 |
| Inferior vena cava, | 15 |
| Branches of the inferior vena cava, | 16 |
| Vertebral sinuses and veins of the spinal marrow, | 17 |
| Veins of the heart, | 18 |
| Coronary Veins, | 18 |
| Abdominal Department of the Venous System, | 19 |
| Vena Portæ — Branches of, | 19 |

## CHAPTER III.

Page.
Of the Capillaries, . . . . . 21

# ARTICLE VI.

### ORGANS OF ABSORPTION.

## CHAPTER I.

Lymphatic Glands, . . . . . 22
Structure of the Lymphatic Vessels, . . . 24
Lymphatic Glands in General, . . . . 24
Lymphatic Glands in Particular, . . . . 25
Lymphatic glands of the inferior extremities, . . 25
Lymphatic glands of the pelvis, . . . . 26
Lymphatic glands of the abdomen, . . . 26
Lymphatic glands of the thorax, . . . . 27
Lymphatic glands of the superior extremities, . . 27
Lymphatic glands of the head and neck, . . . 28

## CHAPTER II.

Particular Lymphatic Vessels, . . . . 29
Lymphatic Vessels terminating in the Thoracic Duct, 29
Lymphatic vessels of the inferior extremities, . . 29
Lymphatic vessels of the perinæum, loins, etc., . . 31
Deep seated obturator, ischiatic and genital lymphatic vessels, 31
Lymphatics of the urinary organs, . . . . 32
Lymphatics of the parietes of the pelvis and abdomen, . 33
Lymphatics of the stomach and intestines, . . . 34
Lymphatics of the spleen, pancreas and liver, . . 36
The Thoracic Duct, . . . . . 37
Lymphatics which open directly into the thoracic duct, . 38

Page.
Lymphatics of the lungs, . . . . . 38
Lymphatics of the diaphragm, heart, thymus and œsophagus, 39
Lymphatics of the superior extremities, . . . 40
Lymphatics of the anterior parietes of the thorax, . 41
Lymphatics of the posterior region of the neck and thorax, 41
Lymphatics of the axilla, . . . . . 41
Lymphatics of the head and anterior part of the neck, . 42
Deep lymphatics of the head and neck, . . . 42
The office of the lymphatics and their glands, . . 43

## ARTICLE VII.

### NERVOUS SYSTEM.

### CHAPTER I.

General Divisions of the Nervous System, . . 44
Cerebral Department of the Nervous System, . . 45
The brain in general, . . . . . 51
The exterior of the cerebrum, . . . . 55
The exterior of the cerebellum, . . . . 56
The exterior of the pons Varolii, . . . . 57
The medulla oblongata, . . . . . 58
The medulla spinalis, . . . . . 60
The internal organization of the brain, . . . 61
Chemical analysis of the brain, . . . . 61
Parts observed in the lateral ventricles, . . . 66
The internal structure of the cerebellum, . . . 69

### CHAPTER II.

The Membranous Envelopes of the Brain, . . 74
The dura mater, . . . . . 74
Sinuses of the dura mater, . . . . 75
The arachnoid membrane, . . . . . 78

Page.
The pia mater, . . . . . 79
Granulations of the membranes of the brain, . . 80
The proper membrane of the spinal marrow, . . 81
Ligamentum denticulatum, . . . . . 81
The Nerves in General, . . . . . 82
Nerves of the Cerebral Department, . . . 83
Olfactory, . . . . . 83
Optic, . . . . . 84
Motores oculorum, . . . . . 85
Pathetic, . . . . . 86
Trifacial, . . . . . 86
1. Opthalmic branch, . . . . 87
2. Superior maxillary, . . . . 88
3. Inferior maxillary, . . . . 88
Abducent, . . . . . 91
Facial, . . . . . 91
Auditory, . . . . . 94
Glosso-pharyngæal, . . . . . 94
Pneumo-gastric, . . . . . 95
Hypoglossal, . . . . . 97
Spinal accessory, . . . . . 98
Spinal nerves, . . . . . 100
First pair of cervical, . . . . . 100
Second pair of cervical, . . . . . 101
Third and fourth pair of cervical, . . . 101
Cervical plexus, . . . . . 101
Fourth, fifth, sixth and seventh pairs of cervical nerves, 103
Brachial, or axillary plexus, . . . . . 103
Thoracic branches, . . . . . 104
Nerves of the arm, . . . . . 104
Internal cutaneous nerve, . . . . . 104
External, or musculo-cutaneous, . . . . 105
The median nerve, . . . . . 107
The ulnar nerve, . . . . . 108
Radial nerve, . . . . . 109

Page.
Circumflex nerve, . . . . . 110
Dorsal nerves, . . . . . 110
Lumbar nerves, . . . . . 111
First lumbar, . . . . . 111
Second lumbar, . . . . . 112
Third lumbar, . . . . . 112
Fourth and fifth lumbar, . . . . . 112
Lumbo-abdominal, or lumbar plexus, . . . 113
Musculo-cutaneous branches, . . . . 113
Genito-crural nerve, . . . . . 114
Crural nerve, . . . . . 114
Obturator nerve, . . . . . 115
Lumbo-sacral nerve, . . . . . 116
Glutæal nerve, . . . . . 116
Sacral nerves, . . . . . 116
Sciatic nerve, . . . . . 117
External poplitæal nerve, . . . . . 117
Internal poplitæal nerve, . . . . . 118

## CHAPTER III.

Ganglionic Department of the Nervous System, . 120
Particular Ganglia, . . . . . 122
Ganglia of the Head, . . . . . 122
Lenticular ganglion, . . . . . 122
Spheno-palatine ganglion, . . . . . 122
Ganglia of the Neck, . . . . . 125
Superior cervical ganglion, . . . . 125
Middle cervical ganglion, . . . . . 126
Inferior cervical ganglion, . . . . 126
Cardiac nerves, . . . . . 126
Cardiac plexus, or ganglion, . . . . 127
Thoracic Ganglia, . . . . . 128
Splanchnic nerve, . . . . . 128

Page.
Great splanchnic nerve, . . . . . 128
Small splanchnic nerve, . . . . . 129
Ganglia of the Abdomen, . . . . . 129
Semilunar ganglia and solar plexus, . . . 129
The lumbar ganglia, . . . . . 130
The sacral ganglia, . . . . . 131
Hypogastric plexus, . . . . . 131
Great Sympathetic Nerve, . . . . . 133
Formative Fibres of the Brain, according to Gall and Spurzheim, . . . . . 134

## ARTICLE VIII.

### PARTICULAR ORGANS OF SENSATION.

### CHAPTER I.

The Eye and its Appendages, . . . . 137
Eyebrows, . . . . . 137
Eyelids, . . . . . 138
The globe of the eye in general, . . . . 140
The sclerotica, . . . . . 140
The cornea, . . . . . 140
The choroid membrane, . . . . . 141
The ciliary circle, or ligament, . . . . 142
The iris, . . . . . 143
The retina, . . . . . 144
The aqueous humour, . . . . . 146
The crystalline lens, . . . . . 147
The vitreous humour, . . . . . 148

### CHAPTER II.

The Ear and its Appendages, . . . . 150
The external ear, . . . . . 150
Fibro-cartilage of the ear, . . . . . 152

Page.
The auditory canal, . . . . . 153
The internal ear, . . . . . 154
Bones of the ear, . . . . . 155
The labyrinth, . . . . . 156
The cochlea, . . . . . 157
The semicircular canals, . . . . . 159
Auditory nerve, . . . . . 159
Mechanism of hearing, . . . . . 160

## CHAPTER III.

The Nose, . . . . . 163
Mechanism of smell, . . . . . 165

## CHAPTER IV.

The Tongue, . . . . . 166
Taste, . . . . . 168

## CHAPTER V.

The Skin, . . . . . 169
The dermis, . . . . . 170
The rete mucosum, . . . . . 171
The epidermis, . . . . . 172
The sense of touch, . . . . . 174
The Hair, . . . . . 175
Organization of the hair, . . . . . 177
The Nails, . . . . . 177

## CHAPTER VI.

Muscular Sensation, . . . . . 178

## CHAPTER VII.

Visceral Sensation, . . . . . 182

SURGEON GENERAL'S LIBRARY

## ARTICLE IX.

### ORGANS OF DIGESTION.

Page.
The Mouth, . . . . . 185
The Palate, . . . . . 186
The Pharynx, . . . . . 187
The Œsophagus, . . . . . 188
The Stomach, . . . . . 190
Organization of the stomach, . . . . 191
Office of the stomach, . . . . . 193
The Intestinal Canal, . . . . . 193
The small intestine, . . . . . 194
The duodenum, . . . . . 194
The jejunum and ilium, . . . . . 195
The large intestine, . . . . . 197
The Mesentery, . . . . . 202
Digestion, . . . . . 203

## ARTICLE X.

### ORGANS OF RESPIRATION.

The Lungs, . . . . . 207
Organization of the lungs, . . . . . 210
Changes which take place in Respiration, . . 212
The Trachea and Bronchi, . . . . . 215
Organization of the trachea and bronchi, . . 217

## ARTICLE XI.

### ORGANS OF THE VOICE.

The Larynx, . . . . . 219
Cartilages of the larynx, . . . . . 219

Page.
Thyroid cartilage, . . . . . 219
Cricoid cartilage, . . . . . 220
Arytenoid cartilages, . . . . . 221
Epiglottis, . . . . . 222
The ligaments of the larynx, . . . . 223
The muscles of the larynx, . . . . 224
Crico-thyroideus, . . . . . 224
Crico-arytenoideus posticus, . . . . 225
Crico-arytenoideus lateralis, . . . . . 226
Thyro-arytenoideus, . . . . . 226
Arytenoideus, . . . . . 227
Mucous membrane of the larynx, . . . 227
The gland of the epiglottis, . . . . . 227
The arytenoid glands, . . . . . 228
The office of the larynx, . . . . . 228
The thyroid gland, . . . . . 229

## ARTICLE XII.

### ORGANS OF SECRETION.

Organs for the Secretion and Transmission of Tears, 230
The lachrymal gland, . . . . . 230
The caruncula lachrymalis, . . . . 231
The puncta lachrymalia, . . . . . 231
The lachrymal sac, . . . . . 232
The nasal duct, . . . . . 232
The Salivary Glands, . . . . . 232
The parotid gland, . . . . . 233
The submaxillary gland, . . . . 234
The sublingual gland, . . . . . 234
The Pancreas, . . . . . 235
Organs for the Secretion and Transmission of the Bile, 236
The liver, . . . . . 236

Page.
Ligaments of the liver, . . . . . 238
Envelopes of the liver, . . . . . 239
The hepatic duct, . . . . . 239
The gall bladder, . . . . . 240
Cystic duct, . . . . . 240
The ductus communis choledochus, . . . 240
Secretion of bile, . . . . . 241
The Spleen, . . . . . 242
Organization of the spleen, . . . . 243
Office of the spleen, . . . . . 243
Supra-Renal Capsules, . . . . . 245
The Kidneys, . . . . . 245
Organization of the kidneys, . . . . 246
The calyces, pelvis, and ureter, . . . . 247
The Bladder, . . . . . 250
The organization of the bladder, . . . . 251
The office of the kidneys and bladder, . . . 252
The urine, . . . . . 253

## ARTICLE XIII.

### ORGANS OF GENERATION IN THE MALE.

The Testicles and their Appendages, . . . 255
Envelopes of the testicles, . . . . 255
The testicles, . . . . . 256
Organization of the testicle, . . . . 257
Epididymis, . . . . . 258
Vas deferens, . . . . . 258
Spermatic cord, . . . . . 259
Vesiculæ seminales, . . . . . 260
Prostate gland, . . . . . 261
Cowper's glands, . . . . . 262
Ejaculatory ducts, . . . . . 262

Page.
Penis, . . . . . 264
Integuments of the penis and prepuce, . . . 264
Corpus cavernosum, . . . . . 264
Organization of the corpus cavernosum, . . . 265
Urethra, . . . . . 266
Organization of the urethra, . . . . . 267
Glans penis, . . . . . 268

## ARTICLE XIV.

### ORGANS OF GENERATION, ETC. IN THE FEMALE.

Organs of Generation, and for the Nutrition of the Child, in the Female, . . . . . 269
Organization of the Vagina, . . . . . 271
The Uterus and its Appendages, . . . . . 272
Organization of the uterus, . . . . . 273
The broad ligament, . . . . . 276
The round ligaments, . . . . . 276
The Fallopian, or uterine tubes, . . . . . 276
The ovaries, . . . . . 277
The gravid uterus, . . . . . 280
Developement of the ovum in the uterus, . . 282
Membranes which inclose the Fœtus, . . . 283
Liquor Amnii, . . . . . 284
The Placenta, . . . . . 284
Office of the placenta, . . . . . 287
Funis Umbilicalis, . . . . . 287
Umbilical Vesicle, . . . . . 288
The Mammæ, . . . . . 289
Organization of the mammæ, . . . . 289
Office of the mammæ, . . . . . 291

## ARTICLE XV.

### THE FŒTUS.

Page.
Peculiarities of the Fœtus, . . . . 293

## ARTICLE XVI.

### SEROUS SYSTEM AND CELLULAR TISSUE.

The Pleura and the Peritonæum, . . . . 304
Omenta, or Epiploa, . . . . . 308
Cellular Tissue, &c. . . . . 311
Fat, . . . . . 314

# ANATOMY

OF

# THE HUMAN BODY.

---

## CHAP. II.

### OF THE VEINS IN GENERAL.

It has been already stated, that it is the office of the arteries to convey the blood from the heart to the different parts of the body, for the purpose of nourishing and building up the animal fabric: now there is a corresponding series of sanguineous canals which return the blood from all the organs, again to continue the stream of the circulation; these are the VEINS. By the aid of a microscope, the extreme branches of the arteries may be observed communicating with the minute radicles of the venous system, and transferring their blood to that series of vessels. The curious and beautiful phenomena of the circulation are evident, when the tail of a fish, or the web of a frog's foot, is placed in the field of a powerful magnifier; and we are assured of the fact of the continuity of the two sets of vessels in the human subject, by the circumstance of fine injections passing readily from the arteries into the veins.

There are two departments of the venous system: the 1st, or *general department of the venous system*, more extensive than the other, commences in the head, trunk and

limbs, and transmits the blood to the heart by the venæ cavæ. The 2d, or *abdominal department of the venous system*, is confined to the cavity of the abdomen, and is formed by the veins of all the chylopoetic viscera, with the exception of those of the liver, and terminates in the vena portæ, which subdivides and distributes the blood through the liver.

The veins are far more numerous, and, considered as a whole, they are much more capacious than the arteries.

The distribution of veins is somewhat similar to that of the arteries, but their number and size are greater. In general a cellular space, common to all, receives both the trunks of the two species of vessels and those of the nerves. In the head, limbs, and every other part, there are two sets of veins; the superficial and the deep seated: the 1st lie immediately under the skin, or run above the fasciæ, and are in some parts very large and numerous and do not possess any corresponding arteries. The 2d, or deep seated veins, directly attend the arteries. The union between the branches of the veins is very frequent; they communicate in right lines or in arches, and the smaller are so multiplied as to form complicated meshes of network; but the minute ramifications of veins ultimately form an inconceivable number of small canals in the tissue of organs, of such extreme tenuity, as to render it impossible to understand their final distribution.

### STRUCTURE OF VEINS.

The veins are formed of only two membranes; the *outer* is composed of longitudinal fibres, very easily distinguished in the large trunks, and surrounded by a sheath of cellular tissue, the layers of which are placed very densely on each other. The *inner membrane* is thin, smooth, and glossy;

and in appearance resembles the membrane which lines the arterial tubes, but it is more extensible and less brittle.

Valves are formed in the general department of the venous system, but there are none in the system of the vena portæ, the umbilical vein, the trunk of the inferior cava, in the veins of the brain, of the vertebræ, of the spinal marrow, of the heart, of the kidneys and of the uterus. There are but very few in the vena azygos, and pulmonary veins. These valves consist of a number of semilunar folds of the inner membrane of the vein, precisely similar to those which exist at the commencement of the aorta and the pulmonary artery.

The valves are sometimes single; they are, however, more frequently arranged in pairs, at other times there are three together. Apparently, their office is to support the column of blood, and to prevent its return by the veins from the heart to the surface of the body; for the valves are pressed close to the sides of the vessels during its flow towards the heart, but they are raised when the blood, from any accidental circumstance, is disposed to pass in a retrograde direction. Fig. 1 represents a vein laid open, thus shewing the single, duplex and triplex valvular apparatus.

Fig. 1.

The veins are supplied by very minute nutrient vessels *(vasa vasorum)* and nervous filaments, which ramify in the cellular membrane, and which penetrating the venous tissue, finally terminate in the inner surface of the vessels.

Veins may be distinguished from the arteries by their membranes being much thin-

ner, by their greater number and size, by their having no pulsation, by the dark color of the blood they contain, and in many instances by the peculiarity of their numerous valves.

## GENERAL DEPARTMENT OF THE VENOUS SYSTEM.

### I. VEINS WHICH, BY THEIR UNION, FORM THE EXTERNAL SUPERIOR VENA CAVA.

Fig. 2.

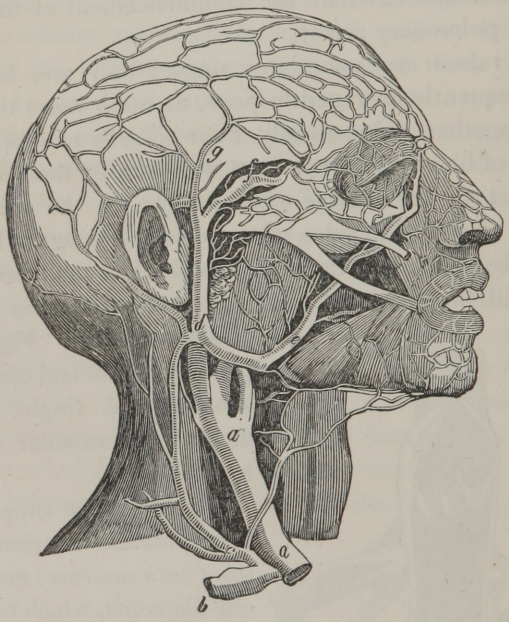


#### 1. VEINS WHICH GIVE RISE TO THE EXTERNAL JUGULAR VEIN.

The *internal maxillary vein* commences in all the parts to which the artery of the same name is distributed ; it is consequently composed of the *pterygoid*, *spheno palatine*, *alveolar*, *infra-orbitar*, *mental*, *inferior dental*, and *deep*

*temporal veins.* It communicates with the sinuses of the base of the skull by means of small twigs which pass through the foramina of that region. Upon the side of the neck the internal maxillary vein frequently communicates with the facial and pharyngeal veins. This disposition produces the *pharyngeal plexus.*

The *superficial temporal vein*, *g*, commences in all those parts where the corresponding artery is distributed. It is composed of the *middle temporal vein*, *f*, the *anterior auricular veins*, and the *transverse veins of the face.* Thus formed it descends before the ear, and unites with the preceding.

The vein which results from this union passes through the parotid gland, communicates with the internal jugular vein, and receives the following:

The *posterior auricular vein*, which collects the blood from the mastoid region and from the ear. The trunk then takes the name of

The *external jugular vein;* it extends from *d* to *c*, and is placed between the sterno-cleido-mastoideus and the platysma myoides muscles. In its course along the neck it receives the following:

The *cervical cutaneous*, the *trachelo-scapular*, and other veins which arise in the vicinity of the neck and shoulder. At the inferior part of the neck the external jugular opens near *c* into *b*, the superior part of the subclavian vein, a little on the outer side of *a*, *a*, the internal jugular vein.

2. VEINS WHICH GIVE RISE TO THE INTERNAL JUGULAR VEIN.

The *superior cerebral veins* commence upon the convex surface of the two hemispheres of the brain, from the substance of which they issue by a multitude of minute branches, and are continued into the superior longitudinal and lateral sinuses.

The *vein of the corpus striatum* is extended over the surface of that body, and, exactly following the course of the tenia semicircularis, unites with the following:

The *veins of the choroid plexus*, which return the blood into the *venæ* GALENI, and from thence into the right sinus of the dura mater.

The *superior cerebellar veins* convey the blood from the whole upper surface, and from the substance of the cerebellum, into the torcular HEROPHILI and the venæ GALENI.

The *inferior cerebellar veins* unite on each side of the cerebellum, and return their blood into the corresponding lateral sinuses.

The *lateral and inferior cerebral veins* are very numerous; they unite on each side and leave the brain to open into the lateral sinuses.

The *ophthalmic vein* commences from all parts within the orbit, and unites on each side into three or four trunks, so that this vein is formed of the *lachrymal*, the *central vein of the retina*, the *infra orbitar*, the *ciliary*, the *ethmoidal*, the *palpebral*, and the *nasal veins*. The ophthalmic then passes out of the orbit, by the inner part of the sphenoidal fissure, and conveys the blood into the cavernous sinus.

All the blood of the brain is returned into the sinuses of the dura mater, which terminate at the foramen lacerum posterius. This point is the commencement of the jugular vein, and as it is here considerably dilated, it is named the *sinus of the internal jugular vein*. This vein advances a little forwards, and descends with the carotid artery, covered by the styloid process of the temporal bone, and by the muscles which are attached to it. It communicates at first with the external jugular vein, by a branch of large size, and at the level of the upper part of the larynx, it receives the facial vein.

The *facial vein*, *e*, commences on the summit of the head and forehead, and when it has arrived at the side of the nose, near the eye, it has the name of the *angular vein*, and receives the blood from the ophthalmic, the *palpebral* and the *superciliary veins*. It follows the direction we observe in the figure, receiving the *dorsal veins of the nose*, the *superior* and the *inferior coronary veins of the lips*, and several *buccal* and *masseteric veins*. It is afterwards augmented by the *ranine*, the *submental*, and the *inferior palatine veins*, and then becomes united to the internal jugular vein.

A little below the facial vein, the internal jugular is augmented by the *lingual* and *pharyngeal veins:* and at the level with the superior edge of the larynx, it receives the *superior thyroid*, the *occipital*, and the *veins of the diploe* of the bones of the skull.

After receiving the above branches, the internal jugular vein descends vertically at the side of the neck, and opens into the subclavian vein.

### 3. VEINS OF THE SUPERIOR EXTREMITY WHICH, BY UNITING, FORM THE SUBCLAVIAN VEINS, Fig. 3.

The collateral arteries of the fingers, the radial and ulnar arteries, and all their divisions are each accompanied by two venous branches, which become larger as they ascend toward the elbow joint, where they unite so as afterwards to constitute two large trunks, which run along the brachial artery and open into the axillary vein. They receive in their course all the veins which attend the divisions of the artery.

The *cephalic vein* commences by a great number of branches, disposed in the form of a net work, on the back of the hand and upon the muscles of the thumb; these unite into a trunk, which ascends upon the anterior and

external part of the fore-arm, where it forms the *superficial radial vein*, and on arriving at the bend of the arm unites with the *median cephalic vein*, which communicates with the *median basilic*.

The united veins which form the trunk of the cephalic ascend on the outer and fore part of the arm, then bending inwards, open into the axillary vein.

The *basilic vein* is larger than the cephalic, and is formed of three branches, which are named from their situation, the *posterior ulnar*, the *anterior ulnar*, and the *median basilic veins*.

Fig. 3.

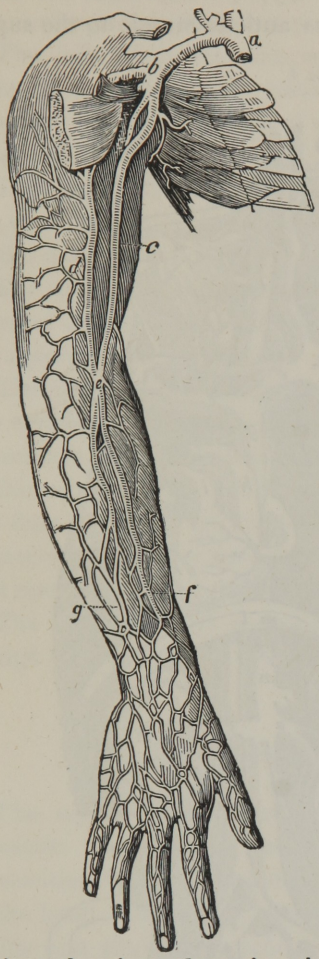


The basilic vein ascends on the inner part of the arm and unites frequently, as at *e*, with the cephalic vein. It then passes into the axilla, being continuous with the axillary vein.

Fig. 3, *b*, the axillary vein.

*d*, the cephalic vein.

*c*, the basilic vein.

*f*, the radial vein.

*g*, the anterior ulnar vein.

The *axillary vein* is therefore the result of the union of the veins of the hand, fore-arm and arm; it proceeds obliquely under the clavicle, and in front of the axillary artery, and becomes continuous with *a*, the subclavian vein. See also, Fig. 4, *t*, the axillary, and *f*, the subclavian veins.

In this course it receives the *circumflex veins*, the *inferior scapular*, the *long thoracic*, the *superior thoracic*, and the *acromial veins*.

The *subclavian veins*, Fig. 4, *f*, *u*, extend from the inferior extremity of the scalenus anticus muscle to the supe-

Fig. 4.

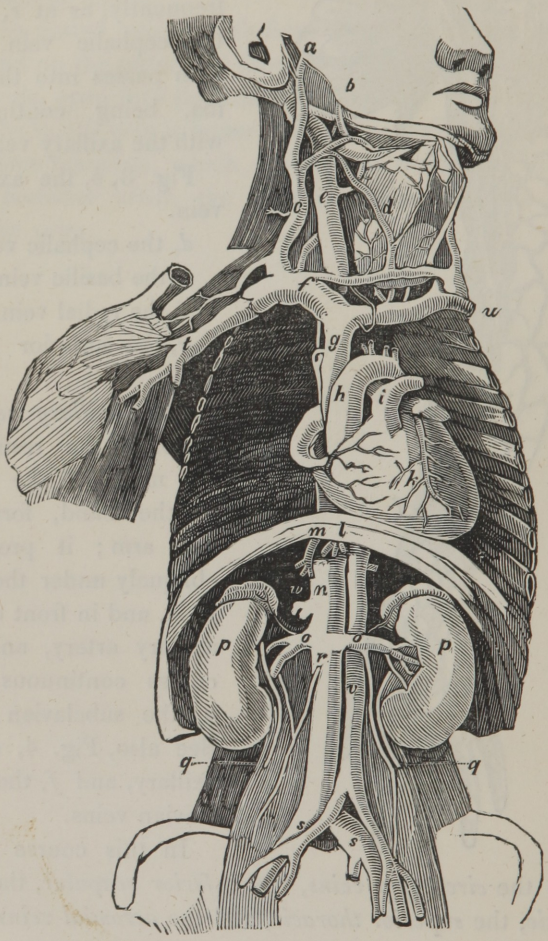


rior vena cava, but they present differences according as they are examined on the right or on the left side, on account of the position of, *g*, the superior vena cava.

Thus the right subclavian vein, *f*, is very short, and its size is always less than that of the left.

The left subclavian vein, *u*, is much longer than the right, and receives two veins which the right does not receive ; viz. the *left internal mammary* and the *left inferior thyroid.*

That part of the left subclavian vein nearest the descending cava, which lies before the trachea, is generally known as the *vena innominata.*

The two subclavian veins equally receive besides the internal and the external jugular veins, the *vertebral* and the *superior intercostal veins.*

The *vertebral vein* descends in the canal which contains the vertebral artery, and issuing from thence at the sixth or seventh cervical vertebra it unites with another considerable vein, which communicates with the lateral sinus of the dura mater by the mastoid foramen. After this union it receives numerous branches from the adjacent muscles, and opens into the subclavian vein.

The *right* and *left superior intercostal* veins also discharge their blood into the subclavian veins.

### SUPERIOR VENA CAVA, *g*.

The *superior vena cava* forms the grand trunk which transmits the blood of the head, the neck, the superior extremities, and a portion of the circulation of the thorax, to the heart. This vein commences opposite the cartilage of the first rib, and descends to the base of the pericardium, from which it receives a fibrous sheath. It then enters that membranous sac, descends vertically on the right of the aorta, and opens into the right auricle of the heart.

Before entering the pericardium the superior vena cava receives the following branches : —

1st. The right *internal mammary vein*, which differs from the left only in its termination.

2d. The *inferior thyroid vein*, opening into the superior vena cava, between the two subclavian veins.

3d. The *vena azygos*, Fig. 5, *a*, *a*, *a*, is remarkable for having no corresponding vein, and in forming a communication between the two venæ cavæ. It opens into the superior vena cava immediately above the right branches, and passing through the pillars of the diaphragm, with the aorta and thoracic duct, opens into the inferior vena cava, or into one of the lumbar veins.

Fig. 5.

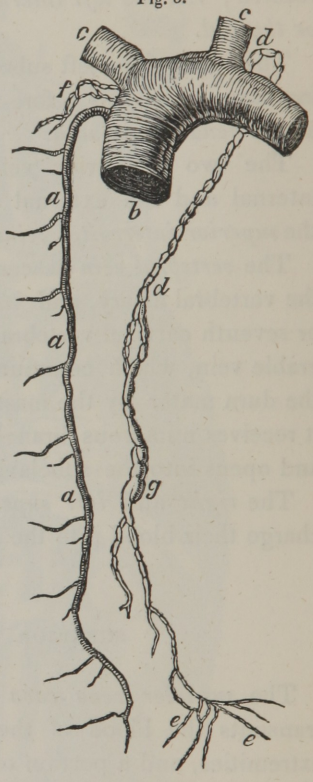


4th. The vena azygos at the convexity of its curve receives the *right bronchial vein*, and anteriorly branches from the aorta and œsophagus. To the right it receives the corresponding *intercostal veins*. To the left, towards the seventh rib, the *vena semi-azygos*, a considerable branch which ascends parallel to the vena azygos, on the left side of the vertebræ, and which receives the inferior intercostal veins of the left side.

## II. VEINS WHICH, BY THEIR UNION, FORM THE INFERIOR VENA CAVA.

### 1. VEINS WHICH, BY THEIR UNION, FORM THE EXTERNAL ILIAC VEINS.

The *popliteal vein*, commences by *three veins* which accompany the anterior, posterior and fibular arteries; the *external saphena vein* also contributes to its formation, by collecting the blood upon the front and outer side of the foot, and passing into the ham, opens into the popliteal vein.

The *femoral* or *crural vein* is a continuation of the popliteal vein; it ascends obliquely at the inner and fore part of the thigh, close to the femoral artery, following the same course up to the crural arch. In its progress it receives a great number of deep branches, precisely similar to those of the artery, and the following remarkable superficial branch:

Fig. 6.

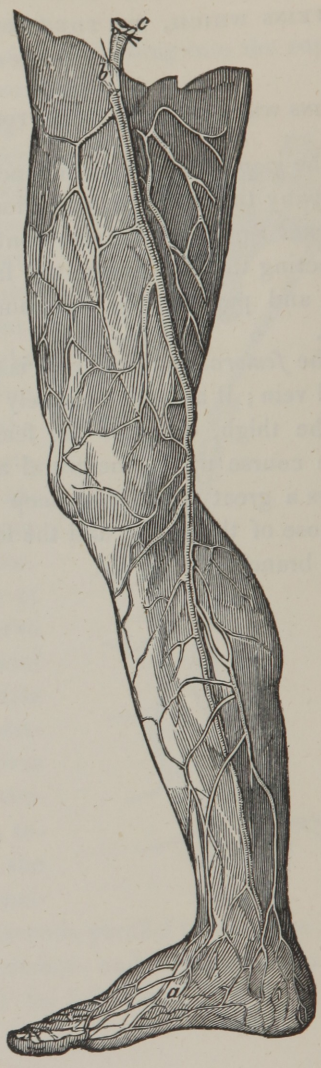


The *internal vena saphena*, Fig. 6, collects the blood from the inner part of, *a*, the foot and toes; it is united to the external saphena by a transverse arch; these united branches ascend before the inner ancle, and form a trunk which is continued on the inner part of the leg, and passing behind the inner condyle of the femur, it proceeds on the inside of the thigh to an opening in the fascia lata, *b*, where it discharges itself into, *c*, the femoral vein. At this part it receives *several superficial abdominal veins*, the *circumflex iliac vein*, and *the external pudic veins*.

The *external iliac vein* receives branches corresponding to the artery of the same name, and in the male it receives a large vein which originates in the envelope of the testicle.

2. THE VEINS WHICH, BY THEIR UNION, FORM THE INTERNAL ILIAC VEIN.

The internal iliac vein, Fig. 4, *s*, *s*, is situated in the cavity of the pelvis, behind the artery of the same name; its branches correspond exactly to those of the artery, with the exception of the following:

The *vesical veins* are large and very numerous, but differ according to the sex of the subject we examine.

In the *male* they commence upon the glands and unite into two trunks, the *dorsal veins of the penis*, which run upon the back of that organ, and afterwards wind downwards upon the organs of generation, and continuing their course on the sides of the bladder, and over the prostate gland, open into the internal iliac vein.

In the *female* the vesical veins commence by the *veins of the clitoris* and the labia, and unite with the numerous vessels of the vagina and rectum.

The *sacro-lateral veins*, communicate in the sacral canal with the vertebral sinuses, and emerging from the anterior sacral foramina join the internal iliac vein.

COMMON ILIAC VEINS.

The *common iliac veins* result from the union of the external and internal veins; they extend from the sacro-iliac symphysis to the fifth lumbar vertebra, where they give rise to the inferior vena cava.

INFERIOR VENA CAVA. Fig. 4, *n*, *r*.

The *inferior vena cava* is larger than the superior, and extends from the articulation of the fourth and fifth lumbar

vertebræ to the right auricle of the heart. It ascends on the right side of the bodies of the lumbar vertebræ, passes above and behind the liver, and advancing through a wide aperture of the aponeurosis of the diaphragm, introduces itself into the pericardium, and enters the right auricle of the heart by an aperture which is bounded by the Eustachian valve.

### BRANCHES OF THE INFERIOR VENA CAVA.

The *middle sacral vein* ascends upon the coccyx and sacrum, in the angle formed by the union of the common iliac veins.

The *lumbar veins* are four in number on each side, and commence by an *abdominal branch*, and a *dorsal branch*, corresponding to the branches of the lumbar arteries; the dorsal communicates by the intervertebral foramina, with the vertebral sinuses. The lumbar veins of the left side pass under the aorta and are in consequence longer than the right.

The *spermatic veins*, see Fig. 4, *r*, differ in their origin in the two sexes. In the *male* they commence by the *spermatic plexus*, the roots of which are expanded in the testicle, they anastomose with the neighboring veins, and collect into four or five branches, which envelope the vas deferens, and passing through the inguinal ring, unite and form a single trunk, which extends upwards and inwards on the psoas muscle, as far as the upper part of the pelvis, where the spermatic vein forms another plexus named the *corpus pampiniforme:* these veins again unite and convey their blood into the inferior vena cava on the right side, and into the corresponding renal vein on the left side.

In the *female*, the spermatic veins originate in the ovari-

um, Fallopian tube, ligamentum teres, and sides of the uterus; they afterwards collect between the laminæ of the broad ligament of the uterus, and then follow the same course as in the male.

The *renal veins*, see Fig. 4, *o*, *o*, are of great size. Their roots exactly correspond to the minute ramifications of the renal arteries. They unite in the fissure of *p*, *p*, the kidneys, into several branches, which collect into a trunk opening into the cava.

The *capsular* and *adipose veins* frequently open into the renal veins, and in other respects have the same disposition as the arteries to which they correspond.

The *hepatic veins* have their roots in the substance of the liver: some of them are of small size and enter the vena cava separately; others, namely, the *middle hepatic veins*, open into the vena cava between the right and left hepatic veins.

The *middle hepatic veins* open into the vena cava between the right and left hepatic veins.

The *left hepatic veins* ramify in the left lobe of the liver, and proceed from thence into the vena cava, opposite the aperture of the diaphragm, through which it passes.

The *right hepatic veins* issue from the right lobe of the liver, and open into the vena cava below the preceding.

The *inferior diaphragmatic veins* are two in number, and are similar to the arteries of the same name.

### VERTEBRAL SINUSES AND VEINS OF THE SPINAL MARROW.

There exist in the whole length of the vertebral cavity two great venous canals, named the *vertebral sinuses*, and which communicate with the internal jugular vein. These sinuses have the same structure as the sinuses of the dura mater, in being traversed in various directions by irregularly distributed membranous bridles.

At their inner side, they communicate with each other by *transverse sinuses*, occupying the middle of the body of each vertebra, then passing under the posterior vertebral ligament, they receive the veins which transmit the blood from the envelopes of the spinal marrow, and the spongy tissue of the vertebræ.

The *veins of the spinal marrow* accompany the arteries of that name, and open into the inferior cerebellar veins.

The *veins of the sacral canal* are of considerable size; they are immersed in cellular tissue, and have no adhesion to the osseous parts. Their inferior extremities are lost in very delicate ramifications upon the os coccygis. Externally, they form communications with the lateral sacral veins; and, internally, their transverse branches anastomose with each other.

## VEINS OF THE HEART.

### CORONARY VEINS.

The *great right coronary vein* collects the blood from the apex of the heart, passes into the groove which separates the auricles from the ventricles, and receives a great number of lateral branches which terminate in the right auricle, close by the entrance of the inferior vena cava, where the coronary is covered by a semilunar valve.

The *small right coronary vein* unites with the preceding, and passes in the same direction to the posterior surface of the heart.

The *left coronary veins* are smaller than the right. They commence, with the preceding, at the apex of the heart, by numerous roots, which unite, upon the convex surface of that organ, into a single trunk, which discharges its blood with the other veins at the posterior part of the right auricle.

There are a number of veins which terminate directly in the cavity of the right side of the heart, by minute orifices, which have been termed, by their original describer, the foramina THEBESII.

## ABDOMINAL DEPARTMENT OF THE VENOUS SYSTEM.

### VENA PORTÆ.

#### BRANCHES OF THE VENA PORTÆ.

The *vena portæ* derives its blood from all the organs of digestion in the cavity of the abdomen, excepting the liver. It is formed principally by three large trunks, the coronary vein of the stomach, the splenic and the mesenteric veins, all which unite to form the middle part or trunk of the vena portæ.

The *coronary vein of the stomach* corresponds to the artery of the same name. It is the smallest of the three branches. It empties into the trunk of the vena portæ, behind the pyloric portion of the stomach.

The *splenic vein* collects the blood from the spleen by a number of branches, which, after a short course, unite upon the pancreas into a single trunk, which extends from left to right to unite with the superior mesenteric vein, opposite the vertebral column. It likewise receives the veins which correspond to the *vasa breviora*, the *right* and *left gastro-epiploic*, the *duodenal*, and the *pancreatic veins*, and the *small mesenteric vein*. The last named vein receives the blood from the left part of the colon and the rectum. Its branches correspond to those of the inferior mesenteric artery.

The *superior mesenteric vein* is distributed in the same manner as that of the artery of the same name, to the right, and a little in front, of which it is placed. It is

formed by the veins of the small intestines, and by those which correspond to the right colic arteries; and in the mesentery it constitutes a net-work, very similar to the ramifications of the artery. At the edge of the transverse mesocolon, the trunk of this vein, after receiving several branches from the duodenum and pancreas, unites with the splenic vein.

The *trunk of the vena portæ* is formed by the junction of the splenic and superior mesenteric veins with the coronary vein of the stomach; it extends from the vertebral column to the groove of the liver, and separating into two branches, nearly at a right angle, seems to form under the liver a horizontal canal, which has been termed the *sinus of the vena portæ*. These vessels are extended through the lobes of the liver in innumerable ramifications. In its passage under the small extremity of the pancreas, it is united to the cystic and hepatic ducts, the hepatic artery, and a number of nervous filaments and lymphatic vessels; all which are surrounded by a fibrous envelope named the *capsule* of GLISSON.

Injections thrown into the vena portæ penetrate into the other vessels of the liver, and *vice versa*.

## CHAP. III.

### OF THE CAPILLARIES.

The delicate branches of the final ramifications of the arteries and of the minute origins of the veins, are called the *capillaries*. In these small vessels most of the important functions of life take place, as secretion, nutrition, exhalation, calorification, &c. They are of such extreme tenuity that they escape detection by the naked eye. Their existence may be demonstrated not only by microscopical observation as observed in the last chapter, but by the fact, that a colored fluid may be thrown from the arteries into the veins, without any extravasation between them.

There are two parts in the capillary system. One is diffused over the whole body, being placed between the terminating branches of the arteries and the roots of the veins, the other part is between the minute ramifications of the pulmonary arteries and the origins of the pulmonary veins. In the first the arterial blood is changed to venous; in the last, the reverse. Their intimate organization is unknown.

Though these capillaries exist everywhere in the body, still they are more or less numerous in the various organs. They are more abundant in the secretory organs, the skin, the mucous membranes, and the lungs, and less so in the fibrous structures; in short the capillary system is as much more developed in a part, says Bichat, as it has more functions to sustain, and do not exist in organs in proportion to their size.

# ART. VI.

## CHAP. I.

### ORGANS OF ABSORPTION.

The organs of absorption consist of *lymphatic vessels* and *lymphatic glands;* the latter also are named *lymphatic ganglia.* This system of vessels was perfectly unknown until a celebrated anatomist of the name of Asellius, in the year 1622, discovered, upon the mesentery of a dog, white lines extending from the intestine to the glands. He observed that they contained a milk-like fluid, and hence termed them *lacteals.* By a series of experiments he found that these vessels absorbed the chyle, and conveyed it to the blood ; and subsequent inquiries proved that the same system of vessels was minutely distributed over the whole human frame ; and that, at the angle formed by the union of the subclavian with the internal jugular vein, upon either side of the neck, one or more of these vessels discharges their contents into the current of blood.

The lymphatic vessels are small pellucid tubes, which occur in all parts of the body ; they originate on the surface of the membranes, and in the tissue of all the organized structures ; and they transport all the absorbed fluids to the venous system. Those absorbents which take up

the chyle in the intestines, during the process of digestion, are named *lacteals;* and, although they differ in their uses from the other absorbent vessels, they have precisely the same anatomical character.

The ultimate arrangement of the lymphatic vessels has not been demonstrated, but the whole exterior of the body is known to be covered by a net-work of these vessels, placed in the subjacent cellular tissue, and others occupy the muscular intervals and organs of the body; nor is this system of vessels confined to the limbs only, for it exists in the surface and substance of each particular organ, as in the lungs, liver, spleen, pancreas, and other viscera, where both superficial and deep seated lymphatics are uniformly distributed.

Generally these vessels are straight in their course, but their communications with each other are very numerous, and they frequently form successive meshes. They are also remarkable for their alternate unions and divisions, so that a great number of vessels, after being collected into a single trunk, separate a second time, and again form one or more trunks, which appear most conspicuous in the vicinity of their glands.

### THORACIC DUCT.

All the absorbent vessels discharge themselves into the subclavian and internal jugular veins, by considerable trunks, called the *thoracic duct*, and *great right lymphatic duct*. These convey the absorbed fluids into the circulation. See Fig. 5, *d*, the left, and *f*, the right thoracic ducts.

### STRUCTURE OF THE LYMPHATIC VESSELS.

The lymphatic vessels are formed of an external cellular membrane, and an internal membrane similar to that of the veins; the latter is folded upon itself, producing valves at intervals, which are generally disposed in pairs. These valves are usually more numerous as the vessels diminish in caliber. So that the thoracic canal contains fewer than the others.

### LYMPHATIC GLANDS IN GENERAL.

The branches of the principal lymphatic trunks traverse a greater or less number of *lymphatic glands;* that is to say, small bodies of various forms and size, and collected together in greater or less quantity, or sometimes isolated. These glands are not numerous in the extremities, but they occur abundantly in the thorax and abdomen. Each gland receives lymphatic vessels, which subdivide and form an inextricable interlacement, which is lost in its substance, without our being able to trace its distribution, or display the minute structure. These glands vary in diameter from the twentieth of an inch to an inch. They are in general red and vascular; some, however, are of a gray or blackish color. These bodies have been denominated also lymphatic *ganglions*, because some anatomists have supposed, that they bear the same relation to their vessels, as the nervous ganglions do to the nerves.

The absorbents which enter the glands are called *vasa inferentia*, and those which pass out of them, are termed vasa *efferentia*.

Fig. 7. Fig. 8. Fig. 9.

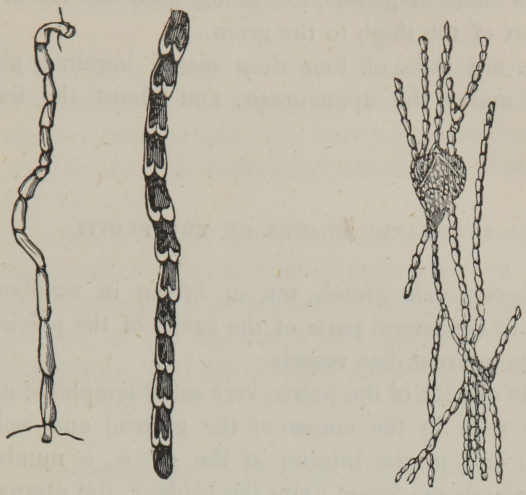

Fig. 7, a lymphatic vessel.
Fig. 8, a lymphatic vessel laid open, shewing its valves.
Fig. 9, lymphatic vessels and their glands.

## LYMPHATIC GLANDS IN PARTICULAR.

### LYMPHATIC GLANDS OF THE INFERIOR EXTREMITIES.

The *anterior tibial gland* is the only gland in the leg. It is found between the tibia and fibula, on the lower extremity of the inter-osseous ligament.

The *popliteal glands* are three or four in number, and are situated in the ham.

The *inguinal glands* are situated on the upper part of the thigh, and in the groin; the *superficial* are found between the skin and aponeurosis, surrounding the termination of the internal saphena vein; their number varies from eight to twelve, and they are sometimes observed

to form a chain of glands, extending from the middle and inner part of the thigh to the groin.

There are three of four *deep seated* inguinal glands, situated under the aponeurosis, and about the femoral artery.

### LYMPHATIC GLANDS OF THE PELVIS.

The *hypogastric glands*, ten or fifteen in number, are situated in the lateral parts of the cavity of the pelvis, and about the internal iliac vessels.

On the outside of the pelvis, very small lymphatic glands are met with in the course of the glutæal and ischiatic arteries; and in the interior of the pelvis, a number of minute glands are found upon the bladder, the uterus, and the vesiculæ seminales.

The *sacral glands* are situated in the hollow of the sacrum, between the laminæ of the meso-rectum.

The *external iliac glands* vary in number from six to fifteen, they are situated in the course of the external iliac vessels, and form a chain of glands extending from the crural arch to the lower part of the vertebral column.

### LYMPHATIC GLANDS OF THE ABDOMEN.

The *lumbar glands* are large and numerous; they occupy the region of the loins, and surround the aorta and the inferior vena cava; they are also situated upon the crura of the diaphragm, and are thickly arranged over the renal arteries. These glands furnish vessels which immediately communicate with the thoracic duct.

The *hepatic*, *pancreatic*, and *splenic glands* are situated round the vena portæ and along the splenic artery; they

receive the lymphatic vessels of the liver, aorta, and pancreas.

The *mesenteric glands* are numerous, sometimes exceeding a hundred, and are in general of considerable size; they are situated between the two laminæ of the mesentery, and receive the lacteals or absorbents of the chyle. See Fig. 11, *c*, *d*.

The *mesocolic glands* are fewer than the preceding, and are placed between the laminæ of the mesocolon.

The *gastro-epiploic glands* occupy the greater and smaller curvature of the stomach; they surround the gastro-epiploic arteries, and the coronary artery of the stomach.

### LYMPHATIC GLANDS OF THE THORAX.

The *glands of the mediastinum.* Upon the diaphragm and pericardium there are six or eight of these bodies; and there are twelve or sixteen surrounding the thymus gland, and large vessels of the base of the heart.

The *bronchial glands* are very numerous; they are situated before the division of the trachea, around the bronchi, and even in the interior of the lungs; but they will be more particularly noticed in the description of the trachea and bronchi.

### LYMPHATIC GLANDS OF THE SUPERIOR EXTREMITY.

The *glands of the arm* are distributed in the line of the brachial artery; they are not often met with in the fore-arm, although, not unfrequently, we find a few at the bend of the arm near the inner condyle.

The *axillary glands* are situated in the cellular tissue of the armpit, around the axillary vessels and their

branches; they are of large size, and vary from six to twelve in number. Some are met with under the collar bone and between the ribs.

### LYMPHATIC GLANDS OF THE HEAD AND NECK.

The *glands of the skull* are few in number; several small glands are found behind the ear, and two or three are also observed under the zygomatic arch. No lymphatic glands have been traced in the interior of the skull.

The *glands of the face* are situated upon the buccinator muscle, and along the base of the jaw, where they surround the anterior portion of the digastric muscle.

The *glands of the neck* are *superficial* and *deep seated*; the former are situated beneath the platysma myoides, in the course of the external jugular vein and its branches. The others, called *glandulæ concatenatæ*, occur in the vicinity of the internal jugular vein and common carotid artery. Their size is small, but their number is very great. In children they frequently present a kind of knotty cord, extending from behind the ear to the collar bone.

# CHAP. II.

## PARTICULAR LYMPHATIC VESSELS.

### LYMPHATIC VESSELS WHICH TERMINATE IN THE THORACIC DUCT.

#### 1. LYMPHATICS OF THE INFERIOR EXTREMITY.

THE *superficial lymphatics of the lower extremities* consist of very numerous vessels, which are found in the cellular tissue, between the skin and muscles. Their commencement can be traced with little difficulty in the toes, round which they form a very delicate plexus, and form by their successive union from sixteen to twenty branches, which cover the surface of the foot and pass up the inner side of the leg; those of the side of the foot collect and form two or three branches, which ascend around the tendo Achilles.

Thus united, the principal trunks of the lymphatics of the leg pass over the calf, and the ham, and ascend upon the inner and outer side of the thigh, approaching each other and continually communicating, until, at length, they terminate in the superficial inguinal glands.

Fig. 10.

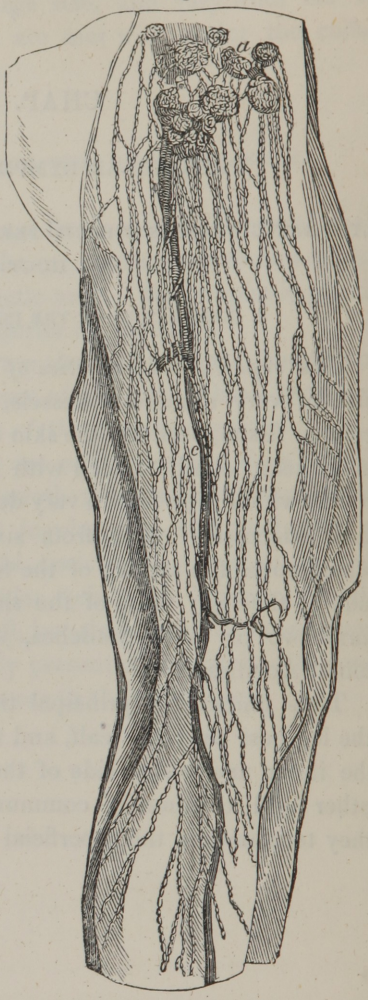


Fig. 10, the lymphatic vessels of the inner part of the thigh.

All these vessels are immersed in the subcutaneous cellular tissue; and their communications are so frequent and numerous, that they form, upon the foot, leg and thigh, a net-work which completely surrounds these parts.

The *deep lymphatic vessels of the lower extremities* may be distinguished into four series: namely, the *anterior tibial*, the *posterior tibial*, and the *fibular lymphatics*, according as they accompany the anterior and posterior tibial and fibular arteries. They terminate in the popliteal glands. Indeed most of the deep seated lymphatics of the leg and foot have the same termination. These glands are connected together by a great number of smaller vessels, which form a plexus, whence issue several trunks which ascend upon the popliteal and femoral vessels, receiving all the deep lymphatics of the thigh, and subdividing up to, *a*, the deep inguinal glands.

### 2. SUPERFICIAL LYMPHATIC VESSELS OF THE HIPS, PERINÆUM, LOINS, EXTERNAL PARTS OF GENERATION, ETC.

The *lymphatics of the hips* are numerous, and pass over the outer and inner part of the thigh, to unite with the superficial absorbents of the perinæum, and inguinal glands.

The *lymphatics of the loins* descend from the lumbar vertebræ over the crest of the ilium, and divide in the superficial inguinal glands.

The *lymphatics of the lower part of the parieties of the abdomen* commence on the level of the umbilicus, and form a net-work over the whole anterior region of the abdomen ; they collect inferiorly into a few trunks which terminate in the superficial glands.

The *lymphatics of the perinæum, scrotum, and penis,* are very numerous ; those of the scrotum ascend on each side to the inner part of the thigh, where they unite with those of the perinæum and penis : they all terminate in the superficial glands.

In the female, the lymphatics of the external parts of the organs of generation have the same termination.

### 3. DEEP SEATED OBTURATOR, ISCHIATIC, AND GENITAL LYMPHATIC VESSELS.

The *obturator lymphatics* are distributed over the adductor muscles and neighboring parts, and take the direction of the obturator artery, through the obturator foramen, to terminate in the hypogastric glands.

The *ischiatic lymphatics* are distributed to the muscles of the pelvis, and terminate in the same glands as the former.

The *glutæal lymphatics* have the same distribution as the

glutæal artery, and, passing into the pelvis, terminate in the same glands as the preceding.

The *deep lymphatics of the penis and clitoris* follow the course of the interal pudic artery, and terminate in the same glands.

The *lymphatics of the testicle* are numerous, and are among the largest of the body; some of them are the size of a crow-quill: they unite upon the spermatic cord into six or eight branches, and ascend with it towards the inguinal ring, through which they pass to follow the spermatic artery, and terminate in the lumbar glands.

The *lymphatics of the prostate gland and vesiculæ seminales* unite with those of the bladder, and enter into the hypogastric glands.

The *lymphatics of the uterus* unite with those which are distributed to the vagina, to terminate in the same glands. Those which are found upon the broad ligament and ovarium, ascend with the spermatic lymphatics to the lumbar glands.

#### 4. LYMPHATIC VESSELS OF THE URINARY ORGANS.

The *lymphatics of the bladder* follow the course of its blood vessels, and open into the hypogastric glands.

The *lymphatics of the kidneys* unite towards their fissure, and then proceed upon the sides of the aorta to the lumbar glands. The ureters also are furnished with numerous absorbents, which surround those tubes, and communicate freely with each other, and with the last named glands.

The *capsular lymphatics* proceed to the hepatic and splenic glands, and several pass to the glands upon the pillar of the diaphragm.

### 5. LYMPHATIC VESSELS OF THE PARIETES OF THE PELVIS AND ABDOMEN.

The *ileo-lumbar lymphatics* are a set of absorbents which originate in the iliacus muscle, and upon the hip bone; they pass under the psoas muscle, and communicating with the inferior lumbar glands, contribute to the formation of the *external iliac lymphatic plexus*, or the assemblage of lymphatics which accompany the external iliac vessels.

The *sacral lymphatics* are extended over the adipose tissue of the rectum, and region of the sacrum; they terminate in the inferior lumbar or hypogastric glands. Those lymphatics, which contribute to form the *hypogastric plexus*, are placed on the sides of the pelvis, and consist of an interlacement of vessels and glands, in which the obturator, glutæal, ischiatic, uterine, and vesical lymphatics terminate.

The *epigastric lymphatics* commence in the vicinity of the umbilicus, and proceed from the interior, through the abdominal muscles and their aponeuroses; then unite into several trunks, which descend in the course of the epigastric vessels, and terminate in the external iliac plexus.

The *circumflex iliac lymphatics* are distributed in the integuments of the sides of the abdomen, and descend towards the crest of the ilium, to one of the external iliac glands.

The *lumbar lymphatics* are distributed to the muscles of the lumbar region, but they unite before the vertebral column, where their numerous communications, with those of almost all the other trunks, which have just been described, constitute the *lumbar lymphatic plexus*.

### 6. LYMPHATIC VESSELS OF THE STOMACH AND INTESTINES.

The *lymphatics of the stomach* are distributed into two distinct orders; the *superficial*, which are situated beneath the peritoneal, and the *deep*, which are distributed to the muscular and mucous membranes. Some of these commence at the large extremity of the stomach, and join the lymphatics of the spleen; others proceed from the small curvature of the stomach, and communicate with the glands in that situation, and in the vicinity of the liver. After this, they descend behind the pancreas to the roots of the thoracic duct.

Although in some animals these vessels have been found to contain chyle, in the human subject they have never been observed to be filled with it.

The *lymphatics of the intestines* are usually called the LACTEALS, on account of their conveying a fluid like milk from the intestines to the thoracic duct. Each lacteal takes its origin from the villi of the intestines, by numerous short radiated branches, and each branch is furnished with an orifice for imbibing the chyle.

From the villi, the lacteals pass under the muscular membrane of the intestines, and then obliquely through it, uniting in their course into larger branches, following the course of the mesenteric blood vessels. They are found situated on each side of the arteries.

It is observed that there are a much greater number of lymphatics in the small intestines than in the large; the descending colon and rectum present but few aborbents, and these are connected with the lumbar and hypogastric glands, or those of the mesorectum.

The lacteals of the small intestines, after passing through the different glands of the mesentery, form several trunks,

which accompany the superior mesenteric artery, until they arrive at the thoracic duct.

Fig. 11.

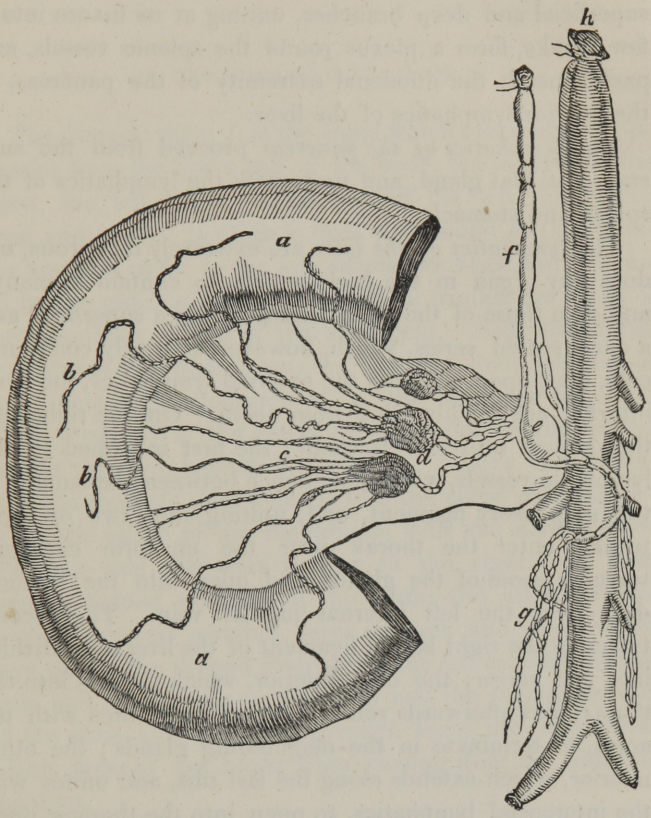


Fig. 11, *a*, *a*, part of the small intestine; *b*, *b*, lacteals; *c*, the mesentery; *d*, the mesenteric glands.

The *lymphatics of the great omentum* ascend to unite with the lymphatics of the stomach, and terminate in the glands of the great curvature.

### 7. LYMPHATIC VESSELS OF THE SPLEEN, PANCREAS, AND LIVER.

The *lymphatics of the spleen* are very numerous; the superficial and deep branches, uniting at its fissure into a few trunks, form a plexus round the splenic vessels, and pass beneath the duodenal extremity of the pancreas, to the inferior lymphatics of the liver.

The *lymphatics of the pancreas* proceed from the substance of that gland, and unite with the lymphatics of the spleen and stomach.

The *lymphatics of the liver* are extremely numerous, nor does any organ in the body appear to contain so many; and, like those of the other viscera, it has a superficial and a deep seated series, which, however, so freely communicate, that, upon injecting the external lymphatics, the deep internal are readily filled from them. On the right lobe they collect into four fasciculi; the first is formed by the lymphatic vessels, which commence between the laminæ of the suspensory ligament, and, uniting into two or three trunks, enter the thorax near the ensiform cartilage, traverse some of the glands, and open into the thoracic duct near the left internal jugular vein. The second traverses the right lateral ligament of the liver, and divides into two series; the one superior, which mounts into the thorax, and afterwards returns into the abdomen with the aorta, to terminate in the neighboring glands; the other inferior, which extends along the last ribs, and unites with the intercostal lymphatics, to open into the thoracic duct. The third fasciculus is distributed to the middle of the right lobe, and unites with the preceding at the posterior part of the liver. The fourth fasciculus commences in the anterior part of the right lobe, and unites with the deep series, and with some glands near the pylorus.

In the left lobe of the liver, the lymphatics unite with

the preceding and to those of the spleen ; those from the posterior part of the left lobe descend towards the cardia, and proceed to the glands of the small curvature of the stomach.

### 8. THE THORACIC DUCT. See Fig. 11.

The thoracic duct, *f*, is the canal which receives the lymphatics from the lower half of the body, the interior of the chest, the left upper extremity, and the left side of the head and neck. It extends from the second or third lumbar vertebra as far as the left subclavian vein, and is formed by the union of, *g*, five or six large trunks, the result of the absorbent plexus of the abdomen. Near the aortic aperture of the diaphragm, the thoracic duct presents a very remarkable enlargement, *e*, the *receptaculum chyli*, which is placed at the anterior and left part of the second lumbar vertebra, behind, *h*, the aorta. Above this dilatation, the thoracic duct ascends into the chest, entering between the pillars of the diaphragm, with the aorta on the left side, and the vena azygos to the right. It then ascends behind the arch of the aorta, and arrives at the seventh cervical vertebra, turns inwards and downwards, then passes the thyroid artery, and the left internal jugular vein, and opens close to the latter into the subclavian vein of the same side. At its aperture there are two valves which prevent the blood from passing from the vein into the duct.

Although the lymphatics have hitherto been described by anatomists as collecting into trunks to transmit their contents into the subclavians only ; MAGENDIE* and a few other celebrated physiologists and experimentalists

* MAGENDIE, in his Physiology, relates some very curious and striking experiments, which, if confirmed by others, must set the question at rest.

are of opinion, that many other communications, between the lymphatics and veins, take place in the extremities and other parts of the body. Professor Mayo seems to have arrived at the same conclusion ; I give his own words. "For my own part, I think it likely, that such communications do exist. At all events, when believing that they did not, I have witnessed the mercury thrown into the absorbents of the limbs unaccountably make its way into the veins."*

### 9. LYMPHATIC VESSELS WHICH THE THORACIC DUCT DIRECTLY RECEIVES.

Several branches of lymphatics from the liver, and the glands surrounding the cæliac artery, have been already described.

The *intercostal lymphatics* are distributed to the muscles of the thorax and the intercostals; they communicate with some glands found between the external and internal intercostal planes of the muscles. On the sides of the vertebræ, these vessels unite with others which proceed from the spinal canal and the muscles of the back, then spread out into a plexus before the vertebral column. From thence they descend and open into the thoracic duct.

### 10. LYMPHATIC VESSELS OF THE LUNGS.

The *lymphatics of the lungs* are distributed upon their surface in a series of areolæ of various forms, more commonly hexagonal, and unite into a number of trunks which

* Outlines of Human Physiology, by Herbert Mayo, Professor of Anat. King's College, London.

enter the glands, with which the bronchus is surrounded at its entrance into that organ. The deep lymphatics occupy the whole tissue of the lungs, communicate with the superficial, unite into the bronchial glands, and ascend upon the trachea.

From a large bronchial gland, which is found in the angle formed by the division of the trachea, there issue several lymphatic branches, which ascend upon the trachea, and, traversing some glands, unite and open into the right great lymphatic vessel. Others traverse glands upon the trachea, under the thyroid gland, and collect into two trunks, which incline obliquely to the left, behind the internal jugular vein, to discharge themselves into the thoracic duct.

### 11. SUBSTERNAL, DIAPHRAGMATIC, CARDIAC, THYMIC, AND ŒSOPHAGEAL LYMPHATIC VESSELS.

The *substernal lymphatics* commence from the upper part of the parietes of the abdomen; they enter the thorax between the ensiform cartilage and the diaphragm, ascend behind the sternum, traverse some glands, and form some meshes, which unite into trunks, one of which communicates with the inferior jugular glands, and terminates in the thoracic duct. The others open on the right side into the subclavian and internal jugular veins.

The *lymphatics of the diaphragm* are distributed on its convex surface, and unite with the intercostal and hepatic lymphatics, then proceed through the inferior glands of the mediastinum, and join the preceding behind the sternum.

The *lymphatics of the pericardium and thymus* are a numerous set of reticulated vessels, which are intimately connected with the substernal and pulmonary lymphatics.

The *lymphatics of the heart* are distributed to the whole surface; the principal trunks following the course of the coronary vessels. Some of these trunks ascend upon the anterior part of the aorta, and terminate in the thoracic duct; others pass obliquely between the aorta and pulmonary artery, traverse some small glands, and arrive at the thoracic duct.

The *lymphatics of the œsophagus* are reticulated around that tube; they unite with those of the heart and lungs, and terminate in the predorsal ganglia.

### 12. LYMPHATIC VESSELS OF THE SUPERIOR EXTREMITIES.

The *superficial lymphatics of the upper extremities* collect into fasciculi on the sides of the fingers, and proceed over the metacarpus to the posterior surface of the fore-arm, where their numbers are greatly increased by the addition of small vessels from that part of the extremity. Near the elbow joint the lymphatics are very distinct; and, upon the anterior surface of the fore-arm, they unite with others, which arrive from the fingers and palm of the hand. They then ascend on the fore and inner part of the arm, and, becoming large and numerous, terminate in the axillary and subclavian glands.

Some of the *brachial lymphatics* pursue the course of the cephalic vein, and unite with some reticulated vessels and glands under the clavicle.

The *deep lymphatics of the upper extremities* constantly accompany the arteries which are distributed to these parts, and terminate in the axillary glands.

### 13. LYMPHATIC VESSELS OF THE ANTERIOR PARIETES OF THE THORAX.

The *lymphatics of the anterior part of the thorax* commence immediately under the integuments, and, proceeding upwards and outwards, terminate in the glands of the axilla.

Some of these vessels originate more deeply in the substance of the pectoralis major, pectoralis minor, and serratus magnus muscles, but they have the same termination.

### 14. LYMPHATIC VESSELS OF THE POSTERIOR REGION OF THE NECK AND THORAX.

The *lymphatics of the neck* commence in the cellular tissue, towards the occiput, and upon the spinous processes of the neck; they descend outwardly in the direction of the fibres of the trapezius, and unite with the anterior thoracic, and dorsal lymphatics in the axilla.

The *lymphatics of the back* commence in the integuments, and are extended to the whole of the muscles of the back; like the preceding, they terminate in the axilla.

### 15. LYMPHATIC VESSELS OF THE AXILLA.

The *axillary lymphatics* are remarkably reticulated, in consequence of their connection with a great number of glands, and with the vessels which terminate in them, or issue from them. The latter concentrate into three or four trunks, which proceed round the subclavian vein, and open into it, and into the thoracic duct. Those on the right

side generally furnish a trunk, which transmits its fluid to the angle formed by the right internal jugular and subclavian veins; and is named the *right great lymphatic duct.* See Fig. 5, *f.*

### 16. LYMPHATIC VESSELS OF THE HEAD AND ANTERIOR PART OF THE NECK.

The *epicranial lymphatics* are arranged on all sides beneath the skin of the cranium, and may be distinguished into three orders of fasciculi. The *occipital*, the *temporal*, and the *frontal;* all which proceed to the glands of the neck.

The *lymphatics of the face* follow the direction of the principal veins, and proceed to the submaxillary glands.

The *superficial lymphatics of the neck* form a plexus, which accompanies the subcutaneous veins of the neck; they open into the right great lymphatic vessel, and the thoracic duct.

### 17. DEEP LYMPHATIC VESSELS OF THE HEAD AND NECK.

The *lymphatics of the brain.* Although the most minute researches have been made in those parts, there have been discovered a few lymphatics only in the dura mater.

The *deep lymphatics of the tongue, palate, nose, orbits, pharynx, muscles of the face,* etc. These absorbents accompany the blood vessels, and terminate in the right and left great thoracic ducts.

## THE OFFICE OF LYMPHATIC VESSELS AND THEIR GLANDS.

The most important office of the lymphatic system is to collect the chyle for the supply of the waste of the body, during the exercise of its several functions.

The lymphatics, therefore, take in the fluids, it is supposed, by capillary attraction, and afterwards, by a contractile power, inherent in the vessels, conduct their contents into the mass of the blood. The absorbents also have the power of removing the solid parts of the body, and by thus making way for the disposition of new matter, contribute to the growth and renovation of the animal fabric.

By means of these vessels, on the one hand, many contagious diseases are communicated; and, on the other hand, diseases are removed: thus, when lymph is formed, or pus collected, or blood effused in the tissue of organs, the lymphatics have the power of taking away the extraneous or diseased matter. And even solid tumours often are known to disappear entirely by the action of this system of vessels. The obvious use of the absorbent vessels is to convey the lymph and the chyle into the venous system; the former, the residue of nutrition, and the latter, the product of digestion.

I cannot dismiss this subject without informing the uninitiated student, that there is much difficulty in exhibiting the lymphatics. They must be injected with quicksilver, and, owing to the minuteness and delicacy of the vessels, it requires the most acute sight of the anatomist to distinguish, and to introduce an instrument into the smaller branches. Caution and patience, however, will surmount this difficulty; and nothing will more repay the trouble, or reflect more credit on the skill of a practical anatomist, than a good preparation of the lacteals, or other lymphatics.

# ART. VII.

## CHAP. I.

### NERVOUS SYSTEM.

THE *nervous system* is destined to regulate the functions of the animal economy, and to receive impressions of external objects, and transmit them to the understanding.

The nervous system consists of, 1st, the brain ; 2d, the medulla oblongata ; 3d, the spinal marrow ; 4th, the nerves ; 5th, the ganglia.

### GENERAL DIVISIONS OF THE NERVOUS SYSTEM.

There are two general departments, essentially distinct from each other, to which the nervous system may be referred ; the 1st *department* consists of the brain and its dependencies, the 2d, of the ganglia and their nervous radiations. The *first department* appertains particularly to animal life ; on the one hand it is the agent which transmits impressions calculated to produce sensations ; on the other hand it serves to convey the volitions to those organs which receive them. The *second department* is almost invariably distributed to the organs of digestion,

of circulation, respiration, and the secretions, and belongs in a more particular manner to the internal organs, where it acts a more obscure part than the preceding. The two departments frequently communicate with each other, but there is a sufficiently distinctive line to establish their difference; as a simple exposition of each will sufficiently demonstrate.

### 1. THE CEREBRAL DEPARTMENT OF THE NERVOUS SYSTEM.

This department of the nervous system, like all organs of animal life, is exactly symmetrical. The nerves commence alike from each side of the brain and spinal cord: hence the appellation of *pair of nerves*, by which the double corresponding trunk is described. This is a term which we cannot apply to the irregularly distributed ganglionic department.

Each department of the nervous system receives impressions of objects, and transmits them to the sensorium; and these impressions or affections of the nerves, accompanied by consciousness, bear the name of sensation. The nerves, which constitute the immediate instruments of sensation, are of different kinds, and are distributed in different proportions in the various organs of the body: most of them are capable of being excited by agents both from without and from within, and the impressions they receive are transmitted to the brain, their common centre, and frequently to the other organs with which they are connected. That the nerves are truly the organs of sensation cannot be disputed; for sensation is found to be most acute in those parts which are furnished with most nerves, and the sensation ceases when the nerves are destroyed. When the nerve is stimulated, the muscle which

it supplies is convulsed ; when it is tied, compressed, or divided, palsy of the muscle ensues.

My present arrangement of the departments of the nervous system, is chiefly founded on the anatomy and distribution of the nerves. And here science must acknowledge its obligation to Sir CHARLES BELL, for his important discoveries, relative to the functions of the nerves. So that, by the operation of new views, many formerly received opinions must be reformed, or altogether expunged. As I proceed, therefore, in the work, I shall endeavor to demonstrate, from anatomical and physiological facts, that every part of the system has its peculiar endowment of nervous matter, fitting it for the peculiar function it has to perform. For example, it is necessary to distinguish nerves into sensitive, motive, compound and organic, and in addition to the limited number of senses, usually reckoned in the human subject, there are other inward organs of sensation, which will subsequently be described, which have distinct functions, and depend on as distinct departments of the nervous system, as either seeing, hearing, or touch.

I shall now claim the attention of the reader to the general distribution of the nervous system.

The brain appears to be the most remarkable part of the nervous system, since all intellectual phenomena must be referred to the cerebral mass. This organ furnishes generally the motive for all our actions upon exterior bodies, exerts a greater or less influence upon all the properties of life, establishes an active relation amongst the different organs, and is the principal agent of sympathies. It is, moreover, in a sensible relation with the objects with which we are surrounded.

There are two orders of the cerebral department of nerves ; the 1st constitutes the nerves of sensation ; the 2d, the nerves of motion.

The nerves of sensation of the first order, which are immediately connected with the brain, are endowed with particular properties, which adapt them to the impression of special bodies; namely, the first pair of nerves perceives odours, the second light, the eighth sound; and the lingual branch of the inferior maxillary nerve distinguishes the taste and flavor of bodies. The special senses, however, I shall hereafter more particularly refer to.

The medullary column, or spinal marrow, appears next in importance to the brain. It is an irregularly cylindrical prolongation of the brain; it is not like the Grecian shaft, a simple column, but like the Gothic, a compound column, having several shafts combined. In other words, the spinal marrow is composed of four parts or cords, two on each side, which are united the whole length. From the anterior cord, of each side of the column, issue the nerves of motion; from the posterior cords, the nerves of sensation. There is another column, which is only continued the length of the medulla oblongata, from which the respiratory nerves take their origin.

The spinal nerves are perfectly regular in their derivation and distribution. There are thirty, or thirtytwo, on each side; this variation in the statement of the number depends on the method of reckoning. Each nerve commences by two distinct roots; Fig. 12, the one, *c*, proceeding

Fig. 12.

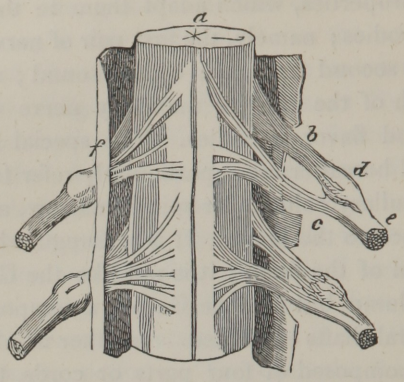


from the anterior; the other, *b*, from the posterior division of, *a*, the medullary column; and each of these roots is composed of a number of small filaments, which, immediately after their origin, approach each other; the posterior filaments form, *d*, a ganglion, and then join the anterior to form, *e*, a spinal nerve: each nervous filament must be considered as continuing distinct to its ultimate destination, though, by the union of the anterior and posterior, the several spinal nerves possess the double property of conveying sensation, and producing motion. There are other nerves of the fifth, sixth, and ninth, which are distributed separately, and are solely motive nerves, but the fifth nerve of the encephalon is like the spinal nerves, in having a double derivation, and a twofold function of sense and motion. Sir Charles Bell performed numerous experiments to prove the correctness of his theory, and these experiments have been repeated on the Continent by Magendie and others, who have been perfectly satisfied with the accuracy of

his conclusions.* It must, therefore, now be considered as an established fact, acknowledged by all anatomists, that the nerves, proceeding from the anterior cord of the spinal marrow, bestow the power of muscular motion; and that those which proceed from the posterior part of the medullary column, produce sensation. When, for instance, the roots of the anterior nerves of the leg are divided, the animal loses all the power of moving the leg, although the limb retains its sensibility; but, if the roots of the posterior nerves are cut, the power of motion continues, though sensibility is destroyed. The experiments have been repeated and varied, yet with similar results. Thus, on the posterior part of the spinal cord being irritated with a pointed instrument, the animal immediately manifested signs of pain; but no apparent effect was produced by irritating the anterior part. Every muscle, then, has two distinct orders of nerves; the one a motive, and the other a sensitive; and nerves of each of these orders are distributed to every muscular fibre.

It requires, therefore, for the full operation of muscular power, two different orders of filaments, and these establish a circle between the sensorium and the muscle; so that the nerves of the one order carry the influence of the will towards the muscles, which nerves have no power of transmitting an impression back again to the brain. The nerves of the other order connect the muscles with the brain, by acting as a sensitive agent in conveying the impression of the condition of the muscle to the common sensorium; but the last mentioned nerves have no operation in a direction from the brain to the muscle, and, in consequence, do not excite the muscle however irritated.

We find, however, that the brain and medulla spinalis,

* For details, I refer to the papers of Sir CHARLES BELL, in the Philo. Transac. of the Royal Society.

as also the nerves communicating with them, are endowed with different properties; the common design of which is to give us correct intelligence of the relative condition of our existence. The assemblage of these different parts has, consequently, with propriety, been called THE NERVOUS DEPARTMENT OF EXTERNAL LIFE, or of animal life. When the functions of this part of the nervous system are suspended, as by a fit of apoplexy, the individual is deprived of feeling, and is perfectly insensible to every surrounding object.

It has already been observed, that these nerves are endowed with two properties, viz.: sensibility, and vis-motrix; hence, it follows, that there must be nerves of sensation and motion. And physiological experiments, and the observations drawn from pathological anatomy, evidently prove, that sensation resides in the nervous filaments, connected with the posterior column of the medulla spinalis; and motion in those which are extended from the anterior column.

As general corollaries, the nerves of sensation receive the impressions which external agents produce upon us, and transmit them to the brain. If a ligature be applied around a nerve, or if the nerve be cut transversely, we find that sensation is totally destroyed in that part to which the nerve is distributed, because the brain is not in direct communication with it. "The brain, therefore, is the only organ that enables us to appreciate the objects which surround us; the senses being its advanced guards, and the nerves its media of communication."

1. The senses receive impressions.

2. The nerves convey impressions to the brain.

3. The brain perceives and judges, according as they appear useful, agreeable, or hurtful.

In conclusion it appears, that, without the due functions of the brain, we should neither possess external sensation,

nor be competent to execute any voluntary movement; consequently, it has been said, with much truth, that *the nervous system is, in fact, all the animal;** the other systems being vegetative and automatic, and existing only to nourish and defend it. Besides the properties of sensation and volition, which are common to other animals, man is distinguished from them by that faculty which he possesses from the Creator, of being able, by means of his nervous system, to compare, associate, and judge of the impressions which he does or has received, and to deduce from them the greatest consequences.

Possessing a faculty which constitutes the most beautiful and most noble attribute of our species, nature also ordained that its functions should correspond with the degree of perfection and extension of the cerebral mass. A deficiency in the general conformation of the brain, the slight developement of some of its parts, and the evident or obscure alteration occurring in its structure, are so many causes capable of deranging the whole or part of the intellectual faculties of man.† Anatomists and physiologists have failed in the attempt to trace the precise differences between the organization of the idiot and another man; though there is no doubt that the defect exists in the organization of the brain, since an idiot possesses a soul in common with another man.

## CEREBRAL DEPARTMENT OF THE NERVOUS SYSTEM.

### THE BRAIN IN GENERAL.

The brain is that mass which fills the cavity of the skull. It is distinguished by its divisions into the cerebrum,

* Baron Cuvier. † Manec.

the cerebellum, the pons VAROLII, and the medulla oblongata, all of which, in the adult, weigh about three pounds; occasionally the brain is found to exceed this weight by several ounces, according to the size of the head. In the dimensions of the brain there is a great difference in different individuals. The volume is generally in proportion to the mental capacity. Let us not suppose, however, that every person having a large head is necessarily a person of superior intelligence, for there are many causes of an augmentation of the head besides the size of the brain.

The color of the brain varies in different individuals and at different ages; the color probably depending on the quantity of blood sent to it: hence, it has a redder hue in early than in advanced life, and becomes still more deeply colored in consequence of inflammation.

The weight of the brain of a full grown man is about three pounds; that of a woman is somewhat less.

Baron WENZEL paid great attention to this department of anatomy, and has published a very interesting table, of which the subjoined is an extract.

| Age. | Weight of whole brain. | Weight of brain only. | Weight of cerebellum. | Proportion of brain to cerebellum. |
|---|---|---|---|---|
| | Grains. | Grains. | Grains. | |
| Male embryo of 5 months | 720 | 683 | 37 | $18\frac{17}{37}$ : 1 |
| Female embryo of 8 months | 4960 | 4610 | 350 | $13\frac{6}{35}$ : 1 |
| Girl at birth . . . . | 6150 | 5700 | 450 | $12\frac{2}{3}$ : 1 |
| Girl at 3 years old . . . | 15240 | 13380 | 1860 | $7\frac{6}{11}$ : 1 |
| Boy 3 years . . . . | 13050 | 11490 | 1560 | $7\frac{57}{156}$ : 1 |
| Man 18 years . . . . | 20940 | 18474 | 2466 | $7\frac{202}{411}$ : 1 |
| Man 31 years . . . . | 24120 | 21480 | 2700 | $8\frac{1}{21}$ : 1 |
| Man 54 years . . . . | 20580 | 18060 | 2320 | $7\frac{35}{81}$ : 1 |
| Man 63 years . . . . | 22500 | 19780 | 2720 | $7\frac{37}{116}$ : 1 |
| Man 72 years . . . . | 22620 | 20200 | 2420 | $8\frac{42}{121}$ : 1 |
| Man 80 years . . . . | 19080 | 16500 | 2580 | $6\frac{51}{129}$ : 1 |

Fig. 13.

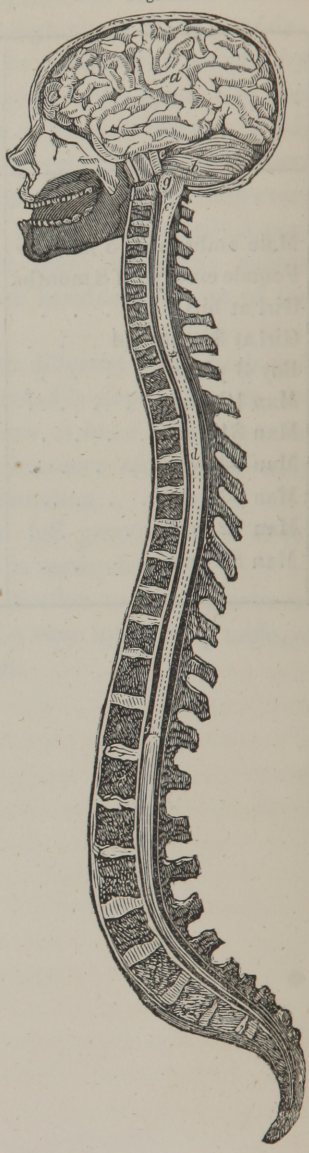


Fig. 13. The left side of the brain and spinal marrow, shown by making a section of the cranium and the spinal column, and removing the dura mater.

*a*, the convolutions of the cerebrum.

*b*, the laminæ of the cerebellum.

*e*, the pons VAROLII.

*g*, the medulla oblongata.

*c*, *d*, *f*, the medulla spinalis, extending from the first cervical to the first lumbar vertebra, and terminating in the cauda equina.

The *cerebrum* is the largest portion of the brain, and occupies the whole upper cavity of the skull. It rests anteriorly, upon the arches of the orbits; in the centre, upon the middle fossæ of the base of the skull; and posteriorly, upon the tentorium cerebelli.

### THE EXTERIOR OF THE CEREBRUM.

The upper surface of the cerebrum is divided into two parts, termed *hemispheres*, which are separated by the falx cerebri.

The surface of the cerebrum in general, both above and below, is intersected by deep fissures and eminences, which produce numerous turnings and windings, termed *convolutions*; these take a variety of directions, and differ in extent in different parts of the brain.

The convolutions are smallest at the anterior part of the brain, larger posteriorly, and are largest at the superior and central part of the hemispheres, where each convolution is about half an inch in breadth.

The number and size of the convolutions vary exceedingly in different individuals; and, indeed, they are seldom found the same in the two hemispheres. They extend into the substance of the brain about an inch, and are lined by prolongations of the pia mater.

The lower surface of the brain is formed into three distinct regions, which are named *lobes*. The anterior lobes are separated by the termination of the grand division which separates the hemispheres. On each of these lobes we observe a deep rectilinear groove, directed from behind forwards, for lodging the trunk of the olfactory nerve.

The anterior and middle lobes are separated by the *fissura* SYLVII.

Between these interlobular fissures, is the union or *commissure of the optic nerves*. Behind this commissure is the *cineritious tubercle*, which forms the floor of the third ventricle, and contains in its centre a small white nucleus.

From the middle of this tubercle, a sort of slender conical prolongation, of a reddish color, descends obliquely

forwards, named the *pituitary stem*.* It passes under the commissure of the optic nerve, and terminates in a small body, situated in the pituitary fossa of the sphenoid bone.

The *pituitary body*† is the small organ just alluded to. It has not the vascular structure peculiar to glands, but is composed of two portions: the first is of a grayish yellow color; the second is soft, and impregnated with a whitish viscid fluid. The pituitary body, in the adult, generally contains small calculus concretions.

The *corpora albicantia*, or mammalaria, are situated behind the cineritious tubercle; they consist of two small bodies of the form and size of peas, which are white externally, and of a gray color internally; they are united to each other by a small grayish band, which contributes to form the floor of the third ventricle.

### THE EXTERIOR OF THE CEREBELLUM.

The *cerebellum* is situated in the inferior fossæ of the occipital bone, under the posterior lobes of the cerebrum, and is separated from those lobes by the tentorium. It is about a sixth part of the size of the cerebrum, and has been compared to two depressed spheroids, placed beside each other on a horizontal plane. These are divided posteriorly by the falx minor. The surface of the cerebellum presents an assemblage of gray laminæ, over which the arachnoid membrane passes. Each lobe commonly has from sixty to sixtyfive of these laminæ. But, on separating these principal laminæ, we perceive many other smaller, concealed in the grooves, and partly covering each other.

* Formerly denominated the infundibulum.

† Formerly denominated the pituitary gland.

The *upper surface of the cerebellum* presents, on its fore and middle part, an elongated eminence, termed the *superior vermiform process*, which is formed by the reciprocal crossing of the laminæ, of which the two lobes of this organ are composed. The whole of the upper surface is occupied by five fasciculated lobules, common to both lobes, and disposed in transverse arched bands.

The *lower surface of the cerebellum* presents a deep depression in the middle line, named, the *valley*, in which is lodged the commencement of the spinal marrow; posteriorly, it is divided into two, by a large eminence, called the *inferior vermiform process*. Anteriorly, it is terminated by a narrow rounded prolongation, named the *mammillary eminence* of the inferior vermiform process.

The inferior part of the cerebellum presents a convex surface, on which we may distinguish four lobules, which describe concentric arches. At the outer side of the first lobule is a small foliated tuft, distinguished by the smallness of its laminæ, named, the *lobule of the par vagum*.

### THE EXTERIOR OF THE PONS VAROLII.*

The *pons* VAROLII forms as it were the centre of the brain, and of which it weighs only the sixtieth part. It is placed between the cerebrum and cerebellum, and is formed by processes from them, termed their *crura*.

The *anterior surface of the pons* VAROLII is named, by GALL, the *commissure of the cerebellum*. Along the median line we observe a depression occasioned by the situation of the basilar artery.

The *posterior surface of the pons* VAROLII presents, on its upper part, four tubercles, which are white externally,

* Tuber annulare, or nodus cerebri.

and gray internally; these are termed the *tubercula quadragemina*. The two upper are named the *nates*, the two lower the *testes*. The pineal body corresponds to the point of intersection of the two grooves which separate the tubercles. Behind the tubercula quadragemina is a pulpy lamina, of a grayish color, which ascends towards the cerebellum, called the *valvula* VIEUSSENII. Behind the point where it leaves the pons VAROLII, we may observe an aperture, which is the posterior orifice of the *aqueduct of* SYLVIUS, by which the third and fourth ventricles communicate across the substance of the pons VAROLII. Farther down, is a slightly excavated surface, which forms the anterior part of the fourth ventricle. It is separated in its whole length by a narrow angular groove, which commences at the aqueduct of SYLVIUS, and terminates in the spinal marrow opposite the atlas. This groove is called the *calamus scriptorius*, from its supposed resemblance to a pen.

### THE MEDULLA OBLONGATA.

The *medulla oblongata* is that portion of the cerebral formation, which extends from the pons VAROLII, to the great foramen of the occipital bone.

Upon the surface of the medulla oblongata there are two small eminences, which run longitudinally, and contiguous to each other, and from their form have obtained the name of the *corpora pyramidalia*. Between these eminences there is a deep fissure, into which the blood-vessels of the pia mater penetrate, to supply the interior of the medulla.

On the outside of the former eminences are two others, which, having somewhat the figure of olives, they are termed the *corpora olivaria*.

Fig. 14.

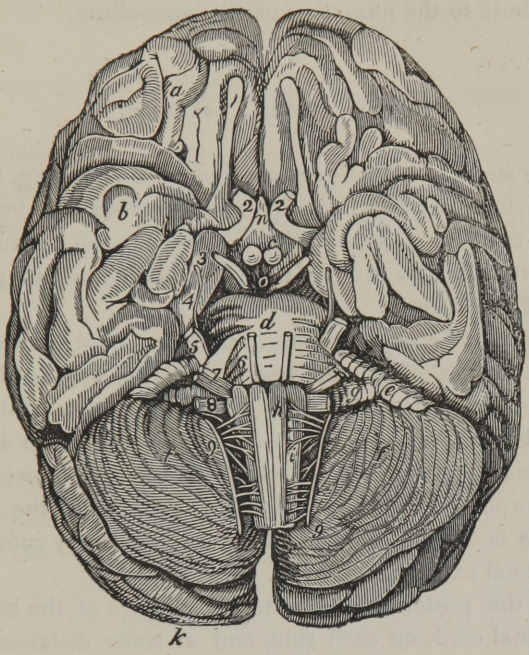


Fig. 14, the base of the brain.

*a*, the anterior lobes. *b*, the middle lobes.

*k*, the posterior lobes. *n*, the pituitary stem.

*c*, the corpora albicantia, or mammallaria.

*d*, the pons VAROLII.

*h*, *h*, the medulla oblongata. The letters are placed on the corpora pyramidalia.

*f*, the cerebellum.

*i*, *i*, the corpora olivaria.

*e*, the superior vermiform process.

*g*, the inferior vermiform process.

The *posterior surface* of the medulla oblongata is directly continuous with the pons VAROLII, and contributes to form the fourth ventricle. On each side of the upper and back

part of the medulla oblongata, we observe two whitish oblong eminences, named the *corpora restiformia*, which contribute to the formation of the cerebellum.

### THE MEDULLA SPINALIS.

The *medulla spinalis* or *spinal marrow* is a long, irregularly cylindrical cord, which extends within the vertebral canal, from the great occipital foramen, to the second lumbar vertebra. Its weight is about one-twentieth part of that of the brain.

The *anterior surface* of the medullary cord corresponds to the bodies of the vertebræ. A very deep and distinct fissure is extended its whole length, dividing it into two equal lateral portions. Its *posterior surface* is also divided by a similar median line, which commences between the two corpora restiformia. By this disposition, the spinal marrow is divided into a double cord, intimately connected in its total extent.

On the posterior and anterior surfaces of the body of the spinal cord, on each side, and at some distance from the median groove, are collateral depressed lines, in which we find the roots of the spinal nerves.

Finally, it presents a great number of small transverse grooves particularly apparent from the last cervical to the ninth dorsal vertebra.

The exterior of the spinal cord consists of a layer of white substance, half a line thick, and after immersion in alcohol, this peels readily into longitudinal fibres, which are separable into filaments that continually branch, and thus attach themselves to those adjoining.

Upon making a *transverse section* of the spinal cord, a thin curved layer of gray matter is seen in each lateral

half, the convex margin of which is inwards, and is joined to its fellow by a transverse layer.

### THE INTERNAL ORGANIZATION OF THE BRAIN.

The brain is soft and pulpy, but its density varies according to the age. In infancy it is extremely tender and yielding, and it acquires firmness as the person advances in life. Its specific gravity, in the adult, is 1310. The cerebral tissue is soluble in water, insoluble in alcohol and fixed oils.

### CHEMICAL ANALYSIS OF THE BRAIN.

According to M. Vauquelin there is no difference of composition in the different parts of the nervous system: the analysis of the brain, of the cerebellum, of the spinal marrow, and the nerves gives the same result. He found in them all the same matter, the composition of which is of

| | |
|---|---|
| Water, . . . . . | 80·00 |
| White fatty matter, . . . | 4·53 |
| Red fatty matter, . . . | 0·70 |
| Osmazome, . . . . . | 1·12 |
| Albumen, . . . . . | 7·00 |
| Phosphorus, . . . . . | 1·50 |
| Sulphur and salts, such as Phosphate of potass, . " of lime, . . " of magnesia, | 5·15 |

The substance of the brain presents two distinct modifications.

1st. The *cortical* or *cineritious substance* covering the brain in general, about the sixth of an inch in thickness; it also enters deep between its convolutions, and is distributed through different parts of its interior. This part of the brain, when examined with a microscope, appears to consist of minute molecules, smaller than the red particles of the blood. They are connected together by a transparent tissue, containing a serous fluid, and supplied with very minute and infinitely numerous blood-vessels.

2d. The *medullary* or *white substance* is firmer and denser than the former; its mass is also much greater than that of the corticular substance, and is filled with a great quantity of vascular ramifications, which, on making a section of the brain, present so many red points with the blood oozing from them.

All the fasciculi of medullary fibres placed in the medulla oblongata, appear to expand so as to form the mass of the brain; and more especially to originate from the pyramidal and olivary eminences. The fibres of the former on the one side proceed to the opposite side, crossing each other, and progressively acquiring more volume as they ascend to form the cerebral mass.

These two substances of the brain do not constitute one homogeneous mass, but are arranged into a great variety of eminences, cavities, laminæ, partitions, etc. differing in their color, consistence, and volume. I shall now proceed to demonstrate the brain in each of these particulars, not by attempting to unfold the structure in the manner of Reil and Spurzheim, but shall describe the several parts as they are exhibited in the recent and most familiar modes of dissection.*

The *corpus collosum* or *commissura magna* is the centre

* In order to exhibit the fibrous and lamelated structure of the brain, it must be immersed for a requisite time in alcohol.

of communication between the hemispheres: it is seen, without making an incision, by merely separating these hemispheres with the fingers. It consists of a large portion of medullary matter, which by transverse fibres, incorporates and unites the two lateral divisions of the cerebrum.

The *centrum ovale* is the appearance which is exhibited when the brain is cut horizontally, on the level of the corpus callosum; the corpus callosum constitutes the centre of the great medullary mass of the cerebrum, and the cortical substance, being on its edges, forms the central white mass into an irregular oval.

In the middle of the corpus callosum there is a longitudinal line called the *raphe;* it has a medullary cord on each side, from which numerous short transverse lines proceed, termed the *transverse medullary traces.*

Fig. 15.

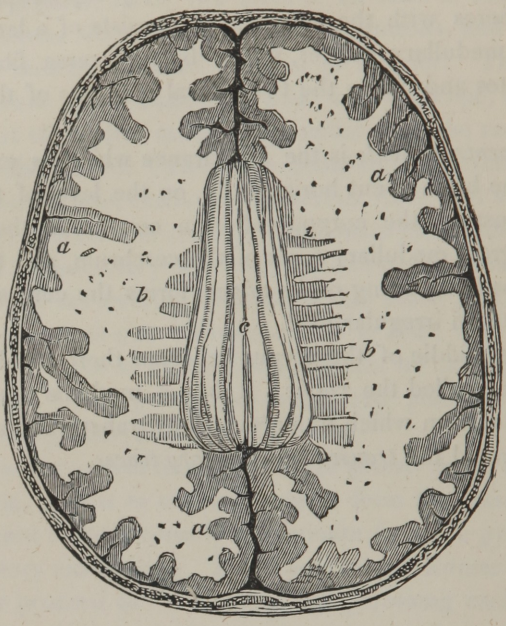


Fig. 15, a transverse section of the brain, upon a level with the corpus callosum.

*a*, *a*, *a*, the corticular part of the convolutions, with the fissures between them.

*b*, *b*, the medullary part, forming the centrum ovale of Vieussens.

*c*, the raphe, on each side of which are longitudinal elevated lines, and transverse striæ.

In the substance of the brain we find four cavities termed the *ventricles*.

There are two *lateral ventricles*, one is situated in the central part of each hemisphere. They are of an irregular form, lying under the centrum ovale, and each having three winding prolongations termed *cornua*. The anterior cornua are separated from each other by a partition, called

the *septum lucidum;* the posterior cornua are at a considerable distance from each other, but as they curve inwardly and dip into the middle lobes of the brain, they approach nearer at their pointed extremities. The cavities of these ventricles are principally situated between the corpus callosum and the corpora striata, and thalami nervorum opticorum.

Fig. 16.

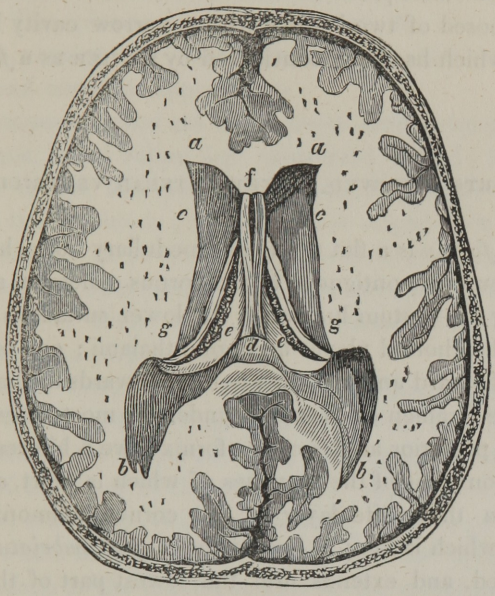


Fig. 16, a horizontal section of the cerebrum, a little deeper than in Fig. 15.

*a*, *a*, the anterior cornua of the lateral ventricles.

*b*, *b*, the posterior cornua.

*c*, *c*, the corpora striata.

*e*, *e*, the optic thalami.

*f*, *d*, the septum lucidum, showing the fissure termed the fifth ventricle and extending between the two letters,—

*g*, *g*, the choroid plexus.

The lateral ventricles communicate with each other, and with the third ventricle by an opening, named the *foramen* MONROIANUM, under the arch of the fornix.

The *septum lucidum*, or septum of the ventricles, is a soft and thin medullary production, which is continuous above with the middle part of the inferior surface of the corpus callosum; inferiorly, it is connected with the fornix, and forms a distinct partition between the lateral ventricles. It is composed of two laminæ with a narrow cavity between them, which has been considered by CUVIER as a *fifth ventricle*.

### PARTS OBSERVED IN THE LATERAL VENTRICLES.

The *fornix* is a flat triangular medullary body, having its upper surface contiguous to the corpus callosum, and supporting the septum lucidum. Its lower surface is situated upon the choriod plexus and optic thalami; one of the angles is forward and the other two are towards the back part; and the foramen of MONRO is under the most anterior part.

The posterior angles of the fornix have a bifurcated prolongation; one of the branches of which is short, and loses itself in the white layer of the cornua ammonis. The other, which is long, is named the *corpus fimbriatum*; it is flattened, and extends into the lowest part of the lateral ventricle.

The *corpora fimbriata*, or *tænia hippocampi*, are the plaiting of the margin of the processes of the fornix, which pass into the inferior cornua of the ventricles.

The *pes hippocampi*, or cornu ammonis, is found at the termination of the line called tænia hippocampi, at the posterior prolongation of the fornix.

The *psalterium*, or *lyra*, consists of numerous transverse lines, which are impressed upon the under surface of the posterior part of the body of the fornix.

The *choroid plexus* is displayed by dividing the body of the fornix and inverting it. This plexus consists of a spongy mass of tortuous vessels and reddish granulations, covering the optic thalami and corpora striata, and continued into the inferior cornua of the lateral ventricles. The plexus of each side is connected to its fellow by the *velum interpositum*, a vascular membrane which passes under the fornix, and lies on the third ventricle and corpora quadrigemina. The plexus returns its blood by two parallel branches, termed the venæ GALENI; these veins run backwards, and enter the sinus rectus.

The *corpora striata* are two smooth cineritious pyriform eminences, broad before and contracted behind; they are situated in the fore part of the lateral ventricle. Their color at the outside is gray, somewhat tinged with brown; but on cutting them obliquely, cineritious and medullary substances are seen disposed in their interior, in alternate streaks. The white fibres may be traced to the original fasciculi of the corpora olivaria.

The *optic thalami* are two oval medullary eminences, placed by the side of each other, between the diverging extremities of the corpora striata; their upper surface forms a part of the floor of the ventricles; their lower surface presents, externally, two prominences. The *corpora geniculata*, which furnish several filaments to the optic nerve, may be seen at the inferior surface of the cerebrum.

The *commissura mollis* is a band of a gray color, connecting the convex surfaces of the optic thalami.

The *tænia semicircularis* is a line of white semitransparent substance, running between the convex surface of the optic thalami and the corpora striata.

Fig. 17.

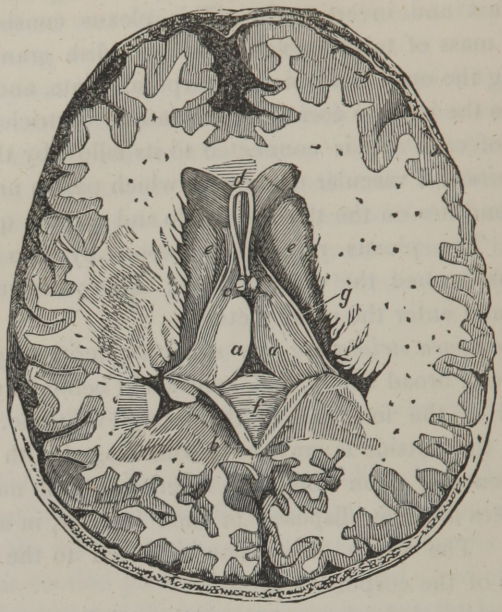


Fig. 17. *a*, *a*, the optic thalami, on the outer margin of which is seen the tænia semicircularis.

*e*, *e*, the corpora striata.

*d*, the cavity (termed the fifth ventricle) which exists between the two laminæ of the septum lucidum.

*c*, the anterior pillars of the fornix cut off at their base.

*b*, the fornix turned back, shewing on its inferior surface—

*f*, the lyra.

*g*, the tænia semicircularis or white line separating the surface of the corpora striata and the thalami.

The *commissura anterior cerebri* is a short cylindrical medullary cord, extending transversely between the corpora striata, immediately under the anterior prolongations of the fornix.

The *vulva* is a small aperture formed by the anterior prolongations of the fornix, bifurcating and adhering on each

side, between the corpus striatum, and the thalamus nervi optici. This aperture is the part by which the three ventricles communicate.

The *third ventricle* is situated between the optic thalami and the crura cerebri; it is a deep fissure. At the upper and fore part it communicates with the lateral ventricles, and, at the lower part, with the infundibulum. The latter opening is called *iter ad infundibulum*. A canal extends backwards under the tubercula quadrigemina, into the fourth ventricle. This passage is called the *aqueduct of* SYLVIUS.

The *anus*, or *foramen commune posterius*, is situated behind the commissure of the optic thalami, and is the anterior aperture of the aqueduct of SYLVIUS.

The *commissura posterior* is a transverse cord at the posterior part of the third ventricle.

The *pineal gland* is situated beneath and behind the fornix, and above the tubercula quadrigemina; it is a small grayish body of the size of a pea; it is perfectly isolated from the cerebral substance, excepting at the fore part, where it is connected to the optic thalami by two medullary cords,—the *peduncles of the pineal gland*. In the adult it contains little calculi, very hard and resembling grains of coarse sand.

### THE INTERNAL STRUCTURE OF THE CEREBELLUM.

The substance of the cerebellum is composed of cineritious and medullary matter, as in the cerebrum. The cineritious, however, bears a much greater proportion in the former than in the latter.

The *arbor vitæ* is a beautiful tree-like appearance, which we observe on making a vertical section of the cerebellum. This appearance is formed by the peculiar arrangement of medullary and cineritious matter.

The *corpora restiformia* are processes of medullary matter, which extend from the medulla oblongata to the medullary crura of the cerebellum.

The *fourth ventricle* is the ventricle of the cerebellum; the sides of this cavity are formed by it, the anterior part by the medulla oblongata, and the upper and back part by the valvula VIEUSSENII.

The *calamus scriptorius* is the groove and its pointed termination in the fourth vetricle, which VESALIUS conceived to have a great resemblance to a writing pen.

The aqueduct of SYLVIUS enters the upper part of this ventricle, and the valvula VIEUSSENII hangs over it.

Fig. 18.

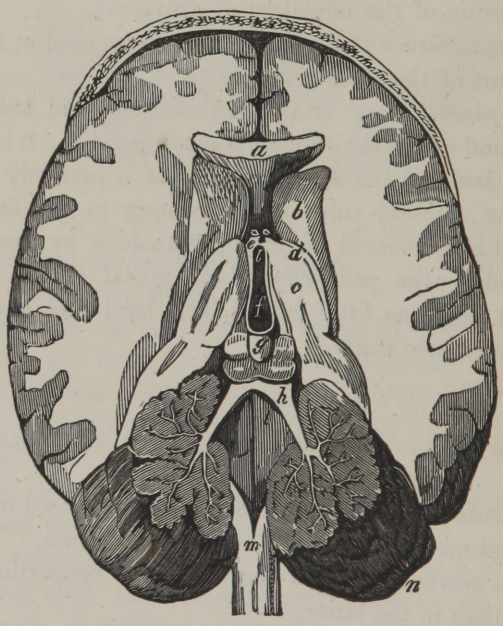


Fig. 18, a horizontal section of the cerebrum and an oblique division of the cerebellum.

*a*, the anterior part of the corpus callosum.

*b*, the corpus striatum.

*c*, the optic thalamus.

*d*, the tænia semicircularis.

*e*, the anterior pillars of the fornix cut off at their base.

*f*, the commissure of the optic thalami.

*g*, the pineal gland, situated on the four eminences, termed the corpora quadrigemina.

*h*, valvula VIEUSSENII.

*k*, the arbor vitæ shewn by an oblique section of, *n*, the cerebellum.

*l*, the fourth ventricle, terminating in,—

*m*, the calamus scriptorius.

*n*, the cerebellum.

The arteries of the cerebrum and cerebellum are branches of the internal carotid and vertebral arteries, from the latter of which arises the basilar artery; ramifications of these vessels communicate with each other, and form, what is termed, the *arterial circle of* WILLIS.

The spinal marrow receives its arteries from the vertebral, dorsal, lumbar, and sacral arteries.

The veins of the brain are very delicate in their structure; they communicate with the sinuses of the dura mater, and the sinuses pour their contents into the internal jugular veins.

The veins of the spinal marrow terminate in the vertebral, dorsal, lumbar, and sacral veins.

No lymphatic vessels have yet been discovered in the brain.

Fig. 19.

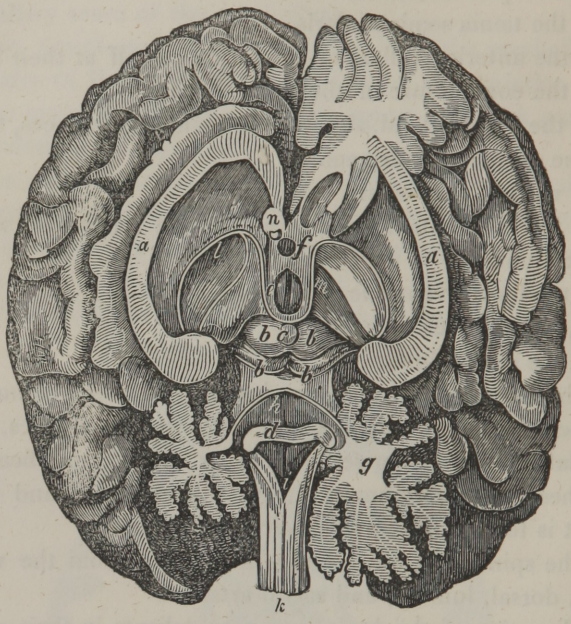


Fig. 19, exhibits the brain placed on its base, with a vertical incision made through the corpus callosum, as far as the anterior commissure, and continued posteriorly to the tubercula quadrigemina. The hemispheres are separated from each other and turned to each side. The septum lucidum and fornix are removed. The cerebellum, in a similar manner, is divided as far as the fourth ventricle.

*a*, *a*, the cut edges of the corpus callosum.

*b*, *b*, *b*, *b*, the tubercula quadrigemina.

*c*, the pineal gland.

*d*, medullary striæ in the fourth ventricle, which form the beginnings of the auditory nerves.

*e*, the third ventricle.

*f*, part of the pituitary stem.

*g*, the medullary portion of the cerebellum.

*h*, the fourth ventricle.

*i*, the calamus scriptorius, at the inferior part of the fourth ventricle.

*k*, the medulla spinalis.

*l*, the tænia semicircularis.

*m*, the peduncle of the pineal gland.

*n*, a section of the anterior commissure of the brain.

The brain is the primary organ of sensation ; the mind is supposed to be most immediately and intimately connected with it, and, from observations and experiments, it is found to communicate nervous influence to all the other parts of the body. That the brain is the organ of the mind, is evident by the connection between the brain and the organs of sense, by our consciousness, and by the mental disturbance which ensues under disease of the brain. In asserting, however, that the brain is the organ or instrument of the mind, it is not intended to convey an idea that the mind is material, but that the exercise of the mental powers depend on the living brain.

## CHAP. II.

### THE MEMBRANOUS ENVELOPES OF THE BRAIN.

The membranes of the brain are called *matres* by the ancients, from a notion that they gave origin to all the other membranes of the body : no argument is required to refute so absurd an opinion.

The membranous envelopes of the brain consist of the *dura mater*, the *tunica arachnoidea*, and the *pia mater*.

#### 1. THE DURA MATER.

The *dura mater* is the outermost envelope of the brain ; it is common to that organ and to the skull, that is, it incloses the brain and its appendages, and performs the office of an internal periosteum to the cranium.

This membrane is of a very firm and compact texture ; it is composed of tendinous-like fibres, which have a glossy, semitransparent, and pearly appearance. It is divisible by maceration into two or more fibrous layers.

The *outer surface* of the dura mater adheres rather loosely to the bones of the skull, and is easily detached from them ; but at the sutures and foramina it is more firmly connected than elsewhere.

The *inner surface* of the dura mater is remarkably smooth, and forms several folds, which are named the *falx cerebri*, the *tentorium cerebelli*, and the *falx cerebelli*.

The *falx cerebri* is a duplicature or process of the dura mater, and has some resemblance in shape to the blade of a sickle, from which circumstance it has obtained the name of falx. It separates the two hemispheres of the brain from each other. Its upper edge, which is extended from the frontal ridge to the middle groove of the occipital bone,

lodges the superior longitudinal sinus. Its lower edge passes over the corpus callosum, and contains the inferior longitudinal sinus. Its anterior extremity is attached to the crista galli; the posterior is continued into the tentorium, and contains the straight sinus.

The *tentorium cerebelli* is a membranous partition which separates the cerebrum from the cerebellum. Like the falx cerebri, it is in a continual state of tension. Its outer circumference contains the lateral sinus, and is connected to the edges of the lateral groove of the occipital bone. The inner edge corresponds to the cerebral protuberances. The extremities of the tentorium meet at an acute angle, and cross over each other, like the letter X, to be attached to the clinoid processes of the sphenoid bone.

The *falx cerebelli* is a process of the dura mater, which is placed between the lobes of the cerebellum, and is extended from the internal occipital protuberance, to the great occipital foramen.

The dura mater is evidently fibrous, and its fibres are very apparent in the folds just mentioned, and, in particular, at the upper part of the falx cerebri. Some minute nervous filaments have been discovered in the course of the arteries of the dura mater. The blood vessels are not very numerous. The principal branches of the arteries are distributed upon the external surface; minute ramifications only being observed on its inner surface. The smaller veins of this membrane accompany the arteries, the larger veins constitute the sinuses which I am about to describe.

### SINUSES OF THE DURA MATER.

The sinuses of the dura mater are merely the large veins of the brain, which are received into triangular canals of the dura mater; they vary in their dimensions, and are dis-

posed in a regular symmetrical manner. They are formed externally by the dura mater, and internally by a smooth membrane, similar to that which is met with in the veins. As they are constantly stretched in all point of their extent, they can neither change their situation nor contract upon themselves. They are remarkable for having at intervals fibrous bridles, which pass irregularly from side to side of the canal. All the veins of the dura mater and of the brain pour their blood into the sinuses.

Fig. 20.

Fig. 20, *a*, a transverse section of the superior longitudinal sinus.

*b*, a similar section of the inferior longitudinal sinus.

*c*, a portion of the cranium.

The *superior longitudinal sinus* is a long triangular canal, which, commencing at the crista galla of the ethmoid bone, and extending along the upper edge of the falx cerebri, becomes gradually larger in its progress, and terminates in the lateral sinuses.

The *inferior longitudinal sinus* is much smaller than the preceding, and is situated at the inferior margin of the falx, extending from its anterior third to the tentorium cerebelli, terminating posteriorly by two branches in the straight sinus.

The *torcular* HEROPHILI* is an irregular cavity situated at the union of the three great folds of the dura mater; it presents six apertures, viz.: 1st, that of the superior longitudinal sinus; 2d, two inferior, corresponding to the occipital sinuses; 3d, one anterior belonging to the straight sinus; 4th, two lateral openings on the right and left leading into the lateral sinuses.

The *straight sinus* is situated at the base of the falx; it is a continuation of the vena GALENI, and extends from

* The term *torcular* was originally applied, from a supposition that the blood is squeezed in this sinus as in a wine press.

the termination of the inferior longitudinal sinus to the torcular HEROPHILI.

The *occipital sinuses* are situated on the sides of the occipital foramen, and passing into the falx cerebelli, open into the torcular HEROPHILI.

The *lateral sinuses* are very large, and extend from the torcular HEROPHILI to the commencement of the jugular veins, occupying the lateral grooves of the occipital bone, as far as the foramen lacerum posterius.

The *coronary sinus* surrounds the pituitary fossa; it is very small in its whole course, and opens to the right and left into the cavernous sinuses.

The *cavernous sinuses* are very broad and short; they are situated in the lateral grooves of the sphenoid bone. They commence beneath the anterior clinoid processes, and terminate in the inferior petrous sinuses. The outer parietes of this sinus contain, in their substance, the common motor, the pathetic, and ophthalmic nerves. The cavity of the cavernous sinus is occupied by a number of reticulated filaments; the internal carotid artery, and the external motor nerve of the eye.

Beneath the pituitary body the two cavernous sinuses communicate by the *sinus transversalis sellæ turcicæ*.

The *superior petrous sinuses* extend from the termination of the preceding sinuses, towards the summit of the petrous portion of the temporal bone, and open into the lateral sinuses.

The *inferior petrous sinuses* extend from the cavernous sinuses, to the inferior edge of the petrous and basilary processes, and terminate in the lateral sinuses.

The *anterior occipital sinus* forms a communication between the two petrous sinuses and the cavernous sinus, by extending transversely, at the upper part of the basillary process.

Fig. 21.

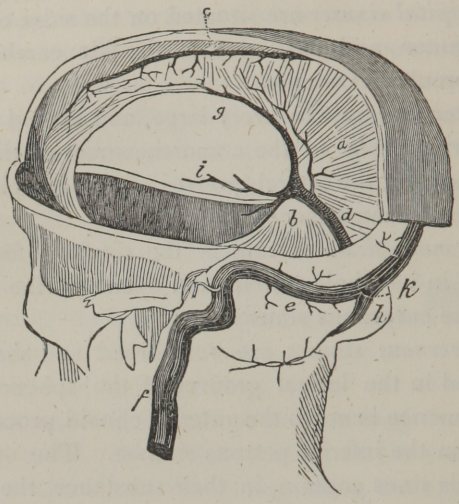


Fig. 21. A lateral view of the veins of the processes of the dura mater, termed the sinuses.

*a*, the falx.
*b*, the tentorium cerebelli.
*c*, the superior longitudinal sinus.
*d*, the straight sinus.
*e*, the lateral sinus.
*f*, the internal jugular vein.
*g*, the inferior longitudinal sinus.
*h*, the occipital sinus.
*i*, the vena GALENI.
*k*, the torcular HEROPHILI.

### 2. THE ARACHNOID MEMBRANE.

The *arachnoid membrane* is situated between the dura mater and pia mater; it has been named arachnoid, from

its extreme thinness, resembling a spider's web; it is extended over the convolutions of the cerebrum, the cerebellum, and the base of the pons VAROLII.

The *exterior arachnoid membrane* does not adhere to the other membranes of the brain, for it can be very easily raised by insufflation with a blow pipe; it possesses no apparent vascularity, but is constantly moistened with a serous fluid, and forms a sheath or envelope for all the nerves and all the vessels which enter or issue from the skull. This membrane also passes downwards into the vertebral canal, around the spinal marrow, and furnishes a conical sheath for each of the vertebral nerves.

The *interior arachnoid membrane* is continuous with the preceding; penetrating into the third ventricle by a small oval opening, found between the corpus callosum and tubercula quadrigemina, and lining the third ventricle, and extending over the choroid plexus, it is continued over the parietes of the lateral and fourth ventricles, into which it passes through the aqueduct of SYLVIUS.

### 3. THE PIA MATER.

The *pia mater* is the third membrane of the brain; it is a cellular, loose, transparent web, in which a multitude of blood vessels, more or less delicate, cross each other in a thousand different directions, and it is attached to the surface of the brain by the minute branches of these vessels, which penetrate into the latter organ. It invests the brain on all sides, dipping into the convolutions of the hemispheres, and covering the superior surface of the corpus callosum; covering inferiorly the base of the brain and the pons VAROLII: it is also reflected over the cerebellum, and sinks between its concentric laminæ.

The pia mater penetrates into the third and lateral ventricles by the great fissure, which is situated between the corpus callosum and the pons VAROLII, and by the two lateral fissures. It forms, 1st, the *choroid web*, a triangular membranous prolongation, lining the posterior part of the corpus callosum, and the inferior surface of the fornix, to which it adheres by numerous small vessels. 2d, the *choroid plexus*, an elongated fold of the pia mater, having an appearance of vascular cords, attached to the choroid web, and extending into the lateral ventricles, along the sides of the fornix; this plexus communicates with that part of the external pia mater which descends between the thalami of the optic nerves and the fimbriated bodies. We perceive in the choroid plexus a number of small granulations which many anatomists have considered as glands; but CHAUSSIER asserts that they are membranous fringes, which may be unfolded by agitating them in water. We also occasionally find among the vessels of this plexus small vesicles filled with serum.

### GRANULATIONS OF THE MEMBRANES OF THE BRAIN.

On the various parts of the dura and pia mater, there are small whitish bodies, of the intimate texture and office of which we are entirely ignorant.

The superior longitudinal sinus contains a great number of these granulations; they are designated by the name of the *glands of* PACCHIONI.

Sometimes a few of them are found in the torcular HEROPHILI, and at the orifices of the venæ GALENI. All the other sinuses are destitute of them.

Graniform bodies, similar to those met with in the sinuses, are also found in the pia mater, especially about

the outside of the superior longitudinal sinus, and around the cerebral veins.

The internal pia mater contains some of these granulations; they are also observed in the choroid plexus, the velum interpositum, and in the web of the fourth ventricle.

### THE PROPER MEMBRANE OF THE SPINAL MARROW.

The character of this membrane is sufficiently marked to distinguish it from the pia mater. It is not, therefore, a continuation of the latter, but a strong and somewhat fibrous tissue, of a yellowish color, corresponding, by its external surface, to the arachnoid, without uniting with it; laterally it is continuous with the neurilemma of the vertebral nerves, and ligamentum denticulatum. By its internal surface it is adherent to the spinal marrow.

### LIGAMENTUM DENTICULATUM.

The *ligamentum denticulatum* is a whitish, transparent, thin, but strong band, extending, on each side, between the anterior and posterior roots of the vertebral nerves, from the occipital foramen, to the termination of the spinal marrow. In the interval of each cervical and dorsal pair of nerves, its external border presents twenty or twenty-two denticulated portions, the points of which are fixed to the dura mater. Its internal border adheres to the proper membrane of the spinal marrow. Its use appears to be to keep the spinal marrow steady in its canal.

### THE NERVES IN GENERAL.

The nerves are either cylindrical or flattened white cords, which are extended from the brain, or from the spinal marrow, to every part of the system.

All the nerves are arranged symmetrically and in pairs, and are composed of a greater or less number of filaments, connected together by cellular tissue. The filaments which terminate the branches of the nerves unite with other nervous filaments, or elude our observation in the tissue of the organs which they supply. Fig. 22, a portion of a

Fig. 22.

nerve invested with its neurilemma, and consisting of distinct filaments, one of which is drawn out.

If two or more nervous branches are connected together by numerous filaments sent to each other, so that there results a sort of net-work, the name of *plexus* is given to this distribution. Fig. 23, is an instance drawn from the *axillary plexus.*

Fig. 23.

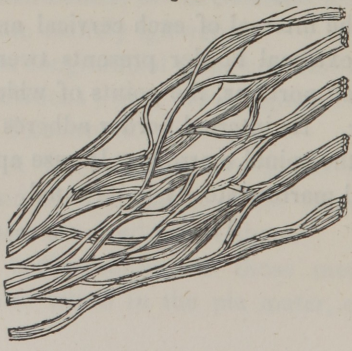

Most of the nerves are composed of a greater or less number of cords, formed of filaments of the same nature. On separating these cords and fibres, we perceive that they send frequent branches to each other, so as to form a kind of plexus in the very substance of the nerve.

The *neurilemma* is the external membrane which forms a canal for the white medullary matter of the nerve: this may be readily shewn by immersing a nerve in an alkaline solution, by which the medullary matter is removed; and the nerve appears like a fasciculus of tubes. The olfactory nerve has no neurilemma, and it is only found round the optic nerve after its commissure.

The nerves are amply supplied with blood vessels, which are distributed on their surface, and penetrated into their substance, and between their component fasciculi.

In some of the principal nerves absorbent vessels may be traced, and reasoning from analogy, we may conclude that there are no nerves destitute of them.

## NERVES OF THE CEREBRAL DEPARTMENT.

By the older anatomists, the cerebral nerves were divided into nine pairs; the facial and auditory nerves being termed the seventh pair, and the eighth consisting of the glosso-pharyngæal, par vagum and the spinal accessory. The division at present adopted, is into twelve pairs.

### OLFACTORY NERVES, OR FIRST PAIR.

The *olfactory nerves* are very soft in their texture, and after death are soon decomposed; they should, therefore, be demonstrated in a recent subject. They are connected to the brain by three filaments; the 1st, is external and

medullary, and is in union with the corpus striatum ; the 2d, internal and medullary, is united to the white substance which occupies the internal part of the fissure of SYLVIUS ; the 3d is cortical, and is situated at the point of junction of the two preceding, uniting to them by its summit. At the point of their union, the olfactory nerve presents a triangular enlargement. Fig. 24, *a*, extending

Fig. 24.

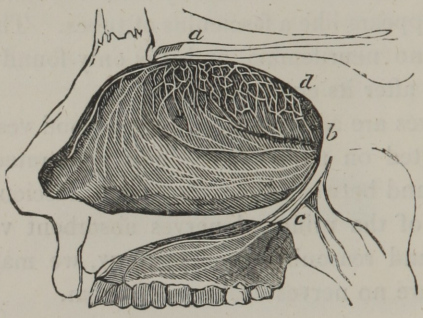


horizontally forwards and inwards, and dividing into a greater or less number of branches which traverse the foramina of the cribriform plate of the ethmoid bone, to be distributed at *d*, on the turbinated bones of the nasal fossa, the septum narium, and the roof of the nasal fossa.

This nerve transmits to the brain the impression which odours produce upon the pituitary membrane.

### OPTIC NERVES, OR SECOND PAIR.

The *optic nerve*, with the exception of the trifacial nerve, is the largest nerve that issues from the cranium. It is connected to the optic thalami and the tubercula quadrigemina by two bands, which are extended from these eminences to the optic thalami. The two nerves unite

in front of the pituitary fossa, and are so confounded with each other, as to render it impossible to affirm, in a positive manner, whether they cross each other, as many anatomists have supposed, or whether their substance is mingled and identified at their union; the latter opinion is most probable.

The optic nerves afterwards separate; each nerve being perfectly cylindrical, isolated and enveloped in a neurilemma; it then passes through the optic foramen, and surrounded by the recti muscles in the orbit, arrives at the posterior and inner part of the globe of the eye; entering the sclerotic and choroid membranes, it terminates in the retina.

### THIRD PAIR OF NERVES.

The *third pair*, or *motores oculorum*, Fig. 25, *a*, are smaller than, *c*, the optic nerve; each nerve is attached to the back part of the crura cerebri, by filaments which are

Fig. 25.

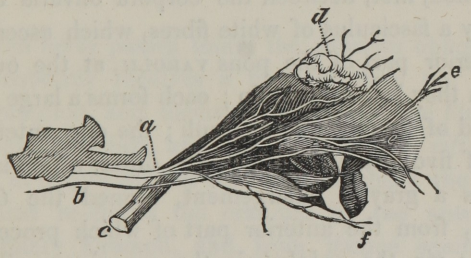


soon collected into their several trunks. These pass on the upper part of the cavernous sinus, on the outside of the foramen lacerum, into the orbit, and divide into the following branches: 1st, the *superior branch*, *e*, *e*, which is

distributed to the superior rectus and levator palpebræ; 2d, the *inferior branch, f,* which supplies the other recti muscles; 3d, a filament to the lenticular ganglion, and inferior oblique muscle.

### FOURTH PAIR OF NERVES.

The *fourth pair of nerves* or *nervi pathetici, b,* are the most slender of the body. Each nerve is attached by three or four filaments, beneath the tubercula quadrigemina, and the lateral part of the valve of VIEUSSENS. This nerve turns round the crus cerebri, perforates the dura mater at the edge of the tentorium, passes the cavernous sinus on the outer side of the third nerve, and proceeds through the foramen lacerum, to supply the superior oblique muscle of the eye.

### FIFTH PAIR, OF TRIFACIAL NERVES.

The *trifacial nerves* are the largest of the brain; they are attached, first, between the corpora olivaria and restiformia by a fasciculus of white fibres, which ascend above the posterior part of the pons VAROLII, at the outer edge of which they leave the brain; each forms a large flat cord, composed of two distinct fasciculi; the one anterior, consisting of five or six filaments; the other, which is posterior, forms a grayish enlargement, termed the *Gasserian ganglion,* from the anterior part of which proceed three branches; viz. the *ophthalmic,* the *superior maxillary,* and the *inferior maxillary.*

### 1. THE OPHTHALMIC, OR FIRST BRANCH OF THE FIFTH PAIR OF NERVES.

The *ophthalmic nerve* passes the external part of the cavernous sinus, receiving a filament from the superior cervical ganglion, and, passing through the foramen lacerum orbitale, divides into the *lachrymal*, the *frontal*, and the *nasal* nerves.

The *lachrymal nerve* proceeds along the external part of the orbit, gives off the spheno-maxillary branch, which unites with a branch of the superior maxillary nerve; and the molar branch, which unites with a branch of the facial nerve; it furnishes also several branches to the lachrymal gland, and to the superior eyelid.

The *frontal nerve* is found in the upper part of the orbit, where it divides into two filaments. The *internal frontal*, which is distributed to the frontal sinus, the corrugator supercilii, and frontalis muscles, and the subcutaneous cellular tissue of the forehead.

The *external frontal filament*, passes through the supra orbitary foramen, and is distributed to the frontalis muscles, and to the integuments extending over the summit of the head.

The *nasal nerve* passes under the superior oblique muscle; it frequently receives a filament from the superior cervical ganglion, and furnishes a very delicate filament to the lenticular ganglion, and also, two or three *ciliary filaments:* it at length divides into two branches; the *internal nasal*, which re-enters the cranium by the anterior internal orbitary foramen, and from thence again passes down through one of the perforations of the cribriform plate of the ethmoid bone, to be distributed to the septum narium and the nasal fossæ. The *external branch* passes out of the orbit, beneath the pulley of the superior oblique

muscle, and is distributed to the lachrymal passages and dorsum of the nose.

### 2. THE SUPERIOR MAXILLARY NERVE, OR SECOND BRANCH OF THE FIFTH PAIR.

The *superior maxillary nerve* is extended from the ganglion of the fifth pair; it enters through the foramen rotundum of the sphenoid bone into the spheno-maxillary fossa, where it receives filaments from the spheno-palatine ganglion; it then passes through the infra-orbitar canal and terminates on the cheek. It furnishes, 1st, the *orbital branch* which passes into the orbit by the spheno-maxillary fissure, and there divides into the *malar* and *temporal filaments*. 2d. The *posterior* and *superior dental branches* which enter the passages in the maxillary tuberosity, and dividing into many filaments are distributed to the roots of the three last molar teeth, and to the gums. 3d. The *anterior dental branch* which descends into the anterior dental canal, and divides into filaments, which are distributed to the incisor, the canine, and the two small molar teeth. 4th. The *infra-orbitar branches* which form the termination of the superior maxillary nerve; these pass out by the infra-orbitar foramen, and uniting with filaments from the facial, nasal and buccal branches, are distributed to the muscles and integuments of the cheek.

### 3. THE INFERIOR MAXILLARY NERVE, OR THIRD BRANCH OF THE FIFTH PAIR.

The *inferior maxillary nerve* passes through the foramen ovale of the sphenoid bone, and is distributed to the lower jaw, and the muscles situated between it

and the os hyoides; it furnishes the following branches viz. —

1st. *Two deep temporal nerves* which are distributed to the inner part of the temporal muscle.

2d. The *masseteric nerves* which are distributed to the articulation of the jaw and the masseter muscle.

3d. The *buccal nerve* which passes between the pterygoid muscles, and divides into six or seven filaments which are distributed to the temporal, buccinator, and levator anguli oris muscles, to the angle of the mouth, and finally to the integuments.

4th. The *pterygoid nerves*, two very delicate filaments which are directed downwards, and terminate in the internal pterygoid muscles.

5th. The *lingual* or *gustatory nerve*, of considerable size, and which receives the filament called the *corda tympani*, which extends from the spheno-palatine ganglion. The lingual nerve afterwards descends between the pterygoidei muscles, and furnishes in its passage a filament to the internal pterygoid muscle; several to the tonsils and to the superior constrictor of the pharynx; two or three to the back part of the gums, and to the submaxillary gland; several filaments are distributed to the sublingual gland, and to the mucous membrane of the mouth: lastly, it divides into numerous filaments which penetrate the muscular tissue of the tongue, and ascending towards the superior surface terminate in the numerous papillæ; in consequence of which, this branch is considered as the principal nerve of the organ of taste.

6th. The *inferior dental nerve*, which enters the dental canal, and is divided into branches which are distributed to the teeth and to the cancelli of the bone: some filaments, named the *mental nerves*, pass out of the anterior maxillary foramen, and are distributed to the lower lip and chin.

The *auricular* or *superficial temporal nerve*, proceeds backwards and outwards between the condyle of the jaw and the auditory canal; it communicates with the facial nerve, giving off branches to the temporo-maxillary articulation, and to the pavilion and integuments of the ear; it is ultimately distributed to the integuments of the temples and forehead.

Fig. 26.

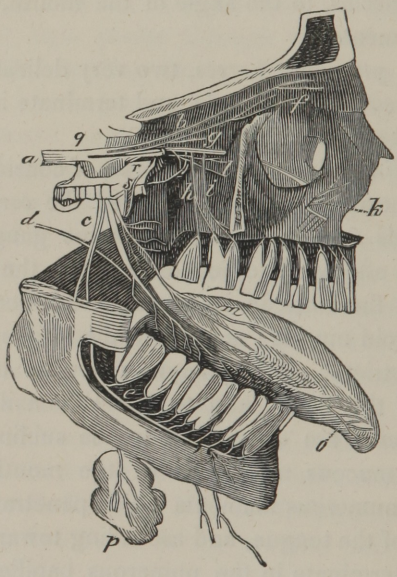


Fig. 26, exhibits the trifacial nerve and the distribution of its three principal branches.

*a*, the trunk of the trifacial nerve.

*q*, the Gasserian ganglion.

*b*, the frontal.

*f*, the lachrymal.

*g*, the nasal nerves of the ophthalmic branch.

*r*, the superior maxillary branch.
*l*, the malar.
*i*, the anterior dental.
*h*, the posterior dental.
*k*, the infra orbitar nerves.
*c*, the inferior maxillary branch
*s*, the two deep temporal.
*t*, the masseteric.
*n*, *o*, the lingual.
*e*, the inferior dental.
*p*, the sublingual nerves.

### SIXTH PAIR OF NERVES.

The *sixth pair of nerves* are very small; they are attached to the sides of the corpora pyramidalia, each proceeds to the line which separates the pons VAROLII from the medulla oblongata; here the filaments unite and proceed along the basilar groove through the cavernous sinus, pass through the foramen lacerum orbitale, and are distributed to the external rectus muscle of the eye.

While in the cavernous sinus, the sixth nerve is placed between the ophthalmic nerve and the carotid artery, upon the surface of the latter of which, two or three filaments are extended to the great sympathetic nerve.

### SEVENTH PAIR OF NERVES, OR FACIAL NERVES.

The *facial nerve* is the *portio dura* of the old anatomists; it appears beneath the posterior and external part of the pons VAROLII, from the line between the corpora olivaria and restiformia; it enters the internal auditory foramen with the acoustic nerve, then leaves the latter to

proceed into the aqueduct of FALLOPIUS, passing out of the cranium by the stylo-mastoid foramen. On a level with the hiatus FALLOPII, it receives a filament of the Vidian nerve, which enters the cavity of the tympanum, under the name of *corda tympani*. The facial nerve also furnishes filaments to the muscles of the tympanum, the pavilion, and the integuments of the ear. On its exit from the stylo-mastoid foramen, it gives off the *posterior auricular*, the *stylo-hyoid*, and the *sub-mastoid branches*.

The facial nerve then enters the parotid gland, and is distributed to the muscles and the integuments of the face. These branches separate and reunite at different places, so as to form a plexus on the side of the face, which has been called the *pes anserinus*.

Fig. 27.

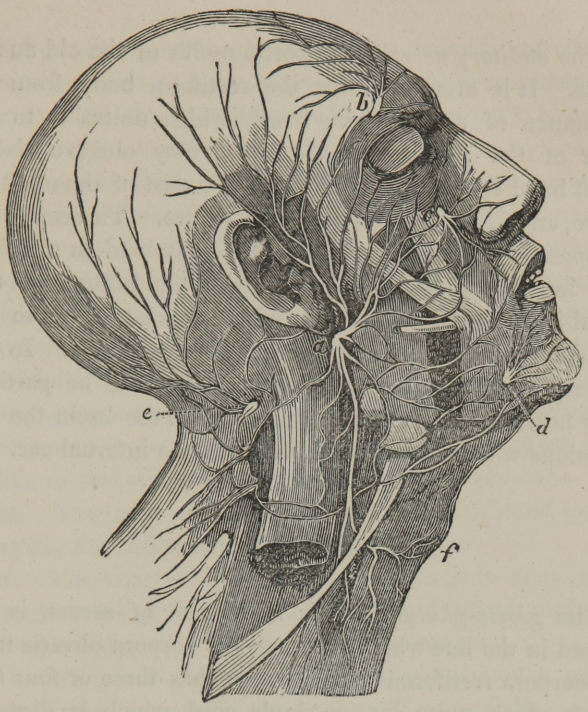


Fig. 27, exhibits the superficial nerves of the face and neck: the parotid gland is removed to shew the divisions of the facial nerve which pass through it.

*a*, the divisions of the facial nerve, termed the pes anserinus.

*b*, the supra orbitary nerve.

*c*, the infra orbitary nerve.

*d*, the mental nerves.

*e*, the first cervical nerve.

*f*, descending branches communicating with the hypoglossal and cervical nerves.

### EIGHTH PAIR, OR AUDITORY NERVES.

The *auditory nerve* is the portio mollis of the old anatomists. It is attached over the restiform body, from the substance of a small gray band, which unites it to the floor of the fourth ventricle. We may observe also a small band which seems to unite this part of the auditory nerve, and furnishes it with a commissure. This nerve accompanies the facial, so long as it is contained in the skull and internal auditory canal; but at the bottom of this canal it divides into branches, which are distributed to the cochlea, the vestibule and the semicircular canals. In the description of the organ of hearing, these will be particularly noticed. This nerve transmits to the brain the impressions which sound produces upon the internal ear.

### NINTH PAIR OF NERVES.

The *glosso-pharyngeal*, or *ninth pair of nerves*, is attached in the line which separates the corpora olivaria from the corpora restiformia; each nerve has three or four filaments which unite into a single cord, which is directed through the foramen lacerum, and is separated from the pneumo-gastric nerve by the internal jugular vein. After its exit from the cranium, it sends a filament to the auditory canal, receives a filament from the facial, and another from the pneumo-gastric nerve; several filaments are distributed to the carotid artery, and others communicate with the cervical ganglia. It gives branches also to the muscles of the pharynx, to the mucous glands, to the fauces, and at length terminates in the tongue.

It gives motion to the muscles of the tongue and pharynx, but more especially to those necessary for the articulation of the voice.

### TENTH PAIR OF NERVES.

The *pneumo-gastric nerves*, or *par vagum*, sometimes called the eighth pair, are connected to the brain, immediately beneath the preceding, behind the corpora olivaria, near the corpora restiformia. Each commences by numerous filaments, which unite and form two or three fasciculi, placed under each other; but, on passing out of the cranium through the foramen lacerum posterius, they form a round cord, which descends with the great sympathetic, on the lateral part of the neck, on the outer side of the primitive carotid, and posterior to the jugular vein; it passes into the chest behind the subclavian vein, and accompanies the œsophagus to the stomach. It presents a multitude of variations in its secondary divisions, so that we seldom find it alike in two subjects; but it constantly furnishes —

1st. The *pharyngeal nerve*, which is distributed to the pharynx, and forms the pharyngeal plexus.

2d. The *superior laryngeal nerve*, which is distributed to the muscles of the larynx, the thyroid gland, and the mucous membrane of the larynx and pharynx.

3d. The *cardiac nerves*. On the right side the pneumo-gastric nerve supplies two or three filaments, descending with itself to the stomach, and uniting with the cardiac filaments of the cervical ganglion; on the left side it furnishes only one filament, which terminates in the cardiac plexus.

4th. The *recurrent* or *inferior laryngeal nerves*. These differ on the right and left sides; the left turns round the arch of the aorta; the right passes round the subclavian artery: both ascend on the side of the trachea, and terminate at the larynx.

Fig. 28.

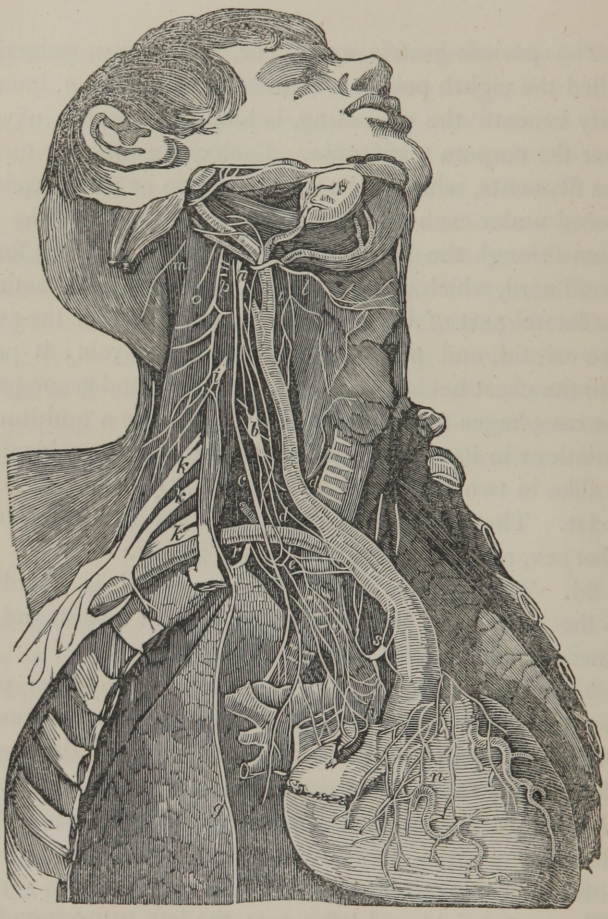

Fig. 28, exhibits the general course of the deep seated nerves of the neck and thorax.

*a*, the superior cervical ganglion of the great sympathetic nerve.

*b*, the middle cervical ganglion.

*c*, the pneumo-gastric nerve.

*d*, *d*, the recurrent, or inferior laryngeal nerve.

*l*, the pharyngeal nerve.

*t*, the superior laryngeal nerve.

*s*, the cardiac plexus.

*n*, the coronary nerves.

*k*, *k*, *k*, the cervical nerves, forming the brachial plexus.

*o*, *p*, the cervical plexus.

*i*, the commencement of the phrenic nerve from the fourth cervical nerve. *g*, its course over the lungs to the diaphragm.

The pneumo-gastric nerve gives filaments to the œsophagus and stomach; it also unites by numerous radiations with the hepatic, the splenic, the cœliac, and the right gastro-epiploic plexus: other filaments are interlaced with the meshes of the solar plexus, and several expand on the vena portæ, the pancreas, the duodenum, and the gall bladder.

On account of the very extensive distribution, and numerous communications of the pneumo-gastric nerve, it is called by some authors the *middle sympathetic nerve*.

### ELEVENTH PAIR, OR HYPOGLOSSAL NERVES.

The *hypoglossal nerve* is connected by several filaments with the fissure which separates the olivary and pyramidal eminences; these filaments form a cord, which passes out of the cranium by the anterior condyloid foramen. The hypoglossal is then united to the pneumo-gastric nerve for a short distance, but at the angle of the jaw it is directed downwards and forwards, curving under the tendon of the digastricus, towards the tongue. From the convexity of the curve it gives off, —

The *descending cervical branch*. In the former mode of enumerating the cranial nerves, it was termed the *descend-*

*ens noni;* it passes in front of the internal jugular vein, and communicates with the internal branch of the cervical plexus. The hypoglossal nerve then passes between the mylo-hyoideus and hyoglossus; it furnishes branches to the adjacent muscles, and is finally distributed to the tongue.

It gives the power of motion to the muscles of the tongue; principally, however, to those concerned in the process of mastication and deglutition.

### TWELFTH PAIR, OR ACCESSORY NERVE OF WILLIS.

The *spinal accessory nerve* (called by Sir CHARLES BELL the *superior respiratory of the trunk*) is singular in its origin and progress. It commences at the lateral parts of the spinal cord; the first point of union with the medulla spinalis is about the sixth vertebra of the cervical region; it ascends between the ligamentum denticulatum and posterior roots of the cervical nerves, receiving from the latter new filaments which increase its size; it then passes through the great occipital foramen, and makes its exit by the foramen lacerum posterius with the pneumo-gastric, to which it sends a filament; it then leaves the latter and adheres to the hypoglossal, from which it again separates, passes through the sterno-cleido-mastoideus muscle, and terminates in the trapezius. Fig. 28, *m*.

Recent investigations have decidedly proved, that the spinal accessory nerve, both in its commencement and disposition, conforms to the spinal nerves, and is never deprived of a posterior root, as some have imagined.

This nerve gives the power of motion to the sterno-cleido-mastoideus, and to the trapezius.

Fig. 29.

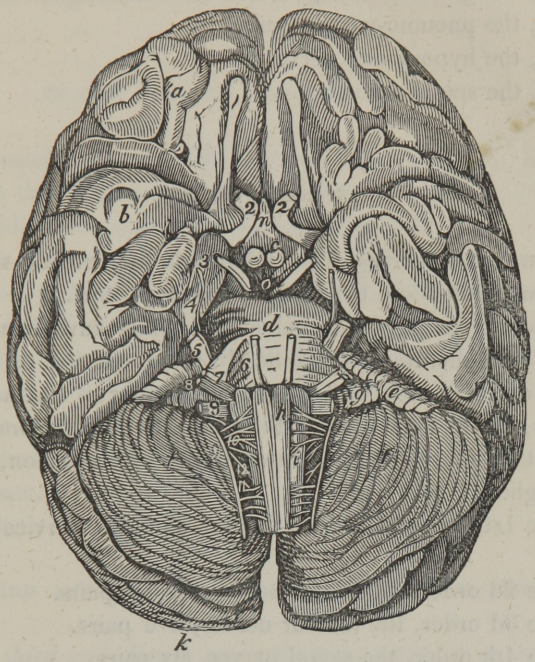


This figure was before given to shew the basis of the brain, etc. It is again introduced to exhibit the commencement of the cerebral nerves. They are numbered, as they have been described, according to the most modern arrangement.

1, the olfactory nerve, having several roots behind, and a bulbous extremity before.

2, 2, the optic nerves united before, *n*, the infundibulum.

3, the common motor nerve.

4, the patheticus.

5, the trigeminus.

6, the abducens or external motor nerve.

7, the facial nerve, or portio dura.
8, the auditory nerve, or portio mollis.
9, the glosso-pharyngeal nerve.
10, the pneumo-gastric nerve.
11, the hypoglossal nerve.
12, the spinal accessory.

### SPINAL NERVES.

The *spinal nerves* are divided into four orders, viz. the *cervical*, the *dorsal*, the *lumbar*, and the *sacral*.

The nerves of the spinal cord, which have been previously enumerated, commence by two species of roots. Each of these roots is formed by a number of distinct filaments, but in their passage through the intervertebral foramina they unite; the posterior root, at their union, forms a ganglion. See Fig. 12.

The 1st order of spinal nerves are the cervical, nine pairs.

The 2d order, the dorsal nerves, twelve pairs.

The 3d order, the lumbar nerves, five pairs.

The 4th order, the sacral nerves, six pairs.

### FIRST PAIR OF CERVICAL NERVES.

The *first pair of cervical nerves* commences at the sides of the spinal cord, beneath its superior enlargement; each nerve proceeds from the vertebral canal, between the atlas and dentata, and divides into two parts: the first of which is joined to the accessory nerve, and by branches of the hypoglossal; it is also connected by a gangliform root, with the upper ganglion of the sympathetic nerve, and it gives filaments to muscles connected with the anterior part

of the cervical vertebræ. The second part of this nerve is distributed to the extensors of the head and neck, and forms the *occipital nerve*.

### SECOND PAIR OF CERVICAL NERVES.

The *anterior branch* of this pair of cervical nerves passes between the transverse processes of the two first vertebræ, and divides into numerous filaments, one of which unites with the first pair; another joins the superior cervical ganglion; a third is distributed to the anterior rectus of the head; a fourth contributes to form a cervical plexus; and a fifth communicate with the pneumo-gastric nerves.

The *posterior branch* is reflected upwards, under the obliquus capitis inferior, traverses the great complexus, and is distributed to the occipito-frontalis muscle and to the integuments.

### THIRD AND FOURTH PAIRS OF CERVICAL NERVES.

The *third* and *fourth cervical nerves* proceed in similar directions; the anterior part sending off branches to form the cervical plexus; while the posterior supplies the muscles and integuments of the back part of the neck.

### CERVICAL PLEXUS.

The *cervical plexus* is situated on the lateral part of the neck, on a level with the second, third, and fourth vertebræ, and is formed by the anterior branches of the second, third and fourth cervical nerves, which communicate and form arches, the convexities of which send off filaments,

which again unite, and communicate superiorly with the first pair; inferiorly, with the brachial plexus. The cervical furnishes very many ascending and descending branches.

1st. The *internal descending branch*, formed by two filaments of the second and third pair, which uniting descends on the sterno-cleido-mastoideus muscle, and communicates with the hypoglossal nerve.

2d. The *phrenic nerve* or the internal respiratory nerve, is principally composed of a branch of the fifth pair, but receives a filament from the fourth, and two or three from the brachial plexus; it descends upon the anterior part of the neck, between the anterior rectus and anterior scalenus muscles, communicating with the inferior cervical ganglion, and passing into the thorax between the subclavian artery and subclavian vein; it enters the anterior mediastinum, then descends between the pleura and the lateral parts of the pericardium, and terminates in numerous filaments which ramify on the superior surface of the diaphragm. See Fig. 28, *i*, *g*.

3d. The *external descending branches* of the cervical plexus, are distributed in numerous filaments to the muscles and integuments of the mastoid, auricular, and scapular regions. Some are superficial, others deep. The superficial descend to the clavicle and acromion process, supply the superficial muscles in their course, and terminate in the pectoral and deltoid muscles, and in the integuments. The deep branches descend behind the clavicle, supply the deep muscles on the side of the neck, and those connected to the scapula. One of these branches, remarkable for its length, and of the same size of the phrenic, is named the *external respiratory nerve*. This nerve proceeds from the back part of the plexus, chiefly from the fourth cervical. It has also filaments connecting it to the third and second and to the phrenic. It descends behind the scaleni muscles and beneath the trapezius and levator anguli scapulæ,

and is almost exclusively distributed to the serratus magnus muscle.

4th. The *superficial ascending branches* are derived principally from the third pair; they are distributed to the sterno-cleido-mastoideus, the platysma myoides, the skin of the neck, and the inferior maxillary region, and communicate with the facial nerve.

### FOURTH, FIFTH, SIXTH, AND SEVENTH PAIRS OF CERVICAL NERVES.

The *posterior branches* of these nerves descend obliquely outwards, traverse the splenius and trapezius, and are distributed to the muscles and integuments of the back part of the neck.

The *anterior branches* furnish filaments which communicate with the cervical ganglia, and some others which are distributed to the scaleni muscles: they then communicate and form the brachial plexus. It may be observed, that a filament of the fourth contributes to the formation of the phrenic nerve.

### BRACHIAL OR AXILLARY PLEXUS.

The *brachial plexus* consists of an interlacement of the anterior branches of the last four cervical nerves and the first dorsal. The brachial plexus extends from the lateral and inferior part of the neck to the axilla, where it divides into several branches, which are distributed to the thorax, shoulder and arm. It is situated between the scaleni muscles, and above the subclavian artery.

### THORACIC BRANCHES.

The *anterior thoracic branch* is chiefly derived from the seventh cervical nerve ; it descends behind the clavicle, and divides into numerous filaments, some of which surround the axillary artery, others descend on the chest and are distributed to the pectoral muscles.

The *posterior thoracic branch* is furnished by the sixth and seventh cervical nerve ; it descends on the sides of the thorax, and is distributed to the serratus magnus.

The *supra scapular branch* is supplied by the 5th nerve ; it descends obliquely backwards towards the upper edge of the scapula, passes under the ligament which converts the coracoid notch into a foramen, and after giving a branch to the subscapularis muscle, it passes into the infra-spinatus fossa, where its ramifications are lost in the infra-spinatus and teres major muscles.

The *sub-scapular branches* commence at variable points of the brachial plexus ; they descend behind the axillary vessels and are distributed to the muscles under the scapula, and in the teres major and minor.

## NERVES OF THE ARM.

### INTERNAL CUTANEOUS NERVE.

The *internal cutaneous nerve* is the smallest of the branches which terminate the brachial plexus, from the lower part of which it proceeds ; namely, from the last cervical and the first dorsal ; it descends along the internal surface of the arm, under the brachial aponeurosis, near the basilic vein, and divides at the internal condyle of the os brachii into two branches. The *external branch* passes

along the border of the biceps towards the wrist, where it is distributed to the integuments. The *internal branch* descends on the brachialis internus, supplies the integuments of the back part of the fore-arm, and finally terminates at the back of the hand and the little finger.

### EXTERNAL CUTANEOUS NERVE, OR MUSCULO-CUTANEOUS.

The external cutaneous nerve is derived from the fifth and sixth cervical nerves ; it proceeds through the fibres of the coraco-brachialis muscle, (from which circumstance it is named the *perforans* CASSERII,) and descends along the anterior part of the arm, between the biceps and brachialis internus, towards the wrist, where it divides into two branches ; an *external*, which sends branches to the back of the fingers ; an *internal*, which is distributed to the thumb and the palm of the hand ;—and a multitude of filaments from this nerve may be traced to the fingers.

Fig. 30.

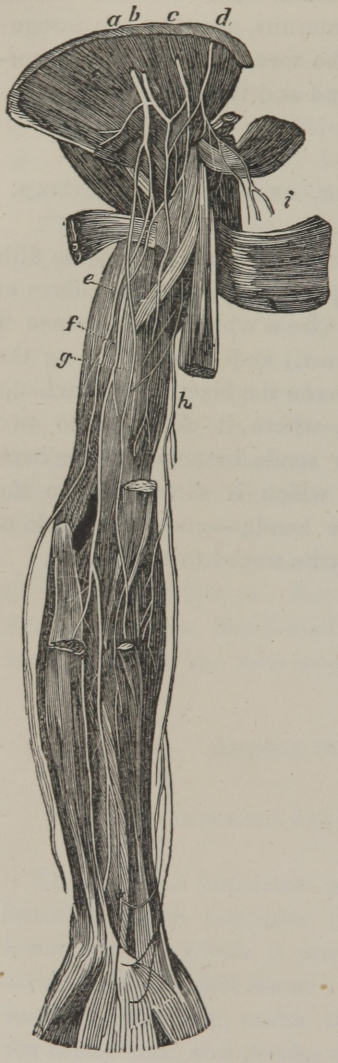


Fig. 30, exhibits some of the principal nerves of the front of the arm.

*a*, *b*, *c*, *d*, the axillary plexus.

*e*, the ulnar or cubital nerve.

*f*, the median nerve.

*g*, the radial nerve.

*h*, the internal cutaneous nerve.

*i*, the articular nerve.

### THE MEDIAN NERVE.

The *median nerve* is the largest of the brachial plexus; it is principally formed by the two lower cervical and the first dorsal nerves. Descending behind the internal part of the biceps, on the inner side of the brachial artery, and dipping between the brachialis internus and pronator teres, it descends along the fore-arm, between the superficial and deep seated flexor muscles. It then proceeds under the annular ligament of the carpus, and divides in the hand into digital filaments, which are distributed to the fingers. Before this division, however, it furnishes considerable branches to the muscles of the fore-arm.

Fig. 31.

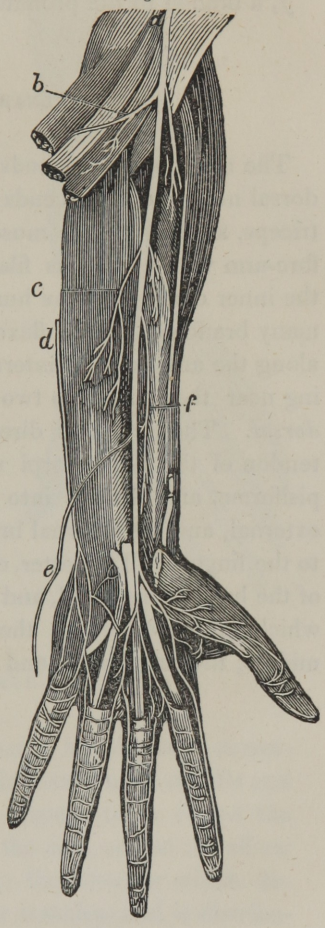


Fig. 31, exhibits the distribution of the principal branches of the median nerve on the fore-arm.

*a*, the trunk of the median nerve.

*b*, a branch given to the supinator muscles.

*c*, a branch to the interosseous ligament, and to the flexor profundus muscle.

*d*, the ulnar nerve cut off.

*e*, the palmar branch given to the integuments of the hand.

*f*, a branch to the pronator muscles.

### ULNAR NERVE.

The *ulnar nerve* proceeds from the last cervical and first dorsal nerves, and descends along the internal border of the triceps, supplying this muscle and the upper part of the fore-arm with numerous filaments; then passing between the inner condyle of the humerus and the olecranon, gives many branches to the flexor carpi ulnaris, and descends along the anterior and internal part of the fore-arm, dividing near the wrist into two branches, the *palmar* and the *dorsal*. The former is directed on the outer part of the tendon of the flexor-carpi ulnaris, on the side of the os pisiforme, and divides into the deep, the superficial, the external, and the internal branches, which are distributed to the fingers. The latter, or dorsal, gains the internal part of the back of the hand, and divides into internal branches, which are extended to the corresponding surface of the middle, the ring finger, and the little finger.

Fig. 32, exhibits the distribution of the principal branches of the ulnar nerve.

*a*, the ulnar nerve perforating the heads of the flexor muscles.

*b*, *c*, branches distributed to the common extensor of the fingers.

*d*, a branch distributed to the interosseous ligament.

*e*, a branch distributed to the wrist and the back of the hand.

Fig. 32.

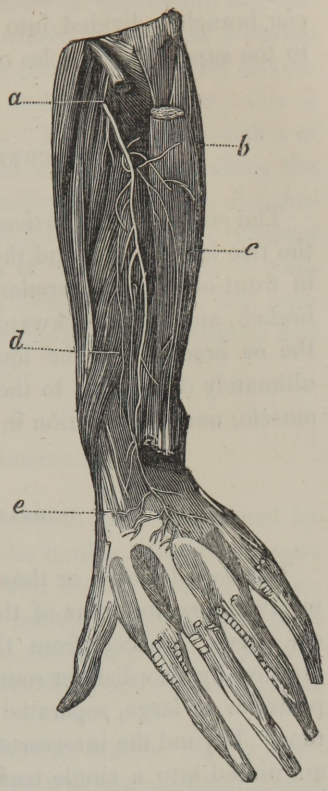


RADIAL NERVE.

The *radial* or *muscular spiral nerve*, has the same derivation as the preceding; it descends between the middle and the short portions of the triceps muscle, turns round the os brachii to the external part of the arm, and at the elbow joint divides into two branches; the *anterior* which descends between the two supinator muscles, and is distributed to the thumb, and the inner side and back of the fore

finger, and the outer side of the middle finger. Its *posterior* branch is divided into filaments, which are distributed to the superficial muscles of the fore-arm.

### CIRCUMFLEX NERVE.

The *circumflex*, or *articular nerve*, is usually formed by the two last cervical and the first dorsal nerve; it descends in front of the subscapularis muscle, to which it gives a branch, and turns backwards, between the superior part of the os brachii and the long portion of the triceps: it is ultimately distributed to the internal surface of the deltoid muscle, near its insertion in the os brachii.

### DORSAL NERVES.

The *dorsal nerves*, or those which are transmitted by the intervertebral foramina of the dorsal region, like the cervical nerves, proceed from the lateral parts of the spinal marrow by two distinct roots, an anterior or small, and a posterior or large, separated by the ligamentum denticulatum. Beyond the intervertebral foramen, the double roots are united into a single trunk, and a small gray and hard ganglion is formed by the posterior roots. These nerves divide into dorsal and intercostal branches.

The *dorsal branches* pass backwards between the transverse processes of the dorsal vertebræ, and are distributed to the muscles and integuments of the back and loins.

The *intercostal branches*, near their commencement, receive a filament from each thoracic ganglion, pass outwards between the ribs, covered by the pleura, as far as the angle of these bones, where they are found between the two strata of intercostal muscles. The anterior branch of the

second follows the internal surface of the second rib, and sends off a brachial filament, which pierces the external intercostal muscle, and descends along the posterior and internal part of the arm, and is lost at the elbow: this is named the nerve of WRISBERG. The anterior branches of the fourth to the eleventh dorsal nerve, proceed along the inferior margin of the corresponding ribs, and are distributed to the muscles and the integuments of their different regions. The anterior branch of the twelfth, at its commencement, communicates by a filament with the first lumbar nerve, and is afterwards distributed to the muscles and the integuments of the abdomen.

### LUMBAR NERVES.

The *lumbar nerves*, or those which are transmitted by the intervertebral foramina of the lumbar vertebræ, consist of five pair; commencing by two broad fasciculi of filaments, which the older writers termed *cauda equina*, from the resemblance they bear to the tail of a horse; especially when the nervous fibres are unravelled, and separated from each other.

The anterior branches of the five lumbar nerves form, by their union, the *lumbar plexus*, which is situated behind the psoas muscle, on the lateral parts of the bodies of the second, third, and fourth lumbar vertebræ.

### FIRST LUMBAR NERVE.

The *posterior branch* of this nerve is distributed to the multifidus spinæ, traverses the sacro-spinalis muscle, and passing under the aponeuroses of the abdominal muscles, finally ramifies in the integuments of the upper part of the hip.

The *anterior branch* receives a communicating filament from the lumbar ganglia, and from the twelfth dorsal nerve, and terminates in the lumbar plexus.

### SECOND LUMBAR NERVE.

The *posterior branch* of this nerve takes nearly the same course as the former, and is expanded by a great number of subdivisions on the upper and back part of the thigh.

The *anterior branch* has extensive communications with the lumbar ganglia, the anterior branches of the first and second pairs of the lumbar region, and with the lumbo-abdominal plexus.

### THIRD LUMBAR NERVE.

The *posterior branch* is distributed precisely in the same manner as the former.

The *anterior branch* communicates with the second and the fourth lumbar nerves, giving contributions as the preceding.

### FOURTH AND FIFTH LUMBAR NERVES.

The *posterior* and *anterior branches* have a similar distribution to those just described; some filaments, however, of the latter are continued into the pelvis, to unite with the sciatic plexus.

### LUMBO-ABDOMINAL, OR LUMBAR PLEXUS.

This plexus is formed by the union of the *anterior branches* of the five lumbar nerves; it is situated on the lateral parts of the bodies of the second, third, and fourth lumbar vertebræ, behind the psoas magnus. It terminates in the *musculo-cutaneous*, the *genito-crural*, the *crural*, the *obturator*, and the *lumbo-sacral nerves*.

### MUSCULO-CUTANEOUS BRANCHES.

These branches are commonly three in number; 1st, the *superior*, proceeding from the first lumbar nerve, descends on the quadratus lumborum as far as the crest of the ilium, pierces the transversalis muscle, and ramifying in the muscles and integuments of the abdomen, and extending to the abdominal ring, is distributed to the groin, the pubic region, the scrotum in the male, and the labia pudendi in the female. 2d, the *middle branch* descends on the outer margin of the psoas muscle, perforates the transversalis and is distributed to the cellular tissue of the abdomen; one filament is transmitted to the superior part of the scrotum. 3d, the *inferior branch* extending from the second lumbar nerve, and passing out of the pelvis, between the superior and the inferior spinous processes of the ilium, is distributed to the posterior superior part of the thigh. An internal filament pierces the fascia lata and descends to the external part of the knee.

### GENITO-CRURAL NERVE.

This nerve proceeds from the first lumbar nerve; it descends in the substance of the psoas muscle, and afterwards divides into an *internal branch*, which accompanies the spermatic cord; and an *external*, which, at the crural arch, is distributed in a multitude of filaments in the subcutaneous cellular tissue.

### CRURAL NERVE.

This nerve commences at the first four lumbar nerves; it passes out of the abdomen under the crural arch, on the outer side of the femoral artery, and then divides into deep seated and superficial branches.

1st. The *superficial branches* perforate the fascia lata, and are distributed in the integuments of the anterior and inner part of the thigh, descending as far as the superior part of the leg.

2d. The *deep seated branches* divide into numerous filaments, which are distributed to the iliacus, the sartorius, and the triceps extensor cruris muscles. The internal branches supply the muscles on the corresponding part of the thigh; one of these, more conspicuous than the other branches, termed the *internal saphena nerve*, accompanies the vena saphena in all its divisions to the great toe.

Fig. 33, exhibits the principal nerves of the front of the thigh.

*a*, a branch of the first lumbar nerve.

*b*, a branch of the second lumbar nerve.

*c*, the crural nerve, with its divisions into the branches which supply the front of the thigh.

*d*, a branch to the triceps extensor cruris muscle.

*e*, *e*, the saphena nerve, sent from the crural nerve to the inner part of the leg.

*f*, the external cutaneous nerve.

*g*, the femoral artery.

*h*, the anterior obturator nerve.

Fig. 33.

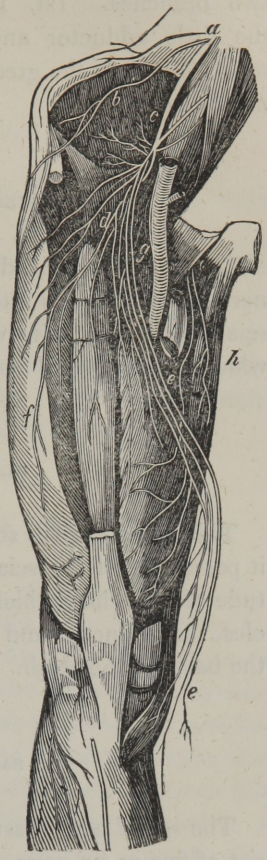


OBTURATOR NERVE.

This nerve issues principally from the second, third, and sometimes from the fourth, lumbar nerves; it descends on the inner margin of the psoas muscle, gives a branch to the obturator muscles, traverses the obturator foramen,

and between the pectineus and first adductor, divides into two branches. 1st. Its *anterior branch* distributed to the little adductor and vastus internus. 2d. Its *posterior branch* to the great adductor and external obturator muscles.

### LUMBO-SACRAL NERVE.

This nerve is derived from the fourth and fifth lumbar nerves; it descends into the pelvis, and unites with the sciatic plexus. In its course it furnishes a single branch, which is the *glutæal nerve*.

### GLUTÆAL NERVE.

This nerve derives some roots from the sciatic plexus; it passes out of the sciatic notch, and divides into a multitude of branches, which are distributed to the glutæi muscles, the perineum and the subcutaneous cellular tissue at the back of the thigh.

### SACRAL NERVES.

The *sacral nerves* issue from the sacral canal; they consist of five or six pairs, derived from the inferior part of the spinal cord. Their posterior branches supply the various muscles in their vicinity; while the anterior branches of the first four sacral, with those of the fifth lumbar, form the SACRAL or SCIATIC PLEXUS. These branches, again uniting, form a large nerve, termed the *sciatic nerve*. It also furnishes the *hæmorrhoidal*, the *vesical*, the *uterine*, and the *vaginal nerve* (which are small and interlacing

with each other); and the *inferior gluteal* and *pudic*, which are distributed to those parts the several names indicate.

### SCIATIC NERVE.

The *sciatic nerve* terminates the plexus of the same name, and is the largest of all the nerves of the body; it passes out of the pelvis by the sciatic notch, between the pyramidalis and superior gemellus, and descends along the posterior part of the thigh as far as the ham, where it divides into two branches, termed the popliteal. As the sciatic nerve proceeds down the leg, it furnishes filaments to the adjacent muscles, and to the integuments.

### EXTERNAL POPLITEAL NERVE.

This nerve has also the name of *fibular*, or *peroneal nerve;* it descends behind the external condyle of the femur, and passes between the fibula and the peroneus longus muscle, and divides into the musculo-cutaneous, and the anterior tibial. The *musculo-cutaneous*, or *external fibular nerve*, descends between the peroneus longus, and the extensor digitorum pedis, and afterwards between this latter and the peroneus brevis. Towards the middle of the leg it becomes superficial, and divides near the foot into filaments, which are distributed to the back of the foot and to the toes.

The *anterior tibial nerve* descends in front of the interosseous ligament, ramifies in the extensor brevis digitorum pedis, and gives filaments to the first two toes.

### INTERNAL POPLITEAL NERVE.

This nerve is larger than the preceding, and descends into the ham, passing behind the articulation, and between the heads of the gastrocnemii and the popliteus muscles, then between the latter and the soleus muscle; there it passes through the arched aperture which that muscle presents, and takes the name of the *tibial nerve*. This nerve descends between the soleus and tibialis posticus posteriorly, and the flexor longus digitorum pedis anteriorly, and is closely connected with the posterior tibial artery:—beneath the os calcis it divides into the *external* and *internal plantar nerves*. The tibial nerve furnishes, above the external condyle of the femur, the *external saphena nerve*. In the ham it supplies filaments to the muscles of the superior part of the leg, and to the articulation of the knee; to the interosseous ligament and to the anterior muscles of the leg. Near the inner malleolus, it sends a filament to the sole of the foot.

The *internal plantar branch* proceeds directly forwards above the adductor proprius pollicis pedis, and is distributed to the internal part of the foot and to the toes.

The *external plantar branch* is directed forwards and outwards, and is distributed to the external border of the foot and to the interosseous muscles.

Fig. 34, exhibits the principal nerves of the back part of the thigh.

*a*, the sciatic nerve, passing out of the pelvis.

*b*, the posterior superior cutaneous nerve.

*c*, the trunk of the sciatic nerve, sending branches to the muscles of the back part of the thigh.

*d*, the division of this nerve into,—

*e*, the tibial nerve, and,—

*f*, the fibular nerve.

Fig. 34.

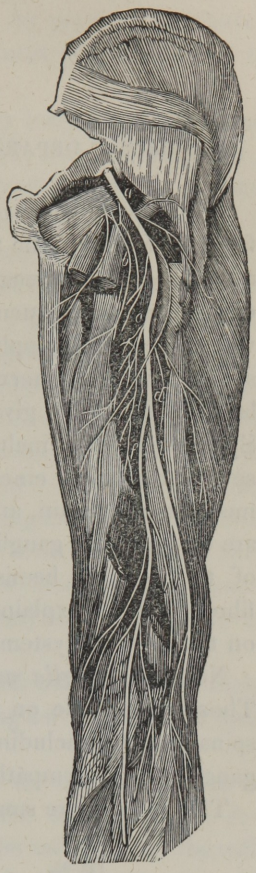

## CHAP. II.

### GANGLIONIC DEPARTMENT OF THE NERVOUS SYSTEM.

It has been before remarked in this work, that in the infancy of anatomy the term "ganglion" was used to denote a swelling in the thecæ of tendons, and even at the present day it is not unfrequently employed in the same sense. It was subsequently applied to the knotted appearance presented by certain nerves, but of late years a considerable latitude has been given to its signification by Gall and Spurzheim, who include within its comprehension, the several masses of cineritious substance inclosed within the medulla and brain, and which according to their theory, are considered "ganglia of increase" to the formative fibres of the cerebral hemispheres. ☞The term "formative fibres" will be explained at the termination of the article on the nervous system.

Nervous *ganglia* may be divided into two orders. 1. Those observable on the posterior roots of the cerebro-spinal nerves, including that of the fifth nerve; 2. The ganglia of the sympathetic.

The *ganglia* are small nervous centres, (see Fig. 35, and

Fig. 35.

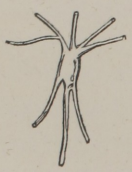

Fig. 36.

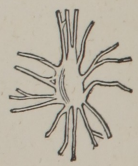

36,) which some anatomists have designated by the appellation of "diminutive brains." They extend from the cra-

nium to the pelvis, mostly lying along the vertebral column, and presenting a series connected by nervous filaments, each ganglion being considered by most physiologists as a special centre of nervous influence.

The forms of the ganglia are very irregular; in general they are somewhat round; occasionally they are elongated; in other instances they are of a semilunar form, as that which bears this name. In general all their forms, as I have just noticed, are remarkably irregular.

Each ganglion transmits nerves upwards and downwards to the ganglia which are contiguous; and other nerves to the cerebral or spinal nerves. The greater part, however, of the nervous filaments radiating from the ganglia are interwoven, in the form of a net-work or plexus; the most remarkable of which is the solar plexus, which is formed by the innumerable nerves proceeding from the semilunar, the hypogastric, and the cardiac ganglia. The filaments of the ganglia, as it were, exchange their connections and their direction, and form angles and meshes so intricate that it is not possible to distinguish anything more than a mass of nerves.

The ganglia are amply supplied with blood-vessels which penetrate them on all sides, ramifying on their surface and uniting in their interior.

The cerebro-spinal department of the nervous system is the immediate agent of the will, whilst the *ganglionic department* presides altogether out of the influence of the will of the individual. Thus, for example, the heart contracts without our possessing the power of accelerating or retarding its movements, in any sudden way, according to our will; the stomach in like manner acts on the aliments, and digests them without our being able to exercise any control over its operations; and for this reason, these organs are under the direction of the ganglionic department of the nervous system.

## PARTICULAR GANGLIA.

### GANGLIA OF THE HEAD.

#### LENTICULAR GANGLION.

The *lenticular ganglion* is situated on the external side of the optic nerve, near its entry into the orbit; its form is oblong and very small. Posteriorly, it receives a filament from the nasal branch of the ophthalmic, and one from the third nerve; anteriorly, it furnishes the ciliary nerves.

The *ciliary nerves* are very delicate, and are divided into two fasciculi; the superior fasciculus is formed of six filaments, which extend to the globe of the eye above the optic nerve. The inferior fasciculus is composed of eight or ten nervous filaments, which proceed on the outer and inferior part of the optic nerve.

These nerves, consisting of from twelve to seventeen, pass obliquely through the sclerotica, and proceed in a parallel direction between the latter membrane and the choroid, and, reaching the ciliary circle, each filament subdivides and is extended to the ciliary ligament and the iris.

#### SPHENO-PALATINE GANGLION.

This ganglion, denominated also the *ganglion* of MECKEL, is a small triangular reddish body; it is not very readily discovered, being concealed in the adipose cellular tissue of the pterygo-maxillary fissure. This ganglion furnishes the following branches: —

The *ascending branches*, two in number, which pass upwards, and join the superior maxillary, or second branch of

the fifth pair, previously to its entrance into the infra-orbitar canal.

The *spheno-palatine nerves*, varying in number from three to five; they pass into the nasal fossa by the spheno-palatine foramen. Two or three filaments ramify on the concave surface of the superior turbinated bone, and in the corresponding meatus; some extend to the middle turbinated bone, and others are distributed to the posterior part of the septum narium. The most considerable filament, termed the *naso-palatine*, is directed to the superior part of the septum, and terminates in the naso-palatine ganglion.

The *palatine nerves* are, 1st, the *great* or *inferior palatine*, which furnishes a filament to the middle and inferior turbinated bones; it afterwards enters the posterior palatine canal, and before its exit gives another filament to the nasal fossæ, which is lost on the ascending process of the superior maxillary bone. Other filaments are distributed to the velum palati, the arch of the palate, the alveoli, and the gums.

2d. The *middle palatine nerves*, which are distributed to the amygdalæ and to the velum palati.

3d. The *lesser palatine nerves*, which are situated between the external pterygoid muscle and the superior maxillary bone; they are destined for the tonsils and the mucous follicles of the membrane of the palate.

4th. The *Vidian nerve* leaves the spheno-palatine ganglion and enters the pterygoid canal, giving filaments to the adjacent parts; then divides into two branches, 1st, the *inferior* or *carotid branch*, which descends into the carotid canal, and unites with the superior cervical ganglion. 2d. The *superior branch*, which takes rather a complicated course, enters the cranium between the petrous portion of the temporal and the sphenoid bones, and is directed backwards and outwards on the superior surface of the former bone, where it is lodged in a small groove cov-

ered by the inferior maxillary nerve and the dura mater; it then passes with a small artery into the hiatus FALLOPII, and, on arriving at the aqueduct of FALLOPIUS, is found in apposition with the facial nerve. It then penetrates the cavity of the tympanum, where it is denominated the *corda tympani;* above the tensor tympani it enlarges, and is directed downwards and forwards, passes out of the glenoid, or Glasserian fissure, and is attached to the lingual branch of the inferior maxillary nerve. Opposite the submaxillary gland it separates from it to proceed to the ganglion of the same name.

Fig. 37.

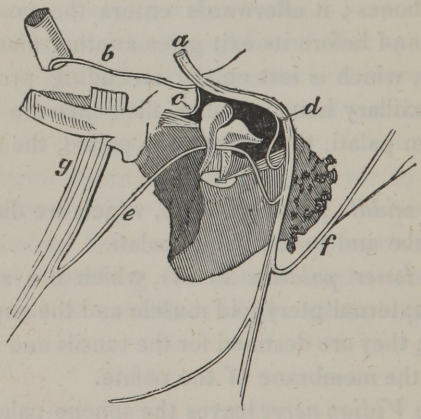


Fig. 37, exhibits the course of the corda tympani, on the left side.

*a*, the facial nerve in the aqueduct of FALLOPIUS.

*b*, the Vidian nerve communicating with the facial in the aqueduct of FALLOPIUS.

*c*, a filament of the facial given to the laxator tympani.

*d*, a filament given to the muscle of the stapes.

*e*, the corda tympani, separating from the facial, passing

through the cavity of the tympanum, and uniting with, *g*, the inferior maxillary nerve.

Besides those before described, the following ganglia are met with in the head, namely—

The *cavernous ganglion*, situated on the outer side of the internal carotid artery in the cavernous sinus.

The *naso-palatine ganglion*, situated in the anterior palatine foramen.

The *submaxillary ganglion*, occurring on a level with the submaxillary gland, and apparently formed by the superior filament of the Vidian nerve.

### GANGLIA OF THE NECK.

#### SUPERIOR, OR GREAT CERVICAL GANGLION. Fig. 28, *a*.

This ganglion is found under the angle of the inferior maxilla, and is remarkable for its size and the regularity of its occurrence; it is of a reddish gray color and is intimately united to the pneumo-gastric and hypoglossal nerves. It lies on the rectus anticus muscle, concealed by the jugular vein and carotid artery. A number of nervous filaments issue from it, which are distinguished into superior, inferior, external, and anterior.

The *superior* or *ascending filaments* ascend into the carotid canal, and unite with the superior filament of the Vidian nerve, with the sixth pair in the cavernous sinus, with a filament from the glosso-pharyngeal, and by other filaments with the ophthalmic and nasal branches.

The *inferior* or *descending filaments* pass in front of the anterior recti and longus colli muscles, covered by the carotid artery, the jugular vein, the pneumo-gastric, and the hypoglossal nerves, and terminate on a level with the fifth or sixth vertebra in the middle cervical ganglion.

Filaments from the superior ganglion unite with the external laryngeal nerve, and others which enter the thorax concur in forming the cardiac plexus. The external, internal, and anterior filaments, communicate with nerves in their vicinity ; thus the first unites with the cervical nerves, the second with the pneumo-gastric, forming the pharyngeal plexus; and the third with the pneumo-gastric and the facial nerves, forming a plexus upon the primitive carotid : finally, the latter filaments of the superior cervical ganglion unite to form the superior cardiac nerve.

### MIDDLE CERVICAL GANGLION. Fig. 28, *b*.

This ganglion varies extremely in size, and, indeed, is not constantly found ; it is situated opposite the fifth or sixth cervical vertebra, and before the carotid artery and jugular vein. Its anterior filaments form the middle cardiac nerves.

### INFERIOR CERVICAL GANGLION.

This ganglion is frequently continuous with the middle cervical ganglion ; it is situated behind the vertebral artery, between the transverse process of the seventh vertebra, and the neck of the first rib. Numerous filaments issue from this ganglion, which unite with the cervical nerves, the first thoracic ganglion, and the inferior cardiac nerves.

### CARDIAC NERVES. Fig. 28, *n*.

These nerves are particularly destined to supply the

heart: there are three on each side, which terminate in the cardiac plexus.

The *superior cardiac nerves*, on the right side, are formed by five or six filaments which proceed from the superior cervical ganglion; they descend on the side of the trachea, penetrate the thorax behind the subclavian vein and receive filaments from the inferior cervical ganglion, and the recurrent nerve of the pneumo-gastric. Those of the left side are situated between the primitive carotid and the subclavian arteries, and proceed on the aorta to unite with the inferior cardiac nerves.

The *middle cardiac nerves*, on the right side, proceed by five or six filaments from the middle cervical ganglion; these descend near the primitive carotid, uniting with the recurrent, and terminating in the cardiac plexus. That of the left side receives its principal filament from the inferior cervical ganglion, and descends behind the subclavian artery and the arch of the aorta.

The *inferior cardiac nerves*, on the right side, descend from the inferior cervical ganglion, and proceed on the anterior part of the arch of the aorta, as far as the cardiac plexus.

The middle, and the inferior cardiac nerves, on the left side, are united into a single trunk.

### CARDIAC PLEXUS, OR GANGLION. Fig. 28, *s*.

The *cardiac plexus* is situated behind the arch of the aorta, and consists of a central point of union of the cardiac nerves, a great number of which issue from it, and others are connected with it in every direction: some ramify on the aorta; others terminate in the pulmonary plexus; several are distributed to the pulmonary artery; and a considerable nerve interlaces its filaments in the direction of

the posterior coronary artery, forming the *coronary plexus*. Filaments also proceed in the direction of the anterior coronary artery, and are therefore denominated the *anterior coronary plexus*.

### THORACIC GANGLIA.

These ganglia are smaller than the cervical ganglia;—there are twelve on each side, disposed in the same line in front of the head of each rib. Their form and size resemble grains of barley; they communicate by vertical filaments with each other, and furnish also external and internal filaments: the former unite with each of the branches of the dorsal nerves, at the point of their exit from their foramina; the latter concur in the formation of the splanchnic nerves.

### SPLANCHNIC NERVES.

There are two splanchnic nerves on each side, distinguished into the great and small.

### GREAT SPLANCHNIC NERVE.

This nerve is connected with the internal part of the sixth, seventh, eighth, ninth, and sometimes the tenth thoracic ganglia, by filaments which descend on the sides of the vertebral column, and unite into a single trunk, on a level with the eleventh dorsal vertebra: this nervous cord enters the abdomen, passes behind the stomach, and terminates in the semilunar ganglion.

### SMALL SPLANCHNIC NERVE.

This nerve is formed of two branches from the tenth and the eleventh thoracic ganglia; these branches unite into a small cord on the twelfth dorsal vertebra, enter the abdomen, and, communicating with the former, terminate in the *renal ganglion.*

### GANGLIA OF THE ABDOMEN.

### SEMILUNAR GANGLIA AND SOLAR PLEXUS.

The *semilunar ganglia* are two in number, situated on each side of the aorta, on a level with the cœliac artery; they are larger than any other ganglia, and have a form somewhat corresponding to the name. The superior and external extremity of each ganglion receives the great splanchnic nerves; by the inferior they form a communication with each other. The two semilunar ganglia are surrounded by a multitude of other smaller ganglia, communicating with them by short filaments, which issue from their circumference; and the secondary ganglia also are united to each other by very numerous filaments, which form areolæ. It is this remarkable assemblage of ganglia, and interlacing of nervous filaments, that constitutes the SOLAR PLEXUS.

The plexus just named, appears to be particularly destined for the aorta, being distributed to all its divisions, and following all its immediate branches with a corresponding number of secondary plexuses, such as,—

1. The *sub-diaphragmatic plexus*, which is composed of a small number of filaments, which unite with the phrenic nerve and are distributed to the diaphragm.

2. The *cœliac plexus* is merely a prolongation of the solar plexus, upon the triple division of the cœliac artery; —it is composed of several ganglia, varying in form and size.

3. The *hepatic plexus* is associated with the hepatic artery and the vena portæ;—it follows their principal divisions.

4. The *splenic plexus* follows the course of the splenic artery, and is distributed to the spleen.

5. The *superior mesenteric plexus* descends with the superior mesenteric artery, and forms a web of great extent, the filaments of which are distributed to the lymphatic glands of the mesentery, and follow the ramifications of the artery, so as to cover the whole surface of the small intestines. This plexus also furnishes nerves to the ascending colon and cœcum.

6. The *inferior mesenteric plexus* accompanies the inferior mesenteric artery, enters the iliac mesocolon, and is distributed to the adjacent parts.

7. The *renal plexus* commences by several ganglia, situated on the renal artery, and is distributed to the substance of the kidney.

8. The *surrenal plexus* is found at the commencement of the capsular artery, and supplies the part which the name implies.

9. The *spermatic plexus* descends from the renal, and follows the direction of the spermatic artery, to the testicle in the male, and to the ovarium and the Fallopian tube in the female.

### THE LUMBAR GANGLIA.

These ganglia are situated on the anterior and lateral parts of the bodies of the lumbar vertebræ: they are com-

monly five in number on each side, and have communicating nervous branches, and external and internal filaments, which contribute to supply the adjacent organs, and are united with the sacral ganglia.

### THE SACRAL GANGLIA.

There are three or four of these ganglia found on each side of the anterior foramina of the sacrum; they communicate with the lumbar ganglia, and contribute to form the hypogastric plexus.

### HYPOGASTRIC PLEXUS.

This plexus is composed of numerous filaments from the vesical, uterine, vaginal, and hæmorrhoidal nerves of the sciatic plexus. The hypogastric plexus distributes its ramifications to the organs of generation (within the pelvis), to the os coccygis, and to the rectum.

Fig. 38.

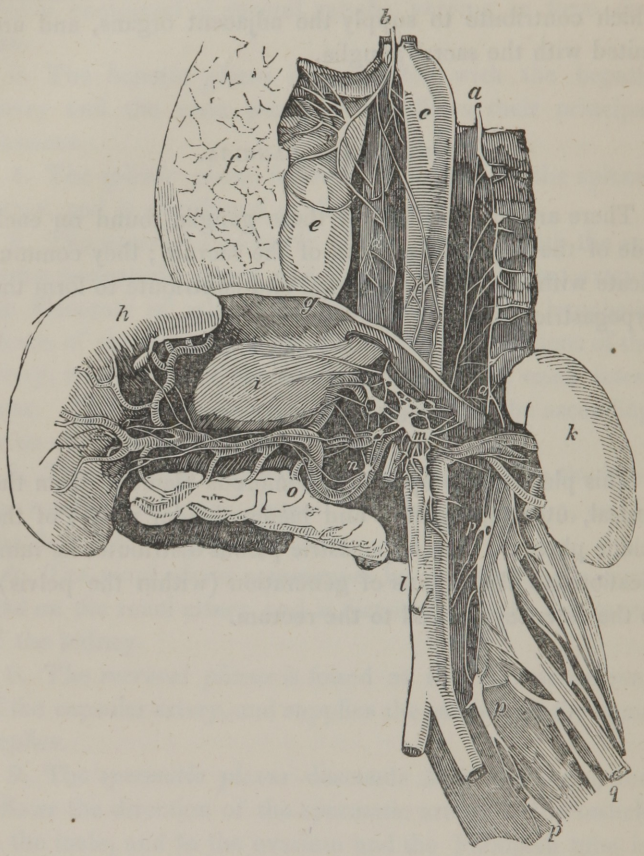


Fig. 38, exhibits some of the principal nervous ganglia and plexuses of the thorax and abdomen, on the left side, and the pneumo-gastric nerve, on the same side.

*a*, *a*, thoracic ganglia.

*b*, the pneumo-gastric nerve.

*c*, a branch of the former, called the inferior laryngeal or recurrent, curving round the arch of the aorta.

*d*, the œsophageal plexus.
*e*, the pericardium. *f*, the lungs.
*r*, the pulmonary plexus.
*g*, the diaphragm. *h*, the spleen.
*i*, the stomach.
The two last named organs are turned to the opposite side to shew the distribution of the nerves.
*k*, the kidney. *l*, the abdominal aorta.
*m*, the semilunar ganglion, and solar plexus, the latter radiating to all the divisions of the aorta.
*n*, the splenic plexus. *o*, the pancreas.
*p*, *p*, *p*, the lumbar ganglia.
*q*, the obturator nerve.

### THE TERM GREAT SYMPATHETIC NERVE.

After studying this department of the nervous system, we can see the reason why it is usually denominated, the *great sympathetic nerve*. It is in fact a collection of filaments from every nerve in the animal fabric, which join each other at the adjacent ganglia. It seems to spring from the sixth nerve, and from the Vidian branch of the fifth, and is reinforced by filaments from the seventh, eighth, ninth, and all the spinal nerves, to the lumbar region, and terminates in the pelvis.

This name, which has been given to the ganglia and their nervous radiations, expresses the conviction of anatomists, that its office is to associate the affections of different parts. And we cannot doubt that this department directs and controls the actions, and endows organic life, or the parts within, with its due sensibilities; the visceral sensations are always involuntary; they are generally vague, confused, and usually more or less fugitive, and do not, for any length of time, become fixed in the mind.

If our internal organs act according to the ordinary laws of organization, the sensations which arise from them are agreeable, and the healthy actions may give us the most vivid pleasure; but if the actions of our functions are interrupted, if our organs are wounded or diseased, the internal sensations are painful, and according to the disordered state, or the injury, they assume a different character.

### FORMATIVE FIBRES OF THE BRAIN ACCORDING TO GALL AND SPURZHEIM.

Having completed the anatomy of the nervous system as usually described in elementary treatises on the subject, it may not be considered superfluous to give briefly the views of Drs Gall and Spurzheim, relative to the manner in which the cerebral hemispheres are formed. The following appears to be the simplest exposition, and is selected from recent writers. The cerebral hemispheres are considered by the above anatomists as resulting from an expansion of the fibres of the medulla; hence they are termed *primitive* or *formative* fasciculi. The fibres of the anterior pyramids may be traced upwards to the margin of the pons, where they become somewhat constricted. From the inner border of each, fibres pass across the middle sulcus, and mutually change place, or decussate, those of the right side passing to the left and vice versa. If an incision, a line or two in depth, be made through the pons, so that one lateral half of it may be turned outwards, the fibres of the pyramid will be observed to pass into a quantity of gray substance lodged in the interior of the nodus encephali. In this situation the fibres diverge and separate, and are also considerably increased: at the upper margin of the pons they become continuous with the crus cerebri. Here an additional increase is derived from their

passage through the gray substance lodged in the interior of the crus, after which they proceed through the inferior cerebral ganglion *(thalamus nervi optici)*, and in the next place through the superior one *(corpus striatum)*, being successively increased and rendered still more divergent, until they finally reach the anterior and middle lobes, where they are evolved into their inferior, external, and anterior convolutions. The corpus olivare contains within itself a small ganglion ; its fibres pass, without any decussation, into the gray substance lodged in the cerebral protuberance, where, like the pyramids, they receive additions, after which they pass into the crus cerebri, of which they form the posterior and inner part. Continuing their ascent, they pass through the optic thalamus, and thence into the corpus striatum, receiving additions as they radiate through each, and finally, are continued upwards into the convolutions at the summit of the hemisphere, and backwards into those of the posterior lobe. Previously to entering the optic thalamus, some fibres of the corpus olivare have been observed to turn inwards, so as to give to the tubercula quadrigemina their medullary investment, and also to unite with those of the opposite side, to form the valve of Vieussens. The *diverging* fibres thus traced up through their successive steps of increase, terminate in the gray substance of the convolutions ; but another order of fibres may be observed quite distinct from these and taking a different direction. These are called the *converging fibres*, as they commence at the peripheral terminations of the preceding set, and pass from without inwards to the middle line, so as to connect the lateral parts, and bring them into relation with one another : on which account they are called *commissures*. The anterior and posterior commissures are formed in this way, as is also the corpus callosum ; though the greater number of the fibres which compose the latter are transverse, those towards its extremities are

oblique. This is owing to the manner in which the converging fibres of the anterior lobe are constrained to pass from before backwards, and those of the posterior lobe from behind forwards, in order to gain the corresponding borders of the corpus callosum. By this arrangement a greater number of fibres are collected to its extremities, which renders them thicker (particularly the posterior one) than any other part of its extent. Some of the inferior fibres thus traced from without inwards, instead of uniting with the corresponding set along the middle line, become reflected downwards from the under surface of the corpus callosum to the fornix, the fibres of which are stretched from behind forwards in such a way, that whilst its body is in a manner unattached, the extremities are identified with the parts just referred to.

The formative fibres of the cerebellum are derived from the posterior pyramids, or corpora restiformia: they pass upwards and outwards, and soon meet the corpus rhomboideum, which is considered as the ganglion of the cerebellum: the fibres are supposed to proceed through the gray substance of which it is composed, though it is difficult to demonstrate the fact; after which they pass outwards, diverging into the lobes of the cerebellum. The converging fibres, by their union, form the crura cerebelli, and the fibres of the crus, expanding as they pass downwards and inwards, constitute by their junction the pons Varolii, which brings the lateral lobes of the cerebellum into relation, and forms their commissure. The processus a cerebello ad testes bring the lobes of the cerebellum into intimate connexion with the cerebral hemispheres.

# ART. VIII.

## CHAP. I.

### PARTICULAR ORGANS OF SENSATION.

#### THE EYE AND ITS APPENDAGES.

The eye and its appendages consist of the globe of the eye, the eyebrow, the eyelids, the ciliæ, the Meibomian, and the lachrymal glands.

#### EYEBROWS.

The eyebrows are covered with short stiff hairs, generally of the same color as the hair of the head. The skin in which the bulbs of the hair are implanted, is placed upon a thick layer of adipose cellular tissue. The frontal, the corrugator supercilii, and the orbicularis palpebrarum muscles move them in the various expressions of the face.

The projection of the eyebrow guards the eye against external violence; the hairs, on account of their oblique direction, and the oily matter with which they are covered, prevent the perspiration from flowing towards, or irritating

the eye; they direct it towards the temple, and the root of the nose.

### EYELIDS. (PALPEBRÆ.)

The eyelids are those movable veils which cover the anterior part of the globe of the eye.

The *upper eyelid* is possessed of great mobility; it is chiefly by it that the eye is closed, for the motion of the lower eyelid is very limited.

The two eyelids are united at their extremities, forming two angles, of which the inner is more open than the outer. The edges of the eyelids are supported by fibro-cartilages, named the *tarsal cartilages*, which keep the eyelids always extended and accommodated to the form of the globe of the eye.

The posterior edges of the cartilages are so shaped as to form a triangular groove for the tears, when the eyelids are shut, and as the outer angle of the eyelids is higher than the inner, the tears are directed towards the puncta lachrymalia, which are situated at the inner angle.

The eyelids cover the eye during sleep, and preserve it from the injurious effects of extraneous particles flying about in the air; they defend it from sudden shocks by an instantaneous closure; and by their repeated motions (nictation) diffuse the lachrymal fluid over the surface, and preserve it in that polished state which is necessary for perfect vision. The eyelids also by their partial closure, moderate the effects of too brilliant a light, by admitting only so much as will not offend the eye.

The *eyelashes*, or *ciliæ*, are strong hairs, most commonly of the same color as the hair of the head, and are arranged in double or triple rows on the edges of the eyelids; those of the upper eyelid are longer than those of the lower, and

are curved upwards ; those of the under eyelid are directed downwards.

These hairs act as a shade to the eye, moderate the intensity of the light, and prevent dust and other extraneous substances from falling into the eye.

The *Meibomian glands*, or *ciliary follicles*, are small glandular bodies situated in grooves, between the tarsal cartilages and the tunica conjunctiva ; they are arranged in two vertical lines ; these follicles communicate with each other, and those nearest the edges of the eyelid open by minute orifices behind the ciliæ.

A sebaceous matter exudes through the orifices of these glands, and which may be seen in the form of minute cylinders, on pressing the tarsal cartilages.

The *tunica conjunctiva*, or *tunica adnata*, is a very thin transparent mucous membrane, which lines the posterior surface of the eyelids, and is continued over the fore part of the globe of the eye. It becomes thin and transparent on the cornea, so much so, that some anatomists have doubted whether it extends over the entire of its surface.

On the inner angle of the eye the tunica conjunctiva forms a small crescent-shaped fold, which has some resemblance to the third eyelid of birds, and is therefore named by some anatomists the *membrana nictitans*.*

The *caruncula lachrymalis*, is a small membranous elevation situated in the inner angle of the eye ; it is formed by a fold of the tunica conjunctiva, in the substance of which are mucous follicles, and the bulbs of some very minute hairs.

The rose color of this small body indicates the energy of

* This loose fold of the conjunctiva has not the office nor the muscular apparatus of the nictitating membrane, and is consequently very erroneously named.

the general system, and its paleness, on the contrary, denotes a state of debility and sickness.*

### THE GLOBE OF THE EYE IN GENERAL.

The eye is composed of two distinct portions of a sphere united to each other; the anterior segment, which forms about the fifth part of the globe, has the smallest diameter. See Fig. 39.

#### 1. THE SCLEROTICA.

The *sclerotica, (cornea opaca)* is a strong, opaque, fibrous substance, which preserves the globular figure of the eye; it is an envelope which defends its more delicate internal structure, and serves as a point of insertion for those muscles which move the eye. It forms about four fifths of the external investment of the eye, extending from the entrance of the optic nerve to the border of the cornea. The external surface is in relation with the conjunctiva, the expansions of the muscles, and the vessels and nerves of the orbit. It has on its internal face the choroid membrane. Posteriorly it is pierced by the optic nerve, and this aperture is divided by a number of septa, so as to constitute a cribriform plate through which the pulp of the nerve passes. Anteriorly it receives the cornea which is inserted into it somewhat like a watch-glass into its case.

#### 2. THE CORNEA.

The *cornea (cornea pellucida)* forms the anterior trans-

*A description of the lachrymal apparatus is given in the article on the *organs of secretion.*

parent portion of the globe of the eye; it is not perfectly circular, the transverse diameter being a little longer than the vertical. The cornea is encased in an aperture of the sclerotica, and presents the appearance of a segment of a small sphere added to a larger. Its anterior surface, which is convex, is in contact with the conjunctiva; the posterior is concave, and is lined by the membrane of the aqueous humor. Its degree of convexity varies in different individuals, and at the different periods of life.

The cornea is thicker than the sclerotica, and is composed of several distinct laminæ superimposed on each other; it does not appear to contain either blood-vessels or nerves. When the eye is removed from its socket, and compressed between the fingers, a serous fluid exudes from between the laminæ of the cornea.

Part of the light which reaches the cornea is reflected from its finely polished surface, and thus contributes to the brilliancy of the eye; but its principal office is to cause the rays to converge to the axis of the eye.

### THE CHOROID MEMBRANE.

The *choroid*, or the second membrane, is of a dark brown color, soft, cellular, and vascular; it is situated on the inner surface of the sclerotica; its outer surface is connected to the sclerotica by vessels and nerves; its inner surface is merely contiguous to the retina without adhering to it.

The choroid membrane is chiefly composed of minute arteries* and veins, united by fine cellular tissue; it is so

* The ciliary arteries are described in Vol. I. p. 370. The veins have a peculiar arrangement, being disposed in whirls, and are therefore denominated *vasa vorticosa*, and open into the ophthalmic vein.

exceedingly vascular, that after a successful injection of its blood vessels, it assumes a uniform red color. These vessels form two laminæ, which may be separated from each other. The inner lamina was first successively injected by RUYSCH, and his son subsequently named it *tunica Ruyschiana.*

The *pigmentum nigrum* is a dark brown substance, covering the outer and inner surface of the choroid membrane; on the latter surface this substance is more abundant, and is in immediate contact with the retina. Its office is, apparently, to absorb the rays of light immediately after they have impinged on the sensible surface of the retina.*

Persons termed *Albinoes* have no pigmentum nigrum, therefore the iris and pupil appear of a red color, and their vision is very imperfect, that is, they cannot view objects in a strong light; even during the day time they can scarcely see sufficiently to go about.

### THE CILIARY CIRCLE OR LIGAMENT.

Towards the margin of the cornea, the choroid adheres firmly to the sclerotica, constituting what is termed the *ligamentum ciliare;* within, it has the appearance of folds, which are called the *ciliary processes;* they indent the hya-

* Mr G. H. Fielding, in a communication delivered at Oxford, before a meeting of the British Association, stated his opinion, that this substance does not at all possess the properties of a pigment; that its colors are not, as it has been supposed to be, the result of any secreted matter; that it consists of layers separable from the Ruyschiana: that it possesses *elasticity,* and above all, circulation; he thinks, therefore, that we are warranted in coming to the conclusion, that it is a *membrane,* and not a *pigment.*

To this membrane he has given the name of MEMBRANA VERSICOLOR, from the great variety of color it has in different animals. He supposes that it receives the impression of images through the transparent retina.

loid membrane, where it splits to form the Petitian canal. The intervals of these processes are covered by the pigmentum nigrum.

These *ciliary processes* are sixty or seventy in number, arranged in a radiated manner around the lens, on the forepart of the vitreous humour. Each extends inwards and backwards from the ciliary ligament as far as the border of the lens. The anterior edge of each process is connected to the ciliary ligament and iris, the posterior to the vitreous humour; and the internal is loose, and forms the circumference of the posterior chamber of the eye.

### THE IRIS.

The iris is a delicate circular membrane, floating in the aqueous humour, and suspended vertically behind the cornea, so as to divide the space between this and the lens into two chambers, an anterior and posterior; the former is the larger of the two. These chambers communicate through the central aperture in the iris, the *pupil.*

The iris is so named from its being of different colors ;* it is a kind of circular curtain placed in the anterior part of the eye, to regulate the quantity of light passing to the back part of the eye.

The *outer circumference* is attached to the ciliary circle ; its *inner circumference* forms the limits of the pupil.

The iris floats in the aqueous humour, and is of a very contractile nature, so that when the eye is exposed to a strong light, or when we look upon a near object, the diameter of the pupil is diminished ; and *vice versa.*

Upon the back part of the iris there is a dark colored

* The color of the iris in general corresponds with that of the hair, being blue or gray where the hair is light, and brown or black where the hair and complexion are of a dark color.

secretion, resembling the pigmentum nigrum. This surface is called the *uvea*.

The iris is composed of two laminæ, intimately united near the pupil. Some anatomists of great merit state that these laminæ are two sets of muscular fibres, the one concentric, round the pupil, composed of circular fibres contracting the pupil in the manner of a *sphincter;* the other radiated, and having by its muscular action the power of contracting the iris, and consequently enlarging the pupil.

The ciliary arteries, which supply the opposite sides of the iris, freely unite with each other: and the smaller vessels of the iris form a circle round the pupil.

The iris is supplied with nerves by filaments from the ciliary nerves.

The motions of the iris are involuntary, and depend on the quantity of light falling on the retina; for when the retina loses its sensibility, the iris does not move, but remains dilated.

The pupil in the fœtus is closed by a delicate but vascular membrane, termed the *membrana pupillaris*, which is either ruptured at, or a short time previous to birth.

### THE RETINA.

The *retina (tunica nervea)* is called the third membrane of the eye; it is a soft, thin, semitransparent, nervous expansion, extending from the optic nerve to the crystalline lens, embracing the vitreous body, and lining the choroid membrane without adhering to either of these two parts.

At the posterior part of the retina, and exactly in the axis of vision, there is a circular foramen surrounded by a bright yellow border. This was discovered by Soem-

MERING, and is named the *foramen centrale*, or more frequently the *foramen of* SOEMMERING; it is about one thirtythird of an inch in diameter, but its office is not perfectly understood. BLUMENBACH supposed that it might serve as a kind of pupil, through which concentric rays might be absorbed by the choroid, when the eye was in danger by a very strong light.

The retina is divisible into three layers; viz. serous, nervous and vascular. The external or serous is extremely delicate and is the one discovered by Dr JACOB, and is now known as *Jacob's membrane*.

The retina is the seat of vision, therefore the primary part of the eye, to which all the other parts, within the orbit, are subservient; nevertheless, that part of the retina which lies over the entrance of the optic nerve is insensible to light.

For the perfect functions of the retina, it requires the light within a certain degree of intensity: a very feeble light is not felt by the retina; too strong a light hurts it, and renders it for some time unfit for action.

Fig. 39.

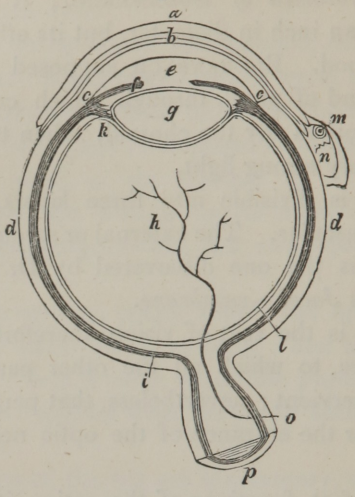


Fig. 39. A diagram of the eye.

*a*, the eyelid.

*b*, the tunica conjunctiva lining the eyelids, and reflected over the anterior part of the eye.

*c*, *c*, the cornea. *d*, *d*, the sclerotica.

*e*, the aqueous humour. *f*, the iris.

*g*, the crystalline lens. *h*, the vitreous humour.

*i*, the choroid tunic with its pigmentum nigrum.

*k*, the ciliary processes. *l*, the retina.

*m*, the punctum lachrymale.

*n*, the caruncula lachrymalis.

*o*, the central artery of the retina.

*p*, the optic nerve.

### THE AQUEOUS HUMOUR.

The aqueous humour is as clear as the purest water, but its specific gravity is somewhat greater; it is about five

grains in weight, and consists of water impregnated with albumen, gelatin, and muriate of soda.

The aqueous humour is situated between the cornea and crystalline lens, and, being confined in this space, forms a meniscus, which assists in collecting and transmitting the rays of light to the inner part of the eye.

The light only which passes the pupil can be of use in vision; that which falls on the iris is reflected, returns through the cornea, and exhibits the color of the iris.

The *membrane of the aqueous humour* is extremely thin, and perfectly transparent, lining all the anterior chamber of the eye, but not extending to the posterior chamber. The first of these chambers is about two lines, the latter about half a line in depth. This membrane secretes the aqueous humour in the first instance, and reproduces it when evacuated by accident or during operations.

### THE CRYSTALLINE LENS.

The crystalline lens is a transparent body placed between the aqueous humour and the vitreous body, lying behind the iris, surrounded by the ciliary processes. It is a double convex lens, of which the anterior surface is flatter than the posterior, the diameter of which is four lines, and its thickness about two; its axis corresponds to the centre of the pupil.

The lens appears to be composed of several distinct layers, an exterior, very soft and easily removed, and the interior forming a more solid nucleus, made up of a great number of concentric superimposed laminæ; and each of these laminæ is composed of very fine fibres, like those of spun glass.

If the lens be dried it may also be divided into three segments of a sphere, in the centre of which there exists a small transparent globule.

In its chemical composition it differs very little from the aqueous humour, only in having a larger proportion of gelatin and albumen, and in being free from saline matters.

The *membrane*, or *capsule*, of the lens is also perfectly pellucid, and adheres very slightly to the lens, so that when the capsule is punctured, upon making gentle pressure on the eye, the lens starts out. The capsule receives a minute branch of the central artery of the retina, and ramifications of the vessels of the ciliary processes. It encloses a small quantity of fluid which is termed *liquor Morgagni*.

The crystalline lens is retained in its situation by numerous delicate transparent filaments, which pass from the ciliary processes to the circumference of the capsule of the lens.

The office of the lens is not only to assemble the rays of light upon a certain part of the retina, but to increase the intensity of the light, which is directed towards the back of the eye. It may also be added, that the light which passes near the circumference of the crystalline lens, is probably refracted in a different manner from that which passes through the centre; so that its peculiar structure is supposed to have the effect of correcting that aberration which is always produced by the sphericity of ordinary lenses.

### THE VITREOUS BODY.

The *vitreous body*, or *humour*, is so called from its resemblance to melted glass: it is a perfectly transparent tremulous mass, occupying the globe of the eye, from the entrance of the optic nerve to the surface of the crystalline lens, or about the posterior two-thirds of the globe. It is invested, in nearly its whole extent, by the retina, but to which it is not adherent; so that its connection with the

other parts of the eye, is merely by the central artery of the optic nerve, which passes through it, to the posterior part of the capsule of the lens.

The vitreous body is composed of a fluid or humour contained in cells, formed of the hyaloid membrane.

The chemical properties of the fluid of the vitreous body are similar to those of the aqueous humour.

The *hyaloid membrane*, which contains the vitreous humour, is excessively thin and transparent, and constitutes an innumerable mass of *cellules* which communicate with each other, so that by making a puncture in the hyaloid membrane the whole humour will escape.

Fig. 40.

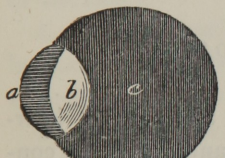


Fig. 40, the refracting media of the eye.

*a*, the aqueous humour.

*b*, the crystalline lens.

*c*, the vitreous humour.

The *Petitian canal* is named after Petit, who discovered it. This canal, Fig. 41, is formed merely by, *b*, the laminæ of the vitreous humour which passes before and behind, *a*, the lens, and becomes identified with its capsule; thus, leaving at, *c*, its margin, a somewhat triangular space, which may be demonstrated by inflation: although, strictly speaking, it does not exist in its natural state, for the laminæ are in perfect contact, the canal being formed artificially, by blowing air between the posterior surface of the capsule of the lens, and the hyaloid membrane on which the lens rests.

Fig. 41.

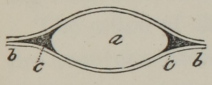


The anterior lamina of the canal of Petit presents radiated striæ and contractions, corresponding to the ciliary process, forming a curious and beautiful appearance.

The vitreous body possesses a less refractive power than

the crystalline, therefore, after the rays are collected by the latter, the vitreous body continues their convergence, increases the field of vision, and assists in bringing the rays to an accurate focus on the retina.

---

## CHAP. II.

### THE EAR AND ITS APPENDAGES.

There are a number of organs in the apparatus of hearing, which, by their physical properties and functions, concur in collecting and transmitting sounds, and there is a nerve for the purpose of receiving and conveying the impressions of sonorous vibrations to the sensorium.

The organ of hearing is divisible into three parts, viz. the external ear, or auricula, the tympanum, and the labyrinth.

#### THE EXTERNAL EAR.

The *external ear* comprehends the *pinna* or *auricle*, and the *meatus auditorius externus*.

The *auricle* consists of the *pavilion* or *ala*, which is by much the greater part of it, and the *lobus* which is the most dependent portion.

The exterior of the ear presents the following remarkable prominences and depressions, viz:—

Fig. 42.

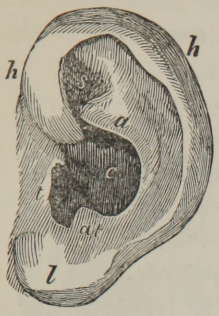


1. *h, h*, Fig. 42, the *helix*, a rim of nearly a semicircular shape surrounding its upper edge; and continued to, *l*, the lobe of the ear.

2. *a*, the *anti-helix*, an inner semicircular eminence, which is situated within the former, and is formed superiorly of two ridges uniting together below—

*s*, the *scapha*, the depression which separates the two roots of the anti-helix.

3. *t*, the *tragus*, a small eminence situated over the meatus externus, and connected to the under and fore part of the helix.

4. *a, t*, the *anti-tragus*, is another eminence situated behind, nearly opposite to the tragus, and at the inferior extremity of the anti-helix.

5. *c*, the *concha*, is a large cavity under the anti-helix, and leading to the meatus auditorius.

6. *l*, the *lobe of the ear*, is the inferior soft part of the ear, and is composed of cellular tissue with a small quantity of fat. This is the part which it has been customary, in many countries, to perforate for the purpose of suspending rings and other ornaments.

The office of the auricle of the external ear is to collect the sonorous radiations, and to direct them towards the auditory passage.

### FIBRO-CARTILAGE OF THE EAR.

Fig. 43.

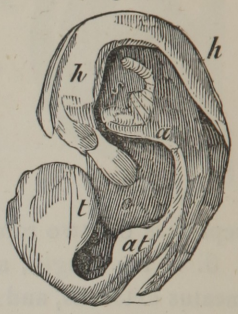


The fibro-cartilage of the ear, Fig. 43, constitutes its basis, determining the form of that part: in its consistence and elasticity, it is analogous to those of the nose.

All the eminences and depressions just described are formed by it, as may be seen in the annexed figure—*h*, *h*, the cartilage of the helix; *a*, the anti-helix; *s*, the scapha; *t*, the tragus; *a*, *t*, the anti-tragus; *c*, the concha. These fibro-cartilages are covered by a dermal layer, having a great number of sebaceous follicles disposed through it. The inner surface of, *t*, the tragus is furnished with hairs, which appear destined to prevent small particles, which float in the atmosphere, from entering the auditory passage.

There are ligaments which serve to fix the fibro-cartilage to the side of the head, called the *superior*, the *anterior*, and the *posterior ligaments;* they are more cellular than fibrous, and are intermingled with the muscular fibres of the auricle.

The principal muscles of the ear have been already described, and those that remain, which belong to the cartilage, are of small size; one or more of them are sometimes absent; at other times, Cloquet states, he could meet with none; indeed, so insignificant are these muscles that I am not aware that, in any person, they possess the power of moving the part they are attached to. The following, however, is an enumeration of them.

1. The *transversus auris*, extending from the convexity

of the concha, to the prominence which the groove of the helix forms posteriorly.

2. The *tragicus* is of a triangular form, and almost entirely covers the outer surface of the tragus.

3. The *anti-tragicus* occupies the interval which separates the anti-tragus from the anti-helix.

4. The *helicis major* covers, for a few lines, the helix above the tragus.

5. The *helicis minor* is situated beneath and behind the preceding, on the prominence of the helix.

The muscles of the external ear, no doubt, are calculated to expand the different hollows of which the surface is formed. Among savage tribes the ear is prominent and movable, like the ears of animals; their hearing is more acute than that of civilized nations; and it is probable, that the motion of the external ear assists them in discriminating the nature of different sounds.

### THE AUDITORY CANAL.

This canal extends from the concha of the ear to the membrane of the tympanum; it is composed of bone and cartilage, lined by a very fine skin, and defended by a peculiar acrid sebaceous substance, the *cerumen*, or the wax, furnished by the *cerumenous glands;* this canal is also fenced by a number of hairs. It takes a direction first forwards, upwards, and inwards, then downwards and inwards. It is therefore curved, or concave downwards, and about an inch in length.

### THE INTERNAL EAR.

The internal ear consists of the cavity of the tympanum, the vestibule, the cochlea, and the parts communicating with them.

The *tympanum* is a narrow chamber which opens into the posterior fauces through the *Eustachian tube*, and is continued backwards into the cells of the mastoid process of the temporal bone.

The *Eustachian tube* descends obliquely forwards and inwards, and terminates in a trumpet-shaped mouth, behind the posterior nares, on a level with the inferior spongy bone. It is small and osseous posteriorly; anteriorly it is large, and formed externally of membrane, and internally of fibro-cartilage. It is lined by mucous membrane. Through this tube, the air can pass from the fauces into the tympanum, to support the latter on its internal surface.

The *membrana tympani* is extended over the circular opening, at the bottom of the external meatus.

The *foramen ovale*, or *fenestra ovalis*, is an aperture of a shape which the name implies; it forms a communication between the tympanum and vestibule.

The *foramen rotundum*, or *fenestra rotunda*, is of smaller dimensions than the preceding foramen, and forms a communication between the inner scala of the cochlea and the tympanum.

The *promontorium* is an eminence formed by the outer side of the vestibule, and by the corresponding scala of the cochlea.

## THE BONES CONTAINED IN THE CAVITY OF THE TYMPANUM, OR THE OSSICULA AUDITUS.

A series of very small bones* extends from the membrana tympani to the fenestra ovalis and consequently to the labyrinth. These convey to the deepest parts of the internal ear, the changes which supervene in the membrane of the tympanum. They are named the *malleus*, the *incus*, the *os orbiculare*, and the *stapes*, and there are muscles appropriated to put them into motion.

Fig. 44.

The *malleus*, Fig. 44, which is described as having a head, a neck, a handle, and a process.

The handle of the malleus is attached to the membrana tympani, being situated between the layers of it.

Fig. 45.

The *incus*, Fig. 45, consists of a body and two crura. It is articulated to the malleus, and is fixed by a ligament to the sides of the mastoid cells.

Fig. 46.

The *os orbiculare*, Fig. 46, is articulated to the long process of the incus.

Fig. 47.

The *stapes*, Fig. 47, is distinguished into a head, crura, and base. This bone is placed horizontally, with its base resting against the fenestra ovalis, and its head articulated with the os orbiculare.

There are three muscles by which this series of bones is moved: —

* The annexed figures of the bones, as well as those which follow with the muscles attached to them, are magnified to twice the natural size.

Fig. 48.

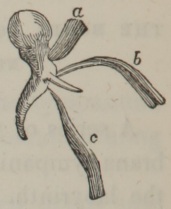


1. The *laxator tympani*, Fig. 48, *a*, is attached to the upper part of the edge of the tympanum, near to the part to which the membrane of the tympanum adheres, and is extended to the handle of the malleus.

2. The *tensor tympani*, *c*, is attached to the upper part of the Eustachian tube, and to the handle of the malleus below its process.

3. The *extensor mallei*, *b*, or the *musculus processus minoris* of VALSALVA, is figured by Sir C. BELL, but it is not acknowledged by CLOQUET and some other anatomists to be of the nature of a muscle.

Fig. 49.

4. The *stapedius*, Fig. 49, *a*, is the smallest muscle, and is attached near the mastoid cells, and into the head of, *b*, the stapes.

THE LABYRINTH. Fig. 50.*

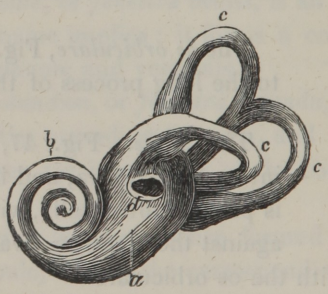


* To obtain the exact form of the exterior of these parts, we may pour melted lead into the external meatus of the temporal bone, the bone may be afterwards easily removed, and we have a metallic cast of these delicate parts.

The *labyrinth*, so called from its sinuosities and windings, is situated between the tympanum and the meatus auditorius internus ; it is formed of several cavities, which are designated by the names of, *a*, the vestibule, *b*, the cochlea, and, *c*, *c*, *c*, the semicircular canals.

The *vestibule*, named from its forming an entry to the cochlea and semicircular canals, is a cavity of an irregular form, containing several apertures, which communicate with the neighboring parts, which we must again notice, viz : —

1st. *d*, the *fenestra ovalis*, or *foramen ovale*, which communicates with the tympanum, and upon which is placed the base of the stapes. 2d. Superiorly, the two anterior orifices of the superior vertical and horizontal semicircular canals. 3d. Posteriorly, the two separate openings of the semicircular canals, and one opening common to the two vertical canals. 4th. On the inner side is a number of small perforations for the transmission of blood-vessels and branches of the auditory nerve. 5th. Near the common orifice of the vertical canals we find the opening of the aqueduct of the vestibulum, extremely small, extending from this cavity to the posterior surface of the petrous portion of the temporal bone.

### THE COCHLEA.

The *cochlea*, Fig. 51, is situated on the inner side of the vestibulum, in the anterior part of the petrous portion of the temporal bone : it is an osseous, shell-like cavity, formed by two conical canals, twisted in a spiral direction. See Fig. 50, *b*.

Fig. 51.

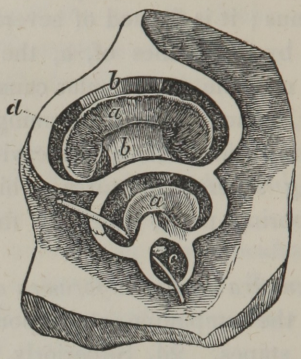


Fig. 51, represents a section of that part of the petrous portion of the temporal bone which contains the cochlea.

1st. *b*, *b*, the *modiolus*, an osseous conical pillar in the centre of the cochlea, terminating in a small cavity, *c*, called the *infundibulum*.

2d. *a*, *a*, the *lamina spiralis*, formed round, *b*, *b*, the modiolus, takes two turns and a half, and terminates by a hook at *c*, in the infundibulum.

3d. The *spiral septum*, dividing the cavity of the cochlea into two smaller ones.

4th. The *gyri*, which are the spiral cavities formed by the septum.

5th. The *aqueduct*, an extremely narrow passage opening, superiorly, into the cavity of the tympanum, near the foramen rotundum; inferiorly, in the posterior petrous portion of the temporal bone.

### THE SEMICIRCULAR CANALS.

The form of the three canals, Fig. 50, *c*, *c*, *c*, is indicated by the name; they are situated in the substance of the petrous portion of the temporal bone, and open into the vestibulum by five orifices.

The cavities of the internal ear are lined by a very delicate membrane; and each of the semicircular canals contains a membranous tube, opening into a common sac, which occupies a portion of, *d*, the vestibulum, and contains a small quantity of a peculiar fluid. The vestibulum also is lined by another membranous sac, filled with a limpid fluid, called the *liquor of* COTUNNIUS; it sends a prolongation of its membrane into the aqueduct of the vestibulum, and this prolongation terminates in a small cul-de-sac under the dura mater.

The membrane of the vestibule appears to introduce itself into the cochlea by the orifice of the external scala, lines all its cavities, is continued into the aqueduct of the cochlea, and terminates by a cul-de-sac under the dura mater.

### THE ACOUSTIC, OR AUDITORY NERVE.

The acoustic nerve proceeds parallel to the facial, so long as it is contained within the skull; it then introduces itself with it into the internal auditory canal, and divides into two branches:—

Fig. 52.

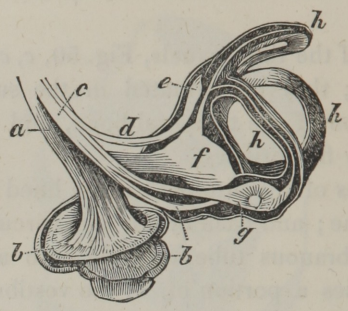


1. The *branch of the cochlea*, Fig. 52,* *a*, on arriving at the base of the cochlea, divides into a great number of very slender filaments, which enter into apertures of the cochlea, and spread out their ramifications on, *b*, *b*, the lamina spiralis in a very dense net-work.

2. The *branch of the vestibule and semicircular canals*, *c*, *d*, *g*, is at first united to the preceding, but afterwards separates from it, and forms an enlargement, from which proceed filaments which are distributed to, *f*, the vestibule, and to, *h*, *h*, *h*, the semicircular canals. At the entrance of the posterior vertical canal, we observe, at *g*, the increased size of the nerve in the ampulla, or enlargement of the extremities of the canals.

## MECHANISM OF HEARING.

The external ear collects the sonorous radiations, and directs them towards the auditory passage; and this tube transmits sound in the same manner as any other canal, partly by the air it contains, and partly by its parietes,

* The three last figures are considerably enlarged views.

until it arrives at the membrane of the tympanum; this membrane vibrates under the influence of the sonorous undulations which the meatus conducts to it. The series of little bones, next, has a peculiar action upon the membrane of the fenestra ovalis, so that the liquor of Cotunnius receives vibrations which are impressed on the acoustic nerve.

The gyri of the cochlea receive the vibrations principally by the membranes of the fenestra ovalis; the vestibule, by the series of bones: the semicircular canals, by the sides of the tympanum: but the assistance which is given to hearing by the several parts of the internal ear is totally unknown.

It is, however, certain that impressions are received and transmitted to the brain by the auditory nerve; and the brain perceives them with more or less facility and exactness in different individuals.

Fig. 53.

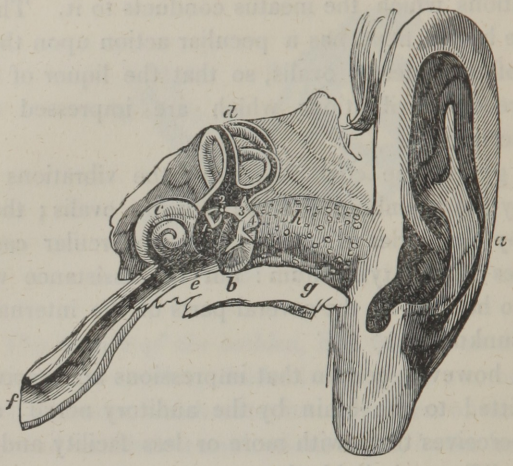


Fig. 53, exhibits the organ of hearing, of the natural size.

*a*, the external ear.

*b*, the tympanum, exposed by opening the vestibule.

*c*, the cochlea.

*d*, the three semicircular canals laid open.

*e*, the osseous part of the Eustachian tube.

*f*, the membranous extremity of the Eustachian tube, opening into the fauces.

*g*, the petrous portion of the temporal bone.

*h*, the meatus auditorius externus, on which is seen the cerumenous glands.

1, the stapes; 2, the os orbiculare; 3, the incus; 4, the malleus; a series of bones which transmits the vibrations of the tympanum.

## CHAP. III.

### THE NOSE, OR ORGAN OF SMELL.

The external part of the organ of smelling, or the nose, properly so called, is composed superiorly of bones, and inferiorly of cartilages; it has a partial covering from muscles, and a general one from the common integuments.

Fig. 54.

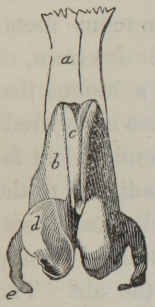


The osseous part of the nose has already been described; the ossa nasi, Fig. 54, *a*, forms the bridge.

The fore part of the nose contains five cartilages, of a regular figure, and some smaller pieces which are more irregular.

The *middle cartilage*, *c*, is the most considerable, and supports the rest; it constitutes the cartilaginous part of the septum narium, and is united to the anterior edge of the nasal lamella of the ethmoid bone, to the anterior edge of the vomer, and to the fore part of the spinous process of the superior maxillary bones.

*b*, the two superior *lateral cartilages* are placed somewhat anteriorly, so that by their union they form the centre of the nose; *d*, the two inferior, laterally and at the extremity, so as to form the tip of the nose; and, *e*, the alæ nasi.

Between the anterior and posterior cartilages we find additional cartilages, the number, size, and figure, varying in different individuals.

The elasticity of the cartilages contributes to the defence of the nose against external injuries.

The muscles which move the cartilages of the nose have been described.

The internal cavities of the nose extend upwards to the cribriform plate of the ethmoid, and to the body of the sphenoid bone. At the inner side, they are bounded by the septum narium, and on the outer side, by the turbinated bones, which, as we have seen in the skeleton, project considerably into the nasal cavities, and increase the surface of the membrane of the organ of smell.

The floor of the nostrils passes directly backwards in a horizontal direction to the throat.

The nose is lined by a thick and spongy mucous membrane, termed, the *membrana pituitaria* of SCHNEIDER, or the *Schneiderian membrane;* which secretes a mucus that defends the nerves from the current of air which is respired; by this mean they are preserved moist, and rendered fit for the impression of effluvia. This membrane adheres to the periosteum, to the sinuses, to the lachrymal sacs, Eustachian tubes, pharynx, and palate, and is intended to stop any foreign body which may be mixed with the air. The pituitary membrane is extremely vascular, and over the whole of it is distributed filaments of, —

Fig. 55.

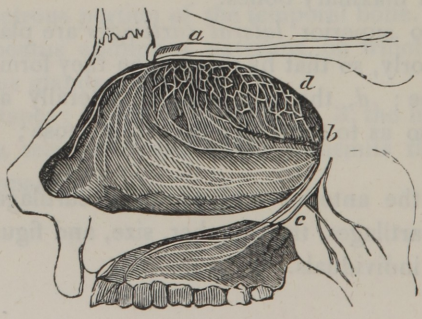

*b*, Fig. 55, the fifth pair of nerves, which endue the membrane with ordinary sensibility. The distribution of the first nerve, *a*, *d*, the olfactory, is more limited. The latter perforates the cribriform plate of the ethmoid bone, and spreads in numerous filaments over the septum narium, and surface of the upper turbinated bones; this nerve is the essential organ of smell, and conveys a perception of odors to the sensorium.

The maxillary and sphenoid sinuses, and the ethmoid cells, open into the nasal cavity, and are lined by a continuation of the mucous membrane just described.

### MECHANISM OF SMELL.

A great many substances in nature emit certain particles of extreme tenuity, which are carried by the air, often to a great distance; these particles constitute odors; the organ of smelling is destined to perceive and appreciate them; thus an important relation is established between animals and other bodies. The mechanism by which we smell, is extremely simple: it is only necessary that the odoriferous particles should be detained upon the pituitary membrane, particularly in the parts where it receives the filaments of the olfactory nerve. The nose also contributes to the general purposes of respiration and the modulation of the voice, and receives the superabundant fluid from the external surface of the eyes.

## CHAP. IV.

### THE TONGUE, OR ORGAN OF TASTE.

The *tongue* is a muscular organ, possessing great mobility, and is the principal organ of taste; but this is not its only use, for it is the chief instrument of speech, and contributes to the acts of sucking, mastication, and deglutition.

The *muscular portion of the tongue* forms the greater part of its substance, and is composed of the fibres of the stylo-glossi, the hyo-glossi, and the genio-glossi muscles, which have already been described: beneath, and on each side also, are two parallel fasciculi of fibres, which are named the lingual muscles. All these muscles, however, have their fibres interwoven in a most inextricable manner. In the upper part of the tongue, there are interposed small adipose globules.

At the centre of this fleshy tissue there is a fibro-cartilaginous septum, which gives attachment to the muscular fibres.

The *mucous membrane*, which lines the whole interior of the mouth, passes to the under surface of the tongue, forming in the centre a fold which is named the *frænum linguæ*. The same membrane then extends on each side, beneath the tongue, ascends upon its edges, passes over its upper surface, and forms three folds near the epiglottis.

On the upper surface of the tongue the mucous membrane presents a very different appearance to that on its inferior surface; there it assumes a distinct epidermis, under which is a tissue formed of numberless vessels and nerves, which constitute a net-work, surrounding the pa-

pillæ and mucous follicles, and which give to the tongue the red color peculiar to it. The upper surface is rendered rough and uneven by the existence of a very great number of projections differing in their form. These are the *papillæ*, which may be distinguished into three kinds.

1. The *lenticular papillæ* vary in number from nine to fifteen; they are observed only at the posterior part of the tongue, arranged in oblique lines, like the letter v, and meeting at a considerable depression, termed the *foramen cæcum* of MORGAGNI, by whom it was first described.

The lenticular papillæ are generally spherical or oval; they are not like the other papillæ, organs of taste, but are simply mucous follicles, which open upon the tongue by very small orifices.

Fig. 56.

2. The *fungiform papillæ*, Fig. 56, of a whitish appearance, are disseminated irregularly near the edges of the tongue; they present a rounded flattened head, supported by a narrow pedicle.

Fig. 57.

3. The *conical papillæ*, Fig. 57, or *papillæ mediæ*.—These are by much the most numerous, and occupy almost the whole upper surface of the tongue, becoming gradually shorter at the sides, and longer and more abundant at the apex, where the sensation of taste is most acute.

These papillæ resemble small cones, attached to the tongue by their base, and free at their summit; they are placed close to each other, but at many parts leave irregular intervals in the form of clefts.

Fig. 58.

The *filiform papillæ*, Fig. 58, are observed at the edges of the tongue; they assume a shred-like appearance, and are of a similar fabric to the last.

Fig. 59.

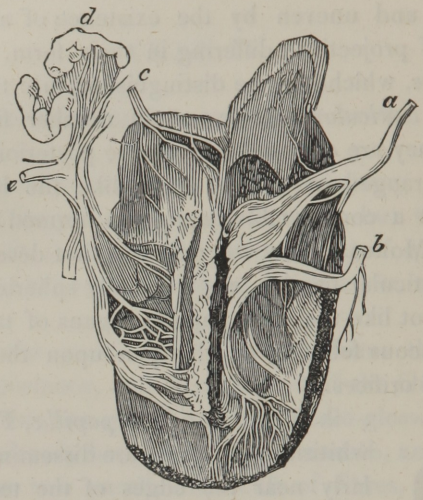


The nerves of the tongue, as we may observe in the annexed figure, are very abundant, and are furnished by, *b*, *e*, the inferior maxillary; *c*, the glosso-pharyngeal; and, *a*, the hypoglossal nerves.

Behind the fringes formed under the tongue, we perceive an amygdaloid granular mass, amply supplied by blood-vessels, and by filaments of the lingual nerve.

## TASTE.

Although the tongue is the principal organ of taste, the lips, the internal surface of the cheeks, the palate, and even the teeth are sensible to the impression of sapid bodies.

To excite a sensation of taste, a substance must be in a liquid state: to promote this object, when a solid is placed

in the mouth, the saliva is observed to flow abundantly, and its sapid qualities are perceived in proportion as it dissolves; and there are many substances which we cannot perfectly taste unless their fumes ascend into the cavity of the nostrils: indeed, sensations of taste are not perfect until the mouth is closed, and the tongue pressed against the palate, by which means the sapid body is brought more immediately into contact with the surface of the tongue, and perhaps forced into the nervous membrane, at the same time that the fumes are driven through the posterior fauces into the nasal cavities.

The choice of food entirely depends on the taste; joined to smell, it enables us to distinguish between substances which are hurtful, and those that are nutritious.

---

## CHAP. V.

### THE SKIN.

The skin is a dense membrane of variable thickness, according to the part which it covers; it is very flexible, and envelopes the whole body: at the circumference of the apertures, as at the nose, the mouth, etc. it is continuous with the mucous membrane which lines those cavities.

The skin is composed of three very distinct layers; the *dermis*, or *chorion*, the *rete mucosum*, and the *epidermis*, or *cuticle*.

The *external surface* of the skin is covered by a vast number of small projections, resembling papillæ, and it is furrowed by a multitude of wrinkles, some of which are occasioned by the action of muscles, as in the forehead, the hand, and the sole of the foot; others are produced by the flexure of joints, or by the rows of papillæ, as we observe at the extremities of the fingers.

This surface of the skin presents a multitude of pores, very visible by the aid of a microscope; it has been questioned whether these pores are the terminations of exhalent vessels, out of which the drops of sweat issue; but they may be considered as perforations made by the excretory ducts of sebaceous follicles, or by the hairs.

### 1. THE DERMIS.

The *dermis* is the thickest layer of the skin, and is formed of fibres, interwoven in an inextricable manner, and is so plentifully furnished with blood-vessels and nerves, that the smallest puncture cannot be made, in any part of it, without occasioning pain and a discharge of blood.

The dermis is strong and elastic, and forms the most substantial part of the skin; indeed, it is that part, in quadrupeds, of which leather is made.

The outer part is very compact, the inner more loose, and it gradually degenerates into the common cellular tissue.

The dermis is covered in all its regions with more or less distinct prominences, and irregular depressions, which appear through the epidermis. The asperities are named the papillæ, and are divided by a series of small depressions, to the number of four or five in the extent of a line. On the points of the toes, and on the tips of the fingers, the papillæ generally take a somewhat spiral and parallel direction.

Blood-vessels twine in the subcutaneous cellular tissue, and project an infinitude of small branches, which penetrate into the remotest areolæ of the dermis, unite in a variety of ways, cross the external surface, and finally give rise to that capillary net, which I shall describe in speaking of the rete mucosum.

The nerves are distributed nearly in the same order as the blood-vessels ; there is a subcutaneous stratum of the nervous system from which pass all the filaments which penetrate the dermis. These filaments frequently unite and insinuate themselves into the internal areolæ, and undoubtedly terminate in giving origin to the papillæ. In the hand, and at the points of the fingers, where the papillæ are remarkably conspicuous, there is a larger proportion of subcutaneous nerves than in any other part of the body ; and it cannot be doubted that the soles of the feet, the palms of the hands, and the tips of the fingers, are gifted with much more sensibility than any other parts.

### 2. THE RETE MUCOSUM.

This tissue lies immediately under the dermis, and is the chief cause of that variety of color which characterises the natives of different climates, and different people of the same climate ; being white, or rather of a light gray in the European, brown in the Asiatic, and black in the African. And, on account of the thinness and transparency of the dermis, the color of the rete mucosum appears through it.

The rete mucosum then may be conceived as a general capillary system, enveloping the cutaneous organ, and forming, in common with the papillæ, a stratum interposed between the dermis and the epidermis. In different subjects it has a different hue, forming the *complexion* of the individual, and there is every intermediate color from the

swarthy hue of the negro, to the fairest skin of the European. Hence, the complexion depends on the substance which exists in the very minute vessels of the skin.

It is likewise the cause of the difference of color in different parts of the body of the same person, and is composed, according to GAULTIER, of four distinct layers; the first counting from within outwards, is formed of blood-vessels arranged like granulations, on the asperities of the dermis; the second is whitish, and applied upon the former, in the irregularities of the dermis, and there are numerous prolongations of this layer which penetrate into the substance of the dermis; the third layer is composed of minute convex bodies, containing the coloring matter of the skin; the fourth layer is white, of extreme tenuity, perforated by the hairs, and adherent to the epidermis.

### 3. THE EPIDERMIS.

The *epidermis*, or *cuticle*, is the most superficial layer, and is separated from the dermis by the rete mucosum. It presents all the wrinkles and furrows which have been mentioned in the description of the outer surface of the dermis; it is thin, and transparent, and formed of numerous scales in close apposition with one another. The inner surface is very firmly attached to the dermis, on removing it by maceration, we observe a multiplicity of small prolongations, which appear to be nothing more than processes which line the passages through which hairs grow and the sebaceous follicles open.

A great number of sebaceous follicles are seated under the skin, and open by small ducts on its surface; Mr CHEVALIER* counted one hundred and forty in the space of a quar-

* Lectures on the General Structure of the Human Body, delivered at the Royal College of Surgeons.—p. 186.

ter of an inch, which will make one hundred and twenty millions on the surface of the whole body. These follicles, or glands, secrete an oily fluid which serves to lubricate the skin, and defend it from the inclemency of the weather, or from the effects of friction.

Immense multitudes of perforations have been supposed to exist in the epidermis, for the purpose of allowing the perspirable matter to escape from the body. But are there any in reality? A microscope of high powers will not detect them; we can only discern those apertures which belong to the hairs, and the sebaceous follicles. The serum, produced by a blister, will not exude from within, nor will water or other fluids penetrate from without. How then is the office of perspiration carried on through the cuticle? Instead of porosity, this appearance results from an infinite number of velaminæ, regularly arranged, of exquisite tenuity, presenting a follicular appearance, and separated from each other by filaments crossing in a thousand different directions. The terminal vessels of the cutaneous apparatus transmit the perspiration through this tissue, without the inconvenience of perforated pores. Perspiration then is a secretion produced by the action of the sudatory vessels, and not an exudation, and the skin constitutes one wide and diffused perspiratory gland; a subtile fluid is separated from the circulation by it, from the invisible vapor of perfect health and ease, to the profuse and colliquative sweat of a languishing hectic. The skin, therefore, seems the natural and appropriate recipient of the capillary vessels of the cutaneous secretion, which it transmits through that exquisitely fine gauze of the epidermis. Perspiration liberates from the blood superfluous animal gas, and water; and by its copious evaporation in summer, and its partial suppression in winter, it regulates the temperature of our bodies, and thus the skin acts as the safety-valve of life and health.

Exhalents, absorbent vessels, and hairs pass through the epidermis, but no blood-vessels have been traced in it, either by the eye or by the assistance of glasses: it possesses, therefore, none of the properties of life: it wears away and is renewed continually, and its thickness lessens or augments, as it is needed; it becomes hard and thick on the hands of the laborer, and soft and delicate on the hands of those who are occupied in lighter employments.

## THE SENSE OF TOUCH.

This is the fifth sense, and must be included in the description of the skin. None of the vertebrata inferior to man are endowed with the special organ of touch; and although the general surface is in most animals an organ of sense, the distinct faculty of touch is entirely wanting, or exists in a very modified degree. It is in the sense of touch, says CUVIER, that we excel every other animal, why? Because this sense is quite different from the others; this is consequent to them, and rectifies their errors: we feel, because we have seen, heard, tasted, or smelt the objects. Touch is voluntary, and reflection is necessary to exercise it, while the other four require none. Light, sound, etc. may strike their respective organs unnoticed, but we touch nothing without a preliminary act of the intellectual functions.

Sensibility to cold and various stimuli does not prove that the lower grades of animals have the sense of touch; our own species inherits this *common sensibility*, which we maintain essential to all other organized structures; but, in addition to this, we possess the special sense of TOUCH, which enables us to ascertain the properties of bodies, for almost all the physical properties of bodies are capable of

acting on the organs of touch; form, dimensions, locomotion, and vibration, are all appreciated by the organ of touch.

The whole cuticular surface may be said to have a modified sense of touch, and this kind of feeling is likewise shared by the mucous membrane of the eyes, nose and mouth, the larynx, rectum, and the external genital organs. But the hand only can be truly designated as the organ of touch; the hand is expressly constructed for the purpose of examining the qualities of objects: the tips of the fingers especially have practically the finest discrimination of the tangible qualities of bodies. This delicacy of touch in the fingers has given man a great advantage over the animals: his touch is so delicate that it has been considered the source of his intelligence. This sense is capable of arriving at a very great degree of perfection, as is seen in many professions; and MAGENDIE observes, that, "for medical men, a very delicate sense of touch is absolutely necessary." This property then, of the nervous system, as before mentioned, which depends on the extreme pulpy distribution of the posterior roots of the spinal nerves, can be assigned only to man.

### THE HAIR.

Hair exists on almost all parts of the surface of the body and limbs, except the palm of the hand and the sole of the foot.

The *head* is that part wherein the hair is most abundant; it occupies the whole space corresponding with the occipital, the parietal, the squamous portion of the temporal, and the upper part of the frontal bones. It seems to be provided as a protection against mechanical injuries of the head. The hair on the face and other parts is, in general, much less, though still in great quantity.

The difference in the nature of the hair considerably influences it length ; lank hair is generally the longest. The more it curls the shorter it is, as exemplified in the African and even in Europeans.

The color of the hair varies considerably, according to the different countries, latitudes and climates. Naturalists have considered the color of the hair, as well as that of the skin, as forming one of the characteristic distinctions of the human races.

The *eyebrows* form arches to shade the eyes, and their motions are intended to protect them from the too powerful impression of luminous beams. Their actions also are very expressive of the passions and mental emotions, which affect the individual. Painters have paid much more attention than anatomists to the varied position of the eyebrows.

The *eyelashes* have a similar use; they moderate the light, and likewise guard the eye from substances floating in the atmosphere.

The *hair on the chin and upper lip* is the peculiar attribute of the male; and appears towards the period of virility, when the animal powers increase.

The *hair on the trunk* varies most astonishingly; some men are almost completely hairy, whilst others are not at all so. Generally speaking, the fore part of the body possesses much more than the back part: in men it is particularly met with along the median line of the chest.

In both sexes a considerable quantity shades the genital organs.

The *hair on the limbs*, in man, is abundant on the whole surface: the proportion is the same in all, but its length and fineness vary considerably. In some it consists of a mere down, in others it is coarse and thick, giving to the limbs a hairy aspect.

### ORGANIZATION OF THE HAIR.

The hair may vary in respect to form, length, and fineness, but its organization is the same in all. It generally arises from the subcutaneous cellular tissue: every individual hair originates in a bulb, or root, and each bulb has two capsules, containing an oily fluid between them, which gives color to the hair; a deficiency of this is supposed to occasion a change of the color, and the whiteness we observe in advanced life.

In general the color of the hair has some relation to the rete mucosum; as in the negro, the hair corresponds with the tint of the skin, and in a person with light or with dark colored hair, there is a florid or a dark complexion.

The hairs in passing from the skin, are supposed to carry with them a sheath of the epidermis, which is thin, but hard, and so transparent, as to allow the color of the hair to appear through it. With the aid of a good glass we may observe canals for containing their nourishing fluid, termed the medulla, which constitutes the coloring matter of the hair. The chemical properties of the hair appear to be of the same nature as the epidermis, cartilage and the nails.

The hair serves in general for ornament, to retain animal heat, or to protect the different parts on or near which it is situated.

### THE NAILS.

The fingers are provided, at their extremities, with a hard, transparent, and flexible kind of plate, of a similar nature to that of horn.

The upper part of the nail, which is concealed, forms

nearly a sixth part of its whole extent: its surface adheres strongly to the epidermis, which, to fix it, is disposed in the following manner:—after having covered the portion of the finger, corresponding to the last joint, it is reflected over the concave border, where the skin ends, and the nail begins to emerge; the epidermis having formed a kind of ridge, is again reflected, insinuates itself between the skin and the nail, and adheres to the concave surface without being confounded with it; for it is easily removed by maceration or with the dissecting knife. Thus the nail is placed in a folding of the skin; there is, however, a cuticular covering to it, which appears to be derived from a lamina of the epidermis.

The nails strengthen and defend the ends of the fingers and toes; they afford a support to the ends of the fingers in grasping bodies, and they are particularly useful in taking hold of minute objects.

---

## CHAP. VI.

### MUSCULAR SENSATION.

To the sensitive department of the fifth pair, and the compound spinal nerves, is assigned muscular sensation. This is the SIXTH SENSE. All our conceptions of weight and resistance, and motion in general, are derived from our muscles. The muscular system, then, may be considered a

distinct organ of sense as well as motion; each motion of the invisible muscles is accompanied with a certain feeling, which may indeed be complex, as arising from various muscles, but which is considered by the mind as one, and it is this peculiar feeling, attending the action of the muscular fibres, which we distinguish from every other sensation. To exemplify this, I might refer to the state of the muscles in cramp of the limbs, and in rheumatic affections; in such morbid conditions their structure becomes painfully sensible. But let us call to mind the phenomenon which every one must have experienced, I mean the feeling of fatigue; this is a muscular sensation: a sensation of which the muscles are the organs, as much so as the eye, and the ear, are the organs of sight and hearing. Every bodily effort depends on muscular contraction; and long and frequent contractions, that is, continued exercise, occasion a peculiar uneasiness which demands repose. Powerful and protracted exertions produce painful sensations to the muscular sense: a more moderate degree of exercise is attended with agreeable sensations. With a healty state of body, there is a muscular pleasure in exertion. Thus the child who is not playful, is not healthy. There is a muscular gratification, if I may so express myself, in every limb, in the games and pastimes of the school boy.

Dr Brown, without being aware that there was a peculiar set of nerves appropriated to muscular sensation, observes, that "nature in the other animals, whose sources of general pleasure are more limited, has converted their muscular system into an organ of delight. It is not in search of richer pasture that the horse gallops over the field, or the goat leaps from rock to rock, it is for the luxury of the exercise itself. It is this appearance of active life which spreads a charm over every little group with which the Deity animates the scenery of nature." We may, therefore, consider that the muscular system is not

merely the living machinery of motion, but that it is also truly an *organ of sense.*

The muscular sensation commences in infancy; there is a feeling of danger when the child is first tossed in the nurse's arms, and afterwards, when it essays to walk, there is evidently an apprehension of falling. Sir C. Bell* has shown that we have a muscular sense, and that without it we could have no guidance of our frame; that we could not command our muscles in standing, far less in walking, leaping, or running, had we not a perception of the condition of the muscles.

Without a sense of muscular action or consciousness of the effort made, the proper sense of touch could hardly be an inlet to knowledge. The property of the hand in ascertaining the size, the weight, the form, the hardness and softness, the roughness or smoothness of objects, results from the combined perception — through the sensibility of the proper organ of touch, and the motion of the hand, arm and fingers. But the *motion* of the fingers is especially necessary to the sense of touch; they bend, extend, or expand like palpa, with the advantage of embracing the object, and feeling on all its surfaces; sensible to its solidity and to its resistance when grasped; moving round it and gliding over its surface, and, therefore, feeling every asperity.

The same author has given an admirable description of the pleasures arising from the muscular sense.

"The exercise of the muscular frame is the source of much of the knowledge which is usually supposed to be obtained through the organs of sense; and to this source, also, we must trace some of our own chief enjoyments. We may, indeed, affirm that it is benevolently provided that vigorous circulation, and, therefore, the healthful con-

* Bridgewater Treatise. On the Hand, its Mechanism and vital Endowments.—p. 189.

dition both of the mind and the body, shall result from muscular exertion and the alternation of activity and repose.

"The pleasure which arises from the activity of the body is also attended by gratification from the exercise of a species of power—as in mere dexterity, successful pursuit in the field, or the accomplishment of some work of art. This activity is followed by weariness and a desire for rest, and although unattended with any describable pleasure or local sensation, there is diffused through every part of the frame, after fatigue and whilst the active powers are sinking into repose, a feeling almost voluptuous. To this succeeds the impatience of rest, and thus we are urged to the alternations which are necessary to health, and invited on from stage to stage of our existence.

"We owe other enjoyments to the muscular sense. It would appear that in modern times we know comparatively little of the pleasures arising from motion. The Greeks, and even the Romans, studied elegance of attitude and movement. Their apparel admitted of it, and their exercises and games must have led to it. Their dances were not the result of mere exuberance of spirits and activity; they studied harmony in the motion of the body and limbs, and majesty of gait. Their dances consisted more of the unfolding of the arms, than the play of the feet: 'their arms sublime that floated on the air.' The Pyrrhic dances were elegant movements, joined to the attitudes of combat, and performed in correct coincidence with the expression of the music. The spectators in their theatres must have had very different associations from ours, to account for the national enthusiasm arising from music, and their rage excited by a mere error in time.

"This reminds us that the diversions in music in some degree belong to the muscular sense. A man will put down his staff in regulated time, and the sound of his steps will fall into a measure, in his common walk. A boy striking

the railing in mere wantonness, will do it with a regular succession of blows. This disposition of the muscular frame to put itself into motion, with an accordance of time, is the source of much that is pleasing in music, and aids the effect of melody. There is thus established the closest connection between the enjoyments of the sense of hearing, and the exercise of the MUSCULAR SENSE."

---

## CHAP. VII.

### VISCERAL SENSATION.

I HAVE elsewhere stated that the ganglionic department of the nervous system belongs to organic life. The whole series of actions resulting from this department are *instinctive*. And we are conscious that the nerves of the ganglia are the seat of certain sensations. This is the SEVENTH or VISCERAL SENSE. The ganglionic nerves, throughout the whole animal kingdom, preside over the organic or vegetative functions, so as to control and direct their operation; but their sensation or perception, in man, is connected frequently with certain affections of the mind. MAGENDIE said "the passions were the triumph of the viscera over the intellect." It is, however, with great diffidence that I proceed to a description of this ganglionic or visceral sensation, although I am convinced of its existence.

1st. In the viscera of the chest;—strong mental emo-

tion, as anger, first exalts, and then exhausts the powers of the heart: and extreme grief, says BICHAT, has been known so to debilitate the circulatory powers, as to render them incapable of returning to their usual condition. DESAULT, the late chief surgeon of the *Hotel Dieu*, has remarked, that diseases of the heart, and aneurisms of the aorta, were augmented in number during the Revolution, in proportion to the evils which it produced. The united testimony of mankind concurs in referring all the finer feelings (sensations) to the heart; and this view of the subject of visceral sensation, I imagine must be confirmed by our own individual experience and perceptions.*

Of this species of sensation is profound sorrow; it is felt in the lungs; hence, the sense of oppression, anxiety, suffocation, and involuntary sighs, which visibly agitate the pulmonary organs.

2d. The abdominal organs possess similar visceral sensation. The stomach is affected by any kind of trouble: frequently it will cause a painful sensation in that organ, and an interruption of the digestive process; and the sad forebodings and darker affections of the mind, have a sensible effect on the digestive organs.

It has been very judiciously observed by HALLER, that the sensation we experience in parts receiving nerves from the ganglions have a peculiar character; that they do not resemble those experienced in such parts as are supplied with cerebral nerves. BROUSSAIS ascribes the pleasure and pain which accompany the exercise of the intellectual faculties, as having the same seat as the pleasure and pain of

* Dr SPURZHEIM denies that the feelings depend on the viscera of the thorax or abdomen. "The influence of the abdominal and thoracic viscera or the manifestations of the mind is only mediate; their functions contribute to the organic constitution of the brain as well as of the body in general, but they are not the seat of the affective faculties."

the passions; for the sensorium cannot feel without a corresponding feeling in the viscera.

Are not hunger and thirst also instinctive and visceral sensations? Are they not important indications to the individual of the wants of the animal economy, and do they not incite the animal to acts which contribute and are essential to self-preservation? And the solicitation for food and drink must be obeyed, or alienation of the mind, or death of the body must ensue.

Hunger is characterised by a peculiar sensation in the region of the stomach; there is a sense of drawing and oppression in that part, and when the cravings of hunger are not appeased, it amounts to severe pain in the stomach, and a general feebleness of the whole frame.

It might be easily proved that all the abdominal viscera are capable of transmitting impressions to the brain, without the intervention of any external cause; and examples might be multiplied, were it necessary, to establish the theory of *visceral sensation*, without referring to the morbid states to which the internal organs are liable.

The ganglionic visceral feelings are instinctive, and constitute a separate department of sense; the impressions conveyed by this department of the nervous system, to the common sensorium, being totally dissimilar to those which result from any other order of nerves.*

* There are several species of sensation resulting from the ganglionic department, which, in an elementary work of this kind, cannot be discussed even in the most transitory manner, but which may be compressed in the generic term, *visceral sensation*, every species of which is instinctive; namely, sensations determined by the viscera, and which solicit the nervous centre to execute acts necessary for the exercise of their functions.

# ART. IX.

## ORGANS OF DIGESTION.

### THE MOUTH.

THE *mouth* is circumscribed laterally by the cheeks, anteriorly by the lips, posteriorly by the velum palati, above by the arch of the palate, and below by the tongue. The cavity of the mouth, and the organs which it contains, are lined by a common mucous membrane.

This membrane forms a fold opposite the symphysis of the chin, which is named the *frænum of the under lip*. The mucous membrane passes into each alveolus, a prolongation of which adheres to the roots of the teeth, and indeed lines the cavities into which they are inserted. Beneath the tongue we find another fold, called the *frænum of the tongue*. This membrane is then continued over the epiglottis into the larynx and pharynx.

About the middle of the lining of the cheeks we observe the *orifice of the parotid duct*, and in other parts a great number of mucous follicles.

The *lips* are principally composed of muscles which have been described; they are covered outwardly by the common integuments, and lined within by the membrane of the mouth.

The lips possess a small proportion of adipose tissue; but there is a considerable quantity generally found in the cheeks, which give shape to the face.

### THE PALATE.

The *palate*, or roof of the mouth, represents a kind of parabolic arch; a white depressed line extends from the anterior to the posterior part of the palate, in the median line of the body.

On the arch of the palate, the common mucous membrane is much more dense and thick than on the other parts of the mouth, and is interspersed with small perforations, which are the orifices of mucous follicles, situated between it and the osseous part of the palate.

The *gums* are continuous with the membrane of the palate, and are formed of a similar kind of compact red tissue, the intimate structure of which it is difficult to explain: they are, however, prolonged into the alveolar cavities, and send into the root of each tooth a bulbous process, named the pulp of the tooth.

The *velum palati*, or *soft palate*, is a soft, broad, mobile partition, situated at the extremity of the palate, and separating the mouth from the palate. Its upper edge is adherent to the arch of the os palati; its lower edge is extended over the root of the tongue. It presents, at its middle part, a prolongation, termed the *uvula;* which forms the inferior edge of the palate into a double arch.

The velum palati acts like a valve, in preventing what we swallow from passing into the nose.

The *pillars* of the velum palati are united above, but diverge below, and are separated by a triangular space in which the tonsils are lodged.

The *tonsils* are of a light red color, somewhat of the size

and figure of almonds; they are full of cells which communicate with each other, and have large irregular openings which convey a transparent mucous into the throat: they are situated between the anterior and the posterior pillars of the soft palate, and close by the sides of the base of the tongue.

### THE PHARYNX.

The *pharynx* is a funnel-shaped musculo-membranous canal, situated behind the tongue; it extends from the base of the skull to near the middle of the neck; it rests on the vertebral column, and on its sides is in contact with the common and internal carotid arteries, the internal jugular veins and the pneumo-gastric nerves. It is connected with those different parts by a cellular tissue of a very extensile character, and destitute of adipose substance.

Anteriorly, on a level with the nasal fossa and mouth, the cavity of the pharynx is open; opposite the commencement of the trachea, it contracts, and terminates in the œsophagus.

The pharynx has several openings by which it communicates with the neighboring cavities; two of these, called the *posterior nares*, lead upwards and forwards; two others, called the *Eustachian tubes*, proceed laterally to the ears; one passes forward, termed the *fauces*, or upper part of the throat, to the mouth; one downwards, through the larynx and trachea, to the lungs; and another, which is a continuation of the pharynx, leads directly downwards by the œsophagus to the stomach.

The muscles of which it is composed are the six constrictors, which have been described; their fibres, which differ in their obliquity, form planes crossing each other in different directions. See vol. I. fig. 120.

A *mucous membrane* lines the whole cavity of the pharynx, which has a very deep red tint. It is smooth, or presents only a few inequalities, arising from the presence of the mucous follicles.

The pharynx receives the aliments from the mouth, and, by the action of its muscles, conveys them to the œsophagus. It also receives the air we inspire, and assists in the modulation of the voice.

### THE ŒSOPHAGUS.

The *œsophagus*, or *gullet*, is a musculo-membranous canal, extending from the lower part of the pharynx to the upper orifice of the stomach.

It is situated between the trachea and the vertebræ, and in the neck it deviates a little to the left; in the thorax it proceeds behind the base of the heart, and between the layers of the posterior mediastinum, from which it receives a covering. On entering the thorax, it passes downwards upon the right side of the aorta. It then perforates the diaphragm, and, after a very short course, arrives at the stomach.

It is connected to the adjacent parts by a loose and extensile cellular tissue, which contains a number of lymphatic glands.

Its outer surface is smooth in its whole extent, and of a red color above, but becoming paler as it descends: its inner surface is whiter than that of the pharynx, and presents longitudinal folds.

The œsophagus, like the pharynx, is composed of a muscular coat, and a mucous membrane.

The *muscular coat* consists of two strata; the external of which has thick, strong, longitudinal fibres, somewhat fasciculated; the internal is formed of circular or transverse fibres, and is thinner than the former.

The longitudinal fibres diverge toward the stomach, and may be traced over its cardiac extremity, while the circular fibres entirely disappear where the œsophagus terminates.

The outer stratum of fibres is fitted for shortening and relaxing, and the inner for contracting the canal, during deglutition.

The *mucous membrane* is soft, delicate and white ; it appears continuous above with the membrane of the pharynx, and is formed into numerous longitudinal folds, arising from the contraction of its muscular fibres.

Between the muscular and mucous coats there is a dense and compact cellular tissue, to which the older anatomists gave the name of the *nervous coat:* it is merely the connecting medium of the two former.

The *mucous follicles* of the œsophagus are thinly distributed ; they are furnished with numerous foramina, which supply a mucus for lubricating the passage and facilitating deglutition.

The office of the œsophagus is to convey the food from the pharynx into the stomach ; for the aliment does not descend into the stomach by its own weight, as we are able to swallow solids or fluids with the head more dependent than the stomach ; and, indeed, we see animals feeding in this position, namely, with the head lower than the body : it is, therefore, from a successive dilatation and contraction of the muscular fibres of the canal, that the contents are urged on to the stomach.

Fig. 60.

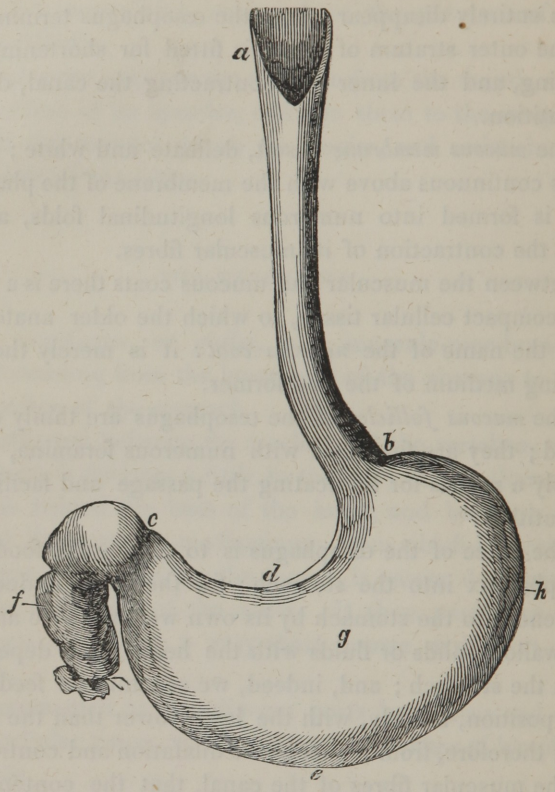


THE STOMACH.

The *stomach (ventriculus)*, Fig. 60, is the principal organ of digestion; it is a conoid, elongated, musculo-membranous reservoir: continuous on the one hand with, *a*, *b*, the œsophagus, on the other with, *f*, the duodenum. It is situated beneath the diaphragm, between the liver and the spleen, occupying at the upper part of the

abdomen, the epigastrium and a portion of the left hypochondrium. The stomach is destined to receive the food from the œsophagus, and afterwards to convert it into chyme, before transmitting it to the intestines.

The dimensions of this organ vary according to the quantity of aliment it contains; it is much larger in those individuals who eat much, than in other persons.

The *cardiac*, or *large extremity*, *h*, is situated in the left hypochondriac region, approaches the spleen, and is considerably higher than the small extremity.

The *upper surface*, *g*, is turned towards the diaphragm, the *under*, towards the intestines; but when we examine the abdomen after death, unless the stomach is considerably distended, it falls on the spine, so that the superior surface becomes anterior, and the inferior surface posterior.

The *large curvature*, *e*, is situated obliquely forwards and downwards; the *small curvature*, *d*, is opposite to the large one, and towards the spine.

The *left*, or *cardiac aperture*, of the stomach, is the termination of, *b*, the œsophagus.

The *right aperture*, or the *pylorus*, *c*, terminates the stomach to the right, and communicates with, *f*, the duodenum: it consists of a duplicature of the two inner tunics, which project into the passage, dividing the stomach, and intestines; it contains circular muscular fibres, called the *sphincter pylori:* or, I should rather describe it, as a solid fibrous ring, interposed between the peritonæal and mucous surface of the pylorus.

### THE ORGANIZATION OF THE STOMACH.

The stomach is formed of three membranes, a serous, a muscular, and a mucous; these are connected together by cellular tissue, and supplied with vessels and nerves.

The *serous membrane* is merely the peritonæal covering, and, in this situation, has a transparent, smooth and white appearance; it is externally lubricated by a serous fluid. It is united to the muscular membrane by a cellular tissue.

The *muscular membrane*, or tunic, is composed of pale fibres, disposed in three different directions. 1st. Some of these fibres, which are more *longitudinal*, are superficial; others, which are extended over the surface, are more irregularly distributed. The 2d plane of fibres lies immediately under the former; these fibres are *circular*, and run parallel to each other. In the 3d series the fibres are *oblique*, and may be observed in broad fasciculi upon the extremities of the stomach.

A layer of dense cellular tissue unites the muscular to the mucous tissue. This layer has been very improperly named, by the old anatomists, the *nervous coat*.

The *mucous membrane*, or tunic, forms the inner surface of the stomach; it is of a pale pink color, and marbled appearance, crowded with villosities which seem to constitute a downy and colored tissue, continually covered with an abundant, viscid, inodorous fluid. When the stomach is empty this membrane, from the contraction of the muscular fibres, presents numerous wrinkles, which are termed the *rugæ* of the stomach.

This surface has a velvet-like appearance, and when injected and examined with a powerful lens, we find it formed of fine, short, prominent *villi*, which are crowded with an infinity of small vessels, whose office is to furnish that particular fluid, called the *gastric juice*, which is the principal agent of digestion.

There is also a number of orifices on the mucous membrane; these are the openings of the mucous follicles, which are distributed in very regular order.

### OFFICE OF THE STOMACH.

It is the office of the stomach to receive the food after it is prepared by mastication, likewise liquid nutriment or other fluids, and to secrete the gastric juice, and subsequently to transmit the digested mass to the small intestines. In the stomach, the food is converted into *chyme* by the solvent power of the gastric fluid, which gradually acts on the ingesta, from the superficies to the centre of the mass, and as soon as a portion of it is reduced to a homogeneous consistence, it passes into the duodenum, without waiting till the same change has pervaded the whole.

The stomach is amply furnished with nerves from each nervous department,—hence, its great sensibility to all kinds of stimuli, and its disturbance by mental causes,—hence, also, the surprising sympathy existing between it and most functions of the system, so that the healthy condition of the stomach actually depends upon the tranquillity of the mind.

### THE INTESTINAL CANAL.

The *intestinal canal* extends from the pylorus to the anus, and in the human subject varies from thirty to thirty-five feet in length. It is coiled on itself, so as to form folds or convolutions, and is divisible into two parts, differing in size and situation, as well as external conformation, the division between them being moreover marked by a peculiar valvular structure, which prevents a reflux of the ingesta after they have passed beyond it. The part of the canal between the pylorus and the valve just referred to, is called the small intestine, the remainder thence onward to the anus, the large intestine.

## THE SMALL INTESTINE.

The term *small intestines* is calculated to give us a false idea of the nature of the smaller portion of the alimentary canal, the small intestines being only one continued cylindrical tube, but on account of the situations of its various parts, or other circumstances which will subsequently be adverted to, it is convenient to distinguish it into three divisions; namely, the *duodenum*, the *jejunum*, and the *ilium*.

## THE DUODENUM.

This portion of the intestines differs, however, so materially from the others, as scarcely to admit of the above arrangement; for it is not invested with a serous membrane, the peritoneum being only partially applied upon it in a small extent, nor is it supported by the mesentery, and its volume is so large, that it frequently equals the stomach in size; for this reason, and others which will be presently noticed, it has obtained the name of ventriculus succenturiatus.

The *duodenum* is so named on account of its length being commonly estimated at twelve fingers' breadth; it is that portion of the intestinal canal, which immediately succeeds to the stomach; it occupies the middle part of the abdomen, where it is concealed by the transverse mesocolon and the stomach.

The duodenum commences at the valve of the pylorus, where it is covered in the greater part of its extent by the peritonæum; here we often observe it tinged yellow by the transudation of bile from the gall bladder. The intestine we are speaking of proceeds horizontally backwards, and

to the right, to near the neck of the gall bladder; then descends vertically to the left, as far as the third lumbar vertebra, and terminates by being directed upwards and forwards, towards the extremity of the mesentery, above the superior mesenteric vessels.

The duodenum, consequently, forms a kind of semicircle, having its convexity to the left, and embracing the pancreas in its concavity.

The *inner surface* of the duodenum, like that of the stomach, is covered by a mucous membrane, upon which we may observe a number of folds, more or less, surrounding the intestine, and very close to each other; these are the *valvulæ conniventes*. Fig. 61, represents the inner surface of a portion of the small intestine. These valves are formed by plaitings of the mucous membrane only, and they project three or four lines into its cavity.

Fig. 61.

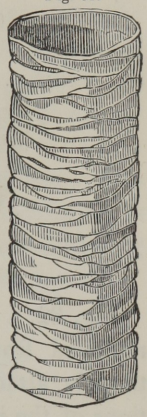

In the interior of the duodenum we observe a small tubercle, at the point of which are seen the united or separate orifices of the ductus communis choledochus and the pancreatic ducts.

### THE JEJUNUM AND ILIUM, PROPERLY CALLED THE SMALL INTESTINE.

The *small intestine* is continuous with the duodenum, without any distinct line of demarcation to distinguish it. The small intestine is the longest portion of the digestive canal, its length being about twenty-six feet, or five times that of the whole body. It forms a number of curves, of which the concavities are connected with the mesentery,

while the convexities are free and floating, and folded upon each other in different directions a number of times, forming what are termed *convolutions*.

Fig. 62.

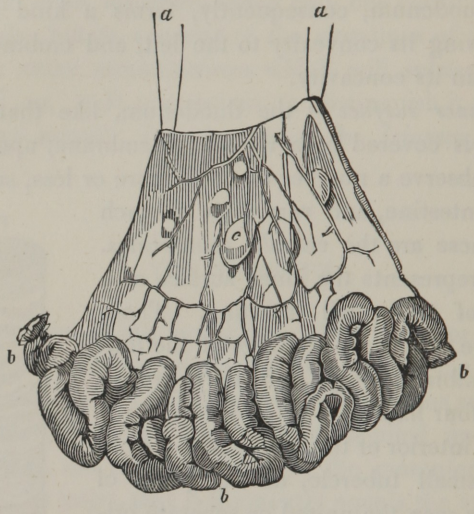


Fig. 62, a portion of the mesentery and small intestine removed from the body, and suspended by, *a*, *a*, two threads attached to the mesentery; *b*, *b*, *b*, the convolutions of the intestine attached to it; *c*, one of the mesenteric glands.

The small intestine commences under the superior mesenteric vessels, and terminates in the cœcum. Anatomists usually divided it into two portions, although it is impossible to assign distinct limits to each of them. The upper portion is named the *jejunum*, from its being commonly more empty than the other part of the intestine; the other is called the *ilium*, from its position in the fossæ of that name. The jejunum occupies the upper part of the umbilical region, the ilium extends as far as the hypogastric

and iliac regions. An examination of the small intestine, however, shows no natural division of this kind, so that the limits of the two portions are quite arbitrary.

Its whole *outer surface* is perfectly smooth, and contained between the two laminæ of the mesentery; its *inner surface* has the same structure and appearance as the duodenum; the villi of the small intestine are larger than those of the stomach; there are about four thousand to the space of a square inch, and their length is about one-fourth of a line: but the valvulæ conniventes are gradually less conspicuous as they are examined towards the cœcum.

The *muscular membrane* is interposed between the two others; its fibres are pale and not very apparent; the superficial layer is longitudinal and the deep fibres are curved in the transverse direction of the intestine; not passing entirely round it, but like the longitudinal are interrupted from space to space and seem composed of shorter fibres, whose extremities pass between each other. The longitudinal fibres shorten the canal, and the circular fibres diminish its calibre; together they produce an undulating movement of the intestine termed the *peristaltic motion.*

### THE LARGE INTESTINE. See Fig. 64.

The *large*, like the small, intestine forms one continued alimentary canal, the former extending from the termination of the ilium to the anus. The large intestine, however, is distinguished not only by its size, but by its outer surface presenting irregular enlargements and depressions, interrupted in three places by longitudinal bands of muscular fibres. One of these depressions is anterior; the other two are posterior; the annexed figure shews its form and its course better than any verbal description. Its length is that of the body, or about six feet. Its volume

is generally triple that of the small intestine, and it also differs from it in having papillæ of fat, called *appendices pinguedinosæ*, attached externally to it.

Like the small intestine, it is distinguished into three portions; termed the *cæcum*, the *colon*, and the *rectum*.

The *cæcum* is only three or four inches in length, and nearly the same in diameter; it consists of that part of the intestine which is under the extremity of the ilium. It is situated in the right iliac region, resting on the cavity of the corresponding os ilium. The inferior part forms a closed sac, the mouth of which is directed towards the colon.

At the left extremity of the cœcum there is a process of about the same length, and of the same nature with itself, but the diameter is not larger than that of a writing quill,—termed the *appendix cœci vermiformis*. It is hollow in its whole extent, and communicates with the cœcum. It is constantly filled with mucus, but its uses are entirely unknown. We must again recur to the union of the small intestine with the large; at the opening of the former into the latter is situated the *ilio-cæcal valve*, or the *valve of Bauhin;* this, however, is merely a projecting of the intestinum ilium into the cœcum, so that the folding of its extremity does not prevent the fæces from passing downwards, but, by the pressure of the edges against the sides, and the contraction of its muscular fibres, it offers a resistance, under most circumstances, to a retrograde movement of the contents of the intestine.

Fig. 63.

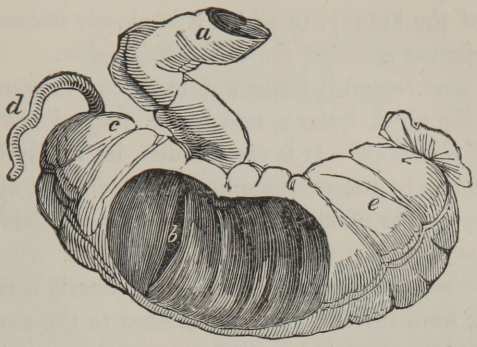


Fig. 63, exhibits the insertion of the small into the large intestine, the drawing from which this was taken was inflated, dried, and a large opening cut into it to show the valve.

*a*, the intestinum ilium, —

*b*, its valvular opening into the cavity of the colon.

*c*, the caput cœci.

*d*, the appendix cœci vermiformis.

*e*, a portion of the colon.

The *colon* forms the most considerable portion of the large intestine ; it nearly encircles the small intestine, and is a continuation of the cœcum, or that portion of the intestine which is extended from the right iliac region to the left. The colon commences at the cœcum, and terminates in the rectum.

The colon ascends in the right lumbar region, over the kidney of that side, and is here termed the *ascending colon.*

From the kidney it proceeds forwards, and crosses the abdomen in the epigastric and hypochondriac regions, beneath the stomach and above the small intestine ; it is here called the *transverse arch of the colon.*

On the right side the arch is situated under the liver and gall bladder, the latter of which, after death, usually stains

it with bile. In the hypochondrium it turns backward under the spleen, and descends in the left lumbar region in front of the kidney, to which it is closely connected; in this situation it is called the *descending colon.*

In the iliac region it forms a double curve, compared in shape to the greek letter ς, and hence termed the *sigmoid flexure of the colon.* It is surrounded in nearly its whole circumference by the peritonæum, which fixes it above and behind, by means of an extended and loose fold, termed the *iliac mesocolon.*

The *rectum* has its name from being nearly a right line, extending from the last lumbar vertebra to the anus: it is, however, accommodated to the curve of the sacrum. The rectum is smaller than the cœcum or colon, but is capable of great dilatation, and does not present those intersections and muscular bands which we find in the other portions of the large intestines. At the anus it contracts into a narrow orifice, the sides of which are compressed into close, longitudinal folds, by the sphincter ani and the two levatores ani.

The structure of the large intestine is the same as that of the small intestine, but it is less muscular. The villi of the inner part are smaller, the mucous glands or follicles are very apparent, and there are no valvulæ conniventes. The most characteristic distinction in the general appearance of the large intestine, is the intersected and cellular divisions throughout its whole extent. These cells retain the matter, and prevent its too rapid descent into the rectum, and thus allow time for the lymphatic vessels to collect the fluid from the digestive canal.

Fig. 64.

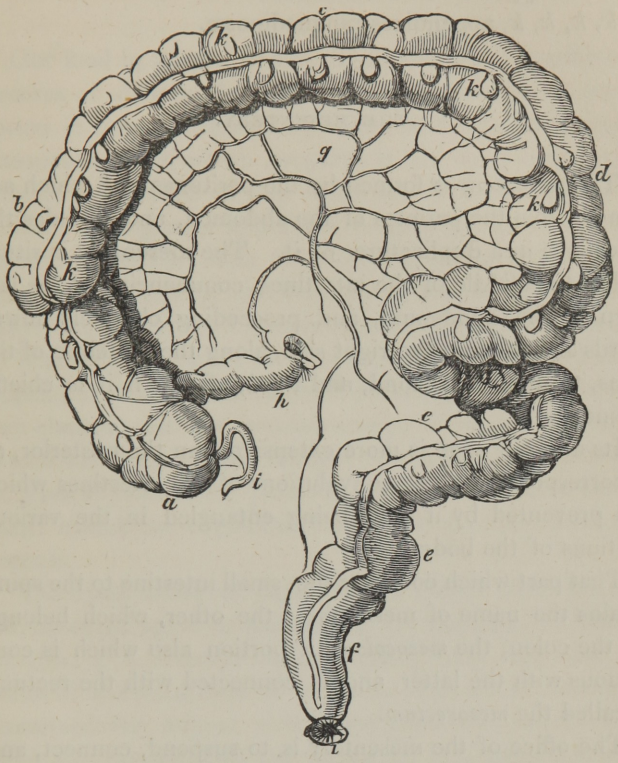


Fig. 64, exhibits the sacculated appearance and course of the large intestine.

*a*, the caput coli.

*b*, the ascending colon.

*c*, the transverse arch of the colon.

*d*, the descending colon.

*e*, the sigmoid flexure of the colon.

*f*, the rectum.

*g*, the mesocolon.

*h*, the termination of the ilium.
*i*, the appendix cœci vermiformis.
*k*, *k*, *k*, *k*, appendices pinguedinosæ.

### THE MESENTERY.

The *mesentery* is formed by the peritonæum,* which advances from the parietes of the abdomen, and includes the intestines in a duplicature of it. The mesentery is situated in the middle of the intestines, commencing at the last turn of the duodenum, and proceeding obliquely downwards and towards the right side, along the vertebræ of the loins, to the first, second, and third, of which it is chiefly connected.

Its anterior edge is more extensive than the posterior, as it corresponds to the convolutions of the intestines which are prevented by it from being entangled in the various motions of the body.

That part which connects the small intestine to the spine retains the name of mesentery; the other, which belongs to the colon, the *mesocolon;* a portion also which is continuous with the latter, and is connected with the rectum, is called the *mesorectum.*

The office of the mesentery is to suspend, connect, and retain the intestinal canal in its proper situation; at the same time allowing it a certain degree of motion; it also furnishes it with an exterior covering, lodges numerous glands, and affords a support to the vessels and nerves which are distributed to the intestines.

* The peritonæum is a serous membrane investing the inner surface of the abdomen, and prolonged under the form of an envelope over most of the viscera contained in it. See Article XVI.

### DIGESTION.

Our food in general is first submitted to the mechanical process of division by the teeth; and during its mastication it becomes intimately mixed and combined with a chemical solvent, which prepares it for the process it has shortly to undergo in the stomach. This solvent is the saliva. The glands appointed to produce this fluid seem to act in sympathy with the stomach, being with it simultaneously excited by the stimulus of the food, "or even (says Dr. PARIS) by the contemplation of a favorite meal."

When the alliment is introduced into the stomach, it appears to remain there a short period before it undergoes any change; but the solvent energy of the peculiar fluid, which has already been referred to under the appellation of *gastric juice*, soon produces that change upon the aliment called the digestion, which converts the food into CHYME.

The exact nature of chyme is not easy to describe; but physiologists agree in considering it a homogeneous paste, grayish, of a sweetish taste, slightly acid, and retaining some of the properties of the food. MAGENDIE has lately examined the subject with great precision, and it follows from his experiments, that there are as many species of chyme as there are varieties of food; if, at least, we may judge by color, consistence and sensible qualities. Whatever be the nature of the alimentary substance, introduced into the stomach, the chyme will possess the invariable property of an acid, reddening litmus paper, and it always has a sharp odor and taste. As the parts of the food are digested, that is, converted into chyme, they pass out of the stomach into the duodenum, there to undergo further changes. In this process the pylorus must, as its name implies, be endowed with a peculiar sensibility, and

vigilance, by which it is enabled to distinguish between the crude and chymified portion, so as to admit the latter, while it usually opposes the exit of the former. Sometimes the pylorus seems so far to resist the egress of the contents of the stomach as to occasion an inverted action, and to expel the food by vomiting.

If a liquid holding nutritive matter is taken into the stomach, it is either coagulated by the gastric fluid, or its watery part is absorbed, and the solid matter deposited in the stomach; in both cases the product is afterwards chymified in the manner already described. Part of the liquid passes through the pylorus into the intestines, to be absorbed with the chyle, or to be rejected with the feces; and a large portion of the liquids is conveyed directly from the stomach into the circulation.

Many anatomists have considered the duodenum as a subordinate stomach, for, immediately the chyme has arrived at this part of the alimentary canal, it becomes converted into a more highly animalized product, termed CHYLE, or the milk-like fluid which is imbibed by the lacteals. Chyle has been frequently chemically examined, but it presents a difference in composition, according to the nature of the aliment from which it has been elaborated. If the animal has eaten substances of a fatty nature, the chyle will be found milky white, a little heavier than water, with a strong and peculiar odor, and a saline and sensibly alkaline taste; but if the food should not have contained fat, it will be opaline and almost transparent. Very soon after chyle is extracted from the living animal, it becomes firm, by coagulation: it then gradually separates into three distinct parts; the one solid, which remains at the bottom of the vessel, the second liquid, and a third that forms a very thin layer at the surface. The more solid part seems to be an intermediate substance between albumen and fibrin, for it unites several properties common

to both. The liquid part of the chyle resembles the serum of the blood ; the other part which appears on its surface is a fatty substance, which imparts to the fluid the appearance of milk. The comparison, however, which has been made between chyle and milk has no real foundation ; for the former contains nothing which exactly agrees with the constituents of the latter.

The lacteal vessels which absorb this fluid have been already described ; they commence in the very extended valvular apparatus of the mucous membrane of the intestine, by thousands and tens of thousands of orifices which imbibe the chyle.*

The function, consequently, of the small intestine is to separate the nutritious matter from the feculent, and to convey the latter into the colon. In its progress, the nutritive principles of the aliment having been absorbed into the circulation, the residue is urged forward by the action termed the *peristaltic motion ;* the ingesta losing, as it proceeds towards the cœcum, any portion of the chyle which may have escaped the lacteals in the first portion of the small intestine. The remainder of the contents accumulates to a certain extent in the colon, and acquires the peculiar fetor which distinguishes the feces. In its passage in this part of the digestive canal, it is considerably retarded by the cells or compartments into which the large intestine is divided. But the principal function of the

* It is probable that the mesenteric glands through which they pass produce an important change in the chyle ; but the nature of this change is wholly unknown : it is certain that these glands secrete a fluid, which may be compressed from them with the fingers ; hence, some physiologists have supposed that they add a fluid to the chyle in order to purify it ; while others, again, have contended that their use is to produce a more intimate union of the aliments which compose it. The chyle is, at length, poured into the thoracic duct, together with the lymph which is brought from all parts of the system, by the absorbent vessels, and together they furnish new materials to repair the waste which the body is perpetually undergoing.

large intestine, is to imbibe the remaining fluid in proportion to the wants of the system; another office obviously performed by this portion of the alimentary canal is to carry out of the system the waste, incident to the changes of the economy, which is not removed by the kidneys. The fecal matter as it passes along the colon gradually becomes more solid, and at length, when it enters the rectum, it forms a mass of considerable bulk, which distends its parietes, and then creates a sensation of uneasiness, which announces the necessity for relief.

# ART. X.

## ORGANS OF RESPIRATION.

### THE LUNGS.

The *lungs* are two cellular, or spongy organs, occupying the greater part of the cavity of the thorax: they are separated from each other by the mediastina and the heart, and are surrounded by membranes which are named pleuræ, with which they are in contact, so that no air can intervene between them, unless an opening is made into the bag of the pleura, when the lungs would instantly collapse.

In *figure* they are somewhat conical, their shape corresponding exactly with the cavity of the thorax, being rounded towards the ribs, and irregularly depressed towards the mediastinum and heart. In all instances, the volume of the lungs is in proportion to the capacity of the thorax, and they are compressed or dilated according to the expansion or contraction of the parietes; nor (in a healthy state of these organs) does any vacuity exist in the interior of the chest.

The *color* of the lungs is a pale yellowish red, more florid in children, and of a deeper and purple hue in age; but the lung is always more colored on the side on which a dead body has lain; but this deeper tinge is owing merely

to the blood, from its own gravity, falling to the most dependent part of the lung. The general color of the lungs is also interrupted by small black spots, irregularly dispersed on their surface, and more or less numerous, some of which are entirely superficial, others penetrate more or less deeply into the tissue of the lungs. These spots do not appear till the age of ten or twelve years.

The specific gravity of the lungs is much less than that of the other organs ; when in their natural state, they swim in water, and this lightness depends upon a large quantity of air penetrating their whole tissue. In infants, who have never breathed, the lungs generally sink if immersed in water. The absolute weight, however, of the lungs varies in different individuals, depending on the greater or less quantity of blood remaining in them at the moment of death.

Fig. 65.

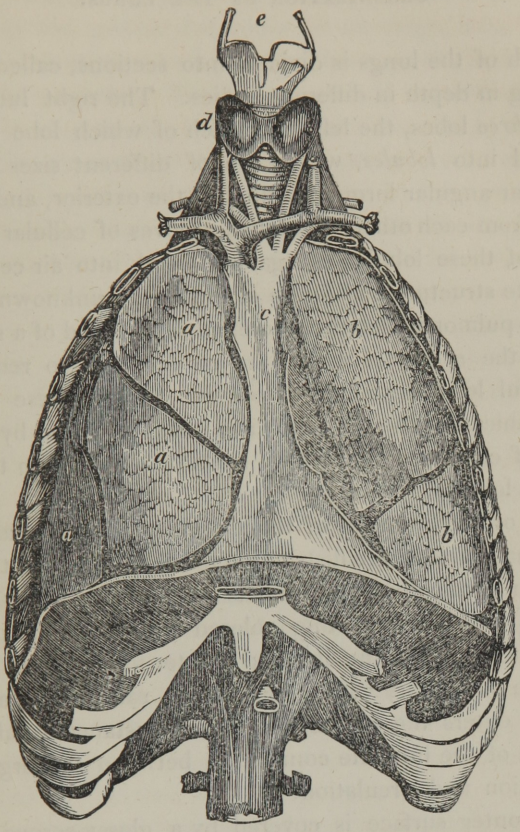


SURGEON'S LIBRARY OFFICE

In this figure (65) the ribs are sawn through at the sides, and the anterior parietes of the thorax removed, in order to exhibit the natural situation of the lungs.

*a*, *a*, *a*, the three lobes of the right lung.

*b*, *b*, the two lobes of the left lung.

*c*, the anterior mediastinum.

*d*, the thyroid gland, situated on the trachea.

*e*, the thyroid cartilage.

### ORGANIZATION OF THE LUNGS.

Each of the lungs is divided into sections, called *lobes*, varying in depth in different bodies. The right lung contains *three* lobes, the left *two;* each of which lobe is subdivided into *lobules*, which are of different sizes and of irregular angular forms; distinct at the exterior, and separated from each other by whitish grooves of cellular tissue. Each of these lobules is again divided into air cells, the intricate structure and figure of which are unknown.

The pulmonary lobules, therefore, are formed of a spongy tissue, the *areolæ* of which are so small as to require a powerful lens distinctly to observe them: these areolæ communicate with each other, and are surrounded by a thin layer of cellular tissue, which separates them from the adjoining lobules.

One of the branches of the air tubes (bronchi), and the pulmonary artery, are distributed to the lobule, and the latter then terminates in the radicles of the pulmonary veins. This is proved by injecting colored water into the pulmonary artery, when the injected matter immediately passes into the pulmonary veins; but, at the same time, a small portion enters the bronchi: this circumstance establishes the fact of the intimate connection between the organs of respiration and circulation.

The outer surface is covered by a glossy serous membrane, named the *pleura*,* which will be subsequently described.

The lungs are very elastic, and constantly kept in a state of distention by the pressure of the atmosphere: this is proved by puncturing the parietes of the thorax, when they instantly collapse. During inspiration the intercostal mus-

* See Article XVI.

cles raise and draw out the ribs, and the diaphragm descends; the enlargement of the thoracic cavity follows of necessity the greater distention of the lungs, from the diminished resistance to the air gravitating in the bronchi and pulmonary areolæ. The diaphragm and muscles of respiration ceasing to act, the substance of the lungs, from its elasticity, recovers its former dimensions, and expels the additional volume of air just admitted, and the respiratory muscles follow the shrinking substance of the lungs, offering from their relaxation no resistance to the atmosphere pressing on the surface of the chest and abdomen. Thus expiration is produced: thus the lungs are continually expanding to admit the atmospheric air, or contracting to expel it, from the hour of birth to the latest moment of our existence. This alternation occurs in an adult at rest about twenty times in a minute—once to about three pulsations of the heart—this will give twentyeight thousand eight hundred inspirations in twentyfour hours.

The mean quantity of air that enters the lungs at each inspiration, is forty cubic inches; and the ordinary quantity of air contained in the lungs is two hundred and eighty.* Thus, supposing twenty inspirations in a minute, the quantity of air that would enter and pass out in this time would be eight hundred inches, which make fortyeight thousand in the hour, and in twentyfour hours is one million one hundred and fiftytwo thousand cubic inches.

Inspiration and expiration are intended to renew, in part, the mass of air contained in the lungs: it may be here remarked, that the portion of air expired, is not exactly that which was inspired immediately before, but a portion only of the quantity which the lungs contained after inspiration.

The office of the lungs is to produce certain atmospheric changes in the blood, which are essential for the support of life.

* Dr. Thompson.

The air in its passage to the lungs, by passing through the mouth or the nose, the pharynx, the trachea, and the bronchi, becomes of a similar temperature with the body, and is charged with the vapor which it carries from the air passages; and in this state, rarefied and humid, it arrives in the pulmonary lobules, to mix with that which the lungs contained before.

### PHYSICAL AND CHEMICAL CHANGES WHICH TAKE PLACE IN RESPIRATION.

The air, in its exit from the lungs, partakes of the temperature of the body; there escapes with it a great quantity of aqueous vapor, called *pulmonary transpiration*, and its chemical composition is very different from the inspired air.

The atmospheric air we breathe contains 0·21 of oxygen, and a trace of carbonic acid; the air which passes out of the lungs contains 0·14 or 0·15 of oxygen, and 0·6 to 0·7 of carbonic acid: generally, the quantity of carbonic acid is less than the quantity of oxygen which has disappeared.

The quantity of oxygen consumed by an adult, according to Lavoisier and Sir H. Davy, is thirtytwo cubic inches in a minute, which gives, for twentyfour hours, fortysix thousand and thirtyseven inches.

We may, therefore, easily calculate the quantity of carbonic acid that passes out of the lungs in the same time, since it nearly represents the volume of oxygen that has disappeared. Thompson values it at forty thousand cubic inches, though, he says, it is probably a little less: now this quantity of carbonic acid represents twelve ounces of solid carbon.

If we are attentive to our respiration, we shall find the degree of alteration that the air undergoes in our lungs, by

a feeling which inclines us to renew it: if the breathing is suspended for many seconds, there is anxiety and fear, and, as it were, an instinctive warning of the importance of respiration.

The changes of the quality of the air during respiration have been described, in which time the blood circulating through the lungs also undergoes a corresponding and remarkable alteration. That the oxygen exerts an agency on the blood, is a fact shown by direct experiments; the blood, whether arterial or venous, when agitated in contact with common air, imparts carbon, and converts the oxygen into carbonic acid: it is, therefore, a fair inference that, in the body, the change of inspired oxygen into carbonic acid is effected in the same manner. In the areolæ, or air cells of the lungs, the oxygen may be considered as almost in contact with the blood contained in the ramifications of the pulmonary vessels; inasmuch as nothing but the exceedingly thin substance of the vessels is interposed. When the oxygen of the air is taken into the lungs, after a momentary contact, as it may be called, with the blood, it is discharged again during expiration; but part of it has combined with carbon. As it regards this combination, there have been two opinions. The one is that the oxygen of the air instantly dissolves, and combines with the carbonaceous matter found in the blood, and immediately after is expired as carbonic acid. The other is, that the oxygen of the air is absorbed by the blood in the lungs; that it circulates with the blood throughout the whole system, during which it combines with carbon; and that, on the return of the sanguineous current to the lungs, the carbonic acid thus produced exudes through the coats of the minuter vessels, and is expired. This latter opinion is most probable. For if blood is merely exposed to the atmosphere for the space of three minutes, no change is produced; but if it is *agitated* with it during the same time, carbonic acid is

produced. Independently of the evidence afforded by this experiment, it might be reasonably expected that the carbon of the blood would require more than an instantaneous contact with the oxygen of the air, before a combination could take place. Such a condition would be fulfilled, if the oxygen were to circulate with the blood for two minutes and a half; for this, as far as is known, is the space of time which the whole volume of the blood requires to travel from the lungs back again to the lungs; and this is the space of time found necessary to continue the agitation of the blood in the experiment just named. If in that experiment, actual contact of the blood with oxygen during three minutes did not evolve any carbonic acid, it would be singular if, in the lungs, carbonic acid could be formed during the time occupied by one inspiration, especially as the substance of the blood-vessels and air tubes are interposed.

To confine the office of the lungs to the mere removal of redundant carbon from venous blood, is to take a limited view of its operation, and to underrate the utility and necessity of the complex and astonishing mechanism by which so simple an object would be accomplished. To the process of respiration, the construction of the chief parts of the animal system are subservient; if respiration be suspended, so is life: even the atmosphere is constituted in such a way as to conduce to the due performance of this function. We know the important and extensive agency of oxygen in creation: can we doubt in the laboratory of the body, where chemical changes are incessantly taking place, that oxygen is less constantly in demand? And is it not probable that the medium of supply of oxygen to all these parts is that obvious one, which, in order to receive the supply, is presented in thousands of currents, to thousands of currents of air, the absorption being promoted by the two most efficacious means — motion and extensive surface?

The view here taken of the phenomena of respiration

corresponds with the conclusions arrived at, from an extended series of experiments made by Dr. Edwards,* who appears to have established four fundamental points.

1st. The absorption of oxygen, which disappears.

2d. The exhalation of carbonic acid, which disappears.

3d. The absorption of azote.

4th. The exhalation of azote.

The oxygen which disappears in the respiration of atmospheric air is wholly absorbed. It is afterwards wholly, or in part, conveyed into the circulation. It is replaced by exhaled carbonic acid, which proceeds wholly, or in part, from that which is contained in the mass of the blood.

An animal breathing atmospheric air also absorbs azote; this is likewise conveyed wholly, or in part, into the mass of blood.

In different individuals, it has been found that different quantities of oxygen is consumed, and of course different quantities of carbonic acid returned. The breath expired has been shown to contain from six to eight per cent of carbonic acid. Drs. Prout and Fyfe have proved experimentally, that particular conditions of body or mind render the quantity of carbonic acid variable. The former has shown that the quantity depends also on the time of day: at noon it is at its maximum; it decreases until nine at night; it then remains at its minimum for six hours, and at four in the morning it begins to increase. Probably it may vary likewise with the seasons of the year. The above were the results obtained in the month of August.

### THE TRACHEA AND BRONCHI.

The *trachea* is a cylindrical fibro-cartilaginous and membranous tube, a little flattened posteriorly. It is situated

* On the Influence of Physical Agents on Life.

before the vertebral column, in the posterior mediastinum, resting on the œsophagus, which however, inclines somewhat to its left side, and extends from the lower part of the larynx to opposite the second or third dorsal vertebra. It is inclosed between the great vessels of the neck, and covered partly by the thyroid gland, and its veins, also by the sterno-hyoid and sterno-thyroid muscles, and crossed by the vena innominata, the arteria innominata, and the arch of the aorta. At the second or third dorsal vertebra it divides into two lateral branches, termed bronchi, one of which passes to the right lung, and the other, which is the longest of the two, proceeds under the arch of the aorta to the left lung.

Each of the bronchi is subdivided where it enters the lung; the right separating into three principal branches, corresponding to the number of the lobes on that side; the left into only two, which are distributed to the same number of lobes of the lungs on the left side. When the bronchi have arrived in the lungs, they divide and subdivide throughout the whole pulmonary tissue, ramifying almost ad infinitum, so that it is extremely difficult to trace them to their termination. Malpighi thought that they ended in rounded membranous vesicles. Senec describes the lobules of the lungs to be composed of polyhedral vesicles, into each of which a twig of the bronchi enters. If a lung be inflated and dried, its substance when divided, independently of the arteries cut through, appears uniformly porous. Some of the pores appear sections of tubes, others are small cups, being sections of air-cells, a hundredth of an inch in diameter.*

*After injection, a thin section of the lung may be made, and submitted to the microscope, when it will be found that the size of the areolæ, in the adult, is nearly as here stated; and the shape of the areolæ appears to me, to be, as stated by Senec, polyhedral.

## THE ORGANIZATION OF THE TRACHEA AND BRONCHI.

The air tubes of the lungs are composed of fibro-cartilaginous, incomplete rings, membranous mucous follicles, bronchial glands, vessels and nerves.

The *fibro-cartilaginous rings* in the trachea, Fig. 66, are from sixteen to twenty in number; they are not complete behind, but united by a fibrous membrane, which is closely connected with the œsophagus, and yields to it in the time of deglutition. Each cartilage forms nearly two thirds of a circle, as in Fig. 67, *a, a*; they are situated transversely with respect to the length of the trachea, and have their edges opposed to each other, leaving small spaces between them. These spaces consist of the same fibrous membrane which completes the canal at the posterior part: it has great elasticity, so that when the lungs are removed from the body, it draws the fibro-cartilages together.

Fig. 66.

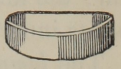

Fig. 67.

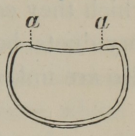


At the superior part of the trachea the cartilages are sometimes united, but below they are perfectly distinct from each other; and the inferior cartilage is triangular, to adapt itself to the bifurcation of the bronchi.

In the *bronchi*, the primary ramifications are similar to those of the trachea, only thinner and smaller, and sometimes composed of several pieces. But in the secondary and ultimate ramifications, they are merely small irregular tubes, which gradually diminish until they arrive at the areolæ of the lungs.

The *outer membrane* is formed of longitudinal and parallel fibres, of which the most superficial is red, the deeper white. This membrane alone, posteriorly, connects the cartilages, and completes the diameter of the trachea. Ante-

riorly, the fibro-cartilages appear developed in its substance.

Posteriorly, this membrane contains numerous mucous follicles, the excretory ducts of which open on its inner surface. They are named the *glands of the trachea.*

The *mucous membrane* is a continuation of the membrane of the larynx, and extends to the termination of the bronchi; the mucous follicles constantly pour out a thick fluid on its inner surface.

The *lymphatic glands of the bronchi*, are situated at the bifurcation of the trachea, around the bronchi, and are found even in the interior of the lungs. Their color is blackish; they are easily compressed under the fingers, to which they easily communicate their color. Their excretory ducts have not been discovered, and their functions also are unknown.

# ART. XI.

## ORGANS OF THE VOICE.

### THE LARYNX.

The *larynx* is a complicated apparatus situated at the upper part of the trachea, with which cavity it communicates; it is immediately under the os hyoides which is placed at the root of the tongue. It is broader above than below, and is composed of several cartilages, muscles, ligaments, membranes, and mucous glands.

### THE CARTILAGES OF THE LARYNX.

#### THYROID CARTILAGE.

The *thyroid cartilage*, Fig. 68, is the largest and most prominent of the pieces composing the larynx, and occupies its anterior and lateral parts: in its natural situation it forms two lateral wings, or portions of a quadrangular form, uniting in the middle in a longitudinal angle, which can readily be felt in the fore part of the throat; and from its being

Fig. 68.

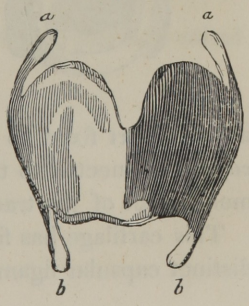

larger and more projecting in men than in women, has obtained the name of *pomum Adami*. The upper part of the angle is formed into a notch, from which, and from the upper edge of the cartilage in general, a broad ligament ascends to unite it to the inferior part of the os hyoides.

From the posterior angles we observe four projecting processes called cornua, two of which *a*, *a*, are termed the *superior cornua*, and are connected by round ligaments to the os hyoides. The other two, *b*, *b*, are called the *inferior cornua;* these are shorter than the superior, and somewhat moved backwards, to be attached by smooth articulating surfaces to the sides of the cricoid cartilage.

### CRICOID CARTILAGE.

The *cricoid cartilage* is placed below the thyroid, and like it can readily be felt in the fore part of the neck. It is narrow anteriorly, see Fig. 69; and thick, broad, and strong, posteriorly, see Fig. 70: its *superior edge* has its

Fig. 69.

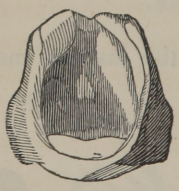

Fig. 70.

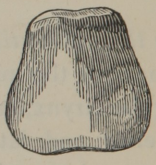

anterior part fixed to the thyroid cartilage; the *inferior edge* is connected to the whole circumference of the commencement of the trachea.

This cartilage has four small articulating surfaces, with distinct capsular ligaments; two of which are situated at

its upper part, for the articulation of the arytenoid cartilages, and two at the under part, for the attachment of the inferior cornua of the thyroid cartilage.

### ARYTENOID CARTILAGES.

The *arytenoid cartilages* (Fig. 71, the outer, and Fig. 72, the inner view), are two in number; they are situated at

Fig. 71.

Fig. 72.

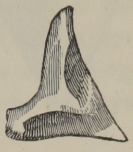

the upper and back part of the larynx, above the cricoid cartilage. Their form is before us; the anterior surface is convex, but upon each convexity there is a depression, which is occupied by glands. Their upper extremities are placed towards each other: their lower extremities are broad, and are articulated by capsular ligaments with the cricoid cartilage, upon which they are moved by the action of various muscles. They are also connected to each other, and to the adjacent cartilages, by ligaments and muscles.

The aperture between the arytenoid cartilages is called the *glottis*.

## EPIGLOTTIS.

The *epiglottis* (Fig. 73, the outer, and Fig. 74, the inner view), has obtained its name from its situation above the

Fig. 73.

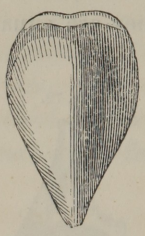

Fig. 74.

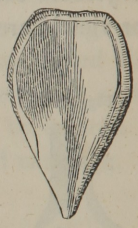

glottis: it is a fibro-cartilage, situated at the upper part of the larynx, behind the base of the tongue; its form is ovoid, its color a pale yellow, and its tissue very elastic. It is placed obliquely over the glottis, and may be seen and examined in the living body by pressing down the tongue.

This cartilage is attached by a broad and short ligament to the notch of the thyroid cartilage; laterally it is united to the arytenoid cartilages, forming at this part the superior opening of the larynx. It is united to the os hyoides and tongue by a ligament which is termed the *frænum epiglottidis*.

The surface is covered by a number of small perforations and depressions, which contain mucous follicles, or transmit nervous filaments.

## THE LIGAMENTS OF THE LARYNX.

The *thyro-hyoid articulation.* The thyroid cartilage is connected at its upper part with the os hyoides by a broad yellowish membrane. The superior cornua of this cartilage is connected to the extremities of that bone by two round, fibrous cords, about an inch in length.

The *crico-thyroid articulation.* The thyroid cartilage, in the middle and anteriorly, is connected with the cricoid, by the *crico-thyroid membrane*, and on the sides, the inferior cornua of the thyroid cartilage are articulated with the cricoid cartilage, by means of a loose and humid synovial membrane. There are also two ligaments extending from the inferior cornua of the thyroid cartilage to the arytenoid cartilages where they are expanded.

The *crico-arytenoid articulation.* Each arytenoid cartilage is articulated with the cricoid, by a synovial capsule, which is strengthened by fasciculi of ligamentous fibres.

The *vocal ligaments*, or the *thyro-arytenoid articulation.* On the inside of the larynx we observe two ligaments, Fig. 75, *a*, about two lines in breadth, formed of elastic and parallel fibres, contained in a fold of the mucous membrane; they are extended horizontally from the anterior prominence of the arytenoid cartilage, to the centre of the retiring angle of the thyroid cartilage. They are named the *vocal cords.*

Fig. 75.

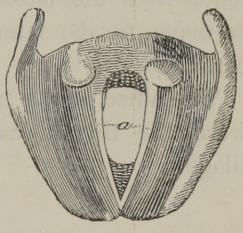

## THE MUSCLES OF THE LARYNX.

### CRICO-THYROIDEUS.

This muscle, Fig. 76, *a*, *a*, is situated on the side and at the anterior and inferior part of the larynx; it ex-

Fig. 76.

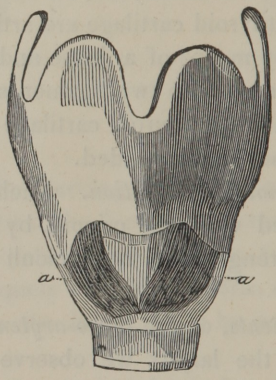


tends from the lateral and anterior edge of the cricoid cartilage, to the lateral and inferior edge of the thyroid cartilage.

The office of this muscle is to depress and draw forward the thyroid cartilage, or to raise the cricoid cartilage.

CRICO-ARYTENOIDEUS POSTICUS.

This muscle, Fig. 77, *b*, is extended from the back part

Fig. 77.

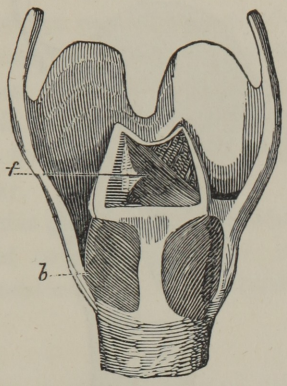


of the base of the arytenoid cartilage, to the posterior part of the cricoid cartilage.

Its office is to draw back the arytenoid cartilage.

### CRICO-ARYTENOIDEUS LATERALIS.

This muscle, Fig. 78, *c*, is extended from the lateral and

Fig. 78.

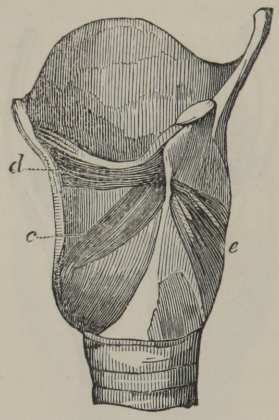


inferior part of the arytenoid cartilage, to the lateral part of the cricoid cartilage.

Its office is to separate the arytenoid cartilages, and with them the glottis.

### THYRO-ARYTENOIDEUS.

This muscle, *e*, extends from the fore part of the arytenoid cartilage to the inferior and posterior part of the thyroid cartilage.

Its office is to draw the arytenoid cartilage outwards and forwards, and thereby to enlarge the glottis, and to shorten and relax the vocal cords.

A small fasciculus of this muscle, on its upper part, is called by ALBINUS *thyro-arytenoideus alter minor.*

### ARYTENOIDEUS.

This is a single muscle, Fig. 77, *f*, situated at the superior and posterior part of the larynx ; it is formed of several planes of fibres, which have occasioned it to be divided by many anatomists into several distinct muscles. It is attached to the posterior part of each of the arytenoid cartilages, from whence the fibres take different directions; some extend from the base of the right cartilage to the summit of the left, others take an inverse course, and some pass horizontally from the middle part of one to the same point of the other.

The office of this muscle is to close the glottis, by drawing the arytenoid cartilages together; at the same time they bring the vocal cords in nearer apposition.

### MUCOUS MEMBRANE OF THE LARYNX.

This membrane is continuous superiorly with the mucous membrane of the mouth ; inferiorly, with that of the trachea and bronchial tubes; posteriorly, with that of the pharynx. Its tissue is very firm, but yet highly vascular, and it contains in its substance a number of mucous follicles, the orifices of which are easily perceived. It secretes a somewhat tenacious fluid, which keeps its inner surface in a moist state.

### THE GLAND OF THE EPIGLOTTIS.

This gland consists of small granulations, deeply immersed in a quantity of adipose cellular tissue, and occupying a triangular space at the lower part of the anterior

surface of the epiglottis. It pours its secretion upon the laryngeal surface of the epiglottis.

### THE ARYTENOID GLANDS.

These glands are situated in the folds which the mucous membrane presents in passing from the epiglottis to the arytenoid cartilages, and from these to the thyroid cartilage. They are composed of small granulations resembling those of the lachrymal gland.

There is much difficulty in discovering their excretory orifices.

### THE OFFICE OF THE LARYNX.

All the modifications of the voice are produced by the air passing from the lungs through the larynx; sounds may also be produced by it in the time that air traverses the larynx to pass into the trachea, but these tones are produced with more difficulty, and are not according to the ordinary laws of economy. If we blow air into the trachea towards the larynx, at the same time bringing the arytenoid cartilages together, a sound will be produced something like the voice of the animal, to which the larynx used in the experiment belongs.

The sound will be dull or sharp according as the cartilages are pressed, more or less forcibly, together, and its intensity will be according to the force of the current of the air. We may observe, in this experiment, that the sound is produced by the vibrations of the vocal cords.

The strength of the voice depends upon the extent of the vibrations of the vocal cords, and these will be in proportion to the force with which the air is expelled from the

chest. The tone of the voice generally agrees with the state of the cartilages of the larynx.

We can, therefore, account for the production of voice on physical principles. I will transcribe the explanation given by MAGENDIE. "The air being pressed from the lungs, proceeds in a pipe of considerable size; this pipe very soon becomes contracted, and the air is forced to pass through a very narrow slit, the two sides of which are vibrating plates, which permit and intercept the air, like the plates of reeds, and in the same manner, by these alternations, produce sonorous undulations in the transmitted current of air."

## THE THYROID GLAND.

Fig. 79.

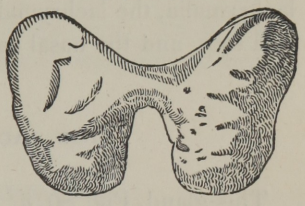

This body, Fig. 79, covers the lower and anterior part of the larynx, and the first two or three cartilages of the trachea: it is composed of two lobes, generally united in a great part of their extent; but frequently they are unconnected, except by a sort of transverse cord.

The structure of the thyroid body is soft and spongy; most commonly it is of a brownish red color, and is composed of a number of distinct lobules. An oily or a milky fluid may be pressed from its areolæ, but it is an organ respecting the office of which we are totally ignorant, and which anatomists usually describe after the larynx, merely on account of its situation.

# ART. XII.

## ORGANS OF SECRETION.

### ORGANS FOR THE SECRETION AND TRANSMISSION OF THE TEARS.

These organs consist of the lachrymal glands, the puncta lachrymalia, the lachrymal ducts, the caruncula, the lachrymal sacs, and the nasal canals.

### THE LACHRYMAL GLAND.

This gland, Fig. 80, *a*, is situated in a depression of the frontal bone, at the upper, outer and fore part of the orbit. It is about the size of a small almond, but the form is various, most commonly it is a flattened ovoid. Its color is light yellow, inclining to red.

Fig. 80.

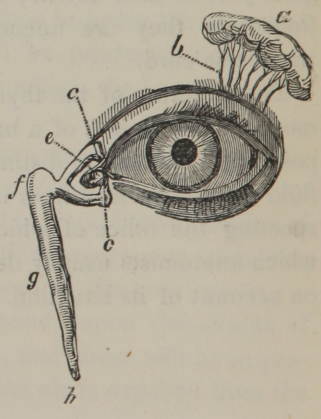


The lachrymal gland is formed of a considerable

number of lobules, connected by cellular tissue, and these lobules are composed of granulations, the intimate structure of which is still entirely unknown. It is supposed that from each of them issues a small excretory tube, which unites with others in its vicinity, and forms trunks more distinct. It appears that there are six or seven in number, *b*, and that they open on the inner surface of the eyelid.

A fibro-cellular capsule of considerable thickness envelopes the lachrymal gland.

### THE CARUNCULA LACHRYMALIS.

The *caruncula lachrymalis*, *e*, is a small red tubercle, situated in the inner angle of the eyelids: it consists of a mass of mucous crypts or follicles, covered by the conjunctiva, and forming, on its outer side, a fold* which allows of the motion of the globe of the eye. Each orifice of the crypts is furnished with hairs of excessive delicacy, and visible only with a lens.

### THE PUNCTA LACHRYMALIA.

The *puncta lachrymalia* are two in number, one for each eyelid; they occupy the centre of a small tubercle at *c*, *c*, these are the orifices of the lachrymal ducts, which convey the tears into, *f*, the lachrymal sac.

* This folding of the conjunctiva is termed by anatomical writers, the *remains of the membrana nictitans:* such a name, however, is quite absurd, as it has no such office, structure, or muscular apparatus, as that membrane. The use of this fold is simply to permit of the turning of the eye outwards: for that purpose there is a similar lax fold at the opposite angle, and at the connexion of the superior and the inferior palpebræ with the globe of the eye. If these foldings of the conjunctiva did not exist, the eye would be fixed, and it would be impossible that the eye could be revolved in any direction.

### THE LACHRYMAL SAC.

The *lachrymal sac*, *f*, is a small membranous bag, situated in a groove of the os unguis, and ascending process of the upper maxillary bone. It receives the lachrymal ducts, and is continued into the nasal duct.

### THE NASAL DUCT.

This canal, *g*, is continued from the lachrymal sac, and opens, at *h*, into the nasal fossa, beneath the inferior turbinated bone, by an orifice provided with a circular fold of the pituitary membrane. This canal is lined by a continuation of the mucous membrane of the lachrymal sac.

The nasal duct conveys the tears into the nose, which the puncta lachrymalia have absorbed.

### THE SALIVARY GLANDS.

There are three salivary glands situated behind and below the lower jaw. They do not receive vessels at a determinate point, but are penetrated on all sides by adjacent vessels which ramify in their texture. They are surrounded by a layer of cellular tissue, and have excretory ducts which open into the mouth.

Fig. 81.

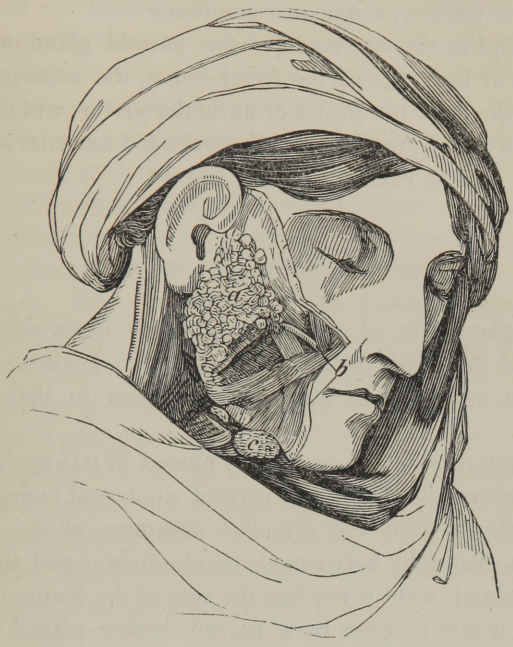


1. THE PAROTID GLAND.

The parotid gland, Fig. 81, *a*, is situated in the recess which exists on the side of the face, between the posterior border of the lower jaw and the ear, and extends from the zygomatic arch as far as the angle of the inferior maxilla.

This gland is of a grayish white color, and is composed of granulations united into lobules and lobes by condensed cellular tissue. These granulations give origin to excretory ducts, which, uniting, form *b*, the *duct of* STENO, which proceeds over the masseter muscle, and, perforating the buccinator muscle, opens into the mouth, on a level with

the second superior molar tooth.* The duct is formed of two membranes; one exterior, white, thick and resistant; the other interior, a mucous membrane.

We find in the substance of the parotid gland a great number of branches of the facial nerve, the transverse artery of the face, the posterior auricular artery, and the vein which forms a communication between the external and the internal jugular vein.

### 2. THE SUBMAXILLARY GLAND.

This gland, Fig. 81, *c*, is situated on the inner side of the ramus of the lower jaw, between the two portions of the digastric muscle. Its structure is similar to that of the parotid.

Its excretory duct is commonly named WHARTON'S *duct;* it is much smaller than the parotid duct, and commences by minute roots in the granular substance of the gland, passes horizontally between the genio-glossus and the sublingual gland, until it reaches the side of the frænum of the tongue, where it opens by a narrow orifice placed on the centre of a small tubercle.

### 3. THE SUBLINGUAL GLAND.

This gland is situated under the fore part of the tongue; it is smaller than the submaxillary gland, and nearly of the shape of an almond; it is covered by the mucous membrane of the mouth, beneath which it forms a prominence. It has several very slender excretory ducts: six or eight proceed from its upper part to open upon the sides

*The duct of the parotid may be exposed by cutting in the direction of a line drawn from the lobe of the ear to the anterior openings of the nares.

of the frænum linguale, while five or six others issue from the lateral parts, and perforate singly the mucous membrane of the inferior part of the mouth. Two or three of these may be seen terminating in the submaxillary duct.

The organization is similar to the other salivary glands.

The saliva which these glands secrete flows constantly into the mouth, and mixes with the fluids produced by the membranes and mucous follicles. This liquid has been analyzed by BERZELIUS, and found to contain: water 93·9; a particular animal matter 2·9; mucus 1·4; muriate of soda and potass 0·7; tartarite of soda and animal matter 0·9; soda 0·2. The composition of the saliva is known to be variable, for in some instances it is sensibly acid.

The saliva is one of the most useful digestive fluids; it is favorable to mastication and division of the food; it assists in deglutition, and the conversion of the aliment into chyme; it also renders more easy the motion of the tongue in speech and in singing. The greatest portion of the fluid is carried into the stomach by the motion of deglutition; another portion must evaporate and go out of the mouth with the expired air.

## THE PANCREAS.

The *pancreas*, Fig. 82, is a gland situated transversely in the abdomen, behind the stomach. Its form is irregular

Fig. 82.

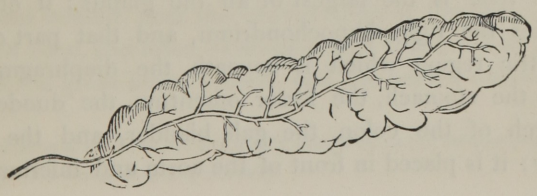

and very variable; its weight is from three to six ounces. Its *anterior surface* is covered by the transverse mesocolon, the stomach, and the first portion of the duodenum. Its *posterior surface* presents, at its upper part, a groove which contains the splenic vessels. There is very frequently beneath it a small detached glandular mass, of the same structure, named the *small pancreas*.

The pancreas bears an exact resemblance to the salivary glands in its structure: its color is light red, and from its lobules we can trace the radicles of its excretory duct, which, progressively increasing in size, proceeds in a serpentine form towards the duodenum, where it is as large as a crow-quill. Near its termination it receives the excretory duct from the small pancreas, and after a short passage, the common pancreatic duct opens into the ductus communis choledochus; or rather adheres to it as it enters the duodenum at the same point.

The pancreatic fluid, I believe, has never been collected in sufficient quantity to be analyzed; but it is generally considered to be analagous to saliva. Its office, therefore, is merely conjectural; and it is only known that this fluid mingles with the bile and is poured into the duodenum.

## ORGANS FOR THE SECRETION AND TRANSMISSION OF THE BILE.

### THE LIVER.

The *liver* is the largest of all the glands; it entirely occupies the right hypochondrium, and that part of the epigastric region which is beneath the diaphragm and above the stomach, the lesser omentum, the duodenum, the arch of the colon, the gall bladder, and the right kidney; it is placed in front of the aorta and inferior vena

cava, and behind the anterior parietes of the abdomen. It is very dense, its weight, in the adult, varying from two to five pounds. It is convex on the superior surface and irregularly concave on the inferior surface. It is divided into three lobes.

1. The *great lobe* is situated obliquely in the right hypochondriac region; it corresponds with the curve of the diaphragm, and rests upon the pylorus, colon, and superior extremity of the right kidney.

2. The *small lobe* is partially separated from the greater by a broad ligament, and is situated almost horizontally in the epigastric region; only a small part extending to the left hypochondriac region.

3. The lobulus SPIGELII is situated on the left side of the great lobe, and is of a pyramidal form, projecting between the cardia and vena cava, at the small curvature of the stomach. Two prolongations* appear to connect its base to the great lobe of the liver; one of these gradually loses itself at its surface; the other ascends posteriorly towards the groove of the inferior vena cava, and contributes to its formation.

The liver has several depressions and fissures, namely:

The *fissura umbilicalis*, or *the groove of the umbilical vein*, situated between the large and small lobes, at the under and fore part of the liver, which, in the fœtus, contains the umbilical vein; and in the adult it is occupied by the fibrous cords which are formed by the remains of these obliterated vessels.

The *sinus portarum*, or groove of the inferior vena cava, is situated behind, near the convex edge of the liver: it is short but deep, and often exists as a true canal. The porta receives the great blood vessels, and the nerves which pass

* These parts of the liver are frequently described as the *lobulus caudatus*, and the *lobulus anonymus*, or *quadratus*.

into the liver, and the biliary ducts and absorbents which proceed from it.

### LIGAMENTS OF THE LIVER.

The liver is retained in its position by folds of the peritonæum, termed the ligaments:—

1. The *ligamentum latum*, which is united to the diaphragm and the tip of the ensiform cartilage, and then descends in an oblique direction, adhering to the inner edge of the vagina of the rectus abdominis of the right side as far as the umbilicus.

2. The *ligamentum rotundum*, which was the umbilical vein in the fœtus, is placed in a duplicature of the ligamentum latum, and united to the umbilicus.

3. The *ligamentum coronarium*, unites the root or posterior part of the liver to the tendinous portion of the diaphragm.

4. The *ligamentum dextrum*, or right lateral ligament, connects the posterior part of the great lobe of the liver to the diaphragm.

5. The *ligamentum sinistrum*, or left lateral ligament, connects the small lobe to the diaphragm. The two lateral ligaments are merely the extension of the coronary ligament.

Haller has described two other ligaments, the one connecting the gall bladder and the contiguous sinus portarum to the colon, called the *hepato-colic* ligament; the other termed the *hepato-renal*, which unites the liver to the kidney.

### ENVELOPES OF THE LIVER.

The *peritonæal envelope* is reflected from the lower surface of the diaphragm over the liver, and gives it externally its shining appearance.

The *cellular envelope* covers all the parts of the liver, and is extended into its substance, forming sheaths which accompany the branches and twigs of the vena portæ, the hepatic artery, and hepatic duct. These sheaths have been designated the *capsule* of GLISSON.

The interior substance of the liver is of a reddish brown, or yellowish color. Its general aspect is porous ; this, however, arises from the great number of small vessels which are divided in cutting it. If the tissue of the liver is torn instead of being cut, it then appears composed of an immense quantity of granulations, in which the extreme ramifications of the blood vessels and biliary ducts terminate. The most minute researches have disclosed nothing further with respect to its intimate structure.

### THE HEPATIC DUCT.

The *hepatic duct* commences by a great number of very slender radicles in the granulations of the liver; these radicles, termed *pori biliarii*, unite successively into branches, accompanied by the divisions of the vena portæ and hepatic artery, and form two principal trunks, one from the left lobe, the other from the right; these proceed outwards, and, uniting at a right angle, form the hepatic duct. This duct is about an inch and a half in length, and a line and a half in diameter ; it ascends between the two folds of the gastro-hepatic omentum, before the vena portæ, on the left of the neck of the gall bladder, and unites with the cystic duct.

### THE GALL BLADDER.

The gall bladder is a membranous reservoir, situated in a superficial depression of the inferior surface of the right lobe of the liver. It is composed of three membranes. 1st. A *serous membrane*, which is the peritonæal covering on the lower surface. 2d. A *cellular membrane*, which unites the serous to the inner membrane. 3d. A *mucous membrane* of considerable thickness, which lines the interior, and has a peculiar honey-comb appearance. At the neck of the gall bladder this membrane forms several folds, which, from their arrangement, have been called the spiral valve.

### CYSTIC DUCT.

This duct, which is situated in the gastro-hepatic omentum, forms a continuation with the neck of the gall bladder, of about one inch and a half in length; it is in apposition with the hepatic duct for a short distance, and afterwards unites with it, forming the *ductus communis choledochus*, or the common canal for the transit of the bile.

### THE DUCTUS COMMUNIS CHOLEDOCHUS.

This duct is formed by the junction of the cystic and hepatic. It is from three to four inches in length, and is situated between the two folds of the gastro-hepatic omentum. It opens with the pancreatic duct obliquely, into the duodenum near its last curve.

Fig. 83.

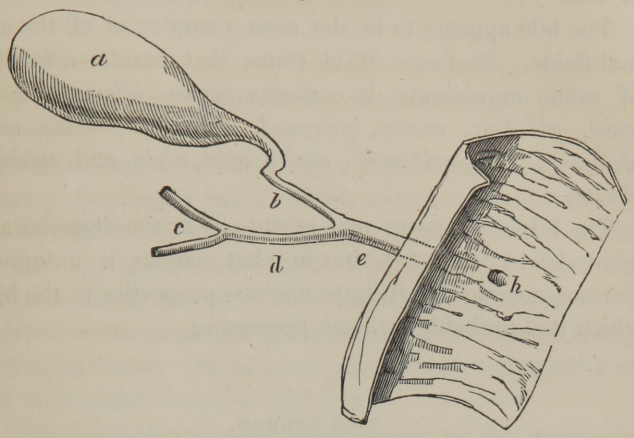


Fig. 83, *a*, the gall bladder, *b*, the cystic duct, *c*, the principal branches of, *d*, the hepatic duct; these unite and form, *e*, the ductus communis choledochus, which terminates at, *h*, by an aperture in the inner surface of the duodenum.

### SECRETION OF BILE.

The circulation in the liver is very remarkable, from its receiving blood from two sources; the hepatic arteries, and from the department of veins continued from the vena portæ, which are distributed after the manner of an artery throughout the substance of the liver. There is another department of veins for returning the blood, consisting of the venæ cavæ hepaticæ, which open into the inferior cava. Fluids injected into the hepatic artery, or into the vena portæ, readily pass into the venæ cavæ hepaticæ, and into the hepatic ducts. We may infer from this that

both venous and arterial blood may serve for the secretion of bile.

The bile appears to be the most complex of all the animal fluids. Professor Mayo states that, besides a number of saline ingredients, it contains *mucus*, *albumen*, *osmazome*, *gliadine*, *caseïn*, *picromel*, *asparagin*, *acetic acid*, *oleïc acid*, *margaric acid*, *cholic acid*, *resin* and *coloring matter*.

The bile contributes very essentially in the digestive and assimulative processes, but in what manner is unknown. Persons commonly attribute noxious properties to the bile, which it is probably far from possessing.

## THE SPLEEN.

Fig. 84.

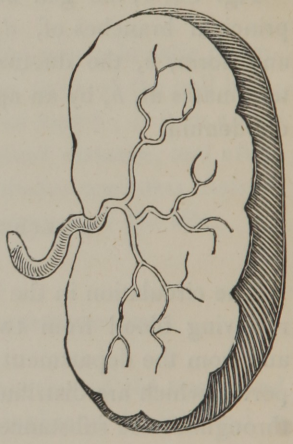

The spleen is situated in the posterior part of the left hypochondrium, beneath the diaphragm, behind the descending colon, and immediately over the left kidney. Fig. 84, shows its form; its weight cannot be precisely stated, as it presents the most numerous variations.

It is attached to the surrounding organs in a loose manner by folds of the peritonæum, and by a great number of vessels.

The spleen is single, but I have several times found a supernumerary spleen adjacent to it.

The *outer surface* is convex; the *inner* is divided by a

groove called the *fissure of the spleen*, which is filled by vessels and a certain quantity of fat.

### ORGANIZATION OF THE SPLEEN.

It is of a spongy consistence: it always contains a very large proportion of blood, which seems identified with its tissue, and which is found not only in its vessels, but also in the very numerous cellules and areolæ of which this organ is chiefly formed. It contains also a number of soft grayish, semitransparent granulations, disseminated irregularly in its tissue. MALPHIGHI considers them small glands, but their nature is quite unknown.

Sometimes two or more small bodies, of the same color and structure of the spleen, are found in its vicinity, between the laminæ of the omentum.

### OFFICE OF THE SPLEEN.

Regarding the office of the spleen, there has been a number of speculations; I shall only refer to some of the most plausible, and those which meet with the most general support. Dr. HAIGHTON advanced it as his opinion, that the spleen was subservient to digestion, by occasioning an increased secretion of the gastric and pancreatic fluids, at the precise time when they are most required. In explaining the mode in which this effect is to be produced, he agreed with HALLER in the opinion, that the stomach, when distended with food, makes sufficient pressure on the spleen, to prevent the ordinary supply of its cells, and to direct the blood, commonly sent to it, to the stomach itself, and to the pancreas.

It is suggested by Sir ASTLEY COOPER, that it is a part

of the function of the spleen to elaborate venous blood, and thus assist the liver in the formation of bile.

Sir C. Bell also regards it "as a provision for giving the vessels of the stomach an occasional power and greater activity, enabling them to pour out a quantity of fluid proportioned to the necessity of digestion."

My talented and indefatigable friend, Dr. Hodgkin, has devoted much attention to this subject, and from considering the situation and structure of the spleen — the different appearances which it assumes, according to the circumstances under which death has taken place — the causes which derange it, and the effects which it produces on the system when deranged — together with the result of experiments made on inferior animals — he has been induced to adopt a very different opinion: he believes, "that the spleen performs, in the animal system, a similar office to that which tubes and valves of safety do in various chemical and mechanical apparatuses." By this comparison he (Dr. Hodgkin) would wish it to be understood; "that the spleen tends to obviate any inconvenience which might arise from a sudden disturbance of the proportion between the capacity of the vascular system, and the fluids which circulate in it. These disturbances," he adds, "must, I conceive, be frequently induced by various causes to which the animal system is continually exposed, and which operate more powerfully than the elasticity of the vessels alone can compensate for, and more readily than absorption, secretion, and excretion can, in every case, counteract."

## SUPRA-RENAL CAPSULES.

Fig. 85.

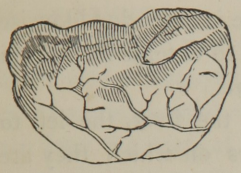

The *supra-renal capsules*, Fig. 85, are two small bodies, situated above the kidneys ; they are of a light brown color, and consist of a small bag, the exterior of which is granulated and collected into lobules. In its interior we observe a narrow, smooth, triangular cavity, without any known orifice : it is furnished in its inferior part with a prominent ridge, and it contains, in the fœtus, a considerable quantity of a reddish viscid albuminous fluid. In after life this fluid is of a deeper color.

The office of these capsules has hitherto eluded research ; their volume is much greater in the fœtus than in the adult. On this account it is supposed that they have some connection with the exercise of nutrition in the first stages of life, or that these organs are useful in the fœtal state, by deriving the blood from the kidneys, those glands not then having undertaken their proper functions of secreting urine.

## THE KIDNEYS.

The *kidneys* are two glandular bodies, situated in the lumbar regions, on the sides of the vertebral column, opposite the two last dorsal and the two first lumbar vertebræ. The right kidney is placed at the under and back part of the large lobe of the liver, and is usually a little lower than the left kidney ; the latter is placed under the back part of the spleen, and behind the left portions of the stomach, pancreas, and colon.

The kidney is four or five inches in length, and in shape, as we may see in the following figures, resembles the kidney bean which is named from it.

It is totally imbedded in a very solid and more or less thick mass of fat. This adipose tunic is extended likewise to the renal vessels, and is supposed to defend them from the pressure of the surrounding viscera.

The right kidney is connected to the liver, the left to the spleen, and both to the muscles on which they are placed, and to the supra-renal glands and colon by cellular tissue: the peritonæum is reflected from the liver and the spleen to the kidneys.

### ORGANIZATION OF THE KIDNEYS.

The surface of the kidney is usually smooth and uniform, though sometimes it is irregular, in consequence of the lobes which originally form it not being so completely incorporated. Each kidney receives from the aorta an artery of considerable diameter, and returns its blood by a large vein into the inferior vena cava. A very distinct nervous plexus surrounds these vessels, and the lymphatics are very easily to be traced.

The kidney appears to be formed of two distinct substances; an external or *cortical*, and an internal *tubular*, or medullary substance.

The *cortical substance* of the kidneys forms the external layer of these organs, and internally it is prolonged into them in the form of septa, between which we find the conical fasciculi of the tubular substance. When viewed with a microscope, the cortical substance appears composed of solid granulations of a very small size, formed by the capillary extremities of the renal arteries and veins.

The *tubular substance* presents a number of conical fas-

ciculi, surrounded on all sides, except at their summits, by the cortical substance. The base of each cone is directed towards the circumference of the kidney, and their summits, on the contrary, are directed towards the pelvis, or fissure of the kidney.

The color of this substance is a pale red ; its tissue is dense and is formed of a multitude of very minute convergent canals, termed *tubuli uriniferi*, which derive their origin from the cortical substance, and terminating in larger ducts at the summits of the cones, present so many mammillæ,* at the points of which the urine oozes out. The number of mammillæ is twelve or fourteen ; the orifices of the canals (called the ducts of Belini) of the tubular substance are less numerous than the canals themselves, on which account it is to be presumed that several of these uriniferous tubes unite before they terminate.

### THE CALYCES, PELVIS, AND URETER.

The *calyces*, or *infundibula*, are membranous tubes which embrace the mammillæ, and which receive the urine from them. The infundibula are commonly the same in number as the mammillæ ; the number, however, varies in different subjects, two or more mammillæ sometimes opening into the same infundibulum.

The *pelvis* is a membranous bag formed by the union of the infundibula ; it is contracted at the inferior part to be continued into the ureter.

The *ureters*, or the excretory ducts of the kidneys are long membranous canals, of a cylindrical form, and about the size of a writing quill ; each extends from the pelvis of the kidney, with which it is continuous, to the fundus of the bladder into which it opens.

* Frequently termed *papillæ*.

The uterers descend in the loins obliquely inwards behind the peritonæum, and over the psoas and iliac muscles, and, passing into the pelvis, terminate in the under, outer, and back part of the bladder, by a narrow oblique orifice.

The infundibula, pelvis and ureters appear to have the same organization; being composed of two membranes, namely, an *outer*, thick, white, opaque membrane, which may be considered as a prolongation of the fibrous capsule of the kidney; and an *inner*, mucous, transparent membrane, which is extended from the infundibula over the mammillæ, and perhaps even introduced into the uriniferous tubes.

Where the ureters open into the bladder, some few pale muscular fibres may in general be found. These have been named the *muscles of the ureters*, by Sir Charles Bell, who describes each as arising from the vesical extremity of the ureter, and thence descending obliquely forwards and inwards, to be inserted by a tendon common to its fellow into the tubercle or uvula of the urethra. The use which he assigns to them is, to restrain the termination of the ureters, and preserve the obliquity of the passage of these tubes through the coats of the bladder when it is contracted; for without this provision, he remarks, the urine would be sent retrograde into the ureters, instead of forward into the urethra.

Fig. 86.

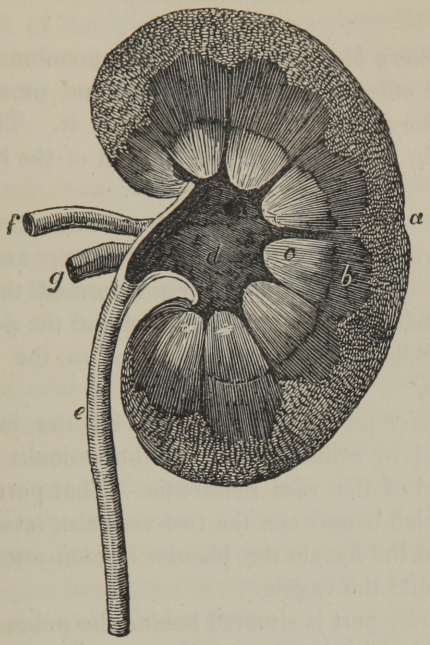


Fig. 86, exhibits a section of the kidney.
*a*, the cortical substance.
*b*, the tubular substance.
*c*, the mammillæ, around which are the infundibula.
*d*, the pelvis.
*e*, the ureter.
*f*, the renal artery.
*g*, the renal vein.

## THE BLADDER.

The *urinary bladder* is a musculo-membranous reservoir, whose office it is to retain for some time the urine which is afterwards to be ejected from it. The bladder is situated in the pelvis at the bottom of the hypogastric region.

The *superior* part of the bladder is in contact with the inferior convolutions of the small intestine; and from its centre we observe a fibrous cord termed the *urachus*, which ascends between the linea alba and the peritonæum to the umbilicus, where it terminates in the abdominal aponeurosis.

The *inferior* part or fundus of the bladder, in the male, is connected by cellular tissue to the vesiculæ seminales, and the end of the vasa deferentia. That portion of the bladder, which is between the two vesiculæ, rests upon the rectum. In the female the bladder is connected with the levator ani and the vagina.

The *anterior* part is situated behind the pubes, but when the organ is distended by urine, we find it in the hypogastric region. Their is a fasciculus of fibrous membrane which attaches the anterior part of the bladder to the symphysis of the pubes, named the *anterior ligament of the bladder*.

The *posterior* part is entirely covered by the peritonæum, and is contiguous, in the male, to the rectum, and in the female, to the uterus.

The *internal* surface of the bladder is formed by a mucous membrane, which, in its empty state, presents numerous irregular rugæ, but these disappear when the bladder is full; and we always find on the fundus a remarkable triangular space where the mucous membrane is

destitute of rugæ; it is named the *trigonal space of the bladder.*

The *neck* of the bladder has a crescent-like form, the margin of which is very thick, and it embraces a small tubercle, designated by the name of the *uvula vesicæ.*

### THE ORGANIZATION OF THE BLADDER.

The *peritonæal membrane* is reflected over part of the superior, posterior and lateral portions of the bladder, and it is united to the muscular membrane by loose cellular tissue.

The *muscular membrane* consists of muscular fibres, spread out in various directions over the bladder; the greater number, however, are longitudinal, a few only being transverse. These fibres are stronger on the anterior and posterior surfaces than on the sides. On the latter region they run obliquely. The anterior fibres, from having a fixed attachment, are called by some anatomists the *detrusor urinæ muscle.*

The *neck of the bladder* is formed of a firm, white, extensile, fibrous membrane, with muscular fibres, having the same arrangement as on the bladder itself; this is generally designated by anatomists as the sphincter vesicæ. J. Cloquet altogether denies that it is a sphincter muscle, and states it to be merely the fleshy fibres brought closer together than elsewhere.

The *cellular membrane* is that which connects together the mucous and muscular structure of the bladder, and in which we observe the most numerous vessels and nerves.

The *mucous membrane* is continuous with the inner surface of the ureters and the urethra. Its villosities are

very delicate and not easily detected: in its natural state no mucous follicles are to be observed, but in certain morbid conditions their presence is very apparent.

### THE OFFICE OF THE KIDNEYS AND THE BLADDER.

The kidneys separate the urine from the blood, and convey it by means of the ureters to the bladder. There is every reason to suppose that substances hurtful to the animal economy are discharged in this fluid; for when there is a total suppression of this secretion, or when the renal arteries are tied, death occurs in a short space of time.

When the pelvis of a kidney is cut open, in the living animal, the urine may be seen to pass out slowly at the points of the excretory cones. Or if we remove the kidney from the body, and compress the uriniferous cones, we observe a considerable quantity of this fluid issuing from them. The urine then enters the pelvis of the kidney, and by small quantities proceeds through the ureter by a constant exudation, and slowly distends the bladder. The urine is prevented from flowing back into the ureters, by these conduits passing a considerable distance into the sides of the bladder, so that, in proportion as the urine distends this organ, it compresses the ureters, and closes them more firmly as it is more abundant. This mechanism may be observed in the dead body, for if we inject the bladder with water or even air, by the urethra, we find that it never enters the ureters.

## THE URINE.

There is no fluid of the human body so variable with respect to quantity and quality; for it varies according to age, to the quantity of fluids drank, the nature of the aliments or medicines taken, or according to the season of the year: in the winter it is more copious, and in the summer, from the increased transpiration, it is more sparing and high colored. Affections of the mind also influence the secretion; thus fright makes the urine pale and copious.

The numerous researches made concerning urine have given the following as its component parts: 1 water; 2 urea; 3 phosphoric acid; 4, 5, 6, 7, phosphates of lime, magnesia, soda, and ammonia; 8, 9, 10, 11, lithic, rosacic, benzoic, and carbonic acid; 12 carbonate of lime; 13, 14, muriates of soda and ammonia; 15 gelatin; 16 albumen; 17 resin; 18 sulphur.*

* Dr. Ure.

According to Berzelius the following are the ingredients of 1000 parts of healthy urine.

| | |
|---|---|
| Water, | 933·00 |
| Urea, | 30·10 |
| Sulphate of potass, | 3·71 |
| Sulphate of soda, | 3·16 |
| Phosphate of soda, | 2·94 |
| Muriate of soda, | 4·45 |
| Phosphate of ammonia, | 1·65 |
| Muriate of ammonia, | 1·50 |
| Free lactic acid — lactate of ammonia — animal matter soluble in alcohol — urea not separable from the preceding, | 17·14 |
| Earthy phosphate, with a trace of fluate of lime, | 1·00 |
| Uric acid, | 1·00 |
| Mucus of the bladder, | 0·32 |
| Silex, | 0·03 |
| | 1000·00 |

# ART. XIII.

## ORGANS OF GENERATION IN THE MALE.

These consist of the testicles and their appendages, the vesiculæ seminales, the prostate, the ductus ejaculatorii, and the penis.

### THE TESTICLES AND THEIR APPENDAGES.

#### 1. THE ENVELOPES OF THE TESTICLES.

1st. The *scrotum*, or the cutaneous envelope of the testicles, is a continuation of the skin of the adjacent parts. It is remarkable for having a deeper color than other parts of the skin, for the great number of mucous follicles which it contains in its substance, and for its long and scattered hairs which are inserted obliquely, and so superficially that their bulbs produce distinct elevations of the skin. Upon the surface of the scrotum there is a superficial, longitudinal, elevated line, called the *raphe*, which divides it into two equal parts, and extends as far as the anterior part of the anus.

2d. The *dartos* is a filamentous cellular membrane of a rose color, entirely destitute of adipose substance, in which an infinite number of vessels are distributed; and although some authors have described it as a muscle, it certainly does not exhibit the smallest appearance of muscular fibres. It is attached to the ischium and pubes; meeting in the middle that of the opposite side, thus forming a septum which separates the testicles. The inner surface is applied to the fibrous tunic of these organs, and on the extremity of the cremaster muscle; the outer surface adheres to the scrotum.

3d. The *cremaster muscle*. This has been already described. See Vol. I. page 213, Fig. 131.

4th. The *fibrous tunic* is thin, transparent and very little resistant; it forms an elongated sac, placed within each dartos. Superiorly, it forms a sheath for the spermatic cord, and, inferiorly, it contains the testicle and epididymis.

5th. The *tunica vaginalis*, a serous membrane which constitutes, like all other serous membranes, a sac without an opening; it covers the whole internal surface of the fibrous tunic, and is extended to the epididymis and testicle; entirely covering the latter excepting at its upper edge. In infancy it is manifestly continuous with the peritonæum, having descended with it into the scrotum. This circumstance explains the formation of that species of hernia in which the intestine is in immediate contact with the testicle.

### 2. THE TESTICLES.

The testicles are two ovoid glandular organs, lodged in the scrotum. The right testicle is generally a little higher than the left.

### ORGANIZATION OF THE TESTICLE.

The *tunica albuginea* is a fibrous membrane, white and opaque, not unlike the sclerotica; it serves as a direct envelope to the testicle. Its outer surface is covered by the serous membrane; its inner is applied upon the proper substance of the testicle, and sends into the interior of it a number of delicate prolongations, directed towards its posterior part. These septa divide the testicle into several cells which contain the seminal vessels.

On the inner side of this membrane we observe the *corpus Highmorianum*, an elongated prominence at the superior part of the testicle, across which the principal trunks of the seminal vessels pass obliquely towards the epididymis.

The *parenchyma of the testicle* is soft, of a gray color marbled with red, and is formed of an immense number of very minute tortuous tubes, slightly connected to each other. According to the observations of Monro, they do not exceed the two hundredth part of an inch in diameter; these tubes, termed *vasa seminalia*, or *tubuli seminiferi*, do not ramify, but their length is very great; the same author estimates their number at about sixtytwo thousand five hundred, and he considers their total length to be five thousand two hundred feet: capillary arteries and veins of still greater minuteness are observed among them.

The seminal ducts just described are all directed towards the superior part of the testicle, where they form from twenty to thirty considerable trunks, which traverse the corpus Highmorianum, opposite and a little below the epididymis, where they dilate and give origin to the duct which forms the epididymis.

### 3. EPIDIDYMIS.

This name is given to the canal formed by the union of all those smaller tubes, which compose the body of the testes and the corpus Highmorianum. The epididymis is situated upon the upper part of the testicle, is inclosed in the same covering with it, and is exceedingly convoluted until it passes into the spermatic cord. Its superior part arises from the corresponding part of the testicle, where it receives the *vasa efferentia;* its inferior part is adherent to the testicle, and is continuous with the *vas deferens;* its middle portion is adherent to the testicle.

### 4. VAS DEFERENS.

The *vas deferens* is the large excretory duct of the testicle. It commences at the lower part of the epididymis, ascends, describing many flexuosities, behind the testicle, and immediately enters the spermatic cord, where it is placed behind, and internally to the artery and nerves which accompany it. After passing the ring it leaves the other vessels of the cord, and descends backwards and inwards upon the side of the bladder. Then, arriving under the inferior and posterior region of the bladder, it approaches its fellow, and proceeds along the inner edge of the vesiculæ seminales. At the base of the prostate gland, it receives a canal from the vesiculæ seminales, and is continued into the ejaculatory duct.

The vas deferens is slender near its origin, but on passing through the abdominal ring it increases in size, and becomes twice as large along the vesiculæ seminales: at its termination, however, it resumes its original size. The parietes of this duct are very thick, and have almost a

cartilaginous consistence ; its cavity is so small as scarcely to admit a hair, except near the vesiculæ, where it is much larger.

### 5. SPERMATIC CORD.

The *spermatic cord* is composed of the last mentioned duct, namely, the vas deferens, the spermatic artery and vein, of some other inconsiderable and irregular blood vessels, lymphatics, and nerves. It is enveloped by several membranous layers, and contains a large quantity of cellular tissue in the intervals of its component parts. It ascends from the upper part of the testicle, and enters into the abdomen by the inguinal ring. The organs of which it is composed then separate from each other, and follow a course with which we are already acquainted.

Fig. 87. Posterior view of the testis and tunica vaginalis.

*a*, the spermatic cord.

*b*, the vas deferens.

*c*, the commencement of the epididymis.

*d*, the testis devoid of the tunica vaginalis.

*e*, the tunica vaginalis.

Fig. 87.

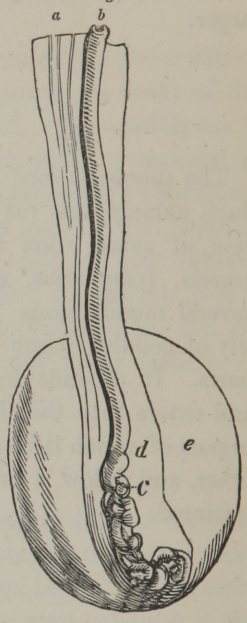


## THE VESICULÆ SEMINALES, PROSTATE, COWPER'S GLANDS, AND DUCTUS EJACULATORII.

### 1. VESICULÆ SEMINALES.

The vesiculæ seminales are situated beneath the bladder, in front of the insertion of the ureters, and on the outer side of the vas deferens. They are two membranous reservoirs about two inches and a half in length, and six or seven lines in breadth. In dried preparations the vesiculæ appear as a cavity composed of numerous cells; but if they are carefully dissected they present a flexuous canal.

These vesiculæ are filled with a thick yellowish fluid, which has been supposed to have retrograded from the vasa deferentia; but as, in some animals, the vesiculæ seminales have no connection with the excretory ducts of the testes, we may reasonably infer that they are not mere receptacles of the secretion of the testicles. The vesiculæ are organs of secretion, producing a peculiar fluid which is ejected at the same moment as the secretion just mentioned.

### 2. PROSTATE GLAND.

The *prostate gland* is a body of the size and figure of a chesnut, formed of an assemblage of mucous follicles surrounding the neck of the bladder and the commencement of the male urethra.

This gland has a division forming it into two lateral lobes, and there is sometimes an inferior lobe at the base of the prostate, first noticed by Morgagni, and subsequently very particularly described by Sir Everard Home. It is called *lobus* Morgagni.

The upper surface is covered by the inferior ligament of the bladder; the lower surface rests upon the rectum. Its base forms a very remarkable prominence round the neck of the bladder; its summit terminates upon the membranous portion of the urethra.

The prostate gland is of a light gray color, and its structure is very dense and firm; it is filled with a great number of small follicles containing a viscid fluid. From these follicles ten or fifteen excretory ducts arise and open into the urethra, on the sides and at the surface of the Verumontanum. When we remove this gland from the dead body and compress it, the fluid it contains is made to issue from the orifices of these ducts.

### 3. COWPER'S GLANDS.

These are two small granulated glandular bodies, placed parallel to each other before the prostate. They are of a red color, about the size of a pea, and of a structure resembling the salivary glands. Each of these glands has an excretory duct, which proceeds obliquely inwards and forwards in the spongy tissue of the urethra, and opens before the Verumontanum. These glands are for the purpose of secreting a mucus, to be discharged into the urinary passage.

### 4. EJACULATORY DUCTS.

These ducts commence at an acute angle, formed by the junction of the vasa deferentia with those which terminate the vesiculæ seminales; they are about an inch in length, and proceed parallel to each other, in the substance of the prostate gland, opening into the urethra by two small oblong orifices, situated upon the lateral and anterior part of the Verumontanum.

Fig. 88.

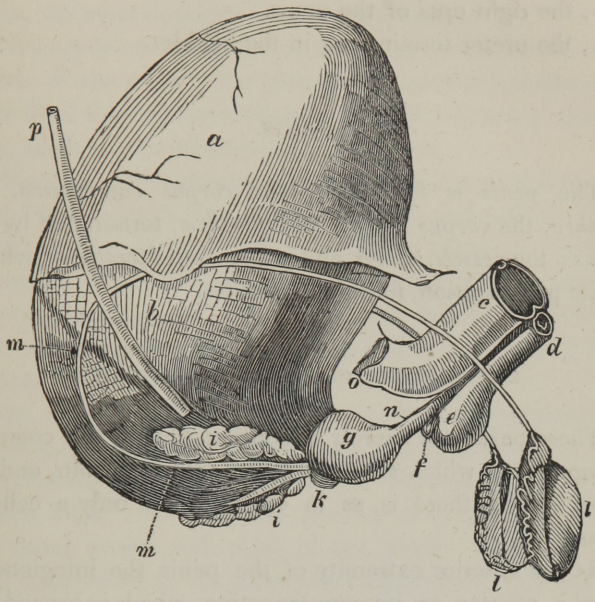


Fig. 88, exhibits the urinary bladder inflated, and the principal parts of the organs of generation of the male.

*a*, the peritonæum covering the bladder.

*b*, the muscular membrane of the bladder.

*c*, the corpus cavernosum penis.

*d*, the corpus spongiosum urethræ.

*e*, the bulb of the urethra.

*f*, one of Cowper's glands.

*g*, the prostate gland surrounding the neck of the bladder.

*k*, the inferior lobe of the prostate gland.

*i*, *i*, the vesiculæ seminales.

*l*, *l*, the testes.

*m*, *m*, vas deferens.
*n*, the membranous portion of the urethra.
*o*, the right crus of the penis.
*p*, the ureter terminating in the bladder.

## PENIS.

The *penis* is formed by the *corpus cavernosum*, the *urethra*, the *corpus spongiosum urethræ*, terminated by the *glans;* the *vessels*, *nerves*, and a *cutaneous investment*, which, by its prolongation, forms the *prepuce*.

### 1. INTEGUMENTS OF THE PENIS AND PREPUCE.

These parts are merely a continuation of the common integuments, which are here more delicately thin, and instead of fat, there is, as in the scrotum, only a cellular tissue.

At the anterior extremity of the penis the integuments form a greater or less prolongation, which is termed the *prepuce*, which covers the glans when the penis is in a state of relaxation. The prepuce is connected to the under part of the glans by a triangular fold, termed the *frænum preputii*.

The prepuce is composed of two membranous layers, between which is a plane cellular tissue; the outer layer is formed by the skin; the inner is of the nature of a mucous membrane, and is furnished with sebaceous follicles, termed the *glandulæ odorifiræ*.

### 2. CORPUS CAVERNOSUM.

Most writers on anatomy describe two corpora cavernosa penis, but there exists only one; there are certainly two

roots, and a septum in part of its extent, but it is so incomplete a partition, that, with CLOQUET, CHAUSSIER and others, we must consider it as a single body.

The corpus cavernosum forms about two-thirds of the volume of the penis: it is placed over the urethra, and extends from the anterior and inner part of the sciatic tuberosity, as far as the substance of the glans.

The *roots* of the corpus cavernosum are attached to the inner border of the ramus of the ischium and pubes; they are about two inches in length, commencing in front of the sciatic tuberosity, and uniting at the inferior part of the symphysis pubis. The triangular space which separates them from each other, is occupied by fat and by the urethra.

The *anterior extremity* of the corpus cavernosum is united to the base of the glans, and perforated by several apertures for the passage of vessels. Its *upper surface* is marked with a longitudinal groove, in which we observe the dorsal artery and veins of the penis. Posteriorly it gives attachment to the suspensory ligament of this organ, being a fibrous fasciculus attached to the inferior part of the symphysis pubis. The inferior surface is marked by a broad, deep groove, which receives the superior side of the canal of the urethra, to which it adheres by a filamentous cellular tissue.

### ORGANIZATION OF THE CORPUS CAVERNOSUM.

The *corpus cavernosum* is composed of a very strong fibrous tunic, of an opaque white appearance, excepting at its roots and at the anterior extremity, where its color is more or less livid. Its fibres are for the most part longitudinal, and are interwoven posteriorly with the periosteum

of the bones of the ilium, and the aponeurosis of the muscles, which are attached to their lower edge.

The cavity of this fibrous membrane is partially divided into two lateral portions, but the partition does not extend beyond two thirds of its length; it is then continued merely as a few fibrous fasciculi to the glans.

The *spongy tissue*, enveloped by the preceding membrane, appears to consist of a complicated net-work of arterial and venous vessels, probably of nerves also, and of small fibrous laminæ, which latter form numerous cellules communicating with each other, and with the blood vessels, and always containing a greater or less quantity of blood. An injection made by the cavernous artery passes into these cellules, and if, on the contrary, we inflate these cellules with air, it passes into the cavernous vein, so that we may conclude that they are intermediate with the arteries and veins.

### 3. URETHRA.

The *urethra* extends from the neck of the bladder to the extremity of the glans penis; its capacity very much exceeds that of any other excretory duct. Its parietes are partly spongy and partly membranous. At first its course is directed a little forwards and downwards; next traversing the prostate gland, it passes through a circular aperture of the triangular ligament of the bladder, and under the symphysis pubis mounts in front of it between the two roots of the corpus cavernosum, and then descends in the groove, in the superior surface of the latter as far as the summit of the glans penis, where it opens by a vertically elongated orifice. It is distinguished into three portions:

1st. The *prostatic portion*, which is from fifteen to eighteen lines in length, and passes obliquely through the prostate gland.

2d. The *membranous portion* is thin and contracted; it is from eight to ten lines in length, and united to the rectum inferiorly and posteriorly, and anteriorly approaching the inferior part of the symphysis pubes.

3d. The *spongy portion* commences posteriorly by the bulb of the urethra, which is situated beneath the angle of union of the roots of the corpus cavernosum. Anteriorly it expands to form the glans penis.

The cavity of the urethra has not the same dimensions through its whole extent; it is rather broad at its origin; it contracts and again dilates in the centre of the prostate gland. The membranous portion is much narrower than any other part of the canal, and in its spongy portion its breadth is very nearly equal except towards its extremity, where there is a remarkable dilation, termed the *fossa navicularis*.

The *interior* of the urethra, through the whole length of the canal, presents two white lines, the one superior, the other inferior; the latter line terminates posteriorly in a prominence, about an inch long, named the *verumontanum*, or the *caput gallinaginis*, continuous posteriorly with a small fold of the mucous membrane: the orifices of the ejaculatory ducts open at its sides; those of the prostate on its surface, and those of COWPER'S glands in front of it.

### ORGANIZATION OF THE URETHRA.

The *mucous lining* of the urethra is continuous at the one extremity with that which covers the glans, and at the other, with the mucous membrane of the bladder. Its color is a bright red near its orifice, but it becomes pale and white through the remainder of its extent. A great number of small foramina are observed opening on its surface, named *sinuses of* MORGAGNI; and by a folding of the

membrane they form so many lacunæ, commencing at the bulb and becoming more numerous towards the fossa navicularis.

The *spongy tissue* surrounds the three anterior fourths of the length of the urethra; it is somewhat thick at the bulb, then becomes contracted into a cylindrical tube as far as the glans penis; this spongy tissue being expanded so as to form this part.

The membranous portion of the urethra is braced to the arch of the pubes by muscular fibres, discovered by Mr Wilson, and named by him the *compressor urethræ:* when this muscle acts it compresses the urethra so as to close it as completely as a sphincter, while, from its attachments, it draws the urethra towards the pubes.

### GLANS PENIS.

The glans is covered by a very delicate epidermis; and is circumscribed by a prominent ridge, called the *corona glandis*. Its internal tissue has the same characteristics as the corpus cavernosum, only appearing more dense.

Fig. 89, exhibits a section of the penis.

*a*, *a*, the corpus cavernosum penis.

*b*, the corpus spongiosum urethræ.

*c*, the urethra.

Fig. 89.

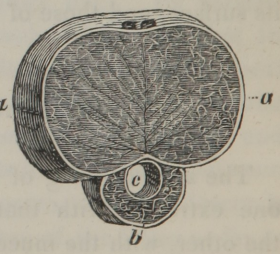

# ART. XIV.

## ORGANS OF GENERATION, AND FOR THE NUTRITION OF THE CHILD, IN THE FEMALE.

The genital organs of the female consist of the vulva, the vagina, and the uterus, and its appendages.

The *vulva*, or *pudendum*, is the name given to the external parts of generation in the female, under which are comprehended —

1st. The *labia pudendi*, two membranous folds, formed by a prolongation of the skin, beneath which there are a considerable number of sebaceous follicles. The integument on the fore part of the symphysis pubis is slightly elevated by a quantity of cellular and adipose substance deposited beneath it, and is covered with hair. This part, from its surmounting the labia, has been called *Mons Veneris*. The inner surface of the labia is a red mucous membrane, continuous with the other parts of the vulva. The intervening substance, that is, between the skin and the mucous membrane, consists of adipose tissue and some fibres of the constrictor vaginæ muscle. The labia unite both beneath the mons, and before the perinæum, the points of union being called commissures. The inferior one has also received the name of *fourchette*, and the in-

terval between this and the entrance of the vagina has been called *fossa navicularis*.

2d. The *clitoris*, a small elongated tubercle, placed at the middle and superior part of the vulva: it is supposed to bear some analogy to the penis of the male, in having a sort of glans surrounded by a fold of the mucous membrane similar to the prepuce. It has also a corpus cavernosum, of a spongy texture, adherent by two roots to the rami of the ischia; it receives a great quantity of nerves.

3d. The *nymphæ* are two membranous crescent-like folds, extending from the prepuce of the clitoris to the middle of the orifice of the vagina; each of the nymphæ is formed of two laminæ of the mucous membrane of the vulva; they contain also in their substance a small quantity of spongy erectile tissue.

4th. The *urethra* is only an inch in length; it is wide at its commencement, and descends obliquely forwards, terminating at the superior part of the entrance of the vagina, by an orifice called the *meatus urinarius:* in its course it describes a slight curve, the concavity of which is turned upwards. It is lined by a vascular mucous membrane, and contains a great number of mucous lacunæ.

5th. The *orifice of the vagina* commences beneath the meatus urinarius; it is occupied by the *hymen*, or by the *carunculæ myrtiformes*.

The *hymen* is considered as one of the surest signs of virginity; it consists of a more or less distinct fold of the mucous membrane of the vulva; at the entrance of the vagina; its form is semilunar, consequently not completely closing the opening.

The *carunculæ myrtiformes* are small red tubercles, existing only after the rupture of the hymen; they are in fact the remains of the lacerated hymen.

The *vagina* is situated in the pelvis, between the bladder and the rectum, and extends from the vulva to the neck of

the uterus. It is from six to eight inches long, somewhat curved, its concavity being next to the bladder, therefore shorter before than behind, and somewhat more contracted at its extremes than in the middle part: its position is nearly vertical, or rather directed a little downwards and forwards.

The *outer surface* is invested superiorly, to a small extent, by the peritonæum; inferiorly it is contiguous with and between the bladder and rectum, being connected with these parts by a dense cellular tissue. On the sides it corresponds above to the broad ligaments of the uterus, and below to a mass of cellular tissue which separates it from the levatores ani muscles.

The *internal surface* is covered by the mucous membrane, and presents numerous transverse wrinkles termed *rugæ*, which are less distinct on the sides, and are most prominent inferiorly; near the uterus the rugæ follow every variety of direction. There are also two longitudinal ridges formed by the mucous membrane, and intersecting the former at right angles.

### ORGANIZATION OF THE VAGINA.

The *mucous membrane* is continuous with that of the vulva and the uterus. Between the rugæ it is perforated by a multitude of orifices of mucous follicles.

The *erectile spongy tissue* forms around the inferior part of the vagina, a layer about an inch broad, and two or three lines thick: it is described by De Graaf under the name of *retiformis*, and by later anatomists under that of the *corpus cavernosum vaginæ*. Superiorly it becomes very thin, but it may be traced as far as the uterus, and seems to be continuous with the proper tissue of that organ.

### THE UTERUS AND ITS APPENDAGES.

The *uterus*, or *womb*, is situated in the middle of the pelvis, between the bladder and rectum, above the vagina, with which it is intimately connected, and beneath the inferior convolutions of the small intestine. Its figure is annexed. It is flattened from before backwards and is nearly an inch in thickness. Superiorly it is about two inches broad, but it is contracted inferiorly towards the vagina, and terminates by a narrow portion called the *neck*, to distinguish it from the other part of the organ, which is called its *body*. The *fundus* is the broad part which projects above the attachments of the Fallopian tubes, surmounting the body. It presents a convex border, and is covered by peritonæum in its entire extent.

The *body of the uterus* is about two inches in length; its surfaces are convex, and invested with the peritonæum; its anterior part is in contact with the bladder, its posterior with the rectum. The *cervix*, or *neck of the uterus*, is about fourteen lines in length, its transverse diameter from eight to ten. Its upper part is embraced by the vagina; the orifice of the uterus, called the *os tincæ*, projects into the superior part of that canal.

The *cavity of the uterus* is small in proportion to the volume of the organ. It is triangular and compressed; its edges are curved, and its upper angles present the extremities of the minute openings of the Fallopian tubes. Each of its surfaces are traversed by a longitudinal slightly elevated line. The cavity of the cervix is nearly cylindrical, and somewhat dilated before it terminates in the vagina. It presents a continuation of the vertical lines I have just mentioned, and some faint rugæ taking a transverse direction.

Fig. 90.

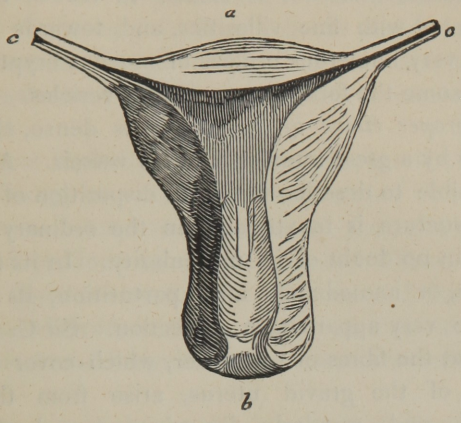


Fig. 90, exhibits a section of the unimpregnated uterus, in which we observe the relative size of its cavity and the thickness of its parietes.

*a*, fundus uteri.

*b*, os tincæ.

*c*, *c*, a section of the uterine extremities of the Fallopian tubes.

### ORGANIZATION OF THE UTERUS.

The *serous membrane* is a covering formed by the peritonæum, which adheres firmly to its upper edge, but upon the two surfaces it is separated from the proper tissue of this organ by a quantity of cellular tissue and blood vessels. In uniting with the lateral borders, it forms two angles, at the middle part of which the Fallopian tubes terminate, above the insertion of the ligament of the ovary

which is posteriorly, and of that of the round ligament which is anteriorly.

The *mucous membrane* is similar to that of the vagina. It is covered with fine villosities, and, towards the neck, presents very numerous orifices of mucous crypts, some of which assume the form of transparent vesicles.

The *proper tissue of the uterus* is dense, elastic, and traversed by a great number of blood vessels. Although it is impossible to describe the exact disposition of its fibres, as its structure is inextricable in the ordinary state, yet I entertain no doubt of its muscularity. In its impregnated state, or immediately after parturition, its muscular fibres are very apparent in dissection. Sir C. Bell has stated that the fibres of one order, which cover the upper segment of the gravid uterus, arise from the round ligaments, and, regularly diverging, spread themselves over the fundus, until they unite and form the exterior stratum of the proper tissue of the uterus. On the outer surface and lateral parts, other muscular fibres have an appearance of irregularity among the larger blood vessels; but they are so disposed that they are well calculated to compress the vessels, whenever the uterus is excited to contraction. Those who have the opportunity of examining the gravid uterus in its recent state, will feel convinced, that it is distinctly and powerfully muscular; but the course of the interior fibres are less easily described than we might imagine. This is owing to the intricate interweaving of the fibres with each other; an intertexture, however, which gradually increases the extent of their power in diminishing the cavity of the uterus. After making sections of the substance of the womb in different directions, says the eminent anatomist just mentioned, "I have no hesitation in saying that, towards the fundus, the circular fibres prevail; that, towards the orifice, the longitudinal fibres are most appa-

rent; and that, on the whole, the general course of the muscular fasciculi is from the fundus towards the orifice." This prevalence of longitudinal fibres is undoubtedly a provision for diminishing the length of the uterus, by drawing one extreme towards the other. At the same time, such an arrangement of the fibres, by their action, must dilate the orifice.

The inner surface of the fundus consists of two sets of fibres, running in concentric circles round the orifices of the Fallopian tubes: these circles, at their circumference, unite and produce an intricate tissue. There are other strata of fibres commencing at the centre of the last muscular fasciculi, and, having a course at first circular, then descend in broad irregular bands towards the orifice of the uterus.

The arteries of the uterus are derived from the spermatic and hypogastric; their principal branches are very flexuous, and unite frequently together beneath the peritonæum. Its veins follow the same course, but are still more tortuous, and form cavities in its parietes, which become so large, during gestation, as to obtain the term of *uterine sinuses*.

When the uterus is contracted, the blood vessels are invisible, but, during pregnancy, they are so large and distinct, that the orifices of some of them, when divided, will admit the end of the little finger. This fact, then, of the natural closing of the vessels by uterine contraction, leads us to contemplate this organ as admirably constructed for the reception of the ovum, the growth of the fœtus, and the expulsion of the placenta without dangerous hæmorrhage.

### THE BROAD LIGAMENTS.

The *broad ligaments** are two folds of the peritonæum; they form, with the uterus and the upper part of the vagina, a transverse septum, which divides the cavity of the pelvis into two parts. These ligaments are continuous by the inner edge, with the peritonæum which invests the two surfaces of the uterus, and are externally expanded upon the sides of the excavation of the pelvis. They are formed of two peritonæal laminæ, the interval of which contains cellular tissue; and superiorly on each side, the Fallopian tubes; beneath and anteriorly, the round ligaments; and posteriorly, the ovaries. The tubes occupy the free edge of the ligament; the other two organs raise its surface and form two smaller foldings.

### THE ROUND LIGAMENTS.

The *round ligaments* are two long and slender cords, commencing immediately before and below the Fallopian tubes, near the angles of the uterus, from which they descend in the broad ligaments, and, diminishing a little in their course, direct themselves towards the internal inguinal ring, pass through it, and terminate by expanding in the cellular tissue of the pudendum.

Their structure is dense and fibrous, with an interposed cellular tissue and an evident vascularity.

### THE FALLOPIAN, OR UTERINE TUBES.

The *Fallopian tubes*, formerly very well named the *ovi-*

* *Ligamenta lata*, termed sometimes *alæ vespertilionis*.

*ducts*, are two canals placed at the superior edge, and in the duplicature of the broad ligaments. They are about four or five inches in length, and extended from the upper angles of the cavity of the uterus, to near the side of the upper diameter of the pelvis. In the inward half of their length they are small and straight; afterwards these tubes become larger and more flexuous, and terminate in a wide floating fringed extremity, called *fimbriæ*.

The cavities of the Fallopian tubes are very small, indeed scarcely admitting the entrance of a bristle; they gradually become larger as they approach the sides of the pelvis; near their outer extremity they are considerably dilated, but are afterwards suddenly contracted, and terminate by an opening of sufficient size to admit the point of a writing quill.

These tubes are lined by a very thin mucous membrane, of a florid color, slightly villous, and presenting several longitudinal plicæ. No mucous follicles have hitherto been discovered in them.

Externally, these organs are formed by a layer of spongy and erectile tissue, similar to that of the urethra, and, as before noticed, invested by the peritonæum.

### THE OVARIES.

The *ovaries*, anciently termed *testes muliebres*, are two compressed oval bodies placed in the substance of the broad ligament; they are of a pale red color, and somewhat irregular at their surface. Their outer extremity is attached to one of the fimbriæ of the Fallopian tubes; the inner is connected to the uterus by a small filamentous cord, about an inch and a half long, called the *ligament of the ovary*.

Each ovary is enveloped in a dense cellular membrane,

which is prolonged into the parenchyma of the organ, the texture of which is composed of a loose and spongy substance. When minutely examined we perceive cellular and vascular lobules, of a gray color, filled with fluid. In the midst of these lobules we find from fifteen to twenty transparent small vesicles, called *ova;* these are formed by a very delicate membrane filled with an albuminous fluid.

The *ova* differ in the same ovarium from the size of a mustard seed to that of a pea, and the largest are commonly situated nearest the surface.

In the prime of life the ovaria are large and uniform at their surface ; but in females advanced in life they become small, unequal, and irregularly formed ; and in those who have borne many children a similar irregularity is apparent.

The ovaria are intended for the nourishment of the ova, which contain the embryo or rudiments of the fœtus.

Fig. 91.

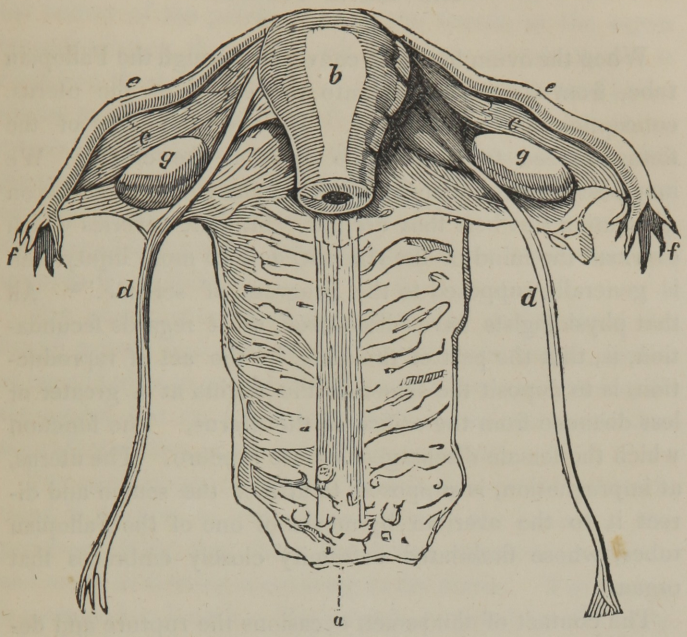


Fig. 91, exhibits the vagina, the uterus, and its appendages.

*a*, the vagina cut open, shewing on its inner surface the rugæ and caruncule.

*b*, the uterus.

*c*, *c*, the broad ligaments.

*d*, *d*, the round ligaments.

*e*, *e*, the Fallopian tubes.

*f*, *f*, the external opening of those tubes with their fimbriæ.

*g*, *g*, the ovaria.

## THE GRAVID UTERUS.

When the ovum has been conveyed through the Fallopian tube, from its receptacle, into the cavity of the uterus, conception has taken place. Do the rudiments of the fœtus proceed from the male or from the female? We may pass over the theories of the ancients and moderns on generation; at best they are but "brilliant reveries which overload the mind of the student, and do more injury than is generally supposed to the progress of science."* All that physiologists have discovered, as it regards fecundation, is, that the part of the male, in the act of reproduction, is to deposit the semen in the vagina at a greater or less distance from the orifice of the uterus. The function which the female discharges is more obscure. The uterus, at impregnation, is supposed to attract the semen and direct it to the ovarium by means of one of the Fallopian tubes, whose fimbriated extremity closely embraces that organ.

The contact of the semen occasions the rupture and delivery of one of the ova, and the fluid that passes from it, or the ovum itself passes into the uterus, where the new individual is to be developed.

The time which intervenes between the instant of fecundation and the delivery of the child, is called *uterogestation*, or *pregnancy;* it is generally nine calendar months or forty weeks.

When the ovum has arrived in the cavity of the uterus, it closely unites with the interior of this organ; here it receives the materials necessary for its growth, and acquires, by degrees, a considerable volume: the uterus yields to this augmentation, and consequently, changes its form and position.

* Magendie.

During the first three months of pregnancy, the developement of the uterus is inconsiderable, and takes place in the hollow of the pelvis ; but, in the fourth, as the organ becomes larger, this cavity will no longer contain it, and it rises into the hypogastrium. The uterus continues to increase in all directions until the eighth month, when it occupies a large space in the abdomen, compresses and displaces the surrounding organs, and crowds the intestines into the lumbar and iliac regions, and its fundus reaches the epigastric region. After this period the fundus recedes towards the umbilicus.

The cervix uteri becomes softer and wider about the fourth month, and afterwards diminishes in length, and is so expanded as to entirely disappear ; at the seventh month the uterus has an ovoid form, and its volume is twelve times larger than in its unimpregnated state.

The appendages of the uterus are also considerably altered in relation to the adjoining part; the laminæ of the peritonæal folds, that form the broad ligaments, separate and assist in forming a covering to the uterus. The vagina is increased in length. The ovaria, retained by their vessels, do not ascend with the fundus uteri; but, with the Fallopian tubes, are now situated on its lateral parts. The round ligaments are thicker, more vascular, and yield to its elevation.

The abdominal parietes suffer very considerable distention, so that the umbilical depression is entirely obliterated.

As the magnitude of the uterus increases, it assumes a cellular appearance of a deep red color, and its fibres become more evident. On the exterior, they take a direction I have already described ; but the internal fibres of the uterine tissue have some analogy with those of the heart and the tongue, in presenting an inextricable interlacement, where no regular arrangement can be distinguished. Its interior surface contains, immediately after impregna-

tion, an albuminous layer, which increases with the organ in the earlier periods of pregnancy, and subsequently becomes a vascular membrane. Dr. HUNTER, who first carefully described it, called it the *decidua*, from its being ultimately cast off from the uterus. It is supposed to favor the adherence of the ovum to the internal surface of the uterus.

The arteries are now observed to have very frequent communications, and in their course are remarkably enlarged and convoluted. But the veins are much larger than the arteries, their diameter, as we have stated, being such as to distinguish them as sinuses; these materially contribute to form the great bulk of the uterine parietes. The lymphatic vessels also become very voluminous. It is evident that the quantity of blood that traverses the uterus, is in relation to the changes it has undergone, and the new functions it is required to fulfil.

### DEVELOPEMENT OF THE OVUM IN THE UTERUS.

The ovum is quite unattached during the first period of its abode in the uterus; but in the course of the second month its dimensions have increased; it becomes covered with filaments which ramify in the manner of blood vessels, and are implanted into the decidua. About the third month they exist on one side of the ovum only, and are connected with that part of the deciduous membrane, forming the *placenta*. The ovum in the remainder of its surface, presents a flocculent layer, sometimes termed the *decidua reflexa*.

The ovum, at the termination of the second month, is of the size of an egg; and, when there has been an abortion, we trace very distinctly the membranes which inclose the embryo, viz.:—

MEMBRANES WHICH INCLOSE THE FŒTUS.

1st. The *amnion*, a membrane placed next to and directly enveloping the fœtus; it is very thin and pellucid, but firm in texture, and not easily torn; it covers the placenta, is reflected over the umbilical cord, and terminates at the umbilicus. It is united to the chorion by the intervention of a gelatinous substance.

2d. The *chorion*, a flocculent, spongy membrane, completely investing the ovum, and lining the uterus; this membrane is considerably thicker in the earlier than in the more advanced stages of utero-gestation; it then becomes transparent, and is united to the amnion in the manner just mentioned.

3d. The *decidua*, which may be properly considered as the membrane lining the uterine cavity; it is much thicker than either of the other membranes, but its texture is less dense, and it is very easily torn. It is placed between the proper membranes of the impregnated ovum and the uterine surface. The decidua is only formed by the uterus during impregnation: its formation commences with conception. At first it is a mere fluid secretion, which afterwards assumes a flocculent membranous appearance; it increases in extension and thickness in proportion to the evolution of the uterus. It is adherent to the inner surface of that organ, and is extended over the chorion, to which it is connected by a vascular attachment; it is always thrown off after parturition.

The decidua serves as a capillary system, intended to be the medium of communication between the blood vessels of the mother and the fœtus. The decidual vessels receive the arterial blood of the former, and these vessels are extended over a very considerable surface of tubular structure, which, in its distribution, is in apposition with the

infinite ramifications of the umbilico-placental vessels at innumerable points; and by these means the required changes in the blood of the fœtus are as effectually produced, as the changes called for in the pulmonic blood are produced by the peculiar arrangement of the pulmonary apparatus. When the arterial blood of the mother has produced the desired effect on that of the fœtus, it is returned by the decidual veins to the surface of the uterus, where it enters into the general venous system of the mother.

### LIQUOR AMNII.

The membranes contain a quantity of fluid termed liquor amnii, which is augmented in proportion to the advanced state of gestation. According to Professor VAUQUELIN, it is formed of water, albumen, soda, muriate of soda, and phosphate of lime. The uses of this fluid are to afford a soft medium for the residence of the fœtus, to which it allows a free motion, and protects its delicate structure from any external injury, to which, from the exertions of the mother, it might occasionally be liable. The waters of the amnios are also useful in parturition, by dilating the orifice of the uterus, and lubricating the external organs of generation.

### THE PLACENTA. (Fig. 95.)

The *placenta* is a rounded, oblong and soft mass, by means of which the ovum is attached most intimately to the uterus. This body is generally about eight inches in its greatest diameter, six in the smallest, and one thick; but it gradually becomes thinner towards the circumfer-

ence. Its thickest portion is where the umbilical cord is connected to it.

This organ forms a most important part of the uterine contents: its structure is entirely vascular, with the simple interpositon of cellular membrane; so that in its general substance, when excluded from the uterus, it is found to consist of the different branches and divarications of the umbilical arteries and veins, united together by a fine cellular tissue. The whole of this organ is strictly fœtal: it contains within its structure cells or sinuses of considerable extent, into which the uterine vessels at the point of contact open, and over which their contents are circulated and returned, as long as the organ is attached to the uterine surface. This cellular part of the placenta has acquired the name of the maternal portion.

The placenta possesses within its structure the means of two distinct circulations, each of which is continued through distinct channels: the one passes the blood from the uterine parietes into the placental cells, and returns it back to the uterus: this is properly the *maternal circulation*, and continues as long as the placenta is attached to the uterine surface. The other conveys the blood of the child from its body, and back again through the numerous ramifications of the umbilical vessels: this forms the *fœtal circulation*. These two circulations are so completely separate and distinct, that they do not interfere with each other: each is entirely unconnected with, and independent of the other; as far as positive communications of vessels are concerned, the fœtal vessels do not pass their contents into the placental cells, neither do the uterine vessels, communicating with the placental cells, pass their contents into the fœtal structure. There is no mixture of fœtal and maternal blood; and no circulating communication, direct or indirect, exists between the fœtus, from apposition at

the part to which the placenta is attached and through its medium.

A satisfactory notion, therefore, of the mode in which the principles of life are communicated to the embryo, of the materials from which it is evolved, or the manner in which the placenta is appropriated to its service, has hitherto never been obtained; yet there are some points which are obvious and acknowledged. The following are facts which almost admit of demonstration.

1st. When conception has taken place, a principle of internal action and growth is established in the uterus, by which its parietes are enlarged in every direction, and its cavity is increased in capacity. 2d. One of the immediate effects of this primary change, is a secretion furnished by the vessels of its internal surface, which at first becomes the connecting medium between the mother and the embryo, and afterwards the deciduous membrane. 3d. When the ovum is received into the uterine cavity, it attaches itself to a point to which the uterine vessels are more particularly directed, and at which also certain vessels from itself are implanted. 4th. These several parts increase in size until the rudiments of the placenta are formed, and there is a regular increase of its whole substance, proportionate to the demand of the embryo for nourishment, and to the uterine growth.

The placenta adheres to the uterus by a simple apposition of parts, and by that peculiar connection of vascular circulation which subsists between the uterine vessels at the point of contact, and the placental cells. The blood vessels of the gravid uterus run through its parietes in a serpentine direction: and, in the distribution of blood, the venous system possesses a larger diameter than the arterial. Though the placenta is in apposition in so simple a manner with the uterine surface, it is not in immediate contact with it, the deciduous membrane being interposed

becomes the bond of union between the two, except at those points at which the uterine vessels pass their blood into the placental cells.

The placenta is commonly attached to the fundus uteri, but there is no part of its internal surface at which this organ may not occasionally be found.

### OFFICE OF THE PLACENTA.

The office of the placenta is strictly fœtal; it is an organ originally formed for and appropriated to the service of the fœtus, and is the only communication between the mother and her infant: it is the sole medium through which the principles of nourishment and growth can be conveyed from the one to the other. The fœtal blood distributed by the branches of the umbilical arteries over the placental mass, receives, as before stated, from the decidual apparatus, certain additions in that circulation necessary to fœtal life; and is returned to the child by the umbilical vein, replete with that vitality which it has acquired in its passage through the placenta. The blood of the child under this state of improvement, if I may be allowed the expression, may be compared to that of the adult after its passage through the lungs. Thus if interruption to the return of the fœtal blood, from the placental circulation, occurs from any cause, the life of the fœtus is as certainly destroyed, as if the free passage of the air into the lungs was prevented during breathing life.

### FUNIS UMBILICALIS.

The *funis umbilicalis* is that vascular cord which, passing from the placenta to the umbilicus of the child, maintains

the communication between the fœtus and the placenta. Its length is almost two feet; it is composed of two arteries and one vein, the spaces between which are occupied by a gelatinous substance, contained in cells, which serves to prevent any obstruction to the current of the blood from accidental compression. The funis is covered by the amnion, or inner membrane of the ovum, and the vein is sufficiently large to reconduct to the fœtus the whole or an equal quantity of blood to that which is conveyed from the two arteries from it to the placenta. The arteries twist round the vein in a beautiful spiral manner.

The funis seems to be the production of the placenta, for, soon after the birth of the child, there is a spontaneous separation of the funis at the umbilicus.

### UMBILICAL VESICLE.

In the first months of gestation, a vesicle is found in the body of the umbilical cord, between the chorion and amnion, near the umbilicus: it receives small vessels from a prolongation of the mesenteric artery and the meseraic vein. It contains a yellowish fluid, the uses of which are not known: after the fourth month it becomes absorbed.

Sometimes this vesicle has been observed, at the full period of gestation, placed near the placenta; it is connected, as before stated, by vessels to the intestines, at the termination of the ilium or cœcum. At the lower end of the anal intestines there projects another vesicle or sac to which the name of *allantoid* has been given; it exists in all the mammalia, and in the human embryo it appears about the fourth week, but by the third month it disappears: the use of this vesicle also is unknown.

## THE BREASTS (MAMMÆ).

The breasts form part of the generative organs; before the age of puberty they are small and flat, but in the adult and well formed female, they present two hemispheres, or conical eminences, covered by a smooth semitransparent skin, softer and less colored than that of the other parts of the body.

Near the centre of each breast the color of the skin abruptly changes, and assumes a rosy tint in young females, and a reddish brown one in women who are pregnant or have suckled several children. This deep colored circle is called the *areola* of the nipple.

The *nipple (papilla)* rises in the middle of the areola; and is always of the same color: it is susceptible of a kind of erection.

The skin of the areola and nipple has a wrinkled appearance, and is remarkable for its tenuity: it presents a number of sebaceous glands, which furnish an unctuous fluid calculated to protect these parts against the action of the saliva of the child. We observe upon the surface of the nipple numerous very fine papillæ, in which are the orifices of the lactiferous ducts.

## ORGANIZATION OF THE BREASTS.

Beneath the skin there is a layer of *adipose tissue*, and it is chiefly to this that the breast owes its size and form.

The *mammary gland* is situated behind the adipose tissue, and before the great pectoral muscle; it has a convex and uneven surface, and an irregularly circumscribed base. Adipose tissue is also found in the intervals which intersect the lobules.

The tissue of the mammary gland consists of an assemblage of lobes of different sizes, closely connected with each other by a dense cellular tissue. Each of these lobes is composed of several lobules, which are obviously formed of granulations of a pink color, and the size of a poppy seed. If we further examine these small granules, we find that they consist of a number of minute vesicles and an organized tissue.

Fig. 92.

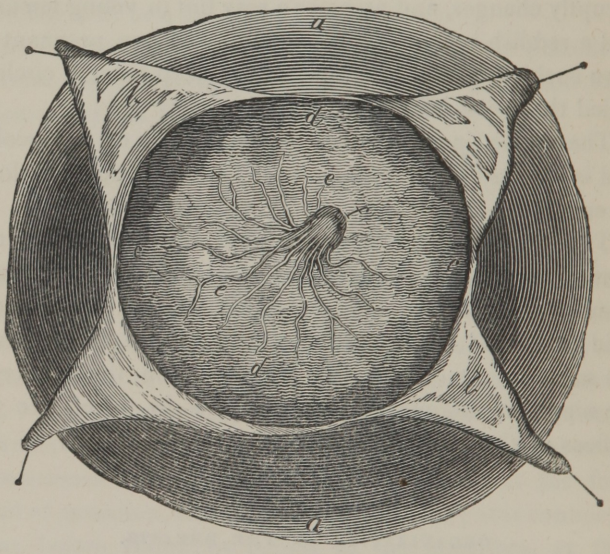


Fig. 92, represents one of the mammæ dissected from the pectoralis major muscle.

*a*, the skin.

*b*, the same dissected and reflected to show

*c*, *d*, the mammary glands;

*e*, the origins of the lactiferous ducts, and

*f*, the nipple.

The lactiferous ducts arise from the granulations of the vesicles just mentioned ; they commence in capillary tubes, termed the *tubuli lactiferi*, which uniting into branches, collect into trunks, and proceed towards the centre of the gland. Those of the different lobes do not communicate with the others, so that there are as many series of vessels as there are lobes in the gland ; but they all terminate in fifteen or sixteen sinuses in the centre of the nipple, and open separately on its surface.

When the nipple is contracted, the lactiferous canals are compressed, and the milk usually ceases to flow ; but by the sucking of the child a vacuum is produced, into which the milk very readily escapes from the orifices of these canals.

### OFFICE OF THE MAMMÆ.

The child continues for some time after birth, dependent upon the maternal system for its nourishment, and a food is provided which alone is suitable to the delicacy of the infantine organs. This food is the milk ; it is furnished by the mammæ until the termination of nursing, or continues until the end of the second year.

The color, odor, and taste of milk is known to every one ; it is one of the most azotised glandular liquids : but there is no fluid secretion more readily modified by the diet, by the time after delivery, by medicines, or by affections of the mind. On the average, the milk of a healthy person, according to Berzelius, is composed of milk, properly so called, and cream.

Milk contains:

| | |
|---|---|
| Water, . . . . . | 928·75 |
| Cheese with a trace of sugar, | 28·00 |
| Sugar of milk, . . . . . | 35·00 |
| Muriate of potass, . . . . | 1·70 |
| Phosphate of potass, . . . | 0·25 |
| Lactic acid, acetate of potass, and lactate of iron, . . . . | 6·00 |
| Phosphate of lime, . . . . | 0·30 |

Cream contains:

| | |
|---|---|
| Butter, . . . . . | 4·5 |
| Cheese, . . . . . | 3·5 |
| Whey, . . . . . | 92·0 |

In this last 4·4 of sugar of milk, and salt is found.

# ART. XV.

## THE FŒTUS.

### PECULIARITIES OF THE FŒTUS.

The osseous system of the fœtus is found in a very different state to that of the adult; the fœtal bones are soft and yielding. The situations of many of them are occupied by mere cartilage; indeed, all the bones, prior to their assuming a regular form, are of a cartilaginous consistence, and the parts termed epiphyses, that is, the extremities of long bones, up to the period of birth have entirely this character. Most of the cylindrical and some of the flat and irregular bones, are formed of several distinct parts, each of which has its centre of ossification, and these parts can be easily separated by boiling, or by maceration in water.

In the chemical composition of the bones of the fœtus, there is a smaller proportion of the phosphate of lime, than in the adult. The fœtal bones are also more uniform on their surface, as they are not marked by the action of muscles; their cavities are filled with gelatin instead of marrow.

The head is large in proportion to the body, and in the bones of the cranium we may observe very distinctly their

fibrous structure. In a fœtus about three months after conception, the commencement of ossification in each bone is like a fine irregular net-work, in the centre of which, the fibres are more closely connected than at its circumference. In viewing the flat bones of the fœtus, at a more advanced period, the osseous particles are observed to have a radiated appearance; as the fœtus, however, attains a larger growth, the osseous fibres increase in number, until a lamina is produced; and in the progress of ossification, other laminæ are added, and a succession of these laminæ form the more solid fabric of the bone.

Fig. 93.

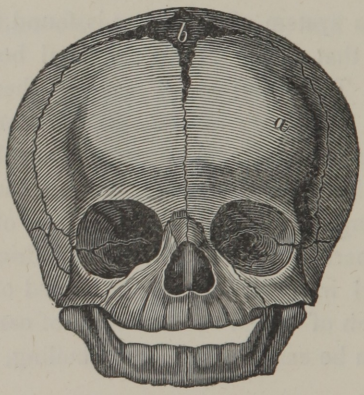


*a*, the os frontis, which at early life consists of two pieces divided by a vertical suture termed the *frontal*.

*b*, the anterior fontanel.

In the child the cranium bears a large proportion to the face, owing to the size of the brain, the absence of the sinuses in the forehead, and of the teeth in the gums; and the younger the embryo, the greater is the dispro-

portion between the head and the rest of the body. Between the frontal and parietal bones, is the space called *anterior bregma*, or *fontanel*, (Fig. 93, *b*,) formed by an irregular quadrangular membranous substance, which commonly disappears before the child attains the age of two years, the margins of the bones being then united. Between the middle of the lambdoidal and posterior extreme of the sagittal suture, a similar membrane of a triangular form is also frequently observed, termed the *posterior bregma*, or *fontanel*, (Fig. 94, *c*,) but in a well formed head it is scarcely to be traced.

Fig. 94.

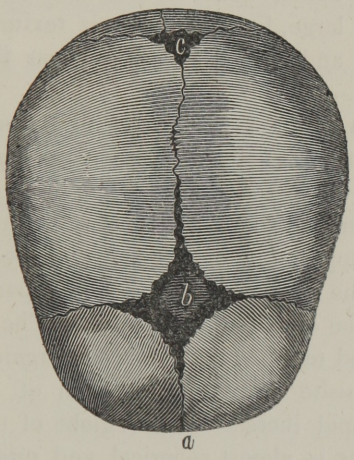


*a*, the frontal suture.

*b*, the anterior fontanel.

*c*, the posterior.

The rudiments of the teeth are situated in canals in the jaws, in sacs called the capsules of the teeth ; these consist of two membranes, containing a pulpy matter. The

inner membrane, about the sixth month, forms a thin layer of enamel; and at the period of birth the shells of ten teeth are found in each jaw.

The fluids in the fœtus, are proportionally large in quantity, and the solids generally softer than in the adult.

The skin is of a florid color, in consequence of a greater degree of vascularity, and is generally covered with an unctuous substance, supposed to be secreted by the vessels of the rete mucosum.

Adeps is chiefly found near the surface of the body; very little is formed in the interior parts until later in life, when, in healthy persons, it afterwards gradually accumulates as they advance to a certain age.

The brain, spinal marrow, and nervous system, are proportionally large, but soft in their texture. The vascular system, and glandular organs bear the same proportion.

The cornea of the fœtal eye is thick and prominent. The pupil is occupied by the *membrana pupillaris*, which is attached to the circumference of the inner margin of the iris, and continues there until the seventh month, when it gradually disappears in consequence of being absorbed. This membrane is very vascular, and separates the two chambers of the eye from each other. The only use that can be assigned to it is, that it is an organ of secretion, which is requisite for the production of the humours during the rapid increase of the globe of the eye. The crystalline lens is almost spherical, and numerous vessels pass from the ciliary process to be dispersed upon its capsules.

The meatus auditorius is wholly cartilaginous, and adheres to a ring of bone in which the membrana tympani is placed. The meatus externus, and membrana tympani, are lined by a mucous membrane which separates after birth.

In this stage of existence certain glandular bodies are developed, the uses of which are still unknown, but which continue large and vascular till towards puberty, and afterwards shrink and waste. The *thymus gland* is one of these: it is situated in the upper part of the thorax, between the laminæ of the anterior mediastinum, and over the pericardium; processes of this gland always ascend on each side, as far as the neck. It abounds with a milky fluid; but it has never yet been observed to have any excretory duct; nor has the use of the fluid or of the gland yet been ascertained. Part of the thymus gland remains during youth, but it usually disappears altogether in old age. The *supra-renal capsules* of the fœtus are large, when compared to their diminished capacity in after life.

As the *lungs* have not commenced their functions, their appearance is extremely different from what it is after they have been inflated by the inspiration of air: they are proportionally much smaller, their color is darker, their substance denser, and their specific gravity is so much greater that they sink in water.

The *heart*, in the fœtus, is proportionally larger than in the adult, and the Eustachian valve is more distinct; it is supposed to direct the current of blood, coming from the abdomen, through the passage immediately to be mentioned, existing in the septum of the auricles:—

This opening is denominated the *foramen ovale:* it is situated obliquely in the partition which separates the right and left auricles; it is nearly of the dimensions of the orifice of the cava, and it is bounded by a muscular margin, termed *annulus foraminis.* The greatest part of the blood which arrives from the inferior cava, is poured into the left auricle, during the diastole of the ventricles. A falciform valve, placed over the foramen, prevents its return, and appears likewise to preclude its course into the

left auricle, during the systole of the auricles. The blood passing through the foramen ovale keeps up the balance of the circulation between the sides of the heart, till the lungs are ready to receive it. The foramen is then generally soon obliterated.

The pulmonary artery divides into three branches; the right and the left of which proceed to the lungs, while the middle one, termed *ductus arteriosus*, (Fig. 95, *m*,) which is larger than both the other branches, passes in an oblique direction to the beginning of the descending aorta. The ductus arteriosus is therefore another temporary passage for carrying a part of the blood of the right ventricle into the aorta, without passing the circuitous route through the lungs; it thereby assists the foramen ovale, in keeping up the communication required between each side of the heart, till the child has breathed; and by these means also the aorta receives the force of both ventricles, to move the blood through the umbilical arteries; without this joint action it is probable the blood would not reach the placenta, and again return to the heart.

According to this dispositon of the circulating apparatus of the fœtus, it is evident that the motion of the blood must be different from that in the adult. The blood from the placenta passes through the umbilical vein as far as the liver; then one part of the blood proceeds into the liver and the other into the vena cava; from these two parts it arrives at the heart, and rushes into the right auricle, by the inferior cava, and into the left by the foramen ovale. The contraction of the auricles succeeds their dilation, and the blood is compressed into the ventricles; these in their turn contract and propel the blood into the aorta, except a very small portion, which goes to the lungs. By the united influence of the two ventricles, the stream of blood is forced through all the divisions of the aorta, and returns to the heart by the venæ

cavæ. Lastly, it is transmitted to the placenta by the umbilical arteries, and returns to the fœtus by the vein of the funis.

The motions of the heart in the fœtus are very rapid; they generally exceed one hundred and twenty in a minute: the circulation necessarily possesses a proportionate rapidity.

The abdomen is proportionally larger; and the stomach is rounder than in the adult, and commonly contains a small quantity of gelatinous matter. The omentum has a very small quantity of fat between its laminæ. From the remarkable mode of nutrition of the fœtus, it is clear that its alimentary canal and the chylopoietic system must be very peculiar. The valvulæ conniventes of the small intestine are scarcely perceptible. The appendix vermiformis is very large, and is inserted into the extremity of the colon, which at this time does not project to form a proper cæcum. The large intestine very nearly resembles the small, its longitudinal muscular bands being very indistinct. The colon contains a blackish green feces, of a viscid consistence, termed *meconium*, which appears to be a mixture of bile with secretions from the intestines.

The liver is so large as to occupy both hypochondriac regions, and to extend some distance below the margin of the thorax. The gall-bladder is filled with bile of an extremely dark color.

The umbilical vein passes from the umbilicus, in a duplicature of the peritonæum, behind the recti muscles, to the fossa umbilicalis of the liver, and thence to the left branch of the vena portæ, and transmits the blood from the placenta to the liver. From the umbilical vein, where it terminates in the liver, a branch, called *ductus venosus*, (Fig. 95, *h*,) proceeds in a somewhat waving direction, and joins the left vena hepatica, where that vein enters the cava. The ductus venosus transports part of the blood of that

vein directly to the heart, without the intervention of the hepatic circulation. The reason for this distribution of the umbilical vein is not understood.

The pancreas and other glandular organs are large in their relative dimensions. The kidneys are formed of lobes, in number nearly corresponding with the papillæ.

The pelvis of the fœtus is commonly so small, that the principal parts of the organs, afterwards situated in it, are at this time contained in the cavity of the abdomen. The urinary bladder is of a long form, and extends almost to the umbilicus.

The *urachus* is a solid fibrous substance ; it is attached to the fundus of the bladder, between the umbilical arteries, and, passing behind the linea alba to the umbilicus, disappears by degrees in the umbilical cord. In some instances it is hollow in a part or through the whole of its extent.

The common iliac arteries divide, on each side, into a small external, and a large internal branch : the umbilical arteries arise from the internal iliacs, are directed over the sides of the bladder, attach themselves to the urachus, pass out of the abdomen by the umbilicus, and are distributed to the placenta.

Soon after parturition the foramen ovale, ductus arteriosus et venosus, with the umbilical vein and arteries begin to contract and are in general completely closed, the vessels appearing like ligaments within a year after birth.

In the very young male fœtus, the testes are situated in the cavity of the abdomen, over the psoæ muscles, and a little below the kidneys, so that they constitute a part of the abdominal organs, and in a similar manner with them, are connected to the body by a process of peritonæum, which subsequently forms the tunica albuginea. Between the testis and scrotum a fibrous and vascular substance is extended, called by Hunter, *gubernaculum*, which he con-

sidered as a principal agent in directing the course of the testis in its descent. This remarkable passage of the testis from the abdomen, through the ring into the scrotum, is limited to no period, but it usually occurs about the last month of gestation. No satisfactory explanation has ever been offered as to the cause of this singular transit of an important organ to a distant situation. It has been adduced, by BLUMENBACH, as a striking illustration of a vita propria, without the peculiar influence of which, so remarkable and unique a movement, similar to no other function in the system, cannot even be imagined.

Fig 95.

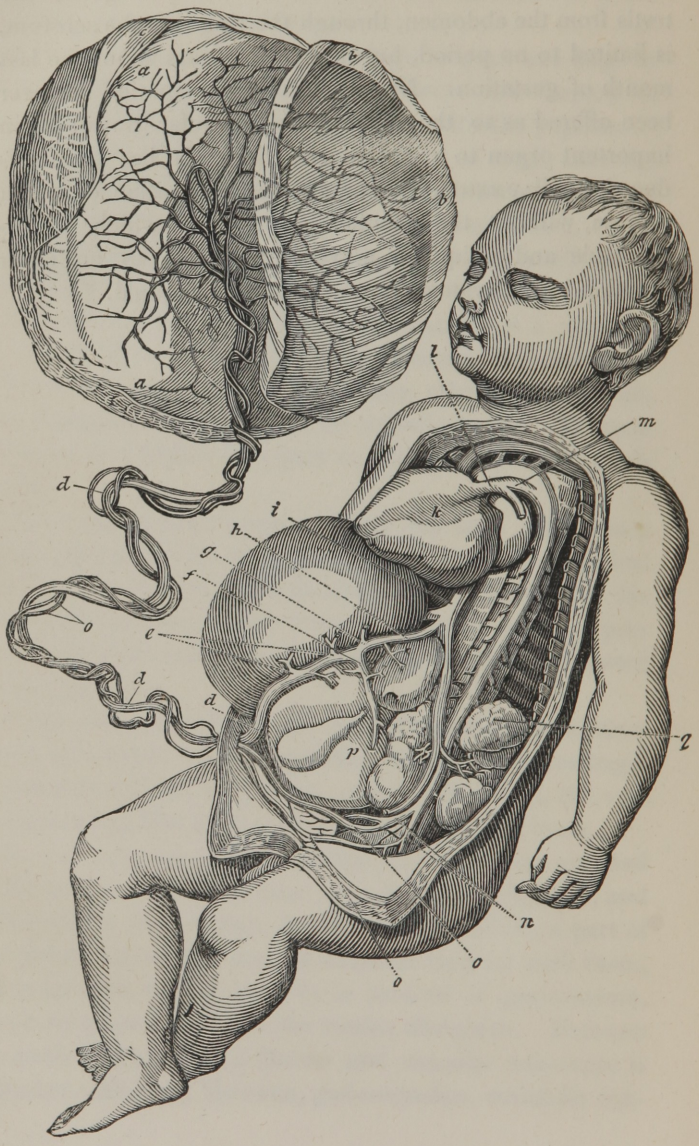

Fig. 95, is a representation of the manner in which the fœtal circulation is carried on.

*a*, the placenta.

*b*, portion of the amnion which covers the placenta.

*c*, the chorion.

*d*, the umbilical vein.

*e*, branches of the umbilical vein going to the liver.

*f*, the vena portæ.

*g*, hepatic branches of the preceding.

*h*, the ductus venosus.

*i*, the vena cava ascendens or inferior.

*k*, the heart turned to the right.

*l*, the vena cava superior or descendens.

*m*, the ductus arteriosus.

*n*, the iliac arteries, the internal giving off

*o*, *o*, the two umbilical arteries going to the placenta.

*p*, the liver turned to the right side in order to show the veins beneath it.

# ART. XVI.

## SEROUS SYSTEM, AND CELLULAR TISSUE.

### THE PLEURA AND THE PERITONÆUM.

Although, in the description of the contents of the thorax and the abdomen, we have frequently had occasion to advert to the serous membrane covering the several organs, still the serous membranes in general, and the pleura and peritonæum in particular, claim a more extended notice; indeed, the two latter can be studied with greater advantage, after an acquaintance with the anatomy of those organs which they invest.

The serous system occupies the exterior of the major part of those organs, which are lined by the mucous membranes: such as the stomach, the intestines, and the lungs. It is found round all those parts which are essential to life, as the brain, the heart, and the abdominal viscera. It also lines the sides of the cavities of the chest and abdomen, so that the organs are not in contact with the sides, or with the adjoining organs, except by the intermediation of the peritonæum.

The serous membranes present generally an envelope, investing the organs so as not to be contained within, and which, if it were possible to dissect these organs from their

spective surfaces, would be removed perfectly entire. This envelope, in this respect, has been compared to a double night cap placed on the head, a trifling simile, but which however, conveys a correct idea of the manner in which these membranes are situated. From this disposition, it is easily conceived, that the serous membranes are not perforated by the vessels and nerves of their respective organs, but that by doubling they provide a sheath for those organs.

The internal surface of this membrane, although in apposition with, completely separates the adjoining organs over which these membranes are spread, forming, as it were, an integument to the internal organs, which may be compared to the skin investing the exterior of the body.

The external surface of the serous membranes adheres to the adjacent organs: these membranes are rarely found unconnected on both surfaces. The tunica arachnoides, at the base of the brain, and a few others are exceptions; and where serous membrane is adherent it is perfectly distinct from the organ it invests: there is no connection between their reciprocal organizations; they are merely united by a loose cellular tissue.

All the serous membranes are composed of a single sheet, which, where it is thick, may be separated into cellular laminæ; it only differs from the cellular tissue in being more condensed. By inflating the tissue beneath, the cellular structure is rendered very apparent. No fibres are met with in its structure (a distinctive character of other organs), it is therefore similar to the cellular tissue.

The *pleura* is one of the class of serous membranes, one portion of which forms the investing tunic of the lungs, while the other is attached to the inner surface of the ribs, the upper surface of the diaphragm, the mediastinum and the intercostal muscles. The pleura, covering the lungs, is

termed *pleura pulmonalis*, the reflected portion, *pleura costalis*, *pleura diaphragmatica*, or *pleura pericardiaca*, in reference to the surface to which it adheres.

The surface of the heart is invested by a similar serous membrane, and it is reflected so as to form a sac, termed *pericardium*, which contains the heart.

The *peritonæum* is the most extensive of the serous membranes: it is thin and transparent; it has a very complicated course; not only does it invest the inner surface of the parietes of the abdomen, but it forms several remarkable folds in that cavity, and is prolonged under the form of an envelope over most of the abdominal organs.

It is usual to describe the peritonæum as presenting a sac without aperture, enveloping those organs whose external appearance is smooth and glossy, but, in reality, it is covered by fine villosities. It is everywhere in contact with itself. I have stated that it is an imperforated sac, but, in the female, there is a slight exception, for it is found to be perforated by the fimbriated extremity of the Fallopian tube, the mucous membrane of which seems to be continuous with the peritonæum.

In the umbilical region, the peritonæum lines the posterior part of the linea alba, closes the posterior orifice of the umbilicus, and is extended behind the wide muscles of the abdomen. On the right, it meets the ascending colon; on the left, the descending colon; and forms around this intestine two folds, which are named the *lumbar mesocolon*, and which serves to attach the intestine to the posterior part of the abdomen. The peritonæum passes before the kidneys, being separated from them by a greater or less quantity of fat and cellular tissue; then covering the uterus, the spermatic and renal vessels, the vena cava and the aorta, it advances on each side towards the vertebral column, before which it is reflected to form

the mesentery, or that immense fold which supports and envelopes the small intestine.

In the hypogastric region, the peritonæum descends from the umbilicus to the pubes, and, covering the urachus and the umbilical arteries, it is directed over the summit and the posterior part of the bladder. It presents, however, differences according to the sex: in the male, it invests the base of the vesiculæ seminales, and is reflected over the rectum, constituting the mesorectum. In the female, the peritonæum is extended from the bladder in front of the vagina; it then invests the anterior and posterior surface of the uterus, and is prolonged, laterally, so as to form the broad ligaments.

In the lateral parts of the hypogastric region, it is first reflected upon the parietes of the abdomen, over the iliac fossa, covering part of the iliac and psoæ muscles, embracing, to the left, the sigmoid flexure of the colon, by means of the *iliac mesocolon*, and, to the right, the cœcum and its appendix, by means of the *mesocœcum*. From thence it ascends forwards behind POUPART's ligament, and forms two depressions on each side, termed the inguinal fossæ, which are separated from each other by the fold of membrane which supports the remains of the umbilical artery. The external fossa is generally widest, and its peritonæum dips a little into the orifice of the inguinal canal: posteriorly, the peritonæum is continued from the iliac fossa to the lumbar mesocolon.

The epigastric portion of the peritonæum, to the left, invests a considerable part of the inferior surface of the diaphragm, and sinks into the most retired parts of the region of the hypochondrium, as far as the vertebral column, whence it is reflected over the surface of the spleen, and the posterior surface of its vessels. At the cardiac extremity of the stomach, it is continued into the anterior lamina of the great omentum. The laminæ of peritonæum,

which are comprised between the spleen and the stomach, are called the *gastro-splenic omenta.* In the centre, the peritonæum passes from the diaphragm, upon the anterior surface of the stomach, descends over the intestines to the most dependent part of the abdomen, and is reflected from below upwards, as far as the convex edge of the colon, thus contributing to form the *great omentum.* It then invests the inferior arch of the colon, forms the inferior lamina of the transverse mesocolon, and is continuous with the lamina of the mesentery.

On the right, the peritonæum is reflected over the liver, and forms foldings which constitute its ligaments.

Under the neck of the gall bladder we find a triangular aperture, the foramen of Winslow, through which is seen the laminæ of the peritonæum, constituting the hypogastric omentum, or the *capsule* of Glisson; which contains in its duplicature the hepatic and pyloric vessels, the coronary vessels of the stomach, and the cystic and hepatic ducts, together with the ductus communis choledochus. This lamina is then directed over the posterior surface of the stomach, covers the upper surface of the mesocolon, and the concave surface of the right lobe of the liver.

### OMENTA, OR EPIPLOA.

The omenta are composed of folds of the peritonæum connected together by cellular tissue, containing fat. Although I have referred to them in the preceding description of the peritonæum, still it is an advantage to the student to have before him a succinct and methodical arrangement of them.

The *hepato-gastric omentum*, or the *smaller omentum.* The peritonæum passes off double from the liver to the lesser curvature of the stomach. It is limited, on the right,

by the large hepatic vessels and biliary ducts, which are inclosed in the capsule of Glisson; and, on the left, by the œsophagus and the cardiac orifice of the stomach. Behind the capsule, just named, we find an aperture large enough to admit a finger, which was first described by Winslow, and has been called the foramen of Winslow: this foramen maintains a communication between the large sac of the omentum, and the common cavity of the abdomen. The two peritonæal laminæ of the smaller omentum separate from each other and invest the stomach, and, by their continuation, form the anterior lamina of—

The *great omentum*, a large fold of peritonæum: it is free and floating upon the front of the convolutions of the small intestine.* It is irregularly quadrilateral: it is attached, anteriorly, to the great curvature of the stomach; and, posteriorly, to the arch of the colon. It is formed of two laminæ, each composed of two lamellæ of peritonæum. The anterior lamina is a continuation of the serous covering, from the superior and inferior surfaces of the stomach; it extends, laterally, as far as the commencement of the duodenum and the inner surface of the spleen, to both of which it is connected. The posterior lamina has its origin in a similar manner from the serous membrane of the surfaces of the colon. At the opposite side of the colon, the laminæ unite to form the mesocolon. By the membrane thus continued, a large irregular sac is formed, of which the smaller omentum, stomach, and anterior portion of the great omentum, constitute the anterior, and the posterior portion of the great omentum, the colon, and mesocolon, the posterior part of the sac. In young subjects, the parietes of the sac is so complete, that it may be inflated from the foramen of Winslow; but in old and emaciated persons, the laminæ of which it is composed become reticular in consequence of absorption.

* See Vol. I. Fig. 197, *i*, *i*, *i*.

We find, between the laminæ of the great omentum, a considerable quantity of fat and blood vessels.

The *colic omentum* is situated behind the great omentum; it consists of a fold of the peritonæum which exists on the right side only, nearly filling the angle formed by the union of the right and transverse portions of the colon. Frequently it extends as far as the cœcum or to the spleen. Its two laminæ are separated by arteries and veins belonging to the colon.

The *gastro-splenic omentum* is formed in a similar manner by the peritonæum, which, from the fissure of the spleen, proceeds over the cardiac extremity of the stomach. It contains in its substance the splenic vessels and vasa breviora.

The omenta, as well as the internal surface of other serous membranes, are constantly moistened with a fluid nearly resembling the serum of the blood. This fluid is incessantly poured out by the exhalents, and constantly taken up by the absorbents. Its quantity varies; in the natural state it is merely a dew, but in dropsies of the abdomen it amounts to several gallons. Indeed the quantity of serous fluid varies astonishingly in the different acute and chronic diseases; and the exhalent surfaces pour out more or less of this fluid, according as they may be primarily or sympathetically affected.

The serous exhalations give a facility to the due actions of the respective organs, by permitting them to move on each other without injury. The great omentum is supposed to preserve the intestines from the ill effects which might result from violent exertions; it serves to retain their temperature, and to receive the superfluous depositions of fat.

## CELLULAR TISSUE, ETC.

The cellular tissue is distributed throughout the animal system; it is composed of a very fine web, formed of a great number of thin plates, which crossing in an endless variety of directions, have between them interstices or cells, which communicate together and serve for the reception of fat or serum. The cellular system, examined in respect to the organs, presents, 1st, an envelope or outward limit to the organs: 2d, it enters freely into the texture of each organ, and constitutes a part of its structure.

In many parts the cellular tissue is very elastic, and capable of extension, but in other parts it is more dense and resistant. In some instances the cellular tissue adheres to one of the surfaces of an organ, as, for instance, the skin; in others it entirely envelopes it, as in parts where it is universally connected with the adjacent parts. The skin universally exhibits, wherever you examine it, a subjacent cellular stratum. This subcutaneous cellular tissue varies considerably in its texture; its density in the scalp is remarkable, which on this account is not easily separated from its aponeurotic and muscular connection. In the face, it is very loose, and extremely abundant: it is equally lax in almost all parts of the thorax, and in the extremities; and therefore, accomodates itself easily to the motions of the muscles. It is only in the palm of the hand and the sole of the foot, that its texture, increasing in density, forms a stronger adhesion to the fascia and the skin. This arrangement is highly favorable to the uses of these two parts, which must accommodate themselves to bodies, particularly enabling the hand to seize, grasp and hold them.

The texture of the subcutaneous cellular tissue is dense about the capsular ligaments, for which reason the adhe-

sion of the skin is stronger; hence, the contractions we observe at those parts in the extremities of infants, very little fat being admitted into the condensed tissue.

There is a submucous cellular tissue, but its texture is more compressed than that of the tissue we have been considering above. Consequently there is a difficulty in dissecting, and separating it distinctly from its connections.

Under almost every part of the serous system, and likewise in the two preceding situations, we find a cellular layer generally very abundant and very loose.

Around each of the arteries there is a strong, dense and elastic layer, which is sometimes considered as one of its proper membranes: it arises almost imperceptibly from the adjacent cellular tissue, which becomes condensed, and is so intimately united to the vessel, that it may be wholly detached, and forms a sheath or canal corresponding to that of the artery it surrounds and supports. Veins are provided with an external covering of cellular tissue analogous to that of the arteries.

With the exception we have named, all the organs are completely surrounded by a covering of cellular tissue, more or less extensive, forming a peculiar medium for each; a medium in which they are entirely immerged, that insulates them from each other. After investing the several organs, the cellular tissue enters into their intimate structure, and forms one of their elements. In those organs which are composed of several parts, these parts are united together by it: thus in the stomach, intestines, etc. the different membranes of which they are composed are connected together by this web. It sends a multitude of processes into the structure of the lungs, between the serous membrane and their parenchyma, between this and the bronchi, and between the bronchi and the mucous surface.

In the muscles and other organs the cellular tissue first attends and surrounds, through their whole course, the

vascular and nervous ramifications which are found in their composition; and afterwards unites the different parts which compose each organ. "Every muscular fasciculus or fibre, or vessel, or nervous filament; every portion of fascia or ligament; every glandular particle, is inclosed in a sheath of peculiar cellular tissue, which, in respect to those parts, fulfils the same purpose as the larger envelope does in respect to the whole organ."*

Many fruitless researches have been made to determine the peculiar organization of the cellular tissue, yet but little is known, except that on a minute inspection we find an assemblage of innumerable whitish filaments of extreme tenuity, that are spread over the thin transparent plates that form the cellulæ. Examined in a favorable light, we may distinguish its exquisite delicacy, and when inflated, it may be compared to the air bubbles in a solution of soap.† There is no doubt, however, but some of the filaments which compose this tissue are exhalent and absorbent vessels; and this opinion is confirmed when we succeed in making a very fine injection; we then observe a multitude of vessels woven in every direction with each other, changing its white and transparent hue, and converting it into a vascular net-work.

Nerves are plentifully distributed in the cellular tissue, but their ramifications are as white as the tissue in which they abound, so that they cannot be satisfactorily distinguished from it.

The plates of the cellular tissue exhale a fluid which has the greatest analogy with that of the serous membranes, and which appears to have the same uses; namely, to render the friction of the plates easy on each other, and therefore to favor the reciprocal motions of the organs, and

* Bichat.

† A beautiful preparation may be made of cellular tissue, by inflating, drying, and suspending it in rectified oil of turpentine.

even the relative change of the different parts of which they are composed.

### FAT.

Besides the serum, a fluid is found in many parts of the cellular tissue of a very different nature, which is the *fat*. This substance is contained in distinct cells that do not appear to communicate with the adjoining ones. The size and form of these cells are not less variable than the quantity which they contain. In some individuals scarcely a few ounces exist, while in others there is one or two hundred pounds.

Human fat is of a yellow color; inodorous,—becoming solid at 89° F. It is composed of two proximate principles, recently discovered by Chevreul, *elaine* and *stearine*.

Some of the offices of the cellular tissue may be collected from the preceding observations: a description of this part of the animal fabric may very properly conclude a work on descriptive anatomy, since the cellular tissue constitutes a bond of union, which, diffusing itself everywhere, connects and preserves the whole natural connection of each part of the organized structure. The subcutaneous cellular tissue has many other uses; from it the skin acquires a freedom of motion over the organ it covers, and which is particularly observable in muscular actions. It is also to this tissue, that organs subjacent to the skin partly owe the facility with which they move, in those rapid or powerful contractions of which they are capable.

As fat is a very slow conductor of caloric, it retains animal heat, and consequently is useful in the animal economy by contributing to secure the subjacent parts against the vicissitudes of the atmosphere. In the orbit it forms a sort of elastic cushion upon which the eye moves with facility.

In the palms of the hands and the soles of the feet, and about the hips, it forms a layer, which renders pressure upon the skin and other soft parts less severe. But principally this substance is deposited in cellular tissue, as a store of nourishment intended to supply the exigencies of the animal system; as in instances where food cannot be obtained, and in often supporting the body under wasting disease, by being absorbed and carried again into the circulation.

Together, the cellular tissue and fat, are useful as an elastic vest, which guards the more sensitive parts of the interior mechanism. But in contemplating this as well as every other part of our organization, we cannot but admit the admirable mechanism exhibited in the human structure and economy, and the infinite resources displayed by that WISE and BENEVOLENT BEING, who planned the constitution and preservation of our bodies.

ERRATA.

Page 4, line 6 from top, omit EXTERNAL.
" 21, " 2 from bottom, read does for do.
" 29, " 6 from bottom, read Achillis for Achilles.
" 31, " 10 from top, read *parietes* for *parieties*.
" 264, " 4 from bottom, read *odoriferæ* for *odorifiræ*.
" 303, " 6 from bottom, read pulmonary artery, for the vena cava superior or descendens.

# GLOSSARY.

---

Abdomen, (*abdere*, to hide), the lower venter or belly, containing or hiding the intestines, etc.

Acantha, (ἄκανθα, a spine or thorn), sometimes used for the spine.

Acetabulum, (*acetum*, vinegar), the socket for the head of the thigh-bone, resembling an ancient vessel for holding vinegar.

Acini, (*acinus*, a grape seed), the internal structure of several glands.

Acoustic, (ακουω, to hear), a term applied to parts belonging to the ear, or to sound.

Acromion, (ακρος, the extremity, and ὠμος, the shoulder), a process of the scapula.

Adenology, (αδην, a gland, and λογος, a discourse), the doctrine of the glands.

Adeps, fat, an oily matter contained in the cellular tissue.

Adnata, (*adnascor*, to grow to), the external coat of the eye.

Albuginea Tunica. The inner proper coat of the testicle is thus named from its whiteness.

Albumen, an animal substance of the same nature as the white of an egg.

Alveoli, (*alveus*, a cavity), the sockets for the teeth.

Amnion, (αμνος, a lamb), the soft membrane immediately surrounding the fœtus.

Amphiarthrosis, (αμφω, both, and αρθρον, articulation), an articulation admitting of an obscure motion.

Anastomosis, (*ανα*, through, and *στομα*, a mouth), the communication of vessels with one another.

Anatomy, (*ανα*, through, and *τεμνω*, to cut), dissection, or that knowledge of animal bodies acquired by dissection.

Ancon, the elbow, (from *ἀγκῶν*), because the bones, being there united, are folded one into another. Hence also,

Anconeus, a muscle situated there, and,

Anconoid, a process of the cubit, from *αγκων*, the elbow, and *ειδος*, shape.

Angeiology, (*αγγειον*, a vessel, and *λογος*, a discourse), a description of the vessels.

Antagonist, (*αντι*, against, and *αγων*, a struggle), an epithet of a muscle acting contrary to another.

Antihelix, (*αντι*, against, and *ειλω*, to turn about), the external part of the ear opposite to the helix.

Antithenar, (*αντι*, against, and *θεναρ*, the palm of the hand), one of the muscles extending the thumb.

Antitragus, (*αντι*, against, and *τραγος*, a part of the ear), a prominence of the ear opposite to the tragus.

Aorta, (*αορτη*; from *αηρ*, air, and *τηρεω*, to keep), the great artery of the heart.

Aponeurosis, (*απο*, from, and *νευρον*, a nerve), a tendinous expansion, supposed by the ancients to be that of a nerve.

Apophysis, (*αποφυω*, to spring from), the process of a bone, and a part of the same bone. Epiphysis, a process attached to a bone, and not a part of the same bone.

Arachnoides, (*αραχνη*, a spider's web, and *ειδος*, likeness), a cobweb-like membrane, the second covering of the brain.

Arteria, (*αηρ*, air, and *τηρεω*, to keep), because the ancients thought that air was contained in the arteries.

Arthrodia, (*αρθρον*, a joint), that kind of articulation which is shallow.

Arytenoides, (*αρυταινα*, an ewer, and *ειδος*, shape), two cartilages of the larynx.

Aspera Arteria, (*asper*, rough, and *arteria*, an air-vessel), the trachea or windpipe.

Astragalus, (*αστραγαλος*, a die), a bone of the tarsus: the corresponding bones of some animal were used by the ancients as dice.

Atlas, the first of the cervical vertebræ, so named from supporting the head, as Atlas was supposed to support the world.

Axilla, the arm-pit.

Azygos, (*α*, without and *ζυγος*, a yoke), a term applied to any part, not having a corresponding part.

## B.

Basilica, (*βασιλευς*, a king), an epithet, by way of eminence, given to one of the veins of the arm, to an artery of the brain, and to a process of the occipital bone.

Biceps, (*bis*, twice, and *caput*, a head), composed of two heads.

Brachium (*βραχυς*, short), because, in general, from the shoulder to the hand is shorter than from the hip to the foot.

Bregma, (*βρεχω*, to moisten), the space between the bones of the infant head through which the superfluous humours of the brain were supposed to pass.

Bronchi, (*βρογχος*, the windpipe), the ramifications of the trachea.

Buccinator, (*buccina*, a trumpet), a muscle of the cheek, much used by trumpeters.

Bursalogy, (*βυρσα*, a purse, and *λογος*, a discourse), a description of the bursæ mucosæ.

## C.

Cæcum, blind: a term applied in anatomy to an impervious canal, or to a part which terminates abruptly in a pouch.

Calcaneum, (*calx*, the heel), the name of the os calcis.

Calvaria, or Calva, (*calvus*, bald), the upper part of the cranium, which turns first bald.

Cancelli, (lattice-work), the spongy substance in bones.

Capillary Vessels, (*capillus*, a hair), the small ramifications of the arteries and veins.

Capsule, a membranous production inclosing a part like a bag.

Caput Gallinaginis, (a wood-cock's head), a little eminence in the urethra at the termination of the ductus ejaculatorius.

Cardia, (καρδια, the heart), the superior opening of the stomach, so called from being situated near the heart.

Carnivora, (*caro*, flesh, and *voro*, to devour), animals that live on flesh.

Carotid, (καροω, to induce sleep), arteries of the head and neck, which if tied, the animal becomes comatose, or has the appearance of being asleep.

Carpus, (καρπος), the wrist.

Cartilage, gristle, a matter softer than bone, but harder than ligament.

Caruncula. This word is a dimunitive from *caro*, flesh.

Cellula, (dimunitive of *cella*, a cell), a little cavity or cell.

Cephalic Vein, (κεφαλη, the head), the ancients being accustomed to open this vein in disorders of the head.

Ceratoglossus, κερας, a horn, and γλωσσα, a tongue), a muscle running from one of the cornua of the os hyoides to the tongue.

Cerebellum, dim. of Cerebrum, the brain, (καρη, the head).

Cervix, the hinder part of the neck, the fore part being called Collum.

Choledochus Ductus (χολη, bile, and δεχομαι, to receive), the common bile-duct.

Chorda, (χορδη, a cord or assemblage of fibres), a term applied to a nerve of the tympanum, to the spermatic vessels, etc.

Chorion, (χωριον, domicilium), the outer membrane involving the fœtus; or χορος, a chorus, this membrane being supplied with many blood vessels in the quadruped.

Choroides, so called on account of its many blood vessels, resembling the chorion.

Chyle, (χυλος, the juice), the milk-like fluid in the lacteal vessels.

Crystalline, (κρυσταλλος), a term applied to the lens, from its resemblance to ice.

Clavicula, (dim. of *clavis*, a key), the clavicle or collar-bone; so called from its resemblance to an ancient key.

Clinoid, (κλινη, a bed, and ειδος, shape), processes of the sella turcica of the sphenoid bone, so called from their resemblance to a couch.

Clitoris, (κλειω, to conceal), a part of the female pudendum concealed by the labia majora.

Coccyx, (κοκκυξ, a cuckoo), the lower end of the spine, so called from its resemblance to the beak of that bird.

Cochlea, (κοχλος, a conch), a cavity of the ear resembling the shell of a snail.

Cœcum, the blind intestine.

Cœliaca, (κοιλια, the belly), the name of an artery in the abdomen.

Colon, (κωλον), the first portion of the large intestine.

Commissura, (*committo*, to join together), applied to parts which unite the hemispheres of the brain.

Concha, (κογχη, a shell) applied to the hollow of the ear from its resemblance to a shell.

Condyle, (κονδυλος, a joint, a knuckle, a knot), an eminence in several of the joints.

Conglobate, (*conglobatus*, gathered together in a circle), a gland subsisting by itself, like those of the absorbent system.

Conglomerate, (*conglomeratus*, heaped together), a gland composed of various glands.

Coraco; names compounded with this word belong to muscles which are attached to the coracoid process of the scapula.

Coracoid, (κορακ, a crow, and ειδος, resemblance), like the beak of a crow.

Cornu, (a horn), applied to a process resembling a horn.

Coronary, (*corona*, a crown), vessels so called from surrounding the parts like a crown.

Coronoid, (κορωνη, a crown, and ειδος, shape), a process shaped like a crown.

Corpus Callosum, (*corpus*, a body, and *callus*, hard), part of the medullary substance of the brain, supposed to be firmer than the rest.

Corticalis Substantia, *(cortex*, bark), the exterior or cortical substance of the brain.

Costæ, *(custodio*, to guard), the ribs, because they guard the heart, etc.

Cotyledons, (κοτυλη, a cavity), glands, in some animals, dispersed over the chorion.

Cotyloid, (κοτυλη, an old measure, and ειδος, shape), the cavity for receiving the head of the thigh-bone, resembling the rotuli.

Coxæ, the haunches.

Cranium, (κρανιον, the skull, quasi, καρανιον, from καρα), the head.

Cremaster, (κρεμαω, to suspend), a muscle so called, because it suspends the testicle.

Cribriform, *(cribrum*, a sieve), perforated like a sieve.

Cricoid, (κρικος, a ring, and ειδος, shape), the annular cartilage of the larynx.

Crista Galli, a portion of the ethmoid bone, so called from its resemblance to a cock's comb. *Crista*, a term applied to other parts which resemble a crest.

Crura, *(crus*, a leg), applied to some parts, from their resemblance or analogy to a leg.

Crypts, (κρυπτω, to hide), mucous follicles which are concealed.

Cubitus, *(a cubando)*, that part of the arm from the elbow to the wrist; because the ancients, during meals, used to recline upon it.

Cuboides, (κυβος, a cube, and ειδος, shape), a bone of the foot, resembling a cube.

Cucullaris, *(cucullus*, a cowl or hood), a broad muscle of the scapula, so called from its shape.

Cuneiform, *(cuneus*, a wedge), wedge-shaped.

Cuticula, (the dim. of *cutis*, the skin), the scarf-skin.

Cutis, the skin.

Cysticus Ductus (κυστις, a bladder, *ductus*, a duct), the duct leading from the gall-bladder.

## D.

DARTOS (δερω, to excoriate), muscular fibres which contract the scrotum.

DECIDUA, (*decido*, to fall off), a membrane thrown off from the uterus after parturition.

DELTOID, (Δελτα, the fourth letter of the Greek alphabet, and ειδος, shape), resembling the Greek letter Δ.

DERMIS, (δερμα), the more solid skin.

DETRUSOR URINÆ, (*detrudere*), to thrust or squeeze out of.

DIAPHRAGM, (διαφραασσω, a partition), the transverse muscle which separates the thorax from the abdomen.

DIASTOLE, (διαστελλω, to relax), the dilatation of the heart, auricles, and arteries, opposed to SYSTOLE, the contraction of the same parts.

DIARTHROSIS, (διαρθροω, to articulate), a movable connection of bones.

DIGASTRIC, (δις, twice, and γαστηρ, a belly), having two bellies.

DIPLOE, (διπλοος, double), the spongy substance between the two tables of the skull.

DUODENUM, (*duodenus*, consisting of twelve, viz. fingers' breadth), the first portion of the small intestine, so called from its general length.

DURA MATER, (*durus*, hard, and *mater*, a mother), the outermost membrane of the brain; the ancients finding it harder than, and supposing it to give origin to, the other membranes of the body.

## E.

ELAINE, (ελαιον, oil), the more fluid part of one of the proximate principles of fat.

EMBRYO, (εν, in, and βρυω, to germinate), the ovum in utero before the fourth month, after which it is called fœtus.

Emulgents, *(emulgeo*, to milk out), the arteries, and veins of the kidneys, so called because, according to the ancients, they strained, and, as it were, milked the serum through the kidneys.

Emunctores, *(emungo*, to wipe away), glands which, according to the ancients, received the excrementitious matter from the noble parts; as the parotids from the brain, the axillary glands from the heart, and inguinal glands from the liver.

Enarthrosis, (*εν*, in, and *αρθρον*, a joint), an articulation of bones, the same as *arthrosis*.

Encephalon, (*εν*, in, and *κεφαλη*, the head), the brain.

Enteric, (*εντερον*, an intestine), belonging to the intestines.

Epicranium, (*επι*, and *κρανιον*), the integuments and aponeurotic expansion which are extended over the cranium.

Epidermis, (*επι*, upon, and *δερμα*, the skin), the cuticle.

Epididymis, (*επι*, upon, and *διδυμος*, twins, the testicles), the small oblong body which lies above the testicle.

Epigastric, (*επι*, upon, and *γαστηρ*, the stomach), the superior part of the abdomen.

Epiglottis, (*επι*, upon, and *γλωττις*, *lingula)*, one of the five cartilages of the larynx, situated above the glottis.

Ephippium, (*επι*, upon, and *ιππος*, a horse), part of the os sphenoides, so called from its resemblance to a saddle.

Epiphysis, (*επι*, upon, and *φυω*, to grow), see Apophysis.

Epiploon, (*επι*, upon, and *πλεω*, to sail), the omentum, or that serous membrane of the abdomen which covers the intestines, and hangs from the bottom of the stomach.

Ethmoid, (*ηθμος*, a sieve), so called because it is perforated like a sieve.

## F.

Falciform, *(falx*, a scythe), shaped like a scythe.

Fascia, *(fascia*, a band), a membranous expansion of certain muscles like a sheath.

Fasciculus, a little bundle, diminutive of fascis, a bundle.

Fauces, (the plural of *faux*), the top of the throat.

Fibrin, a peculiar organic compound, which is the most abundant constituent of the soft solids of animals.

Fibula, (a clasp), the lesser bone of the leg, which is thus named from being placed opposite to the part where the knee-buckle or clasp was formerly used.

Fimbria, a fringe, a term applied to parts of a fringe-like appearance.

Fœtus, the child in the womb past the fourth month, and fully formed.

Follicle, (*follis*, a bag), very minute secreting cavities.

Frænum, (a bridle), the membranous ligament under the tongue, and the one tying the prepuce to the glans.

## G.

Galactophorous, (γαλα, milk, and φερω, to carry), conveying the milk.

Ganglion, (γαγγλιον), an enlargement in the course of a nerve.

Gastric, (γαστηρ, the stomach), appertaining to the stomach.

Gastrocnemius, (γαστηρ, the belly, and κνημη, the leg), the muscle forming the thick of the leg.

Gastro-Epiploic, (γαστηρ, the stomach, and επιπλοον, the caul), belonging to the stomach and omentum.

Gelatine, (*gelu*), jelly.

Genio, (γενειον, the chin); names compounded with this word belong to muscles attached to the chin.

Gestation, (*gestatio uterina*), the period of pregnancy.

Ginglymus (γιγγλυμος, a hinge), articulation admitting flexion and extension.

Glandula, (dim. of *glans*), a nut or acorn.

Glenoid, (γληνη, a cavity), a part having a shallow cavity.

Gliadine, (γλια, glue), one of the constituents of gluten.

Glomer, a convoluted bundle of glands.

Glosso, (γλωσσα, the tongue); names compounded with this word are applied to muscles attached to the tongue.

Glottis, (*γλωττις, lingula*), the superior opening of the larynx.

Gluteus, (*γλουτος*, the buttock), muscles forming part of the buttocks.

Gomphosis, (*γομφοω*, to drive in a nail), an articulation of bones, like a nail in a piece of wood.

## H.

Hæmorrhoidal, (*αιμα*, blood, and *ῥεω*, to flow), a term applied to the vessels of the rectum, because they often bleed.

Harmonia, (*ἁρμονια*, a close joining), a species of immovable articulation.

Helix, (*ειλω*, to turn about), the outer bar or margin of the external ear.

Hepatic, (*ηπαρ*, the liver), applied to parts belonging to the liver.

Hyaloid, (*υαλος*, glass), the capsule of the vitreous humour of the eye.

Hymen, (the god of marriage), the membrane situated at the entrance of the virgin vagina.

Hyo; names compounded with this word belong to muscles which are attached to the —

Hyoides, Os, (*υ*, and *ειδος*, shape), a bone of the tongue resembling the Greek upsilon, *υ*.

Hypochondrium, (*ὑπο*, under, and *χονδρος*, a cartilage), the upper region of the abdomen, under the cartilages of the ribs.

Hypogastric, (*ὑπο*, under, and *γαστηρ*, the belly), the lower region of the fore part of the abdomen.

Hypoglossus, (*ὑπο*, under, and *γλωσσα*, the tongue), parts which lie under the tongue.

Hypothenar, (*ὑπο*, under, and *θεναρ*, the palm of the hand), one of the muscles contracting the thumb.

## I.

Ileum, (*ειλεο*, to turn), a portion of the small intestine, so called from being found convoluted.

INCISORES, *(incidere*, to cut), the fore-teeth.

INCUS, (an anvil), a small bone of the internal ear, with which the malleus is articulated.

INDEX, *(indico*, to point out), the fore finger.

INFUNDIBULUM, (a funnel), a tube leading from the brain to the pituitary gland.

INNOMINATUM, parts which have no proper name.

INTERFEMINEUM; *vide* PERINÆUM.

INTEROSSEOUS, *(inter* and *os)*, a term applied to parts situated between bones.

IRIS, (the rainbow), the membrane round the pupil of the eye, deriving its name from its various colors.

ISCHIUM, (*ισχω*, to support), that part of the os innominatum upon which we sit.

## J.

JEJUNUM, (empty), a portion of the small intestine, so called from being generally found empty.

JUGALE, Os, the zygoma.

## L.

LACUNÆ, (little cavities), the excretory ducts of the urethra, vagina, etc.

LAMBDOIDAL, resembling the Greek lambda, *Λ*.

LAMELLA, dim. of—

LAMINA, a scale or plate. It is used for the foliated structure of bones or other organs.

LARYNX, (*λαρυγξ*), the superior part of the trachea.

LINEA ALBA, a white line formed by the meeting of the tendons of the abdominal muscles.

LUMBRICALES, *(lumbricus*, an earth-worm), four muscles of the hand and foot.

## M.

Masseter, (*μασσαομαι*, to chew), a muscle which assists in chewing.

Mastoid, (*μαστος*, a breast), shaped like a nipple or breast.

Maxilla, the jaw.

Meconium, (*μηκων*, a poppy), the excrements of the fœtus are thus called, because they have some resemblance to opium in color.

Mediana Vena, the middle vein of the arm, between the basilic and cephalic.

Mediastinum, (*medium*, the middle), a middle portion separating parts from each other.

Medulla Spinalis, the spinal marrow or cord.

Membrana Nictitans, (*nicto*, to wink), a membrane with which birds can occasionally cover the eye.

Meninges, (*μηνιγξ*, a membrane,) membranes which inclose the brain.

Mesentery, (*μεσος*, the middle, and *εντερον*, the intestine), the membrane in the middle of the intestines, by which they are attached to the spine.

Meseraic, (*μεσος*, the middle, and *αρ̣αια*, the small intestine,) the same as the last article.

Mesocolon, (*μεσος*, the middle, *κωλον*, the colon), that part of the mesentery in the middle of the colon.

Metacarpus, (*μετα*, after, and *καρ̣πος*, the wrist), that part of the hand between the carpus and fingers.

Metatarsus, (*μετα*, after, and *ταρ̣σος*, the tarsus), that part of the foot between the tarsus and toes.

Mitralis Valvula, (*mitra*, a mitre), valves at the left ventricle of the heart, like a mitre.

Molar Teeth, the double, or grinding teeth.

Mucus, (*μυξα*, the mucus of the nostrils), a transparent, saline, glutinous fluid.

Mylo, (*μυλη*, a grinder tooth); names compounded of this word belong to muscles that are attached near the grinders.

MYOIDES PLATYSMA, a muscular expansion on the neck. See PLATYSMA.

MYOLOGY, (*μυς* and *λογος*), the doctrine of the muscles.

## N.

NAVICULARE, (*navicula*, a small boat), a bone of the carpus, and also of the tarsus.

NEURILEMMA, (*νευρον*, a nerve, and *λεμμα*, a coat), the sheath of a nerve.

NEUROLOGY, (*νευρον*, a nerve), the doctrine of the nerves.

NYMPHÆ, two semicircular glandular membranes in the *pudendum mulibre*, so called because they direct the course of the urine.

## O.

ODONTOIDES, (*οδους*, a tooth, and *ειδος*, shape), tooth-like.

ŒSOPHAGUS, (*οιω*, to carry, *φαγω*, to eat), the canal leading from the pharynx to the stomach, carrying what is swallowed into the stomach.

OLECRANON, (*ωλενη*, the cubit, *κρανον*, the head), the elbow, or head of the ulna.

OMENTUM, (*omen*, a guess), the caul, so called because the ancient priests prophesied from an inspection of this viscus.

OMO, (*ωμος*, the shoulder); names compounded of this word belong to muscles which are attached to the scapula.

OMO-PLATA, (*ωμος*, the shoulder, and *πλατυς*, broad), the scapula or shoulder-blade.

OPHTHALMIC, (*οφθαλμος*, an eye), relating to the eye.

ORGAN, (*οργανον*), a part which has a determined office in the animal economy.

OSMAZOME, (*οσμη*, flavor, and *ζωμος*, broth), a peculiar principle obtained from muscular fibre, having the taste and smell of broth.

OSTEOLOGY, (*οστεον*, bone, and *λογος*, a discourse), the doctrine of the bones.

## P.

Palpi, (*palpo*, to grope or feel one's way), feelers.

Pampiniformis, (*pampinus*, a vine-tendril, and *forma*, shape). The spermatic vessels form a plexus, which, from its similitude to the tendrils of a vine is called pampiniformis.

Pancreas, (παν, all, and κρεας, flesh), a gland of the abdomen.

Panniculus Carnosus, (*pannus*, a covering, and *caro*, flesh,) a fleshy covering.

Parenchyma, (παρεγχεω, to pour through), a substance connecting the vessels, etc. of the lungs, liver, etc.

Parietalia, (*paries*, a wall), bones of the cranium, serving as a wall to the brain.

Parotid, (παρα, near, and ωτος, the gen. of ους, the ear), a gland situated near the ear.

Patella, (dim. of *patina*, a pan), the knee-pan.

Patheticæ, (παθος, passion), the fourth pair of nerves, because by means of these, the eyes express certain passions.

Pelvis, (πελυξ, a basin), the basin of the kidneys, or the lower part of the abdomen, in which the bladder and rectum (and in women also the uterus) are contained.

Pericardium, (περι, around, and καρδια, the heart), the membrane surrounding the heart.

Perichondrium, (περι and χονδρος), synovial membrane covering cartilage.

Pericranium, (περι, around, and κρανιον, the cranium), the membrane covering the bones of the cranium.

Perinæum, (περιναιον, to flow round, because that part is generally moist), the space between the external parts of generation and the anus.

Periosteum, (περι, around, and οστεον, a bone), the membrane surrounding the bones.

Peristaltic, (περιστελλω, to contract), the motion of the intestines.

Peritonæum, (περιτενω, to extend round), the membrane lining the abdomen, and covering its organs.

PERONE, (περονη), the fibula or small bone of the leg.

PETROSUM, Os, (πετρα, a rock), part of the temporal bone.

PHALANX, (an army), the bones of the fingers and toes are called phalanges, from their regularity.

PHARYNX, (φαρυγξ), a membranous bag at the back end of the mouth, leading to the stomach.

PHRENIC, (φρενες, the diaphragm, φρην, the mind, because the diaphragm was supposed to be the seat of the mind), the name of a nerve, etc.

PHYSIOLOGY, (φυσις, nature), that science which has for its object a knowledge of the actions and functions of the living body.

PIA MATER, the innermost membrane around the brain.

PICROMEL, (πικρος, bitter, and μελι, honey), the characteristic principle of bile.

PISIFORM, (pea-like), a term applied to the fourth bone of the first row of the carpus.

PITUITARY, (producing phlegm), a term applied to the membrane of the nose, etc.

PLACENTA, (πλαξ, a cake), the after-birth.

PLANTARIS, *(planta*, the sole), parts situated in the sole.

PLATYSMA-MYOIDES, (πλατυς, broad, μυς, a muscle, and ειδος, shape), a muscle of the neck.

PLEURA, (πλευρα, the side), a serous membrane lining the cavity of the thorax.

PLEXUS, *(plecto*, to weave together), a kind of net-work of blood vessels or nerves.

PNEUMONIC, (πνευμων, the lung), appertaining to the lungs.

POPLITEUS, *(poples*, the ham), a muscle of the leg.

PREPUCE, the fore-skin of the penis, which the eastern nations generally cut off.

PROCESSUS, *(procedo*, to start out), an eminence of bone.

PROSTATE, (προ, before, and ιστημι, to stand), a gland situated before the *vesiculæ seminales.*

PSOAS, (ψοαι, the loins), a muscle so named from its situation.

PTERYGOID, (πτερυξ, a wing), a process resembling a wing.

Pterygo-Staphylini, (*πτερυξ*, a wing, and *σταφυλη*, a grape), muscles arising from the pterygoid process of the os sphenoides, and inserted into the uvula.

Pudenda, *(pudor*, shame), the parts of generation.

Pupilla, ( a little puppet), the round aperture in the iris of the eye.

Pylorus, (*πυλωρος*, the keeper of a gate), the lower orifice of the stomach, guarding the entrance of the bowels.

Pyramidalis, a muscle having the form of a pyramid.

Pyriform, *(pyrus)*, a muscle having the form of a pear.

## R.

Rachidian, (*ραχις*, the spine), appertaining to the spine.

Radius, (the spoke of a wheel), the small bone of the fore-arm.

Ranular, like a frog or toad.

Raphe, (*ραπτω*, to sew), a line having the appearance of a seam.

Rectum, the straight gut, the last of the intestines.

Region, a term applied to the respective divisions of the body.

Renal, appertaining to the kidney, from —

Renes, the kidneys, through which the urine flows.

Retina, *(rete*, a net), the net-like expansion of the optic nerve on the inner surface of the eye.

Rhomboides, a muscle so called from resembling a geometrical figure (*ρομβος*), the sides of which are equal, but not right angled.

Rotula, (dim. of *rota*, a wheel), the knee-pan.

## S.

Sacrum, (sacred), a bone so called because it was offered in sacrifice.

Sagittalis, *(sagitta*, an arrow), a suture in the cranium.

Saliva, the fluid secreted in the mouth.

Salvatella, *(salvo*, to preserve), a vein of the foot, the opening of which was said to preserve health and cure melancholy.

Sanguis, the blood.

Saphena, (*σαφης*, manifest), the most obvious vein of the leg.

Sartorius, (*sartor*, a tailor), the muscle by means of which the tailor lays his legs across.

Scaleni, (σκαληνος, a geometrical figure with three unequal sides), muscles of the neck.

Scapha, (σκαφη, a little boat), the depression of the outer ear before the anti-helix.

Scaphoides, (resembling a boat), a bone of the carpus, and also of the tarsus.

Scapula, the shoulder-blade.

Sclerotic, (σκληρος, hard), the outermost or hardest membrane of the eye.

Scutiform, shaped like a shield.

Sebaceous, suety ; a term applied to glands which secrete an unctuous matter.

Sella Turcica, Sella Equina, Sella Sphenoides, are various names for a part of the sphenoid bone resembling a Turkish saddle.

Septum Cordis, (*sepes*, a hedge), the fleshy substance which separates the right from the left ventricle of the heart.

Sesamoid, (σησαμη, an Indian bean), small bones in the hands and feet resembling the *semen sesami*.

Sigmoid, resembling the Greek ς, sigma.

Skeleton, (σκελλω, to dry), the articulated dry bones of an animal.

Soleus, (*solea*, sole), a muscle of the leg having the form of that fish.

Spermatic, (σπερμα, seed), parts belonging to the testis or ovarium.

Sphenoid, (σφην, a wedge), shaped like a wedge.

Sphincter, (σφιγγω, to constrict), the name of several muscles, the office of which is to close the apertures around which they are placed.

Splanchnology, (σπλαγχνον, the viscera), the description of the internal organs.

Splenius, (σπλην, the spleen), a muscle so named from its resemblance to that organ.

Squamous, (*squama*, a scale), covering as the scales of fishes do each other.

Stapes, (a stirrup), one of the small bones of the internal ear.

Stearine, (*στεαρ*, fat), the more solid part of one of the proximate principles of fat.

Stomachus, (*στομα*, a mouth, and *χεω*, to pour), the stomach.

Styloid, *(stylus*, a pencil), a process like a pencil on the temporal and other bones.

Succenturiatus, *(succenturiare)*, to supply the place of another.

Suture, *(sutura*, a seam), an appearance which is most obvious in in that union of the bones of the skull constituting the dove tail suture.

Symphysis, (*συμφυω*, to grow together), the connection of bones which have no manifest motion.

Synarthrosis, (*συν*, with, and *αρθρον*, a joint), articulation without manifest motion.

Synchondrosis, (*συν*, with, and *χονδρος*, a cartilage), articulation by means of intervening cartilage.

Syndesmology, (*συνδεσμος*, a ligament), the doctrine of ligaments.

Syndesmosis, the connection of bones by ligaments.

Syneurosis, (*συν*, with, and *νευρον*, a nerve), the connection of bones by tendon, formerly mistaken for nerve.

Synthesis, (*συντιθημι*, to put together), the anatomical connection of the bones of the skeleton.

Syssarcosis, (*συν*, with, and *σαρξ*, flesh), the connection of bones by muscle.

Systole, (*συστελλω*, to contract); *vide* Diastole.

## T.

Talus, (a die), a bone of the tarsus.

Tarsus, the space between the bones of the leg and the metatarsus.

Temporal; bones, etc. have been so named on account of occupying the region of the head on which the hair generally first begins to turn gray, thus indicating the age.

Tendon, (*τεινω*, to extend), a fibrous cord at the extremity of a muscle.

Tentacula, *(tento*, to seize), organs by which certain animals attach themselves to surrounding objects.

TERES, (round), the name of a muscle.

TESTIS, (a witness, *quia est quasi testis virilitatis)*, the testicle.

THALAMUS, (*θαλαμος*, a bed), applied to a part of the brain from which the optic nerve takes its origin.

THECA, (a sheath); the spinal canal is often called theca vertebralis.

THENAR, (the palm of the hand), a muscle extending the thumb.

THORAX, (*θορᾳξ*, the chest), or that part of the body which contains the heart and lungs.

THYMUS, (*θυμος*, a bulbous root), a temporary gland in the thorax.

THYREO; names compounded with this word belong to muscles which are attached to the —

THYROID, (*θυρεος*, a shield), a cartilage of the larynx compared to a shield.

TIBIA, (a pipe or flute), the great bone of the leg.

TONSILS, the round glands placed between the arches of the palate.

TRACHEA, (*τραχυς*, rough), the windpipe.

TRAGUS, (a goat), a small eminence of the external ear, upon which hair often grows like the beard of a goat.

TRAPEZOID, like a trapezium.

TROCHANTER, (*τροχαω*, to run or to roll), a process of the thigh bone, the muscles inserted into which greatly contribute to the action of running.

TROCHLEA, (*τροχαλια*, a pulley), a kind of cartilaginous pulley.

TROCHLEARIS, an articulation where one part moves round another like a pulley.

TUBÆ FALLOPIANÆ, two canals at the fundus uteri of a trumpet form, described by FALLOPIUS.

TYMPANUM, the drum of the ear.

## U.

ULNA, (*ωλενη*, the cubit), one of the bones of the fore-arm.

UMBILICUS, (*ομφαλος*), the navel.

URACHUS, (*ουρον*, urine, and *χεω*, to pour), a ligament of the bladder, occupying the place of the urinary passage of the fœtal quadruped, which goes into the allantois.

URETER, (*ουρον*, urine), the canal that transmits the urine from the kidney into the bladder.

URETHRA, (*ουρηθρα*), the canal through which urine passes from the bladder.

UTERUS, (*υστερα*, *matrix*), the womb.

UVEA, (*uva*, a grape), the posterior lamina of the iris.

UVULA, the pendulous body which hangs down from the middle of the soft palate.

## V.

VALVES, (*valvæ*, folding doors), little membranes preventing the return of the fluids in the blood vessels and absorbents.

VENTRICLE, (*venter*, the stomach), applied in anatomy to the cavities of the brain and heart.

VERTEBRÆ, (*verto*, to turn), the bones of the spine.

VESICLE, (*vesica*, bladder), a small bladder-like cavity.

VOMER, (a ploughshare), a bone of the nose.

## X.

XIPHOID, (*ξιφος*, a sword,) like a sword, a term applied to the cartilage of the sternum.

## Z.

ZYGOMA, (*ζυγος*, a yoke), the arch formed by the zygomatic processes of the temporal and cheek bones.

SURGEON GEN'L'S OFFICE LIBRARY

NATIONAL LIBRARY OF MEDICINE
NLM 03206763 0