NATIONAL LIBRARY OF MEDICINE
Washington

PROPERTY OF

JAMES B. ELMENDORF.

THE

LONDON DISSECTOR.

Printed by T. & G. Palmer.

FINLEY AND HOPKINS' EDITION.

THE LONDON DISSECTOR,

OR

SYSTEM OF DISSECTION

PRACTISED IN

The Hospitals and Lecture Rooms of the Metropolis;

EXPLAINED BY THE CLEAREST RULES,

FOR THE USE OF STUDENTS:

COMPRISING

A Description of the Muscles, Vessels, Nerves, and Viscera of the Human Body, as they appear on Dissection;

With Directions for their Demonstration.

FIRST AMERICAN,

FROM THE LAST LONDON EDITION.

To which is added,

AN APPENDIX,

CONTAINING

THE RUYSCHIAN ART AND METHOD OF MAKING PREPARATIONS TO EXHIBIT THE STRUCTURE OF THE HUMAN BODY,

Illustrated with a Representation of the Quicksilver Tray and its Appendages.

PHILADELPHIA,

PUBLISHED BY A. FINLEY AND W. H. HOPKINS;

SOLD ALSO BY

HOPKINS & EARLE AND M. CAREY.

1809.

PREFACE.

THE writer of the following pages, having frequently witnessed the difficulties which attend the pursuit of Practical Anatomy, conceived that some assistance might be derived from a Compendium, describing the various parts of the human body as they come into view under the knife of the dissector. With this intention the present performance is offered to the public.

The muscles are demonstrated in the order of their situation, this being the only method that can be pursued in actual dissection.

The relative situation of the several parts is minutely attended to, and, at the same time, repetitions are avoided, as far as the nature of the arrangement adopted would allow. Should this work in any degree facilitate the progress of the anatomical student, the object of the author will be attained.

CONTENTS.

	Page
GENERAL Rules for Dissection	1
CHAP. I. DISSECTION OF THE ABDOMEN.	
SECT. I. MUSCLES OF THE ABDOMEN	5
Obliquus Descendens Externus	ib.
Obliquus Ascendens Internus	11
Cremaster	13
Transversalis Abdominis	14
Fascia Transversalis	15
Rectus Abdominis	16
Pyramidalis	17
SECT. II. DISSECTION OF THE CAVITY OF THE ABDOMEN	17
General Situation of the Viscera	18
Peritoneum, and its Reflections	ib.
Liver	20
Gall-bladder	22
Stomach	23
Intestines	ib.
Spleen	26
Pancreas	ib.
Kidneys	27

		Page
Chap. I.	Renal Capsules	28
	Diaphragm	ib.
	Psoas Parvus	30
	Psoas Magnus	31
	Iliacus Internus	ib.
	Fascia Iliaca	32
	Quadratus Lumborum	ib.
	Of the vessels and nerves situated behind the peritoneum	33
	Aorta and its ramifications	ib.
	Vena Cava Abdominalis	39
	Vena Portarum	40
	Par Vagum	ib.
	Anterior Intercostal Nerve	ib.
	Posterior Intercostal	41
	Thoracic duct	ib.
Chap. II.	Dissection of the Perineum and Organs of Generation in the Male.	
	General Remarks	42
	Erector Penis	43
	Accelerator Urinæ	44
	Transversus Perinei	45
	Sphincter Ani	46
	Levator Ani	ib.
	Coccygeus	47
	Connection of the Bladder and Rectum	48
	Prostate Gland	ib.
	Urethra	ib.
	Corpus Spongiosum, and Bulb of the Urethra	49
	Glandulæ Anteprostatæ	ib.
	Vesiculæ Seminales	ib.
	Vasa Deferentia	ib.
	Corpora Cavernosa Penis	50
	Bladder	ib.
	Rectum, &c.	51

Page

CHAP. II. Vessels and Nerves contained within the Pelvis 52
Internal Iliac Artery and Branches ib.
Internal Iliac Vein and its Branches 54
Nerves of the Pelvis ib.
Course of the Anterior Crural Nerve ib.
Course of the Obturator Nerve 55
Course of the Great Sciatic Nerve ib.
Of the Scrotum ib.

CHAP. III. DISSECTION OF THE ORGANS OF GENERATION IN THE FEMALE.

Mons Veneris 56
Labia Externa 57
Clitoris ib.
Perineum ib.
Nymphæ 58
Vestibulum ib.
Hymen, and Carunculæ Myrtiformes ib.
Vagina and Os Tincæ 59
Erector Clitoridis 60
Transversus Perinei ib.
Sphincter Vaginæ 61
Sphincter Ani ib.
Levator Ani ib.
Coccygeus ib.
Plexus Retiformis ib.
Vagina ib.
Uterus 62
Fallopian tubes ib.
Ovaria 63
Bladder ib.
Urethra ib.
Ureter ib.

CHAP. IV. DISSECTION OF THE THIGH.

SECT. I. OF THE ANTERIOR PART OF THE THIGH.

Page

CHAP. IV. § 1. Of the Fascia of the Thigh, Cutaneous sels and Nerves, &c. 64
§ 2. Muscles situated on the Fore-part and Inside of the Thigh 67
Tensor Vaginæ Femoris ib.
Sartorius ib.
Rectus Femoris 68
Vastus Externus 69
Vastus Internus 70
Cruralis 71
Gracilis 72
Pectinalis ib.
Triceps Adductor Femoris 73
§ 3. Of the Vessels and Nerves situated on the Fore-part and Inside of the Thigh 75
Femoral Artery and its Branches ib.
Obturator Artery 78
Femoral Vein ib.
Obturator Vein ib.
Anterior Crural Nerve ib.
Obturator Nerve 79
SECT. II. OF THE POSTERIOR PART OF THE THIGH.
§ 1. Of the Fascia, &c. 79
§ 2. Of the Muscles on the Back-part of the Thigh 80
Gluteus Maximus ib.
Gluteus Medius 81
Gluteus Minimus 82
Pyriformis 83
Gemini 84
Obturator Internus ib.
Quadratus Femoris 85
Obturator Externus 86
Biceps Flexor Cruris ib.
Semitendinosus 87

Page

CHAP. IV. Semimembranosus 88

§ 3. Of the Vessels and Nerves on the Posterior Part of the Thigh 89

Arteria Glutea ib.

Arteria Sciatica ib.

Veins 90

Nervus Sciaticus ib.

SECT. III. DISSECTION OF THE HAM AND FASCIA ON THE BACK-PART OF THE LEG 91

Of the Fascia ib.

Sciatic Nerve ib.

Popliteal Vein ib.

Popliteal Artery 92

CHAP. V. DISSECTION OF THE LEG AND FOOT.

SECT. I. OF THE FORE-PART OF THE LEG AND FOOT 94

Of the Fascia, Cutaneous Vessels, and Nerves, &c. ib.

Of the Muscles situated on the Fore-part and Outside of the leg 95

Tibialis Anticus ib.

Extensor Longus Digitorum Pedis 96

Peroneus Tertius 97

Extensor Proprius Pollicis Pedis ib.

Peroneus Longus 98

Peroneus Brevis 99

Of the Muscles on the Upper Part of the Foot 100

Extensor Brevis Digitorum Pedis ib.

Of the Vessels and Nerves situated on the Fore-part of the Leg and Foot 101

Anterior Tibial Artery ib.

Anterior Tibial Vein 103

Anterior Tibial Nerve ib.

SECT. II. DISSECTION OF THE POSTERIOR PART OF THE LEG.

Muscles situated on the Posterior Part of the Leg 104

		Page
CHAP. V.	Gastrocnemius Externus, seu Gemellus	104
	Soleus	105
	Plantaris	106
	Popliteus	107
	Flexor Longus Digitorum Pedis	108
	Flexor Longus Pollicis Pedis	109
	Tibialis Posticus	ib.
	Vessels and Nerves of the Back-part of the Leg	111
	Posterior Tibial Artery, and Ramifications	ib.
	Posterior Tibial Vein	113
	Posterior Tibial Nerve	ib.
SECT. III.	DISSECTION OF THE SOLE OF THE FOOT	114
	Aponeurosis Plantaris	ib.
	First order of Muscles in the Sole of the Foot	ib.
	Abductor Pollicis Pedis	115
	Abductor Minimi Digiti Pedis	ib.
	Flexor Brevis Digitorum Pedis	ib.
	Second Order of Muscles in the Sole of the Foot	116
	Tendon of the Flexor Digitorum Longus	ib.
	Tendon of the Flexor Longus Pollicis	ib.
	Flexor Digitorum Accessorius	117
	Lumbricales Pedis	ib.
	Third Order of Muscles in the Sole of the Foot	ib.
	Flexor Brevis Pollicis Pedis	ib.
	Adductor Pollicis Pedis	118
	Flexor Brevis Minimi Digiti	ib.
	Transversalis Pedis	ib.
	Tendon of the Tibialis Posticus	119
	Fourth Order of Muscles in the Sole of the Foot	ib.

		Page
Chap. V.	Tendon of the Peroneus Longus	119
	Interossei Interni	120
	Interossei Externi	ib.
Chap. VI.	Dissection of the Head.	
Sect. I.	Of the External Parts of the Head	121
	Integuments	ib.
	Occipito-frontalis	ib.
	Muscles of the Ear	122
	1. Common :—	
	Attollens Aurem	ib.
	Anterior Auris	ib.
	Retrahentes Auris	ib.
	2. Proper :—	
	Helicis Major	123
	Helicis Minor	ib.
	Tragicus	ib.
	Antitragicus	ib.
	Transversus Auris	124
	3. Internal :—	
	Laxator Tympani	ib.
	Tensor Tympani	125
	Stapedius	ib.
Sect. II.	Of the Contents of the Cranium, or of the Brain and its Membranes	126
	Dura Mater	ib.
	Pia Mater	129
	Cerebrum	130
	Cerebellum	138
	Medulla Oblongata, and Nerves of the Brain	144
	Medulla Spinalis, and Nervi Spinales	146
	Course of the Great Sympathetic Nerve	149
	Course of the Par Vagum	ib.

		Page
Chap. VI.	Vessels of the Brain	150
Chap. VII.	Dissection of the Anterior Part of the Neck.	
Sect. I.	Of the Muscles	152
	Playtsma Myoides	153
	Sterno-cleido-mastoideus	ib.
	Os Hyoides, Larynx, Trachea	154
	Sterno-hyoideus	155
	Omo-hyoideus	ib.
	Sterno-thyroideus	156
	Thyro-hyoideus	ib.
	Crico-thyroideus	157
	Digastricus	ib.
	Stylo-hyoideus	158
	Stylo-glossus	ib.
	Stylo-pharyngeus	159
	Mylo-hyoideus	ib.
	Genio-hyoideus	160
	Genio-hyo-glossus	161
	Hyo-glossus	ib.
	Lingualis	ib.
Sect. II.	Of the Vessels and Nerves seen in the Dissection of the Neck	162
	Carotid Artery and its Ramifications	ib.
	Internal Jugular Vein and its Branches	164
	Eighth Pair of Nerves, or Par Vagum	165
	Intercostal, or Great Sympathetic Nerve	166
	Ninth Pair, or Lingual Nerve	167
	Lingual Branch of the Fifth Pair	168
	Spinal Accessory Nerve	ib.
	Cervical Nerves	ib.
	Phrenic Nerve	ib.
	Recurrent Nerve	169
Chap. VIII.	Dissection of the Thorax.	
Sect. I.	Of the Muscles which lie upon the outside of the Thorax	169

		Page
Chap. VIII.	Pectoralis Major	170
	Pectoralis Minor	171
	Subclavius	ib.
Sect. II.	Of the Parts contained within the Cavity of the Thorax	172
	General Appearances	ib.
	Pleura	173
	Lungs	174
	Pericardium	ib.
	Heart	ib.
Sect. III.	Of the Great Vessels of the Heart	176
	Vena Cava Superior	ib.
	Vena Cava Inferior	177
	Aorta and Ramifications	ib.
	Thymus	178
	Course of the Subclavian Artery and its Branches	ib.
	Course of the Subclavian Vein	180
	Course of the Brachial Plexus of Nerves	181
	Scalenus Anticus	ib.
	Scalenus Medius	ib.
	Scalenus Posticus	182
Sect. IV.	Dissection of the Axilla, or Arm-Pit	ib.
	Axillary Vein	183
	Axillary Artery	184
	Axillary Plexus of Nerves	185
Sect. V.	Dissection of the Posterior Mediastinum, and of the Nerves and Vessels which have their Course through the Thorax	187
	Course of the Phrenic Nerve through the Thorax	ib.
	Trachea	ib.

		Page
Chap. VIII.	Course of the Intercostal, or Great Sympathetic Nerve	188
	Vena Azygos	189
	Aorta, and its Ramifications in the Thorax	ib.
	Thoracic Duct	190
	OEsophagus	191
	Course of the Par Vagum in the Thorax	194
	Dorsal Nerves	ib.
Sect. VI.	Dissection of the Heart, when removed from the body	193
Chap. IX.	Dissection of the Face.	
Sect. I.	Of the Muscles	197
	Orbicularis Palpebrarum	ib.
	Corrugator Supercilii	198
	Compressor Naris	ib.
	Levator Labii Superioris Alæque Nasi	199
	Zygomaticus Minor	200
	Zygomaticus Major	ib.
	Levator Anguli Oris	201
	Depressor Anguli Oris	ib.
	Depressor Labii Inferioris	ib.
	Buccinator	202
	Orbicularis Oris	203
	Depressor Labii Superioris Alæque Nasi	ib.
	Levator Labii Inferioris	204
	Masseter	ib.
	Temporalis	205
	Pterygoideus Externus	206
	Pterygoideus Internus	207
	Parotid Gland	ib.
Sect. II.	Of the Vessels and Nerves	208
	External Maxillary Artery	ib.

		Page
Chap. IX.	External Carotid Artery and Ramifications	209
	Frontal Artery	210
	Veins	211
	Portio Dura of the Seventh Pair, or Facial Nerve	ib.
	Superior Cervical Nerve	ib.
	Superior Maxillary Nerve	212
	Inferior Maxillary Nerve	ib.
	Frontal Nerve	213
Chap. X.	Dissection of the Throat	214
Sect. I.	Muscles situated about the Entry of the Fauces	215
	Constrictor Isthmi Faucium	ib.
	Palato-pharyngeus	ib.
	Circumflexus, seu Tensor Palati	216
	Levator Palati	217
	Azygos Uvulæ	ib.
Sect. II.	Muscles situated on the Posterior Part of the Pharynx	218
	Constrictor Pharyngis Inferior	ib.
	Constrictor Pharyngis Medius	ib.
	Constrictor Pharyngis Superior	219
Sect. III.	Muscles of the Larynx	220
	Crico-arytænoideus Posticus	ib.
	Crico-artyænoideus Lateralis	221
	Thyreo-arytænoideus	ib.
	Arytænoideus Obliquus	ib.
	Arytænoideus Transversus	222
	Thyreo-epiglottideus	ib.
	Arytæno-epiglottideus	ib.
Chap. XI.	Dissection of the Orbit of the Eye.	
Sect. I.	Muscles situated within the Orbit	223

		Page
Chap. XI.	Levator Palpebræ Superioris	224
	Levator Oculi	ib.
	Depressor Oculi	ib.
	Adductor Oculi	225
	Abductor Oculi	ib.
	Obliquus Superior, seu Trochlearis	ib.
	Obliquus Inferior	226
	Lacrymal Gland, Puncta and Sac,—— Caruncula Lacrymalis	226, 227
Sect. II.	Of the Vessels and Nerves met with in the Dissection of the Orbit	227
	Ophthalmic Artery	ib.
	Infra-orbitary Artery	228
	Veins	ib.
	Optic Nerve	ib.
	Nerve of the Third Pair, and its Ramifications	ib.
	Nerve of the Fourth Pair	229
	First Branch of the Fifth Pair	ib.
	Infra-orbitary Nerve	230
	Sixth Pair	ib.
Chap. XI	Dissection of the Muscles situated on the Posterior Part of the Trunk and Neck.	
	Trapezius, seu Cucullaris	231
	Latissimus Dorsi	232
	Rhomboideus	233
	Levator Scapulæ	234
	Serratus Magnus	ib.
	Serratus Superior Posticus	235
	Splenius	236
	Serratus Posticus Inferior	237
	Sacro-lumbalis	238
	Longissimus Dorsi	238

		Page
Chap. XII.	Spinalis Dorsi	239
	Cervicalis Descendens	240
	Transversalis Colli	ib.
	Trachelo mastoideus	241
	Complexus	ib.
	Semi-spinalis Colli	242
	Semi-spinalis Dorsi	243
	Rectus Capitis Posticus Major	ib.
	Rectus Capitis Posticus Minor	244
	Obliquus Capitis Superior	ib.
	Obliquus Capitis Inferior	245
	Multifidus Spinæ	ib.
	Interspinales Colli, Dorsi, et Lumborum	246
	Intertransversales Colli, Dorsi, et Lumborum	ib.
Chap. XIII.	Dissection of the Muscles situated between the Ribs, and on the Inner Surface of the Sternum.	
	Intercostales Externi, and Levatores Costarum	247
	Intercostales Interni	248
	Triangularis Sterni	249
Chap. XIV.	Dissection of the Muscles situated on the Anterior Part of the Neck, close to the Vertebræ.	
	Longus Colli	250
	Rectus Capitis Internus Major	ib.
	Rectus Capitis Internus Minor	251
	Rectus Capitis Lateralis	ib.
Chap. XV.	Dissection of the Superior Extremity.	
Sect. I.	Of the Dissection of the Shoulder and Arm	252

		Page
Chap. XV.	Cutaneous Veins and Nerves	252, 253, 254
	Muscles situated on the Shoulder and Arm	254
	Deltoides	ib.
	Supra-spinatus	256
	Infra-spinatus	257
	Teres Minor	ib.
	Teres Major	258
	Subscapularis	259
	Biceps Flexor Cubiti	ib.
	Coraco-brachialis	261
	Brachialis Internus	262
	Triceps Extensor Cubiti	263
Sect. II.	Dissection of the Fascia and Muscles situated on the Cubit or Fore-arm	264
	Fascia	265
	Situation of the Vessels at the Bend of the Arm	ib.
	Muscles situated on the Fore-part of the Cubit, and arising from the Inner Condyle of the Os Humeri	265
	1. Superficial:—	
	Pronator Radii Teres	ib.
	Flexor Carpi Radialis	267
	Palmaris Longus	268
	Flexor Carpi Ulnaris	269
	Flexor Sublimis Perforatus	ib.
	2. Deep-seated:—	
	Flexor Profundus Perforans	271
	Flexor Longus Pollicis	ib.
	Pronator Quadratus	272
	Muscles situated on the outer and back-part of the Fore-Arm, and arising from the outer Condyle of the Os Humeri	273

		Page
Chap. XV.	1. Superficial :—	
	Supinator Radii Longus	273
	Extensor Carpi Radialis Longior	274
	Extensor Carpi Radialis Brevior	275
	Extensor Digitorum Communis	276
	Extensor Carpi Ulnaris	277
	Anconeus	ib.
	2. Deep-seated :—	
	Supinator Radii Brevis	278
	Extensor Ossis Metacarpi Pollicis Manus	279
	Extensor Primi Internodii Pollicis Manus	ib.
	Extensor Secundi Internodii Pollicis Manus	280
	Indicator	ib.
Sect. III.	Dissection of the Palm of the Hand	282
	Fascia Palmaris	283
	Palmaris Brevis	ib.
	Flexor Tendons	ib.
	Lumbricales	ib.
	Short Muscles of the Thumb and Fore-finger	ib.
	Abductor Pollicis Manus	ib.
	Flexor Ossis Metacarpi Pollicis	285
	Flexor Brevis Pollicis Manus	ib.
	Adductor Pollicis Manus	286
	Abductor Indicis	ib.
	Short Muscles of the Little Finger	287
	Abductor Minimi Digiti Manus	ib.
	Flexor Parvus Minimi Digiti Manus	288
	Abductor Metacarpi Minimi Digiti Manus	ib.
	Interossei Interni	289

Page

CHAP. XV. Interossei Externi 289

SECT. IV. OF THE VESSELS AND NERVES OF THE SUPERIOR EXTREMITY 290

Brachial Artery and its Ramifications ib.

Venæ Comites 291

Nerves of the Axillary Plexus 297

APPENDIX.

THE RUYSCHIAN ART AND METHOD OF MAKING PREPARATIONS TO EXHIBIT THE STRUCTURE OF THE HUMAN BODY.

The Injecting Tray and its Appendages 302

Explanation of the Plate 303

Preparations of the Viscera 304

General Observations ib.

Preparations of Morbid Parts ib.

Preparations made by Macerating 305

General Observations ib.

Bones ib.

A Fœtus ib.

Cuticle 306

Injecting Instruments ib.

Injections ib.

Coarse Injections ib.

Fine Injections 307

Minute Injections ib.

General Observations 308

Preparation made with Coarse Injection ib.

General Observations 309

Blood-vessel Subject ib.

A Head, for Arteries and Veins 310

	Page
An Arm, for Arteries and Veins	311
A Lower Extremity, for Arteries and Veins	312
The Gravid Uterus, for Arteries and Veins	ib.
A Placenta, for Arteries and Veins	313
The Heart, in Situ; with the Head and Adjacent Vessels	ib.
A Fœtus, to exhibit the Peculiarities of its Circulation	314
Penis	315
Testicle	316
The System of the Vena Portæ	ib.
Heart	317
Stomach. Intestines. Bladder	ib.
General Observations	ib.
Preparations with Minute Injection	318
Bones	ib.
A Fœtus	ib.
Uterus	319
An Adult Head	320
Preparations with Quicksilver	ib.
General Observations	321
A Superior Extremity	ib.
An Inferior Extremity	ib.
A Parotid Gland	ib.
Liver	322
Lungs	ib.
Hand	ib.
Lacteals	323
Corroded Preparations	ib.
General Observations	ib.
Heart and Lungs	324
Heart	ib.
Liver	ib.
Kidney	325

COMPENDIUM

OF

PRACTICAL ANATOMY.

GENERAL RULES FOR DISSECTION.

DEXTERITY in the manual operation of dissection can only be acquired by practice; the observance, however, of certain general rules will facilitate the labour of the student.

1. The position of the hand in dissecting should be the same as in writing or drawing; and the knife, held, like the pen or pencil, by the thumb and the two first fingers, should be moved by means of them only; while the hand rests firmly on the two other fingers bent inwards as in writing, and on the wrist. The instrument can be guided with much more steadiness and precision in this way, than when it is moved by means of the wrist, elbow, or shoulder, in the manner which young dissectors often fall into.

2. No more of the integuments should at any time be removed, than is necessary for the present dissection, as exposure to the air renders the parts dry and indistinct.

3. In dissecting muscular parts, the muscles should be extended; the cellular membrane which connects them to the integuments should be placed on the stretch, and entirely removed with the skin; the knife should be kept close to the muscles, and carried steadily in the direction of their fibres, separating a fasciculus at each stroke:—thus the exposed surface will appear clean, and the course of the fibres distinct.

4. When small vessels are to be demonstrated, another method is to be followed; the skin only must be removed, and the cellular membrane cautiously and slowly dissected from the vessels.

5. During dissection, every little operation should be practised, which can give the dexterity of hand so essential to the surgeon: such are, the use of the catheter and probang, the introduction of a probe through the nose into the Eustachian tube, or nasal duct, and the cutting down to the various arteries which may become the object of surgical operations: as the external iliac, femoral, anterior and posterior tibial, brachial, radial, and ulnar, &c.

The grand object of the surgical student is to acquire a knowledge of the relative situation of parts. This should be kept in view in all his anatomical labours. Hence, when he is dissecting the muscles, he should carefully expose the chief blood-vessels and nerves, and attentively consider their position with regard to each other, and to the surrounding parts. This species of knowledge will afford him the most essential assistance in his future operations on the living subject; in which, indeed, it is so necessary,

that we are perfectly astonished to see persons rash enough to use the knife without possessing this information; but we view the hesitation, confusion, and blunders by which such operators betray their ignorance to the bystander, as the natural result, and the well-merited but too light punishment, of such criminal temerity. The smaller arteries and veins, and the minute nervous ramifications, will be more advantageously studied in subjects devoted to those purposes, and prepared by means of injection, immersion in spirits of wine, &c.

The reader will observe, that, in general, the muscles of one side of the body only are described, because all the muscles of the body have correspondent ones on the opposite side, with a few exceptions, which are pointed out. To the description of each muscle are subjoined the synonyma of the best myological writers, and the names * proposed by professor Dumas, of Montpellier, in his new nomenclature.

* These names will be distinguished by being placed last among the synonyma of each muscle; their terminations, as adapted to the French language, are retained. The following is the list of the changes made in the names of the bones, on which the new nomenclature of Dumas is founded.

Sus-Acromion is the name given to the edge of the clavicle placed above the acromion of the scapula.

Sous-Acromion to the edge of the same bone situated underneath.

Scapulum to the scapula.

Trochiter to the greater protuberance near the head of the os humeri.

The Bursæ Mucosæ met with in the dissection of the muscles are not regularly enumerated; but it is to be understood, that wherever tendons are described as rubbing on bones, muscles, or other tendons, a sac is formed by the surrounding cellular membrane, secreting synovia, to lubricate the parts in motion.

Trochanter	to the great trochanter of the os femoris.
Trochin	to the lesser protuberance near the head of the os humeri.
Trochantin	to the lesser trochanter of the os femoris.
Epitrochlée	to the internal condyle of the os humeri.
Epicondyle	to the external condyle of the os humeri.
Phalange	to the first phalanx of the fingers or toes.
Phalangine	to the second phalanx.
Phalangette	to the third phalanx.

Sus, above—*sous*, below—*pré*, before.

These synonyma, however, are rather to be considered as a matter of curiosity, than as names which have any chance of coming into general use. Being intended to convey a sort of anatomical description of the muscles, a great proportion of them are by far too long for names. The disadvantages of that nomenclature are pointed out by Dr. Barclay, of Edinburgh, in a late work on the subject, a work which discovers abilities of the first order. From the specimens which this anatomist has already given, it is to be expected, that he will soon present the world with a complete list of names, much better adapted to general use than any that have hitherto been employed. New terms, however, ought first to be given in the Latin language. They would thus be more easily adopted by anatomists of all countries, and might afterwards, if necessary, be translated into the various modern languages, in such a manner as would best suit the genius of each.

CHAP I.

DISSECTION OF THE ABDOMEN.

IN dissecting a subject, it is usual to begin with the MUSCLES of the ABDOMEN.

SECT I.

MUSCLES OF THE ABDOMEN, AND THE PARTS CONNECTED WITH THEM IN DISSECTION.

THESE muscles are ten in number, five on each side.

An incision should be made through the integuments, from the sternum to the os pubis; and this should be crossed by another passing immediately below the umbilicus: dissect off the flaps; this will lay bare,

1. THE OBLIQUUS DESCENDENS EXTERNUS.—*Origin:* By eight triangular fleshy slips, from the lower edges and external surfaces of the eight inferior ribs, at a little distance from their cartilages; the five superior slips meet on the ribs an equal number of the digitations of the serratus major anticus, and the three inferior are connected with the attachments which the latissimus dorsi has to the ribs. Often there are only seven portions. To gain a complete

view of this muscle, the neighbouring portions of the pectoralis major, serratus anticus, and latissimus dorsi should be dissected with it.

The muscular fibres proceed obliquely downwards and forwards, and about the middle of the side of the belly terminate abruptly in a thin broad tendon, which is continued in the same direction over all the fore-part of the belly. Here it covers the anterior surface of the rectus abdominis; it is very thin at the upper part, where the rectus lies on the cartilages of the ribs, and is often removed by the beginner, unless he is very cautious.

Insertion: Tendinous and fleshy, into two anterior thirds of the outer edge of the spine of the os ilium; tendinous, into the whole length of Poupart's ligament, into the os pubis, into the ensiform cartilage, and into the whole length of the linea alba.

Situation: It is quite superficial, and covers the whole of the anterior part of the abdomen. The muscular part is closely covered by a thin expansion of cellular substance, which might be mistaken for tendinous fibres, but it is only the cellular membrane condensed, and ought to be removed along with the integuments.

Use: To draw down the ribs in expiration, to bend the trunk forwards when both muscles act, or to bend it obliquely to one side when one of them acts singly; to raise the pelvis obliquely when the ribs are fixed; to compress the abdominal viscera, to thrust the diaphragm upwards, to assist in the expulsion of the urine and fæces, and of the fœtus.

Synonyma: Obliquus externus abdominis;—obli-

quus descendens;—obliquus major;—ilio pubi-costo-abdominal.

In the course of the dissection of this single muscle, the following points must be attended to.

The Linea Alba, a white line running along the middle of the abdomen, from the cartilago ensiformis to the os pubis; formed by the tendinous fibres of the two obliqui and the transversalis muscles, interlaced with those of the same muscles on the opposite side; it is half an inch broad at the navel; and decreases gradually both above and below that part; but particularly in the latter situation, where it is reduced at last to a mere line.

Linea Semilunaris, a semicircular white line, running from the os pubis obliquely upwards over the side of the abdomen, at the distance of about four inches from the linea alba; formed by the tendons of the two oblique and transverse muscles uniting at the edge of the rectus, before they separate to form the sheath for that muscle.

Lineæ Transversæ, three or four white lines, crossing from the linea semilunaris to the linea alba; formed by the tendinous intersections of the recti shining through the strong sheath which covers them: —These are not evident in all subjects in this stage of the dissection.

Umbilicus, or Navel. This which, before the integuments were removed, was a depression, appears now a prominence; it consists of condensed cellular membrane:—In the fœtus, it was a foramen which gave passage to the two umbilical arteries, the umbilical vein, and the urachus.

Annulus Abdominalis, or Ring, an oblique slit or opening just above the angle of the pubis; formed by the tendon of the external oblique, divided into two portions called the *pillars* or *columns* of the ring, one of which (the *superior* or *internal)* is attached to the symphysis, and the other (the *inferior* or *external)* to the angle of the pubis; and allowing a passage to the spermatic cord in the male, and the ligamentum teres of the uterus in the female. This slit is very improperly named a ring, since its figure is triangular; the pubis is the base, the two columns are the two sides of the triangle. The apex has indeed a rounded figure in consequence of some transverse fibres, which connect the two columns where they first separate; and it points obliquely upwards and outwards. It belongs to the external oblique alone, there being no such opening, either in the internal oblique, or the transversalis; it is much smaller in the female than in the male.

Ligamentum Inguinale, seu *Poupartii*, seu *Fallopii*, a strong ligament, stretching from the anterior superior spinous process of the os ilium, to be fixed to the spine of the os pubis. This in truth is merely the lower edge of the tendon of the obliquus externus abdominis, extended from the anterior superior spinous process of the ilium to the angle of the pubis, although, in compliance with received notions, I have described it as a separate ligament. It covers the femoral vessels and nerves, and certain muscles, and has lately been often described under the name of the Crural Arch. It is also the same part as the posterior column of the abdominal ring. The stu-

dent will be much confused by this multitude of names, unless he remembers that they denote only one object; that the *crural arch*, the *inferior* or *outer column of the abdominal ring*, *Poupart's* or *the inguinal ligament*, are so many names applied to the inferior border of the tendon of the external oblique muscle of the abdomen.

I would advise the student, before he proceeds to the dissection of the other abdominal muscles, to dissect the parts in the groin, and to examine the situation of the great inguinal vessels.

In taking off the skin from the groin, you will not find a strong regular fascia, as on the outer part of the thigh, but a confused and irregular aponeurosis coming off from the abdomen, and going down upon the thigh, strengthened by the intermixture of condensed cellular substance, and very loose above the great vessels.

Immediately under the skin, and above this aponeurosis, you perceive a congeries of lymphatic glands, and sometimes the lymphatic vessels themselves can be distinguished by their semi-transparent coats, and knotted appearance. Also, immediately under the skin, you will find the VENA SAPHENA running from below upwards, at first lying on the fascia, and then gradually sinking through it to join the femoral vein, about an inch below Poupart's ligament.

On removing this irregular fascia, we come down upon the great vessels, which lie deeply imbedded in cellular substance, and are closely invested and supported by a firm sheath, or fascia, consisting chiefly of cellular substance, very much condensed. This

should all be cautiously removed with the scissars, along with some lymphatic glands which lie amongst the fat. Observe the order in which the parts are situated under the crural arch:—that the great external iliac vein lies next to the pubis;—that the external iliac artery is on the outside of this, in close contact with it;—that the anterior crural nerve is half an inch exterior to the artery, and lies on the iliacus internus;—and that the outer half of the space left under the crural arch is filled by the psoas magnus and iliacus internus muscles. Observe how the crural arch is stretched over the parts just enumerated;—how it forms a thin, but firm, sharp, and crescent-shaped edge towards the pubis (constituting the seat of stricture in the femoral hernia, and sometimes called *Gimbernat's ligament*);—how the artery is placed in relation to the angle of the pubis and spine of the ilium;—how it passes under the middle of the arch, and, before it has fairly emerged into the thigh, sends off two considerable branches.

(1.) A. Circumflexa Ilii is sent off from the outside, passes upwards and outwards, runs along the inside of Poupart's ligament, till it arrives at the anterior superior spinous process of the os ilium; thence it is continued along the inside of the spine of the ilium, lying close upon the bone between the transversalis abdominis and the upper edge of the iliacus internus, to both of which it gives twigs, and ends in inosculating with the ileo-lumbar artery. That distribution, however, cannot be seen in this stage of the dissection.

(2.) A. Epigastrica comes off from the inside of

the artery, crosses the external iliac vein, passes obliquely upwards and inwards, under Poupart's ligament, to which it is but loosely connected, and runs behind the upper extremity of the abdominal ring and spermatic cord, to reach the rectus abdominis. At first it is situated between the posterior surface of that muscle and the peritoneum, but higher up between the muscular fibres and the sheath. It terminates in ramifications, which supply the rectus, and which inosculate with the ramifications of the mammaria interna, sent down from the thorax on each side of the sternum.

The dissection of the other abdominal muscles may now be continued.

Dissect off the serrated origin of the external oblique from the ribs, and from the spine of the os ilium, and detach it from the obliquus internus, which lies below it, and which is connected to it by loose cellular substance, and by small vessels. Continue to separate the two muscles, till you find their tendons firmly attached, *i. e.* a little way beyond the linea semilunaris. Separate the tendon from the crural arch to within half an inch of the abdominal ring.

2. Obliquus Ascendens Internus.—*Arises* by short tendinous fibres, which soon become fleshy, from the whole length of the spine of the os ilium, and from the fascia lumborum*; also fleshy from the

* Some describe it as arising from the sacrum and three inferior lumbar vertebræ; but this is not accurate. It arises from a tendinous fascia common to it and to certain muscles of the back, as the serratus posticus inferior; this may with propriety be named *Fascia Lumborum*.

upper part of Poupart's ligament at the part next to the os ilium.

The fibres run in a radiated direction; those which originate from the back-part of the os ilium, run obliquely upwards; those from the fore-part of the ilium pass more transversely across the belly; and from Poupart's ligament the fibres descend. The fleshy belly is continued rather more forward than that of the external oblique, before it terminates in a flat tendon.

Inserted into the cartilages of the six or seven lower ribs,—fleshy into the three inferior, and, by a tendinous expansion, which is extremely thin, resembling cellular membrane, into the four superior, and also into the ensiform cartilage. The sheet of tendon in which the fleshy belly ends, is continued, single and undivided, into the linea semilunaris, where, adhering pretty firmly to the tendons of the obliquus externus and transversalis, it divides into two layers. The anterior and more considerable layer joins the tendon of the external oblique, and runs over the rectus, to be inserted into the whole length of the linea alba: the posterior and thinner layer, adhering to the anterior surface of the transversalis, passes into the linea alba behind the rectus, as low as half-way between the umbilicus and os pubis; but below this place the whole tendon of the internal oblique passes along with that of the external oblique before the rectus, and is inserted into the lower part of the linea alba. The inferior edge of the muscle extends in a nearly straight direction over the spermatic chord to

be fixed by a tendinous attachment to the angle of the pubis.

Situation: It is covered by the obliquus descendens externus and latissimus dorsi.

Use: To assist the obliquus externus; but it bends the trunk in the reverse direction, so that the muscle on each side co-operates with the obliquus externus of the opposite side.

Synonyma: Obliquus internus abdominis;—obliquus ascendens;—obliquus minor;—ilio-lumbo-costi-abdominal.

About the middle of Poupart's ligament, a delicate fasciculus of fibres is sent off from this muscle over the spermatic cord, where it passes under its edge in its way to the ring. This is named the

Cremaster, and is continued down on the cord, till it is insensibly lost on the tunica vaginalis testis; it will be seen in the dissection of the scrotum: Its *use* is to suspend, draw up, and compress the testicle.

We must now dissect the attachments of the internal oblique from the cartilages of the ribs, from the fascia lumborum, and from the spine of the os ilium, and, by continuing our dissection from behind forwards, separate it from the transversalis abdominis, which lies under it. This separation may be continued as far as where the tendons of the two muscles are inseparable, *i. e.* rather more forward than the linea semilunaris. As this muscle lies very close upon the transversalis, caution is required to avoid detaching both muscles together. Let the student begin his separation at the crista of the ilium, where the course of the circumflexa ilii artery and vein will show

him when he has arrived at the surface of the transversalis.

3. Transversalis Abdominis.——*Arises*, tendinous, from the fascia lumborum, and back part of the spine of the os ilium; fleshy from all the remaining part of the spine of the ilium, and from the inner surface of Poupart's ligament; and fleshy from the inner or back part of the cartilages of the seven lower ribs, where its fibres meet those of the diaphragm.

The fleshy fibres proceed transversely, and end in a flat sheet of tendon, which, after being connected to the other tendons at the linea semilunaris, passes with the posterior layer of the internal oblique behind the rectus, and is *inserted* into the ensiform cartilage, and into the whole length of the linea alba, excepting its lowermost part; for, at the middle distance between the umbilicus and os pubis, a slit or fissure is formed in this tendon, through which the rectus abdominis passes; and the remainder of the tendon passes before the rectus, to be inserted into the lower part of the linea alba. Its inferior edge is connected with that of the preceding muscle in its insertion into the pubis.

Situation: It is covered by the obliquus descendens internus, and is lined by the peritoneum.

Use: To support and compress the viscera of the abdomen.

Synonyma: Transversus abdominis;—lumbo-ili-abdominal.

Where the transversalis is detached from its origins, and turned back towards the linea semilunaris, the peritoneum is laid bare, except in the neighbourhood

of the crural arch, where it is covered by a thin fascia arising from Poupart's ligament, and continued upwards between the peritoneum and transversalis muscle, until it is gradually lost. This is named by Mr. Cooper, its discoverer, the *fascia transversalis*, and prevents the bowels from being protruded under the inferior margins of the obliquus internus and transversalis muscles. It is perforated about the middle between the ilium and pubes, by an opening for the passage of the spermatic chord, which then goes obliquely downwards inwards and forwards to the ring of the external oblique. Thus the abdominal ring is a canal, having an upper or internal opening, formed in the fascia transversalis, and a lower or external one in the tendon of the obliquus externus*.

The sheath of the rectus is now to be attended to; it is formed by the tendons of the three other muscles, viz. the two obliqui, and the transversalis: These, when they reach the edge of the rectus, form the appearance named Linea Semilunaris; they then split and inclose the rectus in their duplicature; the whole tendon of the external oblique, with the anterior layer of the internal oblique, passes before the rectus; and the whole posterior layer of the internal oblique, together with the whole tendon of the transversalis muscle, passes behind the rectus, excepting at the lower part; but, for two or three inches above the pubis, all the tendons go in front of the muscle,

* For more complete descriptions of these very important parts, see Mr. Cooper's Works on Hernia, or Mr. Lawrence's Treatise on the same subject.

and the posterior part of the sheath is consequently deficient, the rectus lying naked on the peritoneum.

The two oblique muscles are now to be replaced; then, making an incision by the side of the linea alba, and thus opening the sheath of the rectus through its whole length, you dissect it back towards the linea semilunaris, and thus lay bare the fibres of the muscle next to be described.

4. RECTUS ABDOMINIS.—*Arises*, by a flat tendon, from the fore-part of the os pubis; as it ascends, its fleshy belly becomes broader and thinner.

Inserted, by a thin fleshy expansion, into the ensiform cartilage, and into the cartilages of the three inferior true ribs.

Situation: This pair of muscles is situated on each side of the linea alba, under the tendons of the oblique muscles. The muscle is generally divided by three tendinous intersections; the first is at the umbilicus, the second where it runs over the cartilage of the seventh rib, and the third in the middle between these; and there is commonly a half intersection below the umbilicus. By these intersections the muscle is connected firmly to the anterior part of its sheath, forming the LINEÆ TRANSVERSÆ; while it adheres very slightly by loose cellular substance to the posterior layer.

Use: To compress the fore-part of the abdomen, to bend the trunk forwards, or to raise the pelvis.

Synonyma: Pubio-sternal.

On each side of the linea alba, and inclosed in the lower part of the sheath of the rectus, is sometimes found a small muscle, named

5. PYRAMIDALIS.—*Origin:* Tendinous and fleshy, of the breadth of an inch from the os pubis, anterior to the origin of the rectus.

Insertion: By an acute termination, near half-way between the os pubis and umbilicus, into the linea alba and inner edge of the rectus muscle.

Situation: It lies betwixt the lower portion of the two recti muscles.

Use: To assist the lower part of the rectus.

Synonyma: Pyramidalis, vel succenturiatus, pubio-umbilical.

SECT. II.

DISSECTION OF THE CAVITY OF THE ABDOMEN.

THE abdomen is divided into three regions, each of which is again subdivided.

1. The EPIGASTRIC, or upper region, includes the part covered at the side by the ribs; its lateral portions are named the right and left HYPOCHONDRIA, and the depression in its middle the scrobiculus cordis.

2. The UMBILICAL, or middle region, is the space immediately under the former; and it extends below to the anterior superior spines of the ilia. Its sides are called the lumbar or iliac regions.

3. The HYPOGASTRIC, or lowest region, is subdivided into three parts, one middle, termed RE-

GIO PUBIS, and two lateral, named INGUINAL regions.

Make a longitudinal incision from the scrobiculus cordis to the umbilicus, and from that point an oblique incision on each side towards the anterior spinous process of the os ilium, forming thus three triangular flaps. In doing this, avoid cutting the intestines, by raising the muscles from them after the first puncture.

Before you disturb the viscera, observe the general situation of those parts which appear on first opening the abdomen.

1. The internal surface of the PERITONEUM, smooth, shining, and colourless, covering the parietes of the abdomen, and the surface of all the viscera.

2. In the triangular portion of integument folded down over the pubes, three ligamentous cords project through the peritoneum, two running laterally, and the other in the middle, towards the navel. These are the remains of the two umbilical arteries and the urachus.

3. The epigastric artery, accompanied by two veins, may be seen through the peritoneum, ascending obliquely upwards and inwards from under Poupart's ligament.

4. The upper edge of the liver is seen extending from the right hypochondriac region, across the epigastric, into the left hypochondriac region; in it a fissure is seen, into which enters, inclosed in a duplicature of peritoneum, the ligamentum teres, which was, in the fœtus, the umbilical vein. The fundus of the

gall-bladder, if distended, is sometimes seen projecting from under the edge of the liver.

5. The STOMACH will be found lying in the left hypochondriac region, and upper part of the epigastric; but, if distended, it protrudes into the umbilical region.

6. The GREAT OMENTUM proceeds from the great curvature of the stomach, and stretches down like a flap over the intestines.

7. The GREAT TRANSVERSE ARCH OF THE COLON will be seen projecting through the omentum; it mounts up from the os ilium of the right side, crosses the belly under the edge of the liver, and under the greater curvature of the stomach, and descending again upon the left side, sinks under the small intestines, and rests upon the wing of the left or ilium.

8. The SMALL INTESTINES lie convoluted in the lower part of the belly, surrounded by the arch of the colon.

Such is the general appearance on first opening the abdomen; but this will vary somewhat, as one intestine may happen to be more inflated than another, or as the position of the body may have been after death.

It will now be proper to consider the parts more minutely:

1. The PERITONEUM.—Observe how it is reflected from the parietes of the abdomen over all the viscera, so that they may be said to be situated behind it; trace its reflections from side to side, and from above downwards; you will see that the external coat of

every viscus, and all the connecting ligaments, are reflections or continuations of this membrane.

(1.) The FOUR LIGAMENTS of the LIVER are formed by the peritoneum, continued from the diaphragm and parietes of the abdomen.

a, The MIDDLE or SUSPENSORY LIGAMENT, inclosing in its duplicate the LIGAMENTUM TERES.

b, The CORONARY LIGAMENT, connecting the upper surface of the liver to the diaphragm.

c, The BROAD LIGAMENT of the right side.

d, The BROAD LIGAMENT of the left side.

(2.) The LESSER OMENTUM, or EPIPLOON, or the MESOGASTRION, is formed by two laminæ of peritoneum, passing from the under surface of the liver to the lesser curvature of the stomach, and containing in its duplicate the vessels of the liver.

(3.) The GREAT EPIPLOON or OMENTUM.—Observe, that the peritoneum, coming from both surfaces of the stomach, and from the spleen, proceeds downwards into the abdomen, and is then reflected back upon itself, till it reaches the transverse arch of the colon, where its laminæ separate to invest that intestine. This reflection is named the Great Omentum; it is a pouch or bag, composed of four laminæ of peritoneum, and the opening into it is by the FORAMEN of WINSLOW: Observe the situation of this semilunar opening; it is on the right side of the abdomen, at the root of the lesser lobe, or lobulus spigelii of the liver; it leads under the little epiploon, under the posterior surface of the stomach, but above the pancreas and colon, into the sac of the omentum; —the omentum sometimes reaches to the lower part

of the hypogastric region, sometimes not beyond the navel; it contains in its duplicature more or less of adipose substance.

(4.) The MESENTERY.—Observe, that the peritoneum, reflected from each side of the vertebræ, proceeds forward, to connect the intestines loosely to the spine; that it begins opposite to the first lumbar vertebra, crosses obliquely from left to right, and ends half-way between the last lumbar vertebra and the groin. At its commencement, it binds down the extremity of the duodenum, and it terminates where the head of the colon begins. The great circumference which is in contact with the intestines, is very much plaited or folded, and is several yards in length. Between the laminæ of mesentery, observe the CONGLOBATE GLANDS, less numerous in old age: the branches of the superior mesenteric artery ramifying and forming arches; the mesenteric veins accompanying the arteries; the trunk of the lacteals, situated contiguous to the mesenteric artery on its left side. It may sometimes be inflated by the blow-pipe. Nerves also run in the mesentery, but are not easily demonstrated.

(5.) The MESOCOLON is similar to the mesentery, and connects, in like manner, the colon to the spine.

2. HEPAR, the LIVER.—*Situation*: Partly in the right hypochondrium, which it fills up, reaching as low as the kidney of that side, partly in the epigastrium, and running also some way into the left hypochondrium.

Connected by its four ligaments to the inferior surface of the diaphragm, and by the lesser epiploon to

the small curvature of the stomach :—The little epiploon should now be removed, to discover the different parts of the liver.

Observe the superior or convex surface adapted to the arch of the diaphragm ; the inferior or concave surface resting on the stomach ;—the posterior or thick edge lying against the vertebræ, and the anterior thin margin corresponding to the lower edge of the chest ;—Observe the three lobes of the liver ;—the great or right lobe ;—the small or left lobe ;—the lobulus spigelii ;—the great fissure, separating the right and left lobe, and receiving the suspensory ligament, and the ligamentum teres ;—the cavity of the portæ between the great lobe and lobulus spigelii ;—the fissure on the right side of the lobulus for the vena cava inferior, which fissure is almost a complete foramen ; —the notch in the back-part for the vertebræ ;—the depression in the right lobe for the gall-bladder. Observe the vessels in the cavity of the portæ, the hepatic artery on the left side, the ductus communis choledochus on the right side, and betwixt, but at the same time behind them, the vena portæ ; they are all surrounded by a plexus of nerves. These vessels and nerves pass along the edge of the mesogaster, or little omentum, surrounded and connected by adipose and cellular substance ; the part is called Capsula Glissoni. Observe that the ligamentum teres was the umbilical vein of the fœtus, entering the vena portæ, and that the ductus venosus in the fœtus (obliterated in the adult), leaving the vena portæ, passed into one of the venæ cavæ hepaticæ.

3. Vesicula Fellis, the Gall-Bladder.—

Situation: In the right hypochondrium, in a superficial depression on the under surface of the right lobe of the liver; it sends off the DUCTUS CYSTICUS, which, uniting with the DUCTUS HEPATICUS, forms the DUCTUS COMMUNIS CHOLEDOCHUS; this perforates the first curvature of the duodenum.

4. VENTRICULUS, the STOMACH.—*Situation:* In the left hypochondriac and epigastric regions: *Connected* to part of the inferior surface of the diaphragm, to the concave surface of the liver by the little epiploon, to the spleen by a reflection of peritoneum, and to the arch of the colon by the great omentum. Observe its greater curvature looking downwards, its lesser curvature looking upwards; and its two lateral surfaces. In the living body, the greater curvature is turned forward, and a little downward, the lesser arch backward, *i. e.* towards the spine, while one of the lateral convex sides is turned upwards, and the other downwards. Observe the bulging extremity on the left side, the cardia or upper orifice, where the œsophagus enters half-way between this great extremity and the lesser arch: the pylorus, or lower orifice, at the end of the small extremity, situated under the liver, and rather to the right side of the spine, feeling hard when touched.

5. The INTESTINES.—These form one continuous tube, but are divided into two portions, differing in their figure, structure, and functions, and distinguished by the names of small and large.

The small intestine is divided into duodenum, jejunum, and ileum; the large into cæcum, colon, and rectum.

(1.) SMALL INTESTINE;—about four times as large as the body.

a, The DUODENUM is broader than any other part of the small intestine, but is short: it takes a turn from the pylorus upwards, and to the right side, passing under the liver and gall-bladder; then, turning upon itself, it descends, passing as low as the right kidney; it is in this space that it receives the pancreatic and gall ducts; thence it crosses before the renal vessels, before the aorta, and upon the last vertebra of the back, firmly bound down by the peritoneum, which covers only its anterior surface; it then ascends from right to left, till it is lost under the root of the mesocolon.

Turning back the colon and omentum, fixing them over the brim of the thorax, and pushing down the small intestines towards the pelvis, you find the duodenum coming out from under the mesocolon, but still tied close to the spine; it terminates in the jejunum, exactly where the mesentery begins. The intestine in this course forms nearly a circle, the root of the mesocolon being the only part lying between its two extremities.

You have now to trace the rest of the small intestine, which lies convoluted in the umbilical and hypogastric regions.

b, JEJUNUM constitutes the first or upper half of the remaining small intestine, and is situated more in the upper part of the abdomen; it is redder, and its coats feel thicker to the touch, from the greater number of the valvulæ conniventes on its inner surface; its diameter exceeds that of the ilium.

c, The lower half is named ILEUM; it is situated more in the lower part of the abdomen, and terminates in the great intestine, by entering the caput coli, or beginning of the colon.

As a general observation it may be said, that the convolutions of the small intestine occupy the middle of the umbilical and hypogastric regions; but their situation varies much, particularly according to the state of the bladder and rectum. The course of the tube, independently of its convolutions, is from the left lumbar region, where the duodenum emerges from under the mesocolon to the right inguinal region, where the ileum terminates in the caput coli.

(2.) Great intestine.

d, The CÆCUM, or blind gut, is tied down by the peritoneum to the loins on the right side, lying in the space under the right kidney, hid by the convolutions of the ileum. On its posterior part there is a little appendage, of the shape of an earth-worm, named *Appendix Cæci Vermiformis.*

e, The COLON.—Its commencement at the cæcum is termed CAPUT COLI, or head of the colon; it mounts upwards from the cæcum over the anterior surface of the right kidney, to which it is connected by cellular substance, passes under the gall-bladder, which, after death, tinges it with bile; and then, going across the upper part of the belly, forms its GREAT TRANSVERSE ARCH. In its whole course it is contracted into cells by its muscular fibres, which are united together, forming longitudinal bands; and it has some fatty projections attached to its surface, named Appendices Epiploïcæ. Both these circum-

stances distinguish the large from the small intestine; which the difference of size does not always. When the large intestine is empty, it contracts, and may be even smaller than the small; but if it were inflated, it could be distended to a much greater degree. The colon then goes backwards under the stomach and spleen into the left hypochondrium; and then, descending over the left kidney, it is again tied down; it afterwards turns over the brim of the pelvis, being at this part unconfined, and forming a loose and remarkable curvature, which is named the SIGMOID or ILIAC FLEXURE. After this convolution, the intestine assumes the name of

The RECTUM.—Drawing aside the intestines, you find the gut continued over the anterior surface of the sacrum and os coccygis to the anus.

On pulling the stomach towards the right side, you will perceive,

6. The LIEN, or SPLEEN.—*Situation:* In the left hypochondriac region, between the great extremity of the stomach, and the neighbouring false ribs, under the edge of the diaphragm, and above the left kidney; to all of which it is connected by the peritoneum. It is of an oval figure; its external surface is gently convex; its internal surface irregularly concave, and divided by a longitudinal fissure, into which its vessels enter.

7. The PANCREAS.—*Situation:* This gland was in part seen on removing the little epiploon; it is more fully exposed, by tearing through the great epiploon between the great curvature of the stomach, and the transverse arch of the colon. It lies in the cavity in-

to which the foramen of Winslow leads; it extends from the fissure of the spleen across the spine, under the posterior surface of the stomach, and terminates within the circle formed by the duodenum; it is only covered on its anterior surface by the peritoneum.

The Pancreatic Duct pierces the coats of the duodenum, and enters the cavity of that intestine, by an orifice common to it, and to the ductus communis choledochus. The duct runs along the very centre of the gland, where the whiteness of its coats will readily enable the student to distinguish it.

All the abdominal viscera may now be removed, except the rectum, where it descends into the pelvis, which, being tied, should be allowed to remain, for it belongs to the demonstration of those parts: or the liver and its vessels, with the pancreas, may be left, and the vessels entering the portæ of the liver traced.

The peritoneum should now be carefully dissected from the diaphragm, and from the sides and back-part of the abdomen; thus the parts which lie more immediately behind that membrane may be examined.

8. Renes, the Kidneys.—Two glandular bodies, situated in the posterior part of the cavity of the abdomen, on each side of the lumbar vertebræ, between the last false rib and the spine of the ileum, and imbedded in a quantity of adipose membrane.

In each kidney you may observe a lesser arch or concavity turned obliquely forwards and inwards; a greater arch or convexity turned obliquely backwards and outwards;—two lateral surfaces;—two extremities, the superior of which is nearer to that of the opposite kidney than the inferior. Observe the renal or emul-

gent artery entering the lesser arch, the vein and ureter passing out. Observe the course of the ureter; it passes behind the peritoneum over the psoas muscle into the pelvis, and runs between the rectum and bladder, which last it enters.

9. The CAPSULÆ RENALES.—Two glandular bodies, situated on the upper extremity of each kidney, of an irregular figure, crescent-like, or somewhat triangular.

By the removal of the peritoneum, several muscles are exposed, situated at the superior and posterior parts of the abdomen.

One single muscle is situated in the superior part of the abdomen,

DIAPHRAGMA, the DIAPHRAGM, or MIDRIFF.—This is a broad, thin, muscular septum between the thorax and abdomen, situated obliquely; it is concave below, and convex above, the middle of it on each side reaching as high within the thorax as the fourth rib. It is divided into two portions:

1. The superior or greater muscle of the diaphragm, forms the transverse partition between the chest and abdomen,

Arising, by distinct fleshy fibres, 1. From the posterior surface of the ensiform cartilage; 2. From the cartilages of the seventh, and all the false ribs; 3. From the ligamentum arcuatum, which is a ligament extended, somewhat indistinctly, from the top of the twelfth rib to the lumbar vertebræ, forming an arch over the psoas and quadratus lumborum muscles. From these origins the fibres run, in different direc-

tions, like radii from the circumference to the centre of a circle, and are

Inserted into a broad tendon (*tendinous centre*, or *cordiform tendon*), which is situated in the middle of the diaphragm, and in which, therefore, the fibres from the opposite sides are interlaced.

2. The inferior or lesser muscle, or appendix of the diaphragm, lies on the bodies of the vertebræ, and

Arises, by four small tendinous feet, on each side, from the second, third, and fourth lumbar vertebræ; these tendons soon join, to form a strong pillar on each side, named the Crus of the Diaphragm. The crura run obliquely upwards and forwards, form two fleshy bellies, a fasciculus of each of which crossing over to the other, decussates with the opposite one, and thus forms the interval of the two crura into a superior and inferior opening.

Inserted into the posterior part of the middle cordiform tendon.

Situation: The diaphragm is covered on its superior surface by the pleura, and on its inferior by the peritoneum; it separates the thoracic from the abdominal viscera: It is perforated in its fleshy and tendinous parts by several blood-vessels, and other important organs.

(1.) The aorta passes between the tendinous part of the crura, lying close upon the spine; and the thoracic duct passes betwixt the aorta and the right crus.

(2.) A little above, and to the left side of the aorta, the œsophagus, with the eighth pair of nerves attach-

ed to it, passes through an oval fissure formed in the fleshy columns of the inferior muscle. These two parts are separated by the decussating fasciculi just described.

(3.) The vena cava perforates the tendon towards the right side by a triangular hole.

(4.) The posterior intercostal nerve, and branches of the vena azygos, perforate some of the posterior fibres of the crura:—The splanchnic, or anterior intercostal nerve, also passes through an opening in the substance of the crura.

(5.) On each side of the sternum there is a small fissure, where the peritoneum and pleura are only separated by adipose membrane.

Use: The diaphragm is one of the chief agents in respiration; in contraction it enlarges the cavity of the thorax, and produces inspiration; in expiration it is relaxed, and pushed up by the pressure of the viscera, from the action of the muscles of the abdomen, so as to diminish the cavity of the chest: it also acts in coughing, laughing, and speaking, and in the expulsion of the urine and fæces.

Synonyma: Septum transversum;—septum musculare;—Thoraco abdominal. Winslow calls the middle aponeurosis the aponeurotic plane of the diaphragm; by others it is called the centrum tendinosum.

Four pair of muscles are situated within the posterior part of the cavity of the abdomen.

1. The Psoas Parvus.—It *arises*, fleshy, from the sides of the last dorsal, and first lumbar vertebræ; it

sends off a small long tendon, which, running on the inside of the psoas magnus, is

Inserted, thin and flat, into the brim of the pelvis, at the junction of the os ilium and pubis.

Situation: This muscle lies on the anterior part of the loins, betwixt the psoas magnus and the vertebræ; sometimes, however, it is wanting.

Use: To assist the psoas magnus in bending the loins forwards: in some positions, it will bend the pelvis on the loins.

Synonyma: Pré-lumbo pubien.

2. The Psoas Magnus.—It *arises*, fleshy, from the side of the body, and transverse process of the last vertebra of the back, and in the same manner from all those of the loins, by as many distinct slips. It runs down over the brim of the pelvis, and is

Inserted, tendinous, into the trochanter minor of the os femoris, and fleshy, into that bone immediately below the trochanter.

Situation: It is situated betwixt the psoas parvus and iliacus internus, close to the fore-part and sides of the lumbar vertebræ: at its origin it has some connection with the diaphragm, and with the quadratus lumborum.

Use: To bend the thigh forwards, and roll it outwards; or, when the inferior extremity is fixed, to assist in bending the body.

Synonyma: Lumbaris internus;—Pré-lumbo-trochantin.

3. The Iliacus Internus.—It *arises*, fleshy, from the transverse process of the last vertebra of the loins, from all the inner margin of the spine of the os ileum,

from the edge of that bone between its anterior superior spinous process and the acetabulum, and from all its hollow part between the spine and the linea innominata. Its fibres descend under the outer half of Poupart's ligament, and join the tendon of the psoas magnus.

Inserted with the psoas magnus.

Situation: It fills up the internal concave surface of the os ileum, and is situated on the outside of the psoas magnus. It is covered by a pretty strong fascia, which is inserted into the crista of the ileum, and into the crural arch: FASCIA ILIACA. The latter insertion prevents the bowels from descending under Poupart's ligament, except at the inner edge of the iliac vein, which is accordingly the situation of the crural hernia, and which the student should examine most carefully. A part of this fascia is also continued behind the femoral vessels over the pubis, to form a part of the sheath which incloses those vessels*.

Use: To assist in bending the thigh, and in bringing it directly forwards.

Synonyma: Iliacho-trochantin.

N. B. The insertion of the two last-described muscles cannot be seen till the thigh is dissected, when it will be found to lie between the vastus internus and the pectinæus.

4. The QUADRATUS LUMBORUM.—This muscle *arises*, tendinous and fleshy, from rather more than the posterior third part of the spine of the os ileum.

* See the second part of Mr. Cooper's work on Hernia, and Mr. Lawrence's treatise quoted before.

Inserted into the transverse processes of all the vertebræ of the loins, into the posterior half of the last rib, and, by a small tendon, into the side of the last vertebra of the back.

Situation: It is situated laterally at the lower part of the spine, more outwardly than the psoas magnus, between the origin of the psoas and the transversalis abdominis.

Use: To move the loins to one side, pull down the last rib, and, when both muscles act, to bend the loins forwards.

Synonyma: Lumbaris externus;—Ilio-lumbi-costal.

OF THE VESSELS AND NERVES SITUATED BEHIND THE PERITONEUM.

I. THE ARTERIES, VIZ. THE AORTA ABDOMINALIS, AND ITS BRANCHES*.

THE Aorta passes from the thorax into the abdomen, between the crura of the diaphragm, close upon the spine. It then descends on the fore-part of the vertebræ, lying not exactly in the middle, but rather inclined to the left side. On the fourth lumbar ver-

* In the description of the blood-vessels, the ramifications of the principal trunks are enumerated; but the student must remember that these can be seen only when injected, and when the subject is dissected for the express purpose of tracing the arteries. In an ordinary dissection, the trunks only can be demonstrated.

tebra, it bifurcates into the two primitive or common iliac arteries.

Branches of the Abdominal Aorta.

1. The two Phrenic Arteries arise from the Aorta, before it has fairly entered into the abdomen, and ramify over the diaphragm;—sometimes they come off in one trunk, which bifurcates; sometimes one of them arises from the cœliac.

2. The Cœliac Artery comes off at the point where the aorta has fairly extricated itself from the diaphragm; it is a single, large, but short trunk situated between the inferior surface of the liver, and the small curvature of the stomach, and surrounded by the meshes of the semilunar ganglion. It divides at once into three branches; and as they depart in different directions from one point, as from a centre, the trunk is called the Axis Arteriæ Cœliacæ.

(1.) A. Coronaria Ventriculi, the middle branch, is the smallest of the three; it passes from the axis towards the left side, and arriving at the cardiac orifice of the stomach, where it attaches itself to that organ, sends a branch round the cardia, named *Ramus Coronariæ Dexter*. The trunk itself is then continued along the lesser curvature from left to right, to inosculate with the pylorica or coronaria dextra: it sends off branches to the little epiploon, &c. It sometimes terminates in the liver, entering at the portæ, and then it is the largest of the branches of the cœliac. In this case, the trunk, after ascending towards the left to reach the cardia, is reflected to the right, in

its way to the liver; and, at the point of reflection, gives off the *coron. ventric.*

(2.) Arteria Splenica, leaving the trunk of the cœliac, goes directly to the side, passes under the stomach, and along the upper border of the pancreas, running in a tortuous and serpentine course: it enters the left concave surface of the spleen in several branches, but, before doing so, it gives off the following branches:

a, Pancreatice Parvæ to the pancreas, where it runs along the border of that viscus.

b, Vasa Brevia to the bulging extremity of the stomach.

c, A. Gastro-epiploica Sinistra, which runs along the greater curvature of the stomach, inosculating with the gastro-epiploica dextra.

(3.) Arteria Hepatica runs in a direction opposite to the splenic, towards the right side; but not more than half of its blood goes to the liver: It sends off the following branches:

a, Pylorica, or Coronaria Dextra, sometimes comes off from the trunk of the hepatic, sometimes from one of its branches:—reaching the pyloric end of the stomach, it sends its ramifications along the lesser curvature, to inosculate with the proper coronary artery.

b, Gastro-epiploica Dextra, or Gastro-duodenalis, passes under the pylorus, to reach the great curvature of the stomach, along which it runs, inosculating with the gastro-epiploica sinistra, and sending branches upwards to the stomach, and downwards to the omentum; it also supplies the upper

part of the duodenum, and sends off a considerable branch to the right extremity of the pancreas.

The hepatic artery then divides into the right and left hepatic. The RIGHT is distributed to the right lobe of the liver, and to the gall-bladder. The LEFT supplies the whole of the left lobe, the lobulus Spigelii, and part of the right lobe of the liver.

3. The SUPERIOR MESENTERIC ARTERY is a single trunk; it leaves the aorta about half an inch lower than the cœliac artery,—it comes out from under the mesocolon, and stretches over the duodenum; it enters the fold of peritoneum forming the mesentery, and runs down in this, gradually incurvating from the left to the right side.

From the right side or concavity of this arch, three branches are given to the colon.

(1.) A. ILEO-COLICA runs down to the caput coli and last turns of the ileum; its branches upon the small intestines inosculate with those branches of the superior mesenteric distributed to the small intestines in general; and on the great intestine, it inosculates with the next branch.

(2.) A. COLICA DEXTRA.—This artery runs from the root of the superior mesenteric artery, across towards the right side of the colon, where that intestine begins to rise over the kidney.

(3.) A. COLICA MEDIA.—This branch goes directly upwards from the trunk of the superior mesenteric, as it comes out from under the mesocolon. After running a little way upon the mesocolon, it divides; and the division going towards the right

side, makes a large inosculation with the colica dextra, while the left branch makes an opposite sweep, and joins the colica sinistra, which is a branch of the inferior mesenteric.

Often there are only two branches instead of these three; viz. *ileo-colica* and *colica dextra;* then the *c. media* is a branch of the latter. Frequently too there is only *one* branch, called *colica dextra*, and dividing after its origin into the three above named.

The left side or convexity of the arch of the superior mesenteric sends off from sixteen to twenty branches, which, after forming frequent anastomoses and arches, proceed to the small intestines.

4. The Renal or Emulgent Arteries are two in number. Each artery arising, below the superior mesenteric, from the side of the aorta, passes to the kidney, and after having given twigs to the renal capsule and adipose membrane, enters the lesser arch of the kidney. The right artery is longer than the left, and passes behind the vena cava ascendens.

5. The Spermatic Arteries are also two; they come off about an inch below the emulgent from the fore-part of the aorta. Each artery descends behind the peritoneum, giving twigs to the parts in its course, and accompanied by the spermatic vein and nerves. It then passes through the abdominal ring, and enters the upper part of the testicle in five or six branches. In the female it supplies the ovaria and fundus uteri.

6. The Inferior Mesenteric is a single trunk, which comes off rather from the left side of the aorta, below the spermatic arteries; it passes in the mesentery

to the left side of the abdomen, where it divides as follows.

(1.) The Colica Sinistra, an artery which ascends along the left side of the colon, to inosculate with the A. Colica Media.

(2.) Branches which pass to the sigmoid flexure.

(3.) The great trunk of the artery runs down behind the rectum, on which it ramifies largely, and is termed Art. Hemorrhoidalis Interna.

7. The Lumbar Arteries are five or six small arteries on each side, which arise from the back-part of the aorta, and are distributed to the spinal canal, peritoneum, muscles of the spine, and of the sides of the abdomen and pelvis. They inosculate with the A. Epigastrica, Circumflexa ilii, &c.

8. A. Sacra Media is a single artery, arises from the back-part of the aorta at its bifurcation, and descends along the anterior surface of the sacrum, giving twigs to all the neighbouring parts.

At the fourth lumbar vertebra, the aorta bifurcates into the two primitive or common iliacs.

The Iliaca Communis runs along the edge of the psoas muscle, and at an inch or two from its origin divides into,

(1.) The Internal Iliac, which passes down into the pelvis.

(2.) The External Iliac, which, following the direction of the psoas muscle, passes under Poupart's ligament, and becomes the inguinal artery.

2. VEINS.

The VENA CAVA ABDOMINALIS, vel Inferior, is formed by the junction of the two common iliac veins, it passes up through the abdomen on the lumbar vertebræ, and on the right side of the aorta.

In this course it receives the following veins, which resemble their corresponding arteries.

1. The Lumbar Veins.

2. The Emulgent or Renal Veins;—the left is the longest, as it crosses over the fore-part of the aorta.

3. The Right Spermatic Vein;—the left enters the left renal vein.

The vena cava then passes through the fissure of the liver, being nearly surrounded by that viscus, and receiving three branches from it, called the VENÆ HEPATICÆ. It then perforates the diaphragm, and enters the thorax.

The common iliac vein of each side is formed by the union of two branches, the EXTERNAL and INTERNAL ILIAC VEINS, which accompany the arteries of the same name:—The common iliac vein of each side lies on the inside of its artery; hence both veins cross behind the right iliac artery, to unite and form the vena cava, on the fore-part of the lumbar vertebræ*.

* It may be here proper to observe, that generally a great vein accompanies every great artery; but when the ramifications become small, each artery is attended by two veins.

The Superior Mesenteric Vein, the Inferior Mesenteric Vein, and the Splenic Vein, do not join the cava, but are united behind the pancreas, to form the Vena Portæ. This vein ramifies anew through the liver, and its blood is returned into the vena cava by the venæ cavæ hepaticæ.

Although the trunks just enumerated are the chief veins that contribute to form the vena portæ, yet the returning veins of all the viscera enclosed in the peritoneum, except the liver, are included in the same system, and join one or other of the large trunks. This is the case with the stomach, pancreas, gall-bladder, and omentum. The blood which goes to the spleen, large, and small intestines, is all returned by the three great trunks.

3. NERVES.

1. The eighth pair, or Par Vagum, descending on each side of the œsophagus through the diaphragm, forms the two Stomachic Plexuses on the anterior and posterior surfaces of the stomach. These plexuses send some branches to the cœliac, to the hepatic, and to the splenic plexus.

2. The Splanchnic Nerve, or Anterior Intercostal, a branch sent off by the intercostal nerve in the thorax, enters the abdomen betwixt the crura of the diaphragm; here each nerve forms a Semilunar Ganglion by the side of the cœliac artery.

From this ganglion, on each side, branches are sent across, which communicate intimately together, and form round the root of the cœliac artery, a very intimate plexus, containing several ganglia of various sizes, formerly called the SOLAR, but now more correctly the CŒLIAC PLEXUS. Nerves pass from this plexus, with the branches of the aorta, to the various viscera of the abdomen: in a common dissection these nerves cannot be clearly demonstrated, as they lie very close on the respective arteries, and are surrounded by much condensed cellular substance; they form the hepatic, splenic, superior, and inferior mesenteric, renal, and spermatic plexuses.

3. The trunk of the intercostal nerve, the *posterior* intercostal, perforates the small muscle of the diaphragm close to the spine, runs down on the sides of the lumbar vertebræ, and along the upper edge of the psoas magnus. It terminates on the extremity of the os coccygis, by union with the nerve of the opposite side, in a ganglion named GANGLION IMPAR. In this course, it communicates with the lumbar nerves, and the various abdominal plexuses.

The THORACIC DUCT may be seen passing from the abdomen into the thorax, between the aorta and the right crus of the diaphragm. It is larger here than in its subsequent course, and the dilated portion is called *receptaculum chyli*, as the lacteals pour in the chyle in this situation.

CHAP. II.

DISSECTION OF THE PERINEUM, AND OF THE MALE ORGANS OF GENERATION.

THE muscles and vessels to be demonstrated, lie deep amongst much loose cellular substance; and unless great caution is used, important parts will be removed, while the student supposes he is only clearing away cellular substance:—The rectum having been cleansed, a little baked hair may be introduced into its extremity, which will keep the anus gently protruding during the dissection; or a cork, with a loop attached to it, may be introduced, and the mouth of the gut tied upon it;—this last method is preferable, as the intestine can then be turned in every direction:—The dissection will also be facilitated by introducing a staff into the bladder, in order to mark out the situation of the urethra; the subject should be placed in the same position as for the lateral operation of lithotomy.

* This dissection will be more complete, if the pelvis and lower extremities are injected; for thus the important branches of the pudic artery will be more easily traced.

The muscles of the perineum consist of five pair, and a single muscle:

- Erector Penis, Accelerator Urinæ, Transversus Perinei, Levator Ani, Coccygeus — on each side.
- Sphincter Ani, single muscle.

In commencing this important dissection, recollect that the erector muscle, covering the crus of the penis, arises from the tuber ischii, and ascends on the inside of the ramus of that bone;—that the transversus perinei arises from nearly the same point, and crosses the perineum, lying often at a considerable depth in the adipose substance. The tuber ischii then becomes a proper place for the commencement of the dissection; carefully tracing the muscles arising from that point, remove all the cellular substance, situated in the perineum, while the muscular fibres are left untouched; the Raphe or line running along the skin of the perineum, marks the place where the opposite muscles meet. The appearance of these muscles will vary in different subjects. In those who have died weak and emaciated, the fibres will be pale, and not very evident, while in strong muscular men, who have expired suddenly, they will be very distinct. This dissection is to be continued till all the parts between the tuberosities of the ischia on each side, and between the pubis before, and the tip of the os coccygis behind, are fairly brought into view. Observe

The Erector Penis covering the crus of the penis.

The Accelerator Urinæ embracing the bulb

and lower part of the CORPUS SPONGIOSUM of the Urethra.

The SPHINCTER ANI, encircling the anus.

The TRANSVERSUS PERINEI, crossing the perineum transversely.

1. The ERECTOR PENIS—*Arises*, tendinous and fleshy, from the tuberosity of the os ischium; its fleshy fibres proceed upwards over the crus of the penis, adhering to the outer and inner edges of the ascending ramus of the os ischium, and of the descending ramus of the os pubis;—but before the two crura meet to form the body of the penis, it ends in a flat tendon, which is lost in the strong tendinous membrane that covers the corpus cavernosum.

Situation: This muscle covers all the surface of the crus penis that is not in contact with bone; it arises on each side of the attachment of the crus to the bone.

Use: It was formerly supposed to compress the crus penis, and thereby to propel the blood into the forepart of the corpus cavernosum; and to press the penis upwards against the pubis. But its obvious effect must be that of drawing the crus downwards to the tuber ischii; which cannot have any influence in contributing to the erect state of the organ.

Synonyma: Ischio-cavernosus;—Ischio-caverneux.

2. The ACCELERATOR URINÆ—*Arises*, by a thin tendinous expansion, from the descending ramus of the pubis, and from the ascending ramus of the ischium, nearly as far down as the tuber;—this origin lies under the crus of the penis, and the fleshy fibres are seen coming out from the angle between the crus

and the corpus spongiosum urethræ; they proceed obliquely downwards and backwards, embrace the bulb and lower part of the corpus spongiosum, and are

Inserted into a white tendinous line in the middle of the bulb of the urethra, joining there with the muscle of the opposite side. The lowermost fibres run nearly transversely, while the superior fibres are very oblique.

Use: To drive the urine and semen forwards, by compressing the lower part of the urethra, and to propel the blood towards the corpus spongiosum and the glans penis.

Synonyma: Ejaculator seminis;—Bulbo-cavernosus; Bulbo-syndesmo-caverneux.

3. The TRANSVERSUS PERINEI—*Arises* from the tough fatty membrane that covers the tuber ischii, immediately behind the attachment of the erector penis; thence its fibres run transversely inwards.

Inserted into the central point of union where the sphincter ani touches the accelerator urinæ, and where a kind of tendinous projection is formed, common to the five muscles.

Use: To dilate the bulb of the urethra, to prevent the anus from being too much protruded, and to retract it when protruded.

Synonyma: Transversalis penis;—Transversalis urethræ;—Levator parvus, seu externus;—Ischio-pubi-prostatique.

There is sometimes another slip of fibres, the TRANSVERSUS PERINEI ALTER, which has the same

course, and is inserted into the posterior part of the bulb of the urethra.

4. The Sphincter Ani consists of two semicircular planes, which run round the extremity of the rectum, passing nearly as far out as the tuber ischii; the fibres of each side decussate where they meet, and are

Inserted into the extremity of the os coccygis behind*; and before, into a tendinous point common to this muscle, and to the acceleratores urinæ and transversi perinei. This tendinous point is worthy of remark; it seems to consist in part of an elastic ligamentous substance.

Use: To close the anus, or extremity of the rectum, and to pull down the bulb of the urethra. It is in a state of constant contraction, independently of the will, in order to prevent the contents of the rectum from escaping except at those times when we make an effort to evacuate them.

Synonyma: Sphincter externus;—Sphincter cutaneus;—Coccygi-cutané-sphincter.

More deeply seated than the muscles now described, we see some of the fibres of

The Levator Ani.—This muscle *arises* from the inside of the os pubis, at the upper edge of the foramen thyroideum, from the inside of the os ischium, from the tendinous membrane covering the obtu-

* The sphincter ani often arises by an elastic tendon, approaching to the nature of a ligament, from the apex of the os coccygis. This tendon is of some length; it gives off muscular fibres, which surround the extremity of the rectum.

rator internus and coccygeus muscles;—from the semicircular origin its fibres run down like radii towards a centre, and are

Inserted into the two last bones of the os coccygis, and into the extremity of the rectum, passing within the fibres of the sphincter ani, but on the outside of the longitudinal fibres of the gut itself.

Situation: This muscle, with its fellow, very much resembles a funnel, surrounding the extremity of the rectum, the neck of the bladder (which passes through a slit in its fibres), the prostate gland, and part of the vesiculæ seminales.

Use: To draw the rectum upwards after the evacuation of the fæces, to assist in shutting it, and to compress the vesiculæ seminales, and other viscera of the pelvis.

Synonyma: Musculus ani latus;—Levator magnus, seu internus;—Pubio-coccigi-annulaire.

6. The Coccygeus *arises*, tendinous and fleshy, from the spinous process of the os ischium, and covers the inside of the posterior sacro-sciatic ligament; it forms a thin fleshy belly.

Inserted into the extremity of the os sacrum, and into the lateral surface of the coccygis, immediately before the gluteus maximus.

Situation: It is placed betwixt the levator ani, and edge of the gluteus maximus.

Use: To support and move the os coccygis forwards, and connect it more firmly with the sacrum.

Synon. Ischio-coccigien.

The acceleratores urinæ and transversi perinei must now be removed from their insertions. They may be

left suspended by their attachments to the bone. The rectum must be separated from the bladder, and pulled downwards. This dissection will expose a great part of the levator ani;—the neck and body of the bladder;—the prostate gland;—the vesiculæ seminales;—the glandulæ anteprostatæ;—part of the vasa deferentia;—part of the ureters;—the urethra, its membranous part, its bulb, and corpus spongiosum;—the crura penis, and their origins from the ischium;—Observe,

1. The connection of the bladder and rectum, and the cellular substance interposed between them.

2. The prostate gland: *Situated* between the bladder and rectum, surrounding the beginning of the urethra in such a manner, that one third of its thickness is situated above the urethra, and two thirds below it; its shape is somewhat pyriform, and its consistence between cartilage and ligament.

3. The URETHRA.—The curve should be carefully observed. The urethra begins at the neck of the bladder; it is a continuation of that part of the bladder which in the erect posture is lowest. (1.) Its beginning is embedded in the prostate gland. (2.) Its membranous part is very short,—situated between the prostate gland and bulb of the urethra:—in dissecting, remark, that there is a firm fasciculus of fibres surrounding it, and connecting it and the prostate gland to the arch of the pubis; this fasciculus gives support to the urethra, and is termed the ligamentum triangulare urethræ. It is sometimes described as a compressor muscle of the prostate gland. (3.) The urethra then enters the corpus spongiosum.

4. The CORPUS SPONGIOSUM URETHRÆ consists of a plexus of minute veins covered externally by a thin but uniform tendinous sheet; it surrounds the urethra from a short distance from the bladder to its extremity: at its beginning, it forms a considerable body of a pyriform shape, termed the *Bulb of the Urethra;* that part of the bulb which is below the urethra, is named the pendulous part of the bulb. The corpus spongiosum is expanded at its anterior extremity to form the glans penis.

5. The GLANDULÆ ANTEPROSTATÆ, or Cowper's Glands, are two small glands of the size of peas, situated immediately before the prostate, and between the membranous part and bulb of the urethra.

6. The VESICULÆ SEMINALES are two soft, whitish, knotted bodies, about three or four fingers-breadth in length, and one in breadth, and about three times as broad as thick: *Situated* between the rectum and lower part of the bladder obliquely, so that their inferior extremities are contiguous, and are affixed to the base of the prostate gland, while their superior extremities are at a distance from each other extending outwards and upwards, and terminating just on the inside of the insertion of the ureters in the bladder.

7. The two VASA DEFERENTIA are seen running betwixt the vesiculæ seminales, and united to them and to the base of the prostate. Observe that part of the bladder, left between these tubes, and connected by cellular substance to the rectum, which is pierced when the bladder is punctured from the latter part.

8. The CORPORA CAVERNOSA PENIS arise, on each side, by a process named the CRUS, from the ramus and from the tuber ischii, ascend along the ischium and pubis, and are united immediately before the cartilaginous arch of the pubis ;—they are covered by a strong, white, shining, fibrous, ligamento-tendinous substance, which is very elastic. Internally they are cavernous, and are separated from each other by a septum, which, from being perforated, is named *Septum pectiniforme*.

By the union of the two corpora cavernosa, two grooves are formed :—(1.) A smaller one above, in which two arteries pass, a large vein or two betwixt them, and some large twigs of nerves. (2.) A larger groove below, which receives the urethra.

9. The VESICA, URINARIA, or URINARY BLADDER, is situated within the pelvis, immediately behind the ossa pubis, and before the rectum. It is covered on its upper and back part by a reflection of peritoneum : in front and below (where it is contiguous to the rectum), it is connected by cellular membrane to the surrounding parts. *Shape*, oval, but flattened before and behind, and, while in the pelvis, somewhat triangular. *Divided* into the fundus or bottom, corpus or body, and cervix or neck. In the contracted state, the fundus is the broadest and roundest part, but, when distended, the cervix is broader than any other part. At the top of the bladder, above the symphysis pubis, may be observed, the superior ligament of the bladder, consisting of the *Urachus*, a ligamentous cord, which runs up between the peritoneum and linea alba, as far as the

navel*, and two of the ligamentous cords, which are the remains of the umbilical arteries, and run up from the sides of the bladder.—The ligamentum inferius vesicæ connects the bladder to the upper and inner side of the ossa pubis.

Observe the parts of the bladder not covered by peritoneum; as they are the situations of surgical operations. These are the whole *anterior surface*, lying against the pubis, and rising above it, when the bladder is distended, so that it may be punctured above the pubis;—the *sides*, at the very lowest part of which the cut is made in the lateral operation of lithotomy, and where the viscus may be punctured from the perineum;—and the inferior surface, resting on the rectum, and allowing us to puncture from it. Observe also the direction of the axis of the bladder, in conformity with which all instruments should be introduced: this is in a line drawn from the navel to the os coccygis.

10. The entrance of the ureters into the bladder on the outside of the vesiculæ seminales.

11. The rectum, following the curve of the os sacrum, and os coccygis.

12. The prepuce is a fold of skin forming a sheath or covering for the glans penis. It makes a duplicature extending along the flat part of the glans from its basis to the orifice of the urethra, termed Frænum Præputii.

To have a more connected view of the relative situation of these important parts, one side of the pelvis

* In the fœtus, it is a prolongation or production of the coats of the bladder.

should now be removed, by dividing the symphysis pubis, and by sawing through the os ileum, or separating it at its junction with the sacrum. By carefully removing all the cellular membrane, the student will be enabled more accurately to examine the situation of the parts above described.

OF THE VESSELS AND NERVES CONTAINED WITHIN THE PELVIS.

1. ARTERIES.

The A. Iliaca Interna, having left the trunk of the iliaca communis, passes immediately into the pelvis, where it gives off several large arteries.

1. A. Ileo-Lumbalis supplies the psoas and iliacus internus muscles.

2. A. Sacræ Laterales, two or three small vessels which supply the sacrum, cauda equina, and neighbouring parts.

3. A. Glutea (or *iliaca posterior*), a very large branch, passes out of the pelvis through the upper part of the sciatic notch to supply the haunch, but, in its passage, it gives some branches to the os sacrum, os coccygis, the rectum, and the muscles situated within the pelvis.

4. A. Sciatica passes out of the pelvis by the sciatic notch, and below the pyriformis muscle to supply the hip: in its passage it gives branches to the neighbouring parts.

5. A. Pudica (*pudenda communis* or *interna*) is

the branch of the internal iliac, which is more immediately destined to supply the parts of generation, perineum, and lower part of the rectum: it goes out of the pelvis above the superior sacro-sciatic ligament, twists round it, and re-enters the pelvis above and before the inferior sacro-sciatic ligament; it then descends on the inside of the tuber ischii, ascends on the inner surface of the rami of the ischium and pubis, and, reaching the root of the penis, divides into two branches.

(1.) A. Perinei, a branch which, after giving twigs to the bulb of the urethra and neighbouring muscles, enters the crus of the penis, and subdivides into branches which pass to both extremities of the crus.

(2.) A. Dorsalis Penis, passes under the arch of the pubis, runs along the dorsum penis, and is distributed to the integuments.

In its course the pudic artery gives off many branches.

(1.) While in the pelvis, it gives twigs to the bladder, prostate, and rectum.

(2.) A. Hæmorrhoidales Externæ come from the pudic while passing by the anus.

(3.) A. Transversa Perinei, following the course of the transversus perinei muscle.

6. A. Obturatrix descends on the inside of the psoas muscle, passes through the foramen in the obturator ligament to the muscles on the inside of the thigh.

7. A. Hypogastrica, which in the fœtus sends off the umbilical artery, is in the adult continued only

to the side of the bladder, to which it gives branches; in the female, it enters the neck of the uterus, and gives branches to the vagina.

You must not expect to meet with uniformity in the distribution of these vessels in all subjects: sometimes the gluteal and pudic arteries come off by one trunk, sometimes the pudic and sciatic, &c. &c.

2. VEINS.

The veins attend the arteries and their ramifications; they unite to form the internal iliac vein, except the veins from the rectum, named *Hæmorrhoidales*, which ascend along its back-part to join the inferior mesenteric vein.

3. NERVES.

The nerves met with in this dissection consist of numerous twigs sent off from the lumbar and sacral nerves to supply the parts about the pelvis.

But, in this dissection, we meet with three pair of large nerves, which have their course through the pelvis, and pass to the thigh.

1. Course of the Anterior Crural Nerve while in the pelvis. The anterior crural nerve is formed by branches of the first, second, third, and fourth lumbar nerves; at its origin, it lies under the psoas magnus, and, as it descends, passes betwixt the psoas magnus and iliacus internus, till, having passed under Poupart's ligament, it emerges from betwixt those muscles, and appears on the outer side of the inguinal artery.

2. Course of the OBTURATOR NERVE within the pelvis. This nerve is formed by branches of the second, third, and fourth lumbar nerves: it lies under the internal border of the psoas magnus, descends into the pelvis, and goes obliquely downwards, to accompany the obturator artery through the thyroid hole.

3. Course of the GREAT SCIATIC NERVE within the pelvis. This nerve arises by branches from the fourth and fifth lumbar, and three first sacral nerves, which unite together to form the largest nervous trunk in the body. The nerve passes betwixt the pyriformis and gemini, and thus escapes from the back-part of the pelvis by the sciatic notch. Sometimes one of the branches goes through the pyriformis, and joins the sciatic trunk at the back of the pelvis.

OF THE SCROTUM.

THE scrotum consists externally of a loose, rugose skin, and internally of condensed cellular membrane, which has been described as a muscle, under the name of Dartos.

On dividing the anterior part of the scrotum, on either side of the raphe, we expose,

1. The Testicle, a gland of an oval flattened form, covered by the tunica vaginalis, having on its upper edge an appendage termed Epididymis.

2. The Spermatic Chord, connecting the testicle to the abdominal ring. It consists of,

a, The spermatic artery, a branch of the aorta; this

divides into several branches, which enter the upper edge of the testicle.

b, The spermatic veins, which form a plexus, that terminates in the abdomen, in a single vein.

c, The spermatic nerves, which come from the intercostal and lumbar nerves.

d, The vas deferens, or excretory duct of the testicle;—this is situated in the back-part of the chord, and is distinguished by its firm cartilaginous feel.

e, The spermatic absorbents.

f, These parts are all connected by cellular membrane, and by the tunica vaginalis, which is covered by a thin muscle.

g, The cremaster;—this arises from the obliquus descendens internus, and is lost on the tunica vaginalis.

CHAP. III.

DISSECTION OF THE ORGANS OF GENERATION IN THE FEMALE.

PREVIOUS to the dissection, it will be proper to examine the external parts.

The Mons Veneris is a rounded prominence, covered with hairs after puberty, situated at the lower part of the belly, and arising on each side gradually

from the groins; it consists of the common integuments, with an additional quantity of cellular and adipose substance, and lies upon the fore-part of the ossa pubis. From the inferior part of the mons veneris arise

The Labia Externa, called also the labia or alæ pudendi:—they are continued downwards and forwards in the direction of the symphysis pubis, and terminate in the perineum anterius: they consist of integuments, cellular substance, and fat,—are thicker above than below,—and are red and vascular on their inner side. The places where the labia are joined to each other above and below, are termed Commissures.

The longitudinal cavity or fissure, situated betwixt the labia, and extending from the mons veneris to the perineum anterius, is sometimes called the Sinus Pudoris; it is broader above than below, and contains several other parts.

On separating the labia, we see, immediately below the superior commissure,

The Clitoris, a red projecting body, situated below the arch of the pubis, and partly covered by its Prepuce: The prepuce is a fold of skin, continued from the inner surface of the labia, so as to cover the superior and lateral parts of the clitoris.—The clitoris resembles the penis of the male, and consists of two cavernous bodies; these cannot, however, be traced in this stage of the dissection. That part of the body which forms an obtuse projection externally, is called the Glans.

The Perineum Anterius is that portion of the

soft parts which extends from the inferior commissure of the labia to the anus.

The Perineum Posterius is the space betwixt the anus and point of the os coccygis.

The Nymphæ are two prominent doublings of the integuments, extending from the glans of the clitoris to the sides of the vagina. Their external side is continued from the inner surface of the labia, and from the prepuce of the clitoris, while their internal surface seems immediately continued from the fine, thin, vascular integuments covering the clitoris itself; they are spongy, and consist internally of cellular and adipose substance.

A little lower, we see the orifice of the urethra; it is situated below the clitoris and arch of the pubis, betwixt the nymphæ, and above the orifice of the vagina: it consists of a small rising prominence like a pea, in the centre of which is a small opening or hole.

On each side of the orifice of the urethra, we meet generally with the orifices of two mucous glands, which by some are named Cowper's Glands of the female.

On separating the lower part of the labia pudendi, we see the Vestibulum, a space which leads to the vagina; it is bounded behind, by the caruncul æ myrtiformes, or by the hymen in virgins; on the sides, by the labia; before, by the perineum anterius, which projects forwards, forming a kind of valve, so that a little pit is formed behind it, which is termed Fossa Navicularis, or Scaphoides.

The Hymen, or Circulus Membranosus, is a thin and extensile membrane, formed by a doubling of

the inner surface of the vestibulum and lower part of the vagina, the entrance of which is by its means much contracted in virgins. It generally has an opening in its upper part, but it is completely ruptured in the first coitus: its form is various, frequently semilunar, and then its base is attached to the vestibulum, while its cornua extend upwards as far as the sides of the urethra.

After the destruction of the hymen, in married women, we see some irregular projections marking the orifice of the vagina, and termed CARUNCULÆ MYRTIFORMES: they are generally supposed to be the remains of the hymen, but are not exactly in the same situation.

Behind these is the VAGINA, or canal leading to the uterus; at the extremity of which may be felt projecting the OS INTERNUM UTERI, or OS TINCÆ, but it cannot be seen without dissection.

The skin should now be divided on the side of the right labium, and the dissection should be carried from the groin to the side of the anus; the cellular membrane must be carefully removed, in order to expose the following parts.

We find the CLITORIS consisting of two spongy bodies termed Crura, which unite and form the body. The crus of each side is a cavernous body, arising from the ramus and upper part of the tuberosity of the ischium, continued along the ramus of the os pubis, and uniting with its fellow opposite to the symphysis pubis. The body formed by the crura does not extend upwards, but forms a curve downwards towards the urethra; it is divided internally by the

Septum Pectiniforme, and is attached to the symphysis pubis by a suspensory ligament; it is invested by a ligamentous membrane.

The muscles which are met with in this dissection consist of four pair, and two single muscles.

The Erector Clitoridis,
Tranversus Perinei,
Levator Ani,
Coccygeus,
} on each side.

The Sphincter Ani,
Sphincter Vaginæ,
} two single muscles.

1. The Erector Clitoridis *arises*, fleshy and tendinous, from the tuber ischii, from the inside of the ramus of the os ischium, and from the ramus of the os pubis: It passes over the crus of the clitoris, and, becoming tendinous, is lost upon it.

Use: To draw the clitoris downwards and forwards, and, by compressing it, to propel the blood.

Synonyma: First muscle of the clitoris;—Ischio-cavernosus;—Ischio-clitoridien.

Arising from the same point, and surrounded by much cellular membrane, we find

2. The Transversus Perinei.—Its *origin* is the same as in the male.

It is *inserted* into a ligamentous substance in the perineum anterius, at the point where the sphincter ani and sphincter vaginæ meet.

This ligamentous or tendinous substance deserves atention. Here, as in the male, it is the point of union into which different muscles are inserted.

Use: to sustain the perineum.

3. Surrounding the extremity of the vagina, and a

small part of the vestibulum, we find the SPHINCTER VAGINÆ; it *arises*, anteriorly, from the crura of the clitoris on each side; it surrounds the orifice of the vagina, and is

Inserted into the ligamentous point of the perineum, where the fibres of each side meet, and are connected with those of the transversi perinei, and with the sphincter ani.

Use: To contract the mouth of the vagina, and compress the plexus retiformis.

Synonyma: Constrictor cunni;—Second muscle of the clitoris;—Anulo-syndesmo-clitoridien.

4. The SPHINCTER ANI exactly resembles the same muscle in the male.

5. The LEVATOR ANI resembles the same muscle of the male; it surrounds the sides of the vagina in part, and consequently assists in constricting and supporting it.

6. The COCCYGEUS is longer than in the male, from the greater transverse diameter of the inferior aperture of the pelvis.

Under the fibres of the sphincter vaginæ, you will find the PLEXUS RETIFORMIS, or CORPUS CAVERNOSUM VAGINÆ, a spongy body, consisting of cellular substance, interwoven with a number of convoluted blood-vessels; it arises from the sides of the clitoris, passes on each side of the extremity of the vagina, is not continued completely around it, but is lost on its posterior part.

The VAGINA is the canal leading from the vestibulum to the uterus. It lies betwixt the rectum and inferior surface of the urethra and bladder, and is con-

nected to them by cellular membrane. It is composed of fibrous substance, partly ligamentous, and perhaps in part muscular; its inner surface is rugose, vascular, and occupied by mucous glands. On slitting it up, we see, at its posterior extremity, the Os Uteri, a rounded projection, with a transverse fissure.

The Uterus, or Womb.—This organ is best seen from the cavity of the abdomen. It is situated betwixt the bladder and rectum, to both of which it is connected by reflections of peritoneum; it is of the shape of a pear, somewhat flattened, inwardly hollow, outwardly of a whitish colour, and of a firm consistence. The broad upper part of the womb is called the Fundus Uteri, the narrower part is named the neck, or Cervix Uteri, and the intermediate part its Body.

The uterus has four ligaments, two on each side:

1. The Ligamentum Teres, or Round Ligament. It is a round long cord, extending from the side of the fundus uteri, and passing through the abdominal ring, to be lost in the groin.

The Ligamentum Latum, or Broad Ligament, is a broad fold of peritoneum, reflected from the body of the uterus, and connecting it on the sides of the pelvis. The uterus, together with its two broad ligaments, divides the pelvis into an anterior and posterior half; in the former of which is the bladder, and in the latter the rectum. The duplicature of the broad ligament encloses the Fallopian tube, ovary, and round ligament.

The Fallopian Tubes are two. Each tube is contained in the upper part of the doubling of the broad

ligament; it goes out from the fundus of the womb, and is a slender hollow tube: its outer end is curved downwards and backwards, and terminates by a broad fringed extremity, termed Morsus Diaboli, or the Fimbriæ.—This broad extremity is connected to the next pair of organs.

The Ovaria are two small oval bodies, white and flat, situated by the sides of the uterus, and inclosed in the posterior fold of the broad ligament behind the Fallopian tube; each ovarium is connected to the fundus uteri by a short round ligament.

The Bladder is situated before the uterus, and is described in the preceding chapter.

The Urethra is short in females, and near the bladder is surrounded by a spongy fleshy substance,—is connected to the cartilaginous arch of the pubis by the ligamentum inferius vesicæ.

The Ureter descends from the kidneys over the psoas muscle; it runs for some space betwixt the bladder and vagina, and at last perforates the bladder near the neck.

The Rectum lies behind the uterus.—See the preceding chapter.

To obtain a more satisfactory knowledge of the relative situation of the parts, the left side of the pelvis should be removed as in the male, and the parts examined in that situation.

CHAP. IV.

DISSECTION OF THE THIGH.

SECT. I.

OF THE ANTERIOR PART OF THE THIGH.

§ 1. OF THE FASCIA, CUTANEOUS VESSELS, AND NERVES.

BENEATH the integuments common to every part of the body, you will find a strong fascia, or aponeurotic expansion, investing the whole thigh. This expansion is named the FASCIA LATA FEMORIS; it consists partly of tendinous, partly of ligamentous fibres; it surrounds and covers all the muscles, and sends septa or partitions between them:—It is very strong, smooth, and tendinous on the outer part of the thigh; but, on the anterior and inner part, it is very thin, and of a cellular texture. Therefore, if you wish to demonstrate the whole extent of this fascia, it should be first exposed on the outside of the thigh, and the dissection should be continued very carefully inwards on the fore-part, where it is with difficulty distinguished from the common cellular membrane.

But, in removing the common integuments from

the fore-part of the thigh, it will be proper to attend to some parts which are situated above the fascia.

1. The VENA SAPHENA MAJOR is seen running up in the inside of the knee and thigh. At first it lies very superficial, betwixt the skin and fascia, and involved in the intermediate cellular membrane. As it ascends, it is gradually enveloped by the fibres of the fascia, and then sinks beneath it to join the femoral vein about an inch below Poupart's ligament:—In its course it is joined by several cutaneous veins.

2. Immediately under the true skin, and more superficial than the veins or nerves, you may occasionally perceive the LYMPHATIC VESSELS running, like lines of a whitish colour, to enter the inguinal glands: they are more numerous on the fore-part, than on the outside of the thigh.

3. Several CUTANEOUS NERVES are seen ramifying above the fascia. They all come from the lumbar or anterior crural nerve, pierce the fascia about the lower part of the abdomen and groin, and are distributed to the groin, and integuments on the fore-part of the thigh.

The fascia may now be exposed distinctly. Observe how extensively it arises from the bones, tendons, and ligaments. On the anterior and superior part of the thigh, it arises from Poupart's ligament*,

* At this part the fascia of the thigh is covered by a more superficial expansion, which lies over the lower part of the aponeurosis of the external oblique muscle, completely covers the crural arch, and descends some little way beyond the bend of the thigh. It has been called the *superficial fascia*. It covers the absorbent glands, &c. at the groin, and often consists of several

from the os pubis, from the descending ramus of that bone, and from the ascending ramus and tuberosity of the ischium;—behind, and on the outside, from the whole spine of the ileum, and from the sacro-sciatic ligaments. It receives a number of fibres from a muscle belonging to it, viz. the tensor vaginæ femoris, and from the tendon of the gluteus maximus;—it passes down over the whole thigh, is firmly fixed to the linea aspera, to the condyles of the femur, and to the patella, and is continued over the knee, to be attached to the heads of the tibia and fibula, after which it forms the fascia of the leg.

On the upper and anterior part of the thigh, there is a slight hollow, where the great vessels descend under the crural arch. The fascia lata forms just on the outside and upper part of this, a crescent-shaped fold, called its *semilunar edge*, which is strongly connected to the crural arch, and sometimes contributes to the strangulation in femoral hernia.

The fascia should now be dissected back; and, in lifting up the thicker part of it, which covers the outside of the thigh, you may observe that it is composed of two laminæ of fibres: the fibres of the outer lamina run in circles round the thigh, while those on the inside, which are stronger, and more firmly connected, run longitudinally.

layers separated by three glands and adipose substance. It has rather the appearance of condensed cellular membrane, than of a tendinous fascia.

§ 2. MUSCLES SITUATED ON THE FORE-PART AND INSIDE OF THE THIGH.

These are nine in number.

1. The Tensor Vaginæ Femoris—*Arises*, by a narrow, tendinous, and fleshy origin, from the external part of the anterior superior spinous process of the os ileum: it forms a considerable fleshy belly.

Inserted into the inner side of the great fascia, where it covers the outside of the thigh, and a little below the trochanter major.

Situation: Its origin lies between the origin of the sartorius, and the anterior fibres of the gluteus medius, betwixt which muscles it descends; it does not lie external to the fascia of the thigh, but is inclosed in a duplicature of it; its insertion lies anterior to that part of this membrane which arises from the tendon of the gluteus maximus.

Use: To stretch the great fascia of the thigh, to assist in the abduction of the thigh, and in its rotation inwards.

Synonyma: Musculus fasciæ latæ;—Fascialis;—Membranosus;—Ilio-aponeuri-femoral.

2. The Sartorius—*Arises*, by short tendinous fibres, from the anterior superior spinous process of the os ileum, soon becomes fleshy, extends obliquely across the thigh, and passes behind the inner condyle.

Inserted, by a broad and thin tendon, into the inner side of the tibia, immediately below its anterior tubercle.

Situation: Its origin lies between that of the tensor

vaginæ femoris, and the outer attachment of Poupart's ligament, and above the anterior fibres of the iliacus internus. It lies before the muscles of the thigh, crossing them like a strap about two inches in breadth; it runs down for some space upon the rectus femoris, passes over the vastus internus, and then over the triceps adductor longus. At the lower part of the thigh, it runs between the tendon of the triceps adductor magnus, and that of the gracilis.—In all this course, it is firmly bound down by the common fascia of the thigh. It is inserted above the tendons of the gracilis and semitendinosus, over which it sends an aponeurotic expansion.

Use: To bend the leg obliquely inwards on the thigh, and to bend the thigh forwards.

Synonyma: Longissimus femoris;—Ilio-creti-tibial.

3. The Rectus Femoris—*Arises*, by a strong tendon, from the inferior anterior spinous process of the os ileum; and, by another strong tendon, from the dorsum of that bone a little above the acetabulum, and from the capsular ligament of the hip-joint. The two tendons soon unite, and send off a large belly, which runs down over the anterior part of the thigh, forming a complete penniform muscle, and terminates in a flat but strong tendon, which is

Inserted into the upper extremity of the patella; where a thin aponeurosis is sent from it over the forepart of that bone, to terminate on the strong ligament which connects the lower part of the patella to the tibia, and is called Ligamentum Patellæ.

Situation: To expose the tendinous origins of this muscle, the origins of the sartorius and tensor vaginæ

femoris must be raised; and then that tendon, which proceeds from the inferior spinous process, may be seen partly covered with the outer edge of the iliacus internus, while the other tendon is exposed by raising the anterior and inferior fibres of the gluteus minimus. The fleshy belly, at its uppermost part, is covered by the sartorius, and, to allow that muscle to slide over it, is tendinous; below this, it is situated superficially, immediately under the fasciæ, runs down over the vasti and cruræus; and on its posterior surface, where it is in contact with those muscles, it is tendinous. Its insertion lies between the two vasti.

Use: To extend the leg on the thigh, and to bend the thigh on the pelvis; to bring the pelvis and thigh forwards on the leg.

Synonyma: Rectus cruris;—Rectus anterior;—Gracilis anterior;—Ilio-rotulien.

Under the rectus, and partly covered by it, there is a large mass of flesh, which, at first sight, appears to form but one muscle. It may, however, be divided into three; the separation on the external surface is not generally very evident, but, by following the course of the vessels which enter this mass, and by cutting through perhaps a few fibres externally, you will discover the line of separation; and this separation, as you proceed deeper with your dissection, will become very distinct. The three muscles are named vastus externus, vastus internus, and cruræus: at the upper and middle parts of the thigh, they may be separated very distinctly; but for two or three inches above the condyles, they are connected inseparably.

4. The Vastus Externus—*Arises*, tendinous and

fleshy, from the anterior surface of the root of the trochanter major, from the outer edge of the linea aspera, its whole length,—from the oblique line running to the external condyle,—and from the whole external flat surface of the thigh bone. The fleshy fibres run obliquely forwards.

Inserted into the external surface of the tendon of the rectus cruris, and into the side of the patella:—Part of it ends likewise in an aponeurosis which passes over the side of the knee to the leg, and is firmly fixed to the head of the tibia, closely adhering to the capsule of the knee-joint.

Situation: This muscle forms the large mass of flesh on the outside of the thigh; it is in part concealed by the rectus: on its outer surface it appears tendinous at its upper part, and fleshy lower down; on its internal surface, it is fleshy above and tendinous below;—it laps over the outside of the cruræus, where it arises from the linea aspera; it is situated anterior to the tendinous insertion of the gluteus maximus, and to the origin of the short head of the biceps flexor cruris.

Use: To extend the leg, or to bring the thigh forwards upon the leg.

5. The Vastus Internus—*Arises*, tendinous and fleshy, from the fore-part of the root of the trochanter minor, from all the upper edge of the linea aspera from the oblique line running to the inner condyle, and from the whole internal surface of the thigh bone. Its fibres descend obliquely downwards and forwards.

Inserted into the lateral surface of the tendon of the

rectus cruris, and into the side of the patella; it also sends off an aponeurosis, which is continued down to the leg, and covers the inner part of the capsule of the knee.

Situation: This muscle embraces the inside of the femur in the same manner as the last-described muscle does the outside, but it is much smaller;—it is also in part covered by the rectus. At its upper part the sartorius passes over it obliquely; it laps over the cruræus, and is separated from it with greater difficulty than the vastus externus is. Where it arises from the root of the trochanter, it lies anterior to the common tendon of the iliacus internus and psoas magnus; and where it arises from the linea aspera and oblique line, it is situated anterior to, and in contact with, the insertions of the pectineus and triceps adductor femoris. Like the vastus externus, its outer surface is tendinous above, while below its inner surface is tendinous, and the fleshy fibres pass obliquely from the one tendinous expansion to the other.

Use: Same as the last.

6. The CRURÆUS, or CRULALIS—*Arises*, fleshy, from between the two trochanters of the os femoris, from all the fore-part of the bone, and from the outside as far back as the linea aspera; but from the inside of the bone it does not arise, for between the fore-part of the femur and the inner edge of the linea aspera, there is a smooth plain surface, of the breadth of an inch, extending nearly the whole length of the bone, from which no muscular fibres arise.

Inserted into the posterior surface of the tendon of the rectus, and upper edge of the patella.

Situation: The principal part of this muscle is lapped over, and concealed, by the bellies of the two vasti; and the small part, which is seen projecting between the anterior edges of those muscles, lies behind the belly of the rectus cruris.

Use: Same as the last.

Synonyma: These three muscles are described by Dumas as a triceps, which he names Tri-femoro rotulien.

7. The GRACILIS *arises*, by a broad thin tendon, from the lower half of that part of the os pubis which forms the symphysis, and from the inner edge of the descending ramus:—It soon grows fleshy, and forms a belly, which, becoming narrower as it descends, terminates in a tendon, which passes behind the inner condyle of the thigh bone, and is reflected forwards, to be

Inserted in the inside of the tibia.

Situation: It arises from the os pubis on the inside of the origins of the triceps adductor femoris, lying betwixt it and the crus penis; from the pubis to the knee it runs immediately under the integuments on the inside of the thigh; it is inserted below the tendon of the sartorius, and above that of the semitendinosus.

Use: To bring the thigh inwards and forwards, and to assist in bending the leg.

Synonyma: Gracilis interior;—Rectus interior;—Sous-pubi-creti-tibial.

8. The PECTINALIS—*Arises*, fleshy, from that ridge of the os pubis which forms the brim of the

pelvis, and from the concave surface below the ridge: It forms a thick flat belly,

Inserted, by a flat tendon into the linea aspera, immediately below the lesser trochanter.

Situation: Its origin lies on the inside of the belly of the psoas magnus, where that muscle slides over the brim of the pelvis, and on the outside of the origin of the adductor longus:—It descends between the lower edge of the psoas, and the upper edge of the adductor longus; and it is inserted between these two muscles, and posterior to the origin of the vastus internus.

Use: To bend the thigh forwards, to move it inwards, and to perform rotation, by turning the toes outwards.

Synonyma: Pectinæus;—Pubio-femoral.

9. The Triceps Adductor Femoris consists of three distinct muscles, which, passing from the pelvis to the thigh, lie in different layers upon one another, and have nearly the same action.

(1.) The Adductor Longus—*Arises*, by a short strong tendon, from the upper and inner part of the os pubis, near its symphysis;—forms a large triangular belly, which, as it descends, becomes broader, but less thick.

Inserted, tendinous, into the middle part of the linea aspera, occupying rather more than one-third of its length.

Situation: It arises betwixt the pectinalis and gracilis, and above the adductor brevis:—The upper edge of its belly ranges with the lower edge of the pectinalis; and its insertion lies posterior to the origin of the

vastus internus, and anterior to the insertion of the adductor magnus.

Synonyma: Adductor primus;—Triceps primus;—long head of the triceps;—Spino-pubio-femoral.

(2.) The ADDUCTOR BREVIS—*Arises*, fleshy and tendinous, from the os pubis, between the lower part of the symphysis pubis, and the foramen thyroideum:—it forms a fleshy belly,

Inserted, tendinous, into the upper third of the linea aspera.

Situation: Its origin lies under the origins of the pectinalis and adductor longus, and on the outside of the tendon of the gracilis:—Its belly descends behind the belly of the pectinalis, and behind the superior fibres of the adductor longus; and its largest part is therefore concealed, but a small part appears between the lower edge of the pectinalis, and upper edge of the adductor longus:—It is inserted behind those muscles, but before the adductor magnus.

Synonyma: Triceps secundus;—Adductor secundus;—Short head of the triceps;—Sous-pubio-femoral.

(3.) The ADDUCTOR MAGNUS—*Arises*, principally fleshy, from the lower part of the body, and from the descending ramus of the os pubis, and from the ascending ramus of the ischium, as far as the tuberosity of that bone. The fibres run outwards and downwards, having various degrees of obliquity.

Inserted, fleshy, into the whole length of the linea aspera, into the oblique ridge above the internal condyle of the os femoris, and, by a roundish long tendon, into the upper part of that condyle.

Situation: This large muscle arises behind and below the two other adductors; it forms a flat partition betwixt the muscles on the fore and back parts of the thigh;—its insertion lies behind the insertions of the long and short adductors, and on the inside of the tendinous insertion of the gluteus maximus, and of the origin of the short head of the biceps flexor cruris: the superior fibres which cross the thigh transversely run along the lower edge of the quadratus femoris.

Use: To approximate the thighs to each other;—to roll them outwards. The two anterior heads will bend the thigh; the posterior will extend it, if it be bent forwards.

Synonyma: Adductor tertius et Adductor quartus;—Triceps tertius;—Great head of the triceps;—Ischio-pubi-femoral.

§ 3. ARTERIES, VEINS, AND NERVES ON THE FORE-PART AND INSIDE OF THE THIGH.

1. ARTERIES.

THE FEMORAL ARTERY may be said to pass along the inside of the thigh, where it emerges from under Poupart's ligament; it lies cushioned on the fibres of the psoas magnus, is called the Inguinal artery, and is very nearly in the mid space between the angle of the pubis, and the anterior superior spine of the ileum, nearer, however, by a finger's breadth to the former; having left the groin, it assumes the name of Femoral, and, in its course down the thigh, runs over the following muscles:—The pectinalis, part of

the adductor brevis, where that muscle projects betwixt the pectinalis and adductor longus; the whole of the adductor longus, and about an inch of the adductor magnus: It then slips betwixt the tendon of the adductor magnus and the bone, and, entering the ham, becomes the Popliteal artery. To find the artery in any part of its course from the crural arch to the tendinous opening, turn out the foot, ascertain the place of that vessel at the crural arch, according to the above description, and then draw a straight line downwards. —In this course, it has the belly of the vastus internus situated on its outside; it lies between the origin of that muscle, and the tendinous insertion of the muscles over which it crosses; and there is a strong interlacing of the tendinous fibres, forming a deep groove for the artery; it is also invested by a firm sheath, which consists of condensed cellular membrane, intermixed with some tendinous fibres:—For some inches below Poupart's ligament, this artery is on its fore-part only covered by cellular substance, absorbent glands, and the general fascia of the thigh; but, meeting with the inclined line of the sartorius, it is, during the rest of its course, covered by that muscle. It perforates the tendon of the adductor magnus, at the distance of rather more than one-third of the length of the bone from its lower extremity.

Observe that in popliteal aneurism the artery may be taken up either at the upper or inner, the lower or outer, margin of the Sartorius, or immediately behind that muscle: of which situations the first is the best, the second next best, and the third by far the least eligible.

Branches of the Femoral Artery*.

The A. Profunda comes off from the femoral artery at the distance of three or four inches from Poupart's ligament; it is nearly as large as the femoral itself, runs down for some little way behind it, and terminates in three or four branches, which, perforating the triceps adductor, are named Arteriæ Perforantes. These, ramifying in every direction, supply all the great mass of muscles situated on the back-part of the thigh, and inosculate largely with the sciatic, gluteal, and obturator arteries. The profunda also sends off two considerable branches, which, encircling the upper part of the thigh, are named Circumflexa Interna, and Circumflexa Externa.

The profunda is the only branch of the femoral artery which is constant in its size and situation; for though, during the whole of its course, the femoral gives off branches to the muscles, yet these muscular arteries vary much, sometimes coming off from the great artery, sometimes from the profunda, sometimes coming off as a large single trunk which subdivides, while at other times there are three or four distinct arteries.

The branches of the femoral artery may be enumerated as follows:—1. Some twigs to the inguinal glands, and some to the external parts of generation, named

* The Epigastrica and Circumflexa ilii are before described as branches of the inguinal artery.

Pudicæ Externæ. 2. Muscularis interna. 3. Muscularis externa. 4. Profunda.

The Obturator Artery, arteria obturatrix, which is a branch of the internal iliac artery, passes through the notch at the upper part of the foramen thyroideum, and ramifies on the deep-seated muscles at the upper and inner part of the thigh.

2. VEINS.

The Femoral Vein adheres closely to the femoral artery in its passage out of the abdomen, and accompanies it in its course down the thigh, where it passes under Poupart's ligament; it lies on the inside of the artery, but, as it descends, it turns more and more posteriorly, so that where they perforate the tendon of the adductor magnus, the vein is situated fairly behind the artery.

Its branches correspond to those of the femoral artery; but about an inch below Poupart's ligament, it receives the vena saphena major, to which there is no corresponding artery.

The Obturator Vein accompanies the obturator artery, and has the same distribution.

3. NERVES.

Nervus Cruralis Anterior, or the Anterior Crural nerve, where it passes from under Poupart's ligament, lies about half an inch on the outside of the femoral artery; it immediately divides into a number of branches, which supply the muscles and integu-

ments on the fore-part and outside of the thigh: A considerable branch, however, accompanies the femoral artery, crosses that vessel where it is about to perforate the adductor magnus, runs behind the sartorius, and appears as a cutaneous nerve on the inside of the knee; proceeding downwards on the inside of the leg, it is largely distributed over the tibia, is intricated with the vena saphena major, and terminates on the inner ankle, and upper part of the foot. This branch is named Nervus Saphenus, or Cutaneus Longus.

Another branch, which is distributed to the vastus internus, generally runs for some way in company with the femoral vessels.

Nervus Obturator, or the obturator nerve, is found accompanying the obturator artery and vein; it has the same distribution, and some branches extend as far as the internal condyle of the thigh bone, and communicate with the nervus saphenus.

SECT. II.

OF THE POSTERIOR PART OF THE THIGH.

§ 1. OF THE FASCIA.

Above that part of the great fascia which invests the thigh behind, we meet with several cutaneous nerves; these are of little importance;—they have their origin either from the lumbar nerves, and come over the spine of the os ilium, or from the great sciatic

nerve, and emerge under the lower margin of the gluteus maximus. Other twigs come from the sacral nerves, and from the sciatic in its course down the thigh.

§ 2. MUSCLES SITUATED ON THE BACK-PART OF THE THIGH.

THESE are eleven.

On removing the integuments and fascia from the hip, we denude,

1. The GLUTEUS MAXIMUS.—It *arises*, fleshy, from the posterior third of the spine of the os ileum, from the whole lateral surface of the sacrum, below the posterior spinous process of the ileum; from the back-part of the posterior or inferior sacro-sciatic ligament*, over which the edge of this muscle hangs in a folded manner, and from the lateral surface of the os coccygis.

The fleshy fibres proceed obliquely forwards and downwards, forming a thick broad coarse muscle, and, converging gradually, terminate in a strong flat tendon. This tendon slides over the posterior part of

* The sacro-sciatic ligaments are two in number; they pass between the ischium and sacrum.

1. The external or inferior, or posterior, sacro-sciatic ligament arises from the external edge of the transverse processes of the sacrum, descends obliquely, and is inserted into the tuberosity of the os ischium.

2. The internal, or anterior, arises from the edge of the transverse processes of the sacrum, and of the os coccygis; it passes across on the inside of the external, and is inserted into the point of the spinous process of the ischium.

the trochanter major; sends off a great quantity of tendinous fibres, to be inseparably joined to the fascia lata of the thigh; and is

Inserted, into a rough surface at the upper and outer part of the linea aspera, immediately below the trochanter major; also very extensively into the fascia lata, which covers the former insertion.

Situation: It is quite superficial, covering all the other muscles which are situated on the back-part of the hip, covering also the tuber ischii, and the tendons of the muscles which arise from that projection. Its insertion lies between the vastus externus and the adductor magnus femoris, and immediately above the origin of the short head of the biceps flexor cruris:—so much adipose membrane is entangled with this muscle, that it is very difficult to dissect it clean, and quite impossible, if you do not dissect in the course of the fibres, which are divided into very large and strong fasciculi.

Use: To restore the thigh, after it has been bent;—to rotate it outwards; to extend the pelvis on the thigh, and maintain it in that position in the erect posture of the body.

Synonyma: Gluteus magnus;—Gluteus major;—Ilio-sacro-femoral.

The muscle is now to be lifted from its origin, and left hanging by its tendon; remark the large bursa mucosa formed between the tendon and the trochanter major; and another between its insertion into the fascia and the tendon of the vastus externus.

2. The Gluteus Medius—*Arises*, fleshy, from

all the outer edge of the spine of the os ileum, as far as the posterior tuberosity; from the dorsum of the bone, between the spine, and semicircular ridge (which passes from the anterior superior spinous process to the ischiatic notch); also from the rough surface which extends from the anterior superior to the anterior inferior spinous process, and from the inside of a fascia which covers its anterior part. The fibres converge into a strong and broad tendon, which is

Inserted into the upper and outer part of the great trochanter.

Situation: The posterior part of the belly and the tendon are concealed by the gluteus maximus, but the anterior and largest part of this muscle is superficial, being only covered by a fascia; it lies behind the origin of the tensor vaginæ femoris, and above the belly of the pyriformis; it covers the gluteus minimus.

Use: To draw the thigh bone outwards, or away from the opposite limb; to maintain the pelvis in a state of equilibrium on the thigh in progression, while the other foot is raised from the ground; by its posterior fibres to rotate the limb outwards; and by its anterior inwards.

Synonyma: Ilio-trochanterien.

Having lifted up this muscle from its origin, you will discover,

3. The Gluteus Minimus.—It *arises*, fleshy, from the semicircular ridge of the ileum, and from the dorsum of the bone below the ridge within half an inch of the acetabulum. Its fibres run

in a radiated direction towards a strong tendon, which is

Inserted into the anterior and superior part of the great trochanter.

Situation: It is entirely concealed by the gluteus medius, and between their tendons there is a bursa mucosa.

Use: Same as that of the preceding.

Synonyma: Gluteus minor;—Ilio-ischii-trochanterien.

4. The PYRIFORMIS—*Arises*, within the pelvis, by three tendinous and fleshy origins, from the second, third, and fourth false vertebræ or divisions of the sacrum. It forms a thick belly, which passes out of the pelvis below the niche in the posterior part of the ileum (from which it receives a few fleshy fibres), and above the superior sacro-sciatic ligament.

Inserted, by a roundish tendon, into the uppermost part of the cavity at the root of the trochanter major.

Situation: Like the other small muscles of the hip, it is entirely concealed by the gluteus maximus; its belly lies behind and below the gluteus medius, but is not at all covered by it, and above the superior gemellus. Its tendon is covered, at the place of insertion, by the posterior fibres of the gluteus medius. Sometimes the pyriformis is divided into two distinct muscles, by a branch of the great sciatic nerve.

Use: To move the thigh a little upwards, and roll it outwards.

Synonyma: Iliacus externus;—Sacro-trochanterien.

5. The GEMINI consist of two heads, which are distinct muscles.

(1.) The superior arises from the back-part of the spinous process of the ischium.

(2.) The inferior from the upper part of the tuberosity of the os ischium, and the anterior surface of the posterior sacro-sciatic ligament.

Inserted, tendinous and fleshy, into the cavity at the root of the trochanter major, immediately below the insertion of the pyriformis, and above the insertion of the obturator externus.

Situation: Like the other muscles, they are covered by the gluteus maximus; they lie below the pyriformis, and above the quadratus femoris; they are united by a tendinous and fleshy expansion, which forms a purse or sheath for the tendon of the obturator internus

Use: To roll the thigh outwards, and to bind down the tendon of the obturator internus.

Synonyma: Gemelli;—Part of the marsupialis;—Ischio-spini-trochanterien.

Lying between the bellies of the gemini, you will perceive,

6. The OBTURATOR INTERNUS.—It *arises*, tendinous and fleshy, from more than one-half of the internal circumference of the foramen thyroideum, and from the inner surface of the ligament which fills up that hole; its inside is covered by a portion of the levator ani; it forms a flattened tendon, which passes out of the pelvis in a sinuosity betwixt the spinous process and tuberosity of the ischium; and, becoming rounder, is

Inserted into the pit at the root of the trochanter major.

Situation: Its origin lies within the pelvis, and cannot be exposed till the contents of that cavity are removed; the tendon, where it passes through the notch in the ischium, is seen projecting between the two origins of the gemelli, and is covered by the gluteus maximus; but, farther forward, it is inclosed as in a sheath, and concealed by the gemelli, and is inserted between them. There is a bursa mucosa betwixt the tendon of this muscle, and the surface of ischium over which it glides.

Use: To roll the os femoris obliquely outwards.

Synonyma: Marsupialis seu Bursalis;—Intra-pelvio-trochanterien.

7. The QUADRATUS FEMORIS—*Arises*, tendinous and fleshy, from an oblique ridge, which descends from the inferior edge of the acetabulum along the body of the ischium, between its tuberosity and the foramen thyroideum: its fibres run transversely, to be

Inserted, fleshy, into a rough ridge on the back part of the femur, extending from the root of the greater trochanter to the root of the lesser.

Situation: It is concealed by the gluteus maximus, lies below the inferior head of the gemini, and above the superior fibres of the adductor magnus; its origin is in contact with the origin of the hamstring muscles.

Use: To roll the thigh outwards.

Synonyma: Tuber-ischio-trochanterien.

On lifting up the quadratus femoris from its origin, and leaving it suspended by its insertion, you

discover, running in the same direction, the strong tendon of,

8. The Obturator Externus.—This muscle *arises*, fleshy, from almost the whole circumference of the foramen thyroideum, and from the external surface of the obturator ligament; its fibres pass outwards through the notch placed between the inferior margin of the acetabulum and the tuberosity of the ischium, wind around the cervix of the os femoris, adhering to the capsular ligament, and terminate in a strong tendon, which is

Inserted into the lowermost part of the cavity, at the root of the trochanter major, immediately below the insertion of the inferior head of the gemini.

Situation: This muscle cannot be distinctly seen, until all the muscles which run from the pelvis to the upper part of the thigh are removed, both on the fore and back-part; its origin lies on the fore-part, and is concealed by the muscles situated there, as the pectinæus, triceps, &c. and on the back-part the tendon is concealed by the quadratus femoris, and, when that muscle is removed, it is found to run along the lower edge of the inferior head of the gemini.

Use: To roll the thigh bone obliquely outwards.

Synonyma: Extra-pelvio-pubi-trochanterien.

9. The Biceps Flexor Cruris—*Arises*, by two distinct heads; the first, called the Long Head, arises in common with the semitendinosus, by a short tendon, from the outer part of the tuberosity of the ischium, and, descending, forms a thick fleshy belly. —The second, termed the Short Head, arises, tendinous and fleshy, from the linea aspera, immediately

below the insertion of the gluteus maximus; and from the oblique ridge running to the outer condyle, where it is connected with the fibres of the vastus externus. The two heads unite at an acute angle, a little above the external condyle, and terminate in a strong tendon, which is

Inserted into a rough surface on the outside of the head of the fibula.

Situation: The long head of this muscle is concealed at its upper part by the inferior fibres of the gluteus maximus; below this, it is situated quite superficial, immediately under the fascia, running from the pelvis to the knee between the vastus externus and semitendinosus, and forming the outer hamstring.—The short head is partly concealed by the long head; its fibres arise from the linea aspera, between those of the adductor magnus and vastus externus;—it forms the outer hamstring.

Use: To bend the leg, and particularly by means of its shorter head to twist the leg outwards in the bent state of the knee.

Synonyma: Biceps cruris;—Ischio-fémoro-péronien.

10. The Semitendinosus—*Arises*, tendinous, in common with the long head of the biceps, from the tuberosity of the ischium; it has also some fleshy fibres arising from that projection more outwardly:—as it descends, it arises, for two or three inches, fleshy, from the inside of the tendon of the biceps; forms a thick belly, and terminates at the distance of three or four inches from the knee in a long round tendon, which, be-

coming flat, passes behind the head of the tibia, and is reflected forwards, to be

Inserted into the anterior angle of that bone, some little way below its tubercle.

Situation: This muscle, as well as the biceps, is covered above by the gluteus maximus; its belly lies between the biceps flexor and gracilis, and is situated entirely superficial; its tendon is inserted below that of the gracilis: The belly of this muscle is intersected, about its middle, by a narrow transverse tendinous line.

Use: To bend the leg backwards, and a little inwards.

Synonyma: Seminervosus;—Ischio-creti-tibial.

11. The SEMIMEMBRANOSUS—*Arises*, by a strong round tendon, from the upper and outer part of the tuberosity of the ischium; the tendon, soon becoming broader, sends off obliquely a fleshy belly; this muscle is continued, fleshy, much lower down than that last described.—The fleshy fibres terminate obliquely in another flat tendon, which passes behind the inner condyle, sends off a thin aponeurotic expansion under the inner head of the gastrocnemius, to cover the posterior part of the capsule of the knee-joint, and to be affixed to the external condyle: the tendon then becoming rounder, is

Inserted into the inner and back part of the head of the tibia.

Situation: This is a semi-penniform muscle; its origin lies anterior to the tendinous origin of the two last muscles, and at the same time more outwardly,

being situated between them and the origin of the quadratus femoris :—its belly, in its descent, is at first concealed by the biceps and semitendinosus; but, at its lower part, it appears projecting between them. It lies in contact with the posterior surface of the triceps magnus.

Use: To bend the leg backwards.

Synonyma: Ischio popliti-tibial.

The two last-described muscles properly form the inner hamstring; but some enumerate among the tendons of the inner hamstring, the sartorius and gracilis.

§ 3. VESSELS AND NERVES ON THE POSTERIOR PART OF THE THIGH.

ARTERIES.

1. Arteria Glutea, or Iliaca Posterior.—This is the largest branch of the internal iliac artery; it passes out of the pelvis at the upper part of the sciatic notch. On raising the gluteus maximus and medius, this artery is seen coming over the pyriformis, betwixt the superior edge of that muscle and the inferior edge of the os ileum (where that bone forms the upper part of the sciatic notch), and immediately behind the posterior fibres of the gluteus minimus. The principal trunk passes under the gluteus medius, and ramifies on the dorsum of the os ileum; other large branches are also continued to the gluteus maximus, and the muscles situated on the back-part of the pelvis.

2. Arteria Sciatica, vel Ischiatica, is another large branch of the internal iliac, which comes out

from under the pyriformis, betwixt the lower edge of that muscle and the superior sacro-sciatic ligament; it lies upon the back-part of the hip, under the gluteus maximus;—its principal branches descend between the trochanter major and tuberosity of the ischium; it sends other twigs round towards the anus and perineum.

Both these arteries inosculate with the other branches of the internal and external iliac.

The VEINS correspond exactly to the arteries. They terminate in the internal iliac vein.

NERVES.

NERVUS SCIATICUS, vel ISCHIATICUS, or the Great Sciatic Nerve, is seen coming out of the pelvis, along with the sciatic artery, below the pyriformis. It descends over the gemini and quadratus femoris in the hollow betwixt the great trochanter and the tuberosity of the ischium,—runs down the back-part of the thigh, anterior to, *i. e.* nearer the bone than the hamstring muscles; being situated between the anterior surface of the semimembranosus, and the posterior surface of the triceps adductor longus. After sending off the peroneal nerve, it arrives in the ham, and becomes the POPLITEAL NERVE. In this course it gives off several branches to the muscles and integuments. It sometimes perforates the belly of the pyriformis by distinct trunks, which afterwards unite.

SECT. III.

DISSECTION OF THE HAM AND FASCIA ON THE BACK-PART OF THE LEG.

On removing the integuments from the back-part of the knee-joint and leg, we observe a Fascia, which covers the great vessels and the muscles. It is evidently continued from the great fascia of the thigh, is strengthened by adhesions to the condyles of the femur, and to the head of the fibula, and is prolonged upon the muscles on the back of the leg.

Upon dissecting back that part of the fascia which covers the ham, the Great Sciatic Nerve appears, lying between the outer and inner hamstring-muscles. This nerve, having given off branches about the ham, and to the integuments on the back of the leg, divides at some distance above the condyles of the femur into two large branches.

1. The Greater Nerve continues its course betwixt the heads of the gastrocnemii muscles. In the ham it is named the Popliteal Nerve, and where it descends in the leg, the Posterior Tibial.

2. The Lesser Nerve, which is the external branch, is named the Peroneal or Fibular Nerve; it passes outwards and obliquely downwards, runs between the external head of the gastrocnemius, and the tendon of the biceps flexor cruris; and sinks among the muscles which surround the head of the fibula.

Branches of the Peroneal Nerve.

(1.) Cutaneous branches are sent off from the peroneal nerve at its uppermost part over the gastrocnemius to the integuments in the back-part of the leg, and outer side of the foot. Branches also are distributed about the joint.

(2.) A large branch, the Anterior Tibial Nerve, passes under the flesh of the peroneus longus and extensor longus digitorum, where those muscles arise from the heads of the fibula and tibia; and comes in contact with the anterior tibial artery, which it accompanies down the leg.

(3.) Another branch passes into the upper extremity of the peroneus longus, and is continued in the substance of that muscle for some space. It then emerges from beneath it, and continues its course under the muscles on the fore-part and outside of the leg; it pierces this fascia, and, becoming cutaneous, is lost on the ankle and upper surface of the foot.

Below the great sciatic nerve, there is much cellular membrane and fat, which being removed, the Great Popliteal Vein is exposed. It adheres to the Popliteal Artery, which lies under it close upon the bone.

Arteria Poplitea is the trunk of the Femoral, which assumes that name, after it has perforated the tendon of the triceps. It lies between the condyles of the femur, close upon the bone, and descends between the heads of the gastrocnemius. It runs over the popliteus, and under the gastrocnemius, that is, in the

erect position it is anterior to the gastrocnemius, and posterior to the popliteus: at the lower edge of the popliteus, the popliteal artery divides into the Anterior and Posterior Tibial Arteries.

Branches.

1. Two Perforating Arteries come off from the artery immediately after it has entered the ham;—they are small, and perforate from the ham to the fore-part of the thigh.

2. Articular Arteries are four or five small twigs, ramifying over the knee-joint and neighbouring muscles, inosculating with one another, and with the arteries below the knee.

3. Two branches are sent to the two heads of the gastrocnemii muscles; twigs are also given to the soleus, plantaris, &c.

The Popliteal Vein receives branches corresponding to those of the artery; it lies behind the artery in the erect posture.

About two inches above the condyle, it receives the Vena Saphena Minor, which returns the blood from the outer side of the foot;—the trunk of this vein lies under the fascia.

CHAP. V.

DISSECTION OF THE LEG AND FOOT.

SECT. I.

OF THE FORE-PART OF THE LEG AND FOOT.

ON dissecting off the integuments from the fore-part of the leg, we find a strong fascia continued from the thigh; it adheres firmly to every projecting point of bone, to the head and spine of the tibia, and to the fibula; it grows thinner towards the lower part of the leg; but where it passes over the ankle, it again becomes very strong by its adhesions to the outer and inner ankle, and forms a strong ANNULAR or TRANSVERSE LIGAMENT, which binds down the tendons, and is evidently but a thicker and stronger part of the general fascia of the leg. This annular ligament seems to consist of two distinct cross bands, which, going from the point of the outer ankle and neighbouring part of the os calcis, are fixed to the malleolus internus, and to the inside of the os naviculare.

Before removing the fascia, it will be proper to remark,

1. The vena saphena major, running upon the in-

side of the tibia, and accompanied by a cutaneous nerve, the nervus saphenus.

2. Several cutaneous nerves, branching on the outer and fore-part of the leg and foot, and derived from the nervus peroneus.

The fascia should then be dissected off; and, in doing this, remark, that it is firmly attached to the bones, and also to the bellies of the muscles at the upper part of the leg, so that their surfaces appear ragged, where the fibres are separated which arose from the inside of the fascia: Remark also, that it sends down processes between the muscles; these are named intermuscular ligaments, or tendons; they give origin to the fibres of all the muscles betwixt which they pass, connecting them together inseparably, so that the dissection is difficult, and has a rough appearance.

MUSCLES SITUATED ON THE FORE-PART AND OUTSIDE OF THE LEG.

These are six in number.

1. The Tibialis Anticus—*Arises*, principally fleshy, from the exterior surface of the tibia, from its anterior angle or spine, and from nearly half of the interosseous ligament; from these surfaces it continues to arise down two-thirds of the length of the bone; also from the inner surface of the fascia of the leg, and from the intermuscular ligaments. The fleshy fibres descend obliquely, and terminate in a strong tendon, which crosses from the outside to the fore-part of the tibia, passes through a distinct ring of the annular liga-

ment near the inner ankle, runs over the astragulus and os naviculare, and is

Inserted into the upper and inner part of the os cuneiforme internum, and the base of the metatarsal bone supporting the great toe.

Situation: The belly is quite superficial, lying under the fascia of the leg on the outside of the spine of the tibia; the insertion of the tendon is concealed in part by the abductor and flexor brevis of the great toe. Between the tendon of this muscle and the os cuneiforme, we find a small bursa mucosa.

Use: To draw the foot upwards and inwards; or, in other words, to bend the ankle-joint.

Synonyma: Tibio-sus-metatarsien.

2. Extensor Longus Digitorum Pedis—*Arises*, tendinous and fleshy, from the outer part of the head of the tibia; from the head of the fibula; from the anterior angle of the fibula almost its whole length; and from part of the smooth surface between the anterior and internal angles; from a small part of the interosseous ligament; from the fascia and intermuscular ligaments.

Below the middle of the leg, it splits into four round tendons, which pass under the annular ligament, become flattened, and are

Inserted into the root of the first phalanx of each of the four small toes, and expanded over the upper side of the toes as far as the root of the last phalanx.

Situation: This muscle also runs entirely superficial; it lies between the tibialis anticus and peroneus longus, being firmly connected to them by intermus-

cular ligaments; but, at the lower part of the leg, it is separated from the tibialis anticus by the extensor pollicis longus, and from the peroneus longus by the peroneus brevis.

Use: To extend all the joints of the four small toes; —to bend the ankle joint.

Synonyma: Peronéo-tibi-sus-phalangettien commun.

3. Peroneus Tertius—*Arises*, fleshy, from the anterior angle of the fibula, and from part of the smooth surface between the anterior and internal angles, extending from below the middle of the bone downwards to near its inferior extremity;—sends its fleshy fibres forwards to a tendon, which passes under the annular ligament in the same sheath as the extensor digitorum longus, and is

Inserted into the base of the metatarsal bone that supports the little toe.

Situation: The belly is inseparably connected with the extensor longus digitorum, and is properly the outer part of it; it lies between that muscle and the peroneus brevis. The tendon runs down on the outside of that tendon of the extensor longus digitorum which goes to the little toe. The whole of the muscle is superficial.

Use: To assist in bending the foot.

Synonyma: Nonus Vesalii;—Petit-peroneo-sus-metatarsien.

4. Extensor Proprius Pollicis Pedis—*Arises*, tendinous and fleshy, from part of the smooth surface between the anterior and internal angles of the fibula, and from the neighbouring part of the interosseous

ligament, extending from some distance below the head of the bone to near its inferior extremity ; a few fibres also arise from the lower part of the tibia;—the fibres pass obliquely downwards and forwards into a tendon, which, inclining inwards, passes over the fore-part of the astragalus and os naviculare, and over the junction of the os cuneiforme internum and os cuneiforme medium, to be

Inserted into the base of the first and of the second phalanges of the great toe*.

Situation : The belly is concealed between the tibialis anticus and extensor digitorum longus, and cannot be seen till those muscles are separated from one another;—the tendon is superficial, running between the tendons of those two muscles.

Use : To extend the great toe; and to bend the ankle.

Synonyma : Extensor longus pollicis;—Péronéo-susphalanginien du pouce.

The Peroneus Longus—*Arises*, tendinous and fleshy, from the fore-part and outside of the head of the fibula, and from the adjacent part of the tibia, from the external angle of the fibula, and from the smooth surface between the anterior and external angles as far down as one-third of the length of the bone from its lower extremity; also from the fascia of the leg and intermuscular ligaments. The fibres run obliquely outwards into a tendon, which passes behind the outer ankle, through a groove in the

* N. B. It is to be understood, that the great toe has only two phalanges.

lower extremity of the fibula; is then reflected forwards through a superficial fossa in the outside of the os calcis, passes over a projection, runs in a groove in the os cuboides, passes over the muscles in the sole of the foot, and is

Inserted, tendinous, into the outside of the base of the metatarsal bone that sustains the great toe, and into the os cuneiforme internum.

Situation: The belly is quite superficial; it lies between the outer edge of the extensor longus digitorum and the anterior edge of the soleus, connected to both by intermuscular ligaments. The tendon is superficial where it crosses the outside of the os calcis, but, in the sole of the foot, is concealed by the muscles situated there, and will be seen in the dissection of that part.

Use: To extend the ankle-joint, turning the sole of the foot outwards.

Synonyma: Peroneus maximus, vulgo, Peroneus posterior;—Peroneus primus, seu posticus;—Tibi-péroneo-tarsien.

6. The Peroneus Brevis—*Arises*, fleshy, from the outer edge of the anterior angle of the fibula, and from part of the smooth surface behind that angle; beginning about one-third down the bone, and continuing its adhesion to near the ankle; from the fascia of the leg, and from the intermuscular ligaments:—The fibres run obliquely towards a tendon, which passes through the groove of the fibula behind the outer ankle, being there inclosed in the same ligament with the tendon of the peroneus longus, then through a se-

parate groove on the outside of the os calcis, and is

Inserted into the external part of the base of the metatarsal bone that sustains the little toe.

Situation: This muscle arises between the extensor longus digitorum and peroneus longus; its belly is overlapped, and concealed by the belly of the peroneus longus; but, as it continues fleshy lower down, it is seen, above the ankle, projecting on each side of the tendon of that muscle:—Below, it is separated from the peroneus tertius by that projection of the fibula which forms the outer ankle, and which is only covered by the common integuments. The tendon, where it passes through the groove of the fibula, lies under that of the peroneus longus, *i. e.* nearer the bone; but it is soon seen before it, and, on the side of the os calcis, runs above it.

Use: Same as that of the peroneus longus.

Synonyma: Peroneus medius vel anticus;—Peroneus secundus;—Peroneus brevis;—Grand peroneo-sus-metatarsien.

MUSCLES ON THE UPPER PART OF THE FOOT.

Only one muscle is found in this situation.

Extensor Brevis Digitorum Pedis—*Arises*, fleshy and tendinous, from the anterior and upper part of the os calcis, from the os cuboides, and from the astragalus; forms a fleshy belly, divisible into four portions; these send off four slender tendons, which are

Inserted, the first tendon, into the first phalanx of the great toe; and the other three into all the small toes except the little one, uniting with the tendons of the extensor digitorum longus, and being attached to the upper convex surface of all the phalanges.

Situation: The belly of this muscle lies under the tendons of the extensor digitorum longus and peroneus brevis; it is not, however, concealed, but is seen projecting behind and betwixt these tendons; it assists in forming the tendinous membrane which invests the upper surface of all the phalanges of the toes.

Use: To extend the toes.

Synonyma: It is sometimes described as two muscles, the extensor brevis pollicis pedis, and extensor brevis digitorum pedis;—Calcaneo-sus-phalangéttien commun.

OF THE VESSELS AND NERVES IN THE FORE-PART OF THE LEG AND FOOT.

1. ARTERIES.

Arteria Tibialis Antica.—The anterior tibial artery passes from the ham betwixt the inferior edge of the popliteus, and the superior fibres of the soleus, and then through a large perforation in the interosseous ligament, to reach the fore-part of the leg; this perforation is much larger than the size of the artery, and is filled up by the fibres of the musculus tibialis posticus, which may thus be said to arise from the fore-part of the tibia.—The artery then runs down

close upon the middle of the interosseous ligament, between the tibialis anticus and extensor proprius pollicis; below the middle of the leg, it leaves the interosseous ligament, and passes gradually more forwards; it crosses under the tendon of the extensor proprius pollicis*, and is then situated between that tendon, and the first tendon of the extensor longus digitorum: at the ankle it runs over the fore-part of the tibia, being now situated more superficially; then over the astragalus and os naviculare, and over the junction of the os cuneiforme internum and medium; crossing under that tendon of the extensor brevis digitorum which goes to the great toe.—Arriving at the space between the basés of the two first metatarsal bones, it plunges into the sole of the foot, and immediately joins the plantar arch.

BRANCHES.

1. A. Recurrens, which ramifies over the fore-part of the knee, inosculating with the articular arteries.

2. Numerous twigs to the tibialis anticus, extensor pollicis, and other muscles on the fore-part of the leg.

3. A. Malleolaris Interna ramifies over the inner ankle, and inosculates with the perineal and posterior tibial arteries.

4. The External Malleolar ramifies over the outer ankle.

* It is crossed by that tendon just above the lower head of the tibia, while under the annular ligament.

5. The TARSAL and METATARSAL ARTERIES are two small branches which cross the tarsal and metatarsal bones, and pass obliquely to the outer edge of the foot.

From the tarsal or metatarsal artery come off the INTEROSSEAL ARTERIES, which supply the interosseal spaces, and the back-part of the toes.

6. A large branch comes off from the anterior tibial, where it is about to plunge into the sole of the foot; it runs along the space betwixt the two first metatarsal bones, and at the anterior extremity of those bones, bifurcates into,

(1.) A. DORSALIS HALLUCIS, a considerable branch which runs on the back-part of the great toe.

(2.) A branch which runs on the inner edge of the toe next to the great one.

2. VEINS.

The ANTERIOR TIBIAL VEIN consists of two branches, which accompany the artery and its ramifications.

3. NERVES.

The ANTERIOR TIBIAL NERVE is a branch of the peroneal nerve; it is seen in the ham arising from the peroneal, and crossing under the muscles on the outside of the fibula:—It emerges from under the extensor longus digitorum, comes in contact with the anterior tibial artery, and accompanies it down the leg; it is distributed on the back of the foot and toes.

SECT. II.

DISSECTION OF THE POSTERIOR PART OF THE LEG.

THE fascia which invests the posterior part of the leg, is much thinner and less strong than in the fore-part; it must be removed, to expose the parts now to be described.

MUSCLES ON THE POSTERIOR PART OF THE LEG.

THESE are seven in number.

1. The GASTROCNEMIUS EXTERNUS, or GEMELLUS—*Arises*, by two distinct heads:—The first, or Internal Head, arises, tendinous, from the upper and back part of the internal condyle of the os femoris, and fleshy from the oblique ridge over that condyle.—The second, or External Head, arises, in the same manner, from the external condyle. Each of the heads forms a fleshy belly, the fibres of which are oblique, passing from a tendinous expansion which covers the posterior surface of the muscle, to another tendinous expansion which covers the anterior surface, or that surface which lies nearest the bones. The two bellies, of which the internal is by much the largest, are separated by a considerable triangular interval, in which the popliteal blood-vessels and nerves pass to the leg, but descending, unite a little below the knee-joint in a middle tendinous line, and below the middle of the tibia send off a broad flat tendon, which unites a little above the ankle with the tendon of the soleus.

Reflect the two heads of the gastrocnemius from the femoral condyles, and you will then expose,

2. The SOLEUS, or GASTROCNEMIUS INTERNUS—which *arises*, by two origins or heads. The first, or External Origin, which is by much the largest, arises, principally fleshy, from the posterior surface of the head of the fibula, and from the external angle of that bone, for two-thirds of its length, immediately behind the peroneus longus. The second, or internal head, arises, fleshy, from an oblique ridge on the posterior surface of the tibia, just below the popliteus, and from the inner angle of that bone, during the middle third of its length. The two heads which are separated at first by the posterior tibial artery and nerve, unite immediately, form a large belly, which, covered by the tendon of the gastrocnemius, is continued, fleshy, to within a short distance of the ankle-joint; a little above which the tendons of the gastrocnemius and soleus unite, and form a strong round tendon, named the TENDO ACHILLIS, which slides over the upper and posterior part of the os calcis, where it is furnished with a small bursa mucosa, to be

Inserted into a rough surface on the back-part of that bone.

Situation: The gastrocnemius arises between the hamstring-tendons: Its belly is superficial, and forms the upper or greater calf of the leg; on lifting it up, the tendon is seen continued some way on its inner surface.

The soleus has its largest part concealed by the gastrocnemius, but part of it appears on each side of the belly of that muscle; and, at the lower part of the leg,

the belly is seen projecting through the tendon of the gastrocnemius, and forming the lower calf. Its fleshy belly is tendinous on its posterior surface, where the tendon of the gastrocnemius slides over it; and there is a bursa mucosa betwixt the upper part of the os calcis and the tendo Achillis.

Use: To elevate the os calcis, and thereby to lift up the whole body, as a preparatory measure to its being carried forward in progression;—to carry the leg backwards on the foot when that is fixed;—the gastrocnemius, from its origin in the thigh, also bends the leg on the thigh.

Synonyma: GASTROCNEMIUS:—Bi-femoro-calcanien.

SOLEUS:—Tibio-peronei-calcanien.

Both muscles are sometimes called Extensor Tarsi Suralis, vel Extensor Magnus.

The heads of the gastrocnemius should now be lifted up, which will expose,

3. The PLANTARIS.—This muscle *arises*, fleshy, from the upper part of the external condyle, and from the oblique ridge above that condyle; forms a pyramidal belly about three inches in length, which adheres to the capsule of the knee-joint, runs over the popliteus, and terminates in a long, slender, thin tendon. This tendon passes obliquely inwards over the inner head of the soleus, and under the gastrocnemius; emerges from between those two muscles, where their tendons unite, and then runs down by the inside of the tendo Achillis, to be

Inserted into the posterior part of the os calcis, on

the inside of the insertion of the tendo Achillis, and somewhat before it.

Situation: The origin and belly of this muscle are concealed by the external head of the gastrocnemius; the lower part of the tendon is the only part that is superficial.

Use: To extend the foot, and roll it inwards, and to assist in bending the leg.

Synonyma: Tibialis gracilis;—Extensor tarsi minor;—Petit-femoro-calcanien.

4. The Popliteus—*Arises*, within the capsular ligament of the knee, by a round tendon, from a deep pit or hollow on the outer side of the external condyle; adheres to the posterior and outer surface of the external semilunar cartilage; passes, within the cavity of the joint, over the side of the condyle to its back-part; perforates the capsular ligament, and forms a fleshy belly, which runs obliquely inwards, being covered by a thin tendinous fascia, to be

Inserted, broad, thin, and fleshy, into an oblique ridge on the posterior surface of the tibia, a little below its head, and into the triangular space above that ridge.

Situation: This muscle is concealed entirely by the gastrocnemius; it lies above the inner head of the soleus; it is more deeply situated than the plantaris, which crosses over it.

Use: To bend the leg, and, when bent, to roll it, so as to turn the toes inwards.

Synonyma: Femora-popliti-tibial.

The belly of the soleus should now be lifted, in order to expose the deeply-seated muscles. A strong

membranous fascia is seen connecting and investing them, which is to be removed. This fascia also covers the posterior tibial vessels and nerve, but the description of the course of these vessels, though seen in this stage of the dissection, must be deferred.

The deep-seated muscles are,

The Flexor Longus Digitorum Pedis, situated behind the tibia.

The Flexor Longus Pollicis Pedis, situated behind the fibula.

The Tibialis Posticus, which is almost concealed by the two other muscles, and by the fascia, which connects them, and binds them down.

5. The Flexor Longus Digitorum Pedis Perforans—*Arises*, fleshy, from the posterior flattened surface of the tibia, between its internal and external angles, below the attachment of the soleus, and continues to arise from the bone to within two or three inches of the ankle; the fibres pass obliquely into a tendon which is situated on the posterior edge of the muscle. This tendon runs behind the inner ankle in a groove of the tibia, passes under a stong ligament which goes from the inner ankle to the os calcis, and, having received a strong tendinous slip from the flexor pollicis longus, divides about the middle of the sole of the foot into four tendons, which pass through the slits in the tendons of the flexor digitorum brevis, and are

Inserted into the extremity of the last joint of the four lesser toes.

Situation: The belly of this muscle is concealed by the soleus, and lies on the inside of the flexor longus

pollicis. The situation of the tendon is described with the muscles situated in the sole of the foot.

Use: To bend the last joint of the toes, and to assist in extending the foot.

Synonyma: Flexor tertii internodii digitorum pedis; —Tibio-phalangéttien-commun.

6. Flexor Longus Pollicis Pedis—*Arises*, fleshy, from the posterior flat surface of the fibula, continuing its origin from some distance below the head of the bone to within an inch of the ankle. The fleshy fibres terminate in a tendon, which passes behind the inner ankle through a groove in the tibia; next through a groove in the astragalus, crosses in the sole of the foot the tendon of the flexor longus digitorum, to which it gives a slip of tendon; passes between the two sesamoid bones, and is

Inserted into the last joint of the great toe.

Situation: The belly of this muscle is covered by the soleus; it lies on the outside of the flexor longus digitorum, between that muscle and the peroneus longus; the tendon, where it passes behind the inner ankle, is situated more backward than the tendon of the flexor digitorum longus, that is, nearer the os calcis, and will be seen in the foot.

Use: To bend the last joint of the great toe, and, being connected by a cross slip to the flexor digitorum communis, to assist in bending the other toes.

Synonyma: Péronéo-phalanginien du gros orteil.

7. The Tibialis Posticus—*Arises*, fleshy, from the posterior surface of both the tibia and fibula, immediately below the upper articulation of these bones with each other; from the whole of the interosseous liga-

ment; from the angles of the bones to which that ligament is attached; and from the flat surface of the fibula behind its internal angle for more than two-thirds of its length. The fibres run obliquely towards a middle tendon, which, becoming round, passes behind the inner ankle through a groove in the tibia.

Inserted into the upper and inner part of the os naviculare, being further continued through a groove in that bone to the internal and external cuneiform bones; it also sends some tendinous filaments to the os calcis, the os cuboides, and the bases of the metatarsal bones supporting the second and middle toe.

Situation: This muscle may be said to arise from the tibia and fibula before the interosseous ligament, as its fibres fill up a perforation in the upper extremity of that ligament. The belly is concealed at its lower part by the flexor longus digitorum and flexor pollicis, and cannot be seen till those muscles are separated; but a part of it is discovered above the upper extremity of these muscles, and immediately below the fibres of the popliteus; and this part must lie under the anterior surface of the soleus. The tendon crosses under that of the flexor longus digitorum above the ankle, and, where it passes through the groove in the tibia, is situated more forward than the tendon of that muscle. It is thickened where it runs through the groove of the os naviculare; and its insertion lies close in contact with the bones, and is concealed by the muscles in the sole of the foot.

Use: To extend the foot, and turn it inwards.

Synonyma: Tibio-tarsien.

VESSELS AND NERVES OF THE POSTERIOR PART OF THE LEG.

1. ARTERIES.

Arteria Tibialis Postica.—The posterior tibial artery, which is the continued trunk of the popliteal, sinks under the origins of the soleus, and runs down the leg between that muscle and the more deeply scattered flexors of the toes: It does not lie in immediate contact with the fibres of the flexors, but, like the femoral artery, is invested by a strong sheath of condensed cellular membrane. It is, together with its veins and accompanying nerve, also supported by the fascia which binds down the deep-seated muscles. As it descends, it gradually advances more forwards, following the course of the flexor tendons: it passes behind the inner ankle, in the sinuosity of the os calcis, lying posterior to the tendon of the flexor longus digitorum, and anterior to that of the flexor longus pollicis. Here it is close upon the bone, and its pulsation may be felt. It sinks under the abductor pollicis, arising from the os calcis, and immediately divides into two branches:

(1.) The Internal Plantar Artery is the smallest, and ramifies among the mass of muscles situated on the inner edge of the sole of the foot.

(2.) The External Plantar Artery directs its course outwards, and having reached the metatarsal bone of the little toe, forms the Plantar Arch, which crosses the three middle metatarsal bones obliquely, about their middle, and terminates at the space betwixt the two first metatarsal bones, where the trunk

of the anterior tibial artery joins the arch. The convexity of this arch is towards the toes, and sends off the following branches.

a, A small branch to the outside of the little toe.

b, Ramus digitalis primus, or the first digital artery, which runs along the space between the two last metatarsal bones, and bifurcates into two branches, one to the inner side of the little toe, and the other to the outer side of the next toe.

c, The second digital artery, which runs along the next interosseous space, and bifurcates in a similar manner.

d, The third digital artery.

e, The fourth, or great digital artery, which supplies the great toe, and the inner side of the toe next to it.

The concavity of the arch sends off the interosseal arteries, three or four small twigs, which go to the deep-seated parts in the sole of the foot, and, perforating between the metatarsal bones, inosculate with the superior interosseal arteries on the upper side of the foot.

The branches of the Posterior Tibial Artery in the leg are,

1. The Peroneal Artery, which comes off from the tibial a little after it has sent off the anterior tibial, of which this artery is sometimes a branch; it is generally of a considerable size, sometimes nearly as large as the tibial itself; it runs upon the inside of the fibula, giving numerous branches to the peroneal muscles and flexor of the great toe; but its course is irregular and inconstant. At the lower part of the leg, it splits into,

a, A. Peronea Anterior, which passes betwixt

the lower heads of the tibia and fibula, to the fore-part of the ankle, where it is lost.

b, A. Peronea Posterior is properly the termination of the artery; it descends along the sinuosity of the os calcis, inosculating with the branches of the tibialis postica, and terminates in the posterior part of the sole of the foot.

2. Muscular branches arise from the artery as it descends; twigs also are sent over the heel and ankle.

2. VEINS.

Venæ Tibiales Posticæ.—The posterior tibial veins are generally two in number; they accompany the artery, and terminate in the popliteal vein; they are formed of branches, which correspond to those of the artery.

3. NERVES.

The Posterior Tibial Nerve, which is the continuation of the great sciatic nerve, sinks below the soleus, and accompanies the posterior tibial artery; it gives off numerous filaments to the muscles in its neighbourhood. At first it continues, as in the ham, immediately behind the artery, but it gradually gets on the outside of it as it descends; so that where they pass along the sinuosity of the os calcis, the nerve is situated close in contact with the side of the artery, but nearer to the projection of the heel than that vessel is. With the artery, it divides into,

1. The internal plantar nerve, and,

2. The external plantar nerve.—These nerves supply the muscles and integuments in the sole of the foot.

SECT. III.

DISSECTION OF THE SOLE OF THE FOOT.

THE cuticle is very much thickened on the sole of the foot from constant pressure; betwixt the integuments and plantar aponeurosis, we find a tough granulated fat, which adheres firmly to the aponeurosis, and is dissected off with difficulty.

APONEUROSIS, seu FASCIA PLANTARIS, is a very strong, tendinous expansion, which arises from the projecting extremity of the os calcis, and passes to the root of the toes, covering and supporting the muscles of the sole of the foot. Where it arises from the heel, it is thick, but narrow; as it runs over the foot, it becomes broader and thinner; and it is fixed to the head of each of the metatarsal bones by a bifurcated extremity, which, by its splitting, leaves room for the tendons, &c. to pass. It seems divided into three portions, which are connected by strong fasciculi of tendinous fibres; and fibres are sent down, forming perpendicular partitions among the muscles, and separating them into three classes:

1. The middle portion, which is the largest, and under which are contained the flexor brevis digitorum, and the tendons of the flexor longus and lumbricales.

2. The external lateral portion, which covers the muscles of the little toe.

3. The internal lateral portion, concealing the muscles of the great toe.

On removing the plantar aponeurosis, the first

order of muscles in the sole of the foot is exposed: it consists of three muscles:

Abductor Pollicis, situated on the side of the great toe.

Abductor Minimi Digiti, on the side of the little toe.

Flexor Brevis Digitorum Pedis, the mass in the middle, situated between the two abductors.

1. Abductor Pollicis Pedis—*Arises*, tendinous and fleshy, from the lower and inner part of the os calcis; from a ligament which extends from the os calcis to the os naviculare; from the inside of the os naviculare and cuneiforme internum; and from the fascia plantaris.

Inserted, tendinous, into the internal sesamoid bone, and base of the first phalanx of the great toe.

Use: To move the great toe from the rest.

Synonyma: Thenar-calcanéo-phalangien du pouce.

2. Abductor Minimi Digiti Pedis—*Arises*, tendinous and fleshy, from the outer side of the os calcis; and from a strong ligament, which passes from the os calcis to the metatarsal bone of the little toe; also from the fascia plantaris.

Inserted, tendinous, into the base of the metatarsal bone of the little toe, and into the outside of the base of the first phalanx.

This muscle can frequently be divided distinctly into two portions.

Use: To move the little toe from the other toes.

Synonyma: Parathenar major, and metatarseus;—Calcaneo-phalangien du petit doigt.

3. Flexor Brevis Digitorum Pedis Perfora-

TUS—*Arises*, fleshy, from the anterior and inferior part of the protuberance of the os calcis, and from the inner surface of the fascia plantaris; also from the tendinous partitions betwixt it and the abductors of the great and little toe:—it forms a thick fleshy belly, and sends off four tendons, which split for the passage of the tendons of the flexor longus digitorum, and are

Inserted into the second phalanx of the four lesser toes.

The tendon of the little toe is often wanting.

Use: To bend the second joint of the toes.

Synonyma: Calcaneo phalanginien commun.

Situation: The muscles of this order are quite superficial, being only covered by the fascia plantaris.

The first order of muscles being removed, or being lifted from their origins, and left hanging by their tendons, the second order is exposed.

1. The tendon of the Flexor longus digitorum pedis is seen coming from the inside of the os calcis; and, having reached the middle of the foot, dividing into its four tendons, which pass through the slits of the tendons of the flexor digitorum brevis, and are inserted into the base of the last phalanx of the four lesser toes.

2. The tendon of the Flexor longus pollicis is seen crossing under* the tendon of the flexor longus digitorum, and, having given to it a short slip of tendon,

* In the erect posture, it crosses above, lying nearer to the metatarsal bones than that tendon; but in the description, the sole of the foot is supposed to be placed uppermost.

proceeding between the two sesamoid bones to the base of the last phalanx of the great toe.

3. Flexor Digitorum Accessorius, or Massa Carnea Jacobi Sylvii—*Arises*, fleshy, from the sinuosity at the inside of the os calcis, and, tendinous, from that bone more outwardly:—it forms a belly of a square form.

Inserted into the outside of the tendonof the flexor digitorum longus, just at its division.

Use: To assist the flexor longus.

4. Lumbricales Pedis—*Arise*, by four tendinous and fleshy beginnings, from the tendons of the flexor longus digitorum, immediately after their division.

Inserted, by four slender tendons, into the inside of the first phalanx of the four lesser toes, and into the tendinous expansion that is sent from the extensors to cover the upper part of the toes.

Use: To promote the flexion of the toes, and to draw them inwards.

Situation: The muscles of the second order are covered and concealed by those of the first order; but the insertion of their tendinous extremities may be seen on removing the integuments.

The second order of muscles being removed, we expose the third order.

1. Flexor Brevis Pollicis Pedis.—It arises, tendinous, from the under and fore-part of the os calcis, where it joins with the os cuboides; also from the os cuneiforme externum; it forms a fleshy belly, which is connected inseparably to the abductor and adductor pollicis.

Inserted, by two tendons, into the external and in-

ternal sesamoid bones; and it is continued on into the base of the first phalanx of the great toe.

Use: To bend the first joint of the great toe.

Synonyma: Tarso-phalangien du pouce.

2. Adductor Pollicis Pedis—*Arises*, tendinous and fleshy, from a strong ligament which extends from the os calcis to the os cuboides, and from the roots of the second, third, and fourth metatarsal bones; it forms a fleshy belly, which seems at its beginning divided into two portions.

Inserted, tendinous, into the external sesamoid bone, and root of the metatarsal bone of the great toe.

Use: To bring this toe nearer the rest.

Synonyma: Antithenar-tarso-metatarso-phalangien du pouce.

3. Flexor Brevis Minimi Digiti Pedis—*Arises*, tendinous and fleshy, from the os cuboides, and from the root of the metatarsal bone of the little toe.

Inserted, tendinous, into the base of the first phalanx of the little toe, and into the anterior extremity of the metatarsal bone.

Use: To bend this toe.

Synonyma: Parathenar minor;—Flexor primi internodii minimi digiti;—Metatarso-phalangien du petit doigt.

4. Transversalis Pedis—*Arises*, tendinous, from the anterior extremity of the metatarsal bone supporting the little toe; becoming fleshy, it crosses over the anterior extremities of the other metatarsal bones.

Inserted, tendinous, into the anterior extremity of the metatarsal bone of the great toe, and into the in-

ternal sesamoid bone, adhering to the adductor pollicis.

Use: To contract the foot, by bringing the toes nearer each other.

Synonyma: Métatarso-phalangien du pouce.

Ranging with this order of muscles, we may also observe

A broad, strong ligament, passing from the anterior sinuosity of the os calcis over the surface of the os cuboides.

The tendon of the tibialis posticus, dividing into numerous tendinous slips, to be inserted into the bones of the tarsus.

Situation: The muscles of the third order lie under those of the second order, but are only partially concealed:—The flexor brevis pollicis lies under the tendon of the flexor longus pollicis; the adductor pollicis lies on the outer side of the flexor brevis, and is in part concealed by the tendons of the flexor digitorum longus. —The flexor brevis minimi digiti is a small fleshy mass, lying on the metatarsal bone of the little toe, and not concealed by any muscle of the second order.—The transversalis pedis runs across under the tendons of the flexor digitorum longus and lumbricales, and is seen projecting betwixt those tendons.

Having removed the muscles last described, we expose the fourth and last order.

The tendon of the peroneus longus is seen passing along a groove in the os cuboides, and crossing the tarsal bones, to be inserted into the base of the metatarsal bone of the great toe, and into the internal cuneiform and second metatarsal bones.

Interossei Pedis Interni, are three in number, situated in the sole of the foot.—They *arise*, tendinous and fleshy, from between the metatarsal bones of the four lesser toes, and are

Inserted, tendinous, into the inside of the base of the first phalanx of each of the three lesser toes.

Use: To move the three lesser toes inwards towards the great toe.

Synonyma: Interossei inferiores:—Abductor medii digiti, abductor tertii, and minimi digiti pedis;—Sous metatarso-lateri-phalangiens.

Interossei Pedis Externi, are four in number, larger than the internal interossei, and situated on the back of the foot; they are bicipites, or arise by two slips.

Arise, tendinous and fleshy, between the metatarsal bones of all the toes.

Inserted, the first, abductor indicis pedis, into the inside of the base of the first phalanx of the fore-toe;—the second, adductor indicis pedis, into the outside of the same toe;—the third, adductor medii digiti pedis, into the outside of the middle toe;—the fourth, adductor tertii digiti pedis, into the outside of the third toe.

Use: To separate the toes.

Synonyma: Sus-metatarso-lateri phalangiens.

CHAP. VI.

DISSECTION OF THE HEAD.

SECT. I.

OF THE EXTERNAL PARTS OF THE HEAD.

THE integuments of the head are thick, and covered with hair; under the cutis there is a cellular substance, which is much condensed, and closely connected with the epicranium, or expanded tendon of the occipito-frontalis. This connection renders the dissection of that muscle difficult.

The OCCIPITO-FRONTALIS is the only muscle which properly belongs to the hairy scalp; it is a single broad digastric muscle,

Arising, on each side of the head, fleshy and tendinous, from the transverse ridge of the occipital bone, as far forward as the mastoid process;—it forms a broad thin tendon, which covers the whole upper part of the cranium.

Inserted, fleshy, on each side, into the orbicularis palpebrarum, skin of the eye-brows, and the internal angular process of the os frontis and os nasi.

Situation: The tendon adheres firmly by cellular membrane to the skin, but very loosely to the pericranium, or periosteum of the cranium. At its insertion it intermixes with the muscles of the upper part of the face.

Use: To pull the skin of the head backwards, raise the eye-brows, and corrugate the skin of the forehead.

Synonyma: Epicranius;—Frontalis et occipitalis.

The muscles of the ear are of three classes.

1. The common muscles move the external ear; they are not always so distinct as to admit of a clear demonstration.

(1.) Attollens Aurem—*Arises* from the tendon of the occipito-frontalis, and from the aponeurosis of the temporal muscle.

Inserted into the upper part of the root of the cartilage of the ear, opposite to the antihelix.

Use: To draw the ear upwards.

Synonyma: Attollens auriculæ;—Superior auris;—Temporo-conchinien.

(2.) Anterior Auris—*Arises*, thin and membranous, from the posterior part of the zygomatic process of the temporal bone.

Inserted into a small eminence on the back of the helix, opposite to the concha.

Use: To draw the eminence a little forwards and upwards.

Synonyma: Anterior auriculæ;—Zygomato-conchinien.

(3.) The Retrahentes Auris—*Arise*, by two or three distinct slips, from the external and posterior

part of the mastoid process, immediately above the insertion of the sterno-cleido mastoideus.

Inserted into that back-part of the ear which is opposite to the septum, dividing the scapha and concha.

Use: To draw the ear back, and stretch the concha.

Synonyma: Deprimens auriculæ;—Posterior auris;—Mastoido-conchinien.

2. The proper muscles of the ear must be here described, but the student must not expect to meet with them distinctly marked in every subject; in general they are very confused and indistinct.

(1.) Helicis Major—*Arises* from the upper and acute part of the helix, anteriorly.

Inserted into its cartilage, a little above the tragus.

Use: To depress the part from which it arises.

Synonyma: Helix.

(2.) Helicis Minor—*Arises* from the inferior and anterior part of the helix.

Inserted into the crus of the helix, near the fissure in the cartilage opposite to the concha.

Use: To contract the fissure.

Synonyma: Concho-helix.

(3.) Tragicus—*Arises* from the middle and outer part of the concha, at the root of the tragus, along which it runs.

Inserted into the point of the tragus.

Use: To pull the point of the tragus a little forwards.

Synonyma: Concho-tragique.

(4.) Antitragicus—*Arises* from the internal part

of the cartilage that supports the antitragus; and, running upwards, is

Inserted into the tip of the antitragus as far as the inferior part of the antihelix.

Use: To turn the tip of the antitragus a little outwards, and depress the extremity of the antihelix towards it.

Synonyma: Anthela-tragique.

(5.) TRANSVERSUS AURIS—*Arises* from the prominent part of the concha on the dorsum of the ear.

Inserted opposite to the outer side of the antihelix.

Use: It draws the parts to which it is connected towards each other, and stretches the scapha and concha.

Synonyma: Concho anthélix.

3. The muscles of the internal ear are situated within the temporal bone itself; they are very small, and can only be seen when the internal parts of the organ of hearing are prepared; but, in order to render the history of the muscles complete, I shall insert a description of them.

(1.) LAXATOR TYMPANI—*Arises*, by a small beginning, from the spinous process of the sphenoid bone, and side of the Eustachian tube. It runs backwards, and a little upwards, along with the nerve called Chorda Tympani, in a fissure of the glenoid or articular cavity of the os temporis.

Inserted into the long process of the malleus.

Use: To draw the malleus obliquely forwards towards its origin, and consequently the membrana tympani by which that membrane is made less concave, or is relaxed.

Synonyma: Externus mallei;—Obliquus auris;—Anterior mallei;—Spheni-salpingo-malléen.

(2.) Tensor Tympani—*Arises*, by a small fleshy beginning, from the cartilaginous extremity of the Eustachian tube, just where it begins to be covered by the pars petrosa and spinous process of the sphenoid bone, and runs along the bony half-canal of the typanum, where it is invested by a membranous vagina.

Inserted into the neck of the malleus, above the small process, advancing likewise as far as the handle.

Use: To pull the malleus and membrana tympani towards the pars petrosa, by which that membrane is made more concave and tense.

Synonyma: Internus auris;—Internus mallei;—Salpingo-malléen.

A third muscle has by some been described, under the name of External or Superior Muscle of the malleus; but this is much less distinct. It is described as

Arising from the internal, superior, and posterior part of the meatus externus, to be fixed by a small tendon to the neck of the malleus.

Synonyma: Acoustico-malléen.

3. Stapedius is a short and thick muscle.—It *arises* from, and lies concealed within, the small bony pyramid at the bottom of the tympanum; the cavity it fills is near the bony canal of the portio dura of the auditory nerve. It terminates in a small tendon, which goes out of the cavity through the small hole in the apex of the pyramid, runs forwards, and is

Inserted into the neck of the stapes, on the sides of the longest and most crooked leg of that bone.

Use: To draw the stapes obliquely upwards towards the pyramid, by which the posterior part of its base is moved inwards, and the anterior part outwards.

Synonyma: Musculus stapedis;—Pyramidal stapedien.

SECT. II.

OF THE CONTENTS OF THE CRANIUM, OR THE BRAIN AND ITS MEMBRANES.

A TRANSVERSE incision, extending from ear to ear over the crown of the head, being made through the tendon of the occipito-frontalis, the two flaps may, with facility, be inverted on the face and neck. Remove the superior part of the cranium by a saw directed anteriorly through the frontal bone above the orbitar process, and posteriorly as low as the transverse ridge of the occipital bone. Thus the subsequent demonstration of the brain will be conducted with greater facility.

When the superior part of the cranium, commonly called the Calvarium, or skull-cap, is torn off, which requires considerable force, you expose the DURA MATER, a firm, compact, and whitish membrane, somewhat shining, rough on its outer surface, from the rupture of vessels which connected it to the cranium, and covered with bloody spots in consequence of the blood effused from these ruptured orifices. It

is described as being separable into many laminæ, into two with facility ; and it is said that these two laminæ, by separating and re-uniting, form the triangular cavities, named Sinuses, which are in fact large veins. This division of layers can hardly be admitted as correct in the recent state of the membrane.

The Superior Longitudinal Sinus lies in a groove formed by the two parietal bones ; it extends along the sagittal suture from the crista galli of the ethmoid bone to the middle of the os occipitis, where it bifurcates into the two lateral sinuses ; in its passage backwards, its size is increased. When slit open, its triangular form is evident ; it is lined by a smooth membrane, and in it may be remarked the numerous openings of the veins of the pia mater, the frena, or slips of fibres crossing from side to side, glandulæ Pacchioni internæ et externæ, little bodies like millet-seed seen on the outer and inner surface of the sinus.

The arteries of the dura mater are divided into the anterior, middle, and posterior.

1. Arteria Meningea Media (called also the Spinalis or Spheno-spinalis), the great middle artery, is a branch of the internal maxillary ; it passes through the spinous hole of the sphenoid bone, and is seen rising from the anterior inferior angle of the parietal bone (in a groove of which it lies), and spreading its numerous branches over the dura mater.

The anterior and posterior arteries are small.

2. A. Meningea Anterior is sent off from the

external carotid, and enters the cranium by the foramen lacerum orbitale superius.

3. A. Meningea Posterior is given off by the vertebral artery; the dura mater also receives small twigs from the occipital, pharyngeal arteries, &c.

The nerves of the dura mater are said to come from the fifth pair; if they exist at all, they are small, and seldom demonstrated.

Of the Septa of the Brain, or Processes of the Dura Mater.

1. The Falx (septum sagittale, verticale, mediastinum cerebri, or falciform process) is a long and broad fold, or duplicature of the inner lamina of the dura mater, dividing the cerebrum into two hemispheres, extending from the crista galli of the ethmoid bone, along the middle of the os frontis and point of junction of the two parietal bones, to the crucial ridge of the occipital bone, where it terminates in the middle of the next septum.

2. The Tentorium Cerebelli, or transverse septum. This separates the cerebrum from the cerebellum, and is formed by the inner lamina of the dura mater, reflected off from the os occipitis along the groove of the lateral sinuses, and the edge or angle of the temporal bones. It is frequently called Tentorium Cerebello Super Extensum. Its position is horizontal.

There are some other folds of the dura mater, not visible in this stage of the dissection.

3. The falx of the cerebellum, or small occipital septum, will be seen when the cerebrum is removed. It extends from the middle of the tentorium along the middle spine of the os occipitis to the foramen magnum, dividing the cerebellum into two parts.

4. The sphenoidal folds, two small folds of the dura mater, one on each side of the sella turcica, stretching from the posterior to the anterior clinoid processes.

The dura mater also, in many parts of the brain, separates its laminæ to form sinuses; the principal of these will be noticed in the course of the dissection. This membrane should now be divided in the line of the division of the cranium; its internal surface is smooth, glistening, and free from adhesion, except in the course of the longitudinal sinus, into which veins pass from the pia mater.

Detach the falx from the crista galli, and turn it backwards; observe in its lower edge the Inferior Longitudinal Sinus, which enters a sinus in the Tentorium, termed Torcular Herophili, or straight sinus. This will fully expose the convolutions of the brain, which are closely invested by the pia mater.

The Pia Mater consists of two membranes.

1. The Tunica Arachnoides is a fine membrane, covering uniformly the surface of the pia mater, without passing into the interstices of its duplicatures. It is attached to it, is extremely thin, transparent, without vessels, demonstrated with difficulty on the upper surface of the brain by the blow-pipe (which

raises it into cells), but on the base of the brain it can be distinctly seen.

2. The proper Pia Mater, or tunica vasculosa, is a very vascular membrane, transparent in the interstices of its vessels, investing the substance of the brain, descending betwixt all its convolutions, and lining its different cavities; but, where it lines the ventricles, it is fine, delicate, and less vascular, than on the surface, and betwixt the convolutions of the brain: It is connected to the dura mater by its veins passing into the longitudinal sinus.

The brain is divided into three parts: 1. The cerebrum; 2. The cerebellum; 3. The medulla oblongata.

The CEREBRUM consists of two distinct substances:

1. The cineritious or cortical substance forming the outer part.

2. The white or medullary substance forming the inner part.

The brain is divided by the falx into two hemispheres, and by the pia mater into numerous convolutions.

Each hemisphere is divided into three lobes.

1. The ANTERIOR LOBES rest on that part of the cranium which forms the two orbits, and is called the anterior fossæ of the basis of the cranium.

2. The MIDDLE LOBES are situated before and above the medulla oblongata, and rest on the middle fossæ of the basis cranii, which are formed by the sphenoid and temporal bones.

3. The Posterior Lobes are supported by the tentorium.

The anterior and middle lobes are parted by a deep narrow sulcus, which ascends obliquely backwards from the temporal ala of the os sphenoides to near the middle of the os parietale; it is termed Fissura Cerebri, or Fissura Magna Silvii.

By gently separating with the fingers the two hemispheres of the brain*, we see passing betwixt them a longitudinal white convex body, the Corpus Callosum; it lies under the falx, incurvates downwards at both its extremities, and is continued anteriorly into the medullary substance betwixt the corpora striata, posteriorly into the fornix and inferior cornu of the lateral ventricle on each side. On the surface of the corpus callosum is seen the Raphe, formed by two longitudinal medullary lines united by transverse fibres.

When the brain is cut horizontally on the level of the corpus callosum, an appearance is produced, termed the Medullary arch, or Centrum Ovale.

Under this arch are the two lateral ventricles†. If one of these be cautiously perforated on the side of the corpus callosum, and gently inflated by a blow-pipe, its extent may be seen; but, if much force be used, the air will pass into the other ventricle.

* Between the hemispheres and on the surface of the corpus callosum, we observe the arteriæ callosæ, which are the continuation of the trunks of the anterior cerebri.

† To show the lateral ventricles, the corpus callosum should be cut away close to the septum lucidum, and then the ventricle of that body, and the thickness and breadth of the septum itself, will be more clearly seen.

The two ventricles are separated by a medullary partition, which descends from the inferior surface of the corpus callosum to the fornix, the SEPTUM LUCIDUM; it consists of two laminæ, with a narrow cavity between. To see this septum, one of the ventricles must be laid open, and the septum pulled gently to the other side.

The LATERAL VENTRICLES are two, right and left, lined with a fine membrane, narrow, consisting of a body, and three prolongations or cornua.

1. The body is formed betwixt the corpus callosum, the medulla of the brain, the convexity of the corpus striatum, and the thalamus nervi optici.

2. The anterior cornu or horn is formed betwixt the more acute convexity of the corpus striatum, and the anterior part of the corpus callosum.

3. The posterior cornu (called also the digital cavity) may be traced stretching backwards and downwards into the posterior lobe of the brain.

4. The inferior or descending cornu cannot be traced in this stage of the dissection; it seems like the continued cavity of the ventricle, takes a curve backwards and outwards, and then, turning forwards, descends into the middle lobe of the brain.

The lateral ventricles communicate with each other, and with the third ventricle, by an opening under the fore-part of the arch of the fornix*.

* It has been doubted whether or not this be an opening; the choroid plexus passes through it, and seems to unite the surfaces; it is absurdly named the Foramen Monroianum, from a mistaken notion that Dr. Monro discovered it, and may be seen by gently turning the anterior crus of the fornix to one

In the lateral ventricles we meet with

The Fornix, a medullary body, flat, and of a triangular shape, which divides the two lateral and the third ventricles. It is exposed on tearing away the septum lucidum; its lower surface is towards the third ventricle; its lateral margins are in the lateral ventricles; on its upper surface it supports the septum lucidum, and under its most anterior part is the foramen Monroianum:—One of the angles of this body is forward, and the other two towards the back-part; it rests chiefly on the thalami nervorum opticorum, but is separated from them by a vascular membrane called the velum.

The extremities of the body of the fornix are named its Crura.

1. The crus anterius is double, bends downwards before the anterior commissure of the brain, with which it is connected, and may be traced into the corpora caudicautia.

2. The two crura posteriora, coalescing with the back-part of the corpus callosum, pass, on each side, into the inferior cornu of the lateral ventricle, and terminate in a pointed form on the hippocampus major.

Divide the body of the fornix, invert it, by turning

side; it is a space betwixt the most anterior part of the convexity of the thalami nervorum opticorum, and the anterior crus of the fornix.

This foramen may always be easily found by following the course of the plexus choroides, as it passes forwards in the ventricle. It is a slit, rather than a round hole, in the natural state.

the anterior crus forwards, and the posterior crura backwards; on the under surface of the latter is an appearance of transverse lines, named Corpus Psalloides, psalterium, or lyra.

The inversion of the fornix exposes

The Plexus Choroides.—This is a continuation of the pia mater, a spongy mass, consisting of folds of tortuous vessels, partly covering the thalami nervorum opticorum, and continued into the inferior cornu of the lateral ventricles. The plexus of each side is connected to its fellow by the velum interpositum. a membrane which passes under the fornix, and lies on the third ventricle and corpora quadrigemina.

From this plexus the blood is received by the Vena Galeni, situated in the middle of the velum which consists of two parallel branches; these run backwards, unite, and enter the fourth sinus of the dura mater, called Torcular Herophili.

This plexus should now be detached at its fore-part, and turned back: it will remain as a guide to the knife in tracing the inferior cornu of the lateral ventricle.

We now see

The Corpora Striata, two smooth cineritious convexities, in the fore-part of the lateral ventricle, broad, and rounded anteriorly, becoming narrow, and diverging as they pass backwards, consisting of medullary and cortical substance disposed in striæ.

The Thalami Nervorum Opticorum, two large oval whitish eminences, placed by the side of each other between the diverging extremities or crura of the corpora striata; towards their fore-part is a

peculiar eminence or convexity, called the Anterior Tubercle; they are elongated downwards, to form the optic nerves.

Tænia Semicircularis, a white medullary line, running in the angle betwixt the corpus striatum and thalamus nervi optici of each side.

Commissura Anterior Cerebri, a short cylindrical medullary cord, stretched transversely between the fore and lower part of the corpora striata, immediately under the anterior crura of the fornix.

Just above the commissura anterior, and before the thalami, is the Vulva, or foramen commune anterius, a small slit or indentation, formed by the anterior crus of the fornix, bifurcating, and inserting itself, on each side, between the corpus striatum and thalamus nervi optici. This slit is the space by which the three ventricles communicate.

Commissura Mollis is an exceedingly soft, broad, cineritious junction betwixt the convex surfaces of the thalami nervorum opticorum.

On separating the optic thalami, we discover the Third Ventricle.—This is a longitudinal sulcus, or slit, situated betwixt the thalami nervorum opticorum, and betwixt the crura cerebri. Above, it is covered by the fornix and velum interpositum; at its upper and fore-part, it communicates with the two lateral ventricles; below the commissura anterior, it opens into the infundibulum. This opening is termed iter ad infundibulum. Backwards, it is continued by a canal which passes under the tubercula quadrigemina into the fourth ventricle.—This passage is named iter

ad quartum ventriculum, aquæductus Sylvii, or canalis medius.

Anus, or foramen commune posterius, is situated behind the commissure of the optic thalami, and before the corpora quadragemina. It is closed up by the velum interpositum, and, when that is removed, leads into the back-part of the third ventricle.

The Pineal Gland, a small, soft, greyish, and conical body, of the size of a pea, is seated above the tubercula quadrigemina, and behind the thalami, to which it is connected by two white pedunculi, or foot-stalks; its base is turned forwards, and the apex backwards; it is covered by the plexus choroides and posterior crura of the fornix. It contains an earthy matter, either in its own substance, or that of the pedunculi, resembling sand, and, when viewed by a magnifier, assuming a granulated and clear light yellow appearance. It was named by Sœmmerring, who first discovered that it belongs to the healthy structure of the brain, the Acervulus Glandulæ Pinealis.

Commissura Posterior, a transverse cord at the back-part of the third ventricle, before the tubercula quadrigemina, and above the iter ad quartum ventriculum.

Tubercula Quadrigemina, four small white bodies, adhering together, lying under the pineal gland, behind the third ventricle, and above the fourth. The uppermost two are named Nates, and the other two Testes.

From the under part of the testes, there projects backwards, connecting itself with the crura cerebelli,

a thin medullary lamina, which is the valvula Vieussenii, processus a cerebello ad testes, velum interjectum, valvula major.

The inferior cornu of the lateral ventricle, which descends into the middle lobe of the brain, may now be traced, by following the tract of the choroid plexus*; in it is seen

The HIPPOCAMPUS MAJOR, or Cornu Ammonis. At its commencement it is narrow, but it becomes a broad medullary projection of the floor of the ventricle, and its extremity, which is called PES HIPPOCAMPI, is curved inwards. The thin edge on its inside, which follows the whole of its circuit, is named the CORPUS FIMBRIATUM, or Tænia Hippocampi. The posterior crus of the fornix runs along its inner and anterior part, in the form of a thin floating edge.

In the posterior cornu of the lateral ventricle, which passes into the posterior lobe of the brain, there is a similar medullary projection, but smaller, the HIPPOCAMPUS MINOR.

In the anterior part of the third ventricle, below the iter ad infundibulum, are seen the CORPORA ALBICANTIA Willisii (corpora mamillaria or subrotunda), two medullary eminences of the size of peas; the remainder of these bodies is seen on the outer surface of the base of the brain.

This completes the demonstration of the cerebrum. The whole of the posterior lobes, and the lateral part of the middle lobes, may be removed. This exposes to your view

* Or it may be exhibited by cutting away successive slices of the side of the brain, until the ventricle is exposed.

The TENTORIUM, and the FALX CEREBELLI. At this point you should trace the bifurcation of the longitudinal sinus into the two lateral sinuses. The lateral sinuses are formed by the splitting of the laminæ of the tentorium; hence they follow the course of that membrane, run along their grooves in the occipital bone, and dip downwards and forwards through the foramen lacerum in basi cranii, to terminate in the internal jugular veins.

The TORCULAR HEROPHILI, or fourth sinus, runs along the middle of the tentorium, and joins the extremity of the longitudinal sinus at the point where it bifurcates.

The great notch of the tentorium is a circular opening left on the anterior part of the tentorium, allowing a junction between the cerebrum and cerebellum.

Now proceed to the examination of the cerebellum; and, in order to accomplish this demonstration, it will be convenient to remove the posterior part of the os occipitis.

CEREBELLUM.—This part of the brain, divided into two lobes by the falx cerebelli, or septum occipitale, is covered by a vascular membrane; consists of medullary and cineritious substance; but, instead of convolutions, has numerous deep sulci, into which the pia mater dips, and forms thin flat strata.

Remark the following processes.

1. Appendix, vel processus vermiformis superior, situated under the pia mater, on the anterior and superior part of the cerebellum.

2. Appendix, or processus vermiformis posterior,

will be found situated between the two lobes on the under surface of the cerebellum, and immediately behind the medulla oblongata.

On separating the two lobes behind, and making a deep incision, we discover

The Fourth Ventricle.—The sides of this ventricle are formed by the cerebellum, the anterior part by the medulla oblongata, the upper and back part by the valvula cerebri; it is lined by a thin vascular membrane, and has on its fore part a groove or fissure, which, terminating in a sharp point, is named Calamus Scriptorius. On each side of this groove are seen several medullary lines, which are the origin of the portio mollis of the seventh pair of nerves. The iter a tertio ad quartum ventriculum enters the upper part of the fourth ventricle. The valvula cerebri hangs over it.

On cutting the cerebellum perpendicularly, there is formed, from the intermixture of cineritious and medullary matter, a tree-like appearance, named Arbor Vitæ, of which the trunk is termed the peduncle of the cerebellum, and is continued to the back-part of the medulla oblongata. This concludes the demonstration of the cerebellum.

To demonstrate the medulla oblongata and nerves, either the brain must be removed from the cranium, or it may be gradually inverted in the progress of the demonstration;—and this is the better method. The inversion must be begun at the fore-part, by raising the anterior lobes of the cerebrum. Thus you will see,

1. The First Pair of Nerves, the Olfactory, called also Processus Mammillares. They arise from

the outside of the corpora striata, between the anterior and middle lobe of the brain; run under the anterior lobes, being lodged on two superficial grooves, and lying between the pia and dura mater; expand into a small oval ganglion, from which several small filaments descend through the cribriform plate of the ethmoid bone, to ramify on the membrane lining the nose.

2. The Second Pair, the Optic, arise from the posterior part of the optic thalami, and also from the tubercula quadrigemina; they make a circle round the crura cerebri called the Tractus Opticus. The two nerves approach gradually, and unite, just before the pituitary gland, on the fore-part of the sella Turcica. They then diverge, and each nerve passes out at the foramen opticum of the sphenoid bone, to form the retina of the eye.

On each side of these nerves are seen the Carotid Arteries. Each artery emerges from the cavernous sinus by the side of the anterior clinoid process: sends a branch forwards, which, uniting with a similar branch of the other carotid, forms the anterior part of the Circulus Arteriosus Willisii; while other branches, passing backwards, and uniting with branches of the basilar artery, complete the posterior part of the arterial circle.

A fold of dura mater passes from the anterior to the posterior clinoid process of each side. This fold is double, and forms by its duplicature the Cavernous Sinus.

On dividing the optic nerves, and inverting them, we see the infundibulum, a funnel of cineritious sub-

stance, leading from the inferior and anterior extremity of the third ventricle to the pituitary gland; it is generally imperforate before it reaches the gland.

The Pituitary Gland, a reddish body, somewhat globular, consisting of two lobes, is situated in the sella Turcica of the sphenoid bone, partly covered by a fold of dura mater, and attached to the infundibulum. The circular sinus is situated at this point.

On detaching the cerebrum from the back-part of the sella Turcica, the tunica arachnoides is very evident.

3. The Third Pair of Nerves, Motores Oculorum, arise from the crura cerebri*, pass outwards and forwards on the outer side of the posterior clinoid process into the cavernous sinus, and run through the foramen lacerum orbitale superius to the muscles of the eye.

Between these two nerves are seen the two vertebral arteries, ascending and uniting, to form the basilary artery.

4. The Fourth Pair, Trochleares or Pathetici, are very slender, and situated immediately under the edge of the tentorium. This nerve arises from the valvula cerebri, comes out from betwixt the cerebrum and cerebellum, passes by the side of the pons Varolii, and, passing through the cavernous sinus, continues its course through the foramen lacerum orbitale superius, to supply the obliquus superior muscle of the eye.

* The two crura pass obliquely backwards and inwards, so as to converge and meet in front of the tuber annulare; it is from the hollow formed by their convergence, and named by Vicq d'Azyr, *fosse des nerfs occulo-musculaires*, that the third pair arise.

5. The Fifth Pair, Trigemini, are much larger than the fourth, and are situated more outwards and backwards. Each of these nerves arises, by a number of filaments, from the anterior and lowest part of the crus cerebelli, where the crus unites with the pons Varolii;—it passes forwards, enters the cavernous sinus, where it untwists itself, and forms a flat irregular ganglion, the Ganglion Gasserianum, and then divides into three great branches.

(1.) Ramus Ocularis.—The ophthalmic nerve of Willis passes through the foramen lacerum orbitale superius to the appendages of the eye.

(2.) Ramus Maxillaris Superior passes through the foramen rotundum to the upper jaw and face.

(3.) Ramus Maxillaris Inferior passes through the foramen ovale to the lower jaw and tongue.

6. The Sixth Pair, Motores Oculorum Externi, or abductores.—This nerve is small, but not so small as the fourth pair; it is seen arising betwixt the pons Varolii and corpora pyramidalia: it enters the cavernous sinus,—it there runs by the side of the carotid artery, and passes through the foramen lacerum orbitale superius to the rectus externus oculi.

While in the cavernous sinus, it gives off the small twig, which, uniting with filaments from the second branch of the fifth pair, forms the beginning of the intercostal nerve, and passes out of the cranium through the foramen caroticum with the carotid artery.

7. The Seventh Pair, Nervi Auditorii, consists of two portions.

(1.) The Portio Dura, or the fascial nerve, arises from the crus cerebelli, and comes out from the fossa or groove betwixt the pons Varolii, corpora olivaria, and crura cerebelli.

(2.) The Portio Mollis, or more properly the auditory nerve, arises from the inner surface of the fourth ventricle; it has a groove on its surface for receiving the portio dura;—accompanied by an artery, they enter the meatus auditorius internus, where the portio mollis is distributed to the parts of the internal ear, while the portio dura runs through the aqueduct of Fallopius, and comes out at the stylo-mastoid foramen below the ear, to form the principal nerve of the face.

8. The Eighth Pair, Par Vagum, arises by numerous filaments from the sides of the corpora olivaria and medulla oblongata. Two distinct fasciculi are formed, the uppermost called nervus glossopharyngeus, the other the proper par vagum;—they unite, run towards the foramen lacerum in basi cranii, pierce the dura mater, and pass out through the anterior part of that hole, having been first joined by the

Nervus Accessorius ad Par Vagum, which runs up from the medulla spinalis through the great occipital foramen.

The great Lateral Sinus passes out by the back-part of the same foramen, to form the internal jugular vein; it is separated from the nerve by a slip of cartilage.

9. The NINTH PAIR, LINGUALES, Linguales Medii, Hypoglossi.—This nerve arises from the furrow betwixt the corpora olivaria and pyramidalia, by several filaments which often pierce the dura mater separately. It passes through the anterior condyloid hole of the occipital bone, to supply the muscles of the tongue.

Immediately after leaving the cranium, the eighth and ninth pair, and the ganglion of the intercostal, are connected together.

10. The TENTH PAIR*, SUBOCCIPITALES, arise, on each side, by two bundles, from the extremity of the medulla oblongata, and upper part of the spinal marrow, pass through the dura mater by the same foramen which gives entrance to the vertebral artery, and run through the foramen magnum occipitale to the muscles at the base of the cranium.

The corpora albicantia Willisii, are again seen, two white bodies, on the base of the brain, behind the infundibulum, and above the pons Varolii.

The MEDULLA OBLONGATA remains to be demonstrated. It should be removed from the bone, and examined in an inverted position. On its under surface are seen the two vertebral arteries, ascending from the foramen magnum, and uniting, to form one trunk, the basilar artery.

On removing the pia mater, the whole surface appears medullary; but an incision shows it to be intermixed with the cineritious substance.

The CRURA or PEDUNCULI CEREBRI are two

* These are now perhaps as frequently described as the first pair of cervical nerves.

considerable medullary fasciculi, proceeding from the centre of the medulla of the brain, more immediately from the corpora striata; they unite at an acute angle, and are united to the pons Varolii*.

The Crura or Pedunculi Cerebelli are very large, and pass from the medullary part of the cerebellum which forms the arbor vitæ to the pons Varolii.

The Pons Varolii, Tuber Annulare, or Nodus Cerebri, is a medullary protuberance, formed by the union of the crura cerebri and cerebelli, over which it is stretched like a bridge: on its surface is a raphe, or transverse fibres passing into a middle longitudinal narrow depression.

Below the pons Varolii, and separated from it by a sulcus, are seen four eminences:

1. The two external are named Corpora Olivaria.

2. The two internal are named Corpora Pyramidalia, and, by separating these two bodies, medullary cords, passing transversely, appear, the nervi intercerebrales.

The point of union betwixt the corpora pyramidalia and pons Varolii, is sometimes called foramen cæcum.

The medulla oblongata now contracts itself, and passing through the foramen magnum occipitale, assumes the name of

* On making a section of the crura cerebri, near to their union with the pons Varolii, a portion of a dark-brown colour, surrounded with white medullary substance, is seen, termed Locus Niger Crurum Cerebri.

MEDULLA SPINALIS, or the Spinal Marrow.—This part of the nervous or sensorial system must be here described, although its dissection cannot be performed till all the muscles of the back are removed, so that the posterior part of the spinal canal may be sawed off.

The spinal canal is lined by a strong ligamentous sheath, and the dura mater is continued down upon this sheath in the form of a funnel.

The spinal marrow consists externally of medullary substance, internally of cineritious. It runs down to the first lumbar vertebra, where it terminates by numerous filaments, which form the cauda equina.—It is closely embraced by the pia mater, while the tunica arachnoides adheres to that membrane very loosely. During the whole of its passage, there is on each side a membranous connection betwixt the pia and dura mater, by distinct slips, irregular and pointed, which connection is named LIGAMENTUM DENTICULATUM. The arteries of the medulla may be seen running down on its anterior and posterior surfaces; they are branches of the vertebral artery.

The spinal accessory nerve is seen arising by small twigs from the posterior bundles of the fourth, fifth, sixth, and seventh cervical nerves; it then ascends along the spinal canal, enters the foramen, and passes forwards, to accompany the par vagum.

The spinal marrow sends off twenty-nine pair of spinal nerves, which pass through the foramina formed betwixt the bodies of the vertebræ. They consist of seven cervical, twelve dorsal, five lumbar, and five sacral pairs of nerves. Each of these nerves

arises in two fasciculi, one from the fore-part, the other from the back-part, of the spinal marrow; these fasciculi penetrate the dura mater separately; the posterior bundle forms a ganglion, and afterwards unites with the anterior fasciculus, to form the nerve.

A general view of the distribution of the spinal nerves may be usefully subjoined in this place, to complete the description of the nerves.

1. The Cervical Nerves consist of seven pairs; they spread their branches over the side of the neck, and to the muscles moving the head and shoulders. The superior nerves send branches to the side of the head, and the inferior to the upper part of the chest and back. They also communicate freely with each other, and with all the neighbouring nerves;—high in the neck, and under the jaw, with the portio dura of the seventh pair, with the fifth, eighth, and ninth pairs, and with the great sympathetic;—towards the middle of the neck, with the descendens noni, the sympathetic and eighth pair, and in the lower part of the neck with the sympathetic.

The Phrenic Nerve is formed by branches of the third, fourth, and fifth cervical nerves, passes obliquely down the neck through the thorax, then on each side of the pericardium, and is distributed to the diaphragm.

The Axillary Plexus is formed by the principal parts of the trunks of the fourth, fifth, sixth, and seventh cervical, and first dorsal nerves.

2. The Dorsal Nerves are twelve pairs.—They arise from the spinal marrow in the same manner as the cervical. Each nerve emerges betwixt the heads

of the ribs, gives twigs to the great sympathetic nerve, and twigs which pierce backwards to the muscles of the back; then, entering the groove in the lower edge of each rib, it accompanies the intercostal artery, and runs towards the anterior part of the thorax, supplying the great muscles of the chest, giving twigs to the diaphragm, and muscles of the abdomen.

3. The Lumbar Nerves are five pairs.—They arise in the same manner; their trunks are covered by the psoas magnus muscle. Each nerve gives twigs to the muscles of the loins and back, and to the sympathetic nerves, and runs obliquely downwards to supply the abdominal muscles and integuments of the groin and scrotum; but the trunks of these nerves assist in forming the nerves of the thigh.

4. The Sacral Nerves are five on each side, arising from the cauda equina. They come out through the anterior foramina, and send small branches to the neighbouring parts; but the great trunks of these nerves are united with the lumbar nerves, to form the nerves of the lower extremity, viz.

(1.) The Anterior Crural Nerve, passing out under Poupart's ligament to the extensor muscles of the leg, is formed by branches of the first, second, third, and fourth lumbar nerves.

(2.) The Obturator Nerve, leaving the pelvis by the thyroid holes, and being distributed to the deep-seated muscles on the inside of the thigh, arises from branches of the second, third, and fourth lumbar nerves.

(3.) The Ischiatic or Sciatic Nerve, the

greatest nerve of the body, passes out from the back-part of the pelvis, through the sacro-sciatic notch, and takes its course along the back of the thigh, to supply the thigh, leg, and foot; it is formed from the two last nerves of the loins and three first of the sacrum.

All these nerves of the spine communicate freely by numerous twigs, and by the intervention of

The GREAT SYMPATHETIC NERVE, or INTERCOSTAL.—This nerve, originally derived from the sixth pair, and from some filaments of the fifth, passes out of the cranium with the carotid artery. It then descends through the neck, and forms three ganglions in its course, which give twigs to the neighbouring parts, and are joined by filaments from the cervical nerves, and the eighth and ninth pairs. The intercostal then enters the thorax, and descends by the side of the vertebræ, behind the pleura, giving filaments, which, joining with twigs of the eighth pair, form several plexuses to supply the heart, lungs, &c. In the abdomen it descends on the lumbar vertebræ, and at last terminates in the pelvis on the extremity of the coccyx.

While in the thorax, it gives off a branch, which, uniting with branches of the dorsal nerves, forms

The ANTERIOR INTERCOSTAL, or SPLANCHNIC NERVE.—This nerve, passing betwixt the crura of the diaphragm, enters the abdomen, forms the semilunar ganglion, and is distributed by numerous plexuses to all the abdominal viscera.

The eighth pair, or par vagum, has also a very long course; it arises in the head, passes through the neck,

to which it gives several branches. It enters the thorax anterior to the subclavian artery; here it gives off a remarkable branch, called the Recurrent, because it is reflected round the arch of the aorta on the left side, and round the subclavian artery on the right, and ascends to be distributed on the trachea, œsophagus, and larynx. The nerve then passes through the thorax, and, entering the abdomen, terminates in the stomach; in this course it has frequent communications with the great sympathetic, which it assists in forming the different plexuses that supply the thoracic and abdominal viscera. It is distributed to the heart, lungs, liver, spleen, stomach, and duodenum.

OF THE VESSELS OF THE BRAIN.

The arteries ramify largely on the pia mater, before they enter the substance of the brain; they come from two large branches.

1. The Internal Carotid Artery enters the skull by a winding course through the foramen caroticum of the temporal bone. After passing through the cavernous sinus, it divides into three branches: 1. Anterior cerebri, passing between the two anterior lobes; 2. Media cerebri, entering the fissura sylvii; 3. Ramus communicans, uniting with the basilar. The carotid, while in the cavernous sinus, gives off the arteria ophthalmica, which passes through the foramen opticum to the eye and its appendages.

2. The Vertebral Artery arises from the subclavian, ascends through the foramina in the transverse processes of the cervical vertebræ, enters the cranium

by the foramen magnum, and gives branches to the dura mater and spinal marrow.—Uniting with its fellow, it forms the basilar artery, which gives branches to the internal ear, branches to form the circulus arteriosus, and then divides into two large branches called Posteriores Cerebri, which supply the back-parts of the cerebrum.

The Veins pour their blood into the sinuses, which are numerous. None of these veins require particular attention, except the ophthalmic vein, which passes through the foramen lacerum orbitale superius. The principal sinuses, viz. the longitudinal, the two lateral, the inferior longitudinal, &c. have been described in the dissection of the brain. The remainder of these sinuses are situated in folds of the dura mater, but are not regular in their situation. They transmit their blood to the longitudinal and lateral sinuses, which terminate in forming the internal jugular veins.

CHAP. VII.

DISSECTION OF THE ANTERIOR PART OF THE NECK.

SECT. I.

OF THE MUSCLES.

THE utility of this dissection must be evident, when you consider how many important parts are contained in the fore-part of the neck. The tube which conveys air to the lungs, the vessels which are sent from the heart to the brain, and the nerves which are destined to supply the thoracic and abdominal viscera, are situated in the neck; and all these parts lie imbedded in cellular substance; hence the dissection is intricate, and requires the utmost care in its performance.

The muscles of the anterior part of the neck, are sixteen in number on each side. They may be divided into muscles situated superficially, muscles at the upper part of the neck, and those situated at the lower part.

The superficial muscles are two.

Immediately under the integuments, and adhering to them,

1. The Musculus Cutaneus, vulgo, Platysma myoides.—It *arises*, by slender separate fleshy fibres, from the cellular substance, covering the upper part of the deltoid and pectoral muscles. These fibres form a thin broad muscle, which runs obliquely upwards, and is

Inserted into the skin and muscles covering the lower jaw and cheek. This muscle should be dissected in the course of its fibres; the skin, therefore, must be dissected off in an oblique direction from the clavicle to the chin.

Use: To draw the skin of the cheek downwards, and, when the mouth is shut, to draw the skin under the lower jaw upwards.

Synonyma: Quadratus genæ;—Latissimus colli;—Thoraco-maxilli-facial.

Remove the platysma myoides from its origin, and invert it over the face. Immediately beneath it is seen the external jugular vein, which is formed of branches from the temple, side of the face, and throat. It crosses obliquely over the sterno-mastoideus, passes behind the outer edge of that muscle, and dives beneath the clavicle, to enter the subclavian vein.

2. The Sterno-Cleido-Mastoideus—*Arises*, by two distinct origins; the anterior, tendinous and fleshy, and somewhat round, from the top of the sternum, near its junction with the clavicle; the posterior or outer, fleshy and flat, from the upper

and anterior part of the clavicle. These two origins soon unite, and form a strong muscle, which ascends obliquely upwards and outwards, to be

Inserted, tendinous, into the outside of the mastoid process, and into the transverse ridge behind that process.

Use: When one acts singly, it turns the head to one side. When both act together, they bend the head forwards.

Synonyma: Sterno-mastoideus et cleido-mastoideus ;—Mastoideus ;—Sterno-clavio mastoidien.

The muscle should be detached from the sternum and clavicle, and left suspended by its insertion. It is pierced by several branches of the cervical nerves, and, about its middle, it is perforated by the Nervus Accessorius. These nerves ramify on the neighbouring muscles of the neck and shoulder. Between the posterior edge of the sterno-cleido-mastoideus and the fore-part of the trapezius muscles, is seen a quantity of loose fatty substance, intermixed with branches of nerves. This fatty substance is watery and granulated ; it must not be removed roughly, lest important nerves and vessels be injured ; it is continued around the vessels under the clavicle.

In the middle of the throat you see,

(1.) The Os Hyoides, or bone of the tongue, forming the uppermost of the projections beneath the chin.

(2.) The Larynx, or upper part of the trachea, consisting of five cartilages, of which two are evident externally, viz. 1. the uppermost and largest is the

thyroid cartilage; 2. the inferior is the cricoid cartilage. The two arytenoid cartilages, and the epiglottis, lie behind this.

(3.) The Trachea, consisting of cartilaginous rings, and extending into the thorax.

(4.) Behind the larynx is situated the pharynx. At the part where the larynx terminates in the trachea, the pharynx contracts itself, and forms the œsophagus, or muscular tube, conveying the food to the stomach, which descends behind the trachea, situated rather to the left side of the cervical vertebræ.

These parts are covered by muscles, and on each side of the trachea lie the great vessels and nerves.

Muscles at the lower part of the neck are five.

3. The Sterno-Hydoideus—*Arises*, thin and fleshy, from the upper and inner part of the sternum, clavicle, and first rib:—It forms a flat narrow muscle.

Inserted into the base of the os hyoides.

Situation: This pair of muscles is seen on removing the platysma myoides, between the sterno-cleido mastoidei.

Use: To pull the os hyoides downwards.

Synonyma: Sterno-hyoidien.

4. The Omo-Hyoideus—*Arises*, broad, thin, and fleshy, from the root of the coracoid process, and semilunar notch of the scapula, ascends across the neck, and forms a middle tendon, where it passes below the sterno-cleido-mastoideus. Becoming fleshy again, it runs up, and is

Inserted into the base of the os hyoides, between its cornu and the insertion of the sterno-hyoïdeus.

Situation: The lower part of this muscle is covered by the trapezius; its middle by the sterno-cleido-mastoideus; its anterior part is seen on removing the platysma myoides; it crosses over the carotid artery, and internal jugular vein.

Use: To pull the os hyoides obliquely downwards.

Synonyma: Coraco-hyoideus;—Scapulo-hyoidien.

On dividing the sterno-hyoideus, observe,

5. The STERNO THYROIDEUS.—This muscle *arises*, fleshy, from the inside of the sternum, and of the extremity of the first rib; forms a flat muscle, and is

Inserted into the inferior edge of the oblique ridge in the ala or side of the thyroid cartilage.

Situation: Beneath the sterno-hyoideus.

Use: To draw the thyroid cartilage, and consequently the larynx, downwards.

Synonyma: Sterno-thyroidien.

Under the sterno-thyroideus, we find situated the

THYROID GLAND, a large reddish mass, situated on the superior rings of the trachea, below the cricoid cartilage; in form somewhat like a crescent, with the cornua turned upwards.

6. The THYRO-HYROIDEUS—*Arises*, fleshy, from the upper surface of the oblique ridge in the ala of the thyroid cartilage, and passes upwards, to be

Inserted into part of the base, and almost all the cornu of the os hyoides.

Use: To pull the os hyoides downwards, or the thyroid cartilage upwards.

Situation: Concealed by the sterno-hyoideus.

Synonyma: Hyo-thyroideus;—Hyo-thyroidien.

7. The CRICO-THYROIDEUS—*Arises*, tendinous and fleshy, from the side and fore-part of the cricoid cartilage, and runs obliquely upwards.

Inserted, by two fleshy portions, the first into the lower part of the thyroid cartilage, and the second into its inferior cornu.

Situation: On the side of the larynx, and under the sterno-thyroideus.

Use: To pull forwards and depress the thyroid, or to elevate and draw backwards the cricoid cartilage.

Synonyma: Crico-thyroidien.

The muscles at the upper part of the neck consist of nine pair.

8. The DIGASTRICUS—*Arises*, principally fleshy, from the fossa at the root of the mastoid process of the temporal bone; its fleshy belly terminates in a strong round tendon, which runs downwards and forwards, passes through the fleshy belly of the stylo-hyoideus, is fixed by strong ligamentous and tendinous fibres to the os hyoideus, from which it receives an addition of fibres; it then becomes again fleshy, and runs obliquely upwards, to be

Inserted into a rough sinuosity on the anterior inferior edge of that part of the lower jaw called the Chin.

Situation: Its posterior belly is covered by the sterno-

cleido-mastoideus; its anterior belly lies immediately under the skin and platysma myoides.

Use: To open the mouth, by pulling the lower jaw downwards and backwards; and, when the jaws are shut, to raise the larynx, and consequently the pharynx, upwards, as in deglutition.

Synonyma: Biventer-maxillæ;—Mastoidi-hyogenien.

In the triangular space formed by the two bellies of this muscle, and the base of the lower jaw, lies the SUBMAXILLARY GLAND. It lies upon a flat muscle, the mylo-hyoideus, which is seen between the two bellies of the digastricus; the gland is surrounded by little absorbent glands.

9. The STYLO-HYOIDEUS—*Arises*, tendinous, from the middle and inferior part of the styloid process of the temporal bone; its fleshy belly is generally perforated by the digastricus.

Inserted, tendinous, into the os hyoides at the juncture of its base and cornu.

Situation: The origin of this muscle is situated more inwards than the last, and nearer the base of the cranium; it is the most superficial of three muscles which arise from the styloid process; sometimes it is accompanied by another small muscle, having the same origin and insertion, the stylo-hyoideus alter.

Use: To pull the os hyoides to one side, and a little upwards.

Synonyma: Stylo-hyoidien.

10. The STYLO-GLOSSUS—*Arises*, tendinous and fleshy, from the styloid process, and from a ligament

that connects that process to the angle of the lower jaw. It descends, and becomes broader, but less thick.

Inserted into the root of the tongue, runs along its side, and is insensibly lost near its tip.

Situation: This muscle lies within and rather above the stylo-hyoideus; underneath it is a ligament, extending from the styloid process to the angle of the os hyoides.—Ligamentous fibres are also seen passing from that process to the inside of the angle of the lower jaw.

Use: To move the tongue laterally and backwards.

11. The Stylo-Pharyngeus—*Arises*, fleshy, from the root and inner part of the styloid process.

Inserted into the side of the pharynx and back-part of the thyroid cartilage.

Situation: It is situated deeper, and behind the stylo-glossus.

Use: To dilate and raise the pharynx and thyroid cartilage upwards.

Synonyma: Stylo-thyro-pharyngien.

On removing the submaxillary glands, and detaching the digastric muscle from the os hyoides and chin, we expose the next muscle.

12. The Mylo-Hyoideus—*Arises*, fleshy, from all the inside of the lower jaw, between the last dens molaris and the middle of the chin; the fibres form a flat muscle, converge, and are

Inserted into the lower edge of the base of the os hyoides.

Situation: This muscle unites with its fellow in a

middle tendinous line which extends from the os hyoides to the chin; its posterior part is lined by the internal membrane of the mouth; it lies under the digastricus, but is seen betwixt its bellies.

Use: To pull the os hyoides forwards, upwards, and to either side.

Synonyma: Mylo-hyoidien.

The submaxillary gland sends off a duct, which passes behind the posterior edge of the mylo-hyoideus, then runs along the inner surface of this muscle forwards and upwards, on the inside of the sublingual gland, to open into the mouth on the side of the frenum of the tongue.

The SUBLINGUAL GLAND lies immediately above the mylo-hyoideus, betwixt it and the internal membrane of the mouth, where it lines the side and inferior surface of the tongue. It sends off several ducts, which open into the mouth between the root of the tongue and side of the lower jaw.

The removal of the mylo-hyoideus exposes a pair of muscles, which are closely attached to one another.

13. The GENIO-HYOIDEUS—*Arises*, tendinous, from a projection on the inside of that part of the lower jaw which is called the Chin;—it descends, becoming broader, and is

Inserted into the basis of the os hyoides.

Use: To draw the os hyoides forwards and upwards to the chin.

Synonyma: Genio-hyoidien.

By removing this muscle, or turning it back from its origin from the jaw, we discover the next muscle.

14. The Genio-Hyo-Glossus—*Arises*, tendinous, from a rough protuberance on the inside of the lower jaw, higher up than the origin of the genio-hyoideus; its fibres run forwards, upwards, and backwards, in a very wide and radiated manner, to be

Inserted, some into the posterior part of the base of the os hyoides, near its cornu, others into the tip, middle, and root of the tongue.

Situation: This muscle lies under the genio-hyoideus before, and more outwardly under the mylo-hyoideus.

Use: According to the direction of its fibres, to draw the tip of the tongue backwards into the mouth, the middle downwards, and to render its dorsum concave; to draw its root and the os hyoides forwards, and to thrust the tongue out of the mouth.

Synonyma: Genio-glossus;—Genio-glosse.

15. The Hyo-Glossus—*Arises*, broad and fleshy, from half of the base, and part of the cornu of the os hyoides; the fibres run upwards, to be

Inserted into the side of the tongue.

Situation: It is situated more outwardly than the genio-hyo-glossus, and, at its insertion into the tongue, mixes with the stylo-glossus.

Use: To move the tongue inwards and downwards.

Synonyma: Basio-cerato-chondro-glossus;—Cerato-glossus;—Hyo-condro-glosse.

16. The Lingualis—*Arises* from the root of the tongue laterally, and runs forwards between the hyo-glossus and genio-hyo-glossus, to be

Inserted into the tip of the tongue, along with part of the stylo-glossus.

Use: To contract the substance of the tongue, and bring it backwards.

SECT. II.

OF THE VESSELS AND NERVES SEEN IN THE DISSECTION OF THE NECK.

ARTERIES.

THE carotid artery ascends from the thorax by the side of the trachea; on its outer side it has the internal jugular vein, and behind it the par vagum and intercostal nerves. All these parts are connected and inclosed by condensed cellular membrane, which forms a kind of sheath for containing them. At the bottom, and in the middle of the neck, the carotid is covered by the sterno-cleido-mastoideus; at the upper part, by adipose membrane, absorbent glands, and by the platysma myoides. It lies deep on the muscles of the spine, and gives off no branches, until it reaches the space between the larynx and angle of the jaw, just below the cornu of the os hyoides, where it divides into the external and internal carotids.

Of the two, the internal carotid is situated most outwardly; it passes deep to the base of the cranium, where it enters the foramen caroticum, to supply the brain.

The external carotid immediately begins to send off branches.

Anteriorly it sends off,

1. The A. Thyroidea Superior.—This artery passes downwards and forwards, to ramify on the thyroid gland, where it inosculates with the artery of the other side, and with the inferior thyroid arteries. In this course, it sends ramifications to the integuments, the outside of the larynx, the muscles, &c. and one remarkable branch, the A. Laryngea, which sometimes arises from the trunk of the external carotid; it is a small artery which divides betwixt the os hyoides and thyroid cartilages, to supply the internal parts of the larynx.

2. A. Lingualis, vel Ranina.—The sublingual artery passes over the cornu of the os hyoides, then behind the mylo-hyoideus, over the stylo-glossus, hyo-glossus, and genio-hyo-glossus, to which it gives branches, and terminates in running along the inferior part of the tongue from its base to its apex. It gives branches, to the muscles about the chin, and to the substance and back-part of the tongue.

3. A. Maxillaris Externa.—The external maxillary artery passes under the stylo-hyoideus and posterior belly of the digastricus, then buries itself under the submaxillary gland. It runs over the lower jaw before the anterior edge of the masseter muscle, to supply the face.

In its passage, it gives off numerous branches.—One is worthy of notice, which runs along under the line of the lower jaw, and passing over the jaw near

the symphysis, supplies the chin. Other twigs supply the submaxillary gland, &c.

Posteriorly the carotid sends off,

4. A. Occipitalis.—The occipital artery crosses backwards and upwards, over the internal jugular vein and internal carotid artery, under the belly of the digastric muscle: it passes through a slight groove in the mastoid process below its great fossa, and ramifies on the back-part of the head. A remarkable branch of the occipital passes towards the base of the skull, to inosculate near the foramen magnum occipitis, with branches from the vertebral and posterior cervical arteries.

5. A. Pharyngea is a small branch of the carotid, which passes inwards to the pharynx and base of the skull.

6. Posterior Auris, which passes backwards and upwards in the fold between the ear and scalp, and is distributed on the integuments of the head.

The external carotid ascends behind the angle of the jaw, and enters the parotid gland, where it divides into,

7. A. Maxillaris Externa.

8. A. Temporalis.

9. A. Transversalis Faciei.

These arteries will be described in the dissection of the face.

VEINS.

The Internal Jugular Vein is a continuation of the lateral sinus which passes through the

foramen lacerum in the base of the cranium. It comes out deep from under the angle of the jaw, and in its course down the neck, it runs on the outer side of the carotid artery, before it reaches the thorax; it passes rather more forwards than the artery, to join the subclavian vein.

Its branches accompany the ramifications of the external carotid. At first the vein which accompanies each artery is a single branch, but it soon subdivides, so that two veins accompany one artery.

NERVES.

1. The Eighth Pair, or Par Vagum.—On separating the internal jugular vein, and trunk of the carotid artery, the par vagum is seen lying in the same sheath of cellular substance with those vessels. It lies in the triangular space formed betwixt the back-part of the artery and vein, and the subjacent muscles. This nerve comes out of the foramen lacerum with the jugular vein; hence it adheres to that vein more closely than to the artery or muscles; it runs down the neck behind these vessels.

In this course it gives off several nerves.

(1.) At the base of the cranium, it sends off several filaments, which are connected with the other nerves coming out of the base of the skull, such as the ninth pair, the superior cervical ganglion of the intercostal, &c.

(2.) Nervus Glosso-Pharyngeus is sent off from the eighth pair, deep under the angle of the jaw. It passes behind the carotids towards the muscles arising

from the styloid process; one principal branch of it passes between the stylo-pharyngeus and stylo-glossus to the tongue, while other twigs run behind the stylo-pharyngeus, to supply the pharynx.

(3.) Nervus Laryngeus Superior, vel Internus.—The superior or internal laryngeal nerve passes behind the internal carotid artery, obliquely, downwards and forwards; then, under the hyo-thyroideus muscle, it plunges betwixt the os hyoides and thyroid cartilage, accompanying the laryngeal artery, and supplying the internal parts of the larynx.

(4.) In the neck, also, the par vagum gives off filaments to the cervical ganglions of the intercostal nerve, and to communicate with the other nerves of the neck. Filaments also unite with twigs of the intercostal, and run down over the carotid artery to the great vessels of the heart, where they form the superior cardiac plexus.

The par vagum enters the thorax by passing betwixt the subclavian artery and vein.

2. The Intercostal, or Great Sympathetic Nerve.—This nerve lies behind the carotid, in the cellular membrane, betwixt that vessel and the muscles covering the vertebræ of the neck. It is distinguished from the par vagum by being smaller, lying nearer the trachea, and adhering to the muscles of the spine; also by its forming several ganglions. It arises from the sixth pair in the cranium, and comes out by the same foramen as the carotid artery.

Immediately after its exit from the skull, it forms the Superior Cervical Ganglion, which is very long, and of a reddish colour. The nerve afterwards

becomes smaller, and descends; and opposite the fifth or sixth cervical vertebra, it forms another swelling, the Inferior Cervical Ganglion. Sometimes it has another ganglion about the fourth or fifth vertebra of the neck, the Middle Cervical Ganglion; but this is not a constant appearance. The nerve then passes behind the subclavian artery into the thorax.

The branches of the intercostal nerve are numerous, and they generally pass off from the ganglions. Immediately below the base of the cranium, twigs go to the eighth and ninth pairs, and to the upper cervical nerves. In the middle of the neck, some twigs pass over the carotid; others go to the parts covering the trachea, and uniting with filaments of the par vagum, form the external laryngeal nerves; others unite with the descendens noni, or descending branch of the ninth pair, and some filaments assist the twigs of the par vagum to form the superior cardiac nerve. In the lower part of the neck, twigs are sent to communicate with the cervical nerves, &c.

3. The Ninth Pair, Nervus Hypo-glossus, or Lingual nerve, having left the skull by the anterior condyloid foramen, is connected with the eighth pair and intercostal nerve. Like them, it lies deep, and comes out from under the angle of the jaw. It is seen passing from behind the internal jugular vein, and then over the carotid artery, running betwixt these two vessels. It next passes under the mylo-hyoideus, running over the stylo-glossus, hyo-glossus, and genio-hyo-glossus, which last muscle its numerous branches perforate.

Branches.—While the nerve is passing betwixt the jugular vein and the carotid artery, it sends off the Descendens Noni.—This small and delicate nerve descends on the fore-part of the vein and artery, and is distributed to the muscles on the anterior part of the trachea. It is joined by filaments of the cervical nerves.

4. The Lingual Branch sent off by the third branch of the fifth pair of nerves, is also seen in the dissection of the neck. It is found under the mylo-hyoideus; it lies close upon the lower edge of the jaw-bone, betwixt the inferior edge of the pterygoideus internus and the upper part of the mylo-hyoideus. It gives numerous twigs to the sublingual gland and submaxillary duct, which are situated near it, and is lost in the substance of the tongue.

5. Nervus Accessorius ad Par Vagum.—The accessory nerve, having passed out of the cranium with the par vagum, separates from it, passes behind the internal jugular vein obliquely downwards and backwards; it perforates the mastoid muscle, and is distributed to the trapezius and muscles about the shoulder; it is much connected with the third and fourth cervical nerves.

6. The Seven Cervical Nerves come out from the foramina betwixt the vertebræ of the neck. They send numerous branches to the muscles, &c. on the side of the neck, and communicate by filaments with all the other nerves in the neck.

In this stage of the dissection, we may also see,

7. The Phrenic Nerve, formed by branches of the third and fourth cervical nerves.—This small nerve

lies upon the belly of the anterior scalenus muscle, and dives into the thorax, betwixt the subclavian artery and vein.

8. The RECURRENT NERVE, a branch sent off from the par vagum in the thorax, is also seen in the neck. Dissect between the under surface of the trachea and œsophagus at the lower part of the neck, and you will find the recurrent nerve situated there.

9. The upper part of the GREAT BRACHIAL PLEXUS may be seen, arising on the side of the neck, fro the lower cervical nerves, and passing behind the anterior scalenus, to reach the arm.

CHAP. VIII.

DISSECTION OF THE THORAX.

SECT. I.

OF THE MUSCLES WHICH LIE UPON THE OUTSIDE OF THE THORAX.

IN removing the integuments from the fore-part of the thorax, the pectoralis major and interior edge of the deltoid muscle should be dissected in the course of their fibres; and to do this, it will be necessary to remember that the fibres run obliquely from the sternum

and clavicle to the upper part of the os humeri*. They are not covered by any fascia, but by a condensed cellular membrane, which is similar to a thin aponeurosis, and is with difficulty dissected away, unless it be done very regularly.

Three pair of muscles are described in this dissection.

1. The PECTORALIS MAJOR—*Arises*, tendinous, from the anterior surface of the sternum, its whole length; fleshy, from the cartilages of the fifth, sixth, and sometimes the seventh ribs, and from two anterior thirds of the clavicle. The fleshy fibres run obliquely across the breast, and, converging, form a strong flat tendon, which is

Inserted into the ridge of the os brachii on the outside of the groove for the long tendon of the biceps flexor cubiti.

Situation: The belly of this muscle is superficial. It is separated from the deltoid muscle by cellular membrane, and fat, by the cephalic vein, and a small artery, named A. Thoracica Humeraria. Its tendinous fibres, arising from the sternum, are interlaced with those of the opposite, so as to form a kind of fascia covering the bone; and the origins from the ribs are intermixed with the obliquus externus abdominis. The clavicular and thoracic portions of the muscle are separated by a line of cellular membrane. The tendon is covered by the anterior edge of the deltoid; it forms the anterior fold of the arm-pit, and appears twisted, for the fibres which proceed from the thoracic portion of the muscle, seem to pass behind

* Called also, Os Brachii.

those proceeding from the clavicle, and to be inserted into the os humeri somewhat higher up.

Use: To move the arm forwards, and obliquely upwards, towards the sternum.

Synonyma: Pectoralis;—Sterno-costo-clavio-humeral.

The pectoralis major should be lifted up from its origin, and suspended by its tendon.—This will expose the next two muscles.

2. The Pectoralis Minor—*Arises*, by three tendinous and fleshy digitations, from the upper edges of the third, fourth, and fifth ribs, near their cartilages; it forms a fleshy triangular belly, which becomes thicker and narrower as it ascends, and is

Inserted, by a short flat tendon, into the anterior part of the coracoid process of the scapula.

Situation: The belly of this muscle is covered by the pectoralis major; the tendon passes under the anterior edge of the deltoid, and is connected at its insertion with the origins of the coraco-brachialis, and of the short head of the biceps flexor cubiti, and also with the ligamentum proprium scapulæ anticum, a strong ligagament, which passes from the external edge of the coracoid process, to be affixed to the posterior margin of the acromion of the scapula.

Use: To draw the scapula forwards and downwards, and, when that bone is fixed, to elevate the ribs.

Synonyma: Serratus anticus;—Serratus minor anticus;—Costo-coracoidien.

3. The Subclavius—*Arises*, by a flat tendon, from

the cartilage of the first rib, and forms a broad fleshy belly, which is

Inserted into the inferior surface of the clavicle, beginning about one inch from the sternum, and continuing as far as the ligamentous connection of the clavicle to the coracoid process.

Situation: This muscle is situated between the clavicle and sternum, concealed by the pectoralis major, and anterior part of the deltoides.

Use: To draw the clavicle downwards and forwards, and perhaps to elevate the first rib.

Synonyma: Costo-claviculaire.

Having lifted up the pectoralis minor from its origin, the situation of the subclavian vessels which pass under the clavicle, and over the first rib, may be seen. (See the dissection of the Axilla.)

SECT. II.

OF THE PARTS CONTAINED WITHIN THE CAVITY OF THE THORAX.

THE cavity of the thorax may now be opened, by cutting through the cartilages of the ribs on each side, and separating the lower part of the sternum from the diaphragm. That bone must then be lifted upwards, and the first and second parts of which it is composed divided by an incision along the inner surface of their junction; or the whole sternum may be removed, by separating it at its articulations with

the clavicle. The latter method is preferable, as it allows us to examine more readily the great vessels passing out of the thorax.

On looking under the sternum, while it is lifted up, we see the Mediastinum, separating, as it is gradually torn from the posterior surface of the sternum, into two layers, and thus forming a triangular cavity. This cavity is artificially produced, and is entirely owing to the method of raising the sternum.

When the sternum is laid back or removed, the following parts are to be observed:

The MEDIASTINUM, now collapsed, dividing the thorax into two distinct cavities, of which the right is the largest.

The lungs of each side lying distinct in these cavities.

The Pericardium, containing the heart, situated in the middle of the thorax, between the two laminæ of the mediastinum, and protruding into the left side.

The internal surface of the pleura, smooth, colourless, and glistening, lining the ribs, and reflected over the lungs.

1. The PLEURA.—Each side of the thorax has its particular pleura:—The pleuræ are like two bladders, situated laterally with respect to each other; by adhering together in the middle of the thorax, and passing obliquely* from the posterior surface of the

* They run obliquely, not being in general attached to the middle of the sternum, but towards its left side, especially at the lower part of the bone, near the diaphragm. Besides the pericardium, the mediastinum contains betwixt its laminæ some adipose membrane and absorbent glands.

ste rnum to the dorsal vertebræ, they form the mediastinum.—The pleura lines the ribs, and the upper surface of the diaphragm, and is reflected over the lung, which is in fact behind it; it forms the ligamentum latum pulmonis, a reflection of this membrane, which connects the inferior edge of the lungs to the spine and diaphragm.

2. The LUNGS.—*Colour*, reddish in children, greyish in adults, and bluish in old age.—*Shape*, corresponding to that of the thorax, somewhat pyramidal, convex towards the ribs, concave towards the diaphragm, and irregularly flatted next the mediastinum.

Division (1.) The Right Lung is the largest, and is divided into three lobes, two greater ones, and an intermediate lesser lobe.

(2.) The Left Lung has two lobes, and also a square notch opposite the apex of the heart. Into the sulci or grooves which form the divisions of the lungs into lobes, the pleura enters; that part of the lung which is affixed to the spine, is called its root: it is the part by which the great vessels enter.

3. The PERICARDIUM is a strong, white, and compact membrane, smooth, and lubricated upon the inside, forming a bag for containing the heart, and having its inner lamina reflected over the substance of the heart itself.

4. When you slit open the fore-part of the pericardium, you expose the HEART. The right ventricle protrudes; the right auricle also is towards you; while the left auricle is retired, and its tip is seen lapping round upon the left ventricle. From

under this tip of the left auricle, a branch of the coronary vein, and one of the coronary artery, ramify towards the apex of the heart, marking the situation of the septum cordis. The left ventricle will be found firm, fleshy, and resisting, whilst the right ventricle is more loose, and seems partly wrapt round the other.

The heart is situated obliquely in the middle of the breast; its posterior surface is flat, and lies upon the diaphragm; its apex is turned forwards, and towards the left side, so that, in the living body, it is felt striking between the fifth and sixth ribs, at the point where the cartilages and bony extremities are united. The Vena Cava Superior is seen coming down from the upper angle of the pericardium. The Inferior Cava is seen coming up through the diaphragm; but only a very small part of this vein is covered by the pericardium; the two veins enter the right auricle. The Right Auricle is turned forwards, and might be called the anterior; it generally appears black, by the blood shining through its thin coats. The Right Ventricle is situated almost directly opposite. The Pulmonary Artery arises from the right ventricle; its root is concealed by the right auricle; it ascends on the left side of the aorta; it divides into, 1. the right pulmonary artery, which passes under the arch of the aorta, crosses behind it and the vena cava superior to the right lung, and is the longest; and, 2. the left pulmonary artery, which passes to the left lung, crossing the descending aorta anteriorly. The Pulmonary Veins enter the left auricle, two veins come from each lung; the right veins are longest as they pass

behind the vena cava superior. The left auricle is situated on the left side of the right auricle, and somewhat behind it; its tip is seen lapping round upon the LEFT VENTRICLE; this is situated behind and on the left side of the right ventricle; its substance is stronger and more firm to the touch. The AORTA arises from the back-part and right side of the left ventricle; its root is covered by the pulmonary artery; it then ascends betwixt that artery and the vena cava superior. Immediately from the root of the aorta, within the pericardium, the two coronary arteries are sent off to supply the heart itself.

SECT. III.

DISSECTION OF THE GREAT VESSELS OF THE HEART.

THE VENA CAVA SUPERIOR will be seen descending before the root of the lungs, and on the right side of the aorta. Immediately before perforating the pericardium, it is joined upon its posterior part by the vena azygos, which comes forwards from the spine, returning the blood from the intercostal spaces.

Behind the sternum, and just above the arch of the aorta, the superior cava is seen receiving two great branches.

1. A branch coming from the right side, formed

by the right subclavian vein, and the right internal jugular.

2. A larger branch coming from the left side; it is formed by the left subclavian and left internal jugular, which unite to form a trunk. This trunk crosses before the arteries arising from the arch of the aorta, and then enters the superior vena cava. Into the posterior part of the angle formed by the union of the left subclavian and the left jugular, the thoracic duct empties itself.

On each side, the internal jugular vein descends along the neck by the side of the carotid, while the subclavian vein comes from the arm.

The VENA CAVA INFERIOR, immediately after passing through the diaphragm from the abdomen, enters the pericardium.

The AORTA leaves the heart opposite the fourth dorsal vertebra; it crosses over the pulmonary artery, ascends obliquely upwards, backwards, and to the right side, as high as the second dorsal vertebra. Here it forms an ARCH or incurvation, which passes from the right to the left side, and at the same time obliquely from before backwards; it then comes in contact with the upper part of the third dorsal vertebra, and descends along the spine in the posterior mediastinum. This arch of the aorta is situated behind the first bone of the sternum, behind and somewhat below the left branch of the vena cava superior.

From the upper part of the arch come off three large arteries.

1. The ARTERIA INNOMINATA, or common trunk

of the right carotid and subclavian, ascends about an inch, and bifurcates into,

a, The right carotid, which ascends in the neck by the side of the trachea.

b, The right subclavian, which passes outwards to the arm.

2. The left carotid.

3. The left subclavian comes off from the extremity of the arch.

The arch of the aorta also gives off some small twigs which pass to the pleura, the mediastinum, and thymus.

The THYMUS is a soft glandular body, lying, before the lower part of the trachea and great vessels of the heart, a little higher than the tops of the two pleuræ. It is very large in the fœtus, smaller in adults, and nearly disappears in the aged.

Where the aorta begins to descend, it is connected to the pulmonary artery by a ligament, which, in the fœtus, was a large canal, the DUCTUS ARTERIOSUS.

COURSE OF THE SUBCLAVIAN ARTERY ON EACH SIDE.

THE subclavian artery passes upwards and outwards, runs under the clavicle, and over the middle of the first rib; it passes between the bellies of the anterior and middle scaleni muscles, then runs under the arch of the pectoralis minor, and enters the axilla, where it assumes the name of Axillary Artery.

The order in which the following arteries are sent off from the subclavian varies much; sometimes they come off singly, at other times in large trunks, which subdivide.

Backwards the subclavian sends off,

1. The Vertebral Artery.—This artery arises from the back-part of the subclavian, passes outwards and enters the foramen in the transverse process of the last cervical vertebra, and ascends through the transverse processes of the vertebræ, to enter the foramen magnum of the occipital bone.

2. The Inferior Thyroid Artery ascends obliquely inwards, passes behind the internal jugular vein, to ramify on the thyroid gland, where it inosculates largely with the superior thyroid arteries. Branches from this artery pass to the trachea and œsophagus, to the muscles of the neck, and of the scapula: one of these is the supra scapulary artery. (See the account of the branches of the axillary artery.)

2. A. Cervicalis Anterior, vel Profunda, passes deep to the muscles situated on the fore-part of the cervical vertebræ, and ascends as high as the base of the skull.

4. A. Cervicalis Posterior, vel Superficialis, is larger than the last; it ascends obliquely outwards, generally passes betwixt the transverse processes of the last cervical and first dorsal vertebræ, and ascends on the back-part of the neck, deeply seated; some of its branches pass down the back superficially.

Anteriorly, the subclavian artery gives off,

5. A. Mammaria Interna. The internal mammary arises from the fore-part of the subclavian, opposite the cartilage of the first rib; it runs down on the inside of the cartilages of the ribs, and terminates in the abdominal muscles, where it inosculates with the epigastric. It is a large artery, and its branches are very numerous. They pass to the external muscles of the chest, to the intercostal muscles, pleura, &c. It also sends off the Arteria Phrenica Superior, vel comes nervi phrenici, which, with two veins, accompanies the phrenic nerve to the diaphragm.

6. The subclavian artery gives twigs to the root of the neck, and to the muscles about the scapula.

7. A. Intercostalis Superior. Frequently a trunk comes off from the subclavian, especially on the right side, which passes downwards and backwards, and lodges itself by the spine, to supply the two or three superior intercostal spaces.

COURSE OF THE SUBCLAVIAN VEIN.

The subclavian vein is situated anteriorly to the subclavian artery; it passes inwards behind and under the subclavius muscle, and before and over the belly of the anterior scalenus (so that this last muscle lies betwixt the vein and artery). It runs over the first rib, from under the arch of the pectoralis minor, where it is found in contact with the axillary artery, and is called the Axillary Vein.

The branches of this vein accompany and correspond to the ramifications of the subclavian artery, returning

the blood from the thyroid gland, neck, chest, intercostal spaces, &c. The subclavian vein also receives the internal jugular, which passes down behind the clavicle.

THE COURSE OF THE BRACHIAL PLEXUS OF NERVES

May also be examined. This plexus is formed by branches of the four lower cervical and first dorsal nerves, which pass between the anterior and middle scaleni muscles into the axilla. In this passage they are situated higher up than the artery.

A considerable part of the scaleni muscles may now be seen; the upper insertion of these muscles must be dissected with the muscles of the back-part of the neck.

1. The SCALENUS ANTICUS—*Arises*, by three tendons, from the transverse processes of the fourth, fifth, and sixth vertebræ of the neck.

Inserted, tendinous and fleshy, into the upper edge of the first rib, near its cartilage.

Synonyma: Scalenus prior;—First scalenus;—Anterior portion of the first scalenus;—Trachelocostal.

2. The SCALENUS MEDIUS—*Arises*, tendinous, from the transverse processes of all the vertebræ of the neck.

Inserted into the upper and outer part of the first rib, from its root to within the distance of half an inch from the scalenus anticus.

Synonyma: Second Scalenus;—posterior portion of the first scalenus;—Trachelo-costal.

3. The SCALENUS POSTICUS—*Arises*, tendinous, from the transverse processes of the fifth and sixth vertebræ of the neck.

Inserted into the upper edge of the first rib, near the spine.

Synonyma: Third scalenus;—Scalenus secundus;—Trachelo-costal.

Situation: These muscles are covered before by the sterno-mastoideus and trapezius, behind by the trapezius and levator scapulæ; but the scaleni are so connected with the muscles of the spine, that the whole of them cannot be demonstrated till the muscles of the back and neck are dissected.

Use of these three muscles: To bend the neck to one side, and, when the muscles of both sides act, to bend it forwards; or, when the neck is fixed, to elevate the ribs, and dilate the chest.

SECT. IV.

DISSECTION OF THE AXILLA, OR ARM-PIT.

THERE is a considerable resemblance in the dissection of the axilla to that of the ham or groin; in each of these situations we meet with important blood-vessels and nerves, closely connected together,

embedded in adipose membrane, and seated in the flexure of a joint.

The axilla is formed by two muscular folds which bound a middle cavity. The anterior fold is formed by the pectoralis major passing from the thorax to the arm, the posterior by the latissimus dorsi coming from the back.

In the intermediate cavity there is a quantity of cellular membrane and absorbent glands, covering and connecting the great vessels and nerves. This cellular and adipose membrane is continued from the interstice above the clavicle betwixt the edges of the trapezius and mastoid muscles. All the space before the root of the neck above the first rib, and under the clavicle and coracoid process of the scapula, and the interstices of the muscles passing through that space, are filled up by a quantity of adipose membrane; and this is not exactly similar to the fat in other parts of the body; it is more granulated, watery, and of a reddish colour; it surrounds the great vessels and nerve, rendering the dissection both tedious and difficult.

The Axillary Vein will be found lying anterior to the artery, that is, nearer the integuments. It seems to be a continuation of the basilic vein, which runs along the inside of the arm quite superficial, and of the two or three venæ satellites, or veins which accompany the brachial artery. The axillary vein receives branches corresponding to the ramifications of the artery. Passing under the clavicle, it becomes the subclavian vein, and runs over the first rib,

and before the anterior scalenus muscle into the thorax.

Deeper seated, and immediately behind the axillary vein, lies the Axillary Artery. It is seen coming from under the clavicle; from under the arch formed by the pectoralis minor, it comes over the middle of the first rib, and between the anterior and middle scaleni muscles. In the axilla it is surrounded by the meshes of the nerves, and runs along the inferior edge of the coraco-brachialis muscle; when it has passed the anterior edge of the pectoralis major, it assumes the name of the Brachial Artery.

The branches of the axillary artery are,

1. A. Mammaria Externa, called also, A. Thoracicæ Externæ.——The external mammary artery consists of three or four branches which run downwards and forwards obliquely over the chest. These branches sometimes come off separately from the axillary artery, at other times by one or two common trunks, which subdivide. They supply the pectoral muscles and mamma. Some of their branches pass to the muscles of the shoulder, to the side of the chest, and to the muscles on the inside of the scapula.

2. A. Scapularis Interna, Supra-scapularis, or Dorsalis Scapulæ, is sent off from the back-part of the axillary artery. It runs across the bottom of the neck towards the root of the coracoid process, and passes through the semilunar notch in the superior costa of the scapula; it supplies the supra-spinatus

muscle, and then passes under the acromion, to ramify on the muscles below the spine of the scapula. It is generally a branch of the A. Thyroidea Inferior, and is then named A. Transversalis Humeri.

3. A. Scapularis Externa, Infrascapularis, or Thoracica Posterior, arises from the under and back part of the axillary artery, attaches itself to the inferior costa of the scapula, where it splits into two great branches: 1. A large branch, which passes to the outer surface of the scapula below the spine, and has its principal ramifications close upon the bone. 2. The other branch (which is larger) passes to the inner surface of the scapula, supplies the subscapularis, and sends branches downwards to the muscles of the back and loins.

4. Arteria Circumflexa Humeri Posterior, Humeralis, or Reflexa Articularis, arises from the lower and fore-part of the axillary artery, and runs backwards close to the bone, surrounds its neck, and is lost on the inner surface of the deltoid; it gives also twigs to the joint and neighbouring muscles.

5. A. Circumflexa Anterior is a much smaller artery, often a branch of the circumflexa posterior; it encircles the neck of the bone on its fore-part, and is lost on the inner surface of the deltoides, where it inosculates with the posterior circumflex artery.

The Great Brachial Nerves accompany the subclavian artery over the first rib. In the axilla they are united by numerous cross branches, forming the Axillary or Brachial Plexus, which is continued from

the clavicle as low as the edge of the tendon of the latissimus dorsi, and which surrounds the axillary artery with its meshes.

From the axillary plexus seven nerves pass off.

1. Nervus Supra-scapularis, Scapularis Externus, Scapularis.—This nerve comes off from the upper edge of the plexus; it crosses the axilla at the highest part, runs towards the superior costa of the scapula, accompanies the external scapular artery through the semilunar notch, and supplies the muscles on the posterior surface of the scapula.

2. N. Circumflexus, Articularis, Axillaris, or Humeralis, lies deep: it passes from the back-part of the plexus, goes backwards round the neck of the bone, accompanying the posterior circumflex artery, and is distributed to the musculus deltoides, and the muscles on the outside of the arm. Small nerves also pass from the axillary plexus to the subscapular muscle, the teres major, latissimus dorsi, and pectoral muscles.

3. The External Cutaneous Nerve, or Nervus-Musculo-cutaneus.

4. The Radial Nerve.

5. The Ulnar Nerve.

6. The Muscular or Spiral Nerve.

7. The Internal Cutaneous Nerve.

These five nerves will be described in the dissection of the arm and fore-arm.

SECT. V.

DISSECTION OF THE POSTERIOR MEDIASTINUM*, AND OF THE NERVES AND VESSELS WHICH HAVE THEIR COURSE THROUGH THE THORAX.

Course of the Phrenic Nerve through the thorax.—On each side this nerve is seen entering the thorax betwixt the subclavian artery and subclavian vein; it then proceeds downwards and forwards before the root of the lungs, and on the outside of the pericardium, betwixt that bag and the pleura; it is lost on the diaphragm. The left phrenic nerve has a somewhat longer course than the nerve of the right side, as it passes over the pericardium, where that bag covers the apex of the heart. This nerve is accompanied by one artery and two veins; some twigs pass from the phrenic nerve into the abdomen, to the liver, &c.

Behind the arch of the aorta and great vessels passing from the heart, is seen the Trachea. It enters the thorax between the two pleuræ, and, opposite the third or fourth dorsal vertebra, bifurcates into two parts: one of which passes toward the right, the other toward the left, to enter the lung of each side.

By folding back the lungs towards the left side of the chest, we expose the pleura reflected from the

* By *Posterior Mediastinum* is designed that part of the mediastinum situated behind the root of the lungs.

under surface of the root of the lungs to the spine and ribs. A triangular space is formed betwixt the two pleuræ and the bodies of the dorsal vertebræ; this space or cavity is named the cavity of the posterior mediastinum. It contains many important parts, and must therefore be carefully dissected.

But first let us attend to the course of the intercostal, or great sympathetic nerve, which is seen running by the side of the spine.

The Intercostal Nerve, where it enters the thorax, is situated behind the great vessels; close upon the articulation of the first rib with the body of the first dorsal vertebra, it forms a ganglion, a twig of which fairly encircles the subclavian artery, while other filaments are entwisted round the root of the vertebral artery. The intercostal nerve then descends along the thorax; it lies upon the heads of the ribs, where they are articulated with the vertebræ; it receives additional branches from all the dorsal nerves, and in each intercostal space it forms a ganglion. This nerve may be dissected with greater facility when the lungs are removed, and the ribs sawed off near the spine, which will enable the dissector to trace its branches more fully. It lies behind the pleura, but is seen through it; it passes into the abdomen by the side of the spine, running through the fibres of the small muscle of the diaphragm.

Branches of the Intercostal in the Thorax.

The Anterior Intercostal, or Splanchnic Nerve, should be attended to. It is formed by

three or four twigs, which come off from the intercostal betwixt the fourth and eighth dorsal vertebræ; these twigs, passing forwards on the bodies of the vertebræ, unite to form the splanchnic nerve, which may be traced entering the abdomen, betwixt the crura of the small muscle of the diaphragm.

From the intercostal, also, twigs are given off, which assist the branches of the par vagum, and of the dorsal nerves, in forming several plexuses to supply the viscera of the thorax.

The right intercostal nerve lies under the pleura by the right side of the spine. Still nearer the middle of the spine, you see the Vena Azygos. In dissecting, it is found situated betwixt the right intercostal nerve and the aorta; it begins below from ramifications of the lumbar arteries, which pierce the small muscle of the diaphragm. This vein ascends along the spine, receiving veins from each of the intercostal spaces of the right side, and, about the middle of the back, it receives a considerable trunk, which comes from under the aorta, and returns the blood from the left side of the thorax. At the fourth dorsal vertebra, the vena azygos leaves the spine; it makes a curve forward, and empties its blood into the back-part of the vena cava superior, immediately before that vein enters the pericardium.

Descending through the posterior mediastinum, will be also found the Aorta. This great artery, having formed its arch, comes in contact with the third dorsal vertebra, and is now called the Descending Aorta, or Thoracic Aorta. It descends along the bodies of the dorsal vertebræ, rather on their left side; it lies behind

the œsophagus, and passes betwixt the crura of the diaphragm into the abdomen.

Branches of the Aorta in the Thorax.

1. A. Intercostales Inferiores.—The arteries which supply the three or four superior intercostal spaces, generally come off in one common trunk, which afterwards subdivides

The Intercostalis Superior, on the right side, is mostly sent off by the subclavian; on the left side, by the aorta.

The Inferior Intercostals are eight or nine in number on each side of the thorax; they come off separately from the side or back-part of the aorta, and seem to tie that great artery to the spine. Each intercostal artery passes immediately into the interval betwixt two ribs, and there subdivides into,

(1.) A branch which perforates between the heads of the ribs to the muscles of the back; this branch also gives twigs which enter the spinal canal.

(2.) The continued trunk of the artery runs forwards, in the interval of the two ribs, giving many branches to the intercostal muscles. When it reaches the anterior part of the thorax, it is lost in the muscles.

Each intercostal artery is accompanied by one or two veins, branches of the vena azygos, and by an intercostal or dorsal nerve.

2. A. Bronchiales are two, sometimes three, small twigs of the aorta, one of which passes to the lungs on each side; they sometimes arise from the subclavian and superior intercostal.

3. Small arteries pass forwards from the aorta on

the œsophagus, named A. Œsophageæ; others run to the pericardium and pleura.

The dissector also finds in the posterior mediastinum the THORACIC DUCT. He must look for it behind the œsophagus, betwixt the vena azygos and aorta; it is collapsed, and appears like cellular membrane condensed, and can only be distinguished when inflated or injected; it was seen in the abdomen close to the aorta, and passing into the thorax between the crura of the diaphragm. It ascends along the posterior mediastinum, and, about the fourth dorsal vertebra, passes obliquely to the left side, behind the aorta descendens, and behind the great arch of the aorta, until it reaches the left carotid artery. It runs behind this artery, and behind the left internal jugular vein; and, after forming a circular turn or arch (the convexity of which is turned upwards), it descends, and enters the left subclavian vein at the point where that vein is joined by the left internal jugular. In its course along the spine, the thoracic duct frequently splits into two branches, which re-unite. The absorbents of the right superior extremity, and of the right side of the head and thorax, usually form a trunk, which enters the right subclavian vein.

The ŒSOPHAGUS is also situated betwixt the layers of the posterior mediastinum. It lies immediately before the aorta, but rather towards its left side; it is seen descending from the neck behind the trachea; it passes through an opening in the lesser muscle of the diaphragm, and immediately expands into the stomach.

Behind the trachea and vessels going to the lungs, and on the fore-part of the œsophagus, we meet with a congeries of lymphatic glands.

COURSE OF THE PAR VAGUM, OR EIGHTH PAIR OF NERVES, IN THE THORAX.

From the neck, the par vagum passes betwixt the subclavian vein and artery into the thorax; it immediately sends off a large branch, the RECURRENT NERVE, back into the neck. On the right side, this branch twists round under the arteria innominata; on the left side, under the arch of the aorta, it ascends behind the carotid, and lodges itself betwixt the trachea and œsophagus, to both of which it gives branches.

The par vagum, having given off the recurrent, descends by the side of the trachea, and behind the root of the lungs. It here sends off numerous filaments to the lungs, which, uniting with twigs from the great sympathetic, form the ANTERIOR and POSTERIOR PULMONARY PLEXUSES; these plexuses lie on the anterior and posterior surfaces of the root of the lungs. Other twigs of the par vagum pass, to form the inferior CARDIAC PLEXUS about the pericardium.

The trunk of the eighth pair soon reaches the œsophagus; the left par vagum runs on the fore-part of the œsophagus, the right nerve on its back-part. Here they split on into several branches, which unite again, and form a PLEXUS. This plexus is called the ŒSOPHAGEAL. The two nerves continue their course

along the œsophagus, and pass with it through the diaphragm, to ramify on the stomach, and form the stomachic plexus.

The twelve dorsal or intercostal nerves are also seen in this dissection, emerging from the spinal canal, between the bodies of the vertebræ, and supplying the intercostal muscles, &c.

SECT. VI.

DISSECTION OF THE HEART, WHEN REMOVED FROM THE BODY.

The heart consists of three tunics or coats. 1. An external smooth one, which is a reflection of the internal lamina of the pericardium. 2. A middle muscular coat. 3. A smooth internal coat, which is a continuation of the internal coat of the great veins and arteries. In the right side of the heart we always meet with a considerable quantity of coagulated blood. In the left side there is much less.

Slit open with the scissars the two venæ cavæ on their fore-part, the inner surface of these veins, and of the right auricle, will be seen lined by a smooth membrane; and in the auricle, the musculi pectinati, or bundles of muscular fibres, will be seen projecting. At the point of union between the two cavæ, there is a projection formed by the thickening of the muscular coat, the Tuberculum Loweri. The Septum Auricularum is seen separating the right from the

left auricle;—observe that it is thin, that in it there is an oval depression, named Fossa Ovalis. Round this fossa the fibres are thicker, forming the annulus ovalis; this is the remains of the Foramen Ovale of the fœtus; and in many adult subjects a probe may be passed through the superior part of the fossa obliquely into the left auricle. The Valvula Nobilis, or Eustachian Valve, is a membrane-like duplicature of the inner coat of the auricle, observed where the vena cava inferior is continued into the auricle, and stretching from that vein towards the opening into the right ventricle. This valve is sometimes found reticulated. Behind this valve is the orifice of the Coronary Vein, with its small valve.

The Foramina Thebesii are minute orifices of veins, which open into all the cavities of the heart; they are most numerous, however, in the right auricle.

The Ostium Venosum, or opening of the right auricle into the right ventricle, is somewhat oval; it has a valve which projects into the right ventricle.

The Right Ventricle may now be opened by an incision, carried from the root of the pulmonary artery down to the apex of the heart. This incision should be made with care, lest the parts on the inside of the ventricle be destroyed by it; it should pass along the right side of the septum ventriculorum, the situation of which is marked out by large branches of the coronary artery and vein. A small opening should first be made, into which one blade of the scissars can be introduced: the incision may be continued through

the apex of the heart, or a flap may be made by another cut, passing from the beginning of the first along the margin of the right auricle.—In this ventricle, observe the projecting bundles of muscular fibres, the TRICUSPID VALVES arising from the margin of the ostium venosum, and projecting into the right ventricle. This valve forms a complete circle at its base, but has its edge divided into three parts, which are attached by tendinous filaments, named CHORDÆ TENDINEÆ, to the CARNEÆ COLUMNÆ, or muscular bundles of the ventricle.

The SEPTUM VENTRICULORUM, or partition of the two ventricles, is marked out externally by two veins running from the apex to the basis of the heart.

Slit up the pulmonary artery; observe how it arises from the back-part of the right ventricle, how smooth the inside of the ventricle becomes as it approaches the entrance of the artery, or ostium arteriosum. Observe the three SEMILUNAR or Sigmoid VALVES. Their bases arise from the artery, their loose edges project into its cavity, and in the middle of the loose edge of each valve is seen a small white body, termed CORPUS SESAMOIDEUM Arantii. The artery is seen bifurcating into the right and left pulmonary arteries, and, just before its bifurcation, sending off to the aorta the ductus arteriosus, which in the adult is a ligament.

The LEFT AURICLE has four pulmonary veins opening into its cavity, which may be exposed by slitting up two of these veins. Observe that its coats are thicker than those of the right auricle. The septum auricularum, with the fossa ovalis, is here seen less

distinctly than on the right side. Observe also the ostium venosum, opening into the left ventricle, and giving attachment to the VALVULA MITRALIS.

The LEFT VENTRICLE may be opened in the same manner as the right, by an incision carefully made in the left side of the septum or partition of the ventricles, and continued round the upper part of the ventricle, under the auricle. Observe the great thickness of the muscular coat; the VALVULA MITRALIS, forming two projections, which are attached by the chordæ tendineæ to the fleshy columns of this ventricle.

Slit up the aorta; it has three semilunar valves, which resemble those of the pulmonary artery:—behind these valves the artery bulges out, forming the SINUSES of the aorta. Above two of the valves lie the orifices of the two coronary arteries, of which the left is the largest.

CHAP. IX.

DISSECTION OF THE FACE.

SECT. I.

OF THE MUSCLES.

UNDER the integuments of the face, there is always a considerable quantity of adipose membrane; many of the muscles are very slender, and, lying embedded in this fat, require careful dissection. The whole side of the face is also supplied with numerous ramifications of the fascial nerve, or portio dura of the seventh pair. These nervous twigs are generally removed with the integuments.

Twelve pair of muscles, and one single muscle, are described in this dissection.

1. The ORBICULARIS PALPEBRARUM—*Arises*, from the internal angular process of the frontal bone, and from a tendon at the inner angle of the eye, by a number of fleshy fibres which pass round the orbit, covering first the superior, and then the inferior eye-lid, and also the bony edges of the orbit.

Inserted, by a short round tendon, into the nasal process of the superior maxillary bone.

Situation: This muscle is intermixed, at its upper part, with the occipito-frontalis; it covers the upper part of the lacrymal sac.

Use: To shut the eye, by bringing down the upper lid, and pulling up the lower; the fibres contracting towards the inner angle, as to a fixed point, compress the eye-ball and lacrymal gland, and convey the tears towards the puncta lacrymalia.

Synonyma: Orbicularis palpebrarum et ciliaris;—The ciliaris is only a part of the muscle covering the cartilages of the eye-lids, which are called the Cilia or Tarsi;—Maxillo-palpebral.

2. The CORRUGATOR SUPERCILII—*Arises*, fleshy, from the internal angular process of the os frontis; it runs outwards and a little upwards, to be

Inserted into the inferior fleshy part of the occipito-frontalis muscle, extending outwards as far as the middle of the superciliary ridge.

Situation: This muscle is concealed by the occipito-frontalis. It lies close to the upper and inner part of the orbicularis palpebrarum, with which it is connected.

Use: To smooth the skin of the fore-head, by pulling it down after the action of the occipito-frontalis. When it acts more forcibly, it pulls down the eye-brow and skin of the fore-head, and produces vertical wrinkles.

Synonyma: Musculus supercilii;—Musculus frontalis verus, seu corrugator;—Cutaneo-sourcillier.

3. The COMPRESSOR NARIS—*Arises*, narrow, from the outer part of the ala nasi, and neighbouring part of the os maxillare superius. From this origin

a number of thin separate fibres run up obliquely along the cartilage of the nose toward the dorsum nasi, where the muscle joins its fellow, and is

Inserted, slightly, into the lower part of the os nasi and nasal process of the superior maxillary bone.

Situation: It is superficial; its origin is connected with the levator labii superioris alæque nasi; and its upper part with some of the descending fibres of the occipito-frontalis.

Use: To compress the ala towards the septum nasi; but, if the fibres of the occipito-frontalis, which adhere to it, act, the upper part of this muscle assists in pulling the ala outwards: It also corrugates the skin of the nose.

Synonyma: Transversalis seu myrtiformis;—Dilatores alarum nasi;—Constrictor nasi;—Maxillo-narinal.

4. Levator Labii Superioris Alæque Nasi—*Arises* by two distinct origins; the first from the nasal process of the superior maxillary bone, where it joins the os frontis at the inner canthus of the eye; it descends along the nasal process, and is *inserted* into the outer part of the ala nasi, and into the upper lip.—The second *arises*, broad and fleshy, from the external orbitar process of the superior maxillary bone, immediately above the foramen infra-orbitarium; it runs down, becoming narrower, and is *inserted* into the upper lip and orbicularis oris.

Situation: The first portion is sometimes called Levator Labii Superioris Alæque Nasi, and the second Levator Labii Superioris Proprius. Their origins are partly covered by the orbicularis palpebra-

rum. They descend more outwardly than the ala nasi.

Use: To raise the upper lip towards the orbit, and a little outwards; the first portion will also draw the ala nasi upwards and outwards.

Synonyma: Incisivus lateralis et pyramidalis;—Elevator labii superioris proprius;—Maxillo-labii-nasal.

The infra-orbitary artery, vein, and nerve, are seen emerging from the infra-orbitary foramen under this muscle.

5. Zygomaticus Minor—*Arises* from the upper prominent part of the os malæ, and, descending obliquely downwards and forwards, is

Inserted into the upper lip near the corner of the mouth.

Situation: Its origin is covered by the orbicularis palpebrarum; it has its course between the levator labii superioris alæque nasi and the zygomaticus major. Frequently the orbicularis palpebrarum sends down a slip of fibres to the upper lip, which slip runs between the zygomaticus minor and levator labii superioris alæque nasi.

Use: To draw the corner of the mouth and upper lip obliquely upwards and outwards.

Synonyma: Petit zygomata-labial.

6. Zygomaticus Major—*Arises*, fleshy, from the os malæ, near the zygomatic suture.

Inserted into the angle of the mouth, appearing to be lost in the depressor anguli oris, and orbicularis oris.

Situation: Its origin is partially covered by the or-

bicularis palpebrarum; it lies more outwardly than the zygomaticus minor.

Use: To draw the corner of the mouth and under lip upwards and outwards.

Synonyma: Zygomaticus;—Grand zygomato-labial.

7. The Levator Anguli Oris—*Arises*, thin and fleshy, from a depression of the superior maxillary bone, betwixt the root of the socket of the first dens molaris, and the foramen infra-orbitarium.

Inserted, narrower, into the angle of the mouth.

Situation: It lies more outwardly than the levator labii superioris alæque nasi; it is in part concealed by that muscle, by the zygomaticus minor, and part of the zygomaticus major. At its insertion it is particularly connected with the depressor anguli oris.

Use: To draw the corner of the mouth upwards.

Synonyma: Levator labiorum communis;—Canninus;—Sus-maxillo-labial.

8. The Depressor Anguli Oris—*Arises*, broad and fleshy, from the lower edge of the inferior maxillary bone, at the side of the chin, and, gradually becoming narrower, is

Inserted into the angle of the mouth.

Situation: This muscle is firmly connected with the platysma myoides; at its insertion it is blended with the zygomaticus major and levator anguli oris.

Use: To pull down the corner of the mouth.

Synonyma: Depressor labiorum communis;—Triangularis;—Sous maxillo-labial.

9. The Depressor Labii Inferioris—*Arises*, fleshy and broad, from the side of the lower jaw, a

little above its lower edge; it runs obliquely upwards and inwards, and is

Inserted into the edge of the under lip.

Situation: This muscle, at its insertion, decussates with its fellow. It is in part covered by the depressor anguli oris. It forms the thick part of the chin, and has its fibres interwoven with fat.

Use: To pull the under lip downwards.

Synonyma: Depressor labii inferioris proprius;—Quadratus;—Mentonier-labial.

10. The BUCCINATOR—*Arises*, tendinous and fleshy, from the lower jaw, as far back as the root of the coronoid process; from the upper jaw, as far back as the pterygoid process of the sphenoid bone; it then continues to arise from the alveolar processes of both jaws, as far forwards as the dentes cuspidati. The fibres run forwards, and are

Inserted into the angle of the mouth.

Situation: This muscle lies deep, adheres to the membrane that lines the mouth; and a quantity of fat is always found between its fibres and the other muscles and integuments. It is partly concealed by the masseter, and by the muscles which pass to the angle of the mouth, as the levator and depressor anguli oris, and zygomaticus major. It is inserted behind these muscles. In the cheek it is connected with the platysma myoides.

Use: To draw the angle of the mouth backwards and outwards, and to contract its cavity, by pressing the cheek inwards.

Synonyma: Retractor anguli oris;—Alveolo-maxillaire.

The single muscle is the

Orbicularis Oris.—It consists of two planes of semicircular fibres, which decussate at the angles of the mouth. These fibres are formed chiefly by the muscles which are inserted into the lips; they surround the mouth. The superior portion runs along the upper lip, the inferior portion along the under lip.

Situation: It is connected and intermixed with the insertions of all the preceding muscles of the face. Some of the fibres are connected to the septum nasi, and are by Albinus termed Nasalis Labii Superioris.

Use: To shut the mouth, by contracting and drawing both lips together.

Synonyma: Sphincter labiorum;—Semi-orbicularis superior et inferior;—Constrictor labiorum;—Labial.

11. Depressor Labii Superioris Alæque Nasi—*Arises*, thin and fleshy, from the os maxillare superius, where it forms the alveoli of the dentes incisiva and dens caninus; thence it runs up under part of the levator labii superioris alæque nasi.

Inserted into the upper lip and root of the ala nasi.

Situation: It is concealed by the orbicularis oris and levator labii superioris alæque nasi. It may be discovered by inverting the upper lip, and dissecting on the side of the frenum which connects the lip to the gums.

Use: To draw the upper lip and ala nasi downwards and backwards.

Synonyma: Depressor alæ nasi;—Incisivus medius;—Depressor labii superioris proprius;—Maxillo-alveoli-nasal.

12. The LEVATOR LABII INFERIORIS—*Arises* from the lower jaw at the root of the alveolus of the lateral incisor.

Inserted into the under lip and skin of the chin.

Situation: Those two small muscles are found by the side of the frenum of the lower lip. They lie under the depressor labii inferioris.

Use: To raise the under lip and skin of the chin.

Synonyma: Levator menti;—Incisivus inferior;—Elevator labii inferioris proprius;—Sous-maxillo-cutané.

On the side of the face we observe two strong muscles, and two other muscles are concealed by the angle of the inferior maxilla.

1. The MASSETER is divided into two portions, which decussate one another.

The anterior portion *arises*, tendinous and fleshy, from the superior maxillary bone, where it joins the os malæ; from the lower edge of the os malæ, and from its zygomatic process. The strong fibres run obliquely downwards and backwards, and are *inserted* into the outer surface of the side of the lower jaw, extending as far back as its angle.

The Posterior Portion *arises*, principally fleshy, from the inferior surface of the os malæ, and of the whole of the zygomatic process, as far back as the tubercle before the socket for the condyle of the lower jaw. The fibres slant forwards, and are *inserted*, tendinous, into the outer surface of the coronoid process of the lower jaw.

Situation: The anterior portion conceals almost the whole of the posterior portion. The greater part

of this muscle is superficial. Below, it is covered by the platysma myoides; and above, a small portion of it is concealed by the origin of the zygomaticus major.

Use: To pull the lower to the upper jaw, and to move it forwards and backwards.

Synonyma: Zygomato-maxillaire.

2. TEMPORALIS—*Arises*, fleshy, from a semicircular ridge in the lower and lateral part of the parietal bone, from all the squamous portion of the temporal bone, from the external angular process of the os frontis, from the temporal process of the sphenoid bone, and from an aponeurosis which covers the muscle. From these different origins the fibres converge, descend under the bony jugum formed by the zygomatic processes of the temporal and cheek bones.

Inserted, by a strong tendon, into the upper part of the coronoid process of the lower jaw, to which it adheres on every side, but more particularly its fore-part, where the insertion is continued down to near the last dens molaris.

Situation: This muscle is of a semicircular shape. It is covered by a fascia or aponeurosis. This fascia adheres to the bones which give origin to the upper part of the muscle, and, descending over it, is inserted into the jugum, and adjoining part of the os malæ and os frontis. The temporalis, at its origin, lies under the expanded tendon of the occipito-frontalis, and under the small tendons which move the external ear. Its insertion is concealed by the jugum and by the mas-

seter; so that, to expose it, the masseter must be cut away.

Use: To pull the lower jaw upwards, and press it against the upper.

Synonyma: Crotaphites;——Arcadi-temporo-maxillaire.

In order to expose the following muscles, we must remove the muscles of the cheek and jaw, the masseter and insertion of the temporalis must be taken away, and the coronoid process of the inferior maxilla removed by a saw.

3. The Pterygoideus Externus—*Arises*, from the outer side of the external plate of the pterygoid process of the sphenoid bone, from part of the tuberosity of the os maxillare adjoining to it, and from the root of the temporal process of the sphenoid bone. It passes backwards and outwards, to be

Inserted into a depression in the neck of the condyloid process of the lower jaw, and into the anterior and inner part of the ligament of the articulation of that bone.

Situation: This muscle passes almost transversely from the skull to its insertion. It is concealed by the muscles of the face and neck, and by the ascending processes of the lower jaw.

Use: When this pair of muscles act together, they bring the jaw horizontally forwards. When they act singly, the jaw is moved forwards, and to the opposite side.

Synonyma: Pterygoideus minor;——Pterigo-colli-maxillaire.

4. The PTERYGOIDEUS INTERNUS—*Arises*, tendinous and fleshy, from the inner and upper part of the internal plate of the pterygoid process of the sphenoid bone, filling all the space between the two plates; and from the pterygoid process of the os palati between these plates.

Inserted, by tendinous and fleshy fibres, into the inside of the angle of the lower jaw.

Situation: To expose this muscle, the jaw must be removed from its articulating cavity, and then pulled forwards, and toward the opposite side; or it may be sawn across at its sympyhsis, and the other half removed. It is larger than the pterygoideus externus; and betwixt the two muscles there is a considerable quantity of cellular membrane, and the trunk of the inferior maxillary and gustatory nerves. Like that muscle, it is concealed by the lower jaw and facial muscles. Along its posterior edge we observe the Ligamentum Laterale Maxillæ Inferioris, a ligamentous band, which extends from the back-part of the styloid process to the angle of the lower jaw.

Use: To draw the jaw upwards, and obliquely towards the opposite side.

Synonyma: Pterygoideus major;—Pterigo-anguli-maxillaire.

On the side of the face is situated a considerable salivary gland, the PAROTID GLAND, a large white mass, irregularly oblong and protuberant, filling up all the space betwixt the angle and ascending processes of the jaw, the mastoid processes, root of the cartilage of the ear, and zygomatic process of the temporal bone. From its anterior and upper part a white canal or duct

passes forwards over the masseter, and perforates the buccinator from without inwards, opening into the mouth opposite the first dens molaris. The coats of this duct are very thick and firm, consisting of a ligamentous substance.

SECT. II.

OF THE VESSELS AND NERVES OF THE FACE.

ARTERIES.

The A. Maxillaris Externa, the third branch of the carotid, comes from the neck over the lower jaw at the anterior edge of the masseter. It then runs under the depressor anguli oris, passes towards the angle of the mouth, and is often much contorted. Here it is named the A. Facialis or Angularis. It ascends by the side of the nose, and, reaching the inner angle of the eye, is lost on the muscles situated there, inosculating freely with the temporal, internal maxillary, and ophthalmic arteries. In this course it gives off many branches: 1. Twigs to the masseter, depressor anguli oris, and chin; 2. A. Coronaria Labiorum. This artery is very much contorted.—At the angular commissure of the lips, it divides itself into two branches, which run along the superior and inferior portions of the orbicularis oris, and join the same branches of the other side. 3. While the facial artery ascends by the side of the nose, it gives

off the external nasal arteries to the outside of the nose, and the A. Buccales to the cheek.

The External Carotid is found ascending behind the parotid gland. It perforates the gland at its upper part, ascends over the zygomatic process immediately before the ear, and divides into the anterior, middle, and posterior temporal arteries, which ramify over the side of the head, giving also branches to the forehead and occiput.

But the carotid, while it lies embedded under the parotid, sends several twigs to the substance of that gland, and a considerable artery which passes forwards, and, ramifying on the side of the face, is named A. Transversalis Faciei. At this point also, the carotid sends off a large artery, the A. Maxillaris Interna. As many branches of this artery are met with in the dissection of the face, it is proper to give a view of its distribution.

The Internal Maxillary passes behind the condyloid process of the lower jaw: it directs its course towards the bottom of the orbit of the eye; and it is at this point that it sends off its numerous branches. (1.) Arteria Media Duræ Matris (or Meningea spheno-spinalis or spinosa) passes through the spinal hole of the sphenoid bone into the cranium, and is distributed to the dura mater. (2.) A. Maxillaris Inferior, vel Dentalis Inferior, runs downwards, enters the foramen at the root of the ascending processes of the lower jaw; then passes through the canal of the lower jaw, supplying the teeth and sockets, and emerges by the foramen mentale, to be distributed to the chin. It is accompa-

nied by a nerve and one or two veins. (3.) A. Pterygoideæ and A. Temporales Profundæ, are small branches of the internal maxillary which pass to the pterygoid muscles, and to the inner part of the temporal muscle. (4.) A. Pharyngeæ, branches to the pharynx, palate, and base of the skull. (5.) A. Alveolaris, which gives branches to the teeth of the upper jaw, and to the jaw-bone itself. (6.) A Branch through the foramen spheno-palatinum to the nose; and, (7.) An Artery through the palato-maxillary canal to the palate.

The continued trunk of the internal maxillary enters the orbit by the spheno-maxillary slit. It sends off a branch which runs along the inner side of the orbit, and passes out at the inner canthus of the eye on the forehead. The artery itself runs along the bottom of the orbit in a canal on the upper part of the great tuberosity of the os maxillare superius, and emerges by the foramen infra-orbitarium on the face; hence it is termed A. Infra-Orbitaria, and is distributed to the cheek and side of the nose.

The Frontal Artery is also seen in the dissection of the face, passing from the orbit through the foramen supra-orbitarium to be distributed to the forehead. This artery is sent off from the ophthalmic artery, which is a branch of the internal carotid.

If the face be injected, a remarkable anastomosis of arteries will be observed at the inner angle of the eye.

VEINS.

The veins of the face are numerous, and pass into the external and internal jugular veins.

NERVES.

1. The PORTIO DURA of the seventh pair, Nervus Communicans Faciei, or Facial Nerve, after its course through the temporal bone in the aqueduct of Fallopius, comes out by the foramen stylo-mastoideum. It immediately gives off branches to the neighbouring parts, as behind the ear. It then passes through the substance of the parotid gland, and emerges on the face in three great branches, which have frequent mutual communications: this division of the nerve is called PES ANSERINUS.

(1.) The ascending branch ramifies on the temple and forehead.

(2.) The middle branch sends its ramifications over the side of the face, the proper Facial Nerves.

(3.) The descending branch sends its twigs along the chin, down upon the neck, and backwards upon the occiput.

(2.) The SUPERIOR CERVICAL NERVES send off several branches, which ramify on the side of the face and head, and communicate freely with the branches of the portio dura.

As, in the course of this dissection, we meet with many twigs of the second and third branches of the fifth pair of nerves, it will be advisable here to describe these nerves.

3. Nervus Maxillaris Superior, or Second Branch of the Fifth Pair. The superior maxillary nerve, having left the cranium by the foramen rotundum of the sphenoid bone, emerges behind the antrum maxillare, at the lower back part of the orbit, and at the root of the pterygoid process of the sphenoid bone. It immediately sends out branches: 1. A small branch which passes through the spheno-maxillary slit to the periosteum and fat of the orbit. 2. The largest branch is the Infra-Orbitary Nerve. It enters the channel in the top of the antrum maxillare, accompanying the infra-orbitary artery, comes out at the foramen infra-orbitarium, and is widely distributed to the cheek, under lip, and outside of the nose, communicating with ramifications of the portio dura. 3. Branches to the temporal muscle, os malæ, &c. 4. Other branches form a small ganglion at the root of the orbit, which sends twigs, named the superior Nasal Nerves, through the foramen spheno-palatinum to the nose. 5. The Vidian Nerve, which enters the foramen pterygoideum, and passes again into the cranium, to connect itself with the portio dura. 6. The Palatine Nerve, which runs through the palato-maxillary canal to the palate. 7. Twigs which supply the gums and alveoli of the upper jaw.

4. Nervus Maxillaris Inferior, or Third Branch of the Fifth Pair. The inferior maxillary nerve leaves the cranium by the foramen ovale of the sphenoid bone. It has its course downwards and outwards; and, having given twigs to the parts near which it passes, as the masseter, pterygoid, and tem-

poral muscles, it divides at the angle of the lower jaw into two branches. 1. The Nervus Dentalis Inferior enters the foramen at the angle of the lower jaw; accompanies the inferior dental artery along the canal in that bone, giving nerves to the teeth; emerges by the foramen mentale, and is distributed to the chin. 2. The Nervus Gustatorius, vel Lingualis, passes to the tongue. It was seen in the dissection of the neck lying close upon the lower jaw-bone, below the inferior edge of the pterygoideus internus, and above the superior fibres of the mylo-hyoideus. It supplies the substance of the tongue, and the salivary glands situated at the root of the tongue.

This nerve receives the chorda tympani, a small twig which comes from the seventh pair through the slit in the articulating cavity of the temporal bone.

5. In the dissection of the face, we also meet with the Frontal Nerve, which comes from the first branch of the fifth pair, and which is seen accompanying the frontal artery through the foramen supra-orbitarium. It is distributed to the fore-head.

CHAP. X.

DISSECTION OF THE THROAT.

ON looking into the mouth, we observe a soft curtain hanging from the palate bones, named the VELUM PENDULUM PALATI, or Soft Palate. The apex of the velum forms a small projecting glandular body, termed the UVULA, or pap of the throat. From each side of the Uvula, two muscular half-arches or columns are sent down, the anterior to the root of the tongue, the posterior to the side of the pharynx. Between these half-arches on each side, are situated the glands termed Amygdalæ, or Tonsils. The common opening behind the anterior arch is named the Fauces, or Top of the Throat, from which there are six passages, two upwards, being one to each nostril, called the Posterior Nostrils; two at the sides, called Eustachian Tubes, passing on each side to the ear*; two downwards, of which the anterior is the passage through the glottis and larynx into the

* A probe may be introduced through the anterior nostrils into the Eustachian tube; the tube opens into the pharynx in a direction opposite to the space between the roots of the middle and inferior turbinated bones.

trachea; the posterior, which is the largest, is the pharynx, or top of the œsophagus, and leads to the stomach.

SECT. I.

MUSCLES SITUATED ABOUT THE ENTRY OF THE FAUCES.

These consist of four pairs, and a single muscle in the middle.

1. Constrictor Isthmi Faucium—*Arises*, by a slender beginning, from the side of the tongue, near its root; thence running upwards within the anterior arch, before the amygdala, it is

Inserted into the middle of the velum pendulum palati, as far as the root of the uvula. It is here connected with its fellow, and with the beginning of the palato-pharyngeus.

Situation: It forms the anterior half-arch.

Use: To draw the velum towards the root of the tongue, which at the same time it raises, and, with its fellow, to contract the opening into the fauces.

Synonyma: Glosso-staphylinus.

2. The Palato-Pharyngeus—*Arises*, by a broad beginning, from the root of the uvula in the middle of the velum pendulum palati, and from the tendinous expansion of the circumflexus palati. The

fibres pass along the posterior arch behind the amygdalæ, and run backwards to the superior and lateral part of the pharynx, where they are scattered, and mixed with those of the stylo-pharyngeus.

Inserted into the edge of the upper and back part of the thyroid cartilage, and into the back part of the pharynx.

Situation: It forms the posterior half-arch or column.

Use: To draw the uvula and velum downwards and backwards, and pull the thyroid cartilage and pharynx upwards; to shut the passage into the nostrils, and, in swallowing, to thrust the food from the fauces into the pharynx.

Synonyma: Thyro-staphylinus;—Thyreo-pharyngo-staphylinus;—Palato-pharyngien.

The SALPINGO-PHARYNGEUS of Albinus is composed of a few fibres of this muscle, which *arise* from the anterior and lower part of the cartilaginous extremity of the Eustachian tube, and are *inserted* into the inner part of the last-mentioned muscle.

3. The CIRCUMFLEXUS, or Tensor Palati,—*Arises*, from the spinous process of the sphenoid bone, behind the foramen ovale, and from the Eustachian tube near its osseous part; runs down along the pterygoideus internus, and forms a round tendon, which passes over the hook of the internal plate of the pterygoid process of the sphenoid bone, and soon spreads into a broad tendinous expansion.

Inserted into the velum pendulum palati, and semilunar edge of the os palati.

Situation: Its insertion extends as far as the suture which joins the two ossa palati. Some of its posterior fibres generally join with the constrictor pharyngis superior and palato-pharyngeus.

Use: To stretch the velum, to draw it downwards, and to one side.

Synonyma: Spheno-salpingo-staphylinus, seu Staphylinus externus;—Musculus tubæ novus, vel Palato-salpingeus;—Pterygo-staphylinus;—Spheno-salpingo-staphilin.

4. The LEVATOR PALATI—*Arises*, tendinous and fleshy, from the extremity of the petrous portion of the temporal bone, and from the Eustachian tube.

Inserted into the whole length of the velum pendulum palati, as far as the root of the uvula, uniting with its fellow.

Use: To draw the velum upwards and backwards, so as to shut the passage from the fauces into the mouth and nose.

Synonyma: Levator palati mollis;—Petro-salpingo-staphylinus, vel Salpingo-staphylinus internus;—Salpingo-staphylinus Valsalvæ, vel Pterygo-staphylinus externus;—Spheno-staphylinus;—Petro-salpingo-staphilin.

The single muscle is the

AZYGOS UVULÆ.—It *arises*, fleshy, from the extremity of the suture which unites the ossa palati; runs down the whole length of the velum, like a small earth-worm, adhering to the tendons of the circumflexi palati.

Inserted into the tip of the uvula.

Use: To raise the uvula upwards and forwards, and shorten it.

Synonyma: Staphylinus, or Epistaphylinus;—Palato-staphylinus.

SECT. II.

MUSCLES SITUATED ON THE POSTERIOR PART OF THE PHARYNX.

Of these there are three pair.

1. The Constrictor Pharyngis Inferior. This muscle *arises*, from the outside of the ala of the thyroid cartilage, near the attachment of the thyreo-hyoideus muscle, and from the side of the cricoid cartilage, near the crico-thyroideus.

Inserted into the white line on the back-part of the pharynx, where it is united to its fellow.

Situation: This muscle covers the under part of the middle constrictor; the superior fibres run obliquely upwards, while the inferior fibres have a transverse direction.

Use: To compress that part of the pharynx which it covers, and to raise it with the larynx a little upwards.

Synonyma: Thyro-pharyngeus and crico-pharyngeus;—Crico-thyro-pharyngien.

2. The Constrictor Pharyngis Medius—*Arises* from the superior edge of the cornu of the os

hyoides, extending as far forwards as the graniform process, or appendix; and from the ligament which connects it to the thyroid cartilage. The superior fibres ascend obliquely, the others run more transversely.

Inserted into the cuneiform process of the os occipitis, before the foramen magnum, and into a white line in the middle of the posterior surface of the pharynx, where it is joined to its fellow.

Situation: The lower part of this muscle is covered by the muscle last described, while the upper part covers the inferior fibres of the constrictor superior.

Use: To compress that part of the pharynx which it invests, and to draw it and the os hyoides upwards.

Synonyma: Hyo-pharyngeus, and Chondro-pharyngeus;—Hyo-glosso-basi-pharyngien.

3. Constrictor Pharyngis Superior—*Arises*, above, from the cuneiform process of the os occipitis, before the foramen magnum; lower down from the pterygoid process of the sphenoid bone; from the upper and under jaw, near the alveolar processes of the last dentes molares; and from the back-part of the buccinator muscle. Some fibres also come from the root of the tongue, and from the palate.

Inserted into a white line in the middle of the posterior surface of the pharynx.

Situation: The larger part of this muscle is covered by the constrictor medius.

Use: To compress the upper part of the pharynx, and draw it forwards and upwards.

Synonyma: Cephalo-pharyngeus, Pterygo-pharyngeus, mylo-pharyngeus, and glosso-pharyngeus;—Pterigo-syndesmo-staphili-pharyngien.

SECT. III.

MUSCLES OF THE LARYNX.

The Larynx is composed of five Cartilages: 1. The Thyroid Cartilage, situated immediately below the os hyoides in the middle of the throat. 2. The Cricoid Cartilage, situated immediately below the thyroid cartilage, betwixt it and the superior rings of the trachea. 3. The Epiglottis, a broad triangular cartilage, very elastic, situated behind the root of the tongue, and covering the entrance into the upper part of the larynx. 4 & 5. The arytenoid cartilages, two small bodies, like peas, situated behind the thyroid cartilage, on the upper edge of the back-part of the cricoid cartilage, and between the two alæ or wings of the thyroid cartilage. These two small cartilages form betwixt themselves and the thyroid a longitudinal fissure, extending from before backwards, which is called the Glottis, or Rima Glottidis, and leads to the trachea.

The muscles situated about the glottis consist of four pair of small muscles, and a single one.

1. The Crico-Arytænoideus Posticus—*Arises*, fleshy, from the posterior part of the cricoid cartilage, and is

Inserted, narrow, into the back-part of the arytenoid cartilage of the same side.

Use: To open the rima glottidis a little, and, by pulling back the arytenoid cartilage, to render the ligament of the glottis tense.

Synonyma: Crico-creti-arithenoidien.

2. The CRICO-ARYTÆNOIDEUS LATERALIS—*Arises*, fleshy, from the side of the cricoid cartilage, where it is covered by the ala of the thyroid cartilage.

Inserted into the outer side of the arytenoid cartilage.

Situation: It lies more forward than the last-described muscle.

Use: To open the rima glottidis, by pulling the ligaments from each other.

Synonyma: Crico-lateri-arithenoidien.

3. The THYREO-ARYTÆNOIDEUS—*Arises* from the middle and inferior part of the posterior surface of the thyroid cartilage; runs backwards, and a little upwards, and is

Inserted into the fore-part of the arytenoid cartilage.

Situation: It is situated more forwards than the muscle last described.

Use: To pull the arytenoid cartilage forwards, and thus shorten the ligament of the larynx or glottis.

ARYTÆNOIDEUS OBLIQUUS—*Arises* from the base of one arytenoid cartilage; and, crossing its fellow, is

Inserted into the tip of the other arytenoid cartilage.

Use: When both act, they pull the arytenoid cartilages towards each other.

Synonyma: Arytænoideus minor.

The single muscle is the

ARYTÆNOIDÆUS TRANSVERSUS, which *arises* from the whole length of one arytenoid cartilage, and passes across, to be

Inserted into the whole length of the other arytenoid cartilage.

Situation: It is situated anterior to the arytænoidei obliqui.

Use: To shut the rima glottidis, by bringing the arytenoid cartilages together.

On each side of the larynx, there are also a few muscular fibres, which are named as follows.

1. THYREO-EPIGLOTTIDEUS—*Arising*, by a few pale separated fibres, from the thyroid cartilage, and

Inserted into the epiglottis laterally.

Use: To draw the epiglottis obliquely downwards, or, when both muscles act, directly downwards; and at the same time to expand it.

2. The ARYTÆNO-EPIGLOTTIDEUS—*Arises*, by a few slender fibres, from the lateral and upper part of the arytenoid cartilage, and is

Inserted into the epiglottis, along with the former muscle.

Use: When both muscles act, to pull the epiglottis close upon the glottis.

CHAP. XI.

DISSECTION OF THE ORBIT OF THE EYE.

THE globe or ball of the eye is situated about the middle of the orbit. It is connected to the bone by its muscles, and by the optic nerve; and all these parts are embedded posteriorly in a soft, fatty substance, which fills up the bottom of the orbit.—The tunica, or membrana conjunctiva, is seen lining the inner surface of the eye-lids, and reflected from them over the anterior part of the globe of the eye, so that the back-part of the eye-ball, and all the muscles and nerves, are situated behind it. This membrane must therefore be dissected away, the upper part of the orbit, which is formed by the os frontis, removed with a saw, and the fat surrounding the muscles, vessels, and nerves, cautiously dissected away with the scissars.

SECT. I.

MUSCLES SITUATED WITHIN THE ORBIT.

SEVEN muscles are contained within the orbit, of which one belongs to the upper eye-lid, and six to the globe of the eye.

1. The LEVATOR PALPEBRÆ SUPERIORIS—*Arises*, by a small tendon, from the upper part of the foramen opticum of the sphenoid bone; the tendon forms a broad flat belly.

Inserted, by a broad thin tendon, into the upper eye-lid, adhering to the tarsal cartilage, which gives form to the eye-lid.

Use: To open the eye, by drawing the superior eye-lid upwards.

Synonyma: Aperiens palpebram rectus;—Orbito-sus-palpebral.

There are four straight muscles, or recti, belonging to the globe of the eye. These four muscles resemble each other, all arising by narrow tendons from the margin of the foramen opticum, where they surround the optic nerve; all forming strong fleshy bellies, and inserted, by broad, thin tendons, at the fore-part of the globe of the eye, into the tunica sclerotica, or outer tunic of the eye, and under the tunica conjunctiva.

2. The LEVATOR OCULI—*Arises*, by a narrow tendon, from the upper part of the foramen opticum of the sphenoid bone; it forms a fleshy belly, and is

Inserted into the superior and anterior part of the tunica sclerotica, by a broad thin tendon.

Situation: It lies below the levator palpebræ superioris.

Use: To raise the globe of the eye.

Synonyma: Elevator;—Rectus attollens oculi;—Sus-optico-spheni-scleroticien.

3. The DEPRESSOR OCULI—*Arises* from the inferior margin of the foramen opticum, and is

Inserted into the inferior and anterior part of the tunica sclerotica.

Use: To move the globe of the eye downwards.

Synonyma: Rectus deprimens oculi;—sous-opti-spheno-scleroticien.

4. The ADDUCTOR OCULI—*Arises* from the inner part of the foramen opticum, and is

Inserted into the inner and anterior part of the tunica sclerotica.

It is the shortest of the four recti muscles.

Use: To draw the eye towards the nose.

Synonyma: Rectus adducens oculi;—Orbito-intus-scleroticien.

5. The ABDUCTOR OCULI—*Arises* from the outer part of the foramen opticum.

Inserted into the outer part of the tunica sclerotica.

It is the longest of the recti.

Use: To move the globe outwards.

Synonyma: Rectus abducens oculi;—Orbito-extus-scleroticien.

The two next are oblique muscles.

6. The OBLIQUUS SUPERIOR, or Trochlearis,—*Arises*, by a small tendon, from the margin of the foramen opticum, between the levator and abductor oculi. Its long slender belly runs along the inner side of the orbit to the internal angular process of the os frontis, where a cartilaginous pulley is fixed. The muscle then forms a tendon, which passes through the pulley, runs obliquely downwards and outwards, inclosed in a membranous sheath; and becoming broader and thinner, is

Inserted into the tunica sclerotica, about half-way

between the insertion of the levator oculi, and the entrance of the optic nerve.

Use: To roll the globe of the eye, and turn the pupil downwards and outwards.

Synonyma: Obliquus major;—Optico-trochlei-scleroticien.

7. The Obliquus Inferior—*Arises*, narrow, and principally tendinous, from the outer edge of the orbitar process of the superior maxillary bone, near its junction with the os unguis. It runs obliquely outwards and backwards, under the depressor oculi, and is

Inserted, by a broad thin tendon, into the sclerotica, between the entrance of the optic nerve, and the insertion of the abductor oculi.

Use: To draw the globe of the eye forwards, inwards, and downwards, and to turn the pupil upwards.

Synonyma: Obliquus minor;—Maxillo-scleroticien.

In the orbit, we also meet with the Lachrymal Gland.—This gland is of a yellowish colour; it is situated in a depression of the os frontis near the temple. It adheres closely to the fat which surrounds the muscles and posterior convexity of the eye. It sends off several small ducts which pierce the tunica conjunctiva lining the upper eye-lid; these ducts cannot be seen, unless the part be macerated in water, when they are filled with the liquid.

The Puncta Lachrymalia are two small holes near the internal angle of the palpebræ, situated one in each eye-lid. They lead into the Lachrymal

Sac. This sac is an oblong membranous bag, situated at the inner angle of the eye, in a depression formed by the os unguis, and nasal process of the superior maxillary bone. It receives the tears by the puncta lachrymalia, and from the sac they are conveyed into the nose by a Duct, named the Lachrymal, or Nasal. The lower extremity of this duct opens into the nose on one side of the antrum maxillare, and under the os spongiosum inferius. A probe, with its extremity bent, may be introduced from the nose through this duct into the lachrymal sac.

The Caruncula Lachrymalis is a small reddish granulated body, situated at the internal angle of the palpebræ.

SECT. II.

OF THE VESSELS AND NERVES MET WITH IN THE ORBIT OF THE EYE.

ARTERIES.

The Ophthalmic, or Ocular Artery, is a branch of the internal carotid. It enters the orbit from the basis of the cranium by the foramen opticum. It gives branches to the lachrymal gland, fat, muscles, and globe of the eye. One twig, named the A. Centralis Retinæ, enters the substance of the optic nerve, and is continued on to the retina;

twigs also pass to the eye-lids, and to the inner angle of the eye. The Arteria Frontalis is a branch of this artery; it is seen running towards the supra-orbitary notch or foramen, and is distributed to the forehead.

The Infra-Orbitary Artery is found in the lower part of the orbit; it is the continued trunk of the internal maxillary, entering the orbit by the spheno-maxillary slit. It is seen passing along the canal in the upper part of the great tuberosity of the os maxillare superius, and emerges on the face by the infra-orbitary hole.

VEINS.

These correspond with the arteries; they discharge their blood partly into the branches of the external jugular vein near the forehead and temples, and partly into the internal jugular.

NERVES.

1. The Optic Nerve is seen coming through the foramen opticum, and entering the back part of the globe of the eye, to form the retina.

2. The Nerve of the Third Pair, Motor Oculi, having entered the orbit through the superior orbitary fissure, or foramen lacerum, is divided into four branches.

(1.) The first runs upwards, and subdivides into two nerves, of which one supplies the levator oculi, and the other the levator palpebræ superioris.

(2.)The second branch goes to the depressor oculi, and is short.

(3.) The third branch supplies the obliquus inferior, and also gives off a twig, which assists in forming the lenticular ganglion.

(4.) The fourth branch supplies the adductor oculi.

3. The Nerve of the Fourth Pair, N. Patheticus, or Trochlearis, enters the orbit by the superior orbitary fissure, and runs to the obliquus superior.

4. The first branch of the Nerve of the Fifth Pair, named Ophthalmic, or Orbitary, enters the orbit by the superior orbitary fissure, and divides into three branches.

(1.) The Frontal, Supra-orbitary, or Superciliary Nerve, accompanies the frontal artery along the upper part of the orbit, close to the bone; and having passed through the supra-orbitary notch, is distributed to the forehead.

(2.) The Nasal Nerve, or inner branch, runs towards the nose, and is distributed to the inner side of the orbit, and to the nose.

(3.) The Temporal or Lachrymal Branch supplies the lachrymal gland, and the parts at the outer side of the orbit.

The Lenticular Ganglion is a small ganglion, situated within the orbit, formed by short branches of the ophthalmic nerve, and by a twig of the third pair. It sends off delicate nerves, which run along the sides of the optic nerve, and pierce the coats of the eye.

5. The second branch of the Fifth Pair, called the Superior Maxillary Nerve, sends off a branch through the bony canal in the bottom of the orbit. This

is the INFRA-ORBITARY NERVE. It accompanies the artery of the same name, and emerges on the face by the infra-orbitary hole.

6. The Trunk of the Sixth Pair of Nerves passes through the superior orbitary fissure to the abductor oculi.

These delicate nerves are surrounded by the adipose substance found in the orbit, and require to be dissected with the utmost care.

CHAP. XII.

DISSECTION OF THE MUSCLES SITUATED ON THE POSTERIOR PART OF THE TRUNK AND NECK.

FROM the number and intimate connection of these muscles, their description necessarily is complicated, and their dissection difficult. The smaller muscles, indeed, cannot be separated, without dividing some of their fibres. We do not here, as in the limbs, find the muscles distinctly marked, loosely connected by cellular membrane, and separated with facility; but closely united, and in many places having their fibres so intermixed, as to render their divisions indistinct and uncertain.

In this dissection we meet with twenty-two distinct pair of muscles, besides a number of small muscles situated between the processes of contiguous vertebræ.

On removing the integuments of the posterior part of the neck and back, we expose,

1. The TRAPEZIUS.—It *arises*, by a thick round tendon, from the lower part of the protuberance in the middle of the os occipitis behind, and, by a thin tendinous expansion, from the superior transverse ridge of that bone; from the five superior cervical spinous processes by the ligamentum nuchæ; tendinous, from the two inferior cervical spinous processes, and from the spinous processes of all the vertebræ of the back. The fleshy fibres coming from the neck descend obliquely, while those from the back ascend.

Inserted, fleshy, into the posterior third part of the clavicle; tendinous and fleshy, into the acromion, and into the upper edge of all the spine of the scapula. The fibres slide over a triangular surface at the extremity of the spine of that bone.

Situation: This muscle is quite superficial, and conceals all the muscles situated in the posterior part of the neck, and upper part of the back. It adheres to its fellow the whole length of its origin. Its anterior fibres lie posterior to those of the sterno-mastoideus, but are not in contact with them, a considerable quantity of adipose substance being interposed. The posterior cervical ligament (ligamentum nuchæ vel colli) is a ligament which arises from the middle of the occipital bone, runs down on the back-part of the neck, adhering to the spinous processes of the cervical vertebræ, and

giving origin to the fibres of the trapezius, and of other muscles.

Use: To move the scapula in different directions. The superior fibres draw it obliquely upwards, the middle transverse ones draw it directly backwards, and the inferior fibres move it obliquely downwards and backwards. Also, to draw back the head, and contribute to its rotatory motions.

Synonyma: Cucullaris ;——Occipiti-dorso-clavi-sus-acromien.

It should be reflected from the spine and head.

2. The Latissimus Dorsi—*Arises*, by a broad thin tendon, from all the spinous processes of the os sacrum, and of the lumbar vertebræ ; from the spinous processes of the seven inferior dorsal vertebræ ; from the posterior part of the spine of the os ilium ; also from the extremities of the four inferior false ribs, by four distinct fleshy digitations, which intermix with those of the obliquus externus abdominis. The inferior fleshy fibres ascend obliquely ; the superior run transversely : they pass over the inferior angle of the scapula (from which the muscle often receives a thin fasciculus of fibres), to reach the axilla, where they are all collected and twisted.

Inserted, by a strong flat tendon, into the inner edge of the groove in the os humeri, which receives the long tendon of the biceps flexor cubiti.

Situation: Where this muscle arises from the dorsal vertebræ, it is concealed by the origin of the trapezius. The remainder of it is placed immediately under the skin, and covers the deeper seated mus-

cles of the loins and back. It is situated superior to the gluteus maximus, and posterior to the obliquus externus abdominis. Its insertion cannot be traced till the muscles of the arm are dissected; it forms the fold on the posterior part of the hollow of the arm-pit. The tendon of this muscle, with the subjacent tendon of the serratus posticus inferior, assists in forming the fascia lumborum.

Use: To pull the arm backwards and downwards, and to roll the os humeri.

It should be reflected from the spine, pelvis, and ribs.

Synonyma: Ani-scalptor;—Dorsi-lumbo-sacro-humeral.

Remove the trapezius and latissimus dorsi, and two muscles will be seen passing from the neck to the scapula.

3. The Rhomboideus. This muscle is divided into two portions.

(1.) Rhomboideus major (the inferior portion) *arises*, tendinous, from the spinous processes of the four or five superior dorsal vertebræ.

Inserted into all the base of the scapula below its spine, extending as far as its inferior angle.

(2.) Rhomboideus Minor (the superior portion) *arises*, tendinous, from the spinous processes of the three inferior vertebræ of the neck, and from the ligamentum nuchæ.

Inserted into the base of the scapula, opposite to the triangular plain surface at the root of the spine.

Situation: This muscle lies beneath the trapezius and latissimus dorsi; a small part of the rhomboideus

major may be seen between these muscles, and the inferior part of the base of the scapula.

Use: To draw the scapula obliquely upwards, and directly backwards.

Synonyma: Cervici-dorso-scapulaire.

The rhomboidei should be reflected from the spine.

4. The Levator Scapulæ—*Arises* from the transverse processes of the five superior vertebræ of the neck, by five distinct, tendinous, and fleshy slips, which unite and form a considerable muscle.

Inserted, tendinous and fleshy, into the base of the scapula, above the root of the spine, and under the superior angle (not into the angle itself, as it is usually described).

Situation: This muscle is concealed by the trapezius and sterno-mastoideus; but a small part of its belly may be seen in the space between the edges of these muscles. The origin of the levator scapulæ is partly concealed by the splenius capitis; and the digitations, where they arise from the transverse processes, lie betwixt similar attachments of the scaleni muscles before, and of the splenius colli behind.

Use: To draw the scapula upwards, and a little forwards.

Synonyma: Elevator, seu Musculus Patientiæ;—Angularis, vel Levator proprius;—Trachélo-anguli-scapulaire.

Detaching the rhomboideus from its origin in the spine, you will see another muscle passing from the whole of the basis of the scapula.

5. The Serratus Magnus—*Arises*, by nine fleshy digitations, from the nine superior ribs. These

digitations are seen on the anterior part of the thorax; they pass obliquely backwards, and form a strong fleshy muscle.

Inserted, principally fleshy, into the whole of the base of the scapula.

Situation: This muscle lies between the scapula and the ribs, so that, to see its course, the articulation of the clavicle to the sternum should be divided, and the scapula lifted from the trunk. It is concealed by the latissimus dorsi, by the two pectoral muscles, and the scapula. The only part of it which can be seen before the removal of those muscles, projects betwixt and below them on the side of the trunk. The lower digitations, which pass more anteriorly than the edge of the latissimus dorsi, are intermixed with the superior digitations of the obliquus externus abdominis. The superior digitations arise behind the pectoralis minor. The insertion of the muscle is between the subscapularis, which arises from the internal surface of the scapula, and the insertions of the rhomboideus and levator scapulæ.

Use : To move the scapula forwards, and, when the scapula is forcibly raised, to draw the ribs upwards.

Synonyma: Serratus major anticus;—Costo-basi-scapulaire*.

The removal of the rhomboideus also exposes,

6. The Serratus Superior Posticus. This muscle *arises*, by a thin broad tendon, from the spinous

* The upper extremity may now be removed from the trunk.

processes of the three inferior cervical vertebræ, and of the two superior dorsal.

Inserted, by distinct fleshy slips, into the second, third, fourth, and sometimes the fifth ribs, a little beyond their angle.

Situation: This muscle is concealed by the rhomboideus and scapula, except a few of its superior fibres, which appear above the upper edge of the rhomboideus minor. It covers part of the origin of the splenius.

Use: To elevate the ribs, and dilate the thorax.

Synonyma: Cervici dorso-costal.

Reflect it from the spine.

7. The SPLENIUS is divided into two portions:

(1.) The Splenius Capitis—*Arises*, tendinous, from the spinous processes of the two superior dorsal, and five inferior cervical vertebræ. It forms a flat broad muscle, which ascends obliquely, and is *inserted*, tendinous, into the posterior part of the mastoid process, and into a small part of the os occipitis, immediately below its superior transverse ridge.

Situation: This muscle is covered by the trapezius, and by the insertion of the sterno-cleido-mastoideus, and a small part of it is seen on the side of the neck betwixt those two muscles. The lower part of its origin is covered by the serratus superior posticus.

Reflect it from the occiput.

(2.) The Splenius Colli—*Arises*, tendinous, from the spinous processes of the third, fourth, fifth, and sometimes the sixth dorsal vertebræ. It forms a small fleshy belly, which ascends by the side of the vertebræ, and is *inserted* into the transverse processes of

the four or five superior cervical vertebræ, by distinct tendons, which lie behind similar tendons of the levator scapulæ.

Situation: This muscle is concealed by the serratus superior posticus, and splenius capitis.

Use: To bring the head and upper vertebræ of the neck obliquely backwards. When both muscles act, they pull the head directly backwards.

Synonyma: Cervici-dorsi-mastoidien, et dorso-trachelien.

Reflect it from the dorsal vertebræ.

8. The SERRATUS POSTICUS INFERIOR—*Arises*, by a broad thin tendon, from the spinous processes of the two or three inferior dorsal vertebræ, and from the three superior lumbar spines by the fascia lumborum.

Inserted, by distinct fleshy slips, into the lower edges of the four inferior ribs, at a little distance from their cartilages.

Situation: This is a thin muscle, of considerable breadth, situated at the lower part of the back, under the middle of the latissimus dorsi. Its tendon lies under that of the latissimus dorsi, but, although firmly adhering to it, is distinct, and may be separated by cautious dissection. Its insertion into the ribs is situated immediately behind the attachments connecting the latissimus dorsi to the ribs, which attachments must therefore lie behind the obliquus externus abdominis, and serratus posticus inferior.

Use: To pull the ribs downwards and backwards.

Synonyma: Dorso-lumbo-costal.

Reflect it from the spine.

The Fascia Lumborum is now seen. It is a tendinous fascia, arising from the lumbar vertebræ and os sacrum, giving origin to the lower part of the serratus posticus inferior, and to the posterior fibres of the obliquus internus and transversalis abdominis. It is also connected with the tendon of the latissimus dorsi.

On detaching from the spine of this fascia, and the serratus posticus inferior, we expose a thick muscular mass, filling up all the space betwixt the spinous processes of the vertebræ, and the angles of the ribs. This mass consists of three muscles:

(1.) Sacro-Lumbalis on the outside,

(2.) Longissimus Dorsi in the middle,

(3.) Spinalis Dorsi close to the spinous processes.

These three muscles are closely connected together; so that, to effect their separation, it is necessary to divide some of the fibres.

9 and 10. The Sacro-Lumbalis and Longissimus Dorsi—*Arise*, by one common origin, tendinous externally, and fleshy internally, from the spinous processes and posterior surface of the os sacrum; from the posterior part of the spine of the os ilium, extending nearly as far forwards as the highest part of that bone when the body is erect; from the spinous processes, and from the roots of the transvere processes of all the lumbar vertebræ.

The thick fleshy belly, formed by this extensive origin, ascends, and, opposite to the last rib, divides into the two muscles.

The sacro-lumbalis is *inserted* into all the ribs near their angles, by long and thin tendons. The tendons

which pass to the superior ribs, are longer, ascend nearly straight, and are situated nearer to the spine than those tendons which pass to the lower ribs. On separating the inner edge of this muscle (*i. e.* the edge next to the spine) from the latissimus dorsi, and turning the belly towards the ribs, we see six or eight small tendinous and fleshy bundles, which pass from the inner side of this muscle, to be inserted into the upper edge of the six or eight inferior ribs. These are called the Musculi Accessorii ad Sacro-Lumbalem.

Use: To pull the ribs downwards, to assist in erecting the trunk of the body, and in turning it to one side.

Synonyma: Lumbo-costo-trachelien.

The longissimus dorsi is *inserted* into all the ribs except the two inferior, betwixt their tubercles and angles, by slips which are tendinous and fleshy, and into the transverse processes of all the dorsal vertebræ by small double tendons. The insertions in the ribs proceed from the outer side of the muscle, while the attachments to the transverse processes are seen on separating the longissimus dorsi from the spinalis dorsi.

Use: To extend the vertebræ, and keep the body erect.

Synonyma: Lumbo-dorso-trachelien.

11. The Spinalis Dorsi is much smaller than the two last-described muscles; below, it cannot be separated from the longissimus dorsi, without dividing some fibres; it lies betwixt that muscle and the spine.

Arises, tendinous, from the spinous processes of the two superior lumbar vertebræ, and of the three inferior dorsal.

Inserted into the spinous processes of the nine upper vertebræ of the back, except the first, by as many distinct tendons.

Use: To extend the vertebræ, and to assist in raising the spine.

Synonyma: Lumbo-dorso-spinal.

The three last-described muscles are covered below by the serratus posticus inferior and latissimus dorsi; above, by the rhomboideus, serratus superior posticus, and trapezius.

12. The CERVICALIS DESCENDENS—*Arises* from the upper edge of the four or five superior ribs, by as many distinct tendons, which lie on the inside of the tendinous insertions of the sacro-lumbalis. It forms a small belly, which ascends upwards, and is

Inserted, by three distinct tendons, into the fourth, fifth, and sixth cervical vertebræ.

Situation: This muscle is small, it is frequently described as an appendage to the sacro-lumbalis. It arises between the sacro-lumbalis and longissimus dorsi, and is inserted into the transverse processes between the splenius colli and levator scapulæ; of course it is concealed by the rhomboideus, &c. It often receives a fleshy slip from the upper part of the longissimus dorsi.

Use: To turn the neck obliquely backwards.

Synonyma: Transversalis collateralis colli.

13. The TRANSVERSALIS COLLI—*Arises* from the transverse processes of the five superior dorsal

vertebræ, by five tendinous and fleshy slips, and is

Inserted, tendinous, into the transverse processes of the five or six inferior cervical vertebræ.

Situation: The origin of this muscle lies on the inside of the longissimus dorsi, and is sometimes considered as an appendage to it. The insertion is situated between the cervicalis descendens and trachelo-mastoideus.

Use: To turn the neck obliquely backwards, and a little to one side.

Synonyma: Transversalis cervicis;—Transversalis colli major.

14. The TRACHELO-MASTOIDEUS lies nearer to the bone than the last-described muscle.

Arises from the transverse processes of the three uppermost vertebræ of the back, and of the five inferior of the neck, by as many thin tendons, which unite and form a fleshy belly.

Inserted, tendinous, into the posterior surface of the mastoid process.

Situation: This muscle lies on the outside of the complexus, and on the inside of the transversalis colli; its insertion is concealed by the splenius capitis; it is covered also by the levator scapulæ.

Use: To keep the head and neck erect, and to draw the head backwards, and to one side.

Synonyma: Trachelo-mastoideus, seu Capitis par tertium Fallopii;—Complexus minor, seu Mastoides lateralis.

15. The COMPLEXUS—*Arises*, by tendinous and fleshy fibres, from the transverse processes of the se-

ven superior dorsal, and of the four or five inferior cervical vertebræ. It forms a thick, tendinous, and fleshy belly.

Inserted, tendinous and fleshy, into the hollow betwixt the two transverse ridges of the os occipitis, extending from the middle protuberance of that bone, nearly as far as the mastoid process.

Situation: This is a large muscle. Its origin from the cervical vertebræ is nearer to the spine than the trachelo-mastoideus, and it arises in the back nearer to the spine than the transversalis colli; it is covered by the splenius; but a large portion of it is seen between the splenius and spine, immediately on removing the trapezius.

Use: To draw the head backwards and to one side.

Synonyma: Complexus, seu Biventer cervicis;—Complexus major;—Dorso-trachelo-occipital.

On removing the complexus from the occiput, we find, close to the spine,

16. The Semi-Spinalis Colli.—It *arises*, by distinct tendons, from the transverse processes of the six superior dorsal vertebræ, ascends obliquely close to the spine, and is

Inserted into the spinous processes of all the vertebræ of the neck, except the first and the last.

Situation: This muscle is situated close to the vertebræ at the posterior part of the neck and back. It arises on the outside of the semi-spinalis dorsi; its greater part is concealed by the complexus and longissimus dorsi; and the part which projects between these muscles, is concealed by the serratus superior posticus.

Use: To extend the neck obliquely backwards.

Synonyma: Spinalis cervicis;—Transverso-spinalis colli.

17. Semi-Spinalis Dorsi—*Arises* from the transverse processes of the seventh, eighth, and ninth vertebræ of the back, by distinct tendons which soon grow fleshy.

Inserted, by distinct tendons, into the spinous processes of the five superior dorsal vertebræ, and of the two lower cervical.

Situation: This muscle lies nearer the spine than the lower part of the semi-spinalis colli; its inferior origins lie on the outside of the insertion of the spinalis dorsi.

Use: To extend the spine obliquely backwards.

Synonyma: Semi-spinalis externus, seu Transverso-spinalis dorsi.

The removal of the complexus brings also into view several small muscles situated at the superior part of the neck, immediately below the occiput.

18. The Rectus Capitis Posticus Major—*Arises*, fleshy, from the side of the spinous process of the dentata, or second cervical vertebra. It ascends obliquely outwards, becoming broader, and is

Inserted, tendinous and fleshy, into the inferior transverse ridge of the os occipitis, and into part of the concavity above that ridge.

Situation: This muscle is situated obliquely between the occiput and the second vertebra of the neck. It lies under the complexus; its outer fibres also pass under the insertion of the obliquus capitis superior.

Use: To extend and pull the head backwards, and to assist in its rotation.

Synonyma: Rectus major;—Spino-axoido-occipital.

19. The RECTUS CAPITIS POSTICUS MINOR—*Arises*, tendinous and narrow, from an eminence in the middle of the back part of the atlas, or first cervical vertebra. It becomes broader, and is

Inserted, fleshy, into the inferior transverse ridge of the os occipitis, and into the surface betwixt that ridge and the foramen magnum.

Situation: It is partly covered by the rectus capitis posticus major; but a large portion of this pair of muscles is seen projecting between the recti majores, and is situated beneath the complexus.

Use: To draw the head backwards.

Synonyma: Rectus minor;—Tuber-atloido-occipital.

20. OBLIQUUS CAPITIS SUPERIOR—*Arises*, tendinous, from the upper and posterior part of the transverse process of the first cervical vertebra.

Inserted, tendinous and fleshy, into the inferior transverse ridge of the os occipitis behind the mastoid process, and into a small part of the surface above and below that ridge.

Situation: This muscle is situated laterally between the occiput and atlas. It is inserted under the complexus and trachelo-mastoideus, and it covers some of the outer fibres of the insertion of the rectus capitis posticus major.

Use: To draw the head backwards, and to assist in rolling it.

Synonyma: Obliquus superior, sive Minor;—Trachelo-atloido-occipital.

21. Obliquus Capitis Inferior—*Arises*, tendinous and fleshy, from the side of the spinous process of the dentata or second cervical vertebra. It forms a thick belly, and is

Inserted into the under and back-part of the transverse process of the atlas.

Situation: This muscle is obliquely situated between the two first vertebræ of the neck. It is covered by the complexus and trachelo-mastoideus, except a small part which is seen between these two muscles, and is concealed by the splenius. Its origin lies between the origin of the rectus capitis posticus major, and the superior insertion of the semi-spinalis colli.

Use: To rotate the head, by turning the first vertebra upon the second.

Synonyma: Obliquus inferior, sive Major;—Spini-axoido-tracheli-atloidien.

22. The Multifidus Spinæ.

On removing the muscles of the spine which have been described, we find situated beneath them the Multifidus Spinæ. It is that mass of muscular flesh which lies close to the spinous and transverse processes of the vertebræ, extending from the dentata to the os sacrum. The bundles of which it is composed seem to pass from the transverse, to be inserted into the spinous processes.

Arises, tendinous and fleshy, from the spinous processes and back-part of the os sacrum, and from the posterior adjoining part of the os ilium; from the

oblique and transverse processes of all the lumbar vertebræ; from the transverse processes of all the dorsal vertebræ; and from those of the cervical vertebræ, excepting the three first. The fibres arising from this extensive origin pass obliquely, to be

Inserted, by distinct tendons, into the spinous processes of all the vertebræ of the loins and back, and into those of the six inferior vertebræ of the neck. The fibres arising from each vertebra are inserted into the second one above it, and sometimes more.

Use: To extend the back obliquely, or move it to one side. When both muscles act, they extend the vertebræ backwards.

Synonyma: Transversalis lumborum dorsi et colli;—Transverso-spinalis lumborum, dorsi et colli; vel Semi-spinalis.

The small muscles situated between the processes of the vertebræ are,

1. Interspinales colli, dorsi, et lumborum.—These are small bundles of fibres, which fill up the spaces between the spinous processes of the vertebræ. Each of these little muscles arises from the surface of one spinous process, and is inserted into the next spinous process.

In the neck they are large, and appear double, as the spinous processes of the cervical vertebræ are bifurcated. In the back and loins they are indistinct, and are rather small tendons than muscles.

Use: To draw the spinous processes nearer to each other.

2. The Intertransversalis colli, dorsi, et

lumborum, are small muscles which fill up, in a similar manner, the spaces between the transverse processes of the vertebræ. In the neck they are bifurcated and distinct, in the back they are small and slender, and in the loins they are strong and fleshy.

Use: To draw the transverse processes towards each other.

CHAP. XIII.

DISSECTION OF THE MUSCLES SITUATED BETWEEN THE RIBS, AND ON THE INNER SURFACE OF THE STERNUM.

THE muscles which fill up the space between the ribs are named Intercostals; they are disposed on each side of the thorax in two layers; and each layer consists of eleven muscles.

The INTERCOSTALES EXTERNI—*Arise* from the inferior acute edge of each superior rib, extending from the spine to near the junction of the ribs with their cartilages. The fibres run obliquely forwards and downwards, and are

Inserted into the upper obtuse edge of each inferior rib, from the spine to near the cartilage of the rib.

Situation: These muscles are seen on removing the muscles which cover the thorax.

Synonyma: Inter-lateri-costaux.

The LEVATORES COSTARUM are twelve small muscles, situated on each side of the dorsal vertebræ. They are portions of the external intercostals. Each of these small muscles *arises* from the transverse process of one of the dorsal vertebræ, and passes downwards, to be *inserted* into the upper side of the rib next below the vertebra, near its tuberosity.

The first of these muscles passes from the last cervical vertebra, the eleven others from the eleven superior dorsal vertebræ. The three or four inferior Levatores are longer, and run down to the second rib below the transverse process from which they arise. Hence Albinus names them the Levatores Costarum, Longiores et Breviores.

Synonyma: Supra-costales.

2. The INTERCOSTALES INTERNI—*Arise* from the inferior acute edge of each superior rib, beginning at the sternum, and extending as far as the angle of the rib. The fibres run obliquely downwards and backwards, and are

Inserted into the superior obtuse edge of each inferior rib from the sternum to the angle. Portions of the internal intercostals pass over one rib, and are inserted into the next below it.

Synonyma: Inter-pleuri-costaux.

Thus the intercostal muscles decussate, and are double on the sides of the thorax; but, from the spine to the angles of the ribs, there are only the external intercostals, and, from the cartilages to the

sternum, only the internal, and some cellular membrane covering them. The whole of the internal intercostals, and the back-part of the external, are lined by the pleura.

Use: To elevate the ribs, so as to enlarge the cavity of the thorax.

One pair of muscles is situated on the inner surface of the sternum.

The Triangularis Sterni, or Sterno-Costalis,—*Arises*, tendinous and fleshy, from the edge of the whole cartilago ensiformis, and from the edge of the lower half of the middle bone of the sternum. The fibres ascend obliquely upwards and outwards, and form a flat muscle, which is

Inserted, by three or four triangular fleshy and tendinous terminations, into the cartilages of the third, fourth, fifth, and sixth ribs.

Situation: This muscle lies on the inside of the ribs and sternum, and is lined by the pleura.

Use: To depress the cartilages and the bony extremities of the ribs, and consequently to assist in lessening the cavity of the thorax.

CHAP. XIV.

DISSECTION OF THE MUSCLES SITUATED ON THE ANTERIOR PART OF THE NECK, CLOSE TO THE VERTEBRÆ.

FOUR pair of muscles are here situated.

1. The LONGUS COLLI—*Arises*, tendinous and fleshy, from the sides of the bodies of the three superior dorsal vertebræ, and from the anterior surface of the transverse processes of the four or five lower cervical vertebræ.

Inserted, tendinous and fleshy, into the fore-part of the bodies of all the vertebræ of the neck.

Situation: This muscle lies behind the œsophagus, and behind the great vessels and nerves of the neck.

Use: To bend the neck forwards, and to one side.

Synonyma: Pré-dorso-cervical.

2. The RECTUS CAPITIS INTERNUS MAJOR—*Arises*, tendinous and fleshy, from the anterior points of the transverse processes of the third, fourth, fifth, and sixth cervical vertebræ. It forms a considerable fleshy belly.

Inserted into the cuneiform process of the os occipitis a little before the condyloid process.

Situation: This muscle lies before the scaleni, and more outwardly than the longus colli, over the part of which it passes.

Use: To bend the head forwards.

Synonyma: Rectus anterior longus;—Grand trachelo-basilaire.

3. The Rectus Capitis Internus Minor—*Arises*, fleshy, from the fore part of the body of the first vertebra of the neck, near its transverse process; and, ascending obliquely, is

Inserted near the root of the condyloid process of the occipital bone, under the last-described muscle.

Use: To bend the head forwards.

Synonyma: Rectus anterior brevis;—Petit-trachelo-basilaire.

4. The Rectus Capitis Lateralis—*Arises*, fleshy, from the anterior and upper part of the transverse process of the atlas.

Inserted, tendinous and fleshy, into a scabrous ridge of the os occipitis, which extends from the condyloid process of that bone towards the mastoid process.

Situation: It is situated immediately behind the internal jugular vein, where it comes out from the cranium.

Use: To pull the head a little to one side.

Synonyma: Transversalis anticus primus;—Trachéli atloido-lateral.

CHAP. XV.

DISSECTION OF THE SUPERIOR EXTREMITY.

SECT. I.

OF THE SHOULDER AND ARM.

IN the thigh we saw a strong fascia, arising from the neighbouring bones and ligaments, firmly investing the muscles, and giving origin to some of their fibres; but, on removing the integuments of the shoulder and arm, we do not meet with any regular fascia. The muscles, like those on the outside of the thorax, are covered by condensed cellular substance; and this substance might be taken for a thin aponeurosis; but it is widely different in its nature, and ought to be regularly dissected off with the integuments.

In removing the integuments, we meet with several cutaneous veins and nerves.

The cutaneous veins* of the upper extremity are the following.

1. The BASILIC VEIN is seen arising from a small

* The veins are described from their origin in the fore-arm, for the sake of perspicuity; they ramify above the fascia of the fore-arm.

vein on the outside of the little finger, named Salvatella. It then runs along the inside of the fore-arm near the ulna, receiving the internal and external ulnar veins from the anterior and posterior surface of the fascia. It passes over the fold of the arm near the inner condyle of the humerus; here it is superficial. It ascends along the arm, becoming more deeply seated, and included in the sheath which invests the brachial artery. As it approaches the neck of the humerus, it sinks deep betwixt the folds of the arm-pit, and terminates in the axillary vein, which may be considered as a continuation of the basilic vein. It communicates with the deeper-seated veins, and receives numerous branches from the muscles.

2. The Cephalic Vein begins on the back of the hand, between the thumb and metacarpal bone of the fore-finger, by a small vein, named Cephalica Pollicis. It runs along the radius between the muscles and integuments, receiving the internal and external radial veins. It passes over the bend of the arm near the external condyle, and ascends along the outside of the arm near the outer edge of the biceps flexor cubiti. It then runs betwixt the edge of the deltoid and pectoral muscles, dips down under the clavicle, and enters the subclavian vein. In all this course, the cephalic vein receives branches.

3. The Median Vein. Several veins are seen running along the middle of the anterior part of the fore-arm. The trunk formed by these veins is called the Mediana Major. It ascends on the flat part of the fore-arm, betwixt the basilic and cephalic veins,

and bifurcates at the fold of the arm into two branches: 1. The Mediana Basilica, passing off obliquely to join the basilic vein; 2. The Mediana Cephalica, which joins the cephalic.

The cutaneous nerves of the arm are seen ramifying above the muscles; they consist of,

1. The Internal Cutaneous Nerve, a branch of the axillary plexus. It is seen accompanying the basilic vein, and twisting its fibres over it. It descends along the inside of the arm, crosses over the fore-part of the elbow-joint, and, in the dissection of the fore-arm, will be seen dividing itself into twigs, which ramify between the fascia and integuments, and are distributed to the inside of the fore-arm and wrist.

2. The upper part of the arm receives cutaneous nerves from the branches of the dorsal nerves, which come out of the thorax between the ribs.

3. The shoulder and back-part of the scapula receive twigs from the cervical nerves.

4. The external cutaneous, ulnar, and spiral nerves, also send twigs to the integuments of the arm and fore-arm.

MUSCLES SITUATED ON THE SHOULDER AND ARM.

These are ten in number.

1. The Deltoides—*Arises*, tendinous and fleshy, from the posterior third of the clavicle, from the whole edge of the acromion, and from the lower margin of the whole spine of the scapula. From

these several origins the fibres run in different directions, and converge. Those arising from the clavicle run outwards and downwards: those from the spine of the scapula outwards, forwards, and downwards; and those from the acromion directly downwards.

Inserted, tendinous, into a triangular rough surface on the outer side of the os humeri, near its middle.

Situation: This muscle is entirely superficial, except where the thin fibres of the platysma myoides arise from its anterior surface. It arises from the same extent of bone as the trapezius is inserted into, and is therefore opposite to that muscle which passes upwards from its origin, while the deltoid runs downwards. It forms a strong coarse muscle, consisting of large fasciculi of fibres. It conceals the insertion of the pectoralis major, and the origins of the biceps flexor cubiti and coraco-brachialis, and covers the whole of the fore-part and outside of the shoulder-joint. Its insertion is situated betwixt the biceps flexor cubiti and the short head of the triceps extensor, and immediately above the origin of the brachilis internus. Its external surface is quite fleshy; but, on cutting it across, its internal surface is found tendinous: and, where it slides over the great tuberosity of the humerus, there is a large bursa, or sacculus mucosus.

From the insertion of the deltoid to the outer condyle of the os humeri, is extended an Intermuscular Ligament, which separates the muscles on the anterior part of the arm from those on the posterior part,

and gives attachment to the fibres of both. It is named the External Intermuscular Ligament.

Use: To draw the arm directly upwards, and to move it a little forwards or backwards, according to the different directions of its fibres. Reflect it from the scapula and clavicle, that you may expose more completely the muscles on the dorsum of the former bone.

Synonyma: Sous-acromio-clavi-humeral.

The following two muscles, which fill up the posterior surface of the scapula, are covered by a fascia, which adheres to the spine and edges of that bone. On dissecting off this fascia, the fleshy fibres of the muscles will be found arising from its inner surface.

2. The SUPRA-SPINATUS—*Arises*, fleshy, from all that part of the base of the scapula that is above its spine, from the superior costa as far forwards as the semilunar nitch, from the spine itself, and from the concave surface betwixt it and the superior costa. The fleshy fibres, as they approach the neck of the scapula, terminate in a tendon which passes under the acromion, slides over the neck of the scapula (to which it is connected by loose cellular membrane), adheres to the capsular ligament of the shoulder-joint, and is

Inserted into the anterior and superior part of the great tuberosity near the head of the os humeri.

Situation: This muscle fills up the fossa or cavity above the spine of the scapula, and is entirely concealed. Its belly is covered by the fibres of the tra-

pezius, passing into the spine of the scapula; and its tendon passes under the deltoid.

Use: To raise the arm.

Synonyma: Super-scapularis;—Sus-spini-scapulo-trochiterien.

3. The INFRA-SPINATUS—*Arises*, principally fleshy, from the lower part of the spine of the scapula as far back as the triangular flat surface; from the base of the bone below the spine to near the inferior angle; from the posterior ridge of the inferior costa; and from all the dorsum of the bone below the spine. The fibres ascend and descend towards a middle tendon, which runs forwards over the neck of the bone, and adheres to the capsular ligament.

Inserted, by a strong short tendon, into the middle part of the great tuberosity of the os humeri.

Situation: This muscle is in part concealed. The anterior part of its belly, and its tendinous insertion, are covered by the deltoid, and the trapezius passes over its upper and back part; but a considerable portion of the belly of this muscle is seen betwixt these two muscles, and above the superior fibres of the latissimus dorsi. It is inserted below the tendon of the supra-spinatus.

Use: To roll the humerus outwards, to assist in raising the arm, and in moving it outwards when raised.

Synonyma: Sous spini-scapulo-trochiterien.

4. The TERES MINOR—*Arises*, fleshy, from the narrow depression between the two ridges in the inferior costa of the scapula, extending from the neck of the bone to within an inch or two of the inferior

angle. It passes forwards along the inferior edge of the infra-spinatus, adheres to the capsular ligament of the shoulder-joint, and is

Inserted, tendinous and fleshy, into the lower and back-part of the great tuberosity of the os humeri.

Situation: It is inserted below the tendon of the infra-spinatus. Its origin lies between the infra-spinatus and teres major, and is partly concealed by them. The middle of its belly is superficial, and not covered by any muscle; but its insertion is concealed by the deltoid. The fascia which covers the infra-spinatus envelopes also the teres minor; and the two muscles are, in some subjects, so closely united, as to be with difficulty separated.

Use: To draw the humerus downwards and backwards, and to roll it outwards.

Synonyma: Margini-sus-scapulo-trochiterien.

5. The TERES MAJOR—*Arises*, from an oblong, rough, flatted surface, at the inferior angle of the scapula. It forms a thick belly, which passes forwards and upwards towards the inside of the arm.

Inserted, by a broad thin tendon, into the ridge of the os humeri, at the inner side of the groove for lodging the tendon of the long head of the biceps flexor cubiti.

Situation: The origin of this muscle is superficial, and adheres to the lower fibres of the infra-spinatus. Its belly passes before the long head of the triceps extensor cubiti. Its tendon is inserted along with the tendon of the latissimus dorsi. Observe the relative situation of these tendons: they both pass under the coraco-brachialis and short head of the biceps flexor.

to reach the place of their insertion. They appear at first inseparably united, but, on dividing them with some care, we find an intermediate cavity lubricated with synovia. The tendon of the latissimus dorsi is anterior to the tendon of the teres major; but the lower edge of the latter extends farther down the arm.

Use: To roll the humerus inwards, and to draw it backwards and downwards.

Synonyma: Anguli-scapulo-humeral.

6. The SUBSCAPULARIS—*Arises*, fleshy, from all the base of the scapula internally, from the superior and inferior costæ, and from the whole internal surface of the bone. It consists of tendinous and fleshy bundles, which converge, slide over the inner surface of the neck of the scapula, pass in the hollow under the root of the coracoid process, and adhere to the inner part of the capsular ligament of the shoulder-joint.

Inserted, by a strong tendon, into the lesser tuberosity near the head of the os humeri.

Situation: The whole of this muscle is concealed by the scapula and muscles of the shoulder. It lies betwixt that bone and the serratus magnus; the tendon passes under the coraco-brachialis and short head of the biceps flexor, to reach the lesser tuberosity. The lower edge of this muscle is in contact with the upper edge of the teres major.

Use: To roll the os humeri inwards, and to draw it to the side of the body.

Synonyma: Sous-scapulo-trochinien.

7. The BICEPS FLEXOR CUBITI—*Arises* by two heads. The first and outermost, called the Long

Head, arises, by a strong tendon, from a smooth surface in the upper edge of the glenoid cavity of the scapula. It passes over the head of the os humeri, within the capsular ligament of the shoulder-joint, and enters a groove betwixt the two tuberosities of that bone. It forms a strong fleshy belly. The second and innermost, called the Short Head, arises, tendinous, from the lower part of the coracoid process of the scapula, in common with the coraco-brachialis, and sends off a fleshy belly.

These two fleshy bellies are at first only connected by condensed cellular membrane. They form a thick mass, and, below the middle of the arm, become inseparably united. They send off a strong tendon, which is at first broad, but soon becomes rounder, and passes over the fore-part of the elbow-joint. It then slides over the cartilaginous middle surface of the tubercle at the upper end of the radius, and is

Inserted into the posterior and internal rough part of that tubercle. A bursa mucosa is placed between the tendon and front of the tubercle.

Situation: The tendon of the long head cannot be seen till the capsular ligament of the shoulder is opened. Where it runs in the groove of the os humeri, it lies betwixt the pectoralis major and latissimus dorsi, and is firmly bound down by tendinous fibres passing from the capsular ligament and adjacent tendons. The short head arises from the coracoid process, betwixt the origin of the coraco-brachialis and the strong ligament which passes from the coracoid process to the acromion. These two origins are concealed by the deltoides and pectoralis major. The belly of

the muscle is immediately under the integuments, and so is the tendon where it passes over the elbow-joint. It is seen sinking between the supinator radii longus and pronator teres, to arrive at its point of insertion; and at the bend of the elbow, it sends off from its inside an aponeurosis, which assists in forming the fascia of the fore-arm.

Use: To turn the hand supine, to bend the fore-arm on the arm, and the arm on the shoulder.

Synonyma: Biceps brachii;—Biceps, sive Coraco-radialis;—Biceps internus;—Scapulo-coraco-radial.

8. The Coraco Brachialis—*Arises*, tendinous and fleshy, from the middle part of the apex of the coracoid process of the scapula. Its fibres, as it descends, also arise from the edge of the short tendon of the biceps flexor cubiti. It forms a flat fleshy belly which is always perforated by the nerve, named Musculo-Cutaneus.

Inserted, tendinous and fleshy, about the middle of the internal part of the os humeri, into a rough ridge.

Situation: This muscle is much connected with the short head of the biceps flexor cubiti. It arises betwixt that muscle and the origin of the pectoralis minor. In the arm, it lies behind, and on the inside of the biceps, and is concealed by the pectoralis major and deltoides, excepting a small part of it which is seen projecting betwixt the biceps flexor and triceps extensor cubiti. It is inserted immediately below the tendons of the latissimus dorsi and teres major, and before the brachialis externus. The lower part of

its insertion passes betwixt the brachialis internus and brachialis externus.

The internal intermuscular ligament is seen extending from the lower part of this muscle along a ridge to the internal condyle, and separating the brachialis internus from the brachialis externus, or third head of the triceps extensor cubiti.

Use: To move the arm upwards and forwards.

Synonyma: Coraco-humeral.

9. The BRACHIALIS INTERNUS—*Arises* from the middle of the os humeri, by two fleshy slips, which pass on each side of the insertion of the deltoid muscle; fleshy from all the fore-part of the bone below, nearly as far as the condyles. The fibres converge, pass over the elbow-joint, and adhere to the capsular ligament.

Inserted, by a strong short tendon, into the rough surface immediately below the coronoid process of the ulna.

Situation: The most external of the fleshy slips of this muscle lies between the deltoid and short head of the triceps extensor, the internal between the deltoid and coraco-brachialis. The belly is almost entirely concealed by the biceps flexor cubiti, excepting a small portion which projects beyond the outer edge of that muscle. The tendon dips down betwixt the supinator radii longus and pronator teres, crosses under the tendon of the biceps flexor, and is inserted on the inside of that tendon.

Use: To bend the fore-arm.

Synonyma: Brachiæus;—Humero-cubital.

10. The TRICEPS EXTENSOR CUBITI is the great muscle which covers all the back-part of the arm.— It *arises* by three heads. The first, or long head, arises, by a broad tendon, from the inferior costa of the scapula near its cervix, and forms a large belly, which covers the back-part of the os humeri. The second, or short head, arises, on the outer and back-part of the os humeri, by an acute tendinous and fleshy beginning, from a ridge which runs from the back-part of the great tuberosity towards the outer condyle. The fibres begin to arise a little below the tuberosity, and are continued down to the condyle. They also arise from the surface of bone behind the ridge, and from the intermuscular ligament which separates them from the muscles on the fore-part of the arm. The third head, called BRACHIALIS EXTERNUS, arises, by an acute beginning, from the inside of the os humeri above its middle, and from a ridge extending to the inner condyle. It also arises from the surface behind this ridge, and from the internal intermuscular ligament.

The three heads unite above the middle of the os humeri, and invest the whole back-part of the bone. They form a thick strong tendon, which is

Inserted into the rough back-part of the process of the ulna, called Olecranon, and partly into the condyles of the os humeri, adhering firmly to the capsular ligament.

Situation: The long head, where it arises from the scapula, is concealed by the deltoid; it arises betwixt the teres minor and teres major, and passes betwixt those muscles to the arm; and, in the remainder of

its course, is superficially seated. The short head arises immediately below the insertion of the teres minor, its upper part is therefore covered by the deltoides. Below the deltoid, it is superficial, and arises more outwardly than the brachialis internus, supinator radii longus, and extensors of the carpus. The brachialus externus is situated immediately under the integuments; it begins to arise below the insertion of the teres major. It passes down the arm between the triceps longus and coraco brachialis at first, afterwards between the triceps longus and brachialis internus. The tendon of the triceps sends off a thin fascia, which covers the triangular surface of the ulna, on which we commonly lean. Numerous fibres are also sent off, to assist in forming the fascia of the fore-arm.

Use: To extend the fore-arm. The long head will also assist in drawing the arm backwards.

Synonyma: Anconeus major, Anconeus externus, and Anconeus internus;—Biceps externus, and Brachialis externus;—Triceps Brachii;—Tri-scapulo-humero-olecranien.

SECT. II.

DISSECTION OF THE FASCIA AND MUSCLES SITUATED ON THE CUBIT OR FORE-ARM*.

On removing the integuments of the fore-arm, we

* In the following description, the palm of the hand is supposed to be turned forwards, so that the radius and thumb are upon the outer side of the fore-arm, and the ulna and little finger upon its inner side.

find, as in the leg, a strong fascia investing all the muscles. This fascia is continued from the intermuscular ligaments which pass down to the condyles of the os humeri. It is attached to the condyles, and it adheres firmly to the olecranon of the ulna. It receives, on the posterior part, a great addition of fibres from the tendon of the triceps extensor; and on the fore-part of the arm, it appears to be a continuation of the aponeurosis which is sent off from the biceps flexor cubiti.

Above the fascia, we meet with several cutaneous veins and nerves. The veins have been already described: the nerves are twigs of the branches of the brachial plexus.

The relative situation of the vessels at the bend of the arm should be well attended to. The cutaneous veins situated here vary much in size. The vena basilica is seen running over the fore-part of the bend of the arm near the inner condyle, the vena cephalica situated near the outer condyle; and each of these veins receives a branch passing obliquely from the vena mediana major. These vessels lie above the fascia, while the brachial artery lies deep beneath the fascia, in a hollow resembling that of the axilla. It descends over the joint near the inner condyle, on the inside of the tendon of the biceps flexor cubiti, and under the aponeurosis sent off from that muscle to the common fascia of the fore-arm. It lies embedded in cellular substance, betwixt the pronator teres and flexor muscles of the wrist and fingers on one side, and the supinator longus and extensor muscles on the other. In this hollow it divides into the radial, ul-

nar, and interosseal arteries. The artery is accompanied by two veins, and on its inner side runs the radial nerve.

The dissection of the fascia of the fore-arm is similar to that of the fascia of the leg. It is found firmly attached to the fibres of the muscles, so that the exposed surface appears ragged. It sends down betwixt them partitions, named Intermuscular Ligaments or Tendons, which connect the muscles, and give origin to many of their fibres.

MUSCLES SITUATED ON THE FORE-PART OF THE CUBIT, AND ARISING FROM THE INNER CONDYLE OF THE OS HUMERI.

These are eight in number, and may be divided into two classes: the superficial, and the deep-seated.

First, The superficial.

All the muscles passing from the inner condyle may be said to arise by one common tendinous head from the condyle; and this head may be said to divide into the different muscles; but they will be here described as arising distinct from the condyle. It must, however, be recollected, that their origins are intimately connected by intermuscular ligaments, and that they cannot be separated without dividing some of their fibres.

1. The Pronator Radii Teres—*Arises*, tendinous and fleshy, from the anterior surface of the inner condyle of the os humeri, and from the coronoid process of the ulna. It also arises from the fascia of

the fore-arm. The fibres pass outwards, run by the side of the tubercle of the radius, and pass over the outer edge of that bone, to be

Inserted, tendinous and fleshy, into a rough surface on the back-part of the radius about its middle.

Situation: Of the muscles which pass from the internal condyle, the pronator teres is situated nearest the outer edge of the arm. It lies immediately on the inside of the tendon of the brachialis internus. Its tendon, to arrive at its place of insertion, passes under the belly of the supinator longus, and, when that muscle is removed, will be found inserted into the radius immediately below the supinator brevis.

Use: To roll the radius, together with the hand, inwards.

Synonyma: Pronator teres, sive Obliquus;—Epitrochlo-radial.

2. The FLEXOR CARPI RADIALIS—*Arises*, by a narrow tendinous begining, from the lower and fore-part of the internal condyle of the os humeri; fleshy from the fascia and intermuscular ligaments, and from the upper end of the ulna. It forms a thick belly, which runs down the fore-arm, and terminates in a flat tendon. This tendon passes under the annular ligament * of the wrist, runs through a groove in the os trapezium, and is

* The annular ligament of the wrist consists of two parts. 1. The ligamentum carpi transversale externum passes from the styloid process of the ulna and os pisiforme, transversely, over the back of the wrist, and spreads out broad, to be affixed to the styloid process of the radius. Under it pass the tendons of the extensor muscles. 2. The ligamentum carpi transversale

Inserted into the fore-part of the base of the metacarpal bone sustaining the fore-finger.

Situation: This muscle is situated immediately under the fascia, excepting its upper extremity, over which the pronator teres crosses. It arises between the pronator teres and palmaris longus, and descends betwixt those muscles. Below the insertion of the pronator, it is situated betwixt the supinator radii longus and palmaris longus. Its insertion cannot be seen till the palm of the hand is dissected, where it will be found concealed by the muscles of the ball of the thumb.

Use: To bend the hand, and to assist in its pronation.

Synonyma: Radialis internus;—Epitrochlo-métacarpien.

3. The PALMARIS LONGUS—*Arises*, by a slender tendon, from the fore-part of the inner condyle of the os humeri; and fleshy, from the intermuscular ligaments; it forms a short fleshy belly, which soon sends off a long slender tendon. This tendon descends along the fore-arm, and is

Inserted, near the root of the thumb, into the ligamentum carpi transversale internum, and into a tendinous membrane that covers the palm of the hand, named Fascia, or Aponeurosis Palmaris.

Situation: It arises betwixt the flexor carpi radialis and flexor ulnaris. Its tendon descends betwixt these

internum is a strong ligament, which passes across the fore-part of the wrist. It arises from the os pisiforme and os unciforme on the inner edge of the wrist, and is attached to the os scaphoides and os trapezium on the outer edge. Under it pass the tendons of the flexor muscles.

two muscles, and above the fibres of the flexor digitorum sublimis. This muscle is sometimes wanting.

Use: To bend the hand, and to stretch the palmar aponeurosis.

Synonyma: Ulnaris gracilis;—Epitrochlo-carpi-palmaire.

4. The Flexor Carpi Ulnaris—*Arises*, tendinous, from the inferior part of the internal condyle of the os humeri; tendinous and fleshy, from the inner side of the olecranon, and by a tendinous expansion from the posterior ridge * of the ulna, to near the lower end of the bone. It also arises from the intermuscular ligaments and fascia of the fore-arm. The fibres pass obliquely forwards into a tendon which runs over the fore-part of the ulna, and is

Inserted into the os pisiforme, and sometimes sends its fibres over a small ligament which goes to the base of the metacarpal bone of the little finger.

Situation: This muscle arises behind the other muscles which pass from the internal condyle. It runs along the inner edge of the fore-arm, between the flexor sublimis on the fore-part, and the extensor carpi ulnaris on the back-part of the ulna. The tendon is bound down by a thin aponeurotic slip, which passes from the inner part of the annular ligament of the wrist.

Use: To bend the hand.

Synonyma: Ulnaris internus;—Epitrochli-cubito-carpien.

5. The Flexor Sublimis Perforatus—*Arises*, tendinous and fleshy, from the under part of the inter-

* The ridge which leads to the styloid process.

nal condyle of the os humeri; tendinous, from the lower part of the coronoid process of the ulna; fleshy, from the tubercle of the radius, from the middle of the fore-part of that bone, and from the middle third of its outer edge. These origins form a strong fleshy mass, which sends off four tendons. The tendons are connected by cellular membrane, and pass together under the annular ligament of the wrist; after which they separate, become thinner and flatter, pass along the metacarpal bone and first phalanx of each of the fingers, and are

Inserted into the anterior and upper part of the second phalanx, each tendon being, near the extremity of the first phalanx, divided for the passage of a tendon of the flexor profundus.

Situation: To expose the origin of this muscle, the bellies of the pronator teres, flexor carpi radialis, and palmaris longus, must be detached from the condyle. It arises behind these muscles, and is connected to them by intermuscular ligaments. It descends along the fore-arm under these muscles, but a part of it is seen projecting towards the inner edge of the arm, betwixt the tendons of the palmaris longus and flexor carpi ulnaris. It arises from the radius immediately below the insertion of the biceps flexor cubiti, and on the inside of the insertion of the pronator teres. Its tendons will be seen in the dissection of the palm of the hand.

Use: To bend the second joint or phalanx of the fingers.

Synonyma: Sublimis;—Perforatus;—Epitrochlo-coroni-phalanginien.

By removing the belly of the flexor sublimis, we expose the deep-seated muscles.

6. The Flexor Profundus Perforans—*Arises*, fleshy, from the smooth concavity on the inside of the ulna, betwixt the coronoid process and the olecranon; from the smooth flat surface of the ulna, betwixt its posterior and internal angles; from the under part of the coronoid process; from the fore-part of the ulna below that process, and betwixt the internal angle and that angle which gives attachment to the interosseous ligament. It also arises from the inner half of the interosseous ligament. This muscle forms a thick mass, which descends along the fore-part of the ulna, adhering to that bone as low as one-third of its length from its inferior extremity, and terminates in sending off four tendons. These tendons are flat, pass together under the annular ligament of the wrist, run through the slits in the tendons of the flexor sublimis, and are

Inserted into the fore and upper part of the third or last phalanx of all the fingers.

Situation: This muscle is concealed by the flexor sublimis and flexor carpi ulnaris. Its tendons will be seen in dissecting the hand.

Use: To bend the last joint of the fingers.

Synonyma: Profundus;--Perforans;—Cubito-phalangettien commun.

7. Flexor Longus Pollicis Manus—*Arises*, by an acute fleshy beginning, from the upper and fore part of the radius, immediately below its tubercle, fleshy, from the outer edge and anterior surface of that

bone as low as two inches above its inferior extremity, and from the outer part of the interosseous ligament. It has also generally a tendinous origin from the internal condyle of the os humeri. This origin forms a distinct fleshy slip, which is joined to the inner and upper part of the portion of the muscle arising from the radius. The fibres pass obliquely into a tendon on the anterior surface of the muscle. The tendon passes under the annular ligament of the wrist, runs between the two heads of the short flexor of the thumb, and between the two sesamoid bones, and is

Inserted into the base of the extreme phalanx of the thumb.

Situation: This muscle lies by the side of the flexor profundus; the portion which arises from the inner condyle passes over the belly of the flexor profundus, and under the flexor sublimis. The whole muscle is concealed by the flexor sublimis; its tendon will be seen in dissecting the short muscles of the thumb.

Use: To bend the last joint of the thumb.

Synonyma: Flexor tertii internodii;—Radio-phalangettien du pouce.

On separating the lower part of the two last-described muscles, we expose a small square muscle, passing transversely just above the wrist.

8. The Pronator Quadratus—*Arises*, broad, tendinous, and fleshy, from the inner edge of the ulna, extending from the lower extremity of the bone two inches up its edge. The fibres run transversely, adhere to the interosseous ligament, and are

Inserted into the lower and anterior part of the radius.

Situation: This muscle lies close to the bones, covered by the flexor longus pollicis and flexor digitorum sublimis.

Use: To turn the radius, together with the hand, inwards.

Synonyma: Cubito-radial.

MUSCLES SITUATED ON THE OUTER AND BACK PART OF THE FORE-ARM, AND ARISING FROM THE OUTER CONDYLE OF THE OS HUMERI.

THESE muscles are eleven in number, and may be divided into two classes: 1. The Superficial; and, 2. The Deep seated.

THE SUPERFICIAL.

The muscles which arise from the outer condyle are much more distinct in their origins than those which arise from the inner condyle. Several of them arise a considerable way up the os humeri; but there is here also a common tendinous origin, from which the extensor carpi radialis brevior, extensor digitorum communis, and extensor carpi radialis, proceed; so that these muscles are intimately connected.

1. SUPINATOR RADII LONGUS—*Arises*, tendinous and fleshy, from the external ridge of the os humeri which leads to the outer condyle. It begins to arise nearly as far up as the middle of the bone, and ceases to adhere about two inches above the con-

dyle. It forms a thick fleshy belly, which passes over the side of the elbow-joint, becomes smaller, and terminates above the middle of the fore-arm in a flat tendon. The tendon becomes gradually rounder, and is

Inserted into a rough surface on the outer side of the inferior extremity of the radius.

Situation: This muscle is situated immediately under the integuments along the outer edge of the arm and fore-arm. It begins to arise from the os humeri immediately below the insertion of the deltoid. Its origin lies betwixt the brachialis internus and short head of the triceps extensor cubiti, from which it is separated by the external intermuscular ligament. It descends along the radius, placed at first between the extensor carpi radialis longior and pronator teres, lower down between the tendons of the flexor carpi radialis and extensor radialis longior. Its insertion is crossed by the extensors of the thumb.

Use: To roll the radius outwards, and turn the palm of the hand upwards; also to bend the fore-arm on the humerus.

Synonyma: Supinator longus, sive major;—Humé-ro-sus-radial.

2. The Extensor Carpi Radialis Longior—*Arises*, tendinous and fleshy, from the external ridge of the os humeri, beginning immediately below the origin of the supinator longus, and continuing to arise as far as the upper part of the outer condyle. It forms a thick short belly, which passes over the side of the elbow-joint, and terminates above the middle

of the radius in a flat tendon. The tendon runs along the radius, and, becoming rounder, passes through a groove in the back-part of the inferior extremity of that bone, to be

Inserted into the posterior and upper part of the metacarpal bone of the fore-finger.

Situation: The belly lies under the supinator longus, but part of it projects behind that muscle. The tendon descends behind that of the supinator, and passes under the extensors of the thumb, and annular ligament of the wrist, to arrive at the place of its insertion.

Use: To extend the wrist, and move the hand backwards, and to assist in bending the fore-arm.

Synonyma: Radialis externus longior;—Radialis externus primus;—Humero-sus-metacarpien.

3. The Extensor Carpi Radialis Brevior—*Arises*, tendinous, from the under and back-part of the external condyle of the os humeri, and from the external lateral ligament of the elbow-joint. Its thick belly runs along the outside of the radius, and terminates in a tendon, which passes through the same groove in the radius as the extensor radialis longior, and under the annular ligament.

Inserted, by a round tendon, into the upper and back part of the metacarpal bone that supports the middle finger.

Situation: This muscle lies partly under the extensor radialis longior; but it also projects behind it. The tendon is seen behind, or more inwardly than

the tendon of the long extensor; it passes under the extensors of the thumb and the indicator.

Use: To extend the hand.

Synonyma: Radialis externus brevior;—Radialis secundus epicondylo-sus-metacarpien.

4. The Extensor Digitorum Communis—*Arises*, tendinous, from the under part of the external condyle of the os humeri; fleshy, from the intermuscular ligaments which connect it to the extensor carpi radialis brevior before, and the extensor carpi ulnaris behind, and from the inner surface of the fascia. It descends along the back-part of the fore-arm, and adheres to the ulna where it passes over it. The fleshy belly terminates in four flat tendons, which pass under the annular ligament in a depression on the back-part of the radius, and are

Inserted into the posterior part of all the bones of the fingers by a tendinous expansion.

Situation: It arises betwixt the extensor radialis brevior and the extensor carpi ulnaris. It descends betwixt these muscles, and is situated immediately under the integuments. The tendons are connected on the back of the metacarpal bone by cross slips.—The inner part of this muscle is sometimes described as a separate muscle, and is called Extensor Proprius Minimi Digiti, vel Auricularis. It passes through a separate depression of the radius, and a particular ring of the annular ligament.

Use: To extend all the joints of the fingers.

Synonyma: Epicondylo-sus-phalangéttien commun.

The posterior surface of each finger is covered with

a tendinous expansion which is formed by the tendons of the common extensor, of the lumbricales, and interossei. This tendinous expansion terminates in the third or extreme phalanx.

5. The Extensor Carpi Ulnaris—*Arises*, tendinous, from the under part of the external condyle; fleshy, from the intermuscular ligaments and inside of the fascia. It crosses towards the ulna, and arises, fleshy, from the back-part of that bone. It terminates in a strong tendon, which passes through a groove in the back-part of the lower end of the ulna, under the annular ligament, and is

Inserted into the posterior and upper part of the metacarpal bone of the little finger.

Situation: This muscle is entirely superficial. It arises from the condyle betwixt the extensor digitorum communis and anconeus. It descends along the fore-arm betwixt the extensor digitorum communis and flexor carpi ulnaris.

Use: To extend the wrist, and bring the hand backwards; but chiefly to bend the hand laterally towards the ulna, as it will appear by pulling its tendon in the dissected subject.

Synonyma: Ulnaris externus;—Epicondylo-cubito-sus-metacarpien.

6. The Anconeus is a small triangular muscle, situated at the outer side of the olecranon, immediately under the integuments.

It *arises*, tendinous, from the posterior and lower part of the external condyle of the os humeri; forms a thick triangular fleshy mass, adhering to the capsular ligament of the elbow-joint, and is

Inserted into the concave surface on the outside of the olecranon, and into the posterior edge of the ulna.

Situation: This muscle lies betwixt the upper part of the extensor carpi ulnaris and the olecranon. It is partly covered by the tendon of the triceps extensor cubiti, and is enveloped in a fascia sent off from that tendon.

Use: To assist in extending the fore-arm.

Synonyma: Anconeus minor;—Anconeus vel Cubitalis;—Epicondylo-cubital.

By removing the superficial muscles, we expose

The Deep-seated.

7. The Supinator Radii Brevis—*Arises*, tendinous, from the lower part of the external condyle of the os humeri; tendinous and fleshy, from the ridge running down from the coronoid process along the outer surface of the ulna. The fibres adhere firmly to the ligament that joins these two bones, pass outwards round the upper part of the radius, and are

Inserted into the upper and outer edge of the tubercle of the radius, and into an oblique ridge extending from the tubercle downwards and outwards to the insertion of the pronator teres.

Situation: This muscle nearly surrounds the upper and outer part of the radius. It is concealed at the outer edge of the arm by the supinator longus and extensores carpi radialis; behind, by the extensor digitorum communis, extensor carpi ulnaris, and anco-

neus; before, by the brachialis internus, and by the tendon of the biceps flexor cubiti, close to which tendon this muscle is inserted.

Use: To roll the radius outwards, and bring the hand supine.

Synonyma: Epicondylo-radial.

On the back-part of the fore-arm we meet with three muscles going to the thumb, and one to the fore-finger.

8. The Extensor Ossis Metacarpi Pollicis —*Arises*, fleshy, from the middle and posterior part of the ulna, immediately below the termination of the anconeus, from the interosseous ligament, and from the posterior surface of the radius below the insertion of the supinator radii brevis. The fleshy fibres terminate in a tendon which passes through a groove in the outer edge of the lower extremity of the radius.

Inserted, generally by two tendons, into the os trapezium, and into the upper and back-part of the metacarpal bone of the thumb.

Use: To extend the metacarpal bone of the thumb outwardly.

Synonyma: Abductor longus pollicis manus;—Extensor primi internodii;—Extensor primus pollicis;—Cubito-radi-sus-métacarpien du pouce.

9. The Extensor Primi Internodii Pollicis Manus—*Arises*, fleshy, from the back-part of the ulna below its middle, from the interosseous ligament and radius. It runs along the lower edge of the extensor ossis metacarpi, and forms a tendon, which

passes through the same groove as the tendon of that muscle, and is

Inserted into the posterior part of the first bone of the thumb. Part of the tendon is also continued into the base of the second or extreme phalanx.

Use: To extend the first phalanx of the thumb obliquely outwards.

Synonyma: Extensor minor pollicis manus;—Extensor secundi internodii;—Extensor pollicis primus;—Cubito-sus-phalangien du pouce.

10. The Extensor Secundi Internodii Pollicis Manus—*Arises*, tendinous and fleshy, from the posterior surface of the ulna above its middle, and from the interosseous ligament. Its belly partly covers the origins of the two other extensors of the thumb, and terminates in a tendon, which runs through a distinct groove in the back-part of the radius, and is

Inserted into the posterior and upper part of the second or extreme phalanx of the thumb.

Use: To extend the last joint of the thumb obliquely backwards.

Synonyma: Extensor major pollicis manus;—Extensor pollicis secundus;—Extensor tertii internodii;—Cubito-sus-phalangéttien du pouce.

Situation of the extensors of the thumb.—The origins of these muscles are concealed by the extensor digitorum communis and extensor carpi ulnaris.—Their bellies are seen coming from betwixt the extensor digitorum communis and extensor carpi radialis brevior, and, passing under the annular ligament of

the wrist, to arrive at the place of their insertion.—The tendon of the extensor secundi internodii is at a considerable distance from the tendons of the two other extensors; so that, in the intermediate space, we see the terminations of the tendons of the extensores carpi radiales. They invest the back-part of the thumb with a fascia.

11. The INDICATOR—*Arises*, by an acute fleshy beginning, from the middle of the back-part of the ulna, and from the interosseous ligament. Its tendon passes through the same sheath of the annular ligament with the extensor digitorum communis, and is

Inserted into the posterior part of the fore-finger with the tendon of the common extensor.

Situation: It arises nearer to the inner edge of the arm than the extensor secundi internodii pollicis. It is concealed by the extensor digitorum communis and extensor carpi ulnaris. The tendon passes under that of the common extensor.

Use: To assist in extending the fore-finger.

Synonyma: Extensor secundi internodii indicis proprius;—Extensor indicis proprius;—Cubito-sus-phalangéttien de l'index.

General Observations.—In dissecting the fore-arm, you will not expect to find each muscle separate from the contiguous ones, as far as its very origin from the bones. The partitions of fascia unite them most firmly to a considerable distance from their commencement; and these connections should not be disturbed, since they are as justly to be regarded in the light of origins of the muscles, as the attachments

which the fibres have to the bone. The muscles are divided into two masses; of which one lies over the radius and back of the fore-arm, and contains the supinators and extensors: the other, situated over the ulna, and inner side of the fore-arm, consists of the pronators and flexors. Although some muscles in each of these masses arise quite separately, others are joined into a common tendinous and fleshy origin, in the way above described. First clean all the muscles as they lie; and after observing them in their relative position, reflect each muscle, beginning with the superficial ones, and reading its description at the same time.

SECT. III.

DISSECTION OF THE PALM OF THE HAND.

The tendons which pass over the bones of the carpus into the palm of the hand are firmly bound down by the annular ligament of the wrist. They are invested and connected by cellular membrane, which forms sheaths, and secretes synovia to facilitate their motions.

In the sole of the foot we saw a strong fascia, supporting and covering the muscles, and passing from the heel to the toes. On removing the integuments from the palm of the hand, we meet with a similar fascia. It arises from the tendon of the palmaris longus, and from the annular ligament of the wrist,

expands over all the palm of the hand, and is fixed to the roots of the fingers, splitting, to transmit their tendons. This is the Fascia or Aponeurosis Palmaris. It is triangular. Where it arises from the wrist, it is narrow, and does not cover the bases of the metacarpal bones of the little and fore-finger.—As it runs over the hand, it becomes broader, and is fixed by a bifurcated extremity in the lower end of each of the metacarpal bones of the four fingers.—The palmar fascia is strong and thick, conceals and supports the muscles of the hand, and may be distinguished into four portions, which are connected by transverse fibres, while other fibres pass from them downwards, adhere strongly to the edges of the metacarpal bones, and separate the tendons of each finger.

There is a small thin cutaneous muscle situated between the wrist and the little finger.

The Palmaris Brevis—*Arises* from the annular ligament of the wrist, and from the inner edge of the fascia palmaris.

Inserted, by small scattered fibres, into the skin and fat which covers the short muscles of the little finger and inner edge of the hand.

Use: To assist in contracting the palm of the hand.

Synonyma: Palmaris cutaneus.

The fascia palmaris may now be removed. Under it will be seen the four tendons of the flexor sublimis perforatus. They are seen coming from beneath the annular ligament of the wrist, and diverging as they

pass towards their respective fingers. Each tendon splits at the extremity of the first phalanx, for the passage of the tendon of the flexor profundus perforatus, and inserted into the base of the second phalanx.

Under the flexor sublimis are the four tendons of the flexor profundus perforans, which pass through the slits in the tendons of the former, and are inserted into the bases of the third phalanges of the fingers.

The LUMBRICALES are four small muscles, which *arise*, tendinous and fleshy, from the outer side of the tendons of the flexor profundus perforans, soon after those tendons have passed the ligamentum carpi annulare. Each of these muscles has a small belly, which terminates in a tendon. The tendon runs along the outer edge of the finger, and is

Inserted into the tendinous expansion which covers the back-part of the phalanges of the fingers, about the middle of the first joint.

Use: To bend the first phalanges of the fingers, the flexor profundus being previously in action, to afford them a fixed point.

Synonyma: Annuli-tendino-phalangiens.

The short muscles of the thumb and fore-finger are five in number.

1. The ABDUCTOR POLLICIS MANUS—*Arises*, by a broad tendinous and fleshy origin, from the anterior surface of the annular ligament of the wrist, and from the os naviculare and os trapezium.

Inserted, tendinous, into the outer side of the root

of the first phalanx of the thumb, and into the tendinous membrane which covers the back-part of all the phalanges.

Situation: This muscle is situated immediately under the integuments, and is the outermost portion of the muscular mass forming the ball of the thumb.

Use: To draw the thumb from the fingers.

Synonyma: Abductor brevis pollicis manus, and abductor brevis alter;—Abductor, Thenar;—Scapho-sus-phalanginien du pouce.

2. The Flexor Ossis Metacarpi Pollicis, or Opponens Pollicis—*Arises*, broad and fleshy, from the annular ligament of the wrist, and from the os naviculare and os trapezium.

Inserted, tendinous and fleshy, into the anterior and lower part of the metacarpal bone of the thumb.

Situation: It lies under the abductor pollicis, and is almost entirely concealed; but a few of its fibres are seen projecting beyond the edge of that muscle.

Use: To bring the first bone of the thumb inwards.

Synonyma: Flexor primi internodii;—Antithenar, sive Semi-interosseus pollicis;—Carpo-phalangien du pouce.

3. The Flexor Brevis Pollicis Manus arises by two distinct heads.

(1.) The outer head *arises* from the inside of the annular ligament; from the anterior surface of the os trapezium and os trapezoides; and from the root of the metacarpal bone of the fore-finger.

Inserted into the outer sesamoid bone, which is

connected by a ligament to the root of the first phalanx of the thumb.

(2.) The inner head *arises* from the upper part of the os magnum and os unciforme, and from the root of the metacarpal bone of the middle finger.

Inserted into the inner sesamoid bone, which is connected by a ligament to the root of the first phalanx of the thumb.

Situation: This muscle is in great part concealed by the abductor pollicis. Its inner origin is under the first lumbricalis; its upper part is seen projecting; and between its two portions we find the tendon of the flexor longus pollicis.

Use: To bend the first joint of the thumb.

Synonyma: Flexor secundi internodii;—Thenar;—Carpo-phalanginien du pouce.

4. The Abductor Pollicis Manus—*Arises*, fleshy, from almost the whole length of the metacarpal bone sustaining the middle finger. The fibres converge, and pass over the metacarpal bone of the fore-finger, to be

Inserted, tendinous, into the inner part of the root of the first phalanx of the thumb.

Situation: The belly of this muscle is concealed, as it lies close to the bone under the tendons of the flexor profundus and lumbricales. The tendon is seen where it is inserted into the thumb, and runs along the inner edge of the flexor brevis pollicis.

Use: To pull the thumb towards the fingers.

Synonyma: Adductor ad minimum digitum;—Mesothenar;—Metacarpo-phalanginien du pouce.

5. The Abductor Indicis Manus—*Arises*, ten-

dinous and fleshy, from the os trapezium, and from the inner side of the metacarpal bone of the thumb. It forms a fleshy belly, runs over the side of the first joint of the fore-finger, and is

Inserted, by a short tendon, into the outer side of the root of the first phalanx of the fore-finger.

Situation: This muscle is seen most distinctly on the back of the hand. It is there superficial, and is crossed by the tendon of the extensor secundi internodii pollicis. In the palm of the hand it is concealed by the muscles of the ball of the thumb.

Use: To move the fore-finger towards the thumb, or the thumb towards the fore-finger.

Synonyma: Semi-interosseus.

The insertion of the flexor carpi radialis is exposed by removing the muscles of the thumb.

The short muscles of the little finger are three in number.

1. The Abductor Minimi Digiti Manus—*Arises*, fleshy, from the os pisiforme, and adjacent part of the annular ligament of the wrist. Its fibres extend along the metacarpal bone of the little finger.

Inserted, tendinous, into the inner side of the first phalanx, and into the tendinous expansion which covers the back-part of the little finger.

Situation: The belly of this muscle is superficial. It is only covered by the straggling fibres of the palmaris brevis.

Use: To draw the little finger from the rest.

Synonyma: Hypothenar minor;—Extensor tertii internodii minimi digiti;—Carpo-phalangien du petit doigt.

2. The Flexor Parvus Minimi Digiti—*Arises*, fleshy, from the outer side of the os unciforme, and from the annular ligament of the wrist, where it is affixed to that bone.

Inserted, by a roundish tendon, into the base of the first phalanx of the little finger.

Situation: This muscle is also covered by the fibres of the palmaris brevis. It lies on the inner side of the abductor minimi digiti, and its tendon is firmly connected to the tendon of that muscle.

Use: To bend the little finger, and bring it towards the other fingers.

Synonyma: Abductor minimi digiti;—Carpo phalangien second.

3. Adductor Metacarpi Minimi Digiti Manus—*Arises*, fleshy, from the os unciforme, and adjacent part of the annular ligament of the wrist. It forms a thick mass, which is

Inserted, tendinous, into the fore-part of the metacarpal bone of the little finger, nearly its whole length.

Situation: It is concealed by the bellies of the abductor and flexor brevis minimi digiti.

Use: To bend and bring the metacarpal bone of the little finger towards the rest.

Synonyma: Metacarpus;—Flexor primi internodii minimi digiti;—Carpo-metacarpien du petit doigt.

The Interossei are small muscles situated between the metacarpal bones, and extending from the bones of the carpus to the fingers. They are exposed by removing the other muscles of the thumb and fingers.

The Interossei Interni are seen in the palm of the hand, and are four in number. They arise, tendinous and fleshy, from the base and sides of the metacarpal bones, and are inserted into the side of the first phalanx of the fingers, and into the tendinous expansion which covers the posterior surface of all the phalanges.

1. The First, named Prior Indicis, *arises* from the outer part of the metacarpal bone of the fore-finger; and is *inserted* into the outer side of the first phalanx of that finger. *Use:* To draw the fore-finger towards the thumb.

2. The Second, named Posterior Indicis, *arises* from the root and inner side of the metacarpal bone of the fore-finger; and is *inserted* into the inner side of the first phalanx of the fore-finger. *Use:* To draw that finger outwards.

3. The Third, named Prior Annularis, *arises* from the root and outer side of the metacarpal bone of the ring-finger; and is *inserted* into the outer side of the first phalanx of the same finger. *Use:* To pull the ring-finger towards the thumb.

4. The Fourth, named Interosseus Auricularis, *arises* from the root and outer side of the metacarpal bone of the little finger; and is *inserted* into the outer side of the first phalanx of the little finger. *Use:* To draw the little finger outwards.

The internal interossei also assist in extending the fingers obliquely.

Synonyma: Sous-metacarpo lateri-phalangiens.

The Interossei Externi, seu Bicipites, are three in number. They are larger than the internal, and are situated betwixt the metacarpal bones on the

back of the hand. Each of these muscles *arises*, by a double head, from two metacarpal bones, and is *inserted* into the side of one of the fingers, and into the tendinous expansion which covers the posterior part of the phalanges.

1. The First, named Prior Medii, *arises* from the roots of the metacarpal bones of the fore and middle fingers; and is *inserted* into the outer side of the middle finger. *Use:* To draw the middle finger towards the thumb.

2. The Second, named Posterior Medii, *arises* from the roots of the metacarpal bones of the middle and ring fingers; and is *inserted* into the inner side of the middle finger. *Use:* To draw the middle finger towards the ring-finger.

3. The Third, named Posterior Annularis, *arises* from the roots of the metacarpal bones of the ring and little fingers; and is *inserted* into the inner side of the ring-finger. *Use:* To draw the ring-finger inwards. The external interossei also extend the fingers. *Synonyma:* Sous-metacarpo-lateri-phalangiens.

SECT. IV.

OF THE VESSELS AND NERVES OF THE SUPERIOR EXTREMITY.

ARTERIES.

THE subclavian and axillary arteries have been described.

The BRACHIAL ARTERY may be said to have its course along the inside of the arm. Having left the

axilla, it runs along the inferior edge of the coraco-brachialis. Rather higher up than the middle of the os humeri, it crosses over the tendinous insertion of that muscle, being here situated between the belly of the biceps flexor cubiti, and the superior fibres of the brachialis externus. The artery then passes behind the inner edge of the biceps flexor cubiti, descending betwixt that muscle and the fibres of the brachialis internus. In dissecting this vessel, we find it invested by a fascia or sheath, formed by cellular membrane and some tendinous fibres. This fascia may be traced extending from the internal intermuscular ligament. It covers the brachial artery and radial nerve; and the great basilic vein, as it enters into the axilla, is found lying in the fore and inner part of this sheath. It supports and connects these vessels. On dissecting this fascia, we find, close to the margin of the coraco-brachialis and biceps flexor cubiti, the great radial nerve; under it the brachial artery; and, more superficially seated, the venæ comites and the vena basilica. As the artery approaches the lower extremity of the os humeri, it inclines forwards toward the fold of the arm, and dives beneath the aponeurosis which arises from the inside of the tendon of the biceps flexor cubiti. Its situation at the fold of the arm has been described.

Branches of the Brachial Artery.

1. A. Profunda Humeri Superior, or Muscularis Superior, is sent off from the inner side of the brachial artery, immediately where it has left the fold of the arm-pit. It passes downwards and backwards round the os humeri, and is accompanied by

the muscular or spiral nerve. It passes betwixt the brachialus externus and short head of the triceps extensor cubiti. Here it lies deep among the muscles, and divides into two branches. One accompanying the nerve spreads its ramifications over the outer condyle, and anastomoses with the arteries below the elbow. The other branch is distributed along the inside of the arm, and about the inner condyle.

2. A. Profunda Humeri Inferior, vel Minor, or Muscularis Inferior, is smaller than the last, and is sent off from the brachial artery about two inches lower down. It descends among the muscles on the inside of the arm, and is lost about the inner condyle.

3. The anastomosing or collateral arteries are as follow.

(1.) The Ramus Anastomoticus Major passes from the inside of the brachial artery, about two or three inches above the inner condyle. It is distributed about the condyle; and its principal branch accompanies the ulnar nerve in the groove betwixt the olecranon and inner condyle, to anastomose with the recurrent branches of the arteries of the fore-arm.

(2.) There are two or three more anastomosing branches, which are sent off from the brachial artery, and ramify over the anterior and posterior surfaces of the two condyles.

4. Small branches to the muscles of the arm.

The Brachial Artery, where it lies deep under the aponeurosis of the biceps, divides into three branches. 1. The radial; 2. The ulnar; and, 3. The interosseous artery. The two last generally come off by one trunk, which subdivides.

1. Arteria Radialis, the radial artery, is smaller than the ulnar, and in its course more superficial. It leaves the ulnar artery, and inclines towards the radial or outer edge of the fore-arm. At first it lies betwixt the pronator teres and supinator longus. It then descends close along the inner edge of the supinator longus, and about the middle of the fore-arm passes over the insertion of the pronator teres. It then holds its course betwixt the supinator longus and flexor carpi radialis, and is accompanied by a branch of the muscular or spiral nerve. In this situation the artery continues its course along the radius, till, reaching the lower extremity of that bone, it divides into two branches.

(1.) Ramus Volaris, A. Superficialis Volæ, is by much the smallest of the two branches. It passes into the muscular mass which forms the ball of the thumb, and spreads its ramifications on the palmar fascia, annular ligament of the wrist, and muscles of the thumb, anastomosing with the ramifications of the superficial palmar arch.

(2.) The trunk of the radial artery crosses over the lower extremity of the radius to the back of the hand. It passes under the extensors of the thumb, over the os scaphoides and the junction of the os trapezium and trapezoides, and, arriving at the space betwixt the bases of the metacarpal bones of the thumb and fore-finger, plunges into the palm of the hand.

The branches of the radial artery, in its course along the fore-arm, are the following.

(1.) The recurrent artery is sent off from the radial immediately after it leaves the ulnar artery, and

is distributed over the anterior part of the outer condyle, where it anastomoses with branches of the brachial artery.

(2.) Small arteries to the muscles of the fore-arm, and to the radius.

(3.) A branch leaves the artery immediately after it has turned over the edge of the radius, and, ramifying on the back of the hand, is named Dorsalis Carpi.

(4.) Small vessels are sent off to the back-part of the thumb, named A. Dorsales Pollicis.

Having reached the palm of the hand, the radial artery divides into two branches.

(1.) A. Pollicis, which sends two or three arteries along the anterior part of the thumb, and also often gives off a twig, the A. Radialis Indicis, which passes along the outer edge of the fore-finger, and inosculates with a branch of the ulnar artery.

(2.) The trunk of the radial artery forms the Deep-seated Palmar Arch. From the root of the thumb, it passes across the metacarpal bones near their bases, and terminates at the metacarpal bone of the little finger, inosculating with a branch of the ulnar artery. This arch lies deep, close to the bones. It supplies the interosseous muscles and deep-seated parts of the palm, and some of its branches pass betwixt the metacarpal bones to the back of the hand.

2. Arteria Ulnaris, or Cubitalis. The ulnar artery is the largest branch of the brachial, and generally gives off the interosseous artery. It takes its course deep among the muscles on the inside of the fore-arm. It is seen passing under the pronator teres,

flexor carpi radialis, palmaris longus, and flexor sublimis perforatus, but over the flexor profundus perforans. It descends in the connecting cellular membrane between the flexor sublimis and profundus; but about the middle of the fore-arm, it emerges from these muscles, and appears at the ulnar edge of the arm, betwixt the flexor sublimis and flexor carpi ulnaris. It passes over the annular ligament of the wrist, which binds down the flexor tendons of the fingers, but is covered by the fascia which ties down the tendon of the flexor carpi ulnaris. It passes under the palmar aponeurosis, on the inside of the os pisiforme, reaches the base of the metacarpal bone of the little finger, and begins to form the SUPERFICIAL PALMAR ARCH. This arch lies above the tendons of the flexor sublimis perforatus, immediately beneath the palmar aponeurosis. It crosses the metacarpal bones betwixt their bases and the middle of their bodies. It begins at the root of the little finger, and terminates at the root of the thumb, in inosculations with the branches of the radial artery. The convex side of the arch is turned towards the fingers, and sends off five branches.

(1.) A branch to the muscles and inner edge of the little finger.

(2.) Ramus digitalis primus, or the first digital artery, which runs along the space betwixt the two last metacarpal bones, and bifurcates into two branches, one to the outer side of the little finger, and the other to the inner side of the ring-finger.

(3.) The second digital artery, which bifurcates in a similar manner, and supplies the outer edge of the ring-finger, and the inner side of the middle finger.

(4.) The third digital artery, which is distributed to the outer edge of the middle finger, and to the inner side of the fore-finger.

(5.) The ramus pollicis ulnaris is the last branch of the ulnar artery, and is sent to the muscles of the thumb.

From the concavity of the arch are sent off the interosseous arteries of the palm, small twigs which supply the deep-seated parts, and perforate betwixt the metacarpal bones to the back of the hand.

The branches of the ulnar artery, in its course along the fore-arm and wrist, are the following.

(1.) The Recurrent Arteries are two in number. They are sent off from the ulnar artery immediately below the elbow, sometimes in one common branch, which subdivides. The anterior recurrent runs over the fore-part of the inner condyle; the posterior recurrent passes over the back-part. These arteries inosculate with branches of the brachial.

(2.) Twigs to the muscles of the fore-arm.

(3.) A. Dorsalis Carpi is sent off from the ulnar artery a little above the wrist to the back of the hand. Twigs are also given off to the annular ligament and neighbouring parts.

(4.) A. Palmaris Profunda is sent off from the ulnar artery, where it descends on the inside of the os pisiforme. It passes into the flesh at the root of the little finger, and inosculates with the termination of the deep-seated palmar arch of the radial artery.

3. Arteria Interossea (or Interossea Communis). This artery is generally sent off from the ulnar. It immediately divides into two branches:

(1.) The external or posterior interosseous artery

is the smallest branch. It passes through the upper part of the interosseous ligament, to supply the muscles on the posterior part of the fore-arm. It sends off the A. Recurrens Interossea, which ramifies on the middle of the back-part of the elbow-joint.

(2.) The internal or anterior interosseous artery descends close upon the middle of the interosseous ligament, betwixt the flexor longus pollicis and flexor profundus perforans, giving twigs to the adjacent muscles. Arriving at the upper edge of the pronator quadratus, it perforates betwixt the radius and ulna to the back-part of the arm, and spreads its extreme branches on the wrist and back of the hand.

VEINS.

The cutaneous veins have been already described.

The brachial artery is accompanied by two veins, named Venæ Comites, or Satellites. These receive branches corresponding to the ramifications of the artery.

NERVES.

In the dissection of the axilla, we demonstrated the great axillary plexus, and traced its two first branches, the external scapular and circumflex nerves. The distribution of the five remaining branches of the plexus must now be described.

(3.) The External Cutaneous Nerve (Musculo-cutaneus, or Perforans Casserii) is the third branch of the axillary plexus. It passes through the belly of the coraco-brachialis muscle. After its passage, it continues its course obliquely across the arm, betwixt the Biceps flexor cubiti and the Brachialis internus. It gives twigs to these muscles, and appears

as a superficial nerve on the edge of the supinator longus. It runs over the outer condyle, and is distributed to the integuments on the outside of the fore-arm, and back of the hand.

(4.) The Radial (or Median) Nerve accompanies the brachial artery to the bend of the elbow, and is contained in the same sheath as the artery. In its passage down the arm, it lies before that vessel, but at the elbow is situated on its inside. It gives off no branches until it has sunk under the aponeurotic expansion of the biceps flexor. Here it distributes many nerves to the muscles of the fore-arm, to the pronator teres, flexor carpi radialis, the flexors of the thumb and fingers, and the pronator quadratus. The trunk of the nerve perforates the pronator teres, passes betwixt the flexor digitorum sublimis and flexor profundus, and continues its course betwixt these muscles down to the wrist. Near the wrist it becomes more superficial, lying amongst the tendons of the flexors, and before it descends under the annular ligament, sends a superficial branch to the integuments and short muscles of the thumb. The nerve itself passes with the flexor tendons of the fingers under the annular ligament of the wrist, emerges from these tendons, and appears on their outside, near the root of the thumb. It ramifies superficially in the hand, setting off four branches. The first branch passes to the thumb; the second to the side of the fore-finger next the thumb; the third divides into two nerves, of which one passes to the inner side of the fore-finger; the fourth also subdivides into two, to the inside of the middle finger, and outer side of the ring-finger. These nerves pass before the flexor

tendons, but behind the superficial palmar arterial arch, to reach the fingers.

(5.) The Ulnar Nerve descends along the inside of the arm. It is at first situated immediately under the integuments, but below the middle of the arm is tied down by the intermuscular ligament which passes to the inner condyle of the humerus. The nerve becomes here more deeply seated; it runs between the inner condyle in the hollow behind it and the olecranon, and in the flesh of the brachialis externus, or third head of the triceps extensor. After passing the condyle, it continues its course betwixt the two heads of the flexor carpi ulnaris, till it reaches the ulnar artery. It then accompanies the ulnar artery, lying on its inside, and running along the fore-arm betwixt the flexor ulnaris and flexor digitorum sublimis. It sends twigs to the neighbouring muscles, and, when arrived near the wrist, divides into two branches. 1. The Smaller Branch, called Ramus Posticus, passes under the tendon of the flexor carpi ulnaris, and over the lower end of the ulna, to be distributed to the back of the hand, and of the little and ring fingers. 2. The continued trunk of the nerve passes, on the inside of the ulnar artery, over the annular ligament of the wrist. It passes under the palmar aponeurosis, and divides into three principal branches. The first supplies the integuments and muscles on the ulnar edge of the hand, and the inner side of the little finger. The second is distributed to the outer side of the little finger, and inner side of the ring-finger. The third branch passes deep under the long tendons, accompanies the deep-seated palmar arch, and terminates in the short muscles of the thumb and fore-finger, communicating with the radial nerve.

(6.) The Muscular or Spiral Nerve (Radial of some anatomists) passes from the axilla behind the os humeri, making a spiral turn round the bone to reach the outside of the arm. It first descends between the brachialis externus and short head of the biceps extensor cubiti, accompanying the arteria profunda humeri superior, and passing deep into the flesh of the arm. Before it makes this turn, it gives branches to the muscles, also a cutaneous branch, which descends on the inside of the arm. From the back-part of the arm the great trunk of the nerve is reflected spirally forwards. It is seen emerging betwixt the supinator longus and brachialis internus, seated deep and close to the bone. It descends betwixt these muscles, keeping close to the edge of the supinator longus. Immediately after passing the fold of the arm, it sends off a nerve, which descends, superficial, upon the radial edge of the fore-arm, as far as the wrist; and, at this point, the trunk of the muscular nerve divides itself into two branches. The first, a large branch, perforates the supinator brevis, and supplies the extensor muscles of the hand and fingers. The second branch accompanies the supinator longus down the fore-arm, and near the wrist turns under the tendon of that muscle, over the edge of the radius. It then divides into several branches, which ramify on the back of the wrist, thumb, and fore-finger.

(7.) The Internal Cutaneous Nerve descends superficial, along the inside of the arm and fore-arm. It was described among the cutaneous nerves of the arm.

APPENDIX:

CONTAINING

THE RUYSCHIAN ART AND METHOD

OF

MAKING PREPARATIONS

TO EXHIBIT

THE

STRUCTURE OF THE HUMAN BODY.

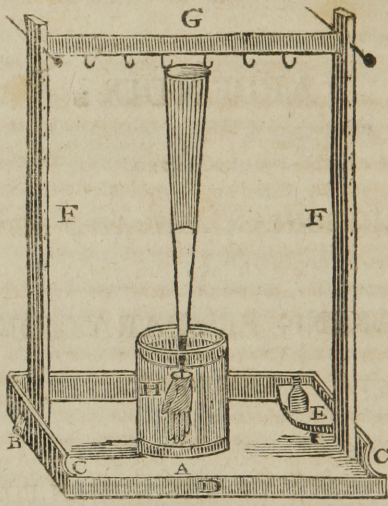

THE INJECTING TRAY AND ITS APPENDAGES,

For the purpose of facilitating the process of Quicksilver Injections, and preventing the loss of Quicksilver, which is constantly occasioned by the old method.

EXPLANATION OF THE PLATE.

A. The tray. This should be made of mahogany, about three-quarters of an inch in thickness, and the several parts should be joined together with screws; every joint should be made perfectly water-tight, and the inside painted black, as this is much more favourable for seeing the fine parts of white membranes lying upon it, and the quicksilver flowing through the minute ramifications of their vessels. The machine being made in this form, is intended to be occasionally filled with water, for the purpose of injecting broad and flat parts, which require to be so managed as to prevent their drying, and to which the common jar, represented in the plate, is not adapted, as placentæ, large portions of mesentery and intestine, female breasts, &c.

B. An iron pipe with an ivory plug, for the purpose of drawing off the water and quicksilver remaining in the tray after the injection is finished; it is made of iron, that it may not be affected by the quicksilver.

C. C. The right and left sides of the tray, cut down to form a rest for the arms, whilst the hands are employed upon a preparation at the bottom of it. The front D, is also made considerably lower than the sides, for the more convenient management of the preparation. The bottom of the tray should be about twenty inches square; the front about three inches high, and the sides four and a half: the clear dimensions on the inside are here meant.

E. A ledge in one corner, for the convenience of fixing the bottle containing the quicksilver; it has a hole sufficiently large to receive the bottle, which is let through, and stands on the bottom of the tray to preserve it from any accident, which it is very liable to from its weight.

F. F. Two uprights; the foot of each fixes in two square staples, within the right and left sides of the tray, and ought to be about twenty-four inches high.

G. The cross-piece, the ends of which slide up or down in the mortise of the uprights, and are fixed to any height, by means of pins passing through them and the ends of the cross-piece, to keep them steadily fixed to each other. In the lower edge of this cross-piece is fixed several small hooks, from which may be suspended one or more injecting tubes.

H. Is a glass jar containing water, in which is immersed a hand, with the quicksilver injecting pipe fixed in the artery, as in the process of filling the vessels. The hand is suspended by a string from the edge of the jar.

PREPARATIONS OF THE VISCERA.

THE various parts of the body may be preserved in a healthy state, either to exhibit their form or structure, or to compare them with morbid parts.

GENERAL OBSERVATIONS.

1. When removed from the body, and the useless parts dissected away, the part to be preserved is to be soaked in water, in order to get out the blood.

2. When it is necessary to give parts their natural form, which is lost by macerating, put them into a saturated solution of alum, retaining them by any means in the required form, until they become hardened. If it be a hollow part, as the stomach, bladder, &c. fill it with, and immerse it in, the solution.

3. When an opening is to be exhibited, as that of the ureter, the bile-duct, the lacunæ of the urethra, Stenonian duct, Fallopian tube, &c. introduce a bristle. After this manner preserve the uterus and its appendages, cutting open the vagina and cavity of the uterus, the bladder, intestine, stomach, heart in the pericardium, liver, spleen, kidney, &c. &c.

4. All preparations of the brain are best hardened in a saturated solution of corrosive sublimate.

5. The parts are to be suspended in proof spirit by raw silk, in a tie-over bottle, and covered with bladder, taking care to exclude all air. When dry, varnish the bladder with mucilage of gum arabic several times; then put a sheet of thin lead over, and varnish its edges with mucilage; and lastly, tie another bladder over, and give it a coat of common spirit varnish, in which lamp-black, or other colouring matter, is mixed.

PREPARATIONS OF MORBID PARTS.

All morbid parts should, immediately after their removal from the body, be put into rectified spirit of wine for a day or two, and then preserved in proof spirit. These preparations foul a great quantity of spirit, and should therefore be kept in stopper glasses, from which the spirit can easily be removed, and fresh put in, until the preparation ceases to foul the spirit, when it may be put into a tie-over bottle.

PREPARATIONS MADE BY MACERATING.

Preparations obtained by this process are very various.

GENERAL OBSERVATIONS.

1. Let the water be frequently changed, until it is no longer coloured with blood, but never after the blood is steeped away.
2. Let the macerating pan be placed in a warm place, to facilitate putrefaction.
3. The macerating pan should never be in a cold place, for the spermaceti-like conversion of the soft parts will be formed, and the bones spoiled.
4. The soft parts surrounding bones are a long time before they detach themselves from the bones.
5. Bones, when macerated, should be exposed to the sun's rays, and frequently wetted with clean water, or they may be bleached with the diluted oxygenated muriatic acid.

BONES.

Bones are macerated to be preserved whole, or they are sawed to expose their internal structure.

Bones of the head. Put the whole head, without disturbing the flesh or brains, into the pan. When sufficiently macerated, all the soft parts will come away with the periosteum; then detach the vertebræ, and wash out the brain. Bones are separated from each other by filling the cranium with peas, and putting it into water. The same method is to be adopted with other bones.

Bones in general, for structure. Divide the femur into two halves: the os innominatum, the petious portion of the temporal bone, the parietal bones, &c. these, when macerated, will exhibit the compact, the spongy, laminated, and reticular substance of bones.

A FOETUS.

Cut carefully away the fatty substance enveloping a fœtus, but do not cut any of the cartilages. Steep out its blood, and macerate. It should be frequently looked at, and taken out when the flesh is all destroyed, before the cartilages are separated. The following preparations are obtained in this way:

1. The superior extremity, to show its bones, the progress of ossification, and the cartilage to be formed into bone.
2. The lower extremity, to expose the same circumstance.
3. The spine, which forms a beautiful preparation.
4. The pelvis, not less elegant.

Preservation. The above all to be preserved in proof spirit.

CUTICLE.

The cuticle of the hand and foot may be separated by maceration; the former is called *chorotheca*, the latter *podatheca*. The arm and foot of a large fœtus are to be preferred; they are first to be well washed with a soft spunge in soap and water.

Preservation. Suspend them in proof spirit; first tie the part by which they are to be suspended, then put them into the bottle with the spirit, and gently pour some spirit into the cuticle, to distend it like a glove or stocking.

INJECTING INSTRUMENTS.

The celebrated Dutch anatomist, *Ruysch*, first invented the art of injecting animal bodies.

There are three kinds of apparatus used in making injected preparations. The one for the coarse and fine injections, and the minute injection; the other for injecting with quicksilver; and the third, called the oyster syringe, for injecting minute preparations with the minute injection only.

The first consists of a brass syringe made for the purpose, of various sizes, from one carrying six ounces to one sufficiently large to hold two pounds. The point of these syringes is adapted to the pipes into which it is to be affixed. To this syringe belong a stop-cock, and a great variety of pipes.

The instrument for injecting quicksilver consists of a long glass tube, at whose end is fixed, by screwing in, a steel pipe, the end of which is extremely fine.

The oyster syringe is similar to the large syringe, except in size. It is so small, that when the syringe is in the hand, and full, its piston may be commanded by the thumb of that hand to throw its contents into any preparation in the other hand.

The pipe affixed by being screwed to the end of this syringe is nearly as small as that belonging to the quicksilver tube.

These instruments are always to be had at the surgical instrument makers.

INJECTIONS.

The injections employed for anatomical purposes are of four different kinds: coarse, fine, minute, and mercurial.

COARSE INJECTIONS.

Red. Yellow bees' wax, sixteen ounces—the palest resin, eight ounces—turpentine varnish, six ounces, by measure—finely levigated vermilion, three ounces.

Yellow. Yellow bees' wax, sixteen ounces—pale resin, eight ounces—turpentine varnish, six ounces—king's yellow, two ounces and a half.

White. Fine virgin's wax, sixteen ounces—pale resin, eight ounces—turpentine varnish, six ounces—best flake white, five ounces and a half.

Pale blue. Fine virgins' wax, sixteen ounces—pale resin, eight ounces—turpentine varnish, six ounces—best flake white, three ounces and a half—fine blue smalt, three ounces and a half.

Dark blue. Fine virgins' wax, sixteen ounces—pale resin, eight ounces—turpentine varnish, six ounces—blue verditer, ten ounces and a half.

Black. Yellow bees' wax, sixteen ounces—pale resin, eight ounces—turpentine varnish, six ounces—pure lamp-black, one ounce.

Green. Yellow bees' wax, sixteen ounces—pale resin, eight ounces—turpentine varnish, six ounces—levigated crystallized verdigrise, four ounces and a half—best flake white, one ounce—levigated gamboge, one ounce.

Liquefy the wax, resin, and turpentine varnish over a slow fire, in an earthen pipkin; then add the colouring matter, having previously mixed it in another pipkin, with a very small quantity of the melted composition. Stir the whole well together with a wooden pestle, so that the colouring ingredients may be intimately and smoothly blended; place the whole again over the fire, and, when they have acquired their due heat, the injection will be fit for use.

FINE INJECTIONS.

Brown spirit varnish, white spirit varnish, of each four ounces—turpentine varnish, one ounce.

These are to be put together in an earthen pipkin, over a slow fire, until they have acquired the necessary degree of heat. To make it of a red colour, put one ounce of finely levigated vermilion into another pipkin, and gradually add the heated materials, stirring the whole with a wooden pestle, that the colour may be equally diffused.

One ounce and a quarter of king's yellow—two ounces of best flake white—one ounce and a half of fine blue smalt, with one ounce and a quarter of best flake white—four ounces of blue verditer—half an ounce of pure lamp-black—are the proportions for the various colours to the quantity of ingredients ordered above.

MINUTE INJECTIONS.

The size, which forms the vehicle to the colouring matter in these injections, is made in the following manner:

Take, of the finest and most transparent glue, one pound, break it into small pieces, put it into an earthen pot, and pour on it three pints of cold water, let it stand twenty-four hours, stirring it now and then with a stick; then set it over a slow fire for half an hour, or until all the pieces are perfectly dissolved; skim off the froth from the surface, and strain it through a flannel for use.

Isinglass and the cuttings of parchment make an elegant size for very particular injections; and those who are not very nice may use the best double size of the shops.

Red. Size one pint—Chinese vermilion, two ounces.

Yellow. Size, one pint—king's yellow, two ounces and a half.

White. Size, one pint—best flake white, three ounces and a half.

Blue. Size, one pint—fine blue smalt, six ounces.

Green. Size, one pint—levigated crystalized verdigrise, two ounces—best flake white, levigated gamboge, of each eight scruples.

Black. Size, one pint—lamp-black, one ounce.

GENERAL OBSERVATIONS.

1. All injections are to be heated to such a degree as not to destroy the texture of the vessels they are intended to fill; the best criterion of this degree of heat is dipping the finger into the injection. If the finger can bear the heat, the texture of the vessels will not be hurt.

2. All the coloured materials should be as finely levigated as possible, before they are mixed with the injection.

3. Great care should be taken lest the oily ones boil over, or bubble; and that the heat be gentle, otherwise the colour will be altered.

4. They should be constantly stirred, lest the colouring material, which is much heavier than the vehicle, fall to the bottom.

5. The instrument to stir them with should be a wooden pestle, and there should be one for each colour.

6. A large tin pan to contain water, with two or three lesser ones fixed in it for the injections, will be found very useful, and prevent all accidents, and the colour from spoiling, when on the fire.

PREPARATION MADE WITH COARSE INJECTION.

The blood-vessels are mostly filled with coarse injection, and the parts dissected, to show their course; and when the

anatomist wishes to exhibit the minuter branches, the fine injection is to be thrown in first, and followed by the coarse.

GENERAL OBSERVATIONS.

There are several circumstances to be observed in injecting with the fine and coarse injections, which are applicable to every part into which they are thrown ; these are—

1. The part to be injected should be freed from its blood as much as possible, by steeping it for several hours in warm water, and repeatedly changing it.

2. Having emptied the part of its blood, the pipes are to be fixed in their proper vessels, and all other vessels to be tied with a ligature.

3. The heat of the water is then to be gradually increased to the same temperature with the injection to be thrown in.

4. The injecting syringe should be steeped in the water with the part to be injected, until wanted.

5. The injection being finished, and the subject cold, remove the pipes, and tie up the parts they were in. Whenever a vessel is open, by accident or otherwise, be sure to secure it by a ligature, or cover it with a piece of thin and moist bladder, or the injection will always be oozing out.

6. The parts dissected and dried are to be varnished twice with copal or hard varnish, first washing them free from grease with some soap lees, and well drying them again.

BLOOD-VESSEL SUBJECT.

Select an emaciated subject, between the age of two and fourteen years.

Preparation. Make an incision through the integuments the whole length of the sternum ; then, with a saw, divide the sternum longitudinally into two equal parts ; introduce a dissecting knife under the divided bone on each side, separate it from the mediastinum, and lay open the thorax, by bending back the two portions of the sternum and the cartilages of the ribs : an incision is then to be made into the pericardium, and the left ventricle of the heart, and a large pipe introduced into the aorta, and secured by a ligature. The subject is next to be put into warm water, and gradually heated. The time generally required to heat the whole subject is four hours, in a large body of water.

If the veins are to be injected, three more pipes are required : one to be put into the angular vein, at the corner of the orbit ; another into a vein as near the fingers as possible ; and the third into a vein as near the toes as possible.

Injection. The subject and injection being properly heated, throw the coarse red injection into the heart pipe, which will fill the arterial system; and then the coarse yellow injection into the head pipe first, and next into the pipes of the extremities. The subject, when injected, should be put into cold water, with its face downwards.

Dissection. Open the abdomen by an incision from the sternum to the umbilicus, and from thence to each ilium. Cut away the abdominal viscera, the stomach, spleen, and intestines, leaving the mesenteric vessels as long as possible: dissect away the liver, leaving the vena portæ and hepatic artery as long as possible. This done, dissect away the fat and cellular membrane from the vessels; secure the mesenteric vessels in an arborescent form on a piece of pasteboard. The kidneys, urinary bladder, uterus, and its appendages, are to be preserved and dried in their situations. From the thorax are to be removed, the lungs and heart, or the latter may remain. The integuments being carefully dissected from the sternum, it is to be bent back, and kept in that situation, to expose the internal mammary arteries. The dissecting away the skin is next, in order to exhibit the muscles, and expose the arteries and veins. The skin should only be removed from time to time to carry on the dissection, and never more than that covering the part to be dissected; otherwise the parts from which the skin is removed will become dry, and the dissection be spoiled. In dissecting the arteries and veins, the dissector will find no difficulty, if he proceeds cautiously from the larger trunks towards their extremities. The brain is to be removed by sawing away a large portion of the bone on each side of the longitudinal sinus of the dura mater. The cheeks should be pushed out by introducing horse hair into the mouth.

Drying. When dissected, or before, the subject should be hung up by the head in a frame: one arm is to be placed at a little distance from the side, and the other turned up over the head, with the palm of the hand in front; the legs at a little distance from each other, and kept in these postures by packthread. Should any muscles obstruct the sight of the arteries, they are to be separated to a proper distance by pieces of wood. This done, expose it to a current of air, in a place where it cannot get wet; and if the weather be moist, remove, from time to time, all moisture, by a soft spunge.

Preservation. Varnish it several times, and keep it in a dry place, and in a proper case, with a glass front and back.

A HEAD, FOR ARTERIES AND VEINS.

Choose an emaciated head of an adult, separated from the body, by a transverse section, about the sixth or seventh vertebra.

Preparation. Put a pipe into each carotid, or, what is better, one pipe with a bifurcation; remove a portion of bone over the longitudinal sinus of the dura mater, about the middle of the parietal bones, and secure a pipe in the longitudinal sinus, pointed towards the occiput. Put the head into warm water, to soak, pressing the blood occasionally out of the external and internal jugulars. Then tie up the jugular veins and vertebral arteries, and all the small vessels.

Injection. Into the carotids throw the red injection, and the yellow, or dark blue, into the pipe in the sinus of the dura mater. The former will fill the arteries, the latter the veins.

Dissection. Follow the course of the larger trunks, dissect out the globes of the eyes, and remove, with a fine saw, the portion of the jaw-bone behind the last molaris, to show the course of the internal carotids. To prepare the whole head, a portion of the cranium must be removed, by sawing on one side of the longitudinal sinus of the dura mater from the frontal sinus to the horizontal spine of the occipital bone, and then sawing horizontally above the ear, from one extremity of the former incision to the other. The dura mater should be removed with a pair of scissars, the brain carefully washed out, and the tentorium and falx preserved. It is better to make a perpendicular section of the head, a little to one side of the sagittal suture, through the nose, foramen magnum, and vertebræ; and thus prepare each side. The course of the cervical artery is to be shown by dissecting away the muscles, &c. from between the transverse processes.

Preservation. Varnish it several times, and keep it in a glass case, suspended; or fix it by the neck, and cover it with a glass bell.

AN ARM, FOR ARTERIES AND VEINS.

Remove the superior extremity from the trunk, by separating the clavicle from the sternum, raising it, and passing the knife under it to the articulation, including the greater part of the pectoral muscle. Then cut under the scapula, so as to remove with the arm the clavicle, scapula, and subscapularis muscle.

Preparation. After soaking it in warm water, force out the blood from the veins, by pressing the extremity from the fingers toward the shoulder. Fix a pipe in the axillary artery, and another in the largest vein on the back of the hand; some warm water may be injected into the vein, so as to wash out the blood; and, when pressed out, the axillary vein should be tied. Tie any muscular branches that may be gaping.

Injection. Red injection may be thrown into the artery, and yellow, or dark blue, into the vein.

Dissection. This is very simple; it requires only the remo-

val of all the cellular and fatty membrane, and exposing the course of the vessels. Tie up the limb by the clavicle.

Preservation. When varnished, keep it in a cool and dry place.

A LOWER EXTREMITY, FOR ARTERIES AND VEINS.

Having removed the contents of the abdomen, make a section through the symphysis of the pubis, and the ligaments connecting the ilium and sacrum, so as to remove one side of the pelvis.

Preparation. Fix a pipe in a vein as near the toes as possible, and another in the iliac artery. When the limb has been well soaked in warm water, press out the blood from the veins, or throw in some warm water at the venal pipe; but carefully press it out again, and tie up the iliac vein. Secure all divided vessels.

Injection. Blue injection, or yellow, may be put into the vein, and red into the artery.

Dissection. Expose the course of the artery and veins, particularly the profunda of the thigh.

THE GRAVID UTERUS, FOR ARTERIES AND VEINS.

The gravid uterus, or the uterus soon after it has expelled the fœtus, may be injected, to show its large and tortuous vessels.

It may be injected whilst in the body: but this is always attended with much difficulty, and never succeeds so well as when removed from the body. Therefore separate the spermatic and hypogastric vessels as far from the uterus as possible, and cut out the uterus with the bladder, vagina, and external parts of generation.

Preparation. Put a pipe in each spermatic artery, and each hypogastric, and also one into each spermatic and hypogastric vein; so that, at least, there will be four pipes for arteries, and four for veins, necessary. Be very careful that all the divided vessels be secured by ligature, which only can ensure success.

Injection. Red and yellow are mostly preferred; the former for the arteries, the latter for the veins. Be careful that the red be thrown into all the arterial pipes, and the yellow into the venal; and, to prevent mistakes, it will be better to have the pipes of the veins different from those of the arteries.

Dissection. Distend the vagina and uterus with horse hair, either by introducing it through the vagina, or, if the fœtus

be in it, by a perpendicular section through the anterior parietes, which is to be sewed up again. Then dissect away all loose cellular structure and fat, preserving the round and broad ligaments, and Fallopian tubes. Should the fœtus be in the uterus, an incision should be made, as above directed, except the placenta be adhering there, which is known by the great number of vessels, and then on the opposite side, and through the membranes, to remove the child; cut the umbilical cord close to the fœtus, and fix a pipe in one umbilical artery, and another in the umbilical vein; the latter, carrying arterial blood, should be filled with red injection, and the artery with yellow; the cord is to be laid round the placenta.

Preservation. When well varnished, suspend it in a case, with a glass front and back.

A PLACENTA, FOR ARTERIES AND VEINS.

This is perhaps the easiest preparation to make with coarse injection, and should, therefore, be the first attempt of the student.

Preparation. Fix a large pipe in the vein, and a small one in one of the arteries. The difficulty usually attendant on getting the pipe into the artery is obviated in a great measure by introducing the point of the scissars into these vessels, and slitting them down for about half an inch, then spreading the artery open upon the fore-finger, and keeping it so by pressure with the thumb, by which the pipe may be carried in without difficulty. A ligature should be passed round each pipe with a needle, taking care not to puncture any of the vessels.

Injection. The usual colours are to be selected; but instead of throwing the yellow into the vein, it should be pushed into the artery, for the artery here performs the function of a vein, and *vice versa*. When there are two placentæ, there should be different colours used.

Dissection. The spongy substance is to be carefully dissected away from the injected vessels, the placenta soaked in cold water, to get rid of its blood, and then dried, curling the cord around it; and should the membranes not be much torn, they may be distended with curled hair over it.

Preservation. Varnish it well; fix its bottom in a case with a glass top.

THE HEART, IN SITU; WITH THE HEAD AND ADJACENT VESSELS.

For this purpose choose the head of a young subject, or an adult whose heart is free from fat. The liver, stomach, spleen, &c. are to be removed from the abdomen, and the

aorta divided just as it gives off the cœliac artery. The incision into the chest should be carried through the integuments, from the trachea to the ensiform cartilage, the sternum sawed through, and bent one half on each side, from the extremity of the cartilages nearest the ribs; then divide one of the pulmonary veins as near as possible to the lungs, and remove a portion of bone over the longitudinal sinus of the dura mater.

Preparation. Having well soaked the parts in warm water, and squeezed the blood from the heart and vessels, by the inferior cava and pulmonary vein, put a pipe into the longitudinal sinus of the dura mater, pointed towards the occipital bone, another into the pulmonary vein, a third into the vena azygos, and one into the receptaculum chyli, or thoracic duct. Tie up carefully the aorta and the vena cava inferior, and put a strong ligature around the middle of each arm.

Injection. Three colours are required;—one for the arteries, which should be red; another for the veins, which may be yellow or blue; and the third for the thoracic duct, which should be white, to imitate chyle. Throw the red injection into the pipe in the pulmonary vein, which will fill the left auricle, ventricle, aorta, and all the arteries. The pipe in the head is for the yellow injection; by this will be filled the veins of the head, face, neck, and chest, the right auricle of the heart, the right ventricle, and the pulmonary arteries. Should the vena azygos not be injected, the yellow injection is to be thrown into it. A small quantity of white injection is sufficient for the thoracic duct.

Dissection. Remove the body by a transverse section at the last dorsal vertebra, then amputate the arms at their middle, saw away one side of the bones of the scull, and wash away the brain: then dissect away all the loose cellular membrane and fat, and expose the various parts in the best manner; dissect away the lungs, leaving the pulmonary arteries as long as possible.

Preservation. This is, when well done, a valuable preparation, and deserving of great care. Varnish it well, and preserve it in a square glass case.

A FOETUS, TO EXHIBIT THE PECULIARITIES OF ITS CIRCULATION.

For this purpose select a still-born fœtus; and, if possible, one that died from a flooding of the mother.

Preparation. Dissect the umbilical vein from the arteries, about four inches from the umbilicus, and fix a pipe in it, taking care not to include the arteries. Throw warm water into this pipe, and wash out the blood, which will flow out by the umbilical arteries. Having drained away as much of the

water as possible, tie a ligature very loose on the umbilical arteries.

Injection. The fœtus being heated, throw in gently any coloured injection. The water will come away first through the umbilical arteries; and, when the injection appears, make the ligature firm, to prevent its further egress.

Dissection. The peculiarities in the fœtal circulation are the umbilical cord, the ductus venosus, the ductus arteriosus, and foramen ovale. When the body is cold, proceed to the dissection; remove the head from the cervical vertebræ, the arms, with the scapulæ, and pectoral muscles; the inferior extremity at the articulation with the pelvis, the whole of the parietes of the abdomen, leaving the arteries running to the cord by the sides of the bladder; the anterior part of the thorax, with the sternum, cartilages, and part of the ribs, the integuments and muscles of the back. Next cut away the lungs, and remove the pericardium; keep the diaphragm in its place, and turn up the liver, so as to expose the ductus venosus. Some dissection and care is here necessary. Dissect away the stomach and intestines, and lay out the mesenteric vessels, distend the bladder with air, and cut away any thing that may obstruct the view of the vessels. The foramen ovale cannot be exhibited.

Preservation. After having varnished it, hang it in a glass bell, with a hook at its top.

PENIS.

The penis may be injected, to show the two corpora cavernosa, the corpus spongiosum, and glans, with the arteries and veins. For this purpose any healthy penis will do, but large ones are generally preferred. Having cut through the integuments and soft parts in the pelvis, in the direction the saw is to be passed, saw through the middle of each crista of the pubis, straight down and through the ascending ramus of each ischium, close to their commencement, and thus remove the pubis, with the bladder and external parts of generation.

Preparation. Make an incision into either of the crura of the corpora cavernosa, and into the bulbous part of the urethra, as near to the prostate gland as possible; soak it in hot water, and carefully press out the blood from every part. Introduce a probe along the vena magna ipsius penis, by an incision at its root, to break down its valves: fix a pipe in each of these incisions, and another in each vas deferens, at its entrance into the vesiculæ seminales, and secure all the divided vessels.

Injection. Four colours are necessary; those generally preferred are red, yellow, blue, and white. Throw the red into the corpus spongiosum, which will distend the glans; the yel-

low into the corpus cavernosum pipe; the blue into the vena magna ipsius penis; and the white into the vasa deferentia.

Dissection. Inflate the bladder, dissect away all the soft parts, and keep the penis erect against the symphysis pubis.

Preservation. In a covered box.

TESTICLE.

A testicle of an adult should be chosen free from disease, and great care is requisite in removing it from the body. First, enlarge the ring of the oblique muscle, push the testicle through from the scrotum, and separate its cellular connecting substance; then cut the spermatic artery and pampiniform plexus as high as possible, and then the vas deferens.

Preparation. When well soaked, press out the blood from the veins; put a pipe into the spermatic artery, and another into a vein; and secure all other open mouths.

Injection. Red is to be sent into the artery, and yellow or blue into the vein, which is without valves. Then fix the quicksilver tube in the vas deferens, and suspend it in water; this done fill it with mercury, and in twenty-four hours it may be removed to be dissected.

Dissection. Cut away the tunica vaginalis, and the tunica albuginea, which requires great care: then remove all the cellular and adipose membrane, and dry it on a board previously waxed.

Preservation. In a common preparation glass, on a blue or green paper ground.

THE SYSTEM OF THE VENA PORTÆ.

Remove the liver, spleen, stomach, and intestines altogether, of a person whose mesentery is free from fat, cutting away at the root of the mesentery, behind the peritoneum.

Preparation. Cut into a mesenteric vein, as near to the intestine as possible, and secure it with a ligature passed around it with a needle, taking care not to wound any other vein. Inject warm water, and let it again run out by the divided vessels. Drain its water off, and secure all the veins, the hæmorrhoidal especially.

Injection. Throw any colour into the pipe, which will pass into the splenic, mesenteric, and internal hæmorrhoidal vein, and into the vena portæ.

Dissection. Remove all the soft parts; the stomach, spleen, and intestines; cutting the vessels as long as possible, and dry them in the best manner, either attached to the liver, or dissect away the liver from the vena portæ, taking care to preserve some of its ramifications.

Preservation. In a covered box.

HEART.

The heart is mostly injected out of the body, to show its common and proper vessels. For this purpose, choose a lean heart. Cut through the thoracic viscera immediately at the top of the thorax; divide the intercostal arteries by drawing the knife down the pleura, over the ribs beyond their origin, separate the vena cava inferior and aorta, in the abdomen, with the cavæ hepaticæ; and remove the thoracic viscera, with the portion of the diaphragm surrounding the vessels.

Preparation. Soak the blood and coagula out of the cavities of the heart, and press the blood from the coronaries. Put a pipe into the vena cava superior, and another into one of the pulmonary veins. Then tie the lungs at their root, the vena cava inferior, the arteria innominata, the left carotid and subclavian; and pass a ligature, with a slip knot, round the sinus of the aorta, and secure all other open vessels.

Injection. The common coloured injections, red and yellow, only are wanted. Throw the former into the pulmonary vein, which will fill the left auricle, ventricle, aorta, and coronary arteries. The yellow, being sent into the superior cava, will distend the right auricle, coronary veins, right ventricle, and pulmonary artery. In order to fill the coronaries well, the injector must stop two or three times in the course of the process, to squeeze on the injection in them with his nail; then heat the whole again, and throw in more injection. The preparation having cooled, a pipe is to be fixed at the bottom of the aorta, and some red injection, just hot enough to run through the syringe, is to be pushed along the aorta, an assistant throwing cold water on the intercostals, if the injection runs through them.

Dissection. Cut away the lungs, pericardium, and all the soft parts.

Preservation. Either in a covered box, or under a glass bell.

STOMACH. INTESTINES. BLADDER.

These are best injected with the whole subject, but may be removed and injected separately.

GENERAL OBSERVATIONS.

1. The anatomist can only succeed by having the preparation constantly heated as he is throwing in the injection.
2. The injection should be thrown in very gradually.
3. When injected, the part should be immediately immersed in cold water.

PREPARATIONS WITH MINUTE INJECTION.

BONES.

The vascularity of bones is to be demonstrated, by throwing fine injection into an extremity, cutting out the bone when cold, separating it from all the soft parts, immersing it in water for a few days, to soak out the blood, and then putting it into a mixture of muriatic acid and water in the proportion of one ounce to a quart, for three or four months, adding about, every month, a drachm of acid. The limb of a ricketty child is to be chosen.

Injection. Put a pipe into the largest artery of the extremity, and throw gradually the red injection into it, fixing the stop-cock in the pipe.

A FOETUS.

Still-born children, when injected with minute injection, afford a number of beautiful preparations.

Preparation. No water should be thrown into the vessels. Fix a pipe with a stop-cock into the umbilical vein, and tie the arteries in the ligature.

Injection. Red injection is always chosen for this purpose; and throw it in with great care, until the abdomen and skin all over become very tumid. First mucus comes from the nose and mouth, then the meconium from the anus, and often pure size.

Dissection. Cut off the head from the shoulders, the arms below the shoulder joint, and the legs just below the acetabulum; then preserve a small quantity of the integuments around the navel, and remove all the anterior parietes of the abdomen and chest, so as to exhibit the thoracic and abdominal viscera. Cut away the integuments and posterior part of the theca vertebralis, to exhibit the medulla spinalis.

Preservation. Soak out the blood, and preserve it in proof spirit, to show the viscera and their vascularity.

From a well-injected fœtus may be obtained the following preparations.

1. If the fœtus be about seven months old, the *membrana pupillaris.*
2. If it be male of this age, the *testicle* in the abdomen, with the *gubernaculum.*
3. The *vascular* and radiated fibres of the *parietal bones.*
4. The *vascular membrane*, including the *teeth.*
5. The *viscera of the chest* separate, if better injected than those of the abdomen, showing the vascularity of the lungs, thymas gland, and heart.

6. The *stomach*, which is to be inverted, to show its vascular *villous coat.*

7. The *intestines*, which are to be separated from the mesentery, and inverted, to show their *villous coat.*

8. The *glandulæ renales* and *kidnies* together, to exhibit their relative size, and the lobulated structure of the kidney.

9. The *uterus and its appendages*, to show the long ovaria and plicæ of the neck of the uterus and vagina.

10. The external parts of the female organs of generation, to show the *hymen.*

11. A red portion of the *skin*, to exhibit its vascularity.

12. The *medulla spinalis*, to show its vessels, and the *caudæ equina.*

13. The *membrana tympani*, to exhibit its vascularity.

14. The *cavity of the tympanum*, to show its vascularity, and that of the periosteum of its bones.

15. The *vestibulum and cochlea*, to show the membranous semicircular canals of the former, with their ampullæ injected, and the vascularity of the zona mollis.

16. The *head*, to show the natural appearance of the face, the papillæ of the lips, tongue, &c.

17. The *hand*, to show its natural colour.

Preservation. The above preparations are all to be well soaked from their blood, and preserved in proof spirit of wine.

18. A portion of *skin*, freed of its adeps, to show its vascularity.

19. The *membrani tympani*, to show its vessels.

20. The *heart*, to show the foramen ovale, by distending the cavities with air; and, when dry, cutting away the outermost sides of the auricles, and introducing a bristle.

21. Any large muscle, freed from its cellular membrane and fat, and dried, to show the *vascularity of the muscle.*

Preservation. These are all to be dried, well varnished, and preserved in bottles. Some prefer putting them into spirit of turpentine; but this should be avoided as much as possible, for the turpentine is always oozing in warm water, and dirtying the glass.

UTERUS.

The object of injecting a uterus with fine injection is to exhibit the vascularity of its internal membrane, which furnishes the catamenia. For this purpose the uterus of a person whose menstruation has not been stopped by age or disease is to be selected.

Preparation. Remove the uterus, by dividing the vessels as long as possible, the round and broad ligaments, and as much as possible of the vagina. Tie a pipe in each hypogastric artery, and secure all the divided vessels.

Injection. Any coloured injection may be chosen, but red looks best.

Dissection. Cut away all the loose cellular membrane, bladder, and rectum, if there be any, from around the vagina, and cut it open along the middle of its superior part; continue this incision on each side of the anterior part of the uterus, so as to exhibit the posterior surface of its cavity.

Preservation. If the injection be successful, which it seldom is more than one time in ten, suspend it by the ligaments, and preserve it in the proof spirit.

AN ADULT HEAD.

Separate the head as low as the last cervical vertebra from the shoulders.

Preparation. Put a bifurcated pipe into the carotids. Secure the vertebral arteries and jugular veins, and all the divided parts.

Injection. The red injection is always preferred.

From an adult head injected in this way may be made the following preparations:

1. The upper eyelid, to show the vascularity of *Meibomius's glands.*
2. The *choroid membrane*, exhibiting its vascularity.
3. The *retina*, suspended by the optic nerve, exhibiting its vascularity.
4. A section of the optic nerve, to exhibit the *central artery.*
5. The whole of the *cerebrum*, *cerebellum*, and *medulla oblongata*, with the pia mater; or,
6. The pia mater separated from the convolutions of the brain, to exhibit the *intergyral processes* and the *tomentum cerebri.*
7. One half of the nostrils, to exhibit the vascularity of *Schneider's membrane*, and that of the membrane lining the antrum of Highmore.
8. The *tongue*, lying in the jaw, and suspended by the *palatum molle*, with the posterior fauces cut away, to show the *epiglottis* and *glottis*, the *uvula* and *velum pendulum palati*, the tongue, its papillæ and excretory ducts, and the vascularity of the gums and *sublingual glands.*

Preservation. The above preparations are to be soaked well in cold water, to get out all the blood, and then preserved in proof spirit.

PREPARATIONS WITH QUICKSILVER.

Mercury cannot be coloured by any substances; it must, therefore, always present the same silver colour.

GENERAL OBSERVATIONS.

1. The part should always be injected in a proper tray, that the mercury may be easily collected.

2. A lancet, with a curved needle ready threaded, should be always at hand.

3. A bottle, whose neck is not so wide as to permit the quicksilver tube going to the bottom, when put into it.

4. When injecting, if any circumstance renders it necessary for the injector to put aside the tube with the mercury, it should be placed in the bottle, the mercury remaining in it, to be handy and prevent delay.

5. Injecting with mercury is always tedious, and frequently unsuccessful. The parts exposed must be kept moist, by sprinkling them with cold water.

A SUPERIOR EXTREMITY.

To inject the lymphatics of an arm, choose one from a dropsical subject, without fat; make an incision into the skin around the wrist, and seek diligently, with a magnifying glass, for an absorbent, into which the pipe is to be put, when the quicksilver will immediately run. The shoulder should now be placed considerably lower than the hand; and, when the mercury runs out at the divided vessels in the axilla, tie them up, and also the lymphatic, into which the pipe was introduced. Then seek for another absorbent. When the mercury ceases to run in a lymphatic, tie the vessel, and seek for another.

Dissection. Begin at the lymphatics, where the mercury entered, and trace them; removing every thing that obstructs their view, but preserve the glands.

AN INFERIOR EXTREMITY.

The limb for this purpose should also be taken from a dropsical person, and the same method adopted as with the superior extremity, seeking as near to the toes as possible for the lymphatics.

A PAROTID GLAND.

Cut down upon the masseter muscle, and seek for the Stenonian duct, which is the excretory duct of the parotid. Tie the quicksilver pipe in it, then fix the tube, and pour into it the quicksilver; and, when it ceases to run, remove the tube and pipe, and tie the duct. Be particularly careful, in dissecting away the gland, not to cut it.

Preservation. Dry it on a waxed board, and preserve it on a blue paper and pasteboard, in spirit of turpentine.

LIVER.

The lymphatics running on the peritoneal coat of the liver, and over the gall-bladder, make a beautiful preparation. The liver should be well soaked for several days, and the pipe put into the lymphatics of the suspensory and coronary ligaments, and the mercury forced along them, breaking down the valves with the nail, by pressing on the mercury. Secure the vessels at the portæ of the liver, when the mercury gets there, and tie the lymphatics when filled. Should the anatomist's attempt to force the quicksilver beyond the valves be unsuccessful, he must fix upon the most minute obvious branch, and let it run its proper course.

Preservation. Throw some coarse injection into the cavæ hepaticæ and vena portæ, without heating the liver thoroughly; inflate the gall-bladder, and dry the whole. Varnish it, and preserve it in the best manner under a glass bell, or preserve the injected part in proof spirit, without any wax injection.

LUNGS.

The superficial lymphatics of the lungs are to be filled from the part most remote from the root of the lungs.

Preservation. Cut away the part on which the lymphatics are filled. Dry it on a waxed board, varnish it, and preserve it in a bottle, on a green or blue piece of paper; or preserve it in proof spirit, without drying it.

HAND.

Select the hand of an aged female (separated from the arm by a transverse section, three inches above the wrist) that has died of a lingering disease. Soak out the blood in warm water; fix the pipe in the radial artery, then add the tube, and pour into it the mercury. As the mercury appears in the other arteries and veins, take them up and secure them with ligatures. Should the mercury still escape from small branches, put a cord round the arm, and with a piece of wood tighten it, by twisting the wood, taking care not to prevent the mercury passing into the hand. Then suspend the hand in a glass filled with water, and suspend also the tube and quicksilver in the manner represented in the annexed plate, for a day or two, that the mercury may get into the small vessels. When injected, remove the pipe, and tie, by a strong string,

the fore-arm; put the hand into water, until putrefaction separates the cuticle.

Preservation. Dry it carefully, and varnish it; then fix the fore-arm in a pedestal of plaister of Paris, and keep this beautiful preparation under a glass bell.

LACTEALS.

Remove the mesentery and intestines, if the former be perfectly free from fat, and let them remain several days in water, which should be frequently changed. Search for an absorbent, on the intestine, into which introduce the quicksilver, which will run on to the glands in the mesentery, where it will stop. When the lacteals are filled, the preparation will be more elegant if red and yellow coarse injection be thrown into the mesenteric arteries and veins.

Preservation. Spread the mesentery on a waxed board, inflate a portion of the intestine, clear away all that is useless; dry and varnish, and preserve it in a glass frame.

CORRODED PREPARATIONS.

These preparations are made by filling the vessels with coarse injection, and corroding the soft parts, so as to exhibit those vessels.

GENERAL OBSERVATIONS.

1. The liquor for corrosion is to consist of three parts of muriatic acid, and one of water.
2. The liquor should be kept in a well-glazed earthen vessel, with a top to it, also well glazed.
3. The part to be corroded should be carefully moved in and out of this liquor, as the slightest force may break the vessels.
4. When corroded, the pulpy flesh is to be carefully washed away, by placing it under a cock of water, the water flowing very slowly; or, in some instances, by squirting it away.
5. When the preparation is freed of its flesh, it should be fixed in the situation it is to remain in, either in a plaister of Paris pedestal, or on a flat surface.
6. If the flesh be not perfectly destroyed, the preparation is to be returned to the corroding liquor for a fortnight or month longer, or until it becomes pulpy.

HEART AND LUNGS.

These viscera, occupying less space in children than adults, are to be preferred. It is of no consequence whether they are fat or lean. The integuments should be cut from the fore part of the neck; and the trachea, jugular veins, and carotid arteries removed, and, with them, the viscera of the thorax, carefully separating the subclavian vessels from the clavicle, without injuring them, and dividing the axillary vessels and the cava inferior and aorta, just below the diaphragm.

Preparation. Soak the whole well, to free it of its blood, and press out all the fluids fix a pipe in the inferior cava, and another in one of the pulmonary veins, taking care not to injure the others, by tying it. Then secure the carotids, the jugulars, the axillary vessels, the vertebral artery, the intercostals, the aorta, after it has formed its arch, the internal mammaries, and every vessel that can be found.

Injection. Red and yellow are generally preferred, but red and blue are more proper, and more elegant. Throw the blue into the vena cava inferior, which will distend the right auricle, the superior cava, the jugular veins, and great coronary vein, the right ventricle, and pulmonary arteries. The red injection will fill the left auricle and pulmonary veins, the aorta, subclavians, carotids, &c.

Preservation. Great care is requisite in freeing the injection from the pulpy flesh. When done, let the apex of the heart be placed immediately in a plaister of Paris pedestal, and cover it with a glass. If the pulmonary vessels are well preserved, it forms a valuable preparation. If one good preparation be obtained in ten trials, it will amply repay the anatomist.

HEART.

A fat heart will do for this purpose. Inject it as directed in page 317, and it put into the corroding liquor.

Preservation. Lay it on some cotton, on a pedestal, and cover it with a glass.

LIVER.

The liver of a child is to be preferred to that of an adult, it occupying much less room: its vessels should be cut long, and with it the portion of the duodenum, perforated by the bile duct.

Preparation. Fix a pipe into the hepatic artery, another

into the vena portæ, a third into the ductus communis choledochus, and a fourth into the vena cava hepatica.

Injection. The four injections are to be red, yellow, dark blue, and light blue. First, throw the red injection into the hepatic artery, next the dark blue into the vena portæ, then the light blue into the cavæ hepaticæ, and, lastly, the yellow into the ductus communis choledochus.

Preservation. Remove the pipes as soon as the injection will permit; and, when corroded, fix the trunks in the best manner possible, upon a proper pedestal: then wash away the flesh, dry it, and cover it with a glass.

KIDNEY.

Choose the kidney of an old drunkard. Cut the emulgent vessels close to the aorta and cava, and the ureter, very low; then remove the kidney, with its surrounding adeps.

Preparation. Soak out the blood, and press out all the fluid. Fix a pipe in the emulgent artery, another in the vein, and a third in the ureter; and tie up all the open-mouthed vessels.

Injection. Red, blue, and yellow. First throw the yellow into the vein, then the red into the artery, and, lastly, the blue into the ureter.

Preservation. Under a glass bell.

The kidneys of different animals form a beautiful exhibition.

FINIS.

A. FINLEY AND W. H. HOPKINS,

No. 170, *MARKET-STREET*,

HAVE LATELY PUBLISHED

THE

LIFE OF PETRARCH,

COLLECTED FROM

MÉMOIRES POUR LA VIE DE PÉTRARQUE,

BY MRS. DOBSON.

Rarò magni errores nisi ex magnis ingeniis prodiere.
Petrarch.

Thrice happy minds that feel the power of friendship!
Oft do the Muses, on a beauteous eve,
The sky serene, and drowsy Nature hush'd,
Vouchsafe celestial sounds to friendly ears,
And raise their kindred minds with such
Warm fancy, and ethereal forms,
As 'scape the vulgar intellectual eye.
Why need I launch into the praise of friendship?
Friendship, that best support of wretched man!
Which gives us, when our life is painful to us,
A sweet existence in another's being.

First American, from the seventh London edition.

In two volumes, ornamented with two elegant engravings.

To this edition is added a Translation of several of Petrarch's Sonnets and Odes, not in the London edition.

THEY ARE PUTTING TO PRESS

A

DICTIONARY OF QUOTATIONS

IN MOST FREQUENT USE,

TAKEN CHIEFLY FROM THE

LATIN AND FRENCH,

But comprising many from

THE GREEK, SPANISH, AND ITALIAN LANGUAGES,

TRANSLATED INTO ENGLISH.

With Illustrations, historical and idiomatic.

BY D. E. MACDONNEL,

OF THE MIDDLE TEMPLE.

"He has been at a feast of languages, and stolen away all the scraps." *Shakspeare.*

This compilation is intended *chiefly* for the assistance of the *English reader* (though it will very readily be perceived, that its utility is by no means confined to such), who, not being acquainted with other languages, is interrupted and embarrassed, even in the perusal of the daily journals, by such phrases as the following: *bellum internecinum*, —*hors de combat*,—*statu quo*,—*tout ensemble*,—*sine qua non*,—*je ne sais quoi*,—*uti possidetis*, &c. which, with many thousands of others of greater length, will be found in this work, and the reference is as easy as to any abstruse word in Johnson's Dictionary. To such readers this work will give information *not to be found elsewhere.*

Med. Hist.
WZ
270
H787l
1809
c.1