C. 2. 11

Chas. D. Nobles

ANATOMY,

DESCRIPTIVE AND SURGICAL.

BY

HENRY GRAY, F.R.S.,

FELLOW OF THE ROYAL COLLEGE OF SURGEONS; LECTURER ON ANATOMY AT ST. GEORGE'S HOSPITAL MEDICAL SCHOOL.

A NEW EDITION, THOROUGHLY REVISED

BY

AMERICAN AUTHORITIES,

FROM THE

THIRTEENTH ENGLISH EDITION

EDITED BY T. PICKERING PICK, F.R.C.S.

WITH 772 ILLUSTRATIONS, MANY OF WHICH ARE NEW.



LEA BROTHERS & CO.,
PHILADELPHIA AND NEW YORK.
1897.

QS
4
G779an
1897
Film no. 11065, Item 1

Entered according to Act of Congress, in the year 1897, by
LEA BROTHERS & CO.,
in the office of the Librarian of Congress at Washington. All rights reserved.

WESTCOTT & THOMSON,
Stereotypers and Electrotypers, Philada.

WILLIAM J. DORNAN,
Printer, Philada.

TO

SIR BENJAMIN COLLINS BRODIE, BART.,

F.R.S., D.C.L.,

SERJEANT-SURGEON TO THE QUEEN,

CORRESPONDING MEMBER OF THE INSTITUTE OF FRANCE,

This Work is Dedicated

IN ADMIRATION OF

HIS GREAT TALENTS

AND IN REMEMBRANCE OF

MANY ACTS OF KINDNESS SHOWN TO THE AUTHOR

FROM AN

EARLY PERIOD OF HIS PROFESSIONAL CAREER.

PUBLISHERS' NOTE TO THE NEW AMERICAN EDITION.

In his masterpiece Henry Gray left undying evidence of his anatomical knowledge and of his comprehension of the best method of imparting it to other minds. After forty years its merits are only brightened by the numerous works which have endeavored to contest its supremacy. During that time it has had the benefit of the careful scrutiny of many leading anatomists of the English-speaking race. Anatomy is far from stationary, either in its facts or in improvements in the method of their presentation; hence any work which would faithfully reflect the existing position of the science must be revised at comparatively frequent intervals. Fortunately for students and practitioners, *Gray's Anatomy* enjoys a demand rendering such revision possible.

An evidence of the unremitting attention bestowed on this book is afforded in the issue now presented. Its basis is found in the revision of 1896 by Professor J. Playfair McMurrich and Dr. B. B. Gallaudet. The new chapters on the Brain and the Abdominal Viscera by Dr. Gallaudet and Dr. F. J. Brockway, respectively, have been retained. The section on the Mouth and Teeth has been rewritten by Prof. H. H. Burchard, who has taken account of the latest advances in the highly specialized department which particularly concerns students and practitioners of Dentistry.

The splendid illustrations in *Gray* have long been known as the most effective and intelligible presentations of anatomical structures ever produced. In the edition of 1896 this series was increased by the addition of one hundred and thirty-five new pictures. The total of seven hundred and seventy-two illustrations stands unchanged in the new issue, but it includes a large number of new engravings, no expense having been spared to effect improvement wherever possible.

The practical application of anatomical facts in medicine and surgery has always been a prominent feature of the work, and this distinctive characteristic has received especial care.

In short, this edition is presented to the medical public with the confident expectation that it will be found worthy in every respect to maintain the exalted position which the work has for so many years enjoyed as the most convenient and intelligible exposition of its subject.

PREFACE TO THE THIRTEENTH ENGLISH EDITION.

When Henry Gray published this work in 1858, he entitled it *Anatomy, Descriptive and Surgical*, and he introduced under each subdivision such observations on practical points of Surgery as show the necessity of an accurate acquaintance with the anatomy of the part under examination. This was the first time that such an endeavor had been made by an English Anatomist.

The Editor has endeavored to follow in the lines originally laid down by the Author, and has tried to keep before himself the fact that the work is intended for Students of Surgery rather than for the Scientific Anatomist. Not that the Editor would wish to disparage, for an instant, the study of Philosophical or Scientific Anatomy, but that he thought it right, considering the class of students for whom the work is primarily intended, that he should be practical rather than abstract and theoretical. Accordingly, he has not altered in any way the original plan of the work, but has endeavored to render it more practical, and of more use to the student, who will hereafter have to apply his knowledge of Anatomy to his practice of Surgery, by introducing a considerably increased amount of Surgical Anatomy, and by pointing out the bearings of Anatomy on the practice of Surgery.

In addition to this, the whole work has undergone a careful revision, and in some minor details a rearrangement has been made.

The Editor is deeply indebted to his friend Mr. Ross for much kind assistance in the preparation of this edition, and also for the help that he has rendered him in passing these pages through the press.

To Dr. Leonard Remfry he is also much indebted for his kindness in revising the section on the anatomy of the Female Organs of Generation.

Several new illustrations have been added, principally from dissections in the Hunterian Museum of the Royal College of Surgeons. The Editor takes this opportunity of thanking Prosector Pearson for the kind interest he has displayed and assistance he has rendered in the preparation of these drawings, which were taken from dissections made by this master in the art of dissecting.

CONTENTS.

GENERAL ANATOMY.

	PAGE
The Blood	33
The Lymph and Chyle	37
The Animal Cell	38
Epithelium	41
Connective Tissue	44
Pigment	50
Cartilage	51
White Fibro-cartilage	52
Yellow or Reticular, Elastic Cartilage	53
Bone	54
Development of Bone	59
Muscular Tissue	64
Unstriped Muscle	68
Nervous Tissue	69
The Brain	73
The Nerves	73
The Sympathetic Nerve	75
Origin and Termination of Nerves	75
The Ganglia	79
The Vascular System	80
The Arteries	80
The Capillaries	82
The Veins	84
The Lymphatics	85
The Lymphatic Glands	87
The Skin and its Appendages	89
The Nails	92
The Hair	93
The Sebaceous Glands	94
The Sudoriferous Glands	95
Serous Membranes	96
Synovial Membranes	96
Mucous Membranes	97
Secreting Glands	98

DEVELOPMENT.

Growth and Development of the Body	100
The Ovum	100
Fecundation of	101
Segmentation of	102
Division of Blastodermic Membrane	104
First Rudiments of the Embryo	107
The Amnion	111
The Chorion	112
The Belly-stalk	113
The Decidua	114
The Placenta	115
Development of the Embryo Proper	115
The Spine	115
The Ribs and Sternum	117
The Cranium and Face	117
The Nervous Centres	120
The Nerves	122
The Eye	122
The Ear	124
The Nose	125
The Skin, Glands, and Soft Parts	125
The Limbs	125
The Muscles	126
The Blood-vascular System	126
Vitelline Circulation	126
Placental Circulation	127
The Alimentary Canal and its Appendages	132
The Respiratory Organs	134
The Urinary Organs	135
The Generative Organs	137
Male Organs	137
Female Organs	137
External Organs	139
Chronological Tables of the Development of the Fœtus	141

DESCRIPTIVE AND SURGICAL ANATOMY.

OSTEOLOGY.—THE SKELETON.

The Skeleton	143
Number of the Bones	143
Form of Bones	143
Of the Spine in general	160
Surface Form of Spine	162
Surgical Anatomy of Spine	162

The Spine.

General Characters of a Vertebra	144
Characters of the Cervical Vertebræ	145
Atlas	146
Axis	147
Vertebra Prominens	148
Characters of the Dorsal Vertebræ	149
Peculiar Dorsal Vertebræ	151
Characters of the Lumbar Vertebræ	151
Structure of the Vertebræ	152
Development of the Vertebræ	152
" " Atlas	153
" " Axis	154
" " Seventh Cervical	154
" " Lumbar Vertebræ	154
Progress of Ossification in the Spine	154
Sacrum	155
Coccyx	159

The Skull.

Bones of the Cranium	164
Occipital Bone	164
Parietal Bones	168
Frontal Bone	170
Temporal Bones	173
Sphenoid Bone	180
Ethmoid Bone	185
Development of the Cranium	187
The Fontanelles	188
Wormian Bones	188
Congenital Fissures and Gaps	188
Bones of the Face:	
Nasal Bones	189
Superior Maxillary Bones	189
Changes produced in Upper Jaw by Age	195
Lachrymal Bones	195
Malar Bones	196

PAGE

Palate Bones 197
Inferior Turbinated Bones 200
Vomer 201
Lower Jaw 201
Changes produced in the Lower Jaw by Age 204
Sutures of the Skull 206
Vertex of the Skull 208
Base of the Skull, Internal Surface 208
Anterior Fossa 208
Middle Fossa 210
Posterior Fossa 211
Base of Skull, External Surface 211
Lateral Region of the Skull 214
Temporal Fossa 215
Mastoid Portion 216
Zygomatic Fossa 216
Spheno-maxillary Fossa 216
Anterior Region of the Skull 217
Orbits 217
Nasal Fossæ 219
Surface Form of Skull 222
Surgical Anatomy of Skull 224
Os Hyoides 227

THE THORAX.

The Sternum 228
The Ribs 232
Peculiar Ribs 234
Costal Cartilages 236
Surface Form of Chest 236
Surgical Anatomy of Chest 237

THE UPPER EXTREMITY.

The Shoulder and Pelvic Girdles 238
The Clavicle 238
Surface Form 241
Surgical Anatomy 241
The Scapula 242
Surface Form 247
Surgical Anatomy 247
The Humerus 248
Surface Form 253
Surgical Anatomy 253
The Forearm 254
The Ulna 254
Surface Form 259
The Radius 259
Surface Form 261
Surgical Anatomy of Bones of Forearm . 261

PAGE

The Hand 262
The Carpus 262
Bones of the Upper Row 262
Bones of the Lower Row 266
The Metacarpus 267
Peculiar Characters of the Metacarpal Bones . 268
Phalanges 270
Surface Form of Bones of Hand 270
Surgical Anatomy of Bones of Hand . . 271
Development of the Bones of the Hand . . . 271

THE LOWER EXTREMITY.

The Hip 272
Os Innominatum 272
Ilium 272
Ischium 272
Os Pubis 277
Development of the Os Innominatum 278
The Pelvis 279
Differences between the Male and Female Pelvis 282
Surface Form of Bones of Pelvis 283
Surgical Anatomy of Bones of Pelvis . . 283
The Femur or Thigh-Bone 284
Surface Form 290
Surgical Anatomy 290
The Leg 291
Patella 291
Surface Form 292
Surgical Anatomy 292
Tibia 293
Surface Form 296
Fibula 297
Surface Form 299
Surgical Anatomy of Bones of Leg . . . 299
The Foot 299
Tarsus 299
Os Calcis 299
Astragalus 303
Cuboid 303
Navicular 304
Cuneiform 305
Metatarsal Bones 306
Phalanges 308
Development of the Bones of the Foot . . . 308
Construction of the Foot as a whole . . . 309
Surface Form of Foot 310
Surgical Anatomy of Foot 311
Sesamoid Bones 312

THE ARTICULATIONS.

Structures composing the Joints 313
Articular Lamella of Bone 313
Ligaments 313
Synovial Membrane 313
Bursæ 314
Synovia 314
Forms of Articulation:
Synarthrosis 314
Amphiarthrosis 315
Diarthrosis 315
Movements of Joints 316

ARTICULATIONS OF THE TRUNK.

Articulations of the Vertebral Column 319
" " Atlas with the Axis . . . 323
" " Spine with the Cranium . 325
" " Atlas with the Occipital Bone 325
Articulation of the Axis with the Occipital Bone 326
Surgical Anatomy of Articulations of the Spine. 327
Temporo-maxillary Articulation 327
Surface Form 330
Surgical Anatomy 330
Articulations of the Ribs with the Vertebræ:
Costo-vertebral 330
Costo-transverse 331
Articulations of the Cartilages of the Ribs with the Sternum and Ensiform Cartilage 334
Interchondral Articulations 334
Ligaments of the Sternum 336
Articulation of the Pelvis with the Spine . . . 336
Articulations of the Pelvis:
Articulation of the Sacrum and Ilium . . 336
Ligament between the Sacrum and Ischium 337
Articulation of the Sacrum and Coccyx . 339
Articulation of the Pubes 339

ARTICULATIONS OF THE UPPER EXTREMITY.

Sterno-clavicular 340
Surface Form 342
Surgical Anatomy 342
Acromio-clavicular 342
Surface Form 344
Surgical Anatomy 344
Proper Ligaments of the Scapula 344
Shoulder-joint 345
Surface Form 348
Surgical Anatomy 348
Elbow-joint 349
Surface Form 352
Surgical Anatomy 352
Radio-ulnar Articulations 353
Surface Form 356
Wrist-joint 356
Surface Form 357
Surgical Anatomy 357

PAGE

Articulations of the Carpus 357
" of the first row of Carpal Bones. 357
" of the second row of Carpal Bones 358
" of the two rows of Carpal Bones. 358
Carpo-metacarpal Articulations 359
of the Metacarpal Bone of Thumb and Trapezium 359
of the four inner Metacarpal Bones and Carpus 360
Articulations of the Metacarpal Bones 361
Metacarpo-phalangeal Articulations 361
Surface Form 362
Articulations of the Phalanges 362

ARTICULATIONS OF THE LOWER EXTREMITY.

Hip-joint 362
Surface form 366
Surgical Anatomy 366
Knee-joint 368
Surface Form 374
Surgical Anatomy 374
Articulations between the Tibia and Fibula . 376

PAGE

Ankle-joint 377
Surface Form 379
Surgical Anatomy 379
Articulations of the Tarsus 380
" of the Os Calcis and Astragalus. 380
" of the Os Calcis and Cuboid . . 381
" of the Os Calcis and Navicular . 382
Surgical Anatomy 382
" of the Astragalus and Navicular. 382
" of the Navicular and Cuneiform. 383
" of the Navicular and Cuboid . . 383
" of the Cuneiform with each other 383
" of the External Cuneiform and Cuboid 384
Torso-metatarsal Articulations 384
Articulations of the Metatarsal Bones 385
Synovial Membranes in Tarsal and Metatarsal Joints 385
Metatarso-phalangeal Articulations 386
Articulations of the Phalanges 387
Surface Form 387

MUSCLES AND FASCIÆ.

General Description of Muscle 388
" " Tendons 389
" " Aponeuroses 389
" " Fascia 389

MUSCLES AND FASCIÆ OF THE CRANIUM AND FACE.

Subdivision into Groups 390

Cranial Region.

Dissection 391
Occipito-frontalis 392

Auricular Region.

Dissection 393
Attrahens Aurem 393
Attollens Aurem 394
Retrahens Aurem 394
Actions 394

Palpebral Region.

Dissection 394
Orbicularis Palpebrarum 394
Corrugator Supercilii 395
Tensor Tarsi 395
Actions 395

Orbital Region.

Dissection 396
Levator Palpebræ 396
Rectus Superior, Inferior, Internal, and External Recti 397
Superior Oblique 397
Inferior Oblique 397
Actions 398
Surgical Anatomy 398

Nasal Region.

Pyramidalis Nasi 398
Levator Labii Superioris Alæque Nasi 399
Dilatator Naris, Anterior and Posterior . . . 399
Compressor Nasi 399
Compressor Narium Minor 399
Depressor Alæ Nasi 399
Actions 399

Superior Maxillary Region.

Levator Labii Superioris (Proprius) 400
Levator Anguli Oris 400
Zygomaticus, Major and Minor 400
Actions 400

Inferior Maxillary Region.

Dissection 400
Levator Labii Inferioris 400
Depressor Labii Inferioris 401
Depressor Anguli Oris 401
Actions 401

Intermaxillary Region.

Dissection 401
Orbicularis Oris 401
Buccinator 402
Risorius 402
Actions 402

Temporo-Maxillary Region.

Masseteric Fascia 403
Masseter 403
Temporal Fascia 403
Dissection 403
Temporal 403

Pterygo-Maxillary Region.

Dissection 404
External Pterygoid 404
Internal Pterygoid 405
Actions 405
Surface Form of Muscles of Head and Face . 406

MUSCLES AND FASCIÆ OF THE NECK.

Subdivision into Groups 406

Superficial Region.

Dissection 407
Superficial Cervical Fascia 407
Platysma Myoides 407
Surgical Anatomy 407
Actions 407
Deep Cervical Fascia 407
Sterno-mastoid 409
Boundaries of the Triangles of the Neck . . 409
Actions 410
Surface Form 411
Surgical Anatomy 411

Infra-hyoid Region.

Dissection 411
Sterno-hyoid 411
Sterno-thyroid 411
Thyro-hyoid 411
Omo-hyoid 412
Actions 413

Supra-hyoid Region.

Dissection 413
Digastric 413
Stylo-hyoid 413
Stylo-hyoid Ligament 414
Mylo-hyoid 414
Genio-hyoid 414
Actions 414

Lingual Region.

Dissection 415

PAGE

Genio-hyo-glossus 415
Hyo-glossus 416
Chrondro-glossus 416
Stylo-glossus 416
Palato-glossus 416
Muscular Substance of Tongue 416
Superior Lingualis 417
Transverse Lingualis 418
Vertical Lingualis 418
Inferior Lingualis 418
Surgical Anatomy 418
Actions 418

Pharyngeal Region.

Dissection 419
Inferior Constrictor 419
Middle Constrictor 420
Superior Constrictor 420
Stylo-pharyngeus 420
Actions 420

Palatal Region.

Dissection 421
Levator Palati 421
Tensor Palati 422
Palatine Aponeurosis 422
Azygos Uvulæ 422
Palato-glossus 422
Palato-pharyngeus 422
Salpingo-pharyngeus 423
Actions 423
Surgical Anatomy 423

Vertebral Region (Anterior).

Rectus Capitis Anticus Major 424
Rectus Capitis Anticus Minor 424
Rectus Capitis Lateralis 425
Longus Colli 425

Vertebral Region (Lateral).

Scalenus Anticus 425
Scalenus Medius 425
Scalenus Posticus 426
Actions 426
Surface Form of Muscles of Neck 427

MUSCLES AND FASCIÆ OF THE TRUNK.

Subdivision into Groups 427

The Back.

Subdivision into Layers 427

First Layer.

Dissection 428
Superficial and Deep Fasciæ 428
Trapezius 428
Ligamentum Nuchæ 430
Latissimus Dorsi 430

Second Layer.

Dissection 431
Levator Anguli Scapulæ 431
Rhomboideus Minor 431
Rhomboideus Major 431
Actions 432

Third Layer.

Dissection 432
Serratus Posticus Superior 432
Serratus Posticus Inferior 432
Vertebral Aponeurosis 433
Lumbar Fascia 433
Splenius 433
Splenius Capitis 433
Splenius Colli 433
Actions 434

Fourth Layer.

Dissection 434
Erector Spinæ 434
Ilio-costalis 434
Musculus Accessorius ad Ilio-costalem 436
Cervicalis Ascendens 436

PAGE

Longissimus Dorsi 436
Transversalis Colli 436
Trachelo-mastoid 436
Spinalis Dorsi 436
Spinalis Colli 436
Complexus 437
Biventer Cervicis 437

Fifth Layer.

Dissection 437
Semispinalis Dorsi 437
Semispinalis Colli 437
Multifidus Spinæ 438
Rotatores Spinæ 438
Supraspinales 438
Interspinales 438
Extensor Coccygis 438
Intertransversales 438
Rectus Capitis Posticus Major 439
Rectus Capitis Posticus Minor 439
Obliquus Capitis Inferior 439
Obliquus Capitis Superior 439
Suboccipital Triangle 439
Actions 440
Surface Form of Muscles of Back 440

THE THORAX.

Intercostal Fasciæ 441
Intercostal Muscles 441
External and Internal Intercostals 442
Infracostales (subcostales) 442
Triangularis Sterni 442
Levatores Costarum 442
Actions 443
Muscles of Inspiration and Expiration . . . 444

Diaphragmatic Region.

Diaphragm 444
Actions 446

The Abdomen.

Dissection 447
Superficial Fascia 447
External or Descending Oblique 448
External Abdominal Ring 449
The Intercolumnar Fibres 450
The Intercolumnar Fascia 450
Poupart's Ligament 450
Gimbernat's Ligament 450
Triangular Ligament 451
Internal or Ascending Oblique 451
Cremaster 452
Transversalis 453
Rectus 453
Pyramidalis 455
Linea Alba 455
Lineæ Semilunares, Lineæ Transversæ . . . 456
Actions 456
Fascia Transversalis 456
Internal Abdominal Ring 456
Inguinal Canal 457
The Deep Crural Arch 457
Surface Form of Muscles of Abdomen 457

Deep Muscles of the Abdomen.

Quadratus Lumborum 458
Actions 458

Muscles of the Pelvic Outlet and Perinæum.

Corrugator Cutis Ani 458
External Sphincter Ani 458
Internal Sphincter Ani 459
Levator Ani 459
Coccygeus 460
Superficial Perineal Fascia 460
Central Tendinous Point 460
Transversus Perinæi 461
Accelerator Urinæ 461
Erector Penis 462
Triangular Ligament 463
Compressor Urethræ 464

Muscles of the Perinæum in the Female. PAGE
Transversus Perinæi 464
Sphincter Vaginæ 464
Erector Clitoridis 465
Triangular Ligament 465
Compressor Urethræ 465

MUSCLES AND FASCIÆ OF THE UPPER EXTREMITY.

Subdivision into Groups 465
Dissection of Pectoral Region and Axilla . 466
Fasciæ of the Thorax 466

THE SHOULDER.

Anterior Thoracic Region.

Pectoralis Major 467
Costo-coracoid Membrane 468
Pectoralis Minor 469
Subclavius 469
Actions 470

Lateral Thoracic Region.

Serratus Magnus 470
Actions 471
Superficial Fascia 471

Acromial Region.

Deep Fascia 471
Deltoid 471
Actions 472
Surgical Anatomy 472

Anterior Scapular Region.

Subscapular Fascia 472
Subscapularis 472
Actions 473

Posterior Scapular Region.

Dissection 473
Supraspinous Fascia 473
Supraspinatus 473
Infraspinous Fascia 473
Infraspinatus 473
Teres Minor 474
Teres Major 474
Actions 475

THE ARM.

Anterior Humeral Region.

Dissection 475
Deep Fascia of Arm 475
Coraco-brachialis 476
Biceps 476
Brachialis Anticus 477
Actions 477

Posterior Humeral Region.

Triceps 477
Subanconeus 478
Actions 478
Surgical Anatomy 478

The Forearm.

Dissection 478
Deep Fascia of Forearm 478

Anterior Brachial Region, Superficial Layer.

Pronator Radii Teres 479
Flexor Carpi Radialis 479
Palmaris Longus 480
Flexor Carpi Ulnaris 480
Flexor Digitorum Sublimis 480

Deep Layer.

Dissection 481
Flexor Profundus Digitorum 481
Flexor Longus Pollicis 482
Pronator Quadratus 483
Actions 483

Radial Region. PAGE
Dissection 483
Supinator Longus 483
Extensor Carpi Radialis Longior 484
Extensor Carpi Radialis Brevior 484

Posterior Brachial Region, Superficial Layer.

Extensor Communis Digitorum 485
Extensor Minimi Digiti 485
Extensor Carpi Ulnaris 486
Anconeus 486

Deep Layer.

Supinator Brevis 486
Extensor Ossis Metacarpi Pollicis 486
Extensor Brevis Pollicis 488
Extensor Longus Pollicis 488
Extensor Indicis 488
Actions 488
Surgical Anatomy 489

The Hand.

Dissection 489
Anterior Annular Ligament 489
Synovial Membranes of the Flexor Tendons at the Wrist 489
Posterior Annular Ligament 490
Deep Palmar Fascia 490
Superficial Transverse Ligament of the Fingers 492
Radial Group 492
Abductor Pollicis 492
Opponens Pollicis 492
Flexor Brevis Pollicis 492
Adductor Obliquus Pollicis 493
Adductor Transversus Pollicis 493
Actions 494
Ulnar Group 494
Palmaris Brevis 494
Abductor Minimi Digiti 494
Flexor Brevis Minimi Digiti 494
Opponens Minimi Digiti 495
Actions 496
Middle Palmar Group 496
Lumbricales 496
Interossei Dorsales 496
Interossei Palmares 496
Actions 497
Surface form of Muscles of Upper Extremity . 497

Surgical Anatomy of the Muscles of the Upper Extremity.

Fractures of the Clavicle 499
" " Acromion Process 499
" " Coracoid Process 500
" " Humerus 500
" " Olecranon 501
" " Radius 501
" " Ulna 502
" " Radius and Ulna 502
" " Lower end of Radius 502

MUSCLES AND FASCIÆ OF THE LOWER EXTREMITY.

Subdivision into Groups 502

Iliac Region.

Dissection 503
Iliac Fascia 503
Psoas Magnus 504
Psoas Parvus 504
Iliacus 504
Actions 505
Surgical Anatomy 505

THE THIGH.

Anterior Femoral Region.

Dissection 505
Superficial Fascia 506
Deep Fascia (Fascia Lata) 506
Saphenous Opening 507
Iliac and Pubic portions of Fascia Lata . . . 508
Tensor Vaginæ Femoris 508

PAGE

Sartorius 508
Quadriceps Extensor 509
Rectus Femoris 509
Vastus Externus 509
Vastus Internus and Crureus 510
Subcrureus 510
Actions 510
Surgical Anatomy 511

Internal Femoral Region.

Dissection 511
Gracilis 511
Pectineus 511
Adductor Longus 512
Adductor Brevis 512
Adductor Magnus 513
Actions 513
Surgical Anatomy 513

THE HIP.

Gluteal Region.

Dissection 514
Gluteus Maximus 514
Gluteus Medius 515
Gluteus Minimus 516
Pyriformis 516
Obturator Membrane 516
Obturator Internus 516
Gemelli 517
Gemellus Superior 517
Gemellus Inferior 517
Quadratus Femoris 517
Obturator Externus 518
Actions 518

Posterior Femoral Region.

Dissection 518
Biceps 518
Semitendinosus 519
Semimembranosus 519
Actions 519
Surgical Anatomy of Hamstring Tendons . . 520

The Leg.

Dissection of Front of Leg 520
Deep Fascia of the Leg 520

Anterior Tibio-fibular Region.

Tibialis Anticus 521
Extensor Proprius Hallucis 521
Extensor Longus Digitorum 521
Peroneus Tertius 522
Actions 522

Posterior Tibio-fibular Region, Superficial Layer.

Dissection 522
Gastrocnemius 522

PAGE

Soleus 523
Tendo Achillis 523
Plantaris 524
Actions 524

Deep Layer.

Deep Transverse Fascia of Leg 524
Popliteus 524
Flexor Longus Hallucis 525
Flexor Longus Digitorum 525
Tibialis Posticus 526
Actions 526

Fibular Region.

Peroneus Longus 527
Peroneus Brevis 527
Actions 527
Surgical Anatomy of Tendons around Ankle 528

THE FOOT.

Anterior Annular Ligament 528
Internal Annular Ligament 528
External Annular Ligament 529
Plantar Fascia 529

Dorsal Region.

Extensor Brevis Digitorum 530

Plantar Region.

Subdivision into Groups 530
Subdivision into Layers 530
First Layer 530
Dissection 530
Abductor hallucis 530
Flexor brevis digitorum 530
Fibrous Sheaths of Flexor Tendons . . . 531
Abductor Minimi Digiti 531
Second Layer 532
Flexor Accessorius 532
Lumbricales 532
Third Layer 532
Flexor Brevis Hallucis 532
Adductor Obliquus Hallucis 533
Flexor Brevis Minimi Digiti 533
Adductor Transversus Hallucis 533
Fourth Layer 534
Interossei 534
Surface Form of Muscles of Lower Extremity 535

Surgical Anatomy of the Muscles of the Lower Extremity.

Fracture of the Neck of the Femur 537
" the Femur below Trochanter Minor 537
" the Femur above the Condyles . 538
" the Patella 538
" the Tibia 538
" the Fibula, with Dislocation of the Foot outward 538

THE ARTERIES.

General Anatomy.

Subdivision into Pulmonary and Systemic . . 539
Distribution of—Where found 539
Mode of Division—Anastomoses 539
PULMONARY ARTERY. 540

THE AORTA.

Divisions 541
Ascending Aorta 541
Coronary Arteries 542
Arch of Aorta 543
Peculiarities 543
Surgical Anatomy 544
Branches 545
Peculiarities of Branches 545

Arteria Innominata.

Relations 545
Peculiarities 546
Surgical Anatomy 546

Common Carotid Arteries.

Course and Relations 547
Peculiarities 549
Surface Marking 549
Surgical Anatomy 549

External Carotid Artery.

Course and Relations 551
Surface Marking 551
Surgical Anatomy 551
Branches 551

Superior Thyroid Artery.

Course and Relations 552
Branches 552
Surgical Anatomy 552

Lingual Artery.

Course and Relations 553
Branches 553
Surgical Anatomy 553

PAGE

Facial Artery.

Course and Relations 554
Branches 555
Peculiarities 556
Surgical Anatomy 556

Occipital Artery.

Course and Relations 556
Branches 557

Posterior Auricular Artery.

Course and Relations 557
Branches 557

Ascending Pharyngeal Artery.

Course and Relations 558
Branches 558
Surgical Anatomy 559

Temporal Artery.

Course and Relations 559
Branches 559
Surgical Anatomy 559

Internal Maxillary Artery.

Course and Relations 559
Peculiarities 559
Branches from First Portion 560
" " Second Portion 561
" " Third Portion 562

SURGICAL ANATOMY OF THE TRIANGLES OF THE NECK.

Anterior Triangular Space.

Inferior Carotid Triangle 563
Superior Carotid Triangle 564
Submaxillary Triangle 564

Posterior Triangular Space.

Occipital Triangle 565
Subclavian Triangle 565

Internal Carotid Artery.

Cervical Portion 566
Petrous Portion 566
Cavernous Portion 566
Cerebral Portion 566
Peculiarities 567
Surgical Anatomy 568
Branches 568
Ophthalmic Artery 568
Cerebral Branches of Internal Carotid . . . 570
The Blood-vessels of the Brain 573

ARTERIES OF UPPER EXTREMITY.

Subclavian Arteries.

First Part of Right Subclavian Artery 577
First Part of Left Subclavian Artery 577
Second Part of Subclavian Artery 578
Third Part of Subclavian Artery 578
Peculiarities 579
Surface Marking 579
Surgical Anatomy 579
Branches 581
Vertebral Artery 581
Basilar Artery 583
Circle of Willis 584
Thyroid Axis 584
Inferior Thyroid 584
Suprascapular Artery 585
Transversalis Colli 585
Internal Mammary 586
Superior Intercostal 587
THE AXILLA. 587
Surgical Anatomy of the Axilla 587

Axillary Artery.

First Portion 589
Second Portion 590
Third Portion 590
Peculiarities 590

PAGE

Surface Marking 591
Surgical Anatomy 591
Branches 592

Brachial Artery.

Relations 593
Bend of the Elbow 593
Peculiarities of Brachial Artery 594
Surface Form 595
Surgical Anatomy 595
Branches 596

Radial Artery.

Relations 597
Deep Palmar Arch 598
Peculiarities 598
Surface Marking 598
Surgical Anatomy 598
Branches 599

Ulnar Artery.

Relations 601
Peculiarities of Ulnar Artery 601
Surface Marking 602
Surgical Anatomy 602
Branches 602
Superficial Palmar Arch 604

ARTERIES OF THE TRUNK.

DESCENDING AORTA 605

THORACIC AORTA.

Course and Relations 605
Surgical Anatomy 606
Branches 606

ABDOMINAL AORTA.

Course and Relations 608
Surface Marking 609
Surgical Anatomy 609
Branches 610
Cœliac Axis 610
Gastric Artery 611
Hepatic Artery 611
Splenic Artery 611
Superior Mesenteric Artery 612
Inferior Mesenteric Artery 614
Suprarenal Arteries 615
Renal Arteries 616
Spermatic Arteries 616
Ovarian Arteries 616
Phrenic Arteries 616
Lumbar Arteries 617
Middle Sacral Artery 617
Luschka's Gland 617

COMMON ILIAC ARTERIES.

Course and Relations 618
Branches 618
Peculiarities 618
Surface Marking 619
Surgical Anatomy 619

Internal Iliac Artery.

Course and Relations 620
Peculiarities 621
Surgical Anatomy 621
Branches 622
Vesical Arteries 622
Hæmorrhoidal Arteries 622
Uterine Arteries 622
Vaginal Arteries 622
Obturator Artery 622
Peculiarities 623
Internal Pudic Artery 623
In the Male 623
Peculiarities 624
Surgical Anatomy 624
Branches 625
In the Female 625
Sciatic Artery 626
Lumbar Artery 626

PAGE

Lateral Sacral Artery 627
Gluteal Artery 627
Surface Marking of Branches of Internal Iliac . 627
Surgical Anatomy of Branches of Internal Iliac 628

External Iliac Artery.

Course and Relations 628
Surgical Anatomy 628
Deep Epigastric Artery 629
Deep Circumflex Iliac Artery 629

ARTERIES OF THE LOWER EXTREMITY.

Femoral Artery.

Course and Relations 630
Scarpa's Triangle 630
Hunter's Canal 630
Common Femoral 631
Superficial Femoral 632
Peculiarities 633
Surface Marking 633
Surgical Anatomy 633
Branches 635
Deep Femoral 635
Branches 636
POPLITEAL SPACE 637

Popliteal Artery.

Course and Relations 638
Peculiarities 638

PAGE

Surface Marking 638
Surgical Anatomy 638
Branches 639

Anterior Tibial Artery.

Course and Relations 641
Peculiarities 642
Surface Marking 642
Surgical Anatomy 642
Branches 642

Dorsalis Pedis Artery.

Course and Relations 643
Peculiarities 643
Surface Marking 643
Surgical Anatomy 643
Branches 644

Posterior Tibial Artery.

Course and Relations 645
Peculiarities 645
Surface Marking 645
Surgical Anatomy 645
Branches 646

Peroneal Artery.

Course and Relations 646
Peculiarities 646
Plantar Arteries 647
Surface Marking 648
Surgical Anatomy 648

THE VEINS.

General Anatomy.

Subdivision into Pulmonary, Systemic, and Portal 649
Anastomoses of Veins 649
Superficial Veins 649
Deep Veins, Venæ Comites 649
Sinuses 650
PULMONARY VEINS 650
SYSTEMIC VEINS 650

VEINS OF THE HEAD AND NECK.

Frontal Vein 651
Facial Vein 652
Surgical Anatomy 652
Temporal Vein 652
Internal Maxillary Vein 652
Temporo-maxillary Vein 653
Posterior Auricular Vein 653
Occipital Vein 653

Veins of the Neck.

External Jugular Vein 653
Surgical Anatomy 653
Posterior External Jugular Vein 654
Anterior Jugular Vein 654
Internal Jugular Vein 654
Surgical Anatomy 655
Lingual Vein 654
Pharyngeal Vein 654
Thyroid Veins 654
Vertebral Veins 655
Veins of the Diploë 655

Cerebral Veins.

Superficial Cerebral Veins 656
Deep Cerebral Veins 657
Cerebellar Veins 657

Sinuses of the Dura Mater.

Superior Longitudinal Sinus 657
Inferior Longitudinal, Straight Sinuses . . . 658
Lateral Sinus 658
Occipital Sinuses 659
Cavernous Sinuses 659
Surgical Anatomy 659

Circular Sinus 660
Superior Petrosal Sinus 660
Inferior Petrosal Sinus 660
Transverse Sinuses 661
Emissary Veins 661

VEINS OF THE UPPER EXTREMITY AND THORAX.

Superficial Veins 662
Deep Veins 662
Axillary Vein 664
Surgical Anatomy 665
Subclavian Vein 665
Innominate Veins 665
Peculiarities of 665
Internal Mammary Veins 666
Inferior Thyroid Veins 666
Superior Intercostal Veins 666
Superior Vena Cava 667
Azygos Veins 667
Bronchial Veins 668
Spinal Veins 668

VEINS OF THE LOWER EXTREMITY—ABDOMEN AND PELVIS.

Internal Saphenous Vein 670
External Saphenous Vein 670
Popliteal Vein 671
Femoral Vein 672
Deep Epigastric Veins 672
Deep Circumflex Iliac Veins 672
Internal Iliac Vein 672
Internal Pudic Veins 672
Common Iliac Veins 672
Peculiarities 673
Inferior Vena Cava 673
Peculiarities 674
Lumbar Veins 674
Spermatic Veins 674
Surgical Anatomy 674
Ovarian Veins 674
Renal and Suprarenal Veins 675
Phrenic Veins 675
Hepatic Veins 675

PORTAL SYSTEM OF VEINS. PAGE
Superior Mesenteric Vein 675
Splenic Vein 675
Inferior Mesenteric Vein 675
Gastric Veins 676
Portal Vein 677
CARDIAC VEINS 677
Coronary Sinus 677

THE LYMPHATICS.

General Anatomy.
Subdivision into Deep and Superficial . . . 679
Lymphatic or Conglobate Glands 679
Thoracic Duct 680
Right Lymphatic Duct 680

Lymphatics of Head, Face, and Neck.
Lymphatic Glands of Head 681
Lymphatics of the Head 681
Superficial Lymphatics of the Face 682
Deep Lymphatics of the Face 682
Lymphatics of the Cranium 682
Lymphatic Glands of the Neck 683
Superficial Cervical Glands 683
Deep Cervical Glands 683
Superficial and Deep Cervical Lymphatics . . 684
Surgical Anatomy 684

Lymphatics of the Upper Extremity.
Superficial Lymphatic Glands 684
Deep Lymphatic Glands 684
Axillary Glands 684
Surgical Anatomy 684
Superficial Lymphatics of Upper Extremity . 685
Deep Lymphatics of Upper Extremity 686

Lymphatics of the Lower Extremity.
Superficial Inguinal Glands 686
Surgical Anatomy 686
Deep Lymphatic Glands 686
Anterior Tibial Gland 686
Popliteal Glands 686
Deep Inguinal Glands 686
Gluteal and Ischiatic Glands 686
Superficial Lymphatics of Lower Extremity . 686
Internal Group 686
External Group 687
Deep Lymphatics of Lower Extremity . . . 687

Lymphatics of Pelvis and Abdomen.
Lymphatic Glands of Pelvis 687
External Iliac Glands 687
Internal Iliac Glands 688
Sacral Glands 688
Lumbar Glands 688
Superficial Lymphatics of Wall of Abdomen . 689
" " of Gluteal Region . . 689
" " of Scrotum and Perinæum 689
" " of Penis 689
" " of Labia, Nymphæ, and Clitoris . . . 689
Deep Lymphatics of Pelvis and Abdomen . . 689
Lymphatics of Bladder 689
" of Rectum 689
" of Uterus 689
" of Testicle 690
" of Kidney 690
" of Liver 690
Lymphatic Glands of Stomach 690
Lymphatics of Stomach 690
Lymphatic Glands of Spleen 690
Lymphatics of Spleen 690

Lymphatic System of the Intestine.
Lymphatic Glands of Small Intestines (Mesenteric Glands) 691
Lymphatic Glands of Large Intestine 691
Lymphatics of Small Intestines (Lacteals) . . 691
" of Large Intestine 691

Lymphatics of Thorax.
Lymphatic Glands of Thorax 691
Intercostal Glands 691
Internal Mammary Glands 691
Anterior Mediastinal Glands 691
Posterior Mediastinal Glands 691
Superior Lymphatics on Front of Thorax . . 691
Deep Lymphatics of Thorax 691
Intercostal Lymphatics 691
Internal Mammary Lymphatics 692
Lymphatics of Diaphragm 692
Bronchial Glands 692
Lymphatics of Lung 692
Cardiac Lymphatics 692
Thymic Lymphatics 692
Thyroid Lymphatics 692
Lymphatics of Œsophagus 692

NERVOUS SYSTEM.

General Anatomy.
Subdivision into Cerebro-spinal Axis, Ganglia, and Nerves 693

The Spinal Cord and its Membranes.
Dissection 693
Membranes of the Cord 693
Dura Mater 693
Arachnoid 694
Pia Mater 695
Ligamentum Denticulatum 695
Spinal Cord 695
Fissures of Cord 696
Columns of Cord 697
Structure of the Cord 697
Commissure of the Cord 697
Minute Anatomy of the Cord 698
Neuroglia 698
White Substance 698
Collateral Fibres 700
Gray Substance 701

The Brain and its Membranes.
Membranes of the Brain 702

Dura Mater.
Structure 703
Arteries, Veins 703
Nerves 703
Glandulæ Pacchioni 703
Processes of the Dura Mater 704
Falx Cerebri 704
Tentorium Cerebelli 704
Falx Cerebelli 704

The Arachnoid Membrane.
Subarachnoid Space 705
Cerebro-Spinal Fluid 705
The Pia Mater 705

THE BRAIN.
Subdivision into Cerebrum, Cerebellum, Pons Varolii, Medulla Oblongata 706
Weight of Brain 706

MEDULLA OBLONGATA.
Surface 709
Pyramids 709
Olive or Olivary Body 710

PAGE
Funiculus Gracilis 714
Funiculus Cuneatus 711
Funiculus of Rolando 711
Restiform Bodies 712
External Arciform Fibres 712
Internal Structure 712
White Matter 714
Funiculus of Rolando 714
Funiculus Cuneatus 715
Funiculus Gracilis 715
Gray Matter of the Anterior and Lateral Areas 715
Gray Matter of the Posterior Area 715
Nuclei 715
Nuclei in Relation to Floor of the Fourth Ventricle 716
Nucleus of the Spinal Accessory Nerve . . . 716
Nuclei of the Vagus and Glossopharyngeal Nerves 716
Nuclei of the Auditory Nerve 716
White Matter 716
Pyramid 716
Olivary Body 717
Fibres in the Grooves 717
Restiform Body 717
Fibres of Formatio Reticularis 718
Longitudinal Fibres of the Formatio Reticularis 718
Posterior Longitudinal Bundle 718
Ascending Root of the Fifth Nerve 718
Funiculus Solitarius 718
Transverse and Dorso-ventral Fibres 718
External Arciform Fibres 718
Internal or Deep Arciform Fibres 719
Raphe 719

THE PONS VAROLII.

Ventral Surface 720
Dorsal Surface 720
Relations of the Cerebellar Peduncles to Each Other 720
Deep Portion of the Pons 720
Trapezium 721
Septum or Raphe 721
Gray Matter of the Pons 721
Nuclei Pontis 721
Gray Matter of the Formatio Reticularis . . 721
Superior Olivary Nucleus 722
Nuclei of the Auditory Nerve 722
Nucleus of the Facial Nerve 722
Nucleus of the Sixth Nerve 722
Nuclei of the Fifth Nerve 722
Floor of the Fourth Ventricle 723

THE CEREBELLUM.

Weight of the Cerebellum 725
Main Lobes of the Cerebellum 725
Notches of the Cerebellum 726
Worm 727
Hemispheres 727
Lobules of Superior Worm 728
Lobules of Inferior Worm 728
Structure of Each Lobule 728
Lingula and Frænula 729
Lobulus Centralis and Alæ 729
Tuber Valvulæ and Postero-inferior Lobules . 730
Pyramid and Digastric Lobules 731
Uvula and Amygdalæ 732
Nodulus and Flocculi 732
Peduncles of the Cerebellum 733
Inferior Medullary Velum 734
Tent and Lateral Recess 734
Superior Medullary Velum 734
Arbor Vitæ 734
Fibres of the Peduncles 735
Fibræ Propriæ of the Cerebellum 735
Fourth Ventricle 737
Boundaries of the Fourth Ventricle 738
Roof of Lower Portion of Fourth Ventricle; Lateral Recess; Tela Choroidea Inferior . . 738
Lateral Recess 739
PAGE
Tela Choroidea Inferior 739
Lingula 740
Choroid Plexuses 740

THE MID-BRAIN.

Main Divisions 741
Crustæ 741
Fibres of the Crusta 742
Substantia Nigra 742
Tegmentium 742
Corpora or Tubercula Quadrigemina 743
Aqueduct of Sylvius 744
Central Gray Matter 744
Superior Surface of Mid-brain 745
Posterior Perforated Lamina 745
Subthalamic Region 745

THE INTER-BRAIN.

Optic Thalamus 746
Structure of the Optic Thalamus 747
Third Ventricle 748
Posterior Commissure 748
Pineal Gland 748
Structure 749
Epithelial Roof 749
Velum Interpositum 749
Tela Choroidea Superior 750
Posterior Perforated Lamina 750
Corpora Albicantia 750
Tuber Cinereum 750
Pituitary Body 751
Lamina Cinerea 751
Anterior Boundary 751
Choroid Plexuses 751
Openings 752
Optic Tracts 752

THE HEMISPHERES.

General Considerations and Development.

Frontal Lobes 753
Parietal Lobes 753
Fornix 753
Anterior Commissure 753
Corpus Callosum 753
Septum Lucidum 754
Occipital Lobe 754
Temporal Lobe 754

The Lateral Ventricles, and Structures in Connection therewith.

Corpus Callosum 756
Central Cavity or Body 757
Anterior Cornu 758
Posterior Cornu or Digital Cavity 758
Middle or Descending Cornu 758
Corpus Striatum 759
Internal Capsule 760
Tænia Semicircularis 760
Fornix 760
Anterior Commissure 762
Septum Lucidum 762
Fifth Ventricle 763
Hippocampus major or Cornu Ammonis . 763
Corpus Fimbriatum 763
Eminentia Collateralis or Pes Accessorius 765
Fascia Dentata 765
Choroid Plexuses 766
Choroid Plexus of the Body of the Ventricle 766
Epithelial Floor of the Body of the Ventricle 768
Epithelial Inner Wall of Descending Cornu . 768
Choroid Plexus of Descending Cornu 769
Structure of Choroid Plexus 770
Transverse Fissure 770
Surface Aspect of the Hemispheres 771
Surface of Each Hemisphere 771
Gyri or Convolutions 773
Structure of the Convolutions 774
External Lobes and Fissures of the Hemisphere 774
Fissure of Sylvius 774
Fissure of Rolando 774

PAGE

Parieto-occipital Fissure 774
Frontal Lobe 775
Parietal Lobe 776
Occipital Lobe 777
Temporal Lobe 777
Central Lobe or Island of Reil 778
Mesial Lobes and Fissures of the Hemisphere . 778
Calloso-marginal Fissure 778
Parieto-occipital Fissure 779
Calcarine Fissure 779
Collateral Fissure 779
Dentate or Hippocampal Fissure 779
Lobes or Convolutions Seen on the Internal Surface of the Hemisphere . . . 779
Gyrus Fornicatus 779
Marginal Convolution 780
Quadrate Lobe 780
Cuneate or Occipital Lobule 780
Infracalcarine 780
Fourth Temporal Convolution 781
Hippocampal Convolution 781
Uncinate Gyrus 781
Olfactory Lobe 782
Anterior Olfactory Lobule 782
Posterior Olfactory Lobule or Anterior Perforated Space 784
Olfactory Roots 784
Under Surface or "Base" of the Encephalon 784
Longitudinal Fissure 784
Interpeduncular Space 784
Structure of the Hemisphere 785
Projection or Peduncular Fibres 785
Transverse or Commissural Fibres . . . 786
Association-fibres Connecting Different Structures in the Same Hemisphere 786
Gray Matter of the Cortex 786
Weight of the Encephalon 789
Cerebral Localization and Topography 789
Longitudinal Fissure 790
Fissure of Sylvius 790
Fissure of Rolando 790

THE CRANIAL NERVES.

Enumeration 792
Olfactory Nerve 792
Surgical Anatomy 793
Optic Nerve 793
Tracts 793
Commissure 793
Surgical Anatomy 794
Motor Oculi Nerve 794
Surgical Anatomy 795
Pathetic Nerve 796
Surgical Anatomy 796
Trifacial Nerve 796
Gasserian Ganglion 797
Ophthalmic Nerve 797
Lachrymal and Frontal Branches 798
Nasal Branches 798
Ophthalmic Ganglion 799
Superior Maxillary Nerve 801
Spheno-palatine Ganglion 803
Inferior Maxillary Nerve 805
Auriculo-temporal Branch 806
Lingual Branch 807
Inferior Dental Branch 807
Otic Ganglion 807
Submaxillary Ganglion 808
Surgical Anatomy of Fifth Nerve 809
Abducens Nerve 810
Relations of the Orbital Nerves in the Cavernous Sinus 810
Relations, etc. in the Sphenoidal Fissure . . . 810
" in the Orbit 810
Surgical Anatomy 811
Facial Nerve 811
Branches of Facial Nerve 812
Surgical Anatomy 815
Auditory Nerve 815
Surgical Anatomy 816
Glosso-pharyngeal Nerve 816

PAGE

Pneumogastric (Vagus) Nerve 819
Surgical Anatomy 822
Spinal Accessory Nerve 823
Surgical Anatomy 823
Hypoglossal Nerve 823
Surgical Anatomy 825

THE SPINAL NERVES.

Roots of the Spinal Nerves 826
Origin of Anterior Roots 826
" of Posterior Roots 826
Ganglia of the Spinal Nerves 827
Posterior Divisions of the Spinal Nerves . . . 827
Anterior Divisions of the Spinal Nerves . . . 827

CERVICAL NERVES.

Roots of the Cervical Nerves 828
Posterior Divisions of the Cervical Nerves . . 828
Anterior Divisions of the Cervical Nerves . . 830

THE CERVICAL PLEXUS.

Superficial Branches of the Cervical Plexus . 831
Deep Branches of the Cervical Plexus 832

THE BRACHIAL PLEXUS.

Branches above the Clavicle.

Posterior Thoracic 837
Suprascapular 837

Branches below the Clavicle.

Anterior Thoracic 838
Subscapular Nerves 838
Circumflex Nerve 839
Musculo-cutaneous Nerve 839
Internal Cutaneous Nerve 839
Lesser Internal Cutaneous Nerve 840
Median Nerve 840
Ulnar Nerve 841
Musculo-spiral Nerve 842
Radial Nerve 844
Posterior Interosseous Nerve 844
Surgical Anatomy of Brachial Plexus 844

DORSAL NERVES.

Roots of the Dorsal Nerves 845
Posterior Divisions of the Dorsal Nerves . . . 845
Anterior Divisions of the Dorsal Nerves . . . 846
First Dorsal Nerve 846
Upper Dorsal Nerves 846
Lower Dorsal Nerves 848
Last Dorsal Nerve 848
Surgical Anatomy 848

THE LUMBAR NERVES.

Root of Lumbar Nerves 849
Posterior Divisions of Lumbar Nerves 849
Anterior Divisions of Lumbar Nerves 850

THE LUMBAR PLEXUS.

Branches of Lumbar Plexus 850
Ilio-hypogastric Nerve 851
Ilio-inguinal Nerve 851
Genito-crural Nerve 852
External Cutaneous Nerve 853
Obturator Nerve 854
Accessory Obturator Nerve 854
Anterior Crural Nerve 855
Branches of Anterior Crural 855
Middle Cutaneous 855
Internal Cutaneous 855
Long Saphenous 856
Muscular and Articular Branches 856

THE SACRAL AND COCCYGEAL NERVES.

Roots of, origin of 857
Posterior Divisions of Sacral Nerves 857
Coccygeal Nerve 858
Anterior Divisions of Sacral Nerves 858

THE SACRAL PLEXUS.

Superior Gluteal Nerve 861
Inferior Gluteal Nerve 861

PAGE

Perforating Cutaneous Nerve 861
Pudic Nerve 861
Small Sciatic Nerve 862
Great Sciatic Nerve 862
Internal Popliteal Nerve 863
Posterior Tibial Nerve 863
Plantar Nerves 863
External Popliteal or Peroneal Nerve 864
Anterior Tibial Nerve 865
Musculo-cutaneous Nerve 865
Surgical Anatomy of Lumbar and Sacral Plexus 866

THE SYMPATHETIC NERVE.

Subdivision of, into Parts 867
Branches of the Ganglia, General Description of 867
CERVICAL PORTION OF THE GANGLIATED CORD 869
Superior Cervical Ganglion 869
Carotid Plexus 869
Cavernous Plexus 869
Middle Cervical Ganglion 872
Inferior Cervical Ganglion 872
THORACIC PART OF THE GANGLIATED CORD . 872
Great Splanchnic Nerve 873
Lesser Splanchnic Nerve 873

PAGE

Smallest Splanchnic Nerve 873
LUMBAR PORTION OF THE GANGLIATED CORD 873
PELVIC PORTION OF THE GANGLIATED CORD 874

THE GREAT PLEXUSES OF THE SYMPATHETIC.

Cardiac Plexuses 874
Great Cardiac Plexus 874
Superficial Cardiac Plexus 874
Coronary Plexuses 874
Solar Plexus 875
Phrenic Plexus 875
Suprarenal Plexus 875
Renal Plexus 875
Spermatic Plexus 875
Ovarian Plexus 876
Cœliac Plexus 876
Superior Mesenteric Plexus 877
Aortic Plexus 877
Inferior Mesenteric Plexus 877
Hypogastric Plexus 877
Pelvic Plexus 878
Inferior Hæmorrhoidal Plexus 878
Vesical Plexus 878
Prostatic Plexus 878
Vaginal Plexus 878
Uterine Plexus 878

ORGANS OF SENSE.

TONGUE.

Structure of 879
Papillæ of 880
Glands of 882
Lymphoid Follicles 882
Fibrous Septum of 882
Hyo-glossal Membrane 882
Arteries and Nerves of 882
Muscles of 882
Nerves of 883
Surgical Anatomy of 883

NOSE.

Cartilages of 885
Muscles of 886
Skin 886
Mucous Membrane 886
Arteries, Veins, and Nerves 886

Nasal Fossæ.

Mucous Membrane of 887
Superior, Middle, and Inferior Meatuses . . . 887
Arteries, Veins, and Nerves of Nasal Fossæ . 889
Surgical Anatomy of Nose and Nasal Fossæ . 889

EYE.

Situation, Form of 890
Capsule of Tenon 890
Tunics of, sclerotic 891
Cornea 892
Choroid 894
Ciliary Processes 895
Iris 896
Membrana Pupillaris 898
Ciliary Muscle 898
Retina 898
Structure of Retina 898
Structure of Retina at Yellow Spot 902
Arteria Centralis Retinæ 902

Humors of the Eye.

Aqueous Humor 903
Anterior Chamber 903
Posterior Chamber 903
Vitreous Body 903
Crystalline Lens and its Capsule 904
Changes Produced in the Lens by Age 904
Suspensory Ligament of Lens 905
Canal of Petit 905
Vessels of the Globe of the Eye 905
Nerves of Eyeball 905
Surgical Anatomy of Eye 905

Appendages of the Eye.

Eyebrows 907
Eyelids 907
Eyelashes 907
Structure of the Eyelids 907
Tarsal Plates 908
Meibomian Glands 908
Conjunctiva 908
Carunculæ Lachrymales 909

Lachrymal Apparatus.

Lachrymal Gland 909
" Canals 910
" Sac 910
Nasal Duct 911
Front of Eye 911
Surgical Anatomy 911

EAR.

External Ear.

Pinna, or Auricle 912
Structure of Auricle 912
Ligaments of the Pinna 913
Muscles of the Pinna 913
Arteries, Veins, and Nerves of the Pinna . . 914
Auditory Canal 914
Surface Form 915

Middle Ear, or Tympanum.

Cavity of Tympanum 916
Eustachian Tube 917
Membrani Tympani 918
Structure of 918
Ossicles of the Tympanum 918
Ligaments of the Ossicula 919
Muscles of the Tympanum 920
Mucous Membrane of Tympanum 920
Arteries of Tympanum 920
Veins and Nerves of Tympanum 920

Internal Ear, or Labyrinth.

Vestibule 921
Semicircular Canals:
Superior Semicircular Canal 922
Posterior Semicircular Canal 922
External Semicircular Canal 922
Cochlea:
Central Axis of, or Modiolus 923
Spiral Canal of 923
Scala Tympani, Scala Vestibuli, and Scala Media 924

PAGE

The Organ of Corti 924
Perilymph 926
Membranous Labyrinth 926
Utricle and Saccule 926
Membranous Semicircular Canals 927
Endolymph 927
Otoliths 927
Vessels of the Labyrinth 927
Auditory Nerve, Vestibular Nerve 927
Cochlear Nerve 928
Surgical Anatomy 928

THE ORGANS OF DIGESTION.

Subdivisions of the Alimentary Canal 930
The Mouth 930
The Lips 930
The Cheeks 931
The Gums 931

THE TEETH.

General Characters of 932
Permanent Teeth 932
Incisors 932
Canine 933
Bicuspids 933
Molars 933
Temporary, or Milk Teeth 935
Structure of the Teeth 935
Ivory or Dentine 935
Enamel 937
Cortical Substance 938
Development of the Teeth 938
" of the Permanent Teeth . . 942
Eruption of the Teeth 942

THE PALATE.

Hard Palate 944
Soft Palate 944
Uvula, Pillars of the Soft Palate 944
Mucous Membrane, Aponeurosis, and Muscles of Soft Palate 944

The Tonsils.

Arteries 945
Veins and Nerves of Tonsils 945

THE SALIVARY GLANDS.

Parotid Gland.

Situation and Relations 945
Stenson's Duct 946
Surface Form 947
Vessels and Nerves of Parotid Gland 947

The Submaxillary Gland.

Situation and Relations 947
Wharton's Duct 947
Vessels and Nerves of Submaxillary Gland . . 947

The Sublingual Gland.

Situation and Relations 948
Vessels and Nerves of 948
Structure of Salivary Glands 948
Surface Form of Mouth 949

THE PHARYNX AND ŒSOPHAGUS.

Situation and Relations 951
Structure of Pharynx 951
Surgical Anatomy 952
Relations of Œsophagus 952
Structure 953
Vessels 953
Nerves of 954
Surgical Anatomy 954

THE ABDOMEN.

Boundaries 957
Apertures of 959
Regions 959

The Peritoneum.

Omentum 979
Mesentery 979
Ligament 979
Parietal Peritoneum 986
Anterior Wall 986
Upper Wall 986
Inferior Wall 986
Visceral Peritoneum 988
Lesser Sac or Bursa Omentalis 993
Recessus Peritonei or Retroperitoneal Fossa . 994
Duodenal Fossa 994
Fossa Intersigmoidea 996
Pericæcal Fossæ 997

The Stomach.

Form and Size 999
Position and Relations 1001
Relations in Detail 1003
Alterations in Position 1004
Structure 1004
Mucous Membrane 1006
Vessels and Nerves of Stomach 1007
Surgical Anatomy 1007

Small Intestine.

Duodenum 1008
Course of Adult Duodenum 1009
Peritoneal Relations of Duodenum 1011
Ligaments of Duodenum 1014
Relations of Duodenum 1014
Jejunum and Ileum 1020
Structure of Small Intestine 1020
Mucous Membrane 1021
Valvulæ Conniventes 1021
Villi 1022
Structure of Villi 1023
Follicles 1024
Duodenal Glands 1024
Solitary Glands 1025
Peyer's Glands 1025
Vessels and Nerves of Small Intestine 1026

Large Intestine.

Structure 1028
Vessels and Nerves 1029
Cæcum 1030
Vermiform Appendix 1032
Ileo-colic, Ileo-cæcal Valve or Valvula Bauhini 1033
Colon 1035
Ascending 1035
Transverse 1035
Descending 1035
Sigmoid 1036
Relations of Large Intestine 1036
Rectum 1038
Structure of Rectum 1040
Vessels and Nerves of Rectum 1041
Relations of Rectum 1043
Surface Form 1045
Surgical Anatomy 1045

Liver.

Volume 1047
Weight 1047
Surfaces 1049
Fissures 1051
Longitudinal 1051
Lobes 1052
Right 1052
Left 1052
Quadrate 1052
Caudate 1052
Spigelian 1052

PAGE

Ligaments and Peritoneal Relations 1053
Peritoneal Lines 1054
Relations 1055
Fixation of Liver 1056
Vessels of Liver 1057
Nerves of Liver 1058
Structure of Liver 1059
Microscopic Appearance of Liver 1059
Hepatic Cells 1060
Hepatic Artery 1060
Portal Vein 1060
Excretory Apparatus of Liver 1063
Hepatic Duct 1063

GALL-BLADDER.

Relations of Gall-bladder 1064
Vessels and Nerves of Gall-bladder 1064
Cystic Duct 1064
Ductus Choledochus 1064
Structure 1065
Surface Form of Liver 1065
Surgical Anatomy of Liver 1065

PANCREAS. PAGE

Dissection 1067
Color 1067
Volume 1067
Head 1067
Body and Tail 1069
Relations in Detail 1071
Vessels and Nerves 1072
Surface Form 1073
Surgical Anatomy 1073

SPLEEN.

Form and Relations 1074
Fixation and Peritoneal Relations 1076
Vessels and Nerves 1077
Lymphatic Vessels 1077
Structure 1077
Fibro-elastic Coat 1078
Proper Substance 1078
Surface Form of Spleen 1081
Surgical Anatomy of Spleen 1081

THE THORAX.

Cavity of 1083
Upper Opening 1083
Lower Opening 1083

THE PERICARDIUM.

Structure 1084
Fibrous Layer 1084
Serous Layer 1085
Arteries of Pericardium 1085
Nerves of Pericardium 1085
Vestigial Fold of Pericardium 1085
Surgical Anatomy 1086

THE HEART.

Position 1086
Size 1087
Subdivision into Four Cavities 1087
Circulation of Blood in Adult 1087
Auriculo-ventricular and Ventricular Grooves 1087

The Right Auricle.

Sinus 1088
Appendix 1088
Openings 1088
Valves 1089
Relics of Fœtal Structure 1089
Musculi Pectinati 1089

The Right Ventricle.

Infundibulum 1089
Openings 1090
Tricuspid Valve 1090
Chordæ Tendineæ and Columnæ Carneæ . . . 1090
Semilunar 1090

The Left Auricle.

Sinus 1091
Appendix 1091
Openings 1091
Musculi Pectinati 1092

The Left Ventricle.

Openings 1092
Mitral and Semilunar Valves 1093
Endocardium 1094

Structure of Heart.

Fibrous Rings 1094
Muscular Structure 1094
Muscular Structure of Auricles 1094
Muscular Structure of Ventricles 1094
Vessels and Nerves of Heart 1095
Surface Marking of Heart 1096
Peculiarities in Vascular System of Fœtus . . 1096
Foramen Ovale, Eustachian Valve 1096
Ductus Arteriosus 1097
Umbilical or Hypogastric Arteries 1097
Fœtal Circulation 1097
Changes in Vascular System at Birth 1099

ORGANS OF VOICE AND RESPIRATION.

The Larynx.

Cartilages of the Larynx 1100
Thyroid Cartilage 1100
Cricoid Cartilage 1101
Arytenoid Cartilages, Cartilages of Santorini and Wrisberg 1102
Epiglottis 1102
Ligaments of the Larynx 1102
Ligaments Connecting the Thyroid Cartilage with the Os Hyoides 1103
Ligaments Connecting the Thyroid Cartilage with the Cricoid 1103
Ligaments Connecting the Arytenoid Cartilages to the Cricoid 1103
Ligaments of the Epiglottis 1103
Superior Aperture of the Larynx 1103
Cavity of the Larynx 1104
Rima Glottidis 1104
False Vocal Cords 1105
True Vocal Cords 1105
Ventricle of Larynx, Sacculus Laryngis . . . 1105
Muscles of Larynx 1105
Crico-thyroid 1105
Crico-arytenoideus posticus 1105
Crico-arytenoideus lateralis 1106
Arytenoideus 1106
Thyro-arytenoideus 1106
Muscles of the Epiglottis 1107
Thyro-epiglottideus 1107
Aryteno-epiglottideus, superior 1107
" inferior 1107
Actions of Muscles of Larynx 1107
Mucous Membrane of Larynx 1107
Glands, Vessels, and Nerves of Larynx . . . 1108

PAGE

The Trachea.

Relations 1108
Bronchi 1108
Structure of Trachea 1110
Cartilages 1110
Fibrous Membrane 1111
Muscular Fibres 1111
Mucous Membrane 1111
Glands 1111
Vessels and Nerves 1111
Surface Form 1111
Surgical Anatomy of Laryngo-tracheal Region 1111

The Pleura.

Reflections 1113
Vessels and Nerves 1114
Surgical Anatomy 1114

The Mediastina.

Superior Mediastinum 1115
Anterior Mediastinum 1116
Middle Mediastinum 1116
Posterior Mediastinum 1116

The Lungs.

Surfaces 1117
Borders and Lobes 1117
Root of Lung 1118
Weight, Color, and Properties of Substance of Lung 1118
Structure of Lung 1118
Serous Coat and Subserous Areolar Tissue . 1118
Parenchyma and Lobules of Lung 1118
Bronchi, Arrangement of, in Substance of Lung 1119
Structure of Smaller Bronchial Tubes 1119
The Air-cells 1119
Pulmonary Artery 1119
Pulmonary Capillaries and Veins 1119
Bronchial Arteries and Veins 1120
Lymphatics and Nerves of Lung 1120
Surface Form of Lungs 1120
Surgical Anatomy 1122

The Thyroid Gland.

Surface and Relations 1123
Structure 1123
Vessels and Nerves 1124
Surgical Anatomy 1124

The Thymus Gland.

Relations 1124
Structure 1125
Vessels and Nerves 1126

THE URINARY ORGANS.

The Kidneys.

Relations 1127
Dimensions, Weight 1127
General Structure 1128
Cortical Substance 1129
Medullary Substance 1129
Minute Structure 1129
Malpighian Bodies 1129
" Tufts 1129
" Capsule 1129
Tubuli Uriniferi, Course 1130
" " Structure 1132
Renal Blood-vessels 1133
Renal Veins 1134
Venæ Rectæ 1134
Nerves 1134
Lymphatics 1135
Surface Form 1135
Surgical Anatomy 1135

The Ureters.

Situation 1136
Calices 1136
Course 1136
Relations 1136
Structure 1136

The Suprarenal Capsules.

Relations 1137
Structure 1137
Vessels and Nerves 1139

THE PELVIS.

Boundaries 1139
Contents 1139

The Bladder.

Shape, Position, Relations 1139
Subdivisions 1140
Urachus 1140
Ligaments 1142
Structure 1143
Interior of Bladder 1144
Vessels and Nerves 1144
Surface Form 1144
Surgical Anatomy 1145

Male Urethra.

Divisions 1146
Structure 1147
Surgical Anatomy 1147

MALE GENERATIVE ORGANS.

Prostate Gland 1148
Structure 1149
Vessels and Nerves 1149
Surgical Anatomy 1149
Cowper's Glands 1150
Structure 1150

THE PENIS.

Root 1150
Glans Penis 1150
Body 1150
Structure of Penis 1151
Corpora Cavernosa 1151
Structure 1151
Arteries of the Penis 1152
Corpus Spongiosum 1152
The Bulb 1152
Structure of Corpus Spongiosum 1153
Lymphatics of the Penis 1153
Nerves of the Penis 1153
Surgical Anatomy 1153

THE TESTES AND THEIR COVERINGS.

Scrotum 1153
Coverings of the Testis 1154
Vessels and Nerves of the Coverings of the Testis 1155

The Spermatic Cord.

Its Composition 1155
Relations of, in Inguinal Canal 1155
Arteries of the Cord 1155
Veins of the Cord 1155
Lymphatics and Nerves of the Cord 1155
Surgical Anatomy 1155

THE TESTES.

Form and Situation 1156
Size and Weight 1156
Coverings 1156
Tunica Vaginalis 1156
Tunica Albuginea 1157

PAGE

Mediastinum Testis 1157
Tunica Vasculosa 1157
Structure of the Testis 1157
Lobulus of the Testis 1158
Tubuli Seminiferi 1158
Arrangement in Lobuli 1158
" in Mediastinum Testis 1158
" in Epididymis 1158
Vas Deferens, Course, Relations 1159
Structure 1159
Vas Aberrans 1159
Surgical Anatomy 1159

PAGE

Vesiculæ Seminales 1160
Form and Size 1160
Relations 1160
Structure 1160
Ejaculatory Ducts 1160
Structure 1161
Vessels and Nerves 1161
Surgical Anatomy 1161

Descent of the Testes.

Gubernaculum Testis 1161
Canal of Nuck 1162

FEMALE GENERATIVE ORGANS.

Mons Veneris, Labia Majora 1163
" " Labia Minora 1164
Clitoris 1164
Meatus Urinarius 1165
Hymen, Glands of Bartholin 1165
Female Urethra 1167
Female Rectum 1167

Vagina.

Relations 1167
Structure 1167

Uterus.

Situation, Form, Dimensions 1168
Fundus, Body, and Cervix 1168
Ligaments 1170
Cavity of the Uterus 1171
Cavity of the Cervix 1171
Structure 1171
Vessels and Nerves 1173
Its Form, Size, and Situation in the Fœtus . . 1173
at Puberty 1173
Its Form, Size, etc. during Menstruation . . . 1173
" during Pregnancy 1173
after Parturition 1173
in Old Age 1174

Appendages of the Uterus.

Fallopian Tubes 1174
Structure 1174
Ovaries 1175
Structure 1175
Graafian Follicles 1176
Discharge of the Ovum 1177
Ligament of the Ovary 1177
Round Ligaments 1177
Vessels and Nerves of Appendages 1178

Mammary Glands.

Situation and Size 1178
Nipple 1179
Structure of Mamma 1179
Vessels and Nerves 1279

SURGICAL ANATOMY OF HERNIA.

INGUINAL HERNIA.

COVERINGS OF INGUINAL HERNIA.

Dissection 1180
Superficial Fascia 1180
Superficial Vessels and Nerves 1180
Deep Layer of Superficial Fascia 1181
Aponeurosis of External Oblique 1181
External Abdominal Ring 1182
Pillars of the Ring 1182
Intercolumnar Fibres 1182
" Fascia 1182
Poupart's Ligament 1183
Gimbernat's Ligament 1183
Triangular Ligament 1183
Internal Oblique Muscle 1184
Cremaster 1184
Transversalis Muscle 1184
Spermatic Canal 1185
Fascia Transversalis 1185
Internal Abdominal Ring 1186
Subperitoneal Areolar Tissue 1186
Deep Epigastric Artery 1186
Peritoneum 1186

Oblique Inguinal Hernia.

Course and Coverings of Oblique Hernia . . . 1187
Seat of Stricture 1188
Scrotal Hernia 1189
Bubonocele 1189
Congenital Hernia 1189
Infantile and Encysted Hernia 1189
Hernia into the Funicular Process 1189

Direct Inguinal Hernia.

Course and Coverings of the Hernia 1190
Seat of Stricture 1190
Incomplete Direct Hernia 1191
Comparative Frequency of Oblique and Direct Hernia 1191
Division of Stricture in Inguinal Hernia . . 1191

FEMORAL HERNIA.

Dissection 1191
Superficial Fascia 1191
Cutaneous Vessels 1191
Internal Saphenous Vein 1191
Superficial Inguinal Glands 1193
Cutaneous Nerves 1193
Deep Layer of Superficial Fascia 1193
Cribriform Fascia 1193
Fascia Lata 1193
Iliac Portion 1193
Pubic Portion 1194
Saphenous Opening 1194
Crural Arch 1195
Gimbernat's Ligament 1196
Crural Sheath 1196
Deep Crural Arch 1197
Crural Canal 1197
Femoral or Crural Ring 1198
Position of Parts around the Ring 1198
Septum Crurale 1198
Descent of Femoral Hernia 1199
Coverings of Femoral Hernia 1199
Varieties of Femoral Hernia 1199
Seat of Stricture 1200

SURGICAL ANATOMY OF PERINÆUM AND ISCHIO-RECTAL REGION.

Ischio-Rectal Region.

PAGE

Dissection of 1201
Boundaries of 1201
Superficial Fascia 1201
Ischio-rectal Fossa 1202
Position of Parts contained in 1202

Male Perinæum.

Boundaries and Extent 1202
Deep Layer of Superficial Fascia 1203
Course taken by the Urine in Rupture of the Urethra 1203
Muscles of the Perinæum (Male) 1203
Deep Perineal Fascia 1204
Superficial Layer 1204
Deep Layer 1205
Parts between the two Layers 1205
Compressor Urethræ 1205

PAGE

Cowper's Glands 1205
Dorsal Vessels and Nerves 1205
Artery of the Bulb 1205
Position of the Viscera at Outlet of Pelvis . . 1206
Prostate Gland 1206
Surgical Anatomy of Lithotomy 1207
Parts divided in the Operation 1207
Parts to be avoided in the Operation 1207
Abnormal Course of Arteries in the Perinæum 1207

Female Perinæum.

Superficial Fascia 1207
Deep Fascia 1208
Compressor Urethræ 1208
Perineal Body 1208
Pelvic Fascia 1209
Obturator Fascia 1209
Recto-vesical Fascia 1210

INDEX 1211

[p 26]

Note page numbers
27-32 omitted
text complete

GENERAL ANATOMY.

THE **fluids** of the body, which are intended for its nutrition, are the lymph, the chyle, and the blood. There are other fluids also which partially subserve the same purpose, as the saliva, the gastric juice, the bile, the intestinal secretion; and others which are purely excrementitious, as the urine. But there is no need to describe the rest in this place, since they are the secretions of special organs, and are described, as far as is judged necessary for the purposes of this work, in subsequent pages. We shall here speak first of the blood, and next of the lymph and chyle.

THE BLOOD.

The blood is a thickish, opaque fluid, of a bright-red or scarlet color when it flows from the arteries, of a dark-red or purple color when it flows from the veins. It is viscid, and has a somewhat clammy feeling; it is salt to the taste, and has a peculiar faint odor. It has an alkaline reaction. Its specific gravity at 60° F. is about 1.055, and its temperature is generally about 100° F., though varying slightly in different parts of the body.

General Composition of the Blood.—When blood is drawn from the body and allowed to stand, it solidifies in the course of a very few minutes into a jelly-like mass, which has the same appearance and volume as the fluid blood, and, like it, looks quite uniform. Soon, however, drops of a transparent yellowish fluid begin to ooze out from the surface of this mass and to collect around it. Coincidently with this the clot begins to contract, so that, in the course of about twenty-four hours, the original mass of coagulated blood has become separated into two parts —a "clot" or "coagulum," considerably smaller and firmer than the first-formed jelly-like mass, and a large quantity of yellowish fluid, the *serum*, in which the clot floats.

The clot thus formed consists of a solid, colorless material, called *fibrin*, and a large number of minute cells or corpuscles, called *blood-corpuscles*, which are entangled and enclosed in the fibrin. The fibrin is formed during the act of solidification. In the fluid blood in the living body there is a substance, named *fibrinogen*, which when acted upon by a second material, also contained in the blood, and named a *fibrin-ferment*, forms a solid substance, *fibrin*. This latter in its process of solidification encloses and entangles the blood-corpuscles, and thus the clot is formed.

Recent observations have shown that the presence of a trace of a calcium salt is a necessary condition for the transformation of fibrinogen into fibrin. The fibrin-ferment does not exist as such in the blood contained in the blood-vessels, but seems to result from the destruction of what are known as the white corpuscles and the blood-plaques to be described later. These structures, more especially the plaques, disintegrate very rapidly when blood is drawn from the body, liberating the ferment, and so producing coagulation, and lesions of the cells lining the interior of the blood-vessels seem also to give rise to ferment-production and the intra-vascular formation of fibrin.

We may now consider the constituents of the blood in another way. If a drop of blood is placed in a thin layer on a glass slide and examined under the microscope, it will be seen to consist of a number of minute bodies or corpuscles floating in a clear fluid; and, on more minute examination, it will be found that these corpuscles are principally of two kinds. The one, greatly preponderating over the other in point of numbers, is termed the *colored corpuscle;* the other, fewer in number and less conspicuous, is termed the *colorless corpuscle.* From this we learn that blood is a fluid holding a large number of corpuscles of two varieties in suspension. The fluid is named *liquor sanguinis* or *plasma*, and must not be confused with the serum spoken of above in connection with the coagulation of the blood. It is serum and something more, for it contains one at least of the elements or factors from which fibrin is formed. The relation of these various constituents of blood to each other will be easily understood by a reference to the subjoined plan:

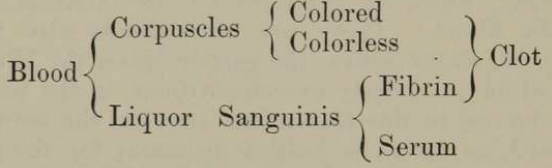

The **blood-corpuscles, blood-disks, blood-globules** are, as before stated, of two kinds: the red or colored, and the white or colorless corpuscles. The relative proportion of the one to the other has been variously estimated and no doubt varies under different circumstances. Thus venesection, by withdrawing a large proportion of the red globules, and by favoring the absorption of lymphatic fluid into the blood, greatly increases the relative proportion of the white corpuscles. Klein states that in healthy human blood there appears to be one white corpuscle for 600–1200 red ones. The proportion of corpuscles, colored and colorless combined, to liquor sanguinis is in one hundred volumes of blood about thirty-six volumes of the former to sixty-four of the latter.

Colored corpuscles when examined under the microscope are seen to be circular disks, biconcave in profile, having a slight central depression, with a raised border (Fig. 1, *b*). When viewed with a moderate magnifying power, this central depression looks darker than the edge. When examined singly by transmitted light, their color appears to be of a faint reddish-yellow when derived from arterial blood, and greenish-yellow in venous blood. It is to their aggregation that blood owes its red hue. Their size varies slightly even in the same drop of blood, but it may be stated that their average diameter is about $\frac{1}{3200}$ of an inch, their thickness about $\frac{1}{12000}$, or nearly one-quarter of their diameter. Besides these, especially in some anæmic and diseased conditions, certain corpuscles are found of a much smaller size, about one-third or half the size of the ordinary one. These, however, are very scarce in normal blood. The number of red corpuscles in the blood is enormous; between 4,000,000 and 5,000,000 are contained in a cubic millimetre. Power states that the red corpuscles of an adult would present an aggregate surface of about 3000 square yards. Human blood-disks present no trace of a nucleus. They consist of two parts: a colorless envelope, or investing membrane, which is composed largely of fatty material; and a colored fluid contents, which is a solution of a substance named *hæmoglobin. Hæmoglobin* is a proteid compound of a very complex constitution, the hæmoglobin of the horse having the formula $C_{712}H_{1130}N_{214}S_2FeO_{245}$. It has a great affinity for oxygen, and when removed from the body crystallizes readily under certain circumstances. It is readily soluble in water, and the addition of this fluid to a drop of blood speedily dissolves out hæmoglobin from the corpuscle.

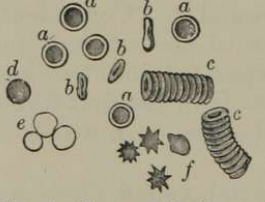

FIG. 1.—Human blood-corpuscles. *a*. Seen from the surface. *b*. Seen from the side. *c* United in rouleaux. *d*. Rendered spherical by water. *e*. Decolorized by the same. *f*. Blood-globules shrunk by evaporation.

If the web of a frog's foot is spread out and examined under the microscope, the blood is seen to flow in a continuous stream through the vessels, and the corpuscles show no tendency to adhere to each other or to the wall of the vessel. Doubtless the same is the case in the human body; but when drawn and examined on a slide without reagents, the blood-globules often collect into heaps like rouleaux of coins (Fig. 1, *c*).

During life the red corpuscles may be seen to change their shape under pressure so as to adapt themselves to some extent to the size of the vessel. They are also highly elastic, for they speedily recover their shape when the pressure is removed. They are soon influenced by the medium in which they are placed, and by the specific gravity of the medium. In water they swell up, lose their shape, and become globular; subsequently the hæmoglobin becomes dissolved out, and the envelope can be barely distinguished as a faint, circular outline. Solutions of salt or sugar, denser than the serum, give them a stellate or crenated appearance; and the usual shape may be restored by diluting the solution to the proper point. The same crenated outline may be produced as the first effect of the passage of an electric shock; subsequently, if sufficiently strong, the shock ruptures the envelope. A solution of salt or sugar of the same specific gravity as serum merely separates the blood-globules mechanically without changing their shape.

The **white corpuscles** (Fig. 2) are rather larger than the red in human blood, measuring from about $\frac{1}{2000}$ to $\frac{1}{2500}$ of an inch in diameter. They consist of a transparent granular-looking protoplasm containing one, two, or more nuclei, and presenting bright granules, which vary in different corpuscles both in quantity and in their behavior to micro-chemical reagents. When absolutely at rest they are rounded or spheroidal, but under ordinary circumstances their form is very various, and they have the remarkable property of undergoing "amœboid" changes (Fig. 3). That is to say, they have the power of sending out finger-shaped or filamentous processes of their own substance, by which they move and take up granules from the surrounding substance.

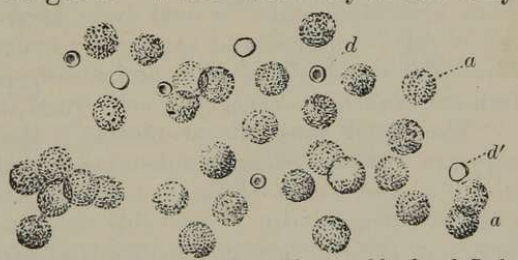

FIG. 2.—*a*. White corpuscles of human blood. *d*. Red corpuscles. High power.

In locomotion the corpuscle pushes out a process of its substance—a *pseudopodium*, as it is called—and then shifts the rest of the body into it. In the same way, when any granule or particle comes in its way it wraps a pseudopodium round it,



FIG. 3.—Human colorless blood-corpuscle, showing its successive changes of outline within ten minutes when kept moist on a warm stage. (Schofield.)

and then, withdrawing it, lodges the particle in its own substance. By means of these amœboid properties they have the power of wandering or emigrating from the blood-vessels by penetrating their coats, and thus finding their way into the perivascular spaces.

The white corpuscle may be taken as the type of a true animal cell. It has no limiting membrane, but consists of a mass of transparent albuminous substance, called *protoplasm*, containing one or more nuclei. These nuclei may assume varying shapes, being sometimes spherical, sometimes horseshoe-shaped, sometimes moniliform, these various shapes being transition stages between the mononuclear and polynuclear corpuscles.

The white corpuscles are very similar to, if not identical with, the corpuscles of lymph and chyle, and they also bear a strong resemblance to the cells found

in pus. From the fact that cells exactly like the colorless corpuscles are being constantly furnished to the blood by the lymphatic vessels and the chyle-ducts, and also from their varying proportions in different parts of the circulation and in different pathological conditions, the colorless corpuscles have been regarded —erroneously, however—as an earlier stage of the colored blood-disks, but the evidence in favor of this must be regarded as quite inconclusive.

There can be no doubt that during embryonic life the red corpuscles are developed from mesoblastic cells in the vascular area of the blastoderm. They are at first nucleated and resemble white corpuscles, except in their color, and, like them, are possessed of amœboid movements. They are succeeded by smaller, non-nucleated corpuscles, having all the characters of adult colored corpuscles, probably formed by a conversion of the former into the latter. So that at birth the nucleated red corpuscles have disappeared. In after life an important source of the red corpuscles is the red marrow of bones, in which certain cells found in the marrow are converted into colored blood-corpuscles by the loss of their nuclei, and by their protoplasm becoming tinged with yellow. It is probable, also, that the spleen may be a place for the formation of red corpuscles. This theory, which was formerly universally believed, and was then discarded for the hypothesis that the spleen was concerned in the destruction of the red corpuscles, has lately been revived by Bizzozero. The question must still be regarded as *sub judice*. The proportion of white corpuscles appears to vary considerably in different parts of the circulation, being much larger in the blood of the splenic vein and hepatic vein than in other parts of the body, while in the splenic artery they are very scanty.

In addition to these corpuscles, a third variety is found in mammalian blood, and has been specially studied and described by Hayem, Bizzozero, and Osler. They are pale circular or oval disks, about one-quarter or one-third the size of the red blood-corpuscles, and apparently contain no nucleus. They have been named *blood-plates* or *blood-plaques*, and are supposed by Bizzozero to originate the fibrin-ferment, and to be especially concerned in the coagulation of the blood.

The **liquor sanguinis** or **plasma** is the fluid part of the blood, and contains in solution various organic substances, such as *fibrinogen*, *paraglobulin* or *serum globulin*, and *serum albumen*, together with certain salts, sugar, fatty matter, and gases. Paraglobulin is probably contained partly in solution in the plasma, and partly in the colorless corpuscles, and can be obtained by diluting the liquor sanguinis with ten times its volume of ice-cold water, and then transmitting through it a stream of carbon dioxide. Fibrinogen may be obtained in the same way as paraglobulin, but the liquor sanguinis must be still further diluted and the current of carbon dioxide must pass for a much longer time. Fibrin may be obtained by whipping the blood, after it has been withdrawn from the body, with a bundle of twigs, to which the fibrin, as it coagulates, adheres. Fibrin may also be obtained by filtering the freshly-drawn blood of an animal whose corpuscles are large, care being taken to retard coagulation as long as possible. Under these circumstances the corpuscles are retained on the filter, and the liquor sanguinis, passing through, coagulates and separates into fibrin, free from corpuscles, and serum.

Fibrin, thus obtained, is a white or buff-colored substance, presenting a stringy appearance, and under the microscope exhibiting fibrillation. When exposed to the air for some time, it becomes hard, dry, brown, and brittle. It is a proteid compound, insoluble in hot or cold water, alcohol or ether. Under the influence of dilute hydrochloric acid it swells up, but does not dissolve; but when thus swollen it is easily dissolved by a solution of pepsin. If heated for a considerable time in a solution of dilute hydrochloric acid, it gradually dissolves.

Serum is the fluid liquor sanguinis after the fibrin has been separated from it. It is a straw-colored fluid having a specific gravity of 1.027, with an alkaline reaction. Upon boiling it becomes solid, on account of the albumen which it contains. It contains also salts, fatty matters, sugar, and gases.

Gases of the Blood.—When blood is exposed to the vacuum of an air-pump, about half its volume is given off in the form of gases. These are carbon dioxide, oxygen, and nitrogen. The relative quantities in 100 volumes of arterial and venous blood, at 0° C. and 1 m. pressure of mercury are shown in the accompanying table:

	Oxygen.	Carbon dioxide.	Nitrogen.
Arterial blood,	16 vols.	30 vols.	1 to 2 vols.
Venous blood,	6 to 10 vols.	35 vols.	1 to 2 vols.

Roughly stated, they are as follows: Carbon dioxide about two-thirds of the whole quantity of gas, oxygen rather less than one-third, nitrogen below one-tenth (Huxley). The greater quantity of the oxygen is in loose chemical combination with the hæmoglobin of the blood-corpuscles, but some part is simply absorbed, just as it would be by water. The carbon dioxide is in a state of chemical combination with the salts of the serum, especially the sodium, with which it is combined partly as a carbonate and partly as a bicarbonate. The nitrogen is unimportant. It (or at least the greater part of it) is merely absorbed from the atmosphere under the pressure to which the blood is exposed, and can therefore be mechanically removed.

Blood-crystals.—Hæmoglobin, as stated above, when separated from the blood-corpuscles, readily undergoes crystallization. These crystals, named *hæmoglobin crystals*, all belong, with the exception of those obtained from the squirrel, to the rhombic system. In human blood they are elongated prisms (Fig. 4, A). In the

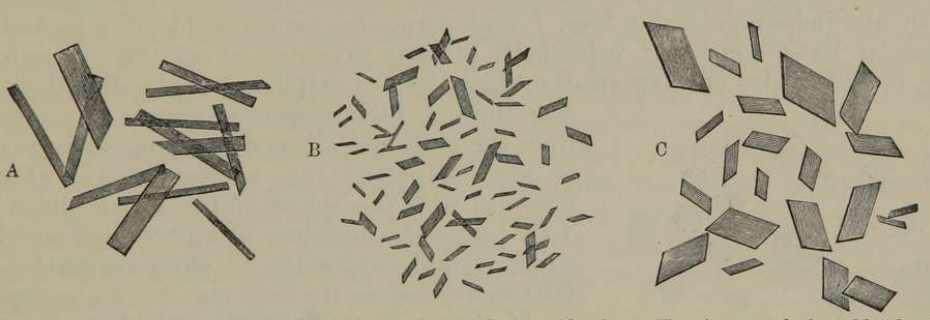

FIG. 4.—Blood-crystals. A. Hæmoglobin crystals from human blood. B. Hæmin crystals from blood treated with acetic acid. C. Hæmatoidin crystals from an old apoplectic clot.

squirrel they are hexagonal plates. Other crystals may be obtained by mixing dried blood with an equal quantity of common salt, and boiling it with a few drops of glacial acetic acid. A drop of the mixture placed on the slide will show the crystals on cooling. These are named *hæmin* crystals, and consist of small acicular prisms (Fig. 4, B). Occasionally in old blood-clots a third form of crystal is found, the hæmatoidin crystal (Fig. 4, C).

LYMPH AND CHYLE.

Lymph is a transparent, colorless, or slightly yellow fluid, which is conveyed by a system of vessels, named *lymphatics*, into the blood. These vessels take their rise in nearly all parts of the body from the interstices of the connective tissue, and take up the fluid contained in these spaces and return it into the veins close to the heart, there to be mixed with the mass of the blood. The greater number of these lymphatics empty themselves into one main duct, the *thoracic duct*, which passes along the front of the spine and opens into one of the large veins at the root of the neck. The remainder empty themselves into a smaller duct, which terminates in the corresponding vein on the opposite side of the neck.

Chyle is an opaque, milky-white fluid, absorbed by the villi of the small intestines from the food, and carried by a set of vessels similar to the lymphatics, named *lacteals*, to the commencement of the thoracic duct, where it is intermingled

with the lymph and poured into the circulation through the same channels. It must be borne in mind that these two sets of vessels, lymphatics and lacteals, though differing in name, are identical in structure, and that the character of the fluid they convey is different only while digestion is going on. At other times the lacteals convey a transparent, nearly colorless fluid not to be distinguished from lymph. Both these sets of vessels, in their passage to the central duct, pass through certain small glandular bodies, termed *lymphatic glands*, where their contents perhaps undergo elaboration.

Lymph, as its name implies, is a watery fluid. It closely resembles the liquor sanguinis, and contains about 5 per cent. of albumen and 1 per cent. of salts. When examined under the microscope, it is found to consist of a clear colorless fluid, in which are floating a number of corpuscles, *lymph-corpuscles*. These bodies are identical in structure, and not to be distinguished from the white blood-corpuscles previously described. They vary in number in different parts of the lymphatic vessels, and indeed are said by Kölliker to be absent in the smaller ones. They are always increased in number after the passage of the lymph through a lymphatic gland, and are said to be increased in size as the fluid ascends higher in the course of the circulation.

Chyle is a milk-white fluid, which exactly resembles lymph in its physical and chemical properties, except that it has, in addition to the other constituents of lymph, an enormous amount of fatty granules, "the molecular basis of chyle," and it is to the presence of these molecules that chyle owes its milky color. Under the microscope it presents a number of corpuscles, named "chyle-corpuscles," which are indistinguishable from lymph-corpuscles or white blood-cells, and the molecular basis, consisting principally of fatty granules of extreme minuteness (Fig. 5, *a*), but also of a few small oil-globules. Lymph and chyle after their passage through their respective glands, if withdrawn from the body and allowed to stand, separate more or less completely into a clear liquid, which is identical with the serum of the blood, and a thin jelly-like clot, consisting of a fibrillated matrix in which lymph-corpuscles or chyle-corpuscles and fatty molecules, as the case may be, are entangled.

FIG. 5.—Chyle from the lacteals.

If the contents of the thoracic duct are examined, especially after a meal, there may be found in it corpuscles with a reddish tinge. These have been regarded, probably erroneously, as *immature* red corpuscles, or lymph- and chyle-corpuscles in process of transformation into blood-globules. They frequently give to the surface of clotted chyle and lymph a pinkish hue. They must not be mistaken for mature blood-globules, which are sometimes found in lymph and chyle, and which are regarded by most observers as accidental—*i. e.* produced by the manipulations of the dissector.

THE ANIMAL CELL.

All the tissues and organs of which the body is composed were originally developed from a microscopic body (the *ovum*), consisting of a soft gelatinous granular material enclosed in a membrane, and containing a vesicle, or small spherical body, inside which are one or more solid spots (see Fig. 73). This may be regarded as a perfect cell. Moreover, all the solid tissues can be shown to consist largely of similar bodies, differing, it is true, in external form, but essentially similar to an ovum. These are also cells.

In the higher organisms all such cells may be defined as "nucleated masses of protoplasm of microscopic size." The two essentials, therefore, of an animal cell in the higher organisms are, the presence of a soft gelatinous granular material,

similar to that found in the ovum, and which is usually styled *protoplasm;* and a small spherical body imbedded in it, and termed a *nucleus;* the remaining constituents of the ovum—viz. its limiting membrane and the solid spot contained in the nucleus, called the *nucleolus*—are not considered essential to the cell, and in fact many cells exist without them.

Protoplasm (*sarcode*, *blastema*, *germinal matter*, or *bioplasm*) is a proteid compound. It also contains certain inorganic substances, as phosphorus and calcium, which latter appears to be essential to its life and function. It is of a semi-fluid, viscid consistence, and appears, sometimes, either as a hyaline substance, homogeneous and clear, or as a granular substance, consisting of minute molecules imbedded in a transparent matrix. These molecules are regarded by some as adventitious material taken in from without, and often probably of a fatty nature, since they are frequently soluble in ether. In most cells, however, protoplasm shows a more definite structure, consisting of minute striæ or fibrils arranged in a clear transparent matrix, or a honeycombed reticulum containing in its interstices a homogeneous substance. Protoplasm is insoluble in water, coagulates at 130° F., and has a great affinity for certain staining reagents, as logwood or carmine.

The most striking characteristics of protoplasm are its vital properties of *motion* and *nutrition*. By motion is meant the power which protoplasm has of changing its shape and position by some internal power in itself, which enables it to thrust out from its main body an irregular process, into which the whole of the protoplasmic substance is gradually drawn, so that the mass comes to occupy a new position. This, on account of its resemblance to the movements observed in the Amœba or Proteus animalcule, has been termed "amœboid movement." Ciliary movement, or the vibration of hair-like processes from the surface of any structure, may also be regarded as a variety of the motion with which protoplasm is endowed. Nutrition is the power which protoplasm has of attracting to itself the materials of growth from surrounding matter. When any foreign particle comes in contact with the protoplasmic substance, it becomes incorporated in it by being enwrapped by one or more processes projected from the parent mass and enclosed by them. When thus taken up, it may remain in the substance of the protoplasm for some time without change, or may be assimilated by the protoplasm.

The **Nucleus** is a minute body, imbedded in the protoplasm, and usually of a spherical or oval form, its size having little relation to the size of the cell. It is usually surrounded by a well-defined wall, the *nuclear membrane*, and its contents, known as the *nuclear substance*, are composed of a stroma or network and an interstitial substance, the relative amount of the two varying in different nuclei. The network appears to be continuous through the nuclear membrane with the protoplasmic reticulum, from which it differs, however, in having strung along it bands of a substance which stains readily with certain dyes, and is therefore named *chromatin*. The chromatin differs chemically from ordinary protoplasm in containing nuclein, in its power of resisting the action of acids and alkalies, in its imbibing more intensely the stain of carmine, hæmatoxylin, etc., and in its remaining unstained by some reagents which color ordinary protoplasm; as, for example, nitrate of silver.

The process of reproduction of cells commences in the nucleus, and is usually described as being brought about by *indirect* or by *direct division*. *Indirect division* or *karyokinesis* (*karyomitosis*) has been observed in all the tissues—generative cells, epithelial tissue, connective tissue, muscular tissue, and nerve-tissue—and it is the typical method by which the division of cells takes place, although the process of reproduction of cells by direct division occurs not infrequently, especially in highly specialized cells.

The process of reproduction by indirect division commences in the nucleus, the stroma of which undergoes complex changes, leading to the division of this body previous to the cleavage of the protoplasm of the cell. The changes consist briefly of the following: (1) At the commencement of the process the nuclear network is

well developed, but shows only slight indications of activity. (2) The chromatic fibrils, after rearranging themselves, become thicker, and probably combine in one long filament, which forms a loose convolution. This is called the *glomerulus* or *skein* (Fig. 6, B). At the same time a number of protoplasmic granules arrange themselves at two points in the cell-protoplasm opposite each other; these points are called the *poles*, and the line midway between them, and bisecting at right

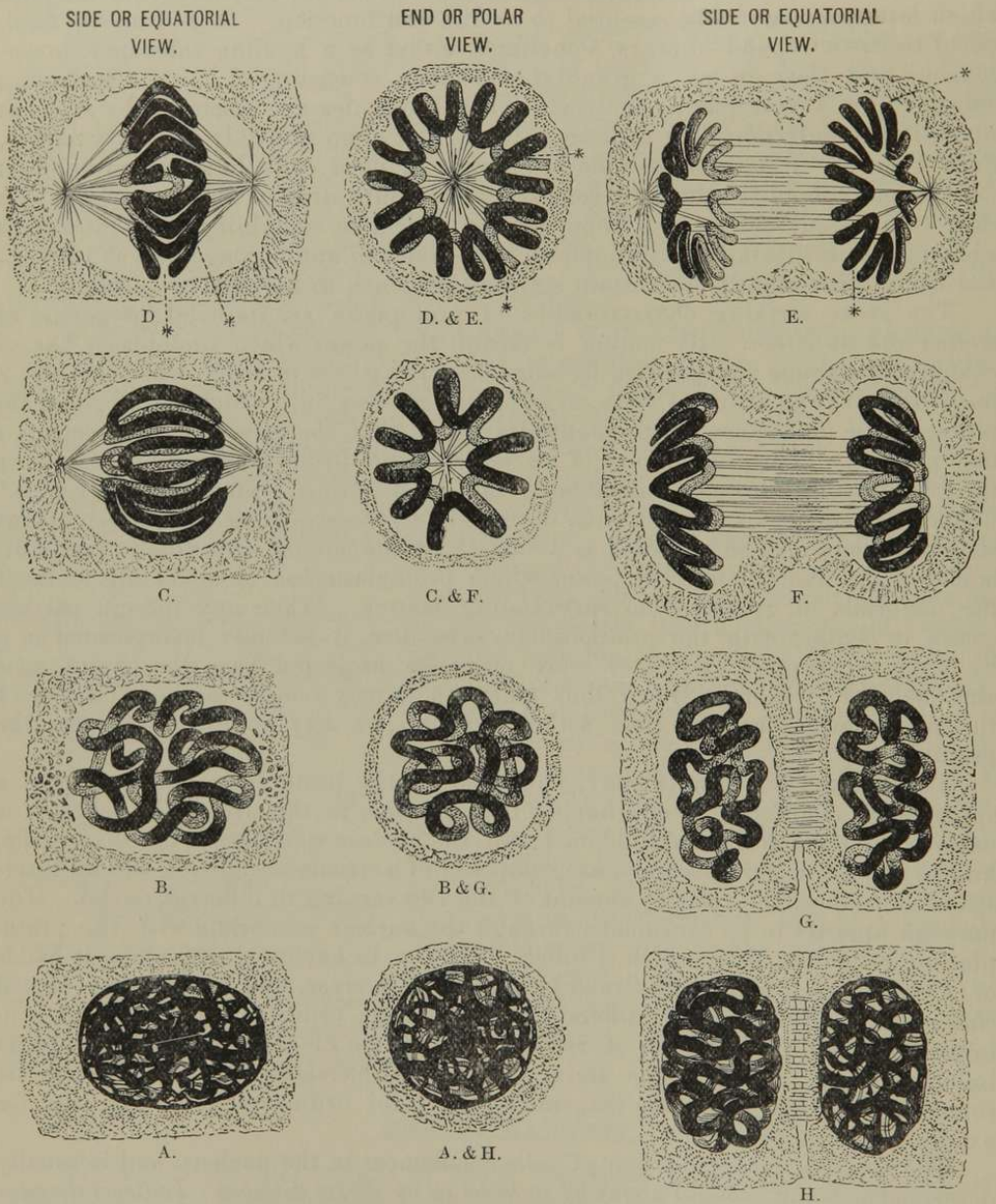

FIG. 6.—Karyokinesis, or indirect cell-division. Diagram explaining the formation of the chromatic and achromatic karyokinetic figures in epithelial cells. The radiating arrangement of protoplasmic granules is also indicated, although it is in the ova of the lower animals that this appearance has been more specially studied. All the figures are simplified for diagrammatic purposes, but represent stages which can easily be recognized in specimens properly stained. The longitudinal splitting of the filaments has not been represented. A. Resting nucleus, the nuclear network deeply stained. B. Glomerulus, convolution or skein. C. Rosette or wreath. D. Aster or monaster. E. Diaster or daughter star. F. Daughter rosettes. G. Daughter glomeruli or skeins. H. Daughter nuclei. (By Dr. S. Delépine.)

angles a line connecting the two, is called the *equator*. The aggregations of protoplasmic granules are termed the *centrosomes*, and they are surrounded by clear protoplasmic areas known as the *archoplasm spheres*. (3) The chromatic

filament becomes arranged in more or less distinct loops converging toward the two poles, resembling somewhat in appearance a *rosette* or *wreath* (Fig. 6, C). From the poles to the loops, fine threads, not staining like the others (achromatic), are seen bridging across the space left between the filament and the cell-protoplasm. These are known as the *nuclear spindle.* (4) The loops now become flattened so as to form a festooned ring or star at the equator of the nucleus. This is known as the *single star*, *aster*, *monaster.* The loops begin to break transversely at the equator (Fig. 6, D*), having sometimes previously broken at their polar ends. The nuclear spindle or achromatin is very distinct, as well as a radiating arrangement of protoplasmic granules toward the poles. It is at this stage, or sometimes after, that a longitudinal splitting of the filaments occurs, so that they become more numerous and more slender. (5) After breaking across at the equator, the chromatic filaments move toward the poles as if they were guided by the achromatic threads. These threads bridge across between the two receding stars, which are known as *diaster* or *daughter stars.* The protoplasm, with its radiating granules, begins to group itself around the two poles (Fig. 6, E). (6) The daughter stars have now reached the poles; the broken ends become united, so that each daughter chromatic filament becomes a single festooned filament, forming a rosette or wreath, the *daughter rosettes* or *wreaths.* There is now distinct evidence of cleavage in the protoplasm (Fig. 6, F). (7) By further irregular contraction the regular arrangement of the loops becomes lost, and the filament presents a convoluted appearance, constituting the *daughter glomeruli* or *skeins* (Fig. 6, G). The cleavage of the protoplasm is now complete except where the achromatic threads are found. (8) By further convolution and contraction the loops of the filament become fused together, and form again a network. The nuclear membrane which disappeared at the beginning of the karyokinesis is formed anew, and two *daughter cells* with *nuclei* are formed (Fig. 6, H). The remains of the achromatic threads bridge across the intercellular substance, but later usually disappear completely.

In the reproduction of cells by *direct* division the process is brought about either by segmentation or by gemmation. In reproduction by *segmentation* or *fission* the nucleus first splits by becoming constricted in its centre, and thus assuming an hour-glass shape. This leads to a cleavage or division of the whole protoplasmic mass of the cell; and thus we find that two new cells have been formed, consisting of the same substance as the original one, and each containing a nucleus. These daughter cells are of course at first smaller than the original mother cell; but they grow, and the process may be repeated in them, so that multiplication may rapidly take place. In reproduction by *gemmation* a budding-off or separation of a portion of the nucleus and parent-cell takes place, and, becoming separated, forms a new organism.

The **cell-wall**, which is not an essential constituent, and in fact is often absent, consists of a flexible, transparent, structureless or finely striated membrane, which is permeable to fluids. As far as is known, every animal cell is derived from a pre-existing cell. The death of cells is accomplished either by their mechanical detachment from the surface, preceded possibly by their bursting and discharging their contents, or by various forms of degeneration—fatty, pigmentary, or calcareous.

EPITHELIUM.

All the surfaces of the body—the external surface of the skin, the internal surface of the digestive, respiratory, and genito-urinary tracts, the closed serous cavities, the inner coat of the vessels, and the ducts of all secreting and excreting glands—are covered by one or more layers of simple cells, called *epithelium* or *epithelial cells.* These cells are also present in the sensory and terminal parts of the organs of special sense, and in some other organs, as the pituitary and thyroid bodies. They serve various purposes, forming in some cases a protective layer, in others acting as an agent in secretion and excretion, and again in others being concerned in the elaboration of the organs of special sense. Thus, in the skin,

the main purpose served by the epithelium (here called the *epidermis*) is that of protection. As the surface is worn away by the agency of friction or change of temperature new cells are supplied, and thus the surface of the true skin and the vessels and nerves which it contains are defended from damage. In the gastro-intestinal mucous membrane and in the glands the epithelial cells appear to be the principal agents in separating the secretion from the blood or from the alimentary fluids. In other situations (as the nose, fauces, and respiratory passages) the chief office of the epithelial cells appears to be to maintain an equable temperature by the moisture with which they keep the surface always slightly lubricated. In the serous cavities they also keep the opposed layers moist, and thus facilitate their movements on each other. Finally, in all internal parts they ensure a perfectly smooth surface.

Of late years there has been a tendency on the part of many histologists to divide these several epithelial linings into two classes: into (1) *epithelial tissue proper*, consisting of nucleated protoplasmic cells, which form continuous masses on the skin and mucous surfaces and the linings of the ducts and alveoli of secreting and excreting glands; and (2) *endothelium*, which is composed of a single layer of flattened transparent squamous cells, joined edge to edge in such a manner as to form a membrane of cells. This is found on the free surfaces of the serous membranes, as the lining membrane of the heart, blood-vessels, and lymphatics; on the surface of the brain and spinal cord, and in the anterior chamber of the eye. And, though the separation must be an artificial one, since every gradation of transition between the two classes may be observed, it would seem advisable for the purpose of description to employ it.

1. **True epithelial tissue** consists of one or more layers of cells, united together

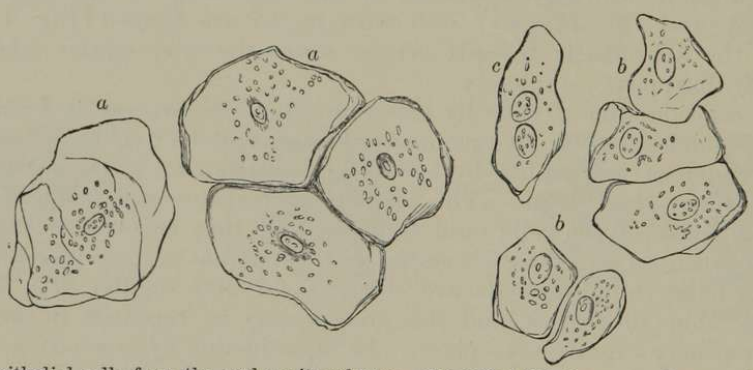

FIG. 7.—Epithelial cells from the oral cavity of man. Magnified 350 times. *a*. Large. *b*. Middle-sized. *c*. The same with two nuclei.

by an interstitial cement-substance, supported on a basement-membrane, and is naturally grouped into two classes, according as there is a single layer of cells (*simple epithelium*) or more than one (*stratified epithelium*). The various kinds of epithelium, whether arranged in a single layer or in more than one layer, are usually spoken of as squamous or pavement, columnar, spheroidal or glandular, and ciliated.

The *pavement* epithelium (Fig. 7) is composed of flat nucleated scales of various shapes, usually polygonal, and varying in size. These cells fit together by their edges, like the tiles of a mosaic pavement. The nucleus is generally flattened, but may be spheroidal. The flattening depends upon the thinness of the cell. The protoplasm of the cell presents a fine reticulum or honeycombed network, which gives to the cell the appearance of granulation. This kind of epithelium is found on the surface of the skin (epidermis) and on mucous surfaces which are subjected to friction. The nails, the hairs, and (in animals) the horns are a variety of this kind of epithelium.

A variety of squamous epithelium which is found in the deeper layers of

stratified pavement-epithelium has been termed *prickle cells*. These cells possess short fine fibrils which pass from their margins to those of neighboring cells, serving to connect them together. They were first probably noticed by Max Schultze and Virchow, and it was believed that by them the cells were dovetailed together. Subsequently this was shown not to be so by Bizzozero, who pointed out that the prickles were attached to each other by their apices and formed minute bridges across spaces occurring between the cells of the epithelium.

The *columnar* or *cylindrical* epithelium (Fig. 8) is formed of cylindrical or rod-shaped cells, each containing a nucleus, and set together so as to form a com-

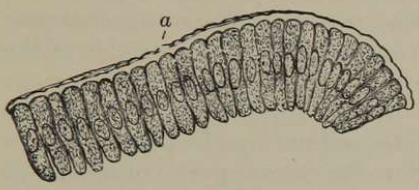

FIG. 8.—Epithelium of the intestinal villi of the rabbit. Magnified 300 times. *a*. Basement-membrane.

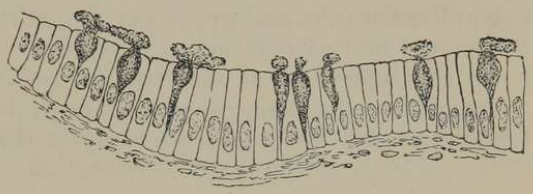

FIG. 9.—Simple columnar epithelium, from the mucous membrane of the intestine, with goblet-cells pouring out their contents. (Klein and Noble Smith.)

plete membrane. The cells have a prismatic figure, more or less flattened from mutual pressure, and are set upright on the surface on which they are supported. Their protoplasm is always more or less longitudinally striated, and they contain a nucleus which is oval in shape and contains an intranuclear network.

This form of epithelium covers the mucous membrane of nearly the whole gastro-intestinal tract and the glands of that part, the greater part of the urethra, the vas deferens, the prostate, Cowper's glands, Bartholini's glands, and a portion of the uterine mucous membrane.

Goblet- or *chalice*-cells are a modification of the columnar cell. They appear to be formed by an alteration in shape of the columnar epithelium (ciliated or otherwise) consequent on the secretion into the interior of the cell of *mucin*, the chief organic constituent of mucus, which distends the upper part of the cell, while the nucleus is pressed down toward its deep part, until the cell bursts and the mucus is discharged on to the surface of the mucous membrane, as shown in Fig. 9.

The *spheroidal* or *glandular* epithelium (Fig. 10) is composed of circular or polyhedral cells. Like other forms of epithelial cells, the protoplasm is a fine

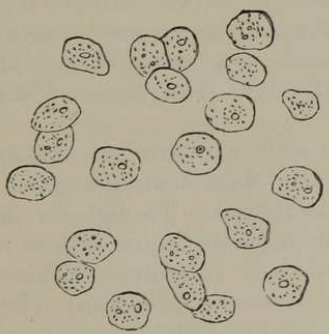

FIG. 10.—Spheroidal epithelium. Magnified 250 times.

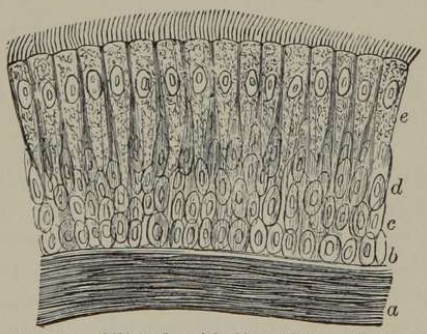

FIG. 11.—Ciliated epithelium from the human trachea. Magnified 350 times. *a*. Innermost layers of the elastic longitudinal fibres. *b*. Homogeneous innermost layers of the mucous membrane. *c*. Deepest round cells. *d*. Middle elongated cells. *e*. Superficial cells, bearing cilia.

reticulum, which gives to the cell the appearance of granulation. They are found in the terminal recesses of secreting glands, and the protoplasm of the cells usually contains the materials which the cells secrete.

Ciliated epithelium (Fig. 11) may be of any of the preceding forms, but usually

inclines to the columnar shape. It is distinguished by the presence of minute processes, which are direct prolongations of the cell-protoplasm standing up from the free surface like hairs or eyelashes (cilia). If the cells are examined during life or immediately on removal from the living body (for which in the human subject the removal of a nasal polypus offers a convenient opportunity) in tepid water, the cilia will be seen in lashing motion; and if the cells are separate, they will often be seen to be moved about in the field by that motion.

The situations in which ciliated epithelium is found in the human body are: the respiratory tract from the nose downward (except over the lower portion of the pharynx and the surface of the vocal cords) the tympanum and Eustachian tube, the Fallopian tube and upper portion of the uterus, the vasa efferentia, coni vasculosi, and first part of the excretory duct of the testicle, and the ventricles of the brain and central canal of the spinal cord.

Stratified epithelium consists of several layers of cells superimposed one on the top of the other and varying greatly in shape. The cells of the deepest layer are for the most part columnar in form, and as a rule form a single layer, placed vertically on the supporting membrane; above these are several layers of spheroidal cells, which as they approach the surface become more and more compressed, until the superficial layers are found to consist of flattened scales, the margins of which overlap one another, so as to present an imbricated appearance. Another form of stratified epithelium is found in what has been termed *transitional* epithelium, such as exists in the ureters and urinary bladder. Here the cells of the most superficial layer are cubical, with depressions on their under surfaces, which fit on to the rounded ends of the cells of the second layer, which are pear-shaped, the apices touching the basement-membrane. Between their tapering points is a third variety of cells, filling in the intervals between them, and of smaller size than those of the other two layers.

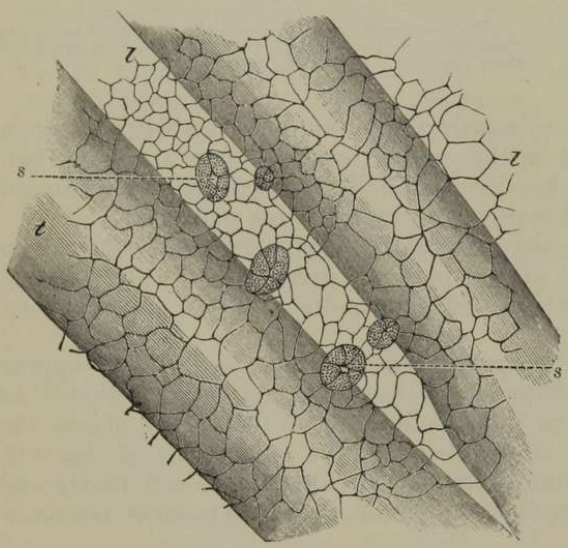

FIG. 12.—Part of peritoneal surface of the central tendon of diaphragm of rabbit, prepared with nitrate of silver. *s*. Stomata. *l*. Lymph-channels. *t*. Tendon-bundles. The stomata are surrounded by cubical endothelial cells. (From *Hand-book for the Physiological Laboratory*, Klein.)

2. **Endothelium.**—As before stated, endothelial cells are flattened, transparent, squamous cells, attached by their margins by a semi-fluid homogeneous cement-substance, so as to form a continuous *endothelial* membrane. Though for the most part these cells are squamous, in some places cells may be found, either isolated or occurring in patches, which are polyhedral or even columnar. These latter cells are frequently to be found lining the stomata of serous membranes (Fig. 12). As a rule, the endothelial cells are polygonal in outline, with sinuous or jagged margins, and are in close apposition, the amount of cohesive matter uniting them being so slight as not to be apparent. Their protoplasmic substance appears to be granular, but consists of fibrillæ arranged in a network in which the nucleus is contained, limited by a membrane and having a well-developed reticulum.

CONNECTIVE TISSUES.

By the term **connective tissue** we mean a number of tissues which possess this feature in common—viz. that they serve the general purpose in the animal economy

of supporting and connecting the tissues of the frame. These tissues may differ considerably from each other in external appearance, but they present nevertheless many points of relationship with each other, and are moreover developed from the same embryonal elements. They are divided into three great groups: (1) the fibrous connective tissues, (2) cartilage, and (3) bone.

The Fibrous Connective Tissues.—Three principal forms or varieties of fibrous connective tissue are recognized: (1) White fibrous tissue; (2) Yellow elastic tissue; (3) Areolar tissue. They are all composed of a matrix in which cells are imbedded, and between the cells are fibres of two kinds, the white and yellow or elastic. The difference between the three forms of tissue depends on the relative proportion of the two kinds of fibre, in the first variety enumerated the *white* fibre preponderating; in the second variety the *yellow elastic* fibres being greatly in excess of the white; and the third form, areolar tissue, the two being blended in much more equal proportions.

The **white fibrous tissue** (Fig. 13) is a true connecting structure, and serves three purposes in the animal economy. It serves to bind bones together in the form of ligaments, it serves to connect muscles to bones or other structures in the form of tendons, and it forms an investing or protecting structure to various organs in the form of membranes. Examples of where it serves this latter office are to be found in the muscular fasciæ or sheaths, the periosteum, and perichondrium; the investments of the various glands, (such as the tunica albuginea testis, the capsule of the kidney, etc.), the investing sheath of the nerves (epineurium), and of various organs, as the penis and the eye (sheath of the corpora cavernosa and corpus spongiosum, and of the sclerotic). But in all these parts the student must bear in mind that the elastic tissue enters in greater or less proportion. It presents to the naked eye the appearance of silvery-white glistening fibres, covered over with a quantity of loose, flocculent tissue which binds the fibres together and carries the blood-vessels. It is not possessed of any elasticity, and only the very slightest extensibility; it is exceedingly strong, so that upon the application of any external violence the bone with which it is connected will fracture before the fibrous tissue will give way. When examined under the microscope it is found to consist of waving bands or bundles of minute, transparent, homogeneous filaments or fibrillæ, held together by an albuminous semi-fluid cement-substance (Fig. 14). In ligaments and tendons these bundles run parallel with each other; in membranes they intersect one another in different places. The bundles have a tendency to split up longitudinally or send off slips to join other bundles and receive others in return. The cells occurring in white fibrous tissue are often called "tendon cells." They are situated on the surface of groups of bundles and are quadrangular in shape, arranged in rows in single file, each cell being separated from its neighbors by a narrow line of cement-substance. The nucleus is generally situated at one end of the cell, the nucleus of the adjoining cell being in close proximity to it (Fig. 15). Upon the addition of acetic acid to white fibrous tissue it swells up into a glassy-looking, indistinguishable mass. When boiled in water it is converted almost completely into gelatin.

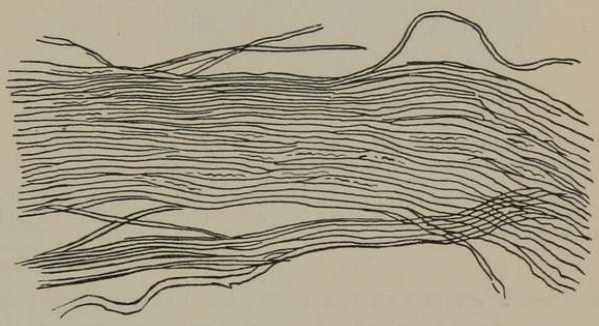

FIG. 13.—White fibrous tissue. High power.

Yellow Elastic Tissue.—In certain parts of the body a tissue is found which when viewed in mass is of a yellowish color, and is possessed of great elasticity, so that it is capable of considerable extension, and when the extending force is withdrawn returns at once to its original condition. This is *yellow elastic tissue*, in

which the elastic fibres greatly preponderate, to the almost complete exclusion of the white fibrous element. It is found in this condition in the ligamenta subflava, in the vocal cords, in the longitudinal coat of the trachea and bronchi, in the inner coats of the blood-vessels, especially the larger arteries, and to a very con-

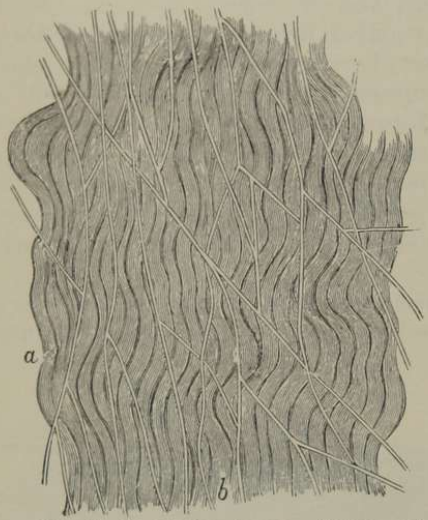

FIG. 14.—Connective tissue. (Klein and Noble Smith.) *a*. The white fibrous element—a layer of more or less sharply-outlined, parallel, wavy bundles of connective-tissue fibrils. On the surface of this layer is *b*, a network of fine elastic fibres.



FIG. 15.—Tendon of mouse's tail, stained with hæmatoxylin, showing chains of cells between the tendon-bundles. (From Quain's *Anatomy*. E. A. Schafer.)

siderable extent in the thyro-hyoid, crico-thyroid, and stylo-hyoid ligaments. It is also found in the ligamentum nuchæ of the lower animals. When viewed under the microscope (Fig. 16) it is seen to consist of an aggregation of curling fibres, with a well-defined outline. They are considerably larger in size than the fibrillæ of the white fibrous element, and vary much, being from the $\frac{1}{24000}$ to the $\frac{1}{4000}$ of an inch in diameter. The fibres form bold and wide curves, branch and freely anastomose with each other. They are homogeneous in appearance, and have a tendency to curl up, especially at their broken ends. In some parts, where the fibres are broad and large and the network close, the tissue presents the appearance of a membrane, with gaps or perforations corresponding to the intervening space. This is to be found in the inner coat of the arteries, and to it the name of *fenestrated membrane* has been given by Henle. The yellow elastic fibres remain unaltered by acetic acid.

Areolar tissue is so called because its meshes are easily distended, and thus separated into areolæ or spaces, which all open freely into each other, and are consequently easily blown up with air, or permeated by fluid when injected into any part of the tissue. Such spaces, however, do not exist in the natural condition of the body, but the whole tissue forms one unbroken membrane composed of a number of interlacing fibres, variously superimposed. Hence the term "the cellular membrane" is in many parts of the body more appropriate than its more modern equivalent. The chief use of the areolar tissue is to bind parts together, while by the laxity of its fibres and the permeability of its areolæ it allows them to move on each other, and affords a ready exit for inflammatory and other effused fluids. It is one of the most extensively distributed of all the tissues in the body. It is found beneath the skin in a continuous layer all over the body, connecting it to the subjacent parts. In the same way it is situated beneath the mucous and serous membranes. It is also found between muscles, vessels, and nerves, forming investing sheaths for them, and connecting them with surrounding structures. In addition to this, it is found in the interior of organs, binding together the various lobes and lobules of the compound glands,

the various coats of the hollow viscera, and the fibres of muscles, etc., and thus forms one of the most important connecting media of the various structures or

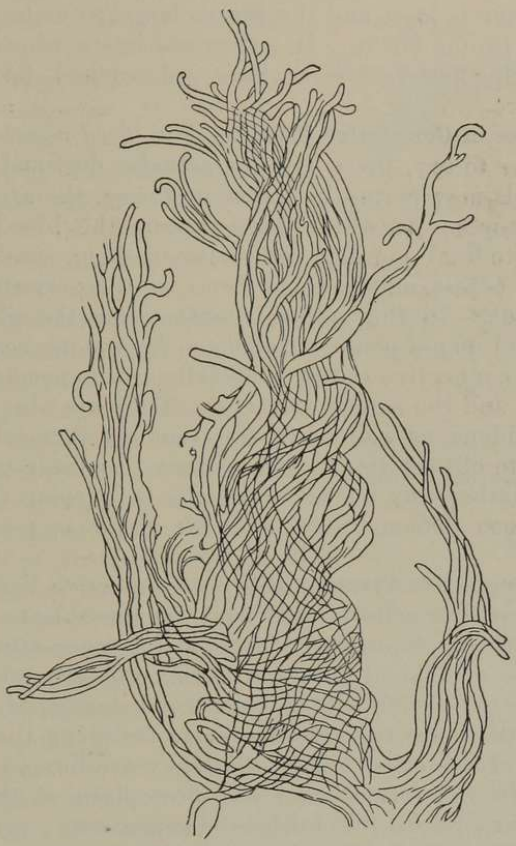

FIG. 16.—Yellow elastic tissue. High power.

organs of which the body is made up. In many parts the areolæ or interspaces of areolar tissue are occupied by fat-cells, constituting *adipose tissue*, which will presently be described.

Areolar tissue presents to the naked eye a flocculent appearance, somewhat like spun silk. When stretched out, it is seen to consist of delicate soft elastic threads interlacing with each other in every direction and forming a network of extreme delicacy. When examined under the microscope it is found to be composed of white fibres and elastic fibres intercrossing in all directions, and united together by a homogeneous cement or ground-substance, and filled by cellular elements, which contain the protoplasm out of which the whole is developed and regenerated.

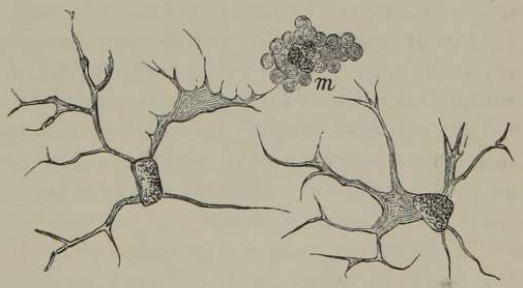

FIG. 17.—Connective-tissue corpuscles. (Klein and Noble Smith.) *m*. Migratory connective-tissue cell. The other two are the ordinary branched cells, each with an oblong nucleus.

These cell-spaces may be brought into view by treating the tissue with nitrate of silver, and exposing it to the light. This will color the fibres and ground-substance, leaving the cell-spaces unstained.

The cells of areolar tissue (Fig. 17) are of two kinds: 1, flattened transparent cells, with an oblong nucleus and more or less branched, and often united together by thin-branched processes; and 2, granular cells, some of which are of the size

of white blood-corpuscles, and like them possessed of amœboid movements; others are of larger size, and do not exhibit amœboid movements to any appreciable extent. They lie imbedded in the ground-substance, and in some situations, where the areolar tissue is loose and the spaces large, so as to contain several cells, they form a sort of lining for it. In other situations where the tissue forms a membranous layer, the flattened cells, here unbranched, form an epithelial-like covering to its surface.

Vessels and Nerves of Connective Tissue.—The *blood-vessels* of connective tissue are very few—that is to say, there are few actually destined for the tissue itself, although many vessels may permeate one of its forms, the areolar tissue, carrying blood to other structures. In white fibrous tissue the blood-vessels usually run parallel to the longitudinal bundles and between them, sending transverse communicating branches across, and in some forms, as the periosteum and dura mater, being fairly numerous. In the yellow elastic tissue the blood-vessels also run between the fibres, and do not penetrate them. *Lymphatic* vessels are very numerous in most forms of connective tissue, especially in the areolar tissue beneath the skin and the mucous and the serous surfaces. They are also found in abundance in the sheaths of tendons, as well as in the tendons themselves. *Nerves* are to be found in the white fibrous tissue, where they terminate in a special manner; but it is doubtful whether any nerves terminate in areolar tissue; at all events, they have not yet been demonstrated, and the tissue is possessed of very little sensibility.

Development of Connective Tissue.—Fibrous connective tissue is developed from embryonic connective-tissue cells derived from the mesoblast. At an early period of development it consists of nucleated cells and a muco-albuminous fluid, which subsequently becomes a pellucid jelly and forms the ground-substance. In this ground-substance the two varieties of fibres become developed. As to the manner in which they do so there are two theories, some believing that they are developed from the protoplasm of the cells, others that they are formed by a deposit in the ground-substance. In the former case the protoplasm of the cells is converted wholly into elementary fibres, the nucleus disappearing; or else the peripheral part of the protoplasm produces the fibrous tissue, the original cell growing again to its original size, and then throwing off a fresh portion to form a new cell, and itself persisting in contact with the fibres it has formed as a permanent connective-tissue corpuscle.

Three special forms of connective tissue must be described: the mucoid, the lymphoid or retiform, and basement-membranes.

1. The **mucoid** or **gelatinous** connective tissue exists chiefly in the "jelly of Wharton," which forms the bulk of the umbilical cord, but is also found in some other situations in the fœtus, as in the pulp of young teeth, and in certain stages of the development of connective tissue in various regions. In the adult the vitreous humor of the eye is formed of the same material. This tissue consists of nucleated cells, which branch and become connected so as to form trabeculæ, which traverse a jelly-like ground substance, containing the chemical principle of mucus, or *mucin*, and in smaller quantities albumen, but no gelatin. Sometimes, as in the vitreous humor of the eye, the cells almost completely disappear and the jelly only remains.

2. **Retiform** connective tissue (Fig. 18) is found extensively in many parts of the body, forming the framework of some organs and entering into the construction of many mucous membranes. It is formed of an interlacement or network of very fine fibres, which closely resemble white fibrous tissue, and in certain situations may be demonstrated to be continuous with it. In their behavior to certain reagents, however, they differ from the ordinary white fibres, and have consequently been held to be a third form of connective-tissue fibres. In many places flattened cells may be seen connected with the fibres and partially concealing them, presenting an appearance as if the tissue were formed of a network of branching and anastomosing cells. This, however, is not so, as the cells can be removed or

brushed away, leaving the fibres intact. In many situations the interstices of the fibres are filled with rounded granular corpuscles, and the tissue is then termed **lymphoid** or **adenoid tissue.** The *neuroglia*, or fine gelatinous connective tissue which supports the nervous elements in the cerebro-spinal axis and in the retina has been regarded as a modified form of the retiform connective tissue. It is now known, however, to consist of cells which send off very numerous fine processes, and develop from the epiblast, certain of the cells forming the wall of the medullary canal, becoming neuroglia cells, while the remainder become nerve-cells.

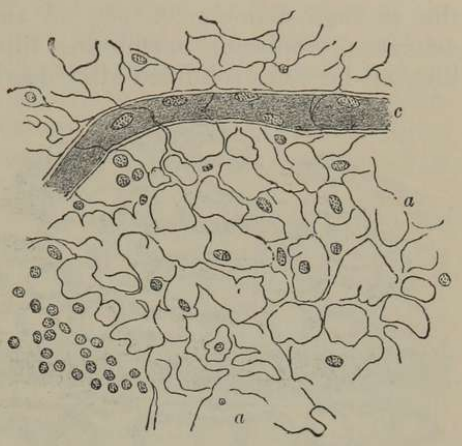

FIG. 18.—Retiform connective tissue, from a lymphatic gland: most of the lymph-corpuscles are removed. (From Klein's *Elements of Histology*.) *a*. The reticulum. *c*. A capillary blood-vessel.

3. **Basement-membranes**, formerly described as homogeneous membranes, are really a form of connective tissue. They constitute the supporting membrane, or membrana propria, supporting the epithelium of mucous membranes or secreting glands, and in other situations. By means of staining with nitrate of silver they may be shown to consist of flattened cells in close apposition, and form therefore an example of an epithelioid arrangement of connective-tissue cells. In some situations the cells, instead of adhering by their edges, give off branching processes, which join with similar processes of other cells, and so form a network rather than a continuous membrane.

Adipose Tissue.—In almost all parts of the body the ordinary areolar tissue contains a variable quantity of adipose or fatty tissue. The principal situations where it is not found are the subcutaneous tissue of the eyelids, the penis and scrotum, the nymphæ, within the cavity of the cranium, and in the lungs, except near the roots. Nevertheless, its distribution is not uniform, in some parts being collected in great abundance, as in the subcutaneous tissue, especially of the abdomen; around the kidneys; on the surface of the heart between the furrows; and in some other situations. Lastly, fat enters largely into the formation of the

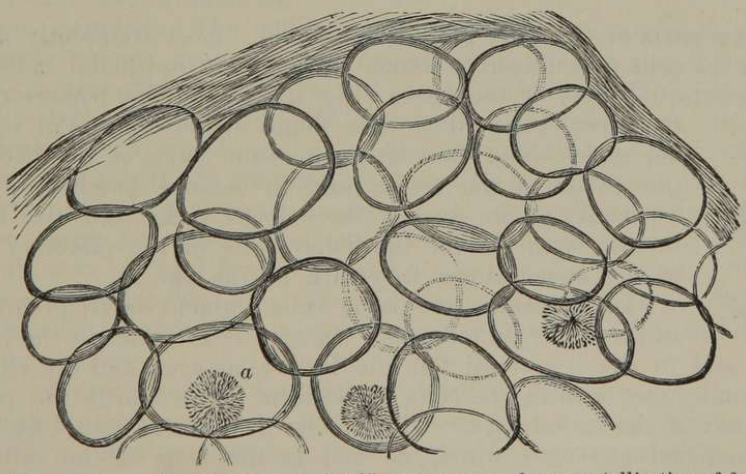

FIG. 19.—Adipose tissue. High power. *a*. Starlike appearance, from crystallization of fatty acids.

marrow of bones. A distinction must, however, be made between fat and adipose tissue; the latter being a distinct tissue, the former an oily matter, which

in addition to its occurrence in adipose tissue is also widely present in the body, as in the fat of the brain and liver and in the blood and chyle, etc.

Fat-cells (Fig. 19) consist of a number of vesicles, varying in size, but of about the average diameter of $\frac{1}{500}$ of an inch. They are formed of an exceedingly delicate protoplasmic membrane, filled with fatty matter, which is liquid during life, but becomes solidified after death. They are round or spherical where they have not been subjected to pressure; otherwise they assume a more or less angular outline. A nucleus is always present, and can be easily demonstrated by staining with hæmatoxylin; in the natural condition it is so compressed by the contained oily matter as to be scarcely recognizable. These fat-cells are contained in clusters in the areolæ of fine connective tissue, and are held together mainly by a network of capillary blood-vessels, which are distributed to them.

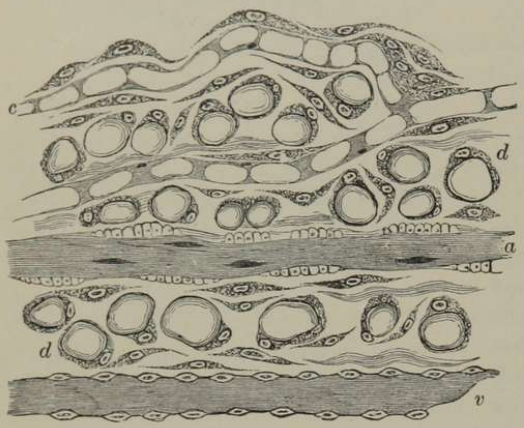

FIG. 20.—Development of fat. (Klein and Noble Smith.) *a*. Minute artery. *v*. Minute vein. *c*. Capillary blood-vessels in the course of formation; they are not yet completely hollowed out, there being still left in them protoplasmic septa. *d*. The ground-substance, containing numerous nucleated cells, some of which are more distinctly branched and flattened than others, and appear therefore more spindle-shaped.

Fat is an inorganized substance, consisting of a liquid material (glycerin) in combination with certain fatty acids, stearic, palmitic, and oleic. Sometimes the acids separate spontaneously before the fat is examined, and are seen under the microscope in a crystalline form, as in Fig. 19, *a*. By boiling the tissue in ether or strong alcohol the fat may be extracted from the vesicle, which is then seen empty and shrunken.

Fat is said to be first detected in the human embryo about the fourteenth week. The fat-cells are formed by the transformation of the protoplasmic connective-tissue corpuscles, into which small globules of fat find their way, and increase until they distend the corpuscle into the thin mantle of protoplasm which forms the cell-wall, and in which its nucleus is still to be seen (Fig. 20).

PIGMENT.

In various parts of the body *pigment* is found; most frequently in epithelial cells and in the cells of connective tissue. Pigmented epithelial cells are found forming the external layer of the retina (Fig. 21) and on the posterior surface of the iris. Pigment is also found in the epithelial cells of the deeper layers of the cuticle in some parts of the body—such as the areola of the nipple and in colored patches of skin, and especially in the skin of the colored races, and also in hair. It is also found in the epithelial cells of the olfactory region and of the membranous labyrinth of the ear.

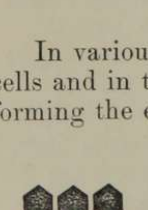

FIG. 21.—Pigment-cells of retina.

In the connective-tissue cells pigment is frequently met with in the lower vertebrates. In man it is found in the choroid coat of the eye, and in the iris of all but the light-blue eyes and the albino. It is also occasionally met with in the cells of retiform tissue and in the pia mater of the upper part of the spinal cord. These cells are characterized by their larger size and branched processes, which, as well as the body of the cells, are filled with granules. The pigment consists of dark-brown or black granules of very small size, closely packed together within the cells, but not invading the nucleus. Occasionally the pigment is yellow, and when occurring in the cells of the cuticle constitutes "freckles."

CARTILAGE.

Cartilage is a non-vascular structure which is found in various parts of the body—in adult life chiefly in the joints, in the parietes of the thorax, and in various tubes, such as the air-passages, nostrils, and ears, which are to be kept permanently open. In the fœtus at an early period the greater part of the skeleton is cartilaginous. As this cartilage is afterward replaced by bone, it is called *temporary*, in contradistinction to that which remains unossified during the whole of life, and which is called *permanent*.

Cartilage is divided, according to its minute structure, into true or hyaline cartilage, fibrous or fibro-cartilage, and yellow or elastic or reticular cartilage. Besides these varieties met with in the adult human subject, there is a variety called *cellular cartilage*, which consists entirely, or almost entirely, of cells, united in some cases by a network of very fine fibres, in other cases apparently destitute of any intercellular substance. This is found in the external ear of rats, mice, and some other animals, and is present in the chorda dorsalis of the human embryo, but is not found in any other human structure. The various cartilages in the body are also classified, according to their function and position, into articular, interarticular, costal, and membraniform.

Hyaline cartilage, which may be taken as the type of this tissue, consists of a gristly mass of a firm consistence, but of considerable elasticity and of a pearly-bluish color. Except where it coats the articular ends of bones, it is enveloped in a fibrous membrane, the *perichondrium*, from the vessels of which it imbibes its nutritive fluids, being itself destitute of blood-vessels; nor have any nerves been traced into it. Its intimate structure is very simple. If a thin slice is examined under the microscope, it will be found to consist of cells of a rounded or bluntly angular form, lying in groups of two or more in a granular or almost homogeneous matrix (Fig. 22). The cells, when arranged in groups of two or more, have generally a straight outline where they are in contact with each other, and in the rest of their circumference are rounded. The cell-contents consist of clear translucent protoplasm containing minute granules, and imbedded in this are one or two nuclei, having usually a granular appearance, but occasionally being clear and occupied by one or more nucleoli. The cells are imbedded in cavities in the matrix, called *cartilage lacunæ*, which are lined by a distinct transparent membrane called the *capsule*. Each lacuna is generally occupied by a single cell, but during the division of the cells it may contain two, four, or eight cartilage-cells. By boiling the cartilage for some hours and treating it with concentrated mineral acid, the capsule may be freed from the matrix, and can then be demonstrated as a distinct vesicle containing the cells. By exposure to the action of an electric shock the cell assumes a jagged outline and shrinks away from the interior of the capsule.

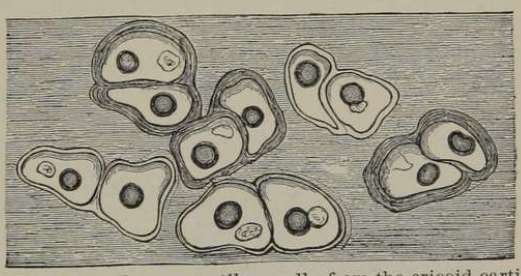

FIG. 22.—Human cartilage-cells, from the cricoid cartilage. Magnified 350 times.

The matrix is transparent and apparently without structure, or else presents a dimly granular appearance, like ground glass. Some observers have shown that the matrix of hyaline cartilage, and especially the articular variety, after prolonged maceration, can be broken up into fine fibrils. These fibrils are probably of the same nature, chemically, as the white fibres of connective tissue. It is believed by some histologists that the matrix is permeated by a number of fine channels, which connect the lacunæ with each other, and that these canals communicate with the lymphatics of the perichondrium, and thus the structure is permeated with a current of nutritious fluid.

The articular cartilages, the temporary cartilages, and the costal cartilages are all of the hyaline variety. They present minute differences in the size and shape of their cells and in the arrangement of their matrix. In the articular cartilages, which show no tendency to ossification, the matrix is finely granular under a high power; the cells and nuclei are small and are disposed parallel to the surface in the superficial part, while nearer to the bone they become vertical. Articular cartilages have a tendency to split in a vertical direction, probably from some peculiarity in the intimate structure or arrangement of the component parts of the matrix. In disease this tendency to a fibrous splitting becomes very manifest. Articular cartilage is not covered by perichondrium, at least on its free surface, where it is exposed to friction, though a layer of connective tissue can be traced in the adult over a small part of its circumference continuous with that of the synovial membrane, and here the cartilage-cells are more or less branched and pass insensibly into the branched connective-tissue corpuscles of the synovial membrane.

Articular cartilage forms a thin incrustation upon the joint-surfaces of the bones, and its elasticity enables it to break the force of any concussion, whilst its smoothness affords ease and freedom of movement. It varies in thickness according to the shape of the bone on which it lies; where this is convex the cartilage is thickest at the centre, where the greatest pressure is received; and the reverse is the case on the concave surfaces of the bones. Articular cartilage appears to imbibe its nutriment partly from the vessels of the neighboring synovial membrane, partly from those of the bone upon which it is implanted. Mr. Toynbee has shown that the minute vessels of the cancellous tissue as they approach the articular lamella dilate and form arches, and then return into the substance of the bone.

In the **costal cartilages** the cells and nuclei are large, and the matrix has a tendency to fibrous striation, especially in old age (Fig. 23). These cartilages are also very prone to ossify. In the thickest parts of the costal cartilages a few large vascular channels may be detected. This appears at first sight an exception to the statement that cartilage is a non-vascular tissue, but is not so really, for the vessels give no branches to the cartilage-substance itself, and the channels may rather be looked upon as involutions of the perichondrium. The ensiform cartilage may be regarded as one of the costal cartilages, and the cartilages of the nose and of the larynx and trachea resemble them in microscopical characters, except the epiglottis and cornicular laryngis, which are of the reticular variety.

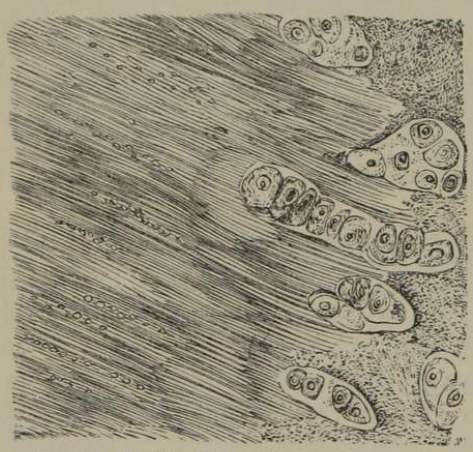

Fig. 23.—Costal cartilage from a man seventy-six years of age, showing the development of fibrous structure in the matrix. In several portions of the specimen two or three generations of cells are seen enclosed in a parent cell-wall. High power.

The hyaline cartilages, especially in adult and advanced life, are prone to calcify—that is to say, to have their matrix permeated by the salts of lime without any appearance of true bone. The process of calcification occurs also and still more frequently, according to Rollett, in such cartilages as those of the trachea, which are prone afterward to conversion into true bone.

White fibro-cartilage consists of a mixture of white fibrous tissue and cartilaginous tissue in various proportions; it is to the first of these two constituents that its flexibility and toughness are chiefly owing, and to the latter its elasticity. When examined under the microscope it is found to be made up of fibrous connective tissue arranged in bundles, with cartilage-cells between the bundles; these

to a certain extent resemble tendon-cells, but may be distinguished from them by being surrounded by an investing capsule and by their being less flattened (Fig. 24). The fibro-cartilages admit of arrangement into four groups —interarticular, connecting, circumferential, and stratiform.

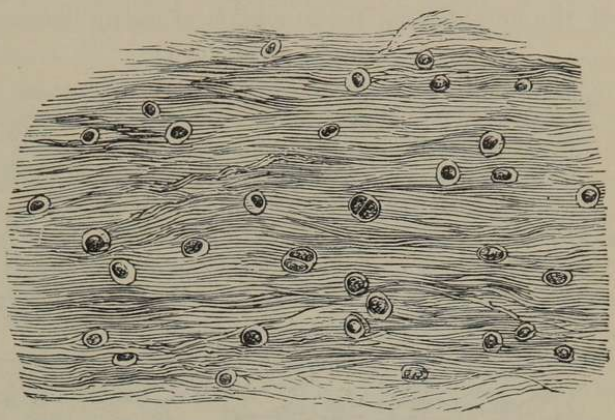

FIG. 24.—White fibro-cartilage from the semilunar disk of the patella joint of an ox. Magnified 100 times.

The **interarticular fibro-cartilages** (*menisci*) are flattened fibro-cartilaginous plates, of a round, oval, triangular, or sickle-like form, interposed between the articular cartilages of certain joints. They are free on both surfaces, thinner toward their centre than at their circumference, and held in position by their margins and extremities being connected to the surrounding ligaments. The synovial membrane of the joint is prolonged over them a short distance from their attached margins. They are found in the temporo-maxillary, sterno-clavicular, acromio-clavicular, wrist and knee-joints. These cartilages are usually found in those joints which are most exposed to violent concussion and subject to frequent movement. Their use is —to maintain the apposition of the opposed surfaces in their various motions; to increase the depth of the articular surfaces and give ease to the gliding movement; to moderate the effects of great pressure and deaden the intensity of the shocks to which the parts may be subjected. Humphry has pointed out that these interarticular fibro-cartilages serve an important purpose in increasing the variety of movements in a joint. Thus, in the knee-joint there are two kinds of motion, —viz. angular movement and rotation, although it is a hinge joint, in which, as a rule, only one variety of motion is permitted; the former movement taking place between the condyles of the femur and the interarticular cartilage, the latter between the cartilage and the head of the tibia. So, also, in the temporo-maxillary joint, the upward and downward movement of opening and shutting the mouth takes place between the cartilage and the jaw-bone, the grinding movement between the glenoid cavity and the cartilage, the latter moving with the jaw-bone.

The **connecting fibro-cartilages** are interposed between the bony surfaces of those joints which admit of only slight mobility, as between the bodies of the vertebræ and between the pubic bones. They form disks, which adhere closely to both of the opposed bones, and are composed of concentric rings of fibrous tissue, with cartilaginous laminæ interposed, the former tissue predominating toward the circumference, the latter toward the centre.

The **circumferential fibro-cartilages** consist of a rim of fibro-cartilage, which surrounds the margin of some of the articular cavities, as the cotyloid cavity of the hip and the glenoid cavity of the shoulder; they serve to deepen the articular surface and to protect the edges of the bone.

The **stratiform fibro-cartilages** are those which form a thin coating to osseous grooves through which the tendons of certain muscles glide. Small masses of fibro-cartilage are also developed in the tendons of some muscles, where they glide over bones, as in the tendons of the peroneus longus and the tibialis posticus.

Yellow, or reticular, elastic cartilage is found in the human body in the auricle of the external ear, the Eustachian tubes, the cornicula laryngis, and the epiglottis. It consists of cartilage-cells and a matrix, the latter being pervaded in every direction, except immediately around each cell, by a network of yellow

elastic fibres, branching and anastomosing in all directions (Fig. 25). The fibres resemble those of yellow elastic tissue, both in appearance and in being unaffected by acetic acid; and according to Rollett their continuity with the elastic fibres of the neighboring tissue admits of being demonstrated.



FIG. 25.—Yellow cartilage, ear of horse. High power.

The distinguishing feature of cartilage as to its chemical composition is that it yields on boiling a substance called *chondrin*, very similar to gelatin, but differing from it in not being precipitated by tannin. According to Kühne there is a small amount of gelatin in hyaline cartilage. Virchow believes that the semilunar disks in the knee-joint are wrongly denominated cartilages, since they yield no chondrin on boiling; and he appears to regard them as a modification of a tendinous structure, which, however, agrees with the cartilages in the important particular of being non-vascular.

Temporary cartilage and the process of its ossification will be described with Bone.

BONE.

Structure and Physical Properties of Bone.—Bone is one of the hardest structures of the animal body; it possesses also a certain degree of toughness and elasticity. Its color, in a fresh state, is of a pinkish white externally, and deep red within. On examining a section of any bone, it is seen to be composed of two kinds of tissue, one of which is dense and *compact* in texture, like ivory; the other consists of slender fibres and lamellæ, which join to form a reticular structure; this, from its resemblance to lattice-work, is called *cancellous*. The compact tissue is always placed on the exterior of the bone; the cancellous is always internal. The relative quantity of these two kinds of tissue varies in different bones, and in different parts of the same bone, as strength or lightness is requisite. Close examination of the compact tissue shows it to be extremely porous, so that the difference in structure between it and the cancellous tissue depends merely upon the different amount of solid matter, and the size and number of spaces in each; the cavities being small in the compact tissue and the solid matter between them abundant, whilst in the cancellous tissue the spaces are large and the solid matter in smaller quantity.

Bone during life is permeated by vessels and is enclosed in a fibrous membrane, the *periosteum*, by means of which many of these vessels reach the hard tissue. If the periosteum is stripped from the surface of the living bone, small bleeding points are seen, which mark the entrance of the periosteal vessels; and on section during life every part of the bone will be seen to exude blood from the minute vessels which ramify in it. The interior of the bones of the limbs presents a cylindrical cavity filled with marrow and lined by a highly vascular areolar structure, called the *medullary membrane* or *internal periosteum*, which, however, is rather the areolar envelope of the cells of the marrow than a definite membrane.

The **periosteum** adheres to the surface of the bones in nearly every part, excepting at their cartilaginous extremities. Where strong tendons or ligaments

are attached to the bone, the periosteum is incorporated with them. It consists of two layers closely united together, the outer one formed chiefly of connective tissue, containing occasionally a few fat-cells; the inner one, of elastic fibres of the finer kind, forming dense membranous networks, which can be again separated into several layers. In young bones the periosteum is thick, and very vascular, and is intimately connected at either end of the bone with the epiphysial cartilage, but less closely with the shaft, from which it is separated by a layer of soft blastema, containing a number of granular corpuscles or "osteoblasts," in which ossification proceeds on the exterior of the young bone. Later in life the periosteum is thinner, less vascular, and the osteoblasts have become converted into an epithelial layer, which is separated from the rest of the periosteum in many places by cleft-like spaces, which are supposed to serve for the transmission of lymph. The periosteum serves as a nidus for the ramification of the vessels previous to their distribution in the bone; hence the liability of bone to exfoliation or necrosis, when denuded of this membrane by injury or disease. Fine nerves and lymphatics, which generally accompany the arteries, may also be demonstrated in the periosteum.

The **marrow** not only fills up the cylindrical cavity in the shafts of the long bones, but also occupies the spaces of the cancellous tissue and extends into the larger bony canals (Haversian canals) which contain the blood-vessels. It differs in composition in different bones. In the shafts of adult long bones the marrow is of a *yellow* color, and contains, in 100 parts, 96 of fat, 1 of areolar tissue and vessels, and 3 of fluid, with extractive matter, and consists of a matrix of fibrous tissue, supporting numerous blood-vessels and cells, most of which are fat-cells, but some few are "marrow-cells." In the flat and short bones, in the articular ends of the long bones, in the bodies of the vertebræ, in the cranial diploë, and in the sternum and ribs, it is of a *red* color, and contains, in 100 parts, 75 of water and 25 of solid matter, consisting of albumen, fibrin, extractive matter, salts, and a mere trace of fat. The red marrow consists of a small quantity of areolar tissue, blood-vessels, and numerous cells, some few of which are fat-cells, but the great majority roundish nucleated cells, the true "marrow-cells" of Kölliker. These marrow-cells resemble in appearance the white corpuscles of the blood, though they are larger and have a relatively larger nucleus and a clearer protoplasm, but, like them, possess amœboid movements. Amongst them may be seen smaller cells (erythroblasts) which possess a slightly pinkish hue; and it has been held by Neumann that they are a transitional stage between marrow-cells and red blood-corpuscles, while others believe them to be the direct descendants of the nucleated embryonic blood-cells (see p. 127), and to be transformed into blood-corpuscles by the loss of their nuclei.

Giant-cells (*myelo-plaques*, *osteoclasts*), large, multinucleated, protoplasmic masses, are also to be found in both sorts of adult marrow, but more particularly in red marrow. They were believed by Kölliker to be concerned in the absorption of bone matrix, and hence the name which he gave to them—*osteoclasts*. They excavate small shallow pits or cavities, which are named *Howship's lacunæ*, in which they are found lying.

Vessels of Bone.—The blood-vessels of bone are very numerous. Those of the compact tissue are derived from a close and dense network of vessels ramifying in the periosteum. From this membrane vessels pass into the minute orifices in the compact tissue, running through the canals which traverse its substance. The cancellous tissue is supplied in a similar way, but by a less numerous set of larger vessels, which, perforating the outer compact tissue, are distributed to the cavities of the spongy portion of the bone. In the long bones numerous apertures may be seen at the ends near the articular surfaces, some of which give passage to the arteries of the larger set of vessels referred to; but the most numerous and largest apertures are for the veins of the cancellous tissue, which run separately from the arteries. The medullary canal in the shafts of the long bones is supplied by one large artery (or sometimes more), which enters the bone at the nutrient foramen

(situated in most cases near the centre of the shaft), and perforates obliquely the compact structure. The *medullary* or *nutrient* artery, usually accompanied by one or two veins, sends branches upward and downward to supply the medullary membrane, which lines the central cavity and the adjoining canals. The ramifications of this vessel anastomose with the arteries both of the cancellous and compact tissues. In most of the flat, and in many of the short spongy bones, one or more large apertures are observed, which transmit, to the central parts of the bone, vessels corresponding to the medullary arteries and veins. The veins emerge from the long bones in three places (Kölliker): (1) by one or two large veins, which accompany the artery; (2) by numerous large and small veins at the articular extremities; (3) by many small veins which arise in the compact substance. In the flat cranial bones the veins are large, very numerous, and run in tortuous canals in the diploic tissue, the sides of the canals being formed by a thin lamella of bone, perforated here and there for the passage of branches from the adjacent cancelli. The same condition is also found in all cancellous tissue, the veins being enclosed and supported by osseous structure and having exceedingly thin coats. When the bony structure is divided, the vessels remain patulous, and do not contract in the canals in which they are contained. Hence the constant occurrence of purulent absorption after amputation in those cases where the stump becomes inflamed and the cancellous tissue is infiltrated and bathed in pus.

Lymphatic vessels, in addition to those found in the periosteum, have been traced by Cruikshank, into the substance of bone, and Klein describes them as running in the Haversian canals.

Nerves are distributed freely to the periosteum, and accompany the nutrient arteries into the interior of the bone. They are said by Kölliker to be most numerous in the articular extremities of the long bones, in the vertebræ and the larger flat bones.



FIG 26.—From a transverse section of the shaft of the humerus. Magnified 350 times. *a*. Haversian canals. *b*. Lacunæ, with their canaliculi in the lamellæ of these canals. *c*. Lacunæ of the interstitial lamellæ. *d*. Others at the surface of the Haversian systems, with canaliculi given off from one side.

Minute Anatomy.—The intimate structure of bone, which in all essential particulars is identical in the compact and cancellous tissue, is most easily studied in a transverse section from the compact wall of one of the long bones after maceration, such as is shown in Fig. 26.

If this is examined with a rather low power the bone will be seen to be mapped out into a number of circular districts, each one of which consists of a central hole, surrounded by a number of concentric rings. These districts are termed *Haversian systems;* the central hole is an *Haversian canal*, and the rings around are layers of bone-tissue arranged concentrically around the central canal, and termed *lamellæ*. Moreover, on closer examination, it will be found that between these lamellæ, and therefore also arranged concentrically around the central canal, are a number of little dark specks, the *lacunæ*, and that these lacunæ are connected with each other and with the central Haversian canal by a number of fine dark lines, which radiate like the spokes of a wheel and are called *canaliculi*. All these structures —the concentric lamellæ, the lacunæ, and the canaliculi—may be seen in any single Haversian system, forming a circular district round a central, Haversian, canal. Between these circular systems, filling in the irregular intervals which are left between them, are other lamellæ, with their lacunæ and canaliculi, running in

various directions, but more or less curved (Fig. 27). These are termed *interstitial* lamellæ. Again, other lamellæ, for the most part found on the surface of the bone, are arranged concentrically to the circumference of bone, constituting, as it were, a single Haversian system of the whole bone, of which the medullary cavity would represent the Haversian canal. These latter lamellæ are termed *circumferential*, or by some authors *primary* or *fundamental* lamellæ, to distinguish them from those laid down around the axis of the Haversian canals, which are then termed *secondary* or *special* lamellæ.

The *Haversian canals*, seen as round holes in a transverse section of bone at or about the centre of each Haversian system, may be demonstrated to be true canals if a longitudinal section is made, as in Fig. 29. It will then be seen that these round holes are tubes cut across, which run parallel with the longitudinal

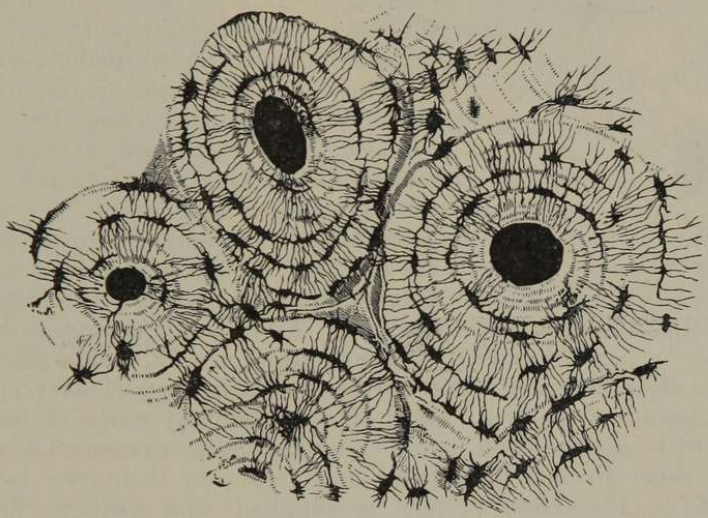

FIG. 27.—Transverse section of compact tissue of bone. Magnified about 150 diameters. (Sharpey.)

axis of the bone for a short distance, and then branch and communicate. They vary considerably in size, some being as large as $\frac{1}{200}$ of an inch in diameter; the average size being, however, about $\frac{1}{500}$ of an inch. Near the medullary cavity the canals are larger than those near the surface of the bone. Each canal, as a rule, contains two blood-vessels, a small artery and vein; the larger ones also contain a small quantity of delicate connective tissue, with branched cells, the processes of which communicate with the branched processes of certain bone-cells in the substance of the bone. Those canals near the surface of the bone open upon it by minute orifices, and those near the medullary cavity open in the same way into this space, so that the whole of the bone is permeated by a system of blood-vessels running through the bony canals in the centre of the Haversian systems.

The *lamellæ* are thin plates of bone-tissue encircling the central canal, and might be compared, for the sake of illustration, to a number of sheets of paper pasted one over another around a central hollow cylinder. After macerating a piece of bone in dilute mineral acid, these lamellæ may be stripped off in a longitudinal direction as thin films. If one of these is examined with a high power under the microscope it will be found to be composed of a finely reticular structure, presenting the appearance of lattice-work made up of very slender, transparent fibres, decussating obliquely, and coalescing at the points of intersection so as to form an exceedingly delicate network. In many places the various lamellæ may be seen to be held together by tapering fibres, which run obliquely through them, pinning or bolting them together. These fibres were first described by Sharpey, and were named by him *perforating fibres*.

The *lacunæ* are situated between the lamellæ, and consist of a number of oblong spaces. In an ordinary microscopic section, viewed by transmitted light, they appear as dark, oblong, opaque spots, and were formerly believed to be solid cells. Subsequently, when it was seen that the Haversian canals were channels which lodge the vessels of the part, and the canaliculi minute tubes by which the plasma of the blood circulates through the tissue, it was taught that the lacunæ were hollow spaces filled during life with the same fluid, and only lined (if lined at all) by a delicate membrane. But this view appears also to be delusive. Examination of the structure of bone, when recent, led Virchow to believe that the lacunæ are occupied during life with a nucleated cell, the processes from which pass down the canaliculi—a view which is now universally received (Fig. 28). It is by means of these cells that the fluids necessary for nutrition are brought into contact with the ultimate tissue of bone.

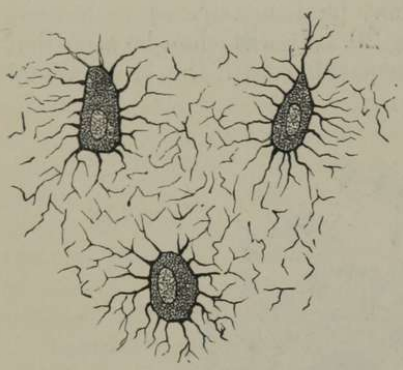

FIG. 28.—Nucleated bone-cells and their processes, contained in the bone-lacunæ and their canaliculi respectively. From a section through the vertebra of an adult mouse. (Klein and Noble Smith.)

The *canaliculi* are exceedingly minute channels, which pass *across* the lamellæ and connect the lacunæ with neighboring lacunæ and also with the Haversian canal. From this central canal a number of the canaliculi are given off, which radiate from it, and open into the first set of lacunæ, arranged around the Haversian canal, between the first and second lamellæ. From these lacunæ a second set of canaliculi are given off, which pass outward to the next series of lacunæ, and so on until they reach the periphery of the Haversian system; here the canaliculi given off from the last series of lacunæ do not communicate with the lacunæ of neighboring Haversian systems, but after passing outward for a short distance form loops and return to their own lacuna. Thus every part of an Haversian system is supplied with nutrient fluids derived from the vessels in the Haversian canals and traversing the canaliculi and lacunæ.

The *bone-cells* are contained in the lacunæ, which, however, they do not completely fill. They are flattened nucleated cells, which Virchow has shown are homologous with those of connective tissue. The cells are branched, and the branches, especially in young bones, pass into the canaliculi from the lacunæ.

If a longitudinal section is examined, as in Fig. 29, the structure is seen to be the same. The appearance of concentric rings is replaced by that of lamellæ or rows of lacunæ, parallel to the course of the Haversian canals, and these canals appear like half-tubes instead of circular spaces. The tubes are seen to branch and communicate, so that each separate Haversian canal runs only a short distance. In other respects the structure has much the same appearance as in transverse sections.

In sections of thin plates of bone (as in the walls of the cells which form the cancellous tissue) the Haversian canals are absent, and the canaliculi open into the spaces of the cancellous tissue (medullary spaces), which thus have the same function as the Haversian canals in the more compact bone.

Chemical Composition.—Bone consists of an animal and an earthy part intimately combined together.

The animal part may be obtained by immersing the bone for a considerable time in dilute mineral acid, after which process the bone comes out exactly the same shape as before, but perfectly flexible, so that a long bone (one of the ribs, for example) can easily be tied in a knot. If now a transverse section is made (Fig. 30), the same general arrangement of the Haversian canals, lamellæ, lacunæ, and canaliculi is seen, though not so plainly, as in the ordinary section.

The earthy part may be obtained separate by calcination, by which the animal matter is completely burned out. The bone will still retain its original form, but it will be white and brittle, will have lost about one-third of its original weight, and will crumble down with the slightest force. The earthy matter confers on bone its hardness and rigidity, and the animal matter its tenacity.

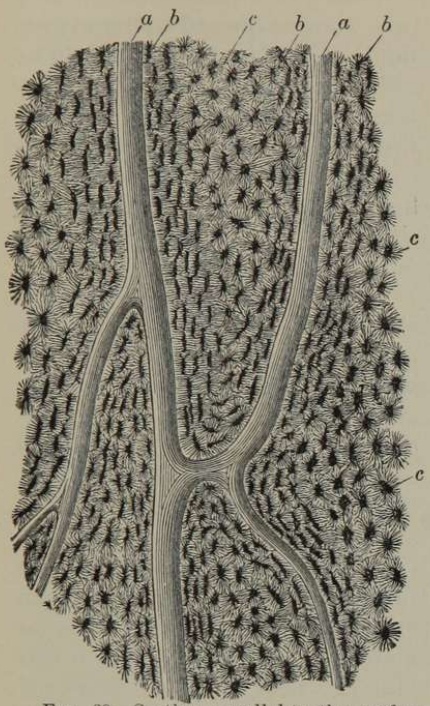

FIG. 29.—Section parallel to the surface from the shaft of the femur. Magnified 100 times. *a*. Haversian canals. *b*. Lacunæ seen from the side. *c*. Others seen from the surface in lamellæ which are cut horizontally.

FIG. 30.—Section of bone after the removal of the earthy matter by the action of acids.

The animal base is often called cartilage, but differs from it in structure, in the fact that it is softer and more flexible, and that when boiled with a high pressure it is almost entirely resolved into gelatin.

The organic constituent of bone forms about *one-third*, or 33.3 per cent.; the inorganic matter, *two-thirds*, or 66.7 per cent.; as is seen in the subjoined analysis of Berzelius:

Organic matter . . .	Gelatin and blood-vessels . . .	33.30
Inorganic or Earthy matter . . .	Phosphate of lime	51.04
	Carbonate of lime	11.30
	Fluoride of calcium	2.00
	Phosphate of magnesia . . .	1.16
	Soda and chloride of sodium . .	1.20
		100.00

Some chemists add to this about 1 per cent. of fat.

Some difference exists in the proportion between the two constituents of bone at different periods of life. In the child the animal matter predominates, whereas in aged people the bones contain a larger proportion of earthy matter, and the animal matter is deficient in quantity and quality. Hence in children it is not uncommon to find, after an injury to the bones, that they become bent or only partially broken, whereas in old people the bones are more brittle and fracture takes place more readily. Some of the diseases, also, to which bones are liable mainly depend on the disproportion between the two constituents of bone. Thus in the disease called rickets, so common in the children of the poor, the bones become bent and curved, either from the superincumbent weight of the body, or under the action of certain muscles. This depends upon some defect of nutrition by which bone becomes deprived of its normal proportion of earthy matter, whilst the animal matter is of unhealthy quality. In the vertebræ of a rickety subject Dr. Bostock found in 100 parts 79.75 animal and 20.25 earthy matter.

Development of Bone.—In the fœtal skeleton some bones, such as the long bones of the limbs, are cartilaginous; others, as the cranial bones, are membranous. Hence two kinds of ossification are described: the *intracartilaginous* and the *intramembranous;* and to these a third is sometimes added, the *subperiosteal;* this, however, is the same as the second, only taking place under different circumstances.

Intracartilaginous Ossification.—Just before ossification begins the bone is entirely cartilaginous, and in a long bone, which may be taken as an example, the process commences in the centre and proceeds toward the extremities, which for some time remain cartilaginous. Subsequently a similar process commences in one or more places in those extremities and gradually extends through it. The extremity does not, however, become joined to the shaft of the bone until growth has ceased, but remains separated by a layer of cartilaginous tissue termed *epiphysial cartilage*.

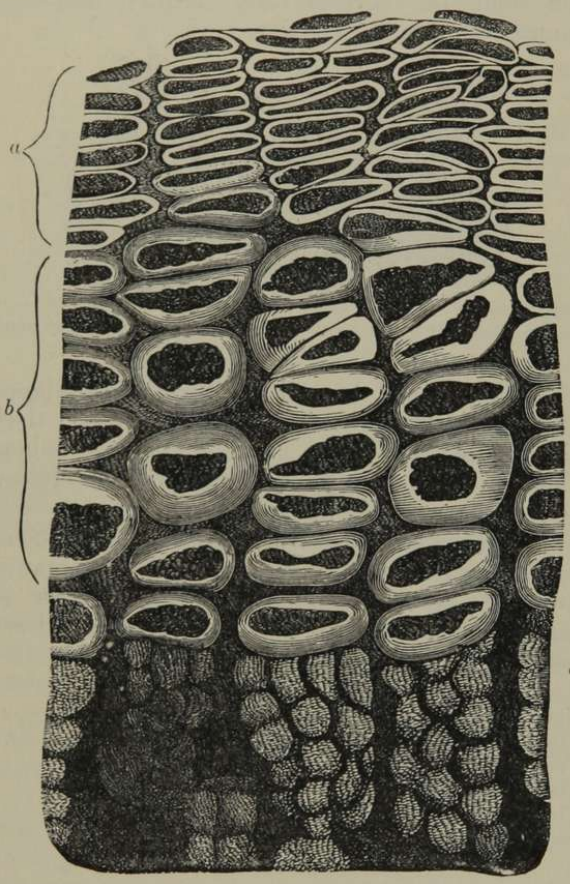

FIG. 31.—Longitudinal section through the ossifying portion of a long bone in the human embryo. *a*. Cartilaginous region. *b*. Region of calcified matrix.

The first step in the ossification of the cartilage is that the cartilage-cells, at the point where ossification is commencing and which is termed a *centre of ossification*, enlarge and arrange themselves in rows (Fig. 31). The matrix in which they are imbedded increases in quantity, so that the cells become further separated from each other. A deposit of calcareous material now takes place in this matrix, between the rows of cells, so that they become separated from each other by longitudinal columns of calcified matrix, presenting a granular and opaque appearance. Here and there the matrix between two cells of the same row also becomes calcified, and thus we have transverse bars of calcified substance stretching across from one calcareous column to another. Thus we have longitudinal groups of the cartilage-cells enclosed in oblong cavities, the walls of which are formed of calcified matrix. These cavities are called the *primary areolæ* (Sharpey).

At the same time that this process is going on in the centre of the cartilage of which the fœtal bone consists, certain changes are taking place on its surface. This is covered by a very vascular membrane, the *periosteum*, on the inner surface of which—that is to say, on the surface in contact with the cartilage—are a number of cells called *osteoblasts*. By the agency of these cells a thin layer of bony tissue is being formed between the periosteum and the cartilage, by the *intramembranous* mode of ossification presently to be described. We have then, in this first stage of ossification, two processes going on simultaneously: in the centre of the cartilage the formation of a number of oblong spaces, enclosed by calcified matrix and containing the cartilage-cells enlarged and arranged in groups, and on the surface of the cartilage the formation of a layer of true membrane-bone. The second stage consists in the prolongation into the cartilage of processes of the deeper or osteogenetic layer of the periosteum (Fig. 32, *ir*). The processes consist of blood-vessels and cells (osteoblasts). They excavate passages through the new-formed bony layer by absorption, and pass through it into the calcified matrix (Fig. 32). Wherever these processes come in contact with the calcified walls of the

primary areolæ they absorb it, and thus cause a fusion of the original cavities and the formation of larger spaces, which are termed the *secondary areolæ* (Sharpey)

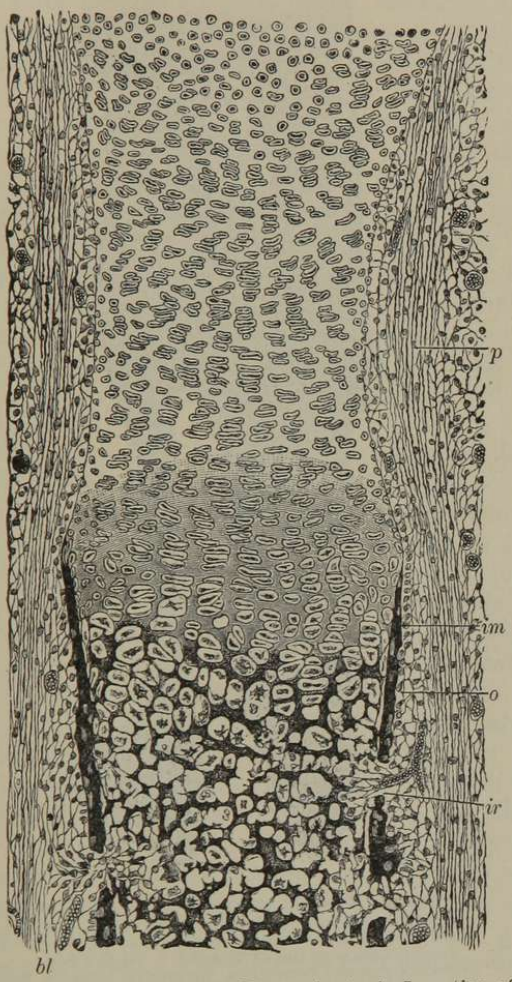

FIG. 32.—Section of fœtal bone of cat. *ir.* Irruption of the subperiosteal tissue. *p.* Fibrous layer of the periosteum. *o.* Layer of osteoblasts. *im.* Subperiosteal bony deposit. (From Quain's *Anatomy*, E. A. Schäfer.)

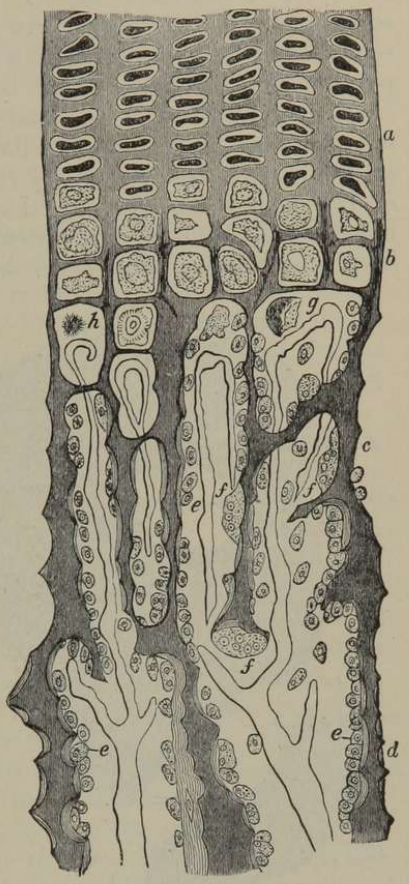

FIG. 33.—Part of a longitudinal section of the developing femur of a rabbit. *a.* Flattened cartilage-cells. *b.* Enlarged cartilage-cells. *c. d.* Newly-formed bone. *e.* Osteoblasts. *f.* Giant-cells or osteoclasts. *g. h.* Shrunken cartilage-cells. (From *Atlas of Histology*, Klein and Noble Smith.)

or *medullary spaces* (Müller). In these secondary spaces the original cartilage-cells disappear, and their cavities become filled with embryonic marrow, consisting of osteoblasts and vessels, and derived, at all events in part, in the manner described above, from the osteogenetic layer of the periosteum (Fig. 33). What becomes of the cartilage-cells is not finally determined. By most histologists they are believed to be converted, after division, into osteoblasts, and so assist in forming the embryonic marrow. Others, on the other hand, believe that they are simply absorbed and take no part in the formation of bone.

Thus far, then, we have got enlarged spaces (secondary areolæ), the walls of which are still formed by calcified cartilage-matrix, containing an embryonic marrow, derived from the processes sent in from the osteogenetic layer of the periosteum, and consisting of blood-vessels and round cells, osteoblasts (Fig. 33), some of which probably are derived from the division of the original cartilage-cells, which have disappeared. The walls of these secondary areolæ are at this time of only inconsiderable thickness, but they now become thickened by the deposition of layers of new bone on their interior. This process takes place in the following manner: Some of the osteoblasts of the embryonic marrow, after undergoing rapid division, arrange themselves as an epithelioid layer on the surface of the

wall of the space (Fig. 34). This layer of osteoblasts forms a bony stratum, and thus the wall of the space becomes gradually covered with a layer of true osseous substance. On this a second layer of osteoblasts arrange themselves, and in their turn form an osseous layer. By the repetition of this process the original cavity becomes very much reduced in size, and at last only remains as a small circular hole in the centre, containing the remains of the embryonic marrow—that is, a blood-vessel and a few osteoblasts. This small cavity constitutes the Haversian canal of the perfectly ossified bone. The successive layers of osseous matter which have been laid down and which encircle this central canal, constitute the lamellæ of which, as we have seen, each Haversian system is made up. As the successive layers of osteoblasts form osseous tissue, certain of the osteoblastic cells remain included between the various bony layers. These continue persistent, and remain as the corpuscles of the future bone, the spaces enclosing them forming the lacunæ (Fig. 34). The mode of the formation of the canaliculi is not known.

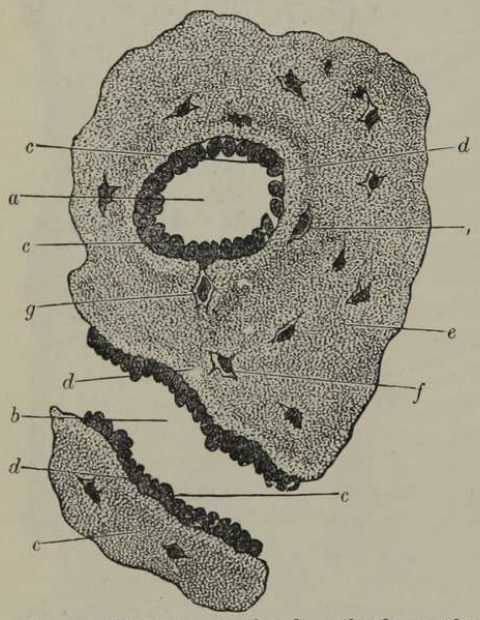

FIG. 34.—Transverse section from the femur of a human embryo about eleven weeks old. *a*. A medullary sinus cut transversely; and *b*, another, longitudinally. *c*. Osteoblasts. *d*. Newly-formed osseous substance of a lighter color. *e*. That of greater age. *f*. Lacunæ with their cells. *g*. A cell still united to an osteoblast.

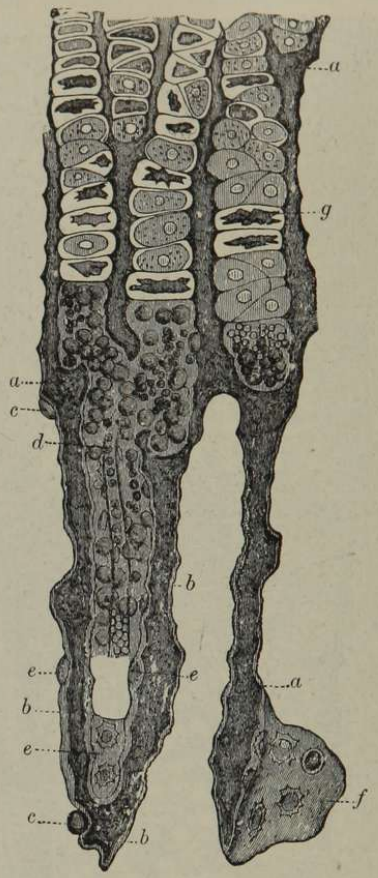

FIG. 35.—Vertical section from the edge of the ossifying portion of the diaphysis of a metatarsal bone from a fœtal calf. (After Müller.) *a*. Ground-mass of the cartilage. *b*. Of the bone. *c*. Newly-formed bone-cells in profile, more or less imbedded in intercellular substance. *d*. Medullary canal in process of formation, with vessels and medullary cells. *e*. *f*. Bone-cells on their broad aspect. *g*. Cartilage-capsules arranged in rows, and partly with shrunken cell-bodies.

Such are the changes which may be observed at one particular point, the centre of ossification. While they have been going on here a similar process has been proceeding in the same manner toward the end of the shaft, so that in the ossifying bone all the changes described above may be seen in different parts, from the true bone in the centre of the shaft to the hyaline cartilage at the extremities. The bone thus formed differs from the bone of the adult in being more spongy and less regularly lamellated.

Thus far, then, we have followed the steps of a process by which a solid bony mass is produced, having vessels running into it from the periosteum, Haversian

canals in which those vessels run, medullary spaces filled with fœtal marrow, lacunæ with their contained bone-cells, and canaliculi growing out of these lacunæ.

This process of ossification, however, is not the origin of the whole of the skeleton, for even in those bones in which the ossification proceeds in a great measure from a single centre, situated in the cartilaginous shaft of a long bone, a considerable part of the original bone is formed by intramembranous ossification beneath the perichondrium or periosteum; so that the girth of the bone is increased by bony deposit from the deeper layer of this membrane. The shaft of the bone is at first solid, but a tube is hollowed out in it by absorption around the vessels passing into it, which becomes the medullary canal. This absorption is supposed to be brought about by large "giant-cells," which have long been recognized as a constituent of fœtal marrow, and which are believed by Kölliker to have the power of absorbing or dissolving bone, and he has therefore named them "osteoclasts" (Fig. 33, *f*). They vary in shape and size, and are known by containing a large number of clear nuclei, sometimes as many as twenty. The occurrence of similar cells in some tumors of bones has led to such tumors being denominated "myeloid."

As more and more bone is removed by this process of absorption from the interior of the bone to form the medullary canal, so more and more bone is deposited on the exterior from the periosteum, until at length the bone has attained the shape and size which it is destined to retain during adult life. As the ossification of the cartilaginous shaft extends toward the articular ends it carries with it, as it were, a layer of cartilage, or the cartilage grows as it ossifies, and thus the bone is increased in length. During this period of growth the articular end, or epiphysis, remains for some time entirely cartilaginous; then a bony centre appears in it, and it commences the same process of intracartilaginous ossification; but this process never extends to any great distance. The epiphyses remain separated from the shaft by a narrow cartilaginous layer for a definite time. This layer ultimately ossifies, the distinction between shaft and epiphysis is obliterated, and the bone assumes its completed form and shape. The same remarks also apply to the processes of bone which are separately ossified, such as the trochanters of the femur. The bones, having been formed, continue to grow until the body has acquired its full stature. They increase in length by ossification continuing to extend in the epiphysial cartilage, which goes on growing in advance of the ossifying process. They increase in circumference by deposition of new bone, from the deeper layer of the periosteum, on their external surface, and at the same time an absorption takes place from within, by which the medullary cavity is increased.

The medullary spaces which characterize the cancellous tissue are produced by the absorption of the original fœtal bone in the same way as the original medullary canal is formed. The distinction between the cancellous and compact tissue appears to depend essentially upon the extent to which this process of absorption has been carried; and we may perhaps remind the reader that in morbid states of the bone inflammatory absorption produces exactly the same change, and converts portions of bone naturally compact into cancellous tissue.

Intramembranous Ossification.—The intramembranous ossification is that by which the bones of the vertex of the skull are entirely formed. In the bones which are so developed no cartilaginous mould precedes the appearance of the bone-tissue. In the membrane which occupies the place of the future bone, a little network of bony spiculæ is first noticed, radiating from the point of ossification. When these rays of growing bone are examined by the microscope, they are found to consist of a network of fine clear fibres and granular cells with a ground-substance between. The fibres are termed *osteogenic* fibres, and soon become dark and granular from calcification, and as they calcify they are found to enclose the granular cells or "osteoblasts" (Fig. 36). The calcification not only involves the osteogenic fibres, but also the ground-substance of the tissue in which they

are contained. The cells at first lie upon the osteogenic fibres, so that they can be removed by brushing the specimen with a hair-pencil, in order to render the fibres clear; but they gradually become involved in the ossifying matrix, and form the corpuscles of the future bone, the spaces in which they are enclosed constituting the lacunæ. As the tissue increases in thickness, vessels shoot into it, grooving for themselves spaces or channels, which become the Haversian canals. Thus, the intramembranous and intracartilaginous processes of ossification are similar in their more essential features.

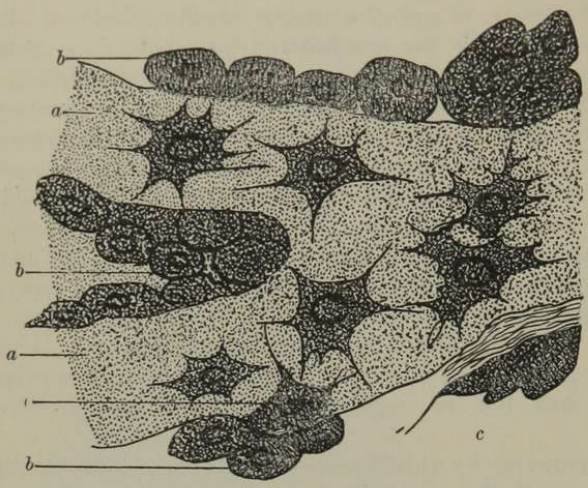

FIG. 36.—Osteoblasts from the parietal bone of a human embryo thirteen weeks old. (After Gegenbauer.) *a*. Bony septa with the cells of the lacunæ. *b*. Layers of osteoblasts. *c*. The latter in transition to bone-corpuscles.

The number of ossific centres is different in different bones. In most of the short bones ossification commences by a single point in the centre, and proceeds toward the circumference. In the long bones there is a central point of ossification for the shaft or diaphysis; and one or more for each extremity, the epiphysis. That for the shaft is the first to appear. The union of the epiphyses with the shaft takes place in the reverse order to that in which their ossification began, and appears to be regulated by the direction of the nutrient artery of the bone. Thus, the nutrient arteries of the bones of the arm and fore-arm are directed toward the elbow, and the epiphyses of the bones forming this joint become united to the shaft before those at the opposite extremity. In the lower limb, on the other hand, the nutrient arteries pass in a direction from the knee: that is, upward in the femur, downward in the tibia and fibula; and in them it is observed that the upper epiphysis of the femur, and the lower epiphysis of the tibia and fibula, become first united to the shaft.

Where there is only one epiphysis, the medullary artery is directed toward that end of the bone where there is no additional centre, as toward the acromial end of the clavicle, toward the distal end of the metacarpal bone of the thumb and great toe, and toward the proximal end of the other metacarpal and metatarsal bones.

Besides these epiphyses for the articular ends, there are others for projecting parts or processes, which are formed separately from the bulk of the bone. For an account of these the reader must be referred to the description of the individual bones in the sequel.

A knowledge of the exact periods when the epiphyses become joined to the shaft is often of great importance in medico-legal inquiries. It also aids the surgeon in the diagnosis of many of the injuries to which the joints are liable; for it not infrequently happens that, on the application of severe force to a joint, the epiphysis becomes separated from the shaft, and such injuries may be mistaken for fracture or dislocation.

MUSCULAR TISSUE.

The **muscles** are formed of bundles of reddish fibres, endowed with the property of contractility. Two kinds of muscular tissue are found in the animal body—viz. that of voluntary or animal life, and that of involuntary or organic life. The muscles of animal life (striped muscles) are capable of being put in action and controlled by the will. They are composed of bundles of fibres enclosed in a

delicate web called the "perimysium," in contradistinction to the sheath of areolar tissue which invests the entire muscle, the "epimysium." The bundles are termed "fasciculi;" they are prismatic in shape, of different sizes in different muscles, and for the most part placed parallel to one another, though they have a tendency to converge toward their tendinous attachments. Each fasciculus is made up of a bundle of *fibres*, which also run parallel with each other, and which are separated from one another by a delicate connective tissue derived from the perimysium, and termed *endomysium* (Fig. 37).

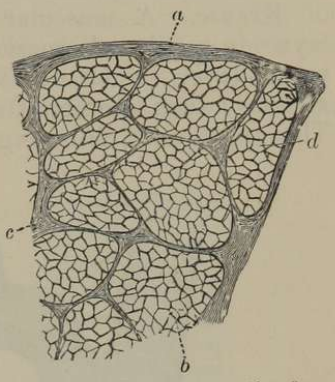

FIG. 37.—Transverse section from the sterno-mastoid in man. Magnified 50 times. *a*. External perimysium. *b*. Fasciculus. *c*. Internal perimysium. *d*. Fibre.

A *muscular fibre* may be said to consist of a soft contractile substance enclosed in a tubular sheath, named by Bowman the *sarcolemma*. The fibres are cylindrical or prismatic in shape, and are of no great length, not extending, it is said, further than an inch and a half. They end either by blending with the tendon or aponeurosis, or else by becoming drawn out into a tapering extremity which is connected to the neighboring fibre by means of the sarcolemma. Their breadth varies in man from $\frac{1}{200}$ to $\frac{1}{600}$ of an inch, the average of the majority being about $\frac{1}{400}$. As a rule, the fibres do not divide or anastomose; but occasionally, especially in the tongue and facial muscles, the fibres may be seen to divide into several branches. The precise mode in which the muscular fibre joins the tendon has been variously described by different observers. It may, perhaps, be sufficient to say that the sarcolemma, or membranous investment of the muscular fibre, appears to become blended with the tissue of the tendon, and prolonged more or less into the tendon, so that the latter forms a kind of sheath around the fibre for a longer or shorter distance. When muscular fibres are attached to the skin or mucous membranes, their sarcolemma probably becomes continuous with the fibres of the areolar tissue.

The *sarcolemma*, or tubular sheath of the fibre, is a transparent, elastic, and apparently homogeneous membrane of considerable toughness, so that it will sometimes remain entire when the included substance is ruptured (see Fig. 38). On the internal surface of the sarcolemma in mammalia, and also in the substance of the fibre in the lower animals, elongated nuclei are seen (Fig. 55), and in connection with these a row of granules, apparently fatty, is sometimes observed.

Upon examination of a muscular fibre by transmitted light under a sufficiently high power, it is found to be apparently marked by alternate light and dark bands or striæ, which pass transversely, or somewhat obliquely, round the fibre (Fig. 38). The dark and light bands are of nearly equal breadth, and alternate with great regularity. Other striæ pass longitudinally over the fibres, though they are less distinct than the former. This longitudinal striation gives the fibre the appearance of being made up of a bundle of fibrillæ. The muscular fibre can be broken up either in a longitudinal or transverse direction (Fig. 39). If hardened in alcohol, it can be broken up longitudinally, and forms the so-called fibrillæ of which some suppose the fibre to be made up. Each fibril is marked by transverse striæ, and appears to consist of a single row of minute quadrangular particles, named "sarcous elements" by Bowman. A still further division, however, is capable of being made, and each of these fibrillæ may be divided into minute threads (Fig. 40, B, *d*). consisting of an alternate dark and light spot. After exposure to the action of dilute hydrochloric acid, the muscular fibre can be broken transversely (Fig. 39, B). It then forms disks or plates, consisting of the same quadrangular particles, attached by their lateral surfaces.

Upon closer examination with a very high power the appearances become more complicated and are susceptible of various interpretations. The transverse striation, which in Figs. 38 and 39 appears as a mere alternation of dark and light

bands, is resolved into the appearance shown in Fig. 40, which shows a series of broad dark bands, separated by a light band, which is itself divided into two by a dark streak. This streak is termed *Krause's membrane ;* it is continuous at each end with the sarcolemma investing the muscular fibre. Thus it may be said that the fibre is divided into a number of transverse compartments by this membrane, each compartment containing in the centre a dark plate with a bright border above and below; that is to say, between the dark central part and the membrane of Krause. A muscular fibre presents, then, the appearance of the following layers in regular alternation: a dark layer, the *transverse disk;* a bright transparent layer, the *lateral disk ;* a dark line, the *intermediate disk* or *membrane of Krause ;* then another lateral disk, a transverse disk, and so on (Figs. 40 and 41). This appearance, following the observations of Rollett, is due to the mode of for-

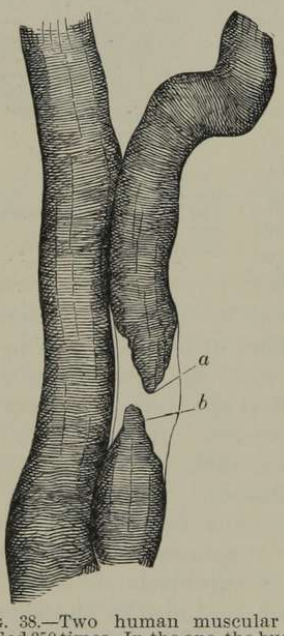

FIG. 38.—Two human muscular fibres. Magnified 350 times. In the one, the bundle of fibrillæ (*b*) is torn, and the sarcolemma (*a*) is seen as an empty tube.

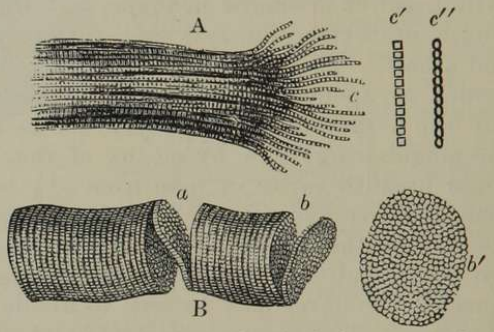

FIG. 39.—Fragments of striped elementary fibres, showing a cleavage in opposite directions. Magnified 300 diameters. A. Longitudinal cleavage. The longitudinal and transverse lines are both seen. Some longitudinal lines are darker and wider than the rest, and are not continuous from end to end. This results from partial separation of the fibrillæ. *c.* Fibrillæ separated from one another by violence at the broken end of the fibre, and marked by transverse lines equal in width to those on the fibre. *c', c''* represent two appearances commonly presented by the separated single fibrillæ (more highly magnified). At *c'* the borders and transverse lines are all perfectly rectilinear, and the included spaces perfectly rectangular. At *c''* the borders are scalloped and the spaces bead-like. When most distinct and definite the fibrilla presents the former of these appearances. B. Transverse cleavage. The longitudinal lines are scarcely visible. *a.* Incomplete fracture following the opposite surfaces of a disk, which stretches across the interval, and retains the two fragments in connection. The edge and surfaces of this disk are seen to be minutely granular, the granules corresponding in size to the thickness of the disk and to the distance between the faint longitudinal lines. *b.* Another disk nearly detached. *b'.* Detached disk, more highly magnified, showing the sarcous elements.

mation of a muscular fibre, which is made up of two principal parts: 1, fibrillæ; and 2, a hyaline or faintly granular substance, resembling protoplasm, and called *sarcoplasm.* The fibrillæ are arranged in bundles called *muscular columns* or *sarcostyles*, and these again in larger groups, which, collected together, form the fibre. The fibrillæ are surrounded by the sarcoplasm, which surrounds also the columns and groups of columns, being in these latter situations greater in amount than between the fibrillæ. So that on transverse section a muscular fibre is seen to be divided into a number of areas, called the *areas of Cohnheim*, more or less polyhedral in shape, and consisting of the columns of fibrillæ surrounded by transparent sheaths of sarcoplasm. And these areas are collected into larger or smaller groups, which in the same manner are surrounded by transparent sarcoplasm. Each area of Cohnheim presents a granular appearance due to the cross-section of its constituent fibrillæ, surrounded by a small amount of the hyaline sarcoplasm. The fibrillæ extend throughout the whole length of, and are parallel to, the long axis of the muscular fibre. They present the following appearances in regular alternation: (1) a dim prismatic or rod-shaped element, the *sarcous element of Bowman ;* (2) a thin bridge, which joins the sarcous element to (3) a dark granule. Then again

another thin bridge joining the same granule to the next sarcous element, and so on. When these fibrillæ are collected together into columns, and the columns into muscular fibres, the appearance mentioned above is produced. The sarcous elements, when arranged side by side and almost touching each other, with very little sarcoplasm between them, represent the transverse disk. The bridges, being much thinner than the sarcous element or the dark granules, have between each other a much larger amount of sarcoplasm, and this gives to this part the transparent appearance of the lateral disk. And, lastly, the granules joined edge to edge in a row present the appearance of a membrane, which represents the intermediate disk.

On the muscular fibre, immediately beneath the sarcolemma, the sarcoplasm

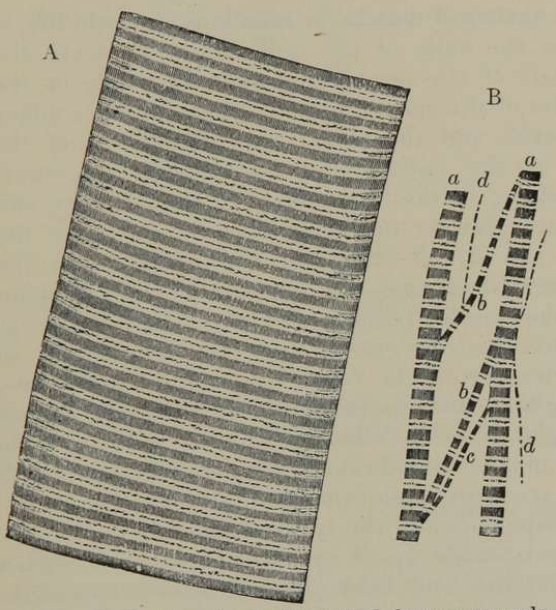

FIG. 40.—Portion of a medium-sized human muscular fibre. Magnified nearly 800 diameters. B. Separated bundles of fibrils, equally magnified. *a. a.* Larger, and *b. b*, smaller collections. *c.* Still smaller. *d. d.* The smallest which could be detached.



FIG. 41.—Part of a striped muscular fibre of the water-beetle, prepared with absolute alcohol. Magnified 300 diameters. (Klein and Noble Smith.) *a.* Sarcolemma. *b.* Membrane of Krause; owing to contraction during hardening, the sarcolemma shows regular bulgings. At the side of Krause's membrane is the transparent lateral disk. Several nuclei of muscle-corpuscles are shown, and in them a minute network.

becomes here and there collected into small, plate-like masses. They contain oval nuclei, and are termed "muscle-corpuscles." Finally, in the centre of each sarcous element a transparent lighter band can sometimes be discerned; this is known as the *median disk* of Hensen, and is due to the substance of the sarcous elements being here thinner.

This form of muscular fibre composes the whole of the voluntary muscles, all the muscles of the ear, those of the larnyx, pharynx, tongue, the upper half of the œsophagus, the heart, and the walls of the large veins at the point where they open into it. The fibres of the heart, however, differ very remarkably from those of other striped muscles. They are smaller by one-third, and their transverse striæ are by no means so distinct. The fibres are made up of distinct quadrangular cells joined end to end (Fig. 42). Each cell contains a clear oval nucleus, situated near the centre of the cell. The extremities of the cells have a tendency to branch or divide, the subdivisions uniting with offsets from other cells, and thus producing an anastomosis of the fibres (Fig. 42). The connective tissue between the bundles of fibres is much less than in ordinary striped muscle, and no sarcolemma has been proved to exist.

The *capillaries* of striped muscle are very abundant, and form a sort of rectangular network, the branches of which run longitudinally in the endomysium between the muscular fibres, and are joined at short intervals by transverse anastomosing branches. The larger vascular channels, arteries and veins, are

found only in the perimysium, between the muscular fasciculi. The smaller vessels present peculiar saccular dilatations, which are supposed to act as receptacles for the blood during the contraction of the muscular fibres, when it is pressed out from some of the capillaries.

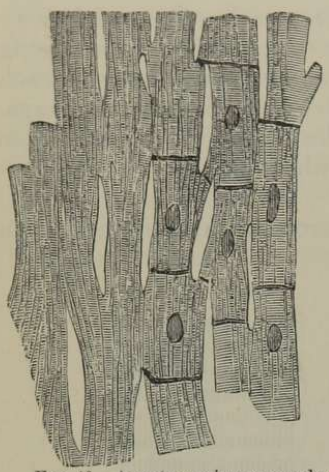

FIG. 42.—Anastomosing muscular fibres of the heart seen in a longitudinal section. On the right the limits of the separate cells with their nuclei are exhibited somewhat diagrammatically.

Nerves are profusely distributed to striped muscle. The mode of their termination will be described on a subsequent page.

The existence of *lymphatic* vessels in striped muscle has not been ascertained, though they have been found in tendons and in the sheath of the muscle.

The **unstriped muscle, or muscle of organic life,** is found in the walls of the hollow viscera—viz. the lower half of the œsophagus and the whole of the remainder of the gastro-intestinal tube; in the trachea and bronchi, and the alveoli and infundibula of the lungs; in the gall-bladder and ductus communis choledochus; in the large ducts of the salivary and pancreatic glands; in the pelvis and calices of the kidney, the ureter, bladder, and urethra; in the female sexual organs—viz. the ovary, the Fallopian tubes, the uterus (enormously developed in pregnancy), the vagina, the broad ligaments, and the erectile tissue of the clitoris; in the male sexual organs—viz. the dartos scroti, the vas deferens and epididymis, the vesiculæ seminales, the prostate gland, and the corpora cavernosa and corpus spongiosum; in the ducts of certain glands, as in Wharton's duct; in the capsule and trabeculæ of the spleen; in the mucous membranes, forming the muscularis mucosæ; in the skin, forming the arrectores pilorum, and also in the sweat-glands; in the arteries, veins, and lymphatics; in the iris and the ciliary muscle.

Plain or unstriped muscular fibre is made up of spindle-shaped cells, called *contractile fibre-cells*, collected into bundles and held together by a cement-substance, in which are contained some connective-tissue corpuscles (Fig. 43). These bundles are further aggregated into larger bundles or flattened bands, and bound together by ordinary connective tissue.

The *contractile fibre-cells* (Fig. 44) are elongated, spindle-shaped, nucleated cells of various lengths, averaging from $\frac{1}{600}$ to $\frac{1}{300}$ of an inch in length, and $\frac{1}{4500}$ to $\frac{1}{3500}$ of an inch in breadth. On transverse section they are more or less polyhedral in shape, from mutual pressure. They present a faintly longitudinal striated appearance, and consist of an elastic cell-wall containing a central bundle of fibrillæ, representing the contractile substance, and an oval or rod-like nucleus, which includes, within a membrane, a fine network communicating at the poles of the nucleus with the contractile fibres (Klein). The adhesive interstitial substance, which connects the fibre-cells together, represents the endomysium, or delicate connective tissue which binds the fibres of striped muscular tissue into fasciculi; while the tissue connecting the individual bundles together represents the perimysium. The unstriped muscle, as a rule, is not under the control of the will, nor is the contraction rapid and involving the whole muscle, as is the case with the muscles of animal life. The membranes which are composed of the unstriped muscle slowly contract in a part of their extent, generally under the influence of a mechanical stimulus, as that of distension or of cold; and then the contracted part slowly relaxes while another portion of the membrane takes up the contraction. This peculiarity of action is most strongly marked in the intestines, constituting their *vermicular motion.*

Chemical Composition of Muscle.—In chemical composition the muscular fibres of both forms consist mainly of a proteid substance—myosin—which is classed as one of the globulins. It is readily converted by the action of dilute acids

into syntonin or acid-albumen, and by the action of dilute alkalies into alkali-albumen. Muscle, which is neutral or slightly alkaline in reaction when at rest,

FIG. 43.—Non-striated elementary fibres from the human colon. *a*. Treated with acetic acid, showing the corpuscles. *b*. Fragment of a detached fibre, not touched with acid.

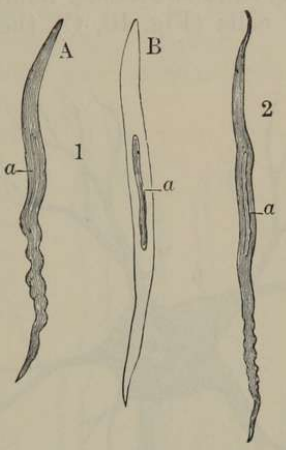

FIG. 44.—Muscular fibre-cells from human arteries. 1. From the popliteal artery. A. without; B. with acetic acid. 2. From a branch of the anterior tibial. *a*. Nuclei of the fibres. Magnified 350 times.

is rendered acid by contraction, from the development probably of sarcolactic acid. After death muscle also exhibits an acid reaction, but this appears to be due to post-mortem change.

NERVOUS TISSUE.

The **nervous tissues** of the body are comprised in two great systems—the *cerebro-spinal* and the *sympathetic;* and each of these systems consist of a *central organ*, or series of central organs, and of *nerves*.

The *cerebro-spinal* system comprises the brain (including the medulla oblongata), the spinal cord, the cranial nerves, the spinal nerves, and the ganglia connected with both these classes of nerves. The *sympathetic* system consists of a double chain of ganglia, with the nerves which go to and come from them. It is not directly connected with the brain or spinal cord, though it is so indirectly by means of its numerous communications with the cranial and spinal nerves.

Both these nervous systems are composed of an aggregation of tissue-elements termed *neurons*, each of which consists of a nucleated cell whose protoplasm is prolonged into a varying number of processes, one of which is usually of considerable length and forms the essential part of a nerve-fibre. The cell-bodies have a tendency to be associated together in more or less definite masses, such as the spinal and sympathetic ganglia, the central portion of the spinal cord, the floor of the medulla oblongata, the cortex of the cerebellum and of the cerebral hemispheres, and the various ganglia distributed through the different parts of the brain. These masses present macroscopically a grayish appearance, which contrasts strongly with the pure white color usually shown by the nerve-fibres, so that it is customary to speak of the nervous system as composed of two substances, the *gray matter* and the *white* or *fibrous matter*. The nerve-fibres of the sympathetic system, however, usually lack the constituent which gives the ordinary fibres their white appearance, and they consequently have a grayish color.

The **gray substance** is distinguished by its dark reddish-gray color and soft consistence. It is found in the brain, spinal cord, and various ganglia, intermingled with the fibrous nervous substance, and also in some of the nerves of special sense, and in gangliform enlargements which are found here and there in the course of certain cerebro-spinal nerves. It is composed, as its name implies,

of cells, commonly called *nerve-cells* or *ganglion-corpuscles*, containing nuclei and nucleoli. The cells together with the blood-vessels in the gray nerve-substance, and the nerve-fibres and vessels in the white nerve-substance, are imbedded in a peculiar ground-substance, named by Virchow *neuroglia*, and consisting of large branched cells (Fig. 46, C), the branches passing in every direction among the nerve-tissue, thus holding it and binding it together. It is developed from the epiblast, and contains neither the characteristic fibres nor cells of connective tissue, and therefore cannot be regarded as belonging to the true connective tissues. Each nerve-cell consists of a finely granular protoplasmic material, of a reddish or yellowish-brown color, which occasionally presents patches of a deeper tint, caused by the aggregation of pigment-granules (Fig. 45). No distinct limiting membrane or cell-wall has been ascertained to exist. The nucleus is, as a rule, a large, well-defined, round, vesicular body, often presenting an intranuclear network, and containing a nucleolus which is peculiarly clear and brilliant. The nerve-cells vary in shape and size; some are small, spherical or ovoid, with generally an even outline, such as those found in the spinal ganglia; others, again, are caudate or stellate in shape, and are characterized by their large size and by their having one or more tail-like processes issuing from them, which occasionally divide and subdivide into numerous branches (Fig. 46, A). These are found in greatest number in the gray matter of the spinal cord. Still others are flask-shaped, as in the cortex of the cerebellum; or conical, as in the cerebral convolutions. For the most part nerve-cells have one or more processes, and they are distinguished by the number of these processes, as unipolar, bipolar, or multipolar cells. These processes are very delicate and are direct continuations of the protoplasm of the nerve-cell. The majority of the processes of a multipolar cell are exceedingly fine, and branch dendritically, spreading out among the adjacent nervous elements; these processes are termed the *protoplasmic processes* or *dendrites*. One of the processes, however, does not thus branch, but gives off from time to time lateral branches termed *collaterals*, and eventually form the axis-cylinder of a nerve-fibre; this is the *axis-cylinder process*.

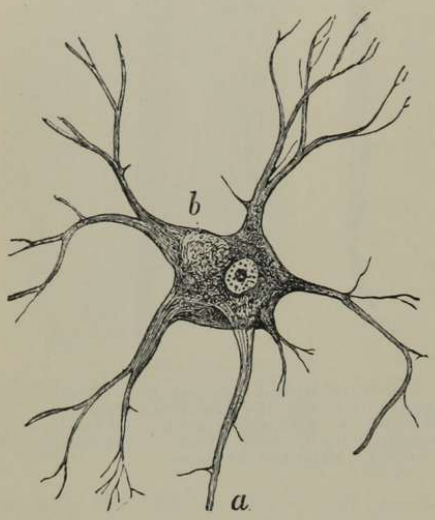

FIG. 45.—Cell from the anterior horn of the gray matter of the spinal cord. *a*, Axis-cylinder process. *b*. Aggregation of pigment-granules. (From Obersteiner.)

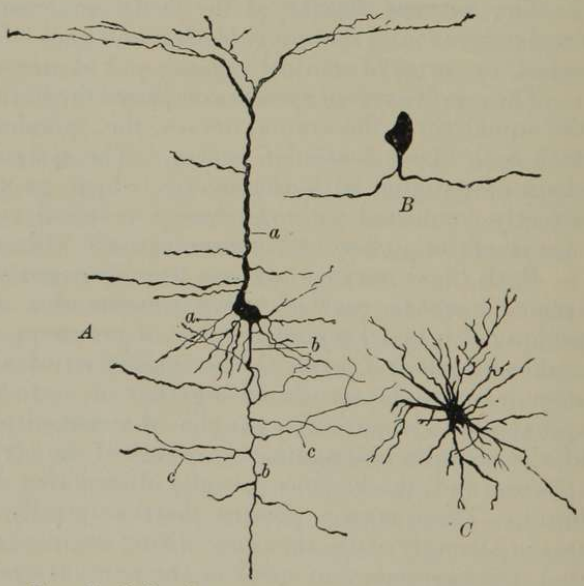

FIG. 46.—Cells of nervous system impregnated with silver (Golgi's method). *A*. Cell from the cortex of the cerebral hemispheres (after van Gehuchten). *a*. Protoplasmic process. *b*. Axis-cylinder process. *c*. Collaterals. *B*. T-shaped cell from spinal root ganglion (after van Gehuchten). *C*. Neuroglia-cell from the white substance of the cerebellum (after Köl-liker).

The **white** or **fibrous** nerve-substance or *nerve-fibre* is found universally in the

nervous cords, and also constitutes a great part of the brain and spinal cord. The fibres of which it consists are of two kinds, the *medullated* or *white* fibres, and the *non-medullated* or *gray* fibres.

The **medullated** fibres form the white part of the brain and spinal cord, and also the greater part of the cerebro-spinal nerves, and give to these structures their opaque, white aspect. When perfectly fresh they appear to be homogeneous; but soon after removal from the body they present, when examined by transmitted light, a double outline or contour, as if consisting of two parts. The central portion is named the *axis-cylinder of Purkinje*: around this is a sort of sheath of fatty material, named the *white substance of Schwann*, which gives to the fibre its double contour, and the whole is enclosed in a delicate membrane, the *neurilemma*,[1] *primitive sheath*, or *nucleated sheath of Schwann* (Fig. 47).

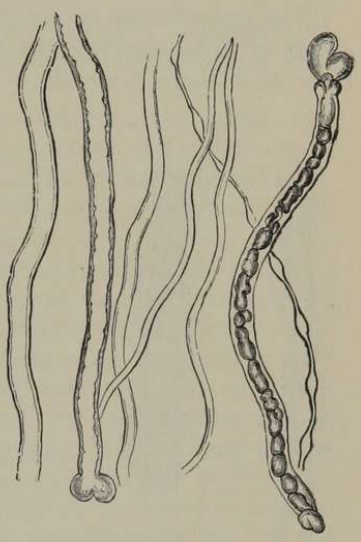

FIG. 47.—Human nerve-fibres. Magnified 350 times. Three of them are fine, one of which is varicose, one of middling thickness, and with a simple contour; and three thick, two of which are double-contoured, and one with grumous contents.

The *axis-cylinder* is the essential part of the nerve-fibre, and is always present; the other parts, the medullary sheath and the neurilemma, being occasionally absent, especially at the origin and termination of the nerve-fibre. It undergoes no interruption from its origin in the nerve-centre to its peripheral termination, and must be regarded as a direct prolongation of a nerve-cell. It constitutes about one-half or one-third of the nerve-fibre, the white substance being greater in proportion in the nerves than in the central organs. It is perfectly transparent, and is therefore indistinguishable in a perfectly fresh and natural state of the nerve. When examined under a high power it presents the appearance of longitudinal striation, as if composed of very fine, homogeneous fibrillæ, held together in a faintly granular interstitial material. Occasionally at its termination the axis-cylinder of a fibre may be seen to break up into exceedingly fine fibrillæ, confirming the view of its fibrillar structure. These fibrillæ have been termed the *primitive fibrillæ* of Schultze. The axis-cylinder is said to be enveloped in a very delicate, hyaline sheath, which separates it from the white matter of Schwann. The *medullary sheath* or *white matter of Schwann* is regarded as being a fatty matter in a fluid state, which insulates and protects the essential part of the nerve—the axis-cylinder. The white matter varies in thickness to a very considerable extent, in some forming a layer of extreme thinness, so as to be scarcely distinguishable, in others forming about one-half the nerve-tube. The size of the nerve-fibres, which varies from $\frac{1}{1200}$ to $\frac{1}{2000}$ of an inch, depends mainly upon the amount of the white substance, though the axis-cylinder also varies in size within certain limits. The white matter of Schwann does not always form a continuous sheath to the axis-cylinder, but undergoes interruptions in its continuity at regular intervals, giving to the fibre the appearance of constriction at these points. These were first described by Ranvier, and are known as the *nodes of Ranvier* (Fig. 48). The portion of nerve-fibre between two nodes is called an *internodal segment*. The neurilemma or primitive sheath is not interrupted at the nodes, but passes over them as a continuous membrane. Each

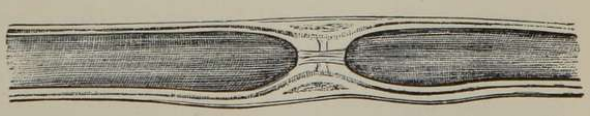

FIG. 48.—A node of Ranvier of a medullated nerve-fibre, viewed from above, magnified about 750 diameters. The medullary sheath is discontinuous at the node, whereas the axis-cylinder passes from one segment into the other. At the node the sheath of Schwann appears thickened. (Klein and Noble Smith.)

[1] In older histological works the term "neurilemma" is used to designate the fibrous envelope of the whole nerve, now called "perineurium."

internodal segment contains an oval nucleus imbedded in the medullary sheath, and occasionally more than one nucleus may be seen in the same internode. Medullated nerve-fibres frequently present a beaded or varicose appearance: this is due to manipulation and pressure causing the oily matter to collect into drops, and in consequence of the extreme delicacy of the primitive sheath even slight pressure will cause the transudation of the fatty matter, which collects as drops of oil outside the membrane. This is, of course, promoted by the action of ether (Fig. 49).

The *neurilemma* or *primitive sheath* (sometimes called the *tubular membrane* or *sheath of Schwann*) presents the appearance of a delicate, structureless membrane. Here and there beneath it, and situated in depressions in the white matter of Schwann, are nuclei surrounded by a small amount of protoplasm. The nuclei are oval and somewhat flattened, and bear a definite relation to the nodes of Ranvier; one nucleus generally lying in the centre of each node, though in some few instances two nuclei may be found in the same node. The sheath of Schwann, it is to be noted, does not occur in the medullated fibres contained within the spinal cord and brain.

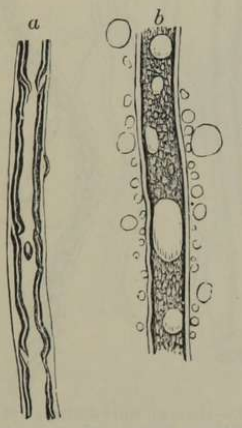

FIG. 49.—Magnified 300 diameters. *a*. Nerve-fibre of the common eel in water. The delicate line on its exterior indicates the neurilemma. The dark double-edged inner one is the white matter of Schwann, slightly wrinkled. *b*. The same in ether. Several oil-globules have coalesced in the interior, and others have accumulated around the exterior of the tube. The white matter has in part disappeared.

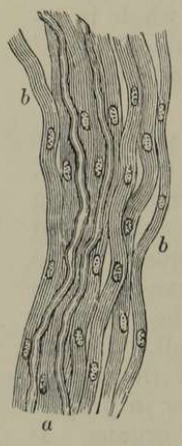

FIG. 50.—A small nervous branch from the sympathetic of a mammal. *a*. Two dark-bordered nerve-tubes among a number of Remak's fibres, *b*.

Non-medullated Fibres.—Most of the nerves of the sympathetic system, and some of the cerebro-spinal (see especially the description of the olfactory nerve), consist of another variety of nervous fibres, which are called the *gray* or *gelatinous* nerve-fibres—*fibres of Remak* (Fig. 50). These consist of a bundle of finely striated fibrillæ enclosed in a sheath. Nuclei may be detected at intervals in each fibre, situated between the axis-cylinder and the neurilemma. In external appearance the gelatinous nerves are semi-transparent and gray or yellowish-gray. The individual fibres vary in size, generally averaging about half the size of the medullated fibres; but, on the one hand, the primitive fibrillæ formed by the breaking up of the cerebro-spinal fibres, as above mentioned, are of hardly appreciable thickness; while, on the other hand, some of the gelatinous fibres (especially those on the olfactory bulb) are said to be three or four times as thick as those of the cerebro-spinal nerves.

Chemical Composition.—The difference in the chemical composition of the white and gray matter is indicated by the following analyses by Petrowsky of the brain of the ox:

	Gray.	White.
Water	81.60%	68.30%
Solids (percentage composition):		
Proteids	55.37	24.72
Lecithin	17.24	9.90
Cholesterin and fat	18.68	51.91
Cerebrin	0.53	9.55
Other organic compounds	6.71	3.34
Salts	1.45	0.57

The proteids in the above analysis practically represent the protoplasm, which

naturally is much greater in the gray than in the white matter. On the other hand, the cholesterin, fat, and cerebrin (the latter ill-defined nitrogenous compounds belonging to the group of glucosides) are probably important constituents of the medullary sheath. Another substance also occurring in the medullary sheath, though not determined separately in the above analysis, is *neurokeratin*, which forms a fibrous network throughout the sheath, and resembles keratin in its marked resistance to reagents. It probably makes up the greater part of the unidentified organic matter of the white substance in the above analysis, while in the gray substance the unidentified matter is probably largely composed of *protagon*, a phosphorized compound closely resembling lecithin, but differing from it by its insolubility in ether.

The nervous structures are divided, as before mentioned, into two great systems—viz. the *cerebro-spinal*, comprising the brain and spinal cord, the nerves connected with these structures, and the ganglia situated on them; and the *sympathetic*, consisting of a double chain of ganglia and the nerves connected with them. All these structures require separate consideration.

The **brain** or **encephalon** is that part of the cerebro-spinal system which is contained in the cavity of the skull. It is divided into several parts, for a description of which reference must be made to the account of the structure of the brain in a subsequent portion of this work. In these parts the gray matter is found partly on the surface of the brain, forming the cortex of the cerebrum and of the cerebellum. Again, gray matter is found in the interior of the brain, collected into large and distinct masses or ganglionic bodies, such as the corpus striatum, optic thalamus, corpora quadrigemina, the olivary bodies, and the corpora dentata of the cerebellum. Finally, gray matter is found intermingled intimately with the white, but without definite arrangement, as in the gray matter in the pons Varolii and the floor of the fourth ventricle.

The white matter of the brain is divisible into three distinct classes of fibres. These are, in the first place, projection fibres, such as the fibres which connect the brain with the spinal cord; that is to say, those which are usually traced upward from the columns of the spinal cord, through the medulla oblongata into the encephalon, chiefly by means of the anterior pyramids, passing through the pons Varolii and crura cerebri to the internal capsules of the corpora striata, and thence to the cerebral cortex, and by means of the restiform bodies into the cerebellum. The second class of white fibres in the brain are commissural, connecting opposite sides of the brain, as, for instance, the fibres of the corpus callosum and the anterior commissure of the thalamencephalon. And the third class are the association fibres which connect different regions of the same side of any of the portions of the brain. The fibres of this last class are more especially developed in the cerebral hemispheres, where they connect different areas of the cortex, as, for example, the cortical centre for sight in the occipital lobe with the motor centre for speech in the frontal lobe.

The manner in which the gray and white matter are intermingled in the brain and spinal cord is very intricate, and can only be fully understood by a careful study of the details of its descriptive anatomy in the sequel. The further consideration of this subject will therefore be deferred until after the description of the various divisions of which the cerebro-spinal system is made up.

The **nerves** are round or flattened cords, formed of the nerve-fibres already described. They are connected at one end with the cerebro-spinal centre or with the ganglia, and are distributed at the other end to the various textures of the body; they are subdivided into two great classes—the *cerebro-spinal*, which proceed from the cerebro-spinal axis, and the *sympathetic* or *ganglionic* nerves, which proceed from the ganglia of the sympathetic. The **cerebro-spinal nerves** consist of numerous nerve-fibres collected together and enclosed in a membranous sheath (Fig. 51). A small bundle of primitive fibres, enclosed in a tubular sheath, is called a *funiculus;* if the nerve is of small size, it may consist only of a single funiculus; but if large, the funiculi are collected together into larger bundles or

fasciculi, which are bound together in a common membranous investment, and constitute the nerve.

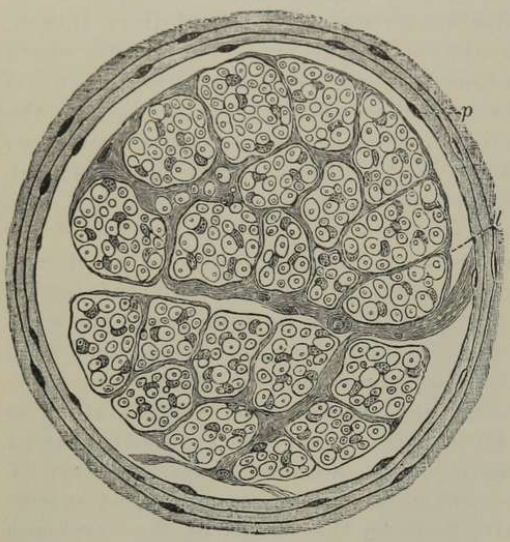

FIG. 51.—Transverse section through a microscopic nerve, representing a compound nerve-bundle, surrounded by epineurium. Magnified 120 diameters. The medullated fibres are seen as circles with a central dot—viz. medullary sheath and axis-cylinder—in transverse section. They are imbedded in endoneurium, containing numerous nuclei, which belong to the connective-tissue cells of the latter. (Klein and Noble Smith.) *p*. Epineurium, consisting of laminæ of fibrous connective tissues, alternating with flattened nucleated connective-tissue cells. *l*. Lymph-space between epineurium and surface of nerve-bundle.

In structure the common membranous investment, or sheath of the whole nerve, which is called the *epineurium*, as well as the septa given off from it, and which separate the fasciculi, consists of connective tissue, composed of white and yellow elastic fibres, the latter existing in great abundance. The tubular sheath of the funiculi, called the *perineurium*, consists of a fine, smooth, transparent membrane, which may be easily separated, in the form of a tube, from the fibres it encloses; in structure it consists of connective tissue, which has a distinctly lamellar arrangement, consisting of several lamellæ, separated from each other by spaces containing lymph. The nerve-fibres are held together and supported within the funiculus by delicate connective tissue, called the *endoneurium*. It is continuous with septa which pass inward from the innermost layer of the perineurium, and consists of a ground-substance in which are imbedded fine bundles of fibrous connective tissue which run for the most part longitudinally. It serves to support the capillary vessels, which are arranged so as to form a network with the elongated meshes. The cerebro-spinal nerves consist almost exclusively of the medullated nerve-fibres, the non-medullated existing in very small proportions.

The blood-vessels supplying a nerve terminate in a minute capillary plexus, the vessels composing which pierce the perineurium and run, for the most part, parallel with the fibres; they are connected together by short, transverse vessels, forming narrow, oblong meshes, similar to the capillary system of muscle. Fine non-medullated nerve-fibres accompany these capillary vessels, *vaso-motor fibres*, and break up into elementary fibrils, which form a network around the vessel. Horsley has also recently demonstrated certain medullated fibres as running in the epineurium and terminating in tactile corpuscles or end-bulbs of Krause, or in small, but perfect, Pacinian corpuscles. These nerve-fibres are termed *nervi nervorum*, and have been considered to have an important bearing upon certain neuralgic pains.

The nerve-fibres, as far as is at present known, do not coalesce, but pursue an uninterrupted course from the centre to the periphery. In separating a nerve, however, into its component funiculi, it may be seen that they do not pursue a perfectly insulated course, but occasionally join at a very acute angle with other funiculi proceeding in the same direction; from this, branches are given off, to join again in like manner with other funiculi. It must be remembered, however, that in these communications the nerve-fibres do not coalesce, but merely pass into the sheath of the adjacent nerve, become intermixed with its nerve-fibres, and again pass on, to become blended with the nerve-fibres in some adjoining funiculus.

Nerves, in their course, subdivide into branches, and these frequently communicate with branches of a neighboring nerve. In the subdivision of a nerve the filaments of which it is composed are continued from the trunk into the branches,

and at their junction with the branches of neighboring nerves the filaments pass to become intermixed with those of the other nerves in their further progress; in no instance, however, have the separate nerve-fibres been shown to inosculate.

The communications which take place between two or more nerves form what is called a *plexus*. Sometimes a plexus is formed by the primary branches of the trunks of the nerves—as the cervical, brachial, lumbar, and sacral plexuses—and occasionally by the terminal funiculi, as in the plexuses formed at the periphery of the body. In the formation of a plexus the component nerves divide, then join, and again subdivide in such a complex manner that the individual funiculi become interlaced most intricately; so that each branch leaving a plexus may contain filaments from each of the primary nervous trunks which form it. In the formation also of smaller plexuses at the periphery of the body there is a free interchange of the funiculi and primitive fibres. In each case, however, the individual filaments remain separate and distinct, and do not inosculate with one another.

It is probable that through this interchange of fibres the different branches passing off from a plexus have a more extensive connection with the spinal cord than if they each had proceeded to be distributed without such connection with other nerves. Consequently the parts supplied by these nerves have more extended relations with the nervous centres; by this means, also, groups of muscles may be associated for combined action.

The **sympathetic** nerves are constructed in the same manner as the cerebro-spinal nerves, but consist mainly of non-medullated fibres, collected into funiculi, and enclosed in a sheath of connective tissue. There is, however, in these nerves a certain admixture of medullated fibres, and the amount varies in different nerves. Those branches of the sympathetic which present a well-marked gray color are composed more especially of non-medullated nerve-fibres, intermixed with a few medullated fibres; whilst those of a white color contain more of the latter fibres and a few of the former. Occasionally, the gray and white cords run together in a single nerve, without any intermixture, as in the branches of communication between the sympathetic ganglia and the spinal nerves, or in the communicating cords between the ganglia. These medullated fibres are derived from the central nervous system through the *rami communicantes*, which pass from the cerebro-spinal nerves to the various sympathetic ganglia.

The nerve-fibres, both of the cerebro-spinal and sympathetic system, convey impressions of a twofold kind. The sensory nerves, called also *centripetal* or *afferent* nerves, transmit to the nervous centres impressions made upon the peripheral extremities of the nerves, and in this way the mind, through the medium of the brain, becomes conscious of external objects. The *motor* nerves, called also *centrifugal* or *efferent* nerves, transmit impressions from the nervous centres to the parts to which the nerves are distributed, these impressions either exciting muscular contraction, or influencing the processes of nutrition, growth, and secretion.

Origin and Termination of Nerves.—By the expression "the termination of nerve-fibres" is signified their connection with the nerve-centres, and with the parts they supply. The former are sometimes called their *origin*, or *central* termination; the latter their *peripheral* termination. The origin in some cases is single—that is to say, the whole nerve emerges from the nervous centre by a single root; in other instances the nerve arises by two or more roots, which come off from different parts of the nerve-centre, sometimes widely apart from each other, and it often happens, when a nerve arises in this way by two roots, that the functions of these two roots are different; as, for example, in the spinal nerves, each of which arises by two roots, the anterior of which is motor and the posterior sensory. The point where the nerve root or roots emerge from the nervous centre is named the *superficial* or *apparent* origin, but the fibres of which the nerve consists can be traced for a certain distance into the nervous centre to some portion of the gray substance, which constitutes the *deep* or *real* origin of the nerve.

In the case of motor or efferent nerve-fibres the deep origin is in cells contained within the spinal cord or brain, the axis-cylinder processes of these cells being prolonged to form the fibres. In the case of the sensory nerves the origin is somewhat different, inasmuch as they arise from the cells of ganglia situated externally to the central nervous system. The sensory fibres of a spinal nerve arise, for instance, from the cells of the ganglion of the posterior root; these cells give off a process which branches in a T-shaped manner (Fig. 46, B), one of the limbs of the T extending peripherally, while the other passes inwards and penetrates the spinal cord. In connection with the sensory cranial nerves, origins are described imbedded within the substance of the brain; these are not, however, the proper origins, but are groups of cells around which the fibres, growing inwards form the ganglion-cells, situated just outside the brain, end, and from which new fibres arise, which pass upwards in the substance of the brain.

Peripheral Terminations of Nerves.—The manner in which nerve-fibres terminate peripherally are several, and may be conveniently studied in the sensory and motor nerves respectively. **Sensory** nerves would appear to terminate either in minute primitive fibrillæ or networks of these; or else in special terminal organs, which have been termed *peripheral end-organs*, and of which there are three principal varieties—viz. the end-bulbs of Krause, the tactile corpuscles of Wagner, and the Pacinian corpuscles.

Termination in Fibrillæ.—When a medullated nerve-fibre approaches its termination, the white matter of Schwann suddenly disappears, leaving only the axis-cylinder surrounded by the neurilemma, and we have now a non-medullated fibre. This undergoes repeated division, and after a time loses its neurilemma, and consists only of an axis-cylinder, which can be seen, in preparations stained with chloride of gold, to be made up of fine varicose fibrils. Finally, the axis-cylinder breaks up into its constituent primitive nerve-fibrillæ, which anastomose with one another, thus forming a network, and often present regular varicosities. This network passes between the elements of the tissue to which the nerves are distributed, which is always epithelial, and the nerve-fibrils end in the interstitial substance between the epithelial cells, or, as is believed by some, actually terminate *within* the cells as minute swellings close to the nucleus. In this way nerve-fibres have been found to terminate in the epithelium of the skin and mucous membranes, and in the anterior epithelium of the cornea.

The **end-bulbs of Krause** (Fig. 52) are minute oblong or cylindrical corpuscles, into the interior of which the axis-cylinder of the nerve-fibre passes, and terminates in a coiled, plexiform mass or in a bulbous extremity. The corpuscle consists of a simple nucleated capsule, containing a soft, homogeneous core, in which the termination of the axis-cylinder is contained. The white matter of Schwann ceases abruptly as the axis-cylinder enters the corpuscle, but the neurilemma is continued inward with the axis-cylinder, and forms an investment of the core, lining the interior of the capsule. The end-bulbs have been described as occurring in the conjunctiva (where, in man, they are spheroidal in shape), in the mucous membrane of the mouth, and in the cutis and mucous membrane of the penis, clitoris, and vagina, where they are termed *genital corpuscles*. The latter have a mulberry-like appearance, from being constricted by connective-tissue septa into from two to six knob-like masses. In the synovial membrane of certain joints (*e. g.* those of the fingers) rounded or oval end-bulbs have been found; these are designated *articular end-bulbs*.

The **tactile corpuscles** (Fig 53), described by Wagner and Meissner, are oval-shaped bodies, made up of connective tissue, and consisting of a capsule, and imperfect membranous septa, derived from it, which penetrate its interior. The axis-cylinders, entering the capsule, pursue a convoluted course, supported by the septa, and terminate in small globular or pyriform enlargements, near the inner surface of the capsule. These tactile corpuscles have been described as occurring in the papillæ of the corium of the hand and foot, the front of the fore-arm, the

skin of the lips, and the mucous membrane of the tip of the tongue, the palpebral conjunctiva, and the skin of the nipple They are not found in all the papillæ;

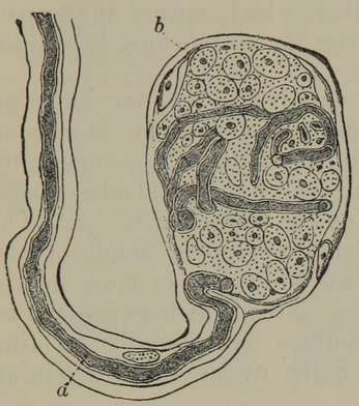

FIG. 52.—End-bulb of Krause. *a*. Medullated nerve-fibre. *b*. Capsule of corpuscle. (From Klein's *Elements of Histology*.)

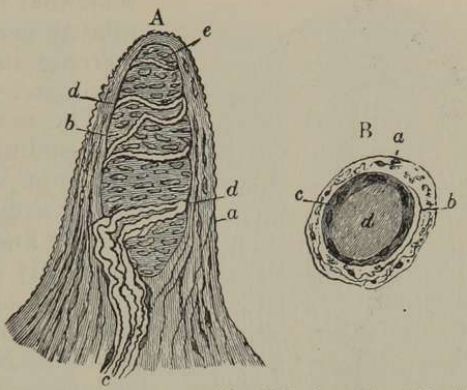

FIG. 53.—Tactile papilla of the hand treated with acetic acid. Magnified 350 times. A. Side view of a papilla of the hand. *a*. Cortical layer. *b*. Tactile corpuscle, with transverse nuclei. *c*. Small nerve of the papilla, with neurilemma. *d*. Its two nervous fibres running with spiral coils around the tactile corpuscle. *e*. Apparent termination of one of these fibres. B. A tactile papilla seen from above, so as to show its transverse section. *a*. Cortical layer. *b*. Nerve-fibre. *c*. Outer layer of the tactile body, with nuclei. *d*. Clear interior substance.

but from their existence in those parts in which the skin is highly sensitive, it is probable that they are specially concerned in the sense of touch, though their absence from the papillæ of other tactile parts shows that they are not essential to this sense.

The **Pacinian corpuscles**[1] (Fig. 54) are found in the human subject chiefly on the nerves of the palm of the hand and sole of the foot and in the genital organs of both sexes, lying in the subcutaneous tissue; but they have also been described as connected with the nerves of the joints, and in some other situations, as the mesentery of the cat and along the tibia of the rabbit. Each of these corpuscles is attached to and encloses the termination of a single nerve-fibre. The corpuscle, which is perfectly visible to the naked eye (and which can be most easily demonstrated in the mesentery of a cat), consists of a number of lamellæ or capsules, arranged more or less concentrically around a central clear space, in which the nerve-fibre is contained. Each lamella is composed of bundles of fine connective-tissue fibres, and is lined on its inner surface by a single layer of nucleated endothelial cells. The central clear space, which is elongated or cylindrical in shape, is filled with a transparent material, in the middle of which is the single medullated fibre, which traverses the space to near its distal extremity. Here it terminates in a rounded knob or end, sometimes bifurcating previously, in which case each branch has a similar arrangement. Todd and Bowman have described minute arteries as entering by the sides of the nerves and forming capillary loops in the intercapsular spaces, and even penetrating into the central space. Other authors describe the artery as entering the corpuscle at the pole opposite to the nerve-fibre.

Herbst has described a somewhat similar "nerve-ending" to the Pacinian corpuscle, as being found in the mucous membrane of the tongue of the duck and in some other situations. It differs, however, from the Pacinian corpuscles, in being smaller, its capsules thinner and more closely approximated, and especially in the fact that the axis-cylinder in the central clear space is coated with a continuous row of nuclei. These bodies are known as the *corpuscles of Herbst*.

Tactile corpuscles have been described by Grandry as occurring in the papillæ of the beak and tongue of birds, and by Merkel as occurring in the papillæ and

[1] Often called in German anatomical works "corpuscles of Vater."

epithelium of the skin of man and animals, especially in those parts of the skin devoid of hair. They consist of a capsule composed of a very delicate, nucleated membrane, and contain two or more granular, somewhat flattened cells, between which the medullated nerve-fibre, which enters the capsule by piercing its investing membrane, is supposed to terminate.

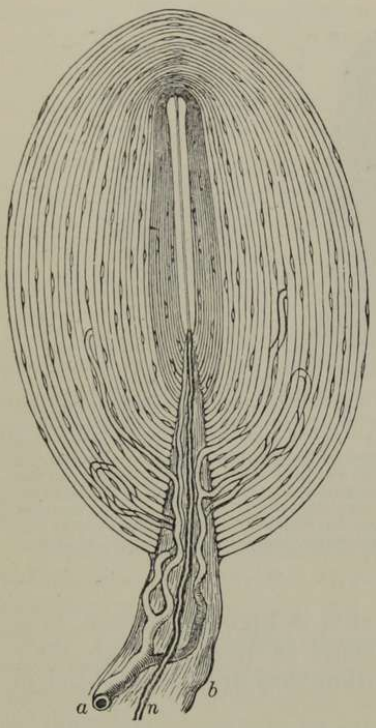

FIG. 54.—Pacinian corpuscle, with its system of capsules and central cavity. *a*. Arterial twig, ending in capillaries, which form loops in some of the intercapsular spaces, and one penetrates to the central capsule. *b*. The fibrous tissue of the stalk prolonged from the perineurium. *n*. Nerve-tube advancing to the central capsule, there losing its white matter, and stretching along the axis to the opposite end, where it is fixed by a tubercular enlargement.

The nerves supplying tendons have peculiar nerve-endings, and are especially numerous near the point where the tendon becomes muscular. In this situation spindle-shaped bodies are found, and are known as the *organs of Golgi*. They are apparently composed of several tendinous bundles fused into one, into which one or more nerve-fibres pass, and, dividing, spread out between the tendon-bundles. Nerve-fibres occasionally terminate in tendons as end-bulbs or as small Pacinian corpuscles.

In the organs of **special sense** the nerves seem to terminate in cells, which are modified epithelial cells, and have received the name of *sensory* or *nerve-epithelium* cells. In reality, however, the nerve-fibre is in these cases a process of the epithelial cell, and if followed centrally will be found to end by branching around a ganglion-cell. From this an axis-cylinder continues the path along which the stimulus travels toward the brain. These nerve-epithelium cells are to be regarded as specially modified neurons.

Motor nerves are to be traced either into unstriped or striped muscular fibres. In the **unstriped** or **involuntary** muscles the nerves are derived from the sympathetic, and are composed mainly of the non-medullated fibres. Near their termination they divide into a number of branches, which communicate and form an intimate plexus. At the junction of the branches groups of ganglion-cells are situated. From these plexuses minute branches are given off, which divide and break up into the ultimate fibrillæ of which the nerve is composed. These fibrillæ course between the involuntary muscle-cells, and, according to Elischer, terminate on the surface of the cell, opposite the nucleus, in a minute swelling. Arnold and Frankenhäuser believed that these ultimate fibrillæ penetrated the muscular cell and ended in the nucleus. More recent observation has, however, tended to disprove this.

In the **striped** or **voluntary** muscle, the nerves supplying the muscular fibres are derived from the cerebro-spinal nerves, and are composed mainly of medullated fibres. The nerve, after entering the sheath of the muscle, breaks up into fibres, or bundles of fibres, which form plexuses, and gradually divide until, as a rule, a single nerve-fibre enters a single muscular fibre. Sometimes, however, if the muscular fibre is long, more than one nerve-fibre enters it. Within the muscular fibre the nerve terminates in a special expansion, called by Kühne, who first accurately described them, *motorial end-plates* (Fig. 55).[1] The nerve-fibre, on approaching the muscular fibre, suddenly loses its white matter of Schwann, which abruptly terminates; the neurilemma becomes continuous with the sarcolemma of the muscle, and only the axis-cylinder enters the muscular fibre, where it immediately spreads out, ramifying like the roots of a tree, immediately beneath

[1] They had, however, previously been noticed, though not accurately described, by Doyere, who named them "nerve-hillocks."

the sarcolemma, and is imbedded in a layer of granular matter, containing a number of clear, oblong nuclei, the whole constituting an end-plate from which the contractile wave of the muscular fibre is said to start.

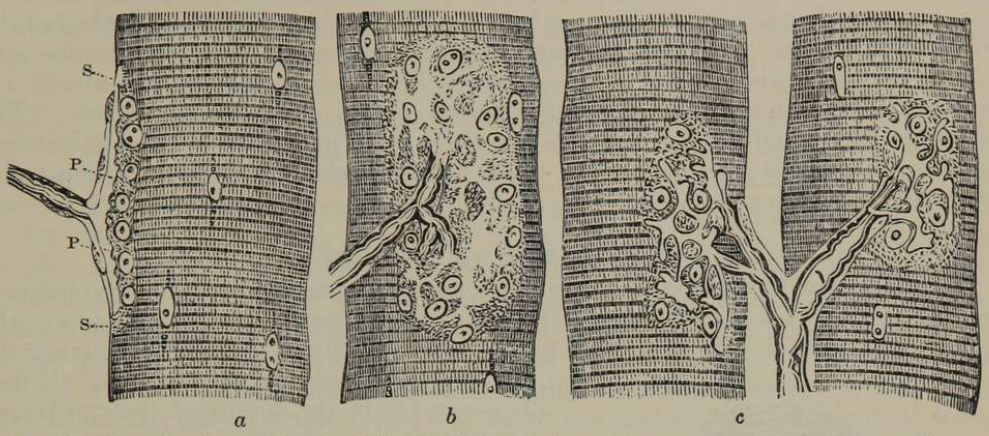

FIG. 55.—Muscular fibres of *Lacerta viridis* with the terminations of nerves. *a*. Seen in profile. P.P. The nerve end-plates. S.S. The base of the plate, consisting of a granular mass with nuclei. *b*. The same as seen in looking at a perfectly fresh fibre, the nervous ends being probably still excitable. (The forms of the variously-divided plate can hardly be represented in a woodcut by sufficiently delicate and pale contours to reproduce correctly what is seen in nature.) *c*. The same as seen two hours after death from poisoning by curare.

The **Ganglia** may be regarded as separate and independent nervous centres, of smaller size and less complex structure than the brain, connected with each other, with the cerebro-spinal axis, and with the nerves in various situations. They are found on the posterior root of each of the spinal nerves; on the posterior or sensory root of the fifth cranial nerve; on the facial and auditory nerves; and on the glosso-pharyngeal and pneumogastric nerves. They are also found in a connected series along each side of the vertebral column, forming the trunk of the sympathetic; and on the branches of that nerve, generally in the plexuses or at the point of junction of two or more nerves with each other or with branches of the cerebro-spinal system. On section they are seen to consist of a reddish-gray substance, traversed by numerous white nerve-fibres; they vary considerably in form and size; the largest are found in the cavity of the abdomen; the smallest, not visible to the naked eye, exist in considerable numbers upon the nerves distributed to the different viscera. The ganglia are invested by a smooth and firm, closely-adhering, membranous envelope, consisting of dense areolar tissue; this sheath is continuous with the perineurium of the nerves, and sends numerous processes into the interior of the ganglion, which support the blood-vessels supplying its substance.

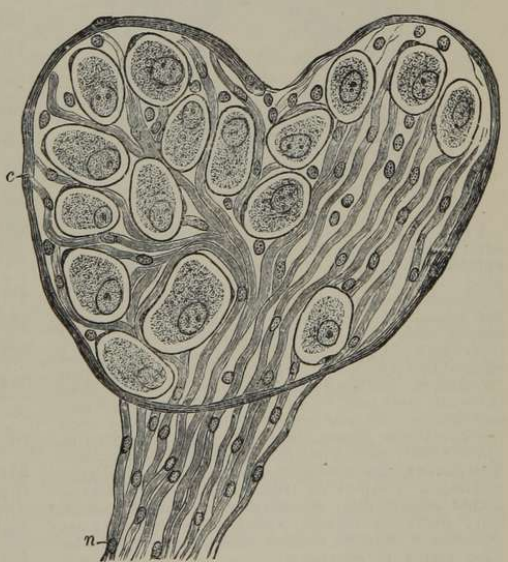

FIG. 56.—Section through a microscopic ganglion. Magnified 300 diameters. (Klein and Noble Smith.) *c*. Capsule of the ganglion. *n*. Nerve-fibres passing out of the ganglion. The nerve-fibres which entered the ganglion are not represented. The nerve-fibres are ordinary medullated fibres, but the details of their structure are not shown, owing to the low magnifying power. The ganglion-cells are invested by special capsules, lined by a few nuclei, which are here represented as if contained *in* the capsule.

In structure all ganglia are essentially similar (Fig. 56), consisting of the same structural elements as the other nervous centres—viz. a collection of nerve-cells and nerve-fibres. The nerve- or ganglion-cells in the ganglia of the spinal nerves are pyriform in shape, the

smaller end being drawn out into a process which bifurcates at its extremity in a T-like manner, the two limbs of the T forming the axis-cylinder of the peripheral and central portions of a sensory nerve-fibre. In the sympathetic ganglia the cells are multipolar, and give off a single unbranched axis-cylinder. Cells of this type are found in the ciliary, spheno-palatine, submaxillary, and otic ganglia attached to certain of the cranial nerves, and these may in consequence be considered as the cranial portion of the sympathetic system. The ganglion-cells are usually enclosed in a transparent capsule with nuclei on its inner surface. The nerve-fibres on entering the ganglion lay aside their perineurium, which becomes continuous with the capsule. Some fibres run through the ganglion without being connected with the cells.

THE VASCULAR SYSTEM.

The **Vascular System,** exclusive of its central organ, the heart, is divided into four classes of vessels: the arteries, capillaries, veins, and lymphatics; the minute structure of which we will now proceed briefly to describe, referring the reader to the body of the work for all that is necessary in the details of their ordinary anatomy.

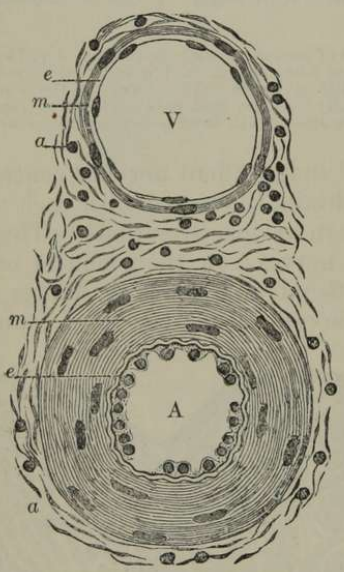

FIG. 57.—Transverse section through a small artery and vein of the mucous membrane of the epiglottis of a child. Magnified about 350 diameters. (Klein and Noble Smith.) A. Artery, showing the nucleated endothelium, *e*, which lines it: the vessel being contracted, the endothelial cells appear very thick. Underneath the endothelium is the wavy elastic intima. The chief part of the wall of the vessel is occupied by the circular muscle-coat *m*: the staff-shaped nuclei of the muscle-cells are well seen. Outside this is *a*, part of the adventitia. This is composed of bundles of connective-tissue fibres, shown in section, with the nuclei of the connective-tissue corpuscles. The adventitia gradually merges into the surrounding connective tissue. V. Vein showing a thin endothelial membrane, *e*, raised accidentally from the intima, which on account of its delicacy is seen as a mere line on the media *m*. This latter is composed of a few circular unstriped muscle-cells. *a*. The adventitia, similar in structure to that of an artery.

Structure of Arteries (Fig. 57).—The arteries are composed of three coats: internal or endothelial coat (*tunica intima* of Kölliker); middle muscular coat (*tunica media*); and external cellular coat (*tunica adventitia*).

The two inner coats together are very easily separated from the external, as by the ordinary operation of tying a ligature on an artery. If a fine string be tied forcibly upon an artery and then taken off, the external coat will be found undivided, but the internal coats are divided in the track of the ligature and can easily be further dissected from the outer coat. The *inner coat* can be separated from the middle by a little maceration, or it may be stripped off in small pieces; but, on account of its friability, it cannot be separated as a complete membrane. It is a fine, transparent, colorless structure which is highly elastic, and is commonly corrugated into longitudinal wrinkles. The inner coat consists of—1. A layer of pavement-epithelium, the cells of which are polygonal, oval, or fusiform, and have very distinct round or oval nuclei. This endothelium, as it is now generally called, is brought into view most distinctly by staining with nitrate of silver. 2. A subepithelial layer, consisting of delicate connective tissue with branched cells lying in the interspaces of the tissue. 3. An elastic or fenestrated layer, which consists of an elastic membrane containing a network of elastic fibres, having principally a longitudinal direction and in which, under the microscope, small, elongated apertures or perforations may be seen, giving it a fenestrated appearance. It was therefore called by Henle the *fenestrated membrane*. This membrane forms the chief thickness of the inner coat, and can be separated into several layers, some of which present the appearance of a network of longitudinal elastic

fibres, and others present a more membranous character, marked by pale lines having a longitudinal direction. In arteries of less than a line in diameter the subepithelial layer consists of a single layer of stellate cells, and the connective tissue is only largely developed in the large-sized vessels. The fenestrated membrane in microscopic arteries is a very thin layer, but in the larger arteries, and especially in the aorta, it has a very considerable thickness.

The *middle* coat (*tunica media*) is distinguished from the inner by its color and by the transverse arrangement of its fibres, in contradistinction to the longitudinal direction of those of the inner coat. It consists of two varieties of structure, *yellow elastic* tissue and *muscular* tissue, which are present in varying quantities in different vessels, according to their size, the former tissue preponderating in the larger vessels and the latter in the smaller ones. In the largest arteries this coat is of great thickness, of a yellow color, and highly elastic; it diminishes in thickness and becomes redder in color as the arteries become smaller, and finally becomes very thin and disappears. In small arteries this coat is purely muscular, consisting of muscle fibre-cells (Fig. 44) united to form lamellæ which vary in number according to the size of the artery; the very small arteries having only a single layer, and those not larger than one-tenth of a line in diameter three or four layers. In arteries of medium size (Fig. 58) this coat becomes thicker in proportion to the size of the vessel; its layers of muscular tissue are more numerous and intermixed with numerous fine elastic fibres which unite to form broad-meshed networks. In the larger vessels, as the femoral, superior mesenteric, cœliac axis, external iliac, brachial and popliteal arteries, the elastic fibres unite to form lamellæ, which alternate with the layers of muscular fibre. In the largest arteries the muscular tissue is only slightly developed and forms about one-third or one-fourth of the whole substance of the middle coat; this is especially the case in the aorta and trunk of the pulmonary artery, in which the individual cells of the muscular layer are imperfectly formed, while in the carotid, axillary, iliac, and subclavian arteries the muscular layer of the middle coat is more developed. The elastic lamellæ are well marked, may amount to fifty or sixty in number, and alternate regularly with the layers of muscular tissue. They are most distinct and arranged with greatest regularity in the abdominal aorta, innominate artery, and common carotid. In the larger arteries bundles of white connective-tissue fibres have also been found in small quantity in the middle coat.

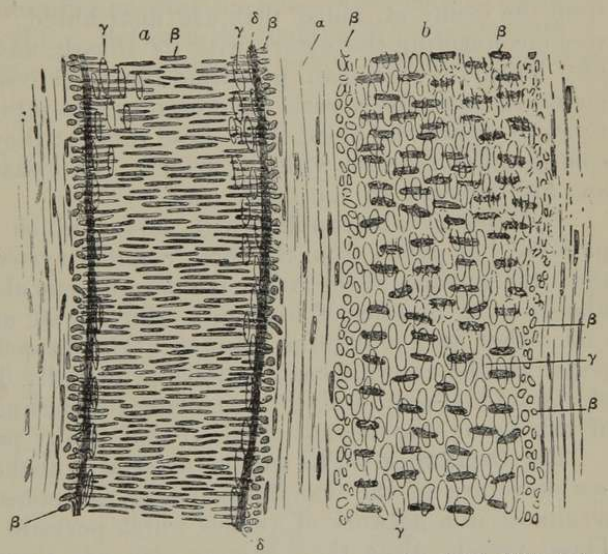

FIG. 58.—An artery from the mesentery of a child, .062‴, and *b*, vein .067‴ in diameter, treated with acetic acid and magnified 350 times. *α*. Tunica adventitia, with elongated nuclei. *β*. Nuclei of the contractile fibre-cells of the tunica media, seen partly from the surface, partly apparent in transverse section. *γ*. Nuclei of the endothelial cells. *δ*. Elastic longitudinal fibrous coat.

The *external* coat (*tunica adventitia*) consists mainly of fine and closely felted bundles of white connective tissue, but also contains elastic fibres in all but the smallest arteries. The elastic tissue is much more abundant next the tunica media, and it is sometimes described as forming here, between the adventitia and media, a special layer, the *tunica elastica externa* of Henle. This layer is most marked in arteries of medium size. In the largest vessels the external coat is relatively thin; but in small arteries it is as thick or thicker than the middle coat.

In the smaller arteries it consists of a single layer of white connective tissue and elastic fibres; while in the smallest arteries, just above the capillaries, the elastic fibres are wanting, and the connective tissue, of which the coat is composed, becomes more homogeneous the nearer it approaches the capillaries, and is gradually reduced to a thin membranous envelope which finally disappears.

Some arteries have extremely thin coats in proportion to their size; this is especially the case in those situated in the cavity of the cranium and spinal canal, the difference depending on the greater thinness of the external and middle coats.

The arteries, in their distribution throughout the body, are included in a thin fibro-areolar investment, which forms what is called their *sheath*. In the limbs this is usually formed by a prolongation of the deep fascia; in the upper part of the thigh it consists of a continuation downward of the transversalis and iliac fasciæ of the abdomen; in the neck, of a prolongation of the deep cervical fascia. The included vessel is loosely connected with its sheath by a delicate areolar tissue; and the sheath usually encloses the accompanying veins, and sometimes a nerve. Some arteries, as those in the cranium, are not included in sheaths.

All the larger arteries are supplied with blood-vessels like the other organs of the body; they are called the *vasa vasorum*. These nutrient vessels arise from a branch of the artery or from a neighboring vessel, at some considerable distance from the point at which they are distributed; they ramify in the loose areolar tissue connecting the artery with its sheath, and are distributed to the external coat, but do not, in man, penetrate the other coats; though in some of the larger mammals some few vessels have been traced into the middle coat. Minute veins serve to return the blood from these vessels; they empty themselves into the venæ comites in connection with the artery. Lymphatic vessels and lymphatic spaces are also present in the outer coat.

Arteries are also supplied with nerves, which are derived chiefly from the sympathetic, but partly from the cerebro-spinal system. They form intricate plexuses upon the surfaces of the larger trunks, and run along the smaller branches as single filaments or bundles of filaments, which twist around the vessel and unite with each other in a plexiform manner. The branches derived from these plexuses penetrate the external coat, and are principally distributed to the muscular tissue of the middle coat, and thus regulate, by causing the contraction and relaxation of this tissue, the amount of blood sent to any part.

The Capillaries.—The smaller arterial branches (excepting those of the cavernous structure of the sexual organs, of the spleen, and in the uterine placenta) terminate in a network of vessels which pervade nearly every tissue of the body. These vessels, from their minute size, are termed capillaries (*capillus*, a hair). They are interposed between the smallest branches of the arteries and the commencing veins, constituting a network, the branches of which maintain the same diameter throughout; the meshes of the network being more uniform in shape and size than those formed by the anastomoses of the small arteries and veins.

The *diameter* of the capillaries varies in the different tissues of the body, their usual size being about $\frac{1}{3000}$ of an inch. The smallest are those of the brain and the mucous membranes of the intestines; and the largest those of the skin and the marrow of bone, where they are stated to be as large as $\frac{1}{1200}$ of an inch.

The *form* of the capillary net varies in the different tissues, the meshes being generally rounded or elongated. The *rounded form of mesh* is most common, and prevails where there is a dense network, as in the lungs, in most glands and mucous membranes, and in the cutis; here the meshes are more or less angular, sometimes nearly quadrangular or polygonal; more frequently irregular.

Elongated meshes are observed in the bundles of fibres composing muscles and nerves, the meshes being usually of a parallelogram form, the long axis of the mesh running parallel with the long axis of the nerve and fibre. Sometimes the capillaries have a *looped* arrangement; a single vessel projecting from the

common network and returning after forming one or more loops, as in the papillæ of the tongue and skin. The number of the capillaries, and the size of the meshes, determine the degree of vascularity of a part. The closest network and the smallest interspaces are found in the lungs and in the choroid coat of the eye. In these situations the interspaces are smaller than the capillary vessels themselves. In the kidney, in the conjunctiva, and in the cutis the interspaces are from three to four times as large as the capillaries which form them; and in the brain from eight to ten times as large as the capillaries in their long diameter, and from four to six times as large in their transverse diameter. In the adventitia of arteries the width of the meshes is ten times that of the capillary vessels. As a general rule, the more active the function of the organ, the closer is its capillary net and the larger its supply of blood; the network being very narrow in all growing parts, in the glands, and in the mucous membranes; wider in bones and ligaments, which are comparatively inactive; and nearly altogether absent in tendons, in which very little organic change occurs after their formation.

Structure.—The walls of the capillaries consist of a fine, transparent, endothelial layer, composed of cells joined edge to edge by an interstitial cement-substance, and continuous with the endothelial cells which line the arteries and veins. When stained with nitrate of silver the edges which bound the endothelial cells are brought into view (Fig. 59). These cells are of large size and of an irregular polygonal or lanceolate shape, each containing an oval nucleus which may be brought into view by carmine or hæmatoxylin. Between their edges, at various points of their meeting, roundish dark spots are sometimes seen, which have been described as

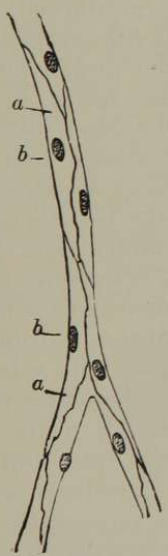

FIG. 59.—Capillaries from the mesentery of a guinea-pig after treatment with solution of nitrate of silver. *a*. Cells. *b*. Their nuclei.

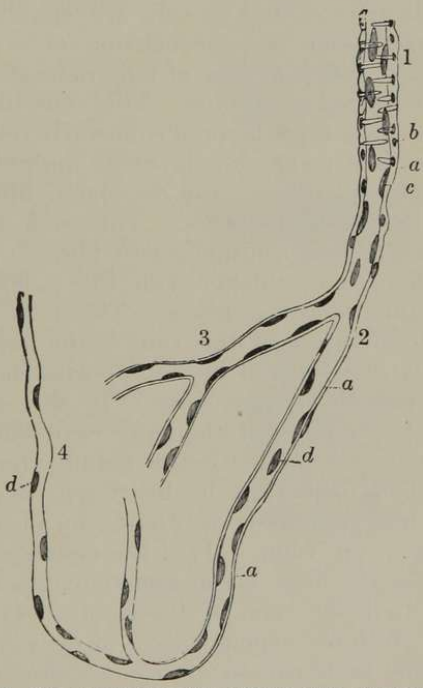

FIG. 60.—Finest vessels on the arterial side. From the human brain. Magnified 300 times. 1. Smallest artery. 2. Transition vessel. 3. Coarser capillaries. 4. Finer capillaries. *a*. Structureless membrane still with some nuclei, representative of the tunica adventitia. *b*. Nuclei of the muscular fibre-cells. *c*. nuclei within the small artery, perhaps appertaining to an endothelium. *d*. Nuclei in the transition vessels.

stomata, though they are closed by intercellular substance. They have been believed to be the situation through which the white corpuscles of the blood, when migrating through the blood-vessels, emerge; but this view, though probable, is not universally accepted.

In many situations a delicate sheath or envelope of branched nucleated connec-

tive-tissue cells is found around the simple capillary tube, particularly in the larger ones, and in places such as the lymphatic glands where the capillaries are supported by a retiform connective tissue.

In the largest capillaries (which ought, perhaps, to be described rather as the smallest arteries) there is, outside the endothelial layer, a muscular layer, consisting of contractile fibre-cells, arranged transversely, as in the tunica media of the larger arteries (Fig. 60).

The **veins**, like the arteries, are composed of three coats—internal, middle, and external; and these coats are, with the necessary modifications, analogous to the coats of the arteries; the internal being the endothelial, the middle the muscular, and the external the connective or areolar. The main difference between the veins and the arteries is the comparative weakness of the middle coat of the former, and to this it is due that the veins do not stand open when divided, as the arteries do, and that they are passive rather than active organs of the circulation.

In the veins immediately above the capillaries the three coats are hardly to be distinguished. The endothelium is supported on an outer membrane separable into two layers, the outer of which is the thicker, and consists of a delicate, nucleated membrane (adventitia), while the inner is composed of a network of longitudinal elastic fibres (media). In the veins next above these in size (one-fifth of a line, according to Kölliker) a muscular layer and a layer of circular fibres can be traced, forming the middle coat, while the elastic and connective elements of the outer coat become more distinctly perceptible. In the middle-sized veins the typical structure of these vessels becomes clear. The endothelium is of the same character as in the arteries, but its cells are more oval, less fusiform. It is supported by a connective-tissue layer, consisting of a delicate network of branched cells, and external to this is a layer of longitudinal elastic fibres, but seldom any appearance of a fenestrated membrane. This constitutes the *internal* coat. The *middle* coat is composed of a thick layer of connective tissue with elastic fibres, intermixed, in some veins, with a transverse layer of muscular fibres. The white fibrous element is in considerable excess, and the elastic fibres are in much smaller proportion in the veins than in the arteries. The *outer* coat consists of areolar tissue, as in the arteries, with longitudinal elastic fibres. In the largest veins the outer coat is from two to five times thicker than the middle coat, and contains a large number of longitudinal muscular fibres. This is most distinct in the inferior vena cava, and at the termination of this vein in the heart, in the trunks of the hepatic veins, in all the large trunks of the vena portæ, in the splenic, superior mesenteric, external iliac, renal, and azygos veins. In the renal and portal veins it extends through the whole thickness of the outer coat, but in the other veins mentioned a layer of connective and elastic tissue is found external to the muscular fibres. All the large veins which open into the heart are covered for a short distance with a layer of striped muscular tissue continued on to them from the heart. Muscular tissue is wanting in the veins—(1) of the maternal part of the placenta; (2) in the venous sinuses of the dura mater and the veins of the pia mater of the brain and spinal cord; (3) in the veins of the retina; (4) in the veins of the cancellous tissue of bones; (5) in the venous spaces of the corpora cavernosa. The veins of the above-mentioned parts consist of an internal endothelial lining supported on one or more layers of areolar tissue. The internal and external jugular veins and the subclavian vein are said to contain either no muscular fibres at all, or at all events only a slight amount in their middle coat.

Most veins are provided with valves, which serve to prevent the reflux of the blood. They are formed by a reduplication of the inner coat, strengthened by connective tissue and elastic fibres, and are covered on both surfaces with endothelium, the arrangement of which differs on the two surfaces. On the surface of the valve next the wall of the vein the cells are arranged transversely; whilst on the other surface, over which the current of blood flows, the cells are arranged vertically in the direction of the current. Their form is semilunar. They are

attached by their convex edge to the wall of the vein; the concave margin is free, directed in the course of the venous current, and lies in close apposition with the wall of the vein as long as the current of blood takes its natural course; if, however, any regurgitation takes place, the valves become distended, their opposed edges are brought into contact, and the current is intercepted. Most commonly two such valves are found placed opposite one another, more especially in the smaller veins or in the larger trunks at the point where they are joined by smaller branches; occasionally there are three and sometimes only one. The wall of the vein on the cardiac side of the point of attachment of each segment of the valve is expanded into a pouch or sinus, which gives to the vessel, when injected or distended with blood, a knotted appearance. The valves are very numerous in the veins of the extremities, especially of the lower extremities, these vessels having to conduct the blood against the force of gravity. They are absent in the very small veins—*i. e.* those less than $\frac{1}{12}$ of an inch in diameter; also in the venæ cavæ, the hepatic veins, portal vein and its branches, the renal, uterine, and ovarian veins. A few valves are found in the spermatic veins, and one also at their point of junction with the renal vein and inferior vena cava in both sexes. The cerebral and spinal veins, the veins of the cancellated tissue of bone, the pulmonary veins, and the umbilical vein and its branches, are also destitute of valves. They are occasionally found, few in number, in the venæ azygos and intercostal veins.

The veins are supplied with nutrient vessels, *vasa vasorum*, like the arteries. Nerves also are distributed to them in the same manner as to the arteries, but in much less abundance.

The **lymphatic** vessels, including in this term the lacteal vessels, which are identical in structure with them, are composed of three coats. The *internal* is an endothelial and elastic coat. It is thin, transparent, slightly elastic, and ruptures sooner than the other coats. It is composed of a layer of elongated epithelial cells with serrated margins, by which the adjacent cells are dovetailed into one another. These are supported on a single layer of longitudinal elastic fibres. The *middle* coat is composed of smooth muscular and fine elastic fibres, disposed in a transverse direction. The *external*, or fibro-areolar, coat consists of filaments of connective tissue, intermixed with

FIG. 61.—Transverse section through the coats of the thoracic duct of man. Magnified 30 times. *a*. Endothelium, striated lamellæ, and inner elastic coat. *b*. Longitudinal connective tissue of the middle coat. *c*. Transverse muscles of the same. *d*. Tunica adventitia, with *e*, the longitudinal muscular fibres.

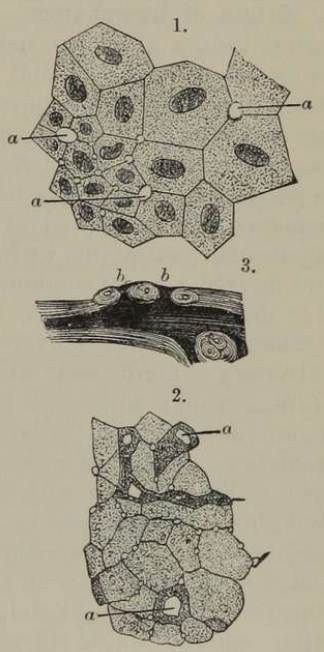

FIG. 62.—1. Endothelium from the under surface of the *centrum tendineum* of the rabbit. *a*. Stomata. 2. Endothelium of the mediastinum of the dog. *a*. Stomata. 3. Section through the pleura of the same animal. *b*. Free orifices of short lateral passages of the lymph-canals. (Copied from Ludwig, Schweigger-Seydel, and Dybkowsky.)

smooth muscular fibres, longitudinally or obliquely disposed. It forms a protective covering to the other coats, and serves to connect the vessel with the neighboring structures. The above description applies only to the larger lymphatics; in the smaller vessels there is no muscular or elastic coat, and their structure consists only of a connective-tissue coat, lined by endothelium. The thoracic duct (Fig. 61) is a somewhat more complex structure than the other lymphatics; it presents a distinct subepithelial layer of branched corpuscles, similar to that found in the arteries, and in the middle coat is a layer of connective tissue with its fibres

arranged longitudinally. The lymphatics are supplied by nutrient vessels, which are distributed to their outer and middle coats; but no nerves have at present been traced into them.

The lymphatics are very generally provided with valves, which assist materially in effecting the circulation of the fluid they contain. These valves are formed of a thin layer of fibrous tissue, lined on both surfaces by endothelium. Their form is semilunar; they are attached by their convex edge to the sides of the vessel, the concave edge being free and directed along the course of the contained current. Usually two such valves, of equal size, are found opposite one another; but occasionally exceptions occur, especially at or near the anastomoses of lymphatic vessels. Thus, one valve may be of very rudimentary size and the other increased in proportion.

The valves in the lymphatic vessels are placed at much shorter intervals than in the veins. They are most numerous near the lymphatic glands, and they are found more frequently in the lymphatics of the neck and upper extremity than in the lower. The wall of the lymphatics immediately above the point of attachment of each segment of a valve is expanded into a pouch or sinus, which gives to these vessels, when distended, the knotted or beaded appearance which they present. Valves are wanting in the vessels composing the plexiform network in which the lymphatics usually originate on the surface of the body.

Origin of Lymphatics.—The finest visible lymphatic vessels (lymphatic capillaries) form a plexiform network in the tissues and organs, and they consist of a single layer of endothelial plates, with more or less sinuous margins. These vessels commence in an intercommunicating system of clefts or spaces in the connective tissue of the different organs, which have no complete endothelial lining. They have been named the *rootlets* of the lymphatics, and are identical with the spaces in which the connective-tissue corpuscles are contained. This then is properly regarded as one method of their commencement, when the lymphatic vessels are apparently continuous with spaces in the connective tissue, and Klein has described and figured a direct communication between these spaces and the lymphatic vessel.[1] But the lymphatics have also other modes of origin, for the intestinal lacteals commence by closed extremities, though some observers believe that the closed extremity is continuous with a minute network contained in the substance of the villus, through which the lacteal is connected with the epithelial cells covering it. Again, it seems now to be conclusively proved that the serous membranes present stomata or openings between the epithelial cells (Fig. 62) by which there is an open communication with the lymphatic system, and through which the lymph is thought to be pumped by the ultimate dilatation and contraction of the serous surface, due to the movements of respiration and circulation,[2] so that the serous and synovial sacs may be regarded, in a certain sense, as large lymph-cavities or sinuses. Von Recklinghausen was the first to observe the passage of milk and other colored fluids through these stomata on the peritoneal surface of the central tendon of the diaphragm. Again, in most glandular structures the lymphatic capillaries have a lacunar origin. Here they begin in irregular clefts or spaces in the tissue of the part; occupying the penetrating connective tissue and surrounding the lacunæ or tubules of the gland, and in many places separating the capillary network from the alveolus or tubule, so that the interchange between the blood and the secreting cells of the part must be carried on through this lymph-space or lacuna. Closely allied to this is the mode of origin of lymphatics in perivascular and perineural spaces. Sometimes a minute artery may be seen to be ensheathed for a certain distance by a lymphatic capillary vessel, which is often many times wider than a blood-capillary. These are known as perivascular lymphatics.

[1] *Atlas of Histology*, pl. viii. fig. xiv.

[2] The resemblance between lymph and serum led Hewson long ago to regard the serous cavities as sacs into which the lymphatics open. Recent microscopic discoveries confirm this opinion in a very interesting manner.

Terminations of Lymphatics.—The lymphatics, including the lacteals, discharge their contents into the veins at two points; namely, at the angles of junction of the subclavian and internal jugular veins: on the left side by means of the thoracic duct, and on the right side by the right lymphatic duct. (See description of lymphatics on a subsequent page.)

Lymphatic glands (*conglobate glands*) are small oval or bean-shaped bodies, situated in the course of lymphatic and lacteal vessels, so that the lymph and chyle pass through them on their way to the blood. They generally present on one side a slight depression—the *hilum*—through which the blood-vessels enter and leave the interior. The efferent lymphatic vessel also emerges from the gland at this spot, while the afferent vessels enter the organ at different parts of the periphery. On section (Fig. 63), a lymphatic gland displays two different structures: an external, of lighter color—the *cortical;* and an internal, darker—the *medullary*. The cortical structure does not form a complete investment, but is deficient at the hilum, where the medullary portion reaches the surface of the gland; so that the efferent vessel is derived directly from the medullary structure, while the afferent vessels empty themselves into the cortical substance.

Lymphatic glands consist of (1) a fibrous envelope, or *capsule*, from which a framework of processes (*trabeculæ*) proceed inward, dividing the gland into open spaces (*alveoli*) freely communicating with each other; (2) a quantity of adenoid tissue occupying these spaces without completely filling them; (3) a free supply of blood-vessels, which are supported on the trabeculæ; and (4) the *afferent* and *efferent* vessels. Little is known of the nerves, though Kölliker describes some fine nervous filaments passing into the hilum.

The *capsule* is composed of a layer of connective tissue, and from its internal surface are given off a number of membranous septa or lamellæ, consisting, in man, of connective tissue, with a small admixture of muscular fibre-cells; but in many of the lower animals composed almost entirely of involuntary muscular fibre. They pass inward, radiating toward the centre of the gland, for a certain distance; that is to say, for about one-third or one-fourth of the space between the circumference and the centre of the gland. They thus divide the outer part of its interior into a number of oval compartments or *alveoli* (Fig. 63). This is the cortical portion of the gland. After having penetrated into the gland for some distance, these septa break up into a number of smaller trabeculæ, which form flattened bands or cords, interlacing with each other in all directions, forming in the central part of the organ a number of intercommunicating spaces, also called *alveoli*. This is the medullary portion of the gland, and the spaces or alveoli in it not only freely communicate with each other, but also with the alveoli of the cortical portion. In these alveoli or spaces (Fig. 64) is contained the proper gland-substance or lymphoid tissue. The gland-pulp does not, however, completely fill the alveolar spaces, but leaves, between its outer margin and the trabeculæ forming the alveoli a channel or space of uniform width throughout. This is termed the *lymph-path* or *lymph-sinus* (Fig. 66). Running across it are a number of trabeculæ of retiform connective tissue, the fibres of which are, for the most part, covered by ramified cells. This tissue appears to serve the purpose of maintaining the gland-pulp in the centre of the space in its proper position.

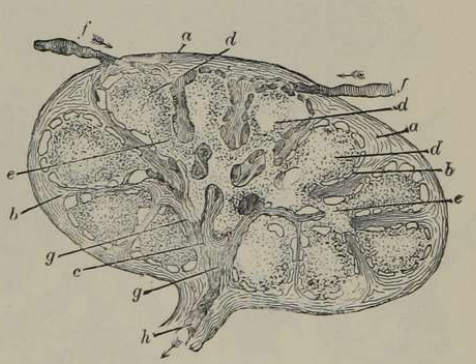

FIG. 63.—Section of small lymphatic gland, half-diagrammatically given, with the course of the lymph. *a*. The envelope. *b*. Septa between the follicles or alveoli of the cortical part. *c*. System of septa of the medullary portion, down to the hilum. *d*. The follicles. *e*. Lymph-tubes of the medullary mass. *f*. Different lymphatic streams which surround the follicles, and flow through the interstices of the medullary portion. *g*. Confluence of these passing through the efferent vessel. *h*, at the hilum.

On account of the peculiar arrangement of the framework of the organ, the

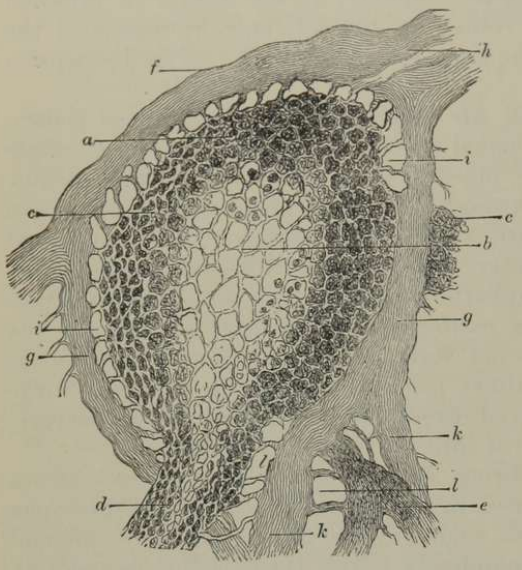

FIG. 64.—Follicle from a lymphatic gland of the dog, in vertical section. *a*. Reticular sustentacular substance of the more external portion, *b*, of the more internal, and *c*, of the most external and most finely webbed part on the surface of the follicle. *d*. Origin of a large lymph-tube. *e*. Of a smaller one. *f*. Capsule. *g*. Septa. *h*. Vas afferens. *i*. Investing space of the follicle, with its retinacula. *k*. One of the divisions of the septa. *l,l*. Attachment of the lymph-tubes to the septa.

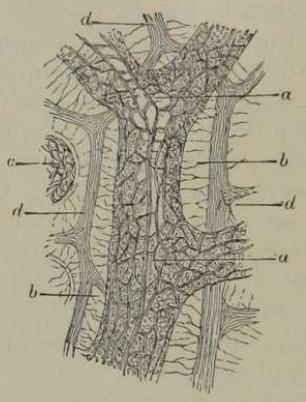

FIG. 65.—From the medullary substance of an inguinal gland of the ox. (After His.) *a*. Lymph-tube, with its complicated system of vessels. *b*. Retinacula stretched between the tube and the septa. *c*. Portion of another lymph-tube. *d*. Septa.

gland-pulp in the cortical portion is disposed in the form of nodules, and in the medullary part in the form of rounded cords. It consists of ordinary lymphoid tissue, being made up of a delicate reticulum of retiform tissue, which is continuous with that in the lymph-paths, but marked off from it by a closer reticulation; in its meshes are closely packed lymph-corpuscles, traversed by a dense plexus of capillary blood-vessels.

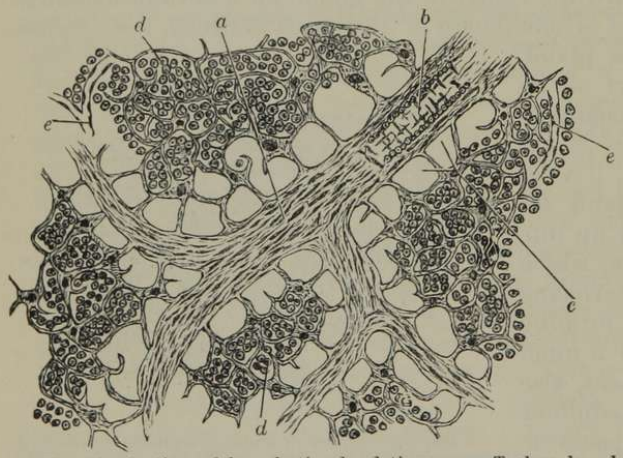

FIG. 66.—Section of lymphatic gland tissue. *a*. Trabeculæ. *b*. Small artery in substance of same. *c*. Lymph-paths. *d*. Lymph-corpuscles. *e*. Capillary plexus.

The *afferent vessels*, as above stated, enter at all parts of the periphery of the gland, and after branching and forming a dense plexus in the substance of the capsule, open into the lymph-sinuses of the cortical part. In doing this they lose all their coats except their endothelial lining, which is continuous with a layer of similar cells lining the lymph-paths. In like manner the *efferent* vessel commences from the lymph-sinuses of the medullary portion. The stream of lymph carried to the gland by the afferent vessel thus passes through the plexus in the capsule to the lymph-paths of the cortical portion, where it is exposed to the action of the gland-pulp; flowing through these, it enters the paths or sinuses of the medullary portion, and finally emerges from the hilum by means of the efferent vessel. The stream of lymph in its passage through the lymph-sinuses is much retarded by the presence of the reticulum. Hence morphological elements, either normal or

morbid, are easily arrested and deposited in the sinuses. This is a matter of considerable importance in connection with the subject of poisoned wounds and the absorption of the poison by the lymphatic system, since by this means septic organisms carried along the lymphatic vessels may be arrested in the lymph-sinuses of the gland tissue, and thus be prevented from entering the general circulation. The arteries of the gland enter at the hilum, and either pass at once to the gland-pulp, to break up into a capillary plexus, or else run along the trabeculæ, partly to supply them and partly running across the lymph-paths to assist in forming the capillary plexus of the gland-pulp. This plexus traverses the lymphoid tissue, but does not pass into the lymph-sinuses. From it the veins commence, and emerge from the organ at the same place as that at which the artery enters.

THE SKIN AND ITS APPENDAGES.

The **skin** (Fig. 67) is the principal seat of the sense of touch, and may be regarded as a covering for the protection of the deeper tissues; it is also an important excretory and absorbing organ. It consists principally of a layer of vascular connective tissue, named the *derma*, *corium*, or *cutis vera*, and an external covering of epithelium, termed the *epidermis* or *cuticle*. On the surface of the former layer

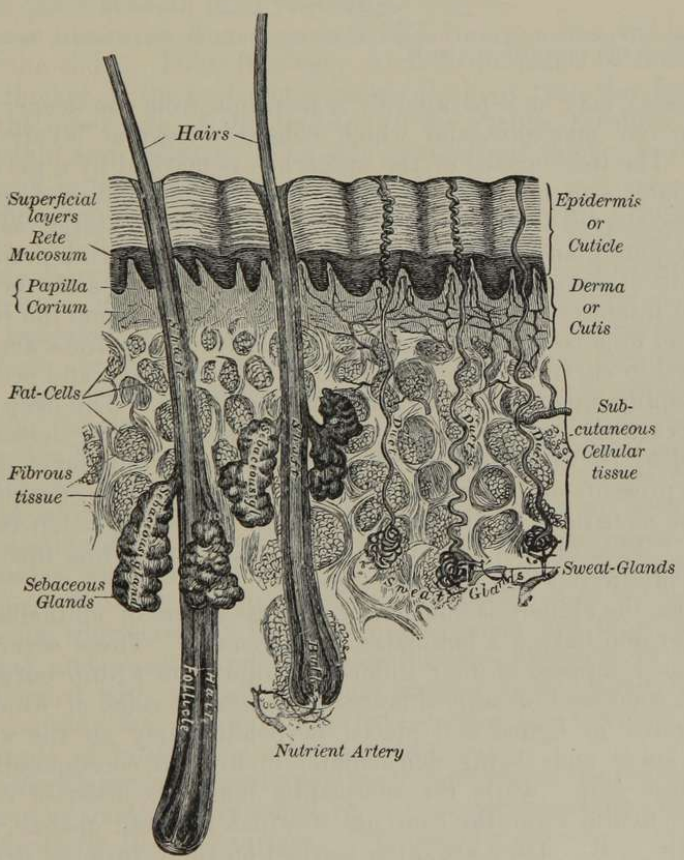

FIG. 67.—A sectional view of the skin (magnified).

are the sensitive *papillæ;* and within, or imbedded beneath it, are certain organs with special functions—namely, the *sweat-glands*, *hair-follicles*, and *sebaceous glands*.

The **epidermis** or **cuticle** (*scarf-skin*, Fig. 68) is an epithelial structure belonging to the class of stratified epithelium. It is accurately moulded on the papillary layer of the derma. It forms a defensive covering to the surface of the true skin, and limits the evaporation of watery vapor from its free surface. It varies in thickness in different parts. In some situations, as in the palms of the hands and soles of the feet, it is thick, hard, and horny in texture. This may be partly due

to the fact that these parts are exposed to intermittent pressure, but that this is not the only cause is proved by the fact that the condition exists to a very considerable extent at birth. The more superficial layer of cells, called the *horny* layer

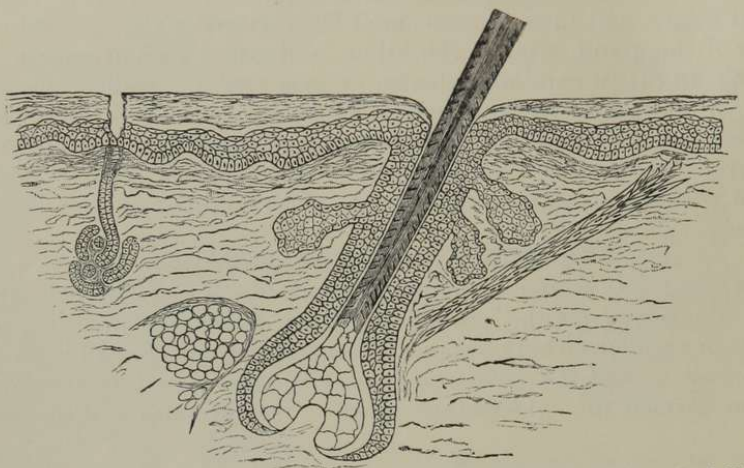

FIG. 68.—Microscopic section of skin, showing the epidermis and derma; a hair in its follicle: the erector pili muscle: sebaceous and sudoriferous glands.

(*stratum corneum*), may be separated by maceration from the deeper layers, which are called the *rete mucosum*, and which consist of several layers of differently shaped cells. The free surface of the epidermis is marked by a network of linear furrows of variable size, marking out the surface into a number of spaces of polygonal or lozenge-shaped form. Some of these furrows are large, as opposite the flexures of the joints, and correspond to the folds in the derma produced by their movements. In other situations, as upon the back of the hand, they are exceedingly fine, and intersect one another at various angles; upon the palmar surface of the hand and fingers and upon the sole of the foot these lines are very distinct and are disposed in curves. They depend upon the large size and peculiar arrangement of the papillæ upon which the epidermis is placed. The deep surface of the epidermis is accurately moulded upon the papillary layer of the derma, each papilla being invested by its epidermic sheath; so that when this layer is removed by maceration, it presents on its under surface a number of pits or depressions corresponding to the elevations in the papillæ, as well as the ridges left in the intervals between them. Fine tubular prolongations are continued from this layer into the ducts of the sudoriferous and sebaceous glands.

In structure, the epidermis consists of several layers of epithelial cells agglutinated together and having a laminated arrangement. These several layers may be described as composed of four different strata from within outward: (1) The *rete Malpighii*, composed of several layers of epithelial cells, of which the deepest layer is elongated in figure and placed perpendicularly on the surface of the corium, their lower ends being denticulate, to fit into corresponding denticulations of the true skin; while the succeeding laminæ consist of cells of a more rounded or polyhedral form, the contents of which are soft, opaque, granular, and soluble in acetic acid. They are often marked on their surfaces with ridges and furrows, and are covered with numerous fibrils, which connect the surfaces of the cells: these are known as *prickle* cells (see page 43). (2) Immediately superficial to these is a single layer of flattened, spindle-shaped cells, the *granular layer*, which contain granules that become deeply stained in hæmatoxylin, and are composed of a substance termed *eleidin*. They are supposed to be cells in a transitional stage between the protoplasmic cells of the rete Malpighii and the horny cells of the superficial layers. (3) Above this layer the cells become indistinct, and appear, in sections, to form a homogeneous or dimly striated membrane composed of closely-packed scales, in which traces of a flattened nucleus

may be found. It is called the *stratum lucidum.* (4) As these cells successively approach the surface by the development of fresh layers from beneath, they assume a flattened form from the evaporation of their fluid contents, and consist of many layers of horny epithelial scales in which no nucleus is discernible, forming the *stratum corneum.* These cells apparently become changed in their chemical composition, as they are now unaffected by acetic acid. The deepest layer of the rete Malpighii is separated from the papillæ by an apparently homogeneous basement membrane, which is most distinctly brought into view in specimens prepared with chloride of gold. This, according to Klein, is merely the deepest portion of the epithelium, and is "made up of the basis of the individual cells, which have undergone a chemical and morphological alteration." The black color of the skin in the negro and the tawny color among some of the white races is due to the presence of pigment in the cells of the cuticle. This pigment is more especially distinct in the cells of the deeper layer or rete mucosum, and is similar to that found in the cells of the pigmentary layer of the retina. As the cells approach the surface and desiccate, the color becomes partially lost.

The **derma, corium,** or **cutis vera,** is tough, flexible, and highly elastic, in order to defend the parts beneath from violence.

It varies in thickness, from a quarter of a line to a line and a half, in different parts of the body. Thus it is very thick in the palms of the hands and soles of the feet; thicker on the posterior aspect of the body than the front, and on the outer than the inner side of the limbs. In the eyelids, scrotum, and penis it is exceedingly thin and delicate. The skin generally is thicker in the male than in the female, and in the adult than in the child.

The corium consists of fibrous connective tissue, with a large admixture of elastic fibres and numerous blood-vessels, lymphatics, and nerves. The fibro-areolar tissue forms the framework of the cutis, and is differently arranged in different parts, so that it is usual to describe it as consisting of two layers: the deeper or *reticular* layer, and the superficial or *papillary* layer. Unstriped muscular fibres are found in the superficial layers of the corium, wherever hairs are found; and in the subcutaneous areolar tissue of the scrotum, penis, labia majora of the female, and the nipples. In the latter situation the fibres are arranged in bands, closely reticulated and disposed in superimposed laminæ.

The *reticular* layer consists of strong interlacing fibrous bands, composed chiefly of the white variety of fibrous tissue, but containing, also, some fibres of the yellow elastic tissue, which vary in amount in different parts, and connective-tissue corpuscles, which are often to be found flattened against the white fibrous tissue-bundles. Toward the attached surface the fasciculi are large and coarse, and the areolæ which are left by their interlacement are large, and occupied by adipose tissue and sweat-glands. Below this the elements of the skin become gradually blended with the subcutaneous areolar tissue, which, except in a few situations, contains fat. Toward the free surface the fasciculi are much finer, and their mode of interlacing close and intricate.

The *papillary layer* is situated upon the free surface of the *reticular layer;* it consists of numerous small, highly sensitive, or vascular eminences, the *papillæ*, which rise perpendicularly from its surface. The papillæ are conical-shaped eminences, having a round or blunted extremity, occasionally divided into two or more parts and connected by a thin base with the free surface of the corium. Their average length is about $\frac{1}{100}$ of an inch, and they measure at their base $\frac{1}{250}$ of an inch in diameter. On the general surface of the body, more especially in those parts which are endowed with slight sensibility, they are few in number, short, exceedingly minute, and irregularly scattered over the surface; but in some situations, as upon the palmar surface of the hands and fingers, upon the plantar surface of the feet and toes, and around the nipple, they are long, of large size, closely aggregated together, and arranged in parallel curved lines, forming the elevated ridges seen on the free surface of the epidermis. In these ridges the larger papillæ are arranged in a

double row, with smaller papillæ between them; and these rows are subdivided into small square-shaped spaces by short transverse furrows, regularly disposed; in the centre of each of these transverse furrows is the minute orifice of the duct of a sweat-gland. No papillæ exist in the grooves between the ridges. In structure the papillæ consist of very small and closely interlacing bundles of finely fibrillated tissue, with a few elastic fibres. The majority of the papillæ contain loops of blood-vessels, and these are known as the vascular papillæ in contradistinction to others which usually possess no blood-vessels, but contain tactile corpuscles. These tactile papillæ are most numerous in the derma of the palm of the hand and of the sole of the foot, but occur also in smaller numbers on the back of the hand and foot, on the flexor surface of the forearm, and on the nipple.

The *arteries* supplying the skin form a network in the subcutaneous tissue, from which branches are given off to supply the sweat-glands, the hair-follicles, and the fat. Other branches are given off which form a plexus immediately beneath the corium; from this fine capillary vessels pass into the papillæ, forming, in the smaller papillæ, a single capillary loop, but in the larger a more or less convoluted vessel. There are numerous *lymphatics* supplied to the skin which form two networks, superficial and deep, communicating with each other and with those of the subcutaneous tissue by oblique branches. They originate in the cell-spaces of the tissue.

The *nerves* of the skin terminate partly in the epidermis and partly in the cutis vera. The former form a dense plexus in the superficial layer of the corium, which extends horizontally and gives off numerous fibrils; these are prolonged into the epidermis, and terminate between the cells, either in bulbous extremities or in a network; or, according to some observers, in the deep epithelial cells themselves. The latter terminate in end-bulbs, touch-corpuscles, or Pacinian bodies in the manner already described; and, in addition to these, a considerable number of fibrils are distributed to the hair-follicles, which are said to entwine the follicle in a circular manner. Other nerve-fibres are supplied to the plain muscular tissues of the hair-muscles (arrectores pili) and to the muscular coat of the blood-vessels. These are probably non-medullated fibres.

The **appendages of the skin** are the nails, the hairs, the sudoriferous and sebaceous glands, and their ducts.

The nails and hairs are peculiar modifications of the epidermis, consisting essentially of the same cellular structure as that tissue.

The **nails** are flattened, elastic structures of a horny texture, placed upon the dorsal surface of the terminal phalanges of the fingers and toes. Each nail is convex on its outer surface, concave within, and is implanted by a portion, called the *root*, into a groove in the skin; the exposed portion is called the *body*, and the anterior extremity the *free edge*. The nail has a very firm adhesion to the cutis, being accurately moulded upon its surface, as the epidermis is in other parts. The part of the cutis beneath the body and root of the nail is called the *matrix*, because it is the part from which the nail is produced. Corresponding to the body of the nail, the matrix is thick, and covered with large, highly vascular papillæ, arranged in longitudinal rows, the color of which is seen through the transparent tissue. Behind this, near the root of the nail, the papillæ are small, less vascular, and have no regular arrangement, and here the tissue of the nail is somewhat more opaque; hence this portion is of a whiter color, and is called the *lunula* on account of its shape.

The cuticle, as it passes forward on the dorsal surface of the finger or toe, is attached to the surface of the nail, a little in advance of its root; at the extremity of the finger it is connected with the under surface of the nail a little behind its free edge. The cuticle and horny substance of the nail (both epidermic structures) are thus directly continuous with each other. The nails, in structure, consist of cells having a laminated arrangement, and these are essentially similar to those composing the epidermis. The deepest layer of cells, which lie in contact with the papillæ of the matrix, are of elongated form, arranged perpendicularly to the

surface; those which succeed them are of a rounded or polygonal form, the more superficial ones becoming broad, thin, and flattened, and so closely compacted as to make the limits of each cell very indistinct. It is by the successive growth of new cells at the root and under surface of the body of the nail that it advances forward and maintains a due thickness, whilst, at the same time, the growth of the nail in the proper direction is secured. As these cells in their turn become displaced by the growth of new cells, they assume a flattened form, their nuclei become indistinct, and they finally become closely compacted together into a firm, dense, horny texture. In *chemical composition* the nails resemble epidermis. According to Mulder, they contain a somewhat larger proportion of carbon and sulphur.

The **hairs** are peculiar modifications of the epidermis, and consist essentially of the same structure as that membrane. They are found on nearly every part of the surface of the body, excepting the palms of the hands, soles of the feet, and the penis. They vary much in length, thickness, and color in different parts of the body and in different races of mankind. In some parts, as in the skin of the eyelids, they are so short as not to project beyond the follicles containing them; in other parts, as upon the scalp, they are of considerable length: again, in other parts, as the eyelashes, the hairs of the pubic region, and the male whiskers and beard, they are remarkable for their thickness. The hairs generally present a cylindrical or more or less flattened form and a reniform outline upon transverse section.

A hair consists of a *root*, the part implanted in the skin; the *shaft* or *stem*, the portion projecting from its surface; and the *point*.

The *root of the hair* presents at its extremity a bulbous enlargement, which is whiter in color and softer in texture than the shaft, and is lodged in a follicular involution of the epidermis called the *hair-follicle*. When the hair is of considerable length the follicle extends into the subcutaneous areolar tissue. The hair-follicle commences on the surface of the skin with a funnel-shaped opening, and passes inward in an oblique direction to become dilated at its deep extremity, to correspond with the bulbous condition of the hair which it contains. It has opening into it, near its free extremity, the orifices of the ducts of one or more sebaceous glands (Fig. 68). At the bottom of each hair-follicle is a small conical vascular, eminence or papilla, similar in every respect to those found upon the surface of the skin; it is continuous with the dermic layer of the follicle, is highly vascular and supplied with nervous fibrils; this is the part through which material is supplied for the production and constant growth of the hair. In structure the hair-follicle consists of two coats—an outer or *dermic*, and an inner or *epidermic*.

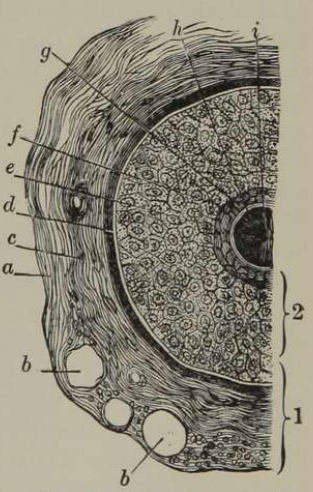

FIG. 69.—Transverse section of hair-follicle. 1. Dermic coat of follicle. 2. Epidermic coat or root-sheath. *a*. Outer layer of dermic coat, with blood-vessels. *b, b*. Vessels cut across. *c*. Middle layer. *d*. Inner or hyaline layer. *e*. Outer root-sheath. *f, g*. Inner root-sheath. *h*. Cuticle of root-sheath. *i*. Hair. (From Quain's *Anatomy*, Biesiadecki.)

The *outer* or *dermic* coat is formed mainly of fibrous tissue; it is continuous with the corium, is highly vascular, and supplied by numerous minute nervous filaments. It consists of three layers (Fig. 69). The most internal, next the cuticular lining of the follicle, consists of a hyaline basement-membrane, having a glassy, transparent appearance, which is well marked in the larger hair-follicles, but is not very distinct in the follicles of minute hairs. It is continuous with the basement-membrane of the surface of the corium. External to this is a layer of spindle-shaped cells, arranged in a circular manner around the follicle and imbedded in a somewhat fibrous matrix, but reaching only as high as the entrance of the ducts of the sebaceous glands. Externally is a thick layer of

connective tissue, arranged in longitudinal bundles, in which are contained the blood-vessels and nerves.

The *inner* or *epidermic* layer is closely adherent to the root of the hair, so that when the hair is plucked from its follicle this layer most commonly adheres to it and forms what is called the *root-sheath.* It consists of two strata, named respectively the *outer* and *inner root-sheath;* the former of these corresponds with the Malpighian layer of the epidermis, and resembles it in the rounded form and soft character of its cells; at the bottom of the hair-follicle these cells become continuous with those of the root of the hair. The *inner* root-sheath consists of a delicate cuticle next the hair; then of one or two layers of horny, flattened, nucleated cells, known as *Huxley's layer;* and finally of a single layer of non-nucleated, horny, flattened cells, called *Henle's layer.*

The hair-follicle contains the root of the hair, which terminates in a bulbous extremity, and is excavated so as to exactly fit the papilla from which it grows. The bulb is composed of polyhedral epithelial cells, which as they pass upward into the root of the hair become elongated and spindle-shaped, except some in the centre which remain polyhedral. Some of these latter cells contain pigment-granules, which give rise to the color of the hair. It occasionally happens that these pigment-granules completely fill the cells in the centre of the bulb, which gives rise to the dark tract of pigment often found, of greater or less length, in the axis of the hair.

The *shaft of the hair* consists of a central pith or medulla, the fibrous part of the hair, and the cortex externally. The medulla occupies the centre of the shaft and ceases toward the point of the hair. It is usually wanting in the fine hairs covering the surface of the body, and commonly in those of the head. It is more opaque and deeper colored when viewed by transmitted light than the fibrous part; but when viewed by reflected light it is white. It is composed of rows of polyhedral cells, which contain air-bubbles. The fibrous portion of the hair constitutes the chief part of the shaft; its cells are elongated and unite to form flattened fusiform fibres. Between the fibres are found minute spaces which contain either pigment-granules in dark hair or minute air-bubbles in white hair. In addition to this there is also a diffused pigment contained in the fibres. The cells which form the cortex of the hair consist of a single layer which surrounds those of the fibrous part; they are converted into thin, flat scales, having an imbricated arrangement.

Connected with the hair-follicles are minute bundles of involuntary muscular fibres, termed *arrectores pili.* They arise from the superficial layer of the corium, and are inserted into the outer surface of the hair-follicle, below the entrance of the duct of the sebaceous gland. They are placed on the side toward which the hair slopes, and by their action elevate the hair (Fig. 68).

The **sebaceous glands** are small, sacculated, glandular organs, lodged in the substance of the corium. They are found in most parts of the skin, but are most abundant in the scalp and face: they are also very numerous around the apertures of the anus, nose, mouth, and external ear; but are wanting in the palms of the hands and soles of the feet. Each gland consists of a single duct, more or less capacious, which terminates in a cluster of small secreting pouches or saccules. The sacculi connected with each duct vary, as a rule, in numbers from two to five, but, in some instances, may be as many as twenty. They are composed of a transparent, colorless membrane, enclosing a number of cells. Of these the outer layer or marginal cells are small, polyhedral, epithelial cells, continuous with the lining cells of the duct. The remainder of the sac is filled with larger cells, containing fat, except in the centre, where the cells have become broken up, leaving a cavity containing the débris of cells and a mass of fatty matter, which constitutes the sebaceous secretion. The orifices of the ducts open most frequently into the hair-follicles, but occasionally upon the general surface. On the nose and face the glands are of large size, distinctly lobulated, and often become much enlarged

from the accumulation of pent-up secretion. The largest sebaceous glands are those found in the eyelids—the Meibomian glands.

The **sudoriferous** or **sweat glands** are the organs by which a large portion of the aqueous and gaseous materials are excreted by the skin. They are found in almost every part of this structure, and are situated in small pits in the deep parts of the corium, or, more frequently, in the subcutaneous areolar tissue, surrounded by a quantity of adipose tissue. They are small, lobular, reddish bodies, consisting of a single convoluted tube, from which the efferent duct proceeds upward through the corium and cuticle, becomes somewhat dilated at its extremity, and opens on the surface of the cuticle by an oblique valve-like aperture. The efferent duct, as it passes through the epidermis, presents a spiral arrangement, being twisted like a corkscrew, in those parts where the epidermis is thick; where, however, it is thin, the spiral arrangement does not exist. In the superficial layers of the corium the duct is straight, but in the deeper layers it is convoluted or even twisted. The spiral course of these ducts is especially distinct in the thick cuticle of the palm of the hand and sole of the foot. The size of the glands varies. They are especially large in those regions where the amount of perspiration is great, as in the axillæ, where they form a thin, mammillated layer of a reddish color, which corresponds exactly to the situation of the hair in this region; they are large also in the groin. Their number varies. They are most numerous on the palm of the hand, presenting, according to Krause, 2800 orifices on a square inch of the integument, and are rather less numerous on the sole of the foot. In both of these situations the orifices of the ducts are exceedingly regular, and correspond to the small transverse grooves which intersect the ridges of the papillæ. In other situations they are more irregularly scattered, but in nearly equal numbers, over parts including the same extent of surface. In the neck and back they are least numerous, their number amounting to 417 on the square inch (Krause). Their total number is estimated by the same writer at 2,381,248, and, supposing the aperture of each gland to represent a surface of $\frac{1}{56}$ of a line in diameter, he calculates that the whole of these glands would present an evaporating surface of about eight square inches. Each gland consists of a single tube intricately convoluted, terminating at one end by a blind extremity, and opening at the other end upon the surface of the skin. In the larger glands this single duct usually divides and subdivides dichotomously; the smaller ducts ultimately terminating in short cæcal pouches, rarely anastomosing. The wall of the duct is thick, the width of the canal rarely exceeding one-third of its diameter. The tube, both in the gland and where it forms the excretory duct, consists of two layers—an outer, formed by fine areolar tissue, and an inner layer of epithelium. The external or fibro-cellular coat is thin, continuous with the superficial layer of the corium, and extends only as high as the surface of the true skin. The epithelial lining in the distal part of the coiled tube of the gland proper consists of a single layer of cubical epithelium, supported on a basement membrane, and beneath it, between the epithelium and the fibro-cellular coat, there is a layer of what are usually regarded as plain muscular fibres, arranged longitudinally. In the duct and the proximal part of the coiled tube of the gland proper there are two or more layers of polyhedral cells, lined on their internal surface—*i. e.* next the lumen of the tube—by a delicate membrane or cuticle, and on their outer surface by a limiting membrana

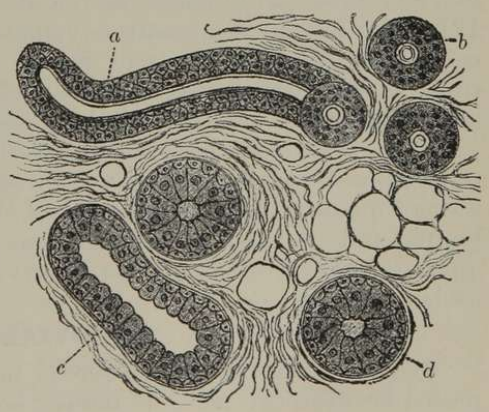

FIG. 70.—Coiled tube of a sweat-gland cut in various directions. *a*. Longitudinal section of the proximal part of the coiled tube. *b*. Transverse section of the same. *c*. Longitudinal section of the distal part of the coiled tube. *d*. Transverse section of the same. (From Klein and Noble Smith's *Atlas of Histology*.)

propria, but there are no muscular fibres. The epithelium is continuous with the epidermis and with the delicate internal cuticle, which is all that is present in the epidermic portion of the tube. When the cuticle is carefully removed from the surface of the cutis, these convoluted tubes of epithelium may be drawn out and form short, thread-like processes on its under surface.

The contents of the smaller sweat-glands are quite fluid; but in the larger glands the contents are semi-fluid and opaque, and contain a number of colored granules and cells which appear analogous to epithelial cells.

SEROUS MEMBRANES.

The **serous membranes** form shut sacs and may be regarded as lymph-sacs, from which lymphatic vessels arise by stomata or openings between the epithelial cells (see page 86). The sac consists of one portion which is applied to the walls of the cavity which it lines—the *parietal* portion; and another reflected over the surface of the organ or organs contained in the cavity—the *visceral* portion. Sometimes the sac is arranged quite simply, as the tunica vaginalis testis; at others with numerous involutions or recesses, as the peritoneum, in which, nevertheless, the membrane can always be traced continuously around the whole circumference. The sac is completely closed, so that no communication exists between the serous cavity and the parts in its neighborhood. An apparent exception exists in the peritoneum of the female; for the Fallopian tube opens freely into the peritoneal cavity in the dead subject, so that a bristle can be passed from the one into the other. But this communication is closed during life, except at the moment of the passage of the ovum out of the ovary into the tube, as is proved by the fact that no interchange of fluids ever takes place between the two cavities in dropsy of the peritoneum or in accumulation of fluid in the Fallopian tubes.[1] The serous membrane is often supported by a firm, fibrous layer, as is the case with the pericardium, and such membranes are sometimes spoken of as "fibro-serous."

The various serous membranes are the peritoneum, lining the cavity of the abdomen; the two pleuræ and the pericardium, lining the lungs and heart respectively; and the tunicæ vaginales, surrounding each testicle in the scrotum.[2] Serous membranes are thin, transparent, glistening structures, lined on their inner surface by a single layer of polygonal or pavement endothelial cells, supported on a matrix of fibrous connective tissue, with networks of fine elastic fibres, in which is contained numerous capillaries and lymphatics. On the surface of the endothelium between the cells numerous apertures or interruptions are to be seen. Some of these are stomata, surrounded by a ring of cubical epithelium (see Fig. 12), and communicating with a lymphatic capillary (see p. 86); others (*pseudostomata*) are mere interruptions in the epithelial layer, and are occupied by processes of the branched connective-tissue corpuscle of the subjacent tissue or by accumulations of the intercellular cement-substance.

The secretion of these membranes is, in most cases, only sufficient in quantity to moisten the surface, but not to furnish any appreciable quantity of fluid. When a small quantity can be collected, it appears to resemble in many respects the lymph, and like that fluid coagulates spontaneously; but when secreted in large quantities, as in dropsy, it is a watery fluid, which gives a precipitate of albumen on boiling.

SYNOVIAL MEMBRANES.

Synovial membranes, like serous membranes, are connective-tissue membranes placed between two movable tissues, so as to diminish friction, as between the two articular ends of the bones forming a movable joint; between a tendon and a

[1] The communication between the uterine cavity and the peritoneal sac is not only apparent in the dead subject, but is an anatomical fact, which is established by the continuity of its epithelium with that covering the uterus, Fallopian tubes, and fimbriæ.

[2] The arachnoid membrane, lining the brain and spinal cord was formerly regarded as a serous membrane, but is now no longer classed with them, as it differs from them in structure, and does not form a shut sac as do the other serous membranes.

bone, where the former glides over the latter; and between the skin and various subcutaneous bony prominences.

The synovial membranes are composed essentially of connective tissue, containing numerous vessels and nerves. It was formerly supposed that these membranes were analogous in structure to the serous membranes, and consisted of a layer of flattened cells on a basement-membrane. No such cells, however, exist, and the only ones found on the surface are irregularly branched connective-tissue corpuscles, similar to those found throughout the tissue. Here and there these cells are collected in patches and present the appearance of epithelium, but do not possess the true characters of an endothelial layer. They are surrounded and held together by an albuminous ground-substance. A further description of the synovial membranes will be found in the descriptive anatomy of the joints.

MUCOUS MEMBRANE.

Mucous membranes line all those passages by which the internal parts communicate with the exterior, and are continuous with the skin at the various orifices of the surface of the body. They are soft and velvety, and very vascular, and their surface is coated over by their secretion, *mucus*, which is of a tenacious consistence, and serves to protect them from the foreign substances introduced into the body with which they are brought in contact.

They are described as lining the two tracts—the gastro-pulmonary and the genito-urinary; and all, or almost all, mucous membranes may be classed as belonging to and continuous with the one or the other of these tracts.

The external surfaces of these membranes are attached to the parts which they line by means of connective tissue, which is sometimes very abundant, forming a loose and lax bed, so as to allow considerable movement of the opposed surfaces on each other. It is then termed the *submucous tissue*. At other times it is exceedingly scanty, and the membrane is closely connected to the tissue beneath; sometimes, for example, to muscle, as in the tongue; sometimes to cartilage, as in the larynx; and sometimes to bone, as in the nasal fossæ and sinuses of the skull.

In structure a mucous membrane is composed of *corium* and *epithelium*. The epithelium is of various forms, including the squamous, columnar, and ciliated, and is often arranged in several layers (see Fig. 11). This epithelial layer is supported by the corium, which is analogous to the derma of the skin, and consists of connective tissue, either simply areolar or containing a greater or less quantity of lymphoid tissue. This tissue is usually covered on its external surface by a transparent structureless basement-membrane, and internally merges into the submucous areolar tissue. It is only in some situations that the basement-membrane can be demonstrated. The corium is an exceedingly vascular membrane, containing a dense network of capillaries, which lie immediately beneath the epithelium, and are derived from small arteries in the submucous tissue.

The fibro-vascular layer of the corium contains, besides the areolar tissue and vessels, unstriped muscle-cells, which form in many situations a definite layer, called the *muscularis mucosæ*. These are situated in the deepest part of the membrane, and are plentifully supplied with nerves. Other nerves pass to the epithelium and terminate between the cells. Lymphatic vessels are found in great abundance, commencing either by cæcal extremities or in networks, and communicating with plexuses in the submucous tissue.

Imbedded in the mucous membrane are found numerous glands, and projecting from it are processes (villi and papillæ) analogous to the papillæ of the skin. These glands and processes, however, exist only at certain parts, and it will be more convenient to defer their description to the sequel, where the parts are described as they occur.

SECRETING GLANDS.

The **secreting glands** are organs whose cells manufacture a secretion of a more or less definite composition, the material for the secretion being primarily selected from the blood. The essential parts, therefore, of a secreting gland are *cells*, which have the power of extracting from the blood certain matters, and in some cases converting them into new chemical compounds; and *blood-vessels*, by which the blood is brought into close relationship with these cells. The general arrangement in all secreting structures—that is to say, not only in secreting glands, but also in secreting membranes—is that the cells are arranged on one surface of an extravascular basement-membrane, which supports them, and a minute plexus of capillary vessels ramifies on the other surface of the membrane. The cells then extract from the blood certain constituents which pass through the membrane into the cells, where they are prepared and elaborated. The basement-membrane does not, however, always exist, and any free surface would appear to answer the same purpose in some cases.

By the various modifications of this secreting surface the different glands are formed. This is generally effected by an invagination of the membrane in different ways, the object being to increase the extent of secreting surface within a given bulk.

In the simplest form a single invagination takes place, constituting a *simple* gland; this may be either in the form of an open tube (Fig. 71, A), or the walls

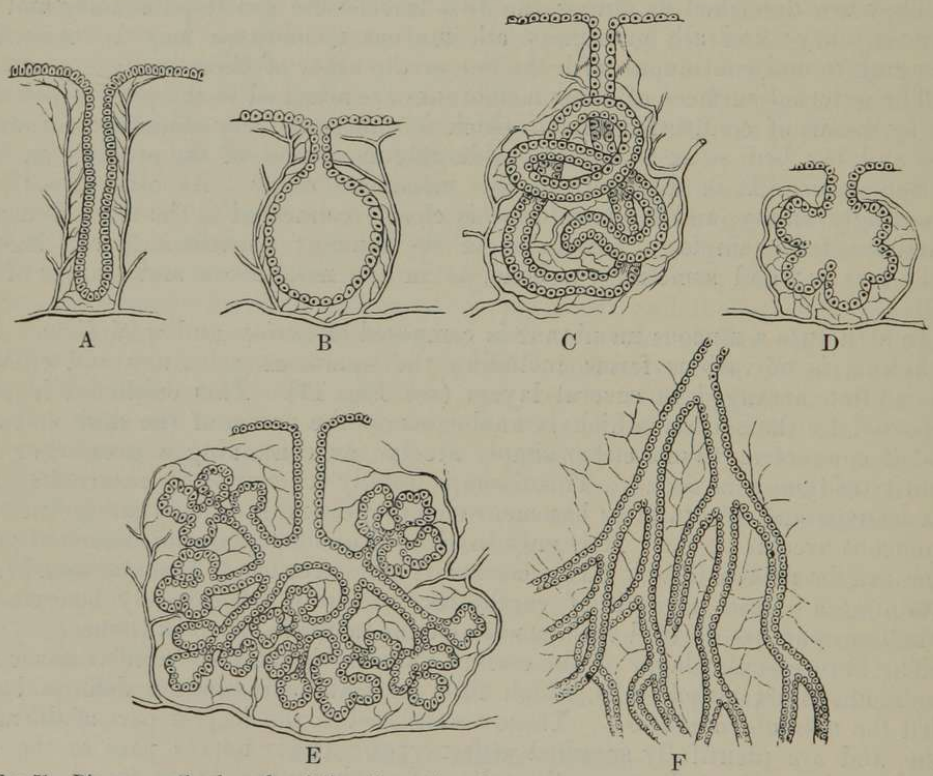

FIG. 71.—Diagrammatic plan of varieties of secreting glands. A. Simple gland. B. Sacculated simple gland. C. Simple convoluted tubular gland. D, E. Racemose gland. F. Compound tubular gland.

of the tube may be dilated so as to form a saccule (Fig. 71, B). These are named the *simple tubular* or *saccular* glands. Or, instead of a short tube, the invagination may be lengthened to a considerable extent, and then coiled up to occupy less space. This constitutes the *simple convoluted tubular* gland, an example of which may be seen in the sweat-glands of the skin (Fig. 71, C).

If, instead of a single invagination, secondary invaginations take place from

the primary one, as in Fig. 71, D and E, the gland is then termed a compound one. These secondary invaginations may assume either a saccular or tabular form, and so constitute the two subdivisions—the *compound saccular* or *racemose* gland, and the *compound tubular*. The racemose gland in its simplest form consists of a primary invagination which forms a sort of duct, upon the extremity of which are found a number of secondary invaginations called saccules or alveoli, as in Brunner's glands (Fig. 71, D). But, again, in other instances, the duct, instead of being simple, may divide into branches, and these again into other branches, and so on; each ultimate ramification terminating in a dilated cluster of saccules, and thus we may have the secreting surface almost indefinitely extended, as in the salivary glands (Fig. 71, E). In the *compound tubular* glands the division of the primary duct takes place in the same way as in the racemose glands, but the branches retain their tubular form, and do not terminate in saccular recesses, but become greatly lengthened out (Fig. 71, F). The best example of this form of gland is to be found in the kidney. All these varieties of glands are produced by a more or less complicated invagination of a secreting membrane, and they are all identical in structure; that is to say, the saccules or tubes, as the case may be, are lined with cells, generally spheroidal or columnar in figure, and on their outer surface is an intimate plexus of capillary vessels. The secretion, whatever it may be, is eliminated by the cells from the blood, and is poured into the saccule or tube, and so finds it way out through the primary invagination on to the free surface of the secreting membrane. In addition, however, to these glands, which are formed by an *invagination* of the secreting membrane, there are some few others which are formed by an *evagination* or *protrusion* of the same structure, as in the vascular fringes of synovial membranes. This form of secreting structure is not nearly so frequently met with.

ORIGIN AND DEVELOPMENT OF THE BODY.

THE whole body is developed out of the **ovum** (Fig. 72) when fertilized by the spermatozoon, the ovum being merely a simple nucleated cell. All the complicated changes by which the various intricate organs of the whole body are formed from one simple cell may be reduced to two general processes—viz. the *segmentation* or *cleavage* of cells, and their *differentiation*. The former process consists in the splitting of the nucleus and its surrounding protoplasm, whereby the original cell is represented by two. The differentiation of cells is a term used to describe that unknown power or tendency impressed on cells which, to all methods of examination now known, seem absolutely identical, whereby they grow into different forms; so that (to take the first instance which occurs in the growth of the embryo) the indifferent cells of the vascular area are differentiated, some of them into blood-globules, others into the solid tissue which forms the blood-vessels. The extreme complexity of the process of develop-

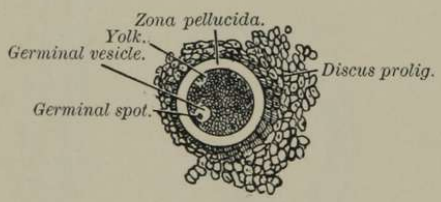

FIG. 72.—Ovum of the sow.

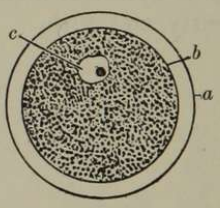

FIG. 73.—Human ovum from a middle-sized follicle. Magnified 350 times. *a*. Vitelline membrane or *zona pellucida*. *b*. External border of the yolk and internal border of the vitelline membrane. *c*. Germinal vesicle and germinal spot.

ment renders it at all times difficult to describe it intelligibly, and still more so in a work like this, where adequate space and illustration can hardly be afforded, having respect to the main purpose of the work. I can only hope to render the leading features of the process tolerably plain, and must refer the reader who wishes to follow the various changes more minutely to the special works on the subject, and especially the works of Minot and Hertwig. Many of the statements which are accepted in human embryology are made only on the strength of observations on the lower animals, many stages in the development of the human embryo being yet unknown to us.

The ovum is a small spheroidal body situated in immature Graafian vesicles near their centre, but in the mature ones in contact with the membrana granulosa[1] at that part of the vesicle which projects from the surface of the ovary. The cells of the membrana granulosa are accumulated round the ovum in greater number than at any other part of the vesicle, forming a kind of granular zone, the *discus proligerus*.

The human ovum (Fig. 73) is extremely minute, measuring from $\frac{1}{240}$ to $\frac{1}{120}$ of an inch in diameter. It is a cell consisting externally of a transparent envelope, the *zona pellucida* or *vitelline membrane*. Within this, and in close contact with it, is the cell-protoplasm containing granules of *yolk* or *vitellus;* imbedded in the

[1] See the description of the ovary at a future page.

substance of the yolk is a small vesicular body, the *germinal vesicle* (*vesicle of Purkinje*), the nucleus of the cell; and this contains as its nucleolus a small spot, the *macula germinativa*, or *germinal spot* of Wagner.

The **zona pellucida**, or **vitelline membrane**, is a thick, colorless, transparent membrane, which appears under the microscope as a radially striated membrane, bounded externally and internally by a dark outline. The striæ are believed to be minute pores, and are regarded as the channels by which nutritive particles are admitted into the interior of the ovum, and possibly the way by which the spermatozoa gain access into the interior of the ovum, after the rupture of the Graafian follicle. The presence of these striæ has given to the zona pellucida the name of *zona radiata*, or striated membrane of the ovum.

The **yolk** consists of granules or globules of various sizes imbedded in a finely reticulated matrix of protoplasm. The smaller granules resemble pigment; the larger granules, which are in the greatest number at the periphery, resemble fat-globules. In the human ovum the number of granules is comparatively small. Before and immediately after fertilization the cell protoplasm shows distinct movements of contraction and expansion.

The **germinal vesicle** consists of a fine, transparent, structureless membrane containing a clear matrix, in which are occasionally found a few granules. It is about $\frac{1}{720}$ of an inch in diameter, and in immature ova lies nearly in the centre of the yolk; but as the ovum becomes developed it approaches the surface and enlarges somewhat.

The **germinal spot** occupies that part of the periphery of the germinal vesicle which is nearest to the periphery of the ovum. It is opaque, of a yellow color, and finely granular in structure, measuring from $\frac{1}{3600}$ to $\frac{1}{2400}$ of an inch.

The phenomena attending the discharge of the ova from the Graafian vesicles, since they belong as much or more to the ordinary function of the ovary than to the general subject of the growth of the body, are described with the anatomy of the ovaries on a subsequent page.

Either before its escape from the Graafian follicle or immediately after, the ovum undergoes a peculiar change, which results in the formation of one or more peculiar bodies, the *polar globules* of Robin, and also of another body, which is named the "female pronucleus." The manner in which these bodies are developed from the germinal vesicle is briefly as follows: Usually before the rupture of the Graafian follicle, but after the ovum has become mature or ripe, a portion of the germinal vesicle with a small amount of surrounding protoplasm is protruded outside the yolk, but still remains within the vitelline membrane; this forms a small globular mass and constitutes the first polar globule. After a time, generally not till the ovum has entered the tube, a second protrusion of a portion of the germinal vesicle takes place, and forms a second polar globule. We have thus about three-quarters of the germinal vesicle extruded from the yolk and about one-quarter remaining behind, and at the ejection of each of these bodies a visible shrinking of the yolk takes place. The portion of the germinal vesicle which remains behind recedes from the surface toward the centre of the yolk and assumes a spherical form, and is now termed the "female pronucleus." All these changes, it must be understood, occur at each expulsion of an ovum, and are quite independent of fecundation.

The first changes in the ovum which take place at the time of conception appear to be as follows: A spermatozoon penetrates the ovum, and comes into contact with the portion of the germinal vesicle remaining in the ovum. It seems as if this normally occurs in the Fallopian tube,[1] but it is possible that it sometimes occurs before the ovum has entered the tube, or after it has passed through the tube and reached the cavity of the uterus; abnormally it may even

[1] Many physiologists, as Bischoff and Dr. M. Barry, taught that the ovum is fecundated in the ovary, but the reasoning of Dr. Allen Thomson appears very cogent in proving that the usual spot at which the spermatozoa meet the ovum is in the tube, down which it slowly travels to the uterus, in its course becoming surrounded by an albuminous envelope derived from the walls of the tube.

take place in the peritoneal cavity. The spermatozoon becomes buried in the yolk, the tail disappears, and the head, which is really the nucleus of the spermatozoon, constitutes the "male pronucleus." This gradually approaches the female pronucleus, which by this time is situated in the centre of the ovum. As soon as they come into contact they fuse into one, and thus fecundation is effected (Fig. 74).[1]

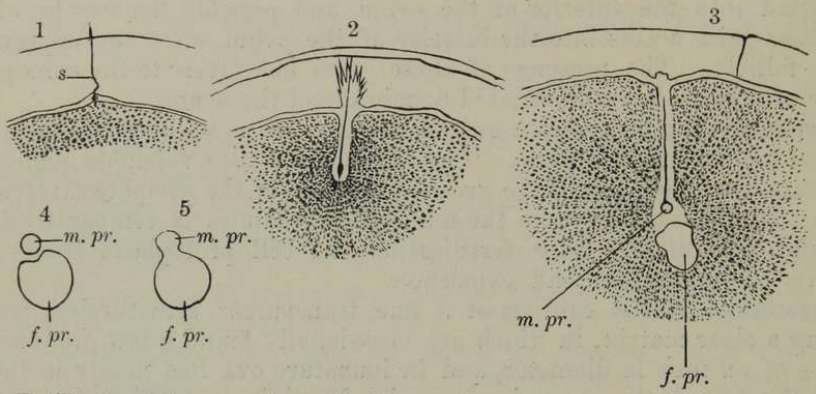

FIG. 74.—Fertilization of the ovum of an echinoderm. *s.* Spermatozoon. *m. pr.* Male pronucleus. *f. pr.* Female pronucleus. 1. Accession of a spermatozoon to the periphery of the vitellus. 2. Its penetration. 3. Transformation of the head of the spermatozoon into the male pronucleus. 4, 5. Blending of the male and female pronuclei. (From Quain's *Anatomy*, Selenka.)

The first result of the fertilization of the ovum is its cleavage or multiplication, it being first cleft into two masses, the germinal vesicle having previously

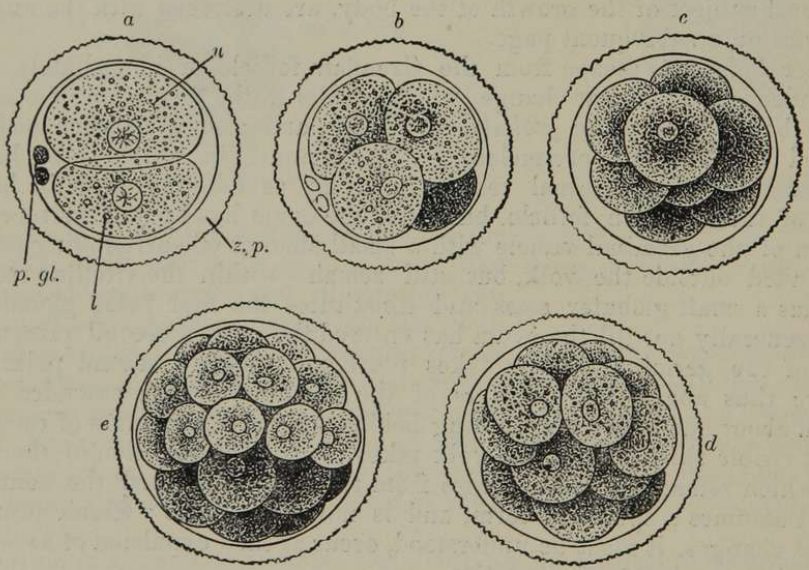

FIG. 75.—First stages of segmentation of a mammalian ovum; semi-diagrammatic. (From a drawing by Allen Thomson.) *z. p.* Zona pellucida, *p. gl.* Polar globules. *u.* Upper cell. *l.* Lower cell, *a.* Division into two spheres. *b.* Stage of four spheres. *c.* Eight spheres, the upper cells partially enclosing the lower cells. *d. e.* Succeeding stages of segmentation, showing the more rapid division of the upper cells and the enclosure of the lower cells by them.

split up into two nuclei; so that it now consists of two separate masses of protoplasm, each containing a nucleus, situated within the original vitelline membrane,

[1] If the student refers to the development of the generative organs, he will find that the ovum of the female and the spermatozoon of the male are derived from fundamentally the same structures, and therefore their fusion is the union of two elements of very similar morphological value.

which takes no part in this process of division. Then, each of these two daughter elements divides in like manner, and thus four nucleated elements are formed, and so on, until at length a mulberry-like agglomeration of nucleated masses of protoplasm results (Fig. 75). These masses are sometimes termed *segmentation spherules.*

The manner in which segmentation occurs is somewhat peculiar. The two spheres resulting from the first cleavage are of unequal size. One, which for the sake of distinction we will call the *upper* cell, is larger than the other, the *lower* cell. And after they have divided three or four times the rate of cleavage in the spheres derived from the upper segment becomes more rapid than in those derived from the lower segment. In addition to this, the spheres derived from the upper segment have a tendency to spread over and enclose those from the lower segment; so that by about the ninth or tenth division there is an external layer of spheres derived from the primary upper segment surrounding and almost enclosing a mass of spheres, which in consequence of their diminished rate of cleavage are fewer in number and larger in size, derived from the primary lower segment (Fig. 76, A). Fluid collects between the two sets of

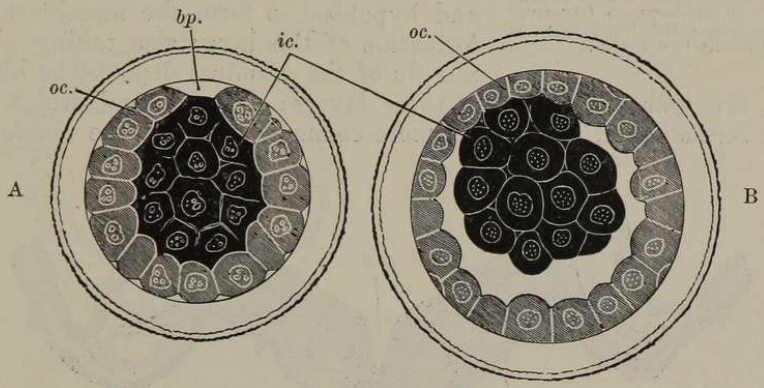

FIG. 76.—Ovum of the rabbit at the end of the process of segmentation. *oc.* Outer cells. *ic.* Inner cells. *bp.* Place where the outer cells have not yet covered the inner cells. (From Balfour, after Ed. van Beneden.)

spheres, except at one part, where they remain in contact, and the ovum is converted into a sac, formed by a layer of spheres derived from the upper primary segment, and containing at one part another mass of spheres derived from the lower primary segment (Fig. 76, B). The inner cells are rather more granular than the outer, beneath which they gradually spread, becoming applied over a part of their inner surface in a single layer; so that the cavity is afterward enclosed more or less completely in a double layer of cells.

The ultimate destination of the outermost complete layer of spheres is at present doubtful. That portion of it which covers the inner cells is believed to be transitory and to gradually disappear in the course of formation of the various layers of the blastodermic vesicle, while the remainder forms the outer layer (epiblast) of this vesicle. Adopting this view, the ovum would consist of a cavity surrounded by (1) a layer of cells completely lining the interior of the vitelline membrane, and (2) by a second layer internal to these and partially lining the interior of the outer layer, both sets of cells derived from the segmentation of the ovum. The sphere formed by this double layer of cells is called the "blastodermic vesicle."

At first the area of the blastodermic vesicle, which consists of both the inner and outer layers of cells, is a small disk, in which the first traces of the embryo are seen; hence it is called the *germinal disk* or *area germinativa* (Fig.

77). The first trace of the embryo appears as a faint streak at the posterior end of the area germinativa, called the *primitive trace*. After the formation of the primitive trace, but previous to the appearance of the next parts of the embryo, presently to be described—viz. the laminæ dorsales and the notochord—the blastodermic membrane consists of only two layers, the *epiblast* and *hypoblast*, but after the formation of these structures a third layer makes its appearance. This is the *mesoblast*, and is situated between the other two (Fig. 78). The epiblast of the germinal disk is formed of the most superficial layers of the inner cells which were exposed by the disappearance of the outer cells, which originally covered them, the remaining epiblast of the blastodermic vesicle being probably the persistent outer cells, while the hypoblast is formed by the rest of the inner cells. In the region of the primitive trace the epiblast and hypoblast fuse together, and from the sides of this line of fusion cells grow out laterally into the space between the epiblast and hypoblast to form the mesoblast, a further formation of this layer also taking place at the margin of the germinal disk. The blastodermic membrane thus comes to consist of three layers: The external, which used to be called the serous layer, but is now more commonly termed the *epiblast*, or *ecto-*

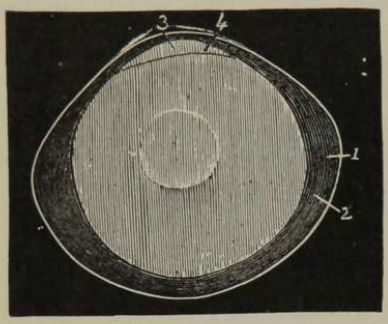

FIG. 77.—Ovum with the germinal area, seen in profile to show the division of the blastodermic membrane. 1. Vitelline membrane. 2. Blastoderm. 3. Germinal area. 4. Place where the blastoderm is just divided into its two layers.

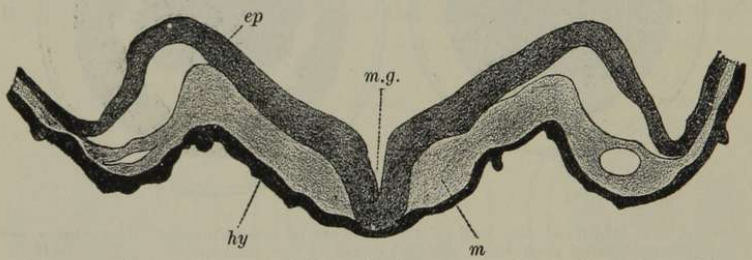

FIG. 78.—Section across the anterior part of the medullary groove of an early embryo of the guinea pig. (By Schafer. From Quain's *Anatomy*, 1890.) *ep.* Folds of epiblast rising up on either side of the middle line, and thus bounding the medullary groove. *m.g.* Middle of medullary groove. *hy.* Hypoblast, which is in contact with the medullary epiblast at the middle of the groove, but is elsewhere separated from it by mesoblast, *m*, which has burrowed forward between the two primary layers. A cleft is seen in the mesoblast on either side; this is the commencement of the anterior part of the body-cavity.

derm: the internal, the mucous layer, the *hypoblast*, or *entoderm;* and the middle, which is now usually called the *mesoblast* or *mesoderm*, but which was formerly named the "vascular layer."

The *epiblast* is mainly concerned in the formation of the external cuticle and the whole of the nervous system. It consists of cells of an epithelial character; that is to say, cells of an irregular columnar shape, forming, for the most part, a single stratum, but becoming more numerous and flattened at the germinal disk. The epidermis of the body and all the involutions of the epidermis in the ducts of superficial glands, as the mammæ, as well as the brain, the spinal cord, the nerves, and the portions of the nose, eye, and ear, which are directly formed from the brain, are developed from it. The external layer of the amnion is also formed from the epiblast, and probably also a portion of the chorion.

The *hypoblast* is mainly concerned in forming the internal epithelium—viz. that of the whole alimentary passages except the mouth and a small portion of the rectum near the anus (which are formed by involutions of the epiblast); that of the respiratory tract, which is originally an offset from the alimentary canal; and the epithelium of all the glandular organs which open into the intestinal tract. The hypoblast forms also the deeper layer of the umbilical vesicle and allantois.

Its cells are epithelial, and are at first flattened, but subsequently become columnar and larger than those of the epiblast.

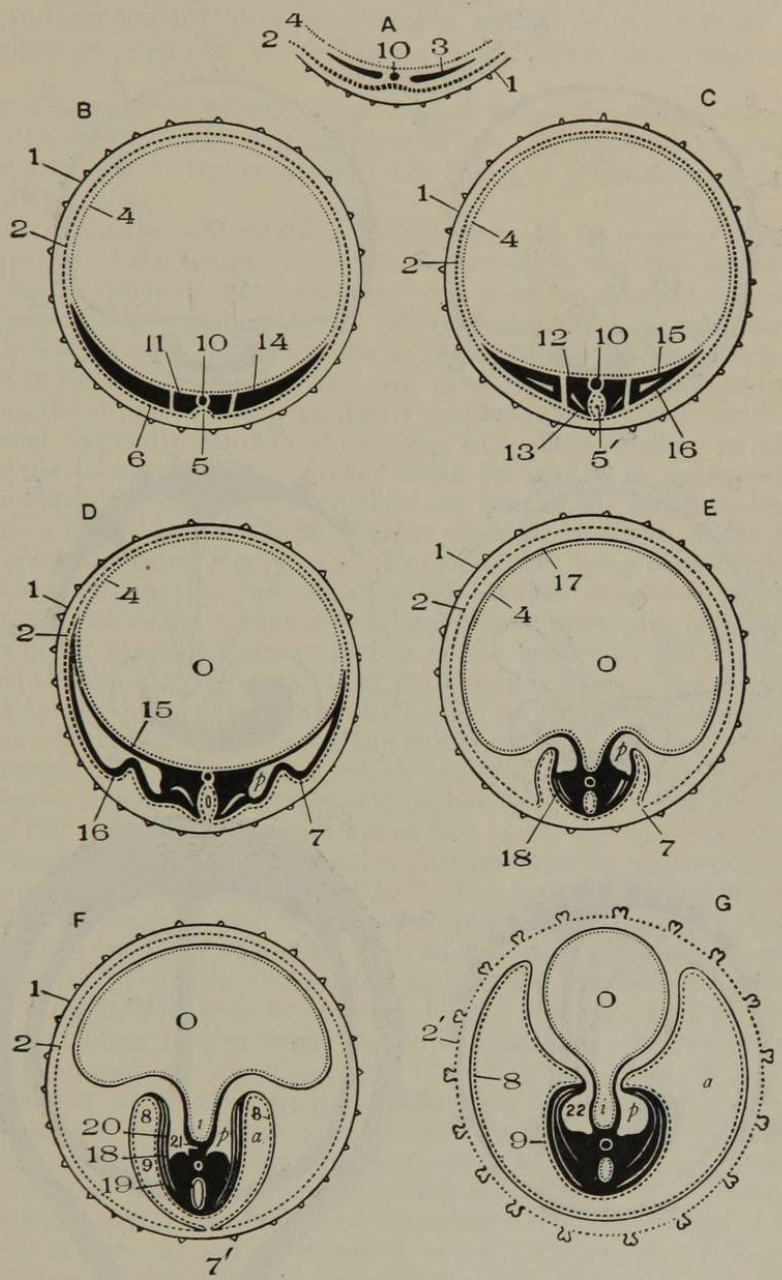

FIG. 79.*—Diagrams to show the development of the three layers of the blastodermic membrane on transverse section. A. Portion of the ovum with the zona pellucida and the germinal area. B C D E F G. Different stages of development. *o.* Umbilical vesicle. *a.* Amnion. *i.* Intestine. *p.* Peritoneal cavity, bounded by the splanchno-pleural and somato-pleural layers of mesoblast. 1. Vitelline membrane. 2. External blastodermic layer. 3. Middle layer. 4. Internal layer. 5. Medullary laminæ and groove. 5′. Medullary canal. 6. Epidermic laminæ. 7. Lateral folds of the amnion. 7′. The same almost in contact. 8. Internal epithelial layer of the amnion. 9. Epidermis of the embryo. 10. Chorda dorsalis. 11. Vertebral laminæ. 12. Protovertebræ proper. 13. Muscular laminæ. 14. Lateral laminæ. 15. Splanchnopleure. 16. Somatopleure. 17. Splanchnopleure of the umbilical vesicle. 18. Muscle plate. 19. External layer of the somatopleure. 20. Internal layer of the same. 21. Mesentery. 22. Splanchnopleure of the intestine.

*The dotted lines indicate the parts belonging to the internal blastodermic layer; the plain lines, those belonging to the middle; the interrupted lines, those belonging to the external. The embryo has been represented, in this and the following diagram, lying on its back. The natural position is generally assumed to be the reverse.

All the rest of the embryo is formed from the mesoblast—viz. all the vascular

and locomotive system, the cutis, all the connective tissues, and the genito-urinary organs—with the exception of the epithelium of the bladder and urethra, which is

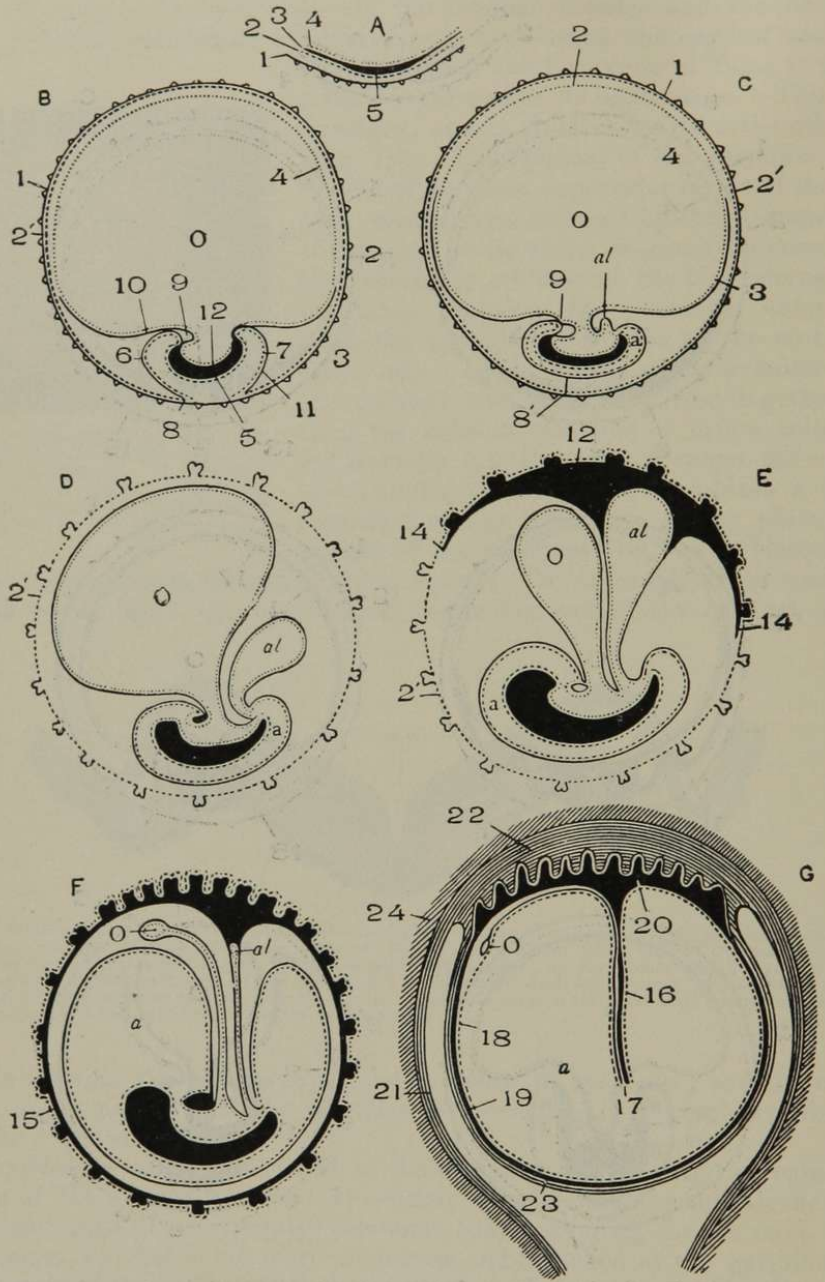

FIG. 80.*—Diagrams to show the development of the three blastodermic layers on antero-posterior section. A Portion of ovum with the vitelline membrane and germinal area. B C D E F. Various stages of development. G. Ovum in the uterus and formation of decidua. 1. Vitelline membrane. 2. External blastodermic layer. 2′. Vesicula serosa. 3. Middle blastodermic layer. 4. Internal layer. 5. Vestige of the future embryo. 6. Cephalic flexure of the amnion. 7. Caudal flexure. 8. Spot where the amnion and vesicula serosa are continuous. 8′. Posterior umbilicus. 9. Cardiac cavity. 10. Splanchnopleure layer of the umbilical vesicle. 11. Somatopleure layer of the amnion. 12. Internal layer of the blastoderm forming the intestine. 13, 14. External layer of the placenta, extending to the inner surface of the vesicula serosa. 15. The same, now completely applied to the inner surface of the vesicula serosa. 16. Umbilical cord. 17. Umbilical vessels. 18. Amnion. 19. Chorion. 20. Fœtal placenta. 21. Mucous membrane of uterus. 22. Maternal placenta. 23. Decidua reflexa. 24. Muscular wall of uterus.

* The same note applies to this as to the preceding diagram.

developed from the hypoblast. The vascular system of the fœtus extends to the yolk and the maternal parts along the umbilical vesicle and allantois, so that the

greater part of these bodies and the outer layer of the amnion are also formed out of the mesoblast. The fœtal portion of the placenta, being essentially a vascular structure, is also developed from the mesoblast. Its cells are irregular and branched and surrounded by a considerable amount of intercellular fluid. It may therefore be regarded as resembling more closely embryonic connective tissue.

First Rudiments of the Embryo (Figs. 79 and 80).—The *primitive trace* alluded to above as appearing in the *area germinativa* is a very transitory structure, which marks the direction of the embryonic axis, and is gradually lost sight of as development proceeds.

The first real approach toward a definite form in the embryo is made (1) by the development of the central nervous system ; (2) by the cleavage of the middle layer of the blastodermic membrane into a series of segments; and (3) by the development of an axial embryonic skeletal structure, the notochord.

First, a folding up of the cells of the epiblast or outer layer takes place. This commences in the anterior part of the area germinativa, and extends in the same direction as the primitive trace, gradually enclosing this latter until it is lost at the caudal extremity of the embryo (Fig. 81). This folding up of the epiblast gives rise to a longitudinal groove down its centre, in consequence of the manner in which the cells of the epiblast are heaped up into two longitudinal ridges, with a furrow between them, so that the sides and base of the groove are formed of epiblastic cells (Fig. 82, A). The mesoblast, lying between the epiblast and hypoblast, fills up the space thus caused between these two layers, so that the sides of the groove are occupied by a longitudinal thickening of mesoblast; the two masses being separated at the bottom of the groove by the junction of the epiblast and hypoblast at the situation of the primitive trace. The groove becomes deeper and deeper in consequence of the further growing up of the cells to form the ridge on either side. In this way the ridges eventually become two plates, the *laminæ dorsales* or *medullary plates*, which finally coalesce and thus form a closed tube, the *neural canal*, lined by epiblast and having a covering of the same membrane (Fig. 82). These membranes are at first in contact with one another, but eventually become separated, mesoblastic structures growing up between them, and the line of coalescence becomes obliterated. The coalescence first takes place in the middle of the embryo, then toward the cephalic end, and lastly at the caudal extremity. The lining of this tube is developed into the nervous centres, the covering into the epidermis of the back and head. The cephalic extremity of the neural canal is soon seen to be more dilated than the rest, and to present constrictions dividing it imperfectly into three chambers: the brain is developed from this dilated portion; the spinal cord takes its origin from the remainder of the tube. Below the neural canal the hypoblast and epiblast are in contact, separating the two longitudinal thickenings of mesoblast on either side of the canal. Here a thickening of the hypoblast, commencing from the anterior end of the primitive trace, takes place, and gradually separates itself off from the hypoblast, lying between this membrane and the epiblast below the bottom of the neural canal. This is known as the *notochord* or *chorda dorsalis*. This when fully developed, forms a continuous rod-shaped body lying below the primitive groove and composed of clear epithelium-like cells. It is essentially an embryonic structure, though traces of it remain in the centre of the intervertebral disks throughout life. The collection of mesoblastic cells, which forms a thick longitudinal column on either side of the neural canal, becomes separated from the rest of the mesoblastic layer. It undergoes a series of transverse segmentations and becomes converted into a row of well-defined, dark, square segments or masses, separated by clear, transverse intervals, called the *protovertebræ* or *mesoblastic somites*. They first make their appearance in the region which afterward becomes the neck, then further forward toward the head, and afterward extend along the body. These bodies, as will be explained hereafter, are not the same as the permanent vertebræ, but they are differentiated, partly into the vertebræ and partly into the

muscles and true skin. On either side of the protovertebræ the mesoblast splits into two layers, the upper, or that covered by epiblast, is called *somatopleure*, and the lower, lined by hypoblast, the *splanchnopleure* (Fig. 82, B, 5–5′). From the

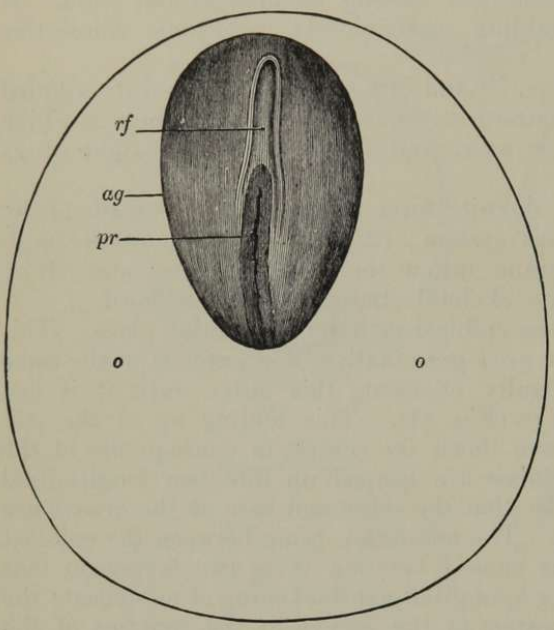

FIG. 81.—Embryonic area of the ovum of a rabbit at the seventh day. *ag.* Embryonic area. *o, o.* Region of the blastodermic vesicle immediately surrounding the embryonic area. *pr.* Primitive streak. *rf.* Medullary groove (From Kölliker.)

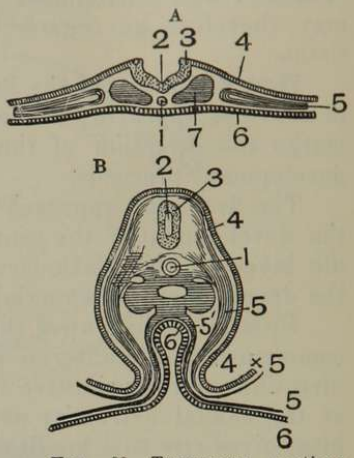

FIG. 82.—Transverse sections through the embryo-chick before and some time after the closure of the medullary canal, to show the upward and downward inflections of the blastoderm. (After Remak.) A. At the end of the first day. 1. Notochord. 2. Primitive groove in the medullary canal. 3. Edge of the dorsal lamina. 4. Epiblast. 5. Mesoblast divided in its inner part. 6. Hypoblast. 7. Section of protovertebral plate. B. On the third day in the lumbar region. 1. Notochord in its sheath. 2. Medullary canal now closed in. 3. Section of the medullary substance of the spinal cord. 4. Epiblast. 5. Somatopleure of the mesoblast. 5′. Splanchnopleure (one figure is placed in the pleuro-peritoneal cavity). 6. Layers of hypoblast in the intestines spreading also over the yolk. 4×5. Part of the fold of the amnion formed by epiblast and somatopleure.

former the skeleton muscles and true skin of the external parts of the body are derived, from the lat

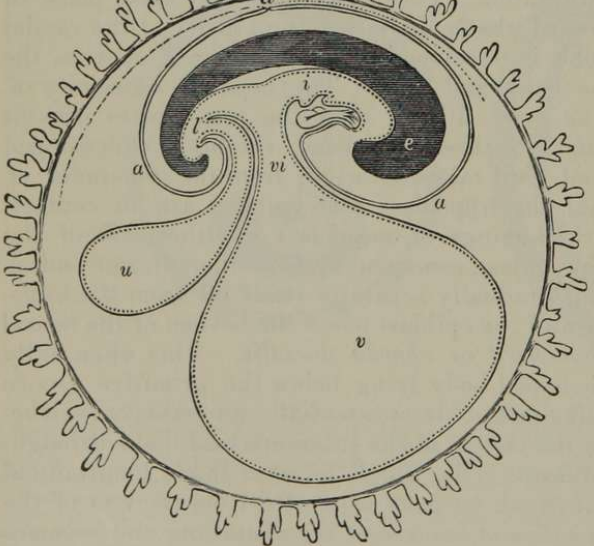

FIG. 83.—Diagrammatic section through the ovum of a mammal in the long axis of the embryo. *e.* The cranio-vertebral axis. *l, i.* The cephalic and caudal portions of the primitive alimentary canal. *a.* The amnion. *a′.* The point of reflection into the false amnion. *v.* Yolk-sac, communicating with the middle part of the intestine by *v i*, the vitello-intestinal duct. *u.* The allantois. The ovum is surrounded externally by the villous chorion.

aptly compared to a canoe turned over (Fig. 83).

ter, the muscular and other mesoblastic portions of the viscera. The space between them is the common pleuro-peritoneal cavity. Whilst the parietes of the body are still unclosed, this common pleuro-peritoneal cavity is continuous with the space between the amnion and chorion, as seen in Fig. 79, F. The embryo, which at first seems to be a mere streak, extends longitudinally and laterally. As it grows forward the cephalic end becomes remarkably curved on itself (cephalic flexure), and a smaller but distinct flexure takes place at its hinder end (caudal flexure). At the same time the sides of the embryo grow and curve toward each other; so that the embryo is In consequence of this incurv-

ing of the embryo, both in an antero-posterior and a lateral direction, the original ovum, with the three layers derived from the cleavage of the blastodermic membrane which cover it, is converted into a sort of hour-glass shape with two unequal globes. The smaller globe is formed by the part of the blastodermic membrane (area germinativa) which has already undergone certain changes in the formation of the embryo, and constitutes the part which has been compared to a canoe. The larger globe is called the *yolk-sac* or *umbilical vesicle*, and is formed by the rest of the blastodermic membrane—*i. e.* that part which is not concerned in the formation of the area germinativa. The two freely communicate through the constriction which is the site of the future umbilicus, and through this constriction the internal layer of the blastodermic membrane (the hypoblast) and the innermost of the two layers into which, as has been already stated, the mesoblast divides—viz. the splanchnopleure, pass out; the incurving having only involved the somato-pleural layer of the mesoblast and the epiblast (Fig. 84). The umbilical vesicle is, therefore, at

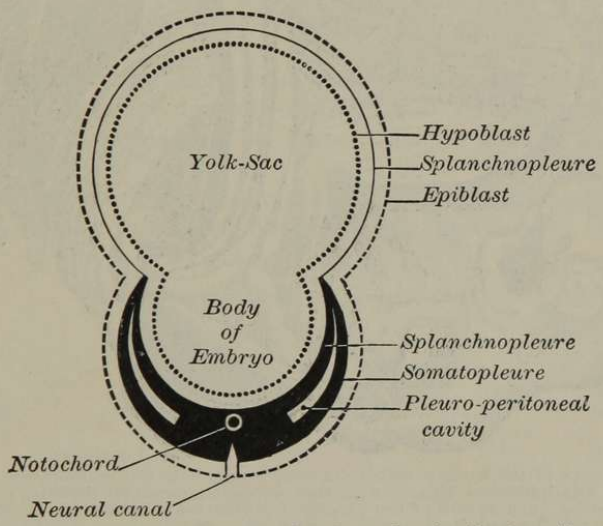

FIG. 84.—Diagrammatic section of embryo, showing the formation of the umbilical vesicle.

first a mere part of the general cavity of the yolk, partly enclosed by the embryo; but as the latter grows round on all sides toward the umbilical aperture, the yolk becomes distinguished into two portions. One lies inside the embryo, and eventually forms a part of the intestinal cavity (out of which also, as will hereafter be seen, the bladder is developed). The other lies external to the embryo and remains therefore for a time a part of what is, in a more restricted sense, the ovum. The two parts are almost separated from each other by the meeting of the abdominal walls of the embryo at the umbilicus, through which they still communicate by a passage, the *omphalo-mesenteric duct*, the destination of which will be pointed out presently. The extra-embryonic portion is of small importance and very temporary duration in the human subject. It is for the purpose of supplying nutrition to the embryo during the very earliest period, before it can obtain it from the uterine sinuses of the mother. In the oviparous animals, however, where no supply of nutrition can be obtained from the mother, since the egg is entirely separated from her, the yolk-sac is large and of great importance, as it supplies nutrition to the chick during the whole of fœtation. Vessels developed in the middle blastodermic layer soon cover the umbilical vesicle, forming the *vascular* area, the chief vessels of which are the *omphalo-mesenteric*, two in number (Fig. 85). The vessels of this area appear to absorb the fluid of the umbilical vesicle, which as the fluid is absorbed dries up and has no further function. The activity of the umbilical vesicle ceases about the fifth or sixth week, at the same time that the allantois, which is the great bond

of vascular connection between the embryo and the uterine tissues, is formed. In fact, the umbilical vesicle provides for the nutrition of the fœtus from the ovum

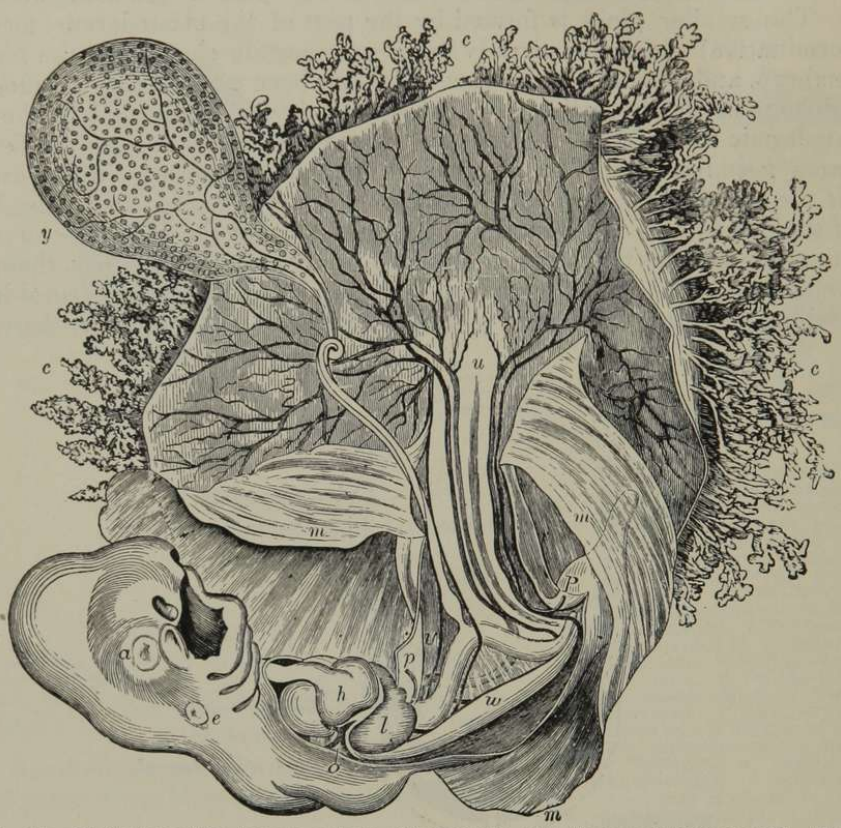

FIG. 85.—Magnified view of the human embryo of four weeks, with the membranes opened. (From Leishmann after Coste.) *y*. The umbilical vesicle with the omphalo-mesenteric vessels, *v*, and its long tubular attachment to the intestine. *c*. The villi of the chorion. *m*. The amnion opened. *u*. Cul-de-sac of the allantois, and on each side of this the umbilical vessels passing out to the chorion. In the embryo: *a*. The eye. *e*. The ear-vesicle. *h*. The heart. *l*. The liver. *o*. The upper; *p*, the lower limb. *w*. Wolffian body, in front of which are the mesentery and fold of intestine. The Wolffian duct and tubes are not represented.

itself, while the allantois is the channel whereby it is nourished from the uterine tissues. The umbilical vesicle, containing fluid, remains visible, however, up to the fourth or fifth month, with its pedicle and the omphalo-mesenteric vessels. The latter vessels become atrophied as the functional activity of the body with which they are connected ceases.

So far we have traced—(1) the segmentation or cleavage of the yolk into a number of nucleated cells or "spherules." (2) The accumulation of fluid within the ovum, and the arrangement of the spherules around the fluid on the internal surface of the vitelline membrane, forming a second membrane, the "blastodermic membrane." (3) The separation of the blastodermic membrane into three layers, named, from within outward, the "hypoblast," the "mesoblast," and the "epiblast." (4) The formation of an elongated, oval-shaped disk, called the "area germinativa." (5) The appearance in the centre of the area germinativa of a delicate line or furrow, running longitudinally, and called the "primitive trace." (6) The formation of a distinct groove in the situation of this primitive trace, caused by the growing-up of the cells on either side of it, so as to form two longitudinal ridges, called the "laminæ dorsales." (7) The increase and incurvation of these laminæ dorsales, until they meet behind, enclosing a canal lined by epiblast. The canal is the neural canal, and from the epiblast which lines it the nervous centres are developed. (8) The formation, in the hypoblast immediately under this canal, of a continuous rod-shaped body, the "chorda dorsalis," or "notochord." (9) The formation from the mesoblast, on either side of the notochord, of a longi-

tudinal column, divided into a number of square segments, the "protovertebræ." (10) The splitting of the mesoblast, external to the protovertebræ, into two layers—the outer, called the "somatopleure," lined externally by the epiblast; the inner, called the "splanchnopleure," lined internally by the hypoblast, a space being left between the two which forms the "pleuro-peritoneal cavity." (11) The curving of the embryo on itself, both longitudinally and laterally, so as to be comparable to a canoe; the walls being formed of all three layers of the blastodermic membrane and the well of the canoe—that is the intestinal cavity of the embryo, opening into the cavity of the yolk-sac. (12) A portion of the yolk-sac lying in the body-cavity of the embryo, and a portion outside it; the two communicating by a duct, the "omphalo-mesenteric" duct. The portion of the yolk-sac external to the body-cavity is termed the umbilical vesicle, and provides nutrition to the embryo until such time as the placenta is formed; vessels, developed from the middle blastodermic layer, ramifying over it, and gradually absorbing its contents.[1]

The next step toward a clear understanding of the development of the embryo is to have a proper conception of the manner in which the membranes enveloping the fœtus are formed.

The **membranes** investing the fœtus are the amnion, the chorion, and the decidua. The two former are developed from fœtal structures, and are proper to the fœtus; the latter is formed in the uterus, and is derived from the maternal structures.

The Amnion.—The amnion is the membrane which immediately surrounds the embryo. It is of small size at first, but increases considerably toward the middle

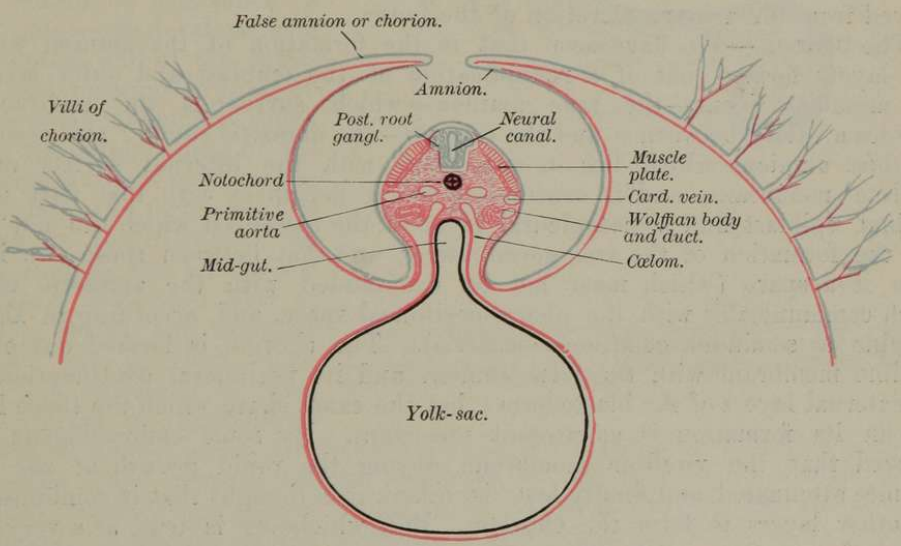

FIG. 86.—Diagram of a transverse section of a mammalian embryo, showing the mode of formation of the amnion. The amniotic folds have nearly united in the middle line. (From Quain's *Anatomy*, vol. i. pt. 1, 1890.) Epiblast, blue; mesoblast, red; hypoblast and notochord, black.

of pregnancy, as the fœtus acquires the power of independent movement. It exists only in reptiles, birds, and mammals, which are hence called "Amniota," but is absent in amphibia and fishes. It is formed thus: At or near the extremities of the incurved fœtus—that is to say, at the point of constriction of the blastodermic membrane, where the portion which has undergone changes to form the body of the embryo joins the part devoted to the formation of the umbilical vesicle—an inflection of the epiblast and outer layer of the mesoblast, which have become separated from the inner layer of the mesoblast and hypoblast by the formation of the pleuro-peritoneal cavity, takes place (Fig. 79, D 7). These inflections or back-

[1] According to Professor John A. Ryder, it is "very doubtful if any considerable amount of nutriment is supplied to the embryo from the yolk-sac at any time."

ward folds commence first at the cephalic extremity, and subsequently at the caudal end and sides, and deepen more and more, in consequence of the sinking of the embryo into the blastodermic vesicle, until, gradually approaching, they meet one another (Fig. 79, E 7). After they come in contact they fuse together, and the septum between them disappears; so that the inner layer of the cephalic fold becomes continuous with the inner layer of the caudal fold, and the outer with the outer (Fig. 79, F 7′). Thus we have two membranes, one formed by the inner layer of the fold—the *true amnion*—which encloses a space over the back of the embryo—the *amniotic cavity* (Fig. 79, F and G, *a*)—containing a clear fluid, the *liquor amnii*.[1] The other, the outer layer of the fold—the *false amnion*—lines the internal surface of the original vitelline membrane. Between the two is an interval, which of course communicates with the pleuro-peritoneal cavity. This it continues to do until the body-walls of the embryo have grown up and coalesced at the umbilicus. Then the amniotic fold is carried downward, and encloses the umbilical cord, by which the fœtus is attached to the placenta. The true amnion—or, as it is usually called, the amnion—is formed of two layers, derived respectively from the epiblast and from the parietal layer of the mesoblast.

The amnion is at first in close contact with the surface of the body of the embryo, but about the fourth or fifth week fluid begins to accumulate, and thus separates the two. The quantity steadily increases up to about the sixth month of pregnancy, after which it diminishes somewhat. The use of the liquor amnii is believed to be chiefly to allow of the movements of the fœtus in the later stages of pregnancy, though it no doubt serves other purposes also. It contains about 1 per cent. of solid matter, chiefly albumen, with traces of urea, the latter possibly derived from the urinary secretion of the fœtus.

The Chorion.—We have seen that in the formation of the amnion we had two layers formed out of a reduplication of the epiblast and outer layer of the mesoblast: one—the *true* amnion—which surrounds the embryo and encloses a cavity between it and the embryo—the *amniotic cavity;* and secondly, the *false* amnion, which lies in apposition with the internal surface of the vitelline membrane, and is continuous at its periphery with that part of the original epiblast and somatopleural layer of the mesoblast which did not enter into the formation of the area germinativa; and that between these two layers there is a space (which must not be confounded with the amniotic cavity) which communicates with the pleuro-peritoneal space, and, according to Dalton, contains a semifluid, gelatinous material. The chorion is formed out of the vitelline membrane with the false amnion and its peripheral continuation with the external layers of the blastoderm; but the exact share which the three layers take in its formation is at present uncertain. By some embryologists it is believed that the vitelline membrane during the rapid growth of the ovum becomes attenuated, and finally lost; by others it is thought that it combines with the other layers to form the chorion. But, whichever is true, at a very early period of gestation cellular processes or fringes grow outward from the external surface of the chorion, and have been likened by Dalton to tufts of seaweed. They are at first destitute of vessels, and are of simple cellular structure. These fringes, or villi, as they subsequently become, cover at first the whole surface of the chorion; but as development progresses and the placenta, by which the extent of the attachment of the ovum to the uterine walls is to be limited, is about to be formed, the villi are not further developed over the rest of the chorion, but are confined to that part only which is to form the fœtal portion of the placenta. They may, however, be recognized all over the chorion as abortive processes during the whole of fœtal gestation.

[1] The student should be careful not to confound this cavity with that formed between the true and false amnion, which communicates with the pleuro-peritoneal cavity of the embryo. This latter space ought with more propriety to be called the "amniotic cavity," since it is contained between the layers of the amnion; whereas the so-called amniotic cavity is not really between the layers of the amnion at all, but between the inner layer of the amnion and the body of the embryo.

The **Belly Stalk.**—During the formation of the amnion the anterior end of the embryo sinks down into the blastodermic vesicle much more rapidly than the posterior end, the latter, in fact, remaining attached to the surface of the blastoderm (Fig. 87, A). As the formation of the amnion proceeds the embryo becomes separated more and more from the surface of the vesicle, eventually being united with it only by a short stalk arising from its ventral surface (Fig. 87, B). This is the "belly stalk," in the interior of which is to be found the umbilical vesicle, which has been carried backward by the constriction which produced the stalk, and has been reduced to a small pyriform vesicle supported upon a long pedicle. This pedicle is connected with the digestive tract of the embryo, and behind its attachment a small outgrowth develops from the ventral wall of the intestine, and, pushing in front of it the splanchnopleure which forms the outer lining of the intestine, extends out into the belly stalk and forms what is known as the *allantois*. In some animals the allantois is a hollow projection and is usually styled the *allantoic vesicle;* but in most mammals, and especially in man, the external or mesoblastic element undergoes great development, while the internal or hypoblastic element undergoes little increase beyond the body of the embryo, so that it is very doubtful whether any cavity exists in the allantois beyond the limits of the umbilicus. A portion of the allantoic vesicle *within* the body cavity is eventually destined to form the bladder, while the remainder forms an impervious cord, the *urachus*, stretching from the summit of the bladder to the umbilicus. The belly stalk is at first hollow, its cavity being continuous with the pleuro-peritoneal cavity of the embryo (Fig. 87), but it soon becomes solid by the extensive growth of the mesoblastic tissue which it contains. Over that portion of the wall of the blastodermic vesicle with which the outer end of the belly stalk is connected the chorionic villi, already referred to, reach their greatest development, this being the region of the *placenta*.[1] In the walls of the allantois vessels are formed which extend their branches out into the surrounding mesoblast and into the chorionic villi. The allantois, accordingly, though much reduced in man in comparison with the lower mammals, is still the tract along which the vessels extend which convey the blood of the embryo to the fœtal chorion, where it is

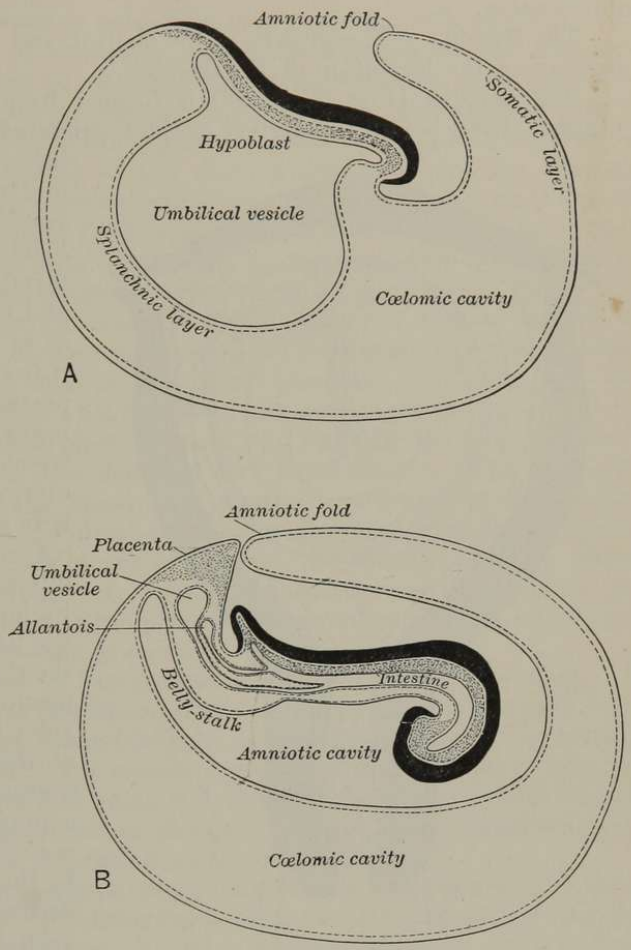

FIG. 87.—Diagrams showing the formation of the belly stalk. The heavy black line represents the embryonic portion of the epiblast, the dotted portions and broken lines the mesoblast, and the inner continuous line the hypoblast

[1] In some animals some of the vessels of the villi of the chorion are derived from the yolk-sac—that is from the omphalo-mesenteric vessels.

exposed to the influence of the maternal blood circulating in the decidua or uterine portion of the placenta, from which it imbibes the materials of nutrition, and to which it gives up effete material, the removal of which is necessary for its purification.

The Decidua.—The growth of the chorion and placenta can only be understood by tracing the formation of the decidua.

The decidua (Figs. 80 G, 88) is formed from the mucous membrane of the uterus. Even before the arrival of the fecundated ovum in the uterus the mucous membrane of the latter is vascular and tumid, and when the ovum has reached the uterus it becomes imbedded in the folds of the mucous membrane, which grow up around it and finally completely encircle it, so as to cover it in entirely and exclude it from the uterine cavity. Thus two portions of the uterine mucous membrane (decidua) are formed—viz. that which coats the muscular wall of the uterus, *decidua vera*, and that which is in contact with the ovum, *decidua reflexa*. The decidua vera at the os internum and at the openings of the Fallopian tubes is continuous with the lining membrane of these canals, the thickening of the original mucous membrane of the uterus which converts it into decidua abruptly ceasing at these points. The neck of the uterus after conception is closed by a plug of mucus. The decidua vera is perforated by the openings formed by the enlarged uterine glands, which become much hypertrophied and developed into tortuous tubes. It contains at a later period numerous arteries and venous channels, continuous with the uterine sinuses, and it is from it that the uterine part of the placenta is developed. The portion of the decidua vera which takes part in the formation of the placenta is called the *decidua serotina* (Fig. 88, *f*).

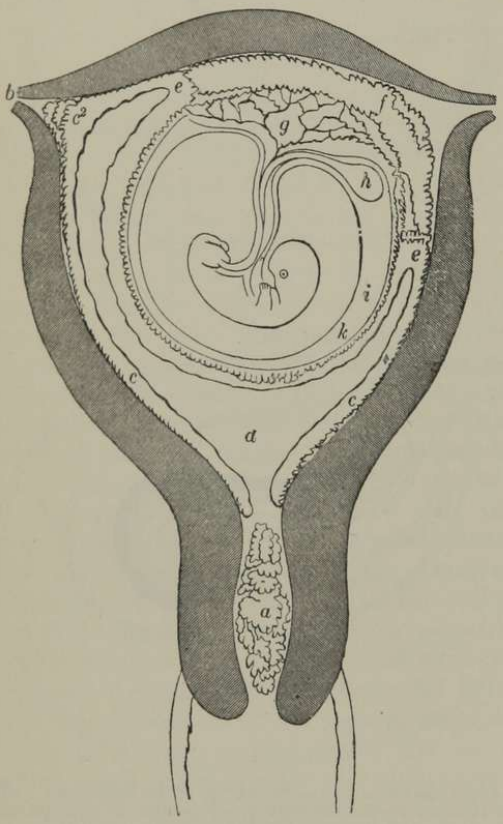

FIG. 88.—Sectional plan of the gravid uterus in the third and fourth month. (From Wagner.) *a*. Plug of mucus in the neck of the uterus. *b*. Fallopian tube. *c*. The decidua vera. c^2. The decidua vera passing into the right Fallopian tube: the cavity of the uterus is almost completely occupied by the ovum. *e*, *e*. Points of reflection of the decidua reflexa (in nature the united decidua do not stop here, but pass over the whole uterine surface of the placenta). *g*. Supposed allantois. *h*. Umbilical vesicle. *i*. Amnion. *k*. Chorion, covered with the decidua reflexa. *d*. Cavity of the decidua. *f*. Decidua serotina, or placental decidua.

The decidual reflexa is shaggy on its outer aspect, but smooth within. The vessels which it contains at first disappear after about the third month. About the fifth or sixth month the space between the two layers of the decidua disappears, and toward the end of pregnancy the decidua reflexa is transformed into a thin yellowish membrane, which constitutes the external envelope of the ovum.

Much additional interest has been given to the physiology of the decidua by the fact, which seems to be now established by the researches of Dr. John Williams, that every discharge of an ovum, whether impregnated or not, is, as a rule, accompanied by the formation of a decidua, and that the essence of menstruation consists in the separation of a decidual layer of the mucous membrane from the uterus; while in the case of pregnancy there is no exfoliation of the

membrane, but, on the contrary, it undergoes further development in the manner described above.

The **Placenta** is the organ by which the connection between the fœtus and mother is maintained. It therefore subserves the purposes both of circulation and respiration. It is formed of two parts, as already shown—viz. the maternal portion, which is developed out of the decidua vera (serotina), and the fœtal portion formed out of the villi of the chorion. Its shape in the human subject is that of a disk, one surface of which adheres to the uterine wall, while the other is covered by the amnion. The villi of the chorion gradually enlarge, forming large projections—" cotyledons "—which each contain the ramifications of vessels communicating with the umbilical (allantoic) arteries and veins of the fœtus. These vascular tufts are covered with epithelium, and project into corresponding depressions in the mucous membrane (decidua vera) of the uterine wall. The maternal portion of the placenta consists of a large number of sinuses formed by an enlargement of the vessels of the uterine wall. These bring the uterine blood into close proximity with the villi of the fœtal placenta, which dip into the sinuses. The interchange of fluids necessary for the growth of the fœtus and for the depuration of the blood takes place through the walls of the villi, but there is no direct continuity between the maternal and fœtal vessels. The fœtal vessels form tufts of capillaries, the blood from which is returned by small veins, which end in tributaries of the umbilical vein. The maternal arteries open into spaces somewhat after the manner of the arteries of the erectile tissues. These spaces communicate with a plexus of veins which anastomose freely with one another, and give rise, at the edge of the placenta, to a venous channel which runs around its whole circumference—the *placental sinus*.

The **umbilical cord** is formed by the gradual elongation of the belly stalk. It contains the coils of two arteries (*umbilical*, originally *allantoic*), and a single vein, united together by a gelatinous tissue (*jelly of Wharton*). There are originally two umbilical veins, but one of these vessels becomes obliterated, as do also the two omphalo-mesenteric arteries and veins and the duct of the umbilical vesicle, all of which are originally contained in the belly stalk. The permanent structures of the cord are, therefore, furnished by the allantois.

In this manner the human embryo eventually becomes surrounded by three membranes: (1) the *amnion*, derived from the outer layer of the mesoblast and the epiblast; (2) the *chorion*, formed from the false amnion (which is derived from the outer layer of the mesoblast and the epiblast), and (3) the *decidua*, derived from the mucous membrane of the uterus.

Development of the Embryo proper.—The further development of the embryo will, perhaps, be better understood if we follow as briefly as possible the principal facts relating to the chief parts of which the body consists—viz. the spine, the cranium, the pharyngeal cavity, mouth, etc., the nervous centres, the organs of the senses, the circulatory system, the alimentary canal and its appendages, the organs of respiration, and the genito-urinary organs.[1] The reader is also referred to the chronological table of the development of the fœtus at the end of this section.

Development of the Spine.—We have already traced the first steps in the formation of the spine: (1) The looping up of two longitudinal folds from the cells of the epiblast on either side of the primitive streak, so as to form a groove, and the gradual growing together of these ridges (*laminæ dorsales*) so as to convert the groove into a canal, which is lined by epiblast, and out of which the spinal cord is developed. (2) The formation in front of this groove of a continuous cellular cord enclosed in a structureless sheath, the *notochord* or *chorda dorsalis* (Fig. 89). The notochord extends from the cephalic to the caudal

[1] The scope of this work only permits the briefest possible reference to these subjects. Those who wish to study the subject of embryology in more detail are referred to Kölliker's *Entwickelungsgeschichte;* to vol i. pt. 1, of the tenth edition of Quain's *Anatomy;* or to the works of Professors Minot and Hertwig.

extremity of the embryo, and lies in the place which is afterward occupied by the bodies of the vertebræ. (3) On either side of the neural canal a portion of the mesoblastic layer is divided longitudinally from the rest of the mesoblast, so as to form a thick column, which extends from the cephalic to the caudal

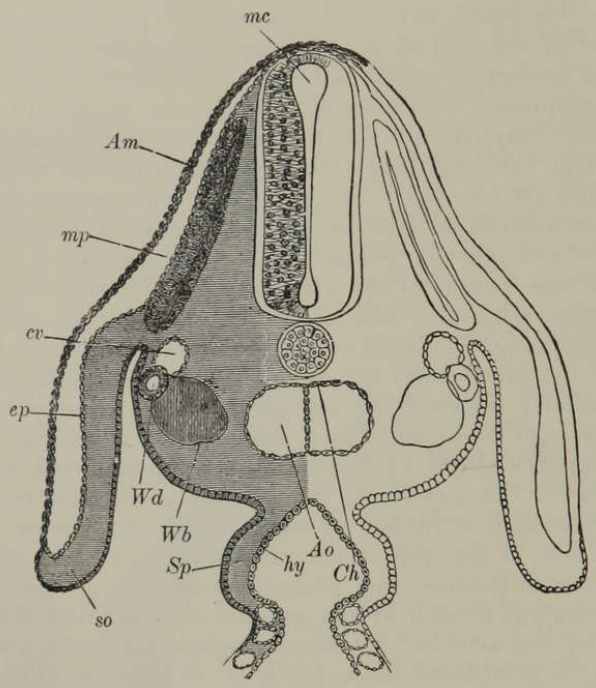

FIG. 89.—Transverse section through the dorsal region of an embryo chick, end of third day. (From Foster and Balfour.) *Am.* Amnion. *mp.* Muscle-plate. *cv.* Cardinal vein. *Ao.* Dorsal aorta at the point where its two roots begin to join. *Ch.* Notochord. *Wd.* Wolffian duct. *Wb.* Commencement of formation of Wolffian body. *ep.* Epiblast. *so.* Somatopleure. *hy.* Hypoblast. The section passes through the place where the alimentary canal (*hy*) communicates with the yolk-sac.

extremity of the embryo on either side of the spinal canal and notochord (Fig. 82, A 7); this is the *protovertebral column*. From a part of it is derived the vertebral column, a considerable portion at the upper and outer part being differentiated from it and eventually forming the muscles of the back. (4) This column undergoes a process of transverse segmentation and becomes converted into a number of quadrilateral blocks, the *protovertebral somites*. The process of segmentation commences in the cervical region and proceeds successively through the other regions of the body until a number of segments are formed, which correspond very closely to the number of the permanent vertebræ. (5) From each of these protovertebral somites masses of cells are budded off towards the middle line, the masses of opposite sides meeting around the notochord, which they enclose, and extending dorsally around the spinal cord, which they also enclose. The notochord and the spinal canal are thus surrounded by a cellular mass derived from the mesoblastic layer, which constitutes the *membranous matrix* of the vertebræ. (6) The next step is the conversion of this primitive membranous matrix into cartilage. This takes place probably about the fourth or fifth week in the human embryo (Kölliker). At intervals along that portion of the membranous matrix which encloses the notochord the cells become pushed apart by the formation between them of a homogeneous substance and the tissue becomes converted into cartilage. The regions which are thus chondrified correspond to the intervals between the successive pairs of protovertebral somites, and form the bases of the bodies of the future vertebræ, the segments of the spinal column thus alternating in position with the protovertebræ. In the regions opposite each protovertebral somite chondrification does not take place, but the membranous matrix assumes a fibrous structure, forming the intervertebral disks.

Similar changes occur in the portion of the matrix which surrounds the spinal cord. Opposite each vertebral body chondrification takes place, producing the cartilaginous vertebral arches, the intervening tissue becoming transformed into the ligaments which extend between the arches, chiefly the interspinous ligaments and the ligamenta subflava. Below each subflavan ligament an opening is left, through which the spinal nerves make their exit from the spinal canal, the nerves, like the provertebræ, alternating in position with the vertebral centra. (7) The notochord contained in the centre of this chondrifying mass does not continue to grow, but becomes in the human subject relatively smaller, so as, at last, to form a mere slender thread, except opposite the secondary segmentations; that is to say, corresponding to the intervals between the bodies of the permanent vertebræ. Here it presents thickenings and forms an irregular network, the remains of which are to be found at all periods of life in the central pulp of the intervertebral disks.

Development of the Ribs and Sternum.—The ribs are formed by extensions of the blastema of the vertebræ in the mesoblastic layer of the blastodermic membrane. These speedily undergo chondrification, and appear as cartilaginous bars, and become separated from the vertebræ at their posterior extremities. At their anterior ends the costal bars, which are to form the nine upper ribs, turn upward and fuse together so as to form a cartilaginous strip bounding a central median fissure. The strips on either side then join in the middle line from before backward, and so give rise to a longitudinal piece of cartilage, which represents the manubrium and gladiolus of the sternum. In the process of development the sternal attachment of the eighth rib disappears, while that of the ninth subdivides, one portion remaining attached to the inferior extremity of the cartilaginous sternum and becoming developed into the ensiform cartilage; the other portion receding from the sternum and becoming attached to the rib above.

The further development of the vertebræ, ribs, and sternum, and the ossification of their cartilaginous structure, are described in the body of the work.

Development of the Cranium in general, and the Face.—We have seen that the first trace of the embryo consists in the formation of a longitudinal fold of the epiblast on either side of a median groove, and that these folds or ridges grow backward and meet in the median line, thus forming a canal. This canal, at the cephalic extremity of the embryo, is dilated and forms a bulbous enlargement. The bulbous enlargement soon expands into three vesicular dilatations, which are known as the three *primary cerebral vesicles*, from which all the different parts of the encephalon are presently to be developed. The most anterior of the three forms the thalamencephalon, whilst a hollow projection from it forms the cerebral hemispheres; the middle one forms the mesencephalon; the posterior the metencephalon and the myelencephalon. The primary cerebral vesicles are at this time, of course, hollow, and their cavities freely communicate with each other at the points of constriction. As the embryo grows, the cerebral vesicles become twice bent forward on their own axis (Figs. 90, 91, A and B). The upper or posterior curvature is called the cerebral, the lower or anterior, the frontal protuberance.

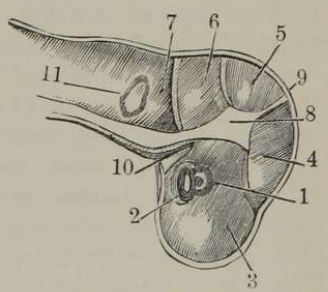

FIG. 90.—Longitudinal section of the head of an embryo four weeks old, seen from the inside. 1. Ocular vesicle. 2. Optic nerve flattened out. 3. Fore brain. 4. Intermediary brain. 5. Middle brain. 6. Hinder brain. 7. After brain. 8. Anterior portion of the tentorium cerebelli. 9. Its lateral portion intervening between Nos. 4 and 5. 10. The pharyngeal curve, bent into a *cul-de-sac*. 11. The auditory vesicle.

Thus, we have a triple cavity (see Fig. 91, A, where the three cavities are marked *c*, *mc*, and *mo*) lined by epiblast and covered by the same structure. Between these two layers of epiblast, a layer of mesoblast, derived from the protovertebral plates of the trunk, is prolonged and spreads over the whole surface of the cerebral vesicles. From these structures the cranium and its contents are developed. The external layer of the epiblast forms the superficial epithelium

of the scalp. The mesoblastic layer forms the true skin, the blood-vessels, muscles, connective tissue, bones of the skull, and membranes of the brain. The layer of epiblast lining the cavity forms the nervous substance of the encephalon, while the cavity itself constitutes the ventricles.

The upper end of the notochord terminates at its cephalic end in a pointed extremity which extends as far forward as the situation of the body of the future sphenoid bone, and is there imbedded in a mass of tissue, the "investing mass of Rathke." This mass, derived from mesoblastic tissue, becomes cartilaginous, and

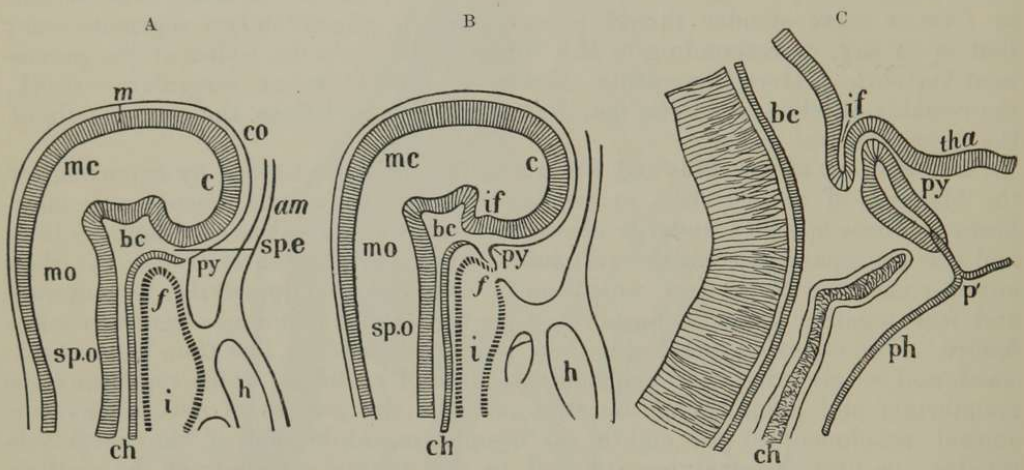

FIG. 91.—Vertical section of the head in early embryos of the rabbit. Magnified. (From Mihalkovics). A. From an embryo of five millimètres long. B. From an embryo of six millimètres long. C. Vertical section of the anterior end of the notochord and pituitary body, etc. from an embryo sixteen millimètres long. In A, the faucial opening is still closed. In B, it is formed. *c.* Anterior cerebral vesicle. *mc.* Mesocerebrum. *mo.* Medulla oblongata. *co.* Epiblast. *m.* Wall of medullary canal. *if.* Infundibulum. *am.* Amnion. *spe.* Spheno-ethmoidal. *bc.* Central (dorsum sellæ), and *spo*, spheno-occipital parts of the basis cranii. *h.* Heart. *f.* Anterior extremity of primitive alimentary canal and opening (later) of the fauces. *i.* Cephalic portion of primitive intestine. *tha.* Thalamus. *p'.* Closed opening or the involuted part of the pituitary body (*py*). *ch.* Notochord. *ph.* Pharynx.

from it is developed the basi-occipital and basi-sphenoid bones; and by lateral expansions from it the occipitals, the greater wings of the sphenoid, and the periotic mass of cartilage surrounding the primary auditory vesicles. From the front of the investing mass of Rathke, which corresponds in position to the future dorsum sellæ, two lateral bars are directed forward, enclosing a space which forms the pituitary fossa, in which the pituitary body is eventually developed. These bars are named the *trabeculæ cranii*, and extend as far forward as the anterior extremity of the head, where they coalesce with each other. From them the pre-sphenoid and lateral masses of the ethmoid are developed; and from their coalescence a process is prolonged downward to form a portion of the framework of the face hereafter to be described. From the pre-sphenoids, which are developed from these trabeculæ, a lateral expansion takes place, which forms the orbito-sphenoid or lesser wings of the sphenoid, enclosing the optic foramen.

The portions of the base of the skull above enumerated are formed from cartilage; the remaining parts, comprising the vault of the skull, are of membranous formation.

The head at first consists simply of a cranial cavity, the face being subsequently developed in the manner now to be described by a series of arches with clefts between them (Fig. 92). On the outer surface of what represents the upper neck region of the embryo four linear vertical grooves make their appearance on each side. Corresponding grooves are also formed in the wall of the intestine, the hypoblast of the pharynx being thus brought into contact with the epiblast of the outer surface of the body along the lines of the grooves. These grooves represent the *branchial* or *visceral clefts*, which become actual perforations in the lower vertebrates, and place the cavity of the pharynx in communication with the exterior. On either side of each groove a thickening of the mesoderm occurs, so that five ridges are formed, the first of which is in front of the

first groove, and the last behind the last groove, while the second, third, and fourth are between successive grooves. These are the *branchial arches*, the first of which has its upper end bent so as to lie at an angle with the lower end, each half of the arch being thus <-shaped. The upper limb of the < is termed the maxillary, and the lower, the mandibular process, and between the two there lies a depression, the *oral sinus*. The outline of this depression is pentagonal, since the ends of the two maxillary processes do not unite, but have projecting down between them a broad plate, the *fronto-nasal process*. In the mesoblast which occupies the axis of each branchial arch a cartilaginous bar develops, serving as a support for the arch.

The *maxillary* processes unite with the *fronto-nasal* process. The latter consists of three plates, a central single one and two lateral ones. The *central* is called the "*mid-frontal*" process. It is free in front and below, but behind it is united with the coalesced portion of the trabeculæ cranii, which therefore probably assists in the formation of the septum nasi, and, in addition, of the prominent part of the future nose. The *lateral* plates of the fronto-nasal process are separated from the central one by a depression or furrow on either side; these furrows form the primary nasal pits or fossæ. The lateral plates project downward parallel to the mid-process for a certain distance, and then, curving inward, unite with it, thus shutting off the nasal fossæ from the rest of the face. The lateral masses of the ethmoid and lachrymal bones are developed in the lateral plates, and by their union with the mid-frontal process form the intermaxillary bone and the *lunula*, or central part of the upper lip.

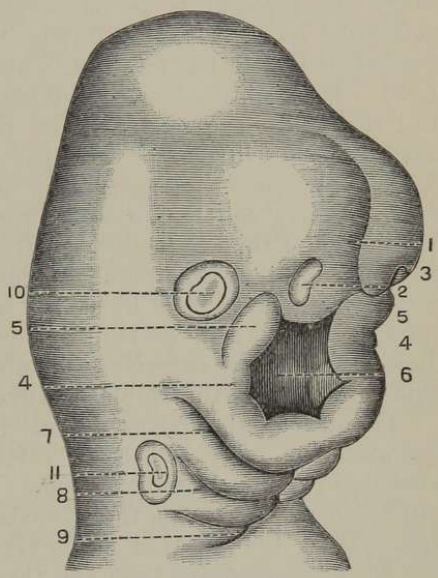

FIG. 92.—Face of an embryo of 25 to 28 days. Magnified 15 times. 1. Frontal prominence. 2, 3. Right and left olfactory fossæ. 4. Inferior maxillary tubercles, united in the middle line. 5. Superior maxillary tubercles. 6. Mouth of fauces. 7. Second pharyngeal arch. 8. Third. 9. Fourth. 10. Primitive ocular vesicle. 11. Primitive auditory vesicle.

The *maxillary* processes descend for a short distance, forming the outer wall of the orbit, in which the malar bone is developed; they then incline inward, and, meeting the lateral plate of the fronto-nasal process, form the floor of the orbit, and shut it off from the rest of the face; then, continuing their course downward and inward, they join the mid-frontal process, and with it complete the alveolar arch and the superior maxillary bone. Finally, palatal processes are formed by an extension of the inner sides of this arch; these coalesce with each other in the median line, thus separating the cavity of the mouth from the nasal fossæ, and completing the palate. In front, however, the palatal processes do not join with the mid-frontal process, but a cleft is left which constitutes the naso-palatine canal.

The mandibular process forms the lower jaw or mandible, the cartilage which it contains being known as *Meckel's cartilage*. This becomes ossified, and unites with membrane-bones, developing in the mesoblastic tissue around it, to form the mandibular bone. Its upper end is in contact with the periotic capsule, and from it two portions are separated and ossify to form two of the bones of the middle ear, the malleus and incus. The second arch is named the *hyoid* arch; from it is formed the styloid process, the stylo-hyoid ligament, and the lesser cornu of the hyoid bone. The third, or *thyro-hyoid* arch, gives origin to the great cornu of the hyoid bone, while the body of this bone is formed between the second and third arches. The fourth and fifth arches do not reach so great a development as the others, and their cartilages likewise only partially develop.

The lower ends of their cartilages unite together to form the thyroid cartilage of the larynx.

Between the mandibular and maxillary processes the buccal cavity or mouth is formed; this therefore owes its origin to the formation of the processes, and consists of mesoblastic tissue lined by epiblast. As has been already stated (page 108), the cephalic end of the embryo becomes remarkably curved on itself, the fore- and mid-brain bending downward over the anterior portion of the original blastodermic membrane, which remains within the body of the embryo and from which the fore-gut is to be developed. This fore-gut terminates as a blind extremity beneath the head (Fig. 91, A, *f*). Another prominence forms on the ventral surface of the fore-gut, which represents the rudimentary heart (Fig. 91, A, *h*). Between these two prominences, caused by the projection of the fore-brain and the heart, an involution of the epiblast takes place, gradually deepening until it comes in contact with the upper part of the alimentary canal. This is the *stomodæum* or *mouth*, which becomes bounded by prominences constituting the maxillary and mandibular processes. It is at first quite distinct from the upper part of the alimentary canal, which, as we shall hereafter see, is formed by the inner or splanchno-pleural layer of the mesoblast and the hypoblast, the two cavities being separated by all the layers of the blastodermic membrane. A communication between the two is, however, gradually effected by the absorption of these layers at the anterior extremity of the primitive alimentary cavity and the hinder portion of the epiblastic involution from which the mouth is formed.

The branchial grooves are at first fully exposed on the surface of the neck region of the body, but later a fold of skin grows backward from the lower border of each mandibular process. This fuses below with the side of the body and completely conceals the grooves, which disappear, with the exception of the first. Both the internal and external parts of this persist, the former giving rise to the Eustachian tube and the tympanic cavity, while the upper portion of the latter forms the meatus auditorius.

Development of the Nervous Centres and the Nerves.—The medullary groove above described (page 107) presents, about the third week, three dilatations at its upper end, separated by two constrictions, and at its posterior part another dilatation, called the *rhomboidal sinus*. Soon afterward the groove become a closed canal (*medullary canal*), exhibiting corresponding dilatations. This is the rudiment of the cerebro-spinal axis. As the embryo grows, its cephalic part becomes more curved, and the three dilatations at the anterior end of the primitive cerebro-spinal axis become vesicles distinctly separate from each other (Fig. 90). These are the cerebral vesicles—anterior, middle, and posterior. The anterior cerebral vesicle (situated, at this period, quite below the middle vesicle) is the rudiment of the third ventricle, and of the parts surrounding it—viz. the optic thalami and all the parts which form the floor of the third ventricle. The middle vesicle represents the aqueduct of Sylvius, with the corpora quadrigemina. The posterior vesicle is developed into the fourth ventricle, and its walls form the pons Varolii, cerebellum, medulla oblongata, and parts in the floor of the fourth ventricle.

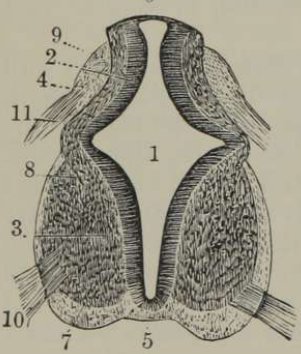

FIG. 93.—Section of the medulla in the cervical region, at six weeks. Magnified 50 diameters. 1. Central canal. 2. Its epithelium. 3. Anterior gray matter. 4. Posterior gray matter. 5. Anterior commissure. 6. Posterior portion of the canal, closed by the epithelium only. 7. Anterior column. 8. Lateral column. 9. Posterior column. 10. Anterior roots. 11. Posterior roots.

At an early period in the development of this primitive brain a protrusion takes place from the anterior vesicle, which is at first simple, but soon becomes divided into two parts by an antero-posterior fissure. These expand laterally, and the cerebral hemispheres and corpora striata are developed from them. In the roof of the forepart of the posterior cerebral vesicle a thickening takes place, forming the rudi-

ment of the cerebellum. In consequence of these protrusions or outgrowths taking place, the three primary cerebral vesicles are now converted into six permanent rudiments of the brain and medulla oblongata. The anterior part of the original anterior cerebral vesicle (fore-brain, prosencephalon), now divided into two, constitutes the cerebral hemispheres, corpus callosum, corpora striata, fornix, lateral ventricles, and olfactory bulbs. The hemispheres are at first relatively small and do not conceal the parts formed from the middle primary vesicle or the optic thalami, which with the optic nerves, the third ventricle, and the parts in its floor, are furnished by the posterior portion of the anterior vesicle (inter-brain, thalamencephalon). By the third month, however, the hemispheres have risen above the optic thalami, and by the sixth month above the cerebellum. Fissures are seen on the surface of the hemispheres at the third month, but all except one disappear. This one persists, and forms the fissure of Sylvius. The permanent fissures for the convolutions do not form till about the seventh or eighth month. The middle cerebral vesicle (mid-brain, mesencephalon) is at first situated at the summit of the angle shown on Fig. 90. Its smooth surface is soon divided, by a median and transverse groove, into four tubercles (tubercula quadrigemina), which are gradually overlapped by the growth of the cerebral hemispheres. Its cavity diminishes as its walls thicken, and contracts to form the aqueduct of Sylvius. The crura cerebri are also formed from this vesicle. The third primary cerebral vesicle at an early period (between the ninth and twelfth week) consists of the hind-brain or metencephalon, forming the cerebellum, pons Varolii, and anterior part of the fourth ventricle, and of the after-brain or myelencephalon, which forms the medulla oblongata with the rest of the fourth ventricle.

The development of the pituitary body has of late received much attention. It is mainly formed by a diverticulum from the buccal involution of epiblast. At its upper and front part this involution, from which the mouth or stomodæum is developed, forms a hollow saccular protrusion, which extends into the angle formed by the bend of the fore-with the mid-brain. Here it comes in contact with a median hollow protrusion, which passes downward and backward from the posterior portion of the anterior cerebral vesicle (Fig. 91, c, *if*). They become intimately connected, and together form the pituitary body or hypophysis.

When the medullary groove is first closed, the fœtal spinal cord occupies its whole length, and presents a large central canal, which gradually contracts in consequence of the thickening and rapid growth of the epiblast around it. This increase in thickness takes place principally at the sides, so that eventually the central canal acquires on section the appearance of a slit. The two sides of this slit eventually join in the middle, and the original canal is divided into two: an *anterior*, which becomes the central permanent canal, which in after life is no longer perceptible to the eye, though it is still visible on microscopic section; and a *posterior*, which becomes filled about the ninth week with a septum of connective tissue from the pia mater, and forms the posterior fissure of the cord. The anterior fissure is formed simply as a cleft left between the lateral halves of the cord.

After the fourth month the spinal column begins to grow in length more rapidly than the medulla spinalis, so that the latter no longer occupies the whole canal. The cord is composed at first entirely of uniform-looking cells, which soon separate into two layers, the inner of which is composed of cells which increase by division, and develop outgrowths which become axis-cylinders of nerve-fibres. These cells are termed *neuroblasts*. The cells of the outer layer, known as *spongioblasts*, scatter themselves among the neuroblasts, forming the neuroglia cells, some of them migrating inwards to form the ependymal lining of the cavities of the cord and brain.

The cerebral and spinal membranes are, according to Kölliker, a production from the protovertebral somites, and are recognizable about the sixth week. As the fissures separating the segments of the cerebro-spinal axis appear, the mem-

branes extend through them and the pia mater passes into the cerebral ventricles.

The Nerves.—The nerves are developed, like the rest of the nervous system, from epiblast. The spinal nerves are developed as follows: Close to the point of involution of the epiblast in the median line—that is to say, in the angle of junction of the neural and general epiblast—a cellular swelling constituting the *neural crest* appears, and forms a continuous ridge on the dorsal aspect of the neural canal. On this crest enlargements occur, corresponding with the middle of each protovertebral segment. These grow downward between the neural canal and the mesoblastic tissue forming the protovertebræ, and occupy a position on the lateral wall of the canal. These enlargements are the rudiments of the ganglion of the posterior root; they are at first attached to the neural crest from which they spring, but subsequently this attachment becomes lost, and they then form isolated masses on either side of the neural canal, which now contains the rudimentary cord. They consist of oval cells, from either end of which a process eventually springs; one, passing centrally, grows into the embryonic cord and constitutes the posterior root of the nerve; the other, growing peripherally, joins the fibres of the anterior root to form the spinal nerve.

The anterior root is, according to the researches of His, a direct outgrowth of certain cells which are found in the rudimentary cord, and which are named *neuroblasts*. These cells, like those mentioned above, are oval, and have a prolongation directed outward toward the surface of the cord. These processes pass out of the cord in bundles and penetrate the mesoblast and join with fibres of the posterior root, and from the point of union the nerve grows toward its peripheral termination.

Most of the cranial nerves are developed in the same manner as the posterior roots of the spinal nerves. That is to say, the neural crest, developed from the epiblast, is continued onward, along the dorsal surface of the cephalic portion of the neural tube, as far as the mid-brain. From this a series of swellings at irregular intervals form the rudimentary ganglia, from the polar cells of which the nerve is formed and its connection with the brain established. This appears to be the case with the sensory portion of the fifth, the portion of the facial connected with the geniculate ganglion, the auditory and the sensory portions of the glossopharyngeal and pneumogastric. The motor portions of the mixed nerves and the third, fourth, sixth, spinal accessory and hypoglossal arise like the anterior roots of the spinal nerves from neuroblasts in the floor of the aqueduct of Sylvius and of the fourth ventricle.

The olfactory tract and bulb is a protrusion of the antero-ventral part of each cerebral hemisphere. This protrusion comes in contact with the thickened epiblast of the olfactory area (see page 125), from which neuroblastic cells, which are formed within the area, pass out and form a ganglion between the area and the olfactory bulb. From this ganglion cell-processes grow centripetally to form the nerve-roots, and centrifugally to form the olfactory nerves which ramify on the Schneiderian membrane.

The optic nerve arises in a manner somewhat different from any of the other cranial nerves. It will be considered in connection with the development of the eye.

The sympathetic nerves are probably developed as outgrowths from the ganglia of the spinal and cranial nerves.

Development of the Eye.—The nervous elements and non-vascular parts of the eye are formed from the epiblast, and the vascular portions from the mesoblast; but the method of development is somewhat complicated. The essential portion of the eye—*i. e.* the retina and the parts immediately connected with it—is an outgrowth from the rudimentary brain (primitive ocular vesicle), and this outgrowth is met by an ingrowth from the common epidermic or corneous layer of the epiblast, out of which the lens and the conjunctival and corneal epithelium are developed.

The first appearance of the eye consists in the protrusion or evagination from the medullary wall of the thalamencephalon, or inter-brain, of a vesicle, called the *primitive ocular vesicle*. This is at first an open cavity communicating by a hollow stalk with the general cavity of the cerebral vesicle. As the primitive ocular vesicle is prolonged forward, it meets the epidermic layer of the epiblast, which at the point of contact becomes thickened, and then forms a depression which gradually encroaches on the most prominent part of the primitive ocular vesicle, which in its turn appears to recede before it, so as to become at first depressed and then inverted in the manner indicated by the annexed figure (Fig. 94, A), so that the cavity is finally almost obliterated by the folding back of its anterior half, and the original sac converted into a cup-shaped cavity, the *ocular cup*, in which the involuted epiblastic layer, the rudiment of the lens, is received (Fig. 94, B). This cup-shaped cavity consists therefore of two layers: one, the outer, originally the posterior half of the primitive ocular vesicle, is thin, and eventually forms the pigmental layer of the retina;[1] the other layer, the inner, originally the anterior or more prominent half, which has become folded back, and is much thicker, is converted into the nervous layers of the retina. Between the two are the remains of the cavity of the original primary vesicle, which finally becomes obliterated by the union of its two layers. The optic nerve fibres originate from the cells of the ganglionic layer of the retina, which thus correspond to the cells of the posterior root ganglia of the spinal nerves. From these cells the fibres grow toward the brain, choosing the optic stalk as a path along which to grow, the stalk thus becoming gradually replaced by the optic nerve. As development proceeds the cup-shaped cavity or ocular cup increases in size, and thus a space is formed between it and the rudimentary lens which it contains; this is the *secondary ocular vesicle*, and in it the vitreous humor is developed (Fig. 94, C). The folding in of the primary optic vesicle to produce the optic cup proceeds from above downward, and gradually surrounds the lens, but leaves an aperture or fissure below, the *choroidal fissure* or *ocular cleft*, through which vascular elements, within the vesicle and derived from the mesoblast, retain their connection with the rest of the mesoblast. This gap or cleft is continued for some distance

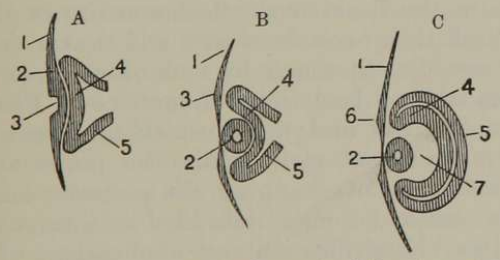

FIG. 94.—Diagram of development of the lens. A B C. Different stages of development. 1. Epidermic layer. 2. Thickening of this layer. 3. Crystalline depression. 4. Primitive ocular vesicle, its anterior part pushed back by the crystalline depression. 5. Posterior part of the primitive ocular vesicle, forming the external layer of the secondary ocular vesicle. 6. Point of separation between the lens and the epidermic layer. 7. Cavity of the secondary ocular vesicle, occupied by the vitreous.

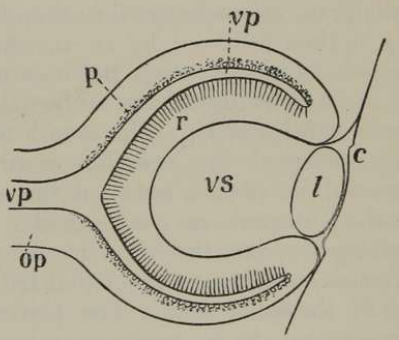

FIG. 95.—Diagrammatic sketch of a vertical longitudinal section through the eyeball of a human fœtus of four weeks. (After Kölliker). Magnified 100 diameters. The section is a little to the side, so as to avoid passing through the ocular cleft. *c.* The cuticle, where it becomes later the cornea. *l.* The lens. *op.* The pedicle of the primary optic vesicle. *vp.* Primary medullary cavity of the optic vesicle. *p.* The pigment-layer of the outer wall. *r.* The inner wall forming the retina. *vs.* Secondary optic vesicle, containing the rudiment of the vitreous humor.

into the stalk of the optic vesicle, and thus allows a process of the mesoblast to extend down the stalk to form the arteria centralis retinæ and its accompanying vein. The lens is at first a thickening of the epiblast; then a depression or involution takes place, thus forming an open follicle, the margins of which gradually approach each other and coalesce, forming a cavity enclosed by epiblastic cells

[1] This layer forms functionally part of the choroid, and was formerly described as belonging to this membrane; it is now described as part of the retina, on account of its method of development.

(Fig. 94). At the point of involution the external layer of epiblast separates from the ball of the lens and passes freely over the surface, so that the lens becomes disconnected from the epiblastic layer from which it was developed, and recedes into the ocular cup, while the cuticular layer covering it is developed into the corneal epithelium. The cells forming the posterior or inner wall of the cavity, which is to form the lens, rapidly increase in size, becoming elongated and developed into fibres, and, filling up the cavity, convert it into a solid body. The cells on the anterior wall undergo no change and retain their cellular character. The secondary ocular vesicle, or space between the lens and the hollow of the ocular cup (Fig. 94, c 7, and 95), contains a quantity of mesoblastic tissue continuous through the ocular cleft with the rest of the mesoblast, and into this blood-vessels project themselves through the ocular cleft. The iris and ciliary processes are formed from this vascular tissue, and the choroid is developed in the mesoblast surrounding the ocular vesicle. A portion of this tissue also becomes converted into the vitreous humor, and surrounds the lens with a vascular membrane—the *vascular capsule of the lens*, which is connected with the termination of the temporary artery (hyaloid) that forms the continuation of the central artery of the retina through the vitreous chamber. This vascular capsule of the crystalline lens forms the membrana pupillaris (described on a subsequent page), and also attaches the borders of the iris to the capsule of the lens. It disappears about the seventh month.

The eyelids are formed at the end of the third month as small cutaneous folds, which come together and unite in front of the globe and cornea. This union is broken up and the eyelids separate before the end of fœtal life.

The lachrymal canal develops as a thickening of the epiblastic cells at the bottom of the groove which extends upward toward the eye between the maxillary and the fronto-nasal processes. The thickening becomes hollowed out into a canal, and the lips of the groove meet over it, thus removing it from the surface.

Development of the Ear.—The first rudiment of the ear appears shortly after that of the eye, in the form of a thickening of the epiblast, on the outside of that part of the third primary cerebral vesicle which eventually forms the medulla oblongata, opposite the dorsal end of the second pharyngeal arch. The thickening is then followed by an involution of the epiblast, which becomes deeper and deeper, sinking toward the base of the skull, and a flask-shaped cavity is formed; by the narrowing of the external aperture the neck of the flask constitutes the *recessus labyrinthi*. The mouth of the flask then becomes closed, and thus a shut sac is formed, the *primitive auditory* or *otic vesicle*, which by its sinking inward comes to be placed between the ali-sphenoid and basi-occipital matrices. From it the internal ear is formed. The middle ear and the Eustachian tube are developed from the remains of the first branchial cleft, while the pinna and external meatus are developed from the soft parts overhanging the posterior margin of the same cleft. The primary otic vesicle becomes imbedded in a mass of mesoblastic tissue, which rapidly undergoes chondrification and ossification. It, as before stated, is at first flask- or pear-shaped, the neck of the flask, or *recessus labyrinthi*, prolonged backward, forms the aquæductus vestibuli. From it are given off certain prolongations or diverticula, from which the various parts of the labyrinth are formed. One from the anterior end gradually elongates, and, forming a tube bends on itself from left to right and becomes the cochlea. Three others, which appear on the surface of the vesicle, form the semicircular canals. Subsequently, a constriction takes place in the original vesicle, which, gradually increasing, divides it into two, and from these are formed the utricle and saccule. Finally, the auditory nerve, which has been developed from the "neural crest" in the manner above described (page 122), pierces the auditory capsule in two main divisions—one for the vestibule, the other for the cochlea. The middle ear and Eustachian tube are the remains of the first pharyngeal or branchial cleft (hyo-mandibular), and are, from an early period, closed by the formation of the membrana tympani, which consists of a layer of epiblast externally, a layer of hypoblast internally, and between the two of mesoblastic tissue consti-

tuting its fibrous and vascular layer. With regard to the exact mode of development of the ossicles of the middle ear there is considerable difference of opinion. The *malleus* and *incus*, however, seem to be developed from the proximal end of the mandibular (Meckel's) cartilage, while the *stapes* seems to have a double origin, its plate being an ossification of the cartilage which fills the foramen ovale in the embryonic condition, while its arch is an ossification of the upper end of the cartilage of the hyoid arch.

The external auditory meatus is developed, like the pinna, from the soft parts on the posterior margin of the first visceral cleft by an outgrowth of the tissues in this situation.

Development of the Nose.—The olfactory fossæ, like the primary auditory vesicles, are formed in the first instance by a thickening and involution of the epiblast, which takes place at a point below and in front of the ocular vesicle (Fig. 92, 2, 3). The thickening appears at a very early period, about the fourth week. The borders of the involuted portion very soon become prominent, in consequence of the development of the mid-frontal and lateral naso-frontal plates above spoken of (page 119), which are formed on either side of the rudimentary fossæ. As these processes increase the fossæ deepen and become converted into a deep channel, which eventually forms the upper part of the nasal fossæ—that is, the two superior meatuses, the part to which the olfactory nerves are distributed. At this time they are continuous with the buccal cavity, a portion of which forms the lower part, or inferior meatus of the nasal fossæ. For as the palatine septum is formed the buccal cavity is divided into two parts, the upper of which forms the lower part of the nasal fossæ, while the remainder forms the permanent mouth.

The soft parts of the nose are formed from the coverings of the frontal projections and of the olfactory fossæ. The nose is perceptible about the end of the second month. The nostrils are at about the third month closed by the growth of their epithelium, but this condition disappears about the fifth month.

The olfactory nerve, as above pointed out, is formed from the anterior cerebral vesicle as a secondary vesicle on its under surface, and it lies upon the involuted epiblast, which subsequently forms the nasal fossæ.

Development of the Skin, Glands, and Soft Parts.—The epidermis is produced from the external, the true skin from the middle, blastodermic layer (Fig. 79, 19, 20). About the fifth week the epidermis presents two layers, the deeper one corresponding to the rete mucosum. The subcutaneous fat forms about the fourth month, and the papillæ of the true skin about the sixth. A considerable desquamation of epidermis takes place during fœtal life, and this desquamated epidermis, mixed with a sebaceous secretion, constitutes the *vernix caseosa*, with which the skin is smeared during the last three months of fœtal life. The nails are formed at the third month, and begin to project from the epidermis about the sixth. The hairs appear between the third and fourth months in the form of depressions of the deeper layer of the epithelium, which then become inverted by a projection from the papillary layer of the skin. The papillæ grow into the interior of the epithelial layer; and finally, about the fifth month, the fœtal hairs (*lanugo*) appear first on the head and then on the other parts. These hairs drop off after birth, and give place to the permanent hairs. The cellular structure of the sudoriferous and sebaceous glands is formed from the epithelial layer, while the connective tissue and blood-vessels are derived from the mesoblast about the fifth or sixth month. The mammary gland is also formed: partly from mesoblast—its blood-vessels and connective tissue; and partly from epiblast—its cellular elements. Its first rudiment is seen about the third month, in the form of a small projection inward of epithelial elements, which invade the mesoblast; from this similar tracts of cellular elements radiate; these subsequently give rise to the glandular follicles and ducts. The development of the former, however, remains imperfect, except in the adult female.

Development of the Limbs.—The upper and lower limbs begin to project, as

buds, from the anterior and posterior part of the embryo about the fourth week. These buds are formed by a projection of the somatopleure (*i. e.* the outer layer of the mesoblast and the epiblast), from the point where the mesoblast splits into its parietal and visceral layers, just external to the vertebral somites, of which they may be regarded as lateral extensions. The division of the terminal portion of the bud into fingers and toes is early indicated, and soon a notch or constriction marks the future separation of the hand or foot from the forearm or leg. Next, a similar groove appears at the site of the elbow or knee. The indifferent tissue or blastema, of which the whole projection is at first composed, is differentiated into muscle and cartilage before the appearance of any internal cleft for the joints between the chief bones.

The **muscles** become visible about the seventh or eighth week. They are derived from the protovertebral somites, and are consequently at first arranged in segments, a condition which is retained by some of the deeper muscles of the back and by the intercostal muscles. Fusion of successive segments takes place, however, and further differentiation of the muscular sheet thus formed into a varying number of muscular bundles brings about the adult condition. The muscles of the limbs are produced from outgrowths from the protovertebral somites in the regions in which the limb buds appear.

Development of the Blood-vascular System.—There are three distinct stages in the development of the circulatory system before it arrives at its complete or adult condition, in accordance with the manner in which nourishment is provided for at different periods of the existence of the individual. In the first stage there is the *vitelline circulation*, during which nutriment is extracted from the yolk or contents of the vitelline membrane. In the second stage there is the *placental circulation*, which commences after the formation of the placenta, and during which nutrition is obtained by means of this organ from the blood of the mother. In the third stage there is the *complete circulation of the adult*, commencing at birth, and during which nutrition is provided for by the organs of the individual itself.

1. The **vitelline circulation** is carried on partly within the body of the embryo and partly external to it in the vascular area of the yolk. It consists of a median tubular heart, from which two vessels (arteries) project anteriorly. These carry the blood to a plexus of capillaries spread over the area vasculosa, and also, though to a less extent, in the body of the embryo. From this plexus the blood is returned by two vessels (veins) which enter the heart posteriorly, and thus a complete circulation is formed.

In these vessels and the heart a fluid (*blood*) is contained, in which rudimentary corpuscles are found. The mode of formation of these elementary parts will have first to be considered.

In mammalia the heart is formed as a longitudinal fold of the splanchnopleure on either side of the median line in front of the anterior extremity of the rudimentary pharynx, at about the level of the posterior primary cerebral vesicle, the folds projecting dorsally into the cœlom. The walls of the folds thicken and present two distinct strata of cells; the inner and thinner layer forms the endocardium, the outer and thicker the muscular wall of the heart. In its very earliest and primitive condition the heart consists, therefore, of a pair of tubes, one on either side of the body. These, however, soon coalesce in the median line, and, fusing together, form a single central tube.[1] Each of the two primary tubes receives posteriorly a large vessel (a vein), and is prolonged anteriorly into a second vessel (an artery). So that after fusion of the heart-tubes has taken place, there is, in the primitive vitelline circulation, as above mentioned, a single tubular heart, with two arteries proceeding from it and two veins emptying themselves into it. The earliest *vessels* are also formed in the visceral layer of the mesoblast. They are developed from that part of the mesoblast which surrounds the portion of blastoderm which is occupied by the developing body of the

[1] In most fishes and in amphibia the heart originates as a single median tube.

embryo, and which is known as the "vascular area." So that the first blood-vessels are developed outside the body of the embryo. Some of the cells of which the vascular area is composed arrange themselves in cords, the cords forming a network. Fluid begins to collect in the interior of the cords, forcing apart the cells of which they are composed, and converting them into canals, some of the cells collecting here and there into groups adherent to the walls of the canals and projecting into their lumen. These are the so-called "blood-islands" (Fig. 96, *c*), and the cells which compose them separate later on and become the embryonic blood-corpuscles. The blood-vessels early extend in toward the embryo from the vascular area, the new vessels arising as bud- or spur-like outgrowths from those already existing. Eventually, the vasifactive process reaches the embryo and the developing vessels come into contact and communicate with the heart, which by this time has been formed and is already pulsating before the vessels reach it.

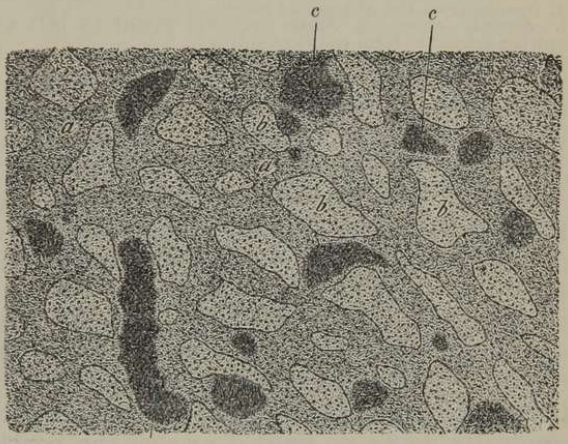

FIG. 96.—A portion of the vascular area of a chick embryo. *a*. Blood-vessels forming a network. *b*. Meshes of the net work. *c*. Blood-islands. (From Kölliker.)

The earliest embryonic red blood-corpuscles are all nucleated and are more properly termed *blood-cells*, true blood-corpuscles, which in all the mammalia are non-nucleated, making their appearance about the second month of development and gradually replacing the embryonic blood-cells. The origin of the corpuscles is somewhat uncertain; some embryologists believe them to be formed from the blood-cells by the extrusion of the nuclei of the latter, while others maintain that they are special formations developing in the protoplasm of the red blood-cells and being thus from the beginning non-nucleated. In later life the formation of red corpuscles seems to occur in the marrow of the bones. The white corpuscles or *leucocytes* appear very early in development, but their exact origin is not known; probably they arise from the mesoblastic tissue outside the blood-vessels and migrate into their interior, The vitelline circulation commences about the fifteenth day and lasts till the fifth week. When fully established it is carried on as follows: Proceeding from the tubular heart are two arteries, the first aortic arteries (Fig. 97), which unite at some distance from the heart into a single artery. This runs down in front of the primitive vertebræ and behind the walls of the intestinal cavity, and again divides into two *primitive aortæ* or *vertebral* arteries, and these give off five or six *omphalo-mesenteric* arteries, which ramify in that part of the blastoderm which surrounds the developing body of the embryo, and which is known as the *vascular area.* They terminate peripherally in a circular vessel—the *terminal sinus.* This vessel surrounds the vascular portion of the germinal area, but does not extend up to the anterior end of the embryo. It terminates on either side in a vein called the *omphalo-mesenteric.* The two omphalo-mesenteric veins open into the opposite extremity of the heart to that from which the arteries proceeded.

2. **The Placental Circulation.**—As the umbilical vesicle diminishes, the allantois and the placenta develop in the manner already indicated. When the umbilical vesicle disappears the latter becomes the only source of nutrition for the embryo. The allantois carries with it to the placenta two arteries, derived from branches of the primitive aorta, and two veins; these vessels become much enlarged as the placental circulation is established, but subsequently one of the veins disappears, and in the later stages of uterine life the circulation is

carried on between the fœtus and the placenta by two arteries and one vein (*umbilical*).

During the occurrence of these changes great alterations take place in the primitive heart and blood-vessels, above alluded to, which will now require description.

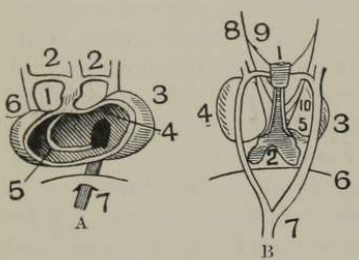

FIG. 97.—Heart at the fifth week. A. Opened from the abdominal aspect. 1. Arterial sinus. 2. Aortic arches uniting behind to form the descending aorta. 3. Auricle. 4. Auriculo-ventricular orifice. 5. Commencing septum ventriculorum. 6. Ventricle. 7. Inferior vena cava. B. Posterior view of the same. 1. Trachea. 2. Lungs. 3. Ventricles. 4, 5. Auricles. 6. Diaphragm. 7. Descending aorta. 8, 9, 10. Pneumogastric nerves and their branches.

Further Development of the Heart.—The simple median tube, formed by the coalescence of the pair of tubes of which the primitive heart consists, becomes elongated and bent on itself, so as to form an S-shaped tube, the anterior part of the tube bending over to the right, and the posterior to the left. At the same time the middle portion is protruded forward and arches transversally from right to left and at the same time becomes twisted on itself, so that the extremity from which the arteries are prolonged is situated in front and to the right, and that into which the veins enter is behind and to the left. The bent tube then becomes divided by two transverse constrictions into three parts. One, the posterior, becomes the auricles, the middle one forms the two ventricular cavities, while the anterior forms the aortic bulb, from which the commencement of the aorta and pulmonary artery is developed. A division of each of these cavities now takes place, so as to convert them into right and left ventricle, right and left auricle, and aorta and pulmonary artery respectively. In the middle portion of the tubular heart, the rudimentary ventricular cavities (Fig. 97, A, 5), a partition rises up from the lower part of the right wall of this cavity, and gradually grows up until it reaches the constrictions which separate it from the other two, and thus the interventricular septum is completed. At the same time a cleft appears on the outside, a little to the right of the most prominent point, which ultimately becomes the apex of the heart. The cleft becomes less marked as development progresses, but remains to some extent persistent throughout life as the interventricular groove.

The first appearance of a division in the posterior or auricular portion of the tubular heart makes its appearance, at a very early period of development, in the shape of two projecting pouches, one on either side; these are the rudiments of the auricular appendages, but the actual division of the cavity by a septum does not occur until some time later. This is formed by the growth of a partition from the anterior wall of the auricular cavity, which grows backward, and partially separates the cavity into two. The partition, however, is not completed until after birth, a part remaining undeveloped, and thus permitting of a communication (*foramen ovale*) between the two auricles during the whole of fœtal life. In a like manner the aortic bulb is divided into two by the growth of a septum downward, from the distal end of the bulb, which divides the cavity into the permanent aorta and the pulmonary artery, and, uniting below with the upper edge of the interventricular septum, places the aorta in communication with the left, and the pulmonary artery with the right ventricle. Very soon a superficial furrow appears on the external surface of this portion of the heart corresponding to the septum internally, and, becoming deeper, the two vessels are gradually separated from each other through the septum, in the immediate neighborhood of the ventricular portion of the heart, whilst beyond this they still remain joined together, and give origin to the fourth and fifth aortic arches, presently to be described.

Further Development of the Arteries.—In the vitelline circulation two arteries were described as coming off from the primitive heart, and running down in front of the developing vertebræ. The first change consists in the fusion of these arteries into one at some distance from the heart, thus forming the descending

thoracic and abdominal aorta. In consequence of the heart falling backward to the lower part of the neck and then into the thorax as the head is developed, the two original arteries, proceeding from the heart to the point of fusion in the common descending aorta become elongated, and assume an arched form, curving backward on each side, from the front of the body toward the vertebral column (Fig. 98, A). These are the first or primitive aortic arches. As the heart recedes into the thorax, and these arches, which correspond in position to the first pharyngeal or mandibular arch, become elongated, four pairs of arches are formed behind

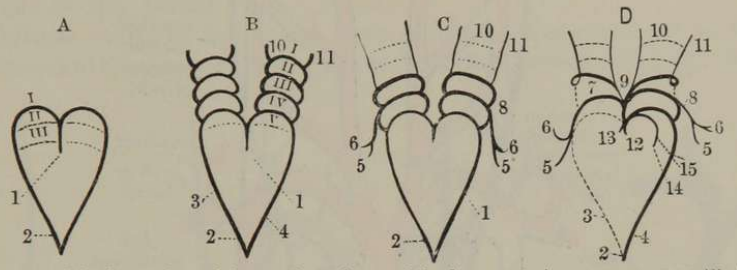

FIG. 98.—Diagram of the formation of the aortic arches and the large arteries. I. II. III. IV. V. First, second, third, fourth, and fifth aortic arches. A. Common trunk from which the first pair spring; the place where the succeeding pairs are formed is indicated by dotted lines. B. Common trunk, with four arches and a trace of the fifth. C. Common trunk, with the three last pairs, the first two having been obliterated. D. The persistent arteries, those which have disappeared being indicated by dotted lines. 1. Common arterial trunk. 2. Thoracic aorta. 3. Right branch of the common trunk which is only temporary. 4. Left branch, permanent. 5. Axillary artery. 6. Vertebral. 7, 8. Subclavian. 9. Common carotid. 10. External; and 11, Internal carotid. 12. Aorta. 13. Pulmonary artery. 14, 15. Right and left pulmonary arteries.

them around the pharynx (Fig. 98). The arches, five in number, remain permanent in fishes, giving off from their convex borders the branchial arteries to supply the gills. In many animals the five pairs do not exist together, for the first two have disappeared before the others are formed; but this is not so in man, where all five arches are present and pervious during a certain period of embryonic existence. Only some of the arches in mammalia remain as permanent structures; other arches, or portions of them, become obliterated or disappear. The first two arches entirely disappear. The third remains as a part of the internal carotid artery, the remainder being formed by the upper part of the posterior aortic root—*i. e.* the descending part of the original vessel which proceeded from the rudimentary tubular heart. The common and external carotid are formed from the anterior aortic root; that is, the ascending portion of the same primitive vessel. The fourth arch on the left side becomes developed into the permanent arch of the aorta in mammals; but in birds it is the fourth arch on the right side which forms the aortic arch; while in reptiles the fourth arch on both sides persists, as there is a permanent double aortic arch. The fourth arch on the right side forms the subclavian artery, and by the junction of its commencement with the anterior aortic root, from which the common carotid is developed, it forms the innominate artery.[1] The fifth arch on the left side forms the pulmonary artery and the ductus arteriosus; that on the right side becomes atrophied and disappears. The first part of the fifth left arch remains connected with that part of the bulbous aorta which is separated as the pulmonary stem, and with it forms the common pulmonary artery. From about the middle of this arch two branches are given off, which form the right and left pulmonary arteries respectively, and the remaining portion—*i. e.* the part beyond the origin of the branches, communicating with the left fourth arch, that is, the descending part of the arch of the aorta—constitutes the ductus arteriosus. This duct remains pervious during the whole of fœtal life, and after birth becomes obliterated.

The development of the arteries in the lower part of the body is going on during the same time. We have seen that originally there were two primitive arteries coming off from the primary tubular heart, and that these two vessels, at some

[1] This is interesting in connection with the position of the recurrent laryngeal nerve, which is thus seen to hook round the *same* primitive fœtal structure, which becomes on the right side the subclavian artery, on the left the arch of the aorta.

distance from the heart, became fused together to form a single median artery, which coursed down in front of the vertebræ to the bottom of the spinal column, forming the permanent descending aorta. From the extremity of this the two vitelline arteries, which were originally parts of the primitive main trunks, pass to the area vasculosa. As the umbilical vesicle dwindles and the allantois grows,

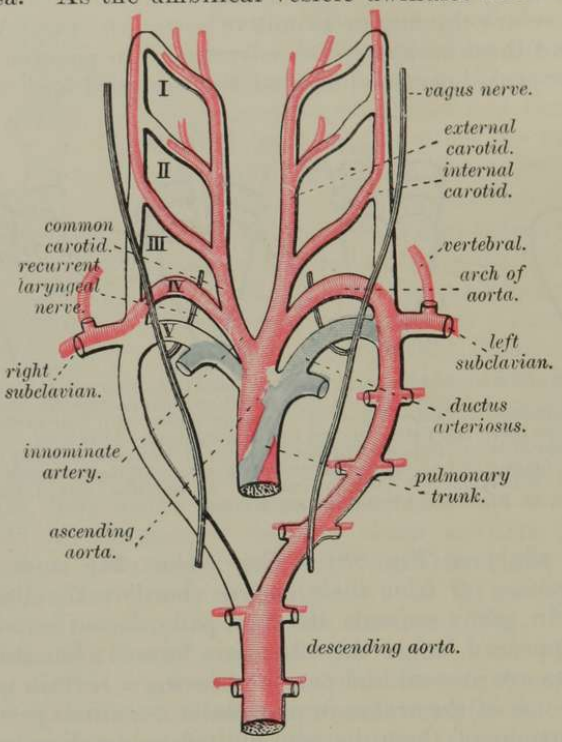

FIG. 99.—Diagram to show the destination of the arterial arches in man and mammals. (Modified from Rathke. From Quain's *Anatomy*, vol i. pt. 1, 1890.) The truncus arteriosus and the five arterial arches springing from it are represented in outline only; the permanent vessels in colors—those belonging to the aortic system red, to the pulmonary system blue.

two large branches are formed as lateral offshoots of the median aorta. These are the two *umbilical* or *hypogastric* arteries, and are concerned in the placental circulation. The portion of the median aorta beyond this point becomes much diminished in size, and eventually forms the sacra media artery, and thus the two umbilical branches become in appearance bifurcating branches of the main aorta. The common and internal iliac arteries are developed from the proximal end of these umbilical arteries; the middle portion of the vessel, after birth, becomes partially atrophied, but in part remains pervious as the superior vesical artery; the distal portion becomes obliterated, constituting part of the superior ligament of the bladder. The external iliac and femoral arteries are developed from a small branch given off from the umbilical arteries near their origin, and are at first of comparatively small size.

Development of the Veins.—The formation of the great veins of the embryo may be best considered under two groups, visceral and parietal.

The visceral are derived from the vitelline and umbilical veins. In the earliest period of the circulation of the embryo, we have seen that there were two veins (vitelline or omphalo-mesenteric) returning the blood from the vitelline membrane. These unite together to form a single channel, the *sinus venosus*, which opens into the auricular extremity of the heart. As soon as the placenta begins to be formed two umbilical veins appear and open into the sinus venosus, close to the vitelline veins. The two vitelline veins enter the abdomen and run upward on either side of the intestinal canal; at the upper part of the abdomen, in the site of the future liver, which now begins to form around them, transverse communications are formed, which encircle the duodenum and enclose it in two vascular rings. The

portion of veins above these vascular rings loses its connection with the sinus, while the portion between them breaks up into a capillary plexus, which ramifies in the now partially developed liver together with capillary vessels from the upper venous ring. Of these latter, some pass toward the heart and join the sinus. They have received the name of the *venæ hepaticæ revehentes*, and eventually become the hepatic veins; others ramify in the liver, under the name of *venæ hepaticæ advehentes*, and become the branches of the portal vein. The lower vascular ring receives veins from the stomach and intestines, and becomes the commencement of the portal vein.

The umbilical veins at first open into the sinus venosus near to the vitelline veins. Subsequently this communication becomes interrupted by the develop-

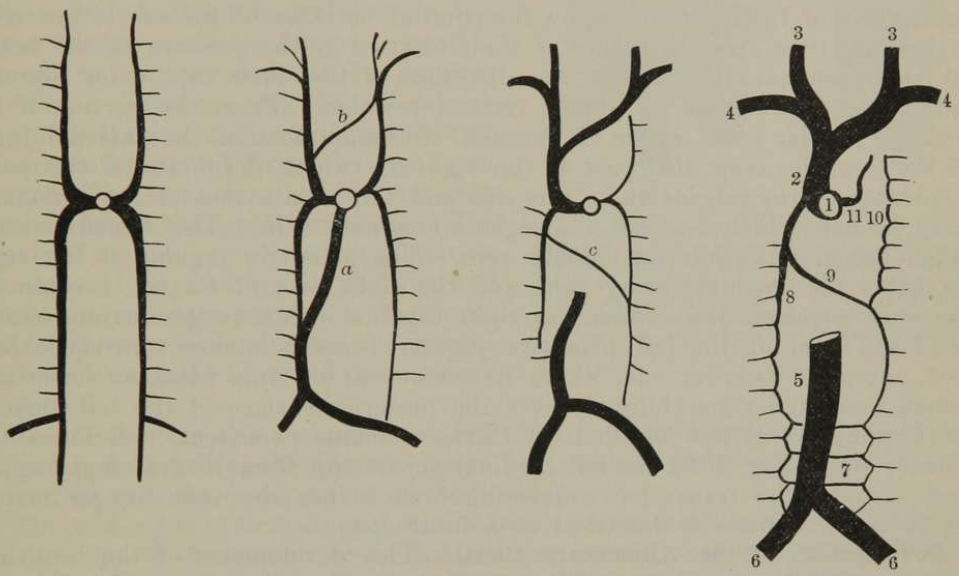

FIG. 100.—Diagrams illustrating the development of the great veins. The first figure shows the cardinal veins emptying into the heart by two lateral trunks, "the ducts of Cuvier." The second figure shows the formation of the venæ cavæ and the union of the left iliac with the right cardinal. *a*. Inferior vena cava. *b*. Left innominate vein. The third figure shows the cardinal veins much diminished in size and the duct of Cuvier, on the left side, gradually diminishing. *c*. Vena azygos minor. The fourth figure shows the adult condition of the venous system. 1. Right auricle of heart. 2. Vena cava superior. 3. Jugular veins. 4. Subclavian veins. 5. Vena cava inferior. 6. Iliac veins. 7. Lumbar veins. 8. Vena azygos major. 9. Vena azygos minor. 10. Superior intercostal vein. 11. Coronary sinus, the remains of the left duct of Cuvier. (Modified from Dalton.)

ment of a vascular network; the vein on the right side atrophies and disappears, while that on the left side greatly enlarges, as the placental circulation becomes established, and communicates with the upper venous circle of the vitelline circulation. Finally a branch is formed between the upper venous circle and the right hepatic veins, which becomes the *ductus venosus*, and by it most of the blood from the umbilical vein is carried direct to the heart.

The Parietal Veins.—The first appearance of a parietal system consists in the appearance of two short transverse veins (the *ducts of Cuvier*), which open on either side of the auricular portion of the heart. Each of these ducts is formed by an ascending and descending vein. The ascending veins return the blood from the parietes of the trunk and the Wolffian bodies, and are called *cardinal* veins. The two descending ones return the blood (Fig. 100) from the head, and are called *primitive jugular* veins. The cardinal veins receive the blood returning from the lower limb through the iliac veins. At first the right and left iliac veins open into the corresponding cardinals, but later a connecting vein forms between the lower portions of the cardinals, and through this the blood of the left iliac flows over to join the right cardinal. At the same time a large venous trunk, which receives the blood from the kidneys, forms along the middle line of the posterior abdominal wall and unites below with the right cardinal and above with the common trunk of the vitelline and umbilical veins above the point of entrance of the venæ revehentes. This is the inferior vena cava. A portion of the right cardi-

nal, above the point of junction of the vena cava, becomes obliterated, the upper portion, which receives some of the lumbar and the intercostal veins, persisting as the vena azygos major; while the left cardinal, separating below from the left iliac, sends a branch across the middle line of the body to form a communication with the azygos major and persists as the azygos minor.

The veins first formed in the upper part of the trunk are, as above stated, the *primitive jugular* veins. In the greater part of their extent they become the internal jugular vein. Shortly, two small branches may be noticed opening into them near their termination; these form the subclavian veins. From the point of junction of these veins on the left side, a communicating branch makes its appearance, running obliquely across the neck downward and to the right, to open into the primitive jugular vein of the right side below the point of entrance of the subclavian vein. At the same time, in consequence of the alteration in the position of the heart, and its descent into the thorax, the direction of the ducts of Cuvier becomes altered, and they assume an almost vertical position. From the portion of the primitive jugular veins, above the branch of communication, the internal jugulars are formed, except that part of the right one which lies between the point of entrance of the subclavian of this side and the termination of the communicating branch, which becomes the right innominate vein. The communicating branch becomes the left innominate vein. The primitive jugular of the right side, below the communicating vein, and the right duct of Cuvier, become the vena cava superior, into which the right cardinal (vena azygos major) enters. The lower part of the left primitive jugular becomes almost entirely obliterated, except at its lower end, where it remains as a fibrous band, or sometimes a small vein, and runs obliquely over the posterior surface of the left auricle. The termination of the left duct of Cuvier remains persistent, and forms the coronary sinus (Fig. 100), the left cardinal separating from it and emptying its blood through the transverse connecting branch into the vena azygos major. The fœtal circulation is described at a future page.

Development of the Alimentary Canal.—The development of the intestinal cavity is, as shown above (page 109), one of the earliest phenomena of embryonic life. The original intestine consists of an inflection of the hypoblast extending from one end of the embryo to the other, and is situated just below the primitive vertebral column. At either extremity it forms a closed tube, in consequence of the cephalic and caudal flexures (page 109), and this manifestly divides it into three parts; a front part, enclosed in the cephalic fold, called the *fore-gut;* a posterior part, enclosed in the caudal fold, the *hind-gut;* and a central part or *mid-gut*,

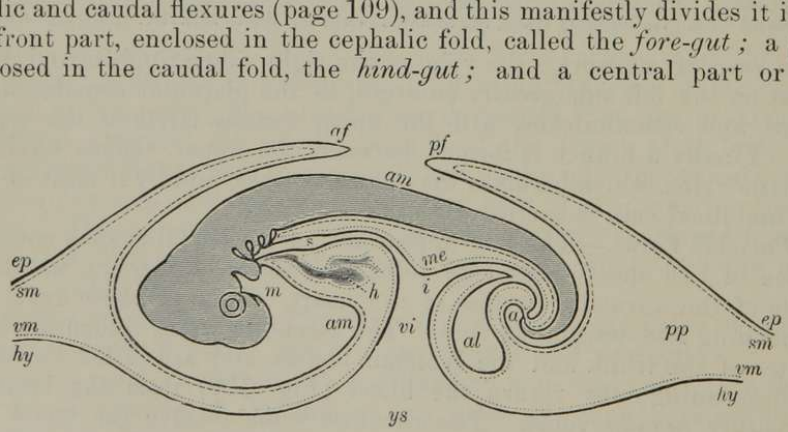

Fig. 101.—Diagrammatic outline of a longitudinal vertical section of the chick on the fourth day. *ep.* Epiblast. *sm.* Somatic mesoblast. *hy.* Hypoblast. *vm.* Visceral mesoblast. *af.* Cephalic fold. *pf.* Caudal fold *am.* Cavity of true amnion. *ys.* Yolk-sac. *i.* Intestine. *s.* Stomach and pharynx. *a.* Future anus, still closed. *m.* The mouth. *me.* The mesentery. *al.* The allantoic vesicle. *pp.* Space between inner and outer folds of amnion. (From Quain's *Anatomy*, Allen Thomson.)

which at this time freely communicates with the umbilical vesicle (Fig. 101). The ends of the fore- and hind-gut do not communicate with the surface of the body, the buccal and anal orifices being subsequently formed by involutions of the epiblast, which later on form communications with the gut. From the fore-gut

are developed the pharynx, œsophagus, stomach, and duodenum; from the hind-gut, a part of the rectum: and from the middle division, the rest of the intestinal tube (Figs. 102 and 103). The changes which take place in the fore-gut are as follows: The middle portion becomes dilated to form the stomach, and undergoes a vertical rotation to the right, so that the posterior border, by which it is attached to the vertebral column by a mesentery, is now directed to the left, and the anterior border to the right. At this time it is straight, but it soon undergoes a lateral curve or bend to the right at its upper end. It thus assumes an oblique direction, and the left border (originally the posterior or attached border) becomes inferior, and forms the great curvature. The mesentery by which it was attached forms the great omentum. The portion of the fore-gut above this dilatation remains straight, forming the pharynx and œsophagus, while the part below the dilated stomach forms the duodenum, and in connection with this the liver and pancreas are developed.

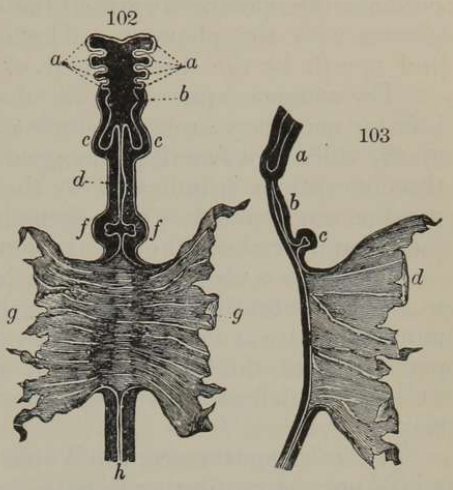

FIGS. 102 AND 103.—Early form of the alimentary canal. (From Kölliker, after Bischoff.) In 102 a front view, and in 103 an antero-posterior section are represented. *a*. Four pharyngeal or visceral plates. *b*. The pharynx. *c*, *c*. The commencing lungs. *d*. The stomach. *f*, *f*. The diverticula connected with the formation of the liver. *g*. The yolk-sac into which the middle intestinal groove opens. *h*. The posterior part of the intestine.

The *hind-gut* is also a closed tube, and from it the middle third of the rectum is developed, as well as the allantois (page 113), which will be again referred to in connection with the development of the bladder.

The *mid-gut* is at first an open cavity freely communicating with the umbilical vesicle. As the body-walls grow, this communication contracts very materially, though it still exists to a certain extent, and the open cavity becomes converted into a straight tube, still open where it communicates with the umbilical vesicle. This tube grows rapidly in length, and presents a primitive curve or loop downward and forward, and, in consequence of its growth exceeding that of the walls of the body-cavity, a portion of the loop protrudes into the stalk of the umbilical vesicle. At a subsequent period, however, the walls of the abdomen grow more rapidly than the intestine, which again recedes into the body-cavity. At a short distance below the most prominent point of this loop a diverticulum arises, which marks the separation between the large and small intestine. The lower part of this diverticulum forms the vermiform appendix; the proximal part, by its continued growth, constitutes the cæcum. After this the anterior or upper part of the gut, corresponding to the small intestine, rapidly increases in length, and about the eighth week becomes convoluted. The lower or posterior part, corresponding to the large intestine, is at first less in calibre than the upper part, and lies wholly to the left side of the convolutions of the small intestine; but later on the curve of the large intestine begins to form, and the first part (ascending colon) slowly crosses over to the right side, first lying in the middle line, just below the liver. It is not until the sixth month that the cæcum descends into the right iliac fossa, and so drags the ascending colon into its normal position in the right flank.

The peritoneal cavity is the space left between the visceral and parietal layers of the mesoblast, and the serous membrane is developed from these structures. The mesenteries are formed from mesoblastic tissue extending between the vertebræ and the gut which develops the vascular and connective-tissue elements of these parts.

The *buccal* cavity is formed by an involution of the external layers of the blastodermic membrane, which passes inward and meets the pharynx, or upper part of the fore-gut. The two cavities are, however, at first completely separated from each other by all the layers of the blastoderm; but at an early period of

development a vertical slit appears between them; this gradually widens and becomes the opening by which the common cavity of the nose and mouth communicates with the pharynx. The common cavity is afterward divided into nose and mouth by the development of the palate, in the manner spoken of above.

The *tongue* appears about the fifth week as a small elevation behind the inferior maxillary arch, to which a pair of elevations, arising from the junction of the third and fourth pharyngeal arches, is united. The line of union of the three elevations is indicated by the V-shaped groove in which the circumvallate papillæ are situated. The epithelial layer is furnished by the epiblast. The tonsils appear about the fourth month.

The *anus* is also formed by an inflection of the epiblast, which extends inward to a slight extent, and approaches the termination of the hind-gut and finally communicates with it by a solution of continuity in the septum between the two. The persistence of the fœtal septum at either the buccal or anal orifices constitutes a well-known deformity—imperforate œsophagus or imperforate rectum, as the case may be.

The *liver* appears after the Wolffian bodies, about the third week, in the form of a bifid process, projecting from the intestine at that part which afterward forms the duodenum. This process grows rapidly, its terminal lobes branching abundantly to form a complicated tubular gland. The duct of the gland becomes the main duct of the liver, while the lobes become transformed into the right and left lobes of the liver and surround the vitelline and, later, the umbilical veins, which break up into a capillary plexus and ramify in their substance. About the third month the liver almost fills the abdominal cavity. From this period the relative development of the liver is less active, more especially that of the left lobe, which now becomes smaller than the right; but the liver remains up to the end of fœtal life relatively larger than in the adult.

The *gall-bladder* appears about the second month, as an extension of the cavity from which the main duct of the liver is developed; and bile is detected in the intestines by the third month.

The *pancreas* is also an early formation, being far advanced in the second month. It, as well as the salivary glands, which appear about the same period, originates in a projection from the hypoblastic canal, which afterward forms a cavity, and the lobules of the gland are developed from the ramifications of this cavity. The projection for the pancreas appears on the dorsal wall of the intestine, while that for the liver is on the ventral surface, and the ducts of the two glands are at first usually separated. During development the duct of the pancreas shifts its position toward the ventral surface and finally, as a rule, joins that from the liver.

The *spleen* is entirely of mesoblastic origin, as it originates from the mesenteric fold which connects the stomach to the vertebral column (mesogastrium).

Development of the Respiratory Organs.—The lungs appear somewhat later than the liver. They are developed from a small median *cul-de-sac* or diverticulum from the upper part of the fore-gut, immediately behind the fourth visceral cleft, as a projection from the epithelial and fibrous laminæ of the intestines. During the fourth week a pouch is formed on either side of the central diverticulum, and opens freely through it into the fore-gut (pharynx). From these, other (secondary) pouches are given off, so that by the eighth week the form of the lobes of the lungs may be made out. The two primary pouches have thus a common pedicle of communication with the pharynx. This is developed into the trachea (Fig. 97, B), the cartilaginous rings of which are perceptible about the seventh week. The parts which afterward form the larynx are recognized as early as the sixth week—viz. a projection on either side of the pharyngeal opening, which is the rudiment of the arytenoid cartilage and a transverse elevation from the third pharyngeal arch, which afterward becomes the epiglottis; the vocal cords and ventricles of the larynx are seen about the fourth month. Traces of the diaphragm appear in the form of a fine membrane, separating the lungs

from the Wolffian bodies, the stomach, and the liver, whilst the heart is still near the head. As the diaphragm extends forward from the vertebral column it separates the common pleuro-peritoneal cavity into two parts, a thoracic and abdominal.

Development of the Urinary Organs.—Three distinct sets of urinary organs occur in the embryo at different periods of development, two of them being more or less transitory, while the third becomes the permanent kidney. The first to appear is the *pronephros* or *head-kidney* and it consists of a small number of somewhat convoluted tubules which develop immediately behind the heart in the mesoblast of certain of the protovertebral somites. The tubules are segmentally arranged, one corresponding to each protovertebra, and they communicate at one extremity with the cœlom and at the other with a longitudinal canal known as the *segmental* or *Wolffian duct*. Later the second kidney appears below the pronephros, developing in a similar manner and forming the *mesonephros* or *Wolffian body*, whose tubules are also at first arranged segmentally, though later they become more numerous than the protovertebræ from which they arise, by the formation of secondary and tertiary tubules by budding from those already present. These tubules likewise communicate with the Wolffian duct, and in connection with each of them there is developed a little knot of blood-vessels which projects into the lumen of the tubule, whose wall it pushes in front of it, and forms the *Malpighian body* or *glomerulus*. The third and last kidney to appear is the *metanephros* or permanent kidney, which, together with the ureter, arises as an outgrowth from the lower end of the Wolffian duct.

The Wolffian duct is perceptible about the third week, forming an elongated ridge of cells situated on either side of the primitive vertebræ and extending from the heart to the lower end of the embryo. It makes its appearance below the heart and behind the common pleuro-peritoneal cavity, from the mesoblast at the point of separation of its two layers into somatopleure and splanchnopleure, this portion of the mesoblast being termed the "intermediate cell mass." The ridge is at first solid, but soon a tube is hollowed out in it, and continuing to develop posteriorly it unites with the proximal end of the allantois which forms what is termed the urogenital sinus. Thus a communication is established through the Wolffian tubes and ducts between the pleuro-peritoneal cavity and the cloaca or hinder part of the alimentary canal. The next step is the formation of a second duct in the neighborhood of the original duct, with which some of the tubules of the anterior part of the segmental body (pronephros) are connected. This is the Müllerian duct. The ureter, which is formed later, is, as has been described, an offshoot from the hinder part of the Wolffian duct.

The structure of the Wolffian body is in many respects analogous to that of the permanent kidney (Fig. 104). It is composed partly of an excretory canal or duct, into which open numerous "conduits," rectilinear at first, but afterward tortuous, and partly of a cellular or glandular structure, in which Malpighian tufts are found. It is fixed to the diaphragm by a superior ligament, and to the spinal column by an inferior or inguinal ligament. Its office is the same as that of the kidneys—viz. to secrete fluid containing urea, which accumulates in the bladder. When the permanent kidneys are formed, the greater part of the Wolffian body disappears. The rest takes part in the formation of the organs of generation.

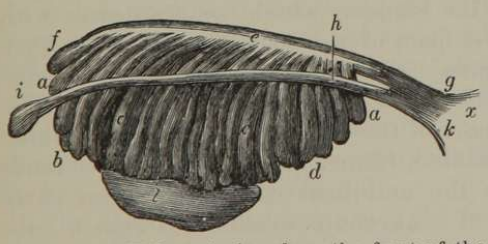

FIG. 104.—Enlarged view from the front of the left Wolffian body before the establishment of the distinction of sex. (From Farre, after Kobelt.) *a, a, b, d.* Tubular structure of the Wolffian body. *e.* Wolffian duct. *f.* Its upper extremity. *g.* Its termination in *x*, the urogenital sinus. *h.* The duct of Müller. *i.* Its upper, still closed, extremity. *k.* Its lower end, terminating in the urogenital sinus. *l.* The mass of blastema for the reproductive organ, ovary or testicle.

The functional activity of the Wolffian bodies is very transitory; they attain their highest development by the sixth

week, after which time they begin to decrease in size and have nearly disappeared by the end of the third month. The upper part of the segmental body, the pronephros, also undergoes atrophy and disappears. In the male, the Wolffian duct persists, and becomes converted into the vas deferens, the Müllerian duct undergoing atrophy, a vestige of it, however, remaining as the sinus prostaticus; whereas, on the other hand, in the female, the Müllerian duct remains and becomes converted into the whole length of the genital passages, while the Wolffian duct almost entirely disappears and remains only as a vestige. Prior to this, however, the Wolffian and Müllerian ducts (together with the ureter when formed) open into the common urogenital sinus referred to above, and which on its part communicates with the terminal portion of the intestinal cavity which is known as the cloaca (Fig. 105).

As the allantois expands into the urinary bladder this common cavity is divided into two by a septum, and the urogenital sinus then communicates with the anterior division and the rectum with the posterior. The Wolffian and Müllerian ducts are soon connected by cellular substance into a single mass—the *genital cord*—in which the Wolffian ducts lie side by side in front, and the ducts of Müller behind, at first separate, but later on uniting with each other.

It has been stated that the kidney (metanephros) is developed from the lower part of the Wolffian duct. It commences as a tubular diverticulum from the lower part of the segmental duct, close to the cloaca. It extends upward, and becomes divided into a number of cæcal tubules, which represent the commencement of the several divisions of the pelvis of the kidney. These tubules are prolonged into a solid mesoblastic blastema situated near the lower end of the mesonephros. The tubules then become convoluted, and masses of cells accumulate on their exterior, so as to give to the organ an appearance of lobulation. Between these cells vessels are developed, and the vascular glomeruli are gradually formed. The kidneys at first, therefore, consist of cortical substance only, but later on the proximal ends of the tubes become straight and arranged in bundles, and thus the pyramidal structure is developed. The lobulation of the kidney is perceptible for some time after birth.

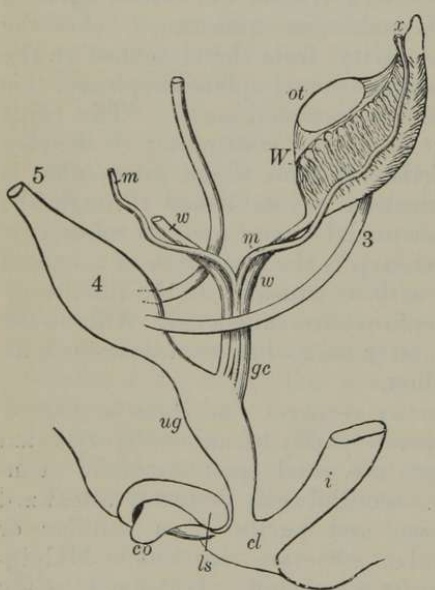

FIG. 105.—Diagram of the primitive urogenital organs in the embryo previous to sexual distinction. The parts are shown chiefly in profile, but the Müllerian and Wolffian ducts are seen from the front. 3. Ureter. 4. Urinary bladder. 5. Urachus. *ot.* The mass of blastema from which ovary or testicle is afterward formed. *W.* Left Wolffian body. *x.* Part at the apex from which the coni vasculosi are afterward developed. *w, w.* Right and left Wolffian ducts. *m, m.* Right and left Müllerian ducts uniting together and with the Wolffian ducts in *gc*, the genital cord. *ug.* Sinus urogenitalis. *i.* Lower part of the intestine. *cl.* Common opening of the intestine and urogenital sinus. *cp.* Elevation which becomes clitoris or penis. *ls.* Ridge from which the labia majora or scrotum are formed.

The *urinary bladder*, as before stated, is formed by a dilatation of the lower part of the stalk of the allantois. At the end of the second month this forms a spindle-shaped cavity, the bladder, which communicates with the lower part of the primitive intestine by a short canal, the urogenital sinus, which becomes the first part of the urethra. The upper part of the stalk of the allantois, which is not dilated, forms the *urachus*; this extends up into the umbilical cord, and at an early period of embryonic existence forms a tube of communication with the allantois. It is obliterated before the termination of fœtal life, but the cord formed by its obliteration is perceptible throughout life, passing from the upper part of the bladder to the umbilicus, and it occasionally remains patent in the adult, constituting a well-known malformation.

The *suprarenal* bodies are developed from two different sources. The medul-

lary part of the organ is of epiblastic origin, and is derived from the tissues forming the sympathetic ganglia of the abdomen, while the cortical portion is of mesoblastic origin, and originates in the mesoblast just above the kidneys. The two parts are at first quite distinct, but become combined in the process of development. The suprarenal capsules are at first larger than the kidney, but become equal in size about the tenth week, and from that time decrease relatively to the kidney, though they remain, throughout fœtal life, much larger in proportion than in the adult.

Development of the Generative Organs.—The first appearance of the reproductive organs is essentially the same in the two sexes, and consists in a thickening at one spot of the epithelial layer which lines the peritoneal or body cavity, with a slight increase of the connective tissue beneath it, forming a low ridge. This is termed the *genital ridge*, and is situated on the mesial side of each Wolffian body, and from it the testicle in the one sex, and the ovary in the other, are developed. The ridge, as the embryo grows, gradually becomes pinched off from the Wolffian body, with which it is at first continuous, though it still remains connected to the remnant of this body by a fold of peritoneum, the *mesorchium* or *mesovarium*. About the seventh week the distinction of sex begins to be perceptible. The epithelium on the genital ridge, which is called "germ-epithelium," in the female becomes distinctly columnar, multiplies rapidly, and begins to form *primitive ova*, in a manner presently to be described; whereas in the male, though the germ-epithelium has a tendency to become columnar, the cells are, on the whole, flatter and smaller than in the female.

Development of Male Organs.—The tubuli seminiferi of the testicle appear at an early period. It is believed that they are formed by the extension of epithelial cells on the surface of the genital ridge into the connective tissue or stroma on which they rest; rows of cells are thus developed which become the lining cells of the seminal ducts. From the mesonephros tubules grow toward the kidney, entering into relation with the seminal ducts and forming the tubuli recti and rete testis, through which the semen escapes from the testis and passes into the tubules of the upper part of the mesonephros, which persist as the epididymis, and thence make their way to the urethra (urogenital sinus) by the Wolffian duct, which becomes the vas deferens and ejaculatory duct of the adult.

The Müllerian ducts disappear in the male sex, with the exception of their lower ends. These unite in the middle line, and open by a common orifice into the urogenital sinus. This constitutes the *uterus masculinus* or *sinus prostaticus*. Occasionally, however, the upper end of the duct of Müller remains visible in the male, constituting the little pedunculated body, called the hydatid of the epididymis, sometimes found in the neighborhood of the epididymis,[1] between the testes and globus major.

It has been seen that the upper portion of the mesonephros and the Wolffian ducts persist. The rest of the mesonephros disappears almost entirely, a few of its tubules forming the vas aberrans and a structure described by Giraldès, and called, after him, "the organ of Giraldès," which bears a good deal of resemblance to the organ of Rosenmüller in the other sex. It consists of a number of convoluted tubules lying in the cellular tissue in front of the cord, and close to the head of the epididymis.

The descent of the testis and the formation of the gubernaculum are described in the body of the work.

Development of Female Organs.—The ovary, as above stated, is formed from the genital ridge, which becomes pinched off from the remains of the Wolffian body, but is still attached by a mesovarium. It consists of a central part of connective tissue covered by a layer of germ-epithelium, from which the ova are developed. This epithelium undergoes repeated division, so that it rapidly increases

[1] Mr. Osborn, in the St. Thomas's Hospital Reports, 1875, has written an interesting paper pointing out the probable connection between this fœtal structure and one form of hydrocele.

in thickness and forms several layers. Next certain of the cells become enlarged and spherical, and form what are called the *primitive ova*. Around these, other epithelial cells have a tendency to arrange themselves, so as to enclose the ovum in a follicle. The permanent ova, enclosed in their Graafian follicles, are thus formed.

The Fallopian tube is developed from that portion of the duct of Müller which lies above the lumbar ligament of the Wolffian body. This duct is at first completely closed at its upper extremity, and its closed extremity remains permanent, forming a small cystic body attached to the fimbriated end of the Fallopian tube, and called the "hydatid of Morgagni." Below this a cleft forms in the duct, and is developed into the fimbriated opening of the Fallopian tube.

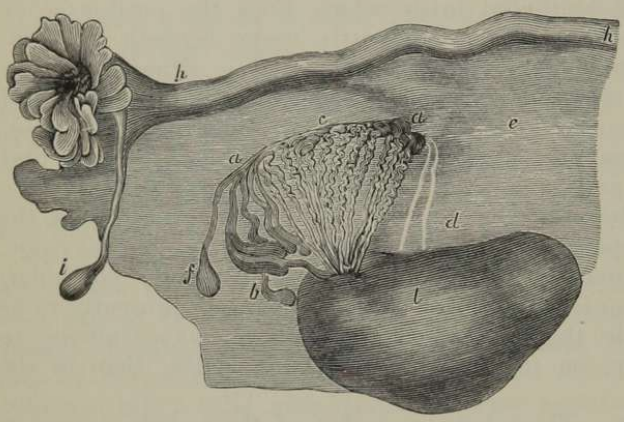

FIG. 106.—Adult ovary, parovarium, and Fallopian tube. (From Farre, after Kobelt). *a, a.* Epoophoron formed from the upper part of the Wolffian body. *b.* Remains of the uppermost tubes, sometimes forming hydatids. *c.* Middle set of tubes. *d.* Some lower atrophied tubes. *e.* Atrophied remains of the Wolffian duct. *f.* The terminal bulb or hydatid. *h.* The Fallopian tube, originally the duct of Müller. *i.* Hydatid attached to the extremity. *l.* The ovary.

Below this the duct of Müller and the ducts of the Wolffian bodies are united together in a structure called "the genital cord," in which the two Müllerian ducts approach each other, lying side by side, and finally coalesce to form the cavity of the vagina and uterus. This coalescence commences in the middle of the genital cord, and corresponds to the body of the uterus. The upper parts of the Müllerian ducts in the genital cord constitute the cornua of the uterus, little developed in the human species. The only remains of the Wolffian body in the com-

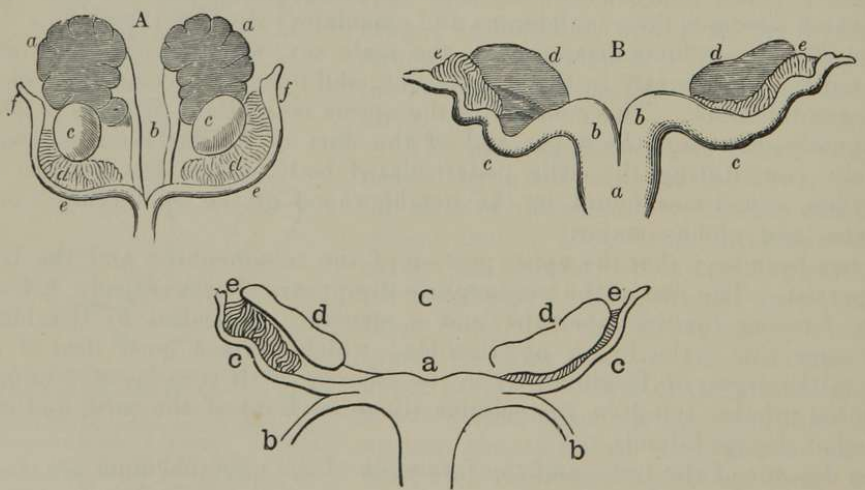

FIG. 107.—Female genital organs of the embryo, with the remains of the Wolffian bodies. (After J. Müller.) A. From a fœtal sheep. *a.* The kidneys. *b.* The ureters. *c.* The ovaries. *d.* Remains of Wolffian bodies. *e.* Fallopian tubes. *f.* Their abdominal openings. B. More advanced, from a fœtal deer: *a.* Body of the uterus. *b.* Cornua. *c.* Tubes. *d.* Ovaries. *e.* Remains of Wolffian bodies. C. Still more advanced, from the human fœtus of three months: *a.* The body of the uterus. *b.* The round ligament. *c.* The Fallopian tubes. *d.* The ovaries. *e.* Remains of the Wolffian bodies.

plete condition of the female organs are two rudimentary or vestigial structures, which can be found, on careful search, in the broad ligament near the ovary; the *parovarium* or *organ of Rosenmüller* and the *paroöphoron* (Fig. 106). The

organ of Rosenmüller consists of a number of the tubules of the upper part of the Wolffian body, and, consequently, is homologous with the epididymis of the male, while the paroöphoron is formed by a few persistent tubules of the lower part of the body, corresponding, therefore, to the organ of Giraldès and the vas aberrans of the male. The lower portions of the Wolffian ducts also persist in the form of a

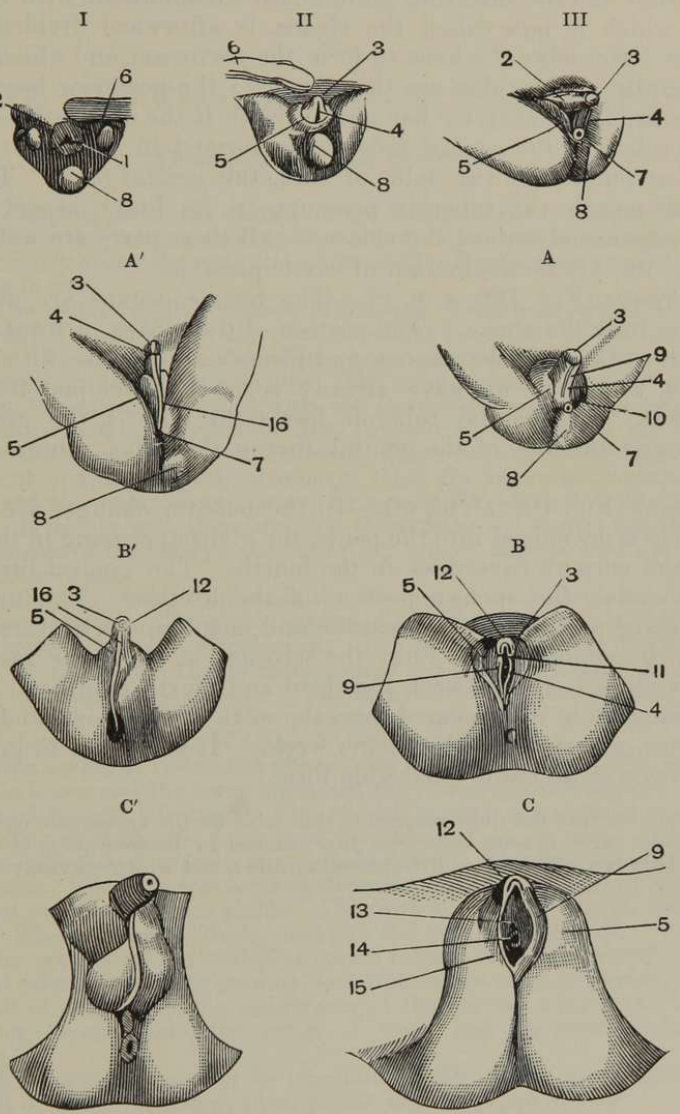

FIG. 108.—Development of the external genital organs. *Indifferent type*, I. II. III. *Female.* A and B. At the middle of the fifth month. C. At the beginning of the sixth. *Male.* A′. At the beginning of the fourth month. B′. At the middle of the fourth month. C′. At the end of the fourth month. 1. Cloaca. 2. Genital tubercle. 3. Glans penis or clitoridis. 4. Genital furrow. 5. External genital folds (labia majora or scrotum). 6. Umbilical cord. 7. Anus. 8. Caudal extremity and coccygeal tubercle. 9. Labia minora. 10. Urogenital sinus. 11. Frænum clitoridis. 12. Preputium penis or clitoridis. 13. Opening of the urethra. 14. Opening of the vagina. 15. Hymen. 16. Scrotal raphe.

pair of tube-like structures, found one on each side in the walls of the uterus and termed the *ducts of Gärtner.* About the fifth month an annular constriction marks the position of the neck of the uterus, and after the sixth month the walls of the uterus begin to thicken. The round ligament is derived from the inguinal ligament of the Wolffian body, the peritoneum constitutes the broad ligament; the superior ligament of the Wolffian body disappears with that structure (Fig. 107).

The **external organs of generation,** like the internal, pass through a stage in which there is no distinction of sex (Fig. 108, II, III). We must therefore

describe this stage, and then follow the development of the female and male organs respectively.

As stated above, the anal depression at an early period is formed by an involution of the external epithelium, and the intestine is still closed at its lower end. When the septum between the two opens, which is about the fourth week, the allantois in front and the intestine behind both communicate with the anal depression. This, which is now called the cloaca, is afterward divided by a vertical septum, whose lower edge thickens to form the *perineum*, and which appears about the second month. Two tubes are thus formed; the posterior becomes the lower part of the rectum, the anterior has uniting with it the urogenital sinus. In the sixth week a tubercle, the *genital tubercle*, is formed in front of the cloaca, and this is soon surrounded by two folds of skin, the *genital folds*. Toward the end of the second month the tubercle presents, on its lower aspect, a groove, the *genital furrow*, turned toward the cloaca. All these parts are well developed by the second month, yet no distinction of sex is possible.

Female Organs (Fig. 108, A, B, C).—The female organs are developed by an easy transition from the above. The portion of the cloaca in front of the septum persists as the vestibule of the vagina, and forms a single tube with the upper part of the vagina, which, as we have already seen, is developed from the united Müllerian ducts. The genital tubercle forms the clitoris, the genital folds the labia majora, and the lips of the genital furrow the labia minora, which remain open.

Male Organs (Fig. 108, A′, B′, C′).—In the male the changes are greater. The genital tubercle is developed into the penis, the glans appearing in the third month, the prepuce and corpora cavernosa in the fourth. The genital furrow closes and thus forms a canal, the spongy portion of the urethra. The urogenital sinus becomes elongated and forms the prostatic and membranous urethra. The genital folds unite in the middle line to form the scrotum, at about the same time as the genital furrow closes—viz. between the third and fourth months.

The following table is translated from the work of Beaunis and Bouchard, with some alterations, especially in the earlier weeks. It will serve to present a *resumé* of the above facts in an easily accessible form.[1]

[1] It will be noticed that the time assigned in this table for the appearance of the first rudiment of some of the bones varies in some cases from that assigned in the description of the various bones in the sequel. This is a point on which anatomists differ, and which probably varies in different cases.

CHRONOLOGICAL TABLE

OF

THE DEVELOPMENT OF THE FŒTUS.

(From Beaunis and Bouchard.)

First Week.—During this period the ovum is in the Fallopian tube. Having been fertilized in the upper part of the tube, it slowly passes down, undergoing segmentation, and reaches the uterus probably about the end of the first week. During this time it does not undergo much increase in size.

Second Week.—The ovum rapidly increases in size and becomes imbedded in the decidua, so that it is completely enclosed in the decidua reflexa by the end of this period. An ovum believed to be of the thirteenth day after conception is described by Reichert. There was no appearance of any embryonic structure. The equatorial margins of the ovum were beset with villi, but the surface in contact with the uterine wall and the one opposite to it were bare. In another ovum, described by His, believed to be of about the fourteenth day, there was a distinct indication of an embryo. There was a medullary groove bounded by folds. In front of this a slightly prominent ridge, the rudimentary heart. The amnion was formed and the embryo was attached by a stalk, the allantois, to the inner surface of the chorion. It may be said, therefore, that these parts, the amnion and the allantois, and the first rudiments of the embryo, the medullary groove, and the heart, are formed at the end of the second week.

Third Week.—By the end of the third week the flexures of the embryo have taken place, so that it is strongly curved. The protovertebral disks, which begin to be formed early in the third week, present their full complement. In the nervous system the primary divisions of the brain are visible, and the primitive ocular and auditory vesicles are already formed. The primary circulation is established. The alimentary canal presents a straight tube communicating with the yolk-sac. The pharyngeal arches are formed. The limbs have appeared as short buds. The Wolffian bodies are visible.

Fourth Week.—The umbilical vesicle has attained its full development. The caudal extremity projects. The upper and the lower limbs and the cloacal aperture appear. The heart separates into a right and left heart. The special ganglia and anterior roots of the spinal nerves, the olfactory fossæ, the lungs and the pancreas can be made out.

Fifth Week.—The allantois is vascular in its whole extent. The first traces of the hands and feet can be seen. The primitive aorta divides into aorta and pulmonary artery. The duct of Müller and genital gland are visible. The ossification of the clavicle and the lower jaw commences. The cartilage of Meckel occupies the first post-oral arch.

Sixth Week.—The activity of the umbilical vesicle ceases. The pharyngeal clefts disappear. The vertebral column, primitive cranium, and ribs assume the cartilaginous condition. The posterior roots of the nerves, the membranes of the nervous centres, the bladder, kidney, tongue, larynx, thyroid body, the germs of teeth, and the genital tubercle and folds are apparent.

Seventh Week.—The muscles begin to be perceptible. The points of ossification of the ribs, scapula, shaft of humerus, femur, tibia, palate, and upper jaw appear.

Eighth Week.—The distinction of arm and forearm, and of thigh and leg, is apparent, as well as the interdigital clefts. The capsule of the lens and pupillary membrane, the interventricular and commencement of the interauricular septum, the salivary glands, the spleen, and suprarenal capsules are distinguishable. The larynx begins to become cartilaginous. All the vertebral bodies are cartilaginous. The points of ossification for the ulna, radius, fibula, and ilium make their appearance. The two halves of the hard palate unite. The sympathetic nerves are now for the first time to be discerned.

Ninth Week.—The corpus striatum and the pericardium are first apparent. The ovary and testicle can be distinguished from each other. The genital furrow appears. The osseous nuclei of the bodies and arches of the vertebræ, of the frontal, vomer, and malar bones of the shafts of the metacarpal and metatarsal bones, and of the phalanges appear. The union of the hard palate is completed. The gall-bladder is seen.

Third Month.—The formation of the fœtal placenta advances rapidly. The projection of the caudal extremity disappears. It is possible to distinguish the male and female organs from each other. The cloacal aperture in divided into two parts. The cartilaginous arches on the dorsal region of the spine close. The points of ossification for the occipital, sphenoid, lachrymal, nasal, squamous portion of temporal and ischium appear, as well as the orbital

centre of the superior maxillary. The pons Varolii and fissure of Sylvius can be made out. The eyelids, the hair, and the nails begin to form. The mammary gland, the epiglottis, and prostate are beginning to develop. The union of the testicle with the canals of the Wolffian body takes place.

Fourth Month.—The closure of the cartilaginous arches of the spine is complete. Osseous points for the first sacral vertebra and os pubis appear. The ossification of the malleus and incus takes place. The corpus callosum, the membrana lamina spiralis, the cartilage of the Eustachian tube, and the tympanic ring are seen. Fat is first developed in the subcutaneous cellular tissue. The tonsils are seen, and the closure of the genital furrow and the formation of the scrotum and prepuce take place.

Fifth Month.—The two layers of the decidua begin to coalesce. Osseous nuclei of the axis and odontoid process, of the lateral points of the first sacral vertebra, of the median points of the second, and of the lateral masses of the ethmoid make their appearance. Ossification of the stapes and the petrous bone and ossification of the germs of the teeth take place. The germs of the permanent teeth and the organ of Corti appear. The eruption of hair on the head commences. The sudoriferous glands, Brunner's glands, the follicles of the tonsil and base of the tongue, and the lymphatic glands appear at this period. The differentiation between the uterus and vagina becomes apparent.

Sixth Month.—The points of ossification for the anterior root of the transverse process of the seventh cervical vertebra, the lateral points of the second sacral vertebra, the median points of the third, the manubrium sterni and the os calcis appear. The sacro-vertebral angle forms. The cerebral hemispheres cover the cerebellum. The papillæ of the skin, the sebaceous glands, and Peyer's patches make their appearance. The free border of the nail projects from the corium of the dermis. The walls of the uterus thicken.

Seventh Month.—The additional points of the first sacral vertebra, the lateral points of the third, the median point of the fourth, the first osseous point of the body of the sternum, and the osseous point for the astragalus appear. Meckel's cartilage disappears. The cerebral convolutions, the island of Reil, and the tubercula quadrigemina are apparent. The pupillary membrane atrophies. The testicle passes into the vaginal process of the peritoneum.

Eighth Month.—Additional points for the second sacral vertebra, lateral points for the fourth and median points for the fifth sacral vertebræ, can be seen.

Ninth Month.—Additional points for the third sacral vertebra, lateral points for the fifth, osseous points for the middle turbinated bone, for the body and great cornu of the hyoid, for the second and third pieces of the body of the sternum, and for the lower end of the femur appear. Ossification of the bony lamina spiralis and axis of the cochlea takes place. The eyelids open, and the testicles are in the scrotum.

DESCRIPTIVE AND SURGICAL ANATOMY.

OSTEOLOGY—THE SKELETON.

THE entire skeleton in the adult consists of 200 distinct bones. These are—

The spine or vertebral column (sacrum and coccyx included)	26
Cranium	8
Face	14
Os hyoides, sternum, and ribs	26
Upper extremities	64
Lower extremities	62
	200

In this enumeration the patellæ are included as separate bones, but the smaller sesamoid bones and the ossicula auditûs are not reckoned. The teeth belong to the tegumentary system.

These bones are divisible into four classes: *Long*, *Short*, *Flat*, and *Irregular*.

The **Long Bones** are found in the limbs, where they form a system of levers, which have to sustain the weight of the trunk and to confer the power of locomotion. A long bone consists of a shaft and two extremities. The *shaft* is a hollow cylinder, contracted and narrowed to afford greater space for the bellies of the muscles; the walls consist of dense, compact tissue of great thickness in the middle, but becoming thinner toward the extremities; the spongy tissue is scanty, and the bone is hollowed out in its interior to form the *medullary canal*. The *extremities* are generally somewhat expanded for greater convenience of mutual connection, for the purposes of articulation, and to afford a broad surface for muscular attachment. Here the bone is made up of spongy tissue with only a thin coating of compact substance. The long bones are not straight, but curved, the curve generally taking place in two directions, thus affording greater strength to the bone. The bones belonging to this class are the *clavicle*, *humerus*, *radius*, *ulna*, *femur*, *tibia*, *fibula*, *metacarpal* and *metatarsal* bones, and the *phalanges*.

Short Bones.—Where a part of the skeleton is intended for strength and compactness, and its motion is at the same time slight and limited, it is divided into a number of small pieces united together by ligaments, and the separate bones are short and compressed, such as the bones of the *carpus* and *tarsus*. These bones, in their structure, are spongy throughout, excepting at their surface, where there is a thin crust of compact substance. The *patellæ* also, together with the other sesamoid bones, are by some regarded as short bones.

Flat Bones.—Where the principal requirement is either extensive protection or the provision of broad surfaces for muscular attachment, we find the osseous structure expanded into broad, flat plates, as is seen in the bones of the skull and the shoulder-blade. These bones are composed of two thin layers of compact tissue enclosing between them a variable quantity of cancellous tissue. In the cranial bones these layers of compact tissue are familiarly known as the *tables* of the

skull; the outer one is thick and tough; the inner one thinner, denser, and more brittle, and hence termed the *vitreous table*. The intervening cancellous tissue is called the *diploë*. The flat bones are: the *occipital*, *parietal*, *frontal*, *nasal*, *lachrymal*, *vomer*, *scapula*, *os innominatum*, *sternum*, *ribs*, and *patella*.

The **Irregular** or **Mixed Bones** are such as, from their peculiar form, cannot be grouped under either of the preceding heads. Their structure is similar to that of other bones, consisting of a layer of compact tissue externally, and of spongy cancellous tissue within. The irregular bones are: the *vertebræ*, *sacrum*, *coccyx*, *temporal*, *sphenoid*, *ethmoid*, *malar*, *superior maxillary*, *inferior maxillary*, *palate*, *inferior turbinated*, and *hyoid*.

Surfaces of Bones.—If the surface of any bone is examined, certain eminences and depressions are seen to which descriptive anatomists have given the following names.

These eminences and depressions are of two kinds: *articular* and *non-articular*. Well-marked examples of articular eminences are found in the heads of the humerus and femur and of articular depressions in the glenoid cavity of the scapula and the acetabulum. Non-articular eminences are designated according to their form. Thus, a broad, rough, uneven elevation is called a *tuberosity;* a small, rough prominence, a *tubercle;* a sharp, slender, pointed eminence, a *spine;* a narrow, rough elevation, running some way along the surface, a *ridge* or *line*.

The non-articular depressions are also of very variable form, and are described as *fossæ*, *grooves*, *furrows*, *fissures*, *notches*, etc. These non-articular eminences and depressions serve to increase the extent of surface for the attachment of ligaments and muscles, and are usually well marked in proportion to the muscularity of the subject.

A prominent process projecting from the surface of a bone, which it has never been separate from or movable upon is termed an *apophysis* (from *ἀπόφυσις*, an excrescence); but if such process is developed as a separate piece from the rest of the bone, to which it is afterward joined, it is termed an *epiphysis* (from *ἐπίφυσις*, an accretion). *Diaphysis* means *main part* of a bone or *shaft* of a long bone.

THE SPINE.

The **Spine** is a flexuous and flexible column formed of a series of bones called *vertebræ* (from *vertere*, to turn).

The **Vertebræ** are thirty-three in number, exclusive of those which form the skull, and have received the names *cervical*, *dorsal*, *lumbar*, *sacral*, and *coccygeal*, according to the position which they occupy; seven being found in the cervical region, twelve in the dorsal, five in the lumbar, five in the sacral, and four in the coccygeal.

This number is sometimes increased by an additional vertebra in one region, or the number may be diminished in one region, the deficiency being supplied by an additional vertebra in another. These observations do not apply to the cervical portion of the spine, the number of bones forming which is seldom increased or diminished.

The vertebræ in the upper three regions of the spine are separate throughout the whole of life; but those found in the sacral and coccygeal regions are in the adult firmly united, so as to form two bones—*five* entering into the formation of the upper bone or *sacrum*, and *four* into the terminal bone of the spine or *coccyx*.

General Characters of a Vertebra.

Each **vertebra** consists of two essential parts—an anterior solid segment or *body*, and a posterior segment or *arch*. The arch (*neural*) is formed of two *pedicles* and two *laminæ*, supporting seven *processes*—viz. four *articular*, two *transverse*, and one *spinous*.

The bodies of the vertebræ are piled one upon the other, forming a strong pillar for the support of the cranium and trunk; the arches forming a hollow cylinder behind the bodies for the protection of the spinal cord. The different

vertebræ are connected together by means of the articular processes and the intervertebral cartilages; while the transverse and spinous processes serve as levers for the attachment of muscles which move the different parts of the spine. Lastly, between each pair of vertebræ apertures exist through which the spinal nerves pass from the cord. Each of these constituent parts must now be separately examined.

The **Body** or **Centrum** is the largest and most solid part of a vertebra. Above and below it is flattened; its upper and lower surfaces are rough for the attachment of the intervertebral fibro-cartilages, and present a rim around their circumference. In front, it is convex from side to side, concave from above downward. Behind, it is flat from above downward and slightly concave from side to side. Its anterior surface is perforated by a few small apertures, for the passage of nutrient vessels; whilst on the posterior surface is a single large, irregular aperture, or occasionally more than one, for the exit of veins from the body of the vertebra—the *venæ basis vertebræ.*

The **Pedicles** project backward, one on each side, from the upper part of the body of the vertebra, at the line of junction of its posterior and lateral surfaces. The concavities above and below the pedicles are the *intervertebral notches;* they are four in number, two on each side, the inferior ones being generally the deeper. When the vertebræ are articulated the notches of each contiguous pair of bones form the intervertebral foramina, which communicate with the spinal canal and transmit the spinal nerves and blood-vessels.

The **Laminæ** are two broad plates of bone which complete the vertebral arch behind, enclosing a foramen, the *spinal foramen*, which serves for the protection of the spinal cord; they are connected to the body by means of the pedicles. Their upper and lower borders are rough, for the attachment of the *ligamenta subflava.*

The **Spinous Process** projects backward from the junction of the two laminæ, and serves for the attachment of muscles.

The **Articular Processes,** four in number, two on each side, spring from the junction of the pedicles with the laminæ. The two superior project upward, their articular surfaces being directed more or less backward; the two inferior project downward, their articular surfaces looking more or less forward.[1]

The **Transverse Processes,** two in number, project one at each side from the point where the articular processes join the pedicle. They also serve for the attachment of muscles.

Character of the Cervical Vertebræ (Fig. 109).

The **Cervical Vertebræ** are smaller than those in any other region of the spine, and may readily be distinguished by the foramen in the transverse process, which does not exist in the transverse process of either the dorsal or lumbar vertebræ.

The **Body** is small, comparatively dense, and broader from side to side than from before backward. The anterior and posterior surfaces are flattened and of equal depth; the former is placed on a lower level than the latter, and its inferior border is prolonged downward, so as to overlap the upper and fore part of the vertebræ below. Its upper surface is concave transversely, and presents a projecting lip on each side; its lower surface is convex from side to side, concave from before backward, and presents laterally a shallow concavity which receives the corresponding projecting lip of the adjacent vertebra. The *pedicles* are directed obliquely outward, and the superior intervertebral notches are deeper, but narrower, than the inferior. The *laminæ* are narrow, long, thinner above than below, and overlap each other, enclosing the spinal foramen, which is very large, and of a triangular form. The *spinous processes* are short, and bifid at the extremity to afford greater extent of surface for the attachment of muscles, the two divisions being often of unequal size. They increase in length from the

[1] It may, perhaps, be as well to remind the reader that the direction of a surface is determined by that of a line drawn at right angles to it.

fourth to the seventh. The *articular processes* are oblique: the superior are of an oval form, flattened, and directed backward and upward; the inferior forward and downward. The *transverse processes* are short, directed downward, outward, and forward, bifid at their extremity, and marked by a groove along their upper surface, which runs downward and outward from the superior intervertebral notch, and serves for the transmission of one of the cervical nerves. They are situated in front of the articular processes and on the outer side of the pedicles. The transverse processes are pierced at their base by a foramen, for the transmission of the vertebral artery, vein, and plexus of nerves. Each process is formed by two roots: the anterior root, sometimes called the *costal process*, arises from the side of the body, and is the homologue of the rib in the dorsal region of the spine; the posterior root springs from the junction of the pedicle with the lamina, and corresponds with the transverse process in the dorsal region. It is by the

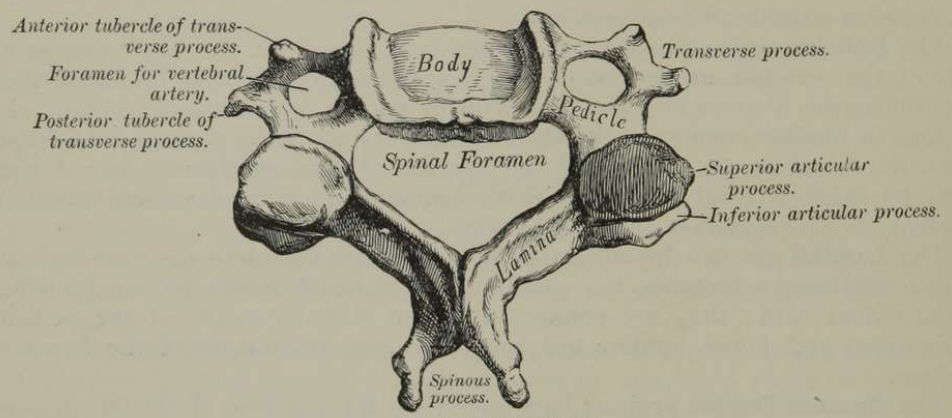

FIG. 109.—Cervical vertebra.

junction of the two that the foramen for the vertebral vessels is formed. The extremity of each of these roots forms the *anterior* and *posterior tubercles* of the transverse processes.[1]

The peculiar vertebræ in the cervical region are the first, or *Atlas;* the second, or *Axis;* and the seventh, or *Vertebra prominens*. The great modifications in the form of the atlas and axis are designed to admit of the nodding and rotatory movements of the head.

The **Atlas** (Fig. 110) is so named from supporting the globe of the head. The chief peculiarities of this bone are that it has neither body nor spinous process. The body is detached from the rest of the bone, and forms the odontoid process of the second vertebra; while the parts corresponding to the pedicles join in front to form the anterior arch. The atlas consists of an anterior arch, a posterior arch, and two lateral masses. The *anterior* arch forms about one-fifth of the bone: its anterior surface is convex, and presents about its centre a *tubercle*, for the attachment of the Longus colli muscle; posteriorly it is concave, and marked by a smooth, oval or circular facet, for articulation with the odontoid process of the axis. The upper and lower borders give attachment to the anterior occipito-atlantal and the anterior atlanto-axial ligaments, which connect it with the occipital bone above and the axis below. The *posterior* arch forms about two-fifths of the circumference of the bone; it terminates behind in a *tubercle*, which is the rudiment of a spinous process, and gives origin to the Rectus capitis posticus minor. The diminutive size of this process prevents any interference in the movements between it and the cranium. The posterior part of the arch presents above and behind a rounded edge for the attachment of the posterior occipito-atlantal liga-

[1] The anterior tubercle of the transverse process of the sixth cervical vertebra is of large size, and is sometimes known as "Chassaignac's" or the "carotid tubercle." It is in close relation with the carotid artery, which lies in front and a little external to it so that, as was first pointed out by Chassaignac, the vessel can with ease be compressed against it.

ment, while in front, immediately behind each superior articular process, is a groove, sometimes converted into a foramen by a *delicate bony spiculum* which arches backward from the posterior extremity of the superior articular process. These grooves represent the superior intervertebral notches, and are peculiar from being situated behind the articular processes, instead of in front of them, as in the other vertebræ. They serve for the transmission of the vertebral artery, which, ascending through the foramen in the transverse process, winds round the lateral mass in a direction backward and inward. They also transmit the suboccipital nerve. On the under surface of the posterior arch, in the same situation, are two other grooves, placed behind the lateral masses, and representing the inferior intervertebral notches of other vertebræ. They are much less marked than the superior. The lower border also gives attachment to the posterior atlanto-axial ligament, which connects it with the axis. The *lateral masses* are the most bulky and solid parts of the atlas, in order to support the weight of the head; they present two articulating processes above, and two below. The two superior

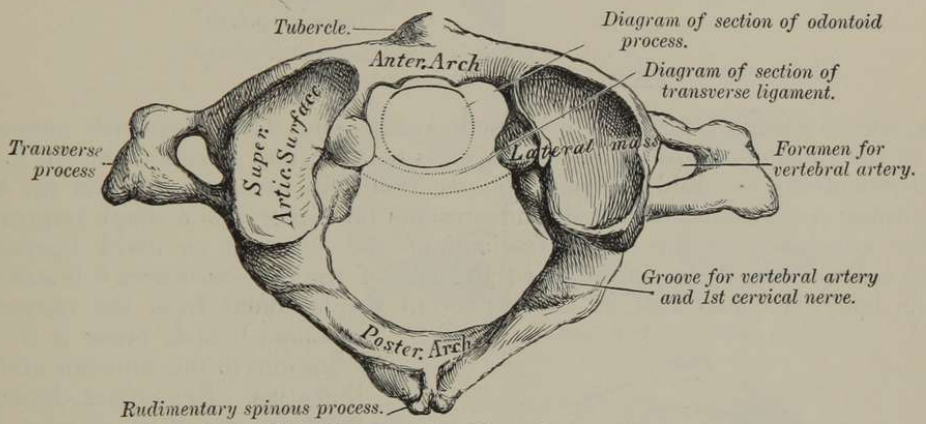

FIG. 110.—First cervical vertebra, or atlas.

are of large size, oval, concave, and approach each other in front, but diverge behind; they are directed upward, inward, and a little backward, forming a kind of cup for the condyles of the occipital bone, and are admirably adapted to the nodding movements of the head. Not unfrequently they are partially subdivided by a more or less deep indentation which encroaches upon each lateral margin. The inferior articular processes are circular in form, flattened or slightly concave, and directed downward and inward, articulating with the axis, and permitting the rotatory movements. Just below the inner margin of each superior articular surface is a small tubercle, for the attachment of the transverse ligament, which, stretching across the ring of the atlas, divides it into two unequal parts; the anterior or smaller segment receiving the odontoid process of the axis, the posterior allowing the transmission of the spinal cord and its membranes. This part of the spinal canal is of considerable size, to afford space for the spinal cord; and hence lateral displacement of the atlas may occur without compression of this structure. The *transverse processes* are of large size, project directly outward from the lateral masses, and serve for the attachment of special muscles which assist in rotating the head. They are long, not bifid, and perforated at their base by a canal for the vertebral artery, which is directed from below, upward and backward.

The **Axis** (Fig. 111) is so named from forming the pivot upon which the first vertebra, carrying the head, rotates. The most distinctive character of this bone is the strong, prominent process, tooth-like in form (hence the name *odontoid*), which rises perpendicularly from the upper surface of the body. The *body* is of a triangular form, deeper in front than behind, and prolonged downward anteriorly so as to overlap the upper and fore part of the adjacent vertebra. It presents in front a median longitudinal ridge, separating two lateral depressions for the attach-

ment of the Longus colli muscle of either side. The *odontoid process* presents two articulating surfaces: one in front, of an oval form, for articulation with the

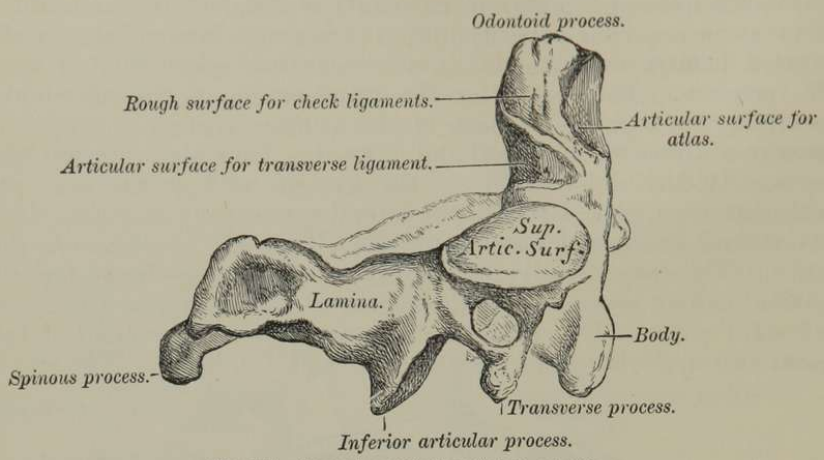

FIG. 111.—Second cervical vertebra, or axis.

atlas; another behind, for the transverse ligament—the latter frequently encroaching on the sides of the process. The apex is pointed, and gives attachment to one fasciculus of the odontoid ligament (*ligamentum suspensorium*). Below the apex the process is somewhat enlarged, and presents on either side a rough impression for the attachment of the *lateral* fasciculi of the odontoid or *check* ligaments, which connect it to the occipital bone; the base of the process, where it is attached to the body, is constricted, so as to prevent displacement from the transverse ligament, which binds it in this situation to the anterior arch of the atlas. Sometimes, however, this process does become displaced, especially in children, in whom the ligaments are more relaxed: instant death is the result of this accident. The *pedicles* are broad and strong, especially their anterior extremities, which coalesce with the sides of the body and the root of the odontoid process. The *laminæ* are thick and strong, and the spinal foramen large, but smaller than that of the atlas. The *transverse processes* are very small, not bifid, and perforated by the vertebral foramen, or foramen for the vertebral artery, which is directed obliquely upward and outward. The *superior articular surfaces* are round, slightly convex, directed upward and outward, and are peculiar in being supported on the body, pedicles, and transverse processes. The *inferior articular surfaces* have the same direction as those of the other cervical vertebræ. The *superior intervertebral notches* are very shallow, and lie behind the articular processes; the *inferior* in front of them, as in the other cervical vertebræ. The *spinous process* is of large size, very strong, deeply channelled on its under surface, and presents a bifid, tubercular extremity for the attachment of muscles which serve to rotate the head upon the spine.

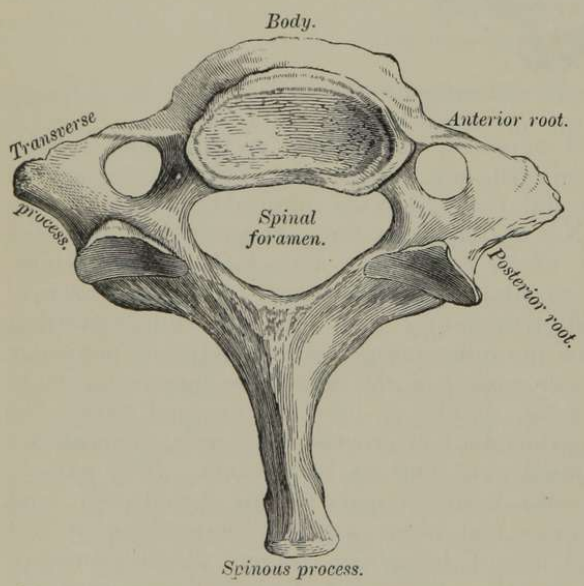

FIG. 112.—Seventh cervical vertebra, or vertebra prominens.

Seventh Cervical (Fig. 112).—The most distinctive character of this vertebra is

the existence of a very long and prominent spinous process; hence the name "vertebra prominens." This process is thick, nearly horizontal in direction, not bifurcated, and has attached to it the ligamentum nuchæ. The *transverse process* is usually of large size, especially its posterior root; its upper surface has usually a shallow groove, and it seldom presents more than a trace of bifurcation at its extremity. The vertebral foramen is sometimes as large as in the other cervical vertebræ, but is usually smaller on one or both sides, and sometimes wanting. On the left side it occasionally gives passage to the vertebral artery; more frequently the vertebral vein traverses it on both sides; but the usual arrangement is for both artery and vein to pass in front of the transverse process, and not through the foramen.

Characters of the Dorsal Vertebræ.

The **Dorsal Vertebræ** are intermediate in size between those in the cervical and those in the lumbar region, and increase in size from above downward, the upper

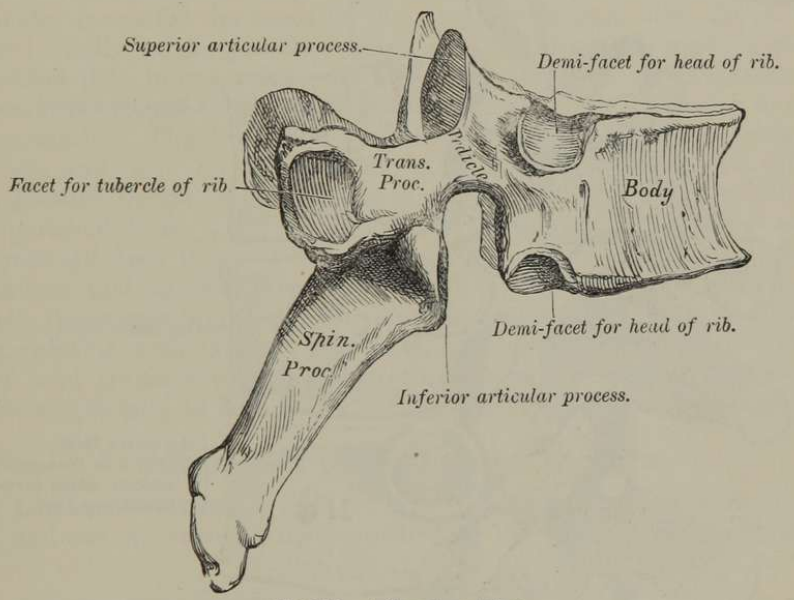

FIG. 113.—A dorsal vertebra.

vertebræ in this segment of the spine being much smaller than those in the lower part of the region. The dorsal vertebræ may be at once recognized by the presence on the sides of the body of one or more facets or half-facets for the heads of the ribs.

The **bodies** of the dorsal vertebræ resemble those in the cervical and lumbar regions at the respective ends of this portion of the spine; but in the middle of the dorsal region their form is very characteristic, being heart-shaped, and as broad in the antero-posterior as in the lateral direction. They are thicker behind than in front, flat above and below, convex and prominent in front, deeply concave behind, slightly constricted in front and at the sides, and marked on each side, near the root of the pedicle, by two demi-facets, one above, the other below. These are covered with cartilage in the recent state, and, when articulated with the adjoining vertebræ, form, with the intervening fibro-cartilage, oval surfaces for the reception of the heads of the corresponding ribs. The *pedicles* are directed backward, and the inferior intervertebral notches are of large size, and deeper than in any other region of the spine. The *laminæ* are broad, thick, and imbricated—that is to say, overlapping one another like tiles on a roof. The spinal foramen is small, and of a circular form. The *spinous processes* are long, triangular in form (bayonet-shaped), directed obliquely downward, and terminate in a tubercular extremity. They overlap one another from the fifth to the eighth, but are less

oblique in direction above and below. The *articular processes* are flat, nearly vertical in direction, and project from the upper and lower part of the pedicles;

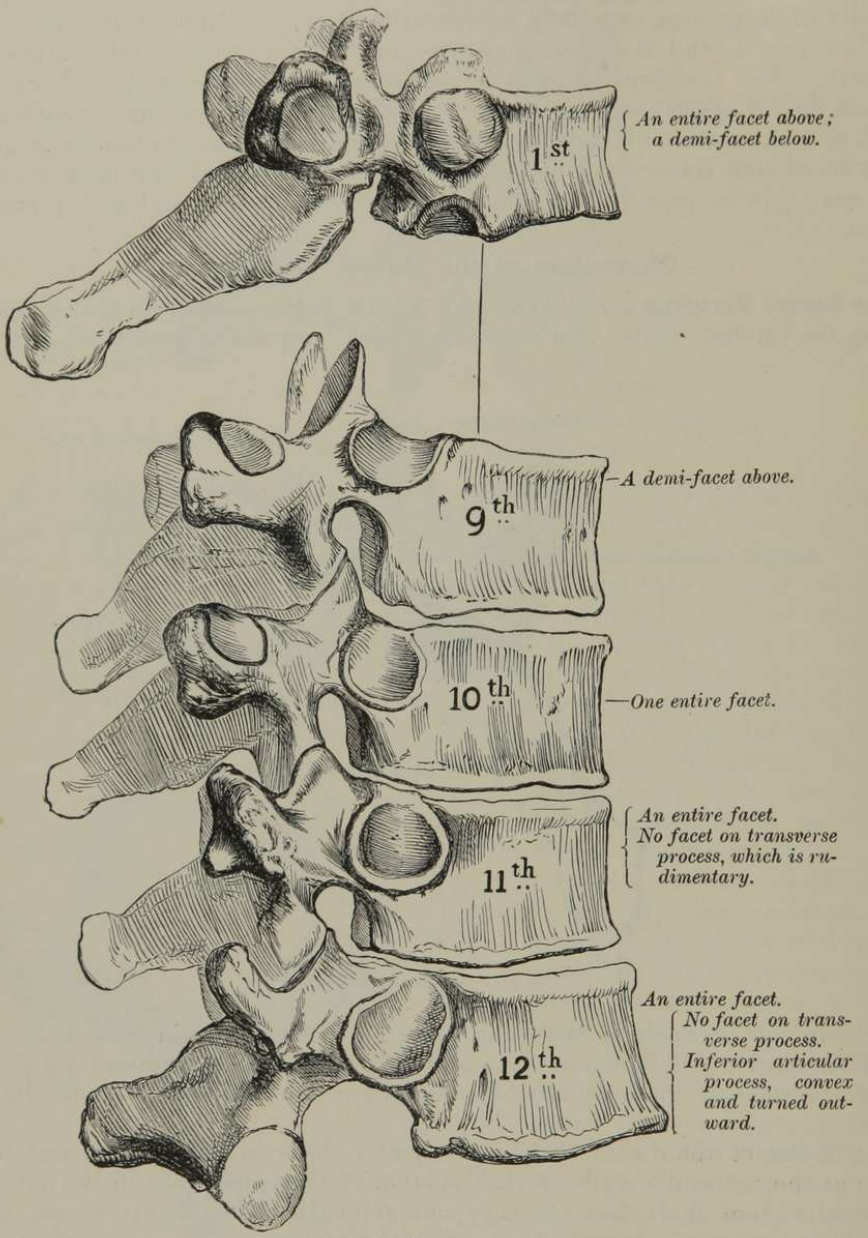

FIG. 114.—Peculiar dorsal vertebræ.

the superior being directed backward and *slightly* outward and upward, the inferior forward and a little inward and downward. The *transverse processes* arise from the same parts of the arch as the posterior roots of the transverse processes in the neck, and are situated behind the articular processes and pedicles; they are thick, strong, and of great length, directed obliquely backward and outward, presenting a clubbed extremity, which is tipped on its anterior part by a small concave surface, for articulation with the tubercle of a rib. Besides the articular facet for the rib, *three indistinct tubercles* may be seen rising from the transverse processes, one at the upper border, one at the lower border, and one externally. In man they are comparatively of small size, and serve only for the attachment of muscles. But in some animals they attain considerable magnitude, either for

the purpose of more closely connecting the segments of this portion of the spine or for muscular and ligamentous attachment. (See below, *twelfth* dorsal vertebra.)

The peculiar dorsal vertebræ are the *first*, *ninth*, *tenth*, *eleventh*, and *twelfth* (Fig. 114).

The **First Dorsal Vertebra** presents, on each side of the *body*, a single entire articular facet for the head of the first rib and a half facet for the upper half of the second. The upper surface of the body is like that of a cervical vertebra, being broad transversely, concave, and lipped on each side. The *articular surfaces* are oblique, and the *spinous process* thick, long, and almost horizontal.

The **Ninth Dorsal** has no demi-facet below. In some subjects, however, the ninth has two demi-facets on each side, then the tenth has a demi-facet at the upper part; none below.

The **Tenth Dorsal** has (except in the cases just mentioned) an entire articular facet on each side above, which is partly placed on the outer surface of the pedicle. It has no demi-facet below.

In the **Eleventh Dorsal** the body approaches in its form and size to the lumbar. The articular facets for the heads of the ribs, one on each side, are of large size, and placed chiefly on the pedicles, which are thicker and stronger in this and the next vertebra than in any other part of the dorsal region. The *spinous* process is short, nearly horizontal in direction, and presents a slight tendency to bifurcation at its extremity. The *transverse* processes are very short, tubercular at their extremities, and have no articular facets for the tubercles of the ribs.

The **Twelfth Dorsal** has the same general characters as the eleventh, but may be distinguished from it by the inferior articular processes being convex and turned outward, like those of the lumbar vertebræ; by the general form of the body, laminæ, and spinous process, approaching to that of the lumbar vertebræ; and by the transverse processes being shorter, and marked by three elevations, the superior, inferior, and external tubercles, which correspond to the mammillary, accessory, and transverse processes of the lumbar vertebræ. Traces of similar elevations are usually to be found upon the other dorsal vertebræ (*vide ut supra*).

Characters of the Lumbar Vertebræ.

The **Lumbar Vertebræ** (Fig. 115) are the largest segments of the vertebral column, and can at once be distinguished by the absence of the foramen in the

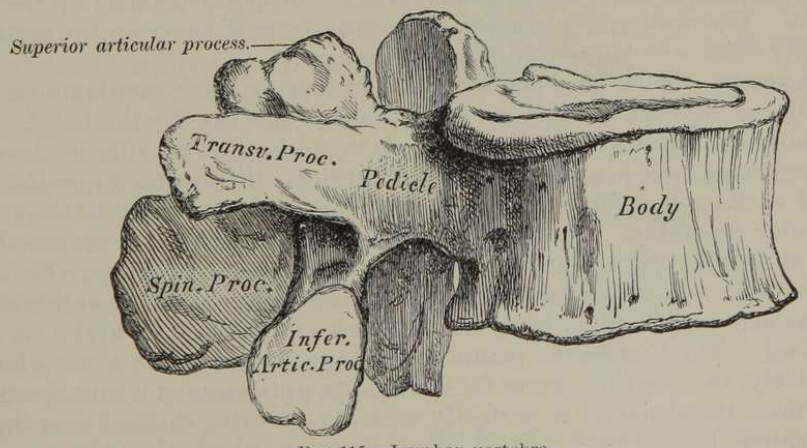

FIG. 115.—Lumbar vertebra.

transverse process, the characteristic point of the cervical vertebræ, and by the absence of any articulating facet on the side of the body, the distinguishing mark of the dorsal vertebræ.

The **body** is large, and has a greater diameter from side to side than from before backward, slightly thicker in front than behind, flattened or slightly concave above and below, concave behind, and deeply constricted in front and at the sides,

presenting prominent margins, which afford a broad basis for the support of the superincumbent weight. The *pedicles* are very strong, directed backward from the upper part of the bodies; consequently, the inferior intervertebral notches are of considerable depth. The *laminæ* are broad, short, and strong, and the spinal foramen triangular, larger than in the dorsal, smaller than in the cervical, region. The *spinous processes* are thick and broad, somewhat quadrilateral, horizontal in direction, thicker below than above, and terminating by a rough, uneven border. The *superior articular processes* are concave, and look backward and inward; the *inferior*, convex, look forward and outward; the former are separated by a much wider interval than the latter, embracing the lower articulating processes of the vertebra above. The *transverse processes* are long, slender, directed transversely outward in the upper three lumbar vertebræ, slanting a little upward in the lower two. They are situated in front of the articular processes, instead of behind them as in the dorsal vertebræ, and are homologous with the ribs. Of the three tubercles noticed in connection with the transverse processes of the twelfth dorsal vertebra, the *superior* ones become connected in this region with the back part of the superior articular processes, and have received the name of *mammillary* processes; the *inferior* are represented by a small process pointing downward, situated at the back part of the base of the transverse process, and called the *accessory* processes: these are the true transverse processes, which are rudimental in this region of the spine; the *external* ones are the so-called transverse processes, the homologue of the rib, and hence sometimes called costal processes. Although in man these are comparatively small, in some animals they attain considerable size, and serve to lock the vertebræ more closely together.

The **Fifth Lumbar** vertebra is characterized by having the body much thicker in front than behind, which accords with the prominence of the sacro-vertebral articulation; by the smaller size of its spinous process; by the wide interval between the inferior articulating processes; and by the greater size and thickness of its transverse processes.

Structure of the Vertebræ.—The structure of a vertebra differs in different parts. The body is composed of light, spongy, cancellous tissue, having a thin coating of compact tissue on its external surface perforated by numerous orifices, some of large size, for the passage of vessels; its interior is traversed by one or two large canals, for the reception of veins, which converge toward a single large, irregular aperture or several small apertures at the posterior part of the body of each bone. The arch and processes projecting from it have, on the contrary, an exceedingly thick covering of compact tissue.

Development.—Each vertebra is formed of four primary cartilaginous portions (Fig. 116), one for each lamina and its processes, and two for the body. Ossification commences in the laminæ about the sixth week of fœtal life, in the situation where the transverse processes afterward project, the ossific granules shooting backward to the spine, forward into the pedicles, and outward into the transverse and articular processes. Ossification in the body commences in the middle of the cartilage about the eighth week by two closely approximated centres, which speedily coalesce to form one central ossific point. According to some authors, ossification commences in the laminæ only in the upper vertebræ—*i. e.* in the cervical and upper dorsal. The first ossific points in the lower vertebræ are those which are to form the body, the osseous centres for the laminæ appearing at a subsequent period. At birth these three pieces are perfectly separate. During the first year the laminæ become united behind by a portion of cartilage in which the spinous process is ultimately formed, and thus the arch is completed. About the third year the body is joined to the arch on each side, in such a manner that the body is formed from the three original centres of ossification, the amount contributed by the pedicles increasing in extent from below upward. Thus the bodies of the sacral vertebræ are formed almost entirely from the central nuclei; the bodies of the lumbar are formed laterally and behind by the pedicles; in the dorsal region the pedicles advance as far forward as the articular depressions for the head of the

ribs, forming these cavities of reception; and in the neck the lateral portions of the bodies are formed entirely by the advance of the pedicles. Before puberty

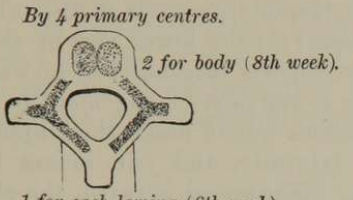

FIG. 116.—Development of a vertebra.

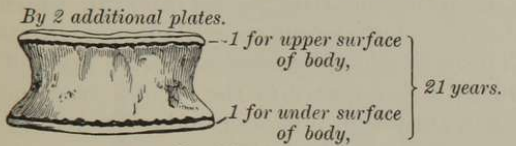

FIG. 117.

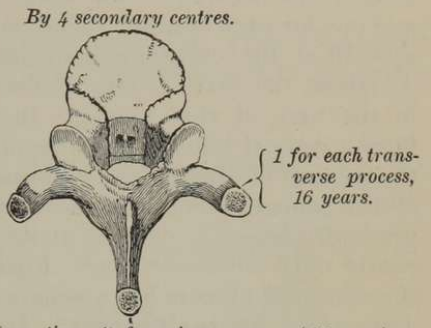

FIG. 118.

no other changes occur, excepting a gradual increase in the growth of these primary centres; the upper and under surfaces of the bodies and the ends of the transverse and spinous processes being tipped with cartilage, in which ossific granules are not as yet deposited. At sixteen years (Fig. 118), four secondary centres appear, one for the tip of each transverse process, and two (sometimes united into one) for the end of the spinous process. At twenty-one years (Fig. 117), a thin circular epiphysial plate of bone is formed in the layer of cartilage situated on the upper and under surfaces of the body, the former being the thicker of the two. All these become joined, and the bone is completely formed between the twenty-fifth and thirtieth year of life.

Exceptions to this mode of development occur in the first, second, and seventh cervical, and in the vertebræ of the lumbar region.

The **Atlas** (Fig. 119).—The number of centres of ossification of the atlas is very variable. It may be developed from two, three, four, or five centres. The most frequent arrangement is by three centres. Two of these are destined for the two lateral or neural masses, the ossification of which commences about the seventh week near the articular processes, and extend backward; these portions of bone are separated from one another behind, at birth, by a narrow interval filled in with cartilage. Between the second and third years they unite either directly or through the medium of a separate centre developed in the cartilage in the middle line. The anterior arch, at birth, is altogether cartilaginous, and in this a separate nucleus appears about the end of the first year after birth, and, extending laterally, joins the neural processes in front of the pedicles. Sometimes there are two nuclei developed in the cartilage, one on either side of the median line, which join to form a single mass. And occasionally there is no separate centre, but the

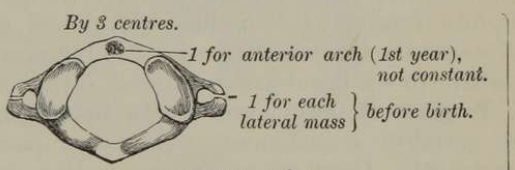

FIG. 119.—Atlas.

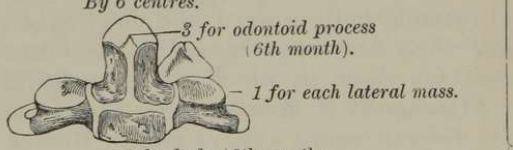

FIG. 120.—Axis.

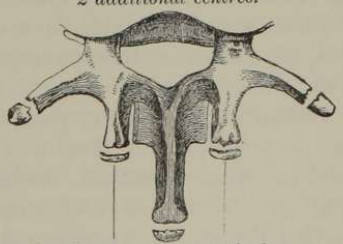

FIG. 121.—Lumbar vertebra.

Exceptional cases.

anterior arch is formed by the gradual extension forward and ultimate junction of the two neural processes.

The **Axis** (Fig. 120) is developed by *six* centres. The body and arch of this bone are formed in the same manner as the corresponding parts in the other vertebræ: one centre (or two, which speedily coalesce) for the lower part of the body, and one for each lamina. The odontoid process consists originally of an extension upward of the cartilaginous mass in which the lower part of the body is formed. At about the sixth month of fœtal life two osseous nuclei make their appearance in the base of this process: they are placed laterally, and join before birth to form a conical bilobed mass deeply cleft above; the interval between the cleft and the summit of the process is formed by a wedge-shaped piece of cartilage, the base of the process being separated from the body by a cartilaginous interval, which gradually becomes ossified at its circumference, but remains cartilaginous in its centre until advanced age.[1] Finally, as Humphry has demonstrated, the apex of the odontoid process has a separate nucleus, which appears in the second year and joins about the twelfth year. In addition to these there is a secondary centre for a thin epiphysial plate on the under surface of the body of the bone.

The **Seventh Cervical.**—The anterior or costal part of the transverse process of the seventh cervical is developed from a separate osseous centre at about the sixth month of fœtal life, and joins the body and posterior division of the transverse process between the fifth and sixth years. Sometimes this process continues as a separate piece, and, becoming lengthened outward, constitutes what is known as a cervical rib.

The **Lumbar Vertebræ** (Fig. 121) have *two additional centres* (besides those peculiar to the vertebræ generally) for the mammillary tubercles, which project from the back part of the superior articular processes. The transverse process of the first lumbar is sometimes developed as a separate piece, which may remain permanently unconnected with the remaining portion of the bone, thus forming a lumbar rib—a peculiarity which is rarely met with.

Progress of Ossification in the Spine generally.—Ossification of the laminæ of the vertebræ commences at the upper part of the spine, and proceeds gradually downward. Ossification of the bodies, on the other hand, commences a little below the centre of the spinal column (about the ninth or tenth dorsal vertebra), and extends both upward and downward. Although, however, the ossific nuclei make their first appearance in the lower dorsal vertebræ, the lumbar and first sacral are those in which these nuclei are largest at birth.

Attachment of Muscles.—To the *Atlas* are attached nine pairs: the Longus colli, Rectus capitis anticus minor, Rectus lateralis, Obliquus capitis superior and inferior, Splenius colli, Levator anguli scapulæ, First Intertransverse, and Rectus capitis posticus minor.

To the *Axis* are attached eleven pairs: the Longus colli, Levator anguli scapulæ, Splenius colli, Scalenus medius, Transversalis colli, Intertransversales, Obliquus capitis inferior, Rectus capitis posticus major, Semispinalis colli, Multifidus spinæ, Interspinales.

To the remaining vertebræ, generally, are attached thirty-five pairs and a single muscle: *anteriorly*, the Rectus capitis anticus major, Longus colli, Scalenus anticus medius and posticus, Psoas magnus and parvus, Quadratus lumborum, Diaphragm, Obliquus abdominis internus, and Transversalis abdominis—*posteriorly*, the Trapezius, Latissimus dorsi, Levator anguli scapulæ, Rhomboideus major and minor, Serratus posticus superior and inferior, Splenius, Erector spinæ, Ilio-costalis, Longissimus dorsi, Spinalis dorsi, Cervicalis ascendens, Transversalis colli, Trachelo-mastoid, Complexus, Biventer cervicis, Semispinalis dorsi and colli, Multifidus spinæ, Rotatores spinæ, Interspinales, Supraspinales, Intertransversales, Levatores costarum.

[1] See Cunningham, *Journ. Anat.*, vol. xx. p. 238.

Sacral and Coccygeal Vertebræ.

The **Sacral** and **Coccygeal Vertebræ** consist, at an early period of life, of nine separate pieces, which are united in the adult so as to form two bones, five entering into the formation of the sacrum, four into that of the coccyx. Occasionally, the coccyx consists of five bones.[1]

The **Sacrum** (sacer, sacred) is a large, triangular bone (Fig. 122), situated at the lower part of the vertebral column, and at the upper and back part of the pelvic

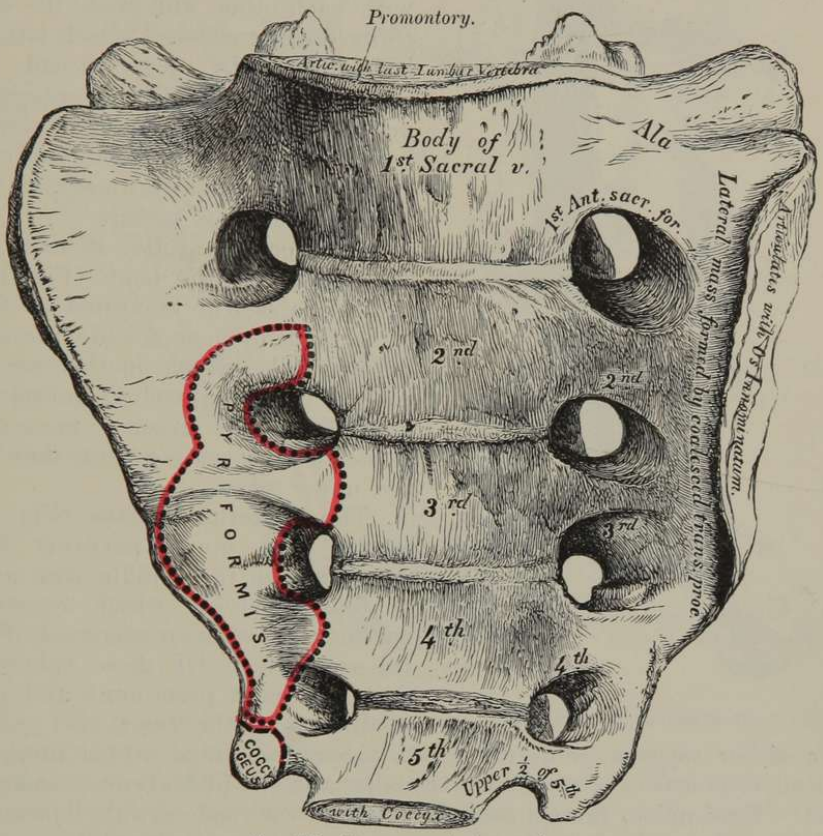

FIG. 122.—Sacrum, anterior surface.

cavity, where it is inserted like a wedge between the two innominate bones; its upper part or base articulating with the last lumbar vertebræ, its apex with the coccyx. The sacrum is curved upon itself, and placed very obliquely, its upper extremity projecting forward, and forming, with the last lumbar vertebra, a very prominent angle, called the *promontory* or *sacro-vertebral angle;* whilst its central part is directed backward, so as to give increased capacity to the pelvic cavity. It presents for examination an anterior and posterior surface, two lateral surfaces, a base, an apex, and a central canal.

The **Anterior Surface** is concave from above downward, and slightly so from side to side. In the middle are seen four transverse ridges, indicating the original division of the bone into five separate pieces. The portions of bone intervening between the ridges correspond to the bodies of the vertebræ. The body of the first segment is of large size, and in form resembles that of a lumbar vertebra; the succeeding ones diminish in size from above downward, are flattened from before backward, and curved so as to accommodate themselves to the form of the sacrum, being concave in front, convex behind. At each end of the ridges above mentioned are seen the *anterior sacral foramina*, analogous to the intervertebral foramina,

[1] Sir George Humphry describes this as the usual composition of the coccyx.—*On the Skeleton*, p. 456.

four in number on each side, somewhat rounded in form, diminishing in size from above downward, and directed outward and forward; they transmit the anterior branches of the sacral nerves. External to these foramina is the *lateral mass*, consisting at an early period of life of separate segments; these become blended, in the adult, with the bodies, with each other, and with the posterior transverse processes. Each lateral mass is traversed by four broad, shallow grooves, which lodge the anterior sacral nerves as they pass outward, the grooves being separated by prominent ridges of bone, which give attachment to the slips of the Pyriformis muscle.

FIG. 123.—Vertical section of the sacrum.

If a vertical section is made through the centre of the bone (Fig. 123), the bodies are seen to be united at their circumference by bone, a wide interval being left centrally, which, in the recent state, is filled by intervertebral substance. In some bones this union is more complete between the lower segments than between the upper ones.

The **Posterior Surface** (Fig. 124) is convex and much narrower than the anterior. In the middle line are three or four tubercles, which represent the rudimentary spinous processes of the sacral vertebræ. Of these tubercles, the first is usually prominent, and perfectly distinct from the rest; the second and third are either separate or united into a tubercular ridge, which diminishes in size from above downward; the fourth usually, and the fifth always, remaining undeveloped. External to the spinous processes on each side are the *laminæ*, broad and well marked in the first three pieces; sometimes the fourth, and generally the fifth, being undeveloped: in this situation the lower end of the sacral canal is exposed, and is liable to be opened in the sloughing of bed-sores. External to the laminæ is a linear series of indistinct tubercles representing the *articular processes;* the upper pair are large, well developed, and correspond in shape and direction to the superior articulating processes of a lumbar vertebra; the second and third are small; the fourth and fifth (usually blended together) are situated on each side of the sacral canal: they are called the *sacral cornua*, and articulate with the cornua of the coccyx. External to the articular processes are the four *posterior sacral foramina;* they are smaller in size and less regular in form than the anterior, and transmit the posterior branches of the sacral nerves. On the outer side of the posterior sacral foramina is a series of tubercles, the rudimentary *transverse processes* of the sacral vertebræ. The first pair of transverse tubercles are large, very distinct, and correspond with each *superior lateral angle* of the bone; the second, small in size, enter into the formation of the sacro-iliac articulation; the third give attachment to the oblique fasciculi of the posterior sacro-iliac ligaments; and the fourth and fifth to the great sacro-sciatic ligaments. The interspace between the spinous and transverse processes on the back of the sacrum presents a wide, shallow concavity, called the *sacral groove:* it is continuous above with the vertebral groove, and lodges the origin of the Erector spinæ.

The **Lateral Surface,** broad above, becomes narrowed into a thin edge below. Its upper half presents in front a broad, ear-shaped surface for articulation with

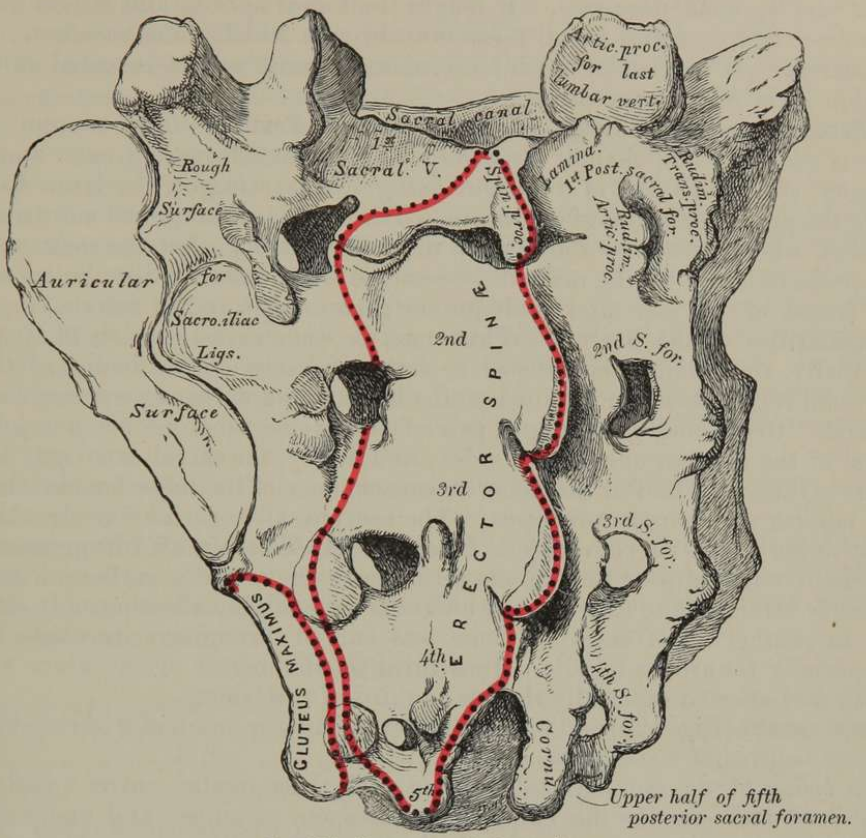

FIG. 124.—Sacrum, posterior surface.

the ilium. This is called the *auricular* surface, and in the fresh state is coated with fibro-cartilage. It is bounded posteriorly by deep and uneven impressions, for the attachment of the posterior sacro-iliac ligaments. The lower half is thin and sharp, and ends in a prominence, the *inferior lateral angle;* the border gives attachment to the greater and lesser sacro-sciatic ligaments, and to some fibres of the Gluteus maximus; below the *angle* is a deep notch, which is converted into a foramen by the transverse process of the upper piece of the coccyx, and transmits the anterior division of the fifth sacral nerve.

The **Base** of the sacrum, which is broad and expanded, is directed upward and forward. In the middle is seen a large oval articular surface, which is connected with the under surface of the body of the last lumbar vertebra by a fibre-cartilaginous disk. It is bounded behind by the large, triangular orifice of the sacral canal. The orifice is formed behind by the laminæ and spinous process of the first sacral vertebra: the superior articular processes project from it on each side; they are oval, concave, directed backward and inward, like the superior articular processes of a lumbar vertebra; and in front of each articular process is an intervertebral notch, which forms the lower half of the last intervertebral foramen. Lastly, on each side of the large oval articular surface is a broad and flat triangular surface of bone, which extends outward, supports the Psoas magnus muscle and lumbo-sacral cord, and is continuous on each side with the iliac fossa. This is called the *ala* of the sacrum, and gives attachment to a few of the fibres of the Iliacus muscle.

The **Apex,** directed downward and forward, presents a small, oval, concave surface for articulation with the coccyx.

The **Spinal Canal** runs throughout the greater part of the bone; it is large

and triangular in form above, small and flattened, from before backward, below. In this situation its posterior wall is incomplete, from the non-development of the laminæ and spinous processes. It lodges the sacral nerves, and is perforated by the anterior and posterior sacral foramina, through which these pass out.

Structure.—It consists of much loose, spongy tissue within, invested externally by a thin layer of compact tissue.

Differences in the Sacrum of the Male and Female.—The sacrum in the female is usually wider than in the male; the lower half forms a greater angle with the upper, the upper half of the bone being nearly straight, the lower half presenting the greatest amount of curvature. The bone is also directed more obliquely backward, which increases the size of the pelvic cavity; but the sacro-vertebral angle projects less. In the male the curvature is more evenly distributed over the whole length of the bone, and is altogether greater than in the female.

Peculiarities of the Sacrum.—This bone, in some cases, consists of six pieces; occasionally, the number is reduced to four. Sometimes the bodies of the first and second segments are not joined or the laminæ and spinous processes have not coalesced. Occasionally the upper pair of transverse tubercles are not joined to the rest of the bone on one or both sides; and, lastly, the sacral canal may be open for nearly the lower half of the bone, in consequence of the imperfect development of the laminæ and spinous processes. The sacrum, also, varies considerably with respect to its degree of curvature. From the examination of a large number of skeletons it would appear that in one set of cases the anterior surface of this bone was nearly straight, the curvature, which was very slight, affecting only its lower end. In another set of cases the bone was curved throughout its whole length, but especially toward its middle. In a third set the degree of curvature was less marked, and affected especially the lower third of the bone.

Development (Fig. 125).—The sacrum, formed by the union of five vertebræ, has *thirty-five* centres of ossification.

The *bodies* of the sacral vertebræ have each three ossific centres: one for the central part, and one for the epiphysial plates on its upper and under surface. Occasionally the primary centres for the bodies of the first and second piece of the sacrum are double.

The arch of each sacral vertebra is developed by two centres, one for each lamina. These unite with each other behind, and subsequently join the body.

The *lateral masses* have six additional centres, two for each of the first three vertebræ. These centres make their appearance above and to the outer side of the anterior sacral foramina (Fig. 125), and are developed into separate segments

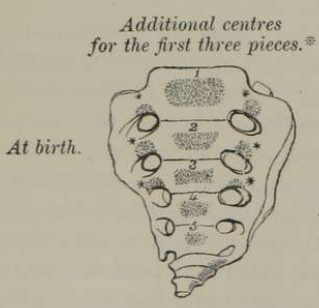

Fig. 125.—Development of the sacrum.

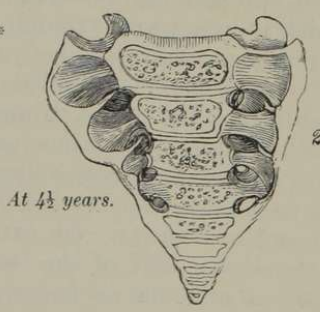

Fig. 126.

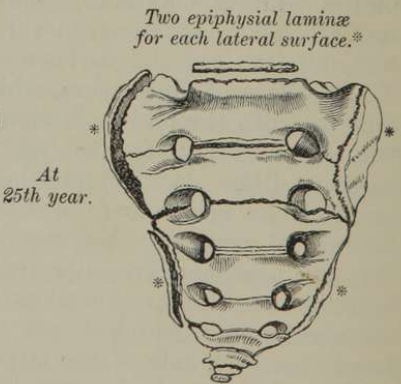

Fig. 127.

(Fig. 126); they are subsequently blended with each other, and with the bodies and transverse processes to form the lateral mass.

Lastly, each *lateral surface* of the sacrum is developed by two epiphysial plates (Fig. 127): one for the auricular surface, and one for the remaining part of the thin lateral edge of the bone.

Period of Development.—At about the eighth or ninth week of fœtal life ossification of the central part of the bodies of the first three vertebræ commences, and at a somewhat later period that of the last two. Between the sixth and eighth months ossification of the laminæ takes place; and at about the same period the characteristic osseous tubercles for the first three sacral vertebræ make their appearance. The period at which the arch becomes completed by the junction of the laminæ with the bodies in front and with each other behind varies in different segments. The junction between the laminæ and the bodies takes place first in the lower vertebræ as early as the second year, but is not effected in the uppermost until the fifth or sixth year. About the sixteenth year the epiphyses for the upper and under surfaces of the bodies are formed, and between the eighteenth and twentieth years those for each lateral surface of the sacrum make their appearance. The bodies of the sacral vertebræ are, during early life, separated from each other by intervertebral disks. But about the eighteenth year the two lowest segments become joined together by ossification extending through the disk. This process gradually extends upward until all the segments become united, and the bone is completely formed from the twenty-fifth to the thirtieth year of life.

Articulations.—With four bones: the last lumbar vertebra, coccyx, and the two ossa innominata.

Attachment of Muscles.—To eight pairs: in front, the Pyriformis and Coccygeus, and a portion of the Iliacus to the base of the bone; behind, the Gluteus maximus, Latissimus dorsi, Multifidus spinæ, and Erector spinæ, and sometimes the Extensor coccygis.

The Coccyx.

The **Coccyx** (*κόκκυξ*, cuckoo), so called from having been compared to a cuckoo's beak (Fig. 128), is usually formed of four small segments of bone, the most rudimentary parts of the vertebral column. In each of the first three segments may be traced a rudimentary body, articular and transverse processes; the last piece (sometimes the third) is a mere nodule of bone, without distinct processes. All the segments are destitute of pedicles, laminæ, and spinous processes, and, consequently, of intervertebral foramina and spinal canal. The first segment is the largest: it resembles the lowermost sacral vertebra, and often exists as a separate piece; the last three, diminishing in size from above downward, are usually blended together so as to form a single bone. The gradual diminution in the size of the pieces gives this bone a triangular form, the base of the triangle joining the end of the sacrum. It presents for examination an anterior and posterior surface, two borders, a base, and an apex. The *anterior surface* is slightly concave, and marked with three transverse grooves, indicating the points of junction of the different pieces. It has attached to it the anterior sacro-coccygeal ligament and Levator ani muscle, and supports the lower end of the rectum. The *posterior surface* is convex, marked by transverse grooves similar to those on the anterior surface; and presents on each side a lineal row of tubercles, the rudimentary articular processes of the coccygeal vertebræ. Of these, the superior pair are large, and are called the *cornua of the coccyx;* they project upward, and articulate with the cornua of the sacrum, the junction between these two bones completing the fifth posterior sacral foramen for the transmission of the posterior division of the fifth sacral nerve. The *lateral borders* are thin, and present a

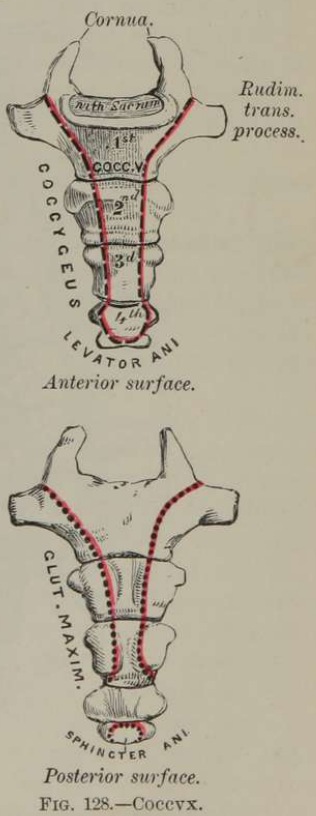

FIG. 128.—Coccyx.

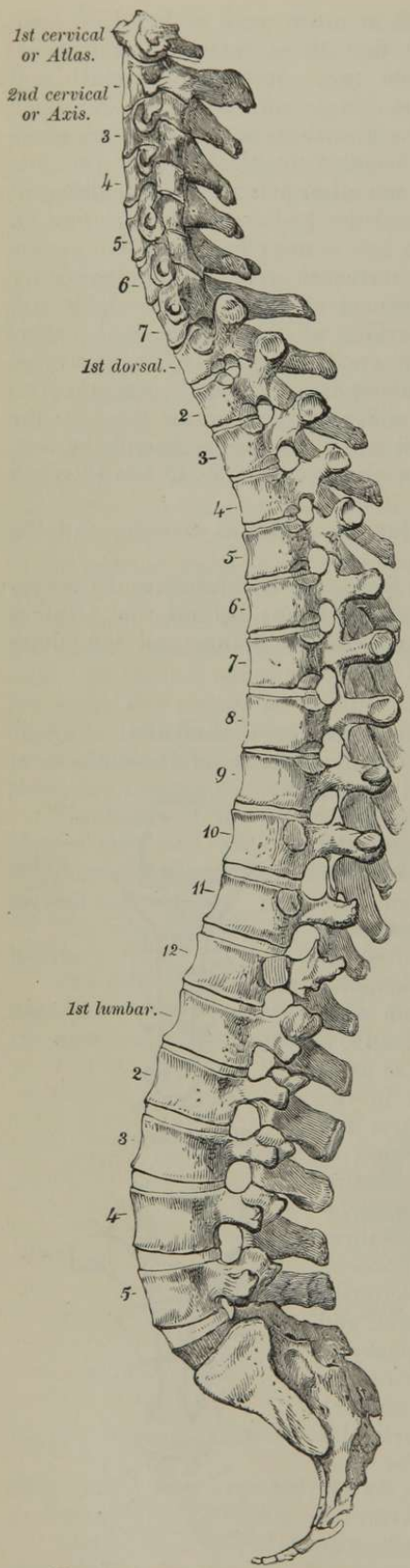

FIG. 129.—Lateral view of the spine.

series of small eminences, which represent the transverse processes of the coccygeal vertebræ. Of these, the first on each side is the largest, flattened from before backward, and often ascends to join the lower part of the thin lateral edge of the sacrum, thus completing the fifth anterior sacral foramen for the transmission of the anterior division of the fifth sacral nerve; the others diminish in size from above downward, and are often wanting. The *borders* of the coccyx are narrow, and give attachment on each side to the sacro-sciatic ligaments, to the Coccygeus muscle in front of the ligaments, and to the Gluteus maximus behind them. The *base* presents an oval surface for articulation with the sacrum. The *apex* is rounded, and has attached to it the tendon of the external Sphincter muscle. It is occasionally bifid, and sometimes deflected to one or other side.

Development.—The coccyx is developed by *four* centres, one for each piece. Occasionally one of the first three pieces of this bone is developed by two centres, placed side by side. The ossific nuclei make their appearance in the following order: in the first segment, at birth; in the second piece, at from five to ten years; in the third, from ten to fifteen years; in the fourth, from fifteen to twenty years. As age advances these various segments become united in the following order: the first two pieces join; then the third and fourth; and, lastly, the bone is completed by the union of the second and third. At a late period of life, especially in females, the coccyx often becomes joined to the end of the sacrum.

Articulation.—With the sacrum.

Attachment of Muscles.—To four pairs and one single muscle: on either side, the Coccygeus; behind, the Gluteus maximus and Extensor coccygis, when present; at the apex, the Sphincter ani; and in front, the Levator ani.

The Spine in General.

The **Spinal Column,** formed by the junction of the vertebræ, is situated in the median line, at the posterior part of the trunk; its average length is about two feet two or three inches, measuring along the curved anterior surface of the column. Of this length the cervical part measures about five, the dorsal about eleven, the lumbar about seven inches, and the sacrum and coccyx the remainder. The female spine is about one inch less than the male.

Viewed in front, it presents two pyramids joined together at their bases, the upper one being formed by all the vertebræ from the second cervical to the last lumbar, the lower one by the sacrum and coccyx. When examined more closely, the upper pyramid is seen to be formed of three smaller pyramids. The uppermost of these consists of the six lower cervical vertebræ, its apex being formed by the axis or second cervical, its base by the first dorsal. The second pyramid, which is inverted, is formed by the four upper dorsal vertebræ, the base being at the first dorsal, the smaller end at the fourth. The third pyramid commences at the fourth dorsal, and gradually increases in size to the fifth lumbar.

Viewed laterally (Fig. 129), the spinal column presents several curves, which correspond to the different regions of the column, and are called *cervical*, *dorsal*, *lumbar*, and *pelvic*. The *cervical* curve commences at the apex of the odontoid process, and terminates at the middle of the second dorsal vertebra; it is convex in front, and is the least marked of all the curves. The *dorsal* curve, which is concave forward, commences at the middle of the second, and terminates at the middle of the twelfth dorsal. Its most prominent point behind corresponds to the spine of the seventh dorsal vertebra. The *lumbar* curve commences at the middle of the last dorsal vertebra, and terminates at the sacro-vertebral angle. It is convex anteriorly; the convexity of the lower three vertebræ being much greater than that of the upper ones. The *pelvic* curve commences at the sacro-vertebral articulation and terminates at the point of the coccyx. It is concave anteriorly. The dorsal and pelvic curves are the primary curves, and begin to be formed at an early period of fœtal life, and are due to the shape of the bodies of the vertebræ. The cervical and lumbar curves are compensatory or secondary, and are developed after birth in order to maintain the erect position. They are due mainly to the shape of the intervertebral disks.

The spine has also a slight lateral curvature, the convexity of which is directed toward the right side. This is most probably produced, as Bichat first explained, chiefly by muscular action, most persons using the right arm in preference to the left, especially in making long-continued efforts, when the body is curved to the right side. In support of this explanation it has been found by Béclard that in one or two individuals who were left-handed the lateral curvature was directed to the left side.

The spinal column presents for examination an anterior, a posterior, and two lateral surfaces; a base, summit, and spinal canal.

The **anterior surface** presents the bodies of the vertebræ separated in the recent state by the intervertebral disks. The bodies are broad in the cervical region, narrow in the upper part of the dorsal, and broadest in the lumbar region. The whole of this surface is convex transversely, concave from above downward in the dorsal region, and convex in the same direction in the cervical and lumbar regions.

The **posterior surface** presents in the median line the spinous processes. These are short, horizontal, with bifid extremities, in the cervical region. In the dorsal region they are directed obliquely above, assume almost a vertical direction in the middle, and are horizontal below, as are also the spines of the lumbar vertebræ. They are separated by considerable intervals in the loins, by narrower intervals in the neck, and are closely approximated in the middle of the dorsal region. Occasionally one of these processes deviates a little from the median line—a fact to be remembered in practice, as irregularities of this sort are attendant also on fractures or displacements of the spine. On either side of the spinous processes, extending the whole length of the column, is the vertebral groove formed by the laminæ in the cervical and lumbar regions, where it is shallow, and by the laminæ and transverse processes in the dorsal region, where it is deep and broad. In the recent state these grooves lodge the deep muscles of the back. External to the vertebral grooves are the articular processes, and still more externally the transverse process. In the dorsal region the latter processes stand backward, on

a plane considerably posterior to the same processes in the cervical and lumbar regions. In the cervical region the transverse processes are placed in front of the articular processes, and on the outer side of the pedicles, between the intervertebral foramina. In the dorsal region they are posterior to the pedicles, intervertebral foramina, and articular processes. In the lumbar they are placed also in front of the articular processes, but behind the intervertebral foramina.

The **lateral surfaces** are separated from the posterior by the articular processes in the cervical and lumbar regions, and by the transverse processes in the dorsal. These surfaces present in front the sides of the bodies of the vertebræ, marked in the dorsal region by the facets for articulation with the heads of the ribs. More posteriorly are the intervertebral foramina, formed by the juxtaposition of the intervertebral notches, oval in shape, smallest in the cervical and upper part of the dorsal regions, and gradually increasing in size to the last lumbar. They are situated between the transverse processes in the neck, and in front of them in the back and loins, and transmit the spinal nerves.

The **base** of that portion of the vertebral column formed by the twenty-four movable vertebræ is formed by the under surface of the body of the fifth lumbar vertebra; and the **summit** by the upper surface of the atlas.

The **vertebral** or **spinal canal** follows the different curves of the spine; it is largest in those regions in which the spine enjoys the greatest freedom of movement, as in the neck and loins, where it is wide and triangular; and narrow and rounded in the back, where motion is more limited.

Surface Form.—The only part of the vertebral column which lies closely under the skin, and so directly influences surface form, is the apices of the spinous processes. These are always distinguishable at the bottom of a median furrow, which, more or less evident, runs down the mesial line of the back from the external occipital protuberance above to the middle of the sacrum below. In the neck the furrow is broad, and terminates below in a conspicuous projection, which is caused by the spinous process of the seventh cervical vertebra (vertebra prominens). Above this the spinous process of the sixth cervical vertebra may sometimes be seen; the other cervical spines are sunken, and are not visible, though the spine of the axis can be felt, and generally also the spines of the third, fourth, and fifth cervical vertebræ. In the dorsal region the furrow is shallow, and during stooping disappears, and then the spinous processes become more or less visible. The markings produced by these spines are small and close together. In the lumbar region the furrow is deep, and the situation of the lumbar spines is frequently indicated by little pits or depressions, especially if the muscles in the loins are well developed and the spine incurved. They are much larger and farther apart than in the dorsal region. In the sacral region the furrow is shallower, presenting a flattened area which terminates below at the most prominent part of the posterior surface of the sacrum, formed by the spinous process of the third sacral vertebra. At the bottom of the furrow may be felt the irregular posterior surface of the bone. Below this, in the deep groove leading to the anus, the coccyx may be felt. The only other portions of the vertebral column which can be felt from the surface are the transverse processes of three of the cervical vertebræ—viz. the first, the sixth, and the seventh. The transverse process of the atlas can be felt as a rounded nodule of bone just below and in front of the apex of the mastoid process, along the anterior border of the sterno-mastoid. The transverse process of the sixth cervical vertebra is of surgical importance. If deep pressure be made in the neck in the course of the carotid artery, opposite the cricoid cartilage, the prominent anterior tubercle of the transverse process of the sixth cervical vertebra can be felt. This has been named *Chassaignac's tubercle*, and against it the carotid artery may be most conveniently compressed by the finger. The transverse process of the seventh cervical vertebra can also often be felt. Occasionally the anterior root, or costal process, is large and segmented off, forming a cervical rib.

Surgical Anatomy.—Occasionally the coalescence of the laminæ is not completed, and consequently a cleft is left in the arches of the vertebræ, through which a protrusion of the spinal membranes (dura mater and arachnoid), and sometimes of the spinal cord itself, takes place, constituting the disease known as *spina bifida*. This disease is most common in the lumbo-sacral region, on account of the fact, previously stated, that the closure of the arches takes place gradually from above downward; but it may occur in the dorsal or cervical region, or the arches throughout the whole length of the canal may remain unapproximated. In some rare cases, in consequence of the non-coalescence of the two primary centres from which the body is formed, a similar condition may occur in front of the canal, the bodies of the vertebræ being found cleft and the tumor projecting into the thorax, abdomen, or pelvis, between the lateral halves of the bodies affected.

The construction of the spinal column of a number of pieces, securely connected together and enjoying only a slight degree of movement between any two individual pieces, though per-

mitting of a very considerable range of movement as a whole, allows a sufficient degree of mobility without any material diminution of strength. The many joints of which the spine is composed, together with the very varied movements to which it is subjected, render it liable to sprains; but so closely are the individual vertebræ articulated that these sprains are rarely or ever severe, and any amount of violence sufficiently great to produce tearing of the ligaments would tend rather to cause a dislocation or fracture. The further safety of the column and its less liability to injury is provided for by its disposition in curves, instead of in one straight line. For it is an elastic column, and must first bend before it breaks: under these circumstances, being made up of three curves, it represents three columns, and greater force is required to produce bending of a short column than of a longer one that is equal to it in breadth and material. Again, the safety of the column is provided for by the interposition of the intervertebral disk between the bodies of the vertebræ, which act as admirable buffers in counteracting the effects of violent jars or shocks. Fracture-dislocation of the spine may be caused by direct or indirect violence, or by a combination of the two, as when a person, falling from a height, strikes against some prominence and is doubled over it. The fractures from indirect violence are the more common, and here the bodies of the vertebræ are compressed, whilst the arches are torn asunder; whilst in fractures from direct violence the arches are compressed and the bodies of the vertebræ separated from each other. It will therefore be seen that in both classes of injury the spinal marrow is the part least likely to be injured, and may escape damage even where there has been considerable lesion of the bony framework. For, as Mr. Jacobson states, "being lodged in the centre of the column, it occupies neutral ground in respect to forces which might cause fracture. For it is a law in mechanics that when a beam, as of timber, is exposed to breakage and the force does not exceed the limits of the strength of the material, one division resists compression, another laceration of the particles, while the third, between the two, is in a negative condition."[1] Applying this principle to the spine, it will be seen that, whether the fracture-dislocation be produced by direct violence or indirect, one segment, either the anterior or posterior, will be exposed to compression, the other to laceration, and the intermediate part, where the cord is situated, will be in a neutral state. When a fracture-dislocation is produced by indirect violence the displacement is almost always the same, the upper segment being driven forward on the lower, so that the cord is compressed between the body of the vertebra below and the arch of the vertebra above.

The parts of the spine most liable to be injured are (1) the dorsi-lumbar region, for this part is near the middle of the column, and there is therefore a greater amount of leverage, and moreover the portion above is comparatively fixed, and the vertebræ which form it, though much smaller, have nevertheless to bear almost as great a weight as those below; (2) the cervico-dorsal region, because here the flexible cervical portion of the spine joins the more fixed dorsal region; and (3) the alto-axoid region, because it enjoys an extensive range of movement, and, being near the skull, is influenced by violence applied to the head. In fracture-dislocation it has been proposed to trephine the spine and remove portions of the laminæ and spinous processes. The operation can only be of use when the paralysis is due to the pressure of bone or the effusion of blood, and not to cases, which are by far the most common, where the cord is crushed to a pulp. And even in those cases where the cord is compressed by bone the portion of displaced bone which presses on the cord is generally the body of the vertebra below, and is therefore inaccessible to operation. The operative proceeding is one of great severity, involving an extensive and deep wound and great risk of septic meningitis, and, as the advantages to be derived from it are exceedingly problematical and confined to a very few cases, it is not often resorted to. Trephining has also been resorted to in some cases of paraplegia due to Pott's disease of the spine. Here the paralysis is due to the pressure of inflammatory products, and where this is new scar-tissue, formed by the organization of granulation tissue, its removal has been attended with a very considerable amount of success.

THE SKULL.

The **Skull**, or superior expansion of the vertebral column, has been described as if composed of four vertebræ, the elementary parts of which are specially modified in form and size, and almost immovably connected, for the reception of the brain and special organs of the senses. These vertebræ are the occipital, parietal, frontal, and nasal. Descriptive anatomists, however, divide the skull into two parts, the Cranium and the Face. The Cranium (*κράνος*, a helmet) is composed of *eight* bones—viz. the *occipital*, two *parietal*, *frontal*, two *temporal*, *sphenoid*, and *ethmoid*. The Face is composed of *fourteen* bones—viz. the two *nasal*, two *superior maxillary*, two *lachrymal*, two *malar*, two *palate*, two *inferior turbinated*, *vomer*, and *inferior maxillary*. The *ossiculi auditûs*, the *teeth*, and *Wormian bones* are not included in this enumeration.

[1] Holmes's *System of Surgery*, vol. i. p. 529, 1883.

- *Skull*, 22 *bones*
  - *Cranium*, 8 *bones*.
    - Occipital.
    - Two Parietal.
    - Frontal.
    - Two Temporal.
    - Sphenoid.
    - Ethmoid.
  - *Face*, 14 *bones*
    - Two Nasal.
    - Two Superior Maxillary.
    - Two Lachrymal.
    - Two Malar.
    - Two Palate.
    - Two Inferior Turbinated.
    - Vomer.
    - Inferior Maxillary.

THE CRANIUM.

The Occipital Bone.

The **Occipital Bone** (*ob*, *caput*, against the head) is situated at the back part

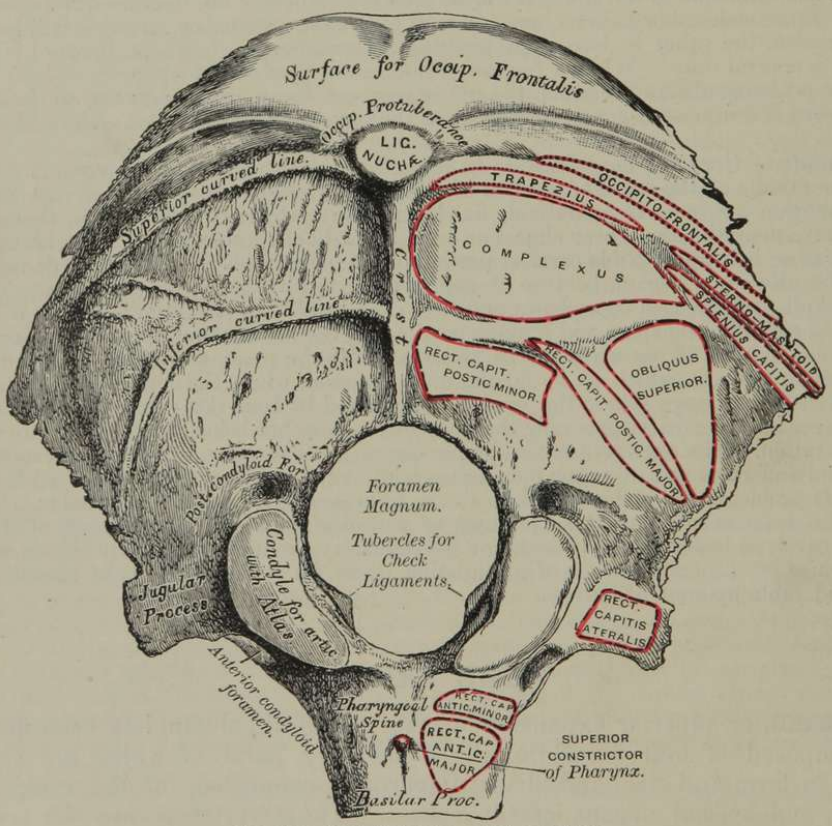

FIG. 130.—Occipital bone. Outer surface.

and base of the cranium, is trapezoid in form (Fig. 130), curved upon itself, and presents for examination two surfaces, four borders, and four angles.

The **external surface** is convex. Midway between the summit of the bone and the posterior margin of the foramen magnum is a prominent tubercle, the *external occipital protuberance*, for the attachment of the Ligamentum nuchæ; and, descending from it as far as the foramen, a vertical ridge, the *external occipital crest*. This tubercle and crest vary in prominence in different skulls. Passing outward from the occipital protuberance is a semicircular ridge on each side, the

superior curved line. Above this line there is often a second less distinctly marked ridge, called the *highest curved line* (*linea suprema*); to it the epicranial aponeurosis is attached. The bone between these two lines is smoother and denser than the rest of the surface. Running parallel with these from the middle of the crest is another semicircular ridge on each side, the *inferior curved lines*. The surface of the bone above the superior curved lines is rough and porous, and in the recent state is covered by the Occipito-frontalis muscle, while the ridges, as well as the surface of the bone between them, serve for the attachment of numerous muscles. The superior curved line gives attachment internally to the Trapezius, externally to the muscular origin of the Occipito-frontalis, and to the Sterno-cleido-mastoid to the extent shown in Fig. 130; the depressions between the curved lines to the Complexus internally, the Splenius capitis and Obliquus capitis superior externally. The inferior curved line and the depressions below it afford insertion to the Rectus capitis posticus, major and minor.

The **foramen magnum** is a large, oval aperture, its long diameter extending from before backward. It transmits the medulla oblongata and its membranes, the spinal accessory nerves, the vertebral arteries, the anterior and posterior spinal arteries, and the occipito-axial ligaments. Its back part is wide for the transmission of the medulla, and the corresponding margin rough for the attachment of the dura-mater enclosing it; the fore part is narrower, being encroached upon by the condyles; it has projecting toward it, from below, the odontoid process, and its margins are smooth and bevelled internally to support the medulla oblongata. On each side of the foramen magnum are the *condyles*, for articulation with the atlas; they are convex, oblong, or reniform in shape, and directed downward and outward; they converge in front, and encroach slightly upon the anterior segment of the foramen. On the inner border of each condyle is a rough tubercle for the attachment of the ligaments (*check*) which connect this bone with the odontoid process of the axis; whilst external to them is a rough tubercular prominence, the *transverse* or *jugular process* (the representative of the transverse process of a vertebra), channelled in front by a deep notch, which forms part of the jugular foramen or foramen lacerum posterius. The under surface of this process presents an eminence which represents the *paramastoid process* of some mammals. The eminence is occasionally large, and extends as low as the transverse process of the atlas. This surface affords attachment to the Rectus capitis lateralis muscle and to the lateral occipito-atlantal ligament; its upper or cerebral surface presents a deep groove which lodges part of the lateral sinus, whilst its external surface is marked by a quadrilateral rough facet, covered with cartilage in the fresh state, and articulating with a similar surface on the petrous portion of the temporal bone. On the outer side of each condyle, near its fore part, is a foramen, the *anterior condyloid*; it is directed downward, outward, and forward, and transmits the hypoglossal nerve, and occasionally a meningeal branch of the ascending pharyngeal artery. This foramen is sometimes double. Behind each condyle is a fossa,[1] sometimes perforated at the bottom by a foramen, the *posterior condyloid*, for the transmission of a vein to the lateral sinus. In front of the foramen magnum is a strong quadrilateral plate of bone, the *basilar process*, wider behind than in front; its under surface, which is rough, presenting in the median line a tubercular ridge, the *pharyngeal spine*, for the attachment of the tendinous raphe and Superior constrictor of the pharynx; and on each side of it rough depressions for the attachment of the Rectus capitis anticus, major and minor.

The **Internal** or **Cerebral Surface** (Fig. 131) is deeply concave. The posterior or occipital part is divided by a crucial ridge into four fossæ. The two superior fossæ receive the occipital lobes of the cerebrum, and present slight eminences and depressions corresponding to their convolutions. The two inferior, which receive the hemispheres of the cerebellum, are larger than the former, and com-

[1] This fossa presents many variations in size. It is usually shallow, and the foramen small; occasionally wanting on one or both sides. Sometimes both fossa and foramen are large, but confined to one side only; more rarely, the fossa and foramen are very large on both sides.

paratively smooth; both are marked by slight grooves for the lodgment of arteries. At the point of meeting of the four divisions of the crucial ridge is an eminence, the *internal occipital protuberance*. It nearly corresponds to that on the outer surface, and is perforated by one or more large vascular foramina. From this eminence the superior division of the crucial ridge runs upward to the superior angle of the bone; it presents a deep groove for the superior longitudinal sinus, the margins of which give attachment to the falx cerebri. The inferior division, the *internal occipital crest*, runs to the posterior margin of the foramen magnum,

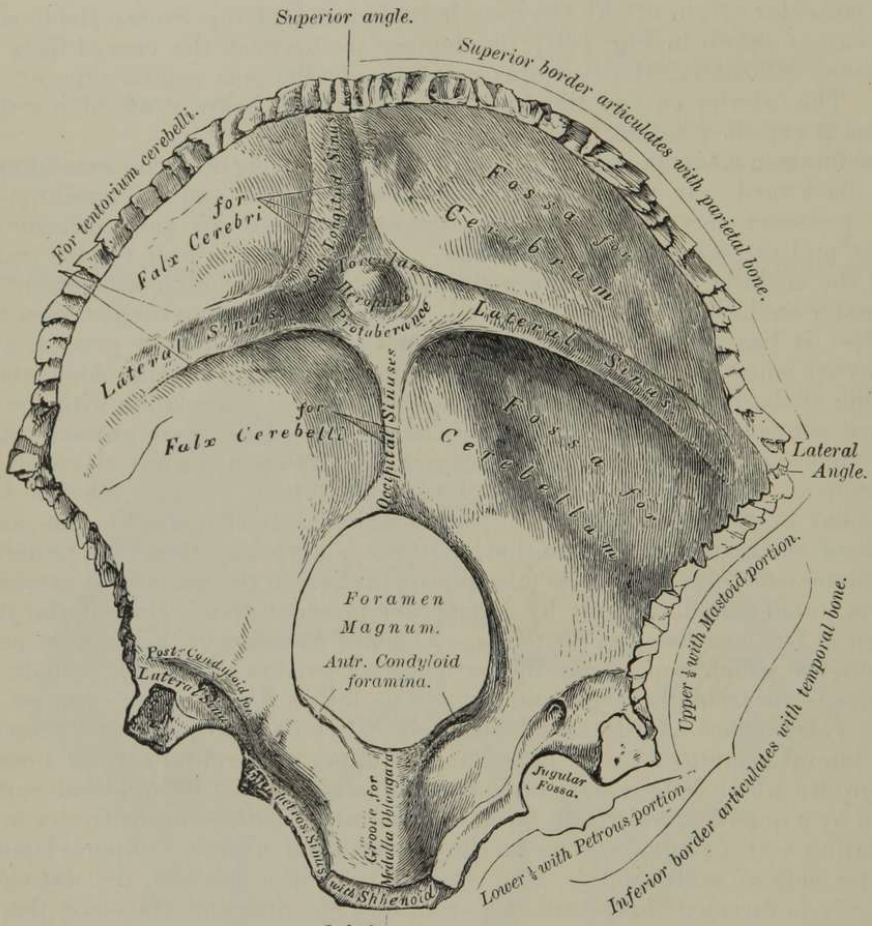

FIG. 131.—Occipital bone. Inner surface

on the edge of which it becomes gradually lost; this ridge, which is bifurcated below, serves for the attachment of the falx cerebelli. It is usually marked by a single groove, which commences at the back part of the foramen magnum and lodges the occipital sinus. Occasionally the groove is double where two sinuses exist. The transverse grooves pass outward to the lateral angles; they are deeply channelled, for the lodgment of the lateral sinuses, their prominent margins affording attachment to the tentorium cerebelli.[1] At the point of meeting of these grooves is a depression, the *torcular Herophili*,[2] placed a little to one or the other side of the internal occipital protuberance. More anteriorly is the foramen magnum, and on each side of it, but nearer its anterior than its posterior part, the

[1] Usually one of the transverse grooves is deeper and broader than the other; occasionally, both grooves are of equal depth and breadth, or both equally indistinct. The broader of the two transverse grooves is nearly always continuous with the vertical groove for the superior longitudinal sinus.

[2] The columns of blood coming in different directions were supposed to be *pressed* together at this point (*torcular*, a wine-press).

internal openings of the anterior condyloid foramina; the internal openings of the posterior condyloid foramina are a little external and posterior to them, protected by a small arch of bone. At this part of the internal surface there is a very deep groove in which the posterior condyloid foramen, when it exists, has its termination. This groove is continuous, in the complete skull, with the transverse groove on the posterior part of the bone, and lodges the end of the same sinus, the lateral. In front of the foramen magnum is the basilar process, presenting a shallow depression, the *basilar groove*, which slopes from behind, upward and forward, and supports the medulla oblongata and part of the pons Varolii, and on each side of the basilar process is a narrow channel, which, when united with a similar channel on the petrous portion of the temporal bone, forms a groove which lodges the inferior petrosal sinus.

Angles.—The *superior* angle is received into the interval between the posterior superior angles of the two parietal bones: it corresponds with that part of the skull in the fœtus which is called the *posterior fontanelle*. The *inferior* angle is represented by the square-shaped surface of the basilar process. At an early period of life a layer of cartilage separates this part of the bone from the sphenoid, but in the adult the union between them is osseous. The *lateral* angles correspond to the outer ends of the transverse grooves, and are received into the interval between the posterior inferior angles of the parietal and the mastoid portion of the temporal.

Borders.—The *superior* border extends on each side from the superior to the lateral angle, is deeply serrated for articulation with the parietal bone, and forms, by this union, the lambdoid suture. The *inferior* border extends from the lateral to the inferior angle; its upper half is rough, and articulates with the mastoid portion of the temporal, forming the masto-occipital suture; the inferior half articulates with the petrous portion of the temporal, forming the petro-occipital suture; these two portions are separated from one another by the jugular process. In front of this process is a deep notch, which, with a similar one on the petrous portion of the temporal, forms the *foramen lacerum posterius* or *jugular foramen*. This notch is occasionally subdivided into two parts by a small process of bone, and it generally presents an aperture at its upper part, the internal opening of the posterior condyloid foramen.

Structure.—The occipital bone consists of two compact laminæ, called the *outer* and *inner tables*, having between them the diploic tissue; this bone is especially thick at the ridges, protuberances, condyles, and internal part of the basilar process; whilst at the bottom of the fossæ, especially the inferior, it is thin, semi-transparent, and destitute of diploë.

Development. (Fig. 132).—At birth the bone consists of four distinct parts: a *tabular* or expanded portion, which lies behind the foramen magnum; two *condylar* parts, which form the sides of the foramen; and a *basilar* part, which lies in front of the foramen. The number of nuclei for the tabular part vary. As a rule, there are four, but there may be only one (Blandin) or as many as eight (Meckel). They appear about the eighth week of fœtal life, and soon unite to form a single piece, which is, however, fissured in the direction indicated in the plate. The basilar and two condyloid portions are each developed from a single nucleus, which appears a little later. The upper portion of the tabular surface—that is to say, the portion above the transverse fissure—is developed from membrane; the rest of the bone is developed from cartilage.

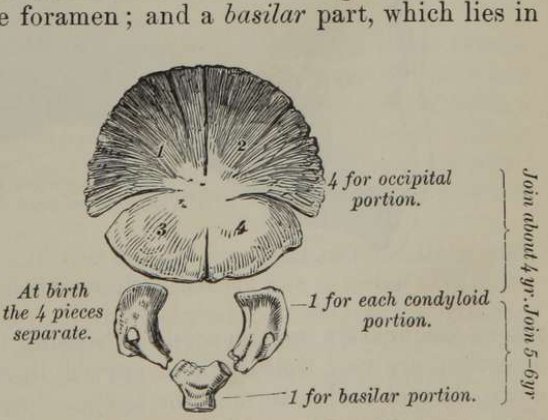

FIG. 132.—Development of occipital bone. By seven centres.

At about the fourth year the tabular and the two condyloid pieces join, and about the sixth year the bone consists of a single piece. At a later period, between the eighteenth and twenty-fifth years, the occipital and sphenoid become united, forming a single bone.

Articulations.—With six bones: two parietal, two temporal, sphenoid, and atlas.

Attachment of Muscles.—To twelve pairs: to the superior curved line are attached the Occipito-frontalis, Trapezius, and Sterno-cleido-mastoid. To the space between the curved lines, the Complexus,[1] Splenius capitis, and Obliquus capitis superior; to the inferior curved line, and the space between it and the foramen magnum, the Rectus capitis posticus, major and minor; to the transverse process, the Rectus capitis lateralis; and to the basilar process, the Rectus capitis anticus, major and minor, and Superior constrictor of the pharynx.

The Parietal Bones.

The **Parietal Bones** (*paries*, a wall) form, by their union, the sides and roof of the skull. Each bone is of an irregular quadrilateral form, and presents for examination two surfaces, four borders, and four angles.

Surfaces.—The *external surface* (Fig. 133) is convex, smooth, and marked about its centre by an eminence called the *parietal eminence*, which indicates the point

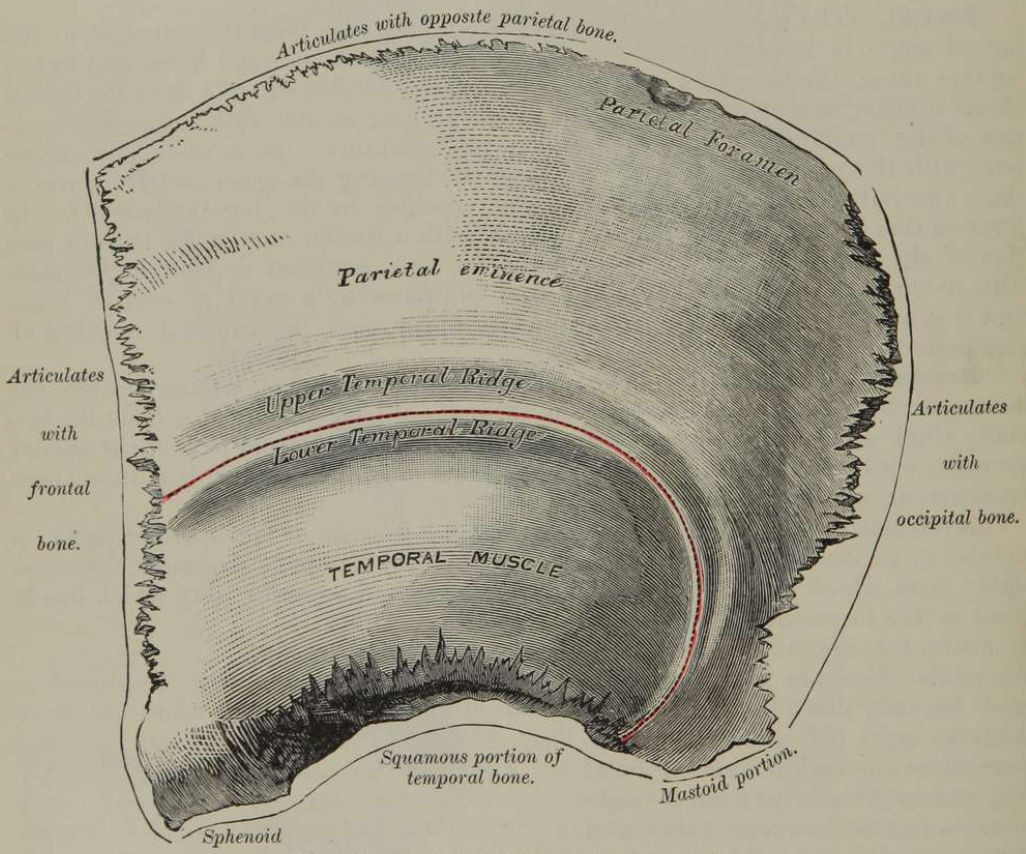

FIG. 133.—Left parietal bone. External surface.

where ossification commenced. Crossing the middle of the bone in an arched direction are two well-marked curved lines or ridges, of which the lower is the more distinct and is termed the *temporal ridge;* it marks the upper attachment of the temporal muscle and follows a semicircular course across the bone. The upper ridge is less marked, and pursues a similar course across the bone, but about two-

[1] To these the Biventer cervicis should be added, if it is regarded as a separate muscle.

fifths of an inch above the temporal ridge; it marks the attachment of the temporal fascia. Above these ridges the surface of the bone is rough and porous, and covered by the aponeurosis of the Occipito-frontalis; between them the bone is smoother and more polished than the rest; below them the bone forms part of the temporal fossa, and affords attachment to the temporal muscle. At the back part of the superior border, close to the sagittal suture, is a small foramen, the *parietal foramen*, which transmits a vein to the superior longitudinal sinus, and sometimes a small branch of the occipital artery. Its existence is not constant, and its size varies considerably.

The **internal surface** (Fig. 134), concave, presents eminences and depressions for lodging the convolutions of the cerebrum and numerous furrows for the ramifications of the meningeal arteries; the latter run upward and backward from the

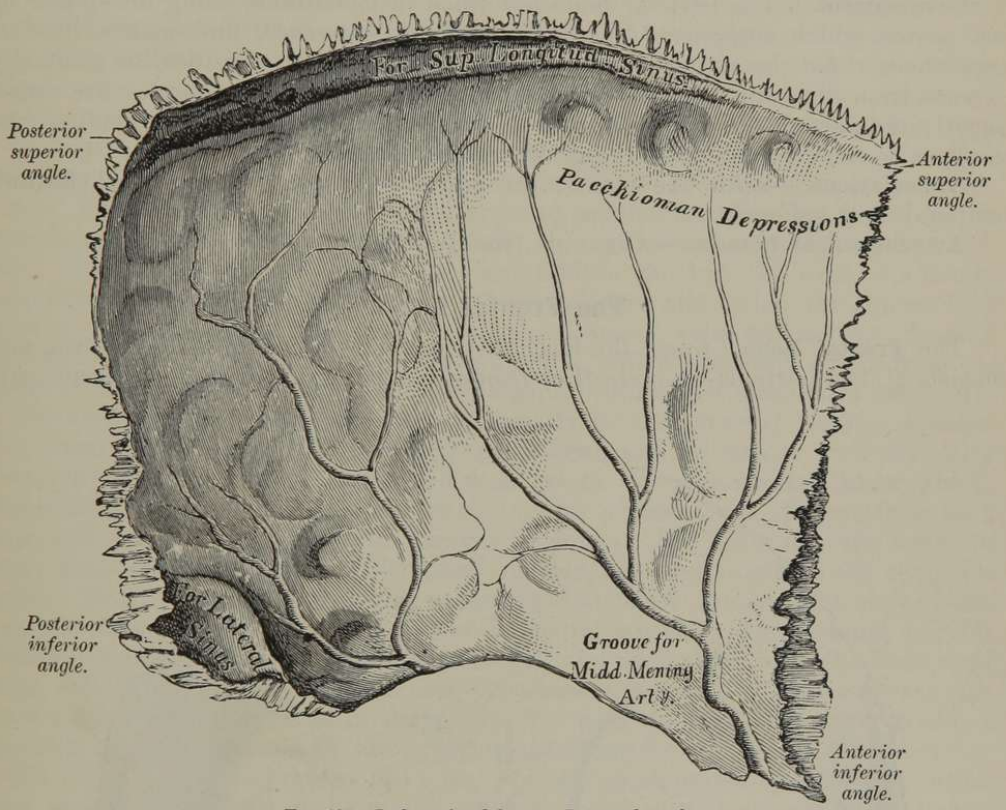

FIG. 134.—Left parietal bone. Internal surface.

anterior inferior angle and from the central and posterior part of the lower border of the bone. Along the upper margin is part of a shallow groove, which, when joined to the opposite parietal, forms a channel for the superior longitudinal sinus, the elevated edges of which afford attachment to the falx cerebri. Near the groove are seen several depressions, especially in the skulls of old persons; they lodge the Pacchionian bodies. The internal opening of the parietal foramen is also seen when that aperture exists.

Borders.—The *superior*, the longest and thickest, is dentated to articulate with its fellow of the opposite side, forming the sagittal suture. The *inferior* is divided into three parts: of these, the anterior is thin and pointed, bevelled at the expense of the outer surface, and overlapped by the tip of the great wing of the sphenoid; the middle portion is arched, bevelled at the expense of the outer surface, and overlapped by the squamous portion of the temporal; the posterior portion is thick and serrated for articulation with the mastoid portion of the temporal. The *anterior* border, deeply serrated, is bevelled at the expense of the outer surface above and of the inner below; it articulates with the frontal bone, forming the

coronal suture. The *posterior* border, deeply denticulated, articulates with the occipital, forming the *lambdoid suture*.

Angles.—The *anterior superior* angle, thin and pointed, corresponds with that portion of the skull which in the fœtus is membranous and is called the *anterior fontanelle*. The *anterior inferior* angle is thin and lengthened, being received in the interval between the great wing of the sphenoid and the frontal. Its inner surface is marked by a deep groove, sometimes a canal, for the anterior branch of the middle meningeal artery. The *posterior superior* angle corresponds with the junction of the sagittal and lambdoid sutures. In the fœtus this part of the skull is membranous, and is called the *posterior fontanelle*. The *posterior inferior* angle articulates with the mastoid portion of the temporal bone, and generally presents on its inner surface a broad, shallow groove for lodging part of the lateral sinus.

Development.—The parietal bone is formed in membrane, being developed by *one* centre, which corresponds with the parietal eminence, and makes its first appearance about the seventh or eighth week of fœtal life. Ossification gradually extends from the centre to the circumference of the bone: the angles are consequently the parts last formed, and it is in their situation that the fontanelles exist previous to the completion of the growth of the bone.

Articulations.—With five bones: the opposite parietal, the occipital, frontal, temporal, and sphenoid.

Attachment of Muscles.—One only, the Temporal.

The Frontal Bone.

The **Frontal Bone** (*frons*, the forehead) resembles a cockle-shell in form, and consists of two portions—a *vertical* or *frontal* portion situated at the anterior part

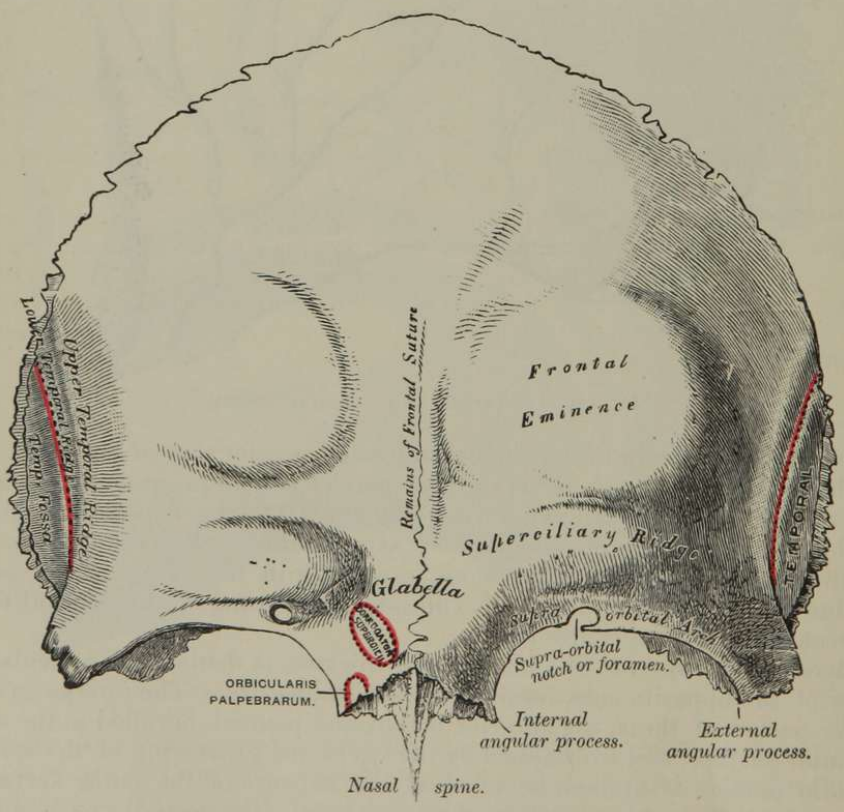

FIG. 135.—Frontal bone. Outer surface.

of the cranium, forming the forehead; and a *horizontal* or *orbito-nasal* portion which enters into the formation of the roof of the orbits and nasal fossæ.

Vertical Portion.—*External Surface* (Fig. 135).—In the median line, traversing the bone from the upper to the lower part, is occasionally seen a slightly-elevated ridge, and in young subjects a suture, which represents the line of union of the two lateral halves of which the bone consists at an early period of life; in the adult this suture is usually obliterated and the bone forms one piece; traces of the obliterated suture are, however, generally perceptible at the lower part. On either side of this ridge, a little below the centre of the bone, is a rounded eminence, the *frontal eminence*. These eminences vary in size in different individuals, and are occasionally unsymmetrical in the same subject. They are especially prominent in cases of well-marked cerebral development. The whole surface of the bone above this part is smooth, and covered by the aponeurosis of the Occipito-frontalis muscle. Below the frontal eminence, and separated from it by a slight groove, is the *superciliary ridge*, broad internally, where it is continuous with the nasal eminence, but less distinct as it arches outward. These ridges are caused by the projection outward of the frontal sinuses,[1] and give attachment to the Orbicularis palpebrarum and Corrugator supercilii. Between the two superciliary ridges is a smooth surface, the *glabella* or *nasal eminence*. Beneath the superciliary ridge is the *supraorbital arch*, a curved and prominent margin, which forms the upper boundary of the orbit, and separates the vertical from the horizontal portion of the bone. The outer part of the arch is sharp and prominent, affording to the eye, in that situation, considerable protection from injury; the inner part is less prominent. At the junction of the internal and middle third of this arch is a notch, sometimes converted into foramen by a bony process, and called the *supraorbital notch* or *foramen*. It transmits the supraorbital artery, vein, and nerve. A small aperture is seen in the upper part of the notch, which transmits a vein from the diploë to join the supraorbital vein. The supraorbital arch terminates externally in the *external angular process* and internally in the *internal angular process*. The external angular process is strong, prominent, and articulates with the malar bone; running upward and backward from it are two well-marked lines, which, commencing together from the external angular process, soon diverge from each other and run in a curved direction across the bone. The lower one, the *temporal ridge*, gives attachment to the Temporal muscle, the upper one to the temporal fascia. Beneath them is a slight concavity that forms the anterior part of the temporal fossa and gives origin to the Temporal muscle. The internal angular processes are less marked than the external, and articulate with the lachrymal bones. Between the internal angular processes is a rough, uneven interval, the *nasal notch*, which articulates in the middle line with the nasal bone, and on either side with the nasal process of the superior maxillary bone. From the concavity of this notch projects a process, the *nasal process*, which extends beneath the nasal bones and nasal processes of the superior maxillary bones and supports the bridge of the nose. On the under surface of this is a long pointed process, the *nasal spine*, and on either side a small grooved surface enters into the formation of the roof of the nasal fossa. The nasal spine forms part of the septum of the nose, articulating in front with the nasal bones and behind with the perpendicular plate of the ethmoid.

Internal Surface (Fig. 136).—Along the middle line is a vertical groove, the edges of which unite below to form a ridge, the *frontal crest;* the groove lodges the superior longitudinal sinus, whilst its margins afford attachment to the falx cerebri. The crest terminates below at a small notch which is converted into a foramen by articulation with the ethmoid. It is called the *foramen cæcum*, and varies in size in different subjects: it is sometimes partially or completely impervious, lodges a process of the falx cerebri, and when open transmits a vein

[1] Some confusion is occasioned to students commencing the study of anatomy by the name "sinuses" having been given to two perfectly different kinds of spaces connected with the skull. It may be as well, therefore, to state here, at the outset, that the "sinuses" in the interior of the cranium which produce the grooves on the inner surface of the bones are venous channels along which the blood runs in its passage back from the brain, while the "sinuses" external to the cranial cavity (the frontal, sphenoidal, ethmoidal, and maxillary) are hollow spaces in the bones themselves which communicate with the nostrils, and contain air.

from the lining membrane of the nose to the superior longitudinal sinus. On either side of the groove the bone is deeply concave, presenting eminences and depressions for the convolutions of the brain, and numerous small furrows for lodging the ramifications of the anterior meningeal arteries. Several small, irregular fossæ are also seen on either side of the groove, for the reception of the Pacchionian bodies.

Horizontal Portion.—*External Surface.*—This portion of the bone consists of two thin plates, which form the vault of the orbit, separated from one another by the ethmoidal notch. Each orbital vault consists of a smooth, concave, triangular plate of bone, marked at its anterior and external part (immediately beneath the

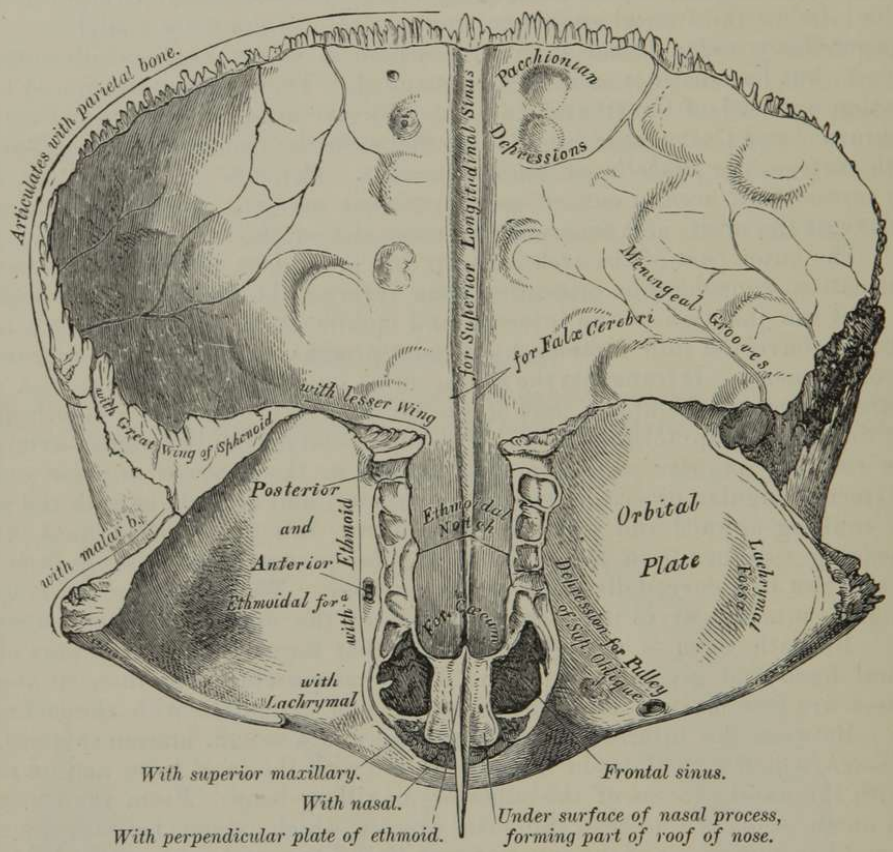

FIG. 136.—Frontal bone. Inner surface.

external angular process) by a shallow depression, the *lachrymal fossa*, for lodging the lachrymal gland; and at its anterior and internal part by a depression (sometimes a small tubercle) for the attachment of the cartilaginous pulley of the Superior oblique muscle of the eye. The ethmoidal notch separates the two orbital plates; it is quadrilateral, and filled up, when the bones are united, by the cribriform plate of the ethmoid. The margins of this notch present several half-cells, which, when united with corresponding half-cells on the upper surface of the ethmoid, complete the ethmoidal cells; two grooves are also seen crossing these edges transversely; they are converted into canals by articulation with the ethmoid, and are called the *anterior* and *posterior ethmoidal* canals: they open on the inner wall of the orbit. The anterior one transmits the nasal nerve and anterior ethmoidal vessels, the posterior one the posterior ethmoidal vessels. In front of the ethmoidal notch, on either side of the nasal spine, are the openings of the frontal sinuses. These are two irregular cavities, which extend upward and outward, a variable distance, between the two tables of the skull, and are separated from one another by a thin, bony septum. They give rise to the

prominences above the supraorbital arches called the *superciliary ridges*. In the child they are generally absent, and they become gradually developed as age advances. These cavities vary in size in different persons, are larger in men than in women, and are frequently of unequal size on the two sides, the right being commonly the larger. They are subdivided by a bony lamina, which is often displaced to one side. They are lined by mucous membrane, and communicate with the nose by the infundibulum, and occasionally with each other by apertures in their septum.

The **internal surface of the horizontal portion** presents the convex upper surfaces of the orbital plates, separated from each other in the middle line by the ethmoidal notch, and marked by eminences and depressions for the convolutions of the frontal lobes of the brain.

Borders.—The border of the vertical portion is thick, strongly serrated, bevelled at the expense of the internal table above, where it rests upon the parietal bones, and at the expense of the external table at each side, where it receives the lateral pressure of those bones; this border is continued below into a triangular rough surface which articulates with the great wing of the sphenoid. The border of the horizontal portion is thin, serrated, and articulates with the lesser wing of the sphenoid.

Structure.—The vertical portion and external angular processes are very thick, consisting of diploic tissue contained between two compact laminæ. The horizontal portion is thin, translucent, and composed entirely of compact tissue; hence the facility with which instruments can penetrate the cranium through this part of the orbit.

Development (Fig. 137).—The frontal bone is formed in membrane, being developed by *two* centres, one for each lateral half, which make their appearance about the seventh or eighth week, above the orbital arches. From this point ossification extends, in a radiating manner, upward into the forehead and backward over the orbit. At birth the bone consists of two pieces, which afterward become united, along the middle line, by a suture which runs from the vertex to the root of the nose. This suture usually becomes obliterated within a few years after birth; but it occasionally remains throughout life. Occasionally secondary centres of ossification appear for the nasal spine—one on either side at the internal angular process where it articulates with the lachrymal bone; and sometimes there is one on either side at the lower end of the coronal suture. This latter centre sometimes remains ununited, and is known as the pterion ossicle, or it may join with the parietal, sphenoid, or temporal bone.

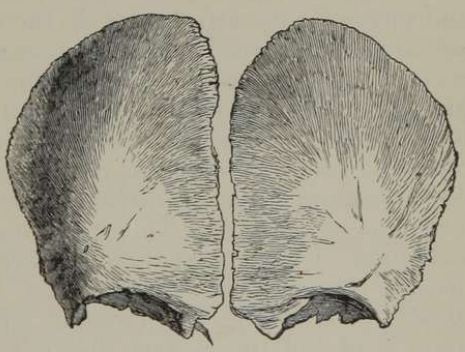

FIG. 137.—Frontal bone at birth. Developed by two lateral halves.

Articulations.—With twelve bones: two parietal, the sphenoid, the ethmoid, two nasal, two superior maxillary, two lachrymal, and two malar.

Attachment of Muscles.—To three pairs: the Corrugator supercilii, Orbicularis palpebrarum, and Temporal, on each side.

The Temporal Bones.

The **Temporal Bones** (*tempus*, time) are situated at the sides and base of the skull, and present for examination a *squamous*, *mastoid*, and *petrous* portion.

The **squamous portion** (*squama*, a scale), the anterior and upper part of the bone, is scale-like in form, and thin and translucent in texture (Fig. 138). Its *outer surface* is smooth, convex, and grooved at its back part for the deep temporal arteries; it affords attachment to the Temporal muscle and forms part of the temporal fossa. At its back part may be seen a curved ridge—part of the *temporal*

ridge; it serves for the attachment of the temporal fascia, limits the origin of the Temporal muscle, and marks the boundary between the squamous and mastoid

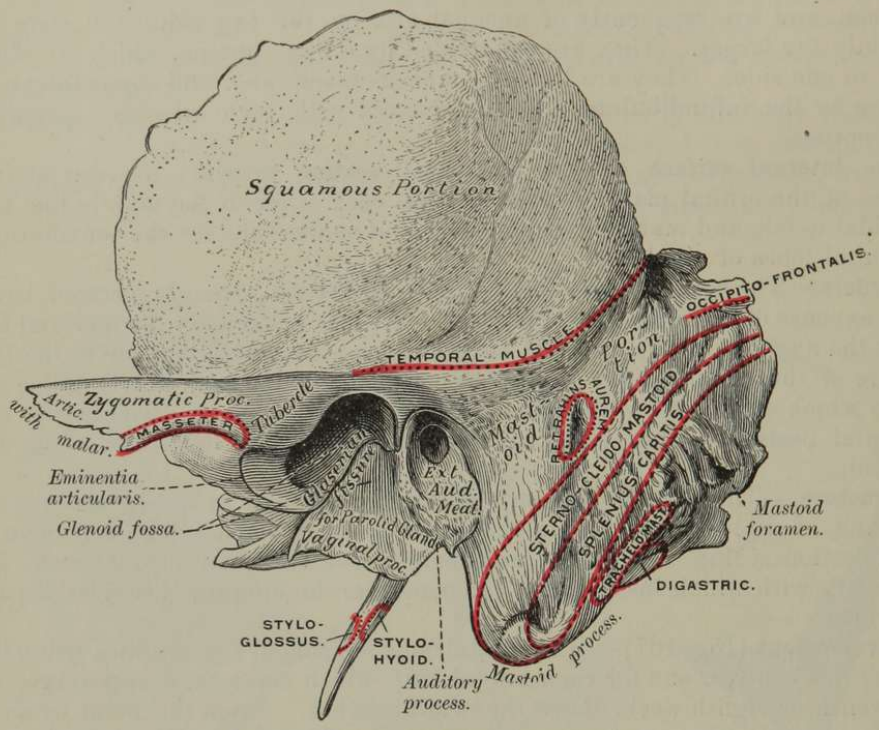

FIG. 138.—Left temporal bone. Outer surface.

portions of the bone. Projecting from the lower part of the squamous portion is a long, arched process of bone, the *zygoma* or zygomatic process. This process is at first directed outward, its two surfaces looking upward and downward; it then appears as if twisted upon itself, and runs forward, its surfaces now looking inward and outward. The superior border of the process is long, thin, and sharp, and serves for the attachment of the temporal fascia. The inferior, short, thick, and arched, has attached to it some fibres of the Masseter muscle. Its outer surface is convex and subcutaneous; its inner is concave, and also affords attachment to the Masseter. The extremity, broad and deeply serrated, articulates with the malar bone. The zygomatic process is connected to the temporal bone by three divisions, called its *roots*—an anterior, middle, and posterior. The anterior, which is short, but broad and strong, is directed inward, to terminate in a rounded eminence, the *eminentia articularis*. This eminence forms the front boundary of the glenoid fossa, and in the recent state is covered with cartilage. The middle root (*post-glenoid process*) forms the posterior boundary of the *mandibular* portion of the glenoid fossa; while the posterior root, which is strongly marked, runs from the upper border of the zygoma, in an arched direction, upward and backward, forming the posterior part of the temporal ridge (*supramastoid crest*). At the junction of the anterior root with the zygoma is a projection, called the *tubercle*, for the attachment of the external lateral ligament of the lower jaw; and between the anterior and middle roots is an oval depression, forming part (mandibular) of the glenoid fossa (γλήνη, a socket), for the reception of the condyle of the lower jaw. This fossa is bounded, in front, by the eminentia articularis; behind, by the tympanic plate and the auditory process; and is divided into two parts by a narrow slit, the *Glaserian fissure*. The anterior or mandibular part, formed by the squamous portion of the bone, is smooth, covered in the recent state with cartilage, and articulates with the condyle of the lower jaw. This part of the glenoid fossa is separated from the auditory process by the *post-glenoid process*, the representative of a prominent tubercle

which, in some of the mammalia, descends behind the condyle of the jaw, and prevents it being displaced backward during mastication (Humphry). The posterior part of the glenoid fossa, which lodges a portion of the parotid gland, is formed chiefly by the *tympanic plate*, a lamina of bone, which forms the anterior wall of the tympanum and external auditory meatus. This plate of bone terminates externally in the auditory process, above in the Glaserian fissure, and below forms a sharp edge, the *vaginal* process, which gives origin to some of the fibres of the Tensor palati muscle. The Glaserian fissure, which leads into the tympanum, lodges the processus gracilis of the malleus, and transmits the tympanic branch of the internal maxillary artery. The chorda tympani nerve passes through a separate canal, parallel to the Glaserian fissure (*canal of Huguier*), on the outer side of the Eustachian tube, in the retiring angle between the squamous and petrous portions of the temporal bone.[1]

The **internal surface** of the squamous portion (Fig. 139) is concave, presents

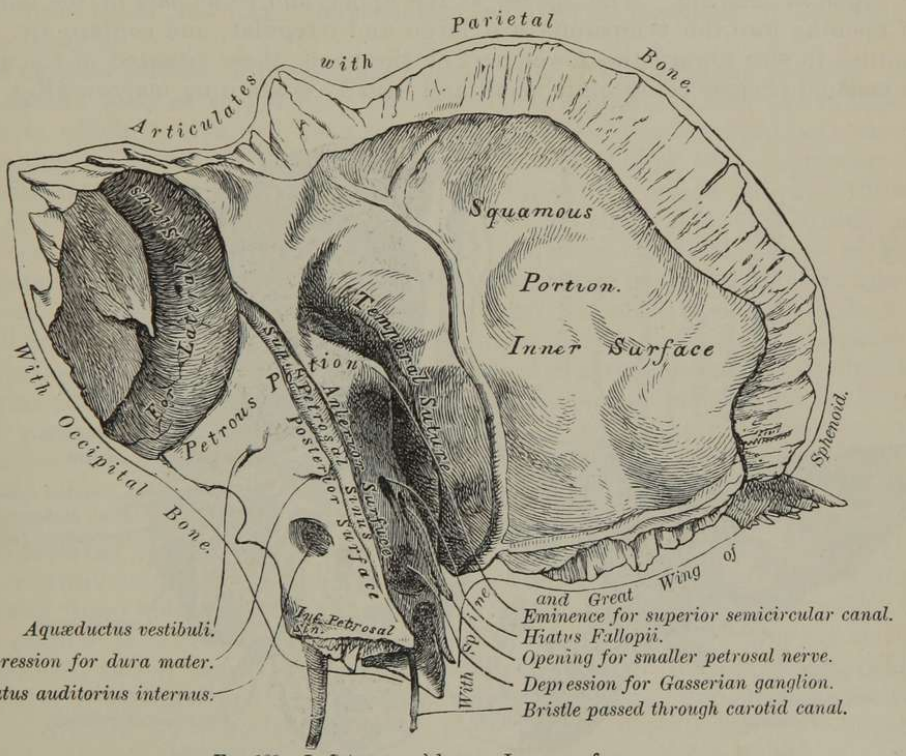

FIG. 139.—Left temporal bone. Inner surface.

numerous eminences and depressions for the convolutions of the cerebrum, and two well-marked grooves for the branches of the middle meningeal artery.

Borders.—The superior border is thin, bevelled at the expense of the internal surface, so as to overlap the lower border of the parietal bone, forming the squamous suture. The anterior inferior border is thick, serrated, and bevelled, alternately at the expense of the inner and outer surfaces, for articulation with the great wing of the sphenoid.

The **Mastoid Portion** (*μαστός*, a nipple or teat) is situated at the posterior part of the bone; its outer surface is rough, and gives attachment to the Occipito-frontalis and Retrahens aurem muscles. It is perforated by numerous foramina; one of these, of large size, situated at the posterior border of the bone, is termed the *mastoid foramen;* it transmits a vein to the lateral sinus and a small artery from the occipital to supply the dura mater. The position and size of this foramen

[1] This small fissure must not be confounded with the large canal which lies above the Eustachian tube and transmits the Tensor tympani muscle.

are very variable. It is not always present; sometimes it is situated in the occipital bone or in the suture between the temporal and the occipital. The mastoid portion is continued below into a conical projection, the *mastoid process*, the size and form of which vary somewhat. This process serves for the attachment of the Sterno-mastoid, Splenius capitis, and Trachelo-mastoid muscles. On the inner side of the mastoid process is a deep groove, the *digastric fossa*, for the attachment of the Digastric muscle; and, running parallel with it, but more internal, the *occipital groove*, which lodges the occipital artery. The internal surface of the mastoid portion presents a deep, curved groove, the *fossa sigmoidea*, which lodges part of the lateral sinus; and into it may be seen opening the mastoid foramen. A section of the mastoid process shows it to be hollowed out into a number of cellular spaces, communicating with each other, called the *mastoid cells;* they open by a single or double orifice into the back of the tympanum, are lined by a prolongation of its lining membrane, and probably form some secondary part of the organ of hearing. The spaces at the upper and front part of the bone near the opening into the tympanum are large and irregular, and contain air. They diminish in size toward the lower part of the bone, those situated at the apex of the mastoid process being quite small and usually containing marrow (Fig. 140).

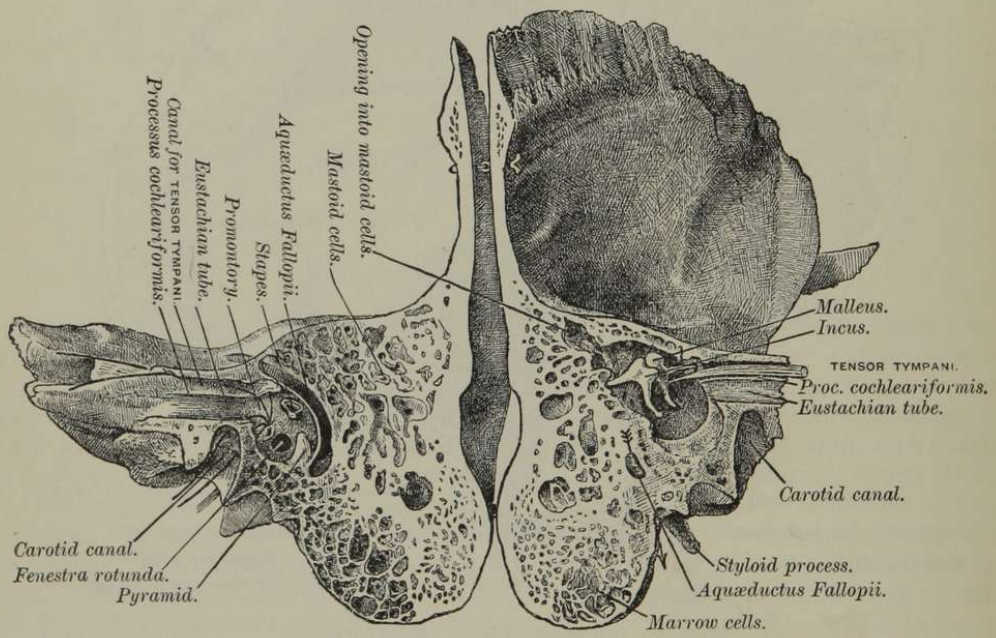

FIG. 140.—Section through the petrous and mastoid portions of the temporal bone, showing the communication of the cavity of the tympanum with the mastoid cells.

The mastoid cells, like the other sinuses of the cranium, are not developed until after puberty; hence the prominence of this process in the adult.

In consequence of the communication which exists between the tympanum and mastoid cells, inflammation of the lining membrane of the former cavity may easily travel backward to that of the mastoid cells, leading to caries and necrosis of their walls and the risk of transference of the inflammation to the lateral sinus or encephalon.

Borders.—The superior border of the mastoid portion is broad and rough, its serrated edge sloping outward, for articulation with the posterior inferior angle of the parietal bone. The posterior border, also uneven and serrated, articulates with the inferior border of the occipital bone between its lateral angle and jugular process.

The **Petrous Portion** (*πέτρος*, a stone), so named from its extreme density and hardness, is a pyramidal process of bone wedged in at the base of the skull between the sphenoid and occipital bones. Its direction from without is inward,

forward, and a little downward. It presents for examination a base, an apex, three surfaces, and three borders, and contains, in its interior, the essential parts of the organ of hearing. The *base* is applied against the internal surface of the squamous and mastoid portions, its upper half being concealed; but its lower half is exposed by the divergence of those two portions of the bone, which brings into view the oval expanded orifice of a canal leading into the tympanum, the *meatus auditorius externus*. This canal is situated in front of the mastoid process, and between the posterior and middle roots of the zygoma; its upper margin is smooth and rounded, but the greater part of its circumference is surrounded by a curved plate of bone, the *auditory process*, the free margin of which is thick and rough, for the attachment of the cartilage of the external ear.

The **apex** of the petrous portion, rough and uneven, is received into the angular interval between the posterior border of the greater wing of the sphenoid and the basilar process of the occipital; it presents the anterior or internal orifice of the carotid canal, and forms the posterior and external boundary of the foramen lacerum medium.

The **anterior surface** of the petrous portion (Fig. 139) forms the posterior part of the middle fossa of the skull. This surface is continuous with the squamous portion, to which it is united by a suture, the *temporal* or *petro-squamous suture*, the remains of which are distinct even at a late period of life; it presents six points for examination: 1, an eminence near the centre, which indicates the situation of the superior semicircular canal; 2, on the outer side of this eminence a depression indicating the position of the tympanum; here the layer of bone which separates the tympanum from the cranial cavity is extremely thin, and is known as the *tegmen tympani;* 3, a shallow groove, sometimes double, leading outward and backward to an oblique opening, the *hiatus Fallopii*, for the passage of the petrosal branch of the Vidian nerve and the petrosal branch of the middle meningeal artery; 4, a smaller opening, occasionally seen external to the latter, for the passage of the smaller petrosal nerve; 5, near the apex of the bone, the termination of the carotid canal, the wall of which in this situation is deficient in front; 6, above this canal a shallow depression for the reception of the Gasserian ganglion.

The **posterior surface** forms the front part of the posterior fossa of the skull, and is continuous with the inner surface of the mastoid portion of the bone. It presents three points for examination: 1. About its centre, a large orifice, the *meatus auditorius internus*, whose size varies considerably; its margins are smooth and rounded, and it leads into a short canal, about four lines in length, which runs directly outward and is closed by a vertical plate, the *lamina cribrosa*, which is divided by a horizontal crest, the *crista falciformis*, into two unequal portions; the lower presenting three foramina or sets of foramina; one, just below the posterior part of the crest, consisting of a number of small openings for the nerves to the saccule; a second, below and posterior to this, for the nerve to the posterior semicircular canal; and a third, in front and below the first, consisting of a number of small openings which terminate in the canalis centralis cochleæ and transmit the nerve to the cochlea; the upper portion, that above the crista, presents behind a series of small openings for the passage of filaments to the vestibule and superior and external semicircular canal, and, in front, one large opening, the commencement of the aquæductus Fallopii, for the passage of the facial nerve. 2. Behind the meatus auditorius, a small slit, almost hidden by a thin plate of bone, leading to a canal, the *aquæductus vestibuli*, which transmits a small artery and vein and lodges a process of the dura mater. 3. In the interval between these two openings, but above them, an angular depression which lodges a process of the dura mater, and transmits a small vein into the cancellous tissue of the bone.

The **inferior** or **basilar** surface (Fig. 141) is rough and irregular, and forms part of the base of the skull. Passing from the apex to the base, this surface presents eleven points for examination: 1, a rough surface, quadrilateral in form, which

serves partly for the attachment of the Levator palati and Tensor tympani muscles; 2, the large, circular aperture of the carotid canal, which ascends at first vertically, and then, making a bend, runs horizontally forward and inward; it transmits the internal carotid artery and the carotid plexus; 3, the *aquæductus cochleæ*, a small, triangular opening, lying on the inner side of the latter, close to the posterior border of the petrous portion; it transmits a vein from the cochlea which joins the internal jugular; 4, behind these openings a deep depression, the *jugular fossa*, which varies in depth and size in different skulls; it lodges the lateral sinus, and, with a similar depression on the margin of the jugular process of the occipital bone, forms the foramen lacerum posterius or jugular foramen; 5, a small foramen for the passage of Jacobson's nerve (the tympanic branch of the glosso-pharyngeal): this foramen is seen in front of the bony ridge dividing

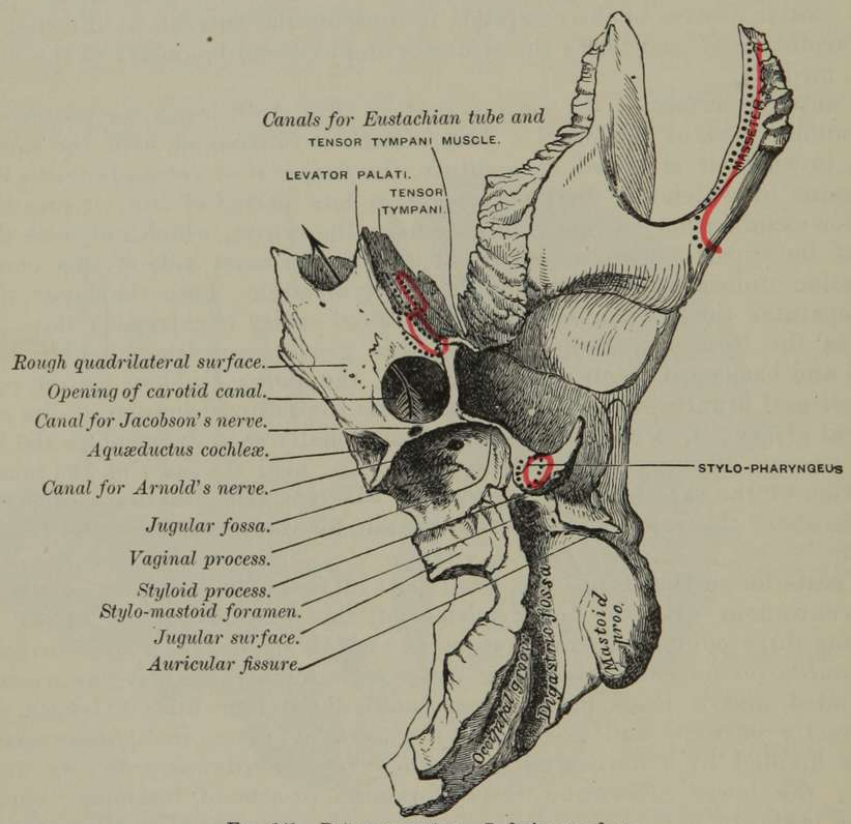

FIG. 141.—Petrous portion. Inferior surface.

the carotid canal from the jugular fossa; 6, a small foramen on the outer wall of the jugular fossa, for the entrance of the auricular branch of the pneumogastric (Arnold's) nerve; 7, behind the jugular fossa a smooth, square-shaped facet, the *jugular surface;* it is covered with cartilage in the recent state, and articulates with the jugular process of the occipital bone; 8, the *vaginal process*, a very broad, sheath-like plate of bone, which extends backward from the carotid canal and gives attachment to part of the Tensor palati muscle: this plate divides behind into two laminæ, the outer of which is continuous with the auditory process, the inner with the jugular process: between these laminæ is the ninth point for examination, the *styloid process*, a long, sharp spine, about an inch in length: it is directed downward, forward, and inward, varies in size and shape, and sometimes consists of several pieces, united by cartilage; it affords attachment to three muscles, the Stylo-pharyngeus, Stylo-hyoideus, and Stylo-glossus, and two ligaments, the stylo-hyoid and stylo-maxillary; 10, the *stylo-mastoid foramen*, a rather large orifice, placed between the styloid and mastoid processes: it is the termina-

tion of the aquæductus Fallopii, and transmits the facial nerve and stylo-mastoid artery; 11, the *auricular fissure*, situated between the auditory and mastoid processes, for the exit of the auricular branch of the pneumogastric nerve.

Borders.—The *superior*, the longest, is grooved for the superior petrosal sinus, and has attached to it the tentorium cerebelli; at its inner extremity is a semilunar notch, upon which the fifth nerve lies. The *posterior* border is intermediate in length between the superior and the anterior. Its inner half is marked by a groove, which, when completed by its articulation with the occipital, forms the channel for the inferior petrosal sinus. Its outer half presents a deep excavation—the *jugular fossa*—which, with a similar notch on the occipital, forms the foramen lacerum posterius. A projecting eminence of bone occasionally stands out from the centre of the notch, and divides the foramen into two parts. The *anterior* border is divided into two parts—an outer joined to the squamous portion by a suture, the remains of which are distinct; an inner, free, articulating with the spinous process of the sphenoid. At the angle of junction of the petrous and squamous portions are seen two canals, separated from one another by a thin plate of bone, the *processus cochleariformis;* they both lead into the tympanum, the upper one transmitting the Tensor tympani muscle, the lower one the Eustachian tube.

Structure.—The squamous portion is like that of the other cranial bones; the mastoid portion, cellular; and the petrous portion, dense and hard.

Development (Fig. 142).—The temporal bone is developed by *ten* centres, exclusive of those for the internal ear and the ossicula—viz. one for the squamous portion including the zygoma, one for the tympanic plate, six for the petrous and mastoid parts, and two for the styloid process. Just before the close of fœtal life the temporal bone consists of four parts: 1. The *squamo-zygomatic*, which is ossified in membrane from a single nucleus, which appears at its lower part about the second month. 2. The *tympanic plate*, an imperfect ring, which encloses the tympanic membrane. This is also ossified from a single centre, which appears rather later than that for the squamous portion. 3. The *petro-mastoid*, which is developed from six centres, which appear about the fifth or sixth month. Four of these are for the petrous portion, and are placed around the labyrinth, and two for the mastoid (Vrolik). According to Huxley, the centres are more numerous, and are disposed so as to form three portions: (1) including most of the labyrinth, with a part of the petrous and mastoid, he has named *prootic;* (2) the rest of the petrous, the *opisthotic;* and (3) the remainder of the mastoid, the *epiotic*. The petro-mastoid is ossified in cartilage. 4. The *styloid process* is also ossified in cartilage from two centres: one for the base, which appears before birth, and is termed the *tympano-hyal;* the other, comprising the rest of the process, is named the *stylo-hyal*, and does not appear until after birth. Shortly before birth the tympanic plate joins with the squamous. The petrous and mastoid join with the squamous during the first year, and the tympano-hyal portion of the styloid process about the same time. The stylo-hyal does not join the rest of the bone until after puberty, and in some skulls never becomes united. The subsequent changes in this bone are, that the tympanic plate extends outward, so as to form the meatus auditorius;

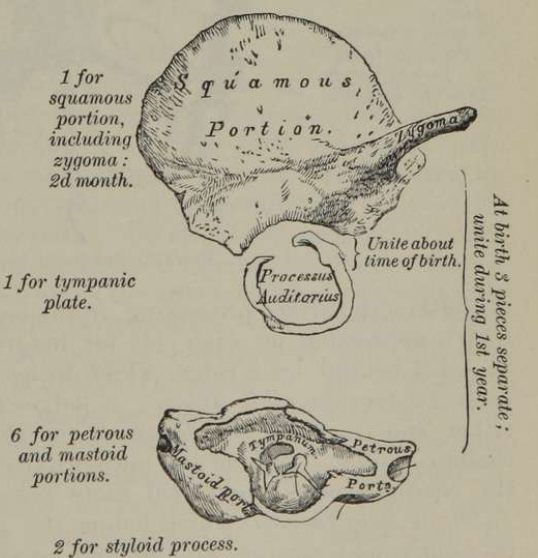

FIG. 142.—Development of the temporal bone. By ten centres.

the glenoid fossa becomes deeper; and the mastoid part, which at an early period of life is quite flat, enlarges from the development of the cellular cavities in its interior.

Articulations.—With five bones—occipital, parietal, sphenoid, inferior maxillary, and malar.

Attachment of Muscles.—To fifteen: to the squamous portion, the Temporal; to the zygoma, the Masseter; to the mastoid portion, the Occipito-frontalis, Sterno-mastoid, Splenius capitis, Trachelo-mastoid, Digastricus, and Retrahens aurem; to the styloid process, the Stylo-pharyngeus, Stylo-hyoideus, and Stylo-glossus; and to the petrous portion, the Levator palati, Tensor tympani, Tensor palati, and Stapedius.

The Sphenoid Bone.

The **Sphenoid Bone** (*σφήν*, a wedge) is situated at the anterior part of the base of the skull, articulating with all the other cranial bones, which it binds firmly and solidly together. In its form it somewhat resembles a bat with its wings extended; and is divided into a central portion or body, two greater and two lesser wings extending outward on each side of the body, and two processes—the pterygoid processes—which project from it below.

The **body** is of large size, cuboid in form, and hollowed out in its interior so as to form a mere shell of bone. It presents for examination *four* surfaces—a superior, an inferior, an anterior, and a posterior.

The Superior Surface (Fig. 143).—In front is seen a prominent spine, the *ethmoidal spine*, for articulation with the cribriform plate of the ethmoid; behind

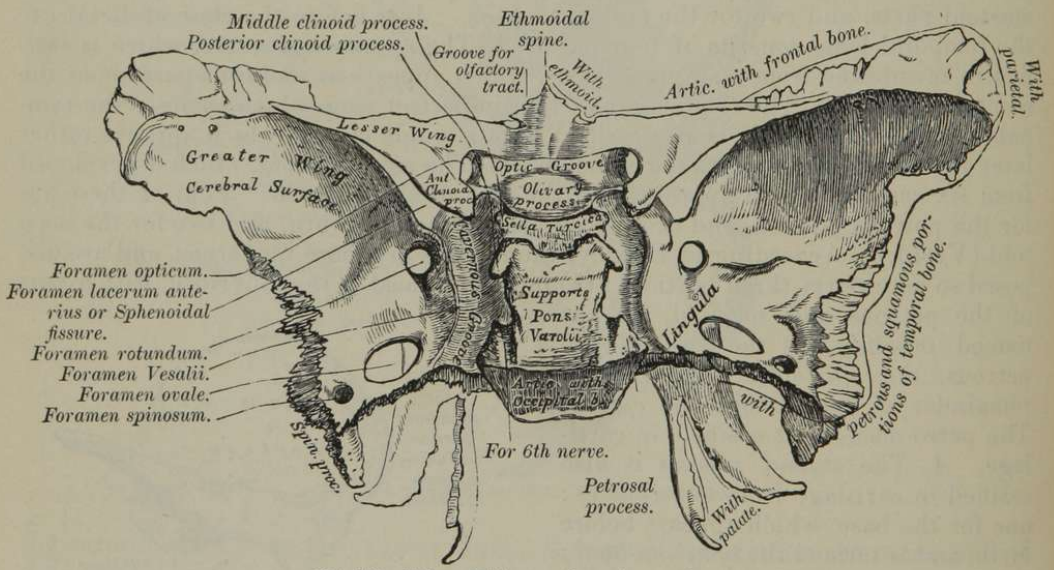

FIG. 143.—Sphenoid bone. Superior surface.

this a smooth surface presenting, in the median line, a slight longitudinal eminence, with a depression on each side for lodging the olfactory tracts. This surface is bounded behind by a ridge, which forms the anterior border of a narrow, transverse groove, the *optic groove;* it lodges the optic commissure, and terminates on either side in the *optic foramen*, for the passage of the optic nerve and ophthalmic artery. Behind the optic groove is a small eminence, olive-like in shape, the *olivary process;* and still more posteriorly, a deep depression, the *pituitary fossa*, or *sella turcica*, which lodges the pituitary body. This fossa is perforated by numerous foramina, for the transmission of nutrient vessels into the substance of the bone. It is bounded in front by two small eminences, one on either side, called the *middle clinoid processes* (*κλίνη*, a bed), which are sometimes connected by a spiculum of bone to the anterior clinoid processes, and behind by a square-

shaped plate of bone, the *dorsum ephippii* or *dorsum sellæ*, terminating at each superior angle in a tubercle, the *posterior clinoid processes*, the size and form of which vary considerably in different individuals. These processes deepen the pituitary fossa, and serve for the attachment of prolongations from the tentorium cerebelli. The sides of the dorsum ephippii are notched for the passage of the sixth pair of nerves, and below present a sharp process, the *petrosal process*, which is joined to the apex of the petrous portion of the temporal bone, forming the inner boundary of the middle lacerated foramen. Behind this plate the bone presents a shallow depression, which slopes obliquely backward, and is continuous with the basilar groove of the occipital bone; it is called the *clivus*, and supports the upper part of the pons Varolii. On either side of the body is a broad groove, curved something like the italic letter *f;* it lodges the internal carotid artery and the cavernous sinus, and is called the *carotid* or *cavernous groove*. Along the outer margin of this groove, at its posterior part, is a ridge of bone in the angle between the body and greater wing, called the *lingula*. The **posterior surface**, quadrilateral

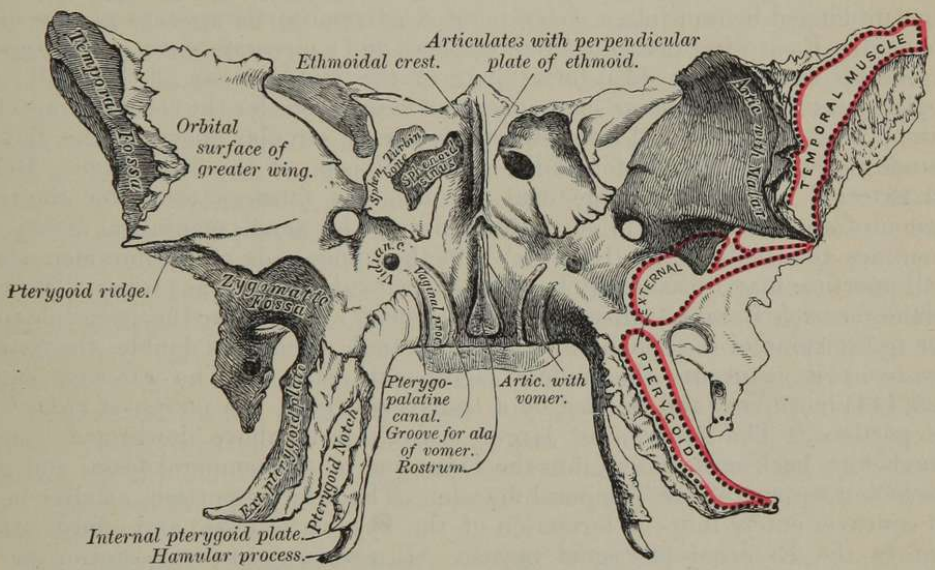

FIG. 144.—Sphenoid bone. Anterior surface.[1]

in form, is joined to the basilar process of the occipital bone. During childhood these bones are separated by a layer of cartilage; but in after-life (between the eighteenth and twenty-fifth years) this becomes ossified, ossification commencing above and extending downward; and the two bones then form one piece. The **anterior surface** (Fig. 144) presents, in the middle line, a vertical ridge of bone, the *ethmoidal crest*, which articulates in front with the perpendicular plate of the ethmoid, forming part of the septum of the nose. On either side of it are irregular openings leading into the *sphenoidal cells* or *sinuses*. These are two large irregular cavities hollowed out of the interior of the body of the sphenoid bone, and separated from one another by a more or less complete perpendicular bony septum. Their form and size vary considerably; they are seldom symmetrical, and are often partially subdivided by irregular osseous laminæ. Occasionally, they extend into the basilar process of the occipital nearly as far as the foramen magnum. The septum is seldom quite vertical, being commonly bent to one or the other side. These sinuses do not exist in children, but they increase in size as age advances. They are partially closed, in front and below, by two thin, curved plates of bone, the *sphenoidal turbinated* bones, leaving a round opening at their upper parts, by which they communicate with the upper and back part of the nose, and occasionally

[1] In this figure, both the anterior and inferior surfaces of the body of the sphenoid bone are shown, the bone being held with the pterygoid processes almost horizontal.

with the posterior ethmoidal cells or sinuses. The lateral margins of this surface present a serrated edge, which articulates with the os planum of the ethmoid, completing the posterior ethmoidal cells; the lower margin, also rough and serrated, articulates with the orbital process of the palate bone, and the upper margin with the orbital plate of the frontal bone. The **inferior surface** presents, in the middle line, a triangular spine, the *rostrum*, which is continuous with the ethmoidal crest on the anterior surface, and is received into a deep fissure between the alæ of the vomer. On each side may be seen a projecting lamina of bone, which runs horizontally inward from near the base of the pterygoid process: these plates, termed the *vaginal processes*, articulate with the edges of the vomer. Close to the root of the pterygoid process is a groove, formed into a complete canal when articulated with the sphenoidal process of the palate bone; it is called the *pterygo-palatine canal*, and transmits the pterygo-palatine vessels and pharyngeal nerve.

The **Greater Wings** are two strong processes of bone which arise from the sides of the body, and are curved in a direction upward, outward, and backward, being prolonged behind into a sharp-pointed extremity, the *spinous process* of the sphenoid. Each wing presents three surfaces and a circumference. The *superior* or *cerebral* surface (Fig. 143) forms part of the middle fossa of the skull; it is deeply concave, and presents eminences and depressions for the convolutions of the brain. At its anterior and internal part is seen a circular aperture, the *foramen rotundum*, for the transmission of the second division of the fifth nerve. Behind and external to this is a large oval foramen, the *foramen ovale*, for the transmission of the third division of the fifth nerve, the small meningeal artery, and sometimes the small petrosal nerve.[1] At the inner side of the foramen ovale a small aperture may occasionally be seen opposite the root of the pterygoid process; it is the *foramen Vesalii*, transmitting a small vein. Lastly, in the posterior angle, near to the spine of the sphenoid, is a short canal, sometimes double, the *foramen spinosum;* it transmits the middle meningeal artery. The *external* surface (Fig. 144) is convex, and divided by a transverse ridge, the *pterygoid ridge*,[2] into two portions. The superior or larger, convex from above downward, concave from before backward, enters into the formation of the temporal fossa, and gives attachment to part of the Temporal muscle. The inferior portion, smaller in size and concave, enters into the formation of the zygomatic fossa, and affords attachment to the External pterygoid muscle. It presents, at its posterior part, a sharp-pointed eminence of bone, the *spinous process*, to which are connected the internal lateral ligament of the lower jaw and the Tensor palati muscle. The pterygoid ridge, dividing the temporal and zygomatic portions, gives attachment to part of the External pterygoid muscle. At its inner and anterior extremity is a triangular spine of bone which serves to increase the extent of origin of this muscle. The *anterior* or *orbital* surface, smooth and quadrilateral in form, assists in forming the outer wall of the orbit. It is bounded above by a serrated edge, for articulation with the frontal bone; below, by a rounded border which enters into the formation of the spheno-maxillary fissure. Internally, it presents a sharp border, which forms the lower boundary of the sphenoidal fissure, and has projecting from about its centre a little tubercle of bone, which gives origin to one head of the External rectus muscle of the eye; and at its upper part is a notch for the transmission of a branch of the lachrymal artery; externally it presents a serrated margin for articulation with the malar bone. One or two small foramina may occasionally be seen for the passage of branches of the deep temporal arteries; they are called the *external orbital foramina*. *Circumference of the great wing* (Fig. 143): commencing from behind, from the body of the sphenoid to the spine, the outer half of this margin is serrated, for articulation with the petrous portion of the temporal bone, whilst the inner half forms the anterior

[1] The small petrosal nerve sometimes passes through a special foramen between the foramen ovale and foramen spinosum.

[2] Sometimes called *infratemporal crest.*

boundary of the foramen lacerum medium, and presents the posterior aperture of the Vidian canal for the passage of the Vidian nerve and artery. In front of the spine the circumference of the great wing presents a serrated edge, bevelled at the expense of the inner table below and of the external above, which articulates with the squamous portion of the temporal bone. At the tip of the great wing a triangular portion is seen, bevelled at the expense of the internal surface, for articulation with the anterior inferior angle of the parietal bone. Internal to this is a broad, serrated surface, for articulation with the frontal bone: this surface is continuous internally with the sharp inner edge of the orbital plate, which assists in the formation of the sphenoidal fissure, and externally with the serrated margin for articulation with the malar bone.

The **Lesser Wings** (*processes of Ingrassias*) are two thin, triangular plates of bone which arise from the upper and lateral parts of the body of the sphenoid, and, projecting transversely outward, terminate in a sharp point (Fig. 143). The superior surface of each is smooth, flat, broader internally than externally, and supports part of the frontal lobe of the brain. The inferior surface forms the back part of the roof of the orbit and the upper boundary of the sphenoidal fissure or foramen lacerum anterius. This fissure is of a triangular form, and leads from the cavity of the cranium into the orbit; it is bounded internally by the body of the sphenoid—above, by the lesser wing; below, by the internal margin of the orbital surface of the great wing—and is converted into a foramen by the articulation of this bone with the frontal. It transmits the third, the fourth, the three branches of the ophthalmic division of the fifth, the sixth nerve, some filaments from the cavernous plexus of the sympathetic, the orbital branch of the middle meningeal artery, a recurrent branch from the lachrymal artery to the dura mater, and the ophthalmic vein. The anterior border of the lesser wing is serrated for articulation with the frontal bone; the posterior, smooth and rounded, is received into the fissure of Sylvius of the brain. The inner extremity of this border forms the *anterior clinoid process*. The lesser wing is connected to the side of the body by two roots, the upper thin and flat, the lower thicker, obliquely directed, and presenting on its outer side, near its junction with the body, a small tubercle, for the attachment of the common tendon of three of the muscles of the eye. Between the two roots is the *optic foramen*, for the transmission of the optic nerve and ophthalmic artery.

The **Pterygoid Processes** (πτέρυξ, a wing; εἶδος, likeness), one on each side, descend perpendicularly from the point where the body and greater wing unite (Fig. 145). Each process consists of an external and an internal plate, separated behind by an intervening notch—the *pterygoid fossa;* but joined partially in front. The *external pterygoid plate* is broad and thin, turned a little outward, and forms part of the inner wall of the zygomatic fossa. It gives attachment, by its outer surface, to the External pterygoid; its inner surface forms part of the pterygoid fossa, and gives attachment to the Internal pterygoid. The *internal pterygoid plate* is much narrower and longer, curving outward, at its extremity, into a hook-like process of bone, the *hamular process*, around which turns the tendon of the Tensor palati muscle. On the posterior surface of the base of this plate is a small, oval, shallow depression, the *scaphoid fossa*, from which arises

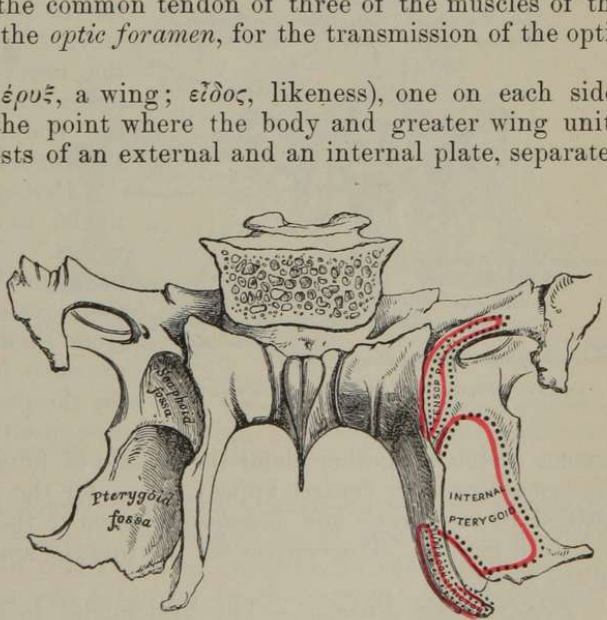

FIG. 145.—Sphenoid bone. Posterior surface.

the Tensor palati, and above which is seen the posterior orifice of the Vidian canal. Below and to the inner side of the Vidian canal, on the posterior surface of the base of this plate, is a little prominence, which is known by the name of the *pterygoid tubercle*. The outer surface of this plate forms part of the pterygoid fossa, the inner surface forming the outer boundary of the posterior aperture of the nares. The Superior constrictor of the pharynx is attached to its posterior edge. The two pterygoid plates are separated below by an angular interval, in which the pterygoid process, or tuberosity, of the palate bone is received. The anterior surface of the pterygoid process is very broad at its base, and forms the posterior wall of the spheno-maxillary fossa. It supports Meckel's ganglion. It presents, above, the anterior orifice of the Vidian canal; and below, a rough margin, which articulates with the perpendicular plate of the palate bone.

The **Sphenoidal Spongy Bones** are two thin, curved plates of bones, which exist as separate pieces until puberty, and occasionally are not joined to the sphenoid in the adult. They are situated at the anterior and inferior part of the body of the sphenoid, an aperture of variable size being left in their anterior wall, through which the sphenoidal sinuses open into the nasal fossæ. They are irregular in form and taper to a point behind, being broader and thinner in front. Their upper surface, which looks toward the cavity of the sinus, is concave; their under surface convex. Each bone articulates in front with the ethmoid, externally with the palate; its pointed posterior extremity is placed above the vomer, and is received between the root of the pterygoid process on the outer side and the rostrum of the sphenoid on the inner.[1]

Development.—Up to about the eighth month of fœtal life the sphenoid bone consists of two distinct parts: posterior or *post-sphenoid* part, which comprises the pituitary fossa, the greater wings, and the pterygoid processes; and an anterior or *pre-sphenoid* part, to which the anterior part of the body and lesser wings belong. It is developed by fourteen centres: eight for the posterior sphenoid division, and six for the anterior sphenoid. The eight centres for the posterior sphenoid are—one for each greater wing and external pterygoid plate, one for each internal pterygoid plate, two for the posterior part of the body, and one on each side for the lingula. The six for the anterior sphenoid are one for each lesser wing, two for the anterior part of the body, and one for each sphenoidal turbinated bone.

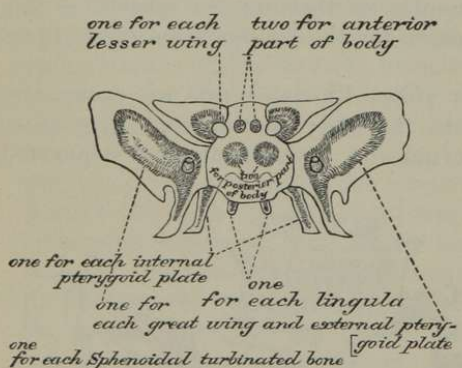

FIG. 146.—Plan of the development of sphenoid. By fourteen centres.

Post-sphenoid Division.—The first nuclei to appear are those for the greater wings. They make their appearance between the foramen rotundum and foramen ovale about the eighth week, and from them the external pterygoid plates are also formed. Soon after, the nuclei for the posterior part of the body appear, one on either side of the sella turcica, and become blended together about the middle of fœtal life. About the fourth month the remaining four centres appear, those for the internal pterygoid plates being ossified in membrane and becoming joined to the external pterygoid plate about the sixth month. The centres for the lingulæ speedily become joined to the rest of the bone.

Pre-sphenoid Division.—The first nuclei to appear are those for the lesser wings. They make their appearance about the ninth week, at the outer borders of the optic foramina. A second pair of nuclei appear on the inner side of the

[1] A small portion of the sphenoidal turbinated bone sometimes enters into the formation of the inner wall of the orbit, between the os planum of the ethmoid in front, the orbital plate of the palate below, and the frontal above.—Cleland, *Roy. Soc. Trans.*, 1862.

foramina shortly after, and, becoming united, form the front part of the body of the bone. The remaining two centres for the sphenoidal turbinated bones do not make their appearance until the end of the third year.

The pre-sphenoid is united to the body of the post-sphenoid about the eighth month, so that at birth the bone consists of three pieces—viz. the body in the centre, and on each side the great wings with the pterygoid processes. The lesser wings become joined to the body at about the time of birth. At the first year after birth the greater wings and body are united. From the tenth to the twelfth year the spongy bones are partially united to the sphenoid, their junction being complete by the twentieth year. Lastly, the sphenoid joins the occipital from the eighteenth to the twenty-fifth year.

Articulations.—The sphenoid articulates with *all* the bones of the cranium, and five of the face—the two malar, two palate, and vomer: the exact extent of articulation with each bone is shown in the accompanying figures.[1]

Attachment of Muscles.—To eleven pairs: the Temporal, External pterygoid, Internal pterygoid, Superior constrictor, Tensor palati, Levator palpebræ, Obliquus oculi superior, Superior rectus, Internal rectus, Inferior rectus, External rectus.

The Ethmoid Bone.

The **Ethmoid** (ἠθμός, a sieve) is an exceedingly light, spongy bone, of a cubical form, situated at the anterior part of the base of the cranium, between the two orbits, at the root of the nose, and contributing to form each of these cavities. It consists of three parts: a horizontal plate, which forms part of the base of the cranium; a perpendicular plate, which forms part of the septum nasi; and two lateral masses of cells.

The **Horizontal** or **Cribriform Plate** (Fig. 147) forms part of the anterior fossa of the base of the skull, and is received into the ethmoid notch of the frontal bone between the two orbital plates. Projecting upward from the middle line of this plate is a thick, smooth, triangular process of bone, the *crista galli*, so called from its resemblance to a cock's comb. Its base joins the cribriform plate. Its posterior border, long, thin, and slightly curved, serves for the attachment of the falx cerebri. Its anterior border, short and thick, articulates with the frontal bone, and presents two small projecting alæ, which are received into corresponding depressions in the frontal, completing the foramen cæcum behind. Its sides are smooth and sometimes bulging; in which case it is found to enclose a small sinus.[2] On each side of the crista galli the cribriform plate is narrow and deeply grooved, to support the bulb of the olfactory tract, and perforated by foramina for the passage of the olfactory nerves. These foramina are arranged in three rows: the innermost, which are the largest and least numerous, are lost in grooves on the upper part of the septum; the foramina of the outer row are continued on to the surface of

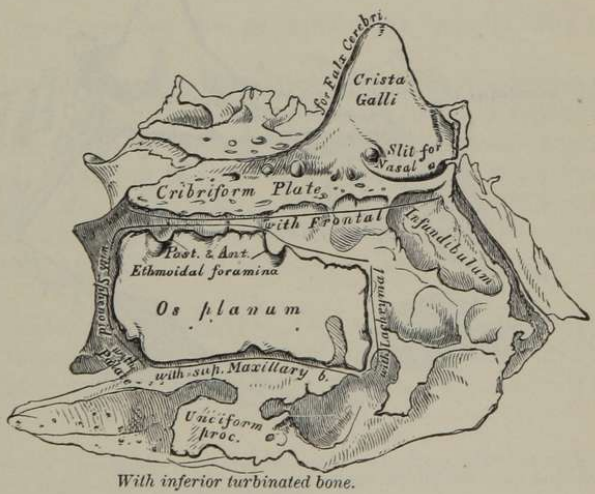

FIG. 147.—Ethmoid bone. Outer surface of right lateral mass (enlarged).

[1] It also sometimes articulates with the tuberosity of the superior maxilla (see p. 190).

[2] Sir George Humphry states that the crista galli is commonly inclined to one side, usually the opposite to that toward which the lower part of the perpendicular plate is bent.—(*The Human Skeleton*, 1858, p. 277.)

the upper spongy bone. The foramina of the middle row are the smallest; they perforate the bone and transmit nerves to the roof of the nose. At the front part of the cribriform plate, on each side of the crista galli, is a small fissure, which transmits the nasal branch of the ophthalmic nerve; and at its posterior part a a triangular notch, which receives the ethmoidal spine of the sphenoid.

The **Perpendicular Plate** (Fig. 148) is a thin, flattened lamella of bone, which descends from the under surface of the cribriform plate, and assists in forming the septum of the nose. It is much thinner in the middle than at the circumference, and is generally deflected a little to one side. Its anterior border articulates with the nasal spine of the frontal bone and crest of the nasal bones. Its posterior border, divided into two parts, articulates by its upper half with the ethmoidal crest of the sphenoid, by its lower half with the vomer. The inferior border serves for the attachment of the triangular cartilage of the nose. On each side of the perpendicular plate numerous grooves and canals are seen, leading from foramina on the cribriform plate; they lodge filaments of the olfactory nerves.

The **Lateral Masses** of the ethmoid consist of a number of thin-walled cellular cavities, the *ethmoidal cells*, interposed between two vertical plates of bone, the outer one of which forms part of the orbit, and the inner one part of the nasal fossa of the corresponding side. In the disarticulated bone many of these cells appear to be broken; but when the bones are articulated they are closed in at every part. The upper surface of each lateral mass presents a number of apparently half-broken cellular spaces; these are closed in when articulated by the edges of the ethmoidal notch of the frontal bone. Crossing this surface are two grooves on each side, converted into canals by articulation with the frontal; they are the *anterior* and *posterior ethmoidal* foramina, and open on the inner wall of the orbit. The posterior surface also presents large, irregular cellular cavities, which are closed in by articulation with the sphenoidal turbinated bones and orbital process of the palate. The cells at the anterior surface are completed by the lachrymal bone and nasal process of the superior maxillary, and those below also by the superior maxillary. The outer surface of each lateral mass is formed of a thin, smooth, square plate of bone, called the *os planum;* it forms part of the inner wall of the orbit, and articulates, above, with the orbital plate of the frontal; below, with the superior maxillary; in front, with the lachrymal; and behind, with the sphenoid and orbital process of the palate.

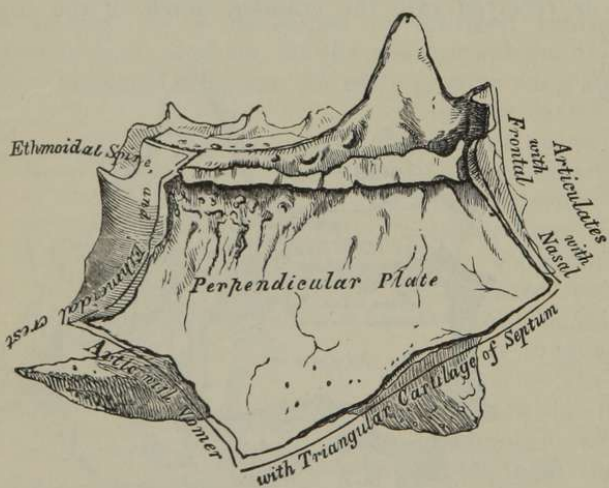

FIG. 148.—Perpendicular plate of ethmoid (enlarged), shown by removing the right lateral mass.

From the inferior part of each lateral mass, immediately beneath the os planum, there projects downward and backward an irregular lamina of bone, called the *unciform process*, from its hook-like form: it serves to close in the upper part of the orifice of the antrum, and articulates with the ethmoidal process of the inferior turbinated bone. It is often broken in disarticulating the bones.

The inner surface of each lateral mass forms part of the outer wall of the nasal fossa of the corresponding side. It is formed of a thin lamella of bone, which descends from the under surface of the cribriform plate, and terminates below in a free, convoluted margin, the *middle turbinated* bone. The whole of this sur-

face is rough and marked above by numerous grooves, which run nearly vertically downward from the cribriform plate; they lodge branches of the olfactory nerve, which are distributed on the mucous membrane covering the bone. The back part of this surface is subdivided by a narrow oblique fissure, the *superior meatus* of the nose, bounded above by a thin, curved plate of bone, the *superior turbinated* bone. By means of an orifice at the upper part of this fissure the posterior ethmoidal cells open into the nose. Below, and in front of the superior meatus, is seen the convex surface of the middle turbinated bone. It extends along the whole length of the inner surface of each lateral mass; its lower margin is free and thick, and its concavity, directed outward, assists in forming the middle meatus. It is by a large orifice at the upper and front part of the middle meatus that the anterior ethmoidal cells, and through them the frontal sinuses, communicate with the nose by means of a funnel-shaped canal, the *infundibulum*. The cellular cavities of each lateral mass, thus walled in by the os planum on the outer side and by the other bones already mentioned, are divided by a thin transverse bony partition into two sets, which do not communicate with each other; they are termed the *anterior* and *posterior ethmoidal cells* or *sinuses*. The former, more numerous, communicate with the frontal sinuses above and the middle meatus below by means of a long, flexuous canal, the *infundibulum;* the posterior, less numerous, open into the superior meatus, and communicate (occasionally) with the sphenoidal sinuses.

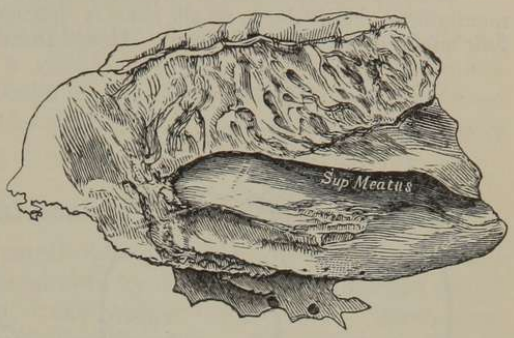

FIG. 149.—Ethmoid bone. Inner surface of right lateral mass (enlarged).

Development.—By *three* centres: one for the perpendicular lamella, and one for each lateral mass.

The lateral masses are first developed, ossific granules making their appearance in the os planum between the fourth and fifth months of fœtal life, and extending into the spongy bones. At birth the bone consists of the two lateral masses, which are small and ill-developed. During the first year after birth the perpendicular and horizontal plates begin to ossify, from a single nucleus, and become joined to the lateral masses about the beginning of the second year. The formation of the ethmoidal cells, which completes the bone, does not commence until about the fourth or fifth year.

Articulations.—With fifteen bones: the sphenoid, two sphenoidal turbinated, the frontal, and eleven of the face—the two nasal, two superior maxillary, two lachrymal, two palate, two inferior turbinated, and the vomer. No muscles are attached to this bone.

DEVELOPMENT OF THE CRANIUM.

The early stages of the development of the cranium have already been described (see page 115). We have seen that it is formed from a layer of mesoblast, derived from the protovertebral plates of the trunk, which is spread over the whole surface of the rudimentary brain. That portion of this layer from which the bones of the skull are to be developed consists of a thin, membranous capsule.

Ossification commences in the roof, and is preceded by the deposition of a membranous blastema upon the surface of the cerebral capsule, in which the ossifying process extends, the primitive membranous capsule becoming the internal periosteum, and being ultimately blended with the dura mater. Although the bones of the vertex of the skull appear before those at the base, and make considerable progress in their growth, at birth ossification is more advanced in the base, this portion of the skull forming a solid, immovable groundwork.

The Fontanelles.

Before birth the bones at the vertex and side of the skull are separated from each other by membranous intervals in which bone is deficient. These intervals are principally found at the four angles of the parietal bones. Hence there are six fontanelles. Their formation is due to

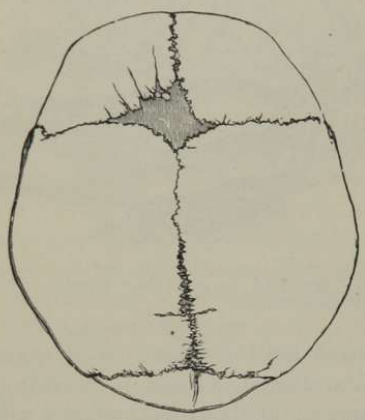

FIG. 150.—Skull at birth, showing the anterior and posterior fontanelles.

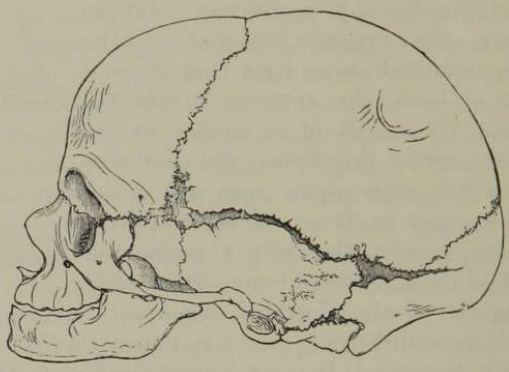

FIG. 151.—The lateral fontanelles.

the wave of ossification being circular and the bones quadrilateral; the ossific matter first meets at the margins of the bones, at the points nearest to their centres of ossification, and vacuities or spaces are left at the angles, which are called *fontanelles*, so named from the pulsations of the brain, which are perceptible at the anterior fontanelle, and were likened to the rising of water in a fountain. The anterior fontanelle is the largest, and corresponds to the junction of the sagittal and coronal sutures; the posterior fontanelle, of smaller size, is situated at the junction of the sagittal and lambdoid sutures; the remaining ones are situated at the inferior angles of each parietal bone. The latter are closed soon after birth; the two at the two superior angles remain open longer; the posterior being closed in a few months after birth; the anterior remaining open until the first or second year. These spaces are gradually filled in by an extension of the ossifying process or by the development of a Wormian bone. Sometimes the anterior fontanelle remains open beyond two years, and is occasionally persistent throughout life.

Supernumerary or Wormian[1] Bones.

In addition to the constant centres of ossification of the skull, additional ones are occasionally found in the course of the sutures. These form irregular, isolated bones, interposed between the cranial bones, and have been termed *Wormian bones* or *ossa triquetra*. They are most frequently found in the course of the lambdoid suture, but occasionally also occupy the situation of the fontanelles, especially the posterior and, more rarely, the anterior. Frequently one is found between the anterior inferior angle of the parietal bone and the greater wing of the sphenoid, the *pterion ossicle* (Fig. 151). They have a great tendency to be symmetrical on the two sides of the skull, and they vary much in size, being in some cases not larger than a pin's head, and confined to the outer table; in other cases so large that one pair of these bones may form the whole of the occipital bone above the superior curved lines, as described by Béclard and Ward. Their number is generally limited to two or three, but more than a hundred have been found in the skull of an adult hydrocephalic skeleton. In their development, structure, and mode of articulation they resemble the other cranial bones.

Congenital Fissures and Gaps.

An arrest in the ossifying process may give rise to deficiencies or gaps; or to fissures, which are of importance in a medico-legal point of view, as they are liable to be mistaken for fractures. The fissures generally extend from the margins toward the centre of the bone, but the gaps may be found in the middle as well as at the edges. In course of time they may become covered with a thin lamina of bone.

BONES OF THE FACE.

The Facial Bones are fourteen in number—viz. the

Two Nasal.	Two Palate.
Two Superior Maxillary.	Two Inferior Turbinated.
Two Lachrymal.	Vomer.
Two Malar.	Inferior Maxillary.

[1] Wormius, a physician in Copenhagen, is said to have given the first detailed description of these bones.

"Of these, the upper and lower jaws are the fundamental bones for mastication, and the others are accessories; for the chief function of the facial bones is to provide an apparatus for mastication, while subsidiary functions are to provide for the sense-organs (eye, nose, tongue) and a vestibule to the respiratory and vocal organs. Hence the variations in the shape of the face in man and the lower animals depend chiefly on the question of the character of their food and their mode of obtaining it."[1]

The Nasal Bone.

The **Nasal** (*nasus*, the nose) are two small oblong bones, varying in size and form in different individuals; they are placed side by side at the middle and upper part of the face, forming, by their junction, "the bridge" of the nose. Each bone presents for examination two surfaces and four borders. The *outer* surface is concave from above downward, convex from side to side; it is covered by the Pyramidalis and Compressor nasi muscles, and give attachment at its upper part to a few fibres of the Occipito-frontalis muscle (Theile). It is marked by numerous small arterial furrows, and perforated about its centre by a foramen, sometimes double, for the transmission of a small vein. Sometimes this foramen is absent on one or both sides, and occasionally the foramen cæcum opens on this surface. The *inner* surface is concave from side to side, convex from above downward; in which direction it is traversed by a longitudinal groove (sometimes a canal), for the passage of a branch of the nasal nerve. The *superior* border is narrow, thick, and serrated, for articulation with the nasal notch of the frontal bone. The *inferior* border is broad, thin, sharp, inclined obliquely downward, outward, and backward, and serves for the attachment of the lateral cartilage of the nose. This border presents, about its middle, a notch, through which passes the branch of the nasal nerve above referred to, and is prolonged at its inner extremity into a sharp spine, which, when articulated with the opposite bone, forms the *nasal angle*. The *external* border is serrated, bevelled at the expense of the internal surface above and of the external below, to articulate with the nasal process of the superior maxillary. The *internal* border, thicker above than below, articulates with its fellow of the opposite side, and is prolonged behind into a vertical crest which forms part of the septum of the nose; this crest articulates with the nasal spine of the frontal above, and the perpendicular plate of the ethmoid below.

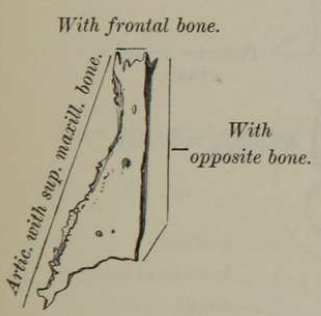

Outer Surface.

FIG. 152.—Right nasal bone.

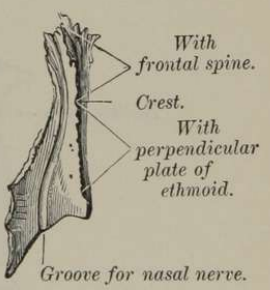

Inner Surface.

FIG. 153.—Left nasal bone.

Development.—By *one* centre for each bone, which appears about the same period as in the vertebræ.

Articulations.—With four bones: two of the cranium, the frontal and ethmoid, and two of the face, the opposite nasal and the superior maxillary.

Attachment of Muscles.—A few fibres of the Occipito-frontalis muscle.

The Superior Maxillary Bones.

The **Superior Maxillary** (*maxilla*, the jaw-bone) is one of the most important bones of the face from a surgical point of view, on account of the number of diseases to which some of its parts are liable. Its careful examination becomes, therefore, a matter of considerable interest. It is the largest bone of the face, excepting the lower jaw, and forms, by its union with its fellow of the opposite side, the whole

[1] W. W. Keen, American edition, p. 185.

of the upper jaw. Each bone assists in the formation of three cavities, the roof of the mouth, the floor and outer wall of the nasal fossæ, and the floor of the orbit, and also enters into the formation of two fossæ, the zygomatic and spheno-maxillary, and two fissures, the spheno-maxillary and pterygo-maxillary.

The bone presents for examination a body and four processes—malar, nasal, alveolar, and palate.

The **body** is somewhat cuboid, and is hollowed out in its interior to form a large cavity, the *antrum of Highmore*. Its surfaces are four—an external or facial, a posterior or zygomatic, a superior or orbital, and an internal.

The **external** or **facial surface** (Fig. 154) is directed forward and outward. Just above the incisor teeth is a depression, the *incisive* or *myrtiform fossa*, which gives origin to the Depressor alæ nasi; and below it to the alveolar border is attached a slip of the Orbicularis oris. Above and a little external to it the Compressor nasi arises. More external is another depression, the *canine fossa*,

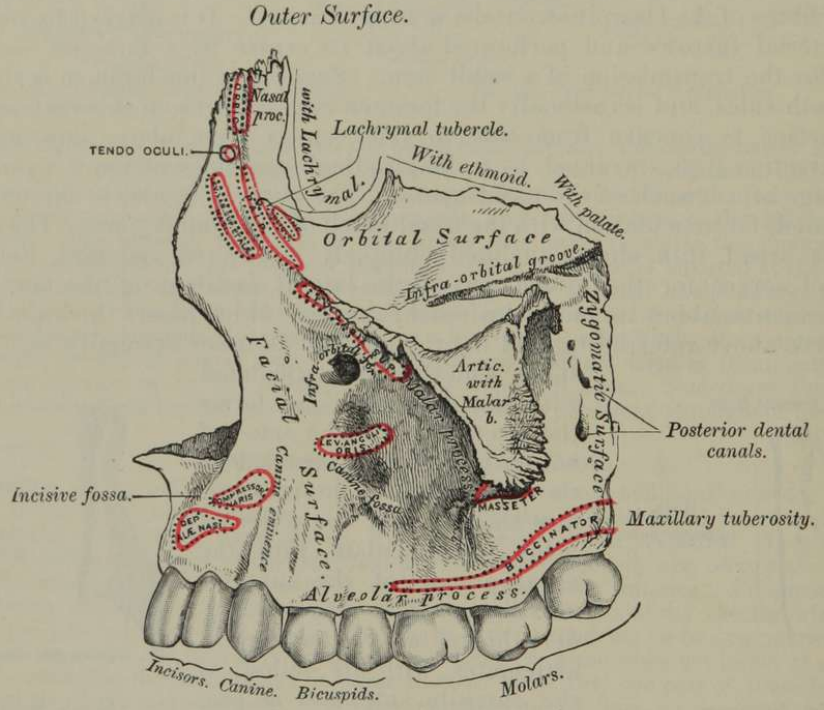

FIG. 154.—Left superior maxillary bone. Outer surface.

larger and deeper than the incisive fossa, from which it is separated by a vertical ridge, the *canine eminence*, corresponding to the socket of the canine tooth. The canine fossa gives origin to the Levator anguli oris. Above the canine fossa is the *infraorbital foramen*, the termination of the infraorbital canal; it transmits the infraorbital vessels and nerve. Above the infraorbital foramen is the margin of the orbit, which affords partial attachment to the Levator labii superioris proprius. To the sharp margin of bone which bounds this surface in front and separates it from the internal surface is attached the Dilator naris posterior.

The **posterior** or **zygomatic surface** is convex, directed backward and outward, and forms part of the zygomatic fossa. It presents about its centre several apertures leading to canals in the substance of the bone; they are termed the *posterior dental canals*, and transmit the posterior dental vessels and nerves. At the lower part of this surface is a rounded eminence, the *maxillary tuberosity*, especially prominent after the growth of the wisdom-tooth, rough on its inner side for articulation with the tuberosity of the palate bone, and sometimes with the external pterygoid plate. It gives attachment to a few fibres of origin of the Internal

pterygoid muscle. Immediately above the rough surface is a groove which, running obliquely down on the inner surface of the bone, is converted into a canal by articulation with the palate-bone forming the *posterior palatine* canal.

The **superior** or **orbital surface** is thin, smooth, triangular, and forms part of the floor of the orbit. It is bounded internally by an irregular margin which in front presents a notch, the *lachrymal notch*, which receives the lachrymal bone; in the middle articulates with the os planum of the ethmoid, and behind with the orbital process of the palate bone; bounded externally by a smooth, rounded edge which enters into the formation of the spheno-maxillary fissure, and which sometimes articulates at its anterior extremity with the orbital plate of the sphenoid; bounded in front by part of the circumference of the orbit, which is continuous on the inner side with the nasal, on the outer side with the malar, process. Along the middle line of the orbital surface is a deep groove, the *infraorbital*, for the passage of the infraorbital vessels and nerve. The groove commences at the middle of the outer border of this surface, and, passing forward, terminates in a canal, which subdivides into two branches. One of the canals, the *infraorbital*, opens just below the margin of the orbit; the other, which is smaller, runs in the substance of the anterior wall of the antrum; it is called the *anterior dental* canal, and transmits the anterior dental vessels and nerve to the front teeth of the upper jaw. From the back part of the infraorbital canal a second small canal is sometimes given off, which runs in the substance of the bone, and conveys the middle dental nerve to the bicuspid teeth. Occasionally, this canal is derived from the anterior dental. At the inner and fore part of the orbital surface, just external to the lachrymal groove for the nasal duct, is a depression which gives origin to the Inferior oblique muscle of the eye.

The **internal surface** (Fig. 155) is unequally divided into two parts by a horizontal projection of bone, the *palate process:* the portion above the palate process

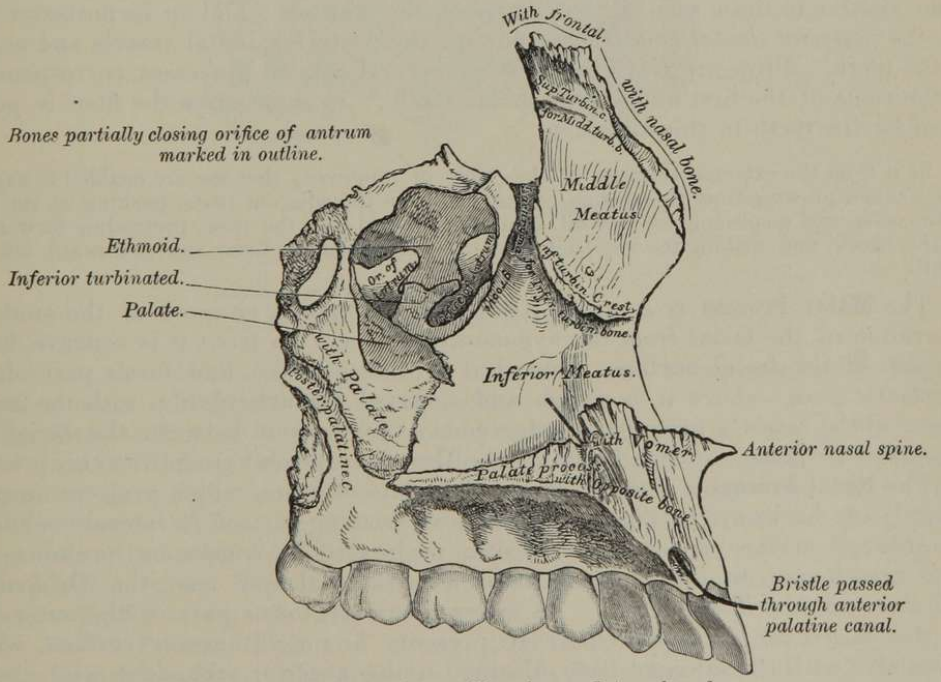

FIG. 155.—Left superior maxillary bone. Internal surface.

forms part of the outer wall of the nasal fossæ; that below it forms part of the cavity of the mouth. The superior division of this surface presents a large, irregular opening leading into the *antrum of Highmore*. At the upper border of this aperture are numerous broken cellular cavities, which in the articulated skull are closed in by the ethmoid and lachrymal bones. Below the aperture is a smooth

concavity which forms part of the inferior meatus of the nasal fossæ, and behind it is a rough surface which articulates with the perpendicular plate of the palate bone, traversed by a groove which, commencing near the middle of the posterior border, runs obliquely downward and forward, and forms, when completed by its articulation with the palate bone, the *posterior palatine canal*. In front of the opening of the antrum is a deep groove, converted into a canal by the lachrymal and inferior turbinated bones. It is called the *lachrymal groove*, and lodges the nasal duct. More anteriorly is a well-marked rough ridge, the *inferior turbinated crest*, for articulation with the inferior turbinated bone. The concavity above this ridge forms part of the middle meatus of the nose, whilst that below it forms part of the inferior meatus. The portion of this surface below the palate process is concave, rough and uneven, and perforated by numerous small foramina for the passage of nutrient vessels. It enters into the formation of the roof of the mouth.

The **Antrum of Highmore**, or **Maxillary Sinus**, is a large, pyramidal cavity hollowed out of the body of the maxillary bone: its apex, directed outward, is formed by the malar process; its base, by the outer wall of the nose. Its walls are everywhere exceedingly thin, and correspond to the orbital, facial, and zygomatic surfaces of the body of the bone. Its inner wall, or base, presents, in the disarticulated bone, a large, irregular aperture, which communicates with the nasal fossa. The margins of this aperture are thin and ragged, and the aperture itself is much contracted by its articulation with the ethmoid above, the inferior turbinated below, and the palate bone behind.[1] In the articulated skull this cavity communicates with the middle meatus of the nasal fossæ, generally by two small apertures left between the above-mentioned bones. In the recent state usually only one small opening exists, near the upper part of the cavity, sufficiently large to admit the end of a probe, the other being closed by the lining membrane of the sinus.

Crossing the cavity of the antrum are often seen several projecting laminæ of bone, similar to those seen in the sinuses of the cranium; and on its posterior wall are the *posterior dental canals*, transmitting the posterior dental vessels and nerves to the teeth. Projecting into the floor are several conical processes, corresponding to the roots of the first and second molar teeth;[2] in some cases the floor is perforated by the teeth in this situation.

It is from the extreme thinness of the walls of this cavity that we are enabled to explain how a tumor growing from the antrum encroaches upon the adjacent parts, pushing up the floor of the orbit, and displacing the eyeball, projecting inward into the nose, protruding forward on to the cheek, and making its way backward into the zygomatic fossa and downward into the mouth.

The **Malar Process** is a rough, triangular eminence, situated at the angle of separation of the facial from the zygomatic surface. In front it is concave, forming part of the facial surface; behind it is also concave, and forms part of the zygomatic fossa; above it is rough and serrated for articulation with the malar bone; whilst below a prominent ridge marks the division between the facial and zygomatic surfaces. A small part of the Masseter muscle arises from this process.

The **Nasal Process** is a thick, triangular plate of bone, which projects upward, inward, and backward by the side of the nose, forming part of its lateral boundary. Its *external* surface is concave, smooth, perforated by numerous foramina, and gives attachment to the Levator labii superioris alæque nasi, the Orbicularis palpebrarum, and Tendo oculi. Its *internal* surface forms part of the outer wall of the nose: at its upper part it presents a rough, uneven surface, which articulates with the ethmoid bone, closing in the anterior ethmoidal cells; below this is a transverse ridge, the *superior turbinated crest*, for articulation with the

[1] In some cases, at any rate, the lachrymal bone encroaches slightly on the anterior superior portion of the opening, and assists in forming the inner wall of the antrum.

[2] The number of teeth whose fangs are in relation with the floor of the antrum is variable. The antrum "may extend so as to be in relation to all the teeth of the true maxilla, from the canine to the *dens sapientiæ*." (See Mr. Salter on Abscess of the Antrum, in a *System of Surgery*, edited by T. Holmes, 2d ed. vol. iv. p. 356.)

middle turbinated bone of the ethmoid, bounded below by a smooth concavity which forms part of the middle meatus; below this again is the inferior turbinated crest (already described), where the process joins the body of the bone. Its upper border articulates with the frontal bone. The *anterior* border of the nasal process is thin, directed obliquely downward and forward, and presents a serrated edge for articulation with the nasal bone; its *posterior* border is thick, and hollowed into a groove, the *lachrymal groove*, for the nasal duct: of the two margins of this groove, the inner one articulates with the lachrymal bone, the outer one forms part of the circumference of the orbit. Just where the latter joins the orbital surface is a small tubercle, the *lachrymal tubercle;* this serves as a guide to the position of the lachrymal sac in the operation for fistula lachrymalis. The lachrymal groove in the articulated skull is converted into a canal by the lachrymal bone and lachrymal process of the inferior turbinated; it is directed downward, and a little backward and outward, is about the diameter of a goose-quill, slightly

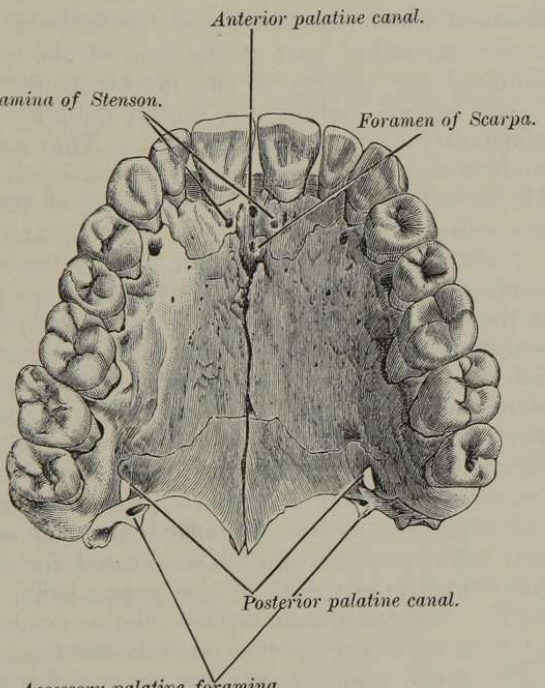

FIG. 156.—The palate and alveolar arch.

narrower in the middle than at either extremity, and terminates below in the inferior meatus. It lodges the nasal duct.

The **Alveolar Process** is the thickest and most spongy part of the bone, broader behind than in front, and excavated into deep cavities for the reception of the teeth. These cavities are eight in number, and vary in size and depth according to the teeth they contain. That for the canine tooth is the deepest; those for the molars are the widest, and subdivided into minor cavities; those for the incisors are single, but deep and narrow. The Buccinator muscle arises from the outer surface of this process, as far forward as the first molar tooth.

The **Palate Process,** thick and strong, projects horizontally inward from the inner surface of the bone. It is much thicker in front than behind, and forms a considerable part of the floor of the nostril and the roof of the mouth.

Its *inferior* surface (Fig. 156) is concave, rough and uneven, and forms part of the roof of the mouth. This surface is perforated by numerous foramina for the passage of the nutrient vessels, channelled at the back part of its alveolar border by a longitudinal groove, sometimes a canal, for the transmission of the posterior palatine vessels, and the anterior and external palatine nerves from Meckel's gan-

glion, and presents little depressions for the lodgment of the palatine glands. When the two superior maxillary bones are articulated together, a large orifice may be seen in the middle line, immediately behind the incisor teeth. This is the *anterior palatine canal* or *fossa*. This canal, as it passes through the thickness of the palate process, is divided into four compartments; that is to say, two canals branch off laterally to the right and left nasal fossæ, and two canals, one in front and one behind, lie in the middle line. The former pair of these canals is named the *foramina of Stenson*, and through them passes the anterior or terminal branch of the descending or posterior palatine arteries, which ascend from the mouth to the nasal fossæ. The remaining pair of canals is termed the *foramina of Scarpa*, and transmit the naso-palatine nerves, the left passing through the anterior, and the right through the posterior, canal. On the palatal surface of the process a delicate linear suture may sometimes be seen extending from the anterior palatine fossa to the interval between the lateral incisor and the canine tooth. This marks out the intermaxillary or incisive bone which in some animals exists permanently as a separate piece. It includes the whole thickness of the alveolus, the corresponding part of the floor of the nose, and the anterior nasal spine, and contains the sockets of the incisor teeth. One or two small foramina in the alveolar margin behind the incisor teeth are occasionally seen in the adult, almost constantly in the young subject. They are called the incisive foramina, and transmit vessels and nerves to the incisor teeth. The *upper* surface is concave from side to side, smooth, and forms part of the floor of the nose. It presents the upper orifices of the foramina of Stenson and Scarpa, the former being on each side of the middle line, the latter being situated in the intermaxillary suture, and therefore not visible unless the two bones are placed in apposition. The *outer* border of the palate process is incorporated with the rest of the bone. The *inner* border is thicker in front than behind, and is raised above into a ridge, the *nasal crest*, which, with the corresponding ridge in the opposite bone, forms a groove for the reception of the vomer. In front this crest rises to a considerable height, and this portion is named the *incisor crest*. The *anterior* margin is bounded by the thin, concave border of the opening of the nose, prolonged forward internally into a sharp process, forming, with a similar process of the opposite bone, the *anterior nasal spine*. The *posterior* border is serrated for articulation with the horizontal plate of the palate bone.

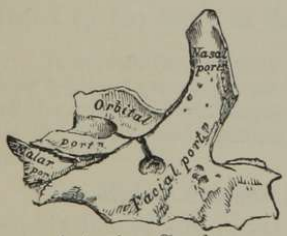

Anterior Surface.

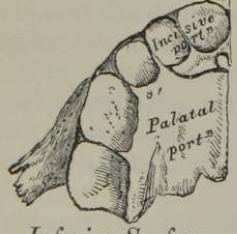

Inferior Surface.

FIG. 157.—Development of superior maxillary bone. At birth.

Development.—This bone commences to ossify at a very early period, and ossification proceeds in it with great rapidity, so that it is difficult to ascertain with certainty its precise number of centres. It appears, however, probable that it is ossified by five primary and two secondary centres. The primary centres appear about the seventh or eighth week; first, one each for the facial surface, the posterior part of the alveolus, and the orbital plate, and a few days later one for the palate process, and one for the front part of the alveolus, which carries the incisor teeth, and which corresponds to the pre-maxillary bone of the lower animals. All these, except the last, speedily fuse, and the two secondary centres, one for the nasal process and the other for the malar process, appear and join the rest of the bone. By the tenth week the bone consists of two portions—the greater part of the bone formed of six out of the seven centres and the pre-maxillary portion. The suture between these two portions on the palate persists till middle life, but is not to be seen on the facial surface. This is believed by Callender to be due to the fact that the front wall of the sockets of the incisive teeth is not formed by the pre-maxillary bone, but by an outgrowth from the facial part of the

superior maxilla. The antrum appears as a shallow groove on the inner surface of the bone at an earlier period than any of the other nasal sinuses, its development commencing about the fourth month of fœtal life. The sockets for the teeth are formed by the growing downward of two plates from the dental groove, which subsequently becomes divided by partitions jutting across from the one to the other.

Articulations.—With *nine* bones: two of the cranium, the frontal and ethmoid, and seven of the face—viz. the nasal, malar, lachrymal, inferior turbinated, palate, vomer, and its fellow of the opposite side. Sometimes it articulates with the orbital plate of the sphenoid, and sometimes with its external pterygoid plate.

Attachment of Muscles.—To twelve: the Orbicularis palpebrarum, Obliquus oculi inferior, Levator labii superioris alæque nasi, Levator labii superioris proprius, Levator anguli oris, Compressor nasi, Depressor alæ nasi, Dilatator naris posterior, Masseter, Buccinator, Internal pterygoid, and Orbicularis oris.

CHANGES PRODUCED IN THE UPPER JAW BY AGE.

At birth and during infancy the diameter of the bone is greater in an antero-posterior than in a vertical direction. Its nasal process is long, its orbital surface large, and its tuberosity well marked. In the adult the vertical diameter is the greater, owing to the development of the alveolar process and the increase in size of the antrum. In old age the bone approaches again in character to the infantile condition: its height is diminished, and after the loss of the teeth the alveolar process is absorbed, and the lower part of the bone contracted and diminished in thickness.

The Lachrymal Bones.

The **Lachrymal** (*lachryma*, a tear) are the smallest and most fragile bones of the face. They are situated at the front part of the inner wall of the orbit, and resemble somewhat in form, thinness, and size, a finger-nail; hence they are termed the *ossa unguis*. Each bone presents for examination two surfaces and four borders. The **external** or **orbital** surface (Fig. 158) is divided by a vertical ridge, the *lachrymal crest*, into two parts. The portion of bone in front of this ridge presents a smooth, concave, longitudinal groove, the free margin of which unites with the nasal process of the superior maxillary bone, completing the lachrymal groove. The upper part of this groove lodges the lachrymal sac; the lower part lodges the nasal duct. The portion of bone behind the ridge is smooth, slightly concave, and forms part of the inner wall of the orbit. The ridge, with a part of the orbital surface immediately behind it, affords attachment to the Tensor tarsi: the ridge terminates below in a small, hook-like projection, the *hamular process*, which articulates with the lachrymal tubercle of the superior maxillary bone, and completes the upper orifice of the lachrymal groove. It sometimes exists as a separate piece, which is then called the *lesser lachrymal bone*. The *internal* or *nasal* surface presents a depressed furrow, corresponding to the ridge on its outer surface. The surface of bone in front of this forms part of the middle meatus, and that behind it articulates with the ethmoid bone, filling in the anterior ethmoidal cells. Of the *four borders*, the *anterior* is the longest, and articulates with the nasal process of the superior maxillary bone. The *posterior*, thin and uneven, articulates with the os planum of the ethmoid. The *superior*, the shortest and thickest, articulates with the internal angular process of the frontal bone. The *inferior* is divided by the lower edge of the vertical crest into two parts; the posterior part articulates with the orbital plate of the superior maxillary bone; the anterior portion is prolonged downward into a pointed process, which articulates with the lachrymal process of the inferior turbinated bone and assists in the formation of the lachrymal groove.

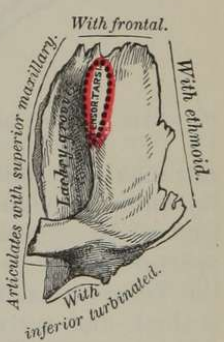

FIG. 158.—Left lachrymal bone. External surface. (Slightly enlarged.)

Development.—By a single centre, which makes its appearance soon after ossification of the vertebræ has commenced.

Articulations.—With four bones: two of the cranium, the frontal and ethmoid, and two of the face, the superior maxillary and the inferior turbinated.

Attachment of Muscles.—To one muscle, the Tensor tarsi.

The Malar Bones.

The **Malar** (*mala*, the cheek) are two small, quadrangular bones, situated at the upper and outer part of the face: they form the prominence of the cheek, part of the outer wall and floor of the orbit, and part of the temporal and zygomatic fossæ. Each bone presents for examination an external and an internal surface; four processes, the frontal, orbital, maxillary, and zygomatic; and four borders. The **external surface** (Fig. 159) is smooth, convex, perforated near its centre by one or two small apertures, the *malar foramina*, for the passage of nerves and vessels, covered by the Orbicularis palpebrarum muscle, and affords attachment to the Zygomaticus major and minor muscles.

The **internal surface** (Fig. 160), directed backward and inward, is concave, presenting internally a rough, triangular surface, for articulation with the supe-

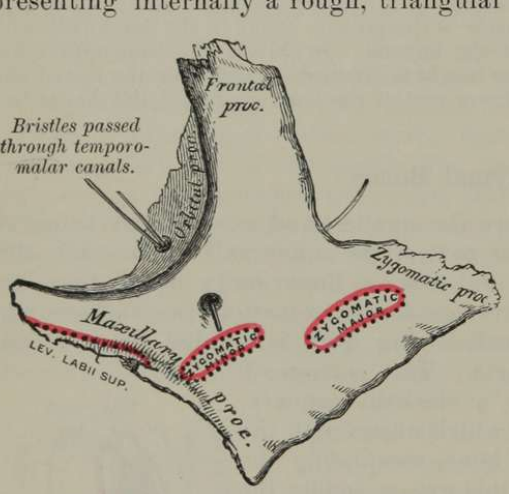

FIG. 159.—Left malar bone. Outer surface.

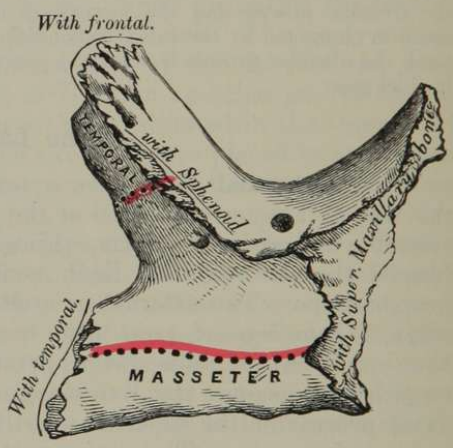

FIG. 160.—Left malar bone. Inner surface.

rior maxillary bone; and externally, a smooth, concave surface, which above forms the anterior boundary of the temporal fossa, and below, where it is wider, forms part of the zygomatic fossa. This surface presents, a little above its centre, the aperture of one or two malar canals, and affords attachment to part of two muscles, the Temporal above and the Masseter below. Of the four processes, the **frontal** is thick and serrated, and articulates with the external angular process of the frontal bone. The **orbital** process is a thick and strong plate, which projects backward from the orbital margin of the bone. Its *supero-internal* surface, smooth and concave, forms, by its junction with the orbital surface of the superior maxillary bone and with the great wing of the sphenoid, part of the floor and outer wall of the orbit. Its *infero-external* surface, smooth and convex, forms part of the zygomatic and temporal fossæ. Its *anterior* margin is smooth and rounded, forming part of the circumference of the orbit. Its *superior* margin, rough and directed horizontally, articulates with the frontal bone behind the external angular process. Its *posterior* margin is rough, and serrated for articulation with the sphenoid; *internally* it is also serrated for articulation with the orbital surface of the superior maxillary. At the angle of junction of the sphenoidal and maxillary portions a short, rounded, non-articular margin is generally seen; this forms the anterior boundary of the spheno-maxillary fissure: occasionally, no such non-articular margin exists, the fissure being completed by the direct junction of the maxillary and sphenoid bones or by the interposition of a small

Wormian bone in the angular interval between them. On the *upper* surface of the orbital process are seen the orifices of one or two temporo-malar canals; one of these usually opens on the posterior surface, the other (occasionally two) on the facial surface: they transmit filaments (temporo-malar) of the orbital branch of the superior maxillary nerve. The **maxillary** process is a rough, triangular surface which articulates with the superior maxillary bone. The **zygomatic** process, long, narrow, and serrated, articulates with the zygomatic process of the temporal bone. Of the **four borders,** the *antero-superior* or *orbital* is smooth, arched, and forms a considerable part of the circumference of the orbit. The *antero-inferior* or *maxillary* border is rough, and bevelled at the expense of its inner table, to articulate with the superior maxillary bone; affording attachment by its margin to the Levator labii superioris proprius, just at its point of junction with the superior maxillary. The *postero-superior* or *temporal* border, curved like an italic letter *f*, is continuous above with the commencement of the temporal ridge; below, with the upper border of the zygomatic arch: it affords attachment to the temporal fascia. The *postero-inferior* or *zygomatic* border is continuous with the lower border of the zygomatic arch, affording attachment by its rough edge to the Masseter muscle.

Development.—The malar bone ossifies generally from two, but occasionally from three, centres. One, which forms the chief part of the bone, appears about the seventh week, near the orbital margin. The second appears somewhat later, along the lower margin. The third, when it exists, is found in the hinder border. The bone is sometimes, after birth, seen to be divided by a horizontal suture into an upper and larger division and a lower and smaller. This divided condition is probably due to the persistent separation of the two centres of ossification. In some quadrumana the malar bone consists of two parts, an orbital and a malar, which are ossified by separate centres.

Articulations.—With four bones: three of the cranium, frontal, sphenoid, and temporal; and one of the face, the superior maxillary.

Attachment of Muscles.—To five: The Levator labii superioris proprius, Zygomaticus major and minor, Masseter, and Temporal.

The Palate Bones.

The **Palate Bones** (*palatum*, the palate) are situated at the back part of the nasal fossæ: they are wedged in between the superior maxillary bones and the pterygoid processes of the sphenoid. Each bone assists in the formation of three cavities: the floor and outer wall of the nose, the roof of the mouth, and the floor of the orbit, and enters into the formation of two fossæ, the spheno-maxillary and pterygoid; and one fissure, the spheno-maxillary. In form the palate bone somewhat resembles the letter L, and may be divided into an inferior or horizontal plate and a superior or vertical plate.

The **Horizontal Plate** is thick, of a quadrilateral form, and presents two surfaces and four borders. The *superior* surface, concave from side to side, forms the back part of the floor of the nostril. The *inferior* surface, slightly concave and rough, forms the back part of the hard palate. At its posterior part may be seen a transverse ridge, more or less marked, for the attachment of part of the aponeurosis of the Tensor palati muscle. At the outer extremity of this ridge is a deep groove converted into a canal by its articulation with the tuberosity of the superior maxillary bone, and forming the *posterior palatine canal.* Near this groove the orifices of one or two small canals, *accessory posterior palatine*, may be seen. The *anterior* border is serrated, bevelled at the expense of its inferior surface, and articulates with the palate process of the superior maxillary bone. The *posterior* border is concave, free, and serves for the attachment of the soft palate. Its inner extremity is sharp and pointed, and, when united with the opposite bone, forms a projecting process, the *posterior nasal spine*, for the attachment of the Azygos uvulæ. The *external* border is united with the lower part of the perpen-

dicular plate almost at right angles. The *internal* border, the thickest, is serrated for articulation with its fellow of the opposite side; its superior edge is raised into a ridge, which, united with the opposite bone, forms a crest in which the vomer is received.

The **Vertical Plate** (Fig. 161) is thin, of an oblong form, and directed upward and a little inward. It presents two surfaces, an external and an internal, and four borders.

The **internal surface** presents at its lower part a broad, shallow depression, which forms part of the inferior meatus of the nose. Immediately above this is a well-marked horizontal ridge, the *inferior turbinated crest*, for articulation with the inferior turbinated bone; above this, a second broad, shallow depression, which forms part of the middle meatus, surmounted above by a horizontal ridge less prominent than the inferior, the *superior turbinated crest*, for articulation with the middle turbinated bone. Above the superior turbinated crest is a narrow, horizontal groove, which forms part of the superior meatus.

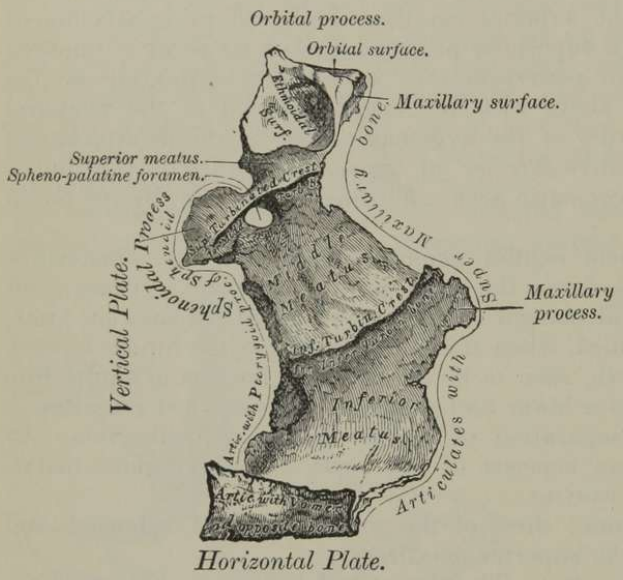

FIG. 161.—Left palate bone. Internal view. (Enlarged.)

The **external surface** is rough and irregular throughout the greater part of its extent, for articulation with the inner surface of the superior maxillary bone, its upper and back part being smooth where it enters into the formation of the spheno-maxillary fossa; it is also smooth in front, where it covers the orifice of the antrum. Toward the back part of this surface is a deep groove, converted into a canal, the *posterior palatine*, by its articulation with the superior maxillary bone. It transmits the posterior or descending palatine vessels and one of the descending palatine branches from Meckel's ganglion.

The *anterior* border is thin, irregular, and presents, opposite the inferior turbinated crest, a pointed, projecting lamina, the *maxillary process*, which is directed forward, and closes in the lower and back part of the opening of the antrum. The *posterior* border (Fig. 162) presents a deep groove, the edges of which are serrated for articulation with the pterygoid process of the sphenoid. At the lower part of this border is seen a pyramidal process of bone, the *pterygoid process* or tuberosity of the palate, which is received into the angular interval between the two pterygoid plates of the sphenoid at their inferior extremity. This process presents at its back part a median groove and two lateral surfaces. The groove is smooth, and forms part

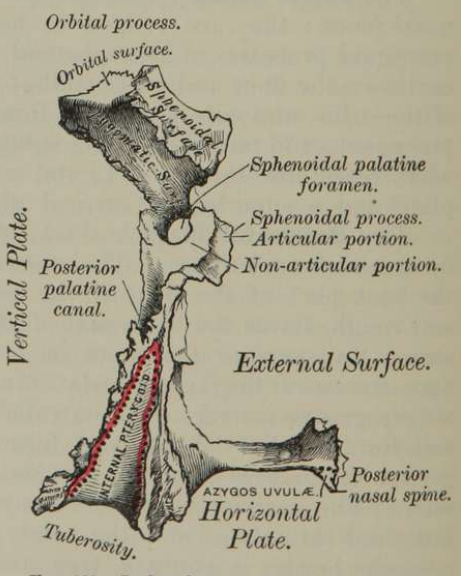

FIG. 162.—Left palate bone. Posterior view. (Enlarged.)

of the pterygoid fossa, affording attachment to the Internal pterygoid muscle; whilst the lateral surfaces are rough and uneven, for articulation with the anterior border of each pterygoid plate. A few fibres of the Superior constrictor arise from the tuberosity of the palate bone. The base of this process, continuous with the horizontal portion of the bone, presents the apertures of the *accessory descending palatine canals*, through which pass the two smaller descending branches of Meckel's ganglion; whilst its outer surface is rough for articulation with the inner surface of the body of the superior maxillary bone.

The *superior* border of the vertical plate presents two well-marked processes separated by an intervening notch or foramen. The anterior, or larger, is called the *orbital process;* the posterior, the *sphenoidal.*

The **Orbital Process,** directed upward and outward, is placed on a higher level than the sphenoidal. It presents five surfaces, which enclose a hollow cellular cavity, and is connected to the perpendicular plate by a narrow, constricted neck. Of these five surfaces, three are articular, two non-articular or free surfaces. The three articular are the *anterior* or *maxillary* surface, which is directed forward, outward, and downward, is of an oblong form, and rough for articulation with the superior maxillary bone. The *posterior* or *sphenoidal* surface is directed backward, upward, and inward. It ordinarily presents a small, open cell, which communicates with the sphenoidal cells, and the margins of which are serrated for articulation with the vertical part of the sphenoidal turbinated bone. The *internal* or *ethmoidal* surface is directed inward, upward, and forward, and articulates with the lateral mass of the ethmoid bone. In some cases the cellular cavity above mentioned opens on this surface of the bone; it then communicates with the posterior ethmoidal cells. More rarely it opens on both surfaces, and then communicates both with the posterior ethmoidal and the sphenoidal cells. The non-articular or free surfaces are the *superior* or *orbital*, directed upward and outward, of triangular form, concave, smooth, and forming the back part of the floor of the orbit; and the *external* or *zygomatic* surface, directed outward, backward, and downward, of an oblong form, smooth, lying in the spheno-maxillary fossa, and looking into the zygomatic fossa. The latter surface is separated from the orbital by a smooth, rounded border, which enters into the formation of the spheno-maxillary fissure.

The **Sphenoidal Process** of the palate bone is a thin, compressed plate, much smaller than the orbital, and directed upward and inward. It presents three surfaces and two borders. The *superior* surface, the smallest of the three, articulates with the under surface of the sphenoidal turbinated bone; it presents a groove, which contributes to the formation of the pterygo-palatine canal. The *internal* surface is concave, and forms part of the outer wall of the nasal fossa. The *external* surface is divided into an articular and a non-articular portion: the former is rough, for articulation with the inner surface of the pterygoid process of the sphenoid; the latter is smooth, and forms part of the spheno-maxillary fossa. The *anterior* border forms the posterior boundary of the spheno-palatine foramen. The *posterior* border, serrated at the expense of the outer table, articulates with the inner surface of the pterygoid process.

The orbital and sphenoidal processes are separated from one another by a deep notch, which is converted into a foramen, the *spheno-palatine*, by articulation with the sphenoidal turbinated bone. Sometimes the two processes are united above, and form between them a complete foramen, or the notch is crossed by one or more spiculæ of bone, so as to form two or more foramina. In the articulated skull this foramen opens into the back part of the outer wall of the superior meatus, and transmits the spheno-palatine vessels and the superior nasal and naso-palatine nerves.

Development.—From a single centre, which makes its appearance about the second month at the angle of junction of the two plates of the bone. From this point ossification spreads inward to the horizontal plate, downward into the tuberosity, and upward into the vertical plate. In the fœtus the horizontal plate

is much longer than the vertical, and even after it is fully ossified the whole bone is at first remarkable for its shortness.

Articulations.—With six bones: the sphenoid, ethmoid, superior maxillary, inferior turbinated, vomer, and opposite palate.

Attachment of Muscles.—To four: the Tensor palati, Azygos uvulæ, Internal pterygoid, and Superior constrictor of the pharynx.

The Inferior Turbinated Bones.

The **Inferior Turbinated Bones** (*turbo*, a whirl) are situated one on each side of the outer wall of the nasal fossæ. Each consists of a layer of thin, spongy bone, curled upon itself like a scroll—hence its name "turbinated"—and extends horizontally along the outer wall of the nasal fossa, immediately below the orifice of the antrum. Each bone presents two surfaces, two borders, and two extremities.

The **internal surface** (Fig. 163) is convex, perforated by numerous apertures, and traversed by longitudinal grooves and canals for the lodgment of arteries and

FIG. 163.—Right inferior turbinated bone. Internal surface.

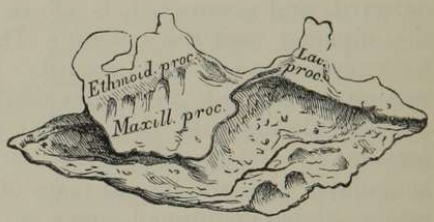

FIG. 164.—Right inferior turbinated bone. External surface.

veins. In the recent state it is covered by the lining membrane of the nose. The **external surface** is concave (Fig. 164), and forms part of the inferior meatus. Its *upper border* is thin, irregular, and connected to various bones along the outer wall of the nose. It may be divided into three portions: of these, the anterior articulates with the inferior turbinated crest of the superior maxillary bone; the posterior with the inferior turbinated crest of the palate bone; the middle portion of the superior border presents three well-marked processes, which vary much in their size and form. Of these, the anterior and smallest is situated at the junction of the anterior fourth with the posterior three-fourths of the bone: it is small and pointed, and is called the *lachrymal process;* it articulates by its apex with the anterior inferior angle of the lachrymal bone, and by its margins with the groove on the back of the nasal process of the superior maxillary, and thus assists in forming the canal for the nasal duct. At the junction of the two middle fourths of the bone, but encroaching on its posterior fourth, a broad, thin plate, the *ethmoidal process*, ascends to join the unciform process of the ethmoid; from the lower border of this process a thin lamina of bone curves downward and outward, articulating by its lower margin with the lower edge of the orifice of the antrum: it is called the *maxillary process*, and fixes the bone firmly on to the outer wall of the nasal fossa. The *inferior border* is free, thick, and cellular in structure, more especially in the middle of the bone. Both *extremities* are more or less narrow and pointed, the posterior being the more tapering. If the bone is held so that its outer concave surface is directed backward (*i. e.* toward the holder), and its superior border, from which the lachrymal and ethmoidal processes project, upward, the lachrymal process will be directed to the side to which the bone belongs.[1]

Development.—By a single centre, which makes its appearance about the middle of fœtal life.

Articulations.—With four bones: one of the cranium, the ethmoid, and three of the face, the superior maxillary, lachrymal, and palate.

No muscles are attached to this bone.

[1] If the lachrymal process is broken off, as is often the case, the side to which the bone belongs may be known by recollecting that the maxillary process is nearer the back than the front of the bone.

The Vomer.

The **Vomer** (*vomer*, a ploughshare) is a single bone, situated vertically at the back part of the nasal fossæ, forming part of the septum of the nose. It is thin, somewhat like a ploughshare in form; but it varies in different individuals, being frequently bent to one or the other side; it presents for examination two surfaces and five borders. The *lateral surfaces* are smooth, marked by small furrows for the lodgment of blood-vessels, and by a groove on each side, sometimes a canal, the *naso-palatine*, which runs obliquely downward and forward to the intermaxillary suture; it transmits the naso-palatine nerve. The *postero-superior border*, the thickest, presents a deep groove, bounded on each side by a horizontal projecting ala of bone; the groove receives the rostrum of the sphenoid, whilst the alæ are overlapped and retained by laminæ (the *vaginal processes*) which project from the under surface of the body of the sphenoid at the base of the pterygoid processes. At the front of the groove a fissure is left for the transmission of blood-vessels to the substance of the bone. The *inferior border*, the longest, is broad and uneven in front, where it articulates with the two superior maxillary bones; thin and sharp behind, where it joins with the palate bones. The upper half of the *antero-superior border* usually consists of two laminæ of bone, between which is received the perpendicular plate of the ethmoid; the lower half, also separated into two laminæ, receives between them the lower margin of the triangular cartilage of the nose. The *anterior border* is short and vertical, and articulates with the posterior margin of the incisor crest of each superior maxilla. The *posterior border* is free, concave, and separates the nasal fossæ behind. It is thick and bifid above, thin below.

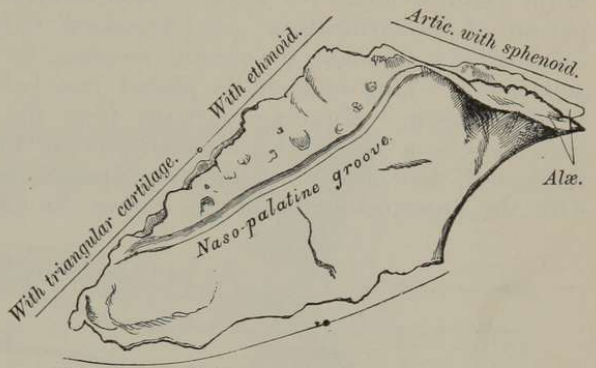

FIG. 165.—The vomer.

The surfaces of the vomer are covered by mucous membrane, which is intimately connected with the periosteum, with the intervention of very little, if any, submucous connective tissue.

Development.—The vomer at an early period consists of two laminæ, separated by a very considerable interval, and enclosing between them a plate of cartilage, which is prolonged forward to form the remainder of the septum. Ossification commences in it by a single centre about the eighth week. From this nucleus the two laminæ are formed. They begin to coalesce at the lower part, but their union is not complete until after puberty.

Articulations.—With six bones: two of the cranium, the sphenoid and ethmoid; and four of the face, the two superior maxillary and the two palate bones; and with the cartilage of the septum.

The vomer has no muscles attached to it.

The Inferior Maxillary Bone.

The **Inferior Maxillary Bone** (the *Mandible*), the largest and strongest bone of the face, serves for the reception of the lower teeth. It consists of a curved, horizontal portion, the *body*, and two perpendicular portions, the *rami*, which join the back part of the body nearly at right angles.

The **Horizontal Portion** or **Body** (Fig. 166), is convex in its general outline, and curved somewhat like a horseshoe. It presents for examination two surfaces and two borders. The **external surface** is convex from side to side, concave from

above downward. In the median line is a vertical ridge, the *symphysis*, which extends from the upper to the lower border of the bone, and indicates the point of junction of the two pieces of which the bone is composed at an early period of life. The lower part of the ridge terminates in a prominent triangular eminence, the *mental process*. This eminence is rounded below, and often presents a median depression separating two processes, the *mental tubercles*. It forms the chin, a feature peculiar to the human skull. On either side of the symphysis, just below the cavities for the incisor teeth, is a depression, the *incisive fossa*, for the attachment of the Levator menti (or Levator labii inferioris); more externally is attached a portion of the Orbicularis oris (*Accessorii Orbicularis inferioris*), and, still more externally, a foramen, the *mental foramen*, for the passage of the mental vessels and nerve. This foramen is placed just below the interval between the two bicuspid teeth. Running outward from the base of the mental process on each side is a ridge, the *external oblique* line. The ridge is at first nearly horizontal, but afterward inclines upward and backward, and is continuous with the anterior border of the ramus: it affords attachment to the Depressor

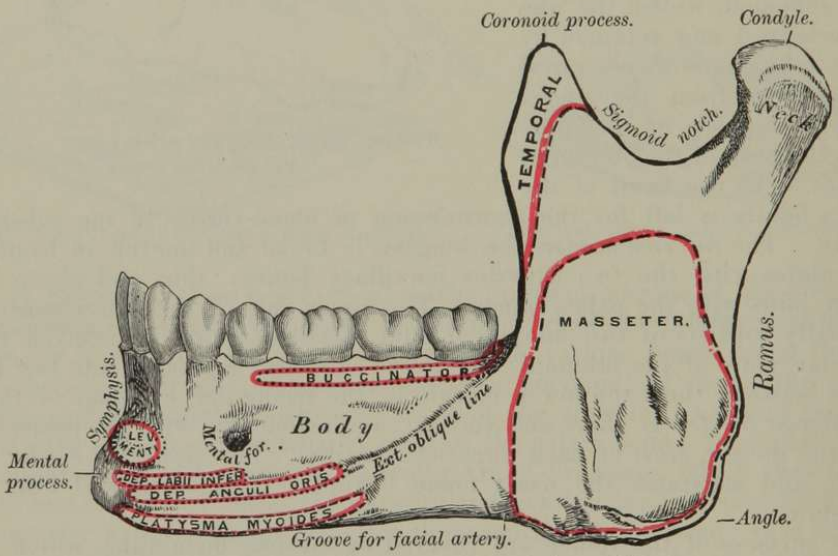

FIG. 166.—Inferior maxillary bone. Outer surface. Side view.

labii inferioris and Depressor anguli oris; below it the Platysma myoides is attached.

The **internal surface** (Fig. 167) is concave from side to side, convex from above downward. In the middle line is an indistinct linear depression, corresponding to the symphysis externally; on either side of this depression, just below its centre, are four prominent tubercles, placed in pairs, two above and two below; they are called the *genial tubercles* or *mental spines*, and afford attachment, the upper to the Genio-hyo-glossi, the lower to the Genio-hyoidei muscles. Sometimes the tubercles on each side are blended into one; at others they all unite into an irregular eminence; or, again, nothing but an irregularity may be seen on the surface of the bone at this part. On either side of the genial tubercles is an oval depression, the *sublingual fossa*, for lodging the sublingual gland; and beneath the fossa a rough depression on each side which gives attachment to the anterior belly of the Digastric muscle. At the back part of the sublingual fossa the *internal oblique line* (*mylo-hyoidean*) commences; it is at first faintly marked, but becomes more distinct as it passes upward and outward, and is especially prominent opposite the last two molar teeth; it affords attachment throughout its whole extent to the Mylo-hyoid muscle; the Superior constrictor of the pharynx with the pterygo-maxillary ligament being attached above its posterior extremity, near the alveolar margin. The portion of the bone above this ridge is smooth, and covered by the

mucous membrane of the mouth ; the portion below presents an oblong depression, the *submaxillary fossa*, wider behind than in front, for the lodgment of the sub-

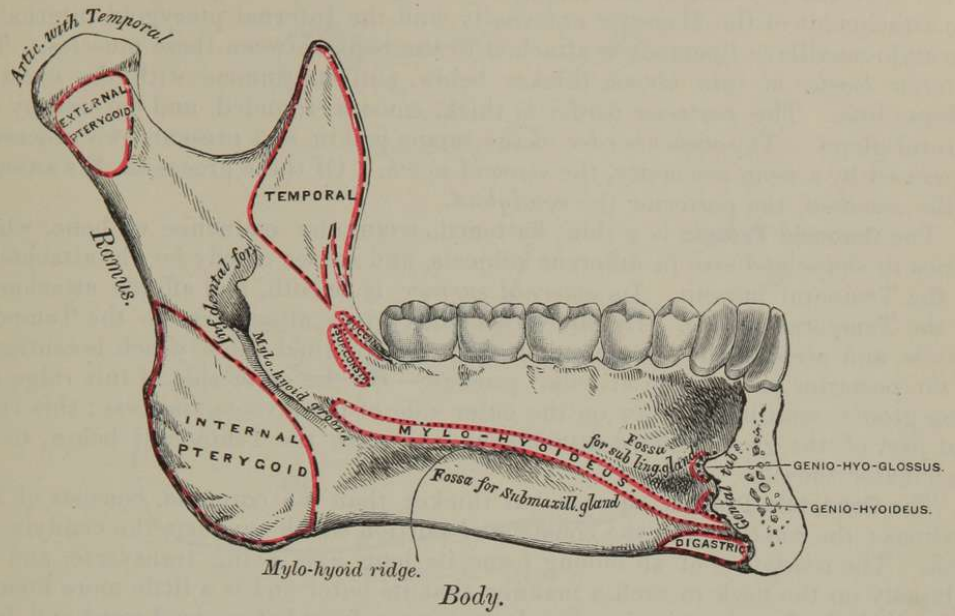

FIG. 167.—Inferior maxillary bone. Inner surface. Side view.

maxillary gland. The external oblique line and the internal or mylo-hyoidean line divide the body of the bone into a superior or alveolar and an inferior or basilar portion.

The **superior** or **alveolar** border is wider, and its margins thicker, behind than in front. It is hollowed into numerous cavities, for the reception of the teeth ; these cavities are sixteen in number, and vary in depth and size according to the teeth which they contain. To its outer side, the Buccinator muscle is attached as far forward as the first molar tooth. The **inferior** border is rounded, longer than the superior, and thicker in front than behind ; it presents a shallow groove, just where the body joins the ramus, over which the facial artery turns.

The **Perpendicular Portions,** or **Rami,** are of a quadrilateral form. Each presents for examination two surfaces, four borders, and two processes. The *external surface* is flat, marked with ridges, and gives attachment throughout nearly the whole of its extent to the Masseter muscle. The *internal surface* presents about its centre the oblique aperture of the inferior dental canal, for the passage of the inferior dental vessels and nerve. The margin of this opening is irregular ; it presents in front a prominent ridge, surmounted by a sharp spine, the *lingula*, which gives attachment to the internal lateral ligament of the lower jaw, and at its lower and back part a notch leading to a groove, the *mylo-hyoidean*, which runs obliquely downward to the back part of the submaxillary fossa, and lodges the mylo-hyoid vessels and nerve. Behind the groove is a rough surface, for the insertion of the Internal pterygoid muscle. The inferior dental canal runs obliquely downward and forward in the substance of the ramus, and then horizontally forward in the body ; it is here placed under the alveoli, with which it communicates by small openings. On arriving at the incisor teeth, it turns back to communicate with the mental foramen, giving off two small canals, which run forward, to be lost in the cancellous tissue of the bone beneath the incisor teeth. This canal, in the posterior two-thirds of the bone, is situated nearer the internal surface of the jaw ; and in the anterior third, nearer its external surface. Its walls are composed of compact tissue at either extremity, and of cancellous in the centre. It contains the inferior dental vessels and nerve, from which branches are distributed to the teeth through small apertures at the bases of the alveoli. The

lower border of the ramus is thick, straight, and continuous with the body of the bone. At its junction with the posterior border is the *angle of the jaw*, which is either inverted or everted, and marked by rough, oblique ridges on each side, for the attachment of the Masseter externally, and the Internal pterygoid internally; the stylo-maxillary ligament is attached to the bone between these muscles. The *anterior border* is thin above, thicker below, and continuous with the external oblique line. The *posterior border* is thick, smooth, rounded, and covered by the parotid gland. The *upper border* of the ramus is thin, and presents two processes, separated by a deep concavity, the *sigmoid notch*. Of these processes, the anterior is the *coronoid*, the posterior the *condyloid*.

The **Coronoid Process** is a thin, flattened, triangular eminence of bone, which varies in shape and size in different subjects, and serves chiefly for the attachment of the Temporal muscle. Its *external surface* is smooth, and affords attachment to the Temporal muscle. Its *internal surface* gives attachment to the Temporal muscle, and presents the commencement of a longitudinal ridge, which is continued to the posterior part of the alveolar process. On the outer side of this ridge is a deep groove, continued below on the outer side of the alveolar process; this ridge and part of the groove afford attachment, above, to the Temporal; below, to the Buccinator muscle.

The **Condyloid Process**, shorter but thicker than the coronoid, consists of two portions: the *condyle*, and the constricted portion which supports the condyle, the *neck*. The *condyle* is of an oblong form, its long axis being transverse, and set obliquely on the neck in such a manner that its outer end is a little more forward and a little higher than its inner. It is convex from before backward and from side to side, the articular surface extending farther on the posterior than on the anterior aspect. The *neck* of the condyle is flattened from before backward, and strengthened by ridges which descend from the fore part and sides of the condyle. Its lateral margins are narrow, and present externally a tubercle for the external lateral ligament. Its posterior surface is convex; its anterior is hollowed out on its inner side by a depression (the *pterygoid fossa*), for the attachment of the External pterygoid.

The **Sigmoid Notch,** separating the two processes, is a deep semilunar depression, crossed by the masseteric vessels and nerve.

Development.—The lower jaw is developed principally from membrane, but partly from cartilage. The process of ossification commences early—before, indeed, any bone except the clavicle. Between the fifth and sixth week a centre of ossification appears in the membrane on the outer surface of Meckel's cartilage (see page 118), from which the greater part of the bone is formed. A second centre appears in the membrane on the inner surface of the tooth-sockets, from which the inner wall of the sockets of the teeth is formed; this terminates above in the lingula. The anterior extremity of Meckel's cartilage becomes ossified, forming the body of the bone on each side of the symphysis. And, finally, two supplemental patches of cartilage appear at the condyle and at the angle, in which centres of ossification for these parts appear. At birth the bone consists of two halves, united by a fibrous symphysis, in which ossification takes place during the first year.

Articulation.—With the glenoid fossæ of the two temporal bones.

Attachment of Muscles.—To fifteen pairs: to its external surface, commencing at the symphysis, and proceeding backward: Levator menti, Depressor labii inferioris, Depressor anguli oris, Platysma myoides, Buccinator, Masseter; a portion of the Orbicularis oris (Accessorii orbicularis inferioris) is also attached to this surface. To its internal surface, commencing at the same point: Genio-hyoglossus, Genio-hyoideus, Mylo-hyoideus, Digastric, Superior constrictor, Temporal, Internal pterygoid, External pterygoid.

CHANGES PRODUCED IN THE LOWER JAW BY AGE.

The changes which the lower jaw undergoes after birth relate (1) to the alterations effected in the body of the bone by the first and second dentitions, the loss of the teeth in the aged, and

SIDE VIEW OF THE LOWER JAW AT DIFFERENT PERIODS OF LIFE.

FIG. 168.—At birth.

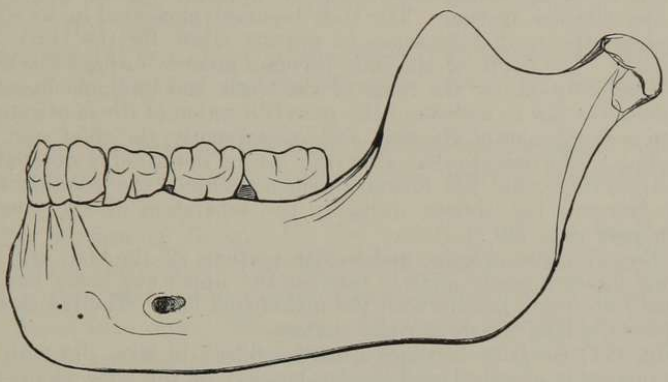

FIG. 169.—At 7 years.

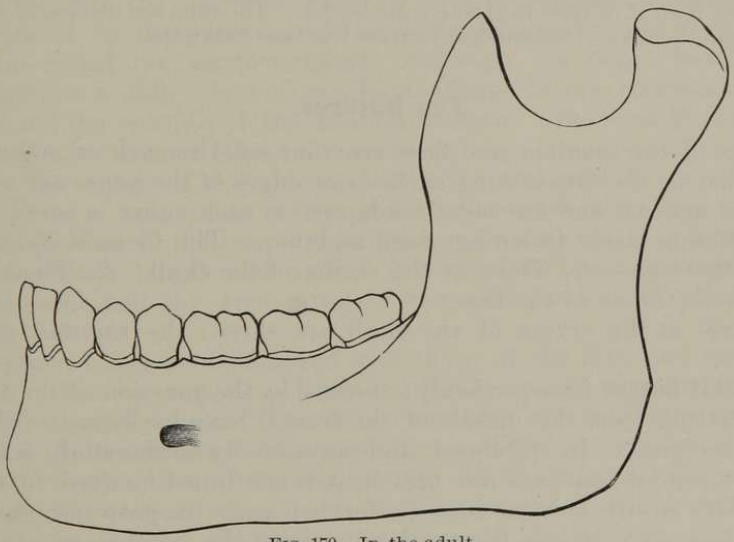

FIG. 170.—In the adult.

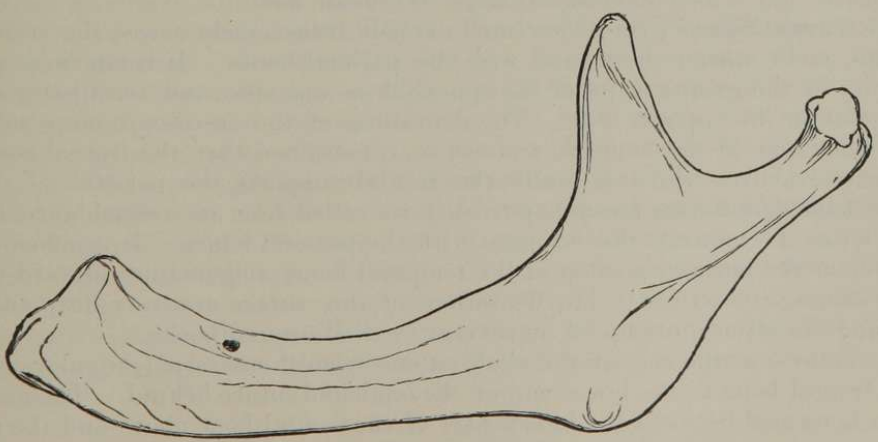

FIG. 171.—In old age.

the subsequent absorption of the alveoli; (2) to the size and situation of the dental canal; and (3) to the angle at which the ramus joins with the body.

At birth (Fig. 168) the bone consists of lateral halves, united by fibrous tissue. The body is a mere shell of bone, containing the sockets of the two incisor, the canine, and the two temporary molar teeth, imperfectly partitioned from one another. The dental canal is of large size, and runs near the lower border of the bone, the mental foramen opening beneath the socket of the first molar. The angle is obtuse (175°), and the condyloid portion nearly in the same horizontal line with the body; the neck of the condyle is short, and bent backward. The coronoid process is of comparatively large size, and situated at right angles with the rest of the bone.

After birth (Fig. 169) the two segments of the bone become joined at the symphysis, from below upward, in the first year; but a trace of separation may be visible in the beginning of the second year near the alveolar margin. The body becomes elongated in its whole length, but more especially behind the mental foramen, to provide space for the three additional teeth developed in this part. The depth of the body becomes greater, owing to increased growth of the alveolar part, to afford room for the fangs of the teeth, and by thickening of the subdental portion, which enables the jaw to withstand the powerful action of the masticatory muscles; but the alveolar portion is the deeper of the two, and, consequently, the chief part of the body lies above the oblique line. The dental canal after the second dentition is situated just above the level of the mylo-hyoid ridge, and the mental foramen occupies the position usual to it in the adult. The angle becomes less obtuse, owing to the separation of the jaws by the teeth. (About the fourth year it is 140°.)

In the adult (Fig. 170) the alveolar and basilar portions of the body are usually of equal depth. The mental foramen opens midway between the upper and lower border of the bone, and the dental canal runs nearly parallel with the mylo-hyoid line. The ramus is almost vertical in direction, and joins the body nearly at right angles.

In old age (Fig. 171) the bone becomes greatly reduced in size; for with the loss of the teeth the alveolar process is absorbed, and the basilar part of the bone alone remains; consequently, the chief part of the bone is *below* the oblique line. The dental canal, with the mental foramen opening from it, is close to the alveolar border. The rami are oblique in direction, the angle obtuse, and the neck of the condyle more or less bent backward.

The Sutures.

The bones of the cranium and face are connected to each other by means of *Sutures*. That is, the articulating surfaces or edges of the bones are more or less roughened or uneven, and are closely adapted to each other, a small amount of intervening fibrous tissue fastening them together. The *Cranial Sutures* may be divided into three sets: 1. Those at the vertex of the skull. 2. Those at the side of the skull. 3. Those at the base.

The sutures at the vertex of the skull are three: the *sagittal*, *coronal*, and *lambdoid*.

The **Sagittal Suture** (*interparietal*) is formed by the junction of the two parietal bones, and extends from the middle of the frontal bone backward to the superior angle of the occipital. In childhood, and occasionally in the adult, when the two halves of the frontal bone are not united, it is continued forward to the root of the nose. This suture is sometimes perforated, near its posterior extremity, by the parietal foramen; and in front, where it joins the coronal suture, a space is occasionally left which encloses a large Wormian bone.

The **Coronal Suture** (*fronto-parietal*) extends transversely across the vertex of the skull, and connects the frontal with the parietal bones. It commences at the extremity of the greater wing of the sphenoid on one side, and terminates at the same point on the opposite side. The dentations of the suture are more marked at the sides than at the summit, and are so constructed that the frontal rests on the parietal above, whilst laterally the frontal supports the parietal.

The **Lambdoid Suture** (*occipito-parietal*), so called from its resemblance to the Greek letter *Λ*, connects the occipital with the parietal bones. It commences on each side at the mastoid portion of the temporal bone, and inclines upward to the end of the sagittal suture. The dentations of this suture are very deep and distinct, and are often interrupted by several small Wormian bones.

The sutures at the side of the skull extend from the external angular process of the frontal bone to the lower end of the lambdoid suture behind. The anterior portion is formed between the lateral part of the frontal bone above and the malar and great wing of the sphenoid below, forming the *fronto-malar* and *fronto-*

sphenoidal sutures. These sutures can also be seen in the orbit, and form part of the so-called *transverse facial* suture. The posterior portion is formed between the parietal bone above and the great wing of the sphenoid, the squamous and mastoid portions of the temporal bone, forming the *spheno-parietal*, *squamo-parietal*, and *masto-parietal* sutures.

The **Spheno-parietal** is very short; it is formed by the tip of the great wing of the sphenoid, which overlaps the anterior inferior angle of the parietal bone.

The **Squamo-parietal,** or **Squamous Suture,** is arched. It is formed by the squamous portion of the temporal bone overlapping the middle division of the lower border of the parietal.

The **Masto-parietal** is a short suture, deeply dentated, formed by the posterior inferior angle of the parietal and the superior border of the mastoid portion of the temporal.

The sutures at the base of the skull are the *basilar* in the centre, and on each side the *petro-occipital*, the *masto-occipital*, the *petro-sphenoidal*, and the *squamo-sphenoidal.*

The **Basilar Suture** is formed by the junction of the basilar surface of the occipital bone with the posterior surface of the body of the sphenoid. At an early period of life a thin plate of cartilage exists between these bones, but in the adult they become fused into one. Between the outer extremity of the basilar suture and the termination of the lambdoid an irregular suture exists, which is subdivided into two portions. The inner portion, formed by the union of the petrous part of the temporal with the occipital bone, is termed the **petro-occipital.** The outer portion, formed by the junction of the mastoid part of the temporal with the occipital, is called the **masto-occipital.** Between the bones forming the petro-occipital suture a thin plate of cartilage exists; in the masto-occipital is occasionally found the opening of the mastoid foramen. Between the outer extremity of the basilar suture and the spheno-parietal an irregular suture may be seen, formed by the union of the sphenoid with the temporal bone. The inner and smaller portion of this suture is termed the **petro-sphenoidal**; it is formed between the petrous portion of the temporal and the great wing of the sphenoid: the outer portion, of greater length and arched, is formed between the squamous portion of the temporal and the great wing of the sphenoid; it is called the **squamo-sphenoidal.**

The cranial bones are connected with those of the face, and the facial bones with each other, by numerous sutures, which, though distinctly marked, have received no special names. The only remaining suture deserving especial consideration is the **transverse.** This extends across the upper part of the face, and is formed by the junction of the frontal with the facial bones: it extends from the external angular process of one side to the same point on the opposite side, and connects the frontal with the malar, the sphenoid, the ethmoid, the lachrymal, the superior maxillary, and the nasal bones on each side.

The sutures remain separate for a considerable period after the complete formation of the skull. It is probable that they serve the purpose of permitting the growth of the bones at their margins, while their peculiar formation, together with the interposition of the sutural ligament between the bones forming them, prevents the dispersion of blows or jars received upon the skull. Humphry remarks, "that, as a general rule, the sutures are first obliterated at the parts in which the ossification of the skull was last completed—viz. in the neighborhood of the fontanelles; and the cranial bones seem in this respect to observe a similar law to that which regulates the union of the epiphyses to the shafts of the long bones." The same author remarks that the time of their disappearance is extremely variable: they are sometimes found well marked in skulls edentulous with age, while in others which have only just reached maturity they can hardly be traced.

THE SKULL AS A WHOLE.

The Skull, formed by the union of the several cranial and facial bones already described, when considered as a whole is divisible into five regions: a superior region or vertex, an inferior region or base, two lateral regions, and an interior region, the face.

The Vertex of the Skull.

The **Superior Region,** or **Vertex,** presents two surfaces, an external and an internal.

The **external surface** is bounded, in front, by the glabella and supraorbital ridges; behind, by the occipital protuberance and superior curved lines of the occipital bone; laterally, by an imaginary line extending from the outer end of the superior curved line, along the temporal ridge, to the external angular process of the frontal. This surface includes the vertical portion of the frontal, the greater part of the parietal, and the superior third of the occipital bone; it is smooth, convex, of an elongated oval form, crossed transversely by the coronal suture, and from before backward, by the sagittal, which terminates behind in the lambdoid. The point of junction of the coronal and sagittal sutures is named the *bregma*, and is represented by a line drawn vertically upward from the external auditory meatus, the head being in its normal position. The point of junction of the sagittal and lambdoid sutures is called the *lambda*, and is about $2\frac{3}{4}$ inches above the external occipital protuberance. From before backward may be seen the frontal eminences and remains of the suture connecting the two lateral halves of the frontal bone; on each side of the sagittal suture are the parietal foramen and parietal eminence, and still more posteriorly the convex surface of the occipital bone. In the neighborhood of the parietal foramen the skull is often flattened, and to this region the name of *obelion* is sometimes given.

The **internal surface** is concave, presents eminences and depressions for the convolutions of the cerebrum, and numerous furrows for the lodgment of branches of the meningeal arteries. Along the middle line of this surface is a longitudinal groove, narrow in front, where it commences at the frontal crest, but broader behind, where it lodges the superior longitudinal sinus, and by its margin affords attachment to the falx cerebri. On either side of it are several depressions for the Pacchionian bodies, and at its back part the internal openings of the parietal foramina. This surface is crossed, in front, by the coronal suture; from before backward by the sagittal; behind, by the lambdoid.

The Base of the Skull.

The **Inferior Region,** or **Base of the Skull,** presents two surfaces—an internal or cerebral, and an external or basilar.

The **internal** or **cerebral surface** (Fig. 172) presents three fossæ, called the *anterior*, *middle*, and *posterior* fossæ of the cranium.

The **Anterior Fossa** is formed by the orbital plates of the frontal, the cribriform plate of the ethmoid, the anterior third of the superior surface of the body, and the upper surface of the lesser wings of the sphenoid. It is the most elevated of the three fossæ, convex externally where it corresponds to the roof of the orbit, concave in the median line in the situation of the cribriform plate of the ethmoid. It is traversed by three sutures, the *ethmo-frontal*, *ethmo-sphenoidal*, and *fronto-sphenoidal*, and lodges the frontal lobe of the cerebrum. It presents, in the median line, from before backward, the commencement of the groove for the superior longitudinal sinus and the frontal crest for the attachment of the falx cerebri; the *foramen cæcum*, an aperture formed between the frontal bone and the crista galli of the ethmoid, which, if pervious, transmits a small vein from the nose to the superior longitudinal sinus; behind the foramen cæcum, the *crista galli*, the posterior margin of which affords attachment to the falx cerebri; on either side of the crista galli, the *olfactory groove*, which supports the bulb of the olfactory

tract, and presents three rows of foramina for its filaments, and in front a slit-like opening for the nasal branch of the ophthalmic division of the fifth nerve. On

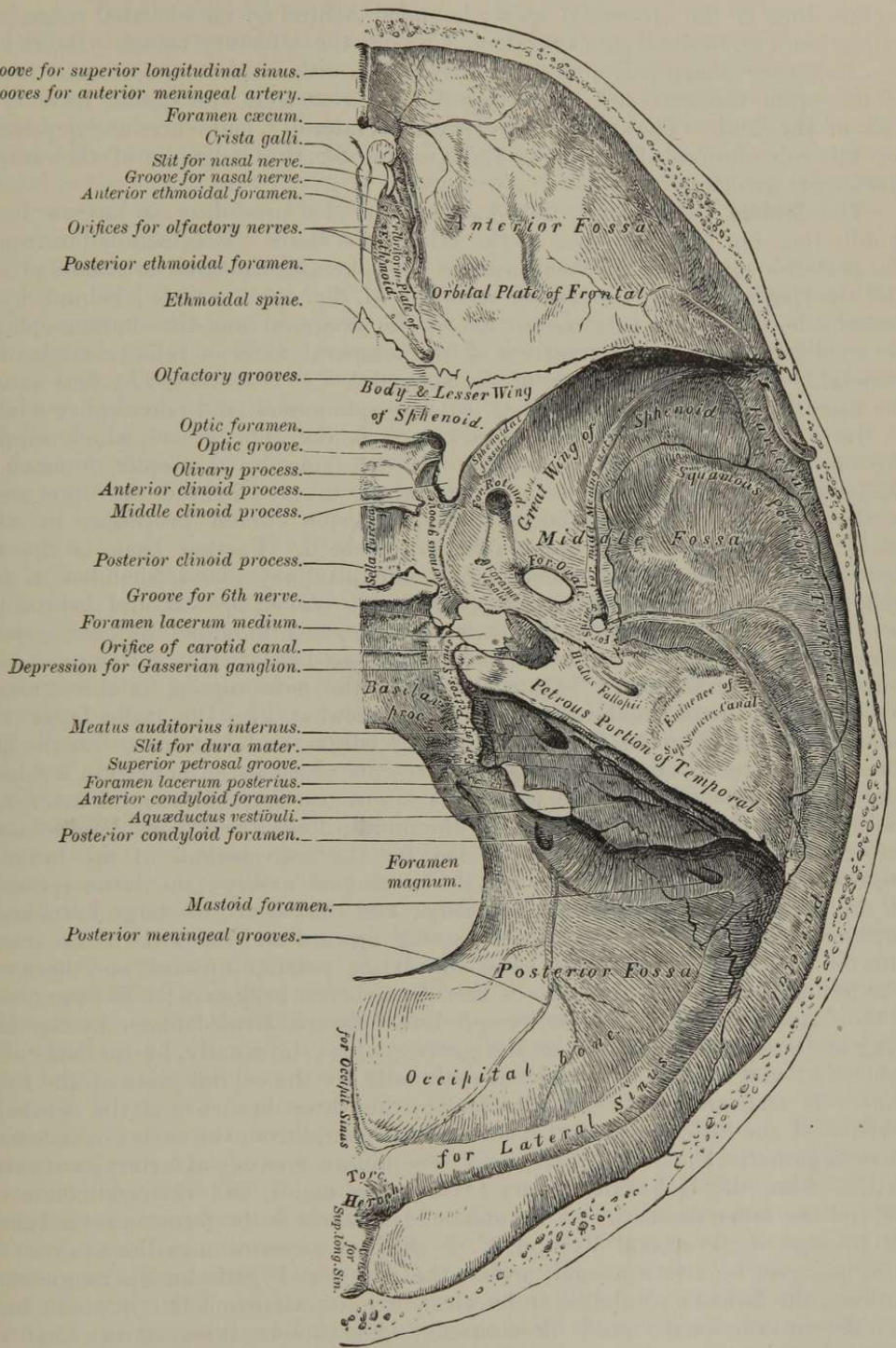

FIG. 172.—Base of the skull. Inner or cerebral surface.

the outer side of each olfactory groove are the internal openings of the *anterior* and *posterior ethmoidal foramina;* the former, situated about the middle of the outer margin of the olfactory groove, transmits the anterior ethmoidal vessels and the nasal nerve, which latter runs in a depression along the surface of the ethmoid to

the slit-like opening above mentioned; whilst the posterior ethmoidal foramen opens at the back part of this margin under cover of the projecting lamina of the sphenoid, and transmits the posterior ethmoidal vessels. Farther back in the middle line is the *ethmoidal spine*, bounded behind by an elevated ridge, separating two longitudinal grooves which support the olfactory tracts. Behind this is a transverse sharp ridge, running outward on either side to the anterior margin of the optic foramen, and separating the anterior from the middle fossa of the base of the skull. The anterior fossa presents, laterally, eminences and depressions for the convolutions of the brain and grooves for the lodgment of the anterior meningeal arteries.

The **Middle Fossa,** somewhat deeper than the preceding, is narrow in the middle line, but becomes wider at the side of the skull. It is bounded in front by the posterior margin of the lesser wing of the sphenoid, the anterior clinoid process, and the ridge forming the anterior margin of the optic groove; behind, by the superior border of the petrous portion of the temporal and the dorsum ephippi; externally by the squamous portion of the temporal, anterior inferior angle of the parietal bone, and greater wing of the sphenoid. It is traversed by four sutures, the squamo-parietal, spheno-parietal, squamo-sphenoidal, and petro-sphenoidal.

In the middle line, from before backward, is the *optic groove*, which supports the optic commissure, and terminates on each side in the optic foramen, for the passage of the optic nerve and ophthalmic artery; behind the optic groove is the *olivary process*, and laterally the *anterior clinoid processes*, to which are attached processes of the tentorium cerebelli. Farther back is the *sella turcica*, a deep depression which lodges the pituitary gland, bounded in front by a small eminence on either side, the *middle clinoid process*, and behind by a broad square plate of bone, the *dorsum ephippi*, surmounted at each superior angle by a tubercle, the *posterior clinoid process;* beneath the latter process is a notch, for the sixth nerve. On each side of the sella turcica is the *cavernous groove:* it is broad, shallow, and curved somewhat like the italic letter *f;* it commences behind at the foramen lacerum medium, and terminates on the inner side of the anterior clinoid process, and presents along its outer margin a ridge of bone. This groove lodges the cavernous sinus, the internal carotid artery, and the nerves of the orbit. The sides of the middle fossa are of considerable depth; they present eminences and depressions for the convolutions of the brain and grooves for the branches of the middle meningeal artery; the latter commence on the outer side of the foramen spinosum, and consist of two large branches, an anterior and a posterior; the former passing upward and forward to the anterior inferior angle of the parietal bone, the latter passing upward and backward. The following foramina may also be seen from before backward: Most anteriorly is the *foramen lacerum anterius*, or *sphenoidal fissure*, formed above by the lesser wing of the sphenoid; below, by the greater wing; internally, by the body of the sphenoid; and sometimes completed externally by the orbital plate of the frontal bone. It transmits the third, the fourth, the three branches of the ophthalmic division of the fifth, the sixth nerve, some filaments from the cavernous plexus of the sympathetic, the orbital branch of the middle meningeal artery, a recurrent branch from the lachrymal artery to the dura mater, and the ophthalmic vein. Behind the inner extremity of the sphenoidal fissure is the *foramen rotundum*, for the passage of the second division of the fifth or superior maxillary nerve; still more posteriorly is seen a small orifice, the *foramen Vesalii*, an opening situated between the foramen rotundum and ovale, a little internal to both: it varies in size in different individuals, and is often absent; when present, it transmits a small vein. It opens below into the pterygoid fossa, just at the outer side of the scaphoid depression. Behind and external to the latter opening is the *foramen ovale*, which transmits the third division of the fifth or inferior maxillary nerve, the small meningeal artery, and the small petrosal nerve.[1] On the outer side of the foramen ovale is the *foramen spinosum*, for the passage of the middle meningeal artery; and

[1] See footnote, p. 182.

on the inner side of the foramen ovale, the *foramen lacerum medium*. This aperture is filled up with fibrous tissue in the recent state. The Vidian nerve and a meningeal branch from the ascending pharyngeal artery pierce this cartilage. On the anterior surface of the petrous portion of the temporal bone is seen, from without inward, the eminence caused by the projection of the superior semicircular canal; outside this a depression corresponding to the roof of the tympanum; the groove leading to the hiatus Fallopii, for the transmission of the petrosal branch of the Vidian nerve and the petrosal branch of the middle meningeal artery; beneath it, the smaller groove, for the passage of the lesser petrosal nerve; and, near the apex of the bone, the depression for the Gasserian ganglion; and the orifice of the carotid canal, for the passage of the internal carotid artery and carotid plexus of nerves.

The **Posterior Fossa**, deeply concave, is the largest of the three, and situated on a lower level than either of the preceding. It is formed by the posterior third of the superior surface of the body of the sphenoid, by the occipital, the petrous and mastoid portions of the temporal, and the posterior inferior angle of the parietal bone; it is crossed by four sutures, the petro-occipital, the masto-occipital, the masto-parietal, and the basilar; and lodges the cerebellum, pons Varolii, and medulla oblongata. It is separated from the middle fossa in the median line by the dorsum ephippii, and on each side by the superior border of the petrous portion of the temporal bone. This border serves for the attachment of the tentorium cerebelli, is grooved for the superior petrosal sinus, and at its inner extremity presents a notch, upon which rests the fifth nerve. The circumference of the fossa is bounded posteriorly by the grooves for the lateral sinuses. In the centre of this fossa is the *foramen magnum*, bounded on either side by a rough tubercle, which gives attachment to the odontoid or check ligaments; and a little above these are seen the internal openings of the *anterior condyloid foramina*, through which pass the hypoglossal nerve and a meningeal branch from the ascending pharyngeal artery. In front of the foramen magnum is a grooved surface, formed by the basilar process of the occipital bone and by the posterior third of the superior surface of the body of the sphenoid, which supports the medulla oblongata and pons Varolii, and articulates on each side with the petrous portion of the temporal bone, forming the petro-occipital suture, the anterior half of which is grooved for the inferior petrosal sinus, the posterior half being encroached upon by the *foramen lacerum posterius*, or *jugular foramen*. This foramen presents three compartments: through the anterior passes the inferior petrosal sinus; through the posterior, the lateral sinus and some meningeal branches from the occipital and ascending pharyngeal arteries; and through the middle, the glosso-pharyngeal, pneumogastric, and spinal accessory nerves. Above the jugular foramen is the *internal auditory meatus*, for the facial and auditory nerves and auditory artery; behind and external to this is the slit-like opening leading into the aquæductus vestibuli; whilst between the two latter, and near the superior border of the petrous portion, is a small, triangular depression which lodges a process of the dura mater and occasionally transmits a small vein into the substance of the bone. Behind the foramen magnum are the *inferior occipital fossæ*, which lodge the hemispheres of the cerebellum, separated from one another by the *internal occipital crest*, which serves for the attachment of the falx cerebelli and lodges the occipital sinus. The posterior fossæ are surmounted, above, by the deep transverse grooves for the lodgment of the *lateral sinuses*. These channels, in their passage outward, groove the occipital bone, the posterior inferior angle of the parietal, the mastoid portion of the temporal, and the jugular process of the occipital, and terminate at the back part of the jugular foramen. Where this sinus grooves the mastoid portion of the temporal bone the orifice of the *mastoid foramen* may be seen, and just previous to its termination it has opening into it the *posterior condyloid foramen*. Neither foramen is constant.

The **External Surface** of the Base of the Skull (Fig. 173) is extremely irregular. It is bounded in front by the incisor teeth in the upper jaws; behind by the

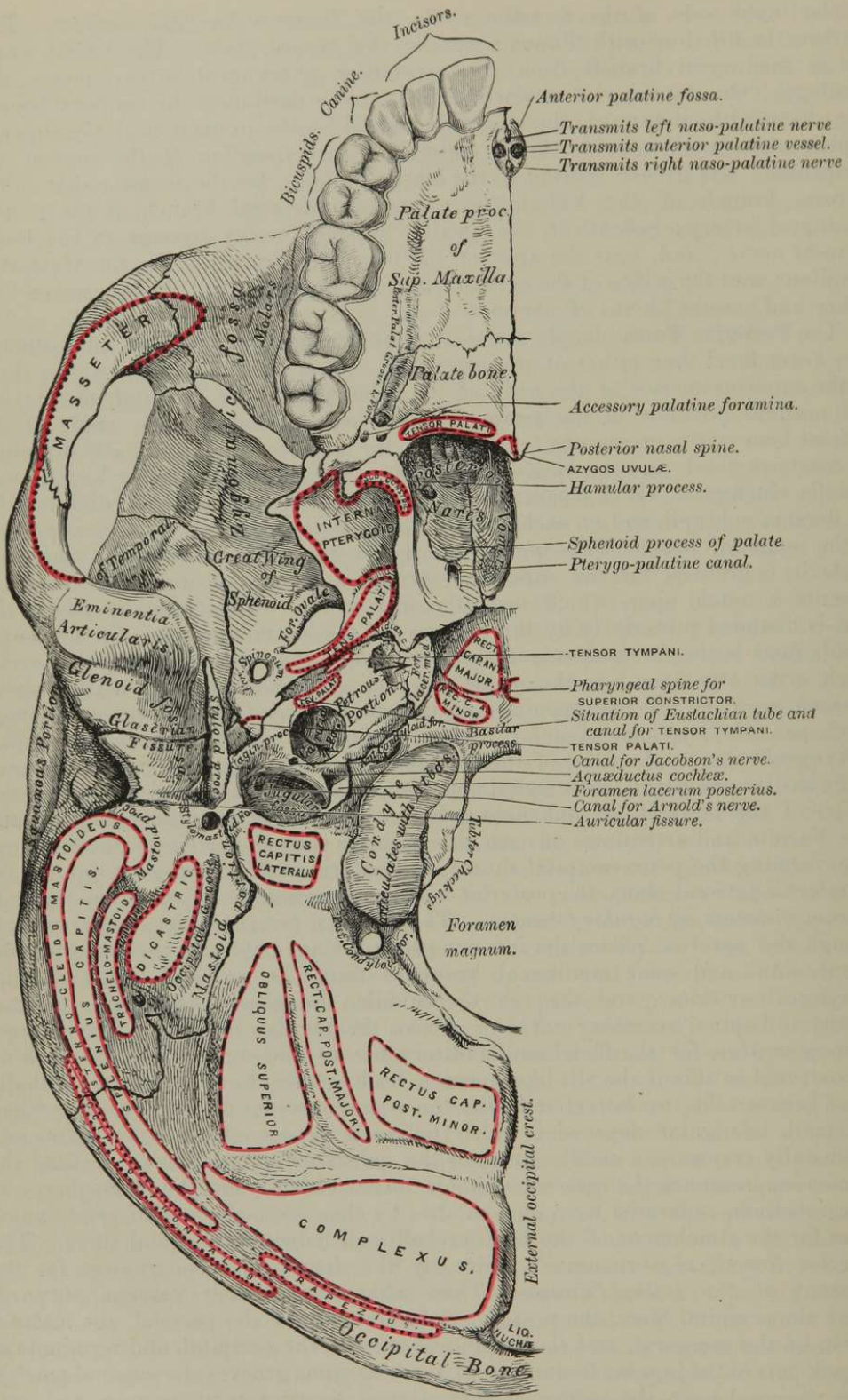

FIG. 173.—Base of the skull. External surface.

superior curved lines of the occipital bone; and laterally by the alveolar arch, the lower border of the malar bone, the zygoma, and an imaginary line extending from the zygoma to the mastoid process and extremity of the superior curved line

of the occiput. It is formed by the palate processes of the superior maxillary and palate bones, the vomer, the pterygoid processes, under surface of the great wing, spinous processes and part of the body of the sphenoid, the under surface of the squamous, mastoid, and petrous portions of the temporal, and the under surface of the occipital bone. The anterior part of the base of the skull is raised above the level of the rest of this surface (when the skull is turned over for the purpose of examination), surrounded by the alveolar process, which is thicker behind than in front, and excavated by sixteen depressions for lodging the teeth of the upper jaw, the cavities varying in depth and size according to the teeth they contain. Immediately behind the incisor teeth is the *anterior palatine fossa*. At the bottom of this fossa may usually be seen four apertures: two placed laterally, the *foramina of Stenson*, which open above, one in the floor of each nostril, and transmit the anterior branch of the posterior palatine vessels, and two in the median line in the intermaxillary suture, the *foramina of Scarpa*, one in front of the other, the anterior transmitting the left, and the posterior (the larger) the right, naso-palatine nerve. These two latter canals are sometimes wanting, or they may join to form a single one, or one of them may open into one of the lateral canals above referred to. The palatine vault is concave, uneven, perforated by numerous foramina, marked by depressions for the palatine glands, and crossed by a crucial suture, formed by the junction of the four bones of which it is composed. At the front part of this surface a delicate linear suture may frequently be seen, marking off the pre-maxillary portion of the bone. One or two small foramina in the alveolar margin behind the incisor teeth, occasionally seen in the adult, almost constantly in young subjects, are called the *incisive foramina;* they transmit nerves and vessels to the incisor teeth. At each posterior angle of the hard palate is the *posterior palatine foramen*, for the transmission of the posterior palatine vessels and large descending palatine nerve; and running forward and inward from it a groove, for the same vessels and nerve. Behind the posterior palatine foramen is the *tuberosity of the palate bone*, perforated by one or more accessory posterior palatine canals, and marked by the commencement of a ridge, which runs transversely inward, and serves for the attachment of the tendinous expansion of the Tensor palati muscle. Projecting backward from the centre of the posterior border of the hard palate is the *posterior nasal spine*, for the attachment of the Azygos uvulæ. Behind and above the hard palate is the posterior aperture of the nares, divided into two parts by the vomer, bounded above by the body of the sphenoid, below by the horizontal plate of the palate bone, and laterally by the pterygoid processes of the sphenoid. Each aperture measures about an inch and a quarter in the vertical and about half an inch in the transverse direction. At the base of the vomer may be seen the expanded alæ of this bone, receiving between them the rostrum of the sphenoid. Near the lateral margins of the vomer, at the root of the pterygoid processes, are the *pterygo-palatine canals*. The pterygoid process, which bounds the posterior nares on each side, presents near its base the *pterygoid* or *Vidian canal*, for the Vidian nerve and artery. Each process consists of two plates, which bifurcate at the extremity to receive the tuberosity of the palate bone, and are separated behind by the pterygoid fossa, which lodges the Internal pterygoid muscle. The internal plate is long and narrow, presenting on the outer side of its base the *scaphoid fossa*, for the origin of the Tensor palati muscle, and at its extremity the *hamular process*, around which the tendon of this muscle turns. The external pterygoid plate is broad, forms the inner boundary of the zygomatic fossa, and affords attachment by its outer surface to the External pterygoid muscle.

Behind the nasal fossæ in the middle line is the basilar surface of the occipital bone, presenting in its centre the *pharyngeal spine*, for the attachment of the Superior constrictor muscle of the pharynx, with depressions on each side for the insertion of the Rectus capitis anticus major and minor. At the base of the external pterygoid plate is the *foramen ovale;* behind this, the *foramen spinosum* and the prominent spinous process of the sphenoid, which gives attachment to the internal lateral ligament of the lower jaw and the Tensor palati muscle. External

to the spinous process is the *glenoid fossa*, divided into two parts by the Glaserian fissure (page 176), the anterior portion concave, smooth, bounded in front by the eminentia articularis, and serving for the articulation of the condyle of the lower jaw; the posterior portion rough, bounded behind by the tympanic plate, and serving for the reception of part of the parotid gland. Emerging from between the laminæ of the vaginal process of the tympanic plate is the *styloid process*, and at the base of this process is the *stylo-mastoid foramen*, for the exit of the facial nerve and entrance of the stylo-mastoid artery. External to the stylo-mastoid foramen is the *auricular fissure*, for the auricular branch of the pneumogastric, bounded behind by the mastoid process. Upon the inner side of the mastoid process is a deep groove, the *digastric fossa;* and a little more internally the *occipital groove*, for the occipital artery. At the base of the internal pterygoid plate is a large and somewhat triangular aperture, the *foramen lacerum medium*, bounded in front by the great wing of the sphenoid, behind by the apex of the petrous portion of the temporal bone, and internally by the body of the sphenoid and basilar process of the occipital bone: it presents in front the posterior orifice of the Vidian canal; behind, the aperture of the carotid canal. The basilar surface of this opening is filled up in the recent state by fibrous tissue; across its upper or cerebral aspect pass the internal carotid artery and Vidian nerve. External to this aperture the *petro-sphenoidal suture* is observed, at the outer termination of which is seen the orifice of the canal for the Eustachian tube and that for the Tensor tympani muscle. Behind this suture is seen the under surface of the petrous portion of the temporal bone, presenting, from within outward the quadrilateral, rough surface, part of which affords attachment to the Levator palati and Tensor tympani muscles; external to this surface the orifices of the carotid canal and the aquæductus cochleæ, the former transmitting the internal carotid artery and the ascending branches of the superior cervical ganglion of the sympathetic, the latter serving for the passage of a small artery and vein to the cochlea. Behind the carotid canal is a large aperture, the *jugular fossa*, formed in front by the petrous portion of the temporal, and behind by the occipital; it is generally larger on the right than on the left side, and is divided into three compartments by processes of dura mater. The anterior is for the passage of the inferior petrosal sinus; the posterior, for the lateral sinus and some meningeal branches from the occipital and ascending pharyngeal arteries; the central one, for the glosso-pharyngeal, pneumogastric, and spinal accessory nerves. On the ridge of bone dividing the carotid canal from the jugular fossa is the small foramen for the transmission of Jacobson's nerve; and on the outer wall of the jugular foramen, near the root of the styloid process, is the small aperture for the transmission of Arnold's nerve. Behind the basilar surface of the occipital bone is the *foramen magnum*, bounded on each side by the condyles, rough internally for the attachment of the cheek or odontoid ligaments, and presenting externally a rough surface, the *jugular process*, which serves for the attachment of the Rectus capitis lateralis muscle and the lateral occipito-atloid ligament. On either side of each condyle anteriorly is the *anterior condyloid fossa*, perforated by the anterior condyloid foramen, for the passage of the hypoglossal nerve and a meningeal artery. Behind each condyle is the *posterior condyloid fossa*, perforated on one or both sides by the posterior condyloid foramina, for the transmission of a vein to the lateral sinus. Behind the foramen magnum is the *external occipital crest*, terminating above at the *external occipital protuberance*, whilst on each side are seen the *superior* and *inferior curved lines;* these, as well as the surfaces of bone between them, are rough for the attachment of the muscles, which are enumerated on page 168.

The Lateral Region of the Skull.

The **Lateral Region** of the Skull is of a somewhat triangular form, the base of the triangle being formed by a line extending from the external angular process of the frontal bone along the temporal ridge backward to the outer extremity of

the superior curved line of the occiput: and the sides by two lines, the one drawn downward and backward from the external angular process of the frontal bone to the angle of the lower jaw, the other from the angle of the jaw upward and

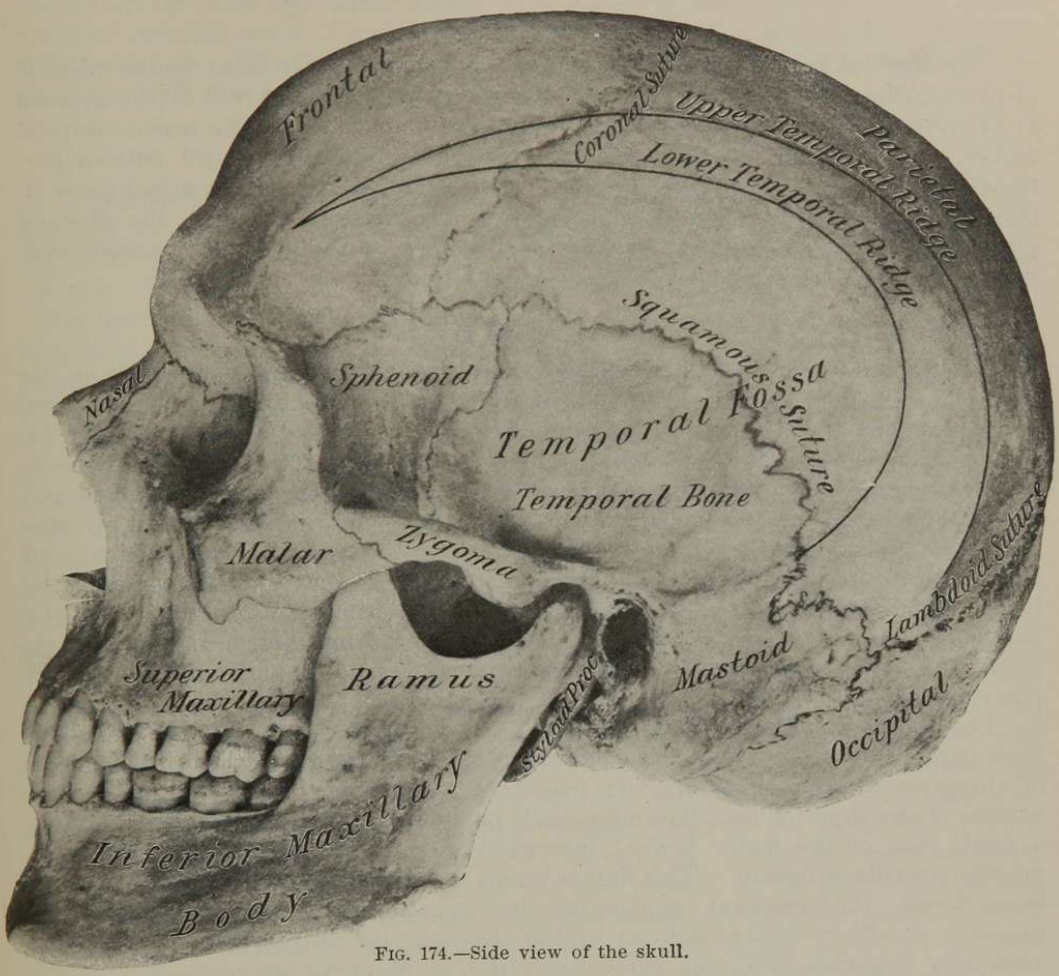

FIG. 174.—Side view of the skull.

backward to the outer extremity of the superior curved line. This region is divisible into three portions—temporal fossa, mastoid portion, and zygomatic fossa.

The Temporal Fossa.

The **Temporal Fossa** is bounded above and behind by the temporal ridge, which extends from the external angular process of the frontal upward and backward across the frontal and parietal bones, curving downward behind to terminate in the posterior root of the zygomatic process. This ridge is generally double—at all events in front, where it is most marked. In front it is bounded by the frontal, malar, and great wing of the sphenoid: externally by the zygomatic arch formed conjointly by the malar and temporal bones; below it is separated from the zygomatic fossa by the pterygoid ridge, seen on the outer surface of the great wing of the sphenoid. This fossa is formed by five bones, part of the frontal, great wing of the sphenoid, parietal, squamous portion of the temporal, and malar bones, and is traversed by six sutures, part of the transverse facial, spheno-malar, coronal, spheno-parietal, squamo-parietal, and squamo-sphenoidal. The point where the coronal suture crosses the temporal ridge is sometimes named the *stephanion*; and the region where the four bones, the parietal, the frontal, the squamous, and the greater wing of the sphenoid, meet, at the anterior inferior angle of the parietal bone, is named the *pterion*. This point is about on a level with the

external angular process of the frontal bone and about one and a half inches behind it. This fossa is deeply concave in front, convex behind, traversed by grooves which lodge branches of the deep temporal arteries, and filled by the Temporal muscles.

The Mastoid Portion.

The **Mastoid Portion** of the side of the skull is bounded in front by the tubercle of the zygoma; above, by a line which runs from the posterior root of the zygoma to the end of the masto-parietal suture; behind and below by the masto-occipital suture. It is formed by the mastoid and part of the squamous and petrous portions of the temporal bone; its surface is convex and rough for the attachment of muscles, and presents, from behind forward, the mastoid foramen, the mastoid process, the external auditory meatus surrounded by the auditory process, and, most anteriorly, the temporo-maxillary articulation.

The Zygomatic Fossa.

The **Zygomatic Fossa** is an irregularly shaped cavity, situated below and on the inner side of the zygoma; bounded, in front, by the tuberosity of the superior maxillary bone and the ridge which descends from its malar process; behind, by the posterior border of the pterygoid process and the eminentia articularis; above, by the pterygoid ridge on the outer surface of the great wing of the sphenoid and the under part of the squamous portion of the temporal; below, by the alveolar border of the superior maxilla; internally, by the external pterygoid plate; and externally, by the zygomatic arch and ramus of the lower jaw. It contains the lower part of the Temporal, the External and Internal pterygoid muscles, the internal maxillary artery, and inferior maxillary nerve and their branches. At its upper and inner part may be observed two fissures, the spheno-maxillary and pterygo-maxillary.

The **Spheno-maxillary Fissure,** horizontal in direction, opens into the outer and back part of the orbit. It is formed above by the lower border of the orbital surface of the great wing of the sphenoid; below, by the external border of the orbital surface of the superior maxilla and a small part of the palate bone; externally, by a small part of the malar bone:[1] internally, it joins at right angles with the pterygo-maxillary fissure. This fissure opens a communication from the orbit into three fossæ—the temporal, zygomatic, and spheno-maxillary; it transmits the superior maxillary nerve and its orbital branch, the infraorbital vessels, and ascending branches from the spheno-palatine or Meckel's ganglion.

The **Pterygo-maxillary Fissure** is vertical, and descends at right angles from the inner extremity of the preceding; it is a V-shaped interval, formed by the divergence of the superior maxillary bone from the pterygoid process of the sphenoid. It serves to connect the spheno-maxillary fossa with the zygomatic fossa, and transmits branches of the internal maxillary artery. It forms the entrance from the zygomatic fossa to the spheno-maxillary fossa.

The Spheno-maxillary Fossa.

The **Spheno-maxillary Fossa** is a small, triangular space situated at the angle of junction of the spheno-maxillary and pterygo-maxillary fissures, and placed beneath the apex of the orbit. It is formed above by the under surface of the body of the sphenoid and by the orbital process of the palate bone; in front, by the superior maxillary bone; behind, by the anterior surface of the base of the pterygoid process and lower part of the anterior surface of the great wing of the sphenoid; internally, by the vertical plate of the palate. This fossa has three fissures terminating in it—the *sphenoidal*, *spheno-maxillary*, and *pterygo-maxillary;* it communicates with three fossæ, the *orbital*, *nasal*, and *zygomatic*, and with the cavity of the cranium, and has opening into it five foramina. Of these, there are

[1] Occasionally the superior maxillary bone and the sphenoid articulate with each other at the anterior extremity of this fissure; the malar is then excluded from entering into its formation.

three on the posterior wall: the *foramen rotundum* above; below and internal to this, the *Vidian;* and still more inferiorly and internally, the *pterygo-palatine*. On the inner wall is the *spheno-palatine foramen*, by which the spheno-maxillary communicates with the nasal fossa; and below is the superior orifice of the *posterior palatine canal*, besides occasionally the orifices of the *accessory posterior palatine* canals. The fossa contains the superior maxillary nerve and Meckel's ganglion, and the termination of the internal maxillary artery.

The Anterior Region of the Skull.

The **Anterior Region** of the Skull, which forms the face, is of an oval form, presents an irregular surface, and is excavated for the reception of two of the organs of sense, the eye and the nose. It is bounded above by the glabella and margins of the orbit; below, by the prominence of the chin; on each side by the malar bone and anterior margin of the ramus of the jaw. In the median line are seen from above downward the glabella, and diverging from it are the *superciliary ridges*, which indicate the situation of the frontal sinuses and support the eyebrows. Beneath the glabella is the fronto-nasal suture, the mid-point of which is termed the *nasion*, and below this is the arch of the nose, formed by the nasal bones, and the nasal processes of the superior maxillary. The nasal arch is convex from side to side, concave from above downward, presenting in the median line the internasal suture formed between the nasal bones, laterally the naso-maxillary suture formed between the nasal bone and the nasal process of the superior maxillary bone. Below the nose is seen the opening of the anterior nares, which is heart-shaped, with the narrow end upward, and presents laterally the thin, sharp margins serving for the attachment of the lateral cartilages of the nose, and in the middle line below a prominent process, the *anterior nasal spine*, bounded by two deep notches. Below this is the *intermaxillary suture*, and on each side of it the *incisive fossa*. Beneath this fossa are the alveolar processes of the upper and lower jaws, containing the incisor teeth, and at the lower part of the median line the *symphysis of the chin*, the *mental process*, with its two *mental tubercles*, separated by a median groove, and the *incisive fossa* of the lower jaw.

On each side, proceeding from above downward, is the *supraorbital ridge*, terminating externally in the external angular process at its junction with the malar, and internally in the internal angular process; toward the inner third of this ridge is the *supraorbital notch* or *foramen*, for the passage of the supraorbital vessels and nerve, and at its inner side a slight depression, for the attachment of the pulley of the Superior oblique muscle. Beneath the supraorbital ridge is the opening of the orbit, bounded externally by the orbital ridge of the malar bone; below, by the orbital ridge formed by the malar and nasal process of superior maxillary; internally, by the nasal process of the superior maxillary and the internal angular process of the frontal bone. On the outer side of the orbit is the quadrilateral anterior surface of the malar bone, perforated by one or two small malar foramina. Below the inferior margin of the orbit is the *infraorbital foramen*, the termination of the infraorbital canal, and beneath this the *canine fossa*, which gives attachment to the Levator anguli oris; bounded below by the alveolar processes, containing the teeth of the upper and lower jaws. Beneath the alveolar arch of the lower jaw is the *mental foramen*, for the passage of the mental vessels and nerve, the *external oblique line*, and at the lower border of the bone, at the point of junction of the body with the ramus, a shallow groove for the passage of the facial artery.

The Orbits.

The **Orbits** (Fig. 175) are two quadrilateral pyramidal cavities, situated at the upper and anterior part of the face, their bases being directed forward and outward, and their apices backward and inward, so that the axes of the two, if continued backward, would meet over the body of the sphenoid bone. Each orbit is formed of *seven* bones, the frontal, sphenoid, ethmoid, superior maxillary, malar,

lachrymal, and palate; but three of these, the frontal, ethmoid, and sphenoid, enter into the formation of *both* orbits, so that the two cavities are formed of *eleven* bones only. Each cavity presents for examination a roof, a floor, an inner and an outer wall, four angles, a circumference or base, and an apex. The roof is concave, directed downward and forward, and formed in front by the orbital plate of the frontal; behind by the lesser wing of the sphenoid. This surface presents internally the depression for the cartilaginous pulley of the Superior oblique muscle; externally, the depression for the lachrymal gland; and posteriorly, the suture connecting the frontal and lesser wing of the sphenoid.

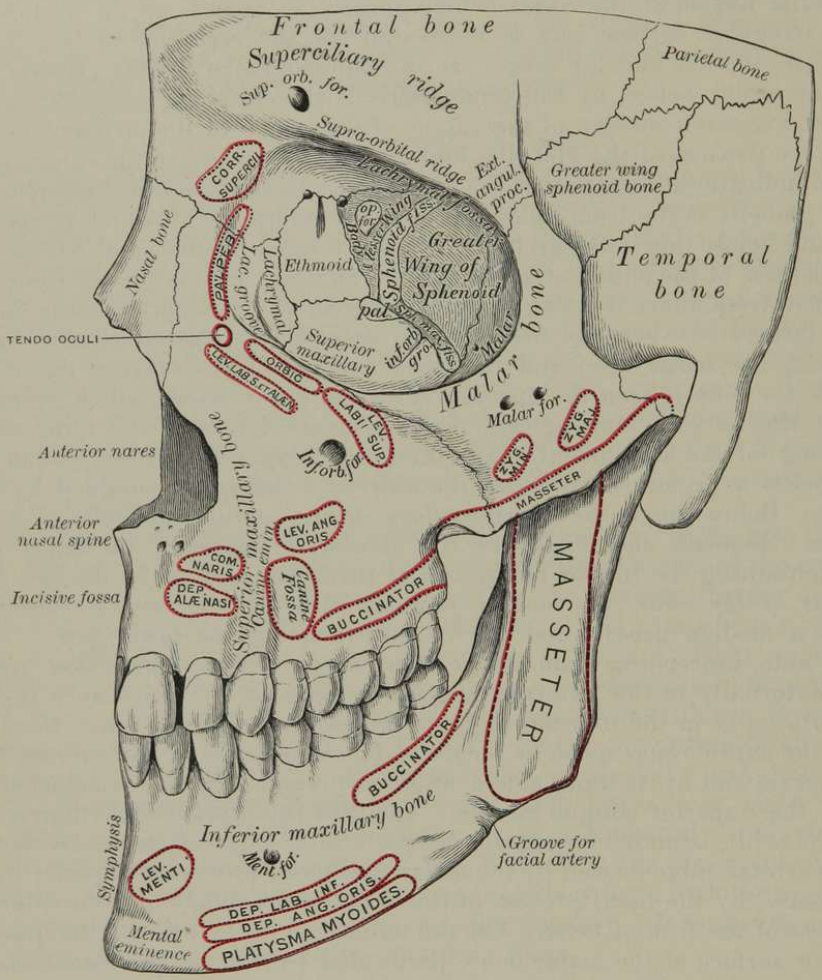

FIG. 175.—Antero-lateral region of the skull. (Cryer.)

The **floor** is nearly flat, and of less extent than the roof; it is formed chiefly by the orbital surface of the superior maxillary; in front, to a small extent, by the orbital process of the malar, and behind, by the superior surface of the orbital process of the palate. This surface presents at its anterior and internal part, just external to the lachrymal groove, a depression for the attachment of the Inferior oblique muscle; externally, the suture between the malar and superior maxillary bones; near its middle, the infraorbital groove; and posteriorly, the suture between the maxillary and palate bones.

The **inner wall** is flattened, and formed from before backward by the nasal process of the superior maxillary, the lachrymal, os planum of the ethmoid, and a small part of the body of the sphenoid. This surface presents the lachrymal groove and crest of the lachrymal bone, and the sutures connecting the lachrymal

with the superior maxillary, the ethmoid with the lachrymal in front, and the ethmoid with the sphenoid behind.

The **outer wall** is formed in front by the orbital process of the malar bone; behind, by the orbital surface of the sphenoid. On it are seen the orifices of one or two malar canals, and the suture connecting the sphenoid and malar bones.

Angles.—The *superior external angle* is formed by the junction of the upper and outer walls; it presents, from before backward, the suture connecting the frontal with the malar in front and with the great wing of the sphenoid behind; quite posteriorly is the foramen lacerum anterius, or sphenoidal fissure, which transmits the third, the fourth, the three branches of the ophthalmic division of the fifth, the sixth nerve, some filaments from the cavernous plexus of the sympathetic, the orbital branch of the middle meningeal artery, a recurrent branch from the lachrymal artery to the dura mater, and the ophthalmic vein. The *superior internal angle* is formed by the junction of the upper and inner wall, and presents the suture connecting the frontal bone with the lachrymal in front and with the ethmoid behind. The point of junction of these three sutures has been named the *dacryon*. This angle presents two foramina, the anterior and posterior ethmoidal, the former transmitting the anterior ethmoidal vessels and nasal nerve, the latter the posterior ethmoidal vessels. The *inferior external angle*, formed by the junction of the outer wall and floor, presents the spheno-maxillary fissure, which transmits the superior maxillary nerve and its orbital branches, the infra-orbital vessels, and the ascending branches from the spheno-palatine or Meckel's ganglion. The *inferior internal angle* is formed by the union of the lachrymal and os planum of the ethmoid with the superior maxillary and palate bones. The *circumference*, or base, of the orbit, quadrilateral in form, is bounded above by the supraorbital ridge; below, by the anterior border of the orbital plate of the malar, superior maxillary, and its nasal process; externally, by the external angular process of the frontal and the malar bones; internally, by the internal angular process of the frontal and the nasal process of the superior maxillary. The circumference is marked by three sutures, the fronto-maxillary internally, the fronto-malar externally, and the malo-maxillary below; it contributes to the formation of the lachrymal groove, and presents, above, the supraorbital notch (or foramen), for the passage of the supraorbital vessels and nerve. The *apex*, situated at the back of the orbit, corresponds to the optic foramen, a short, circular canal, which transmits the optic nerve and ophthalmic artery. It will thus be seen that there are *nine* openings communicating with each orbit—viz. the optic foramen, foramen lacerum anterius, spheno-maxillary fissure, supraorbital foramen, infraorbital canal, anterior and posterior ethmoidal foramina, malar foramina, and canal for the nasal duct.

The Nasal Fossæ.

The **Nasal Fossæ** are two large, irregular cavities situated on either side of the middle line of the face, extending from the base of the cranium to the roof of the mouth, and separated from each other by a thin vertical septum. They communicate by two large apertures, the anterior nares, with the front of the face, and by the two posterior nares with the pharynx behind. These fossæ are much narrower above than below, and in the middle than at the anterior or posterior openings; their depth, which is considerable, is much greater in the middle than at either extremity. Each nasal fossa communicates with four sinuses, the frontal above, the sphenoidal behind, and the maxillary and ethmoidal on the outer wall. Each fossa also communicates with four cavities: with the orbit by the lachrymal groove, with the mouth by the anterior palatine canal, with the cranium by the olfactory foramina, and with the spheno-maxillary fossa by the spheno-palatine foramen; and they occasionally communicate with each other by an aperture in the septum. The bones entering into their formation are fourteen in number: three of the cranium, the frontal, sphenoid, and ethmoid, and all the bones of the

face, excepting the malar and lower jaw. Each cavity is bounded by a roof, a floor, an inner and an outer wall.

The **upper wall, or roof** (Fig. 176), is formed in front by the nasal bones and groove lateral to the nasal spine of the frontal; this part is directed downward and forward; in the middle, by the cribriform plate of the ethmoid, which is horizontal; and behind, by the under surface of the body of the sphenoid, sphenoidal process of the palate bone, and ala of the vomer, which are directed downward and backward. This surface presents, from before backward, the internal aspect of the nasal bones; on their outer side, the suture formed between the nasal bone and the nasal process of the superior maxillary; on their inner side, the elevated crest which receives the nasal spine of the frontal and the perpendicular plate of the ethmoid, and articulates with its fellow of the opposite side; whilst the surface

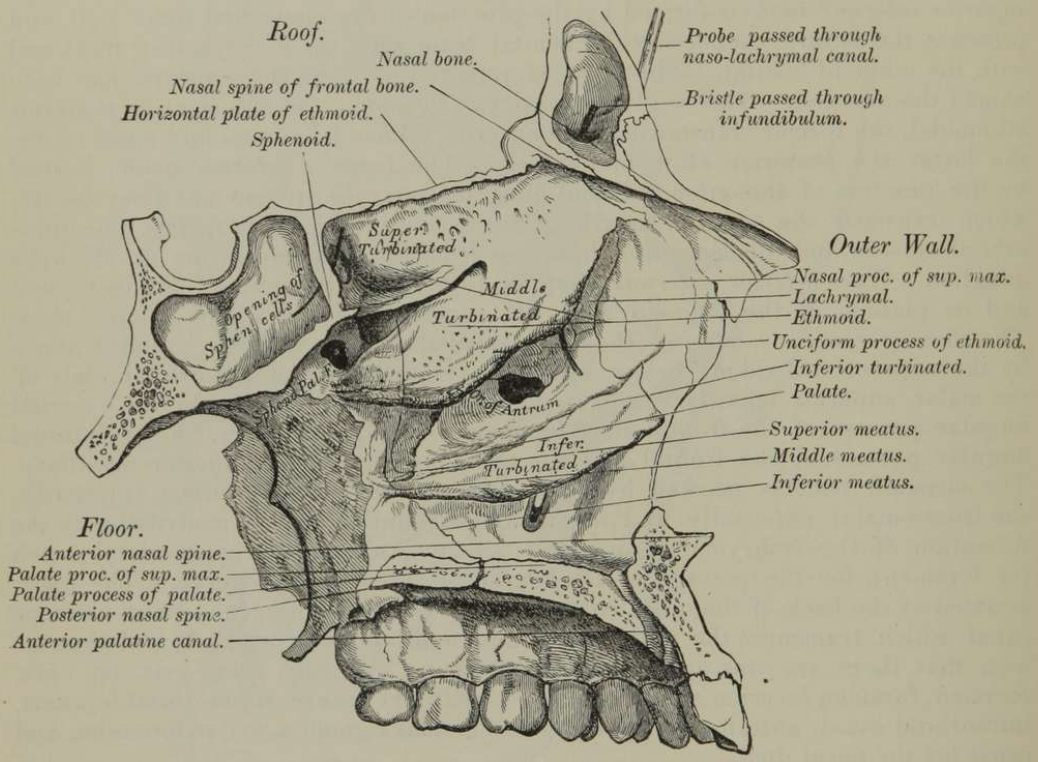

FIG. 176.—Roof, floor, and outer wall of left nasal fossa.

of the bones is perforated by a few small vascular apertures, and presents the longitudinal groove for the nasal nerve; farther back is the transverse suture, connecting the frontal with the nasal in front, and the ethmoid behind, the olfactory foramina and nasal slit on the under surface of the cribriform plate, and the suture between it and the sphenoid behind: quite posteriorly are seen the sphenoidal turbinated bones, the orifices of the sphenoidal sinuses, and the articulation of the alæ of the vomer with the under surface of the body of the sphenoid.

The **floor** is flattened from before backward, concave from side to side, and wider in the middle than at either extremity. It is formed in front by the palate process of the superior maxillary; behind, by the palate process of the palate bone. This surface presents, from before backward, the anterior nasal spine; behind this, the upper orifices of the anterior palatine canal; internally, the elevated crest which articulates with the vomer; and behind, the suture between the palate and superior maxillary bones, and the posterior nasal spine.

The **inner wall, or septum** (Fig. 177), is a thin vertical partition which separates the nasal fossæ from one another; it is occasionally perforated, so that the

fossæ communicate, and it is often bent considerably to one side.[1] It is formed, in front, by the crest of the nasal bones and nasal spine of the frontal; in the middle, by the perpendicular plate of the ethmoid; behind, by the vomer, rostrum and ethmoidal crest of the sphenoid; below, by the crests of the superior maxillary and palate bones. It presents, in front, a large, triangular notch, which receives the triangular cartilage of the nose; and behind, the guttural edge of the vomer. Its surface is marked by numerous vascular and nervous canals and the groove for

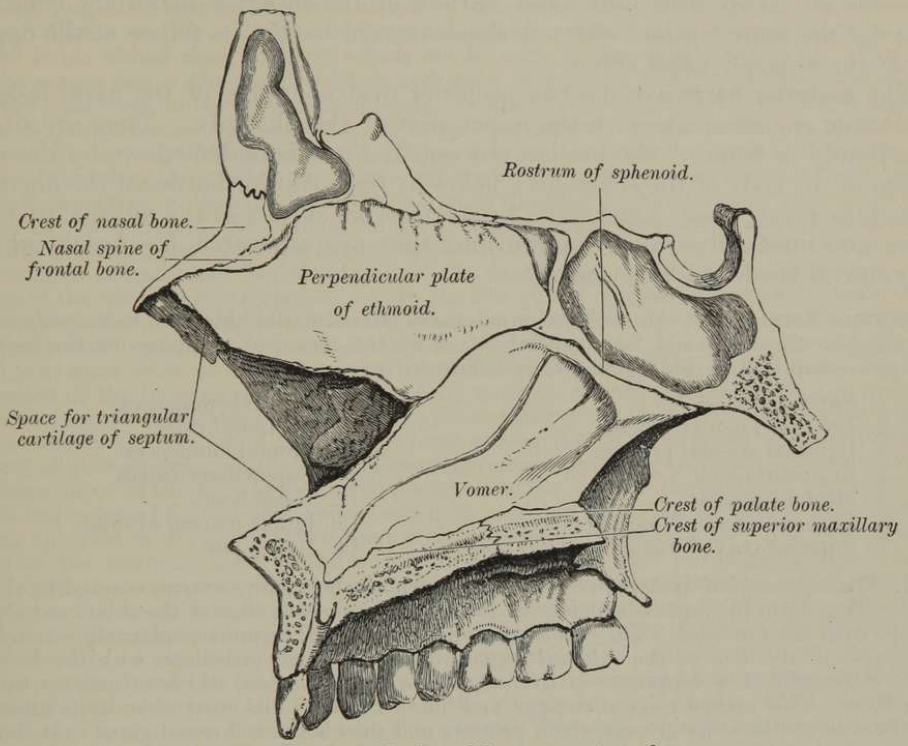

FIG. 177.—Inner wall of nasal fossæ, or septum of nose.

the naso-palatine nerve, and is traversed by sutures connecting the bones of which it is formed.

The **outer wall** (Fig. 176) is formed, in front, by the nasal, the nasal process of the superior maxillary and lachrymal, bones; in the middle, by the ethmoid and inner surface of the superior maxillary and inferior turbinated bones; behind, by the vertical plate of the palate bone and the internal pterygoid plate of the sphenoid. This surface presents three irregular longitudinal passages, or *meatuses*, formed between three plates of bone that spring from it; they are termed the superior, middle, and inferior meatuses of the nose. The *superior meatus*, the smallest of the three, is situated at the upper and back part of each nasal fossa, occupying the posterior third of the outer wall. It is situated between the superior and middle turbinated bones, and has opening into it two foramina, the *spheno-palatine* at the back of its outer wall, and the *posterior ethmoidal cells* at the front part of the outer wall. The opening of the sphenoidal sinus is at the upper and back part of the nasal fossa immediately behind the superior turbinated bone and into a groove, the *spheno-ethmoidal recess*. The *middle meatus* is situated between the middle and inferior turbinated bones, and occupies the posterior two-thirds of the outer wall of the nasal fossa. It has two apertures: in front that of the *infundibulum*, by which the meatus communicates with the anterior ethmoidal cells, and through these with the frontal sinuses; near the centre is the *orifice of the antrum*, which varies somewhat as to its exact position in different skulls. The *inferior meatus*, the largest of the three, is the space between the inferior turbinated

[1] See footnote, p. 185.

bone and the floor of the nasal fossa. It extends along the entire length of the outer wall of the nose, is broader in front than behind, and presents anteriorly the lower *orifice of the canal for the nasal duct.*

The **anterior nares** present a heart-shaped or pyriform opening whose long axis is vertical and narrow extremity upward. This opening in the recent state is much contracted by the cartilages of the nose. It is bounded above by the inferior border of the nasal bone; laterally by the thin, sharp margin which separates the facial from the nasal surface of the superior maxillary bone; and below by the same border, where it slopes inward to join its fellow of the opposite side at the anterior nasal spine.

The **posterior nares** are the two posterior oval openings of the nasal fossæ, by which they communicate with the upper part of the pharynx. They are situated immediately in front of the basilar process, and are bounded above by the under surface of the body of the sphenoid; below by the posterior border of the horizontal plate of the palate bone; externally, by the internal surface of the internal pterygoid plate; and internally, in the middle line, they are separated from each other by the guttural border of the vomer.

Surface Form.—The various bony prominences or landmarks which are to be easily felt and recognized in the head and face, and which afford the means of mapping out the important structures comprised in this region, are as follows:

1. Supraorbital arch.
2. Internal angular process.
3. External angular process.
4. Zygomatic arch.
5. Mastoid process.
6. External occipital protuberance.
7. Superior curved line of occipital bone.
8. Parietal eminences.
9. Temporal ridge.
10. Frontal eminences.
11. Superciliary ridges.
12. Nasal bones.
13. Lower margin of orbit.
14. Lower jaw.

1. The *supraorbital arches* are to be felt throughout their entire extent, covered by the eyebrows. They form the upper boundary of the circumference or base of the orbit, and separate the face from the forehead. They are strong and arched, and terminate internally on each side of the root of the nose in the *internal angular process*, which articulates with the lachrymal bone. Externally they terminate in the *external angular process*, which articulates with the malar bone. This arched ridge is sharper and more defined in its outer than in its inner half, and forms an overhanging process which protects and shields the lachrymal gland. It thus protects the eye in its most exposed situation and in the direction from which blows are most likely to descend. Tho supraorbital arch varies in prominence in different individuals. It is more marked in the male than in the female, and in some races of mankind than others. In the less civilized races, as the forehead recedes backward, the supraorbital arch becomes more prominent, and approaches more to the characters of the monkey tribe, in which the supraorbital arches are very largely developed, and acquire additional prominence from the oblique direction of the frontal bone. 2. The *internal angular process* is scarcely to be felt. Its position is indicated by the angle formed by the suprao ital arch with the nasal process of the superior maxillary bone and the lachrymal bone at the inner side of the orbit. Between the internal angular processes of the two sides is a broad surface which assists in forming the root of the nose, and immediately above this a broad, smooth, somewhat triangular surface, the *glabella*, situated between the superciliary ridges. 3. The *external angular process* is much more strongly marked than the internal, and is plainly to be felt. It is formed by the junction or confluence of the supraorbital and temporal ridges, and, articulating with the malar bone, it serves to a very considerable extent to support the bones of the face. In carnivorous animals the external angular process does not articulate with the malar, and therefore this lateral support to the bones of the face is not present. 4. The *zygomatic* arch is plainly to be felt throughout its entire length, being situated almost immediately under the skin. It is formed by the malar bone and the zygomatic process of the temporal bone. At its anterior extremity, where it is formed by the malar bone, it is broad and forms the prominence of the cheek; the posterior part is narrower, and terminates just in front and a little above the tragus of the external ear. The lower border is more plainly to be felt than the upper, in consequence of the dense temporal fascia being attached to the upper border, which somewhat obscures its outline. Its shape differs very much in individuals and in different races of mankind. In the most degraded type of skull—as, for instance, in the skull of the negro of the Guinea Coast—the malar bones project forward and not outward, and the zygoma at its posterior extremity extends farther outward before it is twisted on itself to be prolonged forward. This makes the zygomatic arch stand out in bold relief, and affords greater space for the Temporal muscle. In skulls which have a more pyramidal shape, as in the Esquimaux or Greenlander, the malar bones do not project forward and downward under the eyes, as in the preceding form, but take a direction outward, forming with the zygoma a large, rounded sweep or segment of a circle. Thus it happens that if two lines are drawn from the

zygomatic arches, touching the temporal ridges, they meet over the top of the head, instead of being parallel, or nearly so, as in the European skull, in which the zygomatic arches are not nearly so prominent. This gives to the face a more or less oval type. 5. Behind the ear is the *mastoid portion of the temporal bone*, plainly to be felt, and terminating below in a nipple-shaped process. Its anterior border can be traced immediately behind the concha, and its apex is on about a level with the lobule of the ear. It is rudimentary in infancy, but gradually develops in childhood, and is more marked in the negro than in the European. 6. The *external occipital protuberance* is always plainly to be felt just at the level where the skin of the neck joins that of the head. At this point the skull is thick for the purposes of safety, while radiating from it are numerous curved arches or buttresses of bone which give to this portion of the skull further security. 7. Running outward on either side from the external occipital protuberance is an arched ridge of bone, which can be more or less plainly perceived. This is the *superior curved line* of the occipital bone, and gives attachment to some of the muscles which keep the head erect on the spine; accordingly, we find it more developed in the negro tribes, in whom the jaws are much more massive, and therefore require stronger muscles to prevent their extra weight carrying the head forward. Below this line the surface of bone at the back of the head is obscured by the overlying muscles. Above it, the vault of the cranium is thinly covered with soft structures, so that the form of this part of the head is almost exactly that of the upper portion of the occipital, the parietal, and the frontal bones themselves; and in bald persons even the lines of junction of the bones, especially the junction of the occipital and parietal at the lambdoid suture, may be defined as a slight depression, caused by the thickening of the borders of the bones in this situation. 8. In the line of the greatest transverse diameter of the head, on each side of the middle line, are generally to be found the *parietal eminences*, though sometimes these eminences are not situated at the point of the greatest transverse diameter, which is at some other prominent part of the parietal region. They denote the point where ossification of the bone began. They are much more prominent and well-marked in early life, in consequence of the sharper curve of the bone at this period, so that it describes the segment of a smaller circle. Later in life, as the bone grows, the curve spreads out and forms the segment of a larger circle, so that the eminence becomes less distinguishable. In consequence of this sharp curve of the bone in early life, the whole of the vault of the skull has a squarer shape than it has in later life, and this appearance may persist in some rickety skulls. The eminence is more apparent in the negro's skull than in that of the European. This is due to greater flattening of the temporal fossa in the former skull to accommodate the larger Temporal muscle which exists in these races. The parietal eminence is particularly exposed to injury from blows or falls on the head, but fracture is to a certain extent prevented by the shape of the bone, which forms an arch, so that the force of the blow is diffused over the bone in every direction. 9. At the side of the head may be felt the *temporal ridge*. Commencing at the external angular process, it may be felt as a curved ridge, passing upward and then curving backward, on the frontal bone, separating the forehead from the temporal fossa. It may then be traced, passing backward in a curved direction, over the parietal bone, and, though less marked, still generally to be recognized. Finally, the ridge curves downward, and terminates in the posterior root of the zygoma, which separates the squamous from the subcutaneous mastoid portion of the temporal bone. Mr. Victor Horsley has recently shown, in an article on the "Topography of the Cerebral Cortex," that the second temporal ridge (see page 170) can be made out on the living body. 10. The *frontal eminences* vary a good deal in different individuals, being considerably more prominent in some than in others, and they are often not symmetrical on the two sides of the body, the one being much more pronounced than the other. This is often especially noticeable in the skull of the young child or infant, and becomes less marked as age advances. The prominence of the frontal eminences depends more upon the general shape of the whole bone than upon the size of the protuberances themselves. As the skull is more highly developed in consequence of increased intellectual capacity, so the frontal bone becomes more upright and the frontal eminences stand out in bolder relief. Thus they may be considered as affording, to a certain extent, an indication of the development of the hemispheres of the brain beneath, and of the mental powers of the individual. They are not so much exposed to injury as the parietal eminences. In falls forward the upper extremities are involuntarily thrown out, and break the force of the fall, and thus shield the frontal bone from injury. 11. Below the frontal eminences on the forehead are the *superciliary ridges*, which denote the position of the frontal sinuses, and vary according to the size of the sinuses in different individuals, being, as a rule, small in the female, absent in children, and sometimes unusually prominent in the male, when the frontal sinuses are largely developed. They commence on either side of the glabella, and at first present a rounded form, which gradually fades away at their outer ends. 12. The *nasal bones* form the prominence of the nose. They vary much in size and shape, and to them is due the varieties in the contour of this organ and much of the character of the face. Thus, in the Mongolian or Ethiopian they are flat, broad and thick at their base, giving to these tribes the flattened nose by which they are characterized, and differing very decidedly from the Caucasian, in whom the nose, owing to the shape of the nasal bones, is narrow, elevated at the bridge, and elongated downward. Below, the nasal bones are thin and connected with the cartilages of the nose, and the angle or arch formed by their union serves to throw out the bridge of the nose, and is much more marked in some individuals than others. 13. The *lower margin of the orbit*, formed by the superior maxillary bone and the malar bone, is plainly to be felt throughout its entire length. It is continuous internally with the nasal process of the superior

maxillary bone, which forms the inner boundary of the orbit. At the point of junction of the lower margin of the orbit with the nasal process is to be felt a little tubercle of bone, which can be plainly perceived by running the finger along the bone in this situation. This tubercle serves as a guide to the position of the lachrymal sac, which is situated above and behind it. 14. The outline of the *lower jaw* is to be felt throughout its entire length. Just in front of the tragus of the external ear, and below the zygomatic arch, the condyle can be made out. When the mouth is opened this prominence of bone can be perceived advancing out of the glenoid fossa on to the eminentia articularis, and receding again when the mouth is closed. From the condyle the posterior border of the ramus can be felt extending down to the angle. A line drawn from the condyle to the angle would indicate the exact position of this border. From the angle to the symphysis of the chin the lower, rounded border of the body of the bone is plainly to be felt. At the point of junction of the two halves of the bone is a well-marked triangular eminence, the *mental process*, which forms the prominence of the chin.

Surgical Anatomy.—An arrest in the ossifying process may give rise to deficiencies or gaps; or to fissures, which are of importance in a medico-legal point of view, as they are liable to be mistaken for fractures. The fissures generally extend from the margin toward the centre of the bone, but gaps may be found in the middle as well as at the edges. In course of time they may become covered with a thin lamina of bone.

Occasionally a protrusion of the brain or its membranes may take place through one of these gaps in an imperfectly developed skull. When the protrusion consists of membranes only, and is filled with cerebro-spinal fluid, it is called a *meningocele;* when the protrusion consists of brain as well as membranes, it is termed an *encephalocele;* and when the protruded brain is a prolongation from one of the ventricles, and is distended by a collection of fluid from an accumulation in the ventricle, it is termed an *hydrencephalocele.* This latter condition is frequently found at the root of the nose, where a protrusion of the anterior horn of the lateral ventricle takes place through a deficiency of the fronto-nasal suture. These malformations are usually found in the middle line, and most frequently at the back of the head, the protrusion taking place through the fissures which separate the four centres of ossification from which the tabular portion is originally developed (see page 167). They most frequently occur through the upper part of the vertical fissure, which is the last to ossify, but not uncommonly through the lower part, when the foramen magnum may be incomplete. More rarely these protrusions have been met with in other situations than those two above mentioned, both through normal fissures, as the sagittal, lambdoid, and other sutures, and also through abnormal gaps and deficiencies at the sides, and even at the base of the skull.

Fractures of the skull may be divided into those of the vault and those of the base. Fractures of the vault are usually produced by direct violence. This portion of the skull varies in thickness and strength in different individuals, but, as a rule, is sufficiently strong to resist a very considerable amount of violence without being fractured. This is due to several causes: the rounded shape of the head and its construction of a number of secondary elastic arches, each made up of a single bone; the fact that it consists of a number of bones, united, at all events in early life, by a sutural ligament, which acts as a sort of buffer and interrupts the continuity of any violence applied to the skull; the presence of arches or ridges, both on the inside and outside of the skull, which materially strengthen it; and the mobility of the head upon the spine which further enables it to withstand violence. The elasticity of the bones of the head is especially marked in the skull of the child, and this fact, together with the wide separation of the individual bones from each other, and the interposition between them of other softer structures renders fracture of the bones of the head a very uncommon event in infants and quite young children; as age advances and the bones become joined, fracture is more common, though still less liable to occur than in the adult. Fractures of the vault may, and generally do, involve the whole thickness of the bone; but sometimes one table may be fractured without any corresponding injury to the other. Thus, the outer table of the skull may be splintered and driven into the diploë, or in the frontal or mastoid regions into the frontal or mastoid cells, without any injury to the internal table. And on the other hand, the internal table has been fractured, and portions of it depressed and driven inward, without any fracture of the outer table. As a rule, in fractures of the skull the inner table is more splintered and comminuted than the outer, and this is due to several causes. It is thinner and more brittle; the force of the violence as it passes inward becomes broken up, and is more diffused by the time it reaches the inner table; the bone, being in the form of an arch, bends as a whole and spreads out, and thus presses the particles together on the convex surface of the arch—*i. e.* the outer table—and forces them asunder on the concave surface or inner table; and, lastly, there is nothing firm under the inner table to support it and oppose the force. Fractures of the vault may be simple fissures or starred and comminuted fractures, and these may be depressed or elevated. These latter cases of fracture with elevation of the fractured portion are uncommon, and can only be produced by direct wound. In comminuted fracture a portion of the skull is broken into several pieces, the lines of fracture radiating from a centre where the chief impact of the blow was felt; if depressed, a fissure circumscribes the radiating line, enclosing a portion of skull. If this area is circular, it is termed a "pond" fracture, and would in all probability have been caused by a round instrument, as a life-preserver or hammer; if elliptical in shape, it is termed a "gutter fracture," and would owe its shape to the instrument which had produced it, as a poker.

Fractures of the base are most frequently produced by the extension of a fissure from the

vault, as in falls on the head, where the fissure starts from the part of the vault which first struck the ground. Sometimes, however, they are caused by direct violence, when foreign bodies have been forced through the thin roof of the orbit, through the cribriform plate of the ethmoid from being thrust up the nose, or through the roof of the pharynx. Other cases of fracture of the base occur from indirect violence, as in fracture of the occipital bone from impaction of the spinal column against its condyles in falls on the buttocks, knees, or feet, or in cases where the glenoid cavity has been fractured by the violent impact of the condyle of the lower jaw against it from blows on the chin.

The most common place for fracture of the base to occur is through the middle fossa, and here the fissure usually takes a fairly definite course. Starting from the point struck, which is generally somewhere in the neighborhood of the parietal eminence, it runs downward through the parietal and squamous portion of the temporal bone and across the petrous portion of this bone, frequently traversing and implicating the internal auditory meatus, to the middle lacerated foramen. From this it may pass across the body of the sphenoid, through the pituitary fossa to the middle lacerated foramen of the other side, and may indeed travel round the whole cranium, so as to completely separate the anterior from the posterior part. The course of the fracture should be borne in mind, as it explains the symptoms to which fracture in this region may give rise; thus, if the fissure pass across the internal auditory meatus, injury to the facial and auditory nerves may result, with consequent facial paralysis and deafness; or the tubular prolongation of the arachnoid around these nerves in the meatus may be torn, and thus permit of the escape of the cerebro-spinal fluid should there be a communication between the internal ear and the tympanum and the membrana tympani be ruptured, as is frequently the case; again, if the fissure passes across the pituitary fossa and the muco-periosteum covering the under surface of the body of the sphenoid is torn, blood will find its way into the pharynx and be swallowed, and after a time vomiting of blood will result. Fractures of the anterior fossa, involving the bones forming the roof of the orbit and nasal fossa, are generally the results of blows on the forehead; but fracture of the cribriform plate of the ethmoid may be a complication of fracture of the nasal bone. When the fracture implicates the roof of the orbit, the blood finds its way into this cavity, and, travelling forward, appears as a subconjunctival ecchymosis. If the roof of the nasal fossa be fractured, the blood escapes from the nose. In rare cases there may be also escape of cerebro-spinal fluid from the nose where the dura mater and arachnoid have been torn. In fractures of the posterior fossa extravasation of blood may appear at the nape of the neck.

The bones of the skull, being subcutaneous, are frequently the seat of nodes, and not uncommonly necrosis results from this cause, as well as from injury. Necrosis may involve the entire thickness of the skull, but is usually confined to the external table. Necrosis of the internal table alone is rarely met with. The bones of the skull are also frequently the seat of sarcomatous tumor.

The skull in rickets is peculiar: the forehead is high, square, and projecting, and the antero-posterior diameter of the skull is long in relation to the transverse diameter. The bones of the face are small and ill-developed, and this gives the appearance of a larger head than actually exists. The bones of the head are often thick, especially in the neighborhood of the sutures, and the anterior fontanelle is late in closing, sometimes remaining unclosed till the fourth year. The condition of *craniotabes* has by some been also believed to be the result of rickets, by others is believed to be due to inherited syphilis. In these cases the bone undergoes atrophic changes in patches, so that it becomes greatly thinned in places, generally where there is pressure, as from the pillow or nurse's arm. It is, therefore, usually met with in the parietal bone and vertical plate of the occipital bone.

In congenital syphilis deposits of porous bone are often found at the angles of the parietal bones and two halves of the frontal bone which bound the anterior fontanelle. These deposits are separated by the coronal and sagittal sutures, and give to the skull an appearance like a "hot cross bun." They are known as Parrot's nodes, and such a skull has received the name of *natiform*, from its fancied resemblance to the buttocks.

In connection with the bones of the face a common malformation is *cleft palate*, owing to the non-union of the palatal processes of the maxillary or pre-oral arch (see page 118). This cleft may involve the whole or only a portion of the hard palate, and usually involves the soft palate also. The cleft is in the middle line, except it involves the alveolus in front, when it follows the suture between the main portion of the bone and the pre-maxillary bone. Sometimes the cleft runs on either side of the pre-maxillary bone, so that this bone is quite isolated from the maxillary bones and hangs from the end of the vomer. The malformation is usually associated with hare-lip, which, when single, is almost always on one side, corresponding to the position of the suture between the lateral incisor and canine tooth. Some few cases of median hare-lip have been described. In double hare-lip there is a cleft on each side of the middle line.

The bones of the face are sometimes fractured as the result of direct violence. The two most commonly broken are the nasal bone and the inferior maxilla, and of these the latter is by far the most frequently fractured of all the bones of the face. Fracture of the *nasal* bone is for the most part transverse, and takes place about half an inch from the free margin. The broken portion may be displaced backward or more generally to one side by the force which produced the lesion, as there are no muscles here which can cause displacement. The *malar* bone is probably never broken alone; that is to say, unconnected with a fracture of the other bones of the face. The *zygomatic arch* is occasionally fractured, and when this occurs from

direct violence, as is usually the case, the fragments may be displaced inward. This lesion is often attended with great difficulty or even inability to open and shut the mouth, and this has been stated to be due to the depressed fragments perforating the temporal muscle, but would appear rather to be caused by the injury done to the bony origin of the Masseter muscle. Fractures of the *superior maxilla* may vary much in degree, from the chipping off of a portion of the alveolar arch, a frequent accident when the "old key" instrument was used for the extraction of teeth, to an extensive comminution of the whole bone from severe violence, as the kick of a horse. The most common situation for a fracture of the *inferior maxillary bone* is in the neighborhood of the canine tooth, as at this spot the jaw is weakened by the deep socket for the fang of this tooth; it is next most frequently fractured at the angle; then at the symphysis, and finally the neck of the condyle or the coronoid process may be broken. Occasionally a double fracture may occur, one in either half of the bone. The fractures are usually compound, from laceration of the mucous membrane covering the gums. The displacement is mainly the result of the same violence as produced the injury, but may be further increased by the action of the muscles passing from the neighborhood of the symphysis to the hyoid bone.

The superior and inferior maxillary bones are both of them frequently the seat of necrosis, though the disease affects the lower much more frequently than the upper jaw, probably on account of the greater supply of blood to the latter. It may be the result of periostitis, from tooth irritation, injury, or the action of some specific poison, as syphilis, or from salivation by mercury; it not unfrequently occurs in children after attacks of the exanthematous fevers, and a special form occurs from the action of the fumes of phosphorus in persons engaged in match-making.

Tumors attack the jaw-bones not infrequently, and these may be either innocent or malignant: in the upper jaw cysts may occur in the antrum, constituting the so-called dropsy of the antrum; or, again, cysts may form in either jaw in connection with the teeth: either cysts connected with the roots of fully-developed teeth, the "dental cyst;" or cysts connected with imperfectly developed teeth, the "dentigerous cyst." Solid innocent tumors include the fibroma, the chondroma, and the osteoma. Of malignant tumors there are two classes, the sarcomata and the epithelioma. The sarcoma are of various kinds, the spindle-celled and round-celled, of a very malignant character, and the myeloid sarcoma, principally affecting the alveolar margin of the bone. Of the epitheliomata we find the squamous variety spreading to the bone from the palate or gum, and the cylindrical epithelioma originating in the antrum or nasal fossæ.

Both superior and inferior maxillary bones occasionally require removal for tumors and in some other conditions. The upper jaw is removed by an incision from the inner canthus of the eye, along the side of the nose, round the ala, and down the middle line of the upper lip. A second incision is carried outward from the inner canthus of the eye along the lower margin of the orbit as far as the prominence of the malar bone. The flap thus formed is reflected outward and the surface of the bone exposed. The connections of the bone to the other bones of the face are then divided with a narrow saw. They are (1) the junction with the malar bone, passing into the spheno-maxillary fissure; (2) the nasal process; a small portion of its upper extremity, connected with the nasal bone in front, the lachrymal bone behind, and the frontal bone above, being left; (3) the connection with the bone on the opposite side and the palate in the roof of the mouth. The bone is now firmly grasped with lion-forceps, and by means of a rocking movement upward and downward the remaining attachments of the orbital plate with the ethmoid, and the back of the bone with the palate, broken through. The soft palate is first separated from the hard with a scalpel, and is not removed. Occasionally in removing the upper jaw it will be found that the orbital plate can be spared, and this should always be done if possible. A horizontal saw-cut is to be made just below the infraorbital foramen and the bone cut through with a chisel and mallet. Removal of one-half of the lower jaw is sometimes required. If possible, the section of the bone should be made to one side of the symphysis, so as to save the genial tubercles and the origin of the genio-hyo-glossus muscle, as otherwise the tongue tends to fall backward and may produce suffocation. Having extracted the central or preferably the lateral incisor tooth, a vertical incision is made down to the bone, commencing at the free margin of the lip, and carried to the lower border of the bone; it is then carried along its lower border to the angle and up the posterior margin of the ramus to a level with the lobule of the ear. The flap thus formed is raised by separating all the structures attached to the outer surface of the bone. The jaw is now sawn through at the point where the tooth has been extracted, and the knife passed along the inner side of the jaw, separating the structures attached to this surface. The jaw is now grasped by the surgeon and strongly depressed, so as to bring down the coronoid process and enable the operator to sever the tendon of the temporal muscle. The jaw can be now further depressed, care being taken not to evert it or rotate it outward, which would endanger the internal maxillary artery, and the external pterygoid torn through or divided. The capsular ligament is now opened in front and the lateral ligaments divided, and the jaw removed with a few final touches of the knife.

The antrum occasionally requires tapping for suppuration. This may be done through the socket of a tooth, preferably the first molar, the fangs of which are most intimately connected with the antrum, or through the facial aspect of the bone above the alveolar process. This latter method does not perhaps afford such efficient drainage, but there is less chance of food finding its way into the cavity. The operation may be performed by incising the mucous membrane above the second molar tooth, and driving a trocar or any sharp-pointed instrument into the cavity.

THE HYOID BONE.

The **Hyoid bone** is named from its resemblance to the Greek upsilon; it is also called the *lingual bone*, because it supports the tongue and gives attachment to its numerous muscles. It is a bony arch, shaped like a horseshoe, and consisting of five segments, a body, two greater cornua, and two lesser cornua. It is suspended from the tip of the styloid processes of the temporal bone by ligamentous bands, the *stylo-hyoid* ligaments.

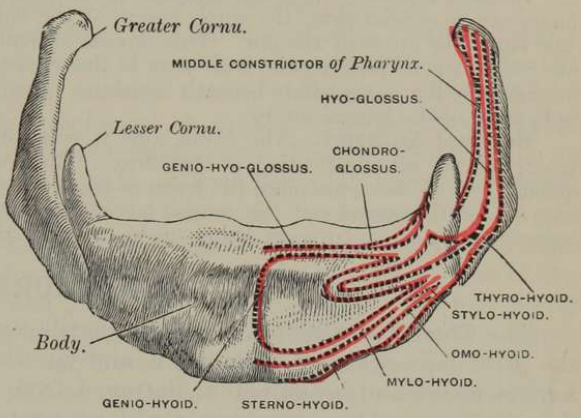

FIG. 178.—Hyoid bone. Anterior surface. (Enlarged).

The **Body** (*basi-hyal*) forms the central part of the bone, and is of a quadrilateral form; its *anterior surface* (Fig. 178), convex, directed forward and upward, is divided into two parts by a vertical ridge which descends along the median line, and is crossed at right angles by a horizontal ridge, so that this surface is divided into four spaces or depressions. At the point of meeting of these two lines is a prominent elevation, the *tubercle*. The portion above the horizontal ridge is directed upward, and is sometimes described as the superior border. The anterior surface gives attachment to the Genio-hyoid in the greater part of its extent; above, to the Genio-hyo-glossus; below, to the Mylo-hyoid, Stylo-hyoid, and aponeurosis of the Digastric (suprahyoid aponeurosis); and between these to part of the Hyo-glossus. The *posterior surface* is smooth, concave, directed backward and downward, and separated from the epiglottis by the thyro-hyoid membrane and by a quantity of loose areolar tissue. The *superior border* is rounded, and gives attachment to the thyro-hyoid membrane, part of the Genio-hyo-glossi and Chondro-glossi muscles. The *inferior border* gives attachment, in front, to the Sterno-hyoid; behind, to the Omo-hyoid and to part of the Thyro-hyoid at its junction with the great cornu. It also gives attachment to the Levator glandulæ thyroideæ when this muscle is present. The *lateral surfaces* are small, oval, convex facets, covered with cartilage for articulation with the greater cornua.

The **Greater Cornua** (*thyro-hyal*) project backward from the lateral surfaces of the body; they are flattened from above downward, diminish in size from before backward, and terminate posteriorly in a tubercle for the attachment of the lateral thyro-hyoid ligament. The outer surface gives attachment to the Hyo-glossus, their upper border to the Middle constrictor of the pharynx, their lower border to part of the Thyro-hyoid muscle. In youth the great cornua are connected to the body by cartilaginous surfaces and held together by ligaments; in middle life they usually become joined.

The **Lesser Cornua** (*cerato-hyals*) are two small, conical-shaped eminences attached by their bases to the angles of junction between the body and greater cornua, and giving attachment by their apices to the stylo-hyoid ligaments.[1] The smaller cornua are connected to the body of the bone by a distinct diarthrodial joint, which usually persists throughout life, but occasionally becomes ankylosed.

Development.—By *five* centres: one for the body, and one for each cornu. Ossification commences in the body about the eighth month, and in the greater cornua toward the end of fœtal life. Ossification of the lesser cornua commences some months after birth.

Attachment of Muscles.—Sterno-hyoid, Thyro-hyoid, Omo-hyoid, aponeurosis

[1] These ligaments in many animals are distinct bones, and in man are occasionally ossified to a certain extent.

of the Digastric, Stylo-hyoid, Mylo-hyoid, Genio-hyoid, Genio-hyo-glossus, Chondro-glossus, Hyo-glossus, Middle constrictor of the pharynx, and occasionally a few fibres of the Lingualis. It also gives attachment to the thyro-hyoidean membrane and the stylo-hyoid, thyro-hyoid, and hyo-epiglottic ligaments.

Surface Form.—The hyoid bone can be felt in the receding angle below the chin, and the finger can be carried along the whole length of the bone to the greater cornu, which is situated just below the angle of the jaw. This process of bone is best perceived by making pressure on one cornu, and so pushing the bone over to the opposite side, when the cornu of this side will be distinctly felt immediately beneath the skin. This process of bone is an important landmark in ligature of the lingual artery.

Surgical Anatomy.—The hyoid bone is occasionally fractured, generally from direct violence, as in the act of garrotting or throttling. The great cornu is the part of the bone most frequently broken, but sometimes the fracture takes place through the body of the bone. In consequence of the muscles of the tongue having important connections with this bone, there is great pain upon any attempt being made to move the tongue, as in speaking or swallowing.

THE THORAX.

The **Thorax,** or **Chest,** is an osseo-cartilaginous cage containing and protecting the principal organs of respiration and circulation. It is conical in shape, being narrow above and broad below, flattened from before backward, and longer behind than in front. It is somewhat cordiform on transverse section.

Boundaries.—The *posterior* surface is formed by the twelve dorsal vertebræ and the posterior part of the ribs. It is convex from above downward, and presents on each side of the middle line a deep groove in consequence of the direction backward and outward which the ribs take from their vertebral extremities to their angles. The *anterior* surface is flattened or slightly convex, and inclined forward from above downward. It is formed by the sternum and costal cartilages. The *lateral* surfaces are convex; they are formed by the ribs, separated from each other by spaces, the *intercostal spaces.* These are eleven in number, and are occupied by the intercostal muscles.

The *upper opening* of the thorax is reniform in shape, being broader from side to side than from before backward. It is formed by the first dorsal vertebra behind, the upper margin of the sternum in front, and the first rib on each side. It slopes downward and forward, so that the anterior part of the ring is on a lower level than the posterior. The antero-posterior diameter is about two inches. The *lower* opening is formed by the twelfth dorsal vertebra behind, by the twelfth rib at the sides, and in front by the cartilages of the eleventh, tenth, ninth, eighth, and seventh ribs, which ascend on either side and form an angle, the *subcostal angle,* from the centre of which the ensiform cartilage projects. It is wider transversely than from before backward. It slopes obliquely downward and backward, so that the cavity of the thorax is much deeper behind than in front. The Diaphragm closes in the opening forming the floor of the thorax.

In the female the thorax differs as follows from the male: 1. Its general capacity is less. 2. The sternum is shorter. 3. The upper margin of the sternum is on a level with the lower part of the body of the third dorsal vertebra, whereas in the male it is on a level with the lower part of the body of the second dorsal vertebra. 4. The upper ribs are more movable, and so allow a greater enlargement of the upper part of the thorax than in the male.

The Sternum.

The **Sternum** (στέρνον, the chest) (Figs. 179, 180) is a flat, narrow bone, situated in the median line of the front of the chest, and consisting, in the adult, of three portions. It has been likened to an ancient sword; the upper piece, representing the handle, is termed the *manubrium;* the middle and largest piece, which represents the chief part of the blade, is termed the *gladiolus;* and the inferior piece, which is likened to the point of the sword, is termed the *ensiform* or *xiphoid appendix.* In its natural position its inclination is oblique from above downward and forward. It is flattened in front, concave behind, broad above becoming

narrowed at the point where the first and second pieces are connected, after which it again widens a little, and is pointed at its extremity. Its average length in the adult is six inches, being rather longer in the male than in the female.

The **First Piece** of the sternum, or **Manubrium** (*pre-sternum*), is of a somewhat triangular form, broad and thick above, narrow below at its junction with the middle piece. Its *anterior surface*, convex from side to side, concave from above downward, is smooth, and affords attachment on each side to the Pectoralis major and sternal origin of the Sterno-cleido-mastoid muscle. In well-marked bones the ridges limiting the attachment of these muscles are very distinct. Its *posterior surface*, concave and smooth, affords attachment on each side to the Sterno-hyoid and Sterno-thyroid muscles. The *superior border*, the thickest, presents at its centre the *pre-sternal notch;* and on each side an oval articular surface, directed upward, backward, and outward, for articulation with the sternal end of the clavicle. The *inferior border* presents an oval, rough surface, covered in the recent state with a thin layer of cartilage, for articulation with the second portion of the bone. The *lateral borders* are marked above by a depression for the first costal cartilage, and below by a small facet, which with a similar facet on the upper angle of the middle portion of the bone, forms a notch for the reception of the costal cartilage of the second rib. These articular surfaces are separated by a narrow, curved edge, which slopes from above downward and inward.

The **Second Piece** of the sternum, or **Gladiolus** (*meso-sternum*), considerably longer, narrower, and thinner than the first piece, is broader below than above. Its *anterior surface* is nearly flat, directed upward and forward, and marked by three transverse lines which cross the bone opposite the third, fourth, and fifth articular depressions. These lines are produced by the union of the four separate pieces of which this part of the bone consists at an early period of life. At the junction of the third and fourth pieces is occasionally seen an orifice, the *sternal foramen;* it varies in size and form in different individuals, and pierces the bone from before backward. This surface affords attachment on each side to the sternal origin of the Pectoralis major. The *posterior surface*, slightly concave, is also marked by three transverse lines, but they are less distinct than those in front: this surface affords attachment below, on each side, to the Triangularis sterni muscle, and occasionally presents the posterior opening of the sternal foramen. The *superior border* presents an oval surface for articulation with the manubrium. The *inferior border* is narrow, and articulates with the ensiform appendix. Each *lateral border* presents, at each superior angle, a small facet, which, with a similar facet on the manubrium, forms a cavity for the cartilage of the second rib; the four succeeding angular depressions receive the cartilages of the third, fourth, fifth, and sixth ribs; whilst each inferior angle presents a small facet, which, with a corresponding one on the ensiform appendix, forms a notch for the cartilage of the seventh rib. These articular depressions are separated by a series of curved interarticular intervals, which diminish in length from above downward, and correspond to the intercostal spaces. Most of the cartilages belonging to the true ribs, as will be seen from the foregoing description, articulate with the sternum at the line of junction of two of its primitive component segments. This is well seen in many of the lower animals, where the separate parts of the bone remain ununited longer than in man. In this respect a striking analogy exists between the mode of connection of the ribs with the vertebral column and the connection of their cartilages with the sternal column.

The **Third Piece** of the sternum, the **Ensiform** or **Xiphoid Appendix** (*meta-sternum*), is the smallest of the three; it is thin and elongated in form, cartilaginous in structure in youth, but more or less ossified at its upper part in the adult. Its *anterior surface* affords attachment to the chondro-xiphoid ligament; its *posterior surface*, to some of the fibres of the Diaphragm and Triangularis sterni muscles; its *lateral borders*, to the aponeurosis of the abdominal muscles. Above it articulates with the lower end of the gladiolus, and at each superior angle presents a facet for the lower half of the cartilage of the seventh rib; below, by

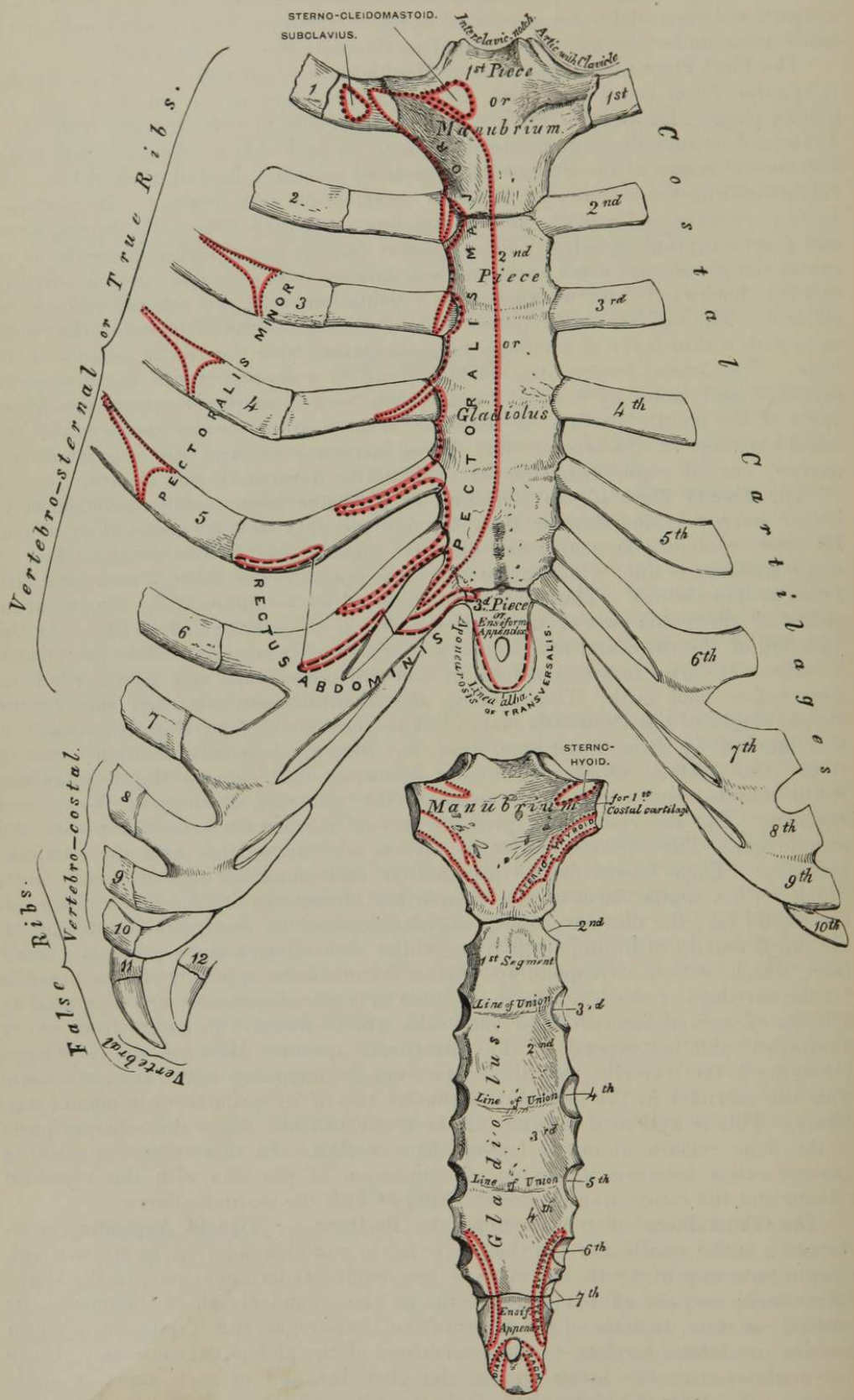

FIG. 179.—Sternum and costal cartilages.

FIG. 180.—Posterior surface of sternum.

its pointed extremity it gives attachment to the linea alba. This portion of the sternum is very various in appearance, being sometimes pointed, broad, and thin, sometimes bifid or perforated by a round hole, occasionally curved or deflected considerably to one or the other side.

Structure.—The bone is composed of delicate cancellous structure, covered by a thin layer of compact tissue, which is thickest in the manubrium between the articular facets for the clavicles.

Development.—The sternum, including the ensiform appendix, is developed by *six* centres: one for the first piece or manubrium, four for the second piece or

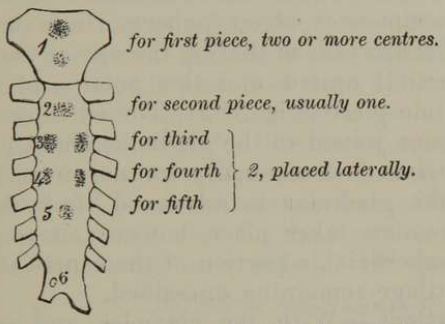

FIG. 181.—Development of the sternum by six centres. Time of appearance.

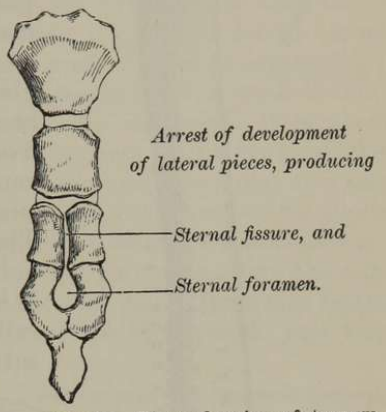

FIG. 182.—Time of union of sternum.

gladiolus, and one for the ensiform appendix. Up to the middle of fœtal life the sternum is entirely cartilaginous, and when ossification takes place the ossific

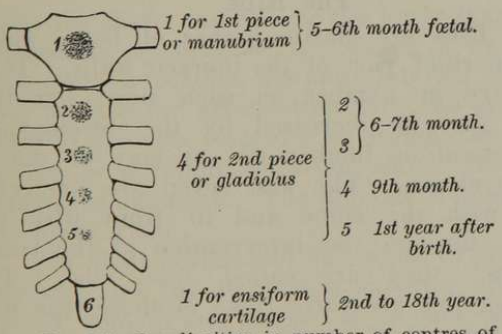

FIG. 183.—Peculiarities in number of centres of sternum.

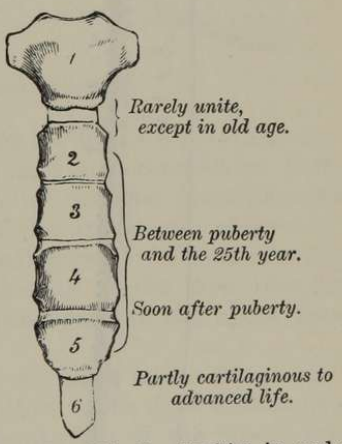

FIG. 184.—Peculiarities in mode of union of sternum.

granules are deposited in the middle of the intervals between the articular depressions for the costal cartilages, in the following order (Fig. 181): In the first piece, between the fifth and sixth months; in the second and third, between the sixth and seventh months; in the fourth piece, at the ninth month; in the fifth, within the first year or between the first and second years after birth; and in the ensiform appendix, between the second and the seventeenth or eighteenth years, by a single centre which makes its appearance at the upper part and proceeds gradually downward. To these may be added the occasional existence, as described by Breschet, of two small episternal centres, which make their appearance one on each side of the interclavicular notch. They are probably vestiges of the episternal bone of the monotremata and lizards. It occasionally happens that some of the segments are formed from more than one centre, the number and position of which vary (Fig. 183). Thus, the first piece may have two, three, or even six centres. When

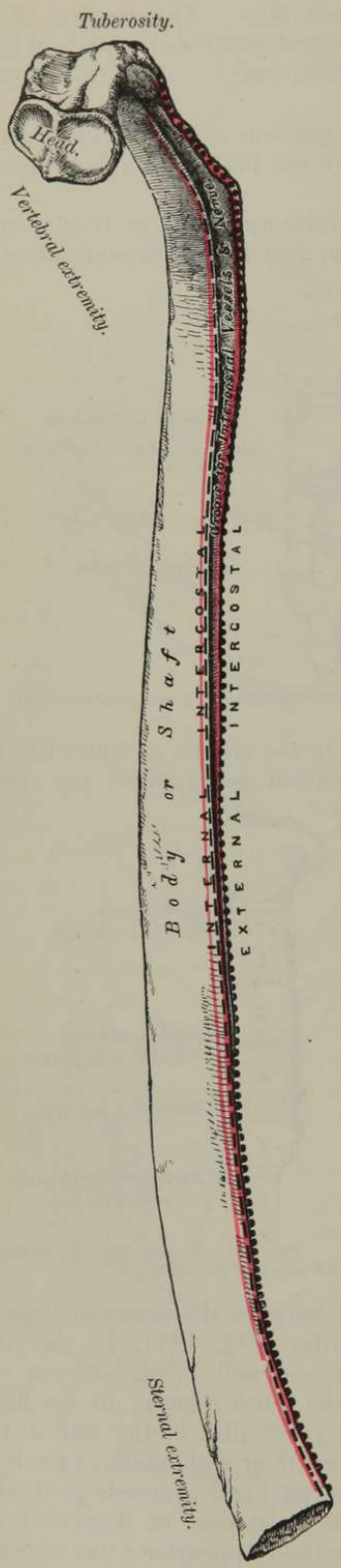

FIG. 185.—A central rib of right side. Inner surface.

two are present, they are generally situated one above the other, the upper one being the larger;[1] the second piece has seldom more than one; the third, fourth, and fifth pieces are often formed from two centres placed laterally, the irregular union of which will serve to explain the occasional occurrence of the sternal foramen (Fig. 184), or of the vertical fissure which occasionally intersects this part of the bone, and which is further explained by the manner in which the cartilaginous matrix, in which ossification takes place, is formed (see page 115). Union of the various centres of the gladiolus commences about puberty, from below, and proceeds upward, so that by the age of twenty-five they are all united, and this portion of bone consists of one piece (Fig. 182). The ensiform cartilage becomes joined to the gladiolus about forty. The manubrium is occasionally, but not invariably, joined to the gladiolus in advanced life by bone. When this union takes place, however, it is generally only superficial, a portion of the centre of the sutural cartilage remaining unossified.

Articulations.—With the clavicles and seven costal cartilages on each side.

Attachment of Muscles.—To nine pairs and one single muscle: the Pectoralis major, Sterno-cleido-mastoid, Sterno-hyoid, Sterno-thyroid, Triangularis sterni, aponeuroses of the Obliquus externus, Obliquus internus, Transversalis, Rectus muscles, and Diaphragm.

The Ribs.

The **Ribs** are elastic arches of bone, which form the chief part of the thoracic walls. They are twelve in number on each side; but this number may be increased by the development of a cervical or lumbar rib, or may be diminished to eleven. The first seven are connected behind with the spine and in front with the sternum, through the intervention of the costal cartilages; they are called *true* ribs. The remaining five are *false* ribs; of these, the first three have their cartilages attached to the cartilage of the rib above: the last two are free at their anterior extremities; they are termed *floating* ribs. The ribs vary in their direction, the upper ones being less oblique than those lower down and occupying the middle of the series. The extent of obliquity reaches its maximum at the ninth rib, and gradually decreases from that rib to the twelfth. The ribs are situated one below the other in such a manner that spaces are left between them, which are called *intercostal spaces*. The length of these spaces corresponds to the length of the ribs; their breadth is more considerable in front than behind, and between the upper than

[1] Sir George Humphry states that this is "probably the more complete condition."

between the lower ribs. The ribs increase in length from the first to the seventh, when they again diminish to the twelfth. In breadth they decrease from above downward; in the upper ten the greatest breadth is at the sternal extremity.

Common Characters of the Ribs (Fig. 185).—A rib from the middle of the series should be taken in order to study the common characters of the ribs.

Each rib presents two extremities, a posterior or vertebral, an anterior or sternal, and an intervening portion—the body or shaft.

The **posterior** or **vertebral extremity** presents for examination a head, neck, and tuberosity. The **head** (Fig. 186) is marked by a kidney-shaped articular surface, divided by a horizontal ridge into two facets for articulation with the costal cavity formed by the junction of the bodies of two contiguous dorsal vertebræ; the upper facet is small, the inferior one of larger size; the ridge separating them serves for the attachment of the interarticular ligament. The **neck** is that flattened portion of the rib which extends outward from the head; it is about an inch long, and is placed in front of the transverse process of the lower of the two vertebræ with which the head articulates. Its *anterior surface* is flat and smooth, its *posterior* rough for the attachment of the middle costo-transverse ligament, and perforated by numerous foramina, the direction of which is less constant than those found on the inner surface of the shaft. Of its two borders the *superior* presents a rough crest for the attachment of the anterior costo-transverse ligament; its *inferior border* is rounded. On the posterior surface of the neck, just where it

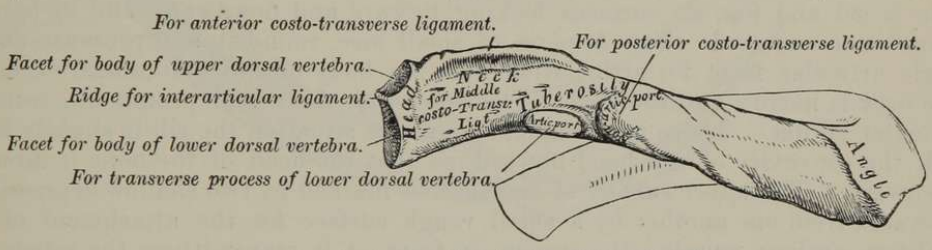

FIG. 186.—Vertebral extremity of a rib. External surface.

joins the shaft, and nearer the lower than the upper border, is an eminence—the **tuberosity**, or **tubercle**; it consists of an articular and a non-articular portion. The *articular portion*, the more internal and inferior of the two, presents a small, oval surface for articulation with the extremity of the transverse process of the lower of the two vertebræ to which the head is connected. The *non-articular portion* is a rough elevation, which affords attachment to the posterior costo-transverse ligament. The tubercle is much more prominent in the upper than in the lower ribs.

The **shaft** is thin and flat, so as to present two surfaces, an external and an internal, and two borders, a superior and an inferior. The *external surface* is convex, smooth and marked at its back part, a little in front of the tuberosity, by a prominent line, directed obliquely from above downward and outward; this gives attachment to a tendon of the Ilio-costalis muscle or of one of its accessory portions, and is called the *angle*. At this point the rib is bent in two directions. If the rib is laid upon its lower border, it will be seen that the portion of the shaft in front of the angle rests upon this border, while the portion of the shaft behind the angle is bent inward and at the same time tilted upward. The interval between the angle and the tuberosity increases gradually from the second to the tenth rib. The portion of bone between these two parts is rounded, rough, and irregular, and serves for the attachment of the Longissimus dorsi muscle. The portion of bone between the tubercle and sternal extremity is also slightly twisted upon its own axis, the external surface looking downward behind the angle, a little upward in front of it. This surface presents, toward its sternal extremity, an oblique line, the *anterior angle*. The *internal surface* is concave, smooth, directed a little upward behind the angle, a little downward in front of it. This surface is marked by a ridge which commences at the lower extremity of the head; it is

strongly marked as far as the inner side of the angle, and gradually becomes lost at the junction of the anterior with the middle third of the bone. The interval between it and the inferior border is deeply grooved, to lodge the intercostal vessels and nerve. At the back part of the bone this groove belongs to the inferior border, but just in front of the angle, where it is deepest and broadest, it corresponds to the internal surface. The superior edge of the groove is rounded; it serves for the attachment of the Internal intercostal muscle. The inferior edge corresponds to the lower margin of the rib and gives attachment to the External intercostal. Within the groove are seen the orifices of numerous small foramina which traverse the wall of the shaft obliquely from before backward. The *superior border*, thick and rounded, is marked by an external and an internal lip, more distinct behind than in front; they serve for the attachment of the External and Internal intercostal muscles. The *inferior border*, thin and sharp, has attached to it the External intercostal muscle. The **anterior** or **sternal extremity** is flattened, and presents a porous, oval, concave depression, into which the costal cartilage is received.

Peculiar Ribs.

The ribs which require especial consideration are five in number—viz. the first, second, tenth, eleventh and twelfth.

The **first rib** (Fig. 187) is one of the shortest and the most curved of all the ribs; it is broad and flat, its surfaces looking upward and downward, and its borders inward and outward. The *head* is of small size, rounded, and presents only a single articular facet for articulation with the body of the first dorsal vertebra. The *neck* is narrow and rounded. The *tuberosity*, thick and prominent, rests on the outer border. There is no angle, but in this situation the rib is slightly bent, with the convexity of the bend upward, so that the head of the bone is directed downward. The *upper surface* of the shaft is marked by two shallow depressions, separated from one another by a small rough surface for the attachment of the Scalenus anticus muscle—the groove in front of it transmitting the subclavian vein, that behind it the subclavian artery. Between the groove for the subclavian artery and the tuberosity is a rough surface, for the attachment of the Scalenus medius muscle. The *under surface* is smooth, and destitute of the groove observed on the other ribs. The *outer border* is convex, thick, and rounded, and at its posterior part gives attachment to the first serration of the Serratus magnus; the *inner* is concave, thin, and sharp, and marked about its centre by the commencement of the rough surface for the Scalenus anticus. The *anterior extremity* is larger and thicker than any of the other ribs.

The **second rib** (Fig. 188) is much longer than the first, but bears a very considerable resemblance to it in the direction of its curvature. The non-articular portion of the tuberosity is occasionally only slightly marked. The *angle* is slight and situated close to the tuberosity, and the shaft is not twisted, so that both ends touch any plane surface upon which it may be laid; but there is a similar though slighter bend, with its convexity upward, to that found in the first rib. The shaft is not horizontal, like that of the first rib, its *outer surface*, which is convex, looking upward and a little outward. It presents, near the middle, a rough eminence for the attachment of the second and third digitations of the Serratus magnus; behind and above which is attached the Scalenus posticus. The *inner surface*, smooth and concave, is directed downward and a little inward; it presents a short groove toward its posterior part.

The **tenth rib** (Fig. 189) has only a single articular facet on its head.

The **eleventh** and **twelfth ribs** (Figs. 190 and 191) have each a single articular facet on the head, which is of rather large size; they have no neck or tuberosity, and are pointed at the extremity. The eleventh has a slight angle and a shallow groove on the lower border. The twelfth has neither, and is much shorter than the eleventh, and the head has a slight inclination downward.

Structure.—The ribs consist of cancellous tissue enclosed in a thin, compact layer.

Development.—Each rib, with the exception of the last two, is developed by *three* centres: one for the shaft, one for the head, and one for the tubercle. The last two have only *two* centres, that for the tubercle being wanting. Ossification commences in the shaft of the ribs at a very early period, before its appearance in the vertebræ. The epiphysis of the head, which is of slightly angular shape, and that for the tubercle, of a lenticular form, make their appearance between the six-

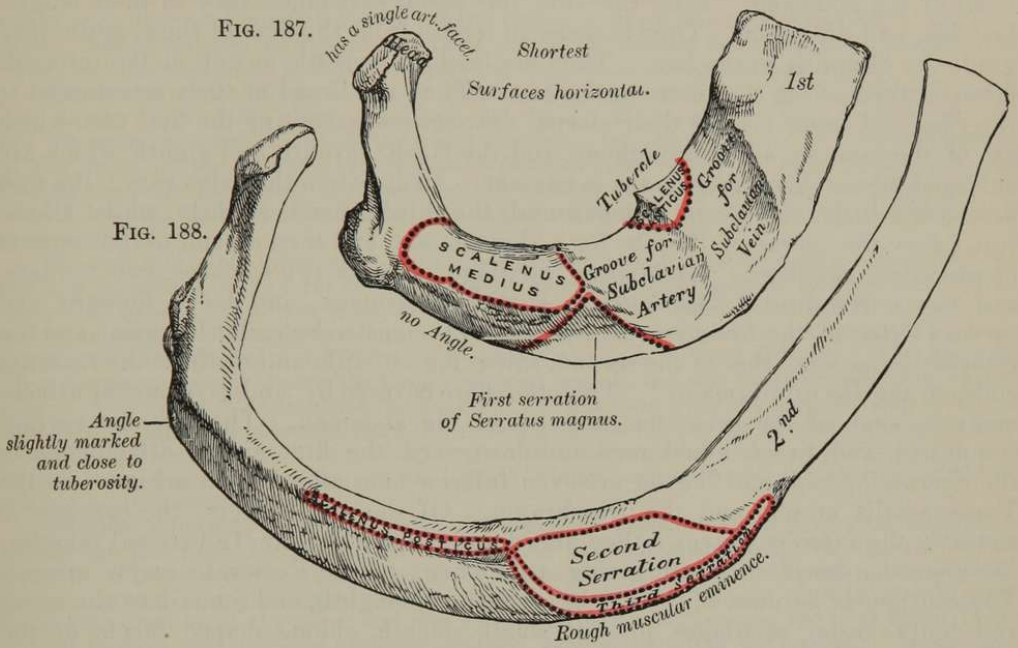

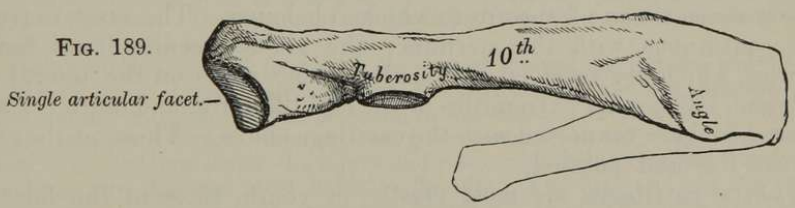





Figs. 187-191.—Peculiar ribs.

teenth and twentieth years, and are not united to the rest of the bone until about the twenty-fifth year.

Attachment of Muscles.—The Internal and External intercostals, Scalenus anticus, Scalenus medius, Scalenus posticus, Pectoralis minor, Serratus magnus, Obliquus externus, Obliquus internus, Transversalis, Quadratus lumborum, Diaphragm, Latissimus dorsi, Serratus posticus superior, Serratus posticus inferior, Ilio-costalis, Musculus accessorius ad ilio-costalem, Longissimus dorsi, Cervicalis ascendens, Levatores costarum, and Infracostales.

The Costal Cartilages.

The **Costal Cartilages** (Fig. 179, p. 230) are white, elastic structures, which serve to prolong the ribs forward to the front of the chest, and contribute very materially to the elasticity of its walls. The first seven are connected with the sternum, the next three with the lower border of the cartilage of the preceding rib. The cartilages of the last two ribs, which have pointed extremities, float freely in the walls of the abdomen. Like the ribs, the costal cartilages vary in their length, breadth, and direction. They increase in length from the first to the seventh, then gradually diminish to the last. They diminish in breadth, as well as the intervals between them, from the first to the last. They are broad at their attachment to the ribs, and taper toward their sternal extremities, excepting the first two, which are of the same breadth throughout, and the sixth, seventh and eighth, which are enlarged where their margins are in contact. In direction they also vary: the first descends a little, the second is horizontal, the third ascends slightly, whilst all the rest follow the course of the ribs for a short extent, and then ascend to the sternum or preceding cartilage. Each costal cartilage presents two surfaces, two borders, and two extremities. The *anterior surface* is convex, and looks forward and upward: that of the first gives attachment to the costo-clavicular ligament and the Subclavius muscle; that of the second, third, fourth, fifth, and sixth, at their sternal ends, to the Pectoralis major.[1] The others are covered by, and give partial attachment to, some of the great flat muscles of the abdomen. The *posterior surface* is concave, and directed backward and downward, the first giving attachment to the Sterno-thyroid, and the six or seven inferior ones affording attachment to the Transversalis muscle and the Diaphragm. Of the two borders, the *superior* is concave, the *inferior* convex: they afford attachment to the Intercostal muscles, the upper border of the sixth giving attachment to the Pectoralis major muscle. The contiguous borders of the sixth, seventh, and eighth, and sometimes the ninth and tenth, costal cartilages present small, smooth, oblong-shaped facets at the points where they articulate. Of the two extremities, the *outer* one is continuous with the osseous tissue of the rib to which it belongs. The *inner* extremity of the first is continuous with the sternum; the six succeeding ones have rounded extremities, which are received into shallow concavities on the lateral margins of the sternum. The inner extremities of the eighth, ninth, and tenth costal cartilages are pointed, and are connected with the cartilage above. Those of the eleventh and twelfth are free and pointed.

The costal cartilages are most elastic in youth, those of the false ribs being more so than the true. In old age they become of a deep yellow color, and are prone to calcify.

Attachment of Muscles.—To nine: the Subclavius, Sterno-thyroid, Pectoralis major, Internal oblique, Transversalis, Rectus, Diaphragm, Triangularis sterni, and Internal intercostals.

Surface Form.—The bones of the chest are to a very considerable extent covered by muscles, so that in the strongly-developed muscular subject they are for the most part concealed. In the emaciated subject, on the other hand, the ribs, especially in the lower and lateral region, stand out as prominent ridges with the sunken, intercostal spaces between them.

In the middle line, in front, the superficial surface of the sternum is to be felt throughout its entire length, at the bottom of a deep median furrow situated between the two great pectoral muscles and called the *sternal furrow*. These muscles overlap the anterior surface somewhat, so that the whole of the sternum in its entire width is not subcutaneous; and this overlapping is greater opposite the centre of the bone than above and below, so that the furrow is wider at its upper and lower parts, but narrower in the middle. The centre of the upper border of the sternum is visible, constituting the pre-sternal notch, but the lateral parts of this border are obscured by the tendinous origins of the Sterno-mastoid muscles, which present themselves as oblique tendinous cords, which narrow and deepen the notch. Lower down on the subcutaneous surface a well-defined transverse ridge is always to be felt. This denotes the line of junction of the manubrium and body of the bone, and is a useful guide to the second costal cartilage, and thus to the identity of any given rib. The second rib being found through its costal cartilage,

[1] The first and seventh also, occasionally, give origin to the same muscle.

it is easy to count downward and find any other Below this point the furrow spreads out, and, exposing more of the surface of the body of the sternum, terminates below in a sudden depression, the *infrasternal depression* or *pit of the stomach* (*scrobiculus cordis*), which corresponds to the ensiform cartilage. This depression lies between the cartilages of the seventh rib, and in it the ensiform cartilage may be felt. The sternum in its vertical diameter presents a general convexity forward, the most prominent point of which is at the joint between the manubrium and gladiolus.

On each side of the sternum the costal cartilages and ribs on the front of the chest are partially obscured by the great pectoral muscle; through which, however, they are to be felt as ridges, with depressed intervals between them, corresponding to the intercostal spaces. Of these spaces, the one between the second and third ribs is the widest, the next two somewhat narrower, and the remainder, with the exception of the last two, comparatively narrow.

The lower border of the Pectoralis major muscle corresponds to the fifth rib, and below this, on the front of the chest, the broad, flat outline of the ribs, as they begin to ascend, and the more rounded outline of the costal cartilages, are often visible. The lower boundary of the front of the thorax, the *abdomino-thoracic arch*, which is most plainly seen by arching the body backward, is formed by the ensiform cartilage and the cartilages of the seventh, eighth, ninth, and tenth ribs, and the extremities of the eleventh and twelfth ribs or their cartilages.

On each side of the chest, from the axilla downward, the flattened external surfaces of the ribs may be defined in the form of oblique ridges, separated by depressions corresponding to the intercostal spaces. They are, however, covered by muscles, which obscure their outline to a certain extent in the strongly developed. Nevertheless, the ribs, with the exception of the first, can generally be followed over the front and sides of the chest without difficulty. The first rib, being almost completely covered by the clavicle and scapula, can only be distinguished in a small portion of its extent. At the back the angles of the ribs form a slightly-marked oblique line on each side of and some distance from the vertebral spines. This line diverges somewhat as it descends, and external to it is a broad, convex surface caused by the projection of the ribs beyond their angles. Over this surface, except where covered by the scapula, the individual ribs can be distinguished.

Surgical Anatomy.—Malformations of the sternum present nothing of surgical importance beyond the fact that abscesses of the mediastinum may sometimes escape through the sternal foramen. Fractures of the sternum are by no means common, owing, no doubt, to the elasticity of the ribs and their cartilages, which support it like so many springs. It is frequently associated with fracture of the spine, and may be caused by forcibly bending the body either backward or forward until the chin becomes impacted against the top of the sternum. It may also be fractured by direct violence or by muscular action. The fracture usually occurs in the upper half of the body of the bone. Dislocation of the gladiolus from the manubrium also takes place, and is sometimes described as a fracture.

The bone, being subcutaneous, is frequently the seat of gummatous tumors, and not uncommonly is affected with caries. Occasionally the bone, and especially its ensiform appendix, becomes altered in shape and driven inward by the pressure, in workmen, of tools against their chest.

The ribs are frequently broken, though from their connections and shape they are able to withstand great force, yielding under the injury and recovering themselves like a spring. The middle of the series are the ones most liable to fracture. The first, and to a less extent the second, being protected by the clavicle, are rarely fractured ; and the eleventh and twelfth, on account of their loose and floating condition, enjoy a like immunity. The fracture generally occurs from indirect violence, from forcible compression of the chest-wall, and the bone then gives way at its weakest part—*i. e.* just in front of the angle. But the ribs may also be broken by direct violence, when the bone gives way and is driven inward at the point struck, or by muscular action. It seems probable, however, that in these latter cases the bone has undergone some atrophic changes. Fracture of the ribs is frequently complicated with some injury to the viscera contained within the thorax or upper part of the abdominal cavity, and this is most likely to occur in fractures from direct violence.

Fracture of the costal cartilages may also take place, though it is a comparatively rare injury.

The thorax is frequently found to be altered in shape in certain diseases.

The *rickety* thorax is caused chiefly by atmospheric pressure. The balance between the air on the inside of the chest and the outside during some stage of respiration is not equal, the preponderance being in favor of the air outside ; and this, acting on the softened ribs, causes them to be forced in at the junction of the cartilages with the bones, which is the weakest part. In consequence of this the sternum projects forward, with a deep depression on either side caused by the sinking in of the softened ribs. The depression is less on the left side, on account of the ribs being supported by the heart. The condition is known as "pigeon-breast." The lower ribs, however, are not involved in this deformity, as they are prevented from falling in by the presence of the stomach, liver, and spleen. And when the liver and spleen are enlarged, as they sometimes are in rickets, the lower ribs may be pushed outward : this causes a transverse constriction just above the costal arch. The anterior extremities of the ribs are usually enlarged in rickets, giving rise to what has been termed the "rickety rosary." The *phthisical chest* is often long and narrow, flattened from before backward, and with great obliquity of the ribs and projection of the scapulæ. In *pulmonary emphysema* the chest is enlarged in all its diameters, and presents on section an almost circular outline. It has received the name of the

"barrel-shaped chest." In severe cases of *lateral curvature of the spine* the thorax becomes much distorted. In consequence of the rotation of the bodies of the vertebræ which takes place in this disease the ribs opposite the convexity of the dorsal curve become extremely convex behind, being thrown out and bulging, and at the same time flattened in front, so that the two ends of the same rib are almost parallel. Coincident with this, the ribs on the opposite side, on the concavity of the curve, are sunk and depressed behind and bulging and convex in front. In addition to this the ribs become occasionally welded together by bony material.

The ribs are frequently the seat of necrosis leading to abscesses and sinuses, which may burrow to a considerable extent over the wall of the chest. The only special anatomical point in connection with these is that care must be taken in dealing with them that the intercostal space is not punctured and the pleural cavity opened or the intercostal vessels wounded.

In cases of empyema the chest requires opening to evacuate the pus. There is considerable difference of opinion as to the best position to do this. Probably the best place in most cases will be found to be between the fifth and sixth ribs, in or a little in front of the mid-axillary line. This is the last part of the cavity to be closed by the expansion of the lung; it is not thickly covered by soft parts; the space between the two ribs is sufficiently great to allow of the introduction of a fair-sized drainage-tube, and the opening is in a dependent position, when the patient is confined to bed, as he usually inclines toward the affected side, so as to allow the sound lung the freest possible play, and so permits of efficient drainage.

OF THE EXTREMITIES.

The extremities, or limbs, are those long, jointed appendages of the body which are connected to the trunk by one end and free in the rest of their extent. They are *four* in number: an *upper* or *thoracic pair*, connected with the thorax through the intervention of the shoulder, and subservient mainly to prehension; and a *lower pair*, connected with the pelvis, intended for support and locomotion. Both pairs of limbs are constructed after one common type, so that they present numerous analogies, while at the same time certain differences are observed in each, dependent on the peculiar offices they have to perform.

The bones by which the upper and lower limbs are attached to the trunk are named respectively the *shoulder* and *pelvic girdles*, and they are constructed on the same general type, though presenting certain modifications relating to the different uses to which the upper and lower limbs are respectively applied. The *shoulder girdle* is formed by the scapula and clavicle, and is imperfect in front and behind. In front, however, the girdle is completed by the upper end of the sternum, with which the inner extremities of the clavicle articulate. Behind, the girdle is widely imperfect and the scapula is connected to the trunk by muscles only. The *pelvic girdle* is formed by the innominate bones, and is completed in front through the symphysis pubis, at which the two innominate bones articulate with each other. It is imperfect behind, but the intervening gap is filled in by the upper part of the sacrum. The pelvic girdle, therefore, presents, with the sacrum, a complete ring, comparatively fixed, and presenting an arched form which confers upon it a solidity manifestly intended for the support of the trunk, and in marked contrast to the lightness and mobility of the shoulder girdle.

With regard to the morphology of these girdles, the blade of the scapula is generally believed to correspond to the ilium; but with regard to the clavicles there is some difference of opinion: formerly it was believed that they corresponded to the ossa pubis, meeting at the symphysis, but it is now generally taught that the clavicle has no homologue in the pelvic girdle, and that the os pubis and ischium are represented by the small coracoid process in man and most mammals.

THE UPPER EXTREMITY.

The bones of the upper extremity consist of those of the shoulder girdle, of the arm, the forearm, and the hand. The shoulder girdle consists of two bones, the clavicle and the scapula.

THE SHOULDER.

The Clavicle.

The **Clavicle** (*clavis*, a key), or collar-bone, forms the anterior portion of the shoulder girdle. It is a long bone, curved somewhat like the italic letter *f*, and

placed nearly horizontally at the upper and anterior part of the thorax, immediately above the first rib. It articulates by its inner extremity with the upper border of the sternum, and by its outer extremity with the acromion process of the scapula, serving to sustain the upper extremity in the various positions which it assumes, whilst at the same time it allows of great latitude of motion in the arm.[1] It presents a double curvature when looked at in front, the convexity being forward at the sternal end and the concavity at the scapular end. Its outer third is flattened from above downward, and extends, in the natural position of the bone, from a point opposite the coracoid process to the acromion. Its inner two-thirds are of a cylindrical form, and extend from the sternum to a point opposite the coracoid process of the scapula.

External or **Flattened Portion.**—The *outer third* is flattened from above downward, so as to present two surfaces, an upper and a lower; and two borders, an anterior and a posterior. The *upper surface* is flattened, rough, marked by impressions for the attachment of the Deltoid in front and the Trapezius behind; between these two impressions, externally, a small portion of the bone is subcutaneous. The *under surface* is flattened. At its posterior border, a little external to the point where the prismatic joins with the flattened portion, is a rough eminence, the *conoid tubercle;* this, in the natural position of the bone, surmounts the coracoid process of the scapula and gives attachment to the conoid ligament. From this tubercle an oblique line, occasionally a depression, passes forward and outward to near the outer end of the anterior border; it is called the *oblique line*, and affords attachment to the trapezoid ligament. The *anterior border* is concave, thin, and rough, and gives attachment to the Deltoid; it occasionally presents, at its inner end, at the commencement of the deltoid impression, a tubercle, the *deltoid tubercle*, which is sometimes to be felt in the living subject. The *posterior border* is convex, rough, broader than the anterior, and gives attachment to the Trapezius.

Internal or **Cylindrical Portion.**—The cylindrical portion forms the *inner two-thirds* of the bone. It is curved so as to be convex in front, concave behind, and is marked by three borders, separating three surfaces. The *anterior border* is continuous with the anterior margin of the flat portion. At its commencement it is smooth, and corresponds to the interval between the attachment of the Pectoralis major and Deltoid muscles; at the inner half of the clavicle it forms the lower boundary of an elliptical space for the attachment of the clavicular portion of the Pectoralis major, and approaches the posterior border of the bone. The *superior border* is continuous with the posterior margin of the flat portion, and separates the anterior from the posterior surface. At its commencement it is smooth and rounded, becomes rough toward the inner third for the attachment of the Sterno-mastoid muscle, and terminates at the upper angle of the sternal extremity. The *posterior* or *subclavian border* separates the posterior from the inferior surface, and extends from the conoid tubercle to the rhomboid impression. It forms the posterior boundary of the groove for the Subclavius muscle, and gives attachment to a layer of cervical fascia covering the Omo-hyoid muscle. The *anterior surface* is included between the superior and anterior borders. It is directed forward and a little upward at the sternal end, outward and still more upward at the acromial extremity, where it becomes continuous with the upper surface of the flat portion. Externally, it is smooth, convex, nearly subcutaneous, being covered only by the Platysma; but, corresponding to the inner half of the bone, it is divided by a more or less prominent line into two parts: a lower portion, elliptical in form, rough, and slightly convex, for the attachment of the Pectoralis major; and an upper part, which is rough, for the attachment of the Sterno-cleido-mastoid. Between

[1] The clavicle acts especially as a fulcrum to enable the muscles to give lateral motion to the arm. It is accordingly absent in those animals whose fore limbs are used only for progression, but is present for the most part in those animals whose anterior extremities are clawed and used for prehension, though in some of them—as, for instance, in a large number of the carnivora—it is merely a rudimentary bone suspended among the muscles, and not articulating either with the scapula or sternum.

the two muscular impressions is a small subcutaneous interval. The *posterior* or *cervical surface* is smooth, flat, and looks backward toward the root of the neck. It is limited, above, by the superior border; below, by the subclavian border; internally, by the margin of the sternal extremity; externally, it is continuous with the posterior border of the flat portion. It is concave from within outward, and is in relation, by its lower part, with the suprascapular vessels. This surface, at about the junction of the inner and outer curves, is also in close relation with the brachial plexus and subclavian vessels. It gives attachment, near the sternal extremity, to part of the Sterno-hyoid muscle; and presents, at or near the middle, a foramen, directed obliquely outward, which transmits the chief nutrient artery of the bone. Sometimes there are two foramina on the posterior surface, or one on the posterior, the other on the inferior surface. The *inferior* or *subclavian*

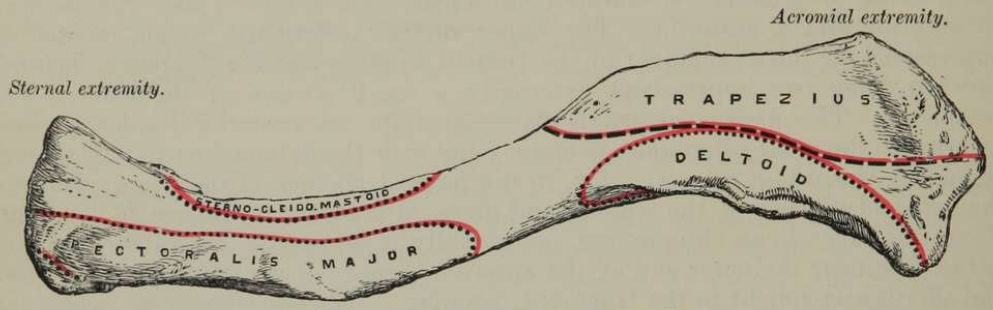

FIG. 192.—Left clavicle. Superior surface.

surface is bounded, in front, by the anterior border; behind, by the subclavian border. It is narrow internally, but gradually increases in width externally, and

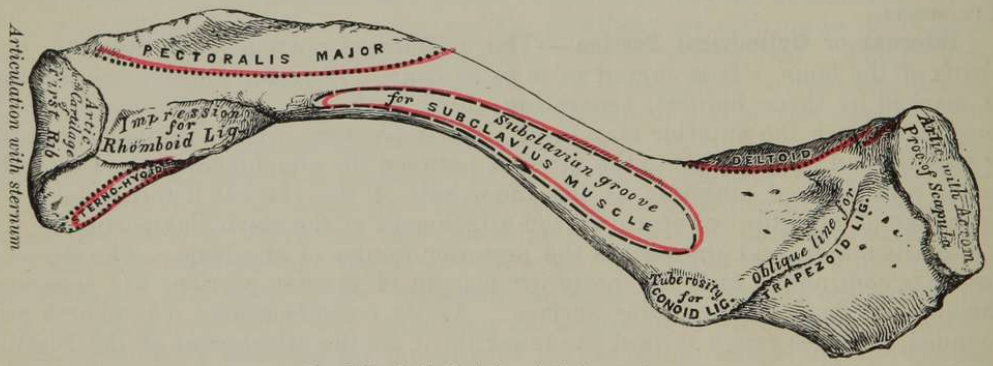

FIG. 193.—Left clavicle. Inferior surface.

is continuous with the under surface of the flat portion. Commencing at the sternal extremity may be seen a small facet for articulation with the cartilage of the first rib. This is continuous with the articular surface at the sternal end of the bone. External to this is a broad, rough impression, the *rhomboid*, rather more than an inch in length, for the attachment of the costo-clavicular (rhomboid) ligament. The remaining part of this surface is occupied by a longitudinal groove, the *subclavian groove*, broad and smooth externally, narrow and more uneven internally; it gives attachment to the Subclavius muscle, and by its anterior margin to the costo-coracoid membrane. Not unfrequently this groove is subdivided into two parts by a longitudinal line, which gives attachment to the intermuscular septum of the Subclavius muscle.

The **internal** or **sternal extremity** of the clavicle is triangular in form, directed inward and a little downward and forward; and presents an articular facet, concave from before backward, convex from above downward, which articulates with the sternum through the intervention of an interarticular fibro-cartilage; the circumference of the articular surface is rough, for the attachment of numerous

ligaments. The posterior border of this surface is prolonged backward, so as to increase the size of the articular facet; the upper border gives attachment to the interarticular fibro-cartilage, and the lower border is continuous with the costal facet on the inner end of the inferior or subclavian surface, which articulates with the cartilage of the first rib.

The **outer** or **acromial extremity,** directed outward and forward, presents a small, flattened, oval facet, which looks obliquely downward, for articulation with the acromion process of the scapula. The circumference of the articular facet is rough, especially above, for the attachment of the acromio-clavicular ligaments.

Peculiarities of the Bone in the Sexes and in Individuals.—In the female the clavicle is generally shorter, thinner, less curved, and smoother than in the male. In those persons who perform considerable manual labor, which brings into constant action the muscles connected with this bone, it becomes thicker and more curved, its ridges for muscular attachment become prominently marked, and its sternal end of a prismatic form. The right clavicle is generally longer, thicker, and rougher than the left.

Structure.—The shaft, as well as the extremities, consists of cancellous tissue, invested in a compact layer much thicker in the middle than at either end. The clavicle is highly elastic, by reason of its curves. From the experiments of Mr. Ward it has been shown that it possesses sufficient longitudinal elastic force to project its own weight nearly two feet on a level surface when a smart blow is struck on it; and sufficient transverse elastic force, opposite the centre of its anterior convexity, to throw its own weight about a foot. This extent of elastic power must serve to moderate very considerably the effect of concussions received upon the point of the shoulder.

Development.—By *two* centres: one for the shaft and one for the sternal extremity. The centre for the shaft appears very early, before any other bone—according to Béclard, as early as the thirtieth day. The centre for the sternal end makes its appearance about the eighteenth or twentieth year, and unites with the rest of the bone about the twenty-fifth year.

Articulations.—With the sternum, scapula, and cartilage of the first rib.

Attachment of Muscles.—To six: the Sterno-cleido-mastoid, Trapezius, Pectoralis major, Deltoid, Subclavius, and Sterno-hyoid.

Surface Form.—The clavicle can be felt throughout its entire length, even in persons who are very fat. Commencing at the inner end, the enlarged sternal extremity, where the bone projects above the upper margin of the sternum, can be felt, forming with the sternum and the rounded tendon of the Sterno-mastoid a V-shaped notch, the *pre-sternal notch.* Passing outward, the shaft of the bone can be felt immediately under the skin, with its convexity forward in the inner two-thirds, the surface partially obscured above and below by the attachments of the Sterno-mastoid and Pectoralis major muscles. In the outer third it forms a gentle curve backward, and terminates at the outer end in a somewhat enlarged extremity which articulates with the acromial process of the scapula. The direction of the clavicle is almost, if not quite, horizontal when the arm is lying quietly by the side, though in well-developed subjects it may incline a little upward at its outer end. Its direction is, however, very changeable with the varying movements of the shoulder-joint.

Surgical Anatomy.—The clavicle is the most frequently broken of any single bone in the body. This is due to the fact that it is much exposed to violence, and is the only bony connection between the upper limb and the trunk. The bone, moreover, is slender, and is very superficial. The bone may be broken by direct or indirect violence or by muscular action. The most common cause is, however, from indirect violence, and the bone then gives way at the junction of the outer with the inner two-thirds of the bone; that is to say at the junction of the two curves, for this is the weakest part of the bone. The fracture is generally oblique, and the displacement of the fragments is inward, away from the surface of the body; hence compound fracture of the clavicle is of rare occurrence. Beneath the bone the main vessels of the upper limb and the great nerve-cords of the brachial plexus lie on the first rib, and are liable to be wounded in fracture, especially in fracture from direct violence, when the force of the blow drives the broken ends inward. Fortunately, the Subclavius muscle is interposed between these structures and the clavicle, and this often protects them from injury.

The clavicle is not uncommonly the seat of sarcomatous tumors, rendering the operation of excision of the entire bone necessary. This is an operation of considerable difficulty and danger. It is best performed by exposing the bone freely, disarticulating at the acromial end, and turning it inward. The removal of the outer part is comparatively easy, but resection of

the inner part is fraught with difficulty, the main danger being the risk of wounding the great veins which are in relation with its under surface.

The Scapula.

The **Scapula** (*σκαπάνη*, a spade) forms the back part of the shoulder girdle. It is a large, flat bone, triangular in shape, situated at the posterior aspect and side of

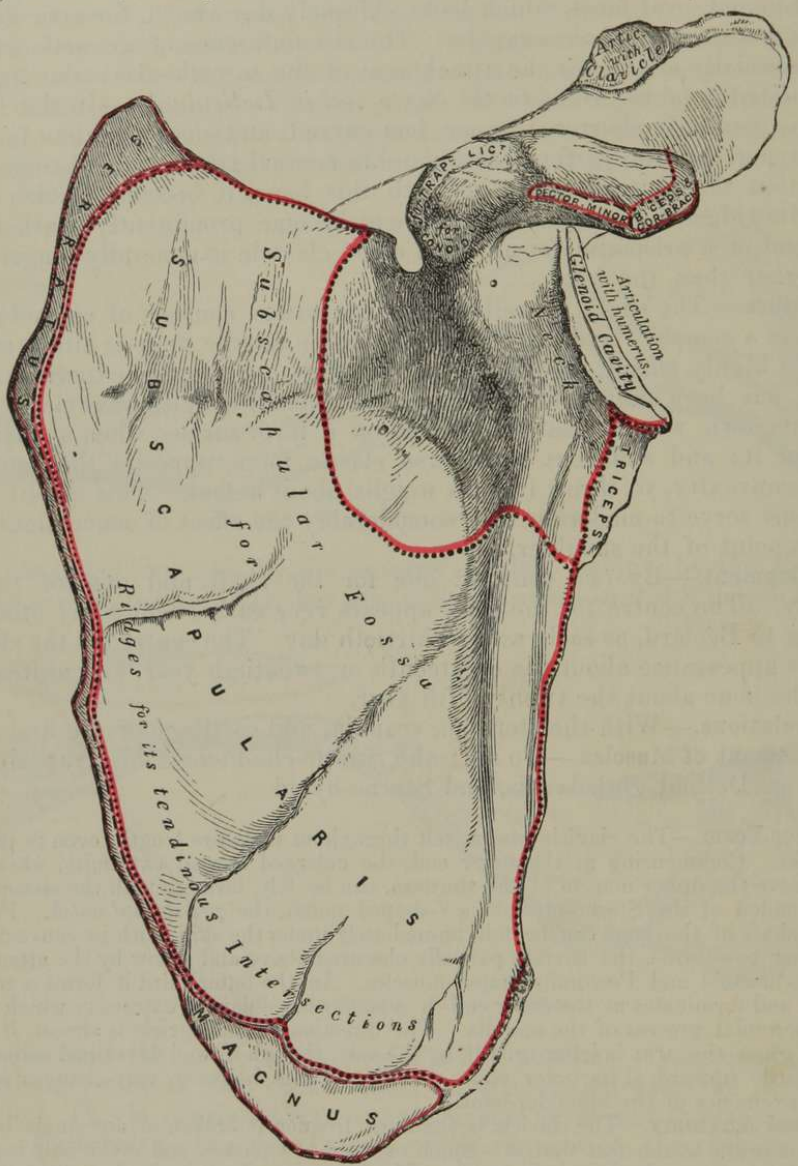

FIG. 194.—Left scapular anterior surface, or venter.

the thorax, between the second and seventh, or sometimes the eighth, ribs, its posterior border or base being about an inch from, and nearly, but not quite parallel with the spinous processes of the vertebræ, so that it is rather closer to them above than below. It presents for examination two surfaces, three borders, and three angles.

The **anterior surface,** or **venter** (Fig. 194), presents a broad concavity, the *subscapular fossa*. It is marked, in the posterior two-thirds, by several oblique ridges, which pass from behind obliquely outward and upward; the anterior third is smooth. The oblique ridges give attachment to the tendinous intersections, and the surfaces between them to the fleshy fibres, of the Subscapularis muscle. The

anterior third of the fossa, which is smooth, is covered by, but does not afford attachment to, the fibres of this muscle. The venter is separated from the posterior border by a smooth, triangular margin at the superior and inferior angles, and in the interval between these by a narrow edge which is often deficient. This marginal surface affords attachment throughout its entire extent to the Serratus magnus muscle. The subscapular fossa presents a transverse depression at its upper part, where the bone appears to be bent on itself, forming a considerable angle, called the *subscapular angle*, thus giving greater strength to the body of the bone from its arched form, while the summit of the arch serves to support the spine and acromion process. It is in this situation that the fossa is deepest, so that the thickest part of the Subscapularis muscle lies in a line perpendicular

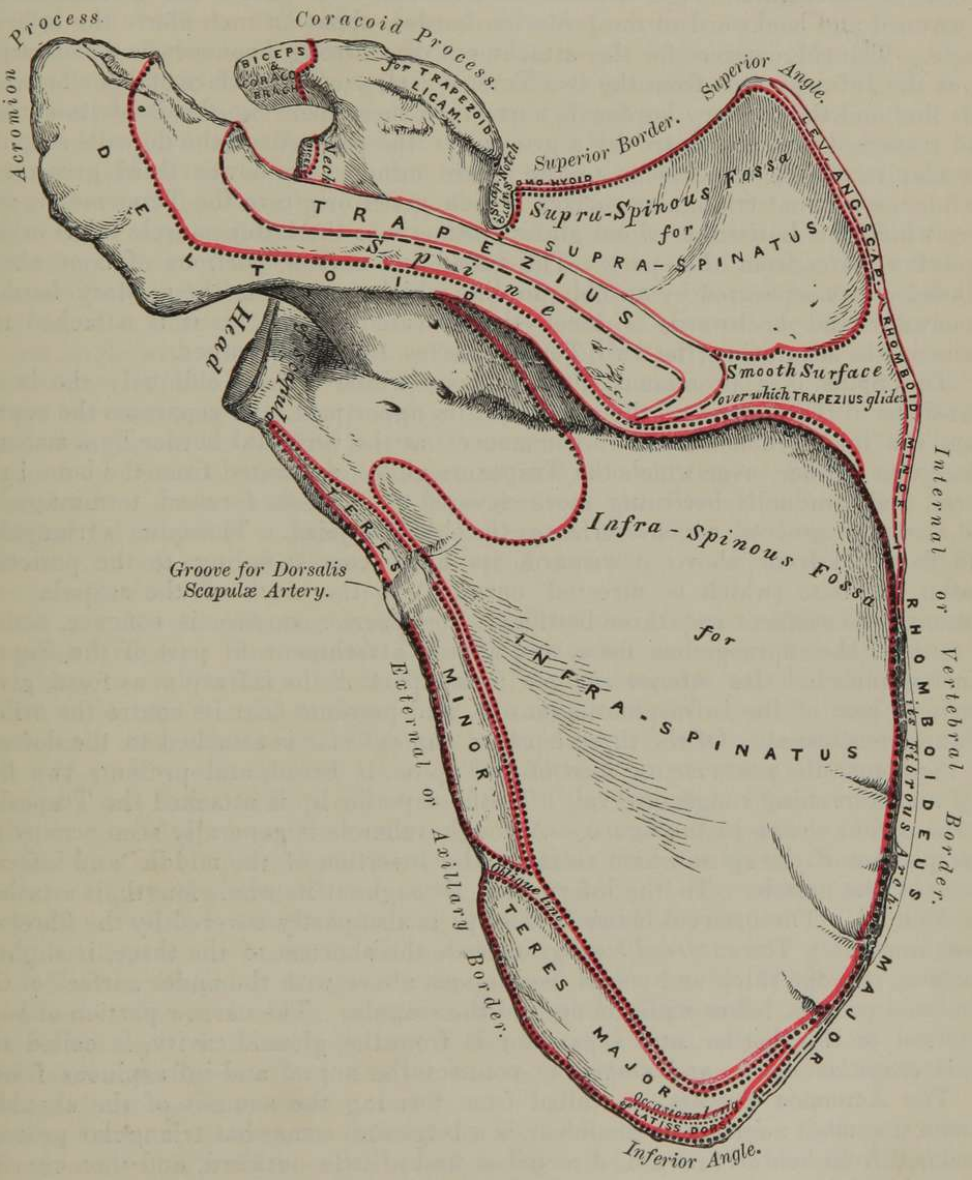

FIG. 195.—Left scapula. Posterior surface, or dorsum.

to the plane of the glenoid cavity, and must consequently operate most effectively on the head of the humerus, which is contained in that cavity.

The **posterior surface,** or **dorsum** (Fig. 195), is arched from above downward, alternately concave and convex from side to side. It is subdivided unequally into

two parts by the *spine:* the portion above the spine is called the *supraspinous fossa*, and that below it the *infraspinous fossa.*

The **supraspinous fossa,** the smaller of the two, is concave, smooth, and broader at the vertebral than at the humeral extremity. It affords attachment by its inner two-thirds to the Supraspinatus muscle.

The **infraspinous fossa** is much larger than the preceding; toward its vertebral margin a shallow concavity is seen at its upper part; its centre presents a prominent convexity, whilst toward the axillary border is a deep groove which runs from the upper toward the lower part. The inner two-thirds of this surface affords attachment to the Infraspinatus muscle; the outer third is only covered by it, without giving origin to its fibres. This surface is separated from the axillary border by an elevated ridge, which runs from the lower part of the glenoid cavity downward and backward to the posterior border, about an inch above the inferior angle. The ridge serves for the attachment of a strong aponeurosis which separates the Infraspinatus from the two Teres muscles. The surface of bone between this line and the axillary border is narrow in the upper two-thirds of its extent, and traversed near its centre by a groove for the passage of the dorsalis scapulæ vessels; it affords attachment to the Teres minor. Its lower third presents a broader, somewhat triangular surface, which gives origin to the Teres major, and over which the Latissimus dorsi glides; sometimes the latter muscle takes origin by a few fibres from this part. The broad and narrow portions of bone above alluded to are separated by an oblique line which runs from the axillary border, downward and backward, to meet the elevated ridge: to it is attached the aponeurosis separating the two Teres muscles from each other.

The **Spine** is a prominent plate of bone which crosses obliquely the inner four-fifths of the dorsum of the scapula at its upper part, and separates the supra- from the infraspinous fossa: it commences at the vertebral border by a smooth, triangular surface, over which the Trapezius glides, separated from the bone by a bursa, and, gradually becoming more elevated as it passes forward, terminates in the acromion process, which overhangs the shoulder-joint. The spine is triangular and flattened from above downward, its apex corresponding to the posterior border, its base (which is directed outward) to the neck of the scapula. It presents two surfaces and three borders. Its *superior surface* is concave, assists in forming the supraspinous fossa, and affords attachment to part of the Supraspinatus muscle. Its *inferior surface* forms part of the infraspinous fossa, gives origin to part of the Infraspinatus muscle, and presents near its centre the orifice of a nutrient canal. Of the three borders, the *anterior* is attached to the dorsum of the bone; the *posterior*, or *crest* of the spine, is broad, and presents two lips and an intervening rough interval. To the superior lip is attached the Trapezius to the extent shown in the figure. A rough tubercle is generally seen occupying that portion of the spine which receives the insertion of the middle and inferior fibres of this muscle. To the inferior lip, throughout its whole length, is attached the Deltoid. The interval between the lips is also partly covered by the fibres of these muscles. The *external border*, or *base*, the shortest of the three, is slightly concave, its edge thick and round, continuous above with the under surface of the acromion process, below with the neck of the scapula. The narrow portion of bone external to this border, and separating it from the glenoid cavity, is called the *great scapular notch*, and serves to connect the supra- and infraspinous fossæ.

The **Acromion Process,** so called from forming the summit of the shoulder (*ἄκρον*, a summit; *ὦμος*, the shoulder), is a large and somewhat triangular process, flattened from behind forward, directed at first a little outward, and then curving forward and upward, so as to overhang the glenoid cavity. Its *upper surface*, directed upward, backward, and outward, is convex, rough, and gives attachment to some fibres of the Deltoid, and in the rest of its extent it is subcutaneous. Its *under surface* is smooth and concave. Its *outer border* is thick and irregular, and presents three or four tubercles for the tendinous origins of the Deltoid muscle. Its *inner margin*, shorter than the outer, is concave, gives attachment to a portion

of the Trapezius muscle, and presents about its centre a small oval surface for articulation with the acromial end of the clavicle. Its *apex*, which corresponds to the point of meeting of these two borders in front, is thin, and has attached to it the coraco-acromial ligament.

Of the three borders or costæ of the scapula, the *superior* is the shortest and thinnest; it is concave, terminating at its inner extremity at the superior angle, at its outer extremity at the coracoid process. At its outer part is a deep, semicircular notch, the *suprascapular*, formed partly by the base of the coracoid process. This notch is converted into a foramen by the transverse ligament, and serves for the passage of the suprascapular nerve. The adjacent margin of the superior border affords attachment to the Omo-hyoid muscle. The *external*, or *axillary*, *border* is the thickest of the three. It commences above at the lower margin of the glenoid cavity, and inclines obliquely downward and backward to the inferior angle. Immediately below the glenoid cavity is a rough impression (the *infraglenoid tubercle*), about an inch in length, which affords attachment to the long head of the Triceps muscle; to this succeeds a longitudinal groove, which extends as far as its lower third and affords origin to part of the Subscapularis muscle. The inferior third of this border, which is thin and sharp, serves for the attachment of a few fibres of the Teres major behind and of the Subscapularis in front. The *internal*, or *vertebral*, *border*, also named the *base*, is the longest of the three, and extends from the superior to the inferior angle of the bone. It is arched, intermediate in thickness between the superior and the external borders, and the portion of it above the spine is bent considerably outward, so as to form an obtuse angle with the lower part. The vertebral border presents an anterior lip, a posterior lip, and an intermediate space. The *anterior lip* affords attachment to the Serratus magnus; the *posterior lip*, to the Supraspinatus above the spine, the Infraspinatus below; the interval between the two lips, to the Levator anguli scapulæ above the triangular surface at the commencement of the spine, the Rhomboideus minor to the edge of that surface; the Rhomboideus major being attached by means of a fibrous arch connected above to the lower part of the triangular surface at the base of the spine, and below to the lower part of the posterior border.

Of the three angles, the *superior*, formed by the junction of the superior and internal borders, is thin, smooth, rounded, somewhat inclined outward, and gives attachment to a few fibres of the Levator anguli scapulæ muscle. The *inferior* angle, thick and rough, is formed by the union of the vertebral and axillary borders, its outer surface affording attachment to the Teres major and occasionally a few fibres of the Latissimus dorsi. The *anterior* angle is the thickest part of the bone, and forms what is called the *head* of the scapula. The head presents a shallow, pyriform, articular surface, the *glenoid cavity* (γλήνη, a socket), whose longest diameter is from above downward, and its direction outward and forward. It is broader below than above; at its apex is a slight impression (*supraglenoid tubercle*) to which is attached the long tendon of the Biceps muscle. It is covered with cartilage in the recent state; and its margins, slightly raised, give attachment to a fibro-cartilaginous structure, the *glenoid ligament*, by which its cavity is deepened. The *neck* of the scapula is the slightly depressed surface which surrounds the head; it is more distinct on the posterior than on the anterior surface, and below than above. In the latter situation it has arising from it a thick prominence, the coracoid process.

The **Coracoid Process,** so called from its fancied resemblance to a crow's beak (κόραξ, a crow), is a thick, curved process of bone which arises by a broad base from the upper part of the neck of the scapula; it is directed at first upward and inward, then, becoming smaller, it changes its direction and passes forward and outward. The ascending portion, flattened from before backward, presents in front a smooth, concave surface over which passes the Subscapularis muscle. The horizontal portion is flattened from above downward, its upper surface is convex and irregular, and gives attachment to the Pectoralis minor; its under surface is

smooth; its inner border is rough, and gives attachment to the Pectoralis minor; its outer border is also rough for the coraco-acromial ligament, while the apex is embraced by the conjoined tendon of origin of the short head of the Biceps and of the Coraco-brachialis. At the inner side of the root of the coracoid process is a rough impression for the attachment of the conoid ligament; and running from it obliquely forward and outward on the upper surface of the horizontal portion, an elevated ridge for the attachment of the trapezoid ligament.

Structure.—In the head, processes, and all the thickened parts of the bone the scapula is composed of cancellous tissue, while in the rest of its extent it is composed of a thin layer of dense, compact tissue. The centre and upper part of the dorsum, but especially the former, are usually so thin as to be semitransparent;

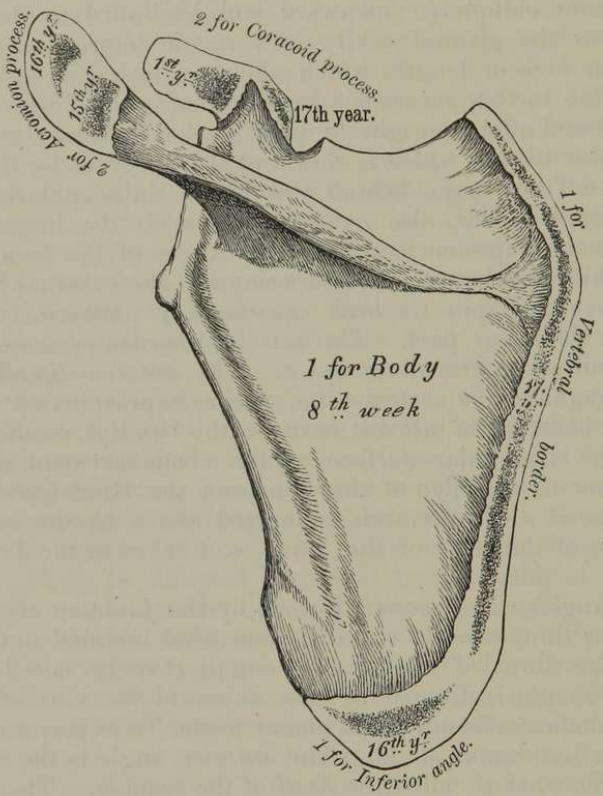

FIG. 196.—Plan of the development of the scapula. By seven centres. The epiphyses (except one for the coracoid process) appear from fifteen to seventeen years, and unite between twenty-two and twenty-five years of age.

occasionally the bone is found wanting in this situation, and the adjacent muscles come into contact.

Development (Fig. 196).—By *seven* centres: one for the body, two for the coracoid process, two for the acromion, one for the vertebral border, and one for the inferior angle.

Ossification of the body of the scapula commences about the second month of fœtal life by the formation of an irregular quadrilateral plate of bone immediately behind the glenoid cavity. This plate extends itself so as to form the chief part of the bone, the spine growing up from its posterior surface about the third month. At birth the chief part of the scapula is osseous, only the coracoid and acromion processes, the posterior border, and inferior angle being cartilaginous. About the first year after birth ossification takes place in the middle of the coracoid process, which usually becomes joined with the rest of the bone at the time when the other centres make their appearance. Between the fifteenth and seventeenth years ossification of the remaining centres takes place in quick succession, and

in the following order: first, near the base of the acromion and in the root of the coracoid process, the latter appearing in the form of a broad scale; secondly, in the inferior angle and contiguous part of the posterior border; thirdly, near the extremity of the acromion; fourthly, in the posterior border. The acromion process, besides being formed of two separate nuclei, has its base formed by an extension into it of the centre of ossification which belongs to the spine, the extent of which varies in different cases. The two separate nuclei unite, and then join with the extension carried in from the spine. These various epiphyses become joined to the bone between the ages of twenty-two and twenty-five years. Sometimes failure of union between the acromion process and spine occurs, the junction being effected by fibrous tissue or by an imperfect articulation; in some cases of supposed fracture of the acromion with ligamentous union it is probable that the detached segment was never united to the rest of the bone. Very often, in addition to these, a minute epiphysis appears at the margin of the glenoid cavity.

Articulations.—With the humerus and clavicle.

Attachment of Muscles.—To seventeen: to the anterior surface, the Subscapularis; posterior surface, Supraspinatus, Infraspinatus; spine, Trapezius, Deltoid; superior border, Omo-hyoid; vertebral border, Serratus magnus, Levator anguli scapulæ, Rhomboideus minor and major; axillary border, Triceps, Teres minor, Teres major; glenoid cavity, long head of the Biceps; coracoid process, short head of the Biceps, Coraco-brachialis, Pectoralis minor; and to the inferior angle occasionally a few fibres of the Latissimus dorsi.

Surface Form.—The only parts of the scapula which are truly subcutaneous are the spine and acromion process, but, in addition to these, the coracoid process, the internal or vertebral border and inferior angle, and, to a less extent, the axillary border, may be defined. The acromion process and spine of the scapula are easily felt throughout their entire length, forming, with the clavicle, the arch of the shoulder. The acromion can be ascertained to be connected to the clavicle at the acromio-clavicular joint by running the finger along it, its position being often indicated by an irregularity or bony outgrowth from the clavicle close to the joint. The acromion can be felt forming the point of the shoulder, and from this can be traced backward to join the spine of the scapula. The place of junction is usually denoted by a prominence, which is sometimes called the angle. From here the spine can be felt as a prominent ridge of bone, marked on the surface as an oblique depression, which becomes less and less distinct, and terminates a little external to the spinous processes of the vertebræ. Its termination is usually indicated by a slight dimple in the skin on a level with the interval between the third and fourth dorsal spines. Below this point the vertebral border of the scapula may be traced, running downward and outward, and thus diverging from the vertebral spines, to the inferior angle of the bone, which can be recognized, although covered by the Latissimus dorsi muscle. From this angle the axillary border can usually be traced through this thick muscular covering, forming, with the muscles, the posterior fold of the axilla. The coracoid process may be felt about an inch below the junction of the middle and outer third of the clavicle. Its position is indicated on the surface of the body by a slight depression which corresponds to the interval between the Pectoralis major and Deltoid muscles. When the arms are hanging by the side, the upper angle of the scapula corresponds to the upper border of the second rib or the interval between the first and second dorsal spines, the inferior angle to the upper border of the eighth rib or the interval between the seventh and eighth dorsal spines.

Surgical Anatomy.—Fractures of the body of the scapula are rare, owing to the mobility of the bone, the thick layer of muscles by which it is encased on both surfaces, and the elasticity of the ribs on which it rests. Fracture of the neck of the bone is also uncommon. The most frequent course of the fracture is from the suprascapular notch to the infraglenoid tubercle, and it derives its principal interest from its simulation to a subglenoid dislocation of the humerus. The diagnosis can be made by noting the alteration in the position of the coracoid process. A fracture of the neck external to, and not including, the coracoid process is said to occur, but it is exceedingly doubtful whether such an accident ever takes place. The acromion process is more frequently broken than any other part of the bone, and there is sometimes, in young subjects, a separation of the epiphysis. It is believed that many of the cases of supposed fracture of the acromion, with fibrous union, which have been found on post-mortem examination are really cases of imperfectly united epiphysis. Sir Astley Cooper believed that most fractures of this bone united by fibrous tissue, and the cause of this mode of union was the difficulty there was in keeping the fractured ends in constant apposition. The coracoid process is occasionally broken off, either from direct violence or perhaps, rarely, from muscular action.

Tumors of various kinds grow from the scapula. Of the innocent form of tumors probably the osteomata are the most common. When it grows from the venter of the scapula, as it

sometimes does, it is of the compact variety, such as usually grows from membrane-formed bones, as the bones of the skull. This would appear to afford evidence that this portion of the bone is formed from membrane, and not, like the rest of the bone, from cartilage. Sarcomatous tumors sometimes grow from the scapula, and may necessitate removal of the bone, with or without amputation of the upper limb. The bone may be excised by a T incision, and, the flaps being reflected, the removal is commenced from the posterior or vertebral border, so that the subscapular vessels which lie along the axillary border are among the last structures divided, and can be at once secured.

THE ARM.

The Humerus.

The **Humerus** is the longest and largest bone of the upper extremity; it presents for examination a shaft and two extremities.

The **Upper Extremity** is the largest part of the bone; it presents a rounded *head*, joined to the shaft by a constricted portion, called the *neck*, and two other eminences, the *greater* and *lesser tuberosities* (Fig. 197).

The **head**, nearly hemispherical in form,[1] is directed upward, inward, and a little backward, and articulates with the glenoid cavity of the scapula; its surface is smooth and coated with cartilage in the recent state. The circumference of its articular surface is slightly constricted, and is termed the *anatomical neck*, in contradistinction to the constriction which exists below the tuberosities. The latter is called the *surgical neck*, from its often being the seat of fracture. It should be remembered, however, that fracture of the *anatomical neck* does sometimes, though rarely, occur.

The **anatomical neck** is obliquely directed, forming an obtuse angle with the shaft. It is more distinctly marked in the lower half of its circumference than in the upper half, where it presents a narrow groove, separating the head from the tuberosities. Its circumference affords attachment to the capsular ligament and is perforated by numerous vascular foramina.

The **greater tuberosity** is situated on the outer side of the head and lesser tuberosity. Its upper surface is rounded and marked by three flat facets, separated by two slight ridges: the highest facet gives attachment to the tendon of the Supraspinatus; the middle one, to the Infraspinatus; the lowest facet and the shaft of the bone below it, to the Teres minor. The outer surface of the great tuberosity is convex, rough, and continuous with the outer side of the shaft.

The **lesser tuberosity** is more prominent, although smaller than the greater: it is situated in front of the head, and is directed inward and forward. Its summit presents a prominent facet for the insertion of the tendon of the Subscapularis muscle. The tuberosities are separated from one another by a deep groove, the *bicipital groove*, so called from its lodging the long tendon of the Biceps muscle, with which runs a branch of the anterior circumflex artery. It commences above between the two tuberosities, passes obliquely downward and a little inward, and terminates at the junction of the upper with the middle third of the bone. It is deep and narrow at the commencement, and becomes shallow and a little broader as it descends. Its borders are called, respectively, the external and internal *bicipital ridges;* to the former of which the name *pectoral ridge* is, also, often applied. In the recent state this groove contains a prolongation of the synovial membrane of the shoulder-joint, and its floor receives that portion of the tendon of insertion of the Latissimus dorsi muscle which is reflected into it from the *internal bicipital ridge.*

The **Shaft** of the humerus is almost cylindrical in the upper half of its extent, prismatic and flattened below, and presents three borders and three surfaces for examination.

The **anterior border** runs from the front of the great tuberosity above to the

[1] Though the head is nearly hemispherical in form, its margin, as Sir G. Humphry has shown, is by no means a true circle. Its greatest measurement is from the top of the bicipital groove in a direction downward, inward, and backward. Hence it follows that the greatest elevation of the arm can be obtained by rolling the articular surface in this direction—that is to say, obliquely upward, outward, and forward.

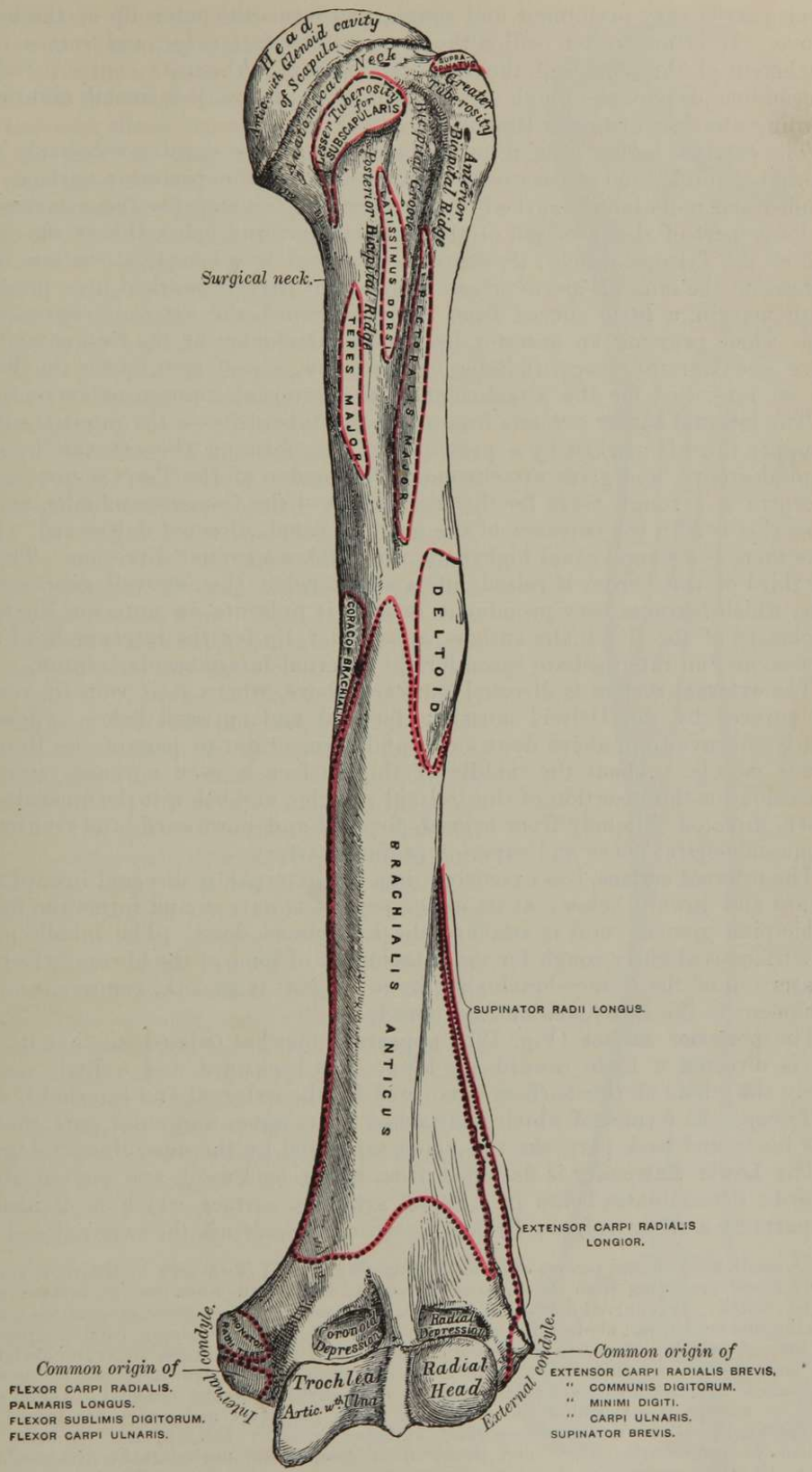

FIG. 197.—Left humerus. Anterior view.

coronoid depression below, separating the internal from the external surface. Its

upper part is very prominent and rough, and forms the outer lip of the bicipital groove. It is here often called the *external bicipital ridge*, and serves for the attachment of the tendon of the Pectoralis major. About its centre it forms the anterior boundary of the rough deltoid impression; below, it is smooth and rounded, affording attachment to the Brachialis anticus.

The **external border** runs from the back part of the greater tuberosity to the external condyle, and separates the external from the posterior surface. It is rounded and indistinctly marked in its upper half, serving for the attachment of the lower part of the insertion of the Teres minor, and below this of the external head of the Triceps muscle; its centre is traversed by a broad but shallow, oblique depression, the *musculo-spiral groove;* its lower part is marked by a prominent, rough margin, a little curved from behind forward, the *external supracondylar ridge*, which presents an anterior lip for the attachment of the Supinator longus above and Extensor carpi radialis longior below, a posterior lip for the Triceps, and an interstice for the attachment of the external intermuscular septum.

The **internal border** extends from the lesser tuberosity to the internal condyle. Its upper third is marked by a prominent ridge, forming the *internal* lip of the bicipital groove, and gives attachment to the tendon of the Teres major. About its centre is a rough ridge for the attachment of the Coraco-brachialis, and just below this is seen the entrance of the nutrient canal, directed downward. Sometimes there is a second canal higher up, which takes a similar direction. The inferior third of this border is raised into a slight ridge, the *internal supracondylar ridge*, which becomes very prominent below; it presents an anterior lip for the attachment of the Brachialis anticus, a posterior lip for the internal head of the Triceps, and an intermediate space for the internal intermuscular septum.

The **external surface** is directed outward above, where it is smooth, rounded, and covered by the Deltoid muscle; forward and outward below, where it is slightly concave from above downward, and gives origin to part of the Brachialis anticus muscle. About the middle of this surface is seen a rough, triangular impression for the insertion of the Deltoid muscle; and below it the musculo-spiral groove, directed obliquely from behind, forward and downward, and transmitting the musculo-spiral nerve and superior profunda artery.

The **internal surface**, less extensive than the external, is directed inward above, forward and inward below; at its upper part it is narrow and forms the floor of the bicipital groove: to it is attached the Latissimus dorsi. The middle part of this surface is slightly rough for the attachment of some of the fibres of the tendon of insertion of the Coraco-brachialis; its lower part is smooth, concave, and gives attachment to the Brachialis anticus muscle.[1]

The **posterior surface** (Fig. 198) appears somewhat twisted, so that its upper part is directed a little inward, its lower part backward and a little outward. Nearly the whole of this surface is covered by the external and internal heads of the Triceps, the former of which is attached to its upper and outer part, the latter to its inner and back part, the two being separated by the musculo-spiral groove.

The **Lower Extremity** is flattened from before backward, and curved slightly forward; it terminates below in a broad, articular surface which is divided into two parts by a slight ridge. Projecting on either side are the external and inter

[1] A small, hook-shaped process of bone, varying from $\frac{1}{10}$ to $\frac{3}{4}$ of an inch in length, is not unfrequently found projecting from the inner surface of the shaft of the humerus two inches above the internal condyle. It is curved downward, forward, and inward, and its pointed extremity is connected to the internal border, just above the inner condyle, by a ligament or fibrous band, completing an arch through which the median nerve and brachial artery pass when these structures deviate from their usual course. Sometimes the nerve alone is transmitted through it, or the nerve may be accompanied by the ulnar artery in cases of high division of the brachial. A well-marked groove is usually found behind the process in which the nerve and artery are lodged. This space is analogous to the supracondyloid foramen in many animals, and probably serves in them to protect the nerve and artery from compression during the contraction of the muscles in this region. A detailed account of this process is given by Dr. Struthers, in his *Anatomical and Physiological Observations*, p. 202. An accessory portion of the Coraco-brachialis muscle is frequently connected with this process, according to Mr. J. Wood, (*Journal of Anat. and Phys.*, No. 1, Nov., 1866, p. 47).

nal condyles. The articular surface extends a little lower than the condyles, and is curved slightly forward, so as to occupy the more anterior part of the bone; its greatest breadth is in the transverse diameter, and it is obliquely directed, so that its inner extremity occupies a lower level than the outer. The outer portion of the articular surface presents a smooth, rounded eminence, which has received the name of the *capitellum*, or *radial head* of the humerus; it articulates with the cup-shaped depression on the head of the radius, and is limited to the front and lower part of the bone, not extending as far back as the other portion of the articular surface. On the inner side of this eminence is a shallow groove, in which is received the inner margin of the head of the radius. Above the front part of the capitellum is seen a slight depression which receives the anterior border of the head of the radius when the forearm is flexed. The inner portion of the articular surface, the *trochlea*, presents a deep depression between two well-marked borders. This surface is convex from before backward, concave from side to side, and occupies the anterior, lower, and posterior parts of the bone. The external border, less prominent than the internal, corresponds to the interval between the radius and the ulna. The internal border is thicker, more prominent, and consequently of greater length, than the external. The grooved portion of the articular surface fits accurately within the greater sigmoid cavity of the ulna: it is broader and deeper on the posterior than on the anterior aspect of the bone, and is inclined obliquely from behind forward and from without inward. Above the front part of the trochlear surface is seen a smaller depression, the *coronoid fossa*, which receives the coronoid process of the ulna during flexion of the forearm. Above the back part of the trochlear surface is a deep, triangular depression, the *olecranon fossa*, in which is received the summit of the olecranon process in extension of the forearm. These fossæ are separated from one another by a thin, transparent lamina of bone, which is sometimes perforated, forming the *supratrochlear foramen;* their upper margins afford attachment to the anterior and posterior ligaments of the elbow-joint, and they are lined, in the recent state, by the synovial membrane of this articulation. The articular surfaces, in the recent state, are covered with a thin layer of cartilage. The external condyle is a small, tubercular eminence, less prominent than the internal, curved a little forward, and giving attachment to the external lateral ligament of the elbow-joint, and to a tendon common to the origin of some of the extensor and supi-

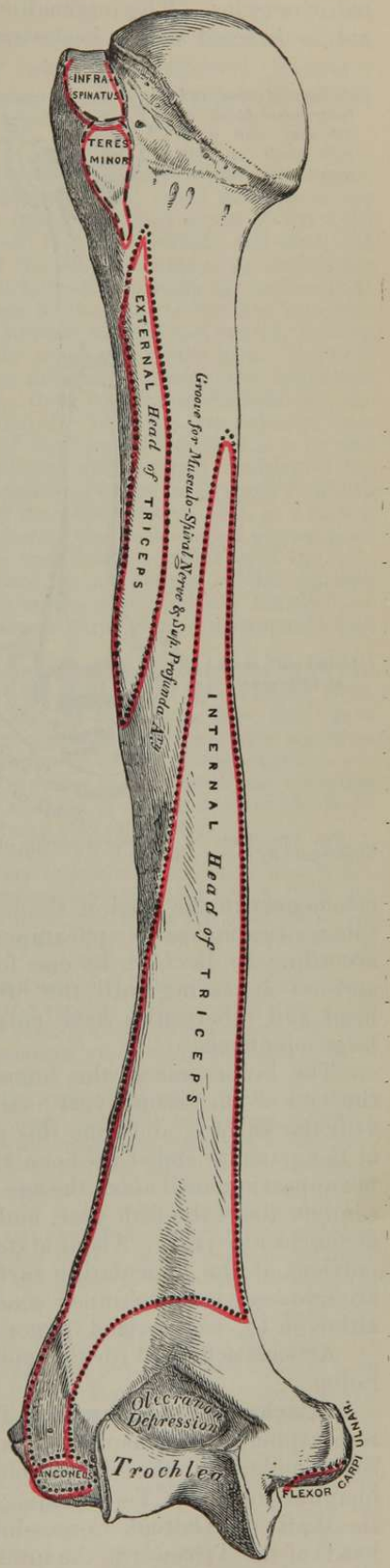

FIG. 198.—Left humerus. Posterior surface.

nator muscles. The internal condyle, larger and more prominent than the external, is directed a little backward: it gives attachment to the internal lateral ligament, to the Pronator radii teres, and to a tendon common to the origin of some of the flexor muscles of the forearm. The ulnar nerve runs in a groove at the back of the internal condyle, or between it and the olecranon process. These eminences are directly continuous above with the external and internal borders—*i. e.* the external and internal condyloid ridges. The great prominence of the inner one renders it more liable to fracture.



FIG. 199.—Plan of the development of the humerus. By seven centres.

Structure.—The extremities consist of cancellous tissue, covered with a thin, compact layer; the shaft is composed of a cylinder of compact tissue, thicker at the centre than at the extremities, and hollowed out by a large medullary canal, which extends along its whole length.

Development.—By *seven*, or occasionally *eight*, centres (Fig. 199), one for the shaft, one for the head, one for the tuberosities, one for the radial head, one for the trochlear portion of the articular surface, and one for each condyle. The nucleus for the shaft appears near the centre of the bone in the eighth week, and soon extends toward the extremities. At birth the humerus is ossified nearly in its whole length, the extremities remaining cartilaginous. At the beginning of the second year ossification commences in the head of the bone, and during the third year the centre for the tuberosities makes its appearance, usually by a single ossific point, but sometimes, according to Béclard, by one for each tuberosity, that for the lesser being small and not appearing until the fifth year. By the sixth year the centres for the head and tuberosities have enlarged and become joined, so as to form a single large epiphysis.

The lower end of the humerus is developed in the following manner: At the end of the second year ossification commences in the radial portion of the articular surface, and from this point extends inward, so as to form the chief part of the articular end of the bone, the centre for the inner part of the articular surface not appearing until about the age of twelve. Ossification commences in the internal condyle about the fifth year, and in the external one not until about the thirteenth or fourteenth year. About sixteen or seventeen years the outer condyle and both portions of the articulating surface (having already joined) unite with the shaft; at eighteen years the inner condyle becomes joined; whilst the upper epiphysis, although the first formed, is not united until about the twentieth year.

Articulations.—With the glenoid cavity of the scapula and with the ulna and radius.

Attachment of Muscles.—To twenty-four: to the greater tuberosity, the Supraspinatus, Infraspinatus, and Teres minor; to the lesser tuberosity, the Subscapularis; to the external bicipital ridge, the Pectoralis major; to the internal bicipital ridge, the Teres major; to the bicipital groove, the Latissimus dorsi; to the shaft, the Deltoid, Coraco-brachialis, Brachialis anticus, external and internal heads of the Triceps; to the internal condyle, the Pronator radii teres, and common tendon of the Flexor carpi radialis, Palmaris longus, Flexor sublimis digitorum.

and Flexor carpi ulnaris; to the external condyloid ridge, the Supinator longus and Extensor carpi radialis longior; to the external condyle, the common tendon of the Extensor carpi radialis brevior, Extensor communis digitorum, Extensor minimi digiti, Extensor carpi ulnaris, and Supinator brevis; to the back of the external condyle, the Anconeus.

Surface Form.—The humerus is almost entirely clothed by the muscles which surround it, and the only parts of this bone which are strictly subcutaneous are small portions of the internal and external condyles. In addition to these, the tuberosities and a part of the head of the bone can be felt under the skin and muscles by which they are covered. Of these the greater tuberosity forms the most prominent bony point of the shoulder, extending beyond the acromion process and covered by the Deltoid muscle. It influences materially the surface form of the shoulder. It is best felt while the arm is lying loosely by the side; if the arm be raised, it recedes from under the finger. The lesser tuberosity, directed forward and inward, is to be felt to the inner side of the greater tuberosity, just below the acromio-clavicular joint. Between the two tuberosities lies the bicipital groove. This can be defined by placing the finger and making firm pressure just internal to the greater tuberosity; then, by rotating the humerus, the groove will be felt to pass under the finger as the bone is rotated. With the arm abducted from the side, by pressing deeply in the axilla the lower part of the head of the bone is to be felt. On each side of the elbow-joint, and just above it, the internal and external condyles of the bone are to be felt. Of these the internal is the more prominent, but the ridge passing upward from it, the internal condyloid ridge, is much less marked than the external, and, as a rule, is not to be felt. Occasionally, however, we find along this border the hook-shaped process mentioned above. The external condyle is most plainly to be seen during semiflexion of the forearm, and its position is indicated by a depression between the attachment of the adjacent muscles. From it is to be felt a strong bony ridge running up the outer border of the shaft of the bone. This is the external condyloid ridge; it is concave forward, and corresponds with the curved direction of the lower extremity of the humerus.

Surgical Anatomy.—There are several points of surgical interest connected with the humerus. First, as regards its development. The upper end, though the first to ossify, is the last to join the shaft, and the length of the bone is mainly due to growth from this upper epiphysis. Hence, in cases of amputation of the arm in young subjects the humerus continues to grow considerably, and the end of the bone which immediately after the operation was covered with a thick cushion of soft tissue, begins to project, thinning the soft parts and rendering the stump conical. This may necessitate the removal of a couple of inches or so of the bone, and even after this operation a recurrence of the conical stump may take place.

There are several points of surgical interest in connection with fractures. First, as regard their causation: the bone may be broken by direct or indirect violence like the other long bones, but, in addition to this, it is probably more frequently fractured by muscular action than any other of this class of bone in the body. It is usually the shaft, just below the insertion of the Deltoid, which is thus broken. I have seen the accident happen from throwing a stone, and in an apparently healthy adult from cutting a piece of hard "cake tobacco" on a table. In this latter case there was no disease of the bone that could be discovered. Fractures of the upper end may take place through the anatomical neck, through the surgical neck, or separation of the greater tuberosity may occur. Fracture of the anatomical neck is a very rare accident; in fact, it is doubted by some whether it ever occurs. These fractures are usually considered to be intracapsular, but they are probably partly within and partly without the capsule, as the lower part of the capsule is inserted some little distance below the anatomical neck, while the upper part is attached to it. They may be impacted or non-impacted. In most cases there is little or no displacement on account of the capsule, in whole or in part, remaining attached to the lower fragment. But occasionally a very remarkable alteration in position takes place; the upper fragment turns on its own axis, so that the cartilaginous surface of the head rests against the upper end of the lower fragment. When the fractured end is entirely separated from all its surroundings, its vascular supply must be entirely cut off, and one would expect it, theoretically, to necrose. But this must be exceedingly rare, for Gurlt was unable to find a single authenticated case recorded. Separation of the upper epiphysis of the humerus sometimes occurs in the young subject, and is marked by a characteristic deformity by which the lesion may be at once recognized. This consists in the presence of an abrupt projection at the front of the joint some short distance below the coracoid process, caused by the upper end of the lower fragment. In fractures of the shaft of the humerus the lesion may take place at any point, but appears to be more common in the lower than in the upper part of the bone. The points of interest in connection with these fractures are—(1) that the musculo-spiral nerve may be injured as it lies in the groove on the bone, or may become involved in the callus which is subsequently thrown out; and (2) the frequency of non-union. This is believed to be more common in the humerus than in any other bone, and various causes have been assigned for it. It would seem most probably to be due to the difficulty that there is in fixing the shoulder-joint and the upper fragment, and possibly also the elbow-joint and lower fragment also. Other causes which have been assigned for the non-union are: (1) that in attempting passive motion of the elbow-joint to overcome any rigidity which may exist, the movement does not take place at the articulation, but at the seat of fracture; or that the patient, in consequence of the rigidity of the elbow, in attempting

to flex or extend the forearm moves the fragment and not the joint. (2) The presence of small portions of muscular tissue between the broken ends. (3) Want of support to the elbow, so that the weight of the arm tends to drag the lower fragment away from the upper. An important distinction to make in fractures of the lower end of the humerus is between those that involve the joint and those which do not; the former always serious, as they may lead to impairment of the utility of the limb. They include the T-shaped fracture and oblique fractures which involve the articular surface. The fractures which do not involve the joint are the transverse above the condyles and detachment of one or other condyle.

Under the head of separation of the epiphysis two separate injuries have been described. One where the whole of the four ossific centres which form the lower extremity of the bone are separated from the shaft; and secondly, where the articular portion is alone separated, the two condyles remaining attached to the shaft of the bone. The epiphysial line between the shaft and lower end runs across the bone just above the tips of the condyles, a point to be borne in mind in performing the operation of excision.

Tumors originating from the humerus are of frequent occurrence. A not uncommon place for a chondroma to grow from is the shaft of the bone somewhere in the neighborhood of the insertion of the deltoid. Sarcomata frequently grow from this bone.

THE FOREARM.

The **Forearm** is that portion of the upper extremity which is situated between the elbow and the wrist. It is composed of two bones, the ulna and radius.

The Ulna.

The **Ulna** (Figs. 200, 201), so called from its forming the elbow (*ὠλένη*), is a long bone, prismatic in form, placed at the inner side of the forearm, parallel with the radius. It is the larger and longer of the two bones. Its upper extremity, of great thickness and strength, forms a large part of the articulation of the elbow-joint; it diminishes in size from above downward, its lower extremity being very small, and excluded from the wrist-joint by the interposition of an interarticular fibro-cartilage. It is divisible into a shaft and two extremities.

The **Upper Extremity,** the strongest part of the bone, presents for examination two large, curved processes, the Olecranon process and the Coronoid process; and two concave, articular cavities, the greater and lesser sigmoid cavities.

The **Olecranon Process** (*ὠλένη*, elbow; *κρανίον*, head) is a large, thick, curved eminence situated at the upper and back part of the ulna. It is curved forward at the summit so as to present a prominent tip, its base being contracted where it joins the shaft. This is the narrowest part of the upper end of the ulna, and, consequently, the most usual seat of fracture. The posterior surface of the olecranon, directed backward, is triangular, smooth, subcutaneous, and covered by a bursa. Its upper surface, directed upward, is of a quadrilateral form, marked behind by a rough impression for the attachment of the Triceps muscle; and in front, near the margin, by a slight transverse groove for the attachment of part of the posterior ligament of the elbow-joint. Its anterior surface is smooth, concave, covered with cartilage in the recent state, and forms the upper and back part of the great sigmoid cavity. The lateral borders present a continuation of the same groove that was seen on the margin of the superior surface; they serve for the attachment of ligaments; viz. the back part of the internal lateral ligament internally, the posterior ligament externally. To the inner border is also attached a part of the Flexor carpi ulnaris, while to the outer border is attached the Anconeus.

The **Coronoid Process** (*κορώνη*, anything hooked like a crow's beak) is a rough, triangular eminence of bone which projects horizontally forward from the upper and front part of the ulna, forming the lower part of the great sigmoid cavity. Its base is continuous with the shaft, and of considerable strength; so much so that fracture of it is an accident of rare occurrence. Its apex is pointed, slightly curved upward, and received into the coronoid depression of the humerus in flexion of the forearm. Its upper surface is smooth, concave, and forms the lower part of the greater sigmoid cavity. The under surface is concave, and marked internally by a rough impression for the insertion of the Brachialis anticus. At the junction of this surface with the shaft is a rough eminence, the *tubercle of*

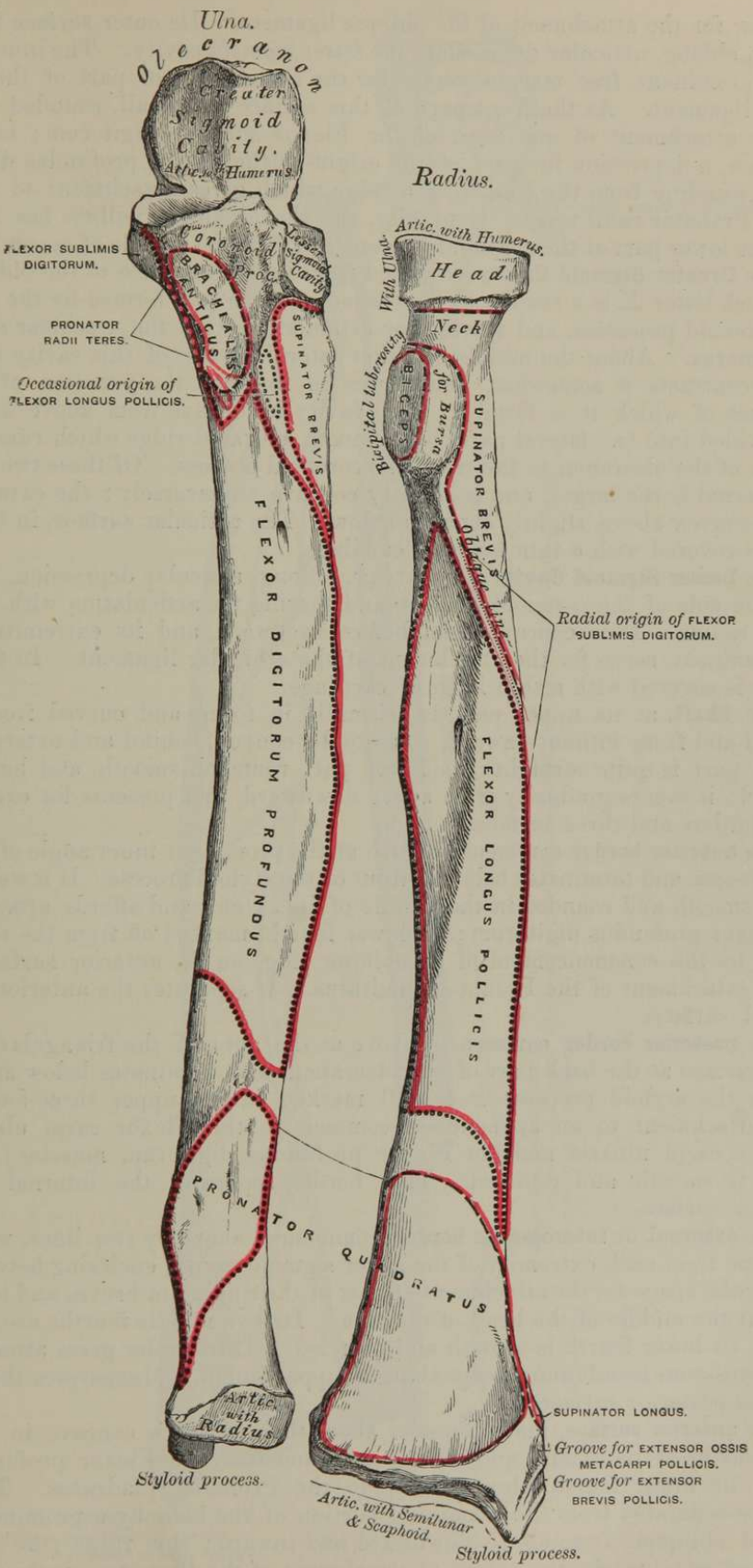

FIG. 200.—Bones of the left forearm. Anterior surface.

the ulna, for the attachment of the oblique ligament. Its outer surface presents a narrow, oblong, articular depression, the *lesser sigmoid* cavity. The inner surface, by its prominent, free margin, serves for the attachment of part of the internal lateral ligament. At the front part of this surface is a small, rounded eminence for the attachment of one head of the Flexor sublimis digitorum; behind the eminence, a depression for part of the origin of the Flexor profundus digitorum; and, descending from the eminence, a ridge which gives attachment to one head of the Pronator radii teres. Generally, the Flexor longus pollicis has an origin from the lower part of the coronoid process by a rounded bundle of muscular fibres.

The **Greater Sigmoid Cavity**, so called from its resemblance to the old shape of the Greek letter Σ, is a semilunar depression of large size, formed by the olecranon and coronoid processes, and serving for articulation with the trochlear surface of the humerus. About the middle of either lateral border of this cavity is a notch which contracts it somewhat, and serves to indicate the junction of the two processes of which it is formed. The cavity is concave from above downward, and divided into two lateral parts by a smooth, elevated ridge which runs from the summit of the olecranon to the tip of the coronoid process. Of these two portions, the internal is the larger, and is slightly concave transversely; the external portion is convex above, slightly concave below. The articular surface, in the recent state, is covered with a thin layer of cartilage.

The **Lesser Sigmoid Cavity** is a narrow, oblong, articular depression, placed on the outer side of the coronoid process, and serving for articulation with the head of the radius. It is concave from before backward, and its extremities, which are prominent, serve for the attachment of the orbicular ligament. In the recent state it is covered with a thin layer of cartilage.

The **Shaft**, at its upper part, is prismatic in form, and curved from behind forward and from without inward, so as to be convex behind and externally; its central part is quite straight; its lower part rounded, smooth, and bent a little outward; it tapers gradually from above downward, and presents for examination three borders and three surfaces.

The **anterior border** commences above at the prominent inner angle of the coronoid process, and terminates below in front of the styloid process. It is well marked above, smooth and rounded in the middle of its extent, and affords attachment to the Flexor profundus digitorum: its lower fourth, marked off from the rest of the border by the commencement of an oblique ridge on the anterior surface, serves for the attachment of the Pronator quadratus. It separates the anterior from the internal surface.

The **posterior border** commences above at the apex of the triangular subcutaneous surface at the back part of the olecranon, and terminates below at the back part of the styloid process; it is well marked in the upper three-fourths, and gives attachment to an aponeurosis common to the Flexor carpi ulnaris, the Extensor carpi ulnaris, and the Flexor profundus digitorum muscles; its lower fourth is smooth and rounded. This border separates the internal from the posterior surface.

The **external** or **interosseous border** commences above by two lines, which converge one from each extremity of the lesser sigmoid cavity, enclosing between them a triangular space for the attachment of part of the Supinator brevis, and terminates below at the middle of the head of the ulna. Its two middle fourths are very prominent, its lower fourth is smooth and rounded. This border gives attachment to the interosseous membrane, except along its upper fourth, and separates the anterior from the posterior surface.

The **anterior surface**, much broader above than below, is concave in the upper three-fourths of its extent, and affords attachment to the Flexor profundus digitorum; its lower fourth, also concave, to the Pronator quadratus. The lower fourth is separated from the remaining portion of the bone by a prominent ridge, directed obliquely from above downward and inward; this ridge (the *oblique* or *Pronator ridge*) marks the extent of attachment of the Pronator quadratus above.

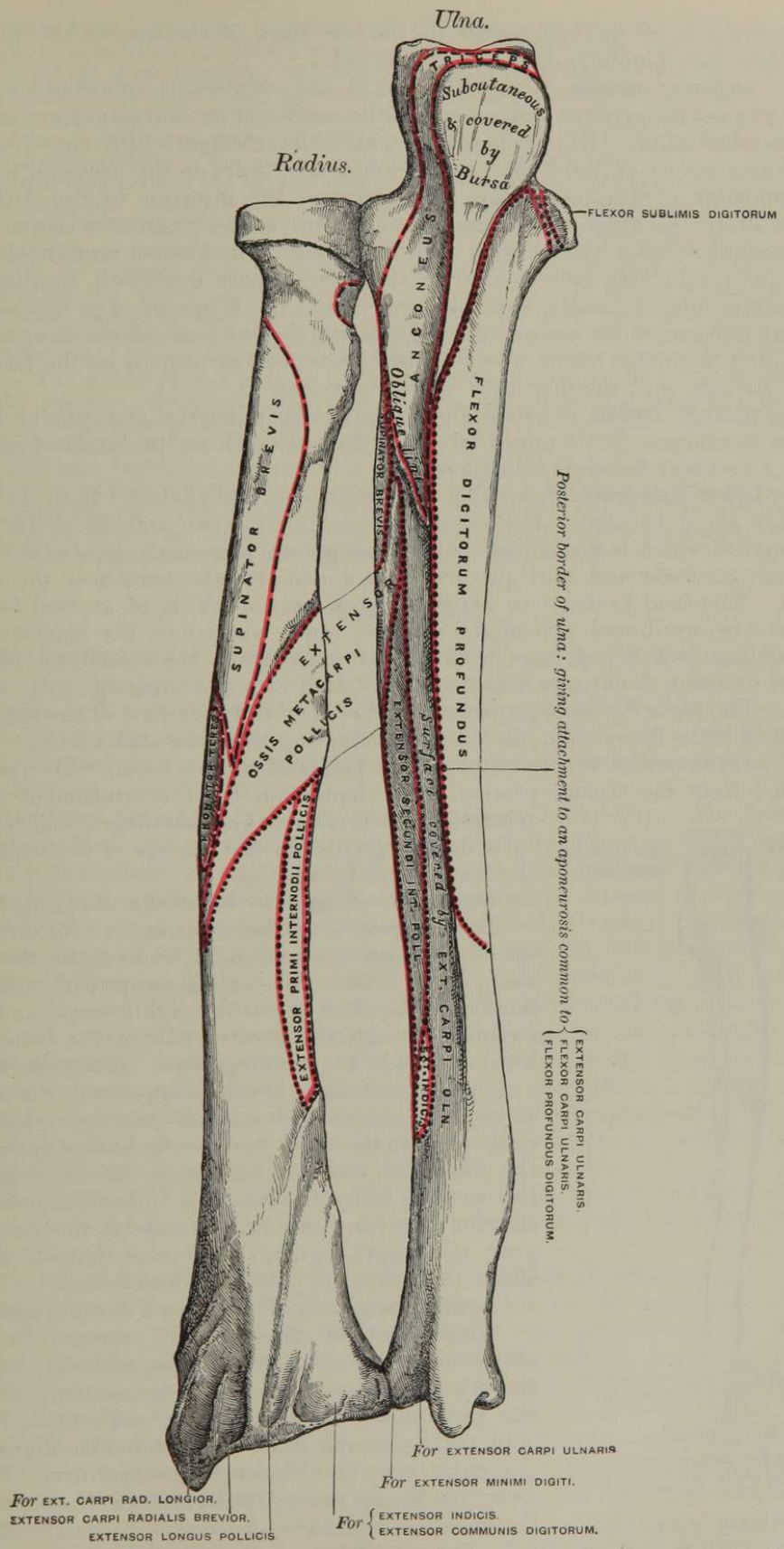

FIG. 201.—Bones of the left forearm. Posterior surface.

At the junction of the upper with the middle third of the bone is the nutrient canal directed obliquely upward and inward.

The **posterior surface**, directed backward and outward, is broad and concave above, somewhat narrower and convex in the middle of its course, narrow, smooth, and rounded below. It presents, above, an oblique ridge, which runs from the posterior extremity of the lesser sigmoid cavity, downward to the posterior border; the triangular surface above this ridge receives the insertion of the Anconeus muscle, whilst the ridge itself affords attachment to the Supinator brevis. The surface of bone below this is subdivided by a longitudinal ridge, sometimes called the *perpendicular line*, into two parts: the internal part is smooth, concave, and gives origin to (occasionally is merely covered by) the Extensor carpi ulnaris; the external portion, wider and rougher, gives attachment from above downward to part of the Supinator brevis, the Extensor ossis metacarpi pollicis, the Extensor longus pollicis, and the Extensor indicis muscles.

The **internal surface** is broad and concave above, narrow and convex below. It gives attachment by its upper three-fourths to the Flexor profundus digitorum muscle: its lower fourth is subcutaneous.

The **Lower Extremity** of the ulna is of small size, and excluded from the articulation of the wrist-joint. It presents for examination two eminences, the outer and larger of which is a rounded, articular eminence, termed the *head* of the ulna, the inner, narrower and more projecting, is a non-articular eminence, the *styloid process*. The *head* presents an articular facet, part of which, of an oval form, is directed downward, and articulates with the upper surface of the interarticular fibro-cartilage which separates it from the wrist-joint; the remaining portion, directed outward, is narrow, convex, and received into the sigmoid cavity of the radius. The *styloid process* projects from the inner and back part of the bone, and descends a little lower than the head, terminating in a rounded summit, which affords attachment to the internal lateral ligament of the wrist. The head is separated from the styloid process, by a depression for the attachment of the triangular interarticular fibro-cartilage; and behind, by a shallow groove for the passage of the tendon of the Extensor carpi ulnaris.

FIG. 202.—Plan of the development of the ulna. By three centres.

Structure.—Similar to that of the other long bones.

Development.—By *three* centres: one for the shaft, one for the inferior extremity, and one for the olecranon (Fig. 202). Ossification commences near the middle of the shaft about the eighth week, and soon extends through the greater part of the bone. At birth the ends are cartilaginous. About the fourth year a separate osseous nucleus appears in the middle of the head, which soon extends into the styloid process. About the tenth year ossific matter appears in the olecranon near its extremity, the chief part of this process being formed from an extension of the shaft of the bone into it. At about the sixteenth year the upper epiphysis becomes joined, and at about the twentieth year the lower one.

Articulations.—With the humerus and radius.

Attachment of Muscles.—To sixteen: to the olecranon, the Triceps, Anconeus, and one head of the Flexor carpi ulnaris. To the coronoid process, the Brachialis anticus, Pronator radii teres, Flexor sublimis digitorum, and Flexor profundus digitorum; generally also the Flexor longus pollicis. To the shaft, the Flexor profundus digitorum, Pronator quadratus, Flexor carpi ulnaris, Extensor carpi ulnaris, Anconeus, Supinator brevis, Extensor ossis metacarpi pollicis, Extensor longus pollicis, and Extensor indicis.

Surface Form.—The most prominent part of the ulna on the surface of the body is the olecranon process, which can always be felt at the back of the elbow-joint. When the forearm is flexed the upper triangular surface can be felt, directed backward; during extension it recedes into the olecranon fossa, and the contracting fibres of the triceps prevent its being perceived. At the back of the olecranon is the smooth, triangular, subcutaneous surface, which below is continuous with the posterior border of the shaft of the bone; this is to be felt in every position of the joint. During extension the upper border of the olecranon is slightly above the level of the internal condyle, and the process itself is nearer to this condyle than the outer one. Running down the back of the forearm, from the apex of the triangular surface which forms the posterior surface of the olecranon, is a prominent ridge of bone, the posterior border of the ulna. This is to be felt throughout the entire length of the shaft of the bone, from the olecranon above to the styloid process below. As it passes down the forearm it pursues a sinuous course and inclines to the inner side, so that, though it is situated in the middle of the back of the limb above, it is on the inner side of the wrist at its termination. It becomes rounded off in its lower third, and may be traced below to the small, subcutaneous surface of the styloid process. Internal to this border the lower fourth of the internal surface is to be felt. The styloid process is to be felt as a prominent tubercle of bone, continuous above with the posterior subcutaneous border of the ulna, and terminating below in a blunt apex, which lies a little internal and behind, but on a level with, the wrist-joint. The styloid process is best felt when the hand is in the same line as the bones of the forearm, and in a position midway between supination and pronation. If the forearm is pronated while the finger is placed on the process, it will be felt to recede, and another prominence of bone will appear just external and above it. This is the head of the ulna, which articulates with the lower end of the radius and the triangular interarticular fibro-cartilage, and now projects between the tendons of the Extensor carpi ulnaris and the Extensor minimi digiti muscles.

The Radius.

The **Radius** (*radius*, a ray, or spoke of a wheel) is situated on the outer side of the forearm, lying side by side with the ulna, which exceeds it in length and size. Its upper end is small, and forms only a small part of the elbow-joint; but its lower end is large, and forms the chief part of the wrist. It is one of the long bones, prismatic in form, slightly curved longitudinally, and, like other long bones, has a shaft and two extremities.

The **Upper Extremity** presents a head, neck, and tuberosity. The *head* is of a cylindrical form, depressed on its upper surface into a shallow cup which articulates with the capitellum or radial head of the humerus. In the recent state it is covered with a layer of cartilage which is thinnest at its centre. Around the circumference of the head is a smooth, articular surface, broad internally where it articulates with the lesser sigmoid cavity of the ulna; narrow in the rest of its circumference, where it rotates within the orbicular ligament. It is coated with cartilage in the recent state. The head is supported on a round, smooth, and constricted portion of bone, called the *neck*, which presents, behind, a slight ridge, for the attachment of part of the Supinator brevis. Beneath the neck, at the inner and front aspect of the bone, is a rough eminence, the *bicipital tuberosity*. Its surface is divided into two parts by a vertical line—a posterior, rough portion, for the insertion of the tendon of the Biceps muscle; and an anterior, smooth portion, on which a bursa is interposed between the tendon and the bone.

The **Shaft** of the bone is prismoid in form, narrower above than below, and slightly curved, so as to be convex outward. It presents three surfaces, separated by three borders.

The **anterior border** extends from the lower part of the tuberosity above to the anterior part of the base of the styloid process below. It separates the anterior from the external surface. Its upper third is very prominent; and from its oblique direction, downward and outward, has received the name of the *oblique line of the radius*. It gives attachment externally to the Supinator brevis, internally to the Flexor longus pollicis, and between these to the Flexor sublimis digitorum. The middle third of the anterior border is indistinct and rounded. Its lower fourth is sharp, prominent, affords attachment to the Pronator quadratus, and terminates in a small tubercle, into which is inserted the tendon of the Supinator longus.

The **posterior border** commences above at the back part of the neck of the

radius, and terminates below at the posterior part of the base of the styloid process; it separates the posterior from the external surface. It is indistinct above and below, but well marked in the middle third of the bone.

The **internal** or **interosseous border** commences above at the back part of the tuberosity, where it is rounded and indistinct, becomes sharp and prominent as it descends, and at its lower part divides into two ridges, which descend to the anterior and posterior margins of the sigmoid cavity. This border separates the anterior from the posterior surface, and has the interosseous membrane attached to it throughout the greater part of its extent.

The **anterior surface** is narrow and concave for its upper three-fourths, and gives attachment to the Flexor longus pollicis muscle; it is broad and flat for its lower fourth, and gives attachment to the Pronator quadratus. A prominent ridge limits the attachment of the Pronator quadratus below, and between this and the inferior border is a triangular rough surface for the attachment of the anterior ligament of the wrist-joint. At the junction of the upper and middle third of this surface is the nutrient foramen, which is directed obliquely upward.

The **posterior surface** is rounded, convex, and smooth in the upper third of its extent, and covered by the Supinator brevis muscle. Its middle third is broad, slightly concave, and gives attachment to the Extensor ossis metacarpi pollicis above, the Extensor brevis pollicis below. Its lower third is broad, convex, and covered by the tendons of the muscles, which subsequently run in the grooves on the lower end of the bone.

The **external surface** is rounded and convex throughout its entire extent. Its upper third gives attachment to the Supinator brevis muscle. About its centre is seen a rough ridge, for the insertion of the Pronator radii teres muscle. Its lower part is narrow, and covered by the tendons of the Extensor ossis metacarpi pollicis and Extensor brevis pollicis muscles.

The **Lower Extremity** of the radius is large, of quadrilateral form, and provided with two articular surfaces—one at the extremity, for articulation with the carpus, and one at the inner side of the bone, for articulation with the ulna. The carpal articular surface is of triangular form, concave, smooth, and divided by a slight antero-posterior ridge into two parts. Of these, the external is large, of a triangular form, and articulates with the scaphoid bone; the inner, smaller and quadrilateral, articulates with the semilunar. The articular surface for the ulna is called the *sigmoid cavity* of the radius; it is narrow, concave, smooth, and articulates with the head of the ulna. The circumference of this end of the bone presents three surfaces—an anterior, external, and posterior. The *anterior surface*, rough and irregular, affords attachment to the anterior ligament of the wrist-joint. The *external surface* is prolonged obliquely downward into a strong, conical projection, the *styloid process*, which gives attachment by its base to the tendon of the Supinator longus, and by its apex to the external lateral ligament of the wrist-joint. The outer surface of this process is marked by a flat groove, which runs obliquely downward and forward, and gives passage to the tendons of the Extensor ossis metacarpi pollicis and the Extensor brevis pollicis. The *posterior surface* is convex, affords attachment to the posterior ligament of the wrist, and is marked by three grooves. Proceeding from without inward, the first groove is broad but shallow, and subdivided into two by a slightly elevated ridge: the outer of these two transmits the tendon of the Extensor carpi radialis longior, the inner the tendon of the Extensor carpi radialis brevior. The second, which is near the centre of the bone, is a deep but narrow groove, bounded on its outer side by a sharply-defined ridge; it is directed obliquely from above, downward and outward, and transmits the tendon of the Extensor longus pollicis. The third, lying most internally, is a broad groove, for the passage of the tendons of the Extensor indicis and Extensor communis digitorum.

Structure.—Similar to that of the other long bones.

Development (Fig. 203).—By *three* centres: one for the shaft and one for each extremity. That for the shaft makes its appearance near the centre of the bone

soon after the development of the humerus commences. At birth the shaft is ossified, but the ends of the bone are cartilaginous. About the end of the second year ossification commences in the lower epiphysis and about the fifth year in the upper one. At the age of seventeen or eighteen the upper epiphysis becomes joined to the shaft, the lower epiphysis becoming united about the twentieth year.

Articulation.—With four bones: the humerus, ulna, scaphoid, and semilunar.

Attachment of Muscles.—To nine: to the tuberosity, the Biceps; to the oblique ridge, the Supinator brevis, Flexor sublimis digitorum, and Flexor longus pollicis; to the shaft (its anterior surface), the Flexor longus pollicis and Pronator quadratus; (its posterior surface), the Extensor ossis metacarpi pollicis and Extensor brevis pollicis; (its outer surface), the Pronator radii teres; and to the styloid process, the Supinator longus.

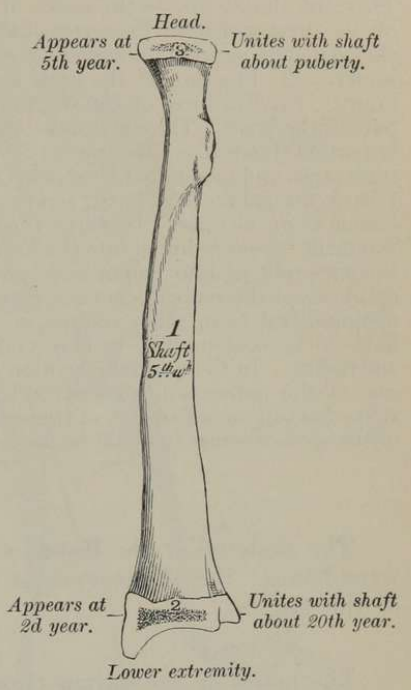

FIG. 203.—Plan of the development of the radius. By three centres.

Surface Form.—Just below and a little in front of the posterior surface of the external condyle a part of the head of the radius may be felt, covered by the orbicular and external lateral ligaments. There is in this situation a little dimple in the skin, which is most visible when the arm is extended, and which marks the position of the head of the bone. If the finger is placed on this dimple and the forearm pronated and supinated, the head of the bone will be distinctly perceived rotating in the lesser sigmoid cavity. The upper half of the shaft of the radius cannot be felt, as it is surrounded by the fleshy bellies of the muscles arising from the external condyle. The lower half of the shaft can be readily examined, though covered by tendons and muscles and not strictly subcutaneous. If traced downward, the shaft will be felt to terminate in a lozenge-shaped, convex surface on the outer side of the base of the styloid process. This is the only subcutaneous part of the bone, and from its lower extremity the apex of the styloid process will be felt bending inward toward the wrist. About the middle of the posterior aspect of the lower extremity of the bone is a well-marked ridge, best perceived when the hand is slightly flexed on the wrist. It bounds the oblique groove on the posterior surface of the bone, through which the tendon of the Extensor longus pollicis runs, and serves to keep that tendon in its place.

Surgical Anatomy.—The two bones of the forearm are more often broken together than is either the radius or ulna separately. It is therefore convenient to consider the fractures of these two bones together in the first instance, and subsequently to mention the principal fractures which take place in each bone individually. These fractures may be produced by either direct or indirect violence, though more commonly by direct violence. When indirect force is applied to the forearm the radius generally alone gives way, though both bones may suffer. The fracture from indirect force generally takes place somewhere about the middle of the bones; fracture from direct violence may occur at any part, more often, however, in the lower half of the bone. The fracture is usually transverse, but may be more or less oblique. A point of interest in connection with these fractures is the tendency that there is for the two bones to unite across the interosseous membrane; the limb should therefore be put up in a position midway between supination and pronation, which is not only the most comfortable position, but also separates the bones most widely from each other, and therefore diminishes the risk of the bones becoming united across the interosseous membrane. The splints, anterior and posterior, which are applied in these cases should be rather wider than the limb, so as to prevent any lateral pressure on the bones. For in these cases there is a greater liability to gangrene from the pressure of the splints than in other parts of the body. This is no doubt due principally to two causes: (1) the flexion of the forearm compressing to a certain extent the brachial artery and retarding the flow of blood to the limb; and (2) the superficial position of the two main arteries of the forearm in a part of their course, and their liability to be compressed by the splints. The special fractures of the ulna are—(1) Fracture of the olecranon. This may be caused by direct violence, falls on the elbow with the forearm flexed, or by muscular action by the sudden contraction of the triceps. The most common place for the fracture to occur is at the constricted portion where the olecranon joins the shaft of the bone, and the fracture may be either transverse or oblique; but any part may be broken, even a thin shell may be torn off. Fractures from direct violence are occasionally comminuted. The displacement is sometimes very slight, owing to the fibrous structures around the process not being torn. (2) Fracture of the coronoid process some-

times occurs as a complication of dislocation backward of the bones of the forearm, but it is doubtful if it ever occurs as an uncomplicated injury. (3) Fractures of the shaft of the ulna may occur at any part, but usually take place at the middle of the bone or a little below it. They are almost always the result of direct violence. (4) The styloid process may be knocked off by direct violence. Fractures of the radius consist of—(1) Fracture of the head of the bone; this generally occurs in conjunction with some other lesion, but may occur as an uncomplicated injury. (2) Fracture of the neck may also take place, but is generally complicated with other injury. (3) Fractures of the shaft of the radius are very common, and may take place at any part of the bone. They may take place from either direct or indirect violence. (4) The most important fracture of the radius is that of the lower end (Colles's fracture). The fracture is transverse, and generally takes place about an inch from the lower extremity. It is caused by falls on the palm of the hand, and is an injury of advanced life, occurring more frequently in the female than the male. In consequence of the manner in which the fracture is caused, the upper fragment becomes driven into the lower, and impaction is the result; or else the lower fragment becomes split up into two or more pieces, so that no fixation occurs. Separation of the lower epiphysis of the radius may take place in the young. This injury and Colles's fracture may be distinguished from other injuries in this neighborhood—especially dislocation, with which it is liable to be confounded—by observing the relative positions of the styloid processes of the ulna and radius. In the natural condition of parts, with the arm hanging by the side, the styloid process of the radius is on a lower level than that of the ulna; that is to say, nearer the ground. After fracture or separation of the epiphysis this process is on the same or higher level than that of the ulna, whereas it would be unaltered in position in dislocation.

THE HAND.

The skeleton of the **Hand** is subdivided into three segments—the Carpus or wrist-bones; the Metacarpus or bones of the palm; and the Phalanges or bones of the fingers.

The Carpus.

The bones of the **Carpus** (*καρπός*, the wrist), eight in number, are arranged in two rows. Those of the upper row, enumerated from the radial to the ulnar side, are the scaphoid, semilunar, cuneiform, and pisiform; those of the lower row, enumerated in the same order, are the trapezium, trapezoid, os magnum, and unciform.

Common Characters of the Carpal Bones.

Each bone (excepting the pisiform) presents six surfaces. Of these the *anterior* or *palmar* and the *posterior* or *dorsal* are rough for ligamentous attachment, the dorsal surface being the broader, except in the scaphoid and semilunar. The *superior* or *proximal* and *inferior* or *distal* are articular, the superior generally convex, the inferior concave; and the *internal* and *external* are also articular when in contact with contiguous bones, otherwise rough and tubercular. The structure in all is similar, consisting of cancellous tissue enclosed in a layer of compact bone. Each bone is also developed from a single centre of ossification.

Bones of the Upper Row (Figs. 204, 205).

The **Scaphoid** (*σκάφη*, a boat; *εἶδος*, like) is the largest bone of the first row. It has received its name from its fancied resemblance to a boat, being broad at one end, and narrowed like a prow at the opposite. It is situated at the upper and outer part of the carpus, its long axis being from above downward, outward and forward. The *superior surface* is convex, smooth, of triangular shape, and articulates with the lower end of the radius. The *inferior surface*, directed downward, outward, and backward, is smooth, convex, also triangular, and divided by a slight ridge into two parts, the external of which articulates with the trapezium, the inner with the trapezoid. The *posterior* or *dorsal surface* presents a narrow, rough groove, which runs the entire breadth of the bone and serves for the attachment of ligaments. The *anterior* or *palmar surface* is concave above, and elevated at its lower and outer part into a prominent, rounded tubercle, which projects forward from the front of the carpus and gives attachment to the anterior annular ligament of the wrist. The *external surface* is rough and narrow, and gives attachment to the external lateral ligament of the wrist. The

internal surface presents two articular facets: of these, the superior or smaller one is flattened, of semilunar form, and articulates with the semilunar; the

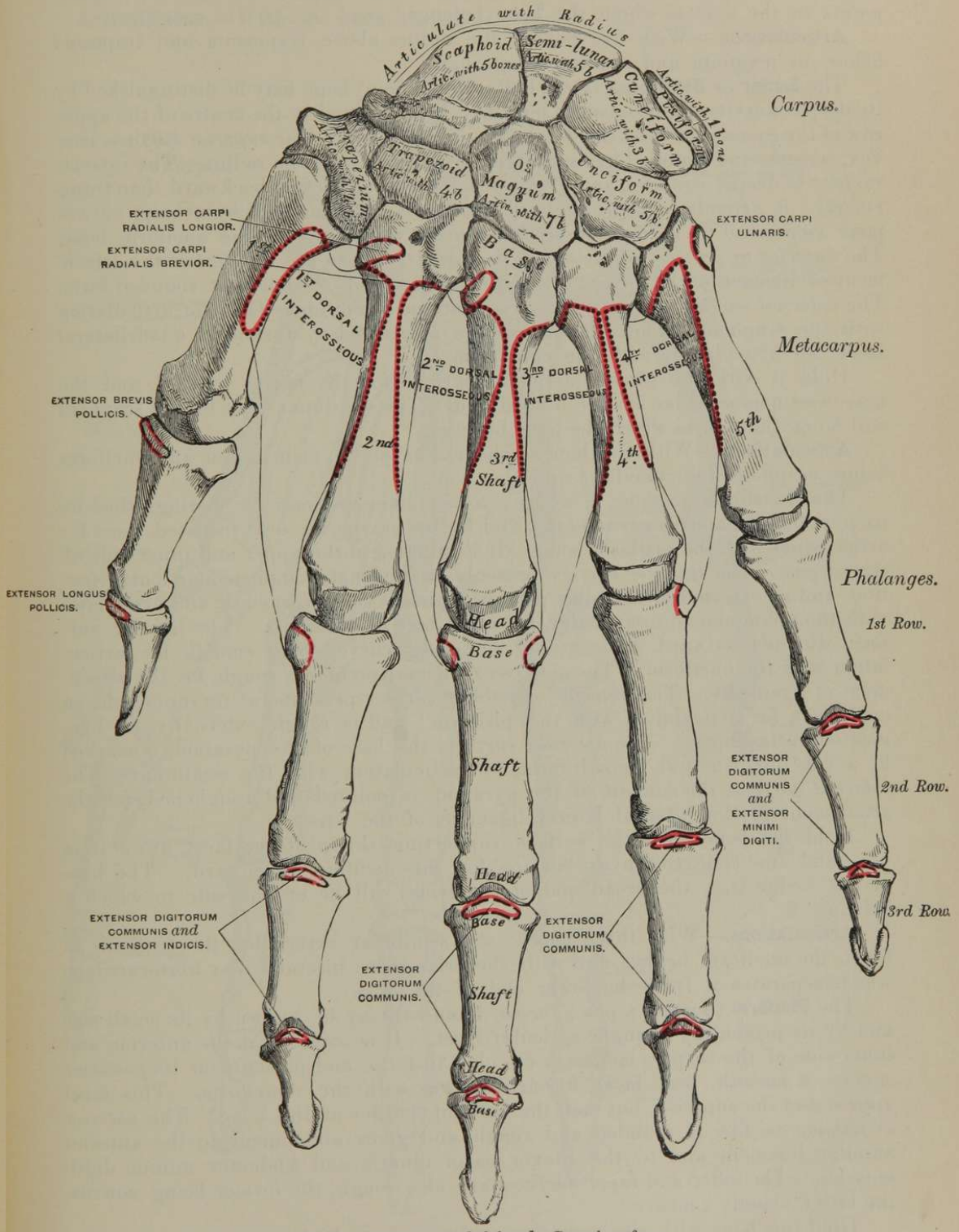

FIG. 204.—Bones of the left hand. Dorsal surface.

inferior or larger is concave, forming, with the semilunar bone, a concavity for the head of the os magnum.

To ascertain to which side the bone belongs, hold it with the superior or radial convex, articular, surface upward, and the posterior surface—*i. e.* the narrow, non-articular, grooved surface—toward you. The tubercle on the outer surface points to the side to which the bone belongs.[1]

Articulations.—With five bones: the radius above, trapezium and trapezoid below, os magnum and semilunar internally.

The **Lunar** or **Semilunar** (*semi*, half; *luna*, moon) bone may be distinguished by its deep concavity and crescentic outline. It is situated in the centre of the upper row of the carpus, between the scaphoid and cuneiform. The *superior surface*, convex, smooth, and bounded by four edges, articulates with the radius. The *inferior surface* is deeply concave, and of greater extent from before backward than transversely: it articulates with the head of the os magnum and by a long, narrow facet (separated by a ridge from the general surface) with the unciform bone. The *anterior* or *palmar* and *posterior* or *dorsal surfaces* are rough, for the attachment of ligaments, the former being the broader and of somewhat rounded form. The *external surface* presents a narrow, flattened, semilunar facet for articulation with the scaphoid. The *internal surface* is marked by a smooth, quadrilateral facet, for articulation with the cuneiform.

Hold it with the convex articular surface for the radius upward, and the narrowest non-articular surface toward you. The semilunar facet for the scaphoid will be on the side to which the bone belongs.

Articulations.—With five bones: the radius above, os magnum and unciform below, scaphoid and cuneiform on either side.

The **Cuneiform** (*cuneus*, a wedge; *forma*, likeness) may be distinguished by its pyramidal shape (*os pyramidale*), and by its having an oval, isolated facet for articulation with the pisiform bone. It is situated at the upper and inner side of the carpus. The *superior surface* presents an internal, rough, non-articular portion, and an external or articular portion, which is convex, smooth, and articulates with the triangular interarticular fibro-cartilage of the wrist. The *inferior surface*, directed outward, is concave, sinuously curved, and smooth for articulation with the unciform. The *posterior* or *dorsal surface* is rough, for the attachment of ligaments. The *anterior* or *palmar surface* presents, at its inner side, an oval facet, for articulation with the pisiform; and is rough externally, for ligamentous attachment. The *external surface*, the base of the pyramid, is marked by a flat, quadrilateral, smooth facet, for articulation with the semilunar. The *internal surface*, the summit of the pyramid, is pointed and roughened, for the attachment of the internal lateral ligament of the wrist.

Hold the bone with the surface supporting the pisiform facet away from you, and the concavo-convex surface for the unciform downward. The base of the wedge (*i. e.* the broad end of the bone) will be on the side to which it belongs.

Articulations.—With three bones: the semilunar externally, the pisiform in front, the unciform below; and with the triangular, interarticular fibro-cartilage which separates it from the lower end of the ulna.

The **Pisiform** (*pisum*, a pea; *forma*, likeness) may be known by its small size and by its presenting a single articular facet. It is situated at the anterior and inner side of the carpus, is nearly circular in form, and presents on its *posterior surface* a smooth, oval facet, for articulation with the cuneiform. This facet approaches the superior, but not the inferior, border of the bone. The *anterior* or *palmar surface* is rounded and rough, and gives attachment to the anterior annular ligament and to the Flexor carpi ulnaris and Abductor minimi digiti muscles. The *outer* and *inner surfaces* are also rough, the former being convex, the latter usually concave.

Hold the bone with the posterior surface—that which presents the articular

[1] In these directions each bone is supposed to be placed in its natural position—that is, such a position as it would occupy when the arm is hanging by the side, the forearm in a position of supination, the thumb being directed outward, and the palm of the hand looking forward.

facet—toward you, in such a manner that the faceted portion of the surface is uppermost. The outer, convex surface will point to the side to which it belongs.

Articulations.—With one bone, the cuneiform.

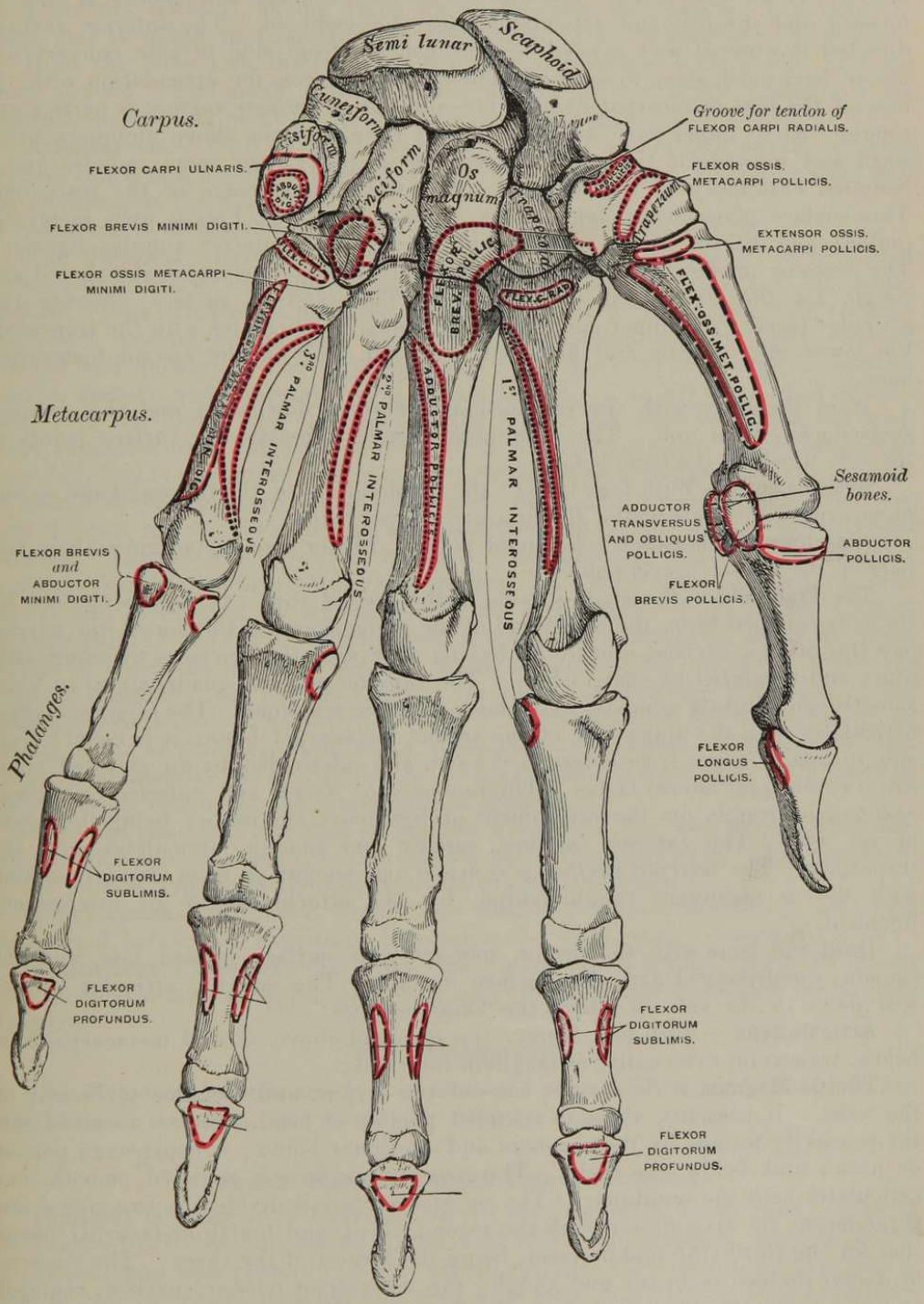

FIG. 205.—Bones of the left hand. Palmar surface.

Attachment of Muscles.—To two: the Flexor carpi ulnaris and Abductor minimi digiti; and to the anterior annular ligament.

Bones of the Lower Row (Figs. 204, 205).

The **Trapezium** (*τράπεζα*, a table) is of very irregular form. It may be distinguished by a deep groove, for the tendon of the Flexor carpi radialis muscle. It is situated at the external and inferior part of the carpus, between the scaphoid and first metacarpal bone. The *superior surface*, concave and smooth, is directed upward and inward, and articulates with the scaphoid. The *inferior surface*, directed downward and inward, is oval, concave from side to side, convex from before backward, so as to form a saddle-shaped surface, for articulation with the base of the first metacarpal bone. The *anterior* or *palmar surface* is narrow and rough. At its upper part is a deep groove running from above obliquely downward and inward; it transmits the tendon of the Flexor carpi radialis, and is bounded externally by a prominent ridge, the oblique ridge of the trapezium. This surface gives attachment to the Abductor pollicis, Flexor ossis metacarpi pollicis, and Flexor brevis pollicis muscles, and the anterior annular ligament. The *posterior* or *dorsal surface* is rough. The *external surface* is also broad and rough, for the attachment of ligaments. The *internal surface* presents two articular facets: the upper one, large and concave, articulates with the trapezoid; the lower one, narrow and flattened, with the base of the second metacarpal bone.

Hold the bone with the saddle-shaped surface downward and the grooved surface away from you. The prominent, rough, non-articular surface points to the side to which the bone belongs.

Articulations.—With four bones: the scaphoid above, the trapezoid and second metacarpal bones internally, the first metacarpal below.

Attachment of Muscles.—Abductor pollicis, Flexor ossis metacarpi pollicis, and part of the Flexor brevis pollicis.

The **Trapezoid** is the smallest bone in the second row. It may be known by its wedge-shaped form, the broad end of the wedge forming the dorsal, the narrow end the palmar, surface, and by its having four articular surfaces touching each other and separated by sharp edges. The *superior surface*, quadrilateral in form, smooth, and slightly concave, articulates with the scaphoid. The *inferior surface* articulates with the upper end of the second metacarpal bone; it is convex from side to side, concave from before backward, and subdivided by an elevated ridge into two unequal lateral facets. The *posterior* or *dorsal* and *anterior* or *palmar surfaces* are rough, for the attachment of ligaments, the former being the larger of the two. The *external surface*, convex and smooth, articulates with the trapezium. The *internal surface* is concave and smooth in front, for articulation with the os magnum; rough behind, for the attachment of an interosseous ligament.

Hold the bone with the larger, non-articular surface toward you, and the smooth, quadrilateral articular surface upward. The convex, articular surface will point to the side to which the bone belongs.[1]

Articulations.—With four bones: the scaphoid above, second metacarpal bone below, trapezium externally, os magnum internally.

The **Os Magnum** is the largest bone of the carpus, and occupies the centre of the wrist. It presents, above, a rounded portion or head, which is received into the concavity formed by the scaphoid and semilunar bones; a constricted portion or neck; and, below, the body. The *superior surface* is rounded, smooth, and articulates with the semilunar. The *inferior surface* is divided by two ridges into three facets, for articulation with the second, third, and fourth metacarpal bones, that for the third (the middle facet) being the largest of the three. The *posterior* or *dorsal surface* is broad and rough; the *anterior* or *palmar*, narrow, rounded, and also rough, for the attachment of ligaments. The *external surface* articulates

[1] Occasionally in a badly marked bone there is some difficulty in ascertaining to which side the bone belongs; the following method will sometimes be found useful: Hold the bone with its broader, non-articular surface upward, so that its sloping border is directed toward you. The border will slope to the side to which the bone belongs.

with the trapezoid by a small facet at its anterior inferior angle, behind which is a rough depression for the attachment of an interosseous ligament. Above this is a deep and rough groove, which forms part of the neck and serves for the attachment of ligaments, bounded superiorly by a smooth, convex surface, for articulation with the scaphoid. The *internal surface* articulates with the unciform by a smooth, concave, oblong facet which occupies its posterior and superior parts, and is rough in front, for the attachment of an interosseous ligament.

Hold the bone with the broader, non-articular surface toward you, and the head upward. The small, articular facet at the anterior inferior angle of the external surface will point to the side to which the bone belongs.

Articulations.—With seven bones: the scaphoid and semilunar above; the second, third, and fourth metacarpal below; the trapezoid on the radial side; and the unciform on the ulnar side.

Attachment of Muscles.—Part of the Adductor obliquus pollicis.

The **Unciform** (*uncus*, a hook; *forma*, likeness) may be readily distinguished by its wedge-shaped form and the hook-like process that projects from its palmar surface. It is situated at the inner and lower angle of the carpus, with its base downward, resting on the two inner metacarpal bones, and its apex directed upward and outward. The *superior surface*, the apex of the wedge, is narrow, convex, smooth, and articulates with the semilunar. The *inferior surface* articulates with the fourth and fifth metacarpal bones, the concave surface for each being separated by a ridge which runs from before backward. The *posterior* or *dorsal surface* is triangular and rough, for ligamentous attachment. The *anterior* or *palmar surface* presents, at its lower and inner side, a curved, hook-like process of bone, the *unciform process*, directed from the palmar surface forward and outward. It gives attachment by its apex to the annular ligament; by its inner surface to the Flexor brevis minimi digiti and the Flexor ossis metacarpi minimi digiti; and is grooved on its outer side, for the passage of the Flexor tendons into the palm of the hand. This is one of the four eminences on the front of the carpus to which the anterior annular ligament is attached, the others being the pisiform internally, the oblique ridge of the trapezium and the tuberosity of the scaphoid externally. The *internal surface* articulates with the cuneiform by an oblong facet cut obliquely from above, downward and inward. The *external surface* articulates with the os magnum by its upper and posterior part, the remaining portion being rough, for the attachment of ligaments.

Hold the bone with the hooked process away from you, and the articular surface, divided into two parts, for the metacarpal bones, downward. The concavity of the process will be on the side to which the bone belongs.

Articulations.—With five bones: the semilunar above, the fourth and fifth metacarpal below, the cuneiform internally, the os magnum externally.

Attachment of Muscles.—To three: the Flexor brevis minimi digiti, the Flexor ossis metacarpi minimi digiti, the Flexor carpi ulnaris; and to the anterior annular ligament.

The Metacarpus.

The **Metacarpal Bones** are five in number: they are long, cylindrical bones, presenting for examination a shaft and two extremities.

Common Characters of the Metacarpal Bones.

The **Shaft** is prismoid in form and curved longitudinally, so as to be convex in the longitudinal direction behind, concave in front. It presents three surfaces: two lateral and one posterior. The *lateral surfaces* are concave, for the attachment of the Interossei muscles, and separated from one another by a prominent line. The *posterior* or *dorsal surface* presents in its distal half a smooth, triangular, flattened area which is covered, in the recent state, by the tendons of the Extensor muscles. This triangular surface is bounded by two lines, which commence in small tubercles situated on the dorsal aspect of either side of the

digital extremity, and, running backward, converge to meet together a little behind the centre of the bone and form a ridge which runs along the rest of the dorsal surface to the carpal extremity. This ridge separates two lateral, sloping surfaces for the attachment of the Dorsal interossei muscles.[1] To the tubercles on the digital extremities are attached the lateral ligaments of the metacarpo-phalangeal joints.

The **carpal extremity,** or **base,** is of a cuboidal form, and broader behind than in front; it articulates above with the carpus, and on each side with the adjoining metacarpal bones; its *dorsal* and *palmar surfaces* are rough, for the attachment of tendons and ligaments.

The **digital extremity,** or **head,** presents an oblong surface, flattened at each side; it articulates with the proximal phalanx; it is broader and extends farther forward in front than behind, and is longer in the antero-posterior than in the transverse diameter. On either side of the head is a tubercle for the attachment of the lateral ligament of the metacarpo-phalangeal joint. The *posterior surface,* broad and flat, supports the Extensor tendons; the *anterior surface* is grooved in the middle line for the passage of the Flexor tendons, and marked on each side by an articular eminence continuous with the terminal articular surface.

Peculiar Characters of the Metacarpal Bones.

The **metacarpal bone of the thumb** is shorter and wider than the rest, diverges to a greater degree from the carpus, and its *palmar surface* is directed inward toward the palm. The *shaft* is flattened and broad on its dorsal aspect, and does not present the ridge which is found on the other metacarpal bones; it is concave from before backward on its palmar surface. The *carpal extremity,* or *base,* presents a concavo-convex surface, for articulation with the trapezium; it has no lateral facets. The *digital extremity* is less convex than that of the other metacarpal bones, broader from side to side than from before backward, and terminates anteriorly in a small articular, eminence on each side, over which play two sesamoid bones.

The side to which this bone belongs may be known by observing the little prominence which is situated on the outer or radial side of its posterior surface just above the base, for the tendon of the Extensor ossis metacarpi pollicis. If the bone is held with the palmar surface upward and the base toward the student, the prominence will point to the side to which the bone belongs. Another means by which the side to which the bone belongs may be ascertained is by holding it in the position it occupies in the hand, with the carpal extremity upward and the dorsal surface backward; the narrower, radial border will point to the side to which it belongs.

The **metacarpal bone of the index finger** is the longest and its base the largest of the other four. Its *carpal extremity* is prolonged upward and inward, forming a prominent ridge. The dorsal and palmar surfaces of this extremity are rough, for the attachment of tendons and ligaments. It presents four articular facets: three on the upper aspect of the base: the middle one of the three is the largest, concave from side to side, convex from before backward, for articulation with the trapezoid; the external one is a small, flat, quadrilateral facet, for articulation with the trapezium; the internal one on the summit of the ridge is long and narrow, for articulation with the os magnum. The fourth facet is on the inner or ulnar side of the extremity of the bone, and is for articulation with the third metacarpal bone.

The side to which this bone belongs is indicated by the absence of the lateral facet on the outer (radial) side of its base, so that if the bone is placed with its base toward the student and the palmar surface upward, the side on which there is no lateral facet will be that to which it belongs.

[1] By these sloping surfaces the metacarpal bones of the hand may be at once differentiated from those of the foot.

The **metacarpal bone of the middle finger** is a little smaller than the preceding: it presents a pyramidal eminence (the styloid process) on the radial side of its base (dorsal aspect) which extends upward behind the os magnum. The carpal, articular facet is concave behind, flat in front, and articulates with the os magnum. On the radial side is a smooth, concave facet, for articulation with the second metacarpal bone, and on the ulnar side two small, oval facets, for articulation with the fourth metacarpal.

The side to which this bone belongs is easily recognized by the styloid process on the radial side of its base. With the palmar surface uppermost and the base toward the student, this process points toward the side to which the bone belongs.

The **metacarpal bone of the ring finger** is shorter and smaller than the preceding, and its base small and quadrilateral; the carpal surface of the base presenting two facets, for articulation with the unciform and os magnum. On the radial side are two oval facets, for articulation with the third metacarpal bone; and on the ulnar side a single concave facet, for the fifth metacarpal.

If this bone is placed with the base toward the student and the palmar surface upward, the radial side of the base, which has two facets for articulation with the third metacarpal bone, will be on the side to which it belongs. If, as sometimes happens in badly-marked bones, one of these facets is indistinguishable, the side may be known by selecting the surface on which the larger articular facet is present. This facet is for the fifth metacarpal bone, and would therefore be situated on the ulnar side; that is, the one to which the bone does *not* belong.

The **metacarpal bone of the little finger** presents on its base one facet, which is concavo-convex, and which articulates with the unciform bone, and one lateral, articular facet, which articulates with the fourth metacarpal bone. On its ulnar side is a prominent tubercle, for the insertion of the tendon of the Extensor carpi ulnaris. The dorsal surface of the shaft is marked by an oblique ridge which extends from near the ulnar side of the upper extremity to the radial side of the lower. The outer division of this surface serves for the attachment of the Fourth dorsal interosseous muscle; the inner division is smooth and covered by the Extensor tendons of the little finger.

If this bone is placed with its base toward the student and its palmar surface upward, the side of the head which has a lateral facet will be that to which the bone belongs.

Articulations.—Besides the phalangeal articulations, the first metacarpal bone articulates with the trapezium; the second with the trapezium, trapezoid, os magnum, and third metacarpal bones; the third with the os magnum and second and fourth metacarpal bones; the fourth with the os magnum, unciform, and third and fifth metacarpal bones; and the fifth with the unciform and fourth metacarpal.

The *first* has no lateral facets on its carpal extremity; the *second* has no lateral facet on its radial side, but one on its ulnar side; the third has one on its radial and two on its ulnar side; the fourth has two on its radial and one on its ulnar side; and the fifth has only one on its radial side.

Attachment of Muscles.—To the metacarpal bone of the thumb, four: the Flexor ossis metacarpi pollicis, Flexor brevis pollicis, Extensor ossis metacarpi pollicis, and First dorsal interosseous. To the second metacarpal bone, six: the Flexor carpi radialis, Extensor carpi radialis longior, Adductor obliquus pollicis, First and Second dorsal interosseous, and First palmar interosseous. To the third, six: the Extensor carpi radialis brevior, Flexor carpi radialis, Adductor transversus pollicis, Adductor obliquus pollicis, and Second and Third dorsal interosseous. To the fourth, three: the Third and Fourth dorsal and Second palmar interosseous. To the fifth, five: the Extensor carpi ulnaris, Flexor carpi ulnaris, Flexor ossis metacarpi minimi digiti, Fourth dorsal and Third palmar interosseous.

The Phalanges.

The **Phalanges** (*internodia*) are the bones of the fingers; they are fourteen in number, three for each finger, and two for the thumb. They are long bones, and present for examination a shaft and two extremities. The *shaft* tapers from above downward, is convex posteriorly, concave in front from above downward, flat from side to side, and marked laterally by rough ridges, which give attachment to the fibrous sheaths of the Flexor tendons. The *metacarpal extremity*, or *base*, in the first row presents an oval, concave, articular surface, broader from side to side than from before backward; and the same extremity in the other two rows, a double concavity, separated by a longitudinal median ridge, extending from before backward. The *digital extremities* are smaller than the others, and terminate, in the first and second rows, in two small, lateral condyles, separated by a slight groove; the articular surface being prolonged farther forward on the palmar than on the dorsal surface, especially in the first row.

The **Ungual Phalanges** are convex on their dorsal, flat on their palmar, surfaces; they are recognized by their small size and by a roughened, elevated surface of a horseshoe form on the palmar aspect of their ungual extremity, which serves to support the sensitive pulp of the finger.

Articulations.—The first row, with the metacarpal bones and the second row of phalanges; the second row, with the first and third; the third, with the second row.

Attachment of Muscles.—To the base of the first phalanx of the thumb, five muscles: the Extensor brevis pollicis, Flexor brevis pollicis, Abductor pollicis, Adductor transversus and obliquus pollicis. To the second phalanx, two: the Flexor longus pollicis and the Extensor longus pollicis. To the base of the first phalanx of the index finger, the First dorsal and the First palmar interosseous; to that of the middle finger, the Second and Third dorsal interosseous; to that of the ring finger, the Fourth dorsal and the Second palmar interosseous; and to that of the little finger, the Third palmar interosseous, the Flexor brevis minimi digiti, and Abductor minimi digiti. To the second phalanges, the Flexor sublimis digitorum, Extensor communis digitorum, and, in addition, the Extensor indicis to the index finger, the Extensor minimi digiti to the little finger. To the third phalanges, the Flexor profundus digitorum and Extensor communis digitorum.

Surface Form.—On the front of the wrist are two subcutaneous eminences, one on the radial side, the larger and flatter, due to the tuberosity of the scaphoid and the ridge on the trapezium; the other, on the ulnar side, caused by the pisiform bone. The tubercle of the scaphoid is to be felt just below and in front of the apex of the styloid process of the radius. It is best perceived by extending the hand on the forearm. Immediately below is to be felt another prominence, better marked than the tubercle; this is the ridge on the trapezium which gives attachment to some of the short muscles of the thumb. On the inner side of the front of the wrist the pisiform bone is to be felt, forming a small but prominent projection in this situation. It is some distance below the styloid process of the ulna, and may be said to be just below the level of the styloid process of the radius. The rest of the front of the carpus is covered by tendons and the annular ligament, and entirely concealed, with the exception of the hooked process of the unciform, which can only be made out with difficulty. The back of the carpus is convex and covered by the Extensor tendons, so that none of the posterior surfaces of the bones are to be felt, with the exception of the cuneiform on the inner side. Below the carpus the dorsal surfaces of the metacarpal bones, except the fifth, are covered by tendons, and are scarcely visible except in very thin hands. The dorsal surface of the fifth is, however, subcutaneous throughout almost its whole length, and is plainly to be perceived and felt. In addition to this, slightly external to the middle line of the hand, is a prominence, frequently well marked, but occasionally indistinct, formed by the base of the metacarpal of the middle finger. The heads of the metacarpal bones are plainly to be felt and seen, rounded in contour and standing out in bold relief under the skin, when the fist is clenched. It should be borne in mind that when the fingers are flexed on the hand, the articular surfaces of the first phalanges glide off the heads of the metacarpal bones on to their anterior surfaces, so that the heads of these bones form the prominence of the knuckles and receive the force of any blow which may be given. The head of the third metacarpal bone is the most prominent, and receives the greater part of the shock of the blow. This bone articulates with the os magnum, so that the concussion is carried through this bone to the scaphoid and semilunar, with which the head of the os magnum articulates, and by these bones is transferred to the radius, along which it may be carried to the capitellum of the humerus. The enlarged extremities of the phalanges are to be plainly felt: they form the

joints of the fingers. When the digits are bent the proximal phalanges of the joints form prominences, which in the joint between the first and second phalanges is slightly hollowed, in accordance with the grooved shape of their articular surfaces, whilst at the last row the prominence is flattened and square-shaped. In the palm of the hand the four inner metacarpal bones are covered by muscles, tendons, and the palmar fascia, and no part of them but their heads is to be distinguished. With regard to the thumb, on the dorsal aspect the base of the metacarpal bone forms a prominence below the styloid process of the radius; the shaft is to be felt, covered by tendons, terminating at its head in a flattened prominence, in front of which can be felt the sesamoid bones.

Surgical Anatomy.—The carpal bones are little liable to fracture, except from extreme violence, when the parts are so comminuted as to necessitate amputation. Occasionally they are the seat of tubercular disease. The metacarpal bone and the phalanges are not unfrequently broken from direct violence. The first metacarpal bone is the one most commonly fractured; then the second, the fourth, and the fifth, the third being the one least frequently broken. There are two diseases of the metacarpal bones and phalanges which require special mention on account of the frequency of their occurrence. One is tubercular dactylitis, consisting in a deposit of tubercular material in the medullary canal, expanding the bone, with subsequent caseation and resulting necrosis. The other is chondroma, which is perhaps more frequently found in connection with the metacarpal bones and phalanges than with any other bones. They are commonly multiple, and may spring either from the medullary canal or from the periosteum.

Development of the Bones of the Hand.

The **Carpal Bones** are each developed by a *single* centre. At birth they are all cartilaginous. Ossification proceeds in the following order (Fig. 206): In the

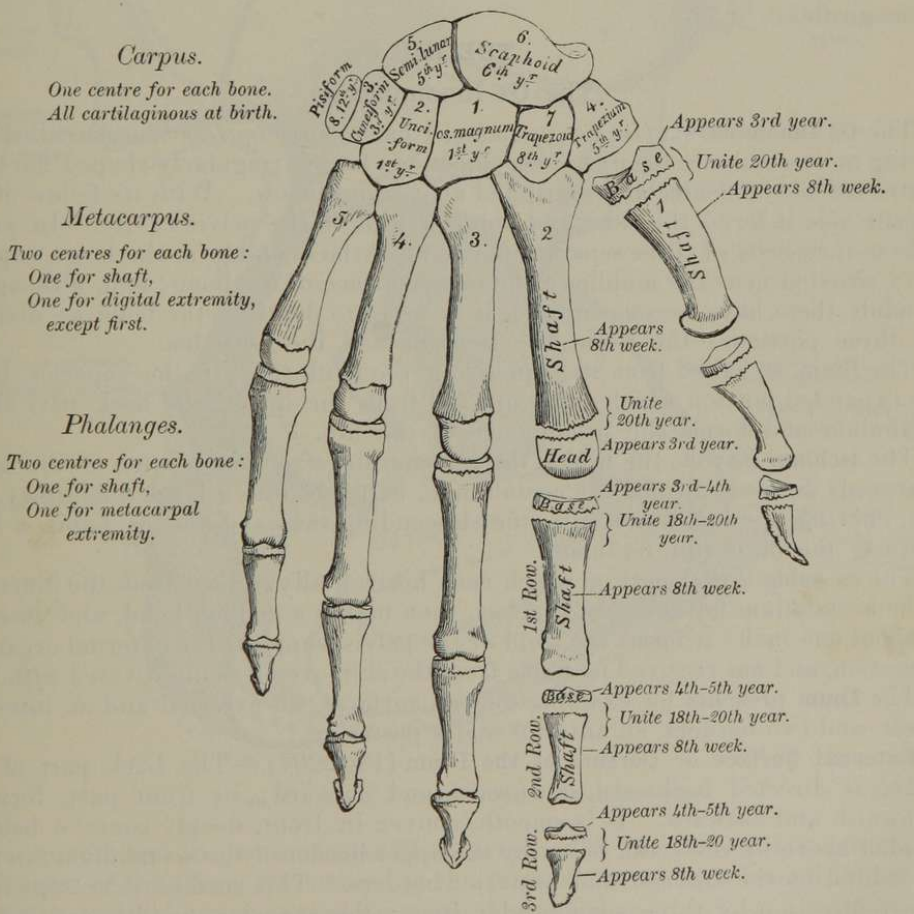

FIG. 206.—Plan of the development of the hand.

os magnum and unciform an ossific point appears during the first year, the former preceding the latter; in the cuneiform, at the third year; in the trapezium and semilunar, at the fifth year, the former preceding the latter; in the scaphoid, at

the sixth year; in the trapezoid, during the eighth year; and in the pisiform, about the twelfth year.

The **Metacarpal Bones** are each developed by *two* centres: one for the shaft and one for the digital extremity for the four inner metacarpal bones; one for the shaft and one for the base for the metacarpal bone of the thumb, which in this respect resembles the phalanges.[1] Ossification commences in the centre of the shaft about the eighth or ninth week, and gradually proceeds to either end of the bone: about the third year the digital extremities of the four inner metacarpal bones and the base of the first metacarpal begin to ossify, and they unite about the twentieth year.

The **Phalanges** are each developed by *two* centres: one for the shaft and one for the base. Ossification commences in the shaft, in all three rows, at about the eighth week, and gradually involves the whole of the bone excepting the upper extremity. Ossification of the base commences in the first row between the third and fourth years, and a year later in those of the second and third rows. The two centres become united, in each row, between the eighteenth and twentieth years.

THE LOWER EXTREMITY.

The **Lower Extremity** consists of three segments, the *thigh*, *leg*, and *foot*, which correspond to the *arm*, *forearm*, and *hand* in the upper extremity. It is connected to the trunk through the os innominatum, or hip-bone, which forms the pelvic girdle.

THE HIP.

The Os Innominatum.

The **Os Innominatum** (*in*, not; *nomino*, I name), or *nameless bone*, so called from bearing no resemblance to any known object, is a large, irregularly-shaped, flat bone, constricted in the centre and expanded above and below. With its fellow of the opposite side it forms the sides and anterior wall of the pelvic cavity. In young subjects it consists of three separate parts, which meet and form the large, cup-like cavity situated near the middle of the outer surface of the bone; and, although in the adult these have become united, it is usual to describe the bone as divisible into three portions—the ilium, the ischium, and the os pubis.

The **ilium**, so called from its supporting the flank (*ilia*), is the superior, broad and expanded portion which runs upward from the upper and back part of the acetabulum and forms the prominence of the hip.

The **ischium** (*ἰσχίον*, the hip) is the inferior and strongest portion of the bone; it proceeds downward from the acetabulum, expands into a large tuberosity, and then, curving upward, forms with the descending ramus of the os pubis, a large aperture, the obturator foramen.

The **os pubis** is that portion which runs horizontally inward from the inner side of the acetabulum for about two inches, then makes a sudden bend, and descends for about one inch: it forms the front of the pelvis, supports the external organs of generation, and has received its name from the skin over it being covered with hair.

The **Ilium** presents for examination two surfaces, an external and an internal; a crest, and two borders, an anterior and a posterior.

External Surface or Dorsum of the Ilium (Fig. 207).—The back part of this surface is directed backward, downward, and outward; its front part, forward, downward, and outward. It is smooth, convex in front, deeply concave behind; bounded above by the crest, below by the upper border of the acetabulum; in front and behind by the anterior and posterior borders. This surface is crossed in an arched direction by three semicircular lines—the superior, middle, and inferior gluteal lines. The *superior gluteal line*, the shortest of the three, commences at

[1] Allan Thomson has demonstrated the fact that the first metacarpal bone is often developed from three centres; that is to say, there is a separate nucleus for the distal end, forming a distinct epiphysis, visible at the age of seven or eight years. He also states that there are traces of a proximal epiphysis in the second metacarpal bone.—*Journal of Anatomy*, 1869.

the crest, about two inches in front of its posterior extremity; it is at first distinctly marked, but as it passes downward and outward to the upper part of the great sacro-sciatic notch, where it terminates, it becomes less marked, and is often altogether lost. Behind this line is a narrow semilunar surface, the upper part of which is rough and affords attachment to part of the Gluteus maximus; the lower

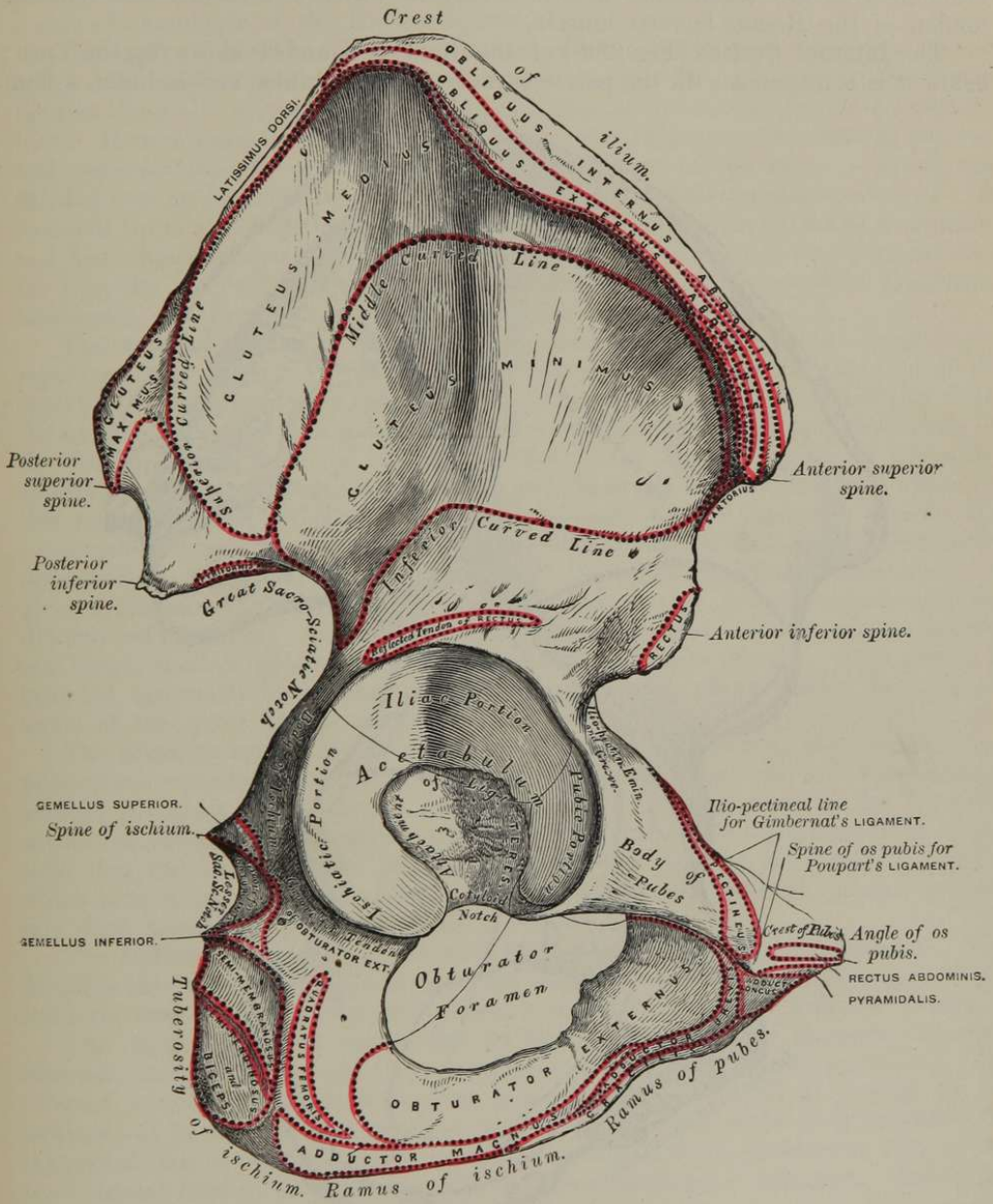

FIG. 207.—Right os innominatum. External surface.

part is smooth and has no muscular fibres attached to it. The *middle gluteal line*, the longest of the three, commences at the crest, about an inch behind its anterior extremity, and, taking a curved direction downward and backward, terminates at the upper part of the great sacro-sciatic notch. The base between the superior and middle curved lines and the crest is concave, and affords attachment to the Gluteus medius muscle. Near the central part of this line may often be observed the orifice of a nutrient foramen. The *inferior gluteal line*, the least distinct of the three, commences in front at the upper part of the anterior inferior spinous process, and,

taking a curved direction backward and downward, terminates at the middle of the great sacro-sciatic notch. The surface of bone included between the middle and inferior curved lines is concave from above downward, convex from before backward, and affords attachment to the Gluteus minimus muscle. Beneath the inferior curved line, and corresponding to the upper part of the acetabulum, is a roughened surface (sometimes a depression), to which is attached the reflected tendon of the Rectus femoris muscle.

The **Internal Surface** (Fig. 208) of the ilium is bounded above by the crest; below it is continuous with the pelvic surface of the os pubis and ischium, a faint

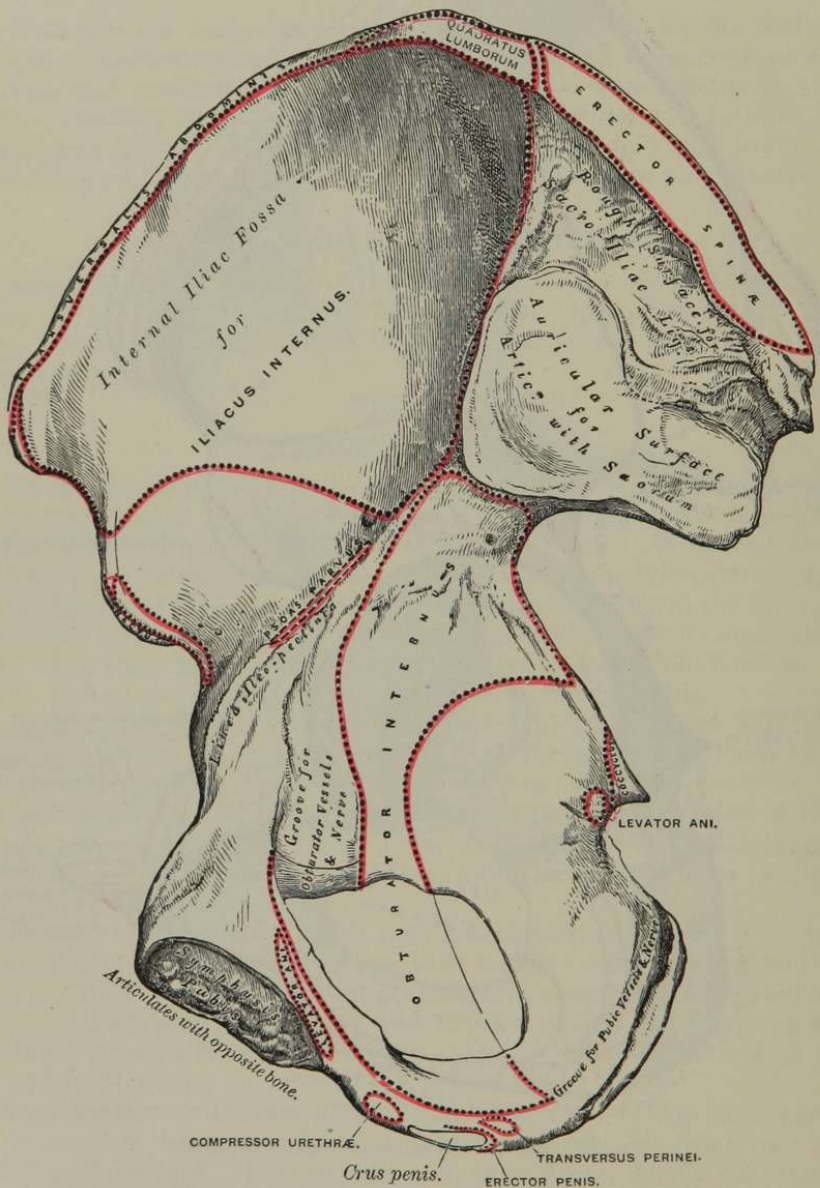

FIG. 208.—Right os innominatum. Internal surface.

line only indicating the place of union; and before and behind it is bounded by the anterior and posterior borders. It presents anteriorly a large, smooth, concave surface, called the *internal iliac fossa*, or *venter of the ilium*, which lodges the Iliacus muscle, and presents at its lower part the orifice of a nutrient canal; and below this a smooth, rounded border (*iliac portion of the linea ilio-pectinea*), which separates the iliac fossa from that portion of the internal surface which enters into

the formation of the true pelvis, and which gives attachment to part of the Obturator internus muscle. Behind the iliac fossa is a rough surface divided into two portions, an anterior and a posterior. The anterior or auricular portion, so called from its resemblance in shape to the ear, is coated with cartilage in the recent state, and articulates with a surface of similar shape on the side of the sacrum. The posterior portion is rough, for the attachment of the posterior sacro-iliac ligaments and for a part of the origin of the Erector spinæ.

The **crest** of the ilium is convex in its general outline and sinuously curved, being bent inward anteriorly, outward posteriorly. It is longer in the female than in the male, very thick behind, and thinner at the centre than at the extremities. It terminates at either end in a prominent eminence, the *anterior superior* and *posterior superior spinous process.* The surface of the crest is broad, and divided into an external lip, an internal lip, and an intermediate space. To the external lip is attached the Tensor vaginæ femoris, Obliquus externus abdominis, and Latissimus dorsi, and by its whole length the fascia lata; to the space between the lips, the Internal oblique; to the internal lip, the Transversalis, Quadratus lumborum, and Erector spinæ, the Iliacus, and the fascia iliaca.

The **anterior border** of the ilium is concave. It presents two projections, separated by a notch. Of these, the uppermost, situated at the junction of the crest and anterior border, is called the *anterior superior spinous process* of the ilium, the outer border of which gives attachment to the fascia lata and the origin of the Tensor vaginæ femoris; its inner border, to the Iliacus; whilst its extremity affords attachment to Poupart's ligament and the origin of the Sartorius. Beneath this eminence is a notch which gives attachment to the Sartorius muscle, and across which passes the external cutaneous nerve. Below the notch is the *anterior inferior spinous process*, which terminates in the upper lip of the acetabulum; it gives attachment to the straight tendon of the Rectus femoris muscle and the ilio-femoral ligament. On the inner side of the anterior inferior spinous process is a broad, shallow groove, over which passes the Iliacus muscle. This groove is bounded internally by an eminence, the *ilio-pectineal*, which marks the point of union of the ilium and os pubis.

The **posterior border** of the ilium, shorter than the anterior, also presents two projections separated by a notch, the *posterior superior* and the *posterior inferior spinous processes.* The former corresponds with that portion of the posterior surface of the ilium which serves for the attachment of the oblique portion of the sacro-iliac ligaments and the Multifidus spinæ; the latter to the auricular portion which articulates with the sacrum. Below the posterior inferior spinous process is a deep notch, the *great sciatic* or *ilio-sciatic.*

The **Ischium** forms the lower and back part of the os innominatum. It is divisible into a thick and solid portion, the *body;* a large, rough eminence, on which the body rests in sitting, the *tuberosity;* and a thin, ascending part, the *ramus.*

The **body,** somewhat triangular in form, presents three surfaces, external, internal, and posterior; and three borders, external, internal, and posterior. The *external surface* corresponds to that portion of the acetabulum formed by the ischium; it is smooth and concave, and forms a little more than two-fifths of the acetabular cavity; its outer margin is bounded by a prominent rim or lip, the external border, to which the cotyloid fibro-cartilage is attached. Below the acetabulum, between it and the tuberosity, is a deep groove, along which the tendon of the Obturator externus muscle runs as it passes outward to be inserted into the digital fossa of the femur. The *internal surface* is smooth, concave, and enters into the formation of the lateral boundary of the true pelvic cavity. This surface is perforated by two or three large, vascular foramina, and affords attachment to part of the Obturator internus muscle. The *posterior surface* is quadrilateral in form, broad and smooth. Below, where it joins the tuberosity, it presents a groove continuous with that on the external surface, for the tendon of the Obturator externus muscle. The lower edge of this groove is formed by the tuberosity of the ischium, and affords attachment to the Gemellus inferior muscle. This surface is

limited, in front, by the margin of the acetabulum; behind, by the posterior border; it supports the Pyriformis, the two Gemelli, and the Obturator internus muscles in their passage outward to the great trochanter. The *external border* forms the prominent rim of the acetabulum, and separates the posterior from the external surface. To it is attached the cotyloid fibro-cartilage. The *internal border* is thin, and forms the outer circumference of the obturator foramen. The *posterior border* of the body of the ischium presents, a little below the centre, a thin and pointed, triangular eminence, the *spine of the ischium*, more or less elongated in different subjects; its external surface gives attachment to the Gemellus superior, its internal surface to the Coccygeus and Levator ani; whilst to the pointed extremity is connected the lesser sacro-sciatic ligament. Above the spine is a notch of a large size, the *great sciatic*, converted into a foramen by the lesser sacro-sciatic ligament; it transmits the Pyriformis muscle, the gluteal vessels and superior gluteal nerve passing out of the pelvis above the muscles; the sciatic vessels, the greater and lesser sciatic nerves, the internal pudic vessels and nerve, and muscular branches from the sacral plexus below it. Below the spine is a smaller notch, the *lesser sciatic;* it is smooth, coated in the recent state with cartilage, the surface of which presents numerous markings corresponding to the subdivisions of the tendon of the Obturator internus, which winds over it. It is converted into a foramen by the sacro-sciatic ligaments, and transmits the tendon of the Obturator internus, the nerve which supplies that muscle, and the internal pudic vessels and nerve.

The **tuberosity** presents for examination three surfaces: external, internal, and inferior. The *external surface* is quadrilateral in shape, and rough for the attachment of muscles. It is bounded above by the groove for the tendon of the Obturator externus; in front it is limited by the posterior margin of the obturator foramen, and below it is continuous with the ramus of the bone; behind, it is bounded by a prominent margin which separates it from the inferior surface. In front of this margin the surface gives attachment to the Quadratus femoris, and anterior to this to some of the fibres of origin of the Obturator externus. The lower part of the surface gives origin to part of the Adductor magnus. The *internal surface* forms part of the bony wall of the true pelvis. In front it is limited by the posterior margin of the obturator foramen. Behind, it is bounded by a sharp ridge, for the attachment of a falciform prolongation of the great sacro-sciatic ligament; it presents a groove on the inner side of this for the lodgment of the internal pudic vessels and nerve; and, more anteriorly, has attached the Transversus perinæi and Erector penis muscles. The *inferior surface* is divided into two portions—an anterior, rough, somewhat triangular part, and a posterior, smooth, quadrilateral portion. The anterior surface is subdivided by a prominent vertical ridge, passing from base to apex, into two parts; the outer one gives attachment to the Adductor magnus; the inner to the great sacro-sciatic ligament. The posterior portion is subdivided into two facets by an oblique ridge; from the upper and outer facet arises the Semimembranosus; from the lower and inner, the Biceps and Semitendinosus.

The **ramus,** or **ascending ramus,** is the thin, flattened part of the ischium which ascends from the tuberosity upward and inward, and joins the ramus of the os pubis, their point of junction being indicated in the adult by a rough line. The outer surface of the ramus is rough, for the attachment of the Obturator externus muscle, and also some fibres of the Adductor magnus; its inner surface forms part of the anterior wall of the pelvis. Its inner border is thick, rough, slightly everted, forms part of the outlet of the pelvis, and presents two ridges and an intervening space. The ridges are continuous with similar ones on the descending ramus of the os pubis: to the outer one is attached the deep layer of the superficial perineal fascia, and to the inner the anterior layer of the triangular ligament of the perinæum. If these two ridges are traced downward, they will be found to join with each other just behind the point of origin of the Transversus perinæi muscle; here the two layers of fascia are continuous behind the posterior border of the muscle. To the inter-

vening space, just in front of the point of junction of the ridges, is attached the Transversus perinæi muscle, and in front of this a portion of the crus penis vel clitoridis and the Erector penis vel clitoridis muscle. Its outer border is thin and sharp, and forms part of the inner margin of the obturator foramen.

The **Os Pubis** forms the anterior part of the os innominatum, and, with the bone of the opposite side, forms the front boundary of the true pelvic cavity. It is divisible into a body, a horizontal ramus, and a descending ramus.

The **body** is somewhat quadrilateral in shape, and presents for examination two surfaces and four borders. The *anterior surface* is rough, directed forward, downward, and outward. To the upper and inner angle, immediately below the crest, is attached the Adductor longus; lower down, from without inward, are attached the Obturator externus, the Adductor brevis, and the upper part of the Gracilis. The *posterior surface*, convex from above downward, concave from side to side, is smooth, and forms part of the anterior wall of the pelvis. It gives attachment to the Levator ani, Obturator internus, a few muscular fibres prolonged from the bladder, and the pubo-prostatic ligaments. On the outer end of the *upper border*, at about its junction with the horizontal ramus, there is a prominent tubercle called the *spine;* to it is attached the outer pillar of the external abdominal ring and Poupart's ligament. Passing outward from the spine is a prominent ridge, *pubic portion of the ilio-pectineal line*, which marks the brim of the true pelvis: to it is attached a portion of the conjoined tendon of the Internal oblique and Transversalis muscles, Gimbernat's ligament, and the triangular ligament of the abdomen. Internal to the spine is the upper border or *crest*, which extends to the inner border of the bone. It affords attachment anteriorly to the conjoined tendon of the Internal oblique and Transversalis, and posteriorly to the Rectus and Pyramidalis muscles. The point of junction of the crest with the inner border of the bone is called the *angle;* to it, as well as to the symphysis, is attached the internal pillar of the external abdominal ring. The *inner border*, together with that of the bone of the opposite side, forms the symphysis; it is oval, covered by eight or nine transverse ridges, or a series of nipple-like processes arranged in rows, separated by grooves; they serve for the attachment of a thin layer of cartilage placed between it and the central fibro-cartilage. The *outer border* is sharp and forms part of the circumference of the obturator foramen. The *lower border* is united to the descending ramus.

The **horizontal ramus** extends from the body to the point of junction of the os pubis with the ilium, and forms the upper part of the circumference of the obturator foramen. It presents for examination a superior, inferior, and posterior surface, and an outer extremity. The *superior surface* presents a continuation of the *pubic portion* of the ilio-pectineal line, already mentioned as commencing at the *spine* of the bone. In front of this ridge the surface of bone is triangular in form, wider externally than internally, smooth, and affords attachment to the Pectineus muscle. The surface is bounded externally by a rough eminence, the *ilio-pectineal*, which serves to indicate the point of junction of the ilium and pubes, and gives attachment to the Psoas parvus when this muscle is present. The *inferior surface* forms the upper boundary of the obturator foramen, and presents externally a broad and deep oblique groove, for the passage of the obturator vessels and nerve; and internally a sharp margin which forms part of the circumference of the obturator foramen, and to which the obturator membrane is attached. The *posterior surface* forms part of the anterior boundary of the true pelvis. It is smooth, convex from above downward, and affords attachment to the upper fibres of the obturator internus. The *outer extremity*, the thickest part of the ramus, forms one-fifth of the cavity of the acetabulum.

The **descending ramus** of the os pubis is thin and flattened. It passes outward and downward, becoming narrower as it descends, and joins with the ramus of the ischium. Its *anterior surface* is rough, for the attachment of muscles—the Gracilis along its inner border; a portion of the Obturator externus where it enters into the formation of the foramen of that name; and between these two muscles the

Adductores brevis and magnus from within outward. The *posterior surface* is smooth, and gives attachment to the Obturator internus and, close to the inner margin, to the Compressor urethræ. The *inner border* is thick, rough, and everted, especially in females. It presents two ridges, separated by an intervening space. The ridges extend downward, and are continuous with similar ridges on the ascending ramus of the ischium; to the external one is attached the deep layer of the superficial perineal fascia, and to the internal one the anterior layer of the triangular ligament of the perinæum. The *outer border* is thin and sharp, forms part of the circumference of the obturator foramen, and gives attachment to the obturator membrane.

The **cotyloid cavity,** or **acetabulum,** is a deep, cup-shaped, hemispherical depression, directed downward, outward, and forward; formed internally by the os pubis, above by the ilium, behind and below by the ischium, a little less than two-fifths being formed by the ilium, a little more than two-fifths by the ischium, and the remaining fifth by the pubic bone. It is bounded by a prominent, uneven rim, which is thick and strong above, and serves for the attachment of a fibro-cartilaginous structure which contracts its orifice and deepens the surface for articulation. It presents, on its inner side, a deep notch, the *cotyloid notch*, which is continuous with a circular depression, the *fossa acetabuli*, at the bottom of the cavity: this depression is perforated by numerous apertures, lodges a mass of fat, and its margins, as well as those of the notch, serve for the attachment of the ligamentum teres. The notch is converted, in the natural state, into a foramen by a dense ligamentous band which passes across it. Through this foramen the nutrient vessels and nerves enter the joint.

The **obturator** or **thyroid foramen** is a large aperture situated between the ischium and os pubis. In the male it is large, of an oval form, its longest diameter being obliquely from above downward; in the female it is smaller and more triangular. It is bounded by a thin, uneven margin to which a strong membrane is attached; and presents at its upper and outer part a deep groove which runs from the pelvis obliquely forward, inward, and downward. This groove is converted into a foramen by the obturator membrane, and transmits the obturator vessels and nerve.

Structure.—This bone consists of much cancellous tissue, especially where it is thick, enclosed between two layers of dense, compact tissue. In the thinner parts of the bone, as at the bottom of the acetabulum and centre of the iliac fossa, it is usually semitransparent, and composed entirely of compact tissue.

Development (Fig. 209).—By *eight* centres: three primary—one for the ilium, one for the ischium, and one for the os pubis; and *five* secondary—one for the crest of the ilium, one for the anterior inferior spinous process (said to occur more frequently in the male than the female), one for the tuberosity of the ischium, one for the symphysis pubis (more frequent in the female than the male), and one for the Y-shaped piece at the bottom of the acetabulum. These various centres appear in the following order: First, in the ilium, at the lower part of the bone, immediately above the sciatic notch, at about the eighth or ninth week; secondly, in the body of the ischium, at about the third month of fœtal life; thirdly, in the body of the os pubis, between the fourth and fifth months. At birth the three primary centres are quite separate, the crest, the bottom of the acetabulum, and the rami of the ischium and pubes being still cartilaginous. At about the seventh or eighth year the rami of the os pubis and ischium are almost completely ossified. About the thirteenth or fourteenth year the three divisions of the bone have extended their growth into the bottom of the acetabulum, being separated from each other by a Y-shaped portion of cartilage, which now presents traces of ossification, often by two or more centres. The ilium and ischium then become joined, and lastly the os pubis, through the intervention of this Y-shaped portion. At about the age of puberty ossification takes place in each of the remaining portions, and they become joined to the rest of the bone about the twenty-fifth year.

Articulations.—With its fellow of the opposite side, the sacrum, and femur.

Attachment of Muscles.—To the *ilium*, sixteen. To the outer lip of the crest, the Tensor vaginæ femoris, Obliquus externus abdominis, and Latissimus dorsi; to the internal lip, the Iliacus, Transversalis, Quadratus lumborum, and Erector spinæ; to the interspace between the lips, the Obliquus internus. To the outer surface of the ilium, the Gluteus maximus, Gluteus medius, Gluteus minimus, reflected tendon of the Rectus; to the upper part of the great sacro-sciatic notch, a portion of the Pyriformis; to the internal surface, the Iliacus; to that portion of the internal surface below the linea ilio-pectinea, the Obturator internus, and the Multifidus spinæ to the internal surface of the posterior superior spine; to the anterior border, the Sartorius and straight tendon of the Rectus. To the *ischium*, fourteen. To the outer surface of the ramus, the Obturator externus and Adductor magnus; to the internal surface, the Obturator internus and Erector penis. To the spine, the Gemellus superior, Levator ani, and Coccygeus. To the tuberosity, the Biceps, Semitendinosus, Semimembranosus, Quadratus femoris, Adductor magnus,

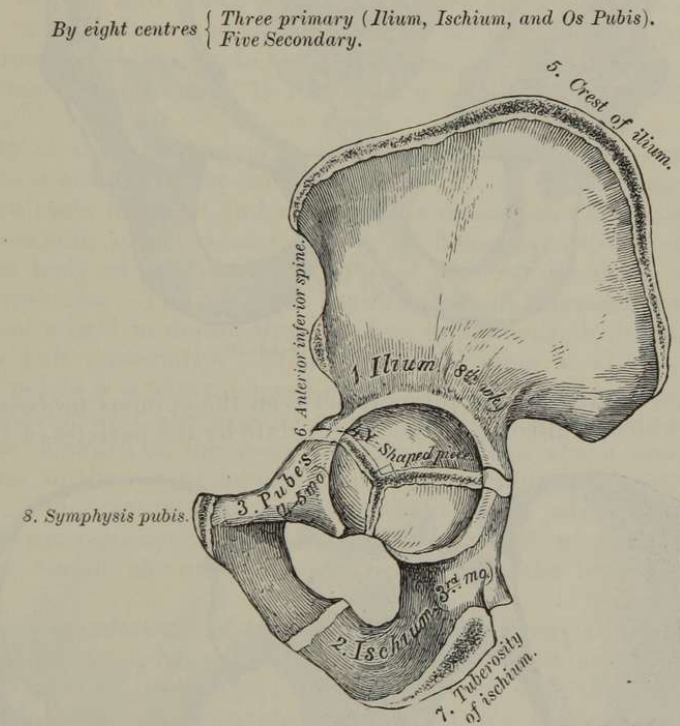

FIG. 209.—Plan of the development of the os innominatum.

Gemellus inferior, Transversus perinæi, Erector penis. To the *os pubis*, sixteen: Obliquus externus, Obliquus internus, Transversalis, Rectus, Pyramidalis, Psoas parvus, Pectineus, Adductor magnus, Adductor longus, Adductor brevis, Gracilis, Obturator externus and internus, Levator ani, Compressor urethræ, and occasionally a few fibres of the Accelerator urinæ.

The Pelvis (Figs. 210, 211).

The **Pelvis**, so called from its resemblance to a basin (L. *pelvis*), is stronger and more massively constructed than either the cranial or thoracic cavity; it is a bony ring, interposed between the lower end of the spine, which it supports, and the lower extremities, upon which it rests. It is composed of four bones: the two ossa innominati, which bound it on either side and in front, and the sacrum and coccyx, which complete it behind.

The pelvis is divided by a plane passing through the prominence of the sacrum,

the linea ilio-pectinea, and the upper margin of the symphysis pubis into the false and true pelvis.

The **false pelvis** is all that expanded portion of the pelvic cavity which is situated above this plane. It is bounded on each side by the ossa ilii; in front it

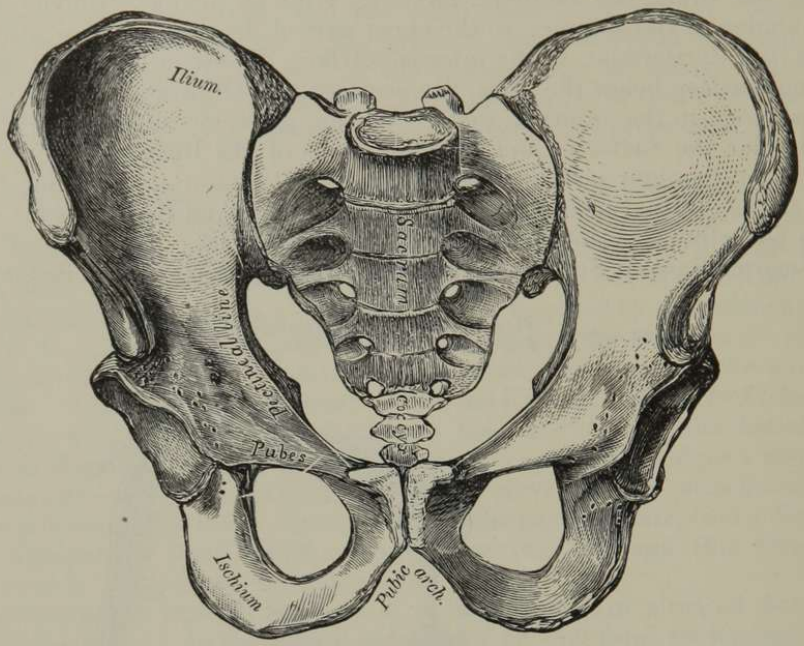

FIG. 210.—Male pelvis (adult).

is incomplete, presenting a wide interval between the spinous processes of the ilia on either side, which is filled up in the recent state by the parietes of the abdomen;

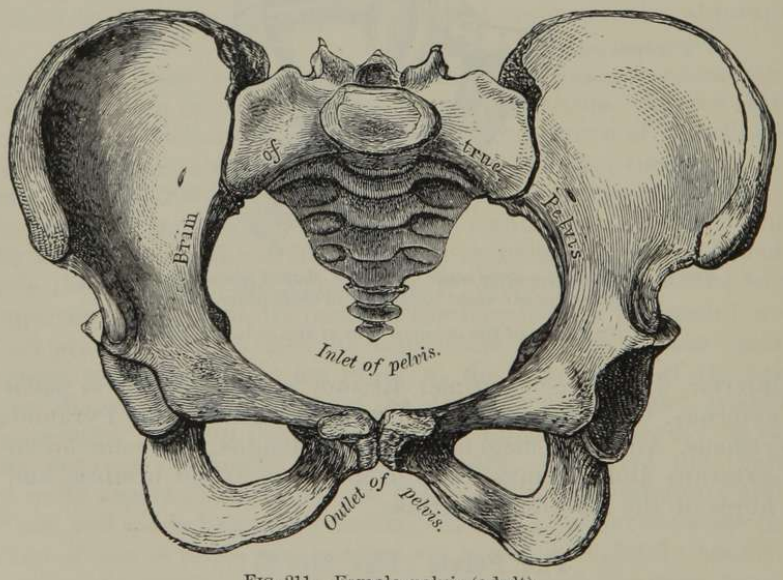

FIG. 211.—Female pelvis (adult).

behind, in the middle line, is a deep notch. This broad, shallow cavity is fitted to support the intestines and to transmit part of their weight to the anterior wall of the abdomen, and is, in fact, really a portion of the abdominal cavity. The term false pelvis is incorrect, and this space ought more properly to be regarded as part of the hypogastric region of the abdomen.

The **true pelvis** is all that part of the pelvic cavity which is situated beneath

the plane. It is smaller than the false pelvis, but its walls are more perfect. For convenience of description it is divided into a superior circumference or inlet, an inferior circumference or outlet, and a cavity.

The **superior circumference** forms the margin or brim of the pelvis, the included space being called the *inlet*. It is formed by the linea ilio-pectinea, completed in front by the crests of the pubic bones, and behind by the anterior margin of the base of the sacrum and sacro-vertebral angle. The *inlet* of the pelvis is somewhat heart-shaped, obtusely pointed in front, diverging on either side, and encroached upon behind by the projection forward of the promontory of the sacrum. It has three principal diameters: antero-posterior (sacro-pubic), transverse, and oblique. The antero-posterior extends from the sacro-vertebral angle to the symphysis pubis; its average measurement is four inches in the male, four and three-quarters in the female. The transverse extends across the greatest width of the inlet, from the middle of the brim on one side to the same point on the opposite; its average measurement is four and a half in the male, five and a quarter in the female. The oblique extends from the margin of the pelvis, corresponding to the ilio-pectineal eminence on one side, to the sacro-iliac symphysis on the opposite side; its average measurement is four and a quarter in the male, and five in the female.

The **cavity** of the true pelvis is bounded in front by the symphysis pubis; behind, by the concavity of the sacrum and coccyx, which, curving forward above and below, contracts the inlet and outlet of the canal; and laterally it is bounded by a broad, smooth, quadrangular surface of bone, corresponding to the inner surface of the body of the ischium and that part of the ilium which is below the ilio-pectineal line. The cavity is shallow in front, measuring at the symphysis an inch and a half in depth, three inches and a half in the middle, and four inches and a half posteriorly. From this description it will be seen that the cavity of the pelvis is a short, curved canal, considerably deeper on its posterior than on its anterior wall, and broader in the middle than at either extremity, from the projection forward of the sacro-coccygeal column above and below. This cavity contains, in the recent subject, the rectum, bladder, and part of the organs of generation. The rectum is placed at the back of the pelvis, and corresponds to the curve of the sacro-coccygeal column; the bladder in front, behind the symphysis pubis. In the female the uterus and vagina occupy the interval between these parts.

The **lower circumference** of the pelvis is very irregular, and forms what is called the *outlet*. It is bounded by three prominent eminences: one posterior, formed by the point of the coccyx; and one on each side, the tuberosities of the ischia. These eminences are separated by three notches; one in front, the *pubic arch*, formed by the convergence of the rami of the ischia and pubic bones on each side. The other notches, one on each side, are formed by the sacrum and coccyx behind, the ischium in front, and the ilium above; they are called the *sacro-sciatic notches;* in the natural state they are converted into foramina by the lesser and greater sacro-sciatic ligaments. In the recent state, when the ligaments are *in situ*, the outlet of the pelvis is lozenge-shaped, bounded in front by the subpubic ligament and the rami of the os pubis and ischium; on each side by the tuberosities of the ischia; and behind by the great sacro-sciatic ligaments and the tip of the coccyx.

The diameters of the outlet of the pelvis are two, antero-posterior and transverse. The *antero-posterior* extends from the tip of the coccyx to the lower part of the symphysis pubis; its average measurement is three and a quarter inches in the male and five in the female. The antero-posterior diameter varies with the length of the coccyx, and is capable of increase or diminution on account of the mobility of that bone.[1] The *transverse* extends from the posterior part of one

[1] The measurements of the pelvis given above are, I believe, fairly accurate, but different measurements are given by various authors, no doubt due in a great measure to differences in the physique and stature of the population from whom the measurements have been taken. The accompany-

ischiatic tuberosity to the same point on the opposite side: the average measurement is three and a half inches in the male and four and three-quarters in the female.

Position of the Pelvis.—In the erect posture the pelvis is placed obliquely with regard to the trunk of the body: the bony ring, which separates the true from the false pelvis, and which forms the essential part of the pelvis, is placed so as to form an angle of about 60° to 65° with the ground on which we stand. The pelvic surface of the symphysis pubis looks upward and backward, the concavity of the sacrum and coccyx downward and forward, the base of the sacrum in well-formed female bodies being nearly four inches above the upper border of the symphysis pubis, and the apex of the coccyx a little more than half an inch above its lower border. The obliquity is much greater in the fœtus and at an early period of life than in the adult. In consequence of this obliquity of the pelvis the line of gravity of the head, which passes through the middle of the odontoid process of the axis and through the points of junction of the curves of the vertebral column to the sacro-vertebral angle, descends toward the front of the cavity, so that it bisects a line drawn transversely through the middle of the heads of the thigh-bones. And thus the centre of gravity of the head is placed immediately over the heads of the thigh-bones on which the trunk is supported.

Axes of the Pelvis (Fig. 212).—The plane of the inlet of the true pelvis will be represented by a line drawn from the base of the sacrum to the upper margin of the symphysis pubis. A line carried at right angles with this at its middle would correspond at one extremity with the umbilicus, and at the other with the middle of the coccyx: the axis of the inlet is therefore directed downward and backward. The axis of the outlet, produced upward, would touch the base of the sacrum, and is therefore directed downward and forward. The axis of the cavity is curved like the cavity itself: this curve corresponds to the concavity of the sacrum and coccyx, the extremities being indicated by the central points of the inlet and outlet. A knowledge of the direction of these axes serves to explain the course of the fœtus in its passage through the pelvis during parturition. It is also important to the surgeon, as indicating the direction of the force required in the removal of calculi from the bladder, and as determining the direction in which instruments should be used in operations upon the pelvic viscera.

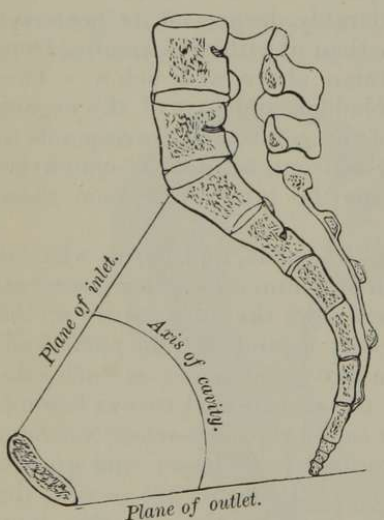

FIG. 212.—Vertical section of the pelvis, with lines indicating the axes of the pelvis.

Differences between the Male and Female Pelvis.—The *female* pelvis, looked at as a whole, is distinguished from the *male* by the bones being more delicate, by its width being greater and its depth smaller. The whole pelvis is less massive, and its bones are lighter and more slender, and its muscular impressions are slightly marked. The iliac fossæ are broad and expanded, and the anterior iliac spines widely separated; hence the greater prominence of the hips. The *inlet* in the female is larger than in the male; it is more nearly circular, and the sacro-vertebral angle projects less forward. The *cavity* is shallower and wider; the sacrum is shorter and wider, and its lower half forms a greater angle with its upper; the obturator foramina are triangular, and smaller in size than in the male. The *outlet* is larger and the coccyx more movable. The spines of the ischia project less in-

ing chart has been formulated to show the measurements of the pelvis, which are adopted by many obstetricians.—ED.

	A. P.	Obl.	Tr.
Inlet	4	4½	5
Cavity	4½	4½	4½
Outlet	5	4½	4

ward. The tuberosities of the ischia and the acetabula are wider apart. The *pubic arch* is wider and more rounded than in the male, where it is an angle rather than an arch; its pillars are somewhat excavated, and sloped from within outward, so that their inner surfaces look forward. In consequence of this the width of the fore part of the pelvic outlet is much increased and the passage of the fœtal head facilitated.

The size of the pelvis varies, not only in the two sexes, but also in different members of the same sex. This does not appear to be influenced in any way by the height of the individual. Women of short stature, as a rule, have broad pelves. Occasionally the pelvis is equally contracted in all its dimensions, so much so that all its diameters measure an inch less than the average, and this even in women of average height and otherwise well formed. The principal divergences, however, are found at the inlet, and affect the relation of the antero-posterior to the transverse diameter. Thus we may have a pelvis the inlet of which is elliptical either in a transverse or antero-posterior direction; the transverse diameter in the former and the antero-posterior in the latter greatly exceeding the other diameters. Again, the inlet of the pelvis in some instances is seen to be almost circular.

The same differences are found in various races. European women are said to have the most roomy pelves. That of the negress is smaller, circular in shape, and with a narrow pubic arch. The Hottentots and Bushwomen possess the smallest pelves.

In the *fœtus* and for several years after birth the pelvis is small in proportion to that of the adult. The cavity is deep, and the projection of the sacro-vertebral angle less marked. The antero-posterior and transverse diameters are nearly equal. *About puberty* the pelvis in both sexes presents the general characters of the adult male pelvis; but *after puberty* it acquires its proper sexual characters.

Surface Form.—The pelvic bones are so thickly covered with muscles that it is only at certain points that they approach the surface and can be felt through the skin. In front, the anterior superior spinous process is easily to be recognized; a portion of it is subcutaneous, and in thin subjects may be seen to stand out as a prominence at the outer extremity of the fold of the groin. In fat subjects its position is marked by an oblique depression amongst the surrounding fat, at the bottom of which the bony process may be felt. Proceeding upward and outward from this process, the crest of the ilium may be traced throughout its whole length, sinuously curved. It is represented, in muscular subjects, on the surface, by a groove or furrow, the *iliac furrow*, caused by the projection of fleshy fibres of the External oblique muscle of the abdomen. It terminates behind in the posterior superior spinous process, the position of which is indicated by a slight depression on a level with and on each side of the spinous process of the second sacral vertebra. Between the two posterior superior spinous processes, but at a lower level, is to be felt the spinous process of the third sacral vertebra (see page 164). Another part of the bony pelvis which is easily accessible to the touch is the tuberosity of the ischium, situated beneath the gluteal fold, and, when the hip is flexed, easily to be felt, as it is then to a great extent uncovered by muscle. Finally, the spine of the os pubis can always be readily felt, and constitutes an important surgical guide, especially in connection with the subject of hernia. It is nearly in the same horizontal line with the upper edge of the great trochanter. In thin subjects it is very apparent, but in the obese it is obscured by the pubic fat. It can, however, be detected by following up the tendon of origin of the Adductor longus muscle.

Surgical Anatomy.—There is arrest of development in the bones of the pelvis in cases of extroversion of the bladder; the anterior part of the pelvic girdle being deficient, the bodies of the pubic bones imperfectly developed, and the symphysis absent. The pubic bones are separated to the extent of from two to four inches, the superior rami shortened and directed forward, and the obturator foramen diminished in size, narrowed, and turned outward. The iliac bones are straightened out more than normal. The sacrum is very peculiar. The lateral curve, instead of being concave, is flattened out or even convex, with the ilio-sacral facets turned more outward than normal, while the vertical curve is straightened.[1]

Fractures of the pelvis are divided into fractures of the false pelvis and of the true pelvis. Fractures of the false pelvis vary in extent: a small portion of the crest may be broken or one of the spinous processes may be torn off, and this may be the result of muscular action; or the bone may be extensively comminuted. This latter accident is the result of some crushing violence, and may be complicated with fracture of the true pelvis. These cases may be accompanied by injury to the intestine as it lies in the hollow of the bone, or to the iliac vessels as they course along the margin of the true pelvis. Fractures of the true pelvis generally occur through the horizontal ramus of the os pubis and the ascending ramus of the ischium, as this is the weakest part of the bony ring, and may be caused either by crushing violence applied

[1] Wood. Heath's *Dictionary of Practical Surgery*, i. 426.

in an antero-posterior direction, when the fracture occurs from direct force, or by compression laterally, when the acetabula are pressed together, and the bone gives way in the same place from indirect violence. Occasionally the fracture may be double, occurring on both sides of the body. It is in these cases that injury to the contained viscera is liable to take place: the urethra, the bladder, the rectum, the vagina in the female, the small intestines, and even the uterus, have all been lacerated by a displaced fragment. Fractures of the acetabulum are occasionally met with: either a portion of the rim may be broken off, or a fracture may take place through the bottom of the cavity, and the head of the femur driven inward and project into the pelvic cavity. Separation of the Y-shaped cartilage at the bottom of the acetabulum may also occur in the young subject, separating the bone into its three anatomical portions.

The sacrum is occasionally, but rarely, broken by direct violence—*i. e.* blows, kicks, or falls on the part. The lesion may be complicated with injury to the nerves of the sacral plexus, leading to paralysis and loss of sensation in the lower extremity, or to incontinence of fæces from paralysis of the sphincter ani.

The pelvic bones often undergo important deformity in rickets, the effect of which in the adult woman may interfere seriously with childbearing. In consequence of the yielding nature of the bones, the acetabula become approximated, the symphysis is pushed forward, and the antero-posterior diameter lessened. In osteo-malacia also great deformity may occur, the pelvis becoming beak-shaped. The promontory of the sacrum is pushed forward by the weight of the body, and the sides of the pelvis are approximated by the pressure of the two thigh-bones: this gives to the pelvis the peculiar deformity which is characteristic of this disease.

THE THIGH.

The Femur, or Thigh-Bone.

The **Femur** (*femur*, the thigh) is the longest,[1] largest, and strongest bone in the skeleton, and almost perfectly cylindrical in the greater part of its extent. In the erect posture it is not vertical, being separated from its fellow above by a considerable interval, which corresponds to the entire breadth of the pelvis, but inclining gradually downward and inward, so as to approach its fellow toward its lower part, for the purpose of bringing the knee-joint near the line of gravity of the body. The degree of this inclination varies in different persons, and is greater in the female than the male, on account of the greater breadth of the pelvis. The femur, like other long bones, is divisible into a shaft and two extremities.

The **Upper Extremity** presents for examination a head, a neck, and the great and lesser trochanters.

The **head**, which is globular, and forms rather more than a hemisphere, is directed upward, inward, and a little forward, the greater part of its convexity being above and in front. Its surface is smooth, coated with cartilage in the recent state, except at a little behind and below its centre, where is an ovoid depression, for the attachment of the ligamentum teres. The **neck** is a flattened pyramidal process of bone which connects the head with the shaft. It varies in length and obliquity at various periods of life and under different circumstances. The angle is widest in infancy, and becomes lessened during growth, so that at puberty it forms a gentle curve from the axis of the shaft. In the adult it forms an angle of about 130° with the shaft, but varies in inverse proportion to the development of the pelvis and the stature. In consequence of the prominence of the hips and widening of the pelvis in the female, the neck of the thigh-bone forms more nearly a right angle with the shaft than it does in man. It has been stated that the angle diminishes in old age and the direction of the neck becomes horizontal, but this statement is founded on insufficient evidence. Sir George Humphry states that the angle decreases during the period of growth, but after full growth has been attained it does not usually undergo any change, even in old age. He further states that the angle varies considerably in different persons of the same age. It is smaller in short than in long bones, and when the pelvis is wide.[2] The neck is flattened from before backward, contracted in the middle, and broader at its outer extremity, where it is connected with the shaft, than at its summit, where it is attached to the head. The vertical diameter of the outer

[1] In a man six feet high it measures eighteen inches—one-fourth of the whole body.
[2] *Journal of Anatomy and Physiology.*

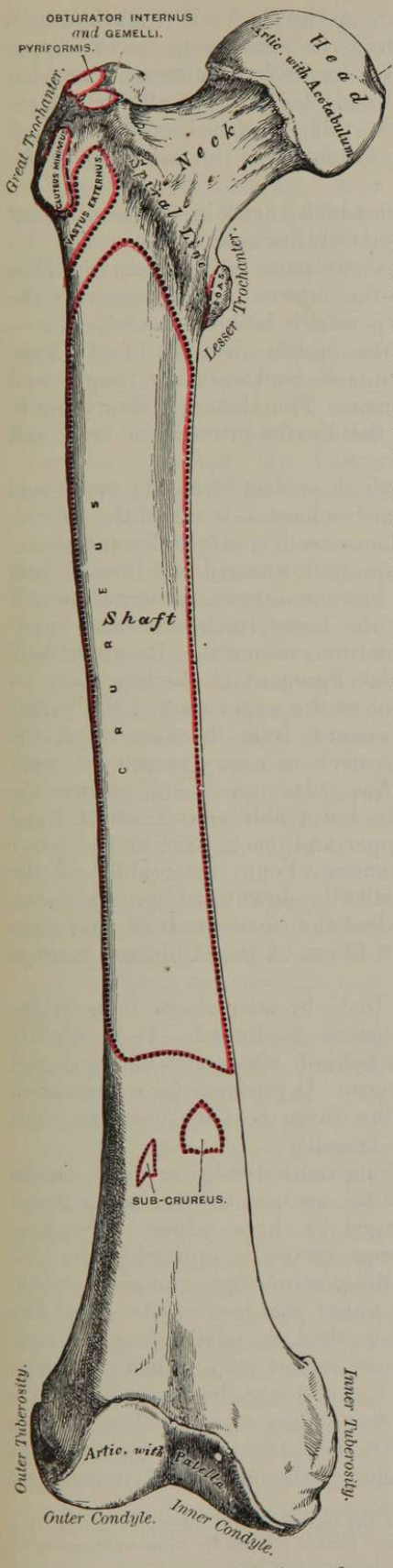

FIG. 213.—Right femur. Anterior surface.

half is increased by the thickening of the lower edge, which slopes downward to join the shaft at the lesser trochanter, so that the outer half of the neck is flattened from before backward, and its vertical diameter measures one-third more than the antero-posterior. The inner half is smaller and of a more circular shape. The *anterior surface* of the neck is perforated by numerous vascular foramina. The *posterior surface* is smooth, and is broader and more concave than the anterior; it gives attachment to the posterior part of the capsular ligament of the hip-joint, about half an inch above the posterior intertrochanteric line. The *superior border* is short and thick, and terminates externally at the great trochanter; its surface is perforated by large foramina. The *inferior border*, long and narrow, curves a little backward, to terminate at the lesser trochanter.

The **Trochanters** (τροχάω, to run or roll) are prominent processes of bone which afford leverage to the muscles which rotate the thigh on its axis. They are two in number, the great and the lesser.

The **Great Trochanter** is a large, irregular, quadrilateral eminence, situated at the outer side of the neck, at its junction with the upper part of the shaft. It is directed a little outward and backward, and in the adult is about three-quarters of an inch lower than the head. It presents for examination two surfaces and four borders. The *external surface*, quadrilateral in form, is broad, rough, convex, and marked by a prominent diagonal line, which extends from the posterior superior to the anterior inferior angle; this line serves for the attachment of the tendon of the Gluteus medius. Above the line is a triangular surface, sometimes rough for part of the tendon of the same muscle, sometimes smooth for the interposition of a bursa between that tendon and the bone. Below and behind the diagonal line is a smooth, triangular surface, over which the tendon of the Gluteus maximus muscle plays, a bursa being interposed. The *internal surface* is of much less extent than the external, and presents at its base a deep depression, the *digital* or *trochanteric fossa*, for the attachment of the tendon of the Obturator externus muscle, and in front of this an impression for the attachment of the Obturator internus and Gemelli. The *superior border* is free; it is thick and irregular, and marked near the centre by an impression for the attachment of the Pyriformis. The *inferior border* corresponds to the point of junction of

the base of the trochanter with the outer surface of the shaft; it is marked by a rough, prominent, slightly curved ridge, which gives attachment to the upper part of the Vastus externus muscle. The *anterior border* is prominent, somewhat irregular, as well as the surface of bone immediately below it; it affords attachment at its outer part to the Gluteus minimus. The *posterior border* is very prominent, and appears as a free, rounded edge, which forms the back part of the digital fossa.

The **Lesser Trochanter** is a conical eminence which varies in size in different subjects; it projects from the lower and back part of the base of the neck. Its base is triangular, and connected with the adjacent parts of the bone by three well-marked borders: two of these are above—the *internal* continuous with the lower border of the neck, the *external* with the posterior intertrochanteric line—while the *inferior border* is continuous with the middle division of the linea aspera. Its summit, which is directed inward and backward, is rough, and gives insertion to the tendon of the Psoas magnus. The Iliacus is inserted into the shaft below the lesser trochanter between the Vastus internus in front and the Pectineus behind.

A well-marked prominence of variable size, which projects from the upper and front part of the neck at its junction with the great trochanter, is called the *tubercle of the femur;* it is the point of meeting of the Gluteus minimus externally and above, and the Vastus externus below. Running obliquely downward and inward from the tubercle is the *spiral line* of the femur, or *anterior intertrochanteric line;* it winds round the inner side of the shaft, below the lesser trochanter, and terminates in the linea aspera, about two inches below this eminence. Its upper half is rough, and affords attachment to the capsular ligament of the hip-joint; its lower half is less prominent, and gives attachment to the upper part of the Vastus internus. Running obliquely downward and inward from the summit of the great trochanter on the posterior surface of the neck is a very prominent, well-marked ridge, the *posterior intertrochanteric line*. Its upper half forms the posterior border of the great trochanter, and its lower half runs downward and inward across the neck of the bone to the upper and back part of the lesser trochanter. A slight ridge sometimes commences about the middle of the posterior intertrochanteric line, and passes vertically downward for about two inches along the back part of the shaft: it is called the *linea quadrati*, and gives attachment to the Quadratus femoris and a few fibres of the Adductor magnus muscles.[1]

The **Shaft**, almost cylindrical in form, is a little broader above than in the centre, and somewhat flattened below, from before backward. It is slightly arched, so as to be convex in front and concave behind, where it is strengthened by a prominent longitudinal ridge, the *linea aspera*. It presents for examination three borders, separating three surfaces. Of the three borders, one, the linea aspera, is posterior; the other two are placed laterally.

The **linea aspera** (Fig. 214) is a prominent longitudinal ridge or crest, on the middle third of the bone, presenting an external lip, an internal lip, and a rough intermediate space. Above, this crest is prolonged by three ridges. The most external one is very rough, and is continued almost vertically upward to the base of the great trochanter. It is sometimes termed the *gluteal ridge*, and gives attachment to part of the Gluteus maximus muscle; its upper part is often elongated into a roughened crest, on which is a more or less well-marked, rounded tubercle, a rudimental third trochanter. The middle ridge, the least distinct, is continued to the base of the trochanter minor, and the internal one is lost above in the spiral line of the femur. Below, the linea aspera is prolonged by two ridges, which enclose between them a triangular space, the *popliteal surface*. Of these two ridges, the outer one is the more prominent, and descends to the summit of the outer condyle (*external*

[1] Generally there is merely a slight thickening about the centre of the intertrochanteric line, marking the point of attachment of the Quadratus femoris. This is termed by some anatomists the *tubercle of the Quadratus*.

supracondylar line). The inner one (*internal supracondylar line*) is less marked, especially at its upper part, where it is crossed by the femoral artery. It terminates, below, at the summit of the internal condyle, in a small tubercle, the *Adductor tubercle*, which affords attachment to the tendon of the Adductor magnus.

To the inner lip of the linea aspera and its inner prolongation above and below is attached the Vastus internus, and to the outer lip and its outer prolongation above is attached the Vastus externus. The Adductor magnus is attached to the linea aspera, to its outer prolongation above and its inner prolongation below. Between the Vastus externus and the Adductor magnus are attached two muscles—viz. the Gluteus maximus above, and the short head of the Biceps below. Between the Adductor magnus and the Vastus internus four muscles are attached: the Iliacus and Pectineus above (the latter to the middle of the upper divisions); below these, the Adductor brevis and Adductor longus. The linea aspera is perforated a little below its centre by the nutrient canal, which is directed obliquely upward.

The *two lateral borders* of the femur are only slightly marked, the outer one extending from the anterior inferior angle of the great trochanter to the anterior extremity of the external condyle; the inner one from the spiral line, at a point opposite the trochanter minor, to the anterior extremity of the internal condyle. The internal border marks the limit of attachment of the Crureus muscle internally.

The **anterior surface** includes that portion of the shaft which is situated between the two lateral borders. It is smooth, convex, broader above and below than in the centre, slightly twisted, so that its upper part is

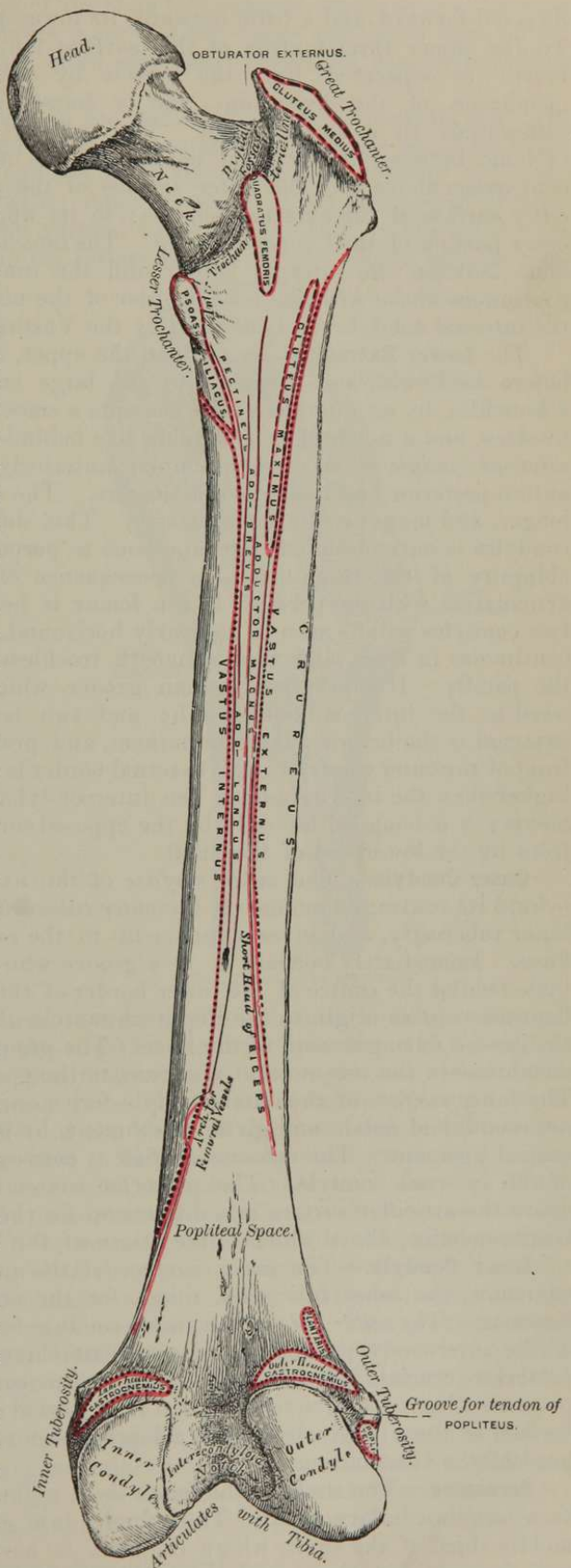

FIG. 214.—Right femur. Posterior surface.

directed forward and a little outward, its lower part forward, and a little inward. To the upper three-fourths of this surface the Crureus is attached; the lower fourth is separated from the muscle by the intervention of the synovial membrane of the knee-joint and a bursa, and affords attachment to the Subcrureus to a small extent. The *external surface* includes the portion of bone between the external border and the outer lip of the linea aspera: it is continuous above with the outer surface of the great trochanter, below with the outer surface of the external condyle; to its upper three-fourths is attached the outer portion of the Crureus muscle. The *internal surface* includes the portion of bone between the internal border and the inner lip of the linea aspera; it is continuous above with the lower border of the neck, below with the inner side of the internal condyle: it is covered by the Vastus internus muscle.

The **Lower Extremity**, larger than the upper, is of a cuboid form, flattened from before backward, and divided into two large eminences, the *condyles* (*κόνδυλος*, a knuckle), by an interval which presents a smooth depression in front called the *trochlea*, and a notch of considerable size behind—the *intercondyloid notch*. The *external condyle* is the more prominent anteriorly, and is the broader both in the antero-posterior and transverse diameters. The *internal condyle* is the narrower, longer, and more prominent inferiorly. This difference in the length of the two condyles is only observed when the bone is perpendicular, and depends upon the obliquity of the thigh-bones, in consequence of their separation above at the articulation with the pelvis. If the femur is held obliquely, the surfaces of the two condyles will be seen to be nearly horizontal. The two condyles are directly continuous in front, and form a smooth trochlear surface, which articulates with the patella. It presents a median groove, which extends downward and backward to the intercondyloid notch; and two lateral convexities, of which the external is the broader, more prominent, and prolonged farther upward upon the front of the outer condyle. The external border is also more prominent, and ascends higher than the internal one. The intercondyloid notch lodges the crucial ligaments; it is bounded laterally by the opposed surfaces of the two condyles, and in front by the lower end of the shaft.

Outer Condyle.—The *outer surface* of the external condyle presents, a little behind its centre, an eminence, the *outer tuberosity;* it is less prominent than the inner tuberosity, and gives attachment to the external lateral ligaments of the knee. Immediately beneath it is a groove which commences at a depression a little behind the centre of the lower border of this surface: the front part of this depression gives origin to the Popliteus muscle, the tendon of which is lodged in the groove during flexion of the knee. The groove is smooth, lined with synovial membrane in the recent state, and runs to the posterior extremity of the condyle. The *inner surface* of the outer condyle forms one of the lateral boundaries of the intercondyloid notch, and gives attachment, by its posterior part, to the anterior crucial ligament. The *inferior surface* is convex, smooth, and broader than that of the internal condyle. The posterior extremity is convex and smooth: just above the articular surface is a depression for the tendon of the outer head of the Gastrocnemius, above which is the origin of the Plantaris.

Inner Condyle.—The *inner surface* of the inner condyle presents a convex eminence, the *inner tuberosity*, rough for the attachment of the internal lateral ligament. The *outer side* of the inner condyle forms one of the lateral boundaries of the intercondyloid notch, and gives attachment, somewhat posteriorly, to the posterior crucial ligament. Its *inferior* or *articular surface* is convex, and presents a less extensive surface than the external condyle. Just above the articular surface of the condyle, behind, is a depression for the tendon of origin of the inner head of the Gastrocnemius.

Structure.—The shaft of the femur is a cylinder of compact tissue, hollowed by a large medullary canal. The cylinder is of great thickness and density in the middle third of the shaft, where the bone is narrowest and the medullary canal well formed; but above and below this the cylinder gradually becomes thinner,

owing to a separation of the layers of the bone into cancelli, which project into the medullary canal and finally obliterate it, so that the upper and lower ends of the shaft, and the articular extremities more especially, consist of cancellated tissue invested by a thin, compact layer.

The arrangement of the cancelli in the ends of the femur is remarkable. In the upper end they are arranged in two sets. One, starting from the top of the head, the upper surface of the neck, and the great trochanter, converge to the inner circumference of the shaft (Fig. 215); these are placed in the direction of greatest pressure, and serve to support the vertical weight of the body. The second set are planes of lamellæ intersecting the former nearly at right angles, and are situated in the line of the greatest tension—that is to say, along the lines in which the muscles and ligaments exert their traction. In the head of the bone these

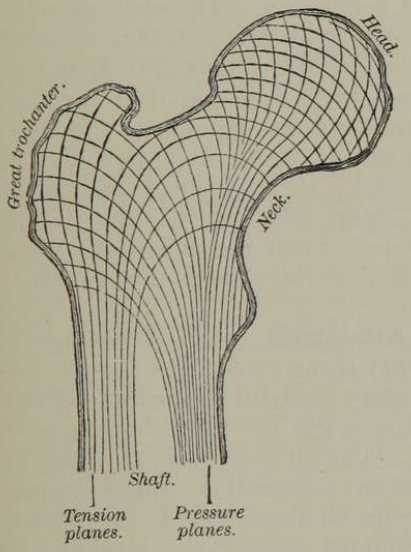

FIG. 215.—Diagram showing the arrangement of the cancelli of the neck of the femur.

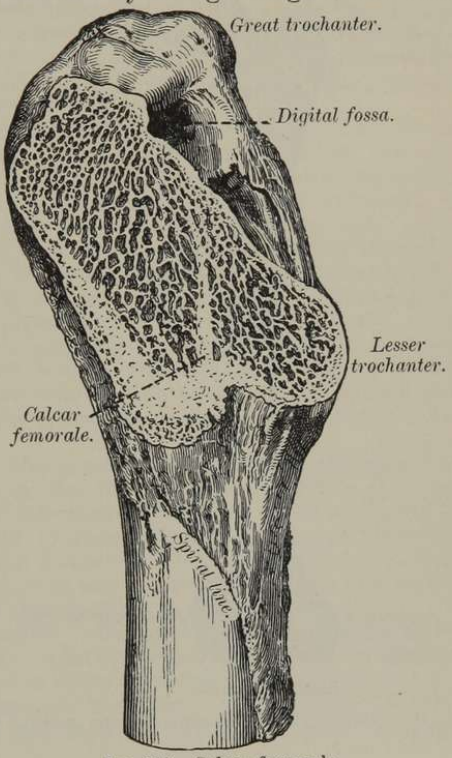

FIG. 216.—Calcar femorale.

planes are arranged in a curved form, in order to strengthen the bone when exposed to pressure in all directions. In the midst of the cancellous tissue of the neck is a vertical plane of compact bone, the *femoral spur* (*calcar femorale*) which commences at the point where the neck joins the shaft midway between the lesser trochanter and the internal border of the shaft of the bone, and extends in the direction of the digital fossa (Fig. 216). This materially strengthens this portion of the bone. Another point in connection with the structure of the neck of the femur requires mention, especially on account of its influence on the production of fracture in this situation. It will be noticed that a considerable portion of the great trochanter lies behind the level of the posterior surface of the neck; and if a section be made through the trochanter at this level, it will be seen that the posterior wall of the neck is prolonged into the trochanter. This prolongation is termed by Bigelow the "true neck,"[1] and forms a thin, dense plate of bone, which passes beneath the posterior intertrochanteric ridge toward the outer surface of the bone.

In the lower end the cancelli spring on all sides from the inner surface of the cylinder, and descend in a perpendicular direction to the articular surface, the cancelli being strongest and having a more accurately perpendicular course above the condyles. In addition to this, however, horizontal planes of cancellous tissue

[1] *Bigelow on the Hip*, p. 121.

are to be seen, so that the spongy tissue in this situation presents an appearance of being mapped out into a series of rectangular areas.

Articulations.—With three bones: the os innominatum, tibia, and patella.

Development (Fig. 217).—The femur is developed by *five* centres: one for the shaft, one for each extremity, and one for each trochanter. Of all the long bones, except the clavicle, it is the first to show traces of ossification: this commences in the shaft, at about the fifth week of fœtal life, the centres of ossification in the epiphyses appearing in the following order: First, in the lower end of the bone, at the ninth month of fœtal life[1] (from this the condyles and tuberosities are formed); in the head at the end of the first year after birth; in the great trochanter, during the fourth year; and in the lesser trochanter, between the thirteenth and fourteenth. The order in which the epiphyses are joined to the shaft is the reverse of that of their appearance: their junction does not commence until after puberty, the lesser trochanter being first joined, then the great, then the head, and, lastly, the inferior extremity (the first in which ossification commenced), which is not united until the twentieth year.

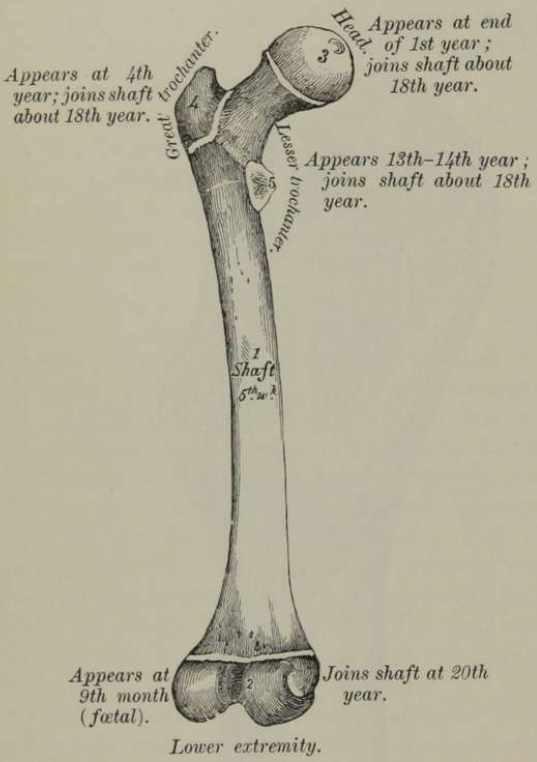

FIG. 217.—Plan of the development of the femur. By five centres.

Attachment of Muscles.—To twenty-three. To the great trochanter: the Gluteus medius, Gluteus minimus, Pyriformis, Obturator internus, Obturator externus, Gemellus superior, Gemellus inferior, and Quadratus femoris. To the lesser trochanter: the Psoas magnus and the Iliacus below it. To the shaft: the Vastus externus, Gluteus maximus, short head of the Biceps, Vastus internus, Adductor magnus, Pectineus, Adductor brevis, Adductor longus, Crureus, and Subcrureus. To the condyles: the Gastrocnemius, Plantaris, and Popliteus.

Surface Form.—The femur is covered with muscles, so that in fairly muscular subjects the shaft is not to be detected through its fleshy covering, and the only parts accessible to the touch are the outer surface of the great trochanter and the lower expanded end of the bone. The external surface of the great trochanter is to be felt, especially in certain positions of the limb. Its position is generally indicated by a depression, owing to the thickness of the Gluteus medius and minimus, which project above it. When, however, the thigh is flexed, and especially if crossed over the opposite one, the trochanter produces a blunt eminence on the surface. The upper border is about on a line with the spine of the os pubis, and its exact level is indicated by a line drawn from the anterior superior spinous process of the ilium, over the outer side of the hip, to the most prominent point of the tuberosity of the ischium. This is known as Nélaton's line. The outer and inner condyles of the lower extremity are easily to be felt. The outer one is more subcutaneous than the inner one, and readily felt. The tuberosity on it is comparatively little developed, but can be more or less easily recognized. The inner condyle is more thickly covered, and this gives a general convex outline to this part, especially when the knee is flexed. The tuberosity on it is easily felt, and at the upper part of the condyle the sharp tubercle for the insertion of the tendon of the Adductor magnus can be recognized without difficulty. When the knee is flexed, and the patella situated in the interval between the condyles and the upper end of the tibia, a part of the trochlear surface of the femur can be made out above the patella.

Surgical Anatomy.—There are one or two points about the ossification of the femur

[1] This is the only epiphysis in which ossification begins before birth.

bearing on practice to which allusion must be made. It has been stated above that the lower end of the femur is the only epiphysis in which ossification has commenced at the time of birth. The presence of this ossific centre is, therefore, a proof, in newly-born children found dead, that the child has arrived at the full period of utero-gestation, and is always relied upon in medico-legal investigations. The position of the epiphysial line should be carefully noted. It is on a level with the adductor tubercle, and the epiphysis does not, therefore, form the whole of the cartilage-clad portion of the lower end of the bone. It is essential to bear this point in mind in performing excision of the knee, since growth in length of the femur takes place chiefly from the lower epiphysis, and any interference with the epiphysial cartilage in a young child would involve such ultimate shortening of the limb, from want of growth, as to render it almost useless. Separation of the lower epiphysis may take place up to the age of twenty, at which time it becomes completely joined to the shaft of the bone; but, as a matter of fact, few cases occur after the age of sixteen or seventeen. The upper epiphysis of the femur is of interest principally on account of its being the seat of origin of a large number of cases of tubercular disease of the hip-joint. The disease commences in the majority of cases in the highly vascular and growing tissue in the neighborhood of the epiphysis, and from here extends into the joint.

Fractures of the femur are divided, like those of the other long bones, into fractures of the upper end; of the shaft; and of the lower end. The fractures of the upper end may be classified into (1) fracture of the neck; (2) fracture at the junction of the neck with the great trochanter; (3) fracture of the great trochanter; and (4) separation of the epiphysis, either of the head or of the great trochanter. The first of these, fracture of the neck, is usually termed intracapsular fracture, but this is scarcely a correct designation, as, owing to the attachment of the capsular ligament, the fracture may be partly within and partly without the capsule, when the fracture occurs at the lower part of the neck. It generally occurs in old people, principally women, and usually from a very slight degree of indirect violence. Probably the main cause of the fracture taking place in old people is in consequence of the degenerative changes which the bone has undergone. Merkel believes that it is mainly due to the absorption of the calcar femorale. These fractures are occasionally impacted. As a rule they unite by fibrous tissue, and frequently no union takes place, and the surfaces of the fracture become smooth and eburnated.

Fractures at the junction of the neck with the great trochanter are usually termed extracapsular, but this designation is also incorrect, as the fracture is partly within the capsule, owing to its attachment in front to the anterior intertrochanteric line, which is situated below the line of fracture. These fractures are produced by direct violence to the great trochanter, as from a blow or fall laterally on the hip. From the manner in which the accident is caused, the neck of the bone is driven into the trochanter, where it may remain impacted, or the trochanter may be split up into two or more fragments, and thus no fixation takes place.

Fractures of the great trochanter may be either "oblique fracture through the trochanter major, without implicating the neck of the bone" (Astley Cooper), or separation of the great trochanter. Most of the recorded cases of this latter injury occurred in young persons, and were probably cases of separation of the epiphysis of the great trochanter. Separation of the epiphysis of the head of the femur has been said to occur, but, as far as I know, has never been verified by post-mortem examination.

Fractures of the shaft may occur at any part, but the most usual situation is at or near the centre of the bone. They may be caused by direct or indirect violence or by muscular action. Fractures of the upper third of the shaft are almost always the result of indirect violence, whilst those of the lower third are the result, for the most part, of direct violence. In the middle third fractures occur from both forms of injury in about equal proportions. Fractures of the shaft are generally oblique, but they may be transverse, longitudinal, or spiral. The transverse fracture occurs most frequently in children. The fractures of the lower end of the femur include transverse fracture above the condyles, the most common; and this may be complicated by a vertical fracture between the condyles, constituting the T-shaped fracture. In these cases the popliteal artery is in danger of being wounded. Oblique fracture, separating either the internal or external condyle, and a longitudinal incomplete fracture between the condyles, may also take place.

The femur as well as the other bones of the leg are frequently the seat of acute necrosis in young children. This is no doubt due to their greater exposure to injury, which is often the exciting cause of this disease. Tumors not unfrequently are found growing from the femur: the most common forms being sarcoma, which may grow either from the periosteum or from the medullary tissue within the interior of the bone; and exostosis, which is commonly found originating in the neighborhood of the epiphysial cartilage of the lower end.

THE LEG.

The skeleton of the Leg consists of three bones: the Patella, a large sesamoid bone, placed in front of the knee; the Tibia; and the Fibula.

The Patella (Figs. 218, 219.)

The **Patella** (*patella*, a small pan) is a flat, triangular bone, situated at the

anterior part of the knee-joint. It is usually regarded as a sesamoid bone, developed in the tendon of the Quadriceps extensor. It resembles these bones (1) in its being developed in a tendon; (2) in its centre of ossification presenting a knotty or tuberculated outline similar to other sesamoid bones; (3) in its structure being composed mainly of dense cancellous tissue, as in the other sesamoid bones. It serves to protect the front of the joint, and increases the leverage of the Quadriceps extensor by making it act at a greater angle. It presents an anterior and posterior surface, three borders, and an apex.

FIG. 218.—Right patella. Anterior surface.

FIG. 219.—Right patella. Posterior surface.

The **anterior surface** is convex, perforated by small apertures, for the passage of nutrient vessels, and marked by numerous rough, longitudinal striæ. This surface is covered, in the recent state, by an expansion from the tendon of the Quadriceps extensor, which is continuous below with the superficial fibres of the ligamentum patellæ. It is separated from the integument by a bursa. The **posterior surface** presents a smooth, oval-shaped, articular surface, covered with cartilage in the recent state, and divided into two facets by a vertical ridge, which descends from the superior border toward the inferior angle of the bone. The ridge corresponds to the groove on the trochlear surface of the femur, and the two facets to the articular surfaces of the two condyles; the outer facet, for articulation with the outer condyle, being the broader and deeper. This character serves to indicate the side to which the bone belongs. Below the articular surface is a rough, convex, non-articular depression, the lower half of which gives attachment to the ligamentum patellæ, the upper half being separated from the head of the tibia by adipose tissue, in which may be found a *bursa*.

The **superior border** is thick, and sloped from behind, downward and forward: it gives attachment to that portion of the Quadriceps extensor which is derived from the Rectus and Crureus muscles. The **lateral borders** are thinner, converging below. They give attachment to that portion of the Quadriceps extensor derived from the external and internal Vasti muscles.

The **apex** is pointed, and gives attachment to the ligamentum patellæ.

Structure.—It consists of a nearly uniform dense cancellous tissue covered by a thin compact lamina. The cancelli immediately beneath the anterior surface are arranged parallel with it. In the rest of the bone they radiate from the posterior articular surface toward the other parts of the bone.

Development.—By a single centre, which makes its appearance, according to Béclard, about the third year. In two instances I have seen this bone cartilaginous throughout, at a much later period (six years). More rarely, the bone is developed by two centres, placed side by side. Ossification is completed about the age of puberty.

Articulations.—With the two condyles of the femur.

Attachment of Muscles.—To four: the Rectus, Crureus, Vastus internus, and Vastus externus. These muscles, joined at their insertion, constitute the Quadriceps extensor cruris.

Surface Form.—The external surface of the patella can be seen and felt in front of the knee. In the extended position of the limb the internal border is a little more prominent than the outer, and if the Quadriceps extensor is relaxed, the bone can be moved from side to side and appears to be loosely fixed. If the joint is flexed, the patella recedes into the hollow between the condyles of the femur and the upper end of the tibia, and becomes firmly fixed against the femur.

Surgical Anatomy.—The main surgical interest about the patella is in connection with fractures; which are of common occurrence. They may be produced by muscular action; that

is to say, by violent contraction of the Quadriceps extensor while the limb is in a position of semi-flexion, so that the bone is snapped across the condyles; or by direct violence, such as falls on the knee. In the former class of cases the fracture is transverse; in the latter it may be oblique, longitudinal, stellate, or the bone variously comminuted. The principal interest in these cases attaches to their treatment. Owing to the wide separation of the fragments, and the difficulty there is in maintaining them in apposition, union takes place by fibrous tissue, and this may subsequently stretch, producing wide separation of the fragments and permanent lameness. Various plans, including opening the joint and suturing the fragments, have been advocated for overcoming this difficulty.

In the larger number of cases of fracture of the patella the knee-joint is involved, the cartilage which covers its posterior surface being also torn. In some cases of fracture from direct violence, however, this need not necessarily happen, the lesion involving only the superficial part of the bone; and, as Morris has pointed out, it is an anatomical possibility, in complete fracture, if the lesion involve only the lower and non-articular part of the bone, for it to take place without injury to the synovial membrane.

The Tibia (Figs. 220, 221).

The **Tibia** (*tibia*, a flute or pipe) is situated at the front and inner side of the leg, and, excepting the femur, is the longest and largest bone in the skeleton. It is prismoid in form, expanded above, where it enters into the knee-joint, more slightly enlarged below. In the male its direction is vertical and parallel with the bone of the opposite side; but in the female it has a slightly oblique direction downward and outward, to compensate for the oblique direction of the femur inward. It presents for examination a shaft and two extremities.

The **Upper Extremity**, or **Head**, is large, and expanded on each side into two lateral eminences, the *tuberosities*. *Superiorly*, the tuberosities present two smooth, concave surfaces, which articulate with the condyles of the femur; the internal, articular surface is longer, deeper, and narrower than the external, oval from before backward, to articulate with the internal condyle; the external one is broader, flatter, and more circular, to articulate with the external condyle. Between the two articular surfaces, and nearer the posterior than the anterior aspect of the bone, is an eminence, the *spinous process* of the tibia, surmounted by a prominent tubercle on each side, which gives attachment to the extremities of the semilunar fibro-cartilages; in front and behind the spinous process is a rough depression for the attachment of the anterior and posterior crucial ligaments and the semilunar fibro-cartilages. The *anterior surfaces* of the tuberosities are continuous with one another, forming a single large surface, which is somewhat flattened: it is triangular, broad above, and perforated by large vascular foramina; narrow below, where it terminates in a prominent oblong elevation of large size, the *tubercle* of the tibia; the lower half of this tubercle is rough, for the attachment of the ligamentum patellæ; the upper half presents a smooth facet supporting, in the recent state, a bursa which separates the ligament from the bone. *Posteriorly* the tuberosities are separated from each other by a shallow depression, the *popliteal notch*, which gives attachment to part of the posterior crucial ligament and part of the posterior ligament of the knee-joint. The *inner tuberosity* presents posteriorly a deep transverse groove, for the insertion of one of the fasciculi of the tendon of the Semi-membranosus. Its *lateral surface* is convex, rough, and prominent: it gives attachment to the internal lateral ligament. The *outer tuberosity* presents posteriorly a flat articular facet, nearly circular in form, directed downward, backward, and outward, for articulation with the fibula. Its lateral surface is convex and rough, more prominent in front than the internal: it presents a prominent rough eminence, situated on a level with the upper border of the tubercle of the tibia, for the attachment of the ilio-tibial band. Just below this the Extensor longus digitorum and a slip from the Biceps are attached.

The **Shaft** of the tibia is of a triangular prismoid form, broad above, gradually decreasing in size to its most slender part, at the commencement of its lower fourth, where fracture most frequently occurs; it then enlarges again toward its lower extremity. It presents for examination three borders and three surfaces.

The **anterior border**, the most prominent of the three, is called the *crest of the*

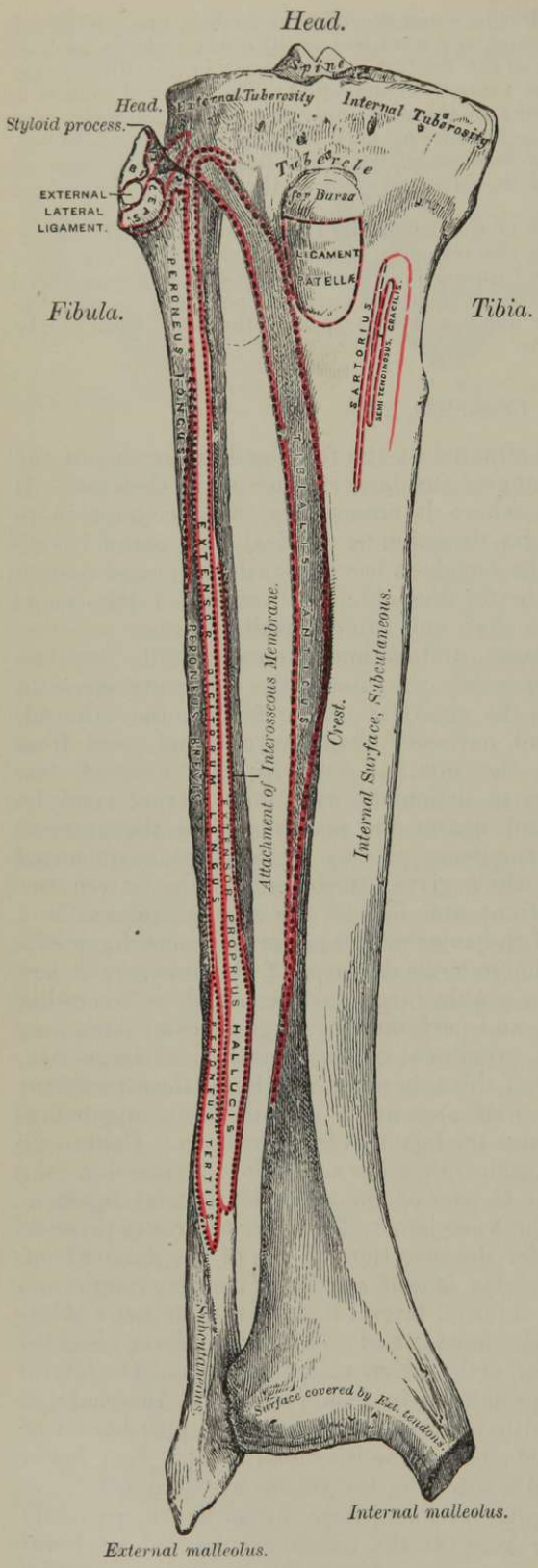

FIG. 220.—Bones of the right leg. Anterior surface.

tibia, or, in popular language, the *shin*; it commences above at the tubercle, and terminates below at the anterior margin of the inner malleolus. This border is very prominent in the upper two-thirds of its extent, smooth and rounded below. It presents a very flexuous course, being usually curved outward above and inward below; it gives attachment to the deep fascia of the leg.

The **internal border** is smooth and rounded above and below, but more prominent in the centre; it commences at the back part of the inner tuberosity, and terminates at the posterior border of the internal malleolus; its upper part gives attachment to the internal lateral ligament of the knee to the extent of about two inches, and to some fibres of the Popliteus muscle; its middle third to some fibres of the Soleus and Flexor longus digitorum muscles.

The **external border, or interosseous ridge,** is thin and prominent, especially its central part, and gives attachment to the interosseous membrane; it commences above in front of the fibular articular facet, and bifurcates below, to form the boundaries of a triangular rough surface, for the attachment of the interosseous ligament connecting the tibia and fibula.

The **internal surface** is smooth, convex, and broader above than below; its upper third, directed forward and inward, is covered by the aponeurosis derived from the tendon of the Sartorius, and by the tendons of the Gracilis and Semitendinosus, all of which are inserted nearly as far forward as the anterior border; in the rest of its extent it is subcutaneous.

The **external surface** is narrower than the internal; its upper two-thirds presents a shallow groove for the attachment of the Tibialis anticus muscle; its lower third is smooth, convex, curves gradually forward to the anterior part of the bone, and is covered from within

outward by the tendons of the following muscles: Tibialis anticus, Extensor proprius hallucis, Extensor longus digitorum.

The **posterior surface** (Fig. 221) presents, at its upper part, a prominent ridge, the *oblique line* of the tibia, which extends from the back part of the articular facet for the fibula obliquely downward, to the internal border, at the junction of its upper and middle thirds. It marks the limit for the insertion of the Popliteus muscle, and serves for the attachment of the popliteal fascia and part of the Soleus, Flexor longus digitorum, and Tibialis posticus muscles; the triangular concave surface, above and to the inner side of this line, gives attachment to the Popliteus muscle. The middle third of the posterior surface is divided by a vertical ridge into two lateral halves: the ridge is well marked at its commencement at the oblique line, but becomes gradually indistinct below; the inner and broader half gives attachment to the Flexor longus digitorum, the outer and narrower to part of the Tibialis posticus. The remaining part of the bone presents a smooth surface covered by the Tibialis posticus, Flexor longus digitorum, and Flexor longus hallucis muscles. Immediately below the oblique line is the medullary foramen, which is directed obliquely downward.

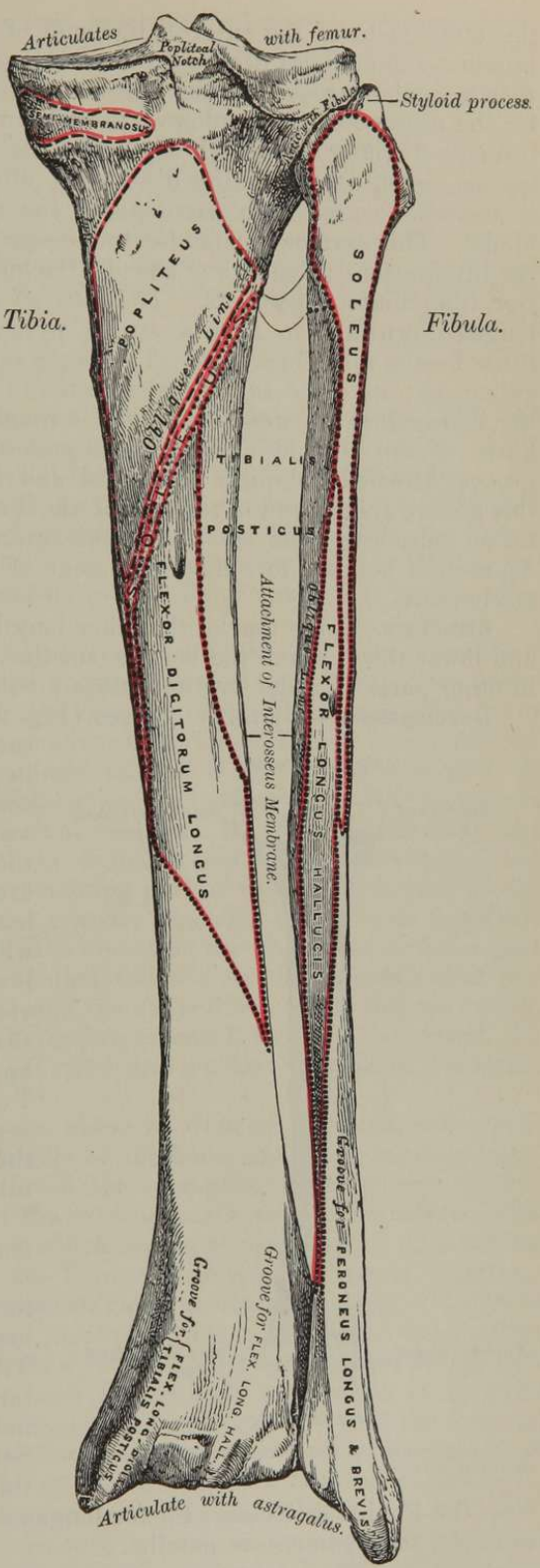

FIG. 221.—Bones of the right leg. Posterior surface.

The **Lower Extremity**, much smaller than the upper, presents five surfaces; it is prolonged downward, on its inner side to a strong process, the *internal malleolus*. The *inferior surface* of the bone is quadrilateral, and smooth for articulation with the astragalus. This surface is concave from before backward, and broader in front than behind. It is traversed from before backward by a slight elevation, separating two lateral depressions. It is narrow internally, where the articular surface becomes continuous with that on the inner malleolus. The *anterior surface* of the lower extremity is smooth and rounded above, and covered by the tendons of the Extensor muscles of the toes; its lower margin presents a rough transverse depression, for

the attachment of the anterior ligament of the ankle-joint; the *posterior surface* presents a superficial groove directed obliquely downward and inward, continuous with a similar groove on the posterior extremity of the astragalus, and serving for the passage of the tendon of the Flexor longus hallucis; the *external surface* presents a triangular rough depression for the attachment of the inferior interosseous ligament connecting it with the fibula; the lower part of this depression is smooth, covered with cartilage in the recent state, and articulates with the fibula. This surface is bounded by two prominent ridges, continuous above with the interosseous ridge; they afford attachment to the anterior and posterior inferior tibio-fibular ligaments. The *internal surface* of the lower extremity is prolonged downward to form a strong pyramidal process, flattened from without inward—the *inner malleolus*. The *inner surface* of this process is convex and subcutaneous; its *outer surface* is smooth and slightly concave, and articulates with the astragalus; its *anterior border* is rough, for the attachment of the anterior fibres of the Deltoid ligament; its *posterior border* presents a broad and deep groove, directed obliquely downward and inward, which is occasionally double: this groove transmits the tendons of the Tibialis posticus and Flexor longus digitorum muscles. The *summit* of the internal malleolus is marked by a rough depression behind, for the attachment of the internal lateral ligament of the ankle-joint.

Structure.—Like that of the other long bones. At the junction of the middle and lower third, where the bone is smallest, the wall of the shaft is thicker than in other parts, in order to compensate for the smallness of the calibre of the bone.

Development.—By *three* centres (Fig. 222): one for the shaft, and one for each extremity. Ossification commences in the centre of the shaft about the seventh week, and gradually extends toward either extremity. The centre for the upper epiphysis appears during the first year; it is flattened in form, and has a thin, tongue-shaped process in front which forms the tubercle. That for the lower epiphysis appears in the second year. The lower epiphysis joins the shaft at about the eighteenth, and the upper one about the twentieth, year. Two additional centres occasionally exist—one for the tongue-shaped process of the upper epiphysis, which forms the tubercle, and one for the inner malleolus.

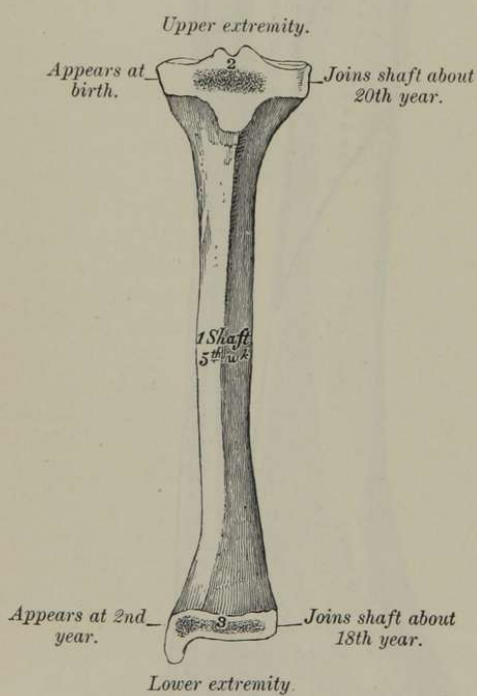

FIG. 222.—Plan of the development of the tibia. By three centres.

Articulations.—With three bones: the femur, fibula, and astragalus.

Attachment of Muscles.—To twelve: to the inner tuberosity, the Semimembranosus; to the outer tuberosity, the Tibialis anticus and Extensor longus digitorum and Biceps; to the shaft, its internal surface, the Sartorius, Gracilis, and Semitendinosus; to its external surface, the Tibialis anticus; to its posterior surface, the Popliteus, Soleus, Flexor longus digitorum, and Tibialis posticus; to the tubercle, the ligamentum patellæ.

Surface Form.—A considerable portion of the tibia is subcutaneous and easily to be felt. At the upper extremity the tuberosities are to be recognized just below the knee. The internal one is broad and smooth, and merges into the subcutaneous surface of the shaft below. The external one is narrower and more prominent, and on it, about midway between the apex of the patella and the head of the fibula, may be felt a prominent tubercle for the insertion of the ilio-

tibial band. In front of the upper end of the bone, between the tuberosities, is the tubercle of the tibia, forming an oval eminence, which is continuous below with the anterior border or crest of the bone. This border can be felt, forming the prominence of the shin, in the upper two-thirds of its extent being sharp and presenting a somewhat flexuous course, being curved outward above and inward below. In the lower third of the leg the border disappears, and the bone is concealed by the tendons of the muscles on the front of the leg. Internal to the anterior border is to be felt the broad internal surface of the tibia, slightly encroached upon by the muscles in front and behind. It commences above at the wide expanded inner tuberosity, and terminates below at the internal malleolus. The internal malleolus is a broad prominence situated on a higher level and somewhat farther forward than the external malleolus. It overhangs the inner border of the arch of the foot. Its anterior border is nearly straight; its posterior border presents a sharp edge, which forms the inner margin of the groove for the tendon of the Tibialis posticus muscle.

The Fibula (Figs. 220, 221).

The **Fibula** (*fibula*, a clasp) is situated at the outer side of the leg. It is the smaller of the two bones, and, in proportion to its length, the most slender of all the long bones; it is placed nearly parallel but behind the level of the tibia. Its upper extremity is small, placed toward the back of the head of the tibia and below the level of the knee-joint, and excluded from its formation; the lower extremity inclines a little forward, so as to be on a plane anterior to that of the upper end, projects below the tibia, and forms the outer ankle. It presents for examination a shaft and two extremities.

The **Upper Extremity,** or **Head,** is of an irregular quadrate form, presenting above a flattened articular facet, directed upward, forward, and inward, for articulation with a corresponding facet on the external tuberosity of the tibia. On the outer side is a thick and rough prominence, continued behind into a pointed eminence, the *styloid process*, which projects upward from the posterior part of the head. The *prominence* gives attachment to the tendon of the Biceps muscle and to the long external lateral ligament of the knee, the ligament dividing the tendon into two parts. The *summit* of the styloid process gives attachment to the short external lateral ligament. The remaining part of the circumference of the head is rough, for the attachment of the anterior superior tibio-fibular ligament, presenting, in front, a tubercle for the attachment of the upper and anterior part of the Peroneus longus; and behind, another tubercle for the attachment of the posterior superior tibio-fibular ligament and the upper fibres of the Soleus muscle.

The **shaft** presents four borders—the antero-external, the antero-internal, the postero-external, and the postero-internal; and four surfaces—anterior, posterior, internal, and external.

The **antero-external border** commences above in front of the head, runs vertically downward to a little below the middle of the bone, and then, curving somewhat outward, bifurcates so as to embrace the triangular subcutaneous surface immediately above the outer surface of the external malleolus. This border gives attachment to an intermuscular septum, which separates the extensor muscles on the anterior surface of the leg from the Peroneus longus and brevis muscles.

The **antero-internal border,** or **interosseous ridge,** is situated close to the inner side of the preceding, and runs nearly parallel with it in the upper third of its extent, but diverges from it so as to include a broader space in the lower two-thirds. It commences above just beneath the head of the bone (sometimes it is quite indistinct for about an inch below the head), and terminates below at the apex of a rough triangular surface immediately above the articular facet of the external malleolus. It serves for the attachment of the interosseous membrane, and separates the extensor muscles in front from the flexor muscles behind.

The **postero-external border** is prominent; it commences above at the base of the styloid process, and terminates below in the posterior border of the outer malleolus. It is directed outward above, backward in the middle of its course, backward and a little inward below, and gives attachment to an aponeurosis which separates the Peronei muscles on the outer surface of the shaft from the flexor muscles on its posterior surface.

The **postero-internal border,** sometimes called the *oblique line*, commences above at the inner side of the head, and terminates by becoming continuous with the antero-internal border or interosseous ridge at the lower fourth of the bone. It is well marked and prominent at the upper and middle parts of the bone. It gives attachment to an aponeurosis which separates the Tibialis posticus from the Soleus above and the Flexor longus hallucis below.

The **anterior surface** is the interval between the antero-external and antero-internal borders. It is extremely narrow and flat in the upper third of its extent; broader and grooved longitudinally in its lower third; it serves for the attachment of three muscles, the Extensor longus digitorum, Peroneus tertius, and Extensor proprius hallucis.

The **external surface** is the space between the antero-external and postero-external borders. It is much broader than the preceding, and often deeply grooved, is directed outward in the upper two-thirds of its course, backward in the lower third, where it is continuous with the posterior border of the external malleolus. This surface is completely occupied by the Peroneus longus and brevis muscles.

The **internal surface** is the interval included between the antero-internal and the postero-internal borders. It is directed inward, and is grooved for the attachment of the Tibialis posticus muscle.

The **posterior surface** is the space included between the postero-external and the postero-internal borders; it is continuous below with the rough triangular surface above the articular facet of the outer malleolus; it is directed backward above, backward and inward at its middle, directly inward below. Its upper third is rough, for the attachment of the Soleus muscle; its lower part presents a triangular rough surface, connected to the tibia by a strong interosseous ligament, and between these two points the entire surface is covered by the fibres of origin of the Flexor longus hallucis muscle. At about the middle of this surface is the nutrient foramen, which is directed downward.

The **Lower Extremity, or external malleolus,** is of a pyramidal form, somewhat flattened from without inward, and is longer, and descends lower than the internal malleolus. Its *external surface* is convex, subcutaneous, and continuous with the triangular (also subcutaneous) surface on the outer side of the shaft. The *internal surface* presents in front a smooth triangular facet, broader above than below, and convex from above downward, which articulates with a corresponding surface on the outer side of the astragalus. Behind and beneath the articular surface is a rough depression which gives attachment to the posterior fasciculus of the external lateral ligament of the ankle. The *anterior border* is thick and rough, and marked below by a depression for the attachment of the anterior fasciculus of the external lateral ligament. The *posterior border* is broad and marked by a shallow groove, for the passage of the tendons of the Peroneus longus and brevis muscles. The *summit* is rounded, and gives attachment to the middle fasciculus of the external lateral ligament.

In order to distinguish the side to which the bone belongs, hold it with the lower extremity downward and the broad groove for the Peronei tendons backward—*i. e.* toward the holder: the triangular subcutaneous surface will then be directed to the side to which the bone belongs.

Articulations.—With two bones: the tibia and astragalus.

Development.—By *three* centres (Fig. 223): one for the shaft, and one for each extremity. Ossification commences in the shaft about the eighth week of fœtal life, a little later than in the tibia, and extends gradually toward the extremities. At birth both ends are cartilaginous. Ossification commences in the lower end in the second year, and in the upper one about the fourth year. The lower epiphysis, the first in which ossification commences, becomes united to the shaft about the twentieth year; the upper epiphysis joins about the twenty-fifth year. Ossification appearing first in the lower epiphysis is contrary to the rule which prevails with regard to the commencement of ossification in epiphyses —viz. that that epiphysis toward which the nutrient artery is directed commences

to ossify last; but it follows the rule which prevails with regard to the union of epiphyses, by uniting first.

Attachment of Muscles.—To nine: to the head, the Biceps, Soleus, and Peroneus longus; to the shaft, its anterior surface, the Extensor longus digitorum, Peroneus tertius, and Extensor proprius hallucis; to the internal surface, the Tibialis posticus; to the posterior surface, the Soleus and Flexor longus hallucis; to the external surface, the Peroneus longus and brevis.

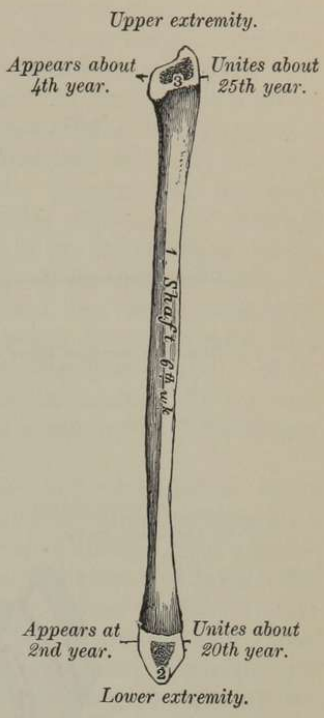

FIG. 223.—Plan of the development of the fibula. By three centres.

Surface Form.—The only parts of the fibula which are to be felt are the head and the lower part of the external surface of the shaft and the external malleolus. The head is to be seen and felt behind and to the outer side of the outer tuberosity of the tibia. It presents a small, prominent triangular eminence slightly above the level of the tubercle of the tibia. The external malleolus presents a narrow elongated prominence, situated on a plane posterior to the internal malleolus and reaching to a lower level. From it may be traced the lower third or half of the external surface of the shaft of the bone in the interval between the Peroneus tertius in front and the other two Peronei tendons behind.

Surgical Anatomy.—In fractures of the bones of the leg both bones are usually fractured, but each bone may be broken separately, the fibula more frequently than the tibia. Fracture of both bones may be caused either by direct or indirect violence. When it occurs from indirect force, the fracture in the tibia is at the junction of the middle and lower third of the bone. Many causes conduce to render this the weakest part of the bone. The fracture of the fibula is usually at rather a higher level. These fractures present great variety, both as regards their direction and condition. They may be oblique, transverse, longitudinal, or spiral. When oblique, they are usually the result of indirect violence, and the direction of the fracture is from behind, downward, forward, and inward in many cases, but may be downward and outward or downward and backward. When transverse, the fracture is often at the upper part of the bone, and is the result of direct violence. The spiral fracture usually commences as a vertical fissure, involving the ankle-joint, and is associated with fracture of the fibula higher up. It is the result of torsion, from twisting of the body whilst the foot is fixed.

Fractures of the tibia alone are almost always the result of direct violence, except where the malleolus is broken off by twists of the foot. Fractures of the fibula alone may arise from indirect or direct force, those of the lower end being usually the result of the former, and those higher up being caused by a direct blow on the part.

The tibia and fibula, like the femur, are frequently the seat of acute necrosis. Chronic abscess is more frequently met with in the cancellous tissue of the head and lower end of the tibia than in any other bone of the body. The abscess is of small size, very chronic, and the result of rarefying osteitis of a localized portion of the cancellous tissue.

The tibia is the bone which is most frequently and most extensively distorted in rickets. It gives way at the junction of the middle and lower third, its weakest part, and presents a curve forward and outward.

THE FOOT (Figs. 224, 225).

The skeleton of the Foot consists of three divisions: the Tarsus, Metatarsus, and Phalanges.

The Tarsus.

The bones of the **Tarsus** are seven in number: viz. the calcaneum or os calcis, astragalus, cuboid, navicular, internal, middle, and external cuneiform bones.

The Calcaneum.

The **Calcaneum,** or **Os Calcis** (*calx*, the heel), is the largest and strongest of the tarsal bones. It is irregularly cuboidal in form, having its long axis directed forward and outward. It is situated at the lower and back part of the foot, serving to transmit the weight of the body to the ground, and forming a strong

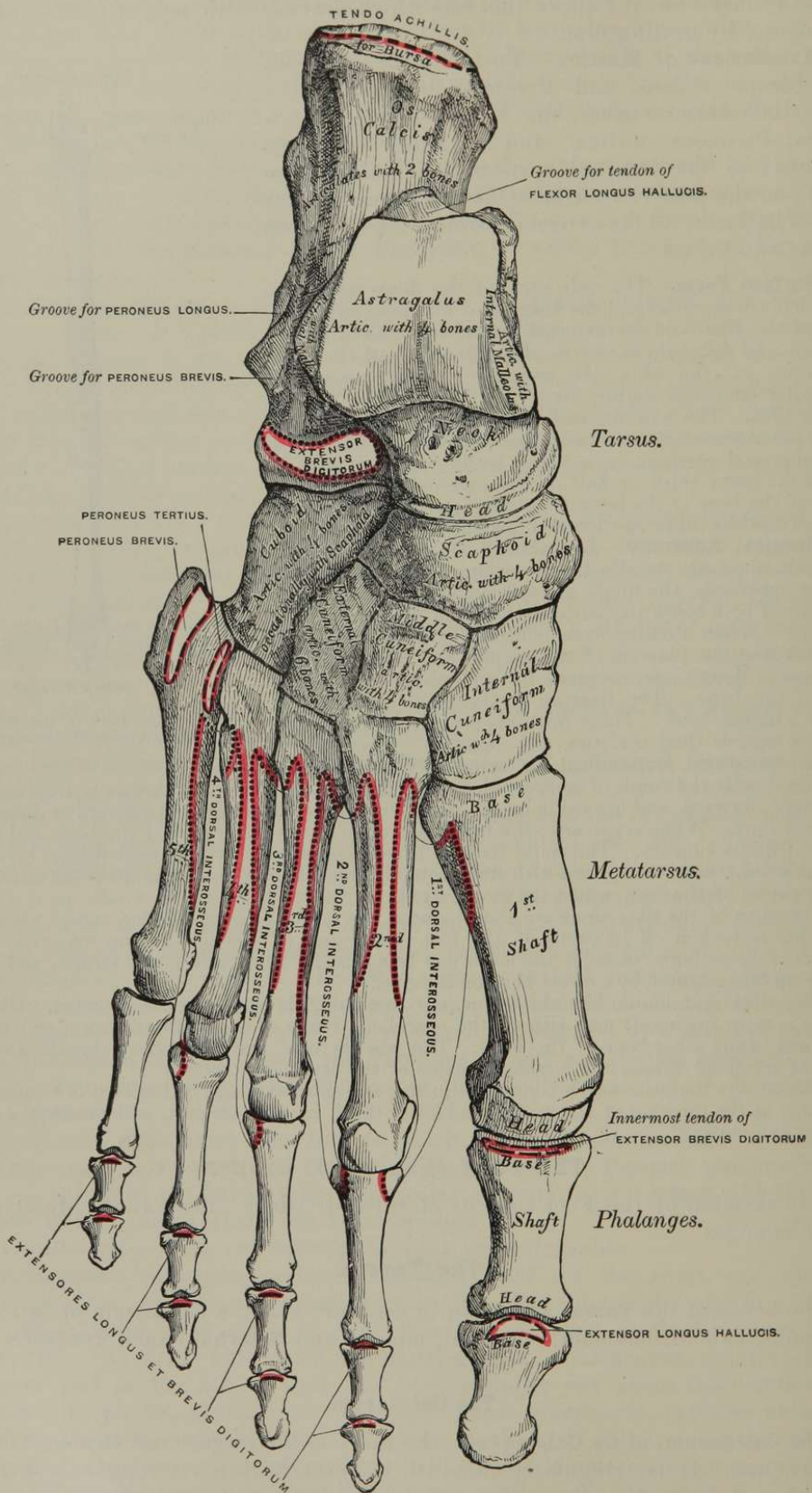

FIG. 224.—Bones of the right foot. Dorsal surface.

lever for the muscles of the calf. It presents for examination six surfaces: superior, inferior, external, internal, anterior, and posterior.

The **superior surface** is formed behind by the upper aspect of that part of the os calcis which projects backward to form the heel. It varies in length in different individuals; is convex from side to side, concave from before backward, and corresponds above to a mass of adipose substance placed in front of the tendo Achillis. In the middle of the superior surface are two (sometimes three) articular facets, separated by a broad shallow groove, which is directed obliquely forward and outward, and is rough for the attachment of the interosseous ligament connecting the astragalus and os calcis. Of the two articular surfaces, the *external* is the larger, and situated on the body of the bone: it is of an oblong form, wider behind than in front, and convex from before backward. The *internal articular surface* is supported on a projecting process of bone, called the *lesser process* of the calcaneum (*sustentaculum tali*); it is also oblong, concave longitudinally, and sometimes subdivided into two parts, which differ in size and shape. More anteriorly is seen the upper surface of the *greater process*, marked by a rough depression for the attachment of numerous ligaments, and a tubercle for the origin of the Extensor brevis digitorum muscle.

The **inferior surface** is narrow, rough, uneven, wider behind than in front and convex from side to side; it is bounded posteriorly by two tubercles separated by a rough depression; the *external*, small, prominent, and rounded, gives attachment to part of the Abductor minimi digiti: the *internal*, broader and larger, for the support of the heel, gives attachment, by its prominent inner margin, to the Abductor hallucis, and in front to the Flexor brevis digitorum muscles; the depression between the tubercles gives attachment to the Abductor minimi digiti and plantar fascia. The rough surface in front of the tubercles gives attachment to the long plantar ligament and to the outer head of the Flexor accessorius muscle; and to a prominent tubercle nearer the anterior part of this surface, as well as to a transverse groove in front of it, is attached the short plantar ligament.

The **external surface** is broad, flat, and almost subcutaneous; it presents near its centre a tubercle, for the attachment of the middle fasciculus of the external lateral ligament. At its upper and anterior part this surface gives attachment to the external calcaneo-astragaloid ligament; and in front of the tubercle it presents a narrow surface marked by two oblique grooves, separated by an elevated ridge which varies much in size in different bones; it is named the *peroneal ridge*, and gives attachment to a fibrous process from the external annular ligament. The *superior groove* transmits the tendon of the Peroneus brevis; the *inferior*, the tendon of the Peroneus longus.

The **internal surface** presents a deep concavity, directed obliquely downward and forward, for the transmission of the plantar vessels and nerves into the sole of the foot; it affords attachment to part of the Flexor accessorius muscle. This surface presents an eminence of bone, the *lesser process* or *sustentaculum tali*, which projects horizontally inward from its upper and fore part, and to which a slip of the tendon of the Tibialis posticus is attached. This process is concave above, and supports the anterior articular surface of the astragalus; below, it is grooved for the tendon of the Flexor longus hallucis. Its free margin is rough, for the attachment of part of the internal lateral ligament of the ankle-joint.

The **anterior surface**, of a somewhat triangular form, articulates with the cuboid. It is concave from above downward and outward, and convex in the opposite direction. Its inner border gives attachment to the inferior calcaneo-navicular ligament.

The **posterior surface** is rough, prominent, convex, and wider below than above. Its lower part is rough, for the attachment of the tendo Achillis and of the Plantaris muscle; its upper part is smooth, and is covered by a bursa which separates the tendon from the bone.

Articulations.—With two bones: the astragalus and cuboid.

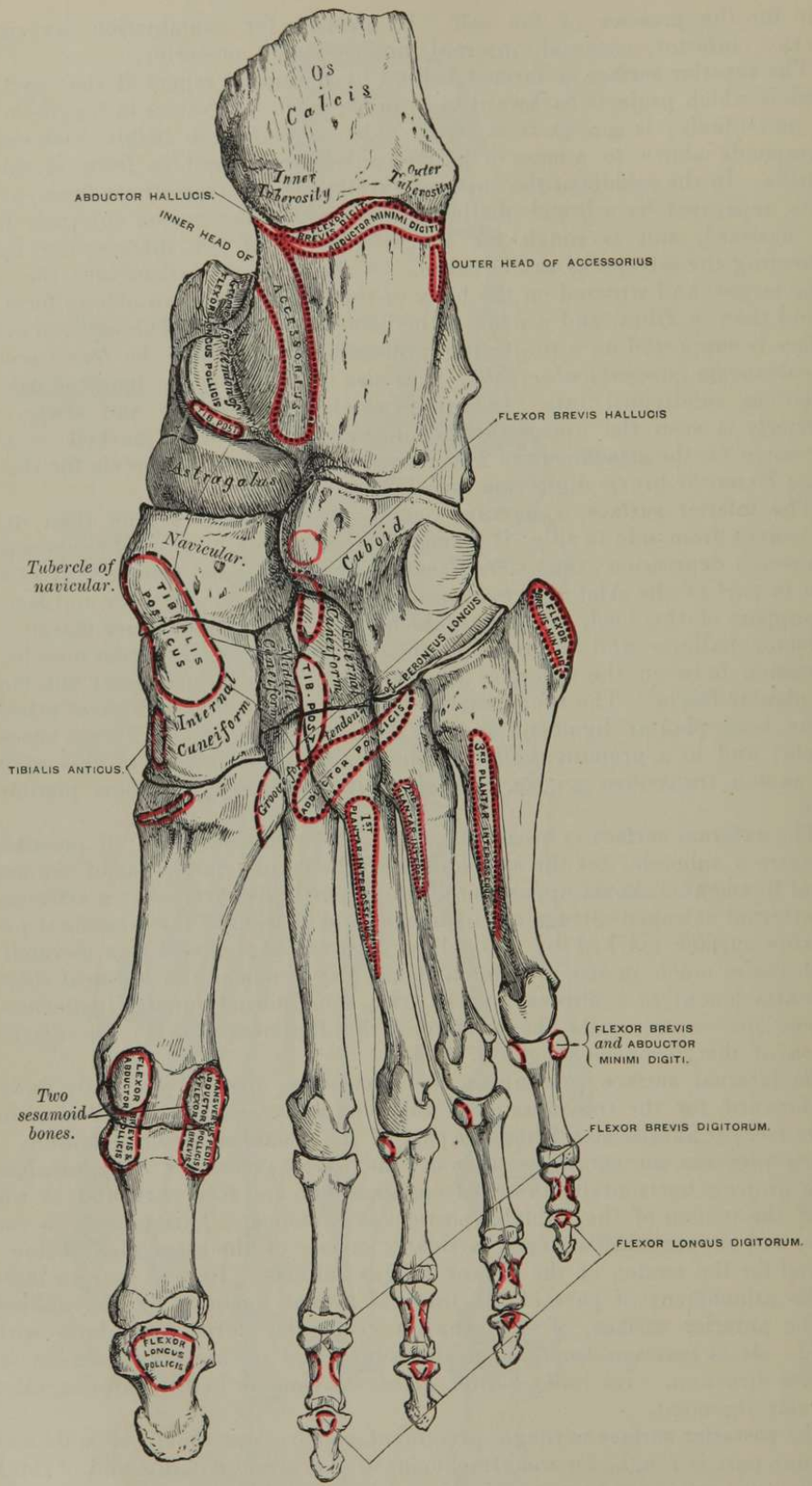

FIG. 225.—Bones of the right foot. Plantar surface.

Attachment of Muscles.—To eight: part of the Tibialis posticus, the tendo

Achillis, Plantaris, Abductor hallucis, Abductor minimi digiti, Flexor brevis digitorum, Flexor accessorius, and Extensor brevis digitorum.

The Astragalus.

The **Astragalus** (*ἀστράγαλος*, a die) is the largest of the tarsal bones, next to the os calcis. It occupies the middle and upper part of the tarsus, supporting the tibia above, articulating with the malleoli on either side, resting below upon the os calcis, and joined in front to the navicular. This bone may easily be recognized by its large rounded head, by the broad articular facet on its upper convex surface, or by the two articular facets separated by a deep groove on its under concave surface. It presents six surfaces for examination.

The **superior surface** presents, behind, a broad smooth trochlear surface for articulation with the tibia. The trochlea is broader in front than behind, convex from before backward, slightly concave from side to side; in front of it is the upper surface of the neck of the astragalus, rough for the attachment of ligaments. The *inferior surface* presents two articular facets separated by a deep groove. The groove runs obliquely forward and outward, becoming gradually broader and deeper in front: it corresponds with a similar groove upon the upper surface of the os calcis, and forms, when articulated with that bone, a canal, filled up in the recent state by the interosseous calcaneo-astragaloid ligament. Of the two articular facets, the posterior is the larger, of an oblong form and deeply concave from side to side; the anterior, although nearly of equal length, is narrower, of an elongated oval form, convex longitudinally, and often subdivided into two by an elevated ridge; of these, the posterior articulates with the lesser process of the os calcis; the anterior, with the upper surface of the inferior calcaneo-navicular ligament. The *internal surface* presents at its upper part a pear-shaped articular facet for the inner malleolus, continuous above with the trochlear surface; below the articular surface is a rough depression, for the attachment of the deep portion of the internal lateral ligament. The *external surface* presents a large triangular facet, concave from above downward for articulation with the external malleolus; it is continuous above with the trochlear surface; and in front of it is a rough depression for the attachment of the anterior fasciculus of the external lateral ligament of the ankle-joint. The *anterior surface*, convex and rounded, forms the *head* of the astragalus; it is smooth, of an oval form, and directed obliquely inward and downward; it articulates with the navicular. On its under surface is a small facet, continuous in front with the articular surface of the head, and behind with the smaller facet for the os calcis. This rests on the inferior calcaneo-navicular ligament, being separated from it by the synovial membrane, which is prolonged from the anterior calcaneo-astragaloid joint to the astragalo-navicular joint. The head is surrounded by a constricted portion, the *neck* of the astragalus. The *posterior surface* is narrow, and traversed by a groove, which runs obliquely downward and inward, and transmits the tendon of the Flexor longus hallucis, external to which is a prominent tubercle, to which the posterior fasciculus of the external lateral ligament is attached. To the inner side of the groove is a second, but less marked tubercle.

To ascertain to which foot the bone belongs, hold it with the broad articular surface upward, and the rounded head forward; the lateral triangular articular surface for the external malleolus will then point to the side to which the bone belongs.

Articulations.—With four bones: tibia, fibula, os calcis, and navicular.

The Cuboid.

The **Cuboid** (*κύβος*, a cube; *εἶδος*, like) bone is placed on the outer side of the foot, in front of the os calcis, and behind the fourth and fifth metatarsal bones. It is of a pyramidal shape, its base being directed upward and inward, its apex downward and outward. It may be distinguished from the other tarsal bones by

the existence of a deep groove on its under surface, for the tendon of the Peroneus longus muscle. It presents for examination six surfaces: three articular and three non-articular.

The **non-articular surfaces** are the superior, inferior, and external. The *superior* or *dorsal surface*, directed upward and outward, is rough, for the attachment of numerous ligaments. The *inferior* or *plantar surface* presents in front a deep groove, which runs obliquely from without, forward and inward; it lodges the tendon of the Peroneus longus, and is bounded behind by a prominent ridge, to which is attached the long calcaneo-cuboid ligament. The ridge terminates externally in an eminence, the *tuberosity of the cuboid*, the surface of which presents a convex facet, for articulation with the sesamoid bone of the tendon contained in the groove. The surface of bone behind the groove is rough, for the attachment of the short plantar ligament, a few fibres of the Flexor brevis hallucis, and a fasciculus from the tendon of the Tibialis posticus. The *external surface*, the smallest and narrowest of the three, presents a deep notch formed by the commencement of the peroneal groove.

The **articular surfaces** are the posterior, anterior, and internal. The *posterior surface* is smooth, triangular, and concavo-convex, for articulation with the anterior surface of the os calcis. The *anterior*, of smaller size, but also irregularly triangular, is divided by a vertical ridge into two facets: the inner one, quadrilateral in form, articulates with the fourth metatarsal bone; the outer one, larger and more triangular, articulates with the fifth metatarsal. The *internal surface* is broad, rough, irregularly quadrilateral, presenting at its middle and upper part a smooth oval facet, for articulation with the external cuneiform bone; and behind this (occasionally) a smaller facet, for articulation with the navicular; it is rough in the rest of its extent, for the attachment of strong interosseous ligaments.

To ascertain to which foot the bone belongs, hold it so that its under surface, marked by the peroneal groove, looks downward, and the large concavo-convex articular surface backward toward the holder: the narrow non-articular surface, marked by the commencement of the peroneal groove, will point to the side to which the bone belongs.

Articulations.—With four bones: the os calcis, external cuneiform, and the fourth and fifth metatarsal bones; occasionally with the navicular.

Attachment of Muscles.—Part of the Flexor brevis hallucis and a slip from the tendon of the Tibialis posticus.

The Navicular.

The **Navicular** or **Scaphoid bone** is situated at the inner side of the tarsus, between the astragalus behind and the three cuneiform bones in front. It may be distinguished by its form, being concave behind, convex and subdivided into three facets in front.

The *anterior surface*, of an oblong form, is convex from side to side, and subdivided by two ridges into three facets, for articulation with the three cuneiform bones. The *posterior surface* is oval, concave, broader externally than internally, and articulates with the rounded head of the astragalus. The *superior surface* is convex from side to side, and rough for the attachment of ligaments. The *inferior* is irregular, and also rough for the attachment of ligaments. The *internal surface* presents a rounded tubercular eminence, the *tuberosity* of the navicular, the lower part of which projects, and gives attachment to part of the tendon of the Tibialis posticus. The *external surface* is rough and irregular, for the attachment of ligamentous fibres, and occasionally presents a small facet for articulation with the cuboid bone.

To ascertain to which foot the bone belongs, hold it with the concave articular surface backward, and the convex dorsal surface upward; the external surface—*i. e.* the surface opposite the tubercle—will point to the side to which the bone belongs.

Articulations.—With four bones: astragalus and three cuneiform; occasionally also with the cuboid.

Attachment of Muscles.—Part of the Tibialis posticus.

The Cuneiform Bones.

The **Cuneiform Bones** have received their name from their wedge-like shape (*cuneus*, a wedge; *forma*, likeness). They form, with the cuboid, the anterior row of the tarsus, being placed between the navicular behind, the three innermost metatarsal bones in front, and the cuboid externally. They are called the *first*, *second*, and *third*, counting from the inner to the outer side of the foot, and, from their position, *internal*, *middle*, and *external*.

The **Internal Cuneiform** is the largest of the three. It is situated at the inner side of the foot, between the navicular behind and the base of the first metatarsal in front. It may be distinguished from the other two by its large size, and its more irregular, wedge-like form. Without the others, it may be known by the large kidney-shaped anterior articulating surface and by the prominence on the inferior or plantar surface for the attachment of the Tibialis posticus. It presents for examination six surfaces.

The *internal surface* is subcutaneous, and forms part of the inner border of the foot; it is broad, quadrilateral, and presents at its anterior inferior angle a smooth oval facet, into which the tendon of the Tibialis anticus is partially inserted; in the rest of its extent it is rough, for the attachment of ligaments. The *external surface* is concave, presenting, along its superior and posterior borders, a narrow reversed L-shaped surface for articulation with the middle cuneiform behind, and second metatarsal bone in front; in the rest of its extent it is rough for the attachment of ligaments and part of the tendon of the Peroneus longus. The *anterior surface*, kidney-shaped, much larger than the posterior, articulates with the metatarsal bone of the great toe. The *posterior surface* is triangular, concave, and articulates with the innermost and largest of the three facets on the anterior surface of the navicular. The *inferior* or *plantar surface* is rough, and presents a prominent tuberosity at its back part for the attachment of part of the tendon of the Tibialis posticus. It also gives attachment in front to part of the tendon of the the Tibialis anticus. The *superior surface* is the narrow-pointed end of the wedge, which is directed upward and outward; it is rough for the attachment of ligaments.

To ascertain to which side the bone belongs, hold it so that its superior narrow edge looks upward, and the long, kidney-shaped, articular surface forward; the external surface, marked by its vertical and horizontal articular facets, will point to the side to which it belongs.

Articulations.—With four bones: navicular, middle cuneiform, first and second metatarsal bones.

Attachment of Muscles.—To three: the Tibialis anticus and posticus, and Peroneus longus.

The **Middle Cuneiform**, the smallest of the three, is of very regular wedge-like form, the broad extremity being placed upward, the narrow end downward. It is situated between the other two bones of the same name, and articulates with the navicular behind and the second metatarsal in front. It may be distinguished from the external cuneiform bone, which it much resembles in general appearance, by the articular facet, of angular form, which runs round the upper and back part of its inner surface; and if the two bones from the same foot are together, the middle cuneiform is much the smaller.

The *anterior surface*, triangular in form and narrower than the posterior, articulates with the base of the second metatarsal bone. The *posterior surface*, also triangular, articulates with the navicular. The *internal surface* presents a reversed L-shaped articular facet, running along the superior and posterior borders, for articulation with the internal cuneiform, and is rough in the rest of its extent for the attachment of ligaments. The *external surface* presents posteriorly a smooth facet for articulation with the external cuneiform bone. The *superior*

surface forms the base of the wedge; it is quadrilateral, broader behind than in front, and rough for the attachment of ligaments. The *inferior surface*, pointed and tubercular, is also rough for ligamentous attachment and for the insertion of a slip from the tendon of the Tibialis posticus.

To ascertain to which foot the bone belongs, hold its superior or dorsal surface upward, the broadest edge being toward the holder: the smooth facet (limited to the posterior border) will then point to the side to which it belongs.

Articulations.—With four bones: navicular, internal and external cuneiform, and second metatarsal bone.

Attachment of Muscles.—A slip from the tendon of the Tibialis posticus is attached to this bone.

The **External Cuneiform**, intermediate in size between the two preceding, is of a very regular wedge-like form, the broad extremity being placed upward, the narrow end downward. It occupies the centre of the front row of the tarsus between the middle cuneiform internally, the cuboid externally, the navicular behind, and the third metatarsal in front. It is distinguished from the internal cuneiform bone by its more regular wedge-like shape and by the absence of the kidney-shaped articular surface: from the middle cuneiform, by the absence of the reversed L-shaped facet, and by the two articular facets which are present on both its inner and outer surfaces. It has six surfaces for examination.

The *anterior surface*, triangular in form, articulates with the third metatarsal bone. The *posterior surface* articulates with the most external facet of the navicular, and is rough below for the attachment of ligamentous fibres. The *internal surface* presents two articular facets, separated by a rough depression; the anterior one, sometimes divided into two, articulates with the outer side of the base of the second metatarsal bone; the posterior one skirts the posterior border and articulates with the middle cuneiform; the rough depression between the two gives attachment to an interosseous ligament. The *external surface* also presents two articular facets, separated by a rough non-articular surface; the anterior facet, situated at the superior angle of the bone, is small, and articulates with the inner side of the base of the fourth metatarsal; the posterior and larger one articulates with the cuboid; the rough, non-articular surface serves for the attachment of an interosseous ligament. The three facets for articulation with the three metatarsal bones are continuous with one another, and covered by a prolongation of the same cartilage; the facets for articulation with the middle cuneiform and navicular are also continuous, but that for articulation with the cuboid is usually separate. The *superior* or *dorsal surface* is of an oblong square form, its posterior external angle being prolonged backward. The *inferior* or *plantar surface* is an obtuse rounded margin, and serves for the attachment of part of the tendon of the Tibialis posticus, part of the Flexor brevis hallucis, and ligaments.

To ascertain to which side the bone belongs, hold it with the broad dorsal surface upward, the prolonged edge backward; the separate articular facet for the cuboid will point to the proper side.

Articulations.—With six bones: the navicular, middle cuneiform, cuboid, and second, third, and fourth metatarsal bones.

Attachment of Muscles.—To two: part of the Tibialis posticus, and Flexor brevis hallucis.

The Metatarsal Bones.

The **Metatarsal Bones** are five in number; they are long bones, and present for examination a shaft and two extremities.

Common Characters.—The *shaft* is prismoid in form, tapers gradually from the tarsal to the phalangeal extremity, and is slightly curved longitudinally, so as to be concave below, slightly convex above. The *posterior extremity*, or *base*, is wedge-shaped, articulating by its terminal surface with the tarsal bones, and by its lateral surfaces with the contiguous metatarsal bones, its dorsal and plantar surfaces being rough for the attachment of ligaments. The *anterior extremity*,

or *head*, presents a terminal rounded articular surface, oblong from above downward and extending farther backward below than above. Its sides are flattened, and present a depression, surmounted by a tubercle, for ligamentous attachment. Its under surface is grooved in the middle line for the passage of the Flexor tendon, and marked on each side by an articular eminence continuous with the terminal articular surface.

Peculiar Characters.—The **First** is remarkable for its great thickness, but is the shortest of all the metatarsal bones. The *shaft* is strong and of well-marked prismoid form. The *posterior extremity* presents at times a lateral articular facet for the second metatarsal; its terminal articular surface is of large size, kidney-shaped; its circumference is grooved, for the tarso-metatarsal ligaments, and internally gives attachment to part of the tendon of the Tibialis anticus: its inferior angle presents a rough oval prominence for the insertion of the tendon of the Peroneus longus. The *head* is of large size; on its plantar surface are two grooved facets, over which glide sesamoid bones; the facets are separated by a smooth elevated ridge.

This bone is known by the single kidney-shaped articular surface on its base, the deeply grooved appearance of the plantar surface of its head, and its great thickness relatively to its length. When it is placed in its natural position, the concave border of the kidney-shaped articular surface on its base points to the side to which the bone belongs.

The **Second** is the longest and largest of the remaining metatarsal bones, being prolonged backward into the recess formed between the three cuneiform bones. Its *tarsal extremity* is broad above, narrow and rough below. It presents four articular surfaces: one behind, of a triangular form, for articulation with the middle cuneiform; one at the upper part of its internal lateral surface, for articulation with the internal cuneiform: and two on its external lateral surface, a posterior and anterior, separated by a vertical ridge. Each of these external articular surfaces is divided by a rough depression into two parts; the two anterior facets articulate with the third metatarsal; the two posterior (sometimes continuous) with the external cuneiform. Occasionally, in front of and below the facet for the internal cuneiform, is found an indistinct facet for the first metatarsal.

The facets on the tarsal extremity of the second metatarsal bone serve at once to distinguish it from the rest, and to indicate the foot to which it belongs. The fact that the two posterior subdivisions of the external facets sometimes run into one should not be forgotten.

The **Third** articulates behind, by means of a triangular smooth surface, with the external cuneiform; on its inner side, by two facets, with the second metatarsal; and on its outer side, by a single facet, with the fourth metatarsal. The latter facet is of circular form and situated at the upper angle of the base.

The third metatarsal is known by its having at its tarsal end two undivided facets on the inner side, and a single facet on the outer. This distinguishes it from the second metatarsal, in which the two facets, found on one side of its tarsal end, are each subdivided into two. The single facet (when the bone is put in its natural position) is on the side to which the bone belongs.

The **Fourth** is smaller in size than the preceding; its *tarsal extremity* presents a terminal quadrilateral surface, for articulation with the cuboid; a smooth facet on the inner side, divided by a ridge into an anterior portion for articulation with the third metatarsal, and a posterior portion for articulation with the external cuneiform; on the outer side a single facet, for articulation with the fifth metatarsal.

The fourth metatarsal is known by its having a single facet on either side of the tarsal extremity, that on the inner side being divided into two parts. If this subdivision be not recognizable, the fact that its tarsal end is bent somewhat outward will indicate the side to which it belongs.

The **Fifth** is recognized by the tubercular eminence on the outer side of its base. It articulates behind, by a triangular surface cut obliquely from without inward, with the cuboid, and internally with the fourth metatarsal.

The projection on the outer side of this bone at its tarsal end at once distinguishes it from the others, and points to the side to which it belongs.

Articulations.—Each bone articulates with the tarsal bones by one extremity, and by the other with the first row of phalanges. The number of tarsal bones with which each metatarsal articulates is one for the first, three for the second, one for the third, two for the fourth, and one for the fifth.

Attachment of Muscles.—To the first metatarsal bone, three: part of the Tibialis anticus, the Peroneus longus, and First dorsal interosseous. To the second, four: the Adductor obliquus hallucis and First and Second dorsal interosseous, and a slip from the tendon of the Tibialis posticus, and occasionally a slip from the Peroneus longus. To the third, five: the Adductor obliquus hallucis, Second and Third dorsal, and First plantar interosseous, and a slip from the tendon of the Tibialis posticus. To the fourth, five: the Adductor obliquus hallucis, Third and Fourth dorsal, and Second plantar interosseous, and a slip from the tendon of the Tibialis posticus. To the fifth, six: the Peroneus brevis, Peroneus tertius, Flexor brevis minimi digiti, Adductor transversus hallucis, Fourth dorsal, and Third plantar interosseous.

The Phalanges.

The **Phalanges** of the foot, both in number and general arrangement, resemble those in the hand; there being two in the great toe and three in each of the other toes.

The phalanges of the *first row* resemble closely those of the hand. The *shaft* is compressed from side to side, convex above, concave below. The *posterior extremity* is concave; and the *anterior extremity* presents a trochlear surface, for articulation with the second phalanges.

The phalanges of the *second row* are remarkably small and short, but rather broader than those of the first row.

The *ungual* phalanges in form resemble those of the fingers; but they are smaller, flattened from above downward, presenting a broad base for articulation with the second row, and an expanded extremity for the support of the nail and end of the toe.

Articulation.—The first row, with the metatarsal bones behind and second phalanges in front; the second row of the four outer toes, with the first and third phalanges; of the great toe, with the first phalanx; the third row of the four outer toes, with the second phalanges.

Attachment of Muscles.—To the first phalanges. Great toe, five muscles: innermost tendon of Extensor brevis digitorum, Abductor hallucis, Adductor obliquus hallucis, Flexor brevis hallucis, Adductor transversus hallucis. Second toe, three muscles: First and Second dorsal interosseous and First lumbrical. Third toe, three muscles: Third dorsal and First plantar interosseous and Second lumbrical. Fourth toe, three muscles: Fourth dorsal and Second plantar interosseous and Third lumbrical. Fifth toe, four muscles: Flexor brevis minimi digiti, Abductor minimi digiti, and Third plantar interosseous, and Fourth lumbrical.—Second phalanges. Great toe; Extensor longus hallucis, Flexor longus hallucis. Other toes; Flexor brevis digitorum, one slip of the common tendon of the Extensor longus and brevis digitorum.[1]—Third phalanges: two slips from the common tendon of the Extensor longus and Extensor brevis digitorum, and the Flexor longus digitorum.

Development of the Foot (Fig. 226).

The **Tarsal bones** are each developed by a single centre, excepting the os calcis, which has an epiphysis for its posterior extremity. The centres make their appearance in the following order: os calcis, at the sixth month of fœtal life; astragalus,

[1] Except the second phalanx of the fifth toe, which receives no slip from the Extensor brevis digitorum.

about the seventh month; cuboid, at the ninth month; external cuneiform, during the first year; internal cuneiform in the third year; middle cuneiform and navicular in the fourth year. The epiphysis for the posterior tuberosity of

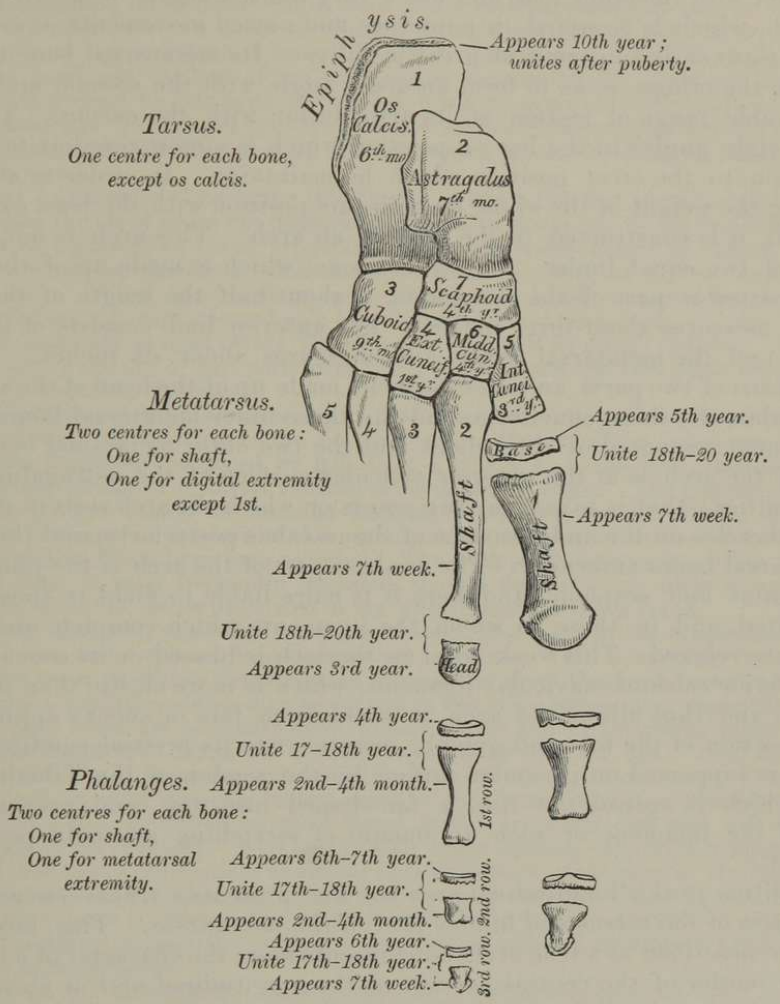

FIG. 226.—Plan of the development of the foot.

the os calcis appears at the tenth year, and unites with the rest of the bone soon after puberty.

The **Metatarsal bones** are each developed by *two* centres: one for the shaft and one for the digital extremity in the four outer metatarsal; one for the shaft and one for the base in the metatarsal bone of the great toe.[1] Ossification commences in the centre of the shaft about the ninth week, and extends toward either extremity. The centre in the proximal end of the first metatarsal bone appears about the third year, the centre in the distal end of the other bones between the fifth and eighth years; they become joined between the eighteenth and twentieth years.

The **Phalanges** are developed by *two* centres for each bone: one for the shaft and one for the metatarsal extremity.

Construction of the Foot as a Whole.

The foot is constructed on the same principles as the hand, but modified to form a firm basis of support for the rest of the body when in the erect position. It

[1] As was noted in the first metacarpal bone, so in the first metatarsal, there is often to be observed a tendency to the formation of a second epiphysis in the distal extremity. (See footnote, p. 274).

is more solidly constructed, and its component parts are less movable on each other than in the hand. This is especially the case with the great toe, which has to assist in supporting the body, and is therefore constructed with greater solidity; it lies parallel with the other toes, and has a very limited degree of mobility, whereas the thumb, which is occupied in numerous and varied movements, is constructed in such a manner as to permit of great mobility. Its metacarpal bone is directed away from the others, so as to form an acute angle with the second, and it enjoys a considerable range of motion at its articulation with the carpus. The foot is placed at right angles to the leg—a position which is almost peculiar to man, and has relation to the erect position which he maintains. In order to allow of its supporting the weight of the whole body in this position with the least expenditure of material, it is constructed in the form of an arch. This arch is not, however, made up of two equal limbs. The hinder one, which is made up of the os calcis and the posterior part of the astragalus, is about half the length of the anterior limb, and measures about three inches. The anterior limb consists of the rest of the tarsal and the metatarsal bones, and measures about six inches. It may be said to consist of two parts, an inner segment made up of the head of the astragalus, the navicular, the three cuneiform, and the three inner metatarsal bones; and an outer segment composed of the cuboid and the two outer metatarsal bones. The summit of the arch is at the superior articular surface of the astragalus; and its two extremities—that is to say, the two points on which the arch rests in standing—are the tubercles on the under surface of the os calcis posteriorly, and the heads of the metatarsal bones anteriorly. The weakest part of the arch is the joint between the astragalus and scaphoid, and here it is more liable to yield in those who are overweighted, and in those in whom the ligaments which complete and preserve the arch are relaxed. This weak point in the arch is braced on its concave surface by the inferior calcaneo-navicular ligament, which is more elastic than most other ligaments, and thus allows the arch to yield from jars or shocks applied to the anterior portion of the foot and quickly restores it to its pristine condition. This ligament is supported on its under surface by the tendon of the Tibialis posticus muscle, which is spread out into a fan-shaped insertion, and prevents undue tension of the ligament or such an amount of stretching as would permanently elongate it.

In addition to this longitudinal arch the foot presents a transverse arch, at the anterior part of the tarsus and hinder part of the metatarsus. This, however, can scarcely be described as a true arch, but presents more the character of a half-dome. The inner border of the central portion of the longitudinal arch is elevated from the ground, and from this point the bones arch over to the outer border, which is in contact with the ground, and, assisted by the longitudinal arch, produce a sort of rounded niche on the inner side of the foot, which gives the appearance of a transverse as well as a longitudinal arch.

The arch of the foot, from the point of the heel to the toes, is not quite straight, but is directed a little outward, so that the inner border is a little convex and the outer border concave. This disposition of the bones becomes more marked when the longitudinal arch of the foot is lost, as in the disease known under the name of "flat-foot."

Surface Form.—On the dorsum of the foot the individual bones are not to be distinguished with the exception of the head of the astragalus, which forms a rounded projection in front of the ankle-joint when the foot is forcibly extended. The whole surface forms a smooth convex outline, the summit of which is the ridge formed by the head of the astragalus, the navicular, the middle cuneiform, and the second metatarsal bones; from this it gradually inclines outward and more rapidly inward. On the inner side of the foot, the internal tuberosity of the os calcis and the ridge separating the inner from the posterior surface of the bone may be felt most posteriorly. In front of this, and below the internal malleolus, may be felt the projection of the sustentaculum tali. Passing forward is the well-marked tuberosity of the navicular bone, situated about an inch or an inch and a quarter in front of the internal malleolus. Further toward the front, the ridge formed by the base of the first metatarsal bone can be obscurely felt, and from this the shaft of the bone can be traced to the expanded head articulating with the base of the first phalanx of the great toe. Immediately beneath the base of this phalanx, the

internal sesamoid bone is to be felt. Lastly, the expanded ends of the bones forming the last joint of the great toe are to be felt. On the outer side of the foot the most posterior bony point is the outer tuberosity of the os calcis, with the ridge separating the posterior from the outer surface of the bone. In front of this the greater part of the external surface of the os calcis is subcutaneous; on it, below and in front of the external malleolus, may be felt the peroneal ridge, when this process is present. Farther forward, the base of the fifth metatarsal bone forms a prominent and well-defined landmark, and in front of this the shaft of the bone, with its expanded head, and the base of the first phalanx may be defined. The sole of the foot is almost entirely covered by soft parts, so that but few bony parts are to be made out, and these somewhat obscurely. The hinder part of the under surface of the os calcis and the heads of the metatarsal bones, with the exception of the first, which is concealed by the sesamoid bones, may be recognized.

Surgical Anatomy.—Considering the injuries to which the foot is subjected, it is surprising how seldom the tarsal bones are fractured. This is no doubt due to the fact that the tarsus is composed of a number of bones, articulated by a considerable extent of surface and joined together by very strong ligaments, which serve to break the force of violence applied to this part of the body. When fracture does occur, these bones, being composed for the most part of a soft cancellous structure, covered only by a thin shell of compact tissue, are often extensively comminuted, especially as most of the fractures are produced by direct violence. And having only a very scanty amount of soft parts over them, the fractures are very often compound, and amputation is frequently necessary.

When fracture occurs in the anterior group of tarsal bones, it is almost invariably the result of direct violence; but fractures of the posterior group, that is, of the calcaneum and astragalus, are most frequently produced by falls from a height on to the feet; though fracture of the os calcis may be caused by direct violence or by muscular action. The posterior part of the bone, that is, the part behind the articular surfaces, is almost always the seat of the fracture, though some few cases of fracture of the sustentaculum tali and of vertical fracture between the two articulating facets have been recorded. The neck of the astragalus, being the weakest part of the bone, is most frequently fractured, though fractures may occur in any part and almost in any direction, either associated or not with fracture of other bones.

In cases of club-foot, especially in congenital cases, the bones of the tarsus become altered in shape and size, and displaced from their proper positions. This is especially the case in congenital equino-varus, in which the astragalus, particularly about the head, becomes twisted and atrophied, and a similar condition may be present in the other bones, more especially the navicular. The tarsal bones are peculiarly liable to become the seat of tubercular caries from comparatively trivial injuries. There are several reasons to account for this. They are composed of a delicate cancellated structure, surrounded by intricate synovial membranes. They are situated at the farthest point from the central organ of the circulation and exposed to vicissitudes of temperature; and, moreover, on their dorsal surface are thinly clad with soft parts which have but a scanty blood-supply. And finally, after slight injuries, they are not maintained in a condition of rest to the same extent as similar injuries in some other parts of the body. Caries of the calcaneum and astragalus may remain limited to the one bone for a long period, but when one of the other bones is affected, the remainder frequently become involved, in consequence of the disease spreading through the large and complicated synovial membrane which is more or less common to these bones.

Amputation of the whole or a part of the foot is frequently required either for injury or disease. The principal amputations are as follow: (1) Syme's: amputation at the ankle-joint by a heel-flap, with removal of the malleoli and sometimes a thin slice from the lower end of the tibia. (2) Roux's: amputation at the ankle-joint by a large internal flap. (3) Pirogoff's amputation: removal of the whole of the tarsal bones, except the posterior part of the os calcis and a thin slice from the tibia and fibula including the two malleoli. The sawn surface of the os calcis is then turned up and united to the similar surface of the tibia. (4) Subastragaloid amputation: removal of the foot below the astragalus through the joint between it and the os calcis. This operation has been modified by Hancock, who leaves the posterior third of the os calcis and turns it up against the denuded surface of the astragalus. This latter operation is of doubtful utility and is rarely performed. (5) Chopart's or medio-tarsal: removal of the anterior part of the foot with all the tarsal bones except the os calcis and astragalus; disarticulation being effected through the joints between the scaphoid and cuboid in front, and the astragalus and os calcis behind. (6) Lisfranc's: amputation of the anterior part of the foot through the tarso-metatarsal joints. This has been modified by Hey, who disarticulated through the joints of the four outer metatarsal bones with the tarsus, and sawed off the projecting internal cuneiform; and by Skey, who sawed off the base of the second metatarsal bone and disarticulated the others.

The bones of the tarsus occasionally require removal individually. This is especially the case with the astragalus and os calcis for disease limited to the one bone, or again the astragalus may require excision in cases of subastragaloid dislocation, or, as recommended by Mr. Lund, in cases of inveterate talipes. The cuboid has been removed for the same reason by Mr. Solly. But both these two latter operations have fallen very much into disuse, and have been superseded by resection of a wedge-shaped piece of bone from the outer side of the tarsus. Finally, Mickulicz and Watson have devised operations for the removal of more extensive portions of the tarsus. Mickulicz's operation consists in the removal of the os calcis and astragalus, along

with the articular surfaces of the tibia and fibula, and also of the scaphoid and cuboid. The remaining portion of the tarsus is then brought into contact with the sawn surfaces of the tibia and fibula, and fixed there. The result is a position of the shortened foot resembling talipes equinus. Watson's operation is adapted to those cases where the disease is confined to the anterior tarsal bones. By two lateral incisions he saws through the bases of the metatarsal bones in front and opens up the joints between the scaphoid and astragalus, and the cuboid and os calcis, and removes the intervening bones.

The metatarsal bones and phalanges are nearly always broken by direct violence, and in the majority of cases the injury is the result of severe crushing accidents, necessitating amputation. The metatarsal bones and especially the one of the great toe, are frequently diseased, either in tubercular subjects or in perforating ulcer of the foot.

Sesamoid Bones.

These are small rounded masses, cartilaginous in early life, osseous in the adult, which are developed in those tendons which exert a great amount of pressure upon the parts over which they glide. It is said that they are more commonly found in the male than in the female, and in persons of an active muscular habit than in those who are weak and debilitated. They are invested throughout their whole surface by the fibrous tissue of the tendon in which they are found, excepting upon that side which lies in contact with the part over which they play, where they present a free articular facet. They may be divided into two kinds: those which glide over the articular surfaces of joints, and those which play over the cartilaginous facets found on the surfaces of certain bones.

The sesamoid bones of the joints in the upper extremity, are two on the palmar surface of the metacarpo-phalangeal joint in the thumb, developed in the tendons of the Flexor brevis pollicis; occasionally one or two opposite the metacarpo-phalangeal articulations of the fore and little fingers; and, still more rarely, one opposite the same joints of the third and fourth fingers. In the lower extremity, the patella, which is developed in the tendon of the Quadriceps extensor; two small sesamoid bones, found in the tendons of the Flexor brevis hallucis, opposite the metatarso-phalangeal joint of the great toe; and occasionally one in the metatarso-phalangeal joint of the second toe, the little toe, and, still more rarely, the third and fourth toes.

Those found in the tendons which glide over certain bones occupy the following situations: one sometimes found in the tendon of the Biceps cubiti, opposite the tuberosity of the radius: one in the tendon of the Peroneus longus, where it glides through the groove in the cuboid bone; one appears late in life in the tendon of the Tibialis anticus, opposite the smooth facet of the internal cuneiform bone; one is found in the tendon of the Tibialis posticus, opposite the inner side of the head of the astragalus; one in the outer head of the Gastrocnemius, behind the outer condyle of the femur; and one in the conjoined tendon of the Psoas and Iliacus, where it glides over the os pubis. Sesamoid bones are found occasionally in the tendon of the Gluteus maximus, as it passes over the great trochanter, and in the tendons which wind round the inner and outer malleoli.

THE ARTICULATIONS.

THE various bones of which the Skeleton consists are connected together at different parts of their surfaces, and such a connection is designated by the name of *Joint* or *Articulation*. If the joint is *immovable*, as between the cranial and most of the facial bones, the adjacent margins of the bones are applied in almost close contact, a thin layer of fibrous membrane, the *sutural ligament*, and, at the base of the skull, in certain situations, a thin layer of cartilage, being interposed. Where slight movement is required, combined with great strength, the osseous surfaces are united by tough and elastic fibro-cartilages, as in the joints between the bodies of the vertebræ and interpubic articulations; but in the *movable* joints the bones forming the articulation are generally expanded at the ends for greater convenience of mutual connection, covered by *cartilage*, held together by strong bands or capsules of fibrous tissue called *ligaments*, and partially lined by a membrane, the *synovial membrane*, which secretes a fluid to lubricate the various parts of which the joint is formed; so that the structures which enter into the formation of a joint are bone, cartilage, fibro-cartilage, ligament, and synovial membrane.

Bone constitutes the fundamental element of all the joints. In the long bones the extremities are the parts which form the articulations; they are generally somewhat enlarged, consisting of spongy cancellous tissue, with a thin coating of compact substance. In the flat bones the articulations usually take place at the edges, and, in the short bones at various parts of their surface. The layer of compact bone which forms the articular surface, and to which the cartilage is attached, is called the *articular lamella*. It is of a white color, extremely dense, and varies in thickness. Its structure differs from ordinary bone-tissue in this respect, that it contains no Haversian canals, and its lacunæ are much larger than in ordinary bone and have no canaliculi. The vessels of the cancellous tissue, as they approach the articular lamella, turn back in loops, and do not perforate it; this layer is consequently more dense and firmer than ordinary bone, and is evidently designed to form a firm and unyielding support for the articular cartilage.

The **cartilage,** which covers the articular surfaces of bone, and is called the *articular*, will be found described, with the other varieties of cartilage, in the section on General Anatomy (page 51).

Ligaments consist of bands of various forms, serving to connect together the articular extremities of bones, and composed mainly of bundles of *white fibrous tissue* placed parallel with, or closely interlaced with, one another, and presenting a white, shining, silvery aspect. A ligament is pliant and flexible, so as to allow of the most perfect freedom of movement, but strong, tough, and inextensile, so as not readily to yield under the most severely applied force; it is consequently well adapted to serve as the connecting medium between the bones. Some ligaments consist entirely of *yellow elastic tissue*, as the ligamenta subflava, which connect together the adjacent arches of the vertebræ and the ligamentum nuchæ in the lower animals. In these cases it will be observed that the elasticity of the ligament is intended to act as a substitute for muscular power.

Synovial membrane is a thin, delicate membrane of connective tissue, with branched connective-tissue corpuscles. Its secretion is thick, viscid, and glairy, like the white of egg, and is hence termed *synovia*. The synovial membranes found in the body admit of subdivision into three kinds—articular, bursal, and vaginal.

The *articular synovial membranes* are found in all the freely movable joints. In the fœtus this membrane is said, by Toynbee, to be continued over the surface

of the cartilages; but in the adult it is wanting, excepting at their circumference, upon which it encroaches for a short distance, and to which it is firmly attached; it then invests the inner surface of the capsular or other ligaments enclosing the joint, and is reflected over the surface of any tendons passing through its cavity, as the tendon of the Popliteus in the knee and the tendon of the Biceps in the shoulder. Hence the articular synovial membrane may be regarded as a short wide tube, attached by its open ends to the margins of the articular cartilages, and covering the inner surface of the various ligaments which connect the articular surfaces, so that along with the cartilages it completely encloses the joint-cavity. In some of the joints the synovial membrane is thrown into folds, which pass across the cavity. They are called *synovial ligaments*, and are especially distinct in the knee. In other joints there are flattened folds, subdivided at their margins into fringe-like processes, the vessels of which have a convoluted arrangement. These latter generally project from the synovial membrane near the margin of the cartilage and lie flat upon its surface. They consist of connective tissue covered with endothelium, and contain fat-cells in variable quantities, and, more rarely, isolated cartilage-cells. The larger folds often contain considerable quantities of fat. They were described by Clopton Havers as *mucilaginous glands*, and as the source of the synovial secretion. Under certain diseased conditions similar processes are found covering the entire surface of the synovial membrane, forming a mass of pedunculated fibro-fatty growths which project into the joint. Similar structures are also found in some of the bursal and vaginal synovial membranes.

The *bursal synovial membranes* are found interposed between surfaces which move upon each other, producing friction, as in the gliding of a tendon or of the integument over projecting bony surfaces. They admit of subdivision into two kinds, the *bursæ mucosæ* and the *bursæ synoviæ*. The *bursæ mucosæ* are large, simple, or irregular cavities in the subcutaneous areolar tissue, enclosing a clear viscid fluid. They are found in various situations, as between the integument and the front of the patella, over the olecranon, the malleoli, and other prominent parts. The *bursæ synoviæ* are found interposed between muscles or tendons as they play over projecting bony surfaces, as between the Glutei muscles and the surface of the great trochanter. They consist of a thin wall of connective tissue, partially covered by patches of cells, and contain a viscid fluid. Where one of these exists in the neighborhood of a joint, it usually communicates with its cavity, as is generally the case with the bursa between the tendon of the Psoas and Iliacus and the capsular ligament of the hip, or the one interposed between the under surface of the Subscapularis and the neck of the scapula.

The *vaginal synovial membranes* (*synovial sheaths*) serve to facilitate the gliding of tendons in the osseo-fibrous canals through which they pass. The membrane is here arranged in the form of a sheath, one layer of which adheres to the wall of the canal, and the other is reflected upon the surface of the contained tendon, the space between the two free surfaces of the membrane being partially filled with synovia. These sheaths are chiefly found surrounding the tendons of the flexor and extensor muscles of the fingers and toes as they pass through the osseo-fibrous canals in the hand or foot.

Synovia is a transparent, yellowish-white or slightly reddish fluid, viscid like the white of egg, having an alkaline reaction and slightly saline taste. It consists, according to Frerichs, in the ox, of 94.85 water, 0.56 mucus and epithelium, 0.07 fat, 3.51 albumen and extractive matter, and 0.99 salts.

The articulations are divided into three classes: *synarthrosis*, or immovable; *amphiarthrosis*, or mixed; and *diarthrosis*, or movable joints.

1. Synarthrosis. Immovable Articulations.

Synarthrosis includes all those articulations in which the surfaces of the bones are in almost direct contact, fastened together by an intervening mass of connective tissue, and in which there is no appreciable motion, as the joints between the bones

of the cranium and face, excepting those of the lower jaw. The varieties of synarthrosis are four in number: Sutura, Schindylesis, Gomphosis, and Synchondrosis.

Sutura (a seam) is that form of articulation where the contiguous margins of flat bones are united by a thin layer of fibrous tissue. It is met with only in the skull. Where the articulating surfaces are connected by a series of processes and indentations interlocked together, it is termed *sutura vera*, of which there are three varieties: sutura dentata, serrata, and limbosa. The surfaces of the bones are not in direct contact, being separated by a layer of membrane continuous externally with the pericranium, internally with the dura mater. The *sutura dentata* (*dens*, a tooth) is so called from the tooth-like form of the projecting articular processes, as in the suture between the parietal bones. In the *sutura serrata* (*serra*, a saw) the edges of the two bones forming the articulation are serrated like the teeth of a fine saw, as between the two portions of the frontal bone. In the *sutura limbosa* (*limbus*, a selvage), besides the dentated processes, there is a certain degree of bevelling of the articular surfaces, so that the bones overlap one another, as in the suture between the parietal and frontal bones. When the articulation is formed by roughened surfaces placed in apposition with one another, it is termed the *false suture* (*sutura notha*), of which there are two kinds: the *sutura squamosa* (*squama*, a scale), formed by the overlapping of two contiguous bones by broad bevelled margins, as in the squamo-parietal (squamous) suture; and the *sutura harmonia* (ἁρμονία, a joining together), where there is simple apposition of two contiguous rough bony surfaces, as in the articulation between the two superior maxillary bones or of the horizontal plates of the palate bones.

Schindylesis (σχινδύλησις, a fissure) is that form of articulation in which a thin plate of bone is received into a cleft or fissure formed by the separation of two laminæ in another bone, as in the articulation of the rostrum of the sphenoid and perpendicular plate of the ethmoid with the vomer, or in the reception of the latter in the fissure between the superior maxillary and palate bones.

Gomphosis (γόμφος, a nail) is an articulation formed by the insertion of a conical process into a socket, as a nail is driven into a board; this is not illustrated by any articulation between bones, properly so called, but is seen in the articulation of the teeth with the alveoli of the maxillary bones.

Synchondrosis.—Where the connecting medium is cartilage the joint is termed a synchondrosis. This is a temporary form of joint, for the cartilage becomes converted into bone before adult life (*synostosis*). Such a joint is found between the epiphyses and shafts of long bones.

2. Amphiarthrosis. Mixed Articulations.

In this form of articulation the contiguous osseous surfaces are connected together by broad flattened disks of fibro-cartilage, of a more or less complex structure, which adhere to the end of each bone, as in the articulation between the bodies of the vertebræ and the pubic symphyses. This is termed **Symphysis.** Or, secondly, the bony surfaces are united by an interosseous ligament, as in the inferior tibio-fibular articulation. To this the term **Syndesmosis** is applied.

3. Diarthrosis. Movable Articulations.

This form of articulation includes the greater number of the joints in the body, mobility being their distinguishing character. They are formed by the approximation of two contiguous bony surfaces covered with cartilage, connected by ligaments and lined by synovial membrane. The varieties of joints in this class have been determined by the kind of motion permitted in each. There are two varieties in which the movement is uniaxial; that is to say, all movements take place around one axis. In one form, the Ginglymus, this axis is, practically speaking, transverse; in the other, the trochoid or pivot-joint, it is longitudinal. There are two varieties where the movement is biaxial, or around two horizontal

axes at right angles to each other or at any intervening axis between the two. These are the condyloid and saddle-joint. There is one form of joint where the movement is polyaxial, the enarthrosis or ball-and-socket joint. And finally there are the Arthrodia or Gliding joints.

Ginglymus or **Hinge-joint** (*γίγλυμος*, a hinge).—In this form of joint the articular surfaces are moulded to each other in such a manner as to permit motion only in one plane, forward and backward; the extent of motion at the same time being considerable. The direction which the distal bone takes in this motion is never in the same plane as that of the axis of the proximal bone, but there is always a certain amount of alteration from the straight line during flexion. The articular surfaces are connected together by strong lateral ligaments, which form their chief bond of union. The most perfect forms of ginglymus are the interphalangeal joints and the joint between the humerus and ulna; the knee and ankle are less perfect, as they allow a slight degree of rotation or lateral movement in certain positions of the limb.

Trochoides (pivot-joint).—Where the movement is limited to rotation, the joint is formed by a pivot-like process turning within a ring, or the ring on the pivot, the ring being formed partly of bone, partly of ligament. In the superior radio-ulnar articulation the ring is formed partly by the lesser sigmoid cavity of the ulna; in the rest of its extent, by the orbicular ligament; here the head of the radius rotates within the ring. In the articulation of the odontoid process of the axis with the atlas the ring is formed in front by the anterior arch of the atlas; behind, by the transverse ligament; here the ring rotates round the odontoid process.

Condyloid Articulations.—In this form of joint an ovoid articular head, or condyle, is received into an elliptical cavity in such a manner as to permit of flexion and extension, adduction and abduction and circumduction, but no axial rotation. The articular surfaces are connected together by anterior, posterior, and lateral ligaments. An example of this form of joint is found in the wrist.

Articulations by Reciprocal Reception (saddle-joint).—In this variety the articular surfaces are concavo-convex; that is to say, they are inversely convex in one direction and concave in the other. The movements are the same as in the preceding form; that is to say, there is flexion, extension, adduction, abduction, and circumduction, but no axial rotation. The articular surfaces are connected by a capsular ligament. The best example of this form of joint is the carpo-metacarpal joint of the thumb.

Enarthrosis is that form of joint in which the distal bone is capable of motion around an indefinite number of axes which have one common centre. It is formed by the reception of a globular head into a deep cup-like cavity (hence the name "ball-and-socket"), the parts being kept in apposition by a capsular ligament strengthened by accessory ligamentous bands. **Examples** of this form of articulation are found in the hip and shoulder.

Arthrodia is that form of joint which admits of a gliding movement; it is formed by the approximation of plane surfaces or one slightly concave, the other slightly convex, the amount of motion between them being limited by the ligaments, or osseous processes, surrounding the articulation; as in the articular processes of the vertebræ, the carpal joints, except that of the os magnum with the scaphoid and semilunar bones, and the tarsal joints with the exception of the joint between the astragalus and the navicular.

On the next page, in a tabular form, are the names, distinctive characters, and examples of the different kinds of articulations.

The Kinds of Movement admitted in Joints.

The movements admissible in joints may be divided into four kinds: gliding, angular movement, circumduction, and rotation. These movements are often, however, more or less combined in the various joints, so as to produce an infinite variety, and it is seldom that we find only one kind of motion in any particular joint.

- *Synarthrosis*, or Immovable Joint. Surfaces separated by fibrous membrane or by line of cartilage, without any intervening synovial cavity, and immovably connected with each other. As in joints of cranium and face (except lower jaw).
  - *Sutura*. Articulation by processes and indentations interlocked together.
    - *Sutura vera* (true), articulate by indented borders.
      - *Dentata*, having tooth-like processes. As in interparietal suture.
      - *Serrata*, having serrated edges like the teeth of a saw. As in interfrontal suture.
      - *Limbosa*, having bevelled margins and dentated processes. As in fronto-parietal suture.
    - *Sutura notha* (false), articulate by rough surfaces.
      - *Squamosa*, formed by thin bevelled margins, overlapping each other. As in squamo-parietal suture.
      - *Harmonia*, formed by the apposition of contiguous rough surfaces. As in intermaxillary suture.
  - *Schindylesis*.—Articulation formed by the reception of a thin plate of one bone into a fissure of another. As in articulation of rostrum of sphenoid with vomer.
  - *Gomphosis*.—Articulation formed by the insertion of a conical process into a socket: the teeth.
  - *Synchondrosis*.—*Epiphysial lines*.
- *Amphiarthrosis*, Mixed Articulation.
  - *Symphysis*.—Surfaces connected by fibro-cartilage, not separated by synovial membrane, and having limited motion. As in joints between bodies of vertebræ.
  - *Syndesmosis*.—Surfaces united by an interosseous ligament. As in the inferior tibio-fibular articulation.
- *Diarthrosis*, Movable Joint.
  - *Ginglymus*.—Hinge-joint; motion limited to two directions, forward and backward. Articular surfaces fitted together so as to permit of movement in one plane. As in the interphalangeal joints and the joint between the humerus and the ulna.
  - *Trochoides, or Pivot-joint*.—Articulation by a pivot process turning within a ring or ring around a pivot. As in superior radio-ulnar articulation and atlanto-axial joint.
  - *Condyloid*.—Ovoid head received into elliptical cavity. Movements in every direction except axial rotation. As the wrist-joint.
  - *Reciprocal Reception* (saddle-joint).—Articular surfaces inversely convex in one direction and concave in the other. Movement in every direction except axial rotation. As in the carpo-metacarpal joint of the thumb.
  - *Enarthrosis*.—Ball-and-socket joint; capable of motion in all directions. Articulations by a globular head received into a cup-like cavity. As in hip- and shoulder-joints.
  - *Arthrodia*.—Gliding joint; articulations by plane surfaces, which glide upon each other. As in carpal and tarsal articulations.

Gliding movement is the most simple kind of motion that can take place in a joint, one surface gliding or moving over another without any angular or rotatory movement. It is common to all movable joints, but in some, as in the articulations of the carpus and tarsus, it is the only motion permitted. This movement is not confined to plane surfaces, but may exist between any two contiguous surfaces, of whatever form, limited by the ligaments which enclose the articulation.

Angular movement occurs only between the long bones, and by it the angle between the two bones is increased or diminished. It may take place in four directions: forward and backward, constituting flexion and extension, or inward and outward, from the mesial line of the body (or in the fingers and toes from the middle line of the hand or foot), constituting adduction and abduction. The strictly ginglymoid or hinge-joints admit of flexion and extension only. Abduction and adduction, combined with flexion and extension, are met with in the more movable joints; as in the hip, shoulder, and metacarpal joint of the thumb, and partially in the wrist.

Circumduction is that limited degree of motion which takes place between the head of a bone and its articular cavity, whilst the extremity and sides of the limb are made to circumscribe a conical space, the base of which corresponds with the inferior extremity of the limb, the apex with the articular cavity; this kind of motion is best seen in the shoulder- and hip-joints.

Rotation is the movement of a bone upon an axis, which is the axis of the pivot on which the bone turns, as in the articulation between the atlas and axis, when the odontoid process serves as a pivot around which the atlas turns; or else is the axis of a pivot-like process which turns within a ring, as in the rotation of the radius upon the humerus.

Ligamentous Action of Muscles.—The movements of the different joints of a limb are combined by means of the long muscles which pass over more than one joint, and which, when relaxed and stretched to their greatest extent, act to a certain extent as elastic ligaments in restraining certain movements of one joint, except when combined with corresponding movements of the other, these latter movements being usually in the opposite direction. Thus the shortness of the hamstring muscles prevents complete flexion of the hip, unless the knee-joint be also flexed, so as to bring their attachments nearer together. The uses of this arrangement are threefold: 1. It co-ordinates the kinds of movement which are the most habitual and necessary, and enables them to be performed with the least expenditure of power. "Thus in the usual gesture of the arms, whether in grasping or rejecting, the shoulder and the elbow are flexed simultaneously, and simultaneously extended," in consequence of the passage of the Biceps and Triceps cubiti over both joints. 2. It enables the short muscles which pass over only one joint to act upon more than one. "Thus, if the Rectus femoris remain tonically of such length that, when stretched over the extended hip, it compels extension of the knee, then the Gluteus maximus becomes not only an extensor of the hip, but an extensor of the knee as well." 3. It provides the joints with ligaments which, while they are of very great power in resisting movements to an extent incompatible with the mechanism of the joint, at the same time spontaneously yield when necessary. "Taxed beyond its strength, a ligament will be ruptured, whereas a contracted muscle is easily relaxed; also, if neighboring joints be united by ligaments, the amount of flexion or extension of each must remain in constant proportion to that of the other; while, if the union be by muscles, the separation of the points of attachment of those muscles may vary considerably in different varieties of movement, the muscles adapting themselves tonically to the length required." The quotations are from a very interesting paper by Dr. Cleland in the *Journal of Anatomy and Physiology*, No. 1, 1866, p. 85; by whom I believe this important fact in the mechanism of joints was first clearly pointed out, though it has been independently observed afterward by other anatomists. Dr. W. W. Keen points out how important it is "that the surgeon should remember this ligamentous action of

muscles in making passive motion—for instance, at the wrist after Colles's fracture. If the fingers be extended, the wrist can be flexed to a right angle. If, however, they be first flexed, as in "making a fist," flexion at the wrist is quickly limited to from forty to fifty degrees in different persons, and is very painful beyond that point. Hence passive motion here should be made with the fingers extended. In the leg, when flexing the hip, the knee should be flexed." Dr. Keen further points out that "a beautiful illustration of this is seen in the perching of birds, whose toes are forced to clasp the perch by just such a passive ligamentous action so soon as they stoop. Hence they can go to sleep and not fall off the perch."

The articulations may be arranged into those of the trunk, those of the upper extremity, and those of the lower extremity.

ARTICULATIONS OF THE TRUNK.

These may be divided into the following groups, viz.:

I. Of the vertebral column.
II. Of the atlas with the axis.
III. Of the atlas with the occipital bone.
IV. Of the axis with the occipital bone.
V. Of the lower jaw.
VI. Of the ribs with the vertebræ.
VII. Of the cartilages of the ribs with the sternum and with each other.
VIII. Of the sternum.
IX. Of the vertebral column with the pelvis.
X. Of the pelvis.

I. Articulations of the Vertebral Column.

The different segments of the spine are connected together by ligaments, which admit of the same arrangement as the vertebræ. They may be divided into five sets: 1. Those connecting the *bodies* of the vertebræ. 2. Those connecting the *laminæ*. 3. Those connecting the *articular processes*. 4. Those connecting the *spinous processes*. 5. Those of the *transverse processes*.

The articulations of the *bodies* of the vertebræ with each other form a series of amphiarthrodial joints (*symphyses*); those between the *articular processes* form a series of arthrodial joints.

1. The Ligaments of the Bodies.

Anterior Common Ligament. Posterior Common Ligament.
Intervertebral Substance.

The **Anterior Common Ligament** (Figs. 227, 228, 235, 239) is a broad and strong band of ligamentous fibres which extends along the front surface of the bodies of the vertebræ from the axis to the sacrum. It is broader below than above, thicker in the dorsal than in the cervical or lumbar regions, and somewhat thicker opposite the front of the body of each vertebra than opposite the intervertebral substance. It is attached, above, to the body of the axis by a pointed process, where it is continuous with the anterior atlanto-axial ligament, and is connected with the tendon of insertion of the Longus colli muscle, and extends down as far as the upper bone of the sacrum. It consists of dense longitudinal fibres, which are intimately adherent to the intervertebral substance and the prominent margins of the vertebræ, but less closely to the middle of the bodies. In the latter situation the fibres are exceedingly thick, and serve to fill up the concavities on their front surface and to make the anterior surface of the spine more even. This ligament is composed of several layers of fibres, which vary in length, but are closely interlaced with each other. The most superficial or longest fibres extend between four or five vertebræ. A second subjacent set extend between two or three vertebræ, whilst a third set, the shortest and deepest, extend from one vertebra to the next. At the side of the bodies the ligament consists of a few short fibres, which pass from one vertebra to the next, separated from the median portion by large oval apertures for the passage of vessels.

The **Posterior Common Ligament** (Figs. 227, 231) is situated within the spinal

canal, and extends along the posterior surface of the bodies of the vertebræ from the body of the axis above, where it is continuous with the occipito-axial ligament, to the sacrum below. It is broader above than below, and thicker in the dorsal than in the cervical or lumbar regions. In the situation of the intervertebral substance and contiguous margins of the vertebræ, where the ligament is more intimately adherent, it is broad, and presents a series of dentations with intervening concave margins; but it is narrow and thick over the centre of the bodies, from which it is separated by the *venæ basis vertebræ*. This ligament is composed of smooth, shining, longitudinal fibres, denser and more compact than those of the anterior ligament, and composed of a superficial layer occupying the interval between three or four vertebræ, and of a deeper layer which extends between one vertebra and the next adjacent to it. It is separated from the dura mater of

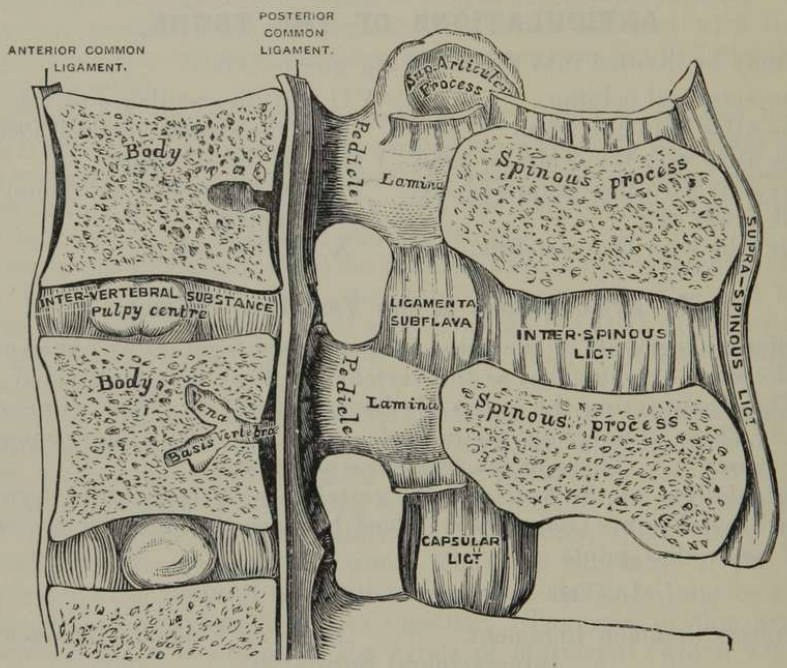

FIG. 227.—Vertical section of two vertebræ and their ligaments, from the lumbar region.

the spinal cord by some loose connective tissue which is very liable to serous infiltration.

The **Intervertebral Substance** (Figs. 227, 236) is a lenticular disk of composite structure interposed between the adjacent surfaces of the bodies of the vertebræ from the axis to the sacrum, and forming the chief bond of connection between those bones. These disks vary in shape, size, and thickness in different parts of the spine. In *shape* they accurately correspond with the surfaces of the bodies between which they are placed, being oval in the cervical and lumbar regions, and circular in the dorsal. Their *size* is greatest in the lumbar region. In *thickness* they vary not only in the different regions of the spine, but in different parts of the same disk: thus, they are much thicker in front than behind in the cervical and lumbar regions, while they are uniformly thick in the dorsal region. The intervertebral disks form about one-fourth of the spinal column, exclusive of the first two vertebræ; they are not equally distributed, however, between the various bones; the dorsal portion of the spine having, in proportion to its length, a much smaller quantity than in the cervical and lumbar regions, which necessarily gives to the latter parts greater pliancy and freedom of movement. The intervertebral disks are adherent, by their surfaces, to a thin layer of hyaline cartilage which covers the upper and under surfaces of the bodies of the vertebræ, and in which the epiphysial plate develops, and by their circumference are closely connected in

front to the anterior, and behind to the posterior common ligament; whilst in the dorsal region they are connected laterally, by means of the interarticular ligament, to the heads of those ribs which articulate with two vertebræ; they, consequently, form part of the articular cavities in which the heads of these bones are received.

Structure of the Intervertebral Substance.—The intervertebral substance is composed, at its circumference, of laminæ of fibrous tissue and fibro-cartilage; and, at its centre, of a soft, pulpy, highly elastic substance, of a yellowish color, which rises up considerably above the surrounding level when the disk is divided horizontally. This pulpy substance, which is especially well developed in the lumbar region, is the remains of the chorda dorsalis, and, according to Luschka, contains a small synovial cavity in its centre. The laminæ are arranged concentrically one within the other, the outermost consisting of ordinary fibrous tissue, but the others and more numerous consisting of white fibro-cartilage. These plates are not quite vertical in their direction, those near the circumference being curved outward and closely approximated; whilst those nearest the centre curve in the opposite direction, and are somewhat more widely separated. The fibres of which each plate is composed are directed, for the most part, obliquely from above downward, the fibres of adjacent plates passing in opposite directions and varying in every layer; so that the fibres of one layer are directed across those of another, like the limbs of the letter X. This laminar arrangement belongs to about the outer half of each disk. The pulpy substance presents no concentric arrangement, and consists of a fine fibrous matrix, containing angular cells, united to form a reticular structure.

2. Ligaments connecting the Laminæ.

Ligamenta Subflava.

The **Ligamenta Subflava** (Fig. 227) are interposed between the laminæ of the vertebræ, from the axis to the sacrum. They are most distinct when seen from the interior of the spinal canal; when viewed from the outer surface they appear short, being overlapped by the laminæ. Each ligament consists of two lateral portions, which commence on each side at the root of either articular process, and pass backward to the point where the laminæ converge to form the spinous process, where their margins are in contact and to a certain extent united; slight intervals being left for the passage of small vessels. These ligaments consist of yellow elastic tissue, the fibres of which, almost perpendicular in direction, are attached to the anterior surface of the laminæ above, some distance from its inferior margin, and to the posterior surface, as well as to the margin of the lamina below. In the cervical region they are thin in texture, but very broad and long; they become thicker in the dorsal region, and in the lumbar acquire very considerable thickness. Their highly elastic property serves to preserve the upright posture and to assist in resuming it after the spine has been flexed. These ligaments do not exist between the occiput and atlas or between the atlas and axis.

3. Ligaments connecting the Articular Processes.

Capsular.

The **Capsular Ligaments** (Fig. 229) are thin and loose ligamentous sacs, attached to the contiguous margins of the articulating processes of each vertebra through the greater part of their circumference, and completed internally by the ligamenta subflava. They are longer and looser in the cervical than in the dorsal or lumbar regions. The capsular ligaments are lined on their inner surface by synovial membrane.

4. Ligaments connecting the Spinous Processes.

Supraspinous. Interspinous.

The **Supraspinous Ligament** (Fig. 227) is a strong fibrous cord, which connects

together the apices of the spinous processes from the seventh cervical to the spinous processes of the sacrum. It is thicker and broader in the lumbar than in the dorsal region, and intimately blended, in both situations, with the neighboring aponeurosis. The most superficial fibres of this ligament connect three or four vertebræ; those deeper-seated pass between two or three vertebræ; whilst the deepest connect the contiguous extremities of neighboring vertebræ. It is continued upward to the external occipital protuberance, as the posterior margin of the ligamentum nuchæ, which, in the human subject, is comparatively thin and forms an intermuscular septum.

The **Interspinous Ligaments** (Fig. 227), thin and membranous, are interposed between the spinous processes. Each ligament extends from the root to the summit of each spinous process and connects together their adjacent margins. They are narrow and elongated in the dorsal region; broader, quadrilateral in form, and thicker in the lumbar region; and only slightly developed in the neck.

5. Ligaments connecting the Transverse Processes.

Intertransverse.

The **Intertransverse Ligaments** consist of bundles of fibres interposed between the transverse processes. In the cervical region they consist of a few irregular, scattered fibres; in the dorsal, they are rounded cords intimately connected with the deep muscles of the back; in the lumbar region they are thin and membranous.

Actions.—The movements permitted in the spinal column are, Flexion, Extension, Lateral Movement, Circumduction, and Rotation.

In *Flexion*, or movement of the spine forward, the anterior common ligament is relaxed, and the intervertebral substances are compressed in front, while the posterior common ligament, the ligamenta subflava, and the inter- and supraspinous ligaments are stretched, as well as the posterior fibres of the intervertebral disks. The interspaces between the laminæ are widened, and the inferior articular processes of the vertebræ above glide upward upon the articular processes of the vertebræ below. Flexion is the most extensive of all the movements of the spine.

In *Extension*, or movement of the spine backward, an exactly opposite disposition of the parts takes place. This movement is not extensive, being limited by the anterior common ligament and by the approximation of the spinous processes.

Flexion and extension are most free in the lower part of the lumbar region between the third and fourth and fourth and fifth lumbar vertebræ; above the third they are much diminished, and reach their minimum in the middle and upper part of the back. They increase again in the neck, the capability of motion backward from the upright position being in this region greater than that of the motion forward, whereas in the lumbar region the reverse is the case.

In *Lateral Movement*, the sides of the intervertebral disks are compressed, the extent of motion being limited by the resistance offered by the surrounding ligaments and by the approximation of the transverse processes. This movement may take place in any part of the spine, but is most free in the neck and loins.

Circumduction is very limited, and is produced merely by a succession of the preceding movements.

Rotation is produced by the twisting of the intervertebral substances; this, although only slight between any two vertebræ, produces a great extent of movement when it takes place in the whole length of the spine, the front of the column being turned to one or the other side. This movement takes place only to a slight extent in the neck, but is freer in the upper part of the dorsal region, and is altogether absent in the lumbar region.

It is thus seen that the *cervical region* enjoys the greatest extent of each variety of movement, flexion and extension especially being very free. In the *dorsal region* the three movements of flexion, extension, and circumduction are only permitted to a slight extent, while rotation is very free in the upper part and

ceases below. In the lumbar region there is free flexion, extension, and lateral movement, but no rotation.

As Sir George Humphry has pointed out, the movements permitted are mainly due to the shape and position of the articulating processes. In the loins the inferior articulating processes are turned outward and embraced by the superior; this renders rotation in this region of the spine impossible, while there is nothing to prevent a sliding upward and downward of the surfaces on each other, so as to allow of flexion and extension. In the dorsal region, on the other hand, the articulating processes, by their direction and mutual adaptation, especially at the upper part of the series, permit of rotation, but prevent extension and flexion, while in the cervical region the greater obliquity and lateral slant of the articular processes allow not only flexion and extension, but also rotation.

The principal muscles which produce *flexion* are the Sterno-mastoid, Rectus capitis anticus major, and Longus colli; the Scaleni; the abdominal muscles and the Psoas magnus. *Extension* is produced by the fourth layer of the muscles of the back, assisted in the neck by the Splenius, Semispinalis dorsi et colli, and the Multifidus spinæ. *Lateral* motion is produced by the fourth layer of the muscles of the back, by the Splenius and the Scaleni, the muscles of one side only acting; and *rotation* by the action of the following muscles of one side only—viz. the Sterno-mastoid, the Rectus capitis anticus major, the Scaleni, the Multifidus spinæ, the Complexus, and the abdominal muscles.

II. Articulation of the Atlas with the Axis.

The articulation of the Atlas with the Axis is of a complicated nature, comprising no fewer than four distinct joints. There is a pivot articulation between the odontoid process of the axis and the ring formed between the anterior arch of the atlas and the transverse ligament (see Fig. 230). Here there are two joints: one in front between the posterior surface of the anterior arch of the atlas and the front of the odontoid process (the *atlo-odontoid joint of Cruveilhier*); the other between the anterior surface of the transverse ligament and the back of the process (the *syndesmo-odontoid joint*). Between the articular processes of the two bones there is a double arthrodia or gliding joint. The ligaments which connect these bones are the

Two Anterior Atlanto-axial.	Transverse.
Posterior Atlanto-axial.	Two Capsular.

Of the **Two Anterior Atlanto-axial Ligaments** (Fig. 228), the more superficial is a rounded cord, situated in the middle line; it is attached, above, to the tubercle on the anterior arch of the atlas; below, to the base of the odontoid process and to the front of the body of the axis. The deeper ligament is a membranous layer, attached, above, to the lower border of the anterior arch of the atlas; below, to the base of the odontoid process and front of the body of the axis. These ligaments are in relation, in front, with the Recti antici majores.

The **Posterior Atlanto-axial Ligament** (Fig. 229) is a broad and thin membranous layer, attached, above, to the lower border of the posterior arch of the atlas; below, to the upper edge of the laminæ of the axis. This ligament supplies the place of the ligamenta subflava, and is in relation, behind, with the Inferior oblique muscles.

The **Transverse Ligament** [1] (Figs. 230, 231) is a thick and strong ligamentous band, which arches across the ring of the atlas, and serves to retain the odontoid process in firm connection with its anterior arch. This ligament is flattened from before backward, broader and thicker in the middle than at either extremity, and

[1] It has been found necessary to describe the transverse ligament with those of the atlas and axis; but the student must remember that it is really a portion of the mechanism by which the movements of the head on the spine are regulated; so that the connections between the atlas and axis ought always to be studied together with those between the latter bones and the skull.

firmly attached on each side to a small tubercle on the inner surface of the lateral mass of the atlas. As it crosses the odontoid process, a small fasciculus is derived from its upper and lower borders; the former passing upward, to be inserted into the basilar process of the occipital bone; the latter, downward, to be attached to the posterior surface of the body of the axis; hence, the whole ligament has received the name of *cruciform*. The transverse ligament divides the ring of the atlas into two unequal parts: of these, the posterior and larger serves for the transmission of the cord and its membranes and the spinal accessory nerves; the anterior and smaller contains the odontoid process. Since the space between the anterior arch of the atlas and the transverse ligament is smaller at the lower

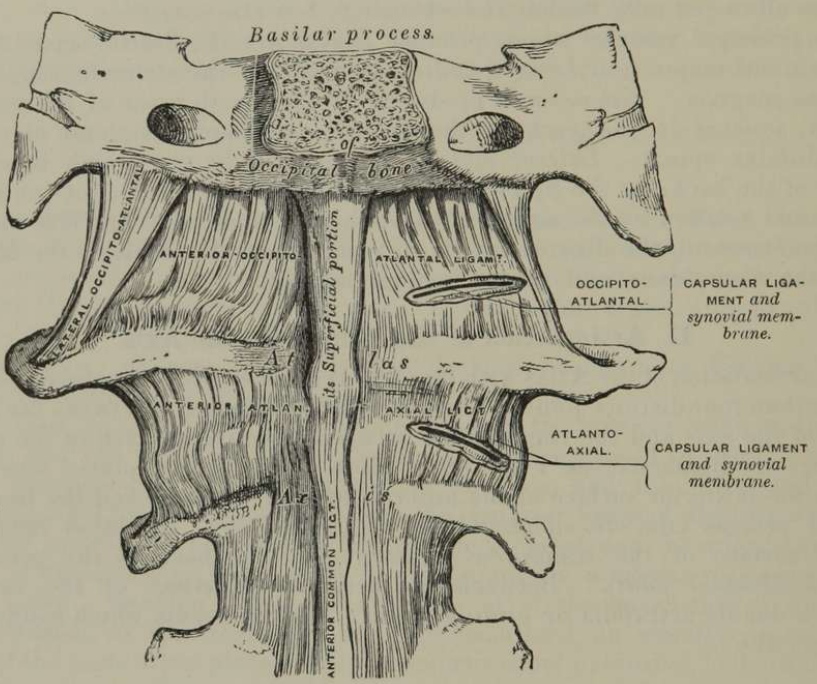

FIG. 228.—Occipito-atloid and atlo-axoid ligaments. Front view.

part than the upper (because the transverse ligament embraces firmly the narrow neck of the odontoid process), this process is retained in firm connection with the atlas after all the other ligaments have been divided.

The **Capsular Ligaments** connect the articular processes of the atlas and axis, the fibres being strongest on the posterior and internal part of the articulation, *accessory ligaments;* these latter extend downward and inward to the body of the axis.

There are *four* **Synovial Membranes** in this articulation: one lining the inner surface of each of the capsular ligaments; one between the anterior surface of the odontoid process and the anterior arch of the atlas, the *atlo-odontoid joint;* and one between the posterior surface of the odontoid process and the transverse ligament, the *syndesmo-odontoid joint.* The latter often communicates with those between the condyles of the occipital bone and the articular surfaces of the atlas.

Actions.—This joint allows the rotation of the atlas (and, with it, of the cranium) upon the axis, the extent of rotation being limited by the odontoid ligaments.

The principal muscles by which this action is produced are the Sterno-mastoid and Complexus of one side, acting with the Rectus capitis anticus major, Splenius, Trachelo-mastoid, Rectus capitis posticus major, and Inferior oblique of the other side.

ARTICULATIONS OF THE SPINE WITH THE CRANIUM.

The ligaments connecting the spine with the cranium may be divided into two sets—those connecting the occipital bone with the atlas, and those connecting the occipital bone with the axis.

III. Articulation of the Atlas with the Occipital Bone.

This articulation is a double condyloid joint. Its ligaments are the

Two Anterior Occipito-atlantal.	Two Lateral Occipito-atlantal.
Posterior Occipito-atlantal.	Two Capsular.

Of the **Two Anterior Occipito-atlantal Ligaments** (Fig. 228), the superficial is a strong, narrow, rounded cord, attached, above, to the basilar process of the

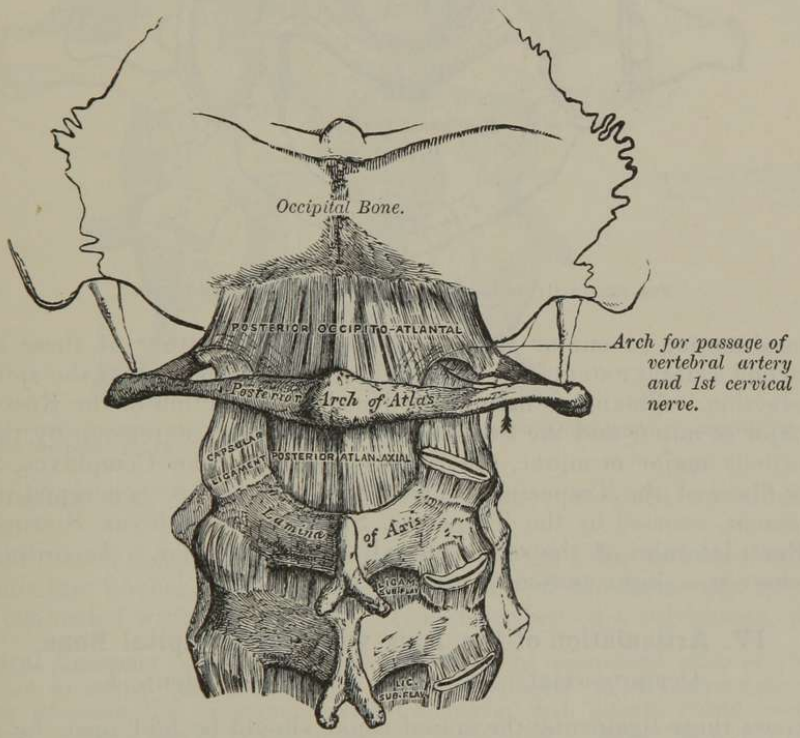

FIG. 229.—Occipito-atloid and atlo-axoid ligaments. Posterior view.

occiput; below, to the tubercle on the anterior arch of the atlas: the deeper ligament is a broad and thin membranous layer which passes between the anterior margin of the foramen magnum above, and the whole length of the upper border of the anterior arch of the atlas below. This ligament is in relation, in front, with the Recti antici minores; behind, with the odontoid ligaments.

The **Posterior Occipito-atlantal Ligament** (Fig. 229) is a very broad but thin membranous lamina intimately blended with the dura mater. It is connected, above, to the posterior margin of the foramen magnum; below, to the upper border of the posterior arch of the atlas. This ligament is incomplete at each side, and forms, with the superior intervertebral notch, an opening for the passage of the vertebral artery and suboccipital nerve. It is in relation, behind, with the Recti postici minores and Obliqui superiores; in front, with the dura mater of the spinal canal, to which it is intimately adherent.

The **Lateral Ligaments** are strong fibrous bands, directed obliquely upward and inward, attached above to the jugular process of the occipital bone; below, to the base of the transverse process of the atlas.

The **Capsular Ligaments** surround the condyles of the occipital bone, and con-

nect them with the articular processes of the atlas; they consist of thin and loose capsules, which enclose the synovial membrane of the articulation.

Synovial Membranes.—There are two synovial membranes in this articulation, one lining the inner surface of each of the capsular ligaments. These occasionally communicate with that between the posterior surface of the odontoid process and the transverse ligament.

Actions.—The movements permitted in this joint are flexion and extension, which give rise to the ordinary forward and backward nodding of the head, besides

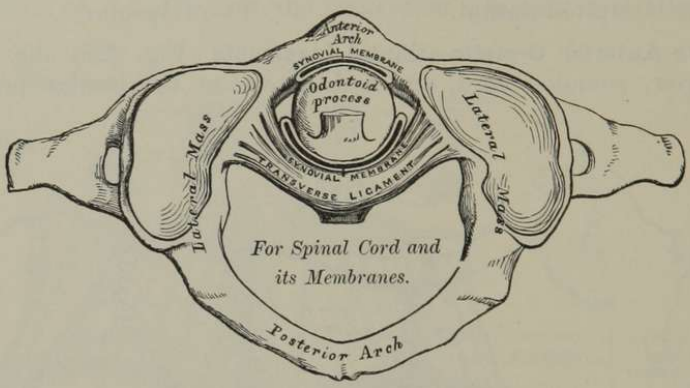

FIG. 230.—Articulation between odontoid process and atlas.

slight lateral motion to one or the other side. When either of these actions is carried beyond a slight extent, the whole of the cervical portion of the spine assists in its production. Flexion is mainly produced by the action of the Rectus capitis anticus major et minor and the Sterno-mastoid muscles; extension by the Rectus capitis posticus major et minor, the Superior oblique, the Complexus, Splenius, and upper fibres of the Trapezius. The Recti laterales are concerned in the lateral movement, assisted by the Trapezius, Splenius, Complexus, Sterno-mastoid, and the Recti laterales of the same side, all acting together. According to Cruveilhier, there is a slight motion of rotation in this joint.

IV. Articulation of the Axis with the Occipital Bone.

Occipito-axial. Three Odontoid.

To expose these ligaments the spinal canal should be laid open by removing the posterior arch of the atlas, the laminæ and spinous process of the axis, and the portion of the occipital bone behind the foramen magnum, as seen in Fig. 231.

The **Occipito-axial Ligament** (*apparatus ligamentosus colli*) is situated within the spinal canal. It is a broad and strong ligamentous band, which covers the odontoid process and its ligaments, and appears to be a prolongation upward of the posterior common ligament of the spine. It is attached, below, to the posterior surface of the body of the axis, and, becoming expanded as it ascends, is inserted into the basilar groove of the occipital bone, in front of the foramen magnum, where it becomes blended with the dura mater of the skull.

Relations.—By its anterior surface with the transverse ligament, by its posterior surface with the dura mater.

The **Lateral Odontoid** or **Check Ligaments** (*alar ligaments*) are strong, fibrous cords, which arise one on either side of the upper part of the odontoid process, and, passing obliquely upward and outward, are inserted into the rough depressions on the inner side of the condyles of the occipital bone. In the triangular interval between these ligaments another strong fibrous cord (*ligamentum suspensorium* or **middle odontoid ligament**) may be seen, which passes almost perpendicularly from the apex of the odontoid process to the anterior margin of the foramen, being intimately blended with the deep portion of the

anterior occipito-atloid ligament and upper fasciculus of the transverse ligament of the atlas.

Actions.—The odontoid ligaments serve to limit the extent to which rotation

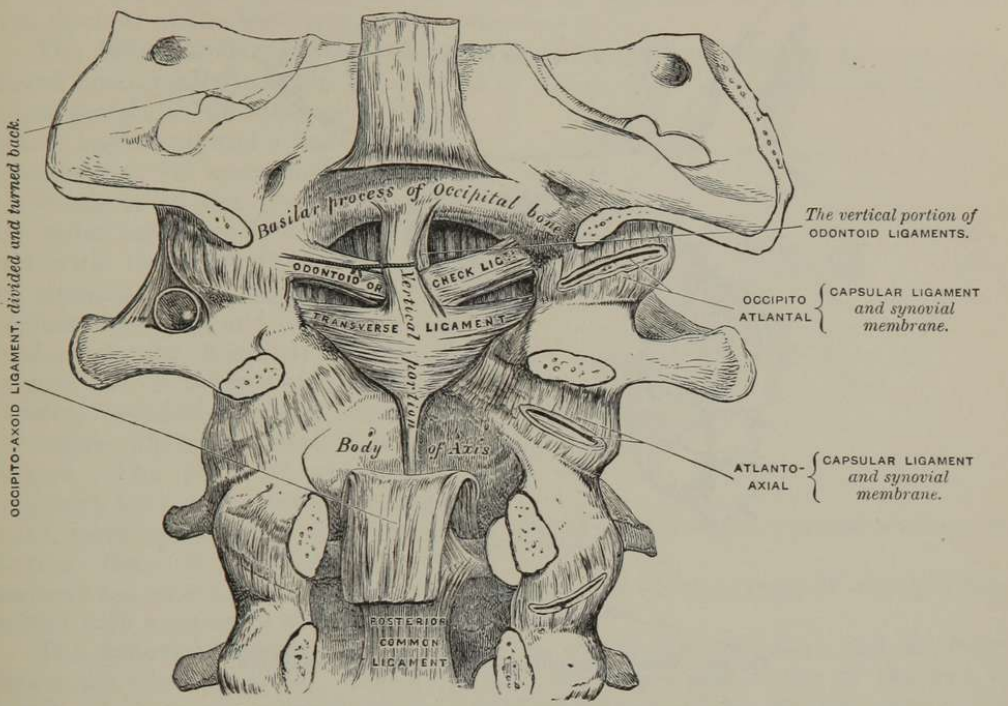

FIG. 231.—Occipito-axoid and atlo-axoid ligaments. Posterior view, obtained by removing the arches of the vertebræ and the posterior part of the skull.

of the cranium may be carried; hence they have received the name of *check ligaments.*

In addition to these ligaments, which connect the atlas and axis to the skull, the ligamentum nuchæ must be regarded as one of the ligaments by which the spine is connected with the cranium. It is described on a subsequent page.

Surgical Anatomy.—The ligaments which unite the component parts of the vertebræ together are so strong, and these bones are so interlocked by the arrangement of their articulating processes, that dislocation is very uncommon, and, indeed, unless accompanied by fracture, rarely occurs, except in the upper part of the neck. Dislocation of the occiput from the atlas has only been recorded in one or two cases; but dislocation of the atlas from the axis, with rupture of the transverse ligament, is much more common: it is the mode in which death is produced in many cases of execution by hanging. In the lower part of the neck—that is, below the third cervical vertebra—dislocation unattended by fracture occasionally takes place.

V. Temporo-maxillary Articulation.

This is a double or bilateral condyloid joint: the parts entering into its formation on each side are, above, the anterior part of the glenoid cavity of the temporal bone and the eminentia articularis; and, below, the condyle of the lower jaw. The ligaments are the following:

External Lateral.	Stylo-maxillary.
Internal Lateral.	Capsular.
Interarticular Fibro-cartilage.	

The **External Lateral Ligament** (Fig. 232) is a short, thin, and narrow fasciculus, attached, above, to the outer surface of the zygoma and to the rough tubercle on its lower border; below, to the outer surface and posterior border of the neck of the lower jaw. It is broader above than below; its fibres are placed

parallel with one another, and directed obliquely downward and backward. Externally, it is covered by the parotid gland and by the integument. Internally,

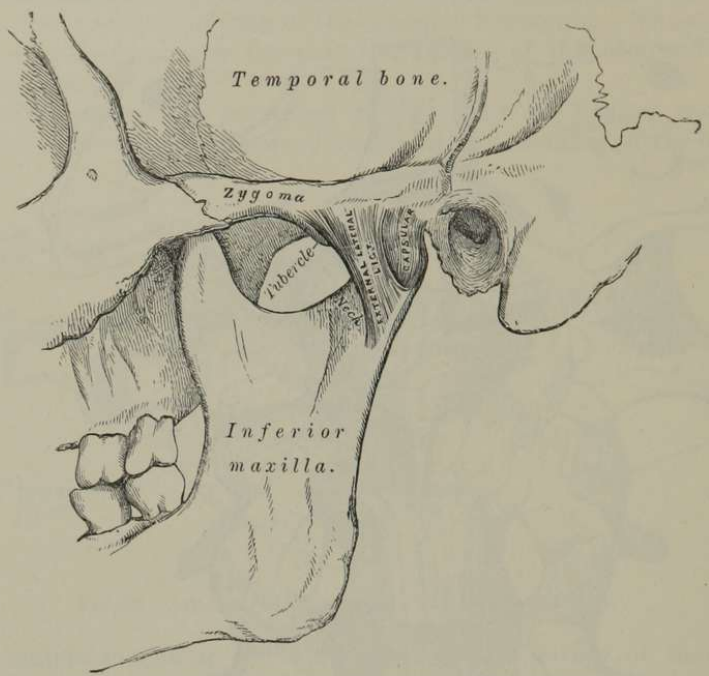

FIG. 232.—Temporo-maxillary articulation. External view.

it is in relation with the capsular ligament, of which it is an accessory band, and not separable from it.

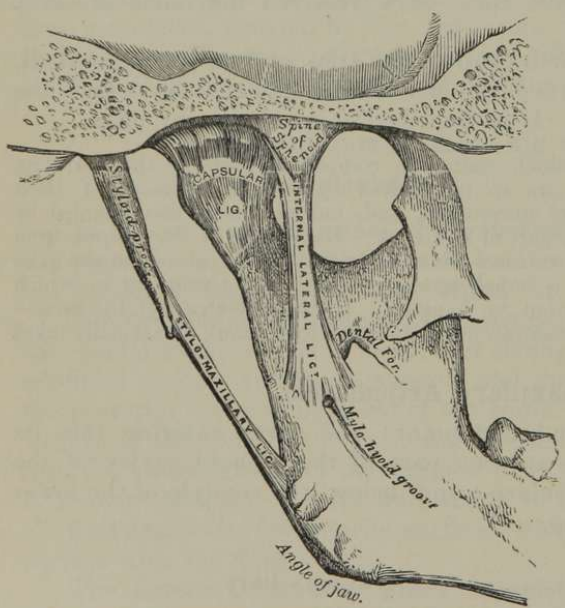

FIG. 233.—Temporo-maxillary articulation. Internal view.

The **Internal Lateral Ligament** (Fig. 233) is a specialized band of cervical fascia which is attached above to the spinous process of the sphenoid bone, and, becoming broader as it descends, is inserted into the lingula and margin of the dental foramen. Its outer surface is in relation, above, with the External pterygoid muscle; lower down, it is separated from the neck of the condyle by the internal maxillary artery; and still more inferiorly, the inferior dental vessels and nerve separate it from the ramus of the jaw. The inner surface is in relation with the Internal pterygoid.

The **Stylo-maxillary Ligament** is also a specialized band of the cervical fascia, which extends from near the apex of the styloid process of the temporal bone to the angle and posterior border of the ramus of the lower jaw, between the Masseter and Internal pterygoid muscles. This ligament separates the parotid from the submaxillary gland, and has attached to its inner side part of the fibres of origin of the Stylo-glossus muscle. Although usually classed among the ligaments of the jaw, it can only be considered as an accessory in the articulation.

The **Capsular Ligament** forms a thin and loose ligamentous capsule, attached above to the circumference of the glenoid cavity and the articular surface immediately in front; below, to the neck of the condyle of the lower jaw. It consists of a few thin scattered fibres, and can hardly be considered as a distinct ligament; it is thickest at the back part of the articulation.[1]

The **Interarticular Fibro-cartilage** (Fig. 234) is a thin plate of an oval form, placed horizontally between the condyle of the jaw and the glenoid cavity. Its upper surface is concavo-convex from before backward, and a little convex transversely, to accommodate itself to the form of the glenoid cavity. Its under surface, where it is in contact with the condyle, is concave. Its circumference is connected to the capsular ligament, and in front to the tendon of the External pterygoid muscle. It is thicker at its circumference, especially behind, than at its centre, where, at times, it is perforated. The fibres of which it is composed have a concentric arrangement, more apparent at the circumference than at the centre. Its surfaces are smooth. It divides the joint into two cavities, each of which is furnished with a separate synovial membrane.

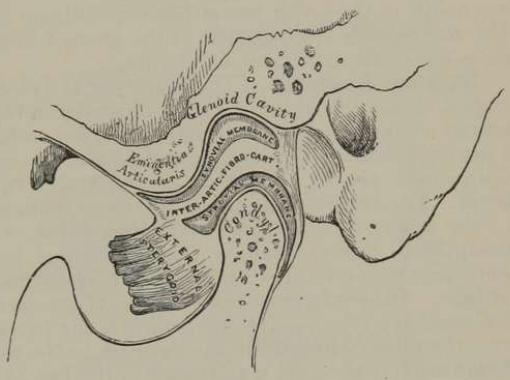

FIG. 234.—Vertical section of temporo-maxillary articulation.

The **Synovial Membranes,** two in number, are placed, one above, and the other below, the fibro-cartilage. The upper one, the larger and looser of the two, is continued from the margin of the cartilage covering the glenoid cavity and eminentia articularis on to the upper surface of the fibro-cartilage. The lower one passes from the under surface of the fibro-cartilage to the neck of the condyle of the jaw, being prolonged downward a little farther behind than in front.

The *nerves* of this joint are derived from the auriculo-temporal and masseteric branches of the inferior maxillary. The *arteries* are derived from the temporal branch of the external carotid.

Actions.—The movements permitted in this articulation are very extensive. Thus, the jaw may be depressed or elevated, or it may be carried forward or backward or from side to side. It is by the alternation of these movements, performed in succession, that a kind of rotatory motion of the lower jaw upon the upper takes place, which materially assists in the mastication of the food.

If the movement of depression is carried only to a slight extent, the condyles remain in the glenoid cavities, rotating on a transverse axis against the interarticular fibro-cartilage; but if the depression is considerable, the condyles glide from the glenoid fossæ on to the articular eminences, carrying with them the interarticular fibro-cartilages, so that in opening the mouth widely the two movements are combined—*i. e.* the condyle rotates on a transverse axis against the fibro-cartilage, and at the same time glides forward, carrying the fibro-cartilage with it. When the jaw is elevated after forced depression, the condyles and fibro-cartilages return to their original position. When the jaw is carried forward and backward or from side to side, an oblique gliding movement of the fibro-cartilages and condyles upon the glenoid cavities takes place in the corresponding direction.

The lower jaw is *depressed* by its own weight, assisted by the Platysma, the Digastric, the Mylo-hyoid, and the Genio-hyoid. It is *elevated* by the anterior part of the Temporal, Masseter, and Internal pterygoid. It is drawn *forward* by

[1] Sir G. Humphry describes the internal portion of the capsular ligament separately, as the short internal lateral ligament; and it certainly seems as deserving of a separate description as the external lateral ligament is.

the simultaneous action of the External pterygoid and the superficial fibres of the Masseter; and it is drawn *backward* by the deep fibres of the Masseter and the posterior fibres of the Temporal muscle. The grinding movement is caused by the alternate action of the two External pterygoids.

Surface Form.—The temporo-maxillary articulation is quite superficial, situated below the base of the zygoma, in front of the tragus and external auditory meatus, and behind the posterior border of the upper part of the Masseter muscle. Its exact position can be at once ascertained by feeling for the condyle of the jaw, the working of which can be distinctly felt in the movements of the lower jaw either vertically or from side to side. When the mouth is opened wide, the condyle advances out of the glenoid fossa on to the eminentia articularis and a depression is felt in the situation of the joint.

Surgical Anatomy.—The lower jaw is dislocated only in one direction—viz. forward. The accident is caused by violence or muscular action. When the mouth is open, the condyle is situated on the eminentia articularis, and any sudden violence, or even a sudden muscular spasm, as during a convulsive yawn, may displace the condyle forward into the zygomatic fossa. The displacement may be unilateral or bilateral, according as one or both of the condyles are displaced. The latter of the two is the more common.

Sir Astley Cooper described a condition which he termed "subluxation." It occurs principally in delicate women, and is believed by some to be due to the relaxation of the ligaments, permitting too free movement of the bone, and possibly some displacement of the fibro-cartilage. Others have believed that it is due to gouty or rheumatic changes in the joint. In close relation to the condyle of the jaw is the external auditory meatus and the tympanum; any force, therefore, applied to the bone is liable to be attended with damage to these parts, or inflammation in the joint may extend to the ear, or on the other hand inflammation of the middle ear may involve the articulation and cause its destruction, thus leading to ankylosis of the joint. In children, arthritis of this joint may also follow the exanthemata, and in adults occurs as the result of some constitutional conditions, as rheumatism or gout. The temporo-maxillary joint is also frequently the seat of osteo-arthritis, leading to great suffering during efforts of mastication. A peculiar affection sometimes attacks the neck and condyle of the lower jaw, consisting in hypertrophy and elongation of these parts and consequent protrusion of the chin to the opposite side.

VI. Articulations of the Ribs with the Vertebræ.

The articulations of the ribs with the vertebral column may be divided into two sets: 1. Those which connect the heads of the ribs with the bodies of the vertebræ, *costo-central.* 2. Those which connect the necks and tubercles of the ribs with the transverse processes, *costo-transverse.*

1. Articulations between the Heads of the Ribs and the Bodies of the Vertebræ (Fig. 235).

These constitute a series of arthrodial joints, formed by the articulation of the heads of the ribs with the cavities on the contiguous margins of the bodies of the dorsal vertebræ, connected together by the following ligaments:

Anterior Costo-central or Stellate.
Capsular. Interarticular.

The **Anterior Costo-vertebral** or **Stellate Ligament** connects the anterior part of the head of each rib with the sides of the bodies of two vertebræ and the intervertebral disk between them. It consists of three flat bundles of ligamentous fibres, which radiate from the anterior part of the head of the rib. The superior fasciculus passes upward to be connected with the body of the vertebra above; the inferior one descends to the body of the vertebra below; and the middle one, the smallest and least distinct, passes horizontally inward, to be attached to the intervertebral substance.

Relations.—In front, with the thoracic ganglia of the sympathetic, the pleura, and, on the right side, with the vena azygos major; behind, with the interarticular ligament and synovial membranes.

In the first rib, which articulates with a single vertebra only, this ligament does not present a distinct division into three fasciculi; its fibres, however, radiate, and are attached to the body of the last cervical vertebra, as well as to the body of the vertebra with which the rib articulates. In the tenth, eleventh, and twelfth ribs also, which likewise articulate with a single vertebra, the division does not

exist; but the fibres of the ligament in each case radiate and are connected with the vertebra above, as well as that with which the ribs articulate.

The **Capsular Ligament** is a thin and loose ligamentous bag, which surrounds the joint between the head of the rib and the articular cavity formed by the intervertebral disk and the adjacent vertebra. It is very thin, firmly connected with the anterior ligament, and most distinct at the upper and lower parts of the articulation. Behind, some of its fibres pass through the intervertebral foramen to the back of the intervertebral disk. This is the analogue of the *ligamentum conjugale* of some mammals, which unites the heads of opposite ribs across the back of the intervertebral disk.

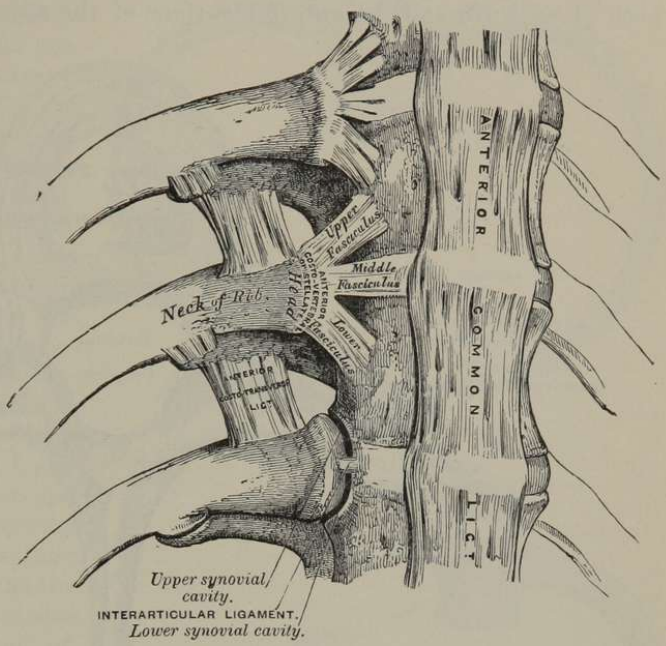

FIG. 235.—Costo-vertebral and costo-transverse articulations. Anterior view.

The **Interarticular Ligament** is situated in the interior of the joint. It consists of a short band of fibres, flattened from above downward, attached by one extremity to the sharp crest on the head of the rib, and by the other to the intervertebral disk. It divides the joint into two cavities, which have no communication with each other. In the first, tenth, eleventh, and twelfth ribs the interarticular ligament does not exist; consequently, there is but one synovial membrane.

The Synovial Membrane.—There are two synovial membranes in each of the articulations in which there is an interarticular ligament, one on each side of this structure.

2. Articulations of the Necks and Tubercles of the Ribs with the Transverse Processes (Fig. 236).

The articular portion of the tubercle of the rib and adjacent transverse process form an arthrodial joint.

In the *eleventh* and *twelfth ribs* this articulation is wanting.

The ligaments connecting these parts are the—

Superior Costo-transverse.
Middle Costo-transverse (Interosseous).
Posterior Costo-transverse.
Capsular.

The **Superior Costo-transverse Ligament** has two sets of fibres: the one (*anterior costo-transverse ligament*) is attached to the crest on the upper border of the neck of each rib, and passes obliquely upward and outward to the lower border of the transverse process immediately above; the other (*posterior costo-transverse ligament*) is attached to the neck of the rib, and passes upward and inward to the base of the transverse process and border of the lower articular process of the vertebra above. This ligament is in relation, in front, with the intercostal vessels and nerves; behind, with the Longissimus dorsi. Its *internal border* completes an aperture formed between it and the articular processes, through which pass the

posterior branches of the intercostal vessels and nerves. Its *external border* is continuous with a thin aponeurosis which covers the External intercostal muscle.

The *first rib* has no anterior costo-transverse ligament.

The **Middle Costo-transverse** or **Interosseous Ligament** consists of short but strong fibres which pass between the rough surface on the posterior part of the neck of each rib and the anterior surface of the adjacent transverse process. In

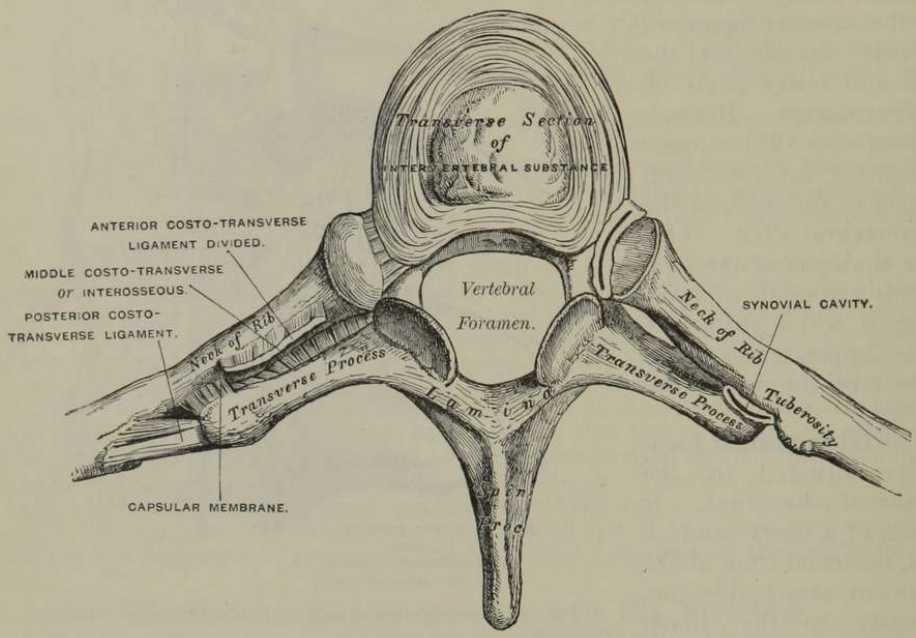

FIG. 236.—Costo-transverse articulation. Seen from above.

order fully to expose this ligament, a horizontal section should be made across the transverse process and corresponding part of the rib; or the rib may be forcibly separated from the transverse process and its fibres put on the stretch.

In the *eleventh* and *twelfth ribs* this ligament is quite rudimentary or wanting.

The **Posterior Costo-transverse Ligament** is a short but thick and strong fasciculus which passes obliquely from the summit of the transverse process to the rough non-articular portion of the tubercle of the rib. This ligament is shorter and more oblique in the upper than in the lower ribs. Those corresponding to the superior ribs ascend, while those of the inferior ribs descend slightly.

In the *eleventh* and *twelfth ribs* this ligament is wanting.

The **Capsular Ligament** is a thin, membranous sac attached to the circumference of the articular surfaces, and enclosing a small synovial membrane.

In the *eleventh* and *twelfth ribs* this ligament is absent.

Actions.—The heads, necks, and tubercles of the ribs are so closely connected to the bodies and transverse processes of the vertebræ that only a slight gliding movement of the articular surfaces on each other can take place in these articulations. The result of this gliding movement is for the *upper six* ribs an elevation of the front and middle portion of the rib, the hinder part being prevented from performing any upward movement by its close connection with the spine. In this gliding movement the rib rotates on an axis corresponding with a line drawn through the two articulations, Costo-central and Costo-transverse, which the rib forms with the spine. Of the *four* succeeding ribs, each one, besides rotating on the above-mentioned axis, also rotates on an axis corresponding with a line drawn from the head of the rib to the sternum. In other words, an *upward* and *backward gliding* is permitted between tubercle and transverse process, owing to the especial degree of *obliquity* existing between the corre-

sponding facets. By the first movement an elevation of the anterior part of the rib takes place, and a consequent enlargement of the antero-posterior diameter of the chest. None of the ribs lie in a truly horizontal plane; they are all directed more or less obliquely, so that their anterior extremities lie on a lower level than their posterior, and this obliquity increases from the first to the seventh, and then again decreases. If we examine any one rib—say, that in which there is the greatest obliquity—we shall see that it is obvious that as its sternal extremity is carried upward, it must also be thrown forward; so that the rib may be regarded as a radius moving on the vertebral joint as a centre, and causing the sternal attachment to describe an arc of a circle in the vertical plane of the body. Since all the ribs are oblique and connected in front to the sternum by the elastic costal cartilages, they must have a tendency to thrust the sternum forward, and so increase the antero-posterior diameter of the chest. By the *second* movement—that of the rotation of the rib on an axis corresponding with a line drawn from the head of the rib to the sternum—an elevation of the middle portion of the rib takes place, and consequently an increase in the transverse diameter of the chest. This elevation of the 3d, 4th, 5th, and 6th ribs is due entirely to the *shapes* of the ribs—i. e. each rib being bent or twisted around *three* axes—and not to this movement (see above). For the 7th, 8th, 9th, and 10th ribs this elevation is due both to their shapes and to this movement. The last two ribs move chiefly backward and forward, and with very little "elevation" of their middle portions (see Fig. 237). The mobility of the different ribs varies very much. The first rib is more fixed than the others, on account of the weight of the upper extremity and the strain of the ribs beneath; but on the freshly dissected thorax it moves as freely as the others. From the same causes the movement of the second rib is also not very extensive. In the other ribs this mobility increases successively down to the last two, which are very movable. The ribs are generally more movable in the female than in the male.

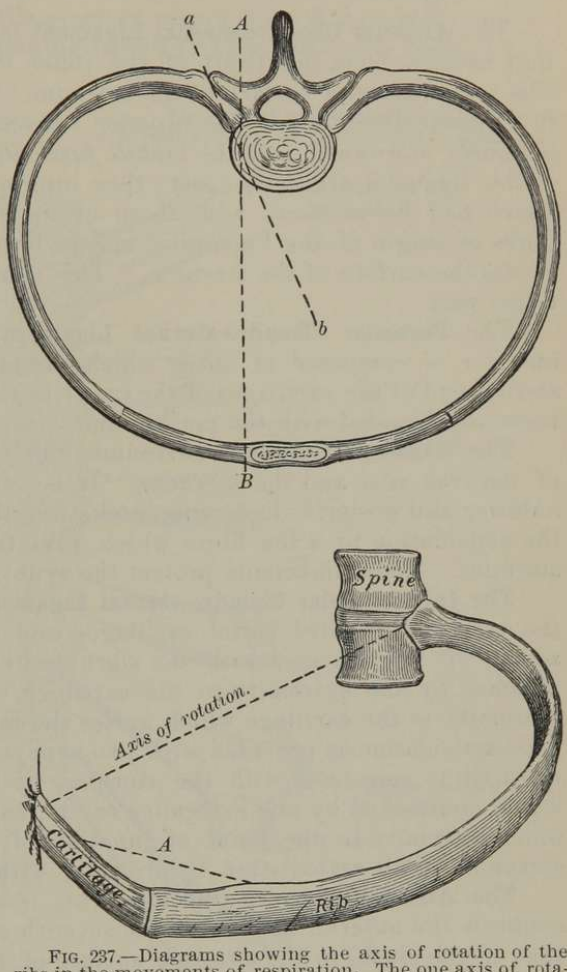

FIG. 237.—Diagrams showing the axis of rotation of the ribs in the movements of respiration. The one axis of rotation corresponds with a line drawn through the two articulations which the rib forms with the spine (*a*, *b*), and the other with a line drawn from the head of the rib to the sternum (A, B). (From Kirke's *Handbook of Physiology.*)

VII. Articulation of the Cartilages of the Ribs with the Sternum, etc. (Fig. 238).

The articulations of the cartilages of the true ribs with the sternum are arthrodial joints, with the exception of the first, in which the cartilage is almost always directly united with the sternum, and which must therefore be regarded as a synarthrodial articulation. The ligaments connecting them are—

Anterior Chondro-sternal.	Interarticular Chondro-sternal.
Posterior Chondro-sternal.	Anterior Chondro-xiphoid.
Capsular.	Posterior Chondro-xiphoid.

The **Anterior Chondro-sternal Ligament** is a broad and thin membranous band that radiates from the front of the inner extremity of the cartilages of the true ribs to the anterior surface of the sternum. It is composed of fasciculi which pass in different directions. The *superior fasciculi* ascend obliquely, the *inferior* pass obliquely downward, and the *middle fasciculi* horizontally. The superficial fibres of this ligament are the longest: they intermingle with the fibres of the ligaments above and below them, with those of the opposite side, and with the tendinous fibres of origin of the Pectoralis major, forming a thick fibrous membrane which covers the surface of the sternum. This is more distinct at the lower than at the upper part.

The **Posterior Chondro-sternal Ligament**, less thick and distinct than the anterior, is composed of fibres which radiate from the posterior surface of the sternal end of the cartilages of the true ribs to the posterior surface of the sternum, becoming blended with the periosteum.

The **Capsular Ligament** surrounds the joints formed between the cartilages of the true ribs and the sternum. It is very thin, intimately blended with the anterior and posterior ligaments, and strengthened at the upper and lower part of the articulation by a few fibres which pass from the cartilage to the side of the sternum. These ligaments protect the synovial membranes.

The Interarticular Chondro-sternal Ligaments.—These are only found between the second and third costal cartilages and the sternum. The cartilage of the *second rib* is connected with the sternum by means of an *interarticular ligament* attached by one extremity to the cartilage of the second rib, and by the other extremity to the cartilage which unites the first and second pieces of the sternum. This articulation is provided with two synovial membranes. The cartilage of the third rib is connected with the sternum by means of an interarticular ligament which is attached by one extremity to the cartilage of the third rib, and by the other extremity to the point of junction of the second and third pieces of the sternum. This articulation is provided with two synovial membranes.

The Anterior Chondro-xiphoid.—This is a band of ligamentous fibres which connects the anterior surface of the seventh costal cartilage, and occasionally also that of the sixth, to the anterior surface of the ensiform appendix. It varies in length and breadth in different subjects.

The **Posterior Chondro-xiphoid** is a similar band of fibres on the internal or posterior surface, though less thick and distinct.

Synovial Membranes.—There is no synovial membrane between the first costal cartilage and the sternum, as this cartilage is directly continuous with the sternum. There are two synovial membranes, both in the articulation of the second and third costal cartilages to the sternum. There is generally one synovial membrane in each of the joints between the fourth, fifth, sixth, and seventh costal cartilages to the sternum; but it is sometimes absent in the sixth and seventh chondro-sternal joints. Thus there are *eight* synovial cavities on each side in the articulations between the costal cartilages of the true ribs and the sternum. After middle life the articular surfaces lose their polish, become roughened, and the synovial membranes appear to be wanting. In old age the articulations do not exist, the cartilages of most of the ribs becoming continuous with the sternum.

Actions.—The movements which are permitted in the chondro-sternal articulations are limited to elevation and depression, and these only to a slight extent.

Articulations of the Cartilages of the Ribs with each other (Interchondral) (Fig. 238).

The contiguous borders of the sixth, seventh, and eighth, and sometimes the ninth and tenth, costal cartilages articulate with each other by small, smooth,

oblong-shaped facets. Each articulation is enclosed in a thin *capsular ligament* lined by *synovial membrane*, and strengthened externally and internally by ligamentous fibres (interchondral ligaments) which pass from one cartilage to the other. Sometimes the fifth costal cartilage, more rarely that of the ninth, articulates, by its lower border, with the adjoining cartilage by a small oval facet; more

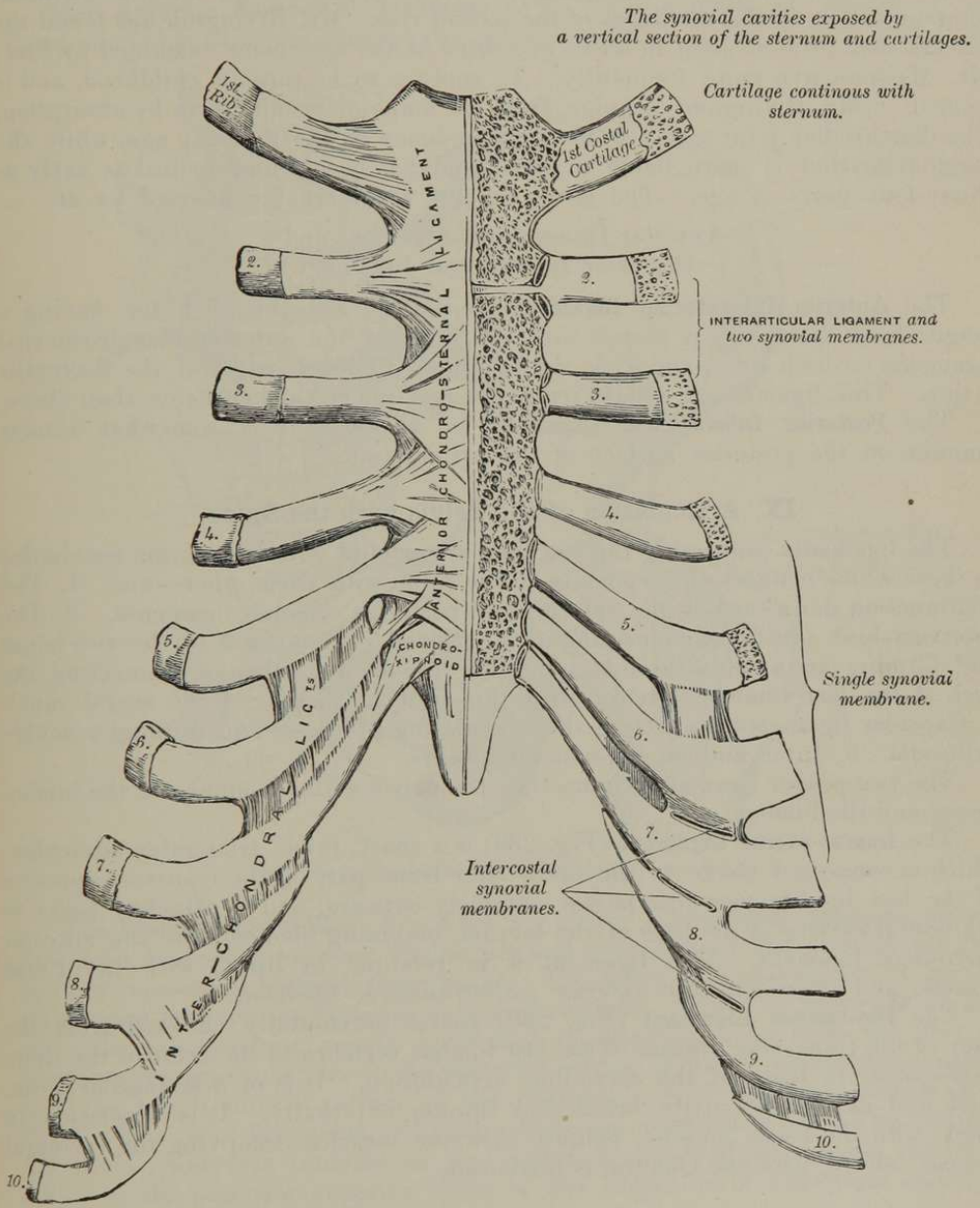

FIG. 238.—Chondro-sternal, chondro-xiphoid, and interchondral articulations. Anterior view.

frequently they are connected together by a few ligamentous fibres. Occasionally the articular surfaces above mentioned are wanting.

Articulations of the Ribs with their Cartilages (Costo-chondral) (Fig. 238).

The outer extremity of each costal cartilage is received into a depression in the sternal end of the ribs, and the two are held together by the periosteum.

VIII. Ligaments of the Sternum.

The first piece of the sternum is united to the second either by an amphiarthrodial joint—a single piece of true fibro-cartilage uniting the segments—or by a diarthrodial joint, in which each bone is clothed with a distinct lamina of cartilage, adherent on one side, free and lined with synovial membrane on the other. In the latter case the cartilage covering the gladiolus is continued without interruption on to the cartilages of the second ribs. Mr. Rivington has found the diarthrodial form of joint in about one-third of the specimens examined by him; Mr. Maisonneuve more frequently. It appears to be rare in childhood, and is formed, in Mr. Rivington's opinion, from the amphiarthrodial form by absorption. The diarthrodial joint seems to have no tendency to ossify at any age, while the amphiarthrodial is more liable to do so, and has been found ossified as early as thirty-four years of age. The two segments are further connected by an

Anterior Intersternal Ligament and a
Posterior Intersternal Ligament.

The **Anterior Intersternal Ligament** consists of a layer of fibres, having a longitudinal direction; it blends with the fibres of the anterior chondro-sternal ligaments on both sides, and with the tendinous fibres of origin of the Pectoralis major. This ligament is rough, irregular, and much thicker below than above.

The **Posterior Intersternal Ligament** is disposed in a somewhat similar manner on the posterior surface of the articulation.

IX. Articulation of the Pelvis with the Spine.

The ligaments connecting the last lumbar vertebra with the sacrum are similar to those which connect the segments of the spine with each other—viz: 1. The continuation downward of the anterior and posterior common ligaments. 2. The intervertebral substance connecting the flattened oval surfaces of the two bones and forming an amphiarthrodial joint. 3. Ligamenta subflava, connecting the arch of the last lumbar vertebra with the posterior border of the sacral canal. 4. Capsular ligaments connecting the articulating processes and forming a double arthrodia. 5. Inter- and supraspinous ligaments.

The two proper ligaments connecting the pelvis with the spine are the lumbo-sacral and ilio-lumbar.

The **Lumbo-sacral Ligament** (Fig. 239) is a short, thick, triangular fasciculus, which is connected above to the lower and front part of the transverse process of the last lumbar vertebra, passes obliquely outward, and is attached below to the lateral surface of the base of the sacrum, becoming blended with the anterior sacro-iliac ligament. This ligament is in relation, in front, with the Psoas muscle, and represents the *anterior costo-transverse ligament.*

The **Ilio-lumbar Ligament** (Fig. 239) passes horizontally outward from the apex of the transverse process of the last lumbar vertebra to the crest of the ilium immediately in front of the sacro-iliac articulation. It is of a triangular form, thick and narrow internally, broad and thinner externally. It is in relation, in front, with the Psoas muscle; behind, with the muscles occupying the vertebral groove; above, with the Quadratus lumborum.

X. Articulations of the Pelvis.

The ligaments connecting the bones of the pelvis with each other may be divided into four groups: 1. Those connecting the sacrum and ilium. 2. Those passing between the sacrum and ischium. 3. Those connecting the sacrum and coccyx. 4. Those between the two pubic bones.

1. Articulations of the Sacrum and Ilium.

The sacro-iliac articulation is formed between the lateral surfaces of the sacrum and ilium. The anterior or auricular portion of each articular surface

is covered with a thin plate of cartilage, thicker on the sacrum than on the ilium. The surfaces of these cartilages are usually in close contact, but not united. Sometimes fine fibres are found running between portions of these surfaces, which in other cases may be, in the adult, rough and irregular, and separated from one another by spaces containing synovial-like fluid. The ligaments connecting these surfaces are the anterior and posterior sacro-iliac.

The **Anterior Sacro-iliac Ligament** (Fig. 239) consists of numerous thin ligamentous bands which connect the anterior surfaces of the sacrum and ilium.

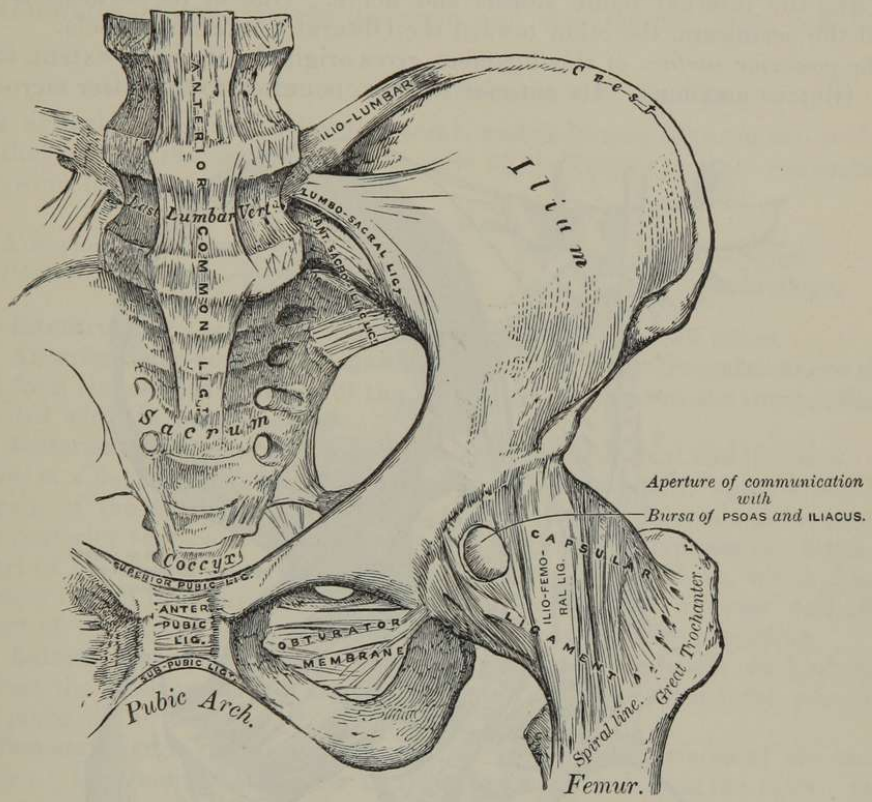

FIG. 239.—Articulations of pelvis and hip. Anterior view.

The **Posterior Sacro-iliac** (Fig. 240) is a strong interosseous ligament, situated in a deep depression between the sacrum and ilium behind, and forming the chief bond of connection between those bones. It consists of numerous strong fasciculi which pass between the bones in various directions. Three of these are of large size: the *two superior*, nearly horizontal in direction, arise from the first and second transverse tubercles on the posterior surface of the sacrum, and are inserted into the rough, uneven surface at the posterior part of the inner surface of the ilium. The third fasciculus, oblique in direction, is attached by one extremity to the third transverse tubercle on the posterior surface of the sacrum, and by the other to the posterior superior spine of the ilium; it is sometimes called the *oblique sacro-iliac ligament.*

The position of the sacro-iliac joint is indicated by the posterior superior spine of the ilium. This process is immediately behind the centre of the articulation.

2. LIGAMENTS PASSING BETWEEN THE SACRUM AND ISCHIUM (Fig. 240).

The Great Sacro-sciatic (Posterior).
The Lesser Sacro-sciatic (Anterior).

The **Great** or **Posterior Sacro-sciatic Ligament** is situated at the lower and back part of the pelvis. It is thin, flat, and triangular in form; narrower in the

middle than at the extremities; attached by its broad base to the posterior inferior spine of the ilium, to the fourth and fifth transverse tubercles of the sacrum, and to the lower part of the lateral margin of that bone and the coccyx. Passing obliquely downward, outward, and forward, it becomes narrow and thick, and at its insertion into the inner margin of the tuberosity of the ischium it increases in breadth, and is prolonged forward along the inner margin of the ramus, forming what is known as the *falciform ligament*. The free concave edge of this prolongation has attached to it the obturator fascia, with which it forms a kind of groove, protecting the internal pudic vessels and nerve. One of its surfaces is turned toward the perinæum, the other toward the Obturator internus muscle.

The *posterior surface* of this ligament gives origin, by its whole extent, to fibres of the Gluteus maximus. Its *anterior surface* is united to the lesser sacro-sciatic

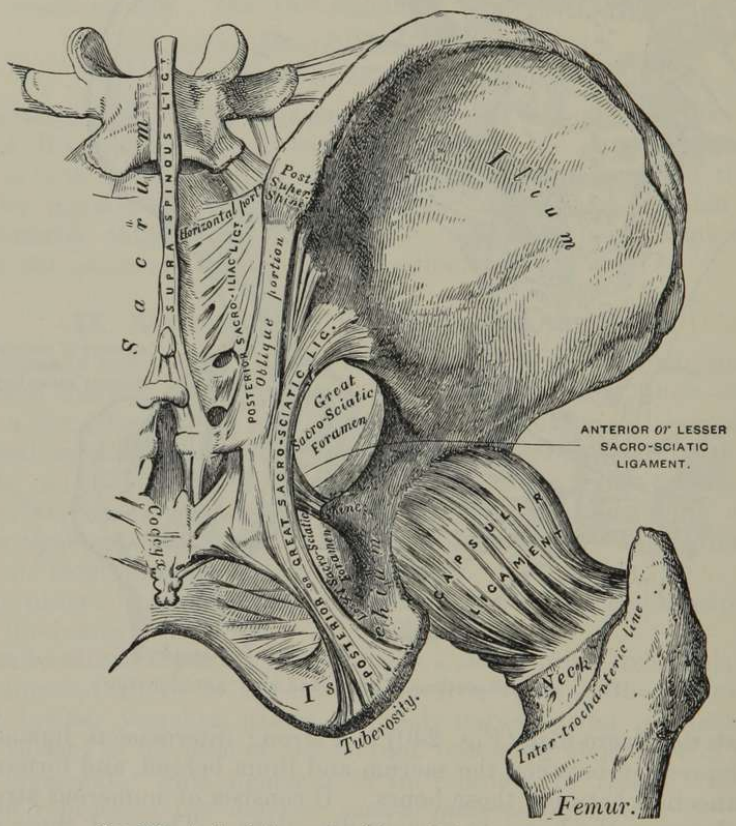

FIG. 240.—Articulations of pelvis and hip. Posterior view.

ligament. Its *external border* forms, above, the posterior boundary of the great sacro-sciatic foramen, and, below, the lower boundary of the lesser sacro-sciatic foramen. Its *lower border* forms part of the boundary of the perinæum. It is pierced by the coccygeal branch of the sciatic artery and coccygeal nerve.

The **Lesser** or **Anterior Sacro-sciatic Ligament,** much shorter and smaller than the preceding, is thin, triangular in form, attached by its apex to the spine of the ischium, and internally, by its broad base, to the lateral margin of the sacrum and coccyx, anterior to the attachment of the great sacro-sciatic ligament, with which its fibres are intermingled.

It is in relation, *anteriorly*, with the Coccygeus muscle; *posteriorly*, it is covered by the great sacro-sciatic ligament and crossed by the internal pudic vessels and nerve. Its *superior border* forms the lower boundary of the great sacro-sciatic foramen; its *inferior border*, part of the lesser sacro-sciatic foramen.

These two ligaments convert the sacro-sciatic notches into foramina. The *superior* or *great* sacro-sciatic foramen is bounded, in front and above, by the

posterior border of the os innominatum; behind, by the great sacro-sciatic ligament; and below, by the lesser sacro-sciatic ligament. It is partially filled up, in the recent state, by the Pyriformis muscle, which passes through it. Above this muscle the gluteal vessels and superior gluteal nerve emerge from the pelvis, and, below it, the sciatic vessels and nerves, the internal pudic vessels and nerve, and muscular branches from the sacral plexus. The *inferior* or *lesser* sacro-sciatic foramen is bounded, in front, by the tuber ischii; above, by the spine and lesser sacro-sciatic ligament; behind, by the greater sacro-sciatic ligament. It transmits the tendon of the Obturator internus muscle, its nerve, and the internal pudic vessels and nerve.

3. Articulation of the Sacrum and Coccyx.

This articulation is an arthrodial joint, and is formed between the oval surface at the apex of the sacrum and the base of the coccyx. It is connected by the following ligaments:

Interarticular.

Anterior Sacro-coccygeal.	Lateral Sacro-coccygeal.
Posterior Sacro-coccygeal.	Interposed Fibro-cartilage.

The **Interarticular Ligaments** connect the cornua of the two bones.

The **Anterior Sacro-coccygeal Ligament** consists of a few irregular fibres which descend from the anterior surface of the sacrum to the front of the coccyx, becoming blended with the periosteum.

The **Posterior Sacro-coccygeal Ligaments** are the *superficial* and the *deep*. The *superficial* is a flat band of ligamentous fibres, of a pearly tint, which arises from the margin of the lower orifice of the sacral canal and descends to be inserted into the posterior surface of the coccyx. This ligament completes the lower and back part of the sacral canal. The *deep* consists of a few fibres, which descend to the coccyx from that part of the sacrum which forms the *anterior* wall of the lower part of the sacral canal. Its lower end blends with the preceding.

The **Lateral Sacro-coccygeal Ligaments** are ligamentous bands, each of which passes from the inferior lateral angle of the sacrum to the transverse process of the first piece of the coccyx.

A **Fibro-cartilage** is interposed between the contiguous surfaces of the sacrum and coccyx. It is somewhat thicker in front and behind than at the sides. Occasionally, a synovial membrane is found when the coccyx is freely movable, which is more especially the case during pregnancy.

The different segments of the coccyx are connected together by an extension downward of the anterior and posterior sacro-coccygeal ligaments, a thin annular disk of fibro-cartilage being interposed between each of the bones. In the adult male all the pieces become ossified, but in the female this does not commonly occur until a later period of life. The separate segments of the coccyx are first united, and at a more advanced age the joint between the sacrum and coccyx is obliterated.

Actions.—The movements which take place between the sacrum and coccyx, and between the different pieces of the latter bone, are slightly forward and backward; they are very limited. Their extent increases during pregnancy.

4. Articulation of the Ossa Pubis (Fig. 241).

The articulation between the pubic bones is an amphiarthrodial joint, formed by the junction of the two oval articular surfaces of the ossa pubis. The articular surface has been described on a former page under the name of *symphysis*, and the same name is given to the joint. The ligaments of this articulation are the

Anterior Pubic.	Posterior Pubic.
Superior Pubic.	Subpubic.

Interpubic disk.

The **Anterior Pubic Ligament** consists of several superimposed layers which pass across the front of the articulation. The superficial fibres pass obliquely from one bone to the other, decussating and forming an interlacement with the fibres of the aponeurosis of the External oblique and the tendon of the Rectus muscles. The deep fibres pass transversely across the symphysis, and are blended with the fibro-cartilage.

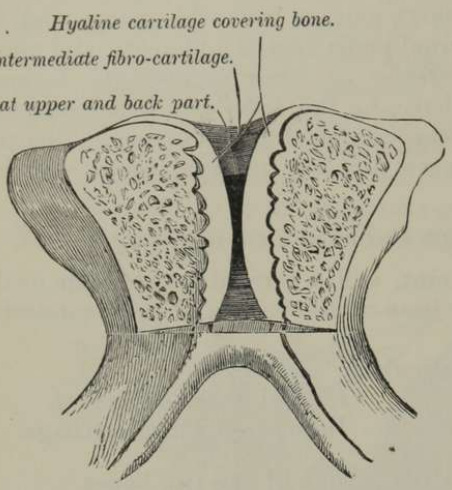

FIG. 241.—Vertical section of the symphysis pubis. Made near its posterior surface.

The **Posterior Pubic Ligament** consists of a few thin, scattered fibres which unite the two pubic bones posteriorly.

The **Superior Pubic Ligament** is a band of fibres which connects together the two pubic bones superiorly.

The **Subpubic Ligament** is a thick, triangular arch of ligamentous fibres, connecting together the two pubic bones below and forming the upper boundary of the pubic arch. Above, it is blended with the interarticular fibro-cartilage; laterally it is united with the rami of the os pubis. Its fibres are closely connected and have an arched direction.

The **Interpubic Disk** consists of a disk of cartilage and fibro-cartilage connecting the surfaces of the pubic bones in front. Each pubic symphysis is covered by a thin layer of hyaline cartilage which is firmly connected to the bone by a series of nipple-like processes which accurately fit within corresponding depressions on the osseous surfaces. These opposed cartilaginous surfaces are connected together by an intermediate stratum of fibrous tissue and fibro-cartilage which varies in thickness in different subjects. It often contains a cavity in its centre, probably formed by the softening and absorption of the fibro-cartilage, since it rarely appears before the tenth year of life, and is not lined by synovial membrane. It is larger in the female than in the male, but it is very questionable whether it enlarges, as was formerly supposed, during pregnancy. It is most frequently limited to the upper and back part of the joint, but it occasionally reaches to the front, and may extend the entire length of the cartilage. This cavity may be easily demonstrated by making a vertical section of the symphysis pubis near its posterior surface.

The **Obturator Ligament** is more properly regarded as analogous to the muscular fasciæ, with which it will be described.

ARTICULATIONS OF THE UPPER EXTREMITY.

The articulations of the upper extremity may be arranged in the following groups: I. Sterno-clavicular articulation. II. Acromio-clavicular articulation. III. Ligaments of the Scapula. IV. Shoulder-joint. V. Elbow-joint. VI. Radio-ulnar articulations. VII. Wrist-joint. VIII. Articulations of the Carpal Bones. IX. Carpo-metacarpal articulations. X. Metacarpo-phalangeal articulations. XI. Articulations of the Phalanges.

I. Sterno-clavicular Articulation (Fig. 242).

The **Sterno-clavicular** is regarded by most anatomists as an arthrodial joint, but Cruveilhier considers it to be an articulation by reciprocal reception. Probably the former opinion is the correct one, the varied movement which the joint enjoys being due to the interposition of an interarticular fibro-cartilage between the joint surfaces. The parts entering into its formation are the sternal end of the

clavicle, the upper and lateral part of the first piece of the sternum, and the cartilage of the first rib. The articular surface of the clavicle is much larger than

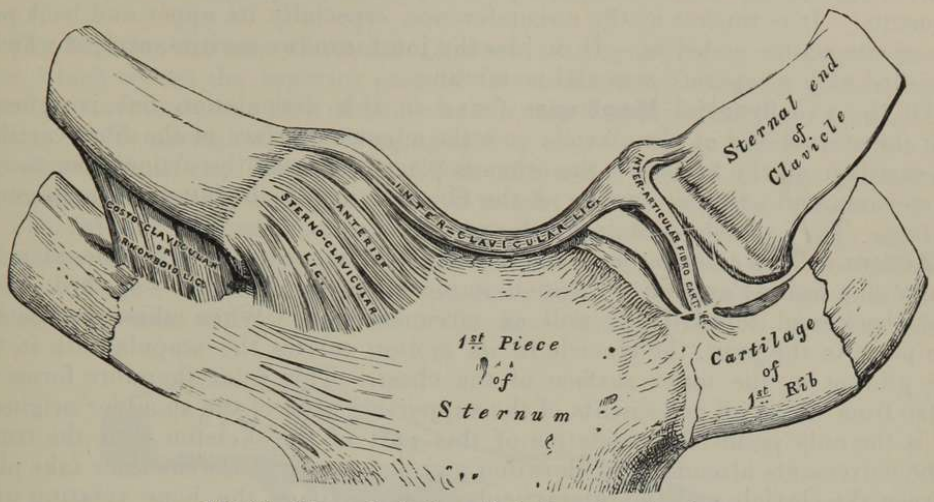

FIG. 242.—Sterno-clavicular articulation. Anterior view.

that of the sternum, and invested with a layer of cartilage [1] which is considerably thicker than that on the latter bone. The ligaments of this joint are the

Anterior Sterno-clavicular.	Interclavicular.
Posterior Sterno-clavicular.	Costo-clavicular (rhomboid).

Interarticular Fibro-cartilage.

The **Anterior Sterno-clavicular Ligament** is a broad band of fibres which covers the anterior surface of the articulation, being attached, above, to the upper and front part of the inner extremity of the clavicle, and, passing obliquely downward and inward, is attached, below, to the upper and front part of the first piece of the sternum. This ligament is covered, in front, by the sternal portion of the Sterno-cleido-mastoid and the integument; behind, it is in relation with the interarticular fibro-cartilage and the two synovial membranes.

The **Posterior Sterno-clavicular Ligament** is a similar band of fibres which covers the posterior surface of the articulation, being attached, above, to the upper and back part of the inner extremity of the clavicle, and, passing obliquely downward and inward, is attached, below, to the upper and back part of the first piece of the sternum. It is in relation, in front, with the interarticular fibro-cartilage and synovial membranes; behind, with the Sterno-hyoid and Sterno-thyroid muscles.

The **Interclavicular Ligament** is a flattened band which varies considerably in form and size in different individuals; it passes in a curved direction from the upper part of the inner extremity of one clavicle to the other, and is closely attached to the upper margin of the sternum. It is in relation, in front, with the integument; behind, with the Sterno-thyroid muscles.

The **Costo-clavicular Ligament** (**rhomboid**) is short, flat, and strong: it is of a rhomboid form, attached, below, to the upper and inner part of the cartilage of the first rib: it ascends obliquely backward and outward, and is attached, above, to the rhomboid depression on the under surface of the clavicle. It is in relation, in front, with the tendon of origin of the Subclavius; behind, with the subclavian vein.

The **Interarticular Fibro-cartilage** is a flat and nearly circular disk, interposed between the articulating surfaces of the sternum and clavicle. It is attached,

[1] According to Bruch, the sternal end of the clavicle is covered by a tissue which is rather fibrous than cartilaginous in structure.

above, to the upper and posterior border of the articular surface of the clavicle; below, to the cartilage of the first rib, at its junction with the sternum; and by its circumference, to the anterior and posterior sterno-clavicular and interclavicular ligaments. It is thicker at the circumference, especially its upper and back part, than at its centre or below. It divides the joint into two cavities, each of which is furnished with a separate synovial membrane.

Of the two **Synovial Membranes** found in this articulation, one is reflected from the sternal end of the clavicle over the adjacent surface of the fibro-cartilage and cartilage of the first rib; the other is placed between the articular surface of the sternum and adjacent surface of the fibro-cartilage; the latter is the larger of the two. They seldom contain much synovia.

Actions.—This articulation is the centre of the movements of the shoulder, and admits of a limited amount of motion in nearly every direction—upward, downward, backward, forward—as well as circumduction. When these movements take place in the joint, the clavicle in its motion carries the scapula with it, this bone gliding on the outer surface of the chest. This joint therefore forms the centre from which all movements of the supporting arch of the shoulder originate, and is the only point of articulation of this part of the skeleton with the trunk. "The movements attendant on elevation and depression of the shoulder take place between the clavicle and the interarticular fibro-cartilage, the bone rotating upon the ligament on an axis drawn from before backward through its own articular facet. When the shoulder is moved forward and backward, the clavicle, with the interarticular fibro-cartilage, rolls to and fro on the articular surface of the sternum, revolving, with a sliding movement, round an axis drawn nearly vertically through the sternum. In the circumduction of the shoulder, which is compounded of these two movements, the clavicle revolves upon the interarticular fibro-cartilage, and the latter, with the clavicle, rolls upon the sternum." [1] Elevation of the clavicle is principally limited by the costo-clavicular ligament; depression, by the interclavicular. The muscles which *raise* the clavicle, as in shrugging the shoulders, are the upper fibres of the Trapezius, the Levator anguli scapulæ, the clavicular head of the Sterno-mastoid, assisted to a certain extent by the two Rhomboids, which pull the inferior angle of the Scapula backward and upward, and so raise the clavicle. The *depression* of the clavicle is principally effected by gravity, assisted by the Subclavius, Pectoralis minor, and lower fibres of the Trapezius. It is drawn *backward* by the Rhomboids and the middle and lower fibres of the Trapezius, and *forward* by the Serratus magnus and Pectoralis minor.

Surface Form.—The position of the sterno-clavicular joint may be easily ascertained by feeling the enlarged sternal end of the collar-bone just external to the long, cord-like, sternal origin of the Sterno-mastoid muscle. If this muscle is relaxed by bending the head forward, a depression just internal to the end of the clavicle, and between it and the sternum, can be felt, indicating the exact position of the joint, which is subcutaneous. When the arm hangs by the side, the cavity of the joint is V-shaped. If the arm is raised, the bones become more closely approximated, and the cavity becomes a mere slit.

Surgical Anatomy.—The strength of this joint mainly depends upon its ligaments, and it is to this, and to the fact that the force of the blow is generally transmitted along the long axis of the clavicle, that dislocation rarely occurs, and that the bone is generally broken rather than displaced. When dislocation does occur, the course which the displaced bone takes depends more upon the direction in which the violence is applied than upon the anatomical construction of the joint; it may be either forward, backward, or upward. The chief point worthy of note, as regards the construction of the joint, in regard to dislocations, is the fact that, owing to the shape of the articular surfaces being so little adapted to each other, and that the strength of the joint mainly depends upon the ligaments, the displacement when reduced is very liable to recur, and hence it is extremely difficult to keep the end of the bone in its proper place.

II. Acromio-clavicular Articulation (Fig. 243).

The **Acromio-clavicular** is an arthrodial joint formed between the outer extremity of the clavicle and the upper edge of the acromion process of the scapula. Its ligaments are the

[1] Humphry, *On the Human Skeleton*, p. 402.

Superior Acromio-clavicular.		Trapezoid
Inferior Acromio-clavicular.	Coraco-clavicular	and
Interarticular Fibro-cartilage.		Conoid.

The **Superior Acromio-clavicular Ligament** is a broad band, of a quadrilateral form, which covers the superior part of the articulation, extending between the upper part of the outer end of the clavicle and the adjoining part of the upper surface of the acromion. It is composed of parallel fibres which interlace with the aponeurosis of the Trapezius and Deltoid muscles; below, it is in contact with the interarticular fibro-cartilage (when it exists) and the synovial membranes.

The **Inferior Acromio-clavicular Ligament,** somewhat thinner than the preceding, covers the under part of the articulation, and is attached to the adjoining surfaces of the two bones. It is in relation, above, with the synovial membranes, and in rare cases with the interarticular fibro-cartilage; below, with the tendon

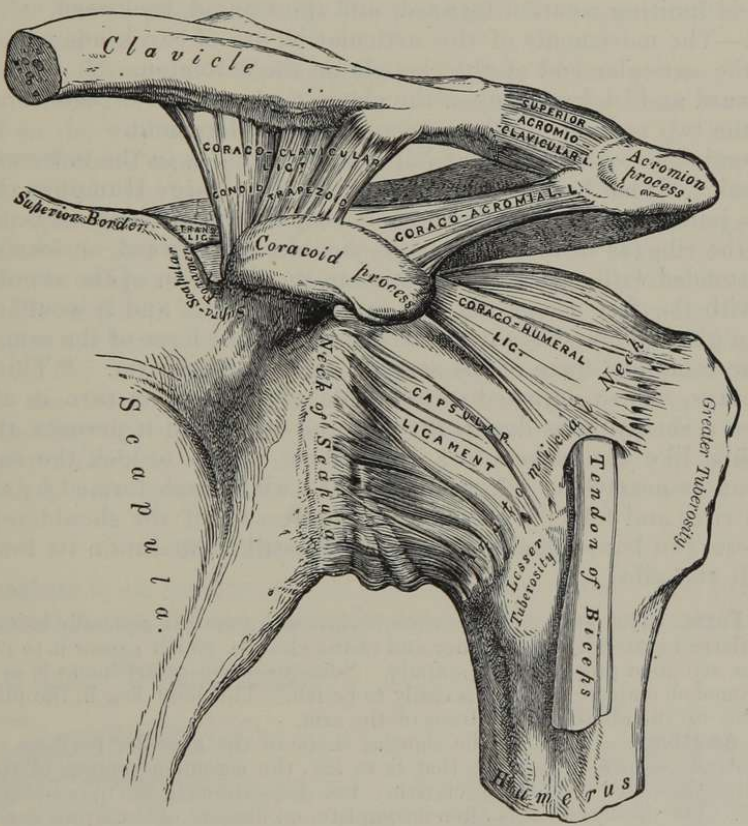

FIG. 243.—The left shoulder-joint, scapulo-clavicular articulations, and proper ligaments of scapula.

of the Supraspinatus. These two ligaments are continuous with each other in front and behind, and form a complete capsule round the joint.

The **Interarticular Fibro-cartilage** is frequently absent in this articulation. When it exists it generally only partially separates the articular surfaces, and occupies the upper part of the articulation. More rarely it completely separates the joint into two cavities.

The Synovial Membrane.—There is usually only one synovial membrane in this articulation, but when a complete interarticular fibro-cartilage exists there are two synovial membranes.

The **Coraco-clavicular Ligament** serves to connect the clavicle with the coracoid process of the scapula. It does not properly belong to this articulation, but as it forms a most efficient means in retaining the clavicle in contact with the acromial

process, it is usually described with it. It consists of two fasciculi, called the *trapezoid* and *conoid ligaments*.

The *Trapezoid Ligament*, the anterior and external fasciculus, is broad, thin, and quadrilateral; it is placed obliquely between the coracoid process and the clavicle. It is attached, below, to the upper surface of the coracoid process; above, to the oblique line on the under surface of the clavicle. Its anterior border is free; its posterior border is joined with the conoid ligament, the two forming by their junction a projecting angle.

The *Conoid Ligament*, the posterior and internal fasciculus, is a dense band of fibres, conical in form, the base being turned upward, the summit downward. It is attached by its apex to a rough impression at the base of the coracoid process, internal to the preceding; above, by its expanded base, to the conoid tubercle on the under surface of the clavicle, and to a line proceeding internally from it for half an inch. These ligaments are in relation, in front, with the Subclavius and Deltoid; behind, with the Trapezius. They serve to limit rotation of the scapula, the Trapezoid limiting rotation forward, and the Conoid backward.

Actions.—The movements of this articulation are of two kinds: 1. A gliding motion of the articular end of the clavicle on the acromion. 2. Rotation of the scapula forward and backward upon the clavicle, the extent of this rotation being limited by the two portions of the coraco-clavicular ligament.

The acromio-clavicular joint has important functions in the movements of the upper extremity. It has been well pointed out by Sir George Humphry that if there had been no joint between the clavicle and scapula the circular movement of the scapula on the ribs (as in throwing both shoulders backward or forward) would have been attended with a greater alteration in the direction of the shoulder than is consistent with the free use of the arm in such position, and it would have been impossible to give a blow straight forward with the full force of the arm; that is to say, with the combined force of the scapula, arm, and forearm. "This joint," as he happily says, "is so adjusted as to enable either bone to turn in a hinge-like manner upon a vertical axis drawn through the other, and it permits the surfaces of the scapula, like the baskets in a roundabout swing, to look the same way in every position or nearly so." Again, when the whole arch formed by the clavicle and scapula rises and falls (in elevation or depression of the shoulders), the joint between these two bones enables the scapula still to maintain its lower part in contact with the ribs.

Surface Form.—The position of the acromio-clavicular joint can generally be ascertained by the slightly enlarged extremity of the outer end of the clavicle, which causes it to project above the level of the acromion process of the scapula. Sometimes this enlargement is so considerable as to form a rounded eminence, which is easily to be felt. The joint lies in the plane of a vertical line passing up the middle of the front of the arm.

Surgical Anatomy.—Owing to the slanting shape of the articular surfaces of this joint, dislocation generally occurs downward; that is to say, the acromion process of the scapula is dislocated under the outer end of the clavicle; but dislocations in the opposite direction have been described. The displacement is often incomplete, on account of the strong coraco-clavicular ligaments, which remain untorn. The same difficulty exists, as in the sterno-clavicular dislocation, in maintaining the ends of the bone in position after reduction.

III. Proper Ligaments of the Scapula (Fig. 243).

The proper ligaments of the scapula are the

Coraco-acromial. Transverse.

The **Coraco-acromial Ligament** is a broad, thin, flat band, of a triangular shape, extended transversely above the upper part of the shoulder-joint, between the coracoid and acromial processes. It is attached, by its apex, to the summit of the acromion just in front of the articular surface for the clavicle, and by its broad base to the whole length of the outer border of the coracoid process. Its posterior fibres are directed obliquely backward and inward, its anterior fibres transversely inward. This ligament completes the vault formed by the coracoid and acromion

processes for the protection of the head of the humerus. It is in relation, above, with the clavicle and under surface of the Deltoid; below, with the tendon of the Supraspinatus muscle, a bursa being interposed. Its anterior border is continuous with a dense cellular lamina that passes beneath the Deltoid upon the tendons of the Supra- and Infraspinatus muscles. This ligament is sometimes described as consisting of two marginal bands and a thinner intervening portion, the two bands being attached respectively to the apex and base of the coracoid process, and joining together at their attachment into the acromion process. When the Pectoralis minor is inserted, as sometimes is the case, into the capsule of the shoulder-joint, instead of into the coracoid process, it passes between these two bands, and the intervening portion is then deficient.

The **Transverse** or **Coracoid** (*suprascapular*) **Ligament** converts the suprascapular notch into a foramen. It is a thin and flat fasciculus, narrower at the middle than at the extremities, attached by one end to the base of the coracoid process, and by the other to the inner extremity of the scapular notch. The suprascapular nerve passes through the foramen; the suprascapular vessels pass over the ligament.

Movements of Scapula.—The scapula is capable of being moved upward and downward, forward and backward, or, by a combination of these movements, circumducted on the wall of the chest. The muscles which *raise* the scapula are the upper fibres of the Trapezius, the Levator anguli scapulæ, and the two Rhomboids; those which *depress* it are the lower fibres of the Trapezius, the Pectoralis minor, and, through the clavicle, the Subclavius. The scapula is drawn *backward* by the Rhomboids and the middle and lower fibres of the Trapezius, and *forward* by the Serratus magnus and Pectoralis minor, assisted, when the arm is fixed, by the Pectoralis major. The mobility of the scapula is very considerable, and greatly assists the movements of the arm at the shoulder-joint. Thus, in raising the arm from the side the Deltoid and Supraspinatus can only lift it to a right angle with the trunk, the further elevation of the limb being effected by the Trapezius moving the scapula on the wall of the chest. This mobility is of special importance in ankylosis of the shoulder-joint, the movements of this bone compensating to a very great extent for the immobility of the joint.

IV. Shoulder-Joint (Fig. 243).

The **Shoulder** is an enarthrodial or ball-and-socket joint. The bones entering into its formation are the large globular head of the humerus, which is received

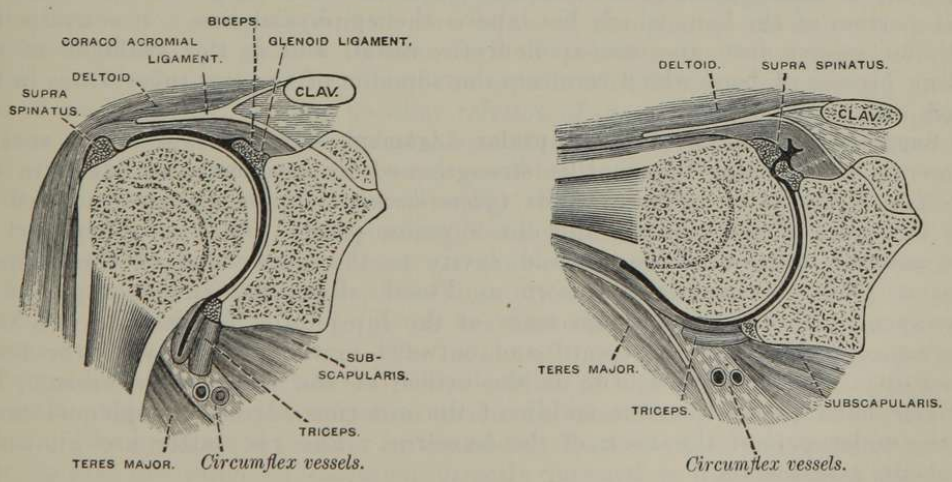

FIG. 244.—Vertical sections through the shoulder-joint, the arm being vertical and horizontal. (After Henle.)

into the shallow glenoid cavity of the scapula—an arrangement which permits of very considerable movement, whilst the joint itself is protected against displacement

by the tendons which surround it and by atmospheric pressure. The ligaments do not maintain the joint surfaces in apposition, because when they alone remain the humerus can be separated to a considerable extent from the glenoid cavity; their use, therefore, is to limit the amount of movement. Above, the joint is protected by an arched vault, formed by the under surface of the coracoid and acromion processes, and the coraco-acromial ligament. The articular surfaces are covered by a layer of cartilage: that on the head of the humerus is thicker at the centre than at the circumference, the reverse being the case in the glenoid cavity. The ligaments of the shoulder are the

Capsular.	Coraco-humeral.
Glenoid.[1]	Transverse humeral.

The **Capsular Ligament** completely encircles the articulation, being attached, above, to the circumference of the glenoid cavity beyond the glenoid ligament; below, to the anatomical neck of the humerus, approaching nearer to the articular cartilage above than in the rest of its extent. It is thicker above and below than elsewhere, and is remarkably loose and lax, and much larger and longer than is necessary to keep the bones in contact, allowing them to be separated from each other more than an inch—an evident provision for that extreme freedom of movement which is peculiar to this articulation. Its superficial surface is strengthened, above, by the Supraspinatus; below, by the long head of the Triceps; posteriorly, by the tendons of the Infraspinatus and Teres minor; and anteriorly, by the tendon of the Subscapularis. The capsular ligament usually presents three openings; one anteriorly, below the coracoid process, establishes a communication between the synovial membrane of the joint and a bursa beneath the tendon of the Subscapularis. The second, which is not constant, exists between the joint and a bursal sac belonging to the Infraspinatus muscle. The third is seen between the two tuberosities, for the passage of the long tendon of the Biceps muscle.

The **Coraco-humeral** is a broad band which strengthens the upper part of the capsular ligament. It arises from the outer border of the coracoid process, and passes obliquely downward and outward to the front of the great tuberosity of the humerus, being blended with the tendon of the Supraspinatus muscle. This ligament is intimately united to the capsular in the greater part of its extent.

The Transverse Humeral Ligament.—This is a broad band of fibrous tissue passing from the lesser to the greater tuberosity of the humerus, and always limited to that portion of the bone which lies above the epiphysial line. It converts the bicipital groove into an osseo-aponeurotic canal, and is the analogue of the strong process of bone which connects the summits of the two tuberosities in the musk ox.

Supplemental Bands of the Capsular Ligament.—In addition to the coraco-humeral, the capsular ligament is strengthened by supplemental bands in the *interior* of the joint. These bands (*gleno-humeral ligaments*) are situated on the fore part of the capsule, and the *superior* passes from the upper part of the anterior margin of the glenoid cavity to the upper end of the bicipital groove. This is sometimes known as Flood's ligament, and is supposed to correspond with the ligamentum teres of the hip-joint. The *middle* one, from the same origin, passes downward and outward to the lower part of the lesser tuberosity. Between these two is the orifice of the *subscapular bursa*. The *inferior* band passes from the middle of the anterior edge of the glenoid cavity to the under part of the neck of the humerus. The two latter are known as Schlemm's ligaments.

The **Glenoid Ligament** is a fibrous rim attached round the margin of the

[1] The long tendon of origin of the Biceps muscle also acts as one of the ligaments of this joint. See the observations on p. 318 on the function of the muscles passing over more than one joint.

glenoid cavity. It is continuous above with the long tendon of the Biceps, which bifurcates at that point.

The **Synovial Membrane** is reflected from the margin of the glenoid cavity over the fibro-cartilaginous rim surrounding it: it is then reflected over the internal surface of the capsular ligament, covers the lower part and sides of the neck of the humerus, and is continued a short distance over the cartilage covering the head of the bone. The long tendon of the Biceps muscle which passes through the capsular ligament is enclosed in a tubular sheath of synovial membrane, which is reflected upon it at the point where it perforates the capsule, and is continued around it as far as the summit of the glenoid cavity. The tendon of the Biceps is thus enabled to traverse the articulation, but it is not contained in the interior of the synovial cavity. The synovial membrane communicates with a large bursal sac beneath the tendon of the Subscapularis, by an opening on the anterior side of the capsular ligament; it also occasionally communicates with another bursal sac, beneath the tendon of the Infraspinatus, through an orifice at its posterior part. A third bursal sac, which does not communicate with the joint, is placed between the under surface of the Deltoid and the outer surface of the capsule.

The *Muscles* in relation with the joint are, above, the Supraspinatus; below, the long head of the Triceps; internally, the Subscapularis; externally, the Infraspinatus and Teres minor; within, the long tendon of the Biceps. The Deltoid is placed most externally, and covers the articulation on its outer side, as well as in front and behind.

The *Arteries* supplying the joint are articular branches of the anterior and posterior circumflex, and suprascapular.

The *Nerves* are derived from the circumflex and suprascapular.

Actions.—The shoulder-joint is capable of movement in every direction, forward, backward, abduction, adduction, circumduction, and rotation. The humerus is drawn *forward* by the Pectoralis major, anterior fibres of the Deltoid, Coracobrachialis, and by the Biceps when the forearm is flexed; *backward*, by the Latissimus dorsi, Teres major, posterior fibres of the Deltoid, and by the Triceps when the forearm is extended; it is *abducted* (elevated) by the Deltoid and Supraspinatus; it is *adducted* (depressed) by the Subscapularis, Pectoralis major, Latissimus dorsi, and Teres major; it is *rotated outward* by the Infraspinatus and Teres minor; and it is *rotated inward* by the Subscapularis, Latissimus dorsi, Teres major, and Pectoralis major.

The most striking peculiarities in this joint are: 1. The large size of the head of the humerus in comparison with the depth of the glenoid cavity, even when supplemented by the glenoid ligament. 2. The looseness of the capsule of the joint. 3. The intimate connection of the capsule with the muscles attached to the head of the humerus. 4. The peculiar relation of the biceps tendon to the joint.

It is in consequence of the relative size of the two articular surfaces that the joint enjoys such free movement in every possible direction. When these movements of the arm are arrested in the shoulder-joint by the contact of the bony surfaces and by the tension of the corresponding fibres of the capsule, together with that of the muscles acting as accessory ligaments, they can be carried considerably farther by the movements of the scapula, involving, of course, motion at the acromio- and sterno-clavicular joints. These joints are therefore to be regarded as accessory structures to the shoulder-joint.[1] The extent of these movements of the scapula is very considerable, especially in extreme elevation of the arm, which movement is best accomplished when the arm is thrown somewhat forward, since the articular surface of the humerus is broader in the middle than at either end, especially the lower, so that the range of elevation directly forward is less, and that directly backward still more restricted. The great width of the central portion of the humeral head also allows of very free horizontal movement when the arm is raised to a right angle, in which movement the arch formed by the acromion, the

[1] See p. 344.

coracoid process, and the coraco-acromial ligament constitutes a sort of supplemental articular cavity for the head of the bone.

The looseness of the capsule is so great that the arm will fall about an inch from the scapula when the muscles are dissected from the capsular ligament and an opening made in it to remove the atmospheric pressure. The movements of the joint, therefore, are not regulated by the capsule so much as by the surrounding muscles and by the pressure of the atmosphere—an arrangement which "renders the movements of the joint much more easy than they would otherwise have been, and permits a swinging, pendulum-like vibration of the limb when the muscles are at rest" (Humphry). The fact, also, that in all ordinary positions of the joint the capsule is not put on the stretch enables the arm to move freely in all directions. Extreme movements are checked by the tension of appropriate portions of the capsule, as well as by the interlocking of the bones. Thus it is said that "abduction is checked by the contact of the great tuberosity with the upper edge of the glenoid cavity, adduction by the tension of the coraco-humeral ligament" (Beaunis et Bouchard).

The intimate union of the tendons of the four short muscles with the capsule converts these muscles into elastic and spontaneously acting ligaments of the joint, and it is regarded as being also intended to prevent the folds into which all portions of the capsule would alternately fall in the varying positions of the joint from being driven between the bones by the pressure of the atmosphere.

The peculiar relations of the Biceps tendon to the shoulder-joint appear to subserve various purposes. In the first place, by its connection with both the shoulder and elbow the muscle harmonizes the action of the two joints, and acts as an elastic ligament in all positions, in the manner previously adverted to.[1] Next, it strengthens the upper part of the articular cavity, and prevents the head of the humerus from being pressed up against the acromion process, when the Deltoid contracts, instead of forming the centre of motion in the glenoid cavity. By its passage along the bicipital groove it assists in rendering the head of the humerus steady in the various movements of the arm. When the arm is raised from the side it assists the Supra- and Infraspinatus in rotating the head of the humerus in the glenoid cavity. It also holds the head of the bone firmly in contact with the glenoid cavity, and prevents its slipping over its lower edge, or being displaced by the action of the Latissimus dorsi and Pectoralis major, as in climbing and many other movements.

Surface Form.—The direction and position of the shoulder-joint may be indicated by a line drawn from the middle of the coraco-acromial ligament, in a curved direction, with its convexity inward, to the innermost part of that portion of the head of the humerus which can be felt in the axilla when the arm is forcibly abducted from the side. When the arm hangs by the side, not more than one-third of the head of the bone is in contact with the glenoid cavity, and three-quarters of its circumference is in front of a vertical line drawn from the anterior border of the acromion process.

Surgical Anatomy.—Owing to the construction of the shoulder-joint and the freedom of movement which it enjoys, as well as in consequence of its exposed situation, it is more frequently dislocated than any other joint in the body. Dislocation occurs when the arm is abducted, and when, therefore, the head of the humerus presses against the lower and front part of the capsule, which is the thinnest and least supported part of the ligament. The rent in the capsule almost invariably takes place in this situation, and through it the head of the bone escapes, so that the dislocation in most instances is primarily subglenoid. The head of the bone does not usually remain in this situation, but generally assumes some other position, which varies according to the direction and amount of force producing the dislocation and the relative strength of the muscles in front and behind the joint. In consequence of the muscles at the back being stronger than those in front, and especially on account of the long head of the Triceps preventing the bone passing backward, dislocation forward is much more common than backward. The most frequent position which the head of the humerus ultimately assumes is on the front of the neck of the scapula, beneath the coracoid process, and hence named subcoracoid. Occasionally, in consequence probably of a greater amount of force being brought to bear on the limb, the head is driven farther inward, and rests on the upper part of the front of the chest, beneath the clavicle (subclavicular). Sometimes it remains in the position in which it was primarily displaced, resting on the axillary border of the scapula (subglenoid),

[1] See p. 318.

and rarely it passes backward and remains in the infraspinatous fossa, beneath the spine (subspinous).

The shoulder-joint is sometimes the seat of all those inflammatory affections, both acute and chronic, which attack joints, though perhaps less frequently than some other joints of equal size and importance. Acute synovitis may result from injury, rheumatism, or pyæmia, or may follow secondarily on the so-called acute epiphysitis of infants. It is attended with effusion into the joint, and when this occurs the capsule is evenly distended and the contour of the joint rounded. Special projections may occur at the site of the openings in the capsular ligament. Thus a swelling may appear just in front of the joint, internal to the lesser tuberosity, from effusion into the bursa beneath the Subscapularis muscle; or, again, a swelling which is sometimes bilobed may be seen in the interval between the Deltoid and Pectoralis major muscles, from effusion into the diverticulum, which runs down the bicipital groove with the tendon of the biceps. The effusion into the synovial membrane can be best ascertained by examination from the axilla, where a soft, elastic, fluctuating swelling can usually be felt.

Tubercular arthritis not unfrequently attacks the shoulder-joint, and may lead to total destruction of the articulation, when ankylosis may result or long-protracted suppuration may necessitate excision. This joint is also one of those which is most liable to be the seat of osteo-arthritis, and may also be affected in gout and rheumatism; or in locomotor ataxy, when it becomes the seat of Charcot's disease.

Excision of the shoulder-joint may be required in cases of arthritis (especially the tubercular form) which have gone on to destruction of the articulation: in compound dislocations and fractures, particularly those arising from gunshot injuries, in which there has been extensive injury to the head of the bone; in some cases of old unreduced dislocation, where there is much pain; and possibly in some few cases of growth connected with the upper end of the bone. The operation is best performed by making an incision from the middle of the coraco-acromial ligament down the arm for about three inches: this will expose the bicipital groove and the tendon of the Biceps, which may be either divided or hooked out of the way, according as to whether it is implicated in the disease or not. The capsule is then freely opened, and the muscles attached to the greater and lesser tuberosities of the humerus divided. The head of the bone can then be thrust out of the wound and sawn off, or divided with a narrow saw *in situ* and subsequently removed. The section should be made, if possible, just below the articular surface, so as to leave the bone as long as possible. The glenoid cavity must then be examined, and gouged if carious.

V. Elbow-Joint.

The **Elbow** is a *ginglymus* or hinge-joint. The bones entering into its formation are the trochlear surface of the humerus, which is received into the greater sigmoid cavity of the ulna, and admits of the movements peculiar to this joint—viz. flexion and extension; whilst the lesser, or radial, head of the humerus articulates with the cup-shaped depression on the head of the radius; the circumference of the head of the radius articulates with the lesser sigmoid cavity of the ulna, allowing of the movement of rotation of the radius on the ulna, the chief action of the superior radio-ulnar articulation. The articular surfaces are covered with a thin layer of cartilage, and connected together by a capsular ligament of unequal thickness, being especially thickened on its two sides and, to a less extent, in front and behind. These thickened portions are usually described as distinct ligaments under the following names:

Anterior.	Internal Lateral.
Posterior.	External Lateral.

The orbicular ligament of the upper radio-ulnar articulation must also be reckoned among the ligaments of the elbow.

The **Anterior Ligament** (Fig. 245) is a broad and thin fibrous layer which covers the anterior surface of the joint. It is attached to the front of the internal condyle and to the front of the humerus immediately above the coronoid fossa; below, to the anterior surface of the coronoid process of the ulna and orbicular ligament, being continuous on each side with the lateral ligaments. Its superficial fibres pass obliquely from the inner condyle of the humerus outward to the orbicular ligament. The middle fibres, vertical in direction, pass from the upper part of the coronoid depression and become partly blended with the preceding, but mainly inserted into the anterior surface of the coronoid process. The deep or transverse set intersects these at right angles. This ligament is in relation, in front, with the Brachialis anticus, except at its outermost part; behind, with the synovial membrane.

The **Posterior Ligament** (Fig. 246) is a thin and loose membranous fold, attached, above, to the lower end of the humerus, on a level with the upper part of the olecranon fossa; below, to the margin of the olecranon. The superficial or transverse fibres pass between the adjacent margins of the olecranon fossa. The deeper portion consists of vertical fibres, which pass from the upper part of the olecranon fossa to the margin of the olecranon. This ligament is in relation, behind, with the tendon of the Triceps and the Anconeus; in front, with the synovial membrane.

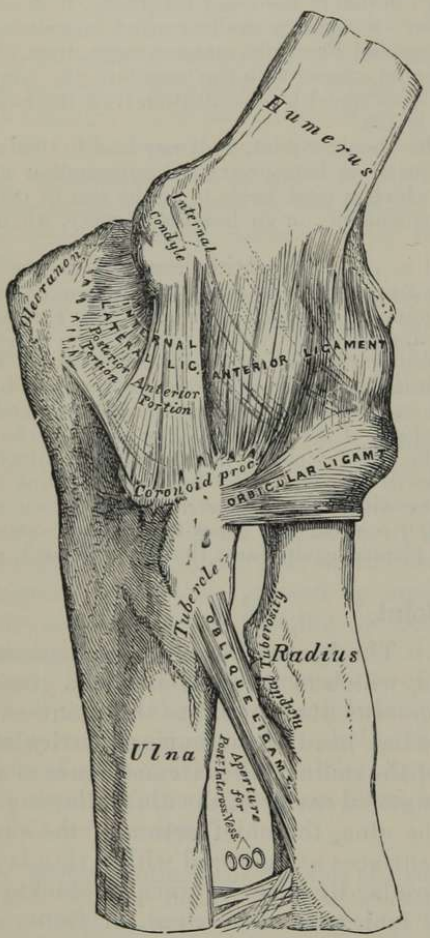

FIG. 245.—Left elbow-joint, showing anterior and internal ligaments.

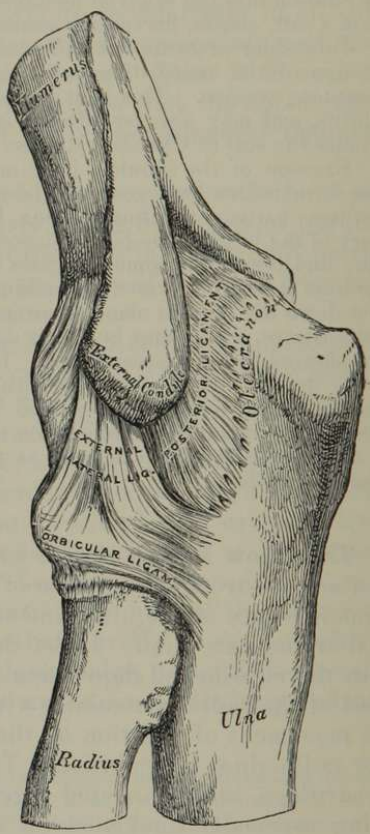

FIG. 246.—Left elbow-joint, showing posterior and external ligaments.

The **Internal Lateral Ligament** (Fig. 245) is a thick triangular band consisting of two portions, an anterior and posterior, united by a thinner intermediate portion. The *anterior portion*, directed obliquely forward, is attached, above, by its apex, to the front part of the internal condyle of the humerus; and, below, by its broad base, to the inner margin of the coronoid process. The *posterior portion*, also of triangular form, is attached, above, by its apex, to the lower and back part of the internal condyle; below, to the inner margin of the olecranon. Between these two bands a few intermediate fibres descend from the internal condyle to blend with a transverse band of ligamentous tissue which bridges across the notch between the olecranon and coronoid processes. This ligament is in relation, internally, with the Triceps and Flexor carpi ulnaris muscles and the ulnar nerve, and gives origin to part of the Flexor sublimis digitorum.

The **External Lateral Ligament** (Fig. 246) is a short and narrow fibrous band, less distinct than the internal, attached, above, to a depression below the external condyle of the humerus; below, to the orbicular ligament, some of its most posterior fibres passing over that ligament, to be inserted into the outer margin of the

ulna. This ligament is intimately blended with the tendon of origin of the Supinator brevis muscle.

The **Synovial Membrane** is very extensive. It covers the margin of the articular surface of the humerus, and lines the coronoid and olecranon fossæ on that bone; from these points it is reflected over the anterior, posterior, and lateral ligaments, and forms a pouch between the lesser sigmoid cavity, the internal surface of the orbicular ligament, and the circumference of the head of the radius.

Between the capsular ligament and the synovial membrane are three masses of fat; one, the largest, above the olecranon fossa, which is pressed into the fossa by the triceps during flexion; a second, over the coronoid fossa; and a third, over the radial fossa. These are pressed into their respective fossæ during extension.

The *Muscles* in relation with the joint are, in front, the Brachialis anticus; behind, the Triceps and Anconeus; externally, the Supinator brevis and the common tendon of origin of the Extensor muscles; internally, the common tendon of origin of the Flexor muscles, and the Flexor carpi ulnaris, with the ulnar nerve.

The *Arteries* supplying the joint are derived from the communicating branches between the superior profunda, inferior profunda, and anastomotica magna arteries, branches of the brachial, with the anterior, posterior, and interosseous recurrent branches of the ulnar and the recurrent branch of the radial. These vessels form a complete chain of inosculation around the joint.

The *Nerves* are derived from the ulnar as it passes between the internal condyle and the olecranon; a filament from the musculo-cutaneous (Rüdinger), and two from the median (Macalister).

Actions.—The elbow-joint comprises three different portions—viz, the joint between the ulna and humerus, that between the head of the radius and the humerus, and the superior radio-ulnar articulation, described below. All these articular surfaces are invested by a common synovial membrane, and the movements of the whole joint should be studied together. The combination of the movements of flexion and extension of the forearm with those of pronation and supination of the hand, which is ensured by the two being performed at the same joint, is essential to the accuracy of the various minute movements of the hand.

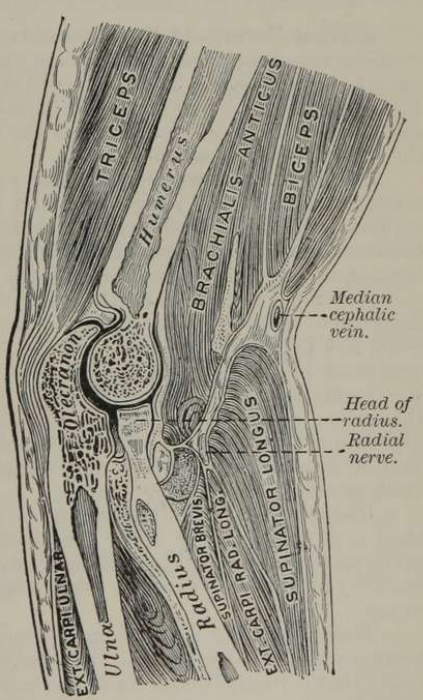

FIG. 247.—Sagittal section of the right elbow-joint, taken somewhat obliquely and seen from the radial aspect. (After Braune.)

The portion of the joint between the ulna and humerus is a simple hinge-joint, and allows of movements of flexion and extension only. Owing to the obliquity of the trochlear surface of the humerus, this movement does not take place in a straight line; so that when the forearm is extended and supinated the axis of the arm and forearm is not in the same line, but the one portion of the limb forms an angle with the others, and the hand, with the forearm, is directed outward. During flexion, on the other hand, the forearm and the hand tend to approach the middle line of the body, and thus enable the hand to be easily carried to the face. The shape of the articular surface of the humerus, with its prominences and depressions accurately adapted to the opposing surfaces of the olecranon, prevents any lateral movement. *Flexion* is produced by the action of the Biceps and Brachialis

anticus, assisted by the muscles arising from the internal condyle of the humerus and the Supinator longus; *extension*, by the Triceps and Anconeus, assisted by the extensors of the wrist and by the Extensor communis digitorum and Extensor minimi digiti.

The joint between the head of the radius and the capitellum or radial head of the humerus is an arthrodial joint. The bony surfaces would of themselves constitute an enarthrosis, and allow of movement in all directions were it not for the orbicular ligament by which the head of the radius is bound down firmly to the sigmoid cavity of the ulna, and which prevents any separation of the two bones laterally. It is to the same ligament that the head of the radius owes its security from dislocation, which would otherwise constantly occur as a consequence of the shallowness of the cup-like surface on the head of the radius. In fact, but for this ligament the tendon of the biceps would be liable to pull the head of the radius out of the joint.[1] In complete extension the head of the radius glides so far back on the outer condyle that its edge is plainly felt at the back of the articulation. Flexion and extension of the elbow-joint are limited by the tension of the structures on the front and back of the joint, the limitation of flexion being also aided by the soft structures of the arm and forearm coming in contact.

In combination with any position of flexion or extension the head of the radius can be rotated in the upper radio-ulnar joint, carrying the hand with it. The hand is articulated to the lower surface of the radius only, and the concave or sigmoid surface on the lower end of the radius travels round the lower end of the ulna. The latter bone is excluded from the wrist-joint (as will be seen in the sequel) by the interarticular fibro-cartilage. Thus, rotation of the head of the radius round an axis which passes through the centre of the radial head of the humerus imparts circular movement to the hand through a very considerable arc.

Surface Form.—If the forearm be slightly flexed on the arm, a curved crease or fold with its convexity downward may be seen running across the front of the elbow, extending from one condyle to the other. The centre of this fold is some slight distance above the line of the joint. The position of the radio-humeral portion of the joint can be at once ascertained by feeling for a slight groove or depression between the head of the radius and the capitellum of the humerus at the back of the articulation.

Surgical Anatomy.—From the great breadth of the joint, and the manner in which the articular surfaces are interlocked, and also on account of the strong lateral ligaments and the support which the joint derives from the mass of muscles attached to each condyle of the humerus, lateral displacement of the bones is very uncommon, whereas antero-posterior dislocation, on account of the shortness of the antero-posterior diameter, the weakness of the anterior and posterior ligaments, and the want of support of muscles, much more frequently takes place, dislocation backward taking place when the forearm is in a position of extension, and forward when in a position of flexion. For, in the former position, that of extension, the coronoid process is not interlocked into the coronoid fossa, and loses its grip to a certain extent, whereas the olecranon process is in the olecranon fossa, and entirely prevents displacement forward. On the other hand, during flexion, the coronoid process is in the coronoid fossa, and prevents dislocation backward, while the olecranon loses its grip and is not so efficient, as during extension, in preventing a forward displacement. When lateral dislocation does take place, it is generally incomplete.

Dislocation of the elbow-joint is of common occurrence in children, far more common than dislocation of any other articulation, for, as a rule, fracture of a bone more frequently takes place, under the application of any severe violence, in young persons than dislocation. In lesions of this joint there is often very great difficulty in ascertaining the exact nature of the injury.

The elbow-joint is occasionally the seat of acute synovitis. The synovial membrane then becomes distended with fluid, the bulging showing itself principally around the olecranon process; that is to say, on its inner and outer sides and above, in consequence of the laxness of the posterior ligament. Occasionally a well-marked, triangular projection may be seen on the outer side of the olecranon, from bulging of the synovial membrane beneath the Anconeus muscle. Again, there is often some swelling just above the head of the radius, in the line of the radio-humeral joint. There is generally not much swelling at the front of the joint, though sometimes deep-seated fulness beneath the Brachialis anticus may be noted. When suppuration occurs the abscess usually points at one or other border of the Triceps muscle; occasionally the pus discharges itself in front, near the insertion of the Brachialis anticus muscle. Chronic synovitis,

[1] Humphry, *op. cit.*, p. 419.

usually of tubercular origin, is of common occurrence in the elbow-joint: under these circumstances the forearm tends to assume the position of semi-flexion, which is that of greatest ease and relaxation of ligaments. It should be borne in mind, that should ankylosis occur in this or the extended position, the limb will not be nearly so useful as if ankylosed in a position of rather less than a right angle. Loose cartilages are sometimes met with in the elbow-joint, not so commonly, however, as in the knee; nor do they, as a rule, give rise to such urgent symptoms as in this articulation, and rarely require operative interference. The elbow-joint is also sometimes affected with osteo-arthritis, but this affection is less common in this articulation than in some other of the larger joints.

Excision of the elbow is principally required for three conditions: viz. tubercular arthritis, injury and its results, and faulty ankylosis; but may be necessary for some other rarer conditions, such as disorganizing arthritis after pyæmia, unreduced dislocations, and osteo-arthritis. The results of the operation are, as a rule, more favorable than those of excision of any other joint, and it is one, therefore, that the surgeon should never hesitate to perform, especially in the first three of the conditions mentioned above. The operation is best performed by a single vertical incision down the back of the joint, a transverse incision, over the outer condyle, being added if the parts are much thickened and fixed. A straight incision is made about four inches long, the mid-point of which is on a level with and a little to the inner side of the tip of the olecranon. This incision is made down to the bone, through the substance of the Triceps muscle. The operator with the point of his knife, and guarding the soft parts with his thumb-nail, separates them from the bone. In doing this there are two structures which he should carefully avoid: the ulnar nerve, which lies parallel to his incision, but a little internal, as it courses down between the internal condyle and the olecranon process, and the prolongation of the Triceps into the deep fascia of the forearm over the Anconeus muscle. Having cleared the bones and divided the lateral and posterior ligaments, the forearm is strongly flexed and the ends of the bone turned out and sawn off. The section of the humerus should be through the base of the condyles, that of the ulna and radius should be just below the level of the lesser sigmoid cavity of the ulna and the neck of the radius. In this operation the object is to obtain such union as shall allow free motion of the bones of the forearm; and, therefore, passive motion must be commenced early, that is to say, about the tenth day.

VI. Radio-ulnar Articulations.

The articulation of the radius with the ulna is effected by ligaments which connect together both extremities as well as the shafts of these bones. They may, consequently, be subdivided into three sets: 1, the superior radio-ulnar, which is a portion of the elbow-joint; 2, the middle radio-ulnar; and, 3, the inferior radio-ulnar articulations.

1. Superior Radio-ulnar Articulation.

This articulation is a trochoid or pivot-joint. The bones entering into its formation are the inner side of the circumference of the head of the radius rotating within the lesser sigmoid cavity of the ulna. Its only ligament is the *annular* or *orbicular*.

The **Orbicular Ligament** (Fig. 246) is a strong, flat band of ligamentous fibres, which surrounds the head of the radius, and retains it in firm connection with the lesser sigmoid cavity of the ulna. It forms about four-fifths of a fibrous ring, attached by each end to the extremities of the lesser sigmoid cavity, and is smaller at the lower part of its circumference than above, by which means the head of the radius is more securely held in its position. Its *outer surface*, is strengthened by the external lateral ligament of the elbow, and affords origin to part of the Supinator brevis muscle. Its *inner surface* is smooth, and lined by synovial membrane. The synovial membrane is continuous with that which lines the elbow-joint.

Actions.—The movement which takes place in this articulation is limited to rotation of the head of the radius within the orbicular ligament, and upon the lesser sigmoid cavity of the ulna, rotation forward being called *pronation;* rotation backward, *supination.* Supination is performed by the Biceps and Supinator brevis, assisted to a slight extent by the Extensor muscles of the thumb and, in certain positions, by the Supinator longus. Pronation is performed by the Pronator radii teres and the Pronator quadratus, assisted, in some positions, by the Flexor carpi radialis.

Surface Form.—The position of the superior radio-ulnar joint is marked on the surface of

the body by the little dimple on the back of the forearm which indicates the position of the head of the radius.

Surgical Anatomy.—Dislocation of the head of the radius alone is not an uncommon accident, and occurs most frequently in young persons from falls on the hand when the forearm is extended and supinated, the head of the bone being displaced forward. It is attended by rupture of the orbicular ligament.

2. Middle Radio-ulnar Articulation.

The interval between the shafts of the radius and ulna is occupied by two ligaments.

Oblique. Interosseous.

The **Oblique** or **Round Ligament** (Fig. 245) is a small, flattened fibrous band which extends obliquely downward and outward from the tubercle of the ulna at the base of the coronoid process to the radius a little below the bicipital tuberosity. Its fibres run in the opposite direction to those of the interosseous ligament, and it appears to be placed as a substitute for it in the upper part of the interosseous interval. This ligament is sometimes wanting.

The **Interosseous Membrane** is a broad and thin plane of fibrous tissue descending obliquely downward and inward, from the interosseous ridge on the radius to that

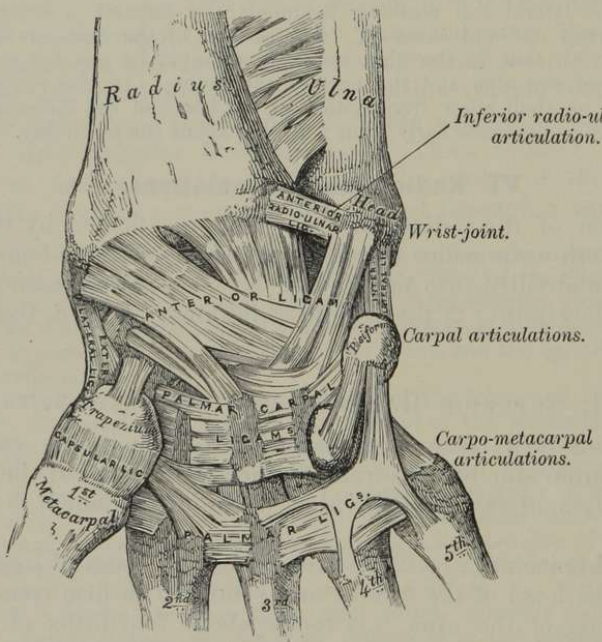

Fig. 248.—Ligaments of wrist and hand. Anterior view.

on the ulna. It is deficient above, commencing about an inch beneath the tubercle of the radius; is broader in the middle than at either extremity; and presents an oval aperture just above its lower margin for the passage of the anterior interosseous vessels to the back of the forearm. This ligament serves to connect the bones and to increase the extent of surface for the attachment of the deep muscles. Between its upper border and the oblique ligament an interval exists through which the posterior interosseous vessels pass. Two or three fibrous bands are occasionally found on the posterior surface of this membrane which descend obliquely from the ulna toward the radius, and which have consequently a direction contrary to that of the other fibres. It is in relation, *in front*, by its upper three-fourths with the Flexor longus pollicis on the outer side, and with the Flexor profundus digitorum on the inner, lying upon the interval between which are the anterior interosseous vessels and nerve; by its lower fourth, with the Pronator quadratus; *behind*, with the Supinator brevis, Extensor ossis metacarpi

pollicis, Extensor brevis pollicis, Extensor longus pollicis, Extensor indicis; and, near the wrist, with the anterior interosseous artery and posterior interosseous nerve.

3. Inferior Radio-ulnar Articulation.

This is a pivot-joint, formed by the head of the ulna received into the sigmoid cavity at the inner side of the lower end of the radius. The articular surfaces are covered by a thin layer of cartilage, and connected together by the following ligaments:

Anterior Radio-ulnar. Posterior Radio-ulnar.
Interarticular Fibro-cartilage.

The **Anterior Radio-ulnar Ligament** (Fig. 248) is a narrow band of fibres extending from the anterior margin of the sigmoid cavity of the radius to the anterior surface of the head of the ulna.

The **Posterior Radio-ulnar Ligament** (Fig. 249) extends between similar points on the posterior surface of the articulation.

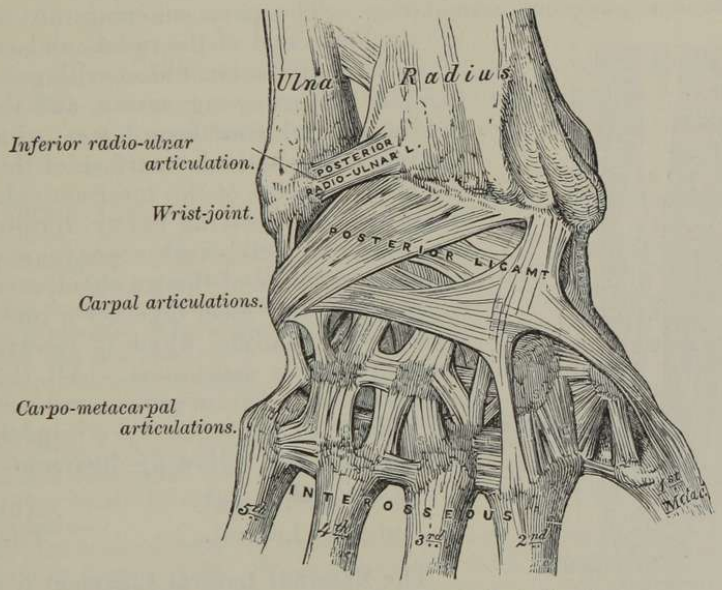

Fig. 249.—Ligaments of wrist and hand. Posterior view.

The **Interarticular Fibro-cartilage** (Fig. 251) is triangular in shape, and is placed transversely beneath the head of the ulna, binding the lower end of this bone and the radius firmly together. Its circumference is thicker than its centre, which is thin and occasionally perforated. It is attached by its apex to a depression which separates the styloid process of the ulna from the head of that bone; and by its base, which is thin, to the prominent edge of the radius, which separates the sigmoid cavity from the carpal articulating surface. Its margins are united to the ligaments of the wrist-joint. Its *upper surface*, smooth and concave, articulates with the head of the ulna, forming an arthrodial joint; its *under surface*, also concave and smooth, forms part of the wrist-joint and articulates with the cuneiform bone. Both surfaces are lined by a synovial membrane—the upper surface, by one peculiar to the radio-ulnar articulation; the under surface, by the synovial membrane of the wrist.

The **Synovial Membrane** (Fig. 251) of this articulation has been called, from its extreme looseness, the *membrana sacciformis;* it extends horizontally inward between the head of the ulna and the interarticular fibro-cartilage, and upward between the radius and the ulna, forming here a very loose *cul-de-sac*. The quantity of synovia which it contains is usually considerable.

Actions.—The movement in the inferior radio-ulnar articulation is just the reverse of that between the two bones above. It consists of a movement of rota-

tion of the lower end of the radius round an axis which corresponds to the centre of the head of the ulna. When the radius rotates forward, *pronation* of the forearm and hand is the result; and when backward, *supination*. It will thus be seen that in pronation and supination of the forearm and hand the radius describes a segment of a cone, the axis of which extends from the centre of the head of the radius to the middle of the head of the ulna. In this movement, however, the ulna is not quite stationary, but is circumducted a little in the opposite direction. So that it also describes the segment of a cone, though of smaller size than that described by the radius. The movement which causes this alteration in the position of the head of the ulna takes place principally at the shoulder-joint by a rotation of the humerus, but possibly also to a slight extent at the elbow-joint.[1]

Surface Form.—The position of the inferior radio-ulnar joint may be ascertained by feeling for a slight groove at the back of the wrist, between the prominent head of the ulna and the lower end of the radius, when the forearm is in a state of almost complete pronation.

VII. Radio-carpal or Wrist-joint.

The **Wrist** is a condyloid articulation. The parts entering into its formation are the lower end of the radius and under surface of the interarticular fibro-cartilage, which form together the receiving cavity, and the scaphoid, semilunar, and cuneiform bones, which form the condyle. The articular surface of the radius and the under surface of the inter-articular fibro-cartilage are the receiving cavity, forming together a transversely elliptical concave surface. The articular surfaces of the scaphoid, semilunar, and cuneiform bones form together a smooth, convex surface, the condyle, which is received into the concavity above mentioned. All the bony surfaces of the articulation are covered with cartilage, and connected together by a capsule, which is divided into the following ligaments:

External Lateral.	Anterior.
Internal Lateral.	Posterior.

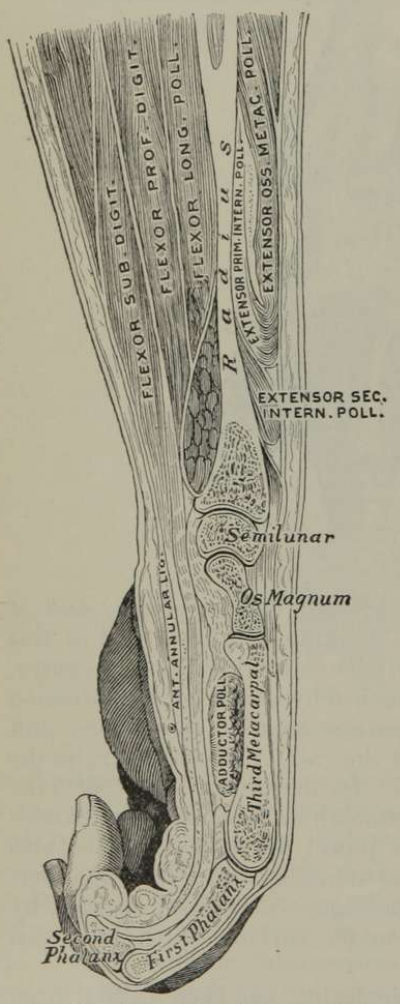

FIG. 250.—Longitudinal section of the right forearm, hand, and third finger, viewed from the ulnar aspect. (After Braune.)

The **External Lateral Ligament** (*radio-carpal*) (Fig. 248) extends from the summit of the styloid process of the radius to the outer side of the scaphoid, some of its fibres being prolonged to the trapezium and annular ligament.

The **Internal Lateral Ligament** (*ulno-carpal*) is a rounded cord, attached, above, to the extremity of the styloid process of the ulna, and dividing below into two fasciculi, which are attached, one to the inner side of the cuneiform bone, the other to the pisiform bone and annular ligament.

The **Anterior Ligament** is a broad membranous band, attached, above, to the anterior margin of the lower end of the radius, its styloid process and the ulna: its fibres pass downward and inward to be inserted into the palmar surface of the scaphoid, semilunar, and cuneiform bones, some of the fibres being continued to the os magnum. In addition to this broad membrane, there is a distinct rounded fasciculus, superficial to the rest, which passes from the base of the styloid process of the ulna to the semilunar and cuneiform bones. This ligament is per-

[1] See *Journ. of Anat. and Phys.*, vol. xix., parts ii., iii., and iv.

forated by numerous apertures for the passage of vessels, and is in relation, in front, with the tendons of the Flexor profundus digitorum and Flexor longus pollicis; behind, with the synovial membrane of the wrist-joint.

The **Posterior Ligament** (Fig. 249), less thick and strong than the anterior, is attached, above, to the posterior border of the lower end of the radius; its fibres pass obliquely downward and inward, to be attached to the dorsal surface of the scaphoid, semilunar, and cuneiform bones, being continuous with those of the dorsal carpal ligaments. This ligament is in relation, behind, with the extensor tendons of the fingers; in front, with the synovial membrane of the wrist.

The **Synovial Membrane** (Fig. 251) lines the inner surface of the ligaments above described, extending from the lower end of the radius and interarticular fibro-cartilage above to the articular surfaces of the carpal bones below. It is loose and lax, and presents numerous folds, especially behind.

Relations.—The wrist-joint is covered in front by the flexor and behind by the extensor tendons; it is also in relation with the radial and ulnar arteries.

The *Arteries* supplying the joint are the anterior and posterior carpal branches of the radial and ulnar, the anterior and posterior interosseous, and some ascending branches from the deep palmar arch.

The *Nerves* are derived from the ulnar and posterior interosseous.

Actions.—The movements permitted in this joint are flexion, extension, abduction, adduction, and circumduction. Its actions will be further studied with those of the carpus, with which they are combined.

Surface Form.—The line of the radio-carpal joint is on a level with the apex of the styloid process of the ulna.

Surgical Anatomy.—The wrist-joint is rarely dislocated, its strength depending mainly upon the numerous strong tendons which surround the articulation. Its security is further provided for by the number of small bones of which the carpus is made up, and which are united by very strong ligaments. The slight movement which takes place between the several bones serves to break the jars that result from falls or blows on the hand. Dislocation backward, which is the more common, simulates to a considerable extent Colles' fracture of the radius, and is liable to be mistaken for it. The diagnosis can be easily made out by observing the relative position of the styloid processes of the radius and the ulna. In the natural condition the styloid process of the radius is on a lower level—*i. e.* nearer the ground—when the arm hangs by the side, than that of the ulna, and the same would be the case in dislocation. In Colles' fracture, on the other hand, the styloid process of the radius is on the same, or even a higher level than that of the ulna.

The wrist-joint is occasionally the seat of acute synovitis, the result of traumatism or arising in the rheumatic or pyæmic state. When the synovial sac is distended with fluid, the swelling is greatest on the dorsal aspect of the wrist, showing a general fulness, with some bulging between the tendons. The inflammation is prone to extend to the intercarpal joints and to attack also the sheaths of the tendons in the neighborhood. Chronic inflammation of the wrist is generally tubercular, and often leads to similar disease in the synovial sheaths of adjacent tendons and of the intercarpal joints. The disease, therefore, when progressive, often leads to necrosis of the carpal bones, and the result is often unsatisfactory.

VIII. Articulations of the Carpus.

These articulations may be subdivided into three sets:

1. The Articulations of the First Row of Carpal Bones.
2. The Articulations of the Second Row of Carpal Bones.
3. The Articulations of the Two Rows with each other.

1. Articulations of the First Row of Carpal Bones.

These are arthrodial joints. The ligaments connecting the scaphoid, semilunar, and cuneiform bones are—

Dorsal. Palmar.

Two Interosseous.

The **Dorsal Ligaments** are placed transversely behind the bones of the first row; they connect the scaphoid and semilunar and the semilunar and cuneiform.

The **Palmar Ligaments** connect the scaphoid and semilunar and the semilunar

and cuneiform bones; they are less strong than the dorsal, and placed very deeply under the anterior ligament of the wrist.

The **Interosseous Ligaments** (Fig. 251) are two narrow bundles of fibrous tissue connecting the semilunar bone on one side with the scaphoid, and on the other with the cuneiform. They are on a level with the superior surfaces of these bones, and close the upper part of the spaces between them. Their upper surfaces are smooth, and form with the bones the convex articular surfaces of the wrist-joint.

The ligaments connecting the pisiform bone are—

Capsular. Two Palmar ligaments.

The **Capsular Ligament** is a thin membrane which connects the pisiform bone to the cuneiform. It is lined with a separate synovial membrane.

The **two Palmar Ligaments** are two strong fibrous bands which connect the pisiform to the unciform, the *piso-uncinate*, and to the base of the fifth metacarpal bone, the *piso-metacarpal ligament* (Fig. 248).

2. Articulations of the Second Row of Carpal Bones.

These are also arthrodial joints. The articular surfaces are covered with cartilage, and connected by the following ligaments:

Dorsal. Palmar.
Three Interosseous.

The **Dorsal Ligaments** extend transversely from one bone to another on the dorsal surface, connecting the trapezium with the trapezoid, the trapezoid with the os magnum, and the os magnum with the unciform.

The **Palmar Ligaments** have a similar arrangement on the palmar surface.

The **three Interosseous Ligaments,** much thicker than those of the first row, are placed one between the os magnum and the unciform, a second between the os magnum and the trapezoid, and a third between the trapezium and trapezoid. The first of these is much the strongest, and the third is sometimes wanting. Sometimes a slender interosseous band connects the os magnum and the scaphoid.

3. Articulations of the Two Rows of Carpal Bones with each Other.

The joint between the scaphoid, semilunar, and cuneiform, and the second row of the carpus, or the *mid-carpal joint*, is made up of three distinct portions; in the centre the head of the os magnum and the superior margin of the unciform articulate with the deep, cup-shaped cavity formed by the scaphoid and semilunar bones, and constitute a sort of ball-and-socket joint. On the outer side the trapezium and trapezoid articulate with the scaphoid, and on the inner side the unciform articulates with the cuneiform, forming gliding joints.

The ligaments are—

Anterior or Palmar. External Lateral.
Posterior or Dorsal. Internal Lateral.

The **Anterior** or **Palmar Ligaments** consist of short fibres, which pass, for the most part, from the palmar surface of the bones of the first row to the front of the os magnum.

The **Posterior** or **Dorsal Ligaments** consist of short, irregular bundles of fibres passing between the bones of the first and second row on the dorsal surface of the carpus.

The **Lateral Ligaments** are very short: they are placed, one on the radial, the other on the ulnar side of the carpus; the former, the stronger and more distinct, connecting the scaphoid and trapezium bones, the latter the cuneiform and unciform; they are continuous with the lateral ligaments of the wrist-joint.

The **Synovial Membrane of the Carpus** is very extensive: it passes from the

under surface of the scaphoid, semilunar, and cuneiform bones to the upper surface of the bones of the second row, sending upward two prolongations—between the scaphoid and semilunar and the semilunar and cuneiform; sending downward three prolongations between the four bones of the second row, which are further continued onward into the carpo-metacarpal joints of the four inner metacarpal bones, and also for a short distance between the metacarpal bones. There is a separate synovial membrane between the pisiform and cuneiform bones.

Actions.—The articulation of the hand and wrist, considered as a whole, is divided into three parts: (1) the radius and the interarticular fibro-cartilage; (2) the meniscus, formed by the scaphoid, semilunar, and cuneiform, the pisiform bone having no essential part in the movements of the hand; (3) the hand proper, the metacarpal bones with the four carpal bones on which they are supported—viz. the trapezium, trapezoid, os magnum, and unciform. These three elements form two joints: (1) the superior (wrist-joint proper), between the meniscus and bones of the forearm; (2) the inferior, between the hand and meniscus (transverse or mid-carpal joint).

(1) The articulation between the forearm and carpus is a true condyloid articulation, and therefore all movements but rotation are permitted. Flexion and extension are the most free, and of these a greater amount of extension than flexion is permitted on account of the articulating surfaces extending farther on the dorsal than on the palmar aspect of the carpal bones. In this movement the carpal bones rotate on a transverse axis drawn between the tips of the styloid processes of the radius and ulna. A certain amount of adduction (or ulnar flexion) and abduction (or radial flexion) is also permitted. Of these the former is considerably greater in extent than the latter. In this movement the carpus revolves upon an antero-posterior axis drawn through the centre of the wrist. Finally, circumduction is permitted by the consecutive movements of adduction, extension, abduction, and flexion, with intermediate movements between them. There is no rotation, but this is provided for by the supination and pronation of the radius on the ulna. The movement of *flexion* is performed by the Flexor carpi radialis, the Flexor carpi ulnaris, and the Palmaris longus; *extension*, by the Extensor carpi radialis longior et brevior and the Extensor carpi ulnaris; *adduction* (ulnar flexion), by the Flexor carpi ulnaris and the Extensor carpi ulnaris; and *abduction* (radial flexion), by the Extensors of the thumb and the Extensor carpi radialis longior et brevior and the Flexor carpi radialis.

(2) The chief movements permitted in the transverse or mid-carpal joint are flexion and extension and a slight amount of rotation. In flexion and extension, which is the movement most freely enjoyed, the trapezium and trapezoid on the radial side and the unciform on the ulnar side glide forward and backward on the scaphoid and cuneiform respectively, while the head of the os magnum and the superior surface of the unciform rotate in the cup-shaped cavity of the scaphoid and semilunar. Flexion at this joint is freer than extension. A very trifling amount of rotation is also permitted, the head of the os magnum rotating round a vertical axis drawn through its own centre, while at the same time a slight gliding movement takes place in the lateral portions of the joint.

IX. Carpo-metacarpal Articulations.

1. Articulation of the Metacarpal Bone of the Thumb with the Trapezium.

This is a joint of reciprocal reception, and enjoys great freedom of movement, on account of the configuration of its articular surfaces, which are saddle-shaped, so that, on section, each bone appears to be received into a cavity in the other, according to the direction in which they are cut. Its ligaments are a capsular ligament and a synovial membrane.

The **Capsular Ligament** is a thick but loose capsule which passes from the circumference of the upper extremity of the metacarpal bone to the rough edge

bounding the articular surface of the trapezium; it is thickest externally and behind, and lined by a separate *synovial membrane.*

Movements.—In the articulation of the metacarpal bone of the thumb with the trapezium the movements permitted are flexion, extension, adduction, abduction, and circumduction. When the joint is flexed the metacarpal bone is brought in front of the palm and the thumb is gradually turned to the fingers. It is by this peculiar movement that the tip of the thumb is opposed to the other digits; for by slightly flexing the fingers the palmar surface of the thumb can be brought in contact with their palmar surfaces one after another.

2. Articulations of the Metacarpal Bones of the Four Inner Fingers with the Carpus.

The joints formed between the carpus and four inner metacarpal bones are arthrodial joints. The ligaments are—

Dorsal. Palmar.
Interosseous.

The **Dorsal Ligaments,** the strongest and most distinct, connect the carpal and metacarpal bones on their dorsal surface. The second metacarpal bone receives two fasciculi—one from the trapezium, the other from the trapezoid; the third metacarpal receives two—one from the trapezoid and one from the os magnum; the fourth two—one from the os magnum and one from the unciform; the fifth receives a single fasciculus from the unciform bone, which is continuous with a similar ligament on the palmar surface, forming an incomplete capsule.

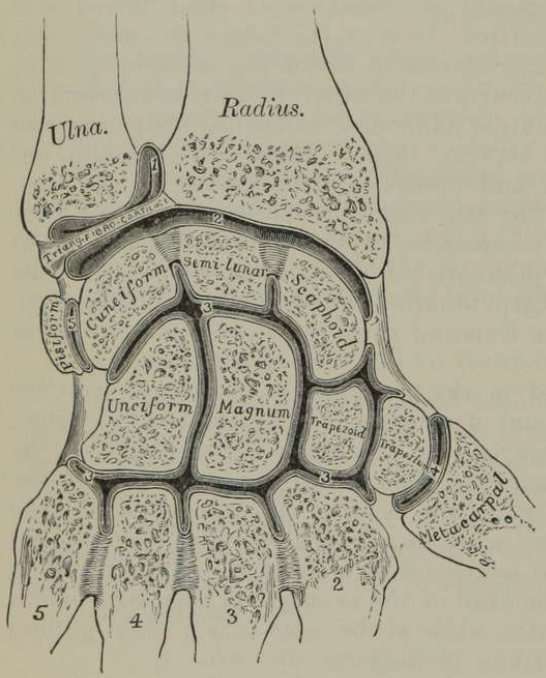

Fig. 251.—Vertical section through the articulations at the wrist, showing the five synovial membranes.

The **Palmar Ligaments** have a somewhat similar arrangement on the palmar surface, with the exception of the third metacarpal, which has three ligaments—an external one from the trapezium, situated above the sheath of the tendon of the Flexor carpi radialis; a middle one, from the os magnum; and an internal one, from the unciform.

The **Interosseous Ligaments** consist of short, thick fibres, which are limited to one part of the carpo-metacarpal articulation; they connect the contiguous inferior angles of the os magnum and unciform with the adjacent surfaces of the third and fourth metacarpal bones.

The **Synovial Membrane** is a continuation of that between the two rows of carpal bones. Occasionally, the articulation of the unciform with the fourth and fifth metacarpal bones has a separate synovial membrane.

The synovial membranes of the wrist and carpus (Fig. 251) are thus seen to be five in number. The *first*, the *membrana sacciformis*, passes from the lower end of the ulna to the sigmoid cavity of the radius, and lines the upper surface of the interarticular fibro-cartilage. The *second* passes from the lower end of the radius and interarticular fibro-cartilage above to the bones of the first row below. The *third*, the most extensive, passes between the contiguous margins of the two rows of carpal bones—between the bones of the second row to the carpal

extremities of the four inner metacarpal bones. The *fourth*, from the margin of the trapezium to the metacarpal bone of the thumb. The *fifth*, between the adjacent margins of the cuneiform and pisiform bones.

Actions.—The movement permitted in the carpo-metacarpal articulations of the four inner fingers is limited to a slight gliding of the articular surfaces upon each other, the extent of which varies in the different joints. Thus the articulation of the metacarpal bone of the little finger is most movable, then that of the ring finger. The metacarpal bones of the index and middle fingers are almost immovable.

3. Articulations of the Metacarpal Bones with each other.

The carpal extremities of the four inner metacarpal bones articulate with one another at each side by small surfaces covered with cartilages, and connected together by dorsal, palmar, and interosseous ligaments.

The **Dorsal** and **Palmar Ligaments** pass transversely from one bone to another on the dorsal and palmar surfaces. The *Interosseous Ligaments* pass between their contiguous surfaces, just beneath their lateral articular facets.

The **Synovial Membrane** between the lateral facets is a reflection from that between the two rows of carpal bones.

The **Transverse Metacarpal Ligaments** (Fig. 252) is a narrow fibrous band which passes transversely across the anterior surfaces of the digital extremities of the four inner metacarpal bones, connecting them together. It is blended anteriorly with the anterior (glenoid) ligament of the metacarpal-phalangeal articulations. To its posterior border is connected the fascia which covers the Interossei muscles. Its superficial surface is concave where the flexor tendons pass over it. Beneath it the tendons of the Interossei muscles pass to their insertion.

X. Metacarpo-phalangeal Articulations (Fig. 252).

These articulations are of the condyloid kind, formed by the reception of the rounded head of the metacarpal bone into a superficial cavity in the extremity of the first phalanx. The ligaments are—

Anterior.
Two Lateral.

The **Anterior Ligaments** (*Glenoid Ligaments* of Cruveilhier) are thick, dense, fibrous structures, placed on the palmar surface of the joints in the intervals between the lateral ligaments, to which they are connected; they are loosely united to the metacarpal bone, but very firmly to the base of the first phalanges. Their palmar surface is intimately blended with the transverse metacarpal ligament, and presents a groove for the passage of the flexor tendons, the

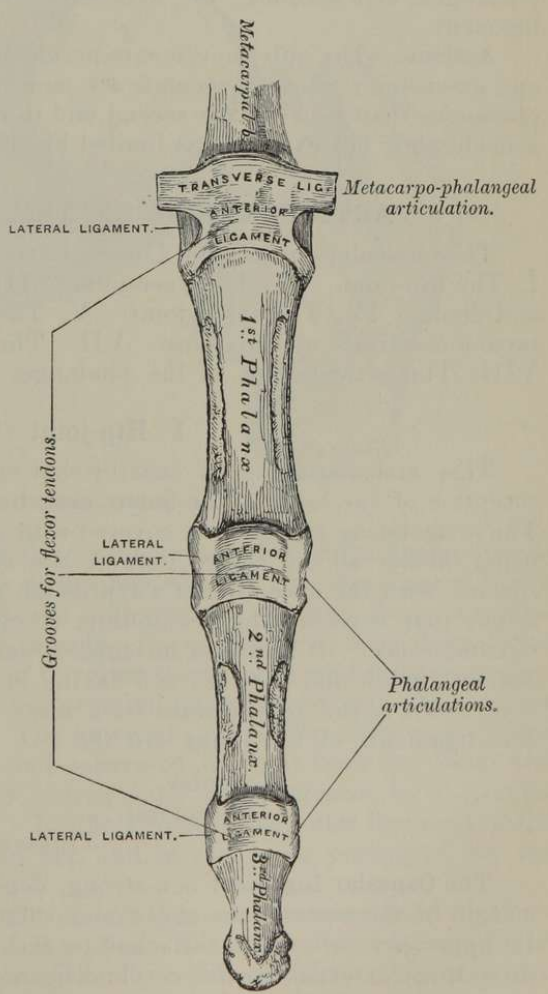

FIG. 252.—Articulations of the phalanges.

sheath surrounding which is connected to each side of the groove. By their deep surface they form part of the articular surface for the head of the metacarpal bone, and are lined by a synovial membrane.

The **Lateral Ligaments** are strong, rounded cords placed one on each side of the joint, each being attached by one extremity to the posterior tubercle on the side of the head of the metacarpal bone, and by the other to the contiguous extremity of the phalanx.

Actions.—The movements which occur in these joints are flexion, extension, adduction, abduction, and circumduction; the lateral movements are very limited.

Surface Form.—The prominences of the knuckles do not correspond to the position of the joints either of the metacarpo-phalangeal or interphalangeal articulations. These prominences are invariably formed by the distal ends of the proximal bone of each joint, and the line indicating the position of the joint must be sought considerably in front of the middle of the knuckle. The usual rule for finding these joints is to flex the distal phalanx on the proximal one to a right angle; the position of the joint is then indicated by an imaginary line drawn along the middle of the lateral aspect of the proximal phalanx.

XI. Articulations of the Phalanges.

These are ginglymus joints. The ligaments are—

Anterior. Two Lateral.

The arrangement of these ligaments is similar to those in the metacarpo-phalangeal articulations; the extensor tendon supplies the place of a posterior ligament.

Actions.—The only movements permitted in the phalangeal joints are flexion and extension; these movements are more extensive between the first and second phalanges than between the second and third. The movement of flexion is very considerable, but extension is limited by the anterior and lateral ligaments.

ARTICULATIONS OF THE LOWER EXTREMITY.

The articulations of the Lower Extremity comprise the following groups: I. The hip-joint. II. The knee-joint. III. The articulations between the tibia and fibula. IV. The ankle-joint. V. The articulations of the tarsus. VI. The tarso-metatarsal articulations. VII. The metatarso-phalangeal articulations. VIII. The articulations of the phalanges.

I. Hip-joint (Fig. 253).

This articulation is an enarthrodial or ball-and-socket joint, formed by the reception of the head of the femur into the cup-shaped cavity of the acetabulum. The articulating surfaces are covered with cartilage, that on the head of the femur being thicker at the centre than at the circumference, and covering the entire surface, with the exception of a depression just below its centre for the ligamentum teres; that covering the acetabulum is much thinner at the centre than at the circumference. It forms an incomplete cartilaginous ring of a horseshoe shape, deficient below and in front, and having in its centre a circular depression, which is occupied in the recent state by a mass of fat covered by synovial membrane. The ligaments of the joints are the

Capsular. Teres.
Ilio-femoral. Cotyloid.
Transverse.

The **Capsular Ligament** is a strong, dense, ligamentous capsule, embracing the margin of the acetabulum above and surrounding the neck of the femur below. Its *upper circumference* is attached to the acetabulum, above and behind, two or three lines external to the cotyloid ligament; but in front it is attached to the outer margin of this ligament, and opposite to the notch where the margin of this cavity is deficient, it is connected to the transverse ligament, and by a few fibres

to the edge of the obturator foramen. Its *lower circumference* surrounds the neck of the femur, being attached, in front, to the spiral or anterior intertrochanteric line; above, to the base of the neck; behind, to the neck of the bone, about half an inch above the posterior intertrochanteric line. From this insertion the fibres are reflected upward over the neck of the femur, forming a sort of tubular sheath (the *cervical reflection*), which blends with the periosteum and can be traced as far as the articular cartilage. It is much thicker at the upper and fore part of the joint, where the greatest amount of resistance is required, than below and internally, where it is thin, loose, and longer than in any other part. It consists of two sets of fibres, circular and longitudinal. The circular fibres are most abundant at the lower and back part of the capsule, while the longitudinal fibres are greatest in

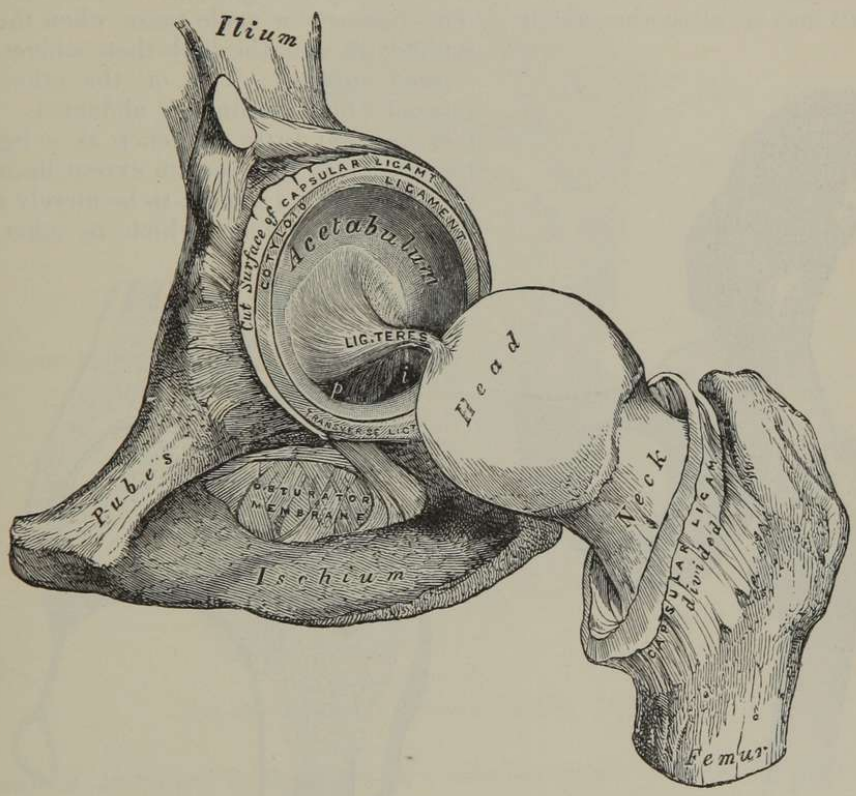

FIG. 253.—Left hip-joint laid open.

amount at the upper and front part of the capsule, where they form distinct bands or accessory ligaments, of which the most important is the *ilio-femoral*. The other accessory bands are known as the *pubo-femoral*, passing from the ilio-pectineal eminence to the front of the capsule; *ilio-trochanteric*, from the anterior inferior spine of the ilium to the front of the great trochanter; and *ischio-capsular*, passing from the ischium, just below the acetabulum, to blend with the circular fibres at the lower part of the joint. The external surface (Fig. 239, page 337) is rough, covered by numerous muscles, and separated in front from the Psoas and Iliacus by a synovial bursa, which not unfrequently communicates, by a circular aperture, with the cavity of the joint. It differs from the capsular ligament of the shoulder in being much less loose and lax, and in not being perforated for the passage of a tendon.

The **Ilio-femoral Ligament** (Figs. 239 and 254) is an accessory band of fibres extending obliquely across the front of the joint; it is intimately connected with the capsular ligament, and serves to strengthen it in this situation. It is attached, above, to the lower part of the anterior inferior spine of the ilium; and, diverging below, forms two bands, of which one passes downward to be inserted into the

lower part of the anterior intertrochanteric line; the other passes downward and outward to be inserted into the upper part of the same line and adjacent part of the neck of the femur. Between the two bands is a thinner part of the capsule. Sometimes there is no division, but the ligament spreads out into a flat, triangular band, which is attached below into the whole length of the anterior intertrochanteric line. This ligament is frequently called the Y-shaped ligament of Bigelow. Its upper band is the ilio-trochanteric ligament.

The **Ligamentum Teres** is a triangular band implanted by its apex into the depression a little behind and below the centre of the head of the femur, and by its broad base into the margins of the cotyloid notch, becoming blended with the transverse ligament. It is formed of connective tissue, surrounded by a tubular sheath of synovial membrane. Sometimes only the synovial fold exists, or the ligament may be altogether absent. The ligament is made tense when the hip is semiflexed, and the limb then adducted and rotated outward; it is, on the other hand, relaxed when the limb is abducted. It has, however, but little influence as a ligament, though it may to a certain extent limit movement, and would appear to be merely a modification of the folds which in other joints

FIG. 254.—Hip-joint, showing the ilio-femoral ligament. (After Bigelow.)

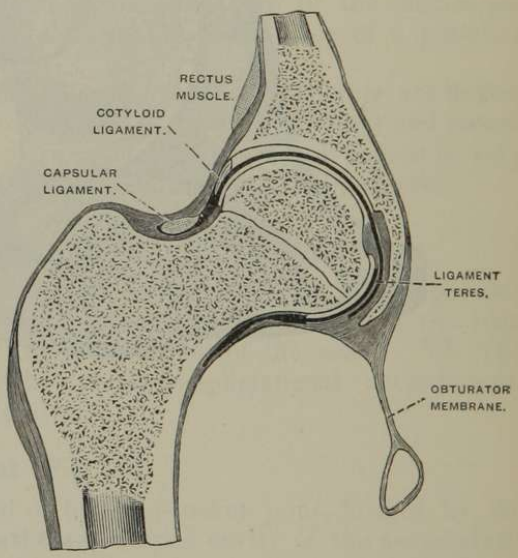

FIG. 255.—Vertical section through hip-joint. (Henle.)

fringe the margins of reflection of synovial membranes (see page 314).

The **Cotyloid Ligament** is a fibro-cartilaginous rim attached to the margin of the acetabulum, the cavity of which deepens; at the same time it protects the edges of the bone and fills up the inequalities on its surface. It bridges over the notch as the *transverse ligament*, and thus forms a complete circle, which closely surrounds the head of the femur, and assists in holding it in its place, acting as a sort of valve. It is prismoid in form, its base being attached to the margin of the acetabulum, and its opposite edge being free and sharp; whilst its two surfaces are invested by synovial membrane, the external one being in contact with the capsular ligament, the internal one being inclined inward, so as to narrow the acetabulum and embrace the cartilaginous surface of the head of the femur. It is much thicker above and behind than below and in front, and consists of close, compact fibres, which arise from different points of the circumference of the acetabulum and interlace with each other at very acute angles.

The **Transverse Ligament** is in reality a portion of the cotyloid ligament,

though differing from it in having no nests of cartilage-cells amongst its fibres. It consists of strong, flattened fibres, which cross the notch at the lower part of the acetabulum and convert it into a foramen. Thus an interval is left beneath the ligament for the passage of nutrient vessels to the joint.

The **Synovial Membrane** is very extensive. Commencing at the margin of the cartilaginous surface of the head of the femur, it covers all that portion of the neck which is contained within the joint; from the neck it is reflected on the internal surface of the capsular ligament, covers both surfaces of the cotyloid ligament and the mass of fat contained in the depression at the bottom of the acetab-

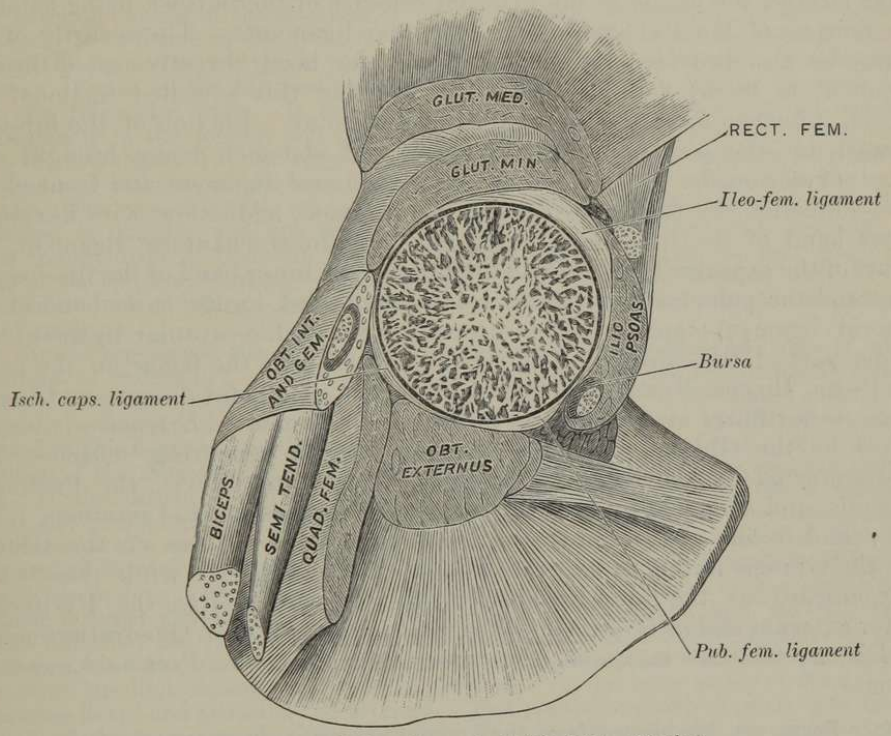

FIG. 256.—Relation of muscles to hip-joint. (Henle.)

ulum, and is prolonged in the form of a tubular sheath around the ligamentum teres as far as the head of the femur.

The muscles in relation with the joint are, in front, the Psoas and Iliacus, separated from the capsular ligament by a synovial bursa; above, the reflected head of the Rectus and Gluteus minimus, the latter being closely adherent to the capsule; internally, the Obturator externus and Pectineus; behind, the Pyriformis, Gemellus superior, Obturator internus, Gemellus inferior, Obturator externus, and Quadratus femoris (Fig. 256).

The arteries supplying the joint are derived from the obturator, sciatic, internal circumflex, and gluteal.

The nerves are articular branches from the sacral plexus, great sciatic, obturator, accessory obturator, and a filament from the branch of the anterior crural supplying the Rectus.

Actions.—The movements of the hip, like those of all enarthrodial joints, are very extensive; they are flexion, extension, adduction, abduction, circumduction, and rotation.

The hip-joint presents a very striking contrast to the other great enarthrodial joint—the shoulder—in the much more complete mechanical arrangements for its security and for the limitation of its movements. In the shoulder, as we have seen, the head of the humerus is not adapted at all in shape to the glenoid cavity, and is

hardly restrained in any of its ordinary movements by the capsular ligament. In the hip-joint, on the contrary, the head of the femur is closely fitted to the acetabulum for a distance extending over nearly half a sphere, and at the margin of the bony cup it is still more closely embraced by the ligamentous ring of the cotyloid ligament, so that the head of the femur is held in its place by that ligament even when the fibres of the capsule have been quite divided (Humphry). The anterior portion of the capsule, described as the ilio-femoral or accessory ligament, is the strongest of all the ligaments in the body, and is put on the stretch by any attempt to extend the femur beyond a straight line with the trunk. That is to say, this ligament is the chief agent in maintaining the erect position without muscular fatigue, the action of the extensor muscles of the buttock being balanced by the tension of the ilio-femoral and capsular ligaments. The security of the joint may be also provided for by the two bones being directly united through the ligamentum teres; but it is doubtful whether this so-called ligament can have much influence upon the mechanism of the joint. Flexion of the hip-joint is arrested by the soft parts of the thigh and abdomen being brought into contact;[1] extension, by the tension of the ilio-femoral ligament and front of the capsule; adduction, by the thighs coming into contact; adduction, with flexion by the outer band of the ilio-femoral ligament, the ilio-trochanteric ligament, the outer part of the capsular ligament; abduction, by the inner band of the ilio-femoral ligament and the pubo-femoral band; rotation outward, by the outer band of the ilio-femoral ligament; and rotation inward, by the ischio-capsular ligament and the hinder part of the capsule. The muscles which *flex* the femur on the pelvis are the Psoas, Iliacus, Rectus, Sartorius, Pectineus, Adductor longus and brevis, and the anterior fibres of the Gluteus medius and minimus. *Extension* is mainly performed by the Gluteus maximus, assisted by the hamstring muscles. The thigh is *adducted* by the Adductor magnus, longus and brevis, the Pectineus, and Gracilis, and *abducted* by the Gluteus maximus, medius, and minimus. The muscles which *rotate* the thigh *inward* are the anterior fibres of the Gluteus medius, the Gluteus minimus, and the Tensor vaginæ femoris; while those which rotate it *outward* are the posterior fibres of the Gluteus medius, the Pyriformis, Obturator externus and internus, Gemellus superior and inferior, Quadratus femoris, Psoas, Iliacus, Gluteus maximus, the three Adductors, the Pectineus, and the Sartorius.

Surface Form.—A line drawn from the anterior superior spinous process of the ilium to the most prominent part of the tuberosity of the ischium (Nélaton's line) runs through the centre of the acetabulum, and would, therefore, indicate the level of the hip-joint; or, in other words, the upper border of the great trochanter, which lies on Nélaton's line, is on a level with the centre of the hip-joint.

Surgical Anatomy.—In dislocation of the hip "the head of the thigh-bone may rest at any point around its socket" (Bryant); but whatever position the head ultimately assumes, the primary displacement is generally downward and inward, the capsule giving way at its weakest—that is, its lower and inner—part. The situation that the head of the bone subsequently assumes is determined by the degree of flexion or extension, and of outward or inward rotation of the thigh at the moment of luxation, influenced, no doubt, by the ilio-femoral ligament, which is not easily ruptured. When, for instance, the head is forced backward, this ligament forms a fixed axis, round which the head of the bone rotates, and is thus driven on to the dorsum of the ilium. The ilio-femoral ligament also influences the position of the thigh in the various dislocations: in the dislocations backward it is tense, and produces inversion of the limb; in the dislocation on to the pubes it is relaxed, and therefore allows the external rotators to evert the thigh; while in the thyroid dislocation it is tense and produces flexion. The muscles inserted into the upper part of the femur, with the exception of the Obturator internus, have very little direct influence in determining the position of the bone. But Bigelow has endeavored to show that the Obturator internus is the principal agent in determining whether, in the backward dislocations, the head of the bone shall be ultimately lodged on the dorsum of the ilium or in or near the sciatic notch. In both dislocations the head passes, in the first instance, in the same direction; but, as Bigelow asserts, in the displacement on to the dorsum, the head of the bone travels up behind the acetabulum, between the muscle and the pelvis; while in the disloca-

[1] The hip-joint cannot be completely flexed, in most persons, without at the same time flexing the knee, on account of the shortness of the hamstring muscles.—Cleland, *Journ. of Anat. and Phys.*, No. 1, Old Series, p. 87.

tion into the sciatic notch, the head passes behind the muscle, and is therefore prevented from reaching the dorsum, in consequence of the tendon of the muscle arching over the neck of the bone, and so remains in the neighborhood of the sciatic notch. Bigelow, therefore, distinguishes these two forms of dislocation by describing them as dislocations backward, "above and below," the Obturator internus.

The ilio-femoral ligament is rarely torn in dislocations of the hip, and this fact is taken advantage of by the surgeon in reducing these dislocations by manipulation. It is made to act as a fulcrum to a lever, of which the long arm is the shaft of the femur, and the short arm the neck of the bone.

The hip-joint is rarely the seat of acute synovitis from injury, on account of its deep position and its thick covering of soft parts. Acute inflammation may, and does, frequently occur as the result of constitutional conditions, as rheumatism, pyæmia, etc. When, in these cases, effusion takes place, and the joint becomes distended with fluid, the swelling is not very easy to detect on account of the thickness of the capsule and the depth of the articulation. It is principally to be found on the front of the joint, just internal to the ilio-femoral ligament; or behind, at the lower and back part. In these two places the capsule is thinner than elsewhere. Disease of the hip-joint is much more frequently of a chronic character and is usually of a tubercular origin. It begins either in the bones or in the synovial membrane, more frequently in the former, and probably, in most cases, at the growing, highly vascular tissue in the neighborhood of the epiphysial cartilage. In this respect it differs very materially from tubercular arthritis of the knee, where the disease usually commences in the synovial membrane. The reasons for this are twofold: first, this part being the centre of rapid growth, its nutrition is unstable and apt to pass into inflammatory action; and, secondly, great strain is thrown upon it, from the frequency of falls and blows upon the hip, which causes crushing of the epiphysial cartilage or the cancellous tissue in its neighborhood, with the results likely to follow such an injury. In addition to these, the depth of the joint protects it from the causes of synovitis.

In chronic hip-disease the affected limb assumes an altered position, the cause of which it is important to understand. In the early stage of a typical case the limb is flexed, abducted, and rotated outward. In this position all the ligaments of the joint are relaxed: the front of the capsule by flexion; the outer band of the ilio-femoral ligament by abduction; and the inner band of this ligament and the back of the capsule by rotation outward. It is, therefore, the position of the greatest ease. The condition is not quite obvious at first upon examining a patient. If the patient is laid in the supine position, the affected limb will be found to be extended and parallel with the other. But it will be found that the pelvis is tilted downward on the diseased side and the limb apparently longer than its fellow, and that the lumbar spine is arched forward (lordosis). If now the thigh is abducted and flexed, the tilting downward and the arching forward of the pelvis disappears. The condition is thus explained. A limb which is flexed and abducted is obviously useless for progression, and, in order to overcome the difficulty, the patient depresses the affected side of his pelvis in order to produce parallelism of his limbs, and at the same time rotates his pelvis on its transverse horizontal axis, so as to direct the limb downward instead of forward. In the latter stages of the disease the limb becomes flexed and abducted and inverted. This position probably depends upon muscular action, at all events as regards the adduction. The Adductor muscles are supplied by the obturator nerve, which also largely supplies the joint. These muscles are therefore thrown into reflex action by the irritation of the peripheral terminations of this nerve in the inflamed articulation. Osteo-arthritis is not uncommon in the hip-joint, and it is said to be more common in the male than in the female, in whom the knee-joint is more frequently affected. It is a disease of middle age or more advanced period of life.

Congenital dislocation is more commonly met with in the hip-joint than in any other articulation. The displacement usually takes place on to the dorsum ilii. It gives rise to extreme lordosis, and a waddling gait is noticed as soon as the child commences to walk.

Excision of the hip may be required for disease or for injury, especially gunshot. It may be performed either by an anterior incision or a posterior one. The former one entails less interference with important structures, especially muscles, than the posterior one, but permits of less efficient drainage. In these days, however, when the surgeon aims at securing healing of his wound without suppuration, this second desideratum is not of so much importance. In the operation in front the surgeon makes an incision three to four inches in length, starting immediately below and external to the anterior superior spinous process of the ilium, downward and inward between the Sartorius and Tensor vaginæ femoris, to the neck of the bone, dividing the capsule at its upper part. A narrow-bladed saw now divides the neck of the femur, and the head of the bone is extracted with sequestrum forceps. All diseased tissue is carefully removed with a sharp spoon or scissors, and the cavity thoroughly flushed out with a hot antiseptic fluid.

The posterior method consists in making an incision three or four inches long, commencing midway between the top of the great trochanter and the anterior superior spine, and ending over the shaft, just below the trochanter. The muscles are detached from the great trochanter, and the capsule opened freely. The head and neck are freed from the soft parts and the bone sawn through just below the top of the trochanter with a narrow saw. The head of the bone is then levered out of the acetabulum. In both operations, if the acetabulum is eroded, it must be freely gouged.

II. Knee-joint.

The knee-joint was formerly described as a ginglymus or hinge-joint, but is really of a much more complicated character. It must be regarded as consisting of three articulations together: one between each condyle of the femur and the corresponding tuberosity of the tibia, which are condyloid joints, and one between the patella and the femur, which is partly arthrodial, but not completely so, since the articular surfaces are not mutually adapted to each other, so that the movement is not a simple gliding one. This view of the construction of the knee-joint receives confirmation from the study of the articulation in some of the lower mammals, where three synovial membranes are sometimes found, corresponding to these three subdivisions, either entirely distinct or only connected together by small communications. This view is further rendered probable by the existence of the two crucial ligaments within the joint, which must be regarded as the external and internal lateral ligaments of the inner and outer joints respectively. The existence of the ligamentum mucosum would further indicate a tendency to separation of the synovial cavity into two minor sacs, one corresponding to each joint.

The bones entering into the formation of the knee-joint are the condyles of the femur above, the head of the tibia below, and the patella in front. The bones are connected together by ligaments, some of which are placed on the exterior of the joint, while others occupy its interior.

External Ligaments.	*Interior Ligaments.*
Anterior, or Ligamentum Patellæ.	Anterior, or External Crucial.
Posterior, or Ligamentum Posticum Winslowii.	Posterior, or Internal Crucial.
Internal Lateral.	Two Semilunar Fibro-cartilages.
Two External Lateral.	Transverse.
Capsular.	Coronary.
	Ligamentum mucosum.
	Ligamenta alaria.

The **Anterior Ligament,** or **Ligamentum Patellæ** (Fig. 257), is the central portion of the common tendon of the Extensor muscles of the thigh which is continued from the patella to the tubercle of the tibia, supplying the place of an anterior ligament. It is a strong, flat, ligamentous band about three inches in length, attached, above, to the apex of the patella and the rough depression on its posterior surface; below, to the lower part of the tubercle of the tibia, its superficial fibres being continuous over the front of the patella with those of the tendon of the Quadriceps extensor. The lateral portions of the tendon of the Extensor muscles pass down on either side of the patella, attached to the borders of this bone and its ligament, to be inserted into the upper extremity of the tibia on each side of the tubercle; externally, these portions merge into the capsular ligament. They are termed *lateral patellar ligaments.* The posterior surface of the ligamentum patellæ can usually be easily separated from the front of the capsular ligament.

The **Posterior Ligament (Ligamentum Posticum Winslowii)** (Fig. 258) is a broad, flat, fibrous band formed of fasciculi, obliquely directed, and separated from one another by apertures for the passage of vessels and nerves. The strongest of these fasciculi is derived from the tendon of the Semimembranosus, and passes from the back part of the inner tuberosity of the tibia obliquely upward and outward to the back part of the outer condyle of the femur, *within* the intercondyloid notch. The posterior ligament forms part of the floor of the popliteal space.

The **Internal Lateral Ligament** is a broad, flat, membranous band, thicker behind than in front, and situated nearer to the back than the front of the joint. It is attached, above, to the inner tuberosity of the femur; below, to the inner tuberosity and inner surface of the shaft of the tibia to the extent of about two inches. It is crossed, at its lower part, by the tendons of the Sartorius, Gracilis, and Semitendinosus muscles, a synovial bursa being interposed. Its *deep surface* covers the anterior portion of the tendon of the Semimembranosus, the synovial

membrane of the joint, and the inferior internal articular vessels and nerve; it is intimately adherent to the internal semilunar fibro-cartilage.

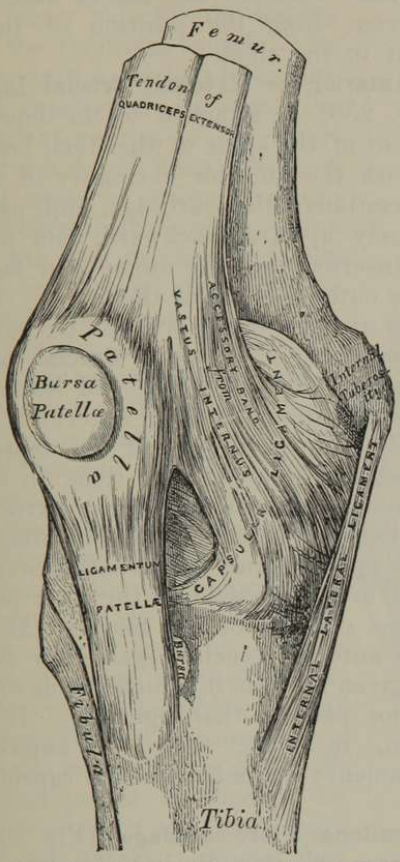

FIG. 257.—Right knee-joint. Anterior view.

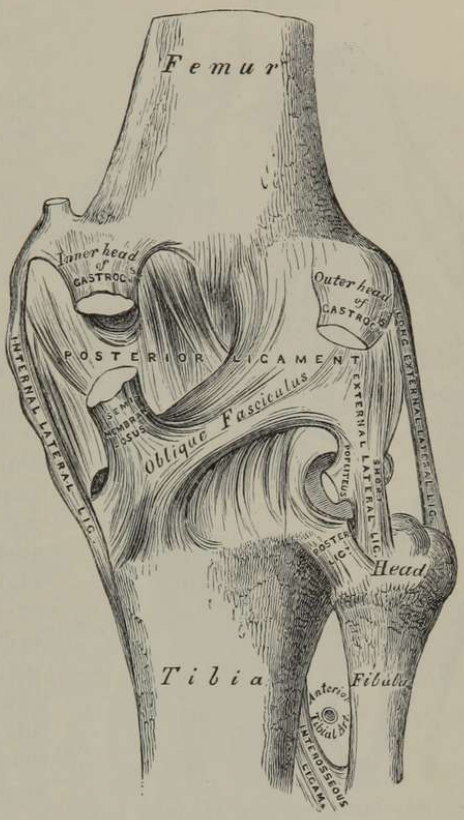

FIG. 258.—Right knee-joint. Posterior view.

The **Long External Lateral Ligament** is a strong, rounded, fibrous cord situated nearer to the back than the front of the joint. It is attached, above, to the back part of the outer tuberosity of the femur; below, to the outer part of the head of the fibula. Its *outer surface* is covered by the tendon of the Biceps, which divides at its insertion into two parts, separated by the ligament. The ligament has, passing beneath it, the tendon of the Popliteus muscle and the inferior external articular vessels and nerve.

The **Short External Lateral Ligament** is a bundle of fibres placed behind the preceding, attached, above, together with the outer head of the Gastrocnemius, to the outer condyle of the femur; below, to the summit of the styloid process of the fibula. This ligament is intimately connected with the capsular ligament, and has, passing beneath it, the tendon of the Popliteus muscle and the inferior external articular vessels and nerve.

The **Capsular Ligament** consists of an exceedingly thin but strong, fibrous membrane which fills in the intervals left between the stronger bands above described, and is inseparably connected with them. In front it blends with the lateral patellar ligaments and fills in the interval between the anterior and lateral ligaments of the joint, with which latter structures it is closely connected. Behind, it is strong, and formed chiefly of vertical fibres, which arise above from the condyles and intercondyloid notch of the femur, and is connected below with the back part of the head of the tibia, being closely united with the origins of the Gastrocnemius, Plantaris, and Popliteus muscles. It passes in front of, but is inseparably connected with, the posterior ligament.

The **Crucial** are two interosseous ligaments of considerable strength situated

in the interior of the joint, nearer its posterior than its anterior part. They are called *crucial* because they cross each other somewhat like the lines of the letter X; and have received the names *anterior* and *posterior*, from the position of their attachment to the tibia.

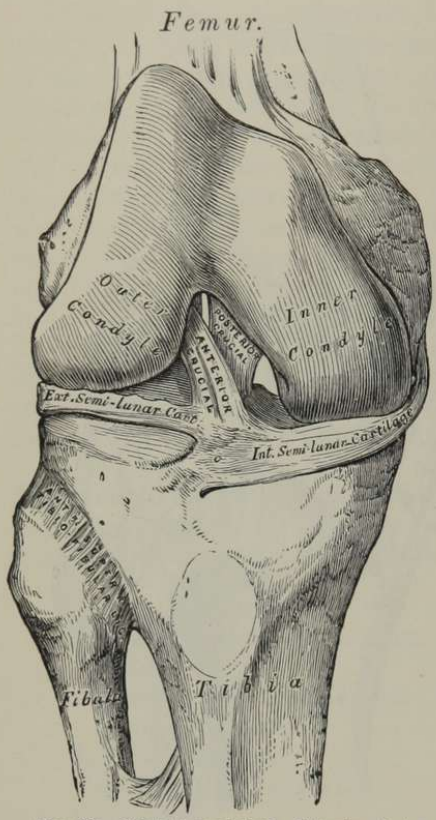

FIG. 259.—Right knee-joint. Showing internal ligaments.

The **Anterior, or External Crucial Ligament** (Fig. 259), is attached to the depression in front of the spine of the tibia, being blended with the anterior extremity of the external semilunar fibro-cartilage, and, passing obliquely upward, backward, and outward, is inserted into the inner and back part of the outer condyle of the femur. Its direction is upward, backward, and outward.

The **Posterior, or Internal Crucial Ligament,** is stronger, but shorter and less oblique in its direction, than the anterior. It is attached to the back part of the depression behind the spine of the tibia, to the popliteal notch, and to the posterior extremity of the external semilunar fibro-cartilage; and passes upward, and somewhat forward, and inward, to be inserted into the outer part of the inner condyle of the femur. As it crosses the anterior crucial ligament a fasciculus is given off from it, which blends with the posterior part of that ligament. It is in relation, in front, with the anterior crucial ligament; behind, with the capsular ligament.

The **Semilunar Fibro-cartilages** (Fig. 260) are two crescentic lamellæ which serve to deepen the surface of the head of the tibia, for articulation with the condyles of the femur. The circumference of each cartilage is thick, convex, and attached to the inside of the capsule of the knee; the inner border is thin, concave and free. Their upper surfaces are concave, and in relation with the condyles of the femur; their lower surfaces are flat, and rest upon the head of the tibia. Each cartilage covers nearly the outer two-thirds of the corresponding articular surface of the tibia, leaving the inner third uncovered; both surfaces are smooth and invested by synovial membrane.

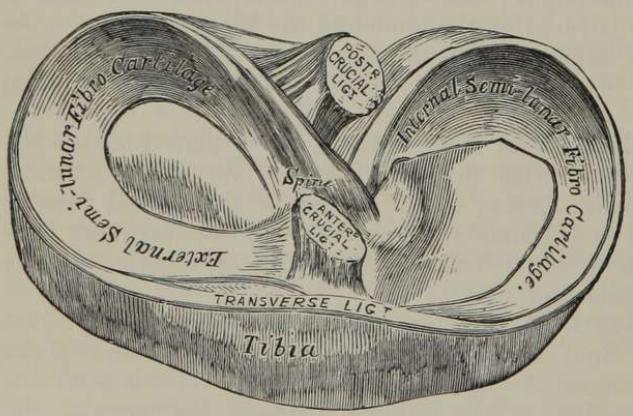

FIG. 260.—Head of tibia, with semilunar cartilages, etc. Seen from above. Right side.

The **Internal Semilunar Fibro-cartilage** is nearly semicircular in form, a little elongated from before backward, and broader behind than in front; its anterior extremity, thin and pointed, is attached to a depression on the anterior margin of the head of the tibia, in front of the anterior crucial ligament; its posterior extremity is attached to the depression behind the spine, between the attachments of the external semilunar fibro-cartilage and the posterior crucial ligaments.

The **External Semilunar Fibro-cartilage** forms nearly an entire circle, covering a larger portion of the articular surface than the internal one. It is grooved on its outer side for the tendon of the Popliteus muscle. Its extremities, at their insertion, are interposed between the two extremities of the internal semilunar fibro-cartilage; the anterior extremity being attached in front of the spine of the tibia to the outer side of, and behind, the anterior crucial ligament, with which it blends; the posterior extremity being attached behind the spine of the tibia, in front of the posterior extremity of the internal semilunar fibro-cartilage. Just before its insertion posteriorly it gives off a strong fasciculus, which passes obliquely upward and inward, to be inserted into the inner condyle of the femur, close to the attachment of the posterior crucial ligament. Occasionally a small fasciculus is given off which passes forward to be inserted into the back part of the anterior crucial ligament. The external semilunar fibro-cartilage gives off from its anterior convex margin a fasciculus which forms the transverse ligament.

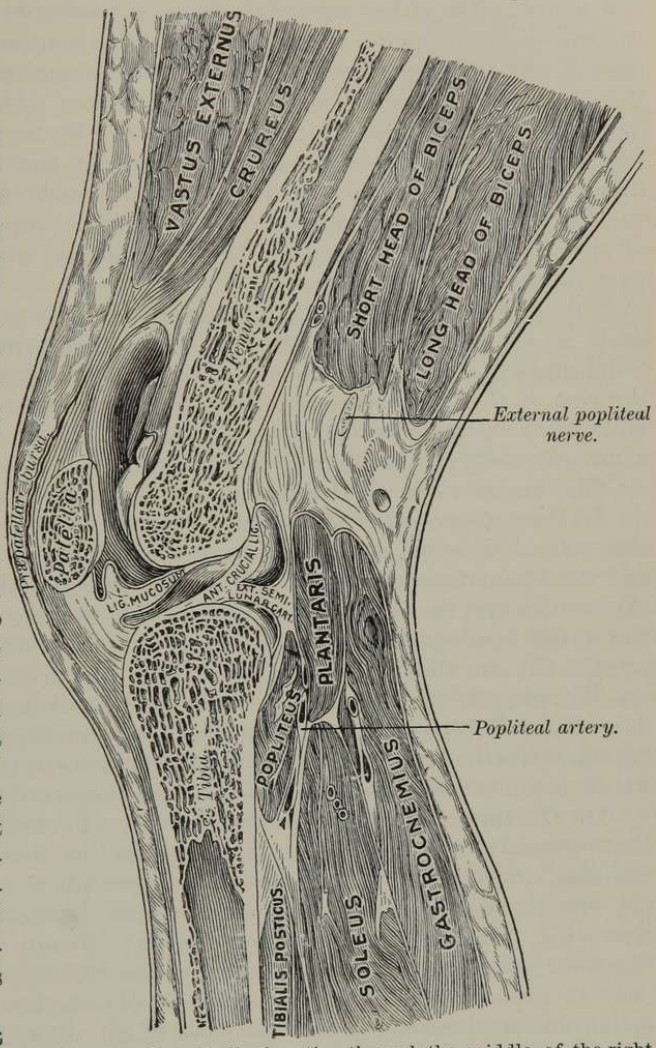

FIG. 261.—Longitudinal section through the middle of the right knee-joint. (After Braune.)

The **Transverse Ligament** is a band of fibres which passes transversely from the anterior convex margin of the external semilunar fibro-cartilage to the anterior convex margin of the internal semilunar fibro-cartilage; its thickness varies considerably in different subjects, and it is sometimes absent altogether.

The **Coronary Ligaments** are merely portions of the capsular ligament, which connect the circumference of each of the semilunar fibro-cartilages with the margin of the head of the tibia.

The **Synovial Membrane** of the knee-joint is the largest and most extensive in the body. Commencing at the upper border of the patella, it forms a short *cul-de-sac* beneath the Quadriceps extensor tendon of the thigh, on the lower part of the front of the shaft of the femur: this communicates with a synovial bursa interposed between the tendon and the front of the femur by an orifice of variable size. On each side of the patella the synovial membrane extends beneath the aponeurosis of the Vasti muscles, and more especially beneath that of the Vastus internus. Below the patella it is separated from the anterior ligament by the anterior part of the capsule and a considerable quantity of adipose tissue. In this situation it sends off a triangular prolongation, containing a few ligamentous fibres, which extends from the anterior part of the joint below the patella to the front of the intercondyloid notch. This fold has been termed the *ligamentum mucosum*. It

also sends off two fringe-like folds, called the *ligamenta alaria*, which extend from the sides of the ligamentum mucosum, upward and laterally between the patella and femur. On either side of the joint it passes downward from the femur, lining the capsule to its point of attachment to the semilunar cartilages; it may then be traced over the upper surfaces of these cartilages to their free borders, and from thence along their under surfaces to the tibia. At the back part of the external one it forms a *cul-de-sac* between the groove on its surface and the tendon of the Popliteus; it surrounds the crucial ligaments and lines the inner surface of the ligaments which enclose the joints. The pouch of synovial membrane between the Extensor tendon and front of the femur is supported, during the movements of the knee, by a small muscle, the Subcrureus, which is inserted into the upper part of the capsular ligament.

The folds of synovial membrane and the fatty processes contained in them act, as it seems, mainly as padding to fill up interspaces and obviate concussions. Sometimes the bursa beneath the Quadriceps extensor is completely shut off from the rest of the synovial cavity, thus forming a closed sac between the Quadriceps and the lower part of the front of the femur, or it may communicate with the synovial cavity by a minute aperture.

The bursæ about the knee-joint are the following:

In front there are three bursæ: one is interposed between the patella and the skin; another, of small size, between the upper part of the tuberosity of the tibia and the ligamentum patellæ; and a third between the lower part of the tuberosity of the tibia and the skin. On the outer side there are four bursæ: (1) one beneath the outer head of the Gastrocnemius (which sometimes communicates with the joint); (2) one above the external lateral ligament between it and the tendon of the Biceps; (3) one beneath the external lateral ligament between it and the tendon of the Popliteus (this is sometimes only an expansion from the next bursa); (4) one beneath the tendon of the Popliteus between it and the condyle of the femur, which is almost always an extension from the synovial membrane.

On the inner side there are five bursæ: (1) one beneath the inner head of the Gastrocnemius, which sends a prolongation between the tendons of the Gastrocnemius and Semimembranosus: this bursa often communicates with the joint; (2) one above the internal lateral ligament between it and the tendons of the Sartorius, Gracilis, and Semitendinosus; (3) one beneath the internal lateral ligament between it and the tendon of the Semimembranosus: this is sometimes only an expansion from the next bursa; (4) one beneath the tendon of the Semimembranosus, between it and the head of the tibia; (5) sometimes there is a bursa between the tendons of the Semimembranosus and of the Semitendinosus.

Structures around the Joint.—In front and at the sides, the Quadriceps extensor; on the outer side, the tendons of the Biceps and the Popliteus and the external popliteal nerve; on the inner side, the Sartorius, Gracilis, Semitendinosus, and Semimembranosus; behind, an expansion from the tendon of the Semimembranosus, the popliteal vessels, and the internal popliteal nerve, Popliteus, Plantaris, and inner and outer heads of the Gastrocnemius, some lymphatic glands, and fat.

The *Arteries* supplying the joint are derived from the anastomotica magna branch of the femoral, articular branches of the popliteal, anterior and posterior recurrent branches of the anterior tibial, and descending branch from the external circumflex of the Profunda.

The *Nerves* are derived from the obturator, anterior crural, and external and internal popliteal.

Actions.—The knee-joint permits of movements of flexion and extension, and, in certain positions, of slight rotation inward and outward. The movement of flexion and extension does not, however, take place in a simple, hinge-like manner, as in other joints, but is a complicated movement, consisting of a certain amount of gliding and rotation; so that the same part of one articular surface is not always applied to the same part of the other articular surface, and the axis

of motion is not a fixed one. If the joint is examined while in a condition of extreme flexion, the posterior part of the articular surfaces of the tibia will be found to be in contact with the posterior rounded extremities of the condyles of the femur; and if a simple hinge-like movement were to take place, the axis, round which the revolving movement of the tibia occurs, would be in the back part of the condyle. If the leg is now brought forward into a position of semiflexion, the upper surface of the tibia will be seen to glide over the condyles of the femur, so that the middle part of the articular facets are in contact, and the axis of rotation must therefore have shifted forward to nearer the centre of the condyles. If the leg is now brought into the extended position, a still further gliding takes place and a further shifting forward of the axis of rotation. This is not, however, a simple movement, but is accompanied by a certain amount of rotation outward round a vertical axis drawn through the centre of the head of the tibia. This rotation is due to the greater length of the internal condyle, and to the fact that the anterior portion of its articular surface is inclined obliquely outward. In consequence of this it will be seen that toward the close of the movement of extension—that is to say, just before complete extension is effected—the tibia glides obliquely upward and outward over this oblique surface of the inner condyle, and the leg is therefore necessarily rotated outward. In flexion of the joint the converse of these movements takes place: the tibia glides backward round the end of the femur, and at the commencement of the movement the tibia is directed downward and inward along the oblique curve of the inner condyle, thus causing an inward rotation to the leg.

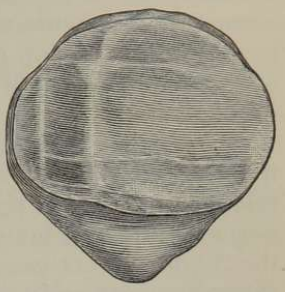

FIG. 262.—View of the posterior surface of the patella, showing diagrammatically the areas of contact with the femur in different positions of the knee.

During flexion and extension the patella moves on the lower end of the femur, but this movement is not a simple gliding one; for if the articular surface of this bone is examined, it will be found to present on each side of the central vertical ridge two less marked transverse ridges, which divide the surface, except a small portion along the inner border, which is cut off by a slight vertical ridge into six facets (see Fig. 262), and therefore does not present a uniform curved surface, as would be the case if a simple gliding movement took place. These six facets—three on each side of the median vertical ridge—correspond to and denote the parts of the bone respectively in contact with the condyles of the femur during flexion, semiflexion, and extension. In flexion only the upper facets on the patella are in contact with the condyles of the femur; the lower two-thirds of the bone rests upon the mass of fat which occupies the space between the femur and tibia. In the semiflexed position of the joint the middle facets on the patella rest upon the most prominent portion of the condyles, and thus afford greater leverage to the Quadriceps by increasing its distance from the centre of motion. In complete extension the patella is drawn up, so that only the lower facets are in contact with the articular surfaces of the condyles. The narrow strip along the inner border is an exception to this, and would appear to be in contact with the internal condyle throughout its whole extent in every position of the joint. As in the elbow, so it is in the knee—the axis of rotation in flexion and extension is not precisely at right angles to the axis of the bone, but during flexion there is a certain amount of alteration of plane; so that, whereas in flexion the femur and tibia are in the same plane, in extension the one bone forms an angle of about ten degrees with the other. There is, however, this difference between the two extremities: that in the upper, during extension, the humeri are parallel and the bones of the forearm diverge; in the lower, the femora converge below and the tibia are parallel.

In addition to the slight rotation during flexion and extension, the tibia enjoys an independent rotation on the condyles of the femur in certain positions of the joint. This movement takes place between the interarticular fibro-cartilages and

the tibia, whereas the movement of flexion and extension takes place between the interarticular fibro-cartilages and the femur. So that the knee may be said to consist of two joints, separated by the fibro-cartilages: an upper (menisco-femoral), in which flexion and extension take place; and a lower (menisco-tibial), allowing of a certain amount of rotation. This latter movement can only take place in the semiflexed position of the limb, when all the ligaments are relaxed.

During *flexion* the ligamentum patellæ is put upon the stretch, as is also the posterior crucial ligament in extreme flexion. The other ligaments are all relaxed by flexion of the joint, though the relaxation of the anterior crucial ligament is very trifling. Flexion is only checked during life by the contact of the leg with the thigh. In *extension* the ligamentum patellæ becomes relaxed, and, in extreme extension completely so, so as to allow free lateral movement to the patella, which then rests on the front of the lower end of the femur. The other ligaments, with the exception of the posterior crucial, which is partly relaxed, are all on the stretch. When the limb has been brought into a straight line, extension is checked mainly by the tension of all the ligaments except the posterior crucial and ligamentum patellæ. The movements of *rotation*, of which the knee is capable, are permitted in the semiflexed condition by the partial relaxation of both crucial ligaments, as well as the lateral ligaments. Rotation inward appears to be limited by the tension of the anterior crucial ligament, and by the interlocking of the two ligaments; but rotation outward does not appear to be checked by either crucial ligament, since they uncross during the execution of this movement, but by the lateral ligaments, especially the internal. The main function of the crucial ligaments is to act as a direct bond of union between the tibia and femur, preventing the former bone from being carried too far backward or forward. Thus the anterior crucial ligament prevents the tibia being carried too far forward by the extensor tendons, and the posterior crucial checks too great movement backward by the flexors. They also assist the lateral ligaments in resisting any lateral bending of the joint. The interarticular cartilages are intended, as it seems, to adapt the surface of the tibia to the shape of the femur to a certain extent, so as to fill up the intervals which would otherwise be left in the varying positions of the joint, and to interrupt the jars which would be so frequently transmitted up the limb in jumping or falls on the feet; also to permit of the two varieties of motion, flexion and extension, and rotation, as explained above. The patella is a great defence to the knee-joint from any injury inflicted in front, and it distributes upon a large and tolerably even surface during kneeling the pressure which would otherwise fall upon the prominent ridges of the condyles; it also affords leverage to the Quadriceps extensor muscle to act upon the tibia; and Mr. Ward has pointed out [1] how this leverage varies in the various positions of the joint, so that the action of the muscles produces velocity at the expense of force in the commencement of extension, and, on the contrary, at the close of extension tends to diminish velocity, and therefore the shock to the ligaments; whilst in the standing position it draws the tibia powerfully forward, and thus maintains it in its place.

Extension of the leg on the thigh is performed by the Quadriceps extensor; *flexion* by the hamstring muscles, assisted by the Gracilis and Sartorius, and, indirectly, by the Gastrocnemius, Popliteus, and Plantaris; *rotation outward*, by the Biceps; and *rotation inward* by the Popliteus, Semitendinosus, and, to a slight extent, the Semimembranosus, the Sartorius, and the Gracilis.

Surface Form.—The interval between the two bones entering into the formation of the knee-joint can always easily be felt. If the limb is extended, it is situated on a slightly higher level than the apex of the patella; but if the limb is slightly flexed, a knife carried horizontally backward immediately below the apex of the patella would pass directly into the joint. When the knee-joint is distended with fluid, the outline of the synovial membrane at the front of the knee may be fairly well mapped out.

Surgical Anatomy.—From a consideration of the construction of the knee-joint it would at first sight appear to be one of the least secure of any of the joints in the body. It is formed

[1] *Human Osteology*, p. 405.

between the two longest bones, and therefore the amount of leverage which can be brought to bear upon it is very considerable; the articular surfaces are but ill adapted to each other, and the range and variety of motion which it enjoys is great. All these circumstances tend to render the articulation very insecure; but, nevertheless, on account of the very powerful ligaments which bind the bones together, the joint is one of the strongest in the body, and dislocation from traumatism is of very rare occurrence. When, on the other hand, the ligaments have been softened or destroyed by disease, partial displacement is very liable to occur, and is frequently brought about by the mere action of the muscles displacing the articular surfaces from each other. The tibia may be dislocated in any direction from the femur—forward, backward, inward, or outward; or a combination of two of these dislocations may occur—that is, the tibia may be dislocated forward and laterally, or backward and laterally; and any of these dislocations may be complete or incomplete. As a rule, however, the antero-posterior dislocations are complete, the lateral ones incomplete.

One or other of the semilunar cartilages may become displaced and nipped between the femur and tibia. The accident is produced by a twist of the leg when the knee is flexed, and is accompanied by a sudden pain and fixation of the knee in a flexed position. The cartilage may be displaced either inward or outward: that is to say, either inward toward the tibial spine, so that the cartilage becomes lodged in the intercondyloid notch; or outward, so that the cartilage projects beyond the margin of the two articulating bones. Acute synovitis, the result of traumatism or exposure to cold, is very common in the knee, on account of its superficial position. When distended with fluid, the swelling shows itself above and at the sides of the patella, reaching about an inch or more above the trochlear surface of the femur, and extending a little higher under the Vastus internus than the Vastus externus. Occasionally the swelling may extend two inches or more. At the sides of the patella the swelling extends lower at the inner side than it does on the outer side. The lower level of the synovial membrane is just above the level of the upper part of the head of the fibula. In the middle line it covers the upper third of the ligamentum patellæ, being separated from it, however, by the capsule and a little fat. Chronic synovitis principally shows itself in the form of pulpy degeneration of the synovial membrane, leading to tubercular arthritis. The reasons why tubercular disease of the knee usually commences in the synovial membrane appear to be the complex and extensive nature of this sac; the extensive vascular supply to it; and the fact that injuries are generally diffused and applied to the front of the joint rather than to the ends of the bones. Syphilitic disease not unfrequently attacks the knee-joint. In the hereditary form of the disease it is usually symmetrical, attacking both joints, which become filled with synovial effusion, and is very intractable and difficult of cure. In the tertiary form of the disease gummatous infiltration of the synovial membrane may take place. The knee is one of the joints most commonly affected with osteo-arthritis, and is said to be more frequently the seat of this disease in women than in men. The occurrence of the so-called loose cartilage is almost confined to the knee, though they are occasionally met with in the elbow, and, rarely, in some other joints. Many of them occur in cases of osteo-arthritis, in which calcareous or cartilaginous material is formed in one of the synovial fringes and constitutes the foreign body, and may or may not become detached, in the former case only meriting the usual term, "loose" cartilage. In other cases they have their origin in the exudation of inflammatory lymph, and possibly, in some rare instances, a portion of the articular cartilage or one of the semilunar cartilages becomes detached and constitutes the foreign body.

Genu valgum, or knock-knee, is a common deformity of childhood, in which, owing to changes in and about the joint, the angle between the outer border of the tibia and femur is diminished, so that as the patient stands the two internal condyles of the femora are in contact, but the two internal malleoli of the tibiæ are more or less widely separated from each other. When, however, the knees are flexed to a right angle, the two legs are practically parallel with each other. At the commencement of the disease there is a yielding of the internal lateral ligament and other fibrous structures on the inner side of the joint; as a result of this there is a constant undue pressure of the outer tuberosity of the tibia against the outer condyle of the femur. This extra pressure causes arrest of growth and, possibly, wasting of the outer condyle, and a consequent tendency for the tibia to become separated from the internal condyle. To prevent this the internal condyle becomes depressed; probably, as was first pointed out by Mikulicz, by an increased growth of the lower end of the diaphysis on its inner side, so that the line of the epiphysis becomes oblique instead of transverse to the axis of the bone, with a direction downward and inward.

Excision of the knee-joint is most frequently required for tubercular disease of this articulation, but is also practised in cases of disorganization of the knee after rheumatic fever, pyæmia, etc., in osteo-arthritis, and in ankylosis. It is also occasionally called for in cases of injury, gunshot or otherwise. The operation is best performed either by a horseshoe incision, starting from one condyle, descending as low as the tubercle of the tibia, where it crosses the leg, and is then carried upward to the other condyle; or by a transverse incision across the patella. In this latter incision the patella is either removed or sawn across, and the halves subsequently sutured together. The bones having been cleared, and in those cases where the operation is performed for tubercular disease all pulpy tissue having been carefully removed, the section of the femur is first made. This should never include, in children, more than, at the most, two-thirds of the articular surface, otherwise the epiphysis will be included, with disastrous results as far as regards the growth of the limb. Afterward a thin slice should be removed from the upper

end of the tibia, not more than half an inch. If any diseased tissue still appears to be left in the bones, it should be removed with the gouge rather than that a further section of the bones should be made.

III. Articulations between the Tibia and Fibula.

The articulations between the tibia and fibula are effected by ligaments which connect both extremities, as well as the shafts of the bones. They may, consequently, be subdivided into three sets: 1. The Superior Tibio-fibular articulation. 2. The Middle Tibio-fibular ligament or interosseous membrane. 3. The Inferior Tibio-fibular articulation.

1. Superior Tibio-fibular Articulation.

This articulation is an arthrodial joint. The contiguous surfaces of the bones present two flat, oval facets covered with cartilage, and connected together by the following ligaments:

Anterior Superior Tibio-fibular.
Posterior Superior Tibio-fibular.

The **Anterior Superior Ligament** (Fig. 259) consists of two or three broad and flat bands which pass obliquely upward and inward from the front of the head of the fibula to the front of the outer tuberosity of the tibia.

The **Posterior Superior Ligament** (Fig. 258) is a single thick and broad band which passes upward and inward from the back part of the head of the fibula to the back part of the outer tuberosity of the tibia. It is covered by the tendon of the Popliteus muscle.

A **Synovial Membrane** lines this articulation, which at its upper and back part is occasionally continuous with that of the knee-joint.

2. Middle Tibio-fibular Ligament or Interosseous Membrane.

An interosseous membrane extends between the contiguous margins of the tibia and fibula, and separates the muscles on the front from those on the back of the leg. It consists of a thin, aponeurotic lamina composed of oblique fibres which pass downward and outward between the interosseous ridges on the two bones. It is broader above than below. Above its upper border is a large, oval aperture for the passage of the anterior tibial vessels forward to the anterior aspect of the leg; and at its lower part an opening for the passage of the anterior peroneal vessels. It is continuous below with the inferior interosseous ligament, and is perforated in numerous parts for the passage of small vessels. It is in relation, in front, with the Tibialis anticus, Extensor longus digitorum, Extensor proprius hallucis, Peroneus tertius, and the anterior tibial vessels and nerve; behind, with the Tibialis posticus and Flexor longus hallucis.

3. Inferior Tibio-fibular Articulation.

This articulation is formed by the rough, convex surface of the inner side of the lower end of the fibula, connected with a concave rough surface on the outer side of the tibia. Below, to the extent of about two lines, these surfaces are smooth, and covered with cartilage, which is continuous with that of the ankle-joint. The ligaments of this joint are—

Anterior Inferior Tibio-fibular.
Posterior Inferior Tibio-fibular.
Transverse.
Inferior Interosseous.

The **Anterior Inferior Ligament** (Fig. 264) is a flat, triangular band of fibres, broader below than above, which extends obliquely downward and outward between the adjacent margins of the tibia and fibula, on the front aspect of the articulation. It is in relation, in front, with the Peroneus tertius, the aponeurosis

of the leg, and the integument; behind, with the inferior interosseous ligament; and lies in contact with the cartilage covering the astragalus.

The **Posterior Inferior Ligament**, smaller than the preceding, is disposed in a similar manner on the posterior surface of the articulation.

The **Transverse Ligament** is a long, narrow band, continuous with the preceding, passing transversely across the back of the joint, from the external malleolus to the posterior border of the articular surface of the tibia, almost as far as its malleolar process. This ligament projects below the margin of the bones, and forms part of the articulating surface for the astragalus.

The **Inferior Interosseous Ligament** consists of numerous short, strong, fibrous bands which pass between the contiguous rough surfaces of the tibia and fibula, and constitute the chief bond of union between the bones. This ligament is continuous above with the interosseous membrane.

The **Synovial Membrane** lining the articular surface is derived from that of the ankle-joint.

Actions.—The movement permitted in these articulations is limited to a very slight gliding of the articular surfaces one upon another.

IV. Ankle-joint.

The **Ankle** is a ginglymus or hinge-joint. The bones entering into its formation are the lower extremity of the tibia and its malleolus and the external malleolus of the fibula. These bones are united above, and form a mortise to receive the upper convex surface of the astragalus and its two lateral facets. The bony surfaces are covered with cartilage, and connected together by a capsule, which in places forms thickened bands constituting the following ligaments:

Anterior.	Internal Lateral.
Posterior.	External Lateral.

The **Anterior Tibio-tarsal Ligament** (Fig. 263) is a broad, thin, membranous layer, attached, above, to the margin of the articular surface of the tibia; below,

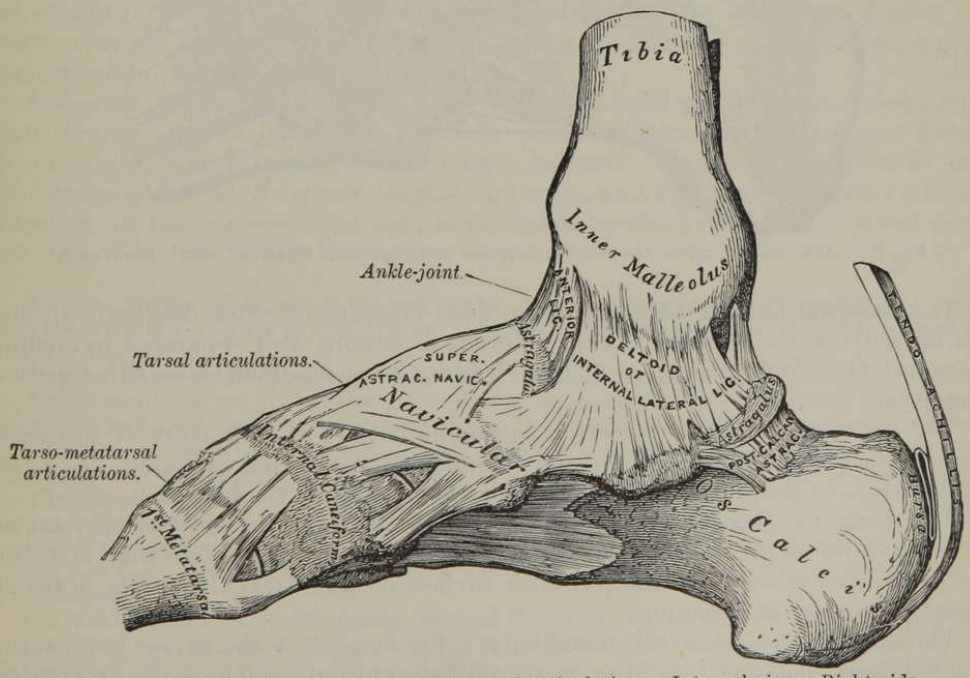

FIG. 263.—Ankle-joint: tarsal and tarso-metatarsal articulations. Internal view. Right side.

to the margin of the astragalus, in front of its articular surface. It is in relation, in front, with the Extensor tendons of the toes, with the tendons of the Tibialis

anticus and Peroneus tertius, and the anterior tibial vessels and nerve; behind, it lies in contact with the synovial membrane.

The **Posterior Tibio-tarsal Ligament** is very thin, and consists principally of transverse fibres. It is attached, above, to the margin of the articular surface of the tibia, blending with the transverse tibio-fibular ligament; below, to the astragalus, behind its superior articular facet. Externally it is thicker than internally, where a somewhat thickened band of transverse fibres is attached to the hollow on the inner surface of the external malleolus.

The **Internal Lateral** or **Deltoid Ligament** is a strong, flat, triangular band, attached, above, to the apex and anterior and posterior borders of the inner malleolus. The most anterior fibres pass forward to be inserted into the navicular bone and the inferior calcaneo-navicular ligament; the middle descend almost perpendicularly to be inserted into the sustentaculum tali of the os calcis; and the posterior fibres pass backward and outward to be attached to the inner side of the astragalus. This ligament is covered by the tendons of the Tibialis posticus and Flexor longus digitorum muscles.

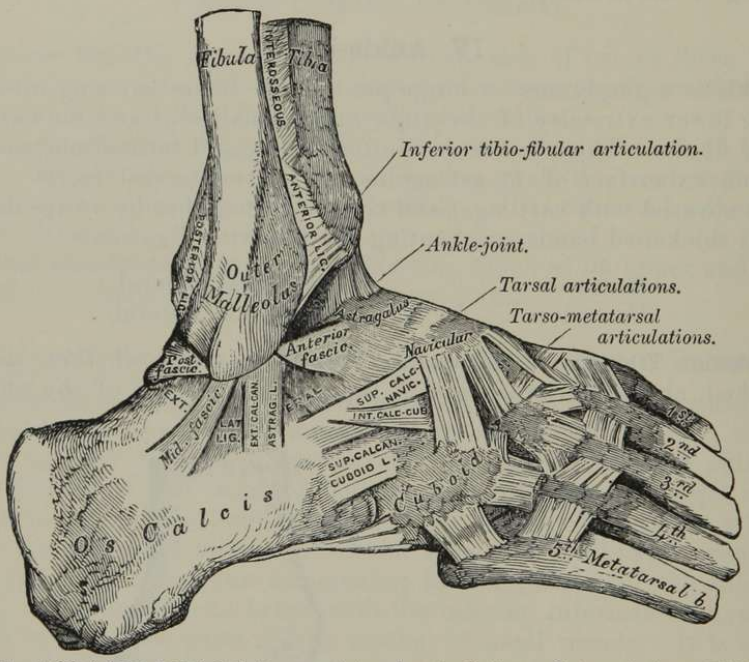

FIG. 264.—Ankle-joint: tarsal and tarso-metatarsal articulations. External view. Right side.

The **External Lateral Ligament** (Fig. 264) consists of three distinctly specialized fasciculi of the capsule, taking different directions and separated by distinct intervals; for which reason it is described by some anatomists as three distinct ligaments.[1]

The *anterior fasciculus* (anterior astragalo-fibular), the shortest of the three, passes from the anterior margin of the summit of the external malleolus, downward and forward, to the astragalus, in front of its external articular facet.

The *posterior fasciculus* (posterior astragalo-fibular), the most deeply seated, passes from the depression at the inner and back part of the external malleolus to a prominent tubercle on the posterior surface of the astragalus. Its fibres are almost horizontal in direction.

The *middle fasciculus* (calcaneo-fibular), the longest of the three, is a narrow, rounded cord passing from the apex of the external malleolus downward and slightly backward to a tubercle on the outer surface of the os calcis. It is covered by the tendons of the Peroneus longus and brevis.

[1] Humphry, *On the Skeleton*, p. 559.

The **Synovial Membrane** invests the inner surface of the ligaments, and sends a duplicature upward between the lower extremities of the tibia and fibula for a short distance.

Relations.—The tendons, vessels, and nerves in connection with the joint are, in front, from within outward, the Tibialis anticus, Extensor proprius hallucis, anterior tibial vessels, anterior tibial nerve, Extensor communis digitorum, and Peroneus tertius; behind, from within outward, the Tibialis posticus, Flexor longus digitorum, posterior tibial vessels, posterior tibial nerve, Flexor longus hallucis; and, in the groove behind the external malleolus, the tendons of the Peroneus longus and brevis.

The *Arteries* supplying the joint are derived from the malleolar branches of the anterior tibial and the peroneal.

The *Nerves* are derived from the anterior and posterior tibial.

Actions.—The movements of the joint are those of flexion and extension. The malleoli tightly embrace the astragalus in all positions of the joint, so that any slight degree of lateral movement which may exist is simply due to stretching of the inferior tibio-fibular ligaments and slight bending of the shaft of the fibula. Of the ligaments, the internal, or deltoid, is of very great power—so much so that it usually resists a force which fractures the process of bone to which it is attached. Its middle portion, together with the middle fasciculus of the external lateral ligament, binds the bones of the leg firmly to the foot and resists displacement in every direction. Its anterior and posterior fibres limit extension and flexion of the foot respectively, and the anterior fibres also limit abduction. The posterior portion of the external lateral ligament assists the middle portion in resisting the displacement of the foot backward, and deepens the cavity for the reception of the astragalus. The anterior fasciculus is a security against the displacement of the foot forward, and limits extension of the joint. The movements of abduction and adduction of the foot, together with the minute changes in form by which it is applied to the ground or takes hold of an object in climbing, etc., are mainly effected in the tarsal joints, the one which enjoys the greatest amount of motion being that between the astragalus and os calcis behind and the navicular and cuboid in front. This is often called the *transverse* or *medio-tarsal joint*, and it can, with the subordinate joints of the tarsus, replace the ankle-joint in a great measure when the latter has become ankylosed.

Extension of the tarsal bones upon the tibia and fibula is produced by the Gastrocnemius, Soleus, Plantaris, Tibialis posticus, Peroneus longus and brevis, Flexor longus digitorum, and Flexor longus hallucis; *flexion*, by the Tibialis anticus, Peroneus tertius, Extensor longus digitorum, and Extensor proprius hallucis;[1] *adduction*, in the extended position, is produced by the Tibialis anticus and posticus; and *abduction* by the Peronei.

Surface Form.—The line of the ankle-joint may be indicated by a transverse line drawn across the front of the lower part of the leg, about half an inch above the level of the tip of the internal malleolus.

Surgical Anatomy.—Displacement of the trochlear surface of the astragalus from the tibio-fibular mortise is not of common occurrence, as the ankle-joint is a very strong and powerful articulation, and great force is required to produce it. Nevertheless, dislocation does occasionally occur, both in an antero-posterior and a lateral direction. In the latter, which is the most common, fracture is a necessary accompaniment of the injury. The dislocation in these cases is somewhat peculiar, and is not a displacement in a horizontally lateral direction, such as usually occurs in lateral dislocations of ginglymoid joints, but the astragalus undergoes a partial rotation round an antero-posterior axis drawn through its own centre, so that the superior surface, instead of being directed upward, is inclined more or less inward or outward according to the variety of the displacement.

The ankle-joint is more frequently sprained than any joint in the body, and this may lead to acute synovitis. In these cases, when the synovial sac is distended with fluid, the bulging appears principally in the front of the joint, beneath the anterior tendons, and on either side, between the Tibialis anticus and the internal lateral ligament on the inner side, and between the

[1] The student must bear in mind that the Extensor longus digitorum and Extensor proprius hallucis are *extensors* of the toes, but *flexors* of the ankle, and that the Flexor longus digitorum and Flexor longus hallucis are *flexors* of the toes, but *extensors* of the ankle.

Peroneus tertius and the external lateral ligament on the outer side. In addition to this, bulging frequently occurs posteriorly, and a fluctuating swelling may be detected on either side of the tendo Achillis.

Chronic synovitis may result from frequent sprains, and when once this joint has been sprained it is more liable to a recurrence of the injury than it was before; or it may be tuber-

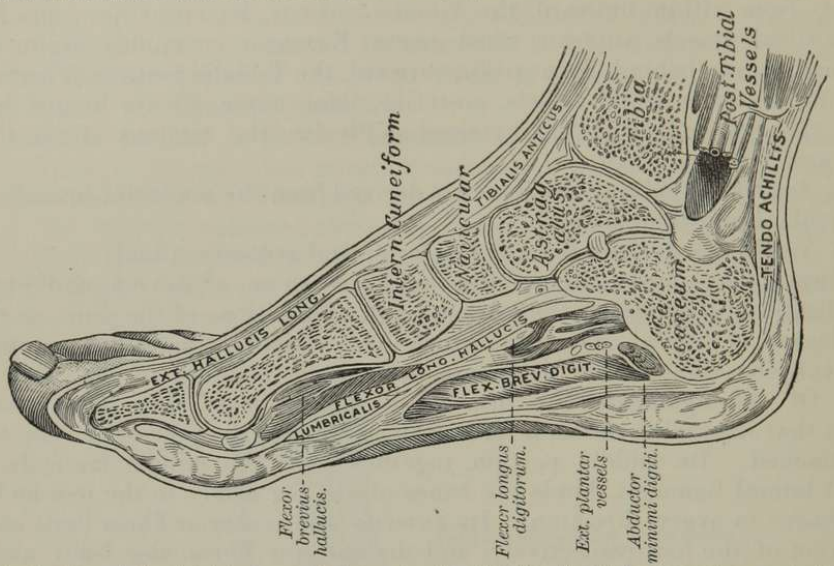

FIG. 265.—Section of the right foot near its inner border, dividing the tibia, astragalus, navicular, internal cuneiform, and first metatarsal bone, and the first phalanx of the great toe. (After Braune.)

cular in its origin, the disease usually commencing in the astragalus and extending to the joint, though it may commence as a tubercular synovitis the result probably of some slight strain in a tubercular subject.

Excision of the ankle-joint is not often performed for two reasons. In the first place, disease of the articulation for which this operation is indicated is frequently associated with disease of the tarsal bones, which prevents its performance; and, secondly, the foot after excision is frequently of very little use; far less, in fact, than after a Symes's amputation, which is often, therefore, a preferable operation in these cases. Excision may, however, be attempted in cases of tubercular arthritis, in a young and otherwise healthy subject, where the disease is limited to the bones forming the joint. It may also be required after injury where the vessels and nerves have not been damaged and the patient is young and free from visceral disease. The excision is best performed by two lateral incisions. One commencing two and a half inches above the external malleolus, carried down the posterior border of the fibula, round the end of the bone, and then forward and downward as far as the calcaneo-cuboid joint, midway between the tip of the external malleolus and the tuberosity on the fifth metatarsal bone. Through this incision the fibula is cleared, the external lateral ligament is divided, and the bone sawn through at the upper end of the incision and removed. A similar curved incision is now made on the inner side of the foot, commencing two and a half inches above the lower end of the tibia, carried down the posterior border of the bone, round the internal malleolus, and forward and downward to the tuberosity of the navicular bone. Through this incision the tibia is cleared in front and behind, the internal lateral, the anterior and posterior ligaments divided, and the end of the tibia protruded through the wound by displacing the foot outward, and sawn off sufficiently high to secure a healthy section of bone. The articular surface of the astragalus is now to be sawn off or the whole bone removed. In cases where the operation is performed for tubercular arthritis the latter course is probably preferable, as the injury done by the saw is frequently the starting point of fresh caries; and after removal of the whole bone the shortening is not appreciably increased, and the result as regards union appears to be as good as when two sawn surfaces of bone are brought into apposition.

V. Articulations of the Tarsus.

1. Articulations of the Os Calcis and Astragalus.

The articulations between the os calcis and astragalus are two in number—anterior and posterior. They are arthrodial joints. The bones are connected together by four ligaments:

External Calcaneo-astragaloid.
Internal Calcaneo-astragaloid.
Posterior Calcaneo-astragaloid.
Interosseous.

The **External Calcaneo-astragaloid Ligament** (Fig. 264) is a short, strong, fasciculus passing from the outer surface of the astragalus, immediately beneath its external malleolar facet, to the outer surface of the os calcis. It is placed in front of the middle fasciculus of the external lateral ligament of the ankle-joint, with the fibres of which it is parallel.

The **Internal Calcaneo-astragaloid Ligament** is a band of fibres connecting the internal tubercle of the back of the astragalus with the back of the sustentaculum tali. Its fibres blend with those of the inferior calcaneo-navicular ligament.

The **Posterior Calcaneo-astragaloid Ligament** (Fig. 263) connects the posterior external tubercle of the astragalus with the upper and inner part of the os calcis; it is a short, narrow band, the fibres of which radiate from their narrow attachment to the astragalus.

The **Interosseous Ligament** forms the chief bond of union between the bones. It consists of numerous vertical and oblique fibres attached by one extremity to the groove between the articulating facets on the under surface of the astragalus; by the other to a corresponding depression on the upper surface of the os calcis. It is very thick and strong, being at least an inch in breadth from side to side, and serves to unite the os calcis and astragalus solidly together.

The **Synovial Membranes** (Fig. 267) are two in number: one for the posterior calcaneo-astragaloid articulation; a second for the anterior calcaneo-astragaloid joint. The latter synovial membrane is continued forward between the contiguous surfaces of the astragalus and navicular bones.

Actions.—The movements permitted between the astragalus and os calcis are limited to a gliding of the one bone on the other in a direction from before backward, and from side to side.

2. Articulations of the Os Calcis with the Cuboid.

The ligaments connecting the os calcis with the cuboid are four in number:

Dorsal.	{ Superior Calcaneo-cuboid. Internal Calcaneo-cuboid (Interosseous).
Plantar.	{ Long Calcaneo-cuboid. Short Calcaneo-cuboid.

The **Superior Calcaneo-cuboid Ligament** (Fig. 264) is a thin and narrow fasciculus which passes between the contiguous surfaces of the os calcis and cuboid on the dorsal surface of the joint.

The **Internal Calcaneo-cuboid (Interosseous) Ligament** (Fig. 264) is a short but thick and strong band of fibres arising from the os calcis, in the deep hollow which intervenes between it and the astragalus, and closely blended, at its origin, with the superior calcaneo-navicular ligament. It is inserted into the inner side of the cuboid bone. This ligament forms one of the chief bonds of union between the first and second rows of the tarsus.

The **Long Calcaneo-cuboid (Long Plantar) Ligament** (Fig. 266), the more superficial of the two plantar ligaments, is the longest of all the ligaments of the tarsus: it is attached to the under surface of the os calcis, from near the tuberosities, as far forward as the anterior tubercle; its fibres pass forward to be attached to the ridge on the under surface of the cuboid bone, the more superficial fibres being continued onward to the bases of the second, third, and fourth metatarsal bones. This ligament crosses the groove on the under surface of the cuboid bone, converting it into a canal for the passage of the tendon of the Peroneus longus.

The **Short Calcaneo-cuboid (Short Plantar) Ligament** lies nearer to the bones than the preceding, from which it is separated by a little adipose tissue. It is exceedingly broad, about an inch in length, and extends from the tubercle and the depression in front of it, on the fore part of the under surface of the os calcis, to the inferior surface of the cuboid bone behind the peroneal groove.

Synovial Membrane.—The synovial membrane in this joint is distinct. It lines the inner surface of the ligaments.

Actions.—The movements permitted between the os calcis and cuboid are limited to a slight gliding upon each other.

3. The Ligaments connecting the Os Calcis and Navicular.

Though these two bones do not directly articulate, they are connected together by two ligaments:

Superior or External Calcaneo-navicular.
Inferior or Internal Calcaneo-navicular.

The **Superior** or **External Calcaneo-navicular** (Fig. 264) arises, as already mentioned, with the internal calcaneo-cuboid in the deep hollow between the astragalus and os calcis; it passes forward from the inner side of the anterior extremity of the os calcis to the outer side of the navicular bone. These two ligaments resemble the letter Y, being blended together behind, but separated in front.

The **Inferior** or **Internal Calcaneo-navicular** (Fig. 266) is by far the larger and stronger of the two ligaments between these bones; it is a broad and thick band of fibres, which passes forward and inward from the anterior margin of the sustentaculum tali of the os calcis to the under surface of the navicular bone. This ligament not only serves to connect the os calcis and navicular, but supports the head of the astragalus, forming part of the articular cavity in which it is received. The *upper surface* presents a fibro-cartilaginous facet, lined by the synovial membrane continued from the anterior calcaneo-astragaloid articulation, upon which the head of the astragalus rests. Its *under surface* is in contact with the tendon of the Tibialis posticus muscle;[1] its inner border is blended with the fore part of the Deltoid ligament, thus completing the socket for the head of the astragalus.

Fig. 266.—Ligaments of the plantar surface of the foot.

Surgical Anatomy.—The inferior calcaneo-navicular ligament, by supporting the head of the astragalus, is principally concerned in maintaining the arch of the foot, and when it yields the head of the astragalus is pressed downward, inward, and forward by the weight of the body, and the foot becomes flattened, expanded, and turned outward, constituting the disease known as *flat-foot*. This ligament contains a considerable amount of elastic fibre, so as to give elasticity to the arch and spring to the foot; hence it is sometimes called the "spring" ligament. It is supported, on its under surface, by the tendon of the Tibialis posticus, which spreads out at its insertion into a number of fasciculi which are attached to most of the tarsal and metatarsal bones; this prevents undue stretching of the ligament and is a protection against the occurrence of flat-foot.

4. Articulation of the Astragalus with the Navicular Bone.

The articulation between the astragalus and navicular is an arthrodial joint: the rounded head of the astragalus being received into the concavity formed by

[1] Mr. Hancock describes an extension of this ligament upward on the inner side of the foot, which completes the socket of the joint in that direction (*Lancet*, 1866, vol. i. p. 618).

the posterior surface of the navicular, the anterior articulating surface of the calcaneum, and the upper surface of the inferior calcaneo-navicular ligament, which fills up the triangular interval between those bones. The only ligament of this joint is the **superior astragalo-navicular.** It is a broad band, which passes obliquely forward from the neck of the astragalus to the superior surface of the navicular bone. It is thin, and weak in texture, and covered by the Extensor tendons. The inferior calcaneo-navicular supplies the place of an inferior ligament.

The **Synovial Membrane** which lines the joint is continued forward from the anterior calcaneo-astragaloid articulation.

Actions.—This articulation permits of considerable mobility, but its feebleness is such as to allow occasionally of dislocation of the other bones of the tarsus from the astragalus.

The *transverse tarsal* or *medio-tarsal joint* is formed by the articulation of the os calcis with the cuboid, and by the articulation of the astragalus with the navicular. The movement which takes place in this joint is more extensive than that in the other tarsal joints, and consists of a sort of rotation by means of which the sole of the foot may be slightly flexed and extended or carried inward and outward.

5. The Articulation of the Navicular with the Cuneiform Bones.

The navicular is connected to the three cuneiform bones by

Dorsal and Plantar ligaments.

The **Dorsal Ligaments** are small, longitudinal bands of fibrous tissue arranged as three bundles, one to each of the cuneiform bones. That bundle of fibres which connects the navicular with the internal cuneiform is continued round the inner side of the articulation to be continuous with the plantar ligament which connects these two bones.

The **Plantar Ligaments** have a similar arrangement to those on the dorsum. They are strengthened by processes given off from the tendon of the Tibialis posticus.

Actions.—The movements permitted between the navicular and cuneiform bones are limited to a slight gliding upon each other.

The **Synovial Membrane** of these joints is part of the great tarsal synovial membrane.

6. The Articulation of the Navicular with the Cuboid.

The navicular bone is connected with the cuboid by

Dorsal, Plantar, and Interosseous ligaments.

The **Dorsal Ligament** consists of a band of fibrous tissue which passes obliquely forward and outward from the navicular to the cuboid bone.

The **Plantar Ligament** consists of a band of fibrous tissue which passes nearly transversely between these two bones.

The **Interosseous Ligament** consists of strong transverse fibres which pass between the rough non-articular portions of the lateral surfaces of these two bones.

Actions.—The movements permitted between the navicular and cuboid bones are limited to a slight gliding upon each other.

The **Synovial Membrane** of this joint is part of the great tarsal synovial membrane.

7. The Articulation of the Cuneiform Bones with each other.

These bones are connected together by

Dorsal, Plantar, and Interosseous ligaments.

The **Dorsal Ligaments** consist of two bands of fibrous tissue which pass transversely, one connecting the internal with the middle cuneiform, and the other connecting the middle with the external cuneiform.

The **Plantar Ligaments** have a similar arrangement to those on the dorsum.

They are strengthened by the processes given off from the tendon of the Tibialis posticus.

The **Interosseous Ligaments** consist of strong transverse fibres which pass between the rough non-articular portions of the lateral surfaces of the adjacent cuneiform bones.

The **Synovial Membrane** of these joints is part of the great tarsal synovial membrane.

Actions.—The movements permitted between the cuneiform bones are limited to a slight gliding upon each other.

8. The Articulation of the External Cuneiform Bone with the Cuboid.

These bones are connected together by

Dorsal, Plantar, and Interosseous ligaments.

The **Dorsal Ligament** consists of a band of fibrous tissue which passes transversely between these two bones.

The **Plantar Ligament** has a similar arrangement. It is strengthened by a process given off from the tendon of the Tibialis posticus.

The **Interosseous Ligament** consists of strong transverse fibres which pass between the rough non-articular portions of the lateral surfaces of the adjacent sides of these two bones.

The **Synovial Membrane** of this joint is part of the great tarsal synovial membrane.

Actions.—The movements permitted between the external cuneiform and cuboid are limited to a slight gliding upon each other.

Nerve-supply.—All the joints of the tarsus are supplied by the anterior tibial nerve.

Surgical Anatomy.—In spite of the great strength of the ligaments which connect the tarsal bones together, dislocation at some of the tarsal joints does occasionally occur; though, on account of the spongy character of the bones, they are more frequently broken than dislocated, as the result of violence. When dislocation does occur, it is most commonly in connection with the astragalus; for not only may this bone be dislocated from the tibia and fibula at the ankle-joint, but the other bones may be dislocated from it, the trochlear surface of the one remaining *in situ* in the tibio-fibular mortise. This constitutes what is known as the *subastragaloid* dislocation. Or, again, the astragalus may be dislocated from all its connections—from the tibia and fibula above, the os calcis below, and the navicular in front—and may even undergo a rotation, either on a vertical or horizontal axis. In the former case the long axis of the bone becoming directed across the joint, so that the head faces the articular surface on one or other malleolus; or, in the latter, the lateral surfaces becoming directed upward and downward, so that the trochlear surface faces to one or the other side. Finally, dislocation may occur at the medio-tarsal joint, the anterior tarsal bones being luxated from the astragalus and calcaneum. The other tarsal bones are also, occasionally, though rarely, dislocated from their connections.

VI. Tarso-metatarsal Articulations.

These are arthrodial joints. The bones entering into their formation are four tarsal bones—viz. the internal, middle, and external cuneiform and the cuboid—which articulate with the metatarsal bones of the five toes. The metatarsal bone of the great toe articulates with the internal cuneiform; that of the second is deeply wedged in between the internal and external cuneiform, resting against the middle cuneiform, and being the most strongly articulated of all the metatarsal bones; the third metatarsal articulates with the extremity of the external cuneiform; the fourth with the cuboid and external cuneiform; and the fifth, with the cuboid. The articular surfaces are covered with cartilage, lined by synovial membrane, and connected together by the following ligaments:

Dorsal. Plantar. Interosseous.

The **Dorsal Ligaments** consist of strong, flat, fibrous bands, which connect the tarsal with the metatarsal bones. The first metatarsal is connected to the internal cuneiform by a single broad, thin, fibrous band; the second has three dorsal

ligaments, one from each cuneiform bone; the third has one from the external cuneiform; the fourth has two, one from the external cuneiform and one from the cuboid; and the fifth, one from the cuboid.

The **Plantar Ligaments** consist of longitudinal and oblique fibrous bands connecting the tarsal and metatarsal bones, but disposed with less regularity than on the dorsal surface. Those for the first and second metatarsal are the most strongly marked; the second and third metatarsal receive strong fibrous bands which pass obliquely across from the internal cuneiform; the plantar ligaments of the fourth and fifth metatarsal consist of a few scanty fibres derived from the cuboid.

The **Interosseous Ligaments** are three in number—internal, middle, and external. The *internal* one passes from the outer extremity of the internal cuneiform to the adjacent angle of the second metatarsal. The *middle* one, less strong than the preceding, connects the external cuneiform with the adjacent angle of the second metatarsal. The *external* interosseous ligament connects the outer angle of the external cuneiform with the adjacent side of the third metatarsal.

The **Synovial Membrane** between the internal cuneiform bone and the first metatarsal bone is a distinct sac. The synovial membrane between the middle and external cuneiform behind, and the second and third metatarsal bones in front, is part of the great tarsal synovial membrane. Two prolongations are sent forward from it—one between the adjacent sides of the second and third metatarsal bones, and one between the third and fourth metatarsal bones. The synovial membrane between the cuboid and the fourth and fifth metatarsal bones is a distinct sac. From it a prolongation is sent forward between the fourth and fifth metatarsal bones.

Actions.—The movements permitted between the tarsal and metatarsal bones are limited to a slight gliding upon each other.

Articulations of the Metatarsal Bones with each other.

The base of the first metatarsal bone is not connected with the second metatarsal bone by any ligaments; but there may be a bursa between the "occasional" face (see page 307).

The bases of the four outer metatarsal bones are connected together by dorsal, plantar, and interosseous ligaments.

The **Dorsal Ligaments** consist of bands of fibrous tissue which pass transversely between the adjacent metatarsal bones.

The **Plantar Ligaments** have a similar arrangement to those on the dorsum.

The **Interosseous Ligaments** consist of strong transverse fibres which pass between the rough non-articular portions of the lateral surfaces.

The **Synovial Membrane** between the second and third and the third and fourth metatarsal bones is part of the great tarsal synovial membrane.

The synovial membrane between the fourth and fifth metatarsal bones is a prolongation of the synovial membrane of the cubo-metatarsal joint.

Actions.—The movement permitted in the tarsal ends of the metatarsal bones is limited to a slight gliding of the articular surfaces upon one another.

The Synovial Membranes in the Tarsal and Metatarsal Joints.

The **Synovial Membranes** (Fig. 267) found in the articulations of the tarsus and metatarsus are six in number: one for the posterior calcaneo-astragaloid articulation; a second for the anterior calcaneo-astragaloid and astragalo-navicular articulations; a third for the calcaneo-cuboid articulation; and a fourth for the articulations of the navicular with the three cuneiform, the three cuneiform with each other, the external cuneiform with the cuboid, and the middle and external cuneiform with the bases of the second and third metatarsal bones, and the lateral surfaces of the second, third, and fourth metatarsal bones with each other; a fifth for the internal cuneiform with the metatarsal bone of the great toe; and a sixth for the articulation of the cuboid with the fourth and fifth metatarsal bones. A

small synovial membrane is sometimes found between the contiguous surfaces of the navicular and cuboid bones.

Nerve-supply.—The nerves supplying the tarso-metatarsal joints are derived from the anterior tibial.

The *digital extremities* of all the metatarsal bones are connected together by the *transverse metatarsal ligament.*

The **Transverse Metatarsal Ligament** is a narrow fibrous band which passes transversely across the anterior extremities of all the metatarsal bones, connecting

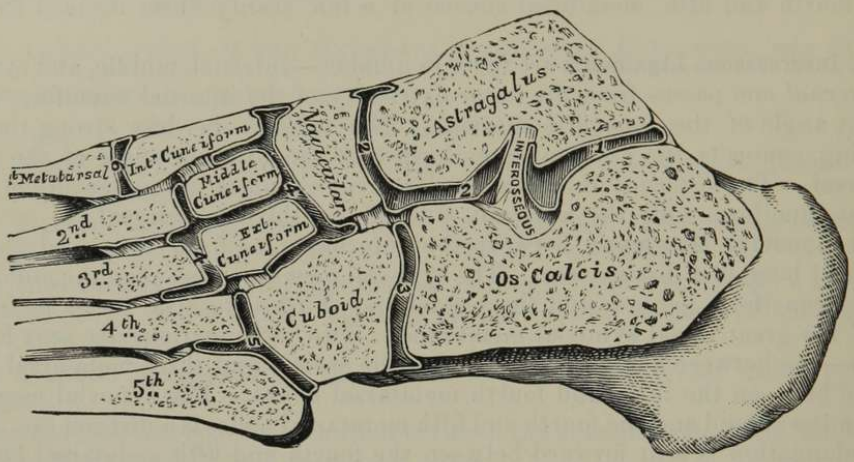

FIG. 267.—Oblique section of the articulations of the tarsus and metatarsus. Showing the six synovial membranes.

them together. It is blended anteriorly with the plantar (glenoid) ligament of the metatarso-phalangeal articulations. To its posterior border is connected the fascia covering the Interossei muscles. Its superficial surface is concave where the Flexor tendons pass over it. Beneath it the tendons of the Interossei muscles pass to their insertion. It differs from the transverse metacarpal ligament in that it connects the metatarsal bone of the great toe with the rest of the metatarsal bones.

VII. Metatarso-phalangeal Articulations.

The metatarso-phalangeal articulations are of the condyloid kind, formed by the reception of the rounded head of the metatarsal bone into a superficial cavity in the extremity of the first phalanx.

The ligaments are—

Plantar. Two Lateral.

The **Plantar Ligaments** (Glenoid ligaments of Cruveilhier) are thick, dense, fibrous structures. Each is placed on the plantar surface of the joint in the interval between the lateral ligaments, to which they are connected; they are loosely united to the metatarsal bone, but very firmly to the base of the first phalanges. Their plantar surface is intimately blended with the transverse metatarsal ligament, and presents a groove for the passage of the Flexor tendons, the sheath surrounding which is connected to each side of the groove. By their deep surface they form part of the articular surface for the head of the metatarsal bone, and are lined by a synovial membrane.

The **Lateral Ligaments** are strong, rounded cords, placed one on each side of the joint, each being attached, by one extremity, to the posterior tubercle on the side of the head of the metatarsal bone; and, by the other, to the contiguous extremity of the phalanx.

The **Posterior Ligament** is supplied by the extensor tendon placed over the back of the joint.

Actions.—The movements permitted in the metatarso-phalangeal articulations are flexion, extension, abduction, and adduction.

VIII. Articulations of the Phalanges.

The articulations of the phalanges are ginglymus joints.

The ligaments are—

Plantar. Two Lateral.

The arrangement of these ligaments is similar to those in the metatarso-phalangeal articulations; the extensor tendon supplies the place of a posterior ligament.

Actions.—The only movements permitted in the phalangeal joints are flexion and extension; these movements are more extensive between the first and second phalanges than between the second and third. The movement of flexion is very considerable, but extension is limited by the anterior and lateral ligaments.

Surface Form.—The principal joints which it is necessary to distinguish, with regard to the surgery of the foot, are the medio-tarsal and the tarso-metatarsal joints. The joint between the astragalus and the navicular is best found by means of the tubercle of the navicular bone, for the line of the joint is immediately behind this process. If the foot is grasped and forcibly extended, a rounded prominence, the head of the astragalus, will appear on the inner side of the dorsum in front of the ankle-joint, and if a knife is carried downward, just in front of this prominence and behind the line of the navicular tubercle, it will enter the astragalo-navicular joint. The calcaneo-cuboid joint is situated midway between the external malleolus and the prominent end of the fifth metatarsal bone. The plane of the joint is in the same line as that of the astragalo-navicular. The position of the joint between the fifth metatarsal bone and the cuboid is easily found by the projection of the fifth metatarsal bone, which is the guide to it. The direction of the line of the joint is very oblique, so that, if continued onward, it would pass through the head of the first metatarsal bone. The joint between the fourth metatarsal bone and the cuboid and external cuneiform is the direct continuation inward of the previous joint, but its plane is less oblique; it would be represented by a line drawn from the outer side of the articulation to the middle of the first metatarsal bone. The plane of the joint between the third metatarsal bone and the external cuneiform is almost transverse. It would be represented by a line drawn from the outer side of the joint to the base of the first metatarsal bone. The tarso-metatarsal articulation of the great toe corresponds to a groove which can be felt by making firm pressure on the inner side of the foot one inch in front of the tubercle on the navicular bone; and the joint between the second metatarsal bone and the middle cuneiform is to be found on the dorsum of the foot, half an inch behind the level of the tarso-metatarsal joint of the great toe. The line of the joints between the metatarsal bones and the first phalanges is about an inch behind the webs of the corresponding toes.

THE MUSCLES AND FASCIÆ.[1]

THE Muscles are connected with the bones, cartilages, ligaments, and skin, either directly or through the intervention of fibrous structures called tendons or aponeuroses. Where a muscle is attached to bone or cartilage, the fibres terminate in blunt extremities upon the periosteum or perichondrium, and do not come into direct relation with the osseous or cartilaginous tissue. Where muscles are connected with the skin, they either lie as a flattened layer beneath it, or are connected with its areolar tissue by larger or smaller bundles of fibres, as in the muscles of the face.

The muscles vary extremely in their form. In the limbs, they are of considerable length, especially the more superficial ones, the deep ones being generally broad; they surround the bones and form an important protection to the various joints. In the trunk they are broad, flattened, and expanded, forming the parietes of the cavities which they enclose; hence the reason of the terms, *long*, *broad*, *short*, etc., used in the description of a muscle.

There is a considerable variation in the arrangement of the fibres of certain muscles with reference to the tendons to which they are attached. In some, the fibres are parallel and run directly from their origin to their insertion; these are quadrilateral muscles, such as the Thyro-hyoid. A modification of these is found in the fusiform muscles, in which the fibres are not quite parallel, but slightly curved, so that the muscle tapers at each end; in their action, however, they resemble the quadrilateral muscles. Secondly, in other muscles the fibres are convergent; arising by a broad origin, they converge to a narrow or pointed insertion. This arrangement of fibres is found in the triangular muscles—*e. g.* the Temporal. In some muscles, which otherwise would belong to the quadrilateral or triangular type, the origin and insertion are not in the same plane, but the plane of the line of origin intersects that of their insertion; such is the case in the Pectineus muscle. Thirdly, in some muscles the fibres are oblique and converge, like the plumes of a pen, to one side of a tendon, which runs the entire length of the muscle. Such a muscle is rhomboidal or penniform, as the Peronei. A modification of these rhomboidal muscles is found in those cases where oblique fibres converge to both sides of a central tendon which runs down the middle of the muscle; these are called bipenniform, and an example is afforded in the Rectus femoris. Finally, we have muscles in which the fibres are arranged in curved bundles in one or more planes, as in the Sphincter muscles. The arrangement of the muscular fibres is of considerable importance in respect to their relative strength and range of movement. Those muscles where the fibres are long and few in number have great range, but diminished strength; where, on the other hand, the fibres are short and more numerous, there is great power, but lessened range.

Muscles differ much in size: the Gastrocnemius forms the chief bulk of the back of the leg, and the fibres of the Sartorius are nearly two feet in length, whilst

[1] The Muscles and Fasciæ are described conjointly, in order that the student may consider the arrangement of the latter in his dissection of the former. It is rare for the student of anatomy in this country to have the opportunity of dissecting the fasciæ separately; and it is for this reason, as well as from the close connection that exists between the muscles and their investing sheaths, that they are considered together. Some general observations are first made on the anatomy of the muscles and fasciæ, the special description being given in connection with the different regions.

the Stapedius, a small muscle of the internal ear, weighs about a grain, and its fibres are not more than two lines in length.

The names applied to the various muscles have been derived—1, from their situation, as the Tibialis, Radialis, Ulnaris, Peroneus; 2, from their direction, as the Rectus abdominis, Obliqui capitis, Transversalis; 3, from their uses, as Flexors, Extensors, Abductors, etc.; 4, from their shape, as the Deltoid, Trapezius, Rhomboideus; 5, from the number of their divisions, as the Biceps, the Triceps; 6, from their points of attachment, as the Sterno-cleido-mastoid, Sterno-hyoid, Sterno-thyroid.

In the description of a muscle the term *origin* is meant to imply its more fixed or central attachment, and the term *insertion*, the movable point to which the force of the muscle is directed; but the origin is absolutely fixed in only a very small number of muscles, such as those of the face, which are attached by one extremity to the bone and by the other to the movable integument; in the greater number the muscle can be made to act from either extremity.

In the dissection of the muscles the student should pay especial attention to the exact *origin*, *insertion*, and *actions* of each, and its more important *relations* with surrounding parts. An accurate knowledge of the points of attachment of the muscles is of great importance in the determination of their action. By a knowledge of the action of the muscles the surgeon is able to explain the causes of displacement in various forms of fracture and the causes which produce distortion in various deformities, and, consequently, to adopt appropriate treatment in each case. The relations, also, of some of the muscles, especially those in immediate apposition with the larger blood-vessels, and the surface-markings they produce, should be especially remembered, as they form useful guides in the application of a ligature to those vessels.

Tendons are white, glistening, fibrous cords, varying in length and thickness, sometimes round, sometimes flattened, of considerable strength, and devoid of elasticity. They consist almost entirely of white fibrous tissue, the fibrils of which have an undulating course parallel with each other and are firmly united together. They are very sparingly supplied with blood-vessels, the smaller tendons presenting in their interior not a trace of them. Nerves also are not present in the smaller tendons, but the larger ones, as the tendo Achillis, receive nerves which accompany the nutrient vessels. The tendons consist principally of a substance which yields gelatin.

Aponeuroses are flattened or ribbon-shaped tendons, of a pearly-white color, iridescent, glistening, and similar in structure to the tendons. They are destitute of nerves, and the thicker ones only sparingly supplied with blood-vessels.

The tendons and aponeuroses are connected, on the one hand, with the muscles, and, on the other hand, with the movable structures, as the bones, cartilages, ligaments, fibrous membranes (for instance, the sclerotic), and the synovial membranes (subcrureus). Where the muscular fibres are in a direct line with those of the tendon or aponeurosis, the two are directly continuous, the muscular fibre being distinguishable from that of the tendon only by its striation. But where the muscular fibre joins the tendon or aponeurosis at an oblique angle the former terminates, according to Kölliker, in rounded extremities, which are received into corresponding depressions on the surface of the latter, the connective tissue between the fibres being continuous with that of the tendon. The latter mode of attachment occurs in all the penniform and bipenniform muscles, and in those muscles the tendons of which commence in a membranous form, as the Gastrocnemius and Soleus.

The fasciæ (*fascia*, a bandage) are fibro-areolar or aponeurotic laminæ of variable thickness and strength, found in all regions of the body, investing the softer and more delicate organs. The fasciæ have been subdivided, from the situation in which they are found, into two groups, superficial and deep.

The *superficial fascia* is found immediately beneath the integument over almost the entire surface of the body. It connects the skin with the deep or aponeurotic

fascia, and consists of fibro-areolar tissue, containing in its meshes pellicles of fat in varying quantity. In the eyelids and scrotum, where adipose tissue is rarely deposited, this tissue is very liable to serous infiltration. The superficial fascia varies in thickness in different parts of the body: in the groin it is so thick as to be capable of being subdivided in several laminæ, but in the palm of the hand it is of extreme thinness and intimately adherent to the integument. The superficial fascia is capable of separation into two or more layers, between which are found the superficial vessels and nerves, as the superficial epigastric vessels in the abdominal region, the radial and ulnar veins in the forearm, the saphenous veins in the leg and thigh, and the superficial lymphatic glands; certain cutaneous muscles also are situated in the superficial fascia, as the Platysma myoides in the neck, and the Orbicularis palpebrarum around the eyelids. This fascia is most distinct at the lower part of the abdomen, the scrotum, perinæum, and extremities; is very thin in those regions where muscular fibres are inserted into the integument, as on the side of the neck, the face, and around the margin of the anus. It is very dense in the scalp, in the palms of the hands, and soles of the feet, forming a fibro-fatty layer which binds the integument firmly to the subjacent structure.

The superficial fascia connects the skin to the subjacent parts, facilitates the movement of the skin, serves as a soft medium for the passage of vessels and nerves to the integument, and retains the warmth of the body, since the fat contained in its areolæ is a bad conductor of heat.

The *deep fascia* is a dense, inelastic, unyielding fibrous membrane, forming sheaths for the muscles and affording them broad surfaces for attachment. It consists of shining tendinous fibres, placed parallel with one another, and connected together by other fibres disposed in a rectilinear manner. It is usually exposed on the removal of the superficial fascia, forming a strong investment, which not only binds down collectively the muscles in each region, but gives a separate sheath to each, as well as to the vessels and nerves. The fasciæ are thick in unprotected situations, as on the outer side of a limb, and thinner on the inner side. The deep fasciæ assist the muscles in their action by the degree of tension and pressure they make upon their surface; and in certain situations this is increased and regulated by muscular action; as, for instance, by the Tensor vaginæ femoris and Gluteus maximus in the thigh, by the Biceps in the upper and lower extremities, and Palmaris longus in the hand. In the limbs the fasciæ not only invest the entire limb, but give off septa which separate the various muscles, and are attached beneath to the periosteum: these prolongations of fasciæ are usually spoken of as intermuscular septa.

The Muscles and Fasciæ may be arranged, according to the general division of the body, into those of the cranium, face, and neck; those of the trunk; those of the upper extremity; and those of the lower extremity.

MUSCLES AND FASCIÆ OF THE CRANIUM AND FACE.

The muscles of the Cranium and Face consist of ten groups, arranged according to the region in which they are situated:

1. Cranial Region.
2. Auricular Region.
3. Palpebral Region.
4. Orbital Region.
5. Nasal Region.
6. Superior Maxillary Region.
7. Inferior Maxillary Region.
8. Intermaxillary Region.
9. Temporo-maxillary Region.
10. Pterygo-maxillary Region.

The muscles contained in each of these groups are the following:

1. *Cranial Region.*

Occipito-frontalis.

2. *Auricular Region.*

Attollens aurem.
Attrahens aurem.
Retrahens aurem.

3. *Palpebral Region.*

Orbicularis palpebrarum.
Corrugator supercilii.
Tensor tarsi.

4. *Orbital Region.*

Levator palpebræ.
Rectus superior.
Rectus inferior.
Rectus internus.
Rectus externus.
Obliquus superior.
Obliquus inferior.

5. *Nasal Region.*

Pyramidalis nasi.
Levator labii superioris alæque nasi.
Dilatator naris posterior.
Dilatator naris anterior.
Compressor nasi.
Compressor narium minor.
Depressor alæ nasi.

6. *Superior Maxillary Region.*

Levator labii superioris.
Levator anguli oris.
Zygomaticus major.
Zygomaticus minor.

7. *Inferior Maxillary Region.*

Levator labii inferioris.
Depressor labii inferioris.
Depressor anguli oris.

8. *Intermaxillary Region.*

Buccinator.
Risorius.
Orbicularis oris.

9. *Temporo-maxillary Region.*

Masseter.
Temporal.

10. *Pterygo-maxillary Region.*

Pterygoideus externus.
Pterygoideus internus.

1. Cranial Region—Occipito-frontalis.

Dissection (Fig. 268).—The head being shaved, and a block placed beneath the back of the neck, make a vertical incision through the skin from before backward, commencing at the root of the nose in front, and terminating behind at the occipital protuberance; make

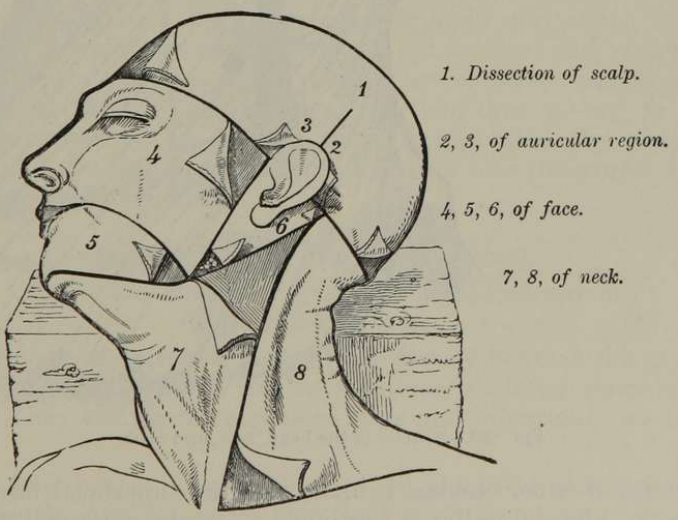

FIG. 268.—Dissection of the head, face, and neck.

a second incision in a horizontal direction along the forehead and round the side of the head, from the anterior to the posterior extremity of the preceding. Raise the skin in front, from the subjacent muscle, from below upward; this must be done with extreme care, removing the integument from the outer surface of the vessels and the nerves which lie between the two.

The Skin of the Scalp.—This is thicker than in any other part of the body. It is intimately adherent to the superficial fascia. The hair-follicles are very closely

set together, and extend throughout the whole thickness of the skin. It also contains a number of sebaceous glands.

The **superficial fascia** in the cranial region is a firm, dense, fibro-fatty layer, intimately adherent to the integument, and to the Occipito-frontalis and its tendi-

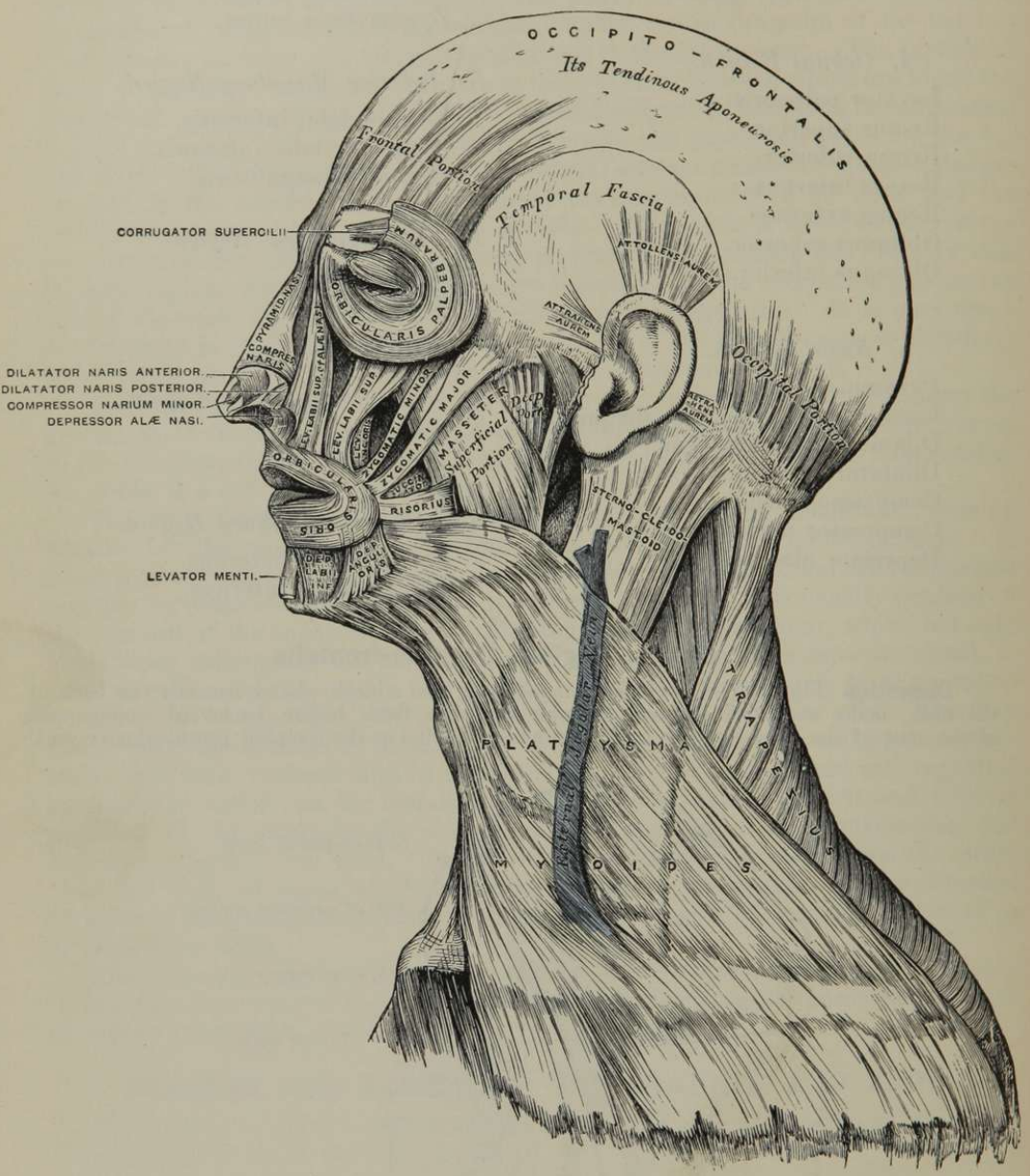

FIG. 269.—Muscles of the head, face, and neck.

nous aponeurosis; it is continuous, behind, with the superficial fascia at the back part of the neck; and, laterally, is continued over the temporal fascia. It contains between its layers the superficial vessels and nerves and much granular fat.

The **Occipito-frontalis** (Fig. 269) is a broad musculo-fibrous layer, which covers the whole of one side of the vertex of the skull, from the occiput to the eyebrow. It consists of two muscular slips, separated by an intervening tendinous aponeurosis. The *occipital portion*, thin, quadrilateral in form, and about an inch and a half in length, arises from the outer two-thirds of the superior curved line of the occipital bone, and from the mastoid portion of the temporal. Its fibres of origin are tendinous, but they soon become muscular, and ascend in a parallel direction to

terminate in a tendinous aponeurosis. The *frontal portion* is thin, of a quadrilateral form, and intimately adherent to the superficial fascia. It is broader, its fibres are longer, and their structure paler than the occipital portion. Its internal fibres are continuous with those of the Pyramidalis nasi. Its middle fibres become blended with the Corrugator supercilii and Orbicularis palpebrarum; and the outer fibres are also blended with the latter muscle over the external angular process. According to Theile, the innermost fibres are attached to the nasal bones, the outer to the external angular process of the frontal bone. From these attachments the fibres are directed upward, and join the aponeurosis below the coronal suture. The inner margins of the frontal portions of the two muscles are joined together for some distance above the root of the nose; but between the occipital portions there is a considerable, though variable, interval, which is occupied by the aponeurosis.

The **aponeurosis** covers the upper part of the vertex of the skull, being continuous across the middle line with the aponeurosis of the opposite muscle. Behind, it is attached, in the interval between the occipital origins, to the occipital protuberance and superior curved lines above the attachment of the Trapezius; in front, it forms a short and narrow prolongation between the frontal portions; and on each side it has connected with it the Attollens and Attrahens aurem muscles; in this situation it loses its aponeurotic character, and is continued over the temporal fascia to the zygoma as a layer of laminated areolar tissue. This aponeurosis is closely connected to the integument by the firm, dense, fibro-fatty layer, which forms the superficial fascia; it is connected with the pericranium by loose cellular tissue, which allows of a considerable degree of movement of the integument.

Nerves.—The frontal portion of the Occipito-frontalis is supplied by the facial nerve; its occipital portion by the posterior auricular branch of the facial, and sometimes by the occipitalis minor.

Actions.—The frontal portion of the muscle raises the eyebrows and the skin over the root of the nose, and at the same time draws the scalp forward, throwing the integument of the forehead into transverse wrinkles. The posterior portion draws the scalp backward. By bringing alternately into action the frontal and occipital portions the entire scalp may be moved forward and backward. In the ordinary action of the muscles, the eyebrows are elevated, and at the same time the aponeurosis is fixed by the posterior portion, thus giving to the face the expression of surprise: if the action is more exaggerated, the eyebrows are still further raised, and the skin of the forehead thrown into transverse wrinkles, as in the expression of fright or horror.

2. Auricular Region (Fig. 269).

Attrahens aurem. Attollens aurem.
Retrahens aurem.

These three small muscles are placed immediately beneath the skin around the external ear. In man, in whom the external ear is almost immovable, they are rudimentary. They are the analogues of large and important muscles in some of the mammalia.

Dissection.—This requires considerable care, and should be performed in the following manner: To expose the Attollens aurem, draw the pinna or broad part of the ear downward, when a tense band will be felt beneath the skin, passing from the side of the head to the upper part of the concha; by dividing the skin over this band, in a direction from below upward, and then reflecting it on each side, the muscle is exposed. To bring into view the Attrahens aurem, draw the helix backward by means of a hook, when the muscle will be made tense, and may be exposed in a similar manner to the preceding. To expose the Retrahens aurem, draw the pinna forward, when the muscle, being made tense, may be felt beneath the skin at its insertion into the back part of the concha, and may be exposed in the same manner as the other muscles.

The **Attrahens aurem** (*Auricularis anterior*), the smallest of the three, is thin, fan-shaped, and its fibres pale and indistinct; they arise from the lateral edge of

the aponeurosis of the Occipito-frontalis, and converge to be inserted into a projection on the front of the helix.

Relations.—*Superficially*, with the skin; *deeply*, with the areolar tissue derived from the aponeurosis of the Occipito-frontalis, beneath which are the temporal artery and vein and the temporal fascia.

The **Attollens aurem** (*Auricularis superior*), the largest of the three, is thin and fan-shaped: its fibres arise from the aponeurosis of the Occipito-frontalis and converge to be inserted by a thin, flattened tendon into the upper part of the cranial surface of the pinna.

Relations.—*Superficially*, with the integument; *deeply*, with the areolar tissue derived from the aponeurosis of the Occipito-frontalis, beneath which is the temporal fascia.

The **Retrahens aurem** (*Auricularis posterior*) consists of two or three fleshy fasciculi, which arise from the mastoid portion of the temporal bone by short aponeurotic fibres. They are inserted into the lower part of the cranial surface of the concha.

Relations.—*Superficially*, with the integument; *deeply*, with the mastoid portion of the temporal bone.

Nerves.—The Attrahens and Attollens aurem are supplied by the temporal branch of the facial; the Retrahens aurem is supplied by the posterior auricular branch of the same nerve.

Actions.—In man, these muscles possess very little action: the Attrahens aurem draws the ear forward and upward; the Attollens aurem slightly raises it; and the Retrahens aurem draws it backward.

3. Palpebral Region (Fig. 269).

Orbicularis palpebrarum.	Levator palpebræ.
Corrugator supercilii.	Tensor tarsi.

Dissection (Fig. 256).—In order to expose the muscles of the face, continue the longitudinal incision made in the dissection of the Occipito-frontalis down the median line of the face to the tip of the nose, and from this point onward to the upper lip; and carry another incision along the margin of the lip to the angle of the mouth, and transversely across the face to the angle of the jaw. Then make an incision in front of the external ear, from the angle of the jaw upward, to join the transverse incision made in exposing the Occipito-frontalis. These incisions include a square-shaped flap, which should be removed in the direction marked in the figure, with care, as the muscles at some points are intimately adherent to the integument.

The **Orbicularis palpebrarum** is a sphincter muscle, which surrounds the circumference of the orbit and eyelids. It arises from the internal angular process of the frontal bone, from the nasal process of the superior maxillary in front of the lachrymal groove for the nasal duct, and from the anterior surface and borders of a short tendon, the *tendo palpebrarum*, placed at the inner angle of the orbit. From this origin the fibres are directed outward, forming a broad, thin, and flat layer, which covers the eyelids, surrounds the circumference of the orbit, and spreads out over the temple and downward on the cheek. The palpebral portion (ciliaris) of the Orbicularis is thin and pale; it arises from the bifurcation of the tendo palpebrarum, and forms a series of concentric curves, which are united on the outer side of the eyelids at an acute angle by a cellular raphe, some being inserted into the external tarsal ligament and malar bone. The orbicular portion (orbicularis latus) is thicker and of a reddish color: its fibres are well developed, and form complete ellipses. The upper fibres of this portion blend with the Occipito-frontalis and Corrugator supercilii.

Relations.—By its *superficial surface*, with the integument. By its *deep surface*, above, with the Occipito-frontalis and Corrugator supercilii, with which it is intimately blended, and with the supra-orbital vessels and nerve; below, it covers the lachrymal sac, and the origin of the Levator labii superioris alæque nasi, the Levator labii superioris, and the Zygomaticus minor muscles. *Inter-*

nally, it is occasionally blended with the Pyramidalis nasi. *Externally*, it lies on the temporal fascia. On the eyelids it is separated from the conjunctiva by the Levator palpebræ, the tarsal ligaments, the tarsal plates, and the Meibomian glands.

The *tendo palpebrarum* (tendo oculi) is a short tendon, about two lines in length and one in breadth, attached to the nasal process of the superior maxillary bone in front of the lachrymal groove for the nasal duct. Crossing the lachrymal sac, it divides into two parts, each division being attached to the inner extremity of the corresponding tarsal plate. As the tendon crosses the lachrymal sac, a strong aponeurotic lamina is given off from the posterior surface, which expands over the sac, and is attached to the ridge on the lachrymal bone. This is the reflected aponeurosis of the tendo palpebrarum.

Use of Tendo oculi.—Besides giving attachment to part of the Orbicularis palpebrarum, and to the tarsal plates, it serves to suck the tears into the lachrymal sac, by its attachment to the sac. Thus, each time the eyelids are closed, the tendo oculi becomes tightened, and draws the wall of the lachrymal sac outward and forward, so that a vacuum is made in the sac, and the tears are sucked along the lachrymal canals into it.

The **Corrugator supercilii** is a small, narrow, pyramidal muscle, placed at the inner extremity of the eyebrow, beneath the Occipito-frontalis and Orbicularis palpebrarum muscles. It arises from the inner extremity of the superciliary ridge; from whence its fibres pass upward and outward, to be inserted into the under surface of the orbicularis, opposite the middle of the orbital arch.

Relations.—By its *anterior surface* with the Occipito-frontalis and Orbicularis palpebrarum muscles; by its *posterior surface*, with the frontal bone and supratrochlear nerve.

The **Levator palpebræ** will be described with the muscles of the orbital region.

The **Tensor tarsi** (Horner's muscle) (Fig. 270) is a small thin muscle about three lines in breadth and six in length, situated at the inner side of the orbit, behind the tendo oculi. It arises from the crest and adjacent part of the orbital surface of the lachrymal bone, and, passing across the lachrymal sac, divides into two slips, which cover the lachrymal canals, and are inserted into the tarsal plates internal to the puncta lachrymalia. Its fibres appear to be continuous with those of the palpebral portion of the Orbicularis palpebrarum; it is occasionally very indistinct.

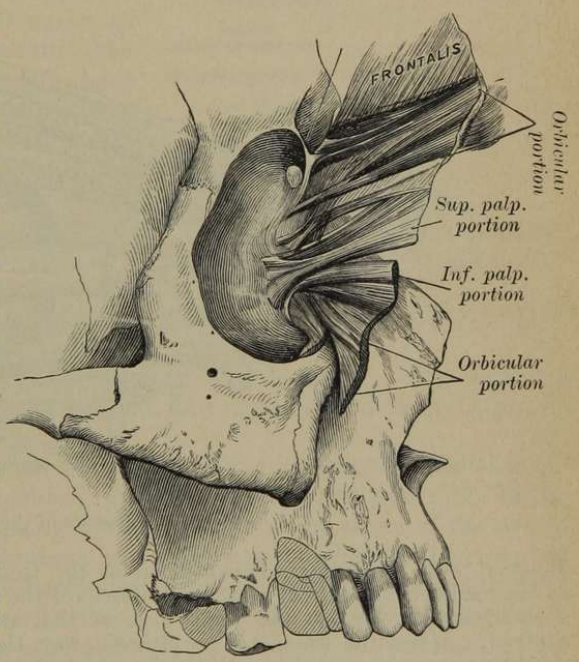

FIG. 270.—Inner part of orbicularis palpebrarum, seen from behind. (Henle.)

Nerves.—The Orbicularis palpebrarum, Corrugator supercilii, and Tensor tarsi are supplied by the facial nerve.

Actions.—The Orbicularis palpebrarum is the sphincter muscle of the eyelids. The palpebral portion acts involuntarily, closing the lids gently, as in sleep or in blinking; the orbicular portion is subject to the will. When the entire muscle is brought into action, the skin of the forehead, temple, and cheek is drawn inward toward the inner angle of the orbit, and the eyelids are firmly closed as in photophobia. When the skin of the forehead, temple, and cheek is thus drawn inward by the

action of the muscle it is thrown into folds, especially radiating from the outer angle of the eyelids, which give rise in old age to the so-called "crow's feet." The Levator palpebræ is the direct antagonist of this muscle; it raises the upper eyelid and exposes the globe. The Corrugator supercilii draws the eyebrow downward and inward, producing the vertical wrinkles of the forehead. It is the "frowning" muscle, and may be regarded as the principal agent in the expression of suffering. The Tensor tarsi draws the eyelids and the extremities of the lachrymal canals inward and compresses them against the surface of the globe of the eye; thus placing them in the most favorable situation for receiving the tears. It serves, also, to compress the lachrymal sac.

4. Orbital Region (Fig. 271).

Levator palpebræ superioris. Rectus internus.
Rectus superior. Rectus externus.
Rectus inferior. Obliquus oculi superior.
Obliquus oculi inferior.

Dissection.—To open the cavity of the orbit, remove the skull-cap and brain; then saw through the frontal bone at the inner extremity of the supraorbital ridge, and externally at its

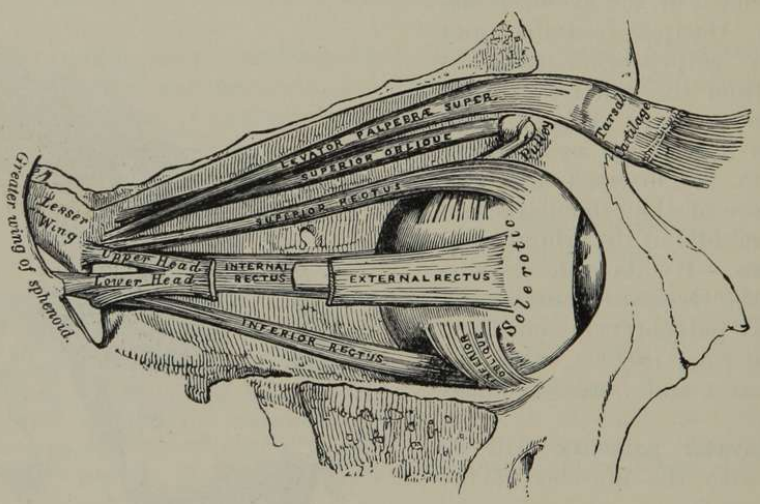

FIG. 271.—Muscles of the right orbit.

junction with the malar. Break in pieces the thin roof of the orbit by a few slight blows of the hammer, and take it away; drive forward the superciliary portion of the frontal bone by a smart stroke, but do not remove it, as that would destroy the pulley of the Obliquus superior. When the fragments are cleared away, the periosteum of the orbit will be exposed; this being removed, together with the fat which fills the cavity of the orbit, the several muscles of this region can be examined. The dissection will be facilitated by distending the globe of the eye. In order to effect this, puncture the optic nerve near the eyeball with a curved needle, and push the needle onward into the globe; insert the point of a blowpipe through this aperture, and force a little air into the cavity of the eyeball; then apply a ligature round the nerve so as to prevent the air escaping. The globe being now drawn forward, the muscles will be put upon the stretch.

The **Levator palpebræ superioris** is thin, flat, and triangular in shape. It arises from the under surface of the lesser wing of the sphenoid, above and in front of the optic foramen, from which it is separated by the origin of the Superior rectus, and is inserted, by a broad aponeurosis, into the anterior surface of the superior tarsal plate. From this aponeurosis a thin expansion is continued onward, passing between the fibres of the Orbicularis to be inserted into the skin of the lid. At its origin it is narrow and tendinous, but soon becomes broad and fleshy, and finally terminates in a broad aponeurosis.

Relations.—By its *upper surface*, with the frontal nerve and supraorbital

artery, the periosteum of the orbit, and, in the lid, with the inner surface of the tarsal ligament; by its *under surface*, with the Superior rectus, and, in the lid, with the conjunctiva. A small branch of the third nerve enters its under surface.

The **Superior rectus**, the thinnest and narrowest of the four Recti, arises from the upper margin of the optic foramen beneath the Levator palpebræ and Superior oblique, and from the fibrous sheath of the optic nerve, and is inserted by a tendinous expansion into the sclerotic coat, about three or four lines from the margin of the cornea.

Relations.—By its *upper surface*, with the Levator palpebræ; by its *under surface*, with the optic nerve, the ophthalmic artery, the nasal nerve, and the branch of the third nerve which supplies it; and, in front, with the tendon of the Superior oblique and the globe of the eye.

The **Inferior** and **Internal Recti** arise by a common tendon (the *ligament of Zinn*),[1] which is attached round the circumference of the optic foramen, except at its upper and outer part. The **External rectus** has two heads: the upper one arises from the outer margin of the optic foramen immediately beneath the Superior rectus; the lower head, partly from the ligament of Zinn and partly from a small pointed process of bone on the lower margin of the sphenoidal fissure. Each muscle passes forward in the position implied by its name, to be inserted by a tendinous expansion (the *tunica albuginea*) into the sclerotic coat, about three or four lines from the margin of the cornea. Between the two heads of the External rectus is a narrow interval, through which passes the third, the nasal branch of the ophthalmic division of the fifth and sixth nerves, and the ophthalmic vein. Although nearly all of these muscles present a common origin and are inserted in a similar manner into the sclerotic coat, there are certain differences to be observed in them as regards their length and breadth. The Internal rectus is the broadest, the External is the longest, and the Superior is the thinnest and narrowest.

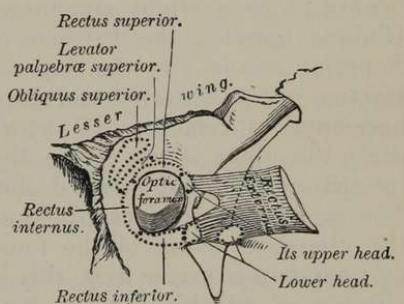

FIG. 272.—The relative position and attachment of the muscles of the left eyeball.

The **Superior oblique** is a fusiform muscle placed at the upper and inner side of the orbit, internal to the Levator palpebræ. It arises about a line above the inner margin of the optic foramen, and, passing forward to the inner angle of the orbit, terminates in a rounded tendon, which plays in a ring or pulley (*trochlea*) formed by fibro-cartilaginous tissue attached to a depression beneath the internal angular process of the frontal bone, the contiguous surfaces of the tendon and ring being lined by a delicate synovial membrane and enclosed in a thin fibrous investment. The tendon is reflected backward, outward, and downward beneath the Superior rectus to the outer part of the globe of the eye, and is inserted into the sclerotic coat, midway between the cornea and entrance of the optic nerve, the insertion of the muscle lying between the Superior and External recti.

Relations.—By its *upper surface*, with the periosteum covering the roof of the orbit and the fourth nerve: the tendon, where it lies on the globe of the eye is covered by the Superior rectus; by its *under surface*, with the nasal nerve and the upper border of the internal rectus.

The **Inferior oblique** is a thin, narrow muscle placed near the anterior margin of the orbit. It arises from a depression on the orbital plate of the superior

[1] The ligament of Zinn ought, perhaps more appropriately, to be termed the *aponeurosis* or *tendon of Zinn*. Mr. C. B. Lockwood has described a somewhat similar structure on the under surface of the Superior rectus muscle, which is attached to the lesser wing of the sphenoid, forming the upper and outer margin of the optic foramen. This *superior tendon* gives origin to the Superior rectus, the superior head of the External rectus, and the upper part of the Internal rectus. (*Journal of Anatomy and Physiology*, vol. xx. part i. p. 1.)

maxillary bone, external to the lachrymal groove for the nasal duct. Passing outward, backward, and upward beneath the Inferior rectus, and then between the eyeball and the External rectus, it is inserted into the outer part of the sclerotic coat between the Superior and External recti, near to, but somewhat behind, the tendon of insertion of the Superior oblique.

Relations.—By its *ocular surface*, with the globe of the eye and with the Inferior rectus; by its *orbital surface*, with the periosteum covering the floor of the orbit, and with the External rectus. Its borders look forward and backward; the posterior one receives a branch of the third nerve.

Nerves.—The Levator palpebræ, Inferior oblique, and all the Recti excepting the External, are supplied by the third nerve; the Superior oblique, by the fourth; the External rectus, by the sixth.

Actions.—The Levator palpebræ raises the upper eyelid, and is the direct antagonist of the Orbicularis palpebrarum. The four Recti muscles are attached in such a manner to the globe of the eye that, acting singly, they will turn it either upward, downward, inward, or outward, as expressed by their names. The movement produced by the Superior or Inferior rectus is not quite a simple one, for, inasmuch as they pass obliquely outward and forward to the eyeball, the elevation or depression of the cornea must be accompanied by a certain deviation inward, with a slight amount of rotation, which, however, is corrected by the Oblique muscles, the Inferior oblique correcting the deviation inward of the Superior rectus, and the Superior oblique that of the Inferior rectus. The contraction of the External and Internal recti, on the other hand, produces a purely horizontal movement. If any two contiguous recti of one eye act together, they carry the globe of the eye in the diagonal of these directions—viz. upward and inward, upward and outward, downward and inward, or downward and outward. The movement of circumduction, as in looking round a room, is performed by the alternate action of the four Recti. The Oblique muscles rotate the eyeball on its *antero-posterior axis*, this kind of movement being required for the correct viewing of an object when the head is moved laterally, as from shoulder to shoulder, in order that the picture may fall in all respects on the same part of the retina of each eye.[1]

Surgical Anatomy.—The position and exact point of insertion of the tendons of the Internal and External recti muscles into the globe should be carefully examined from the front of the eyeball, as the surgeon is often required to divide the one or the other muscle for the cure of strabismus. In convergent strabismus, which is the more common form of the disease, the eye is turned inward, requiring the division of the Internal rectus. In the divergent form, which is more rare, the eye is turned outward, the External rectus being especially implicated. The deformity produced in either case is to be remedied by division of one or the other muscle. The operation is thus performed: The lids are to be well separated; the eyeball being rotated outward or inward, the conjunctiva should be raised by a pair of forceps and divided immediately beneath the lower border of the tendon of the muscle to be divided, a little behind its insertion into the sclerotic; the submucous areolar tissue is then divided, and into the small aperture thus made a blunt hook is passed upward between the muscle and the globe, and the tendon of the muscle and conjunctiva covering it divided by a pair of blunt-pointed scissors. Or the tendon may be divided by a subconjunctival incision, one blade of the scissors being passed upward between the tendon and the conjunctiva, and the other between the tendon and the sclerotic. The student, when dissecting these muscles, should remove on one side of the subject the conjunctiva from the front of the eye, in order to see more accurately the position of the tendons, while on the opposite side the operation may be performed.

5. Nasal Region (Fig. 269).

Pyramidalis nasi.
Levator labii superioris alæque nasi.
Dilatator naris posterior.
Dilatator naris anterior.
Compressor nasi.
Compressor narium minor.
Depressor alæ nasi.

[1] "On the Oblique Muscles of the Eye in Man and Vertebrate Animals," by John Struthers, M. D., in *Anatomical and Physiological Observations*. For a fuller account of the various co-ordinate actions of the muscles of a single eye and of both eyes than our space allows, the reader may be referred to Dr. M. Foster's *Text-book of Physiology*.

The **Pyramidalis nasi** is a small pyramidal slip prolonged downward from the Occipito-frontalis upon the side of the nose, where it becomes tendinous and blends with the Compressor nasi. As the two muscles descend they diverge, leaving an angular interval between them.

Relations.—By its *upper surface*, with the skin; by its *under surface*, with the frontal and nasal bones.

The **Levator labii superioris alæque nasi** is a thin triangular muscle placed by the side of the nose, and extending between the inner margin of the orbit and upper lip. It arises by a pointed extremity from the upper part of the nasal process of the superior maxillary bone, and, passing obliquely downward and outward, divides into two slips, one of which is inserted into the cartilage of the ala of the nose; the other is prolonged into the upper lip, becoming blended with the Orbicularis oris and Levator labii superioris proprius.

Relations.—In front, with the integument, and with a small part of the Orbicularis palpebrarum above.

The **Dilatator naris posterior** is a small muscle which is placed partly beneath the elevator of the nose and lip. It arises from the margin of the nasal notch of the superior maxilla and from the sesamoid cartilages, and is inserted into the skin near the margin of the nostril.

The **Dilatator naris anterior** is a thin delicate fasciculus passing from the cartilage of the ala of the nose to the integument near its margin. This muscle is situated in front of the preceding.

The **Compressor nasi** is a small, thin, triangular muscle arising by its apex from the superior maxillary bone, above and a little external to the incisive fossa; its fibres proceed upward and inward, expanding into a thin aponeurosis which is attached to the fibro-cartilage of the nose and is continuous on the bridge of the nose with that of the muscle of the opposite side and with the aponeurosis of the Pyramidalis nasi.

The **Compressor narium minor** is a small muscle attached by one end to the alar cartilage, and by the other to the integument at the end of the nose.

The **Depressor alæ nasi** is a short radiated muscle arising from the incisive fossa of the superior maxilla; its fibres ascend to be inserted into the septum and back part of the ala of the nose. This muscle lies between the mucous membrane and muscular structure of the lip.

Nerves.—All the muscles of this group are supplied by the facial nerve.

Actions.—The Pyramidalis nasi draws down the inner angle of the eyebrows and produces transverse wrinkles over the bridge of the nose; by some anatomists it is also considered as an elevator of the ala, and, consequently, a dilator of the nose.[1] The Levator labii superioris alæque nasi draws upward the upper lip and ala of the nose: its most important action is upon the nose, which it dilates to a considerable extent. The action of this muscle produces a marked influence over the countenance, and it is the principal agent in the expression of contempt and disdain. The two Dilatatores nasi enlarge the aperture of the nose. Their action in ordinary breathing is to resist the tendency of the nostrils to close from atmospheric pressure, but in difficult breathing they may be noticed to be in violent action, as well as in some emotions, as anger. The Depressor alæ nasi is a direct antagonist of the other muscles of the nose, drawing the ala of the nose downward, and thereby constricting the aperture of the nares. The Compressor nasi depresses the cartilaginous part of the nose and compresses the alæ together.

[1] Although this muscle anatomically seems to be a continuation of the Occipito-frontalis downward, it is really the reverse. Its origin is from the nose below, and its insertion into the Occipito-frontalis and skin. If one pole of a battery be placed in front of the lobe of the ear, and the other (a small pointed one) be carried up and down over the nose and forehead in the middle line, it is easy to find a nodal point of indifference above which the Occipito-frontal draws the parts upward, and below which the Pyramidalis draws them downward (W. W. Keen, M. D., American edition).

6. Superior Maxillary Region (Fig. 269).

Levator labii superioris.
Levator anguli oris.
Zygomaticus major.
Zygomaticus minor.

The **Levator labii superioris (proprius)** is a thin muscle of a quadrilateral form. It arises from the lower margin of the orbit immediately above the infraorbital foramen, some of its fibres being attached to the superior maxilla, others to the malar bone; its fibres converge to be inserted into the muscular substance of the upper lip.

Relations.—By its *superficial surface* above, with the lower segment of the Orbicularis palpebrarum; below, it is subcutaneous. By its *deep surface* it conceals the origin of the Compressor nasi and Levator anguli oris muscles, and the infraorbital vessels and nerve, as they escape from the infraorbital foramen.

The **Levator anguli oris** arises from the canine fossa immediately below the infraorbital foramen; its fibres incline downward and a little outward, to be inserted into the angle of the mouth, intermingling with those of the Zygomaticus major, the Depressor anguli oris, and the Orbicularis.

Relations.—By its *superficial surface*, with the Levator labii superioris and the infraorbital vessels and nerves; by its *deep surface*, with the superior maxilla, the Buccinator, and the mucous membrane.

The **Zygomaticus major** is a slender fasciculus which arises from the malar bone, in front of the zygomatic suture, and, descending obliquely downward and inward, is inserted into the angle of the mouth, where it blends with the fibres of the Levator anguli oris, the Orbicularis oris, and the Depressor anguli oris.

Relations.—By its *superficial surface*, with the subcutaneous adipose tissue; by its *deep surface*, with the malar bone and the Masseter and Buccinator muscles.

The **Zygomaticus minor** arises from the malar bone immediately behind the maxillary suture, and, passing downward and inward, is continuous with the Orbicularis oris at the outer margin of the Levator labii superioris. It lies in front of the preceding.

Relations.—By its *superficial surface*, with the integument and the Orbicularis palpebrarum above; by its *deep surface*, with the Masseter, Buccinator, and Levator anguli oris.

Nerves.—This group of muscles is supplied by the facial nerve.

Actions.—The Levator labii superioris is the proper elevator of the upper lip, carrying it at the same time a little forward. It assists in forming the naso-labial ridge, which passes from the side of the nose to the upper lip and gives to the face an expression of sadness. The Levator anguli oris raises the angle of the mouth, and assists the Levator labii superioris in producing the naso-labial ridge. The Zygomaticus major draws the angle of the mouth backward and upward, as in laughing; whilst the Zygomaticus minor, being inserted into the outer part of the upper lip and not into the angle of the mouth, draws it backward, upward, and outward, and thus gives to the face an expression of sadness.

7. Inferior Maxillary Region (Fig. 269).

Levator labii inferioris (Levator menti).
Depressor labii inferioris (Quadratus menti).
Depressor anguli oris (Triangularis menti).

Dissection.—The muscles in this region may be dissected by making a vertical incision through the integument from the margin of the lower lip to the chin: a second incision should then be carried along the margin of the lower jaw as far as the angle, and the integument carefully removed in the direction shown in Fig. 268.

The **Levator labii inferioris (Levator menti)** is to be dissected by everting the lower lip and raising the mucous membrane. It is a small conical fasciculus placed on the side of the frænum of the lower lip. It arises from the incisive fossa,

external to the symphysis of the lower jaw; its fibres descend to be inserted into the integument of the chin.

Relation.—On its *inner surface*, with the mucous membrane; in the *median line*, it is blended with the muscle of the opposite side; and on its *outer side*, with the Depressor labii inferioris.

The **Depressor labii inferioris** (**Quadratus menti**) is a small quadrilateral muscle. It arises from the external oblique line of the lower jaw, between the symphysis and mental foramen, and passes obliquely upward and inward, to be inserted into the integument of the lower lip, its fibres blending with the Orbicularis oris and with those of its fellow of the opposite side. It is continuous with the fibres of the Platysma at its origin. This muscle contains much yellow fat intermingled with its fibres.

Relations.—By its *superficial surface*, with part of the Depressor anguli oris and with the integument, to which it is closely connected; by its *deep surface*, with the mental vessels and nerves, the mucous membrane of the lower lip, the labial glands, and the Levator menti, with which it is intimately united.

The **Depressor anguli oris** (**Triangularis menti**) is triangular in shape, arising, by its broad base, from the external oblique line of the lower jaw, from whence its fibres pass upward, to be inserted, by a narrow fasciculus, into the angle of the mouth. It is continuous with the Platysma at its origin and with the Orbicularis oris and Risorius at its insertion, and some of its fibres are directly continuous with those of the Levator anguli oris.

Relations.—By its *superficial surface*, with the integument; by its *deep surface*, with the Depressor labii inferioris and Buccinator.

Nerves.—This group of muscles is supplied by the facial nerve.

Actions.—The Levator labii inferioris raises the lower lip and protrudes it forward, and at the same time wrinkles the integument of the chin, expressing doubt or disdain. The Depressor labii inferioris draws the lower lip directly downward and a little outward, as in the expression of irony. The Depressor anguli oris depresses the angle of the mouth, being the antagonist to the Levator anguli oris and Zygomaticus major; acting with these muscles, it will draw the angle of the mouth directly backward.

8. Intermaxillary Region.

Orbicularis oris. Buccinator. Risorius.

Dissection.—The dissection of these muscles may be considerably facilitated by filling the cavity of the mouth with tow, so as to distend the cheeks and lips; the mouth should then be closed by a few stitches and the integument carefully removed from the surface.

The **Orbicularis oris** (Fig. 269) is not a sphincter muscle, like the Orbicularis palpebrarum, but consists of numerous strata of muscular fibres, having different directions, which surround the orifice of the mouth. These fibres are partially derived from the other facial muscles which are inserted into the lips, and are partly fibres proper to the lips themselves. Of the former, a considerable number are derived from the Buccinator and form the deeper stratum of the Orbicularis. Some of them—namely, those near the middle of the muscle—decussate at the angle of the mouth, those arising from the upper jaw passing to the lower lip, and those from the lower jaw to the upper lip. Other fibres of the muscle, situated at its upper and lower part, pass across the lips from side to side without interruption. Superficial to this stratum is a second, formed by the Levator and Depressor anguli oris, which cross each other at the angle of the mouth, those from the Depressor passing to the upper lip, and those from the Levator to the lower lip, along which they run to be inserted into the skin near the median line. In addition to these there are fibres from the other muscles inserted into the lips—the Levator labii superioris, the Levator labii superioris alæque nasi, the Zygomatici, and the Depressor labii inferioris; these intermingle with the transverse fibres above described, and have principally an oblique direction. The proper fibres of

the lips are oblique, and pass from the under surface of the skin to the mucous membrane through the thickness of the lip. And in addition to these are fibres by which the muscle is connected directly with the maxillary bones and the septum of the nose. These consist, in the upper lip, of four bands, two of which (*Accessorii orbicularis superioris*) arise from the alveolar border of the superior maxilla, opposite the lateral incisor tooth, and, arching outward on each side, are continuous at the angles of the mouth with the other muscles inserted into this part. The two remaining muscular slips, called the *Naso-labialis*, connect the upper lip to the back of the septum of the nose: as they descend from the septum an interval is left between them. It is this interval which forms the depression (*philtrum*) seen on the surface of the skin beneath the septum of the nose. The additional fibres for the lower segment (*Accessorii orbicularis inferioris*) arise from the inferior maxilla, externally to the Levator labii inferioris, and arch outward to the angles of the mouth, to join the Buccinator and the other muscles attached to this part.

Relations.—By its *superficial surface*, with the integument, to which it is closely connected; by its *deep surface*, with the buccal mucous membrane, the labial glands, and coronary vessels; by its *outer circumference* it is blended with the numerous muscles which converge to the mouth from various parts of the face. Its *inner circumference* is free, and covered by the mucous membrane.

The **Buccinator** (Fig. 282) is a broad, thin muscle, quadrilateral in form, which occupies the interval between the jaws at the side of the face. It arises from the outer surface of the alveolar processes of the upper and lower jaws, corresponding to the three molar teeth, and, behind, from the anterior border of the pterygo-maxillary ligament. The fibres converge toward the angle of the mouth, where the central fibres intersect each other, those from below being continuous with the upper segment of the Orbicularis oris, and those from above with the inferior segment; the highest and lowest fibres continue forward uninterruptedly into the corresponding segment of the lip, without decussation.

Relations.—By its *superficial surface*, behind, with a large mass of fat, which separates it from the ramus of the lower jaw, the Masseter, and a small portion of the Temporal muscle; anteriorly, with the Zygomatici, Risorius, Levator anguli oris, Depressor anguli oris, and Stenson's duct, which pierces it opposite the second molar tooth of the upper jaw; the facial artery and vein cross it from below upward; it is also crossed by the branches of the facial and buccal nerves; by its *internal surface*, with the buccal glands and mucous membrane of the mouth.

The *pterygo-maxillary ligament* separates the Buccinator muscle from the Superior constrictor of the pharynx. It is a tendinous band, attached by one extremity to the apex of the internal pterygoid plate, and by the other to the posterior extremity of the internal oblique line of the lower jaw. Its *inner surface* corresponds to the cavity of the mouth, and is lined by mucous membrane. Its *outer surface* is separated from the ramus of the jaw by a quantity of adipose tissue. Its *posterior border* gives attachment to the Superior constrictor of the pharynx; its *anterior border*, to the fibres of the Buccinator (see Fig. 282).

The **Risorius (Santorini)** (Fig. 269) consists of a narrow bundle of fibres which arises in the fascia over the Masseter muscle, and, passing horizontally forward, is inserted into the skin at the angle of the mouth. It is placed superficial to the Platysma, and is broadest at its posterior extremity. This muscle varies muchin its size and form.

Nerves.—The Orbicularis oris and the Risorius are supplied by the facial, the Buccinator by the facial and by the buccal branch of the inferior maxillary nerve; which latter, however, is by many anatomists regarded as a sensory nerve only.

Actions.—The Orbicularis oris in its ordinary action produces the direct closure of the lips; by its deep fibres, assisted by the oblique ones, it closely applies the lips to the alveolar arch. The superficial part, consisting principally of the decussating fibres, brings the lips together and also protrudes them forward. The Buccinators contract and compress the cheeks, so that, during the process of mastication, the food is kept under the immediate pressure of the teeth. When

the cheeks have been previously distended with air, the Buccinator muscles expel it from between the lips, as in blowing a trumpet. Hence the name (*buccina*, a trumpet). The Risorius retracts the angles of the mouth, and is therefore regarded as the "smiling" muscle.

9. Temporo-maxillary Region.

Masseter. Temporal.

Masseteric Fascia.—Covering the Masseter muscle, and firmly connected with it, is a strong layer of fascia derived from the deep cervical fascia. Above, this fascia is attached to the lower border of the zygoma, and, behind, it covers the parotid gland, constituting the *parotid fascia*.

The **Masseter** is exposed by the removal of this fascia (Fig. 269); it is a short, thick muscle, somewhat quadrilateral in form, consisting of two portions, superficial and deep. The *superficial portion*, the larger, arises by a thick, tendinous aponeurosis from the malar process of the superior maxilla, and from the anterior two-thirds of the lower border of the zygomatic arch: its fibres pass downward and backward, to be inserted into the angle and lower half of the outer surface of the ramus of the jaw. The *deep portion* is much smaller and more muscular in texture; it arises from the posterior third of the lower border and the whole of the inner surface of the zygomatic arch; its fibres pass downward and forward, to be inserted into the upper half of the ramus and outer surface of the coronoid process of the jaw. The deep portion of the muscle is partly concealed, in front by the superficial portion; behind, it is covered by the parotid gland. The fibres of the two portions are united at their insertion.

Relations.—By its *superficial surface*, with the Zygomatici, the Socia parotidis, and Stenson's duct; the branches of the facial nerve and the transverse facial vessels, which cross it; the masseteric fascia; the Risorius, Santorini, Platysma myoides, and the integument; by its *deep surface*, with the Temporal muscle at its insertion, the ramus of the jaw, and the Buccinator, from which it is separated by a mass of fat. The masseteric nerve and artery enter it on its deep surface. Its *posterior margin* is overlapped by the parotid gland. Its *anterior margin* projects over the Buccinator muscle, and the facial vein lies on it below.

The *temporal fascia* is seen, at this stage of the dissection covering in the Temporal muscle. It is a strong, fibrous investment, covered, on its outer surface, by the Attrahens and Attollens aurem muscles, the aponeurosis of the Occipito-frontalis, and by part of the Orbicularis palpebrarum. The temporal vessels and the auriculo-temporal nerve cross it from below upward. Above, it is a single layer, attached to the entire extent of the upper temporal ridge; but below, where it is attached to the zygoma, it consists of two layers, one of which is inserted into the outer, and the other into the inner, border of the zygomatic arch. A small quantity of fat, the orbital branch of the temporal artery, and a filament from the orbital, or temporo-malar, branch of the superior maxillary nerve, are contained between these two layers. It affords attachment by its inner surface to the superficial fibres of the Temporal muscle.

Dissection.—In order to expose the Temporal muscle, remove the temporal fascia, which may be effected by separating it at its attachment along the upper border of the zygoma, and dissecting it upward from the surface of the muscle. The zygomatic arch should then be divided in front at its junction with the malar bone, and behind near the external auditory meatus, and drawn downward with the Masseter, which should be detached from its insertion into the ramus and angle of the jaw. The whole extent of the Temporal muscle is then exposed.

The **Temporal** (Fig. 273) is a broad, radiating muscle situated at the side of the head and occupying the entire extent of the temporal fossa. It arises from the whole of the temporal fossa except that portion of it that is formed by the malar bone. Its attachment extends from the external angular process of the frontal in front to the mastoid portion of the temporal behind, and from the curved line on the frontal and parietal bones above to the pterygoid ridge on the great wing of

the sphenoid below. It is also attached to the inner surface of the temporal fascia. Its fibres converge as they descend, and terminate in an aponeurosis, the fibres of

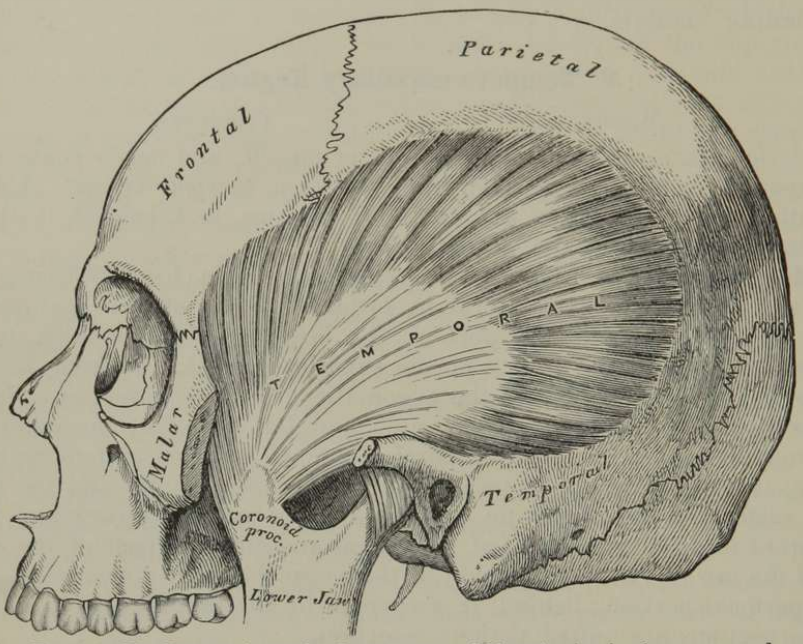

FIG. 273.—The Temporal muscle, the zygoma and Masseter having been removed.

which, radiated at its commencement, converge into a thick and flat tendon, which is inserted into the inner surface, apex, and anterior border of the coronoid process of the jaw, nearly as far forward as the last molar tooth.

Relations.—By its *superficial surface*, with the integument, the Attrahens and Attollens aurem muscles, the temporal vessels and nerves, the aponeurosis of the Occipito-frontalis, the temporal fascia, the zygoma, and Masseter; by its *deep surface*, with the temporal fossa, the External pterygoid and part of the Buccinator muscles, the internal maxillary artery, its deep temporal branches, and the deep temporal nerves. Behind the tendon are the masseteric vessels and nerve, and in front of it the buccal vessels and nerve. Its anterior border is separated from the malar bone by a mass of fat.

Nerves.—Both muscles are supplied by the inferior maxillary nerve.

10. Pterygo-maxillary Region (Fig. 274).

External Pterygoid. Internal Pterygoid.

Dissection.—The Temporal muscle having been examined, saw through the base of the coronoid process, and draw it upward, together with the Temporal muscle, which should be detached from the surface of the temporal fossa. Divide the ramus of the jaw just below the condyle, and also, by a transverse incision extending across the middle, just above the dental foramen; remove the fragment, and the Pterygoid muscles will be exposed.

The **External Pterygoid** is a short, thick muscle, somewhat conical in form, which extends almost horizontally between the zygomatic fossa and the condyle of the jaw. It arises from the pterygoid ridge on the great wing of the sphenoid and the portion of bone included between it and the base of the pterygoid process, and from the outer surface of the external pterygoid plate. Its fibres pass horizontally backward and outward, to be inserted into a depression in front of the neck of the condyle of the lower jaw and into the corresponding part of the interarticular fibro-cartilage. This muscle, at its origin, appears to consist of two portions separated by a slight interval; hence the terms *upper* and *lower* head sometimes used in the description of the muscle.

Relations.—By its *external surface*, with the ramus of the lower jaw, the

internal maxillary artery, which crosses it,[1] the tendon of the Temporal muscle, and the Masseter; by its *internal surface* it rests against the upper part of the Internal pterygoid, the internal lateral ligament, the middle meningeal artery,

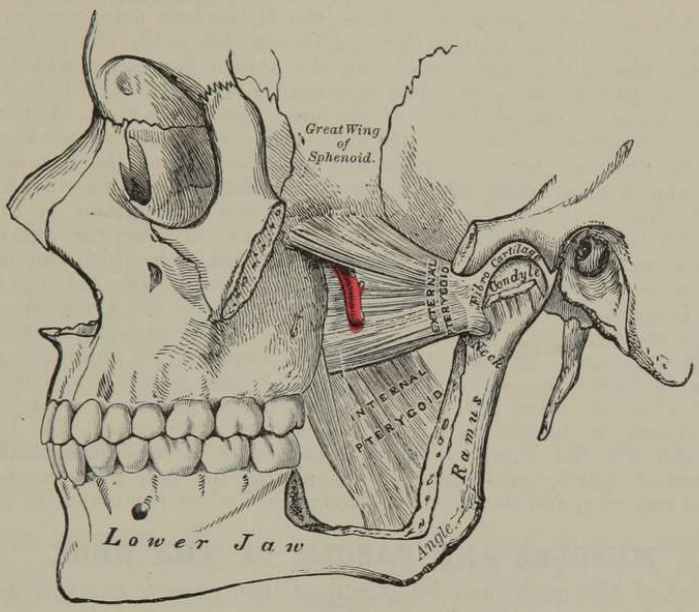

FIG. 274.—The Pterygoid muscles, the zygomatic arch and a portion of the ramus of the jaw having been removed.

and inferior maxillary nerve; by its *upper border* it is in relation with the temporal and masseteric branches of the inferior maxillary nerve; by its *lower border* it is in relation with the inferior dental and gustatory nerves, and it is pierced by the buccal nerve. In the interval between the two portions of the muscle the internal maxillary artery passes, when this vessel lies on the muscle (see Fig. 274).

The **Internal Pterygoid** is a thick, quadrilateral muscle, and resembles the Masseter in form. It arises from the pterygoid fossa, being attached to the inner surface of the external pterygoid plate and to the grooved surface of the tuberosity of the palate bone, and by a second slip from the outer surface of the tuberosity of the palate bone and from the tuberosity of the superior maxillary bone; its fibres pass downward, outward, and backward, to be inserted, by a strong, tendinous lamina, into the lower and back part of the inner side of the ramus and angle of the lower jaw, as high as the dental foramen.

Relations.—By its *external surface*, with the ramus of the lower jaw, from which it is separated, at its upper part, by the External pterygoid, the internal lateral ligament, the internal maxillary artery, the dental vessels and nerves, and the lingual nerve; by its *internal surface*, with the Tensor palati, being separated from the Superior constrictor of the pharynx by a cellular interval.

Nerves.—These muscles are supplied by the inferior maxillary nerve.

Actions.—The Temporal and Masseter and Internal pterygoid raise the lower jaw against the upper with great force. The superficial portion of the Masseter assists the External pterygoid in drawing the lower jaw forward upon the upper, the jaw being drawn back again by the deep fibres of the Masseter and posterior fibres of the Temporal. The External pterygoid muscles are the direct agents in the trituration of the food, drawing the lower jaw directly forward, so as to make the lower teeth project beyond the upper. If the muscle of one side acts, the corresponding side of the jaw is drawn forward, and, the other condyle remaining fixed, the symphysis deviates to the opposite side. The alternation of these movements on the two sides produces trituration.

[1] This is the usual relation, but in many cases the artery will be found below the muscle

Surface Form.—The outline of the muscles of the head and face cannot be traced on the surface of the body, except in the case of two of the masticatory muscles. Those of the head are thin, so that the outline of the bone is perceptible beneath them. Those in the face are small, covered by soft skin, and often by a considerable layer of fat, so that their outline is concealed, but they serve to round off and smooth prominent borders and to fill up what would be otherwise unsightly angular depressions. Thus, the Orbicularis palpebrarum rounds off the prominent margin of the orbit, and the Pyramidalis nasi fills in the sharp depression beneath the glabella, and thus softens and tones down the abrupt depression which is seen on the unclothed bone. In like manner, the labial muscles, converging to the lips and assisted by the superimposed fat, fill in the sunken hollow of the lower part of the face. Although the muscles of the face are usually described as arising from the bones and inserted into the nose, lips, and corners of the mouth, they have fibres inserted into the skin of the face along their whole extent, so that almost every point of the skin of the face has its muscular fibre to move it; hence it is that when in action the facial muscles produce alterations in the skin-surface, giving rise to the formation of various folds or wrinkles, or otherwise altering the relative position of parts, so as to produce the varied expressions with which the face is endowed; hence these muscles are termed the "muscles of expression." The only two muscles in this region which greatly influence surface form are the Masseter and the Temporal. The Masseter is a quadrilateral muscle, which imparts fulness to the hinder part of the cheek. When the muscle is firmly contracted, as when the teeth are clenched, its outline is plainly visible; the anterior border forms a prominent vertical ridge, behind which is a considerable fulness, especially marked at the lower part of the muscle; this fulness is entirely lost when the mouth is opened and the muscle no longer in a state of contraction. The Temporal muscle is fan-shaped, and fills the Temporal fossa, substituting for it a somewhat convex form, the anterior part of which, on account of the absence of hair over the temple, is more marked than the posterior, and stands out in strong relief when the muscle is in a state of contraction.

MUSCLES AND FASCIÆ OF THE NECK.

The muscles of the neck may be arranged into groups corresponding with the region in which they are situated.

These groups are nine in number:

1. Superficial cervical region.
2. Depressors of the Os Hyoides and Larynx.
3. Elevators of the Os Hyoides and Larynx.
4. Muscles of the Tongue.
5. Muscles of the Pharynx.
6. Muscles of the Soft Palate.
7. Muscles of the Anterior Vertebral Region.
8. Muscles of the Lateral Vertebral Region.
9. Muscles of the Larynx.

The muscles contained in each of these groups are the following:

1. *Superficial Region.*

Platysma myoides.
Sterno-cleido-mastoid.

Infra-hyoid Region.

2. *Depressors of the Os hyoides and Larynx.*

Sterno-hyoid.
Sterno-thyroid.
Thyro-hyoid.
Omo-hyoid.

Supra-hyoid Region.

3. *Elevators of the Os hyoides and Larynx.*

Digastric.
Stylo-hyoid.
Mylo-hyoid.
Genio-hyoid.

Lingual Region.

4. *Muscles of the Tongue.*

Genio-hyo-glossus.
Hyo-glossus.
Lingualis.
Stylo-glossus.
Palato-glossus.

5. *Muscles of the Pharynx.*

Constrictor inferior.
Constrictor medius.
Constrictor superior.
Stylo-pharyngeus.
Palato-pharyngeus.

6. *Muscles of the Soft Palate.*

Levator palati.
Tensor palati.
Azygos uvulæ.
Palato-glossus.
Palato-pharyngeus.

7. *Muscles of the Anterior Vertebral Region.*

Rectus capitis anticus major.
Rectus capitis anticus minor.
Rectus lateralis.
Longus colli.

8. *Muscles of the Lateral Vertebral Region.*

Scalenus anticus.
Scalenus medius.
Scalenus posticus.

9. *Muscles of the Larynx.*

Included in the description of the Larynx.

1. Superficial Cervical Region.

Platysma myoides. Sterno-cleido-mastoid.

Dissection.—A block having been placed at the back of the neck, and the face turned to the side opposite that to be dissected, so as to place the parts upon the stretch, make two transverse incisions: one from the chin, along the margin of the lower jaw, to the mastoid process, and the other along the upper border of the clavicle. Connect these by an oblique incision made in the course of the Sterno-mastoid muscle, from the mastoid process to the sternum; the two flaps of integument having been removed in the direction shown in Fig. 268, the superficial fascia will be exposed.

The **Superficial Cervical Fascia** is a thin, aponeurotic lamina which is hardly demonstrable as a separate membrane. Beneath it is found the Platysma myoides muscle.

The **Platysma myoides** (Fig. 269) is a broad, thin plane of muscular fibres placed immediately beneath the superficial fascia on each side of the neck. It arises by thin, fibrous bands from the fascia covering the upper part of the Pectoral and Deltoid muscles; its fibres proceed obliquely upward and inward along the side of the neck. The anterior fibres interlace, in front of the jaw, with the fibres of the muscle of the opposite side; the posterior fibres pass over the lower jaw, a few of them being attached to the bone below the external oblique line, the greater number passing on to be inserted into the skin and subcutaneous tissue of the lower part of the face, many of these fibres blending with the muscles about the angle and lower part of the mouth. Sometimes fibres can be traced to the Zygomatic muscles or to the margin of the Orbicularis palpebrarum. Beneath the Platysma the external jugular vein may be seen descending from the angle of the jaw to the clavicle.

Surgical Anatomy.—It is essential to remember the direction of the fibres of the Platysma in connection with the operation of bleeding from the external jugular vein; for if the point of the lancet is introduced in the direction of the muscular fibres, the orifice made will be filled up by the contraction of the muscle, and blood will not flow; but if the incision is made across the course of the fibres, they will retract and expose the orifice in the vein, and so allow the flow of blood.

Relations.—By its *external surface*, with the integument, to which it is united more closely below than above; by its *internal surface*, with the Pectoralis major, Deltoid, and Trapezius, and with the clavicle; in the *neck*, with the external and anterior jugular veins, the deep cervical fascia, the superficial branches of the cervical plexus, the Sterno-mastoid, Sterno-hyoid, Omo-hyoid, and Digastric muscles; behind the Sterno-mastoid muscle it covers the Scaleni muscles and the nerves of the brachial plexus; on the *face* it is in relation with the parotid gland, the facial artery and vein, and the Masseter and Buccinator muscles.

Action.—The Platysma myoides produces a slight wrinkling of the surface of the skin of the neck, in an oblique direction, when the entire muscle is brought into action. Its anterior portion, the thickest part of the muscle, depresses the lower jaw; it also serves to draw down the lower lip and angle of the mouth on each side, being one of the chief agents in the expression of melancholy.

The **Deep Cervical Fascia** (Fig. 275) is a strong, fibrous layer which invests the muscles of the neck and encloses the vessels and nerves. It commences, as an extremely thin layer, at the back part of the neck, where it is attached to the

ligamentum nuchæ and to the spinous process of the seventh cervical vertebræ, and, passing forward, invests the Trapezius muscle; from the anterior border of

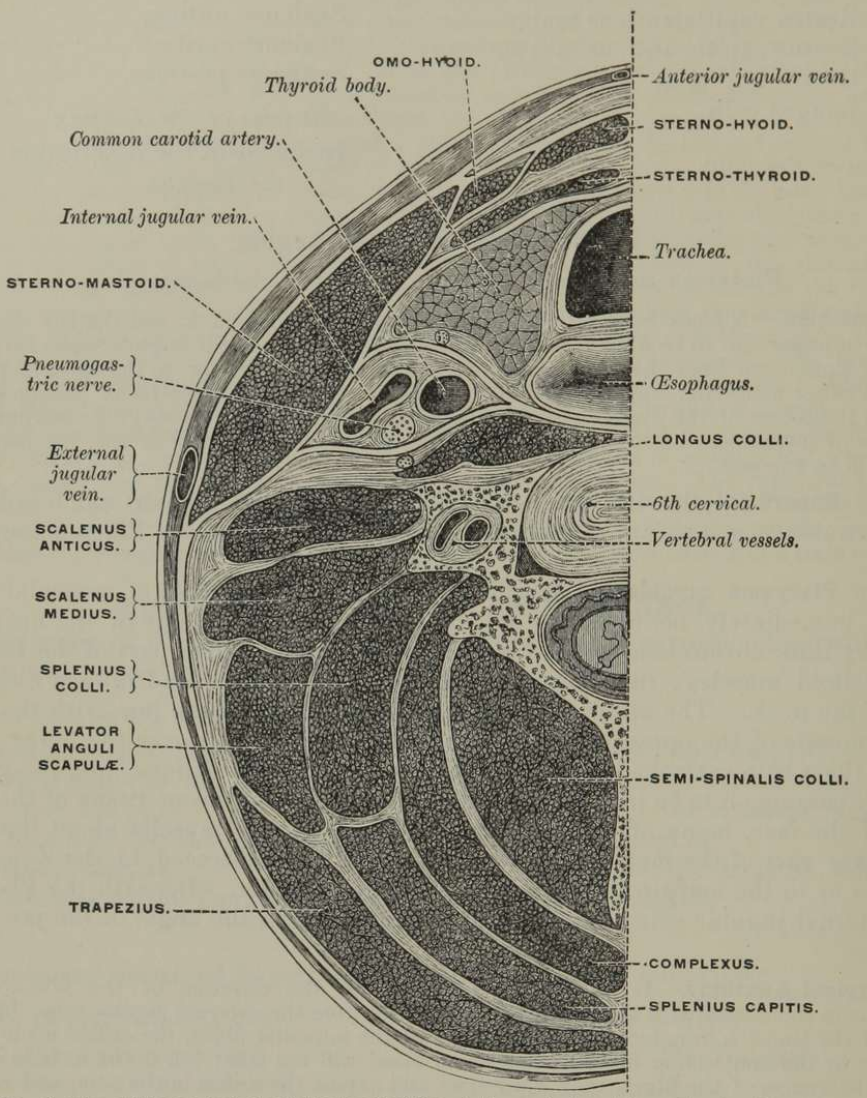

FIG. 275.—Section of the neck at about the level of the sixth cervical vertebra, showing the arrangement of the deep cervical fascia.

this muscle it forms a layer which covers in the posterior triangle of the neck; and, passing forward to the posterior border of the Sterno-mastoid muscle, divides into two layers, one of which passes over, and the other under, that muscle. The layer which passes over the muscle is continued forward to the front of the neck, and blends with the fascia of the opposite side, covering the anterior triangle. It is joined on its under surface, except for about an inch below, by a lamella derived from the layer covering the deep surface of the Sterno-mastoid muscle. Where these two layers do not meet a little space is left between them, as they both pass inward to the middle line of the neck. This is *Burns's space*, and contains a little areolar tissue and fat, and occasionally a small lymphatic gland. If traced upward, the anterior layer of the cervical fascia is found to pass across the parotid gland and Masseter muscle, forming the *parotid* and *masseteric fasciæ*, and is attached to the lower border of the zygoma, and, more anteriorly, to the lower border of the body of the jaw; if traced downward, it is seen to pass to the upper border of the clavicle and sternum, being pierced just above the former bone by the external jugular vein. In the middle line of the neck the fascia is connected to the

symphysis of the inferior maxilla, and, lower down, to the hyoid bone, between which points it is thin; below the hyoid bone it becomes thicker, and is attached below to the anterior margin of the upper border of the sternum. The layer of the deep cervical fascia which passes under the Sterno-mastoid covers the anterior surface of the Scalenus anticus muscle. At the outer side of the carotid vessels it divides into two, one layer passing in front of the vessels, the other behind them. The layer which passes in front of the vessels again divides into *three* lamellæ. Of these, the *anterior* lamella, except for an inch below where it forms the posterior boundary of Burns's space, joins the layer of cervical fascia passing over the Sterno-mastoid, and with it passes to the middle line covering the anterior surface of the Depressor muscles of the hyoid bone. The portion of this lamella which invests the Omo-hyoid is continued downward as a distinct process, which descends to be inserted into the sternum and cartilage of the first rib, and becomes connected with the Costo-coracoid membrane. The *middle* lamella passes behind the depressors of the hyoid bone and in front of the thyroid body to meet its fellow of the opposite side, in front of the trachea. At the root of the neck this middle lamella can be traced downward into the thorax to become continuous with the fibrous layer of the pericardium. The *posterior* lamella passes over to the inner side of the carotid vessels, and joins the layer passing behind them, thus enclosing them in a sheath. The layer of cervical fascia which passes behind the carotid vessels, having been joined by the posterior of the three lamellæ from the layer of fascia passing in front of the vessels, is prolonged inward, behind the pharynx and œsophagus, forming a sheath for the Prevertebral muscles, the *prevertebral fascia.* The layer of the deep cervical fascia, which passes behind the Sterno-mastoid, gives off another lamella, which passes downward and outward over the brachial plexus and subclavian vessels, to assist in forming the axillary sheath. The two layers of the deep cervical fascia, where they unite opposite the angle of the lower jaw, bind the Sterno-mastoid muscle to this part of the bone. From that portion of the cervical fascia which is attached to the angle of the jaw a process of extreme density is found passing behind to the inner side of the parotid gland, to be attached to the apex of the styloid process of the temporal bone; this is termed the *Stylo-maxillary ligament.*

The **Sterno-mastoid** or **Sterno-cleido-mastoid** (Fig. 276) is a large, thick muscle, which passes obliquely across the side of the neck, being enclosed between the two layers of the deep cervical fascia. It is thick and narrow at its central part, but is broader and thinner at each extremity. It arises, by two heads, from the sternum and clavicle. The *sternal portion* is a rounded fasciculus, tendinous in front, fleshy behind, which arises from the upper and anterior part of the first piece of the sternum, and is directed upward, outward, and backward. The *clavicular portion* arises from the inner third of the superior border of the clavicle, being composed of fleshy and aponeurotic fibres; it is directed almost vertically upward. These two portions are separated from one another, at their origin, by a triangular cellular interval, but become gradually blended, below the middle of the neck, into a thick, rounded muscle, which is inserted, by a strong tendon, into the outer surface of the mastoid process, from its apex to its superior border, and by a thin aponeurosis into the outer two-thirds of the superior curved line of the occipital bone. The Sterno-mastoid varies much in its extent of attachment to the clavicle: in one case the clavicular may be as narrow as the sternal portion; in another, as much as three inches in breadth. When the clavicular origin is broad it is occasionally subdivided into numerous slips separated by narrow intervals. More rarely, the corresponding margins of the Sterno-mastoid and Trapezius have been found in contact. In the application of a ligature to the third part of the subclavian artery it will be necessary, where the muscles come close together, to divide a portion of one or of both.

This muscle divides the quadrilateral space at the side of the neck into two triangles, an anterior and a posterior. The boundaries of the *anterior triangle*

are, in front, the median line of the neck; above, the lower border of the body of the jaw, and an imaginary line drawn from the angle of the jaw to the mastoid

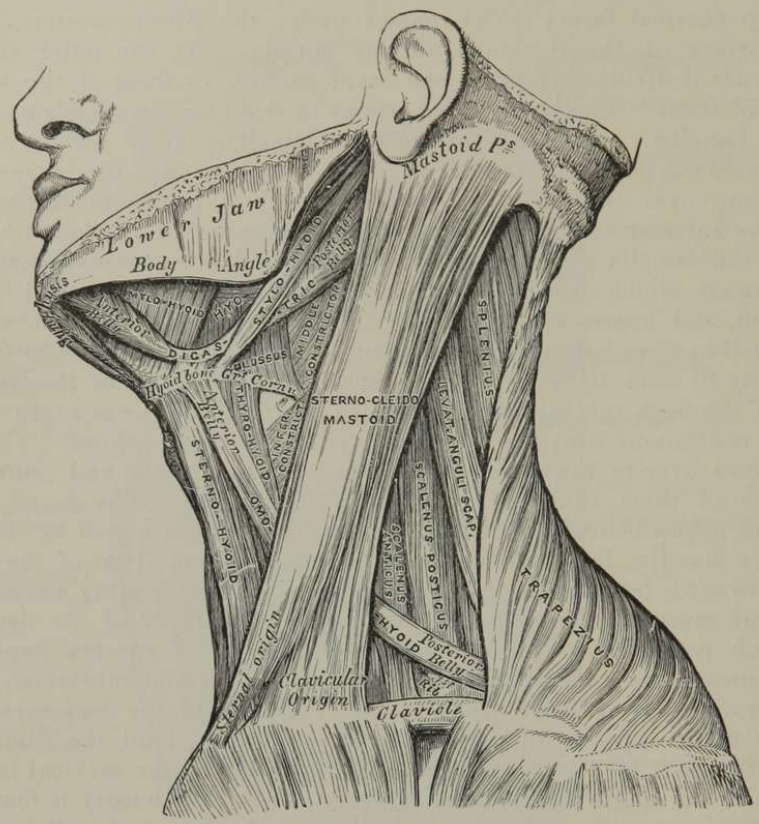

FIG. 276.—Muscles of the neck and boundaries of the triangles.

process; behind, the anterior border of the Sterno-mastoid muscle. The boundaries of the *posterior triangle* are, in front, the posterior border of the Sterno-mastoid; below, the upper border of the clavicle; behind, the anterior margin of the Trapezius.[1]

Relations.—By its *superficial surface*, with the integument and Platysma, from which it is separated by the external jugular vein, the superficial branches of the cervical plexus, and the anterior layer of the deep cervical fascia. By its *deep surface* it is in relation with the Sterno-clavicular articulation; a process of the deep cervical fascia; the Sterno-hyoid, Sterno-thyroid, Omo-hyoid, posterior belly of the Digastric, Levator anguli scapulæ, Splenius and Scaleni muscles; common carotid artery, internal jugular vein, commencement of the internal and external carotid arteries, the occipital, subclavian, transversalis colli, and suprascapular arteries and veins; the pneumogastric, hypoglossal, descendens and communicans hypoglossi nerves, and the spinal accessory nerve, which pierces its upper third; the cervical plexus, part of the parotid gland and deep lymphatic glands.

Nerves.—The Platysma myoides is supplied by the facial and superficial branches of the cervical plexus; the Sterno-cleido-mastoid, by the spinal accessory and deep branches of the cervical plexus.

Actions.—When only one Sterno-mastoid muscle acts, it flexes the head and draws it toward the shoulder of the same side, assisted by the Splenius and the Obliquus capitis inferior of the opposite side. At the same time it rotates the head so as to carry the face toward the opposite side. When both muscles are brought

[1] The anatomy of these triangles will be more exactly described with that of the vessels of the neck.

into action they serve to depress the head upon the neck and the neck upon the chest. If the head is fixed, they assist in elevating the thorax in forced inspiration.

Surface Form.—The anterior edge of the muscle forms a very prominent ridge beneath the skin, which it is important to notice, as it forms a guide to the surgeon in making the necessary incisions for ligature of the common carotid artery and for œsophagotomy.

Surgical Anatomy.—The relations of the sternal and clavicular parts of the Sterno-mastoid should be carefully examined, as the surgeon is sometimes required to divide one or both portions of the muscles in *wry-neck*. One variety of this distortion is produced by spasmodic contraction or rigidity of the Sterno-mastoid; the head being carried down toward the shoulder of the same side, and the face turned to the opposite side and fixed in that position. When there is permanent shortening subcutaneous division of the muscle is resorted to. This is performed by introducing a tenotomy knife beneath it, close to its origin, and dividing it from behind forward whilst the muscle is put well upon the stretch. There is seldom any difficulty in dividing the sternal portion, by making a puncture on the inner side of the tendon, and then pushing a blunt tenotome behind it, and cutting forward. In dividing the clavicular portion care must be taken to avoid wounding the external jugular vein, which runs parallel with the posterior border of the muscle in this situation, or the anterior jugular vein, which crosses beneath it. If the external jugular vein lies near the muscle, it is safer to make the first puncture at the outer side of the tendon, and introduce a blunt tenotome from without inward. Some of the fibres of the Sterno-mastoid muscle are occasionally torn during birth, especially in breech presentations; this is accompanied by hæmorrhage and formation of a swelling within the substance of the muscle. This by some is believed to be one of the causes of wry-neck.

2. Infra-hyoid Region (Figs. 276, 277).

Depressors of the Os Hyoides and Larynx.

Sterno-hyoid.	Thyro-hyoid.
Sterno-thyroid.	Omo-hyoid.

Dissection.—The muscles in this region may be exposed by removing the deep fascia from the front of the neck. In order to see the entire extent of the Omo-hyoid it is necessary to divide the Sterno-mastoid at its centre, and turn its ends aside, and to detach the Trapezius from the clavicle and scapula. This, however, should not be done until the Trapezius has been dissected.

The **Sterno-hyoid** is a thin, narrow, ribbon-like muscle, which arises from the inner extremity of the clavicle and the upper and posterior part of the first piece of the sternum; passing upward and inward, it is inserted, by short, tendinous fibres, into the lower border of the body of the os hyoides. This muscle is separated, below, from its fellow by a considerable interval; but they approach one another in the middle of their course, and again diverge as they ascend. It sometimes presents, immediately above its origin, a transverse tendinous intersection, like those in the Rectus abdominis.

Relations.—By its *superficial surface*, below, with the sternum, the sternal end of the clavicle, and the Sterno-mastoid; and above, with the Platysma and deep cervical fascia; by its *deep surface*, with the Sterno-thyroid, Crico-thyroid, and Thyro-hyoid muscles, the thyroid gland, the superior thyroid vessels, the thyroid cartilage, the crico-thyroid and thyro-hyoid membranes.

The **Sterno-thyroid** is situated beneath the preceding muscle, but is shorter and wider than it. It arises from the posterior surface of the first bone of the sternum, below the origin of the Sterno-hyoid, and from the edge of the cartilage of the first rib, and is inserted into the oblique line on the side of the ala of the thyroid cartilage. This muscle is in close contact with its fellow at the lower part of the neck, and is occasionally traversed by a transverse or oblique tendinous intersection, like those in the Rectus abdominis.

Relations.—By its *anterior surface*, with the Sterno-hyoid, Omo-hyoid, and Sterno-mastoid; by its *posterior surface*, from below upward, with the trachea, vena innominata, common carotid (and on the right side the arteria innominata), the thyroid gland and its vessels, and the lower part of the larynx. The middle thyroid vein lies along its inner border, a relation which it is important to remember in the operation of tracheotomy.

The **Thyro-hyoid** is a small, quadrilateral muscle appearing like a continuation

of the Sterno-thyroid. It arises from the oblique line on the side of the thyroid cartilage, and passes vertically upward to be inserted into the lower border of the body and greater cornu of the hyoid bone.

Relations.—By its *external surface*, with the Sterno-hyoid and Omo-hyoid muscles; by its *internal surface*, with the thyroid cartilage, the thyro-hyoid membrane, and the superior laryngeal vessels and nerve.

The **Omo-hyoid** passes across the side of the neck, from the scapula to the

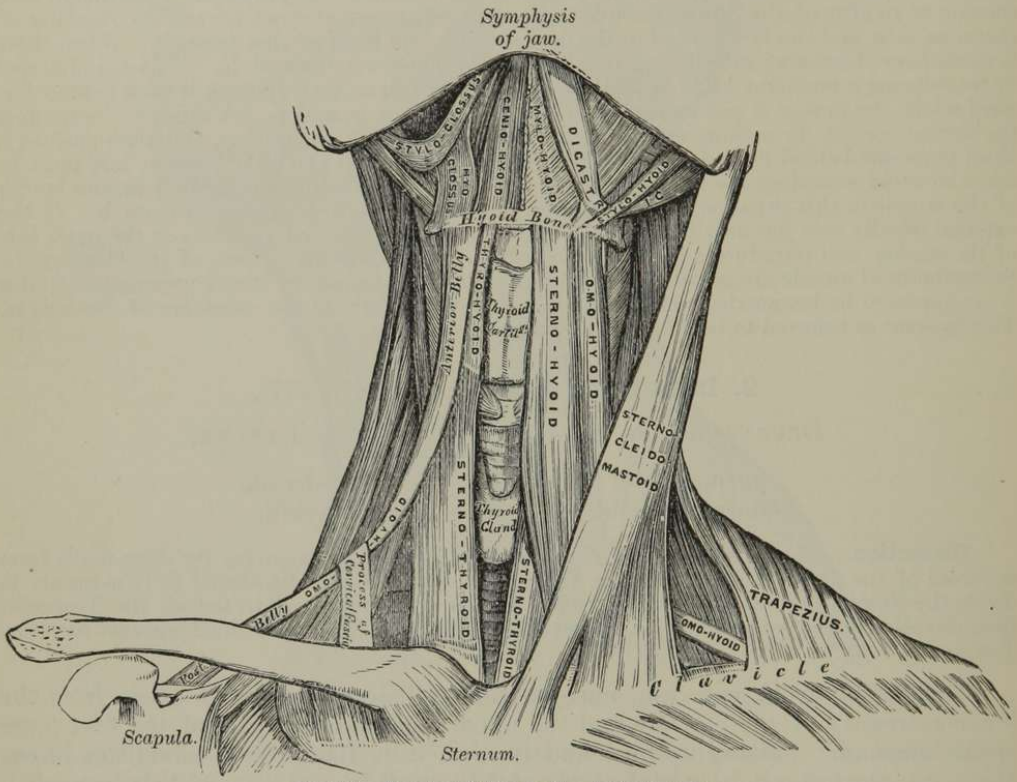

FIG. 277.—Muscles of the neck. Anterior view.

hyoid bone. It consists of two fleshy bellies, united by a central tendon. It arises from the upper border of the scapula close to, and occasionally from the transverse ligament which crosses, the suprascapular notch; its extent of attachment varying from a few lines to an inch. From this origin the posterior belly forms a flat, narrow fasciculus, which inclines forward and slightly upward across the lower part of the neck, behind the Sterno-mastoid muscle, where it becomes tendinous; it then changes its direction, forming an obtuse angle, and terminates in the anterior belly, which passes almost vertically upward, close to the outer border of the body of the os hyoides, just external to the insertion of the Sterno-hyoid. The central tendon of this muscle, which varies much in length and form, is held in position by a process of the deep cervical fascia, which includes it in a sheath. This process is prolonged down, to be attached to the cartilage of the first rib and the sternum. It is by this means that the angular form of the muscle is maintained.

This muscle subdivides each of the two large triangles at the side of the neck into two smaller triangles; the two posterior ones being the *posterior superior* or *occipital*, and the *posterior inferior* or *subclavian;* the two anterior, the *anterior superior* or *superior carotid*, and the *anterior inferior* or *inferior carotid triangle.*

Relations.—By its *superficial surface*, with the Trapezius, the Sterno-mastoid, deep cervical fascia, Platysma, and integument; by its *deep surface*, with the Scaleni muscles, phrenic nerve, lower cervical nerves, which go to form the brachial

plexus, the suprascapular vessels and nerve, sheath of the common carotid artery and internal jugular vein, the Sterno-thyroid and Thyro-hyoid muscles.

Nerves.—The Thyro-hyoid is supplied by the hypoglossal; the other muscles of this group by branches from the loop of communication between the descendens and communicans hypoglossi.

Actions.—These muscles depress the larynx and hyoid bone, after they have been drawn up with the pharynx in the act of deglutition. The Omo-hyoid muscles not only depress the hyoid bone, but carry it backward and to one or the other side. It is concerned especially in the act of sucking, and is also a tensor of the cervical fascia. The Thyro-hyoid may act as an elevator of the thyroid cartilage when the hyoid bone ascends, drawing upward the thyroid cartilage, behind the os hyoides.[1] The Sterno-thyroid acts as a depressor of the thyroid cartilage.

3. Supra-hyoid Region (Figs. 276, 277).

Elevators of the Os Hyoides—Depressors of the Lower Jaw.

Digastric.	Mylo-hyoid.
Stylo-hyoid.	Genio-hyoid.

Dissection.—To dissect these muscles a block should be placed beneath the back of the neck, and the head drawn backward and retained in that position. On the removal of the deep fascia the muscles are at once exposed.

The **Digastric** consists of two fleshy bellies united by an intermediate, rounded tendon. It is a small muscle, situated below the side of the body of the lower jaw, and extending, in a curved form, from the side of the head to the symphysis of the jaw. The *posterior belly*, longer than the anterior, arises from the digastric groove on the inner side of the mastoid process of the temporal bone, and passes downward, forward, and inward. The *anterior belly* arises from a depression on the inner side of the lower border of the jaw, close to the symphysis, and passes downward and backward. The two bellies terminate in the central tendon which perforates the Stylo-hyoid, and is held in connection with the side of the body and the greater cornu of the hyoid bone by a fibrous loop, lined by a synovial membrane. A broad aponeurotic layer is given off from the tendon of the Digastric on each side, which is attached to the body and great cornu of the hyoid bone: this is termed the *supra-hyoid aponeurosis*. It forms a strong layer of fascia between the anterior portion of the two muscles, and a firm investment for the other muscles of the supra-hyoid region which lie deeper.

The Digastric muscle divides the anterior superior triangle of the neck into two smaller triangles; the upper, or *submaxillary*, being bounded, above, by the lower border of the body of the jaw, and a line drawn from its angle to the mastoid process; below, by the posterior belly of the Digastric and the Stylo-hyoid muscles; in front, by the anterior belly of the Digastric, the lower or *superior carotid triangle* being bounded above by the posterior belly of the Digastric, behind by the Sterno-mastoid, below by the Omo-hyoid.

Relations.—By its *superficial surface*, with the Platysma, Sterno-mastoid, part of the Splenius, Trachelo-mastoid, and Stylo-hyoid muscles, and the parotid gland. By its *deep surface*, the anterior belly lies on the Mylo-hyoid; the posterior belly on the Stylo-glossus, Stylo-pharyngeus, and Hyo-glossus muscles, the external carotid artery and its lingual and facial branches, the internal carotid artery, internal jugular vein, and hypoglossal nerve.

The **Stylo-hyoid** is a small, slender muscle, lying in front of, and above, the posterior belly of the Digastric. It arises from the back and outer surface of the styloid process, near the base; and, passing downward and forward, is inserted into the body of the hyoid bone, just at its junction with the greater cornu, and

[1] It is this action of the Thyro-hyoid muscle which, as Dr. Buchanan has pointed out, "causes or permits the folding back of the epiglottis over the upper orifice of the larynx." (*Journ. of Anat. and Phys.* 2d series, No. III. p. 255).

immediately above the Omo-hyoid. This muscle is perforated, near its insertion, by the tendon of the Digastric.

Relations.—The relations are the same as those of the posterior belly of the Digastric.

The Stylo-hyoid Ligament.—In connection with the Stylo-hyoid muscle may be described a ligamentous band, the *Stylo-hyoid ligament*. It is a fibrous cord, often containing a little cartilage in its centre, which continues the styloid process down to the hyoid bone, being attached to the tip of the former and the small cornu of the latter. It is often more or less ossified.

The Digastric and Stylo-hyoid should be removed, in order to expose the next muscle.

The **Mylo-hyoid** is a flat, triangular muscle, situated immediately beneath the anterior belly of the Digastric, and forming, with its fellow of the opposite side, a muscular floor for the cavity of the mouth. It arises from the whole length of the mylo-hyoid ridge, extending from the symphysis in front to the last molar tooth behind. The posterior fibres pass obliquely forward, to be inserted into the body of the os hyoides. The middle and anterior fibres are inserted into a median fibrous raphe, extending from the symphysis of the lower jaw to the hyoid bone, where they join at an angle with the fibres of the opposite muscle. This median raphe is sometimes wanting; the muscular fibres of the two sides are then directly continuous with one another.

Relations.—By its *cutaneous surface*, with the Platysma, the anterior belly of the Digastric, the supra-hyoid aponeurosis, the submaxillary gland, submental vessels, and mylo-hyoid vessels and nerve; by its *deep* or *superior surface*, with the Genio-hyoid, part of the Hyo-glossus, and Stylo-glossus, muscles, the hypoglossal and lingual nerves, the submaxillary ganglion, the sublingual gland, the deep portion of the submaxillary gland and Wharton's duct; the sublingual and ranine vessels, and the buccal mucous membrane.

Dissection.—The Mylo-hyoid should now be removed, in order to expose the muscles which lie beneath: this is effected by detaching it from its attachments to the hyoid bone and jaw, and separating it by a vertical incision from its fellow of the opposite side.

The **Genio-hyoid** is a narrow, slender muscle, situated immediately beneath[1] the inner border of the preceding. It arises from the inferior genial tubercle on the inner side of the symphysis of the jaw, and passes downward and backward, to be inserted into the anterior surface of the body of the os hyoides. This muscle lies in close contact with its fellow of the opposite side, and increases slightly in breadth as it descends.

Relations.—It is covered by the Mylo-hyoid, and lies on the Genio-hyoglossus.

Nerves.—The Digastric is supplied: its anterior belly, by the mylo-hyoid branch of the inferior dental; its posterior belly, by the facial; the Stylo-hyoid, by the facial; the Mylo-hyoid, by the mylo-hyoid branch of the inferior dental; the Genio-hyoid, by the hypoglossal.

Actions.—This group of muscles performs two very important actions. They raise the hyoid bone, and with it the base of the tongue, during the act of deglutition; or, when the hyoid bone is fixed by its depressors and those of the larynx, they depress the lower jaw. During the first act of deglutition, when the mass is being driven from the mouth into the pharynx, the hyoid bone, and with it the tongue, is carried upward and forward by the anterior belly of the Digastric, the Mylo-hyoid, and Genio-hyoid muscles. In the second act, when the mass is passing through the pharynx, the direct elevation of the hyoid bone takes place by the combined action of all the muscles; and after the food has passed the hyoid bone is carried upward and backward by the posterior belly of the Digastric and Stylo-hyoid muscles, which assist in preventing the return of the morsel into the mouth.

[1] This refers to the depth of the muscles from the skin in the order of dissection. In the erect position of the body each of these muscles lies above the preceding.

4. Lingual Region.

Genio-hyo-glossus. Stylo-glossus.
Hyo-glossus. Palato-glossus.
Chondro-glossus.

Dissection.—After completing the dissection of the preceding muscles, saw through the lower jaw just external to the symphysis. Then draw the tongue forward, and attach it, by a stitch, to the nose; when its muscles, which are thus put on the stretch, may be examined.

The **Genio-hyo-glossus** has received its name from its triple attachment to the jaw, hyoid bone, and tongue, but it would be better named the *Genio-glossus*,

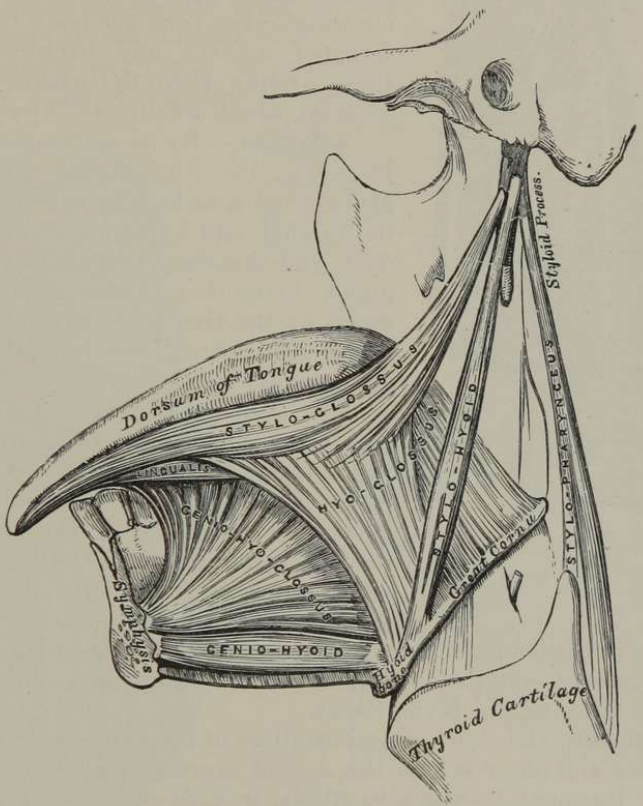

FIG. 278.—Muscles of the tongue. Left side.

since its attachment to the hyoid bone is very slight or altogether absent. It is a flat, triangular muscle, placed vertically on either side of the middle line, its apex corresponding with its point of attachment to the lower jaw, its base with its insertion into the tongue and hyoid bone. It arises by a short tendon from the superior genial tubercle on the inner side of the symphysis of the jaw, immediately above the Genio-hyoid; from this point the muscle spreads out in a fan-like form, a few of the inferior fibres passing downward, to be attached by a thin aponeurosis into the upper part of the body of the hyoid bone; the middle fibres passing backward, and the superior ones upward and forward, to enter the whole length of the under surface of the tongue, from the base to the apex. The two muscles lie on either side of the median plane; behind, they are quite distinct from each other, and are separated at their insertion into the under surface of the tongue by a tendinous raphe, which extends through the middle of the organ; in front, the two muscles are more or less blended: distinct fasciculi are to be seen passing off from one muscle, crossing the middle line, and intersecting with bundles of fibres derived from the muscle on the other side (Fig. 279).

Relations.—By its *internal surface* it is in contact with its fellow of the opposite

side; by its *external surface*, with the Inferior lingualis, the Hyo-glossus, the lingual artery and hypoglossal nerve, the lingual nerve, and sublingual gland; by its *upper border*, with the mucous membrane of the floor of the mouth (frænum linguæ); by its *lower border*, with the Genio-hyoid.

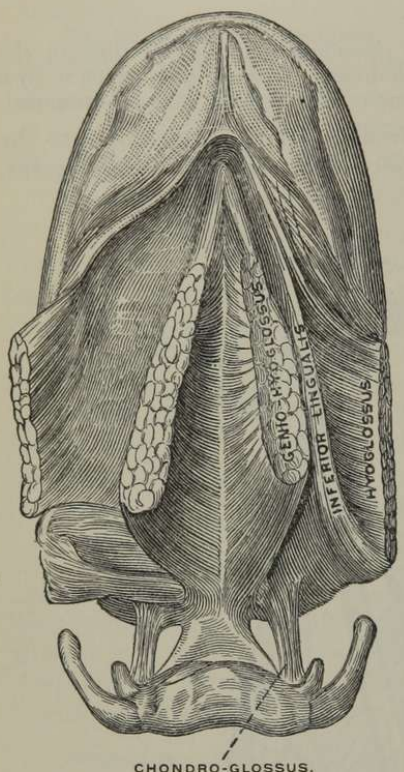

FIG. 279.—Muscles of the tongue from below. (From a preparation in the Museum of the Royal College of Surgeons of England.)

The **Hyo-glossus** is a thin, flat, quadrilateral muscle which arises from the side of the body and whole length of the greater cornu of the hyoid bone, and passes almost vertically upward to enter the side of the tongue, between the Stylo-glossus and Lingualis. Those fibres of this muscle which arise from the body (*basio-glossus*) are directed upward and backward, overlapping those arising from the greater cornu (*kerato-glossus*), which are directed upward and forward.

Relations.—By its *external surface*, with the Digastric, the Stylo-hyoid, Stylo-glossus, and Mylo-hyoid muscles, the submaxillary ganglion, the lingual and hypoglossal nerves, Wharton's duct, and the deep portion of the submaxillary gland; by its *deep surface*, with the Stylo-hyoid ligament, the Genio-hyo-glossus, Lingualis, and Middle constrictor, the lingual vessels, and the glosso-pharyngeal nerve.

The **Chondro-glossus** is a distinct muscular slip, about three-quarters to an inch in length, which arises from the inner side and base of the lesser cornu of the hyoid bone and contiguous portion of the body of the bone, and passes directly upward to blend with the intrinsic muscular fibres of the tongue, between the Hyo-glossus and Genio-hyo-glossus. A small slip of muscular fibre is occasionally found, arising from the cartilago triticea in the thyro-hyoid ligament, and passing upward and forward to enter the tongue with the hindermost fibres of the Hyo-glossus.

The **Stylo-glossus**, the shortest and smallest of the three styloid muscles, arises from the anterior and outer side of the styloid process, near its apex, and from the stylo-maxillary ligament, to which its fibres, in most cases, are attached by a thin aponeurosis. Passing downward and forward between the internal and external carotid arteries, and becoming nearly horizontal in its direction, it divides upon the side of the tongue into two portions: one longitudinal, which enters the side of the tongue near its dorsal surface, blending with the fibres of the Lingualis in front of the Hyo-glossus; the other oblique, which overlaps the Hyo-glossus muscle and decussates with its fibres.

Relations.—By its *external surface*, from above downward, with the parotid gland, the Internal pterygoid muscle, the lingual nerve, and the mucous membrane of the mouth; by its *internal surface*, with the tonsil, the Superior constrictor, and the Hyo-glossus muscle.

The **Palato-glossus**, or **Constrictor isthmi faucium**, although it is one of the muscles of the tongue, serving to draw its base upward during the act of deglutition, is more nearly associated with the soft palate, both in its situation and function; it will consequently be described with that group of muscles.

Nerves.—The Palato-glossus is probably innervated by the spinal accessory nerve, through the pharyngeal plexus; the Inferior lingualis, according to some authors, by the chorda tympani; the remaining muscles of this group, by the hypoglossal.

Muscular Substance of Tongue.—The muscular fibres of the tongue run in various directions. These fibres are divided into two sets—Extrinsic and Intrinsic.

The extrinsic muscles of the tongue are those which have their origin external, and only their terminal fibres contained in the substance of the organ. They are: the Stylo-glossus, the Hyo-glossus, the Palato-glossus, the Genio-hyo-glossus, and part of the Superior constrictor of the pharynx (Pharyngeo-glossus). The intrinsic are those which are contained entirely within the tongue, and form the greater part of its muscular structure.

The tongue consists of symmetrical halves separated from each other in the middle line by a fibrous septum. Each half is composed of muscular fibres arranged in various directions, containing much interposed fat and supplied by vessels and nerves.

To demonstrate the various fibres of the tongue, the organ should be subjected to prolonged boiling, in order to soften the connective tissue; the dissection may then be commenced from the dorsum (Fig. 280). Immediately beneath the mucous membrane is a submucous, fibrous layer, into which the muscular fibres which terminate on the surface of the tongue are inserted. Upon removing this, with the mucous membrane, the first stratum of muscular fibres is exposed. This belongs to the group of intrinsic muscles, and has been named the *Superior lingualis*. It consists of a thin layer of

Cut edge of Superficial lingualis.

FIG. 280.—Muscles on the dorsum of the tongue.

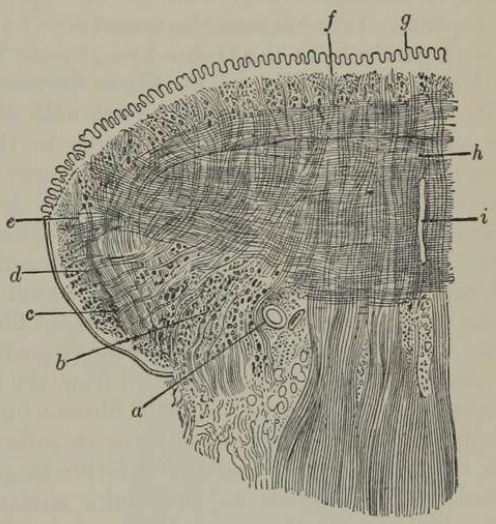

FIG. 281.—Coronal section of tongue. Showing intrinsic muscles. (Altered from Krause.) *a*, lingual artery; *b*, Inferior lingualis, cut through; *c*, fibres of Hyo-glossus; *d*, oblique fibres of Stylo-glossus; *e*, insertion of Transverse lingualis; *f*, Superior lingualis; *g*, papillæ to tongue; *h*, vertical fibres of Genio-hyo-glossus intersecting Transverse lingualis; *i*, septum.

oblique and longitudinal fibres which arise from the submucous fibrous layer, close to the Epiglottis, and from the fibrous septum, and pass forward and outward to the edges of the tongue. Between its fibres pass some vertical fibres derived from the Genio-hyo-glossus and from the vertical intrinsic muscle, which will be described later on. Beneath this layer is the second stratum of muscular fibres, derived principally from the extrinsic muscles. In front it is formed by the fibres derived from the Stylo-glossus, running along the side of the tongue, and sending one set of fibres over the dorsum which runs obliquely forward and inward to the middle line, and another set of fibres, seen at a later period of the dissection, on to the under surface of the sides of the anterior part of the tongue, which run forward and inward, between the fibres of the Hyo-glossus, to the middle line. Behind this layer of fibres, derived from the Stylo-glossus, are fibres derived from the Hyo-glossus, assisted by some few fibres of the Palato-glossus. The Hyo-glossus, entering the side of the under surface of the tongue, between the Stylo-glossus and Inferior lin-

gualis, passes round its margin and spreads out into a layer on the dorsum, which occupies the middle third of the organ, and runs almost transversely inward to the septum. It is reinforced by some fibres from the Palato-glossus; other fibres of this muscle pass more deeply and intermingle with the next layer. The posterior part of the second layer of the muscular fibres of the tongue is derived from those fibres of the Hyo-glossus which arise from the lesser cornu of the hyoid bone, and are here described as a separate muscle—the Chondro-glossus. The fibres of this muscle are arranged in a fan-shaped manner, and spread out over the posterior third of the tongue. Beneath this layer is the great mass of the intrinsic muscles of the tongue, intersected at right angles by the terminal fibres of one of the extrinsic muscles—the Genio-hyo-glossus. This portion of the tongue is paler in color and softer in texture than that already described, and is sometimes designated the medullary portion in contradistinction to the firmer superficial part, which is termed the cortical portion. It consists largely of transverse fibres, the *Transverse lingualis*, and of vertical fibres, the *Vertical lingualis*. The Transverse lingualis forms the largest portion of the third layer of muscular fibres of the tongue. The fibres arise from the median septum, and pass outward to be inserted into the submucous fibrous layer at the sides of the tongue. Intermingled with these transverse intrinsic fibres are transverse extrinsic fibres derived from the Palato-glossus and the Superior constrictor of the pharynx. These transverse extrinsic fibres, however, run in the opposite direction, passing inward, toward the septum. Intersecting the transverse fibres are a large number of vertical fibres derived partly from the Genio-hyo-glossus and partly from vertical intrinsic fibres, the Vertical lingualis. The fibres derived from the Genio-hyo-glossus enter the under surface of the tongue on each side of the median septum from base to apex. They ascend in a radiating manner to the dorsum, being inserted into the submucous fibrous layer covering the tongue on each side of the middle line. The Vertical lingualis is found only at the borders of the fore part of the tongue, external to the fibres of the Genio-hyo-glossus. Its fibres extend from the upper to the under surface of the tongue, decussating with the fibres of the other muscles, and especially with the Transverse lingualis. The fourth layer of muscular fibres of the tongue consists partly of extrinsic fibres derived from the Stylo-glossus, and partly of intrinsic fibres, the *Inferior lingualis*. At the sides of the under surface of the tongue are some fibres derived from the Stylo-glossus, which, as it runs forward at the side of the tongue, gives off fibres which, passing forward and inward between the fibres of the Hyo-glossus, form an inferior oblique stratum which joins in front with the anterior fibres of the Inferior lingualis. The Inferior lingualis is a longitudinal band, situated on the under surface of the tongue, lying in the interval between the Stylo-glossus, in front of the Hyo-glossus, and the Genio-hyo-glossus, and extending from the base to the apex of the organ. Posteriorly, some of the fibres are lost in the base of the tongue, and others are occasionally attached to the hyoid bone. It blends with the fibres of the Hyo-glossus, and is continued forward as far as the apex of the tongue. It is in relation by its under surface with the ranine artery.

Surgical Anatomy.—The fibrous septum which exists between the two halves of the tongue is very complete, so that the anastomosis between the two lingual arteries is not very free, a fact often illustrated by injecting one-half of the tongue with colored size, while the other half is left uninjected or is injected with size of a different color.

This is a point of considerable importance in connection with removal of one-half of the tongue for cancer, an operation which is now frequently resorted to when the disease is strictly confined to one side of the tongue. If the mucous membrane is divided longitudinally exactly in the middle line, the tongue can be split into halves along the median raphe without any appreciable hæmorrhage, and the diseased half can then be removed.

Actions.—The movements of the tongue, although numerous and complicated, may be understood by carefully considering the direction of the fibres of its muscles. The *Genio-hyo-glossi* muscles, by means of their posterior fibres, draw the base of the tongue forward, so as to protrude the apex from the mouth. The anterior fibres draw the tongue back into the mouth. The whole length of these

two muscles, acting along the middle line of the tongue, draw it downward, so as to make it concave from side to side, forming a channel along which fluids may pass toward the pharynx, as in sucking. The *Hyo-glossi* muscles depress the tongue and draw down its sides, so as to render it convex from side to side. The *Stylo-glossi* muscles draw the tongue upward and backward. The *Palato-glossi* muscles draw the base of the tongue upward. With regard to the intrinsic muscles, both the Superior and Inferior linguales tend to shorten the tongue, but the former, in addition, turn the tip and sides upward so as to render the dorsum concave, while the latter pull the tip downward and cause the dorsum to become convex. The Transverse lingualis narrows and elongates the tongue, and the Vertical lingualis flattens and broadens it. The complex arrangement of the muscular fibres of the tongue, and the various directions in which they run, give to this organ the power of assuming the various forms necessary for the enunciation of the different consonantal sounds; and Dr. Macalister states that "there is reason to believe that the musculature of the tongue varies in different races owing to the hereditary practice and habitual use of certain motions required for enunciating the several vernacular languages."

5. Pharyngeal Region.

Inferior constrictor.
Middle constrictor.
Palato-pharyngeus. } (See next section.)
Salpingo-pharyngeus. }
Superior constrictor.
Stylo-pharyngeus.

Dissection (Fig. 282).—In order to examine the muscles of the pharynx, cut through the trachea and œsophagus just above the sternum, and draw them upward by dividing the loose areolar tissue connecting the pharynx with the front of the vertebral column. The parts being drawn well forward, apply the edge of the saw immediately behind the styloid processes, and saw the base of the skull through from below upward. The pharynx and mouth should then be stuffed with tow, in order to distend its cavity and render the muscles tense and easier of dissection.

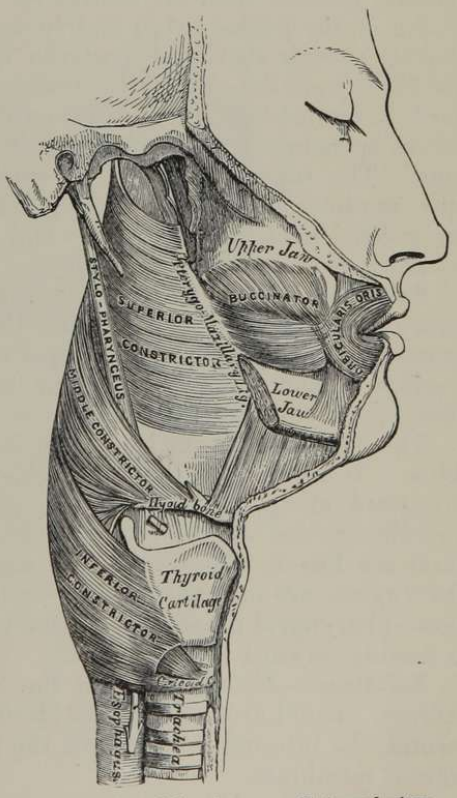

FIG. 282.—Muscles of the pharynx. External view.

The **Inferior constrictor,** the most superficial and thickest of the three constrictors, arises from the sides of the cricoid and thyroid cartilages. To the cricoid cartilage it is attached in the interval between the Crico-thyroid muscle in front and the articular facet for the thyroid cartilage behind. To the thyroid cartilage it is attached to the oblique line on the side of the great ala, the cartilaginous surface behind it, nearly as far as its posterior border, and to the inferior cornu. From these attachments the fibres spread backward and inward, to be inserted into the fibrous raphe in the posterior median line of the pharynx. The inferior fibres are horizontal, and continuous with the fibres of the œsophagus: the rest ascend, increasing in obliquity, and overlap the Middle constrictor. The superior laryngeal nerve and artery pass near the upper border, and the inferior, or recurrent laryngeal, beneath the lower border of this muscle, previous to their entering the larynx.

Relations.—It is covered by a dense cellular membrane which surrounds the

entire pharynx. *Behind*, it is in relation with the vertebral column and the Longus colli muscle; *laterally*, with the thyroid gland, the common carotid artery, and the Sterno-thyroid muscle; by its *internal surface*, with the Middle constrictor, the Stylo-pharyngeus, Palato-pharyngeus, the fibrous coat and mucous membrane of the pharynx.

The **Middle constrictor** is a flattened, fan-shaped muscle, smaller than the preceding. It arises from the whole length of the upper surface of the greater cornu of the hyoid bone, from the lesser cornu, and from the stylo-hyoid ligament. The fibres diverge from their origin, the lower ones descending beneath the Inferior constrictor, the middle fibres passing transversely, and the upper fibres ascending and overlapping the Superior constrictor. The muscle is inserted into the posterior median fibrous raphe, blending in the middle line with the one of the opposite side.

Relations.—This muscle is separated from the Superior constrictor by the glosso-pharyngeal nerve and the Stylo-pharyngeus muscle, and from the Inferior constrictor by the superior laryngeal nerve. *Behind*, it lies on the vertebral column, the Longus colli, and the Rectus capitis anticus major. *On each side* it is in relation with the carotid vessels, the pharyngeal plexus, and some lymphatic glands. Near its origin it is covered by the Hyo-glossus, from which it is separated by the lingual vessels. It lies upon the Superior constrictor, the Stylo-pharyngeus, the Palato-pharyngeus, the fibrous coat, and the mucous membrane of the pharynx.

The **Superior Constrictor** is a quadrilateral muscle, thinner and paler than the other constrictors, and situated at the upper part of the pharynx. It arises from the lower third of the posterior margin of the internal pterygoid plate and its hamular process, from the contiguous portion of the palate bone and the reflected tendon of the Tensor palati muscle, from the pterygo-maxillary ligament, from the alveolar process above the posterior extremity of the mylo-hyoid ridge, and by a few fibres from the side of the tongue. From these points the fibres curve backward, to be inserted into the median raphe, being also prolonged by means of a fibrous aponeurosis to the pharyngeal spine on the basilar process of the occipital bone. The superior fibres arch beneath the Levator palati and the Eustachian tube, the interval between the upper border of the muscle and the basilar process being deficient in muscular fibres and closed by fibrous membrane. This interval is known as the *sinus of Morgagni*.

Relations.—By its *outer surface*, with the vertebral column, the internal carotid artery, the internal jugular vein, the glosso-pharyngeal, pneumogastric, spinal accessory, hypoglossal, and sympathetic nerves, the Middle constrictor, which overlaps it, and the Stylo-pharyngeus; by its *internal surface*, with the Palato-pharyngeus, the tonsil, the fibrous coat and mucous membrane of the pharynx.

The **Stylo-pharyngeus** is a long, slender muscle, round above, broad and thin below. It arises from the inner side of the base of the styloid process, passes downward along the side of the pharynx between the Superior and Middle constrictors, and spreads out beneath the mucous membrane, where some of its fibres are lost in the Constrictor muscles; and others, joining with the Palato-pharyngeus, are inserted into the posterior border of the thyroid cartilage. The glosso-pharyngeal nerve runs on the outer side of this muscle, and crosses over it in passing forward to the tongue.

Relations.—*Externally*, with the Stylo-glossus muscle, the parotid gland, the external carotid artery, and the Middle constrictor; *internally*, with the internal carotid, the internal jugular vein, the Superior constrictor, Palato-pharyngeus, and mucous membrane.

Nerves.—The Constrictors are supplied by branches from the pharyngeal plexus, the Stylo-pharyngeus by the glosso-pharyngeal nerve, and the Inferior constrictor by an additional branch from the external laryngeal nerve and by the recurrent laryngeal.

Actions.—When deglutition is about to be performed, the pharynx is drawn

upward and dilated in different directions, to receive the morsel propelled into it from the mouth. The Stylo-pharyngei, which are much farther removed from one another at their origin than at their insertion, draw the sides of the pharynx upward and outward, and so increase its transverse diameter, its breadth in the antero-posterior direction being increased by the larynx and tongue being carried forward in their ascent. As soon as the morsel is received in the pharynx, the Elevator muscles relax, the bag descends, and the Constrictors contract upon the morsel, and convey it gradually downward into the œsophagus. Besides its action in deglutition, the pharynx also exerts an important influence in the modulation of the voice, especially in the production of the higher tones.

6. Palatal Region.

Levator palati.	Palato-glossus.
Tensor palati.	Palato-pharyngeus.
Azygos uvulæ.	Salpingo-pharyngeus.

Dissection (Fig. 283).—Lay open the pharynx from behind by a vertical incision extending from its upper to its lower part, and partially divide the occipital attachment by a transverse incision on each side of the vertical one; the posterior surface of the soft palate is then exposed. Having fixed the uvula so as to make it tense, the mucous membrane and glands should be carefully removed from the posterior surface of the soft palate, and the muscles of this part are at once exposed.

The **Levator palati** is a long, thick, rounded muscle, placed on the outer side

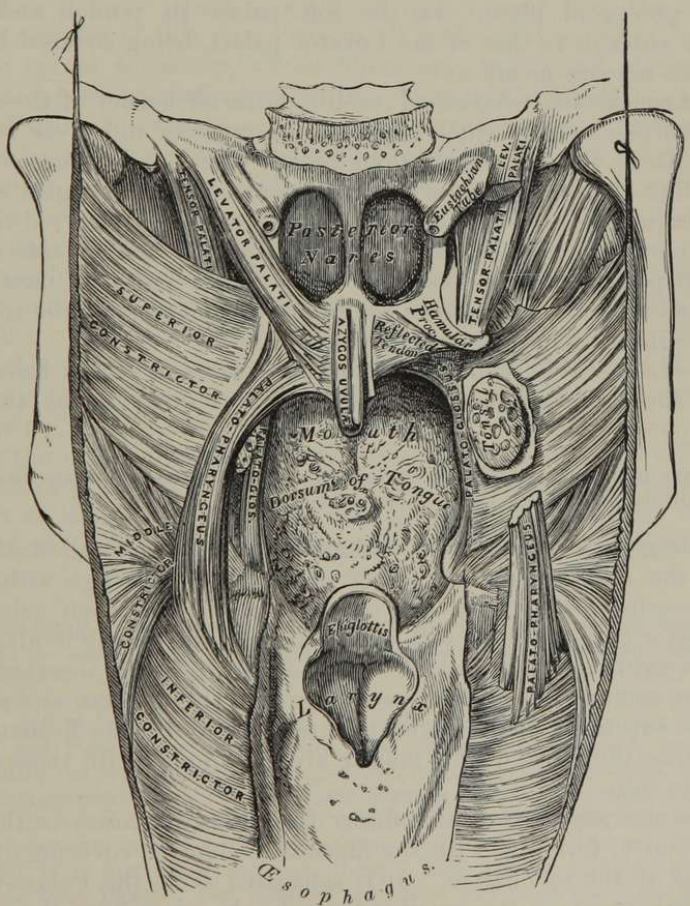

FIG. 283.—Muscles of the soft palate, the pharynx being laid open from behind.

of the posterior nares. It arises from the under surface of the apex of the petrous portion of the temporal bone, and from the adjoining cartilaginous portion of the Eustachian tube; after passing into the pharynx, above the upper concave margin

of the Superior constrictor, it passes obliquely downward and inward, its fibres spreading out in the soft palate as far as the middle line, where they blend with those of the opposite side.

Relations.—*Externally*, with the Tensor palati and Superior constrictor; *internally*, with the mucous membrane of the pharynx; *posteriorly*, with the posterior fasciculus of the Palato-pharyngeus, the Azygos uvulæ, and the mucous lining of the soft palate.

The **Circumflexus** or **Tensor palati** is a broad, thin, ribbon-like muscle, placed on the outer side of the Levator palati, and consisting of a vertical and a horizontal portion. The vertical portion arises by a broad, thin, and flat lamella from the scaphoid fossa at the base of the internal pterygoid plate; from the spine of the sphenoid; the vaginal process of the temporal bone and the anterior aspect of the cartilaginous portion of the Eustachian tube: descending vertically between the internal pterygoid plate and the inner surface of the Internal pterygoid muscle, it terminates in a tendon, which winds round the hamular process, being retained in this situation by some of the fibres of origin of the Internal pterygoid muscle, and lubricated by a bursa. The tendon or horizontal portion then passes horizontally inward, and is inserted into a broad aponeurosis, the *palatine aponeurosis*, and into the transverse ridge on the horizontal portion of the palate bone.

Relations.—*Externally*, with the Internal pterygoid; *internally*, with the Levator palati, from which it is separated by the Superior constrictor, and with the internal pterygoid plate. In the soft palate its tendon and the palatine aponeurosis is anterior to that of the Levator palati, being covered by the Palato-glossus and the mucous membrane.

Palatine Aponeurosis.—Attached to the posterior border of the hard palate is a thin, firm, fibrous lamella which supports the muscles and gives strength to the soft palate. It is thicker above than below, where it becomes very thin and difficult to define. Laterally, it is continuous with the pharyngeal aponeurosis.

The **Azygos uvulæ** is not a single muscle, as would be inferred from its name, but a pair of narrow cylindrical fleshy fasciculi placed side by side in the median line of the soft palate. Each muscle arises from the posterior nasal spine of the palate bone and from the contiguous tendinous aponeurosis of the soft palate, and descends to be inserted into the uvula.

Relations.—*Anteriorly*, with the tendinous expansion of the Levatores palati; *behind*, with the posterior fasciculus of the Palato-pharyngeus and the mucous membrane.

The two next muscles are exposed by removing the mucous membrane from the pillars of the soft palate throughout nearly their whole extent.

The **Palato-glossus** (**Constrictor isthmi faucium**) is a small fleshy fasciculus, narrower in the middle than at either extremity, forming, with the mucous membrane covering its surface, the anterior pillar of the soft palate. It arises from the anterior surface of the soft palate on each side of the uvula, and, passing downward, forward, and outward in front of the tonsil, is inserted into the side of the tongue, some of its fibres spreading over the dorsum, and others passing deeply into the substance of the organ to intermingle with the Transversus linguæ. In the soft palate the fibres of this muscle are continuous with those of the muscle of the opposite side.

The **Palato-pharyngeus** is a long, fleshy fasciculus, narrower in the middle than at either extremity, forming, with the mucous membrane covering its surface, the posterior pillar of the soft palate. It is separated from the Palato-glossus by an angular interval, in which the tonsil is lodged. It arises from the soft palate by an expanded fasciculus, which is divided into two parts by the Levator palati and Azygos uvulæ. The *posterior fasciculus* lies in contact with the mucous membrane, and also joins with the corresponding muscle in the middle line; the *anterior fasciculus*, the thicker, lies in the soft palate between the Levator and Tensor, and

joins in the middle line the corresponding part of the opposite muscle. Passing outward and downward behind the tonsil, the Palato-pharyngeus joins the Stylo-pharyngeus, and is inserted with that muscle into the posterior border of the thyroid cartilage, some of its fibres being lost on the side of the pharynx, and others passing across the middle line posteriorly to decussate with the muscle of the opposite side.

The Salpingo-pharyngeus.—This muscle arises from the inferior part of the Eustachian tube near its orifice; it passes downward and blends with the posterior fasciculus of the Palato-pharyngeus.

Relations.—In the soft palate its *posterior surface* is covered by mucous membrane, from which it is separated by a layer of palatine glands. By its *anterior surface* it is in relation with the Tensor palati. Where it forms the posterior pillar of the fauces it is covered by mucous membrane, excepting on its outer surface. In the *pharynx* it lies between the mucous membrane and the Constrictor muscles.

In a dissection of the soft palate from its posterior or nasal surface to its anterior or oral surface, the muscles would be exposed in the following order: viz. the posterior fasciculus of the Palato-pharyngeus, covered over by the mucous membrane reflected from the floor of the nasal fossæ; the Azygos uvulæ; the Levator palati; the anterior fasciculus of the Palato-pharyngeus; the aponeurosis of the Tensor palati, and the Palato-glossus covered over by a reflection from the oral mucous membrane.

Nerves.—The Tensor palati is supplied by a branch from the otic ganglion; the remaining muscles of this group are in all probability supplied by the internal branch of the spinal accessory, whose fibres are distributed along with certain branches of the pneumogastric through the pharyngeal plexus.[1]

Actions.—During the *first stage* of deglutition the morsel of food is driven back into the fauces by the pressure of the tongue against the hard palate, the base of the tongue being, at the same time, retracted, and the larynx raised with the pharynx, and carried forward under it. During the *second stage* the epiglottis is pressed over the superior aperture of the larynx, and the morsel glides past it; then the Palato-glossi muscles, the constrictors of the fauces, contract behind the food; the soft palate is slightly raised by the Levator palati, and made tense by the Tensor palati; and the Palato-pharyngei, by their contraction, pull the pharynx upward over the morsel of food, and at the same time come nearly together, the uvula filling up the slight interval between them. By these means the food is prevented passing into the upper part of the pharynx or the posterior nares; at the same time the latter muscles form an inclined plane, directed obliquely downward and backward, along the under surface of which the morsel descends into the lower part of the pharynx. The Salpingo-pharyngeus raises the upper and lateral part of the pharynx—*i. e.* that part which is above the point where the Stylo-pharyngeus is attached to the pharynx.

Surgical Anatomy.—The muscles of the soft palate should be carefully dissected, the relations they bear to the surrounding parts especially examined, and their action attentively studied upon the dead subject, as the surgeon is required to divide one or more of these muscles in the operation of staphylorraphy. Sir W. Fergusson was the first to show that in the congenital deficiency called *cleft palate* the edges of the fissure are forcibly separated by the action of the Levatores palati and Palato-pharyngei muscles, producing very considerable impediment to the healing process after the performance of the operation for uniting their margins by adhesion; he, consequently, recommended the division of these muscles as one of the most important steps in the operation. This he effected by an incision made with a curved knife introduced behind the soft palate. The incision is to be halfway between the hamular process and Eustachian tube, and perpendicular to a line drawn between them. This incision perfectly accomplishes the division of the Levator palati. The Palato-pharyngeus may be divided by cutting across the posterior pillar of the soft palate, just below the tonsil, with a pair of blunt-pointed curved scissors; and the anterior pillar may be divided also. To divide the Levator palati the plan recommended by Mr. Pollock is to be greatly preferred. The soft palate being put upon the stretch, a double-edged knife is passed through it just on the inner side of the hamular process

[1] *Journal of Anatomy and Physiology*, vol. xxiii. p. 523.

and above the line of the Levator palati. The handle being now alternately raised and depressed, a sweeping cut is made along the posterior surface of the soft palate, and the knife withdrawn, leaving only a small opening in the mucous membrane on the anterior surface. If this operation is performed on the dead body and the parts afterward dissected, the Levator palati will be found completely divided. In the present day, however, this division of the muscles, as part of the operation of staphylorraphy, is not so much insisted upon. All tension is prevented by making longitudinal incisions on either side, parallel to the cleft and just internal to the hamular process, in such a position as to avoid the posterior palatine artery.

7. Anterior Vertebral Region.

Rectus capitis anticus major.
Rectus capitis anticus minor.
Rectus capitis lateralis.
Longus colli.

The **Rectus capitis anticus major** (Fig. 284), broad and thick above, narrow below, appears like a continuation upward of the Scalenus anticus. It arises by

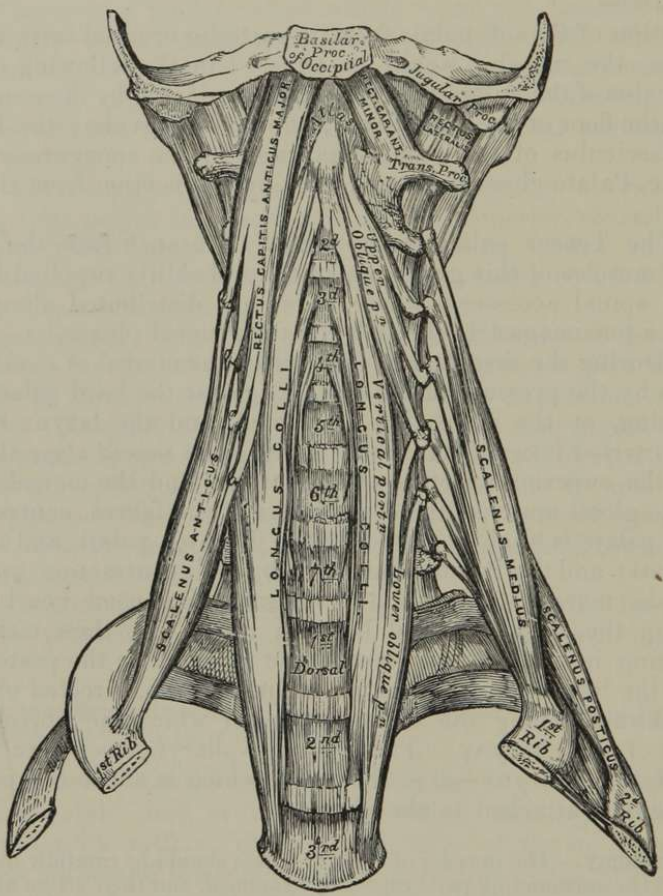

FIG. 284.—The prevertebral muscles.

four tendinous slips from the anterior tubercles of the transverse processes of the third, fourth, fifth, and sixth cervical vertebræ, and ascends, converging toward its fellow of the opposite side, to be inserted into the basilar process of the occipital bone.

Relations.—By its *anterior surface*, with the pharynx, the sympathetic nerve, and the sheath enclosing the internal and common carotid artery, internal jugular vein, and pneumogastric nerve; by its *posterior surface*, with the Longus colli, the Rectus capitis anticus minor, and the upper cervical vertebræ.

The **Rectus capitis anticus minor** is a short, flat muscle, situated immediately behind the upper part of the preceding. It arises from the anterior surface of the lateral mass of the atlas and from the root of its transverse process, and, passing

obliquely upward and inward, is inserted into the basilar process immediately behind the preceding muscle.

Relations.—By its *anterior surface*, with the Rectus capitis anticus major; by its *posterior surface*, with the front of the occipito-atlantal articulation.

The **Rectus capitis lateralis** is a short, flat muscle, which arises from the upper surface of the transverse process of the atlas, and is inserted into the under surface of the jugular process of the occipital bone.

Relations.—By its *anterior surface*, with the internal jugular vein; by its *posterior surface*, with the vertebral artery. On its *outer side* lies the occipital artery; on its *inner side*, the suboccipital nerve.

The **Longus colli** is a long, flat muscle, situated on the anterior surface of the spine, between the atlas and the third dorsal vertebra. It is broad in the middle, narrow and pointed at each extremity, and consists of three portions: a superior oblique, an inferior oblique, and a vertical portion. The *superior oblique portion* arises from the anterior tubercles of the transverse processes of the third, fourth, and fifth cervical vertebræ, and, ascending obliquely inward, is inserted by a narrow tendon into the tubercle on the anterior arch of the atlas. The *inferior oblique portion*, the smallest part of the muscle, arises from the front of the bodies of the first two or three dorsal vertebræ, and, ascending obliquely outward, is inserted into the anterior tubercles of the transverse processes of the fifth and sixth cervical vertebræ. The *vertical portion* lies directly on the front of the spine; it arises, below, from the front of the bodies of the upper three dorsal and lower three cervical vertebræ, and is inserted above into the front of the bodies of the second, third, and fourth cervical vertebræ above.

Relations.—By its *anterior surface*, with the pharynx, the œsophagus, sympathetic nerve, the sheath of the great vessels of the neck, the inferior thyroid artery, and recurrent laryngeal nerve; by its *posterior surface*, with the cervical and dorsal portions of the spine. Its *inner border* is separated from the opposite muscle by a considerable interval below, but they approach each other above.

8. Lateral Vertebral Region.

Scalenus anticus. Scalenus medius.
Scalenus posticus.

The **Scalenus anticus** is a conical-shaped muscle, situated deeply at the side of the neck, behind the Sterno-mastoid. It arises from the anterior tubercles of the transverse processes of the third, fourth, fifth, and sixth cervical vertebræ, and, descending almost vertically, is inserted by a narrow, flat tendon into the impression on the inner border and upper surface of the first rib. The lower part of this muscle separates the subclavian artery and vein, the latter being in front, and the former, with the brachial plexus, behind.

Relations.—*In front*, with the clavicle, the Subclavius, Sterno-mastoid, and Omo-hyoid muscles, the transversalis colli, the suprascapular and ascending cervical arteries, the subclavian vein, and the phrenic nerve; by its *posterior surface*, with the Scalenus medius, pleura, the subclavian artery, and brachial plexus of nerves. It is separated from the Longus colli, on the inner side, by the vertebral artery. On the anterior tubercles of the transverse processes of the cervical vertebræ, between the attachments of the Scalenus anticus and Longus colli, lies the ascending cervical branch of the inferior thyroid artery.

The **Scalenus medius**, the largest and longest of the three Scaleni, arises from the posterior tubercles of the transverse processes of the lower six cervical vertebræ, and, descending along the side of the vertebral column, is inserted by a broad attachment into the upper surface of the first rib, behind the groove for the subclavian artery, as far back as the tubercle. It is separated from the Scalenus anticus by a subclavian artery below and the cervical nerves above. The posterior thoracic, or nerve of Bell, is formed in the substance of the Scalenus medius and emerges from it.

Relations.—By its *anterior surface*, with the Sterno-mastoid; it is crossed by the clavicle, the Omo-hyoid muscle, subclavian artery, and the cervical nerves. To its *outer side* is the Levator anguli scapulæ and the Scalenus posticus muscle.

The **Scalenus posticus**, the smallest of the three Scaleni, arises, by two or three separate tendons, from the posterior tubercles of the transverse processes of the lower two or three cervical vertebræ, and, diminishing as it descends, is inserted by a thin tendon into the outer surface of the second rib, behind the attachment of the Serratus magnus. This is the most deeply placed of the three Scaleni, and is occasionally blended with the Scalenus medius.

Nerves.—The Rectus capitis anticus major and minor and the Rectus lateralis are supplied by the first cervical nerve, and from the loop formed between it and

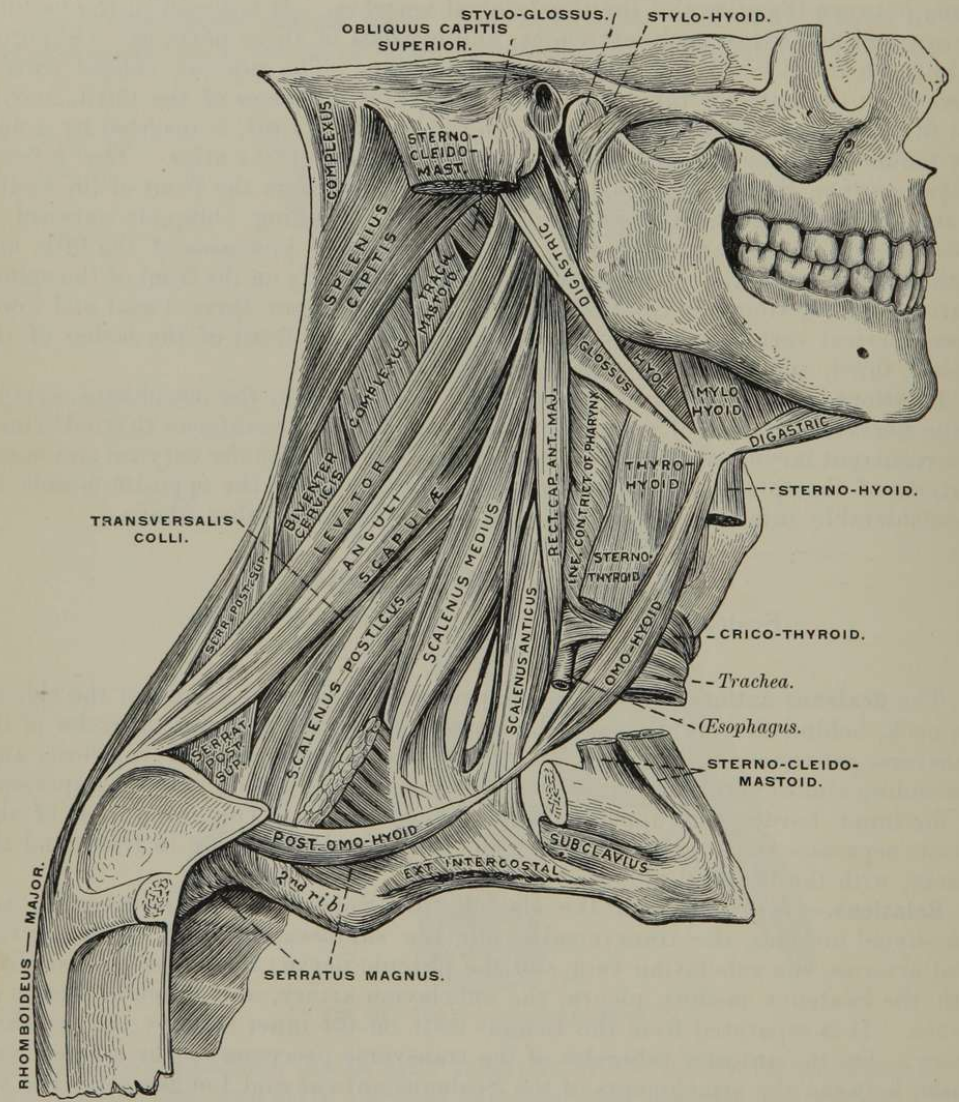

FIG. 285.—Muscles of the neck. (From a preparation in the Museum of the Royal College of Surgeons of England.)

the second; the Longus colli and Scaleni, by branches from the anterior divisions of the lower cervical nerves (fifth, sixth, seventh, and eighth) before they form the brachial plexus. The Scalenus medius also receives a filament from the deep external branches of the cervical plexus.

Actions.—The Rectus anticus major and minor are the direct antagonists of the muscles at the back of the neck, serving to restore the head to its natural position after it has been drawn backward. These muscles also serve to flex the head, and,

from their obliquity, rotate it, so as to turn the face to one or the other side. The Longus colli flexes and slightly rotates the cervical portion of the spine. The Scaleni muscles, when they take their fixed point from above, elevate the first and second ribs, and are, therefore, inspiratory muscles. When they take their fixed point from below, they bend the spinal column to one or the other side. If the muscles of both sides act, lateral movement is prevented, but the spine is slightly flexed. The Rectus lateralis, acting on one side, bends the head laterally.

Surface Form.—The muscles in the neck, with the exception of the Platysma myoides, are invested by the deep cervical fascia, which softens down their form, and is of considerable importance in connection with deep cervical abscesses and tumors, modifying the direction of their growth and causing them to extend laterally instead of toward the surface. The *Platysma myoides* does not influence surface form except it is in action, when it produces wrinkling of the skin of the neck, which is thrown into oblique ridges parallel with the fasciculi of the muscle. Sometimes this contraction takes place suddenly and repeatedly as a sort of spasmodic twitching, the result of a nervous habit. The *Sterno-cleido-mastoid* is the most important muscle of the neck as regards its surface form. If the muscle is put into action by drawing the chin downward and to the opposite shoulder, its surface form will be plainly outlined. The sternal origin will stand out as a sharply-defined ridge, while the clavicular origin will present a flatter and not so prominent an outline. The fleshy middle portion will appear as an oblique roll or elevation, with a thick rounded anterior border gradually becoming less marked above. On the opposite side—*i. e.* on the side to which the head is turned—the outline is lost, its place being occupied by an oblique groove in the integument. When the muscle is at rest its anterior border is still visible, forming an oblique rounded ridge, terminating below in the sharp outline of the sternal head. The posterior border of the muscle does not show above the clavicular head. The anterior border is defined by drawing a line from the tip of the mastoid process to the sterno-clavicular joint. It is an important surface-marking in the operation of ligature of the common carotid artery and some other operations. Between the sternal and clavicular heads is a slight depression, most marked when the muscle is in action. This is bounded below by the prominent sternal extremity of the clavicle. Between the sternal origins of the two muscles is a V-shaped space, the *suprasternal notch*, more pronounced below, and becoming toned down above, where the Sterno-hyoid and Sterno-thyroid muscles, lying upon the trachea, become more prominent. Above the hyoid bone, in the middle line, the anterior belly of the *Digastric* to a certain extent influences surface form. It corresponds to a line drawn from the symphysis of the lower jaw to the side of the body of the hyoid bone, and renders this part of the hyo-mental region convex. In the posterior triangle of the neck, the posterior belly of the *Omo-hyoid*, when in action, forms a conspicuous object, especially in thin necks, presenting a cord-like form running across this region, almost parallel with, and a little above, the clavicle.

MUSCLES AND FASCIÆ OF THE TRUNK.

The muscles of the Trunk may be arranged in four groups : the muscles of the Back, of the Thorax, of the Abdomen, and of the Perinæum.

THE BACK.

The muscles of the Back are very numerous, and may be subdivided into five layers.

First Layer.

Trapezius.
Latissimus dorsi.

Second Layer.

Levator anguli scapulæ.
Rhomboideus minor.
Rhomboideus major.

Third Layer.

Serratus posticus superior.
Serratus posticus inferior.
Splenius capitis.
Splenius colli.

Fourth Layer.

Sacral and Lumbar Regions.

Erector spinæ.

Dorsal Region.

Ilio-costalis.
Musculus accessorius ad ilio-costalem.
Longissimus dorsi.
Spinalis dorsi.

Cervical Region.

Cervicalis ascendens.
Transversalis colli.

Trachelo-mastoid.
Complexus.
Biventer cervicis.
Spinalis colli.

Fifth Layer.

Semispinalis dorsi.
Semispinalis colli.
Multifidus spinæ.
Rotatores spinæ.
Supraspinales.
Interspinales.
Extensor coccygis.
Intertransversales.
Rectus capitis posticus major.
Rectus capitis posticus minor.
Obliquus capitis superior.
Obliquus capitis inferior.

First Layer.

Trapezius. Latissimus dorsi.

Dissection (Fig. 286).—Place the body in a prone position, with the arms extended over the sides of the table, and the chest and abdomen supported by several blocks, so as to render the muscles tense. Then make an incision along the middle line of the back from the occipital protuberance to the coccyx. Make a transverse incision from the upper end of this to the mastoid process, and a third incision from its lower end, along the crest of the ilium to about its middle. This large intervening space should, for convenience of dissection, be subdivided by a fourth incision, extending obliquely from the spinous process of the last dorsal vertebra, upward and outward, to the acromion process. This incision corresponds with the lower border of the Trapezius muscle. The flaps of integument are then to be removed in the direction shown in the figure.

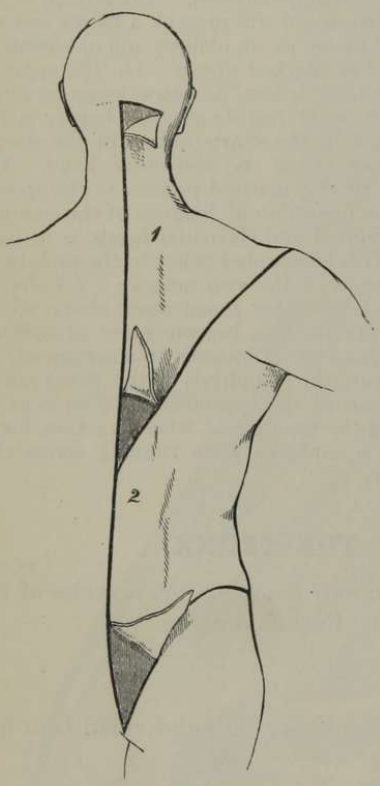

Fig. 286.—Dissection of the muscles of the back.

The **superficial fascia** is exposed upon removing the skin from the back. It forms a layer of considerable thickness and strength, in which a quantity of granular pinkish fat is contained. It is continuous with the superficial fascia in other parts of the body. The **deep fascia** is a dense fibrous layer attached to the occipital bone, the spines of the vertebræ, the crest of the ilium, and the spine of the scapula. It covers over the superficial muscles, forming sheaths for them, and is continuous, in the neck at the anterior border of the Trapezius, with the deep cervical fascia; on the thorax, with the deep fascia of the axilla and chest, and on the abdomen with the fascia covering the abdominal muscles.

The **Trapezius** (Fig. 287) is a broad, flat, triangular muscle, placed immediately beneath the skin and fascia, and covering the upper and back part of the neck and shoulders. It arises from the inner third of the superior curved line of the occipital bone; from the ligamentum nuchæ, the spinous process of the seventh cervical, and those of all the dorsal vertebræ; and from the corresponding portion of the supraspinous ligament. From this origin the superior fibres proceed downward and outward, the inferior ones upward and outward, and the middle fibres horizontally, and are inserted, the superior ones into the outer third of the posterior border of the clavicle; the middle fibres into the inner margin of the acromion process, and into the superior lip of the posterior border or crest of the spine of the scapula; the inferior fibres converge near the scapula, and terminate in a triangular aponeurosis, which glides over a smooth surface at the inner extremity of the spine, to be inserted into a tubercle at the outer part of this smooth surface. The Trapezius is fleshy in the greater part of its extent, but tendinous at its origin

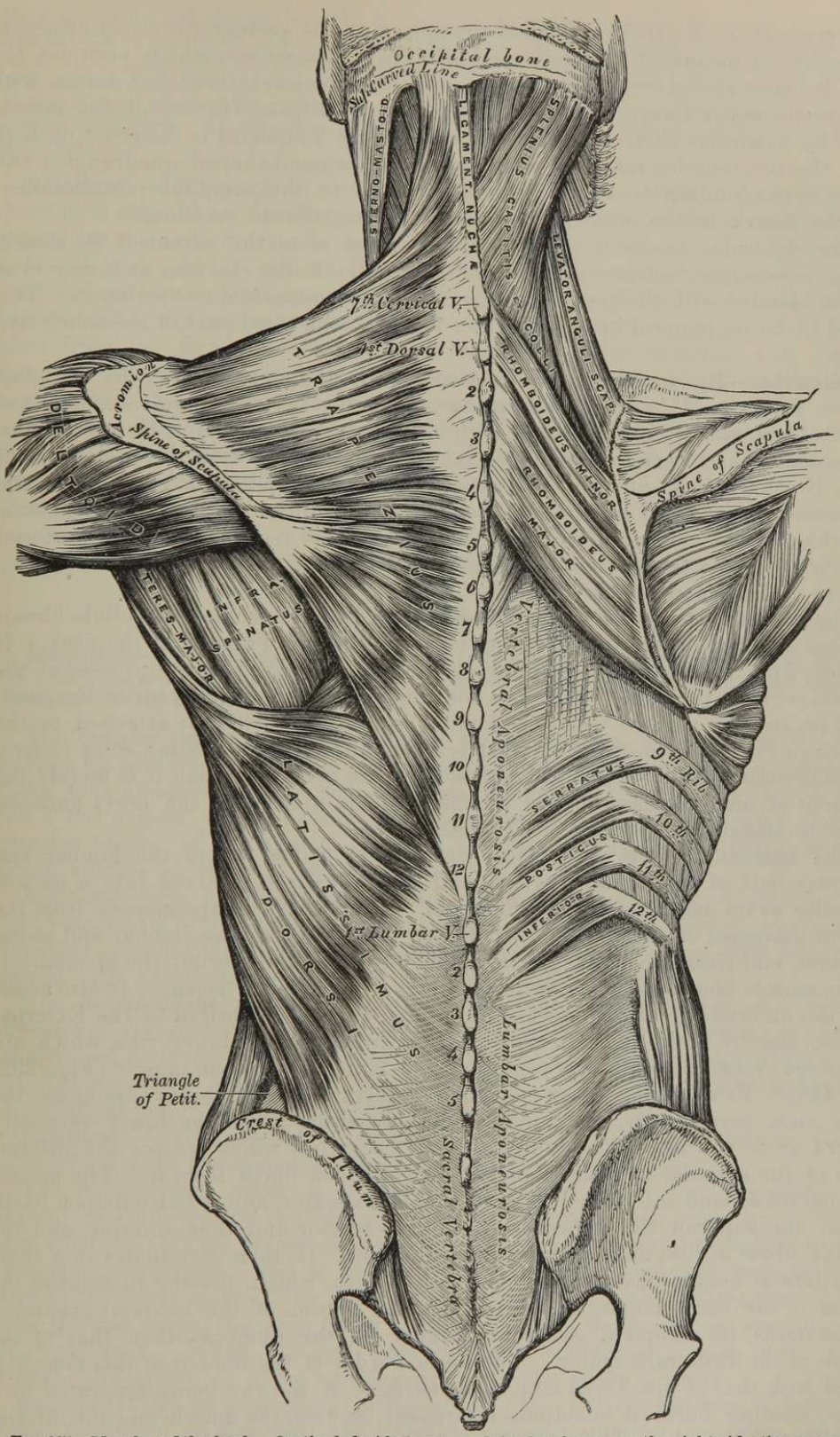

FIG. 287.—Muscles of the back. On the left side is exposed the first layer; on the right side, the second layer and part of the third.

and insertion. At its occipital origin it is connected to the bone by a thin fibrous lamina, firmly adherent to the skin, and wanting the lustrous, shining appearance

of aponeuroses. At its origin from the spines of the vertebræ it is connected to the bones by means of a broad semi-elliptical aponeurosis, which occupies the space between the sixth cervical and the third dorsal vertebræ, and forms, with the aponeurosis of the opposite muscle, a tendinous ellipse. The rest of the muscle arises by numerous short tendinous fibres. If the Trapezius is dissected on both sides, the two muscles resemble a trapezium or diamond-shaped quadrangle; two angles corresponding to the shoulders; a third to the occipital protuberance; and the fourth to the spinous process of the last dorsal vertebra.

The clavicular insertion of this muscle varies as to the extent of its attachment; it sometimes advances as far as the middle of the clavicle, and may even become blended with the posterior edge of the Sterno-mastoid or overlap it. This should be borne in mind in the operation for tying the third part of the subclavian artery.

Relations.—By its *superficial surface*, with the integument; by its *deep surface*, in the neck, with the Complexus, Splenius, Levator anguli scapulæ, and Rhomboideus minor; in the back, with the Rhomboideus major, Supraspinatus, Infraspinatus, and Vertebral aponeurosis (which separates it from the prolongations of the Erector spinæ), and the Latissimus dorsi. The spinal accessory nerve and the superficial cervical artery pass beneath the anterior border of this muscle, near the clavicle. The anterior margin of its cervical portion forms the posterior boundary of the posterior triangle of the neck, the other boundaries being the Sterno-mastoid in front and the clavicle below.

The **Ligamentum nuchæ** (Fig. 287) is a thin band of condensed cellulo-fibrous membrane placed in the line of union between the two Trapezii in the neck. It extends from the external occipital protuberance to the spinous process of the seventh cervical vertebra, where it is continuous with the supraspinous ligament. From its anterior surface a fibrous lamina is given off, which is attached to the spinous process of each of the cervical vertebræ, excepting the atlas, so as to form a septum between the muscles on each side of the neck. In man it is merely the rudiment of an important elastic ligament which, in some of the lower animals, serves to sustain the weight of the head.

The **Latissimus dorsi** is a broad flat muscle which covers the lumbar and the lower half of the dorsal regions, and is gradually contracted into a narrow fasciculus at its insertion into the humerus. It arises by an aponeurosis from the spinous processes of the six inferior dorsal, from those of the lumbar and sacral vertebræ, and from the supraspinous ligament. Over the sacrum the aponeurosis of this muscle blends with the posterior layer of the lumbar fascia. It also arises from the external lip of the crest of the ilium, behind the origin of the External oblique, and by fleshy digitations from the three or four lower ribs, which are interposed between similar processes of the External oblique muscle (Fig. 292, page 449). From this extensive origin the fibres pass in different directions, the upper ones horizontally, the middle obliquely upward, and the lower vertically upward, so as to converge and form a thick fasciculus, which crosses the inferior angle of the scapula, and occasionally receives a few fibres from it. The muscle then curves around the lower border of the Teres major, and is twisted upon itself, so that the superior fibres become at first posterior and then inferior, and the vertical fibres at first anterior and then superior. It then terminates in a short quadrilateral tendon, about three inches in length, which, passing in front of the tendon of the Teres major, is inserted into the bottom of the bicipital groove of the humerus, its insertion extending higher on the humerus than that of the tendon of the Pectoralis major. The lower border of the tendon of this muscle is united with that of the Teres major, the surfaces of the two being separated by a bursa; another bursa is sometimes interposed between the muscle and the inferior angle of the scapula. This muscle at its insertion gives off an expansion to the deep fascia of the arm.

A muscular slip, varying from 3 to 4 inches in length, and from $\frac{1}{4}$ to $\frac{3}{4}$ of an inch in breadth, occasionally arises from the upper edge of the Latissimus dorsi about the middle of the posterior

fold of the axilla, and crosses the axilla in front of the axillary vessels and nerves, to join the under surface of the tendon of the Pectoralis major, the Coraco-brachialis, or the fascia over the Biceps. The position of this abnormal slip is a point of interest in its relation to the axillary artery, as it crosses the vessel just above the spot usually selected for the application of a ligature, and may mislead the surgeon during the operation. It may be easily recognized by the transverse direction of its fibres. Dr. Struther found it, in 8 out of 105 subjects, occurring seven times on both sides.

Relations.—Its *superficial surface* is subcutaneous, excepting at its upper part, where it is covered by the Trapezius, and at its insertion, where its tendon is crossed by the axillary vessels and the brachial plexus of nerves. By its *deep surface* it is in relation with the Lumbar fascia, the Serratus posticus inferior, the lower external intercostal muscles and ribs, inferior angle of the scapula, Rhomboideus major, Infraspinatus, and Teres major. Its outer margin is separated below from the External oblique by a small triangular interval; and another triangular interval exists between its upper border and the margin of the Trapezius, in which the Rhomboideus major muscle is exposed.

Nerves.—The Trapezius is supplied by the spinal accessory, and by branches from the anterior divisions of the third and fourth cervical nerves: the Latissimus dorsi, by the middle or long subscapular nerve.

Second Layer.

Levator anguli scapulæ. Rhomboideus minor.
Rhomboideus major.

Dissection.—The Trapezius must be removed, in order to expose the next layer; to effect this, detach the muscle from its attachment to the clavicle and spine of the scapula, and turn it back toward the spine.

The **Levator anguli scapulæ** is situated at the back part and side of the neck. It arises by tendinous slips from the posterior tubercles of the transverse processes of the four upper cervical vertebræ; these, becoming fleshy, are united so as to form a flat muscle, which, passing downward and backward, is inserted into the posterior border of the scapula, between the superior angle and the triangular smooth surface at the root of the spine.

Relations.—By its *superficial surface*, with the integument, Trapezius, and Sterno-mastoid; by its *deep surface*, with the Splenius colli, Transversalis colli, Cervicalis ascendens, and Serratus posticus superior muscles, and with the transversalis colli and posterior scapular arteries.

The **Rhomboideus minor** arises from the ligamentum nuchæ and spinous processes of the seventh cervical and first dorsal vertebræ. Passing downward and outward, it is inserted into the margin of the triangular smooth surface at the root of the spine of the scapula. This small muscle is usually separated from the Rhomboideus major by a slight cellular interval.

Relations.—By its *superficial (posterior) surface*, with the Trapezius; by its *deep surface*, with the same structures as the Rhomboideus major.

The **Rhomboideus major** is situated immediately below the preceding, the adjacent margins of the two being occasionally united. It arises by tendinous fibres from the spinous processes of the four or five upper dorsal vertebræ and the supraspinous ligament, and is inserted into a narrow tendinous arch attached above to the lower part of the triangular surface at the root of the spine; below, to the inferior angle, the arch being connected to the border of the scapula by a thin membrane. When the arch extends, as it occasionally does, but a short distance, the muscular fibres are inserted into the scapula itself.

Relations.—By its *superficial (posterior) surface*, with the Latissimus dorsi; by its *deep (anterior) surface*, with the Serratus posticus superior, posterior scapular artery, the vertebral aponeurosis which separates it from the prolongations from the Erector spinæ, the Intercostal muscles, and ribs.

Nerves.—The Rhomboid muscles are supplied by branches from the anterior

division of the fifth cervical nerve; the Levator anguli scapulæ, by the anterior division of the third and fourth cervical nerves.

Actions.—The movements effected by the preceding muscles are numerous, as may be conceived from their extensive attachment. The whole of the Trapezius when in action retracts the scapula and rotates it on a sagittal axis; if the head is fixed, the upper part of the *Trapezius* will elevate the point of the shoulder, as in supporting weights; when the lower fibres are brought into action, they assist in depressing the bone. If the scapula is prevented from gliding on the chest, the middle and lower fibres of the muscle cause it to rotate, so that the acromion is raised. If the shoulders are fixed, both Trapezii, acting together, will draw the head directly backward; or if only one acts, the head is drawn to the corresponding side.

The *Latissimus dorsi*, when it acts upon the humerus, draws it backward, adducts, and at the same time rotates it inward. It is the muscle which is principally employed in giving a downward blow, as in felling a tree or in sabre practice. If the arm is fixed, the muscle may act in various ways upon the trunk; thus, it may raise the lower ribs and assist in forcible inspiration; or, if both arms are fixed, the two muscles may assist the Abdominal and great Pectoral muscles in suspending and drawing the whole trunk forward, as in climbing or walking on crutches.

The *Levator anguli scapulæ* raises the superior angle of the scapula, assisting the Trapezius in bearing weights or in shrugging the shoulders. If the shoulder be fixed, the Levator anguli scapulæ inclines the neck to the corresponding side and rotates it in the same direction. The Rhomboid muscles carry the inferior angle backward and upward, thus producing a slight rotation of the scapula upon the side of the chest, the Rhomboideus major acting especially on the lower angle of the scapula through the tendinous arch by which it is inserted. The Rhomboid muscles, acting together with the middle and inferior fibres of the Trapezius, will draw the scapula directly backward toward the spine.

Third Layer.

Serratus posticus superior. Serratus posticus inferior.

Splenius { Splenius capitis. / Splenius colli.

Dissection.—To bring into view the third layer of muscles, remove the whole of the second, together with the Latissimus dorsi, by cutting through the Levator anguli scapulæ and Rhomboid muscles near their insertion, and reflecting them upward, and by dividing the Latissimus dorsi in the middle by a vertical incision carried from its upper to its lower part, and reflecting the two halves of the muscle.

The **Serratus posticus superior** is a thin, flat, quadrilateral muscle situated at the upper and back part of the thorax. It arises by a thin and broad aponeurosis from the ligamentum nuchæ, and from the spinous processes of the last cervical and two or three upper dorsal vertebræ and from the supraspinous ligament. Inclining downward and outward, it becomes muscular, and is inserted, by four fleshy digitations into the upper borders of the second, third, fourth, and fifth ribs, a little beyond their angles.

Relations.—By its *superficial surface*, with the Trapezius, Rhomboidei, and Levator anguli scapulæ; by its *deep surface*, with the Splenius and the vertebral aponeurosis, which separates it from the prolongations of the Erector spinæ, and with the Intercostal muscles and ribs.

The **Serratus posticus inferior** is situated at the junction of the dorsal and lumbar regions; it is of an irregularly quadrilateral form, broader than the preceding, and separated from it by a considerable interval. It arises by a thin aponeurosis from the spinous processes of the last two dorsal and two or three upper lumbar vertebræ, and from the supraspinous ligaments. Passing obliquely upward and outward, it becomes fleshy, and divides into four flat digitations, which are inserted into the lower borders of the four lower ribs, a little beyond their angles.

The thin aponeurosis of origin is intimately blended with the tendon of origin of the Latissimus dorsi muscle and with the lumbar fascia (*posterior layer*).

Relations.—By its *superficial surface*, with the Latissimus dorsi, with the aponeurosis of which its own aponeurotic origin is inseparably blended; by its *deep surface*, the Erector spinæ, ribs, and Intercostal muscles. Its upper margin is continuous with the vertebral aponeurosis.

The *Vertebral aponeurosis* is a thin, fibrous lamina extending along the whole length of the back part of the thoracic region, serving to bind down the long extensor muscles of the back which support the spine and head, and separate them from those muscles which connect the spine to the upper extremity. It consists of longitudinal and transverse fibres blended together, forming a thin lamella, which is attached in the median line to the spinous processes of the dorsal vertebræ; externally, to the angles of the ribs; and below, to the aponeurosis of the Serratus posticus inferior and tendon of origin of the Latissimus dorsi, with both of which it is continuous; above, it passes beneath the Serratus posticus superior, and blends with the deep fascia of the neck.

The *Lumbar fascia* (Figs. 287 and 295) occupies the interval between the last rib and crest of the ilium. It is attached internally to the spinous process of the lumbar and sacral vertebræ; above, to the last rib and to the cartilage of the eleventh rib; below, to the posterior third of the crest of the ilium. The posterior layer of this fascia blends with, and is practically the same thing as, the aponeurosis of the Latissimus dorsi and Serratus posticus inferior. It gives attachment to the Internal oblique muscle of the abdomen. The anterior or deep surface gives off two layers: one lies between the Erector spinæ and Quadratus lumborum, and is attached to the tips of the transverse processes of the lumbar vertebræ (*posterior aponeurosis* of the Transversalis muscle); the other lies on the anterior or internal surface of the Quadratus lumborum, and is attached to the front part of the same transverse processes (*transversalis fascia*). The upper portion of this layer, which extends from the transverse process of the first lumbar vertebra to the apex and lower border of the last rib, constitutes the ligamentum arcuatum externum. Therefore these three layers of the lumbar fascia form two spaces: between the posterior and middle layer is situated the Erector spinæ and the Multifidus spinæ; between the middle and anterior layers is situated the Quadratus lumborum.

Now detach the Serratus posticus superior from its origin, and turn it outward, when the Splenius muscle will be brought into view.

The **Splenius** is situated at the back of the neck and upper part of the dorsal region. At its origin it is a single muscle, narrow, and pointed in form; but it soon becomes broader, and divides into two portions, which have separate insertions. It arises, by tendinous fibres, from the lower half of the ligamentum nuchæ, from the spinous processes of the last cervical and of the six upper dorsal vertebræ, and from the supraspinous ligament. From this origin the fleshy fibres proceed obliquely upward and outward, forming a broad flat muscle, which divides as it ascends into two portions, the Splenius capitis and Splenius colli.

The **Splenius capitis** is inserted into the mastoid process of the temporal bone, and into the rough surface on the occipital bone just beneath the superior curved line.

The **Splenius colli** is inserted, by tendinous fasciculi, into the posterior tubercles of the transverse processes of the two or three upper cervical vertebræ.

The Splenius is separated from its fellow of the opposite side by a triangular interval, in which is seen the Complexus.

Relations.—By its *superficial surface*, with the Trapezius, from which it is separated below by the Rhomboidei and the Serratus posticus superior. It is covered at its insertion by the Sterno-mastoid, and at the lower and back part of the neck by the Levator anguli scapulæ; by its *deep surface*, with the Spinalis dorsi, Longissimus dorsi, Semispinalis colli, Complexus, Trachelo-mastoid, and Transversalis colli.

Nerves.—The Splenius is supplied from the external branches of the posterior divisions of the cervical nerves; the Serratus posticus superior is supplied by the external branches of the posterior divisions of the upper dorsal nerves; the Serratus posticus inferior by the external branches of the posterior divisions of the lower dorsal nerves.

Actions.—The Serrati are respiratory muscles. The Serratus posticus superior elevates the ribs; it is therefore an inspiratory muscle; while the Serratus inferior draws the lower ribs downward and backward, and thus elongates the thorax. It also fixes the lower ribs, thus aiding the downward action of the diaphragm and resisting the tendency which it has to draw the lower ribs upward and forward. It must therefore be regarded as a muscle of inspiration. This muscle is also probably a tensor of the vertebral aponeurosis. The Splenii muscles of the two sides, acting together, draw the head directly backward, assisting the Trapezius and Complexus; acting separately, they draw the head to one or the other side, and slightly rotate it, turning the face to the same side. They also assist in supporting the head in the erect position.

Fourth Layer.

Sacral and Lumbar Regions.

Erector spinæ.

Dorsal Region.

Ilio-costalis.
Musculus accessorius ad ilio-costalem.
Longissimus dorsi.
Spinalis dorsi.

Cervical Region.

Cervicalis ascendens.
Transversalis colli.
Trachelo-mastoid.
Complexus.
Biventer cervicis.
Spinalis colli.

Dissection.—To expose the muscles of the fourth layer, remove entirely the Serrati and the vertebral and lumbar fasciæ. Then detach the Splenius by separating its attachment to the spinous processes and reflecting it outward.

The **Erector spinæ** (Fig. 288) and its prolongations in the dorsal and cervical regions fill up the vertebral groove on each side of the spine. It is covered in the lumbar region by the lumbar fascia; in the dorsal region, by the Serrati muscles and the vertebral aponeurosis; and in the cervical region, by a layer of cervical fascia continued beneath the Trapezius and the Splenius. This large muscular and tendinous mass varies in size and structure at different parts of the spine. In the sacral region the Erector spinæ is narrow and pointed, and its origin chiefly tendinous in structure. In the lumbar region the muscle becomes enlarged, and forms a large fleshy mass. In the dorsal region it subdivides into two parts, which gradually diminish in size as they ascend to be inserted into the vertebræ and ribs. In the cervical region it is gradually lost, where a number of small muscles are continued upward to the head to support it upon the spine.

The Erector spinæ arises from the sacro-iliac groove, and from the anterior surface of a very broad and thick tendon, which is attached, internally, to the spines of the sacrum, to the spinous processes of the lumbar vertebræ, and the supraspinous ligament; externally, to the back part of the inner lip of the crest of the ilium, and to the series of eminences on the posterior part of the sacrum, which represents the transverse processes, where it blends with the great sacro-sciatic ligament. The muscular fibres form a single large fleshy mass, bounded in front by the transverse processes of the lumbar vertebræ and by the middle lamella of the lumbar fascia. Opposite the last rib it divides into two parts, the Ilio-costalis and the Longissimus dorsi.

The **Ilio-costalis** (*Sacro-lumbalis*), the external and smaller portion of the Erector spinæ, is inserted, generally, by six or seven flattened tendons into the angles of the six or seven lower ribs. The number of the tendons of this muscle is, however, very variable, and therefore the number of ribs into which it is inserted. Frequently it is found to possess nine or ten tendons, and sometimes as many tendons as there are ribs, and is then inserted into the angles of all the ribs.

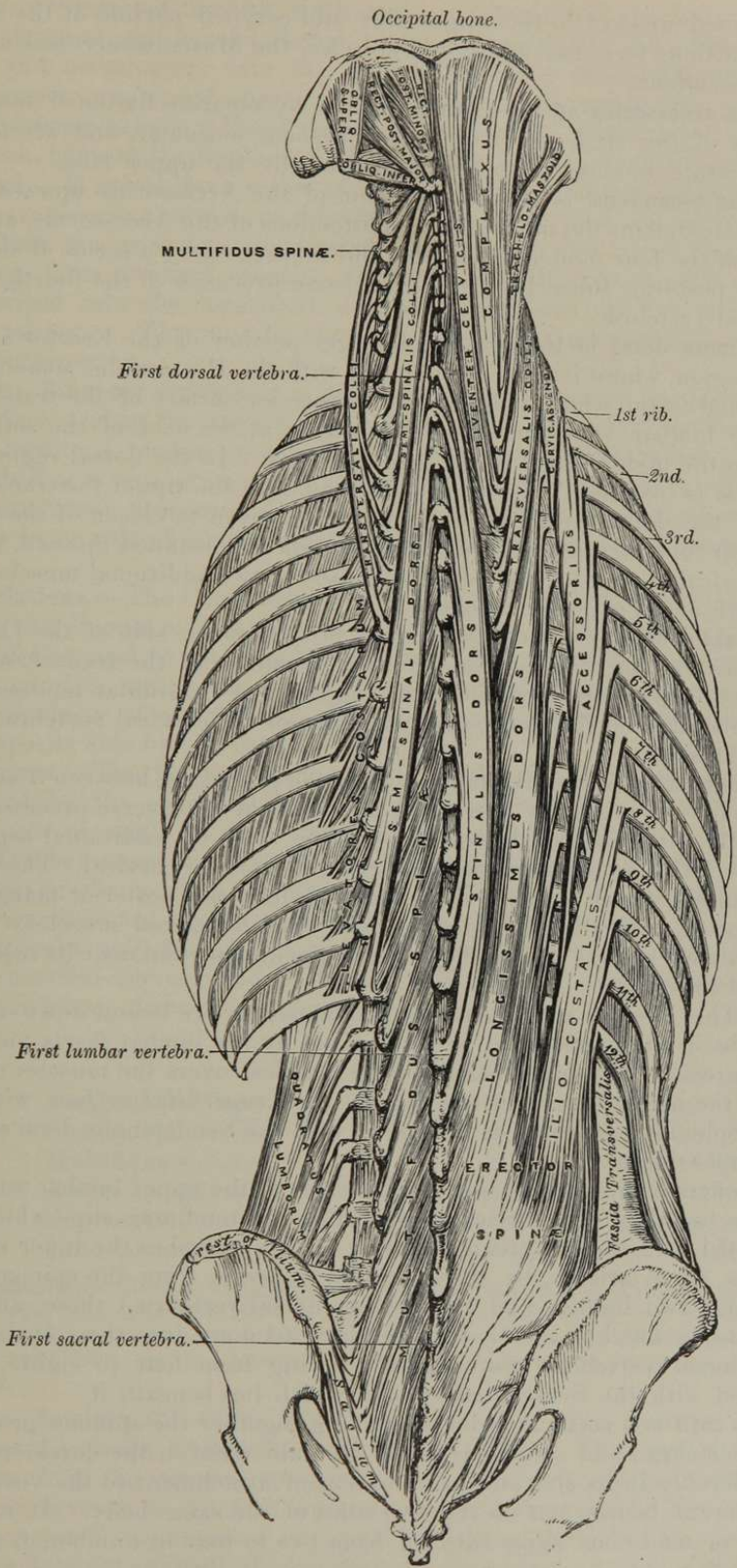

FIG. 288.—Muscles of the back. Deep layers.

If this muscle is reflected outward, it will be seen to be reinforced by a series of muscular slips which arise from the angles of the ribs; by means of these the Ilio-

costalis is continued upward to the upper ribs and cervical portion of the spine. The accessory portions form two additional muscles, the Musculus accessorius and the Cervicalis ascendens.

The **Musculus accessorius ad ilio-costalem** arises, by separate flattened tendons, from the angles of the six lower ribs; these become muscular, and are finally inserted, by separate tendons, into the angles of the six upper ribs.

The **Cervicalis ascendens**[1] is the continuation of the Accessorius upward into the neck; it is situated on the inner side of the tendons of the Accessorius, arising from the angles of the four or five upper ribs, and is inserted by a series of slender tendons into the posterior tubercles of the transverse processes of the fourth, fifth, and sixth cervical vertebræ.

The **Longissimus dorsi** is the inner and larger portion of the Erector spinæ. In the lumbar region, where it is as yet blended with the Ilio-costalis, some of the fibres are attached to the whole length of the posterior surface of the transverse processes of the lumbar vertebræ, to the tubercles at the back of the articular processes, and to the middle layer of the lumbar fascia. In the dorsal region the Longissimus dorsi is inserted, by long thin tendons, into the tips of the transverse processes of all the dorsal vertebræ, and into from seven to eleven of the lower ribs between their tubercles and angles. This muscle is continued upward, to the cranium and cervical portion of the spine by means of two additional muscles, the Transversalis colli and Trachelo-mastoid.

The **Transversalis colli** (or **cervicis**), placed on the inner side of the Longissimus dorsi, arises by long thin tendons from the summits of the transverse processes of the six upper dorsal vertebræ, and is inserted by similar tendons into the posterior tubercles of the transverse processes of the cervical vertebræ from the second to the sixth.

The **Trachelo-mastoid** lies on the inner side of the preceding, between it and the Complexus muscle. It arises, by four tendons, from the transverse processes of the third, fourth, fifth, and sixth dorsal vertebræ, and by additional separate tendons from the articular processes of the three or four lower cervical. The fibres form a small muscle, which ascends to be inserted into the posterior margin of the mastoid process, beneath the Splenius and Sterno-mastoid muscles. This small muscle is almost always crossed by a tendinous intersection near its insertion into the mastoid process.[2]

Relations.—The Erector spinæ and its prolongations are bound down to the vertebræ and ribs in the lumbar and dorsal regions by the lumbar fascia and the vertebral aponeurosis. The inner part of these muscles covers the muscles of the fifth layer. In the neck they are in relation, by their *superficial surface*, with the Trapezius and Splenius; by their *deep surface*, with the Semispinalis dorsi et colli and the Recti and Obliqui.

The **Spinalis dorsi** connects the spinous processes of the upper lumbar and the dorsal vertebræ together by a series of muscular and tendinous slips which are intimately blended with the Longissimus dorsi. It is situated at the inner side of the Longissimus dorsi, arising, by three or four tendons, from the spinous processes of the first two lumbar and the last two dorsal vertebræ: these, uniting, form a small muscle, which is inserted, by separate tendons, into the spinous processes of the dorsal vertebræ, the number varying from four to eight. It is intimately united with the Semispinalis dorsi, which lies beneath it.

The **Spinalis colli** is a small muscle, connecting together the spinous processes of the cervical vertebræ, and analogous to the Spinalis dorsi in the dorsal region. It varies considerably in its size and in its extent of attachment to the vertebræ, not only in different bodies, but on the two sides of the same body. It usually arises by fleshy or tendinous slips, varying from two to four in number, from the

[1] This muscle is sometimes called "Cervicalis descendens." The student should remember that these long muscles take their fixed point from above or from below according to circumstances.

[2] These two muscles are sometimes described as one, having a common origin, but dividing above at their insertion. The Trachelo-mastoid is then termed the *Transversalis capitis*.

spinous processes of the fifth, sixth, and seventh cervical vertebræ, and occasionally from the first and second dorsal, and is inserted into the spinous process of the axis, and occasionally into the spinous processes of the two vertebræ below it. This muscle was found absent in five cases out of twenty-four.

The **Complexus** is a broad thick muscle, situated at the upper and back part of the neck, beneath the Splenius, and internal to the Transversalis colli and Trachelo-mastoid. It arises, by a series of tendons, about seven in number, from the tips of the transverse processes of the upper three dorsal and seventh cervical vertebræ, and from the articular processes of the three cervical above this. The tendons, uniting, form a broad muscle, which passes obliquely upward and inward, and is inserted into the innermost depression between the two curved lines of the occipital bone. This muscle, about its middle, is traversed by a transverse tendinous intersection.

The **Biventer cervicis** is a small fasciculus, situated on the inner side of the preceding, and in the majority of cases blended with it; it has received its name from having a tendon intervening between two fleshy bellies. It is sometimes described as a separate muscle, arising, by from two to four tendinous slips, from the transverse processes of as many of the upper dorsal vertebræ, and inserted, on the inner side of the Complexus, into the superior curved line of the occipital bone.

Relations.—The Complexus is covered by the Splenius and the Trapezius. It lies on the Rectus capitis posticus major and minor, the Obliquus capitis superior and inferior, and on the Semispinalis colli, from which it is separated by the profunda cervicis artery, the princeps cervicis artery, and branches of the posterior cervical plexus of nerves. The Biventer cervicis is separated from its fellow of the opposite side by the ligamentum nuchæ.

Nerves.—The Erector spinæ and its subdivisions in the dorsal region are supplied by the external branches of the posterior divisions of the lumbar and dorsal nerves, while its subdivisions in the cervical region, the Transversalis colli and Trachelo-mastoid, are supplied by the external branches of the posterior divisions of the cervical nerves; the Complexus, by the internal branches of the posterior divisions of the cervical nerves, the suboccipital and great occipital. The Spinalis colli is supplied by the internal branches of the posterior divisions of the cervical nerves; and the Spinalis dorsi, by the internal branches of the posterior divisions of the dorsal nerves.

Fifth Layer.

Semispinalis dorsi.	Extensor coccygis.
Semispinalis colli.	Intertransversales.
Multifidus spinæ.	Rectus capitis posticus major.
Rotatores spinæ.	Rectus capitis posticus minor.
Supraspinales.	Obliquus capitis superior.
Interspinales.	Obliquus capitis inferior.

Dissection.—Remove the muscles of the preceding layer by dividing and turning aside the Complexus; then detach the Spinalis and Longissimus dorsi from their attachments, divide the Erector spinæ at its connection below to the sacral and lumbar spines, and turn it outward. The muscles filling up the interval between the spinous and transverse processes are then exposed.

The **Semispinalis dorsi** (Fig. 288) consists of thin, narrow, fleshy fasciculi interposed between tendons of considerable length. It arises by a series of small tendons from the transverse processes of the lower dorsal vertebræ, from the tenth or eleventh to the fifth or sixth; and is inserted, by five or six tendons, into the spinous processes of the upper four dorsal and lower two cervical vertebræ.

The **Semispinalis colli**, thicker than the preceding, arises by a series of tendinous and fleshy fibres from the transverse processes of the upper four dorsal vertebræ and from the articular processes of the lower four cervical vertebræ; and is inserted into the spinous processes of four cervical vertebræ, from the axis to the

fifth cervical. The fasciculus connected with the axis is the largest, and chiefly muscular in structure.

Relations.—By their *superficial surface*, from below upward, with the Spinalis dorsi, Longissimus dorsi, Splenius, Complexus, the profunda cervicis artery, the princeps cervicis artery, and the internal branches of the posterior divisions of the first, second, and third cervical nerves; by their *deep surface*, with the Multifidus spinæ.

The **Multifidus spinæ** consists of a number of fleshy and tendinous fasciculi which fill up the groove on either side of the spinous processes of the vertebræ, from the sacrum to the axis. In the sacral region these fasciculi arise from the back of the sacrum, as low as the fourth sacral foramen, and from the aponeurosis of origin of the Erector spinæ; in the iliac region, from the inner surface of the posterior superior spine of the ilium and posterior sacro-iliac ligaments; in the lumbar regions, from the articular processes; in the dorsal region, from the transverse processes; and in the cervical region, from the articular processes. Each fasciculus, passing obliquely upward and inward, is inserted into the lamina and whole length of the spinous process of one of the vertebræ above. These fasciculi vary in length: the most superficial, the longest, pass from one vertebra to the third or fourth above; those next in order pass from one vertebra to the second or third above; whilst the deepest connect two contiguous vertebræ.

Relations.—By its *superficial surface*, with the Longissimus dorsi, Spinalis dorsi, Semispinalis dorsi, and Semispinalis colli; by its *deep surface*, with the laminæ and spinous processes of the vertebræ, and with the Rotatores spinæ in the dorsal region.

The **Rotatores spinæ** are found only in the dorsal region of the spine, beneath the Multifidus spinæ; they are eleven in number on each side. Each muscle is small and somewhat quadrilateral in form; it arises from the upper and back part of the transverse process, and is inserted into the lower border and outer surface of the lamina of the vertebra above, the fibres extending as far inward as the root of the spinous process. The first is found between the first and second dorsal; the last, between the eleventh and twelfth. Sometimes the number of these muscles is diminished by the absence of one or more from the upper or lower end.

The **Supraspinales** consist of a series of fleshy bands which lie on the spinous processes in the cervical region of the spine.

The **Interspinales** are short muscular fasciculi, placed in pairs between the spinous processes of the contiguous vertebræ, one on each side of the interspinous ligament. In the *cervical region* they are most distinct, and consist of six pairs, the first being situated between the axis and third vertebra, and the last between the last cervical and the first dorsal. They are small narrow bundles, attached, above and below, to the apices of the spinous processes. In the *dorsal region* they are found between the first and second vertebræ, and occasionally between the second and third; and below, between the eleventh and twelfth. In the *lumbar region* there are four pairs of these muscles in the intervals between the five lumbar vertebræ. There is also occasionally one in the interspinous space, between the last dorsal and first lumbar, and between the fifth lumbar and the sacrum.

The **Extensor coccygis** is a slender muscular fasciculus, occasionally present, which extends over the lower part of the posterior surface of the sacrum and coccyx. It arises by tendinous fibres from the last bone of the sacrum or first piece of the coccyx, and passes downward to be inserted into the lower part of the coccyx. It is a rudiment of the Extensor muscle of the caudal vertebræ which exists in some animals.

The **Intertransversales** are small muscles placed between the transverse processes of the vertebræ. In the *cervical region* they are most developed, consisting of rounded muscular and tendinous fasciculi, which are placed in pairs, passing between the two anterior and the two posterior tubercles of the transverse processes

of two contiguous vertebræ, separated from one another by the anterior division of the cervical nerve, which lies in the groove between them. In this region there are seven pairs of these muscles, the first pair being between the atlas and axis, and the last pair between the seventh cervical and first dorsal vertebræ. In the *dorsal region* they are least developed, consisting chiefly of rounded tendinous cords in the intertransverse spaces of the upper dorsal vertebræ; but between the transverse processes of the lower three dorsal vertebræ, and between the transverse processes of the last dorsal and the first lumbar, they are muscular in structure. In the *lumbar region* they are four in number, and consist of a single muscular layer, which occupies the entire interspace between the transverse processes of the lower lumbar vertebræ, whilst those between the transverse processes of the upper lumbar are not attached to more than half the breadth of the process.

The **Rectus capitis posticus major** arises by a pointed tendinous origin from the spinous process of the axis, and, becoming broader as it ascends, is inserted into the inferior curved line of the occipital bone and the surface of bone immediately below it. As the muscles of the two sides pass upward and outward, they leave between them a triangular space, in which are seen the Recti capitis postici minores muscles.

Relations.—By its *superficial surface*, with the Complexus, and, at its insertion, with the Superior oblique; by its *deep surface*, with part of the Rectus capitis posticus minor, the posterior arch of the atlas, the posterior occipito-atlantal ligament, and part of the occipital bone.

The **Rectus capitis posticus minor**, the smallest of the four muscles in this region, is of a triangular shape; it arises by a narrow pointed tendon from the tubercle on the posterior arch of the atlas, and, becoming broader as it ascends, is inserted into the rough surface beneath the inferior curved line, nearly as far as the foramen magnum, nearer to the middle line than the preceding.

Relations.—By its *superficial surface*, with the Complexus and the Rectus capitis posticus major; by its *deep surface*, with the posterior occipito-atlantal ligament.

The **Obliquus capitis inferior**, the larger of the two Oblique muscles, arises from the apex of the spinous process of the axis, and passes almost horizontally outward, to be inserted into the lower and back part of the transverse process of the atlas.

Relations.—By its *superficial surface*, with the Complexus and with the posterior division of the second cervical nerve, which crosses it; by its *deep surface*, with the vertebral artery and posterior atlanto-axial ligament.

The **Obliquus capitis superior**, narrow below, wide and expanded above, arises by tendinous fibres from the upper surface of the transverse process of the atlas, joining with the insertion of the preceding, and, passing obliquely upward and inward, is inserted into the occipital bone, between the two curved lines, external to the Complexus.

Relations.—By its *superficial surface*, with the Complexus and Trachelo-mastoid. By its *deep surface*, with the posterior occipito-atlantal ligament.

The Suboccipital Triangle.—Between the two oblique muscles and the Rectus capitis posticus major a triangular interval exists, the *suboccipital triangle*. This triangle is bounded, above and internally, by the Rectus capitis posticus major; above and externally, by the Obliquus capitis superior; below and externally, by the Obliquus capitis inferior. It is covered in by a layer of dense fibro-fatty tissue, situated beneath the Complexus muscle. The floor is formed by the posterior occipito-atlantal ligament, the posterior arch of the atlas, and the posterior atlanto-axial ligament. It contains the vertebral artery, as it runs in a deep groove on the upper surface of the posterior arch of the atlas, and the posterior division of the suboccipital nerve.

Nerves.—The Semispinalis dorsi and Rotatores spinæ are supplied by the internal branches of the posterior divisions of the dorsal nerves; the Semispinalis colli, by the internal branches of the posterior divisions of the cervical nerves; the

Supraspinales and Interspinales are supplied by the internal branches of the posterior divisions of the cervical, dorsal, and lumbar nerves in the respective regions; the Intertransversales, by the internal branches of the posterior divisions of the cervical, dorsal, and lumbar nerves; the Multifidus spinæ, by the same, with the addition of the internal branches of the posterior divisions of the sacral nerves. The Recti and Obliqui muscles are all supplied by the suboccipital nerve; the Inferior oblique is also supplied by the great occipital nerve.

Actions.—When both the Spinales dorsi contract, they extend the dorsal region of the spine; when only one muscle contracts, it helps to bend the dorsal portion of the spine to one side. The Erector spinæ, comprising the Ilio-costalis and the Longissimus dorsi with their accessory muscles, serves, as its name implies, to maintain the spine in the erect posture; it also serves to bend the trunk backward when it is required to counterbalance the influence of any weight at the front of the body, as, for instance, when a heavy weight is suspended from the neck, or when there is any great abdominal distension, as in pregnancy or dropsy; the peculiar gait under such circumstances depends upon the spine being drawn backward by the counterbalancing action of the Erector spinæ muscles. The muscles which form the continuation of the Erector spinæ upward steady the head and neck, and fix them in the upright position. If the Ilio-costalis and Longissimus dorsi of one side act, they serve to draw down the chest and spine to the corresponding side. The Cervicales ascendens, taking their fixed points from the cervical vertebræ, elevate those ribs to which they are attached; taking their fixed points from the ribs, both muscles help to extend the neck; while one muscle bends the neck to its own side. The Transversalis colli, when both muscles act, taking their fixed point from below, bend the neck backward. The Trachelo-mastoid, when both muscles act, taking their fixed point from below, bend the head backward; while, if only one muscle acts, the face is turned to the side on which the muscle is acting, and then the head is bent to the shoulder. The two Recti muscles draw the head backward. The Rectus capitis posticus major, owing to its obliquity, rotates the cranium, with the atlas, round the odontoid process, turning the face to the same side. The Multifidus spinæ acts successively upon the different parts of the spine; thus, the sacrum furnishes a fixed point from which the fasciculi of this muscle act upon the lumbar region; these then become the fixed points for the fasciculi moving the dorsal region, and so on throughout the entire length of the spine; it is by the successive contraction and relaxation of the separate fasciculi of this and other muscles that the spine preserves the erect posture without the fatigue that would necessarily have been produced had this position been maintained by the action of a single muscle. The Multifidus spinæ, besides preserving the erect position of the spine, serves to rotate it, so that the front of the trunk is turned to the side opposite to that from which the muscle acts, this muscle being assisted in its action by the Obliquus externus abdominis. The Complexi draw the head directly backward: if one muscle acts, it draws the head to one side, and rotates it so that the face is turned to the opposite side. The Superior oblique draws the head backward, and, from the obliquity in the direction of its fibres, will slightly rotate the cranium, turning the face to the opposite side. The Obliquus capitis inferior rotates the atlas, and with it the cranium, round the odontoid process, turning the face to the same side. The Semispinales, when the muscles of the two sides act together, help to extend the spine; when the muscles of one side only act, they rotate the dorsal and cervical parts of the spine, turning the body to the opposite side. The Supraspinales and Interspinales by approximating the spinous processes help to extend the spine. The Intertransversales approximate the transverse processes, and help to bend the spine to one side. The Rotatores spinæ assist the Multifidus spinæ to rotate the spine, so that the front of the trunk is turned to the side opposite to that from which the muscle acts.

Surface Forms.—The surface forms produced by the muscles of the back are numerous and difficult to analyze unless they are considered in systematic order. The most superficial layer,

consisting of large strata of muscular substance, influences to a certain extent the surface form, and at the same time reveals the forms of the layers beneath. The *Trapezius* at the upper part of the back, and in the neck, covers over and softens down the outline of the underlying muscles. Its anterior border forms the posterior boundary of the posterior triangle of the neck. It forms a slight undulating ridge which passes downward and forward from the occiput to the junction of the middle and outer third of the clavicle. The tendinous ellipse formed by a part of the origin of the two muscles at the back of the neck is always to be seen as an oval depression, more marked when the muscle is in action. A slight dimple on the skin opposite the interval between the spinous processes of the third and fourth dorsal vertebræ marks the triangular aponeurosis by which the inferior fibres are inserted into the root of the spine of the scapula. From this point the inferior border of the muscle may be traced as an undulating ridge to the spinous process of the twelfth dorsal vertebra. In like manner, the *Latissimus dorsi* softens down and modulates the underlying structures at the lower part of the back and lower part of the side of the chest. In this way it modulates the outline of the Erector spinæ; of the Serratus posticus inferior, which is sometimes to be discerned through it, and is sometimes entirely obscured by it; of part of the Serratus magnus and Superior oblique, which it covers; and of the convex oblique ridges formed by the ribs with the intervening intercostal spaces. The anterior border of the muscle is the only part which gives a distinct surface form. This border may be traced, when the muscle is in action, as a rounded edge, starting from the crest of the ilium, and passing obliquely forward and upward to the posterior border of the axilla, where it combines with the Teres major in forming a thick rounded fold, the posterior boundary of the axillary space. The muscles in the second layer influence to a very considerable extent the surface form of the back of the neck and upper part of the trunk. The *Levator anguli scapulæ* reveals itself as a prominent divergent line, running downward and outward, from the transverse processes of the upper cervical vertebræ to the angle of the scapula, covered over and toned down by the overlying Trapezius. The *Rhomboidei* produce, when in action, a vertical eminence between the internal border of the scapula and the spinal furrow, varying in intensity according to the condition of contraction or relaxation of the Trapezius muscle, by which they are for the most part covered. The lowermost part of the Rhomboideus major is uncovered by the Trapezius, and forms on the surface an oblique ridge running upward and inward from the inferior angle of the scapula. Of the muscles of the third layer of the back, the *Serratus posticus superior* does not in any way influence surface form. The *Serratus posticus inferior*, when in strong action, may occasionally be revealed as an elevation beneath the Latissimus dorsi. The *Splenii* by their divergence serve to broaden out the upper part of the back of the neck and produce a local fulness in this situation, but do not otherwise influence surface form. Beneath all these muscles those of the fourth layer—the *Erector spinæ* and its continuations—influence the surface form in a decided manner. In the loins, the Erector spinæ, bound down by the lumbar fascia, forms a rounded vertical eminence, which determines the depth of the spinal furrow, and which below tapers to a point on the posterior surface of the sacrum and becomes lost there. In the back it forms a flattened plane which gradually becomes lost. In the neck the only part of this group of muscles which influences surface form is the *Trachelo-mastoid*, which produces a short convergent line across the upper part of the posterior triangle of the neck, appearing from under cover of the posterior border of the Sterno-mastoid and being lost below beneath the Trapezius.

THE THORAX.

The Muscles exclusively connected with the bones in this region are few in number. They are the

Intercostales externi.	Infracostales.
Intercostales interni.	Triangularis sterni.
Levatores costarum.	

Intercostal Fasciæ.—A thin but firm layer of fascia covers the outer surface of the External intercostal and the inner surface of the Internal intercostal muscles; and a third layer, the middle intercostal fascia, more delicate, is interposed between the two planes of muscular fibres. These are the intercostal fasciæ; they are best marked in those situations where the muscular fibres are deficient, as between the External intercostal muscles and sternum, in front, and between the Internal intercostals and spine, behind.

The **Intercostal muscles** (Fig. 299) are two thin planes of muscular and tendinous fibres, placed one over the other, filling up the intercostal spaces, and being directed obliquely between the margins of the adjacent ribs. They have received the name "external" and "internal" from the position they bear to one another. The tendinous fibres are longer and more numerous than the muscular; hence the walls of the intercostal spaces possess very considerable strength, to which the crossing of the muscular fibres materially contributes.

The **External Intercostals** are eleven in number on each side. They extend from the tubercles of the ribs, behind, to the commencement of the cartilages of the ribs, in front, where they terminate in a thin membranous aponeurosis, which is continued forward to the sternum. They arise from the lower border of each rib, and are inserted into the upper border of the rib below. In the two lowest spaces they extend to the end of the cartilages. Their fibres are directed obliquely downward and forward, in a similar direction with those of the External oblique muscle of the abdomen. They are thicker than the Internal intercostals.

Relations.—By their *outer surface*, with the muscles which immediately invest the chest—viz. the Pectoralis major and minor, Serratus magnus, and Rhomboideus major, Serratus posticus superior and inferior, Scalenus posticus, Ilio-costalis, Longissimus dorsi, Cervicalis ascendens, Transversalis colli, Levatores costarum, and the Obliquus externus abdominis; by their *internal surface*, with the middle intercostal fascia, which separates them from the intercostal vessels and nerve, and the Internal intercostal muscles, and, behind, from the pleura.

The **Internal intercostals** are also eleven in number on each side. They commence anteriorly at the sternum, in the interspaces between the cartilages of the true ribs, and from the anterior extremities of the cartilages of the false ribs, and extend backward as far as the angles of the ribs, whence they are continued to the vertebral column by a thin aponeurosis. They arise from the ridge on the inner surface of each rib, as well as from the corresponding costal cartilage, and are inserted into the upper border of the rib below. Their fibres are directed obliquely downward and backward, passing in the opposite direction to the fibres of the External intercostal muscle.

Relations.—By their *external surface*, with the intercostal vessels and nerves, and the middle intercostal fascia, which separates them from the External intercostal muscles; by their *internal surface*, with the internal intercostal fascia, which separates them from the pleura costalis, Triangularis sterni, and Diaphragm.

The **Infracostales** (**subcostales**) consist of muscular and aponeurotic fasciculi, which vary in number and length: they are placed on the inner surface of the ribs, where the Internal intercostal muscles cease; they arise from the inner surface of one rib, and are inserted into the inner surface of the first, second, or third rib below. Their direction is most usually oblique, like the Internal intercostals. They are most frequent between the lower ribs.

The **Triangularis sterni** is a thin plane of muscular and tendinous fibres, situated upon the inner wall of the front of the chest. It arises from the lower part of the side of the sternum, from the inner surface of the ensiform cartilage, and from the sternal ends of the costal cartilages of the three or four lower true ribs. Its fibres diverge upward and outward, to be inserted by fleshy digitations into the lower border and inner surfaces of the costal cartilages of the second, third, fourth, and fifth ribs. The lowest fibres of this muscle are horizontal in their direction, and are continuous with those of the Transversalis; those which succeed are oblique, whilst the superior fibres are almost vertical. This muscle varies much in its attachment, not only in different bodies, but on opposite sides of the same body.

Relations.—*In front*, with the sternum, ensiform cartilage, costal cartilages, Internal intercostal muscles, and internal mammary vessels; *behind*, with the pleura, pericardium, and anterior mediastinum.

The **Levatores Costarum** (Fig. 288), twelve in number on each side, are small tendinous and fleshy bundles, which arise from the extremities of the transverse processes of the seventh cervical and eleven upper dorsal vertebræ, and, passing obliquely downward and outward, are inserted into the upper border of the rib below them, between the tubercle and the angle. That for the first rib arises from the transverse process of the last cervical vertebra, and that for the last from the eleventh dorsal. The Inferior levatores divide into two fasciculi, one of which is inserted as above described; the other fasciculus passes down to the second rib

below its origin; thus, each of the lower ribs receives fibres from the transverse processes of two vertebræ.

Nerves.—The muscles of this group are supplied by the intercostal nerves.

Actions.—The Intercostals are the chief agents in the movement of the ribs

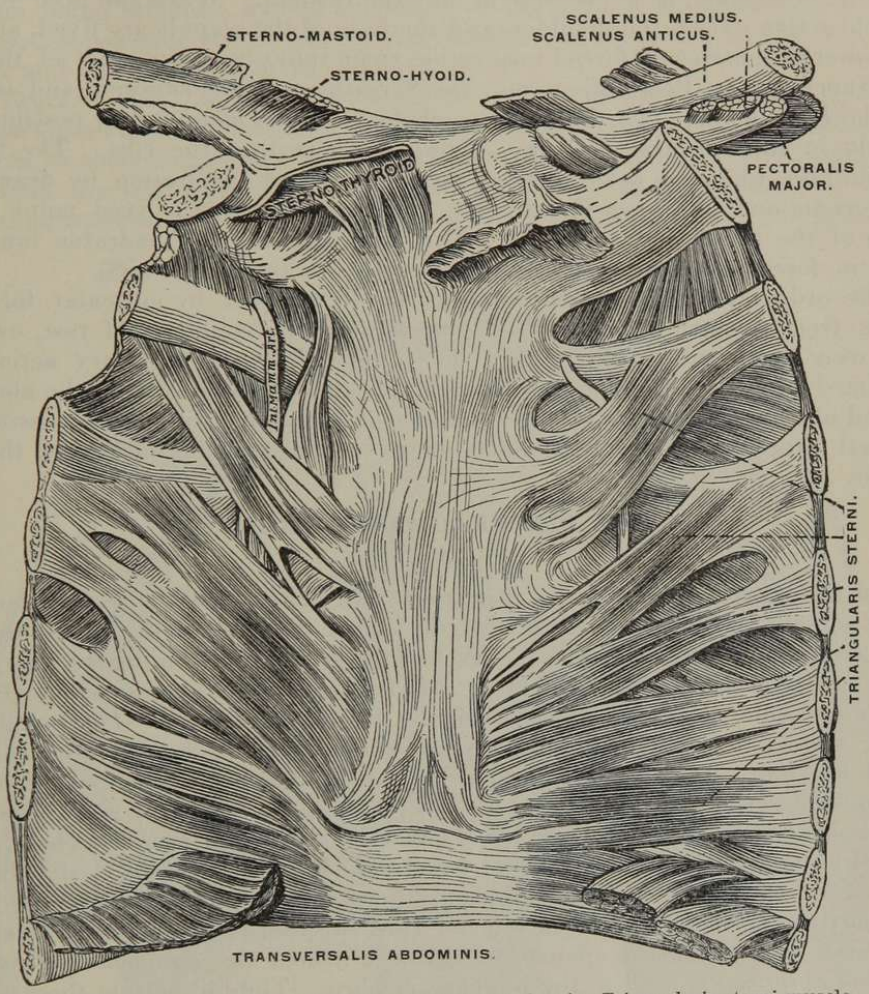

FIG. 289.—Posterior surface of sternum and costal cartilages, showing Triangularis sterni muscle. (From a preparation in the Museum of the Royal College of Surgeons of England.)

in ordinary respiration. When the first rib is elevated and fixed by the Scaleni, the External intercostals raise the other ribs, especially their fore part, and so increase the capacity of the chest from before backward; at the same time they evert their lower borders, and so enlarge the thoracic cavity transversely. The Internal intercostals, at the side of the thorax, depress the ribs and invert their lower borders, and so diminish the thoracic cavity; but at the fore part of the chest these muscles assist the External intercostals in raising the cartilages.[1] The Levatores

[1] The view of the action of the Intercostal muscles given in the text is that which is taught by Hutchinson (*Cycl. of Anat. and Phys.*, art. "Thorax"), and is usually adopted in our schools. It is, however, much disputed. Hamberger believed that the External intercostals act as elevators of the ribs, or muscles of inspiration, while the Internal act in expiration. Haller taught that both sets of muscles act in common—viz. as muscles of inspiration—and this view is adopted by many of the best anatomists of the Continent, and appears supported by many observations made on the human subject under various conditions of disease, and on living animals after the muscles have been exposed under chloroform. The reader may consult an interesting paper by Dr. Cleland in the *Journal of Anat. and Phys.* No. II., May, 1867, p. 209, "On the Hutchinsonian Theory of the Action of the Intercostal Muscles," who refers also to Henle, Luschka, Budge, and Baumler, *Observations on the Action of the Intercostal Muscles*, Erlangen, 1860. (In *New Syd. Soc.'s Year-Book for* 1861, p. 69.) Dr. W. W. Keen has come to the conclusion, from experiments made upon a criminal executed by hanging, that the Exter-

costarum assist the External intercostals in raising the ribs. The Triangularis sterni draws down the costal cartilages; it is therefore an expiratory muscle.

Muscles of Inspiration and Expiration.—The muscles which assist the action of the Diaphragm in ordinary tranquil inspiration are the Intercostals and the Levatores costarum, as above stated, and the Scaleni. When the need for more forcible action exists, the shoulders and the base of the scapula are fixed, and then the powerful muscles of forced inspiration come into play; the chief of these are the Trapezius, the Pectoralis minor, the Serratus posticus superior and inferior, and the Rhomboidei. The lower fibres of the Serratus magnus may possibly assist slightly in dilating the chest by raising and everting the ribs. The Sterno-mastoid also, when the head is fixed, assists in forced inspiration by drawing up the sternum and by fixing the clavicle, and thus affording a fixed point for the action of the muscles of the chest. The Ilio-costalis and Quadratus lumborum assist in forced inspiration by fixing the last rib (see page 458).

The ordinary action of expiration is hardly effected by muscular force, but results from a return of the walls of the thorax to a condition of rest, owing to their own elasticity and to that of the lungs. Forced expiratory actions are performed mainly by the flat muscles (Obliqui and Transversalis) of the abdomen, assisted also by the Rectus. Other muscles of forced expiration are possibly the Internal intercostals and Triangularis sterni (as above mentioned), and the Ilio-costalis.

THE DIAPHRAGMATIC REGION.

Diaphragm.

The **Diaphragm** (*διάφραγμα*, a partition wall) (Fig. 290) is a thin musculo-fibrous septum, placed obliquely at the junction of the upper with the middle third of the trunk, and separating the thorax from the abdomen, forming the floor of the former cavity and the roof of the latter. It is elliptical, its longest diameter being from side to side, somewhat fan-shaped, the broad elliptical portion being horizontal, the narrow part, which represents the handle of the fan, vertical, and joined at right angles to the former. It is from this circumstance that some anatomists describe it as consisting of two portions, the upper or great muscle of the Diaphragm, and the lower or lesser muscle. It arises from the whole of the internal circumference of the thorax; being attached, in front, by fleshy fibres to the ensiform cartilage; on either side, to the inner surface of the cartilages and bony portions of the six or seven inferior ribs, interdigitating with the Transversalis; and behind, to two aponeurotic arches, named the *ligamentum arcuatum externum et internum*, and to the lumbar vertebræ. The fibres from these sources vary in length; those arising from the ensiform appendix are very short and occasionally aponeurotic; those from the ligamenta arcuata, and more especially those from the cartilages of the ribs at the side of the chest, are longer, describe well-marked curves as they ascend, and finally converge to be inserted into the circumference of the central tendon. Between the sides of the muscular slip from the ensiform appendix and the cartilages of the adjoining ribs the fibres of the Diaphragm are deficient, the interval being filled by areolar tissue, covered on the thoracic side by the pleuræ; on the abdominal, by the peritoneum. This is, consequently, a weak point, and a portion of the contents of the abdomen may protrude into the chest, forming phrenic or diaphragmatic hernia, or a collection of pus in the mediastinum may descend through it, so as to point at the epigastrium.

The *ligamentum arcuatum internum* is a tendinous arch, thrown across the upper part of the Psoas magnus muscle, on each side of the spine. It is connected, by one end, to the outer side of the body of the first lumbar vertebra, being continuous with the outer side of the tendon of the corresponding crus; and, by

nal intercostals are muscles of expiration, as they pulled the ribs down, while the Internal intercostals pulled the ribs up and are muscles of inspiration (*Trans. Coll. Phys. Philadelphia*, Third Series, vol. i., 1875, p. 97).

the other end, to the front of the transverse process of the first, and sometimes also to that of the second, lumbar vertebra.

The *ligamentum arcuatum externum* is the thickened upper margin of the anterior lamella of the lumbar fascia; it arches across the upper part of the Quadratus lumborum, being attached, by one extremity, to the front of the transverse process of the first, sometimes also of the second, lumbar vertebra, and, by the other, to the apex and lower margin of the last rib.

The Crura.—The Diaphragm is connected to the spine by two *crura* or *pillars*, which are situated on the bodies of the lumbar vertebræ, on each side of the aorta. The crura, at their origin, are tendinous in structure; the right crus, larger and longer than the left, arising from the anterior surface of the bodies and intervertebral substances of the three or four upper lumbar vertebræ; the left, from

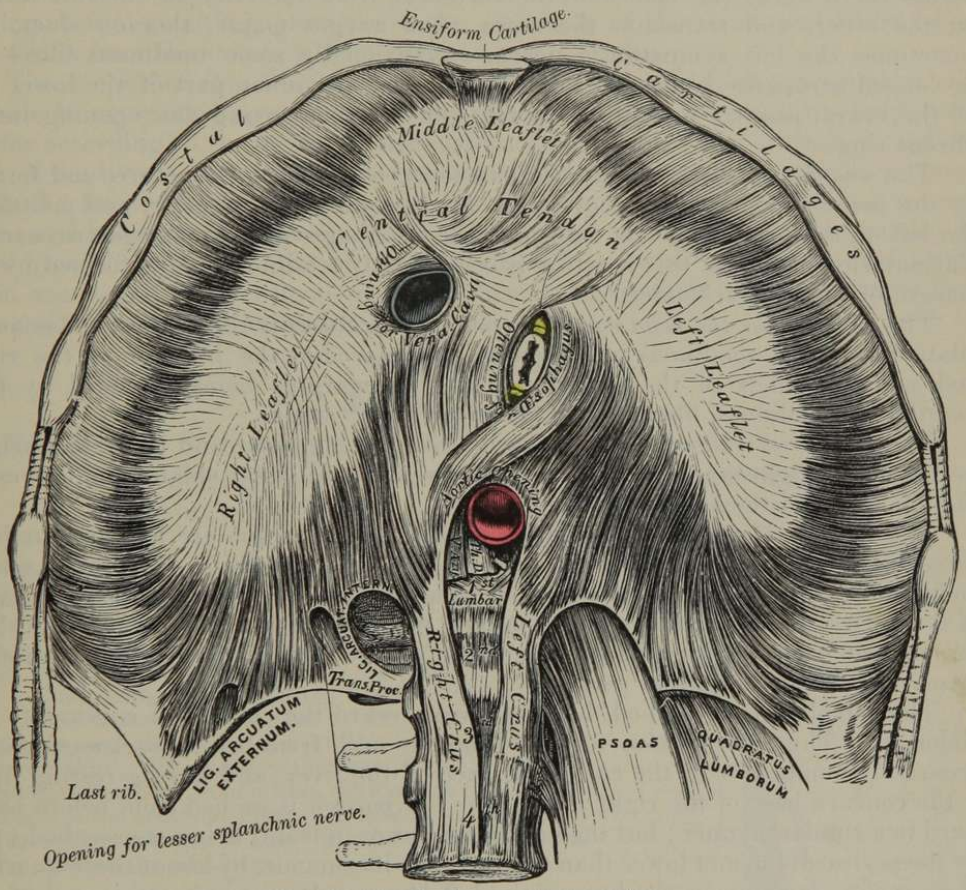

FIG. 290.—The Diaphragm. Under surface.

the two upper; both blending with the anterior common ligament of the spine. These tendinous portions of the crura pass forward and inward, and gradually converge to meet in the middle line, forming an arch, beneath which passes the aorta, vena azygos major, and thoracic duct. From this tendinous arch muscular fibres arise, which diverge, the outermost portion being directed upward and outward to the central tendon; the innermost decussating in front of the aorta, and then diverging, so as to surround the œsophagus before ending in the central tendon. The fibres derived from the right crus are the most numerous and pass in front of those derived from the left.

The *Central* or *Cordiform Tendon* of the Diaphragm is a thin but strong tendinous aponeurosis, situated at the centre of the vault formed by the muscle, immediately below the pericardium, with which its upper surface is blended. It is shaped somewhat like a trefoil leaf, consisting of three divisions, or leaflets,

separated from one another by slight indentations. The right leaflet is the largest: the middle one, directed toward the ensiform cartilage, the next in size; and the left, the smallest. In structure, the tendon is composed of several planes of fibres, which intersect one another at various angles, and unite into straight or curved bundles—an arrangement which affords it additional strength.

The *Openings* connected with the Diaphragm are three large and several smaller apertures. The former are the aortic, the œsophageal, and the opening for the vena cava.

The *aortic opening* is the lowest and the most posterior of the three large apertures connected with this muscle. It is situated in the middle line, immediately in front of the bodies of the vertebræ; and is, therefore, *behind* the Diaphragm, not in it. It is an osseo-aponeurotic aperture, formed by a tendinous arch thrown across the front of the bodies of the vertebræ, from the crus on one side to that on the other, and transmits the aorta, vena azygos major, thoracic duct, and sometimes the left sympathetic nerve. Occasionally some tendinous fibres are prolonged across the bodies of the vertebræ from the inner part of the lower end of the crura, passing behind the aorta, and thus converting the opening into a fibrous ring.

The *œsophageal opening*, elliptical in form, muscular in structure, and formed by the two crura, is placed above, and, at the same time, anterior, and a little to the left of, the preceding. It transmits the œsophagus and pneumogastric nerves. The anterior margin of this aperture is occasionally tendinous, being formed by the margin of the central tendon.

The *opening for the vena cava* (*foramen quadratum*) is the highest; it is quadrilateral in form, tendinous in structure, and placed at the junction of the right and middle leaflets of the central tendon, its margins being bounded by four bundles of tendinous fibres, which meet at right angles.

The *right crus* transmits the sympathetic and the greater and lesser splanchnic nerves of the right side; the *left crus*, the greater and lesser splanchnic nerves of the left side and the vena azygos minor.

The *Serous Membranes* in relation with the Diaphragm are four in number: three lining its upper or thoracic surface; one, its abdominal. The three serous membranes on its upper surface are the pleura on either side and the serous layer of the pericardium, which covers the middle portion of the tendinous centre. The serous membrane covering its under surface is a portion of the general peritoneal membrane of the abdominal cavity.

The Diaphragm is arched, being convex toward the chest and concave to the abdomen. The *right portion* forms a complete arch from before backward, being accurately moulded over the convex surface of the liver, and having resting upon it the concave base of the right lung. The *left portion* is arched from before backward in a similar manner; but the arch is narrower in front, being encroached upon by the pericardium, and lower than the right, at its summit, by about three-quarters of an inch. It supports the base of the left lung, and covers the great end of the stomach, the spleen, and left kidney. At its circumference the Diaphragm is higher in the mesial line of the body than at either side; but in the middle of the thorax the central portion, which supports the heart, is on a lower level than the two lateral portions.

Nerves.—The Diaphragm is supplied by the phrenic nerves and phrenic plexus of the sympathetic.

Actions.—The Diaphragm is the principal muscle of inspiration. When in a condition of rest the muscle presents a domed surface, concave toward the abdomen; and consists of a circumferential muscular and a central tendinous part. When the muscular fibres contract, they become less arched, or nearly straight, and thus cause the central tendon to descend, and in consequence the level of the chest-wall is lowered, the vertical diameter of the chest being proportionally increased. In this descent the different parts of the tendon move unequally. The left leaflet descends to the greatest extent; the right to a less extent, on

account of the liver; and the central leaflet the least, because of its connection to the pericardium. In descending the diaphragm presses on the abdominal viscera, and so to a certain extent causes a projection of the abdominal wall; but in consequence of these viscera not yielding completely, the central tendon becomes a fixed point, and enables the circumferential muscular fibres to act *from* it, and so elevate the lower ribs and expand the lower part of the thoracic cavity; and Duchenne has shown that the Diaphragm has the power of elevating the ribs, to which it is attached, by its contraction, if the abdominal viscera are *in situ*, but that if these organs are removed, this power is lost. When at the end of inspiration the Diaphragm relaxes, the thoracic walls return to their natural position in consequence of their elastic reaction and of the elasticity and weight of the displaced viscera.[1]

In all expulsive acts the Diaphragm is called into action, to give additional power to each expulsive effort. Thus, before sneezing, coughing, laughing, and crying, before vomiting, previous to the expulsion of the urine and fæces, or of the fœtus from the womb, a deep inspiration takes place.

The height of the Diaphragm is constantly varying during respiration, the muscle being carried upward or downward from the average level; its height also varies according to the degree of distension of the stomach and intestines, and the size of the liver. After a forced expiration, the right arch is on a level, in front, with the fourth costal cartilage; at the side, with the fifth, sixth, and seventh ribs; and behind, with the eighth rib, the left arch being usually from one to two ribs' breadth below the level of the right one. In a forced inspiration, it descends from one to two inches; its slope would then be represented by a line drawn from the ensiform cartilage toward the tenth rib.

THE ABDOMEN.

Superficial Muscles.

The Muscles in this region are, the

Obliquus Externus.
Obliquus Internus.
Transversalis.
Rectus.
Pyramidalis.

Dissection (Fig. 291).—To dissect the abdominal muscles, make a vertical incision from the ensiform cartilage to the pubes; a second incision from the umbilicus obliquely upward and outward to the outer surface of the chest, as high as the lower border of the fifth or sixth rib; and a third, commencing midway between the umbilicus and pubes, transversely outward to the anterior superior iliac spine, and along the crest of the ilium as far as its posterior third. Then reflect the three flaps included between these incisions from within outward, in the lines of direction of the muscular fibres. If necessary, the abdominal muscles may be made tense by inflating the peritoneal cavity through the umbilicus.

3. Dissection of inguinal hernia.

FIG. 291.—Dissection of abdomen.

The **Superficial fascia** of the abdomen consists over the greater part of the abdominal wall of a single layer of fascia, which contains a variable amount of fat; but as this layer approaches the groin it is easily divisible into two layers, between which are found the superficial vessels and nerves and the superficial inguinal lymphatic glands. The superficial layer is thick, areolar in texture, containing adipose tissue in its meshes, the quantity of which varies in different subjects. Below it passes over Poupart's ligament, and is continuous with the outer layer of the superficial fascia of the thigh. In the male this fascia is continued over the penis and outer

[1] For a detailed description of the general relations of the Diaphragm, and its action, refer to Dr. Sibson's *Medical Anatomy*.

surface of the cord to the scrotum, where it helps to form the dartos. As it passes to the scrotum it changes its character, becoming thin, destitute of adipose tissue and of a pale reddish color, and in the scrotum it acquires some involuntary muscular fibres. From the scrotum it may be traced backward to be continuous with the superficial fascia of the perinæum. In the female this fascia is continued into the labia majora. The deeper layer (*fascia of Scarpa*) is thinner and more membranous in character than the superficial layer. In the middle line it is intimately adherent to the linea alba; above, it is continuous with the superficial fascia over the rest of the trunk; below, it blends with the fascia lata of the thigh a little below Poupart's ligament; and below and internally it is continued over the penis and spermatic cord to the scrotum, where it helps to form the dartos. From the scrotum it may be traced backward to be continuous with the deep layer of the superficial fascia of the perinæum. In the female it is continued into the labia majora.

The **External** or **Descending Oblique muscle** (Fig. 292) is situated on the side and fore part of the abdomen; being the largest and the most superficial of the three flat muscles in this region. It is broad, thin, and irregularly quadrilateral, its muscular portion occupying the side, its aponeurosis the anterior wall, of the abdomen. It arises, by eight fleshy digitations, from the external surface and lower borders of the eight inferior ribs; these digitations are arranged in an oblique line running downward and backward; the upper ones being attached close to the cartilages of the corresponding ribs; the lowest, to the apex of the cartilage of the last rib; the intermediate ones, to the ribs at some distance from their cartilages. The five superior serrations increase in size from above downward, and are received between corresponding processes of the Serratus magnus; the three lower ones diminish in size from above downward, receiving between them corresponding processes from the Latissimus dorsi. From these attachments, the fleshy fibres proceed in various directions. Those from the lowest ribs pass nearly vertically downward, to be inserted into the anterior half of the outer lip of the crest of the ilium; the middle and upper fibres, directed downward and forward, terminate in tendinous fibres, opposite a line drawn from the prominence of the ninth costal cartilage to the anterior superior spinous process of the ilium, which then spread out into a broad aponeurosis.

The **Aponeurosis of the External Oblique** is a thin, but strong membranous aponeurosis, the fibres of which are directed obliquely downward and inward. It is joined with that of the opposite muscle along the median line, covers the whole of the front of the abdomen; above, it is connected with the lower border of the Pectoralis major; below, its fibres are closely aggregated together, and extend obliquely across from the anterior superior spine of the ilium to the spine of the os pubis and the linea ilio-pectinea. In the median line it interlaces with the aponeurosis of the opposite muscle, forming the linea alba, which extends from the ensiform cartilage to the symphysis pubis.

That portion of the aponeurosis which extends between the anterior superior spine of the ilium and the spine of the os pubis is a broad band, folded inward, and continuous below with the fascia lata; it is called *Poupart's ligament.* The portion which is reflected from Poupart's ligament at the spine of the os pubis along the pectineal line is called *Gimbernat's ligament.* From the point of attachment of the latter to the pectineal line, a few fibres pass upward and inward, behind the inner pillar of the ring, to the linea alba. They diverge as they ascend, and form a thin, triangular, fibrous band, which is called the *triangular ligament of the abdomen.*

In the aponeurosis of the External oblique, immediately above the crest of the os pubis, is a triangular opening, the *external abdominal ring*, formed by a separation of the fibres of the aponeurosis in this situation.

Relations.—By its *external surface*, with the superficial fascia, superficial epigastric and circumflex iliac vessels, and some cutaneous nerves; by its *internal surface*, with the Internal oblique, the lower part of the eight inferior ribs, and

Intercostal muscles, the Cremaster, the spermatic cord in the male, and round ligament in the female. Its *posterior border*, extending from the last rib to the crest of the ilium, is fleshy throughout and free; it is occasionally overlapped by the Latissimus dorsi, though generally a triangular interval exists between the two muscles near the crest of the ilium, in which is seen a portion of the internal oblique. This triangle, *Petit's triangle*, is therefore bounded in front by the

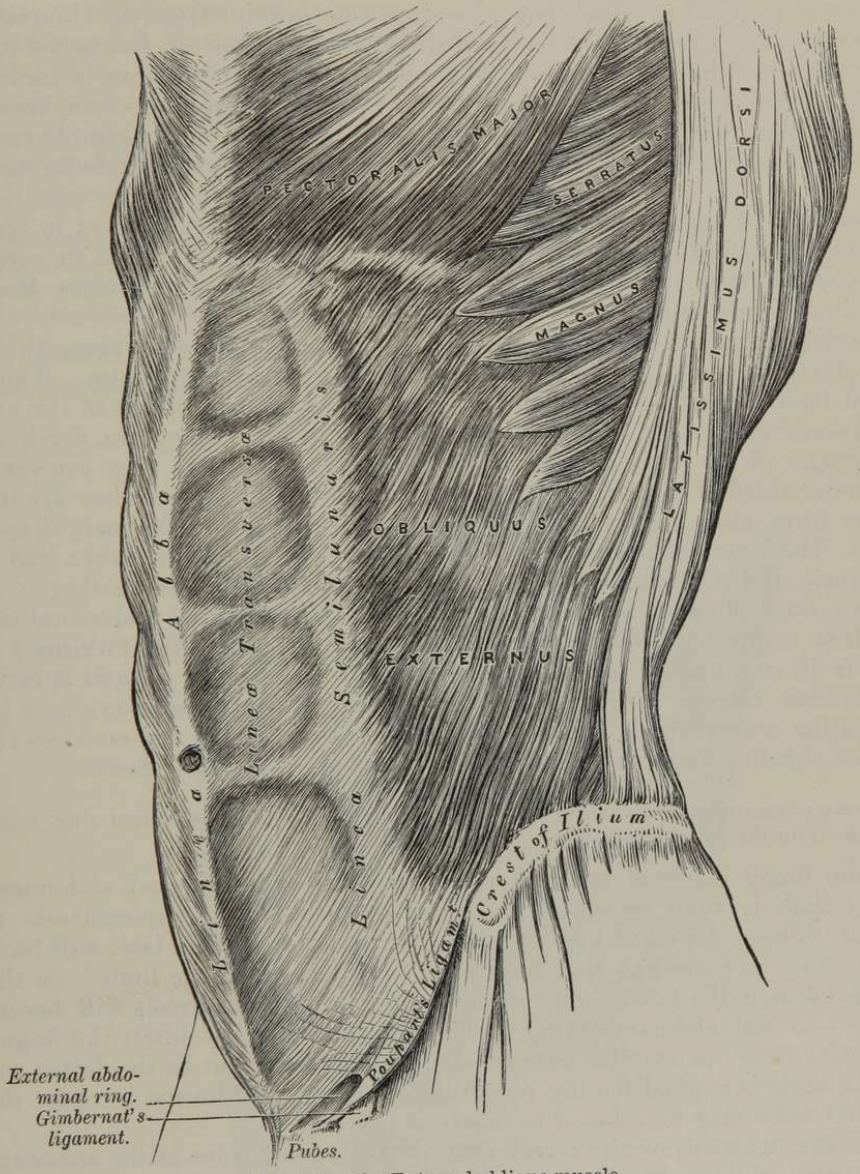

FIG. 292.—The External oblique muscle.

External oblique, behind by the Latissimus dorsi, below by the crest of the ilium, while its floor is formed by the Internal oblique (Fig. 287).

The following parts of the aponeurosis of the External oblique muscle require to be further described: viz. the external abdominal ring, the intercolumnar fibres and fascia, Poupart's ligament, Gimbernat's ligament, and the triangular ligament of the abdomen.

The External Abdominal Ring.—Just above, and to the outer side of the crest of the os pubis, an interval is seen in the aponeurosis of the External oblique, called the *External abdominal ring*. The aperture is oblique in direction, some-

what triangular in form, and corresponds with the course of the fibres of the aponeurosis. It usually measures from base to apex about an inch, and transversely about half an inch. It is bounded below by the crest of the os pubis; above, by a series of curved fibres, the *intercolumnar*, which pass across the upper angle of the ring, so as to increase its strength; and on each side, by the margins of the opening in the aponeurosis, which are called the columns or pillars of the ring.

The external pillar, which is at the same time inferior from the obliquity of its direction, is the stronger: it is formed by that portion of Poupart's ligament which is inserted into the spine of the os pubis; it is curved so as to form a kind of groove, upon which the spermatic cord rests. The internal or superior pillar is a broad, thin, flat band which is attached to the front of the symphysis pubis, interlacing with its fellow of the opposite side, that of the right side being superficial.

The external abdominal ring gives passage to the spermatic cord in the male, and round ligament in the female: it is much larger in men than in women, on account of the large size of the spermatic cord, and hence the greater frequency of inguinal hernia in men.

The **intercolumnar fibres** are a series of curved tendinous fibres, which arch across the lower part of the aponeurosis of the External oblique. They have received their name from stretching across between the two pillars of the external ring, describing a curve with the convexity downward. They are much thicker and stronger at the outer margin of the external ring, where they are connected to the outer third of Poupart's ligament, than internally, where they are inserted into the linea alba. They are more strongly developed in the male than in the female. The intercolumnar fibres increase the strength of the lower part of the aponeurosis, and prevent the divergence of the pillars from one another.

These intercolumnar fibres as they pass across the external abdominal ring are themselves connected together by delicate fibrous tissue, thus forming a fascia, which as it is attached to the pillars of the ring covers it in, and is called the *intercolumnar fascia*. This **intercolumnar fascia** is continued down as a tubular prolongation around the outer surface of the cord and testis, and encloses them in a distinct sheath; hence it is also called the external spermatic fascia.

The sac of an inguinal hernia, in passing through the external abdominal ring, receives an investment from the intercolumnar fascia.

If the finger is introduced a short distance into the external abdominal ring and the limb is then extended and rotated outward, the aponeurosis of the External oblique, together with the iliac portion of the fascia lata, will be felt to become tense, and the external ring much contracted; if the limb is on the contrary flexed upon the pelvis and rotated inward, this aponeurosis will become lax and the external abdominal ring sufficiently enlarged to admit the finger with comparative ease: hence the patient should always be put in the latter position when the taxis is applied for the reduction of an inguinal hernia in order that the abdominal walls may be relaxed as much as possible.

Poupart's ligament, or the **crural arch,** is the lower border of the aponeurosis of the External oblique muscle, and extends from the anterior superior spine of the ilium to the pubic spine. From this latter point it is reflected outward to be attached to the pectineal line for about half an inch, forming Gimbernat's ligament. Its general direction is curved downward toward the thigh, where it is continuous with the fascia lata. Its outer half is rounded and oblique in direction. Its inner half gradually widens at its attachment to the os pubis, is more horizontal in direction, and lies beneath the spermatic cord.

Nearly the whole of the space included between the crural arch and the innominate bone is filled in by the parts which descend from the abdomen into the thigh. These will be referred to again on a subsequent page.

Gimbernat's ligament is that part of the aponeurosis of the External oblique

muscle which is reflected downward and outward from the spine of the os pubis to be inserted into the pectineal line. It is about half an inch in length, larger in the male than in the female, almost horizontal in direction in the erect posture, and of a triangular form with the base directed outward. Its base, or outer margin, is concave, thin, and sharp, and lies in contact with the crural sheath. Its apex corresponds to the spine of the os pubis. Its posterior margin is attached to the pectineal line, and is continuous with the pubic portion of the fascia lata. Its anterior margin is continuous with Poupart's ligament.

The **triangular ligament** of the abdomen is a band of tendinous fibres of a triangular shape, which is attached by its apex to the pectineal line, where it is continuous with Gimbernat's ligament. It passes inward beneath the spermatic cord, and expands into a somewhat fan-shaped fascia, lying behind the inner pillar of the external abdominal ring, and in front of the conjoined tendon, and interlaces with the ligament of the other side at the linea alba.

Dissection.—Detach the External oblique by dividing it across, just in front of its attachment to the ribs, as far as its posterior border, and separate it below from the crest of the ilium as far as the anterior superior spine; then separate the muscle carefully from the Internal oblique, which lies beneath, and turn it toward the opposite side.

The **Internal** or **Ascending oblique muscle** (Fig. 293), thinner and smaller than the preceding, beneath which it lies, is of an irregularly quadrilateral form,

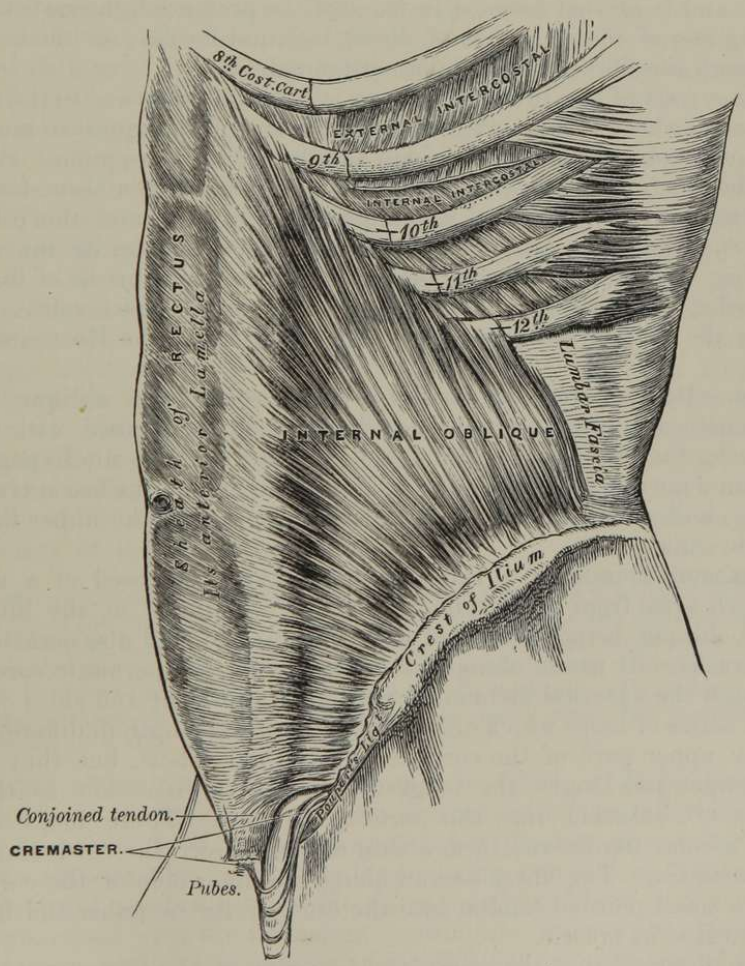

FIG. 293.—The internal oblique muscle.

and situated at the side and fore part of the abdomen. It arises, by fleshy fibres, from the outer half of Poupart's ligament, being attached to the groove on its

upper surface; from the anterior two-thirds of the middle lip of the crest of the ilium, and from the posterior lamella of the lumbar fascia. From this origin the fibres diverge: those from Poupart's ligament, few in number and paler in color than the rest, arch downward and inward across the spermatic cord, and, becoming tendinous, are inserted, conjointly with those of the Transversalis, into the crest of the os pubis and pectineal line, to the extent of half an inch, forming what is known as the conjoined tendon of the Internal oblique and Transversalis; those from the anterior third of the iliac origin are horizontal in their direction, and, becoming tendinous along the lower fourth of the linea semilunaris, pass in front of the Rectus muscle to be inserted into the linea alba; those which arise from the middle third of the origin from the crest of the ilium pass obliquely upward and inward, and terminate in an aponeurosis, which divides opposite the linea semilunaris into two lamellæ, which are continued forward, in front and behind the Rectus muscle, to the linea alba, the posterior lamella being also connected to the cartilages of the seventh, eighth, and ninth ribs; the most posterior fibres pass almost vertically upward, to be inserted into the lower borders of the cartilages of the three lower ribs, being continuous with the Internal intercostal muscles.

The conjoined tendon of the Internal oblique and Transversalis is inserted into the crest of the os pubis and pectineal line, immediately behind the external abdominal ring, serving to protect what would otherwise be a weak point in the abdominal wall. Sometimes this tendon is insufficient to resist the pressure from within, and is carried forward in front of the protrusion through the external ring, forming one of the coverings of direct inguinal hernia; or the hernia forces its way through the fibres of the conjoined tendon.

The aponeurosis of the Internal oblique is continued forward to the middle line of the abdomen, where it joins with the aponeurosis of the opposite muscle at the linea alba, and extends from the margin of the thorax to the os pubis. At the outer margin of the Rectus muscle, this aponeurosis, for the upper three-fourths of its extent, divides into two lamellæ, which pass, one in front and the other behind the muscle, enclosing it in a kind of sheath, and reuniting on its inner border at the linea alba; the anterior layer is blended with the aponeurosis of the External oblique muscle; the posterior layer with that of the Transversalis. Along the lower fourth the aponeurosis passes altogether in front of the Rectus without any separation.

Relations.—By its *external surface*, with the External oblique, Latissimus dorsi, spermatic cord, and external ring; by its *internal surface*, with the Transversalis muscle, the lower intercostal vessels and nerves, the ilio-hypogastric and the ilio-inguinal nerves. Near Poupart's ligament it lies on the fascia transversalis, internal ring, and spermatic cord. Its lower border forms the upper boundary of the spermatic canal.

The **Cremaster muscle** is a thin muscular layer, composed of a number of fasciculi which arise from the middle of Poupart's ligament at the inner side of the Internal oblique, being connected with that muscle, and also occasionally with the Transversalis. It passes along the outer side of the spermatic cord, descends with it through the external abdominal ring upon the front and sides of the cord, and forms a series of loops which differ in thickness and length in different subjects. Those at the upper part of the cord are exceedingly short, but they become in succession longer and longer, the longest reaching down as low as the testicle, where a few are inserted into the tunica vaginalis. These loops are united together by areolar tissue, and form a thin covering over the cord and testis, the *fascia cremasterica*. The fibres ascend along the inner side of the cord, and are inserted by a small pointed tendon into the crest of the os pubis and front of the sheath of the Rectus muscle.

It will be observed that the origin and insertion of the Cremaster is precisely similar to that of the lower fibres of the Internal oblique. This fact affords an easy explanation of the manner in which the testicle and cord are invested by this muscle. At an early period of fœtal life the testis is placed at the lower and back

part of the abdominal cavity, but during its descent toward the scrotum, which takes place before birth, it passes beneath the arched fibres of the Internal oblique. In its passage beneath this muscle some fibres are derived from its lower part which accompany the testicle and cord into the scrotum. It occasionally happens that the loops of the Cremaster surround the cord, some lying behind as well as in front. It is probable that under these circumstances the testis, in its descent, passed through instead of beneath the fibres of the Internal oblique.

In the descent of an oblique inguinal hernia, which takes the same course as the spermatic cord, the Cremaster muscle forms one of its coverings. This muscle becomes largely developed in cases of hydrocele and large old scrotal hernia. No such muscles exist in the female, but an analogous structure is developed in those cases where an oblique inguinal hernia descends beneath the margin of the Internal oblique.

Dissection.—Detach the Internal oblique in order to expose the Transversalis beneath. This may be effected by dividing the muscle, above, at its attachment to the ribs; below, at its connection with Poupart's ligament and the crest of the ilium; and behind, by a vertical incision extending from the last rib to the crest of the ilium. The muscle should previously be made tense by drawing upon it with the fingers of the left hand, and if its division is carefully effected, the cellular interval between it and the Transversalis, as well as the direction of the fibres of the latter muscle, will afford a clear guide to their separation; along the crest of the ilium the circumflex iliac vessels are interposed between them, and form an important guide in separating them. The muscle should then be thrown forward toward the linea alba.

The **Transversalis muscle** (Fig. 294), so called from the direction of its fibres, is the most internal flat muscle of the abdomen, being placed immediately beneath the Internal oblique. It arises by fleshy fibres from the outer third of Poupart's ligament; from the inner lip of the crest of the ilium for its anterior three-fourths; from the inner surface of the cartilages of the six lower ribs, interdigitating with the Diaphragm; and by the middle layer of the lumbar fascia (*posterior aponeurosis* of the muscle itself) from the tips of the transvere processes of the lumbar vertebræ. The muscle terminates in front in a broad aponeurosis, the lower fibres of which curve downward and inward, and are inserted, together with those of the Internal oblique, into the lower part of the linea alba, the crest of the os pubis and pectineal line, forming what is known as the conjoined tendon of the Internal oblique and Transversalis. Throughout the rest of its extent the aponeurosis passes horizontally inward, and is inserted into the linea alba; its upper three-fourths passing behind the Rectus muscle, blending with the posterior lamella of the Internal oblique; its lower fourth passing in front of the Rectus.

Relations.—By its *external surface*, with the Internal oblique, and the inner surface of the cartilages of the lower ribs; by its *internal surface*, with the fascia transversalis, which separates it from the peritoneum. Its lower border forms the upper boundary of the spermatic canal.

Dissection.—To expose the Rectus muscle, open its sheath by a vertical incision extending from the margin of the thorax to the os pubis, and then reflect the two portions from the surface of the muscle, which is easily done, excepting at the lineæ transversæ, where so close an adhesion exists that the greatest care is requisite in separating them. Now raise the outer edge of the muscle, in order to examine the posterior layer of the sheath. By dividing the muscle in the centre, and turning its lower part downward, the point where the posterior wall of the sheath terminates in a thin curved margin will be seen.

The **Rectus abdominis** is a long flat muscle, which extends along the whole length of the front of the abdomen, being separated from its fellow of the opposite side by the linea alba. It is much broader, but thinner, above than below, and arises by two tendons, the external or larger being attached to the crest of the os pubis, the internal, smaller portion interlacing with its fellow of the opposite side, and being connected with the ligaments covering the front of the symphysis pubis. The fibres ascend, and the muscle is inserted by three portions of unequal size into the cartilages of the fifth, sixth, and seventh ribs. Some fibres are occasionally connected with the costo-xiphoid ligaments and side of the ensiform cartilage.

The Rectus muscle is traversed by tendinous intersections, three in number,

which have received the name of *lineæ transversæ*. One of these is usually situated opposite the umbilicus, and two above that point; of the latter, one corresponds to the extremity of the ensiform cartilage, and the other to the interval between the ensiform cartilage and the umbilicus. These intersections pass transversely or obliquely across the muscle in a zigzag course; they rarely extend completely through its substance, sometimes pass only halfway across

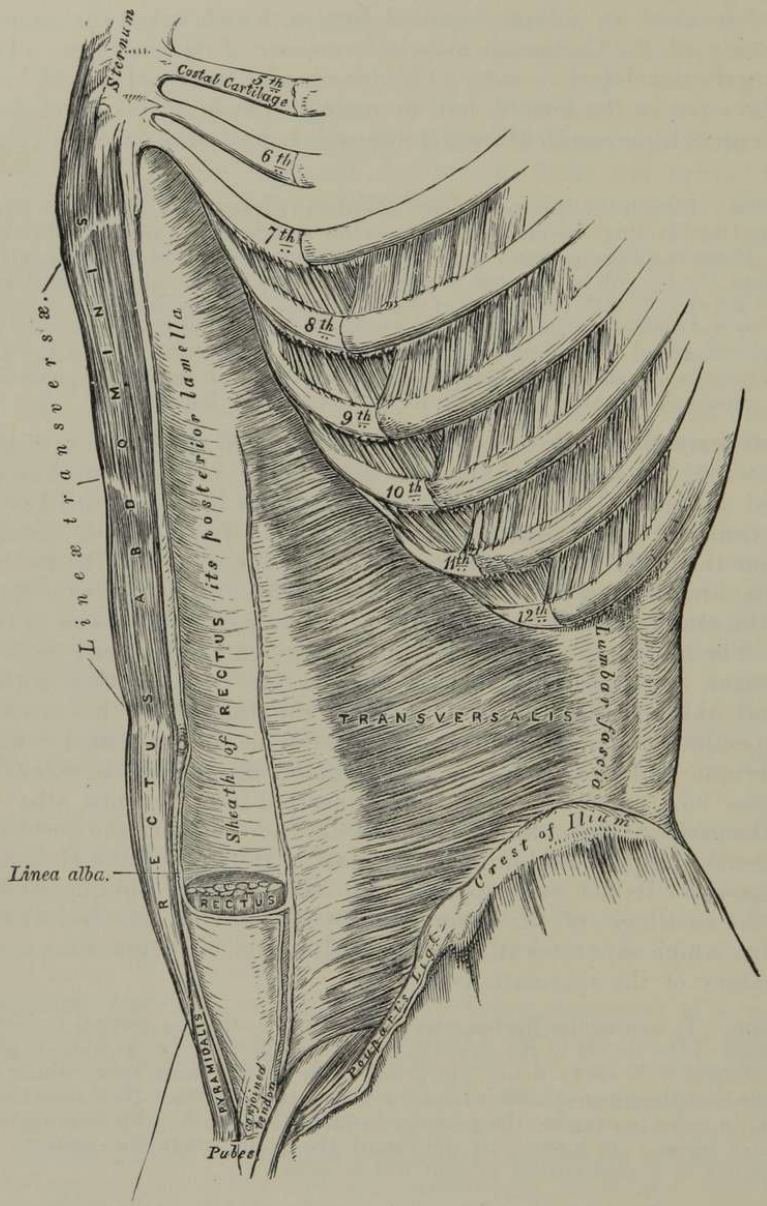

FIG. 294.—The Transversalis, Rectus, and Pyramidalis muscles.

it, and are intimately adherent in front to the sheath in which the muscle is enclosed.

The Rectus is enclosed in a sheath (Fig. 295) formed by the aponeuroses of the Oblique and Transversalis muscles, which are arranged in the following manner. When the aponeurosis of the Internal oblique arrives at the outer margin of the Rectus, it divides into two lamellæ, one of which passes in front of the Rectus, blending with the aponeurosis of the External oblique; the other, behind it, blending with the aponeurosis of the Transversalis; and these, joining again at its

inner border, are inserted into the linea alba. This arrangement of the aponeuroses exists along the upper three-fourths of the muscle: at the commencement of the lower fourth, the posterior wall of the sheath terminates in a thin curved margin, the *semilunar fold of Douglas*, the concavity of which looks downward toward the pubes; the aponeuroses of all three muscles passing in front of the Rectus without any separation. The extremities of the fold of Douglas descend as pillars to the os pubis. The inner pillar is attached to the symphysis pubis; the outer pillar, which is named by Braune the ligament of Hesselbach, divides below to enclose the internal abdominal ring; the internal fibres are attached to the horizontal ramus of the os pubis and the pectineal fascia; the external ones pass to the Psoas fascia and to the Transversalis where it arises from Poupart's ligament on the outer side of the ring. The Rectus muscle, in the situation

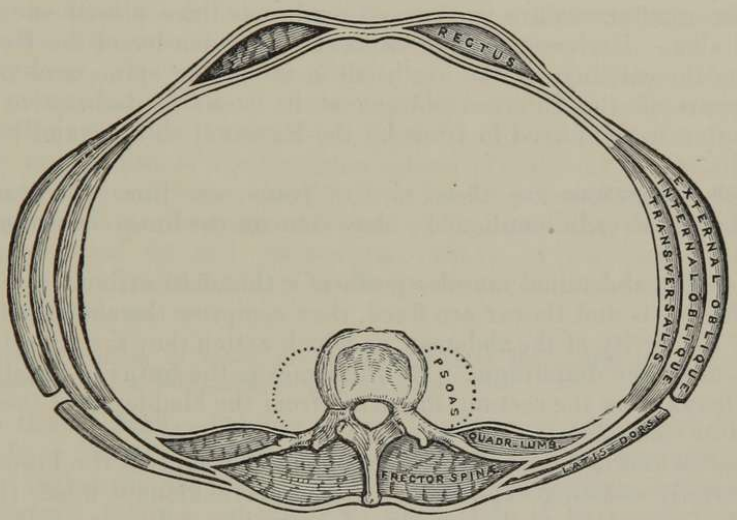

FIG. 295.—A transverse section of the abdomen in the lumbar region.

where its sheath is deficient, is separated from the peritoneum by the transversalis fascia.

The **Pyramidalis** is a small muscle, triangular in shape, placed at the lower part of the abdomen, in front of the Rectus, and contained in the same sheath with that muscle. It arises by tendinous fibres from the front of the os pubis and the anterior pubic ligament; the fleshy portion of the muscle passes upward, diminishing in size as it ascends, and terminates by a pointed extremity, which is inserted into the linea alba, midway between the umbilicus and the os pubis. This muscle is sometimes found wanting on one or both sides; the lower end of the Rectus then becomes proportionately increased in size. Occasionally it has been found double on one side, or the muscles of the two sides are of unequal size. Sometimes its length exceeds what is stated above.

Relations.—Its *anterior surface* is covered by the sheath of the Rectus. Its *posterior surface* rests against the Rectus itself. To expose the Pyramidalis, make, *through the sheath* of the Rectus, a vertical incision the lower end of which should begin just a little to one side of, and on a level with, the *symphysis pubis*.

Nerves.—The abdominal muscles are supplied by the lower intercostal nerves. The Internal oblique also receives a filament from the ilio-inguinal nerve. The Cremaster is supplied by the genital branch of the Genito-crural.

In the description of the abdominal muscles mention has frequently been made of the linea alba, lineæ semilunares, and lineæ transversæ; when the dissection of the muscles is completed these structures should be examined.

The **linea alba** is a tendinous raphe seen along the middle line of the abdomen, extending from the ensiform cartilage to the symphysis pubis, to which it is

attached. It is placed between the inner borders of the Recti muscles, and is formed by the blending of the aponeuroses of the Obliqui and Transversales muscles. It is narrow below, corresponding to the narrow interval existing between the Recti; but broader above, as these muscles diverge from one another in their ascent, becoming of considerable breadth after great distension of the abdomen from pregnancy or ascites. It presents numerous apertures for the passage of vessels and nerves: the largest of these is the umbilicus, which in the fœtus transmits the umbilical vessels, but in the adult is obliterated, the cicatrix being stronger than the neighboring parts; hence umbilical hernia occurs in the adult *near* the umbilicus, whilst in the fœtus it occurs *at* the umbilicus. The linea alba is in relation, in front, with the integument, to which it is adherent, especially at the umbilicus; behind, it is separated from the peritoneum by the transversalis fascia; and below, by the urachus, and the bladder when that organ is distended.

The **lineæ semilunares** are two curved tendinous lines placed one on each side of the linea alba. Each corresponds with the outer border of the Rectus muscle, extends from the cartilage of the ninth rib to the pubic spine, and is formed by the aponeurosis of the Internal oblique at its point of division to enclose the Rectus, where it is reinforced in front by the External oblique and behind by the Transversalis.

The **lineæ transversæ** are three narrow transverse lines which intersect the Recti muscles, as already mentioned; they connect the lineæ semilunares with the linea alba.

Actions.—The abdominal muscles perform a threefold action:

When the pelvis and thorax are fixed, they compress the abdominal viscera, by constricting the cavity of the abdomen, in which action they are materially assisted by the descent of the diaphragm. By these means the fœtus is expelled from the uterus, the fæces from the rectum, the urine from the bladder, and the contents of the stomach in vomiting.

If the pelvis and spine are fixed, these muscles compress the lower part of the thorax, materially assisting expiration. If the pelvis alone is fixed, the thorax is bent directly forward when the muscles of both sides act, or to either side when those of the two sides act alternately, rotation of the trunk at the same time taking place to the opposite side.

If the thorax is fixed, these muscles, acting together, draw the pelvis upward, as in climbing; or, acting singly, they draw the pelvis upward, and rotate the vertebral column to one side or the other. The Recti muscles, acting from below, depress the thorax, and consequently flex the vertebral column; when acting from above, they flex the pelvis upon the vertebral column. The Pyramidales are tensors of the linea alba.

The **fascia transversalis** is a thin aponeurotic membrane which lies between the inner surface of the Transversalis muscle and the peritoneum. It forms part of the general layer of fascia which lines the interior of the abdominal and pelvic cavities, and is directly continuous with the iliac and pelvic fasciæ. In the inguinal region the transversalis fascia is thick and dense in structure, and joined by fibres from the aponeurosis of the Transversalis muscle, but it becomes thin and cellular as it ascends to the diaphragm. Below, it has the following attachments: external to the femoral vessels it is connected to the posterior margin of Poupart's ligament, and is there continuous with the iliac fascia. Internal to the femoral vessels it is thin and attached to the os pubis and pectineal line, behind the conjoined tendon, with which it is united; and, corresponding to the point where the femoral vessels pass into the thigh, this fascia descends in front of them, forming the anterior wall of the crural sheath. The spermatic cord in the male and the round ligament in the female pass through this fascia: the point where they pass through is called the internal abdominal ring. This opening is not visible externally, owing to a prolongation of the transversalis fascia on the structures, forming the infundibuliform process.

The **internal** or **deep abdominal ring** is situated in the transversalis fascia,

midway between the anterior superior spine of the ilium and the spine of the os pubis, and about half an inch above Poupart's ligament. It is of an oval form, the extremities of the oval directed upward and downward, varies in size in different subjects, and is much larger in the male than in the female. It is bounded, above and externally, by the arched fibres of the Transversalis; below and internally, by the deep epigastric vessels. It transmits the spermatic cord in the male and the round ligament in the female. From its circumference a thin funnel-shaped membrane, the *infundibuliform fascia*, is continued round the cord and testis, enclosing them in a distinct pouch.

When the sac of an oblique inguinal hernia passes through the internal or deep abdominal ring, the infundibuliform process of the transversalis fascia forms one of its coverings.

The **inguinal** or **spermatic canal** contains the spermatic cord in the male and the round ligament in the female. It is an oblique canal about an inch and a half in length, directed downward and inward, and placed parallel to and a little above Poupart's ligament. It commences above at the internal or deep abdominal ring, which is the point where the cord enters the spermatic canal, and terminates below at the external ring. It is bounded in front by the integument and superficial fascia, by the aponeurosis of the External oblique throughout its whole length, and by the Internal oblique for its outer third; behind, by the triangular ligament, the conjoined tendon of the Internal oblique and Transversalis, transversalis fascia, and the subperitoneal fat and peritoneum; above, by the arched fibres of the Internal oblique and Transversalis; below, by the union of the fascia transversalis with Poupart's ligament.

That form of protrusion in which the intestine follows the course of the spermatic cord along the spermatic canal is called oblique inguinal hernia.

The Deep Crural Arch.—Passing across the front of the crural arch, on the abdominal side of Poupart's ligament and closely connected with it, is a thickened band of fibres called the deep crural arch. It is apparently a thickening of the fascia transversalis, joining externally to the centre of Poupart's ligament, and arching across the front of the crural sheath to be inserted by a broad attachment into the pectineal line, behind the conjoined tendons. In some subjects this structure is not very prominently marked, and not unfrequently it is altogether wanting.

Surface Form.—The only two muscles of this group which have any considerable influence on surface form are the External oblique and Rectus muscles of the abdomen. With regard to the External oblique, the upper digitations of its origin from the ribs are well marked, intermingled with the serrations of the Serratus magnus; the lower digitations are not visible, being covered by the thick border of the Latissimus dorsi. Its attachment to the crest of the ilium, in conjunction with the Internal oblique, forms a thick oblique roll, which determines the iliac furrow. Sometimes on the front of the lateral region of the abdomen an undulating outline marks the spot where the muscular fibres terminate and the aponeurosis commences. The outer border of the Rectus is defined by the *linea semilunaris*, which may be exactly defined by putting the muscle into action. It corresponds with a curved line, with its convexity outward, drawn from the lowest part of the cartilage of the seventh rib to the spine of the os pubis, so that the centre of the line, at or near the umbilicus, is three inches from the median line. The inner border of the Rectus corresponds to the *linea alba*, marked on the surface of the body by a groove, the *abdominal furrow*, which extends from the infrasternal fossa to, or to a little below, the umbilicus, where it gradually becomes lost. The surface of the Rectus presents three transverse furrows, the *lineæ transversæ*. The upper two of these, one opposite or a little below the tip of the ensiform cartilage, and another, midway between this point and the umbilicus, are usually well marked; the third, opposite the umbilicus, is not so distinct. The umbilicus, situated in the linea alba, varies very much in position as regards its height. It is always situated above a zone drawn round the body opposite the highest point of the crest of the ilium, generally being about three-quarters of an inch to an inch above this line. It generally corresponds, therefore, to the fibro-cartilage between the third and fourth lumbar vertebræ.

Deep Muscles of the Abdomen.

Psoas parvus.
Psoas magnus.
Iliacus.
Quadratus lumborum.

The Psoas magnus, the Psoas parvus, and the Iliacus muscles, with the fascia covering them, will be described with the Muscles of the Lower Extremity (see page 504).

The Fascia covering the Quadratus Lumborum.—This is the most anterior of the two layers of fascia which are given off from the anterior or deep surface of the lumbar fascia (see page 433). It is a thin layer of fascia (part of *transversalis fascia*), which, passing over the anterior surface of the Quadratus lumborum, is attached, internally, to the anterior surface of the transverse processes of the lumbar vertebræ; below to the ilio-lumbar ligament; and above, to the apex and lower border of the last rib.

The portion of this fascia which extends from the transverse process of the first lumbar vertebra to the apex and lower border of the last rib constitutes the ligamentum arcuatum externum.

The **Quadratus lumborum** (Fig. 288, page 435) is situated in the lumbar region. It is irregularly quadrilateral in shape, and broader below than above. It arises by aponeurotic fibres from the ilio-lumbar ligament and the adjacent portion of the crest of the ilium for about two inches, and is inserted into the lower border of the last rib for about half its length and by four small tendons, into the apices of the transverse processes of the four upper lumbar vertebræ. Occasionally a second portion of this muscle is found situated in front of the preceding. This arises from the upper borders of the transverse processes of the lumbar vertebræ, and is inserted into the lower margin of the last rib. The Quadratus lumborum is contained in a sheath formed by the anterior and middle lamellæ of the lumbar fasciæ.

Relations.—Its *anterior surface* (or rather the fascia which covers its anterior surface) is in relation with the colon and the kidney. Its *posterior surface* is in relation with the middle lamella (*posterior aponeurosis* of the Transversalis muscle) of the lumbar fascia, which separates it from the Erector spinæ. The Quadratus lumborum extends, however, beyond the outer border of the Erector spinæ.

Nerve-supply.—The anterior branches of the lumbar nerves.

Actions.—The Quadratus lumborum draws down the last rib, and acts as a muscle of inspiration; and, at the same time, by fixing the last rib, it opposes the tendency of the Diaphragm to draw it upward, and thus it becomes an *assistant* to inspiration. If the thorax and spine are fixed, it may act upon the pelvis, raising it toward its own side when only one muscle is put in action; and when both muscles act together, either from below or above, they flex the trunk.

Muscles of the Pelvic Outlet or of the Ischio-rectal Region and Perinæum.

Corrugator cutis ani.
External sphincter ani.
Internal sphincter ani.
Levator ani.
Coccygeus.

In Male.
- Transversus perinæi.
- Accelerator urinæ.
- Erector penis.
- Compressor urethræ.

In Female.
- Transversus perinæi.
- Sphincter vaginæ.
- Erector clitoridis.
- Compressor urethræ.

The Corrugator Cutis Ani.—Around the anus is a thin stratum of involuntary muscular fibre, which surrounds it in a radiating manner. Internally, the fibres fade off into the submucous tissue, whilst externally they blend with the true skin. By its contraction it raises the skin into ridges radiating from the margin of the anus.

The **External sphincter ani** is a thin, flat plane of muscular fibres, elliptical in shape and intimately adherent to the integument surrounding the margin of the anus. It measures about three or four inches in length from its anterior to its posterior extremity, being about an inch in breadth opposite the anus. It arises from the tip of the coccyx by a narrow tendinous band, and from the superficial fascia in front of that bone; and is inserted into the central tendinous point of the perinæum, joining with the Transversus perinæi, the Levator ani, and the Accelerator urinæ. Like other sphincter muscles, it consists of two planes of muscular

fibre, which surround the margin of the anus, and join in a commissure in front and behind.

Nerve-supply.—A branch from the anterior division of the fourth sacral and the inferior hæmorrhoidal branch of the internal pudic.

Actions.—The action of this muscle is peculiar: 1. It is, like other muscles, always in a state of tonic contraction, and having no antagonistic muscle it keeps the anal orifice closed. 2. It can be put into a condition of greater contraction under the influence of the will, so as to more firmly occlude the anal aperture. 3. Taking its fixed point at the coccyx, it helps to fix the central point of the perinæum, so that the Accelerator may act from this fixed point.

The **Internal sphincter** is a muscular ring which surrounds the lower extremity of the rectum for about an inch, its inferior border being contiguous to, but quite separate from, the External sphincter. This muscle is about two lines in thickness, and is formed by an aggregation of the involuntary circular fibres of the intestine. It is paler in color and less coarse in texture than the External sphincter.

Actions.—Its action is entirely involuntary. It helps the External sphincter to occlude the anal aperture.

The **Levator ani** (Fig. 296) is a broad, thin muscle, situated on each side of the pelvis. It is attached to the inner surface of the sides of the true pelvis, and

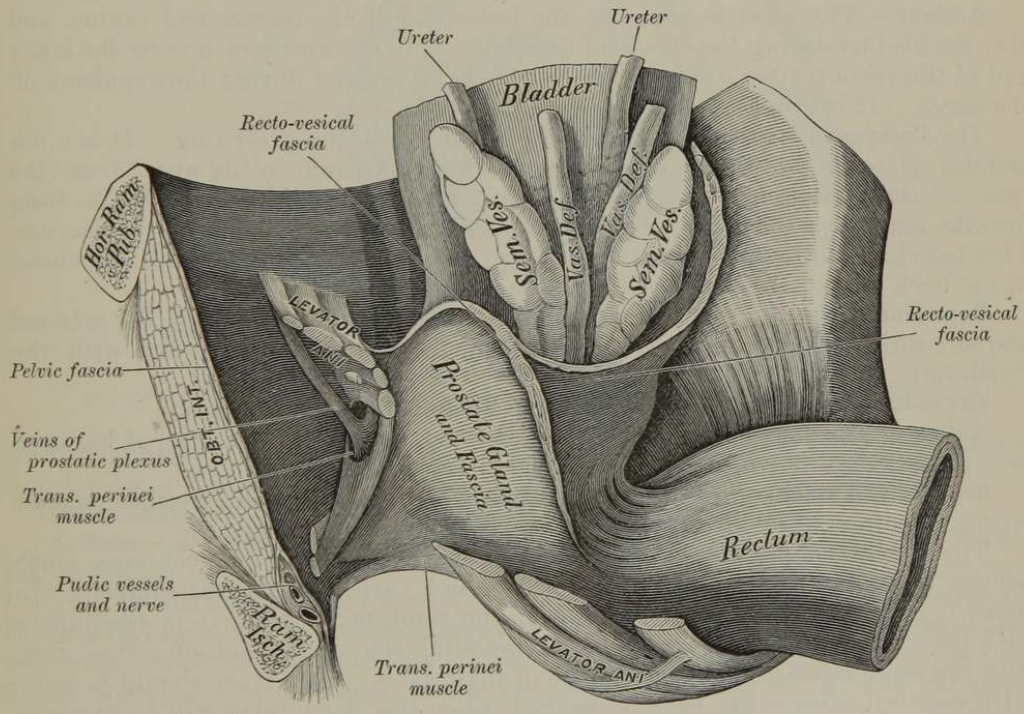

FIG. 296.—Pelvis seen from behind, showing levator ani. (Henle.)

descending unites with its fellow of the opposite side to form the floor of the pelvic cavity. It supports the viscera in this cavity and surrounds the various structures which pass through it. It arises, in front, from the posterior surface of the body and ramus of the os pubis on the outer side of the symphysis; posteriorly, from the inner surface of the spine of the ischium; and between these two points from the angle of division between the obturator and recto-vesical layers of the pelvic fascia at their under part. The fibres pass downward to the middle line of the floor of the pelvis, and are inserted, the most posterior into the sides of the apex of the coccyx; those placed more anteriorly unite with the muscles of the opposite side, in a median fibrous raphe, which extends between the coccyx and the margin of the anus. The middle fibres, which form the larger portion of the muscle, are

inserted into the side of the rectum, blending with the fibres of the Sphincter muscles; lastly, the anterior fibres, the longest, descend upon the side of the prostate gland to unite beneath it with the muscle of the opposite side, blending with the fibres of the External sphincter and Transversus perinæi muscles at the central tendinous point of the perinæum.

The anterior portion is occasionally separated from the rest of the muscle by connective tissue. From this circumstance, as well as from its peculiar relation with the prostate gland, descending by its side, and surrounding it as in a sling, it has been described by Santorini and others as a distinct muscle, under the name of Levator prostatæ. In the female, the anterior fibres of the Levator ani descend upon the side of the vagina.

Relations.—By its *inner* or *pelvic surface*, with the recto-vesical fascia, which separates it from the viscera of the pelvis and from the peritoneum. By its *outer* or *perineal surface*, it forms the inner boundary of the ischio-rectal fossa, and is covered by a thin layer of fascia, the *ischio-rectal* or *anal fascia*, given off from the obturator fascia. Its *posterior border* is continuous with the Coccygeus muscle. Its *anterior border* is separated from the muscle of the opposite side by a triangular space, through which the urethra, and in the female the vagina, passes from the pelvis.

Nerve-supply.—A branch from the anterior division of the fourth sacral nerve.

Actions.—This muscle supports the lower end of the rectum and vagina, and also the bladder during the efforts of expulsion. It elevates and inverts the lower end of the rectum after it has been protruded and everted during the expulsion of the fæces. It is also a muscle of forced expiration.

The **Coccygeus** is situated behind and parallel with the preceding. It is a triangular plane of muscular and tendinous fibres, arising, by its apex, from the spine of the ischium and lesser sacro-sciatic ligament, and inserted, by its base, into the margin of the coccyx and into the side of the lower piece of the sacrum. This muscle is continuous with the posterior border of the Levator ani, and closes in the back part of the outlet of the pelvis.

Relations.—By its *inner* or *pelvic surface*, with the rectum; by its *external surface*, with the lesser sacro-sciatic ligament; by its *posterior border*, with the Pyriformis.

Nerve-supply.—A branch from the fourth and fifth sacral nerves.

Action.—The Coccygei muscles raise and support the coccyx after it has been pressed backward during defecation or parturition.

Superficial Fascia.—The superficial fascia of the perinæum consists of two layers, superficial and deep, as in other regions of the body.

The *superficial layer* is thick, loose, areolar in texture, and contains much adipose tissue in its meshes, the amount of which varies in different subjects. In front, it is continuous with the dartos of the scrotum; behind, it is continuous with the subcutaneous areolar tissue surrounding the anus; and, on either side, with the same fascia on the inner side of the thighs. This layer should be carefully removed after it has been examined, when the deep layer will be exposed.

The *deep layer of superficial fascia* (Fascia of Colles) is thin, aponeurotic in structure, and of considerable strength, serving to bind down the muscles of the root of the penis. It is continuous, in front, with the dartos of the scrotum; on either side it is firmly attached to the margins of the rami of the os pubis and ischium, external to the crus penis, and as far back as the tuberosity of the ischium; posteriorly, it curves down behind the Transversus perinæi muscles to join the lower margin of the deep perineal fascia. This fascia not only covers the muscles in this region, but sends down a vertical septum from its under surface, which separates the back part of the subjacent space into two, being incomplete in front.

The Central Tendinous Point of the Perinæum.—This is a fibrous point in the middle line of the perinæum, between the urethra and the rectum, being about half an inch in front of the anus. At this point four muscles converge and are attached: viz. the External sphincter ani, the Accelerator urinæ, and the two

Transversus perinæi; so that by the contraction of these muscles, which extend in opposite directions, it serves as a fixed point of support.

The **Transversus perinæi** is a narrow muscular slip, which passes more or less transversely across the back part of the perineal space. It arises by a small tendon from the inner and fore part of the tuberosity of the ischium, and, passing inward, is inserted into the central tendinous point of the perinæum, joining in this situation

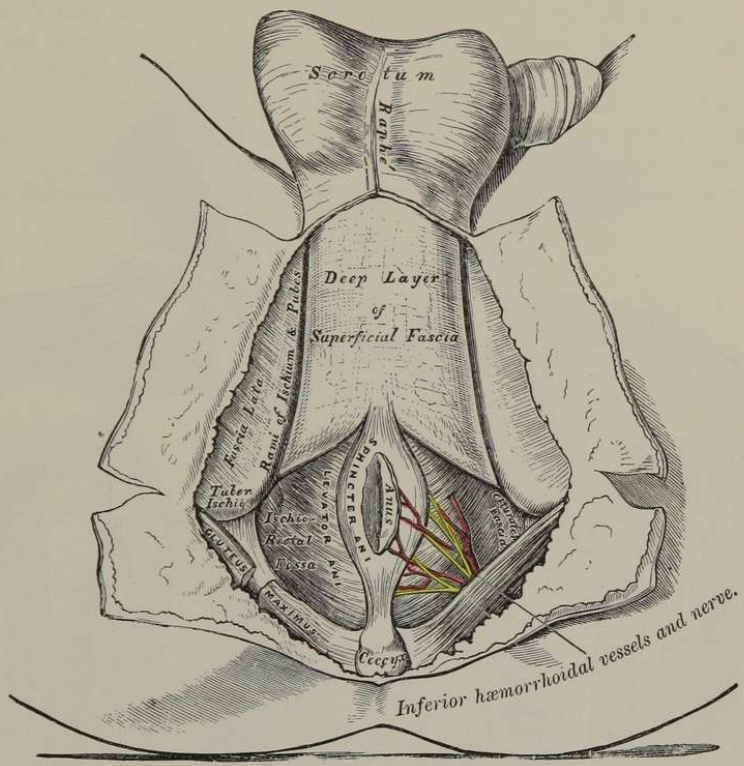

FIG. 297.—The perinæum. The integument and superficial layer of superficial fascia reflected.

with the muscle of the opposite side, the External sphincter ani behind, and the Accelerator urinæ in front.

Nerve-supply.—The perineal branch of the internal pudic.

Actions.—By their contraction they serve to fix the central tendinous point of the perinæum.

The **Accelerator urinæ** (*Ejaculator seminis*, or *Bulbo-cavernosus*) is placed in the middle line of the perinæum, immediately in front of the anus. It consists of two symmetrical halves, united along the median line by a tendinous raphe. It arises from the central tendon of the perinæum, and from the median raphe in front. From this point its fibres diverge like the plumes of a pen; the most posterior form a thin layer, which are lost on the anterior surface of the triangular ligament; the middle fibres encircle the bulb and adjacent parts of the corpus spongiosum, and join with the fibres of the opposite side, on the upper part of the corpus spongiosum, in a strong aponeurosis; the anterior fibres, the longest and most distinct, spread out over the sides of the corpus cavernosum, to be inserted partly into that body, anterior to the Erector penis, occasionally extending to the os pubis; partly terminating in a tendinous expansion, which covers the dorsal vessels of the penis. The latter fibres are best seen by dividing the muscle longitudinally, and dissecting it outward from the surface of the urethra.

Action.—This muscle serves to empty the canal of the urethra, after the bladder has expelled its contents; during the greater part of the act of micturition its fibres are relaxed, and it only comes into action at the end of the process. The middle fibres are supposed, by Krause, to assist in the erection of the corpus

spongiosum, by compressing the erectile tissue of the bulb. The anterior fibres, according to Tyrrel, also contribute to the erection of the penis, as they are inserted into, and continuous with, the fascia of the penis, compressing the dorsal vein during the contraction of the muscle.

The **Erector penis** (*Ischio-cavernous*) covers part of the crus penis. It is an elongated muscle, broader in the middle than at either extremity, and situated on either side of the lateral boundary of the perinæum. It arises by tendinous and

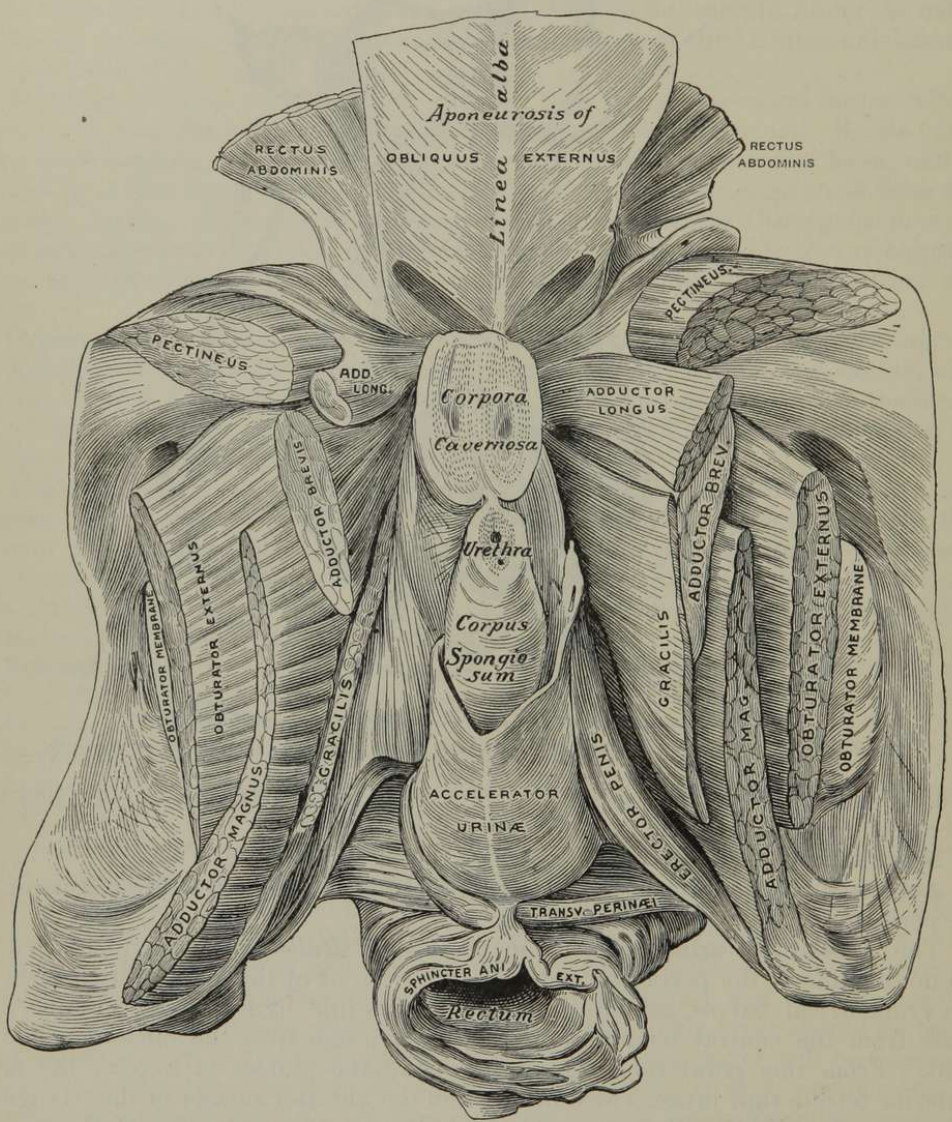

FIG. 298.—The muscles attached to the front of the pelvis. (From a preparation in the Museum of the Royal College of Surgeons of England.)

fleshy fibres from the inner surface of the tuberosity of the ischium, behind the crus penis, from the surface of the crus, and from the adjacent portion of the ramus of the ischium. From these points fleshy fibres succeed, which end in an aponeurosis which is inserted into the sides and under surface of the crus penis.

Nerve-supply.—The perineal branch of the internal pudic.

Actions.—It compresses the crus penis and retards the return of the blood through the veins, and thus serves to maintain the organ erect.

Between the muscles just examined a triangular space exists, bounded internally by the Accelerator urinæ, externally by the Erector penis, and behind

by the Transversus perinæi. The floor of this space is formed by the triangular ligament of the urethra (deep perineal fascia), and running from behind forward in it are the superficial perineal vessels and nerve, and the transverse perineal artery coursing along the posterior boundary of the space on the Transversus perinæi muscle.

The **Triangular Ligament** (*Deep perineal fascia*) is a dense membranous lamina, which closes the front part of the outlet of the pelvis. It is triangular in shape, about an inch and a half in depth, attached above, by its apex, to the under surface of the symphysis pubis and subpubic ligament; and on each side to the rami of the ischium and pubes, beneath the crura penis. Its inferior margin, or base, is directed toward the rectum, and connected to the central tendinous point of the perinæum. It is continuous with the deep layer of the superficial fascia behind the Transversus perinæi muscle, and with a thin fascia which covers the cutaneous surface of the Levator ani muscle (anal or ischio-rectal fascia).

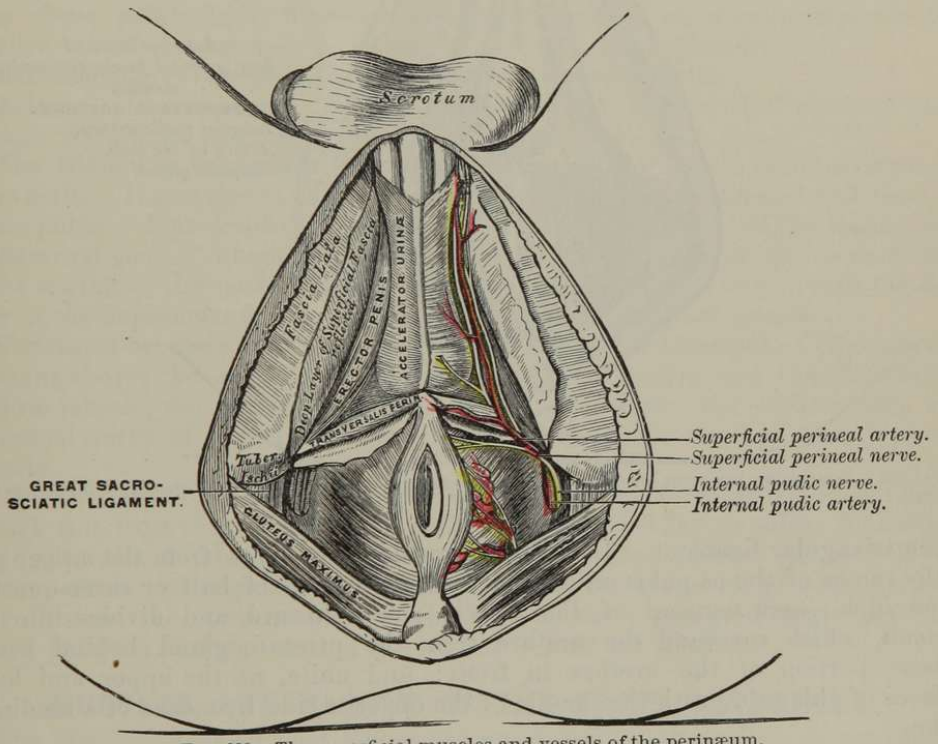

FIG. 299.—The superficial muscles and vessels of the perinæum.

The Triangular ligament is perforated by the urethra, about an inch below the symphysis pubis. The aperture is circular in form, and about three or four lines in diameter. Above this is the aperture for the dorsal vein of the penis; and, outside the latter, branches of the pudic nerve and artery pierce it.

The triangular ligament consists of two layers, superficial or inferior, and deep or superior; these are separated in front, but united behind.

The *superficial layer* on its inferior surface is intimately connected with, and sends an expansion to, the bulb. It is pierced by the duct of Cowper's gland and by the membranous urethra; as is also the following layer.

The *deep layer* is derived laterally from the obturator fascia;[1] superiorly expansions from it are given off into the sheath of the prostate gland, this sheath, in its turn, being formed from the recto-vesical fascia.

Structures between the Two Layers of the Triangular Ligament.—If the superficial layer of this fascia is detached on either side, the following structures

[1] "On the Anatomy of the Posterior Layer of the Triangular Ligament," see a paper by Mr Carrington, *Guy's Hospital Reports.*

will be seen between it and the deep layer: the subpubic ligament above, close to the pubes; the dorsal vein of the penis; the membranous portion of the urethra, and the Compressor urethræ muscle; Cowper's glands and their ducts; the pudic vessels and nerve; the artery and nerve of the bulb, and a plexus of veins.

The **Compressor urethræ** (*Constrictor urethræ*) surrounds the whole length of the membranous portion of the urethra, and is contained between the two layers

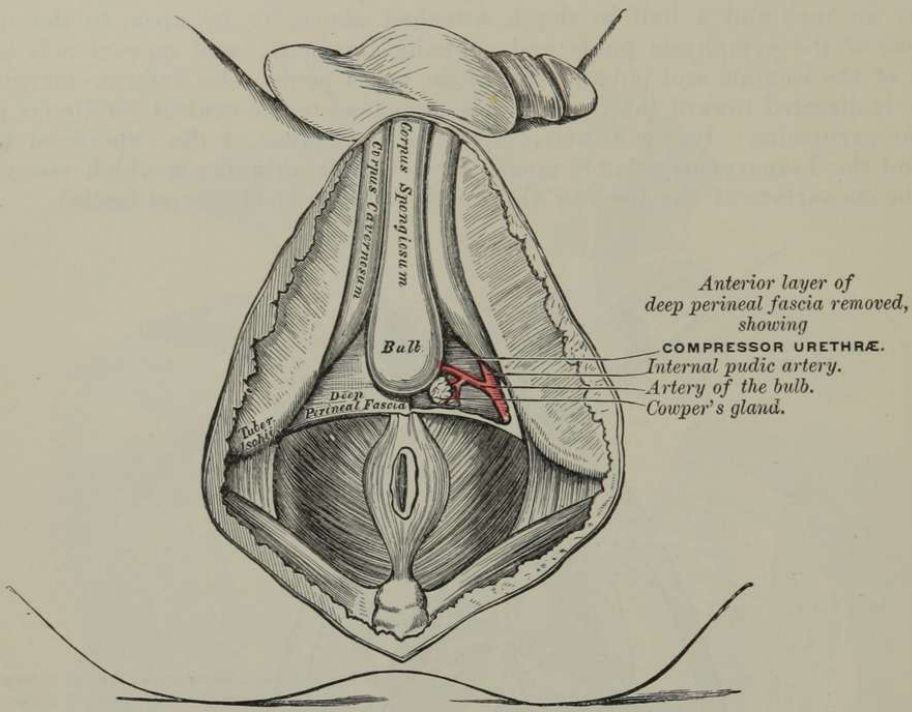

FIG. 300.—Triangular ligament or deep perineal fascia. On the left side the superficial layer has been removed.

of the triangular ligament. It arises, by aponeurotic fibres, from the upper part of the ramus of the os pubis on each side, to the extent of half or three-quarters of an inch: each segment of the muscle passes inward, and divides into two fasciculi, which surround the urethra from the prostate gland behind to the bulbous portion of the urethra in front; and unite, at the upper and lower surfaces of this tube, with the muscle of the opposite side, by means of a tendinous raphe.

Actions.—The muscles of both sides act together as a sphincter, compressing the membranous portion of the urethra. During the transmission of fluids they, like the Acceleratores urinæ, are relaxed, and only come into action at the end of the process to eject the last of the fluid.

Muscles of the Perinæum in the Female.

The **Transversus perinæi** in the **female** is a narrow muscular slip, which passes more or less transversely across the back part of the perineal space. It arises by a small tendon from the inner and fore part of the tuberosity of the ischium, and, passing inward, is inserted into the central line of the perinæum, joining in this situation with the muscle of the opposite side, the External sphincter ani behind, and the Sphincter vaginæ in front.

Nerve-supply.—The perineal branch of the internal pudic.

Actions.—By their contraction they serve to fix the central tendinous point of the perinæum.

The **Sphincter vaginæ** surrounds the orifice of the vagina, and is analogous to the Accelerator urinæ in the male. It is attached posteriorly to the central

tendinous point of the perinæum, where it blends with the External sphincter ani. Its fibres pass forward on each side of the vagina, to be inserted into the corpora cavernosa of the clitoris, a fasciculus crossing over the body of the organ so as to compress the dorsal vein.

Nerve-supply.—The perineal branch of the internal pudic.

Actions.—It diminishes the orifice of the vagina. The anterior fibres contribute to the erection of the clitoris, as they are inserted into and are continuous with the fascia of the clitoris; compressing the dorsal vein during the contraction of the muscle.

The **Erector clitoridis** resembles the Erector penis in the male, but is smaller than it. It covers the unattached part of the crus clitoridis. It is an elongated muscle, broader at the middle than at either extremity, and situated on either side of the lateral boundary of the perinæum. It arises by tendinous and fleshy fibres from the inner surface of the tuberosity of the ischium, behind the crus clitoridis from the surface of the crus, and from the adjacent portion of the ramus of the ischium. From these points fleshy fibres succeed, which end in an aponeurosis, which is inserted into the sides and under surface of the crus clitoridis.

Nerve-supply.—The perineal branch of the internal pudic.

Actions.—It compresses the crus clitoridis and retards the return of blood through the veins, and thus serves to maintain the organ erect.

The **triangular ligament** (*deep perineal fascia*) in the female is not so strong as in the male. It is attached to the pubic arch, its apex being connected with the symphysis pubis. It is divided in the middle line by the aperture of the vagina, with the external coat of which it becomes blended, and in front of this is perforated by the urethra. Its posterior border is continuous, as in the male, with the deep layer of the superficial fascia around the Transversus perinæi muscle.

Structures between the Two Layers of the Triangular Ligament.—The subpubic ligament above, the dorsal vein of the clitoris, the urethra and the Compressor urethræ muscle, the glands of Bartholin and their ducts; the pudic vessels and the dorsal nerve of the clitoris; the artery of the bulbi vestibuli, and a plexus of veins.

The **Compressor urethræ** (*constrictor urethræ* or *deep transversus perinæi*) arises on each side from the margin of the descending ramus of the os pubis. The fibres, passing inward, divide into two sets; those of the fore part of the muscle are directed across the subpubic arch in front of the urethra to blend with the muscular fibres of the opposite side; while those of the hinder and larger part pass inward to blend with the wall of the vagina behind the urethra.

MUSCLES AND FASCIÆ OF THE UPPER EXTREMITY.

The Muscles of the Upper Extremity are divisible into groups, corresponding with the different regions of the limb.

Of the Shoulder.

Anterior Thoracic Region.

Pectoralis major. Pectoralis minor. Subclavius.

Lateral Thoracic Region.

Serratus magnus.

Acromial Region.

Deltoid.

Anterior Scapular Region.

Subscapularis.

Posterior Scapular Region.

Supraspinatus. Teres minor.
Infraspinatus. Teres major.

Of the Arm.

Anterior Humeral Region.

Coraco-brachialis. Biceps. Brachialis anticus.

Posterior Humeral Region.

Triceps. Subanconeus.

Of the Forearm.

Anterior Radio-ulnar Region.

Superficial Layer.
- Pronator radii teres.
- Flexor carpi radialis.
- Palmaris longus.
- Flexor carpi ulnaris.
- Flexor sublimis digitorum.

Deep Layer.
- Flexor profundus digitorum.
- Flexor longus pollicis.
- Pronator quadratus.

Radial Region.

Supinator longus.
Extensor carpi radialis longior.
Extensor carpi radialis brevior.

Posterior Radio-ulnar Region.

Superficial Layer.
- Extensor communis digitorum.
- Extensor minimi digiti.
- Extensor carpi ulnaris.
- Anconeus.

Deep Layer.
- Supinator brevis.
- Extensor ossis metacarpi pollicis.
- Extensor brevis pollicis.
- Extensor longus pollicis.
- Extensor indicis.

OF THE HAND.

Radial Region.

Abductor pollicis.
Flexor ossis metacarpi pollicis (Opponens pollicis).
Flexor brevis pollicis.
Adductor pollicis.

Ulnar Region.

Palmaris brevis.
Abductor minimi digiti.
Flexor brevis minimi digiti.
Flexor ossis metacarpi minimi digiti (Opponens minimi digiti).

Palmar Region.

Lumbricales.
Interossei palmares.
Interossei dorsales.

Dissection of Pectoral Region and Axilla (Fig. 301).—The arm being drawn away from the side nearly at right angles with the trunk, and rotated outward, make a vertical incision through the integument in the median line of the chest, from the upper to the lower part of the sternum; a second incision along the lower border of the Pectoral muscle, from the ensiform cartilage to the inner side of the axilla; a third, from the sternum along the clavicle, as far as its centre; and a fourth, from the middle of the clavicle obliquely downward, along the interspace between the Pectoral and Deltoid muscles, as low as the fold of the armpit. The flap of integument is then to be dissected off in the direction indicated in the figure, but not entirely removed, as it should be replaced on completing the dissection. If a transverse incision is now made from the lower end of the sternum to the side of the chest, as far as the posterior fold of the armpit, and the integument reflected outward, the axillary space will be more completely exposed.

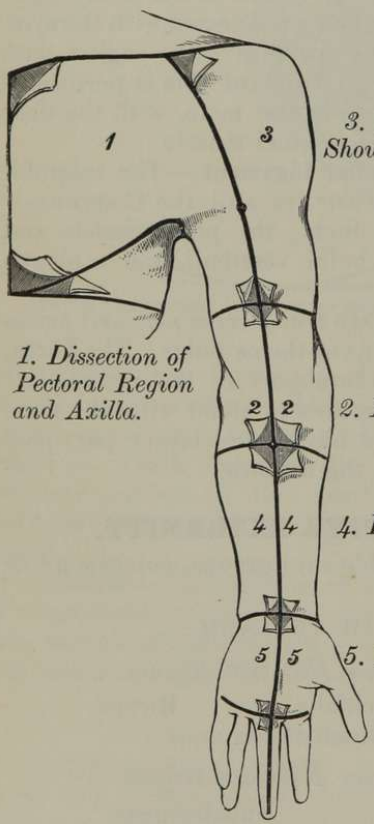

FIG. 301.—Dissection of upper extremity.

Fasciæ of the Thorax.

The **superficial fascia** of the thoracic region is a loose cellulo-fibrous layer enclosing masses of fat in its spaces. It is continuous with the superficial fascia of the neck and upper extremity above, and of the abdomen below. Opposite the mamma, it divides into two layers, one of which passes in front, the other behind that gland; and from both of these layers numerous septa pass into its substance, supporting its various lobes: from the anterior layer fibrous processes pass forward to the integument and nipple. These processes were called by Sir A. Cooper the *ligamenta suspensoria*, from the support they afford to the gland in this situation.

The **deep fascia** of the thoracic region is a thin aponeurotic lamina, covering the surface of the great Pectoral muscle, and sending numerous prolongations

between its fasciculi: it is attached, in the middle line, to the front of the sternum; and, above, to the clavicle. It is very thin over the upper part of the muscle, thicker in the interval between the Pectoralis major and Latissimus dorsi, where it closes in the axillary space, and divides at the outer margin of the latter muscle into two layers, one of which passes in front, and the other behind it; these proceed as far as the spinous processes of the dorsal vertebræ, to which they are attached. At the lower part of the thoracic region this fascia is well developed, and is continuous with the fibrous sheath of the Recti muscles.

THE SHOULDER.

Anterior Thoracic Region.

Pectoralis major. Pectoralis minor.
Subclavius.

The **Pectoralis major** (Fig. 302) is a broad, thick, triangular muscle, situated at the upper and fore part of the chest, in front of the axilla. It arises from the anterior surface of the sternal half of the clavicle; from half the breadth of the anterior surface of the sternum, as low down as the attachment of the cartilage of the sixth or seventh rib; this portion of its origin consists of aponeurotic fibres, which intersect with those of the opposite muscle; it also arises from the cartilages of all the true ribs, with the exception, frequently, of the first or of the seventh, or both; and from the aponeurosis of the External oblique muscle of the abdomen. The fibres from this extensive origin converge toward its insertion, giving to the muscle a radiated appearance. Those fibres which arise from the clavicle pass obliquely outward and downward, and are usually separated from the rest by a cellular interval: those from the lower part of the sternum, and the cartilages of the lower true ribs, pass upward and outward, whilst the middle fibres pass horizontally. They all terminate in a flat tendon, about two inches broad, which is inserted into the anterior bicipital ridge of the humerus. This tendon consists of two laminæ, placed one in front of the other, and usually blended together below. The anterior, the thicker, receives the clavicular and upper half of the sternal portion of the muscle; and its fibres are inserted in the same order as that in which they arise; that is to say, the outermost fibres of origin from the clavicle are inserted at the uppermost part of the tendon; the upper fibres of origin from the sternum pass down to the lowermost part of this anterior lamina of the tendon and extend as low as the tendon of the Deltoid and join with it. The posterior lamina of the tendon receives the attachment of the lower half of the sternal portion and the deeper part of the muscle from the costal cartilages. These deep fibres, and particularly those from the lower costal cartilages, ascend the higher, turning backward successively behind the superficial and upper ones, so that the tendon appears to be twisted. The posterior lamina reaches higher on the humerus than the anterior one, and from it an expansion is given off which covers the bicipital groove and blends with the capsule of the shoulder-joint. Another expansion passes downward to the fascia of the arm.

Relations.—By its *anterior surface*, with the integument, the superficial fascia, the Platysma, the mammary gland, and the deep fascia; by its *posterior surface*: its *thoracic portion*, with the sternum, the ribs and costal cartilages, the costo-coracoid membrane, the Subclavius, Pectoralis minor, Serratus magnus, and the Intercostals; its *axillary portion* forms the anterior wall of the axillary space, and covers the axillary vessels and nerves, the Biceps and Coraco-brachialis muscles. Its *upper border* lies parallel with the Deltoid, from which it is separated by a slight interspace in which lie the cephalic vein and descending branch of the acromial thoracic artery. Its *lower border* forms the anterior margin of the axilla, being at first separated from the Latissimus dorsi by a considerable interval; but both muscles gradually converge toward the outer part of the space.

Dissection.—Detach the Pectoralis major by dividing the muscle along its attachment to the clavicle, and by making a vertical incision through its substance a little external to its line of

attachment to the sternum and costal cartilages. The muscle should then be reflected outward, and its tendon carefully examined. The Pectoralis minor is now exposed, and immediately above it, in the interval between its upper border and the clavicle, a strong fascia, the *costo-coracoid membrane.*

The **costo-coracoid membrane** is a strong fascia placed between the clavicle and the upper border of the Pectoralis minor muscle, which protects the axillary

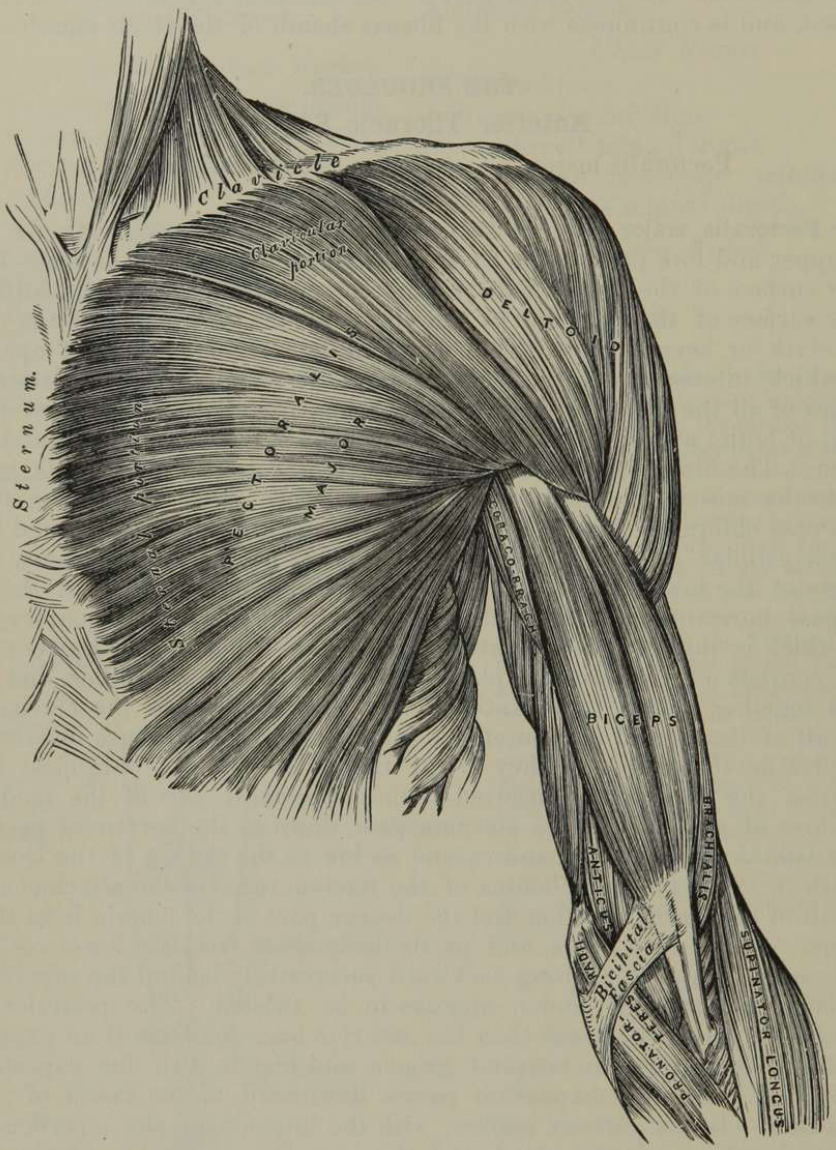

FIG. 302.—Muscles of the chest and front of the arm. Superficial view.

vessels and nerves. Above, it is attached to the anterior margin of the Subclavian groove on the under surface of the clavicle, and is connected with a layer of cervical fascia which overlies the Omo-hyoid muscle, and forms the posterior layer of the sheath of the Subclavius muscle. Internally, it is attached to the first rib internal to the origin of the Subclavius muscle. Externally it is very thick and dense, and is attached to the coracoid process. The portion extending from its attachment to the first rib to the coracoid process is often whiter and denser than the rest; this is sometimes called the *costo-coracoid ligament.* Below, it is thin, and at the upper border of the Pectoralis minor it splits into two layers to invest the muscle; from the lower border of the Pectoralis minor it is continued down-

ward to join the axillary fascia, and outward to join the fascia over the short head of the Biceps. The costo-coracoid membrane is pierced by the cephalic vein, the acromial thoracic artery and vein, superior thoracic artery, and anterior thoracic nerves.

The **Pectoralis minor** (Fig. 303) is a thin, flat, triangular muscle, situated at the upper part of the thorax, beneath the Pectoralis major. It arises by three

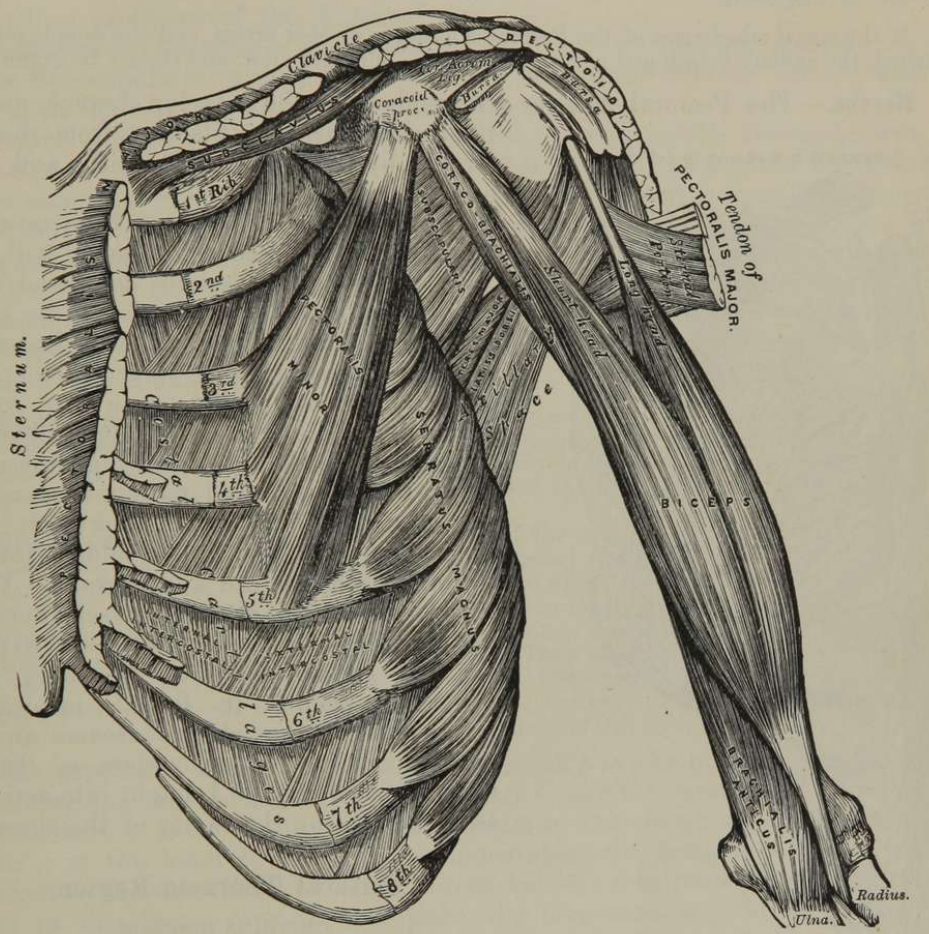

FIG. 303.—Muscles of the chest and front of the arm, with the boundaries of the axilla.

tendinous digitations from the upper margin and outer surface of the third, fourth, and fifth ribs, near their cartilages, and from the aponeurosis covering the Intercostal muscles; the fibres pass upward and outward, and converge to form a flat tendon, which is inserted into the inner border and upper surface of the coracoid process of the scapula.

Relations.—By its *anterior surface*, with the Pectoralis major and the superior thoracic vessels and nerves; by its *posterior surface*, with the ribs, Intercostal muscles, Serratus magnus, the axillary space, and the axillary vessels and nerves. Its upper border is separated from the clavicle by a triangular interval, broad internally, narrow externally, bounded in front by the costo-coracoid membrane, and internally by the ribs. In this space are the first part of the axillary vessels and nerves.

The costo-coracoid membrane should now be removed, when the Subclavius muscle will be seen.

The **Subclavius** is a long, thin, spindle-shaped muscle, placed in the interval between the clavicle and the first rib. It arises by a short, thick tendon from the first rib and its cartilage at their junction, in front of the rhomboid ligament; the

fleshy fibres proceed obliquely upward and outward, to be inserted into a deep groove on the under surface of the middle third of the clavicle.

Relations.—By its *upper surface*, with the clavicle. By its *under surface* it is separated from the first rib by the subclavian vessels and brachial plexus of nerves. Its *anterior surface* is separated from the Pectoralis major by the costo-coracoid membrane, which, with the clavicle, forms an osseo-fibrous sheath in which the muscle is enclosed.

If the costal attachment of the Pectoralis minor is divided across, and the muscle reflected outward, the axillary vessels and nerves are brought fully into view, and should be examined.

Nerves.—The Pectoral muscles are supplied by the anterior thoracic nerves; the Subclavius, by a filament from the cord formed by the union of the fifth and sixth cervical nerves.

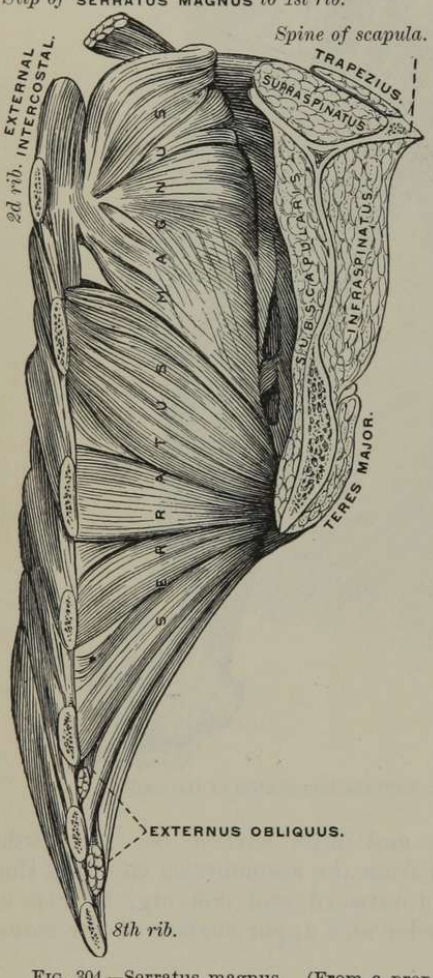

FIG. 304.—Serratus magnus. (From a preparation in the Museum of the Royal College of Surgeons of England.)

Actions.—If the arm has been raised by the Deltoid, the Pectoralis major will, conjointly with the Latissimus dorsi and Teres major, depress it to the side of the chest. If acting alone, it adducts and draws forward the arm, bringing it across the front of the chest, and at the same time rotates it inward. The Pectoralis minor depresses the point of the shoulder, drawing the scapula downward and inward to the thorax, and throwing the inferior angle backward. The Subclavius depresses the shoulder, drawing the clavicle downward and forward. When the arms are fixed, all three muscles act upon the ribs, drawing them upward and expanding the chest, and thus becoming very important agents in forced inspiration. Asthmatic patients always assume an attitude which fixes the shoulders, so that all these muscles may be brought into action to assist in dilating the cavity of the chest.

Lateral Thoracic Region.

Serratus magnus.

The **Serratus magnus** (Fig. 304) is a broad, thin, and irregularly quadrilateral muscle, situated at the upper part and side of the chest. It consists of two triangular or fan-shaped portions; the upper one having the apex of the triangle attached to the first and second ribs, and the base to the upper angle and vertebral border of the scapula; the lower with its apex behind attached to the inferior angle of the scapula, and its base in front connected with the ribs from the second to the eighth. It arises by nine fleshy digitations from the outer surface and upper border of the eight upper ribs (the second rib having two), and from the aponeurosis covering the upper intercostal muscles, and is inserted into the whole length of the anterior aspect of the posterior border of the scapula. The upper fan-shaped portion is attached to the fore part of the outer surfaces of the first and second ribs; its fibres spread out, the upper ones forming a thick fasciculus, which passes upward and backward, and is attached to the triangular smooth surface on the anterior aspect of the superior angle of the scapula; the remaining fibres proceed backward and downward to

be attached to the posterior border of the scapula between the superior and inferior angles. The lower fan-shaped portion is attached posteriorly by its apex to the anterior surface of the inferior angle of the scapula, partly by muscular, partly by tendinous fibres; it spreads out like a fan, the upper fibres passing forward and upward, the lower horizontally forward to be inserted into the outer surface of the fore part of the ribs from the second to the eighth, by a series of muscular digitations. In the intervals between the four lower of these are received corresponding processes of the External oblique.

Relations.—This muscle is covered, in front, by the Pectoral muscle; behind by the Subscapularis; above, by the axillary vessels and nerves. Its *deep surface* rests upon the ribs and Intercostal muscles.

Nerves.—The Serratus magnus is supplied by the posterior thoracic nerve.

Actions.—The Serratus magnus, as a whole, carries the scapula forward, and at the same time raises the vertebral border of the bone. It is therefore concerned in the action of pushing. Its lower and stronger fibres move forward the lower angle and assist the Trapezius in rotating the bone round an axis through its centre, and thus assists this muscle in raising the acromion and supporting weights upon the shoulder. It is possible that when the shoulders are fixed the lower fibres may assist in raising and everting the ribs; but it is not the important inspiratory muscle which it was formerly believed to be.

Surgical Anatomy.—When the muscle is paralyzed the vertebral border, and especially the lower angle, leave the ribs and stand out prominently on the surface, giving a peculiar "winged" appearance to the back. The patient is unable to raise the arm above a right angle, and an attempt to do so is followed by a revolution of the scapula, instead of by the elevation of the arm.

Dissection.—After completing the dissection of the axilla, if the muscles of the back have been dissected, the upper extremity should be separated from the trunk. Saw through the clavicle at its centre, and then cut through the muscles which connect the scapula and arm with the trunk, viz.: the Pectoralis minor in front, Serratus magnus at the side, and the Levator anguli scapulæ, the Rhomboids, Trapezius, and Latissimus dorsi behind. These muscles should be cleaned and traced to their respective insertions. Then make an incision through the integument, commencing at the outer third of the clavicle, and extending along the margin of that bone, the acromion process, and spine of the scapula; the integument should be dissected from above downward and outward, when the fascia covering the Deltoid is exposed (Fig. 301, No. 3).

The **superficial fascia** of the upper extremity is a thin cellulo-fibrous layer, containing the superficial veins and lymphatics, and the cutaneous nerves. It is most distinct in front of the elbow, and contains very large superficial veins and nerves; in the hand it is hardly demonstrable, the integument being closely adherent to the deep fascia by dense fibrous bands. Small subcutaneous bursæ are found in this fascia over the acromion, the olecranon, and the knuckles. The deep fascia of the upper extremity comprises the aponeurosis of the shoulder, arm, and forearm, the anterior and posterior annular ligaments of the carpus, and the palmar fascia. These will be considered in the description of the muscles of the several regions.

Acromial Region.

Deltoid.

The **deep fascia** covering the Deltoid (deltoid aponeurosis) is a fibrous layer which covers the outer surface of the muscle, thick and strong behind, where it is continuous with the infraspinatus fascia, thinner over the rest of its extent. It sends down numerous prolongations between the fasciculi of the muscle. In front, it is continuous with the fascia covering the great Pectoral muscle; behind, with that covering the Infraspinatus; above, it is attached to the clavicle, the acromion, and spine of the scapula; below, it is continuous with the deep fascia of the arm.

The **Deltoid** (Fig. 302) is a large, thick, triangular muscle, which gives the rounded outline to the shoulder, and has received its name from its resemblance to the Greek letter Δ reversed. It surrounds the shoulder-joint in the greater part of its extent, covering it on its outer side, and in front and behind. It arises from

the outer third of the anterior border and upper surface of the clavicle; from the outer margin and upper surface of the acromion process, and from the lower lip of the posterior border of the spine of the scapula, as far back as the triangular surface at its inner end. From this extensive origin the fibres converge toward their insertion, the middle passing vertically, the anterior obliquely backward, the posterior obliquely forward; they unite to form a thick tendon, which is inserted into a rough prominence on the middle of the outer side of the shaft of the humerus. At its insertion the muscle gives off an expansion to the deep fascia of the arm. This muscle is remarkably coarse in texture, and the arrangement of its muscular fibres is somewhat peculiar; the central portion of the muscle—that is to say, the part arising from the acromion process—consists of oblique fibres, which arise in a bipenniform manner from the sides of tendinous intersections, generally four in number, which are attached above to the acromion process and pass downward parallel to one another in the substance of the muscle. The oblique muscular fibres thus formed are inserted into similar tendinous intersections, generally three in number, which pass upward from the insertion of the muscle into the humerus and alternate with the descending septa. The lateral portions of the muscle—that is to say, the fibres arising from the clavicle and spine of the scapula—are not arranged in this manner, but consist of parallel fasciculi passing from their origin above, to be inserted into the margins of the inferior tendon.

Relations.—By its *superficial surface*, with the integument, the superficial fascia, Platysma, and supra-acromial nerves. Its *deep surface* is separated from the head of the humerus by a large sacculated synovial bursa, and covers the coracoid process, coraco-acromial ligament, Pectoralis minor, Coraco-brachialis, both heads of the Biceps, the tendon of the Pectoralis major, the insertions of the Supraspinatus, Infraspinatus, and Teres minor, the scapular and external heads of the Triceps, the circumflex vessels and nerve, and the humerus. Its *anterior border* is separated at its upper part from the Pectoralis major by a cellular interspace, which lodges the cephalic vein and descending branch of the acromial thoracic artery: lower down the two muscles are in close contact. Its *posterior border* rests on the Infraspinatus and Triceps muscles.

Nerves.—The Deltoid is supplied by the circumflex nerve.

Actions.—The Deltoid raises the arm directly from the side, so as to bring it at right angles with the trunk. Its anterior fibres, assisted by the Pectoralis major, draw the arm forward; and its posterior fibres, aided by the Teres major and Latissimus dorsi, draw it backward.

Surgical Anatomy.—The Deltoid is very liable to atrophy, and when in this condition simulates dislocation of the shoulder-joint, as there is flattening of the shoulder and apparent prominence of the acromion process; upon examination, however, it will be found that the relative position of the great tuberosity of the humerus to the acromion and coracoid process is unchanged. Atrophy of the Deltoid may be due to disuse or loss of trophic influence, either from injury to the circumflex nerve or cord lesions, as in infantile paralysis.

Dissection.—Divide the Deltoid across, near its upper part, by an incision carried along the margin of the clavicle, the acromion process, and spine of the scapula, and reflect it downward: the bursa will be seen on its under surface, as well as the circumflex vessels and nerve.

Anterior Scapular Region.

Subscapularis.

The **subscapular fascia** is a thin membrane attached to the entire circumference of the subscapular fossa, and affording attachment by its inner surface to some of the fibres of the Subscapularis muscle: when this is removed, the Subscapularis muscle is exposed.

The **Subscapularis** (Fig. 303) is a large triangular muscle which fills up the subscapular fossa, arising from its internal two-thirds, with the exception of a narrow margin along the posterior border, and the surfaces at the superior and inferior angles which afford attachment to the Serratus magnus. Some fibres

arise from tendinous laminæ, which intersect the muscle, and are attached to ridges on the bone; and others from an aponeurosis, which separates the muscle from the Teres major and the long head of the Triceps. The fibres pass outward, and gradually converging, terminate in a tendon, which is inserted into the lesser tuberosity of the humerus. Those fibres which arise from the axillary border of the scapula are inserted into the neck of the humerus to the extent of an inch below the tuberosity. The tendon of the muscle is in close contact with the capsular ligament of the shoulder-joint, and glides over a large bursa, which separates it from the base of the coracoid process. This bursa communicates with the cavity of the joint by an aperture in the capsular ligament.

Relations.—By its *anterior surface*, with the Serratus magnus, Coracobrachialis, and Biceps, the axillary vessels and nerves, and the subscapular vessels and nerves; by its *posterior surface*, with the scapula and the capsular ligament of the shoulder-joint. Its *lower border* is contiguous with the Teres major and Latissimus dorsi.

Nerves.—It is supplied by the upper and lower subscapular nerves.

Actions.—The Subscapularis rotates the head of the humerus inward; when the arm is raised, it draws the humerus downward. Together with the following muscles it is a defence to the shoulder-joint, as, by their tension, they all prevent displacement of the head of the bone.

Posterior Scapular Region (Fig. 305).

Supraspinatus.	Teres minor.
Infraspinatus.	Teres major.

Dissection.—To expose these muscles, and to examine their mode of insertion into the humerus, detach the Deltoid and Trapezius from their attachment to the spine of the scapula and acromion process. Remove the clavicle by dividing the ligaments connecting it with the coracoid process, and separate it at its articulation with the scapula: divide the acromion process near its root with a saw. The fragments being removed, the tendons of the posterior Scapular muscles will be fully exposed, and can be examined. A block should be placed beneath the shoulder-joint, so as to make the muscles tense.

The **Supraspinous fascia** is a thick and dense membranous layer, which completes the osseo-fibrous case in which the Supraspinatus muscle is contained, affording attachment, by its inner surface, to some of the fibres of the muscle. It is thick internally, but thinner externally under the coraco-acromial ligament. When this fascia is removed, the Supraspinatus muscle is exposed.

The **Supraspinatus muscle** occupies the whole of the supraspinous fossa, arising from its internal two-thirds and from the strong fascia which covers its surface. The muscular fibres converge to a tendon which passes across the capsular ligament of the shoulder-joint, to which it is intimately adherent, and is inserted into the highest of the three facets on the great tuberosity of the humerus.

Relations.—By its *upper surface*, with the Trapezius, the clavicle, the acromion, the coraco-acromial ligament, and the Deltoid; by its *under surface*, with the scapula, the suprascapular vessels and nerve, and upper part of the shoulder-joint.

The **Infraspinous fascia** is a dense fibrous membrane, covering in the Infraspinatus muscle and attached to the circumference of the infraspinous fossa; it affords attachment, by its inner surface, to some fibres of that muscle. At the point where the Infraspinatus commences to be covered by the Deltoid, this fascia divides into two layers: one layer passes over the Deltoid muscle, helping to form the Deltoid fascia already described; the other passes beneath the Deltoid to the shoulder-joint.

The **Infraspinatus** is a thick, triangular muscle, which occupies the chief part of the infraspinous fossa, arising by fleshy fibres from its internal two-thirds, and by tendinous fibres from the ridges on its surface: it also arises from a strong fascia which covers it externally, and separates it from the Teres major and minor. The fibres converge to a tendon which glides over the external border of the spine of the scapula, and, passing across the capsular ligament of the shoulder-

joint, is inserted into the middle facet on the great tuberosity of the humerus. The tendon of this muscle is occasionally separated from the spine of the scapula by a synovial bursa which communicates with the synovial cavity of the shoulder-joint.

Relations.—By its *posterior surface*, with the Deltoid, the Trapezius, Latissimus dorsi, and the integument; by its *anterior surface*, with the scapula, from which

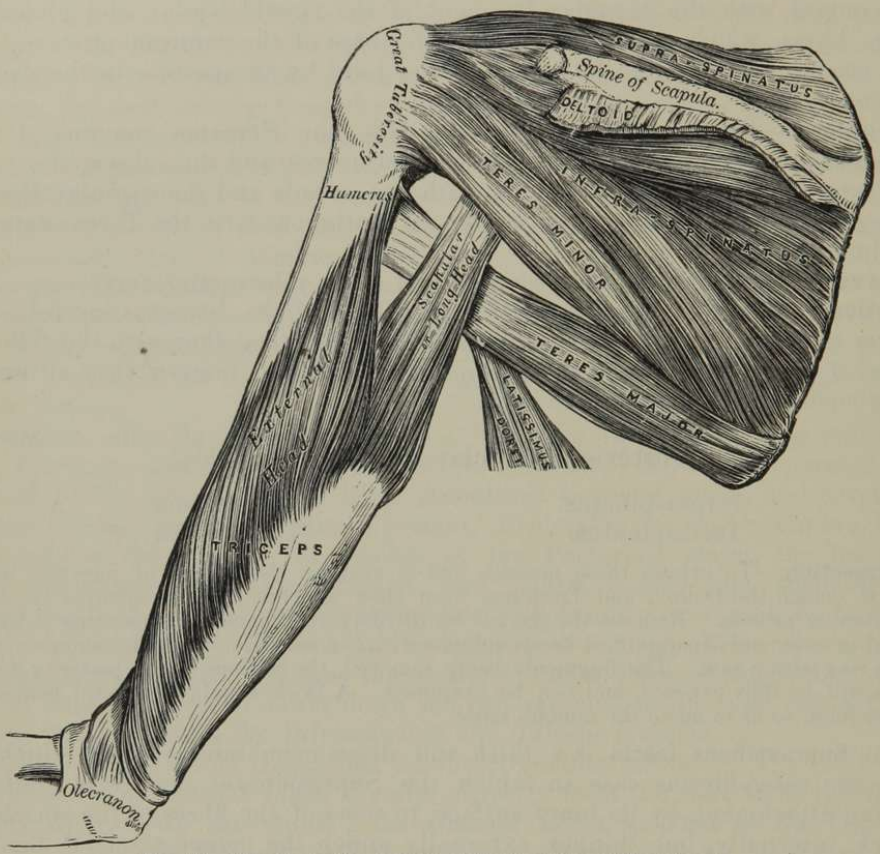

FIG. 305.—Muscles on the dorsum of the Scapula and the Triceps.

it is separated by the suprascapular and dorsalis scapulæ vessels, and with the capsular ligament of the shoulder-joint. Its *lower border* is in contact with the Teres minor, occasionally united with it, and with the Teres major.

The **Teres minor** is a narrow, elongated muscle, which lies along the inferior border of the scapula. It arises from the dorsal surface of the axillary border of the scapula for the upper two-thirds of its extent, and from two aponeurotic laminæ, one of which separates this muscle from the Infraspinatus, the other from the Teres major; its fibres pass obliquely upward and outward, and terminate in a tendon which is inserted into the lowest of the three facets on the great tuberosity of the humerus, and, by fleshy fibres, into the humerus immediately below it. The tendon of this muscle passes across the capsular ligament of the shoulder-joint.

Relations.—By its *posterior surface*, with the Deltoid, and the integument; by its *anterior surface*, with the scapula, and dorsal branch of the subscapular artery, the long head of the Triceps, and the shoulder-joint; by its *upper border*, with the Infraspinatus; by its *lower border*, with the Teres major, from which it is separated anteriorly by the long head of the Triceps.

The **Teres major** is a broad and somewhat flattened muscle, which arises from the dorsal aspect of the inferior angle of the scapula, and from the fibrous septa interposed between it and the Teres minor and Infraspinatus; the fibres are

directed upward and outward, and terminate in a flat tendon, about two inches in length, which is inserted into the internal bicipital ridge of the humerus. The tendon of this muscle, at its insertion into the humerus, lies behind that of the Latissimus dorsi, from which it is separated by a synovial bursa, the two tendons being, however, united along their lower borders for a short distance.

Relations.—By its *posterior surface*, with the integument, from which it is separated, internally, by the Latissimus dorsi; and externally, by the long head of the Triceps; by its *anterior surface*, with the Subscapularis, Latissimus dorsi, Coraco-brachialis, short head of the Biceps, the axillary vessels, and brachial plexus of nerves. Its *upper border* is at first in relation with the Teres minor, from which it is afterward separated by the long head of the Triceps. Its *lower border* forms, in conjunction with the Latissimus dorsi, part of the posterior boundary of the axilla.

Nerves.—The Supra- and Infraspinatus muscles are supplied by the suprascapular nerve; the Teres minor, by the circumflex; and the Teres major, by the lower subscapular.

Actions.—The Supraspinatus assists the Deltoid in raising the arm from the side, and fixes the head of the humerus in its socket. The Infraspinatus and Teres minor rotate the head of the humerus outward: when the arm is raised, they assist in retaining it in that position and carrying it backward. One of the most important uses of these three muscles is the great protection they afford to the shoulder-joint, the Supraspinatus supporting it above, and preventing displacement of the head of the humerus downward, while the Infraspinatus and Teres minor protect it behind, and prevent dislocation forward. The Teres major assists the Latissimus dorsi in drawing the humerus downward and backward, when previously raised, and rotating it inward; when the arm is fixed, it may assist the Pectoral and Latissimus dorsi muscles in drawing the trunk forward.

THE ARM.

Anterior Humeral Region (Fig. 303).

Coraco-brachialis. Biceps. Brachialis anticus.

Dissection.—The arm being placed on the table, with the front surface uppermost, make a vertical incision through the integument along the middle line, from the outer extremity of the anterior fold of the axilla, to about two inches below the elbow-joint, where it should be joined by a transverse incision, extending from the inner to the outer side of the forearm; the two flaps being reflected on either side, the fascia should be examined (Fig. 301).

The **deep fascia** of the arm is continuous with that covering the shoulder and front of the great Pectoral muscle, by means of which it is attached, above, to the clavicle, acromion, and spine of the scapula; it forms a thin, loose, membranous sheath investing the muscles of the arm, sending down septa between them, and composed of fibres disposed in a circular or spiral direction, and connected together by vertical and oblique fibres. It differs in thickness at different parts, being thin over the Biceps, but thicker where it covers the Triceps, and over the condyles of the humerus: it is strengthened by fibrous aponeuroses, derived from the Pectoralis major and Latissimus dorsi on the inner side, and from the Deltoid externally. On either side it gives off a strong *intermuscular septum*, which is attached to the condyloid ridge and condyle of the humerus. These septa serve to separate the muscles of the anterior from those of the posterior brachial region. The external intermuscular septum extends from the lower part of the external bicipital ridge, along the external condyloid ridge, to the outer condyle; it is blended with the tendon of the Deltoid, gives attachment to the Triceps behind, to the Brachialis anticus, Supinator longus, and Extensor carpi radialis longior, in front; and is perforated by the musculo-spiral nerve and superior profunda artery. The internal intermuscular septum, thicker than the preceding, extends from the lower part of the internal lip of the bicipital groove below the Teres major, along the internal condyloid ridge to the inner condyle; it is blended with the tendon of the Coraco-brachialis, and affords attachment to the Triceps behind, and the Brachialis anticus

in front. It is perforated by the ulnar nerve and the inferior profunda and anastomotic arteries. At the elbow the deep fascia is attached to all the prominent points round the joint—viz. the condyles of the humerus and the olecranon process of the ulna—and is continuous with the deep fascia of the forearm. Just below the middle of the arm, on its inner side, in front of the internal intermuscular septum, is an oval opening in the deep fascia which transmits the basilic vein and some lymphatic vessels. On the removal of this fascia the muscles, vessels, and nerves of the anterior humeral region are exposed.

The **Coraco-brachialis**, the smallest of the three muscles in this region, is situated at the upper and inner part of the arm. It arises by fleshy fibres from the apex of the coracoid process, in common with the short head of the Biceps, and from the intermuscular septum between the two muscles; the fibres pass downward, backward, and a little outward, to be inserted by means of a flat tendon into a rough ridge at the middle of the inner surface and internal border of the shaft of the humerus between the origins of the Triceps and Brachialis anticus. It is perforated by the musculo-cutaneous nerve. The inner border of the muscle forms a guide to the position of the brachial artery in tying the vessel in the upper part of its course.

Relations.—By its *anterior surface*, with the Pectoralis major above, and at its insertion with the brachial vessels and median nerve which cross it; by its *posterior surface*, with the tendons of the Subscapularis, Latissimus dorsi, and Teres major, the inner head of the Triceps, the humerus, and the anterior circumflex vessels; by its *inner border*, with the brachial artery, and the median and musculo-cutaneous nerves; by its *outer border*, with the short head of the Biceps and Brachialis anticus.

The **Biceps** (*Biceps flexor cubiti*) is a long fusiform muscle, occuping the whole of the anterior surface of the arm, and divided above into two portions or heads, from which circumstance it has received its name. The short head arises by a thick flattened tendon from the apex of the coracoid process, in common with the Coraco-brachialis. The long head arises from the supraglenoid tubercle on the upper margin of the glenoid cavity, by a long rounded tendon, which is continuous with the glenoid ligament. This tendon arches over the head of the humerus, being enclosed in a special sheath of the synovial membrane of the shoulder-joint; it then passes through an opening in the capsular ligament at its attachment to the humerus, and descends in the bicipital groove, in which it is retained by a fibrous prolongation from the tendon of the Pectoralis major. The fibres from this tendon form a rounded belly, and, about the middle of the arm, join with the portion of the muscle derived from the short head. The belly of the muscle, narrow and somewhat flattened, terminates above the elbow in a flattened tendon, which is inserted into the back part of the tuberosity of the radius, a synovial bursa being interposed between the tendon and the front of the tuberosity. The tendon of the muscle is thin and broad; as it approaches the radius it becomes narrow and twisted upon itself, so that its external border becomes anterior, and its posterior flat surface is applied to the back of the tuberosity: opposite the bend of the elbow the tendon gives off, from its inner side, a broad aponeurosis, the *bicipital fascia* (*semilunar fascia*), which passes obliquely downward and inward across the brachial artery, and is continuous with the deep fascia of the forearm (Fig. 302). The inner border of this muscle forms a guide to the position of the vessel in tying the brachial artery in the middle of the arm.[1]

Relations.—Its *anterior surface* is overlapped above by the Pectoralis major and Deltoid; in the rest of its extent it is covered by the superficial and deep fasciæ and the integument. Its *posterior surface* rests on the shoulder-joint and

[1] A third head to the Biceps is occasionally found (Theile says as often as once in eight or nine subjects), arising at the upper and inner part of the Brachialis anticus, with the fibres of which it is continuous, and inserted into the bicipital fascia and inner side of the tendon of the Biceps. In most cases this additional slip passes behind the brachial artery in its course down the arm. Occasionally the third head consists of two slips which pass down, one in front, the other behind the artery, concealing the vessel in the lower half of the arm.

humerus, from which it is separated by the Subscapularis, Teres major, Latissimus dorsi, Brachialis anticus, and the musculo-cutaneous nerve. Its *inner border* is in relation with the Coraco-brachialis, the brachial vessels, and median nerve; its *outer border*, with the Deltoid and Supinator longus.

The **Brachialis anticus** is a broad muscle, which covers the elbow-joint and the lower half of the front of the humerus. It is somewhat compressed from before backward, and is broader in the middle than at either extremity. It arises from the lower half of the outer and inner surfaces of the shaft of the humerus, and commences above at the insertion of the Deltoid, which it embraces by two angular processes. Its origin extends below, to within an inch of the margin of the articular surface, and is limited on each side by the external and internal borders of the shaft of the humerus. It also arises from the intermuscular septa on each side, but more extensively from the inner than the outer, from which it is separated below by the Supinator longus and Extensor carpi radialis longior. Its fibres converge to a thick tendon, which is inserted into a rough depression on the inferior surface of the coronoid process of the ulna, being received into an interval between two fleshy slips of the Flexor digitorum profundus.

Relations.—By its *anterior surface*, with the Biceps, the brachial vessels, musculo-cutaneous, and median nerves; by its *posterior surface*, with the humerus and front of the elbow-joint; by its *inner border*, with the Triceps, ulnar nerve, and Pronator radii teres, from which it is separated by the intermuscular septum; by its *outer border*, with the musculo-spiral nerve, radial recurrent artery, the Supinator longus, and Extensor carpi radialis longior.

Nerves.—The muscles of this group are supplied by the musculo-cutaneous nerve, but the nerve to the Coraco-brachialis is often an independent branch of the outer cord of the Brachial plexus. The Brachialis anticus usually receives an additional filament from the musculo-spiral.

Actions.—The Coraco-brachialis draws the humerus forward and inward, and assists in elevating it. The Biceps is a flexor of the forearm: it is also a supinator, and makes tense the deep fascia of the forearm by means of the *bicipital fascia*. The Brachialis anticus is a flexor of the forearm, and protects the elbow-joint. When the forearm is fixed, the Biceps and Brachialis anticus flex the arm, as is seen in efforts of climbing.

Posterior Humeral Region.

Triceps. Subanconeus.

The **Triceps** (*Triceps extensor cubiti*) (Fig. 305) is situated on the back of the arm, extending the entire length of the posterior surface of the humerus. It is of large size, and divided above into three parts; hence its name. These three portions have been named (1) the middle, scapular, or long head; (2) the external, or long humeral; and (3) the internal, or short humeral head.

The *middle* or *scapular head* arises, by a flattened tendon, from a rough triangular depression immediately below the glenoid cavity, being blended at its upper part with the capsular ligament; the muscular fibres pass downward between the two other portions of the muscle, and join with them in the common tendon of insertion.

The *external head* arises from the posterior surface of the shaft of the humerus, between the insertion of the Teres minor and the upper part of the musculo-spiral groove; from the external border of the humerus and the external intermuscular septum: the fibres from this origin converge toward the common tendon of insertion.

The *internal head* arises from the posterior surface of the shaft of the humerus, below the groove for the musculo-spiral nerve; commencing above, narrow and pointed, below the insertion of the Teres major, and extending to within an inch of the trochlear surface: it also arises from the internal border of the humerus and internal intermuscular septum. The fibres of this portion of the muscle are

directed, some downward to the olecranon, whilst others converge to the common tendon of insertion.

The *common tendon* of the Triceps commences about the middle of the back part of the muscle: it consists of two aponeurotic laminæ, one of which is subcutaneous and covers the posterior surface of the muscle for the lower half of its extent; the other is more deeply seated in the substance of the muscle: after receiving the attachment of the muscular fibres, they join together above the elbow, and are inserted, for the most part, into the back part of the upper surface of the olecranon process; a band of fibres is, however, continued downward, on the outer side, over the Anconeus, to blend with the deep fascia of the forearm. A small bursa, occasionally multilocular, is situated on the front part of this surface, beneath the tendon.

The long head of the Triceps descends between the Teres minor and Teres major, dividing the triangular space between these two muscles and the humerus into two smaller spaces, one triangular, the other quadrangular (Fig. 305). The triangular space contains the dorsalis scapulæ vessels; it is bounded by the Teres minor above, the Teres major below, and the scapular head of the Triceps externally: the quadrangular space transmits the posterior circumflex vessels and the circumflex nerve; it is bounded by the Teres minor above, the Teres major below, the scapular head of the Triceps internally, and the humerus externally.

Relations.—By its *posterior surface*, with the Deltoid above: in the rest of its extent it is subcutaneous; by its *anterior surface*, with the humerus, musculo-spiral nerve, superior profunda vessels, and back part of the elbow-joint. Its *middle* or *long head* is in relation, behind, with the Deltoid and Teres minor; in front, with the Subscapularis, Latissimus dorsi, and Teres major.

The **Subanconeus** is a name given to a few fibres from the lower part of the Triceps muscle, which are inserted into the posterior ligament of the elbow-joint. By some authors it is regarded as the analogue of the Subcrureus in the lower limb, but it is not a separate muscle.

Nerves.—The Triceps is supplied by the musculo-spiral nerve.

Actions.—The Triceps is the great extensor muscle of the forearm, serving, when the forearm is flexed, to extend the elbow-joint. It is the direct antagonist of the Biceps and Brachialis anticus. When the arm is extended the long head of the muscle may assist the Teres major and Latissimus dorsi in drawing the humerus backward and in adducting it to the thorax. The long head of the Triceps protects the under part of the shoulder-joint, and prevents displacement of the head of the humerus downward and backward. The Subanconeus draws up the posterior ligament during extension of the forearm.

Surgical Anatomy.—The existence of the band of fibres from the Triceps to the fascia of the forearm is of importance in excision of the elbow, and should always be carefully preserved from injury by the operator, as by means of these fibres the patient is enabled to extend the forearm, a movement which would otherwise mainly be accomplished by gravity; that is to say, allowing the forearm to drop from its own weight.

THE FOREARM.

Dissection.—To dissect the forearm, place the limb in the position indicated in Fig. 301; make a vertical incision along the middle line from the elbow to the wrist, and a transverse incision at the extremity of this; the superficial structures being removed, the deep fascia of the forearm is exposed.

The **deep fascia** of the forearm, continuous above with that enclosing the arm, is a dense, highly glistening aponeurotic investment, which forms a general sheath enclosing the muscles in this region; it is attached, behind, to the olecranon and posterior border of the ulna, and gives off from its inner surface numerous intermuscular septa, which enclose each muscle separately. Below, it is continuous in front with the anterior annular ligament, and forms a sheath for the tendon of the Palmaris longus muscle, which passes over the annular ligament to be inserted into the palmar fascia. Behind, near the wrist-joint, it becomes much thickened

by the addition of many transverse fibres, and forms the posterior annular ligament. It consists of circular and oblique fibres, connected together by numerous vertical fibres. It is much thicker on the dorsal than on the palmar surface, and at the lower than at the upper part of the forearm, and is strengthened by tendinous fibres derived from the Brachialis anticus and Biceps in front, and from the Triceps behind. Its inner surface gives origin to muscular fibres, especially at the upper part of the inner and outer sides of the forearm, and forms the boundaries of a series of conical-shaped cavities, in which the muscles are contained. Besides the vertical septa separating each muscle, transverse septa are given off both on the anterior and posterior surfaces of the forearm, separating the deep from the superficial layer of muscles. Numerous apertures exist in the fascia for the passage of vessels and nerves; one of these, of large size, situated at the front of the elbow, serves for the passage of a communicating branch between the superficial and deep veins.

The muscles of the forearm may be subdivided into groups corresponding to the region they occupy. One group occupies the inner and anterior aspect of the forearm, and comprises the Flexor and Pronator muscles. Another group occupies its outer side, and a third its posterior aspect. The two latter groups include all the Extensor and Supinator muscles.

Anterior Radio-Ulnar Region.

Superficial Layer.

Pronator radii teres.
Flexor carpi radialis.
Palmaris longus.
Flexor carpi ulnaris.
Flexor sublimis digitorum.

These muscles take origin from the internal condyle of the humerus by a common tendon.

The **Pronator radii teres** arises by two heads. One, the larger and more superficial, arises from the humerus, immediately above the internal condyle, and from the tendon common to the origin of the other muscles; also from the fascia of the forearm and intermuscular septum between it and the Flexor carpi radialis. The other head is a thin fasciculus which arises from the inner side of the coronoid process of the ulna, joining the preceding at an acute angle. Between the two heads passes the median nerve. The muscle passes obliquely across the forearm from the inner to the outer side, and terminates in a flat tendon, which turns over the outer margin of the radius, and is inserted into a rough impression at the middle of the outer surface of the shaft of that bone.

Relations.—By its *anterior surface*, with the deep fascia, the Supinator longus, and the radial vessels and nerve; by its *posterior surface*, with the Brachialis anticus, Flexor sublimis digitorum, the median nerve, and ulnar artery, the small or deep head being interposed between the two latter structures. Its *outer border* forms the inner boundary of a triangular space (*cubital fossa*) in which is placed the brachial artery, median nerve, and tendon of the Biceps muscle. Its *inner border* is in contact with the Flexor carpi radialis.

Surgical Anatomy.—This muscle, when suddenly brought into very active use, as in the game of lawn tennis, is apt to be strained, producing slight swelling, tenderness, and pain on putting the muscle into action. This is known as "lawn-tennis arm."

The **Flexor carpi radialis** lies on the inner side of the preceding muscle. It arises from the internal condyle by the common tendon, from the fascia of the forearm, and from the intermuscular septa between it and the Pronator radii teres, on the outside, the Palmaris longus internally, and the Flexor sublimis digitorum beneath. Slender and aponeurotic in structure at its commencement, it increases in size, and terminates in a tendon which forms the lower two-thirds of its length. This tendon passes through a canal on the outer side of the annular ligament, runs through a groove in the os trapezium (which is converted into a canal by a fibrous sheath, and lined by a synovial membrane), and is inserted into the base

of the metacarpal bone of the index finger, and by a slip into the base of the metacarpal bone of the middle finger. The radial artery lies between the tendon of this muscle and the Supinator longus, and may easily be tied in this situation.

Relations.—By its *superficial surface*, with the deep fascia and the integument; by its *deep surface*, with the Flexor sublimis digitorum, Flexor longus pollicis, and wrist-joint; by its *outer border*, with the Pronator radii teres and the radial vessels; by its *inner border*, with the Palmaris longus above and the median nerve below.

The **Palmaris longus** is a slender, fusiform muscle lying on the inner side of the preceding. It arises from the inner condyle of the humerus by the common tendon, from the deep fascia, and the intermuscular septa between it and the adjacent muscles. It terminates in a slender, flattened tendon which passes over the annular ligament to end in the palmar fascia, frequently sending a tendinous slip to the short muscles of the thumb. This muscle is often absent; or it may be tendinous above and muscular below; or muscular at both extremities of a middle tendon.

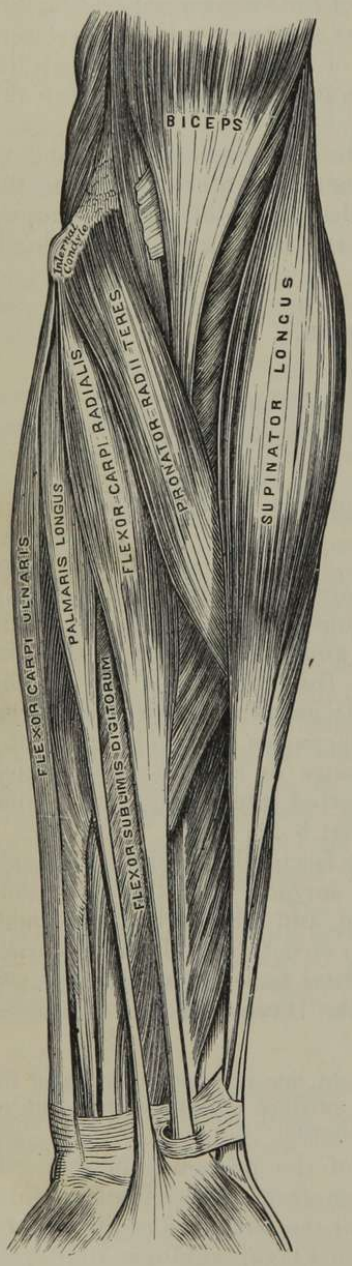

FIG. 306.—Front of the left forearm. Superficial muscles.

Relations.—By its *deep surface*, with the Flexor sublimis digitorum; *internally*, with the Flexor carpi ulnaris; *externally*, with the Flexor carpi radialis. The median nerve lies close to the tendon, just above the wrist, on its inner and posterior side.

The **Flexor carpi ulnaris** lies along the ulnar side of the forearm. It arises by two heads connected by a tendinous arch, beneath which pass the ulnar nerve and posterior ulnar recurrent artery. One head arises from the inner condyle of the humerus by the common tendon; the other, from the inner margin of the olecranon by an aponeurosis which arises also from the upper two-thirds of the posterior border of the ulna, in common with the Extensor carpi ulnaris and the Flexor profundus digitorum; other fibres spring from the septum between it and the Flexor sublimis digitorum. The fibres terminate in a tendon which occupies the anterior part of the lower half of the muscle, and is inserted into the pisiform bone, and is prolonged from this to the fifth metacarpal and unciform bones by the piso-metacarpal and piso-uncinate ligaments and to the annular ligament. The ulnar artery lies on the outer side of the tendon of this muscle, in the lower two-thirds of the forearm, the tendon forming a guide in tying the vessel in this situation.

Relations.—By its *superficial surface*, with the deep fascia, with which it is intimately connected for a considerable extent; by its *deep surface*, with the Flexor sublimis digitorum, the Flexor profundus digitorum, the Pronator quadratus, and the ulnar vessels and nerve; by its *outer* or *radial border*, with the Palmaris longus above, and the ulnar vessels and nerve below.

The **Flexor sublimis digitorum (perforatus)** is placed beneath the preceding muscles, which therefore must be removed in order to bring its attachment into view. It is the largest of the muscles of the superficial layer, and arises by three heads. One head arises from the internal condyle

of the humerus by the common tendon, from the internal lateral ligament of the elbow-joint, and from the intermuscular septum common to it and the preceding muscles. The second head arises from the inner side of the coronoid process of the ulna, above the ulnar origin of the Pronator radii teres (Fig. 200, p. 255). The third head arises from the oblique line and from a portion of the anterior border of the radius, extending to just below the insertion of the Pronator radii teres. The fibres pass vertically downward, forming a broad and thick muscle, which divides into four tendons about the middle of the forearm; as these tendons pass beneath the annular ligament into the palm of the hand they are arranged in pairs, the anterior pair corresponding to the middle and ring fingers, the posterior pair to the index and little fingers. The tendons diverge from one another as they pass onward. Opposite the base of the first phalanges each tendon divides into two slips, to allow of the passage of the corresponding tendons of the Flexor profundus digitorum; the two portions of the tendon then unite and form a grooved channel for the reception of the accompanying deep flexor tendon. Finally they subdivide a second time, to be inserted into the sides of the second phalanges about their middle. After leaving the palm these tendons, accompanied by the deep flexor tendons, lie in osseo-aponeurotic canals formed by the fibrous sheath of the tendons and the bones (Fig. 316).

Relations.—In the forearm, by its *superficial surface*, with the deep fascia and all the preceding superficial muscles; by its *deep surface*, with the Flexor profundus digitorum, Flexor longus pollicis, the ulnar vessels and nerve, and the median nerve. In the hand its tendons are in relation, *in front*, with the palmar fascia, superficial palmar arch, and the branches of the median nerve; *behind*, with the tendons of the deep Flexor and the Lumbricales.

Fibrous Sheath of the Flexor Tendons.—The flexor tendons of the fingers as they run along the phalanges are retained against the bones by a fibrous sheath, forming osseo-aponeurotic canals. These sheaths are formed by strong fibrous bands which arch across the tendons and are attached on each side to the margins of the phalanges. Opposite the middle of the proximal and second phalanges the sheath is very strong, and the fibres pass transversely; but opposite the joints it is much thinner, and the fibres pass obliquely. Each sheath is lined by a synovial membrane, which is reflected on the contained tendon.

Deep Layer.

Flexor profundus digitorum. Flexor longus pollicis.
Pronator quadratus.

Dissection.—Divide each of the superficial muscles at its centre, and turn either end aside; the deep layer of muscles, together with the median nerve and ulnar vessels, will then be exposed.

The **Flexor profundus digitorum (perforans)** (Fig. 307) is situated on the ulnar side of the forearm, immediately beneath the superficial Flexors. It arises from the upper three-fourths of the anterior and inner surfaces of the shaft of the ulna, embracing the insertion of the Brachialis anticus above, and extending, below, to within a short distance of the Pronator quadratus. It also arises from a depression on the inner side of the coronoid process; by an aponeurosis from the upper three-fourths of the posterior border of the ulna, in common with the Flexor and Extensor carpi ulnaris; and from the ulnar half of the interosseous membrane. The fibres form a fleshy belly of considerable size, which divides into four tendons: these pass under the annular ligament beneath the tendons of the Flexor sublimis digitorum. Opposite the first phalanges the tendons pass between the two slips of the tendons of the Flexor sublimis digitorum, and are finally inserted into the bases of the last phalanges. The tendon of the index finger is distinct; the rest are connected together by cellular tissue and tendinous slips as far as the palm of the hand. The tendons of this and those of the Flexor sublimis digitorum, whilst contained in the osseo-aponeurotic canals of the fingers, are invested in a synovial

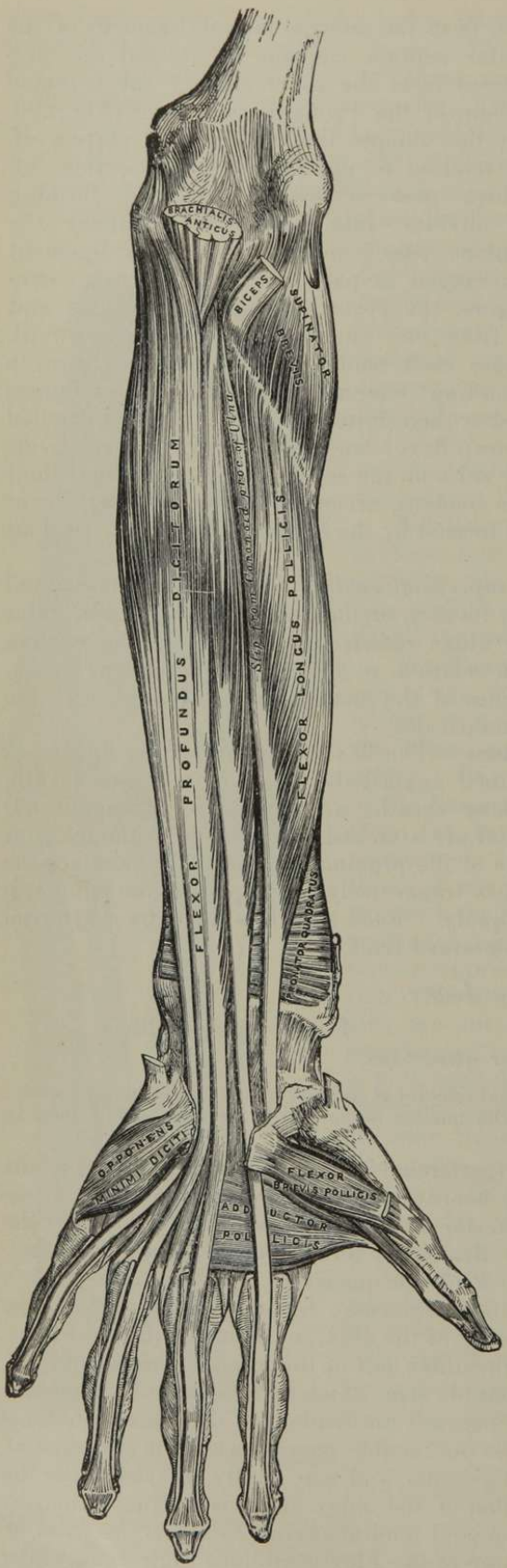

FIG. 307.—Front of the left forearm. Deep muscles.

sheath, and are connected to each other and to the phalanges by slender tendinous filaments, called *vincula accessoria tendinum*. One of these connects the deep tendon to the bone before it passes through the superficial tendon; a second connects the two tendons together, after the deep tendons have passed through; and a third connects the deep tendon to the head of the second phalanx. This last consists largely of yellow elastic tissue, and may assist in drawing down the tendon after flexion of the finger.[1]

Four small muscles, the Lumbricales, are connected with the tendons of the Flexor profundus in the palm. They will be described with the muscles in that region.

Relations.—By its *superficial surface*, in the forearm, with the Flexor sublimis digitorum, the Flexor carpi ulnaris, the ulnar vessels and nerve, and the median nerve; and in the hand, with the tendons of the superficial Flexor; by its *deep surface*, in the forearm, with the ulna, the interosseous membrane, the Pronator quadratus; and in the hand, with the interossei, Adductor pollicis, and deep palmar arch; by its *ulnar border*, with the Flexor carpi ulnaris; by its *radial border*, with the Flexor longus pollicis, the anterior interosseous vessels and nerve being interposed.

The **Flexor longus pollicis** is situated on the radial side of the forearm, lying on the same plane as the preceding. It arises from the grooved anterior surface of the shaft of the radius, commencing above, immediately below the tuberosity and oblique line, and extending below to within a short distance of the Pronator quadratus. It also arises from the adjacent part of the interosseous membrane, and generally by a fleshy slip from the base of the coronoid process. The fibres pass downward, and terminate in a flattened tendon which passes beneath the annular ligament, is then lodged in the interspace between the outer head of the Flexor brevis pollicis and the Adductor obliquus pollicis, and entering an osseo-aponeurotic canal

[1] Marshall, *Brit. and For. Med.-Chir. Rev.*, 1853.

similar to those for the other flexor tendons, is inserted into the base of the last phalanx of the thumb.

Relations.—By its *superficial surface*, with the Flexor sublimis digitorum, Flexor carpi radialis, Supinator longus, and radial vessels; by its *deep surface*, with the radius, interosseous membrane, and Pronator quadratus; by its *ulnar border*, with the Flexor profundus digitorum, from which it is separated by the anterior interosseous vessels and nerve.

The **Pronator quadratus** is a small, flat, quadrilateral muscle, extending transversely across the front of the radius and ulna, above their carpal extremities. It arises from the oblique or pronator ridge on the lower part of the anterior surface of the shaft of the ulna; from the lower fourth of the anterior surface and the anterior border of the ulna; and from a strong aponeurosis which covers the inner third of the muscle. The fibres pass horizontally outward, to be inserted into the lower fourth of the anterior surface and anterior border of the shaft of the radius.

Relations.—By its *superficial surface*, with the Flexor profundus digitorum, the Flexor longus pollicis, Flexor carpi radialis, and the radial vessels; by its *deep surface*, with the radius, ulna, and interosseous membrane.

Nerves.—All the muscles of the superficial layer are supplied by the median nerve, excepting the Flexor carpi ulnaris, which is supplied by the ulnar. Of the deep layer, the Flexor profundus digitorum is supplied conjointly by the ulnar and by the median through its branch, the anterior interosseous nerve, which also supplies the Flexor longus pollicis and Pronator quadratus.

Actions.—These muscles act upon the forearm, the wrist, and hand. The Pronator radii teres helps to rotate the radius upon the ulna, rendering the hand prone: when the radius is fixed it assists the other muscles in flexing the forearm. The Flexor carpi radialis is one of the flexors of the wrist; when acting alone it flexes the wrist, inclining it to the radial side. It can also assist in pronating the forearm and hand, and, by continuing its action, to bend the elbow. The Flexor carpi ulnaris is one of the flexors of the wrist: when acting alone it flexes the wrist, inclining it to the ulnar side, and, by continuing to contract, to bend the elbow. The Palmaris longus is a tensor of the palmar fascia. It also assists in flexing the wrist and elbow. The Flexor sublimis digitorum flexes the second phalanges. It assists in flexing the wrist and elbow. The Flexor profundus digitorum flexes the terminal phalanges (see page 497). After the Flexor sublimis has bent the second phalanx, the Flexor profundus flexes the terminal one, but it cannot do so until after the contraction of the superficial muscle. It also assists in flexing the wrist. The Flexor longus pollicis is a flexor of the phalanges of the thumb. When the thumb is fixed it also assists in flexing the wrist. The Pronator quadratus helps to rotate the radius upon the ulna, rendering the hand prone.

Radial Region (Fig. 308).

Supinator longus. Extensor carpi radialis longior.
Extensor carpi radialis brevior.

Dissection.—Divide the integument in the same manner as in the dissection of the anterior brachial region, and, after having examined the cutaneous vessels and nerves and deep fascia, remove all those structures. The muscles will then be exposed. The removal of the fascia will be considerably facilitated by detaching it from below upward. Great care should be taken to avoid cutting across the tendons of the muscles of the thumb, which cross obliquely the larger tendons running down the back of the radius.

The **Supinator longus** is the most superficial muscle on the radial side of the forearm: it is fleshy for the upper two-thirds of its extent, tendinous below. It arises from the upper two-thirds of the external condyloid ridge of the humerus, and from the external intermuscular septum, being limited above by the

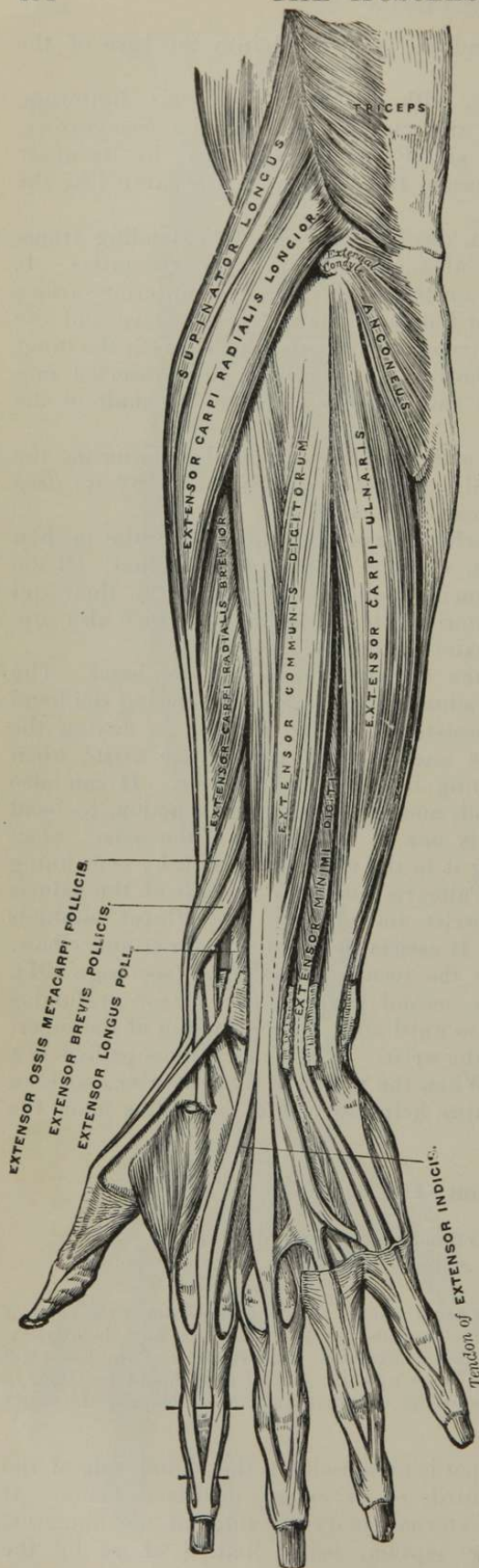

FIG. 308.—Posterior surface of the forearm. Superficial muscles.

musculo-spiral groove. The fibres terminate above the middle of the forearm in a flat tendon which is inserted into the outer side of the base of the styloid process of the radius.

Relations.—By its *superficial surface*, with the integument and fascia for the greater part of its extent; near its insertion it is crossed by the Extensor ossis metacarpi pollicis and the Extensor brevis pollicis; by its *deep surface*, with the humerus, the Extensor carpi radialis longior and brevior, the insertion of the Pronator radii teres, and the Supinator brevis; by its *inner border*, above the elbow, with the Brachialis anticus, the musculo-spiral nerve, and radial recurrent artery; and in the forearm with the radial vessels and nerve.

The **Extensor carpi radialis longior** is placed partly beneath the preceding muscle. It arises from the lower third of the external condyloid ridge of the humerus, and from the external intermuscular septum. The fibres terminate at the upper third of the forearm in a flat tendon, which runs along the outer border of the radius, beneath the extensor tendons of the thumb; it then passes through a groove common to it and the Extensor carpi radialis brevior, immediately behind the styloid process, and is inserted into the base of the metacarpal bone of the index finger, on its radial side.

Relations.—By its *superficial surface*, with the Supinator longus, and fascia of the forearm; its *outer side* is crossed obliquely by the extensor tendons of the thumb; by its *deep surface*, with the elbow-joint, the Extensor carpi radialis brevior, and back part of the wrist.

The **Extensor carpi radialis brevior** is shorter, as its name implies, and thicker than the preceding muscle, beneath which it is placed. It arises from the external condyle of the humerus by a tendon common to it and the three following muscles; from the external lateral ligament of the elbow-joint, from a strong aponeurosis which covers its surface, and from the intermuscular septa between it and the adjacent muscles. The fibres ter-

minate about the middle of the forearm in a flat tendon which is closely connected with that of the preceding muscle, and accompanies it to the wrist, lying in the same groove on the posterior surface of the radius; it passes beneath the extensor tendons of the thumb, then beneath the annular ligament, and, diverging somewhat from its fellow, is inserted into the base of the metacarpal bone of the middle finger, on its radial side.

The tendons of the two preceding muscles pass through the same compartment of the annular ligament, and are lubricated by a single synovial membrane, but are separated from each other by a small vertical ridge of bone as they lie in the groove at the back of the radius.

Relations.—By its *superficial surface*, with the Extensor carpi radialis longior, and with the Extensor muscles of the thumb which cross it; by its *deep surface*, with the Supinator brevis, tendon of the Pronator radii teres, radius, and wrist-joint; by its *ulnar border*, with the Extensor communis digitorum.

Posterior Radio-Ulnar Region (Fig. 308).

Superficial Layer.

Extensor communis digitorum.	Extensor carpi ulnaris.
Extensor minimi digiti.	Anconeus.

The **Extensor communis digitorum** is situated at the back part of the forearm. It arises from the external condyle of the humerus by the common tendon, from the deep fascia, and the intermuscular septa between it and the adjacent muscles. Just below the middle of the forearm it divides into three tendons, which pass, together with the Extensor indicis, through a separate compartment of the annular ligament, lubricated by a synovial membrane. The tendons then diverge, the innermost one dividing into two; and all, after passing across the back of the hand, are inserted into the second and third phalanges of the fingers in the following manner: Each tendon becomes narrow and thickened opposite the metacarpo-phalangeal articulation, and gives off a thin fasciculus upon each side of the joint, which blends with the lateral ligaments and serves as the posterior ligament; after having passed the joint it spreads out into a broad aponeurosis, which covers the whole of the dorsal surface of the first phalanx, being reinforced, in this situation, by the tendons of the Interossei and Lumbricales. Opposite the first phalangeal joint this aponeurosis divides into three slips, a middle and two lateral: the former is inserted into the base of the second phalanx; and the two lateral, which are continued onward along the sides of the second phalanx, unite by their contiguous margins, and are inserted into the dorsal surface of the last phalanx. As the tendons cross the phalangeal joints they furnish them with posterior ligaments. The tendons of the middle, ring, and little fingers are connected together, as they cross the hand, by small, oblique, tendinous slips, or *vincula;* those on each side of the ring finger are strong, and bind the tendon of this finger closely to those of the middle and little finger, so that it cannot, in general, be freely extended without moving the other two. Sometimes there is also a thin slip between the tendons of the index and middle fingers. The tendons of the index and little fingers also receive, before their division, the special extensor tendons belonging to them.

Relations.—By its *superficial surface*, with the fascia of the forearm and hand, the posterior annular ligament, and integument; by its *deep surface*, with the Supinator brevis, the Extensor muscles of the thumb and index finger, the posterior interosseous vessels and nerve, the wrist-joint, carpus, metacarpus, and phalanges; by its *radial border*, with the Extensor carpi radialis brevior; by its *ulnar border*, with the Extensor minimi digiti and Extensor carpi ulnaris.

The **Extensor minimi digiti** is a slender muscle placed on the inner side of the Extensor communis, with which it is generally connected. It arises from the common tendon by a thin, tendinous slip, and from the intermuscular septa between it and the adjacent muscles. Its tendon runs through a separate

compartment in the annular ligament behind the inferior radio-ulnar joint, then divides into two as it crosses the hand, one slip being united to the common extensor by a cross-piece at the metacarpo-phalangeal articulation. Both finally spread into a broad aponeurosis which blends with the common extensor to the finger, and is inserted into the second and third phalanges. The tendon is situated on the ulnar side of, and somewhat more superficial than, the common extensor.

The **Extensor carpi ulnaris** is the most superficial muscle on the ulnar side of the forearm. It arises from the external condyle of the humerus by the common tendon; from the middle third of the posterior surface of the ulna, below the Anconeus, and by an aponeurosis from the posterior border of the ulna in common with the Flexor carpi ulnaris and the Flexor profundus digitorum; and from the deep fascia of the forearm. This muscle terminates in a tendon which runs through a groove behind the styloid process of the ulna, passes through a separate compartment in the annular ligament, and is inserted into the prominent tubercle on the ulnar side of the base of the metacarpal bone of the little finger.

Relations.—By its *superficial surface*, with the deep fascia of the forearm; by its *deep surface*, with the ulna and the muscles of the deep layer.

The **Anconeus** is a small triangular muscle placed behind and below the elbow-joint, and appears to be a continuation of the external portion of the Triceps. It arises by a separate tendon from the back part of the outer condyle of the humerus, and is inserted into the side of the olecranon and upper fourth of the posterior surface of the shaft of the ulna; its fibres diverge from their origin, the upper ones being directed transversely, the lower obliquely inward.

Relations.—By its *superficial surface*, with a strong fascia derived from the Triceps; by its *deep surface*, with the elbow-joint, the orbicular ligament, the ulna, and a small portion of the Supinator brevis.

Deep Layer (Fig. 310).

Supinator brevis. Extensor brevis pollicis.
Extensor ossis metacarpi pollicis. Extensor longus pollicis.
Extensor indicis.

The **Supinator brevis** is a broad muscle, of a hollow cylindrical form, curved round the upper third of the radius. It consists of two distinct planes of muscular fibres, between which lies the posterior interosseous nerve. The two planes arise in common: the superficial one by tendinous, and the deeper by muscular fibres from the external condyle of the humerus; from the external lateral ligament of the elbow-joint and the orbicular ligament of the radius; from the ridge on the ulna, which runs obliquely downward from the posterior extremity of the lesser sigmoid cavity; from the triangular depression in front of this ridge; and from a tendinous expansion which covers the surface of the muscle. The superficial fibres surround the upper part of the radius, and are inserted into the outer edge of the bicipital tuberosity and to the oblique line of the radius, as low down as the insertion of the Pronator radii teres. The upper fibres of the deeper plane form a sling-like fasciculus, which encircles the neck of the radius above the tuberosity and is attached to the back part of its inner surface: the greater part of this portion of the muscle is inserted into the posterior and external surface of the shaft, midway between the oblique line and the head of the bone. Between the insertion of the two planes the posterior interosseous nerve lies on the shaft of the bone.

Relations.—By its *superficial surface*, with the superficial Extensor and Supinator muscles, and the radial vessels and nerve; by its *deep surface*, with the elbow-joint, the interosseous membrane, and the radius.

The **Extensor ossis metacarpi pollicis** is the most external and the largest of the deep extensor muscles: it lies immediately below the Supinator brevis, with which it is sometimes united. It arises from the posterior surface of the shaft of the ulna below the insertion of the Anconeus, from the interosseous membrane,

and from the middle third of the posterior surface of the shaft of the radius. Passing obliquely downward and outward, it terminates in a tendon which runs through a groove on the outer side of the styloid process of the radius, accompanied by the tendon of the Extensor brevis pollicis, and is inserted into the base of the metacarpal bone of the thumb. It occasionally gives off two slips, near its insertion—one to the Trapezium, and the other to blend with the origin of the Abductor pollicis.

Relations.—By its *superficial surface*, with the Extensor communis digitorum, Extensor minimi digiti, and fascia of the forearm, and with the branches of the posterior interosseous artery and nerve which cross it; by its *deep surface*,

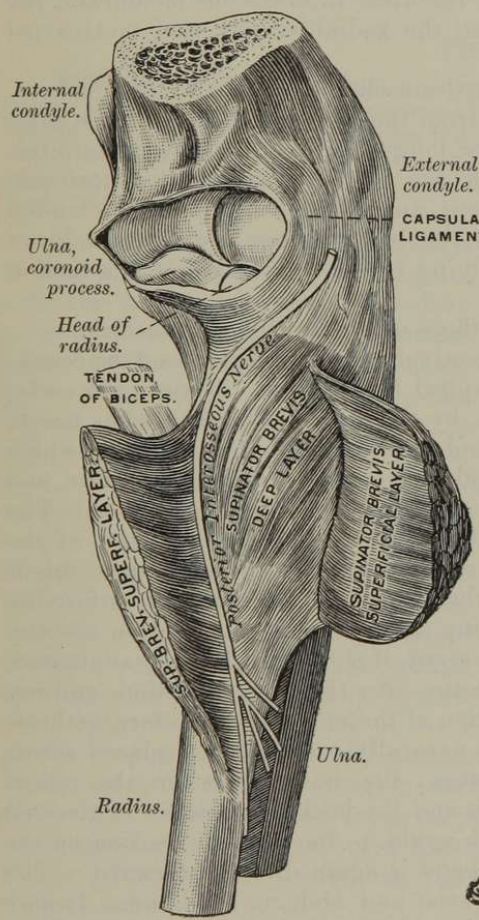

FIG. 309.—Supinator brevis. (From a preparation in the Museum of the Royal College of Surgeons of England).

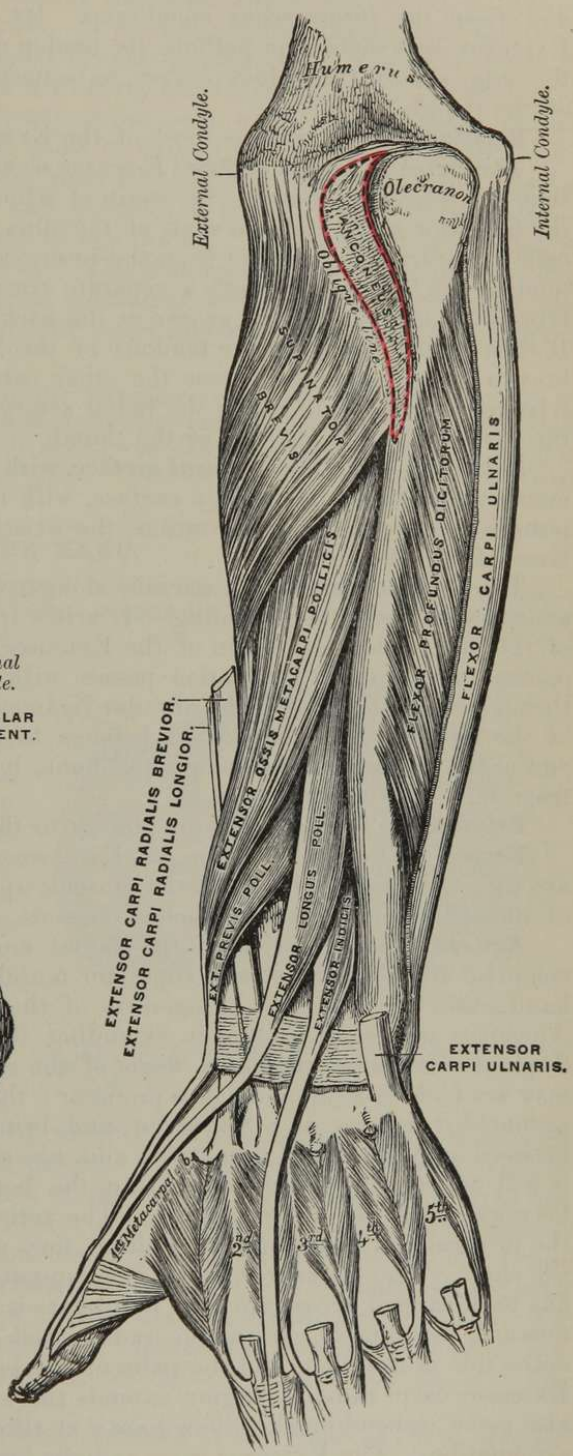

FIG. 310.—Posterior surface of the forearm. Deep muscles.

with the ulna, interosseous membrane, radius, the tendons of the Extensor carpi radialis longior and brevior, which it crosses obliquely, and, at the outer side of the wrist, with the radial vessels; by its *upper border*, with the Supinator brevis; by its *lower border*, with the Extensor brevis pollicis.

The **Extensor brevis pollicis** (*Extensor primi internodii pollicis*), the smallest muscle of this group, lies on the inner side of the preceding. It arises from the posterior surface of the shaft of the radius, below the Extensor ossis metacarpi pollicis, and from the interosseous membrane. Its direction is similar to that of the Extensor ossis metacarpi pollicis, its tendon passing through the same groove on the outer side of the styloid process, to be inserted into the base of the first phalanx of the thumb.

Relations.—The same as those of the Extensor ossis metacarpi pollicis.

The **Extensor longus pollicis** (*Extensor secundi internodii pollicis*) is much larger than the preceding muscle, the origin of which it partly covers in. It arises from the posterior surface of the shaft of the ulna, below the origin of the Extensor ossis metacarpi pollicis, and from the interosseous membrane. It terminates in a tendon which passes through a separate compartment in the annular ligament, lying in a narrow, oblique groove at the back part of the lower end of the radius. It then crosses obliquely the tendons of the Extensor carpi radialis longior and brevior, being separated from the other extensor tendons of the thumb by a triangular interval, in which the radial artery is found, and is finally inserted into the base of the last phalanx of the thumb.

Relations.—By its *superficial surface*, with the same parts as the Extensor ossis metacarpi pollicis; by its *deep surface*, with the ulna, interosseous membrane, the posterior interosseous nerve, radius, the wrist, the radial vessels, and metacarpal bone of the thumb.

The **Extensor indicis** is a narrow, elongated muscle placed on the inner side of, and parallel with, the preceding. It arises from the posterior surface of the shaft of the ulna, below the origin of the Extensor longus pollicis and from the interosseous membrane. Its tendon passes with the Extensor communis digitorum through the same canal in the annular ligament, and subsequently joins the tendon of the Extensor communis which belongs to the index finger, opposite the lower end of the corresponding metacarpal bone, lying to the ulnar side of the tendon from the common Extensor.

Relations.—The relations are similar to those of the preceding muscles.

Nerves.—The Supinator longus, Extensor carpi radialis longior, and Anconeus are supplied by branches from the musculo-spiral nerve; the remaining muscles of the radial and posterior brachial regions, by the posterior interosseous nerve.

Actions.—The muscles of the radial and posterior brachial regions, which comprise all the extensor and supinator muscles, act upon the forearm, wrist, and hand; they are the direct antagonists of the pronator and flexor muscles. The Anconeus assists the Triceps in extending the forearm. The chief action of the Supinator longus is that of a flexor of the elbow-joint, but in addition to this it may act both as a supinator or a pronator; that is to say, if the forearm is forcibly pronated it will act as a supinator, and bring the bones into a position midway between supination and pronation; and, *vice versâ*, if the arm is forcibly supinated, it will act as a pronator, and bring the bones into the same position, midway between supination and pronation. The action of the muscle is therefore to throw the forearm and hand into the position they naturally occupy when placed across the chest. The Supinator brevis is a supinator; that is to say, when the radius has been carried across the ulna in pronation and the back of the hand is directed forward, this muscle carries the radius back again to its normal position on the outer side of the ulna, and the palm of the hand is again directed forward. The Extensor carpi radialis longior extends the wrist and abducts the hand. It may also assist in bending the elbow-joint; at all events, it serves to fix or steady this articulation. The Extensor carpi radialis brevior assists the Extensor carpi radialis longior in extending the wrist, and may also act slightly as an abductor of the hand. The Extensor carpi ulnaris helps to extend the hand, but when acting alone inclines it toward the ulnar side; by its continued action it extends the elbow-joint. The Extensor communis digitorum extends the phalanges, then the wrist, and finally the elbow. It acts principally on the proximal phalanges, the

middle and terminal phalanges being extended by the Interossei and Lumbricales. It has also a tendency to separate the fingers as it extends them. The Extensor minimi digiti extends similarly the little finger, and by its continued action it assists in extending the wrist. It is owing to this muscle that the little finger can be extended or pointed whilst the others are flexed. The chief action of the Extensor ossis metacarpi pollicis is to carry the thumb outward and backward from the palm of the hand, and hence it has been called the *abductor longus pollicis*. By its continued action it helps to extend and abduct the wrist. The Extensor brevis pollicis extends the proximal phalanx of the thumb. By its continued action it helps to extend and abduct the wrist. The Extensor longus pollicis extends the terminal phalanx of the thumb. By its continued action it helps to extend and abduct the wrist. The Extensor indicis extends the first phalanx of the index finger, and by its continued action assists in extending the wrist. It is owing to this muscle that the index finger can be extended or pointed while the others are flexed.

Surgical Anatomy.—The tendons of the Extensor muscles of the thumb are liable to become strained and their sheaths inflamed after excessive exercise, producing a sausage-shaped swelling along the course of the tendon, and giving a peculiar creaking sensation to the finger when the muscle acts. In consequence of its often being caused by such movements as wringing clothes, it is known as "washerwoman's sprain."

THE HAND.

Dissection (Fig. 301).—Make a transverse incision across the front of the wrist, and a second across the heads of the metacarpal bones: connect the two by a vertical incision in the middle line, and continue it through the centre of the middle finger. The anterior and posterior annular ligaments and the palmar fascia should then be dissected.

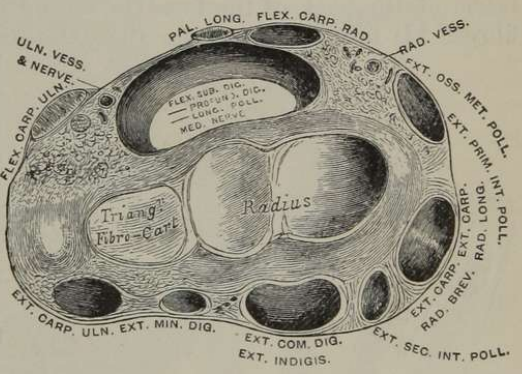

FIG. 311.—Transverse section through the wrist, showing the annular ligaments and the canals for the passage of the tendons.

The **Anterior Annular Ligament** is a strong, fibrous band which arches over the carpus, converting the deep groove on the front of the carpal bones into a canal, beneath which pass the flexor tendons of the fingers. It is attached, internally, to the pisiform bone and unciform process of the unciform bone, and externally to the tuberosity of the scaphoid and to the inner part of the anterior surface and the ridge on the trapezium. It is continuous, above, with the deep fascia of the forearm, of which it may be regarded as a thickened portion, and, below, with the palmar fascia. It is crossed by the ulnar vessels and nerve and the cutaneous branches of the median and ulnar nerves. At its outer extremity is the tendon of the Flexor carpi radialis, which lies in the groove on the trapezium between the attachments of the annular ligament to the bone. It has inserted into its anterior surface the tendon of the Palmaris longus and part of the tendon of the Flexor carpi ulnaris, and has arising from it, below, the small muscles of the thumb and little finger. Beneath it pass the tendons of the Flexor sublimis and profundus digitorum, the Flexor longus pollicis, and the median nerve.

The Synovial Membranes of the Flexor Tendons at the Wrist.—There are two synovial membranes which enclose all the tendons as they pass beneath this ligament—one for the Flexor sublimis and profundus digitorum, the other for the Flexor longus pollicis. They extend up into the forearm for about an inch above the annular ligament, and downward about halfway along the metacarpal bone, where they terminate in a blind diverticulum around each pair of tendons, with the exception of the thumb and sometimes the little finger—in these two fingers

the diverticulum is continued on, and communicates with the synovial sheath of the tendons. In the other three fingers the synovial sheath of the tendons in the fingers begins as a blind pouch without communication with the large synovial sac (Fig. 313).

Surgical Anatomy.—This arrangement of the synovial sheaths explains the fact that thecal abscess in the thumb and little finger is liable to be followed by abscesses in the forearm, from extension of the inflammation along the continuous synovial sheaths. Ganglion is apt to occur in this situation, constituting "compound palmar ganglion": it presents an hour-glass outline, with a swelling in front of the wrist and in the palm of the hand, and a constriction corresponding to the annular ligament between the two. The fluid can be forced from the one swelling to the other under the ligament.

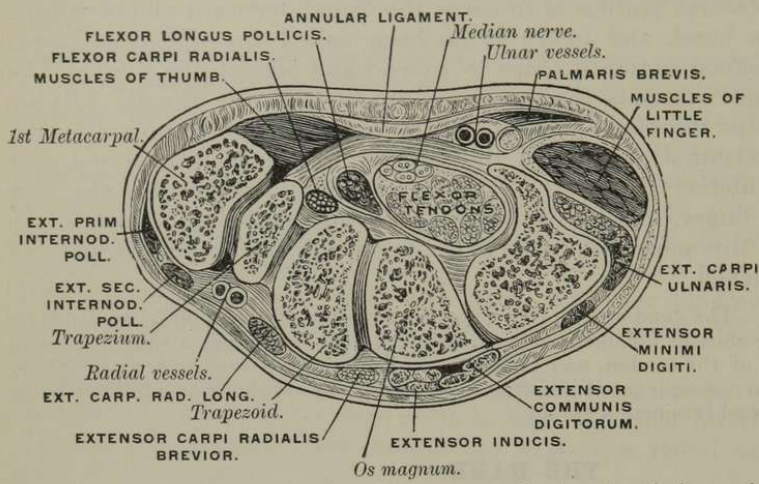

FIG. 312.—Transverse section through the carpus, showing the relative positions of the tendons, vessels, and nerves. (Henle.)

The **Posterior Annular Ligament** is a strong fibrous band extending transversely across the back of the wrist, and consisting of the deep fascia of the back of the forearm, strengthened by the addition of some transverse fibres. It forms a sheath for the extensor tendons in their passage to the fingers, being attached, internally, to the styloid process of the ulna, the cuneiform and pisiform bones; externally, to the margin of the radius; and, in its passage across the wrist, to the elevated ridges on the posterior surface of the radius. It presents six compartments for the passage of tendons, each of which is lined by a separate synovial membrane. These are, from without inward—1. On the outer side of the styloid process, for the tendons of the Extensor ossis metacarpi and Extensor brevis pollicis; 2. Behind the styloid process, for the tendons of the Extensor carpi radialis longior and brevior; 3. About the middle of the posterior surface of the radius, for the tendon of the Extensor longus pollicis; 4. To the inner side of the latter, for the tendons of the Extensor communis digitorum and Extensor indicis; 5. Opposite the interval between the radius and ulna, for the Extensor minimi digiti; 6. Grooving the back of the ulna, for the tendon of the Extensor carpi ulnaris.

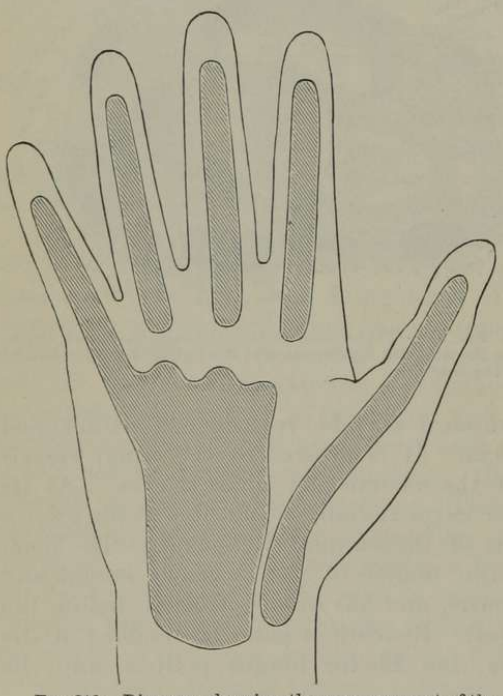

FIG. 313.—Diagram showing the arrangement of the synovial sheaths of the palm and fingers.

The synovial membranes lining these sheaths are usually very extensive, reaching from above the annular ligament, down upon the tendons for a variable distance on the back of the hand.

The **deep palmar fascia** (Fig. 314) forms a common sheath which invests the muscles of the hand. It consists of a central and two lateral portions.

The *central portion* occupies the middle of the palm, is triangular in shape, of

great strength and thickness, and binds down the tendons in this situation. It is narrow above, being attached to the lower margin of the annular ligament, and receives the expanded tendon of the Palmaris longus muscle. Below, it is broad and expanded, and divides into four slips, for the four fingers. Each slip gives off superficial fibres, which are inserted into the skin of the palm and finger, those to the palm joining the skin at the furrow corresponding to the metacarpo-phalangeal articulation, and those to the fingers passing into the skin at the transverse fold at the base of the fingers. The deeper part of each slip subdivides into two processes, which are inserted into the lateral margins of the anterior (glenoid) ligament of the metacarpo-phalangeal joint. From the sides of these processes

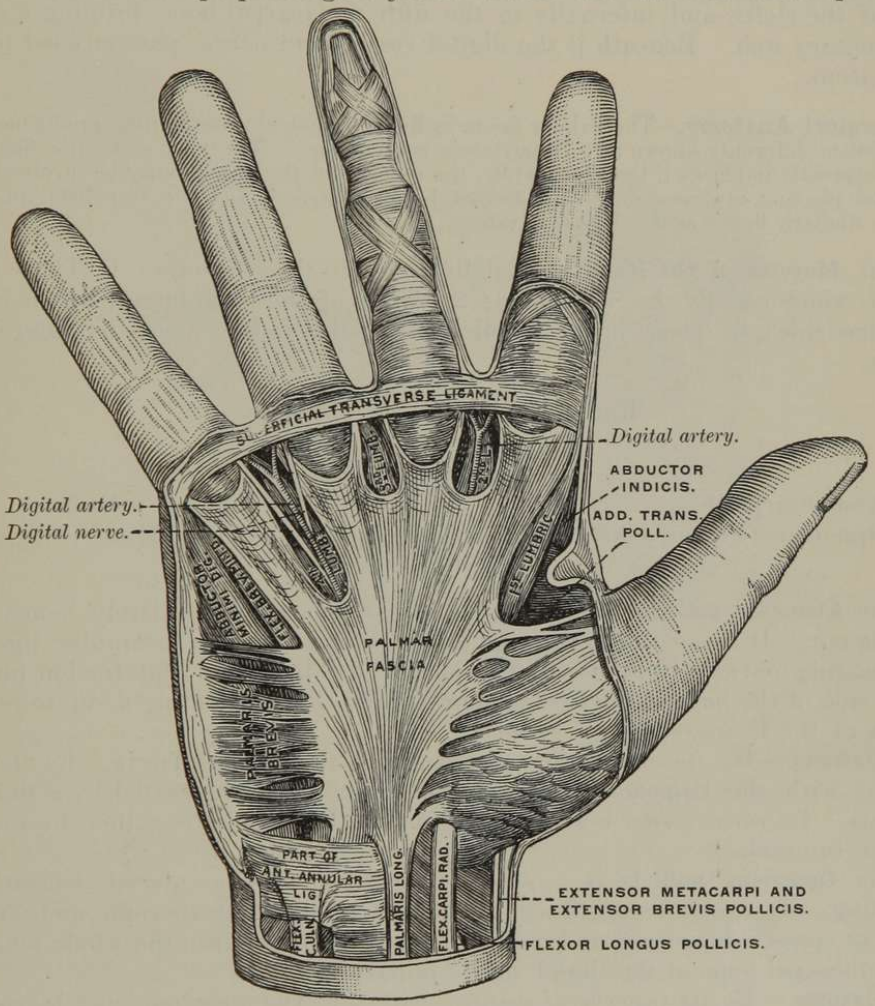

FIG. 314.—Palmar fascia. (Altered from a dissection in the Museum of the Royal College of Surgeons of England.)

offsets are sent backward, to be attached to the borders of the lateral surfaces of the metacarpal bones at their distal extremities. By this arrangement short channels are formed on the front of the lower ends of the metacarpal bones, through which the flexor tendons pass. Dr. W. W. Keen describes a fifth slip as frequently found passing to the thumb. The intervals left in the fascia between the four fibrous slips transmit the digital vessels and nerves and the tendons of the Lumbricales. At the points of division of the palmar fascia into the slips above mentioned numerous strong, transverse fibres bind the separate processes together. The palmar fascia is intimately adherent to the integument by dense fibro-areolar tissue, forming the superficial palmar fascia, and gives origin by its inner margin to the Palmaris brevis: it covers the superficial palmar arch, the

tendons of the flexor muscles, and the branches of the median and ulnar nerves, and on each side it gives off a vertical septum, which is continuous with the interosseous aponeurosis and separates the lateral from the middle palmar group of muscles.

The *lateral portions* of the palmar fascia are thin, fibrous layers, which cover, on the radial side, the muscles of the ball of the thumb, and, on the ulnar side, the muscles of the little finger; they are continuous with the dorsal fascia, and in the palm with the central portion of the palmar fascia.

The **Superficial Transverse Ligament of the Fingers** is a thin, fibrous band which stretches across the roots of the four fingers, and is closely attached to the skin of the clefts, and internally to the fifth metacarpal bone, forming a sort of rudimentary web. Beneath it the digital vessels and nerves pass onward to their destination.

Surgical Anatomy.—The palmar fascia is liable to undergo contraction, producing a very inconvenient deformity known as "Dupuytren's contraction." The ring and little fingers are most frequently implicated, but the middle, the index, and the thumb may be involved. The proximal phalanx is drawn down and cannot be straightened, and the two distal phalanges become similarly flexed as the disease advances.

The **Muscles of the Hand** are subdivided into three groups: 1. Those of the thumb, which occupy the radial side; 2. Those of the little finger, which occupy the ulnar side; 3. Those in the middle of the palm and between the interosseous spaces.

Radial Region (Figs. 315, 316).

Muscles of the Thumb.

Abductor pollicis. Flexor brevis pollicis.
Opponens (Flexor ossis metacarpi) pollicis. Adductor obliquus pollicis.
Adductor transversus pollicis.

The **Abductor pollicis** is a thin, flat muscle placed immediately beneath the integument. It arises from the ridge of the os trapezium and annular ligament, and, passing outward and downward, is inserted by a thin, flat tendon into the radial side of the base of the first phalanx of the thumb, sending a slip to join the tendon of the Extensor longus pollicis.

Relations.—By its *superficial surface*, with the palmar fascia; by its *deep surface*, with the Opponens pollicis, from which it is separated by a thin aponeurosis. Its *inner border* is separated from the Flexor brevis pollicis by a narrow cellular interval.

The **Opponens pollicis** is a small, triangular muscle placed beneath the preceding. It arises from the palmar surface of the trapezium and annular ligament, passes downward and outward, and is inserted into the whole length of the metacarpal bone of the thumb on its radial side.

Relations.—By its *superficial surface*, with the Abductor pollicis; by its *deep surface*, with the trapezio-metacarpal articulation; by its *inner border*, with the Flexor brevis pollicis.

The **Flexor brevis pollicis** is much larger than either of the two preceding muscles, beneath which it is placed. It consists of two portions, outer and inner. The outer and more superficial portion arises from the trapezium and outer two-thirds of the annular ligament, and passes along the outer side of the tendon of the Flexor longus pollicis, and, becoming tendinous, has a sesamoid bone developed in its tendon, and is inserted into the outer side of the base of the first phalanx of the thumb. The inner and deeper portion of the muscle is very small, and arises from the ulnar side of the first metacarpal bone, and is inserted into the inner side of the base of the first phalanx with the Adductor obliquus pollicis. A sesamoid bone is developed in the common tendon of insertion.

Relations.—By its *superficial surface*, with the palmar fascia; by its *deep sur-*

face, with the tendon of the Flexor carpi radialis; by its *external surface*, with the Opponens pollicis; by its *internal surface*, with the Adductor obliquus pollicis.

The **Adductor obliquus pollicis** arises by several slips from the os magnum, the bases of the second and third metacarpal bones, the anterior annular ligament, and the sheath of the tendon of the Flexor carpi radialis. From this origin the greater number of fibres pass obliquely downward and converge to a tendon, which, uniting with the tendons of the deeper portion of the Flexor brevis pollicis and the Adductor transversus, is inserted into the inner side of the base of the first phalanx of the thumb, a sesamoid bone being developed in the tendon of insertion. A considerable fasciculus, however, passes more obliquely outward beneath the

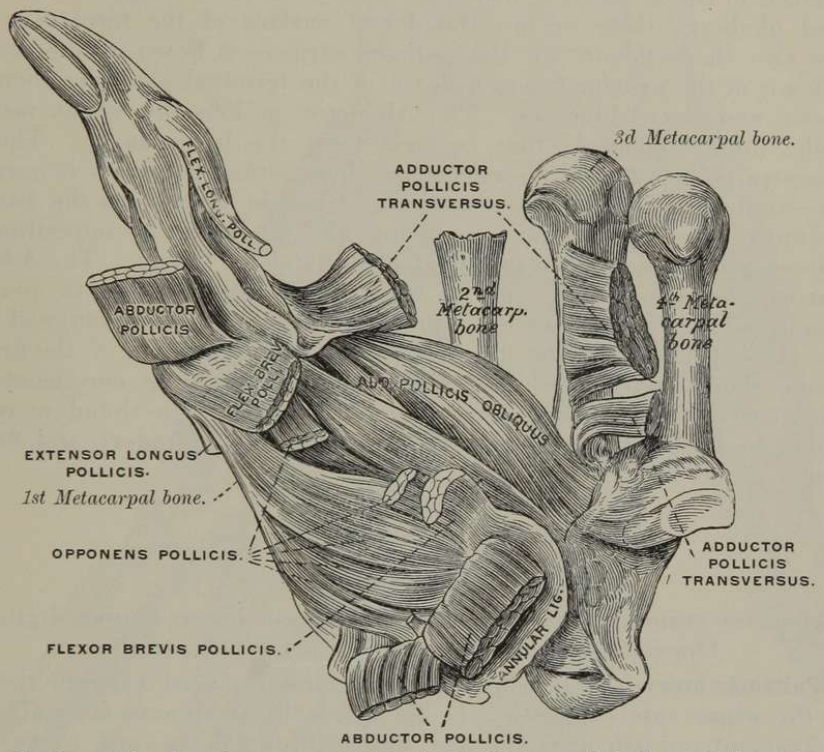

FIG. 315.—Muscles of thumb. (From a preparation in the Museum of the Royal College of Surgeons of England.)

tendon of the long flexor to join the superficial portion of the short flexor and the Abductor pollicis.[1]

Relations.—By its *superficial surface*, with the Flexor longus pollicis and the outer head of the Flexor brevis pollicis. Its *deep surface* covers the Adductor transversus pollicis, and is in relation with the deep palmar arch, which passes between the two adductors.

The **Adductor transversus pollicis** (Fig. 315) is the most deeply seated of this group of muscles. It is of a triangular form, arising, by its broad base, from the lower two-thirds of the metacarpal bone of the middle finger on its palmar surface: the fibres, proceeding outward, converge, to be inserted, with the inner tendon of the Flexor brevis pollicis, and the Adductor obliquus pollicis, into the ulnar side of the base of the first phalanx of the thumb. From the common tendon of insertion a slip is prolonged to the Extensor longus pollicis.

Relations.—By its *superficial surface*, with the Adductor obliquus pollicis, the tendons of the Flexor profundus, and the Lumbricales. Its *deep surface* covers the first two interosseous spaces, from which it is separated by a strong aponeurosis.

Three of these muscles of the thumb, the Abductor, the Adductor transversus,

[1] This muscle was formerly described as the deep portion of the Flexor brevis pollicis.

and the Flexor brevis pollicis, at their insertions give off fibrous expansions which join the tendon of the Extensor longus pollicis. This permits of flexion of the proximal phalanx and extension of the terminal phalanx at the same time. These expansions, originally figured by Albinus, have been more recently described by M. Duchenne (*Physiologie des Mouvements*, page 299).

Nerves.—The Abductor, Opponens, and outer head of the Flexor brevis pollicis are supplied by the median nerve; the inner head of the Flexor brevis, and the Adductors, by the ulnar nerve.

Actions.—The actions of the muscles of the thumb are almost sufficiently indicated by their names. This segment of the hand is provided with three extensors—an extensor of the metacarpal bone, an extensor of the first, and an extensor of the second phalanx; these occupy the dorsal surface of the forearm and hand. There are also three flexors on the palmar surface—a flexor of the metacarpal bone, a flexor of the proximal, and a flexor of the terminal phalanx; there is also an Abductor and two Adductors. The Abductor pollicis moves the metacarpal bone of the thumb outward; that is, away from the index finger. The Flexor ossis metacarpi pollicis flexes the metacarpal bone—that is, draws it inward over the palm—and at the same time rotates the bone, so as to turn the ball of the thumb toward the fingers, thus producing the movement of opposition. The Flexor brevis pollicis flexes the proximal phalanx of the thumb. The Adductores pollicis move the metacarpal bone of the thumb inward; that is, toward the index finger. These muscles give to the thumb its extensive range of motion. It will be noticed, however, that in consequence of the position of the first metacarpal bone these movements differ from the corresponding movements of the metacarpal bones of the other fingers. Thus extension of the thumb more nearly corresponds to the motion of abduction in the other fingers, and flexion to adduction.

Ulnar Region (Fig. 316).

Palmaris brevis.

Muscles of the Little Finger.

Abductor minimi digiti. Flexor brevis minimi digiti.
Opponens (Flexor ossis metacarpi) minimi digiti.

The **Palmaris brevis** is a thin quadrilateral muscle placed beneath the integument on the ulnar side of the hand. It arises by tendinous fasciculi from the annular ligament and palmar fascia; the fleshy fibres pass inward, to be inserted into the skin on the inner border of the palm of the hand.

Relations.—By its *superficial surface*, with the integument, to which it is intimately adherent, especially by its inner extremity; by its *deep surface*, with the inner portion of the palmar fascia, which separates it from the ulnar vessels and nerve, and from the muscles of the ulnar side of the hand.

The **Abductor minimi digiti** is situated on the ulnar border of the palm of the hand. It arises from the pisiform bone, and terminates in a flat tendon which divides into two slips: one passes under the lateral expansion of the extensor tendon, opposite the metacarpo-phalangeal articulation, and is inserted into the ulnar side of the base of the first phalanx of the little finger. The other slip passes over the expansion, and is inserted into the ulnar border of the shaft of the same phalanx.

Relations.—By its *superficial surface*, with the inner portion of the palmar fascia, and the Palmaris brevis; by its *deep surface*, with the Flexor ossis metacarpi minimi digiti; by its *outer border*, with the Flexor brevis minimi digiti.

The **Flexor brevis minimi digiti** lies on the same plane as the preceding muscle, on its radial side. It arises from the tip of the unciform process of the unciform bone and anterior surface of the annular ligament, and is inserted into the base of the first phalanx of the little finger. It is separated from the Abductor at its origin by the deep branches of the ulnar artery and nerve. This muscle is sometimes wanting; the Abductor is then, usually, of large size.

Relations.—By its *superficial surface*, with the internal portion of the palmar fascia, and the Palmaris brevis; by its *deep surface*, with the Opponens.

The **Opponens minimi digiti** (Fig. 307) is of a triangular form, and placed immediately beneath the preceding muscles. It arises from the unciform process

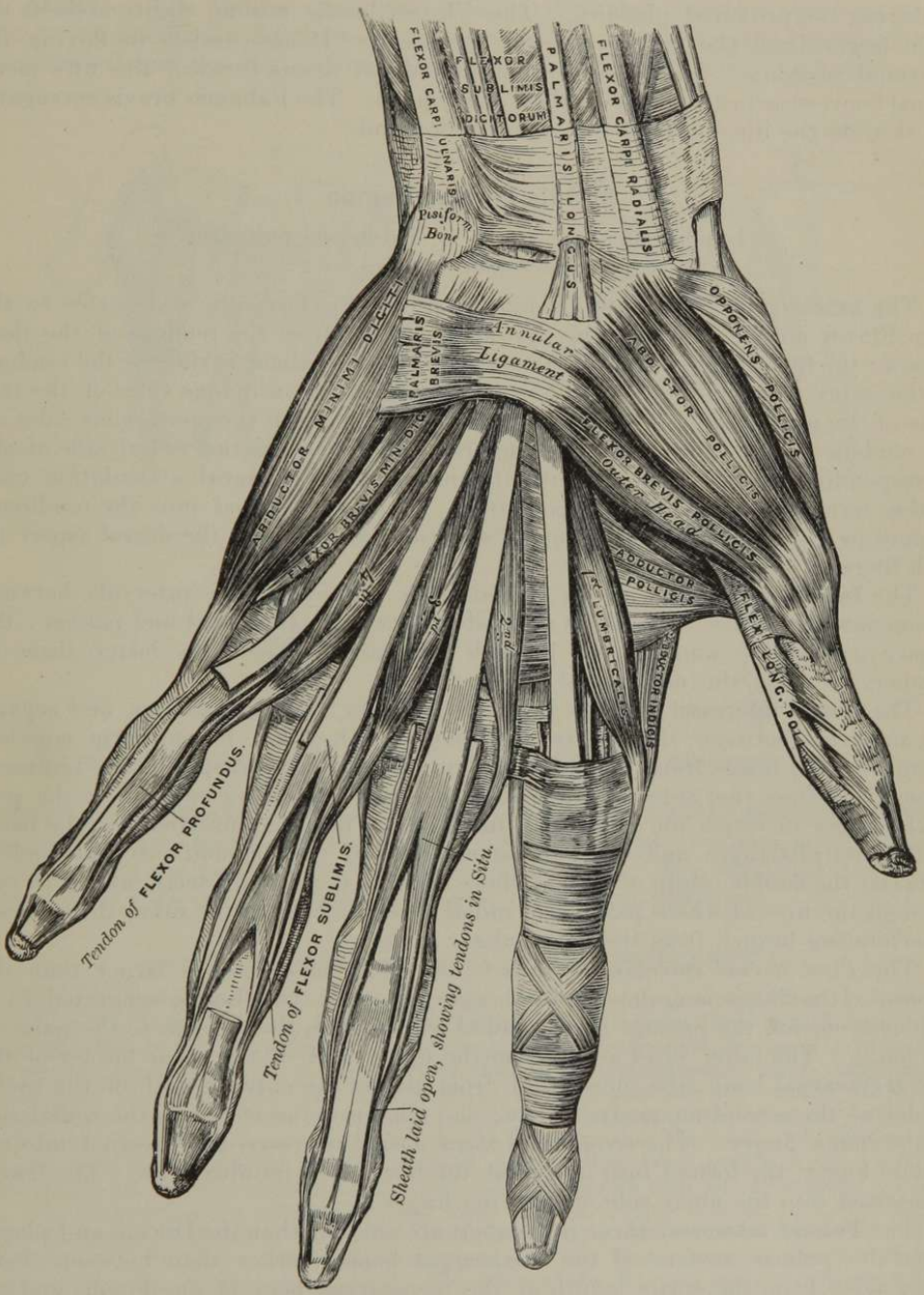

FIG. 316.—Muscles of the left hand. Palmar surface.

of the unciform bone and contiguous portion of the annular ligament; its fibres pass downward and inward, to be inserted into the whole length of the metacarpal bone of the little finger, along its ulnar margin.

Relations.—By its *superficial surface*, with the Flexor brevis and Abductor minimi digiti; by its *deep surface*, with the Interossei muscles in the fourth

metacarpal space, the metacarpal bone, and the Flexor tendons of the little finger.

Nerves.—All the muscles of this group are supplied by the ulnar nerve.

Actions.—The Abductor minimi digiti abducts the little finger from the middle line of the hand. It corresponds to a dorsal interosseous muscle. It also assists in flexing the proximal phalanx. The Flexor brevis minimi digiti abducts the little finger from the middle line of the hand. It also assists in flexing the proximal phalanx. The Opponens minimi digiti draws forward the fifth metacarpal bone, so as to deepen the hollow of the palm. The Palmaris brevis corrugates the skin on the inner side of the palm of the hand.

Middle Palmar Region.

Lumbricales. Interossei palmares.
Interossei dorsales.

The **Lumbricales** (Fig. 316) are four small fleshy fasciculi, accessories to the deep Flexor muscle. They arise by fleshy fibres from the tendons of the deep Flexor: the first and second, from the radial side and palmar surface of the tendons of the index and middle fingers; the third, from the contiguous sides of the tendons of the middle and ring fingers; and the fourth, from the contiguous sides of the tendons of the ring and little fingers. They pass to the radial side of the corresponding fingers, and opposite the metacarpo-phalangeal articulation each tendon terminates in a broad aponeurosis which is inserted into the tendinous expansion from the Extensor communis digitorum, covering the dorsal aspect of each finger.

The **Interossei muscles** are so named from occupying the intervals between the metacarpal bones. They are divided into two sets, a dorsal and palmar; the former are four in number, one in each metacarpal space; the latter, three in number, lie upon the metacarpal bones.

The **Dorsal interossei** are four in number, larger than the palmar, and occupy the intervals between the metacarpal bones. They are bipenniform muscles, arising by two heads from the adjacent sides of the metacarpal bones, but more extensively from that side of the metacarpal bone which corresponds to the side of the finger in which the muscle is inserted. They are inserted into the bases of the first phalanges and into the aponeurosis of the common extensor tendon. Between the double origin of each of these muscles is a narrow triangular interval, through the first of which passes the radial artery; through the other three passes a perforating branch from the deep palmar arch.

The *First dorsal interosseous muscle*, or *Abductor indicis*, is larger than the others. It is flat, triangular in form, and arises by two heads, separated by a fibrous arch, for the passage of the radial artery from the dorsum to the palm of the hand. The outer head arises from the upper half of the ulnar border of the first metacarpal bone; the inner head, from almost the entire length of the radial border of the second metacarpal bone; the tendon is inserted into the radial side of the index finger. The *second* and *third dorsal interossei* are inserted into the middle finger, the former into its radial, the latter into its ulnar side. The *fourth* is inserted into the ulnar side of the ring finger.

The **Palmar interossei**, three in number, are smaller than the Dorsal, and placed upon the palmar surface of the metacarpal bones, rather than between them. They arise from the entire length of the metacarpal bone of one finger, and are inserted into the side of the base of the first phalanx and aponeurotic expansion of the common extensor tendon of the same finger.

The *first* arises from the ulnar side of the second metacarpal bone, and is inserted into the same side of the index finger. The *second* arises from the radial side of the fourth metacarpal bone, and is inserted into the same side of the ring finger. The *third* arises from the radial side of the fifth metacarpal bone, and is inserted into the same side of the little finger. From this account it may be seen

that each finger is provided with two Interossei muscles, with the exception of the little finger, in which the Abductor muscle takes the place of one of the pair.

Nerves.—The two outer Lumbricales are supplied by the median nerve; the rest of the muscles of this group, by the ulnar. All the Interossei are supplied by the ulnar.

Actions.—The Palmar interossei muscles adduct the fingers to an imaginary line drawn longitudinally through the centre of the middle finger; and the Dorsal interossei abduct the fingers from that line. In addition to this, the Interossei, in

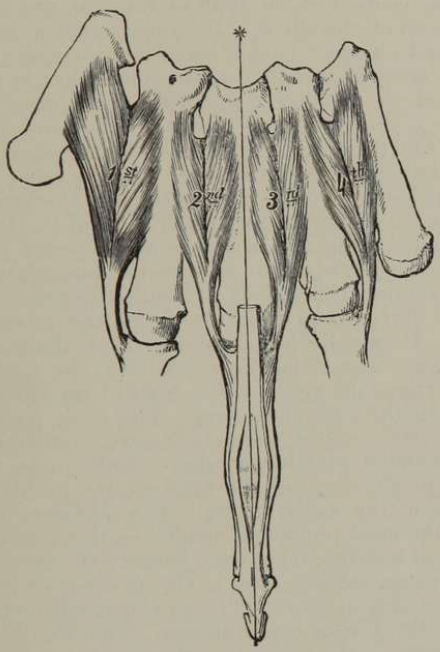

FIG. 317.—The Dorsal interossei of left hand.

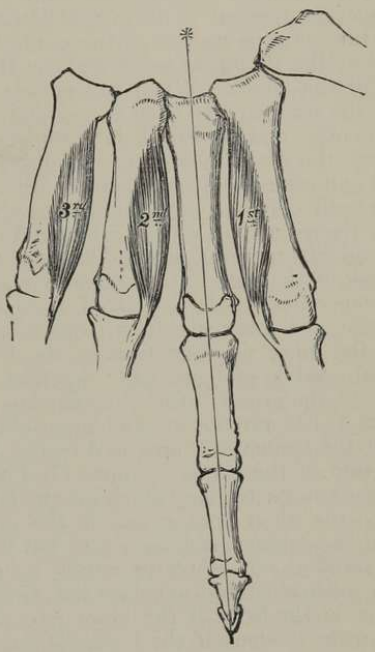

FIG. 318.—The Palmar interossei of left hand.

conjunction with the Lumbricales, *flex the first phalanges* at the metacarpo-phalangeal joints, and extend the second and third phalanges in consequence of their insertion into the expansion of the extensor tendons. The Extensor communis digitorum is believed to act almost entirely on the first phalanges.

SURFACE FORM OF THE UPPER EXTREMITY.

The *Pectoralis major* largely influences surface form and conceals a considerable part of the thoracic wall in front. Its sternal origin presents a festooned border which bounds and determines the width of the sternal furrow. Its clavicular origin is somewhat depressed and flattened, and between the two portions of the muscle is often an oblique depression which differentiates the one from the other. The outer margin of the muscle is generally well marked above, and bounds the infraclavicular fossa, a triangular interval which separates the Pectoralis major from the Deltoid. It gradually becomes less marked as it approaches the tendon of insertion, and becomes more closely blended with the Deltoid muscle. The lower border of the Pectoralis major forms the rounded anterior axillary fold, and corresponds with the direction of the fifth rib. The *Pectoralis minor* influences surface form. When the arm is raised its lowest slip of origin produces a local fulness just below the border of the anterior fold of the axilla, and so serves to break the sharp line of the lower border of the Pectoralis major muscle, which is produced when the arm is in this position. The origin of the *Serratus magnus* produces a very characteristic surface marking. When the arm is raised from the side in a well-developed subject, the five or six lower serrations are plainly discernible, forming a zigzag line, caused by the series of digitations, which diminish in size from above downward, and have their apices arranged in the form of a curve. When the arm is lying by the side, the first serration to appear, at the lower margin of the Pectoralis major, is the one attached to the fifth rib. The *Deltoid*, with the prominence of the upper extremity of the humerus, produces the rounded outline of the shoulder. It is rounder and fuller in front than behind, where it presents a somewhat flattened form. Its anterior border, above, presents a rounded, slightly curved eminence, which bounds externally the infraclavicular fossa; below, it is closely united with the

Pectoralis major. Its posterior border is thin, flattened, and scarcely marked above; below, it is thicker and more prominent. When the muscle is in action, the middle portion becomes irregular, presenting alternate longitudinal elevations and depressions, the elevations corresponding to the fleshy portions, the depressions to the tendinous intersections of the muscle. The insertion of the Deltoid is marked by a depression on the outer side of the middle of the arm. Of the scapular muscles, the only one which materially influences surface form is the *Teres major*, which assists the Latissimus dorsi in forming the thick, rounded fold of the posterior boundary of the axilla. When the arm is raised, the Coraco-brachialis reveals itself as a long, narrow elevation which emerges from under cover of the anterior fold of the axilla and runs downward, internal to the shaft of the humerus. When the arm is hanging by the side, its front and inner part presents the prominence of the Biceps, bounded on either side by an intermuscular depression. This muscle determines the contour of the front of the arm, and extends from the anterior margin of the axilla to the bend of the elbow. Its upper tendons are concealed by the Pectoralis major and the Deltoid, and its lower tendon sinks into the space at the bend of the elbow. When the muscle is in a state of complete contraction—that is to say, when the forearm has been flexed and supinated—it presents a rounded convex form, bulged out laterally, and its length is diminished. On each side of the Biceps, at the lower part of the arm, the *Brachialis anticus* is discernible. On the outer side it forms a narrow eminence which extends some distance up the arm along the border of the Biceps. On the inner side it shows itself only as a little fulness just above the elbow. On the back of the arm the long head of the *Triceps* may be seen as a longitudinal eminence emerging from under cover of the Deltoid, and gradually merging into the longitudinal flattened plane of the muscle on the lower part of the back of the arm. On the anterior aspect of the elbow are to be seen two muscular elevations, one on each side, separated above and converging below so as to form a triangular space. Of these, the inner elevation, consisting of the flexors and pronator, forms the prominence along the inner side and front of the forearm. It is a fusiform mass, pointed above at the internal condyle and gradually tapering off below. The *Pronator radii teres*, the innermost muscle of the group, forms the boundary of the triangular space at the bend of the elbow. It is shorter, less prominent, and more oblique than the outer boundary. The most prominent part of the eminence is produced by the *Flexor carpi radialis*, the muscle next in order on the inner side of the preceding one. It forms a rounded prominence above, and can be traced downward to its tendon, which can be felt lying on the front of the wrist, nearer to the radial than to the ulnar border, and to the inner side of the radial artery. The *Palmaris longus* presents no surface marking above, but below is the most prominent tendon on the front of the wrist, standing out, when the muscle is in action, as a sharp, tense cord beneath the skin. The *Flexor sublimis digitorum* does not directly influence surface form. The position of its four tendons on the front of the lower part of the forearm is indicated by an elongated depression between the tendons of the Palmaris longus and the Flexor carpi ulnaris. The *Flexor carpi ulnaris* occupies a small part of the posterior surface of the forearm, and is separated from the extensor and supinator group, which occupies the greater part of this surface, by the ulnar furrow, produced by the subcutaneous posterior border of the ulna. Its tendon can be perceived along the ulnar border of the front of the forearm, and is most marked when the hand is flexed and adducted. The deep muscles of the front of the forearm have no direct influence on surface form. The external group of muscles of the forearm, consisting of the extensors and supinators, occupy the outer and a considerable portion of the posterior surface of this region. They form a fusiform mass, which is altogether on a higher level than the pronato-flexor group. Its apex emerges from between the Triceps and Brachialis anticus muscles some distance above the elbow-joint, and acquires its greatest breadth opposite the external condyle, and thence gradually shades off into a flattened surface. About the middle of the forearm it divides into two longitudinal eminences which diverge from each other, leaving a triangular interval between them. The outer of these two groups of muscles consists of the Supinator longus and the Extensor carpi radialis longior et brevior, which form a longitudinal eminence descending from the external condyloid ridge in the direction of the styloid process of the radius. The other and more posterior group consists of the Extensor communis digitorum, the Extensor minimi digiti, and the Extensor carpi ulnaris. It commences above as a tapering form at the external condyle of the humerus, and is separated behind at its upper part from the Anconeus by a well-marked furrow, and below, from the pronato-flexor mass, by the ulnar furrow. In the triangular interval left between these two groups the extensors of the thumb and index finger are seen. The only two muscles of this region which require special mention as independently influencing surface form are the Supinator longus and the Anconeus. The inner border of the *Supinator longus* forms the outer boundary of the triangular space at the bend of the elbow. It commences as a rounded border above the condyle, and is longer, less oblique, and more prominent than the inner boundary. Lower down, the muscle forms a full fleshy mass on the outer side of the upper part of the forearm, and below tapers into a tendon, which may be traced down to the styloid process of the radius. The *Anconeus* presents a well-marked and characteristic surface form in the shape of a triangular, slightly elevated surface, immediately external to the subcutaneous posterior surface of the olecranon, and differentiated from the common extensor group by a well-marked oblique longitudinal depression. The upper angle of the triangle corresponds to the external condyle, and is marked by a depression or dimple in this situation. In the triangular interval caused by the divergence from each other of the two groups of muscles into which the extensor and supinator group is divided at the lower part of the forearm an

oblique elongated eminence is seen, caused by the emergence of two of the extensors of the thumb from their deep origin at the back of the forearm. This eminence, full above and becoming flattened out and partially subdivided below, runs downward and outward over the back and outer surface of the radius to the outer side of the wrist-joint, where it forms a ridge, especially marked when the thumb is extended, which passes onward to the posterior aspect of the thumb. The tendons of most of the extensor muscles are to be seen and felt at the level of the wrist-joint. Most externally are the tendons of the Extensor ossis metacarpi pollicis and the Extensor brevis pollicis, forming a vertical ridge over the outer side of the joint from the styloid process of the radius to the thumb. Internal to this is the oblique ridge produced by the tendon of the Extensor longus pollicis, very noticeable when the muscle is in action. The Extensor carpi radialis longior is scarcely to be felt, but the Extensor carpi radialis brevior can be distinctly perceived as a vertical ridge emerging from under the inner border of the tendon of the Extensor longus pollicis, when the hand is forcibly extended at the wrist. Internal to this, again, can be felt the tendons of the Extensor indicis, Extensor communis digitorum, and Extensor minimi digiti; the latter tendon being separated from those of the common extensor by a slight furrow. The muscles of the hand are principally concerned, as far as regards surface-form, in producing the thenar and hypothenar eminences, and individually are not to be distinguished, on the surface, from each other. The *Adductor transversus pollicis* is, however, an exception to this; its anterior border gives rise to a ridge across the web of skin connecting the thumb to the rest of the hand. The thenar eminence is much larger and rounder than the hypothenar one, which presents a longer and narrower eminence along the ulnar side of the hand. When the *Palmaris brevis* is in action it produces a wrinkling of the skin over the hypothenar eminence, and a deep dimple on the ulnar border of the hand. The anterior extremities of the *Lumbrical muscles* help to produce the soft eminences just behind the clefts of the fingers, separated from each other by depressions corresponding to the flexor tendons in their sheaths. Between the thenar and hypothenar eminences, at the wrist-joint, is a slight groove or depression, widening out as it approaches the fingers; beneath this we have the strong central part of the palmar fascia. Here we have some furrows, which are pretty constant in their arrangement, and bear some resemblance to the letter M. One of these furrows passes obliquely outward from the groove between the thenar and hypothenar regions to the head of the metacarpal bone of the index finger. A second passes inward, with a slight inclination upward, from the termination of the first to the ulnar side of the hand. A third runs parallel with the second and about three-quarters of an inch below it. Lastly, crossing these two latter furrows, is an oblique furrow parallel with the first. The skin of the palm of the hand differs considerably from that of the forearm. At the wrist it suddenly becomes hard and dense, and covered with a thick layer of cuticle. The skin in the thenar region presents these characteristics less than elsewhere. In spite of this hardness and density, the skin of the palm is exceedingly sensitive and very vascular. It is destitute of hair, and no sebaceous follicles have been found in this region. Over the fingers the skin again becomes thinner, especially at the flexures of the joints, and over the terminal phalanges it is thrown into numerous parallel ridges in consequence of the arrangement of the papillæ in it. The superficial fascia in the palm is made up of dense fibro-fatty tissue. This tissue binds down the skin so firmly to the deep palmar fascia that very little movement is permitted between the two. On the back of the hand the *Dorsal interossei* produce elongated swellings between the metacarpal bones. The first dorsal interosseous (Abductor indicis), when the thumb is closely adducted to the hand, forms a prominent fusiform bulging; the other interossei are not so marked.

SURGICAL ANATOMY OF THE UPPER EXTREMITY.

The student, having completed the dissection of the muscles of the upper extremity, should consider the effects likely to be produced by the action of the various muscles in fracture of the bones.

In considering the actions of the various muscles upon fractures of the upper extremity, I have selected the most common forms of injury, both for illustration and description.

Fracture of the *middle of the clavicle* (Fig. 319) is always attended with considerable displacement: the inner end of the outer fragment is displaced inward and backward, while the outer end of the same fragment is rotated forward, owing to the displacement backward of its inner end. The whole outer fragment is somewhat depressed.

The displacement is produced as follows: *inward*, by the muscles passing from the chest to the outer fragment of the clavicle, to the scapula, and to the humerus—viz. the Subclavius, the Pectoralis minor and major, and the Latissimus dorsi; *backward*, with consequent rotation of the outer end of the outer fragment forward by the Pectoral muscles. The depression of the whole outer fragment is produced by the weight of the arm and by the contraction of the Deltoid. The outer end of the inner fragment appears to be elevated, the skin being drawn tensely over it; this is owing to the depression of the outer fragment, as the inner fragment is usually kept fixed by the costo-clavicular ligament and by the antagonism between the Sterno-mastoid and Pectoralis major muscles. But it may be raised by an unusually strong Sterno-mastoid, or by the inner end of the outer fragment getting below and behind it. The causes of displacement having been ascertained, it is easy to apply the appropriate treatment. The outer fragment is to be drawn outward, and, together with the scapula, raised upward to a level with the inner fragment, and retained in that position.

In fracture of the *acromial end of the clavicle*, between the conoid and trapezoid ligaments, only slight displacement occurs, as these ligaments, from their oblique insertion, serve to hold both portions of the bone in apposition. Fracture, also, of the *sternal end*, internal to the costo-clavicular ligament, is attended with only slight displacement, this ligament serving to retain the fragments in close apposition.

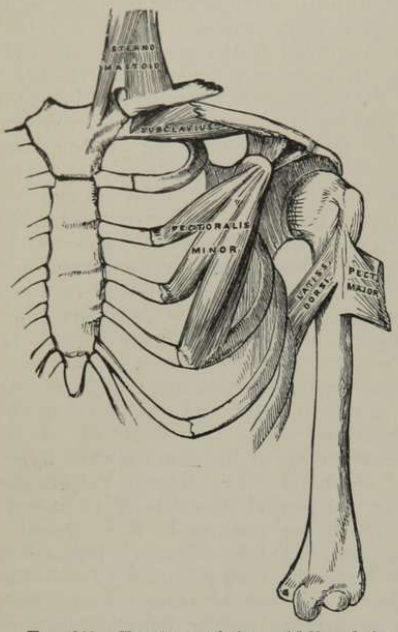

FIG. 319.—Fracture of the middle of the clavicle.

Fracture of the *acromion process* usually arises from violence applied to the upper and outer part of the shoulder; it is generally known by the rotundity of the shoulder being lost, from the Deltoid drawing the fractured portion downward and forward; and the displacement may easily be discovered by tracing the margin of the clavicle outward, when the fragment will be found resting on the front and upper part of the head of the humerus. In order to relax the anterior and outer fibres of the Deltoid (the opposing muscle), the arm should be drawn forward across the chest and the elbow well raised, so that the head of the bone may press the acromion process upward and retain it in its position.

Fracture of the *coracoid process* is an extremely rare accident, and is usually caused by a sharp blow on the point of the shoulder. Displacement is here produced by the combined actions of the Pectoralis minor, short head of the Biceps, and Coraco-brachialis, the former muscle drawing the fragment inward, and the latter directly downward, the amount of displacement being limited by the connection of this process to the acromion by means of the coraco-acromial ligament. In order to relax these muscles and replace the fragments in close apposition, the forearm should be flexed so as to relax the Biceps, and the arm drawn forward and inward across the chest, so as to relax the Coraco-brachialis; the humerus should then be pushed upward against the coraco-acromial ligament, and the arm retained in that position.

Fracture of the *surgical neck of the humerus* (Fig. 320) is very common, is attended with considerable displacement, and its appearances correspond somewhat with those of dislocation of the head of the humerus into the axilla. The upper fragment is slightly elevated under the coraco-acromial ligament by the muscles attached to the greater and lesser tuberosities; the lower fragment is drawn inward by the Pectoralis major, Latissimus dorsi, and Teres major; and the humerus is thrown obliquely outward from the side by the Deltoid, and occasionally elevated so as to project beneath and in front of the coracoid process. The deformity is reduced by fixing the shoulder and drawing the arm outward and downward. To counteract the opposing muscles, and to keep the fragments in position, the arm should be drawn from the side and pasteboard splints applied on its four sides; a large conical-shaped pad should be placed in the axilla, with the base turned upward and the elbow approximated to the side, and retained there by a broad roller passed round the chest; the forearm should then be flexed, and the hand supported in a sling, care being taken not to raise the elbow, otherwise the lower fragment may be displaced upward.

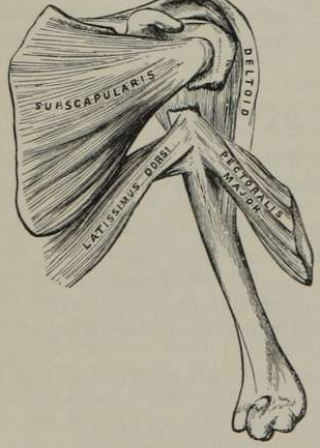

FIG. 320.—Fracture of the surgical neck of the humerus.

In fracture of the *shaft of the humerus* below the insertion of the Pectoralis major, Latissimus dorsi, and Teres major, and above the insertion of the Deltoid, there is also considerable deformity, the upper fragment being drawn inward by the first-mentioned muscles, and the lower fragment upward and outward by the Deltoid, producing shortening of the limb and a considerable prominence at the seat of fracture, from the fractured ends of the bone riding over one another, especially if the fracture takes place in an oblique direction. The fragments may be brought into apposition by extension from the elbow, and retained in that position by adopting the same means as in the preceding injury.

In fractures of the *shaft of the humerus* immediately below the insertion of the Deltoid, the amount of deformity depends greatly upon the direction of the fracture. If it occurs in a transverse direction, only slight displacement takes place, the upper fragment being drawn a little forward; but in oblique fracture the combined actions of the Biceps and Brachialis anticus muscles in front and the Triceps behind draw upward the lower fragment, causing it to glide over the upper fragment, either backward or forward, according to the direction of the fracture. Simple extension reduces the deformity, and the application of splints on the four sides of the arm will retain the fragments in apposition.

Care should be taken not to raise the elbow, but the forearm and hand may be supported in a sling.

Fracture of the *humerus* (Fig. 321) immediately above the condyles deserves very attentive consideration, as the general appearances correspond somewhat with those produced by separation of the epiphysis of the humerus, and with those of dislocation of the radius and ulna backward. If the direction of the fracture is oblique from above, downward and forward, the lower fragment is drawn upward and backward by the Brachialis anticus and Biceps in front and the Triceps behind. This injury may be diagnosed from dislocation by the increased mobility in fracture, the existence of crepitus, and the fact of the deformity being remedied by extension, on the discontinuance of which it is reproduced. The age of the patient is of importance in distinguishing this form of injury from separation of the epiphysis. If fracture occurs in the opposite direction to that shown in the accompanying figure, the lower fragment is drawn upward and forward, causing a considerable prominence in front, and the upper fragment projects backward beneath the tendon of the Triceps muscle.

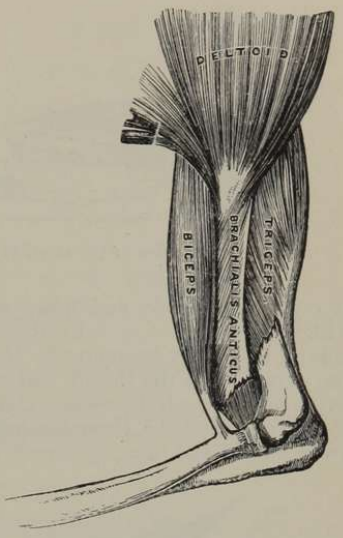

FIG. 321.—Fracture of the humerus above the condyles.

Fracture of the *olecranon process* (Fig. 322) is a frequent accident. The detached fragment is displaced upward, by the action of the Triceps muscle, from half an inch to two inches; the prominence of the elbow is consequently lost, and a deep hollow is felt at the back part of the joint, which is much increased on flexing the limb. The patient at the same time loses, more or less, the power of extending the forearm. The treatment consists in relaxing the Triceps by extending the limb, and retaining it in the extended position by means of a long straight splint applied to the front of the arm; the fragments are thus brought into close apposition, and may be further approximated by drawing down the upper fragment. Union is generally ligamentous.

Fracture of the *neck of the radius* is an exceedingly rare accident, and is generally caused by direct violence. Its diagnosis is somewhat obscure, on account of the slight deformity visible, the injured part being surrounded by a large number of muscles; but the movements of pronation and supination are entirely lost. The upper fragment is drawn outward by the Supinator brevis, its extent of displacement being limited by the attachment of the orbicular ligament. The lower fragment is drawn forward and slightly upward by the Biceps, and inward by the Pronator radii teres, its displacement forward and upward being counteracted in some degree by the Supinator brevis. The treatment essentially consists in relaxing the Biceps, Supinator brevis, and Pronator radii teres muscles by flexing the forearm, and placing it in a position midway between pronation and supination, extension having been previously made so as to bring the parts in apposition.

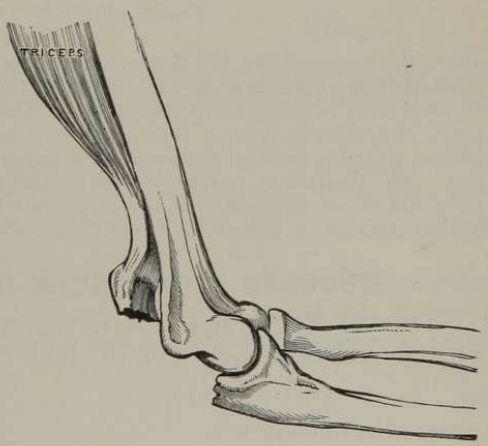

FIG. 322.—Fracture of the olecranon.

In fracture of the *radius* (Fig. 323) near its centre, the upper fragment is drawn upward by the Biceps and inward by the Pronator radii teres, holding a position midway between pronation and supination, and a degree of fulness in the upper half of the forearm is thus produced: the lower fragment is drawn downward and inward toward the ulna by the Pronator quadratus, and thrown into a state of pronation by the same muscle; at the same time, the Supinator longus, by elevating the styloid process, into which it is inserted, will serve to depress the upper end of the lower fragment still more toward the ulna. In order to relax the opposing muscles the forearm should be bent, and the limb placed in a position midway between pronation and supination; the fracture is then easily reduced by extension from the wrist and elbow: well-padded splints should be applied on both sides of the forearm from the elbow to the wrist; the hand being allowed to fall, will, by its own weight, counteract the action of the Pronator quadratus and Supinator longus, and elevate the lower fragment to the level of the upper one.

In fracture of the *shaft of the ulna* the upper fragment retains its usual position, but the lower fragment is drawn outward toward the radius by the Pronator quadratus, producing a well-marked depression at the seat of fracture and some fulness on the dorsal and palmar surfaces of the forearm. The fracture is easily reduced by extension from the wrist and forearm. The forearm should be flexed, and placed in a position midway between pronation and supination, and well-padded splints applied from the elbow to the ends of the fingers.

In fracture of the *shafts of the radius and ulna together* the lower fragments are drawn upward, sometimes forward, sometimes backward, according to the direction of the fracture, by the combined actions of the Flexor and Extensor muscles, producing a degree of fulness on the dorsal or palmar surface of the forearm; at the same time the two fragments are drawn into contact by the Pronator quadratus, the radius being in a state of pronation: the upper fragment of the radius is drawn upward and inward by the Biceps and Pronator radii teres to a higher level than the ulna; the upper portion of the ulna is slightly elevated by the Brachialis anticus. The fracture may be reduced by extension from the wrist and elbow, and the forearm should be placed in the same position as in fracture of the ulna.

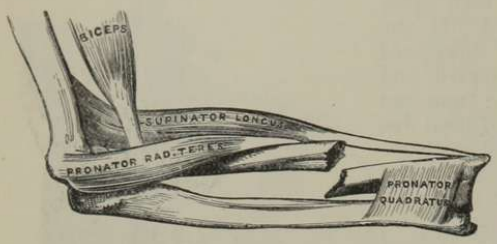

FIG. 323.—Fracture of the shaft of the radius.

In fracture of the *lower end of the radius* (Fig. 324) the displacement which is produced is very considerable, and bears some resemblance to dislocation of the carpus backward, from which it should be carefully distinguished. The lower fragment is drawn upward and backward behind the upper fragment by the combined actions of the Supinator longus and the flexors and the extensors of the thumb and carpus, producing a well-marked prominence on the back of the wrist, with a deep depression above it. The upper fragment projects forward, often lacerating the substance of the Pronator quadratus, and is drawn by this muscle into close contact with the lower end of the ulna, causing a projection on the anterior surface of the forearm, immediately

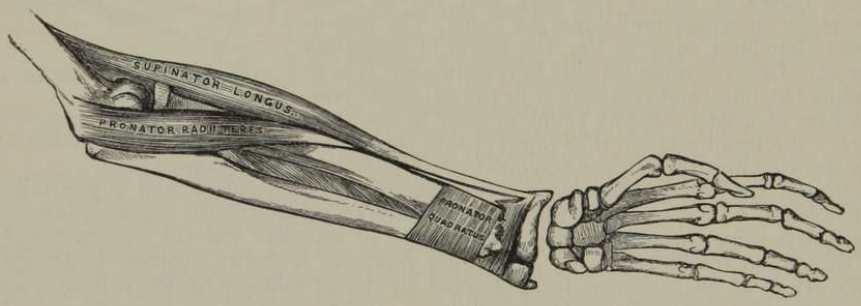

FIG. 324.—Fracture of the lower end of the radius.

above the carpus, from the flexor tendons being thrust forward. This fracture may be distinguished from dislocation by the deformity being removed on making sufficient extension, when crepitus may be occasionally detected; at the same time, on extension being discontinued, the parts immediately resume their deformed appearance (see also page 232). The age of the patient will also assist in determining whether the injury is fracture or separation of the epiphysis. The treatment consists in flexing the forearm, and making powerful extension from the wrist and elbow, depressing at the same time the radial side of the hand, and retaining the parts in that position by well-padded *pistol-shaped* splints.

MUSCLES AND FASCIÆ OF THE LOWER EXTREMITY.

The Muscles of the Lower Extremity are subdivided into groups, corresponding with the different regions of the limb.

ILIAC REGION.

Psoas magnus.
Psoas parvus.
Iliacus.

THIGH.

Anterior Femoral Region.

Tensor vaginæ femoris.
Sartorius.
Rectus.
Vastus externus.
Vastus internus.
Crureus.
Subcrureus.

Internal Femoral Region.

Gracilis.
Pectineus.
Adductor longus.
Adductor brevis.
Adductor magnus.

HIP.

Gluteal Region.

Gluteus maximus.
Gluteus medius.
Gluteus minimus.
Pyriformis.

Gemellus superior.
Obturator internus.
Gemellus inferior.
Obturator externus.
Quadratus femoris.

Posterior Femoral Region.

Biceps.
Semitendinosus.
Semimembranosus.

LEG.

Anterior Tibio-fibular Region

Tibialis anticus.
Extensor longus digitorum.
Extensor proprius hallucis.
Peroneus tertius.

Posterior Tibio-fibular Region.

Superficial Layer.

Gastrocnemius.
Plantaris.
Soleus.

Deep Layer.

Popliteus.
Flexor longus hallucis.
Flexor longus digitorum.
Tibialis posticus.

Fibular Region.

Peroneus longus.
Peroneus brevis.

FOOT.

Dorsal Region.

Extensor brevis digitorum.

Plantar Region.

First Layer.

Abductor hallucis.
Flexor brevis digitorum.
Abductor minimi digiti.

Second Layer.

Flexor accessorius.
Lumbricales.

Third Layer.

Flexor brevis hallucis.
Adductor obliquus hallucis.
Flexor brevis minimi digiti.
Adductor transversus pedis.

Fourth Layer.

The Interossei.

ILIAC REGION.

Psoas magnus. Psoas parvus. Iliacus.

Dissection.—No detailed description is required for the dissection of these muscles. On the removal of the viscera from the abdomen they are exposed, covered by the peritoneum and a thin layer of fascia, the iliac fascia.

The **iliac fascia**[1] is the aponeurotic layer which lines the back part of the abdominal cavity, and covers the Psoas and Iliacus muscles throughout their whole extent. It is thin above, and becomes gradually thicker below as it approaches the crural arch. It is a part of the general *fascia transversalis.*

The *portion covering the Psoas* is attached, above, to the ligamentum arcuatum internum; internally, by a series of arched processes to the intervertebral substances and prominent margins of the bodies of the vertebræ, and to the upper part of the sacrum, the intervals so left, opposite the constricted portions of the bodies, transmitting the lumbar arteries and filaments of the sympathetic nerve. Externally, above the crest of the ilium, this portion of the iliac fascia is continuous with the anterior lamella of the lumbar fascia (see page 433), but below the crest of the ilium it is continuous with the fascia covering the Iliacus.

The *portion investing the Iliacus* is connected externally to the whole length of the inner border of the crest of the ilium, and internally to the brim of the true pelvis or *iliac portion* of the ilio-pectineal line, and at the ilio-pectineal eminence it receives the tendon of insertion of the Psoas parvus, when that muscle exists. External to the femoral vessels, this fascia is intimately connected to the posterior margin of Poupart's ligament, and is continuous with the fascia transversalis. Internal to the vessels it is attached to the ilio-pectineal line behind the conjoined tendon, where it is again continuous with the transversalis fascia; and,

[1] The student must not confound this fascia with the *iliac portion of the fascia lata* (see p. 508).

corresponding to the point where the femoral vessels pass into the thigh, this fascia descends behind them, forming the posterior wall of the crural sheath. This portion of the iliac fascia which passes behind the femoral vessels is also attached to the ilio-pectineal line beyond the limits of the attachment of the conjoined tendon; at this part it is continuous with the pubic portion of the fascia lata of the thigh. The external iliac vessels lie in front of the iliac fascia, but all the branches of the lumbar plexus behind it; it is separated from the peritoneum by a quantity of loose areolar tissue.

The **Psoas magnus** (Fig. 326) is a long fusiform muscle placed on the side of the lumbar region of the spine and margin of the pelvis. It arises from the front of the bases and lower borders of the transverse processes of the lumbar vertebræ by five fleshy slips; also from the sides of the bodies and the corresponding intervertebral substances of the last dorsal and all the lumbar vertebræ. The muscle is connected to the bodies of the vertebræ by five slips; each slip is attached to the upper and lower margins of two vertebræ, and to the intervertebral substance between them, the slips themselves being connected by the tendinous arches which extend across the constricted part of the bodies, and beneath which pass the lumbar arteries and sympathetic nerves. These tendinous arches also give origin to muscular fibres, and protect the blood-vessels and nerves from pressure during the action of the muscle. The first slip is attached to the contiguous margins of the last dorsal and first lumbar vertebræ; the last to the contiguous margins of the fourth and fifth lumbar, and to the intervertebral substance. From these points the muscle passes down across the brim of the pelvis, and, diminishing gradually in size, passes beneath Poupart's ligament, and terminates in a tendon which, after receiving the fibres of the Iliacus, is inserted into the lesser trochanter of the femur.

Relations.—In the lumbar region: by its *anterior surface*, which is placed behind the peritoneum, with the iliac fascia, the ligamentum arcuatum internum, the kidney, Psoas parvus, renal vessels, ureter, spermatic vessels, genito-crural nerve, and the colon; by its *posterior surface*, with the transverse processes of the lumbar vertebræ and the Quadratus lumborum, from which it is separated by the anterior lamella of the lumbar fascia. The anterior crural nerve is at first situated in the substance of the muscle, and emerges from its outer border at the lower part. The lumbar plexus is situated in the posterior part of the substance of the muscle. By its *inner side* the muscle is in relation with the bodies of the lumbar vertebræ, the lumbar arteries, the ganglia of the sympathetic nerve, and their branches of communication with the spinal nerves; the lumbar glands; the vena cava inferior on the right and the aorta on the left side, and along the brim of the pelvis with the external iliac artery. In the thigh it is in relation, in front, with the fascia lata; behind, with the capsular ligament of the hip, from which it is separated by a synovial bursa, which frequently communicates with the cavity of the joint through an opening of variable size; by its *inner border*, with the Pectineus and the femoral artery, which slightly overlaps it: by its *outer border*, with the anterior crural nerve and Iliacus muscle.

The **Psoas parvus** is a long slender muscle placed in front of the Psoas magnus. It arises from the sides of the bodies of the last dorsal and first lumbar vertebræ and from the intervertebral substance between them. It forms a small flat muscular bundle, which terminates in a long flat tendon inserted into the ilio-pectineal eminence, and, by its outer border, into the iliac fascia. This muscle is often absent, and, according to Cruveilhier, sometimes double.

Relations.—It is covered by the peritoneum, and, at its origin, by the ligamentum arcuatum internum; it rests on the Psoas magnus.

The **Iliacus** is a flat, triangular muscle which fills up the whole of the iliac fossa. It arises from the upper two-thirds of this fossa and from the inner margin of the crest of the ilium; behind, from the ilio-lumbar ligament and base of the sacrum; in front, from the anterior superior and anterior inferior spinous processes of the ilium, from the notch between them, and by a few fibres from the capsule

of the hip-joint. The fibres converge to be inserted into the outer side of the tendon of the Psoas, some of them being prolonged into the oblique line which extends from the lesser trochanter to the linea aspera.[1]

Relations.— *Within the pelvis:* by its *anterior surface*, with the iliac fascia, which separates the muscle from the peritoneum, and with the external cutaneous nerve; on the right side, with the cæcum; on the left side, with the sigmoid flexure of the colon; by its *posterior surface*, with the iliac fossa; by its *inner border*, with the Psoas magnus and anterior crural nerve. In the thigh, it is in relation, by its *anterior surface*, with the fascia lata, Rectus, and Sartorius; behind, with the capsule of the hip-joint, a synovial bursa common to it and the Psoas magnus being interposed.

Nerves.—The Psoas magnus, and the Psoas parvus when it exists, are supplied by the anterior branches of the lumbar nerves; the Iliacus by the anterior crural.

Actions.—The Psoas and Iliacus muscles, acting from above, flex the thigh upon the pelvis, and, at the same time, rotate the femur outward, from the obliquity of their insertion into the inner and back part of that bone. Acting from below, the femur being fixed, the muscles of both sides bend the lumbar portion of the spine and pelvis forward. They also serve to maintain the erect position, by supporting the spine and pelvis upon the femur, and assist in raising the trunk when the body is in the recumbent posture.

The *Psoas parvus* is a tensor of the iliac fascia.

Surgical Anatomy.—In the iliac fascia there is no definite septum between the portions of fascia covering the Psoas and Iliacus respectively, and the fascia is only connected to the subjacent muscles by a quantity of loose connective tissue. When abscess forms beneath this fascia, as it is very apt to do, the matter is contained in an osseo-fibrous cavity which is closed on all sides within the abdomen, and is open only at its lower part, where the fascia is prolonged over the muscle into the thigh.

Abscess within the sheath of the Psoas muscle (*Psoas abscess*) is generally due to tubercular caries of the bodies of the lower dorsal and lumbar vertebræ. When the disease is in the dorsal region, the matter tracts down the posterior mediastinum, in front of the bodies of the vertebræ, and, passing beneath the ligamentum arcuatum internum, enters the sheath of the Psoas muscle, down which it passes as far as the pelvic brim; it then gets beneath the iliac portion of the fascia and fills up the iliac fossa. In consequence of the attachment of the fascia to the pelvic brim, it rarely finds its way into the pelvis, but passes by a narrow opening under Poupart's ligament into the thigh, to the outer side of the femoral vessels. It thus follows that a Psoas abscess may be described as consisting of four parts: (1) a somewhat narrow channel at its upper part, in the Psoas sheath; (2) a dilated sac in the iliac fossa; (3) a constricted neck under Poupart's ligament; and (4) a dilated sac in the upper part of the thigh. When the lumbar vertebræ are the seat of the disease, the matter finds its way directly into the substance of the muscle. The muscular fibres are destroyed, and the nervous cords contained in the abscess are isolated and exposed in its interior; the femoral vessels which lie in front of the fascia remain intact, and the peritoneum seldom becomes implicated. All Psoas abscesses do not, however, pursue this course: the matter may leave the muscle above the crest of the ilium, and, tracking backward, may point in the loin (*lumbar abscess*); or it may point above Poupart's ligament in the inguinal region; or it may follow the course of the iliac vessels into the pelvis, and, passing through the great sacro-sciatic notch, discharge itself on the back of the thigh; or it may open into the bladder or find its way into the perinæum.

THE THIGH.

Anterior Femoral Region.

Tensor vaginæ femoris.
Sartorius.
Rectus.
Vastus externus.
Vastus internus.
Crureus.
Subcrureus.

Dissection.—To expose the muscles and fasciæ in this region, make an incision along Poupart's ligament, from the anterior superior spine of the ilium to the spine of the os pubis; a vertical incision from the centre of this, along the middle of the thigh to below the knee-joint; and a transverse incision from the inner to the outer side of the leg, at the lower end of the vertical incision. The flaps of integument having been removed, the superficial and deep fasciæ

[1] The Psoas and Iliacus are sometimes regarded as a single muscle, the *Ilio-psoas*, having two heads of origin and a single insertion.

should be examined. The more advanced student should commence the study of this region by an examination of the anatomy of femoral hernia and Scarpa's triangle, the incisions for the dissection of which are marked out in the figure below.

The **superficial fascia** forms a continuous layer over the whole of the thigh, consisting of areolar tissue, containing in its meshes much fat, and capable of being separated into two or more layers, between which are found the superficial vessels and nerves. It varies in thickness in different parts of the limb: in the groin it is thick, and the two layers are separated from one another by the superficial inguinal lymphatic glands, the internal saphenous vein, and several smaller vessels. One of these two layers, the superficial, is continuous above with the superficial fascia of the abdomen. The deep layer of the superficial fascia is a very thin, fibrous layer, best marked on the inner side of the long saphenous vein and below Poupart's ligament. It is placed beneath the subcutaneous vessels and nerves and upon the surface of the fascia lata. It is intimately adherent to the fascia lata a little below Poupart's ligament. It covers the saphenous opening in the fascia lata, being closely united to its circumference, and is connected to the sheath of the femoral vessels, corresponding to its under surface. The portion of fascia covering this aperture is perforated by the internal saphenous vein and by numerous blood- and lymphatic vessels; hence it has been termed the *cribriform fascia*, the openings for these vessels having been likened to the holes in a sieve. The cribriform fascia adheres closely both to the superficial fascia and to the fascia lata, so that it is described by some anatomists as part of the fascia lata, but is usually considered (as in this work) as belonging to the superficial fascia. It is not until the cribriform fascia has been cleared away that the saphenous opening is seen, so that this opening does not in ordinary cases exist naturally, but is the result of dissection. Mr. Callender, however, speaks of cases in which, probably as the result of pressure from enlarged inguinal lymphatic glands, the fascia has become atrophied, and a saphenous opening exists independent of dissection. A femoral hernia in passing through the saphenous opening receives the cribriform fascia as one of its coverings. A large subcutaneous bursa is found in the superficial fascia over the patella.

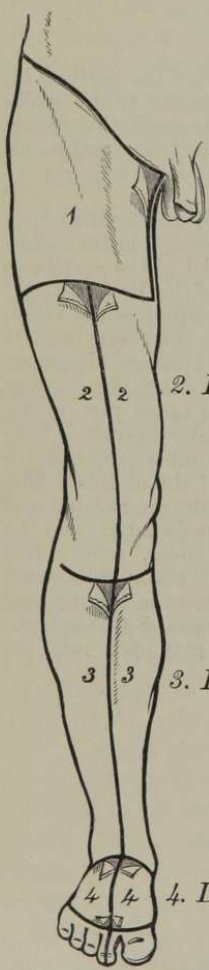

1. *Dissection of femoral hernia, and Scarpa's triangle.*
2. *Front of thigh.*
3. *Front of leg.*
4. *Dorsum of foot.*

FIG. 325.—Dissection of lower extremity. Front view.

The **deep fascia** of the thigh is exposed on the removal of the superficial fascia, and is named, from its great extent, the *fascia lata;* it forms a uniform investment for the whole of this region of the limb, but varies in thickness in different parts; thus, it is thicker in the upper and outer part of the thigh, where it receives a fibrous expansion from the Gluteus maximus muscle, and the Tensor vaginæ femoris is inserted between its layers: it is very thin behind, and at the upper and inner part where it covers the Adductor muscles, and again becomes stronger around the knee, receiving fibrous expansions from the tendon of the Biceps externally, and from the Sartorius internally, and Quadriceps extensor cruris in front. The fascia lata is attached, above and behind, to the back of the sacrum and coccyx; externally, to the crest of the ilium; in front, to Poupart's ligament and to the body of the os pubis; and internally, to the descending ramus

of the os pubis, to the ascending ramus and tuberosity of the ischium, and to the lower border of the great sacro-sciatic ligament. From its attachment to the crest of the ilium it passes down over the Gluteus medius muscle to the upper border of the Gluteus maximus, where it splits into two layers, one passing superficial to and the other beneath this muscle. At the lower border of the muscle the two layers unite. Externally, just below the great trochanter, the fascia lata receives the greater part of the tendon of insertion of the Gluteus maximus, and becomes proportionately thickened. The portion of the fascia lata arising from the front part of the crest of the ilium, corresponding to the origin of the Tensor vaginæ femoris, passes down the outer side of the thigh as two layers, one superficial and the other beneath this muscle; these at its lower end become blended together into a thick and strong band, having first received the insertion of the muscle. This band is continued downward, under the name of the *ilio-tibial band*, to be inserted into the external tuberosity of the tibia. Below, the fascia lata is attached to all the prominent points around the knee-joint—viz. the condyles of the femur, tuberosities of the tibia, and head of the fibula. On each side of the patella it is strengthened by transverse fibres given off from the lower part of the Vasti muscles, which are attached to and support this bone. Of these the outer is the stronger, and is continuous with the ilio-tibial band. From the inner surface of the fascia lata are given off two strong intermuscular septa, which are attached to the whole length of the linea aspera and its prolongations above and below: the external and stronger one, which extends from the insertion of the Gluteus maximus to the outer condyle, separates the Vastus externus in front from the short head of the Biceps behind, and gives partial origin to these muscles; the inner one, the thinner of the two, separates the Vastus internus from the Adductor and Pectineus muscles. Besides these there are numerous smaller septa, separating the individual muscles and enclosing each in a distinct sheath. At the upper and inner part of the thigh, a little below Poupart's ligament, a large oval-shaped aperture is observed after the superficial fascia has been cleared off: it transmits the internal saphenous vein and other smaller vessels, and is termed the *saphenous opening*. In order more correctly to consider the mode of formation of this aperture, the fascia lata in this part of the

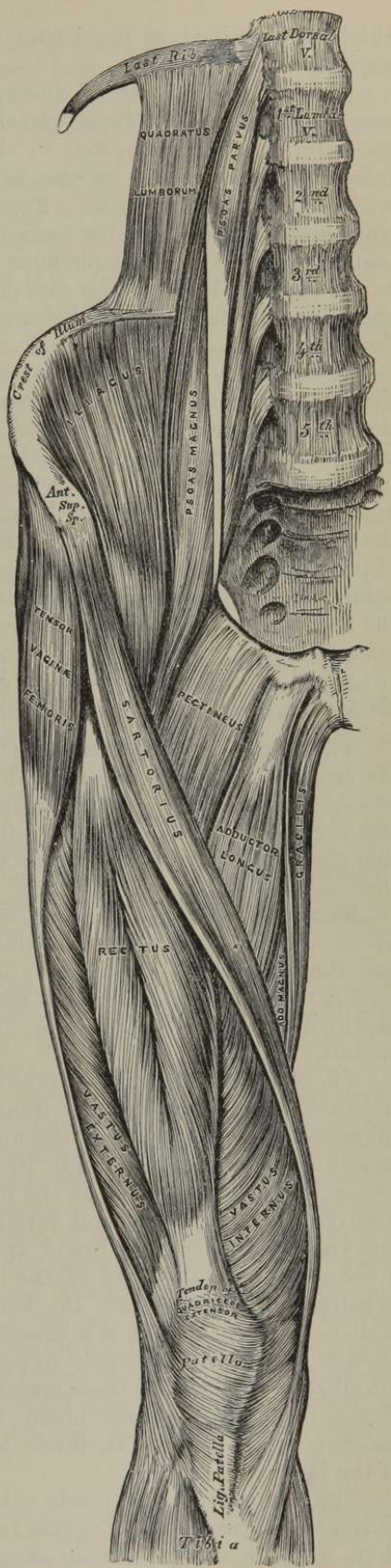

FIG. 326.—Muscles of the iliac and anterior femoral regions.

thigh is described as consisting of two portions—an iliac portion and a pubic portion.

The *iliac portion* is all that part of the fascia lata on the outer side of the saphenous opening. It is attached, externally, to the crest of the ilium and its anterior superior spine, to the whole length of Poupart's ligament as far internally as the spine of the os pubis, and to the pectineal line in conjunction with Gimbernat's ligament. From the spine of the os pubis it is reflected downward and outward, forming an arched margin, the boundary or *falciform process* (*superior cornu*) of the saphenous opening; this margin overlies and is adherent to the anterior layer of the sheath of the femoral vessels: to its edge is attached the cribriform fascia; and, below, it is continuous with the pubic portion of the fascia lata.

The *pubic portion* is situated at the inner side of the saphenous opening: at the lower margin of this aperture it is continuous with the iliac portion; traced upward, it covers the surface of the Pectineus, Adductor longus, and Gracilis muscles, and, passing behind the sheath of the femoral vessels, to which it is closely united, is continuous with the sheath of the Psoas and Iliacus muscles, and is attached above to the ilio-pectineal line, where it becomes continuous with the iliac fascia. From this description it may be observed that the iliac portion of the fascia lata passes in front of the femoral vessels, and the pubic portion behind them, so that an apparent aperture exists between the two, through which the internal saphenous joins the femoral vein.[1]

The fascia should now be removed from the surface of the muscles. This may be effected by pinching it up between the forceps, dividing it, and separating it from each muscle in the course of its fibres.

The **Tensor vaginæ femoris** arises from the anterior part of the outer lip of the crest of the ilium, and from the outer surface of the anterior superior spinous process, between the Gluteus medius and Sartorius. It is inserted into the fascia lata about one-fourth down the outer side of the thigh. From the point of insertion the fascia is continued downward to the head of the tibia as a thickened band, the *ilio-tibial band*.

Relations.—By its *superficial surface*, with the fascia lata and the integument; by its *deep surface*, with the Gluteus medius, Rectus femoris, Vastus externus, and the ascending branches of the external circumflex artery; by its *anterior border*, with the Sartorius, from which it is separated below by a triangular space, in which is seen the Rectus femoris; by its *posterior border*, with the Gluteus medius.

The **Sartorius**, the longest muscle in the body, is flat, narrow, and ribbon-like; it arises by tendinous fibres from the anterior superior spinous process of the ilium and the upper half of the notch below it, passes obliquely across the upper and anterior part of the thigh, from the outer to the inner side of the limb, then descends vertically, as far as the inner side of the knee, passing behind the inner condyle of the femur, and terminates in a tendon which, curving obliquely forward, expands into a broad aponeurosis inserted into the upper part of the inner surface of the shaft of the tibia, nearly as far forward as the crest. This expansion is inserted into the bone by an inverted U-shaped aponeurosis: part of it is inserted behind the attachment of the Gracilis and Semitendinosus, and another part, arching over the upper border of the tendon of the Gracilis, is inserted into the tibia in front of these muscles. An offset is derived from the upper margin of this aponeurosis, which blends with the fibrous capsule of the knee-joint, and another, given off from its lower border, blends with the fascia on the inner side of the leg.

The relations of this muscle to the femoral artery should be carefully examined, as it constitutes the chief guide in tying the artery. In the upper third of the thigh it forms the outer side of a triangular space, *Scarpa's triangle*, the inner

[1] These parts will be again more particularly described with the anatomy of Hernia.

side of which is formed by the Adductor longus, and the base, turned upward, by Poupart's ligament; the femoral artery passes perpendicularly through the middle of this space from its base to its apex. In the middle third of the thigh the femoral artery lies first along the inner border, and then behind the Sartorius.

Relations.—By its *superficial surface*, with the fascia lata and integument; by its *deep surface*, with the Rectus, Iliacus, Psoas, Vastus internus, anterior crural nerve, sheath of the femoral vessels, Adductor longus, Adductor magnus, Gracilis, Semitendinosus, long saphenous nerve, and internal lateral ligament of the knee-joint.

The **Quadriceps extensor** includes the four remaining muscles on the front of the thigh. It is the great Extensor muscle of the leg, forming a large fleshy mass which covers the front and sides of the femur, being united below into a single tendon, attached to the patella, and above subdivided into separate portions, which have received distinct names. Of these, one occupying the middle of the thigh, connected above with the ilium, is called the *Rectus femoris*, from its straight course. The other divisions lie in immediate connection with the shaft of the femur, which they cover from the trochanters to the condyles. The portion on the outer side of the femur is termed the *Vastus externus;* that covering the inner side, the *Vastus internus;* and that covering the front of the femur, the *Crureus*. The two latter portions are, however, so intimately blended as to form but one muscle.

The **Rectus femoris** is situated in the middle of the anterior region of the thigh: it is fusiform in shape, and its superficial fibres are arranged in a bipenniform manner, the deep fibres running straight down to the deep aponeurosis. It arises by two tendons: one the straight tendon, or short head, from the anterior inferior spinous process of the ilium; the other is flattened, and curves outward, to be attached to a groove above the brim of the acetabulum; this is the reflected tendon, or long head, of the Rectus; it unites with the straight tendon at an acute angle, and then spreads into an aponeurosis, from which the muscular fibres arise.[1] The muscle terminates in a broad and thick aponeurosis which occupies the lower two-thirds of its posterior surface, and, gradually becoming narrowed into a flattened tendon, is inserted into the patella in common with the Vasti and Crureus.

Relations.—By its *superficial surface*, with the anterior fibres of the Gluteus minimus, the Tensor vaginæ femoris, the Sartorius, and the Psoas and Iliacus; by its lower three-fourths, with the fascia lata; by its *posterior surface*, with the hip-joint, the external circumflex vessels, and the Crureus and Vasti muscles.

The three remaining muscles have been described collectively by some anatomists, separate from the Rectus, under the name of the *Triceps extensor cruris*.

The **Vastus externus** is the largest part of the Quadriceps extensor. It arises by a broad aponeurosis, which is attached to the tubercle of the femur, to the anterior and inferior borders of the great trochanter, to a rough line leading from the trochanter major to the linea aspera, and to the outer lip of the linea aspera: this aponeurosis covers the upper three-fourths of the muscle, and from its inner surface many fibres arise. A few additional fibres arise from the tendon of the Gluteus maximus and from the external intermuscular septum between the Vastus externus and short head of the Biceps. The fibres form a large fleshy mass which is attached to a strong aponeurosis, placed on the under surface of the muscle at its lower part: this becomes contracted and thickened into a flat tendon, which is inserted into the outer border of the patella, blending with the great extensor tendon.

[1] Mr. W. R. Williams, in an interesting paper in the *Journ. of Anat. and Phys.*, vol. xiii. p. 204, points out that the reflected tendon is the real origin of the muscle, and is alone present in early fœtal life. The direct tendon is merely an accessory band of condensed fascia. The paper will well repay perusal, though in some particulars I think the description in the text more generally accurate.—Ed.

Relations.—By its *superficial surface*, with the Rectus, the Tensor vaginæ femoris, the fascia lata, and the Gluteus maximus, from which it is separated by a synovial bursa; by its *deep surface*, with the Crureus, some large branches of the external circumflex artery and anterior crural nerve being interposed.

The **Vastus internus** and **Crureus** are so inseparably connected together as to form but one muscle, as which it will be accordingly described. It is the smallest portion of the Quadriceps extensor. The anterior portion of it, covered by the Rectus, is called the Crureus; the internal portion, which lies immediately beneath the fascia lata, the Vastus internus. It arises by an aponeurosis, which is attached to the lower part of the line that extends from the inner side of the neck of the femur to the linea aspera, from the inner lip of the linea aspera, from the ridge leading from the linea aspera to the internal condyle and internal intermuscular septum. It also arises from nearly the whole of the internal, anterior, and external surfaces of the shaft of the femur, limited, above, by the line between the two trochanters, and extending, below, to within the lower fourth of the bone. From these different origins the fibres converge to a broad aponeurosis which covers the anterior surface of the middle portion of the muscle (the Crureus) and the deep surface of the inner division of the muscle (the Vastus internus), and which gradually narrows down to its insertion into the patella, where it blends with the other portions of the Quadriceps extensor. The muscular fibres of the Vastus internus extend lower down than those of the Vastus externus, so that the capsule of the joint is less covered with muscular fibres on the outer than on the inner side.

Relations.—By its *superficial surface*, with the Psoas and Iliacus, the Rectus, Sartorius, Pectineus, Adductors, and fascia lata, femoral vessels, and saphenous nerve; by its *deep surface*, with the femur, Subcrureus, and synovial membrane of the knee-joint.

The student will observe the striking analogy that exists between the Quadriceps extensor and the Triceps muscle in the upper extremity. So close is this similarity that M. Cruveilhier has described it under the name of the *Triceps femoralis*. Like the Triceps extensor cubiti, it consists of three distinct divisions, or heads: a middle or long head, the Rectus, analogous to the long head of the Triceps, attached to the ilium, and two other portions, which may be called the external and internal heads of the Triceps femoralis. These, it will be noticed, are strictly analogous to the outer and inner heads of the Triceps in the arm.

The *tendons* of the different portions of the Quadriceps extensor unite at the lower part of the thigh, so as to form a single strong tendon which is inserted into the upper part of the patella. More properly, the patella may be regarded as a sesamoid bone, developed in the tendon of the Quadriceps, and the ligamentum patellæ, which is continued from the lower part of the patella to the tuberosity of the tibia, as the proper tendon of insertion of the muscle. A synovial bursa, the *post-patellar bursa*, is interposed between the tendon and the upper part of the tuberosity of the tibia; and another, the *prepatellar bursa*, is placed over the patella itself. This latter bursa often becomes enlarged, constituting "housemaid's knee."

The **Subcrureus** is a small muscle, usually distinct from the Crureus, but occasionally blended with it, which arises from the anterior surface of the lower part of the shaft of the femur, and is inserted into the upper part of the *cul-de-sac* of the capsular ligament which projects upward beneath the Quadriceps for a variable distance. It sometimes consists of two separate muscular bundles.

Nerves.—The Tensor vaginæ femoris is supplied by the superior gluteal nerve; the other muscles of this region by branches from the anterior crural.

Actions.—The Tensor vaginæ femoris is a tensor of the fascia lata; continuing its action, the oblique direction of its fibres enables it to abduct and to rotate the thigh inward. In the erect posture, acting from below, it will serve to steady the pelvis upon the head of the femur, and by means of the ilio-tibial band it steadies the condyles of the femur on the articular surfaces of the tibia, and assists the

Gluteus maximus in supporting the knee in the extended position. The Sartorius flexes the leg upon the thigh, and, continuing to act, flexes the thigh upon the pelvis; it next rotates the thigh outward. It was formerly supposed to adduct the thigh, so as to cross one leg over the other, and hence received its name of Sartorius, or tailor's muscle (*sartor*, a tailor), because it was supposed to assist in crossing the legs in the squatting position. When the knee is bent the Sartorius assists the Semitendinosus, Semimembranosus, and Popliteus in rotating the tibia inward. Taking its fixed point from the leg, it flexes the pelvis upon the thigh, and, if one muscle acts, assists in rotating the pelvis. The Quadriceps extensor extends the leg upon the thigh. Taking its fixed point from the leg, as in standing, this muscle will act upon the femur, supporting it perpendicularly upon the head of the tibia, and thus maintaining the entire weight of the body, or in the stooping position it will straighten the knee, and therefore assist the trunk in rising into the erect position. The Rectus muscle assists the Psoas and Iliacus in supporting the pelvis and trunk upon the femur or in bending it forward.

Surgical Anatomy.—A few fibres of the Rectus muscle are liable to be ruptured from severe strain. This accident is especially liable to occur during the games of football and cricket, and is sometimes known as "cricket thigh." The patient experiences a sudden pain in the part, as if he had been struck, and the Rectus muscle stands out and is felt to be tense and rigid. The accident is often followed by considerable swelling from inflammatory effusion. Occasionally the Quadriceps extensor may be torn away from its insertion into the patella, or the tendon of the patella may be ruptured about an inch above the bone. This accident is caused in the same manner as fracture of the patella by muscular action is produced—viz. by a violent muscular effort to prevent falling whilst the knee is in a position of semiflexion. A distinct gap can be felt above the patella, and, owing to the retraction of the muscular fibres, union may fail to take place.

Internal Femoral Region.

Gracilis. Adductor longus.
Pectineus. Adductor brevis.
Adductor magnus.

Dissection.—These muscles are at once exposed by removing the fascia from the fore part and inner side of the thigh. The limb should be abducted, so as to render the muscles tense and easier of dissection.

The **Gracilis** (Figs. 326, 329) is the most superficial muscle on the inner side of the thigh. It is thin and flattened, broad above, narrow and tapering below. It arises by a thin aponeurosis, between two and three inches in breadth, from the lower half of the margin of the symphysis and the inner margin of the descending ramus of the os pubis. The fibres pass vertically downward, and terminate in a rounded tendon which passes behind the internal condyle of the femur, and, curving round the inner tuberosity of the tibia, becomes flattened, and is inserted into the upper part of the inner surface of the shaft of the tibia, below the tuberosity. The tendon of this muscle is situated immediately above that of the Semitendinosus, and is surrounded by the tendon of the Sartorius, with which it is in part blended. As it passes across the internal lateral ligament of the knee-joint it is separated from it by a synovial bursa common to it and the Semitendinosus muscle.

Relations.—By its *superficial surface*, with the fascia lata and the Sartorius below: the internal saphenous vein crosses it obliquely near its lower part, lying superficial to the fascia lata; the internal saphenous nerve emerges between its tendon and that of the Sartorius; by its *deep surface*, with the Adductor brevis and the Adductor magnus and the internal lateral ligament of the knee-joint.

The **Pectineus** (Fig. 326) is a flat, quadrangular muscle situated at the anterior part of the upper and inner aspect of the thigh. It arises from the linea iliopectinea, from the surface of the bone in front of it between the pectineal eminence and spine of the os pubis, and from the fascia covering the anterior surface of the muscle; the fibres pass downward, backward, and outward, to be inserted into a rough line leading from the lesser trochanter to the linea aspera.

Relations.—By its *anterior surface*, with the pubic portion of the fascia lata,

which separates it from the femoral vessels and internal saphenous vein; by its *posterior surface*, with the capsular ligament of the hip-joint, the Adductor brevis and Obturator externus muscles, the obturator vessels and nerve being interposed; by its *outer border*, with the Psoas, a cellular interval separating them, through which passes the internal circumflex vessels; by its *inner border*, with the margin of the Adductor longus.

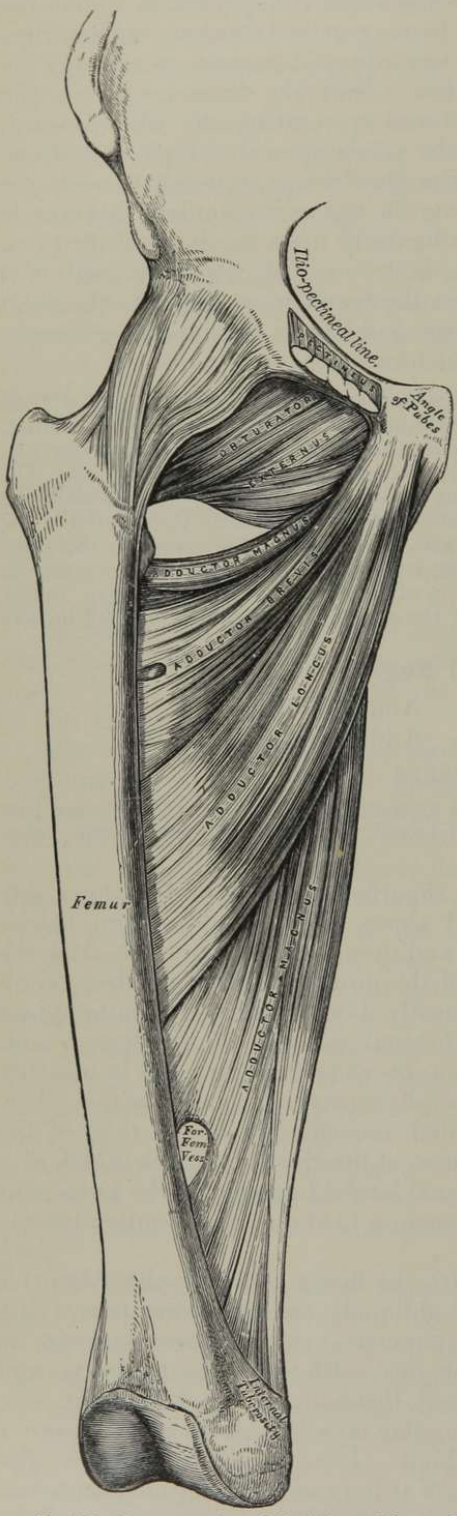

Fig. 327.—Deep muscles of the internal femoral region.

The **Adductor longus**, the most superficial of the three Adductors, is a flat triangular muscle lying on the same plane as the Pectineus. It arises, by a flat narrow tendon, from the front of the os pubis, at the angle of junction of the crest with the symphysis; and soon expands into a broad fleshy belly, which, passing downward, backward, and outward, is inserted, by an aponeurosis, into the linea aspera, between the Vastus internus and the Adductor magnus, with which it is usually blended.

Relations.—By its *anterior surface*, with the fascia lata, the Sartorius, and, near its insertion, with the femoral artery and vein; by its *posterior surface*, with the Adductor brevis and magnus, the anterior branches of the obturator nerve, and with the profunda artery and vein near its insertion; by its *outer border*, with the Pectineus; by its *inner border*, with the Gracilis.

The Pectineus and Adductor longus should now be divided near their origin, and turned downward, when the Adductor brevis and Obturator externus will be exposed.

The **Adductor brevis** is situated immediately behind the two preceding muscles. It is somewhat triangular in form, and arises by a narrow origin from the outer surface of the body and descending ramus of the os pubis, between the Gracilis and Obturator externus. Its fibres, passing backward, outward, and downward, are inserted, by an aponeurosis, into the lower part of the line leading from the lesser trochanter to the linea aspera and the upper part of the linea aspera, immediately behind the Pectineus and upper part of the Adductor longus.

Relations.—By its *anterior surface*, with the Pectineus, Adductor longus, profunda femoris artery, and anterior branches of the obturator nerve; by its *posterior surface*, with the Adductor magnus and posterior branch of the obturator nerve; by its *outer border*, with the Obturator externus and conjoined tendon of the Psoas and Iliacus; by its *inner border*, with the Gracilis and Adductor magnus.

This muscle is pierced, near its insertion, by the middle perforating branch of the profunda femoris artery.

The Adductor brevis should now be cut away near its origin, and turned outward, when the entire extent of the Adductor magnus will be exposed.

The **Adductor magnus** is a large triangular muscle forming a septum between the muscles on the inner and those on the back of the thigh. It arises from a small part of the descending ramus of the os pubis, from the ascending ramus of the ischium, and from the outer margin and under surface of the tuberosity of the ischium. Those fibres which arise from the ramus of the os pubis are very short, horizontal in direction, and are inserted into the rough line leading from the great trochanter to the linea aspera, internal to the Gluteus maximus; those from the ramus of the ischium are directed downward and outward with different degrees of obliquity, to be inserted, by means of a broad aponeurosis, into the linea aspera and the upper part of its internal prolongation below. The internal portion of the muscle, consisting principally of those fibres which arise from the tuberosity of the ischium, forms a thick fleshy mass consisting of coarse bundles which descend almost vertically, and terminate about the lower third of the thigh in a rounded tendon, which is inserted into the Adductor tubercle on the inner condyle of the femur, being connected by a fibrous expansion to the line leading upward from the tubercle to the linea aspera. Between the two portions of the muscle an interval is left, tendinous in front, fleshy behind, for the passage of the femoral vessels into the popliteal space. The external portion of the muscle at its attachment to the femur presents three or four osseo-aponeurotic openings, formed by tendinous arches attached to the bone, from which muscular fibres arise. The three superior of these apertures are for the three perforating arteries, and the fourth, when it exists, for the terminal branch of the profunda.

Relations.—By its *anterior surface*, with the Pectineus, Adductor brevis, Adductor longus, and the femoral and profunda vessels and obturator nerve; by its *posterior surface*, with the great sciatic nerve, the Gluteus maximus, Biceps, Semitendinosus, and Semimembranosus. By its *superior* or *shortest border* it lies parallel with the Quadratus femoris, the internal circumflex artery passing between them; by its *internal* or *longest border*, with the Gracilis, Sartorius, and fascia lata; by its *external* or *attached border* it is inserted into the femur behind the Adductor brevis and Adductor longus, which separate it from the Vastus internus, and in front of the Gluteus maximus and short head of the Biceps, which separate it from the Vastus externus.

Nerves.—All the muscles of this group are supplied by the obturator nerve. The Pectineus receives additional branches from the accessory obturator and anterior crural, and the Adductor magnus an additional branch from the great sciatic.

Actions.—The Pectineus and three Adductors adduct the thigh powerfully: they are especially used in horse exercise, the flanks of the horse being grasped between the knees by the actions of these muscles. In consequence of the obliquity of their insertion into the linea aspera they rotate the thigh outward, assisting the external Rotators, and when the limb has been abducted they draw it inward, carrying the thigh across that of the opposite side. The Pectineus and Adductor brevis and longus assist the Psoas and Iliacus in flexing the thigh upon the pelvis. In progression, also, all these muscles assist in drawing forward the hinder limb. The Gracilis assists the Sartorius in flexing the leg and rotating it inward; it is also an adductor of the thigh. If the lower extremities are fixed, these muscles may take their fixed point from below and act upon the pelvis, serving to maintain the body in an erect posture, or, if their action is continued, to flex the pelvis forward upon the femur.

Surgical Anatomy.—The Adductor longus is liable to be severely strained in those who ride much on horseback, or its tendon to be ruptured by suddenly gripping the saddle. And, occasionally, especially in cavalry soldiers, the tendon may become ossified, constituting the "rider's bone."

THE HIP.

Gluteal Region.

Gluteus maximus.
Gluteus medius.
Gluteus minimus.
Pyriformis.
Gemellus superior.
Obturator internus.
Gemellus inferior.
Obturator externus.
Quadratus femoris.

Dissection (Fig. 328).—The subject should be turned on its face, a block placed beneath the pelvis to make the buttocks tense, and the limbs allowed to hang over the end of the table, with the foot inverted and the thigh abducted. Make an incision through the integument along the crest of the ilium to the middle of the sacrum, and thence downward to the tip of the coccyx, and carry a second incision from that point obliquely downward and outward to the outer side of the thigh, four inches below the great trochanter. The portion of integument included between these incisions is to be removed in the direction shown in the figure.

The **Gluteus maximus** (Fig. 329), the most superficial muscle in the gluteal region, is a very broad and thick, fleshy mass of a quadrilateral shape, which forms the prominence of the nates. Its large size is one of the most characteristic points in the muscular system in man, connected as it is with the power he has of maintaining the trunk in the erect posture. In structure the muscle is remarkably coarse, being made up of muscular fasciculi lying parallel with one another, and collected together into large bundles, separated by deep cellular intervals. It arises from the superior gluteal line of the ilium and the portion of bone, including the crest, immediately behind it; from the posterior surface of the lower part of the sacrum, the side of the coccyx, the aponeurosis of the Erector spinæ muscle, and the great sacro-sciatic ligament. The fibres are directed obliquely downward and outward; those forming the upper together with the *superficial* fibres of the lower portion terminate in a thick tendinous lamina, which passes across the great trochanter, and is inserted into the fascia lata covering the outer side of the thigh, the *deep* fibres of the lower portion being inserted by a tendon into the rough line leading from the great trochanter to the linea aspera between the Vastus externus and Adductor magnus.

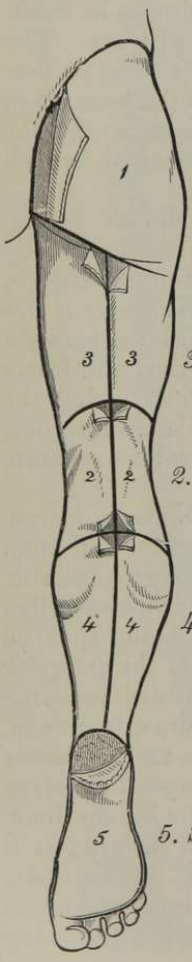

1. *Dissection of gluteal region.*
3. *Back of thigh.*
2. *Popliteal space.*
4. *Back of leg.*
5. *Sole of foot.*

FIG. 328.—Dissection of lower extremity. Posterior view.

Three *synovial bursæ* are usually found in relation with this muscle. One of these, of large size, and generally multilocular, separates it from the great trochanter. A second, often wanting, is situated on the tuberosity of the ischium. A third is found between the tendon of this muscle and the Vastus externus.

Relations.—By its *superficial surface*, with a thin fascia, which separates it from the subcutaneous tissue; by its *deep surface*, from above downward, with the ilium, sacrum, coccyx, and great sacro-sciatic ligament, part of the Gluteus medius, Pyriformis, Gemelli, Obturator internus, Quadratus femoris, the tuberosity of the ischium, great trochanter, the origin of the Biceps, Semitendinosus, Semimembranosus, and Adductor magnus muscles. The gluteal vessels and superior gluteal nerve are seen issuing from the pelvis above the Pyriformis muscle, the sciatic and

internal pudic vesels and nerves, and muscular branches from the sacral plexus below it. Its *upper border* is connected with the Gluteus medius by the fascia lata; its *lower border* is free and prominent.

Dissection.—Now divide the Gluteus maximus near its origin by a vertical incision carried from its upper to its lower border; a cellular interval will be exposed, separating it from the Gluteus medius and External rotator muscles beneath. The upper portion of the muscle is to be altogether detached, and the lower portion turned outward; the loose areolar tissue filling up the interspace between the trochanter major and tuberosity of the ischium being removed, the parts already enumerated as exposed by the removal of this muscle will be seen.

The **Gluteus medius** is a broad, thick, radiated muscle, situated on the outer surface of the pelvis. Its posterior third is covered by the Gluteus maximus; its anterior two-thirds by the fascia lata, which separates it from the integument. It arises from the outer surface of the ilium, between the superior and middle gluteal lines, and from the outer lip of that portion of the crest which is between them; it also arises from the dense fascia (Gluteal aponeurosis) covering its outer surface. The fibres converge to a strong flattened tendon which is inserted into the oblique line which traverses the outer surface of the great trochanter. A synovial bursa separates the tendon of the muscle from the surface of the trochanter in front of its insertion.

Relations.—By its *superficial surface*, with the Gluteus maximus behind, the Tensor vaginæ femoris and deep fascia in front; by its *deep surface*, with the Gluteus minimus and the gluteal vessels and superior gluteal nerve. Its *anterior border* is blended with the Gluteus minimus. Its *posterior border* lies parallel with the Pyriformis, the gluteal vessels intervening.

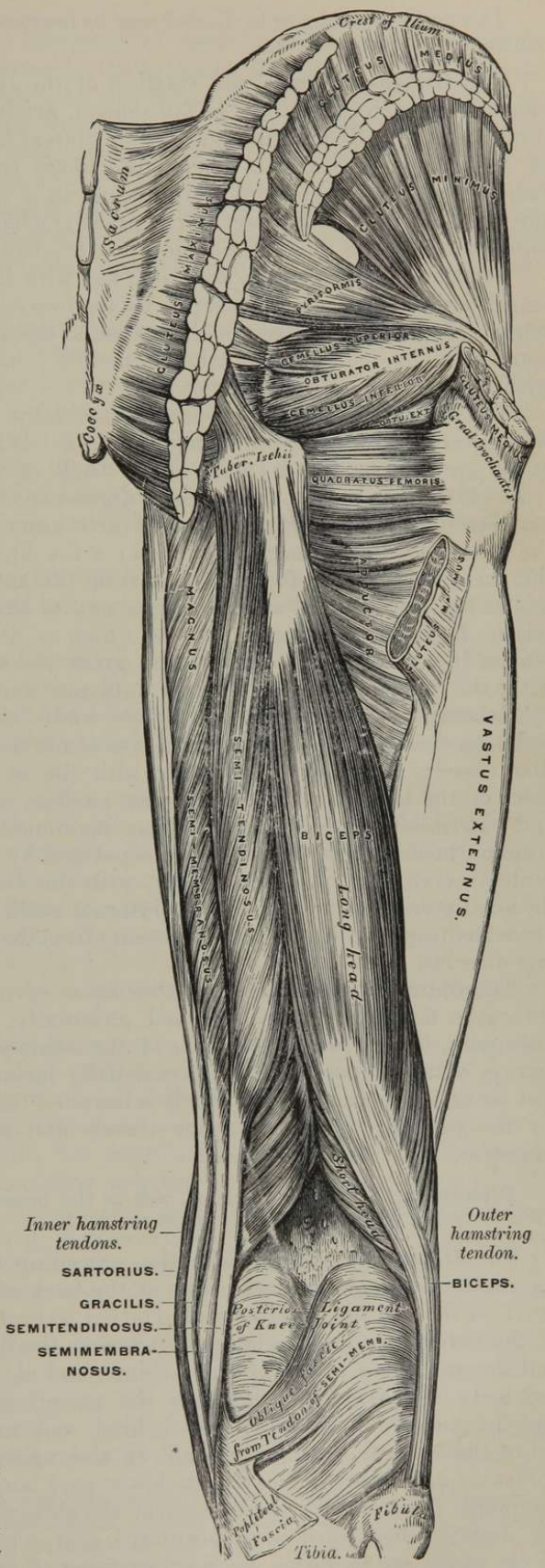

FIG. 329.—Muscles of the hip and thigh.

This muscle should now be divided near its insertion and turned upward, when the Gluteus minimus will be exposed.

The **Gluteus minimus**, the smallest of the three Glutei, is placed immediately beneath the preceding. It is fan-shaped, arising from the outer surface of the ilium, between the middle and inferior gluteal lines, and behind, from the margin of the great sacro-sciatic notch; the fibres converge to the deep surface of a radiated aponeurosis, which, terminating in a tendon, is inserted into an impression on the anterior border of the great trochanter. A synovial bursa is interposed between the tendon and the great trochanter.

Relations.—By its *superficial surface*, with the Gluteus medius, and the gluteal vessels and superior gluteal nerve; by its *deep surface*, with the ilium, the reflected tendon of the Rectus femoris, and capsular ligament of the hip-joint. Its *anterior margin* is blended with the Gluteus medius; its *posterior margin* is often joined with the tendon of the Pyriformis.

The **Pyriformis** is a flat muscle, pyramidal in shape, lying almost parallel with the posterior margin of the Gluteus medius. It is situated partly within the pelvis at its posterior part and partly at the back of the hip-joint. It arises from the front of the sacrum by three fleshy digitations attached to the portions of bone between the first, second, third, and fourth anterior sacral foramina, and also from the groove leading from the foramina: a few fibres also arise from the margin of the great sacro-sciatic foramen and from the anterior surface of the great sacro-sciatic ligament. The muscle passes out of the pelvis through the great sacro-sciatic foramen, the upper part of which it fills, and is inserted by a rounded tendon into the upper border of the great trochanter, behind, but often blended with, the tendon of the Obturator internus and Gemelli muscles.

Relations.—By its *anterior surface, within the pelvis*, with the Rectum (especially on the left side), the sacral plexus of nerves, and the branches of the internal iliac vessels; *external to the pelvis*, with the os innominatum and capsular ligament of the hip-joint; by its *posterior surface, within the pelvis*, with the sacrum, and *external to it*, with the Gluteus maximus; by its *upper border*, with the Gluteus medius, from which it is separated by the gluteal vessels and superior gluteal nerve; by its *lower border*, with the Gemellus superior and Coccygeus, the sciatic vessels and nerves, the internal pudic vessels and nerve, and muscular branches from the sacral plexus, passing from the pelvis in the interval between the two muscles.

The **Obturator membrane** is a thin layer of interlacing fibres which closes the obturator foramen. It is attached, externally, to the margin of the foramen; internally, to the posterior surface of the ischio-pubic ramus, internal to the inner margin of the foramen. It is occasionally incomplete, and presents at its upper and outer part a small canal, which is bounded below by a thickened band of fibres, for the passage of the obturator vessels and nerve. Each obturator muscle is connected with this membrane.

Dissection.—The next muscle, as well as the origin of the Pyriformis, can only be seen when the pelvis is divided and the viscera removed.

The **Obturator internus**, like the preceding muscle, is situated partly within the cavity of the pelvis and partly at the back of the hip-joint. It arises from the inner surface of the anterior and external wall of the pelvis, around the inner side of the obturator foramen, being attached to the descending ramus of the os pubis and the ascending ramus of the ischium, and at the side to the inner surface of the body of the ischium, between the margin of the obturator foramen in front and the great sacro-sciatic notch behind, and to the inner surface of the ilium below the brim of the true pelvis. It also arises from the inner surface of the obturator membrane, except at its lower part, and from the tendinous arch which completes the canal for the passage of the obturator vessels and nerve. The fibres are directed backward and downward, and terminate in four or five tendinous bands which are found on its deep surface: these bands are reflected at a right

angle over the inner surface of the tuberosity of the ischium, which is grooved for their reception: the groove is covered with cartilage and lined with a synovial bursa. The muscle leaves the pelvis by the lesser sacro-sciatic notch, and the tendinous bands unite into a single flattened tendon, which passes horizontally outward, and, after receiving the attachment of the Gemelli, is inserted into the inner surface of the great trochanter in front of the Obturator externus. A synovial bursa, narrow and elongated in form, is usually found between the tendon of this muscle and the capsular ligament of the hip: it occasionally communicates with the bursa between the tendon and the tuberosity of the ischium, the two forming a single sac.

In order to display the peculiar appearances presented by the tendon of this muscle, it must be divided near its insertion and reflected outward.

Relations.— *Within the pelvis* this muscle is in relation, by its *anterior surface*, with the obturator membrane and inner surface of the anterior wall of the pelvis; by its *posterior surface*, with the pelvic and obturator fasciæ, which separate it from the Levator ani; and it is crossed by the internal pudic vessels and nerve. This surface forms the outer boundary of the ischio-rectal fossa. *External to the pelvis* it is covered by the great sciatic nerve and Gluteus maximus, and rests on the back part of the hip-joint.

The **Gemelli** are two small muscular fasciculi, accessories to the tendon of the Obturator internus, which is received into a groove between them. They are called *superior* and *inferior*.

The **Gemellus superior,** the smaller of the two, arises from the outer surface of the spine of the ischium, and, passing horizontally outward, becomes blended with the upper part of the tendon of the Obturator internus, and is inserted with it into the inner surface of the great trochanter. This muscle is sometimes wanting.

Relations.—By its *superficial surface*, with the Gluteus maximus and the sciatic vessels and nerves; by its *deep surface*, with the capsule of the hip-joint; by its *upper border*, with the lower margin of the Pyriformis; by its *lower border*, with the tendon of the Obturator internus.

The **Gemellus inferior** arises from the upper part of the tuberosity of the ischium, where it forms the lower edge of the groove for the Obturator internus tendon, and, passing horizontally outward, is blended with the lower part of the tendon of the Obturator internus, and is inserted with it into the inner surface of the great trochanter.

Relations.—By its *superficial surface*, with the Gluteus maximus and the sciatic vessels and nerves; by its *deep surface*, with the capsular ligament of the hip-joint; by its *upper border*, with the tendon of the Obturator internus; by its *lower border*, with the tendon of the Obturator externus and Quadratus femoris.

The **Quadratus femoris** is a short, flat muscle, quadrilateral in shape (hence its name), situated between the Gemellus inferior and the upper margin of the Adductor magnus. It arises from the external lip of the tuberosity of the ischium, and, proceeding horizontally outward, is inserted into the upper part of the linea quadrati; that is, the line which crosses the posterior intertrochanteric line. A synovial bursa is often found between the under surface of this muscle and the lesser trochanter, to which it extends.

Relations.—By its *posterior surface*, with the Gluteus maximus and the sciatic vessels and nerves; by its *anterior surface*, with the tendon of the Obturator externus and trochanter minor and with the capsule of the hip-joint; by its *upper border*, with the Gemellus inferior. Its *lower border* is separated from the Adductor magnus by the terminal branches of the internal circumflex vessels.

Dissection.—In order to expose the next muscle (the Obturator externus), it is necessary to remove the Psoas, Iliacus, Pectineus, and Adductor brevis and longus muscles from the front and inner side of the thigh, and the Gluteus maximus and Quadratus femoris from the back part. Its dissection should, consequently, be postponed until the muscles of the anterior and internal femoral regions have been explained.

The **Obturator externus** (Fig. 327) is a flat, triangular muscle which covers the outer surface of the anterior wall of the pelvis. It arises from the margin of bone which forms the inner boundary of the obturator foramen—viz. from the body and descending ramus of the os pubis and the ramus of the ischium; it also arises from the inner two-thirds of the outer surface of the obturator membrane, and from the tendinous arch which completes the canal for the passage of the obturator vessels and nerves. The fibres converging pass backward, outward, and upward, and terminate in a tendon which runs under and across the back part of the hip-joint and is inserted into the digital fossa of the femur.

Relations.—By its *anterior surface*, with the Psoas, Iliacus, Pectineus, Adductor magnus, Adductor brevis, and Gracilis, and more externally, with the neck of the femur and capsule of the hip-joint; by its *posterior surface*, with the obturator membrane and Quadratus femoris.

Nerves.—The Gluteus maximus is supplied by the inferior gluteal nerve from the sacral plexus; the Gluteus medius and minimus, by the superior gluteal; the Pyriformis, Gemelli, Obturator internus, and Quadratus femoris, by branches from the sacral plexus; and the Obturator externus, by the obturator nerve.

Actions.—The Gluteus maximus, when it takes its fixed point from the pelvis, extends the femur and brings the bent thigh into a line with the body. Taking its fixed point from below, it acts upon the pelvis, supporting it and the whole trunk upon the head of the femur, which is especially obvious in standing on one leg. Its most powerful action is to cause the body to regain the erect position after stooping by drawing the pelvis backward, being assisted in this action by the Biceps, Semitendinosus, and Semimembranosus. The Gluteus maximus is a tensor of the fascia lata, and by its connection with the ilio-tibial band it steadies the femur on the articular surface of the tibia during standing, when the extensor muscles are relaxed. The lower part of the muscle also acts as an abductor and external rotator of the limb. The Gluteus medius and minimus abduct the thigh when the limb is extended, and are principally called into action in supporting the body on one limb, in conjunction with the Tensor vaginæ femoris. Their anterior fibres, by drawing the great trochanter forward, rotate the thigh inward, in which action they are also assisted by the Tensor vaginæ femoris. Their posterior fibres rotate the thigh outward. The remaining muscles are powerful rotators of the thigh outward. In the sitting posture, when the thigh is flexed upon the pelvis, their action as rotator ceases, and they become abductors, with the exception of the Obturator externus, which still rotates the femur outward. When the femur is fixed, the Pyriformis and Obturator muscles serve to draw the pelvis forward if it has been inclined backward, and assist in steadying it upon the head of the femur.

Posterior Femoral Region.

Biceps. Semitendinosus. Semimembranosus.

Dissection (Fig. 328).—Make a vertical incision along the middle of the thigh, from the lower fold of the nates to about three inches below the back of the knee-joint, and there connect it with a transverse incision carried from the inner to the outer side of the leg. Make a third incision transversely at the junction of the middle with the lower third of the thigh. The integument having been removed from the back of the knee and the boundaries of the popliteal space examined, the removal of the integument from the remaining part of the thigh should be continued, when the fascia and muscles of this region will be exposed.

The **Biceps** (*Biceps flexor cruris*) is a large muscle, of considerable length, situated on the posterior and outer aspect of the thigh (Fig. 329). It arises by two heads. One, the long head, arises from the lower and inner facet on the back part of the tuberosity of the ischium by a tendon common to it and the Semitendinosus. The femoral, or short head, arises from the outer lip of the linea aspera, between the Adductor magnus and Vastus externus, extending up almost as high as the insertion of the Gluteus maximus, and from the external supra-condylar line to within two inches of the outer condyle; it also arises from the

external intermuscular septum. The fibres of the long head form a fusiform belly, which, passing obliquely downward and a little outward, terminates in an aponeurosis which covers the posterior surface of the muscle and receives the fibres of the short head: this aponeurosis becomes gradually contracted into a tendon, which is inserted into the outer side of the head of the fibula, and by a small slip into the lateral surface of the external tuberosity of the tibia. At its insertion the tendon divides into two portions, which embrace the long external lateral ligament of the knee-joint, a strong prolongation being sent forward to the outer tuberosity of the tibia, which gives off an expansion to the fascia of the leg. The tendon of this muscle forms the outer hamstring.

Relations.—By its *superficial surface*, with the Gluteus maximus above, with the fascia lata and integument in the rest of its extent; by its *deep surface*, with the Semimembranosus, Adductor magnus, and Vastus externus, the great sciatic nerve, and, near its insertion, with the external head of the Gastrocnemius, Plantaris, the superior external articular artery, and the external popliteal nerve.

The **Semitendinosus,** remarkable for the great length of its tendon, is situated at the posterior and inner aspect of the thigh. It arises from the lower and inner facet on the tuberosity of the ischium by a tendon common to it and the long head of the Biceps; it also arises from an aponeurosis which connects the adjacent surfaces of the two muscles to the extent of about three inches after their origin. It forms a fusiform muscle, which, passing downward and inward, terminates a little below the middle of the thigh in a long round tendon which lies along the inner side of the popliteal space, then curves around the inner tuberosity of the tibia, and is inserted into the upper part of the inner surface of the shaft of that bone nearly as far forward as its anterior border. This tendon is surrounded by the tendon of the Sartorius, and lies below that of the Gracilis, to which it is united. A tendinous intersection is usually observed about the middle of the muscle.

Relations.—By its *superficial surface*, with the Gluteus maximus and fascia lata; by its *deep surface*, with the Semimembranosus, Adductor magnus, inner head of the Gastrocnemius, and internal lateral ligament of the knee-joint.

The **Semimembranosus,** so called from the membranous expansion on its anterior and posterior surfaces, is situated at the back part and inner side of the thigh. It arises by a thick tendon from the upper and outer facet on the back part of the tuberosity of the ischium, above and to the outer side of the Biceps and Semitendinosus, and is inserted into the groove on the inner and back part of the inner tuberosity of the tibia, beneath the internal lateral ligament. The tendon of the muscle at its origin expands into an aponeurosis which covers the upper part of its anterior surface: from this aponeurosis muscular fibres arise, and converge to another aponeurosis, which covers the lower part of its posterior surface and contracts into the tendon of insertion. The tendon of the muscle at its insertion gives off two fibrous expansions; one of these, of considerable size, passes upward and outward to be inserted into the back part of the outer condyle of the femur, forming part of the posterior ligament of the knee-joint. The second is continued downward to the fascia which covers the Popliteus muscle. The tendon also sends a few fibres to join the internal lateral ligament of the joint.

The tendons of the two preceding muscles, with that of the Gracilis, form the inner hamstring.

Relations.—By its *superficial surface*, with the Semitendinosus, Biceps, and fascia lata; by its *deep surface*, with the popliteal vessels, Adductor magnus, and inner head of the Gastrocnemius, from which it is separated by a synovial bursa; by its *inner border*, with the Gracilis; by its *outer border*, with the great sciatic nerve and its internal popliteal branch.

Nerves.—The muscles of this region are supplied by the great sciatic nerve.

Actions.—The hamstring muscles flex the leg upon the thigh. When the

FIG. 330.—Muscles of the front of the leg.

knee is semiflexed, the Biceps, in consequence of its oblique direction downward and outward, rotates the leg slightly outward; and the Semitendinosus, and to a slight extent the Semimembranosus, rotate the leg inward, assisting the Popliteus. Taking their fixed point from below, these muscles serve to support the pelvis upon the head of the femur and to draw the trunk directly backward, as in feats of strength, when the body is thrown backward in the form of an arch.

Surgical Anatomy.—The tendons of these muscles occasionally require subcutaneous division in some forms of spurious ankylosis of the knee-joint dependent upon permanent contraction and rigidity of the Flexor muscles, or from stiffening of the ligamentous and other tissues surrounding the joint, the result of disease. This is effected by putting the tendon upon the stretch, and inserting a narrow, sharp-pointed knife between it and the skin: the cutting edge being then turned toward the tendon, it should be divided, taking great care that the wound in the skin is not at the same time enlarged. The relation of the external popliteal nerve to the tendon of the Biceps must always be borne in mind in dividing this tendon.

THE LEG.

Dissection (Fig. 325).—The knee should be bent, a block placed beneath it, and the foot kept in an extended position; then make an incision through the integument in the middle line of the leg to the ankle, and continue it along the dorsum of the foot to the toes. Make a second incision transversely across the ankle, and a third in the same direction across the bases of the toes; remove the flaps of integument included between these incisions in order to examine the deep fascia of the leg.

The **Deep fascia of the Leg** forms a complete investment to the muscles, but is not continued over the subcutaneous surfaces of the bones. It is continuous above with the fascia lata, receiving an expansion from the tendon of the Biceps on the outer side, and from the tendons of the Sartorius, Gracilis, and Semitendinosus on the inner side; in front it blends with the periosteum covering the subcutaneous surface of the tibia, and with that covering the head and external malleolus of the fibula; below it is continuous with the annular ligaments of the ankle. It is thick and dense in the upper and anterior part of the leg, and gives attachment, by its deep surface, to the Tibialis anticus and Extensor longus digitorum muscles, but thinner behind, where it covers the Gastrocnemius and Soleus muscles. Over the popliteal space it is much strengthened by transverse fibres which stretch across from the inner to the outer hamstring muscles, and it is here perforated by the external saphenous vein. Its deep surface gives off, on the outer side of the leg, two strong intermuscular septa which enclose the Peronei muscles, and separate them from the muscles on the anterior and posterior tibial regions and several smaller and more slender processes which enclose the indi-

vidual muscles in each region; at the same time a broad transverse intermuscular septum, called the *deep transverse fascia of the leg*, intervenes between the superficial and deep muscles in the posterior tibio-fibular region.

Now remove the fascia by dividing it in the same direction as the integument, excepting opposite the ankle, where it should be left entire. Commence the removal of the fascia from below, opposite the tendons, and detach it in the line of direction of the muscular fibres.

Muscles of the Leg.—These may be subdivided into three groups: those on the anterior, those on the posterior, and those on the outer side.

Anterior Tibio-fibular Region.

Tibialis anticus.	Extensor longus digitorum.
Extensor proprius hallucis.	Peroneus tertius.

The **Tibialis anticus** is situated on the outer side of the tibia; it is thick and fleshy at its upper part, tendinous below. It arises from the outer tuberosity and upper two-thirds of the external surface of the shaft of the tibia; from the adjoining part of the interosseous membrane; from the deep surface of the fascia; and from the intermuscular septum between it and the Extensor longus digitorum: the fibres pass vertically downward, and terminate in a tendon which is apparent on the anterior surface of the muscle at the lower third of the leg. After passing through the innermost compartment of the anterior annular ligament, it is inserted into the inner and under surface of the internal cuneiform bone and base of the metatarsal bone of the great toe.

Relations.—By its *anterior surface*, with the fascia and with the annular ligament; by its *posterior surface*, with the interosseous membrane, tibia, ankle-joint, and inner side of the tarsus: this surface also overlaps the anterior tibial vessels and nerve in the upper part of the leg. By its *inner surface*, with the tibia; by its *outer surface*, with the Extensor longus digitorum and Extensor proprius hallucis, and the anterior tibial vessels and nerve.

The **Extensor proprius hallucis** is a thin, elongated, and flattened muscle situated between the Tibialis anticus and Extensor longus digitorum. It arises from the anterior surface of the fibula for about the middle two-fourths of its extent, its origin being internal to that of the Extensor longus digitorum; it also arises from the interosseous membrane to a similar extent. The fibres pass downward, and terminate in a tendon which occupies the anterior border of the muscle, passes through a distinct compartment in the horizontal portion of the annular ligament, crosses the anterior tibial vessels near the bend of the ankle, and is inserted into the base of the last phalanx of the great toe. Opposite the metatarso-phalangeal articulation the tendon gives off a thin prolongation on each side, which covers the surface of the joint. It usually sends an expansion from the inner side of the tendon, to be inserted into the base of the first phalanx.

Relations.—By its *anterior surface*, with the fascia and the anterior annular ligament; by its *posterior surface*, with the interosseous membrane, fibula, tibia, ankle-joint, and Extensor brevis digitorum; by its *outer side*, with the Extensor longus digitorum above, the dorsalis pedis vessels and anterior tibial nerve below; by its *inner side*, with the Tibialis anticus and the anterior tibial vessels above.

The **Extensor longus digitorum** is an elongated, flattened, semipenniform muscle situated the most externally of all the muscles on the fore part of the leg. It arises from the outer tuberosity of the tibia; from the upper three-fourths of the anterior surface of the shaft of the fibula; from the interosseous membrane; from the deep surface of the fascia; and from the intermuscular septa between it and the Tibialis anticus on the inner and the Peronei on the outer side. The tendon enters a canal in the annular ligament with the Peroneus tertius, and divides into four slips, which run across the dorsum of the foot and are inserted into the second and third phalanges of the four lesser toes. The mode in which the tendons are inserted is the following: The three inner tendons opposite the metatarso-phalangeal articulation are joined, on their outer side, by a tendon of the Extensor

brevis digitorum. They all receive a fibrous expansion from the Interossei and Lumbricales, and then spread out into a broad aponeurosis, which covers the dorsal surface of the first phalanx: this aponeurosis, at the articulation of the first with the second phalanx, divides into three slips—a middle one, which is inserted into the base of the second phalanx, and two lateral slips, which, after uniting on the dorsal surface of the second phalanx, are continued onward, to be inserted into the base of the third.

Relations.—By its *anterior surface*, with the fascia and the annular ligament; by its *posterior surface*, with the fibula, interosseous membrane, ankle-joint, and Extensor brevis digitorum; by its *inner side*, with the Tibialis anticus, Extensor proprius hallucis, and anterior tibial vessels and nerve; by its *outer side*, with the Peroneus longus and brevis.

The **Peroneus tertius** is a part of the Extensor longus digitorum, and might be described as its fifth tendon. The fibres belonging to this tendon arise from the lower fourth of the anterior surface of the fibula, from the lower part of the interosseous membrane, and from an intermuscular septum between it and the Peroneus brevis. The tendon, after passing through the same canal in the annular ligament as the Extensor longus digitorum, is inserted into the dorsal surface of the base of the metatarsal bone of the little toe, on its inner side. This muscle is sometimes wanting.

Nerves.—These muscles are supplied by the anterior tibial nerve.

Actions.—The Tibialis anticus and Peroneus tertius are the flexors of the tarsus upon the leg; the former muscle, from the obliquity in the direction of its tendon, raises the inner border of the foot; and the latter, acting with the Peroneus brevis and longus, draws the outer border of the foot upward and the sole outward. The Extensor longus digitorum and Extensor proprius hallucis extend the phalanges of the toes, the action being the same as that of the corresponding muscles of the hand, and flex the tarsus. Taking their fixed point from below in the erect posture, all these muscles serve to fix the bones of the leg in the perpendicular position.

Posterior Tibio-fibular Region.

Dissection (Fig. 328).—Make a vertical incision along the middle line of the back of the leg, from the lower part of the popliteal space to the heel, connecting it below by a transverse incision extending between the two malleoli; the flaps of integument being removed, the fascia and muscles should be examined.

The muscles in this region of the leg are subdivided into two layers—superficial and deep. The superficial layer constitutes a powerful muscular mass, forming the calf of the leg. Their large size is one of the most characteristic features of the muscular apparatus in man, and bears a direct connection with his ordinary attitude and mode of progression.

Superficial Layer.

Gastrocnemius. Soleus. Plantaris.

The **Gastrocnemius** is the most superficial muscle, and forms the greater part of the calf. It arises by two heads, which are connected to the condyles of the femur by two strong flat tendons. The inner head, the larger and a little the more posterior, arises from a depression at the upper and back part of the inner condyle. The outer head arises from the upper and back part of the external condyle, immediately above the origin of the Popliteus. Both heads, also, arise by a few tendinous and fleshy fibres from the ridges which are continued upward from the condyles to the linea aspera. Each tendon spreads out into an aponeurosis which covers the posterior surface of that portion of the muscle to which it belongs, that covering the inner head being longer and thicker than the outer. From the anterior surface of these tendinous expansions muscular fibres are given off. The fibres in the median line, which correspond to the

accessory portions of the muscle derived from the bifurcations of the linea aspera, unite at an angle upon a median tendinous raphe below: the remaining fibres converge to the posterior surface of an aponeurosis which covers the anterior surface of the muscle, and this, gradually contracting, unites with the tendon of the Soleus, and forms with it the tendo Achillis.

Relations.—By its *superficial surface*, with the fascia of the leg, which separates it from the external saphenous vein and nerve; by its *deep surface*, with the posterior ligament of the knee-joint, the Popliteus, Soleus, Plantaris, popliteal vessels, and internal popliteal nerve. The tendon of the inner head corresponds with the back part of the inner condyle, from which it is separated by a synovial bursa, which, in some cases, communicates with the cavity of the knee-joint. The tendon of the outer head contains a sesamoid fibro-cartilage (rarely osseous) where it plays over the corresponding outer condyle; and one is occasionally found in the tendon of the inner head.

The Gastrocnemius should be divided across, just below its origin, and turned downward, in order to expose the next muscles.

The **Soleus** is a broad flat muscle situated immediately beneath the Gastrocnemius. It has received its name from its resemblance in shape to a sole-fish. It arises by tendinous fibres from the back part of the head of the fibula and from the upper third of the posterior surface of its shaft; from the oblique line of the tibia and from the middle third of its internal border; some fibres also arise from a tendinous arch placed between the tibial and fibular origins of the muscle, beneath which the posterior tibial vessels and nerve pass. The fibres pass backward to an aponeurosis which covers the posterior surface of the muscle, and this, gradually becoming thicker and narrower, joins with the tendon of the Gastrocnemius, and forms with it the tendo Achillis.

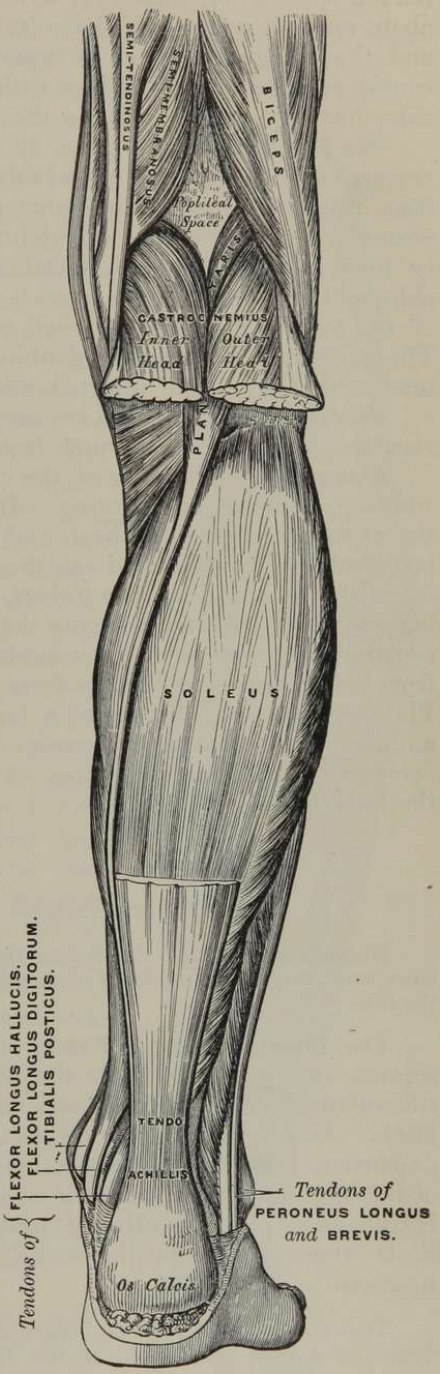

FIG. 331.—Muscles of the back of the leg. Superficial layer.

Relations.—By its *superficial surface*, with the Gastrocnemius and Plantaris; by its *deep surface*, with the Flexor longus digitorum, Flexor longus hallucis, Tibialis posticus, and posterior tibial vessels and nerve, from which it is separated by the transverse intermuscular septum or deep transverse fascia of the leg.

The **Tendo Achillis**, the common tendon of the Gastrocnemius and Soleus, is the thickest and strongest tendon in the body. It is about six inches in length, and commences about the middle of the leg, but receives fleshy fibres on its anterior surface nearly to its lower end. Gradually becoming contracted below, it is inserted into the lower part of the posterior surface of the os calcis, a synovial

bursa being interposed between the tendon and the upper part of this surface. The tendon spreads out somewhat at its lower end, so that its narrowest part is usually about an inch and a half above its insertion. The tendon is covered by the fascia and the integument, and is separated from the deep muscles and vessels by a considerable interval filled up with areolar and adipose tissue. Along its outer side, but superficial to it, is the external saphenous vein.

The **Plantaris** is an extremely diminutive muscle placed between the Gastrocnemius and Soleus, and remarkable for its long and delicate tendon. It arises from the lower part of the outer prolongation of the linea aspera and from the posterior ligament of the knee-joint. It forms a small fusiform belly, about three or four inches in length, terminating in a long slender tendon which crosses obliquely between the two muscles of the calf, and, running along the inner border of the tendo Achillis, is inserted with it into the posterior part of the os calcis. This muscle is occasionally double, and is sometimes wanting. Occasionally, its tendon is lost in the internal annular ligament or in the fascia of the leg.

Nerves.—These muscles are supplied by the internal popliteal nerve, the Soleus receiving an *additional* branch from the posterior tibial nerve.

Actions.—The muscles of the calf are constantly called into use in standing, walking, dancing, and leaping. In walking these muscles draw powerfully upon the os calcis, raising the heel, and with it the entire body, from the ground; the body being thus supported on the raised foot, the opposite limb can be carried forward. In standing, the Soleus, taking its fixed point from below, steadies the leg upon the foot, and prevents the body from falling forward, to which there is a constant tendency from the superincumbent weight. The Gastrocnemius, acting from below, serves to flex the femur upon the tibia, assisted by the Popliteus. The Plantaris is the rudiment of a large muscle which exists in some of the lower animals and serves as a tensor of the plantar fascia. In man it is merely an accessory to the Gastrocnemius, extending the ankle if the foot is free or bending the knee if the foot is fixed.

Deep Layer.

Popliteus.	Flexor longus digitorum.
Flexor longus hallucis.	Tibialis posticus.

Dissection.—Detach the Soleus from its attachment to the fibula and tibia, and turn it downward, when the deep layer of muscles is exposed, covered by the deep transverse fascia of the leg.

The **Deep Transverse Fascia** of the leg is a broad, transverse, intermuscular septum interposed between the superficial and deep muscles in the posterior tibio-fibular region. On either side it is connected to the margins of the tibia and fibula. Above, where it covers the Popliteus, it is thick and dense, and receives an expansion from the tendon of the Semimembranosus; it is thinner in the middle of the leg, but below, where it covers the tendons passing behind the malleoli, it is thickened. It is continued onward in the interval between the ankle and the heel, where it covers the vessels and is blended with the internal annular ligament.

This fascia should now be removed, commencing from below opposite the tendons, and detaching it from the muscles in the direction of their fibres.

The **Popliteus** is a thin, flat, triangular muscle, which forms part of the floor of the popliteal space, and is covered by a tendinous expansion derived from the Semimembranosus muscle. It arises by a strong tendon, about an inch in length, from a deep depression on the outer side of the external condyle of the femur, and from the posterior ligament of the knee-joint, and is inserted into the inner two-thirds of the triangular surface above the oblique line on the posterior surface of the shaft of the tibia, and into the tendinous expansion covering the surface of the muscle. The tendon of the muscle is covered by that of the Biceps and the external lateral ligament of the knee-joint; it grooves the outer border of the

external semilunar fibro-cartilage, and is invested by the synovial membrane of the knee-joint.

Relations.—By its *superficial surface*, with the fascia above mentioned, which separates it from the Gastrocnemius, Plantaris, popliteal vessels, and internal popliteal nerve; by its *deep surface*, with the superior tibio-fibular articulation and back of the tibia.

The **Flexor longus hallucis** is situated on the fibular side of the leg. It arises from the lower two-thirds of the posterior surface of the shaft of the fibula, with the exception of an inch at its lowest part; from the lower part of the interosseus membrane; from an intermuscular septum between it and the Peronei, externally; and from the fascia covering the Tibialis posticus, which is attached to the inner border of the fibula externally and to the posterior surface of the tibia between the origins of the Tibialis posticus and the Flexor longus digitorum, internally. The fibres pass obliquely downward and backward, and terminate round a tendon which occupies nearly the whole length of the posterior surface of the muscle. This tendon passes through a groove on the posterior surface of the lower end of the tibia; it then passes through another groove on the posterior surface of the astragalus, and along a third groove, beneath the sustentaculum tali of the os calcis, into the sole of the foot, where it runs forward between the two heads of the Flexor brevis hallucis, and is inserted into the base of the last phalanx of the great toe. The grooves in the astragalus and os calcis, which contain the tendon of the muscle, are converted by tendinous fibres into distinct canals lined by synovial membrane; and as the tendon crosses the sole of the foot, it is connected to the common flexor by a tendinous slip.

FIG. 332.—Muscles of the back of the leg. Deep layer.

Relations.—By its *superficial surface*, with the Soleus and tendo Achillis, from which it is separated by the deep transverse fascia; by its *deep surface*, with the fibula, Tibialis posticus, the peroneal vessels, the lower part of the interosseous membrane, and the ankle-joint; by its *outer border*, with the Peronei; by its *inner border*, with the Tibialis posticus and posterior tibial vessels and nerve.

The **Flexor longus digitorum** (*perforans*) is situated on the tibial side of the leg. At its origin it is thin and pointed, but gradually increases in size as it descends. It arises from the posterior surface of the shaft of the tibia, immediately below the oblique line, to within three inches of its extremity internal to the tibial origin of the Tibialis posticus; some fibres also arise from the fascia covering the Tibialis posticus. The fibres terminate in a tendon which runs nearly the whole length of the posterior surface of the muscle. This tendon passes behind the internal malleolus in a groove common to it and the Tibialis posticus, but separated from the latter by a fibrous septum, each tendon being contained in a special sheath lined by a separate synovial

membrane. It then passes obliquely forward and outward, crossing over the internal lateral ligament into the sole of the foot (Fig. 334), where, crossing superficially to the tendon of the Flexor longus hallucis,[1] to which it is connected by a strong tendinous slip, it becomes expanded, is joined by the Flexor accessorius, and finally divides into four tendons which are inserted into the bases of the last phalanges of the four lesser toes, each tendon passing through a fissure in the tendon of the Flexor brevis digitorum opposite the base of the first phalanges.

Relations.—*In the leg:* by its *superficial surface*, with the posterior tibial vessels and nerve, and the deep transverse fascia, which separates it from the Soleus muscle; by its *deep surface*, with the Tibia and Tibialis posticus. *In the foot* it is covered by the Abductor hallucis and Flexor brevis digitorum, and crosses superficial to the Flexor longus hallucis.

The **Tibialis posticus** lies between the two preceding muscles, and is the most deeply seated of all the muscles in the leg. It commences above by two pointed processes, separated by an angular interval, through which the anterior tibial vessels pass forward to the front of the leg. It arises from the whole of the posterior surface of the interosseous membrane, excepting its lowest part, from the posterior surface of the shaft of the tibia, external to the Flexor longus digitorum, between the commencement of the oblique line above, and the middle of the external border of the bone below, and from the upper two-thirds of the internal surface of the fibula; some fibres also arise from the deep transverse fascia and from the intermuscular septa, separating it from the adjacent muscles on each side. This muscle, in the lower fourth of the leg, passes in front of the Flexor longus digitorum, and terminates in a tendon which passes through a groove behind the inner malleolus with the tendon of that muscle, but enclosed in a separate sheath; it then passes through another sheath, over the internal lateral ligament into the foot, and then beneath the inferior calcaneo-navicular ligament, and is inserted into the tuberosity of the navicular and internal cuneiform bones. The tendon of this muscle contains a sesamoid fibro-cartilage as it passes over the navicular bone, and gives off fibrous expansions, one of which passes backward to the sustentaculum tali of the os calcis, others outward to the middle and external cuneiform and cuboid, and some forward to the bases of the second, third, and fourth metatarsal bones (Fig. 335).

Relations.—By its *superficial surface*, with the Soleus, from which it is separated by the deep transverse fascia, the Flexor longus digitorum, the posterior tibial vessels and nerve, and the peroneal vessels; by its *deep surface*, with the interosseous ligament, the tibia, fibula, and ankle-joint.

Nerves.—The Popliteus is supplied by the internal popliteal nerve, the remaining muscles of this group by the posterior tibial nerve.

Actions.—The Popliteus assists in flexing the leg upon the thigh; when the leg is flexed it will rotate the tibia inward. It is especially called into action at the commencement of the act of bending the knee, inasmuch as it produces a slight inward rotation of the tibia, which is essential in the early stage of this movement. The Tibialis posticus is a direct extensor of the tarsus upon the leg; acting in conjunction with the Tibialis anticus, it turns the sole of the foot inward, antagonizing the Peroneus longus, which turns it outward. The Flexor longus digitorum and Flexor longus hallucis are the direct flexors of the phalanges, acting as do the similar muscles of the hand, and, continuing their action, extend the foot upon the leg; they assist the Gastrocnemius and Soleus in extending the foot, as in the act of walking or in standing on tiptoe.

In consequence of the oblique direction of the tendon of the long flexor the toes would be drawn inward were it not for the Flexor accessorius muscle, which is inserted into the outer side of its tendon and draws it to the middle line of the foot during its action. Taking their fixed point from the foot, these muscles serve to maintain the upright posture by steadying the tibia and fibula perpendicularly

[1] That is, in the order of dissection of the sole of the foot.

upon the ankle-joint. They also serve to raise these bones from the oblique position they assume in the stooping posture.

Outer or Fibular Region.

Peroneus longus. Peroneus brevis.

Dissection.—The muscles are readily exposed by removing the fascia covering their surface, from below upward, in the line of direction of their fibres.

The **Peroneus longus** is situated at the upper part of the outer side of the leg, and is the more superficial of the two muscles. It arises from the head and upper two-thirds of the outer surface of the shaft of the fibula, from the deep surface of the fascia, and from the intermuscular septa between it and the muscles on the front, and those on the back of the leg. It terminates in a long tendon which passes behind the outer malleolus, in a groove common to it and the Peroneus brevis, the groove being converted into a canal by a fibrous band, and the tendons invested by a common synovial membrane; it is then reflected, obliquely forward, across the outer side of the os calcis, being contained in a separate fibrous sheath lined by a prolongation of the synovial membrane from that which lines the groove behind the malleolus. Having reached the outer side of the cuboid bone, it runs in a groove on the under surface of that bone, which is converted into a canal by the long calcaneo-cuboid ligament, and is lined by a synovial membrane: the tendon then crosses obliquely the sole of the foot, and is inserted into the outer side of the base of the metatarsal bone of the great toe and the internal cuneiform bone. Occasionally it sends a slip to the base of the second metatarsal bone. The tendon changes its direction at two points; first, behind the external malleolus; secondly, on the outer side of the cuboid bone; in both of these situations the tendon is thickened, and in the latter a sesamoid fibro-cartilage, or sometimes a bone, is usually developed in its substance.

Relations.—By its *superficial surface*, with the fascia and integument; by its *deep surface*, with the fibula, the Peroneus brevis, os calcis, and cuboid bone; by its *anterior border*, with an intermuscular septum which intervenes between it and the Extensor longus digitorum; by its *posterior border*, with an intermuscular septum which separates it from the Soleus above and the Flexor longus hallucis below.

The **Peroneus brevis** lies beneath the Peroneus longus, and is shorter and smaller than it. It arises from the lower two-thirds of the external surface of the shaft of the fibula, internal to the Peroneus longus, and from the intermuscular septa separating it from the adjacent muscles on the front and back part of the leg. The fibres pass vertically downward, and terminate in a tendon which runs in front of that of the preceding muscle through the same groove, behind the external malleolus, being contained in the same fibrous sheath and lubricated by the same synovial membrane. It then passes through a separate sheath on the outer side of the os calcis, above that for the tendon of the Peroneus longus, and is finally inserted into the tuberosity at the base of the metatarsal bone of the little toe, on its outer side.

Relations.—By its *superficial surface*, with the Peroneus longus and the fascia of the leg and foot; by its *deep surface*, with the fibula and outer side of the os calcis.

Nerves.—The Peroneus longus and brevis are supplied by the musculo-cutaneous branch of the external popliteal nerve.

Actions.—The Peroneus longus and brevis extend the foot upon the leg in conjunction with the Tibialis posticus, antagonizing the Tibialis anticus and Peroneus tertius, which are flexors of the foot. The Peroneus longus also everts the sole of the foot; hence the extreme eversion occasionally observed in fracture of the lower end of the fibula, where that bone offers no resistance to the action of this muscle. Taking their fixed point below, the Peronei serve to steady the leg upon the foot. This is especially the case in standing upon one leg, when the

tendency of the superincumbent weight is to throw the leg inward: the Peroneus longus overcomes this tendency by drawing on the outer side of the leg, and thus maintains the perpendicular direction of the limb.

Surgical Anatomy.—The student should now consider the position of the tendons of the various muscles of the leg, their relation with the ankle-joint and surrounding blood-vessels, and especially their action upon the foot, as their rigidity and contraction give rise to one or other of the kinds of deformity known as *club-foot*. The most simple and common deformity, and one that is rarely, if ever, congenital, is the *talipes equinus*, the heel being raised by rigidity and contraction of the Gastrocnemius muscle, and the patient walking upon the ball of the foot. In the *talipes varus* the foot is forcibly adducted and the inner side of the sole raised, sometimes to a right angle with the ground, by the action of the Tibialis anticus and posticus. In the *talipes valgus* the outer edge of the foot is raised by the Peronei muscles, and the patient walks on the inner ankle. In the *talipes calcaneus* the toes are raised by the extensor muscles, the heel is depressed, and the patient walks upon it. Other varieties of deformity are met with, as the *talipes equino-varus*, *equino-valgus*, and *calcaneo-valgus*, whose names sufficiently indicate their nature. Of these, the talipes equino-varus is the most common congenital form: the heel is raised by the tendo Achillis, the inner border of the foot drawn upward by the Tibialis anticus, the anterior two-thirds twisted inward by the Tibialis posticus, and the arch increased by the contraction of the plantar fascia, so that the patient walks on the middle of the outer border of the foot. Each of these deformities may be successfully relieved (after other remedies fail) by division of the opposing tendons and fascia: by this means the foot regains its proper position, and the tendons heal by the organization of lymph thrown out between the divided ends. The operation is easily performed by putting the contracted tendon upon the stretch, and dividing it by means of a narrow, sharp-pointed knife inserted beneath it.

Rupture of a few of the fibres of the Gastrocnemius or rupture of the Plantaris tendon not uncommonly occurs, especially in men somewhat advanced in life, from some sudden exertion, and frequently occurs during the game of lawn tennis, and is hence known as "lawn-tennis leg." The accident is accompanied by a sudden pain, and produces a sensation as if the individual had been struck a violent blow on the part. The tendo Achillis is also sometimes ruptured. It is stated that John Hunter ruptured his tendo Achillis whilst dancing at the age of forty.

THE FOOT.

The fibrous bands which bind down the tendons in front of and behind the ankle in their passage to the foot should now be examined; they are termed the *annular ligaments*, and are three in number—anterior, internal, and external.

The **Anterior Annular Ligament** consists of a superior or vertical portion, which binds down the extensor tendons as they descend on the front of the tibia and fibula, and an inferior or horizontal portion, which retains them in connection with the tarsus, the two portions being connected by a thin intervening layer of fascia. The vertical portion is attached externally to the lower end of the fibula, internally to the tibia, and above is continuous with the fascia of the leg; it contains only one synovial sheath, for the tendon of the Tibialis anticus, the other tendons and the anterior tibial vessels and nerve passing beneath it, but without any distinct synovial sheath. The horizontal portion is attached externally to the upper surface of the os calcis, in front of the depression for the interosseous ligament; it passes upward and inward as a double layer, one lamina passing in front, and the other behind, the Peroneus tertius and Extensor longus digitorum. At the inner border of the latter tendon these two layers join together, forming a sort of loop or sheath in which the tendons are enclosed, surrounded by a synovial membrane. From the inner extremity of this loop two bands are given off: one passes upward and inward to be attached to the internal malleolus, passing over the Extensor proprius hallucis and vessels and nerves, but enclosing the Tibialis anticus and its synovial sheath by a splitting of its fibres. The other limb passes downward and inward to be attached to the navicular and internal cuneiform bones, and passes over both the tendon of the Extensor proprius hallucis and the Tibialis anticus, and also the vessels and nerves. These two tendons are contained in separate synovial sheaths situated beneath the ligament. It will thus be seen that the horizontal portion of the ligament is like the letter Y, the foot of the letter being attached to the os calcis, and the two diverging arms to the tibia and navicular and internal cuneiform respectively.

The **Internal Annular Ligament** is a strong fibrous band which extends from the inner malleolus above to the internal margin of the os calcis below, converting

a series of grooves in this situation into canals for the passage of the tendons of the Flexor muscles and vessels into the sole of the foot. It is continuous by its upper border with the deep fascia of the leg, and by its lower border with the plantar fascia and the fibres of origin of the Abductor hallucis muscle. The three canals which it forms transmit, from within outward, first, the tendon of the Tibialis posticus; second, the tendon of the Flexor longus digitorum; then the posterior tibial vessels and nerve, which run through a broad space beneath the ligament; lastly, in a canal formed partly by the astragalus, the tendon of the Flexor longus hallucis. Each of these canals is lined by a separate synovial membrane.

The **External Annular Ligament** extends from the extremity of the outer malleolus to the outer surface of the os calcis: it binds down the tendons of the Peronei muscles in their passage beneath the outer ankle. The two tendons are enclosed in one synovial sac.

Dissection of the Sole of the Foot.—The foot should be placed on a high block with the sole uppermost, and firmly secured in that position. Carry an incision round the heel and along the inner and outer borders of the foot to the great and little toes. This incision should divide the integument and thick layer of granular fat beneath until the fascia is visible; the skin and fat should then be removed from the fascia in a direction from behind forward, as seen in Fig. 328.

The **Plantar Fascia**, the densest of all the fibrous membranes, is of great strength, and consists of dense pearly-white glistening fibres, disposed, for the most part, longitudinally: it is divided into a central and two lateral portions.

The *central portion*, the thickest, is narrow behind and attached to the inner tubercle of the os calcis, behind the origin of the Flexor brevis digitorum, and, becoming broader and thinner in front, divides near the heads of the metatarsal bones into five processes, one for each of the toes. Each of these processes divides opposite the metatarso-phalangeal articulation into two strata, superficial and deep. The superficial stratum is inserted into the skin of the transverse sulcus which divides the toes from the sole. The deeper stratum divides into two slips which embrace the sides of the flexor tendons of the toes, and blend with the sheaths of the tendons, and laterally with the transverse metatarsal ligament, thus forming a series of arches through which the tendons of the short and long flexors pass to the toes. The intervals left between the five processes allow the digital vessels and nerves and the tendons of the Lumbricales muscles to become superficial. At the point of division of the fascia into processes and slips numerous transverse fibres are superadded, which serve to increase the strength of the fascia at this part by binding the processes together and connecting them with the integument. The central portion of the plantar fascia is continuous with the lateral portions at each side, and sends upward into the foot, at their point of junction, two strong vertical intermuscular septa, broader in front than behind, which separate the middle from the external and internal plantar group of muscles; from these, again, thinner transverse septa are derived, which separate the various layers of muscles in this region. The upper surface of this fascia gives attachment behind to the Flexor brevis digitorum muscle.

The *lateral portions* of the plantar fascia are thinner than the central piece, and cover the sides of the foot.

The *outer portion* covers the under surface of the Abductor minimi digiti; it is thick behind, thin in front, and extends from the os calcis, forward, to the base of the fifth metatarsal bone, into the outer side of which it is attached; it is continuous internally with the middle portion of the plantar fascia, and externally with the dorsal fascia.

The *inner portion* is very thin, and covers the Abductor hallucis muscle; it is attached behind to the internal annular ligament, and is continuous around the side of the foot with the dorsal fascia, and externally with the middle portion of the plantar fascia.

The **Muscles of the Foot** are found in two regions: 1. On the dorsum; 2. On the plantar surface.

1. Dorsal Region.

Extensor brevis digitorum.

The **Fascia** on the dorsum of the foot is a thin membranous layer continuous above with the anterior margin of the annular ligament; it becomes gradually lost opposite the heads of the metatarsal bones, and on each side blends with the lateral portions of the plantar fascia; it forms a sheath for the tendons placed on the dorsum of the foot. On the removal of this fascia the muscles and tendons of the dorsal region of the foot are exposed.

The **Extensor brevis digitorum** (Fig. 330) is a broad thin muscle which arises from the fore part of the upper and outer surfaces of the os calcis, in front of the groove for the Peroneus brevis, from the external calcaneo-astragaloid ligament, and from the horizontal portion of the anterior annular ligament. It passes obliquely across the dorsum of the foot, and terminates in four tendons. The innermost, which is the largest, is inserted into the dorsal surface of the base of the first phalanx of the great toe, crossing the Dorsalis pedis artery; the other three, into the outer sides of the long extensor tendons of the second, third, and fourth toes.

Relations.—By its *superficial surface*, with the fascia of the foot, the tendons of the Extensor longus digitorum and Extensor proprius hallucis; by its *deep surface*, with the tarsal and metatarsal bones and the Dorsal interossei muscles.

Nerves.—It is supplied by the anterior tibial nerve.

Actions.—The Extensor brevis digitorum is an accessory to the long Extensor, extending the first phalanges of all four inner toes. The obliquity of its direction counteracts the oblique movement given to the toes by the long Extensor, so that, both muscles acting together, the toes are evenly extended.

2. Plantar Region.

The muscles in the plantar region of the foot may be divided into three groups, in a similar manner to those in the hand. Those of the internal plantar region are connected with the great toe, and correspond with those of the thumb; those of the external plantar region are connected with the little toe, and correspond with those of the little finger; and those of the middle plantar region are connected with the tendons intervening between the two former groups. But in order to facilitate the dissection of these muscles it will be found more convenient to divide them into four layers, as they present themselves, in the order in which they are successively exposed.

First Layer.

Abductor hallucis. Flexor brevis digitorum.
Abductor minimi digiti.

Dissection.—Remove the fascia on the inner and outer sides of the foot, commencing in front over the tendons and proceeding backward. The central portion should be divided transversely in the middle of the foot, and the two flaps dissected forward and backward.

The **Abductor hallucis** lies along the inner border of the foot. It arises from the inner tubercle on the under surface of the os calcis; from the internal annular ligament; from the plantar fascia; and from the intermuscular septum between it and the Flexor brevis digitorum. The fibres terminate in a tendon which is inserted, together with the innermost tendon of the Flexor brevis hallucis, into the inner side of the base of the first phalanx of the great toe.

Relations.—By its *superficial surface*, with the plantar fascia; by its *deep surface*, with the Flexor brevis hallucis, the Flexor accessorius, and the tendons of the Flexor longus digitorum and Flexor longus hallucis, the Tibialis anticus and posticus, the plantar vessels and nerves, and the articulations of the tarsus.

The **Flexor brevis digitorum** (*perforatus*) lies in the middle of the sole of the foot, immediately beneath[1] the plantar fascia, with which it is firmly united. It

[1] That is, in order of dissection of the sole of the foot.

arises by a narrow tendinous process, from the inner tubercle of the os calcis, from the central part of the plantar fascia, and from the intermuscular septa between it and the adjacent muscles. It passes forward, and divides into four tendons. Opposite the bases of the first phalanges each tendon divides into two slips, to allow of the passage of the corresponding tendon of the Flexor longus digitorum; the two portions of the tendon then unite and form a grooved channel for the reception of the accompanying long flexor tendon. Finally, they divide a second time, to be inserted into the sides of the second phalanges about their middle. The mode of division of the tendons of the Flexor brevis digitorum and their insertion into the phalanges is analogous to the Flexor sublimis in the hand.

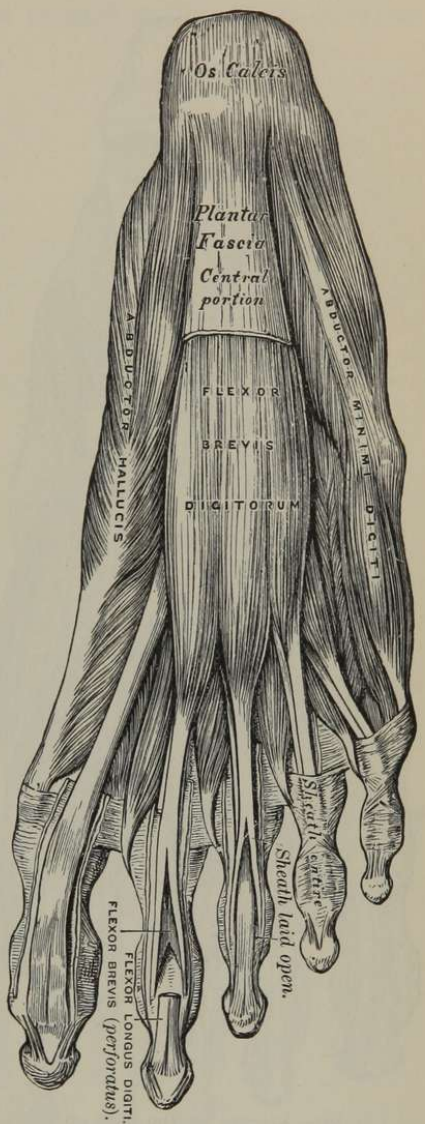

FIG. 333.—Muscles of the sole of the foot. First Layer.

Relations.—By its *superficial surface*, with the plantar fascia; by its *deep surface*, with the Flexor accessorius, the Lumbricales, the tendons of the Flexor longus digitorum, and the external plantar vessels and nerve, from which it is separated by a thin layer of fascia. The *outer* and *inner borders* are separated from the adjacent muscles by means of vertical prolongations of the plantar fascia.

Fibrous Sheaths of the Flexor Tendons.—These are not so well marked as in the fingers. The flexor tendons of the toes as they run along the phalanges are retained against the bones by a fibrous sheath, forming osseo-aponeurotic canals. These sheaths are formed by strong fibrous bands which arch across the tendons and are attached on each side to the margins of the phalanges. Opposite the middle of the proximal and second phalanges the sheath is very strong, and the fibres pass transversely, but opposite the joints it is much thinner, and the fibres pass obliquely. Each sheath is lined by a synovial membrane which is reflected on the contained tendon.

The **Abductor minimi digiti** lies along the outer border of the foot. It arises, by a very broad origin, from the outer tubercle of the os calcis, from the under surface of the os calcis in front of both tubercles, from the fore part of the inner tubercle, from the plantar fascia and the intermuscular septum between it and the Flexor brevis digitorum. Its tendon, after gliding over a smooth facet on the under surface of the base of the fifth metatarsal bone, is inserted with the short Flexor of the little toe into the outer side of the base of the first phalanx of the little toe.

Relations.—By its *superficial surface*, with the plantar fascia; by its *deep surface*, with the Flexor accessorius, the Flexor brevis minimi digiti, the long plantar ligament, and the tendon of the Peroneus longus. On its *inner side* are the external plantar vessels and nerve, and it is separated from the Flexor brevis digitorum by a vertical septum of fascia.

Dissection.—The muscles of the superficial layer should be divided at their origin by inserting the knife beneath each, and cutting obliquely backward, so as to detach them from the bone; they should then be drawn forward, in order to expose the second layer, but not cut

away at their insertion. The two layers are separated by a thin membrane, the *deep plantar fascia*, on the removal of which is seen the tendon of the Flexor longus digitorum, the Flexor accessorius, the tendon of the Flexor longus hallucis, and the Lumbricales. The long flexor tendons cross each other at an acute angle, the Flexor longus hallucis running along the inner side of the foot, on a plane superior to that of the Flexor longus digitorum, the direction of which is obliquely outward.

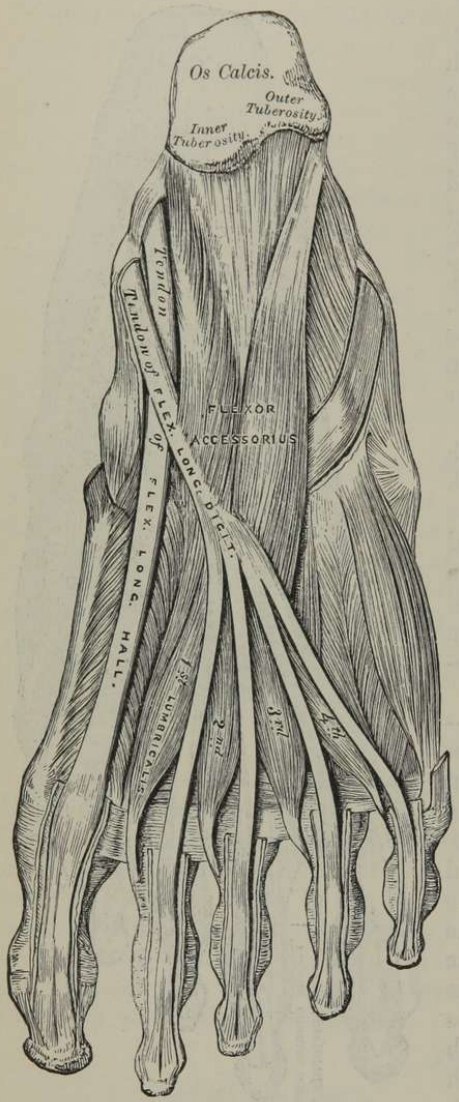

FIG. 334.—Muscles of the sole of the foot. Second layer.

Second Layer.

Flexor accessorius. Lumbricales.

The **Flexor accessorius** arises by two heads; the inner or larger, which is muscular, being attached to the inner concave surface of the os calcis, and to the inferior calcaneo-navicular ligament; the outer head, flat and tendinous, to the under surface of the os calcis, in front of its outer tubercle, and to the long plantar ligament; the two portions join at an acute angle, and are inserted into the outer margin and upper and under surfaces of the tendon of the Flexor longus digitorum, forming a kind of groove in which the tendon is lodged.[1]

Relations.—By its *superficial surface*, with the muscles of the superficial layer, from which it is separated by the external plantar vessels and nerves; by its *deep surface*, with the os calcis and long calcaneo-cuboid ligament.

The **Lumbricales** are four small muscles accessory to the tendons of the Flexor longus digitorum: they arise from the tendons of the long Flexor, as far back as their angle of division, each arising from two tendons, except the internal one. Each muscle terminates in a tendon, which passes forward on the inner side of each of the lesser toes, and is inserted into the expansion of the long Extensor and base of the first phalanx of the corresponding toe.

Dissection.—The flexor tendons should be divided at the back part of the foot, and the Flexor accessorius at its origin, and drawn forward, in order to expose the third layer.

Third Layer.

Flexor brevis hallucis.
Adductor obliquus hallucis.
Flexor brevis minimi digiti.
Adductor transversus hallucis.

The **Flexor brevis hallucis** arises, by a pointed tendinous process, from the inner border of the cuboid bone, from the contiguous portion of the external cuneiform, and from the prolongation of the tendon of the Tibialis posticus, which

[1] According to Turner, the fibres of the Flexor accessorius end in aponeurotic bands, which contribute slips to the second, third, and fourth digits.

is attached to that bone. The muscle divides, in front, into two portions, which are inserted into the inner and outer sides of the base of the first phalanx of the great toe, a sesamoid bone being developed in each tendon at its insertion. The inner portion of this muscle is blended with the Abductor hallucis previous to its insertion, the outer with the Adductor obliquus hallucis, and the tendon of the Flexor longus hallucis lies in a groove between them.

Relations.—By its *superficial surface*, with the Abductor hallucis, the tendon of the Flexor longus hallucis, and plantar fascia; by its *deep surface*, with the tendon of the Peroneus longus and metatarsal bone of the great toe; by its *inner border*, with the Abductor hallucis; by its *outer border*, with the Adductor obliquus hallucis.

The **Adductor obliquus hallucis** is a large, thick, fleshy mass passing obliquely across the foot and occupying the hollow space between the four inner metatarsal bones. It arises from the tarsal extremities of the second, third and fourth metatarsal bones, and from the sheath of the tendon of the Peroneus longus, and is inserted, together with the outer portion of the Flexor brevis hallucis, into the outer side of the base of the first phalanx of the great toe.

The small muscles of the great toe, the Abductor, Flexor brevis, Adductor obliquus, and Adductor transversus, like the similar muscles of the thumb, give off fibrous expansions, at their insertions, to blend with the long Extensor tendon.

The **Flexor brevis minimi digiti** lies on the metatarsal bone of the little toe, and much resembles one of the Interossei. It arises from the base of the metatarsal bone of the little toe, and from the sheath of the Peroneus longus; its tendon is inserted into the base of the first phalanx of the little toe on its outer side.

FIG. 335.—Muscles of the sole of the foot. Third layer.

Relations.—By its *superficial surface*, with the plantar fascia and tendon of the Abductor minimi digiti; by its *deep surface*, with the fifth metatarsal bone.

The **Adductor transversus hallucis** (*Transversus pedis*) is a narrow, flat, muscular fasciculus, stretched transversely across the heads of the metatarsal bones, between them and the flexor tendons. It arises from the inferior metatarso-phalangeal ligaments of the three outer toes, sometimes only from the third and fourth and from the transverse ligament of the metatarsus; and is inserted into the outer side of the first phalanx of the great toe, its fibres being blended with the tendon of insertion of the Adductor obliquus hallucis.

Relations.—By its *superficial surface*, with the tendons of the long and short Flexors and Lumbricales; by its *deep surface*, with the Interossei.

Fourth Layer.

The Interossei.

The **Interossei muscles** in the foot are similar to those in the hand, with this exception, that they are grouped around the middle line of the *second* toe, instead of the middle line of the *third* finger, as in the hand. They are seven in number, and consist of two groups, dorsal and plantar.

The **Dorsal interossei,** four in number, are situated between the metatarsal bones. They are bipenniform muscles, arising by two heads from the adjacent sides of the metatarsal bones, between which they are placed; their tendons are inserted into the bases of the first phalanges, and into the aponeurosis of the common extensor tendon. In the angular interval left between the heads of

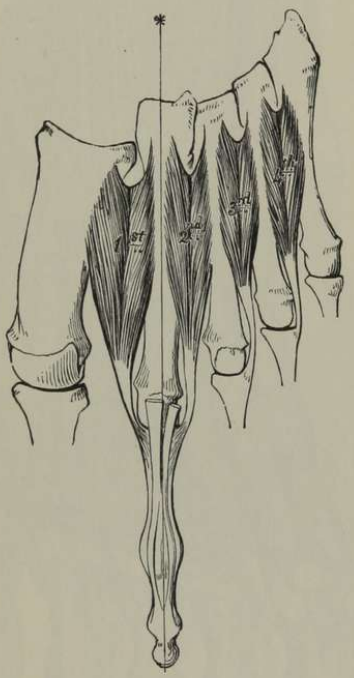

FIG. 336.—The Dorsal interossei. Left foot.

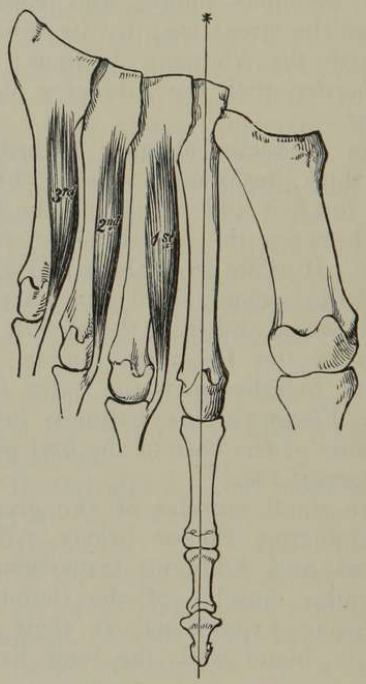

FIG. 337.—The Plantar interossei. Left foot.

each muscle at its posterior extremity the perforating arteries pass to the dorsum of the foot, except in the First interosseous muscle, where the interval allows the passage of the communicating branch of the dorsalis pedis artery. The First dorsal interosseous muscle is inserted into the inner side of the second toe; the other three are inserted into the outer sides of the second, third, and fourth toes.

The **Plantar interossei,** three in number, lie beneath, rather than between, the metatarsal bones. They are single muscles, and are each connected with but one metatarsal bone. They arise from the base and inner sides of the shaft of the third, fourth, and fifth metatarsal bones, and are inserted into the inner sides of the bases of the first phalanges of the same toes, and into the aponeurosis of the common extensor tendon.

Nerves.—The Flexor brevis digitorum, the Flexor brevis and Abductor hallucis, and the two inner Lumbricales are supplied by the internal plantar nerve; all the other muscles in the sole of the foot by the external plantar. The First and Second dorsal interossei muscles receive extra filaments from the ganglionic enlargement of the anterior tibial nerve on the dorsum of the foot.

Actions.—All the muscles of the foot act upon the toes, and for purposes of description as regards their action may be grouped as Abductors, Adductors,

Flexors, or Extensors. The *Abductors* are the Dorsal interossei, the Abductor hallucis, and the Abductor minimi digiti. The Dorsal interossei are abductors from an imaginary line passing through the axis of the second toe, so that the first muscle draws the second toe inward, toward the great toe; the second muscle draws the same toe, outward; the third draws the third toe, and the fourth draws the fourth toe, in the same direction. Like the interossei in the hand, they also flex the proximal phalanges and extend the two terminal phalanges. The Abductor hallucis abducts the great toe from the others, and also flexes the proximal phalanx of this toe. And in the same way the action of the Abductor minimi digiti is twofold—as an abductor of this toe from the others, and also as a flexor of the proximal phalanx. The *Adductors* are the Plantar interossei, the Adductor obliquus hallucis, and the Adductor transversus hallucis. The plantar interosseous muscles adduct the third, fourth, and fifth toes toward the imaginary line passing through the second toe, and by means of their insertion into the aponeurosis of the extensor tendon they flex the proximal phalanges and extend the two terminal phalanges. The Adductor obliquus hallucis is chiefly concerned in adducting the great toe toward the second one, but also assists in flexing this toe. The Adductor transversus hallucis approximates all the toes, and thus increases the curve of the transverse arch of the metatarsus. The *Flexors* are the Flexor brevis digitorum, the Flexor accessorius, the Flexor brevis hallucis, the Flexor brevis minimi digiti, and the Lumbricales. The Flexor brevis digitorum flexes the second phalanges upon the first, and, continuing its action, may flex the first phalanges also and bring the toes together. The Flexor accessorius assists the Long flexor of the toes, and converts the oblique pull of the tendons of that muscle into a direct backward pull upon the toes. The Flexor brevis minimi digiti flexes the little toe and draws its metatarsal bone downward and inward. The Lumbricales, like the corresponding muscles in the hand, assist in flexing the proximal phalanges, and by their insertion into the long Extensor tendon aid in straightening the two terminal phalanges. The only muscle in the *Extensor* group is the Extensor brevis digitorum. It extends the first phalanx of the great toe, and assists the long Extensor in extending the next three toes, and at the same time gives to the toes an outward direction when they are extended.

Surface Form.—Of the muscles of the thigh, those of the iliac region have no influence on surface form, while those of the anterior femoral region, being to a great extent superficial, largely contribute to the surface form of this part of the body. The *Tensor vaginæ femoris* produces a broad elevation immediately below the anterior portion of the crest of the ilium and behind the anterior superior spinous process. From its lower border a longitudinal groove, corresponding to the ilio-tibial band, may be seen running down the outer side of the thigh to the outer side of the knee-joint. The *Sartorius* muscle, when it is brought into action by flexing the leg on the thigh and the thigh on the pelvis, and rotating the thigh outward, presents a well-marked surface form. At its upper part, where it constitutes the outer boundary of Scarpa's triangle, it forms a prominent oblique ridge, which becomes changed into a flattened plane below, and this gradually merges in a general fulness on the inner side of the knee-joint. When the Sartorius is not in action, a depression exists between the Extensor quadriceps and the Adductor muscles, running obliquely downward and inward from the apex of Scarpa's triangle to the inner side of the knee, which corresponds to this muscle. In the depressed angle formed by the divergence of the Sartorius and Tensor vaginæ femoris muscles, just below the anterior superior spinous process of the ilium, the *Rectus femoris muscle* appears, and, below this, determines to a great extent the convex form of the front of the thigh. In a well-developed subject the borders of the muscle, when in action, are clearly to be defined. The *Vastus externus* forms a long flattened plane on the outer side of the thigh, traversed by the longitudinal groove formed by the ilio-tibial band. The *Vastus internus*, on the inner side of the lower half of the thigh, gives rise to a considerable prominence, which increases toward the knee and terminates somewhat abruptly in this situation with a full, curved outline. The *Crureus* and *Subcrureus* are completely hidden, and do not directly influence surface form. The *Adductor muscles*, constituting the internal femoral group, are not to be individually distinguished from each other, with the exception of the upper tendon of the Adductor longus and the lower tendon of the Adductor magnus. The upper tendon of the *Adductor longus*, when the muscle is in action, stands out as a prominent ridge, which runs obliquely downward and outward from the neighborhood of the pubic spine, and forms the inner boundary of a flattened triangular space on the upper part of the front of the thigh, known as Scarpa's triangle. The

lower tendon of the *Adductor magnus* can be distinctly felt as a short ridge extending down to the Adductor tubercle on the internal condyle, between the Sartorius and Vastus internus. The Adductor group of muscles fills in the triangular space at the upper part of the thigh, formed between the oblique femur and the pelvic wall, and to them is due the contour of the inner border of the thigh, the *Gracilis* largely contributing to the smoothness of the outline. These muscles are not marked off on the surface from those of the posterior femoral region by any intermuscular marking; but on the outer side of the thigh these latter muscles are defined from the Vastus externus by a distinct marking, corresponding to the external intermuscular septum. The *Gluteus maximus* and a part of the *Gluteus medius* are the only muscles of the buttock which influence surface form. The other part of the Gluteus medius, the Gluteus minimus, and the External rotators are completely hidden. The *Gluteus maximus* forms the full rounded outline of the buttock; it is more prominent behind, compressed in front, and terminates at its tendinous insertion in a depression immediately behind the great trochanter. Its lower border does not correspond to the gluteal fold, but is much more oblique, being marked by a line drawn from the side of the coccyx to the lower part of the great trochanter. From beneath the fold of the buttock the *hamstring muscles* appear, at first narrow and not well marked, but as they descend becoming more prominent and widened out, and eventually dividing into two well-marked ridges, which form the upper boundaries of the popliteal space, being formed by the tendons of the inner and outer hamstring muscles respectively. In the upper part of the thigh these muscles are not to be individually distinguished from each other, but lower down, the separation between the Semitendinosus and Semimembranosus is denoted by a slight intermuscular marking. The external hamstring tendon formed by the *Biceps* is seen as a thick cord running down to the head of the fibula. The inner hamstring tendons comprise the Semitendinosus, the Semimembranosus, and the Gracilis. The *Semitendinosus* is the most internal of these, and can be felt, in certain positions of the limb, as a sharp cord; the *Semimembranosus* is thick, and the *Gracilis* is situated a little farther forward than the other two. All the muscles on the front of the leg appear to a certain extent somewhere on the surface, but the form of this region is mainly dependent upon the Tibialis anticus and the Extensor longus digitorum. The *Tibialis anticus* is well marked, and presents a fusiform enlargement at the outer side of the tibia, and projects beyond the crest of the shin-bone. From the muscular mass its tendon may be traced downward, standing out boldly, when the muscle is in action, on the front of the tibia and ankle-joint, and coursing down to its insertion along the inner border of the foot. A well-marked groove separates this muscle externally from the *Extensor longus digitorum*, which fills up the rest of the space between the upper part of the shaft of the tibia and fibula. It does not present so bold an outline as the Tibialis anticus, and its tendon below, diverging from the tendon of the Tibialis anticus, forms a sort of plane, in which may be seen the tendon of the Extensor proprius hallucis. A groove on the outer side of the Extensor longus digitorum, seen most plainly when the muscle is in action, separates from it a slight eminence corresponding to the *Peroneus tertius*. The fleshy fibres of the *Peroneus longus* are strongly marked at the upper part of the outer side of the leg, especially when the muscle is in action. It forms a bold swelling, separated by furrows from the Extensor longus digitorum in front and the Soleus behind. Below, the fleshy fibres terminate abruptly in a tendon which overlaps the more flattened form of the *Peroneus brevis*. At the external malleolus the tendon of the Peroneus brevis is more marked than that of the Peroneus longus. On the dorsum of the foot the tendons of the Extensor muscles, emerging from beneath the anterior annular ligament, spread out and can be distinguished in the following order: The most internal and largest is the Tibialis anticus, then the Extensor proprius hallucis: next comes the Extensor longus digitorum, dividing into four tendons to the four outer toes; and lastly, most externally, is the Peroneus tertius. The flattened form of the dorsum of the foot is relieved by the rounded outline of the fleshy belly of the *Extensor brevis digitorum*, which forms a soft fulness on the outer side of the tarsus in front of the external malleolus, and by the Dorsal interossei, which bulge between the metatarsal bones. At the back of the knee is the popliteal space, bounded above by the tendons of the hamstring muscle; below, by the two heads of the Gastrocnemius. Below this space is the prominent fleshy mass of the calf of the leg, produced by the *Gastrocnemius* and *Soleus*. When these muscles are in action, as in standing on tiptoe, the borders of the Gastrocnemius are well defined, presenting two curved lines, which converge to the tendon of insertion. Of these borders, the inner is more prominent than the outer. The fleshy mass of the calf terminates somewhat abruptly below in the tendo Achillis, which stands out prominently on the lower part of the back of the leg. It presents a somewhat tapering form in the upper three-fourths of its extent, but widens out slightly below. When the muscles of the calf are in action, the lateral portions of the *Soleus* may be seen, forming curved eminences, of which the outer is the longer, on either side of the Gastrocnemius. Behind the inner border of the lower part of the shaft of the tibia a well-marked ridge, produced by the tendon of the Tibialis posticus, is visible when this muscle is in a state of contraction.

On the sole of the foot the superficial layer of muscles influences surface form; the *Abductor minimi digiti* most markedly. This muscle forms a narrow rounded elevation along the outer border of the foot, while the *Abductor hallucis* does the same, though to a less extent, on the inner side. The *Flexor brevis digitorum*, bound down by the plantar fascia, is not very apparent; it produces a flattened form, covered by the thickened skin of the sole, which is here thrown into numerous wrinkles.

SURGICAL ANATOMY OF THE LOWER EXTREMITY.

The student should now consider the effects produced by the action of the various muscles in fractures of the bones of the lower extremity. The more common forms of fractures are selected for illustration and description.

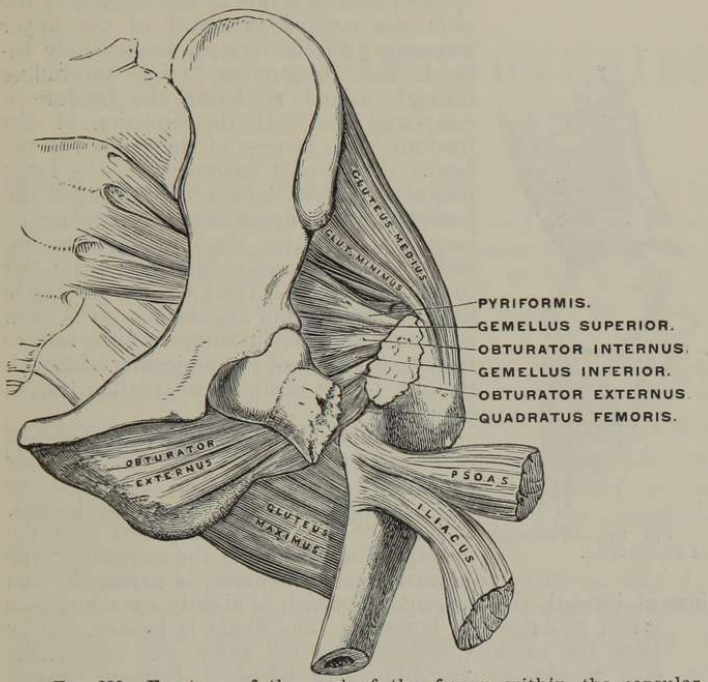

FIG. 338.—Fracture of the neck of the femur within the capsular ligament.

In fracture of the *neck of the femur internal to the capsular ligament* (Fig. 338) the characteristic marks are slight shortening of the limb and eversion of the foot, neither of which symptoms occurs, however, in some cases until some time after the injury. The eversion is caused by the weight of the limb rotating it outward. The shortening is produced by the action of the Glutei, and by the Rectus femoris in front and the Biceps, Semitendinosus, and Semimembranosus behind.

In fracture of the *femur just below the trochanters* (Fig. 339) the upper fragment, the portion chiefly displaced, is tilted forward almost at right angles with the pelvis by the combined action of the Psoas and Iliacus, and, at the same time, everted and drawn outward by the External rotator and Glutei muscles, causing a marked prominence at the upper and outer side of the thigh, and much pain from the bruising and laceration of the muscles. The limb is shortened, in consequence of the lower fragment being drawn upward by the rectus in front, and the Biceps, Semimembranosus, and Semitendinosus behind, and, at the same time, everted, and the upper end thrown outward and the lower inward by the Pectineus and Adductor muscles. This fracture may be reduced in two different methods: either by direct relaxation of all the opposing muscles, to effect which the limb should be placed on a double inclined plane; or by overcoming the contraction of the muscles by continued extension, which may be effected by means of the long splint.

FIG. 339.—Fracture of the femur below the trochanters.

Oblique fracture of the femur *immediately above the condyles* (Fig. 340) is a formidable injury, and attended with considerable displacement. On examination of the limb the lower fragment may be felt deep in the popliteal space, being drawn backward by the Gastrocnemius and Plantaris muscles, and upward by the posterior Femoral and Rectus muscles. The pointed end of the upper fragment is drawn inward by the Pectineus and Adductor muscles, and tilted forward by the Psoas and Iliacus, piercing the Rectus muscle and occasionally the integument. Relaxation of these muscles and direct approximation of the broken fragments are effected by placing the limb on a double inclined plane. The greatest care is requisite in keeping the pointed extremity of the upper fragment in proper position; otherwise, after union of the fracture, the power of extension of the limb is partially destroyed, from the Rectus muscle being held down by the fractured end of the bone, and from the patella, when elevated, being drawn upward against the projecting fragment.

In fracture of the *patella* (Fig. 341) the fragments are separated by the effusion which takes place into the joint, and possibly by the action of the Quadriceps extensor; the extent of separation of the two

fragments depending upon the degree of laceration of the ligamentous structures around the bone.

In oblique fracture of the *shaft of the tibia* (Fig. 342), if the fracture has taken place obliquely from above, downward and forward, the fragments ride over one another, the lower fragments being drawn backward and upward by the powerful action of the muscles of the calf; the pointed extremity of the upper fragment projects forward immediately beneath the integument, often protruding through it and rendering the fracture a compound one. If the direction of the fracture is the reverse of that shown in the figure, the pointed extremity of the lower fragment projects forward, riding upon the lower end of the upper one. By bending the knee, which relaxes the opposing muscles, and making extension from the ankle and counter-extension at the knee, the fragments may be brought into apposition. It is often necessary, however, in compound fracture, to remove a portion of the projecting bone with the saw before complete adaptation can be effected.

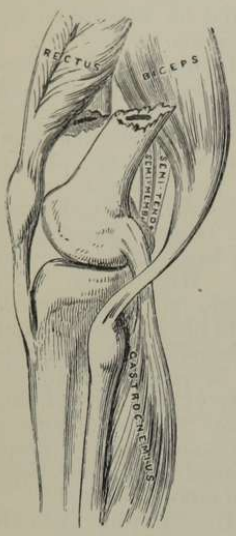

FIG. 340.—Fracture of the femur above the condyles.

FIG. 341.—Fracture of the patella.

Fracture of the *fibula with dislocation of the foot outward* (Fig. 343), commonly known as "Pott's Fracture," is one of the most frequent injuries of the ankle-joint. The end of the tibia is displaced from the corresponding surface of the astragalus; the internal lateral ligament is ruptured; and the inner malleolus projects inward beneath the integument, which is tightly stretched over it and in danger of bursting. The fibula is broken, usually from two to three inches above the ankle, and occasionally that portion of the tibia with which it is more directly connected below; the foot is everted by the action of the Peroneus longus, its inner border resting upon the ground, and at the same time the heel is drawn up by the muscles of the calf. This injury may be at once reduced by flexing the leg at right angles with the thigh, which relaxes all the opposing muscles, and by making extension from the ankle and counter-extension at the knee.

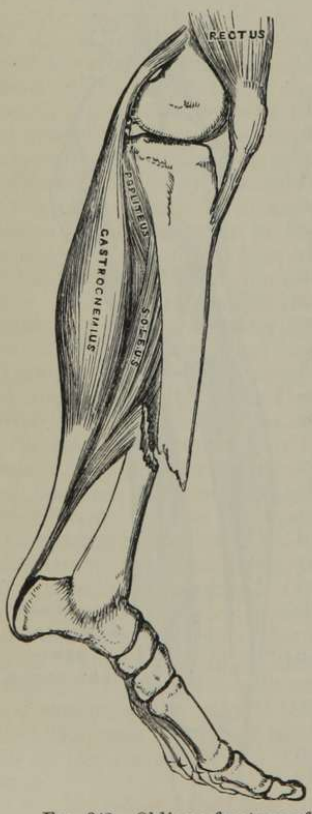

FIG. 342.—Oblique fracture of the shaft of the tibia.

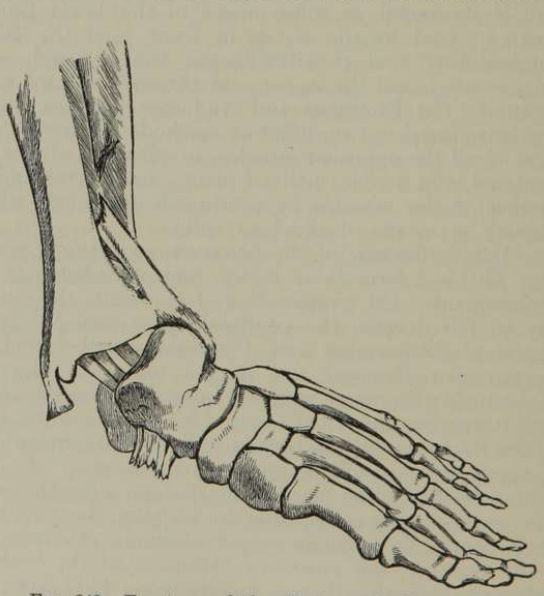

FIG. 343.—Fracture of the fibula with dislocation of the foot outward—"Pott's Fracture."

THE ARTERIES.

THE Arteries are cylindrical tubular vessels which serve to convey blood from both ventricles of the heart to every part of the body. These vessels were named arteries (ἀήρ, air; τηρεῖν, to contain) from the belief entertained by the ancients that they contained air. To Galen is due the honor of refuting this opinion; he showed that these vessels, though for the most part empty after death, contain blood in the living body.

The pulmonary artery, which arises from the right ventricle of the heart, carries venous blood directly into the lungs, whence it is returned by the pulmonary veins into the left auricle. This constitutes the lesser or pulmonic circulation. The great artery which arises from the left ventricle, the *aorta*, conveys arterial blood to the body generally, whence it is brought back to the right side of the heart by means of the veins. This constitutes the greater or systemic circulation.

The distribution of the systemic arteries is like a highly ramified tree, the common trunk of which, formed by the aorta, commences at the left ventricle of the heart, the smallest ramifications corresponding to the circumference of the body and the contained organs. The arteries are found in nearly every part of the body, with the exception of the hairs, nails, epidermis, cartilages, and cornea; and the larger trunks usually occupy the most protected situations, running, in the limbs, along the flexor side, where they are less exposed to injury.

There is considerable variation in the mode of division of the arteries: occasionally a short trunk subdivides into several branches at the same point, as we observe in the cœliac and thyroid axes; or the vessel may give off several branches in succession, and still continue as the main trunk, as is seen in the arteries of the limbs; but the usual division is dichotomous; as, for instance, the aorta dividing into the two common iliacs, and the common carotid into the external and internal.

The branches of arteries arise at very variable angles: some, as the superior intercostal arteries from the aorta, arise at an obtuse angle: others, as the lumbar arteries, at a right angle; or, as the spermatic, at an acute angle. An artery from which a branch is given off is smaller in size, but retains a uniform diameter until a second branch is derived from it. A branch of an artery is smaller than the trunk from which it arises; but if an artery divides into two branches, the combined area of the two vessels is, in nearly every instance, somewhat greater than that of the trunk; and the combined area of all the arterial branches greatly exceeds the area of the aorta; so that the arteries collectively may be regarded as a cone, the apex of which corresponds to the aorta, the base to the capillary system.

The arteries, in their distribution, communicate freely with one another, forming what is called an *anastomosis* (ἀνά, between; στόμα, mouth), or inosculation; and this communication is very free between the large as well as between the smaller branches. The anastomosis between trunks of equal size is found where great freedom and activity of the circulation are requisite, as in the brain; here the two vertebral arteries unite to form the basilar, and the two internal carotid arteries are connected by a short communicating trunk; it is also found in the abdomen, the intestinal arteries having very free anastomoses between their larger

branches. In the limbs the anastomoses are most frequent and of largest size around the joints, the branches of an artery above freely inosculating with branches from the vessels below; these anastomoses are of considerable interest to the surgeon, as it is by their enlargement that a *collateral circulation* is established after the application of a ligature to an artery for the cure of aneurism. The smaller branches of arteries anastomose more frequently than the larger, and between the smallest twigs these inosculations become so numerous as to constitute a close network that pervades nearly every tissue of the body.

Throughout the body generally the larger arterial branches pursue a perfectly straight course, but in certain situations they are tortuous; thus, the facial artery in its course over the face, and the arteries of the lips, are extremely tortuous in their course, to accommodate themselves to the movements of the parts. The uterine arteries are also tortuous, to accommodate themselves to the increase of size which the organ undergoes during pregnancy. Again, the internal carotid and vertebral arteries, previous to their entering the cavity of the skull, describe a series of curves, which are evidently intended to diminish the velocity of the current of blood by increasing the extent of surface over which it moves and adding to the amount of impediment which is produced by friction.

The arteries are dense in structure, of considerable strength, highly elastic, and, when divided, they preserve, although empty, their cylindrical form.

The minute structure of these vessels has been described in the chapter on General Anatomy.

In the description of the arteries we shall first consider the efferent trunk of the pulmonic circulation, the pulmonary artery, and then the efferent trunk of the systemic circulation, the aorta and its branches.

THE PULMONARY ARTERY (Fig. 344).

The **pulmonary artery** conveys the venous blood from the right side of the heart to the lungs. It is a short, wide vessel, about two inches in length, arising from the left side of the base of the right ventricle, in front of the aorta. It passes obliquely upward and backward, passing at first in front of, and then to the left of, the ascending aorta as far as the under surface of the transverse aorta, where it divides into two branches of nearly equal size—the *right* and *left pulmonary arteries.*

Relations.—The whole of this vessel is contained, together with the ascending aorta, in the pericardium, being enclosed with it in a tube of serous membrane, continued upward from the base of the heart, and has attached to it, above, the fibrous layer of the membrane. Behind, it rests at first upon the ascending aorta, and higher up lies in front of the left auricle. On each side of its origin is the appendix of the corresponding auricle and a coronary artery; and higher up it passes to the left side of the ascending aorta.

The **right pulmonary artery,** longer and larger than the left, pierces the pericardium and runs horizontally outward, behind the ascending aorta and superior vena cava, to the root of the right lung, where it divides into two branches, of which the lower, which is the smaller, supplies the lower lobe; the upper supplies the upper lobe, giving a branch to the middle lobe.

The **left pulmonary artery,** shorter and somewhat smaller than the right, pierces the pericardium and passes horizontally in front of the descending aorta and left bronchus to the root of the left lung, where it divides into two branches for the two lobes.

The root of the left pulmonary artery is connected to the under surface of the arch of the aorta (transverse aorta) by a short fibrous cord, the remains of a vessel peculiar to fœtal life, the *ductus arteriosus.*

The terminal branches of the pulmonary artery will be described with the anatomy of the lung.

THE AORTA.

The **aorta** (ἀορτή, arteria magna) is the main trunk of a series of vessels which convey the oxygenated blood to every part of the body for its nutrition. This vessel commences at the upper part of the left ventricle, and, after ascending for a short distance, arches backward to the left side, over the root of the left lung, then descends within the thorax on the left side of the vertebral column, passes through the aortic opening in the Diaphragm, and, entering the abdominal cavity, terminates, considerably diminished in size, opposite the fourth lumbar vertebra,

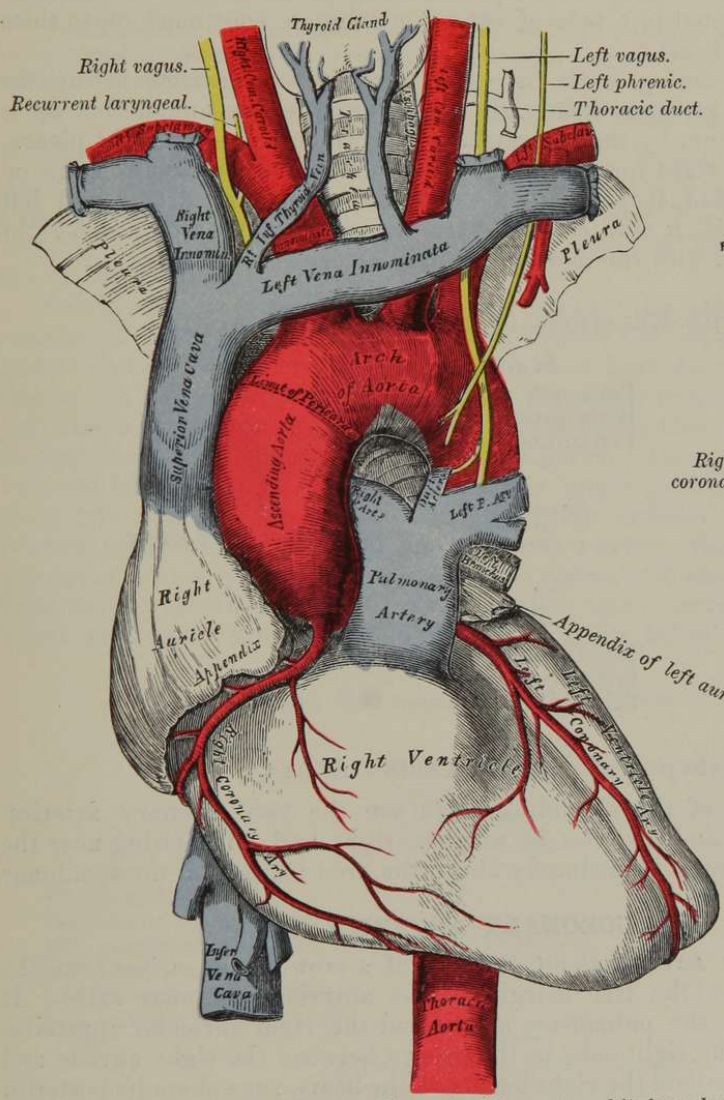

FIG. 344.—The arch of the aorta and its branches.

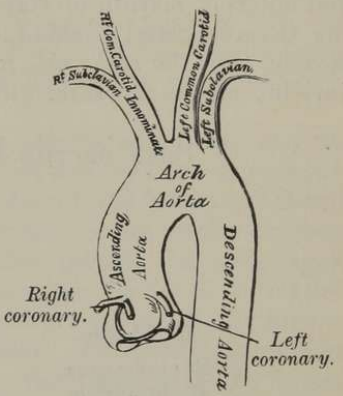

FIG. 345.—Plan of the branches.

where it divides into the right and left common iliac arteries. Hence its division into the *ascending aorta*, the *arch* of the aorta or *transverse aorta*, and the *descending aorta*, which last is again divided into *thoracic aorta* and *abdominal aorta*, from the position of these parts.

THE ASCENDING AORTA.

The **ascending aorta** is about two inches in length. It commences at the upper part of the left ventricle, on a level with the lower border of the third costal cartilage behind the left half of the sternum; it passes obliquely upward, forward,

and to the right in the direction of the heart's axis, as high as the upper border of the second right costal cartilage, describing a slight curve in its course, and being situated, when distended, about a quarter of an inch behind the posterior surface of the sternum. A little above its commencement it is somewhat enlarged, and presents three small dilatations, called the *sinuses of the aorta* (sinuses of Valsalva), opposite to which are attached the three semilunar valves, which serve the purpose of preventing any regurgitation of blood into the cavity of the ventricle. A section of the aorta opposite this part has a somewhat triangular figure, but below the attachment of the valves it is circular. This portion of the aorta is contained in the cavity of the pericardium, and, together with the pulmonary artery, is invested in a tube of serous membrane, continued on to them from the surface of the heart.

Relations.—The ascending aorta is covered at its commencement by the trunk of the pulmonary artery and the right auricular appendix, and, higher up, is separated from the sternum by the pericardium over which lie:—the right pleura, and anterior margin of right lung, some loose areolar tissue, and the remains of the thymus gland; *behind*, it rests upon the right pulmonary artery and left auricle. On the *right side* it is in relation with the superior vena cava and right auricle; on the *left side*, with the main pulmonary artery.

PLAN OF THE RELATIONS OF THE ASCENDING AORTA.

In front.
Pulmonary artery.
Right auricular appendix.
Pericardium.

Right side.
Superior cava.
Right auricle.

Left side.
Pulmonary artery.

Behind.
Right pulmonary artery.
Left auricle.
Pericardium.

BRANCHES OF THE ASCENDING AORTA.

The only branches of the ascending aorta are the two coronary arteries. They supply the heart, and are two in number, right and left, arising near the commencement of the aorta immediately above the free margin of the semilunar valves.

THE CORONARY ARTERIES.

The **Right Coronary Artery**, about the size of a crow's quill, arises from the aorta immediately above the free margin of the anterior semilunar valve. It passes forward between the pulmonary artery and the right auricular appendix, then runs obliquely to the right side in the groove between the right auricle and ventricle, and, curving around the right border of the heart, runs along its posterior surface as far as the posterior interventricular groove, where it divides into two branches, one of which (*transverse*) continues onward in the groove between the left auricle and ventricle, and anastomoses with the left coronary; the other (*descending*) descends along the posterior interventricular furrow, supplying branches to both ventricles and to the septum, and anastomosing at the apex of the heart with the descending branches of the left coronary.

This vessel sends a large branch (*marginal*) along the thin margin of the right ventricle to the apex, and numerous small branches to the right auricle and ventricle, and the commencement of the pulmonary artery (*infundibular*).

The **Left Coronary**, larger than the former, arises immediately above the free

edge of the left posterior semilunar valve, a little higher than the right; it passes forward between the pulmonary artery and the left auricular appendix, and divides into two branches. Of these, one (*transverse*) passes transversely outward in the left auriculo-ventricular groove, and winds around the left border of the heart into its posterior surface, where it anastomoses with the transverse branch of the right coronary; the other (*descending*) descends along the anterior interventricular groove to the apex of the heart, where it anastomoses with the descending branches of the right coronary. The left coronary supplies the left auricle and its appendix, both ventricles, and numerous small branches to the pulmonary artery, and commencement of the aorta.[1]

Peculiarities.—These vessels occasionally arise by a common trunk, or their number may be increased to three, the additional branch being of small size. More rarely, there are two additional branches.

THE ARCH OF THE AORTA.

The **arch,** or **transverse aorta,** commences at the upper border of the second chondro-sternal articulation of the right side, and passes from right to left, and from before backward, to the left side of the lower border of the fourth dorsal vertebra behind. Its upper border is usually about an inch below the upper margin of the sternum.

Relations.—Its *anterior surface* is covered by the pleuræ and lungs and the remains of the thymus gland, and crossed toward the left side by the left pneumogastric and phrenic nerves and superior cardiac branches of the left sympathetic, and by the left superior intercostal vein. Its *posterior surface* lies on the trachea, just above its bifurcation, on the great, or deep, cardiac plexus, the œsophagus, thoracic duct, and left recurrent laryngeal nerve. Its *upper border* is in relation with the left innominate vein, and from its upper part are given off the innominate, left common carotid, and left subclavian arteries. Its *lower border* is in relation with the bifurcation of the pulmonary artery, the remains of the ductus arteriosus, which is connected with the left division of that vessel, and the superficial cardiac plexus; the left recurrent laryngeal nerve winds round it from before backward, whilst the left bronchus passes below it.

PLAN OF THE RELATIONS OF THE ARCH OF THE AORTA.

Above.
Left innominate vein.
Innominate artery.
Left carotid.
Left subclavian.

In Front.
Pleuræ and lungs.
Remains of thymus gland.
Left pneumogastric nerve.
Left phrenic nerve.
Left superior cardiac nerves.
Left superior intercostal vein.

Behind.
Trachea.
Deep cardiac plexus.
Œsophagus.
Thoracic duct.
Left recurrent nerve.

Below.
Bifurcation of pulmonary artery.
Remains of ductus arteriosus.
Superficial cardiac plexus.
Left recurrent nerve.
Left bronchus.

Peculiarities.—The height to which the aorta rises in the chest is usually about an inch below the upper border of the sternum; but it may ascend nearly to the top of that bone. Occasionally it is found an inch and a half, more rarely two or even three inches, below this point.

[1] According to Dr. Samuel West, there is a very free and complete anastomosis between the two coronary arteries (*Lancet*, June 2, 1883, p. 945). This, however, is not the view generally held by anatomists, for, with the exception of the anastomosis mentioned above in the auriculo-ventricular and interventricular grooves, it is believed that the two arteries only communicate by very small vessels in the substance of the heart.

In Direction.—Sometimes the aorta arches over the root of the right instead of the left lung, as in birds, and passes down on the right side of the spine. In such cases all of the viscera of the thoracic and abdominal cavities are transposed. Less frequently, the aorta, after arching over the root of the right lung, is directed to its usual position on the left side of the spine, this peculiarity not being accompanied by any transposition of the viscera.

In Conformation.—The aorta occasionally divides, as in some quadrupeds, into an ascending and descending trunk, the former of which is directed vertically upward, and subdivides into three branches, to supply the head and upper extremities. Sometimes the aorta subdivides soon after its origin into two branches, which soon reunite. In one of these cases the œsophagus and trachea were found to pass through the interval left by their division; this is the normal condition of the vessel in the reptilia.

Surgical Anatomy.—Of all the vessels of the arterial system, the aorta, and more especially its arch, is most frequently the seat of disease; hence it is important to consider some of the consequences that may ensue from aneurism of this part.

It will be remembered that the ascending aorta is contained in the pericardium, just behind the sternum, being crossed at its commencement by the pulmonary artery and right auricular appendix, and having the root of the right lung behind, the vena cava on the right side, and the pulmonary artery and left auricle on the left side.

Aneurism of the ascending aorta, in the situation of the aortic sinuses, in the great majority

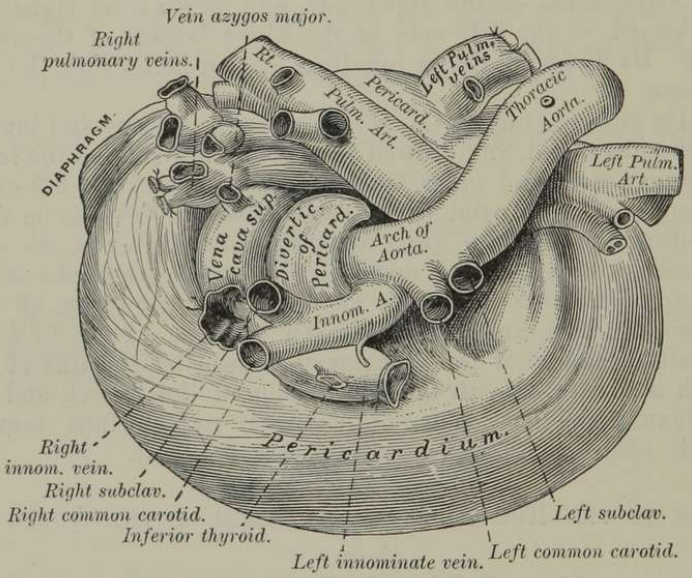

FIG. 346.—Relation of great vessels at base of heart, seen from above. (From a preparation in the Museum of the Royal College of Surgeons.)

of cases, affects the right anterior sinus; this is mainly owing to the fact that the regurgitation of blood upon the sinuses takes place chiefly on the right anterior aspect of the vessel. As the aneurismal sac enlarges it may compress any or all of the structures in immediate proximity with it, but chiefly projects toward the right anterior side, and, consequently, interferes mainly with those structures that have a corresponding relation with the vessel. In the majority of cases it bursts into the cavity of the pericardium, the patient suddenly drops down dead, and, upon a post-mortem examination, the pericardial sac is found full of blood; or it may compress the right auricle, or the pulmonary artery, and adjoining part of the right ventricle, and open into one or the other of these parts, or may press upon the superior vena cava.

Aneurism of the ascending aorta, originating above the sinuses, most frequently implicates the right anterior wall of the vessel; this is probably mainly owing to the blood being impelled against this part. The direction of the aneurism is also chiefly toward the right of the median line. If it attains a large size and projects forward, it may absorb the sternum and the cartilages of the ribs, usually on the right side, and appear as a pulsating tumor on the front of the chest, just below the manubrium; or it may burst into the pericardium, or may compress or open into the right lung, the trachea, bronchi, or œsophagus.

Regarding the transverse aorta, the student is reminded that the vessel lies on the trachea, the œsophagus, and thoracic duct; that the recurrent laryngeal nerve winds around it; and that from its upper part are given off three large trunks, which supply the head, neck, and upper extremities. Now, an aneurismal tumor, taking origin from the posterior part or right aspect of the vessel, its most usual site, may press upon the trachea, impede the breathing, or produce cough, hæmoptysis, or stridulous breathing, or it may ultimately burst into that tube, producing fatal hæmorrhage. Again, its pressure on the laryngeal nerves may give rise to symptoms which so accurately resemble those of laryngitis that the operation of tracheotomy has in some cases

been resorted to, from the supposition that disease existed in the larynx; or it may press upon the thoracic duct and destroy life by inanition; or it may involve the œsophagus, producing dysphagia; or may burst into the œsophagus, when fatal hæmorrhage will occur. Again, the innominate artery, or the subclavian, or left carotid, may be so obstructed by clots as to produce a weakness, or even a disappearance, of the pulse in one or the other wrist or in the left temporal artery; or the tumor may present itself at or above the manubrium, generally either in the median line or to the right of the sternum, and may simulate an aneurism of one of the arteries of the neck.

Branches of the Arch of the Aorta (Figs. 344, 345).

The branches given off from the arch of the aorta are three in number: the innominate artery, the left common carotid, and the left subclavian.

Peculiarities.—Position of the Branches.—The branches, instead of arising from the highest part of the arch (their usual position), may be moved more to the right, arising from the commencement of the transverse or upper part of the ascending portion: or the distance from one another at their origin may be increased or diminished, the most frequent change in this respect being the approximation of the left carotid toward the innominate artery.

The Number of the primary branches may be reduced to two: the left carotid arising from the innominate artery, or (more rarely) the carotid and subclavian arteries of the left side arising from a left innominate artery. But the number may be increased to four, from the right carotid and subclavian arteries arising directly from the aorta, the innominate being absent. In most of these latter cases the right subclavian has been found to arise from the left end of the arch; in other cases it was the second or third branch given off instead of the first. Lastly, the number of trunks from the arch may be increased to five or six; in these instances the external and internal carotids arise separately from the arch, the common carotid being absent on one or both sides.

Number Usual, Arrangement Different.—When the aorta arches over to the right side, the three branches have an arrangement the reverse of what is usual, the innominate supplying the left side, and the carotid and subclavian (which arise separately) the right side. In other cases, where the aorta takes its usual course, the two carotids may be joined in a common trunk, and the subclavians arise separately from the arch, the right subclavian generally arising from the left end of the arch.

Secondary Branches sometimes arise from the arch; most commonly such a secondary branch is the left vertebral, which usually takes origin between the left carotid and left subclavian, or beyond them. Sometimes, a thyroid branch is derived from the arch, or the right internal mammary, or right vertebral, or, more rarely, both vertebral.[1]

THE INNOMINATE ARTERY.

The **innominate artery** (**brachio-cephalic**) is the largest branch given off from the arch of the aorta. It arises opposite the fourth dorsal vertebra from the commencement of the arch of the aorta in front of the left carotid, and, ascending obliquely to the upper border of the right sterno-clavicular articulation, divides into the right common carotid and right subclavian arteries. This vessel varies from an inch and a half to two inches in length.

Relations.—*In front*, it is separated from the first bone of the sternum by the Sterno-hyoid and Sterno-thyroid muscles, the remains of the thymus gland, the left innominate and right inferior thyroid veins which cross its root, and sometimes the inferior cervical cardiac branch of the right pneumogastric. *Behind*, it lies upon the trachea, which it crosses obliquely. On the *right side* is the right innominate vein, right pneumogastric nerve, and the pleura; and on the *left side*, the remains of the thymus gland, the origin of the left carotid artery, the left inferior thyroid vein, and the trachea.

Branches.—The innominate usually gives off no branches, but occasionally a small branch, the *thyroidea ima*, is given off from this vessel. It also sometimes gives off a *thymic* or *bronchial branch*. The **Thyroidea ima** ascends in front of the trachea to the lower part of the thyroid body, which it supplies. It varies greatly in size, and appears to compensate for deficiency or absence of one of the other thyroid vessels. It occasionally is found to arise from the subclavian or internal mammary vessel.

[1] The anomalies of the aorta and its branches are minutely described by Krause in Henle's *Anatomy* (Brunswick, 1868), vol. iii. p. 203 *et seq.*

Plan of the Relations of the Innominate Artery.

In front.

Sternum.
Sterno-hyoid and Sterno-thyroid muscles.
Remains of thymus gland.
Left innominate and right inferior thyroid veins.
Inferior cervical cardiac branch from right pneumogastric nerve.

Right side.

Right innominate vein.
Right pneumogastric nerve.
Pleura.

Left side.

Remains of thymus.
Left carotid.
Left inferior thyroid vein.
Trachea.

Behind.

Trachea.

Peculiarities in Point of Division.—When the bifurcation of the innominate artery varies from the point above mentioned, it sometimes ascends a considerable distance above the sternal end of the clavicle; less frequently it divides below it. In the former class of cases its length may exceed two inches, and in the latter be reduced to an inch or less. These are points of considerable interest for the surgeon to remember in connection with the operation of tying this vessel.

Position.—When the aorta arches over to the right side, the innominate is directed to the left side of the neck instead of the right.

Collateral Circulation.—Allan Burns demonstrated, on the dead subject, the possibility of the establishment of the collateral circulation after ligature of the innominate artery, by tying and dividing that artery, after which, he says, "Even coarse injection, impelled into the aorta, passing freely by the anastomosing branches into the arteries of the right arm, filling them and all the vessels of the head completely" (*Surgical Anatomy of the Head and Neck*, p. 62). The branches by which this circulation would be carried on are very numerous; thus, all the communications across the middle line between the branches of the carotid arteries of opposite sides would be available for the supply of blood to the right side of the head and neck; while the anastomosis between the superior intercostal of the subclavian and the first aortic intercostal (see *infra* on the collateral circulation after obliteration of the thoracic aorta) would bring the blood, by a free and direct course, into the right subclavian: the numerous connections, also, between the intercostal arteries and the branches of the axillary and internal mammary arteries would, doubtless, assist in the supply of blood to the right arm, while the epigastric, from the external iliac, would, by means of its anastomosis with the internal mammary, compensate for any deficiency in the vascularity of the wall of the chest.

Surgical Anatomy.—Although the operation of tying the innominate artery has been performed by several surgeons for aneurism of the right subclavian extending inward as far as the Scalenus, in only two instances has the patient survived.[1] Mott's patient, however, on whom the operation was first performed, lived nearly four weeks, and Graefe's more than two months. The main obstacles to the operation are, as the student will perceive from his dissection of this vessel, the deep situation of the artery behind and beneath the sternum and the number of important structures which surround it in every part.

In order to apply a ligature to this vessel, the patient is to be placed upon his back, with the thorax slightly raised, the head bent a little backward, and the shoulder on the side of the aneurism strongly depressed, so as to draw out the artery from behind the sternum into the neck. An incision three or more inches long is then made along the anterior border of the Sterno-mastoid muscle, terminating at the sternal end of the clavicle. From this point a second incision is carried about the same length along the upper border of the clavicle. The skin is then dissected back, and the Platysma divided on a director: the sternal end of the Sterno-mastoid is now brought into view, and, a director being passed beneath it and close to its under surface, so as to avoid any small vessels, it is to be divided; in like manner the clavicular origin is to be divided throughout the whole or greater part of its attachment. By pressing aside any loose cellular tissue or vessels that may now appear the Sterno-hyoid and Sterno-thyroid muscles will be exposed, and must be divided, a director being previously passed beneath them. The inferior thyroid veins may come into view, and must be carefully drawn, either upward or downward, by means of a blunt hook, or tied with double ligatures and divided. After tearing through a strong fibro-cellular lamina, the right carotid is brought into view, and, being traced downward, the arteria innominata is arrived at. The left innominate vein should now be depressed; the right innominate vein, the internal jugular vein, and the pneumogastric nerve drawn to the right side; and a curved aneurism needle may then be passed around the vessel, close to its surface, and in a direction from below upward and inward, care being taken to avoid the right pleural sac, the trachea, and cardiac nerves. The ligature should be applied to the artery as high as possible, in order to allow room between it and the aorta for the formation of the coagulum.

[1] In one of these the operation was performed by Dr. Smyth of New Orleans. See the New Sydenham Society's *Biennial Retrospect* for 1865–6, p. 346. In the other, the operation was performed by Dr. Mitchell Banks in the Liverpool Infirmary. The case is recorded by Mr. Jacobson in *Operations of Surgery*, p. 536.

The importance of avoiding the thyroid plexus of veins during the primary steps of the operation, and the pleural sac whilst including the vessel in the ligature, should be most carefully borne in mind. The most frequent cause of death after operation is secondary hæmorrhage, which has occurred in almost every case. Other causes are pleurisy, pericarditis, and suppurative cellulitis.

THE COMMON CAROTID ARTERIES.

The **common carotid arteries,** although occupying a nearly similar position in the neck, differ in position, and, consequently, in their relation at their origin. The right carotid arises from the innominate artery, behind the right sterno-clavicular articulation; the left from the highest part of the arch of the aorta. The left carotid is, consequently, longer, and at its origin is contained within the thorax. The course and relations of that portion of the left carotid which intervenes between the arch of the aorta and the left sterno-clavicular articulation will first be described (see Fig. 344).

The left carotid within the thorax ascends obliquely outward from the arch of the aorta to the root of the neck. *In front*, it is separated from the first piece of the sternum by the Sterno-hyoid and Sterno-thyroid muscles, the left innominate vein, and the remains of the thymus gland; *behind*, it lies on the trachea, œsophagus, and thoracic duct. *Internally*, it is in relation with the innominate artery, inferior thyroid veins and remains of thymus gland; *externally*, with the left pneumogastric nerve, left pleura, and lung. The left subclavian artery is posterior and external to it.

PLAN OF THE RELATIONS OF THE LEFT COMMON CAROTID.
THORACIC PORTION.

In front.
Sternum.
Sterno-hyoid and Sterno-thyroid muscles.
Left innominate vein.
Remains of thymus gland.

Internally.
Innominate artery.
Inferior thyroid veins.
Remains of thymus gland.

Left Common Carotid. Thoracic Portion.

Externally.
Left pneumogastric nerve.
Left pleura and lung.
Left subclavian artery.

Behind.
Trachea.
Œsophagus.
Thoracic duct.

In the neck the two common carotids resemble each other so closely that one description will apply to both. Each vessel passes obliquely upward from behind the sterno-clavicular articulation to a level with the upper border of the thyroid cartilage, opposite the third cervical vertebra, where it divides into the external and internal carotid; these names being derived from the distribution of the arteries to the external parts of the head and face and to the internal parts of the cranium and orbit respectively.

At the lower part of the neck the two common carotid arteries are separated from each other by a small interval, which contains the trachea; but at the upper part, the thyroid body, the larynx and pharynx project forward between the two vessels, and give the appearance of their being placed farther back in that situation. The common carotid artery is contained in a sheath derived from the deep cervical fascia, which also encloses the internal jugular vein and pneumogastric nerve, the vein lying on the outer side of the artery, and the nerve between the artery and vein, on a plane posterior to both. On opening the sheath these three structures are seen to be separated from one another, each being enclosed in a separate fibrous investment.

Relations.—At the lower part of the neck the common carotid artery is very

deeply seated, being covered by the integument, superficial fascia, Platysma, and deep cervical fascia, the Sterno-mastoid, Sterno-hyoid, and Sterno-thyroid muscles, and by the Omo-hyoid, opposite the cricoid cartilage; but in the upper part of its course, near its termination, it is more superficial, being covered merely by the integument, the superficial fascia, Platysma, deep cervical fascia, and inner margin of the Sterno-mastoid, and is contained in a triangular space, bounded behind by

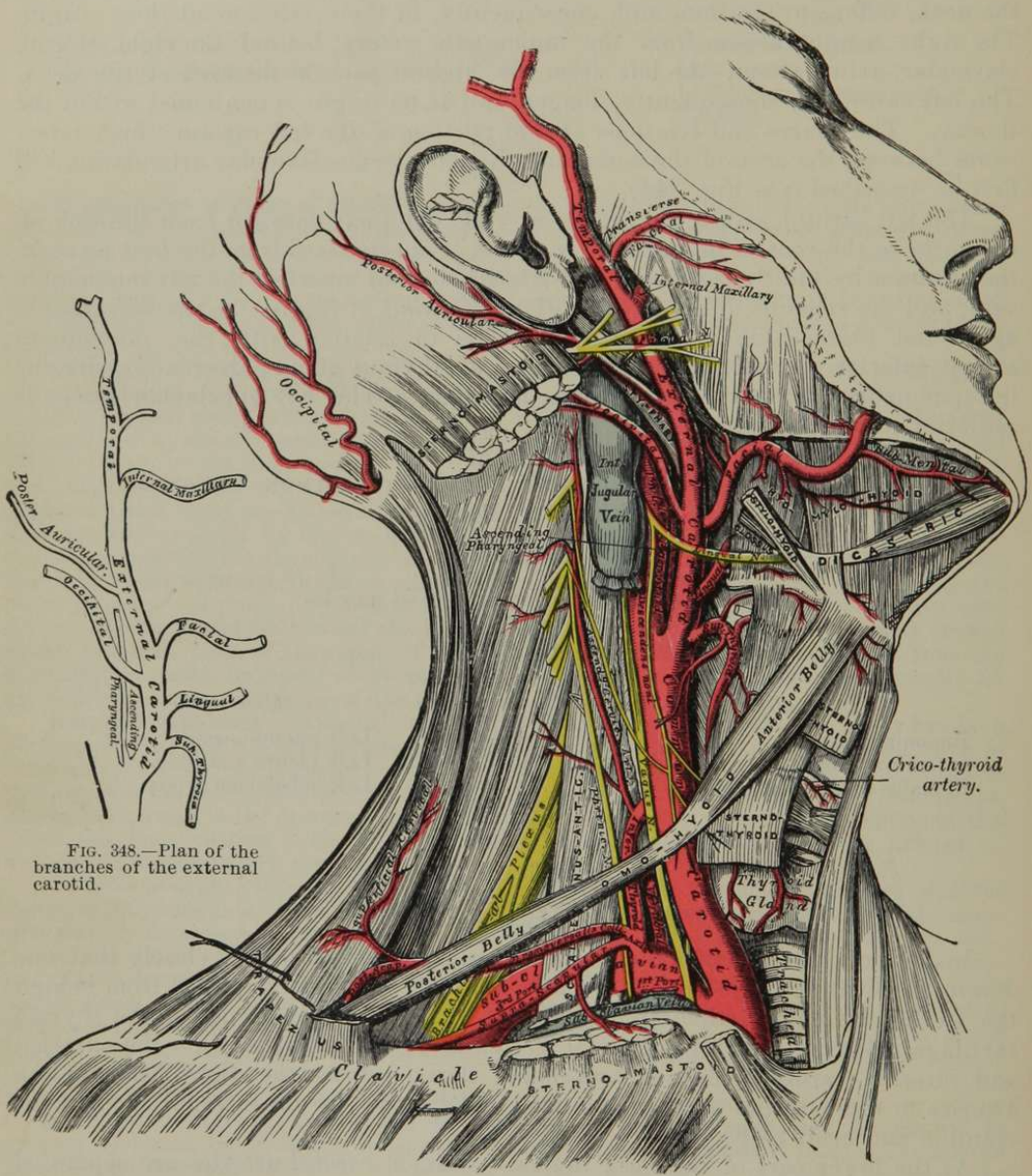

FIG. 348.—Plan of the branches of the external carotid.

FIG. 347.—Surgical anatomy of the arteries of the neck. Right side.

the Sterno-mastoid, above by the posterior belly of the Digastric, and below by the anterior belly of the Omo-hyoid. This part of the artery is crossed obliquely, from within outward, by the sterno-mastoid artery; it is crossed also by one, or sometimes two superior thyroid veins, which terminate in the internal jugular; and, descending on its sheath in front, is seen the descendens hypoglossi nerve, this filament being joined by one or two branches from the cervical nerves, which cross the vessel from without inward. Sometimes the descendens hypoglossi is contained within the sheath. The middle thyroid vein crosses the artery about

its middle, and the anterior jugular vein below. *Behind*, the artery lies in front of the cervical portion of the spine, resting first on the Longus colli muscle, then on the Rectus capitis anticus major, from which it is separated by the sympathetic nerve. The recurrent laryngeal nerve and inferior thyroid artery cross behind the vessel at its lower part. *Internally*, it is in relation with the trachea and thyroid gland, the inferior thyroid artery and recurrent laryngeal nerve being interposed: higher up, with the larynx and pharynx. On its *outer side* are placed the internal jugular vein and pneumogastric nerve.

At the lower part of the neck the internal jugular vein on the right side diverges from the artery, but on the left side it approaches it, and often crosses its lower part. This is an important fact to bear in mind during the performance of any operation on the lower part of the left common carotid artery.

PLAN OF THE RELATIONS OF THE COMMON CAROTID ARTERY.

Externally.

Integument, and superficial fascia.
Deep cervical fascia.
Platysma.
Sterno-mastoid.
Sterno-hyoid.
Sterno-thyroid.
Omo-hyoid.
Descendens and Communicans hypoglossi nerves.
Sterno-mastoid artery.
Superior and middle thyroid veins.
Anterior jugular vein.
Internal jugular vein.
Pneumogastric nerve.

Internally.

Trachea.
Thyroid gland.
Recurrent laryngeal nerve.
Inferior thyroid artery.
Larynx.
Pharynx.

Behind.

Longus colli.
Rectus capitis anticus major.
Sympathetic nerve.
Inferior thyroid artery.
Recurrent laryngeal nerve.

Peculiarities as to Origin.—The *right common carotid* may arise above or below its usual point, the upper border of the sterno-clavicular articulation. This variation occurs in one out of about eight cases and a half, and the origin is more frequently above than below the usual point; or the artery may arise as a separate branch from the arch of the aorta or in conjunction with the left carotid. The *left common carotid* varies more frequently in its origin than the right. In the majority of abnormal cases it arises with the innominate artery, or, if the innominate artery is absent, the two carotids arise usually by a single trunk. The left carotid is occasionally the first branch given off from the arch of the aorta. It rarely joins with the left subclavian, except in cases of transposition of the arch.

Peculiarities as to Point of Division.—The most important peculiarities of this vessel, in a surgical point of view, relate to its place of division in the neck. In the majority of abnormal cases this occurs higher than usual, the artery dividing into two branches opposite the hyoid bone, or even higher; more rarely, it occurs below its usual place, opposite the middle of the larynx or the lower border of the cricoid cartilage; and one case is related by Morgagni where the common carotid, only an inch and a half in length, divided at the root of the neck. Very rarely the common carotid ascends in the neck without any subdivision, the internal carotid being wanting; and in a few cases the common carotid has been found to be absent, the external and internal carotids arising directly from the arch of the aorta. This peculiarity existed on both sides in some instances, on one side in others.

Occasional Branches.—The common carotid usually gives off no branch previous to its bifurcation; but it occasionally gives origin to the superior thyroid or its laryngeal branch, the inferior thyroid, or, more rarely, the vertebral artery.

Surface Marking.—The carotid arteries are overlapped throughout their entire extent by the anterior border of the Sterno-mastoid muscle, but their course does not correspond to the border of the muscle, which passes in a somewhat curved direction from the mastoid process to the sterno-clavicular joint. The course of the artery is indicated more exactly by a line drawn from the sternal end of the clavicle below, to a point midway between the angle of the jaw and the mastoid process above. That portion of the line below the level of the upper border of the thyroid cartilage would represent the course of the vessel.

Surgical Anatomy.—The operation of tying the common carotid artery may be necessary in a case of wound of that vessel or its branches, in aneurism, or in a case of pulsating tumor of the orbit or skull. If the wound involves the trunk of the common carotid, it will be necessary to tie the artery above and below the wounded part. But in cases of aneurism, or where one of

the branches of the common carotid is wounded in an inaccessible situation, it may be judged necessary to tie the trunk. In such cases the whole of the artery is accessible, and any part may be tied except close to either end. When the case is such as to allow of a choice being made, the lower part of the carotid should never be selected as the spot upon which to place a ligature, for not only is the artery in this situation placed very deeply in the neck, but it is covered by three layers of muscles, and, on the left side, the internal jugular vein, in the great majority of cases, passes obliquely in front of it. Neither should the upper end be selected, for here the superior thyroid vein and its tributaries would give rise to very considerable difficulty in the application of a ligature. The point most favorable for the operation is that part of the vessel which is at the level of the cricoid cartilage. It occasionally happens that the carotid artery bifurcates below its usual position: if the artery be exposed at its point of bifurcation, both divisions of the vessel should be tied near their origin, in preference to tying the trunk of the artery near its termination; and if, in consequence of the entire absence of the common carotid or from its early division, two arteries, the external and internal carotids, are met with, the ligature should be placed on that vessel which is found on compression to be connected with the disease.

In this operation the direction of the vessel and the inner margin of the Sterno-mastoid are the chief guides to its performance. The patient should be placed on his back with the head thrown back and turned slightly to the opposite side: an incision is to be made, three inches long, in the direction of the anterior border of the Sterno-mastoid, so that the centre corresponds to the level of the cricoid cartilage: after dividing the integument, superficial fascia, and Platysma, the deep fascia must be cut through on a director, so as to avoid wounding numerous small veins that are usually found beneath. The head may now be brought forward so as to relax the parts somewhat, and the margins of the wound held asunder by retractors. The descendens hypoglossi nerve may now be exposed, and must be avoided, and, the sheath of the vessel having been raised by forceps, is to be opened to a small extent over the artery at its inner side. The internal jugular vein may present itself alternately distended and relaxed; this should be compressed both above and below, and drawn outward, in order to facilitate the operation. The aneurism needle is passed from the outside, care being taken to keep the needle in close contact with the artery, and thus avoid the risk of injuring the internal jugular vein or including the vagus nerve. Before the ligature is tied it should be ascertained that nothing but the artery is included in it.

Ligature of the Common Carotid at the Lower Part of the Neck.—This operation is sometimes required in cases of aneurism of the upper part of the carotid, especially if the sac is of large size. It is best performed by dividing the sternal origin of the Sterno-mastoid muscle, but may be done in some cases, if the aneurism is not of very large size, by an incision along the anterior border of the Sterno-mastoid, extending down to the sterno-clavicular articulation, and by then retracting the muscle. The easiest and best plan, however, is to make an incision two or three inches long down the lower part of the anterior border of the Sterno-mastoid muscle to the sterno-clavicular joint, and a second incision, starting from the termination of the first, along the upper border of the clavicle for about two inches. This incision is made through the superficial and deep fascia, and the sternal origin of the muscle exposed. This is to be divided on a director, and turned up, with the superficial structures, as a triangular flap. Some loose connective tissue is to be divided or torn through, and the outer border of the Sterno-hyoid muscle exposed. In doing this care must be taken not to wound the anterior jugular vein, which crosses the muscle to reach the external jugular or subclavian vein. The Sterno-hyoid, and with it the Sterno-thyroid, are to be drawn inward by means of a retractor, and the sheath of the vessel is exposed. This must be opened with great care on its inner or tracheal side, so as to avoid the internal jugular vein. This is especially necessary on the left side, where the artery is commonly overlapped by the vein. On the right side there is usually an interval between the artery and the vein, and not the same risk of wounding the latter.

The common carotid artery, being a long vessel without any branches, is particularly suitable for the performance of Brasdor's operation for the cure of an aneurism of the lower part of the vessel. Brasdor's procedure consists in ligaturing the artery on the distal side of the aneurism, and in the case of the common carotid there are no branches given off from the vessel between the aneurism and the site of the ligature; hence little or no blood passes through the sac of the aneurism, and consequently it and the vessel shrinks, and a cure is effected.

Collateral Circulation.—After ligature of the common carotid the collateral circulation can be perfectly established, by the free communication which exists between the carotid arteries of opposite sides, both without and within the cranium, and by enlargement of the branches of the subclavian artery on the side corresponding to that on which the vessel has been tied—the chief communication outside the skull taking place between the superior and inferior thyroid arteries, and the profunda cervicis and arteria princeps cervicis of the occipital; the vertebral taking the place of the internal carotid within the cranium.

Sir A. Cooper had an opportunity of dissecting, thirteen years after the operation, the case in which he first successfully tied the common carotid (the second case in which he performed the operation).[1] The injection, however, does not seem to have been a successful one. It showed merely that the arteries at the base of the brain (circle of Willis) were much enlarged on

[1] *Guy's Hospital Reports*, i. 56.

the side of the tied artery, and that the anastomosis between the branches of the external carotid on the affected side and those of the same artery on the sound side was free, so that the external carotid was pervious throughout.

The External Carotid Artery.

The **external carotid artery** (Fig. 347) commences opposite the upper border of the thyroid cartilage, and taking a slightly curved course, passes upward and forward, and then inclines backward to the space between the neck of the condyle of the lower jaw and the external meatus, where it divides into the superficial temporal and internal maxillary arteries. It rapidly diminishes in size in its course up the neck, owing to the number and large size of the branches given off from it. In the child it is somewhat smaller than the internal carotid, but in the adult the two vessels are of nearly equal size. At its commencement this artery is more superficial, and placed nearer the middle line than the internal carotid, and is contained in the triangular space bounded by the Sterno-mastoid behind, the Omo-hyoid below, and the posterior belly of the Digastric and Stylo-hyoid above.

Relations.—It is covered by the skin, superficial fascia, Platysma, deep fascia, and anterior margin of the Sterno-mastoid, crossed by the hypoglossal nerve, and by the lingual and facial veins; it is afterward crossed by the Digastric and Stylo-hyoid muscles, and higher up passes deeply into the substance of the parotid gland, where it lies beneath the facial nerve and the junction of the temporal and internal maxillary veins.

Internally is the hyoid bone, wall of the pharynx, the superior laryngeal nerve, and higher up it is separated from the internal carotid by the Stylo-glossus and Stylo-pharyngeus muscles, the glosso-pharyngeal nerve, and part of the parotid gland. *Anteriorly* is the ramus of the jaw, from which it is separated by a portion of the parotid gland. *Externally*, in the lower part of its course, is the internal carotid artery.

Surface Marking.—The position of the external carotid artery may be marked out with sufficient accuracy by a line drawn from the front of the meatus of the external ear to the side of the cricoid cartilage, slightly arching the line forward.

Surgical Anatomy.—The application of a ligature to the external carotid may be required in case of wounds of this vessel, or of its branches when these cannot be tied, and in some cases of pulsating tumor of the scalp or face. The operation has not received the attention which it deserves, owing to the fear which surgeons have entertained of secondary hæmorrhage, on account of the number of branches given off from the vessel. This fear, however, has been shown by Mr. Cripps not to be well founded.[1] To tie this vessel near its origin, below the point where it is crossed by the Digastric, an incision about three inches in length should be made along the margin of the Sterno-mastoid, from the angle of the jaw to the upper border of the thyroid cartilage. The ligature should be applied between the lingual and superior thyroid branches. To tie the vessel above the Digastric, between it and the parotid gland, an incision should be made, from the lobe of the ear to the great cornu of the os hyoides, dividing successively the skin, Platysma, and fascia. By drawing the Sterno-mastoid outward, and the posterior belly of the Digastric and Stylo-hyoid muscles downward, and separating them from the parotid gland, the vessel will be exposed, and a ligature may be applied to it. The circulation is at once re-established by the free communication between most of the large branches of the artery (facial, lingual, superior thyroid, occipital) and the corresponding arteries of the opposite side, and by the anastomosis of its branches with those of the internal carotid, and of the occipital with the branches of the subclavian, etc.

Plan of the Relations of the External Carotid.

Externally.

Skin, superficial fascia.
Platysma and deep fascia.
Anterior border of Sterno-mastoid.
Hypoglossal nerve.
Lingual and facial veins.
Digastric and Stylo-hyoid muscles.
Parotid gland with facial nerve and temporo-maxillary vein in its substance.
Internal carotid artery.

[1] *Med.-Chir. Trans.*, lxi. 229.

In front.
Ramus of jaw.

Behind.
Parotid gland.

Internally.
Hyoid bone.
Pharynx.
Superior laryngeal nerve.
Stylo-glossus.
Stylo-pharyngeus.
Glosso-pharyngeal nerve.
Parotid gland.

Branches.—The external carotid artery gives off eight branches, which, for convenience of description, may be divided into four sets. (See Fig. 348, Plan of the Branches).

Anterior.	*Posterior.*	*Ascending.*	*Terminal.*
Superior Thyroid.	Occipital.	Ascending Pha-	Superficial Temporal.
Lingual.	Posterior Auricular.	ryngeal.	Internal Maxillary.
Facial.			

The student is here reminded that many variations are met with in the number, origin, and course of these branches in different subjects; but the above arrangement is that which is found in the great majority of cases.

The **Superior Thyroid Artery** (Figs. 347 and 352) is the first branch given off from the external carotid, being derived from that vessel just below the great cornu of the hyoid bone. At its commencement it is quite superficial, being covered by the integument, fascia, and Platysma, and is contained in the triangular space bounded by the Sterno-mastoid, Digastric, and Omo-hyoid muscles. After running upward and inward for a short distance, it curves downward and forward, in an arched and tortuous manner, to the upper part of the thyroid gland, passing beneath the Omo-hyoid, Sterno-hyoid, and Sterno-thyroid muscles, and distributes numerous branches to the anterior surface of the gland, anastomosing with its fellow of the opposite side and with the inferior thyroid arteries. Besides the arteries distributed to the muscles by which it is covered and the substance of the gland, the branches of the superior thyroid are the following:

Hyoid.	Superior Laryngeal.
Superficial descending branch (Sterno-mastoid).	Crico-thyroid.

The **hyoid** is a small branch which runs along the lower border of the os hyoides beneath the Thyro-hyoid muscle; after supplying the muscles connected to that bone it forms an arch, by anastomosing with the vessels of the opposite side.

The **superficial descending branch** runs downward and outward across the sheath of the common carotid artery, and supplies the Sterno-mastoid and neighboring muscles and integument. There is also often a distinct branch from the external carotid distributed to the Sterno-mastoid muscle.

The **superior laryngeal**, larger than either of the preceding, accompanies the superior laryngeal nerve, beneath the Thyro-hyoid muscle: it pierces the thyro-hyoid membrane, and supplies the muscles, mucous membrane, and glands of the larynx, anastomosing with the branch from the opposite side.

The **crico-thyroid** is a small branch which runs transversely across the crico-thyroid membrane, communicating with the artery of the opposite side.

Surgical Anatomy.—The superior thyroid, or some of its branches, is often divided in cases of cut throat, giving rise to considerable hæmorrhage. In such cases the artery should be secured, the wound being enlarged for that purpose, if necessary. The operation may be easily performed, the position of the artery being very superficial, and the only structures of importance covering it being a few small veins. The operation of tying the superior thyroid artery in bronchocele has been performed in numerous instances with partial or temporary success. When,

however, the collateral circulation between this vessel and the artery of the opposite side, and the inferior thyroid, is completely re-established, the tumor usually regains its former size.

The position of the superficial descending branch is of importance in connection with the operation of ligature of the common carotid artery. It crosses and lies on the sheath of this vessel, and may chance to be wounded in opening the sheath. The position of the crico-thyroid branch should be remembered, as it may prove the source of troublesome hæmorrhage during the operation of laryngotomy.

The **Lingual Artery** (Fig. 352) arises from the external carotid between the superior thyroid and facial; it runs obliquely upward and inward to the great cornu of the hyoid bone, then passes horizontally forward parallel with the great cornu, and, ascending perpendicularly to the under surface of the tongue, turns forward on its under surface as far as the tip of that organ, under the name of the *ranine artery*.

Relations.—Its first, or oblique, portion is superficial, being contained in the triangular space already described, resting upon the middle constrictor of the pharynx, and covered by the Platysma and fascia of the neck. Its second, or horizontal, portion also lies upon the middle constrictor, being covered at first by the tendon of the Digastric and the Stylo-hyoid muscle, and afterward by the Hyo-glossus, the latter muscle separating it from the hypoglossal nerve. Its third, or ascending, portion lies between the Hyo-glossus and Genio-hyo-glossus muscles. The fourth, or terminal, part, under the name of the *ranine*, runs along the under surface of the tongue to its tip: it is very superficial, being covered only by the mucous membrane, and rests on the Lingualis on the outer side of the Genio-hyo-glossus. The hypoglossal nerve crosses the lingual artery, and then becomes separated from it, in the second part of its course, by the Hyo-glossus muscle.

The branches of the lingual artery are—the

Hyoid.	Sublingual.
Dorsalis Linguæ.	Ranine.

The **hyoid branch** runs along the upper border of the hyoid bone, supplying the muscles attached to it and anastomosing with its fellow of the opposite side.

The **dorsalis linguæ** (Fig. 352) arises from the lingual artery beneath the Hyo-glossus muscle (which, in the figure, has been partly cut away to show the vessel); ascending to the dorsum of the tongue, it supplies the mucous membrane, the tonsil, soft palate, and epiglottis, anastomosing with its fellow from the opposite side.

The **sublingual**, which may be described as a branch of bifurcation of the lingual artery, arises at the anterior margin of the Hyo-glossus muscle, and runs forward between the Genio-hyo-glossus and the sublingual gland. It supplies the substance of the gland, giving branches to the Mylo-hyoid and neighboring muscles, the mucous membrane of the mouth and gums. One branch runs behind the alveolar process of the lower jaw in the substance of the gum to anastomose with a similar artery from the other side.

The **ranine** may be regarded as the other branch of bifurcation, or, as is more usual, as the continuation of the lingual artery; it runs along the under surface of the tongue, resting on the Inferior lingualis, and covered by the mucous membrane of the mouth; it lies on the outer side of the Genio-hyo-glossus, accompanied by the lingual nerve. On arriving at the tip of the tongue it has been said to anastomose with the artery of the opposite side, but this is denied by Hyrtl. These vessels in the mouth are placed one on each side of the frænum.

Surgical Anatomy.—The lingual artery may be divided near its origin in cases of cut throat, a complication that not unfrequently happens in this class of wounds; or severe hæmorrhage which cannot be restrained by ordinary means may ensue from a wound or deep ulcer of the tongue. In the former case the primary wound may be enlarged if necessary, and the bleeding vessels secured. In the latter case it has been suggested that the lingual artery should be tied near its origin. Ligature of the lingual artery is also occasionally practised, as a palliative measure, in cases of cancer of the tongue, in order to check the progress of the disease by starving the growth, and it is sometimes tied as a preliminary measure to removal of

the tongue. The operation is a difficult one, on account of the depth of the artery, the number of important parts by which it is surrounded, the loose and yielding nature of the parts upon which it is supported, and its occasional irregularity of origin. An incision is to be made in a curved direction from a finger's breadth external to the symphysis of the jaw downward to the cornu of the hyoid bone, and then upward to near the angle of the jaw. Care must be taken not to carry this incision too far backward, for fear of endangering the facial vein. In the first incision the skin, superficial fascia, and Platysma will be divided, and the deep fascia exposed. This is then to be incised and the submaxillary gland exposed and pulled upward by retractors. A triangular space is now exposed, bounded internally by the posterior border of the Mylo-hyoid muscle: below and externally, by the tendon of the Digastric; and above, by the hypo-glossal nerve. The floor of the space is formed by the Hyo-glossus muscle, beneath which the artery lies. The fibres of this muscle are now to be cut through horizontally and the vessel exposed, care being taken, while near the vessel, not to open the pharynx.

Troublesome hæmorrhage may occur in the division of the frænum in children if the ranine artery, which lies on each side of it, is wounded. The student should remember that the operation is always to be performed with a pair of blunt-pointed scissors, and the mucous membrane only is to be divided by a very superficial cut, which cannot endanger any vessel. The scissors, also, should be directed away from the tongue. Any further liberation of the tongue which may be necessary can be effected by tearing.

The **Facial Artery** (Fig. 349) arises a little above the lingual, and passes obliquely upward, beneath the Digastric and Stylo-hyoid muscles; it then runs

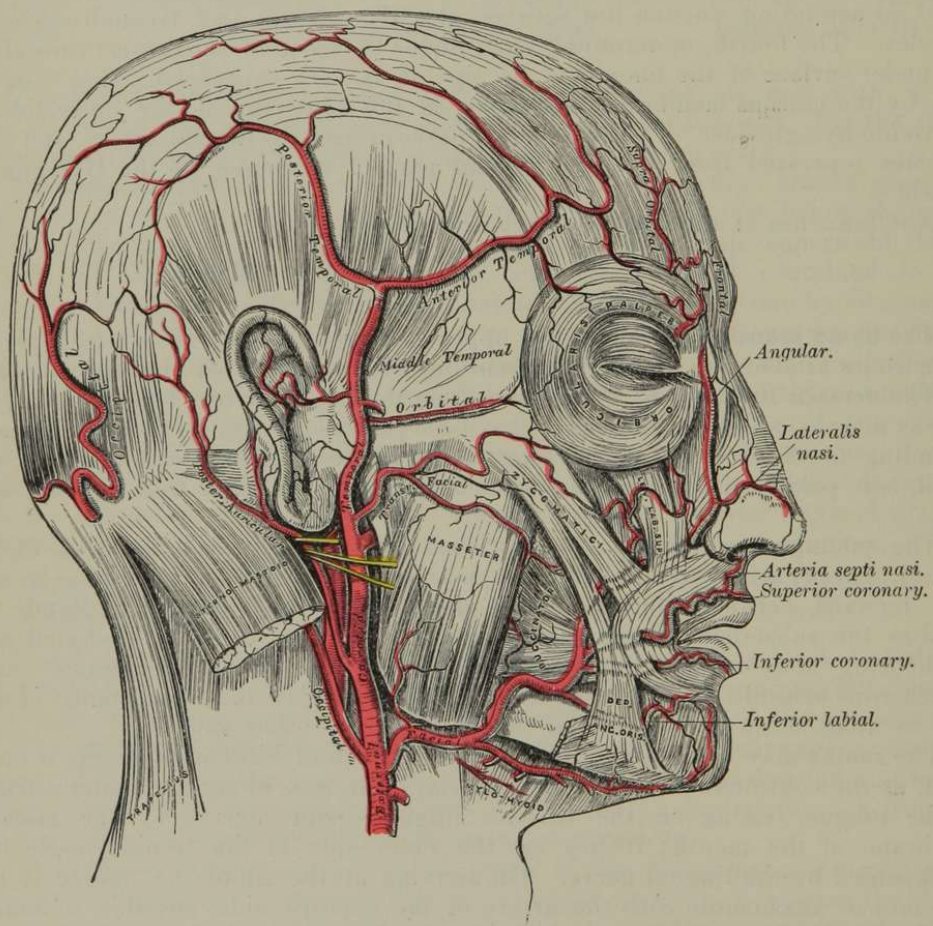

FIG. 349.—The arteries of the face and scalp.[1]

forward under cover of the body of the lower jaw, lodged in a groove on the posterior surface of the submaxillary gland; this may be called the cervical part of the artery. It then curves upward over the body of the jaw at the anterior inferior angle of the Masseter muscle; passes forward and upward across the

[1] The muscular tissue of the lips must be supposed to have been cut away, in order to show the course of the coronary arteries.

cheek to the angle of the mouth, then upward along the side of the nose, and terminates at the inner canthus of the eye, under the name of the *angular artery*. This vessel, both in the neck and on the face, is remarkably tortuous: in the former situation, to accommodate itself to the movements of the pharynx in deglutition, and in the latter to the movements of the jaw and the lips and cheeks.

Relations.—*In the neck* its origin is superficial, being covered by the integument, Platysma, and fascia; it then passes beneath the Digastric and Stylo-hyoid muscles and the submaxillary gland. *On the face*, where it passes over the body of the lower jaw, it is comparatively superficial, lying immediately beneath the Platysma. In this situation its pulsation may be distinctly felt, and compression of the vessel effectually made against the bone. In its course over the face it is covered by the integument, the fat of the cheek, and, near the angle of the mouth, by the Platysma, Risorius, and Zygomatic muscles. It rests on the Buccinator, the Levator anguli oris, and the Levator labii superioris (sometimes piercing or else passing under this last muscle). It is accompanied by the facial vein throughout its entire course; the vein is not tortuous like the artery, and, on the face, is separated from that vessel by a considerable interval, lying to its outer side. The branches of the facial nerve cross the artery, and the infra-orbital nerve lies beneath it.

The branches of this vessel may be divided into two sets: those given off below the jaw (cervical), and those on the face (facial).

Cervical Branches.	*Facial Branches.*
Inferior or Ascending Palatine.	Muscular.
Tonsillar.	Inferior Labial.
Submaxillary.	Inferior Coronary.
Submental.	Superior Coronary.
Muscular.	Lateralis Nasi.
	Angular.

The **inferior** or **ascending palatine** (Fig. 352) passes up between the Stylo-glossus and Stylo-pharyngeus to the outer side of the pharynx. After supplying these muscles, the tonsil, and Eustachian tube, it divides, near the Levator palati, into two branches: one follows the course of the Levator palati, and, winding over the upper border of the Superior constrictor, supplies the soft palate and the palatine glands; the other pierces the Superior constrictor, supplies the tonsil, anastomosing with the tonsillar artery. These vessels also anastomose with the posterior palatine branch of the internal maxillary artery.

The **tonsillar branch** (Fig. 352) passes up between the Internal Pterygoid and Stylo-glossus, and then ascends along the side of the pharynx, perforating the Superior constrictor, to ramify in the substance of the tonsil and root of the tongue.

The **submaxillary** consists of three or four large branches, which supply the submaxillary gland, some being prolonged to the neighboring muscles, lymphatic glands, and integument.

The **submental,** the largest of the cervical branches, is given off from the facial artery just as that vessel quits the submaxillary gland: it runs forward upon the Mylo-hyoid muscle, just below the body of the jaw and beneath the Digastric; after supplying the surrounding muscles, and anastomosing with the sublingual artery by branches which perforate the Mylo-hyoid muscle, it arrives at the symphysis of the chin, where it turns over the border of the jaw and divides into a superficial and a deep branch; the former passes between the integument and Depressor labii inferioris, supplies both, and anastomoses with the inferior labial. The deep branch passes between the latter muscle and the bone, supplies the lip, and anastomoses with the inferior labial and mental arteries.

The **muscular branches** are distributed to the Internal pterygoid and Stylo-hyoid in the neck, and to the Masseter and Buccinator on the face.

The **inferior labial** passes beneath the Depressor anguli oris, to supply the

muscles and integument of the lower lip, anastomosing with the inferior coronary and submental branches of the facial, and with the mental branch of the inferior dental artery.

The **inferior coronary** is derived from the facial artery, near the angle of the mouth: it passes upward and inward beneath the depressor anguli oris, and, penetrating the Orbicularis oris muscle, runs in a tortuous course along the edge of the lower lip between this muscle and the mucous membrane, inosculating with the artery of the opposite side. This artery supplies the labial glands, the mucous membrane, and muscles of the lower lip, and anastomoses with the inferior labial and the mental branch of the inferior dental artery.

The **superior coronary** is larger and more tortuous in its course than the preceding. It follows the same course along the edge of the upper lip, lying between the mucous membrane and the Orbicularis oris, and anastomoses with the artery of the opposite side. It supplies the textures of the upper lip, and gives off in its course two or three vessels which ascend to the nose. One, named the *inferior artery of the septum*, ramifies on the septum of the nares as far as the point of the nose; another, the *artery of the ala*, supplies the ala of the nose.

The **lateralis nasi** is derived from the facial, as that vessel is ascending along the side of the nose; it supplies the ala and dorsum of the nose, anastomosing with its fellow, the nasal branch of the ophthalmic, the inferior artery of the septum, the artery of the ala, and the infra-orbital.

The **angular artery** is the termination of the trunk of the facial; it ascends to the inner angle of the orbit, imbedded in the fibres of the Levator labii superioris alæque nasi, and accompanied by a large vein, the *angular;* it distributes some branches on the cheek which anastomose with the infra-orbital, and after supplying the lachrymal sac and Orbicularis palpebrarum muscle, terminates by anastomosing with the nasal branch of the ophthalmic artery.

The anastomoses of the facial artery are very numerous, not only with the vessel of the opposite side, but, in the neck, with the sublingual branch of the lingual; with the ascending pharyngeal; with the posterior palatine, a branch of the internal maxillary, by its inferior or ascending palatine and tonsillar branches; on the face, with the mental branch of the inferior dental as it emerges from the mental foramen, with the transverse facial, a branch of the temporal; with the infra-orbital, a branch of the internal maxillary, and with the nasal branch of the ophthalmic.

Peculiarities.—The facial artery not unfrequently arises by a common trunk with the lingual. This vessel is also subject to some variations in its size and in the extent to which it supplies the face. It occasionally terminates as the submental, and not unfrequently supplies the face only as high as the angle of the mouth or nose. The deficiency is then supplied by enlargement of one of the neighboring arteries.

Surgical Anatomy.—The passage of the facial artery over the body of the jaw would appear to afford a favorable position for the application of pressure in case of hæmorrhage from the lips, the result either of an accidental wound or during an operation; but its application is useless, except for a very short time, on account of the free communication of this vessel with its fellow and with numerous branches from different sources. In a wound involving the lip it is better to seize the part between the fingers, and evert it, when the bleeding vessel may be at once secured with pressure-forceps. In order to prevent hæmorrhage in cases of removal of diseased growths from the part, the lip should be compressed on each side between the fingers and thumb or by a pair of specially devised clamp-forceps, whilst the surgeon excises the diseased part. In order to stop hæmorrhage where the lip has been divided in an operation, it is necessary, in uniting the edges of the wound, to pass the sutures through the cut edges, almost as deep as its mucous surface; by these means not only are the cut surfaces more neatly and securely adapted to each other, but the possibility of hæmorrhage is prevented by including in the suture the divided artery. If the suture is, on the contrary, passed through merely the cutaneous portion of the wound, hæmorrhage occurs into the cavity of the mouth. The student should, lastly, observe the relation of the angular artery to the lachrymal sac, and it will be seen that, as the vessel passes up along the inner margin of the orbit, it ascends on its nasal side. In operating for fistula lachrymalis the sac should always be opened on its outer side, in order that this vessel may be avoided.

The **Occipital Artery** (Fig. 349) arises from the posterior part of the external carotid, opposite the facial near the lower margin of the Digastric muscle. At its origin it is covered by the posterior belly of the Digastric and Stylo-hyoid muscles,

and the hypoglossal nerve winds around it from behind forward; higher up, it passes across the internal carotid artery, the internal jugular vein, and the pneumogastric and spinal accessory nerves; it then ascends to the interval between the transverse process of the atlas and the mastoid process of the temporal bone, and passes horizontally backward, grooving the surface of the latter bone, being covered by the Sterno-mastoid, Splenius, Trachelo-mastoid, and Digastric muscles, and resting upon the Rectus lateralis, the Superior oblique, and Complexus muscles; it then changes its course and passes vertically upward, pierces the fascia which connects the cranial attachment of the Trapezius with the Sterno-mastoid, and ascends in a tortuous course over the occiput, as high as the vertex, where it divides into numerous branches. It is accompanied in the latter part of its course by the great occipital and a cutaneous filament from the suboccipital nerve.

The branches given off from this vessel are—

Muscular.	Auricular.
Sterno-mastoid.	Meningeal.
Arteria Princeps Cervicis.	

The **Muscular branches** supply the Digastric, Stylo-hyoid, Splenius, and Trachelo-mastoid muscles.

The **sterno-mastoid** is a large and constant branch, generally arising from the artery close to its commencement. It first passes upward and backward, and then turns downward over the hypoglossal nerve, and enters the substance of the muscle, frequently in company with the spinal accessory nerve.

The **auricular branch** supplies the back part of the concha. It frequently gives off a branch, which enters the skull through the mastoid foramen and supplies the dura mater.

The **meningeal branch** ascends with the internal jugular vein, and enters the skull through the foramen lacerum posterius, to supply the dura mater in the posterior fossa.

The **arteria princeps cervicis** (Fig. 352) is a large branch which descends along the back part of the neck and divides into a superficial and deep branch. The former runs beneath the Splenius, giving off branches which perforate that muscle to supply the Trapezius which anastomose with the superficial cervical artery, a branch of the transversalis colli: the latter passes beneath the Complexus between it and the Semispinalis colli, and anastomoses with branches from the vertebral and with the deep cervical artery, a branch of the superior intercostal. The anastomosis between these vessels serves mainly to establish the collateral circulation after ligature of the carotid or subclavian artery.

The cranial branches of the occipital artery are distributed upon the occiput; they are very tortuous, and lie between the integument and Occipito-frontalis, anastomosing with the artery of the opposite side, the posterior auricular and temporal arteries. They supply the back part of the Occipito-frontalis muscle, the integument, and pericranium.

The **Posterior Auricular Artery** (Fig. 349) is a small vessel which arises from the external carotid, above the Digastric and Stylo-hyoid muscles, opposite the apex of the styloid process. It ascends, under cover of the parotid gland, to the groove between the cartilage of the ear and the mastoid process, immediately above which it divides into two branches: an anterior, auricular, passing forward to supply the back of the auricle and anastomose with the posterior division of the temporal; and a posterior, mastoid, to the scalp above and behind the ear, communicating with the occipital. Just before arriving at the mastoid process this artery is crossed by the facial nerve, and has beneath it the spinal accessory nerve.

Besides several small branches to the Digastric, Stylo-hyoid, and Sterno-mastoid muscles and to the parotid gland, this vessel gives off three branches:

Stylo-mastoid.	Auricular.	Mastoid.

The **stylo-mastoid branch** enters the stylo-mastoid foramen, and supplies the

tympanum, mastoid cells, and semicircular canals. In the young subject a branch from this vessel forms, with the tympanic branch from the internal maxillary, a vascular circle, which surrounds the auditory meatus, and from which delicate vessels ramify on the membrana tympani. It anastomoses with the petrosal branch of the middle meningeal artery by a twig which enters the hiatus Fallopii.

The **auricular branch** is distributed to the back part of the cartilage of the ear, upon which it ramifies minutely, some branches curving round the margin of the fibro-cartilage, others perforating it, to supply its anterior surface. It anastomoses with the anterior auricular branches of the temporal.

The **mastoid branch** passes backward, over the Sterno-mastoid muscle, to the scalp above and behind the ear. It supplies the posterior belly of the Occipito-frontalis muscle and the scalp in this situation. It anastomoses with the occipital artery.

The **Ascending Pharyngeal Artery** (Fig. 352), the smallest branch of the external carotid, is a long, slender vessel, deeply seated in the neck, beneath the other branches of the external carotid and the Stylo-pharyngeus muscle. It arises from the back part of the external carotid, near the commencement of that vessel, and ascends vertically between the internal carotid and the side of the pharynx, to the under surface of the base of the skull, lying on the Rectus capitis anticus major. Its branches may be subdivided into three sets:

Prevertebral. Pharyngeal. Meningeal.

The **prevertebral branches** are numerous small vessels which supply the Recti capitis antici and Longus colli muscles, the sympathetic, hypoglossal, and pneumogastric nerves, and the lymphatic glands of the neck, anastomosing with the ascending cervical artery.

The **pharyngeal branches** are three or four in number. Two of these descend to supply the middle and inferior Constrictors and the Stylo-pharyngeus, ramifying in their substance and in the mucous membrane lining them. The largest of the pharyngeal branches passes inward, running upon the Superior constrictor, and sends ramifications to the soft palate and tonsil, which take the place of the ascending palatine branch of the facial artery when that vessel is of small size. A twig from this branch passes up the Eustachian tube to supply the tympanum.

The **meningeal branches** consist of several small vessels, which pass through foramina in the base of the skull, to supply the dura mater. One, the posterior meningeal, enters the cranium through the foramen lacerum posterius; a second passes through the foramen lacerum medium; and occasionally a third through the anterior condyloid foramen. They are all distributed to the dura mater.

Surgical Anatomy.—The ascending pharyngeal artery has been wounded from the throat, as in the case in which the stem of a tobacco-pipe was driven into the vessel, causing fatal hæmorrhage.

The **Superficial Temporal Artery** (Fig. 349), the smaller of the two terminal branches of the external carotid, appears, from its direction, to be the continuation of that vessel. It commences in the substance of the parotid gland, in the interspace between the neck of the condyle of the lower jaw and the external meatus, crosses over the posterior root of the zygoma, passes beneath the Attrahens aurem muscle, and divides, about two inches above the zygomatic arch, into two branches, an anterior and a posterior.

The **anterior temporal** inclines forward over the forehead, supplying the muscles, integument, and pericranium in this region, and anastomoses with the supra-orbital and frontal arteries.

The **posterior temporal**, larger than the anterior, curves upward and backward along the side of the head, lying superficial to the temporal fascia, and inosculates with its fellow of the opposite side, and with the posterior auricular and occipital arteries.

The superficial temporal artery, as it crosses the zygoma, is covered by the Attrahens aurem muscle and by a dense fascia given off from the parotid gland: it is also usually crossed by one or two veins, and accompanied by branches of the

facial and auriculo-temporal nerves. Besides some twigs to the parotid gland, the articulation of the jaw, and the Masseter muscle, its branches are—the

Transverse Facial. Middle Temporal.
Anterior Auricular.

The **transverse facial** is given off from the temporal before that vessel quits the parotid gland; running forward through its substance, it passes transversely across the face, between Stenson's duct and the lower border of the zygoma, and divides on the side of the face into numerous branches, which supply the parotid gland, the Masseter muscle, and the integument, anastomosing with the facial, masseteric, and infra-orbital arteries. This vessel rests on the Masseter, and is accompanied by one or two branches of the facial nerve. It is sometimes a branch of the external carotid.

The **middle temporal artery** arises immediately above the zygomatic arch, and, perforating the temporal fascia, supplies the Temporal muscle, anastomosing with the deep temporal branches of the internal maxillary. It occasionally gives off an orbital branch, which runs along the upper border of the zygoma, between the two layers of the temporal fascia, to the outer angle of the orbit. This branch supplies the Orbicularis palpebrarum, and anastomoses with the lachrymal and palpebral branches of the ophthalmic artery.

The **anterior auricular branches** are distributed to the anterior portion of the pinna, the lobule, and part of the external meatus, anastomosing with branches of the posterior auricular.

Surgical Anatomy.—It occasionally happens that the surgeon is called upon to perform the operation of arteriotomy upon this vessel in cases of inflammation of the eye or brain. If the student will consider the relations of the trunk of this vessel as it crosses the zygomatic arch with the surrounding structures, he will observe that it is covered by a thick and dense fascia, crossed by one or two veins, and accompanied by branches of the facial and auriculo-temporal nerves. Bleeding should not be performed in this situation, as much difficulty may arise from the dense fascia over the vessel preventing a free flow of blood, and considerable pressure is requisite afterward to repress the hæmorrhage. Again, a varicose aneurism may be formed by the accidental opening of one of the veins in front of the artery, or severe neuralgic pain may arise from the operation implicating one of the nervous filaments in the neighborhood. The anterior branch, on the contrary, is subcutaneous, is a large vessel, and is readily compressed; it should consequently always be selected for the operation.

The **Internal Maxillary** (Fig. 350), the larger of the two terminal branches of the external carotid, passes inward, at right angles from that vessel, to the inner side of the neck of the condyle of the lower jaw, to supply the deep structures of the face. At its origin, it is imbedded in the substance of the parotid gland, being on a level with the lower extremity of the lobule of the ear.

In the first part of its course (*maxillary portion*) the artery passes horizontally forward and inward, between the ramus of the jaw and the internal lateral ligament. The artery here lies parallel with the auriculo-temporal nerve; it crosses the inferior dental nerve, and lies along the lower border of the External pterygoid muscle.

In the second part of its course (*pterygoid portion*) it runs obliquely forward and upward upon the outer surface of the External pterygoid muscle, being covered by the ramus of the lower jaw and lower part of the Temporal muscle.

In the third part of its course (*spheno-maxillary portion*) it approaches the superior maxillary bone, and enters the spheno-maxillary fossa in the interval between the two heads of the External pterygoid, where it lies in relation with Meckel's ganglion, and gives off its terminal branches.

Peculiarities.—Occasionally, this artery passes between the two Pterygoid muscles. The vessel in this case passes forward to the interval between the processes of origin of the External pterygoid, in order to reach the superior maxillary bone. Sometimes the vessel escapes from beneath the External pterygoid by perforating the middle of that muscle.

The branches of this vessel may be divided into three groups, corresponding with its three divisions.

BRANCHES OF THE FIRST OR MAXILLARY PORTION OF THE INTERNAL MAXILLARY (Fig. 351).

Tympanic (anterior).	Small Meningeal.
Middle Meningeal.	Inferior Dental.

The **tympanic branch** passes upward behind the articulation of the lower jaw, enters the tympanum through the Glaserian fissure, and ramifies upon the mem-

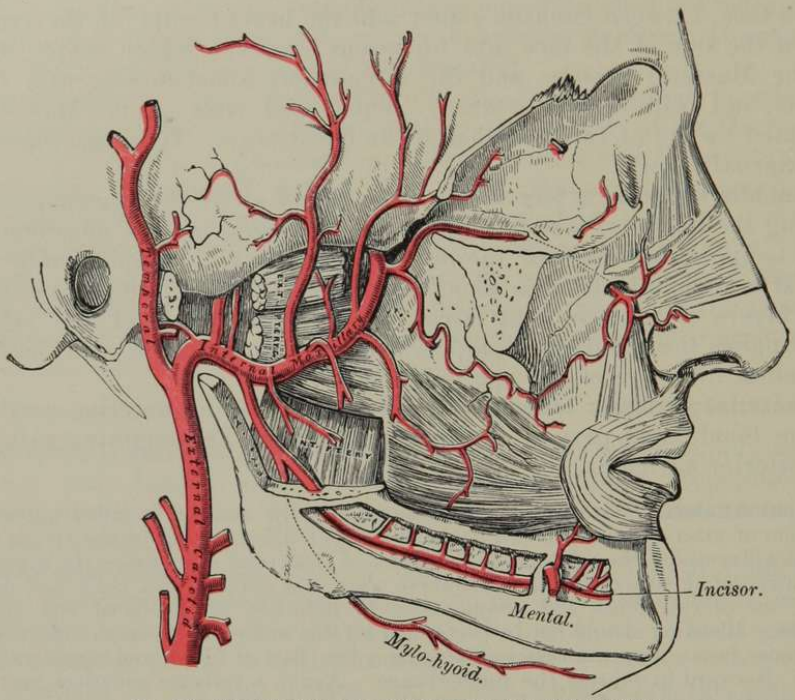

FIG. 350.—The internal maxillary artery, and its branches.

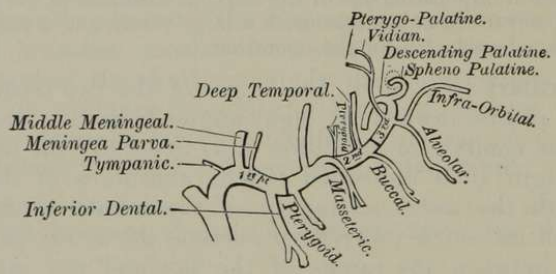

FIG. 351.—Plan of the branches.

brana tympani, forming a vascular circle around the membrane with the stylo-mastoid artery, and anastomosing with the Vidian and the tympanic branch from the internal carotid. It gives off a branch (*deep auricular*) to the external meatus, supplying its lining and the outer surface of the membrana tympani.

The **middle meningeal** is the largest of the branches which supply the dura mater. It arises from the internal maxillary, between the internal lateral ligament and the neck of the jaw, and passes vertically upward between the two roots of the auriculo-temporal nerve to the foramen spinosum of the sphenoid bone. On entering the cranium it divides into two branches, anterior and posterior. The *anterior branch*, the larger, crosses the great ala of the sphenoid, and reaches the groove, or canal, in the anterior inferior angle of the parietal bone: it then divides into branches which spread out between the dura mater and internal surface of the cranium, some passing upward over the parietal bone as far as the vertex, and others backward to the occipital bone. The *posterior branch* crosses the squamous portion of the temporal, and on the inner surface of the parietal

bone divides into branches which supply the posterior part of the dura mater and cranium. The branches of this vessel are distributed partly to the dura mater, but chiefly to the bones; they anastomose with the arteries of the opposite side, and with the anterior and posterior meningeal.

The middle meningeal on entering the cranium gives off the following collateral branches: 1. Numerous small vessels to the ganglion of the fifth nerve and to the dura mater in this situation; 2. A branch (*petrosal branch*), which enters the hiatus Fallopii, supplies the facial nerve, and anastomoses with the stylo-mastoid branch of the posterior auricular artery; 3. Orbital branches, which pass through the sphenoidal fissure or through separate canals in the great wing of the sphenoid to anastomose with the lachrymal or other branches of the ophthalmic artery; 4. Temporal branches, which pass through foramina in the great wing of the sphenoid, and anastomose in the temporal fossa with the deep temporal arteries.

Surgical Anatomy.—The middle meningeal is an artery of considerable surgical importance, as it may be injured in fractures of the temporal region of the skull, and the injury may be followed by considerable hæmorrhage between the bone and dura mater, which may cause compression of the brain and require the operation of trephining for its relief. This artery crosses the anterior inferior angle of the parietal bone at a point 1½ inches behind the external angular process of the frontal bone, and 1¾ inches above the zygoma. From this point the anterior branch passes upward and slightly backward to the sagittal suture, lying about ½ inch to ¾ inch behind the coronal suture. The posterior branch passes upward and backward over the squamous portion of the temporal bone. In order to expose the artery as it lies in the canal in the parietal bone, a semilunar incision, with its convexity upward, should be made, commencing an inch behind the external angular process, and carried backward for 2 inches. The structures cut through are: (1) skin; (2) superficial fascia, with branches of the superficial temporal vessels and nerves; (3) the fascia continued down from the aponeurosis of the Occipito-frontalis; (4) the two layers of the temporal fascia; (5) the temporal muscle; (6) the deep temporal vessels; (7) the pericranium; and (8) the bone.

The **small meningeal** is sometimes derived from the preceding. It enters the skull through the foramen ovale, and supplies the Gasserian ganglion and dura mater. Before entering the cranium it gives off a branch to the nasal fossa, soft palate, and tonsil.

The **inferior dental** descends with the dental nerve to the foramen on the inner side of the ramus of the jaw. It runs along the dental canal in the substance of the bone, accompanied by the nerve, and opposite the first bicuspid tooth divides into two branches, incisor and mental; the former is continued forward beneath the incisor teeth as far as the symphysis, where it anastomoses with the artery of the opposite side; the mental branch escapes with the nerve at the mental foramen, supplies the structures composing the chin, and anastomoses with the submental, inferior labial, and inferior coronary arteries. As the dental artery enters the foramen it gives off a *mylo-hyoid branch*, which runs in the mylo-hyoid groove, and ramifies on the under surface of the Mylo-hyoid muscle. The dental and incisor arteries during their course through the substance of the bone give off a few twigs which are lost in the cancellous tissue, and a series of branches which correspond in number to the roots of the teeth: these enter the minute apertures at the extremities of the fangs and supply the pulp of the teeth.

Branches of the Second or Pterygoid Portion of Internal Maxillary.

Deep Temporal.	Masseteric.
Pterygoid.	Buccal.

These branches are distributed, as their names imply, to the muscles in the maxillary region.

The **deep temporal arteries**, two in number, anterior and posterior, each occupy that part of the temporal fossa indicated by its name. Ascending between the Temporal muscle and pericranium, they supply that muscle and anastomose with the other temporal arteries, the anterior branch communicating with the lachrymal through small branches which perforate the malar bone and great wing of the sphenoid.

The **pterygoid branches**, irregular in their number and origin, supply the Pterygoid muscles.

The **masseteric** is a small branch which passes outward, above the sigmoid notch of the lower jaw, to the deep surface of the Masseter. It supplies that muscle, and anastomoses with the masseteric branches of the facial and with the transverse facial artery.

The **buccal** is a small branch which runs obliquely forward between the Internal pterygoid and the ramus of the jaw, to the outer surface of the Buccinator, to which it is distributed, anastomosing with branches of the facial artery.

Branches of the Third or Spheno-maxillary Portion of Internal Maxillary.

Alveolar.	Vidian.
Infra-orbital.	Pterygo-palatine.
Posterior or Descending Palatine.	Naso- or Spheno-palatine.

The **alveolar** or **posterior dental branch** is given off from the internal maxillary by a common branch with the infra-orbital, and just as the trunk of the vessel is passing into the spheno-maxillary fossa. Descending upon the tuberosity of the superior maxillary bone, it divides into numerous branches, some of which enter the posterior dental canals, to supply the molar and bicuspid teeth and the lining of the antrum, and others are continued forward on the alveolar process to supply the gums.

The **infra-orbital** appears, from its direction, to be the continuation of the trunk of the internal maxillary. It arises from that vessel by a common trunk with the preceding branch, and runs along the infra-orbital canal with the superior maxillary nerve, emerging upon the face at the infra-orbital foramen, beneath the Levator labii superioris. Whilst contained in the canal, it gives off branches which ascend into the orbit, and supply the Inferior rectus and Inferior oblique muscles and the lachrymal gland. Other branches (*anterior dental*) descend through canals in the bone to supply the mucous membrane of the antrum and the front teeth of the upper jaw. On the face some branches pass inward toward the nose, anastomosing with the angular branch of the facial artery and nasal branch of the ophthalmic; and other branches descend beneath the Levator labii superioris and anastomose with the transverse facial and buccal branches.

The four remaining branches arise from that portion of the internal maxillary which is contained in the spheno-maxillary fossa.

The **descending palatine** passes down the posterior palatine canal with the anterior palatine branch of Meckel's ganglion, and, emerging from the posterior palatine foramen, runs forward in a groove on the inner side of the alveolar border of the hard palate to the anterior palatine canal, where the terminal branch of the artery passes upward through the foramen of Stenson to anastomose with the naso-palatine artery. Its branches are distributed to the gums, the mucous membrane of the hard palate, and the palatine glands. Whilst it is contained in the palatine canal it gives off branches, which descend in the accessory palatine canals to supply the soft palate and tonsil, anastomosing with the ascending palatine artery.

The **Vidian branch** passes backward along the Vidian canal with the Vidian nerve. It is distributed to the upper part of the pharynx and Eustachian tube, sending a small branch into the tympanum, which anastomoses with the anterior tympanic.

The **pterygo-palatine** is also a very small branch, which passes backward through the pterygo-palatine canal with the pharyngeal nerve, and is distributed to the upper part of the pharynx and Eustachian tube.

The **spheno-palatine** passes through the spheno-palatine foramen into the cavity of the nose, at the back part of the superior meatus, and divides into two branches: one internal, the *naso-palatine* or *superior artery of the septum*, passes

obliquely downward and forward along the septum nasi, supplies the mucous membrane, and anastomoses in front with the terminal branch of the descending palatine. The external branches, two or three in number, supply the mucous membrane covering the lateral wall of the nose, the antrum, and the ethmoid and sphenoid cells.

SURGICAL ANATOMY OF THE TRIANGLES OF THE NECK.

The student having considered the relative anatomy of the large arteries of the neck and their branches, and the relations they bear to the veins and nerves, should now examine these structures collectively, as they present themselves in certain regions of the neck, in each of which important operations are constantly being performed.

The side of the neck presents a somewhat quadrilateral outline, limited, above, by the lower border of the body of the jaw, and an imaginary line extending from the angle of the jaw to the mastoid process; below, by the prominent upper border of the clavicle; in front, by the median line of the neck; behind, by the anterior margin of the Trapezius muscle. This space is subdivided into two large triangles by the Sterno-mastoid muscle, which passes obliquely across the neck, from the sternum and clavicle below to the mastoid process above. The triangular space in front of this muscle is called the *anterior triangle;* and that behind it, the *posterior triangle.*

Anterior Triangle of the Neck.

The **anterior triangle** is bounded, in front, by a line extending from the chin to the sternum; behind, by the anterior margin of the Sterno-mastoid; its base, directed upward, is formed by the lower border of the body of the jaw and a line extending from the angle of the jaw to the mastoid process; its apex is below, at the sternum. This space is subdivided into three smaller triangles by the Digastric muscle above and the anterior belly of the Omo-hyoid below. These smaller triangles are named, from below upward, the inferior carotid, the superior carotid, and the submaxillary triangle.

The **Inferior Carotid Triangle** is bounded, in front, by the median line of the neck; behind, by the anterior margin of the Sterno-mastoid; above, by the anterior belly of the Omo-hyoid; and is covered by the integument, superficial fascia, Platysma, and deep fascia, ramifying between which is the descending branch of the superficialis colli nerve. Beneath these superficial structures are the Sterno-hyoid and Sterno-thyroid muscles, which, together with the anterior margin of the Sterno-mastoid, conceal the lower part of the common carotid artery.[1]

This vessel is enclosed within its sheath, together with the internal jugular vein and pneumogastric nerve; the vein lying on the outer side of the artery on the right side of the neck, but overlapping it, or passing directly across it on the left side; the nerve lying between the artery and vein, on a plane posterior to both. In front of the sheath are a few filaments descending from the loop of communication between the descendens and communicans hypoglossi; behind the sheath are seen the inferior thyroid artery, the recurrent laryngeal nerve, and the sympathetic nerve; and on its inner side, the trachea, the thyroid gland—much more prominent in the female than in the male—and the lower part of the larynx. By cutting into the upper part of this space and slightly displacing the Sterno-mastoid muscle the common carotid artery may be tied below the Omo-hyoid muscle.

The floor of the inferior carotid triangle is formed by the Longus colli muscle below, by the Scalenus anticus above (see Fig. 284, page 424), between which

[1] Therefore the common carotid artery and internal jugular vein are not, strictly speaking, contained in this triangle, since they are covered by the Sterno-mastoid muscle; that is to say, lie behind the anterior border of that muscle, which forms the posterior border of the triangle. But as they lie very close to the structures which are really contained in the triangle, and whose position it is essential to remember in operating on this part of the artery, it has seemed expedient to study the relations of all these parts together.

muscles the vertebral artery and vein will be found passing into the foramen in the sixth transverse process; a small portion of the origin of the Rectus capitis anticus major may also be seen in the floor of the space.

The **Superior Carotid Triangle** is bounded, behind, by the Sterno-mastoid; below, by the anterior belly of the Omo-hyoid; and above, by the posterior belly of the Digastric muscle. It is covered by the integument, superficial fascia, Platysma, and deep fascia, ramifying between which are branches of the facial and superficialis colli nerves. Its floor is formed by parts of the Thyro-hyoid, Hyo-glossus, and the inferior and middle Constrictor muscles of the pharynx. This space contains the upper part of the common carotid artery, which bifurcates opposite the upper border of the thyroid cartilage into the external and internal carotid. These vessels are occasionally somewhat concealed from view by the anterior margin of the Sterno-mastoid muscle, which overlaps them. The external and internal carotids lie side by side, the external being the more anterior of the two. The following branches of the external carotid are also met with in this space: the superior thyroid, running forward and downward; the lingual, directly forward; the facial, forward and upward; the occipital, backward; and the ascending pharyngeal directly upward on the inner side of the internal carotid. The veins met with are: the internal jugular, which lies on the outer side of the common and internal carotid arteries, and veins corresponding to the above-mentioned branches of the external carotid—viz. the superior thyroid, the lingual, facial, ascending pharyngeal, and sometimes the occipital,—all of which accompany their corresponding arteries and terminate in the internal jugular. The nerves in this space are the following: In front of the sheath of the common carotid is the descendens hypoglossi. The hypoglossal nerve crosses both carotids above, curving round the occipital artery at its origin. Within the sheath, between the artery and vein, and behind both, is the pneumogastric nerve; behind the sheath, the sympathetic. On the outer side of the vessels the spinal accessory nerve runs for a short distance before it pierces the Sterno-mastoid muscle; and on the inner side of the external carotid, just below the hyoid bone, may be seen the superior laryngeal nerve; and, still more inferiorly, the external laryngeal nerve. The upper part of the larynx and lower part of the pharynx are also found in the front part of this space.

The **Submaxillary Triangle** corresponds to the part of the neck immediately beneath the body of the jaw. It is bounded, above, by the lower border of the body of the jaw and a line drawn from its angle to the mastoid process; below, by the posterior belly of the Digastric and Stylo-hyoid muscles; in front, by the anterior belly of the Digastric. It is covered by the integument, superficial fascia, Platysma, and deep fascia, ramifying between which are branches of the facial and ascending filaments of the superficial cervical nerves. Its floor is formed by the anterior belly of the Digastric, the Mylo-hyoid, and the Hyo-glossus muscles. This space contains, in front, the submaxillary gland, imbedded in the substance of which are the facial artery and vein and their glandular branches; beneath this gland, on the surface of the Mylo-hyoid muscle, are the submental artery and the mylo-hyoid artery and nerve. The back part of this space is separated from the front part by the stylo-maxillary ligament: it contains the external carotid artery, ascending deeply in the substance of the parotid gland: this vessel here lies in front of, and superficial to, the internal carotid, being crossed by the facial nerve, and gives off in its course the posterior auricular, temporal, and internal maxillary branches: more deeply are the internal carotid, the internal jugular vein, and the pneumogastric nerve, separated from the external carotid by the Stylo-glossus and Stylo-pharyngeus muscles and the glosso-pharyngeal nerve.[1]

[1] The same remark will apply to this triangle as was made about the inferior carotid triangle. The structures enumerated as contained in the back part of the space lie, strictly speaking, beneath the muscles which form the posterior boundary of the triangle; but as it is very important to bear in mind their close relation to the parotid gland and its boundaries (on account of the frequency of surgical operations on this gland), all these parts are spoken of together.

Posterior Triangle of the Neck.

The **posterior triangle** is bounded, in front, by the Sterno-mastoid muscle; behind, by the anterior margin of the Trapezius; its base corresponds to the upper border of the clavicle; its apex, to the occiput. The space is crossed, about an inch above the clavicle, by the posterior belly of the Omo-hyoid, which divides it unequally into two, an upper or occipital and a lower or subclavian triangle.

The **Occipital**, the larger of the two posterior triangles, is bounded, in front, by the Sterno-mastoid; behind, by the Trapezius; below, by the Omo-hyoid. Its floor is formed from above downward by the Splenius capitis, Levator anguli scapulæ, and the middle and posterior Scaleni muscles. It is covered by the integument, the Platysma below, the superficial and deep fasciæ; the spinal accessory nerve is directed obliquely across the space from the Sterno-mastoid, which it pierces, to the under surface of the Trapezius; below, the descending branches of the cervical plexus and the transversalis colli artery and vein cross the space. A chain of lymphatic glands is also found running along the posterior border of the Sterno-mastoid, from the mastoid process to the root of the neck.

The **Subclavian**, the smaller of the two posterior triangles, is bounded, above, by the posterior belly of the Omo-hyoid; below, by the clavicle, its base, directed forward, being formed by the Sterno-mastoid. The size of the subclavian triangle varies according to the extent of attachment of the clavicular portion of the Sterno-mastoid and Trapezius muscles, and also according to the height at which the Omo-hyoid crosses the neck above the clavicle. Its height also varies much according to the position of the arm, being much diminished by raising the limb, on account of the ascent of the clavicle, and increased by drawing the arm downward, when that bone is depressed. This space is covered by the integument, superficial and deep fasciæ, and crossed by the descending branches of the cervical plexus. Just above the level of the clavicle the third portion of the subclavian artery curves outward and downward from the outer margin of the Scalenus anticus, across the first rib, to the axilla. Sometimes this vessel rises as high as an inch and a half above the clavicle, or to any point intermediate between this and its usual level. Occasionally, it passes in front of the Scalenus anticus or pierces the fibres of that muscle. The subclavian vein lies behind the clavicle, and is usually not seen in this space; but it occasionally rises as high up as the artery, and has even been seen to pass with that vessel behind the Scalenus anticus. The brachial plexus of nerves lies above the artery, and in close contact with it. Passing transversely across the clavicular margin of the space are the suprascapular vessels, and traversing its upper angle in the same direction, the transversalis colli artery and vein. The external jugular vein runs vertically downward behind the posterior border of the Sterno-mastoid, to terminate in the subclavian vein; it receives the transverse cervical and suprascapular veins, which occasionally form a plexus in front of the artery, and a small vein which crosses the clavicle from the cephalic. The small nerve to the Subclavius muscle also crosses this triangle about its middle. A lymphatic gland is also found in the space. Its floor is formed by the first rib with the first digitation of the Serratus magnus.

The Internal Carotid Artery.

The **internal carotid artery** supplies the anterior part of the brain, the eye, and its appendages, and sends branches to the forehead and nose. Its size in the adult is equal to that of the external carotid, though in the child it is larger than that vessel. It is remarkable for the number of curvatures that it presents in different parts of its course. In its cervical portion it occasionally presents one or two flexures near the base of the skull, whilst through the rest of its extent it describes a double curvature which resembles the italic letter *s* placed horizontally. These curvatures most probably diminish the velocity of the current of

blood, by increasing the extent of surface over which it moves and adding to the amount of impediment produced from friction.

In considering the course and relations of this vessel it may be conveniently divided into four portions: a cervical, petrous, cavernous, and cerebral.

Cervical Portion.—This portion of the internal carotid commences at the bifurcation of the common carotid, opposite the upper border of the thyroid cartilage, and runs perpendicularly upward, in front of the transverse processes of the three upper cervical vertebræ, to the carotid canal in the petrous portion of the temporal bone. It is superficial at its commencement, being contained in the superior carotid triangle, and lying on the same level as the external carotid, but behind that artery overlapped by the Sterno-mastoid and covered by the deep fascia, Platysma, and integument: it then passes beneath the parotid gland, being crossed by the hypoglossal nerve, the Digastric and Stylo-hyoid muscles, and the external carotid and occipital arteries. Higher up, it is separated from the external carotid by the Stylo-glossus and Stylo-pharyngeus muscles, the glosso-pharyngeal nerve, and pharyngeal branch of the pneumogastric. It is in relation, *behind*, with the Rectus capitis anticus major, the superior cervical ganglion of the sympathetic, and superior laryngeal nerve; *externally*, with the internal jugular vein and pneumogastric nerve; *internally*, with the pharynx, tonsil, the superior laryngeal nerve, and ascending pharyngeal artery.

Petrous Portion.—When the internal carotid artery enters the canal in the petrous portion of the temporal bone, it first ascends a short distance, then curves forward and inward, and again ascends as it leaves the canal to enter the cavity of the skull. In this canal the artery lies at first anterior to the tympanum, from which it is separated by a thin, bony lamella, which is cribriform in the young subject, and often absorbed in old age. It is separated from the bony wall of the carotid canal by a prolongation of dura mater, and is surrounded by filaments of the carotid plexus.

Cavernous Portion.—The internal carotid artery in this part of its course is situated between the layers of the dura mater forming the cavernous sinus, but covered by the lining membrane of the sinus. It at first ascends to the posterior clinoid process, then passes forward by the side of the body of the sphenoid bone, and again curves upward on the inner side of the anterior clinoid process, and perforates the dura mater forming the roof of the sinus. In this part of its course it is surrounded by filaments of the sympathetic nerve, and has in relation with it externally the sixth nerve.

Cerebral Portion.—Having perforated the dura mater on the inner side of the anterior clinoid process, the internal carotid enters the inner extremity of the fissure of Sylvius, where it gives off its terminal or cerebral branches. This portion of the artery has the optic nerve on its inner side, and the third nerve externally.

PLAN OF THE RELATIONS OF THE INTERNAL CAROTID ARTERY IN THE NECK.

Externally.

Skin, superficial and deep fasciæ.
Platysma.
Sterno-mastoid.
External carotid and occipital arteries.
Hypoglossal nerve.
Parotid gland.
Stylo-glossus and Stylo-pharyngeus muscles.
Glosso-pharyngeal nerve.
Pharyngeal branch of the pneumogastric.
Internal jugular vein.
Pneumogastric nerve.

Internally.

Pharynx.
Superior laryngeal nerve.
Ascending pharyngeal artery.
Tonsil.

Behind.

Rectus capitis anticus major.
Sympathetic.
Superior laryngeal nerve.

Peculiarities.—The length of the internal carotid varies according to the length of the neck, and also according to the point of bifurcation of the common carotid. Its origin some-

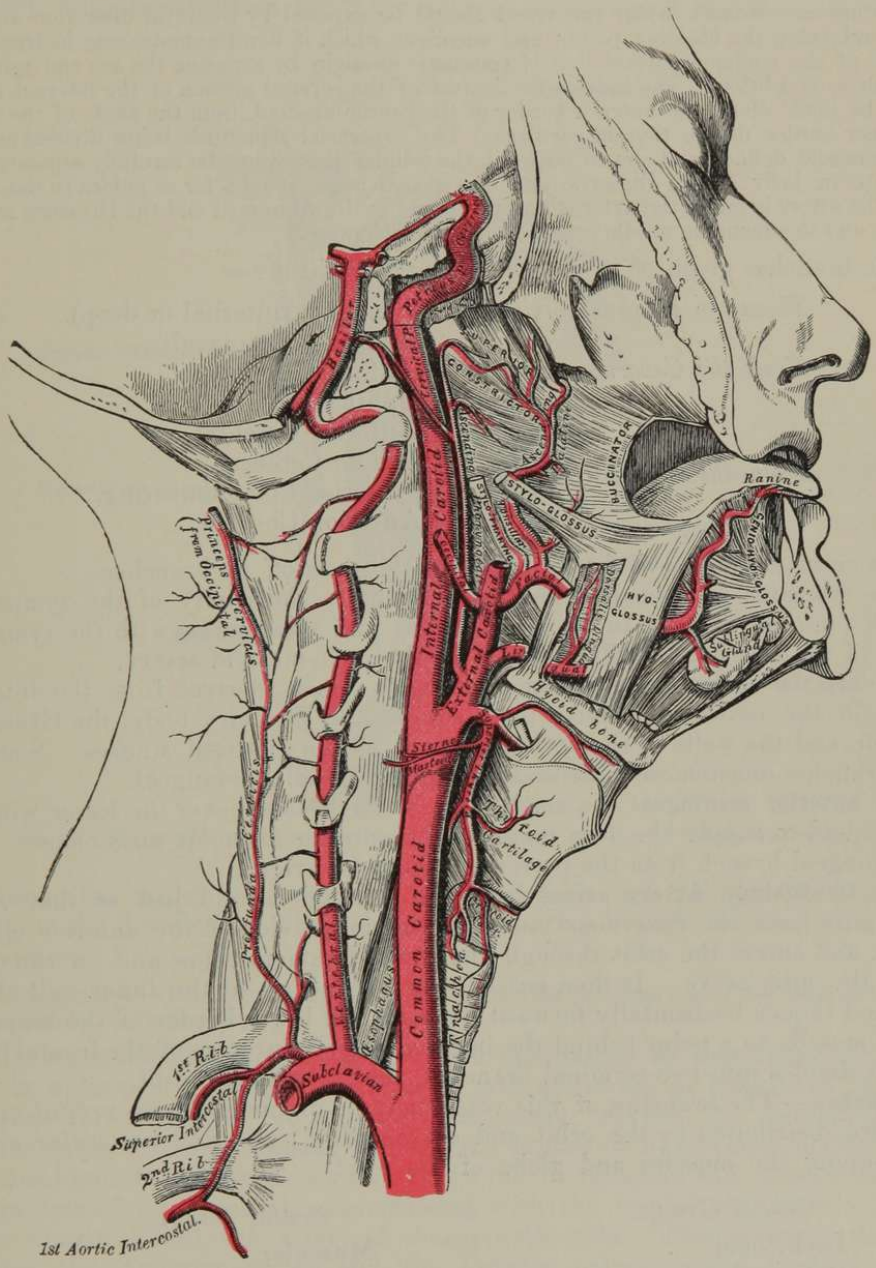

FIG. 352.—The internal carotid and vertebral arteries. Right side.

times takes place from the arch of the aorta; in such rare instances this vessel has been found to be placed nearer the middle line of the neck than the external carotid, as far upward as the larynx, when the latter vessel crossed the internal carotid. The course of the vessel, instead of being straight, may be very tortuous. A few instances are recorded in which this vessel was altogether absent: in one of these the common carotid passed up the neck, and gave off the usual branches of the external carotid, the cranial portion of the internal carotid being replaced by two branches of the internal maxillary, which entered the skull through the foramen rotundum and ovale and joined to form a single vessel.

Surgical Anatomy.—The cervical part of the internal carotid is very rarely wounded. Mr. Cripps, in an interesting paper in the *Medico-Chirurgical Transactions*, compares the rareness of a wound of the internal carotid with one of the external or its branches. It is, however, sometimes injured by a stab or gunshot wound in the neck, or even occasionally by a stab from within the mouth, as when a person receives a thrust from the end of a parasol or falls down with a tobacco-pipe in his mouth. The relation of the internal carotid with the tonsil should be especially remembered, as instances have occurred in which the artery has been wounded during the operation of scarifying the tonsil, and fatal hæmorrhage has supervened. The indications for ligature are wounds, when the vessel should be exposed by a careful dissection and tied above and below the bleeding point; and aneurism, which if non-traumatic may be treated by ligature of the common carotid, but if traumatic in origin by exposing the sac and tying the vessel above and below. The incision for ligature of the cervical portion of the internal carotid should be made along the anterior border of the Sterno-mastoid, from the angle of the jaw to the upper border of the thyroid cartilage. The superficial structures being divided and the Sterno-mastoid defined and drawn outward, the cellular tissue must be carefully separated and the posterior belly of the Digastric and hypoglossal nerve sought for as guides to the vessel. When the artery is found the external carotid should be drawn inward and the Digastric muscles upward, and the aneurism needle passed from without inward.

The branches given off from the internal carotid are—

From the Petrous portion	Tympanic (internal or deep).
From the Cavernous portion	Arteriæ Receptaculi. Anterior Meningeal. Ophthalmic.
From the Cerebral portion	Anterior Cerebral. Middle Cerebral. Posterior Communicating. Anterior Choroid.

The cervical portion of the internal carotid gives off no branches.

The **tympanic** is a small branch which enters the cavity of the tympanum through a minute foramen in the carotid canal, and anastomoses with the tympanic branch of the internal maxillary, and with the stylo-mastoid artery.

The **arteriæ receptaculi** are numerous small vessels, derived from the internal carotid in the cavernous sinus; they supply the pituitary body, the Gasserian ganglion, and the walls of the cavernous and inferior petrosal sinuses. Some of these branches anastomose with branches of the middle meningeal.

The **anterior meningeal** is a small branch which passes over the lesser wing of the sphenoid to supply the dura mater of the anterior fossa; it anastomoses with the meningeal branch from the posterior ethmoidal artery.

The **Ophthalmic Artery** arises from the internal carotid, just as that vessel is emerging from the cavernous sinus, on the inner side of the anterior clinoid process, and enters the orbit through the optic foramen, below and on the outer side of the optic nerve. It then passes over the nerve to the inner wall of the orbit, and thence horizontally forward, beneath the lower border of the Superior oblique muscle, to a point behind the internal angular process of the frontal bone, where it divides into two terminal branches, the *frontal* and *nasal*.

Branches.—The branches of this vessel may be divided into an *orbital group*, which are distributed to the orbit and surrounding parts, and an *ocular group*, which supply the muscles and globe of the eye:

Orbital Group.	*Ocular Group.*
Lachrymal.	Muscular.
Supra-orbital.	Anterior Ciliary.
Posterior Ethmoidal.	Short Ciliary.
Anterior Ethmoidal.	Long Ciliary.
Palpebral.	Arteria Centralis Retinæ.
Frontal.	
Nasal.	

The **lachrymal** is the first and one of the largest branches derived from the ophthalmic, arising close to the optic foramen: not unfrequently it is given off

from the artery before it enters the orbit. It accompanies the lachrymal nerve along the upper border of the External rectus muscle, and is distributed to the lachrymal gland. Its terminal branches, escaping from the gland, are distributed to the eyelids and conjunctiva, anastomosing with the palpebral arteries. The lachrymal artery gives off one or two *malar branches*, one of which passes through a foramen in the malar bone, to reach the temporal fossa, and anastomoses with the deep temporal arteries; the other appears on the cheek and anastomoses with

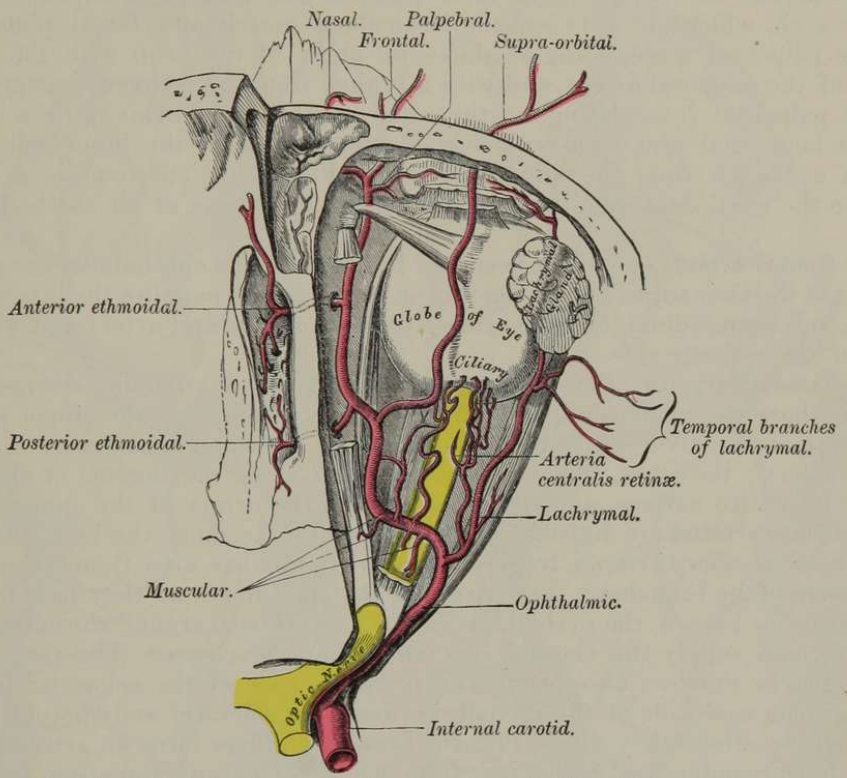

FIG. 353.—The ophthalmic artery and its branches, the roof of the orbit having been removed.

the transverse facial. A branch is also sent backward through the sphenoidal fissure to the dura mater, which anastomoses with a branch of the middle meningeal artery.

Peculiarities.—The lachrymal artery is sometimes derived from one of the anterior branches of the middle meningeal artery.

The **supra-orbital artery** arises from the ophthalmic as that vessel is crossing over the optic nerve. Ascending so as to arise above all the muscles of the orbit, it passes forward, with the supra-orbital nerve, between the periosteum and Levator palpebræ; and, passing through the supra-orbital foramen, divides into a superficial and deep branch, which supply the integument, the muscles, and the pericranium of the forehead, anastomosing with the frontal, the anterior branch of the temporal, and the artery of the opposite side. This artery in the orbit supplies the Superior rectus and the Levator palpebræ, and sends a branch inward, across the pulley of the Superior oblique muscle, to supply the parts at the inner canthus. At the supra-orbital foramen it frequently transmits a branch to the diploë.

The **ethmoidal branches** are two in number—posterior and anterior. The former, which is the smaller, passes through the posterior ethmoidal foramen, supplies the posterior ethmoidal cells, and, entering the cranium, gives off a meningeal branch, which supplies the adjacent dura mater, and nasal branches which descend into the nose through apertures in the cribriform plate, anasto-

mosing with branches of the spheno-palatine. The anterior ethmoidal artery accompanies the nasal nerve through the anterior ethmoidal foramen, supplies the anterior ethmoidal cells and frontal sinuses, and, entering the cranium, gives off a meningeal branch, which supplies the adjacent dura mater, and nasal branches, which descend into the nose, through apertures in the cribriform plate.

The **palpebral arteries,** two in number, superior and inferior, arise from the ophthalmic, opposite the pulley of the Superior oblique muscle; they leave the orbit to encircle the eyelids near their free margin, forming a superior and an inferior arch, which lie between the Orbicularis muscle and tarsal plates; the superior palpebral inosculating at the outer angle of the orbit with the orbital branch of the temporal artery, and with a branch from the lachrymal artery—the inferior palpebral inosculating, at the outer angle of the orbit with a branch from the lachrymal and transverse facial arteries, and at the inner side of the lid with a branch from the angular artery. From this anastomosis a branch passes to the nasal duct, ramifying in its mucous membrane, as far as the inferior meatus.

The **frontal artery,** one of the terminal branches of the ophthalmic, passes from the orbit at its inner angle, and, ascending on the forehead, supplies the integument, muscles, and pericranium, anastomosing with the supraorbital artery and with the artery of the opposite side.

The **nasal artery,** the other terminal branch of the ophthalmic, emerges from the orbit above the tendo oculi, and, after giving a branch to the upper part of the lachrymal sac, divides into two branches, one of which anastomoses with the angular artery; the other, the *dorsalis nasi*, runs along the dorsum of the nose, supplies its entire surface, and anastomoses with the artery of the opposite side.

The **ciliary arteries** are divisible into three groups, the short, the long, and anterior. The *short ciliary arteries*, from six to twelve in number, arise from the ophthalmic or some of its branches; they surround the optic nerve as they pass forward to the posterior part of the eyeball, pierce the sclerotic coat around the entrance of the nerve, and supply the choroid coat and ciliary processes. The *long ciliary arteries*, two in number, also pierce the posterior part of the sclerotic, and run forward, along each side of the eyeball, between the sclerotic and choroid, to the ciliary muscle, where they divide into two branches; these form an arterial circle around the circumference of the iris, from which numerous radiating branches pass forward, in its substance, to its free margin, where they form a second arterial circle around its pupillary margin. The *anterior ciliary arteries* are derived from the muscular branches; they pierce the sclerotic a short distance from the cornea, and terminate in the great arterial circle of the iris.

The **arteria centralis retinæ** is one of the smallest branches of the ophthalmic artery. It arises from the ophthalmic as that vessel is about to cross over the optic nerve; it pierces the optic nerve obliquely, and runs forward in the centre of its substance, and enters the globe of the eye through the porus opticus. Its mode of distribution will be described in the account of the anatomy of the eye.

The **muscular branches,** two in number, superior and inferior, supply the muscles of the eyeball. The superior, the smaller, often wanting, supplies the Levator palpebræ, Superior rectus, and Superior oblique. The inferior, more constant in its existence, passes forward between the optic nerve and Inferior rectus, and is distributed to the External, Internal, and Inferior recti, and Inferior oblique. This vessel gives off most of the anterior ciliary arteries.

The **cerebral branches of the internal carotid** are—the anterior cerebral, the middle cerebral, the posterior communicating, and the anterior choroid.

The **anterior cerebral** arises from the internal carotid at the inner extremity of the fissure of Sylvius. It passes forward in the great longitudinal fissure between the two anterior lobes of the brain, being connected, soon after its origin, with the vessel of the opposite side by a short anastomosing trunk, about two lines in length, the *anterior communicating*. The two anterior cerebral arteries, lying side by side, curve round the anterior border of the corpus callosum, and run along its

upper surface to its posterior part, where they terminate by anastomosing with the posterior cerebral arteries. In their course they give off the following branches:

Antero-median ganglionic.
Anterior and Internal Frontal.
Middle and Internal Frontal.
Posterior and Internal Frontal.

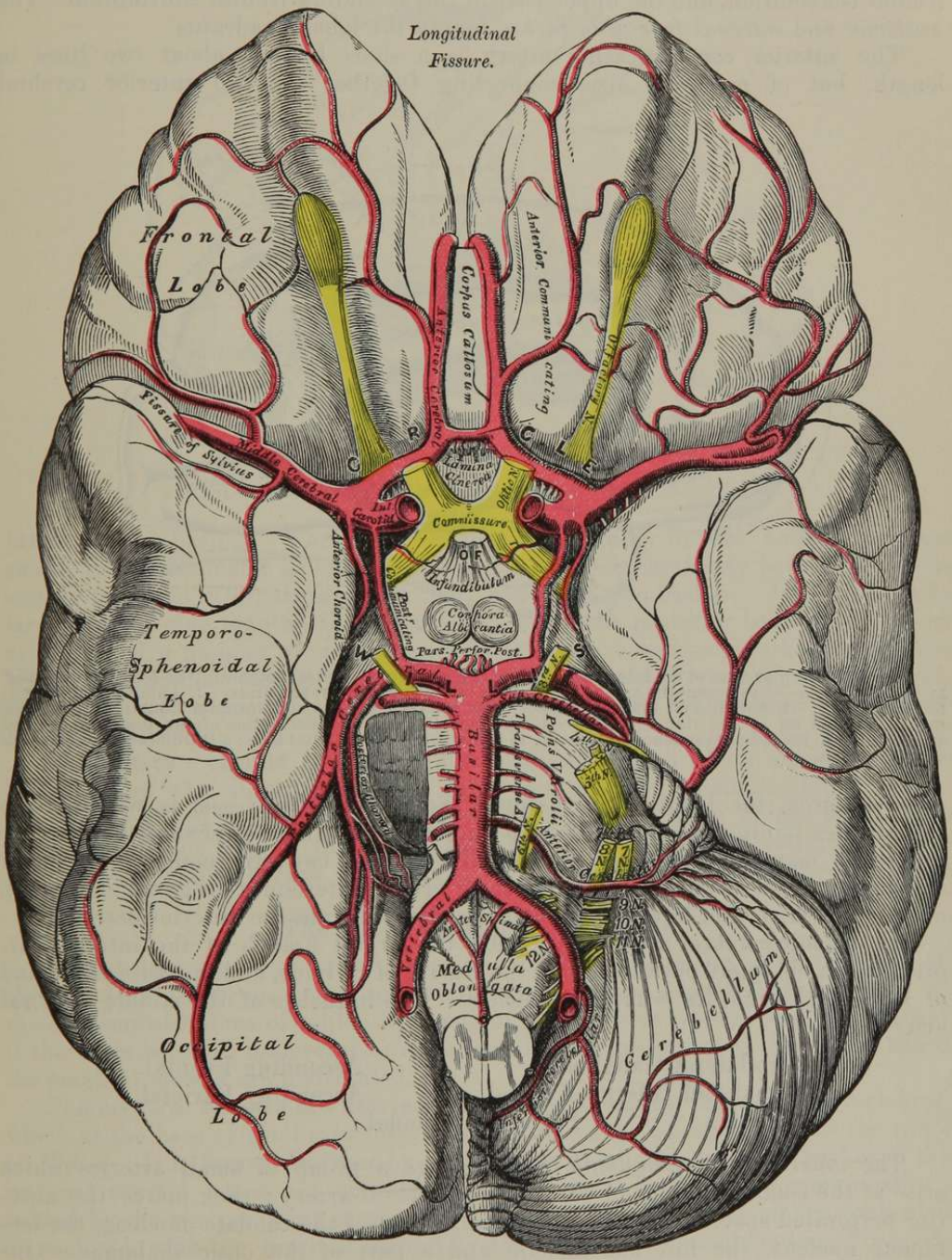

FIG. 354.—The arteries of the base of the brain. The right half of the cerebellum and pons have been removed.

N.B.—It will be noticed that in the illustration the two anterior cerebral arteries have been drawn at a considerable distance from each other: this makes the anterior communicating artery appear very much longer than it really is.

The *antero-median ganglionic* is a group of small arteries which arise at the

commencement of the anterior cerebral artery; they pierce the anterior perforated space and lamina cinerea, and supply the head of the caudate nucleus.

The *anterior* and *internal frontal branches* supply the two inferior frontal convolutions. The *middle* and *internal frontal branches* supply the corpus callosum, the convolution of the corpus callosum, the inner surface of the first frontal convolution, and the upper part of the ascending frontal convolution. The *posterior* and *internal frontal branches* supply the lobus quadratus.

The **anterior communicating artery** is a short branch, about two lines in length, but of moderate size, connecting together the two anterior cerebral

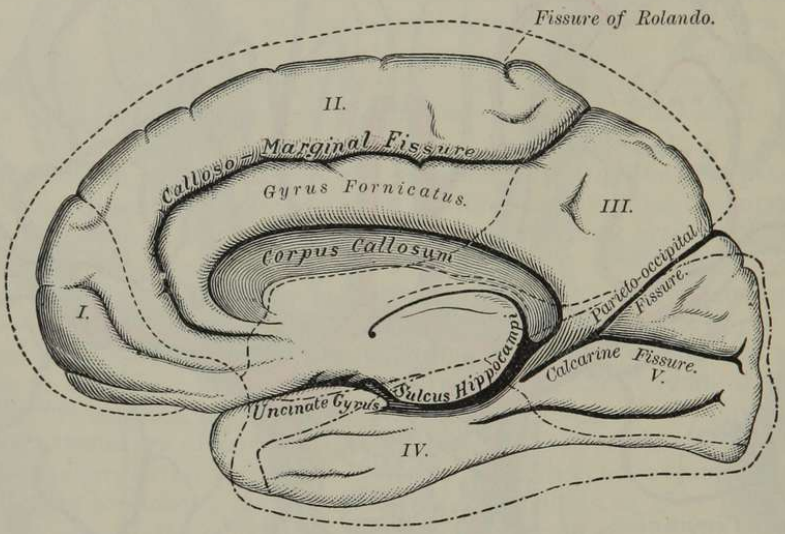

FIG. 355.—Vascular areæ of the internal surface of the cerebrum. (After Charcot.) The regions marked off by the line (— — —) represent the area of distribution of the anterior cerebral artery: I. Anterior and internal frontal arteries. II. Middle and internal frontal arteries. III. Posterior and internal frontal arteries. The regions marked off by the line (— — — —) represent the area of distribution of the posterior cerebral arteries: IV. to the temporo-sphenoidal lobe; V. to the cuneus and occipital lobe; a third branch supplies the uncinate gyrus.

arteries across the longitudinal fissure. Sometimes this vessel is wanting, the two arteries joining together to form a single trunk, which afterward divides. Or the vessel may be wholly or partially divided into two; frequently it is longer and smaller than usual. It gives off some of the antero-median ganglionic group of vessels, which are, however, principally derived from the anterior cerebral.

The **middle cerebral artery** (Fig. 356), the largest branch of the internal carotid, passes obliquely outward along the fissure of Sylvius, and opposite the island of Reil divides into its terminal branches. The branches of the middle cerebral artery are—

Antero-lateral Ganglionic.	Ascending Frontal.
External and Inferior Frontal.	Ascending Parietal.
Parieto-sphenoidal.	

The *antero-lateral ganglionic branches* are a group of small arteries which arise at the commencement of the middle cerebral artery; they pierce the anterior perforated space and supply the greater part of the caudate nucleus, the lenticular nucleus, the internal capsule, and a part of the optic thalamus. One artery of this group, distributed to the lenticular nucleus, is of larger size than the rest, and is of special importance, as being the artery in the brain most frequently ruptured; it has been termed by Charcot the "*artery of cerebral hæmorrhage.*" The *external* and *inferior frontal* supplies the third or inferior frontal convolution (Broca's convolution). The *ascending frontal* supplies the ascending frontal convolution. The *ascending parietal* supplies the ascending parietal con-

volution. The *parieto-sphenoidal* supplies the superior temporo-sphenoidal convolution and the angular gyrus.

The **posterior communicating artery** arises from the back part of the internal carotid, runs directly backward, and anastomoses with the posterior cerebral, a

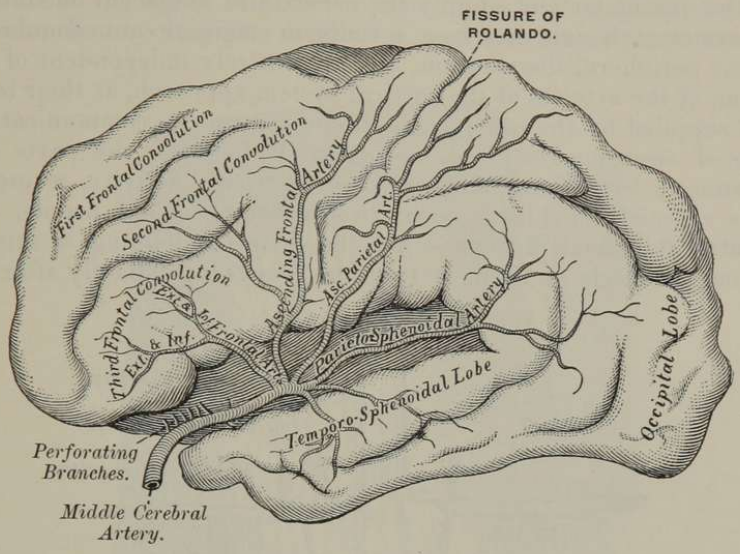

FIG. 356.—The distribution of the middle cerebral artery. (After Charcot.)

branch of the basilar. This artery varies considerably in size, being sometimes small, and occasionally so large that the posterior cerebral may be considered as arising from the internal carotid rather than from the basilar. It is frequently larger on one side than on the other side. From the posterior half of this vessel are given off a number of small branches, the *postero-median ganglionic branches*, which, with similar vessels from the posterior cerebral, pierce the posterior perforated space and supply the internal surfaces of the optic thalami and the walls of the third ventricle.

The **anterior choroid** is a small but constant branch which arises from the back part of the internal carotid, near the posterior communicating artery. Passing backward and outward, it enters the descending horn of the lateral ventricle beneath the edge of the middle lobe of the brain. It is distributed to the hippocampus major, corpus fimbriatum, velum interpositum, and choroid plexus.

The Blood-vessels of the Brain.

Recent investigations have tended to show that the mode of distribution of the vessels of the brain has an important bearing upon a considerable number of the anatomical lesions of which this part of the nervous system may be the seat; it therefore becomes important to consider a little more in detail the way in which the cerebral vessels are distributed.

The cerebral arteries are derived from the internal carotid and the vertebral, which at the base of the brain form a remarkable anastomosis known as the *circle of Willis*. It is formed in front by the anterior cerebral arteries, branches of the internal carotid, which are connected together by the anterior communicating; behind by the two posterior cerebrals, branches of the basilar which are connected on each side with the internal carotid by the posterior communicating (Fig. 354, p. 573). The parts of the brain included within this arterial circle are the lamina cinerea, the commissure of the optic nerves, the infundibulum, the tuber cinereum, the corpora albicantia, and the posterior perforated space.

From the circle of Willis arise the three trunks which together supply each cerebral hemisphere. From its anterior part proceed the two anterior cerebrals, from its antero-lateral part the middle cerebral, and from its posterior part the

posterior cerebrals. Each of these principal arteries gives origin to two very different systems of secondary vessels. One of these systems has been named the *central ganglionic system*, and the vessels belonging to it supply the central ganglia of the brain; the other has been named the *cortical arterial system*, and its vessels ramify in the pia mater and supply the cortex and subjacent medullary matter. These two systems, though they have a common origin, do not communicate at any point of their peripheral distribution, and are entirely independent of each other. Though some of the arteries of the cortical system approach, at their terminations, the regions supplied by the central ganglionic system, no communication between the two sets of vessels takes place, and there is between the parts supplied by the two systems a borderland of diminished nutritive activity, where, it is said, softening is especially liable to occur in the brains of old people.

The Central Ganglionic System.—All the vessels belonging to this system are given off from the circle of Willis or from the vessels immediately after their origin

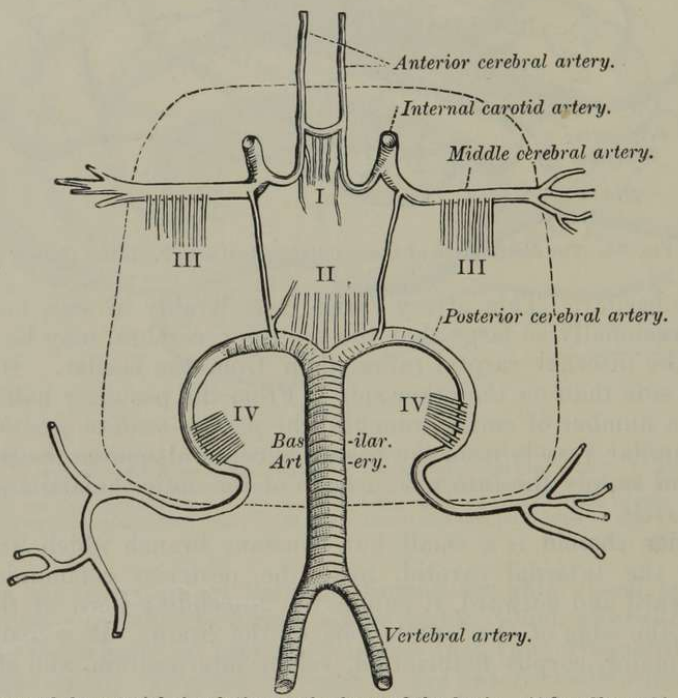

FIG. 357.—Diagram of the arterial circulation at the base of the brain. (After Charcot.) I. Antero-median group of ganglionic branches. II. Postero-median group. III. Right and left antero-lateral group. IV. Right and left postero-lateral group. The dotted line shows the limit of the ganglionic circle.

from it, so that if a circle is drawn at a distance of about an inch from the circle of Willis, it will include the origin of all the arteries belonging to this system (Fig. 357). The vessels of this system form six principal groups: (I.) the *antero-median group*, derived from the anterior cerebrals and anterior communicating; (II.) the *postero-median group*, from the posterior cerebrals and posterior communicating; (III.) the right and left *antero-lateral group*, from the middle cerebrals: and (IV.) the right and left *postero-lateral group*, from the posterior cerebrals, after they have wound round the crura cerebri. The vessels belonging to this system are larger than those of the cortical system, and are what Cohnheim has termed "terminal" arteries; that is to say, vessels which from their origin to their termination neither supply nor receive any anastomotic branch, so that by one of the small vessels only a limited area of the central ganglia can be injected; and the injection cannot be driven beyond the area of the part supplied by the particular vessel which is the subject of the experiment.

The Cortical Arterial System.—The vessels forming this system are the terminal branches of the anterior, middle, and posterior cerebral arteries, described above.

These vessels divide and ramify in the substance of the pia mater, and give off nutrient arteries which penetrate the cortex perpendicularly. These nutrient vessels are divisible into two classes—the long and short. The *long*—or, as they are sometimes called, the *medullary—arteries* pass through the gray matter to penetrate the centrum ovale to the depth of about an inch and a half, without intercommunicating otherwise than by very fine capillaries, and thus constitute so many independ-

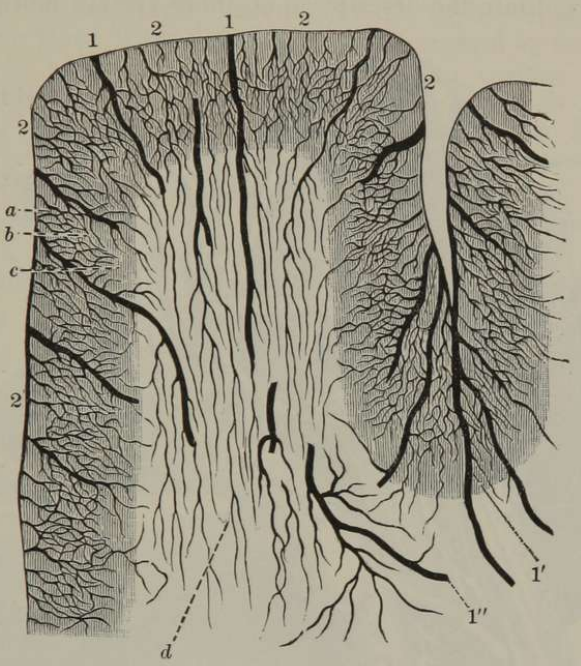

FIG. 358.—Distribution of the cortical arteries. (After Charcot.) 1. Medullary arteries. 1'. Group of medullary arteries in the sulcus between two adjacent convolutions. 1''. Arteries situated among Gratiolet's commissural fibres. 2, 2. Cortical arteries. *a*. Capillary network with fairly wide meshes, situated beneath the pia mater. *b*. Network with more compact, polygonal meshes, situated in the cortex. *c*. Transitional network with wider meshes. *d*. Capillary network in the white matter.

ent small systems. The *short vessels* are confined to the cortex, where they form with the long vessels a compact network in the middle zone of the gray matter, the outer and inner zones being sparingly supplied with blood (Fig. 358). The vessels of the cortical arterial system are not so strictly "terminal" as those of the central ganglionic system, but they approach this type very closely, so that injection of one area from the vessel of another area, though it may be possible, is frequently very difficult, and is only effected through vessels of small calibre. As a result of this, obstruction of one of the main branches or its divisions may have the effect of producing softening in a very limited area of the cortex.[1]

ARTERIES OF THE UPPER EXTREMITY.

The artery which supplies the upper extremity continues as a single trunk from its commencement down to the elbow, but different portions of it have received different names according to the region through which it passes. That part of the vessel which extends from its origin to the lower border of the first rib is termed the subclavian; beyond this point to the lower border of the axilla it is termed the axillary; and from the lower margin of the axillary space to the bend of the elbow it is termed brachial; here the single trunk terminates by dividing into two branches, the radial and ulnar—an arrangement precisely similar to what occurs in the lower limb.

[1] The student who desires further information on this subject is referred to Charcot's *Localization of Cerebral and Spinal Diseases*, p. 42 *et seq.*, whence the facts above given have been principally derived.

THE SUBCLAVIAN ARTERIES (Fig. 359).

The **subclavian artery** on the right side arises from the innominate artery opposite the right sterno-clavicular articulation; on the left side it arises from the arch of the aorta. It follows, therefore, that these two vessels must, in the first part of their course, differ in their length, their direction, and their relation with neighboring parts.

In order to facilitate the description of these vessels, more especially from a

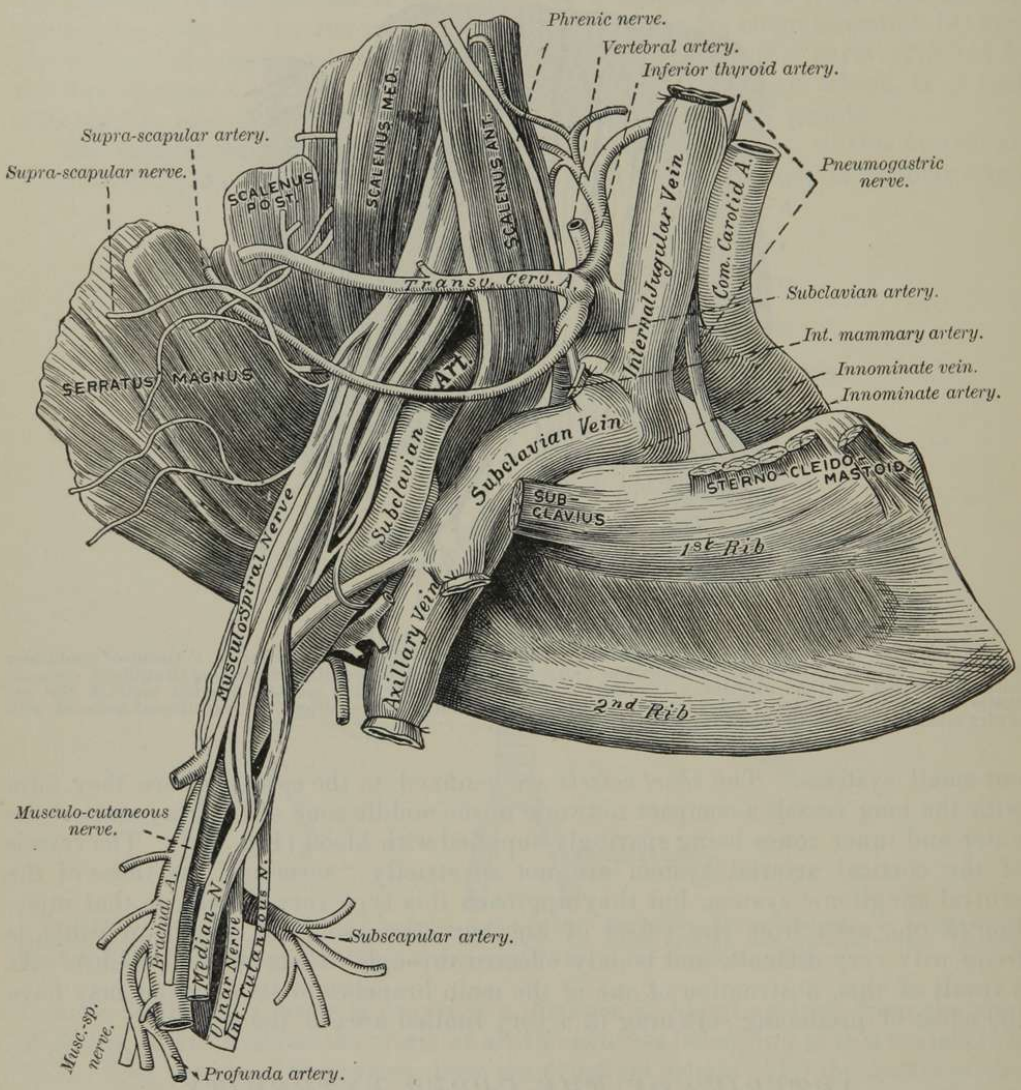

FIG. 359.—The subclavian artery, showing its relations. (From a preparation in the Museum of the Royal College of Surgeons.)

surgical point of view, each subclavian artery has been divided into three parts. The first portion, on the right side, passes upward and outward from the origin of the vessel to the inner border of the Scalenus anticus. On the left side it ascends nearly vertically, to gain the inner border of that muscle. The second part passes outward, behind the Scalenus anticus; and the third part passes from the outer margin of that muscle, beneath the clavicle, to the lower border of the first rib, where it becomes the axillary artery. The first portion of these two vessels differs so much in its course and in its relation with neighboring parts that it will be described separately. The second and third parts are alike on the two sides.

First Part of the Right Subclavian Artery (Figs. 344, 359).

The **right subclavian artery** arises from the arteria innominata, opposite the right sterno-clavicular articulation, and passes upward and outward to the inner margin of the Scalenus anticus muscle. In this part of its course it ascends a little above the clavicle, the extent to which it does so varying in different cases. It is covered, *in front*, by the integument, superficial fascia, Platysma, deep fascia, the clavicular origin of the Sterno-mastoid, the Sterno-hyoid, and Sterno-thyroid muscles, and another layer of the deep fascia. It is crossed by the internal jugular and vertebral veins and by the pneumogastric, the cardiac branches of the sympathetic, and the phrenic nerve. *Beneath*, the artery is invested by the pleura, and *behind*, it is separated by a cellular interval from the Longus colli, the neck of the first rib, and the cord of the sympathetic nerve; the recurrent laryngeal nerve winds round the lower and back part of the vessel. The subclavian vein lies below the subclavian artery, immediately behind the clavicle.

Plan of Relations of First Portion of the Right Subclavian Artery.

In front.

Skin, superficial fascia.
Platysma, deep fascia.
Clavicular origin of Sterno-mastoid.
Sterno-hyoid and Sterno-thyroid.
Internal jugular and vertebral veins.
Pneumogastric, cardiac, and phrenic nerves.

Beneath.
Pleura.

Behind.
Recurrent laryngeal nerve.
Sympathetic.
Longus colli.
Neck of first rib.

First Part of the Left Subclavian Artery (Fig. 344).

The **left subclavian artery** arises from the end of the arch of the aorta, opposite the fourth dorsal vertebra, and ascends nearly vertically to the inner margin of the Scalenus anticus muscle. This part of the vessel is, therefore, longer than the right, situated more deeply in the cavity of the chest, and directed nearly vertically upward, instead of arching outward like the vessel of the opposite side.

It is in relation, *in front*, with the pleura, the left lung, the pneumogastric, cardiac, and phrenic nerves, which lie parallel with it; the left carotid artery, left internal jugular and vertebral veins, and the commencement of the left innominate vein; and is covered by the Sterno-thyroid, Sterno-hyoid, and Sterno-mastoid muscles; it has the left carotid in front of, but not in contact with, it; *behind*, it is in relation with the œsophagus, thoracic duct, inferior cervical ganglion of the sympathetic, Longus colli, and vertebral column. To its *inner side* are the œsophagus, trachea, and thoracic duct; to its *outer side*, the pleura.

Plan of Relations of First Portion of Left Subclavian Artery.

In front.

Pleura and left lung.
Pneumogastric, cardiac, and phrenic nerves.
Left carotid artery.
Left internal jugular, vertebral, and innominate veins.
Sterno-thyroid, Sterno-hyoid, and Sterno-mastoid muscles.

Inner side.
Trachea.
Œsophagus.
Thoracic duct.

Outer side.
Pleura.

Behind.
Œsophagus and thoracic duct.
Inferior cervical ganglion of sympathetic.
Longus colli and vertebral column.

Second and Third Parts of the Subclavian Artery (Fig. 347).

The **Second Portion of the Subclavian Artery** lies behind the Scalenus anticus muscle; it is very short, and forms the highest part of the arch described by that vessel.

Relations.—It is covered, *in front*, by the skin, superficial fascia, Platysma, deep cervical fascia, Sterno-mastoid, and by the phrenic nerve, which is separated from the artery by the Scalenus anticus muscle. *Behind*, it is in relation with the pleura and the middle Scalenus; *above*, with the brachial plexus of nerves; *below*, with the pleura. The subclavian vein lies below and in front of the artery, separated from it by the Scalenus anticus.

Plan of Relations of Second Portion of Subclavian Artery.

In front.
Skin and superficial fascia.
Platysma and deep cervical fascia.
Sterno-mastoid.
Phrenic nerve.
Scalenus anticus.
Subclavian vein.

Above.
Brachial plexus.

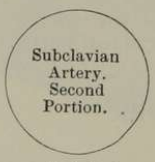

Below.
Pleura.

Behind.
Pleura and Middle Scalenus.

The **Third Portion of the Subclavian Artery** passes downward and outward from the outer margin of the Scalenus anticus to the lower border of the first rib, where it becomes the axillary artery. This portion of the vessel is the most superficial, and is contained in a triangular space, the base of which is formed in front by the Sterno-mastoid, and the two sides by the Omo-hyoid above and the clavicle below.

Plan of Relations of Third Portion of Subclavian Artery.

In front.
Skin and superficial fascia.
Platysma and deep cervical fascia.
Descending branches of cervical plexus. Nerve to Subclavius muscle.
Subclavius muscle, suprascapular artery, and vein.
The external jugular and transverse cervical veins.
The clavicle.

Above.
Brachial plexus.
Omo-hyoid.

Below.
First rib.

Behind.
Scalenus medius.

Relations.—It is covered, *in front*, by the skin, the superficial fascia, the Platysma, deep cervical fascia; by the clavicle, the Subclavius muscle and the suprascapular artery and vein, and the transverse cervical vein; the clavicular descending branches of the cervical plexus and the nerve to the Subclavius muscle pass vertically downward in front of the artery. The external jugular vein crosses it at its inner side, and receives the suprascapular and transverse cervical veins, which occasionally form a plexus in front of it. The subclavian vein is below the artery, lying close behind the clavicle. *Behind*, it lies on the middle Scalenus muscle; *above* it, and to its outer side, is the brachial plexus and Omo-hyoid muscle; *below*, it rests on the upper surface of the first rib.

Peculiarities.—The subclavian arteries vary in their origin, their course, and the height to which they rise in the neck.

The origin of the right subclavian from the innominate takes place, in some cases, above the sterno-clavicular articulation, and occasionally, but less frequently, in the cavity of the thorax, below that joint. Or the artery may arise as a separate trunk from the arch of the aorta. In such cases it may be either the first, second, third, or even the last branch derived from that vessel; in the majority of cases it is the first or last, rarely the second or third. When it is the first branch, it occupies the ordinary position of the innominate artery; when the second or third, it gains its usual position by passing behind the right carotid; and when the last branch, it arises from the left extremity of the arch, at its upper or back part, and passes obliquely toward the right side, usually behind the œsophagus and right carotid, sometimes between the œsophagus and trachea to the upper border of the first rib, whence it follows its ordinary course. In very rare instances this vessel arises from the thoracic aorta, as low down as the fourth dorsal vertebra. Occasionally it perforates the anterior Scalenus; more rarely it passes in front of that muscle. Sometimes the subclavian vein passes with the artery behind the Scalenus. The artery sometimes ascends as high as an inch and a half above the clavicle or any intermediate point between this and the upper border of the bone, the right subclavian usually ascending higher than the left.

The left subclavian is occasionally joined at its origin with the left carotid.

Surface Marking.—The course of the subclavian artery in the neck may be mapped out by describing a curve, with its convexity upward at the base of the posterior triangle. The inner end of this curve corresponds to the sterno-clavicular joint, the outer end to the centre of the lower border of the clavicle. The curve is to be drawn with such an amount of convexity that its mid-point reaches half an inch above the upper border of the clavicle. The left subclavian artery is more deeply placed than the right in the first part of its course, and, as a rule, does not reach quite as high a level in the neck. It should be borne in mind that the posterior border of the Sterno-mastoid muscle corresponds to the outer border of the Scalenus anticus, so that the third portion of the artery, that part most accessible for operation, lies immediately external to the posterior border of the Sterno-mastoid.

Surgical Anatomy.—The relations of the subclavian arteries of the two sides having been examined, the student should direct his attention to a consideration of the best position in which compression of the vessel may be effected, or in what situation a ligature may be best applied in cases of aneurism or wound.

Compression of the subclavian artery is required in cases of operations about the shoulder, in the axilla, or at the upper part of the arm; and the student will observe that there is only one situation in which it can be effectually applied—viz. where the artery passes across the outer surface of the first rib. In order to compress the vessel in this situation, the shoulder should be depressed, and the surgeon, grasping the side of the neck, should press with his thumb in the angle formed by the posterior border of the Sterno-mastoid with the upper border of the clavicle, downward, backward, and inward against the rib; if from any cause the shoulder cannot be sufficiently depressed, pressure may be made from before backward, so as to compress the artery against the middle Scalenus and transverse process of the seventh cervical vertebra. In appropriate cases, a preliminary incision may be made through the cervical fascia, and the finger may be pressed down directly upon the artery.

Ligature of the subclavian artery may be required in cases of wounds or of aneurism in the axilla, or in cases of aneurism on the cardiac side of the point of ligature; and the third part of the artery is that which is most favorable for an operation, on account of its being comparatively superficial and most remote from the origin of the large branches. In those cases where the clavicle is not displaced, this operation may be performed with comparative facility; but where the clavicle is pushed up by a large aneurismal tumor in the axilla the artery is placed at a great depth from the surface, which materially increases the difficulty of the operation. Under these circumstances it becomes a matter of importance to consider the height to which this vessel reaches above the bone. In ordinary cases its arch is about half an inch above the clavicle, occasionally as high as an inch and a half, and sometimes so low as to be on a level with its upper border. If the clavicle is displaced, these variations will necessarily make the operation more or less difficult according as the vessel is more or less accessible.

The chief points in the operation of tying the third portion of the subclavian artery are as follows: The patient being placed on a table in the horizontal position, with the head drawn

over to the opposite side and the shoulder depressed as much as possible, the integument should be drawn downward upon the clavicle, and an incision made through it, upon that bone, from the anterior border of the Trapezius to the posterior border of the Sterno-mastoid, to which may be added a short vertical incision meeting the preceding in its centre. The object in drawing the skin downward is to avoid any risk of wounding the external jugular vein, for as it perforates the deep fascia above the clavicle, it cannot be drawn downward with the skin. The cervical fascia should be divided upon a director, and if the interval between the Trapezius and Sterno-mastoid muscles be insufficient for the performance of the operation, a portion of one or both may be divided. The external jugular vein will now be seen toward the inner side of the wound: this and the suprascapular and transverse cervical veins, which terminate in it, should be held aside. If the external jugular vein is at all in the way and exposed to injury, it should be tied in two places and divided. The suprascapular artery should be avoided, and the Omo-hyoid muscle held aside if necessary. In the space beneath this muscle careful search must be made for the vessel: a deep layer of fascia and some connective tissue having been divided carefully, the outer margin of the Scalenus anticus muscle must be felt for, and, the finger being guided by it to the first rib, the pulsation of the subclavian artery will be felt as it passes over the rib. The aneurism needle may then be passed around the vessel from above downward and inward, so as to avoid including any of the branches of the brachial plexus. If the clavicle is so raised by the tumor that the application of the ligature cannot be effected in this situation, the artery may be tied above the first rib, or even behind the Scalenus anticus muscle; the difficulties of the operation in such a case will be materially increased, on account of the greater depth of the artery and the alteration in position of the surrounding parts.

The second part of the subclavian artery, from being that portion which rises highest in the neck, has been considered favorable for the application of the ligature when it is difficult to tie the artery in the third part of its course. There are, however, many objections to the operation in this situation. It is necessary to divide the Scalenus anticus muscle, upon which lies the phrenic nerve, and at the inner side of which is situated the internal jugular vein; and a wound of either of these structures might lead to the most dangerous consequences. Again, the artery is in contact, below, with the pleura, which must also be avoided; and, lastly, the proximity of so many of its large branches arising internal to this point must be a still further objection to the operation. In cases, however, where the sac of an axillary aneurism encroaches on the neck, it may be necessary to divide the outer half or two-thirds of the Scalenus anticus muscle, so as to place the ligature on the vessel at a greater distance from the sac. The operation is performed exactly in the same way as ligature of the third portion, until the Scalenus anticus is exposed, when it is to be divided on a director (never to a greater extent than its outer two-thirds), and it immediately retracts. The operation is therefore merely an extension of ligature of the third portion of the vessel.

In those cases of aneurism of the axillary or subclavian artery which encroach upon the outer portion of the Scalenus muscle to such an extent that a ligature cannot be applied in that situation, it may be deemed advisable, as a last resource, to tie the first portion of the subclavian artery. On the left side this operation is almost impracticable; the great depth of the artery from the surface, its intimate relation with the pleura, and its close proximity to the thoracic duct and to so many important veins and nerves, present a series of difficulties which it is next to impossible to overcome.[1] On the right side the operation is practicable, and has been performed, though never with success. The main objection to the operation in this situation is the smallness of the interval which usually exists between the commencement of the vessel and the origin of the nearest branch. The operation may be performed in the following manner: The patient being placed on the table in the horizontal position with the neck extended, an incision should be made along the upper border of the inner part of the clavicle, and a second along the inner border of the Sterno-mastoid, meeting the former at an angle. The sternal attachment of the Sterno-mastoid may now be divided on a director and turned outward; a few small arteries and veins, and occasionally the anterior jugular, must be avoided, or, if necessary, ligatured in two places and divided, and the Sterno-hyoid and Sterno-thyroid muscles divided in the same manner as the preceding muscle. After tearing through the deep fascia with the finger-nail, the internal jugular vein will be seen crossing the subclavian artery; this should be pressed aside and the artery secured by passing the needle from below upward, by which the pleura is more effectually avoided. The exact position of the vagus nerve, the recurrent laryngeal, the phrenic and sympathetic nerves should be remembered, and the ligature should be applied near the origin of the vertebral, in order to afford as much room as possible for the formation of a coagulum between the ligature and the origin of the vessel. It should be remembered that the right subclavian artery is occasionally deeply placed in the first part of its course when it arises from the left side of the aortic arch, and passes in such cases behind the œsophagus or between it and the trachea.

Collateral Circulation.—After ligature of the third part of the subclavian artery the collateral circulation is mainly established by three sets of vessels, thus described in a dissection:

"1. A posterior set, consisting of the suprascapular and posterior scapular branches of the subclavian, anastomosing with the median branch from the subscapular from the axillary.

"2. An internal set produced by the connection of the internal mammary on the one hand,

[1] The operation was, however, performed in New York by Dr. J. K. Rodgers, and the case is related in *A System of Surgery*, edited by T. Holmes, 2d ed. vol. iii. pp. 620, etc.

with the superior and long thoracic arteries, and the branches from the subscapular on the other.

"3. A middle or axillary set, which consisted of a number of small vessels derived from branches of the subclavian, above, and, passing through the axilla, terminated either in the main trunk or some of the branches of the axillary below. This last set presented most conspicuously the peculiar character of newly-formed or, rather, dilated arteries, being excessively tortuous, and forming a complete plexus.

"The chief agent in the restoration of the axillary artery below the tumor was the subscapular artery, which communicated most freely with the internal mammary, suprascapular, and posterior scapular branches of the subclavian, from all of which it received so great an influx of blood as to dilate it to three times its natural size." [1]

When a ligature is applied to the first part of the subclavian artery, the collateral circulation is carried on by—1, the anastomosis between the superior and inferior thyroid; 2, the anastomosis of the two vertebrals; 3, the anastomosis of the internal mammary with the deep epigastric and the aortic intercostals; 4, the superior intercostal anastomosing with the aortic intercostals; 5, the profunda cervicis anastomosing with the princeps cervicis; 6, the scapular branches of the thyroid axis anastomosing with the branches of the axillary; and 7, the thoracic branches of the axillary anastomosing with the aortic intercostals.

Branches of the Subclavian Artery.

These are four in number. On the left side all four branches, the *vertebral*, the *internal mammary*, the *thyroid axis*, and the *superior intercostal*, generally arise from the first portion of the vessel; but on the right side the superior intercostal usually arises from the second portion of the vessel. On both sides of the body the first three branches arise close together at the inner margin of the Scalenus anticus, in the majority of cases a free interval of half an inch to an inch existing between the commencement of the artery and the origin of the nearest branch; in a smaller number of cases an interval of more than an inch exists, never exceeding an inch and three-quarters. In a very few instances the interval had been found to be less than half an inch.

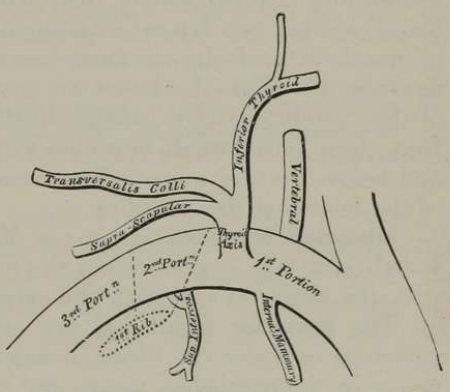

Fig. 360.—Plan of the branches of the right subclavian artery.

The **Vertebral Artery** (Fig. 352) is generally the first and largest branch of the subclavian; it arises from the upper and back part of the first portion of the vessel, and, passing upward, enters the foramen in the transverse process of the sixth cervical vertebra,[2] and ascends through the foramina in the transverse processes of all the vertebræ above this. Above the upper border of the axis it inclines outward and upward to the foramen in the transverse process of the atlas, through which it passes; it then winds backward behind its articular process, runs in a deep groove on the upper surface of the posterior arch of this bone, and, passing beneath the posterior occipito-atlantal ligament, pierces the dura mater and enters the skull through the foramen magnum. It then passes forward and upward to the front of the medulla oblongata, and unites with the vessel of the opposite side at the lower border of the pons Varolii to form the *basilar artery*.

Relations.—At its origin it is situated behind the internal jugular vein and inferior thyroid artery; and near the spine it lies between the Longus colli and Scalenus anticus muscles, having the thoracic duct in front of it on the left side. Within the foramina formed by the transverse processes of the vertebræ it is accompanied by a plexus of nerves from the inferior cervical ganglion of the sympathetic, and is surrounded by a dense plexus of veins which unite to form the

[1] *Guy's Hospital Reports*, vol. i. 1836: case of axillary aneurism, in which Mr. Aston Key had tied the subclavian artery on the outer edge of the Scalenus muscle twelve years previously.

[2] The vertebral artery sometimes enters the foramen in the transverse process of the fifth vertebra. Dr. Smyth, who tied this artery in the living subject, found it, in one of his dissections, passing into the foramen in the seventh vertebra.

vertebral vein at the lower part of the neck. It is situated in front of the cervical nerves as they issue from the intervertebral foramina. Whilst winding round the articular process of the atlas it is contained in a triangular space (*suboccipital triangle*) formed by the Rectus capitis posticus major, the Superior and the Inferior oblique muscles; and at this point is covered by the Complexus muscle. Within the skull, as it winds round the medulla oblongata, it is placed between the hypoglossal nerve and the anterior root of the suboccipital nerve, beneath the first digitation of the ligamentum denticulatum, and finally lies between the dura mater covering the basilar process of the occipital bone and the anterior surface of the medulla oblongata.

Branches.—These may be divided into two sets—those given off in the neck and those within the cranium.

Cervical Branches.	*Cranial Branches.*
Lateral Spinal.	Posterior Meningeal.
Muscular.	Anterior Spinal.
	Posterior Spinal.
	Posterior Inferior Cerebellar.

The **lateral spinal branches** enter the spinal canal through the intervertebral foramina and divide into two branches. Of these, one passes along the roots of the nerves to supply the spinal cord and its membranes, anastomosing with the other arteries of the spinal cord; the other divides into an ascending and a descending branch, which unite with similar branches from the artery above and below, so that two lateral anastomotic chains are formed on the posterior surface of the bodies of the vertebræ near the attachment of the pedicles. From these anastomotic chains branches are given off to supply the periosteum and the bodies of the vertebræ, and to communicate with similar branches from the opposite side; from these latter small branches are given off which join similar branches above and below, so that a central anastomotic chain is formed on the posterior surface of the bodies of the vertebræ.

Muscular branches are given off to the deep muscles of the neck, where the vertebral artery curves round the articular process of the atlas. They anastomose with the occipital and with the ascending and deep cervical arteries.

The **posterior meningeal** are one or two small branches given off from the vertebral opposite the foramen magnum. They ramify between the bone and dura mater in the cerebellar fossæ, and supply the falx cerebelli.

The **anterior spinal** is a small branch, though larger than the posterior spinal, which arises near the termination of the vertebral, and, descending in front of the medulla oblongata, unites with its fellow of the opposite side at about the level of the foramen magnum. The single trunk, thus formed, descends on the front of the spinal cord, and is reinforced by a succession of small branches which enter the spinal canal through the intervertebral foramina; these branches are derived from the vertebral and ascending cervical of the inferior thyroid in the neck; from the intercostal in the dorsal region; and from the lumbar, iliolumbar, and lateral sacral arteries in the lower part of the spine. They unite, by means of ascending and descending branches, to form a single anterior median artery, which extends as far as the lower part of the spinal cord. This vessel is placed in the pia mater along the anterior median fissure: it supplies that membrane and the substance of the cord, and sends off branches at its lower part to be distributed to the cauda equina, and ends on the central fibrous prolongation of the cord.

The **posterior spinal** arises from the vertebral at the side of the medulla oblongata: passing backward to the posterior aspect of the spinal cord, it descends on each side, lying behind the posterior roots of the spinal nerves, and is reinforced by a succession of small branches which enter the spinal canal through the intervertebral foramina, and by which it is continued to the lower part of the

cord and to the cauda equina. Branches from these vessels form a free anastomosis round the posterior roots of the spinal nerves, and communicate, by means of very tortuous transverse branches, with the vessel of the opposite side. At its commencement it gives off an ascending branch, which terminates on the side of the fourth ventricle.

The **posterior inferior cerebellar artery** (Fig. 354), the largest branch of the vertebral, winds backward round the upper part of the medulla oblongata, passing between the origin of the pneumogastric and spinal accessory nerves, over the restiform body to the under surface of the cerebellum, where it divides into two branches—an internal one, which is continued backward to the notch between the two hemispheres of the cerebellum; and an external one, which supplies the under surface of the cerebellum as far as its outer border, where it anastomoses with the anterior inferior cerebellar and the superior cerebellar branches of the basilar artery. Branches from this artery supply the choroid plexus of the fourth ventricle.

Surgical Anatomy.—The vertebral artery has been tied in several instances: 1, for wounds or traumatic aneurism; 2, after ligature of the innominate, either at the same time to prevent hæmorrhage, or later on to arrest bleeding where it has occurred at the seat of ligature; and 3, in epilepsy. In these latter cases the treatment has been recommended by Dr. Alexander of Liverpool, in the hope that by diminishing the supply of blood to the posterior part of the brain and the spinal cord a diminution or cessation of the epileptic fits would result. The operation of ligature of the vertebral is performed by making an incision along the posterior border of the Sterno-mastoid muscle, just above the clavicle. The muscle is pulled to the inner side, and the anterior tubercle of the transverse process of the sixth cervical vertebra sought for. A deep layer of fascia being now divided, the interval between the Scalenus anticus and the Longus colli just below their insertion into the tubercle is defined, and the artery and vein found in the interspace. The vein is to be drawn to the outer side, and the aneurism needle passed from without inward. Drs. Ramskill and Bright have pointed out that severe pain at the back of the head may be symptomatic of disease of the vertebral artery just before it enters the skull. This is explained by the close connection of the artery with the sub-occipital nerve in the groove on the posterior arch of the atlas. Disease of the same artery has been also said to affect speech, from pressure on the hypoglossal where it is in relation with the vessel, leading to paralysis of the muscles of the tongue.

The **Basilar Artery,** so named from its position at the base of the skull, is a single trunk formed by the junction of the two vertebral arteries; it extends from the posterior to the anterior border of the pons Varolii, lying in its median groove, under cover of the arachnoid. It ends by dividing into two branches, the *posterior cerebral arteries.* Its branches are, on each side, the following:

Transverse.	Superior Cerebellar.
Anterior Inferior Cerebellar.	Posterior Cerebral.

The **transverse branches** supply the pons Varolii and adjacent parts of the brain, one branch, the *internal auditory*, accompanies the auditory nerve into the internal auditory meatus; and another, the *anterior inferior cerebellar artery*, passes across the crus cerebelli, to be distributed to the anterior border of the under surface of the cerebellum.

The **superior cerebellar arteries** arise near the termination of the basilar. They wind round the crus cerebri close to the fourth nerve, and, arriving at the upper surface of the cerebellum, divide into branches which ramify in the pia mater and anastomose with the branches of the inferior cerebellar artery. Several branches are given to the pineal gland and also to the velum interpositum.

The **posterior cerebral arteries,** the two terminal branches of the basilar, are larger than the preceding, from which they are separated near their origin by the third nerves. Winding round the crus cerebri, they pass to the under surface of the occipital lobes of the cerebrum and divide into three main branches. Near their origin they receive the posterior communicating arteries from the internal carotid. The branches of the posterior cerebral artery are—

Postero-median Ganglionic.	Postero-lateral Ganglionic.
Posterior Choroid.	Three Terminal.

The *postero-median ganglionic branches* (Fig. 357) are a group of small arteries which arise at the commencement of the posterior cerebral artery; these, with similar branches from the posterior communicating, pierce the posterior perforated space and supply the internal surfaces of the optic thalami and the walls of the third ventricle. The *posterior choroid* enters the interior of the brain beneath the posterior border of the corpus callosum and supplies the velum interpositum and the choroid plexus. The *postero-lateral ganglionic branches* are a group of small arteries which arise from the posterior cerebral artery after it has turned round the crus cerebri; they supply a considerable portion of the optic thalamus. The *terminal branches* are distributed as follows: the first to the uncinate gyrus; the second to the temporo-sphenoidal lobe; and the third to the cuneus or the occipital lobule.

Circle of Willis.—The remarkable anastomosis which exists between the branches of the internal carotid and vertebral arteries at the base of the brain constitutes the *circle of Willis*. It is formed, in front, by the anterior cerebral arteries, branches of the internal carotid, which are connected together by the anterior communicating; behind, by the two posterior cerebrals, branches of the basilar, which are connected on each side with the internal carotid by the posterior communicating arteries (Fig. 354). It is by this anastomosis that the cerebral circulation is equalized, and provision made for effectually carrying it on if one or more of the branches are obliterated. The parts of the brain included within this arterial circle are—the lamina cinerea, the commissure of the optic nerves, the infundibulum, the tuber cinereum, the corpora albicantia, and the posterior perforated space.

The **Thyroid Axis** (Fig. 347) is a short thick trunk which arises from the fore part of the first portion of the subclavian artery, close to the inner border of the Scalenus anticus muscle, and divides, almost immediately after its origin, into three branches—the *inferior thyroid*, *suprascapular*, and *transversalis colli*.

The **Inferior Thyroid Artery** passes upward, in a serpentine course, behind the sheath of the common carotid vessel and sympathetic nerve (the middle cervical ganglion resting upon it), and in front of the vertebral artery, recurrent laryngeal nerve (sometimes *behind* the nerve), and Longus colli muscle, and is distributed to the posterior surface of the thyroid gland, anastomosing with the superior thyroid and with the corresponding artery of the opposite side. Its branches are—the

Inferior Laryngeal.	Œsophageal.
Tracheal.	Ascending Cervical.
Muscular.	

The **inferior laryngeal branch** ascends upon the trachea to the back part of the larynx, in company with the recurrent laryngeal nerve, and supplies the muscles and mucous membrane of this part, anastomosing with the branch from the opposite side and with the laryngeal branch from the superior thyroid artery.

The **tracheal branches** are distributed upon the trachea, anastomosing below with the bronchial arteries.

The **œsophageal branches** are distributed to the œsophagus, and anastomose with the œsophageal branches of the aorta.

The **ascending cervical** is a small branch which arises from the inferior thyroid just where that vessel is passing behind the common carotid artery, and runs up on the anterior tubercles of the transverse processes of the cervical vertebræ in the interval between the Scalenus anticus and Rectus capitis anticus major. It gives branches to the muscles of the neck, which anastomose with branches of the vertebral, and sends one or two branches into the spinal canal through the intervertebral foramina to be distributed to the spinal cord and its membranes, and to the bodies of the vertebræ in the same manner as the lateral spinal branches from the vertebral. It anastomoses with the ascending pharyngeal artery.

The **muscular branches** supply the depressors of the hyoid bone, the Longus colli, the Scalenus anticus, and the Inferior constrictor of the pharynx.

Surgical Anatomy.—This artery is sometimes tied, in conjunction with the superior thyroid, in cases of bronchocele. An incision is made along the anterior border of the Sterno-mastoid down to the clavicle. After the deep fascia has been divided, the Sterno-mastoid and carotid vessels are drawn outward and the carotid (Chassaignac's) tubercle sought for. The vessel will be found just below this tubercle, between the carotid sheath on the outer side of the trachea and œsophagus on the inner side. In passing the ligature great care must be exercised to avoid including the recurrent laryngeal nerve.

The **Suprascapular Artery** (**transversalis humeri**), smaller than the transversalis colli, passes obliquely from within outward, across the root of the neck. It at first lies on the lower part of the Scalenus anticus, being covered by the Sterno-mastoid; it then crosses the subclavian artery, and runs outward behind and parallel with the clavicle and Subclavius muscle, and beneath the posterior belly of the Omo-hyoid, to the superior border of the scapula, where it passes over the transverse ligament of the scapula to the supraspinous fossa. In this situation it lies close to the bone, and ramifies between it and the Supraspinatus muscle, to which it is mainly distributed, giving off a communicating branch which crosses

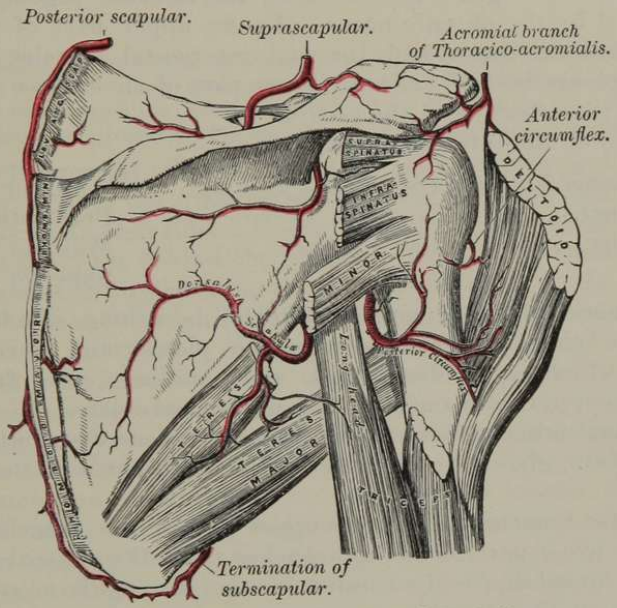

FIG. 361.—The scapular and circumflex arteries.

the neck of the scapula, to reach the infraspinous fossa, where it anastomoses with the dorsal branch of the subscapular artery. Besides distributing branches to the Sterno-mastoid and neighboring muscles, it gives off a *supra-acromial branch*, which, piercing the Trapezius muscle, supplies the cutaneous surface of the acromion, anastomosing with the acromial thoracic artery. As the artery passes over the transverse ligament of the scapula a branch descends into the subscapular fossa, ramifies beneath that muscle, and anastomoses with the posterior and subscapular arteries. It also supplies the shoulder-joint and a nutrient branch to the clavicle.

The **Transversalis Colli** passes transversely outward, across the upper part of the subclavian triangle, to the anterior margin of the Trapezius muscle, beneath which it divides into two branches, the *superficial cervical* and the *posterior scapular*. In its passage across the neck it crosses in front of the Scaleni muscles and the brachial plexus, between the divisions of which it sometimes passes, and is covered by the Platysma, Sterno-mastoid, Omo-hyoid, and Trapezius muscles.

The **superficial cervical** ascends beneath the anterior margin of the Trapezius, distributing branches to it and to the neighboring muscles and glands in the neck, and anastomoses with the superficial branch of the arteria princeps cervicis.

The **posterior scapular**, the continuation of the transversalis colli, passes

beneath the Levator anguli scapulæ to the superior angles of the scapula. It now descends along the posterior border of that bone as far as the inferior angle, where it anastomoses with the subscapular branch of the axillary. In its course it is covered by the Rhomboid muscles, supplying them and the Latissimus dorsi and Trapezius, and anastomosing with the suprascapular and subscapular arteries and with the posterior branches of some of the intercostal arteries.

Peculiarities.—The *superficial cervical* frequently arises as a separate branch from the thyroid axis; and the *posterior scapular*, from the third, more rarely from the second, part of the subclavian. This arrangement is almost as common as the one already given.

The **Internal Mammary** arises from the under surface of the first portion of the subclavian artery, opposite the thyroid axis. It descends behind the costal cartilage of the first rib to the inner surface of the anterior wall of the chest, resting against the costal cartilages about half an inch from the margin of the sternum; and at the interval between the sixth and seventh cartilages divides into two branches, the *musculo-phrenic* and *superior epigastric*.

Relations.—At its origin it is covered by the internal jugular and subclavian veins and crossed by the phrenic nerve. In the upper part of the thorax it lies against the costal cartilages and Internal intercostal muscles in front, and is covered by the pleura behind. At the lower part of the thorax the Triangularis sterni separates the artery from the pleura.

The branches of the internal mammary are—

Comes Nervi Phrenici (Superior Phrenic).	Anterior Intercostal.
Mediastinal.	Perforating.
Pericardiac.	Musculo-phrenic.
Sternal.	Superior Epigastric.

The **comes nervi phrenici (superior phrenic)**, is a long slender branch which accompanies the phrenic nerve, between the pleura and pericardium, to the Diaphragm, to which it is distributed, anastomosing with the other phrenic arteries from the internal mammary and abdominal aorta.

The **mediastinal branches** are small vessels which are distributed to the areolar tissue and lymphatic glands in the anterior mediastinum and the remains of the thymus gland.

The **pericardiac branches** supply the upper part of the anterior surface of the pericardium, the lower part receiving branches from the musculo-phrenic artery.

The **sternal branches** are distributed to the Triangularis sterni and to the posterior surface of the sternum.

The mediastinal, pericardiac, and sternal branches, together with some twigs from the comes nervi phrenici, anastomose with branches from the intercostal and bronchial arteries, and form a minute plexus beneath the pleura, which has been named by Turner the *subpleural mediastinal plexus*.

The **anterior intercostal arteries** supply the five or six upper intercostal spaces. The branch corresponding to each space soon divides into two, or the two branches may come off separately from the parent trunk. The small vessels pass outward in the intercostal spaces, one lying near the lower margin of the rib above, and the other near the upper margin of the rib below, and anastomose with the intercostal arteries from the aorta. They are at first situated between the pleura and the Internal intercostal muscles, and then between the Internal and External intercostal muscles. They supply the Intercostal muscles, and, by branches which perforate the External intercostal muscle, the Pectoral muscles and the mammary gland.

The **perforating arteries** correspond to the five or six upper intercostal spaces. They arise from the internal mammary, pass forward through the intercostal spaces, and, curving outward, supply the Pectoralis major and the integument. Those which correspond to the second, third, and fourth spaces are distributed to the mammary gland. In females, during lactation, these branches are of large size.

The **musculo-phrenic artery** is directed obliquely downward and outward,

behind the cartilages of the false ribs, perforating the Diaphragm at the eighth or ninth rib, and terminating, considerably reduced in size, opposite the last intercostal space. It gives off anterior intercostal arteries to each of the intercostal spaces across which it passes; these diminish in size as the spaces decrease in length, and are distributed in a manner precisely similar to the anterior intercostals from the internal mammary. The musculo-phrenic also gives branches to the lower part of the pericardium, and others which run backward to the Diaphragm and downward to the abdominal muscles.

The **superior epigastric** continues in the original direction of the internal mammary; it descends through the cellular interval between the costal and sternal attachments of the Diaphragm, and enters the sheath of the Rectus abdominis muscle, at first lying behind the muscle, and then perforating it and supplying it, and anastomosing with the deep epigastric artery from the external iliac. Some vessels perforate the sheath of the Rectus, and supply the muscles of the abdomen and the integument, and a small branch, which passes inward upon the side of the ensiform appendix, anastomoses in front of that cartilage with the artery of the opposite side.

Surgical Anatomy.—The course of the internal mammary artery may be defined by drawing a line across the six upper intercostal spaces half an inch from and parallel with the sternum. The position of the vessel must be remembered, as it is liable to be wounded in stabs of the chest-wall. It is most easily reached by a transverse incision in the second intercostal space.

The **Superior Intercostal** (Fig. 352) arises from the upper and back part of the subclavian artery, behind the Anterior scalenus on the right side, and to the inner side of the muscle on the left side. Passing backward, it gives off the *deep cervical branch*, and then descends behind the pleura in front of the necks of the first two ribs, and inosculates with the first aortic intercostal.[1] In the first intercostal space it gives off a branch which is distributed in a manner similar to the distribution of the aortic intercostals. The branch for the second intercostal space usually joins with one from the aortic intercostals. Each intercostal gives off a branch to the posterior spinal muscles, and a small one, *spinal*, which passes through the corresponding intervertebral foramen to the spinal cord and its membranes.

The **deep cervical branch** (**profunda cervicis**) arises, in most cases, from the superior intercostal, and is analogous to the posterior branch of an aortic intercostal artery. Passing backward, between the transverse process of the seventh cervical vertebra and the first rib, it runs up the back part of the neck, between the Complexus and Semispinalis colli muscles, as high as the axis, supplying these and adjacent muscles, and anastomosing with the deep branch of the arteria princeps cervicis of the occipital and with branches which pass outward from the vertebral.

SURGICAL ANATOMY OF THE AXILLA.

The **Axilla** is a pyramidal space, situated between the upper and lateral part of the chest and the inner side of the arm.

Boundaries.—Its *apex*, which is directed upward toward the root of the neck, corresponds to the interval between the first rib, the upper edge of the scapula, and the clavicle, through which the axillary vessels and nerves pass. The *base*, directed downward, is formed by the integument, and a thick layer of fascia extending between the lower border of the Pectoralis major in front, and the lower border of the Latissimus dorsi behind; it is broad internally at the chest, but narrow and pointed externally at the arm. The *anterior boundary* is formed by the Pectoralis major and minor muscles, the former covering the whole of the anterior wall of the axilla, the latter covering only its central part. The *posterior boundary*, which extends somewhat lower than the anterior, is formed by the Subscapularis above, the Teres major and Latissimus dorsi below. On the *inner side* are the first four ribs with their corresponding Intercostal muscles, and part of the Serratus magnus. On the *outer side*, where the anterior and posterior boundaries

[1] See foot-note, p. 607.

converge, the space is narrow, and bounded by the humerus, the Coraco-brachialis and Biceps muscles.

Contents.—This space contains the axillary vessels and brachial plexus of nerves, with their branches, some branches of the intercostal nerves, and a large number of lymphatic glands, all connected together by a quantity of fat and loose areolar tissue.

Their Position.—The axillary artery and vein, with the brachial plexus of nerves, extend obliquely along the outer boundary of the axillary space, from its apex to its base, and are placed much nearer the anterior than the posterior wall, the vein lying to the inner or thoracic side of the artery and partially concealing it. At the fore part of the axillary space, in contact with the Pectoral muscles, are the thoracic branches of the axillary artery, and along the anterior margin

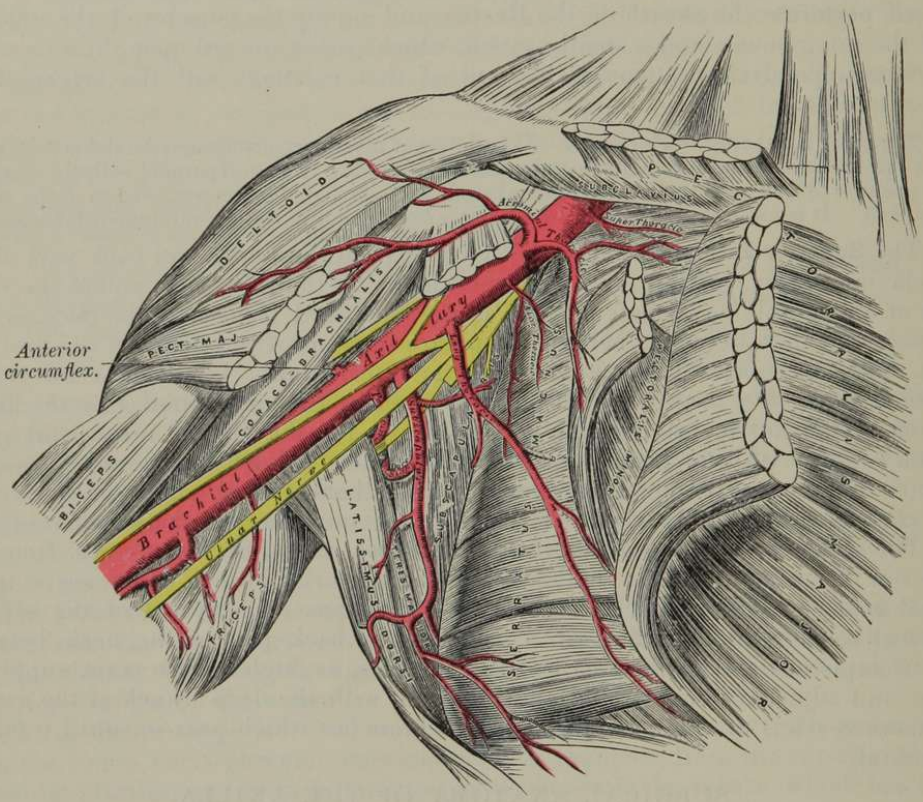

FIG. 362.—The axillary artery and its branches.

of the axilla the long thoracic artery extends to the side of the chest. At the back part, in contact with the lower margin of the Subscapularis muscle, are the subscapular vessels and nerves; winding around the lower border of this muscle is the dorsalis scapulæ artery and veins; and toward the outer extremity of the muscle the posterior circumflex vessels and the circumflex nerve are seen curving backward to the shoulder.

Along the inner or thoracic side no vessel of any importance exists, the upper part of the space being crossed merely by a few small branches from the superior thoracic artery. There are some important nerves, however, in this situation—viz. the posterior thoracic or external respiratory nerve, descending on the surface of the Serratus magnus, to which it is distributed; and perforating the upper and anterior part of this wall, the intercosto-humeral nerve or nerves, passing across the axilla to the inner side of the arm.

The cavity of the axilla is filled by a quantity of loose areolar tissue and a large number of small arteries and veins, all of which are, however, of inconsiderable

size, and numerous lymphatic glands: these are from ten to twelve in number, and situated chiefly on the thoracic side and lower and back part of this space.

Surgical Anatomy.—The axilla is a space of considerable surgical importance. It transmits the large vessels and nerves to the upper extremity, and these may be the seat of injury or disease: it contains numerous lymphatic glands which may require removal when diseased; in it is a quantity of loose connective and adipose tissue which may be readily infiltrated with blood or inflammatory exudation, and it may be the seat of rapidly-growing tumors. Moreover, it is covered at its base by thin skin, largely supplied with sebaceous and sweat glands, which is frequently the seat of small cutaneous abscesses and boils, and of eruptions due to irritation.

In suppuration in the axilla the arrangement of the fasciæ plays a very important part in the direction which the pus takes. As described on page 468, the costo-coracoid membrane, after covering in the space between the clavicle and the upper border of the Pectoralis minor, splits to enclose this muscle, and, reblending at its lower border, becomes incorporated with the fascia covering the Pectoralis major muscle at the anterior fold of the axilla. This is known as the clavi-pectoral fascia. Suppuration may take place either superficial to or beneath this layer of fascia; that is, either between the pectorals or below the pectoralis minor: in the former case, it would point either at the anterior border of the axillary fold or in the groove between the Deltoid and the Pectoralis major; in the latter, the pus would have a tendency to surround the vessels and nerves and ascend into the neck, that being the direction in which there is least resistance. Its progress toward the skin is prevented by the axillary fascia; its progress backward, by the Serratus magnus; forward, by the clavi-pectoral fascia; inward, by the wall of the thorax; and outward, by the upper limb. The pus in these cases, after extending into the neck, has been known to spread through the superior opening of the thorax into the mediastinum.

In opening an axillary abscess the knife should be entered in the floor of the axilla, midway between the anterior and posterior margins and near the thoracic side of the space. It is well to use a director and dressing forceps after an incision has been made through the skin and fascia in the manner directed by the late Mr. Hilton.

The student should attentively consider the relation of the vessels and nerves in the several parts of the axilla, for it not unfrequently happens that the surgeon is called upon to extirpate diseased glands or to remove a tumor from this situation. In performing such an operation it will be necessary to proceed with much caution in the direction of the outer wall and apex of the space, as here the axillary vessels will be in danger of being wounded. Toward the posterior wall it will be necessary to avoid the subscapular, dorsalis scapulæ, and posterior circumflex vessels. Along the anterior wall it will be necessary to avoid the thoracic branches. It is only along the inner or thoracic wall, and in the centre of the axillary cavity, that there are no vessels of any importance—a fortunate circumstance, for it is in this situation more especially that tumors requiring removal are usually situated.

THE AXILLARY ARTERY.

The **Axillary Artery,** the continuation of the subclavian, commences at the lower border of the first rib, and terminates at the lower border of the tendon of the Teres major muscle, where it takes the name of brachial. Its direction varies with the position of the limb: when the arm lies by the side of the chest, the vessel forms a gentle curve, the convexity being upward and outward; when it is directed at right angles with the trunk, the vessel is nearly straight; and when it is elevated still higher, the artery describes a curve the concavity of which is directed upward. At its commencement the artery is very deeply situated, but near its termination is superficial, being covered only by the skin and fascia. The description of the relations of this vessel is facilitated by its division into three portions, the first portion being that above the Pectoralis minor; the second portion, behind; and the third below, that muscle.

The **first portion of the axillary artery** is in relation, *in front*, with the clavicular portion of the Pectoralis major, the costo-coracoid membrane, the external anterior thoracic nerve, and the acromio-thoracic and cephalic veins; *behind*, with the first intercostal space, the corresponding Intercostal muscle, the second and third serrations of the Serratus magnus, and the posterior thoracic nerve; on its *outer side*, with the brachial plexus, from which it is separated by a little cellular interval; on its *inner* or thoracic side, with the axillary vein.

Relations of the First Portion of the Axillary Artery.

In front.

Pectoralis major.
Costo-coracoid membrane.
External anterior thoracic nerve.
Acromio-thoracic and Cephalic veins.

Outer side.
Brachial plexus.

Inner side.
Axillary vein.

Behind.
First Intercostal space, and Intercostal muscle.
Second and third serrations of Serratus magnus.
Posterior and Internal anterior thoracic nerves.

The **second portion of the axillary artery** lies behind the Pectoralis minor. It is covered *in front*, by the Pectoralis major and minor muscles; *behind*, it is separated from the Subscapularis by a cellular interval; on the *inner side* is the axillary vein. The cords of the brachial plexus of nerves surround the artery, and separate it from direct contact with the vein and adjacent muscles.

Relations of the Second Portion of the Axillary Artery.

In front.
Pectoralis major and minor.

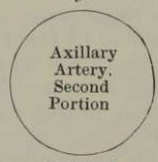

Outer side.
Outer cord of plexus.

Inner side.
Axillary vein.
Inner cord of plexus.

Behind.
Subscapularis.
Posterior cord of plexus.

The **third portion of the axillary artery** lies below the Pectoralis minor. It is in relation, *in front*, with the lower part of the Pectoralis major above, being covered only by the integument and fascia below, where it is crossed by the inner head of the median nerve; *behind*, with the lower part of the Subscapularis and the tendons of the Latissimus dorsi and Teres major; on its *outer side*, with the Coraco-brachialis; on its *inner* or thoracic side, with the axillary vein. The nerves of the brachial plexus bear the following relation to the artery in this part of its course: on the *outer side* is the median nerve, and the musculo-cutaneous for a short distance; on the *inner side*, the ulnar, the internal, and lesser internal cutaneous nerves; and *behind*, the musculo-spiral and circumflex, the latter extending only to the lower border of the Subscapularis muscle.

Peculiarities.—The axillary artery, in about one case out of every ten, gives off a large branch, which forms either one of the arteries of the forearm or a large muscular trunk. In the first set of cases this artery is most frequently the radial (1 in 33), sometimes the ulnar (1 in 72), and, very rarely, the interosseous (1 in 506). In the second set of cases the trunk has been found to give origin to the subscapular, circumflex, and profunda arteries of the arm. Sometimes only one of the circumflex, or one of the profunda arteries, arose from the trunk. In these cases the brachial plexus surrounded the trunk of the branches, and not the main vessel.

Relations of the Third Portion of the Axillary Artery.

In front.
Integument and fascia.
Pectoralis major.
Inner head of median nerve.

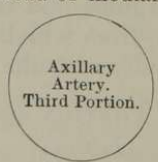

Outer side.
Coraco-brachialis.
Median nerve.
Musculo-cutaneous nerve.

Inner side.
Ulnar nerve.
Internal cutaneous nerves.
Axillary veins.

Behind.
Subscapularis.
Tendons of Latissimus dorsi and Teres major.
Musculo-spiral and circumflex nerves.

Surface Marking.—The course of the axillary artery may be marked out by raising the arm to a right angle and drawing a line from the middle of the clavicle to the point where the tendon of the Pectoralis major crosses the prominence caused by the Coraco-brachialis as it emerges from under cover of the anterior fold of the axilla. The third portion of the artery can be felt pulsating beneath the skin and fascia, at the junction of the anterior with the middle third of the space between the anterior and posterior folds of the axilla, close to the inner border of the Coraco-brachialis.

Surgical Anatomy.—The student, having carefully examined the relations of the axillary artery in its various parts, should now consider in what situation compression of this vessel may be most easily effected, and the best position for the application of a ligature to it when necessary.

Compression of the vessel may be required in the removal of tumors or in amputation of the upper part of the arm; and the only situation in which this can be effectually made is in the lower part of its course; by pressing on it in this situation from within outward against the humerus the circulation may be effectually arrested.

The axillary artery is perhaps more frequently lacerated than any other artery in the body, with the exception of the popliteal, by violent movements of the upper extremity, especially in those cases where its coats are diseased. It has occasionally been ruptured in attempts to reduce old dislocations of the shoulder-joint. This lesion is most likely to occur during the preliminary breaking down of adhesions, in consequence of the artery having contracted adhesions to the capsule of the joint. Aneurism of the axillary artery is of frequent occurrence, a large percentage of the cases being traumatic in their origin, due to the violence to which it is exposed in the varied, extensive, and often violent movement of the limb.

The **application of a ligature to the axillary artery** may be required in cases of aneurism of the upper part of the brachial or as a distal operation for aneurism of the subclavian; and there are only two situations in which it can be secured—viz. in the first and in the third parts of its course; for the axillary artery at its central part is so deeply seated, and, at the same time, so closely surrounded with large nervous trunks, that the application of a ligature to it in that situation would be almost impracticable.

In the **third part** of its course the operation is most simple, and may be performed in the following manner: The patient being placed on a bed and the arm separated from the side, with the hand supinated, an incision is made through the integument forming the floor of the axilla about two inches in length, a little nearer to the anterior than the posterior fold of the axilla. After carefully dissecting through the areolar tissue and fascia, the median nerve and axillary vein are exposed; the former having been displaced to the outer and the latter to the inner side of the arm, the elbow being at the same time bent, so as to relax the structures and facilitate their separation, the ligature may be passed round the artery from the ulnar to the radial side. This portion of the artery is occasionally crossed by a muscular slip derived from the Latissimus dorsi, which may mislead the surgeon during an operation. The occasional existence of this muscular fasciculus was spoken of in the description of the muscles. It may easily be recognized by the transverse direction of its fibres.

The **first portion** of the axillary artery may be tied in cases of aneurism encroaching so far upward that a ligature cannot be applied in the lower part of its course. Notwithstanding that this operation has been performed in some few cases, and with success, its performance is attended with much difficulty and danger. The student will remark that in this situation it would be necessary to divide a thick muscle, and, after separating the costo-coracoid membrane, the artery would be exposed at the bottom of a more or less deep space, with the cephalic and axillary veins in such relation with it as must render the application of a ligature to this part of the vessel particularly hazardous. Under such circumstances it is an easier, and at the same time more advisable, operation to tie the subclavian artery in the third part of its course.

The vessel can be best secured by a curved incision with the convexity downward from a point half an inch external to the Sterno-clavicular joint to a point half an inch internal to the coracoid process. The limb is to be well abducted and the head inclined to the opposite side, and this incision carried through the superficial structures, care being taken of the cephalic vein at the outer angle of the incision. The clavicular origin of the Pectoralis major is then divided in the whole extent of the wound. The arm is now to be brought to the side, and the upper edge of the Pectoralis minor defined and drawn downward. The costo-coracoid membrane is to be carefully torn through with a director close to the coracoid process, and the axillary sheath exposed; this is to be opened with especial care on account of the vein overlapping the artery. The needle should be passed from below, so as to avoid wounding the vein.

In a case of wound of the vessel the general practice of cutting down upon, and tying it above and below the wounded point should be adopted in all cases.

Collateral Circulation after Ligature of the Axillary Artery.—If the artery be tied above the origin of the acromial thoracic, the collateral circulation will be carried on by the same branches as after the ligature of the subclavian; if at a lower point, between the acromial thoracic and subscapular arteries, the latter vessel, by its free anastomoses with the other scapular arteries, branches of the subclavian, will become the chief agent in carrying on the circulation, to which the long thoracic, if it be below the ligature, will materially contribute by its anastomoses with the intercostal and internal mammary arteries. If the point included in the ligature be below the origin of the subscapular artery, it will most probably also be below the origins of the two circumflex arteries. The chief agents in restoring the circulation will then be

the subscapular and the two circumflex arteries anastomosing with the superior profunda from the brachial.

Branches of the Axillary Artery.

The branches of the axillary artery are—

From first part { Superior Thoracic. / Acromial Thoracic. } *From second part* { Long Thoracic. / Alar Thoracic. }

From third part { Subscapular. / Anterior Circumflex. / Posterior Circumflex. }

The **superior thoracic** is a small artery which arises from the axillary separately or by a common trunk with the acromial thoracic. Running forward and inward along the upper border of the Pectoralis minor, it passes between it and the Pectoralis major to the side of the chest. It supplies these muscles and the parietes of the thorax, anastomosing with the internal mammary and intercostal arteries.

The **acromial thoracic** is a short trunk which arises from the fore part of the axillary artery. Projecting forward to the upper border of the Pectoralis minor, it divides into three sets of branches—*thoracic*, *acromial*, and *descending* or *humeral*. The *thoracic branches*, two or three in number, are distributed to the Serratus magnus and Pectoral muscles, anastomosing with the intercostal branches of the internal mammary. The *acromial branches* are directed outward toward the acromion, supplying the Deltoid muscle, and anastomosing, on the surface of the acromion, with the suprascapular and posterior circumflex arteries. The *humeral branch* passes in the space between the Pectoralis major and Deltoid in the same groove as the cephalic vein, and supplies both muscles. The artery also gives off a very small branch, the *clavicular*, which passes upward to the Subclavius muscle.

The **long thoracic** (*external mammary*) passes downward and inward along the lower border of the Pectoralis minor to the side of the chest, supplying the Serratus magnus, the Pectoral muscles, and mammary gland, and sending branches across the axilla to the axillary glands and Subscapularis; it anastomoses with the internal mammary and intercostal arteries. An *accessory* external mammary branch is often found running to the chest behind the long thoracic.

The **alar thoracic** is a small branch which supplies the glands and areolar tissue of the axilla. Its place is frequently supplied by branches from some of the other thoracic arteries.

The **subscapular**, the largest branch of the axillary artery, arises opposite the lower border of the Subscapularis muscle, and passes downward and backward along its lower margin to the inferior angle of the scapula, where it anastomoses with the long thoracic and intercostal arteries and with the posterior scapular. About an inch and a half from its origin it gives off a large branch, the *dorsalis scapulæ*, and terminates by supplying branches to the muscles in the neighborhood.

The **dorsalis scapulæ** is given off from the subscapular about an inch from its origin, and is generally larger than the continuation of the vessel. It curves round the axillary border of the scapula, leaving the axilla through the space between the Teres minor above, the Teres major below, and the long head of the Triceps externally (Fig. 361), and enters the infraspinous fossa, where it anastomoses with the posterior scapular and suprascapular arteries. In its course it gives off two sets of branches: one enters the subscapular fossa beneath the Subscapularis, which it supplies, anastomosing with the posterior scapular and suprascapular arteries; the other is continued along the axillary border of the scapula, between the Teres major and minor, and, at the dorsal surface of the inferior angle of the bone, anastomoses with the posterior scapular. In addition to these, small branches are distributed to the back part of the Deltoid muscle and the long head of the Triceps, anastomosing with an ascending branch of the superior profunda of the brachial.

The **circumflex arteries** wind round the neck of the humerus. The *posterior circumflex* (Fig. 361), the larger of the two, arises from the back part of the axillary opposite the lower border of the Subscapularis muscle, and, passing backward with the circumflex veins and nerve through the quadrangular space bounded by the Teres major and minor, the scapular head of the Triceps and the humerus, winds round the neck of that bone and is distributed to the Deltoid muscle and shoulder-joint, anastomosing with the anterior circumflex and acromial thoracic arteries, and with the superior profunda branch of the brachial artery. The *anterior circumflex* (Figs. 361, 362), considerably smaller than the preceding, arises just below that vessel from the outer side of the axillary artery. It passes horizontally outward beneath the Coraco-brachialis and short head of the Biceps, lying upon the fore part of the neck of the humerus, and, on reaching the bicipital groove, gives off an ascending branch which passes upward along the groove to supply the head of the bone and the shoulder-joint. The trunk of the vessel is then continued outward beneath the Deltoid, which it supplies, and anastomoses with the posterior circumflex artery. The *axillary cutaneous* branch, long and slender, is often found ramifying in the superficial fascia of the floor of the axilla.

THE BRACHIAL ARTERY (Fig. 363).

The **Brachial Artery** commences at the lower margin of the tendon of the Teres major, and, passing down the inner and anterior aspect of the arm, terminates about half an inch below the bend of the elbow, where it divides into the *radial* and *ulnar arteries.*

PLAN OF THE RELATIONS OF THE BRACHIAL ARTERY.

In front.
Integument and fasciæ.
Bicipital fascia, median basilic vein.
Median nerve.

Outer side.
Vena comes.
Median nerve (above).
Coraco-brachialis.
Biceps.

Inner side.
Vena comes.
Internal cutaneous and Ulnar nerves.
Median nerve (below).
Basilic vein (upper half).

Behind.
Triceps.
Musculo-spiral nerve.
Superior profunda artery.
Coraco-brachialis (insertion).
Brachialis anticus.

Relations.—This artery is superficial throughout its entire extent, being covered, *in front*, by the integument, the superficial and deep fascia; the bicipital fascia separates it opposite the elbow from the median basilic vein; the median nerve crosses it at its middle. *Behind*, it is separated from the inner side of the humerus, above, by the long and inner heads of the Triceps, the musculo-spiral nerve and superior profunda artery intervening, and from the front of the bone, below, by the insertion of the Coraco-brachialis muscle and by the Brachialis anticus. By its *outer side* it is in relation with the commencement of the median nerve and the Coraco-brachialis and Biceps muscles, which slightly overlap the artery. By its *inner side* its upper half is in relation with the internal cutaneous and ulnar nerves, its lower half with the median nerve. The basilic vein lies on the inner side of the artery, but is separated from it in the lower part of the arm by the deep fascia. It is accompanied by two venæ comites, which lie in close contact with the artery, being connected together at intervals by short transverse communicating branches.

SURGICAL ANATOMY OF THE BEND OF THE ELBOW.

At the bend of the elbow the brachial artery sinks deeply into a triangular interval, the base of which is directed upward toward the humerus,

and the sides of which are bounded, externally, by the Supinator longus; internally, by the Pronator radii teres; its floor is formed by the Brachialis anticus and Supinator brevis. This space, *cubital fossa*, contains the brachial artery with its accompanying veins, the radial and ulnar arteries, the median and musculo-spiral nerves, and the tendon of the Biceps. The brachial artery occupies the middle line of this space, and divides opposite the neck of the radius into the radial and ulnar arteries; it is covered, *in front*, by the integument, the superficial fascia, and the median basilic vein, the vein being separated from direct contact with the artery by the bicipital fascia. *Behind*, it lies on the Brachialis anticus, which separates it from the elbow-joint. The median nerve lies on the inner side of the artery, close to it above, but separated from it below by the coronoid head of the Pronator radii teres. The tendon of the Biceps lies to the outer side of the space, and the musculo-spiral nerve still more externally, lying upon the Supinator brevis and partly concealed by the Supinator longus.

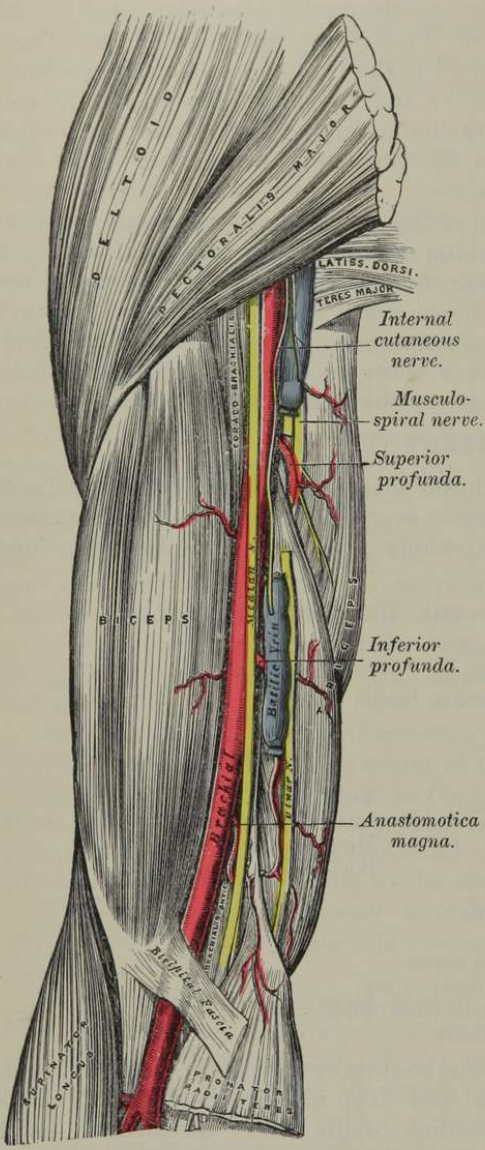

FIG. 363.—The surgical anatomy of the brachial artery.

Peculiarities of the Brachial Artery as regards its Course.—The brachial artery, accompanied by the median nerve, may leave the inner border of the Biceps, and descend toward the inner condyle of the humerus, where it usually curves round a prominence of bone, to which it is connected by a fibrous band; it then inclines outward, beneath or through the substance of the Pronator radii teres muscle, to the bend of the elbow. The variation bears considerable analogy with the normal condition of the artery in some of the carnivora: it has been referred to above in the description of the humerus (page 250).

As regards its Division.—Occasionally, the artery is divided for a short distance at its upper part into two trunks, which are united above and below. A similar peculiarity occurs in the main vessel of the lower limb.

The point of bifurcation may be above or below the usual point, the former condition being by far the more frequent. Out of 481 examinations recorded by Mr. Quain, some made on the right and some on the left side of the body, in 386 the artery bifurcated in its normal position. In one case only was the place of division lower than usual, being two or three inches below the elbow-joint. "In 94 cases out of 481, or about 1 in 5½, there were two arteries instead of one in some part or in the whole of the arm."

There appears, however, to be no correspondence between the arteries of the two arms with respect to their irregular division; for in 61 bodies it occurred on one side only in 43; on both sides, in different positions, in 13; on both sides, in the same position, in 5.

The point of bifurcation takes place at different parts of the arm, being most frequent in the upper part, less so in the lower part, and least so in the middle, the most usual point for the application of a ligature: under any of these circumstances two large arteries would be found in the arm instead of one. The most frequent (in three out of four) of these peculiarities is the high division of the radial. That artery often arises from the inner side of the brachial, and runs parallel with the main trunk to the elbow, where it crosses it, lying beneath the fascia; or it may perforate the fascia and pass over the artery immediately beneath the integument.

The ulnar sometimes arises from the brachial high up, and then occasionally leaves that vessel at the lower part of the arm, and descends toward the inner condyle. In the forearm it gen-

erally lies beneath the deep fascia, superficial to the flexor muscles; occasionally between the integument and deep fascia, and very rarely beneath the flexor muscles.

The interosseous artery sometimes arises from the upper part of the brachial or axillary; as it passes down the arm it lies behind the main trunk, and at the bend of the elbow regains its usual position.

In some cases of high division of the radial the remaining trunk (ulnar interosseous) occasionally passes, together with the median nerve, along the inner margin of the arm to the inner condyle, and then passing from within outward, beneath or through the Pronator radii teres, regains its usual position at the bend of the elbow.

Occasionally the two arteries representing the brachial are connected at the bend of the elbow by a short transverse branch, and are even sometimes reunited.

Sometimes, long slender vessels, *vasa aberrantia*, connect the brachial or axillary arteries with one of the arteries of the forearm or a branch from them. These vessels usually join the radial.

Varieties in Muscular Relations.[1]—The brachial artery is occasionally concealed in some part of its course by muscular or tendinous slips derived from the Coraco-brachialis, Biceps, Brachialis anticus and Pronator radii teres muscles.

Surface Marking.—The direction of the brachial artery is marked, when the arm is extended and supinated, by a line drawn from the junction of the anterior and middle third of the space between the anterior and posterior folds of the axilla; that is to say from the inner side of the prominence of the Coraco-brachialis muscle to the point midway between the condyles of the humerus which corresponds to the depression along the inner border of the Coraco-brachialis and Biceps. In the upper part of its course the artery lies internal to the humerus, but below it is in front of that bone.

Surgical Anatomy.—Compression of the brachial artery is required in cases of amputation and some other operations in the arm and forearm; and it will be observed that it may be effected in almost any part of the course of the artery. If pressure is made in the upper part of the limb, it should be directed from within outward; and if in the lower part, from before backward, as the artery lies on the inner side of the humerus above and in front below. The most favorable situation is about the middle of the arm, where it lies on the tendon of the Coraco-brachialis on the inner flat side of the humerus.

The application of a ligature to the brachial artery may be required in case of wound of the vessel and in some cases of wound of the palmar arch. It is also sometimes necessary in cases of aneurism of the brachial, the radial, ulnar, or interosseous arteries. The artery may be secured in any part of its course. The chief guides in determining its position are the surface markings produced by the inner margin of the Coraco-brachialis and Biceps, the known course of the vessel, and its pulsation, which should be carefully felt for before any operation is performed, as the vessel occasionally deviates from its usual position in the arm. In whatever situation the operation is performed, great care is necessary, on account of the extreme thinness of the parts covering the artery and the intimate connection which the vessel has throughout its whole course with important nerves and veins. Sometimes a thin layer of muscular fibre is met with concealing the artery; if such is the case, it must be cut across in order to expose the vessel.

In the upper third of the arm the artery may be exposed in the following manner: The patient being placed horizontally upon a table, the affected limb should be raised from the side and the hand supinated. An incision about two inches in length should be made on the inner side of the Coraco-brachialis muscle, and the subjacent fascia cautiously divided, so as to avoid wounding the internal cutaneous nerve or basilic vein, which sometimes runs on the surface of the artery as high as the axilla. The fascia having been divided, it should be remembered that the ulnar and internal cutaneous nerves lie on the inner side of the artery, the median on the outer side, the latter nerve being occasionally superficial to the artery in this situation, and that the venæ comites are also in relation with the vessel, one on either side. These being carefully separated, the aneurism needle should be passed round the artery from the inner to the outer side.

If two arteries are present in the arm in consequence of a high division, they are usually placed side by side: and if they are exposed in an operation, the surgeon should endeavor to ascertain, by alternately pressing on each vessel, which of the two communicates with the wound or aneurism, when a ligature may be applied accordingly; or if pulsation or hæmorrhage ceases only when both vessels are compressed, both vessels may be tied, as it may be concluded that the two communicate above the seat of disease or are reunited.

It should also be remembered that two arteries may be present in the arm in a case of high division, and that one of these may be found along the inner intermuscular septum, in a line toward the inner condyle of the humerus, or in the usual position of the brachial, but deeply placed beneath the common trunk: a knowledge of these facts will suggest the precautions necessary in every case, and indicate the measures to be adopted when anomalies are met with.

In the middle of the arm the brachial artery may be exposed by making an incision along the inner margin of the Biceps muscle. The forearm being bent so as to relax the muscle, it should be drawn slightly aside, and, the fascia being carefully divided, the median nerve will be

[1] See Struther's *Anatomical and Physiological Observations.*

exposed lying upon the artery (sometimes beneath); this being drawn inward and the muscle outward, the artery should be separated from its accompanying veins and secured. In this situation the inferior profunda may be mistaken for the main trunk, especially if enlarged, from the collateral circulation having become established; this may be avoided by directing the incision externally toward the Biceps, rather than inward or backward toward the Triceps.

The lower part of the brachial artery is of interest in a surgical point of view, on account of the relation which it bears to the veins most commonly opened in venesection. Of these vessels, the median basilic is the largest and most prominent, and, consequently, the one usually selected for the operation. It should be remembered that this vein runs parallel with the brachial artery, from which it is separated by the bicipital fascia, and that care should be taken in opening the vein not to carry the incision too deeply, so as to endanger the artery.

Collateral Circulation.—After the application of a ligature to the brachial artery in the upper third of the arm, the circulation is carried on by branches from the circumflex and subscapular arteries, anastomosing with ascending branches from the superior profunda. If the brachial is tied *below* the origin of the profunda arteries, the circulation is maintained by the branches of the profundæ, anastomosing with the recurrent radial, ulnar, and interosseous arteries. In two cases described by Mr. South,[1] in which the brachial artery had been tied some time previously, in one "a long portion of the artery had been obliterated, and sets of vessels are descending on either side from above the obliteration, to be received into others which ascend in a similar manner from below it. In the other the obliteration is less extensive, and a single curved artery about as big as a crow-quill passes from the upper to the lower open part of the artery."

The branches of the brachial artery are—the

Superior Profunda.	Inferior Profunda.
Nutrient.	Anastomotica Magna.
Muscular.	

The **superior profunda** arises from the inner and back part of the brachial, just below the lower border of the Teres major, and passes backward to the interval between the outer and inner heads of the Triceps muscle, accompanied by the musculo-spiral nerve; it winds round the back part of the shaft of the humerus in the spiral groove, between the Triceps and the bone, to the outer side of the humerus just above the external condyle, where it divides into two terminal branches. One of these pierces the external intermuscular septum, and descends to the space between the Brachialis anticus and Supinator longus, where it anastomoses with the recurrent branch of the radial artery; while the other, the *posterior articular*, descends along the back of the external intermuscular septum to the back part of the elbow-joint, where it anastomoses with the posterior interosseous recurrent, and across the back of the humerus with the posterior ulnar recurrent, the anastomotica magna, and inferior profunda (Fig. 366). The superior profunda supplies the Triceps muscle and gives off a nutrient artery to the upper end of the humerus. Near its commencement it sends off a branch which passes upward between the external and long heads of the Triceps muscle to anastomose with the posterior circumflex artery, and, while in the groove, a small branch which accompanies a branch of the musculo-spiral nerve through the substance of the Triceps muscle and ends in the Anconeus below the outer condyle of the humerus.

The **nutrient artery** of the shaft of the humerus arises from the brachial, about the middle of the arm. Passing downward it enters the nutrient canal of that bone near the insertion of the Coraco-brachialis muscle.

The **inferior profunda,** of small size, arises from the brachial, a little below the middle of the arm; piercing the internal intermuscular septum, it descends on the surface of the inner head of the Triceps muscle to the space between the inner condyle and olecranon, accompanied by the ulnar nerve, and terminates by anastomosing with the posterior ulnar recurrent and anastomotica magna. It also supplies a branch to the front of the internal condyle, which anastomoses with the anterior ulnar recurrent.

The **anastomotica magna** arises from the brachial about two inches above the

[1] Chelius's *Surgery*, vol. ii. p. 254. See also White's engraving, referred to by Mr. South, of the anastomosing branches after ligature of the brachial, in White's *Cases in Surgery*. Porta also gives a case (with drawings) of the circulation after ligature of both brachial and radial (*Alterazioni Patoligiche delle Arterie*).

elbow-joint. It passes transversely inward upon the Brachialis anticus, and, piercing the internal intermuscular septum, winds round the back part of the humerus between the Triceps and the bone, forming an arch above the olecranon fossa by its junction with the posterior articular branch of the superior profunda. As this vessel lies on the Brachialis anticus, branches ascend to join the inferior profunda, and others descend in front of the inner condyle to anastomose with the anterior ulnar recurrent. Behind the internal condyle an offset is given off which anastomoses with the inferior profunda and posterior ulnar recurrent arteries and supplies the Triceps.

The **muscular** are three or four large branches, which are distributed to the muscles in the course of the artery. They supply the Coraco-brachialis, Biceps, and Brachialis anticus muscles.

The Anastomosis around the Elbow-joint (Fig. 366).—The vessels engaged in this anastomosis may be conveniently divided into those situated *in front* and *behind* the internal and external condyles. The branches anastomosing *in front* of the internal condyle are the anastomotica magna, the anterior ulnar recurrent, and the anterior terminal branch of the inferior profunda. Those *behind* the internal condyle are the anastomotica magna, the posterior ulnar recurrent, and the posterior terminal branch of the inferior profunda. The branches anastomosing *in front* of the external condyle are the radial recurrent and one of the terminal branches of the superior profunda. Those *behind* the external condyle (perhaps more properly described as being situated between the external condyle and the olecranon) are the anastomotica magna, the interosseous recurrent, and one of the terminal branches of the superior profunda. There is also a large arch of anastomosis above the olecranon, formed by the interosseous recurrent, joining with the anastomotica magna and posterior ulnar recurrent (Fig. 366).

From this description it will be observed that the anastomotica magna is the vessel most engaged, the only part of the anastomosis in which it is not employed being that *in front* of the external condyle.

Radial Artery.

The **Radial Artery** appears, from its direction, to be the continuation of the brachial, but in size it is smaller than the ulnar. It commences at the bifurcation of the brachial, just below the bend of the elbow, and passes along the radial side of the forearm to the wrist; it then winds backward, round the outer side of the carpus, beneath the extensor tendons of the thumb, and, finally, passes forward, between the two heads of the First dorsal interosseous muscle, into the palm of the hand, where it crosses the metacarpal bones to the ulnar border of the hand, to form the deep palmar arch. At its termination it inosculates with the deep branch of the ulnar artery. The relations of this vessel may thus be conveniently divided into three parts—viz. in the forearm, at the back of the wrist, and in the hand.

Relations.—*In the forearm* this vessel extends from opposite the neck of the radius to the fore part of the styloid process, being placed to the inner side of the shaft of the bone above and in front of it below. It is superficial throughout its entire extent, being covered by the integument, the superficial and deep fasciæ, and slightly overlapped above by the Supinator longus. In its course downward it lies upon the tendon of the Biceps, the Supinator brevis, the radial origin of the Flexor sublimis digitorum, the Pronator radii teres, the Flexor longus pollicis, the Pronator quadratus, and the lower extremity of the radius. In the upper third of its course it lies between the Supinator longus and the Pronator radii teres; in its lower two-thirds, between the tendons of the Supinator longus and the Flexor carpi radialis. The radial nerve lies along the outer side of the artery in the middle third of its course, and some filaments of the musculo-cutaneous nerve, after piercing the deep fascia, run along the lower part of the artery as it winds round the wrist. The vessel is accompanied by venæ comites throughout its whole course.

PLAN OF THE RELATIONS OF THE RADIAL ARTERY IN THE FOREARM.

In front.
Skin, superficial and deep fasciæ.
Supinator longus.

Inner side.
Pronator radii teres.
Flexor carpi radialis.

Outer side.
Supinator longus.
Radial nerve (middle third).

Behind.
Tendon of Biceps.
Supinator brevis.
Flexor sublimis digitorum.
Pronator radii teres.
Flexor longus pollicis.
Pronator quadratus.
Radius.

At the wrist, as it winds round the outer side of the carpus from the styloid process to the first interosseous space, it lies upon the external lateral ligament, and then upon the scaphoid bone and trapezium, being covered by the extensor tendons of the thumb, subcutaneous veins, some filaments of the radial nerve, and the integument. It is accompanied by two veins and a filament of the musculo-cutaneous nerve.

In the hand it passes from the upper end of the first interosseous space, between the heads of the Abductor indicis or First dorsal interosseous muscle, transversely across the palm, to the base of the metacarpal bone of the little finger, where it inosculates with the communicating branch from the ulnar artery, forming the deep palmar arch. It lies upon the carpal extremities of the metacarpal bones and the Interossei muscles, being covered by the Adductor obliquus pollicis, the flexor tendons of the fingers, the Lumbricales, the Opponens, and Flexor brevis minimi digiti. Alongside of it is the deep branch of the ulnar nerve, but running in the opposite direction; that is to say, from within outward.

Peculiarities.—The origin of the radial artery, according to Quain, is, in nearly one case in eight, higher than usual; more frequently arising from the axillary or upper part of the brachial than from the lower part of this vessel. The variations in the position of this vessel in the arm and at the bend of the elbow have been already mentioned. In the forearm it deviates less frequently from its position than the ulnar. It has been found lying over the fascia instead of beneath it. It has also been observed on the surface of the Supinator longus, instead of along its inner border; and in turning round the wrist it has been seen lying over, instead of beneath, the extensor tendons.

Surface Marking.—The position of the radial artery in the forearm is represented by a line drawn from the outer border of the tendon of the Biceps in the centre of the hollow in front of the elbow-joint with a straight course to the inner side of the fore part of the styloid process of the radius.

Surgical Anatomy.—The radial artery is much exposed to injury in its lower third, and is frequently wounded by the hand being driven through a pane of glass, by the slipping of a knife or chisel held in the other hand, and such-like accidents. The injury is often followed by a traumatic aneurism, for which the old operation of laying open the sac and securing the vessel above and below is required.

The operation of tying the radial artery is required in cases of wounds either of its trunk or of some of its branches, or for aneurism; and it will be observed that the vessel may be exposed in any part of its course through the forearm without the division of any muscular fibres. The operation in the middle or inferior third of the forearm is easily performed, but in the upper third, near the elbow, it is attended with some difficulty, from the greater depth of the vessel and from its being overlapped by the Supinator longus muscle.

To tie the artery in the upper third an incision three inches in length should be made through the integument, in a line drawn from the centre of the bend of the elbow to the front of the styloid process of the radius, avoiding the branches of the median vein; the fascia of the arm being divided and the Supinator longus drawn a little outward, the artery will be exposed. The venæ comites should be carefully separated from the vessel, and the ligature passed from the radial to the ulnar side.

In the middle third of the forearm the artery may be exposed by making an incision of similar length on the inner margin of the Supinator longus. In this situation the radial nerve

lies in close relation with the outer side of the artery, and should, as well as the veins, be carefully avoided.

In the lower third the artery is easily secured by dividing the integument and fascia in the interval between the tendons of the Supinator longus and Flexor carpi radialis muscles.

The branches of the radial artery may be divided into three groups, corresponding with the three regions in which the vessel is situated.

In the Forearm.	Radial Recurrent.
	Muscular.
	Anterior Carpal.
	Superficialis Volæ.
Wrist.	Posterior Carpal.
	Metacarpal.
	Dorsales Pollicis.
	Dorsalis Indicis.
Hand.	Princeps Pollicis.
	Radialis Indicis.
	Perforating.
	Interosseous.
	Palmar Recurrent.

The **radial recurrent** is given off immediately below the elbow. It ascends between the branches of the musculo-spiral nerve lying on the Supinator brevis, and then between the Supinator longus and Brachialis anticus, supplying these muscles and the elbow-joint, and anastomosing with one of the terminal branches of the superior profunda.

The **muscular branches** are distributed to the muscles on the radial side of the forearm.

The **anterior carpal** is a small vessel which arises from the radial artery near the lower border of the Pronator quadratus, and, running inward in front of the radius, anastomoses with the anterior carpal branch of the ulnar artery. From the arch thus formed branches descend to supply the articulations of the wrist.

The **superficialis volæ** arises from the radial artery, just where this vessel is about to wind round the wrist. Running forward, it passes between the muscles of the thumb, which it supplies, and sometimes anastomoses with the palmar portion of the ulnar artery, completing the superficial palmar arch.

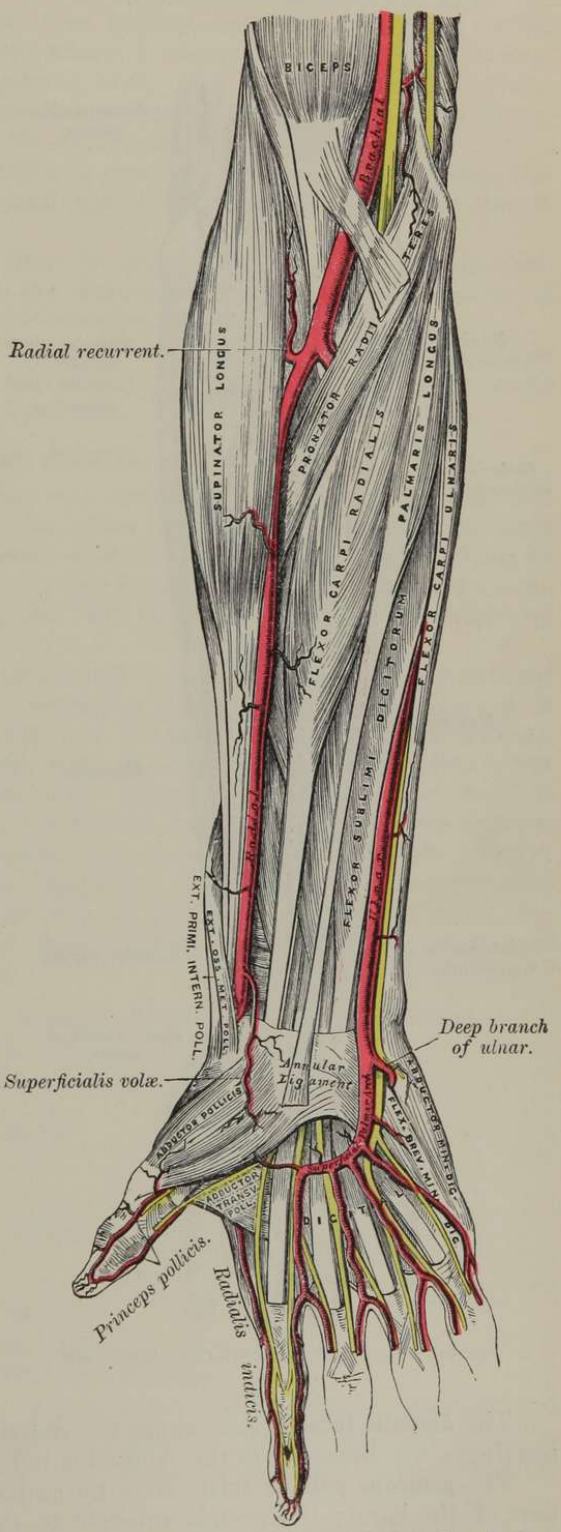

FIG. 364.—The surgical anatomy of the radial and ulnar arteries.

This vessel varies considerably in size:

usually it is very small, and terminates in the muscles of the thumb; sometimes it is as large as the continuation of the radial.

The **posterior carpal** arises from the radial artery beneath the extensor tendons of the thumb; crossing the carpus transversely to its inner border, it anastomoses with the posterior carpal branch of the ulnar, forming the *posterior carpal arch*, which is joined by the termination of the posterior interosseous artery. From this arch are given off descending branches, the *dorsal interosseous arteries* for the third and fourth interosseous spaces, which run forward on the muscles and divide into dorsal digital branches which supply the adjacent sides of the middle, ring, and little fingers respectively, communicating with the digital arteries of the superficial palmar arch. At their origin they anastomose with the superior perforating branches from the deep palmar arch, and at the clefts of the fingers send off *inferior perforating* branches to the corresponding palmar digital arteries.

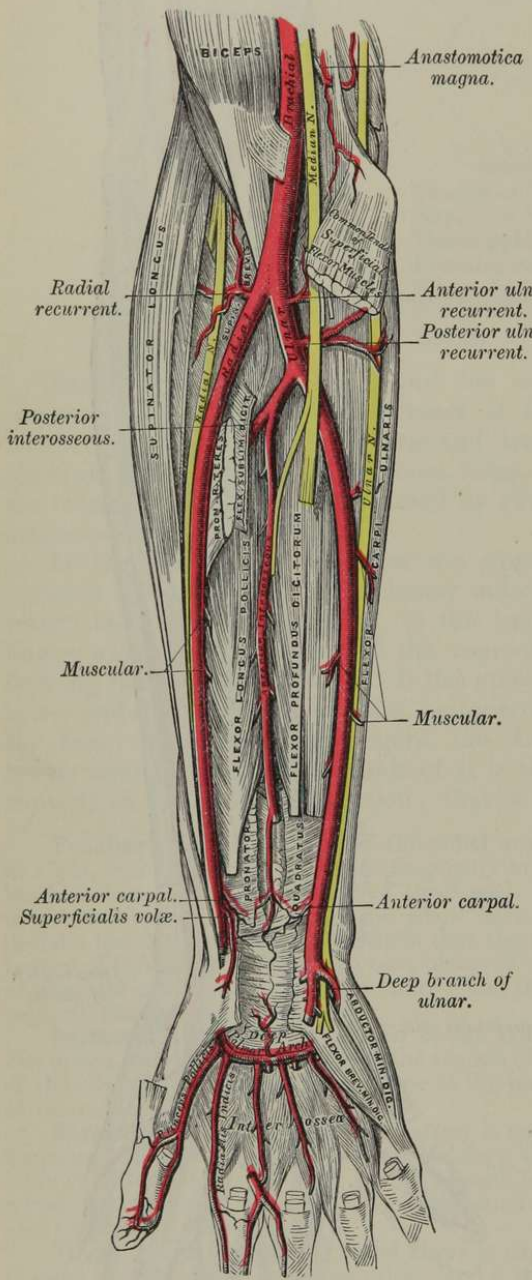

FIG. 365.—Ulnar and radial arteries. Deep view.

The **metacarpal** (**first dorsal interosseous branch**) arises beneath the extensor tendons of the thumb, sometimes with the posterior carpal artery; running forward on the Second dorsal interosseus muscle, it communicates, behind, with the corresponding superior perforating branch of the deep palmar arch; and in front it divides into two *dorsal digital branches*, which supply the adjoining sides of the index and middle fingers, inosculating with the digital branch of the superficial palmar arch. It also has a similar but more constant *inferior perforating* branch,

The **dorsales pollicis** are two vessels which run along the sides of the dorsal aspect of the thumb. They arise separately, or by a common trunk, near the base of the first metacarpal bone.

The **dorsalis indicis** runs along the radial side of the back of the index finger, sending a few branches to the Abductor indicis.

The **princeps pollicis** arises from the radial just as it turns inward to the deep part of the hand; it descends anterior to the Abductor indicis and between the Adductor pollicis muscles, along the ulnar side of the metacarpal bone of the thumb, to the base of the first phalanx, where it divides into two branches, which run along the sides of the palmar aspect of the thumb and form an arch on the under surface

of the last phalanx, from which branches are distributed to the integument and pulp of the thumb.

The **radialis indicis** arises close to the preceding, descends between the Abductor indicis and Adductor transversus pollicis, and runs along the radial side of the index finger to its extremity, where it anastomoses with the collateral digital artery from the superficial palmar arch. At the lower border of the Adductor transversus pollicis this vessel anastomoses with the princeps pollicis, and gives a communicating branch to the superficial palmar arch.

The **superior perforating arteries**, three in number, pass backward between the heads of the last three Dorsal interossei muscles, to inosculate with the dorsal interosseous arteries.

The **palmar interosseous**, three or four in number, are branches of the deep palmar arch; they run forward upon the Interossei muscles, and anastomose at the clefts of the fingers with the digital branches of the superficial arch.

The **palmar recurrent branches** arise from the concavity of the deep palmar arch. They pass upward in front of the wrist, supplying the carpal articulations and anastomosing with the anterior carpal arch.

Ulnar Artery.

The **Ulnar Artery**, the larger of the two terminal branches of the brachial, commences a little below the bend of the elbow, and crosses obliquely the inner side of the forearm, to the commencement of its lower half; it then runs along its ulnar border to the wrist, crosses the annular ligament on the radial side of the pisiform bone, and immediately beyond this bone divides into two branches, superficial and deep palmar.

Relations in the Forearm.—In its *upper half* it is deeply seated, being covered by all the superficial flexor muscles, excepting the Flexor carpi ulnaris; it is crossed by the median nerve (deep head of Pronator radii teres intervening), which lies just above to its inner side, and it lies upon the Brachialis anticus and Flexor profundus digitorum muscles. In the *lower half* of the forearm it lies upon the Flexor profundus, being covered by the integument, the superficial and deep fasciæ, and is placed between the Flexor carpi ulnaris and Flexor sublimis digitorum muscles. It is accompanied by two venæ comites; the ulnar nerve lies on its inner side for the lower two-thirds of its extent, and a small branch from the nerve descends on the lower part of the vessel to the palm of the hand.

PLAN OF RELATIONS OF THE ULNAR ARTERY IN THE FOREARM.

In front.

Superficial layer of flexor muscles. } Upper half.
Median nerve. }
Superficial and deep fasciæ. Lower half.

Inner side.
Flexor carpi ulnaris.
Ulnar nerve (lower two-thirds).

Ulnar Artery in Forearm.

Outer side.
Flexor sublimis digitorum.

Behind.
Brachialis anticus.
Flexor profundus digitorum.

At the wrist (Fig. 364) the ulnar artery is covered by the integument and fascia, and lies upon the anterior annular ligament. On its inner side is the pisiform bone. The ulnar nerve lies at the inner side, and somewhat behind the artery.

Peculiarities.—The ulnar artery has been found to vary in its origin nearly in the proportion of one in thirteen cases, in one case arising lower than usual, about two or three inches below the elbow, and in all other cases much higher, the brachial being a more frequent source of origin than the axillary.

Variations in the position of this vessel are more frequent than in the radial. When its origin is normal the course of the vessel is rarely changed. When it arises high up it is almost invariably superficial to the flexor muscles in the forearm, lying commonly beneath the fascia, more rarely between the fascia and integument. In a few cases its position was subcutaneous in the upper part of the forearm, subaponeurotic in the lower part.

Surface Marking.—On account of the curved direction of the ulnar artery the line on the surface of the body which indicates its course is somewhat complicated. First, draw a line from the front of the internal condyle of the humerus to the radial side of the pisiform bone; the lower two-thirds of this line represents the course of the middle and lower third of the ulnar artery. Secondly, draw a line from the centre of the hollow in front of the elbow-joint to the junction of the upper and middle third of the first line; this represents the course of the upper third of the artery.

Surgical Anatomy.—The application of a ligature to this vessel is required in cases of wound of the artery or of its branches, or in consequence of aneurism. In the upper half of the forearm the artery is deeply seated beneath the superficial flexor muscles, and the application of a ligature in this situation is attended with some difficulty. An incision is to be made in the course of a line drawn from the front of the internal condyle of the humerus to the outer side of the pisiform bone, so that the centre of the incision is three fingers' breadth below the internal condyle. The skin and superficial fascia having been divided and the deep fascia exposed, the white line which separates the Flexor carpi ulnaris from the other flexor muscles is to be sought for, and the fascia incised in this line. The Flexor carpi ulnaris is now to be carefully separated from the other muscles, when the ulnar nerve will be exposed, and must be drawn aside. Some little distance below the nerve the artery will be found accompanied by its venæ comites, and may be ligatured by passing the needle from within outward. In the middle and lower third of the forearm this vessel may be easily secured by making an incision on the radial side of the tendon of the Flexor carpi ulnaris: the deep fascia being divided, and the Flexor carpi ulnaris and its companion muscle, the Flexor sublimis, being separated from each other, the vessel will be exposed, accompanied by its venæ comites, the ulnar nerve lying on its inner side. The veins being separated from the artery, the ligature should be passed from the ulnar to the radial side, taking care to avoid the ulnar nerve.

The branches of the ulnar artery may be arranged in the following groups:

- *Forearm.*
  - Anterior Ulnar Recurrent.
  - Posterior Ulnar Recurrent.
  - Interosseous
    - Anterior Interosseous.
    - Posterior Interosseous.
  - Muscular.
- *Wrist.*
  - Anterior Carpal.
  - Posterior Carpal.
- *Hand.*
  - Superficial Palmar Arch.
  - Deep Palmar or Communicating.

The **anterior ulnar recurrent** (Fig. 365) arises immediately below the elbow-joint, passes upward and inward between the Brachialis anticus and Pronator radii teres, supplies those muscles, and, in front of the inner condyle, anastomoses with the anastomotica magna and inferior profunda.

The **posterior ulnar recurrent** is much larger, and arises somewhat lower than the preceding. It passes backward and inward, beneath the Flexor sublimis, and ascends behind the inner condyle of the humerus. In the interval between this process and the olecranon it lies beneath the Flexor carpi ulnaris, ascending between the heads of that muscle, beneath the ulnar nerve; it supplies the neighboring muscles and joint, and anastomoses with the inferior profunda, anastomotica magna, and interosseous recurrent arteries (Fig. 366).

The **interosseous artery** (Fig. 365) is a short trunk about an inch in length, and of considerable size, which arises immediately below the tuberosity of the radius, and, passing backward to the upper border of the interosseous membrane, divides into two branches, the *anterior* and *posterior interosseous*.

The **anterior interosseous** passes down the forearm on the anterior surface of the interosseous membrane, to which it is connected by a thin aponeurotic arch. It is accompanied by the interosseous branch of the median nerve, and overlapped by the contiguous margins of the Flexor profundus digitorum and Flexor longus pollicis muscles, giving off in this situation muscular branches and the nutrient arteries of the radius and ulna. At the upper border of the Pronator quadratus a branch descends beneath the muscle to anastomose in front of the carpus with

branches from the anterior carpal and deep palmar arch. The continuation of the artery passes behind the Pronator quadratus, and, piercing the interosseous membrane, gets to the back of the forearm, and anastomoses with the posterior interosseous artery (Fig. 366). It then descends to the back of the wrist to join the posterior carpal arch. The anterior interosseous gives off a long, slender branch, the *median artery*, which accompanies the median nerve and gives offsets to its substance. This artery is sometimes much enlarged. It also gives off nutrient branches to the radius and ulna about the middle of the forearm.

The **posterior interosseous artery** passes backward through the interval between the oblique ligament and the upper border of the interosseous membrane. It appears between the contiguous borders of the Supinator brevis and the Extensor ossis metacarpi pollicis, and runs down the back part of the forearm, between the superficial and deep layer of muscles, to both of which it distributes branches. At the lower part of the forearm it anastomoses with the termination of the anterior interosseous artery. Then, continuing its course over the head of the ulna, it joins the posterior carpal branch of the ulnar artery. This artery gives off, near its origin, the *interosseous recurrent branch.*

The **interosseous recurrent artery** is a large vessel which ascends to the interval between the external condyle and olecranon, on or through the fibres of the Supinator brevis, but beneath the Anconeus, anastomosing with a branch from the superior profunda, and with the posterior ulnar recurrent and anastomotica magna.

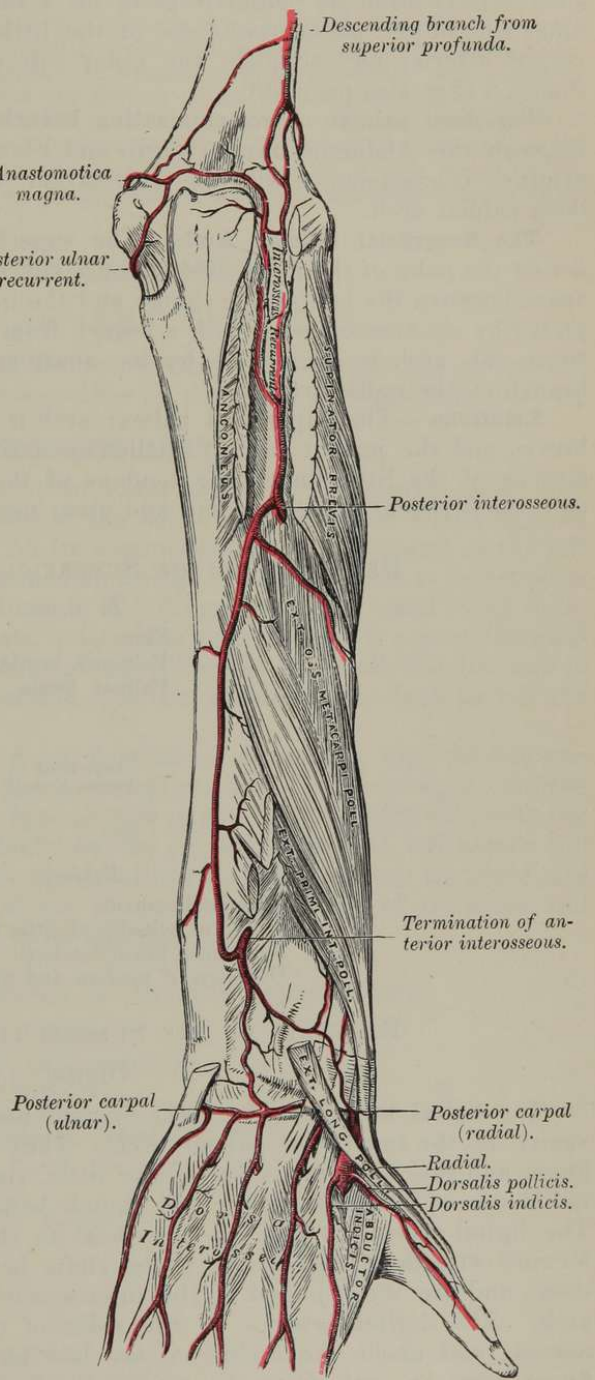

FIG. 366.—Arteries of the back of the forearm and hand.

The **muscular branches** are distributed to the muscles along the ulnar side of the forearm.

The **anterior carpal** is a small vessel which crosses the front of the carpus beneath the tendons of the Flexor profundus, and inosculates with a corresponding branch of the radial artery.

The **posterior carpal** arises immediately above the pisiform bone, and winds backward beneath the tendon of the Flexor carpi ulnaris: it passes across the dorsal surface of the carpus beneath the extensor tendons, anastomosing with a corresponding branch of the radial artery, and forming the *posterior carpal arch.* Immediately after its origin it gives off a small branch which runs along the ulnar side of the metacarpal bone of the little finger, forming one of the *metacarpal arteries*, and supplies the ulnar side of the dorsal surface of the little finger. (See also page 600.)

The **deep palmar** or **communicating branch** (Fig. 365) passes deeply inward between the Abductor minimi digiti and Flexor brevis minimi digiti near their origins; it anastomoses with the termination of the radial artery, completing the deep palmar arch.

The Superficial Palmar Arch.—The superficial palmar arch passes outward across the palm of the hand, describing a curve, with its convexity forward to the space between the ball of the thumb and the index finger, where the arch is completed by its anastomosing with a branch from the radialis indicis, though sometimes the arch is completed by its anastomosing with the superficialis volæ branch of the radial artery.

Relations.—The superficial palmar arch is covered by the skin, the Palmaris brevis, and the palmar fascia. It lies upon the annular ligament, origin of the muscles of the little finger, the tendons of the superficial flexor of the fingers, and, the divisions of the median and ulnar nerves.

Relations of the Superficial Palmar Arch.

In front.

Skin.
Palmaris brevis.
Palmar fascia.

Behind.

Annular ligament.
Origin of muscles of little finger.
Superficial flexor tendons.
Divisions of median and ulnar nerves.

Branches of the Superficial Palmar Arch.

Digital.

The **digital branches** (Fig. 364), four in number, are given off from the convexity of the superficial palmar arch. They supply the ulnar side of the little finger and the adjoining sides of the little, ring, middle, and index fingers, the radial side of the index finger and thumb being supplied from the radial artery. The digital arteries at first lie superficial to the flexor tendons, but as they pass forward with the digital nerves to the clefts between the fingers they lie between them, and are there joined by the interosseous branches from the deep palmar arch. The digital arteries on the sides of the fingers lie behind the digital nerves; and about the middle of the last phalanx the two branches for each finger form an arch, from the convexity of which branches pass to supply the pulp of the finger.

Surface Marking.—The superficial palmar arch is represented by a curved line, starting from the outer side of the pisiform bone and carried downward as far as the middle third of the palm, and then curved outward on a level with the upper end of the cleft between the thumb and index finger.

The deep palmar arch is situated about half an inch nearer to the carpus.

Surgical Anatomy.—Wounds of the palmar arches are of special interest, and are always difficult to deal with. When the wound in the superficial tissues is extensive, it may be possible to secure the bleeding ends of the vessel; but when there is a small punctured wound, as from a penknife or piece of glass, pressure systematically applied is probably the best course of treatment, as there is difficulty in reaching the wounded vessel without damaging important structures. At the same time it must be admitted that pressure applied to the palm of the hand to arrest hæmorrhage from a wound of one of the palmar arches, especially the deep arch, is apt to be followed by sloughing, owing to the rigidity of the parts and the facility with which a considerable amount of pressure can be applied. In wounds of the deep palmar arch a ligature may be applied to the bleeding points from the dorsum of the hand by resection of the upper part of the third metacarpal bone. It is useless in these cases to ligature one of the arteries of the forearm alone, and indeed simultaneous ligature of both radial and ulnar arteries above the wrist is often unsuccessful, on account of the anastomosis carried on by the carpal arches. Therefore, upon the failure of pressure to arrest hæmorrhage it is expedient to apply a ligature to the brachial artery.

THE DESCENDING AORTA.

ARTERIES OF THE TRUNK.

The **Descending Aorta** is divided into two portions, the *thoracic* and *abdominal*, in correspondence with the two great cavities of the trunk in which it is situated.

THE THORACIC AORTA.

The **Thoracic Aorta** commences at the lower border of the fourth dorsal vertebra, on the left side, and terminates at the aortic opening in the Diaphragm, in front of the last dorsal vertebra. At its commencement it is situated on the left side of the spine; it approaches the median line as it descends, and at its termination lies directly in front of the column. The direction of this vessel being influenced by the spine, upon which it rests, it describes a curve which is concave forward in the dorsal region. As the branches given off from it are small, the diminution in the size of the vessel is inconsiderable. It is contained in the back part of the posterior mediastinum.

Relations.—It is in relation, *in front*, from above downward, with the left pulmonary artery, the left bronchus, the pericardium, and the œsophagus; *behind*, with the vertebral column and the vena azygos minor; on the *right side*, with the vena azygos major and thoracic duct; on the *left side*, with the left pleura and lung. The œsophagus with its accompanying nerves lies at first on the right side of the aorta, but at the *lower* part of the thorax it gets in front of the aorta, and close to the Diaphragm is situated to its left side.

PLAN OF THE RELATIONS OF THE THORACIC AORTA.

In front.
Left pulmonary artery.
Left bronchus.
Pericardium.
Œsophagus (below).

Right side.
Œsophagus
Vena azygos major.
Thoracic duct.



Left side.
Pleura.
Left lung.
Œsophagus (below).

Behind.
Vertebral column.
Vena azygos minor.

The aorta is occasionally found to be obliterated at a particular spot—viz. at the junction of the arch with the thoracic aorta, just below the ductus arteriosus. Whether this is the result of disease or of congenital malformation is immaterial to our present purpose; it affords an interesting opportunity of observing the resources of the collateral circulation. The course of the anastomosing vessels, by which the blood is brought from the upper to the lower part of the artery, will be found well described in an account of two cases in the *Pathological Transactions*, vols. viii. and x. In the former (p. 160) Mr. Sydney Jones thus sums up the detailed description of the

anastomosing vessels: "The principal communications by which the circulation was carried on, were—Firstly, the internal mammary, anastomosing with the intercostal arteries, with the phrenic of the abdominal aorta by means of the musculo-phrenic and comes nervi phrenici, and largely with the deep epigastric. Secondly, the superior intercostal, anastomosing anteriorly by means of a large branch with the first aortic intercostal, and posteriorly with the posterior branch of the same artery. Thirdly, the inferior thyroid, by means of a branch about the size of an ordinary radial, formed a communication with the first aortic intercostal. Fourthly, the transversalis colli, by means of very large communications with the posterior branches of the intercostals. Fifthly, the branches (of the subclavian and axillary) going to the side of the chest were large, and anastomosed freely with the lateral branches of the intercostals." In the second case also (vol. x. p. 97) Mr. Wood describes the anastomoses in a somewhat similar manner, adding the remark that "the blood which was brought into the aorta through the anastomoses of the intercostal arteries appeared to be expended principally in supplying the abdomen and pelvis, while the supply to the lower extremities had passed through the internal mammary and epigastrics."

Surgical Anatomy.—The student should now consider the effects likely to be produced by aneurism of the thoracic aorta, a disease of common occurrence. When we consider the great depth of the vessel from the surface and the number of important structures which surround it on every side, it may easily be conceived what a variety of obscure symptoms may arise from disease of this part of the arterial system, and how they may be liable to be mistaken for those of other affections. Aneurism of the thoracic aorta most usually extends backward along the left side of the spine, producing absorption of the bodies of the vertebræ, with curvature of the spine; whilst the irritation or pressure on the cord will give rise to pain, either in the chest, back, or loins, with radiating pain in the left upper intercostal spaces, from pressure on the intercostal nerves; at the same time the tumor may project backward on each side of the spine, beneath the integument, as a pulsating swelling, simulating abscess connected with diseased bone, or it may displace the œsophagus and compress the lung on one or the other side. If the tumor extend forward, it may press upon and displace the heart, giving rise to palpitation and other symptoms of disease of that organ; or it may displace, or even compress, the œsophagus, causing pain and difficulty of swallowing, as in stricture of that tube; and ultimately even open into it by ulceration, producing fatal hæmorrhage. If the disease extends to the right side, it may press upon the thoracic duct; or it may burst into the pleural cavity or into the trachea or lung; and lastly, it may open into the posterior mediastinum.

Branches of the Thoracic Aorta.

Pericardiac. Œsophageal.
Bronchial. Posterior Mediastinal.
Intercostal.

The **pericardiac** are a few small vessels, irregular in their origin, distributed to the pericardium.

The **bronchial arteries** are the nutrient vessels of the lungs, and vary in number, size, and origin. That of the right side arises from the first aortic intercostal, or by a common trunk with the left bronchial from the front of the thoracic aorta. Those of the left side, usually two in number, arise from the thoracic aorta, one a little lower than the other. Each vessel is directed to the back part of the corresponding bronchus along which it runs, dividing and subdividing upon the bronchial tube, supplying them, the cellular tissue of the lungs, the bronchial glands, and the œsophagus.

The **œsophageal arteries**, usually four or five in number, arise from the front of the aorta, and pass obliquely downward to the œsophagus, forming a chain of anastomoses along that tube, anastomosing with the œsophageal branches of the inferior thyroid arteries above, and with ascending branches from the phrenic and gastric arteries below.

The **posterior mediastinal arteries** are numerous small vessels which supply the glands and loose areolar tissue in the mediastinum.

The **Intercostal arteries** arise from the back part of the aorta. They are usually eleven in number on each side, the superior intercostal space being supplied by the superior intercostal, a branch of the subclavian, and the second intercostal space being supplied by a branch from the superior intercostal joining with the first aortic intercostal. The lowest of these branches, the *subcostal artery*, underlies the last rib. The right intercostals are longer than the left, on account of the position of the aorta on the left side of the spine: they pass outward, across the bodies of the vertebræ, to the intercostal spaces, being covered by the pleura, the

œsophagus, thoracic duct, sympathetic nerve, and the vena azygos major; the left passing beneath the superior intercostal vein, the vena azygos minor, and sympathetic. In the intercostal spaces each artery divides into two branches—an anterior, or proper intercostal branch; and a posterior, or dorsal branch.[1]

The **anterior branch** passes outward, at first lying upon the External inter-

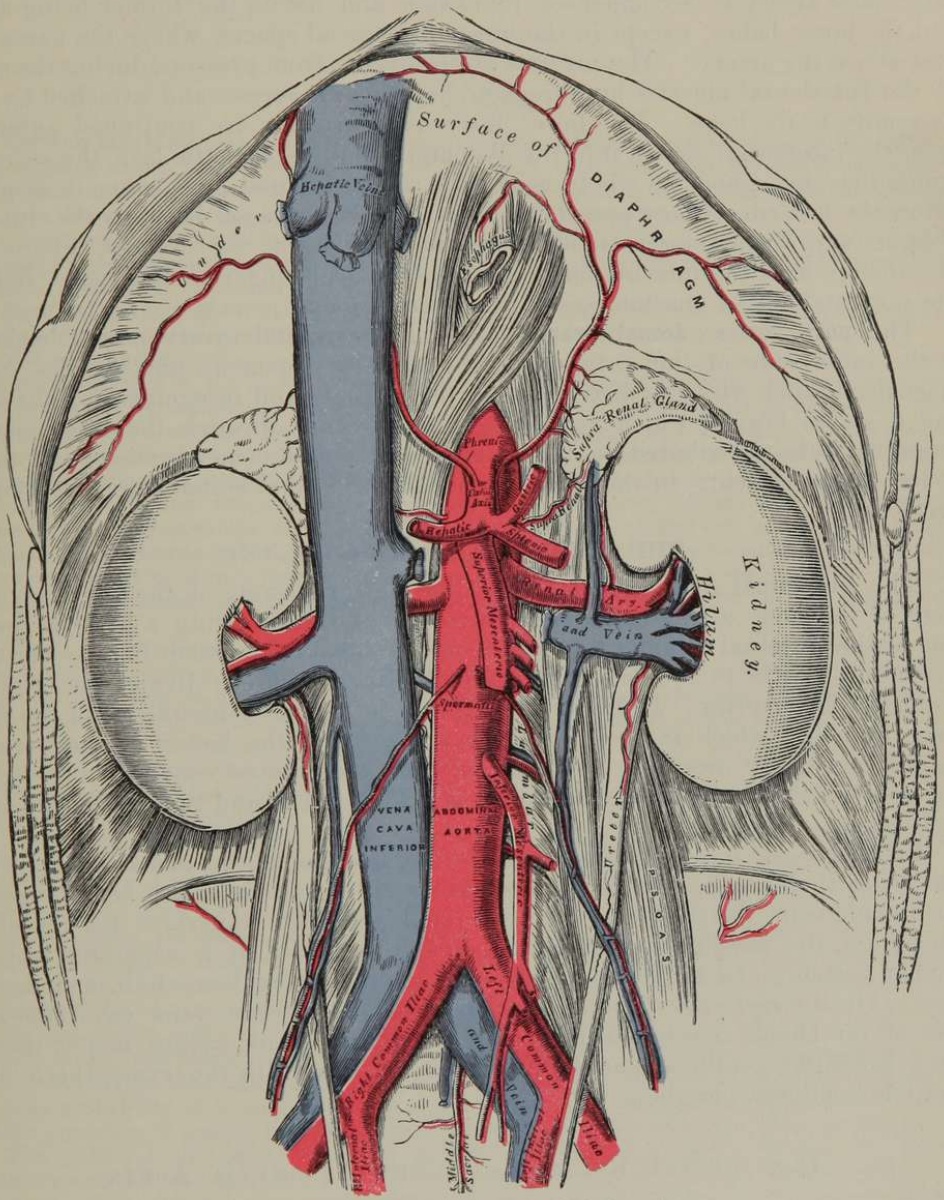

FIG. 367.—The abdominal aorta and its branches.

costal muscle, covered in front by the pleura and a thin fascia. It then passes between the two layers of Intercostal muscles, and, having ascended obliquely to the lower border of the rib above, divides, near the angle of that bone, into two branches: of these the larger runs in the groove on the lower border of the rib above; the smaller branch along the upper border of the rib below; passing

[1] Mr. W. J. Walsham describes a small twig as being given off from each intercostal close to its origin. He states that they can be traced running between the neck of the rib and the transverse process of the corresponding vertebra; they anastomose with similar twigs given off from the intercostal artery next below. In the first and second spaces similar anastomosing twigs are given off from the superior intercostal (*Journal of Anatomy and Physiology*, vol. xvi. part iii. p. 443).

forward, they supply the Intercostal muscle, and anastomose with the anterior intercostal branches of the internal mammary, and with the thoracic branches of the axillary artery. The first aortic intercostal anastomoses with the superior intercostal, and the last three pass between the abdominal muscles, inosculating with the epigastric in front and with the phrenic and lumbar arteries. Each intercostal artery is accompanied by a vein and nerve, the former being above, and the latter below, except in the upper intercostal spaces, where the nerve is at first above the artery. The arteries are protected from pressure during the action of the Intercostal muscles by fibrous arches thrown across, and attached by each extremity to the bone. The lower intercostal arteries are continued anteriorly from the intercostal spaces into the abdominal wall, except the last, the *subcostal*, which lies throughout its whole course in the abdominal wall, since it is placed below the last rib. They pass behind the costal cartilages between the Internal oblique and Transversalis muscle to the sheath of the Rectus, where they anastomose with the internal mammary and the deep epigastric arteries. Behind, the subcostal artery anastomoses with the first lumbar artery.

The **posterior** or **dorsal branch** of each intercostal artery passes backward to the inner side of the anterior costo-transverse ligament, and divides into a muscular branch which is distributed to the muscles and integument of the back, and a spinal branch which enters the spinal canal through the intervertebral foramina to be distributed to the spinal cord and its membranes, and to the bodies of the vertebræ in the same manner as the lateral spinal branches from the vertebral.

THE ABDOMINAL AORTA (Fig. 367).

The **Abdominal Aorta** commences at the aortic opening of the Diaphragm, in front of the body of the last dorsal vertebra, and, descending a little to the left side of the vertebral column, terminates on the body of the fourth lumbar vertebra, commonly a little to the left of the middle line,[1] where it divides into the two common iliac arteries. It diminishes rapidly in size, in consequence of the many large branches which it gives off. As it lies upon the bodies of the vertebræ the curve which it describes is convex forward, the greatest convexity corresponding to the third lumbar vertebra, which is a little above and to the left side of the umbilicus.

Relations.—It is covered, *in front*, by the lesser omentum and stomach, behind which are the branches of the cœliac axis and the solar plexus; below these, by the splenic vein, the pancreas, the left renal vein, the transverse portion of the duodenum, the mesentery, and aortic plexus. *Behind*, it is separated from the lumbar vertebræ by the left lumbar veins, the receptaculum chyli, and thoracic duct. On the *right side* it is in relation with the inferior vena cava (the right crus of the Diaphragm being interposed above), the vena azygos major, thoracic duct, and right semilunar ganglion; on the *left side*, with the sympathetic nerve and left semilunar ganglion.

Plan of the Relations of the Abdominal Aorta.

In front.

Lesser omentum and stomach.
Branches of the cœliac axis and solar plexus.
Splenic vein.
Pancreas.
Left renal vein.
Transverse duodenum.
Mesentery.
Aortic plexus.

[1] Sir Joseph Lister, having accurately examined 30 bodies in order to ascertain the exact point of termination of this vessel, found it "either absolutely, or almost absolutely, mesial in 15, while in 13 it deviated more or less to the left, and in 2 was slightly to the right" (*System of Surgery*, edited by T. Holmes, 2d ed. vol. v. p. 652).

Right side.
Right crus of Diaphragm.
Inferior vena cava.
Vena azygos major.
Thoracic duct.
Right semilunar ganglion.

Left side.
Sympathetic nerve.
Left semilunar ganglion.

Behind.
Left lumbar veins.
Receptaculum chyli.
Thoracic duct.
Vertebral column.

Surface Marking.—In order to map out the abdominal aorta on the surface of the abdomen, a line must be drawn from the middle line of the body, on a level with the distal extremity of the seventh costal cartilage, downward and slightly to the left, so that it just skirts the umbilicus, to a zone drawn round the body opposite the highest point of the crest of the ilium. This point is generally half an inch below and to the left of the umbilicus, but as the position of this structure varies with the obesity of the individual, it is not a reliable landmark as to the situation of the bifurcation of the aorta.

Surgical Anatomy.—Aneurisms of the abdominal aorta near the cœliac axis communicate in nearly equal proportion with the anterior and posterior parts of the artery.

When an aneurismal sac is connected with the back part of the abdominal aorta, it usually produces absorption of the bodies of the vertebræ, and forms a pulsating tumor that presents itself in the left hypochondriac or epigastric regions, and is accompanied by symptoms of disturbance in the alimentary canal. Pain is invariably present, and is usually of two kinds—a fixed and constant pain in the back, caused by the tumor pressing on or displacing the branches of the solar plexus and splanchnic nerves; and a sharp lancinating pain, radiating along those branches of the lumbar nerves which are pressed on by the tumor; hence the pain in the loins, the testes, the hypogastrium, and in the lower limb (usually of the left side). This form of aneurism usually bursts into the peritoneal cavity or behind the peritoneum in the left hypochondriac region; or it may form a large aneurismal sac, extending down as low as Poupart's ligament; hæmorrhage in these cases being generally very extensive, but slowly produced, and not rapidly fatal.

When an aneurismal sac is connected with the front of the aorta near the cœliac axis, it forms a pulsating tumor in the left hypochondriac or epigastric regions, usually attended with symptoms of disturbance of the alimentary canal, as sickness, dyspepsia, or constipation, and accompanied by pain, which is constant, but nearly always fixed in the loins, epigastrium, or some part of the abdomen; the radiating pain being rare, as the lumbar nerves are seldom implicated. This form of aneurism may burst into the peritoneal cavity or behind the peritoneum, between the layers of the mesentery, or, more rarely, into the duodenum; it rarely extends backward so as to affect the spine.

The abdominal aorta has been tied several times, and although none of the patients permanently recovered, still, as one of them lived as long as ten days, the possibility of the re-establishment of the circulation may be considered to be proved. In the lower animals this artery has been often successfully tied. The vessel may be reached in several ways. In the original operation, performed by Sir A. Cooper, an incision was made in the linea alba, the peritoneum opened in front, the finger carried down amongst the intestines toward the spine, the peritoneum again opened behind by scratching through the mesentery, and the vessel thus reached. Or either of the operations described below for securing the common iliac artery may, by extending the dissection a sufficient distance upward, be made use of to expose the aorta. The chief difficulty in the dead subject consists in isolating the artery in consequence of its great depth; but in the living subject the embarrassment resulting from the proximity of the aneurismal tumor, and the great probability of disease in the vessel itself, add to the dangers and difficulties of this formidable operation so greatly that it is very doubtful whether it ought ever to be performed.

The collateral circulation would be carried on by the anastomosis between the internal mammary and the deep epigastric; by the free communication between the superior and inferior mesenterics if the ligature were placed above the latter vessel; or by the anastomosis between the inferior mesenteric and the internal pudic when (as is more common) the point of ligature is below the origin of the inferior mesenteric; and possibly by the anastomoses of the lumbar arteries with the branches of the internal iliac.

The circulation through the abdominal aorta may be commanded, in thin persons, by firm pressure with the fingers. A tourniquet has been invented for this purpose which is sometimes used in amputation at the hip-joint and some other operations.

Branches of the Abdominal Aorta.

Phrenic.		Superior Mesenteric.	Ovarian in female.
Cœliac Axis.	Gastric.	Suprarenal.	Inferior Mesenteric.
	Hepatic.	Renal.	Lumbar.
	Splenic.	Spermatic in male.	Sacra Media.

The branches may be divided into two sets: 1. Those supplying the viscera. 2. Those distributed to the walls of the abdomen.

Visceral Branches.

Cœliac Axis. { Gastric. Hepatic. Splenic.
Superior Mesenteric.
Inferior Mesenteric.
Suprarenal.
Renal.
Spermatic or Ovarian.

Parietal Branches.

Phrenic.
Lumbar.
Sacra Media.

Visceral Branches of the Abdominal Aorta.

The Cœliac Axis (Fig. 368).

To expose this artery raise the liver, draw down the stomach, and then tear through the layers of the lesser omentum.

The **Cœliac Axis** is a short thick trunk, about half an inch in length, which

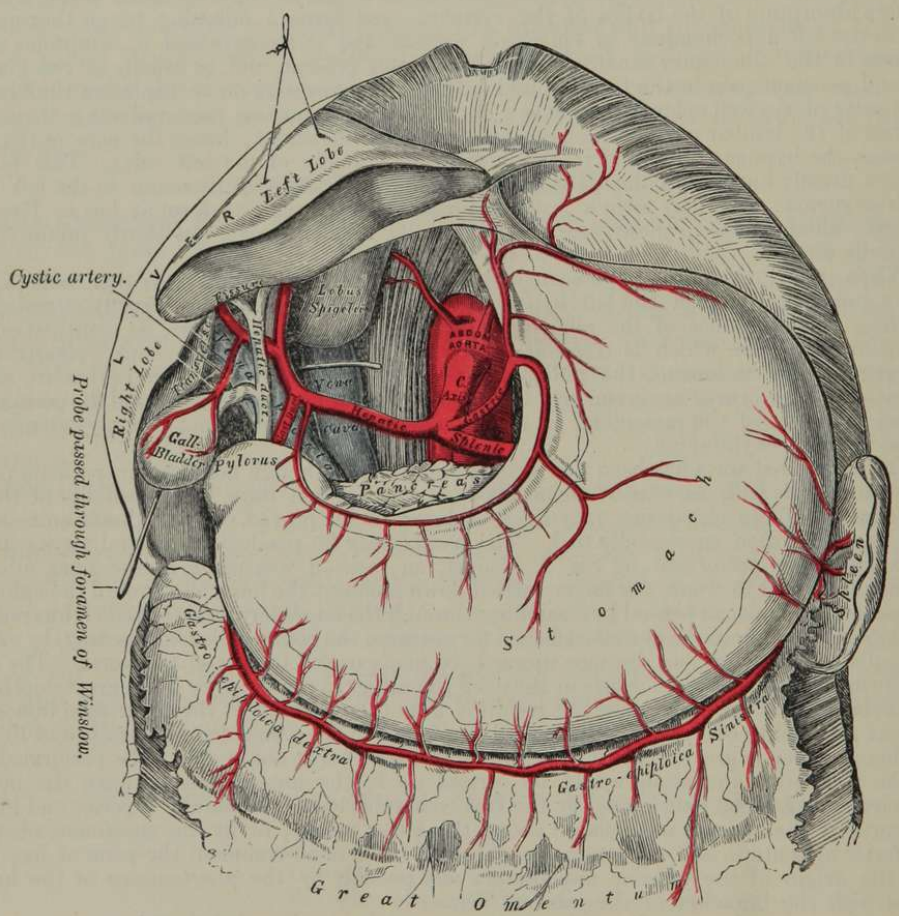

FIG. 368.—The cœliac axis and its branches, the liver having been raised and the lesser omentum removed.

arises from the aorta opposite the margin of the Diaphragm, and, passing nearly horizontally forward (in the erect posture), divides into three large branches, the *gastric*, *hepatic*, and *splenic*, occasionally giving off one of the phrenic arteries.

Relations.—It is covered by the lesser omentum. On the *right side* it is in relation with the right semilunar ganglion, and the lobus Spigelii; on the *left side*, with the left semilunar ganglion and cardiac end of the stomach. *Below*, it rests upon the upper border of the pancreas.

The **Gastric Artery** (*Coronaria ventriculi*), the smallest of the three branches of the cœliac axis, passes upward and to the left side, to the cardiac orifice of the stomach, distributing branches to the œsophagus which anastomose with the aortic œsophageal arteries; others supply the cardiac end of the stomach, inosculating with branches of the splenic artery; it then passes from left to right, along the lesser curvature of the stomach to the pylorus, lying in its course between the layers of the lesser omentum, and giving branches to both surfaces of the organ: at its termination it anastomoses with the pyloric branch of the hepatic.

The **Hepatic Artery** in the adult is intermediate in size between the gastric and splenic; in the fœtus it is the largest of the three branches of the cœliac axis. It is first directed forward and to the right, to the upper margin of the pyloric end of the stomach, crossing under the foramen of Winslow. It then passes upward between the layers of the lesser omentum, near the anterior margin of the foramen of Winslow, to the transverse fissure of the liver, where it divides into two branches, right and left, which supply the corresponding lobes of that organ, accompanying the ramifications of the vena portæ and hepatic duct. The hepatic artery, in its course along the right border of the lesser omentum, is in relation with the ductus communis choledochus and portal veins, the duct lying to the right of the artery and the vena portæ behind.

Its branches are—the

Pyloric.
Gastro-duodenalis { Gastro-epiploica Dextra. / Pancreatico-duodenalis Superior.
Cystic.

The **pyloric branch** arises from the hepatic, above the pylorus, descends to the pyloric end of the stomach, and passes from right to left along its lesser curvature, supplying it with branches and inosculating with the gastric artery.

The **gastro-duodenalis** (Fig. 369) is a short but large branch which descends, near the pylorus, behind the first portion of the duodenum, at the lower border of which it divides into two branches, the *gastro-epiploica dextra* and the *pancreatico-duodenalis superior*. Previous to its division it gives off two or three small inferior pyloric branches to the pyloric end of the stomach and pancreas.

The **gastro-epiploica dextra** runs from right to left along the greater curvature of the stomach, between the layers of the great omentum, anastomosing about the middle of the lower border of the stomach with the gastro-epiploica sinistra from the splenic artery. This vessel gives off numerous branches, some of which ascend to supply both surfaces of the stomach, whilst others descend to supply the great omentum.

The **pancreatico-duodenalis superior** descends between the contiguous margins of the duodenum and pancreas. It supplies both these organs, and anastomoses with the inferior pancreatico-duodenal branch of the superior mesenteric artery and with the pancreatic branches of the splenic.

The **cystic artery** (Fig. 368), usually a branch of the right hepatic, passes upward and forward along the neck of the gall-bladder, and divides into two branches, one of which ramifies on its free surface, the other between it and the substance of the liver.

The **Splenic Artery**, in the adult, is the largest of the three branches of the cœliac axis, and is remarkable for the extreme tortuosity of its course. It passes horizontally to the left side along the upper border of the pancreas, accompanied by the splenic vein, which lies below it, and on arriving near the spleen divides into branches, some of which enter the hilum of that organ to be distributed to its structure, whilst others are distributed to the great end of the stomach. Its branches are—the

Pancreaticæ Parvæ.
Pancreatica Magna.
Gastric (Vasa Brevia).
Gastro-epiploica Sinistra.

The **pancreatic** are numerous small branches derived from the splenic as it runs behind the upper border of the pancreas, supplying its middle and left parts. One of these, larger than the rest, is given off from the splenic near the left extremity of the pancreas; it runs from left to right near the posterior surface of the gland, following the course of the pancreatic duct, and is called the *pancreatica magna*. These vessels anastomose with the pancreatico-

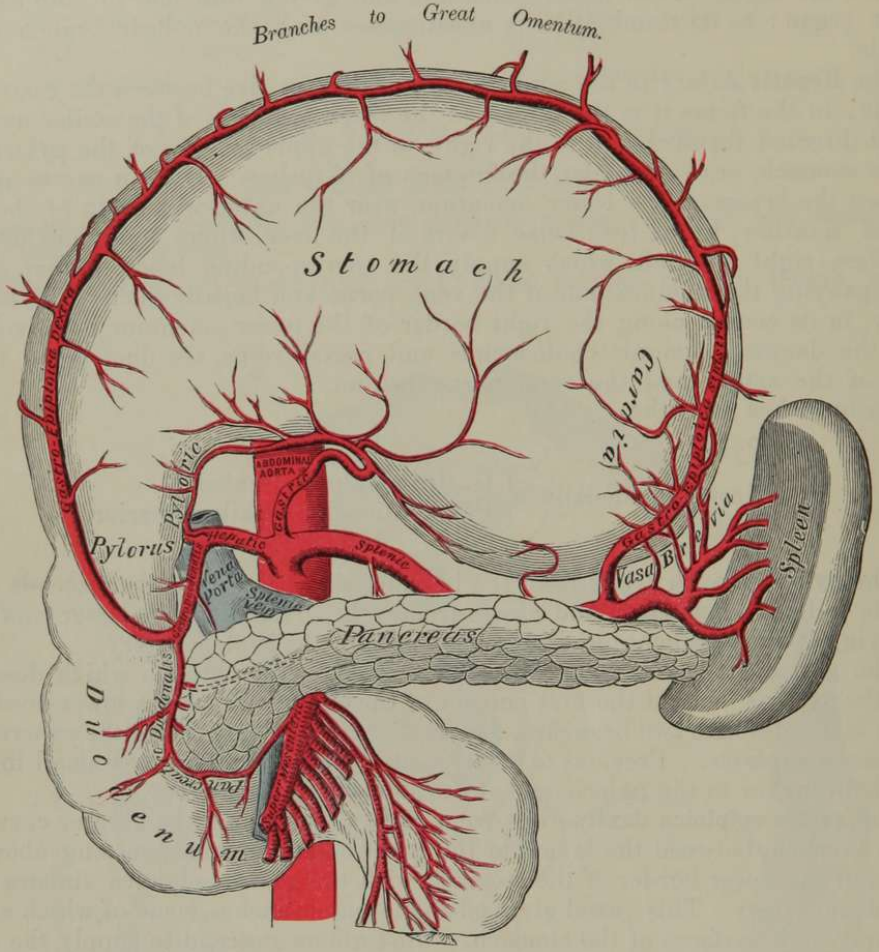

FIG. 369.—The cœliac axis and its branches, the stomach having been raised and the transverse meso-colon removed (semi-diagrammatic).

duodenal arteries, derived from the hepatic on the one hand and superior mesenteric on the other.

The **gastric (vasa brevia)** consists of from five to seven small branches, which arise either from the termination of the splenic artery or from its terminal branches, and, passing from left to right, between the layers of the gastro-splenic omentum, are distributed to the great curvature of the stomach, anastomosing with branches of the gastric and gastro-epiploica sinistra arteries.

The **gastro-epiploica sinistra,** the largest branch of the splenic, runs from left to right along the great curvature of the stomach, between the layers of the great omentum, and anastomoses with the gastro-epiploica dextra. In its course it distributes several branches to the stomach, which ascend upon both surfaces; others descend to supply the omentum.

The Superior Mesenteric Artery (Fig. 370).

In order to expose this vessel raise the great omentum and transverse colon, draw down the small intestines, and cut through the peritoneum where the transverse meso-colon and mesen-

tery join: the artery will then be exposed just as it issues from beneath the lower border of the pancreas.

The **Superior Mesenteric Artery** supplies the whole length of the small intestine, except the first part of the duodenum; it also supplies the cæcum, ascending and transverse colon; it is a vessel of large size, arising from the fore part of the aorta about a quarter of an inch below the cœliac axis; being covered at its origin by the splenic vein and pancreas. It passes forward, between the pancreas and transverse portion of the duodenum, crosses in front of this portion of the intes-

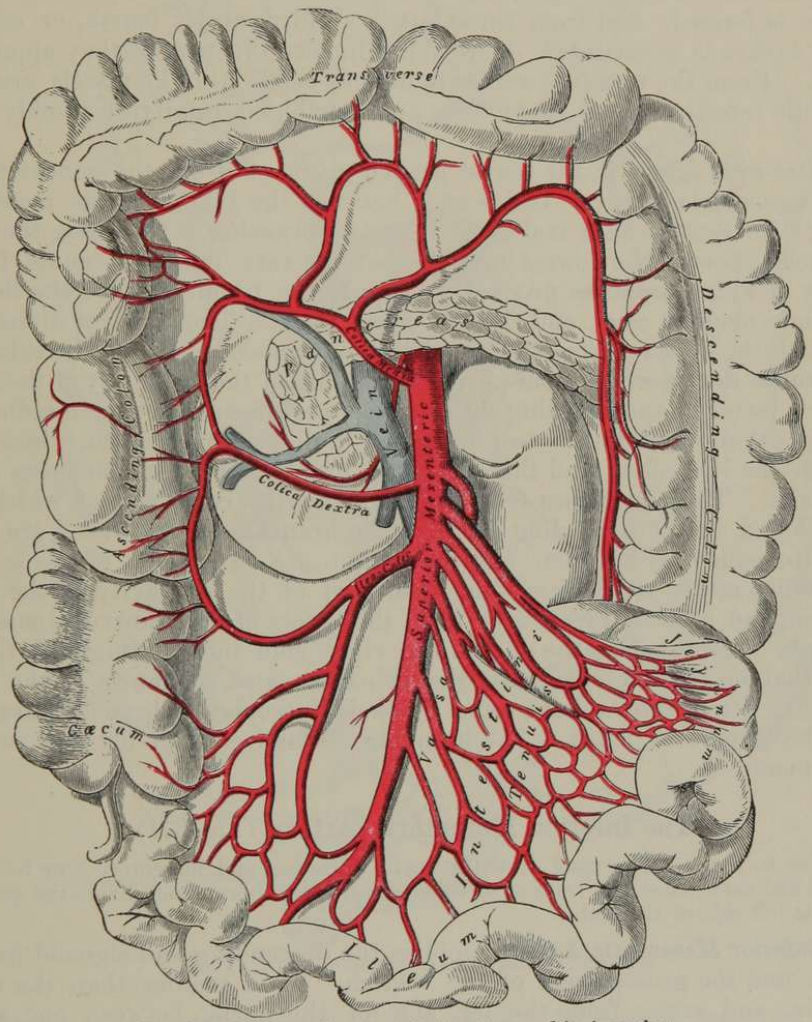

FIG. 370.—The superior mesenteric artery and its branches.

tine, and descends between the layers of the mesentery to the right iliac fossa, where it terminates, considerably diminished in size. In its course it forms an arch, the convexity of which is directed forward and downward to the left side, the concavity backward and upward to the right. It is accompanied by the superior mesenteric vein, and is surrounded by a superior mesenteric plexus of nerves. Its branches are—the

Inferior Pancreatico-duodenal.
Vasa Intestini Tenuis.
Ileo-colic.
Colica Dextra.
Colica Media.

The **Inferior pancreatico-duodenal** is given off from the superior mesenteric behind the pancreas, and is distributed to the head of the pancreas with the

transverse and descending portions of the duodenum, anastomosing with the superior pancreatico-duodenal artery.

The **vasa intestini tenuis** arise from the convex side of the superior mesenteric artery. They are usually from twelve to fifteen in number, and are distributed to the jejunum and ileum. They run parallel with one another between the layers of the mesentery, each vessel dividing into two branches, which unite with a similar branch on each side, forming a series of arches the convexities of which are directed toward the intestine. From this first set of arches branches arise, which again unite with similar branches from either side, and thus a second series of arches is formed; and from these latter, a third, and a fourth, or even fifth, series of arches is constituted, diminishing in size the nearer they approach the intestine. From the terminal arches numerous small straight vessels arise which encircle the intestine, upon which they are distributed, ramifying thickly between its coats.

The **ileo-colic artery** is the lowest branch given off from the concavity of the superior mesenteric artery. It descends between the layers of the mesentery to the right iliac fossa, where it divides into two branches. Of these, the inferior one inosculates with the lowest branches of the vasa intestini tenuis, from the convexity of which branches proceed to supply the termination of the ileum, the cæcum and appendix cæci, and the ileo-cæcal valve. The superior division inosculates with the colica dextra and supplies the commencement of the colon.

The **colica dextra** arises from about the middle of the concavity of the superior mesenteric artery, and, passing behind the peritoneum to the middle of the ascending colon, divides into two branches—a descending branch, which inosculates with the ileo-colic; and the ascending branch, which anastomoses with the colica media. These branches form arches, from the convexity of which vessels are distributed to the ascending colon. The branches of this vessel are covered with peritoneum only on their anterior aspect.

The **colica media** arises from the upper part of the concavity of the superior mesenteric, and, passing forward between the layers of the transverse meso-colon, divides into two branches, the one on the right side inosculating with the colica dextra; that on the left side, with the colica sinistra, a branch of the inferior mesenteric. From the arches formed by their inosculation branches are distributed to the transverse colon. The branches of this vessel lie between two layers of peritoneum.

The Inferior Mesenteric Artery (Fig. 371).

In order to expose this vessel draw the small intestines and mesentery over to the right side of the abdomen, raise the transverse colon toward the thorax, and divide the peritoneum covering the left side of the aorta.

The **Inferior Mesenteric Artery** supplies the descending and sigmoid flexure of the colon and the greater part of the rectum. It is smaller than the superior mesenteric, and arises from the left side of the aorta, between one and two inches above its division into the common iliacs. It passes downward to the left iliac fossa, and then descends, between the layers of the meso-rectum, into the pelvis, under the name of the *superior hæmorrhoidal artery*. It lies at first in close relation with the left side of the aorta, and then passes as the superior hæmorrhoidal in front of the left common iliac artery. Its branches are—the

Colica Sinistra. Sigmoid.
Superior Hæmorrhoidal.

The **colica sinistra** passes behind the peritoneum, in front of the left kidney, to reach the descending colon, and divides into two branches—an ascending branch, which inosculates with the colica media; and a descending branch, which anastomoses with the sigmoid artery. From the arches formed by these inosculations branches are distributed to the descending colon.

The **sigmoid artery** runs obliquely downward across the Psoas muscle to the

sigmoid flexure of the colon, and divides into branches which supply that part of the intestine, anastomosing above with the colica sinistra, and below with the superior hæmorrhoidal artery. This vessel is sometimes replaced by three or four small branches.

The **superior hæmorrhoidal artery,** the continuation of the inferior mesenteric, descends into the pelvis between the layers of the meso-rectum, crossing, in its

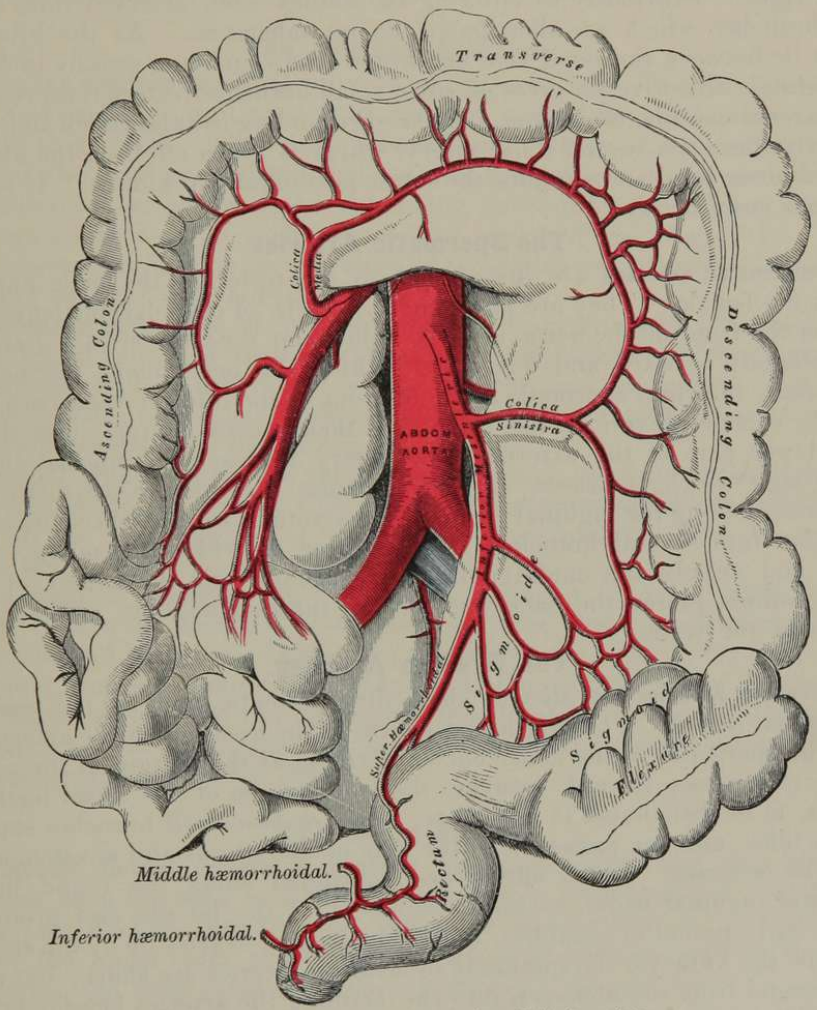

FIG. 371.—The inferior mesenteric and its branches.

course, the ureter and left common iliac vessels. It divides into two branches, which descend one on each side of the rectum, and about five inches from the anus break up into several small branches, which are distributed between the mucous and muscular coats of that tube, nearly as far as its lower end, anastomosing with each other, with the middle hæmorrhoidal arteries, branches of the internal iliac, and with the inferior hæmorrhoidal branches of the internal pudic.

The Suprarenal Arteries.

The **suprarenal arteries** (Fig. 367) (*middle suprarenal*) are two small vessels which arise, one on each side of the aorta, opposite the superior mesenteric artery. They pass obliquely upward and outward, over the crura of the Diaphragm, to the under surface of the suprarenal capsules, to which they are distributed, anastomosing with capsular branches from the phrenic and renal arteries. In the adult these arteries are of small size ; in the fœtus they are as large as the renal arteries.

The Renal Arteries.

The **renal arteries** are two large trunks which arise from the sides of the aorta immediately below the superior mesenteric artery. Each is directed outward across the crus of the Diaphragm, so as to form nearly a right angle with the aorta. The right is longer than the left, on account of the position of the aorta; it passes behind the inferior vena cava. The left is somewhat higher than the right. Previously to entering the kidney each artery divides into four or five branches which are distributed to its substance. At the hilum these branches lie between the renal vein and ureter, the vein being usually in front, the ureter behind. Each vessel gives off some small branches (*inferior suprarenal*) to the suprarenal capsule, the ureter, and the surrounding cellular tissue and muscles. Frequently there is a second renal artery, which is given off from the abdominal aorta at a lower level and supplies the lower portion of the kidney. It is termed the *inferior renal artery*.

The Spermatic Arteries.

The **spermatic arteries** are distributed to the testes in the male and to the ovaria in the female. They are two slender vessels, of considerable length, which arise from the front of the aorta a little below the renal arteries. Each artery passes obliquely outward and downward behind the peritoneum, resting on the Psoas muscle, the right spermatic lying in front of the inferior vena cava, the left behind the sigmoid flexure of the colon. It then crosses obliquely over the ureter and the lower part of the external iliac artery to reach the internal abdominal ring, through which it passes, and accompanies the other constituents of the spermatic cord along the inguinal canal to the scrotum, where it becomes tortuous, and divides into several branches, two or three of which accompany the vas deferens and supply the epididymis, anastomosing with the artery of the vas deferens; others pierce the back part of the tunica albuginea, and supply the substance of the testis.

The Ovarian Arteries.

The **ovarian arteries** are shorter than the spermatic, and do not pass out of the abdominal cavity. The origin and course of the first part of the artery are the same as the spermatic in the male, but on arriving at the margin of the pelvis the ovarian artery passes inward, between the two laminæ of the broad ligament of the uterus, to be distributed to the ovary. One or two small branches supply the Fallopian tube; another passes on to the side of the uterus and anastomoses with the uterine arteries. Other offsets are continued along the round ligament, through the inguinal canal, to the integument of the labium and groin.

At an early period of fœtal life, when the testes or ovaries lie by the side of the spine below the kidneys, the spermatic or ovarian arteries are short; but as these organs descend from the abdomen into the scrotum the arteries become gradually lengthened.

Parietal Branches of the Abdominal Aorta.

The Phrenic Arteries.

The **phrenic arteries** are two small vessels which present much variety in their origin. They may arise separately from the front of the aorta, immediately above the cœliac axis, or by a common trunk, which may spring either from the aorta or from the cœliac axis. Sometimes one is derived from the aorta, and the other from one of the renal arteries. In only one out of thirty-six cases examined did these arteries arise as two separate vessels from the aorta. They diverge from one another across the crura of the Diaphragm, and then pass obliquely upward and outward upon its under surface. The left phrenic passes behind the œsophagus and runs forward on the left side of the œsophageal opening. The right phrenic passes behind the inferior vena cava, and ascends along the right side of the aperture for transmitting that vein. Near the back part of the central tendon each vessel divides into two branches. The internal branch runs forward to the front of the thorax, supplying the Diaphragm and anastomosing with its fellow of

the opposite side, and with the musculo-phrenic and comes nervi phrenici, branches of the internal mammary. The external branch passes toward the side of the thorax and inosculates with the intercostal arteries. The internal branch of the right phrenic gives off a few vessels to the inferior vena cava, and the left one some branches to the œsophagus, Each vessel also sends capsular branches (*superior suprarenal*) to the suprarenal capsule of its own side. The spleen on the left side and the liver on the right also receive a few branches from these vessels.

The Lumbar Arteries.

The **lumbar arteries** are analogous to the intercostal. They are usually four in number on each side, and arise from the back part of the aorta, nearly at right angles with that vessel. They pass outward and backward, around the sides of the body of the lumbar vertebra, behind the sympathetic nerve and the Psoas magnus muscle, those on the right side being covered by the inferior vena cava, and the two upper ones on each side by the crura of the Diaphragm. In the interval between the transverse processes of the vertebræ each artery divides into a *dorsal* and an *abdominal branch.*

The **dorsal branch** gives off, immediately after its origin, a spinal branch, which enters the spinal canal; it then continues its course backward between the transverse processes, and is distributed to the muscles and integument of the back, anastomosing with the similar branches of the adjacent lumbar arteries and with the posterior branches of the intercostal arteries.

The **spinal branch** enters the spinal canal through the intervertebral foramen, to be distributed to the spinal cord and its membranes and to the bodies of the vertebræ in the same manner as the lateral spinal branches from the vertebral (see page 582).

The **abdominal branches** pass outward, having a variable relation to the Quadratus lumborum muscle. Most frequently the first branch passes in front of the muscle and the others behind it; sometimes the order is reversed and the lowest branch passes in front of the muscle. At the outer border of the Quadratus they are continued between the abdominal muscles, anastomose with branches of the epigastric and internal mammary *in front*, the intercostals *above*, and those of the ilio-lumbar and circumflex iliac *below.*

The Sacra Media.

The **Middle Sacral Artery** is a small vessel about the size of a crow-quill, which arises from the back part of the aorta just at its bifurcation. It descends upon the last lumbar vertebra, and along the middle line of the front of the sacrum, to the upper part of the coccyx, where it anastomoses with the lateral sacral arteries, and terminates in a minute branch, which runs down to the situation of the body presently to be described as "Luschka's gland." From it branches arise which run through the meso-rectum to supply the posterior surface of the rectum. Other branches are given off on each side, which anastomose with the lateral sacral arteries, and send off small offsets which enter the anterior sacral foramina.

The artery is the representative of the caudal prolongation of the aorta of animals, and its lateral branches correspond to the intercostal and lumbar arteries in the dorsal and lumbar regions.

Coccygeal Gland, or Luschka's Gland.—Lying near the tip of the coccyx in a small tendinous interval formed by the union of the Levator ani muscles of each side, and just above the coccygeal attachment of the Sphincter ani, is a small conglobate body about as large as a lentil or a pea, first described by Luschka,[1] and named by him the *coccygeal gland.* Its most obvious connections are with the arteries of the part.

Structure.—It consists of a congeries of small arteries with little aneurismal dilatations derived from the middle sacral and freely communicating with each

[1] *Der Hirnanhang und die Steissdrüse des Menschen*, Berlin, 1860; *Anatomie des Menschen*, Tübingen, 1864, vol. ii. pt. 2, p. 187.

other. These vessels are enclosed in one or more layers of polyhedral granular cells, and the whole structure is invested in a capsule of connective tissue which sends in trabeculæ, dividing the interior into a number of spaces in which the vessels and cells are contained. Nerves pass into this little body from the sympathetic, but their mode of termination is unknown. Macalister believes the glomerulus of vessels "consists of the condensed and convoluted metameric dorsal arteries of the caudal segments imbedded in tissue which is possibly a small persisting fragment of the neurenteric canal."

THE COMMON ILIAC ARTERIES.

The abdominal aorta divides into the two **common iliac arteries.** The bifurcation usually takes place on the left side of the body of the fourth lumbar vertebra. This point corresponds to the left side of the umbilicus, and is on a level with a line drawn from the highest point of one iliac crest to the other. The common iliac arteries are about two inches in length; diverging from the termination of the aorta, they pass downward and outward to the margin of the pelvis, and divide opposite the intervertebral substance, between the last lumbar vertebra and the sacrum into two branches, the *external* and *internal iliac arteries*, the former supplying the lower extremity; the latter, the viscera and parietes of the pelvis.

The **right common iliac** is somewhat larger than the left, and passes more obliquely across the body of the last lumbar vertebra. In front of it are the peritoneum, the small intestine, branches of the sympathetic nerve, and, at its point of division, the ureter. *Behind*, it is separated from the last two lumbar vertebræ by the two common iliac veins. On its *outer side*, it is in relation with the inferior vena cava and the right common iliac vein above, and the Psoas magnus muscle below.

The **left common iliac** is in relation, in front, with the peritoneum, the small intestine, branches of the sympathetic nerve, and the superior hæmorrhoidal artery, and is crossed at its point of bifurcation by the ureter. The left common iliac vein lies partly on the inner side and partly beneath the artery; on its outer side the artery is in relation with the Psoas magnus muscle.

PLAN OF THE RELATIONS OF THE COMMON ILIAC ARTERIES.

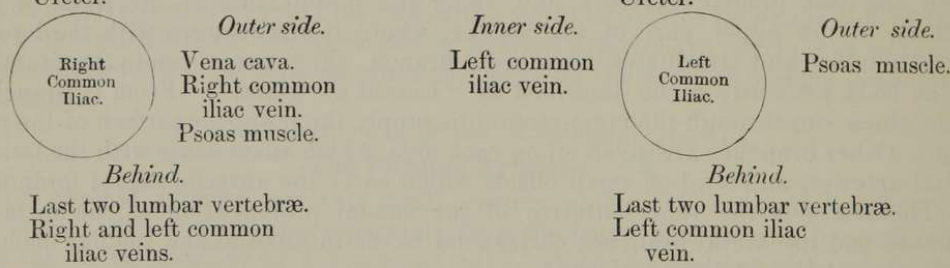

Branches.—The common iliac arteries give off small branches to the peritoneum Psoas magnus, ureters, and the surrounding cellular tissue, and occasionally give origin to the ilio-lumbar or renal arteries.

Peculiarities.—The *point of origin* varies according to the bifurcation of the aorta. In three-fourths of a large number of cases the aorta bifurcated either upon the fourth lumbar vertebra or upon the intervertebral disk between it and the fifth, the bifurcation being, in one case out of nine below, and in one out of eleven above, this point. In ten out of every thirteen cases the vessel bifurcated within half an inch above or below the level of the crest of the ilium more frequently below than above.

The point of division is subject to great variety. In two-thirds of a large number of cases it was between the last lumbar vertebra and the upper border of the sacrum being above that

point in one case out of eight; and below it in one case out of six. The left common iliac artery divides lower down more frequently than the right.

The *relative length*, also, of the two common iliac arteries varies. The right common iliac was the longer in sixty-three cases, the left in fifty-two, whilst they were both equal in fifty-three. The length of the arteries varied in five-sevenths of the cases examined from an inch and a half to three inches; in about half of the remaining cases the artery was longer and in the other half shorter, the minimum length being less than half an inch, the maximum four and a half inches. In two instances the right common iliac has been found wanting, the external and internal iliacs arising directly from the aorta.

Surface Marking.—Draw a zone round the body opposite the highest part of the crest of the ilium; in this line take a point half an inch to the left of the middle line. From this

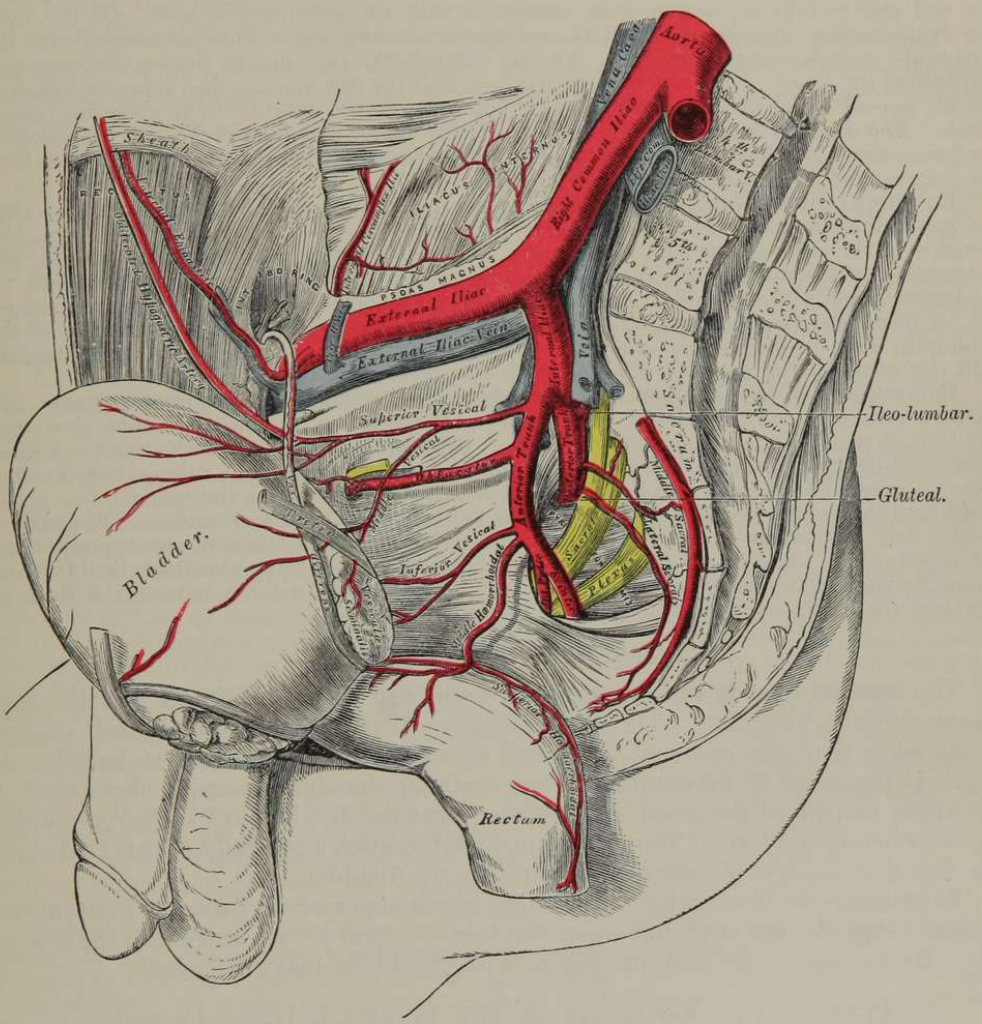

FIG. 372.—Arteries of the pelvis.

draw two lines to points midway between the anterior superior spines of the ilium and the symphysis pubis. These two diverging lines will represent the course of the common and external iliac arteries. Draw a second zone round the body corresponding to the level of the anterior superior spines of the ilium: the portion of the diverging lines between the two zones will represent the course of the common iliac artery; the portion below the lower zone, that of the external iliac artery.

Surgical Anatomy.—The application of a ligature to the common iliac artery may be required on account of aneurism or hæmorrhage implicating the external or internal iliacs. The artery may be tied by one or two incisions: 1, an anterior or iliac incision, by which the vessel is approached more directly from the front; and 2, a posterior abdominal or lumbar incision, by which the vessel is reached from behind. If the surgeon select the iliac region, a curved incision, from five to eight inches in length according to the amount of fat, is made, commencing just outside the middle of Poupart's ligament and a finger's breadth above it, and carried outward toward the anterior superior iliac spine, then upward toward the ribs, and finally curving inward

toward the umbilicus. The abdominal muscles and transversalis fascia are divided, and the peritoneum raised upward and inward until the Psoas is reached. The artery will be found on the inner side of this muscle, and is to be cleared with a director, especial care being taken on the right side, as here the common iliac veins lie behind the artery. The aneurism needle is to be passed from within outward. But if the aneurismal tumor should extend high up in the abdomen, along the external iliac, it is better to select the posterior or lumbar, by making an incision partly in the abdomen, partly in the loin. The incision is commenced at the anterior extremity of the last rib, proceeding directly downward to the ilium; it is then curved forward along the crest of the ilium and a little above it to the anterior superior spine of that bone. The abdominal muscles having been cautiously divided in succession, the transversalis fascia must be carefully cut through, and the peritoneum, together with the ureter, separated from the artery and pushed aside; the sacro-iliac articulation must then be felt for, and upon it the vessel will be felt pulsating, and may be fully exposed in close connection with its accompanying vein. On the right side both common iliac veins, as well the inferior vena cava, are in close connection with the artery, and must be carefully avoided. On the left side the vein usually lies on the inner side and behind the artery; but it occasionally happens that the two common iliac veins are joined on the left instead of the right side, which would add much to the difficulty of an operation in such a case. The common iliac artery may be so short that danger may be apprehended from secondary hæmorrhage if a ligature is applied to it. It would be preferable, in such a case, to tie both the external and internal iliacs near their origin.

Collateral Circulation.—The principal agents in carrying on the collateral circulation after the application of a ligature to the common iliac are—the anastomoses of the hæmorrhoidal branches of the internal iliac with the superior hæmorrhoidal from the inferior mesenteric; the anastomoses of the uterine and ovarian arteries and of the vesical arteries of opposite sides; of the lateral sacral with the middle sacral artery; of the epigastric with the internal mammary, inferior intercostal, and lumbar arteries; of the circumflex iliac with the lumbar arteries; of the ilio-lumbar with the last lumbar artery; of the obturator artery, by means of its pubic branch, with the vessel of the opposite side and with the deep epigastric.

Compression of the Common Iliac Arteries.—The common iliac arteries are most efficiently compressed by Davy's lever. The instrument consists of a gum-elastic tube about two feet long, in which fits a round wooden "lever" considerably longer than the tube. A small quantity of olive oil having been injected into the rectum, the gum-elastic tube, softened in hot water, is passed into the bowel sufficiently far to permit its pressing upon the common iliac artery as it lies in the groove between the last lumbar vertebra and the Psoas muscle. The wooden lever is then inserted into the tube, and the projecting end carried toward the opposite thigh and raised, when it acts as a lever of the first order, the anus being the fulcrum. In cases where the meso-rectum is abnormally short it may be impossible, without unjustifiable force, to compress the artery on the right side.

Internal Iliac Artery (Fig. 372).

The **internal iliac artery** supplies the walls and viscera of the pelvis, the generative organs, and inner side of the thigh. It is a short, thick vessel, smaller in the adult than the external iliac, and about an inch and a half in length. It arises at the point of bifurcation of the common iliac, and, passing downward to the upper margin of the great sacro-sciatic foramen, divides into two large trunks, an *anterior* and *posterior;* from its point of bifurcation a partially obliterated cord, the *hypogastric artery*, extends forward to the bladder.

Relations.—*In front*, with the ureter, which separates it from the peritoneum. *Behind*, with the internal iliac vein, the lumbo-sacral nerve, and Pyriformis muscle. By its *outer side*, near its origin, with the Psoas magnus muscle.

PLAN OF THE RELATIONS OF THE INTERNAL ILIAC ARTERY.

In front.
Peritoneum.
Ureter.

Outer side.
Psoas magnus.

Internal Iliac.

Inner side.
Internal iliac vein.
Peritoneum.

Behind.
External iliac vein (above).
Internal iliac vein.
Lumbo-sacral nerve.
Sacrum.

In the fœtus the internal iliac artery (*hypogastric*) is twice as large as the external iliac, and appears to be the continuation of the common iliac. Instead of dipping into the pelvis, it passes forward to the bladder, and ascends along the sides of that viscus to its summit, to which it gives branches; it then passes upward along the back part of the anterior wall of the abdomen to the umbilicus, converging toward its fellow of the opposite side. Having passed through the umbilical opening, the two arteries twine round the umbilical vein, forming with it the umbilical cord, and ultimately ramify in the placenta. The portion of the vessel within the abdomen is called the *hypogastric artery*, and that external to that cavity, the *umbilical artery*.

At birth, when the placental circulation ceases, the upper portion of the hypogastric artery, extending from the summit of the bladder to the umbilicus, contracts, and ultimately dwindles to a solid fibrous cord; but the lower portion, extending from its origin (in what is now the internal iliac artery) for about an inch and a half to the wall of the bladder, and thence to the summit of that organ, is not totally impervious, though it becomes considerably reduced in size, and serves to convey blood to the bladder under the name of the *superior vesical artery*.

Peculiarities as regards Length.—In two-thirds of a large number of cases the length of the internal iliac varied between an inch and an inch and a half; in the remaining third it was more frequently longer than shorter, the maximum length being three inches, the minimum half an inch.

The lengths of the common and internal iliac arteries bear an inverse proportion to each other, the internal iliac artery being long when the common iliac is short, and *vice versâ*.

As regards its Place of Division.—The place of division of the internal iliac varies between the upper margin of the sacrum and the upper border of the sacro-sciatic foramen.

The arteries of the two sides in a series of cases often differed in length, but neither seemed constantly to exceed the other.

Surgical Anatomy.—The application of a ligature to the internal iliac artery may be required in cases of aneurism or hæmorrhage affecting one of its branches. The vessel may be secured by making an incision through the abdominal parietes in the iliac region in a direction and to an extent similar to that for securing the common iliac; the transversalis fascia having been cautiously divided, and the peritoneum pushed inward from the iliac fossa toward the pelvis, the finger may feel the pulsation of the external iliac at the bottom of the wound, and by tracing this vessel upward the internal iliac is arrived at, opposite the sacro-iliac articulation. It should be remembered that the vein lies behind and on the right side, a little external to the artery, and in close contact with it; the ureter and peritoneum, which lie in front, must also be avoided. The degree of facility in applying a ligature to this vessel will mainly depend upon its length. It has been seen that in the great majority of the cases examined the artery was short, varying from an inch to an inch and a half; in these cases the artery is deeply seated in the pelvis; when, on the contrary, the vessel is longer, it is found partly above that cavity. If the artery is very short, as occasionally happens, it would be preferable to apply a ligature to the common iliac or upon the external and internal iliacs at their origin.

Probably a better method of tying the internal iliac artery is by an abdominal section in the median line and reaching the vessel through the peritoneal cavity. This plan has been advocated by Dennis of New York on the following grounds: (1) It no way increases the danger of the operation; (2) it prevents a series of accidents which have occurred during ligature of the artery by the older methods; (3) it enables the surgeon to ascertain the exact extent of disease in the main arterial trunk, and select his spot for the application of the ligature; and (4) it occupies much less time.

Collateral Circulation.—In Professor Owen's dissection of a case in which the internal iliac artery had been tied by Stevens ten years before death for aneurism of the sciatic artery, the internal iliac was found impervious for about an inch above the point where the ligature had been applied, but the obliteration did not extend to the origin of the external iliac, as the ilio-lumbar artery arose just above this point. Below the point of obliteration the artery resumed its natural diameter, and continued so for half an inch, the obturator, lateral sacral, and gluteal arising in succession from the latter portion. The obturator artery was entirely obliterated. The lateral sacral artery was as large as a crow's quill, and had a very free anastomosis with the artery of the opposite side and with the middle sacral artery. The sciatic artery was entirely obliterated as far as its point of connection with the aneurismal tumor, but on the distal side of the sac it was continued down along the back of the thigh nearly as large in size as the femoral, being pervious about an inch below the sac by receiving an anastomosing vessel from the profunda.[1] The circulation was carried on by the anastomoses of the uterine and ovarian arteries;

[1] *Medico-Chirurgical Trans.*, vol. xvi.

of the opposite vesical arteries; of the hæmorrhoidal branches of the internal iliac with those from the inferior mesenteric; of the obturator artery, by means of its pubic branch, with the vessel of the opposite side and with the epigastric and internal circumflex; of the circumflex and perforating branches of the profunda femoris with the sciatic; of the gluteal with the posterior branches of the sacral arteries; of the ilio-lumbar with the last lumbar; of the lateral sacral with the middle sacral; and of the circumflex iliac with the ilio-lumbar and gluteal.

Branches of the Internal Iliac.

From the Anterior Trunk.	*From the Posterior Trunk.*
Superior Vesical.	Ilio-lumbar.
Middle Vesical.	Lateral Sacral.
Inferior Vesical.	Gluteal.
Middle Hæmorrhoidal.	
Obturator.	
Internal Pudic.	
Sciatic.	
In female { Uterine.	
In female { Vaginal.	

The **superior vesical** is that part of the fœtal hypogastric artery which remains pervious after birth. It extends to the side of the bladder, distributing numerous branches to the apex and body of the organ. From one of these a slender vessel is derived which accompanies the vas deferens in its course to the testis, where it anastomoses with the spermatic artery. This is the *artery of the vas deferens.* Other branches supply the ureter.

The **middle vesical,** usually a branch of the superior, is distributed to the base of the bladder and under surface of the vesiculæ seminales.

The **inferior vesical** arises from the anterior division of the internal iliac, frequently in common with the middle hæmorrhoidal, and is distributed to the base of the bladder, the prostate gland, and vesiculæ seminales. The branches distributed to the prostate communicate with the corresponding vessel of the opposite side.

The **middle hæmorrhoidal artery** usually arises together with the preceding vessel. It supplies the rectum, anastomosing with the other hæmorrhoidal arteries.

The **uterine artery** passes inward from the anterior trunk of the internal iliac to the neck of the uterus. Ascending, in a tortuous course on the side of this viscus, between the layers of the broad ligament, it distributes branches to its substance, anastomosing, near its termination, with a branch from the ovarian artery. Branches from this vessel are also distributed to the bladder and ureter.

The **vaginal artery** is analogous to the inferior vesical in the male; it descends upon the vagina, supplying its mucous membrane, and sending branches to the neck of the bladder and contiguous part of the rectum.

The **Obturator Artery** usually arises from the anterior trunk of the internal iliac, frequently from the posterior. It passes forward, below the brim of the pelvis, to the upper part of the obturator foramen, and, escaping from the pelvic cavity through a short canal formed by a groove on the under surface of the horizontal ramus of the os pubis and the arched border of the obturator membrane, it divides into an internal and external branch. In the pelvic cavity this vessel lies upon the pelvic fascia, beneath the peritoneum, and a little below the obturator nerve.

Branches.— *Within the pelvis,* the obturator artery gives off an *iliac branch* to the iliac fossa, which supplies the bone and the Iliacus muscle, and anastomoses with the ilio-lumbar artery; a *vesical branch,* which runs backward to supply the bladder; and a *pubic branch,* which is given off from the vessel just before it leaves the pelvic cavity. This branch ascends upon the back of the os pubis,

communicating with offsets from the deep epigastric artery and with the corresponding vessel of the opposite side. This branch is placed on the inner side of the femoral ring. *External to the pelvis*, the obturator artery divides into an *internal* and an *external branch*, which are deeply situated beneath the Obturator externus muscle.

The **internal branch** curves downward along the inner margin of the obturator foramen, distributing branches to the Obturator externus muscle, Pectineus, Adductors, and Gracilis, and anastomoses with the external branch and with the internal circumflex artery.

The **external branch** curves round the outer margin of the foramen to the space between the Gemellus inferior and Quadratus femoris, where it anastomoses with the sciatic artery. It supplies the Obturator muscles, anastomoses, as it passes backward, with the internal branch and with the internal circumflex, and

FIG. 373.—Variations in origin and course of obturator artery.

sends a branch to the hip-joint through the cotyloid notch, which ramifies on the round ligament as far as the head of the femur.

Peculiarities.—In two out of every three cases the obturator arises from the internal iliac; in one case in three and a half from the epigastric; and in about two and a half in seventy-two cases by two roots from both vessels. It arises in one and two-tenths per cent. from the external iliac artery. The origin of the obturator from the epigastric is not commonly found on both sides of the same body.

When the obturator artery arises at the front of the pelvis from the epigastric, it descends almost vertically to the upper part of the obturator foramen. The artery in this course usually lies in contact with the external iliac vein and on the outer side of the femoral ring (Fig. 373, A); in such cases it would not be endangered in the operation for femoral hernia. Occasionally, however, it curves inward along the free margin of Gimbernat's ligament (Fig. 373, B), and under such circumstances would almost completely encircle the neck of a hernial sac (supposing a hernia to exist in such a case), and would be in great danger of being wounded if an operation was performed.

The **internal pudic** is the smaller of the two terminal branches of the anterior trunk of the internal iliac, and supplies the external organs of generation. Though the course of the artery is the same in the two sexes, the vessel is much smaller in the female than in the male, and the distribution of its branches somewhat different. The description of its arrangement in the male will first be given, and subsequently the differences which it presents in the female will be mentioned.

The **Internal Pudic Artery in the Male** passes downward and outward to the lower border of the great sacro-sciatic foramen, and emerges from the pelvis between the Pyriformis and Coccygeus muscles: it then crosses the spine of the ischium and re-enters the pelvis through the lesser sacro-sciatic foramen. The artery now crosses the Obturator internus muscle along the outer wall of the ischio-rectal fossa, being situated about an inch and a half above the lower margin of the ischial tuberosity. It is here contained in a sheath of the obturator fascia, and gradually approaches the margin of the ramus of the ischium, along which it passes forward and upward, pierces the posterior layer of the deep perineal fascia, and runs forward along the inner margin of the ramus of the os pubis; finally, it perforates the anterior layer of the deep perineal fascia and divides into its two

terminal branches, the *dorsal artery of the penis* and the *artery of the corpus cavernosum*.

Relations.—In the first part of its course, within the pelvis, it lies in front of the Pyriformis muscle and sacral plexus of nerves, and on the outer side of the rectum (on the left side). As it crosses the spine of the ischium it is covered by the Gluteus maximus. In the pelvis it lies on the outer side of the ischio-rectal fossa, upon the surface of the Obturator internus muscle, contained in a fibrous canal formed by the obturator fascia and the falciform process of the great sacro-sciatic ligament. It is accompanied by the pudic veins and the internal pudic nerve, which lies internal to it on the ischial spine.

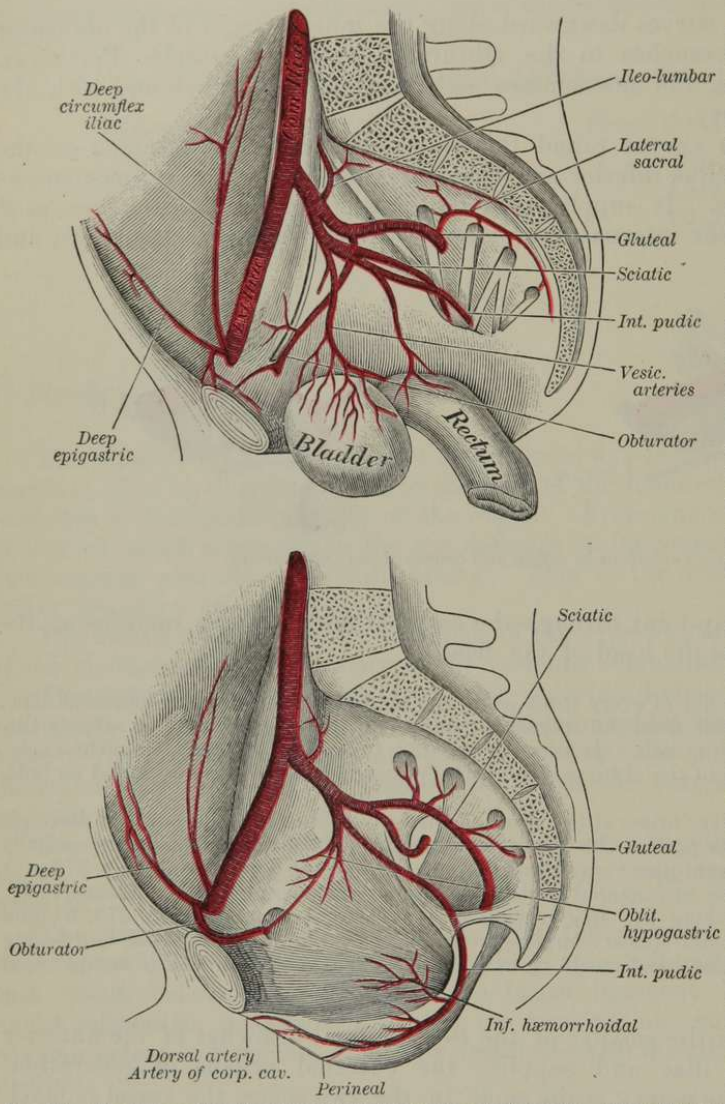

FIG. 374.—The internal pudic artery and its branches in the male. (Gegenbaur.)

Peculiarities.—The internal pudic is sometimes smaller than usual, or fails to give off one or two of its usual branches; in such cases the deficiency is supplied by branches derived from an additional vessel, the *accessory pudic*, which generally arises from the internal pudic artery before its exit from the great sacro-sciatic foramen. It passes forward along the lower part of the bladder and across the side of the prostate gland to the root of the penis, where it perforates the triangular ligament and gives off the branches usually derived from the pudic artery. The deficiency most frequently met with is that in which the internal pudic ends as the artery of the bulb, the artery of the corpus cavernosum and arteria dorsalis penis being derived from the accessory pudic. Or the pudic may terminate as the superficial perineal, the artery of the bulb being derived, with the other two branches, from the accessory vessel.

Surgical Anatomy.—The relation of the accessory pudic to the prostate gland and urethra is of the greatest interest in a surgical point of view, as this vessel is in danger of being wounded in the lateral operation of lithotomy. The student should also study the position of the internal pudic artery and its branches, when running a normal course, with regard to the same operation. The superficial and the transverse perineal arteries are, of necessity, divided in this operation, but the hæmorrhage from these vessels is seldom excessive; should a ligature be required, it can readily be applied on account of their superficial position. The artery of the bulb may be divided if the incision be carried too far forward, and injury of this vessel may be attended with serious or even fatal consequences. The main trunk of the internal pudic artery may be wounded if the incision be carried too far outward; but, being bound down by the strong obturator fascia and under cover of the ramus of the ischium, the accident is not very likely to occur unless the vessel runs an anomalous course.

Branches.—The branches of the internal pudic artery are—

Muscular.	Transverse Perineal.
Inferior Hæmorrhoidal.	Artery of the Bulb.
Superficial Perineal.	Artery of the Corpus Cavernosum.
Dorsal Artery of the Penis.	

The **muscular branches** consist of two sets—one given off in the pelvis, the other as the vessel crosses the ischial spine. The former are several small offsets which supply the Levator ani, the Obturator internus, the Pyriformis, and the Coccygeus muscles. The branches given off outside the pelvis are distributed to the adjacent part of the Gluteus maximus and External rotator muscles. They anastomose with branches of the sciatic artery.

The **inferior hæmorrhoidal** are two or three small arteries which arise from the internal pudic as it passes above the tuberosity of the ischium. Crossing the ischio-rectal fossa, they are distributed to the muscles and integument of the anal region.

The **superficial perineal artery** supplies the scrotum and muscles and integument of the perinæum. It arises from the internal pudic in front of the preceding branches, and turns upward, crossing either over or under the Transversus perinæi muscle, and runs forward, parallel to the pubic arch, in the interspace between the Accelerator urinæ and Erector penis muscles, both of which it supplies, and is finally distributed to the skin and dartos of the scrotum. In its passage through the perinæum it lies beneath the superficial perineal fascia.

The **transverse perineal** is a small branch which arises either from the internal pudic or from the superficial perineal artery as it crosses the Transversus perinæi muscle. It runs transversely inward along the cutaneous surface of the Transversus perinæi muscle, which it supplies, as well as the structures between the anus and bulb of the urethra, and anastomoses with the one of the opposite side.

The **artery of the bulb** is a large but very short vessel which arises from the internal pubic between the two layers of the deep perineal fascia, and, passing nearly transversely inward, pierces the bulb of the urethra, in which it ramifies. It gives off a small branch which descends to supply Cowper's gland.

Surgical Anatomy.—This artery is of considerable importance in a surgical point of view, as it is in danger of being wounded in the lateral operation of lithotomy—an accident usually attended in the adult with alarming hæmorrhage. The vessel is sometimes very small, occasionally wanting, or even double. It sometimes arises from the internal pudic earlier than usual, and crosses the perinæum to reach the back part of the bulb. In such a case the vessel could hardly fail to be wounded in the performance of the lateral operation of lithotomy. If, on the contrary, it should arise from an accessory pudic, it lies more forward than usual and is out of danger in the operation.

The **artery of the corpus cavernosum,** one of the terminal branches of the internal pudic, arises from that vessel while it is situated between the crus penis and the ramus of the os pubis; piercing the crus penis obliquely, it runs forward in the centre of the corpus cavernosum, to which its branches are distributed.

The **dorsal artery of the penis** ascends between the crus and pubic symphysis, and, piercing the suspensory ligament, runs forward on the dorsum of the penis to the glans, where it divides into two branches which supply the glans and prepuce. On the dorsum of the penis it lies immediately beneath the integument, parallel with the dorsal vein and the corresponding artery of the opposite side with the nerve external. It supplies the integument and fibrous sheath of the corpus cavernosum, sending branches through the sheath to anastomose with the preceding vessel.

The **Internal Pudic Artery in the Female** is smaller than in the male. Its origin and course are similar, and there is considerable analogy in the distribution of its branches. The superficial artery supplies the labia pudendi; the artery of the bulb supplies the bulbi vestibuli and the erectile tissue of the vagina; the artery of the corpus cavernosum supplies the cavernous body of the clitoris; and the arteria dorsalis clitoridis supplies the dorsum of that organ, and terminates in the glans and in the membranous fold corresponding to the prepuce of the male.

The **Sciatic Artery** (Fig. 375), the larger of the two terminal branches of the anterior trunk of the internal iliac, is distributed to the muscles at the back of the pelvis. It passes down to the lower part of the great sacro-sciatic foramen behind the internal pudic artery, resting on the sacral plexus of nerves and Pyriformis muscle, and escapes from the pelvis through this foramen between the Pyriformis and Coccygeus. It then descends in the interval between the trochanter major and tuberosity of the ischium, accompanied by the sciatic nerves, and covered by the Gluteus maximus, and is continued down the back of the thigh supplying the skin, and anastomosing with branches of the perforating arteries.

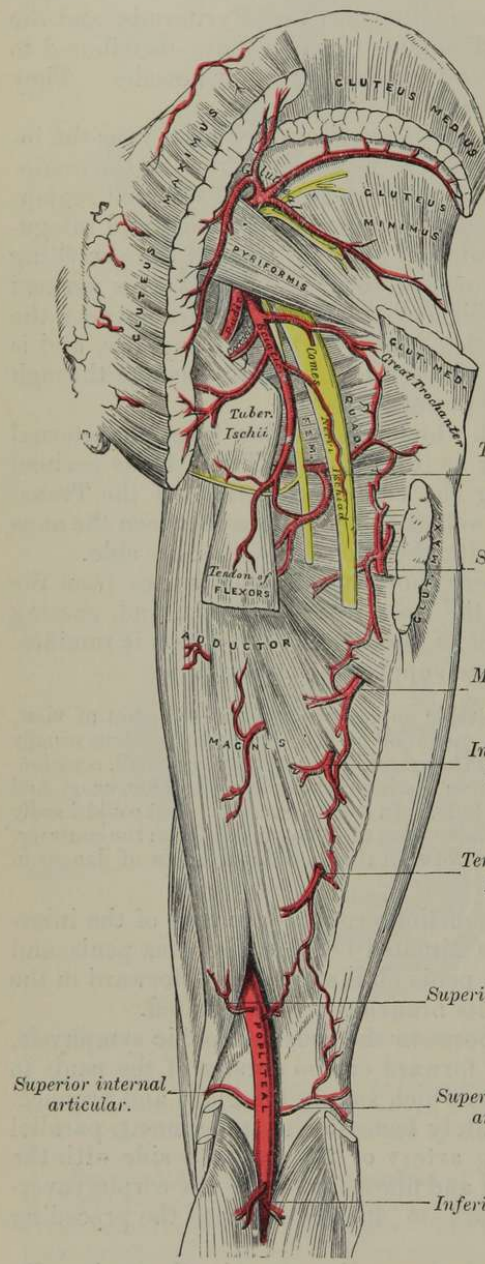

FIG. 375.—The arteries of the gluteal and posterior femoral regions.

Within the pelvis it distributes branches to the Pyriformis, Coccygeus, and Levator ani muscles; some hæmorrhoidal branches, which supply the rectum, and occasionally take the place of the middle hæmorrhoidal artery; and vesical branches to the base and neck of the bladder, vesiculæ seminales, and prostate gland. *External to the pelvis* it gives off the following branches:

Coccygeal.
Inferior Gluteal.
Comes Nervi Ischiadici.
Muscular.
Articular.

The **coccygeal branch** runs inward, pierces the great sacro-sciatic ligament, and supplies the Gluteus maximus, the integument, and other structures on the back of the coccyx.

The **inferior gluteal branches,** three or four in number, supply the Gluteus maximus muscle, anastomosing with the gluteal artery in the substance of the muscle.

The **comes nervi ischiadici** is a long, slender vessel which accompanies the great sciatic nerve for a short distance; it then penetrates it and runs in its substance to the lower part of the thigh.

The **muscular branches** supply the muscles on the back part of the hip, anastomosing with the gluteal, external branch of the obturator, internal and external circumflex, and superior perforating arteries.

Some **articular branches** are distributed to the capsule of the hip-joint.

The **Ilio-lumbar Artery,** given off from the posterior trunk of the internal

iliac, turns upward and outward between the obturator nerve and lumbo-sacral cord, to the inner margin of the Psoas muscle, behind which it divides into a lumbar and an iliac branch.

The **lumbar branch** supplies the Psoas and Quadratus lumborum muscles, anastomosing with the last lumbar artery, and sends a small spinal branch through the intervertebral foramen, between the last lumbar vertebra and the sacrum, into the spinal canal, to supply the spinal cord and its membranes.

The **iliac branch** descends to supply the Iliacus muscle; some offsets, running between the muscle and the bone, anastomose with the iliac branch of the obturator; one of these enters an oblique canal to supply the diploë, whilst others run along the crest of the ilium, distributing branches to the Gluteal and Abdominal muscles, and anastomose in their course with the gluteal, circumflex iliac, and external circumflex arteries.

The **Lateral Sacral Arteries** (Fig. 372) are usually two in number on each side, superior and inferior.

The **superior,** which is of large size, passes inward, and, after anastomosing with branches from the middle sacral, enters the first or second sacral foramen, is distributed to the contents of the sacral canal in the same manner as the lateral spinal branches from the vertebral, and, escaping by the corresponding posterior sacral foramen, supplies the skin and muscles on the dorsum of the sacrum, anastomosing with the gluteal.

The **inferior** passes obliquely across the front of the Pyriformis muscle and sacral nerves to the inner side of the anterior sacral foramina, descends on the front of the sacrum, and anastomoses over the coccyx with the sacra media and opposite lateral sacral arteries. In its course it gives off branches which enter the anterior sacral foramina; these, after giving off branches to be distributed to the contents of the sacral canal in the same manner as the lateral spinal branches from the vertebral, escape by the posterior sacral foramina, and are distributed to the muscles and skin on the dorsal surface of the sacrum, anastomosing with the gluteal.

The **Gluteal Artery** is the largest branch of the internal iliac, and appears to be the continuation of the posterior division of that vessel. It is a short, thick trunk, which passes out of the pelvis above the upper border of the Pyriformis muscle, and immediately divides into a *superficial* and *deep branch.* Within the pelvis it gives off a few muscular branches to the Iliacus, Pyriformis, and Obturator internus, and, just previous to quitting that cavity, a nutrient artery, which enters the ilium.

The **superficial branch** passes beneath the Gluteus maximus and divides into numerous branches, some of which supply that muscle, whilst others perforate its tendinous origin, and supply the integument covering the posterior surface of the sacrum, anastomosing with the posterior branches of the sacral arteries.

The **deep branch** runs between the Gluteus medius and minimus, and subdivides into two. Of these, the superior division, continuing the original course of the vessel, passes along the upper border of the Gluteus minimus to the anterior superior spine of the ilium, anastomosing with the circumflex iliac and ascending branches of the external circumflex artery. The inferior division crosses the Gluteus minimus obliquely to the trochanter major, distributing branches to the Glutei muscles, and inosculates with the external circumflex artery. Some branches pierce the Gluteus minimus to supply the hip-joint.

Surface Marking.—The position of the three main branches of the internal iliac, the sciatic, internal pudic, and gluteal, which may occasionally be the object of surgical interference, is indicated on the surface in the following way: A line is to be drawn from the posterior superior iliac spine to the posterior superior angle of the great trochanter, with the limb slightly flexed and rotated inward: the point of emergence of the *gluteal artery* from the upper part of the sciatic notch will correspond with the junction of the upper with the middle third of this line. A second line is to be drawn from the same point to the middle of the tuberosity of the ischium; the junction of the lower with the middle third marks the point of emergence of the *sciatic* and *pudic arteries* from the great sciatic notch.

Surgical Anatomy.—Any of these three vessels may require ligaturing for a wound or for aneurism, which is generally traumatic, and the operation may be performed by an incision, three or four inches long, in the direction of the fibres of the Gluteus maximus muscle, the middle of the cut corresponding to the point indicating their respective positions.

The External Iliac Artery (Fig. 372).

The **external iliac artery** is larger in the adult than the internal iliac, and passes obliquely downward and outward along the inner border of the Psoas muscle, from the bifurcation of the common iliac to Poupart's ligament, where it enters the thigh and becomes the femoral artery.

Relations.—*In front*, with the peritoneum, subperitoneal areolar tissue, the intestines, ileum on right side, sigmoid flexure on left, and a thin layer of fascia derived from the iliac fascia, which surrounds the artery and vein. At its origin it is occasionally crossed by the ureter. The spermatic vessels descend for some distance upon it near its termination, and it is crossed in this situation by the genital branch of the genito-crural nerve and the circumflex iliac vein; the vas deferens curves down along its inner side. *Behind*, it is in relation with the external iliac vein, which, at Poupart's ligament, lies at its inner side. *Externally*, it rests against the Psoas muscle, from which it is separated by the iliac fascia. The artery rests upon this muscle, near Poupart's ligament, similarly separated by the fascia. Numerous lymphatic vessels and glands are found lying on the front and inner side of the vessel.

PLAN OF THE RELATIONS OF THE EXTERNAL ILIAC ARTERY.

In front.

Peritoneum, intestines, and fascia.

Near Poupart's Ligament:
- Spermatic vessels.
- Genito-crural nerve (genital branch).
- Circumflex iliac vein.

Lymphatic vessels and glands.

Outer side.
Psoas magnus.
Iliac fascia.

External Iliac.

Inner side.
External iliac vein and vas deferens at femoral arch.

Behind.
External iliac vein.
Psoas magnus.
Iliac fascia.

Surface Marking.—The surface line indicating the course of the external iliac artery has been already given (see page 619).

Surgical Anatomy.—The application of a ligature to the external iliac may be required in cases of aneurism of the femoral artery or for a wound of the artery. This vessel may be secured in any part of its course, excepting near its upper end, which is to be avoided on account of the proximity of the great stream of blood in the internal iliac, and near its lower end, which should also be avoided, on account of the proximity of the epigastric and circumflex iliac vessels. One of the chief points in the performance of the operation is to secure the vessel without injury to the peritoneum. The patient having been placed in the recumbent position, an incision should be made, commencing below at a point about three-quarters of an inch above Poupart's ligament, and a little external to its middle, and running upward and outward, parallel to Poupart's ligament, to a point above the anterior superior spine of the ilium. When the artery is deeply seated more room will be required, and may be obtained by curving the incision from the point last named inward toward the umbilicus for a short distance, or, if the lower part of the artery is to be reached, the surgeon may adopt the plan advocated by Sir Astley Cooper, by making an incision close to Poupart's ligament from about half an inch outside of the external abdominal ring to one inch internal to the anterior superior spine of the ilium. This incision, being made in the course of the fibres of the aponeurosis of the external oblique, is less likely to be followed by a ventral hernia, but there is danger of wounding the epigastric artery. Abernethy, who first tied this artery, made his incision in the course of the vessel. The abdominal muscles and transversalis fascia having been cautiously divided, the peritoneum should be separated from the iliac fossa and raised toward the pelvis; and on introducing the finger to the bottom of the wound the artery may be felt pulsating along the inner border of the Psoas muscle. The external iliac vein is generally found on the inner side of the artery,

and must be cautiously separated from it by the finger-nail or handle of the knife, and the aneurism needle should be introduced on the inner side, between the artery and the vein.

Ligature of the external iliac artery has recently been performed in three or more cases by a transperitoneal method. An incision four inches in length is made in the semilunar line, commencing about an inch below the umbilicus and carried through the abdominal wall into the peritoneal cavity. The intestines are then pushed upward and held out of the way by a broad abdominal retractor, and an incision made through the peritoneum at the margin of the pelvis in the course of the artery, and the vessel secured in any part of its course which may seem desirable to the operator. The advantages of this operation appear to be that if it is found necessary the common iliac artery can be ligatured instead of the external iliac without extension or modification of the incision; and secondly, that the vessel can be ligatured without in any way interfering with the coverings of the sac. Possibly a disadvantage may exist in the greater risk of hernia after this method.

Collateral Circulation.—The principal anastomoses in carrying on the collateral circulation, after the application of a ligature to the external iliac, are—the ilio-lumbar with the circumflex iliac; the gluteal with the external circumflex; the obturator with the internal circumflex; the sciatic with the superior perforating and circumflex branches of the profunda artery; and the internal pudic with the external pudic. When the obturator arises from the epigastric, it is supplied with blood by branches, either from the internal iliac, the lateral sacral, or the internal pudic. The epigastric receives its supply from the internal mammary and inferior intercostal arteries, and from the internal iliac by the anastomoses of its branches with the obturator.

In the dissection of a limb eighteen years after the successful ligature of the external iliac artery by Sir A. Cooper, which is to be found in *Guy's Hospital Reports*, vol. i. p. 50, the anastomosing branches are described in three sets: *An anterior set.*—1, a very large branch from the ilio-lumbar artery to the circumflex iliac; 2, another branch from the ilio-lumbar, joined by one from the obturator, and breaking up into numerous tortuous branches to anastomose with the external circumflex; 3, two other branches from the obturator, which passed over the brim of the pelvis, communicated with the epigastric, and then broke up into a plexus to anastomose with the internal circumflex. *An internal set.*—Branches given off from the obturator, after quitting the pelvis, which ramified among the adductor muscles on the inner side of the hip-joint, and joined most freely with branches of the internal circumflex. *A posterior set.*—1, three large branches from the gluteal to the external circumflex; 2, several branches from the sciatic around the great sciatic notch to the internal and external circumflex, and the perforating branches of the profunda.

Branches.—Besides several small branches to the Psoas muscle and the neighboring lymphatic glands, the external iliac gives off two branches of considerable size—the

Deep Epigastric and Deep Circumflex Iliac.

The **Deep Epigastric Artery** arises from the external iliac a few lines above Poupart's ligament. It at first descends to reach this ligament, and then ascends obliquely along the inner margin of the internal abdominal ring, lying between the transversalis fascia and peritoneum, and, continuing its course upward, it pierces the transversalis fascia, and, passing over the semilunar fold of Douglas, enters the sheath of the Rectus muscle. It then ascends on the posterior surface of the muscle, and finally divides into numerous branches, which anastomose, above the umbilicus, with the terminal branches of the internal mammary and inferior intercostal arteries. The deep epigastric artery bears a very important relation to the internal abdominal ring as it passes obliquely upward and inward from its origin from the external iliac. In this part of its course it lies along the lower and inner margin of the ring and beneath the commencement of the spermatic cord. As it winds round the internal abdominal ring it is crossed by the vas deferens in the male and the round ligament in the female.

Branches.—The branches of this vessel are the following: The *cremasteric*, which accompanies the spermatic cord, and supplies the Cremaster muscle and other coverings of the cord, anastomosing with the spermatic artery; a *pubic branch*, which runs along Poupart's ligament, and then descends behind the pubes to the inner side of the femoral ring, and anastomoses with offsets from the obturator artery; *muscular branches*, some of which are distributed to the abdominal muscles and peritoneum, anastomosing with the lumbar and circumflex iliac arteries; others perforate the tendon of the External oblique, and supply the integument, anastomosing with branches of the superficial epigastric.

Peculiarities.—The origin of the epigastric may take place from any part of the external iliac between Poupart's ligament and two inches and a half above it, or it may arise below this ligament, from the femoral or from the deep femoral.

Union with Branches.—It frequently arises from the external iliac by a common trunk with the obturator. Sometimes the epigastric arises from the obturator, the latter vessel being furnished by the internal iliac, or the epigastric may be formed of two branches, one derived from the external iliac, the other from the internal iliac.

Surgical Anatomy.—The deep epigastric artery follows a line drawn from the middle of Poupart's ligament toward the umbilicus; but shortly after this line crosses the linea semilunaris the direction changes, and the course of the vessel is directly upward in the line of junction of the inner third with the outer two-thirds of the Rectus muscle. It has important surgical relations, in addition to the fact that it is one of the principal means, through its anastomosis with the internal mammary, in establishing the collateral circulation after ligature of either the common or external iliac arteries. It lies close to the internal abdominal ring, and is therefore *internal* to an oblique inguinal hernia, but *external* to a direct inguinal hernia, as it emerges from the abdomen. It forms the outer boundary of Hesselbach's triangle. It is in close relationship with the spermatic cord, which lies in front of it in the inguinal canal, separated only by the transversalis fascia. The vas deferens hooks round its outer side.

The **Deep Circumflex Iliac Artery** arises from the outer side of the external iliac nearly opposite the epigastric artery. It ascends obliquely outward behind Poupart's ligament, contained in a fibrous sheath formed by the junction of the transversalis and iliac fasciæ, to the anterior superior spinous process of the ilium. It then runs along the inner surface of the crest of the ilium to about its middle, where it pierces the Transversalis, and runs backward between that muscle and the Internal oblique, to anastomose with the ilio-lumbar and gluteal arteries. Opposite the anterior superior spine of the ilium it gives off a large branch, which ascends between the Internal oblique and Transversalis muscles, supplying them, and anastomosing with the lumbar and epigastric arteries.

ARTERIES OF THE LOWER EXTREMITY.

The Femoral Artery (Fig. 376).

The **femoral artery** is the continuation of the external iliac. It commences immediately behind Poupart's ligament, midway between the anterior superior spine of the ilium and the symphysis pubis, and, passing down the fore part and inner side of the thigh, terminates at the opening in the Adductor magnus, at the junction of the middle with the lower third of the thigh, where it becomes the popliteal artery. The vessel, at the upper part of thigh, lies a little internal to the head of the femur; in the lower part of its course, on the inner side of the shaft of the bone, and between these two parts the vessel is far away from the bone. In the upper third of the thigh it is contained in a triangular space called Scarpa's triangle. In the middle third of the thigh it is contained in an aponeurotic canal called Hunter's canal.

Scarpa's Triangle.—Scarpa's triangle corresponds to the depression seen immediately below the fold of the groin. It is a triangular space, the apex of which is directed downward, and the sides formed externally by the Sartorius, internally by the Adductor longus, and above by Poupart's ligament. The floor of the space is formed from without inward by the Iliacus, Psoas, Pectineus, a small part of the Adductor brevis and the Adductor longus muscles; and it is divided into two nearly equal parts by the femoral vessels, which extend from the middle of its base to its apex, the artery giving off in this situation its cutaneous and profunda branches, the vein receiving the deep femoral and internal saphenous. On the outer side of the femoral artery is the anterior crural nerve dividing into its branches. Besides the vessels and nerves, this space contains some fat and lymphatics.

Hunter's Canal.—This is the aponeurotic space in the middle third of the thigh, extending from the apex of Scarpa's triangle to the femoral opening in the Adductor magnus muscle. It is bounded, externally, by the Vastus internus; postero-internally by the Adductor longus and magnus; and antero-internally by a strong aponeurosis which extends transversely from the Vastus internus, across

the femoral vessels to the Adductor longus and magnus muscles, lying on which aponeurosis is the Sartorius muscle. It contains the femoral artery and vein enclosed in their own sheath of areolar tissue, the vein being behind and on the outer side of the artery, and the internal or long saphenous nerve lying on the outer side of the vessels.

For convenience of description, and also in reference to its surgical anatomy, the femoral artery is divided into a short trunk, about an inch and a half or two inches long, which is known as the *common femoral artery*, and the remainder of the vessel, which is known as the *superficial femoral*, to distinguish it from the deep femoral (profunda femoris), which is a large branch given off from the common femoral at its termination, and which by its derivation from the parent trunk marks the commencement of the superficial femoral artery.

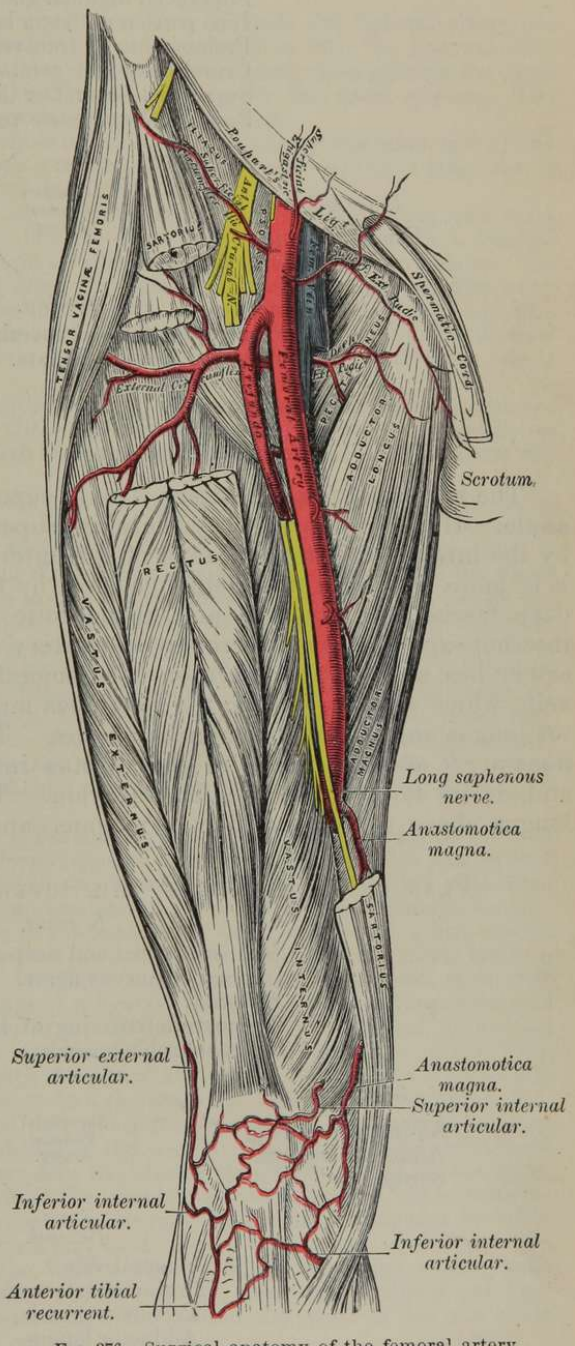

FIG. 376.—Surgical anatomy of the femoral artery.

The **common femoral artery** is very superficial, being covered by the skin and superficial fascia, superficial inguinal lymphatic glands, the iliac portion of the fascia lata, and the prolongation downward of the Transversalis fascia, which forms the sheath of the vessels. It has in front of it filaments from the crural branch of the genito-crural nerve, the superficial circumflex iliac vein, and occasionally the superficial epigastric vein. It rests on the inner margin of the Psoas muscle, which separates it from the capsular ligament of the hip-joint, and a little lower on the Pectineus muscle; and crossing behind it is the branch to the Pectineus from the anterior crural nerve. Separating the artery from the Psoas and Pectineus muscles is the pubic portion of the fascia lata and the prolongation from the fascia covering the Iliacus muscle, which forms the posterior layer of the sheath of the vessels. The anterior crural nerve lies about half an inch to the outer side of the common femoral artery, lying between the Psoas and Iliacus muscles. To the inner side of the artery is the femoral vein, between the margins of the Pectineus and Psoas muscles. The two vessels are enclosed in a strong fibrous sheath formed by the proper sheath of the vessels strengthened by the fascia lata (see page 507); the

artery and vein are separated, however, from one another by a thin fibrous partition.

PLAN OF RELATIONS OF THE COMMON FEMORAL ARTERY.

In front.

Skin and superficial fascia.
Superficial inguinal glands.
Iliac portion of fascia lata.
Prolongation of transversalis fascia.
Crural branch of genito-crural nerve.
Superficial circumflex iliac vein.
Superficial epigastric vein.

Inner side.
Femoral vein.

Outer side.
Anterior crural nerve.

Behind.

Prolongation of fascia covering Iliacus muscle.
Pubic portion of fascia lata.
Nerve to Pectineus.
Psoas muscle.
Pectineus muscle.
Capsule of hip-joint.

The **superficial femoral artery** is only superficial where it lies in Scarpa's triangle. Here it is covered by the skin, superficial and deep fascia, and crossed by the internal cutaneous branch of the anterior crural nerve. In Hunter's canal it is more deeply seated, being covered by the integument, the superficial and deep fascia, the Sartorius and aponeurotic covering of Hunter's canal. The internal saphenous nerve crosses the artery from without inward. Behind, the artery lies at its upper part on the femoral vein and the profunda artery and vein, which separate it from the Pectineus muscle, and lower down on the Adductor longus and Adductor magnus muscles. To the outer side is the long saphenous nerve and the nerve to the Vastus internus, the Vastus internus muscle, and, at its lower part, the femoral vein. To the inner side is the Adductor longus above and the Adductor magnus and Sartorius below.

PLAN OF RELATIONS OF THE SUPERFICIAL FEMORAL ARTERY.

In front.

Skin, superficial and deep fasciæ.
Internal cutaneous nerve.
Sartorius.
Aponeurotic covering of Hunter's canal.
Internal saphenous nerve.

Inner side.
Adductor longus.
Adductor magnus.
Sartorius.

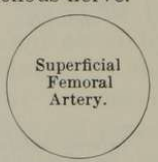

Outer side.
Long saphenous nerve.
Nerve to vastus internus.
Vastus internus.
Femoral vein (below).

Behind.

Femoral vein.
Profunda artery and vein.
Pectineus muscle.
Adductor longus.
Adductor magnus.

The *femoral vein*, at Poupart's ligament, lies close to the inner side of the artery, separated from it by a thin fibrous partition; but lower down it is behind it, and then to its outer side.

The *internal saphenous nerve* is situated on the outer side of the artery, in the

middle third of the thigh, beneath the aponeurotic covering of Hunter's canal, but not usually within the sheath of the vessels. The internal cutaneous nerve passes obliquely across the upper part of the sheath of the femoral artery.

Peculiarities.—Double Femoral reunited.—Several cases are recorded in which the femoral artery divided into two trunks below the origin of the profunda, and became reunited near the opening in the Adductor magnus so as to form a single popliteal artery. One of them occurred in a patient operated upon for popliteal aneurism.

Change of Position.—A few cases have been recorded in which the femoral artery was situated at the back of the thigh, the vessel being continuous above with the internal iliac, escaping from the pelvis through the great sacro-sciatic foramen, and accompanying the great sciatic nerve to the popliteal space, where its division occurred in the usual manner. The external iliac in these cases was small, and terminated in the profunda.

Position of the Vein.—The femoral vein is occasionally placed along the inner side of the artery, throughout the entire extent of Scarpa's triangle, or it may be slit so that a large vein is placed on each side of the artery for a greater or less extent.

Origin of the Profunda.—This vessel occasionally arises from the inner side, and, more rarely, from the back of the common trunk; but the more important peculiarity, in a surgical point of view, is that which relates to the height at which the vessel arises from the femoral. In three-fourths of a large number of cases it arose between one or two inches below Poupart's ligament; in a few cases the distance was less than an inch; more rarely, opposite the ligament; and in one case, above Poupart's ligament, from the external iliac. Occasionally, the distance between the origin of the vessel and Poupart's ligament exceeds two inches, and in one case it was found to be as much as four inches.

Surface Marking.—The upper two-thirds of a line drawn from a point midway between the anterior superior spine of the ilium and the symphysis pubis to the prominent tuberosity on the inner condyle of the femur, with the thigh abducted and rotated outward, will indicate the course of the femoral artery.

Surgical Anatomy.—*Compression* of the femoral artery, which is constantly requisite in amputations and other operations on the lower limb, and also for the cure of popliteal aneurisms, is most effectually made immediately below Poupart's ligament. In this situation the artery is very superficial, and is merely separated from the horizontal ramus of the os pubis by the Psoas muscle; so that the surgeon, by means of his thumb or a compressor, may effectually control the circulation through it. This vessel may also be compressed in the middle third of the thigh by placing a compress over the artery, beneath the tourniquet, and directing the pressure from within outward, so as to compress the vessel against the inner side of the shaft of the femur.

The **application of a ligature** to the femoral artery may be required in the cases of wound or aneurism of the arteries of the leg, of the popliteal or femoral;[1] and the vessel may be exposed and tied in any part of its course. The great depth of this vessel at its lower part, its close connection with important structures, and the density of its sheath render the operation in this situation one of much greater difficulty than the application of a ligature at its upper part, where it is more superficial.

Ligature of the common femoral artery is usually considered unsafe, on account of the connection of large branches with it—viz. the deep epigastric and the deep circumflex iliac arising just above Poupart's ligament; on account of the number of small branches which arise from it in its short course; and on account of the uncertainty of the origin of the profunda femoris, which, if it arise high up, would be too close to the ligature for the formation of a firm coagulum. The profunda sometimes arises higher than the point above mentioned, and rarely between two or three inches (in one case four) below Poupart's ligament. It would appear, then, that the most favorable situation for the application of a ligature to the femoral is between four and five inches from its point of origin. In order to expose the artery in this situation, an incision between two and three inches long should be made in the course of the vessel, the patient lying in the recumbent position, with the limb slightly flexed and abducted. A large vein is frequently met with, passing in the course of the artery to join the saphena: this must be avoided, and, the fascia lata having been cautiously divided and the Sartorius exposed, that muscle must be drawn outward in order to fully expose the sheath of the vessels. The finger being introduced into the wound and the pulsation of the artery felt, the sheath should be opened on the outer side of the vessel to a sufficient extent to allow of the introduction of the ligature, but no farther; otherwise the nutrition of the coats of the vessel may be interfered with, or muscular branches which arise from the vessel at irregular intervals may be divided. In this part of the operation the long saphenous nerve and the nerve to the Vastus internus, which is in close relation with the sheath, should be avoided. The aneurism needle must be carefully introduced and kept close to the artery, to avoid the femoral vein, which lies behind the vessel in this part of its course.

To expose the artery, in Hunter's canal, an incision should be made through the integument, between three and four inches in length, a finger's breadth internal to the line of the artery, in the middle of the thigh—*i. e.* midway between the groin and the knee. The fascia lata having been divided and the Sartorius muscle exposed, it should be drawn inward, when the strong

[1] Ligature of the femoral artery has been also recommended and performed for elephantiasis of the leg and acute inflammation of the knee-joint (Maunder, *Clin. Soc. Trans.*, vol. ii. p. 37).

fascia which is stretched across from the Adductors to the Vastus internus will be exposed, and must be freely divided; the sheath of the vessels is now seen, and must be opened, and the artery secured by passing the aneurism needle between the vein and artery in the direction from without inward. The femoral vein in this situation lies on the outer side of the artery, the long saphenous nerve on its anterior and outer side.

It has been seen that the femoral artery occasionally divides into two trunks below the origin of the profunda. If in the operation for tying the femoral two vessels are met with, the surgeon should alternately compress each, in order to ascertain which vessel is connected with the aneurismal tumor or with the bleeding from the wound, and that one only should be tied which controls the pulsation or hæmorrhage. If, however, it is necessary to compress both vessels before the circulation in the tumor is controlled, both should be tied, as it would be probable that they became reunited, as in the instances referred to above.

In wounds of the femoral artery the question of the mode of treatment is of considerable importance. If the wound in the superficial structures is a large one, the injured vessel must be exposed and tied; but if the wound is a punctured one and the bleeding has ceased, the question will arise whether to cut down upon the artery or to trust to pressure. Mr. Cripps[1] advises that if the wound is in the "upper part of the thigh—that is to say, in a position where the femoral artery is comparatively superficial—the surgeon may enlarge the opening with a good prospect of finding the wounded vessel without an extensive or prolonged operation. If the wound be in the lower half of the thigh, owing to the greater depth of the artery and the possibility of its being the popliteal that is wounded, the search is rendered a far more severe and hazardous operation, and it should not be undertaken until a thorough trial of pressure has proved ineffectual."

Great care and attention are necessary for the successful application of pressure. The limb should be carefully bandaged from the foot upward to the wound, which is not covered, and then onward to the groin. The wound is then dusted with iodoform or boracic powder and a conical pad applied over the wound. Rollers the thickness of the index finger are then placed along the course of the vessel above and below the wound, and the whole carefully bandaged to a back splint with a foot-piece.

Collateral Circulation.—When the common femoral is tied the main channels for carrying on the circulation are the anastomoses of the gluteal and circumflex iliac arteries above with the external circumflex below; of the obturator and sciatic above with the internal circumflex below; and of the comes nervi ischiadici with the arteries in the ham.

The principal agents in carrying on the collateral circulation after ligature of the superficial femoral artery are, according to Sir A. Cooper, as follows:

"The arteria profunda formed the new channel for the blood." "The first artery sent off passed down close to the back of the thigh-bone, and entered the two superior articular branches of the popliteal artery."

"The second new large vessel, arising from the profunda at the same part with the former, passed down by the inner side of the Biceps muscle to a branch of the popliteal which was distributed to the Gastrocnemius muscle; whilst a third artery, dividing into several branches, passed down with the sciatic nerve behind the knee-joint, and some of its branches united themselves with the inferior articular arteries of the popliteal, with some recurrent branches of those arteries, with arteries passing to the Gastrocnemii, and, lastly, with the origin of the anterior and posterior tibial arteries."

"It appears, then, that it is those branches of the profunda which accompany the sciatic nerve that are the principal supporters of the new circulation."[2]

In Porta's work[3] (tab. xii., xiii.) is a good representation of the collateral circulation after the ligature of the femoral artery. The patient had survived the operation three years. The lower part of the artery is at least as large as the upper; about two inches of the vessel appear to have been obliterated. The external and internal circumflex arteries are seen anastomosing by a great number of branches with the lower branches of the femoral (muscular and anastomotica magna) and with the articular branches of the popliteal. The branches from the external circumflex are extremely large and numerous. One very distinct anastomosis can be traced between this artery on the outside and the anastomotica magna on the inside through the intervention of the superior external articular artery, with which they both anastomose; and blood reaches even the anterior tibial recurrent from the external circumflex by means of anastomosis with the same external articular artery. The perforating branches of the profunda are also seen bringing blood round the obliterated portion of the artery into long branches (muscular) which have been given off just below that portion. The termination of the profunda itself anastomoses most freely with the superior external articular. A long branch of anastomosis is also traced down from the internal iliac by means of the comes nervi ischiadici of the sciatic, which anastomoses on the popliteal nerves with branches from the popliteal and posterior tibial arteries. In this case the anastomosis had been too free, since the pulsation and growth of the aneurism recurred, and the patient died after ligature of the external iliac.

There is an interesting preparation in the Museum of the Royal College of Surgeons of a limb on which John Hunter had tied the femoral artery fifty years before the patient's death. The whole of the superficial femoral and popliteal artery seems to have been obliterated. The

[1] Heath's *Dictionary of Practical Surgery*, vol. i. p. 525.

[2] *Med.-Chir. Trans.*, vol. ii. 1811.

[3] *Alterazioni patologiche delle Arterie.*

anastomosis by means of the comes nervi ischiadici, which is shown in Porta's plate, is distinctly seen: the external circumflex and the termination of the profunda artery, seem to have been the chief channels of anastomosis; but the injection has not been a very successful one.

Branches.—The branches of the femoral artery are—the

Superficial Epigastric.		External Circumflex.
Superficial Circumflex Iliac.	Profunda	Internal Circumflex.
Superficial External Pudic.		Three Perforating.
Deep External Pudic.	Muscular.	
	Anastomotica Magna.	

The **superficial epigastric** arises from the femoral about half an inch below Poupart's ligament, and, passing through the saphenous opening in the fascia lata, ascends on the abdomen, in the superficial fascia covering the External oblique muscle, nearly as high as the umbilicus. It distributes branches to the superficial inguinal glands, the superficial fascia, and the integument, anastomosing with branches of the deep epigastric.

The **superficial circumflex iliac,** the smallest of the cutaneous branches, arises close to the preceding, and, piercing the fascia lata, runs outward, parallel with Poupart's ligament, as far as the crest of the ilium, dividing into branches which supply the integument of the groin, the superficial fascia, and the superficial inguinal lymphatic glands, anastomosing with the circumflex iliac and with the gluteal and external circumflex arteries.

The **superficial external pudic** (superior) arises from the inner side of the femoral artery, close to the preceding vessels, and, after passing through the saphenous opening, courses inward, across the spermatic cord or round ligament, to be distributed to the integument on the lower part of the abdomen, the penis and scrotum in the male, and the labium in the female, anastomosing with branches of the internal pudic.

The **deep external pudic** (inferior), more deeply seated than the preceding, passes inward on the Pectineus muscle, covered by the fascia lata, which it pierces at the inner border of the thigh, its branches being distributed, in the male, to the integument of the scrotum and perinæum ; and in the female, to the labium, anastomosing with branches of the superficial perineal artery.

The **Profunda Femoris** (*deep femoral artery*) nearly equals the size of the superficial femoral. It arises from the outer and back part of the femoral artery, from one to two inches below Poupart's ligament. It at first lies on the outer side of the superficial femoral, and then passes behind it and the femoral vein to the inner side of the femur, and, passing downward beneath the Adductor longus, terminates at the lower third of the thigh in a small branch which pierces the Adductor magnus (and from this circumstance is sometimes called the fourth perforating artery), and is distributed to the flexor muscles on the back of the thigh, anastomosing with branches of the popliteal and inferior perforating arteries.

Relations.—*Behind*, it lies first upon the Iliacus, and then on the Pectineus, Adductor brevis, and Adductor magnus muscles. *In front*, it is separated from the femoral artery, above by the femoral and profunda veins, and below by the Adductor longus. On its *outer side* the origin of the Vastus internus separates it from the femur.

PLAN OF THE RELATIONS OF THE PROFUNDA ARTERY.

In front.
Femoral and Profunda veins.
Adductor longus.

Outer side.
Vastus internus.

Behind.
Iliacus.
Pectineus.
Adductor brevis.
Adductor magnus.

The **External Circumflex Artery** supplies the muscles on the front of the thigh. It arises from the outer side of the profunda, passes horizontally outward, between the divisions of the anterior crural nerve and behind the Sartorius and Rectus muscles, and divides into three sets of branches—ascending, transverse, and descending.

The **ascending branches** pass upward, beneath the Tensor vaginæ femoris muscle, to the outer side of the hip, anastomosing with the terminal branches of the gluteal and circumflex iliac arteries.

The **descending branches**, three or four in number, pass downward, behind the Rectus, upon the Vasti muscles, to which they are distributed, one or two passing beneath the Vastus externus as far as the knee, anastomosing with the superior articular branches of the popliteal artery. These are accompanied by the branch of the anterior crural nerve to the Vastus externus.

The **transverse branches**, the smallest and least numerous, pass outward over the Crureus, pierce the Vastus externus, and wind round the femur to its back part, just below the great trochanter, anastomosing at the back of the thigh with the internal circumflex, sciatic, and superior perforating arteries.

The **Internal Circumflex Artery**, smaller than the external, arises from the inner and back part of the profunda, and winds round the inner side of the femur, between the Pectineus and Psoas muscles. On reaching the upper border of the Adductor brevis it gives off two branches, one of which passes inward to be distributed to the Adductor muscles, the Gracilis, and Obturator externus, anastomosing with the obturator artery; the other descends, and passes beneath the Adductor brevis, to supply it and the great Adductor; while the continuation of the vessel passes backward, between the Quadratus femoris and upper border of the Adductor magnus, anastomosing with the sciatic, external circumflex, and superior perforating arteries ("the *crucial anastomosis*"). Opposite the hip-joint this branch gives off an articular vessel, which enters the joint beneath the transverse ligament, and, after supplying the adipose tissue, passes along the round ligament to the head of the bone.

The **Perforating Arteries** (Fig. 375), usually three in number, are so called from their perforating the tendon of the Adductor magnus muscle to reach the back of the thigh. The first is given off above the Adductor brevis, the second in front of that muscle, and the third immediately below it.

The **first** or **superior perforating artery** passes backward between the Pectineus and Adductor brevis (sometimes perforates the latter); it then pierces the Adductor magnus close to the linea aspera, and divides into branches which supply the Adductor brevis, the Adductor magnus, the Biceps, and Gluteus maximus muscles, anastomosing with the sciatic, internal and external circumflex, and middle perforating arteries.

The **second** or **middle perforating artery**, larger than the first, pierces the tendons of the Adductor brevis and Adductor magnus muscles, and divides into ascending and descending branches, which supply the flexor muscles of the thigh,

anastomosing with the superior and inferior perforating. The nutrient artery of the femur is usually given off from this branch.

The **third** or **inferior perforating artery** is given off below the Adductor brevis; it pierces the Adductor magnus, and divides into branches which supply the flexor muscles of the thigh, anastomosing above with the perforating arteries, and below with the terminal branches of the profunda and the muscular branches of the popliteal.

Muscular branches are given off from the superficial femoral throughout its entire course. They vary from two to seven in number, and supply chiefly the Sartorius and Vastus internus.

The **Anastomotica Magna** arises from the femoral artery just before it passes through the tendinous opening in the Adductor magnus muscle, and divides into a superficial and deep branch.

The **superficial branch** accompanies the long saphenous nerve beneath the Sartorius, and, piercing the fascia lata, is distributed to the integument.

The **deep branch** descends in the substance of the Vastus internus, lying in front of the tendon of the Adductor magnus, to the inner side of the knee, where it anastomoses with the superior internal articular artery and anterior recurrent branch of the anterior tibial. A branch from this vessel crosses outward above the articular surface of the femur, forming an anastomotic arch with the superior external articular artery, and supplies branches to the knee-joint.

Popliteal Artery.

The **popliteal artery** commences at the termination of the femoral at the opening in the Adductor magnus, and, passing obliquely downward and outward behind the knee-joint to the lower border of the Popliteus muscle, divides into the *anterior* and *posterior tibial arteries.* A portion of the artery lies in the popliteal space; but above, to a slight extent, and below, to a considerable extent, it is covered by the muscles which form the boundaries of the space, and is therefore beyond the confines of the hollow.

THE POPLITEAL SPACE (Fig. 377).

Dissection.—A vertical incision about eight inches in length should be made along the back part of the knee-joint, connected above and below by a transverse incision from the inner to the outer side of the limb. The flaps of integument included between these incisions should be reflected in the direction shown in Fig. 328, page 514.

Boundaries.—The **popliteal space** is lozenge-shaped, widest at the back part of the knee-joint. It is bounded externally, above the joint, by the Biceps, and, below the joint, by the Plantaris and external head of the Gastrocnemius; internally, above the joint, by the Semimembranosus and Semitendinosus, the latter, however, lying on (*posterior to*) the former, whose *edge* is the real boundary; below the joint, by the inner head of the Gastrocnemius.

Above, it is limited by the apposition of the inner and outer hamstring muscles; below, by the junction of the two heads of the Gastrocnemius. The floor is formed by the lower part of the posterior surface of the shaft of the femur, the posterior ligament of the knee-joint, the upper end of the tibia, and the fascia covering the Popliteus muscle, and the space is covered in by the fascia lata.

Contents.—It contains the popliteal vessels and their branches, together with the termination of the external saphenous vein, the internal and external popliteal nerves and some of their branches, the lower extremity of the small sciatic nerve, the articular branch from the obturator nerve, a few small lymphatic glands, and a considerable quantity of loose adipose tissue.

Position of Contained Parts.—The internal popliteal nerve descends in the middle line of the space, lying superficial and crossing the artery from without inward. The external popliteal nerve descends on the outer side of the space,

lying close to the tendon of the Biceps muscle. More deeply at the bottom of the space are the popliteal vessels, the vein lying superficial and a little external to the artery, to which it is closely united by dense areolar tissue; sometimes the vein is placed on the inner instead of the outer side of the artery; or the vein may be double, the artery lying between the two venæ comites, which are usually connected by short transverse branches. More deeply, and, at its upper part, close to the surface of the bone, is the popliteal artery, and passing off from it at right angles are its articular branches. The articular branch from the obturator nerve descends upon the popliteal artery to supply the knee, and occasionally there is found deep in the space an articular filament from the great sciatic nerve. The popliteal lymphatic glands, four or five in number, are found surrounding the artery: one usually lies superficial to the vessel; another is situated between it and the bone, and the rest are placed on either side of it.

The **Popliteal Artery,** in its course downward from the aperture in the Adductor magnus to the lower border of the Popliteus muscle, rests first on the inner surface of the femur, and is then separated by a little fat from the hollowed popliteal surface of the bone; in the middle of its course it rests on the posterior ligament of the knee-joint, and below on the fascia covering the Popliteus muscle. *Superficially*, it is covered above by the Semimembranosus; in the middle of its course, by a quantity of fat, which separates it from the deep fascia and integument; and below it is overlapped by the Gastrocnemius, Plantaris, and Soleus muscles, the popliteal vein, and the internal popliteal nerve. The popliteal vein, which is intimately attached to the artery, lies superficial and external to it until near the termination of the artery, when the vein crosses it and lies to its inner side. The internal popliteal nerve is still more superficial and external above, but below the joint it crosses the artery and lies on its inner side. *Laterally*, the artery is bounded by the muscles which are situated on either side of the popliteal space.

PLAN OF RELATIONS OF POPLITEAL ARTERY.

In front.
Femur.
Ligamentum posticum.
Popliteus.

Inner side.
Semimembranosus.
Internal condyle.
Gastrocnemius (inner head).
Internal popliteal nerve (below).

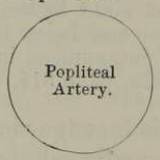

Outer side.
Biceps.
Outer condyle.
Gastrocnemius (outer head).
Plantaris.
Internal popliteal nerve (above).

Behind.
Semimembranosus.
Fascia.
Popliteal vein.
Internal popliteal nerve.
Gastrocnemius.
Plantaris.
Soleus.

Peculiarities in Point of Division.—Occasionally the popliteal artery divides prematurely into its terminal branches; this unusual division occurs most frequently opposite the knee-joint.

Unusual Branches.—The artery sometimes divides into the anterior tibial and peroneal, the posterior tibial being wanting or very small. Occasionally the popliteal is found to divide into three branches, the anterior and posterior tibial and peroneal.

Surface Marking.—The course of the upper part of the popliteal artery is indicated by a line drawn from the outer border of the Semimembranosus muscle at the junction of the middle and lower third of the thigh obliquely downward to the middle of the popliteal space, exactly behind the knee-joint. From this point it passes vertically downward to the level of a line drawn through the lower part of the tubercle of the tibia.

Surgical Anatomy.—The popliteal artery is not infrequently the seat of injury. It may be torn by direct violence, as by the passage of a cart-wheel over the knee or by hyper-extension of the knee; and in the dead body, at all events, the middle and internal coats may be ruptured by extreme flexion. It may also be lacerated by fracture of the lower part of the shaft of the

femur or by antero-posterior dislocation of the knee-joint. It has been torn in breaking down adhesions in cases of fibrous ankylosis of the knee, and is in danger of being wounded, and in fact has been wounded, in performing Macewen's operation of osteotomy of the lower end of the femur for genu valgum. In addition, Spencer records a case in which the popliteal artery was wounded from in front by a stab just below the knee, the knife passing through the interosseous space. The popliteal artery is more frequently the seat of aneurism than is any other artery in the body, with the exception of the thoracic aorta. This is due no doubt, in a great measure to the amount of movement to which it is subjected, and to the fact that it is supported by loose and lax tissue only, and not by muscles, as is the case with most arteries.

Ligature of the popliteal artery is required in cases of wound of that vessel, but for aneurism of the posterior tibial it is preferable to tie the superficial femoral. The popliteal may be tied in the upper or lower part of its course; but in the middle of the ham the operation is attended with considerable difficulty, from the great depth of the artery and from the extreme degree of tension of the lateral boundaries of the space.

In order to expose the vessel in the upper part of its course the patient should be placed in the prone position, with the limb extended. An incision about three inches in length should then be made through the integument, along the posterior margin of the Semimembranosus, and, the fascia lata having been divided, this muscle must be drawn inward. The internal popliteal nerve will be first exposed, lying very superficial and external to the artery; beneath this will be seen the popliteal vein, and, still deeper and to its inner side, the artery. The vein and nerve must be cautiously separated from the artery, and the aneurism needle passed around the vessel from without inward.

To expose the vessel in the lower part of its course, where the artery lies between the two heads of the Gastrocnemius, the patient should be placed in the same position as in the preceding operation. An incision should then be made through the integument in the middle line, commencing opposite the bend of the knee-joint, care being taken to avoid the external saphenous vein and nerve. After dividing the deep fascia and separating some dense cellular membrane, the artery, vein, and nerve will be exposed, descending between the two heads of the Gastrocnemius. Some muscular branches of the popliteal should be avoided if possible, or, if divided, tied immediately. The leg being now flexed, in order the more effectually to separate the two heads of the Gastrocnemius the nerve should be drawn inward and the vein outward, and the aneurism needle passed between the artery and vein from without inward.

In cases where the artery has been wounded during an osteotomy of the lower end of the femur it would be most conveniently secured from the front at the inner side of the thigh. The knee is flexed and the limb placed on its outer side. An incision, three inches long, is made parallel to and immediately behind the tendon of the Adductor magnus from the junction of the middle and lower third of the thigh. Skin, superficial and deep fascia are to be divided, care being taken of the internal saphenous vein; the Adductor magnus is to be drawn forward and the inner hamstring tendons backward, and the artery will be found surrounded by fat. The nerve and vein are usually not seen, as they lie to the outer side of the artery.

The branches of the popliteal artery are—the

Muscular { Superior.	Superior Internal Articular.
Muscular { Inferior or Sural.	Azygos Articular.
Cutaneous.	Inferior External Articular.
Superior External Articular.	Inferior Internal Articular.

The **superior muscular branches,** two or three in number, arise from the upper part of the popliteal artery, and are distributed to the Vastus externus and flexor muscles of the thigh, anastomosing with the inferior perforating and terminal branches of the profunda.

The **inferior muscular (sural)** are two large branches which are distributed to the two heads of the Gastrocnemius and to the Plantaris muscle. They arise from the popliteal artery opposite the knee-joint.

Cutaneous branches descend on each side and in the middle of the limb, between the Gastrocnemius and integument; they arise separately from the popliteal artery or from some of its branches, and supply the integument of the calf.

The **superior articular arteries,** two in number, arise one on each side of the popliteal, and wind round the femur immediately above its condyles to the front of the knee-joint. The *internal branch* passes beneath the tendon of the Adductor magnus, and divides into two, one of which supplies the Vastus internus, inosculating with the anastomotica magna and inferior internal articular; the other ramifies close to the surface of the femur, supplying it and the knee-joint, and anastomosing with the superior external articular artery. The *external branch* passes above the outer condyle, beneath the tendon of the Biceps, and divides into

a superficial and deep branch: the superficial branch supplies the Vastus exter-

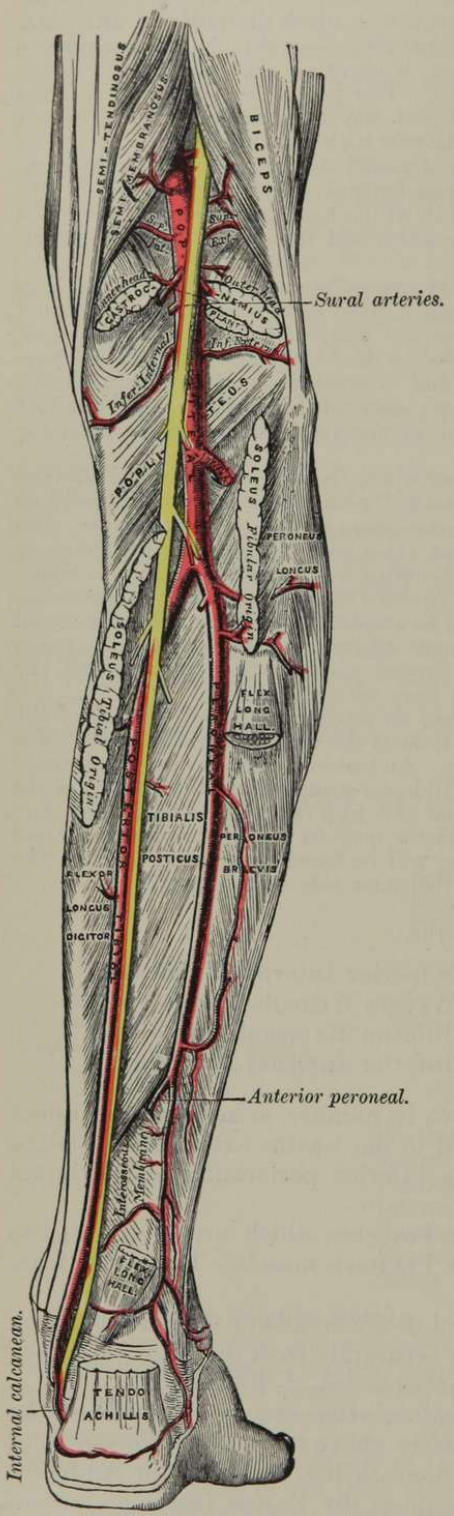

FIG. 377.—The popliteal, posterior tibial, and peroneal arteries.

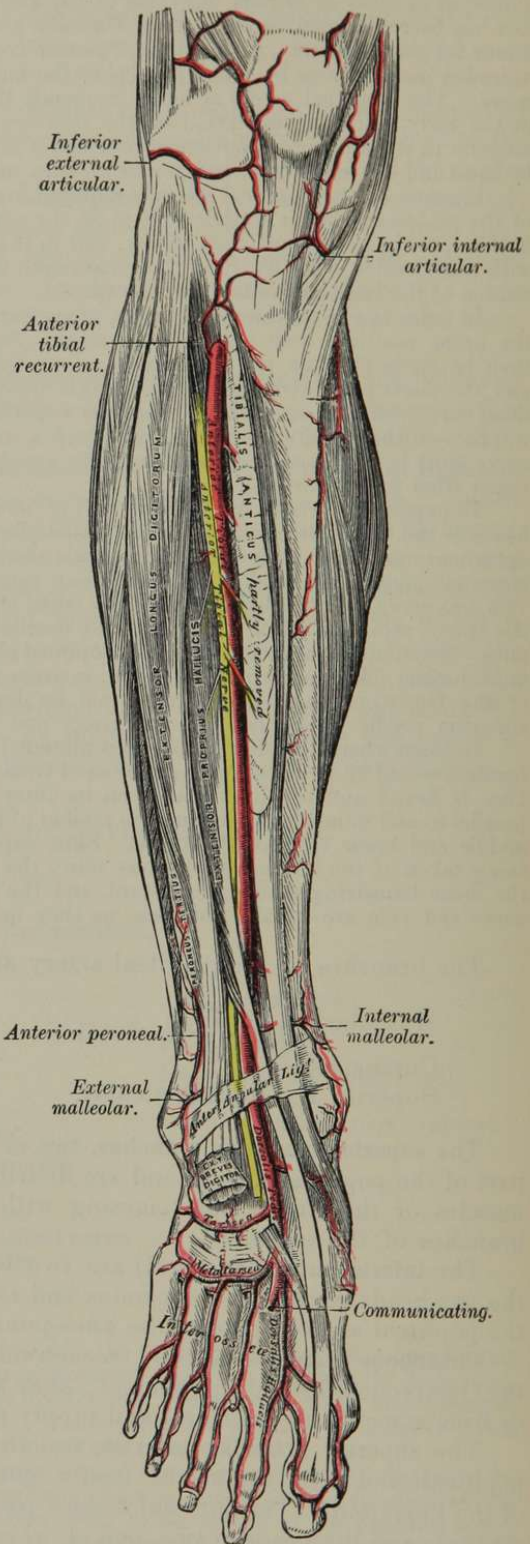

FIG. 378.—Surgical anatomy of the anterior tibial and dorsalis pedis arteries.

nus, and anastomoses with the descending branch of the external circumflex, and the inferior external articular arteries; the deep branch supplies the lower part

of the femur and knee-joint, and forms an anastomotic arch across the bone with the anastomotica magna and the inferior internal articular arteries.

The **azygos articular** is a small branch arising from the popliteal artery opposite the bend of the knee-joint. It pierces the posterior ligament, and supplies the ligaments and synovial membrane in the interior of the articulation.

The **inferior articular arteries,** two in number, arise from the popliteal beneath the Gastrocnemius, and wind round the head of the tibia below the joint. The *internal* one passes below the inner tuberosity, beneath the internal lateral ligament, at the anterior border of which it ascends to the front and inner side of the joint, to supply the head of the tibia and the articulation of the knee, anastomosing with the inferior external articular and superior internal articular arteries. The *external* one passes outward above the head of the fibula, to the front of the knee-joint, passing in its course beneath the outer head of the Gastrocnemius, the external lateral ligament, and the tendon of the Biceps muscle, and divides into branches which anastomose with the inferior internal articular artery, the superior external articular artery, and the anterior recurrent branch of the anterior tibial.

Circumpatellar Anastomosis.—Around and above the patella, and on the contiguous ends of the femur and tibia, is a large network of vessels, forming a superficial and deep plexus from which numerous offsets proceed into the interior of the joint. The arteries from which this plexus is formed are the two internal and two external articular branches of the popliteal, the anastomotica magna, the terminal branch of the profunda, the descending branch from the external circumflex, and the anterior recurrent branch of the anterior tibial.

The Anterior Tibial Artery (Fig. 378).

The **anterior tibial artery** commences at the bifurcation of the popliteal at the lower border of the Popliteus muscle, passes forward between the two heads of the Tibialis posticus, and through the large oval aperture above the upper border of the interosseous membrane to the deep part of the front of the leg: it then descends on the anterior surface of the interosseous membrane, gradually approaching the tibia; and at the lower part of the leg lies on this bone, and then on the anterior ligament of the ankle to the bend of the ankle-joint, where it lies more superficially, and becomes the *dorsalis pedis.*

Relations.—In the upper two-thirds of its extent it rests upon the interosseous membrane, to which it is connected by delicate fibrous arches thrown across it; in the lower third, upon the front of the tibia and the anterior ligament of the ankle-joint. In the upper third of its course it lies between the Tibialis anticus and Extensor longus digitorum; in the middle third, between the Tibialis anticus and Extensor proprius hallucis. At the bend of the ankle it is crossed by the tendon of the Extensor proprius hallucis, and lies between it and the innermost tendon of the Extensor longus digitorum. It is covered, in the upper two-thirds of its course, by the muscles which lie on either side of it and by the deep fascia; in the lower third, by the integument, anterior annular ligament, and fascia.

The anterior tibial artery is accompanied by two veins (venæ comites), which lie one on each side of the artery; the anterior tibial nerve lies at first to its outer side, and about the middle of the leg is placed superficial to it; at the lower part of the artery the nerve is generally again on the outer side.

PLAN OF THE RELATIONS OF THE ANTERIOR TIBIAL ARTERY.

In front.

Integument, superficial and deep fasciæ.
Anterior tibial nerve.
Tibialis anticus (overlaps it in the upper part of the leg).
Extensor longus digitorum, Extensor proprius hallucis } (overlap it slightly).
Anterior annular ligament.

Inner side.
Tibialis anticus.
Extensor proprius hallucis (crosses it at its lower part).

Outer side.
Anterior tibial nerve.
Extensor longus digitorum.
Extensor proprius hallucis.

Behind.
Interosseous membrane.
Tibia.
Anterior ligament of ankle-joint.

Peculiarities in Size.—This vessel may be diminished in size, may be deficient to a greater or less extent, or may be entirely wanting, its place being supplied by perforating branches from the posterior tibial or by the anterior division of the peroneal artery.

Course.—The artery occasionally deviates in its course toward the fibular side of the leg, regaining its usual position beneath the annular ligament at the front of the ankle. In two instances the vessel has been found to approach the surface in the middle of the leg, being covered merely by the integument and fascia below that point.

Surface Marking.—A line drawn from the inner side of the head of the fibula to midway between the two malleoli will mark the course of the artery, the point where the artery comes in front of the interosseous membrane being in this line, one and a quarter inches below the level of the head of the fibula.

Surgical Anatomy.—The anterior tibial artery may be tied in the upper or lower part of the leg. In the upper part the operation is attended with great difficulty, on account of the depth of the vessel from the surface. An incision about four inches in length, should be made through the integument, midway between the spine of the tibia and the outer margin of the fibula, the fascia and intermuscular septum between the Tibialis anticus and Extensor longus digitorum being divided to the same extent. The foot must be flexed to relax these muscles, and they must be separated from each other by the finger. The artery is then exposed deeply seated, lying upon the interosseous membrane, the nerve lying externally, and one of the venæ comites on either side; these must be separated from the artery before the aneurism needle is passed round it.

To tie the vessel in the lower third of the leg above the ankle-joint an incision about three inches in length should be made through the integument between the tendons of the Tibialis anticus and Extensor proprius hallucis muscles, the deep fascia being divided to the same extent. The tendon on either side should be held aside, when the vessel will be seen lying upon the tibia, with the nerve superficial to it and one of the venæ comites on either side.

The branches of the anterior tibial artery are—the

Posterior Recurrent Tibial.	Muscular.
Superior Fibular.	Internal Malleolar.
Anterior Recurrent Tibial.	External Malleolar.

The **posterior recurrent tibial** is not a constant branch, and is given off from the anterior tibial before that vessel passes through the interosseous space. It ascends beneath the Popliteus muscle, which it supplies, and anastomoses with the lower articular branches of the popliteal artery, giving off an offset to the superior tibio-fibular joint.

The **superior fibular** is sometimes given off from the anterior tibial, sometimes from the posterior tibial. It passes outward, round the neck of the fibula, through the Soleus, which it supplies, and ends in the substance of the Peroneus longus muscle.

The **anterior recurrent tibial branch** arises from the anterior tibial as soon as that vessel has passed through the interosseous space; it ascends in the Tibialis anticus muscle, and ramifies on the front and sides of the knee-joint, anastomosing with the articular branches of the popliteal and with the anastomotica magna.

The **muscular branches** are numerous: they are distributed to the muscles

which lie on each side of the vessel, some piercing the deep fascia to supply the integument, others passing through the interosseous membrane, and anastomosing with branches of the posterior tibial and peroneal arteries.

The **malleolar arteries** supply the ankle-joint. The *internal* arises about two inches above the articulation, and passes beneath the tendons of the Extensor proprius hallucis and Tibialis anticus to the inner ankle, upon which it ramifies, anastomosing with branches of the posterior tibial and internal plantar arteries and with the internal calcanean from the posterior tibial. The *external* passes beneath the tendons of the Extensor longus digitorum and Peroneus tertius, and supplies the outer ankle, anastomosing with the anterior peroneal artery and with ascending branches from the tarsal branch of the dorsalis pedis.

The Dorsalis Pedis Artery (Fig. 378).

The **dorsalis pedis,** the continuation of the anterior tibial, passes forward from the bend of the ankle along the tibial side of the foot to the back part of the first intermetatarsal space, where it divides into two branches, the *dorsalis hallucis*, and *communicating*, or *first dorsal interosseous* artery and *plantar digital* respectively.

Relations.—This vessel, in its course forward, rests upon the astragalus, navicular, and internal cuneiform bones and the ligaments connecting them, being covered by the integument and fascia, anterior annular ligament, and crossed near its termination by the innermost tendon of the Extensor brevis digitorum. On its *tibial side* is the tendon of the Extensor proprius hallucis; on its *fibular side*, the innermost tendon of the Extensor longus digitorum, and the termination of the anterior tibial nerve. It is accompanied by two veins.

PLAN OF THE RELATIONS OF THE DORSALIS PEDIS ARTERY.

In front.

Integument and fascia.
Anterior annular ligament.
Innermost tendon of Extensor brevis digitorum.

Tibial side.
Extensor proprius hallucis.

Fibular side.
Extensor longus digitorum.
Anterior tibial nerve.

Behind.

Astragalus.
Navicular.
Internal cuneiform,
and their ligaments.

Peculiarities in Size.—The dorsal artery of the foot may be larger than usual, to compensate for a deficient plantar artery; or it may be deficient in its terminal branches to the toes, which are then derived from the internal plantar; or its place may be supplied altogether by a large anterior peroneal artery.

Position.—This artery frequently curves outward, lying external to the line between the middle of the ankle and the back part of the first interosseous space.

Surface Marking.—The dorsalis pedis artery is indicated on the surface of the dorsum of the foot by a line drawn from the centre of the space between the two malleoli to the back of the first intermetatarsal space.

Surgical Anatomy.—This artery may be tied, by making an incision through the integument between two and three inches in length, on the fibular side of the tendon of the Extensor proprius hallucis, in the interval between it and the inner border of the short Extensor muscle. The incision should not extend farther forward than the back part of the first intermetatarsal space, as the artery divides in that situation. The deep fascia being divided to the same extent, the artery will be exposed, the nerve lying upon its outer side.

Branches.—The branches of the dorsalis pedis are—the

Tarsal.	Dorsalis Hallucis.
Metatarsal—Interosseous.	Communicating.

The **tarsal artery** arises from the dorsalis pedis, as that vessel crosses the navicular bone; it passes in an arched direction outward, lying upon the tarsal bones, and covered by the Extensor brevis digitorum; it supplies that muscle and the articulations of the tarsus, and anastomoses with branches from the metatarsal, external malleolar, peroneal, and external plantar arteries.

The **metatarsal** arises a little anterior to the preceding; it passes outward to the outer part of the foot, over the bases of the metatarsal bones, beneath the tendons of the short Extensor, its direction being influenced by its point of origin; and it anastomoses with the tarsal and external plantar arteries. This vessel gives off three branches, the *interosseous arteries*, which pass forward upon the three outer Dorsal interossei muscles, and, in the clefts between the toes, divide into two dorsal collateral branches for the adjoining toes. At the back part of each interosseous space these vessels receive the posterior perforating branches from the plantar arch, and at the fore part of each interosseous space they are joined by the anterior perforating branches from the digital arteries. The outermost interosseous artery gives off a branch which supplies the outer side of the little toe.

The **dorsalis hallucis** (*first dorsal interosseous*) runs forward along the outer border of the first metatarsal bone, and at the cleft between the first and second toes divides into two branches, one of which passes inward, beneath the tendon of the Extensor proprius hallucis, and is distributed to the inner border of the great toe; the outer branch bifurcates, to supply the adjoining sides of the great and second toes.

The **communicating artery** or **Plantar digital** dips down into the sole of the foot, between the two heads of the First dorsal interosseous muscle, and inosculates with the termination of the external plantar artery to complete the plantar arch. It here gives off two digital branches: one runs along the inner side of the great toe on its plantar surface; the other passes forward along the first interosseous space, and bifurcates at the cleft for the supply of the adjacent sides of the great and second toes.

The Posterior Tibial Artery.

The **posterior tibial** is an artery of large size, which extends obliquely downward from the lower border of the Popliteus muscle, along the tibial side of the leg, to the fossa between the inner ankle and the heel, where it divides beneath the origin of the Abductor hallucis, on a level with a line drawn from the point of the internal malleolus to the centre of the convexity of the heel, into the *internal* and *external plantar arteries*. At its origin it lies opposite the interval between the tibia and fibula; as it descends, it approaches the inner side of the leg, lying behind the tibia, and, in the lower part of its course, is situated midway between the inner malleolus and the tuberosity of the os calcis.

Relations.—It lies successively upon the Tibialis posticus, the Flexor longus digitorum, the tibia, and the back part of the ankle-joint. It is *covered* by the deep transverse fascia, which separates it above from the Gastrocnemius and Soleus muscles. In the lower third, where it is more superficial, it is covered only by the integument and fascia, and runs parallel with the inner border of the tendo Achillis. It is accompanied by two veins, and by the posterior tibial nerve, which lies at first to the inner side of the artery, but soon crosses it, and is, in the greater part of its course, on its outer side.

PLAN OF THE RELATIONS OF THE POSTERIOR TIBIAL ARTERY.

In front.
Tibialis posticus.
Flexor longus digitorum.
Tibia.
Ankle-joint.

Inner side.
Posterior tibial nerve, upper third.

Outer side.
Posterior tibial nerve, lower two-thirds.

Behind.
Integument and fascia.
Gastrocnemius.
Soleus.
Deep transverse fascia.
Posterior tibial nerve.

Behind the Inner ankle the tendons and blood-vessels are arranged in the following order, from within outward: First, the tendons of the Tibialis posticus and Flexor longus digitorum, lying in the same groove, behind the inner malleolus, the former being the most internal. External to these is the posterior tibial artery, having a vein on either side; and, still more externally, the posterior tibial nerve. About half an inch nearer the heel is the tendon of the Flexor longus hallucis.

Peculiarities in Size.—The posterior tibial is not unfrequently smaller than usual, or absent, its place being supplied by a large peroneal artery which passes inward at the lower end of the tibia, and either joins the small tibial artery or continues alone to the sole of the foot.

Surface Marking.—The course of the posterior tibial artery is indicated by a line drawn from a point one inch below the centre of the popliteal space to midway between the tip of the internal malleolus and the centre of the convexity of the heel.

Surgical Anatomy.—The *application of a ligature* to the posterior tibial may be required in cases of wound of the sole of the foot attended with great hæmorrhage, when the vessel should be tied at the inner ankle. In cases of wound of the posterior tibial it will be necessary to enlarge the opening so as to expose the vessel at the wounded point, excepting where the vessel is injured by a punctured wound from the front of the leg. In cases of aneurism from wound of the artery low down, the vessel should be tied in the middle of the leg. But in aneurism of the posterior tibial high up it would be better to tie the femoral artery.

To tie the posterior tibial artery at the ankle, a semilunar incision should be made through the integument, about two inches and a half in length, midway between the heel and inner ankle or a little nearer the latter. The subcutaneous cellular tissue having been divided, a strong and dense fascia, the internal annular ligament, is exposed. This ligament is continuous above with the deep fascia of the leg, covers the vessels and nerves, and is intimately adherent to the sheaths of the tendons. This having been cautiously divided upon a director, the sheath of the vessels is exposed, and, being opened, the artery is seen with one of the venæ comites on each side. The aneurism needle should be passed round the vessel from the heel toward the ankle, in order to avoid the posterior tibial nerve, care being at the same time taken not to include the venæ comites.

The vessel may also be tied in the lower third of the leg by making an incision, about three inches in length, parallel with the inner margin of the tendo Achillis. The internal saphenous vein being carefully avoided, the two layers of fascia must be divided upon a director, when the artery is exposed along the outer margin of the Flexor longus digitorum, with one of its venæ comites on either side and the nerve lying external to it.

To tie the posterior tibial in the middle of the leg is a very difficult operation, on account of the great depth of the vessel from the surface. The patient being placed in the recumbent position, the injured limb should rest on its outer side, the knee being partially bent and the foot extended, so as to relax the muscles of the calf. An incision about four inches in length should then be made through the integument a finger's breadth behind the inner margin of the tibia, taking care to avoid the internal saphenous vein. The deep fascia having been divided, the margin of the Gastrocnemius is exposed, and must be drawn aside, and the tibial attachment of the Soleus divided, a director being previously passed beneath it. The artery may now be felt pulsating beneath the deep fascia about an inch from the margin of the tibia. The fascia having been divided, and the limb placed in such a position as to relax the muscles of the calf as much as possible, the veins should be separated from the artery, and the aneurism needle passed round the vessel from without inward, so as to avoid wounding the posterior tibial nerve.

The branches of the posterior tibial artery are—the

Peroneal.	Nutrient.
Muscular.	Communicating.

Internal Calcanean.

The **Peroneal Artery** lies, deeply seated, along the back part of the fibular side of the leg. It arises from the posterior tibial about an inch below the lower border of the Popliteus muscle, passes obliquely outward to the fibula, and then descends along the inner border of that bone to the lower third of the leg, where it gives off the *anterior peroneal*. It then passes as the *posterior peroneal*, across the articulation between the tibia and fibula to the outer side of the os calcis, where it gives off its terminal branches, the *external calcanean*.

Relations.—This vessel rests at first upon the Tibialis posticus, and then, for the greater part of its course, in a fibrous canal between the origins of the Flexor longus hallucis and Tibialis posticus, covered or surrounded by the fibres of the Flexor longus hallucis. It is *covered*, in the upper part of its course, by the Soleus and deep transverse fascia; *below*, by the Flexor longus hallucis.

PLAN OF THE RELATIONS OF THE PERONEAL ARTERY.

In front.
Tibialis posticus.
Flexor longus hallucis.

Outer side.
Fibula.
Flexor longus hallucis.

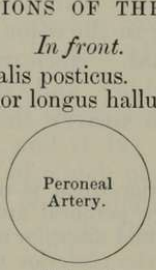

Inner side.
Flexor longus hallucis.

Behind.
Soleus.
Deep transverse fascia.
Flexor longus hallucis.

Peculiarities in Origin.—The peroneal artery may arise three inches below the Popliteus, or from the posterior tibial high up, or even from the popliteal.

Its size is more frequently increased than diminished; and then it either reinforces the posterior tibial by its junction with it, or altogether takes the place of the posterior tibial in the lower part of the leg and foot, the latter vessel only existing as a short muscular branch. In those rare cases where the peroneal artery is smaller than usual a branch from the posterior tibial supplies its place, and a branch from the anterior tibial compensates for the diminished anterior peroneal artery. In one case the peroneal artery has been found entirely wanting.

The anterior peroneal is sometimes enlarged, and takes the place of the dorsal artery of the foot.

The branches of the peroneal are—the

Muscular.	Communicating.
Nutrient.	Posterior Peroneal.
Anterior Peroneal.	External Calcanean.

Muscular Branches.—The **peroneal artery** in its course gives off branches to the Soleus, Tibialis posticus, Flexor longus hallucis, and Peronei muscles.

The *nutrient artery* supplies the fibula.

The *Anterior peroneal* pierces the interosseous membrane, about two inches above the outer malleolus, to reach the fore part of the leg, and, passing down beneath the Peroneus tertius to the outer ankle, ramifies on the front and outer side of the tarsus, anastomosing with the external malleolar and tarsal arteries.

The *communicating* is given off from the peroneal about an inch from its lower end, and, passing inward, joins the communicating branch of the posterior tibial.

The *Posterior peroneal* passes down behind the outer ankle to the back of the external malleolus, to terminate in branches which ramify on the outer surface and back of the os calcis.

The *External calcanean* are the terminal branches of the peroneal artery ; they pass to the outer side of the heel, and communicate with the external malleolar, and, on the back of the heel, with the internal calcanean arteries.

The **nutrient artery** of the tibia arises from the posterior tibial near its origin, and, after supplying a few muscular branches, enters the nutrient canal of that bone, which it traverses obliquely from above downward. This is the largest nutrient artery of bone in the body.

The **muscular branches** of the posterior tibial are distributed to the Soleus and deep muscles along the back of the leg.

The **communicating branch,** to join a similar branch of the peroneal, runs transversely across the back of the tibia, about two inches above its lower end, passing beneath the Flexor longus hallucis.

The **internal calcanean** are several large arteries which arise from the posterior

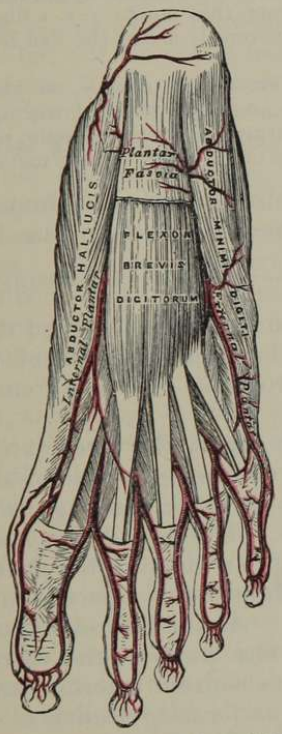

FIG. 379.—The plantar arteries. Superficial view.

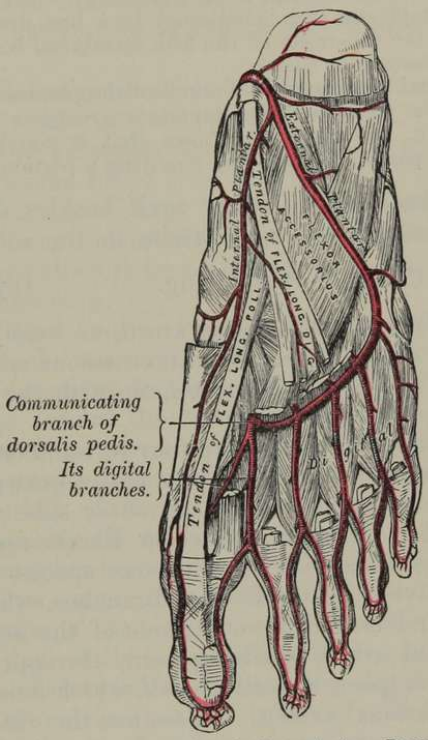

FIG. 380.—The plantar arteries. Deep view.

tibial just before its division: they are distributed to the fat and integument behind the tendo Achillis and about the heel, and to the muscles on the inner side of the sole, anastomosing with the peroneal and internal malleolar, and, on the back of the heel, with the external calcanean arteries.

The **Internal Plantar Artery** (Figs. 379, 380), much smaller than the external, passes forward along the inner side of the foot. It is at first situated above[1] the Abductor hallucis, and then between it and the Flexor brevis digitorum, both of which it supplies. At the base of the first metatarsal bone, where it has become much diminished in size, it passes along the inner border of the great toe, inosculating with its digital branch.

The **External Plantar Artery,** much larger than the internal, passes obliquely outward and forward to the base of the fifth metatarsal bone. It then turns obliquely inward to the interval between the bases of the first and second metatarsal bones, where it anastomoses with the plantar digital branch from the dorsalis pedis artery, thus completing the *plantar arch.* As this artery passes

[1] This refers to the erect position of the body. In the ordinary position for dissection the artery is deeper than the muscle.

outward, it is first placed between the os calcis and Abductor hallucis, and then between the Flexor brevis digitorum and Flexor accessorius, and as it passes forward to the base of the little toe, it lies more superficially between the Flexor brevis digitorum and Abductor minimi digiti, covered by the deep fascia and integument. The remaining portion of the vessel is deeply situated: it extends from the base of the metatarsal bone of the little toe to the back part of the first interosseous space, and forms the plantar arch; it is convex forward, lies upon the Interossei muscles opposite the tarsal ends of the metatarsal bones, and is covered by the Adductor obliquus hallucis, the flexor tendons of the toes, and the Lumbricales.

Surface Marking.—The course of the internal plantar artery is represented by a line drawn from the mid-point between the tip of the internal malleolus and the centre of the convexity of the heel to the middle of the under surface of the great toe; the external plantar by a line from the same point to within a finger's breadth of the tuberosity of the fifth metatarsal bone. The plantar arch is indicated by a line drawn from this point; *i. e.* a finger's breadth internal to the tuberosity of the fifth metatarsal bone transversely across the foot to the back of the first interosseous space.

Surgical Anatomy.—Wounds of the plantar arch are always serious, on account of the depth of the vessel and the important structures which must be interfered with in an attempt to ligature it. Delorme has shown that it may be ligatured from the dorsum of the foot in almost any part of its course by removing a portion of one of the three middle metatarsal bones.

Branches.—The plantar arch, besides distributing numerous branches to the muscles, integument, and fasciæ in the sole, gives off the following branches:

Posterior Perforating. Digital—Anterior Perforating.

The **Posterior Perforating** are three small branches which ascend through the back part of the three outer interosseous spaces, between the heads of the Dorsal interossei muscles, and anastomose with the interosseous branches from the metatarsal artery.

The **Digital Branches** are four in number, and supply the three outer toes and half the second toe. The *first* passes outward from the outer side of the plantar arch, and is distributed to the outer side of the little toe, passing in its course beneath the Abductor and short Flexor muscles. The *second*, *third*, and *fourth* run forward along the interosseous spaces, and on arriving at the clefts between the toes divide into collateral branches, which supply the adjacent sides of the three outer toes and the outer side of the second. At the bifurcation of the toes each digital artery sends upward, through the fore part of the corresponding interosseous space, a small branch, which inosculates with the interosseous branches of the metatarsal artery. These are the *anterior perforating branches*.

From the arrangement already described of the distribution of the vessels to the toes it will be seen that both sides of the three outer toes and the outer side of the second toe are supplied by branches from the plantar arch; both sides of the great toe and the inner side of the second are supplied by the plantar digital branch of the dorsalis pedis.

THE VEINS.

THE Veins are the vessels which serve to return the blood from the capillaries of the different parts of the body to the heart. They consist of two distinct sets of vessels, the *pulmonary* and *systemic*.

The **Pulmonary Veins** are concerned in the circulation in the lungs. Unlike other vessels of this kind, they contain arterial blood, which they return from the lungs to the left auricle of the heart.

The **Systemic Veins** are concerned in the general circulation; they return the venous blood from the body generally to the right auricle of the heart.

The **Portal Vein,** an appendage to the systemic venous system, is confined to the abdominal cavity, returning the venous blood from the viscera of digestion, and carrying it to the liver by a single trunk of large size, the *vena portæ*. This vessel ramifies in the substance of the liver and breaks up into a minute network of capillaries. These capillaries then re-collect to form the hepatic veins, by which the blood is conveyed to the inferior vena cava.

The veins, like the arteries, are found in nearly every tissue of the body. They commence by minute plexuses which receive the blood from the capillaries. The branches which have their commencement in these plexuses unite together into trunks, and these, in their passage toward the heart, constantly increase in size as they receive tributaries or join other veins. The veins are larger and altogether more numerous than the arteries; hence the entire capacity of the venous system is much greater than that of the arterial, the pulmonary veins excepted, which do not exceed in capacity the pulmonary arteries. From the combined area of the smaller venous branches being greater than the main trunks, it results that the venous system represents a cone, the summit of which corresponds to the heart, its base to the circumference of the body. In form the veins are not perfectly cylindrical like the arteries, their walls being collapsed when empty, and the uniformity of their surface being interrupted at intervals by slight constrictions, which indicate the existence of valves in their interior. They usually retain, however, the same calibre as long as they receive no branches.

The veins communicate very freely with one another, especially in certain regions of the body, and this communication exists between the larger trunks as well as between the smaller branches. Thus, in the cavity of the cranium and between the veins of the neck, where obstruction would be attended with imminent danger to the cerebral venous system, we find that the sinuses and larger veins have large and very frequent anastomoses. The same free communication exists between the veins throughout the whole extent of the spinal canal, and between the veins composing the various venous plexuses in the abdomen and pelvis, as the spermatic, uterine, vesical, and prostatic.

The systemic veins are subdivided into three sets: superficial, deep, and sinuses.

The **Superficial** or **Cutaneous Veins** are found between the layers of the superficial fascia, immediately beneath the integument; they return the blood from these structures, and communicate with the deep veins by perforating the deep fascia.

The **Deep Veins** accompany the arteries, and are usually enclosed in the same sheath with those vessels. With the smaller arteries—as the radial, ulnar, brachial, tibial, peroneal—they exist generally in pairs, one lying on each side of the vessel, and are called *venæ comites*. The larger arteries—as the axillary, subclavian, popliteal, and femoral—have usually only one accompanying vein. In certain

organs of the body, however, the deep veins do not accompany the arteries; for instance, the veins in the skull and spinal canal, the hepatic veins in the liver, and the larger veins returning blood from the osseous tissue.

Sinuses are venous channels which, in their structure and mode of distribution, differ altogether from the veins. They are found only in the interior of the skull, and are formed by a separation of the layers of the dura mater, their outer coat consisting of fibrous tissue, their inner of an endothelial layer continuous with the lining membrane of the veins.

Veins have thinner walls than arteries, the difference in thickness being due to the small amount of elastic and muscular tissues which the veins contain. The superficial veins usually have thicker coats than the deep veins, and the veins of the lower limb are thicker than those of the upper.

The minute structure of these vessels has been described in the section on General Anatomy.

THE PULMONARY VEINS.

The *Pulmonary Veins* return the arterial blood from the lungs to the left auricle of the heart. They are four in number, two for each lung. The pulmonary differ from other veins in several respects: 1. They carry arterial instead of venous blood. 2. They are destitute of valves. 3. They are only slightly larger than the arteries they accompany. 4. They accompany those vessels singly. They commence in a capillary network upon the walls of the air-cells, where they are continuous with the ramifications of the pulmonary artery, and, uniting together, form a single trunk for each lobule. These branches, uniting successively, form a single trunk for each lobe, three for the right and two for the left lung. The vein from the middle lobe of the right lung unites with that from the upper lobe, in most cases, forming two trunks on each side, which open separately into the left auricle. Occasionally they remain separate; there are then three veins on the right side. Not unfrequently the two left pulmonary veins terminate by a common opening.

Within the lung, the branches of the pulmonary artery are *in front*, the veins *behind*, and the bronchi *between* the two.

At the root of the lung, the veins are *in front*, the artery *in the middle*, and the bronchus *behind*.

Within the pericardium, their anterior surface is invested by the serous layer of this membrane. The right pulmonary veins pass behind the right auricle and ascending aorta; the left pass in front of the thoracic aorta with the left pulmonary artery.

THE SYSTEMIC VEINS.

The systemic veins may be arranged into three groups: 1. Those of the head and neck, upper extremity, and thorax, which terminate in the superior vena cava. 2. Those of the lower limb, pelvis, and abdomen, which terminate in the inferior vena cava. 3. The cardiac veins, which open directly into the right auricle of the heart.

VEINS OF THE HEAD AND NECK.

The veins of the head and neck may be subdivided into three groups: 1. The veins of the exterior of the head and face. 2. The veins of the neck. 3. The veins of the diploë and interior of the cranium.

Veins of the Exterior of the Head.

The veins of the exterior of the head and face are—the

Frontal.
Supra-orbital.
Angular.
Facial.
Temporal.
Internal Maxillary.
Temporo-maxillary.
Posterior Auricular.
Occipital.

The **frontal vein** commences on the anterior part of the skull by a venous plexus which communicates with the anterior tributaries of the temporal vein. The veins converge to form a single trunk, which runs downward near the middle line of the forehead parallel with the vein of the opposite side, and unites with it at the root of the nose by a transverse branch called the *nasal arch.* Occasionally the frontal veins join to form a single trunk, which bifurcates at the

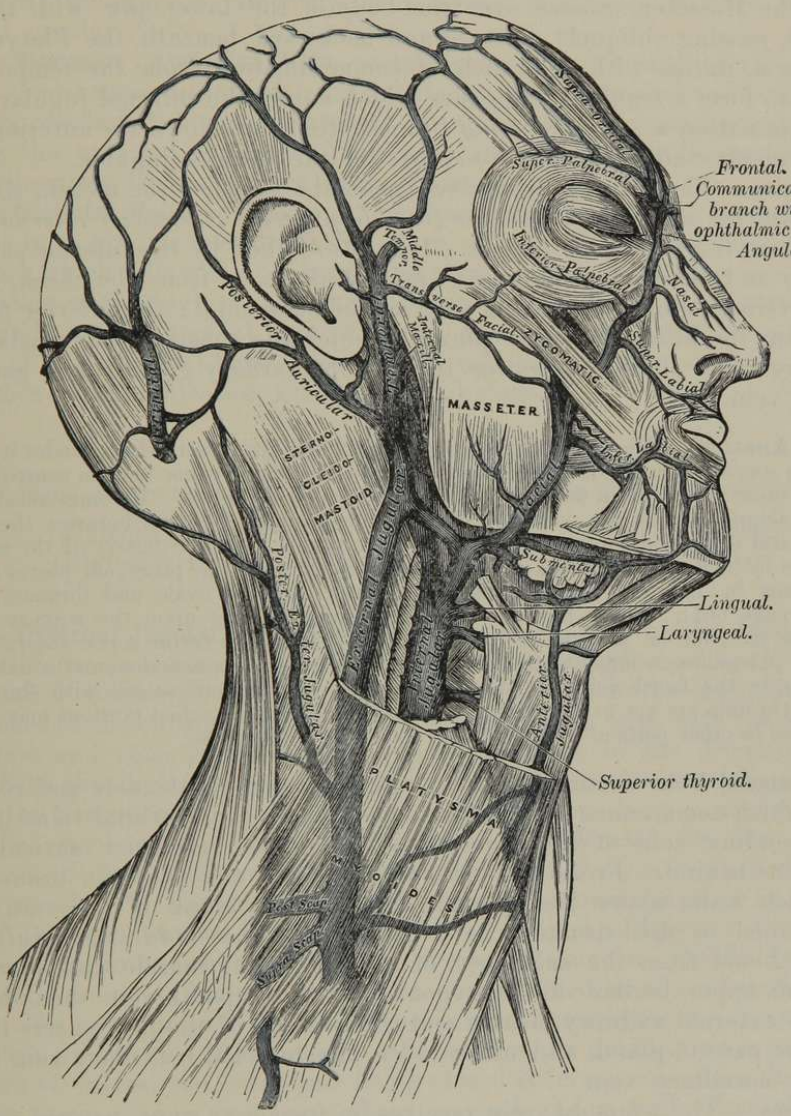

FIG. 381.—Veins of the head and neck.

root of the nose into the two angular veins. At the root of the nose the veins diverge and join the *supra-orbital vein*, at the inner angle of the orbit, to form the *angular vein.*

The **supra-orbital vein** commences on the forehead, communicating with the anterior temporal vein, and runs downward and inward, superficial to the Occipito-frontalis muscle, receiving tributaries from the neighboring structures, and joins the frontal vein at the inner angle of the orbit to form the *angular vein.*

The **angular vein,** formed by the junction of the frontal and supra-orbital veins, runs obliquely downward and outward on the side of the root of the nose, and receives the veins of the ala nasi on its inner side and the superior palpebral veins on its outer side; it moreover communicates with the ophthalmic vein, thus

establishing an important anastomosis between this vessel and the cavernous sinus. Some small veins from the dorsum of the nose terminate in the nasal arch.

The **facial vein** commences at the side of the root of the nose, being a direct continuation of the angular vein. It passes obliquely downward and outward beneath the Zygomaticus major and minor muscles, descends along the anterior border of the Masseter, crosses over the body of the lower jaw with the facial artery, and, passing obliquely outward and backward beneath the Platysma and cervical fascia, unites with a branch of communication from the temporo-maxillary vein to form a trunk of large size which enters the internal jugular. From near its termination a *communicating* branch often runs down the anterior border of the Sterno-mastoid to join the lower part of the anterior jugular.

Tributaries.—The facial vein receives, near the angle of the mouth, communicating tributaries of considerable size (the *deep facial* or *anterior internal maxillary vein*) from the pterygoid plexus. It is also joined by the inferior palpebral, the superior and inferior labial veins, the buccal veins from the cheek, and the masseteric veins. Below the jaw it receives the submental; the inferior palatine, which returns the blood from the plexus around the tonsil and soft palate; the submaxillary vein, which commences in the submaxillary gland; and, generally, the ranine vein.

Surgical Anatomy.—There are some points about the facial vein which render it of great importance in surgery. It is not so flaccid as are most superficial veins, and, in consequence of this, remains more patent when divided. It has, moreover, no valves. It communicates freely with the intracranial circulation, not only at its commencement by its tributaries, the angular and supra-orbital veins, communicating with the ophthalmic vein, a tributary of the cavernous sinus, but also by its deep branch, which communicates through the pterygoid plexus with the cavernous sinus by branches which pass through the foramen ovale and foramen lacerum medium (see page 661). These facts have an important bearing upon the surgery of some diseases of the face, for on account of its patency the facial vein favors septic absorption, and therefore any phlegmonous inflammation of the face following a poisoned wound is liable to set up thrombosis in the facial vein. And on account of its communications with the cerebral sinuses these thrombi are apt to extend upward into them, and detached portions may give rise to purulent foci in other parts of the body, and so induce a fatal issue.

The **Temporal Vein** commences by a minute plexus on the side and vertex of the skull, which communicates with the frontal and supra-orbital veins in front, the corresponding vein of the opposite side, and the posterior auricular and occipital veins behind. From this network anterior and posterior branches are formed which unite above the zygoma, forming the trunk of the vein. This trunk is joined in this situation by a large vein, the *middle temporal*, which receives the blood from the substance of the Temporal muscle and pierces the fascia at the upper border of the zygoma. The temporal vein then descends between the external auditory meatus and the condyle of the jaw, enters the substance of the parotid gland, and unites with the internal maxillary vein to form the temporo-maxillary vein.

Tributaries.—The temporal vein receives in its course some parotid veins, an articular branch from the articulation of the jaw, anterior auricular veins from the external ear, and a vein of large size, the *transverse facial*, from the side of the face. The middle temporal vein, previous to its junction with the temporal vein, receives a branch, the *orbital vein*, which is formed by some external palpebral branches, and passes backward between the layers of the temporal fascia.

The **Internal Maxillary Vein** is a vessel of considerable size, receiving branches which correspond with those of the internal maxillary artery. Thus it receives the middle meningeal veins, the deep temporal, the pterygoid, masseteric, buccal, alveolar, some palatine veins, and the inferior dental. These branches form a large plexus, the *pterygoid*, which is placed between the Temporal and External pterygoid and partly between the Pterygoid muscles. This plexus communicates very freely with the facial vein and with the cavernous sinus by branches through the foramen Vesalii at the base of the skull. The trunk of the vein then passes

backward behind the neck of the lower jaw, and unites with the temporal vein, forming the temporo-maxillary vein.

The **Temporo-Maxillary Vein,** formed by the union of the temporal and internal maxillary veins, descends in the substance of the parotid gland on the outer surface of the external carotid artery, between the ramus of the jaw and the Sterno-mastoid muscle, and divides into two branches, one of which passes inward to join the facial vein; the other is joined by the posterior auricular vein and becomes the external jugular.

The **Posterior Auricular Vein** commences upon the side of the head by a plexus which communicates with the tributaries of the temporal and occipital veins. The vein descends behind the external ear and joins the temporo-maxillary vein, forming the external jugular. This vessel receives the stylo-mastoid vein and some tributaries from the back part of the external ear.

The **Occipital Veins** commence at the back part of the vertex of the skull by a plexus in a similar manner to the other veins. These unite and form one or two veins, which follow the course of the occipital artery, passing deeply beneath the muscles of the back part of the neck, and terminate in the internal jugular, occasionally in the external jugular vein. As these veins pass across the mastoid portion of the temporal bone, one of them receives the mastoid vein, which thus establishes a communication with the lateral sinus.

The Veins of the Neck.

The veins of the neck, which return the blood from the head and face, are—the

External Jugular.	Anterior Jugular.
Posterior External Jugular.	Internal Jugular.
Vertebral.	

The **External Jugular Vein** receives the greater part of the blood from the exterior of the cranium and deep parts of the face, being formed by the junction of the posterior division of the temporo-maxillary and posterior auricular veins. It commences in the substance of the parotid gland, on a level with the angle of the lower jaw, and runs perpendicularly down the neck in the direction of a line drawn from the angle of the jaw to the middle of the clavicle. In its course it crosses the Sterno-mastoid muscle, and runs parallel with its posterior border as far as its attachment to the clavicle, where it perforates the deep fascia, and terminates in the subclavian vein, on the outer side of or in front of the Scalenus anticus muscle. In the neck it is separated from the Sterno-mastoid by the anterior layer of the deep cervical fascia, and is covered by the Platysma, the superficial fascia, and the integument. This vein is crossed about its middle by the superficialis colli nerve, and its upper half is accompanied by the auricularis magnus nerve. The external jugular vein varies in size, bearing an inverse proportion to that of the other veins of the neck; it is occasionally double. It is provided with two pairs of valves, the lower pair being placed at its entrance into the subclavian vein, the upper pair in most cases about an inch and a half above the clavicle. The portion of vein between the two sets of valves is often dilated, and is termed the *sinus*. These valves do not prevent the regurgitation of the blood or the passage of injection from below upward.[1]

Surgical Anatomy.—Venesection used formerly to be performed on the external jugular vein, but is now probably never resorted to. The anatomical point to be remembered in performing this operation is to cut across the fibres of the Platysma myoides in opening the vein, so that by their contraction they will expose the orifice in the vein and so allow the flow of blood.

Tributaries.—This vein receives the occipital occasionally, the posterior external jugular, and near its termination, the suprascapular and transverse cervical veins.

[1] The student may refer to an interesting paper by Dr. Struthers, "On Jugular Venesection in Asphyxia, anatomically and experimentally considered, including the Demonstration of Valves in the Veins of the Neck," in the *Edinburgh Medical Journal* for November, 1856.

It communicates with the anterior jugular, and, in the substance of the parotid, receives a large branch of communication from the internal jugular.

The **Posterior External Jugular Vein** commences in the occipital region, and returns the blood from the integument and superficial muscles in the upper and back part of the neck, lying between the Splenius and Trapezius muscles. It runs down the back part of the neck, and opens into the external jugular just below the middle of its course.

The **Anterior Jugular Vein** commences near the hyoid bone from the convergence of several superficial veins from the submaxillary region. It passes down between the median line and the anterior border of the Sterno-mastoid, and at the lower part of the neck passes beneath that muscle to open into the termination of the external jugular or into the subclavian vein (Fig. 388). This vein varies considerably in size, bearing almost always an inverse proportion to the external jugular. Most frequently there are two anterior jugulars, a right and left, but occasionally only one. This vein receives some laryngeal veins, and occasionally a small thyroid vein. Just above the sternum the two anterior jugular veins communicate by a transverse trunk, which receives tributaries from the inferior thyroid veins. It also communicates with the internal jugular. There are no valves in this vein.

The **Internal Jugular Vein** collects the blood from the interior of the cranium, from the superficial parts of the face, and from the neck. It commences just external to the jugular foramen, at the base of the skull, being formed by the coalescence of the lateral and inferior petrosal sinuses (Fig. 386). At its origin it is somewhat dilated, and this dilatation is called the *sinus*, or *gulf*, of the internal jugular vein. It runs down the side of the neck in a vertical direction, lying at first on the outer side of the internal carotid, and then on the outer side of the common carotid, and at the root of the neck unites with the subclavian vein to form the innominate vein. The internal jugular vein, at its commencement, lies upon the Rectus capitis lateralis, and behind the internal carotid and the nerves passing through the jugular foramen; lower down, the vein and artery lie upon the same plane, the glosso-pharyngeal and hypoglossal nerves passing forward between them; the pneumogastric descends between and behind them in the same sheath, and the spinal accessory passes obliquely outward behind the vein. At the root of the neck the vein of the right side is placed at a little distance from the artery; on the left side it usually lies over the artery at its lower part. The right internal jugular vein crosses the first part of the subclavian artery. The vein is of considerable size, but varies in different individuals, the left one being usually the smaller. It is provided with a pair of valves, which are placed at its point of termination or from half to three-quarters of an inch above it.

Tributaries.—This vein receives in its course the facial, lingual, pharyngeal, superior and middle thyroid veins, and sometimes the occipital. At its point of junction with the branch common to the temporo-maxillary and facial veins it becomes greatly increased in size.

The **lingual veins** commence on the dorsum, sides, and under surface of the tongue, and, passing backward, following the course of the lingual artery and its branches, terminate in the internal jugular. Sometimes the ranine vein, which is a branch of considerable size commencing below the tip of the tongue, joins the lingual. Generally, however, it passes backward, crosses the Hyo-glossus muscle in company with the hypoglossal nerve, and joins the facial.

The **pharyngeal vein** commences in a minute plexus, the *pharyngeal*, at the back part and sides of the pharynx, and, after receiving meningeal tributaries and the Vidian and spheno-palatine veins, terminates in the internal jugular. It occasionally opens into the facial, lingual, or superior thyroid vein.

The **superior thyroid vein** commences in the substance and on the surface of the thyroid gland by tributaries corresponding with the branches of the superior thyroid artery, and terminates in the upper part of the internal jugular vein.

The **middle thyroid vein** collects the blood from the lower part of the lateral lobe of the thyroid gland, and, being joined by some veins from the larynx and trachea, terminates in the lower part of the internal jugular vein.

The **facial** and **occipital veins** have been described above.

Surgical Anatomy.—The internal jugular vein occasionally requires ligature in cases of septic thrombosis of the lateral sinus from suppuration in the middle ear, in order to prevent embolism of the thoracic viscera. This operation has been performed recently in several cases with the most satisfactory results. The cases are generally those of chronic disease of the middle ear, with discharge of pus which perhaps has existed for many years. The patient is seized with acute septic inflammation, spreading to the mastoid cells, and consequent on this septic thrombosis of the lateral sinus extending to the internal jugular vein. Such cases are always extremely grave, for there is a danger of a portion of the septic clot being detached and causing septic embolism in the thoracic viscera. This may be mechanically prevented by ligature of the internal jugular vein in the middle of the neck. The operation is a comparatively simple one, and may be performed by an incision similar to that employed in ligature of the common carotid artery.

The **Vertebral Vein** commences in the occipital region by numerous small tributaries from the deep muscles at the upper and back part of the neck; these pass outward and enter the foramen in the transverse process of the atlas, and descend, forming a dense plexus around the vertebral artery in the canal formed by the transverse processes of the cervical vertebræ. This plexus unites at the lower part of the neck into two main trunks, one of which emerges from the foramen in the transverse process of the sixth cervical vertebra, and the other through that of the seventh, and, uniting, form a single vessel, which terminates at the root of the neck in the back part of the innominate vein near its origin, its mouth being guarded by a pair of valves. On the right side it crosses the first part of the subclavian artery.

Tributaries.—The vertebral vein receives in its course a vein from the inside of the skull through the posterior condyloid foramen; muscular veins from the muscles in the prevertebral region; dorsi-spinal veins, from the back part of the cervical portion of the spine; meningo-rachidian veins, from the interior of the spinal canal; the anterior and posterior vertebral veins; and close to its termination it is joined by a *small vein* from the *first intercostal space* which accompanies the superior intercostal artery. (See page 666.)

The **anterior vertebral vein** commences in a plexus around the transverse processes of the upper cervical vertebræ, descends in company with the ascending cervical artery between the Scalenus anticus and Rectus capitis anticus major muscles, and opens into the vertebral vein just before its termination.

The **posterior vertebral vein** (the **deep cervical**) accompanies the profunda cervicis artery, lying between the Complexus and Semispinalis colli. It commences in the suboccipital region by communicating branches from the occipital vein and tributaries from the deep muscles at the back of the neck. It receives tributaries from the plexuses around the spinous processes of the cervical vertebræ, and terminates in the lower end of the vertebral vein.

The Veins of the Diploë.

The diploë of the cranial bones is channelled in the adult by a number of tortuous canals, which are lined by a more or less complete layer of compact tissue.

The veins they contain are large and capacious, their walls being thin, and formed only of endothelium resting upon a layer of elastic tissue, and they present at irregular intervals pouch-like dilatations, or *culs-de-sac*, which serve as reservoirs for the blood. These are the veins of the diploë; they can only be displayed by removing the outer table of the skull.

In adult life, as long as the cranial bones are distinct and separable, these veins are confined to the particular bones; but in old age, when the sutures are united, they communicate with each other and increase in size. These vessels communicate, in the interior of the cranium, with the meningeal veins and with

the sinuses of the dura mater, and on the exterior of the skull with the veins of the pericranium. They are divided into the *frontal*, which opens into the supra-orbital vein by an aperture in the supra-orbital notch; the *anterior temporal*, which is confined chiefly to the frontal bone, and opens into one of the deep temporal veins, after escaping by an aperture in the great wing of the sphenoid;

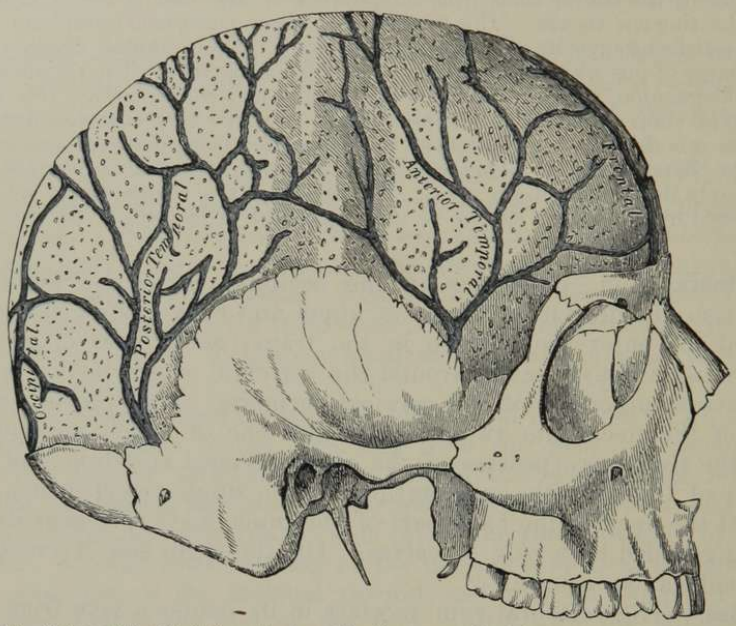

FIG. 382.—Veins of the Diploë as displayed by the removal of the outer table of the skull.

the *posterior temporal*, which is confined to the parietal bone, and terminates in the lateral sinus by an aperture at the posterior inferior angle of the parietal bone; and the *occipital*, the largest of the four, which is confined to the occipital bone, and opens either into the occipital vein or internally into the lateral sinus or torcular Herophili.

The Cerebral Veins.

The **Cerebral Veins** are remarkable for the extreme thinness of their coats in consequence of the muscular tissue in them being wanting, and for the absence of valves. They may be divided into two sets: the superficial, which are placed on the surface, and the deep veins, which occupy the interior of the organ.

The **Superficial Cerebral Veins** ramify upon the surface of the brain, being lodged in the sulci between the convolutions, a few running across the convolutions. They receive branches from the substance of the brain and terminate in the sinuses. They are named, from the position they occupy, superior, median, and inferior cerebral veins.

The **Superior Cerebral Veins**, eight to twelve in number on each side, return the blood from the convolutions on the superior surface of the hemisphere; they pass forward and inward toward the great longitudinal fissure, where they receive the *median cerebral veins;* near their termination they become invested with a tubular sheath of the arachnoid membrane, and open into the superior longitudinal sinus in the opposite direction to the course of the blood.

The **Median Cerebral Veins** return the blood from the convolutions of the mesial surface of the corresponding hemisphere; they open into the superior cerebral veins, or occasionally into the inferior longitudinal sinus.

The **Inferior Cerebral Veins** ramify on the lower part of the outer and on the under surface of the cerebral hemisphere. Some, collecting tributaries from the under surface of the anterior lobes of the brain, terminate in the cavernous sinus. One vein of large size, the *middle cerebral vein*, commences on the under surface

of the temporo-sphenoidal lobe, and, running along the fissure of Sylvius, opens into the cavernous sinus. Another large vein, the *great anastomotic vein of Trolard*, commences on the parietal lobe, runs along the horizontal limb of the fissure of Sylvius, and opens into the anterior part of the cavernous sinus under the lesser wing of the sphenoid. Others commence on the under surface of the base of the brain, and unite to form from three to five veins, which open into the superior petrosal and lateral sinuses from before backward.

The **Deep Cerebral, or Ventricular Veins** (*venæ Galeni*), are two in number. They are formed by the union of two veins, the *vena corporis striati*, and the *choroid vein*, on either side. They run backward, parallel with one another, between the layers of the velum interpositum, and pass out of the brain at the great transverse fissure, between the posterior extremity, or *splenium*, of the corpus callosum and the tubercula quadrigemina, to enter the straight sinus. The two veins usually unite to form one before opening into the straight sinus.

The **vena corporis striati** commences in the groove between the corpus striatum and thalamus opticus, receives numerous veins from both of these parts, and unites behind the anterior pillar of the fornix with the choroid vein to form one of the venæ Galeni.

The **choroid vein** runs along the whole length of the outer border of the choroid plexus, receiving veins from the hippocampus major, the fornix and corpus callosum, and unites, at the anterior extremity of the choroid plexus, with the vein of the corpus striatum.

The **Cerebellar Veins** occupy the surface of the cerebellum, and are disposed in three sets, superior, inferior, and lateral. The *superior* pass forward and inward across the superior vermiform process, and terminate in the straight sinus; some open into the venæ Galeni. The *inferior cerebellar veins*, of large size, run transversely outward, and terminate by two or three trunks in the lateral sinuses. The *lateral cerebellar veins* terminate in the superior petrosal sinuses.

The perivascular lymph-sheaths alluded to above (see page 87) are especially found in connection with the vessels of the brain. These vessels are enclosed in a sheath which acts as a lymphatic channel, through which the lymph is carried to the subarachnoid and subdural spaces, from which it is returned into the general circulation.

The Sinuses of the Dura Mater.

The sinuses of the dura mater are venous channels, analogous to the veins, their outer coat being formed by the dura mater; their inner, by a continuation of the lining membrane of the veins. They are fifteen in number, and are divided into two sets: 1, those situated at the upper and back part of the skull; 2, those at the base of the skull. The former are—the

Superior Longitudinal.	Straight Sinus.
Inferior Longitudinal.	Lateral Sinuses.
Occipital Sinus.	

The **Superior Longitudinal Sinus** occupies the attached margin of the falx cerebri. Commencing at the foramen cæcum, through which it constantly communicates by a small branch with the veins of the nasal fossæ, it runs from before backward, grooving the inner surface of the frontal, the adjacent margins of the two parietal, and the superior division of the crucial ridge of the occipital bone, and terminates by opening into the torcular Herophili. The sinus is triangular in form, narrow in front, and gradually increasing in size as it passes backward. On examining its inner surface it presents the internal openings of the superior cerebral veins, which run, for the most part, from behind forward, and open chiefly at the back part of the sinus, their orifices being concealed by fibrous folds; numerous fibrous bands (*chordæ Willisii*) are also seen, extending transversely across the inferior angle of the sinus; and, lastly, some small, white, projecting bodies, the *glandulæ Pacchioni*. This sinus receives the superior cerebral veins, numerous veins from the diploë and dura mater, and, at the posterior extremity

of the sagittal suture, veins from the pericranium, which pass through the parietal foramen.

The *torcular Herophili* is the dilated extremity of the superior longitudinal sinus. It is of irregular form, and is lodged on one side (generally the right) of the internal occipital protuberance. From it the lateral sinus of the side to which it is deflected is derived. It receives also the blood from the occipital sinus.

The **Inferior Longitudinal Sinus,** more correctly described as the *inferior longitudinal vein*, is contained in the posterior part of the free margin of the falx cerebri. It is of a cylindrical form, increases in size as it passes backward, and terminates in the straight sinus. It receives several veins from the falx cerebri, and occasionally a few from the mesial surface of the hemispheres.

The **Straight Sinus** is situated at the line of junction of the falx cerebri with the tentorium. It is triangular in form, increases in size as it proceeds backward, and runs obliquely downward and backward from the termination of the inferior longitudinal sinus to the lateral sinus of the opposite side to that into which the superior longitudinal sinus is prolonged. It communicates by a cross branch

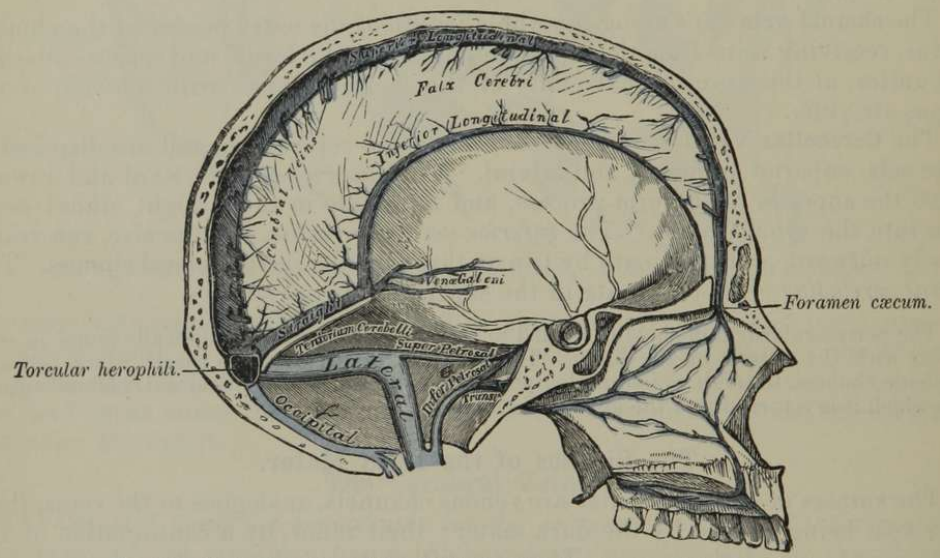

FIG. 383.—Vertical section of the skull, showing the sinuses of the dura mater.

with the torcular Herophili. Beside the inferior longitudinal sinus, it receives the venæ Galeni and the superior cerebellar veins. A few transverse bands cross its interior.

The **Lateral Sinuses** are of large size, and are situated in the attached margin of the tentorium cerebelli. They commence at the internal occipital protuberance, the one, generally the right, being the direct continuation of the superior longitudinal sinus, the other of the straight sinus. They pass horizontally outward to the base of the petrous portion of the temporal bone, then curve downward and inward on each side to reach the jugular foramen, where they terminate in the internal jugular vein. Each sinus rests, in its course, upon the inner surface of the occipital, the posterior inferior angle of the parietal, the mastoid portion of the temporal, and on the occipital, again just before its termination. These sinuses are frequently of unequal size, that formed by the superior longitudinal sinus being the larger, and they increase in size as they proceed from behind forward. The horizontal portion is of a triangular form, the curved portion semicylindrical. Their inner surface is smooth, and not crossed by the fibrous bands found in the other sinuses. These sinuses receive the blood from the superior petrosal sinuses at the base of the petrous portion of the temporal bone, and they unite with the inferior petrosal sinus, just external to the jugular foramen, to form the internal

jugular vein (Fig. 386). They communicate with the veins of the pericranium by means of the mastoid and posterior condyloid veins, and they receive some of the inferior cerebral and inferior cerebellar veins and some veins from the diploë.

The **Occipital** is the smallest of the cranial sinuses. It is generally single, but occasionally there are two. It is situated in the attached margin of the falx cerebelli. It commences by several small veins around the margin of the foramen magnum, one of which joins the termination of the lateral sinus; it communicates with the posterior spinal veins and terminates in the torcular Herophili.

The sinuses at the base of the skull are—the

Cavernous.	Superior Petrosal.
Circular.	Inferior Petrosal.
Transverse.	

The **Cavernous Sinuses** are named from their presenting a reticulated structure. They are two in number, of large size, and placed one on each side of the sella

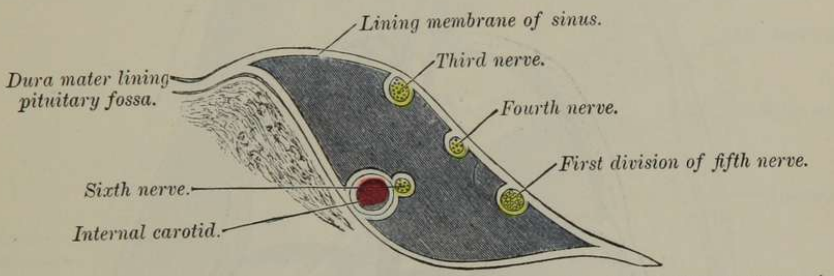

FIG. 384.—Plan showing the relative position of the structures in the right cavernous sinus, viewed from behind.

turcica, extending from the sphenoidal fissure to the apex of the petrous portion of the temporal bone; they receive anteriorly the ophthalmic vein through the sphenoidal fissure, and open behind into the petrosal sinuses. On the inner wall of each sinus is found the internal carotid artery, accompanied by filaments of the carotid plexus and by the sixth nerve; and on its outer wall, the third, fourth, and ophthalmic division of the fifth nerve. These parts are separated from the blood flowing along the sinus by the lining membrane, which is continuous with the inner coat of the veins. The cavity of the sinus, which is larger behind than in front, is intersected by filaments of fibrous tissue and small vessels. The cavernous sinuses receive some of the cerebral veins; they communicate with the lateral sinuses by means of the superior and inferior petrosal, and with the facial vein through the ophthalmic. They also communicate with each other by means of the circular sinus.

Surgical Anatomy.—An arterio-venous communication may be established between the cavernous sinus and the carotid artery, as it lies in it, giving rise to a pulsating tumor in the orbit. These communications may be the result of injury, such as a bullet wound, a stab, or a blow or fall sufficiently severe to cause a fracture of the base of the skull in this situation, or they may occur idiopathically from the rupture of an aneurism or a diseased condition of the internal carotid artery. The disease begins with sudden noise and pain in the head, followed by exophthalmos, and development of a pulsating tumor at the margin of the orbit, with thrill and the characteristic bruit. In some cases the opposite orbit becomes affected by the passage of the arterial blood into the opposite sinus by means of the circular sinus. Or the arterial blood may find its way through the emissary veins (see page 663) into the pterygoid plexus, and thence into the veins of the face. Pulsating tumors of the orbit may also be due to traumatic aneurism of one of the orbital arteries, and symptoms resembling those of pulsating tumor may be produced by pressure on the ophthalmic vein, as it enters the sinus, by an aneurism of the internal carotid artery.

The **ophthalmic** is a large vein which connects the angular vein at the inner angle of the orbit with the cavernous sinus; it pursues the same course as the ophthalmic artery, and receives tributaries corresponding to the branches derived from that vessel. Forming a short single trunk, it passes through

the inner extremity of the sphenoidal fissure and terminates in the cavernous sinus.

The Inferior Ophthalmic Vein.—Sometimes the veins from the floor of the orbit collect into a separate trunk, the *inferior ophthalmic vein*, which either passes out of the orbit through the spheno-maxillary fissure to join the pterygoid plexus of veins, or else, passing backward through the sphenoidal fissure, it enters the cavernous sinus, either by a separate opening or in common with the ophthalmic vein.

The **Circular Sinus** is formed by two transverse vessels which connect together the two cavernous sinuses, the one passing in front and the other behind the pituitary body, and thus forming with the cavernous sinuses a venous circle around the body. The anterior one is usually the larger of the two, and one or other is occasionally found to be absent.

The **Superior Petrosal Sinus** is situated along the superior border of the petrous portion of the temporal bone, in the front part of the attached margin of the tentorium. It is small and narrow, and connects together the cavernous

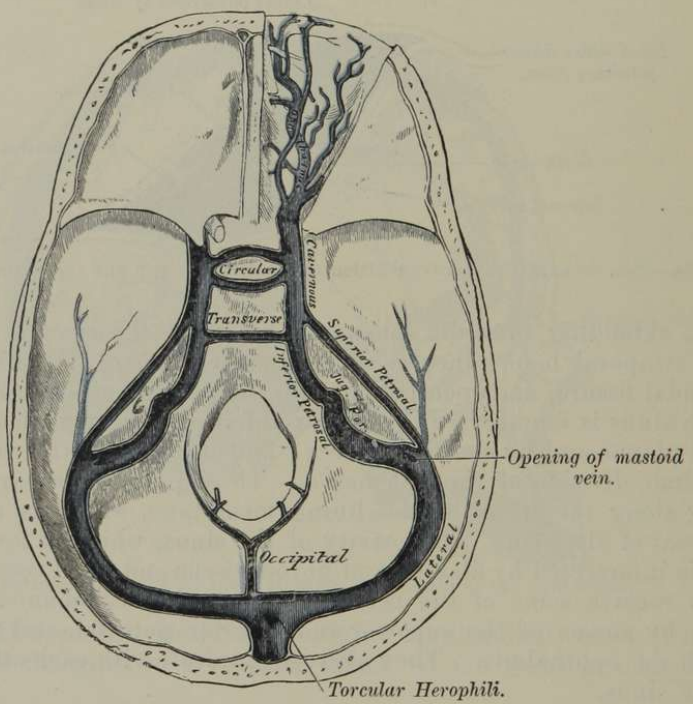

FIG. 385.—The sinuses at the base of the skull.

and lateral sinuses at each side. It receives a cerebellar vein (*anterior lateral cerebellar*) from the anterior border of the cerebellum, and a vein from the internal ear.

The **Inferior Petrosal Sinus** is situated in the groove formed by the junction of the posterior border of the petrous portion of the temporal with the basilar process of the occipital. It commences in front at the termination of the cavernous sinus, and behind joins the lateral sinus after it has passed through the jugular foramen, the junction of these two sinuses forming the commencement of the internal jugular vein.

The junction of the two sinuses takes place at the lower border of, or just external to, the jugular foramen. The exact relation of the parts to one another in the foramen is as follows: The inferior petrosal sinus is in front, with the meningeal branch of the ascending pharyngeal artery, and is directed obliquely downward and backward; the lateral sinus is situated at the back part of the fora-

men with a meningeal branch of the occipital artery, and between the two are the glosso-pharyngeal, pneumogastric, and spinal accessory nerves. These three sets of structures are divided from each other by two processes of fibrous tissue. The junction of the sinuses takes place superficial to the nerves, so that these latter lie a little internal to the venous channels in the foramen (see Fig. 386). These sinuses are semicylindrical in form.

The **Transverse Sinus**, or **basilar sinus**, consists of several interlacing veins between the layers of the dura mater over the basilar process of the occipital bone, which serve to connect the two inferior petrosal sinuses. With them the anterior spinal veins communicate.

Emissary Veins.—The emissary veins are vessels which pass through apertures

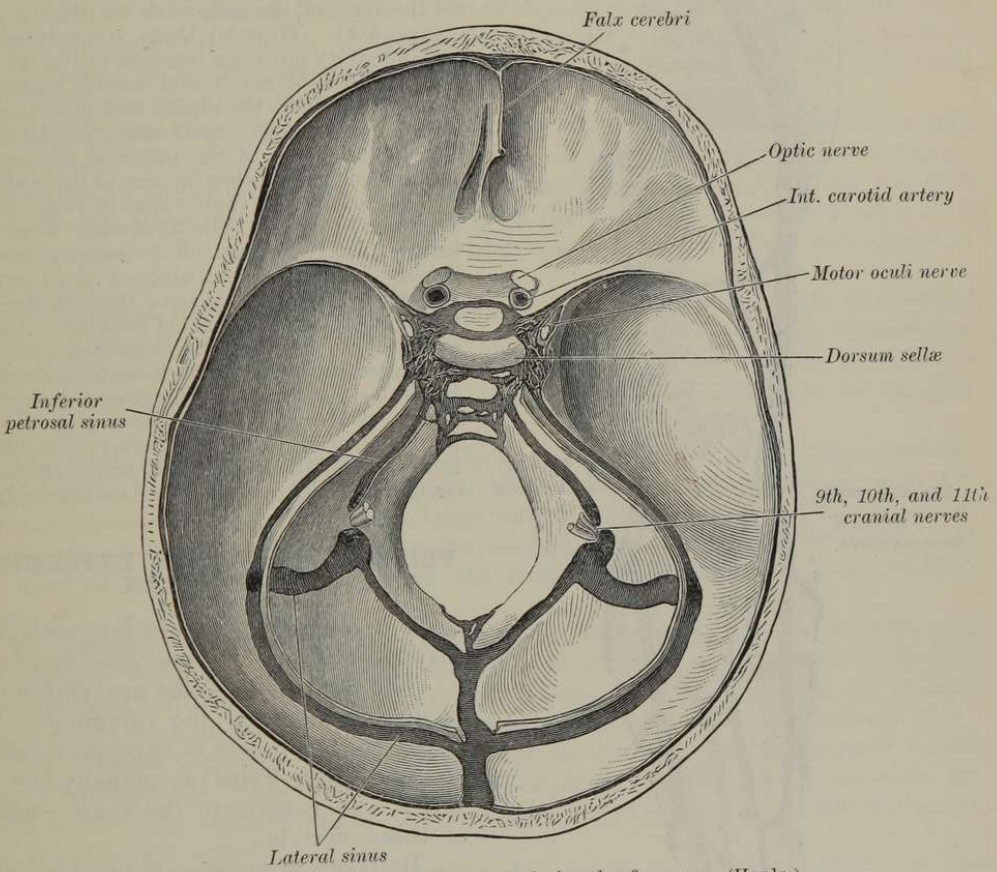

FIG. 386.—Relation of nerves to sinuses in jugular foramen. (Henle.)

in the cranial wall and establish communications between the sinuses inside the skull and the veins external to it. Some of these are always present, others only occasionally so. They vary much in size in different individuals. The principal emissary veins are the following: 1. A vein, almost always present, which passes through the mastoid foramen and connects the lateral sinus with the posterior auricular or with an occipital vein. 2. A vein which passes through the parietal foramen and connects the superior longitudinal sinus with the veins of the scalp. 3. A plexus of minute veins which pass through the anterior condyloid foramen and connect the occipital sinus with the vertebral vein and deep veins of the neck. 4. An inconstant vein which passes through the posterior condyloid foramen and connects the lateral sinus with the deep veins of the neck. 5. One or two veins of considerable size which pass through the foramen ovale and connect the cavernous sinus with the pterygoid and pharyngeal plexuses. 6. Two or three small veins which pass through the foramen lacerum medium and connect the cavernous sinus with the pterygoid and pharyngeal plexuses. 7. There is sometimes a small

vein passing through the foramen of Vesalius connecting the same parts. 8. A plexus of veins passing through the carotid canal and connecting the cavernous sinus with the internal jugular vein.

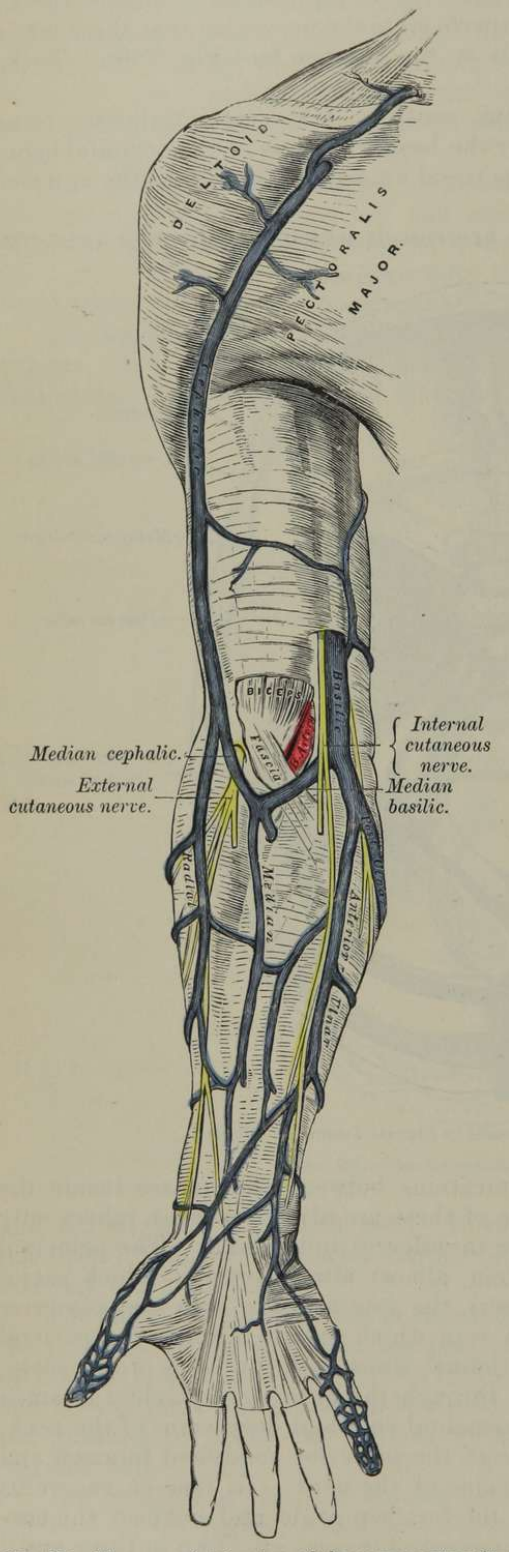

FIG. 387.—The superficial veins of the upper extremity.

Surgical Anatomy.—These emissary veins are of great importance in surgery. In addition to them there are, however, other communications between the intra- and extra-cranial circulation, as, for instance, the communication of the angular and supra-orbital veins with the ophthalmic vein at the inner angle of the orbit (page 653), and the communication of the veins of the scalp with the diploic veins (page 658). Through these communications inflammatory processes commencing on the outside of the skull may travel inward, leading to osteo-phlebitis of the diploë and inflammation of the membranes of the brain. To this must be attributed one of the principal dangers of scalp wounds and other injuries of the scalp.

By means of these emissary veins blood may be abstracted almost directly from the intracranial circulation. For instance, leeches applied behind the ear abstract blood almost directly from the lateral sinus through the vein passing through the mastoid foramen. Again, epistaxis in children will frequently relieve severe headache, the blood which flows from the nose being derived from the longitudinal sinus by means of the vein which passes through the foramen cæcum, which is another communication between the intracranial and extracranial circulation which is constantly found in children.

VEINS OF THE UPPER EXTREMITY AND THORAX.

The veins of the Upper Extremity are divided into two sets, *superficial* and *deep*.

The **Superficial Veins** are placed immediately beneath the integument between the two layers of superficial fascia.

The **Deep Veins** accompany the arteries, and constitute the venæ comites of those vessels.

Both sets of vessels are provided with valves, which are more numerous in the deep than in the superficial.

The superficial veins of the upper extremity are—the

Superficial veins of the Hand.
Anterior Ulnar.
Posterior Ulnar.
Common Ulnar.
Radial.
Median.
Median Basilic.
Median Cephalic.
Basilic.
Cephalic.

The **Superficial Veins of the Hand and Fingers** are principally situated on the

dorsal surface, and form two plexuses, an inner and outer, on the back of the hand. The inner plexus is formed by the veins from the little finger (*vena salvatella*), the ring finger, and the ulnar side of the middle finger; from it the anterior and posterior ulnar veins are derived. The outer plexus is formed by veins from the thumb, the index finger, and radial side of the middle finger; from it the radial vein is derived. These two plexuses communicate on the back of the hand, forming the superficial arch of veins in this situation. The superficial veins from the palm of the hand form a plexus in front of the wrist, from which the median vein is derived.

The **Anterior Ulnar Vein** commences on the anterior surface of the ulnar side of the hand and wrist, and ascends along the anterior surface of the ulnar side of the forearm to the bend of the elbow, where it joins with the posterior ulnar vein to form the common ulnar. Occasionally it opens separately into the median basilic vein. It communicates with branches of the median vein in front and with the posterior ulnar behind.

The **Posterior Ulnar Vein** commences on the posterior surface of the ulnar side of the wrist. It runs on the posterior surface of the ulnar side of the forearm, and just below the elbow unites with the anterior ulnar vein to form the common ulnar, or else joins the median basilic to form the basilic. It communicates with the deep veins of the palm by a branch which emerges from beneath the Abductor minimi digiti muscle.

The **Common Ulnar** is a short trunk which is not constant. When it exists it is formed by the junction of the two preceding veins, and, passing upward and outward, joins the median basilic to form the basilic vein. When it does not exist the anterior and posterior ulnar veins open separately into the median basilic vein.

The **Radial Vein** commences from the dorsal surface of the wrist, communicating with the deep veins of the palm by a branch which passes through the first interosseous space. It forms a large vessel, which ascends along the radial side of the forearm and receives numerous veins from both its surfaces. At the bend of the elbow it unites with the median cephalic to form the cephalic vein.

The **Median Vein** ascends on the front of the forearm, and communicates with the anterior ulnar and radial veins. At the bend of the elbow it receives a branch of communication from the deep veins, and divides into two branches, the median cephalic and median basilic, which diverge from each other as they ascend.

The **Median Cephalic,** usually the smaller of the two, passes outward in the groove between the Supinator longus and Biceps muscles, and joins with the radial to form the cephalic vein. The branches of the external cutaneous nerve pass beneath this vessel.

The **Median Basilic Vein** passes obliquely inward, in the groove between the Biceps and Pronator radii teres, and joins the common ulnar to form the basilic. This vein passes in front of the brachial artery, from which it is separated by a fibrous expansion (the *bicipital fascia*) which is given off from the tendon of the Biceps to the fascia covering the Flexor muscles of the forearm. Filaments of the internal cutaneous nerve pass in front as well as behind this vessel.[1]

Venesection is usually performed at the bend of the elbow, and as a matter of practice the largest vein in this situation is commonly selected. This is usually the median basilic, and there are anatomical advantages and disadvantages in selecting this vein. The advantages are, that in addition to its being the largest, and therefore yielding a greater supply of blood, it is the least movable and can be easily steadied on the bicipital fascia on which it rests. The disadvantages are, that it is in close relationship with the brachial artery, separated only by the bicipital fascia; and formerly, when venesection was frequently practised, arterio-venous aneurism was

[1] Cruveilhier says: "Numerous varieties are observed in the disposition of the veins of the elbow; sometimes the common median vein is wanting; but in those cases its two branches are furnished by the radial vein, and the cephalic is almost always in a rudimentary condition. In other cases only two veins are found at the bend of the elbow, the radial and ulnar, which are continuous, without any demarcation, with the cephalic and basilic."

no uncommon result of this practice. Another disadvantage is, that the median basilic is crossed by some of the branches of the internal cutaneous nerve, and these may be divided in the operation, giving rise to "traumatic neuralgia of extreme intensity" (Tillaux).

The **Basilic Vein** is of considerable size, formed by the coalescence of the common ulnar vein with the median basilic. It passes upward along the inner side of the Biceps muscle, pierces the deep fascia a little below the middle of the arm, and, ascending in the course of the brachial artery, terminates in the axillary vein, which receives, a little higher up, the brachial venæ comites.

The **Cephalic Vein** courses along the outer border of the Biceps muscle, lying in the same groove with the upper external cutaneous branch of the musculo-spiral nerve, to the upper third of the arm; it then passes in the interval between the Pectoralis major and Deltoid muscles, lying in the same groove with the descending branch of the acromial-thoracic artery. It pierces the costo-coracoid membrane, and terminates in the axillary vein just below the clavicle. This vein is occasionally connected with the external jugular or subclavian by a branch which passes from it upward in front of the clavicle.

The **Deep Veins of the Upper Extremity** follow the course of the arteries, forming their venæ comites. They are generally two in number, one lying on each side of the corresponding artery, and they are connected at intervals by short transverse branches.

There are two digital veins accompanying each artery along the sides of the fingers: these, uniting at their base, pass along the interosseous spaces in the palm, and terminate in the two venæ comites which accompany the superficial palmar arch. Branches from these vessels on the radial side of the hand accompany the superficialis volæ, and on the ulnar side terminate in the deep ulnar veins. The deep ulnar veins, as they pass in front of the wrist, communicate with the interosseous and superficial veins, and at the elbow unite with the deep radial veins to form the venæ comites of the brachial artery.

The **Interosseous Veins** accompany the anterior and posterior interosseous arteries. The anterior interosseous veins commence in front of the wrist, where they communicate with the deep radial and ulnar veins; at the upper part of the forearm they receive the posterior interosseous veins, and terminate in the venæ comites of the ulnar artery.

The **Deep Palmar Veins** accompany the deep palmar arch, being formed by tributaries which accompany the ramifications of that vessel. They communicate with the deep ulnar veins at the inner side of the hand, and on the outer side terminate in the venæ comites of the radial artery. At the wrist they receive a dorsal and a palmar tributary from the thumb, and unite with the deep radial veins. Accompanying the radial artery, these vessels terminate in the venæ comites of the brachial artery.

The **Brachial Veins** are placed one on each side of the brachial artery, receiving tributaries corresponding with the branches given off from that vessel; just above the lower margin of the tendon of the Latissimus dorsi they empty into the axillary vein.

These deep veins have numerous anastomoses, not only with each other, but also with the superficial veins.

The **Axillary Vein** is of large size, and is the continuation of the basilic vein, receiving the venæ comites of the brachial artery. It commences at the lower part of the axillary space, increases in size as it ascends by receiving tributaries corresponding with the branches of the axillary artery, and terminates immediately beneath the clavicle at the lower border of the first rib, where it becomes the subclavian vein. This vessel is covered in front by the Pectoral muscles and costo-coracoid membrane, and lies on the thoracic side of the axillary artery, which it partially overlaps. Near its termination it receives the cephalic vein. This vein is provided with a pair of valves opposite the lower border of the Subscapularis muscle; valves are also found at the termination of the cephalic and subscapular veins.

Surgical Anatomy.—There are several points of surgical interest in connection with the axillary vein. Being more superficial, larger, and slightly overlapping the axillary artery, it is more liable to be wounded in the operation of extirpation of the axillary glands, especially as these glands, when diseased, are apt to become adherent to the vessel. When wounded there is always a danger of air being drawn into its interior, and death resulting. This is due not only to the fact that it is near the thorax, and therefore liable to be influenced by the respiratory movements, but also because it is adherent by its anterior surface to the costo-coracoid membrane, and therefore if wounded is likely to remain patulous and favor the chance of air being sucked in. This adhesion of the vein to the fascia prevents its collapsing, and therefore favors the furious bleeding which takes place in these cases.

To avoid wounding the axillary vein in the extirpation of cancerous glands from the axilla, no sharp cutting instruments should be used after the axillary cavity has been freely exposed, and care should be taken to use no undue force in isolating the glands. Should the vein be so imbedded in the malignant deposit that the latter cannot be removed without taking away a part of the vein, this must be done, the vessel having been first ligatured above and below.

The **Subclavian Vein,** the continuation of the axillary, extends from the lower border of the first rib to the inner end of the sterno-clavicular articulation, where it unites with the internal jugular to form the innominate vein. It is in relation, in front, with the clavicle and Subclavius muscle; behind, with the subclavian artery, from which it is separated internally by the Scalenus anticus muscle and phrenic nerve. Below, it rests in a depression on the first rib and upon the pleura. Above, it is covered by the cervical fascia and integument.

The subclavian vein occasionally rises in the neck to a level with the third part of the subclavian artery, and in two instances has been seen passing with this vessel behind the Scalenus anticus. This vessel is usually provided with valves about an inch from its termination in the innominate, just external to the entrance of the external jugular vein.

Tributaries.—It receives the external and anterior jugular veins and a small branch from the cephalic, outside the Scalenus, and on the inner side of that muscle the internal jugular vein. At the angle of junction with the internal jugular the left subclavian vein receives the thoracic duct, while the right subclavian vein receives the right lymphatic duct.

The **Innominate** or **Brachio-cephalic Veins** (Fig. 388) are two large trunks, placed one on each side of the root of the neck, and formed by the union of the internal jugular and subclavian veins of the corresponding side.

The **Right Innominate Vein** is a short vessel, an inch in length, which commences at the inner end of the clavicle, and, passing almost vertically downward, joins with the left innominate vein just below the cartilage of the first rib, close to the right border of the sternum, to form the superior vena cava. It lies superficial and external to the innominate artery; on its right side the pleura is interposed between it and the apex of the lung. This vein, at the angle of junction of the internal jugular with the subclavian, receives the right vertebral vein, and, lower down, the right internal mammary, right inferior thyroid, and sometimes the right superior intercostal veins.

The **Left Innominate Vein,** about two and a half inches in length, and larger than the right, passes from left to right across the upper and front part of the chest, at the same time inclining downward, to unite with its fellow of the opposite side, forming the *superior vena cava.* It is in relation, in front, with the first piece of the sternum, from which it is separated by the Sterno-hyoid and Sterno-thyroid muscles, the thymus gland or its remains, and some loose areolar tissue. Behind, it lies across the roots of the three large arteries arising from the arch of the aorta. This vessel is joined by the left vertebral, left internal mammary, left inferior thyroid, and the left superior intercostal veins, and occasionally some thymic and pericardiac veins. There are no valves in the innominate veins.

Peculiarities.—Sometimes the innominate veins open separately into the right auricle; in such cases the right vein takes the ordinary course of the superior vena cava; but the left vein, after communicating by a small branch with the right one, passes in front of the root of the left lung, and, turning to the back of the heart, receives the cardiac veins and terminates in the back of the right auricle. This occasional condition of the veins in the adult is a regular one in the fœtus at an early period, and the two vessels are persistent in birds and some mammalia. The

subsequent changes which take place in these vessels are the following: The communicating branch between the two trunks enlarges and forms the future left innominate vein; the remaining part of the left trunk is obliterated as far as the heart, where it remains pervious and forms the coronary sinus: a remnant of the obliterated vessel is seen in adult life as a fibrous band passing along the back of the left auricle and in front of the root of the left lung, called by Mr. Marshall the *vestigial fold of the pericardium.*

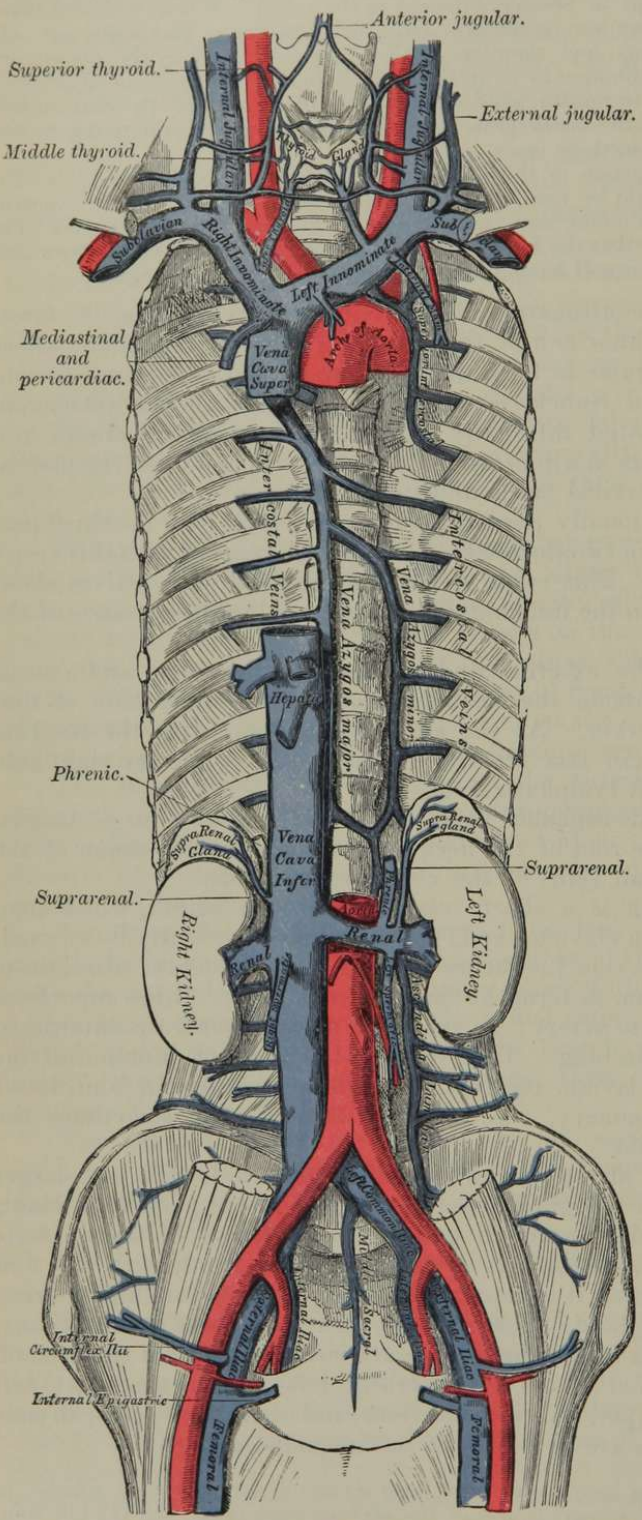

FIG. 388.—The venæ cavæ and azygos veins, with their formative branches.

The **internal mammary veins,** two in number to each artery, follow the course of that vessel, and receive corresponding branches. The two veins of each side unite into a single trunk, which terminates in the corresponding innominate vein.

The **inferior thyroid veins,** two, frequently three or four, in number, arise in the venous plexus on the thyroid body, communicating with the middle and superior thyroid veins. The left one descends in front of the trachea behind the Sterno-thyroid muscle, communicating with its fellow by transverse branches, and terminates in the left innominate vein. The right one, which is placed a little to the right of the median line, opens into the right innominate vein just at its junction with the superior vena cava. These veins receive œsophageal, tracheal, and inferior laryngeal veins, and are provided with valves at their termination in the innominate veins.

The **Superior Intercostal Veins** return the blood from the upper intercostal spaces, below the first.

The *right superior intercostal,* much smaller than the left, closely corresponds with the superior intercostal artery, receiving the blood from the second or second and third intercostal spaces, and, passing down-

ward, terminates in the vena azygos major. Occasionally it opens into the right innominate vein.

The *left superior intercostal* is always larger than the right, but varies in size in different subjects, being small when the left upper azygos vein is large, and *vice versâ*. It is usually formed by branches from two or three upper intercostal spaces below the first, and, passing across the arch of the aorta, terminates in the left innominate vein. The left bronchial vein and the left superior phrenic open into it.

The **Superior Vena Cava** receives the blood which is conveyed to the heart from the whole of the upper half of the body. It is a short trunk, varying from two inches and a half to three inches in length, formed by the junction of the two innominate veins. It commences immediately below the cartilage of the first rib close to the sternum on the right side, and, descending vertically, enters the pericardium about an inch and a half above the heart, and terminates in the upper part of the right auricle opposite the upper border of the third left costal cartilage. In its course it describes a slight curve, the convexity of which is turned to the right side.

Relations.—*In front*, with the pericardium and process of cervical fascia which is continuous with it: this separates it from the thymus gland and from the sternum; *behind*, with the root of the right lung; on its *right side*, with the phrenic nerve and right pleura; on its *left side*, with the commencement of the innominate artery and ascending part of the aorta. The portion contained within the pericardium is covered by the serous layer of that membrane in its anterior three-fourths. It receives the vena azygos major just before it enters the pericardium, and several small veins from the pericardium and parts in the mediastinum. The superior vena cava has no valves.

The **Azygos Veins** connect together the superior and inferior venæ cavæ, taking the place of those vessels in that part of the chest occupied by the heart.

The larger, or *right azygos vein* (vena azygos major), commences opposite the first or second lumbar vertebra by a branch from the right lumbar veins (the *ascending lumbar*); sometimes by a branch from the right renal vein or from the inferior vena cava. It enters the thorax through the aortic opening in the Diaphragm, and passes along the right side of the vertebral column to the fourth dorsal vertebra, where it arches forward over the root of the right lung, and terminates in the superior vena cava just before that vessel enters the pericardium. Whilst passing through the aortic opening of the Diaphragm it lies with the thoracic duct on the right side of the aorta, and in the thorax it lies upon the intercostal arteries on the right side of the aorta and thoracic duct, and is partly covered by pleura.

Tributaries.—It receives, excepting those of the first three spaces, the intercostal veins of the right side, the vena azygos minor, the left upper azygos vein, several œsophageal, mediastinal, and pericardial veins; near its termination, the right bronchial vein; and generally the right superior intercostal vein. A few imperfect valves are found in this vein, but its tributaries are provided with complete valves.

The intercostal veins on the left side, below the two or three upper intercostal spaces, form two trunks, named the left lower and the left upper azygos veins.

The *left lower*, or *smaller azygos vein* (vena azygos minor), commences in the lumbar region by a branch from one of the lumbar veins (*ascending lumbar*) or from the left renal. It passes into the thorax through the left crus of the Diaphragm, and, ascending on the left side of the spine as high as the seventh or eighth dorsal vertebra, passes across the column, behind the aorta and thoracic duct, to terminate in the right azygos vein. It receives the four or five lower intercostal veins of the left side, and some œsophageal and mediastinal veins.

The *left upper azygos vein* varies according to the size of the left superior intercostal, with which it communicates above. It receives veins from the intercostal spaces between the left superior intercostal vein and highest tributary of the left lower azygos. They are usually two or three in number,

and join to form a trunk which ends in the right azygos vein or in the left lower azygos. It sometimes receives the left bronchial vein. When this vein is small or altogether wanting, the left superior intercostal vein will extend as low as the fifth or sixth intercostal space.[1]

Surgical Anatomy.—In obstruction of the superior vena cava the azygos veins are one of the principal means by which the venous circulation is carried on, connecting as they do the superior and inferior venæ cavæ, and communicating with the common iliac veins by the ascending lumbar veins, and with many of the tributaries of the inferior vena cava.

The *bronchial veins* return the blood from the substance of the lungs; that of the right side opens into the vena azygos major near its termination; that of the left side, into the left superior intercostal vein or left upper azygos vein.

THE SPINAL VEINS.

The numerous venous plexuses placed upon and within the spine may be arranged into four sets:

1. Those placed on the exterior of the spinal column (the *dorsi-spinal veins*).
2. Those situated in the interior of the spinal canal, between the vertebræ and the theca vertebralis (*meningo-rachidian veins*).
3. The veins of the bodies of the vertebræ (*venæ basis vertebrarum*).
4. The veins of the spinal cord (*medulli-spinal*).

1. The **Dorsi-spinal Veins** commence by small branches which receive their

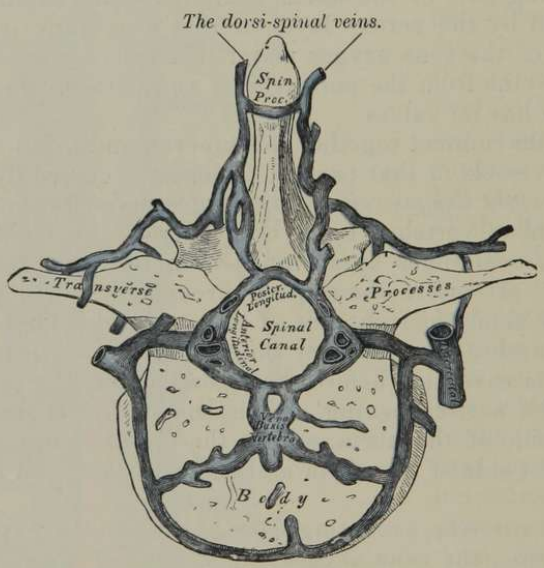

FIG. 389.—Transverse section of a dorsal vertebra, showing the spinal veins.

blood from the integument of the back of the spine and from the muscles in the vertebral grooves. They form a complicated network, which surrounds the spinous processes, the laminæ, and the transverse and articular processes of all the vertebræ. At the bases of the transverse processes they communicate, by means of ascending and descending branches, with the veins surrounding the contiguous vertebræ, and they join with the veins in the spinal canal by branches which perforate the ligamenta subflava. Other branches pass obliquely forward, between the transverse processes, and communicate with the intraspinal veins through the intervertebral foramina. They terminate by joining the vertebral

[1] For an account of the arrangement of the azygos and superior intercostal veins in a number of consecutive cases from the same dissecting-room, see a paper by Mr. B. G. Morison (*Journal of Anatomy and Physiology*, vol. xiii. p. 346). The most important difference between his description and that in the text is, that he always found two superior intercostal veins on both sides, the vein from the first space being separate, and joining the corresponding innominate vein. The lower (and larger) superior intercostal vein he describes as opening into the azygos on the right and innominate on the left side.

veins in the neck, the intercostal veins in the thorax, and the lumbar and sacral veins in the loins and pelvis.

2. **The Meningo-rachidian Veins.**—The principal veins contained in the spinal canal are situated between the theca vertebralis and the vertebræ. They consist of two longitudinal plexuses, one of which runs along the posterior surface of the bodies of the vertebræ (*anterior longitudinal spinal veins*). The other plexus (*posterior longitudinal spinal veins*) is placed on the inner or anterior surface of the laminæ of the vertebræ.

The *Anterior Longitudinal Spinal Veins* consist of two large, tortuous veins which extend along the whole length of the vertebral column, from the foramen magnum where they communicate by a venous ring around that opening, to the base of the coccyx, being placed one on each side of the posterior surface of the bodies of the vertebræ along the margin of the posterior common ligament. These veins communicate together opposite each vertebra by transverse trunks which pass beneath the ligament, and receive the large *venæ basis vertebrarum* from the interior of the body of each vertebra. The anterior longitudinal spinal veins are least developed in the cervical and sacral regions. They are not of

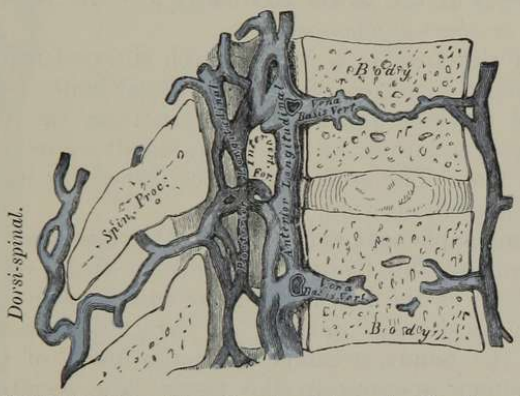

FIG. 390.—Vertical section of two dorsal vertebræ, showing the spinal veins.

uniform size throughout, being alternately enlarged and constricted. At the intervertebral foramina they communicate with the dorsi-spinal veins, and with the vertebral veins in the neck, with the intercostal veins in the dorsal region, and with the lumbar and sacral veins in the corresponding regions.

The *Posterior Longitudinal Spinal Veins*, smaller than the anterior, are situated one on each side, between the inner surface of the laminæ and the theca vertebralis. They communicate (like the anterior) opposite each vertebra by transverse trunks, and with the anterior longitudinal veins by lateral transverse branches which pass from behind forward. These veins, by branches which perforate the ligamenta subflava, join with the dorsi-spinal veins. From them branches are given off which pass through the intervertebral foramina and join the vertebral, intercostal, lumbar, and sacral veins.

3. The **Veins of the Bodies of the Vertebræ** (*venæ basis vertebrarum*) emerge from the foramina on their posterior surface, and join the transverse trunk connecting the anterior longitudinal spinal veins. They are contained in large, tortuous channels in the substance of the bones, similar in every respect to those found in the diploë of the cranial bones. These canals lie parallel to the upper and lower surface of the bones. They commence by small openings on the front and sides of the bodies of the vertebræ, through which communicating branches from the veins external to the bone pass into its substance, and converge to the principal canal, which is sometimes double toward its posterior part, and open into the corresponding transverse branch uniting the anterior longitudinal veins. They become greatly developed in advanced age.

4. The **Veins of the Spinal Cord** (*medulli-spinal*) consist of a minute, tortuous,

venous plexus which covers the entire surface of the cord, being situated between the pia mater and arachnoid. These vessels emerge chiefly from the median furrows, and are largest in the lumbar region. Near the base of the skull they unite and form two or three small trunks, which communicate with the vertebral veins, and then terminate in the inferior cerebellar veins or in the inferior petrosal sinuses. Each of the spinal nerves is accompanied by a branch as far as the intervertebral foramina, where they join the other veins from the spinal canal.

There are no valves in the spinal veins.

VEINS OF THE LOWER EXTREMITY, ABDOMEN, AND PELVIS.

The Veins of the Lower Extremity are subdivided, like those of the upper, into two sets, superficial and deep, the superficial veins being placed beneath the integument, between the two layers of superficial fascia, the deep veins accompanying the arteries and forming the venæ comites of those vessels. Both sets of veins are provided with valves, which are more numerous in the deep than in the superficial set. These valves are also more numerous in the lower than in the upper limb.

The **Superficial Veins of the Lower Extremity** are the *internal* or *long saphenous* and the *external* or *short saphenous*.

On the dorsum of the foot is a venous arch situated in the superficial structures over the anterior extremities of the metatarsal bones. It has its convexity directed forward, and receives digital tributaries from the upper surface of the toes; at its concavity it is joined by numerous small veins which form a plexus on the dorsum of the foot. The arch terminates internally in the long saphenous, externally in a short saphenous vein.

The **internal** or **long saphenous vein** (Fig. 391) commences at the inner side of the arch on the dorsum of the foot; it ascends in front of the inner malleolus and along the inner side of the leg, behind the inner margin of the tibia, accompanied by the internal saphenous nerve. At the knee it passes backward behind the inner condyle of the femur, ascends along the inside of the thigh, and, passing through the saphenous opening in the fascia lata, terminates in the femoral vein about an inch and a half below Poupart's ligament. This vein receives in its course cutaneous tributaries from the leg and thigh, and at the saphenous opening the superficial epigastric, superficial circumflex iliac, and external pudic veins. The veins from the inner and back part of the thigh frequently unite to form a large vessel, which enters the main trunk near the saphenous opening; and sometimes those on the outer side of the thigh join to form another large vessel; so that occasionally three large veins are seen converging from different parts of the thigh toward the saphenous opening. The internal saphenous vein communicates in the foot with the internal plantar vein; in the leg, with the posterior tibial veins by branches which perforate the tibial origin of the Soleus muscle, and also with the anterior tibial veins; at the knee, with the articular veins; in the thigh, with the femoral vein by one or more branches. The valves in this vein vary from two to six in number; they are more numerous in the thigh than in the leg.

The **external** or **short saphenous vein** (Fig. 392) commences at the outer side of the arch on the dorsum of the foot; it ascends behind the outer malleolus, and along the outer border of the tendo Achillis, across which it passes at an acute angle to reach the middle line of the posterior aspect of the leg. Passing directly upward, it perforates the deep fascia in the lower part of the popliteal space, and terminates in the popliteal vein, between the heads of the Gastrocnemius muscle.[1] It receives numerous large tributaries from the back part of

[1] Mr. Gay calls attention to the fact that the external saphenous vein often (he says invariably) penetrates the fascia at or about the point where the tendon of the Gastrocnemius commences, and runs below the fascia in the rest of its course, or sometimes among the muscular fibres, to join the popliteal vein. (See Gay on *Varicose Disease of the Lower Extremities*, p. 24, where there is also a careful and elaborate description of the branches of the saphena veins.)

the leg, and communicates with the deep veins on the dorsum of the foot and behind the outer malleolus. Before it perforates the deep fascia it gives off a communicating branch, which passes upward and inward to join the internal saphenous vein. This vein has a variable number of valves, from three to nine (Gay), one of which is always found near its termination in the popliteal vein. The external saphenous nerve lies close beside this vein.

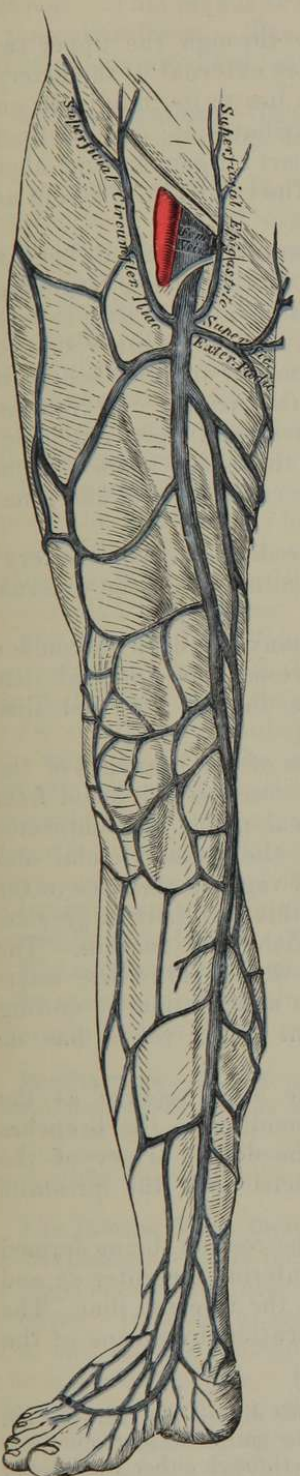

FIG. 391.—The internal or long saphenous vein and its branches.

Surgical Anatomy.—The saphena veins are of considerable surgical importance, since a varicose condition of these vessels is more frequently met with than of those in other parts of the body, except perhaps the spermatic and hæmorrhoidal veins. The course of the internal saphenous is in front of the tip of the malleolus, over the subcutaneous surface of the lower end of the tibia, and then along the internal border of this bone to the back part of the internal condyle of the femur, whence it follows the course of the Sartorius muscle, and is represented on the surface by a line drawn from the posterior border of the Sartorius on a level with the internal condyle to the saphenous opening. The short saphenous lies behind the external malleolus, and from this follows the middle line of the calf to just below the ham. It is not generally so apparent beneath the skin as the internal saphenous. Both these veins in the leg are accompanied by nerves, the internal saphenous being joined by its companion nerve just below the level of the knee-joint. No doubt much of the pain of varicose veins in the leg is due to this fact. On the Continent the internal saphenous vein as it rests on the tibia just above the malleolus is sometimes selected for venesection.

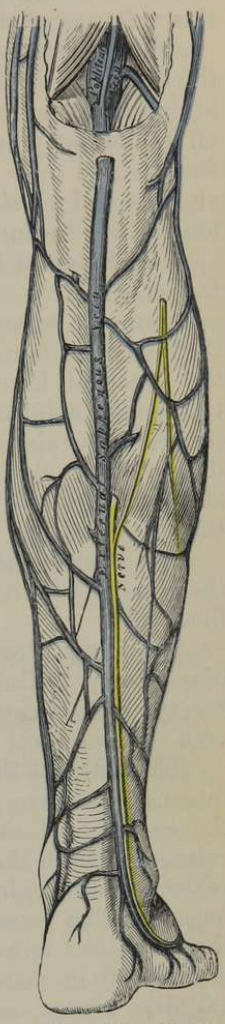

FIG. 392.—External or short saphenous vein.

The **Deep Veins of the Lower Extremity** accompany the arteries and their branches, and are called the *venæ comites* of those vessels.

The **external** and **internal plantar veins** unite to form the **posterior tibial.** They accompany the posterior tibial artery and are joined by the *peroneal veins.*

The **anterior tibial veins** are formed by a continuation upward of the venæ comites of the dorsalis pedis artery. They pass between the tibia and fibula, through the large oval aperture above the interosseous membrane, and form, by their junction with the posterior tibial, the popliteal vein.

The valves in the deep veins are very numerous.

The **Popliteal Vein** is formed by the junction of the venæ comites of the anterior and posterior tibial vessels; it ascends through the popliteal space to the tendinous aperture in the Adductor magnus, where it becomes the femoral vein. In the lower part of its course it is placed internal to the artery; between the

heads of the Gastrocnemius it is superficial to that vessel; but above the knee-joint it is close to its outer side. It receives the sural veins from the Gastrocnemius muscle, the articular veins, and the external saphenous. The valves in this vein are usually four in number.

The **Femoral Vein** accompanies the femoral artery through the upper two-thirds of the thigh. In the lower part of its course it lies external to the artery; higher up it is behind it; and at Poupart's ligament it lies to its inner side and on the same plane. It receives numerous muscular tributaries: the profunda femoris and deep external pudic veins join it near Poupart's ligament and about an inch and a half below the internal saphenous vein. The valves in this vein are four or five in number.

The **External Iliac Vein** commences at the termination of the femoral, beneath the crural arch, and, passing upward along the brim of the pelvis, terminates opposite the sacro-iliac synchondrosis by uniting with the internal iliac to form the common iliac vein. On the right side it lies at first along the inner side of the external iliac artery, but as it passes upward gradually inclines behind it. On the left side it lies altogether on the inner side of the artery. It receives, immediately above Poupart's ligament, the deep epigastric and deep circumflex iliac veins and a small pubic vein, corresponding to the pubic branch of the obturator artery. According to Friedreich, it frequently contains one, and sometimes two valves.

The Deep Epigastric Veins.—Two veins accompany the deep epigastric artery; they usually unite into a single trunk before their termination in the external iliac vein.

The Deep Circumflex Iliac Veins.—Two veins accompany the deep circumflex iliac artery. These unite into a single trunk which crosses the external iliac artery just above Poupart's ligament and terminates in the external iliac vein.

The **Internal Iliac Vein** is formed by the venæ comites of the branches of the internal iliac artery, the umbilical arteries excepted. It receives the blood from the exterior of the pelvis by the gluteal, sciatic, internal pudic, and obturator veins, and from the organs in the cavity of the pelvis by the hæmorrhoidal and vesico-prostatic plexuses in the male, and the uterine and vaginal plexuses in the female. The vessels forming these plexuses are remarkable for their large size, their frequent anastomoses, and the number of valves which they contain. The internal iliac vein lies at first on the inner side, and then behind the internal iliac artery, and terminates opposite the sacro-iliac articulation by uniting with the external iliac to form the common iliac vein. This vessel has no valves.

The **internal pudic veins** (*venæ comites*) have the same course as the internal pudic artery. They receive tributaries corresponding to the branches of the artery, except the tributary corresponding to the dorsal artery of the penis; that is, the dorsal vein of the penis, which opens into the prostatic plexus.

The **hæmorrhoidal plexus** surrounds the lower end of the rectum, being formed by the superior hæmorrhoidal veins (tributaries of the inferior mesenteric), and the middle and inferior hæmorrhoidal, which terminate in the internal iliac. The portal and general venous systems have a free communication by means of the branches composing this plexus.

Surgical Anatomy.—The veins of this plexus are apt to become dilated and varicose and form piles. This is partly due to the free communication between the portal and systemic circulation which here exists, so that any obstruction to the flow of blood through either the inferior vena cava or its main tributaries, or through the portal vein, tends to produce passive congestion of this plexus. The condition is also partly due to the fact that the vessels are contained in very loose, lax connective tissue, so that they get less support from surrounding structures than most other veins, and are less capable of resisting increased blood-pressure. And, finally, the condition is favored by gravitation, inasmuch as the portal vein contains no valves.

The **vesico-prostatic plexus** surrounds the neck and base of the bladder and prostate gland. It communicates with the hæmorrhoidal plexus behind, and receives the dorsal vein of the penis, which enters the pelvis beneath the subpubic ligament. This plexus is supported upon the sides of the bladder by a reflection of the pelvic fascia. The veins composing it are very liable to become varicose, and often contain hard, earthy concretions, called *phleboliths.*

Surgical Anatomy.—This plexus is wounded in the lateral operation of lithotomy, and it is through it that septic matter finds its way into the general circulation after this operation.

The **dorsal vein of the penis** is a vessel of large size which returns the blood from the body of that organ. At first it consists of two branches, which are contained in the groove on the dorsum of the penis, and it receives veins from the glans, the corpus spongiosum, and numerous superficial veins; these unite near the root of the penis into a single trunk, which passes through the suspensory ligament of the penis, pierces the triangular ligament beneath the pubic arch, and divides into two branches, which enter the prostatic plexus.

The **vaginal plexus** surrounds the mucous membrane, being especially developed at the orifice of the vagina; it communicates with the vesical plexus in front, and with the hæmorrhoidal plexus behind.

The **uterine plexus** is situated along the sides and superior angles of the uterus, between the layers of the broad ligament, receiving large venous canals (the *uterine sinuses*) from the substance of the uterus. The veins composing this plexus anastomose frequently with each other and with the ovarian veins. They are not tortuous like the arteries.

The **Common Iliac Veins** are formed by the union of the external and internal iliac veins in front of the sacro-iliac articulation: passing obliquely upward toward the right side, they terminate upon the intervertebral substance between the fourth and fifth lumbar vertebræ, where the veins of the two sides unite at an acute angle to form the inferior vena cava. The *right common iliac* is shorter than the left, nearly vertical in its direction, and ascends behind and then to the outer side of its corresponding artery. The *left common iliac*, longer and more oblique in its course, is at first situated on the inner side of the corresponding artery, and then behind the right common iliac. Each common iliac receives the ilio-lumbar, and sometimes the lateral sacral, veins. The left receives, in addition, the middle sacral vein. No valves are found in these veins.

The **middle sacral veins** accompany the corresponding artery along the front of the sacrum, and terminate in the left common iliac vein; occasionally in the angle of junction of the two iliac veins.

Peculiarities.—The left common iliac vein, instead of joining with the right in its usual position, occasionally ascends on the left side of the aorta as high as the kidney, where, after receiving the left renal vein, it crosses over the aorta, and then joins with the right vein to form the vena cava. In these cases the two common iliacs are connected by a small communicating branch at the spot where they are usually united.[1]

The **Inferior Vena Cava** returns to the heart the blood from all the parts below the Diaphragm. It is formed by the junction of the two common iliac veins on the right side of the intervertebral substance between the fourth and fifth lumbar vertebræ. It passes upward along the front of the spine on the right side of the aorta, and, having reached the under surface of the liver, is contained in a groove on its posterior surface. It then perforates the central tendon of the Diaphragm, enters the pericardium, where it is covered by its serous layer, and terminates in the lower and back part of the right auricle. At its termination in the auricle it is provided with a valve, the *Eustachian*, which is of large size during fœtal life.

Relations.—*In front*, from below upward, with the mesentery, right spermatic artery, transverse portion of the duodenum, the pancreas, portal vein, and the

[1] See two cases which have been described by Mr. Walsham in the *St. Bartholomew's Hospital Reports*, vols. xvi. and xvii.

posterior surface of the liver, which partly and occasionally completely surrounds it; *behind*, with the vertebral column, the right crus of the Diaphragm, the right renal and lumbar arteries, right semilunar ganglion; on the *left side*, with the aorta.

Tributaries.—It receives in its course the following veins:

Lumbar.	Suprarenal.
Right Spermatic.	Phrenic.
Renal.	Hepatic.

Peculiarities.—*In Position.*—This vessel is sometimes placed on the left side of the aorta, as high as the left renal veins, after receiving which it crosses over to its usual position on the right side; or it may be placed altogether on the left side of the aorta, as far upward as its termination in the heart: in such cases the abdominal and thoracic viscera, together with the great vessels, are all transposed.

Point of Termination.—Occasionally the inferior vena cava joins the right azygos vein, which is then of large size. In such cases the superior cava receives the whole of the blood from the body before transmitting it to the right auricle, except the blood from the hepatic veins, which passes directly into the right auricle.

The **lumbar veins**, four in number on each side, collect the blood by dorsal tributaries from the muscles and integument of the loins and by abdominal tributaries from the walls of the abdomen, where they communicate with the epigastric veins. At the spine they receive veins from the spinal plexuses, and then pass forward, round the sides of the bodies of the vertebræ beneath the Psoas magnus, and terminate at the back part of the inferior cava. The left lumbar veins are longer than the right, and pass behind the aorta. The lumbar veins are connected together by a longitudinal vein which passes in front of the transverse processes of the lumbar vertebræ, and is called the *ascending lumbar*. It forms the most frequent origin of the corresponding vena azygos, and serves to connect the common iliac, ilio-lumbar, lumbar, and azygos veins of the corresponding side of the body.

The **spermatic veins** emerge from the back of the testis, and receive tributaries from the epididymis; they unite and form a convoluted plexus called the *spermatic plexus* (*plexus pampiniformis*), which forms the chief mass of the cord: the vessels composing this plexus are very numerous, and ascend along the cord in front of the vas deferens; below the external abdominal ring they unite to form three or four veins, which pass along the spermatic canal, and, entering the abdomen through the internal abdominal ring, coalesce to form two veins, which ascend on the Psoas muscle behind the peritoneum, lying one on each side of the spermatic artery, and unite to form a single vein, which opens on the right side into the inferior vena cava at an acute angle; on the left side into the left renal vein at a right angle. The spermatic veins are provided with valves.[1] The left spermatic vein passes behind the sigmoid flexure of the colon, and is thus exposed to pressure from the contents of that bowel.

Surgical Anatomy.—The spermatic veins are very frequently varicose, constituting the disease known as varicocele. Though it is quite possible that the originating cause of this affection may be a congenital abnormality either in the size or number of the veins of the pampiniform plexus, still it must be admitted that there are many anatomical reasons why these veins should become varicose—viz. the imperfect support afforded to them by the loose tissue of the scrotum; their great length; their vertical course; their dependent position; their plexiform arrangement in the scrotum, with their termination in one small vein in the abdomen; their few and imperfect valves; and the fact that they may be subjected to pressure in their passage through the abdominal wall.

The **ovarian veins** are analogous to the spermatic in the male; they form a plexus near the ovary and in the broad ligament and Fallopian tube, communicating with the uterine plexus. They terminate in the same way as the spermatic veins in the male. Valves are occasionally found in these veins. These vessels, like the uterine veins, become much enlarged during pregnancy.

[1] Rivington has pointed out that a valve is usually found at the orifices of both the right and left spermatic veins. When no valves exist at the opening of the left spermatic vein into the left renal vein, valves are generally present in the left renal vein within a quarter of an inch from the orifice of the spermatic vein (*Journal of Anatomy and Physiology*, vol. vii. p. 163).

The **renal veins** are of large size, and placed in front of the renal arteries.[1] The left is longer than the right, and passes in front of the aorta, just below the origin of the superior mesenteric artery. It receives the left spermatic, the left inferior phrenic, and, generally, the left suprarenal veins. It opens into the vena cava a little higher than the right.

The **suprarenal veins** terminate, on the right side, in the vena cava; on the left side, in the left renal or phrenic vein.

The **phrenic veins** follow the course of the phrenic arteries. The *two superior*, of small size, accompany the phrenic nerve and comes nervi phrenici artery, and join the internal mammary. The *two inferior phrenic veins* follow the course of the phrenic arteries, and terminate, the right in the inferior vena cava, the left in the left renal vein.

The **hepatic veins** commence in the substance of the liver, in the capillary terminations of the portal vein and hepatic artery: these tributaries, gradually uniting, usually form three large veins, which converge toward the posterior surface of the liver and open into the inferior vena cava, whilst that vessel is situated in the groove at the back part of this organ. Of these three veins, one from the right, and another from the left lobe, open obliquely into the inferior vena cava, that from the middle of the organ and lobulus Spigelii having a straight course. The hepatic veins run singly, and are in direct contact with the hepatic tissue. They are destitute of valves.

The Portal System of Veins.

The portal venous system is composed of four large veins which collect the venous blood from the viscera of digestion. The trunk formed by their union (*vena portæ*) enters the liver and ramifies throughout its substance, and its branches, again emerging from that organ as the hepatic veins, terminate in the inferior vena cava. The branches in this vein are in all cases single and destitute of valves.

The veins forming the portal system are—the

Superior Mesenteric.	Inferior Mesenteric.
Splenic.	Gastric.

The **superior mesenteric vein** returns the blood from the small intestines and from the cæcum and ascending and transverse portions of the colon, corresponding with the distribution of the branches of the superior mesenteric artery. The large trunk formed by the union of these branches ascends along the right side and in front of the corresponding artery, passes in front of the transverse portion of the duodenum, and unites, behind the upper border of the pancreas, with the splenic vein to form the vena portæ. It receives the right gastro-epiploic vein.

The **splenic vein** commences by five or six large branches which return the blood from the substance of the spleen. These, uniting, form a single vessel, which passes from left to right, grooving the upper and back part of the pancreas below the artery, and terminates at its greater end by uniting at a right angle with the superior mesenteric to form the vena portæ. The splenic vein is of large size, and not tortuous like the artery. It receives the vasa brevia from the left extremity of the stomach, the left gastro-epiploic vein, pancreatic branches from the pancreas, the pancreatico-duodenal vein, and the inferior mesenteric vein.

The **inferior mesenteric vein** returns the blood from the rectum, sigmoid flexure, and descending colon, corresponding with the ramifications of the branches of the inferior mesenteric artery. Ascending beneath the peritoneum in the lumbar region, it passes behind the transverse portion of the duodenum and pancreas and terminates in the splenic vein. Its hæmorrhoidal branches inosculate with those

[1] The student may observe that all veins above the Diaphragm, which do not lie on the same plane as the arteries which they accompany, lie in front of them, and that all veins below the Diaphragm, which do not lie on the same plane as the arteries which they accompany, lie behind them, except the renal and profunda femoris vein.

of the internal iliac, and thus establish a communication between the portal and the general venous system.[1]

The **gastric veins** are two in number: one, a small vein, corresponds to the pyloric branch of the hepatic artery; the other, considerably larger, corresponds to the gastric artery. The former (*pyloric*, Walsham) runs along the lesser cur-

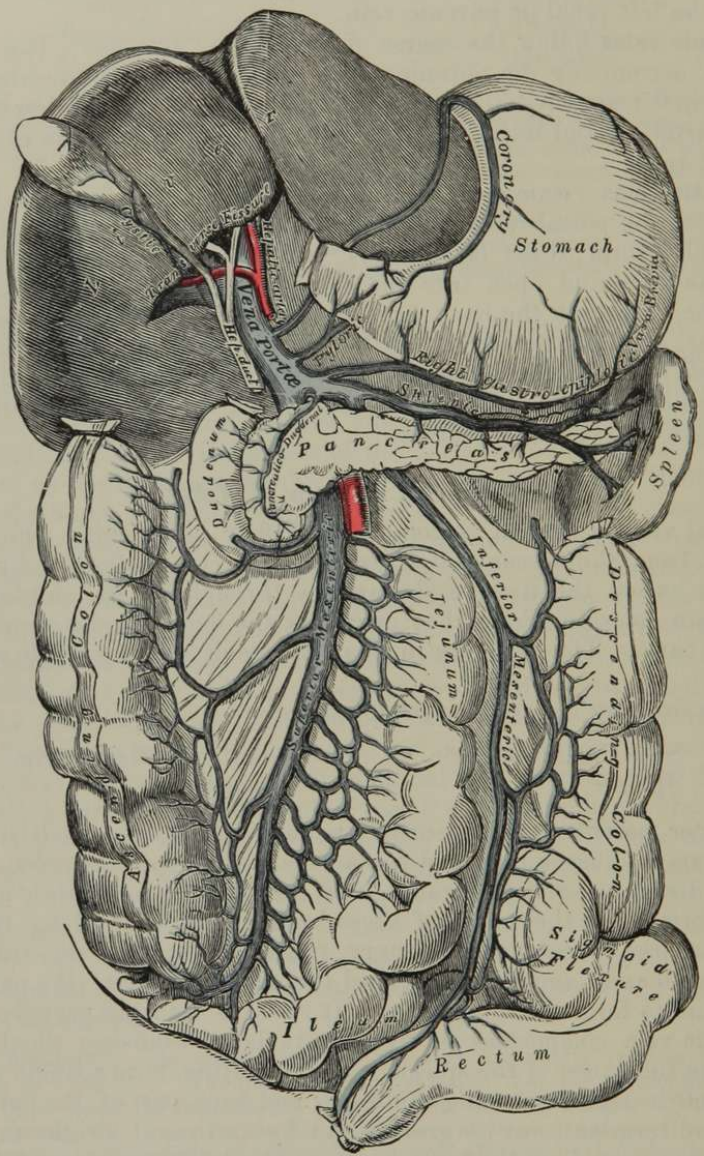

FIG. 393.—Portal vein and its branches.

NOTE.—In this diagram the right gastro-epiploic vein opens into the splenic vein; generally it empties itself into the superior mesenteric, close to its termination.

vature of the stomach toward the pyloric end, receives branches from the pylorus and duodenum, and ends in the vena portæ. The latter (*coronary*, Walsham) begins near the pylorus, runs along the lesser curvature of the stomach toward the

[1] Besides this anastomosis between the portal vein and the branches of the vena cava, other anastomoses between the portal and systemic veins are formed by the communication between the gastric veins and the œsophageal veins, which empty themselves into the vena azygos minor; between the left renal vein and the veins of the intestines, especially of the colon and duodenum; between the veins of the round ligament of the liver and the portal veins; and between the superficial branches of the portal veins of the liver and the phrenic veins, as pointed out by Mr. Kiernan. (See *Physiological Anatomy*, by Todd and Bowman, 1859, vol. ii. p. 348.)

œsophageal opening, and then curves downward and backward between the folds of the lesser omentum, to end in the vena portæ.

The **Portal Vein** is formed by the junction of the superior mesenteric and splenic veins, their union taking place in front of the vena cava and behind the upper border of the great end of the pancreas. Passing upward through the right border of the lesser omentum to the under surface of the liver, it enters the transverse fissure, where it is somewhat enlarged, forming the *sinus* of the portal vein, and divides into two branches which accompany the ramifications of the hepatic artery and hepatic duct throughout the substance of the liver. Of these two branches, the right is the larger, but the shorter, of the two. The portal vein is about three or four inches in length, and, whilst contained in the lesser omentum, lies behind and between the hepatic duct and artery, the former being to the right, the latter to the left. These structures are accompanied by filaments of the hepatic plexus of nerves and numerous lymphatics, surrounded by a quantity of loose areolar tissue (*capsule of Glisson*), and placed between the layers of the lesser omentum. The vena portæ receives the gastric and cystic veins : the latter vein sometimes terminates in the right branch of the vena portæ. Within the liver the portal vein receives the blood from the branches of the hepatic artery.

THE CARDIAC VEINS.

The veins which return the blood from the substance of the heart are—the

Anterior Cardiac Vein.	Right Cardiac Veins.
Posterior Cardiac Vein.	Right or Small Coronary Sinus.
Left Cardiac Veins.	Left or Great Coronary Sinus.

Venæ Thebesii.

The **Anterior Cardiac Vein** (sometimes called *Great Cardiac Vein*) is a vessel of considerable size which commences at the apex of the heart and ascends along the anterior interventricular groove to the base of the ventricles. It then curves to the left side, around the auriculo-ventricular groove, between the left auricle and ventricle, to the back part of the heart, and opens into the great coronary sinus, its aperture being guarded by two valves. It receives, in its course, tributaries from both ventricles, but especially the left, and also from the left auricle ; one of these, ascending along the thick margin of the left ventricle, is of considerable size. The vessels joining it are provided with valves.

The **Middle Cardiac Vein** commences by small tributaries at the apex of the heart, communicating with those of the preceding. It ascends along the posterior interventricular groove to the base of the heart, and terminates in the great coronary sinus, its orifice being guarded by a valve. It receives the veins from the posterior surface of both ventricles.

The **Left** or **Posterior Cardiac Veins** are three or four small vessels which collect the blood from the posterior surface of the left ventricle, and open into the lower border of the great coronary sinus.

The **Right** or **Anterior Cardiac Veins** are three or four small vessels which collect the blood from the anterior surface of the right ventricle. One of these (the *vein of Galen*), larger than the rest, runs along the right border of the heart. They open separately into the lower part of the right auricle.

The **Right** or **Small Coronary Sinus** runs along the groove between the right auricle and ventricle, to open into the right extremity of the great coronary sinus. It receives blood from the back part of the right auricle and ventricle.

The **Left** or **Great Coronary Sinus** is that portion of the anterior cardiac vein which is situated in the posterior part of the left auriculo-ventricular groove. It is about an inch in length, presents a considerable dilatation, and is covered by the muscular fibres of the left auricle. It receives the veins enumerated above, and an *oblique vein* from the back part of the left auricle, the remnant of the obliterated left innominate trunk of the fœtus, described by Mr. Marshall. The

great coronary sinus terminates in the right auricle between the inferior vena cava and the auriculo-ventricular aperture, its orifice being guarded by a semilunar fold of the lining membrane of the heart, the *coronary valve*. All the veins joining this vessel, excepting the oblique vein above mentioned, are provided with valves.

The **Venæ Thebesii** are numerous minute veins, which return the blood directly from the muscular substance, without entering the venous current. They open by minute orifices (*foramina Thebesii*) on the inner surface of the right auricle. Similarly minute veins are said to open into the left auricle and both ventricles.

THE LYMPHATICS.

THE Lymphatics have derived their name from the appearance of the fluid contained in their interior (*lympha*, water). They are also called *absorbents*, from the property they possess of absorbing certain materials from the tissues and conveying them into the circulation.

The lymphatic system includes not only the lymphatic vessels and the glands through which they pass, but also the *lacteal* or *chyliferous vessels*. The lacteals are the lymphatic vessels of the small intestine, and differ in no respect from the lymphatics generally, excepting that they contain a milk-white fluid, the *chyle*, during the process of digestion, and convey it into the blood through the thoracic duct.

The lymphatics are exceedingly delicate vessels, the coats of which are so transparent that the fluid they contain is readily seen through them. They retain a nearly uniform size, being interrupted at intervals by constrictions, which give them a knotted or beaded appearance. These constrictions are due to the presence of valves in their interior. Lymphatics have been found in nearly every texture and organ of the body which contain blood-vessels. Such non-vascular structures as cartilage, the nails, cuticle, and hair have none, but with these exceptions it is probable that eventually all parts will be found to be permeated by these vessels.

The lymphatics are arranged into a superficial and deep set. The superficial lymphatics, on the surface of the body, are placed immediately beneath the integument, accompanying the superficial veins; they join the deep lymphatics in certain situations by perforating the deep fascia. In the interior of the body they lie in the submucous areolar tissue throughout the whole length of the gastro-pulmonary and genito-urinary tracts, and in the subserous tissue in the cranial, thoracic, and abdominal cavities. The method of their origin has been described along with the other details of their minute anatomy (page 86). Here it will be sufficient to say that a plexiform network of minute lymphatics may be found interspersed among the proper elements and blood-vessels of the several tissues, the vessels composing which, as well as the meshes between them, are much larger than those of the capillary plexus. From these networks small vessels emerge, which pass either to a neighboring gland or to join some larger lymphatic trunk. The deep lymphatics, fewer in number and larger than the superficial, accompany the deep blood-vessels. Their mode of origin is probably similar to that of the superficial vessels. The lymphatics of any part or organ exceed the veins in number, but in size they are much smaller. Their anastomoses also, especially those of the large trunks, are more frequent, and are effected by vessels equal in diameter to those which they connect, the continuous trunks retaining the same diameter.

The **lymphatic** or **absorbent glands,** named also *conglobate glands*, are small, solid, glandular bodies situated in the course of the lymphatic and lacteal vessels. In size they vary from a hemp-seed to an almond, and their color, on section, is of a pinkish-gray tint, excepting the bronchial glands, which in the adult are mottled with black. Each gland has a layer or capsule of cellular tissue investing it, from which prolongations dip into its substance, forming partitions. The lymphatic and lacteal vessels pass through these bodies in their passage to the thoracic and lymphatic ducts. A lymphatic or lacteal vessel, previous to

entering a gland, divides into several small branches, which are named *afferent vessels*. As they enter their external coat becomes continuous with the capsule of the gland, and the vessels, much thinned, and consisting only of their internal or endothelial coat, pass into the gland, and branch out upon and in the tissue of the capsule, these branches opening into the lymph-sinuses of the gland. From these sinuses fine branches proceed to form a plexus, the vessels of which unite to form a single *efferent vessel*, which, on emerging from the gland, is again invested with an external coat. (Further details on the minute anatomy of the lymphatic vessels and glands will be found in the chapter on General Anatomy.)

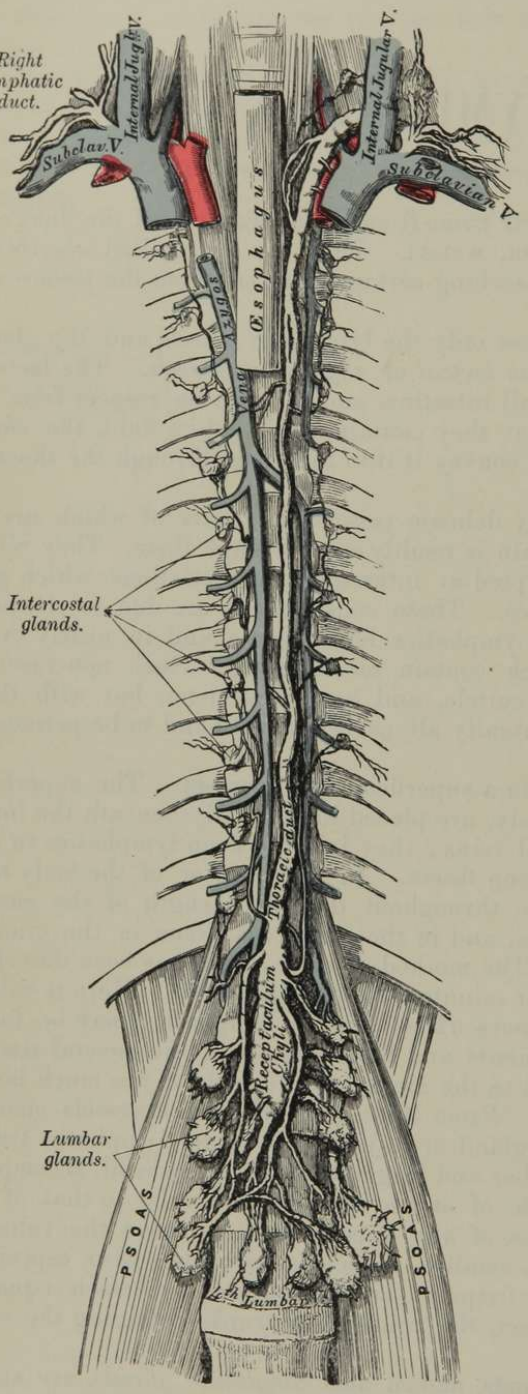

FIG. 394.—The thoracic and right lymphatic duct.

THE THORACIC DUCT.

The **thoracic duct** (Fig. 394) conveys the great mass of lymph and chyle into the blood. It is the common trunk of all the lymphatic vessels of the body, excepting those of the right side of the head, neck, and thorax, and right upper extremity, the right lung, right side of the heart, and the convex surface of the liver. It varies in length from fifteen to eighteen inches in the adult, and extends from the second lumbar vertebra to the root of the neck. It commences in the abdomen by a triangular dilatation, the *receptaculum chyli* (*reservoir* or *cistern of Pecquet*), which is situated upon the front of the body of the second lumbar vertebra, to the right side and behind the aorta, by the side of the right crus of the Diaphragm. It ascends into the thorax through the aortic opening in the Diaphragm, lying to the right of the aorta, and is placed in the posterior mediastinum in front of the vertebral column, lying between the aorta and vena azygos major. Opposite the fourth dorsal vertebra it inclines toward the left side, and ascends behind the arch of the aorta on the left side of the œsophagus, and behind the first portion of the left subclavian artery, to the upper orifice of the thorax. Opposite the seventh cervical vertebra it turns outward and then curves downward over the subclavian artery and in front of the Scalenus anticus muscle, so as to form an arch, and terminates in the left

subclavian vein at its angle of junction with the left internal jugular vein. The thoracic duct, at its commencement, is about equal in size to the diameter of a goosequill, diminishes considerably in its calibre in the middle of the thorax, and is again dilated just before its termination. It is generally flexuous in its course, and constricted at intervals so as to present a varicose appearance. The thoracic duct not unfrequently divides in the middle of its course into two branches of unequal size, which soon reunite, or into several branches, which form a plexiform interlacement. It occasionally divides, at its upper part, into two branches, of which the one on the left side terminates in the usual manner, while that on the right opens into the right subclavian vein, in connection with the right lymphatic duct. The thoracic duct has numerous valves throughout its whole course, but they are more numerous in the upper than in the lower part: at its termination it is provided with a pair of valves, the free borders of which are turned toward the vein, so as to prevent the passage of venous blood into the duct.

Tributaries.—The thoracic duct, at its commencement, receives four or five large trunks from the abdominal lymphatic glands, and also the trunk of the lacteal vessels. Within the thorax it is joined by the lymphatic vessels from the left half of the wall of the thoracic cavity, the lymphatics from the sternal and intercostal glands, those of the left lung, left side of the heart, trachea, and œsophagus; and, just before its termination, it receives the lymphatics of the left side of the head and neck and left upper extremity.

Structure (Fig. 61).—The thoracic duct is composed of three coats, which differ in some respects from those of the lymphatic vessels. The *internal coat* consists of a single layer of flattened lanceolate-shaped endothelial cells with serrated borders; of a subendothelial layer, similar to that found in the arteries; and an elastic fibrous coat, the fibres of which run in a longitudinal direction. The *middle coat* consists of a longitudinal layer of white connective tissue with elastic fibres, external to which are several laminæ of muscular tissue, the fibres of which are for the most part disposed transversely, but some are oblique or longitudinal and intermixed with elastic fibres. The *external coat* is composed of areolar tissue, with elastic fibres and isolated fasciculi of muscular fibres.

The **Right Lymphatic Duct** is a short trunk, about half an inch in length and a line or a line and a half in diameter. It terminates in the right subclavian vein at its angle of junction with the right internal jugular vein. Its orifice is guarded by two semilunar valves, which prevent the passage of venous blood into the duct.

Tributaries.—It receives the lymph from the right side of the head and neck, the right upper extremity, the right side of the thorax, the right lung and right side of the heart, and from part of the convex surface of the liver.

LYMPHATICS OF THE HEAD, FACE, AND NECK.

The **Lymphatic Glands of the Head** (Fig. 395) are of small size, few in number, and confined to its posterior region. They are the *occipital* and *posterior auricular*. The *occipital set* are placed at the back of the head along the attachment of the Occipito-frontalis muscle. The *posterior auricular set* are placed near the upper end of the Sterno-mastoid muscle. Both these sets of glands are affected in cutaneous eruptions and other diseases of the scalp. In the face the superficial lymphatic glands are more numerous: they are the *parotid*, some of which are superficial, and others deeply placed in the substance of the parotid gland; the *zygomatic*, situated under the zygoma; the *buccal*, on the surface of the Buccinator muscle; and the *internal maxillary*, the largest, beneath the ramus of the lower jaw.

The **lymphatic vessels of the scalp** are divided into an *anterior* and a *posterior set*, which follow the course of the temporal and occipital vessels. The *temporal set* accompany the temporal artery in front of the ear, to the parotid lymphatic glands, from which they proceed to the lymphatic glands of the neck. The *occipital set* follow the course of the occipital artery, descend to the occipital

and posterior auricular lymphatic glands, and from thence join the cervical glands.

The **Lymphatic Vessels of the Face** are divided into two sets, *superficial* and *deep*.

The **superficial lymphatic vessels of the face** are more numerous than those of the head, and commence over its entire surface. Those from the frontal region accompany the frontal vessels; they then pass obliquely across the face, running

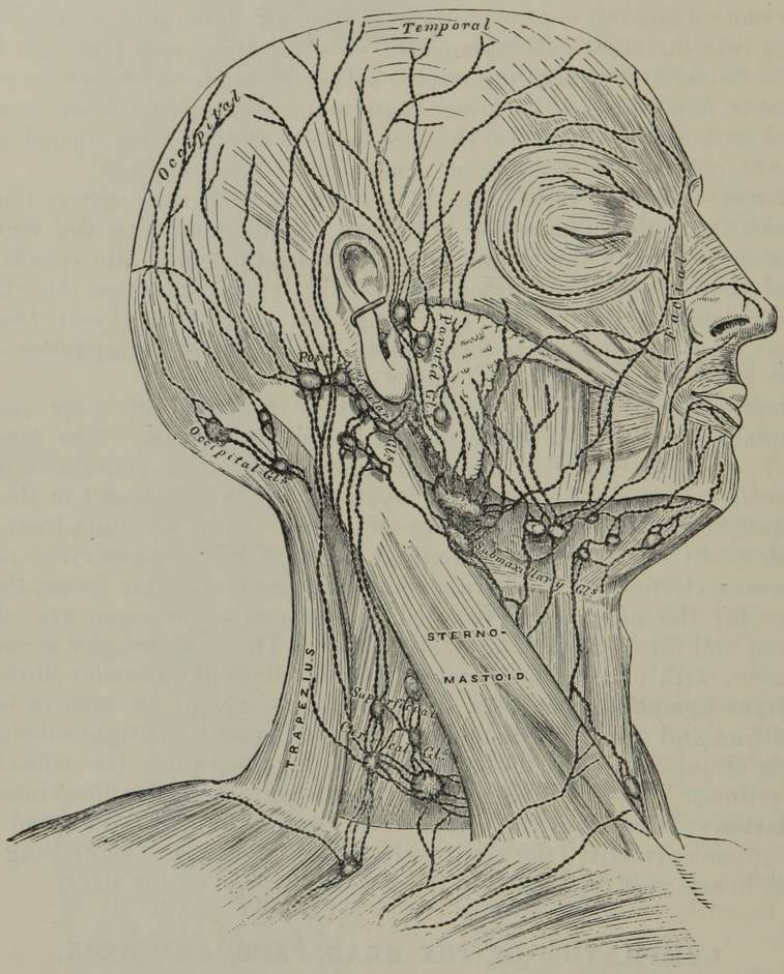

FIG. 395.—The superficial lymphatics and glands of the head, face, and neck.

with the facial vein, pass through the buccal glands on the surface of the Buccinator muscle, and join the submaxillary lymphatic glands. The latter receive the lymphatic vessels from the lips, and are often found enlarged in cases of malignant disease of those parts.

The **deep lymphatic vessels of the face** are derived from the pituitary membrane of the nose, the mucous membrane of the mouth and pharynx, and the contents of the temporal and orbital fossæ; they accompany the branches of the internal maxillary artery, and terminate in the internal maxillary and cervical lymphatic glands.

The **lymphatic vessels of the cranium** consist of two sets, the *meningeal* and *cerebral*. The *meningeal lymphatics* accompany the meningeal vessels, escape through foramina at the base of the skull, and join the deep cervical lymphatic glands. The *cerebral lymphatics* are described by Eshmann as being situated between the arachnoid and pia mater, as well as in the choroid plexuses of the

lateral ventricles; they accompany the trunks of the carotid and vertebral arteries, and probably pass through foramina at the base of the skull to terminate in the deep cervical glands. They have not at present been demonstrated in the dura mater or in the substance of the brain.

The **Lymphatic Glands of the Neck** are divided into two sets, *superficial* and *deep*.

The **superficial cervical glands** may be arranged in three sets: (1) The *submaxillary*, ten to fifteen in number, situated beneath the body of the lower

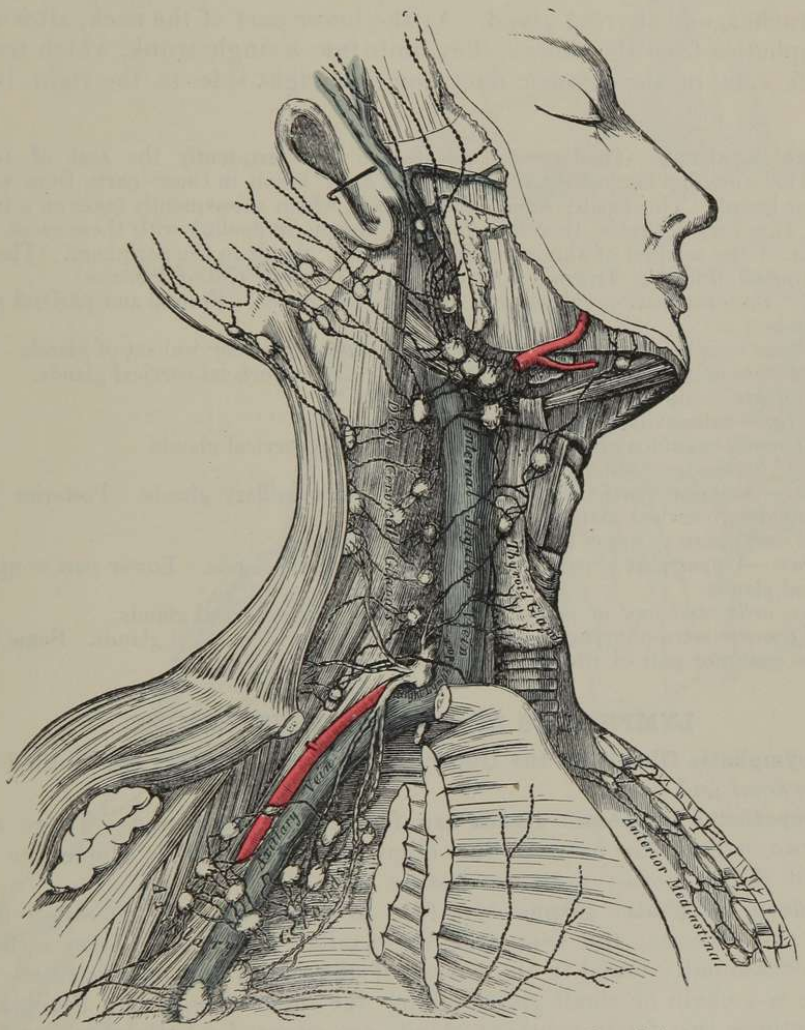

FIG. 396.—The deep lymphatics and glands of the neck and thorax.

jaw in the submaxillary triangle; (2) *suprahyoid*, situated in the middle line of the neck, between the anterior bellies of the two digastric muscles; and (3) *cervical*, placed in the course of the external jugular vein between the Platysma and deep fascia. They are most numerous at the root of the neck, in the triangular interval between the clavicle, the Sterno-mastoid, and the Trapezius, where they are continuous with the axillary glands. A few small glands are also found on the front and sides of the larynx.

The **deep cervical glands** (Fig. 396) are numerous and of large size; they form a chain along the sheath of the carotid artery and internal jugular vein, lying by the side of the pharynx, œsophagus, and trachea, and extending from the base of the skull to the thorax, where they communicate with the lymphatic glands in that cavity. They are subdivided into two sets: an *upper*, ten to twenty in number,

situated about the bifurcation of the common carotid and along the upper part of the internal jugular vein; and a *lower*, ten to fifteen in number, clustered around the lower part of the internal jugular vein, and extending outward into the supraclavicular fossa, where they are continuous with the axillary glands. Internally, this set is continuous with the mediastinal glands.

The **superficial** and **deep cervical lymphatic vessels** are a continuation of those already described on the cranium and face. After traversing the glands in those regions, they pass through the chain of glands which lie along the sheath of the carotid vessels, being joined by the lymphatics from the pharynx, œsophagus, larynx, trachea, and thyroid gland. At the lower part of the neck, after receiving some lymphatics from the thorax, they unite into a single trunk, which terminates, on the left side, in the thoracic duct; on the right side, in the right lymphatic duct.

Surgical Anatomy.—The cervical glands are very frequently the seat of tuberculous trouble. This condition is most usually set up by some lesion in those parts from which they receive their lymph. This excites some inflammation, which subsequently takes on a tuberculous character. It is very desirable, therefore, for the surgeon, in dealing with these cases, to possess a knowledge of the relation of the respective groups of glands to the periphery. The following table is extracted from Mr. Treves's work on *Scrofula and its Gland Diseases:*

Scalp.—Posterior part = suboccipital and mastoid glands. Frontal and parietal portions = parotid glands.

Lymphatic vessels from the scalp also enter the superficial cervical set of glands.

Skin of face and neck = submaxillary, parotid, and superficial cervical glands.

External ear = superficial cervical glands.

Lower lip = submaxillary and suprahyoid glands.

Buccal cavity = submaxillary and upper set of deep cervical glands.

Gums of lower jaw = submaxillary glands.

Tongue.—Anterior portion = suprahyoid and submaxillary glands. Posterior portion = upper set of deep cervical glands.

Tonsils and palate = upper set of deep cervical glands.

Pharynx.—Upper part = parotid and retro-pharyngeal glands. Lower part = upper set of deep cervical glands.

Larynx, orbit, and roof of mouth = upper set of deep cervical glands.

Nasal fossæ = retro-pharyngeal glands, upper set of deep cervical glands. Some lymphatic vessels from posterior part of the fossæ enter the parotid glands.

LYMPHATICS OF THE UPPER EXTREMITY.

The **Lymphatic Glands of the Upper Extremity** (Fig. 397) are divided into two sets, *superficial* and *deep*.

The **superficial lymphatic glands** are few and of small size. There are occasionally two or three in front of the elbow, and one or two above the internal condyle of the humerus, near the basilic vein.

The **deep lymphatic glands** are few in number, and are subdivided into those in the forearm, the arm, and the axilla. In the *forearm* a few small ones are occasionally found in the course of the radial and ulnar vessels. In the *arm* there is a chain of small glands along the inner side of the brachial artery. One, sometimes two, fairly constant glands are situated a little above and in front of the inner condyle of the humerus. In the *axilla* they are of large size, and usually ten or twelve in number. A chain of these glands surrounds the axillary vessels, imbedded in a quantity of loose areolar tissue; they receive the lymphatic vessels from the arm; others are dispersed in the areolar tissue of the axilla; the remainder are arranged in two series, a small chain running along the lower border of the Pectoralis major, receiving the lymphatics from the front of the chest and mamma; and others are placed along the lower margin of the posterior wall of the axilla, which receive the lymphatics from the integument of the back. Two or three subclavian lymphatic glands are placed immediately beneath the clavicle; it is through these that the axillary and deep cervical glands communicate with each other.

Surgical Anatomy.—In malignant diseases, tumors, or other affections implicating the upper part of the back and shoulder, the front of the chest and mamma, the upper part of the

front and side of the abdomen, or the hand, forearm, and arm, the axillary glands are liable to be found enlarged.

The **lymphatic vessels of the upper extremity** are divided into two sets, *superficial* and *deep*.

The **superficial lymphatic vessels of the upper extremity** commence on the fingers, two vessels running along either side of each finger, one on the palmar and the other on the dorsal surface. Those on the palmar surface form an arch in the

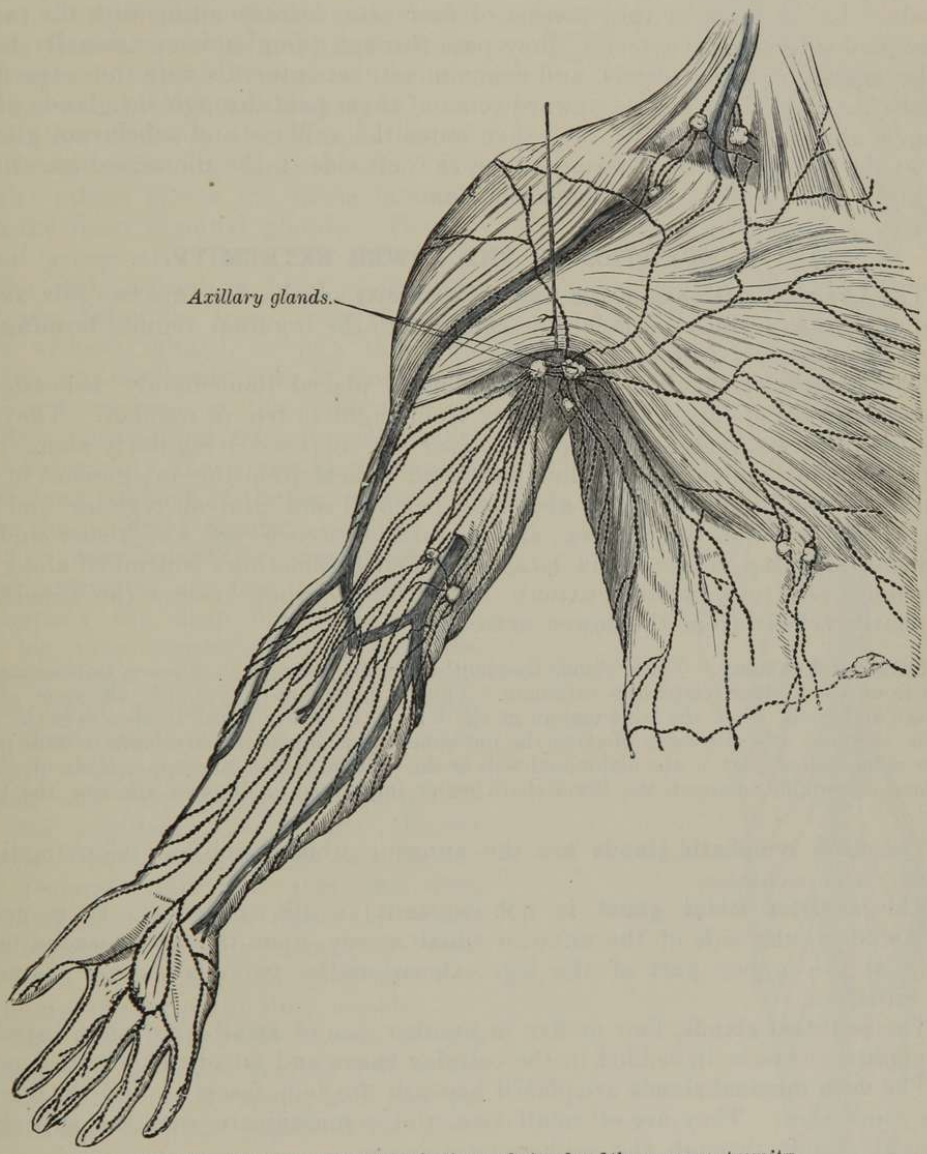

FIG. 397.—The superficial lymphatics and glands of the upper extremity.

palm of the hand, from which are derived two sets of vessels, which pass up the forearm, taking the course of the subcutaneous veins. The lymphatics from the dorsal surface of the fingers form a plexus on the back of the hand, and, winding around the inner and outer borders of the forearm, unite with those in front. Those from the inner border of the hand accompany the ulnar veins along the inner side of the forearm to the bend of the elbow, where they are joined by some lymphatics from the outer side of the forearm: they then follow the course of the basilic vein, communicate with the glands immediately above the elbow, and terminate in the axillary glands, joining with the deep lymphatics. The superficial lymphatics from

the outer and back part of the hand accompany the radial veins to the bend of the elbow. They are less numerous than the preceding. At the bend of the elbow the greater number join the basilic group; the rest ascend with the cephalic vein on the outer side of the arm, some crossing the upper part of the Biceps obliquely, to terminate in the axillary glands, whilst one or two accompany the cephalic vein in the cellular interval between the Pectoralis major and Deltoid, and enter the subclavian lymphatic glands.

The **deep lymphatic vessels of the upper extremity** accompany the deep blood-vessels. In the forearm they consist of four sets, corresponding with the radial, ulnar, and interosseous arteries; they pass through the glands occasionally found in the course of those vessels, and communicate at intervals with the superficial lymphatics. In their course upward some of them pass through the glands which lie upon the brachial artery; they then enter the axillary and subclavian glands, and at the root of the neck terminate on the left side in the thoracic duct, and on the right side in the right lymphatic duct.

LYMPHATICS OF THE LOWER EXTREMITY.

The **Lymphatic Glands of the Lower Extremity** are divided into two sets, *superficial* and *deep*. The superficial are confined to the inguinal region, forming the *superficial inguinal lymphatic glands*.

The **superficial inguinal lymphatic glands**, placed immediately beneath the integument, are of large size, and vary from eight to ten in number. They are divisible into two groups: an upper *oblique* set, disposed irregularly along Poupart's ligament, which receive the lymphatic vessels from the integument of the scrotum, penis, parietes of the abdomen, perineal and gluteal regions, and the mucous membrane of the urethra; and an inferior *vertical* set, which surround the saphenous opening in the fascia lata, a few being sometimes continued along the saphenous vein to a variable extent. This latter group receive the superficial lymphatic vessels from the lower extremity.

Surgical Anatomy.—These glands frequently become enlarged in diseases implicating the parts from which their lymphatics originate. Thus in malignant or syphilitic affections of the prepuce and penis, or of the labia majora in the female, in cancer scroti, in abscess in the perinæum, or in any other diseases affecting the integument and superficial structures in those parts, or the subumbilical part of the abdominal wall or the gluteal region, the upper chain of glands is almost invariably enlarged, the lower chain being implicated in diseases affecting the lower limb.

The **deep lymphatic glands** are the anterior tibial, popliteal, deep inguinal, gluteal, and ischiatic.

The **anterior tibial gland** is not constant in its existence. It is generally found by the side of the anterior tibial artery, upon the interosseous membrane at the upper part of the leg. Occasionally, two glands are found in this situation.

The **popliteal glands**, four or five in number, are of small size; they surround the popliteal vessels, imbedded in the cellular tissue and fat of the popliteal space.

The **deep inguinal glands** are placed beneath the deep fascia around the femoral artery and vein. They are of small size, and communicate with the superficial inguinal glands through the saphenous opening.

The **gluteal** and **ischiatic glands** are placed, the former above, the latter below, the Pyriformis muscle, resting on their corresponding vessels as they pass through the great sacro-sciatic foramen.

The **Lymphatic Vessels of the Lower Extremity**, like the veins, may be divided into two sets, *superficial* and *deep*.

The **superficial lymphatic vessels** are placed beneath the integument in the superficial fascia, and are divisible into two groups: an internal group, which follow the course of the internal saphenous vein; and an external group, which accompany the external saphenous. The *internal group*, the larger, commence on the inner side and dorsum of the foot; they pass, some in front and some behind

the inner ankle, run up the leg with the internal saphenous vein, pass with it behind the inner condyle of the femur, and accompany it to the groin, where they terminate in the group of superficial inguinal lymphatic glands which surround the saphenous opening. Some of the efferent vessels from these glands pierce the cribriform fascia and sheath of the femoral vessels, and terminate in a lymphatic gland contained in the femoral canal, thus establishing a communication between the lymphatics of the lower extremity and those of the trunk; others pierce the fascia lata and join the deep inguinal glands. The *external group* arise from the outer side of the foot, ascend in front of the leg, and, just below the knee, cross the tibia from without inward, to join the lymphatics on the inner side of the thigh. Others commence on the outer side of the foot, pass behind the outer malleolus, and accompany the external saphenous vein along the back of the leg, where they enter the popliteal glands.

The **deep lymphatic vessels of the lower extremity** are few in number and accompany the deep blood-vessels. In the leg they consist of three sets, the anterior tibial, peroneal, and posterior tibial, which accompany the corresponding blood-vessels, two or three to each artery; they ascend with the blood-vessels and enter the lymphatic glands in the popliteal space; the efferent vessels from these glands accompany the femoral vein and join the deep inguinal glands; from these, the vessels pass beneath Poupart's ligament and communicate with the chain of glands surrounding the external iliac vessels.

The deep lymphatic vessels of the gluteal and ischiatic regions follow the course of the blood-vessels, and join the gluteal and ischiatic glands at the great sacro-sciatic foramen.

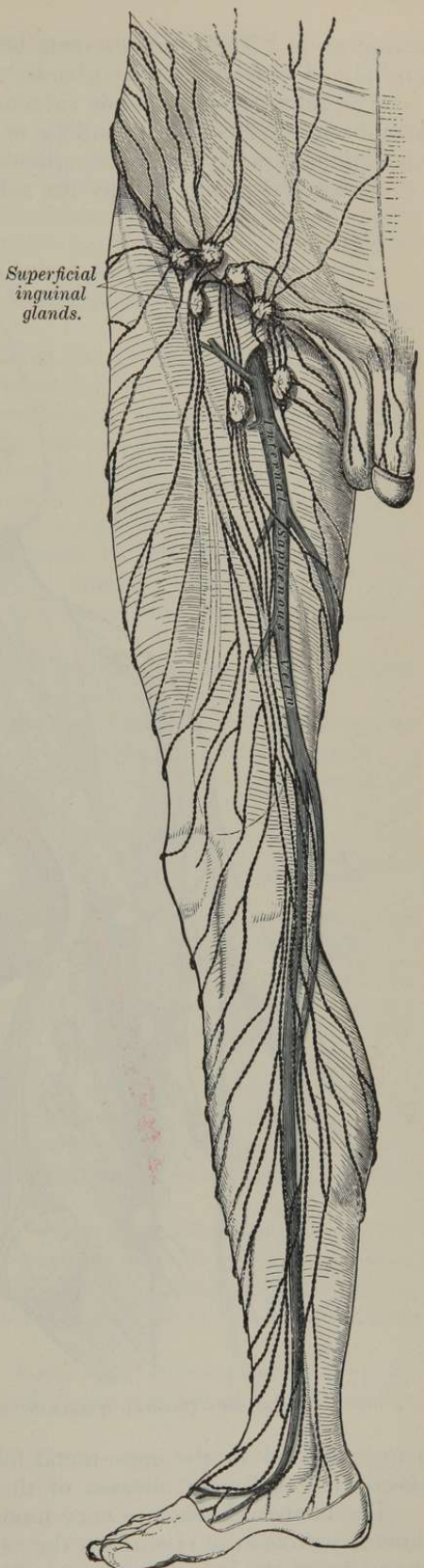

FIG. 398.—The superficial lymphatics and glands of the lower extremity.

LYMPHATICS OF THE PELVIS AND ABDOMEN.

The **Lymphatic Glands in the Pelvis** are the external iliac, the internal iliac, and the sacral. Those of the abdomen are the lumbar glands.

The **external iliac glands** form an uninterrupted chain round the external iliac vessels, three being placed round the commencement of the vessels just behind the

crural arch. They communicate below with the deep inguinal lymphatic glands, and above with the lumbar glands.

The **internal iliac glands** surround the internal iliac vessels; they receive the lymphatic vessels corresponding to the branches of the internal iliac artery, and communicate with the lumbar glands.

The **sacral glands** occupy the sides of the anterior surface of the sacrum, some

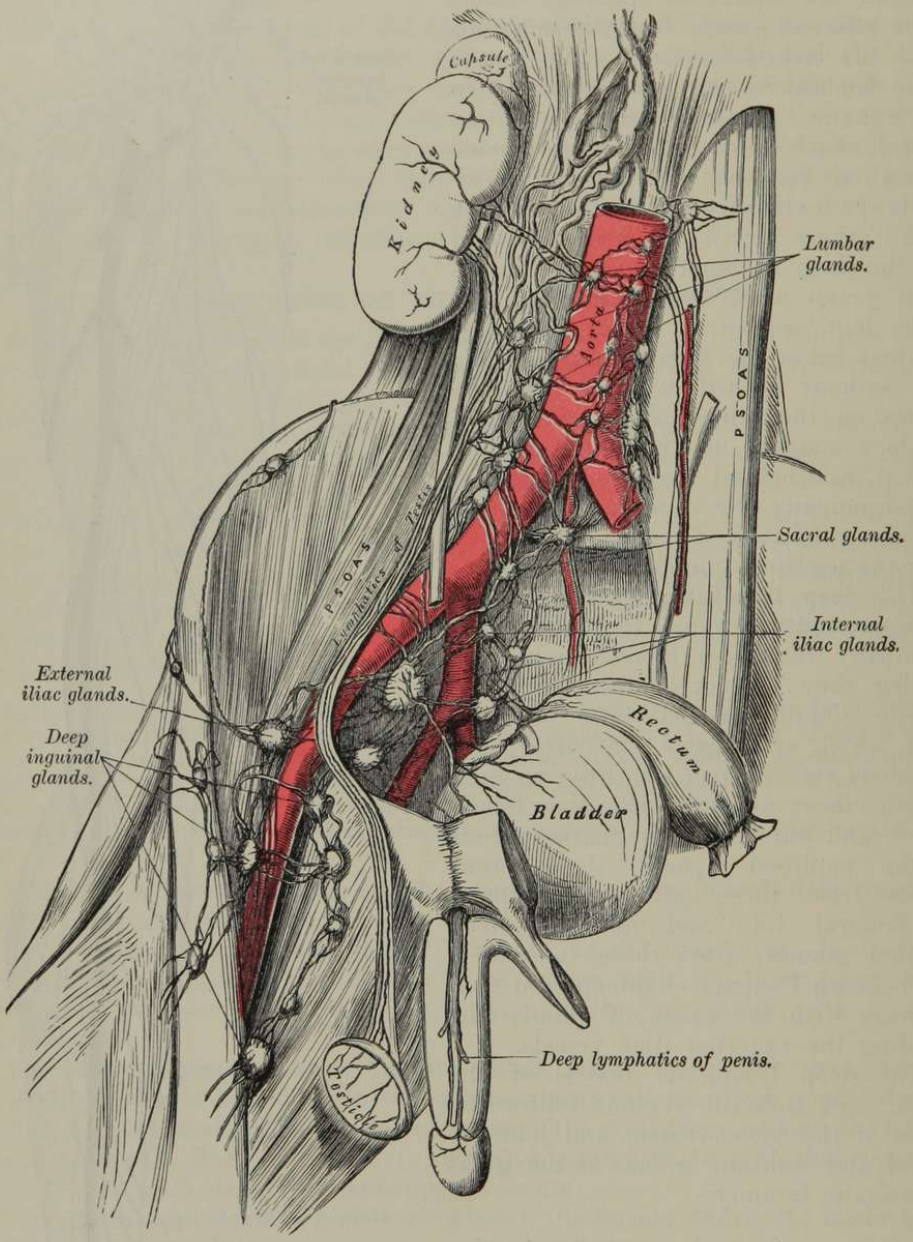

FIG. 399.—The deep lymphatic vessels and glands of the abdomen and pelvis.

being situated in the meso-rectal fold. These and the internal iliac glands are affected in malignant disease of the bladder, rectum, or uterus.

The **lumbar glands** are very numerous; they are situated on the front of the lumbar vertebræ, surrounding the common iliac vessels, the aorta, and vena cava; they receive the lymphatic vessels from the lower extremities and pelvis, as well as from the testes and some of the abdominal viscera: the efferent vessels from these glands unite into a few large trunks, which, with the lacteals, form the commence-

ment of the thoracic duct. In addition to these there are a few small *lateral lumbar glands* which lie between the transverse processes of the vertebræ, behind the Psoas muscle, and receive lymphatics from the back. In some cases of malignant disease these glands become enormously enlarged, completely surrounding the aorta and vena cava, and occasionally greatly contracting the calibre of those vessels. In all cases of malignant disease of the testes and in malignant disease of the lower limb, before any operation is attempted, careful examination of the abdomen should be made, in order to ascertain if any enlargement exists; and if any should be detected, all operative measures should be avoided as fruitless.

The **Lymphatic Vessels of the Abdomen and Pelvis** may be divided into two sets, *superficial* and *deep*.

The **superficial lymphatic vessels of the walls of the abdomen and pelvis** follow the course of the superficial blood-vessels. Those derived from the integument of the lower part of the abdomen below the umbilicus follow the course of the superficial epigastric vessels and converge to the superior group of the superficial inguinal glands; a deeper set accompany the deep epigastric vessels, and communicate with the external iliac glands. The superficial lymphatics from the sides of the lumbar part of the abdominal wall wind round the crest of the ilium, accompanying the superficial circumflex iliac vessels, to join the superior group of the superficial inguinal glands; the greater number, however, run backward along with the ilio-lumbar and lumbar vessels, to join the lateral lumbar glands.

The **superficial lymphatic vessels of the gluteal region** turn horizontally round the outer side of the nates, and join the superficial inguinal glands.

The **superficial lymphatic vessels of the scrotum and perinæum** follow the course of the external pudic vessels, and terminate in the superficial inguinal glands.

The **superficial lymphatic vessels of the penis** occupy the sides and dorsum of the organ, the latter receiving the lymphatics from the skin covering the glans penis; they all converge to the upper chain of the superficial inguinal glans. The **deep lymphatic vessels of the penis** follow the course of the internal pudic vessels, and join the internal iliac glands.

In the female the lymphatic vessels of the mucous membrane of the labia, nymphæ, and clitoris terminate in the upper chain of the inguinal glands.

The **deep lymphatic vessels of the abdomen and pelvis** take the course of the principal blood-vessels. Those of the parietes of the pelvis, which accompany the gluteal, ischiatic, and obturator vessels, follow the course of the internal iliac artery, and ultimately join the lumbar lymphatics.

The efferent vessels from the inguinal glands enter the pelvis beneath Poupart's ligament, where they lie in close relation with the femoral vein; they then pass through the chain of glands surrounding the external iliac vessels, and finally terminate in the lumbar glands. They receive the deep epigastric and circumflex iliac lymphatics.

The **lymphatic vessels of the bladder** arise from the entire surface of the organ;[1] the greater number run beneath the peritoneum on its posterior surface, and, after passing through the lymphatic glands in that situation, join with the lymphatics from the prostate and vesiculæ seminales, and enter the internal iliac glands.

The **lymphatic vessels of the rectum** are of large size; after passing through some small glands that lie upon its outer wall and in the meso-rectum they pass to the sacral glands.

The **lymphatic vessels of the uterus** consist of two sets, *superficial* and *deep*, the former being placed beneath the peritoneum, the latter in the substance of the organ. The lymphatics of the cervix uteri, together with those from the vagina, enter the internal iliac and sacral glands; those from the body and fundus of the uterus pass outward in the broad ligaments, and, being joined by the lymphatics

[1] Curnow states that they are confined to the base of the organ.

from the ovaries, broad ligaments, and Fallopian tubes, ascend with the ovarian vessels to open into the lumbar glands. In the unimpregnated uterus they are small, but during gestation they become very greatly enlarged.

The **lymphatic vessels of the testicle** consist of two sets, *superficial* and *deep:* the former commence on the surface of the tunica vaginalis, the latter in the epididymis and body of the testis. They form several large trunks which ascend with the spermatic cord, and, accompanying the spermatic vessels into the abdomen, terminate into the lumbar glands; hence the enlargement of these glands in malignant disease of the testis.

The **lymphatic vessels of the kidney** arise on the surface, and also in the interior of the organ; they join at the hilum, and, after receiving the lymphatic vessels from the ureter and suprarenal capsules, open into the lumbar glands.

The **lymphatic vessels of the liver** are divisible into two sets, *superficial* and *deep.* The former arise in the subperitoneal areolar tissue over the entire surface of the organ. Those on the convex surface may be divided into four groups: 1. Those which pass from behind forward, consisting of three or four branches, which ascend in the longitudinal ligament and unite to form a single trunk, which passes up between the fibres of the Diaphragm, behind the ensiform cartilage, to enter the anterior mediastinal glands, and finally ascends to the root of the neck, to terminate in the right lymphatic duct. 2. Another group, which also incline from behind forward, are reflected over the anterior margin of the liver to its under surface, and from thence pass along the longitudinal fissure to the glands in the gastro-hepatic omentum. 3. A third group incline outward to the right lateral ligament, and, uniting into one or two large trunks, pierce the Diaphragm, and run along its upper surface to enter the anterior mediastinal glands, or, instead of entering the thorax, turn inward across the crus of the Diaphragm and open into the commencement of the thoracic duct. 4. The fourth group incline outward from the surface of the left lobe of the liver to the left lateral ligament, pierce the Diaphragm, and, passing forward, terminate in the glands in the anterior mediastinum.

The *superficial lymphatics on the under surface of the liver* are divided into three sets: 1. Those on the right side of the gall-bladder enter the lumbar glands. 2. Those surrounding the gall-bladder form a remarkable plexus; they accompany the hepatic vessels, and open into the glands in the gastro-hepatic omentum. 3. Those on the left of the gall-bladder pass to the œsophageal glands and to the glands which are situated along the lesser curvature of the stomach.

The *deep lymphatics* accompany the branches of the portal vein and the hepatic artery and duct through the substance of the liver; passing out at the transverse fissure, they enter the lymphatic glands along the lesser curvature of the stomach and behind the pancreas, or join with one of the lacteal vessels previous to its termination in the thoracic duct.

The **lymphatic glands of the stomach** are of small size; they are placed along the lesser and greater curvatures, some within the gastro-splenic omentum, whilst others surround the cardiac and pyloric orifices.

The **lymphatic vessels of the stomach** consist of two sets, *superficial* and *deep*, the former originating in the subserous, and the latter in the submucous, coat. They follow the course of the blood-vessels, and may consequently be arranged into three groups: The *first group* accompany the gastric vessels along the lesser curvature, receiving branches from both surfaces of the organ, and pass to the glands around the pylorus. The *second group* pass from the great end of the stomach, accompanying the vasa brevia, and enter the splenic lymphatic glands. The *third group* run along the greater curvature with the right gastro-epiploic vessels, and terminate at the root of the mesentery in one of the principal lacteal vessels.

The **lymphatic glands of the spleen** occupy the hilum. Its *lymphatic vessels* consist of two sets, superficial and deep: the former are placed beneath its peritoneal covering, the latter in the substance of the organ; they accompany the

blood-vessels, passing through a series of small glands, and, after receiving the lymphatics from the pancreas, ultimately pass into the thoracic duct.

THE LYMPHATIC SYSTEM OF THE INTESTINES.

The **lymphatic glands of the small intestine** are placed between the layers of the mesentery, occupying the meshes formed by the superior mesenteric vessels, and hence called *mesenteric glands.* They vary in number from a hundred to a hundred and fifty, and in size from that of a pea to that of a small almond. These glands are most numerous, and largest above, near the duodenum, and below, opposite the termination of the ileum in the colon. This latter group becomes enlarged and infiltrated with deposit in cases of fever accompanied with ulceration of the intestines.

The **lymphatic glands of the large intestine** are much less numerous than the mesenteric glands; they are situated along the vascular arches formed by the arteries previous to their distribution, and even sometimes upon the intestine itself. They are fewest in number along the transverse colon, where they form an uninterrupted chain with the mesenteric glands.

The **lymphatic vessels of the small intestine** are called **lacteals,** from the milk-white fluid they usually contain: they consist of two sets, superficial and deep, the former lie between the layers of the muscular coat and between the muscular and peritoneal coats, taking a longitudinal course along the outer side of the intestine; the latter occupy the submucous tissue, and course transversely round the intestine, accompanied by the branches of the mesenteric vessels; they pass between the layers of the mesentery, enter the mesenteric glands, and finally unite to form two or three large trunks which terminate in the thoracic duct.

The **lymphatic vessels of the large intestine** consist of two sets: those of the cæcum, ascending and transverse colon, which, after passing through their proper glands, enter the mesenteric glands; and those of the descending colon, sigmoid flexure, and rectum, which pass to the lumbar glands.

THE LYMPHATICS OF THE THORAX.

The **Lymphatic Glands of the Thoracic Wall** are the intercostal, internal mammary, anterior mediastinal, and posterior mediastinal.

The **intercostal glands** are small, irregular in number, and situated on each side of the spine, near the costo-vertebral articulations, some being placed between the two planes of intercostal muscles.

The **internal mammary glands** are placed at the anterior extremity of each intercostal space, by the side of the internal mammary vessels.

The **anterior mediastinal glands** are placed in the loose areolar tissue of the anterior mediastinum, some lying upon the Diaphragm in front of the pericardium, and others round the great vessels at the base of the heart.

The **posterior mediastinal glands** are situated in the areolar tissue in the posterior mediastinum, forming a continuous chain by the side of the aorta and œsophagus; they communicate on each side with the intercostal, below with the lumbar, and above with the deep cervical glands.

The **Superficial Lymphatic Vessels of the Front of the Thorax** run across the great Pectoral muscle, and those on the back part of this cavity lie upon the Trapezius and Latissimus dorsi; they all converge to the axillary glands. The lymphatics from the greater part of the mammary gland pass outward to the lower border of the Pectoralis major muscle, where they enter a chain of small glands situated in the axillary space along the lower border of its anterior boundary. Some few lymphatics from the inner side of the mammary gland pass through the intercostal spaces to reach the anterior mediastinal glands.

The **Deep Lymphatic Vessels of the Thoracic Wall** are the intercostal, internal mammary, and diaphragmatic.

The **intercostal lymphatic vessels** follow the course of the intercostal vessels,

receiving lymphatics from the intercostal muscles and pleura ; they pass backward to the spine, and unite with lymphatics from the back part of the thorax and spinal canal. After traversing the intercostal glands, they pass down the spine and terminate in the thoracic duct.

The **internal mammary lymphatic vessels** follow the course of the internal mammary vessels; they commence in the muscles of the abdomen above the umbilicus, communicating with the epigastric lymphatics, ascend between the fibres of the Diaphragm at its attachment to the ensiform appendix, and in their course behind the costal cartilages are joined by the intercostal lymphatics; they terminate on the right side in the right lymphatic duct, on the left side in the thoracic duct.

The **lymphatic vessels of the Diaphragm** follow the course of their corresponding vessels, and terminate, some in front in the anterior mediastinal and internal mammary glands, some behind, in the intercostal and posterior mediastinal lymphatics.

The **Lymphatic Glands of the Viscera** are the bronchial glands.

The **bronchial glands** are situated round the bifurcation of the trachea and roots of the lungs. They are ten or twelve in number, the largest being placed opposite the bifurcation of the trachea, the smallest round the bronchi and their primary divisions for some little distance within the substance of the lungs. In infancy they present the same appearance as lymphatic glands in other situations; in the adult they assume a brownish tinge, and in old age a deep black color. Occasionally they become sufficiently enlarged to compress and narrow the canal of the bronchi, and they are often the seat of tubercle or cretaceous deposits.

The **lymphatic vessels of the lung** consist of two sets, *superficial* and *deep:* the former are placed beneath the pleura, forming a minute plexus which covers the outer surface of the lung; the latter accompany the blood-vessels and run along the bronchi: they both terminate at the root of the lungs in the bronchial glands. The efferent vessels from these glands, two or three in number, ascend upon the trachea to the root of the neck, traverse the tracheal and œsophageal glands, and terminate on the left side in the thoracic duct and on the right side in the right lymphatic duct.

The **cardiac lymphatic vessels** consist of two sets, *superficial* and *deep :* the former arise in the subserous areolar tissue of the surface, and the latter in the deeper tissues of the heart. They follow the course of the coronary vessels: those of the right side unite into a trunk at the root of the aorta, which, ascending across the arch of that vessel, passes backward to the trachea, upon which it ascends, to terminate at the root of the neck in the right lymphatic duct. Those of the left side unite into a single vessel at the base of the heart, which, passing along the pulmonary artery and traversing some glands at the root of the aorta, ascends on the trachea to terminate in the thoracic duct.

The **thymic lymphatic vessels** arise from the under surface of the thymus gland, and terminate on each side in the internal jugular veins.

The **thyroid lymphatic vessels** arise from either lateral lobe of this organ: they converge to form a short trunk, which terminates on the right side in the right lymphatic duct, on the left side in the thoracic duct.

The **lymphatic vessels of the œsophagus** form a plexus round that tube, traverse the glands in the posterior mediastinum, and, after communicating with the pulmonary lymphatic vessels near the roots of the lungs, terminate in the thoracic duct.

THE NERVOUS SYSTEM.

THE Nervous System is composed—1. Of a series of large centres of nerve-matter, called, collectively, the *cerebro-spinal centre* or *axis*. 2. Of smaller centres, termed *ganglia*. 3. Of *nerves*, connected either with the cerebro-spinal axis or the ganglia. And 4. Of certain modifications of the peripheral terminations of the nerves, forming the organs of the external senses.

The **Cerebro-spinal Centre** consists of two parts, the spinal cord and the encephalon; the latter may be subdivided into the cerebrum, the cerebellum, the pons Varolii, and the medulla oblongata.

THE SPINAL CORD AND ITS MEMBRANES.

Dissection.—To dissect the cord and its membranes it will be necessary to lay open the whole length of the spinal canal. For this purpose the muscles must be separated from the vertebral grooves, so as to expose the spinous processes and laminæ of the vertebræ; and the latter must be sawn through on each side, close to the roots of the transverse processes, from the third or fourth cervical vertebra above to the sacrum below. The vertebral arches having been displaced by means of a chisel and the separate fragments removed, the dura mater will be exposed, covered by a plexus of veins and a quantity of loose areolar tissue, often infiltrated with serous fluid. The arches of the upper vertebræ are best divided by means of a strong pair of cutting bone-forceps.

MEMBRANES OF THE CORD.

The membranes which envelop the spinal cord are three in number. The most external is the *dura mater*, a strong fibrous membrane which forms a loose sheath around the cord. The most internal is the *pia mater*, a cellulo-vascular membrane which closely invests the entire surface of the cord. Between the two is the *arachnoid membrane*, a non-vascular membrane which envelops the cord and is connected to the pia mater by slender filaments of connective tissue.

The **Dura Mater** of the cord, continuous with that which invests the brain, is a loose sheath which surrounds the cord, and is separated from the bony walls of the spinal canal by a quantity of loose areolar tissue and a plexus of veins. It is attached to the circumference of the foramen magnum and to the posterior common ligament, especially at the lower end of the spinal canal, by fibrous slips, and extends below as far as the third piece of the sacrum; but beyond this point it is impervious, being continued in the form of a slender cord to the back of the coccyx, where it blends with the periosteum. This sheath is much larger than is necessary for its contents, and its size is greater in the cervical and lumbar regions than in the dorsal. Its inner surface is smooth. On each side may be seen the double openings which transmit the two roots of the corresponding spinal nerve, the fibrous layer of the dura mater being continued in the form of a tubular prolongation on them as they pass through these apertures. On opening the lower part of the dura mater—*i. e. below* the termination of the cord proper—the *roots* of the lumbar and sacral nerves are seen. These roots, taken together, form what is known as the *cauda equina*. In the midst of the cauda equina is a delicate process of gray matter within a tube of pia mater. This is the *filum terminale*. This comes off from the *conus terminalis* (Fig. 402) or cone-like ending of the cord, and blends, below, with the slender cord-like prolongation of the dura mater just mentioned. (See page 695.)

The chief peculiarities of the dura mater of the cord, as compared with that investing the brain, are the following:

The dura mater of the cord is not adherent to the bones of the spinal canal, which have an independent periosteum.

It does not send partitions into the fissures of the cord, as in the brain.

Its fibrous laminæ do not separate to form venous sinuses, as in the brain.

Structure.—The dura mater consists of white fibrous and elastic tissue arranged in bands or lamellæ, which, for the most part, are parallel with one another. Its internal surface is covered by a layer of endothelial cells which gives this surface its smooth appearance. It is sparingly supplied with vessels, and some few nerves have been traced into it.

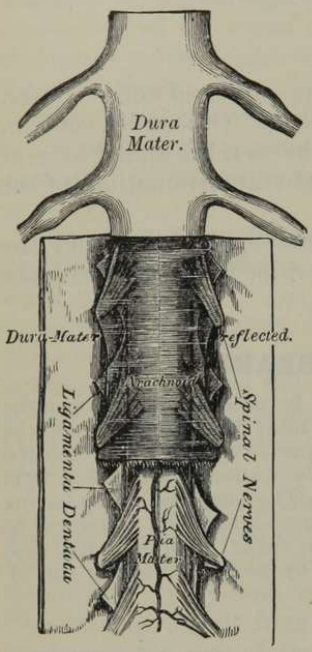

FIG. 400.—The spinal cord and its membranes.

The **Arachnoid** is exposed by slitting up the dura mater and reflecting that membrane to either side (Fig. 400). It is a thin, delicate, tubular membrane which invests the surface of the cord, and is connected to the pia mater by slender filaments of connective tissue. Above, it is continuous with the cerebral arachnoid; on each side it is continued on the various nerves, so as to form a sheath for them as they pass outward to the intervertebral foramina. The outer surface of the arachnoid is in contact with the inner surface of the dura mater, and the two are, here and there, connected together by isolated connective-tissue trabeculæ, especially on the posterior surface of the cord. For the most part, however, the membranes are not connected together, and the interval between them is named the *subdural space*. The inner surface of the arachnoid is separated from the pia mater by a considerable interval, which is called the *subarachnoidean space*. The space is the largest at the lower part of the spinal canal, and encloses the mass of nerves which form the cauda equina. Superiorly it is continuous with the cranial subarachnoid space, and communicates with the general ventricular cavity of the brain by means of an opening in the pia mater at the inferior boundary of the fourth ventricle (*foramen of Majendie*). It contains an abundant serous secretion, the *cerebro-spinal fluid*. This secretion is sufficient in amount to expand the arachnoid membrane, so as to completely fill up the whole of the space included in the dura mater. The subarachnoidean space is occupied by trabeculæ of delicate connective tissue, connecting the pia mater on the one hand with the arachnoid membrane on the other. This is named *subarachnoid tissue*. In addition to this it is partially subdivided by a longitudinal membranous partition, which serves to connect the arachnoid with the pia mater, opposite the posterior median fissure. This partition is incomplete and cribriform in structure, consisting of bundles of white fibrous tissue interlacing with each other. This space is to be regarded as, in reality, a great lymph-space, from which the lymph carried to it by the perivascular lymph-sheath (see page 87) is conveyed back into the circulation.

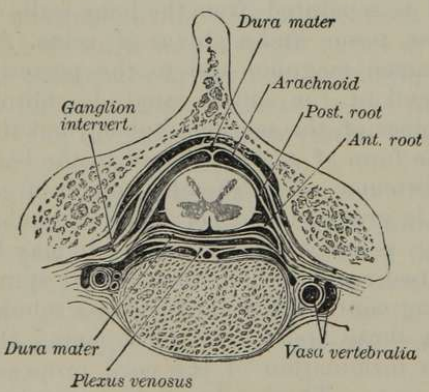

FIG. 401.—Transverse section of the spinal cord and its membranes. (Gegenbaur.)

Structure.—The arachnoid is a delicate membrane made up of closely arranged interlacing bundles of connective tissue in several layers.

The **Pia Mater** of the cord is exposed on the removal of the arachnoid (Fig. 400). It covers the entire surface of the cord, to which it is very intimately adherent, forming its neurilemma, and sending a process downward into its anterior fissure. It also forms a sheath for each of the filaments of the spinal nerves, and invests the nerves themselves. A longitudinal fibrous band extends along the middle line on its anterior surface, called by Haller the *linea splendens;* and a somewhat similar band, the *ligamentum denticulatum*, is situated on each side. At the point where the cord terminates the pia mater becomes contracted, and is continued down as a long, slender filament (*filum terminale*), which descends through the centre of the mass of nerves forming the cauda equina, and is blended with the impervious sheath of dura mater on a level with the third sacral vertebra. It assists in maintaining the cord in its position during the movements of the trunk, and is from this circumstance called the *central ligament* of the spinal cord. It contains a little gray nervous substance, which may be traced for some distance into its upper part, and is accompanied by a small artery and vein. At the upper part of the cord the pia mater presents a grayish, mottled tint, which is owing to yellow or brown pigment-cells scattered among the elastic fibres.

Structure.—The pia mater of the cord is less vascular in structure, but thicker and denser, than the pia mater of the brain, with which it is continuous. It consists of two layers: an outer composed of bundles of connective-tissue fibres, arranged for the most part longitudinally; and an inner, consisting of stiff bundles of the same tissue, which present peculiar angular bends, and is covered on both surfaces by a layer of endothelium. Between the two layers are a number of cleftlike lymphatic spaces which communicate with the subarachnoid cavity, and a number of blood-vessels which are enclosed in a perivascular sheath, derived from the inner layer of the pia mater, into which the lymphatic spaces open. It is also supplied with nerves, which are derived from the sympathetic.

The **Ligamentum Denticulatum** (Fig. 400) is a narrow fibrous band, situated on each side of the spinal cord, throughout its entire length, and separating the anterior from the posterior roots of the spinal nerves. It has received its name from the serrated appearance which it presents. Its inner border is continuous with the pia mater at the side of the cord. Its outer border presents a series of triangular, dentated serrations, the points of which are fixed at intervals to the dura mater. These serrations are twenty-one in number on each side, the first being attached to the dura mater, opposite the margin of the foramen magnum between the vertebral artery and the hypoglossal nerve, and the last near the lower end of the cord. Its use is to support the cord in the fluid by which it is surrounded.

THE SPINAL CORD (Fig. 402).

The **Spinal Cord** (*medulla spinalis*) is the cylindrical, elongated part of the cerebro-spinal axis which is contained in the vertebral canal. Its length is usually about seventeen or eighteen inches, and its weight, when divested of its membranes and nerves, about one ounce and a half, its proportion to the encephalon being about 1 to 33. It does not nearly fill the canal in which it is contained, its investing membranes being separated from the surrounding walls by areolar tissue and a plexus of veins. It occupies, in the adult, the upper two-thirds of the vertebral canal, extending from the upper border of the atlas to the lower border of the body of the first lumbar vertebra, where it terminates in a slender filament of gray substance, which is continued for some distance into the *filum terminale*. In the fœtus, before the third month, it extends to the bottom of the sacral canal, but after this period it gradually recedes from below, as the growth of the bones composing the canal is more rapid in proportion than that

of the cord, so that in the child at birth the cord extends as far as the third lumbar vertebra. Its position varies also according to the degree of curvature of the



FIG. 402.—The spinal cord: *A*, from in front. *B*, from behind. (Gegenbaur and Quain.)

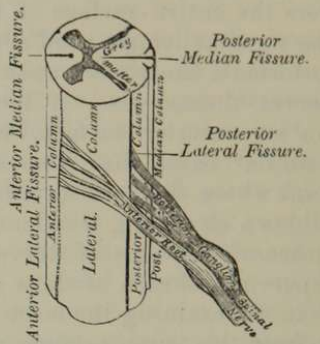

FIG. 403.—Spinal cord. Side view. Plan of the fissures and columns.

spinal column, being raised somewhat in flexion of the spine. On examining its surface it presents a difference in its diameter in different parts, being marked by two enlargements, an upper or cervical, and a lower or lumbar. The cervical enlargement, which is the larger, extends from about the third cervical to the first or second dorsal vertebra: its greatest diameter is in the transverse direction, and it corresponds with the origin of the nerves which supply the upper extremities. The lower, or lumbar, enlargement (*intumescentia*) is situated opposite the last two or three dorsal vertebræ, its greatest diameter being from before backward. It corresponds with the origin of the nerves which supply the lower extremities. In form the spinal cord is a flattened cylinder (Fig. 402).

Fissures.—It presents on its anterior surface, along the middle line, a longitudinal fissure, the *anterior median fissure*, and on its posterior surface another fissure, which also extends along the entire length of the cord, the *posterior median fissure*. These fissures penetrate through the greater part of the thickness of the cord, and incompletely divide the cord into two symmetrical halves, united in the middle line by a transverse band of nervous substance, the *commissure*.

The **Anterior Median Fissure** is wider, but of less depth, than the posterior, extending into the cord for about one-third of its thickness, and is deepest at the lower part of the cord. It con-

tains a prolongation from the pia mater, and its floor is formed by the *anterior white commissure*, which is perforated by numerous blood-vessels passing to the centre of the cord.

The **Posterior Median Fissure** is not an actual fissure, as the space between the lateral halves of the posterior part of the cord is crossed by connective tissue and numerous blood-vessels, so that no actual hiatus exists, and there is consequently no prolongation of the pia mater into it. It extends into the cord to about one half its depth, and its floor is formed by the *posterior gray commissure.*

Lateral Fissures.—On each side of the anterior median fissure a linear series of foramina may be observed, indicating the points where the anterior roots of the spinal nerves emerge from the cord. This is called, by some anatomists, the *antero-lateral fissure* of the cord, although no actual fissure exists in this situation. And on each side of the posterior median fissure, along the line of attachment of the posterior roots of the nerves, a delicate fissure may be seen, leading down to the gray matter which approaches the surface in this situation; this is called the *postero-lateral fissure* of the spinal cord. On the posterior surface of the spinal cord, between the posterior median and the postero-lateral fissure on each side, is a slight longitudinal furrow (*posterior intermediate furrow*) marking off two tracts, the *posterior median columns.* These are most distinct in the cervical region, but are stated by Foville to exist throughout the whole length of the cord.

Columns of the Cord.—Each half of the spinal cord is thus divided into three main columns: an antero-lateral column, a postero-lateral column, and a postero-median column.

The *antero-lateral column*, which forms rather more than two-thirds of the entire circumference of the cord, includes all the portion of the cord between the anterior median fissure and the postero-lateral fissure.

By some anatomists the antero-lateral column is subdivided into an *anterior column*, which includes all the portion of the cord between the anterior median fissure and the line from which the anterior roots of the nerves arise; and a *lateral column*, which includes all the portion between the line of origin of the anterior roots of the spinal nerves and the postero-lateral fissure.

The *postero-lateral column* is situated between the postero-lateral fissure and the posterior intermediate furrow.

The *posterior median column* is that narrow segment of the cord which is seen on each side of the posterior median fissure, usually included with the preceding as the posterior column.

Structure of the Cord.—If a transverse section of the spinal cord be made, it will be seen to consist of white and gray nervous substance. The white matter is situated externally, and constitutes the greater part. The gray substance occupies the centre, and is so arranged as to present on the surface of the section two crescentic masses, placed one in each lateral half of the cord, united together by a transverse band of gray matter, the *gray commissure.* Each crescentic mass has an anterior and posterior horn. The posterior horn is long and narrow, and approaches the surface of the postero-lateral fissure, near which it presents a slight enlargement, the *caput cornu:* from this it tapers to form the *apex cornu*, which at the surface of the cord becomes continuous with the fibres of the posterior roots of the spinal nerves. The anterior horn is short and thick, and does not quite reach the surface, but extends toward the point of attachment of the anterior roots of the nerves. Its margin presents a dentate or stellate appearance. Owing to the projections toward the surface of the anterior and posterior horns of the gray matter, each half of the cord is divided, more or less completely, into three columns, anterior, middle, and posterior, the anterior and middle being joined to form the antero-lateral column, as the anterior horn does not quite reach the surface.

The commissure of the spinal cord is composed of white and gray fibres, hence called the white and gray commissures. The *white commissure* is formed of fibres which, for the most part, pass horizontally between the gray matter of the anterior horn of one side and the anterior white column of the opposite side.

The *gray commissure*, which connects the two crescentic masses of gray matter, is separated from the bottom of the anterior median fissure by the anterior white commissure. It consists of transverse fibres, with a considerable quantity of neuroglia between them. The fibres when they reach the lateral crescents diverge: some pass backward to the posterior roots; others spread out, at various angles, into the cervix cornu.

Running through the gray commissure of the

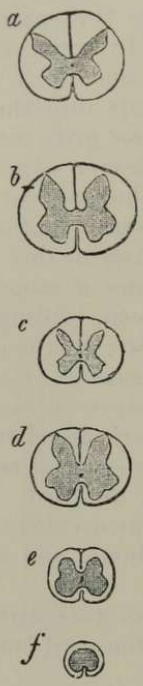

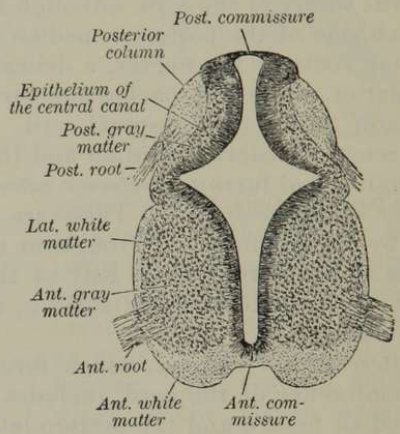

FIG. 404.—Diagram of cross-sections of the cord at various levels. *a*, beginning of the cervical portion. *b*, cervical enlargement. *c*, thoracic or dorsal region. *d*, lumbar enlargement. *e*, end of the same. *f*, end of the cord. (Gegenbaur.)

FIG. 405.—Cross-section of the cervical portion of the spinal cord of a six weeks' embryo. (Kölliker.)

whole length of the cord is a minute canal, which is barely visible to the naked eye in the human cord, but is proportionally larger in some of the lower vertebrata. It is called the *central canal*, and opens above into the fourth ventricle, and terminates below in a somewhat dilated extremity. It is lined in the fœtus by columnar ciliated epithelium, but in the adult very often the cilia have disappeared, and the canal is filled with their remains. The cells are supported on a layer of neuroglia, which is sometimes called the substantia gelatinosa centralis.

The mode of arrangement of the gray matter, and its amount in proportion to the white, vary in different parts of the cord. Thus, the posterior horns are long and narrow in the cervical region; short and narrower in the dorsal; short, but wider, in the lumbar region. In the cervical region the crescentic portions are small, and the white matter more abundant than in any other region of the cord. In the dorsal region the gray matter is least developed, the white matter being also small in quantity. In the lumbar region the gray matter is more abundant than in any other region of the cord. Toward the lower end of the cord the white matter gradually ceases. The crescentic portions of the gray matter soon blend into a single mass, which forms the only constituent of the extreme point of the cord.

Minute Anatomy of the Cord.—The cord consists of an outer part, composed of medullated nerve-fibres, which is the *white substance;* and of a central part, the *gray matter*, both supported in a peculiar kind of tissue, called *neuroglia.*

The **neuroglia** consists of a homogeneous transparent matrix, of a network of very delicate fibrillæ, and of small stellate or branched cells, the *neuroglia-cells.*

In addition to forming a ground substance, in which the nerve-fibres, nerve-cells, and blood-vessels are imbedded, a considerable accumulation of neuroglia takes place in three situations—(1) on the surface of the cord, beneath the pia mater; (2) around the central canal; and (3) in the posterior part of the posterior horn, forming the substantia cinerea gelatinosa.

The **white substance of the cord** consists of medullated nerve-fibres, with blood-vessels and neuroglia. On transverse section of the white substance of the cord a very striking object is presented. It is seen to be studded all over with minute dots, surrounded by a white area, and this again by a dark circle (Fig. 410). This is due to the longitudinal medullated fibres seen on section. The dot is the axis-cylinder, the white area the substance of Schwann, and the dark circle the tubular membrane of the fibres, which seems to consist of several laminæ. Externally, the neuroglia is seen to form a delicate connective sheath round the outer surface of the cord immediately beneath the pia mater, from which numerous

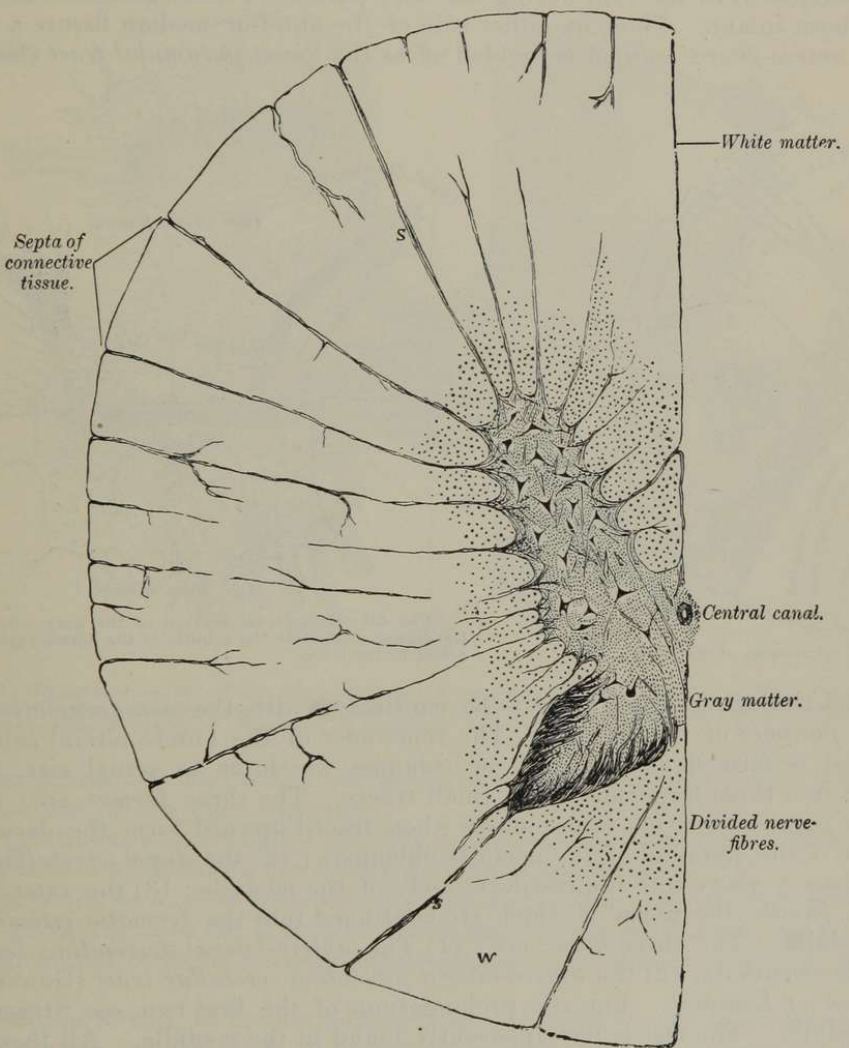

FIG. 406.—Transverse section through the cervical portion of the spinal cord of the calf. Magnified 40 diameters. (Klein and Noble Smith.)

septa pass in to separate the respective bundles of fibres and extend between the individual nerve-fibres, acting as a supporting medium in which they are imbedded. Thus it will be seen that the greater bulk of the white matter of the cord is made up of longitudinal medullated fibres, which are arranged in groups forming the antero-lateral and posterior columns.

There are, however, also *oblique* and *transverse* fibres in the white substance. These are principally found (1) at the bottom of the anterior median fissure, forming the white commissure, the fibres passing from the gray matter of the anterior horn on one side to the white matter of the anterior column of the opposite side; (2) horizontal or oblique fibres passing from the roots of the nerves into

the gray matter; and (3) fibres leaving the gray matter, and pursuing a longer or shorter horizontal course between the bundles of longitudinal fibres, with which many of them are continuous.

The investigation of pathological lesions has shown that of the *main columns* of the cord each consists of certain sub-columns or tracts of fibres, for it has been found that separate lesions are strictly limited to certain well-determined parts of the organ without involving neighboring regions. That these parts or fasciculi correspond to so many distinct anatomical systems, each endowed with special functions, seems abundantly proved by the researches of Flechsig and others on the development of the cord during the later periods of utero-gestation and in the newly-born infant. Thus, on either side of the anterior median fissure a portion of the *antero-lateral column* is divided off as the *direct pyramidal tract* (fasciculus

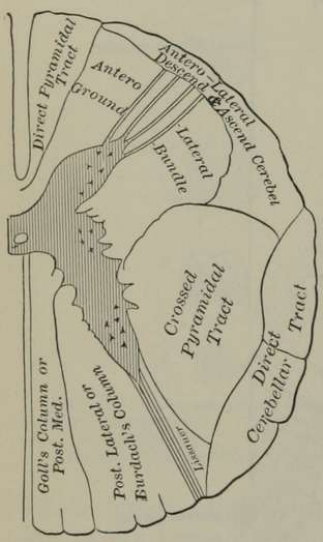

FIG. 407.—Columns of the cord.

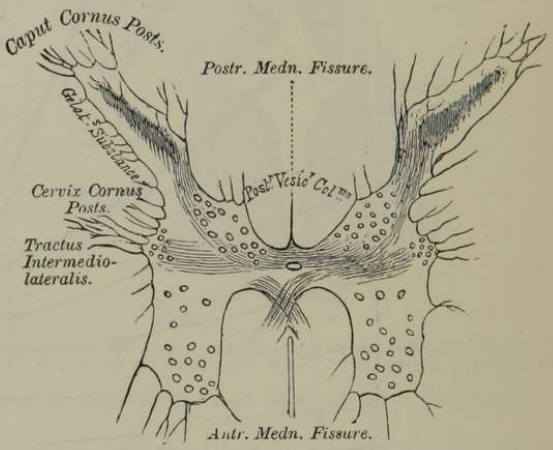

FIG. 408.—Transverse section of the gray substance of the spinal cord, near the middle of the dorsal region. Magnified 13 diameters.

of Türck), which can be traced to be continuous with the *non-decussating fibres* of the *pyramid* of the medulla. The remainder of the antero-lateral column of the cord is formed of six tracts or columns, which, as to actual size, may be divided into three large and three small tracts. The three *former* are: (1) The *crossed pyramidal tract*, whose fibres when traced upward form the decussating portion of the pyramid of the medulla oblongata; (2) the *direct cerebellar tract*, which passes above into the restiform body of the medulla; (3) the *antero-lateral ground bundle*, the fibres of which are continued into the *formatio reticularis* of the medulla. The three *latter* are: (1) The *antero-lateral descending cerebellar tract* (Loewenthal); (2) the *antero-lateral ascending cerebellar tract* (Gowers); (3) the *tract of Lissauer*. For the prolongations of the first two, see Structure of the Medulla. The last is not apparently found in the medulla. All these small tracts occupy the *surface* of the cord (see Fig. 407).

The posterior column of the cord is divided into two: the portion which lies next the posterior median fissure is called the *column of Goll* (*postero-median*), and if traced upward is found to be continuous with the funiculus gracilis of the medulla. The remainder of the posterior column is called the *postero-lateral* or *Burdach's column*, and is prolonged into the medulla under the name of funiculus cuneatus.

Collateral Fibres.—The posterior nerve-roots, on entering the cord, separate into the *component fibres*, each of which *bifurcates* into an ascending and descending branch, which run upward and downward in the posterior column and in the posterior cornu. Furthermore, each of these fibres before bifurcating and each of its bifurcations gives off at intervals *collateral branches*, which penetrate the

gray matter and there break up into an arborization of nerve-fibrils which appears to have some, though not direct, connection with a similar arborization of the *branched* processes from the nerve-cells (see Fig. 411).

The **gray substance of the cord** occupies its central part in the shape of two crescentic horns, joined together by a commissure. Each of these crescents has an anterior and posterior cornu.

The *posterior horn* consists of two parts—the *caput cornu*, or expanded extremity of the horn (Fig. 409), round which is a lighter space or lamina of

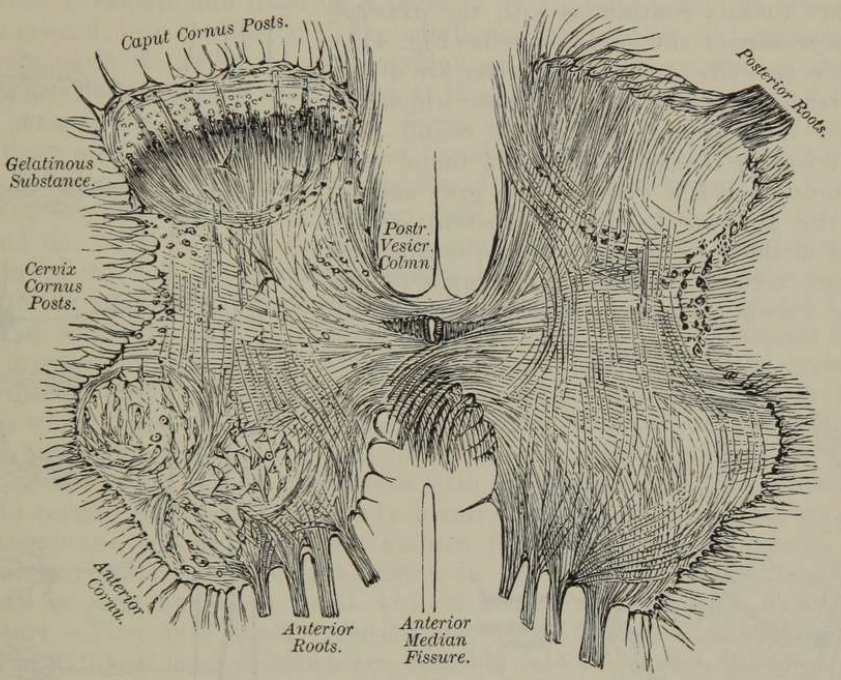

FIG. 409.—Transverse section of the gray substance of the spinal cord through the middle of the lumbar enlargement. On the left side of the figure groups of large cells are seen; on the right side, the course of the fibres is shown without the cells. Magnified 13 diameters.

gelatinous substance; and the *cervix cornu*, or narrower portion, which connects it with the rest of the gray substance.

The gelatinous substance is a peculiar accumulation of neuroglia (Klein), and has been named by Rolando the *substantia cinerea gelatinosa*.

The *anterior horn of the gray substance* in the cervical and lumbar swellings, where it gives origin to the nerves of the extremities, is much larger than in any other region, and contains several distinct groups of large and variously shaped cells.

In addition to this, in certain parts of the cord other horns or projections of the gray matter may be seen on transverse section. One of these, the *lateral horn*, is found projecting outward from the lateral region of the gray matter on a level with the gray commissure in the cervical and upper part of the dorsal region of the cord; and a second, *Clarke's vesicular column*, is found on the inner side of the posterior horn near the gray commissure, in the upper cervical or dorsal regions or at the point of exit of the lower lumbar nerves.

The gray commissure is situated behind the white commissure, which separates it from the bottom of the anterior median fissure.

The **gray substance of the cord** consists of—(1) nerve-fibres of variable but smaller average diameter than those of the columns; (2) nerve-cells of various shapes and sizes, with from two to eight processes; (3) blood-vessels and neuroglia.

The *nerve-fibres* of the gray matter of the *posterior horn* are for the most part

composed of a minute and dense network of minute fibrils, which is termed "Gerlach's nerve-network," intermingled with nerves of a larger size. This network is continuous with the medullated fibres of the posterior nerve-roots on the one hand (Deiters), and with the branched processes of the ganglion-cells on the other (Gerlach), so that the ganglion-cells are connected with the medullated fibres of the posterior nerve-roots only indirectly through the nerve-network. The arrangement of the fibres in the *anterior horn* of the gray matter appears to be somewhat different: here the medullated fibres of the anterior nerve-roots are for the most part directly continuous with the *axis-cylinder* processes of the ganglion-cells (Fig. 411).

The *nerve-cells* of the gray matter are of two kinds, large branched nerve-vesicles which are collected into groups, and small round cells which resemble free nuclei and are found scattered throughout the whole of the gray matter.

In the anterior horn is a constant group, situated at the anterior part of the cornu, and sometimes termed the *vesicular column of the anterior cornu*. It consists of two groups of cells: one mesial, near the anterior column; the other lateral, near the lateral column. At the base of the posterior horn on its inner side, and joining the gray commissure, is a group of nerve-cells, which give rise to the projection mentioned above as being seen on transverse section in the upper part of the cord, which is called Clarke's posterior vesicular column.

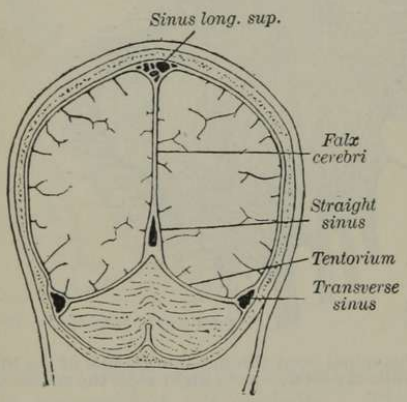

FIG. 410.—Transverse vertical section of the head, occipital region, showing hemispheres and cerebellum. (Gegenbaur.)

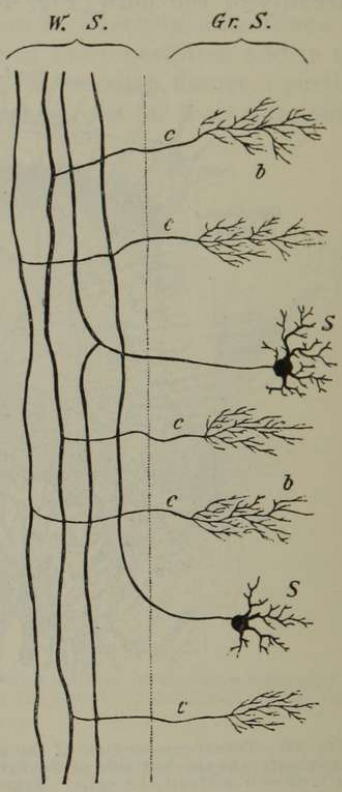

FIG. 411.—Diagram showing collateral fibres (*c*) and arborizations (*b*). *S*, arborization of the *branched* processes of a *cell*, whose axis-cylinder process is seen prolonged as a nerve-fibre. *W. S.* and *Gr. S.*, white and gray substance. (Gegenbaur.)

At the junction of the anterior and posterior cornu, in the outer portion of the gray matter, is a third group of cells, the *tractus intermedio-lateralis*. In certain regions of the cord these cells extend in amongst the fibres of the white matter of the lateral column, and give rise to the lateral horn. In addition to these groups a few large scattered cells are found in the posterior horn, extending into the substantia cinerea gelatinosa.

THE BRAIN AND ITS MEMBRANES.

Dissection.—To examine the brain with its membranes the skull-cap must be removed. In order to effect this, saw through the external table, the section commencing, in front, about an inch above the margin of the orbit, and extending, behind, to a level with the occipital protuberance. Then break the internal table with the chisel and hammer, to avoid injuring the investing membranes or brain; loosen and forcibly detach the skull-cap, when the dura mater will be exposed. The adhesion between the bone and the dura mater is very intimate, and much more so in the young subject than in the adult.

MEMBRANES OF THE BRAIN.

The membranes of the brain are the dura mater, arachnoid membrane, and pia mater.

The Dura Mater.

The **Dura Mater** (Fig. 410) is a thick and dense inelastic fibrous membrane which lines the interior of the skull. Its outer surface is rough and fibrillated, and adheres closely to the inner surface of the bones, forming their internal periosteum, this adhesion being most marked opposite the sutures and at the base of the skull. Its inner surface is smooth and lined by a layer of endothelial cells. It sends three processes inward, into the cavity of the skull, for the support and protection of the different parts of the brain, and is prolonged to the outer surface of the skull through the various foramina which exist at the base, and thus becomes continuous with the pericranium; its fibrous layer forms sheaths for the nerves which pass through these apertures. At the base of the skull it sends a fibrous prolongation into the foramen cæcum; it sends a series of tubular prolongations round the filaments of the olfactory nerves as they pass through the cribriform plate, and also round the nasal nerve as it passes through the nasal slit; a prolongation is also continued through the sphenoidal fissure into the orbit, and another is continued into the same cavity through the optic foramen, forming a sheath for the optic nerve, which is continued as far as the eyeball. In the posterior fossa it sends a process down the internal auditory meatus, ensheathing the facial and auditory nerves; another through the jugular foramen, forming a sheath for the structures which pass through this opening; and a third through the anterior condyloid foramen. Around the margin of the foramen magnum it is closely adherent to the bone, and is continuous with the dura mater lining the spinal canal. In certain situations, as already mentioned (page 650), the fibrous layers of this membrane separate, to form sinuses for the passage of venous blood. Upon the outer surface of the dura mater, in the situation of the longitudinal sinus, may be seen numerous small whitish bodies, the *glandulæ Pacchioni.*

Structure.—The dura mater consists of white fibrous and elastic tissues arranged in flattened laminæ, which are divisible into two layers, the fibres of the two layers intersecting each other obliquely. A layer of nucleated endothelial cells, similar to those found on serous membranes, lines its inner surface; these were formerly regarded as belonging to the arachnoid membrane.

Its *arteries* are very numerous, but are chiefly distributed to the bones. Those found in the anterior fossa are the anterior meningeal branches of the anterior and posterior ethmoidal and internal carotid, and a branch from the middle meningeal. In the middle fossa are the middle and small meningeal branches of the internal maxillary, a branch from the ascending pharyngeal, which enters the skull through the foramen lacerum medium basis cranii, branches from the internal carotid, and a recurrent branch from the lachrymal. In the posterior fossa are meningeal branches from the occipital, one of which enters the skull through the jugular foramen, and the other through the mastoid foramen; the posterior meningeal, from the vertebral; occasionally meningeal branches from the ascending pharyngeal, which enter the skull, one at the jugular foramen, the other at the anterior condyloid foramen, and a branch from the middle meningeal.

The *veins*, which return the blood from the dura mater, and partly from the bones, anastomose with the diploic veins. These vessels terminate in the various sinuses, with the exception of two which accompany the middle meningeal artery, and pass out of the skull at the foramen spinosum to join the internal maxillary vein.

The *nerves* of the dura mater are, the recurrent branch of the fourth and filaments from the Gasserian ganglion, from the ophthalmic and hypoglossal nerves, and from the sympathetic.

The so-called glandulæ Pacchioni are numerous small whitish granulations, usually collected into clusters of variable size, which are found in the following

situations: 1. Upon the outer surface of the dura mater, in the vicinity of the superior longitudinal sinus, being received into little depressions on the inner surface of the calvarium. 2. On the inner surface of the dura mater. 3. In the superior longitudinal sinus. 4. On the pia mater, near the margin of the hemispheres.

These bodies are not glandular in structure, but simply enlarged normal villi of the arachnoid. In their growth they perforate the dura mater, and are thus found on its outer surface, and when of large size they cause absorption of the bone, and come to be lodged in pits or depressions on the inner table of the skull. The manner in which they perforate the dura mater is as follows: At an early period of their growth they project through minute holes in the inner layer of the dura mater, which open into large venous spaces situated in the tissues of the membrane on either side of the longitudinal sinus and communicating with it. In their onward growth the villi push the outer layer of the dura mater before them, and this forms over them a delicate membranous sheath. In structure they consist of trabeculæ of connective tissue covered over by a layer of endothelium. The spongy tissue of which they are composed is continuous with the trabecular tissue of the subarachnoid space.

These bodies are not found in infancy, and very rarely until the third year. They are usually found after the seventh year, and from this period they increase in number as age advances. Occasionally they are wanting.

Processes of the Dura Mater.—The processes of the dura mater, sent inward into the cavity of the skull, are three in number: the falx cerebri, the tentorium cerebelli, and the falx cerebelli.

The *falx cerebri*, so named from its sickle-like form, is a strong arched process of the dura mater, which descends vertically in the longitudinal fissure between the two hemispheres of the brain. It is narrow in front, where it is attached to the crista galli of the ethmoid bone, and broad behind, where it is connected with the upper surface of the tentorium. Its upper margin is convex, and attached to the inner surface of the skull as far back as the internal occipital protuberance. In this situation it is broad, and contains the superior longitudinal sinus. Its lower margin is free, concave, and presents a sharp curved edge, which contains the inferior longitudinal sinus.

The *tentorium cerebelli* is an arched lamina of dura mater, elevated in the middle and inclining downward toward the circumference. It covers the upper surface of the cerebellum, and supports the occipital lobes of the brain, and prevents them pressing upon the cerebellum. It is attached, behind, by its convex border to the transverse ridges upon the inner surface of the occipital bone, and there encloses the lateral sinuses; in front, to the superior margin of the petrous portion of the temporal bone, enclosing the superior petrosal sinuses; and at the apex of this bone the free or internal border and the attached or external border meet, and, forming two processes, cross one another and are continued forward, to be attached to the anterior and posterior clinoid processes respectively. Along the middle line of its upper surface the posterior border of the falx cerebri is attached, the straight sinus being placed at their point of junction. Its anterior border is free and concave, and presents a large oval opening for the transmission of the crura cerebri.

The *falx cerebelli* is a small triangular process of dura mater received into the indentation between the two lateral lobes of the cerebellum behind. Its base is attached, above, to the under and back part of the tentorium; its posterior margin, to the lower division of the vertical crest on the inner surface of the occipital bone. As it descends it sometimes divides into two smaller folds, which are lost on the sides of the foramen magnum.

The Arachnoid Membrane.

The arachnoid (ἀράχνη εἶδος, like a spider's web), so named from its extreme thinness, is a delicate membrane which envelops the brain, lying between the pia

mater internally and the dura mater externally; from this latter membrane it is separated by a space, the *subdural space.*

It invests the brain loosely, being separated from direct contact with the cerebral substance by the pia mater, and a quantity of loose areolar tissue, the *subarachnoidean.* On the upper surface of the cerebrum the arachnoid is thin and transparent, and may be easily demonstrated by injecting a stream of air beneath it by means of a blowpipe; it passes over the convolutions without dipping down into the sulci between them. At the base of the brain the arachnoid is thicker, and slightly opaque toward the central part; it covers the anterior lobes, and extends across between the two temporo-sphenoidal lobes, so as to leave a considerable interval between it and the brain, the *anterior subarachnoidean space;* it is in contact with the pons and under surface of the cerebellum, but between the hemispheres of the cerebellum and the medulla oblongata another considerable interval is left between it and the brain, called the *posterior subarachnoidean space.* These two spaces communicate together across the crura cerebelli. The arachnoid membrane surrounds the nerves which arise from the brain, and encloses them in loose sheaths as far as their point of exit from the skull.

The *subarachnoid space* is the interval between the arachnoid and pia mater: this space is narrow on the surface of the hemispheres, but at the base of the brain a wide interval is left between the two temporo-sphenoidal lobes, and, behind, between the hemispheres of the cerebellum and the medulla oblongata. This space is the seat of an abundant serous secretion, the *cerebro-spinal fluid,* which fills up the interval between the arachnoid and pia mater. The subarachnoid space usually communicates with the general ventricular cavity of the brain by means of an opening in the inferior boundary of the fourth ventricle.

The subdural space also contains fluid; this is, however, small in quantity compared with the cerebro-spinal fluid.

Structure.—The arachnoid consists of bundles of white fibrous and elastic tissue intimately blended together. Its outer surface is covered with a layer of endothelium. From its inner surface are given off a number of bundles of fine connective tissue, which form a sponge-like trabecular network in the subarachnoid space, in the interstices of which the cerebro-spinal fluid is contained. Vessels of considerable size, but few in number, and, according to Bochdalek, a rich plexus of nerves derived from the motor division of the fifth, the facial, and the spinal accessory nerves, are found in the arachnoid.

The *cerebro-spinal fluid* fills up the subarachnoid space. It is a clear, limpid fluid, having a saltish taste and a slightly alkaline reaction. According to Lassaigne, it consists of 98.5 parts of water, the remaining 1.5 per cent. being solid matters, animal and saline. It varies in quantity, being most abundant in old persons, and is quickly reproduced. Its chief use is probably to afford mechanical protection to the nervous centres and to prevent the effects of concussions communicated from without.

The Pia Mater.

The pia mater is a vascular membrane, and derives its blood from the internal carotid and vertebral arteries. It consists of a minute plexus of blood-vessels, held together by an extremely fine areolar tissue. It invests the entire surface of the brain, dipping down between the convolutions and laminæ, and is prolonged into the interior, forming the velum interpositum and choroid plexuses of the fourth ventricle. It represents only the inner layer of the pia mater of the cord. Upon the surfaces of the hemispheres, where it covers the gray matter of the convolutions, it is very vascular, and gives off from its inner surface a multitude of minute vessels, which extend perpendicularly for some distance into the cerebral substance. At the base of the brain, in the situation of the anterior and posterior perforated spaces, a number of long straight vessels are given off, which pass through the white matter to reach the gray substance in the interior. On the

cerebellum the membrane is more delicate, and the vessels from its inner surface are shorter. Upon the crura cerebri and pons Varolii its characters are altogether changed; it here presents a dense fibrous structure, marked only by slight traces of vascularity.

According to Fohmann and Arnold, this membrane contains numerous lymphatic vessels. Its nerves are derived from the sympathetic, and also from the third, fifth, sixth, facial, glosso-pharyngeal, pneumogastric, and spinal accessory. They accompany the branches of the arteries.

THE BRAIN.

[By Bern B. Gallaudet. M. D.,
Demonstrator of Anatomy, College of Physicians and Surgeons (Columbia University); Surgeon to Bellevue Hospital, New York City.]

GENERAL CONSIDERATIONS AND DIVISIONS.

The Brain, or *encephalon*, is that portion of the cerebro-spinal axis which is contained in the cranial cavity. It may be divided into five portions, which, from below upward, are as follows: 1. The medulla oblongata; 2. The pons Varolii and cerebellum; 3. The mid-brain; 4. The inter-brain; 5. The two hemispheres. The inter-brain and the two hemispheres are sometimes grouped together as the *cerebrum*. Commonly, however, the word "cerebrum" means the two hemispheres only.

These various subdivisions of the brain are based on the *method of development* of the brain, each of which corresponds to one of the *five* cerebral vesicles into which the original fœtal brain, a mere tube, is soon divided.

Authorities differ as to the precise method of development of the early fœtal brain *after* it has become a closed tube. Some observers state that this brain-tube becomes partially constricted in *two* places, thus giving rise to three *primary cerebral vesicles*, and that no further constrictions as such occur. Others claim that, while this is true, soon afterward the *anterior* and *posterior* vesicles are further subdivided by similar, though not so well-marked, constrictions.

This latter method seems, perhaps, the simpler, and is the one which will be followed in the present description.

There are thus formed, first, three *primary* cerebral vesicles, and then five *secondary* cerebral vesicles. The three former are known respectively as the *fore-brain*, the *mid-brain*, and the *hind-brain*. Of the five *secondary* vesicles, the first and second result from constriction of the fore-brain; the third is the original mid-brain unchanged, while the fourth and fifth are derived from the hind-brain in a manner similar to that in which the first two are formed from the fore-brain. The first secondary vesicle is known as the *prosencephalon;* the second, as the *thalamencephalon;* the third, as the *mesencephalon*, or mid-brain; the fourth, as the *epencephalon;* and the fifth, as the *metencephalon* (Fig. 412). Each of these subdivisions, of course, contains its own portion of the original brain-cavity, and these various portions are all in direct continuity, one with the other.

In comparing these divisions of the embryonal brain with those of the adult brain already mentioned, it is found that the *prosencephalon*, together with the *thalamencephalon*, develop into or go to form the *inter-brain*, and hence their cavities make up the *third ventricle*, which is the name given to that portion of the general brain-cavity, in the adult, included in the inter-brain. It is common, however, in describing the adult brain to use the names "inter-brain" and "thalamencephalon" interchangeably, thus disregarding the prosencephalon. The reason for this is that the latter, in the adult brain, is merely the extreme anterior part of the true thalamencephalon, while its cavity holds a similar relation to the third ventricle—*i. e.* it is only the anterior end of the ventricle. It is that portion of the third ventricle which has on each side the opening known as the foramen of Monro, the significance of which will be dwelt upon later.

The *mesencephalon*, or mid-brain, simply develops into the corresponding portion of the adult brain which is known by the same name, *mid-brain*. The *epencephalon* becomes the future pons Varolii and cerebellum, while the *metencephalon* develops into the medulla oblongata. These *names*, "prosencephalon," etc., which have been given to the five secondary cerebral vesicles, are also used, sometimes, to designate the corresponding divisions of the adult brain. The terms "hind-brain" and "after-brain" are often employed, the former as a name for the pons and cerebellum, the latter for the medulla.

It will be observed that in making the above comparison there has been no mention of the *hemispheres* nor of a corresponding portion of the embryonal brain. This point will now be touched upon. Soon after the formation of the primary, or simultaneously with that of the secondary, cerebral vesicles there grows out from each side of the front part of the fore-brain or prosencephalon a hollow protrusion. These protrusions from the sides of the prosencephalon are known as the "*hemisphere*" *vesicles*, and each one is to form the corresponding *hemisphere* of the adult brain (Fig. 412). This development is brought about by a process of extension and growth in all directions, forward, backward, upward, and downward, until, as the *hemispheres*, the enormously enlarged hemisphere vesicles come close together above, and overlie from above downward all the remaining divisions of the encephalon. (The term "fore-brain" is sometimes used to designate the prosencephalon *and* the hemispheres.)

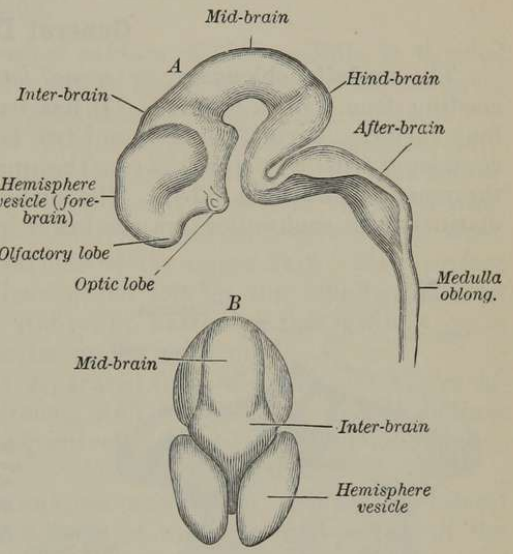

FIG. 412.—Brain of a seven weeks' old embryo, seen, *A*, from the side. *B*, from above. (Mihalkovics.)

It will be remembered that the name "third ventricle" means the cavity of the inter-brain. The cavities of the other divisions are known as follows: That

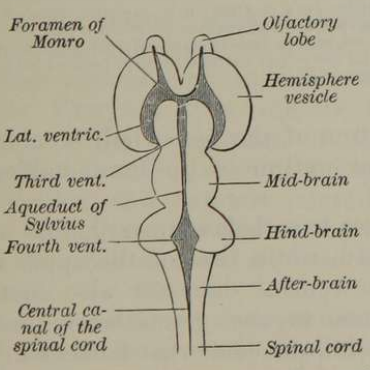

FIG. 413.—Diagram showing intercommunication of the various "brain-cavities." (Gegenbaur.)

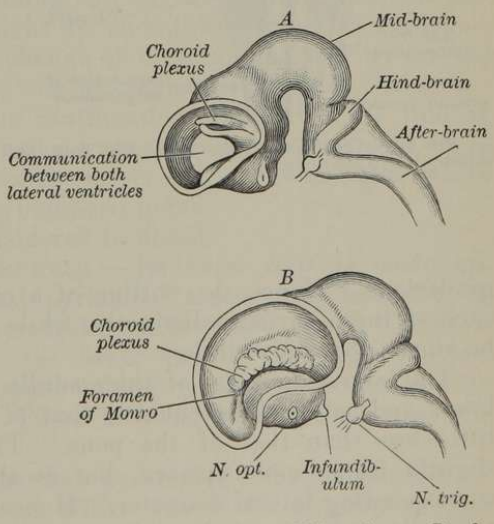

FIG. 414.—*A*, brain of a rabbit embryo. *B*, of a fœtal calf. In *both* the lateral wall of the left hemisphere vesicle is removed. (Mihalkovics.)

of each of the hemispheres is the *lateral ventricle* of the corresponding side; that of the mid-brain is the *aqueduct of Sylvius;* while that of the pons and cerebellum

and of the medulla is described as *one* cavity under the name of the *fourth* ventricle. These spaces all communicate with one another (Fig. 413). Thus the fourth ventricle opens above into the aqueduct of Sylvius, which in its turn leads into the back part of the third ventricle, and this, from its front portion laterally, communicates with each lateral ventricle by means of the corresponding foramen of Monro. It is thus seen that this foramen was originally the simple orifice formed by the protrusion of the hemisphere vesicle from the side of the prosencephalon (Fig. 414).

THE MEDULLA OBLONGATA (Figs. 415 and 416).

General Description.

The **medulla oblongata**, or *spinal bulb*, is the first division of the brain, proceeding from below upward. It has two extremities, superior and inferior, and four surfaces, dorsal, ventral, and two lateral. The inferior extremity is directly connected with the spinal cord; the upper has a similarly direct connection with the pons Varolii (Fig. 415). The surfaces in the upper half of the medulla are distinct from each other; in the lower half each runs into the other by insensible

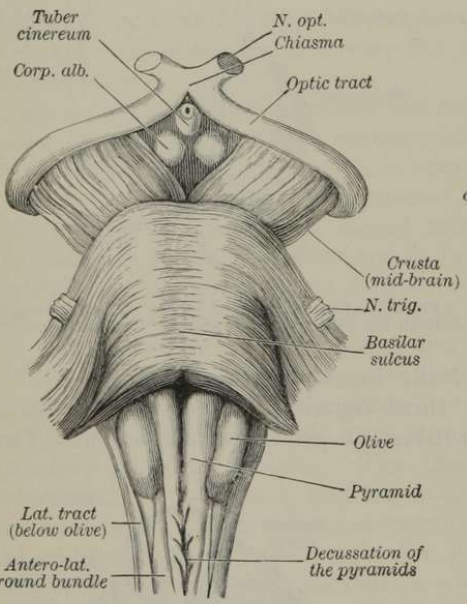

FIG. 415.—Ventral surfaces of medulla, pons, and mid-brain. (Gegenbaur.)

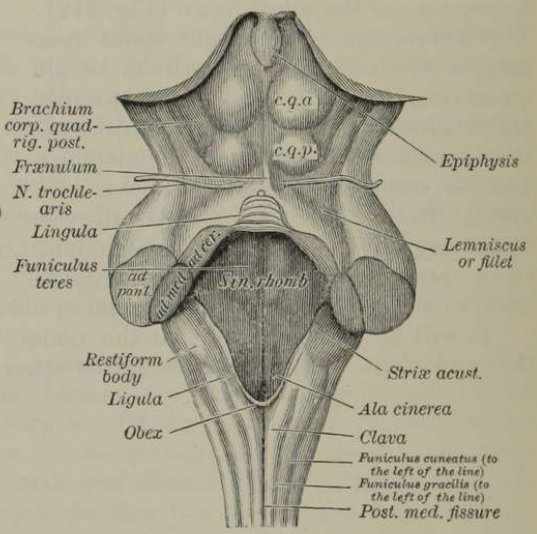

FIG. 416.—Dorsal surfaces of medulla, pons, and mid-brain. *c. q. a.* and *c. q. p.*, corpora quad. ant. and post. ad pont. = cut surface of middle ped. of cerebellum. *ad med.* = cut surface of inf. ped. of cerebellum. *ad cer.* = cut surface of sup. ped. of cerebellum. (Gegenbaur.)

gradations. Hence the outline of a cross-section of the upper half would show each of these surfaces distinctly, while a similar outline of the lower half would be almost that of a circle.

The lateral diameter of the medulla increases from below upward, that of the lower end being about equal to that of the cord, while that of the upper is but little less than that of the pons. The dorso-ventral diameter also increases slightly from below upward, but is always less, at any given level, than the corresponding lateral diameter. Hence the medulla is somewhat flattened dorso-ventrally and expands laterally as it ascends. It is directed obliquely from below upward and forward, and its lower end, which joins the cord, is on a level with the lower margin of the foramen magnum. Its ventral surface rests on the basilar groove of the occipital bone, while its dorsal surface lies under the space which separates the two hemispheres of the *cerebellum*. Ventrally its upper end

is clearly marked off from the pons by prominent transversely directed fibres belonging to the latter; dorsally, however, there is no such line of separation, the dorsal surface passing directly and smoothly into that of the pons. The length of the medulla is nearly 1 inch (20 to 24 mm.); its greatest lateral diameter is about three-quarters of an inch (17 to 18 mm.); its greatest dorso-ventral diameter is somewhat less (15 mm.).

The further description of the medulla will be divided into that of its *surface* and that of its *internal structure.*

Surface.

The Surfaces of the Medulla.—The *ventral surface* of the medulla is divided into two symmetrical lateral halves by the continuation upward of the anterior median fissure of the spinal cord. This continues up to the pons, where it terminates in a recess, the *foramen cæcum* of Vicq d'Azyr. It is interrupted, however, for a short distance after its passage into the medulla by the decussation of the crossed pyramidal tracts of the cord. The *dorsal surface* of the *lower half* of the medulla is similarly divided by the posterior median fissure of the cord, which does not extend on to the dorsal surface of the upper half. This surface is, however, bisected by a groove or sulcus which lies in the middle line and extends from the junction of the upper and lower halves of the medulla on to the dorsal surface of the pons as far as its upper extremity.

Each *lateral surface* of the medulla is separated from the adjacent halves of the dorsal and ventral surfaces by a groove, well marked above, less distinct below. These grooves may be called, respectively, the *dorso-lateral* and *ventro-lateral grooves* of the medulla.

The *dorso-lateral groove* is the continuation upward of the postero-lateral groove of the cord, and from it emerge the fibres of the accessory portion of the spinal accessory nerve, of the vagus, of the glosso-pharyngeal, and, from the extreme upper part, close to the pons, the fibres of the seventh and mesial root of the eighth. There are two points to be noted in connection with this groove: First, it is interrupted at its lower end by the change in position of the *direct cerebellar tract* of the cord. In the cord this tract is *anterior* to the postero-lateral groove, but as it passes upward into the medulla it becomes *dorsal* to the groove, and thus belongs to the corresponding half of the medullary *dorsal* surface. Secondly, its direction is not straight up and down, but is upward, forward, and outward. The reason for this change of direction, as well as for the cessation of the posterior median fissure, will be explained below.

The *ventro-lateral groove* is the direct continuation upward of the line of emergence of the *anterior roots* of the spinal nerves, although in the cord there is no similar sulcus. Out of this groove, in the upper half of the medulla, where it is very distinct, pass the fibres of the hypoglossal nerve.

These various surfaces will now be considered in detail.

The Ventral Surface of the Medulla.—Its *lower half* is made up, mesially, of the decussation of the crossed pyramidal tracts, and, laterally, of the continuations upward of the direct pyramidal tracts of the cord. Hence it is undivided, and extends laterally from the lower part of one ventro-lateral groove of the medulla to the other. Its upper half is divided in two, as already stated, by the anterior median fissure. These two halves are known as the *pyramids.*

The **pyramids** are two prominent, somewhat pyramidally shaped bundles of white matter or nerve-fibres, placed one on either side of the anterior median fissure, each being separated from the upper half of the corresponding *lateral* surface by the upper part of the ventro-lateral groove. Superiorly, they reach to the pons, at the lower border of which they are somewhat constricted. Each, as it descends, becomes somewhat enlarged, and then tapers at its lower extremity. The fibres of which each pyramid is composed are disposed in two bundles,

a large *mesial* and a smaller *lateral* one. The fibres of the former are directly continuous with those of the *crossed* pyramidal tract of the *opposite* side of the cord by means of the decussation already referred to. This decussation is more commonly spoken of as the *decussation of the pyramids*. The fibres of the lateral bundle are directly continuous with those of the *direct* pyramidal tract of *the same* side of the cord. This tract, it will be remembered, in the cord is next to the anterior median fissure. Hence in the pyramid it is displaced laterally by the passage upward, next to the median fissure, of the crossed pyramidal tract after its decussation with its fellow of the opposite side. Each pyramid, close to the pons, is often crossed by a fairly-well marked band of fibres, the *ponticulus* of Arnold. The fibres of the pyramid are continued directly upward into the pons Varolii.

The Lateral Surface of the Medulla.—Each of these surfaces, as already stated, is separated from the corresponding half of the ventral and dorsal surface respectively by the ventro-lateral and dorso-lateral groove. The entire upper half of this surface is occupied by a well-marked olive-shaped prominence, the olive or olivary body. The lower half, below the olive, is often spoken of as the "*lateral tract*" of the medulla. It is not raised up from the general surface, as is the olive, and consists of white fibres derived from the *antero-lateral ground bundle* and antero-lateral *ascending* and *descending cerebellar tracts* of the cord. These fibres pass upward, some going *beneath* the olive (the major part), while others proceed over its surface, thus forming part of its structure, and still others are found in the grooves on each side of the olive. The fibres in the grooves may be considered as coming from the cerebellar tracts (ascending and descending), while those on the surface, and those which dip under or beneath the olive, are direct prolongations of the antero-lateral ground bundle. The further destination of all these fibres will be noted later on.

The Olive or Olivary Body.—This has just been partially described. It is made up of the white fibres above mentioned, and also of a *nucleus* of gray matter in its substance, the projection of which really causes the prominence itself, or the olive. This nucleus is the *olivary nucleus* or *dentate nucleus* of the olivary body. It will be further considered below. The upper end of the olive reaches nearly to the pons, only a short but deep, transversely directed groove intervening. This small groove really connects the upper ends of the dorso-lateral and ventro-lateral grooves, between which the olive is placed, and which are here nearer together than their lower portions, owing to the forward tendency of the former. Between the olive and pyramid (ventro-lateral groove) emerge the fibres of the hypoglossal nerve. The olive is equal in breadth to the pyramid, is a little broader above than below, and is about half an inch in length. Numerous white fibres (*superficial arciform fibres*) are seen winding across the lower half of the pyramid and the olivary body to enter the restiform body (see below).

The Dorsal Surface of the Medulla.—The *lower half* of this surface is divided in two by the posterior median fissure continued upward from the cord. *Each of these halves* of the *lower half* of the dorsal surface of the medulla is separated from the so-called lateral tract or area by the inferior portion of the dorso-lateral groove, and receives the upward prolongation of the **direct cerebellar tract** of the cord, as already mentioned.

Situated in and forming parts of this same portion of the dorsal surface of the medulla are three other columns or tracts of white matter, besides the one just mentioned. These columns are known as funiculi, and are placed side by side, separated by slight grooves, between the direct cerebellar tract laterally and the posterior median fissure mesially. The one next to the direct cerebellar tract is the *funiculus of Rolando*, adjoining which is the *funiculus cuneatus*, and the innermost, next to the fissure, is the *funiculus gracilis*.

The *upper half* of the dorsal surface of the medulla is considerably wider than the lower, this increase in width being progressive from below upward. Its

appearance is therefore somewhat like that of an equilateral triangle, base uppermost and with thick rounded sides. It is divided in two, as before stated, by a longitudinal mesial sulcus or groove. The *lateral* boundary of each of these halves of the *upper half* of the dorsal surface is the superior portion of the dorso-lateral groove, immediately beyond which is, of course, the olivary body on the lateral surface. The thick rounded sides of the "triangle" are the *restiform bodies*, and the space *between* them, including the longitudinal mesial groove, is the *lower half* of the *floor* of the *fourth ventricle*. The restiform bodies project dorsally, so that they are slightly elevated above this part of the floor of the fourth ventricle, which they bound.

The Funiculus Gracilis—Open and Closed Portions of the Medulla.—The *funiculus gracilis* is the column immediately next to the posterior median fissure on the dorsal surface of the lower half of the medulla, and its fibres are continued directly up from the postero-mesial column (column of Goll) of the spinal cord. Its upper end is slightly enlarged, and is somewhat more prominent than the rest of the column. This enlargement and prominence are due to the *nucleus* found in its substance at this point (Fig. 417). The term *clava* is given to this enlarged upper end. The two *clavæ* diverge from each other, and each encroaches somewhat on the *inner aspect* of the lower part of the restiform body, thus excluding this particular part of the restiform body from its place as lateral boundary of this the lowest portion of the floor of the fourth ventricle, and becoming itself such boundary. As each clava ascends it tapers gradually to a point, and is lost on the restiform body. The course of the fibres of the gracilis and its nucleus will be described under the "internal structure" of the medulla. The fibres *do not* join with those of the restiform body. The angle of divergence of the clavæ indicates the points of cessation of the posterior median fissure and of the beginning of the groove which lies along the middle of the floor of the fourth ventricle. In other words, it is at this spot that the lower half of the medulla, which contains the upper part of the central canal of the spinal cord, now begins to widen out and become somewhat flattened dorso-ventrally. This wide separation of its edges necessarily destroys the median fissure and brings to the surface the central canal of the cord, covered in only by the dorsal part of its lining epithelium and a delicate layer of gray matter. The canal now shares in the widening-out process and becomes the lower half of the fourth ventricle, the roof of which is the same layer of epithelium and gray matter, but which now stretches across, as a delicate *triangular-shaped* lamina, between the *inner margins* of the restiform bodies and the *clavæ*, with its apex necessarily right in the angle of divergence of the clavæ. This layer always comes away with the removal of the pia mater; hence in specimens stripped of pia there is seen, of the lower half of the fourth ventricle, only its *floor* and *lateral boundaries*. For this reason also the lower half of the medulla is often called the *closed portion*, and the upper half the *open* or *ventricular* portion. (See *Tela choroidea inferior.*)

The Funiculus Cuneatus.—This column is next to the gracilis, and the fibres of which it is composed are the direct continuations upward of the fibres of the postero-lateral column (column of Burdach) of the cord. Its upper end, lying immediately under the restiform body, is enlarged and prominent, like that of the gracilis, but to a less extent. This prominence is known as the *cuneate tubercle*, and is due to the projection of a *nucleus* within its substance (Fig. 417).

The Funiculus of Rolando.—This column is lateral to the funiculus cuneatus, and, like it, its upper end is somewhat enlarged and prominent, this prominence being known as the *tubercle of Rolando*. There is also a nucleus (Fig. 417) within its substance, and its upper end lies immediately beneath the restiform body. This column is found only in the medulla, it having, apparently, no corresponding column in the cord.

The Lower Half of the Floor of the Fourth Ventricle.—This is the triangular space already mentioned as lying between the restiform bodies and clavæ of the funiculi graciles. Its *base* joins that of a similar triangular space (upper half of

the floor of the fourth ventricle) found on the dorsum of the pons. Its further consideration will be postponed until the floor as a whole is described.

The Restiform Bodies.—These are the largest and thickest "columns" found on the medulla. Each is a well-rounded mass of white fibres, and is directed from below upward, outward, and somewhat forward, diverging from its fellow. Its upper extremity is at the widest part of the medulla, where it bends, almost at a right angle, directly *dorsally* away from the medulla, and immediately enters the cerebellum. Hence a *synonym* of the restiform body is the *inferior peduncle of the cerebellum.* Its lower extremity is somewhat tapering, and not so rounded and prominent as are the succeeding portions. This is due to the fact that the upper ends of the gracilis, cuneatus, and Rolandic columns are not quite on the same level, the cuneatus reaching a little higher than the gracilis, and the Rolandic column a little higher than the cuneatus. The fibres of these three columns end here in a manner to be subsequently described. They do not enter the restiform body, which does receive, on the contrary, all the fibres of the *direct cerebellar tract*, previously mentioned. The "widening-out" of the medulla in its growth explains the divergence and oblique position of the restiform body, as well as the change in direction of the dorso-lateral groove, which separates the restiform body from the *olive*, and out of which emerge the fibres of origin of the seventh to the eleventh, inclusive, cranial nerves (except the lateral root of the eighth).

External Arciform Fibres.—The *external arciform* or *arcuate fibres* are seen on all three surfaces of the medulla. They are small, but vary in number in different medullæ. They emerge from the anterior median fissure, between the pyramids, and curve dorsally on both sides. They pass over the pyramid and olive, and then turn upward to join the restiform body. In doing so they often conceal from view the upper part of the cuneate and Rolandic funiculi. Often these fibres are collected into a well-marked bundle which crosses inferior to the olive, thus obscuring the "lateral tract" and portions of the grooves between the pyramid, olive, and restiform body. Sometimes they spread out over the entire surface of the olivary body.

Internal Structure.

The *internal structure* of the medulla includes that of the *whole* medulla—*i. e.* its various *surfaces*, already described, as well as the *deep portion* surrounded and included by these surfaces.

The *deep portion* is divided into *three bilateral areas*, separated by a *median raphe* or septum, each of which is known respectively as the *anterior*, *lateral*, and *posterior area* of the medulla, and each of which corresponds to, or may be regarded as having for its superficial or "surface" aspect, *one* of the subdivisions of the *surface* of the medulla. Thus, the anterior area corresponds to one-half of the decussation of the pyramids and to the pyramid of its own side; the lateral area, to the olive and lateral tract; the posterior area, to the restiform body, floor of fourth ventricle, and the four small columns below—viz. the direct cerebellar tract, the funiculus of Rolando, cuneatus, and gracilis. These areas, observed in transverse sections, are seen to be somewhat wedge-shaped, especially in the lower half of the medulla, and each to be separated from the adjacent one by a line of nerve-fibres running dorso-ventrally through the substance of the bulb (Fig. 417). Furthermore, the two anterior areas have between them the raphe, while the two posterior, in the lower half of the medulla, are separated by the posterior median fissure. The nerve-fibres referred to above are the root-bundles of the hypoglossal nerve on the one hand, and, depending on the level of the section, of either the seventh, glosso-pharyngeal, vagus, or spinal accessory on the other; the root-bundles of these last being, of course, in the same perpendicular plane. These fibres are all proceeding from their various nuclei of origin in the dorsal part of the medulla, to emerge, those of the hypoglossal

between the pyramid and olive, those of the last-named group between the olive and restiform body. It is thus seen that these fibres, traced dorsally, are right in line with the corresponding groove, ventro-lateral and dorso-lateral, and the similarity between the methods of division of the "deep portion" of the medulla and its "surface" is rendered complete; thus, the root-bundles of the twelfth separate the anterior and lateral areas, while those of the seventh (some of the eighth), ninth, tenth, and eleventh, according to the level, run between the lateral and posterior areas.

Each of the above "*areas*" is made up of gray and white matter, the former being derived in part from that of the cord. The latter is composed of fibres,

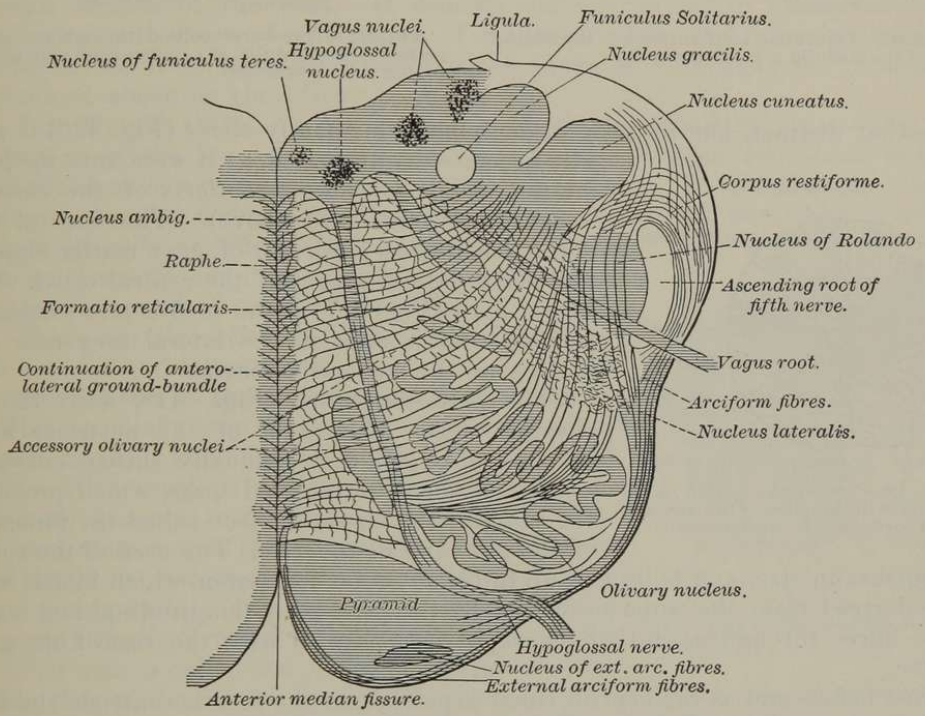

FIG. 417.—Section of the medulla oblongata at about the middle of the olivary body. (Schwalbe.)

some longitudinal, directly continued up from the cord, and others running for the most part transversely, but with a slight dorso-ventral curve, and intersecting the preceding ones. Between these intersecting fibres are scattered the various cells and nuclei of gray matter which, together with their processes, form a network. This network, together with the intersection of the *white fibres*, gives a reticular appearance to cross-sections of the medulla, which is known as the *formatio reticularis*.

As there is quite a difference between the structure and appearance of both *areas* and *formatio reticularis* as they occur in the upper (ventricular) or lower (closed) portion of the medulla, as well as between that of the corresponding *surfaces*, it will be more convenient to describe the internal structure of each half of the medulla separately.

THE LOWER OR CLOSED PART OF THE MEDULLA.—The **gray matter** is here more directly continuous with that of the cord, the central canal of which is still present, but placed dorsally, and the posterior median fissure and decussation of the pyramids are also seen. The "widening-out" of the medulla and the decussation of the crossed pyramidal tracts of the cord are the prime factors in bringing about the following changes in arrangement of the gray matter as compared to that of the cord (see Figs. 418, 419, and 420). The *anterior cornu* (in the cord) is broken up by the crossed pyramidal tract passing through it from behind forward and inward to gain the pyramid of the opposite side. The *caput cornu*

is thus separated from the *base*, and becomes pushed over laterally. At first it is

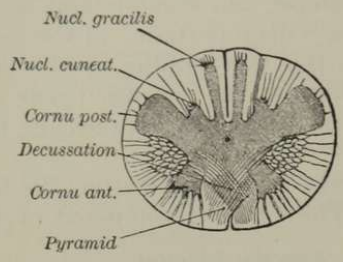

FIG. 418.—Transverse section through the beginning of the medulla × ⅞. (Gegenbaur.)

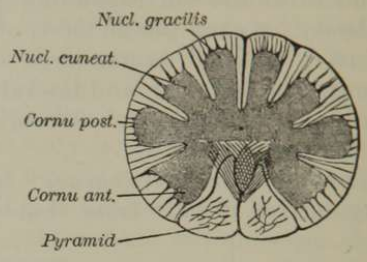

FIG. 419.—Transverse section through the closed portion of the medulla, at a higher level than the preceding × ⅞. (Gegenbaur.)

somewhat distinct, but as seen in sections immediately above (Fig. 420) it rapidly becomes disintegrated, as it were, into the gray matter of the *formatio reticularis* of the *anterior* and *lateral areas* (see above). The *base* of the cornu remains as a portion of gray matter close to the ventro-lateral aspect of the central canal. The *lateral horn* (Fig. 417) of the cord is also somewhat isolated, and is seen in the lateral area near the surface as the *nucleus lateralis*.

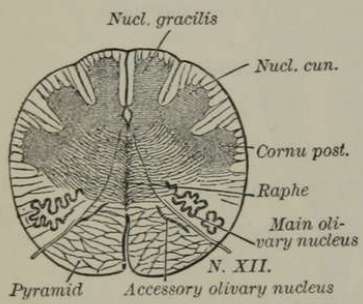

FIG. 420.—Transverse section of the medulla at the junction of the open and closed portions × ⅞. (Gegenbaur.)

The *posterior cornu* (Figs. 418, 419, 420) is changed thus: The *caput* of the posterior horn becomes enlarged, and gradually shifted outward, so that it forms a rounded mass, which produces the prominence on the surface called the funiculus of Rolando and its tubercle. The *neck* of the cornu diminishes in size, and is broken up into a reticular formation, which blends with that derived from the anterior cornu, by the passage of longitudinal and transverse fibres through it, so that the caput is separated from the rest of the gray matter.

Just before and as the central canal expands into the fourth ventricle the *base* of the posterior horn of gray matter is pushed outward into the funiculus cuneatus and funiculus gracilis; in each of these funiculi it forms a distinct accumulation of gray matter, constituting the *nucleus cuneatus* and the *nucleus gracilis*. These nuclei may be regarded as helping to form the "formatio reticularis" of the posterior *area*, although the *reticular* appearance is much less marked than in the lateral or anterior *area*. On the surface these nuclei produce, respectively, the *cuneate tubercle* and *clava*. A small portion of the base of the posterior horn is separated from the remainder, and is placed *lateral to* the cuneate nucleus; it is known as the *accessory cuneate nucleus*, probably derived from Clarke's *vesicular* column (gray matter) of the cord. Fibres from this nucleus run to the restiform body.

The **white matter** of the closed portion of the medulla is made up of white fibres, some collected into large bundles on the *surface*, while others are found in the *formatio reticularis*. The *latter*, being directly continued upward into the fibres of the *formatio reticularis* of the upper or *open portion* of the medulla, will be taken up in the description of that region.

The *fibres on the surface:*

Of these the *decussation of the pyramids*, the "*lateral tract*," and *direct cerebellar tract* have been already dwelt upon. They will again be referred to, however, in connection with the upper part of the bulb.

The **funiculus of Rolando** is due to the enlarged *head* of the posterior cornu of the gray matter, which is displaced laterally in consequence of the increase in size of the posterior columns of the medulla, so that it lies almost at right angles

to the posterior median fissure, and approaching the surface forms a prominence which is covered over by a very thin layer of white matter derived from the funiculus cuneatus. Its most prominent part is its upper end, which is called the *tubercle of Rolando.*

The **funiculus cuneatus** is the direct continuation upward of the postero-lateral column of the cord—*i. e.* its white fibres are derived from this region of the cord. The fibres *end in the gray matter* which forms the so-called *nucleus* of this column: this nucleus, at first narrow, gradually enlarges, and produces, externally, the eminence mentioned above as the tuberculum cuneatum.

The **funiculus gracilis** is the direct continuation upward of the posterior median column of the cord. It consists entirely of white fibres, which are continuous with those of this region of the cord. Like the funiculus cuneatus, its fibres *end in* its so-called *nucleus*, which produces externally the prominence mentioned above as the *clava.*

THE UPPER, OPEN, OR VENTRICULAR PART OF THE MEDULLA.—The **gray matter,** as in the lower part, contributes to form a *formatio reticularis*, but this is confined chiefly to the *anterior* and *lateral* "*areas.*" In the *posterior* "*area*" the gray matter, dorsally, is found to consist mainly of numerous individual *masses of cells* or *nuclei* scattered among fibres which are mostly longitudinal, while ventrally there is a small amount of *reticular* formation.

There are also *other individual nuclei* found in the anterior and lateral areas.

Gray Matter of the Anterior and Lateral Areas.—This is chiefly seen in the *formatio reticularis*, dorsal to the pyramids and olives (Figs. 417 and 421). It is practically a continuation upward of the same structure in the closed portion of the bulb. In the anterior area the nerve-cells are infrequent and small as compared with those in the lateral area, giving a *whiter* appearance on section. Hence that part of the formatio reticularis which is in the anterior area is called the *formatio reticularis alba*, while that of the lateral area is known as the *formatio reticularis grisea.* Just anterior to the latter—in fact, projecting *into* the olive, the prominence of which it produces—is a large isolated nucleus, **the nucleus of the olivary body** (Figs. 417, 420, and 421). This is really a hollow capsule, with an opening or hilum directed toward the middle line. White fibres extend into and proceed out of this capsule through the hilum, constituting the so-called *olivary peduncle.* On section the wall of this capsule is seen to be wavy and irregular in outline; hence the nucleus is often called the *corpus dentatum* or *dentate nucleus* of the olivary body. Microscopically, the wall of the nucleus appears to be made up of neuroglia, in which are placed small multipolar nerve-cells. From the surface this nucleus is not seen, being concealed by the fibres of the *olive.*

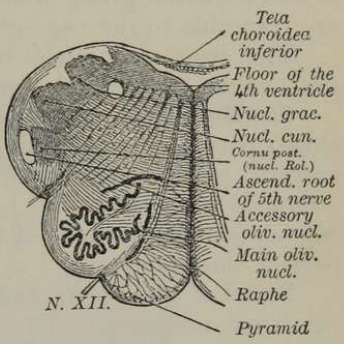

FIG. 421.—Transverse section of the upper part of the medulla × ⅔. (Gegenbaur.)

In addition to the *main* olivary nucleus there are two *accessory olivary nuclei* (Fig. 417), "inner" and "outer" respectively. The former is in the anterior area, dorsal to the pyramid; the latter in the lateral area, dorsal to the main nucleus.

Gray Matter of the Posterior Area (Figs. 417, 420, and 421).—Inferiorly, close to the lower half of the bulb, are seen the *upper ends* of the nuclei of the funiculus cuneatus and gracilis. The bulk of this gray matter, however, is observed, on section, to consist of numerous nuclei, ventral and mesial to which is a small area of reticular formation.

The Nuclei (Fig. 417).—It must be remembered that the region now being considered is just *ventral to the floor of the fourth ventricle* and the restiform bodies. In other words, owing to the "widening-out" process which has occurred in this part of the medulla the *posterior* "*area*" has dorsal to it, *laterally*, the

restiform bodies, and *mesially* the lower half of the floor of the fourth ventricle. It is therefore more convenient to regard these nuclei in their relations to the floor of the fourth ventricle and the restiform body, and especially to the *former*, as there is practically but one nucleus in relation with the latter—viz. the following: Just ventral to the latter is the end of the gray matter of the tubercle of Rolando, showing somewhat indistinctly as a rounded mass traversed by the root-bundles of the vagus (Fig. 417).

Nuclei in Relation to Floor of Fourth Ventricle.—As before stated, in the closed portion of the medulla the *base* of the anterior cornua is found close to the central canal, on its ventro-lateral aspect. As the floor of the canal becomes the floor of the fourth ventricle in passing into the upper part of the medulla, it necessarily follows that this gray matter is shifted still more dorsally and comes to lie *beneath* (ventral to) the floor of the ventricle on each side of the median groove. In this gray matter is a column of large nerve-cells from which the roots of the hypoglossal nerve arise. Hence these cells are called the **hypoglossal nucleus.** This nucleus extends upward to the pons, and is covered dorsally by white fibres, which are known as the *funiculus teres* (see below, floor of fourth ventricle). In these fibres, dorsal and mesial to the hypoglossal nucleus, there is also a smaller group of cells, the *nucleus of the funiculus teres*, from which fibres are traceable to the vago-glossopharyngeal roots.

The remaining nuclei in this region are those of the auditory, glossopharyngeal, vagus, and spinal accessory nerves.

The Nucleus of the Spinal Accessory Nerve.—This group of cells begins in the closed part of the medulla, close to the *base* of the posterior cornu, and extends upward, lying beneath the beginning of the floor of the fourth ventricle, and *lateral* to the hypoglossal nucleus. Its upper extremity reaches to the *eminentia cinerea* (see below, floor of fourth ventricle). This is the nucleus of the *accessory* part of the nerve.

Nuclei of the Vagus and Glossopharyngeal Nerves.—These are known as *principal* and *accessory*. The *principal nuclei* of both these nerves are groups of cells practically in continuity upward with the nucleus of the spinal accessory nerve. These cells lie beneath (ventral to) the *ala cinerea* and *inferior fovea* in the floor of the fourth ventricle (which see), that of the ninth being above the tenth.

The *accessory nuclei* are the upper and lower portions respectively of a small, detached pear-shaped mass of gray matter (*nucleus ambiguus*) containing nerve-cells, which is found in the reticular formation of the posterior area at some distance from the floor of the ventricle, and about on a line, ventrally, with the ala cinerea. Its stalk is seen to extend mesially and dorsally, and fibres run in this, and then turn outward and forward to join the main bundles of their respective nerves. The *nucleus of the funiculus teres* (see above) is also an accessory nucleus of these nerves.

Nuclei of the Auditory Nerve.—These are two, dorsal and ventral. The *dorsal* nucleus lies external to the vago-glossopharyngeal nucleus and underneath the *trigonum acoustici*, which is on the floor of the ventricle just lateral to the inferior fovea. The *ventral* or accessory nucleus lies *between* the two roots of the auditory nerve (which see), ventral and close to the restiform body; above, in the pons, it unites with the *ganglion of the lateral root*, which in this region is found mixed in with the fibres of this root as it passes around the restiform body.

The **white matter** of the upper part of the medulla is, like that of the lower, found *on the surface* in comparatively large bundles of fibres and, as smaller bundles or even as individual fibres, in the *formatio reticularis* of the various "*areas*" of the *deep portion.*

The *surface fibres* are those of the pyramid, the olivary body, and restiform body, together with small bundles in the ventro-lateral and dorso-lateral grooves.

The **pyramid** has already been described in discussing the *ventral surface* of the medulla. It only remains to state here that its fibres all proceed directly

upward into the pons, of which they should be considered a part, and then pass into the *crus cerebri* (mid-brain) and *internal capsule* (hemisphere) of the same side (Fig. 422).

The **olivary body,** due to the projection of its *dentate nucleus* (see above), has on its surface (or is made up of) longitudinal fibres continued up from the *lateral tract* immediately beneath it. The fibres of this lateral tract have already been traced upward from the cord. Some now pass upward over the surface of the olive to its upper end, where they dip into the deep portion of the medulla and join the fibres from the lateral tract, which have already passed *beneath* the olive

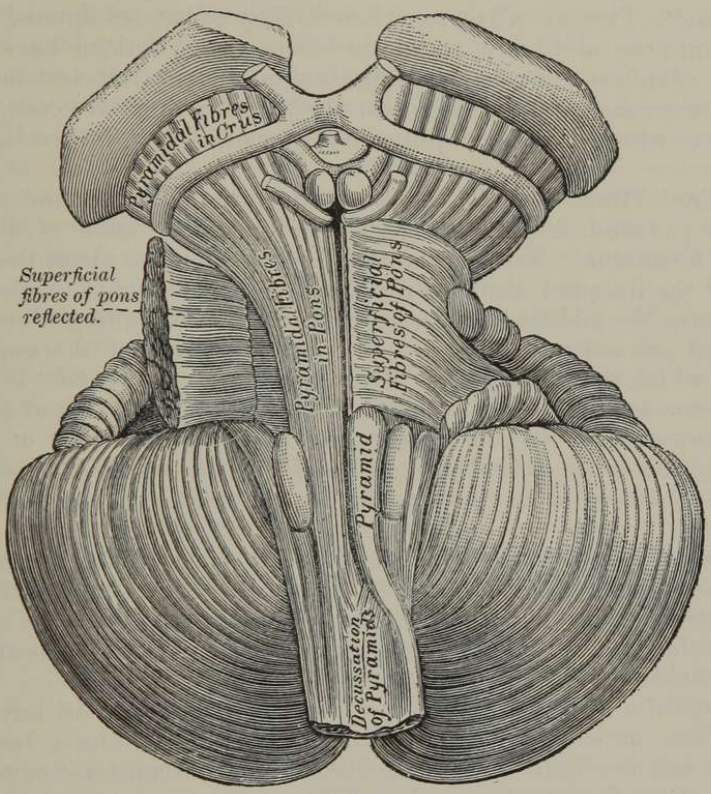

FIG. 422.—Superficial dissection of the medulla oblongata and pons. (Ellis.)

(see "lateral surface" of medulla for this and paragraphs immediately preceding and following).

Fibres in the Grooves.—Those in the *dorso-lateral* groove are the continuations upward of the *antero-lateral ascending cerebellar tract* (column of Gowers) of the cord. At the upper end of the groove they dip into the formatio reticularis, and pass at once into the dorsal part of the pons. Here they reach the corresponding *superior peduncle* of the cerebellum, turn backward and mesially in this, and then pass into the superior medullary velum, and are thus continued into the white matter of the worm or middle lobe of the cerebellum.

Those in the *ventro-lateral groove* on reaching its upper end may be considered to dip into the formatio reticularis, and then bend dorsally over the top of the olive to join the fibres of the restiform body, and thus reach the cerebellum. They are the upward prolongations of the *antero-lateral descending cerebellar tract* (column of Loewenthal) of the cord.

The Restiform Body.—As before stated, each of these columns is the largest tract on its own half of the medulla, and receives the fibres of the *direct cerebellar tract* (dorso-lateral ascending cerebellar tract—Flechsig's column), the antero-lateral descending cerebellar tract of the cord, and the *external arciform fibres.* It receives also other bands of fibres from the formatio reticularis of the medulla,

which will be mentioned below. Each restiform body passes into the cerebellum (see under "dorsal surface" of the medulla), and is therefore known, also, as the *inferior peduncle* of the cerebellum.

The white fibres of the deep portion, or *formatio reticularis*, will now be described.

Fibres of formatio reticularis in both *closed* and *open portions* of the medulla. —These fibres are described as longitudinal, transverse, and dorso-ventral. The longitudinal fibres really make up the bulk of the deep portion (all three "*areas*") of the medulla. Most of them come directly from the *antero-lateral ground bundle* of the cord, while others are derived from cells in the gray matter of the formatio reticularis itself. They are all more or less directly continued upward into the pons, and thence into the mid-brain and inter-brain. All of them have by no means been traced definitely from origin to destination. This last statement is equally true of the transverse and dorso-ventral fibres. But there are certain bundles in all these fibres which have been quite clearly made out, and these will at once be described.

Longitudinal Fibres of the Formatio Reticularis.—In each *anterior area*, just dorsal to the pyramid, is seen on section a well-marked bundle of fibres. This is the **fillet**, or *lemniscus*. Traced downward, each fillet, at about the level of the lower end of the pyramid, bends dorsally and mesially, and then *most* of its fibres *decussate* across the middle line (raphe) with the corresponding fibres of the *opposite fillet*, and proceed to the *cuneate* and *gracilis* nuclei of the opposite side, in the cells of which they terminate. This *decussation of the fillet* is dorsal to and above the decussation of the pyramids. The remaining fibres of each fillet are traceable downward on the *same side* to—(1) the *lateral tract* of the medulla, and thence to the *antero-lateral ground bundle* of the cord; (2) a few fibres run through the *trapezium* of the pons to the ventral auditory nucleus of the opposite side.

The Posterior Longitudinal Bundle.—This is a band of fibres running upward in each anterior area dorsal to the *fillet*. Below, its fibres are continued directly into the "*lateral tract*," and thence into the *antero-lateral ground bundle* of the cord. Both this and the fillet are continued upward into the pons and mid-brain, where their final distribution will be described.

In the *lateral area* the longitudinal fibres do not appear in any well-marked bundles. Those on *each side* of and in front of the olive have been described. Those dorsal are merely indeterminate fibres of the formatio reticularis or belong to the *internal arciform fibres* (see page 719).

In the *posterior area*, besides the indeterminate fibres, two rather distinct bundles are to be noted. One is the *funiculus solitarius*, and the other the *ascending root of the fifth nerve*.

The Ascending Root of the Fifth Nerve.—This is seen on section (Fig. 417) to lie just external to the gray matter of the tubercle of Rolando and dorsal to the issuing root-bundles of the vagus. Lower down, its fibres may take origin from the cells of the tubercle of Rolando, but this is considered doubtful. Passing upward, this root enters the pons, and contributes most of the fibres of the regular *sensory root* of the fifth nerve (see page 722).

The Funiculus Solitarius.—This lies just ventral to the *principal nuclei* of the vagus and glossopharyngeal nerves. It is round on section, and is surrounded by gray matter. Traced downward, this bundle gradually disappears; upward, its fibres join with the roots of origin of the ninth and tenth, especially the former. It may thus be regarded somewhat as an "ascending root" of these nerves.

Transverse and Dorso-ventral Fibres.—The *transverse* fibres are found chiefly in the formatio reticularis of the upper half of the medulla. Of these the most important—or, rather, those which have been more or less definitely traced—are known as *external* and *internal arciform fibres*.

The **external arciform fibres** have already been described on the surface of the

medulla (see page 712). They join the restiform body, and emerge from the anterior median fissure. Traced backward into the fissure, they enter the *raphe*, cross over the median line, still in the raphe, and then bend upward and become longitudinal, after which their course is not traceable. As these fibres emerge from between the pyramids a *few* fibres from each pyramid are said to join with them. As they pass across the ventro-lateral groove and olive they are joined by some of the internal arciform fibres (see below). Scattered amongst these fibres, or between them and adjacent parts of the medulla, are small masses of gray matter with nerve-cells. These masses are the *nuclei* of the external arciform fibres. The largest on each side is ventral to the pyramid.

The Internal or Deep Arciform Fibres.—A portion of these have already been mentioned. Traced upward, they start from the *nuclei* of the *gracilis* and *cuneate columns*, and then constitute the *decussation of the fillet* (see page 718). The remainder of the internal arciform fibres are known as the *olivary peduncle* (see page 715). The fibres of this peduncle decussate across the median line (through the raphe) with those of the opposite peduncle. It must be remembered that this peduncle, as a whole, is really a *lamina* of superimposed transversely running fibres, and not the mere bundle it appears to be on section. Traced from one side to the other, they start from the cells in the gray matter of the *olivary nucleus* (see page 715), and pass mesially out through the hilum. They then decussate, as above mentioned, with the opposite peduncle, and enter, through its hilum, the opposite olivary nucleus. Here they diverge as they approach the gray lamina of the nucleus, and proceed in different directions, after passing *through* the lamina. This "passing through" the lamina is not true for all the fibres, for some end in the nuclei, which in their turn give rise to new fibres which continue the course of the old ones. On "passing through," then, the lamina, the *most posterior* fibres run backward through the lateral area and join the restiform body, and thus reach the cerebellum; the *uppermost* pass upward as longitudinal fibres in the formatio reticularis of the lateral area (see page 718), and have been traced on up to the cerebral hemisphere of the same side; the more *anterior* fibres run between the longitudinal fibres on the surface of the olive or between those in the grooves on each side of the olive, and there bend backward and join the *external* arciform fibres, and are continued to the restiform body and cerebellum.

The Raphe.—The raphe is situated in the middle line of the medulla, above the decussation of the pyramids. It consists of nerve-fibres intermingled with nerve-cells. The fibres have different directions which can only be seen in suitable microscopic sections; thus:

1. Some are dorso-ventral; these are continuous ventrally with the superficial arciform fibres, and dorsally with fibres from the striæ acusticæ.
2. Some are longitudinal; these are derived from the arciform fibres, both sets, which on entering the raphe change their direction and become longitudinal.
3. Some are oblique; these are continuous with the deep arciform fibres which pass from the raphe.

Some of the fibres of the raphe arise from the nuclei ventral to the floor of the fourth ventricle.

THE PONS VAROLII (Figs. 415, 416).

The **pons Varolii** is the ventral portion of the *hind-brain*, the dorsal portion being the *cerebellum*. The *pons* is in direct continuity below with the *medulla*, all the *longitudinal* fibres of each being directly continuous from one to the other, with the exceptions of the *restiform bodies* of the medulla, which go to the cerebellum (inferior peduncles), and the *superior peduncles* of the cerebellum, which, as will be seen, belong to the structure of the pons, after they leave or before they enter, according as they are traced, the cerebellum.

The pons is about one inch long, and somewhat more in width. Dorso-ventrally, it is about three-fourths of an inch (17–18 mm.), hence its thickness is

greater than that of the medulla. There are *four* surfaces to the pons—superior, inferior, ventral, and dorsal; the two latter are free. The *superior* and *inferior surfaces* are seen only on section, the former being attached, by direct continuation of fibres, to the mid-brain, while the latter is similarly attached to the medulla.

The **ventral surface** is markedly *convex* from side to side; it rests upon the grooved dorsal surface of the *dorsum sellæ* of the body of the sphenoid bone. It presents along the middle line a longitudinal groove, wider in front than behind, which lodges the basilar artery. This surface consists entirely of a rather thick layer of well-marked transversely running fibres, extending across the median groove from side to side. The *lowermost* fibres slightly overlap the upper ends of the pyramids and cross over the extreme upper end of the anterior median fissure. The *uppermost* fibres, similarly but to a greater extent, overlap the lower part of the ventral surface of the mid-brain (crura cerebri or crustæ). Hence it follows that this surface has an upper and lower curved free margin, and each somewhat rounded and distinct from the medulla on the one hand and the crura cerebri on the other, and that these margins have nothing to do with the respective *attached* surfaces of the pons. Furthermore, after crossing the middle line the superior fibres bend downward and the inferior upward. The middle fibres are exactly transverse; hence their extremities are overlapped by those of the other two sets. The *extremities* of all these sets of fibres are seen, in horizontal section, on the dorsal aspect of the pons, and they here form, together with other transverse fibres coming from the deep part of the pons, a large rounded bundle of fibres on each side, which is directed dorsally into the cerebellum, and is known as the **middle peduncle** *of the cerebellum* of the corresponding side. Owing to its prominence this surface is often called the *tuber annulare.*

The **dorsal surface** of the pons is almost flat, and, though free, is concealed from above by the cerebellum. It is divided into a mesial and two lateral portions. Each *lateral portion* is raised up somewhat from the mesial, and is seen to be a rather broad, flat band of white fibres. These bands are not parallel, but *converge* from below upward. Superiorly, the fibres of each are continued into the mid-brain; inferiorly, they pass into the cerebellum. These bands are the **superior peduncles** of the cerebellum. Besides being raised from the mesial portion, each of these peduncles *overhangs* it a little by its inner margin. Between the inner margins of these peduncles stretches a delicate layer of white matter (valve of Vieussens) roofing over the following:

The *mesial* portion of the dorsal surface of the pons is the **upper half** of the **floor of the fourth ventricle.** Like the *lower half* (see page 711), it is triangular in shape, but its apex is upward. Its base corresponds to that of the lower or *medullary* half. As these two portions of the floor of the ventricle run into each other without any line of demarkation, it follows that the *entire floor* of the fourth ventricle is rhomboidal or diamond-shaped. The widest part of the floor is the line of union of the two *bases* of the triangles, and, if this line is continued ventrally, it will be found to run close along the lower free margin of the *tuber annulare* (ventral surface of pons). The floor, as a whole, will be described after the description of the pons is completed.

Relations of the Cerebellar Peduncles to Each Other.—If the cerebellum be removed from the pons and medulla by cutting through the three peduncles on each side close to the pons and medulla, it will be found that the cut ends are all grouped together in an area immediately external to the widest part of the floor of the ventricle. In this group the cut end of the *middle* is external to the cut ends of the *superior* and *inferior* peduncles, which here are in contact (see Fig. 416).

Deep Portion of the Pons.—This is comprised between the dorsal and ventral surfaces. It is made up of both longitudinal and transverse fibres and gray matter. The longitudinal and transverse fibres in each lateral half of the pons are arranged in two groups, *ventral* and *dorsal.*

The *ventral longitudinal fibres* are placed just dorsal to, and are concealed from below by, the transverse fibres of the ventral surface just described. They are the direct continuations of the fibres of the *pyramid.* Each of these pyramidal bundles soon after entering the pons breaks up into smaller bundles which are intersected by certain *transverse* fibres (see below). Superiorly, they are continued upward into the crusta of the mid-brain. These fibres lie on each side of the middle line, and cause a corresponding bulging of the tuber annulare. Thus is produced the median groove (*sulcus basilaris*) for the basilar artery. As they pass upward through the pons these fibres are somewhat increased in number from being reinforced by fibres derived from the nerve-cells in the ventral transverse fibres (see below).

The *dorsal longitudinal fibres* are separated by quite an interval from the preceding. This interval is filled in by transverse fibres, especially the trapezium (see below). They are continued upward from the formatio reticularis of the medulla, and among them are especially to be noted the *ascending root of the fifth nerve*, the *fillet*, and the *posterior longitudinal bundle.*

The Transverse Fibres.—These comprise *ventral* and *dorsal*, and must not be confounded, especially the former, with the *superficial* transverse fibres of the *ventral surface* (*tuber annulare*), already described. These transverse fibres now under discussion belong to the "deep portion" of the pons, *dorsal to* those of the ventral surface.

The *ventral transverse fibres* of the deep portion of the pons intersect the bundles of the *pyramidal* fibres (see above), and then curve dorsally and *join with* those of the ventral *surface* to make up the *middle peduncle* of the cerebellum. These transverse fibres, taken together, form a much thicker layer than the superficial set, and contain much gray matter between them. Across the median line, intersecting or dorsal to the pyramidal bundle, they meet and interlace with those coming from the opposite side. Furthermore, *all* of these fibres do not join the middle peduncle, many of them joining the nerve-cells, which are situated in the gray matter (*nuclei pontis*) of this layer. From these cells other fibres are given off which proceed to the pyramidal bundles (see above).

The *dorsal transverse fibres* of the deep portion of the pons, especially in its lower half, are collected into a distinct mass called, from its shape, the *trapezium.*

The **trapezium** is situated just dorsal to the pyramidal bundles, and its fibres proceed laterally on each side, tapering as they go, until they reach the cells (with which they become connected) of the *accessory* (ventral) *auditory nucleus* (Fig. 488), and, through this, the *lateral root* of the auditory nerve. Some of the fibres of the trapezium are connected with the cells of the *superior* olivary nucleus (see below), which lies just dorsally on each side, and others pass to the *fillet.*

The Septum or Raphe.—This is the upward prolongation of the medullary raphe. It is found in that portion of the pons which is dorsal to the trapezium, and does not extend to the ventral surface except at the upper and lower extremities of the pons. At these places certain of the raphe fibres pass out of the median line, and then bend laterally to join with and become part of the upper and lower margins, respectively, of the *tuber annulare.* It follows, therefore (see page 720), that some of the fibres of the *upper* margin of the tuber annulare actually encircle the corresponding crus cerebri.

The Gray Matter of the Pons.—This may be arranged as follows:

(*a*) The **nuclei pontis**, which are small masses of gray matter, containing small multipolar nerve-cells, found scattered between the bundles of the *ventral transverse* fibres (see above), and also to a less extent, between those of the *tuber annulare.* Some of the fibres of the *latter* may have an arrangement—*i. e.* interlacing and taking origin from these nuclei—similar to that already described as occurring in many of the fibres of the *ventral transverse* set.

(*b*) **Gray Matter of the Formatio Reticularis.**—This *formatio*, as before stated, lies dorsal to the trapezium. Its gray matter comprises, first, *its own* gray matter—*i. e.* small reticularly arranged masses with nerve-cells, exactly similar to

those of the formatio reticularis of the medulla. Secondly, and more important, a group, in each lateral half, of much more distinct nuclei, some of which are close under the *floor*, upper half, of the fourth ventricle, while others are more deeply, as well as *laterally*, situated. These *distinct* nuclei merit, each, a separate description, as follows:

The Superior Olivary Nucleus.—This is a mass of small nerve-cells situated just dorsal to the lateral part of the trapezium, and between the issuing root-bundles of the sixth and seventh cranial nerves. Its *structure* is similar to that of the *inferior* olivary nucleus of the medulla, though it has not the *capsular* form of the latter (see p. 715). Its cells give origin to some of the fibres of the trapezium (see p. 721), and these fibres, crossing the median line, pass to the accessory auditory nucleus of the opposite side (see p. 721).

The remaining "distinct" nuclei are those of various cranial nerves: One of these forms the nucleus of the sensory root of the fifth nerve; a second, the nucleus of the motor part of the same nerve; a third, the nucleus of the sixth nerve; and a fourth, the nucleus of the facial nerve. The nuclei of the auditory nerve are also prolonged upward into the pons.

Nuclei of the Auditory Nerve.—The *dorsal* nucleus (see p. 716) is prolonged upward into the pons, beneath the upper half of the floor of the ventricle, where it is shifted laterally and soon tapers away. It is widest at the junction between the pons and medulla. The *ventral* or accessory nucleus lies entirely external to the floor of the ventricle, and rather deeply in the formatio reticularis of the pons. Extremely dorsal to it is the upper end of the corresponding inferior peduncle (restiform body) of the cerebellum. It is the united *accessory* auditory nucleus of the medulla and nucleus of the lateral auditory *root* (see p. 716).

Nucleus of the Facial Nerve.—The nucleus of the *seventh* or *facial* nerve lies deeply in the substance of the formatio reticularis of the pons just dorsal to the superior olivary nucleus. The *fibres of origin* of the facial nerve proceed from this nucleus *dorsally* and *mesially* until they are close under the floor of the ventricle, where they are collected, on each side, into a rounded bundle. This bundle now runs *upward* (*ascending part* of the root) for a short distance close to the median line, having beneath it the nucleus of the sixth, and then makes a *sharp bend*, *ventro-laterally*, and continues its course in this direction through the substance of the pons, to emerge close under the inferior margin of the tuber annulare in the extreme upper end of the *dorso-lateral* medullary groove.

Nucleus of the Sixth Nerve.—This is situated immediately ventral to the upper half of the *funiculus teres* in the floor of the ventricle. It is external to and beneath the *ascending root* of the seventh, just described. The fibres of origin of the sixth nerve proceed from this nucleus obliquely *ventrally* and *downward* and through the pons, and emerge at the *lower margin* of the tuber annulare at a point corresponding to the upper end of the *ventro-lateral* medullary groove close to the pyramid.

Nuclei of the Fifth Nerve.—The *motor nucleus* is higher up in the pons than the nucleus of the *seventh* nerve, but is about on the same line. It is, furthermore, nearer the surface of the floor of the ventricle, being just ventral to the *lateral* margin of the latter. The *sensory nucleus* is larger than the motor and lies to its *outer* side. It would therefore lie beneath the superior peduncle of the cerebellum, and be outside of the limits of the floor of the ventricle. The *cells* of this nucleus are, however, smaller than those of the motor. Special fibres are seen to pass from each of these nuclei to the raphe of the pons, but the regular fibres are those of the root-bundles of the *motor* and *sensory roots*, respectively, of the fifth nerve. These root-bundles proceed ventrally and somewhat laterally through the substance of the pons, and emerge on the surface of the tuber annulare, nearer its superior than its inferior margin, and having between them some of its transverse fibres. All the fibres of each of these roots do not come, however, from its respective nucleus, for, if traced *inward* or *dorsally*, each root is seen to divide, just before reaching its nucleus, into two bundles, the

smaller of which, in each case, goes to the *nucleus*, while the other takes a distinct course, differing for the two roots, thus: The "non-nuclear" division of the motor root passes upward as a distinct bundle through the dorsal part of the pons and into the mid-brain, where its fibres terminate in a group of large nerve-cells situated in the gray matter on the side of the *aqueduct of Sylvius*. This is the so-called *descending root* of the fifth nerve. The "non-nuclear" division of the sensory root is the so-called *ascending root* of the fifth nerve, already sufficiently described.

Floor of the Fourth Ventricle (Fig. 423).

As already stated, the **floor of the fourth ventricle** is made up of the *mesial portions* of the *dorsal surfaces* of, the pons Varolii above and *upper half* of the medulla oblongata below. It is lozenge- or diamond-shaped; that is to say, it is composed of two triangles, with their bases opposed to each other. Hence it is often called the *fossa rhomboidalis*.

The lower triangle is formed by the divergence of the clavæ of the funiculi graciles and the restiform bodies. These columns pass upward and outward at an

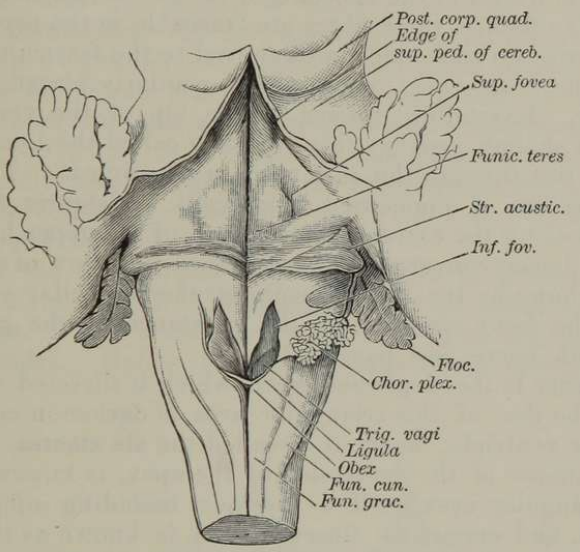

FIG. 423.—Floor of the fourth ventricle. (Henle.)

acute angle, leaving by their divergence a triangular space which forms the lower half of the floor of the fourth ventricle. In like manner the upper triangle is formed by the divergence of the superior peduncles of the cerebellum. These, traced downward, as they emerge from beneath the corpora quadrigemina of the mid-brain, are almost in ontact by their inner margins, but they gradually diverge, passing downward, backward, and outward, to reach the cerebellum, thus enclosing a triangular space which forms the upper half of the floor of the fourth ventricle.

The floor presents *four* angles. The *upper angle* reaches as high as the upper border of the pons; it presents the lower opening of the aqueduct of Sylvius, by which this ventricle communicates with the third ventricle. The *lower angle* is the angle of divergence of the clavæ, and is about on a level with the lower end of the olivary body. It presents a minute opening, the aperture of the central canal of the spinal cord.

The two *lateral angles* are situated each at an end of the conjoined bases of the triangles. The distance between them is the widest part of the floor. Each lateral angle is also the point of the "coming together" of the superior and inferior peduncle (restiform body) just as they pass into the cerebellum.

In the median line of the floor is a *longitudinal groove* which extends between

the upper and lower angles. From the fancied resemblance in the *combined* lower end of this groove and lower angle, to the nib of a writing pen, this lower angle has been named the *calamus scriptorius.*

On each side of the median fissure are two spindle-shaped longitudinal eminences, the **fasciculi** or **funiculi teretes**; they extend the entire length of the floor. Each eminence consists of white fibres, and is due to a portion of the base of the anterior cornu of gray matter of the cord which comes to the surface of the floor of the fourth ventricle after the central canal of the spinal cord has opened out into this cavity. This gray matter of the "base of the anterior cornu" now constitutes the *nuclei of origin* of the *hypoglossal* and *sixth* cranial nerves. The white fibres of the funiculus teres are partially those of the "ascending part" of the root of the seventh nerve (see page 722) and those of the formatio reticularis of the posterior "area" of the medulla.

The widest part of the floor of the ventricle is crossed by several white transverse lines, *lineæ transversæ*, *auditory striæ*, or **striæ acusticæ**; they emerge from the posterior median fissure, and, passing over the fasciculus teres of the same side, some of the fibres enter the *lateral* root of origin of the auditory nerve, while others may be traced to the flocculus of the cerebellum. Ventrally, through the posterior median fissure, these fibres are traceable to the *raphe.*

Below these striæ, on each side, and external to the fasciculus teres, is a little fossa, called the *fovea inferior;* while above, similarly placed, is a fossa, called the **fovea superior.** Extending upward to the top of the ventricle from each superior fovea is a shallow groove; this groove is called the *locus cæruleus*, which presents a bluish tint through the thin stratum covering it. This tint is due to an underlying stratum of pigmented nerve-cells (*substantia ferruginea*). The **locus cæruleus** lies along the extreme lateral limit of the upper half of the floor of the ventricle, and hence converges upward toward its fellow of the opposite side. It is slightly overhung by the inner margin of the cerebellar superior peduncle. Just ventral to the *locus cæruleus* in the substance of the pons is the *motor nucleus* of the fifth nerve (see page 722).

The **fovea inferior** is the depressed *apex*, which is directed upward, of a triangular area. The *floor* of this triangular area is darker in color than the rest of the floor of the ventricle; hence it is called the **ala cinerea.** The *base*, being elevated in consequence of the depression of the apex, is known as the **eminentia cinerea.** The triangular area itself, as a whole, including inferior fovea (apex), ala cinerea (floor), and eminentia cinerea (base), is known as the **trigonum vagi.** Immediately ventral to this trigonum is the *nucleus* of origin of the vagus, and at the apex is that of the glossopharyngeal nerve.

Between the *trigonum vagi* and the mesial groove is the *lower half* of the *funiculus teres.* This is triangular in shape, its *base* turned upward toward the striæ acusticæ. This lower half of the funiculus teres is the **trigonum hypoglossi.** Ventral to it is the *nucleus* of origin of the hypoglossal nerve.

Between the *trigonum vagi* and the restiform body is another triangular area, whose base is also directed upward, and across which the striæ acusticæ pass. This area is the **trigonum acustici.** On its base is a slight eminence, the *tuberculum acusticum.* Ventral to this trigonum and tubercle is the *dorsal nucleus* of the auditory nerve.

Between the *superior fovea* (above the striæ acusticæ) and the middle groove is the *upper half* of the *funiculus teres.* Just ventral to this, but not close to the middle line, is the *nucleus* of origin of the sixth nerve, while the *superior fovea* itself may be taken as indicating the position of the *nucleus* of the seventh nerve, which, however, is quite deeply situated in the pons (see page 722).

THE CEREBELLUM.

The **cerebellum**, together with the pons Varolii, forms the *hind-brain.* It is, morphologically, the enormously thickened and hypertrophied middle portion of the brain-matter forming the roof of that part of the brain-cavity known as the

fourth ventricle (Fig. 424), of which the *ventral* boundaries are, as already described, parts of the dorsal surfaces of the pons and medulla (after-brain).

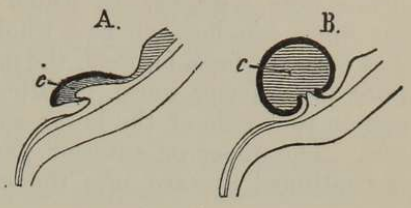

FIG. 424.—Diagram showing development of cerebellum, *c*: *A*, a simple thickening of the roof; *B*, more fully advanced. (Gegenbaur.)

The *cerebellum* is contained in the inferior occipital fossæ. It is situated beneath the occipital lobes of the cerebrum, from which it is separated by the tentorium. In form the cerebellum is oblong, and flattened from above downward, its great diameter being from side to side. It measures from three and a half to four inches (10 centimetres) transversely, and from two to two and a half inches from before backward, being about two inches thick in the centre and about six lines at the circumference, which is the thinnest part. It consists of gray and white matter: the former, darker than that of the cerebrum, occupies the *surface;* the latter, the *interior*. The surface of the cerebellum is not convoluted like the cerebrum, but traversed by numerous curved furrows or sulci, which vary in depth at different parts, and separate the laminæ of which its exterior is composed.

Weight of the Cerebellum.—Its average weight in the male is 5 ozs. 4 drs. It attains its maximum weight between the twenty-fifth and fortieth year, its increase in weight after the fourteenth year being relatively greater in the female than in the male. The proportion between the cerebellum and cerebrum is, in the male, as 1 to $8\frac{4}{7}$, and in the female, as 1 to $8\frac{1}{4}$. In the infant the cerebellum is proportionately much smaller than in the adult, the relation between it and the cerebrum being, according to Chaussier, between 1 to 13 and 1 to 26; by Cruveilhier the proportion was found to be 1 to 20.

Main Lobes of the Cerebellum.—The cerebellum is divided into three large lobes, a middle and two lateral. The middle lobe is the **worm**, and the two lateral are the **hemispheres**. These lobes are not separable from each other, being joined together by their sides. Hence the upper surface of the cerebellum, as a whole,

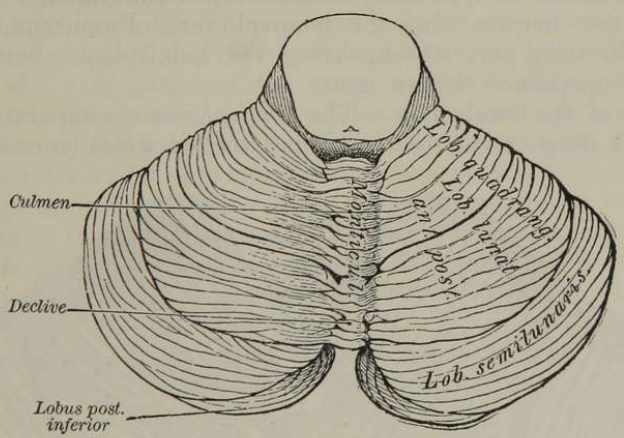

FIG. 425.—Upper surface of cerebellum, × ⅔. (Gegenbaur.)

is the upper surfaces of the two hemispheres connected in the middle line by the *upper surface* of the *worm*, which last appears as a slightly elevated narrow ridge, about 1 centimetre wide, from which the upper surfaces of the *hemispheres* slope away laterally and posteriorly, and are therefore flattened or slightly concave (Fig. 425). The *inferior surfaces* (Fig. 426) of the hemispheres are markedly convex both from before backward and from side to side. In the middle line they partially overlap and conceal the *inferior surface* of the *worm;* but on separating them—which can be done to a certain degree without tearing any tissue—the entire inferior surface of the worm is brought into view. This is far more dis-

tinct than the upper surface, and has on each side of it, marking it off from the hemisphere, a *deep groove* which runs antero-posteriorly. The inferior surface of the worm can be seen as a whole only after removal of the pons and medulla. The space or fossa between the inferior surfaces of the hemispheres, and which contains the inferior worm, is called the *vallecula*, and the *grooves* above mentioned, one on each side of the lower surface of the worm, are known as the *sulci vallecuæ*. The upper or anterior part of the vallecula lies dorsal to the medulla, and is continued upward into the *anterior cerebellar notch;* the lower or posterior

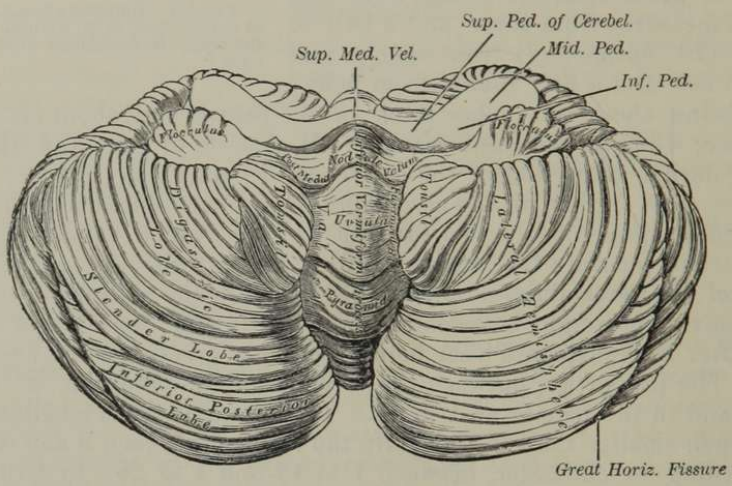

FIG. 426.—Under surface of the cerebellum.

part contains the lower portion of the falx cerebelli, and is continued into the *posterior cerebellar notch* (see below).

Although in the adult human brain each hemisphere is much larger than the worm, still the latter is morphologically the more important, being the part first developed in mammals, and, in many of them lower than man, constituting a large median lobe quite distinct from the hemispheres. Furthermore, in fishes and reptiles it is the only part which exists, the hemispheres being additions and attaining their maximum size in man.

The Notches of the Cerebellum.—The *hemispheres* are separated in front in the middle line by a deep notch, the *anterior cerebellar notch* (*incisura cerebelli anterior*), and also behind (similarly) by a smaller notch, *posterior cerebellar notch* (*incisura cerebelli posterior*) (Fig. 427). The *anterior* notch is much wider, and

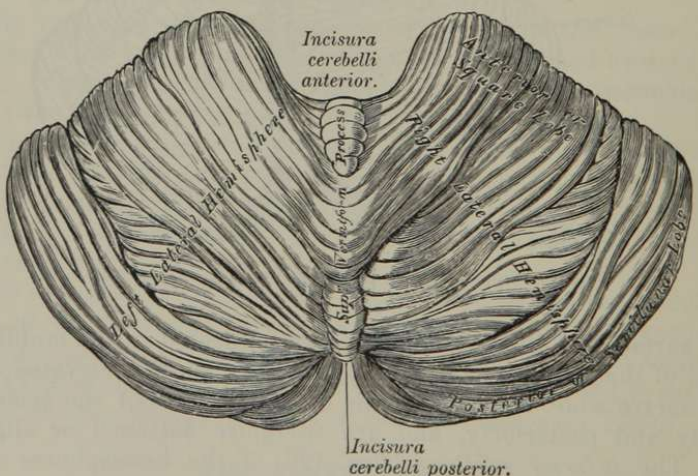

FIG. 427.—Upper surface of the cerebellum.

its sides are much more curved, than those of the *posterior*. This notch is really the deeply hollowed-out "anterior margin" of the cerebellum. It lies close to the pons and upper part of the medulla, while the upper *edge* of the notch extends to or encircles the posterior pair of corpora quadrigemina of the mid-brain. This edge can be raised, however, and then can be seen the superior cerebellar peduncles and valve of Vieussens (see below). The *posterior* notch is free. When within the cranium it contains the upper part of the falx cerebelli. The *sides* of each *notch* are formed by the respective hemispheres, while the bottom of each notch, or its *centre*, is the *anterior* and *posterior extremity*, respectively, of the *worm*.

The *fissures* of the cerebellum are very numerous and dip deeply into its substance. Of these the largest and deepest is the **great horizontal fissure.** This passes completely around the cerebellum, forming its circumference as it were, and its plane is horizontal. As it crosses the median line, in front and behind, it cuts into the *respective extremities* of the *worm*, and splits the *sides* of each of the *notches* as well (see above). Hence this fissure divides each hemisphere and the worm (the entire cerebellum) into an upper and a lower half. The edges and sides of this fissure are everywhere in contact, and lined by gray matter, *except* where it runs across the *anterior cerebellar notch*, where its edges, upper and lower, are separated by the passage between them of the *white matter* of the cerebellum.

All the remaining fissures of the cerebellum are lined by gray matter; their edges are everywhere in contact, and they all terminate, by one extremity at least, in the great horizontal fissure (see below for further details of these fissures).

The Worm.—This, as already stated, is the *middle lobe* of the cerebellum. It has an upper and a lower surface, and two extremities, anterior and posterior. The upper surface is called either the *superior vermiform process* or the *upper worm;* and the lower surface, either the *inferior vermiform process* or the *lower worm.* Its *sides* are attached directly to the mesial sides of the hemispheres, and are not seen except on section. Each *extremity* is divided by that portion of the great horizontal fissure which dips into the corresponding *notch* into an upper and a lower half. Hence each of these *anterior halves* is the anterior extremity, respectively, of the *upper* and *lower worm;* and each *posterior half* is, similarly, the *posterior extremity* of the corresponding worm. The horizontal fissure does not dip into the extremities of the worm nearly so deeply as it does into the *margin* of the hemispheres.

Each surface of the worm, or the *upper* and *lower worm* respectively, is subdivided into *lobules* by *transversely directed fissures* which are continued laterally into and across the corresponding surfaces of the hemisphere to the margin, where they terminate in the great horizontal fissure. Hence any two of these fissures contain between them a *lobule* of the *upper* or *lower worm* in the middle, and, laterally, a portion of the corresponding surfaces of the hemispheres. These fissures are known as *interlobular fissures.*

The Hemispheres.—Each hemisphere has a *side*, an *upper surface*, a *lower surface*, and a *margin*. The *side* of each is directly attached to the corresponding side of the worm. The *margin* is curved and extends around from the side of the *posterior extremity* of the worm to the corresponding side of the *anterior extremity* of the worm. Hence *in* the notches this margin is the same thing as the *side* of the notch. The margins of both hemispheres, together with both extremities of the worm, contain the *great horizontal fissure—i. e.* the *upper edge* of the *fissure* is made up of the *anterior extremity* of the upper worm, the *margin* of the *upper half* of one hemisphere, the *posterior extremity* of the upper worm, the *margin* of the *upper half* of the other hemisphere. The *lower edge* of the fissure is similarly made up.

The *surfaces*, both lower and upper, are, like those of the worm, subdivided into *lobules* by the lateral prolongations of the *interlobular fissures*, already mentioned. On the *upper* surface of each hemisphere these fissures are disposed

quite regularly and with a direction, somewhat curved, concavity forward, which is outward and forward. On the *lower* surface the *interlobular fissures* have not such a regular arrangement, but are much more curved, concavity forward, the curves being greater in those placed anteriorly.

The general outline of each surface has already been mentioned.

Upper Surface of Worm and Hemispheres.—Each of these, as already stated, is subdivided into *lobules* by the *interlobular fissures*. There are five lobules and four fissures on the upper surfaces of the worm and hemispheres, which, *from before backward*, are as follows (Fig. 425):

Lobules of superior worm: *lingula*, *lobulus centralis*, *culmen*, *clivus*, *folium cacuminis*; **lobules of hemisphere** (*upper surface*): *frænulum*, *ala*, *anterior crescentic lobule*, *posterior crescentic lobule*, *postero-superior lobule*.

The *interlobular fissures* are the *precentral*, the *post-central*, the *preclival*, and the *post-clival*.

The complete arrangement is as follows: On each side of the *lingula* is the *frænulum*; these three lobules are separated by the *precentral fissure* from the *lobulus centralis* with its *ala* on each side. These three are in turn separated by the *post-central fissure* from the *culmen*, with the *anterior crescentic lobule* on each side. Posteriorly to these is the *preclival fissure*, behind which are the *clivus* and two *posterior crescentic lobules*, which are separated by the *post-clival fissure* from the *folium cacuminis* and *postero-superior lobules*, and these last are limited below by the *great horizontal fissure*.

Lower Surface of Worm and Hemispheres.—The *lobules* of each of these surfaces are *four* in number, separated by *three* fissures (Fig. 426). They are, from behind forward, as follows:

Lobules of inferior worm: *tuber valvulæ*, *pyramid*, *uvula*, *nodulus*; **lobules of hemisphere** (*lower surface*): *postero-inferior lobule*, *digastric lobule*, *amygdala* or tonsil, *flocculus*.

The *interlobular fissures* are the *post-nodular*, the *prepyramidal*, and the *post-pyramidal*.

The complete arrangement is as follows: The *post-nodular fissure* separates the *nodulus* and the *two flocculi* in front from the *uvula* and *two amygdalæ* behind; the *prepyramidal fissure* lies between the three last-mentioned lobules, and the *pyramid* with a *digastric lobule on each side*, which in their turn are separated by the *post-pyramidal fissure* from the *tuber valvulæ* and *postero-inferior lobules*, while between these last and the *folium cacuminis* and *postero-superior lobules* of the *upper* surface runs the *great horizontal fissure*, which, in front, also runs between the *lingula* and *nodulus* and their prolongations.

Lobules of the Cerebellum.—As above mentioned, each *group* of *three* lobules (*central* of the worm, *lateral* of the hemispheres) is limited either by two *interlobular* fissures or by *one such* fissure and a *portion* of the *great horizontal fissure*. Besides these there are other smaller fissures, known as *intralobular*, which also run more or less transversely and cut up each *lobule* into still smaller subdivisions or *laminæ*, and which are quite irregularly disposed, especially in the hemisphere lobules, where they may run obliquely, and, many of them, stop short of the margin. Furthermore, the lobules vary greatly in size and, on the under surface, in symmetry.

The **structure of each lobule** (Fig. 428) is seen, on an *antero-posterior* section, to consist of white matter surrounded by an irregular margin of gray matter, these irregularities or indentations being due to the *intralobular* fissures; while the *interlobular* fissures are seen to be deep clefts separating the lobules. Hence the *cut surface* of each lobule, whether of worm or hemisphere, looks like a dentated leaf or *folium*, the branching *stems* of which are white matter, and the *margins* gray matter; which last is also continued from lobule to lobule at the bottom of each fissure (see also page 734).

On the other hand, should the cerebellum be sliced from side to side, the plane of each *transverse section* corresponding as nearly as possible to that of each *inter-*

lobular fissure, it would appear that each *group* of three lobules would really constitute a single *lamina*, or sheet, of *white matter* reaching from margin to margin of the cerebellum, the *central* part (worm) being more prominent than the *lateral* portions (hemispheres); while from each surface of this lamina would appear *projecting ridges* also of white matter, the entire lamina and ridges being covered by

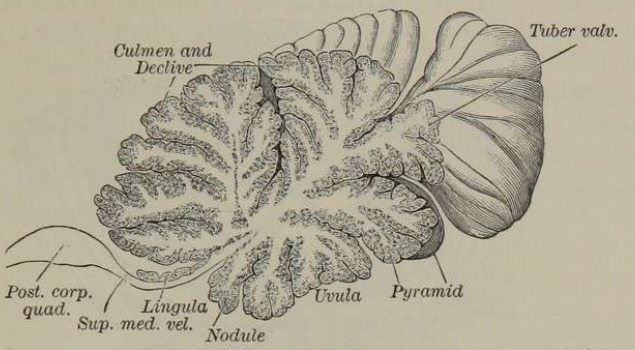

FIG. 428.—Antero-posterior median section of the worm. (Henle.)

gray matter. The spaces between the *ridges* would be, of course, the intralobular fissures.

The Lingula and Frænula.—The *lingula* is the smallest lobule of the upper worm (Figs. 428, 429, 430). It is peculiar from all the other lobules in that its cut surface is not like a *folium*, but appears merely as a series of three or four

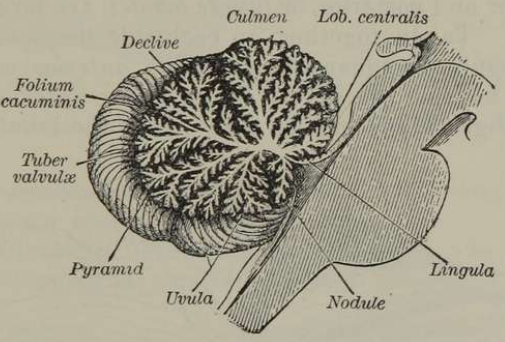

FIG. 429.—Antero-posterior median section of the worm, also showing fourth ventricle, $\times \frac{3}{2}$. (Gegenbaur.)

small elevations on the dorsal surface of a layer of white matter (*valve of Vieussens*), which is here emerging from the middle part of the great horizontal fissure at the bottom of the anterior cerebellar notch. These *elevations* are white matter (derived directly from the valve of Vieussens) covered by a layer of gray matter which dips in between them. Posteriorly, this gray matter is continuous with that of the central lobule; anteriorly, it disappears or is continued merely as an epithelial layer over the dorsal surface of the valve of Vieussens.

The *frænula* (Fig. 430) stretch laterally from each side of the lingula. They are short, not reaching beyond the superior peduncles of the cerebellum, over which they lie. Each frænulum is overlapped considerably by the *ala*.

Lobulus Centralis and Alæ (Figs. 428, 429).—The *central lobule*, though of good size, is much smaller than the culmen, immediately behind, and by which it is overlapped. It, in its turn, overlaps the lingula, and together with it forms the bottom of the anterior notch.

The *alæ* are slender, and are prolonged almost to the lateral limits of the anterior notch. Hence each is curved, with the concavity forward.

Of the remaining lobules of the *upper* surface it may be noted that the **culmen**

and **clivus** or *declive* are each very large as compared to the other divisions of the upper worm (Figs. 425, 428, 429). Taken together, they constitute the bulk of the upper worm, and are the only parts seen in the natural position, for the *culmen* must be lifted anteriorly to show the *central lobule*, and the *clivus* posteriorly

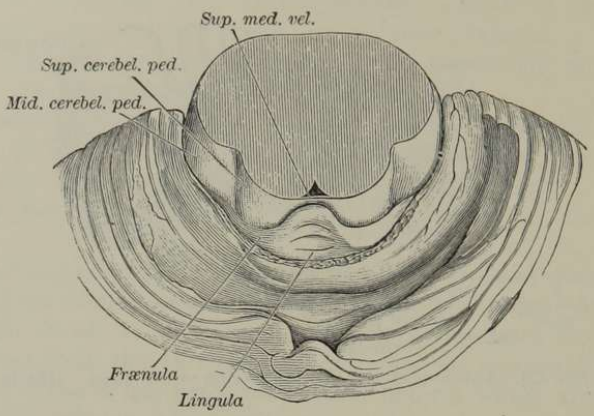

FIG. 430.—Anterior part of cerebellum from above. The central lobule and alæ are drawn backward to disclose lingula. (Henle.)

to show the *folium cacuminis*. On antero-posterior section each appears as made up of a *number of secondary folia* with well-marked *intralobular* fissures. The term *monticulus* is often applied to the *combined* culmen and clivus. The **crescentic lobules, anterior** and **posterior,** or *lunate lobules*, are large and have numerous *intralobular* fissures. Taken together, on each side they constitute the so-called *quadrate* or quadrangular or square *lobule*. The *anterior crescentic* overlaps the *ala* and reaches to beyond the lateral limits of the anterior notch. The **folium cacuminis** (see also Fig. 431) is smaller than any of the lobules of the upper worm

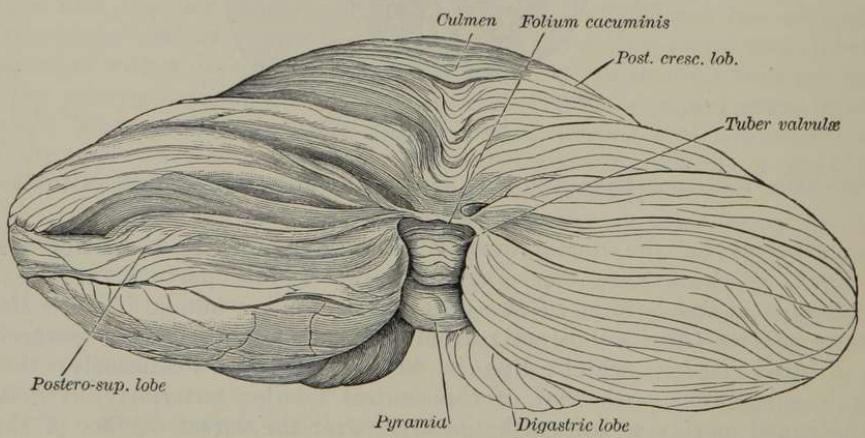

FIG. 431.—The cerebellum from behind. (Henle.)

except the *lingula*. Its cut surface looks like a single leaf or *folium*. Its lateral prolongations, however, the **postero-superior lobules** (*superior semilunar*), are large, each being fully as large, and beset with as many *intralobular* fissures, as either of the *crescentic lobules*.

Tuber Valvulæ and Postero-inferior Lobules (Fig. 431).—The *tuber valvulæ* is the posterior extremity of the inferior worm. It is decidedly larger than the folium cacuminis, and its cut surface shows at least one secondary folium in addition to that of its own cut surface. Its point of junction, on each side, with the postero-inferior lobule is slightly grooved. This *groove* is the posterior extremity

of the corresponding *sulcus valleculæ* (see above), which deepens as it runs forward along the side of the inferior worm. The **postero-inferior lobule** is as large, taken as a whole, as the larger lobules of the upper surface of the hemisphere. It resembles them also in general appearance, except that it is much more convex and its *intralobular* fissures are very large. These fissures are also considerably more curved, concavity forward, than those of the upper surface. Two of them are of especial depth; hence the *postero-inferior lobule* is often described as being made up of *three subdivisions*, the most posterior being called the *inferior semilunar lobule;* the middle one, the *posterior slender lobule;* and the anterior, the *anterior slender lobule* (lobuli graciles). In examining the mesial extremities of these "*sublobules*" it is found that only that of the inferior semilunar actually joins with the tuber valvulæ, while those of the other two terminate abruptly in the sulcus valleculæ, and do not join with any lobule of the inferior worm.

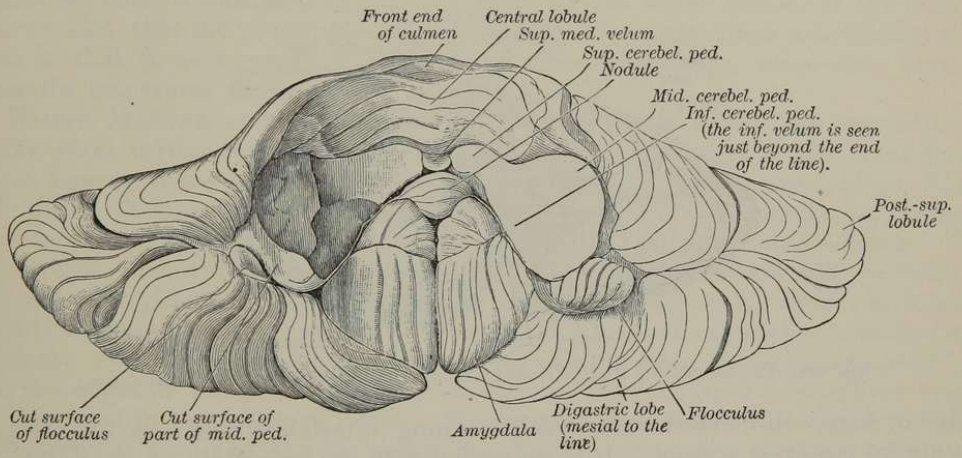

FIG. 432.—The cerebellum from in front, with pons and medulla removed. (Henle.)

Therefore the *post-pyramidal fissure* (see above) is prolonged, on the hemisphere, in front of the *anterior slender lobule*.

Pyramid and Digastric Lobules (Figs. 432, 433; also preceding ones).—The *pyramid* is a large laminated, somewhat conical projection. Its cut surface shows

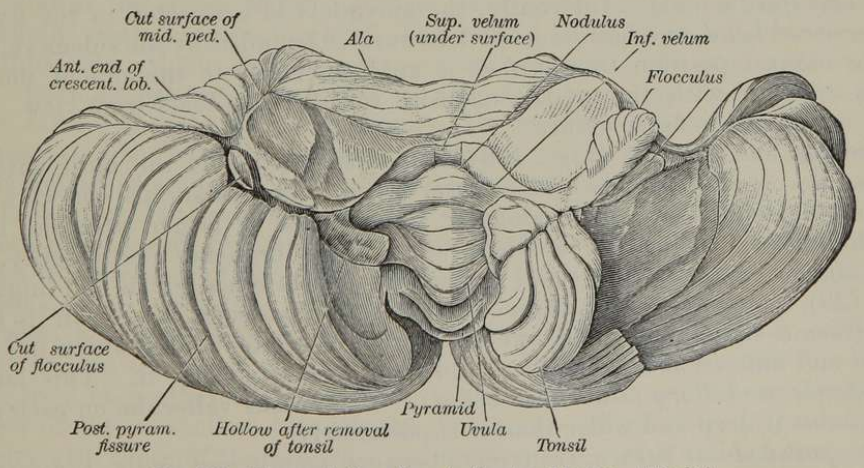

FIG. 433.—The cerebellum from in front and below. (Henle.)

numerous intralobular fissures. On each side of it is the sulcus valleculæ, here quite deep, and it is connected, *across this sulcus*, with the *digastric lobule* by means of a narrow *connecting ridge* of gray matter.

The *digastric* (biventral) *lobule* (see also Fig. 434) is triangular in general out-

line, with the *apex* at the "connecting ridge" just mentioned. Its laminæ or subdivisions, due to its intralobular fissures, are curved, concavity forward and inward, but short, and tend more antero-posteriorly; hence the lobule is embraced posteriorly by the anterior slender lobe and *post-pyramidal fissure*, both of which are decidedly concave, while the laminæ of the former are much longer than those of the digastric lobule. The *base* is anterior, and is on a line with the anterior extremity of the *amygdala*, and is separated from the *flocculus*, just in front, by the prolongation of the *post-nodular fissure*. Mesially the digastric lobule is separated from the amygdala by the *prepyramidal fissure*, which on the hemisphere runs almost antero-posteriorly, while on the inferior worm it is transverse.

Uvula and Amygdalæ (Fig. 434 and those preceding).—The *uvula* is longer than the pyramid. It is more prominent posteriorly than anteriorly. It has

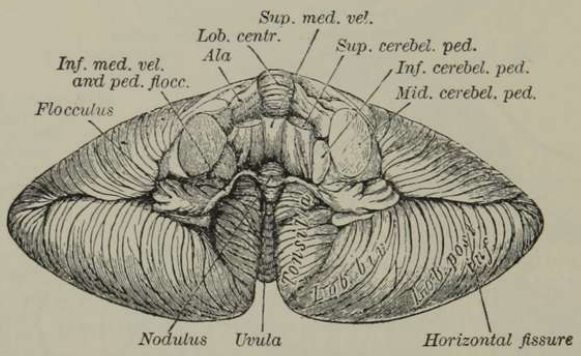

FIG. 434.—The cerebellum from in front and somewhat from below, × ⅔. (Gegenbaur.)

three or four well-marked transversely running intralobular fissures, clearly seen on antero-posterior section. It is connected with the *amygdala* on each side by means of a corrugated ridge of gray matter, the *furrowed band*, which lies in the sulcus valleculæ. The *amygdala* or tonsil is a rounded mass smaller than the digastric lobule. It has a large number of intralobular fissures and laminæ. These last are short and directed sagittally. Externally is the prepyramidal fissure, between it and the digastric. On removal of the amygdala a marked hollow (Fig. 433) is seen on the mesial side of the digastric. This hollow is the *nidus avis* (bird's nest). Internally, the amygdala is connected to the uvula by the *furrowed band*, and besides has a free surface bounded by the sulcus valleculæ. In the natural position this surface is applied closely to the side of the uvula, which, together with that of the opposite tonsil, it conceals from view. Anteriorly is the post-nodular fissure.

Nodulus and Flocculi (Figs. 426–434).—The *nodule* is the most anterior as well as the smallest lobule of the lower worm. Its cut surface shows a single folium indented by a few intralobular fissures. It is larger than the lingula. Its white matter is usually a single stem, which branches peripherally. This stem, furthermore, like the small projections of white matter in the lingula (see page 729), which are derived from the valve of Vieussens, is seen in its turn to come from a similar, but more curved, lamina of white matter which lies at first *ventral* and *anterior to* the nodulus, and then *dorsally* or *over* it. This lamina is the *inferior medullary velum* (see below). The sulcus valleculæ on each side of the nodulus is deep and wider than it is posteriorly.

The *post-nodular fissure*, transverse between nodule and uvula, becomes irregularly curved on the hemisphere. On leaving the worm it is at first concave forward in the sulcus valleculæ, then bends, *convexity* forward, around the front of the amygdala and runs laterally, between the base of the digastric lobe behind and the flocculus in front, to terminate in the great horizontal fissure. In its course it receives the anterior end of the prepyramidal fissure, and at its termination in the horizontal fissure is joined by the anterior end of the post-pyram-

idal fissure. As it lies in the sulcus valleculæ it separates the *furrowed band* from a very slender lamina of gray matter which is continuous with the gray matter of the nodule mesially, and, laterally, follows the course of the post-nodular fissure until it reaches the *flocculus*, with the gray matter of which it is continuous. This slender lamina is known as the *peduncle* of the flocculus.

The *flocculus* is the smallest of the lobules of the inferior surface of the hemisphere, and is situated farther away from its corresponding lobule of the inferior worm than any of the others. It is a rounded, tuft-like body, its expanded extremity looking forward, and it tapers toward its peduncle. It is situated below the middle peduncle of the cerebellum; its surface is composed of gray matter, subdivided into a few small laminæ; it is sometimes called the *pneumogastric lobule*, from being situated behind the pneumogastric nerve.

It is thus seen that the *flocculus*, *amygdala*, and *digastric lobule* differ in regularity, both of outline and position, from all the other lobules of the hemisphere; also that the *prepyramidal fissure* differs from the other interlobular fissures in that *it*, as a whole, is almost "*horseshoe*" in shape, while they have a generally transverse direction.

White Matter of the Cerebellum.—Traced from within the cerebellum, *all* the white matter is found to emerge from *between the edges* of the *great horizontal fissure*, where that fissure *lies in the anterior cerebellar notch* (Figs. 432, 433, 434). It may be described (after removal of pons and medulla by cutting close to the cerebellum) as consisting of two layers, an *upper* and a *lower*. In other words, this white matter on emerging from the cerebellum may be said to *split into* two *diverging* layers. The cleft-like space between these two layers extends entirely across the anterior cerebellar notch, at the lateral extremities of which the two layers are continuous. It has already been noted (see page 727), that the edges of the great horizontal fissure, in close contact everywhere else, are separated in the anterior notch. Hence the *space between the layers* might be regarded as a *part* of the horizontal fissure *lined with white matter*. Of these two layers, the upper is much the thicker and more substantial, the lower being merely a thin, delicate white lamina.

The *upper layer* is divisible into a mesial and two lateral portions, of which the mesial is much thinner than the lateral. This *mesial portion* is the valve of Vieussens or *superior medullary velum*. It is of uniform thickness from side to side. On transverse section, close to the cerebellum, its width is seen to be about equal to that of the upper worm. It has above it the lingula, together with the central lobule resting on the lingula. The *lateral portions* increase in thickness from within outward, so that the cut surface of each looks somewhat racket-shaped. Each *lateral portion* occupies the *side* of the anterior notch, and is made up of the *three peduncles* of the cerebellum, the handle of the racket-shaped surface representing the superior peduncle, while the rounded, expanded head represents, externally, the middle, and, inferiorly and mesially, the inferior, peduncle.

The *lower layer* is the *inferior medullary velum*. It is an exceedingly delicate white lamina stretching from the white matter of one flocculus across the middle line to the white matter of the other flocculus. These different subdivisions will now be considered in detail.

Peduncles of the Cerebellum (Figs. 426, 432, 433).—The *superior peduncles* (Fig. 430) are on the dorsal surface of the pons Varolii, as previously described, diverging from each other from above downward. Each enters the corresponding *hemisphere* of the cerebellum beneath the *frænulum* and *ala* (Fig. 430), where its fibres blend with those of the *two other* peduncles and a part of the inferior medullary velum, to form the white matter of the hemisphere. The superior peduncles form the lateral boundaries of the upper part of the fourth ventricle.

The *middle peduncles* are large rounded bundles made up of most of the transverse fibres of the pons, as already described. Each, bending dorsally from the pons, enters the cerebellum between the edges of the horizontal fissure at the lateral limits of the anterior notch—*i. e.* between the ala and the edge of anterior

crescentic lobule above and flocculus below—and its fibres contribute to form part of the white matter of the hemisphere.

The *inferior peduncle*, restiform body of medulla, as it enters the cerebellum lies a little deeper in the anterior notch than, and inferior to, the middle peduncle. Within the cerebellum its fibres blend with those of the preceding to form the white matter of the *hemisphere*. Just as this peduncle bends sharply backward from the medulla, and just before it actually enters the hemisphere, its under surface is free, and forms, in this situation, the upper boundary of the *cleft*, above referred to, between the layers of the white matter of the cerebellum. The lower boundary of this part of the cleft is the lateral part of the inferior medullary velum.

Inferior Medullary Velum (Figs. 426, 429, 432, 433).—As already mentioned, this is the *lower layer* of the white matter of the cerebellum, and is very thin. Its *central portion* enters the cerebellum *over* or *dorsal to* the *nodulus* at the centre of the anterior notch; and at the bottom of this part of the great horizontal fissure it *joins with* the *superior medullary velum* to enter the cerebellum as the *white matter of the worm*. As it passes over the nodulus it is adherent to it—*i. e.* it sends into the nodule a stem of white matter.

As the velum passes laterally it has a curved direction, concavity forward, and extends almost to the limits of the anterior notch, where it blends with the white matter of the flocculus. These curving portions, lateral to the nodulus, are the so-called *lateral parts* of the velum. Each of these lateral parts, *traced into* the horizontal fissure, passes above or dorsal to the *peduncle of the flocculus* (see above), and blends with the *under surfaces* of the *three peduncles* to form the white matter of the *hemisphere*. Thus it is seen that the *white matter* of the *worm* is made up of the *union* of the *superior medullary velum* above and the *central part* of the *inferior medullary velum* below, while that of the *hemispheres* is the *conjoined three peduncles* and *lateral part* of the *inferior velum*.

Tent and Lateral Recess.—The *cleft* between these layers of white matter is, like them, divisible into a central and two lateral portions. The *central part* lies between the superior velum above and the central portion of the inferior velum below. It is called the *tent*, from its pointed appearance on section. The *lateral portions*, when closed in by the upper ends of the restiform bodies (see page 738), are known as the *lateral recesses* of the fourth ventricle, while the *tent* forms the *roof* of the central part of the fourth ventricle (see page 738).

Superior Medullary Velum.—The *superior medullary velum*, or *valve of Vieussens*, has been partially described. It is a thin lamina of white matter stretched between the inner margins of the superior cerebellar peduncles; it forms the roof of the upper half of the fourth ventricle. It is narrow above, where it passes beneath the lower corpora quadrigemina (mid-brain), and broader below at its connection with the upper vermiform process of the cerebellum. A slight elevated ridge, the *frœnulum*, descends upon the upper part of the valve from between the lower corpora quadrigemina, and on either side of it may be seen the fourth nerve. Its lower half is covered by a thin, transversely-grooved lobule of gray matter prolonged from the anterior border of the cerebellum; this is the *lingula*.

Arbor Vitæ (Figs. 428, 429).—This is the name given to the white matter of either worm or hemisphere when viewed on antero-posterior section. On such a section the white matter looks like a *tree* with a central trunk and branches, with the branches also subdividing into stems. These stems, being surrounded by gray matter, resemble leaves or *folia;* and there may also be *secondary folia* whose stems come from a primary stem, and not from the main trunk of white matter. These *folia*, as already explained (page 728), are merely the cut surfaces of the corresponding *lobules*, whether of worm or hemisphere. The main trunk of the arbor vitæ of the *worm* is slender, while that of the arbor vitæ of each *hemisphere* is thick and bulky. This difference is due to the large amount of white matter resulting from the conjoined *peduncles* and *lateral part* of *inferior velum* as compared with that resulting from the union of the comparatively thin *superior velum* with the *central part* of the *inferior velum*.

Fibres of the Peduncles (Fig. 435).—The fibres of the *superior peduncles* on entering the hemisphere pass to a great extent into the interior of the corpus dentatum (see below), though some wind round it and reach the gray cortical matter, especially on its inferior surface, while others pass into the white matter

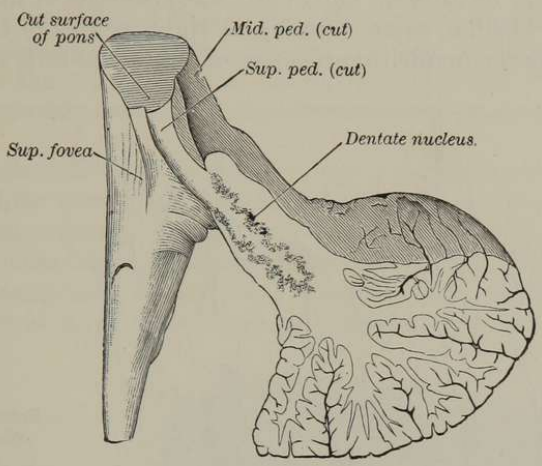

FIG. 435.—A section of the cerebellum to show dentate nucleus. (Henle.)

of the worm. Into the white matter of the worm pass the fibres of the *superior velum*, of which certain longitudinal ones are quite distinct. These last are the *antero-lateral ascending cerebellar tracts* of cord and medulla (see page 717).

The fibres of the *middle peduncles* on entering the hemisphere have a generally *dorsal* tendency, after which they go in various directions: the *upper* fibres of the *tuber annulare* pass to the *lower* part of the hemisphere; the *lower* fibres of the *tuber* pass into the *upper* part of the hemisphere; while the remaining fibres (middle of tuber and dorsal transverse; see Pons) pass for the most part into the middle region of the hemisphere.

The fibres of the *inferior peduncles* on entering the cerebellum are placed *between* the middle peduncle externally and superior internally. They then pass *upward*, and radiate into the *upper* part of the hemisphere, curving over the corpus dentatum; some are extended into the white matter of the *worm*. These last are the continuations of the *direct cerebellar tract*.

The *fibres* already described, which make up the inferior peduncle or *restiform body*, may be summarized as follows: 1. Direct cerebellar tract; 2. External arciform fibres; 3. Internal arciform fibres (from opposite olivary nucleus); 4. Fibres from accessory cuneate nucleus; 5. Fibres from antero-lateral *descending* cerebellar tract of cord; 6. Fibres of Solly. These last are occasionally found, and are seen on the surface of the medulla running upward and backward from the *direct* pyramidal tract of the cord just before it enters the pyramid.

The **fibræ propriæ of the cerebellum** are of two kinds: (1) *commissural fibres*, which cross the middle line to connect the opposite halves of the hemispheres, some at the anterior part, and others at the posterior part, of the vermiform process; (2) *arcuate* or *association fibres*, which connect one lamina with another, arching across the fissures between the laminæ.

The GRAY MATTER OF THE CEREBELLUM is found in two situations: (1) on the surface, forming the cortex; (2) as independent masses in the interior.

(1) The *gray matter of the cortex* presents a characteristic foliated appearance, due to the series of laminæ which are given off from the central white matter; these laminæ give off secondary laminæ which are covered with gray matter. This arrangement gives to the cut surface of the organ the foliated appearance already described. Externally the cortex is covered by pia mater, and internally is the medullary centre, consisting mainly of nerve-fibres.

Microscopical Appearance of the Cortex.—The cortex presents a remarkable structure, consisting of two distinct layers—viz. an external gray or cellular layer, and an internal rust-colored granular layer. Between the two layers, or rather situated in the deepest part of the gray or cellular layer, is an incomplete stratum of the characteristic cells of the cerebellum, the *corpuscles of Purkinje.*

The *external gray* or *cellular layer* (Fig. 436) consists of fibres and cells. The *fibres* are delicate fibrillæ, some running at right angles to the surface-fibres of Bergman. These are the dendritic processes of large *glia-cells* situated in the gran-

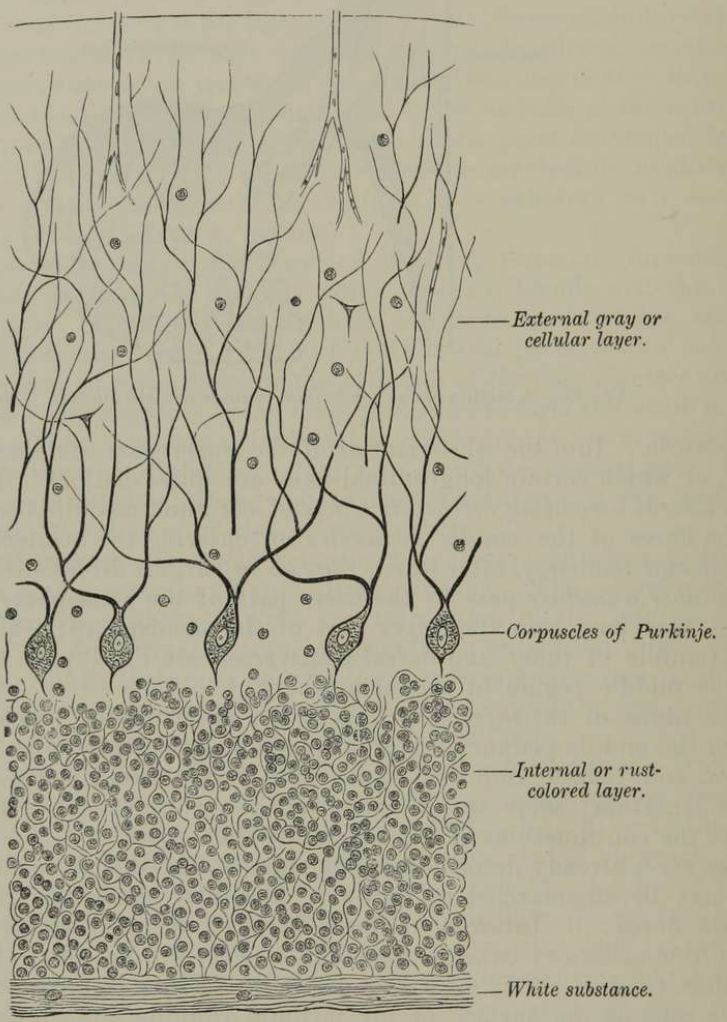

FIG. 436.—Vertical section through the gray matter of the human cerebellum. Magnified about 100 diameters. (Klein and Noble Smith.)

ular layer. On reaching the periphery these fibres expand into small cones, bases superficially, and here form a delicate supporting connective-tissue-like membrane, which spreads out into a broad base against the inner surface of the pia mater. Other fibres are horizontal, and can be observed to unite, by means of a T- or Y-shaped junction, with the long axis-cylinder processes of the *granule-cells* in the granular layer.

The *cells* are small, and are in two layers, outer and inner. All have numerously branching axis-cylinder and protoplasmic processes, the former of which, from the inner cells (basket-cells), give off descending vertical branches which ramify like a basket around the corpuscles of Purkinje.

The *corpuscles of Purkinje* (Fig. 436) are flask-shaped cells in the deepest part of the external gray or cellular layer, resting against the internal rust-colored

layer. From their under surface a slender axis-cylinder process arises, which passes through the internal layer, and becomes continuous with the axis-cylinder of a medullated nerve-fibre in the medullary (white) substance beneath. From the other extremity a number of protoplasmic processes (*dendrites*) are given off, which branch in an antler-like manner in the external layer, all having free terminations.

The *internal* or *rust-colored layer* (Fig. 436) is characterized by containing multitudes of granular-looking cells. There are also minute stellate cells and glia-cells. Between the cells is a fine nerve-network, with which the processes of all the cells are continuous, except the axis-cylinder processes of the granule-cells.

There are still *other fibres* to be found in the cerebellar cortex. These come directly from the white centre, and penetrate through the entire cortex. Each fibre, thus penetrating, gives off branches in the granular layer, the ramuscles exhibiting peculiar moss-like appendages, hence are called "moss-fibres" (Ramon y Cajal). Other ramifications are also found around Purkinje's corpuscles. Finally, in the external layer these fibres terminate by becoming longitudinal and

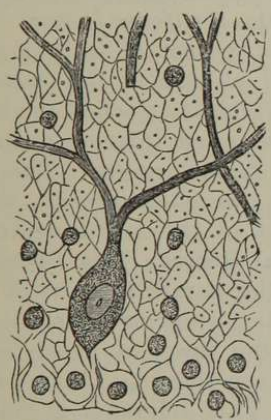

FIG. 437.—A corpuscle of Purkinje, with its dichotomously branched processes.

FIG. 438.—Vertical section of the cerebellum.

horizontal. The *cell-origin* of these fibres is probably situated in the gray matter of the spinal cord.

(2) The *independent centres of gray matter in the cerebellum* are—(1) the *corpus dentatum;* (2) the *roof nuclei of Stilling.*

The *corpus dentatum* (Figs. 435, 438), or *ganglion of the cerebellum*, is situated a little to the inner side of the centre of the stem of white matter. It consists of an open bag or capsule of gray matter, the section of which presents a gray dentated outline, open at its anterior part. It is surrounded by white fibres; white fibres are also contained in its interior, which are derived from the superior peduncles.

The *roof nuclei of Stilling* are two small gray masses situated in the anterior part of the white matter of the worm, close to where the valve of Vieussens begins to assist in the formation of the roof of the fourth ventricle. These can only be seen in microscopic preparations.

The Fourth Ventricle (Figs. 423, 429).

The **Fourth Ventricle**, or *ventricle of the cerebellum*, is the space between the mesial portions of the dorsal surfaces of the medulla oblongata and pons ventrally and the cerebellum dorsally. It consists of a *floor*, *roof*, and *lateral boundaries.*

The *floor* has already been described in detail. It is flat and lozenge-shaped, its upper half being on the dorsal surface of the pons, its lower half lying between the restiform bodies on the upper portion of the dorsal surface of the medulla. Its widest or central portion is at the junction between pons and medulla. Like the floor, the ventricle itself is divided into an upper, a lower, and a middle portion.

Boundaries of the Fourth Ventricle.—The *upper portion* has for its *floor* the central part of the *dorsal surface* of the *pons;* for its *lateral boundaries*, the *inner surfaces* of the *superior cerebellar peduncles;* for its *roof*, the *superior medullary velum.*

The *middle portion* has for its *roof* the *tent*, or *space between central part of inferior medullary velum, below; and that part of superior medullary velum which is below the lingula, above;* and their line of junction dorsally. The tent, on section, appears pointed, the angle projecting dorsally from pons and medulla into the worm, between lingula above and nodulus below. In the complete ventricle the tent lies *dorsal to the widest part* of the *floor;* and the *lateral boundaries* of this particular region of the ventricle are the *lateral angles* (see page 723), each lateral angle being the point of contact of the lower end of the inner surface of the superior peduncle with the upper end of the inner surface of the inferior peduncle, just as each peduncle bends dorsally to enter the hemisphere.

The *lower portion* has for its *floor that part* of the *dorsal surface* of the *medulla* which is between the restiform bodies, and for its *lateral boundaries* the *clavæ* of the *funiculi graciles* and the *inner surfaces* of the *restiform bodies.* The inner surface of the restiform body is merely the inner aspect of its generally rounded, elevated surface. Hence it is not so marked as that of the flattened superior peduncle, which also has an inner *margin*, to which is attached the superior medullary velum; while the inner margin of the rounded inferior peduncle would be merely the line drawn between its *inner* and *dorsal aspects.* The *roof* of the lower portion of the fourth ventricle is the *tela choroidea inferior*, which will now be described, together with the *lateral recesses* of the fourth ventricle.

Roof of Lower Portion of Fourth Ventricle; Lateral Recess; Tela Choroidea Inferior.—In the description of the white matter of the cerebellum, as it lies between the edges of the great horizontal fissure in the anterior notch, it was stated that this white matter was split into two layers, the lower of which is the *inferior medullary velum.* An important difference between these two layers must now be noted, in addition to the others already given. This difference is that, in the complete specimen, the inferior medullary velum, as such, has a *free edge*, while the upper layer is continued directly into the prolongations of its component parts, superior medullary velum and the peduncles of the cerebellum.

This *free edge* of the inferior velum is directed, in the natural position, downward and forward. The free edge of the mesial part lies over the nodulus, which projects somewhat beyond it. Being very thin, it cannot be made out distinctly except on antero-posterior section. The free edges of the *lateral portions*, however, are well seen on removal of cerebellum from pons and medulla and after separating the edges of the great horizontal fissure. In the complete condition each of these lateral free edges of the velum lies just dorsal to the upper extremity of the corresponding restiform body just before it bends backward into the cerebellum, and curves around it, as it were, reaching out laterally to the flocculus, which, in the complete specimen, lies just external to the lateral aspect of the restiform body.

Having thus located the free edge of the entire inferior medullary velum, it now remains to establish its connection with the subjacent parts. This connection is effected by a layer of epithelial cells prolonged from the general epithelial lining of the ventricle. It is understood, of course, that all the ventricles of the brain, as well as the central canal of the cord, are lined with epithelium. Therefore in the fourth ventricle this epithelium lines the under surface of the superior velum; the inner surface of the superior cerebellar peduncle; covers the entire floor, and is also found in the *tent* and its *lateral prolongations.* Therefore it

must also cover the upper surface of the entire inferior medullary velum; and it is the prolongation of this particular layer which was just referred to.

The *epithelium* covering the *central part* of the *inferior velum* on arriving at its free edge is continued over the projecting portion of the upper surface of the nodulus, and then bends sharply downward and backward around the anterior extremity of the nodulus, and is continued on down to the calamus scriptorius—*i. e.* angle of divergence of the clavæ—where it dips into the upper (medullary) part of the central canal of the cord, and becomes continuous with its dorsal lining epithelium. This layer of epithelium, thus traced from above downward, has, of course, *lateral attachments*, and on each side this attachment is mainly the *line*, already referred to, which marks off the *inner* from the *dorsal aspect* of the restiform body. Below, this line of attachment is continued down on the *clava*, and at the calamus scriptorius meets the line from the opposite side. *Along this line* for its entire extent the layer of epithelium is continuous with the epithelium lining the slightly elevated *inner aspect* of the restiform body and that covering the *floor*, but is *not* prolonged over the *dorsal* aspect of the restiform body, which is closely invested with pia mater. Owing to the divergence of the restiform bodies and clavæ, it is evident that this layer of epithelium is triangular in shape, with its *apex* at the calamus scriptorius. This triangular layer of epithelium is the *real roof* of the *lower portion* of the fourth ventricle.

Lateral Recess.—The *epithelium* covering each *lateral* portion of the inferior medullary velum on arriving at its free edge is prolonged directly on to the upper extremity of the restiform body, close to which the free edge lies, and is then reflected upward for a very short distance—*i. e.* to where the restiform body *bends backward* to enter the hemisphere. The epithelium then bends backward also, covering the (now) *under* surface of the inferior cerebellar peduncle, and thus enters the *lateral portion* of the *cleft* (see page 734) between the "laminæ" of the cerebellar white matter; arriving at the bottom of this cleft, it is reflected back again over the upper surface of the lateral part of the inferior medullary velum to its free edge, at which point its tracing was commenced.

The *line of attachment* of the epithelium to the upper end of the restiform body just after its reflection from the edge of the inferior velum is, of course, directed transversely. Its *inner* end bends downward and becomes continuous with the *line* already mentioned on the restiform body, along which the "roof" epithelium blends with that of the side and floor.

Thus is formed the *complete lateral recess*, which, when all the parts are connected, is really a triangular-shaped, tunnel-like prolongation of the cavity of the fourth ventricle, curving around the extreme upper end of the restiform body just before that body bends backward into the hemisphere of the cerebellum.

The *outer extremity* of the lateral recess may be regarded as a pointed cul-de-sac. At its *inner extremity* is an aperture through which its lining epithelium is continuous with that of the fourth ventricle. This aperture is situated just at the *lateral angle* (see above) of the ventricle. The cul-de-sac is situated just between the flocculus externally and the outer aspect of the restiform body internally.

Tela Choroidea Inferior.—The *pia mater* which invests the inferior worm is continued upward and forward, dipping in and out of the various fissures, until it reaches the nodulus. It now closely invests the nodulus and bends sharply around it, forward, upward, and a little backward, following exactly the course of, but lying *posterior to*, the epithelial roof of the ventricle, already described, until it reaches the *free edge* of the inferior velum lying on the nodulus. At this point it is *reflected at an acute angle* right back on itself, and now follows the "epithelial roof" down to the calamus scriptorius. In its course this *reflected layer* of pia mater lies, naturally, *dorsal to* the epithelial roof, and so *closely adherent to it* that the two form one structure. This structure is the *tela choroidea inferior*. It is the *practical roof* of the lower portion of the fourth ventricle, because when the pia mater is pulled away the epithelial layer comes with it, and thus this portion of the ventricle is exposed.

If the pia mater covering the hemisphere on each side of that covering the inferior worm (the lateral extension of the same layer) be traced, it will be found to follow a similar course, thus: After passing upward it reaches the under surface, and then the *free edge*, of the lateral part of the inferior velum. It is now sharply reflected on itself, and passes downward on the dorsal aspect of the restiform body. This is merely the *lateral extension* of the *pia matral portion* of the tela choroidea inferior. As this layer passes from the edge of the inferior velum (lateral part) to the restiform body it is in contact, just at its downward bend, with the *epithelium* of the *lateral recess* just where it is being reflected on to the extreme upper end of the restiform body. It is therefore evident that along the free edge of the entire inferior medullary velum there is attached a margin of pia mater consisting of two layers folded on themselves. For some distance downward these two layers are somewhat adherent to each other.

The Ligula.—In the fourth ventricle, as well as in the other ventricles, the lining epithelium has between it and the surrounding brain-tissue a delicate layer of neuroglia known as the *ependyma*. The upper surface of the inferior velum also has on it some of this ependyma. At the free edge of the velum, however, this ependyma ceases abruptly, and the epithelium comes in direct contact with the pia mater. But where the epithelium leaves the pia mater to be reflected *upward* on the restiform body (lateral recess), or where it leaves the *under surface* of the *tela choroidea inferior* to be reflected on the *inner aspect* of the restiform body and *floor* of the ventricle, the ependyma reappears. Hence this *edge* of ependyma follows the *line of reflection* of epithelium all the way from the calamus scriptorius obliquely upward and outward, and then outward around the upper end of the restiform body. It is not visible to the naked eye until the pia mater is pulled away. This tearing away of the pia mater necessarily brings with it the epithelium lining it, and there is seen a very delicate, jagged line of tissue following the course of the "line of reflection" just described. This *line of tissue* is the edge of the ependyma plus the torn edge of epithelium, and is the *ligula*, not to be confounded with the *lingula*. The union of the lower ends of the two ligulæ in the calamus scriptorius is known as the *obex*.

This tearing away of the pia mater and epithelium also brings into view the free edge of the inferior medullary velum, especially its lateral portions on each side of the nodulus.

Choroid Plexuses.—The *under* surface of the pia-matral portion of the *tela choroidea inferior* is not smooth. It has a linear series, on each side of the middle line, of minute vascular tufts of pia-mater tissue projecting *ventrally*. These tufts, however, do *not* pierce the epithelial "roof," but are covered, ventrally, everywhere by the epithelium. These lines of tufts with their epithelium are the choroid plexuses of the fourth ventricle.

Similar, but longer, tufts of pia-mater tissue are also prolonged from the pia mater which lies beneath the epithelium, closing in the *lateral recess*. These last are collected into quite a distinct bunch, resembling a group of small villi, which is seen between the flocculus and outer aspect of the restiform body. In the middle of these villi is the *pointed cul-de-sac* of the lateral recess, which by some observers is said to be perforated by a minute foramen.

A similar foramen is said to be present in the *tela choroidea inferior* just above the calamus scriptorius. This is the so-called *foramen of Majendie*.

THE MID-BRAIN (Figs. 415, 416, and 439).

The **mid-brain**, or *mesencephalon*, is that portion of the brain which connects the pons Varolii below with the cerebrum (inter-brain and hemispheres) above. On this account it is sometimes called the *isthmus* or the *crus cerebri*. It has four surfaces—a superior, an inferior, a dorsal, and a ventral. The *first two* are flattened and are *attached*, the superior to the cerebrum, the inferior to the pons. They are also nearly parallel with each other. The *two latter* are somewhat curved

transversely, and meet each other on the side of the mid-brain, being separated only by a groove, the *sulcus lateralis*, which runs from below upward and forward. The *dorsal surface* is free, but is concealed from view, from above, in the complete brain by the overhanging hemispheres. The *ventral surface* is also free, and also concealed, from below, by portions of the hemispheres, apices of temporal lobes, which overlap it. These two surfaces are not parallel, as the ventral surface, besides being convex from side to side, is slightly concave from below upward and forward. The *cavity of the mid-brain* is the smallest of all the brain "ventricles." It is called the *aqueduct of Sylvius*, and is a mere tube whose

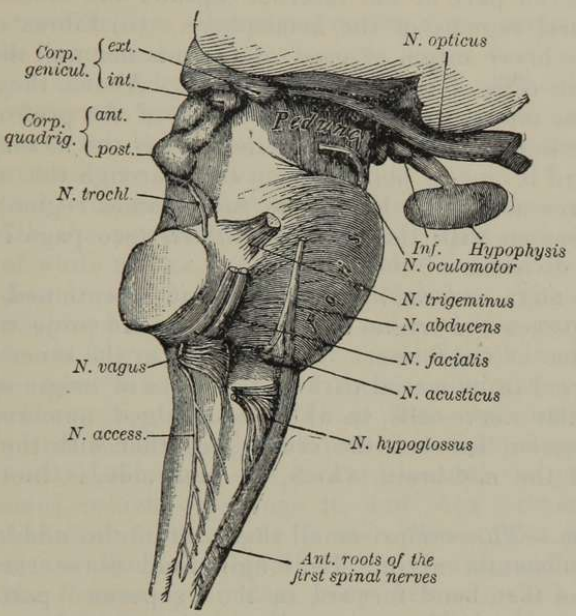

FIG. 439.—Medulla, pons, and mid-brain seen from the right side, × ½. (Gegenbaur.)

diameter is very small compared to the bulk of the mid-brain in which it lies. It is situated close under the *dorsal surface* in the middle line; hence its direction is upward and forward. It opens below into the fourth ventricle and above into the third ventricle.

Main Divisions.—The *mid-brain*, as a whole, is divided into two portions (Fig. 440), a *postero-superior* and an *antero-inferior*, by a lamina of gray matter, the *substantia nigra*, which is seen to be convex downward and from side to side in sections made both dorso-ventrally and from above downward. Hence this lamina, as a whole, has an antero-posterior curve, with the concavity looking ventrally. Its two edges lie along and in the *sulcus lateralis*.

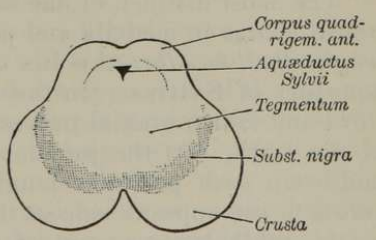

FIG. 440.—Transverse section of mid-brain, × ½. (Gegenbaur.)

All of the mid-brain dorsal to and above (postero-superior) the substantia nigra is called the *tegmentum*, while that portion which is below and anterior (antero-inferior) is known as the *crustæ*.

Crustæ.—There are two crustæ, which diverge from each other from below upward. The lower end of each is overlapped by the upper margin of the tuber annulare of the pons. Each crusta is a thick, wide, rounded bundle of longitudinal white fibres, its outer margin being limited by the sulcus lateralis. Its inner margin is free, and in the interval between it and the opposite crusta is the substantia nigra passing across. Dorsal to each crusta is the substantia nigra, and on the *inner* margin of each, where the substantia nigra is about to cross over, is a *groove*, the *mesial sulcus*, or sulcus oculo-motorius, out of which the roots of the

third nerve pass. The two *crustæ* are often spoken of as the *crura* or *pedunculi cerebri*.

Fibres of the Crusta.—These are—(1) the upward continuations of the fibres of the pyramids, *pyramidal tract*, which in passing through the pons are known as its ventral longitudinal fibres: this pyramidal tract forms about the *middle third* of the crusta. Superiorly, it is continued into the middle part of the internal capsule of the hemisphere, and thence to the fronto-parietal or Rolandic region of the cortex. (2) The *direct sensory tract:* these fibres occupy the *outer third* of the crusta; below, they probably come from the nuclei pontis; above, they pass into the posterior part of the internal capsule, and thence to the cortex of the occipito-temporal regions of the hemisphere. (3) Fibres of the *inner third* of the crusta: the lower origin of most of these is not well defined. They possibly arise from the cells of the substantia nigra. Above, they pass through the anterior part of the internal capsule to the cortex of the prefrontal region of the hemisphere. One bundle, however, is distinct. It is the *mesial fillet* (see below). As it passes upward it crosses obliquely outward through the other fibres of the crusta, and its fibres are finally lost in the subthalamic region, where they probably become continuous with the *ansa lenticularis* (see page 747). Below, it is one of the three divisions of the *fillet*.

The **substantia nigra** or *locus niger* is, as already mentioned, a lamina of gray matter situated between the crustæ and tegmentum and projecting here and there between the bundles of the former. It is thicker at the inner than at the outer side, and is traversed in its mesial part by the fibres of origin of the third nerve. It contains irregular nerve-cells, in which are lodged numerous dark pigment-granules. The portion between the crustæ, together with the crustæ, form the *ventral surface* of the mid-brain, which, on each side, is limited by the *sulcus lateralis*.

The Tegmentum.—This comprises all that part of the mid-brain *dorsal to* and *superior to* the substantia nigra. Its longitudinal fibres run up through the "*dorsal*" part, and then bend forward in the "superior" part, from which they pass to their destination. There are really two *tegmenta*, but each is united with its fellow of the opposite side by a prolongation of the median septum or raphe of the pons.

The tegmentum consists of longitudinal bundles of white fibres interlaced by transverse fibres, together with a quantity of gray matter with scattered nerve-cells. It forms a well-marked *formatio reticularis* similar to that found in the pons and medulla, with which it is continuous, receiving, however, a bundle of fibres (*superior peduncle*) from the cerebellum.

The most distinct of the *longitudinal fibres* comprise the following bundles, whose course in medulla and pons has already been described: (1) The *posterior longitudinal bundle:* this lies on each side of the median line and just below the aqueduct of Sylvius. In the mid-brain it gives off fibres to the nuclei of the third and fourth cranial nerves, and receives fibres, in the pons, from the nucleus of the sixth. At the junction between the dorsal and superior surface of the mid-brain each posterior longitudinal bundle passes *dorsal to* the aqueduct and across to the opposite side in the *posterior commissure;* some fibres, however, pass to the subthalamic region of the same side; there are also decussating fibres between the two "bundles" in the raphe. (2) The *fillet:* its mode of origin and course in the medulla and pons have been described. Arrived at the mid-brain, it divides into *three* subdivisions—the *mesial* fillet, the *upper* fillet, the *lower* or *lateral* fillet. The first has already been described with the crusta. The upper fillet passes to the superior corpus quadrigeminum. The *lower* fillet appears on the *dorsal surface* (see below). Above, its fibres pass to the inferior corpus quadrigeminum, being reinforced by some fibres from the superior medullary velum. It also receives, through the trapezium of the pons, some fibres from the ventral auditory nucleus of the opposite side. (3) *Fibres* from the *superior peduncle of the cerebellum:* these on leaving the pons dip ventrally, and beneath the corpora

quadrigemina the fibres of each peduncle decussate with each other, so that fibres from one half of the cerebrum are continued in the other half of the cerebellum. The fibres thus pass upward into the *optic thalamus*, surrounding, as they go, the *red nucleus*, from and to the cells of which they receive and give fibres. (4) Certain fibres from the *olivary nucleus* of the medulla: above, these are traceable into the internal capsule of the hemisphere.

The *red nucleus* (Fig. 451), or nucleus of the tegmentum, is a cylindrical mass of gray matter on each side of the middle line. On cross-section it is seen as a reddish circle in about the middle of the tegmentum ventral to the aqueduct of Sylvius.

The following structures are all grouped on the **dorsal surface** of the mid-brain. They belong to the tegmentum, since they are dorsal to the substantia nigra. This dorsal surface is limited by the *sulcus lateralis* on each side.

The **corpora** or **tubercula quadrigemina** are four rounded eminences placed in pairs, two in front and two behind, and separated from one another by a median longitudinal and a transverse groove.

They are situated immediately behind the third ventricle and posterior commissure, and beneath the posterior border of the corpus callosum. Below, they rest upon a layer of white matter, the *quadrigeminal lamina*, immediately beneath which, in the median line, is the aqueduct of Sylvius. The *anterior* or *upper pair* are the larger, oblong from before backward, and of a gray color. The *posterior* or *lower pair* are hemispherical in form and lighter in color than the preceding. From the outer side of each of these eminences a prominent white band, termed *brachium*, is continued. Those from the anterior pair (*brachia anteriora*) are long and slender, and each passes at first obliquely outward, and then curves backward, downward, and forward around the posterior extremity of the optic thalamus, which overhangs it, and then between the inner and outer geniculate bodies into the optic tract. Those from the posterior pair (*brachia posteriora*) are comparatively short and broad, and each passes to an oval prominence, the internal geniculate body, beneath which it apparently disappears. Both pairs of these bodies are composed of white matter externally and gray matter within. In fishes, reptiles, and birds these bodies are only two in number, and are called the *optic lobes*, from their connection with the optic nerves; but in mammalia they are four in number, as in man. In the human fœtus they are developed at a very early period, and form a large proportion of the cerebral mass.

These bodies are apparently connected with the cerebellum by means of the *superior peduncles* of the cerebellum, which are continued onward to the optic thalami through the tegmentum, as already mentioned.

Arching over the upper ends of these peduncles is a flattish triangular-shaped band of white fibres, the **lemniscus** or *lower fillet*, which issues from beneath the transverse fibres of the pons to pass obliquely round the upper end of the superior peduncle of the cerebellum and become lost in the inferior quadrigeminal body.

The **corpora geniculata** are two small, flattened, oblong masses, placed on the under and back part of each optic thalamus, and named, from their positions, *corpus geniculatum externum* and *internum*. The two bodies are separated from one another by the brachium anterius from the anterior corpus quadrigeminum.

Structure of the Corpora Quadrigemina and Geniculata.—The *peripheral gray matter of the corpora quadrigemina* differs somewhat in the posterior and anterior bodies. The *posterior* are composed almost entirely of gray matter, covered over by a thin stratum of white matter, and separated from the *central gray matter* of the aqueduct by tracts of transverse white fibres derived from, and forming part of, the lower fillet. The *anterior* are covered superficially by a thin stratum of white matter; beneath this is a layer of gray matter, termed the *stratum cinereum*, and consisting, as well as the gray matter of the posterior lobes, of small multipolar cells imbedded in a fine network of nerves. Beneath this, again, is a characteristic mass of gray matter, termed the *stratum opticum*,

which is made up of fine nerve-fibres, coursing in a longitudinal direction, and containing between them small masses of gray substance, consisting of small multipolar nerve-cells imbedded in gray matter. Lastly, between this body and the central gray matter around the Sylvian aqueduct is a thin lamina of white matter, derived from the upper fillet.

The *geniculate bodies* are continuous with the gray substance of the optic thalamus, and the external one (*corpus geniculatum externum*) is peculiar on account of its dark color, due to its cells containing pigment. It presents a laminated arrangement, and consists of alternate thick layers of gray matter and thin layers of white matter. Its cells are multipolar. The internal body (*corpus geniculatum internum*) is of lighter color, does not present a laminated arrangement, and its cells are smaller in size and fusiform in shape. These bodies, strictly speaking, belong, the *external* to the inter-brain, and the *internal* to the mid-brain.

The *locus niger*, or gray matter of the crus cerebri, like the external geniculate body, is peculiar from the large number of dark pigment-granules which are contained in its ganglion-cells, and which give to it its dark color, from which it has derived its name. Its cells are small and multipolar.

The Aqueduct of Sylvius.—This is the "ventricle" of the mid-brain. It is a narrow tube into which the fourth ventricle opens below, and which opens into the third ventricle above. Hence it is sometimes called the *iter a tertio ad quartum ventriculum*. It is a little over half an inch long. It lies in the tegmentum, and its course is upward and forward, the same direction as that of the *dorsal surface* of the tegmentum, on which the groove between the right and left corpora quadrigemina indicates its position. It lies immediately ventral to this groove. Its *roof* is the lamina quadrigemina, the white layer which supports the corpora quadrigemina, and into which are prolonged the fibres of the superior medullary velum. Its shape, on transverse section, varies, being T-shaped near the fourth ventricle, shield-shaped about midway in its course, and triangular near the third ventricle, into which it opens just at the bend between end of dorsal surface and beginning of the superior surface of the mid-brain.

In all cross-sections through the aqueduct—*i. e.* at right angles to the plane of the dorsal surface, from its beginning to end—a *large amount of tegmental tissue* is to be seen between it and the *substantia nigra*, ventrally. Hence the latter can have nothing to do with the formation of the floor of the aqueduct.

The **central gray matter** surrounding the Sylvian aqueduct presents some features requiring especial mention. It forms a tolerably thick layer surrounding the canal, but is thicker on the lower wall—that is, below the canal—than above. The cells, which are multipolar, are here collected into groups, and form *nuclei* for the *origin* of the *third* and *fourth* cranial nerves. The *nucleus* for the third and fourth consists of a column of cells of large size on either side of, and close to, the median line. In addition to these cells there are found at the periphery of the zone of gray matter surrounding the aqueduct some other, and larger, cells, sometimes single, sometimes grouped in twos or threes, or even more. They are globular, and lie in the midst of well-marked nerve-fibres, with which their processes appear to be continuous. Close to the lateral margin of this gray matter, in its lower part, is the upper end of the *upper nucleus* of the fifth nerve.

The *third nerve* passes from its nucleus in a somewhat curved manner through the tegmentum, and emerges from the oculo-motor groove on the inner margin of the crusta. Some of its fibres, however, from the dorsal part of the nucleus, decussate.

The *fourth nerve* passes downward from its nucleus toward the pons, on entering which it turns *dorsally*, and then runs transversely in the *superior medullary velum*, crossing the middle line and decussating with its fellow, to emerge from the dorsal surface of the velum. It then curves obliquely downward and forward, resting on the *crusta*.

Superior Surface of Mid-brain.—The superior surface of the mid-brain begins just anterior to the anterior pair of the corpora quadrigemina. It is directed downward and forward, and meets the upper extremity of the ventral surface at quite an acute angle. The *central portion* of this surface is narrow and free. It consists of *tegmentum*, and forms the first part (from behind forward) of the *floor* of the *third ventricle* (Fig. 442). Of each *lateral* portion the area *immediately adjacent to* the central portion is also tegmentum, and has resting on it and is closely connected with the *optic thalamus* of the inter-brain. External to *this* area is the "margin" of the superior surface, which, when the mid-brain is isolated by dissection, is seen to consist of the upper ends of the fibres of the crusta, cut across just as they are about to be continuous with those of the internal capsule of the hemisphere (see Figs. 460 and 461).

Posterior Perforated Lamina.—In vertical transverse sections through the *posterior part* of the optic thalami and superior surface of the mid-brain the tegmentum is clearly to be distinguished, both the portions beneath the optic thalami and the central free portion between them (beginning of floor of third ventricle). In all similar sections made anterior to this, however, the tegmentum is seen to become less and less distinct, until it finally disappears, and we have only the optic thalami lying *dorsal to* the substantia nigra, which last also bridges over the interval (third ventricle) between them. *This* portion of the substantia nigra is the anterior part of *that* (already mentioned) which is seen in the interval between the crustæ. It is called the *posterior perforated lamina*, and is the second structure, from behind forward, forming the floor of the third ventricle.

Subthalamic Region.—The gradual disappearance of the tegmentum in the cross-sections just referred to is due to the blending of the tegmental tissue with that of the superjacent portion of the optic thalamus, the central tegmental tissue also thinning out as the lateral parts are thus absorbed. To this tissue, thus made up of tegmentum and optic thalamus, the name *subthalamic tegmental region* is given. In it are seen the remnant of the *red nucleus* on each side, together with what corresponds to the lateral parts of the substantia nigra—*nucleus of Luys*. Dorsal to this is the *zona incerta*, a layer of reticular formation derived from that of the tegmentum proper, and still more dorsally is the *stratum dorsale*, a layer of longitudinal fibres derived from the *posterior longitudinal bundle* and *superior peduncle of the cerebellum* (see page 742).

THE INTER-BRAIN (Fig. 441).

The **inter-brain**, or **thalamencephalon** (*i. e.* thalamencephalon proper *and* prosencephalon, see page 706), together with the hemispheres, constitutes the cerebrum.

Anteriorly, the inter-brain is connected with the combined frontal lobes of each hemisphere; *laterally*, it is connected with the inner aspect of each hemisphere; *superiorly*, it has resting on it, but with two layers of pia mater interposed, the under surface of the combined hemispheres; *posteriorly*, it is connected, mesially, with the lamina quadrigemina of the mid-brain, beyond which connection, on each side, it is free, this free portion being the rounded posterior extremity *pulvinar*) of the optic thalamus.

The *cavity* of the inter-brain is the *third ventricle*, a vertical antero-posterior slit lying between the optic thalami, which are the thick *side-walls* of the *inter-brain* (see also Figs. 447 and 451). The *roof proper* of the *ventricle* is a layer of epithelium, like that of the lower half of the fourth ventricle, which stretches between the optic thalami, and, together with their superior surfaces, constitutes the upper surface of the inter-brain. Hence (see above) the under surface of the combined hemispheres lies, in the middle line, on the roof of the third ventricle, but with two layers of pia mater (velum interpositum) interposed. The *floor* of the third ventricle almost meets the roof posteriorly, being separated from it only by the orifice of the Sylvian aqueduct, and then proceeds downward and forward until it attains its greatest distance from the roof (infundibulum), where it turns upward and forward, and finally upward to meet the anterior end of the roof

proper. This "upward prolongation" of the floor is known as the "anterior boundary" of the ventricle.

The Optic Thalamus.—Each *optic thalamus* is a large oblong mass of, chiefly, gray matter. It has two rounded extremities, anterior and posterior, and four surfaces, superior, inferior, external, and internal.

The *inferior surface* rests upon, and is united with its corresponding part of the *tegmentum*. The *external surface* lies in contact with the *internal capsule* of the *hemisphere*. Its *internal surface* forms the lateral boundary or wall of the

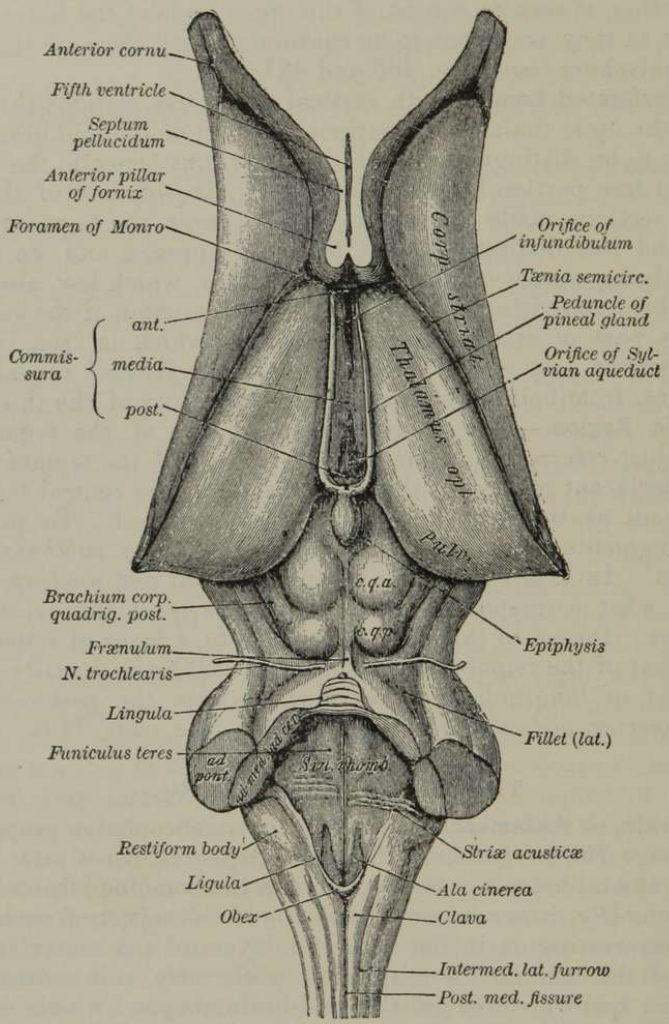

FIG. 441.—Superior surface of inter-brain; dorsal surfaces of mid-brain, pons, and medulla. Most of the cerebral hemispheres and cerebellum are removed, × ½. (Gegenbaur.)

third ventricle (Figs. 447, 442, 441). Its *upper surface* is free, and is traversed by a groove from behind forward and inward. The portion external to this groove is seen in the floor of the body of the lateral ventricle, but it is covered by a layer of epithelium continuous with that lining the lateral ventricle. It is marked in front by an eminence, the *anterior tubercle*. The portion of the upper surface internal to the groove is covered by the velum interpositum.

The *posterior extremity* of the optic thalamus projects beyond the level of the corpora quadrigemina, and forms a well-marked prominence, the *posterior tubercle* or *pulvinar* in close connection with which are two small rounded eminences, the *internal* and *external geniculate bodies*, the *internal* lying *in the groove* between the dorsally projecting pulvinar and side of the mid-brain, the *external* being placed

immediately beneath the pulvinar (Figs. 439 and 443). Its *anterior extremity*, which is rounded and smaller than the posterior, forms the posterior boundary of the foramen of Monro.

Structure of the Optic Thalamus.—The *optic thalamus* is chiefly formed of gray matter, covered over by a superficial layer of white, which on the outer side

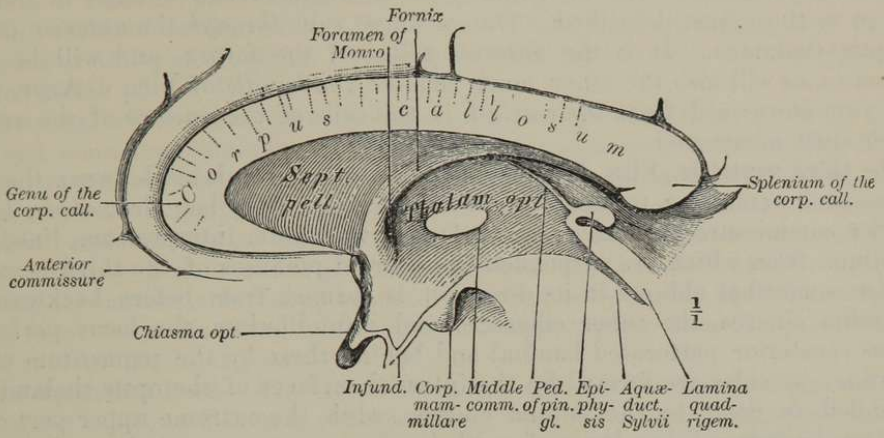

FIG. 442.—The right side of an antero-posterior median section of the parts immediately around the third ventricle. (Gegenbaur.)

(*external medullary lamina*) separates it from the internal capsule. This layer on the upper surface is known as the *stratum zonale*, and is prolonged downward on the internal surface.

The gray matter is arranged in two masses, the *outer* and *inner nuclei*, partially divided by a vertical white septum, S-shaped on section, the *internal medullary lamina*. The thalamus is traversed by numerous nerve-fibres, which for the

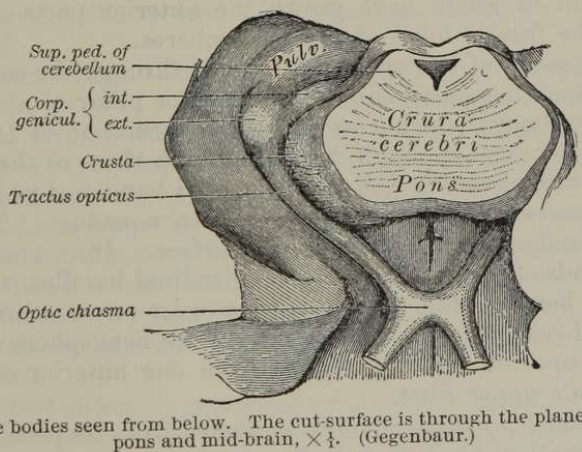

FIG. 443.—Geniculate bodies seen from below. The cut-surface is through the plane of junction between pons and mid-brain, × ½. (Gegenbaur.)

most part have no definite direction: some, however, converge and form various bundles which pass out of the optic thalamus to blend with the white matter of the hemispheres, as follows: (1) from its anterior extremity to the frontal lobes (*anterior stalk* of thalamus); (2) from its lower part (subthalamic region) to (*a*) lenticular nucleus of corpus striatum (*ansa lenticularis*) and (*b*) internal capsule (*ansa peduncularis*), the fibres of which pass below the lenticular nucleus and into the "external capsule" of the hemisphere; (3) from its outer surface through internal capsule to parietal and temporal lobes; (4) from pulvinar (outer aspect) to occipital lobe. These last are long and curve backward, and radiate toward the cortex. They are called the *optic radiations*. They connect, through the pulvinar, with the outer root of the optic tract. The gray matter contains comparatively large nerve-cells, both multipolar and fusiform. The inner nucleus is connected

across the middle line with the inner nucleus of the opposite side by the *middle commissure* of the third ventricle. The outer nucleus is continued into the pulvinar.

There are two other smaller nuclei in the optic thalamus—one the *nucleus* of the *anterior tubercle*, and the other, just beneath the *trigonum habenulæ* (see below), the *ganglion* of the habenula. There are also two bundles of fibres in addition to those just described. One of these runs *through* the *anterior* part of the optic thalamus. It is the *anterior pillar* of the fornix, and will be again referred to, as will also the other, much smaller, the *bundle* of Vicq d' Azyr, whose fibres run downward from their origin in the cells of the *nucleus* of the *anterior tubercle*, just mentioned.

The **third ventricle** (Figs. 442, 447, 451) is the fissure placed between the optic thalami and extending to the base of the brain. It is bounded, *above*, by the posterior commissure and the under surface of the velum interpositum, lined with epithelium, from which are suspended the choroid plexuses of the third ventricle. Its *floor*, somewhat oblique in its direction, is formed, from before backward, by the lamina cinerea, the tuber cinereum and infundibulum, the locus perforatus posticus (posterior perforated lamina) and behind these by the tegmentum of the mid-brain; its sides are formed by the internal surfaces of the optic thalami. It is bounded, *in front*, by the lamina cinerea, while the extreme upper part of its "anterior boundary" is a layer of epithelium covering, *posteriorly*, and through which are seen, from within the ventricle, the anterior pillars of the fornix and middle part of the anterior commissure.

These last-named structures belong to the hemispheres, and the epithelium covering them posteriorly is the same layer as that which lies in contact with the lamina cinerea, which itself, on reaching the anterior commissure, passes in front of it, and is continuous with the corpus callosum of the hemispheres. This extreme upper part of the lamina cinerea is often called the *lamina terminalis*. It is the representative in the adult brain of the anterior end of the primary fore-brain, around and in front of which have grown the anterior parts of the hemisphere vesicles to form the frontal lobes of the hemispheres.

The *lateral extension* of this epithelial layer is through the corresponding foramen of Monro, which lies just behind each anterior pillar of the fornix.

The various structures which enter into the formation of the third ventricle will now be described more in detail, beginning with those of the ROOF (Fig. 442).

The **posterior commissure** is a distinct rounded bundle of white fibres running transversely just above the opening of the Sylvian aqueduct. The pineal gland is placed above it and connected to its upper surface. It is made up of: (1) the combined upper ends of the two posterior longitudinal bundles (see tegmentum of mid-brain) as each bends to the opposite side in order to pass through the opposite optic thalamus and reach the white substance of the hemisphere; (2) commissural fibres between the optic thalami; (3) fibres from one anterior corpus quadrigeminum to the *opposite* upper fillet.

The **pineal gland** (*epiphysis cerebri*), so named from its peculiar shape (*pinus*, a fir-cone), is a small reddish-gray body, conical in form (hence its synonym, *conarium*), placed immediately behind the posterior commissure and between the anterior corpora quadrigemina. It is retained in its position by a duplicature of pia mater derived from the under layer of the velum interpositum, which almost completely invests it. The pineal gland is about four lines in length and from two to three in width at its base, and is said to be larger in the child than in the adult, and in the female than in the male. Its base is connected to the optic thalami by a stalk, which consists of two laminæ, an upper and a lower, the intervening space, apex toward the gland, being known as the *pineal recess*. The lower or *ventral lamina* is derived from the lower aspect of the posterior commissure, and is reflected upward and backward to meet the upper or dorsal layer at the base of the gland. The *dorsal lamina* is the direct continuation backward of the epithelial roof of the third ventricle. When this is torn away the dorsal

lamina necessarily has a free edge looking forward. On each side this lamina is prolonged into a somewhat triangular-shaped, depressed area on the upper surface of the optic thalamus, known as the *trigonum habenulæ*, because the word "habenula" (bridle) is often applied to this dorsal lamina of the stalk. The *free edge* of the lamina is also prolonged as a delicate whitish band on to the optic thalamus, on which it runs forward along the sharp margin which separates the *superior* from the *internal* surface of the thalamus. These bands are the *pineal striæ* or peduncles of the pineal gland. Anteriorly each blends with the corresponding anterior pillar of the fornix.

Structure.—The pineal gland consists of a number of follicles lined by epithelium and connected together by ingrowths of connective tissue. The follicles contain a transparent viscid fluid, and a quantity of sabulous matter, named *acervulus cerebri*, composed of phosphate and carbonate of lime, phosphate of magnesia and ammonia, with a little animal matter. These concretions are almost constant in their existence, and are found at all periods of life. At times the sabulous matter is found upon its surface, and occasionally upon its peduncles. In the fœtal brain the pineal gland is a *hollow protrusion* from the posterior part of the roof of the inter-brain.

The Epithelial Roof.—This stretches across the third ventricle from one *pineal stria* to the other, and then is reflected downward to become continuous with the epithelium covering the side of the ventricle (internal surfaces of thalami). The epithelium is *not* continued on to that part of the superior surface of the thalamus which is *adjacent to* the *pineal stria*, and which is internal to the oblique shallow groove, already referred to, which runs along this surface. External to the groove, however, this upper surface is covered by epithelium, but this epithelium belongs to the lateral ventricle.

The *roof epithelium* of the third ventricle is continued anteriorly between the pineal striæ until just before they join the down-curving anterior pillars of the fornix, where it is interrupted by the foramen of Monro, around the margin of which it passes into continuity with the epithelium, lining its own ventricle and the lateral ventricle.

The **velum interpositum** (Fig. 458) is a vascular membrane, a prolongation from the pia mater. It is of a triangular form, and separates the under surfaces of the body of the fornix, posterior pillars of the fornix, and posterior part of corpus callosum above (the last-named structures representing the "under surface of the combined hemispheres"), from the cavity of the third ventricle and the inner portions of the *superior* surfaces of the optic thalami below. Its anterior extremity, or *apex*, is bifid, each bifurcation lying close to and behind the corresponding anterior pillar of the fornix, and hence "in," but covered by epithelium, the foramen of Monro. Its *base* lies beneath the posterior rounded border of the corpus callosum above, and the optic thalami, the corpora quadrigemina, and pineal gland below.

The velum interpositum is composed of *two layers* of pia mater, which separate from each other at its base, the upper layer passing backward on the under surface of the occipital lobes of the hemispheres, the lower layer passing downward over the mid-brain, pons, and cerebellum. At the apex the two layers are continuous with each other, as well as at the *margins*, which are free and lie along and project a little beyond the *groove*, already referred to, which runs forward and inward on the superior surface of the thalamus. Along this margin is the *choroid plexus of the lateral ventricle*, which is covered by the mesial prolongation of the layer of epithelium covering the outer portion of the upper surface of the thalamus. After investing the margin of the velum interpositum the epithelium, still prolonged mesially, is attached to the edge of the fornix, under which the velum lies and beyond which it projects. As will be seen later, the fornix forms part of the floor of this district of the lateral ventricle; hence the roughened thickened margin (choroid plexus) of the velum interpositum really invaginates *into* the lateral ventricle, *that part* of its *floor* which *has become thinned out to a*

layer of epithelium, and which stretches from the edge of the fornix outward over the thalamus (outer part of its superior surface) to the tænia semicircularis (a structure forming part of the floor of the lateral ventricle), which lies along that margin of the optic thalamus which separates its superior from its external surface.

Tela Choroidea Superior.—From the preceding it is clear that the *under layer* of the velum interpositum has three districts—a mesial and two lateral, the latter resting on the upper surfaces of the thalami, the *former* on the "roof epithelium" of the third ventricle, with which it forms practically one membrane. This membrane is the *tela choroidea superior*, and is exactly similar to the tela choroidea inferior of the fourth ventricle.

The reason, on embryological grounds, for the existence of two layers of the velum interpositum will be given in describing the choroid plexuses of the lateral ventricles.

Of the structures forming the FLOOR (Figs. 442, 446) of the third ventricle, the *tegmentum* of the mid-brain has been described. The rest of the floor, including the "anterior boundary," is a gray lamina prolonged from the *substantia nigra*, and its ventral surface appears at the base of the brain, where, however, the tegmentum cannot be seen (Fig. 473). Various portions of this lamina have received different names. Each of these will now be considered, beginning posteriorly.

The **posterior perforated lamina** succeeds the tegmentum. It is the anterior part of that portion of the substantia nigra which appears in the interval between the diverging crustæ of the mid-brain on each side and the upper margin of the tuber annulare of the pons Varolii posteriorly and below. *Together with that portion* it is often called the **posterior perforated space** (*pons Tarini*). It reaches forward as far as the *mamillary tubercles*, beyond which the gray lamina is known as the *tuber cinereum*.

The "space" is perforated by numerous small orifices for the passage of the postero-median ganglionic branches of the posterior cerebral and posterior communicating arteries.

The **corpora albicantia**, or **mamillaria**, or **mamillary tubercles**, are two small, round, white masses, each about the size of a small pea, placed side by side immediately behind the tuber cinereum. Each projects downward from the under surface of the optic thalamus, the exceedingly narrow interval between them being bridged over by a gray commissure continuous with the posterior perforated lamina behind and the tuber cinereum in front. Each is composed externally of white substance and internally of gray matter, the gray matter of the two being connected by the transverse commissure of the same material just mentioned.

The fibres of the white substance terminate in the cells of the gray matter, and they are derived from two distinct bundles: one, deeply situated in the substance of the optic thalamus, is the *bundle of Vicq d'Azyr*, already mentioned; the other, much larger, is the anterior pillar of the fornix, which, after bending sharply downward around the foramen of Monro, passes obliquely, downward and backward, through the substance of the anterior portion of the thalamus, to terminate in, and thus help to form, the corresponding corpus albicans or bulb of the fornix. In its course through the thalamus it lies quite near the internal surface, and may even cause a slight projection on the side of the third ventricle.

The **tuber cinereum** is the next portion of the general lamina of the floor. It is wider than the posterior perforated lamina, and blends laterally with the substance of the lower and anterior part of the thalamus, while antero-laterally, passing dorsal to the optic tract, it extends beyond the limits of the thalamus into the gray matter of the anterior perforated space on the under surface of the hemisphere. Anteriorly, it is attached to the posterior edge of the optic commissure. From the middle of its under surface a conical tubular process of gray matter, about two lines in length, is continued downward and forward, to be attached to the posterior lobe of the pituitary body: this is the **infundibulum**. Its canal, which is funnel-shaped, communicates with the third ventricle.

The **pituitary body** (*hypophysis cerebri*) is a small reddish-gray vascular mass weighing from five to ten grains, and of an oval form, situated in the sella Turcica, in connection with which it is retained by a process of dura mater derived from the inner wall of the cavernous sinus. This process covers in the pituitary fossa, enclosing the pituitary body, and having a small hole in the centre through which the infundibulum passes. The pituitary body is very vascular, and consists of two lobes, separated from one another by a fibrous lamina. Of these, the anterior is the larger, of an oblong form, and somewhat concave behind, where it receives the posterior lobe, which is round. The two lobes differ both in development and structure. The *anterior lobe*, of a dark, yellowish-gray color, is developed as a tubular prolongation of the epiblast of the buccal cavity, and resembles to a considerable extent, in microscopic structure, the thyroid body. It consists of a number of isolated vesicles and slightly convoluted alveoli lined by epithelium and united together by connective tissue. The epithelium is columnar, and occasionally ciliated. The alveoli sometimes contain a colloid material similar to that found in the thyroid body, and their walls are surrounded by a close network of lymphatics and capillary blood-vessels. The *posterior lobe* is developed by a hollow outgrowth from the embryonic brain, and during fœtal life contains a cavity which communicates through the infundibulum with the cavity of the third ventricle. In the adult it becomes firmer and more solid, owing to the growing in of a sponge-like connective tissue arranged in the form of reticulating bundles, between which are branched cells, some of them containing pigment.

The **lamina cinerea** begins at the posterior border of the optic commissure, in continuity with the tuber cinereum. It passes forward and downward over the commissure, to which it is adherent, and then turns upward, forms the anterior boundary of the third ventricle, and terminates, as the *lamina terminalis*, by blending with the middle portion of the anterior extremity of the corpus callosum. It is continuous on each side with the gray matter of the anterior perforated space. The angle made by the upward bend of the lamina is known as the *optic recess*.

The **anterior boundary** of the third ventricle is the lamina cinerea below; above this, for a very short distance, the anterior boundary is the layer of epithelium covering portions of the posterior aspects of the anterior commissure and anterior pillars of the fornix, as already explained.

The SIDES of the ventricle are the *internal surfaces* of the *thalami*. Each is slightly convex, and just in front of the middle point of each is attached the corresponding extremity of the **middle commissure**, a band of gray matter which passes right across the ventricle. It is frequently broken in examining the brain, and might then be supposed to be wanting. A little more anteriorly is seen a somewhat *curved*, from above downward and backward, *elevation* (anterior pillar of fornix, already explained). As these pillars, traced upward, become *free*, they bend sharply upward and backward, thus forming a completed curve, each enclosing in front and above the **foramen of Monro**, which has for its posterior boundary a part of the anterior extremity of the optic thalamus.

Antero-inferiorly to the curved elevations is still, on each side, a small portion left of the internal surface of the thalamus, connected to the similar opposite portion, below and in front, by the tuber cinereum and lamina cinerea. It is thus seen that all these structures really form the *anterior extremity of the third ventricle* (see page 706), which is the *prosencephalon*, or, in the fœtal brain, the first secondary cerebral vesicle. Hence the "curved elevations" may be regarded as indicating, approximately, the line of division or constriction between the first and second secondary cerebral vesicles (prosencephalon and thalmencephalon proper), while the foramina of Monro are to be regarded as opening from the prosencephalon, and thus represent the fœtal foramina caused by the bulging out of the hemisphere vesicles (see Figs. 412, 413, 414).

The **choroid plexuses** of the third ventricle, formed like those of the fourth, lie along the roof, projecting downward, one on each side of the middle line.

They are covered with epithelium, and are derived from the lower layer of the velum interpositum. Of the *arteries* of the velum interpositum, some branches from the superior cerebellar and posterior cerebral enter from behind beneath the corpus callosum. The *veins* of the velum interpositum, the *venæ Galeni*, two in number, run between its layers; they are formed by the venæ corporis striati and the veins of the choroid plexuses; the venæ Galeni unite posteriorly into a single trunk, which terminates in the straight sinus (Fig. 383).

Openings.—The third ventricle has four openings connected with it. In front are the two foramina of Monro, one on each side, through which the third communicates with the lateral ventricles. Behind is a third opening, that of the *aqueduct of Sylvius*, or *iter a tertio ad quartum ventriculum*. The fourth, situated in the anterior part of the floor of the ventricle, is a deep pit, which leads downward to the funnel-shaped cavity of the infundibulum (*iter ad infundibulum*). A fifth opening exists in the fœtus which communicates behind with the cavity in the pineal gland.

The lining membrane of the lateral ventricles is continued through the foramen of Monro into the third ventricle, and extends along the iter a tertio (aqueduct of Sylvius) into the fourth ventricle; at the bottom of the iter ad infundibulum it ends in a *cul-de-sac*.

The Optic Tracts (Figs. 415, 443).—These are two well-marked flattened bundles of fibres which lie along the upper parts of the crustæ. They are attached only by their *upper edges*, which also serve to mark the transition between upper limit of *crusta* and internal capsule of hemisphere. These edges also mark the limit of separation, without tearing, between the temporo-sphenoidal lobes of the hemispheres, which, at the base of the brain, overlap the optic tracts and the crustæ. Each tract was originally a hollow outgrowth (optic vesicle) from the back part of the fore-brain. Anteriorly each unites with the other to form the *optic commissure*. The *fibres* of each are described in connection with the *optic nerve* (which see).

THE HEMISPHERES.

General Considerations and Development.

The two **hemispheres** are by far the largest portion of the encephalon, each one in bulk exceeding somewhat all the other divisions of the brain. Together with the fore part of the third ventricle they form what is called by some writers the prosencephalon or fore-brain.

Each hemisphere is an enormously developed "hemisphere vesicle" whose cavity is the *lateral ventricle*, and whose walls, originally smooth, thin, and spherical, are convoluted, elongated in various directions, and, for the most part, exceedingly thick. Although the two hemispheres in the adult brain are connected with each other by means of the corpus callosum and anterior commissure, this connection is merely between the adjacent *walls*, and in no wise involves the cavities, each cavity being as distinct from the opposite one as it is in early fœtal life before the intermural connection is established. Each lateral ventricle is, therefore, a complete cavity, communicating only with the third ventricle through the corresponding foramen of Monro.

The **development** of each hemisphere vesicle may be described approximately as follows (Figs. 412, 413, 414): After becoming a rounded hollow projection from the side of the prosencephalon, each hemisphere vesicle expands in an *anterior* direction and approaches close to its fellow. At the same time it grows upward *over* the inter-brain and backward along its side, while from this *latter* portion *two* projections may be said to take place—*one* still farther backward, covering over the dorsal surface of the mid-brain and cerebellum; and the *other*, downward and forward, overlapping somewhat the external surface of the portion from which it is derived, until its lower end projects below, and also overlaps the *ventral* surface of the mid-brain (crustæ). We can thus distinguish four main divisions of the developing hemisphere vesicle: an *anterior*, a *superior*, the latter

giving off an *inferior*, and a *posterior* division. As these *four* divisions represent sufficiently accurately the *four* large divisions or *lobes* of the adult hemisphere, it will be more convenient, in tracing their further development, to give them the same names, thus: the anterior division will be called the *frontal lobe;* the superior, the *parietal lobe;* the posterior, the *occipital lobe;* and the inferior, the *temporal* or *temporo-sphenoidal lobe.* Each of these has its portion of the original cavity, all of which naturally intercommunicate.

The **frontal lobes** are now closely approximated *in front* of the inter-brain, while there is also to be noted the formation of the *optic thalami*, which are merely the thickened sides of the inter-brain (prosencephalon and thalamencephalon).

The **parietal lobes** are similarly approximated *above* the optic thalami, but they have now enlarged, so that the *inner aspect* of each comprises *two* regions (see Fig. 459)—one, just mentioned, close to its fellow *above* the inter-brain; the other, lower region, lying external to the *external surface* of the optic thalamus. Furthermore, the *upper* region is the inner wall of the *cavity* of the parietal lobe, which also comes above the inter-brain, while the lower region is simply the inner aspect of *solid matter—i. e.* a downward thickening of the original wall. Along the floor of that portion of the ventricle contained in the parietal lobe is now seen a thickening which soon resolves itself into a bundle of fibres. This band of fibres, when traced forward, is found to be continuous with a *similar thickening* around the foramen of Monro, which in its turn is continued down through the optic thalamus (anterior pillar of fornix; see page 761). The *curve* of this band is due to the marked *antero-posterior flexure* of the entire fœtal brain which has already taken place, while its transition in *position—i. e.* to the *floor* of the "parietal cavity"—is due to a certain *twisting* or rotation which the hemisphere vesicle now undergoes.

The approximation of the parietal lobes brings these bands very close together as they curve upward, and, as neither one is developed in the cavity of the corresponding *frontal* lobe, each serves, *just here*, as a line of demarkation between the inner wall of the frontal lobe in front and that of the parietal lobe behind. Traced backward, these bands are necessarily found to lie dorsal to the inter-brain, since each is in the floor of the corresponding cavity of the parietal lobe.

Fornix.—The next point to be noted is the *absolute* approximation of the two frontal and of the "upper regions" of the *inner* aspects of the two parietal lobes. As a result of the latter approximation, the two anterior pillars of the fornix, just above the foramen of Monro, are brought together edge to edge, and an actual union takes place between them. *This union* extends posteriorly for more than half the length of the floor of each cavity of the parietal lobe, and is known as the *body of the fornix*, or as "the fornix" in the adult brain. The anterior pillars, however, as they curve downward, are not united, this slight separation persisting in the adult brain.

Anterior Commissure.—Immediately anterior to and connected with each of these pillars, just previous to its passage through the optic thalamus, is a portion of the *inner wall* of the cavity of the frontal lobe, which is now in close contact with the opposite one. Just at this point there now occurs an interchange of fibres between the inner walls of each frontal cavity. These fibres (*anterior commissure*) run transversely across the front of the upper part of the *anterior boundary* of the prosencephalon, and causes an absorption of its tissue, its *epithelial lining* excepted, so that the latter comes to lie directly on the centre part of the *posterior aspect* of the anterior commissure, in the interval between the anterior pillars of the fornix.

The lower part of the anterior boundary of the prosencephalon persists in the adult brain as the upper limit of the lamina cinerea (*lamina terminalis*).

Corpus Callosum.—The frontal lobes having now grown *well forward*, and having also *curved upward* to form the parietal lobes, and the inner surface of each frontal and the "upper region" of the inner surface of the corresponding parietal lobe having met the same structures of the opposite hemisphere, there is formed

a *curved line* of *actual contact*, all along which occurs an interchange of fibres running transversely from one hemisphere to the other. Another factor, besides the upward curve of the parietal lobe, in causing this line of contact to be curved is doubtless the antero-posterior flexure of the whole fœtal brain, already referred to. This large transverse commissure, thus formed, curved anteriorly, is the *corpus callosum* of the adult brain.

This curved line, along which the above-mentioned interchange of fibres takes place, has two extremities, an anterior and a posterior.

The *anterior extremity* is immediately in front of, and in direct contact with, the lateral part of the anterior commissure. Here the corpus callosum itself is thin and conceals the anterior commissure from in front and below; it is also adherent to it and blends inferiorly with the lamina terminalis.

The *posterior extremity* of the curved line is at the posterior part of the inner wall of the cavity of the parietal lobe. Here the corpus callosum itself is very thick and with a free posterior edge, beyond which project, posteriorly, the inner surfaces of the occipital lobes, entirely separate from each other.

This curved line—or the *cut surface of the corpus callosum*, which is the same thing—will now be traced from the posterior to the anterior extremity.

As it passes along anteriorly in the inner wall of the "parietal cavity" it is quite near the floor, so that it soon reaches and becomes adherent to the corresponding half of the "body of the fornix" immediately below it. As it goes forward from this point it separates from its half of the fornix, which is now curving around the foramen of Monro. Continuing forward, the cut edge of the corpus callosum is now on the inner wall of the "frontal cavity." It continues this course for a distance, and then bends sharply *downward*, after which it runs *backward* until it reaches the anterior commissure, by which it is separated from the anterior pillar of the fornix, just as the latter is about to run downward through the optic thalamus.

Septum Lucidum.—There is thus formed a somewhat oval-shaped interval, tapering posteriorly, bounded *above* and *in front* by the corpus callosum; *below*, by the corpus callosum (reflected part) and anterior commissure; behind and below, by the anterior pillar of the fornix and body of the fornix, respectively.

This interval is filled in by a lamina on each side, which is a portion of the inner walls of both frontal and parietal cavities. This lamina is necessarily in close contact with the opposite one, and they both together constitute the *septum lucidum* of the adult brain (Figs. 448, 461).

The *corpus callosum* in addition to forming the commissure just described spreads *outwardly*, also, in the frontal and parietal lobes, and, as it is now quite thick, its under surface forms the *roof* of the "parietal and frontal cavities;" its posterior surface (at the bend) is the *anterior boundary* of the "frontal cavity," while the upper surface of its reflected portion is the *floor* of the frontal cavity.

Along the outer wall of both frontal and parietal cavities the *corpus striatum* is developed as a marked thickening, and close above it passes the corpus callosum. All portions of the frontal and parietal lobes external to the corpus striatum and above the corpus callosum, and those portions of the frontal lobe anterior to and below the corpus callosum, develop into thick, solid matter and project for a considerable distance, but *without* uniting with the opposite side, beyond the corpus callosum in the corresponding directions. This solid matter constitutes the bulk of the lobe.

The "lower region" of the internal surface of the parietal lobe (*internal capsule* of adult brain) is eventually closely united to the external surface of the optic thalamus (Figs. 461, 460).

The **occipital lobe** is the backward extension of the hemisphere. It is entirely separate from the opposite one. Its cavity is roofed over by backward curved prolongations from the corpus callosum.

The **temporal lobe** (*temporo-sphenoidal*) grows downward and forward, as

already described. It carries with it, in its floor, a *prolongation* of its corresponding half of the *fornix*, which, consequently, in the adult brain, is described as dividing posteriorly into its two posterior pillars. As this lobe curves downward it embraces, but *does not adhere to*, the pulvinar of the optic thalamus.

In the fœtal brain a wide shallow cleft (Fig. 444) lies between the temporal and portions of the frontal and parietal lobes, but this deepens and narrows (*fissure of Sylvius*) as the lobe develops. The *cavity* of the temporal lobe lies close to its inner aspect, the bulk of the lobe developing externally. A portion of the corpus callosum roofs over the beginning of the temporal cavity.

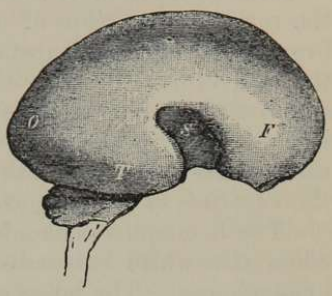

FIG. 444.—Right side of a brain of a five months' fœtus: *F*, frontal; *O*, occipital, and *T*, temporal lobes; *S*, fissure of Sylvius. (Gegenbaur.)

The Lateral Ventricles, and Structures in Connection therewith.

The **lateral ventricles** are the cavities of the hemispheres, each being distinct from the other. In each hemisphere the lateral ventricle is situated in its lower and inner regions, being surrounded above, in front and externally, by the solid, chiefly white, matter of the hemisphere. Each lateral ventricle communicates through the foramen of Monro with the third ventricle, and is lined by a thin diaphanous membrane (the *ependyma*), covered by nucleated epithelium with cilia, scattered here and there in patches. It is moistened by a serous fluid, which is sometimes, even in health, secreted in considerable quantity. Each is separated from the other by a vertical septum, the *septum lucidum*.

Each **lateral ventricle** consists (Fig. 445) of a central cavity, or *body*, and three accessory cavities or *cornua*. The *anterior cornu* curves forward and outward into the substance of the frontal lobe. It comprises that portion of the ventricle which is anterior to the foramen of Monro. The *body* comprises that portion of the ventricle which lies between the foramen of Monro and the posterior part of the corpus callosum. It is situated low down in the parietal lobe. From its posterior extremity diverge the two following: The *posterior cornu*, called the *digital cavity*, curves backward into the occipital lobe; the *middle cornu* descends into the temporal lobe.

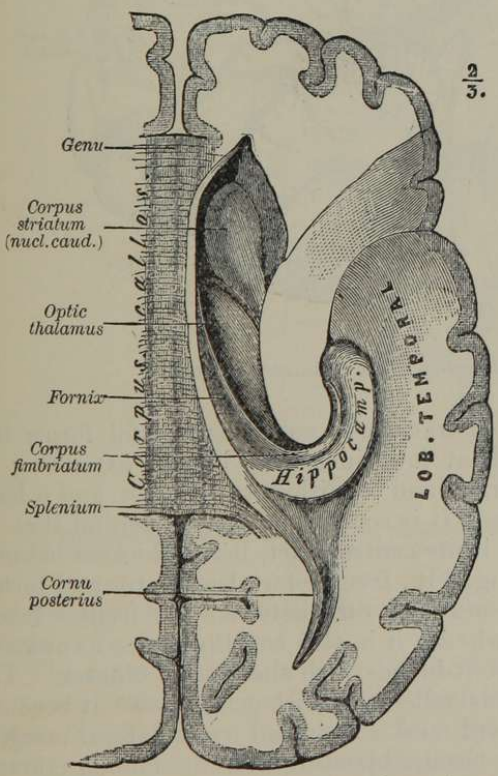

FIG. 445.—Right lateral ventricle seen from above. (Gegenbaur.)

If the upper part of both hemispheres is removed, about half an inch above the level of the corpus callosum, the internal white matter will be exposed. It is an oval-shaped centre, of white substance, surrounded on all sides by a narrow convoluted margin of gray matter, which presents an equal thickness in nearly every part. This white central mass has been called the *centrum ovale minus*. Its surface is studded with numerous minute red dots (*puncta vascu-*

losa), produced by the escape of blood from divided blood-vessels. In inflammation or great congestion of the brain these are very numerous and of a dark color. If the remaining portion of one hemisphere is slightly separated from the other, a broad band of white substance will be observed connecting them at the bottom of the longitudinal fissure; this is the *corpus callosum*. The margins of the hemispheres which overlap this portion of the brain are called the *labia cerebri*. Each labium is part of the convolution of the corpus callosum (*gyrus fornicatus*), and the space between it and the upper surface of the corpus callosum has been termed the *ventricle of the corpus callosum* (Fig. 446).

The hemispheres should now be sliced off to a level with the corpus callosum, when the white substance of that structure will be seen connecting the two hemispheres. The large expanse of medullary matter now exposed, surrounded by the convoluted margin of gray substance, is called the *centrum ovale majus* of Vieussens.

The **corpus callosum** (Figs. 442, 446) is a thick stratum of transverse fibres exposed at the bottom of the longitudinal fissure. It connects the two hemi-

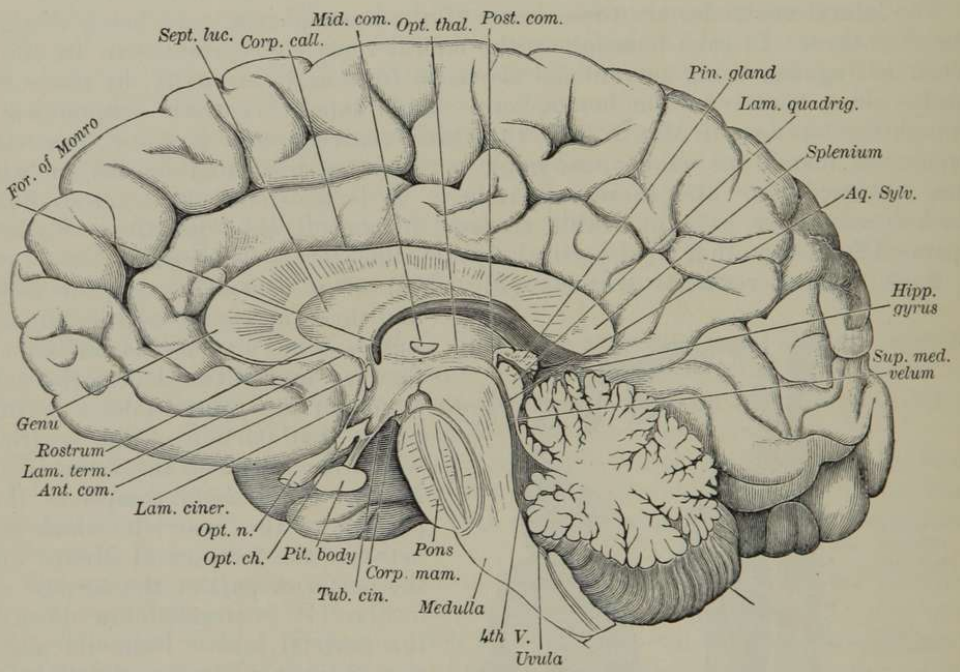

FIG. 446.—Antero-posterior median section of the brain, × ⅔. (Henle.)

spheres of the brain, forming their great transverse commissure, and forms the roof of the *lateral ventricles*. It is about four inches in length, extending to within an inch and a half of the anterior, and to within two inches and a half of the posterior, end of the hemispheres. It is somewhat broader behind than in front, and is thicker at either end than in its central part, being thickest behind. It presents a somewhat arched form (Fig. 446) from before backward, and terminates anteriorly by curving downward and backward between the frontal lobes. This distinct bend is named the *genu*, whence it is still continued downward and backward to the base of the brain, where it blends with the lamina cinerea. The reflected portion of the corpus callosum is called the *beak* or *rostrum:* it becomes gradually narrower as it passes backward, and is attached by its lateral margins to the frontal lobes. At its termination, besides blending with the lamina cinerea, the corpus callosum gives off two small bundles of white substance, which, diverging from one another, pass backward, across the corresponding anterior perforated space, to the entrance of the fissure of Sylvius, to enter the end of the temporal

lobe, where they meet the outer olfactory roots. They are called the *peduncles of the corpus callosum.* Posteriorly, the corpus callosum forms a thick rounded fold, called the *splenium* or *pad*, which is free for a little distance as it curves forward, and is then continuous with the fornix below. On its upper surface the structure of the corpus callosum is very apparent, being collected into coarse transverse bundles. Along the middle line is a linear depression, the *raphe*, bounded laterally by two or more slightly elevated longitudinal bands, called the *striæ longitudinales* or *nerves of Lancisi;* and, still more externally, other longitudinal striæ are seen beneath the convolutions which rest on the corpus callosum. These are the *striæ longitudinales laterales* or *tæniæ tectæ.* The under surface of the corpus callosum is continuous behind with the fornix, being separated from it in front by the septum lucidum, which forms a vertical partition between the two ventricles. On each side the fibres of the corpus callosum extend into the substance of the hemispheres, connecting them together. The greater thickness of the two extremities of this commissure is explained by the fact that the fibres from the anterior and posterior parts of each hemisphere do not pass directly across, but take a curved direction. The *peduncles of the corpus callosum* may be traced upward around the genu to become continuous with the *striæ longitudinales*, or *nerves of Lancisi*, on the upper surface of the corpus callosum.

The fibres from the *splenium*, which curve backward to roof in the posterior cornu are known as the *forceps major;* those from just above the genu, which curve forward to roof in the front part of the anterior cornu constitute

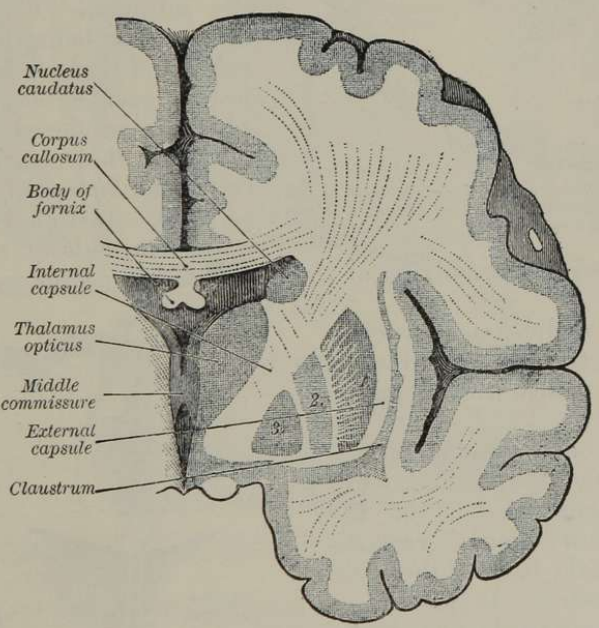

FIG. 447.—Transverse vertical section of the brain, × ⅔, anterior to the middle commissure; the cut surface looks forward. 1. putamen. 2 and 3. globus pallidus. (Gegenbaur.)

the *forceps minor;* while the term *tapetum* is given to the main body of the fibres.

The **central cavity**, or **body**, of the lateral ventricle is comparatively wide, but is a mere slit as regards its perpendicular diameter. It is (Fig. 447) bounded, above, by the under surface of the corpus callosum, which forms the roof of the cavity. Internally is a vertical partition, the posterior portion of the *septum lucidum*, which separates it from the opposite ventricle, and connects the under surface of the corpus callosum with the fornix. Its floor is formed by the following parts, enumerated in their order of position from without inward: the

corpus striatum (caudate nucleus), *tænia semicircularis*, *optic thalamus*, *choroid plexus*, one-half of *body of fornix*, and corresponding *posterior pillar*.

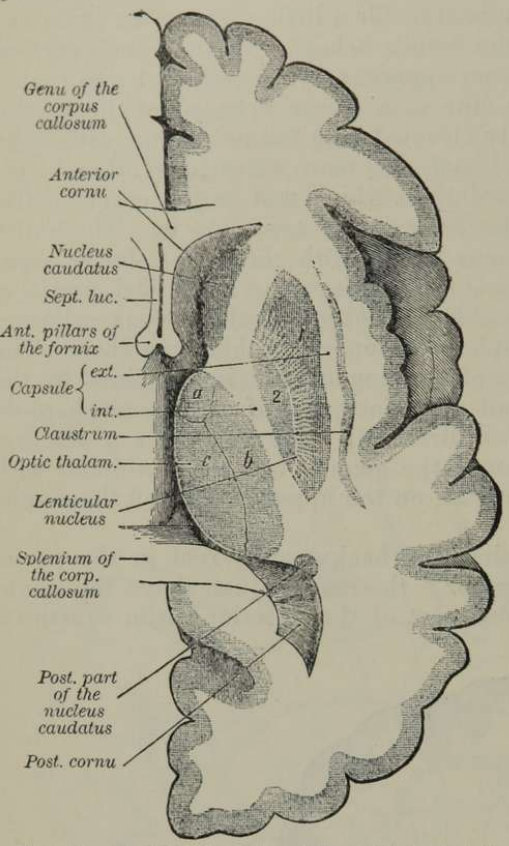

FIG. 448.—Horizontal section of the right half of the cerebrum, × ⅔. 2. putamen. *a*, *b*, and *c* nuclei of the optic thalamus. (Gegenbaur.)

The **anterior cornu** is deep and narrow, passing outward into the frontal lobe and curving round the anterior extremity of the corpus striatum. Its apex points outward. It is bounded, above, by the corpus callosum; externally, by the corpus striatum (*head* of caudate nucleus); in front, by the posterior surface of the *genu* of the corpus callosum; internally, by the anterior or broad portion of the septum lucidum; inferiorly, by the upper surface of the rostrum (each side of its middle line) of the corpus callosum. This last is the *floor* of the cornu, and is exceedingly narrow, the outer wall, convex toward the cavity, almost meeting the lower part of the septum lucidum below (Figs. 448 and 449).

The **posterior cornu, or digital cavity** (Fig. 445), curves backward into the substance of the occipital lobe, its direction being backward and outward, and then inward. On its inner wall is seen a longitudinal eminence which is produced by the extension inward of the calcarine sulcus; this is called the *hippocampus minor*, or *calcar avis*. Just above this is a smaller projection, *bulb of the posterior horn* (Fig. 456), caused by the bulging of the fibres of the *forceps major* of the corpus callosum.

Between the middle and posterior horns a smooth triangular surface is observed. It is called the *trigonum ventriculi*.

The **middle** or **descending cornu**, the longest of the three (Fig. 445), traverses the temporal lobe of the brain, forming in its course a remarkable curve round the back of the optic thalamus (*pulvinar*). It passes, at first, backward, outward, and downward, and then curves round the crusta forward and inward, nearly to the apex of the middle lobe, close to the fissure of Sylvius. Its upper boundary, or *roof*, is formed by the under surface of the corpus callosum, the small portion of the pulvinar of the optic thalamus covered by epithelium, and by the white matter (internal capsule) of the temporal lobe, with which are incorporated the reflected parts of the nucleus caudatus of the corpus striatum and tænia semicircularis, which are prolonged into it. Its lower boundary, or

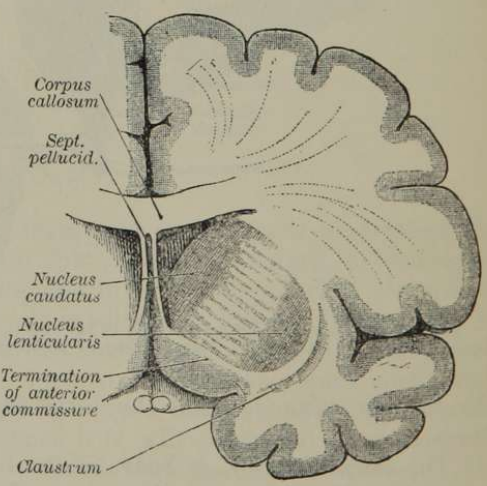

FIG. 449.—Transverse vertical section of the hemispheres through the anterior cornua, × ⅔. The cut surface looks forward. (Gegenbaur.)

floor, presents for examination the following parts: the *hippocampus major*, *pes hippocampi*, *eminentia collateralis* or *pes accessorius*, and *corpus fimbriatum from the fornix*. The *outer wall* is white matter of the temporal lobe. The *inner wall* is a layer of epithelium, prolonged from that covering the pulvinar, just mentioned, which is *invaginated* by a fold of pia mater, and thus is formed the *choroid plexus*.

The **corpus striatum** (Fig. 450) has received its name from the striped appearance which its section presents, in consequence of diverging white fibres being mixed with the gray matter which forms the greater part of its substance. The greater portion of this body is imbedded in the white substance of the hemisphere, and is therefore external to the ventricle. It is termed the *extraventricular por-*

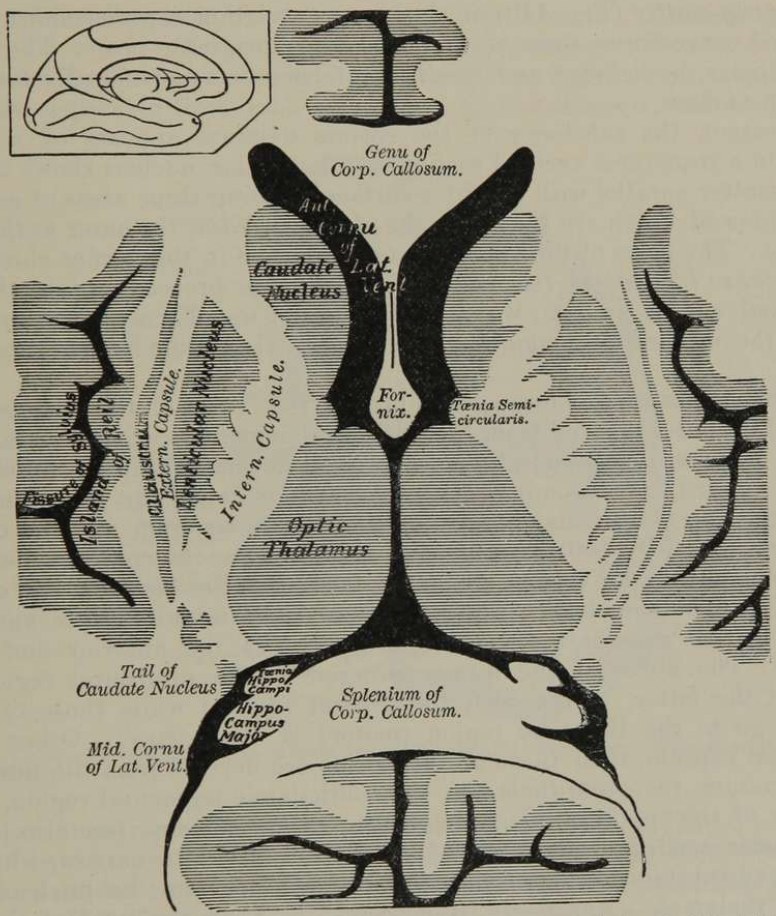

FIG. 450.—Middle part of a horizontal section through the cerebrum at the level of the dotted line in the small figure of one hemisphere. (From Ellis, after Dalton).

tion, or the *nucleus lenticularis:* a part, however, is visible in the ventricle and its anterior cornu; this is the *intraventricular portion*, or the *nucleus caudatus*. The intraventricular portion is a pear-shaped mass of gray matter: its broad anterior extremity is the convex outer wall of the anterior cornu. Its narrow end is directed backward, and lies on the outer part of the floor of the body of the ventricle. It is continued, by a sharp anterior bend, into the *roof* of the descending cornu; it is covered by the lining of the cavity and crossed by some veins of considerable size. It is separated from the extraventricular portion by a lamina of white matter, the *internal capsule*, in contradistinction to a lamina of white matter which covers the outer surface of the extraventricular portion of the corpus striatum, and which is called the *external capsule*.

The extraventricular portion of the corpus striatum, or *nucleus lenticularis*, is oval in form. It does not extend as far forward or backward as the nucleus

caudatus. It is bounded externally by a lamina of white matter called the *external capsule*, which is covered on its outer surface by a thin layer of gray matter termed the *claustrum*. The claustrum presents ridges and furrows on its outer surface, corresponding to the convolutions and sulci of the island of Reil, with the white matter of which it is in immediate relation.

Antero-inferiorly the ends of the two nuclei of the corpus striatum are united by a thin gray lamina which appears at the base of the brain in the anterior perforated space. The caudate nucleus terminates, after running downward and forward in the roof of the descending cornu, in the *nucleus amygdalæ*, a collection of gray matter in the apex of the temporal lobe. The base of the claustrum is also in connection with this nucleus.

The *gray matter* (Fig. 449) of the corpus striatum is permeated by tracts of medullated nerve-fibres, some of which probably originate in it. The nerve-cells are multipolar, both large and small, the larger being principally found in the lenticular nucleus.

On section, the substance of the corpus striatum appears of reddish-gray color. On a transverse vertical section, the lenticular nucleus shows two laminæ of white matter parallel with its outer surface, forming three areas of gray matter, the two inner of which are known as the *globus pallidus*, the outer as the *putamen* (Fig. 447). The *fibres* of the nucleus enter and leave it, the former chiefly derived from the *ansa lenticularis* (see page 747), the latter proceeding into the internal capsule and corona radiata, which last is made up of the *radiating diverging* fibres of the upward prolongation of the internal capsule which extend to the cortex.

The **internal capsule** is formed by fibres of the crusta of the crus cerebri, supplemented by fibres derived from the optic thalamus and corpus striatum on each side. In *horizontal* section it is seen to be somewhat abruptly curved, with its convexity inward; the prominence of the curve is called the *genu*, and projects between the intraventricular portion of the corpus striatum and the optic thalamus (Figs. 447, 448, 450). In front of the genu the internal capsule separates the two portions of the corpus striatum; behind, it lies between the optic thalamus and lenticular nucleus. The portions of the internal *capsule*, anterior and posterior to the genu, are known, respectively, as the anterior and posterior *segments*. The fibres of the former proceed to the prefrontal region of the cortex; of the latter, to the occipito-temporal region; while those of the *middle third* go to the Rolandic region (motor) of the cortex. Other fibres, in the internal capsule, than those of the crusta are derived from the nuclei of the corpus striatum, the optic thalamus, the subthalamic tegmental region, and from the cortex of the opposite side through the corpus callosum (see also page 785).

The **tænia semicircularis** (Figs. 445, 447, and 461) is a narrow, whitish band of medullary substance situated in the depression between the nucleus caudatus and optic thalamus. Anteriorly, it descends, between the head of the caudate nucleus and the anterior extremity of the optic thalamus, to join the anterior pillar of the fornix, below the level of the foramen of Monro, where most of the fibres continue with those of the pillar, while the remainder pass over the anterior commissure and terminate in the gray matter of the anterior perforated space. Behind, it is continued into the roof of the middle or descending horn of the lateral ventricle, lying parallel with the caudate nucleus, to enter, with it, the nucleus amygdalæ. Beneath it is a large vein (*vena corporis striati*), which receives numerous small veins from the surface of the corpus striatum and optic thalamus, and joins the venæ Galeni. On transverse vertical section the *tænia* is seen to lie upon a projection from the internal capsule.

The **fornix** (Figs. 442, 447, 451) is a longitudinal band of white matter situated beneath the corpus callosum, with which it is continuous behind, but separated from it in front by the septum lucidum. It may be described as consisting of two symmetrical halves, one for either hemisphere. These two portions are joined together in the middle line (along which is attached the lower edge of the

septum lucidum), where they form the *body*, but are separated from one another in front and behind, forming the *anterior* and *posterior pillars*, or *columnæ fornicis* and *crura fornicis*, respectively.

The *body of the fornix* is triangular; narrow in front, broad behind. Its upper surface is connected, in the median line, to the septum lucidum in front and the corpus callosum behind, while laterally this surface forms part of the floor of the *body* of each lateral ventricle. Its under surface rests upon the velum interpositum, which separates it from the third ventricle and from the inner portion of the superior surfaces of the optic thalami. Its free outer edge, on each side, is in contact with the choroid plexus, which projects from under it. This *edge*, running from behind forward and inward, rests in the *groove* already referred to, having a similar direction, on the superior surface of the thalamus, but with a portion of the velum interpositum, of course, separating it from the groove.

The *anterior pillars* are rounded bundles which arch downward toward the base of the brain, separated from each other by a narrow interval, and each descends

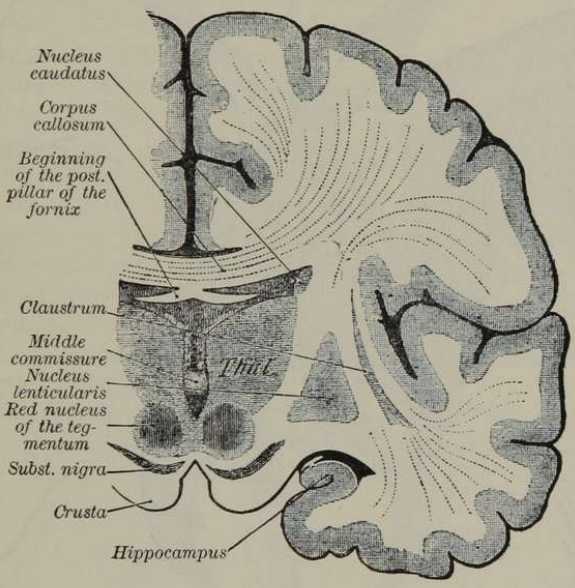

FIG. 451.—Transverse vertical section of brain behind the middle commissure. The cut-surface looks backward, × ⅔. (Gegenbaur.)

through the anterior portion of the optic thalamus. Each is placed immediately behind the anterior commissure. At the base of the brain the white fibres of each pillar make a sudden curve and form the outer part of the corresponding *corpus albicans* (see page 750), from which point they may be traced upward into the substance of the corresponding optic thalamus. The anterior pillars of the fornix are connected in their course with the peduncles of the pineal gland and the superficial fibres of the tænia semicircularis, and receive fibres from the septum lucidum.

Between the anterior pillars of the fornix and the anterior extremities of the optic thalami an oval aperture is seen on each side: this is the **foramen of Monro** (Fig. 442). The two openings descend toward the middle line and lead into the upper part of the third ventricle. Through these openings the lateral ventricles on each side communicate with the third ventricle, and consequently with each other. Its *boundaries* are, therefore, in front, the anterior pillars of the fornix; behind, the anterior extremity of the optic thalamus; above, the body of the fornix; and below, the junction between the anterior pillars of the fornix and the optic thalamus.

The *posterior pillars* are flattened bands, and at their commencement are intimately connected by their upper surfaces with the corpus callosum; diverging from one another, each passes downward around and behind the pulvinar of the

optic thalamus, and then along the floor of the descending horn of the lateral ventricle, where some of its fibres blend with the white matter of the *hippocampus major*, while the remainder are prolonged along its inner border as the *corpus fimbriatum* (Figs. 445, 454), which extends into the white matter of the uncus of the hippocampal gyrus. Upon examining the under surface of the fornix, between its diverging posterior pillars a triangular portion of the under surface of the corpus callosum may be seen, the base of which is the splenium. On it are a number of lines, some transverse, others longitudinal or oblique. This

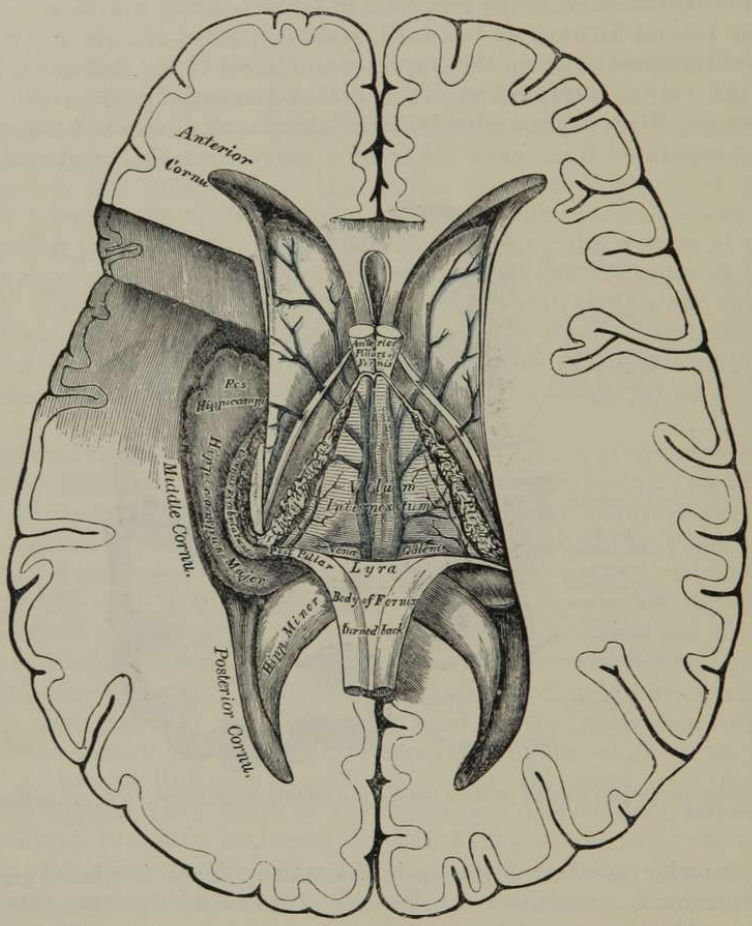

FIG. 452.—The fornix, velum interpositum, and middle or descending cornu of the lateral ventricle.

portion has been termed the *lyra*, from the fancied resemblance it bears to the strings of a harp (Fig. 452). The corpus fimbriatum is often called the *fimbria*.

The **anterior commissure** is a round bundle of white fibres placed in front of the anterior pillars of the fornix, and appears to connect together the corpora striata. It passes outward through the corpus striatum on each side, and then curves backward into the substance of the temporal lobe.

The **septum lucidum** (or pellucidum) (Figs. 446, 449) forms the *internal boundary* of the *body* and *anterior cornu* of the lateral ventricle. It is a thin septum attached, *above*, to the under surface of the corpus callosum; *below*, to the anterior part of the fornix, and in front of this to the *reflected portion* of the corpus callosum and anterior commissure; *behind*, to the anterior pillars of the fornix; *in front*, to the posterior surface of *genu* of the corpus callosum. It is broad in front, and narrow behind, its external surfaces looking toward the cavities of the ventricles. The septum consists of two laminæ, separated by a narrow interval, the *fifth ventricle*.

Fifth Ventricle.—The fifth ventricle was originally a part of the great longitudinal fissure which separated the two hemisphere vesicles, but has become shut off by the union of the hemispheres in the formation of the corpus callosum and the fornix. Its walls are therefore formed by the median wall of the hemispheres, and each consists of an internal layer of gray matter derived from the gray matter of the cortex and an external layer of white substance continuous with the white matter of the cerebral hemispheres. This is lined on its external surface by the ependyma of the corresponding lateral ventricle. The fifth ventricle is not lined by epithelium, but by a delicate layer of modified pia mater. It has no connection with any of the "regular" ventricles.

The structures of the *floor* of the descending cornu will now be considered.

The **hippocampus major**, or **cornu Ammonis** (Figs. 445, 452, 456), so called from its resemblance to a ram's horn, is a white eminence, of a curved elongated form, extending throughout the entire length of the floor of the middle horn of the lateral ventricle. At its lower extremity it becomes enlarged, and presents a number of rounded elevations with intervening depressions, which, from presenting some resemblance to the paw of an animal, is called the *pes hippocampi*. If a transverse section is made through the hippocampus major (Fig. 453), it will be seen that this eminence is produced by the extension inward of the dentate (hippocampal) fissure on the mesial aspect of the temporal lobe. This fissure, like all the other fissures of the hemisphere, is lined by a dipping in and out again of the gray cortex; but, whereas in *these* fissures the gray lining, after coming out, is continuous with that of an adjacent fissure, the gray lining of the *hippocampal fissure*, after turning on itself, comes out and *terminates in a free edge*, forming a notched ridge, the *fascia dentata* (Figs. 453, 454). The hippocampus is covered

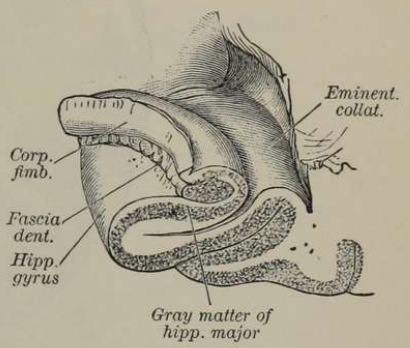

FIG. 453.—Part of left descending cornu. The cut surface looks forward. (Henle.)

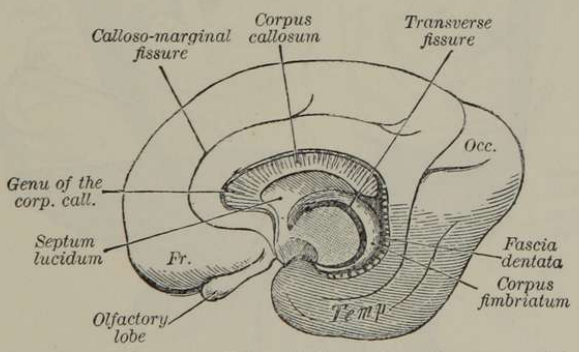

FIG. 454.—The mesial or internal surface of the *right hemisphere* of a six months' fœtus. (Schmidt.)

on its ventricular surface by the lining membrane of the ventricle, beneath which is a thin lamina of white matter (*alveus*), which is continuous with the corpus fimbriatum of the fornix, and beneath *this* is the "gray matter" of the hippocampus—*i. e.* the cortical lining of the hippocampal fissure, just described. This gray matter is seen, on cross-section, to make a secondary turn which embraces a slender process of white matter derived from the white lamina before it emerges as the free edge.

The **corpus fimbriatum** (Figs. 445, 454, 456) (*tænia hippocampi*) is a narrow white band situated immediately below the choroid plexus. It is the thin prolongation of the posterior pillar of the fornix, and is attached by its inner margin

along the curved inner border of the hippocampus major as it descends into the

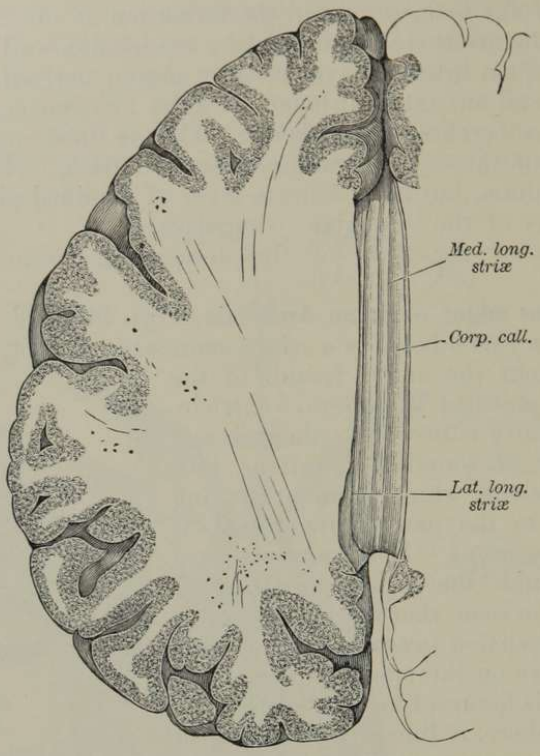

FIG. 455.—Horizontal section of the hemispheres at the level of the corpus callosum. (Henle.)

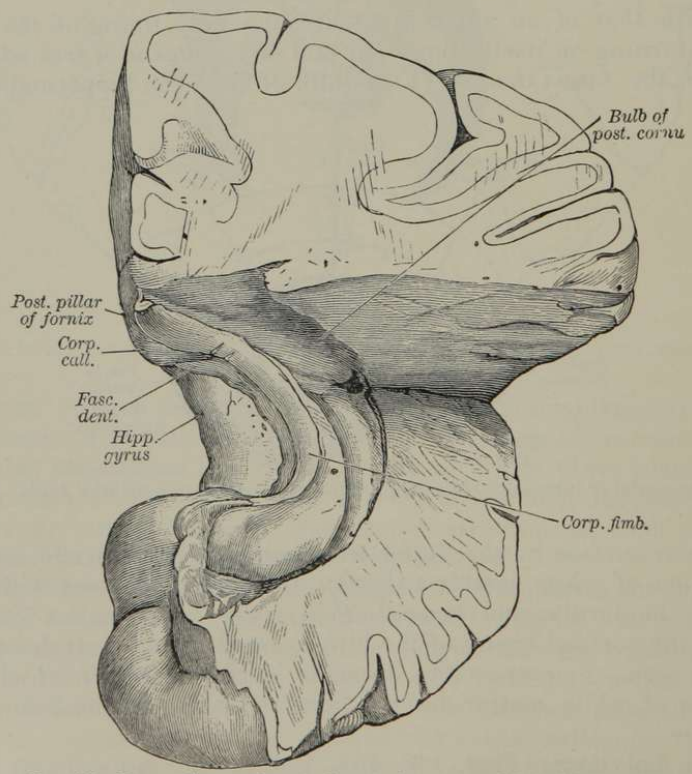

FIG. 456.—Descending and part of posterior cornu of left side. (Henle.)

middle horn of the lateral ventricle. It may be traced as far as the crochet or hook

of the hippocampal convolution. Its outer edge is free, and lies on the surface of the hippocampus. This edge is directed toward the cavity of the descending cornu.

The **eminentia collateralis** (Fig. 453), or **pes accessorius**, is a white eminence, varying in size, placed between the hippocampus major and the outer wall of the cornu. It is formed by the protrusion inward of the *collateral fissure*.

Fascia Dentata (Figs. 453, 454, 456).—On separating the inner border of the corpus fimbriatum from the choroid plexus, and raising the edge of the former, a

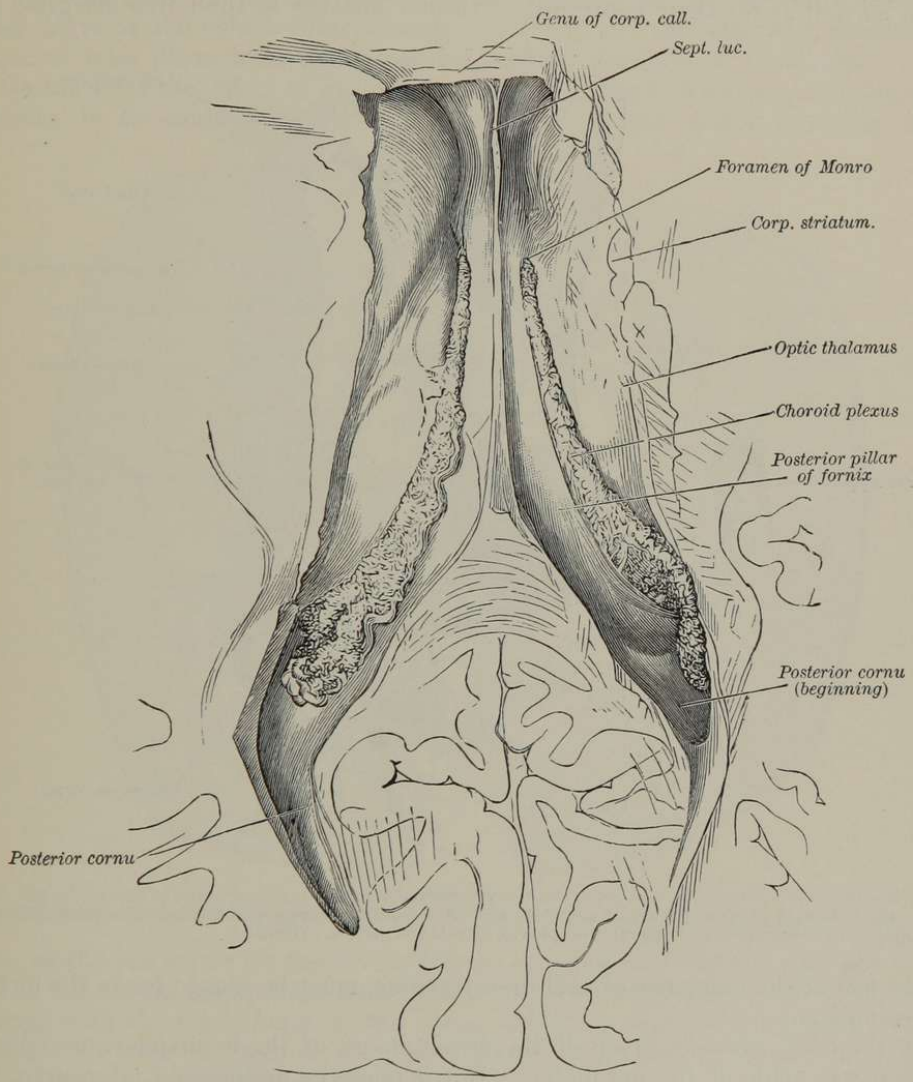

FIG. 457.—The lateral ventricles from above, showing choroid plexuses; the left is in its natural position; the right plexus is somewhat laterally displaced to show the edge of the fornix. (Henle.)

serrated band of gray substance, the edge of the gray substance in the dentate or hippocampal fissure, will be seen beneath it: this is the *fascia dentata*. Correctly speaking, it is not placed within the cavity of the descending cornu. The *fascia dentata* has a curved direction, following the course of the hippocampus, and also runs obliquely from above downward and forward. Its lower extremity is lost in the gray matter of the uncus or hook of the hippocampal gyrus, where it is seen as a small band (Giacomini) passing transversely over the hook. Its upper extremity is well marked (*fasciola cinerea*), and lies immediately behind and below the splenium of the corpus callosum, over and above which it is continuous with the lateral and mesial longitudinal striæ of that body (Fig. 455).

The **choroid plexuses** (Figs. 457, 458) of each lateral ventricle are two in number, *one* in the *floor* of the *body*, and the *other* in the *descending cornu*. Each is a vascular fringe-like membrane with a free edge looking toward the ventricular cavity, and an attached margin which is continuous with two layers of pia mater.

The **choroid plexus of the body of the ventricle** is, as before stated, the thickened, convoluted side of the velum interpositum, which is made up of two layers of pia mater. The reasons for the presence of *two* layers in the velum interpositum, as well as for their continuity with one another at their free margins, and

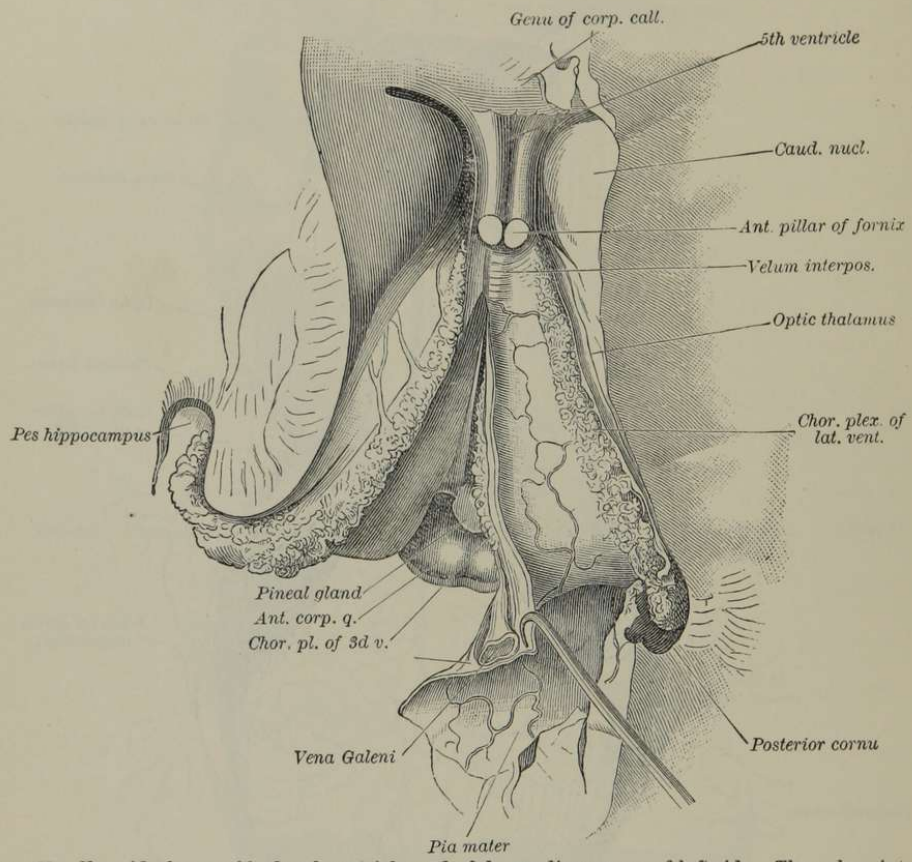

FIG. 458.—Choroid plexus of body of ventricle and of descending cornu of left side. The velum interpositum is split on the left side, showing choroid plexus of third ventricle. (Henle.)

for the fact of the existence of such free margins, must be sought for in the method of development.

In the brief account given of the development of the hemisphere vesicles no mention was made of the pia mater. But it must be understood, of course, that the pia mater covers the entire brain-tube, and takes part in, and adapts itself to, all the different changes in shape and position which the various portions of the brain undergo.

We thus have, at a certain point of development, three "tubes" of pia mater —one encircling the inter-brain, and one investing each hemisphere vesicle (see Fig. 459). As the latter approaches its fellow it also grows in toward the inter-brain. Finally, as already described, actual adhesions take place between the mesial aspects of each hemisphere above the inter-brain, and between *that portion* of the hemisphere which *lies external to the inter-brain* and the side of the inter-brain (optic thalamus); while the *under* surfaces of the hemispheres (corpus callosum and fornix) merely rest on, and are not adherent to, the superior surface of the inter-brain. The effect on the pia mater (see Figs. 460, 461) *mesially* and

above the inter-brain, is thus clear: (1) The pia lining the mesial aspect of each hemisphere is absorbed by the formation of the corpus callosum and the coming together of the two halves of the fornix; hence (2), the part *above* the corpus callosum becomes continuous with that of the other side *across the upper surface* of the corpus callosum; while (3) the pia on the *under* surface of each hemisphere (*below* the corpus callosum and fornix) becomes continuous with that on the under surface of the other, and forms one layer from side to side (upper layer of velum interpositum). This upper layer of the velum interpositum is now in close contact with the layer of the pia covering the superior surface of the inter-brain (lower layer of the velum interpositum), but they are not absorbed, because no adhesions take place between the corresponding portions of the brain.

On the sides the effect of the adhesion between the hemisphere and the optic thalamus is to cause absorption of the layer of pia mater covering each;

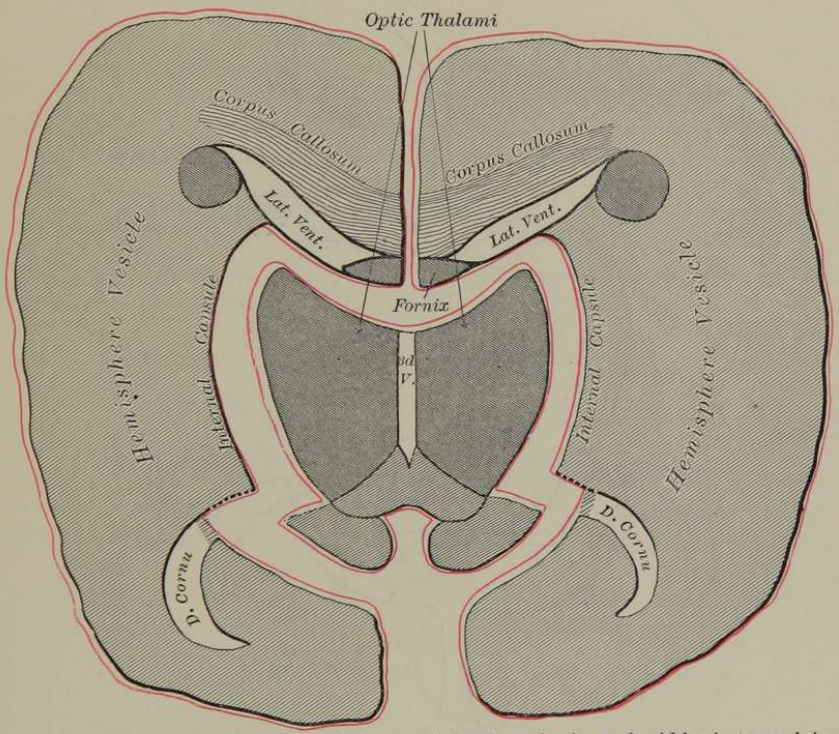

FIG. 459.—Diagram of cross-section of hemisphere vesicles, inter-brain, and mid-brain to explain formation of *velum interpositum* and *choroid plexuses*. The *red line* is the pia mater. (B. B. G.)

hence, as the pia mater on the *hemisphere* is originally continuous with the *upper layer* of the velum interpositum, and the pia mater on the outer side of the optic thalamus with the *lower layer* of the same, it follows that the *two layers* become continuous at their *margins* or along the line where each is "cut off," as it were, from its original prolongation (Figs. 460, 461).

This *margin* is at first *along the border* between the superior and external surface of the thalamus, but soon becomes shifted mesially, so that it comes to lie along the *groove* on the superior surface of the thalamus. This shifting is due to the absorption of the pia-mater layers *external to* the groove, caused by the adhesion which has taken place between the subjacent portion of the thalamus and the superjacent portion (epithelial floor, see below) of the hemisphere.

The *anterior extremity* of the velum interpositum, narrow and bifid, as already described, is necessarily limited by the curve of the anterior pillars of the fornix, behind which the two layers are continuous, because it is at and around this point, which might be regarded as a sort of *hinge*, that the hemispheres swing up and over the inter-brain, carrying with them each one half of the future upper layer of the velum interpositum.

Epithelial Floor of the Body of the Ventricle.—The margin of the velum interpositum thus formed is necessarily situated between the under surface of the floor of the body of lateral ventricle above and the upper surface of optic thalamus below, but it does not reach out over all of this surface, but lies only on its *inner half*, as already explained. Hence a portion of the under surface of the floor of the ventricle must rest on the outer half of the upper surface of the thalamus. Now, this portion of the floor, together with that immediately superjacent to the margin of the velum interpositum, becomes reduced to a *layer of epithelium* which stretches from the *edge of the fornix* over to the *tænia semicircularis*. This epithelium is continuous with that lining the ventricle both at the edge of the fornix and at the tænia. As it passes over the fringe-like margin of the velum interpositum it invests all its processes, and thus forms the true choroid plexus. As it passes over the optic thalamus it has ependyma beneath it, as also where it

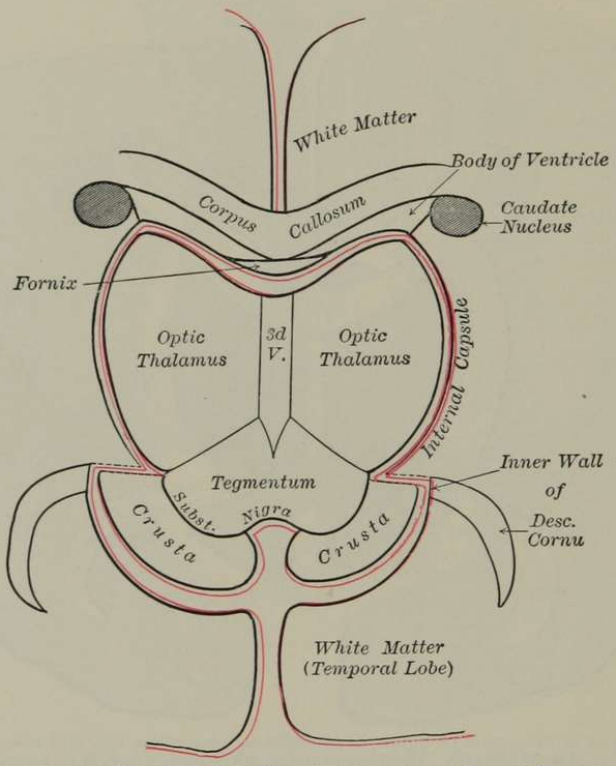

FIG. 460.—The same as preceding figure, but at a supposedly later stage of development. (B. B. G.)

covers tænia semicircularis, caudate nucleus, under surface of corpus callosum, ventricular aspect of septum lucidum, and upper surface of corresponding half of fornix.

Epithelial Inner Wall of Descending Cornu.—The entire inner wall of this cornu is reduced to a layer of epithelium. It is, morphologically, the continuation of the epithelium forming part of the floor of the body of the ventricle just described, and it stretches between the same structures, or rather their prolongations—*i. e. tænia semicircularis* in *roof* of descending cornu and *corpus fimbriatum* in floor (Figs. 460 and 461). In the region of transition from body to descending cornu, just at the curve, the epithelium curves downward also, and stretches, now, between edge of posterior pillar of fornix (posterior part) across, on the rounded pulvinar of the optic thalamus, to the *curved part* of the *tænia*, which is immediately external to and lies against the outer aspect of the pulvinar. Hence this part of the epithelium is, strictly speaking, a portion of the roof of the descending cornu (see p. 758). Just beyond this point the epithelium assumes the mesial position and becomes the regular inner wall of the cornu.

Choroid Plexus of Descending Cornu.—The epithelial inner wall, just described, is invaginated by and closely invests a fringe-like margin of pia mater (Fig. 461), which apparently passes into the ventricle, turns on itself, and passes out again, but is everywhere covered, toward the cavity of the cornu, by the latter's now greatly convoluted inner epithelial wall. This is the *choroid plexus of the descending cornu*, and when seen from above it lies over the hippocampus major and conceals it from view, as well as the corpus fimbriatum.

The two layers of pia mater, of which the margins, covered by epithelium, make up the choroid plexus, are in continuity with the two layers of the velum interpositum, whose margins, also covered by epithelium, form the choroid plexuses of the bodies of the ventricles. But the *upper layer* of the velum is continuous

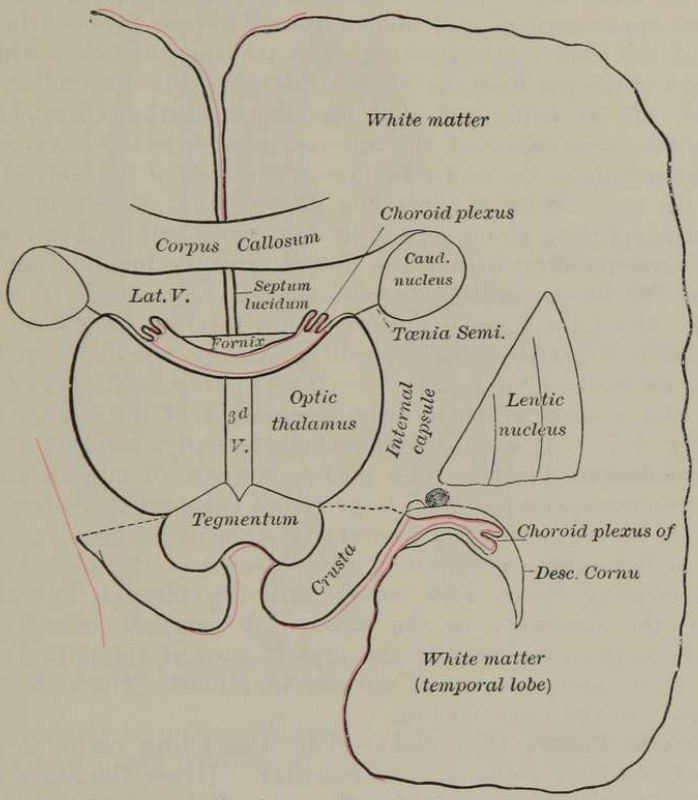

FIG. 461.—The same as the two preceding figures. The *velum interpositum* and *choroid plexuses* are now complete. In the roof of the descending cornu are seen the prolongations of tænia semicircularis and caudate nucleus. (B. B. G.)

with the *lower layer* of the choroid plexus of the cornu, and, *vice versâ*, this relation being due to the bending downward, forward, and inward of the temporal lobe and the descending cornu. This relation may perhaps be better appreciated by tracing these layers separately, thus:

The *lower layer* of the "choroid plexus" of the descending cornu, if traced out of the cornu—*i. e.* toward the median line—passes, at its *lower part*, right around the under surface of the temporal lobe; if traced at its upper part—*i. e.* at the *curve* of junction between this cornu and body of ventricle—this same layer will be found to bend *sharply forward* on itself and to come forward under the edge of the now superiorly placed fornix, and be continuous with the *upper layer* of the velum. Posteriorly and externally, this layer is in continuity with the pia mater covering the under surfaces of the occipital and temporal lobes.

The *upper layer* of the "choroid plexus" of the descending cornu, if traced in the same manner—*i. e.* at two levels—is found, at the lower level, to be continuous with the pia mater covering the crustæ of the mid-brain; at the upper level it also bends sharply forward, comes forward under the fornix, and is con-

tinued into the *lower layer* of the velum interpositum. Just at the *forward bend* this layer is really *anterior to* the other one. Posteriorly, this same layer is in continuity with the pia mater covering the corpora quadrigemina, which, in its turn, if traced ventrally, is seen to be continuous with that already mentioned covering the crustæ.

It would appear, then, from the foregoing, that this whole arrangement of pia mater is a complicated invagination or tucking-in process of an originally single layer. Morphologically, however, we find this arrangement to be caused by the absorption of the contiguous layers of the three "tubes" of pia mater already referred to. Thus (cf. Figs. 459, 460, 461), the pia mater covering the crustæ should be considered, as it really does in an early stage of development, as running up on the outer side of, and around and behind the pulvinar of, the optic thalamus to its upper surface, and thence inward to pass into continuity with the *lower layer* of the velum interpositum, thus making *one tube;* while, similarly, the *upper layer* of the pia from the choroid plexus of the descending cornu should be considered, not as being reflected mesially on to the crustæ, but as running upward along the *inner aspect* of the *internal capsule* to the tænia semicircularis, and thence inward along the *under surface* of the floor of the body of the ventricle to join with the *upper* layer of the velum interpositum, which, in its turn, should be considered as splitting along its middle line, each half to bend upward, lying *mesial to* the corresponding half of the fornix, septum lucidum, and corpus callosum, to meet the corresponding layer of pia mater lining the mesial aspect of the hemisphere above the corpus callosum; thus forming *two* tubes.

At the junction between the choroid plexus of the body and that of the descending cornu in the adult brain there is a twisting backward of the latter, so that its free edge is directed posteriorly, while that of the former looks antero-externally (Fig. 457). It may sometimes look mesially, bending over the fornix.

Structure of Choroid Plexus.—The plexus consists of minute and highly vascular villous processes, composed of large round corpuscles, containing, besides a central nucleus, several yellowish granules and fat-molecules, and covered by a single layer of flattened epithelium. The arteries of the choroid plexus enter along the descending cornu, and, after ramifying through its substance, send branches into the substance of the brain. A constant branch, the anterior choroid, enters at the extremity of the middle horn of the lateral ventricle, and supplies the velum interpositum and the choroid plexus. The veins of the choroid plexus terminate in the venæ Galeni.

The Transverse Fissure (Fig. 454).—The descending cornu is a mere cleft; that is, its roof and floor are very close together. Hence the *tænia semicircularis* of the roof, which runs along in the substance of the white matter of the temporal lobe, this white matter being the outer and under aspect of the beginning of the internal capsule, is quite near the corpus fimbriatum in the floor. Between the two pass the two layers of the pia mater which form the choroid plexus. If this pia mater be pulled out, the epithelial inner wall will necessarily come with it, and a cleft-like orifice into the cornu be produced. A similar cleft above will be caused by removal of the velum interpositum and choroid plexuses of the bodies of the ventricles, and if the plexus of the other cornu be removed also, there will remain two large curved fissures, one on each side, extending from the end of the descending cornu to the corresponding foramen of Monro. Beginning at the foramen, the fissure will be bounded by *edge* of body and posterior pillar of fornix *above*, and upper surface of optic thalamus *below* (Fig. 462). At the *curve* of the descending cornu the cleft will lie between *pulvinar* of optic thalamus *in front* and edge of posterior pillar of fornix (now beginning to twist into its position in the *floor* of the descending cornu as corpus fimbriatum) *behind;* while along the cornu it is bounded *below* by *corpus fimbriatum*, and above by *edge of white matter* of temporal lobe, along which is running the *tænia semicircularis*. These two fissures, taken together, are known as the *transverse fissure* of the brain, and only exist when the pia mater and choroid plexuses are removed. Hence it

is not a real fissure or sulcus, but a rent in part of the floor of the body and in the inner wall of the descending cornu of the lateral ventricle. The cleft formed by removal of the plexus of the body of the ventricle leads mesially into a space whose upper boundary is the under surface of fornix and corpus callosum, the lower boundary being the upper surfaces of the optic thalami on each side, while in the middle part is seen the cavity of the third ventricle, which has necessarily been unroofed by the removal of the velum interpositum. Posteriorly, this space continues into the larger one separating splenium of corpus callosum above and pineal gland and corpora quadrigemina below; while in its turn this interval is

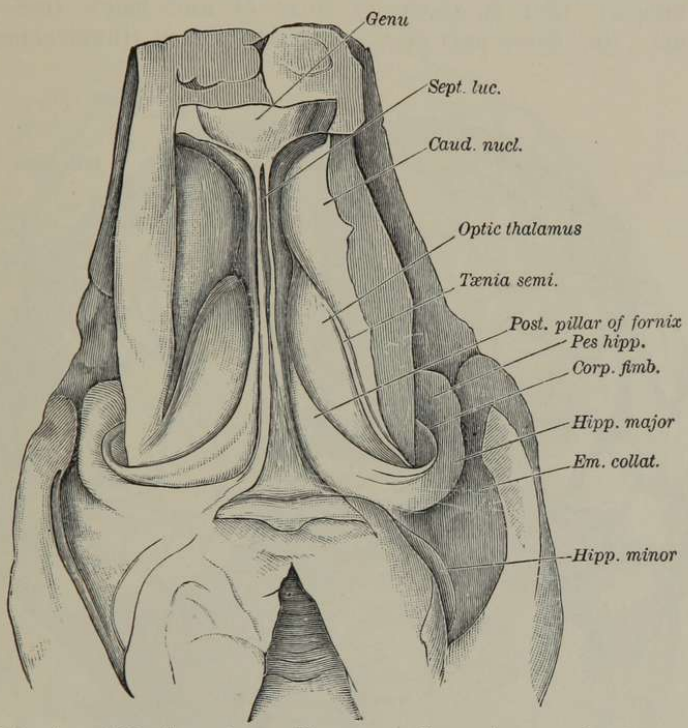

FIG. 462.—The lateral ventricles from above. The corpus callosum is removed and the velum interpositum has been pulled out from beneath the fornix. (Henle.)

prolonged posteriorly into the still larger interspace between under surfaces of occipital lobes and upper surface of cerebellum (Fig. 463).

The Surface Aspect of the Hemispheres.

Each hemisphere, as already stated, has four main lobes, *frontal*, *parietal*, *temporal* or temporo-sphenoidal, and *occipital*. The white substance or medullary centre of each of these lobes lies next to the corresponding portion of the ventricle, and is of course directly continuous with that of an adjacent lobe, so that, as far as the white matter is concerned, there is no actual demarkation between the lobes. The *surfaces* of these lobes, however, can be fairly accurately separated from each other; but, since they constitute, all taken together, the surface of the entire hemisphere, it is more convenient to consider this first, and it is to be remembered that the various "*lobes*" to be mentioned are really the *surfaces* of these lobes.

The **surface of each hemisphere** presents the following general points for consideration: Its *under surface* or base is of an irregular form, resting in front on the anterior and middle fossæ of the skull, behind upon the tentorium cerebelli. There is a small portion of the under surface which is adherent. This is equal in *width* to the internal capsule, and is the line of junction between its fibres and those of the crusta (see Fig. 460). Its *upper surface* is of an ovoid form, broader behind than in front, convex in its general outline, and separated from

that of its fellow by the *great longitudinal fissure*, which extends throughout the entire length of the cerebrum in the middle line, reaching down to the base of the brain in front and behind, but interrupted in the middle by a broad transverse commissure of white matter, the *corpus callosum*, which connects the two hemispheres together. This fissure lodges the falx cerebri, and indicates the original development of the hemispheres by two lateral halves.

Each hemisphere presents also an *outer surface*, which is convex to correspond with the vault of the cranium; an *inner surface*, which is flattened and in contact with the opposite hemisphere (the two inner surfaces forming the sides of the longitudinal fissure); that is, above, in front of, and below (reflected portion) corpus callosum; the *lower* part of the mesial surface (inner aspect of internal

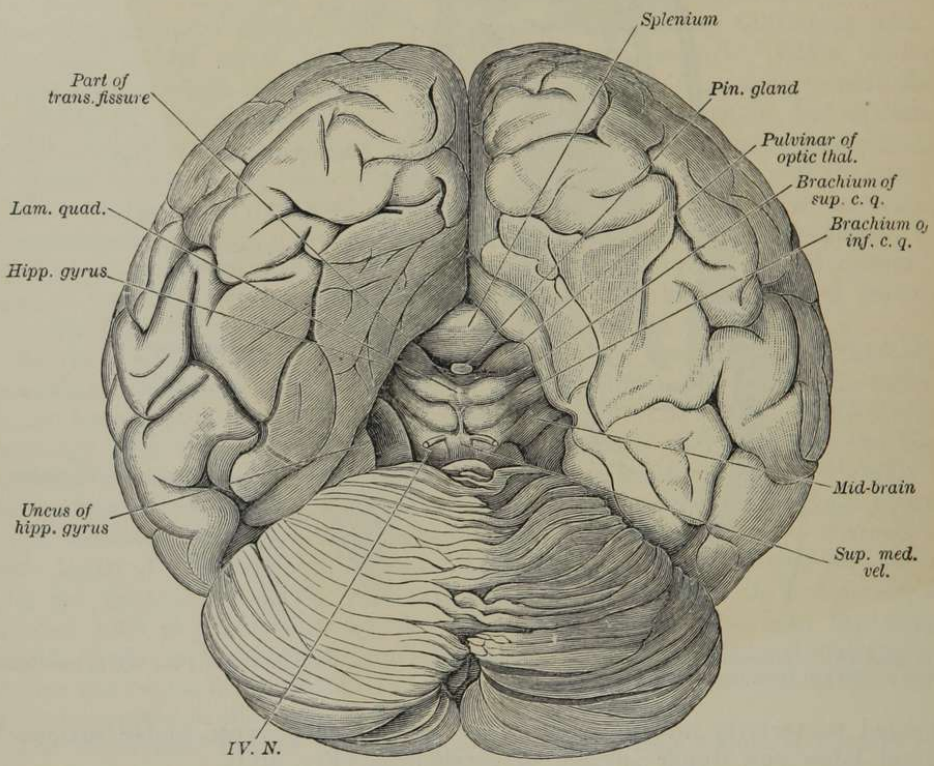

FIG. 463.—The brain from behind. The hemispheres and cerebellum are widely separated. (Henle.)

capsule) resting against and being adherent to outer side of optic thalamus (Fig. 461).

If the arachnoid and pia mater are removed, the entire surface of each hemisphere will be seen to present a number of depressions (*fissures* and *sulci*) separating a number of convoluted eminences (*convolutions* or *gyri*).

The depressions are of two kinds, *fissures* and *sulci*. The *fissures* are few in number; they are constant in their arrangement, and are produced by marked foldings of the hemisphere during the process of development. There are seven —fissure of Sylvius, fissure of Rolando, parieto-occipital, calloso-marginal, hippocampal, calcarine, and collateral fissures. The *first four* serve to mark off from each other the larger lobes of the hemisphere—*i. e. frontal*, *parietal*, *temporal*, and *occipital*—and also two others, the *island of Reil* or *central lobe*, and the *limbic lobe*. There is still one other lobe, the *olfactory*. The three last-named fissures cause elevations in the ventricle—viz. hippocampus major and minor and eminentia collateralis.

The *sulci* are much more numerous; they are depressions of the gray matter which is folded inward and only indents the central white substance; they vary in different brains and in different parts of the same brain.

The terms "fissure" and "sulcus" are often used interchangeably.

The Gyri or Convolutions.—There is no accurate resemblance between the convolutions in different brains, nor are they exactly symmetrical on the two sides of the same brain, but their general arrangement or plan is fairly constant. Certain infoldings of the cerebrum take place at an early period of development and form important landmarks, which are constant and can without difficulty be recognized, but the secondary depressions and convolutions vary considerably.

The number and extent of the convolutions, as well as their depth, appear to bear a close relation to the intellectual power of the individual, as is shown in

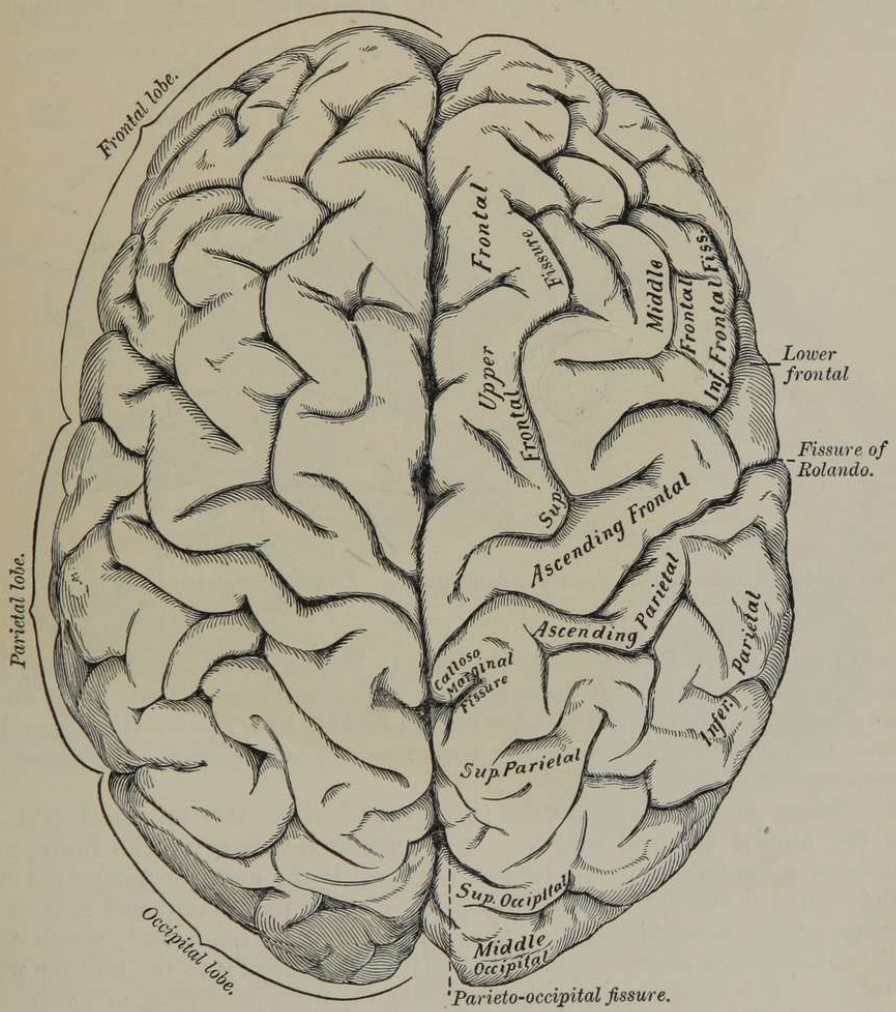

FIG. 464.—Upper surface of the brain, the arachnoid having been removed.

their increasing complexity of arrangement as we ascend from the lowest mammalia up to man. Thus they are absent in some of the lower orders of mammalia, and they increase in number and extent through the higher orders. In man they present the most complex arrangement. Again, in the child at birth, before the intellectual faculties are exercised, the convolutions have a very simple arrangement, presenting few undulations, and the sulci between them are less deep than in the adult.

The convolutions on the outer convex surface of the hemisphere are the largest and most complicated; their general direction is more or less oblique; they frequently branch like the letter **Y** in their course upward and backward toward the longitudinal fissure; these convolutions attain their greatest development in man, and are especially characteristic of the human brain.

Structure of the Convolutions.—The outer surface of each convolution, as well as the sides and bottom of the sulci between them, are composed of gray matter, which is here called the *cortical substance*. The interior of each convolution is composed of white matter, *medullary centre*, the white fibres of which blend with the gray matter not only on the surface of the gyrus, but at the sides and bottom of the sulci as well. By this arrangement the convolutions are adapted to increase the amount of gray matter without occupying much additional space, and to afford a greater extent of surface for the termination of the white fibres.

External Lobes and Fissures of the Hemisphere.—Each hemisphere of

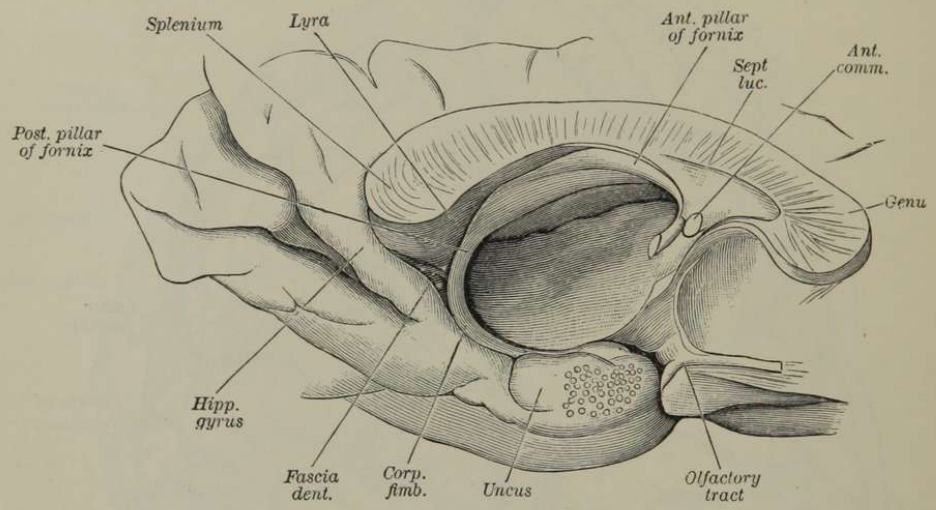

Fig. 465.—Mesial or inner aspect of part of left hemisphere. The large central concavity shows place of removal of optic thalamus. (Henle.)

the brain on its *external surface* is divided into five lobes, the division being made by the main fissures and by imaginary lines drawn to connect them (Fig. 466).

The fissures dividing the five lobes on the external surface of the hemispheres are three in number, and are named *fissure of Sylvius*, *fissure of Rolando*, and *parieto-occipital fissure*.

The **fissure of Sylvius** separates the frontal from the temporal lobe, and lodges the middle cerebral artery. It begins, at the base of the brain, at the outer side of a depression at the bottom of which is the anterior perforated space. This depression is called the *vallecula Sylvii*. It then passes outward to the external surface of the hemisphere, and gives off a short *anterior limb*, which passes forward, and another, *ascending limb*, which passes upward into the inferior frontal convolution. It is then continued backward as the *horizontal limb*, and terminates in the parietal lobe after curving upward for a short distance. It separates the frontal and parietal lobes from the temporal, and occupies about the middle third of the lateral surface of the hemisphere.

The **fissure of Rolando** is situated about the middle of the outer surface of the hemisphere. It commences at or near the longitudinal fissure, and runs downward and forward to terminate a little above the beginning of the horizontal limb of the fissure of Sylvius, and about half an inch behind the ascending limb of the same fissure. It separates the frontal from the parietal lobe.

The **parieto-occipital fissure** is only seen to a slight extent on the outer surface of the hemisphere, and is not so distinctly marked as the others. The portion on the outer surface of the hemisphere is sometimes called the *external parieto-occipital fissure*, to distinguish it from the continuation of the sulcus on the internal surface of the hemisphere, which would then be termed the *internal parieto-occipital fissure*. It commences about midway between the posterior extremity of the

brain and the fissure of Rolando, and runs downward and forward for somewhat less than an inch. It separates the parietal and occipital lobes.

These three fissures divide the external surface of the hemisphere into five lobes—the *frontal*, the *parietal*, the *occipital*, the *temporal*, and the central or *island of Reil.*

The **frontal lobe** is that portion of the brain which is situated in front of the fissure of Rolando and above the horizontal limb of the fissure of Sylvius. Its under surface rests on the orbital plate of the frontal bone, and is termed the *orbital lobe.*

The outer surface of the frontal lobe presents three sulci, which divide it into four primary convolutions: 1. The *precentral sulcus* runs upward through this lobe, parallel to the fissure of Rolando. It may be interrupted by annectant

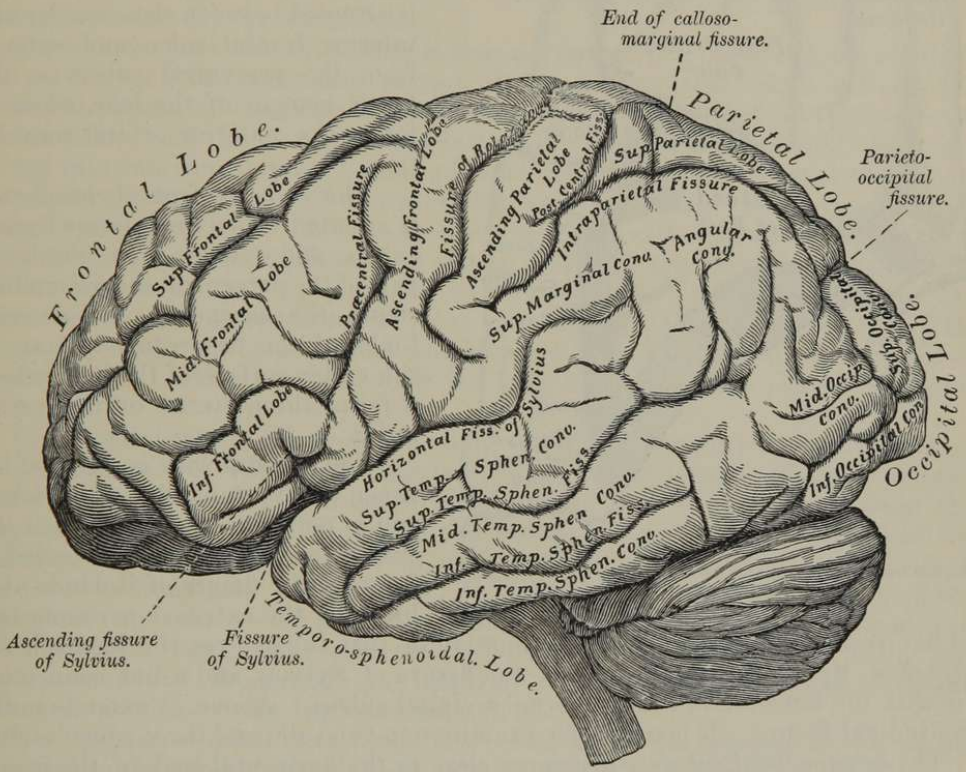

FIG. 466.—Convolutions and fissures of the outer surface of the cerebral hemisphere.

gyri. It divides off a convolution which lies between it and the fissure of Rolando, and which is called the *ascending frontal convolution.* 2 and 3. From it two sulci, the *superior* and *inferior frontal sulci*, run forward and downward, and divide the remainder of the outer surface of the lobe—namely, that part in front of the precentral sulcus—into three principal convolutions, named, respectively, the *superior*, *middle*, and *inferior frontal convolutions* (or "lobes").

The under surface of the frontal lobe, which rests on the orbital plate of the frontal bone, is named the *orbital lobe* (Fig. 467). This surface of the frontal lobe is divided into three convolutions by a well-marked sulcus, the *orbital sulcus.* These are named, from their positions, the *internal*, *anterior*, and *posterior orbital convolutions*, and are the continuations respectively of the superior, middle, and inferior frontal convolutions. The *internal* orbital convolution presents or is subdivided by a well-marked groove or sulcus (*olfactory sulcus*) for the olfactory tract.

The *ascending frontal convolution* is a simple convolution, bounded in front by the precentral sulcus, behind by the fissure of Rolando, and extending from the

upper margin of the hemisphere above to a little behind the bifurcation of the fissure of Sylvius below.

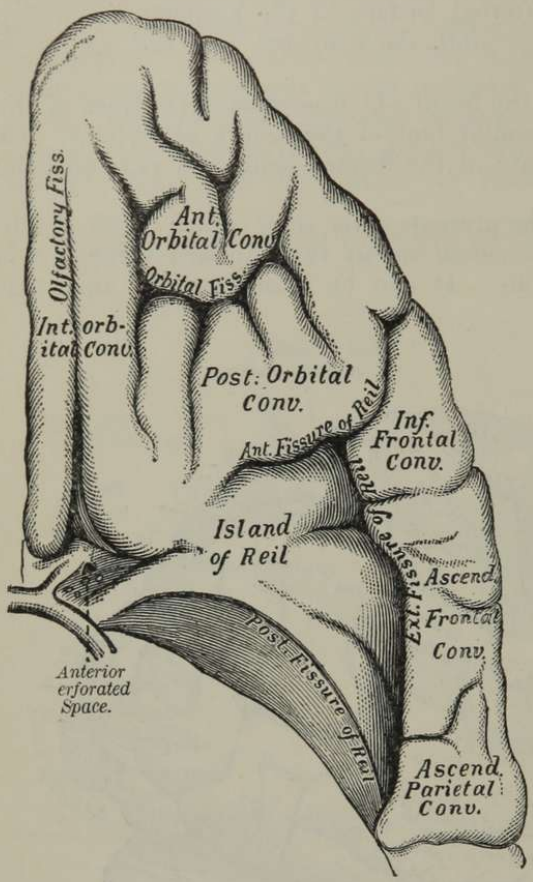

FIG. 467.—Convolutions and fissures of the under surface of the anterior lobe.

The *superior frontal convolution* is situated between the margin of the longitudinal fissure and the superior frontal sulcus. It extends above on to the inner aspect of the hemisphere, forming the marginal convolution, and in front and below on to the orbital surface, forming the internal orbital convolution. It is much divided by secondary sulci.

The *middle frontal convolution* is situated between the superior and inferior frontal sulci, and extends from the precentral sulcus to the lower margin of the lobe, where it forms the anterior orbital convolution.

The *inferior frontal convolution* is situated below the inferior frontal sulcus, and extends from the lower part of the precentral sulcus, circling round the ascending and anterior limbs of the fissure of Sylvius, to the under surface of the lobe, where it forms the posterior orbital convolution.

The **parietal lobe** is situated between the frontal and occipital lobes, and is not much more than half the size of the former. It is bounded in front by the fissure of Rolando; behind, by the external parieto-occipital fissure and a line drawn in continuation of that sulcus over the hemisphere; and below, by the horizontal limb of the fissure of Sylvius and a line connecting this with the lower end of the superior occipital sulcus. Above, it extends to the longitudinal fissure. It presents for examination two sulci and three convolutions.

The *intraparietal sulcus* commences close to the horizontal limb of the fissure of Sylvius, about midway between the fissure of Rolando and the upturned extremity of the fissure of Sylvius. It first runs upward parallel to and behind the lower half of the fissure of Rolando, and then turns backward, extending nearly to the termination of the external parieto-occipital fissure, where it sometimes becomes continuous with the superior occipital sulcus. The ascending portion of this sulcus separates off a convolution, the *ascending parietal*, which lies between it and the fissure of Rolando, whilst the horizontal portion divides the remainder of the parietal lobe into two other convolutions, the *superior* and *inferior parietal*.

The *post-central sulcus* is a slightly marked groove, which is sometimes a branch of the intraparietal sulcus, being given off where the ascending portion of this sulcus turns backward. It lies parallel to and behind the upper part of the fissure of Rolando, and separates the ascending from the superior parietal convolution.[1]

[1] Professor Cunningham describes these two sulci, intraparietal and post-central, somewhat differently. He regards them as both belonging to the intraparietal sulcus, which he divides into three parts: the ascending portion of the intraparietal, as described above, he terms the *ramus verticalis inferior;* the horizontal portion as the *ramus horizontalis;* while the post-central sulcus he denominates the *ramus verticalis superior*. He states that considerable variability is exhibited in the relation to each

The *ascending parietal convolution* is bounded in front by the fissure of Rolando, behind by the ascending portion of the intraparietal and the post-central sulci. It extends from the great longitudinal fissure above to the horizontal limb of the fissure of Sylvius below. It lies parallel with the ascending frontal convolution, with which it is connected below, and also generally above, the termination of the fissure of Rolando.

The *superior parietal convolution* is bounded in front by the post-central sulcus, which separates it from the previous convolution, but with which it is usually connected above the upper extremity of the sulcus; behind, it is bounded by the external parieto-occipital fissure, below the termination of which it is connected with the occipital lobe by a narrow convolution, the *first annectant gyrus*. Below, it is separated from the inferior parietal convolution by the horizontal portion of the intraparietal sulcus; and above it is continuous on the inner surface of the hemisphere with the quadrate lobe.

The *inferior parietal convolution* is that portion of the parietal lobe which is situated between the ascending portion of the intraparietal sulcus in front, the horizontal portion of the same sulcus above, the horizontal limb of the fissure of Sylvius below, and the posterior boundary of the parietal lobe behind. It is subdivided into two convolutions by an indistinct groove. One, the *supramarginal*, lies behind the lower end of the intraparietal sulcus and above the horizontal limb of the fissure of Sylvius. It is connected, in front, with the ascending parietal convolution beneath the intraparietal sulcus, and with the superior temporal convolution behind, around the posterior extremity of the fissure of Sylvius. The other, the *angular*, is connected in front with the foregoing and with the middle temporal convolution by a process which curves round the superior temporal or parallel sulcus. It is connected with the occipital lobe by the *second annectant gyrus*.

The **occipital lobe** is triangular in shape and forms the posterior extremity of the hemisphere. It rests upon the tentorium. Its external surface is bounded in front by the external parieto-occipital fissure and a line drawn from the extremity of this in the direction of the fissure across the outer surface of the hemisphere. It is continuous below and in front with the temporal lobe, and above and in front with the parietal. It is divided on the outer surface of the hemisphere into three convolutions by two indistinct sulci—the *superior* and *middle occipital sulci*. They are directed backward across the lobe, being frequently small and ill-marked; the superior is sometimes continuous with the horizontal portion of the intraparietal sulcus.

The *superior occipital convolution* is situated above the superior sulcus, and is connected to the superior parietal convolution by the *first annectant gyrus*.

The *middle occipital convolution* is situated between the superior and middle occipital sulci, and is connected to the angular convolution by the *second annectant gyrus*, and to the middle temporal by the *third annectant gyrus*.

The *inferior occipital convolution* is situated below the middle occipital sulcus, and is sometimes separated from the external occipito-temporal (*fourth temporal*) convolution on the under surface of the hemisphere by an inconstant sulcus, the *inferior occipital sulcus* (posterior extension of third temporal sulcus; see next page). The *fourth annectant gyrus* unites it with the third temporal gyrus.

The **temporal** (*temporo-sphenoidal*) **lobe** is that portion of the hemisphere which is lodged in the middle fossa of the base of the skull. In front and above it is

other of these different parts of the intraparietal sulcus, but that the one in which the three parts of the sulcus are confluent is by far the most constant condition. Sometimes, however, the three parts of the sulcus may be all separate, or the ramus horizontalis confluent with the ramus verticalis inferior, the ramus verticalis superior remaining separate; or, again, the vertical limbs may be confluent and the horizontal limb separate; or, finally, the ramus horizontalis may be joined to the lower end of the ramus verticalis superior, while the lower vertical limb is separate. The connection which sometimes exists between the intraparietal sulcus and the occipital lobe he calls the *ramus occipitalis*. In the majority of cases, however, the occipital ramus is separated from the main portion of the intraparietal sulcus by a superficial or deep bridging convolution (*Journal of Anatomy and Physiology*, vol. xxiv. part ii. p. 135).

limited by the fissure of Sylvius; behind, on its external surface, it is connected with the parietal and occipital lobes, and is limited artificially by a line continuing the direction of the external parieto-occipital fissure across the outer surface of the hemisphere. It is divided into three convolutions by two sulci. The superior of these runs parallel to the horizontal limb of the fissure of Sylvius. It is named the *superior* or *first temporal* or *parallel sulcus*, and it is well marked and constant. The second, the *middle* or *second temporal*, is not so well marked or constant; it takes the same course at a lower level.

The *superior* or *first temporal convolution* is situated between the horizontal limb of the fissure of Sylvius and the superior temporal sulcus. It is continuous behind with the supramarginal convolution.

The *middle* or *second temporal convolution* is situated between the superior and middle sulci of the same name, and is continuous behind with the angular and middle occipital convolutions.

The *inferior* or *third temporal convolution* is situated below the middle temporal sulcus, and is separated from the external occipito-temporal (*fourth temporal*) convolution, *on the under* (mesial) *surface* of the hemisphere, by a sulcus which is called the *inferior* or *third temporal sulcus*. It is connected with the inferior occipital convolution.

The **central lobe, or island of Reil** (Figs. 467, 468), is situated in the fissure of Sylvius; at the base of the brain it is separated, in front, from the posterior orbital convolution by a nearly transverse sulcus, the *anterior sulcus of Reil*; externally, from the inferior frontal convolution and the lower ends of the ascending frontal and parietal convolutions by another deep sulcus, the *external sulcus of Reil*; and posteriorly, from the temporal lobe by a third sulcus, the *posterior sulcus of Reil*. It is a triangular-shaped (apex downward) prominent cluster of about six convolutions, the *gyri operti*, so called from being covered in by the gyri bounding the fissure. By the removal of these convolutions the extraventricular part of the corpus striatum would be reached.

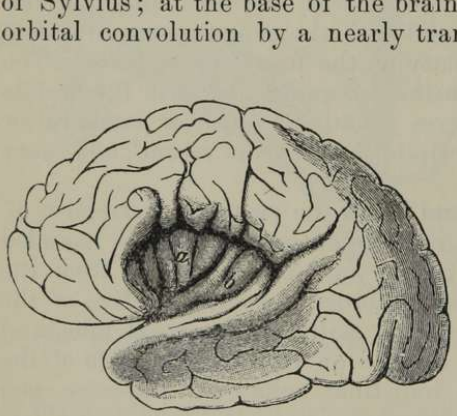

FIG. 468.—External surface of left hemisphere. The island of Reil is shown by raising the opercula and bending outward the upper edge of the temporal lobe. *a* and *b* are the portions of the insula separated by the *sulcus centralis insulæ*. (Gegenbaur.)

These various *sulci* of Reil, taken together, constitute the *sulcus limitans insulæ*. The *sulcus centralis insulæ* divides the lobe into a pre-central and a post-central lobule, of which the former corresponds to, or may be regarded as part of, the frontal lobe; and the latter to the parietal and temporal lobes. Those portions of the corresponding lobes from which the above-mentioned *sulci* separate the *island* overlap it in the normal condition, and are known as the *opercula*.

THE MESIAL LOBES AND FISSURES OF THE HEMISPHERE.—The arrangement of the *convolutions* in this region is less complex: they are generally well defined, and, some of them being of great length, there is not the same subdivision into smaller lobes as on the external surface (Figs. 469, 470). The *fissures* on the internal surface are five in number, and are named the *calloso-marginal*, the *parieto-occipital*, the *calcarine*, the *collateral*, and the *dentate*.

The **calloso-marginal fissure** is seen in front, commencing below the anterior extremity of the corpus callosum: it at first runs forward and upward, parallel with the rostrum of the corpus callosum, and, winding round the genu of that body, it continues from before backward, between the upper margin of the hemisphere and the convolution of the corpus callosum, to about midway between the anterior and posterior extremities of the brain, where it turns upward to reach the upper margin of the inner surface of the hemisphere (*paracentral fissure of*

Wilder) a short distance behind the superior extremity of the furrow of Rolando. It separates the marginal convolution from the gyrus fornicatus or convolution of the corpus callosum (*limbic lobe*).

The **parieto-occipital fissure** (*internal parieto-occipital*) is the continuation of the fissure of the same name seen on the outer surface of the hemisphere. It extends in an oblique direction downward and forward to join the calcarine fissure on a level with the hinder end of the corpus callosum. It separates the quadrate from the cuneate lobe.

The **calcarine fissure** commences, usually by two branches, at the back of the hemisphere, runs nearly horizontally forward, and is joined by the parieto-occipital fissure, and continues nearly as far as the posterior extremity of the corpus callosum, to terminate a little below the level of this commissure. It separates the cuneate

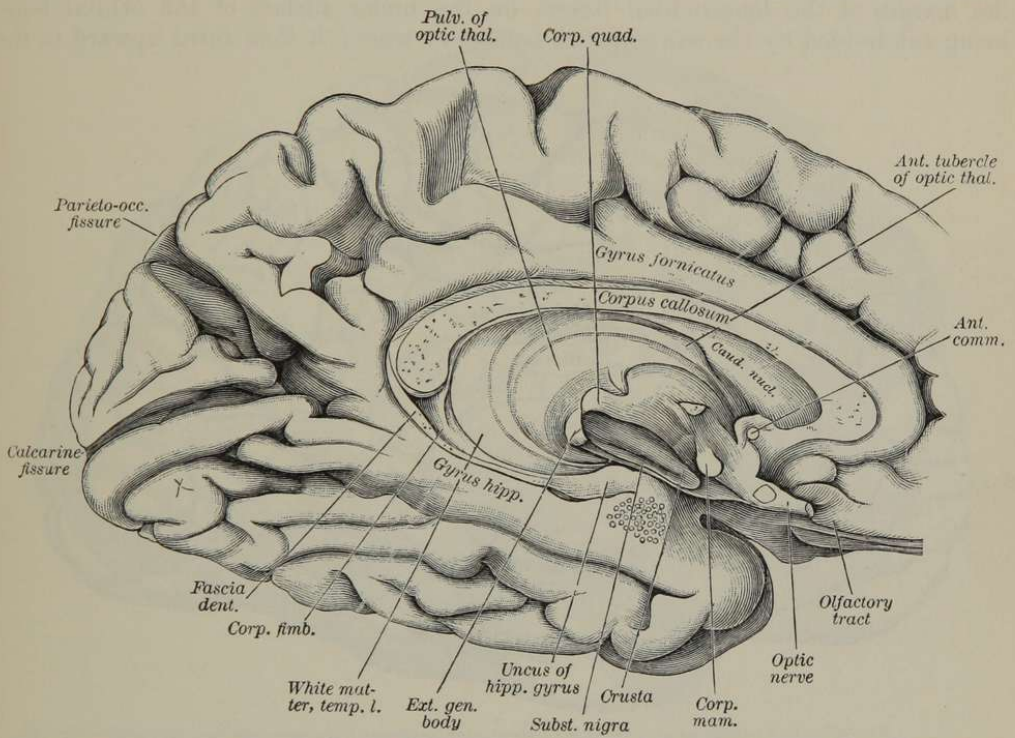

FIG. 469.—Mesial or inner aspect of left hemisphere, together with optic thalamus and part of mid-brain. The temporal lobe is drawn downward and backward away from the optic thalamus. The septum lucidum is removed. (Henle.)

lobe from the fifth temporal or *infracalcarine* gyrus, and causes the prominence in the posterior cornu known as the hippocampus minor or calcar avis, whence its name.

The **collateral fissure** (fourth temporal sulcus) is situated below the preceding, being separated from it by the infracalcarine gyrus. It runs forward, from the posterior extremity of the brain, nearly as far as the commencement of the fissure of Sylvius. It runs, at first, between the fourth temporal (below) and infracalcarine (above) convolutions, and then lies beneath the hippocampal gyrus. It lies below the posterior and middle horn of the lateral ventricle, and causes the prominence in the latter known as the eminentia collateralis.

The **dentate** or **hippocampal fissure** commences immediately below the posterior extremity of the corpus callosum, and runs forward to terminate at the recurved part of the hippocampal gyrus. It corresponds with the prominence of the hippocampus major in the descending horn of the lateral ventricle.

The **lobes** or **convolutions seen on the internal surface of the hemisphere** are as follows: *gyrus fornicatus*, *marginal*, *quadrate*, *cuneate*, *hippocampal*, *uncinate*, *infracalcarine*, *fourth temporal*, and *the paracentral lobule*.

The **gyrus fornicatus**, or convolution of the corpus callosum, is a well-marked

lobe which begins just in front of the anterior perforated space at the base of the brain: it passes forward below the rostrum, and then ascends in front of the genu of the corpus callosum, and runs backward along the upper surface of this body to its posterior extremity, around which it bends to join the hippocampal convolution by a constriction, the *isthmus*. It is bounded below, in front, and above, in the greater part of its extent, by the calloso-marginal fissure, which separates it from the marginal convolution; above and behind its bend it is separated by the *post-limbic fissure* from the quadrate lobe. Between it and the corpus callosum is the *callosal sulcus*.

The **marginal convolution** is situated parallel with the anterior portion of the preceding, and has received its name from its position along the border of the hemisphere. It commences in front of the anterior perforated space, runs along the margin of the longitudinal fissure on the under surface of the orbital lobe, being subdivided by the sulcus for the olfactory tract; it then turns upward to the

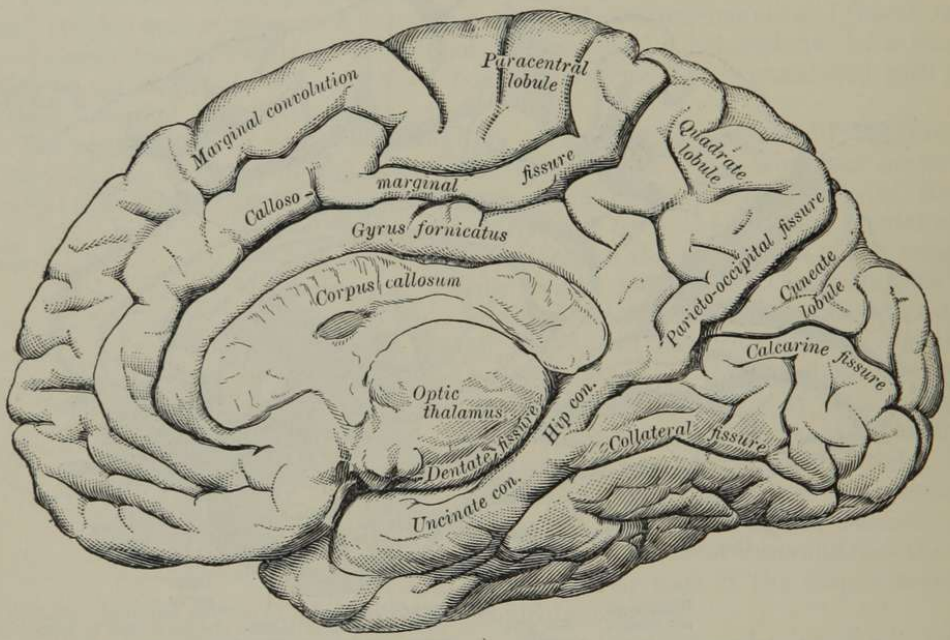

FIG. 470.—Convolutions and fissures of the inner surface of the cerebral hemisphere.

upper surface of the hemisphere and runs backward, forming the marginal convolution, on the inner surface, to the point where the calloso-marginal fissure turns upward to reach the superior border of the hemisphere. At this point, together with the upper extremities of the ascending frontal and parietal gyri, which are bent over on the inner surface of the hemisphere, it forms the **paracentral lobule**. This convolution is regarded as being on the mesial aspect of the frontal lobe.

The **quadrate lobe** (*precuneus*) is the "marginal" convolution of the longitudinal fissure behind the posterior portion (paracentral fissure) of the calloso-marginal sulcus, lying between this fissure in front and the internal parieto-occipital behind. It is separated by the post-limbic fissure from the gyrus fornicatus below, and is continuous above with the superior parietal convolution.

The **cuneate** or **occipital lobule** is triangular in shape, being situated between the internal parieto-occipital and calcarine fissures, which, as above mentioned, meet behind the isthmus of the gyrus fornicatus.

The **infracalcarine** (fifth temporal) convolution extends from the posterior extremity of the temporal lobe to join the hippocampal gyrus, being bounded above by the calcarine and its anterior prolongation, after its junction with the parieto-occipital fissure, and separated below from the fourth temporal convolution by the collateral fissure. The back part of this convolution—that is, the part below the

posterior portion of the calcarine fissure—is sometimes known as the *lingual lobule* or *gyrus*.

The **fourth temporal convolution** is of considerable length, and lies on the inner aspect of the temporal lobe, between the collateral fissure above and the inferior (third) temporal sulcus below, which latter separates it from the inferior (third) temporal convolution on the outer surface of the temporal lobe. Its posterior part is called, at times, the *fusiform lobule*.

The **hippocampal convolution** is the downward and forward prolongation, on the mesial surface of the temporal lobe, of the gyrus fornicatus, just after the latter has bent around and beneath the splenium of the corpus callosum. Its direction is toward the apex of the temporal lobe, just before reaching which, however, its anterior extremity is recurved or bent backward in the form of a hook, which is

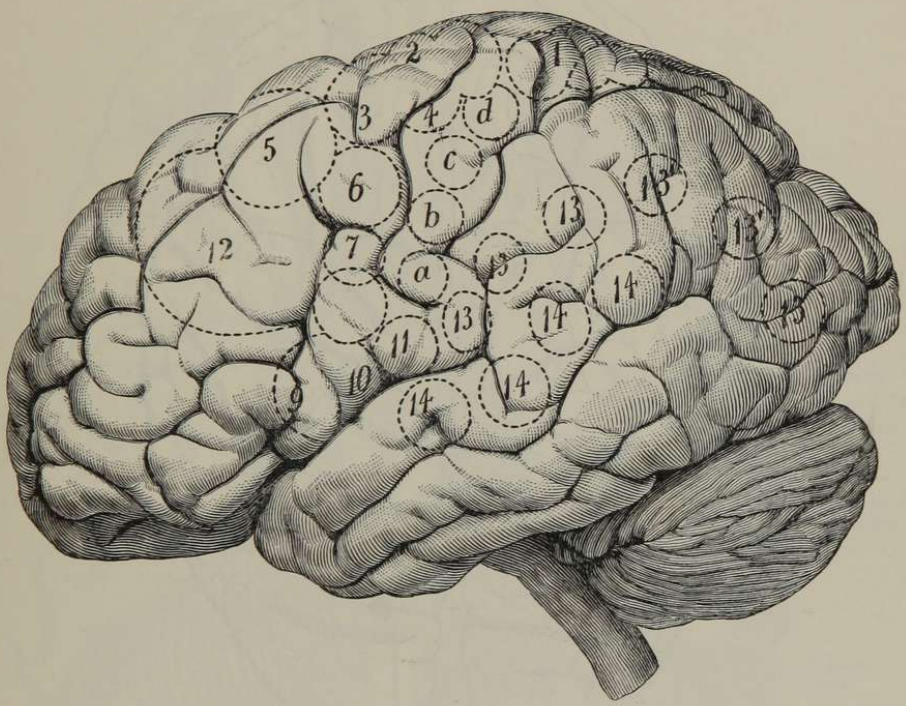

FIG. 471.—Side view of the brain of man, showing the localization of various functions. (After Ferrier.) 1. Centre for movements of opposite leg and foot. 2, 3, 4. Centres for complex movements of the arms and legs, as in swimming. 5. Extension forward of the arm and hand. 6. Supination of the hand and flexion of the forearm. 7, 8. Elevators and depressors of the angle of the mouth. 9, 10. Movements of the lips and tongue. 11. Retraction of the angle of the mouth. 12. Movements of the eyes. 13, 13'. Vision. 14. Hearing. *a, b, c, d.* Movements of the wrists and fingers.

sometimes called the *crochet* or *uncus*. It is bounded below by the *collateral fissure* (anterior portion), and above by the *hippocampal* or dentate *fissure*.

The Uncinate Gyrus.—The hippocampal and infracalcarine gyri are, taken together, often described as one gyrus, the *uncinate*.

Besides the great primary convolutions above named and described, and which can be recognized in almost any well-developed brain, there are a great number of secondary convolutions which pass from one primary convolution to another, and often render the arrangement of the latter somewhat obscure: of these *annectant convolutions* the connections of the occipital lobe, above mentioned, may be taken as examples.

THE LIMBIC LOBE.—By this term is understood a grouping together of certain portions of the hemisphere which have a peculiar course. That is, beginning anteriorly, they curve forward, upward, and backward, then downward and forward, so that their two extremities lie quite close together. The structures of the limbic lobe have all been described, and are as follows: (1) Gyrus fornicatus and hippocampal gyrus; (2) the supracallosal gyrus (see below); (3) each half of the

fornix, with its corresponding anterior and posterior pillar and half of the septum lucidum.

The *supracallosal gyrus*, just mentioned, may be regarded as made up of the peduncles of the corpus callosum, the longitudinal striæ on the upper surface of the same, and the fascia dentata with its upper part, the fasciola cinerea. These structures are continuous with each other, as has already been mentioned in the description of each. The name *dentate gyrus* is often used to designate the combined fasciola cinerea and fascia dentata.

The boundaries of the limbic lobe are the calloso-marginal fissure, the collateral fissure, and the post-limbic fissure.

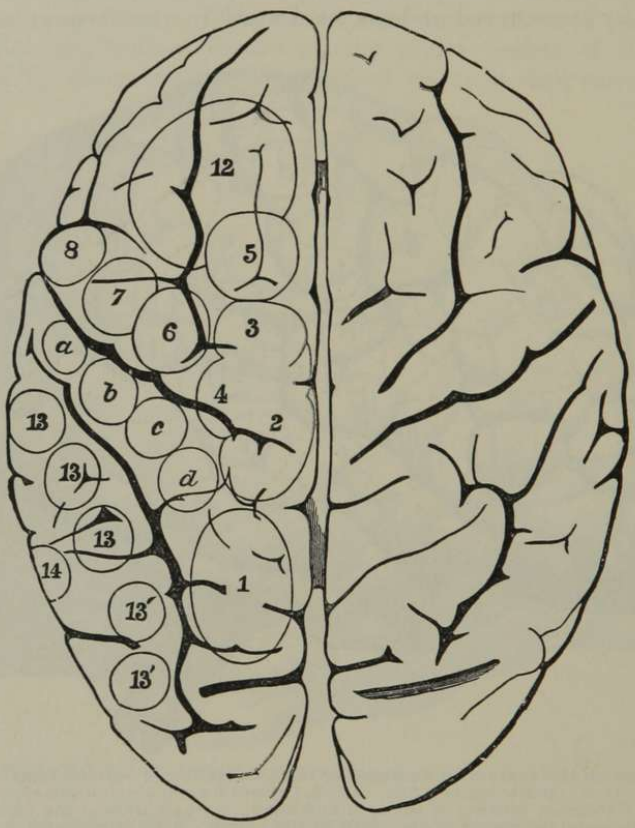

FIG. 472.—Top view of the brain of man, showing the localization of various functions. (After Ferrier.) References the same as in the preceding figure.

THE OLFACTORY LOBE (Fig. 473).—This is situated on the orbital lobe (under surface of frontal lobe). In general outline it is long and slender, widest behind. It is divisible into *two*, anterior and posterior, *olfactory lobules*. The olfactory lobe is developed as a hollow outgrowth from the ventral and lateral part of the corresponding hemisphere vesicle, the cavity of which, in man and primates, is eventually obliterated. In the adult condition the *posterior lobule* is found to have remained on the hemisphere, and thus to form a part of it, while most of the anterior lobule is attached only by a stalk to the posterior, it being freely separable in the rest of its extent; that is, after removal of the membranes.

The **anterior olfactory lobule** is made up of (1) the *olfactory bulb;* (2) the *olfactory tract;* (3) the *trigonum olfactorium;* and (4) the *area of Broca.*

The *olfactory bulb* is an oval mass of a grayish color, which rests on the cribriform plate of the ethmoid bone, and forms the anterior expanded extremity of the slender process of brain-substance, the *olfactory tract* (see page 792). From the under part of this bulb are given off the *olfactory nerves*, which pass through the cribriform foramina and are distributed to the mucous membrane of the nose.

The *olfactory tract*, when traced backward, divides into two slips or roots, external and internal, at its base. The so-called middle or gray root is the *trigonum olfactorium*, which is enclosed by the two roots. Traced forward, these two roots unite and form the *tract*, which is a flat band, narrower in front than behind, and of a somewhat prismoid form on section. It is soft in texture and contains gray matter (neuroglia) in its substance. As it passes forward it is contained in a deep sulcus, the *olfactory sulcus*, which subdivides the internal orbital convolution, lying on the under surface of the frontal lobe on each side of the longitudinal fissure, and is retained in position by the membrane (pia mater), which

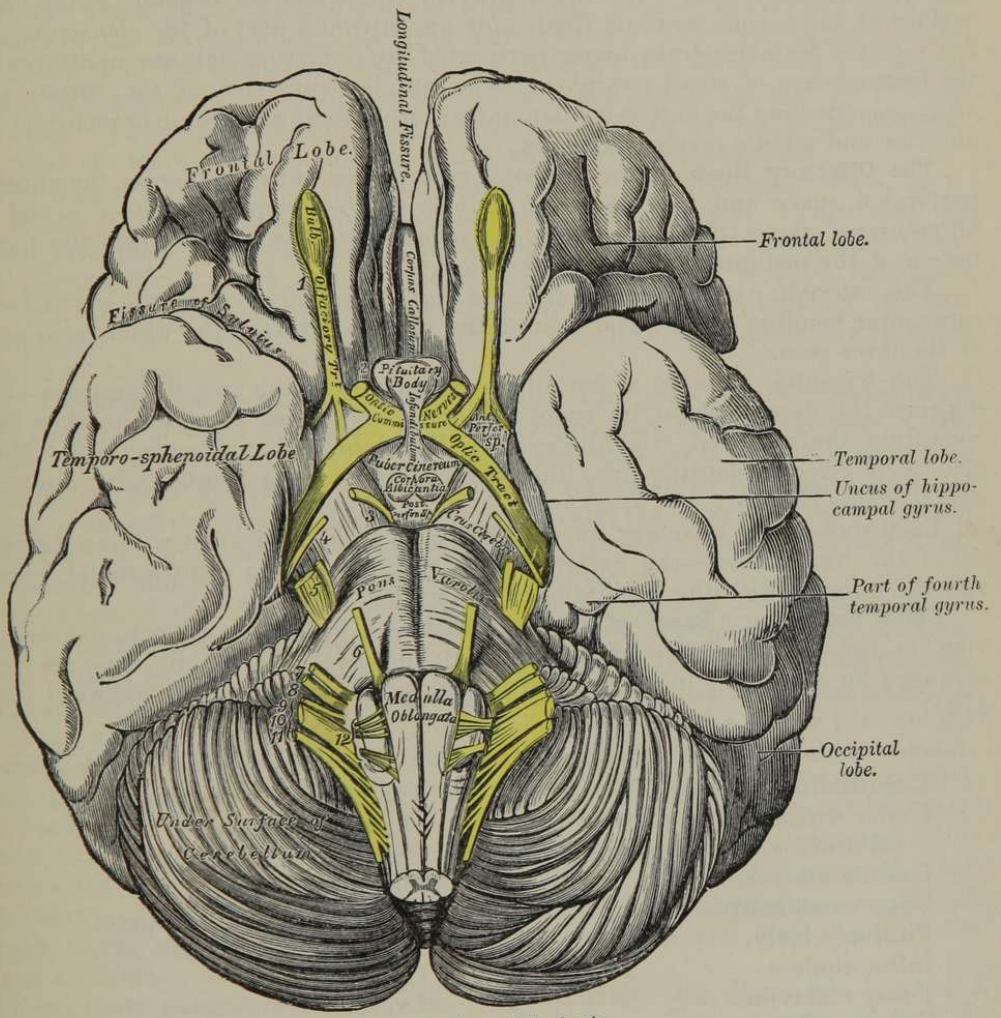

FIG. 473.—Base of the brain.

covers it. On reaching the cribriform plate of the ethmoid bone it expands into the *olfactory bulb*.

The *trigonum olfactorium* and the *area of Broca* constitute one and the same *area of cortical gray matter*, bounded internally and posteriorly by a fissure (*fissura prima*), which separates it from the anterior part of the peduncle of the corpus callosum on its inner aspect, and from the anterior perforated space posteriorly. Externally, this area passes into continuity with the cortical gray matter of the internal orbital gyrus. This area is divided into *three* districts by the passage across it, from before backward, of the *two roots* of the olfactory tract. The internal district, lying between the internal root and anterior part of peduncle of corpus callosum (fissura prima intervening) is the *area of Broca*, continuous with the beginning of the gyrus fornicatus. The middle district, included

between the two roots, is the *trigonum olfactorium*. The external district, external to the external root, is very small and has no especial name.

The **posterior olfactory lobule** or **anterior perforated space** (*anterior perforated lamina*) is situated at the inner side of the fissure of Sylvius. It is bounded in front by the fissura prima (transverse part) and the orbital convolutions of the frontal lobe; behind, by the optic tract; externally, by the temporal lobe and commencement of the fissure of Sylvius (*vallecula*); internally, it is continuous with the lamina cinerea. It is crossed internally and posteriorly by the posterior part of the peduncle of the corpus callosum, and externally by the external olfactory root. It is of a grayish color, and corresponds to the under surface of the corpus striatum (*lenticular nucleus*) and part of the claustrum. It has received its name from being perforated by numerous minute apertures for the transmission of small straight vessels into the substance of the corpus striatum, constituting the antero-median and antero-lateral ganglionic branches of the anterior and middle cerebral arteries.

The Olfactory Roots.—The *external root* passes outward across the anterior perforated space and the fissure of Sylvius to the temporal lobe—*i. e.* end of *hippocampal gyrus* (possibly nucleus amygdalæ also)—where it meets the termination of the peduncle of the corpus callosum.

The *internal root* passes inward and joins the lower end of the *gyrus fornicatus* after bending around and behind the area of Broca, into which also some of its fibres pass.

The *trigonum* receives a few fibres directly from the end of the tract—*i. e.* between the divergence of its roots. When these fibres are well marked they constitute the so-called "middle root." From the end of the tract a few fibres also pass directly dorsally into the white matter of the frontal lobe, *upper* or *dorsal* root (Henle).

Each root of the olfactory tract is thus seen to be connected with an extremity of the limbic lobe—the external with the end of the hippocampal gyrus, and the internal with the beginning of the gyrus fornicatus.

Under Surface or "Base" of the Encephalon.—The various objects exposed to view on the under surface of the brain, in and near the middle line, are here arranged in the order in which they are met with from before backward (Fig. 473):

In the Middle Line.	*Each Side of the Middle Line.*
Longitudinal fissure.	Under surface of frontal lobe.
Under surface of rostrum of corpus callosum and its peduncles.	Olfactory bulb.
	Olfactory tract.
Lamina cinerea.	Olfactory roots.
Optic commissure.	Anterior perforated space.
Pituitary body.	Fissure of Sylvius.
Infundibulum.	Optic tract.
Tuber cinereum.	Crusta.
Corpora albicantia.	Under surface of temporal lobe.
Posterior perforated space.	Under surface of hemisphere of cerebellum.
Tuber annulare of pons.	
Medulla oblongata (ventral surface).	

The **longitudinal fissure** partially separates the two hemispheres from each other: it divides the two frontal lobes in front, and on raising the cerebellum and pons it will be seen completely separating the two occipital lobes. Of these two portions of the longitudinal fissure, that which separates the occipital lobes is the longer. The intermediate portion of the fissure is filled up by the great transverse band of white matter, the *corpus callosum*. In the fissure between the two frontal lobes the anterior cerebral arteries ascend on the corpus callosum.

Interpeduncular Space.—Immediately behind the diverging optic tracts, and

between them and the inner margins of the crustæ or peduncles of the cerebrum (*crura cerebri*), is a lozenge-shaped interval, the *interpeduncular space*, in which are found the following parts: the tuber cinereum, infundibulum, pituitary body, corpora albicantia, and the posterior perforated space.

The remaining structures above enumerated have all been previously described, each in its own region.

Structure of the Hemispheres.

Each hemisphere is made up of gray and white matter. The latter constitutes nearly the whole of the deeper portion (*medullary centre*), and enters into the structure of the convolutions. The gray matter covers in the convolutions, forming the *cortex* of the hemisphere, and also is collected into three masses or nuclei situated in the hemisphere—the *corpus striatum*, the *claustrum*, and the *nucleus amygdalæ*. These last might be regarded as subdivisions of one large nucleus, since they are more or less connected in the anterior perforated space.

The WHITE MATTER OF THE HEMISPHERES consists of medullated fibres, varying in size and arranged in bundles, separated by neuroglia. They may be divided into three distinct systems, according to the course which they take: 1. *Projection fibres*, which connect the hemispheres with the medulla oblongata and cord. 2. *Transverse* or *commissural fibres*, which connect together the two hemispheres. 3. *Association-fibres* (Meynert), which connect different structures in the same hemisphere.

1. The **projection** or **peduncular fibres** consist of a main body, which originates in the cord and medulla oblongata, forms the longitudinal fibres of the pons, which last are then continued up into the mid-brain, where, as has been before described, the fibres are arranged in two strata, which are separated by the locus niger, the ventral or superficial stratum forming the *crusta*, and the dorsal or deeper stratum *the bulk of the tegmentum*. The fibres derived from these two sources take a different course, and will have to be separately considered.

The fibres of the *crusta* are derived from the pyramid of the medulla, which fibres are continued upward through the pons to form the crusta; they are reinforced in their passage through the crus by accessory fibres derived from the central gray matter around the Sylvian aqueduct, from the nuclei pontis, and from the locus niger (see page 742). Most of the fibres of the crusta (except the *mesial fillet*, p. 742) pass into the hemisphere as part of the *internal capsule*, which last, passing upward, diverges into fibres *which radiate* forward, upward, and backward, thus constituting the *corona radiata*. Each fibre of this last-named structure proceeds to the corresponding portion of the *cortex*, where it becomes the direct prolongation of an axis-cylinder process of a pyramidal cell (see below). Some, if not all, of the fibres of the internal capsule give off *collaterals* to the optic thalamus and the nucleus caudatus and lenticularis of the corpus striatum.

From these ganglia (see pages 747, 760) there are also fibres *which proceed into* the internal capsule and the corona radiata, thus forming parts of each *in addition to* the fibres from the crusta. The fibres which arise from the ganglia are more numerous than those which terminate in the ganglia, so that more fibres pass out of the ganglia than pass into them.

The fibres of the *tegmentum* are continuous with those longitudinal fibres of the pons which are derived from the *formatio reticularis* of the medulla (which see), including also fillet (per corpora quadrigemina) and posterior longitudinal bundle. They are reinforced by fibres from the corpora quadrigemina and corpora geniculata, and from the superior peduncle of the cerebellum. Superiorly, some are lost in the subthalamic region, while others enter the optic thalamus and terminate in its gray matter, whence they are continued into the internal capsule as the various bundles of fibres which have been already referred to both in the description of the optic thalamus and just above. Thus, the *tegmental fibres*

which help make up the *projection fibres* do so, not directly, but by the interposition of the optic thalami and corpora striata, *between which* there are also connecting fibres which run through the internal capsule.

2. The **transverse** or **commissural fibres** connect together the two hemispheres. They include (*a*) the transverse fibres of the corpus callosum, and (*b*) the anterior commissure.

The *corpus callosum*, which has already been described, connects together the two hemispheres of the brain, forming their great transverse commissure, penetrating into the medullary substance of the convolutions and intersecting the fibres of the corona radiata. The fibres of the corpus callosum can each be traced either as a direct prolongation of an axis-cylinder process of a pyramidal cell in the gray matter of the cortex, or as a collateral from one of the *projection-fibres* just described.

The *anterior commissure* is a round bundle of white fibres which is placed in front of the anterior pillars of the fornix, and *appears* to connect the corpora striata. It passes outward through the lenticular nucleus of the corpus striatum on each side, and then curves, somewhat twisted on itself, downward and backward into the substance of the temporal lobe, where its fibres radiate from each other.

3. **Association-fibres connecting Different Structures in the Same Hemisphere.**—These fibres are of two kinds: (1) those which connect adjacent convolutions, and which are termed *short association-fibres;* (2) those which connect more distant parts in the same hemisphere—the *long association-fibres.*

The *short association-fibres* are situated immediately beneath the gray substance of the cortex of the hemispheres, and connect together adjacent convolutions, arching beneath the cortical matter which lies at the bottom of the fissures.

The *long association-fibres* include the following:

(*a*) The *uncinate fasciculus* connects the convolutions of the frontal and temporal lobe. It passes across the bottom of the Sylvian fissure and traverses the claustrum.

(*b*) The *fillet of the gyrus fornicatus* or *cingulum* is a band of white matter which encircles the hemisphere in an antero-posterior direction, lying in the substance of the convolution of the corpus callosum. Commencing in front at the anterior perforated space, it passes forward and upward parallel with the rostrum, winds round the genu, runs in the convolution from before backward immediately above the corpus callosum, turns round its posterior extremity, and is continued downward and forward in the hippocampal gyrus to its extremity. In its course it is connected with the secondary convolutions of the gyrus fornicatus by short arcuate fibres.

(*c*) The *superior longitudinal fasciculus* runs along the convex surface of the hemisphere and connects the frontal lobe with the temporal and occipital.

(*d*) The *inferior longitudinal fasciculus* is a collection of fibres which connects the temporal and occipital lobes, running along the outer wall of the middle and posterior cornu.

(*e*) The *perpendicular fasciculus* passes vertically through the front part of the occipital lobe, and connects the *inferior parietal convolution* above with the posterior part (fusiform lobule) of the fourth temporal convolution below.

(*f*) The *fornix* connects the corpus albicans with the *crochet* or *uncus* of the hippocampal convolution in the manner which has already been described.

THE GRAY MATTER OF THE HEMISPHERE is disposed in two regions: 1. The gray matter of the cerebral cortex; 2. The gray matter of the basal ganglia; that is, the corpus striatum and nucleus amygdalæ. As the last two have already been described, there remains only the cortex to be considered.

The **gray matter of the cortex** (Fig. 474) invests the surface of the hemispheres, covering in the convolutions or gyri and lining the intervening fissures or sulci. When a vertical section is made through a gyrus, it is found to be made up of a *white centre* invested by a portion of the *cortex*, which last, if examined microscopically, is found to consist of five separate layers, but to this

there are some exceptions. According to Meynert, *these exceptions* are to be found—(1) in the posterior portion of the occipital lobe; (2) in the gray cortex of the hippocampus major; (3) in the wall of the fissure of Sylvius; and (4) in the olfactory bulb.

The five layers in the *common type* (from parietal lobe) are as follows: (1) The first (*superficial* or *molecular*) *layer* is principally composed of a matrix of neuroglia, through which a few small ganglion-cells are irregularly distributed, and a nerve-fibre network of both non-medullated and medullated fibres, the *latter* constituting a delicate white lamina almost in contact with the pia mater. Of the former, the majority come from the processes of the pyramidal cells in the next layer, the remainder being made up of both dendrites (protoplasmic processes) and axis-cylinder processes of the ganglion-cells in this layer.

(2) The *second layer* consists of numerous *small pryamidal* cells, which have their long axes vertical to the surface of the convolutions, and are closely aggregated together so as to completely fill the layer. The *dendrites* of each of these cells extend into the preceding layer, while the *axis-cylinder process*, starting from the base of the cell, gives off a few collaterals and extends through the white centre of the convolution, and thence to the *corpus striatum*, as a *projection-fibre*.

(3) The *third layer* is made up of cells, which are the same kind as those in the *formation of the cornu Ammonis*. These cells are large *pyramidal cells*, arranged vertically to the surface, as was found in the preceding layer, but they are of very much larger size, and increase progressively toward the deeper parts of the layer, and they are much more widely separated from each other, thus forming groups between which are radiating nerve-fibres. This layer is the principal and broadest one of the series, and is at least twice as deep as the preceding layer. The *axis-cylinder* processes of these cells pass into the white substance, and there become medullated. Previously each gives off a number of *collaterals*, which also become medullated and form ramifications in the layer.

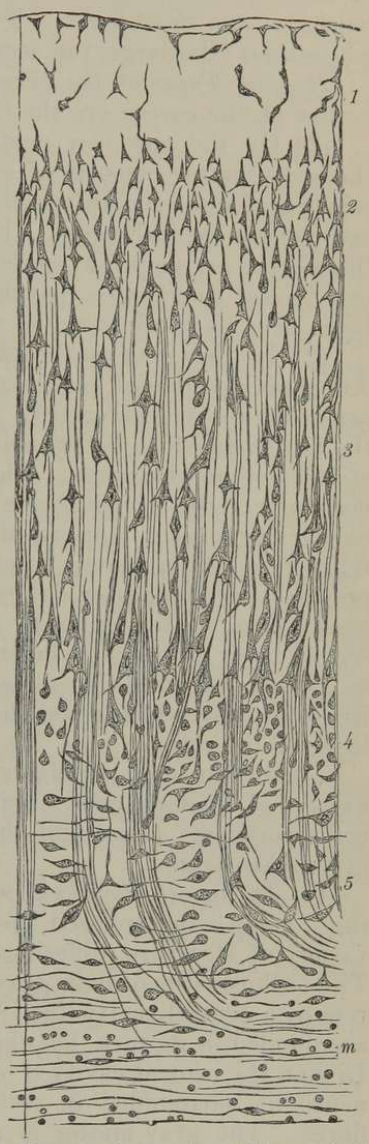

FIG. 474.—Gray matter of the cerebral cortex. (Meynert.)

(4) The *fourth layer* is termed the *layer of polymorphous cells*, and consists of numerous, small, irregular cells, each of which has numerous dendrites, but only one axis-cylinder process. This last, from most of the cells, passes into the white centre, but from some it goes peripherally to the first layer and becomes continuous with one of its fibres.

(5) The *fifth layer* (*layer of fusiform cells*) consists of a very large proportion of spindle-shaped or fusiform cells, which are the peculiar elements of this layer. They are especially numerous in the inner half, and are arranged horizontally, extending parallel to the surface. The *claustrum* is made up almost entirely of an accumulation of cells of the same kind.

The *white centre* lies just beneath the fifth layer, which gradually blends with it. As its fibres radiate into the cortex they become finer, and most of them are continuous, as stated above, with the axis-cylinder processes of the large pyr-

amidal cells in the *third layer* of the cortex. The *collaterals*, already referred to, of these processes become medullated and form two plexuses, one along each border of the third layer. These plexuses appear to the naked eye as two fine white lines (Baillarger) in sections of the cortex of a fresh brain.

Special Types of the Gray Matter of the Cortex.—The special types of gray matter of the cortex are the following:

(1) On the posterior portion of the occipital lobe, near the calcarine fissure, the gray matter consists of six or eight layers. This is produced by the intercalation of intermediate small, irregular cells, similar to those forming the fourth layer of the typical cortex. Furthermore, the large pyramidal cells of the *typical* third layer are very few, while, on the other hand, in the upper part of the *ascending frontal convolution* (psycho-motor region) these pyramidal cells of the third layer are, many of them, of unusual size.

(2) In the gray matter of the cortex of the hippocampus major or cornu Ammonis *pyramidal cells* are found, such as have been described in the third layer of the typical cortex. They constitute the greater part of the structure, the fourth and fifth layers being absent. Hence this layer is called the *formation of the cornu Ammonis*. The bases of these cells are close under the white lamina (alveus) which covers the hippocampus on its ventricular aspect. The second layer—*i. e.* toward the hippocampal fissure—contains no cells. It is represented by a closely interwoven arborization of the *dendrites* (protoplasmic processes) of the pyramidal cells just mentioned, of which the *axis-cylinder* processes pass, in the opposite direction, into the alveus. Finally, beyond the second layer is the first layer of the gray matter of the hippocampus, or, as it is termed, the *granular formation* (Meynert), and consists of numerous small, irregular cells, which resemble the nerves-corpuscles found in the internal granule-layer of the retina.

(3) In the Sylvian fissure the fifth layer of the cortex contains an unusual *number* of fusiform cells; hence this layer, in this region, is called the "claustral formation," because of the number of the same kind of cells in the structure of the claustrum.

(4) In the *olfactory bulb*, which is a portion of the cerebral hemispheres, forming "a cap superimposed upon a conical process of the cerebrum," is another variety of structure, differing from the type of the cortex of the hemispheres. The bulb consists of both gray and white matter, and in most of the lower animals retains a central cavity lined by epithelium, around which is a layer of neuroglia, surrounded in its turn by white fibres, the whole being enclosed by gray matter. In man the central cavity is obliterated, and in the "centre" of the bulb is found neuroglia surrounded in section by a flattened ring (medullary ring) of white fibres. The gray matter is now exceedingly thin dorsally, but very thick *ventrally*, and in section *this ventral portion* shows the following layers from below upward: 1. The *olfactory nerve-layer*, consisting of a plexus of non-medullated nerve-fibres derived from the nerves which supply the olfactory region. These fibres pass *downward* through the foramina in the cribriform plate of the ethmoid, and dorsally into the glomeruli of 2, the *stratum glomerulosum*, consisting of nodulated masses (the glomeruli), each mass consisting of a dense interlacement of fibres, which are partly the prolongations of the olfactory fibres just mentioned, and partly the *dendrites* of the *mitral cells* in the superjacent part of the next layer. Small neuroglia-cells also are found in these glomeruli. 3. The *granular layer*, consisting of (*a*) small irregular nerve-cells resembling those of the granule-layer of the cortex of the cerebellum; (*b*) a deeper layer (next to the stratum glomerulosum) of large, conical cells (*mitral cells*). The dendrites of these pass down to the glomeruli (see above), while their axis-cylinder processes (medullated) pass upward between small cells of the granule-layer to the medullary ring, with the fibres of which, after bending sharply backward, they become continuous, and thence pass backward along the olfactory tract toward the base of the brain; that is, the fibres of the medullary ring are the continuations of these processes.

Weight of the Encephalon.—The average weight of the brain in the adult male is 49½ oz., or a little more than 3 lbs. avoirdupois; that of the female 44 oz.; the average difference between the two being from 5 to 6 oz. The prevailing weight of the brain in the male ranges between 46 oz. and 53 oz., and in the female between 41 oz. and 47 oz. In the male the maximum weight out of 278 cases was 65 oz., and the minimum weight 34 oz. The maximum weight of the adult female brain, out of 191 cases, was 56 oz., and the minimum weight 31 oz. According to Luschka, the average weight of a man's brain is 1424 grammes (about 45 oz.), of a woman's 1272 grammes (about 41 oz.), and, according to Krause, 1570 grammes (about 48½ oz.) for the male, and 1350 (about 43 oz.) for the female. It appears that the weight of the brain increases rapidly up to the seventh year, more slowly to between sixteen and twenty, and still more slowly to between thirty and forty, when it reaches its maximum. Beyond this period, as age advances and the mental faculties decline, the brain diminishes slowly in weight, about an ounce for each subsequent decennial period. These results apply alike to both sexes.

The size of the brain was formerly said to bear a general relation to the intellectual capacity of the individual. Cuvier's brain weighed rather more than 64 oz., that of the late Dr. Abercrombie 63 oz., and that of Dupuytren 62½ oz. On the other hand, the brain of an idiot seldom weighs more than 23 oz. But these facts are by no means conclusive, and it is well known that these weights have been equalled by the brains of persons who never displayed any remarkable intellect. Dr. Haldennan of Cincinnati has recorded the case of a mulatto, aged forty-five, whose brain weighed 68⅜ oz.; he had been a slave, and was never regarded as particularly intelligent; he was illiterate, but is said to have been reserved, meditative, and economical. Dr. Ensor, district medical officer at Port Elizabeth, reports that the brain of Carey, the Irish informer, weighed 61 oz. M. Nikiforoff has published an article on the subject of the weight of brains in the *Novosti*. According to him, the weight of the brain has no influence whatever on the mental faculties. It ought to be remembered that the significance of the weight of the brain should depend upon the proportion it bears to the dimensions of the whole body and to the age of the individual. It is equally important to know what was the cause of death, for long illness or old age exhausts the brain. To define the real degree of development of the brain it is therefore necessary to have a knowledge of the condition of the whole body, and, as this is usually lacking, the mere record of weight possesses little significance.

The human brain is heavier than that of all the lower animals, excepting the elephant and whale. The brain of the former weighs from eight to ten pounds; and that of a whale, in a specimen seventy-five feet long, weighed rather more than five pounds.

Cerebral Localization and Topography.—Within the last few years physiological and pathological research have gone far to prove that the surface of the brain may be mapped out into series of definite areas, each one of which is intimately connected with some well-defined function. And this is especially true with regard to the convolutions on either side of the fissure of Rolando, which are believed by most physiologists of the present day to be concerned in motion, those grouped around the fissure being associated with movements of the extremities of the opposite side of the body, and those around the lower end of the fissure being related to movements of the mouth and tongue.

This is not the place, nor can space be given, to describe these localities. But the two accompanying woodcuts from Ferrier (Figs. 471, 472) have been introduced, and will serve to indicate the position of these areas as far as they have been at present ascertained.

The relation of the principal fissures and convolutions of the cerebrum to the outer surface of the scalp has been the subject of much recent investigation, and many systems have been devised by which one may localize these parts from an examination of the external surface of the head.

These plans can only be regarded as approximately correct for several reasons: in the first place, because the relations of the convolutions and sulci to the surface are found to be very variable in different individuals; secondly, because the surface area of the scalp is greater than the surface area of the brain, so that lines drawn on the one cannot correspond exactly to sulci or convolutions on the other; and thirdly, because the sulci and convolutions in two individuals are never precisely alike. Nevertheless, the principal fissures and convolutions can be mapped

out with sufficient accuracy for all practical purposes, so that any particular convolution can be generally exposed by removing with the trephine a certain portion of the skull's area.

The various landmarks on the outside of the skull, which can be easily felt, and which serve

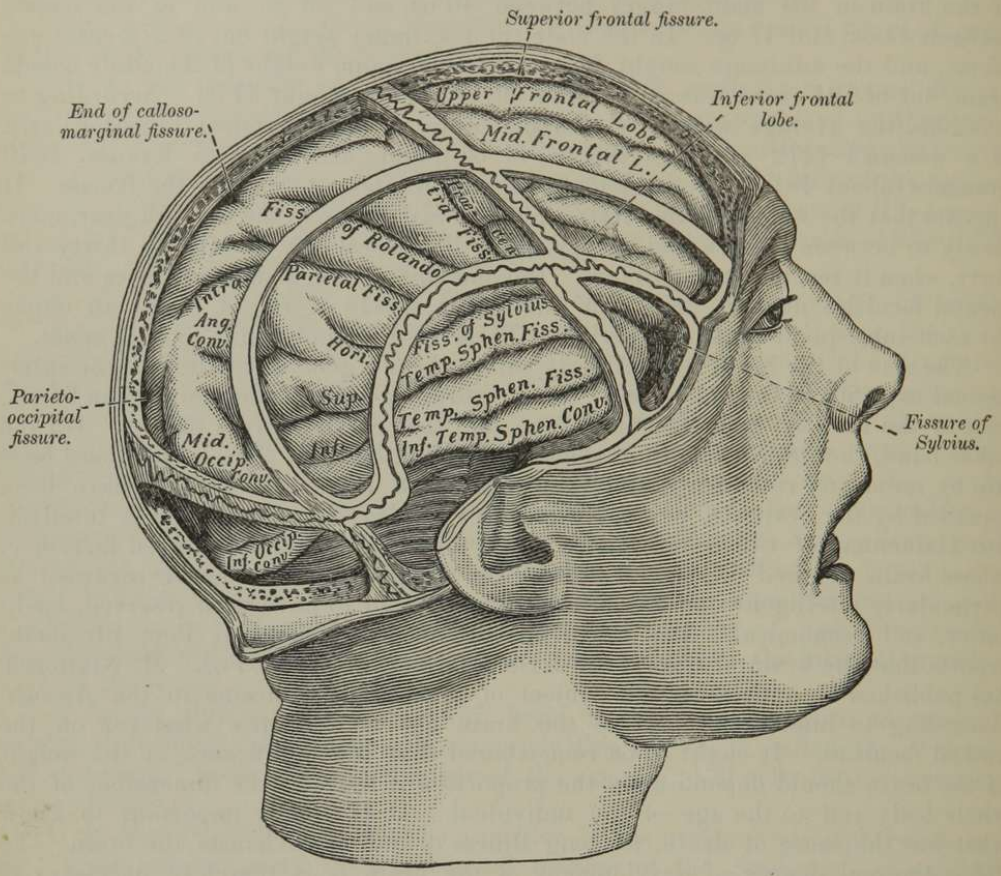

FIG. 475.—Drawing to illustrate cranio-cerebral topography. (Macalister.) Taken from a cast prepared by Professor Cunningham.

as indications of the position of the parts beneath, have been already referred to (see page 222), and the relation of the fissures and convolutions to these landmarks is as follows:

Longitudinal Fissure.—This corresponds to a line drawn from the glabella at the root of the nose to the external occipital protuberance.

The Fissure of Sylvius.—The position of the fissure of Sylvius and its horizontal limb is marked by a line starting from a point one inch and a quarter horizontally behind the external angular process of the frontal bone to a point three-quarters of an inch below the most prominent point of the parietal eminence. The first three-quarters of an inch will represent the main fissure, the remainder the horizontal limb. The bifurcation of the fissure is, therefore, two inches behind and about a quarter of an inch above the level of the external angular process. The ascending limb of the fissure passes upward from this point parallel to, and immediately behind, the coronal suture.

Fissure of Rolando.—To find the upper end of the fissure of Rolando, a measurement should be taken from the glabella to the external occipital protuberance. The position of the top of the sulcus will be, measuring from in front, 55.6 per cent. of the whole distance from the glabella to the external occipital protuberance. Professor Thane adopts a somewhat simpler method. He divides the distance from the glabella to the external occipital protuberance over the top of the head into two equal parts, and, having thus defined the middle point of the vertex, he takes half an inch behind it as the top of the sulcus. This is not quite so accurate as the former method, but it is sufficiently so for all practical purposes, and on account of its simplicity is very generally adopted. From this point the fissure runs downward and forward for 3¾ inches, its axis making an angle of 67° with the middle line. In order to mark this groove, two strips of metal may be employed—one, the shorter, being fixed to the middle of the other at the angle mentioned. If the longer strip is now placed along the sagittal suture so that the junction of the two strips is over the point corresponding to the top of the furrow, the shorter, oblique strip will indicate the direction and 3¾ inches will mark the length of the furrow. Dr. Wilson has devised an instrument, called a cyrtometer, which combines the scale of measurements for

localizing the fissure with data for representing its length and direction.[1] Professor Thane gives the lower end of the furrow as "close to the posterior limb, and about half an inch behind the bifurcation of the fissure of Sylvius." So that, according to this anatomist, a line drawn from a point half an inch behind the mid-point between the glabella and external occipital protuberance to this spot would mark out the fissure of Rolando. Dr. Reid adopts a different method (Fig. 476). He first indicates, on the surface the longitudinal fissure and the horizontal limb of the fissure of Sylvius (as above). He then draws two perpendicular lines from

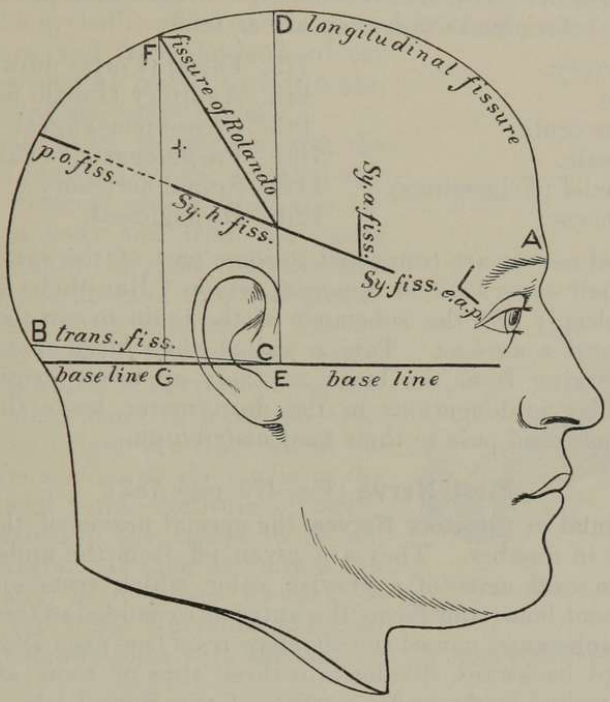

FIG. 476.—Relations of the principal fissures and convolutions of the cerebrum to the outer surface of the scalp. (Reid.)

his "base-line" (that is, a line from the lowest part of the infra-orbital margin through the middle of the external auditory meatus to the back of the head) to the top of the cranium, one (D E, Fig. 476) from the depression in front of the external auditory meatus, and the other (F G, Fig. 476) from the posterior border of the mastoid process at its root. He has thus described on the surface of the head a four-sided figure (F D G E, Fig. 476), and a diagonal line from the posterior superior angle to the anterior perpendicular line where it is crossed by the fissure of Sylvius will represent the furrow.

The *parieto-occipital fissure* on the upper surface of the cerebrum runs outward at right angles to the great longitudinal fissure for about an inch, from a point one-fifth of an inch in front of the lambda (posterior fontanelle). Reid states that if the horizontal limb of the fissure of Sylvius be continued onward to the sagittal suture, the last inch of this line will indicate the position of the sulcus.

The *precentral sulcus* lies in a line drawn vertically downward from the point of junction of the sagittal and coronal sutures. It begins four-fifths of an inch in front of the middle of the fissure of Rolando, and extends nearly, but not quite, to the horizontal limb of the fissure of Sylvius.

The *superior frontal fissure* runs backward from the supra-orbital notch, parallel with the line of the longitudinal fissure to two-fifths of an inch in front of the line indicating the position of the fissure of Rolando.

The *inferior frontal fissure* follows the course of the superior temporal ridge on the frontal bone.

The *intraparietal fissure* begins on a level with the junction of the middle and lower third of the fissure of Rolando, on a line carried across the head from the back of the root of one auricle to that of the other. After passing upward it curves backward, lying parallel to the longitudinal fissure, midway between it and the parietal eminence; it then curves downward to end midway between the posterior fontanelle and the parietal eminence.

[1] *Lancet*, vol. i., 1888, p. 408.

THE CRANIAL NERVES.

The cranial nerves arise from some part of the cerebro-spinal centre, and are transmitted through foramina in the base of the cranium. They have been named numerically, according to the order in which they pass through the dura mater lining the base of the skull. Other names are also given to them, derived from the parts to which they are distributed or from their functions. Taken in their order, from before backward, they are as follows:

1st. Olfactory.
2d. Optic.
3d. Motor oculi.
4th. Pathetic.
5th. Trifacial (Trigeminus).
6th. Abducent.
7th. Facial (Portio dura).
8th. Auditory (Portio mollis).
9th. Glosso-pharyngeal.
10th. Pneumogastric (Par vagum).
11th. Spinal accessory.
12th. Hypoglossal.

All the cranial nerves are connected to some part of the surface of the brain. This is termed their *superficial* or *apparent origin*. But their fibres may, in all cases, be traced deeply into the substance of the brain to some special centre of gray matter, termed a *nucleus*. This is called their *deep* or *real origin*. The nerves, after emerging from the brain at their apparent origin, pass through foramina or tubular prolongations in the dura mater, leave the skull through foramina in its base, and pass to their final distribution.

First Nerve (Fig. 473, page 783).

The **First Cranial** or **Olfactory Nerves,** the special nerves of the sense of smell, are about twenty in number. They are given off from the under surface of the olfactory bulb, an oval mass of a grayish color, which rests on the cribriform plate of the ethmoid bone, and forms the anterior expanded extremity of a slender process of brain-substance, named the *olfactory tract* (see page 783). The olfactory tract, when traced backward, divides into three slips or roots at its base. The middle root is attached to the under surface of the frontal lobe, just in front of the anterior perforated space. The external root passes outward, round the anterior perforated space, across the fissure of Sylvius to the temporo-sphenoidal lobe. The internal root passes inward, and joins the lower end of the gyrus fornicatus.

These three roots unite and form a flat band, narrower in the middle than at either extremity, and of a somewhat prismoid form on section. It is soft in texture and contains a considerable amount of gray matter in its substance. As it passes forward it is contained in a deep sulcus, the *olfactory sulcus*, between two convolutions, lying on the under surface of the frontal lobe, on either side of the longitudinal fissure, and is retained in position by the arachnoid membrane, which covers it. On reaching the cribriform plate of the ethmoid bone it expands into the *olfactory bulb*. From the under part of this bulb are given off the olfactory nerves, which pass through the cribriform foramina and are distributed to the mucous membrane of the nose. Each nerve is surrounded by a tubular prolongation from the dura mater and pia mater; the former being lost on the periosteum lining the nose; the latter, in the neurilemma of the nerve. The nerves, as they enter the nares, are divisible into three groups: an inner group, larger than those on the outer wall, spread out over the upper third of the septum; a middle set, confined to the roof of the nose; and an outer set, which are distributed over the superior and middle turbinated bones and the surface of the ethmoid in front of them. As the filaments descend they unite in a plexiform network, and are believed by most observers to terminate in the *cells of Schultze*.

The olfactory differ in structure from other nerves in being composed exclusively of non-medullated fibres. They are deficient in the white substance of Schwann, and consist of axis-cylinders, with a distinct nucleated sheath, in which there are, however, fewer nuclei than in ordinary non-medullated fibres.

Surgical Anatomy.—In severe injuries to the head the olfactory bulb may become separated from the olfactory nerves, thus producing loss of the sense of smelling (*anosmia*), and with this a considerable loss in the sense of taste, as much of the perfection of the sense of taste is due to the sapid substances being also odorous and simultaneously exciting the sense of smell.

Second Nerve (Fig. 477).

The **Second** or **Optic Nerve,** the special nerve of the sense of sight, is distributed exclusively to the eyeball. The nerves of opposite sides are connected together at the commissure, and from the back of the commissure they may be traced to the brain, under the name of the *optic tracts.*

The *optic tract*, at its connection with the brain, is divided into two bands, external and internal. The *external* arises from the external geniculate body and from the under part of the pulvinar of the optic thalamus, and receives most of the fibres of the brachium of the superior corpus quadrigeminum. The *internal* arises from beneath the internal geniculate body, from which it derives fibres, and joins with the other band to form the optic tract. From this origin the tract winds obliquely across the surface of the crusta in the form of a flattened band, destitute of neurilemma and attached to the crusta by its antero-superior margin. It then assumes a cylindrical form, and, as it passes forward, is connected with the tuber cinereum and lamina cinerea. It finally joins with the tract of the opposite side to form the *optic commissure.*

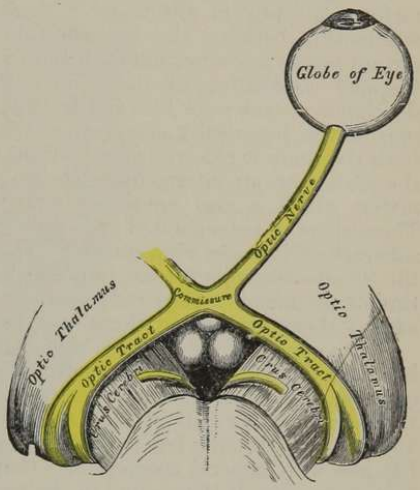

FIG. 477.—The left optic nerve and optic tracts.

The *commissure* or *chiasma*, somewhat quadrilateral in form, rests upon the optic groove of the sphenoid bone, being bounded, above, by the lamina cinerea; behind, by the tuber cinereum; on either side, by the anterior perforated space. Within the commissure the optic nerves of the two sides undergo a partial decussation. The fibres which form the inner margin (*inferior commissure* of Gudden) of each tract are continued across from one to the other side of the brain. These may be regarded as commissural fibres (*intercerebral*) between the internal geniculate bodies. Some fibres are continued across the anterior border of the chiasma, and connect the optic nerves of the two sides, having no relation with the optic tracts.[1] They may be regarded as commissural fibres between the two retinæ (*inter-retinal fibres*). The outer fibres of each tract are continued into the optic nerve of the same side. The central fibres of each tract are continued into the optic nerve of the opposite side, decussating in the commissure with similar fibres of the opposite tract.[2]

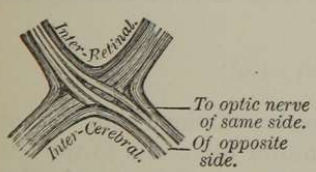

FIG. 478.—Course of the fibres in the optic commissure.

The *optic nerves* arise from the fore part of the commissure, and, diverging from one another, become rounded in form and firm in texture, and are enclosed in a sheath derived from the arachnoid. As each nerve passes through the corresponding optic foramen it receives a sheath from the dura mater; and as it enters the orbit this sheath subdivides into two layers, one of which becomes continuous with the periosteum of the orbit; the other forms the proper sheath of the nerve and

[1] The presence of these fibres has been doubted by some observers, but they have been recently asserted to exist by Stilling.

[2] A specimen of congenital absence of the optic commissure is to be found in the Museum of the Westminster Hospital. (See also Henle, *Nervenlehre*, p. 393, ed. 2.)

surrounds it as far as the sclerotic. The nerve passes through the cavity of the orbit, pierces the sclerotic and choroid coats at the back part of the eyeball, a little to the nasal side of its centre, and expands into the retina. Arnold describes a communication between the optic nerve in the orbit and the ascending branches of Meckel's ganglion. A small artery, the *arteria centralis retinæ*, perforates the optic nerve a little behind the globe, and runs along its interior in a tubular canal of fibrous tissue. It supplies the inner surface of the retina, and is accompanied by corresponding veins.

Surgical Anatomy.—The optic nerve is peculiarly liable to become the seat of neuritis or undergo atrophy in affections of the central nervous system, and, as a rule, the pathological relationship between the two affections is exceedingly difficult to trace. There are, however, certain points in connection with the anatomy of this nerve which tend to throw light upon the frequent association of these affections with intracranial disease: (1) From its mode of development (see page 123) and from its structure the optic nerve must be regarded as a prolongation of the brain-substance, rather than as an ordinary cerebro-spinal nerve. (2) As it passes from the brain it receives sheaths from the three cerebral membranes—a perineural sheath from the pia mater, an intermediate sheath from the arachnoid, and an outer sheath from the dura mater, which is also connected with the periosteum as it passes through the optic foramen. These sheaths are separated from each other by spaces which communicate with the subdural and subarachnoid spaces respectively. The innermost or perineural sheath sends a process around the arteria centralis retinæ into the interior of the nerve, and enters intimately into the structure of the nerve. Thus inflammatory affections of the meninges or of the brain may readily extend themselves along these spaces or along the interstitial connective tissue in the nerve.

The course of the fibres in the optic commissure has an important pathological bearing, and has been the subject of much controversy. Microscopic examination, experiments, and pathology all seem to point to the fact that there is a partial decussation of the fibres, each tract supplying the corresponding half of each eye, so that the right tract supplies the right half of each eye, and the left tract the left half of each eye. At the same time, Charcot believes—and his view has met with general acceptation—that the fibres which do not decussate at the optic commissure have already decussated in the corpora quadrigemina, so that lesion of the cerebral centre of one side causes complete blindness of the opposite eye, because both sets of decussating fibres are destroyed. Whereas should one tract—say the right—be destroyed by disease, there will be blindness of the right half of both retinæ.

An antero-posterior section through the commissure would divide the decussating fibres, and would therefore produce blindness of the inner half of each eye; while a section at the margin of the side of the optic commissure would produce blindness of the external half of the retina of the same side.

The optic nerve may also be affected in injuries or diseases involving the orbit, in fractures of the anterior fossa of the base of the skull, in tumors of the orbit itself, or those invading this cavity from neighboring parts.

Third Nerve (Figs. 384, 479, 480, 481, 486).

The **Third** or **Motor Oculi Nerve** supplies all the muscles of the orbit, except the Superior oblique and External rectus; it also sends motor filaments to the iris and the ciliary muscle. It is a rather large nerve, of rounded form and firm texture. Its apparent origin is from the inner surface of the crus cerebri, immediately in front of the pons Varolii.

The *deep origin* may be traced through the locus niger and tegmentum of the crus to a nucleus situated on either side of the median line beneath the floor of the aqueduct of Sylvius. On emerging from the brain the nerve is invested with a sheath of pia mater, and enclosed in a prolongation from the arachnoid. It then pierces the dura mater in front of and external to the posterior clinoid process, passing between the two processes from the free and attached borders of the tentorium, which are prolonged forward to be connected with the anterior and posterior clinoid processes of the sphenoid bone. It passes along the outer wall of the cavernous sinus, above the other orbital nerves, receiving in its course one or two filaments from the cavernous plexus of the sympathetic and from the ophthalmic division of the fifth nerve. It then divides into two branches, which enter the orbit through the sphenoidal fissure between the two heads of the External rectus muscle. On passing through the fissure the nerve is placed below the fourth and the frontal and lachrymal branches of the ophthalmic nerve, and has passing between its two divisions the nasal nerve.

The *superior division*, the smaller, passes inward over the optic nerve, and supplies the Superior rectus and Levator palpebræ. It occasionally communicates with the ganglionic branch of the nasal nerve.

The *inferior division*, the larger, divides into three branches. One passes beneath the optic nerve to the Internal rectus; another, to the Inferior rectus; and the third, the largest of the three, passes forward between the Inferior and

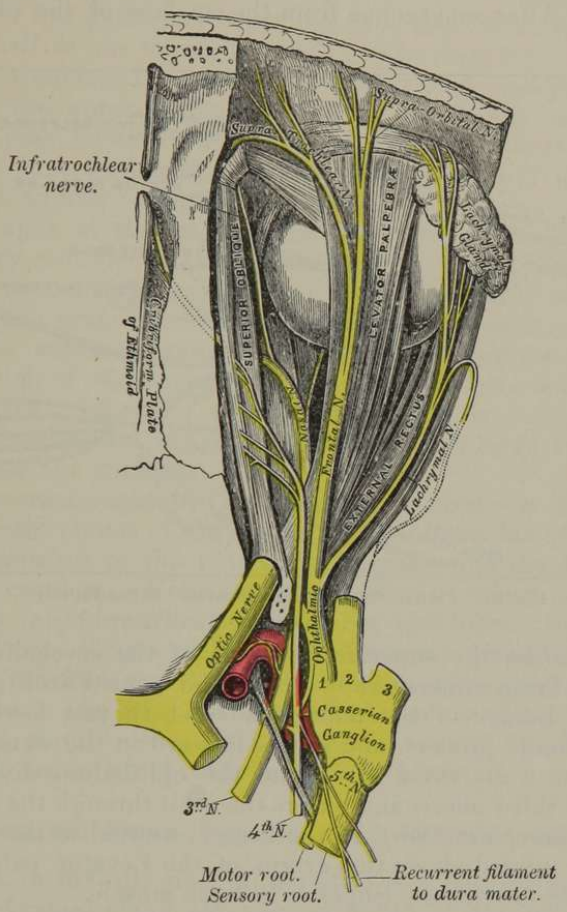

FIG. 479.—Nerves of the orbit. Seen from above.

External recti to the Inferior oblique. From this latter a short, thick branch is given off to the lower part of the lenticular ganglion, which forms its inferior root. It also gives off one or two filaments to the Inferior rectus. All these branches enter the muscles on their ocular surface, except that to the Inferior oblique, which enters its posterior border.

Surgical Anatomy.—Paralysis of the third nerve may be the result of many causes: as cerebral disease; conditions causing pressure on the cavernous sinus; periostitis of the bones entering into the formation of the sphenoidal fissure. It results, when complete, in (1) ptosis, or drooping of the upper eyelid, in consequence of the Levator palpebræ being paralyzed; (2) external strabismus, on account of the unopposed action of the External rectus muscle, which is not supplied by the third nerve, and is not therefore paralyzed; (3) dilatation of the pupil, because the sphincter fibres of the iris are paralyzed; (4) loss of power of accommodation, as the sphincter pupillæ, the ciliary muscle, and the Internal rectus are paralyzed; (5) slight prominence of the eyeball, from the compressing action of the Superior oblique, which is not paralyzed. Occasionally paralysis may affect only a part of the nerve; that is to say, there may be, for example, a dilated and fixed pupil, with ptosis, but no other signs. Irritation of the nerve causes spasm of one or other of the muscles supplied by it; thus, there may be internal strabismus from spasm of the Internal rectus; accommodation for near objects only from spasm of the ciliary muscle, or myosis, contraction of the pupil, from irritation of the sphincter of the pupil.

Fourth Nerve (Figs. 384, 479, 486).

The **Fourth** or **Trochlear Nerve** (*pathetic*), the smallest of the cranial nerves, supplies the Superior oblique muscle. Its *apparent origin* is behind the corpora quadrigemina, from the valve of Vieussens, in the upper surface of which the two nerves decussate. Its *deep origin* may be traced to the nucleus in the floor of the aqueduct of Sylvius immediately below that of the third nerve, with which it is continuous. After emergence from the surface of the valve of Vieussens,

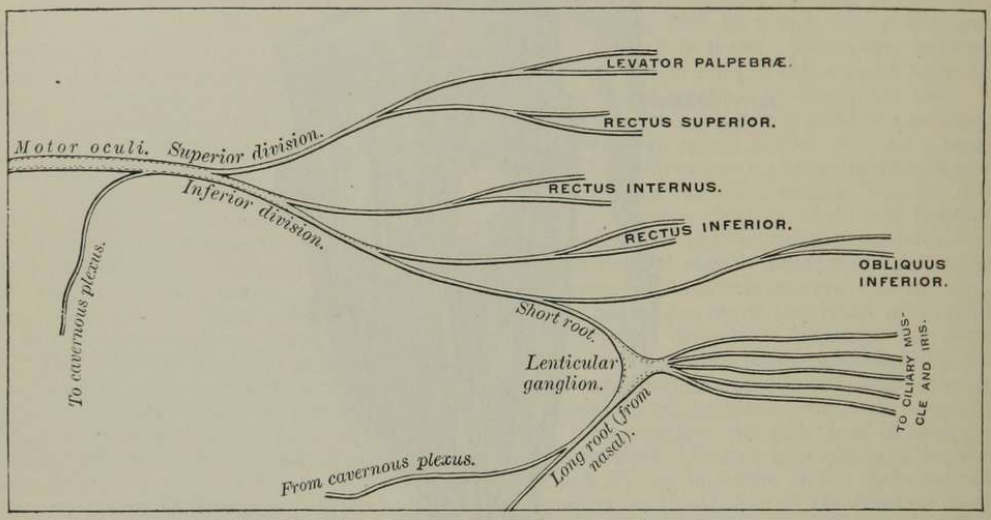

FIG. 480.—Plan of the motor oculi nerve. (After Flower.)

the nerve winds across the superior peduncle of the cerebellum and round the crusta of the mid-brain, immediately above the pons Varolii, pierces the dura mater in the free border of the tentorium cerebelli just behind, and external to, the posterior clinoid process, and passes forward in the outer wall of the cavernous sinus, between the third nerve and the ophthalmic division of the fifth. It then crosses the third nerve, and enters the orbit through the sphenoidal fissure. It now lies at the inner extremity of the fissure internal to the frontal nerve. In the orbit it passes inward above the origin of the Levator palpebræ, and finally enters the *orbital* surface of the Superior oblique muscle.

In the outer wall of the cavernous sinus this nerve receives some filaments from the ophthalmic division of the fifth as well as from the cavernous plexus of the sympathetic, and gives off a recurrent branch, which passes backward between the layers of the tentorium, dividing into two or three filaments which may be traced as far back as the wall of the lateral sinus. In the sphenoidal fissure it occasionally gives off a branch to assist in the formation of the lachrymal nerve.

Surgical Anatomy.—The fourth nerve when paralyzed causes loss of function in the Superior oblique, so that the patient is unable to turn his eye downward and outward. Should the patient attempt to do this, the eye on the affected side is twisted inward, producing diplopia or double vision. Accordingly, it is said that the first symptom of this disease which presents itself is giddiness when going down hill or in descending stairs, owing to the double vision induced by the patient looking at his steps while descending.

Fifth Nerve.

The **Fifth** or **Trifacial Nerve** (*trigeminus*) is the largest cranial nerve. It resembles a spinal nerve (1) in arising by two roots; (2) in having a ganglion developed on its posterior root; and (3) in its function, since it is a compound nerve. It is the great sensory nerve of the head and face and the motor nerve of the muscles of mastication. Its upper two divisions are entirely sensory; the

third division is partly sensory and partly motor. It arises by two roots: of these the anterior is the smaller, and is the motor root; the posterior, the larger and sensory. Its *superficial origin* is from the side of the pons Varolii, nearer to the upper than the lower border. The smaller root consists of three or four bundles; the larger root consists of numerous bundles of fibres, varying in number from seventy to a hundred. The two roots are separated from one another by a few of the transverse fibres of the pons. The *deep origin* of the larger or sensory root is from a nucleus in the pons, just below the floor and just internal to the margin of the upper half of the fourth ventricle. The *deep origin* of the smaller or motor root is from a nucleus internal to the sensory root, and just external to the fasciculus teres on the upper half of the floor of the fourth ventricle. The two roots of the nerve pass forward through an oval opening (*cavum Meckelii*) in the dura mater, on the superior border of the petrous portion of the temporal bone, above the internal auditory meatus: they then run between the bone and the dura mater to the apex of the petrous portion of the temporal bone, where the fibres of the sensory root form a large, semilunar ganglion (*Gasserian*), while the motor root passes beneath the ganglion without having any connection with it, and joins outside the cranium with one of the trunks derived from it.

The **Gasserian** or **semilunar ganglion**[1] is lodged in a depression near the apex of the petrous portion of the temporal bone. It is of somewhat crescentic form, with its convexity turned forward. Its upper surface is intimately adherent to the dura mater. Besides the small or motor root, the large superficial petrosal nerve lies underneath the ganglion.

Branches of Communication.—This ganglion receives, on its *inner side*, filaments from the carotid plexus of the sympathetic. *Branches of Distribution.*—It gives off minute branches to the tentorium cerebelli and the dura mater in the middle fossa of the cranium. From its *anterior border*, which is directed forward and outward, three large branches proceed—the *ophthalmic*, *superior maxillary*, and *inferior maxillary*. The ophthalmic and superior maxillary consist exclusively of fibres derived from the larger root and ganglion, and are solely nerves of common sensation. The third division, or inferior maxillary, is joined outside the cranium by the motor root. This, therefore, strictly speaking, is the only portion of the fifth nerve which can be said to resemble a spinal nerve.

Ophthalmic Nerve (Figs. 384, 479, 481, 482, 486).

The **Ophthalmic**, or first division of the fifth, is a sensory nerve. It supplies the eyeball, the lachrymal gland, the mucous lining of the eye and nasal fossæ, and the integument of the eyebrow, forehead, and nose. It is the smallest of the three divisions of the fifth, arising from the upper part of the Gasserian ganglion. It is a short, flattened band, about an inch in length, which passes forward along the outer wall of the cavernous sinus, below the other nerves, and just before entering the orbit, through the sphenoidal fissure, divides into three branches—*lachrymal*, *frontal*, and *nasal*.

Branches of Communication.—The ophthalmic nerve is joined by filaments from the cavernous plexus of the sympathetic, communicates with the third and sixth nerves, and is not unfrequently joined with the fourth.

Branches of Distribution.—It gives off recurrent filaments (*nervi tentorii*) which pass between the layers of the tentorium along with a branch from the fourth nerve, and then divides into

Lachrymal. Frontal. Nasal.

[1] A Viennese anatomist, Raimund Balthasar Hirsch (1765), was the first who recognized the ganglionic nature of the swelling on the sensory root of the fifth nerve, and called it, in honor of his otherwise unknown teacher, Jon. Laur. Gasser, the "Ganglion Gasseri." Julius Casserius, whose name is given to the musculo-cutaneous nerve of the arm, was professor at Padua, 1545–1605. (See Hyrtl, *Lehrbuch der Anatomie*, p. 895 and p. 55.)

The **Lachrymal** is the smallest of the three branches of the ophthalmic. Not unfrequently it arises by two filaments, one from the ophthalmic, the other from the fourth. It passes forward in a separate tube of dura mater and enters the

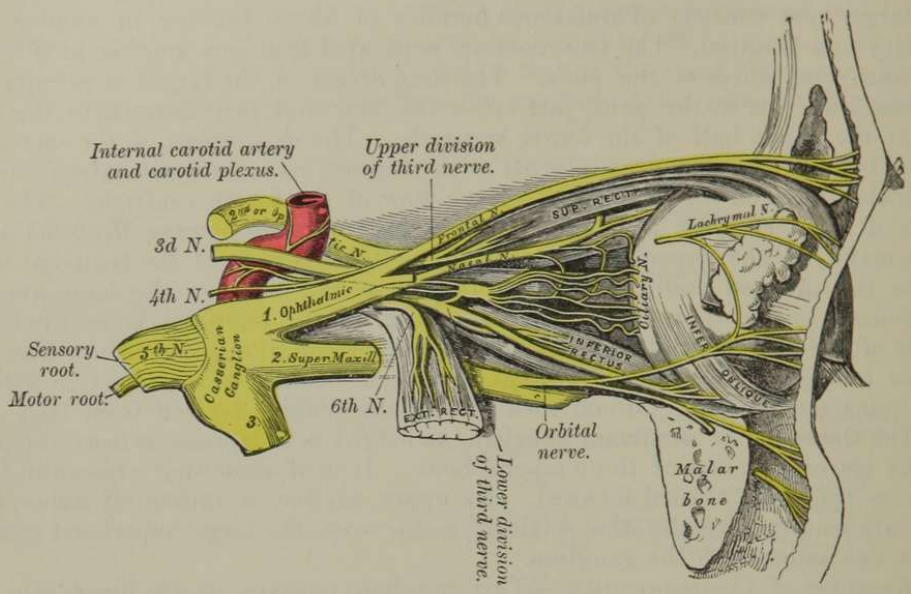

FIG. 481.—Nerves of the orbit and ophthalmic ganglion. Side view.

orbit through the narrowest part of the sphenoidal fissure. In the orbit it runs along the upper border of the External rectus muscle with the lachrymal artery, and sends off a recurrent branch which joins the orbital branch of the superior maxillary nerve, and occasionally takes the place of the temporal branch of this nerve, which is then absent. Within the lachrymal gland it gives off several filaments, which supply the gland and the conjunctiva. Finally, it pierces the tarsal ligaments, and terminates in the integument of the upper eyelid, joining with filaments of the facial nerve.

The **Frontal** is the largest division of the ophthalmic, and may be regarded, both from its size and direction, as the continuation of the nerve. It enters the orbit above the muscles through the highest and broadest part of the sphenoidal fissure, and runs forward along the middle line, between the Levator palpebræ and the periosteum. Midway between the apex and base of the orbit it divides into two branches, supratrochlear and supra-orbital.

The *supratrochlear branch*, the smaller of the two, passes inward above the pulley of the Superior oblique muscle, and gives off a descending filament, which joins with the infratrochlear branch of the nasal nerve. It then escapes from the orbit between the pulley of the Superior oblique and the supra-orbital foramen, curves up on to the forehead close to the bone, and ascends beneath the Corrugator supercilii and Occipito-frontalis muscles, and supplies the integument of the lower part of the forehead on either side of the middle line.

The *supra-orbital branch* passes forward through the supra-orbital foramen, and gives off, in this situation, palpebral filaments to the upper eyelid. It then ascends upon the forehead, and terminates in cutaneous and pericranial branches. The *cutaneous branches*, two in number, an inner and an outer, supply the integument of the cranium as far back as the occiput. They are at first situated beneath the Occipito-frontalis, the inner branch perforating the frontal portion of the muscle, the outer branch its tendinous aponeurosis. The *pericranial branches* are distributed to the pericranium over the frontal and parietal bones.

The **Nasal nerve** is intermediate in size between the frontal and lachrymal, and more deeply placed than the other branches of the ophthalmic. It enters the orbit

between the two heads of the External rectus, and between the two divisions of the third nerve, and passes obliquely inward across the optic nerve, beneath the Superior oblique and Superior rectus muscles, to the inner wall of the orbit, where it enters the anterior ethmoidal foramen. It then enters the cavity of the cranium, traverses a shallow groove on the cribriform plate of the ethmoid bone, and passes down, through the slit by the side of the crista galli, into the nose, where it gives off two branches, an internal and an external. The *internal branch* supplies the mucous membrane near the fore part of the septum of the nose. The *external branch* supplies a few filaments to the mucous membrane covering the fore part of the outer wall of the nares as far as the inferior spongy bone. The nerve then descends in a groove on the back of the nasal bone and leaves the cavity of the nose, between the lower border of the nasal bone and the upper lateral cartilage of the nose, and, passing down beneath the Compressor nasi, supplies the integument of the ala and the tip of the nose, joining with the facial nerve.

The branches of the nasal nerve are the *ganglionic*, *ciliary*, and *infratrochlear*.

The *ganglionic* is a slender branch, about half an inch in length, which usually arises from the nasal, between the two heads of the External rectus. It passes forward on the outer side of the optic nerve, and enters the superior and posterior angle of the ciliary ganglion, forming its superior or long root. It is sometimes joined by a filament from the cavernous plexus of the sympathetic or from the superior division of the third nerve.

The *long ciliary nerves*, two or three in number, are given off from the nasal as it crosses the optic nerve. They join the short ciliary nerves from the ciliary ganglion, pierce the posterior part of the sclerotic, and, running forward between it and the choroid, are distributed to the ciliary muscles, iris, and cornea.

The *infratrochlear branch* is given off just before the nasal nerve passes through the anterior ethmoidal foramen. It runs forward along the upper border of the Internal rectus, and is joined, beneath the pulley of the Superior oblique, by a filament from the supratrochlear nerve. It then passes to the inner angle of the eye, and supplies the integument of the eyelids and side of the nose, the conjunctiva, lachrymal sac, and caruncula lachrymalis.

Ophthalmic Ganglion (Figs. 481, 482).

Connected with the three divisions of the fifth nerve are four small ganglia. With the first division is connected the *ophthalmic ganglion;* with the second division, the *spheno-palatine* or *Meckel's ganglion;* and with the third, the *otic* and *submaxillary ganglia.* All the four receive sensory filaments from the fifth, and motor and sympathetic filaments from various sources; these filaments are called the *roots of the ganglia.*

The **Ophthalmic, Lenticular,** or **Ciliary Ganglion** is a small, quadrangular, flattened ganglion, of a reddish-gray color, and about the size of a pin's head, situated at the back part of the orbit between the optic nerve and the External rectus muscle, lying generally on the outer side of the ophthalmic artery. It is enclosed in a quantity of loose fat, which makes its dissection somewhat difficult.

Its *branches of communication*, or *roots*, are three, all of which enter its posterior border. One, the long or sensory root, is derived from the nasal branch of the ophthalmic and joins its superior angle. The second, the short or motor root, is a short, thick nerve, occasionally divided into two parts, which is derived from the branch of the third nerve to the Inferior oblique muscle, and is connected with the inferior angle of the ganglion. The third, the sympathetic root, is a slender filament from the cavernous plexus of the sympathetic. This is frequently blended with the long root, though it sometimes passes to the ganglion separately. According to Tiedemann, this ganglion receives a filament of communication from the spheno-palatine ganglion.

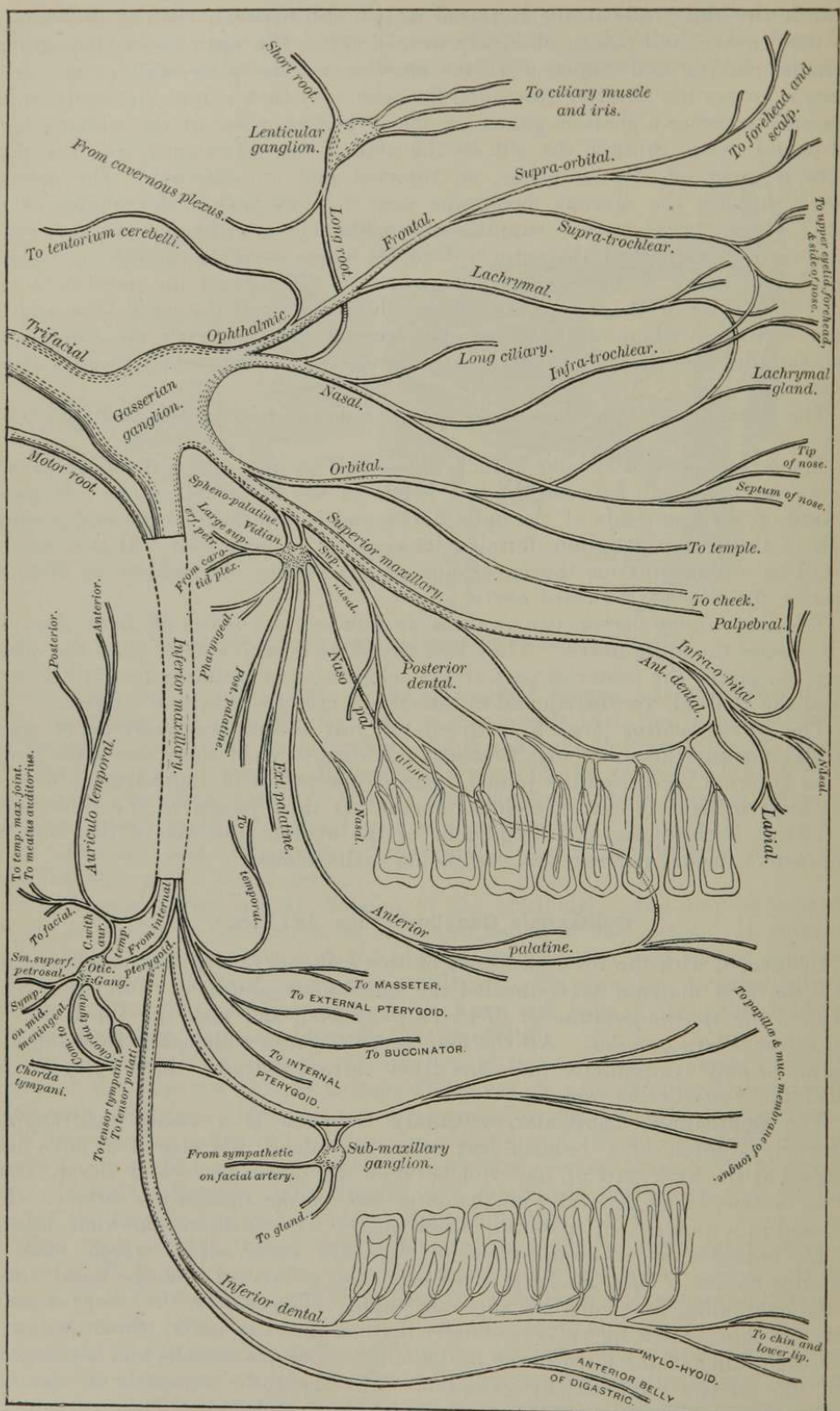

FIG. 482.—Plan of the fifth cranial nerve. (After Flower.)

Its *branches of distribution* are the short ciliary nerves. These are delicate filaments, from six to ten in number, which arise from the fore part of the ganglion

in two bundles, connected with its superior and inferior angles; the lower bundle is the larger. They run forward with the ciliary arteries in a wavy course, one set above and the other below the optic nerve, and are joined by the long ciliary nerves from the nasal. They pierce the sclerotic at the back part of the globe, pass forward in delicate grooves on its inner surface, and are distributed to the ciliary muscle, iris, and cornea. Tiedemann has described one small branch as penetrating the optic nerve with the arteria centralis retinæ.

Superior Maxillary Nerve (Fig. 483).

The **Superior Maxillary,** or second division of the fifth, is a sensory nerve. It is intermediate, both in position and size, between the ophthalmic and inferior maxillary. It commences at the middle of the Gasserian ganglion as a flattened plexiform band, and passes forward through the foramen rotundum, where it becomes more cylindrical in form and firmer in texture. It then crosses the spheno-maxillary fossa, enters the orbit through the spheno-maxillary fissure, traverses the infra-orbital canal in the floor of the orbit, and appears upon the face at the infra-orbital foramen.[1] At its termination the nerve lies beneath the Levator labii superioris muscle, and divides into a leash of branches, which spread out upon the side of the nose, the lower eyelid, and upper lip, joining with filaments of the facial nerve.

Branches of Distribution.—The branches of this nerve may be divided into four groups: 1. Those given off in the cranium. 2. Those given off in the spheno-maxillary fossa. 3. Those in the infra-orbital canal. 4. Those on the face.

In the cranium . . .	Meningeal.
Spheno-maxillary fossa	Orbital or temporo-malar.
	Spheno-palatine.
	Posterior superior dental.
Infra-orbital canal .	Middle superior dental.
	Anterior superior dental.
On the face . .	Palpebral.
	Nasal.
	Labial.

The **meningeal branch** is given off directly after its origin from the Gasserian ganglion, and supplies the dura mater, communicating with a meningeal branch from the inferior maxillary nerve.

The **orbital** or **temporo-malar branch** arises in the spheno-maxillary fossa, enters the orbit by the spheno-maxillary fissure, and divides at the back of that cavity into two branches, temporal and malar.

The *temporal branch* runs in a groove along the outer wall of the orbit (in the malar bone), receives a branch of communication from the lachrymal, and, passing through a foramen in the malar bone, enters the temporal fossa. It ascends between the bone and substance of the Temporal muscle, pierces this muscle and the temporal fascia about an inch above the zygoma, and is distributed to the integument covering the temple and side of the forehead, communicating with the facial and auriculo-temporal branch of the inferior maxillary nerve. As it pierces the temporal fascia it gives off a slender twig, which runs between the two layers of the fascia to the outer angle of the orbit.

The *malar branch* passes along the external inferior angle of the orbit, emerges upon the face through a foramen in the malar bone, and, perforating the Orbicularis palpebrarum muscle, supplies the skin on the prominence of the cheek, and is named *subcutaneus malæ.* It joins with the facial and the palpebral branches of the superior maxillary.

The **spheno-palatine branches,** two in number, descend to the spheno-palatine ganglion.

[1] After it enters the infra-orbital canal, the nerve is frequently called the *infra-orbital.*

The **posterior superior dental branches** arise from the trunk of the nerve just as it is about to enter the infra-orbital canal; they are generally two in number,

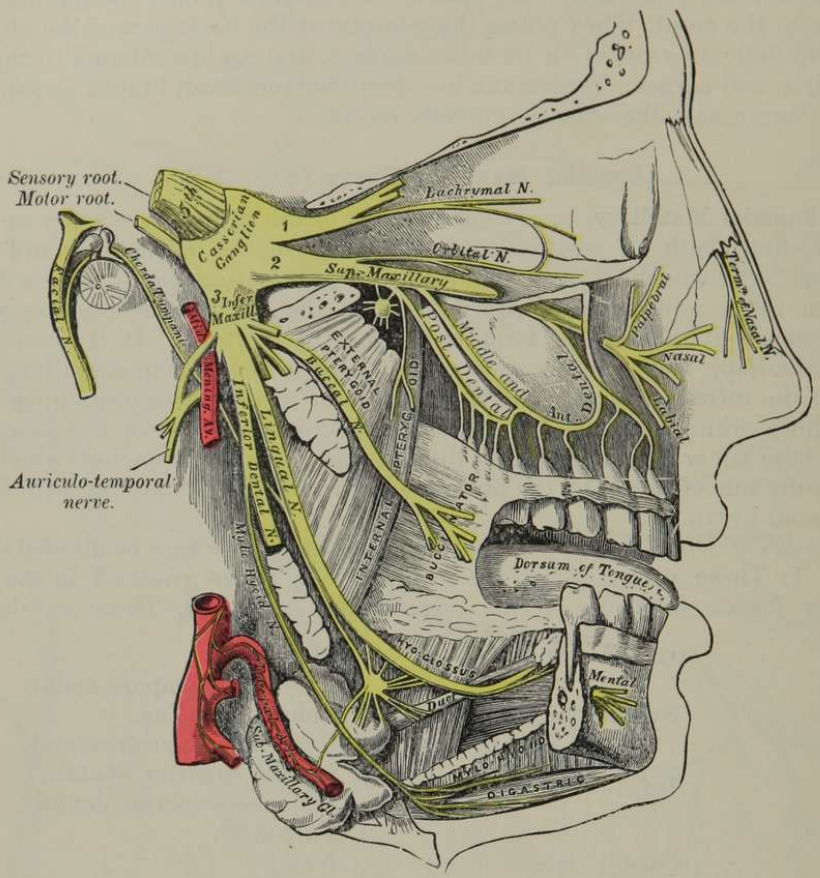

FIG. 483.—Distribution of the second and third divisions of the fifth nerve and submaxillary ganglion.

but sometimes arise by a single trunk, and immediately divide and pass downward on the tuberosity of the superior maxillary bone. They give off several twigs to the gums and neighboring parts of the mucous membrane of the cheek (*superior gingival branches*). They then enter the posterior dental canals on the zygomatic surface of the superior maxillary bone, and, passing from behind forward in the substance of the bone, communicate with the middle dental nerve, and give off branches to the lining membrane of the antrum and three twigs to each of the molar teeth. These twigs enter the foramina at the apices of the fangs and supply the pulp.

The **middle superior dental branch** is given off from the superior maxillary nerve in the back part of the infra-orbital canal, and runs downward and forward in a special canal in the outer wall of the antrum to supply the two bicuspid teeth. It communicates with the posterior and anterior dental branches. At its point of communication with the posterior branch is a slight thickening which has received the name of the *ganglion of Valentin;* and at its point of communication with the anterior branch is a second enlargement, which is called the *ganglion of Bochdalek.* Neither of these is probably a true ganglion.

The **anterior superior dental branch,** of large size, is given off from the superior maxillary nerve just before its exit from the infra-orbital foramen; it enters a special canal in the anterior wall of the antrum, and, coursing from before backward, divides into a series of branches which supply the incisor and canine teeth. It communicates with the middle dental branch, and gives off a *nasal branch,* which passes through a minute canal into the nasal fossa, and supplies the mucous mem-

brane of the fore part of the inferior meatus and the floor of this cavity, communicating with the naso-palatine nerve from Meckel's ganglion.

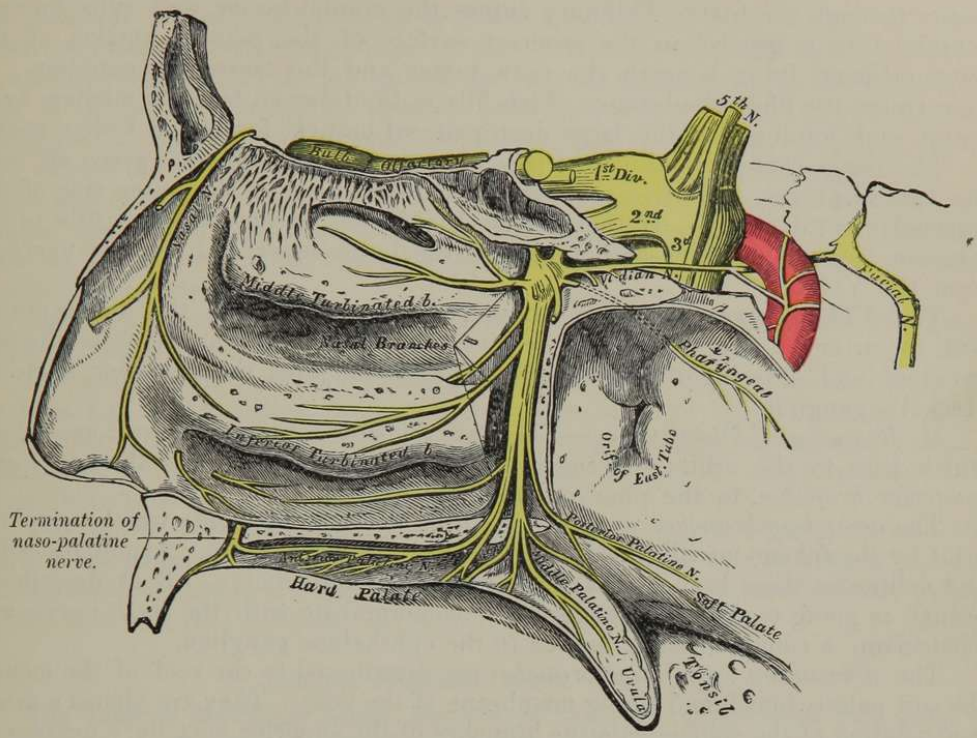

FIG. 484.—The spheno-palatine ganglion and its branches.

The **palpebral branches** pass upward beneath the Orbicularis palpebrarum. They supply the integument and conjunctiva of the lower eyelid with sensation, joining at the outer angle of the orbit with the facial nerve and malar branch of the orbital.

The **nasal branches** pass inward; they supply the integument of the side of the nose and join with the nasal branch of the ophthalmic.

The **labial branches**, the largest and most numerous, descend beneath the Levator labii superioris, and are distributed to the integument of the upper lip, the mucous membrane of the mouth, and labial glands.

All these branches are joined, immediately beneath the orbit, by filaments from the facial nerve, forming an intricate plexus, the *infra-orbital.*

Spheno-palatine Ganglion (Fig. 484).

The **spheno-palatine ganglion** (*Meckel's*), the largest of the cranial ganglia, is deeply placed in the spheno-maxillary fossa, close to the spheno-palatine foramen. It is triangular or heart-shaped, of a reddish-gray color, and is situated just below the superior maxillary nerve as it crosses the fossa.

Its Branches of Communication.—Like the other ganglia of the fifth nerve, it possesses a motor, a sensory, and a sympathetic root. Its *sensory root* is derived from the superior maxillary nerve through its two spheno-palatine branches. These branches of the nerve, given off in the spheno-maxillary fossa, descend to the ganglion. Their fibres, for the most part, pass in front of the ganglion, as they proceed to their destination, in the palate and nasal fossa, and are not incorporated in the ganglionic mass; some few of the fibres, however, enter the ganglion, constituting its sensory root. Its *motor root* is derived from the facial nerve through the large superficial petrosal nerve, and its *sympathetic root* from the carotid plexus, through the large deep petrosal nerve. These two nerves join together to form a single nerve, the *Vidian*, before their entrance into the ganglion.

The *large superficial petrosal branch* (*nervus petrosus superficialis major*) is given off from the intumescentia ganglioformis in the aqueductus Fallopii; it passes through the hiatus Fallopii; enters the cranial cavity, and runs forward contained in a groove on the anterior surface of the petrous portion of the temporal bone, lying beneath the dura mater and the Gasserian ganglion. It then enters the fibrous substance which fills in the foramen lacerum medium basis cranii, and, joining with the large deep petrosal branch, forms the Vidian nerve.

The *large deep petrosal branch* (*nervus petrosus profundus*) is given off from the carotid plexus, and runs through the carotid canal on the outer side of the internal carotid artery. It then enters the fibrous substance which fills in the foramen lacerum medium, and joins with the large superficial petrosal nerve to form the Vidian.

The *Vidian nerve*, thus formed, passes forward through the Vidian canal with the artery of the same name, receives the *sphenoidal* filament from the otic ganglion, and, entering the spheno-maxillary fossa, joins the posterior angle of Meckel's ganglion.

Its *Branches of Distribution.*—These are divisible into four groups: *ascending*, which pass to the orbit; *descending*, to the palate; *internal*, to the nose; and *posterior branches*, to the pharynx and nasal fossæ.

The *ascending branches* are two or three delicate filaments which enter the orbit by the spheno-maxillary fissure and supply the periosteum. Arnold describes and delineates these branches as ascending to the optic nerve. Bock describes a branch as going to the cavernous sinus to communicate with the sixth nerve, and Tiedemann, a communicating branch to the ophthalmic ganglion.

The *descending* or *palatine branches* are distributed to the roof of the mouth, the soft palate, tonsil, and lining membrane of the nose. They are almost a direct continuation of the spheno-palatine branches of the superior maxillary nerve, and are three in number—anterior, middle, and posterior.

The *anterior* or *large palatine nerve* descends through the posterior palatine canal, emerges upon the hard palate at the posterior palatine foramen, and passes forward through a groove in the hard palate nearly as far as the incisor teeth. It supplies the gums, the mucous membrane and glands of the hard palate, and communicates in front with the termination of the naso-palatine nerve. While in the posterior palatine canal it gives off *inferior nasal branches*, which enter the nose through openings in the palate bone, and ramify over the middle meatus and the middle and inferior spongy bones; and, at its exit from the canal a palatine branch is distributed to both surfaces of the soft palate.

The *middle* or *external palatine nerve* descends through one of the accessory palatine canals, distributing branches to the uvula, tonsil, and soft palate. It is occasionally wanting.

The *posterior* or *small palatine nerve* descends with a small artery through the small posterior palatine canal, emerging by a separate opening behind the posterior palatine foramen. It supplies the Levator palati and Azygos uvulæ muscles, the soft palate, tonsil, and uvula. The middle and posterior palatine join with the tonsillar branches of the glosso-pharyngeal to form the plexus around the tonsil (*circulus tonsillaris*).

The *internal branches* are distributed to the septum and outer wall of the nasal fossæ. They are the superior nasal (anterior) and the naso-palatine.

The *superior nasal branches* (*anterior*), four or five in number, enter the back part of the nasal fossa by the spheno-palatine foramen. They supply the mucous membrane covering the superior and middle spongy bones, and that lining the posterior ethmoidal cells, a few being prolonged to the upper and back part of the septum. One branch is continued on to the inner surface of the anterior wall of the antrum, and there forms a communication with the anterior dental nerve. At the point of communication a swelling exists, denominated "the ganglion of Bochdalek," the nature of which seems to be, however, uncertain.

The *naso-palatine nerve* (*Cotunnius*) also enters the nasal fossa through the spheno-palatine foramen, and passes inward across the roof of the nose, below the orifice of the sphenoidal sinus, to reach the septum; it then runs obliquely downward and forward along the lower part of the septum, to the anterior palatine foramen, lying between the periosteum and mucous membrane. It descends to the roof of the mouth through the anterior palatine canal. The two nerves are here contained in separate and distinct canals, situated in the intermaxillary suture, and termed the foramina of Scarpa, the left nerve being usually anterior to the right one. In the mouth they become united, supply the mucous membrane behind the incisor teeth, and join with the anterior palatine nerve. The naso-palatine nerve occasionally furnishes a few small filaments to the mucous membrane of the septum.

The *posterior branches* are the pharyngeal (pterygo-palatine) and the upper posterior nasal branches.

The *pharyngeal nerve* (*pterygo-palatine*) is a small branch arising from the back part of the ganglion, being generally blended with the Vidian nerve. It passes through the pterygo-palatine canal with the pterygo-palatine artery, and is distributed to the mucous membrane of the upper part of the pharynx, behind the Eustachian tube.

The *upper posterior nasal branches* are a few twigs given off from the posterior part of the ganglion, which run backward in the sheath of the Vidian nerve to the mucous membrane at the back part of the roof, septum, and superior meatus of the nose and that covering the end of the Eustachian tube.

Inferior Maxillary Nerve (Fig. 483).

The **Inferior Maxillary Nerve** distributes branches to the teeth and gums of the lower jaw, the integument of the temple and external ear, the lower part of the face and lower lip, and the muscles of mastication; it also supplies the tongue with a large branch. It is the largest of the three divisions of the fifth, and is made up of two roots: a large or sensory root proceeding from the inferior angle of the Gasserian ganglion; and a small or motor root, which passes beneath the ganglion, and unites with the sensory root just after its exit through the foramen ovale. Immediately beneath the base of the skull this nerve divides into two trunks, anterior and posterior. Previous to its division the primary trunk gives off from its inner side a recurrent (meningeal) branch and the nerve to the Internal pterygoid muscle.

The **recurrent branch** is given off directly after its exit from the foramen ovale. It passes backward into the skull through the foramen spinosum with the middle meningeal artery. It divides into two branches, anterior and posterior, which accompany the main divisions of the artery and supply the dura mater. The anterior branch communicates with the meningeal branch of the superior maxillary nerve.

The **Internal Pterygoid Nerve,** given off from the inferior maxillary previous to its division, is intimately connected at its origin with the otic ganglion. It is a long and slender branch, which passes inward to enter the deep surface of the Internal pterygoid muscle.

The *anterior* and smaller division, which receives nearly the whole of the motor root, divides into branches which supply the remaining muscles of mastication. They are the masseteric, deep temporal, buccal, and external pterygoid.

The **masseteric branch** passes outward, above the External pterygoid muscle, in front of the temporo-maxillary articulation, and crosses the sigmoid notch with the masseteric artery to the Masseter muscle, in which it ramifies nearly as far as its anterior border. It occasionally gives a branch to the Temporal muscle and a filament to the articulation of the jaw.

The **deep temporal branches** supply the deep surface of the Temporal muscle. The *posterior branch*, of small size, is placed at the back of the temporal fossa. It is sometimes joined with the masseteric branch. The *anterior branch* is

reflected upward at the pterygoid ridge of the sphenoid to the front of the temporal fossa. It is often given off from the *buccal branch* after the latter has pierced the external pterygoid muscle. The third branch (*middle deep temporal*) passes outward over the External pterygoid muscle and enters the deep surface of the Temporal muscle.

The **buccal branch** passes forward between the two heads of the External pterygoid, and downward beneath the inner surface of the coronoid process of the lower jaw, or through the fibres of the Temporal muscle, to reach the surface of the Buccinator, upon which it divides into a superior and an inferior branch. It gives the branch to the External pterygoid during its passage through that muscle, and is usually joined with the anterior branch of the deep temporal nerve. The *upper branch* supplies the integument and upper part of the Buccinator muscle, joining with the facial nerve round the facial vein. The *lower branch* passes forward to the angle of the mouth : it supplies the integument and Buccinator muscle, as well as the mucous membrane lining the inner surface of that muscle, and joins the facial nerve.[1]

The **External Pterygoid Nerve** is most frequently derived from the buccal, but it may be given off separately from the anterior trunk of the nerve. It enters the muscle on its inner surface.

The *posterior* and larger division of the inferior maxillary nerve is for the most part sensory, but receives a few filaments from the motor root. It divides into three branches : auriculo-temporal, lingual (gustatory), and inferior dental.

The **Auriculo-temporal Nerve** generally arises by two roots, beneath which the middle meningeal artery passes. It runs backward beneath the External pterygoid muscle to the inner side of the neck of the lower jaw. It then turns upward with the temporal artery, between the external ear and condyle of the jaw, under cover of the parotid gland, and, escaping from beneath this structure, ascends over the zygoma and divides into two temporal branches.

The *branches of communication* are with the facial and with the otic ganglion. The branches of communication with the facial, usually two in number, pass forward from behind the neck of the condyle of the jaw, to join the temporo-facial division of this nerve at the posterior border of the Masseter muscle. They form one of the principal branches of communication between the facial and the fifth nerve. The filaments of communication with the otic ganglion are derived from the commencement of the auriculo-temporal nerve.

The *branches of distribution* are—

Auricular, inferior and superior.	Articular.
Branches to the meatus auditorius.	Parotid.
Temporal, anterior and posterior.	

The *inferior auricular* arises behind the articulation of the jaw, and is distributed to the ear below the external meatus: other filaments twine round the internal maxillary artery and communicate with the sympathetic. The *superior auricular* arises in front of the external ear, and supplies the integument covering the tragus and pinna.

Branches to the meatus auditorius, upper and lower, arise from the point of communication between the auriculo-temporal and facial nerves, and are distributed to the meatus. A filament from the upper passes to the membrana tympani.

A *branch to the temporo-maxillary articulation* is usually derived from the auriculo-temporal nerve.

The *parotid branches* supply the parotid gland.

The *anterior temporal* accompanies the temporal artery to the vertex of the skull, and supplies the integument of the temporal region, communicating with the facial nerve and the temporal branch of the temporo-malar from the superior

[1] There seems to be no reason to doubt that the branch supplying the Buccinator muscle is entirely a nerve of ordinary sensation, and that the true motor-supply of this muscle is from the facial.

maxillary. The *posterior temporal*, the smaller of the two, is distributed to the upper part of the pinna and the neighboring tissues.

The **Lingual Nerve** (**gustatory**) supplies the papillæ and mucous membrane of the tongue. It is deeply placed throughout the whole of its course. It lies at first beneath the External pterygoid muscle, together with the inferior dental nerve, being placed to the inner side of the latter nerve, and is occasionally joined to it by a branch which crosses the internal maxillary artery. The chorda tympani also joins it at an acute angle in this situation. The nerve then passes between the Internal pterygoid muscle and the inner side of the ramus of the jaw, and crosses obliquely to the side of the tongue over the Stylo-glossus muscle, and then between the Hyo-glossus muscle and deep part of the submaxillary gland: the nerve lastly runs across Wharton's duct, and along the side of the tongue to its apex, lying immediately beneath the mucous membrane.

The *branches of communication* are with the facial through the chorda tympani, the inferior dental and hypoglossal nerves, and the submaxillary ganglion. The branches to the submaxillary ganglion are two or three in number; those connected with the hypoglossal nerve form a plexus at the anterior margin of the Hyo-glossus muscle.

The *branches of distribution* are few in number. They supply the mucous membrane of the mouth, the gums, and the sublingual gland, while the *lingual* or *terminal* branches supply the mucous membrane of the tongue over its anterior two-thirds, terminating in the filiform and fungiform papillæ.

The **Inferior Dental** is the largest of the three branches of the inferior maxillary nerve. It passes downward with the inferior dental artery, at first beneath the External pterygoid muscle, and then between the internal lateral ligament and the ramus of the jaw to the dental foramen. It then passes forward in the dental canal of the inferior maxillary bone, lying beneath the teeth, as far as the mental foramen, where it divides into two terminal branches, incisor and mental.

The branches of the inferior dental are, the mylo-hyoid, dental, incisive, and mental.

The *mylo-hyoid* is derived from the inferior dental just as that nerve is about to enter the dental foramen. It descends in a groove on the inner surface of the ramus of the jaw, in which it is retained by a process of fibrous membrane. It reaches the under surface of the Mylo-hyoid muscle, and supplies it and the anterior belly of the Digastric, occasionally sending one or two filaments to the submaxillary gland.

The *dental branches* supply the molar and bicuspid teeth. They correspond in number to the fangs of those teeth: each nerve entering the orifice at the point of the fang and supplying the pulp of the tooth.

The *incisive branch* is continued onward within the bone to the middle line, and supplies the canine and incisor teeth.

The *mental branch* emerges from the bone at the mental foramen, and divides beneath the Depressor anguli oris into two or three branches; one descends to supply the skin of the chin, and another (sometimes two) ascends to supply the skin and mucous membrane of the lower lip. These branches communicate freely with the facial nerve.

Two small ganglia are connected with the inferior maxillary nerve—the otic with the trunk of the nerve, and the submaxillary with its lingual branch.

Otic Ganglion (Fig. 485).

The **Otic Ganglion** (*Arnold's*) is a small, oval-shaped, flattened ganglion of a reddish-gray color, situated immediately below the foramen ovale, on the inner surface of the inferior maxillary nerve, and round the origin of the internal pterygoid nerve. It is in relation, *externally*, with the trunk of the inferior maxillary nerve, at the point where the motor root joins the sensory portion; *internally*, with the cartilaginous part of the Eustachian tube, and the origin of the Tensor palati muscle; *behind* it is the middle meningeal artery.

Branches of Communication.—This ganglion is connected with the internal pterygoid branch of the inferior maxillary nerve by two or three short, delicate filaments. From this it may obtain a motor root, and possibly also a sensory root, as these filaments from the nerve to the Internal pterygoid may contain sensory

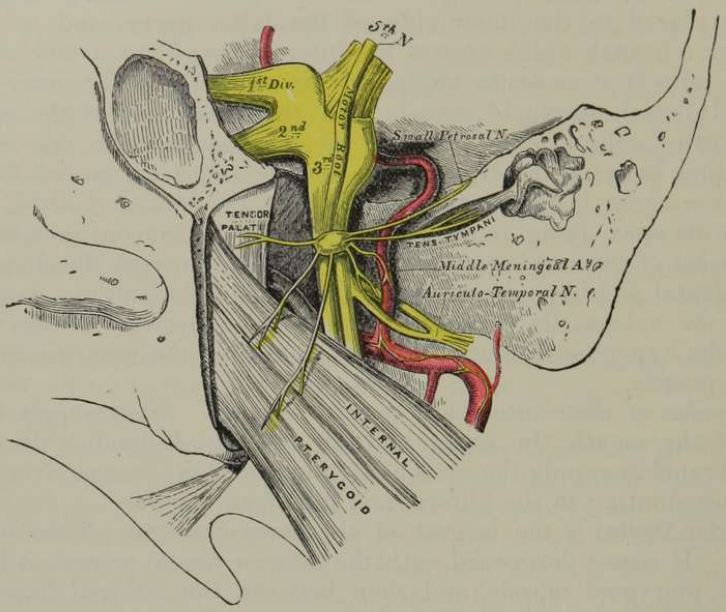

FIG. 485.—The otic ganglion and its branches.

fibres. It communicates with the glosso-pharyngeal and facial nerves through the small superficial petrosal nerve continued from the tympanic plexus (pages 811 and 818), and through this communication it probably receives its sensory root from the glosso-pharyngeal and its motor root from the facial; its communication with the sympathetic is effected by a filament from the plexus surrounding the middle meningeal artery. The ganglion also communicates with the auriculo-temporal nerve. This is probably a branch from the glosso-pharyngeal which passes to the ganglion, and through it and the auriculo-temporal nerve to the parotid gland. The *sphenoidal* filament joins the Vidian nerve.

Its *branches of distribution* are a filament to the Tensor tympani and one to the Tensor palati. The former passes backward on the outer side of the Eustachian tube; the latter arises from the ganglion, near the origin of the internal pterygoid nerve, and passes forward. The fibres of these nerves are, however, mainly derived from the nerve to the Internal pterygoid muscle. It also gives off a small communicating branch to the chorda tympani and one to the buccal nerve (Rauber).

Submaxillary Ganglion (Fig. 483).

The **submaxillary ganglion** is of small size, fusiform in shape, and situated above the deep portion of the submaxillary gland, near the posterior border of the Mylo-hyoid muscle, being connected by filaments with the lower border of the lingual (gustatory) nerve.

Branches of Communication.—This ganglion is connected with the lingual (gustatory) nerve by a few filaments which join it separately at its fore and back part. It also receives a branch from the chorda tympani, by which it communicates with the facial, and communicates with the sympathetic by filaments from the sympathetic plexus around the facial artery.

Branches of Distribution.—These are five or six in number: they arise from the lower part of the ganglion, and supply the mucous membrane of the mouth and

Wharton's duct, some being lost in the submaxillary gland. The branch of communication from the lingual to the fore part of the ganglion is by some regarded as a branch of distribution, by which filaments of the chorda tympani pass from the ganglion to the nerve, and by it are conveyed to the sublingual gland and the tongue.

Surface Marking.—It will be seen from the above description that the three terminal branches of the three divisions of the fifth nerve emerge from foramina in the bones of the skull and face on to the face: the terminal branch of the first division emerging through the supra-orbital foramen; that of the second through the infra-orbital foramen; and the third through the mental foramen. The supra-orbital foramen is situated at the junction of the internal and middle third of the supra-orbital arch between the internal and external angular processes. If a straight line is drawn from this point to the lower border of the inferior maxillary bone, so that it passes between the two bicuspid teeth in both jaws, it will pass over the infra-orbital and mental foramina, the former being situated about one centimetre (two-fifths of an inch) below the margin of the orbit, and the latter varying in position according to the age of the individual. In the adult it is midway between the upper and lower borders of the inferior maxillary bone; in the child it is nearer the lower border; and in the edentulous jaw of old age it is close to the upper margin.

Surgical Anatomy.—The fifth nerve may be affected in its entirety, or its sensory or motor root may be affected, or one of its primary main divisions. In injury to the sensory root there is anæsthesia of the whole of the side of the face on the side of the lesion, with the exception of the skin over the parotid gland; insensibility of the conjunctiva, followed by destructive inflammation of the cornea, partly from loss of trophic influence, and partly from the irritation produced by the presence of foreign bodies on it, which are not perceived by the patient, and therefore not expelled by the act of winking; dryness of the nose, loss to a considerable extent of the sense of taste, and diminished secretion of the lachrymal and salivary glands. In injury to the motor root there is impaired action of the lower jaw from paralysis of the muscles of mastication on the affected side.

The fifth nerve is often the seat of neuralgia, and each of the three divisions has been divided or a portion of the nerve excised for this affection. The supra-orbital nerve may be exposed by making an incision an inch and a half in length along the supra-orbital margin below the eyebrow, which is to be drawn upward, the centre of the incision corresponding to the supra-orbital notch. The skin and Orbicularis palpebrarum having been divided, the nerve can be easily found emerging from the notch and lying in some loose cellular tissue. It should be drawn up by a blunt hook and divided, or, what is better, a portion of it removed. The infra-orbital nerve has been divided at its exit by an incision on the cheek; or the floor of the orbit has been exposed, the infra-orbital canal opened up, and the anterior part of the nerve resected; or the whole nerve, together with Meckel's ganglion as far back as the foramen rotundum, has been removed. This latter operation, though undoubtedly a severe proceeding, appears to have been followed by the best results. The operation is performed as follows: The superior maxillary bone is first exposed by a T-shaped incision, one limb passing along the lower margin of the orbit, the other from the centre of this vertically down the cheek to the angle of the mouth. The nerve is then found, divided, and a piece of silk tied to it as a guide. A small trephine (one-half inch) is then applied to the bone below, but including, the infra-orbital foramen, and the antrum opened. The trephine is now applied to the posterior wall of the antrum, and the spheno-maxillary fossa exposed. The infra-orbital canal is now opened up from below by fine cutting-pliers or a chisel, and the nerve drawn down into the trephine hole, it being held on the stretch by means of the piece of silk; it is severed with fine curved scissors as near the foramen rotundum as possible, any branches coming off from the ganglion being also divided.[1] The inferior dental nerve has been divided at its exit from the foramen by an incision made through the mucous membrane where it is reflected from the alveolar process on to the lower lip; or a portion of the nerve has been resected by an incision on the cheek through the Masseter muscle, exposing the outer surface of the ramus of the jaw. A trephine was then applied over the position of the inferior dental foramen and the outer table removed, so as to expose the inferior dental canal. The nerve was dissected out of the portion of the canal exposed, and, having been divided after its exit from the mental foramen, it was by traction on the end exposed in the trephine hole, drawn out entire, and cut off as high up as possible.[1] The inferior dental nerve has also been divided by an incision within the mouth, the bony point guarding the inferior dental foramen forming the guide to the nerve. The buccal nerve may be divided by an incision through the mucous membrane of the mouth and the Buccinator just in front of the anterior border of the ramus of the lower jaw (Stimson).

The lingual (gustatory) nerve is occasionally divided with the view of relieving the pain in cancerous disease of the tongue. This may be done in that part of its course where it lies below and behind the last molar tooth. If a line is drawn from the middle of the crown of the last molar tooth to the angle of the jaw, it will cross the nerve, which lies about half an inch behind the tooth, parallel to the bulging alveolar ridge on the inner side of the body of the bone. If the knife is entered three-quarters of an inch behind and below the last molar tooth and carried

[1] Carnochan, *Amer. Journ. Med. Science*, 1858, p. 136.
[2] Mears, *Trans. Amer. Surg. Assoc.*, vol. ii. p. 469.

down to the bone, the nerve will be divided. Hilton divided it opposite the second molar tooth, where it is covered only by the mucous membrane, and Lucas pulls the tongue forward and over to the opposite side, when the nerve can be seen standing out as a firm cord under the mucous membrane by the side of the tongue, and can be easily seized with a sharp hook and divided or a portion excised. This is a simple enough operation on the cadaver, but when the disease is extensive and has extended to the floor of the mouth, as is generally the case when division of the nerve is required, the operation is not practicable.

Sixth Nerve (Figs. 384, 481).

The **Sixth** or **Abducent Nerve** supplies the External rectus muscle. Its *superficial origin* is by several filaments from the constricted part of the pyramid close to the pons, or from the lower border of the pons itself in the groove between this body and the medulla. Its *deep origin* is a little lower than the motor root of the fifth, and close to the median line, beneath the superior portion (above the auditory striæ) of the fasciculus teres on the floor of the fourth ventricle.

The nerve pierces the dura mater on the basilar surface of the sphenoid bone, runs through a notch immediately below the posterior clinoid process, and enters the cavernous sinus. It passes forward through the sinus, lying on the outer side of the internal carotid artery. It enters the orbit through the sphenoidal fissure, and lies above the ophthalmic vein, from which it is separated by a lamina of dura mater. It then passes between the two heads of the External rectus, and is distributed to that muscle on its ocular surface.

Branches of Communication.—It is joined by several filaments from the carotid and cavernous plexus, by one from Meckel's ganglion (Bock), and another from the ophthalmic nerve.

The above-mentioned nerve, as well as the third, fourth, and the ophthalmic division of the fifth, as they pass to the orbit, bear a certain relation to each other in the cavernous sinus, at the sphenoidal fissure, and in the cavity of the orbit, which will now be described.

In the *cavernous sinus* (Fig. 384) the third, fourth, and ophthalmic division of the fifth are placed on the outer wall of the sinus, in their numerical order both from above downward and from within outward. The sixth nerve lies at the outer side of the internal carotid artery. As these nerves pass forward to the sphenoidal fissure, the third and fifth nerves become divided into branches, and the sixth approaches the rest, so that their relative position becomes considerably changed.

In the *sphenoidal fissure* (Fig. 486) the fourth and the frontal and lachrymal divisions of the ophthalmic lie upon the same plane, the former being most

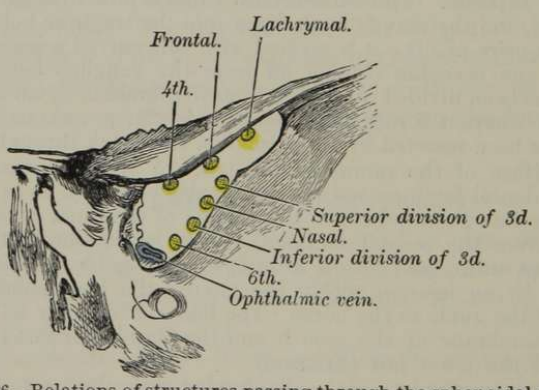

FIG. 486.—Relations of structures passing through the sphenoidal fissure.

internal, the latter external, and they enter the cavity of the orbit above the muscles. The remaining nerves enter the orbit between the two heads of the External rectus. The superior division of the third is the highest of these; beneath this lies the nasal branch of the ophthalmic; then the inferior division of the third; and the sixth lowest of all.

In the *orbit* the fourth and the frontal and lachrymal divisions of the ophthalmic lie on the same plane immediately beneath the periosteum, the fourth nerve being internal and resting on the Superior oblique, the frontal resting on the Levator palpebræ, and the lachrymal on the External rectus. Next in order comes the superior division of the third nerve, lying immediately beneath the Superior rectus, and then the nasal branch of the ophthalmic, crossing the optic nerve from the outer to the inner side of the orbit. Beneath these is found the optic nerve, surrounded in front by the ciliary nerves, and having the lenticular ganglion on its outer side, between it and the External rectus. Below the optic is the inferior division of the third and the sixth, which lies on the outer side of the orbit.

Surgical Anatomy.—The sixth nerve is more frequently involved in fractures of the base of the skull than any other of the cranial nerves. The result of paralysis of this nerve is internal or convergent squint. When injured so that its function is destroyed, there is, in addition to the paralysis of the External rectus muscle, often a certain amount of contraction of the pupil, because some of the sympathetic fibres to the radiating muscle of the iris pass along with this nerve.

Seventh Nerve (Figs. 487 and 489).

The **Seventh** or **Facial Nerve** (*portio dura*) is the motor nerve of all the muscles of expression in the face and of the Platysma and Buccinator, the muscles of the External ear, the posterior belly of the Digastric, and the Stylo-hyoid. Through its chorda tympani it supplies the Lingualis; by its tympanic branch the Stapedius. Its *superficial origin* is from the upper end of the medulla oblongata, in the groove between the olivary and restiform bodies. Its *deep origin* is from a nucleus in the pons, below the floor of the fourth ventricle, somewhat ventral and external to the nucleus of the sixth nerve.

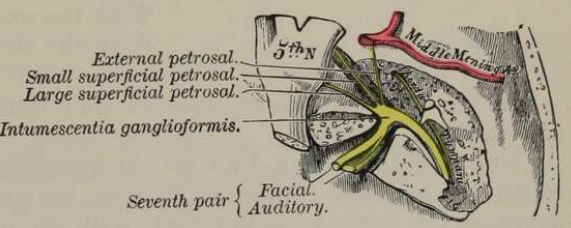

FIG. 487.—The course and connections of the facial nerve in the temporal bone.

The auditory nerve (*portio mollis*) lies to its outer side, and between the two is a small fasciculus (*portio inter duram et mollem* of Wrisberg, or *pars intermedia*), which arises from the medulla and joins the facial nerve in the internal auditory meatus. At its origin it is frequently connected with both the nerves between which it lies.

The facial nerve, firmer, rounder, and smaller than the auditory, passes forward and outward together with that nerve, and with it enters the internal auditory meatus. Within the meatus the facial nerve lies in a groove along the upper and anterior part of the auditory nerve. The pars intermedia is placed between the facial and auditory nerves in the internal auditory meatus; a few of its fibres frequently pass into the auditory nerve, while the remainder join the facial. At the bottom of the meatus it is connected to this nerve by one or two slender filaments.

At the bottom of the meatus the facial nerve enters the aqueductus Fallopii, and follows the serpentine course of that canal through the petrous portion of the temporal bone, from its commencement at the internal meatus to its termination at the stylo-mastoid foramen. It is at first directed outward toward the inner wall of the tympanum, where it forms a reddish gangliform swelling (*intumescentia ganglioformis*, or *geniculate ganglion*), and is joined by several nerves; then bending suddenly backward, it runs in the internal wall of the tympanum, above the fenestra ovalis, and at the back of that cavity passes vertically downward behind the tympanum to the stylo-mastoid foramen. On emerging from this aperture it runs forward in the substance of the parotid gland, crosses the external carotid artery, and divides behind the ramus of the lower jaw into two primary branches, *temporo-facial* and *cervico-facial*, from which numerous offsets are distributed over

the side of the head, face, and upper part of the neck, supplying the superficial muscles in these regions. As the primary branches and their offsets diverge from each other they present somewhat the appearance of a bird's claw; hence the name of *pes anserinus* is given to the divisions of the facial nerve in and near the parotid gland.

The branches of communication of the facial nerve may be thus arranged:

In the internal auditory meatus	With the auditory nerve.
In the aquæductus Fallopii	With Meckel's ganglion by the large superficial petrosal nerve.
	With the otic ganglion by the small superficial petrosal nerve.
	With the sympathetic on the middle meningeal by the external superficial petrosal nerve.
	With the auricular branch of the pneumogastric.
After its exit from the stylo-mastoid foramen	With the glosso-pharyngeal (Digastric).
	With the pneumogastric (Posterior auricular).
	With the carotid plexus (Stylo-hyoid).
	With the auricularis magnus (Posterior auricular).
	With the auriculo-temporal (Temporal).
On the face	With the three divisions of the fifth.

In the internal auditory meatus some minute filaments pass between the facial and auditory nerves.

Opposite the hiatus Fallopii the gangliform enlargement on the facial nerve communicates with Meckel's ganglion by means of the large superficial petrosal nerve, which forms its motor root; with the otic ganglion, by the small superficial petrosal nerve; and with the sympathetic filaments accompanying the middle meningeal artery, by the external petrosal (Bidder). From the gangliform enlargement, according to Arnold, a twig is sent back to the auditory nerve.

Just before leaving the aqueduct a twig joins the auricular branch of the pneumogastric nerve.

Just after its exit from the stylo-mastoid foramen it communicates with the following nerves by means of its respective branches: With the auricular branch of the pneumogastric and auricularis magnus of the cervical plexus, by the Posterior auricular branch; with the glosso-pharyngeal, by the digastric; with the carotid plexus, by the stylo-hyoid; and with the auriculo-temporal, by its temporal branches.

Branches of Distribution.

Within the aqueductus Fallopii	Tympanic.	
	Chorda Tympani.	
At its exit from the stylo-mastoid foramen	Posterior Auricular.	
	Digastric.	
	Stylo-hyoid.	
On the face	Temporo-facial	Temporal.
		Malar.
		Infra-orbital.
	Cervico-facial	Buccal.
		Supramaxillary.
		Inframaxillary.

The **tympanic branch** arises from the nerve opposite the pyramid; it passes through a small canal in the pyramid and supplies the Stapedius muscle.

The **chorda tympani** is given off from the facial as it passes vertically down-

ward at the back of the tympanum, about a quarter of an inch before its exit from the stylo-mastoid foramen. It passes from below upward and forward in a

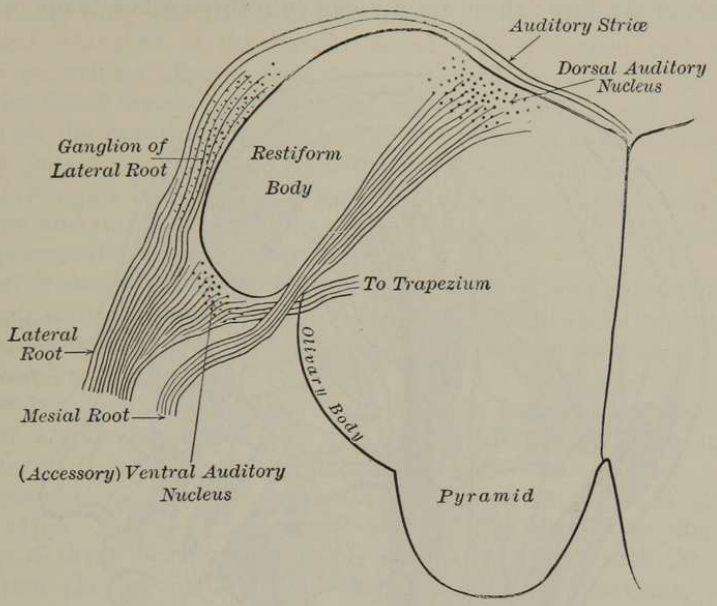

FIG. 488.—Mode of origin of auditory nerve (diagrammatic). [The section is dorso-ventrally, between pons and medulla.]

distinct canal, and enters the cavity of the tympanum through an aperture (*iter chordæ posterius*) on its posterior wall between the opening of the mastoid cells and the attachment of the membrana tympani, and becomes invested with mucous membrane. It passes forward through the cavity of the tympanum, between the handle of the malleus and vertical ramus of the incus, to its anterior inferior angle, and emerges from that cavity through a foramen at the inner end of the Glaserian fissure, which is called the *iter chordæ anterius*, or *canal of Huguier*. It then descends between the two Pterygoid muscles, meets the lingual nerve at an acute angle, and accompanies it to the submaxillary gland; part of it then joins the submaxillary ganglion; the rest is continued onward into the proper muscular fibres of the tongue—the Inferior lingualis muscle. A few of its fibres probably pass through the submaxillary ganglion to the sublingual gland. Before joining the lingual nerve it receives a small communicating branch from the otic ganglion.

The **Posterior auricular nerve** arises close to the stylo-mastoid foramen, and passes upward in front of the mastoid process, where it is joined by a filament from the auricular branch of the pneumogastric, and communicates with the mastoid branch of the auricularis magnus and with the small occipital. As it ascends between the meatus and mastoid process it divides into two branches. The *auricular branch* supplies the Retrahens aurem and the small muscles on the cranial surface of the pinna. The *occipital branch*, the larger, passes backward along the superior curved line of the occipital bone, and supplies the occipital portion of the Occipito-frontalis.

The **digastric branch** usually arises by a common trunk with the Stylo-hyoid branch: it divides into several filaments, which supply the posterior belly of the Digastric; one of these perforates that muscle to join the glosso-pharyngeal nerve.

The **stylo-hyoid** is a long slender branch, which passes inward, entering the Stylo-hyoid muscle about its middle; it communicates with the sympathetic filaments on the external carotid artery.

The **Temporo-facial**, the larger of the two terminal branches, passes upward and forward through the parotid glands, crosses the external carotid artery and

temporo-maxillary vein, and passes over the neck of the condyle of the jaw, being connected in this situation with the auriculo-temporal branch of the inferior maxillary nerve, and divides into branches which are distributed over the temple and upper part of the face; these are divided into three sets—temporal, malar, and infra-orbital.

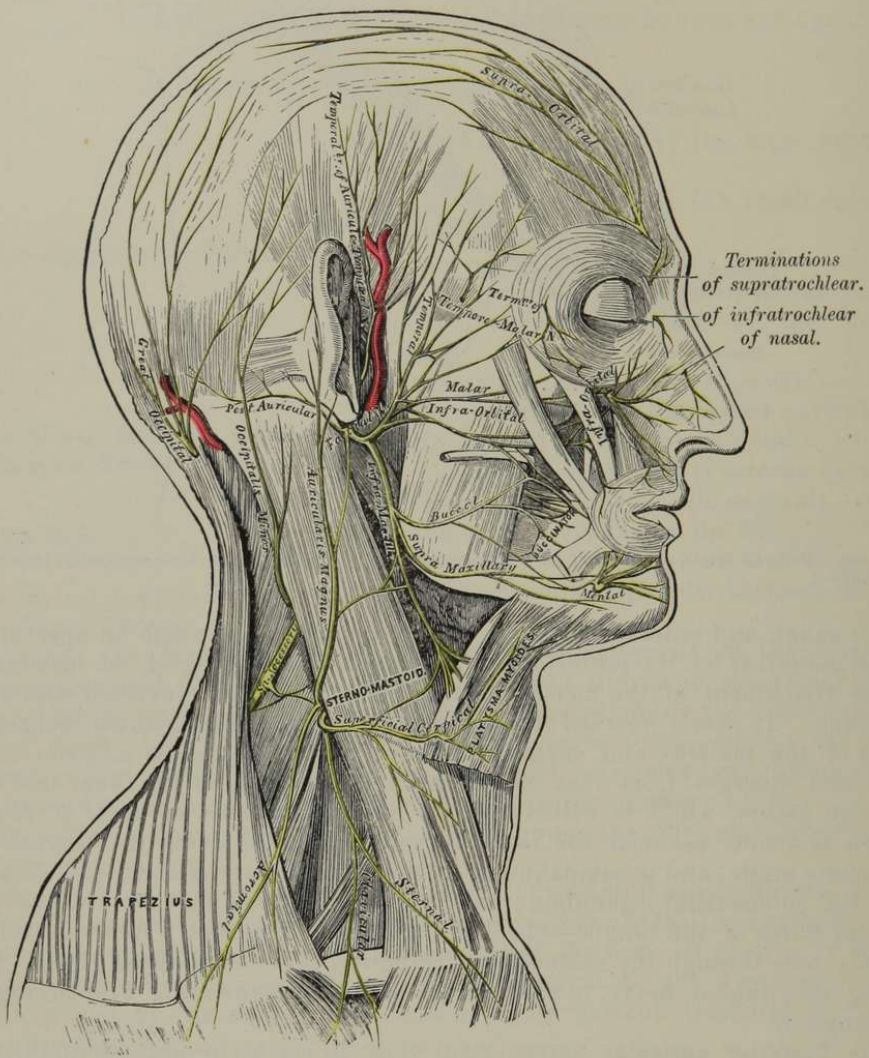

FIG. 489.—The nerves of the scalp, face, and side of the neck.

The *temporal branches* cross the zygoma to the temporal region, supplying the Attrahens and Attollens aurem muscles, and join with the temporal branch of the temporo-malar, a branch of the superior maxillary, and with the auriculo-temporal branch of the inferior maxillary. The more anterior branches supply the frontal portion of the Occipito-frontalis, the Orbicularis palpebrarum, and Corrugator supercilii muscles, joining with the supra-orbital and lachrymal branches of the ophthalmic.

The *malar branches* pass across the malar bone to the outer angle of the orbit, where they supply the Orbicularis palpebrarum muscle, joining with filaments from the lachrymal nerve; others supply the lower eyelid, joining with filaments of the malar branch (*subcutaneus malæ*) of the superior maxillary nerve.

The *infra-orbital*, of larger size than the rest, pass horizontally forward to be distributed between the lower margin of the orbit and the mouth. The *superficial branches* run beneath the skin and above the superficial muscles of the face, which they supply: some branches are distributed to the Pyramidalis nasi, joining at the

inner angle of the orbit with the infratrochlear and nasal branches of the ophthalmic. The *deep branches* pass beneath the Zygomatici and the Levator labii superioris, supplying them and the Levator anguli oris, and form a plexus (*infra-orbital*) by joining with the infra-orbital branch of the superior maxillary nerve and the buccal branches of the cervico-facial. This branch also supplies the Levator labii superioris alæque nasi and the small muscles of the nose.

The **Cervico-facial division of the facial nerve** passes obliquely downward and forward through the parotid gland, crossing the external carotid artery. In this situation it is joined by branches from the great auricular nerve. Opposite the angle of the lower jaw it divides into branches which are distributed on the lower half of the face and upper part of the neck. These may be divided into three sets —buccal, supramaxillary, and inframaxillary.

The *buccal branches* cross the Masseter muscle. They supply the Buccinator and Orbicularis oris, and join with the infra-orbital branches of the temporo-facial division of the nerve, and with filaments of the buccal branch of the inferior maxillary nerve.

The *supramaxillary* or *mandibular branches* pass forward beneath the Platysma and Depressor anguli oris, supplying the muscles of the lower lip and chin, and communicating with the mental branch of the inferior dental nerve.

The *inframaxillary* or *cervical branches* run forward beneath the Platysma, and form a series of arches across the side of the neck over the suprahyoid region. One of these branches descends vertically to join with the superficialis colli nerve from the cervical plexus; others supply the Platysma.

Surgical Anatomy.—The facial nerve is more frequently paralyzed than any of the other of the cranial nerves. The paralysis may depend either upon (1) central causes—*i. e.* blood-clots or intracranial tumors pressing on the nerve before its entrance into the internal auditory meatus. It is also one of the nerves involved in "bulbar paralysis." Or (2) it may be paralyzed in its passage through the petrous bone by damage due to middle-ear disease or by fractures of the base. Or (3) it may be affected at or after its exit from the stylo-mastoid foramen. This is commonly known as "Bell's paralysis." It may be due to exposure to cold or to injury of the nerve, either from accidental wounds of the face or during some surgical operation, as removal of parotid tumors, opening of abscesses, or operations on the lower jaw.

The facial nerve is at fault in cases of so-called "histrionic spasm," which consists in an almost constant and uncontrollable twitching of the muscles of the face. This twitching is sometimes so severe as to cause great discomfort and annoyance to the patient and to interfere with sleep, and for its relief the facial nerve has been stretched. The operation is performed by making an incision behind the ear from the root of the mastoid process to the angle of the jaw. The parotid is turned forward, and the dissection carried along the anterior border of the Sterno-mastoid muscle and mastoid process until the upper border of the posterior belly of the Digastric is found. The nerve is parallel to this on about a level of the middle of the mastoid process. When found, the nerve must be stretched by passing a blunt hook beneath it and pulling it forward and outward. Too great force must not be used, for fear of permanent injury to the nerve.

Eighth Nerve.

The **Eighth** or **Auditory Nerve** (*portio mollis*) is the special nerve of the sense of hearing, being distributed exclusively to the internal ear.

Its *superficial origin* is by two roots. One, the *mesial*, is from the groove between the olivary and restiform bodies at the lower border of the pons. The other, or *lateral* root, winds around the upper end of the restiform body, dorsally, and joins the former at its exit in the groove. This root is apparently continuous with the auditory striæ. The nerve, thus formed, lies external to the facial nerve. Each root has a *deep* origin: 1. The *mesial* root is traceable dorsally, through the substance of the medulla, lying close to the mesial or attached surface of the restiform body, to the *dorsal auditory nucleus*, which lies immediately ventral to a prominence, the *acoustic tubercle*, on the outer side of the inferior fovea on the floor of the fourth ventricle. 2. The fibres of the *lateral* root are traceable dorsally to *four* different sources: (*a*) To the accessory or *ventral auditory nucleus*, which lies close in front of the restiform body and between this root and the mesial; (*b*) to its own ganglion, or *ganglion of the lateral root*, situated among the fibres where they bend around the restiform body; (*c*) to the auditory striæ;

and (*d*) trapezium of the pons. The first-mentioned origin, however, gives most of the fibres (see Fig. 488). The auditory nerve passes forward across the posterior border of the middle peduncle of the cerebellum, in company with the facial nerve, from which it is partially separated by a small artery (auditory). It then enters the internal auditory meatus, with the facial nerve in a groove along its upper and fore part. At the bottom of the meatus it receives one or two filaments from the facial nerve, and then divides into two branches, *cochlear* and *vestibular*. The auditory nerve is soft in texture (hence the name *portio mollis*), and is destitute of neurilemma. The distribution of the auditory nerve in the internal ear will be found described along with the anatomy of that organ in a subsequent page.

Surgical Anatomy.—The auditory nerve is frequently injured, together with the facial nerve, in fractures of the middle fossa of the base of the skull implicating the internal auditory meatus. The nerve may be either torn across, producing permanent deafness, or it may be bruised or pressed upon by extravasated blood or inflammatory exudation, when the deafness will in all probability be temporary. The nerve may also be injured by violent blows on the head without fracture, and deafness may arise from loud explosions from dynamite, etc., probably from some lesion of this nerve, which is more liable to be injured than the other cranial nerves on account of its structure. The test that the nerve is destroyed and that the deafness is not due to some lesion of the auditory apparatus is obtained by placing a vibrating tuning-fork on the head. The vibrations will be heard in cases where the auditory apparatus is at fault, but not in cases of destruction of the auditory nerve.

Ninth Pair (Figs. 490, 491, 492).

The **Ninth** or **Glosso-pharyngeal Nerve** is distributed, as its name implies, to the tongue and pharynx, being the nerve of sensation to the mucous membrane of the pharynx, fauces, and tonsil, and a special nerve of taste to all the parts of the tongue to which it is distributed. Its *superficial origin* is by three or four filaments closely connected together, from the upper part of the medulla oblongata, in the groove between the olivary and the restiform body.

Its *deep origin* may be traced through the fasciculi which lie between the lateral and posterior areas of the medulla to a nucleus of gray matter in the lower part of the floor of the fourth ventricle, beneath the inferior fovea, above the nucleus of the pneumogastric. From its superficial origin it passes outward across the flocculus, and leaves the skull at the central part of the jugular foramen, in a separate sheath of the dura mater, external to and in front of the pneumogastric and spinal accessory nerves (Fig. 386). In its passage through the jugular foramen it grooves the lower border of the petrous portion of the temporal bone, and at its exit from the skull passes forward between the jugular vein and internal carotid artery, and descends in front of the latter vessel, and beneath the styloid process and the muscles connected with it, to the lower border of the Stylo-pharyngeus. The nerve now curves inward, forming an arch on the side of the neck, and lying upon the Stylo-pharyngeus and Middle constrictor of the pharynx, above the superior laryngeal nerve. It then passes beneath the Hyoglossus, and is finally distributed to the mucous membrane of the fauces and base of the tongue, and the mucous glands of the mouth and tonsil.

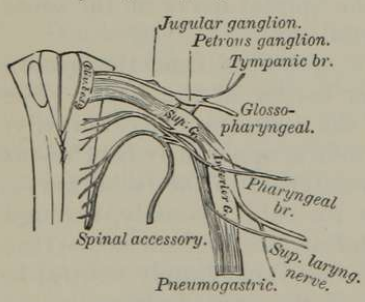

FIG. 490.—9th, 10th, and 11th nerves, their origin, ganglia, and communications.

In passing through the jugular foramen the nerve presents, in succession, two gangliform enlargements. The superior, the smaller, is called the *jugular ganglion;* the inferior and larger, the *petrous ganglion*, or the *ganglion of Andersch.*

The **superior, or jugular, ganglion** is situated in the upper part of the groove in which the nerve is lodged during its passage through the jugular foramen. It is of very small size, and involves only the lower part of the trunk of the nerve. It is usually regarded as a segmentation from the lower ganglion.

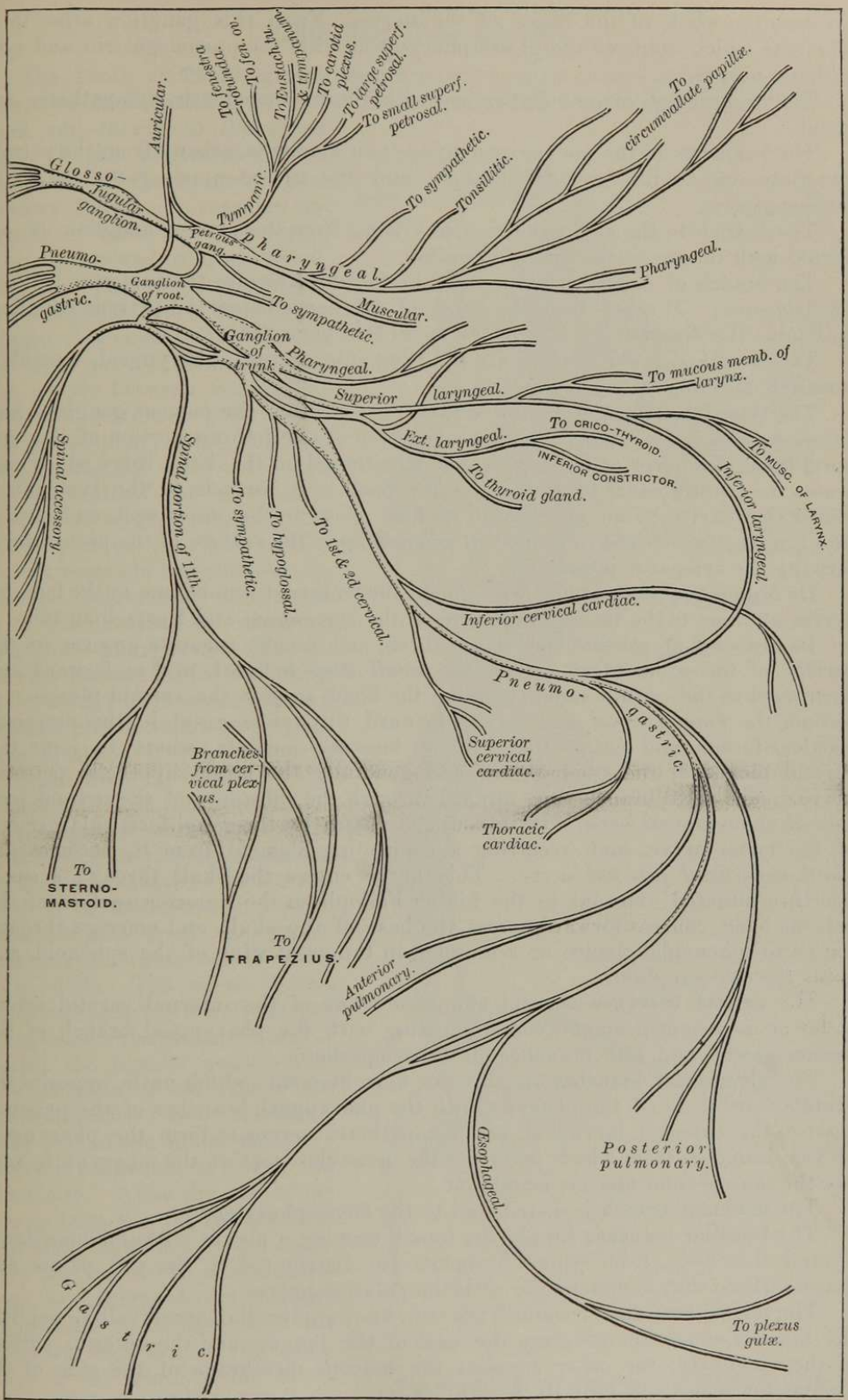

FIG. 491.—Plan of the glosso-pharyngeal, pneumogastric, and spinal accessory nerves. (After Flower.)

The **inferior, or petrous, ganglion** is situated in a depression in the lower border of the petrous portion of the temporal bone; it is larger than the former and

involves the whole of the fibres of the nerve. From this ganglion arise those filaments which connect the glosso-pharyngeal with the pneumogastric and sympathetic nerves.

The *branches of communication* are with the pneumogastric, sympathetic, and facial.

The branches to the pneumogastric are two filaments, arising from the petrous ganglion, one to its auricular branch, and one to the upper ganglion of the pneumogastric.

The branch to the sympathetic, also arising from the petrous ganglion, is connected with the superior cervical ganglion.

The branch of communication with the facial perforates the posterior belly of the Digastric. It arises from the trunk of the nerve below the petrous ganglion, and joins the digastric branch of the facial (see page 813).

The *branches of distribution* are the tympanic, carotid, pharyngeal, muscular, tonsillar, and lingual.

The **tympanic branch** (*Jacobson's nerve*) arises from the petrous ganglion, and enters a small bony canal in the lower surface of the petrous portion of the temporal bone, the lower opening of which is situated on the bony ridge which separates the carotid canal from the jugular fossa. It ascends to the tympanum, enters that cavity by an aperture in its floor close to the inner wall, and divides into branches which are contained in grooves upon the surface of the promontory, forming the tympanic plexus.

Its *branches of distribution* are—one to the fenestra rotunda, one to the fenestra ovalis, and one to the lining membrane of the tympanum and Eustachian tube

Its *branches of communication* are three, and occupy separate grooves on the surface of the promontory. One, the *small deep petrosal*, arches forward and downward to the carotid canal (piercing the bone) to join the carotid plexus. A second, the *long petrosal nerve*, runs forward through a canal in the processus cochleariformis and enters the foramen lacerum medium, where it joins the carotid plexus of the sympathetic, and generally the large superficial petrosal nerve. The third branch runs upward through the substance of the petrous portion of the temporal bone. In its course it passes by the gangliform enlargement of the facial nerve, and, receiving a connecting filament from it, becomes the *small superficial petrosal nerve*. This nerve enters the skull through a small aperture situated external to the hiatus Fallopii on the anterior surface of the petrous bone, courses forward across the base of the skull, and emerges through the petro-sphenoidal fissure or a foramen in the great wing of the sphenoid, and joins the otic ganglion.

The **carotid branches** descend along the trunk of the internal carotid artery as far as its commencement, communicating with the pharyngeal branch of the pneumogastric and with branches of the sympathetic.

The **pharyngeal branches** are three or four filaments which unite opposite the Middle constrictor of the pharynx with the pharyngeal branches of the pneumogastric, the external laryngeal, and sympathetic nerves to form the pharyngeal plexus, branches from which perforate the muscular coat of the pharynx to supply the muscles and mucous membrane.

The **muscular branch** is distributed to the Stylo-pharyngeus.

The **tonsillar branches** supply the tonsil, forming a plexus (*circulus tonsillaris*) around this body, from which branches are distributed to the soft palate and fauces, where they communicate with the palatine nerves.

The **lingual branches** (*terminal*) are two: one supplies the circumvallate papillæ, the mucous membrane covering the base of the tongue, and the anterior surface of the epiglottis; the other supplies the mucous membrane of the side of the tongue for about one-half its length.

Tenth Pair (Figs. 491, 492).

The **Tenth** or **Pneumogastric Nerve** (*nervus vagus* or *par vagum*) has a more extensive distribution than any of the other cranial nerves, passing through the neck and thorax to the upper part of the abdomen. It is composed of both motor and sensory fibres. It supplies the organs of voice and respiration with motor and sensory fibres, and the pharynx, œsophagus, stomach, and heart with motor fibres. Its *superficial origin* is by eight or ten filaments from the groove between the olivary and the restiform body below the glosso-pharyngeal; its *deep origin* may be traced through the fasciculi of the medulla to its nucleus of gray matter in the lower part of the floor of the fourth ventricle beneath the ala cinerea below and continuous with the nucleus of origin of the glosso-pharyngeal. The filaments become united and form a flat cord, which passes outward beneath the flocculus to the jugular foramen, through which it emerges from the cranium. In passing through this opening the pneumogastric accompanies the spinal accessory, being contained in the same sheath of dura mater with it, a membranous septum separating it from the glosso-pharyngeal, which lies in front (Fig. 386). The nerve in this situation presents a well-marked ganglionic enlargement, which is called the *jugular ganglion*, or the *ganglion of the root of the pneumogastric:* to it the accessory part of the spinal accessory nerve is connected by one or two filaments. After the exit of the nerve from the jugular foramen the nerve is joined by the accessory portion of the spinal accessory, and enlarged into a second gangliform swelling, called the *ganglion inferius*, or the *ganglion of the trunk of the nerve*, over which the fibres of the spinal accessory pass unchanged, being principally distributed to the pharyngeal and superior laryngeal branches of the vagus; but some of the filaments from it are continued into the trunk of

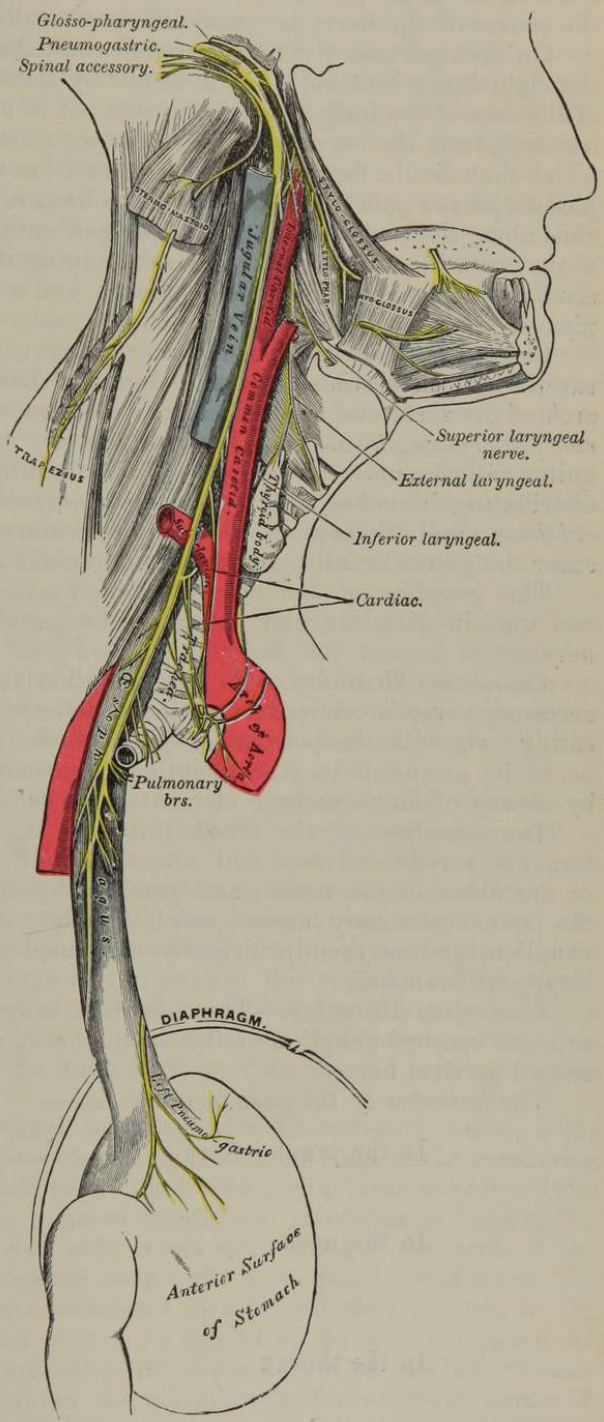

FIG. 492.—Course and distribution of the ninth, tenth, and eleventh nerves.

the vagus below the ganglion, to be distributed with the recurrent laryngeal nerve, and probably also with the cardiac nerves. The nerve passes vertically down the neck within the sheath of the carotid vessels lying between the internal carotid artery and internal jugular vein as far as the thyroid cartilage, and then between the same vein and the common carotid to the root of the neck. Here the course of the nerve becomes different on the two sides of the body.

On the *right side* the nerve passes across the subclavian artery between it and the right innominate vein, and descends by the side of the trachea to the back part of the root of the lung, where it spreads out in a plexiform network (*posterior pulmonary*), from the lower part of which two cords descend upon the œsophagus, on which they divide, forming, with branches from the opposite nerve, the œsophageal plexus (*plexus gulæ*); below, these branches are collected into a single cord, which runs along the back part of the œsophagus, enters the abdomen, and is distributed to the posterior surface of the stomach, joining the left side of the solar plexus, and sending filaments to the splenic plexus and a considerable branch to the cœliac plexus.

On the *left side* the pneumogastric nerve enters the chest between the left carotid and subclavian arteries, behind the left innominate vein. It crosses the arch of the aorta and descends behind the root of the left lung, forming the *posterior pulmonary plexus*, and along the anterior surface of the œsophagus, where it unites with the nerve of the right side in forming the plexus gulæ, to the stomach, distributing branches over its anterior surface, some extending over the great *cul-de-sac*, and others along the lesser curvature. Filaments from these branches enter the gastro-hepatic omentum and join the hepatic plexus.

The *ganglion of the root* is of a grayish color, circular in form, about two lines in diameter, and resembles the ganglion on the large root of the fifth nerve.

Connecting Branches.—To this ganglion the accessory portion of the spinal accessory nerve is connected by several delicate filaments; it also has a communicating twig with the petrous ganglion of the glosso-pharyngeal, with the facial nerve by means of its (the ganglion's) auricular branch, and with sympathetic by means of an ascending filament from the superior cervical ganglion.

The *ganglion of the trunk* (inferior) is a plexiform cord, cylindrical in form, of a reddish color, and about an inch in length; it involves the whole of the fibres of the nerve, and passing through it is the accessory portion of the spinal accessory nerve, which blends with the pneumogastric below the ganglion, and is then principally continued into its pharyngeal and superior laryngeal branches.

Connecting Branches.—This ganglion is connected with the hypoglossal, the superior cervical ganglion of the sympathetic, and the loop between the first and second cervical nerves.

The *branches of the pneumogastric* are—

In the jugular fossa . . .	Meningeal. Auricular.
In the neck	Pharyngeal. Superior laryngeal. Recurrent laryngeal. Cervical cardiac.
In the thorax	Thoracic cardiac. Anterior pulmonary. Posterior pulmonary. Œsophageal.
In the abdomen	Gastric.

The **meningeal branch** is a recurrent branch given off from the ganglion of the root in the jugular foramen. It passes backward, and is distributed to the dura mater covering the posterior fossa of the base of the skull.

The **auricular branch** (*Arnold's*) arises from the ganglion of the root, and is joined soon after its origin by a filament from the petrous ganglion of the glosso-pharyngeal; it passes outward behind the jugular vein, and enters a small canal on the outer wall of the jugular fossa. Traversing the substance of the temporal bone, it crosses the aqueductus Fallopii about two lines above its termination at the stylo-mastoid foramen; here it gives off an ascending branch, which joins the facial: the continuation of the nerve reaches the surface by passing through the auricular fissure between the mastoid process and the external auditory meatus, and divides into two branches, one of which communicates with the posterior auricular nerve, while the other supplies the integument at the back part of the pinna and the posterior part of the external auditory meatus.

The **pharyngeal branch,** the principal motor nerve of the pharynx, arises from the upper part of the inferior ganglion of the pneumogastric. It consists principally of filaments from the accessory portion of the spinal accessory: it passes across the internal carotid artery (in front or behind) to the upper border of the Middle constrictor, where it divides into numerous filaments, which join with those from the glosso-pharyngeal, superior laryngeal (its external branch), and sympathetic, to form the pharyngeal plexus, from which branches are distributed to the muscles and mucous membrane of the pharynx and the muscles of the soft palate. From the pharyngeal plexus a minute filament (*lingual branch*) is given off, which descends and joins the hypoglossal nerve as it winds round the occipital artery.

The **superior laryngeal** is the nerve of sensation to the larynx. It is larger than the preceding, and arises from the middle of the inferior ganglion of the pneumogastric. It consists principally of filaments from the accessory portion of the spinal accessory. In its course it receives a branch from the superior cervical ganglion of the sympathetic. It descends by the side of the pharynx behind the internal carotid, where it divides into two branches, the external and internal laryngeal.

The *external laryngeal branch*, the smaller, descends by the side of the larynx, beneath the Sterno-thyroid, to supply the Crico-thyroid muscle. It gives branches to the pharyngeal plexus and the Inferior constrictor, and communicates with the superior cardiac nerve, behind the common carotid.

The *internal laryngeal branch* descends to the opening in the thyro-hyoid membrane, through which it passes with the superior laryngeal artery, and is distributed to the mucous membrane of the larynx. A small branch communicates with the recurrent laryngeal nerve. The branches to the mucous membrane are distributed, some in front to the epiglottis, the base of the tongue, and the epiglottidean glands; while others pass backward, in the aryteno-epiglottidean fold, to supply the mucous membrane surrounding the superior orifice of the larynx, as well as the membrane which lines the cavity of the larynx as low down as the vocal cord. The filament which joins with the recurrent laryngeal descends beneath the mucous membrane on the inner surface of the thyroid cartilage, where the two nerves become united.

The **inferior** or **recurrent laryngeal,** so called from its reflected course, is the motor nerve of the larynx. It arises on the right side, in front of the subclavian artery; winds from before backward round that vessel, and ascends obliquely to the side of the trachea, behind the common carotid and behind or in front of the inferior thyroid artery. On the left side it arises in front of the arch of the aorta, and winds from before backward round the aorta just beyond where the remains of the ductus arteriosus are connected with it, and then ascends to the side of the trachea. The nerves on both sides ascend in the groove between the trachea and œsophagus, and, passing under the lower border of the Inferior constrictor muscle, enter the larynx behind the articulation of the inferior cornu of the thyroid cartilage with the cricoid, being distributed to all the muscles of the larynx, except the Crico-thyroid. It communicates with the Superior laryngeal nerve and sends twigs to the mucous membrane below the true cords. The recurrent laryngeal, as it winds round the subclavian artery and aorta, gives off several cardiac filaments, which unite with the cardiac branches from the pneu-

mogastric and sympathetic. As it ascends in the neck it gives off œsophageal branches, more numerous on the left than on the right side, which supply the mucous membrane and muscular coat of the œsophagus; tracheal branches to the mucous membrane and muscular fibres of the trachea: and some pharyngeal filaments to the Inferior constrictor of the pharynx.

The **cervical cardiac branches,** two or three in number, arise from the pneumogastric, at the upper and lower part of the neck.

The *superior branches* are small, and communicate with the cardiac branches of the sympathetic. They can be traced to the great or deep cardiac plexus.

The *inferior branches*, one on each side, arise at the lower part of the neck, just above the first rib. On the right side this branch passes in front or by the side of the arteria innominata, and communicates with one of the cardiac nerves proceeding to the great or deep cardiac plexus. On the left side it passes in front of the arch of the aorta and joins the superficial cardiac plexus.

The **thoracic cardiac branches,** on the right side, arise from the trunk of the pneumogastric as it lies by the side of the trachea, and from its recurrent laryngeal branch, but on the left side from the recurrent nerve only; passing inward, they terminate in the deep cardiac plexus.

The **anterior pulmonary branches,** two or three in number, and of small size, are distributed on the anterior aspect of the root of the lungs. They join with filaments from the sympathetic, and form the *anterior pulmonary plexus.*

The **posterior pulmonary branches,** more numerous and larger than the anterior, are distributed on the posterior aspect of the root of the lung, some filaments going to the *pericardium;* they are joined by filaments from the third and fourth (sometimes also first and second) thoracic ganglia of the sympathetic, and form the *posterior pulmonary plexus.* Branches from both plexuses accompany the ramification of the air-tubes through the substance of the lungs.

The **œsophageal branches** are given off from the pneumogastric both above and below the pulmonary branches. The lower are more numerous and larger than the upper. They form, together with branches from the opposite nerve, the *œsophageal plexus*, or *plexus gulæ*, which also supplies the *pericardium.*

The **gastric branches** are the terminal filaments of the pneumogastric nerve. The nerve on the right side is distributed to the posterior surface of the stomach, and joins the left side of the cœliac plexus and the splenic plexus. The nerve on the left side is distributed over the anterior surface of the stomach, some filaments passing across the great *cul-de-sac*, and others along the lesser curvature. They unite with branches of the right nerve and with the sympathetic, some filaments passing through the lesser omentum to the hepatic plexus.

Surgical Anatomy.—The laryngeal nerves are of considerable importance in considering some of the morbid conditions of the larynx. When the peripheral terminations of the superior laryngeal nerve are irritated by some foreign body passing over them, reflex spasm of the glottis is the result. When the trunk of this same nerve is pressed upon by, for instance, a goitre or an aneurism of the upper part of the carotid, we have a peculiar dry, brassy cough. When the nerve is paralyzed, we have anæsthesia of the mucous membrane of the larynx, so that foreign bodies can readily enter the cavity, and, in consequence of its supplying the crico-thyroid muscle, the vocal cords cannot be made tense, and the voice is deep and hoarse. Paralysis of the superior laryngeal nerves may be the result of bulbar paralysis, may be a sequel to diphtheria, when both nerves are usually involved, or it may, though less commonly, be caused by the pressure of tumors or aneurisms, when the paralysis is generally unilateral. Irritation of the inferior laryngeal nerves produces spasm of the muscles of the larynx. When both these recurrent nerves are paralyzed, the vocal cords are motionless, in the so-called "cadaveric position"—that is to say, in the position in which they are found in ordinary tranquil respiration—neither closed as in phonation, nor open as in deep inspiratory efforts. When one recurrent nerve is paralyzed, the cord of the same side is motionless, while the opposite one crosses the middle line to accommodate itself to the affected one; hence phonation is present, but the voice is altered and weak in timbre. The recurrent laryngeal nerves may be paralyzed in bulbar paralysis or after diphtheria, when it usually affects both sides; or they may be affected by the pressure of aneurisms of the aorta, innominate or subclavian arteries; by mediastinal tumors; by bronchocele; or by cancer of the upper part of the œsophagus, when the paralysis is often unilateral.

Eleventh Pair (Figs. 491, 492).

The **Eleventh** or **Spinal Accessory Nerve** consists of two parts—one the accessory part to the vagus, and the other the spinal portion.

The **accessory part** is the smaller of the two. Its *superficial origin* is by four or five delicate filaments from the side of the medulla, below the roots of the vagus. Its *deep origin* may be traced to a nucleus of gray matter in the medulla, just dorsal to the lower third of the olive and dorso-lateral to the hypoglossal nucleus. It passes outward to the jugular foramen, where it joins with the spinal portion, and is connected with the upper ganglion of the vagus by one or two filaments. It then separates from the spinal portion, passes through the foramen, and is continued over but adherent to the surface of the inferior ganglion, or ganglion of the trunk of the vagus, to be distributed principally to the pharyngeal and superior laryngeal branches of the pneumogastric. Through the pharyngeal branch it probably supplies the muscles of the soft palate (see page 425). Some few filaments from it are continued into the trunk of the vagus below the ganglion, to be distributed with the recurrent laryngeal nerve and probably also with the cardiac nerves.

The **spinal portion** is firm in texture. Its *superficial origin* is by several filaments from the lateral tract of the cord, as low down as the sixth cervical nerve. Its *deep origin* may be traced to the intermedio-lateral tract (lateral horn) of the gray matter of the cord, where it forms a column of cells reaching, above, to the lower end of the nucleus of the accessory part of the nerve. This portion of the nerve ascends between the ligamentum denticulatum and the posterior roots of the spinal nerves, enters the skull through the foramen magnum, and is then directed outward to the jugular foramen, through which it passes, lying in the same sheath as the pneumogastric, but separated from it by a fold of the arachnoid. In the jugular foramen it joins with the accessory portion. At its exit from the jugular foramen it passes backward, either in front of or behind the internal jugular vein, and descends obliquely behind the Digastric and Stylo-hyoid muscles to the upper part of the Sterno-mastoid. It pierces that muscle, and passes obliquely across the occipital triangle, to terminate in the deep surface of the Trapezius. This nerve gives several branches to the Sterno-mastoid during its passage through it, and joins in its substance with branches from the second cervical, which supply the muscle. In the occipital triangle it joins with the second and third cervical nerves and assists in the formation of the cervical plexus. Beneath the Trapezius it joins with the third and fourth cervical nerves to form a sort of plexus, from which fibres are distributed to the muscle.

Surgical Anatomy.—In cases of spasmodic torticollis in which all palliative treatment has failed, division or excision of a portion of the spinal accessory nerve has been resorted to. This may be done either along the anterior or posterior border of the Sterno-mastoid muscle. The former operation is performed by making an incision from the apex of the mastoid process, three inches in length, along the anterior border of the Sterno-mastoid muscle. The anterior border of the muscle is defined and pulled backward, so as to stretch the nerve, which is then to be sought for beneath the Digastric muscle, about two inches below the apex of the mastoid process. The other operation consists in making an incision along the posterior border of the muscle, so that the centre of the incision corresponds to the middle of this border of the muscle. The superficial structures having been divided and the border of the muscle defined, the nerve is to be sought for as it emerges from the muscle to cross the occipital triangle. When found, it is to be traced upward through the muscle, and a portion of it excised above the point where it gives off its branches to the Sterno-mastoid. In this operation one of the descending branches of the superficial cervical plexus is liable to be mistaken for the nerve.

Twelfth Pair (Fig. 493).

The **Twelfth** or **Hypoglossal Nerve** is the motor nerve of the tongue. Its *superficial origin* is by several filaments, from ten to fifteen in number, from the groove between the pyramid and olivary body, in a continuous line with the anterior roots of the spinal nerves. Its *deep origin* can be traced to a nucleus of gray matter lying under the lower part of the fasciculus teres (trigonum hypo-

glossi) in the floor of the fourth ventricle, and extending downward into the closed portion of the medulla. The filaments of this nerve are collected into two bundles which perforate the dura mater separately, opposite the anterior condyloid foramen, and unite together after their passage through it. In those cases in which the anterior condyloid foramen in the occipital bone is double these two portions of the nerve are separated by the small piece of bone which divides the foramen. The nerve descends almost vertically to a point corresponding with the angle of the jaw. It is at first deeply seated beneath the internal carotid artery and internal jugular vein, and intimately connected with the pneumogastric nerve; it then passes forward between the vein and artery, and lower down in the neck becomes superficial below the Digastric muscle. The nerve then loops round the occipital artery, the sterno-mastoid branch of which hooks over the nerve, and crosses the external carotid and its lingual branch below the tendon of the Digastric muscle. It then passes beneath the tendon of the digastric, the stylo-hyoid, and the Mylo-hyoid muscles, lying on the Hyo-glossus, accompanied by the ranine vein, and communicates at the anterior border of the latter muscle with the lingual (gustatory) nerve; it is then continued forward in the fibres of the Genio-hyo-glossus muscle as far as the tip of the tongue, distributing branches to its substance.

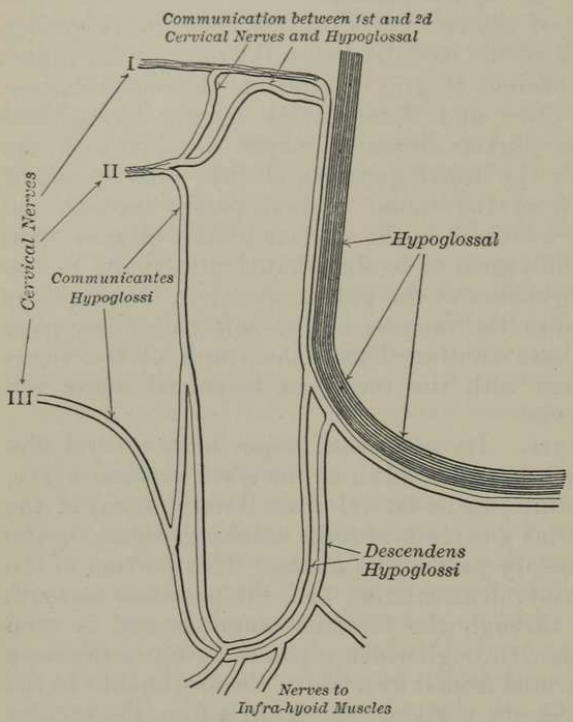

FIG. 493.—Plan of communicantes and descendens hypoglossi nerves.

The *branches of communication* are—with the

Pneumogastric.	First and Second Cervical Nerves.
Sympathetic.	Lingual (gustatory).

The first mentioned takes place close to the exit of the nerve from the skull, numerous filaments passing between the hypoglossal and lower ganglion of the pneumogastric through the mass of connective tissue which here unites the two nerves. It also communicates with the pharyngeal plexus by a minute filament as it winds round the occipital artery (*lingual branch*, see page 821).

The communication with the sympathetic takes place opposite the atlas by branches derived from the superior cervical ganglion, and in the same situation the nerve is joined by filaments derived from the loop connecting the first two cervical nerves.

The communication with the lingual (gustatory) takes place near the anterior border of the Hyo-glossus muscle by numerous filaments which ascend upon it.

The *branches of distribution* are—the

Meningeal.	Thyro-hyoid.
Descendens hypoglossi.	Muscular.

Meningeal Branches.—As the hypoglossal nerve passes through the anterior

condyloid foramen it gives off, according to Luschka, several filaments (*recurrent*) to the dura mater in the posterior fossa of the base base of the skull.

The **descendens hypoglossi** is a long slender branch which quits the hypoglossal where it turns round the occipital artery. It descends obliquely across the sheath of the carotid vessels, and joins the communicating branches from the second and third cervical nerves, just below the middle of the neck, to form a loop. From the convexity of this loop branches pass forward to supply the Sterno-hyoid, Sterno-thyroid, and both bellies of the Omo-hyoid. According to Arnold, another filament descends in front of the vessels into the chest and joins the cardiac and phrenic nerves. The descendens hypoglossi is occasionally contained in the sheath of the carotid vessels, being sometimes placed over, and sometimes beneath, the internal

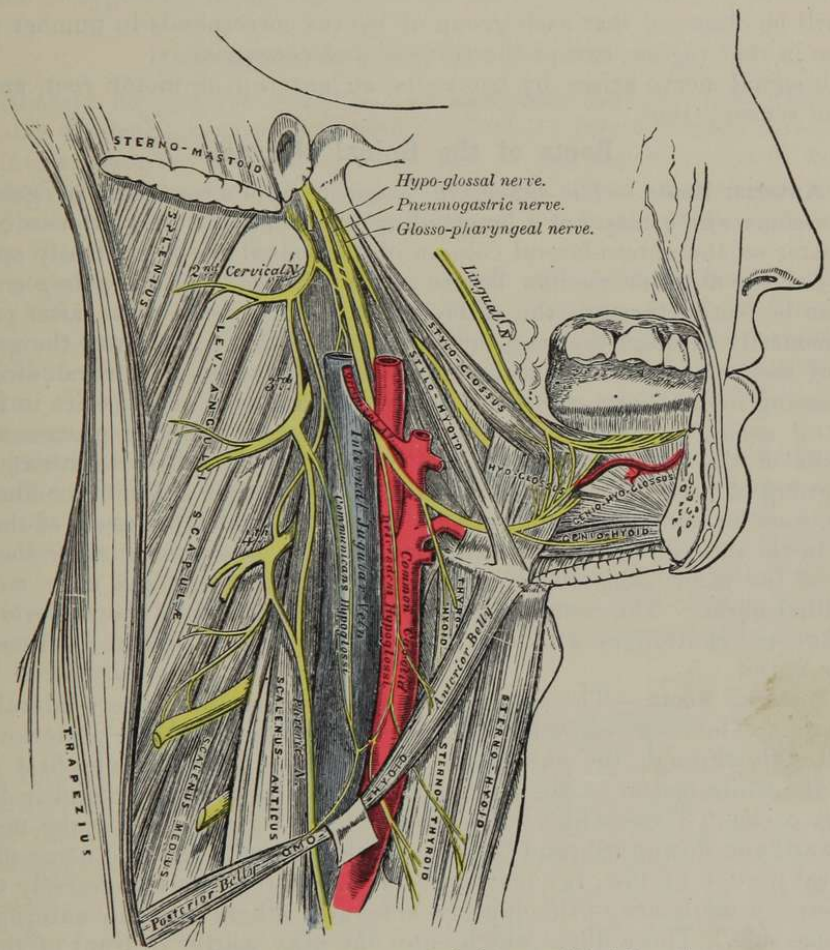

FIG. 494.—Hypoglossal nerve, cervical plexus, and their branches.

jugular vein. The fibres of this nerve are chiefly derived from the first and second cervical nerves by means of the filaments of communication already mentioned.

The **thyro-hyoid** is a small branch arising from the hypoglossal near the posterior border of the Hyo-glossus; it passes obliquely across the great cornu of the hyoid bone and supplies the Thyro-hyoid muscle.

The **muscular branches** are distributed to the Stylo-glossus, Hyo-glossus, Genio-hyoid, and Genio-hyo-glossus muscles. At the under surface of the tongue numerous slender branches pass upward into the substance of the organ to supply its muscular structure.

Surgical Anatomy.—The hypoglossal nerve is an important guide in the operation of ligature of the lingual artery (see page 553).

THE SPINAL NERVES.

The **spinal nerves** are so called because they take their origin from the spinal cord, and are transmitted through the intervertebral foramina on either side of the spinal column. There are thirty-one pairs of spinal nerves, which are arranged into the following groups, corresponding to the region of the spine through which they pass:

Cervical	8 pairs.
Dorsal	12 "
Lumbar	5 "
Sacral	5 "
Coccygeal	1 pair.

It will be observed that each group of nerves corresponds in number with the vertebræ in that region, except the cervical and coccygeal.

Each spinal nerve arises by two roots, an anterior or motor root, and a posterior or sensory root.

Roots of the Spinal Nerves.

The Anterior Roots.—The *superficial origin* is from a somewhat irregular series of depressions which map out a longitudinal area opposite the anterior cornu of gray matter on the antero-lateral column of the spinal cord, gradually approaching toward the anterior median fissure as they descend. To the *deep origin* the fibres can be traced through the antero-lateral column; the roots, after penetrating horizontally through the longitudinal fibres of this tract, enter the gray substance of the anterior cornu, where their fibrils diverge in several directions: some, passing *inward*, are continued across the anterior commissure in front of the central canal, to become continuous with the axis-cylinder processes of the large cells of the anterior cornu of the opposite side; others terminate in the mesial group of cells of the anterior column of the same side; other fibrils pass *outward*, some to become continuous with the axis-cylinder processes of the group of cells in the lateral part of the anterior column; and others enter the lateral column of the same side, where, turning upward, they pursue their course as longitudinal fibres. The remaining fibrils pass *backward* to the posterior horn, where they are continuous with the axis-cylinders of the cells at the base of the posterior cornu.

The Posterior Roots.—The *superficial origin* is from the postero-lateral fissure of the cord. The *deep origin* is from the gray substance of the posterior cornu, either directly through the substantia gelatinosa, or indirectly, by first passing through the white matter of the posterior column and winding round in front of the caput cornu. Those which enter the gray matter at once for the most part turn upward and downward, and become continuous with the fine nerve-plexus in the central portion of the gray matter; some few fibres pass transversely through the posterior commissure to the opposite side, and others into the anterior cornu of the same side. Those fibres which enter the gray matter in front of the caput cornu reach the posterior vesicular column (Clark's column) and blend with it, a few fibres passing through it, to become longitudinal in the posterior column of the cord.

The *anterior roots* are smaller than the posterior, devoid of ganglionic enlargement, and their component fibrils are collected into two bundles near the intervertebral foramina.

The *posterior roots* of the nerves are larger, but the individual filaments are finer and more delicate than those of the anterior. As their component fibrils pass outward, toward the aperture in the dura mater, they coalesce into two bundles, receive a tubular sheath from that membrane, and enter the ganglion which is developed upon each root.

The posterior root of the first cervical nerve forms an exception to these characters. It is smaller than the anterior, has frequently no ganglion developed upon it, and when the ganglion exists it is often situated within the dura mater.

Ganglia of the Spinal Nerves.

A **ganglion** is developed upon the posterior root of each of the spinal nerves. These ganglia are of an oval form and of a reddish color; they bear a proportion in size to the nerves upon which they are formed, and are placed in the intervertebral foramina, external to the point where the nerves perforate the dura mater. Each ganglion is bifid internally, where it is joined by the two bundles of the posterior root, the two portions being united into a single mass externally. The ganglion upon the first and second cervical nerves forms an exception to these characters, being placed on the arches of the vertebræ over which the nerves pass. The ganglia, also, of the sacral nerves are placed within the spinal canal; and that on the coccygeal nerve, also in the canal, about the middle of its posterior root.

Distribution of the Spinal Nerves.

Immediately beyond the ganglion the two roots coalesce, their fibres intermingle, and the trunk thus formed passes out of the intervertebral foramen, and divides into a posterior division for the supply of the posterior part of the body, and an anterior division for the supply of the anterior part of the body, each containing fibres from both roots. Before division each trunk gives off a *recurrent* branch to the dura mater of the cord.

The **posterior divisions of the spinal nerves** are generally smaller than the anterior; they arise from the trunk resulting from the union of the roots in the intravertebral foramina, and, passing backward, divide into internal and external branches, which are distributed to the muscles and integument behind the spine. The first cervical, the fourth and fifth sacral, and the coccygeal nerves are exceptions to these characters.

The **anterior divisions of the spinal nerves** supply the parts of the body in front of the spine, including the limbs. They are for the most part larger than the posterior divisions. Each division is connected with the sympathetic by slender filaments from which a communicating branch runs to the *recurrent* filament from the trunk. In the dorsal region the anterior divisions of the spinal nerves are completely separate from each other, and are uniform in their distribution; but in the cervical, lumbar, and sacral regions they form intricate plexuses previous to their distribution.

Points of Emergence of the Spinal Nerves.

The roots of the spinal nerves from their origin in the cord run obliquely downward to their point of exit from the intervertebral foramina, the amount of obliquity varying in different regions of the spine, and being greater in the lower than the upper part. The level of their emergence from the cord is within certain

Level of Body of	No. of Nerve.	Level of tip of Spine of	Level of Body of	No. of Nerve.	Level of tip of Spine of
C. 1	C. 1	—	D. 8	9	7 d.
2	2	—	9	10	8 d.
	3	1 c.	10	11	9 d.
3	4	2 c.	—	12	10 d.
4	5	3 c.	11	L. 1	11 d.
5	6	4 c.	12	2	—
6	7	5 c.		3	12 d.
—	8	6 c.		4	
7	D. 1	7 c.		5	—
D. 1	2	1 d.		S. 1	
2	3	—	L. 1	2	1 L.
3	4	2 d.		3	
4	5	3 d.		4	
5	6	4 d.	—	5	
6	7	5 d.	—	G. 1	
7	8	6 d.	L. 2	—	—

limits variable, and of course does not correspond to the point of emergence of the nerve from the intervertebral foramina. The preceding table, from Macalister, shows as accurately as can be shown the relation of these points of origin from the spinal cord to the bodies and spinous processes of the vertebræ.

THE CERVICAL NERVES.

The **roots of the cervical nerves** increase in size from the first to the fifth, and then remain the same size to the eighth. The posterior roots bear a proportion to the anterior as 3 to 1, which is much greater than in any other region, the individual filaments being also much larger than those of the anterior roots. In direction the roots of the cervical are less oblique than those of the other spinal nerves. The first cervical nerve is directed a little upward and outward; the second is horizontal; the others are directed obliquely downward and outward, the lowest being the most oblique, and consequently longer than the upper, the distance between their place of origin and their point of exit from the spinal canal never exceeding the depth of one vertebra.

The *trunk of the first cervical nerve* (*suboccipital*) leaves the spinal canal between the occipital bone and the posterior arch of the atlas; the second, between the posterior arch of the atlas and the lamina of the axis; and the eighth (the last), between the last cervical and first dorsal vertebræ.

Each nerve, at its exit from the intervertebral foramen, divides into a posterior and an anterior division. The anterior divisions of the four upper cervical nerves form the cervical plexus. The anterior divisions of the four lower cervical nerves, together with the first dorsal, form the brachial plexus.

Posterior Divisions of the Cervical Nerves (Fig. 495).

The **posterior division of the first cervical** (*suboccipital*) **nerve** differs from the posterior divisions of the other cervical nerves in not dividing into an internal and external branch. It is larger than the anterior division, and escapes from the spinal canal between the occipital bone and the posterior arch of the atlas, lying behind the vertebral artery. It enters the suboccipital triangle formed by the Rectus capitis posticus major, the Obliquus superior, and Obliquus inferior, and supplies the Recti and Obliqui muscles, and the Complexus. From the branch which supplies the Inferior oblique a filament is given off which joins the second cervical nerve. This nerve also occasionally gives off a cutaneous filament, which accompanies the occipital artery and communicates with the occipitalis major and minor nerves.

The **posterior division of the second cervical nerve** is three or four times greater than the anterior division, and the largest of all the posterior cervical divisions. It emerges from the spinal canal between the posterior arch of the atlas and lamina of the axis, below the Inferior oblique. It supplies this muscle, and receives a communicating filament from the first cervical. It then divides into an internal and external branch.

The *internal branch*, called, from its size and distribution, the *occipitalis major*, ascends obliquely inward between the Obliquus inferior and Complexus, and pierces the latter muscle and the Trapezius near their attachments to the cranium. It is now joined by a filament (*third occipital*) from the posterior division of the third cervical nerve, and, ascending on the back part of the head with the occipital artery, divides into two branches, which supply the integument of the scalp as far forward as the vertex, communicating with the occipitalis minor. It gives off an auricular branch to the back part of the ear and muscular branches to the Complexus. The *external branch* is often joined by the external branch of the posterior division of the third, and supplies the Splenius, Trachelo-mastoid, and Complexus.

The **posterior division of the third cervical** is smaller than the preceding, but larger than the fourth; it differs from the posterior divisions of the remaining cervical nerves in its supplying an additional filament, the third occipital nerve,

to the integument of the occiput. The posterior division of the third nerve, like the others, divides into an internal and external branch. The *internal branch* passes between the Complexus and Semispinalis, and, piercing the Splenius and Trapezius, supplies the skin over the latter muscle; the *external branch* joins with that of the posterior division of the second to supply the Splenius, Trachelo-mastoid, and Complexus.

The *third occipital nerve* arises from the internal or cutaneous branch beneath the Trapezius; it then pierces that muscle, and supplies the skin on the lower and

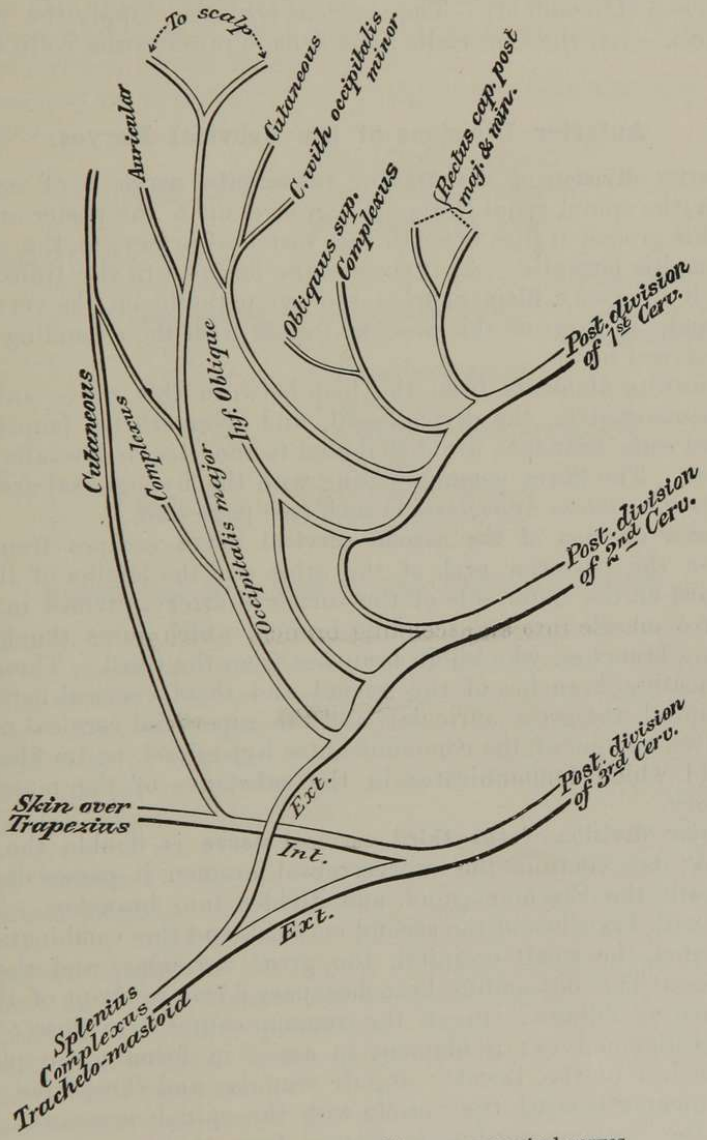

FIG. 495.—Posterior divisions of the upper cervical nerves.

back part of the head. It lies to the inner side of the occipitalis major, with which it is connected.

The posterior division of the suboccipital nerve and the internal branches of the posterior divisions of the second and third cervical nerves are occasionally joined beneath the Complexus by communicating branches. This communication is described by Cruveilhier as the *posterior cervical plexus.*

The **posterior divisions of the fourth, fifth, sixth, seventh, and eighth cervical nerves** (Fig. 502) pass backward, and divide, behind the Posterior intertransverse

muscles, into internal and external branches. The *internal branches*, the larger, are distributed differently in the upper and lower part of the neck. Those derived from the fourth and fifth nerves pass between the Complexus and Semispinalis muscles, and, having reached the spinous processes, perforate the aponeurosis of the Splenius and Trapezius, and are continued outward to the integument over the Trapezius, whilst those derived from the three lowest cervical nerves are the smallest, and are placed beneath the Semispinalis colli, which they supply, and then pass into the Interspinales, Multifidus spinæ, and Complexus, and send twigs through this latter muscle to supply the integument near the spinous processes (Hirschfeld). The *external branches* supply the muscles at the side of the neck—viz. the Cervicalis ascendens, Transversalis colli, and Trachelomastoid.

Anterior Divisions of the Cervical Nerves.

The **anterior division of the first** or **suboccipital nerve** is of small size. It escapes from the spinal canal through a groove upon the posterior arch of the atlas. In this groove it lies beneath the vertebral artery, to the inner side of the Rectus capitis lateralis. As it crosses the foramen in the transverse process of the atlas it receives a filament from the sympathetic on the vertebral artery. It then descends, in front of this process, to join with the ascending branch from the second cervical nerve.

Communicating filaments from the loop between this nerve and the second join the pneumogastric, the hypoglossal, and sympathetic (superior cervical ganglion), and some branches are distributed to the Rectus lateralis and the two Anterior recti. The fibres communicating with the hypoglossal are mostly continued into its *descendens hypoglossi* branch (see page 825).[1]

The **anterior division of the second cervical nerve** escapes from the spinal canal, between the posterior arch of the atlas and the lamina of the axis, and, passing forward on the outer side of the vertebral artery, divides in front of the Intertransverse muscle into an ascending branch, which joins the first cervical, and descending branches, which join branches from the third. These last-named intercommunicating branches of the second and third cervical nerves, give off the small occipital, the great auricular, and the superficial cervical nerves. The nerve also gives off one of the communicantes hypoglossi, and a filament to the Sterno-mastoid which communicates in the substance of the muscle with the spinal accessory.

The **anterior division of the third cervical nerve** is double the size of the preceding. At its exit from the intervertebral foramen it passes downward and outward beneath the Sterno-mastoid, and divides into branches. The ascending ones join with branches of the second cervical, and this combination gives off, as already stated, the small occipital, the great auricular, and the superficial cervical nerves. The descending branches pass down in front of the Scalenus anticus, and are as follows: One of the communicantes hypoglossi; a branch to the supraclavicular nerves; a filament to assist in forming the phrenic; and muscular branches to the Levator anguli scapulæ and Trapezius; this latter nerve communicates beneath the muscle with the spinal accessory. Sometimes the nerve to the Scalenus medius is derived from this source.

The **anterior division of the fourth cervical** is of the same size as the preceding. It sends a communicating branch to the fifth cervical, and, passing downward and outward, unites with a branch from the third, and from this union are derived numerous filaments which cross the posterior triangle of the neck, forming the supraclavicular nerves. It also gives a branch to the phrenic nerve whilst it is contained in the intertransverse space, and sometimes a branch to the Scalenus medius muscle. It also gives a branch to the Levator anguli scapulæ and to the

[1] According to Valentin, the anterior division of the suboccipital also distributes filaments to the occipito-atlantal articulation and mastoid process of the temporal bone.

Trapezius, which unites with the branch given off from the third nerve, and communicates beneath the muscle with the spinal accessory.

The **anterior divisions of the fifth, sixth, seventh, and eighth cervical nerves** are remarkable for their large size. They are much larger than the preceding nerves, and are all of equal size. They assist in the formation of the brachial plexus.

The Cervical Plexus.

The cervical plexus (Fig. 496) is formed, as above described, by the anterior divisions of the four upper cervical nerves. It is situated opposite the four upper cervical vertebræ, resting upon the Levator anguli scapulæ and Scalenus medius muscles, and covered in by the Sterno-mastoid.

Its branches may be divided into two groups, *superficial* and *deep*, which may be thus arranged:

- *Superficial*
  - Ascending
    - Occipitalis minor.
    - Auricularis magnus.
    - Superficialis colli.
  - Descending
    - Supraclavicular
      - Suprasternal.
      - Supraclavicular.
      - Supra-acromial.
- *Deep*
  - Internal
    - Communicating.
    - Muscular.
    - Communicans hypoglossi.
    - Phrenic.
  - External
    - Communicating.
    - Muscular.

Superficial Branches of the Cervical Plexus.

The **Occipitalis minor** (Fig. 502) arises from the second and third cervical nerves; it curves round the posterior border of the Sterno-mastoid, and ascends, running parallel to the posterior border of the muscle, to the back part of the side of the head. Near the cranium it perforates the deep fascia, and is continued upward along the side of the head behind the ear, supplying the integument, and communicating with the occipitalis major, the auricularis magnus, and with the posterior auricular branch of the facial.

This nerve gives off an *auricular branch*, which supplies the integument of the upper and back part of the auricle, communicating with the mastoid branch of the auricularis magnus. This branch is occasionally derived from the great occipital nerve. The occipitalis minor varies in size; it is occasionally double.

The **Auricularis Magnus** is the largest of the ascending branches. It arises from the second and third cervical nerves, winds round the posterior border of the Sterno-mastoid, and, after perforating the deep fascia, ascends upon that muscle beneath the Platysma to the parotid gland, where it divides into facial, auricular, and mastoid branches.

The *facial branches* pass across the parotid, and are distributed to the integument of the face over the parotid gland; others penetrate the substance of the gland and communicate with the facial nerve.

The *auricular branches* ascend to supply the integument of the back part of the pinna, except at its upper part, communicating with the auricular branches of the facial and pneumogastric nerves.

The *mastoid branch* communicates with the occipitalis minor and the posterior auricular branch of the facial, and is distributed to the integument behind the ear.

The **Superficialis Colli** arises from the second and third cervical nerves, turns round the posterior border of the Sterno-mastoid about its middle, and, passing obliquely forward beneath the external jugular vein to the anterior border of that

muscle, perforates the deep cervical fascia, and divides beneath the Platysma into two branches which are distributed to the antero-lateral parts of the neck.

The *ascending branch* gives a filament which accompanies the external jugular vein; it then passes upward to the submaxillary region, and divides into branches, some of which form a plexus with the cervical branches of the facial nerve beneath

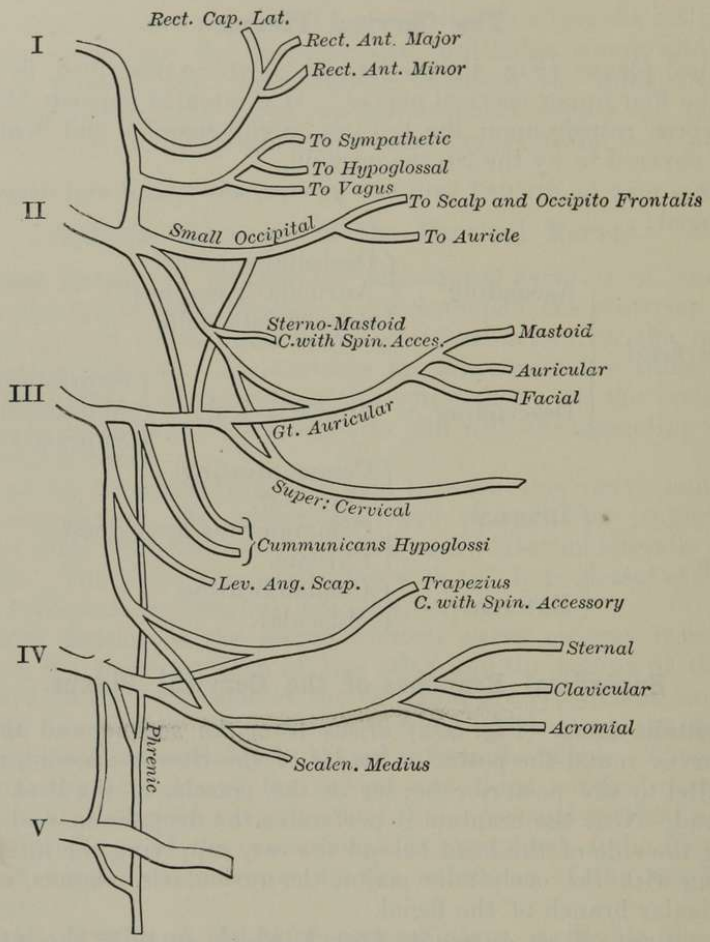

FIG. 496.—Plan of the cervical plexus.

the Platysma; others pierce that muscle, supply it, and are distributed to the integument of the upper half of the neck, at its fore part, as high as the chin.

The *descending branch* (occasionally represented by two or more filaments) pierces the Platysma, and is distributed to the integument of the side and front of the neck, as low as the sternum.

The **Descending** or **supraclavicular branches** arise from the third and fourth cervical nerves: emerging beneath the posterior border of the Sterno-mastoid, they descend in the interval between that muscle and the Trapezius, and divide into branches, which are arranged, according to their position, into three groups.

The *inner* or *suprasternal branches* cross obliquely over the clavicular and sternal attachments of the Sterno-mastoid, and supply the integument as far as the median line.

The *middle* or *supraclavicular branches* cross the clavicle, and supply the integument over the Pectoral and Deltoid muscles, communicating with the cutaneous branches of the upper intercostal nerves.

The *external* or *supra-acromial branches* pass obliquely across the outer surface of the Trapezius and the acromion, and supply the integument of the upper and back part of the shoulder.

Deep Branches of the Cervical Plexus. Internal Series.

The **communicating branches** consist of several filaments which pass from the loop between the first and second cervical nerves in front of the atlas to the pneumogastric, hypoglossal (see page 825 and Fig. 493) and sympathetic, and a communicating branch between the fourth and fifth cervical.

Muscular branches supply the Anterior recti and the Rectus lateralis muscles; they proceed from the first cervical nerve and from the loop formed between it and the second. The Longus colli is supplied from the third and the fourth.

The **Communicans Hypoglossi** (Fig. 493) consists usually of two filaments, one being derived from the second, and the other from the third cervical. These filaments pass downward on the outer side of the internal jugular vein, cross in front of the vein a little below the middle of the neck, and form a loop with the descendens hypoglossi in front of the sheath of the carotid vessels (see page 825). Occasionally, the junction of these nerves takes place within the sheath.

The **Phrenic Nerve** (*internal respiratory of Bell*) arises chiefly from the fourth cervical nerve, with a few filaments from the third and a communicating branch from the fifth. It descends to the root of the neck, running obliquely across the front of the Scalenus anticus, passes over the first part of the subclavian artery, between it and the subclavian vein, and, as it enters the chest, crosses the internal mammary artery near its origin. Within the chest it descends nearly vertically in front of the root of the lung and by the side of the pericardium, between it and the mediastinal portion of the pleura, to the Diaphragm, where it divides into branches, which separately pierce that muscle and are distributed to its under surface.

The two phrenic nerves differ in their length, and also in their relations at the upper part of the thorax.

The *right nerve* is situated more deeply, and is shorter and more vertical in direction than the left; it lies on the outer side of the right vena innominata and superior vena cava.

The *left nerve* is rather longer than the right, from the inclination of the heart to the left side, and from the Diaphragm being lower on this than on the opposite side. At the upper part of the thorax it crosses in front of the arch of the aorta to the root of the lung.

Each nerve supplies filaments to the pericardium and pleura, and near the chest is joined by a filament from the sympathetic, and occasionally by one from the union of the descendens hypoglossi with the spinal nerves: this filament is found, according to Swan, only on the left side. It is also usually connected by a filament with the nerve to the Subclavius muscle. Branches have been described as passing to the peritoneum.

From the *right nerve* one or two filaments pass to join in a small ganglion with phrenic branches of the solar plexus; and branches from this ganglion are distributed to the hepatic plexus, the suprarenal capsule, and inferior vena cava. From the *left nerve* filaments pass to join the phrenic plexus of the sympathetic, but without any ganglionic enlargement.

Deep Branches of the Cervical Plexus. External Series.

Communicating Branches.—The deep branches of the external series of the cervical plexus communicate with the spinal accessory nerve, in the substance of the Sterno-mastoid muscle, in the occipital triangle, and beneath the Trapezius.

Muscular branches are distributed to the Sterno-mastoid, Trapezius, Levator anguli scapulæ, and Scalenus medius.

The branch for the Sterno-mastoid is derived from the second cervical; the Trapezius and Levator anguli scapulæ receive branches from the third and fourth. The Scalenus medius is supplied sometimes from the third, sometimes the fourth, and occasionally from both nerves.

The Brachial Plexus (Fig. 497).

The **Brachial Plexus** is formed by the union of the anterior branches of the four lower cervical and the greater part of the first dorsal nerves, receiving also a fasciculus from the fourth cervical nerve. It extends from the lower part of the side of the neck to the axilla. It is very broad, and presents little of a plexiform arrangement at its commencement. It is narrow opposite the clavicle, becomes broad and forms a more dense interlacement in the axilla, and divides opposite the coracoid process into numerous branches for the supply of the upper limb. The nerves which form the plexus are all similar in size, and their mode of communication is subject to considerable variation, so that no one plan can be given as applying to every case. The following appears, however, to be the most constant arrangement: the fifth and sixth cervical unite together soon after their exit from the intervertebral foramina to form a common trunk. The eighth cervical and first dorsal also unite to form one trunk. So that the nerves forming the plexus, as they lie on the Scalenus medius external to the outer border of the

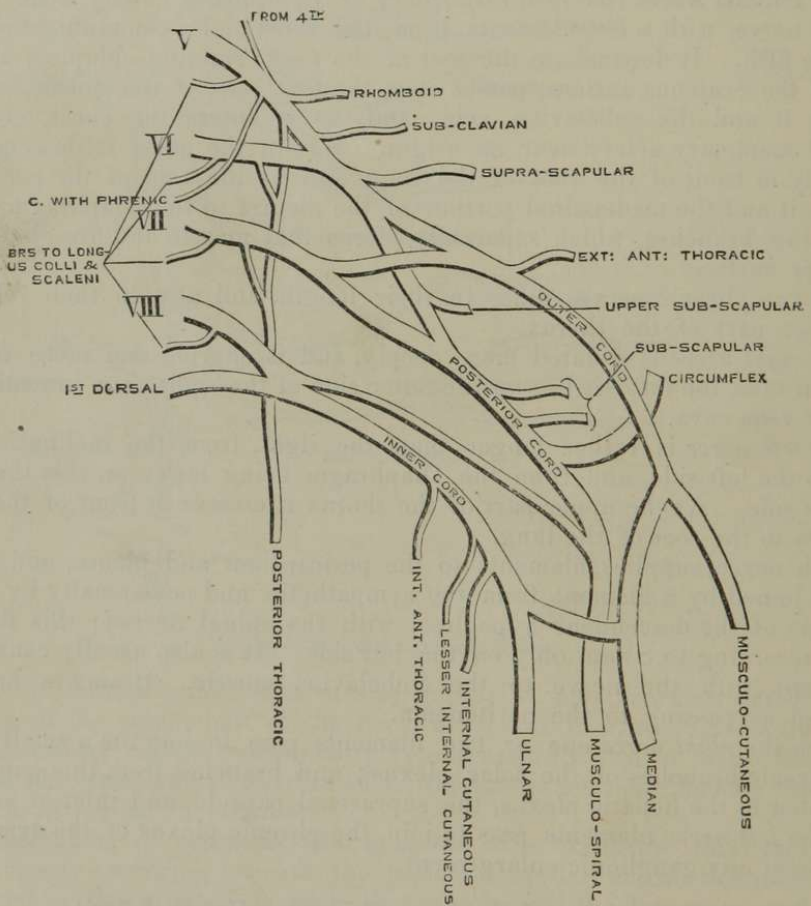

FIG. 497.—Plan of the brachial plexus.

Scalenus anticus, are blended into three trunks—an upper one, formed by the junction of the fifth and sixth cervical nerves; a middle one, consisting of the seventh cervical nerve; and a lower one, formed by the junction of the eighth cervical and first dorsal nerves. As they pass beneath the clavicle, each of these three trunks divides into two branches, an *anterior* and a *posterior*. The anterior divisions of the upper and middle trunks then unite to form a common cord, which is situated on the outer side of the middle part of the axillary artery, and is called the *outer cord* of the brachial plexus. The anterior division of the

lower trunk, formed by the union of the eighth cervical and first dorsal, passes down on the inner side of the axillary artery in the middle of the axilla, and forms the *inner cord* of the brachial plexus. The posterior divisions of the upper

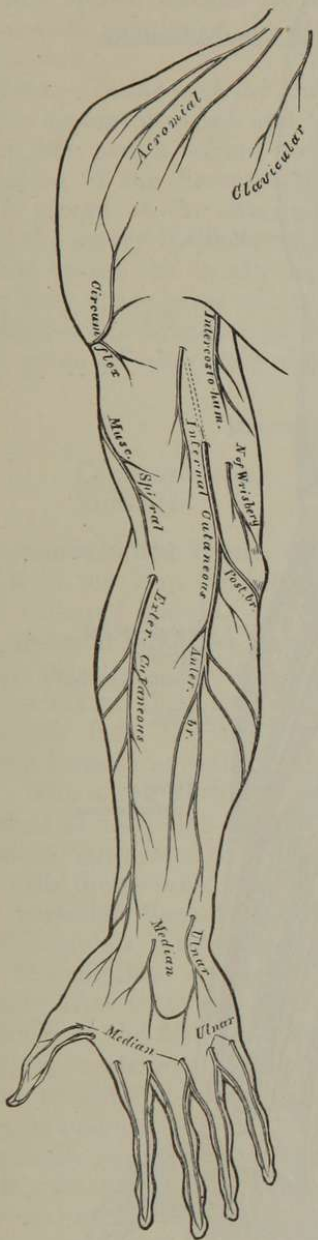

FIG. 498.—Cutaneous nerves of right upper extremity. Anterior view.

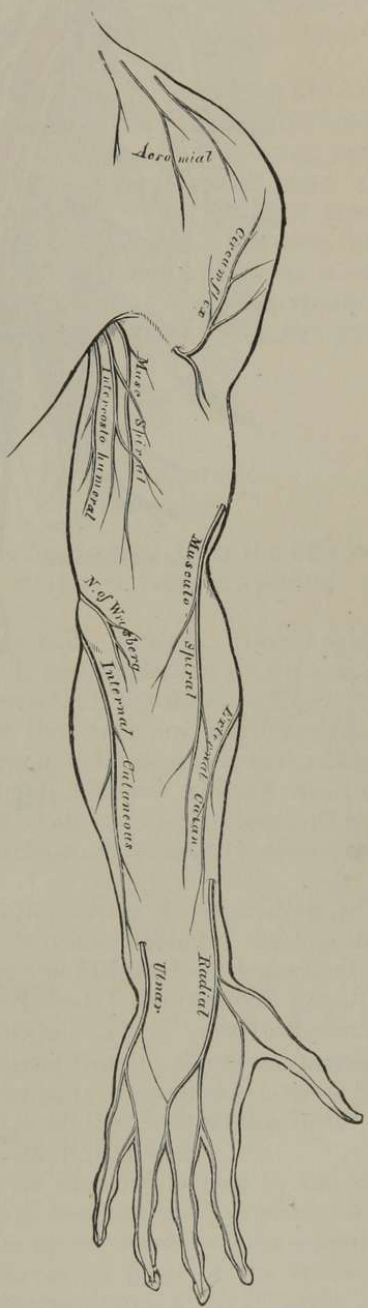

FIG. 499.—Cutaneous nerves of right upper extremity. Posterior view.

trunk (formed by the junction of the fifth and sixth nerves) and of the middle trunk (the seventh nerve) unite together to form the *posterior cord* of the brachial plexus, which is situated behind the second portion of the axillary artery. From this posterior cord are given off the two lower subscapular nerves, the upper subscapular nerve being given off from the posterior division of the outer trunk prior to its junction with the posterior division of the middle trunk. The posterior cord divides into the circumflex and musculo-spiral nerves. The musculo-

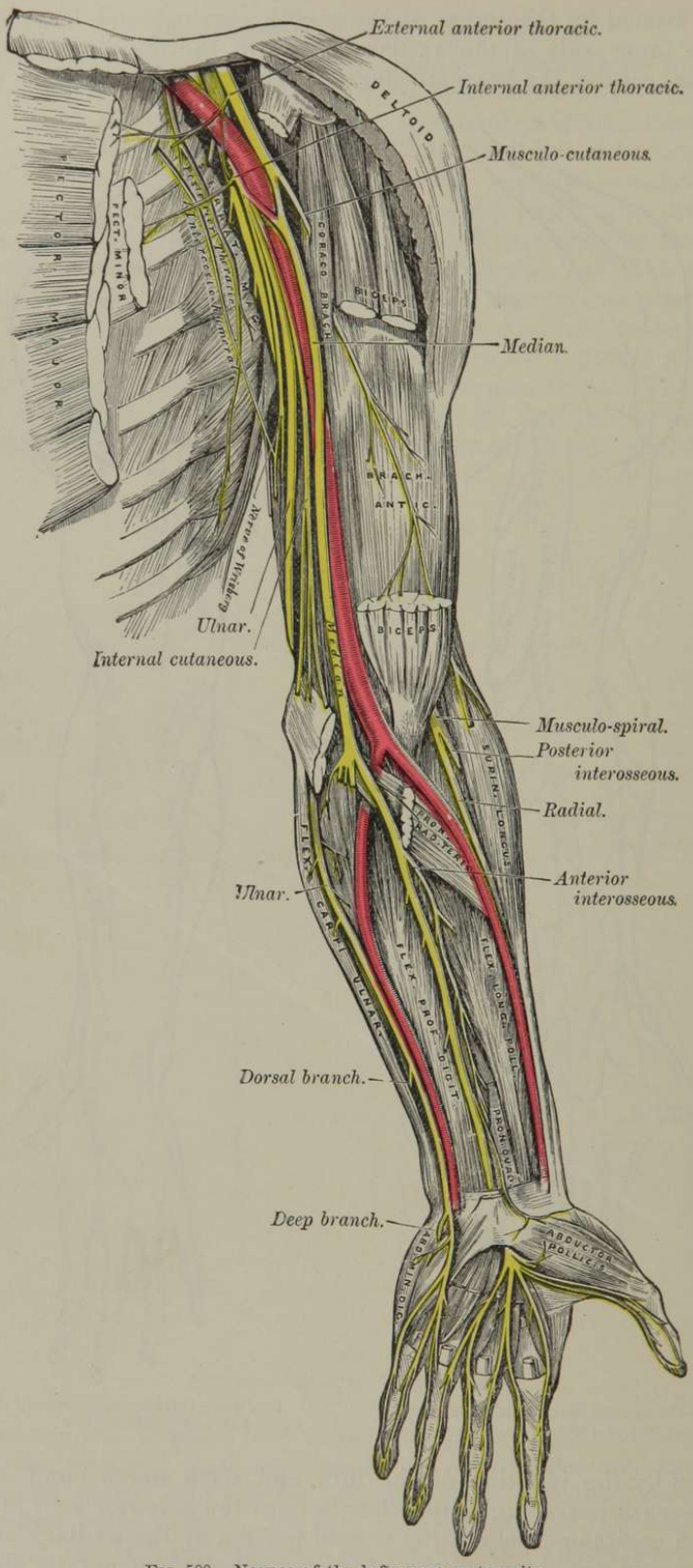

FIG. 500.—Nerves of the left upper extremity.

spiral nerve is subsequently joined by the posterior division of the inner trunk, formed by the union of the eighth cervical and first dorsal.

The brachial plexus communicates with the cervical plexus by a branch from the fourth to the fifth nerve, and with the phrenic nerve by a branch from the fifth cervical, which joins that nerve on the Anterior scalenus muscle: the cervical and first dorsal nerves are also joined by filaments from the middle and inferior cervical ganglia of the sympathetic, close to their exit from the intervertebral foramina.

Relations.—*In the neck* the brachial plexus lies at the first between the Anterior and Middle scaleni muscles, and then above and to the outer side of the subclavian artery: it then passes behind the clavicle and Subclavius muscle, lying upon the first serration of the Serratus magnus, and the Subscapularis muscles. *In the axilla* it is placed on the outer side of the first portion of the axillary artery; it surrounds the artery in the second part of its course, one cord lying upon the outer side of that vessel, one on the inner side, and one behind it, and at the lower part of the axillary space gives off its terminal branches to the upper extremity.

Branches.—The branches of the brachial plexus are arranged in two groups—viz. those given off above the clavicle, and those below that bone.

Branches above the Clavicle.

Communicating.	Posterior thoracic.
Muscular.	Suprascapular.

The **communicating branch** with the phrenic is derived from the fifth cervical nerve or from the loop between the fifth and sixth; it joins the phrenic on the Anterior scalenus muscle.

The **muscular branches** supply the Longus colli, Scaleni, Rhomboidei, and Subclavius muscles. Those for the Longus colli and Scaleni arise from the lower cervical nerves at their exit from the intervertebral foramina. The Rhomboid branch arises from the fifth cervical, pierces the Scalenus medius, and passes beneath the Levator anguli scapulæ, which it occasionally supplies, to the Rhomboid muscles. The nerve to the Subclavius is a small filament which arises from the fifth cervical at its point of junction with the sixth nerve; it descends in front of the subclavian artery to the Subclavius muscle, and is usually connected by a filament with the phrenic nerve.

The **posterior thoracic nerve** (*long thoracic, external respiratory of Bell*) (Fig. 500) supplies the Serratus magnus, and is remarkable for the length of its course. It sometimes arises by two roots from the fifth and sixth cervical nerves immediately after their exit from the intervertebral foramina, but generally by three roots from the fifth, sixth, and seventh nerves. These unite in the substance of the Middle scalenus muscle, and, after emerging from it, the nerve passes down behind the brachial plexus and the axillary vessels, resting on the outer surface of the Serratus magnus. It extends along the side of the chest to the lower border of that muscle, supplying filaments to each of its digitations.

The **suprascapular nerve** (Fig. 501) arises from the cord formed by the fifth and sixth cervical nerves; passing obliquely outward beneath the Trapezius, it enters the supraspinous fossa, through the notch in the upper border of the scapula, and, passing beneath the Supraspinatus muscle, curves in front of the spine of the scapula to the infraspinous fossa. In the supraspinous fossa it gives off two branches to the Supraspinatus muscle, and an articular filament to the shoulder-joint; and in the infraspinous fossa it gives off two branches to the Infraspinatus muscle, besides some filaments to the shoulder-joint and scapula.

Branches below the Clavicle.

The branches below the clavicle are derived from the three cords, as follows:

From the outer cord arise the external of the two anterior thoracic nerves, the musculo-cutaneous nerve, the nerve to the Coraco-brachialis muscle, and the outer head of the median.

From the inner cord arise the internal of the two anterior thoracic nerves, the internal cutaneous, the lesser internal cutaneous (nerve of Wrisberg), the ulnar, and inner head of the median.

From the posterior cord arise two of the three subscapular nerves, the third arising from the posterior division of the trunk formed by the fifth and sixth cervical nerves; the cord then divides into the musculo-spiral and circumflex nerves.

These may be arranged according to the parts they supply:

To the chest	Anterior thoracic.
To the shoulder	Subscapular. Circumflex.
To the arm, forearm, and hand .	Musculo-cutaneous. Internal cutaneous. Lesser internal cutaneous. Median. Ulnar. Musculo-spiral.

The fasciculi of which these nerves are composed may be traced through the plexus to the spinal nerves from which they originate. They are as follows:

External anterior thoracic	from	5th, 6th, and 7th cervical.
Internal anterior thoracic	"	8th cervical and 1st dorsal.
Subscapular	"	5th, 6th, 7th, and 8th cervical.
Circumflex	"	5th, 6th, 7th, and 8th cervical.
Musculo-cutaneous	"	5th, 6th, and 7th cervical.
Internal cutaneous	"	8th cervical and 1st dorsal.
Lesser internal cutaneous	"	1st dorsal.
Median	"	6th, 7th, and 8th cervical, and 1st dorsal.
Ulnar	"	8th cervical and 1st dorsal.
Musculo-spiral	"	6th, 7th, and 8th cervical, and 1st dorsal.

The **Anterior Thoracic Nerves** (Fig. 500), two in number, supply the Pectoral muscles.

The *external* or superficial nerve, the larger of the two, arises from the outer cord of the brachial plexus, through which its fibres may be traced to the fifth, sixth, and seventh cervical nerves. It passes inward, across the axillary artery and vein, pierces the costo-coracoid membrane, and is distributed to the under surface of the Pectoralis major. It sends down a communicating filament to join the internal nerve, which forms a loop round the inner side of the axillary artery.

The *internal* or deep nerve arises from the inner cord, and through it from the eighth cervical and first dorsal. It passes upward between the axillary artery and vein, and joins with the filament from the superficial nerve. It then passes to the under surface of the Pectoralis minor muscle, where it divides into a number of branches, which supply the muscle on its under surface. Some of the branches pass through the muscle; others wind round its upper border and pierce the costo-coracoid membrane to supply the Pectoralis major.

The **Subscapular Nerves,** three in number, supply the Subscapularis, Teres major, and Latissimus dorsi muscles. The fasciculi of which they are composed may be traced to the fifth, sixth, seventh, and eighth cervical nerves.

The *upper subscapular nerve*, the smallest, enters the upper part of the Subscapularis muscle.

The *lower subscapular nerve* enters the axillary border of the Subscapularis and terminates in the Teres major. The latter muscle is sometimes supplied by a separate branch.

The *middle* or *long subscapular*, the largest of the three, follows the course of

the subscapular artery, along the posterior wall of the axilla to the Latissimus dorsi, through which it may be traced as far as its lower border.

The **Circumflex Nerve** (Fig. 501) supplies some of the muscles and the integument of the shoulder and the shoulder-joint. It arises from the posterior cord of the brachial plexus, in common with the musculo-spiral nerve, and its fibres may be traced through the posterior cord to the fifth, sixth, seventh, and eighth cervical nerves. It is at first placed behind the axillary artery, between it and the Subscapularis muscle, and passes downward and outward to the lower border of that muscle. It then winds backward in company with the posterior circumflex artery, through a quadrilateral space bounded above by the Teres minor, below by the Teres major, internally by the long head of the Triceps, and externally by the neck of the humerus, and divides into two branches.

The *upper branch* winds round the surgical neck of the humerus, beneath the Deltoid, with the posterior circumflex vessels, as far as the anterior border of that muscle, supplying it, and giving off cutaneous branches, which pierce the muscle and ramify in the integument covering its lower part.

The *lower branch*, at its origin, distributes filaments to the Teres minor and back part of the Deltoid muscles. Upon the filament to the former muscle a gangliform enlargement usually exists. The nerve then pierces the deep fascia, and supplies the integument over the lower two-thirds of the posterior surface of the Deltoid, as well as that covering the long head of the Triceps.

The circumflex nerve, before its division, gives off an articular filament, which enters the shoulder-joint below the Subscapularis.

The **Musculo-cutaneous Nerve** (Fig. 500) (*external cutaneous* or *perforans Casserii*) supplies some of the muscles of the arm and the integument of the forearm. It arises from the outer cord of the brachial plexus, opposite the lower border of the Pectoralis minor, receiving filaments from the fifth, sixth, and seventh cervical nerves. It perforates the Coraco-brachialis muscle, passes obliquely between the Biceps and Brachialis anticus to the outer side of the arm, and, a little above the elbow, winds round the outer border of the tendon of the Biceps, and, perforating the deep fascia, becomes cutaneous. This nerve in its course through the arm supplies the Coraco-brachialis (this branch often arises separately from the outer cord), Biceps, and part of the Brachialis anticus muscles. It sends a small branch to the bone, which enters the nutrient foramen with the accompanying artery and a filament, from the branch supplying the Brachialis anticus, to the elbow-joint.

The cutaneous portion of the nerve passes behind the median cephalic vein, and divides, opposite the elbow-joint, into an anterior and a posterior branch.

The *anterior branch* descends along the radial border of the forearm to the wrist, and supplies the integument over the outer half of the anterior surface. At the wrist-joint it is placed in front of the radial artery, and some filaments, piercing the deep fascia, accompany that vessel to the back of the wrist, supplying the carpus. The nerve then passes downward to the ball of the thumb, where it terminates in cutaneous filaments. It communicates with a branch from the radial nerve and the palmar cutaneous branch of the median.

The *posterior branch* passes downward along the back part of the radial side of the forearm to the wrist. It supplies the integument of the lower third of the forearm, communicating with the radial nerve and the lower external cutaneous branch of the musculo-spiral.

The **Internal Cutaneous Nerve** (Fig. 500) is one of the smallest branches of the brachial plexus. It arises from the inner cord in common with the ulnar and internal head of the median, and at its commencement is placed on the inner side of the axillary artery. It derives its fibres from the eighth cervical and first dorsal nerves. It passes down the inner side of the arm, pierces the deep fascia with the basilic vein, about the middle of the limb, and, becoming cutaneous, divides into two branches, anterior and posterior.

This nerve gives off, near the axilla, a cutaneous filament, which pierces the

fascia and supplies the integument covering the Biceps muscle nearly as far as the elbow. This filament lies a little external to the common trunk, from which it arises.

The *anterior branch*, the larger of the two, passes usually in front of, but occasionally behind, the median basilic vein. It then descends on the anterior surface of the ulnar side of the forearm, distributing filaments to the integument as far as the wrist, and communicating with a cutaneous branch of the ulnar nerve.

The *posterior branch* passes obliquely downward on the inner side of the basilic vein, passes in front of, or over, the internal condyle of the humerus to the back of the forearm, and descends on the posterior surface of its ulnar side as far as the wrist, distributing filaments to the integument. It communicates, above the elbow, with the lesser internal cutaneous, and above the wrist with the dorsal cutaneous branch of the ulnar nerve (Swan).

The **Lesser Internal Cutaneous Nerve** (*nerve of Wrisberg*) (Fig. 500) is distributed to the integument on the inner side of the arm. It is the smallest of the branches of the brachial plexus, and, arising from the inner cord with the internal cutaneous and ulnar nerves, receives its fibres from the first dorsal nerve. It passes through the axillary space, at first lying behind, and then on the inner side of, the axillary vein, and communicates with the intercosto-humeral nerve. It descends along the inner side of the brachial artery to the middle of the arm, where it pierces the deep fascia, and is distributed to the integument of the back part of the lower third of the arm, extending as far as the elbow, where some filaments are lost in the integument in front of the inner condyle, and others over the olecranon. It communicates with the posterior branch of the internal cutaneous nerve.

In some cases the nerve of Wrisberg and intercosto-humeral are connected by two or three filaments which form a plexus at the back part of the axilla. In other cases the intercosto-humeral is of large size, and takes the place of the nerve of Wrisberg, receiving merely a filament of communication from the brachial plexus, which represents the latter nerve. In other cases this filament is wanting, the place of the nerve of Wrisberg being supplied entirely from the intercosto-humeral.

The **Median Nerve** (Fig. 500) has received its name from the course it takes along the middle of the arm and forearm to the hand, lying between the ulnar and the musculo-spiral and radial nerves. It arises by two roots, one from the outer, and one from the inner, cord of the brachial plexus ; these embrace the lower part of the axillary artery, uniting either in front or on the outer side of that vessel. It receives filaments from the sixth, seventh, and eighth cervical and the first dorsal. As it descends through the arm, it lies at first on the outer side of the brachial artery, crosses that vessel in the middle of its course, usually in front, but occasionally behind it, and lies on its inner side to the bend of the elbow, where it is placed beneath the bicipital fascia, and is separated from the elbow-joint by the Brachialis anticus. *In the forearm* it passes between the two heads of the Pronator radii teres, and descends beneath the Flexor sublimis, lying on the Flexor profundus, to within two inches above the annular ligament, where it becomes more superficial, lying between the tendons of the Flexor sublimis and Flexor carpi radialis, beneath, or rather to the ulnar side of, the tendon of the Palmaris longus, covered by the integument and fascia. It then passes beneath the annular ligament into the hand. In its course through the forearm it is accompanied by a small artery.

Branches.—No branches are given off from the median nerve in the arm. *In the forearm* its branches are muscular, anterior interosseous, and palmar cutaneous, and, according to Rudinger and Macalister, two articular twigs to the elbow-joint.

The *muscular branches* supply all the superficial muscles on the front of the forearm, except the Flexor carpi ulnaris. These branches are derived from the

nerve near the elbow. The radial head and *index finger* belly of the Flexor sublimis, each has a separate filament.

The *anterior interosseous* supplies the deep muscles on the front of the forearm, except the inner half of the Flexor profundus digitorum. It accompanies the anterior interosseous artery along the interosseous membrane, in the interval between the Flexor longus pollicis and Flexor profundus digitorum muscles, both of which it supplies, and terminates below in the Pronator quadratus.

The *palmar cutaneous branch* arises from the median nerve at the lower part of the forearm. It pierces the fascia above the annular ligament, and, descending over that ligament, divides into two branches; of which the *outer* supplies the skin over the ball of the thumb, and communicates with the anterior cutaneous branch of the musculo-cutaneous nerve; and the *inner* supplies the integument of the palm of the hand, communicating with the cutaneous branch of the ulnar.

In the palm of the hand the median nerve is covered by the integument and palmar fascia and crossed by the superficial palmar arch. It rests upon the tendons of the flexor muscles. In this situation it becomes enlarged, somewhat flattened, of a reddish color, and divides into two branches. Of these, the *external* supplies a muscular branch to some of the muscles of the thumb and digital branches to the thumb and index finger; the *internal* supplies digital branches to the contiguous sides of the index and middle and of the middle and ring fingers.

The *branch to the muscles of the thumb* is a short nerve which subdivides to supply the Abductor, Opponens, and outer head of the Flexor brevis pollicis muscles, the remaining muscles of this group being supplied by the ulnar nerve.

The *digital branches* are five in number. The *first* and *second* pass along the borders of the thumb, the external branch communicating with branches of the radial nerve. The *third* passes along the radial side of the index finger, and supplies the First lumbricalis muscle. The *fourth* subdivides to supply the adjacent sides of the index and middle fingers, and sends a branch to the Second lumbrical muscle. The *fifth* supplies the adjacent sides of the middle and ring fingers, and communicates with a branch from the ulnar nerve.

Each digital nerve, opposite the base of the first phalanx, gives off a dorsal branch, which joins the dorsal digital nerve from the radial and runs along the side of the dorsum of the finger, to end in the integument over the last phalanx. At the end of the finger the digital nerve divides into a palmar and a dorsal branch, the former of which supplies the extremity of the finger, and the latter ramifies round and beneath the nail. The digital nerves, as they run along the fingers, are placed superficial to the digital arteries.

The **Ulnar Nerve** (Fig. 500) is placed along the inner or ulnar side of the upper limb, and is distributed to the muscles and integument of the forearm and hand. It is smaller than the median, behind which it is placed, diverging from it in its course down the arm. It arises from the inner cord of the brachial plexus, in common with the inner head of the median and the internal cutaneous nerve, and derives its fibres from the eighth cervical and first dorsal nerves. At its commencement it lies at the inner side of the axillary artery, and holds the same relation with the brachial artery to the middle of the arm. From this point it runs obliquely across the internal head of the Triceps, pierces the internal intermuscular septum, and descends to the groove between the internal condyle and the olecranon, accompanied by the inferior profunda artery. *At the elbow* it rests upon the back of the inner condyle, and passes into the forearm between the two heads of the Flexor carpi ulnaris. *In the forearm* it descends in a perfectly straight course along its ulnar side, lying upon the Flexor profundus digitorum, its upper half being covered by the Flexor carpi ulnaris, its lower half lying on the outer side of the muscle, covered by the integument and fascia. The ulnar artery, in the upper third of its course, is separated from the ulnar nerve by a considerable interval, but in the rest of its extent the nerve lies to its inner side. *At the wrist* the ulnar nerve

crosses the annular ligament on the outer side of the pisiform bone, to the inner side and a little behind the ulnar artery, and immediately beyond this bone divides into two branches, superficial and deep palmar.

The branches of the ulnar nerve are—

In the forearm: Articular (elbow). Muscular. Cutaneous. Dorsal cutaneous. Articular (wrist).

In the hand: Superficial palmar. Deep palmar.

The *articular branches* distributed to the elbow-joint consist of several small filaments. They arise from the nerve as it lies in the groove between the inner condyle and olecranon.

The *muscular branches* are two in number—one supplying the Flexor carpi ulnaris; the other, the inner half of the Flexor profundus digitorum. They arise from the trunk of the nerve near the elbow.

The *cutaneous branch* arises from the ulnar nerve about the middle of the forearm, and divides into two branches.

One branch (frequently absent) pierces the deep fascia near the wrist, and is distributed to the integument, communicating with a branch of the internal cutaneous nerve.

The second branch (*palmar cutaneous*) lies on the ulnar artery, which it accompanies to the hand, some filaments entwining round the vessel; it ends in the integument of the palm, communicating with branches of the median nerve.

The *dorsal cutaneous branch* arises about two inches above the wrist; it passes backward beneath the Flexor carpi ulnaris, perforates the deep fascia, and, along the ulnar side of the back of the wrist and hand, divides into two digital branches, of which one supplies the inner side of the little finger, and the other bifurcates to supply the adjoining sides of the little and ring fingers; it communicates with the posterior branch of the internal cutaneous nerve, and sends a communicating filament to that branch of the radial nerve which supplies the adjoining sides of the middle and ring fingers. Sometimes there is a *third* digital branch which goes to the adjacent sides of the middle and ring fingers. In this case the *radial* nerve-supply is correspondingly diminished.

The *superficial palmar branch* supplies the Palmaris brevis and the integument on the inner side of the hand, and terminates in two digital branches, which are distributed, one to the ulnar side of the little finger, the other to the adjoining sides of the little and ring fingers, the latter communicating with a branch from the median. The digital branches are distributed to the fingers in the same manner as the digital branches of the median. The *dorsal* digital branches, except those on the little finger, do not extend, as a rule, beyond the second phalanx, the remaining portion of the skin being supplied by filaments from the corresponding *palmar* digital branch.

The *deep palmar branch* passes between the Abductor and Flexor brevis minimi digiti muscles, and follows the course of the deep palmar arch beneath the flexor tendons. At its origin it supplies the muscles of the little finger. As it crosses the deep part of the hand it sends two branches to each interosseous space, one for the Dorsal and one for the Palmar interosseous muscle, the branches to the Second and Third palmar interossei supplying filaments to the two inner Lumbrical muscles. At its termination between the thumb and index finger it supplies the Adductores transversus et obliquus pollicis and the inner head of the Flexor brevis pollicis. *Articular branches* to the wrist are derived from this nerve.

The **Musculo-spiral Nerve** (Fig. 501), the largest branch of the brachial plexus, supplies the muscles of the back part of the arm and forearm and the integument of the same parts, as well as that of the back of the hand. It arises from the posterior cord of the brachial plexus by a common trunk with the circumflex

nerve, and is afterward joined by the posterior division of the trunk, formed by the junction of the eighth cervical and first dorsal nerves. It receives filaments from the sixth, seventh, and eighth cervical and first dorsal nerves. At its commencement it is placed behind the axillary and upper part of the brachial arteries, passing down in front of the tendons of the Latissimus dorsi and Teres major. It winds round the humerus in the musculo-spiral groove with the superior profunda artery, passing from the inner to the outer side of the bone, between the internal and external heads of the Triceps muscle. It pierces the external intermuscular septum, and descends between the Brachialis anticus and Supinator longus to the front of the external condyle, where it divides into the radial and posterior interosseous nerves.

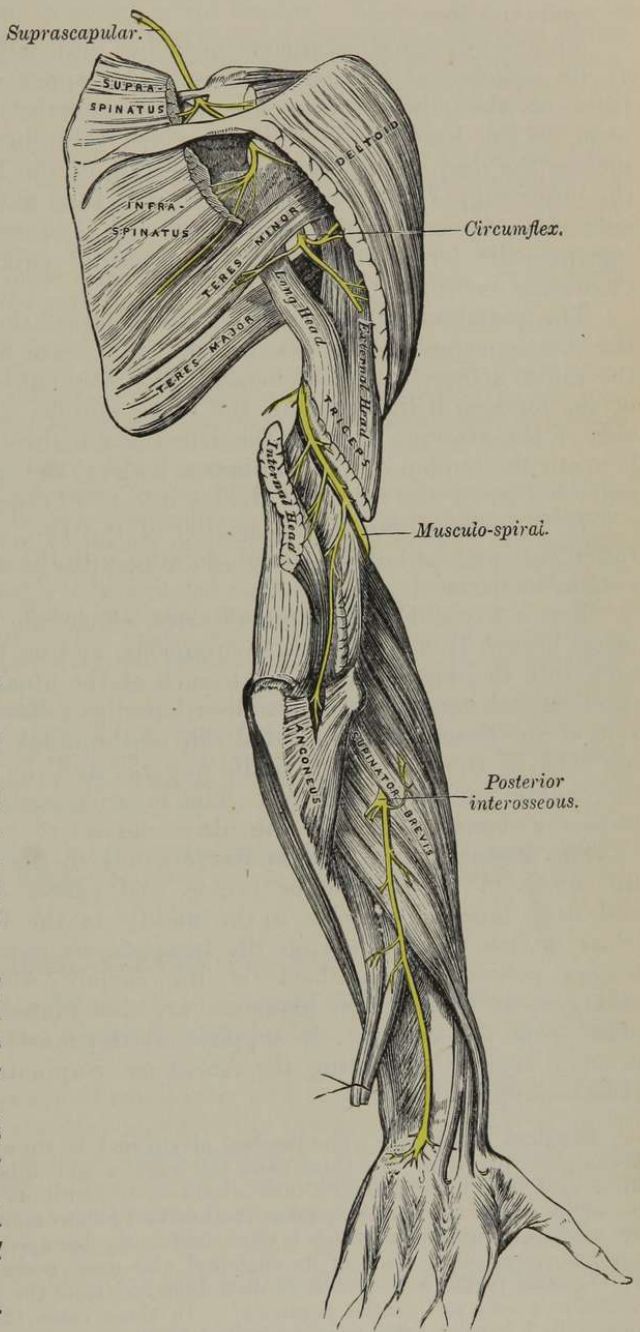

Fig. 501.—The suprascapular, circumflex, and musculo-spiral nerves.

The branches of the musculo-spiral nerve are—

Muscular.
Cutaneous.
Radial.
Posterior interosseous.

The *muscular branches* are divided into internal, posterior, and external; they supply the Triceps, Anconeus, Supinator longus, Extensor carpi radialis longior, and Brachialis anticus. These branches are derived from the nerve at the inner side, back part, and outer side of the arm.

The internal muscular branches supply the inner and middle heads of the Triceps muscle. That to the inner head of the Triceps is a long, slender filament which lies close to the ulnar nerve, as far as the lower third of the arm, and is often intimately connected with it (*ulnar collateral branch*).

The posterior muscular branch, of large size, arises from the nerve in the groove between the Triceps and the humerus. It divides into branches which supply the outer and inner head of the Triceps and Anconeus muscles. The branch for the latter muscle is a long, slender filament which descends in the substance of the Triceps to the Anconeus.

The external muscular branches supply the Supinator longus, Extensor carpi-radialis longior, and (usually) the outer part of the Brachialis anticus.

The *cutaneous branches* are three in number, one internal and two external.

The internal cutaneous branch arises in the axillary space with the inner muscular branch. It is of small size, and passes through the axilla to the inner side of the arm, supplying the integument on its posterior aspect nearly as far as the olecranon. In its course it crosses beneath the intercosto-humeral, with which it communicates.

The two external cutaneous branches perforate the outer head of the Triceps at its attachment to the humerus. The upper and smaller one passes to the front of the elbow, lying close to the cephalic vein, and supplies the integument of the lower half of the arm on its anterior aspect. The lower branch pierces the deep fascia below the insertion of the Deltoid, and passes down along the outer side of the arm and elbow, and then along the back part of the radial side of the forearm to the wrist, supplying the integument in its course, and joining, near its termination, with the posterior cutaneous branch of the musculo-cutaneous nerve.

The **radial nerve** passes along the front of the radial side of the forearm to the commencement of its lower third. It lies at first a little to the outer side of the radial artery, concealed beneath the Supinator longus. In the middle third of the forearm it lies beneath the same muscle, in close relation with the outer side of the artery. It quits the artery about three inches above the wrist, passes beneath the tendon of the Supinator longus, and, piercing the deep fascia at the outer border of the forearm, divides into two branches.

The external branch, the smaller of the two, supplies the integument of the radial side and ball of the thumb, joining with the anterior branch of the musculo-cutaneous nerve.

The internal branch communicates, above the wrist, with the posterior cutaneous branch from the musculo-cutaneous, and on the back of the hand forms an arch with the dorsal cutaneous branch of the ulnar nerve. It then divides into three digital nerves, which are distributed as follows: The first supplies the ulnar side of the thumb and the radial side of the index finger; the second, the adjoining sides of the index and middle fingers; and the third, the adjacent borders of the middle and ring fingers.[1] The latter nerve communicates with a filament from the dorsal branch of the ulnar nerve.

The **Posterior Interosseous Nerve** winds to the back of the forearm through the fibres of the Supinator brevis, and passes down, between the superficial and deep layer of muscles, to the middle of the forearm. Considerably diminished in size, it descends on the interosseous membrane, beneath the Extensor longus pollicis, to the back of the carpus, where it presents a gangliform enlargement from which filaments are distributed to the ligaments and articulations of the carpus. It supplies all the muscles of the radial and posterior brachial regions, excepting the Anconeus, Supinator longus, and Extensor carpi radialis longior.

Surgical Anatomy.—The brachial plexus may be ruptured by traction on the limb leading to complete paralysis. In these cases the lesion would appear to be rather a tearing away of the nerves from the spinal cord than a solution of continuity of the nerve-fibres themselves. In the axilla any of the nerves forming the brachial plexus may be injured in a wound of this part, the median being the one which is most frequently damaged from its exposed position, and the musculo-spiral, on account of its sheltered and deep position, being the least often wounded. The brachial plexus in the axilla is often damaged from the pressure of a crutch, producing the condition known as "crutch paralysis." In these cases the musculo-spiral appears to be the nerve which is most frequently implicated to the greatest extent, the ulnar nerve being the one that appears to suffer next in frequency.

The *circumflex nerve* is of particular surgical interest. On account of its course round the joint it is liable to be torn in fractures of the surgical neck of the humerus and in dislocations of the shoulder-joint, leading to paralysis of the deltoid, and, according to Erb, inflammation of the shoulder-joint is liable to be followed by a neuritis of this nerve from extension of the inflammation to it.

[1] According to Hutchinson, the digital nerve to the thumb reaches only as high as the root of the nail; the one to the forefinger as high as the middle of the second phalanx; and the one to the middle and ring fingers not higher than the first phalangeal joint (*London Hosp. Gaz.* vol. iii. p. 319.)

Mr. Hilton takes the circumflex nerve as an illustration of a law which he lays down, that "the same trunks of nerves whose branches supply the groups of muscles moving a joint furnish also a distribution of nerves to the skin over the insertions of the same muscles, and the interior of the joint receives its nerves from the same source." In this way he explains the fact that an inflamed joint becomes rigid, because the same nerves which supply the interior of the joint supply the muscles also which move that joint.

The *median nerve* is liable to injury in wounds of the forearm. When paralyzed, there is loss of flexion of the second phalanges of all the fingers and of the terminal phalanges of the index and middle fingers. Flexion of the terminal phalanges of the ring and middle fingers is effected by that portion of the Flexor profundus digitorum which is supplied by the ulnar nerve. There is power to flex the proximal phalanges through the Interossei. The thumb cannot be flexed or opposed, and is maintained in a position of extension and adduction. All power of pronation is lost. The wrist can be flexed, if the hand is first adducted, by the action of the Flexor carpi ulnaris. There is loss or impairment of sensation on the palmar surface of the thumb, index, middle, and outer half of the ring fingers, and on the dorsal surface of the same fingers over the last two phalanges; except in the thumb, where the loss of sensation would be limited to the back of the last phalanx. In order to expose the median nerve for the purpose of stretching an incision should be made along the ulnar side of the tendon of the Palmaris longus, which serves as a guide to the nerve.

The *ulnar nerve* is also liable to be injured in wounds of the forearm. When paralyzed, there is loss of power of flexion in the ring and little fingers; there is impaired power of ulnar flexion and adduction; there is inability to spread out the fingers from paralysis of the Interossei; and there is inability to adduct the thumb. Sensation is lost or impaired in the skin supplied by the nerve. In order to expose the nerve in the lower part of the forearm, an incision should be made along the outer border of the tendon of the Flexor carpi ulnaris, and the nerve will be found lying on the ulnar side of the ulnar artery.

The *musculo-spiral nerve* is probably more frequently injured than any other nerve of the upper extremity. In consequence of its close relationship to the humerus as it lies in the musculo-spiral groove, it is frequently torn or injured in fractures of this bone, or subsequently involved in the callus that may be thrown out around a fracture, and thus pressed upon and its functions interfered with. It is also liable to be contused against the bone by kicks or blows or to be divided by wounds of the arm. When paralyzed, the hand is flexed at the wrist and lies flaccid. This is known as "drop-wrist." The fingers are also flexed, and on an attempt being made to extend them the last two phalanges only will be extended through the action of the Interossei, the first phalanges remaining flexed. There is no power of extending the wrist. Supination is completely lost when the forearm is extended on the arm, but it is possible to a certain extent if the forearm is flexed so as to allow of the action of the Biceps. The power of extension of the forearm is lost on account of paralysis of the Triceps. The best position in which to expose the nerve for the purpose of stretching is to make an incision along the inner border of the Supinator longus, just above the level of the elbow-joint. The skin and superficial structures are to be divided and the deep fascia exposed. The white line in this structure indicating the border of the muscle is to be defined, and the deep fascia divided in this line. By now raising the Supinator longus the nerve will be found lying beneath it, on the Brachialis anticus.

THE DORSAL NERVES (Fig. 502).

The **Dorsal Nerves** are twelve in number on each side. The first appears between the first and second dorsal vertebræ, and the last between the last dorsal and first lumbar.

The *roots of the dorsal nerves* are of small size, and vary but slightly from the second to the last. Both roots are very slender, the posterior roots only slightly exceeding the anterior in thickness. They gradually increase in length from above downward, and pass down in contact with the spinal cord for a distance equal to the height of, at least, two vertebræ, in the lower part of the dorsal region, before they emerge from the spinal canal. They then join in the intervertebral foramen, and at their exit divide into two primary divisions, a posterior (dorsal) and an anterior (intercostal).

The first and last dorsal nerves are peculiar in some respects.

Posterior Divisions of the Dorsal Nerves.

The **posterior divisions of the dorsal nerves**, which are smaller than the anterior, pass backward between the transverse processes, and divide into internal and external branches.

The *internal branches of the six upper nerves* pass inward between the Semispinalis dorsi and Multifidus spinæ muscles, which they supply, and then, piercing

the origins of the Rhomboidei and Trapezius muscles, become cutaneous by the side of the spinous processes and ramify in the integument. The internal branches of the six lower nerves are distributed to the Multifidus spinæ, without giving off any cutaneous filaments.

The *external branches* increase in size from above downward. They pass through the Longissimus dorsi to the cellular interval between it and the Iliocostalis, and supply those muscles, as well as their continuations upward to the head, and the Levatores costarum; the five or six lower nerves also give off cutaneous filaments, which pierce the Serratus posticus inferior and Latissimus dorsi in a line with the angles of the ribs, and then ramify in the integument.

The *cutaneous branches of the dorsal nerves* are twelve in number. The six upper cutaneous nerves are derived from the internal branches of the posterior divisions of the dorsal nerves. They pierce the origins of the Rhomboidei and Trapezius muscles, and become cutaneous by the side of the spinous processes, and then ramify in the integument. They are frequently furnished with gangliform enlargements. The six lower cutaneous nerves are derived from the external branches of the posterior divisions of the dorsal nerves. They pierce the Serratus posticus inferior and Latissimus dorsi in a line with the angles of the ribs, and then ramify in the integument.

Anterior Divisions of the Dorsal Nerves.

The **anterior divisions of the dorsal nerves** (*intercostal nerves*) are twelve in number on each side. They are, for the most part, distributed to the parietes of the thorax and abdomen, separately from each other, without being joined in a plexus; in which respect they differ from the other spinal nerves. Each nerve is connected with the adjoining ganglia of the sympathetic by one or two filaments. The intercostal nerves may be divided into two sets, from the difference they present in their distribution. The six upper, with the exception of the first and the intercosto-humeral branch of the second, are limited in their distribution to the parietes of the chest. The six lower supply the parietes of the chest and abdomen, the last one sending a cutaneous filament to the hip.

The First Dorsal Nerve.—The anterior division of the first dorsal nerve divides into two branches: one, the larger, leaves the thorax in front of the neck of the first rib, and enters into the formation of the brachial plexus; the other and smaller branch runs along the first intercostal space, forming the *first intercostal nerve*, and terminates on the front of the chest by forming the first anterior cutaneous nerve of the thorax. Occasionally this anterior cutaneous branch is wanting. The first intercostal nerve, as a rule, gives off no lateral cutaneous branch, but sometimes a small branch is given off which communicates with the intercosto-humeral.

The Upper Dorsal Nerves.—The anterior divisions of the second, third, fourth, fifth, and sixth dorsal nerves and the small branch from the first dorsal are confined to the parietes of the thorax, and are named *upper* or *pectoral intercostal nerves*. They pass forward in the intercostal spaces with the intercostal vessels, being situated below them. At the back of the chest they lie between the pleura and the External intercostal muscle, but are soon placed between the two planes of Intercostal muscles as far as the middle of the rib. They then enter the substance of the Internal intercostal muscles, and, running amidst their fibres as far as the costal cartilages, they gain the inner surface of the muscles and lie between them and the pleura. Near the sternum they cross the internal mammary artery and Triangularis sterni muscle, pierce the Internal intercostal and Pectoralis major muscles, and supply the integument of the front of the chest and over the mammary gland, forming the *anterior cutaneous nerves of the thorax*, the branch from the second nerve becoming joined with the supraclavicular nerves of the cervical plexus.

Branches.—Numerous slender muscular filaments supply the Intercostals, the Infracostales, the Levatores costarum, Serratus posticus superior, and Triangularis

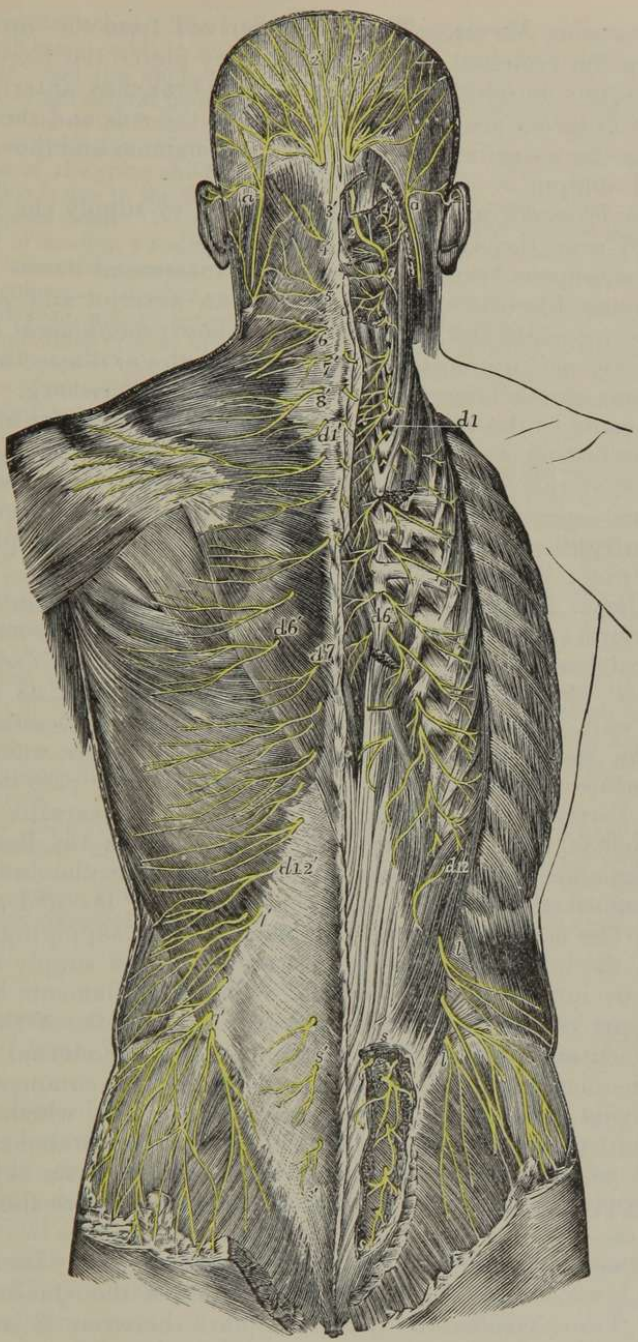

FIG. 502.—Superficial and deep distribution of the posterior branches of the spinal nerves (after Hirschfeld and Leveillé). On the left side the cutaneous branches are represented lying on the superficial layer of muscles. On the right side the superficial muscles have been removed, the Splenius capitis and Complexus divided in the neck, and the Erector spinæ divided and partly removed in the back, so as to expose the posterior divisions of the spinal nerves near their origin. *a a*. Lesser occipital nerve from the cervical plexus. 1. External muscular branches of the first cervical nerve, and union by a loop with the second. 2, placed on the Rectus capitis posticus major muscle, marks the great occipital nerve, passing round the short muscles and piercing the Complexus: the external branch is seen to the outside. 3. External branch from the posterior division of the third nerve. 3′. Its internal branch, sometimes called the third occipital. 4′ to 8′. The internal branches of the several corresponding nerves on the left side. The external branches of these nerves, proceeding to muscles, are displayed on the right side, *d* 1 to *d* 6, and thence to *d* 12. External muscular branches of the posterior divisions of the twelve dorsal nerves on the right side, *d* 1′ to *d* 6′. The internal cutaneous branches of the six upper dorsal nerves on the left side, *d* 7′ to *d* 12. Cutaneous twigs from the external branches of the six lower dorsal nerves. *l l*. External branches from the posterior divisions of several lumbar nerves on the right side, piercing the muscles, the lower descending over the gluteal region. *l′ l′*. The same, more superficially, on the left side. *s s*. The issue and union by loops of the posterior divisions of four sacral nerves on the right side. *s′ s′*. Some of those distributed to the skin on the left side.

sterni muscles. Some of these branches, at the front of the chest, cross the costal cartilages from one to another intercostal space.

Lateral Cutaneous Nerves.—These are derived from the intercostal nerves, midway between the vertebræ and sternum: they pierce the External intercostal and Serratus magnus muscles, and divide into two branches, anterior and posterior.

The *anterior branches* are reflected forward to the side and the fore part of the chest, supplying the integument of the chest and mamma and the upper digitations of the External oblique.

The *posterior branches* are reflected backward to supply the integument over the scapula and over the Latissimus dorsi.

The lateral cutaneous branch of the second intercostal nerve is of large size, and does not divide, like the other nerves, into an anterior and posterior branch. It is named, from its origin and distribution, the *intercosto-humeral nerve* (Fig. 500). It pierces the External intercostal muscle, crosses the axilla to the inner side of the arm, and joins with a filament from the nerve of Wrisberg. It then pierces the fascia, and supplies the skin of the upper half of the inner and back part of the arm, communicating with the internal cutaneous branch of the musculo-spiral nerve. The size of this nerve is in inverse proportion to the size of the other cutaneous nerves, especially the nerve of Wrisberg. A second intercosto-humeral nerve is frequently given off from the third intercostal. It supplies filaments to the armpit and inner side of the arm.

The Lower Dorsal Nerves.—The anterior divisions of the seventh, eighth, ninth, tenth, and eleventh dorsal nerves are continued anteriorly from the intercostal spaces into the abdominal wall, hence these nerves are named *lower* or *abdominal intercostal nerves;* the twelfth dorsal is continued throughout its whole course in the abdominal wall, since it is placed below the last rib (*subcostal nerve*). They have (except the last) the same arrangement as the upper ones as far as the anterior extremities of the intercostal spaces, where they pass behind the costal cartilages, and between the Internal oblique and Transversalis muscles, to the sheath of the Rectus, which they perforate. They supply the Rectus muscle, and terminate in branches which become subcutaneous near the linea alba. These branches are named the *anterior cutaneous nerves of the abdomen.* They are directed outward as far as the lateral cutaneous nerves, supplying the integument of the front of the belly. The lower intercostal nerves supply the Intercostals, Serratus posticus inferior, and Abdominal muscles. Filaments have been traced to the costal part of the Diaphragm. About the middle of their course they give off lateral cutaneous branches, which pierce the External intercostal and External oblique muscles, in the same line as the lateral cutaneous nerves of the thorax, and divide into anterior and posterior branches, which are distributed to the integument of the abdomen and back, the anterior branches passing nearly as far forward as the margin of the Rectus, the posterior branches passing backward to supply the skin over the Latissimus dorsi, where they join the dorsal cutaneous nerves.

The **last dorsal** is larger than the other dorsal nerves. Its anterior division runs along the lower border of the last rib in front of the Quadratus lumborum, perforates the Transversalis, and passes forward between it and the Internal oblique to be distributed in the same manner as the lower intercostal nerves. It communicates with the ilio-hypogastric branch of the lumbar plexus, and is frequently connected with the first lumbar nerve by a slender branch, the *dorso-lumbar nerve*, which descends in the substance of the Quadratus lumborum.

The *lateral cutaneous branch of the last dorsal* is remarkable for its large size: it perforates the Internal and External oblique muscles, passes downward over the crest of the ilium in front of the iliac branch of the ilio-hypogastric (Fig. 509), and is distributed to the integument of the front of the hip, some of its filaments extending as low down as the trochanter major. It does not divide into an anterior and posterior branch like the other lateral cutaneous branches of the intercostal nerves.

Surgical Anatomy.—The lower seven intercostal nerves and the ilio-hypogastric from the first lumbar nerve supply the skin of the abdominal wall. They run downward and inward

fairly equidistant from each other. The sixth and seventh supply the skin over the "pit of the stomach;" the eighth corresponds to about the position of the middle linea transversa; the tenth to the umbilicus; and the ilio-hypogastric supplies the skin over the pubes and external abdominal ring. There are several points of surgical importance about the distribution of these nerves, and it is important to remember their origin and course, for in many diseases affecting the nerve-trunks at or near the origin the pain is referred to their peripheral terminations. Thus in Pott's disease of the spine children will often be brought to the surgeon suffering from pain in the belly. This is due to the fact that the nerves are irritated at the seat of disease as they issue from the spinal canal. When the irritation is confined to a single pair of nerves, the sensation complained of is often a feeling of constriction, as if a cord were tied round the abdomen; and in these cases the situation of the sense of constriction may serve to localize the disease in the spinal column. In other cases, where the bone disease is more extensive and two or more nerves are involved, a more general diffused pain in the abdomen is complained of. A similar condition is sometimes present in affections of the cord itself, as in tabes dorsalis.

Again, it must be borne in mind that the same nerves which supply the skin of the abdomen supply also the planes of muscle which constitute the greater part of the abdominal wall. Hence it follows that any irritation applied to the peripheral terminations of the cutaneous branches in the skin of the abdomen is immediately followed by reflex contraction of the abdominal muscles. A good practical illustration of this may sometimes be seen in watching two surgeons examine the abdomen of the same patient. One, whose hand is cold, causes the muscles of the abdominal wall to at once contract and the belly to become rigid, and thus not nearly so suitable for examination; the other, who has taken the precaution to warm his hand, examines the abdomen without exciting any reflex contraction. The supply of both muscles and skin from the same source is of importance in protecting the abdominal viscera from injury. A blow on the abdomen, even of a severe character, will do no injury to the viscera if the muscles are in a condition of firm contraction; whereas in cases where the muscles have been taken unawares, and the blow has been struck while they were in a state of rest, an injury insufficient to produce any lesion of the abdominal wall has been attended with rupture of some of the abdominal contents. The importance, therefore, of immediate reflex contraction upon the receipt of an injury cannot be overestimated, and the intimate association of the cutaneous and muscular fibres in the same nerve produces a much more immediate response on the part of the muscles to any peripheral stimulation of the cutaneous filaments than would be the case if the two sets of fibres were derived from independent sources.

Again, the nerves supplying the abdominal muscles and skin derived from the lower intercostal nerves are intimately connected with the sympathetic supplying the abdominal viscera through the lower thoracic ganglia from which the splanchnic nerves are derived. In consequence of this, in laceration of the abdominal viscera and in acute peritonitis the muscles of the belly-wall become firmly contracted, and thus as far as possible preserve the abdominal contents in a condition of rest.

THE LUMBAR NERVES.

The **lumbar nerves** are five in number on each side. The first appears between the first and second lumbar vertebræ, and the last between the last lumbar and the base of the sacrum.

The **roots** of the lower lumbar (and upper sacral) nerves are the largest, and their filaments the most numerous, of all the spinal nerves, and they are closely aggregated together upon the lower end of the cord. The anterior roots are the smaller, but there is not the same disproportion between them and the posterior roots as in the cervical nerves. The roots of these nerves have a vertical direction, and are of considerable length, more especially the lower ones, since the spinal cord does not extend beyond the first lumbar vertebra. The roots become joined in the intervertebral foramina, and the nerves so formed divide at their exit into two divisions, posterior and anterior.

Posterior Divisions of the Lumbar Nerves.

The **posterior divisions of the lumbar nerves** (Fig. 502) diminish in size from above downward; they pass backward beneath the transverse processes, and divide into internal and external branches.

The *internal branches*, the smaller, pass inward close to the articular processes of the vertebræ, and supply the Multifidus spinæ and Interspinales muscles.

The *external branches* supply the Erector spinæ and Intertransverse muscles. From the three upper branches cutaneous nerves are derived which pierce the aponeurosis of the Latissimus dorsi muscle and descend over the back part of the

crest of the ilium, to be distributed to the integument of the gluteal region, some of the filaments passing as far as the trochanter major (*nervi clunium superiores*).

Anterior Divisions of the Lumbar Nerves.

The **anterior divisions of the lumbar nerves** increase in size from above downward. At their origin they communicate with the lumbar ganglia of the sympathetic by long, slender filaments, which accompany the lumbar arteries round the sides of the bodies of the vertebræ, beneath the Psoas muscle. The nerves pass obliquely outward behind the Psoas magnus or between its fasciculi, distributing filaments to it and the Quadratus lumborum. The anterior divisions of the four upper nerves give off their branches by a series of anastomotic loops, which are called the *lumbar plexus*. The anterior division of the fifth lumbar, joined with a branch from the fourth, descends across the base of the sacrum to join the anterior division of the first sacral nerve and assist in the formation of the sacral plexus. The cord resulting from the union of the fifth lumbar and the branch from the fourth is called the *lumbo-sacral nerve*.

The Lumbar Plexus.

The **lumbar plexus**, so called, is formed by the anastomotic loops above mentioned. The plexus is narrow above, and often connected with the last dorsal by

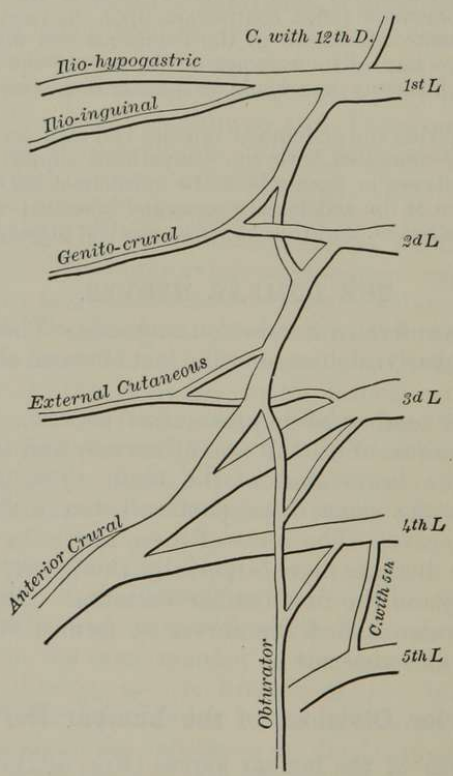

FIG. 503.—Plan of the lumbar plexus.

a slender branch, the *dorso-lumbar nerve;* it is broad below, where it is joined to the sacral plexus by the lumbo-sacral cord. It is situated in the substance of the Psoas muscle near its posterior part, in front of the transverse processes of the lumbar vertebræ.

The mode in which the plexus is formed varies greatly in different subjects. A plan which is often found is the following: The **first lumbar nerve** receives a branch from the last dorsal, and gives off two branches, the upper of which sub-

divides into the ilio-hypogastric and ilio-inguinal; the lower one descends and *subdivides* into two branches, an *anterior* and a *posterior*. The **second lumbar nerve** sends a branch to join with the *anterior* of the two preceding, to form the genito-crural nerve; the rest of the nerve then receives the *posterior* of the two above mentioned, and proceeds downward, giving off an *external*, a *middle*, and an *internal* branch. The **third lumbar nerve** gives off three branches, known as *dorsal*, *middle*, and *ventral*. The **fourth lumbar nerve** also divides into three branches, known as *anterior*, *posterior*, and *inferior*. These various subdivisions now unite as follows: The *external* from the second joins the *dorsal* from the third to form the external cutaneous nerve. The *middle* branches from the second and third together with the *posterior* from the fourth, unite to form the anterior crural nerve; while the remaining (*internal* and *ventral*) branches of the second and third lumbar nerves unite with the *anterior* of the fourth to form the obturator nerve. The remainder of the anterior division of the fourth nerve passes down to communicate with the fifth lumbar nerve. The accessory obturator, when it exists, is formed by a small branch from the third nerve joining with a small branch from the fourth.

From this arrangement it follows that the ilio-hypogastric and ilio-inguinal are derived entirely from the first lumbar nerve; the genito-crural from the first and second nerves; the external cutaneous from the second and third; the anterior crural and obturator by fibres derived from the second, third, and fourth; and the accessory obturator, when it exists, from the third and fourth.

The branches of the lumbar plexus are—the

Ilio-hypogastric.	Anterior crural.
Ilio-inguinal.	Obturator.
Genito-crural.	Accessory obturator.
External cutaneous.	

The **Ilio-hypogastric Nerve** (*superior musculo-cutaneous*) arises from the first lumbar nerve. It emerges from the outer border of the Psoas muscle at its upper part, and crosses obliquely in front of the Quadratus lumborum to the crest of the ilium. It then perforates the Transversalis muscle at its posterior part, near the crest of the ilium, and divides between it and the Internal oblique into two branches, iliac and hypogastric.

The *iliac branch* pierces the Internal and External oblique muscles immediately above the crest of the ilium, and is distributed to the integument of the gluteal region, behind the lateral cutaneous branch of the last dorsal nerve (Fig. 509). The size of this nerve bears an inverse proportion to that of the cutaneous branch of the last dorsal nerve.

The *hypogastric branch* (Fig. 505) continues onward between the Internal oblique and Transversalis muscles. It then pierces the Internal oblique, and near the middle line perforates the aponeurosis of the External oblique, about an inch above and a little to the outer side of the external abdominal ring, and is distributed to the integument of the hypogastric region.

The ilio-hypogastric nerve communicates with the last dorsal and ilio-inguinal nerves.

The **Ilio-inguinal Nerve** (*inferior musculo-cutaneous*), smaller than the preceding, arises with it from the first lumbar nerve. It emerges from the outer border of the Psoas just below the ilio-hypogastric, and, passing obliquely across the Quadratus lumborum and Iliacus muscles, perforates the Transversalis near the fore part of the crest of the ilium, and communicates with the ilio-hypogastric nerve between that muscle and the Internal oblique. The nerve then pierces the Internal oblique, distributing filaments to it; and, accompanying the spermatic cord through the inguinal canal, it escapes at the external abdominal ring, and is distributed to the integument of the upper and inner part of the thigh, and to the scrotum in the male and to the labium in the female. The size of this nerve is in

inverse proportion to that of the ilio-hypogastic. Occasionally it is very small, and ends by joining the ilio-hypogastric; in such cases a branch from the ilio-hypogastric takes the place of the ilio-inguinal, or the latter nerve may be altogether absent.

The **Genito-crural Nerve** arises from the first and second lumbar nerves. It passes obliquely through the substance of the Psoas, and emerges from its inner border at a level corresponding to the intervertebral substance between the third and fourth lumbar vertebræ. It descends on its surface for a variable distance, and divides into a genital and crural branch.

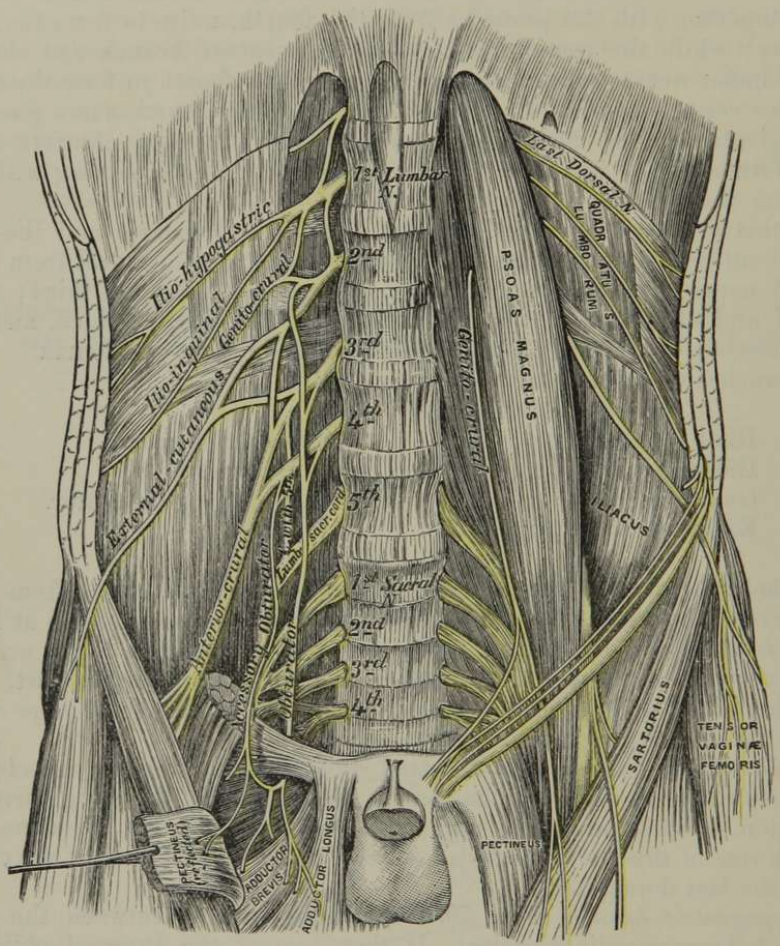

FIG. 504.—The lumbar plexus and its branches.

The *genital branch* passes outward on the Psoas magnus, near the external iliac artery, to which it gives a twig. It then pierces the fascia transversalis or passes through the internal abdominal ring, descends along the back part of the spermatic cord to the scrotum in the male, and supplies the Cremaster muscle. In the female it accompanies the round ligament.

The *crural branch* descends on the external iliac artery, sending a few filaments round it, and, passing beneath Poupart's ligament into the thigh, enters the sheath of the femoral vessels lying superficial and a little external to the femoral artery, to which it also supplies a few filaments. It pierces the anterior layer of the sheath of the vessels, and, becoming superficial by passing through the fascia lata, it supplies the skin of the anterior aspect of the thigh as far as midway between the pelvis and knee. On the front of the thigh it communicates with the outer branch of the middle cutaneous nerve, derived from the anterior crural.

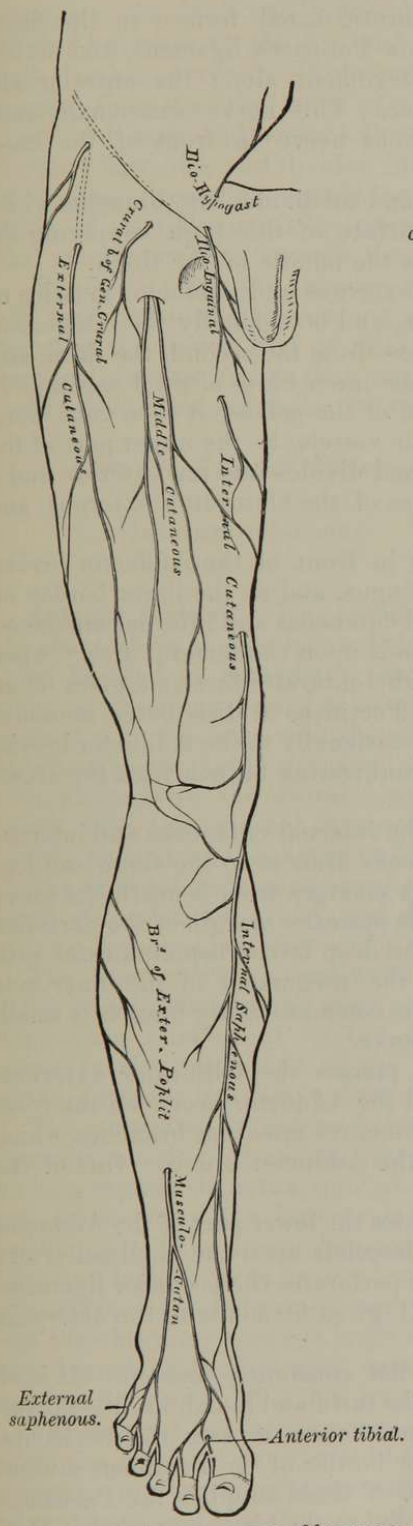

FIG. 505.—Cutaneous nerves of lower extremity. Front view.

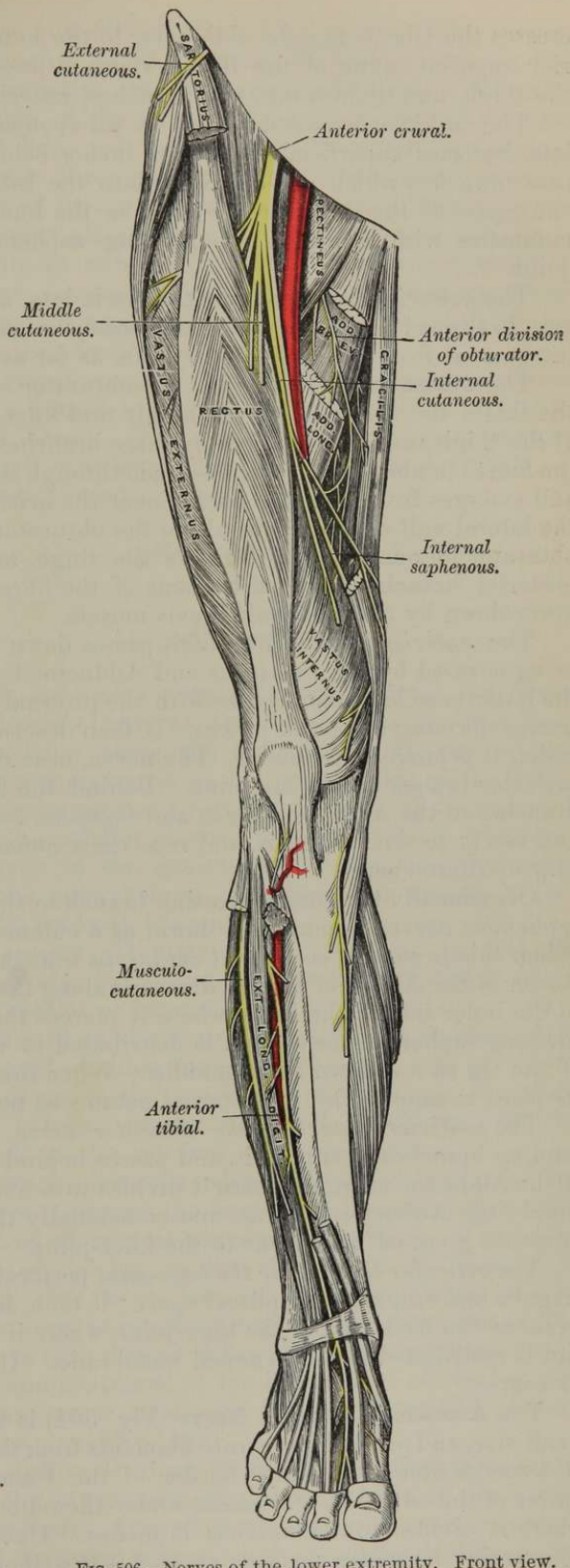

FIG. 506.—Nerves of the lower extremity. Front view.

The **External Cutaneous Nerve** arises from the second and third lumbar nerves. It emerges from the outer border of the Psoas muscle about its middle, and

crosses the Iliacus muscle obliquely, to the notch immediately beneath the anterior superior spine of the ilium, where it passes under Poupart's ligament into the thigh, and divides into two branches, anterior and posterior.

The *anterior branch* descends in an aponeurotic canal formed in the fascia lata, becomes superficial about four inches below Poupart's ligament, and divides into branches which are distributed to the integument along the anterior and outer part of the thigh, as far down as the knee. This nerve occasionally communicates with a branch of the long saphenous nerve in front of the knee-joint.

The *posterior branch* pierces the fascia lata, and subdivides into branches which pass backward across the outer and posterior surface of the thigh, supplying the integument from the crest of the ilium as far as the middle of the thigh.

The **Obturator Nerve** supplies the obturator externus and Adductor muscles of the thigh, the articulations of the hip and knee, and occasionally the integument of the thigh and leg. It arises by three branches—from the second, the third, and the fourth lumbar nerves. It descends through the inner fibres of the Psoas muscle and emerges from its inner border near the brim of the pelvis; it then runs along the lateral wall of the pelvis, above the obturator vessels, to the upper part of the obturator foramen, where it enters the thigh, and divides into an anterior and a posterior branch, separated by some of the fibres of the Obturator externus, and lower down by the Adductor brevis muscle.

The *anterior branch* (Fig. 506) passes down in front of the Adductor brevis, being covered by the Pectineus and Adductor longus, and at the lower border of the latter muscle communicates with the internal cutaneous and internal saphenous nerves, forming a kind of plexus. It then descends upon the femoral artery, upon which it is finally distributed. The nerve, near the obturator foramen, gives off an articular branch to the hip-joint. Behind the Pectineus it distributes muscular branches to the Adductor longus and Gracilis, occasionally to the Adductor brevis, and rarely to the Pectineus, and receives a communicating branch from the accessory obturator nerve.

Occasionally the communicating branch to the internal cutaneous and internal saphenous nerves is continued down, as a cutaneous branch, to the thigh and leg. When this is so, this *occasional cutaneous* branch emerges from beneath the lower border of the Adductor longus, descends along the posterior margin of the Sartorius to the inner side of the knee, where it pierces the deep fascia, communicates with the long saphenous nerve, and is distributed to the integument of the inner side of the leg as low down as its middle. When this communicating branch is small, its place is supplied by the internal cutaneous nerve.

The *posterior branch of the obturator nerve* pierces the Obturator externus, sending branches to supply it, and passes behind the Adductor brevis on the front of the Adductor magnus, where it divides into numerous muscular branches, which supply the Adductor magnus, and occasionally the Adductor brevis. One of the branches gives off a filament to the knee-joint.

The *articular branch for the knee-joint* perforates the lower part of the Adductor magnus and enters the popliteal space; it then descends upon the popliteal artery as far as the back part of the knee-joint, where it perforates the posterior ligament, and is distributed to the synovial membrane. It gives filaments to the artery in its course.

The **Accessory Obturator Nerve** (Fig. 504) is not constantly present. It is of small size, and arises by separate filaments from the third and fourth lumbar nerves. It descends along the inner border of the Psoas muscle, crosses the horizontal ramus of the os pubis, and passes under the outer border of the Pectineus muscle, where it divides into numerous branches. One of these supplies the Pectineus, penetrating its under surface; another is distributed to the hip-joint; while a third communicates with the anterior branch of the obturator nerve. When this nerve is absent the hip-joint receives two branches from the obturator nerve. Occasionally it is very small, and becomes lost in the capsule of the hip-joint.

The **Anterior Crural Nerve** (Figs. 504, 506) is the largest branch of the lumbar plexus. It supplies muscular branches to the Iliacus, Pectineus, and all the muscles on the front of the thigh, excepting the Tensor vaginæ femoris; cutaneous filaments to the front and inner side of the thigh and to the leg and foot; and articular branches to the hip and knee. It arises from the second, third, and fourth lumbar nerves. It descends through the fibres of the Psoas muscle, emerging from it at the lower part of its outer border, and passes down between it and the Iliacus, and beneath Poupart's ligament, into the thigh, where it becomes somewhat flattened, and divides into an anterior part which passes superficial to the external circumflex vessels, and a posterior part which passes beneath these vessels. Under Poupart's ligament it is separated from the femoral artery by the Psoas muscle, and lies beneath the iliac fascia.

Within the pelvis the anterior crural nerve gives off from its outer side some small branches to the Iliacus, and a branch to the femoral artery which is distributed upon the upper part of that vessel. The origin of this branch varies: it occasionally arises higher than usual, or it may arise lower down in the thigh.

External to the pelvis the following branches are given off:

From the Anterior Division.	*From the Posterior Division.*
Middle cutaneous.	Long saphenous.
Internal cutaneous.	Muscular.
Muscular.	Articular.

Anterior Division.—The *middle cutaneous nerve* (Fig. 505) pierces the fascia lata about three inches below Poupart's ligament, and divides into two branches, which descend in immediate proximity along the fore part of the thigh, distributing numerous branches to the integument as low as the front of the knee, where it communicates with the *nervus cutaneus patellæ*, a branch of the internal saphenous nerve, helping to form the patellar plexus. Its outer branch communicates, above, with the crural branch of the genito-crural nerve, and the inner branch with the internal cutaneous nerve below. The Sartorius muscle is frequently pierced by this nerve or by its outer branch.

The *internal cutaneous nerve* passes obliquely across the upper part of the sheath of the femoral artery, and divides in front or at the inner side of that vessel into two branches, anterior and posterior or internal.

The *anterior branch* runs downward on the Sartorius, perforates the fascia lata at the lower third of the thigh, and divides into two branches, one of which supplies the integument as low down as the inner side of the knee; the other crosses to the outer side of the patella, communicating in its course with the nervus cutaneus patellæ, a branch of the internal saphenous nerve.

The *posterior* or *internal branch* descends along the inner border of the Sartorius muscle to the knee, where it pierces the fascia lata, communicates with the long saphenous nerve, and gives off several cutaneous branches. The nerve then passes down the inner side of the leg, to the integument of which it is distributed. This nerve, beneath the fascia lata, at the lower border of the Adductor longus, joins in a plexiform network by uniting with branches of the long saphenous and obturator nerves (Fig. 506). When the communicating branch from the obturator nerve is large and continued to the integument of the leg, the inner branch of the internal cutaneous is small and terminates at the plexus, occasionally giving off a few cutaneous filaments.

The internal cutaneous nerve, before dividing, gives off a few filaments, which pierce the fascia lata, to supply the integument of the inner side of the thigh, accompanying the long saphenous vein. One of these filaments passes through the saphenous opening; a second becomes subcutaneous about the middle of the thigh; and a third pierces the fascia at its lower third.

The *muscular branches* supply the Pectineus and Sartorius. Those to the Pectineus, often united with the internal cutaneous nerve at their origin, are

usually two in number and pass inward behind the femoral vessels, and enter the muscle on its anterior surface. Sometimes one of these nerves is given off in the pelvis, and is then often united with the accessory obturator. The Sartorius is supplied by filaments which arise in common with the middle cutaneous nerve and enter the upper part of the muscle.

Posterior Division.—The *long* or *internal saphenous nerve* is the largest of the cutaneous branches of the anterior crural. It approaches the femoral artery where this vessel passes beneath the Sartorius, and lies at first on its outer side and then crosses over it, beneath the aponeurotic covering of Hunter's canal, as far as the opening in the lower part of the Adductor magnus. It then quits the artery, and descends vertically along the inner side of the knee, beneath the Sartorius, pierces the fascia lata, opposite the interval between the tendons of the Sartorius and Gracilis, and becomes subcutaneous. The nerve then passes along the inner side of the leg, accompanied by the internal saphenous vein, descends behind the internal border of the tibia, and, at the lower third of the leg, divides into two branches: one continues its course along the margin of the tibia, terminating at the inner ankle; the other passes in front of the ankle, and is distributed to the integument along the inner side of the foot, as far as the great toe, communicating with the internal branch of the musculo-cutaneous nerve.

The long saphenous nerve *about the middle of the thigh* gives off a communicating branch which joins the plexus formed by the obturator and internal cutaneous nerves.

At the inner side of the knee it gives off a large branch (*nervus cutaneus patellæ*) which pierces the Sartorius and fascia lata, and is distributed to the integument in front of the patella. This nerve communicates above the knee with the anterior branch of the internal cutaneous and with the middle cutaneous; below the knee, with other branches of the long saphenous; and on the outer side of the joint, with branches of the external cutaneous nerve, forming a plexiform network, the *plexus patellæ*. The cutaneous nerve of the patella is occasionally small, and terminates by joining the internal cutaneous, which supplies its place in front of the knee.

Below the knee the branches of the long saphenous nerve are distributed to the integument of the front and inner side of the leg, communicating with the cutaneous branches from the internal cutaneous or from the obturator nerve.

The *muscular branches* are as follows:

The *branch to the Rectus muscle* enters its under surface high up, sending off a small filament to the hip-joint.

The *branch to the Vastus externus*, of large size, follows the course of the descending branch of the external circumflex artery to the lower part of the muscle. It gives off an articular filament to the knee-joint.

The *branch to the Vastus internus* is a long branch which runs down on the outer side of the femoral vessels in company with the internal saphenous nerve for its upper part. It enters the muscle about its middle, and gives off a filament which can usually be traced downward on the surface of the muscle to the knee-joint.

The *branch to the Crureus* enters the muscle on its anterior surface about the middle of the thigh, and sends a filament through the muscle to the Subcrureus. *Articular branches to the hip-joint* are derived from some of the other muscular branches as well as from the nerve to the Rectus.

The *articular branches to the knee-joint* are two in number. One, a long, slender filament, is derived from the nerve to the Vastus externus. It penetrates the capsular ligament of the joint on its anterior aspect. The other is derived from the nerve to the Vastus internus. It can usually be traced downward on the surface of this muscle to near the joint; it then penetrates the muscular fibres, and accompanies the deep branch of the anastomotica magna artery, pierces the capsular ligament of the joint on its inner side, and supplies the synovial membrane.

THE SACRAL AND COCCYGEAL NERVES.

The *sacral nerves* are five in number on each side. The four upper ones pass from the sacral canal through the sacral foramina; the fifth through the foramen between the sacrum and coccyx.

The *roots of origin of the upper sacral (and lower lumbar) nerves* are the largest of all the spinal nerves, whilst those of the lowest sacral and coccygeal nerve are the smallest.

The **roots** of these nerves are of very considerable length, being longer than those of any of the other spinal nerves, on account of the spinal cord not extending beyond the first lumbar vertebra. From their great length and the appearance they present in connection with the spinal cord the roots of origin of these nerves are called collectively the *cauda equina*. Each sacral and coccygeal nerve divides into two divisions, posterior and anterior.

The **posterior divisions of the sacral nerves** (Fig. 507) are small, diminish in

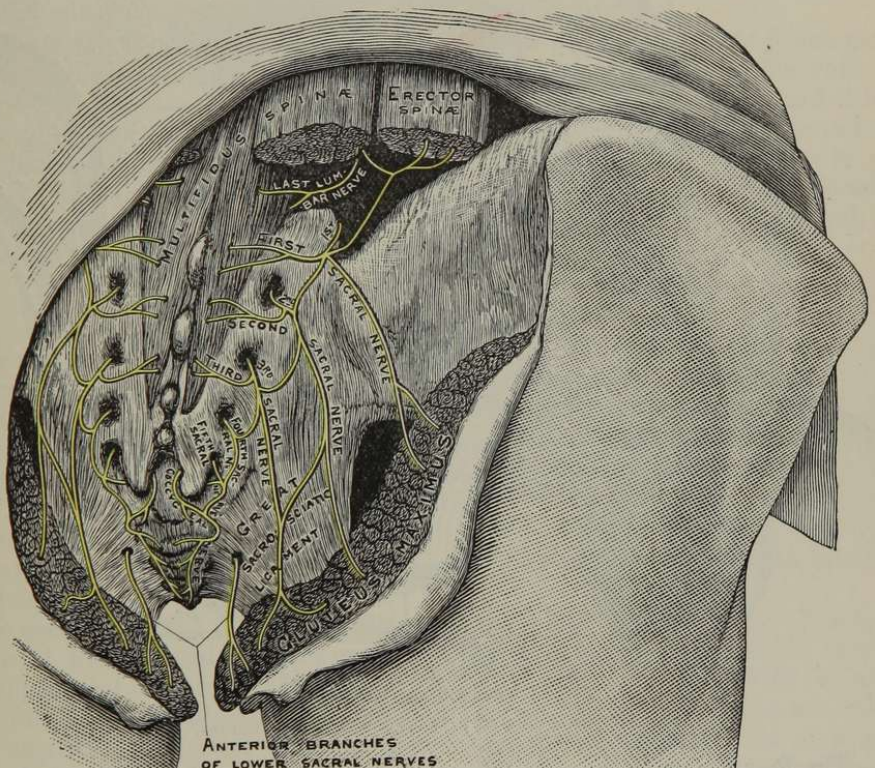

FIG. 507.—The posterior sacral nerves.

size from above downward, and emerge, except the last, from the sacral canal by the posterior sacral foramina.

The *three upper ones* are covered, at their exit from the sacral canal, by the Multifidus spinæ, and divide into internal and external branches.

The *internal branches* are small, and supply the Multifidus spinæ.

The *external branches* join with one another and with the last lumbar and fourth sacral nerves by means of communicating loops. These branches pass outward to the outer surface of the great sacro-sciatic ligament, where they form a second series of loops beneath the Gluteus maximus. Cutaneous branches from this second series of loops, usually three in number, pierce the Gluteus maximus: one near the posterior inferior spine of the ilium; another opposite the end of the sacrum; and the third midway between the other two. They supply the integument over the posterior part of the gluteal region (*nervi clunium medii*).

The *posterior divisions of the two lower sacral nerves* are situated below the Multifidus spinæ. They are of small size, and do not divide into internal and external branches, but join with each other, and with the coccygeal nerve, so as to form loops on the back of the sacrum, filaments from which supply the Extensor coccygis and the integument over the coccyx.

The **coccygeal nerve** divides into its anterior and posterior divisions in the spinal canal. The *posterior division* is the smaller. It does not divide, but receives, as already mentioned, a communicating branch from the last sacral, and is lost in the fibrous structure on the back of the coccyx.

The **anterior divisions of the sacral nerves** diminish in size from above down-

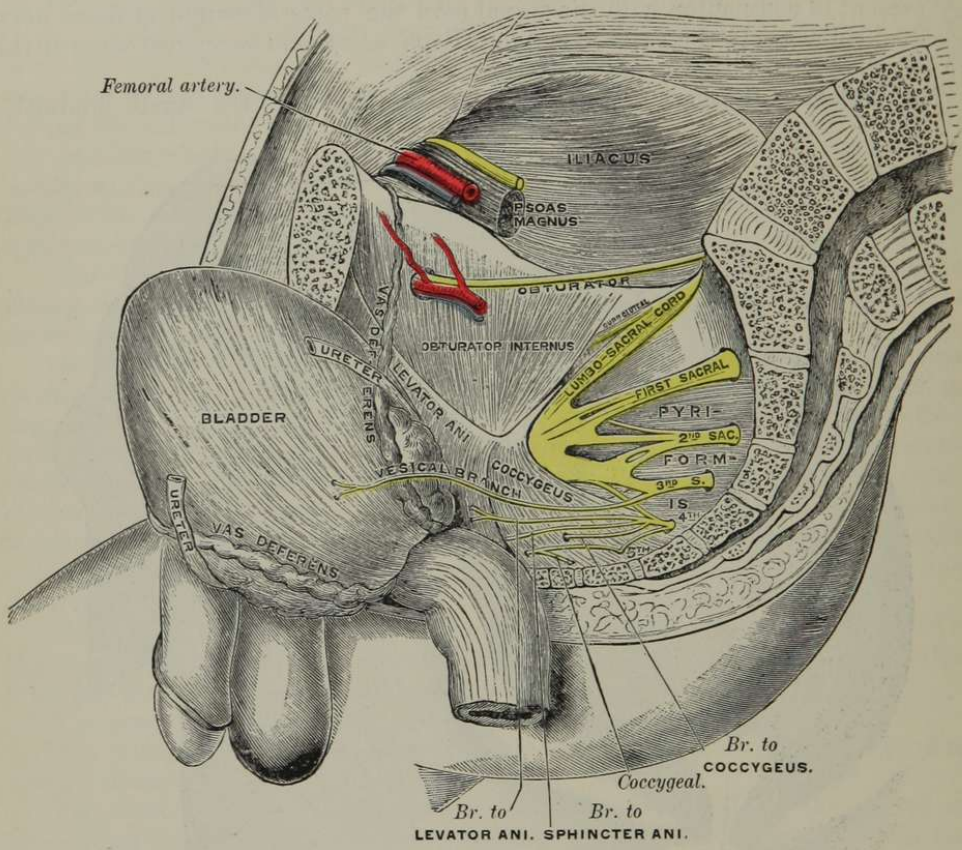

FIG. 508.—Side view of pelvis, showing sacral nerves.

ward. The four upper ones emerge from the anterior sacral foramina: the anterior division of the fifth, after emerging from the spinal canal through its terminal opening, curves forward between the sacrum and the coccyx. All the anterior sacral nerves communicate with the sacral ganglia of the sympathetic at their exit from the sacral foramina. The *first nerve*, of large size, unites with the *lumbo-sacral cord*, formed by the fifth lumbar, and a branch from the fourth lumbar. The *second*, equal in size to the preceding, and the *third*, about one-fourth the size of the second, unite, together with a small fasciculus from the fourth, to form the *sacral plexus*, a visceral branch being given off from the third nerve to the bladder.

The **fourth anterior sacral nerve** sends a branch to join the sacral plexus. The remaining portion of the nerve divides into visceral and muscular branches, and a communicating filament descends to join the fifth sacral nerve. The *visceral branches* are distributed to the viscera of the pelvis, communicating with the sympathetic nerve. These branches ascend upon the rectum and bladder, and in the female upon the vagina, communicating with branches of the sympathetic from the pelvic plexus. The *muscular branches* are distributed to the Levator

ani, Coccygeus, and Sphincter ani. The branch to the Sphincter ani pierces the Levator ani, so as to reach the ischio-rectal fossa, where it is found lying in front of the coccyx. Cutaneous filaments arise from the latter branch, which supply the integument between the anus and coccyx. Another cutaneous branch is frequently given off from this nerve, though sometimes from the pudic (Schwalbe). It perforates the great sacro-sciatic ligament, and, winding round the lower border of the Gluteus maximus, supplies the skin over the lower and inner part of this muscle.

The **fifth anterior sacral nerve,** after passing from the lower end of the sacral canal, curves forward through the fifth sacral foramen, formed between the lower part of the sacrum and the transverse process of the first piece of the coccyx. It pierces the Coccygeus muscle, and descends upon its anterior surface to near the tip of the coccyx, where it again perforates the muscle, to be distributed to the integument over the back part and side of the coccyx. This nerve communicates above with the fourth sacral and below with the coccygeal nerve, and supplies the Coccygeus muscle.

The **anterior division of the coccygeal nerve** is a delicate filament which escapes at the termination of the sacral canal; it passes downward behind the rudimentary transverse process of the first piece of the coccyx, and curves forward through the notch between the first and second pieces, piercing the Coccygeus muscle, and descending on its anterior surface to near the tip of the coccyx, where it again pierces the muscle, to be distributed to the integument over the back part and side of the coccyx. It is joined by a branch from the fifth anterior sacral as it descends on the surface of the Coccygeus muscle.

The Sacral Plexus (Fig. 508).

The **sacral plexus** is formed by the lumbo-sacral cord, the anterior divisions of the three upper sacral nerves, and part of that of the fourth. These nerves proceed in different directions; the upper ones obliquely downward and outward, the lower ones nearly horizontally. The sacral plexus is triangular in form, its base corresponding with the exit of the nerves from the sacrum, its apex with the lower part of the great sacro-sciatic foramen. It rests upon the anterior surface of the Pyriformis, and is covered in front by the pelvic fascia, which separates it from the sciatic and pudic branches of the internal iliac artery and from the viscera of the pelvis.

The special method of the formation of the plexus is as follows: The lumbo-sacral cord, first, second and larger part of the third sacral nerves unite to form a large upper cord or band. The smaller part of the third, together with the branch of the fourth nerve, already mentioned as going to the sacral plexus, unite to form a smaller, lower, cord or band. The larger is continued into the *great sciatic nerve;* the smaller is continuous with the *pudic nerve.* The remaining branches of the plexus are derived separately or by more or less intercommunication from the sacral nerves before the latter form the two principal cords just mentioned.

The branches of the sacral plexus are—

Muscular.	Perforating cutaneous.
Superior gluteal.	Pudic.
Inferior gluteal.	Small sciatic.
Great sciatic.	

The **muscular branches** supply the Pyriformis, Obturator internus, the two Gemelli, and the Quadratus femoris. The branches to the Pyriformis arise from the back of the first and second sacral nerves before they enter the plexus; the branch to the Obturator internus arises from the lumbo-sacral and first two sacral nerves: it passes out of the pelvis through the great sacro-sciatic foramen, crosses the spine of the ischium, and re-enters the pelvis through the lesser sacro-sciatic foramen to the inner surface of the Obturator internus; the branch to the Gemellus superior arises in common with the nerve to the Obturator internus: it

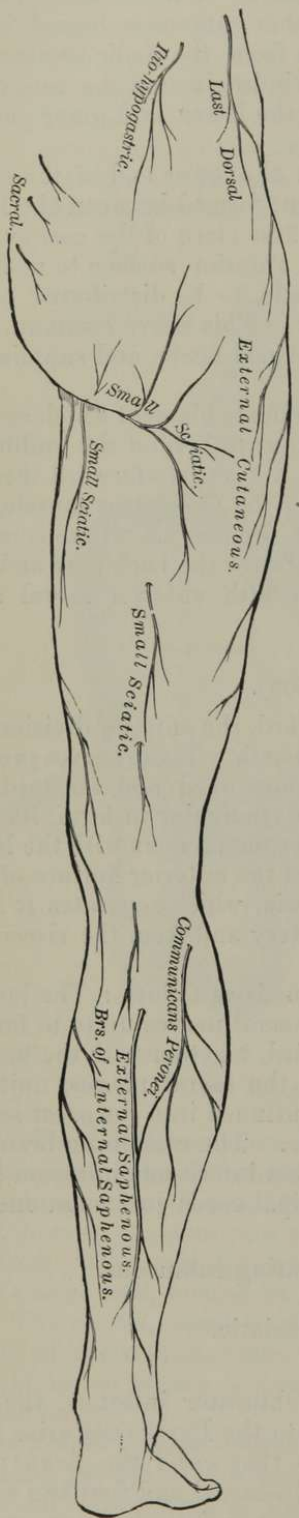

FIG. 509.—Cutaneous nerves of lower extremity. Posterior view.

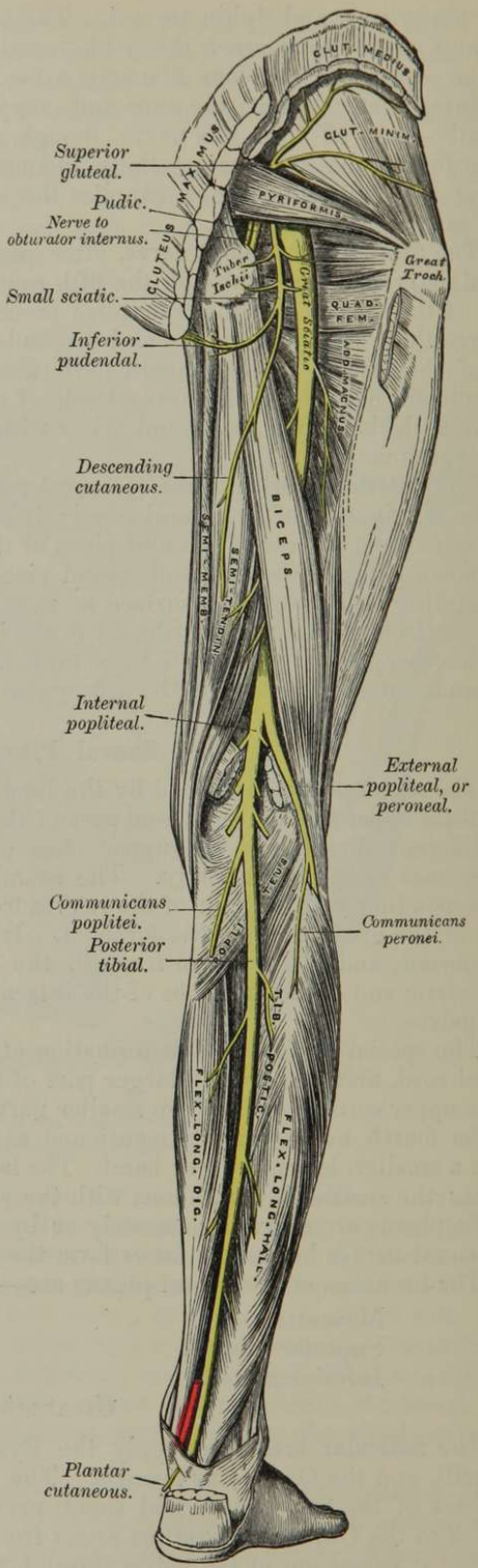

FIG. 510.—Nerves of the lower extremity.[1] Posterior view.

[1] N. B.—In this diagram the external saphenous and communicans peronei are not in their normal position. They have been displaced by the removal of the superficial muscles.

enters the muscle at the upper part of its posterior surface; the small branch to the Gemellus inferior and Quadratus femoris arises from the lumbo-sacral cord and first sacral nerve: it passes through the great sacro-sciatic foramen, and courses down beneath the Gemelli and tendon of the Obturator internus, and supplies the muscles on their deep or anterior surface. It gives off an articular branch to the hip-joint. Another articular branch is occasionally derived from the upper part of the great sciatic nerve.

The **Superior Gluteal Nerve** (Fig. 510) arises from the back part of the lumbo-sacral cord and first sacral nerve: it passes from the pelvis through the great sacro-sciatic foramen above the Pyriformis muscle, accompanied by the gluteal vessels, and divides into a superior and an inferior branch.

The *superior branch* follows the line of origin of the Gluteus minimus, and supplied the Gluteus medius.

The *inferior branch* crosses obliquely between the Gluteus minimus and medius, distributing filaments to both these muscles, and terminates in the Tensor vaginæ femoris, extending nearly to its lower end.

The **Inferior Gluteal** arises from the lumbo-sacral cord and first and second sacral nerves, and is often intimately connected with the small sciatic at its origin. It passes out of the pelvis through the great sciatic notch, beneath the Pyriformis muscle, and, dividing into a number of branches, enters the Gluteus maximus muscle on its under surface.

The **Perforating Cutaneous Nerve** is derived from the second and third sacral nerves. It pierces the great sacro-sciatic ligament and winds round the lower border of the Gluteus maximus muscle to supply the skin of the buttock.

The **Pudic Nerve** arises from the lower cord of the sacral plexus (sometimes containing fibres derived from the second and even first sacral nerves), and leaves the pelvis, through the great sacro-sciatic foramen, below the Pyriformis. It then crosses the spine of the ischium, and re-enters the pelvis through the lesser sacro-sciatic foramen. It accompanies the pudic vessels upward and forward for a short distance along the outer wall of the ischio-rectal fossa, and then divides into three branches, the perineal nerve, the dorsal nerve of the penis, and the inferior hæmorrhoidal nerve.

The *inferior hæmorrhoidal nerve* is occasionally derived separately from the sacral plexus. It passes across the ischio-rectal fossa, with its accompanying vessels, toward the lower end of the rectum, and is distributed to the integument round the anus. Branches of this nerve communicate with the inferior pudendal and superficial perineal nerves at the fore part of the perinæum.

The *perineal nerve*, the largest of the branches of the pudic, is situated below the pudic artery. It accompanies the superficial perineal artery in the perinæum, dividing into cutaneous and muscular branches.

The cutaneous branches (superficial perineal) are two in number, posterior and anterior. The *posterior* or *external branch* passes forward along the outer side of the perineal space parallel to the inferior pudendal nerve, and is distributed to the skin of the scrotum. It communicates with the inferior hæmorrhoidal, the inferior pudendal, and the other superficial perineal nerve. The *anterior* or *internal branch* passes forward nearer to the middle line, to be distributed to the inner and back part of the scrotum. Both these nerves supply the labia majora in the female.

The muscular branches are distributed to the Transversus perinæi, Accelerator urinæ, Erector penis, External sphincter and Levator ani, and Compressor urethræ. A distinct branch is given off from the nerve to the Accelerator urinæ, which pierces this muscle and supplies the corpus spongiosum, ending in the mucous membrane of the urethra. This is the nerve to the bulb.

The *dorsal nerve of the penis* is the deepest division of the pudic nerve; it accompanies the pudic artery along the ramus of the ischium: piercing the posterior layer of the deep perineal fascia, it runs forward along the inner margin of the ramus of the os pubis, between the two layers of the deep fascia. It then

pierces the anterior layer, and, in company with the dorsal artery of the penis, passes through the suspensory ligament, and, running forward, is distributed to the glans. On the penis this nerve gives off a cutaneous branch which runs along the side of the organ; it is joined with branches of the sympathetic, and supplies the integument of the upper surface and sides of the penis and prepuce, giving a large branch to the corpus cavernosum.

In the female the dorsal nerve is very small and supplies the clitoris.

The **Small Sciatic Nerve** (Fig. 510) supplies the integument of the perinæum and back part of the thigh and leg. It is usually formed by the union of three branches, which arise from the first, second, and third nerves of the sacral plexus. It issues from the pelvis through the great sacro-sciatic foramen below the Pyriformis muscle, descends beneath the Gluteus maximus with the sciatic artery, and at the lower border of that muscle passes along the back part of the thigh, beneath the fascia lata, to the lower part of the popliteal region, where it pierces the fascia and becomes cutaneous. It then accompanies the external saphenous vein to about the middle of the leg, its terminal filaments communicating with the external saphenous nerve.

The branches of the small sciatic nerve are all cutaneous, and are as follows: perineal, femoral, and ascending.

The *perineal cutaneous branches* are distributed to the skin at the upper and inner side of the thigh, on its posterior aspect, and to the perinæum. One branch, longer than the rest, the *inferior pudendal*, curves forward below the tuber ischii, pierces the fascia lata, and passes forward beneath the superficial fascia of the perinæum to be distributed to the integument of the scrotum in the male and the labium in the female, communicating with the superficial perineal and inferior hæmorrhoidal nerves.

The *femoral cutaneous branches* consist of filaments, which are derived from both sides of the nerve and are distributed to the skin of the inner and outer side of the thigh on its posterior aspect, as far down as the middle of that region, and also to the skin of the back part of the thigh, popliteal region, and upper part of the leg.

The *ascending cutaneous branches* consist of two or three filaments, which turn upward round the lower border of the gluteus maximus, to supply the integument covering its surface (*nervi clunium inferiores*).

The **Great Sciatic Nerve** (Fig. 510) supplies nearly the whole of the integuments of the leg, the muscles of the back of the thigh, and those of the leg and foot. It is the largest nervous cord in the body, measuring three-quarters of an inch in breadth, and is the continuation of the lower cord of the sacral plexus. It passes out of the pelvis through the great sacro-sciatic foramen, below the Pyriformis muscle. It descends between the trochanter major and tuberosity of the ischium, along the back part of the thigh to about its lower third, where it divides into two large branches, the *internal* and *external popliteal nerves*.

This division may take place at any point between the sacral plexus and the lower third of the thigh. When the division occurs at the plexus, the two nerves descend together, side by side; or they may be separated at their commencement by the interposition of part or the whole of the Pyriformis muscle. As the nerve descends along the back of the thigh it rests at first upon the External rotator muscles, in company with the small sciatic nerve and artery, being covered by the Gluteus maximus; lower down, it lies upon the Adductor magnus and is covered by the long head of the Biceps.

The *branches* of the nerve, before its division, are articular and muscular.

The *articular branches* arise from the upper part of the nerve; they supply the hip-joint, perforating its fibrous capsule posteriorly. These branches are sometimes derived from the sacral plexus.

The *muscular branches* are distributed to the Flexors of the leg—viz. the Biceps, Semitendinosus, and Semimembranosus, and a branch to the Adductor magnus. These branches are given off beneath the Biceps muscle.

The **Internal Popliteal Nerve,** the larger of the two terminal branches of the great sciatic, descends along the back part of the thigh, through the middle of the popliteal space, to the lower border of the Popliteus muscle, where it passes with the artery beneath the arch of the Soleus and becomes the posterior tibial. It is overlapped by the hamstring muscles above, and then becomes more superficial, and lies to the outer side of, and some distance from, the popliteal vessels; opposite the knee-joint it is in close relation with the vessels, and crosses to the inner side of the artery. Below, it is overlapped by the Gastrocnemius.

The *branches* of this nerve are—articular, muscular, and a cutaneous branch, the *communicans poplitei nerve.*

The *articular branches*, usually three in number, supply the knee-joint: two of these branches accompany the superior and inferior internal articular arteries, and a third, the azygos articular artery.

The *muscular branches*, four or five in number, arise from the nerve as it lies between the two heads of the Gastrocnemius muscle; they supply that muscle, the Plantaris, Soleus, and Popliteus. The filaments which supply the Popliteus turn round its lower border and are distributed to its deep surface.

The *communicans poplitei* descends between the two heads of the Gastrocnemius muscle, and about the middle of the back of the leg pierces the deep fascia, and joins a communicating branch (*communicans peronei*) from the external popliteal nerve to form the external or short saphenous (Fig. 509). The external saphenous nerve, formed by the cutaneous branches of the internal and external popliteal nerves, passes downward and outward near the outer margin of the tendo Achillis, lying close to the external saphenous vein, to the interval between the external malleolus and the os calcis. It winds round the outer malleolus, and is distributed to the integument along the outer side of the foot and little toe, communicating on the dorsum of the foot with the musculo-cutaneous nerve. In the leg its branches communicate with those of the small sciatic.

The **Posterior Tibial Nerve** (Fig. 510) commences at the lower border of the Popliteus muscle, and passes along the back part of the leg with the posterior tibial vessels to the interval between the inner malleolus and the heel, where it divides into the *external* and *internal plantar nerves.* It lies upon the deep muscles of the leg, and is covered in the upper part by the muscles of the calf, lower down by the skin and fascia. In the upper part of its course it lies to the inner side of the posterior tibial artery, but it soon crosses that vessel, and lies to its outer side as far as the ankle. In the lower third of the leg it is placed parallel with the inner margin of the tendo Achillis.

The *branches of the posterior tibial nerve* are—muscular, plantar cutaneous, and articular.

The *muscular branches* arise either separately or by a common trunk from the upper part of the nerve. They supply the Tibialis posticus, Flexor longus digitorum, and Flexor longus hallucis muscles, the branch to the latter muscle accompanying the peroneal artery. A branch is also given to the Soleus.

The *plantar cutaneous branch* perforates the internal annular ligament and supplies the integument of the heel and inner side of the sole of the foot.

The *articular branch* is given off just above the bifurcation of the nerve and supplies the ankle-joint.

The **internal plantar nerve** (Fig. 511), the larger of the two terminal branches of the posterior tibial, accompanies the internal plantar artery along the inner side of the foot. From its origin at the inner ankle it passes beneath the Abductor hallucis, and then forward between this muscle and the Flexor brevis digitorum, divides opposite the bases of the metatarsal bones into four digital branches, and communicates with the external plantar nerve.

Branches.—In its course the internal plantar nerve gives off *cutaneous branches*, which pierce the plantar fascia and supply the integument of the sole of the foot; *muscular branches*, which supply the Abductor hallucis and Flexor brevis digitorum; *articular branches*, to the articulations of the tarsus and meta-

tarsus; and *four digital branches*. These pass between the divisions of the plantar fascia in the clefts between the toes, and are distributed in the following manner: The *first* supplies the inner border of the great toe, and sends a filament to the Flexor brevis hallucis muscle; the *second* bifurcates to supply the adjacent sides of the great and second toes, sending a filament to the First lumbrical muscle; the *third digital branch* supplies the adjacent sides of the second and third toes, and the Second lumbrical muscle; the *fourth* supplies the corresponding sides of the third and fourth toes, and receives a communicating branch from the external plantar nerve. It will be observed that the distribution of these branches is precisely similar to that of the median nerve in the hand. Each digital nerve gives off cutaneous and articular filaments, and opposite the last phalanx sends a dorsal branch, which supplies the structure round the nail, the continuation of the nerve being distributed to the ball of the toe.

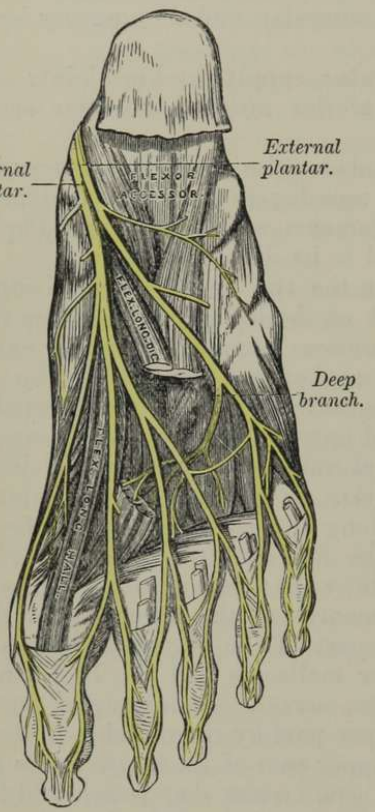

FIG. 511.—The plantar nerves.

The **external plantar nerve**, the smaller of the two, completes the nervous supply to the structures of the sole of the foot, being distributed to the little toe and one-half of the fourth, as well as to most of the deep muscles, its distribution being similar to that of the ulnar in the hand. It passes obliquely forward with the external plantar artery to the outer side of the foot, lying between the Flexor brevis digitorum and Flexor accessorius, and in the interval between the former muscle and Abductor minimi digiti divides into a superficial and a deep branch. Before its division it supplies the Flexor accessorius and Abductor minimi digiti.

The *superficial branch* separates into two digital nerves: one, the smaller of the two, supplies the outer side of the little toe, the Flexor brevis minimi digiti, and the two Interosseous muscles of the fourth metatarsal space; the other and larger digital branch supplies the adjoining sides of the fourth and fifth toes, and communicates with the internal plantar nerve.

The *deep* or *muscular branch* accompanies the external plantar artery into the deep part of the sole of the foot, beneath the tendons of the Flexor muscles and Adductor transversus hallucis, and supplies all the Interossei (except those in the fourth metatarsal space), the two outer Lumbricales, the Adductor obliquus hallucis, and the Adductor transversus hallucis.

The **External Popliteal** or **Peroneal Nerve** (Fig. 510), about one-half the size of the internal popliteal, descends obliquely along the outer sides of the popliteal space to the head of the fibula, close to the inner margin of the Biceps muscle. It is easily felt beneath the skin behind the head of the fibula at the inner side of the tendon of the Biceps. It passes between the tendon of the Biceps and outer head of the Gastrocnemius muscle, winds round the neck of the fibula, pierces the origin of the Peroneus longus, and divides beneath that muscle into the anterior tibial and musculo-cutaneous nerves.

The *branches of the peroneal nerve*, previous to its division, are articular and cutaneous.

The *articular branches* are three in number; two of these accompany the

superior and inferior external articular arteries to the outer side of the knee. The upper one occasionally arises from the great sciatic nerve before its bifurcation. The third (*recurrent*) articular nerve is given off at the point of division of the peroneal nerve; it ascends with the anterior recurrent tibial artery through the Tibialis anticus muscle to the front of the knee, which it supplies.

The *cutaneous branches*, two or three in number, supply the integument along the back part and outer side of the leg as far as its middle or lower part; one of these, larger than the rest, the *communicans peronei*, arises near the head of the fibula, crosses the external head of the Gastrocnemius to the middle of the leg, and joins with the communicans poplitei to form the external saphenous. This nerve occasionally exists as a separate branch, which is continued down as far as the heel.

The **Anterior Tibial Nerve** (Fig. 506) commences at the bifurcation of the peroneal nerve, between the fibula and upper part of the Peroneus longus, passes obliquely forward beneath the Extensor longus digitorum to the fore part of the interosseous membrane, and reaches the outer side of the anterior tibial artery above the middle of the leg; it then descends with the artery to the front of the ankle-joint, where it divides into an external and an internal branch. This nerve lies at first on the outer side of the anterior tibial artery, then in front of it, and again at its outer side at the ankle-joint.

The *branches of the anterior tibial nerve* in its course through the leg are the muscular branches to the Tibialis anticus, Extensor longus digitorum, Peroneus tertius, and Extensor proprius hallucis muscles, and an *articular branch* to the ankle-joint.

The *external* or *tarsal branch of the anterior tibial* passes outward across the tarsus, beneath the Extensor brevis digitorum, and, having become ganglionic, like the posterior interosseous nerve at the wrist, supplies the Extensor brevis digitorum. From the ganglion are given off three minute *interosseous branches* which supply the tarsal joints and the metatarso-phalangeal joints of the second, third, and fourth toes. The first of these sends a filament to the second dorsal interosseous muscle.

The *internal branch*, the continuation of the nerve, accompanies the dorsalis pedis artery along the inner side of the dorsum of the foot, and at the first interosseous space divides into two branches, which supply the adjacent sides of the great and second toes, communicating with the internal branch of the musculo-cutaneous nerve. Before it divides it gives off an *interosseous branch* to the first space, which supplies the metatarso-phalangeal joint of the great toe and sends a filament to the First dorsal interosseous muscle.

The **Musculo-cutaneous Nerve** (Fig. 506) supplies the muscles on the fibular side of the leg and the integument of the dorsum of the foot. It passes forward between the Peronei muscles and the Extensor longus digitorum, pierces the deep fascia at the lower third of the leg on its front and outer side, and divides into two branches. This nerve in its course between the muscles gives off muscular branches to the Peroneus longus and brevis, and cutaneous filaments to the integument of the lower part of the leg.

The *internal branch of the musculo-cutaneous nerve* passes in front of the ankle-joint and along the dorsum of the foot, supplying the inner side of the great toe and the adjoining sides of the second and third toes. It also supplies the integument of the inner ankle and inner side of the foot, communicating with the internal saphenous nerve, and communicates with the anterior tibial nerve between the great and second toes.

The *external branch*, the larger, passes along the outer side of the dorsum of the foot, to be distributed to the adjoining sides of the third, fourth, and fifth toes. It also supplies the integument of the outer ankle and outer side of the foot, communicating with the short saphenous nerve. These dorsal digital nerves reach as far as the last phalanges.

The distribution of these branches of the musculo-cutaneous nerve will be

found to vary; together, they supply all the toes excepting the outer side of the little toe and the adjoining sides of the great and second toes, the former being supplied by the external saphenous, and the latter by the internal branch of the anterior tibial.

Surgical Anatomy.—The lumbar plexus passes through the Psoas muscle, and, therefore in psoas abscess any or all of its branches may be irritated, causing severe pain in the part to which the irritated nerves are distributed. The genito-crural nerve is the one which is most frequently implicated. This nerve is also of importance, as it is concerned in one of the principal reflexes employed in the investigation of diseases of the spine. If the skin over the inner side of the thigh just below Poupart's ligament, the part supplied by the crural branch of the genito-crural nerve, be gently tickled in a male child, the testicle will be noticed to be drawn upward through the action of the Cremaster muscle, supplied by the genital branch of the same nerve. The same result may sometimes be noticed in adults, and can almost always be produced by severe stimulation. This reflex, when present, shows that the portion of the cord from which the first and second lumbar nerves are derived is in a normal condition.

The anterior crural nerve is in danger of being injured in fractures of the true pelvis, since the fracture most commonly takes place through the horizontal ramus of the os pubis, at or near the point where this nerve crosses the bone. It is also liable to be injured in fractures and dislocations of the femur, and is likely to be pressed upon and its functions impaired in some tumors growing in the pelvis. Moreover, on account of its superficial position it is exposed to injury in wounds and stabs in the groin. When this nerve is paralyzed, there is loss of motion in the Iliacus, in the Quadriceps extensor cruris, in the Sartorius, and partial paralysis of the Pectineus. There is loss of sensation down the front and inner side of the thigh, except in that part supplied by the crural branch of the genito-crural and by the ilio-inguinal, as well as down the inner side of the leg and foot as far as the ball of the great toe.

The obturator nerve is of special surgical interest. It is rarely paralyzed alone, but occasionally in association with the anterior crural. The principal interest attached to it is in connection with its supply to the knee, pain in the knee being symptomatic of many diseases in which the trunk of this nerve or one of its branches is irritated. Thus it is well known that in the earlier stages of hip-joint disease the patient does not complain of pain in that articulation, but on the inner side of the knee or in the knee-joint itself. Again, the same thing occurs in sacro-iliac disease. The obturator nerve is in close relationship with the sacro-iliac articulation, passing over it, and, according to some anatomists, distributing filaments to it. Again, in cancer of the sigmoid flexure, and even in cases where masses of hardened fæces are impacted in this portion of the gut, pain is complained of in the knee. Finally, pain in the knee forms an important diagnostic sign in obturator hernia. The hernial protrusion as it passes out through the opening in the obturator membrane presses upon the nerve and causes pain in the parts supplied by its peripheral filaments. When the obturator nerve is paralyzed, the patient is unable to press his knees together or to cross one leg over the other, on account of paralysis of the Adductor muscles. Rotation outward of the thigh is impaired from paralysis of the Obturator externus.

The great sciatic nerve is liable to be pressed upon by various forms of pelvic tumors growing from the pelvic viscera or bones, by aneurisms of some of the branches of the internal iliac artery, calculus in the bladder when of large size, accumulation of fæces in the rectum, giving rise to pain along its trunk, to which the term sciatica is applied. Outside the pelvis exposure to cold, violent movements of the hip-joint, exostoses or other tumors growing from the margin of the sacro-sciatic foramen, may also give rise to the same condition. When paralyzed there is loss of motion in all the muscles below the knee, and loss of sensation in the regions supplied by it.

The sciatic nerve has been frequently cut down upon and stretched for the relief of sciatica, and also in cases of locomotor ataxy, the anæsthesia of leprosy, etc. In order to define it on the surface, a point is taken at the junction of the middle and lower third of a line stretching from the posterior superior spine of the ilium to the outer part of the tuber ischii, and a line drawn from this to the middle of the upper part of the popliteal space. The operation of stretching the sciatic nerve is performed by making an incision over the course of the nerve about the centre of the thigh. The overlying structures having been divided, the interval between the inner and outer hamstrings is to be defined, and these muscles pulled inward and outward with retractors. The nerve will be found a little to the inner side of the Biceps. It is to be separated, hooked up with the finger, and stretched by steady and continuous traction for two or three minutes. The sciatic nerve may also be stretched by what is known as the "dry" plan. The patient is laid on his back, the foot is extended, the leg flexed on the thigh, and the thigh strongly flexed on the abdomen. While the thigh is maintained in this position the leg is forcibly extended to its full extent and the foot as fully flexed on the leg.

The position of the external popliteal, close behind the tendon of the Biceps on the outer side of the ham, should be remembered in subcutaneous division of the tendon.

THE SYMPATHETIC NERVE.

The **Sympathetic Nervous System** consists of (1) a series of ganglia, connected together by intervening cords, extending from the base of the skull to the coccyx, one on each side of the middle line of the body, partly in front and partly on each side of the vertebral column; (2) of three great gangliated plexuses or aggregations of nerves and ganglia, situated in front of the spine in the thoracic, abdominal, and pelvic cavities respectively; (3) of smaller ganglia, situated in relation with the abdominal viscera; and (4) of numerous nerve-fibres. These latter are of two kinds: *communicating*, by which the ganglia communicate with each other and with the cerebro-spinal nerves; and *distributory*, supplying, in general, all the internal viscera and the coats of the blood-vessels.

Each **gangliated cord** may be traced upward from the base of the skull into its cavity by an ascending branch, which passes through the carotid canal, forms a plexus on the internal carotid artery, and communicates with the ganglia on the first and second divisions of the fifth nerve. According to some anatomists, the two cords are joined, at their cephalic extremities, by these ascending branches communicating in a small ganglion (the *ganglion of Ribes*), situated upon the anterior communicating artery. The ganglia of these cords are distinguished as cervical, dorsal, lumbar, and sacral, and except in the neck they correspond pretty nearly in number to the vertebræ against which they lie. They may be thus arranged:

Cervical portion	. .	3 pairs of ganglia.
Dorsal "	. .	12 " "
Lumbar "	. .	4 " "
Sacral "	. .	4 or 5 " "

In the neck they are situated in front of the transverse processes of the vertebræ; in the dorsal region, in front of the heads of the ribs; in the lumbar region, on the sides of the bodies of the vertebræ; and in the sacral region, in front of the sacrum. As the two cords pass into the pelvis they converge and unite together in a single ganglion (*ganglion impar*) placed in front of the coccyx. Each ganglion may be regarded as a distinct centre, and, in addition to its branches of distribution, possesses also branches of communication which communicate with other ganglia and with the cerebro-spinal nerves.

The branches of communication between the ganglia are composed of gray and white nerve-fibres, the latter being continuous with those fibres of the spinal nerves which pass to the ganglia.

The branches of communication between the ganglia and the cerebro-spinal nerves also consist of a white and gray portion, the former proceeding from the spinal nerve *to* the ganglion, the latter passing *from* the ganglion to the spinal nerve, so that a double interchange takes place between the two systems.

The **three great gangliated plexuses** are situated in front of the spine in the thoracic, abdominal, and pelvic regions, and are named, respectively, the *cardiac*, the *solar* or *epigastric*, and the *hypogastric plexus*. They consist of collections of nerves and ganglia, the nerves being derived from the gangliated cords and from the cerebro-spinal nerves. They distribute branches to the viscera.

Smaller ganglia are also found lying amidst the nerves, some of them of microscopic size, in certain viscera—as, for instance, in the heart, the stomach, and the uterus. They serve as additional centres for the origin of nerve-fibres.

The *branches of distribution* derived from the gangliated cords, from the prevertebral plexuses, and also from the smaller ganglia, are principally destined for the blood-vessels and thoracic and abdominal viscera, supplying the involuntary muscular fibre of the coats of the vessels and the hollow viscera, and the secreting cells, as well as the muscular coats of the vessels in the glandular viscera.

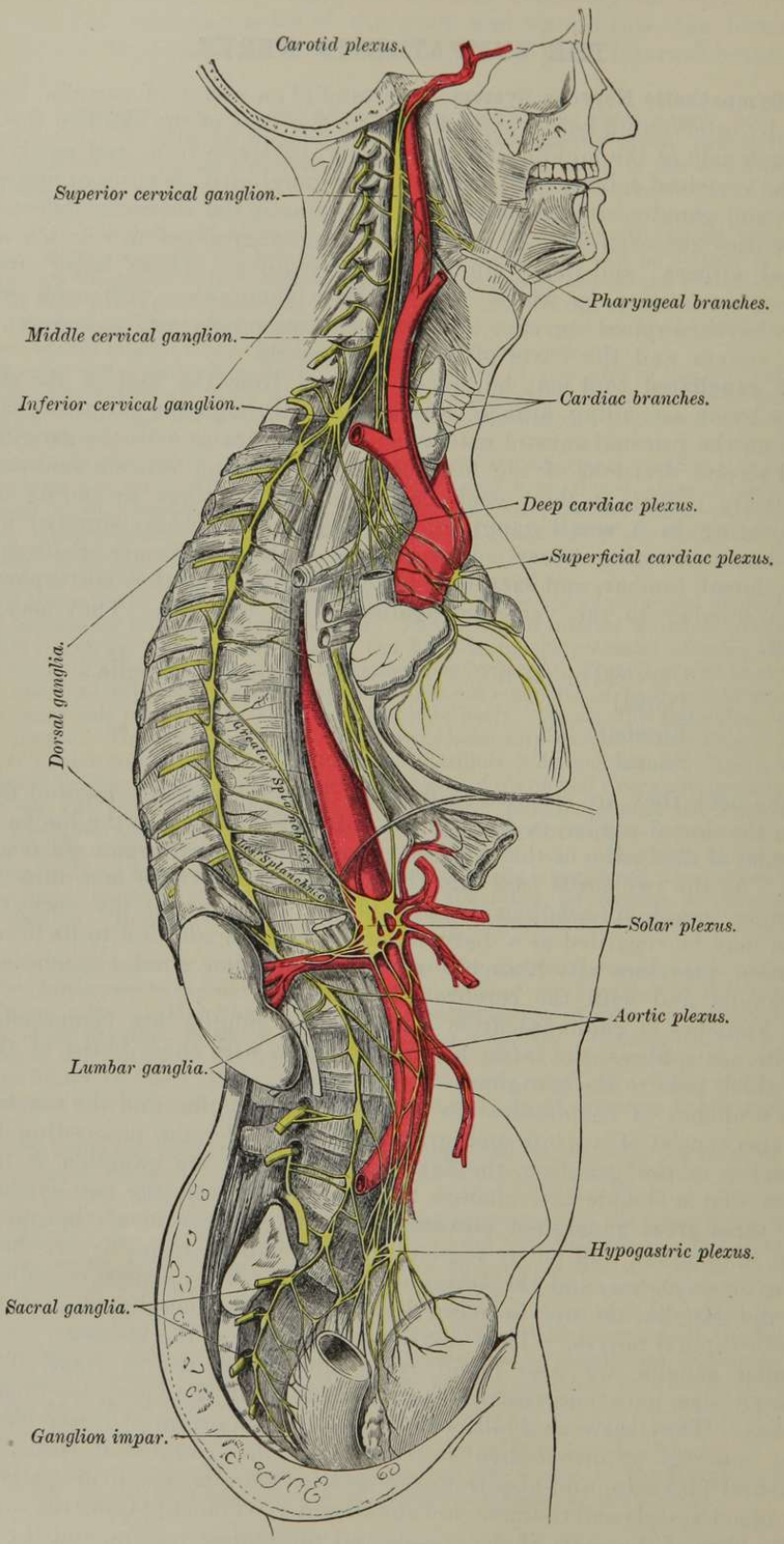

FIG. 512.—The sympathetic nerve.

In addition to these various divisions of the sympathetic, the ganglia connected with the three branches of the fifth cranial nerve are believed by some to constitute a part of the sympathetic system. These ganglia have already been described (page 799 *et seq.*).

THE GANGLIATED CORD.

Cervical Portion of the Gangliated Cord.

The cervical portion of the gangliated cord consists of three ganglia on each side, which are distinguished, according to their position, as the superior, middle, and inferior cervical.

The **Superior Cervical Ganglion,** the largest of the three, is placed opposite the second and third cervical vertebræ, and sometimes as low as the fourth or fifth. It is of a reddish-gray color, and usually fusiform in shape, sometimes broad, and occasionally constricted at intervals, so as to give rise to the opinion that it consists of the coalescence of several smaller ganglia; and it is usually believed that it is formed by the coalescence of the four ganglia, corresponding to the four upper cervical nerves. It is in relation, in front, with the sheath of the internal carotid artery and internal jugular vein; behind, it lies on the Rectus capitis anticus major muscle.

Its branches may be divided into superior, inferior, external, internal, and anterior.

The *superior branch* appears to be a direct prolongation of the ganglion. It is soft in texture and of a reddish color. It ascends by the side of the internal carotid artery, and, entering the carotid canal in the temporal bone, divides into two branches, which lie, one on the outer, and the other on the inner, side of that vessel.

The *outer branch*, the larger of the two, distributes filaments to the internal carotid artery and forms the *carotid plexus.*

The *inner branch* also distributes filaments to the internal carotid, and, continuing onward, forms the *cavernous plexus.*

The Carotid Plexus.

The carotid plexus is situated on the outer side of the internal carotid. Filaments from this plexus occasionally form a small gangliform swelling on the under surface of the artery, which is called the carotid ganglion. The carotid plexus communicates with the Gasserian ganglion, with the sixth nerve, and the spheno-palatine ganglion, and distributes filaments to the wall of the carotid artery and to the dura mater (Valentin), while in the carotid canal it communicates with Jacobson's nerve, the tympanic branch of the glosso-pharyngeal.

The *communicating branches with the sixth nerve* consist of one or two filaments which join that nerve as it lies upon the outer side of the internal carotid. Other filaments are also connected with the Gasserian ganglion. The communication with the spheno-palatine ganglion is effected by a branch, the *large deep petrosal*, which is given off from the plexus on the outer side of the artery, and which passes through the cartilage filling up the foramen lacerum medium, and joins the great superficial petrosal to form the Vidian nerve. The Vidian nerve then proceeds along the pterygoid or Vidian canal to the spheno-palatine ganglion. The communication with Jacobson's nerve is effected by two branches, one of which is called the *small deep petrosal nerve*, and the other the *long petrosal.*

The Cavernous Plexus.

The cavernous plexus is situated below and internal to that part of the internal carotid which is placed by the side of the sella Turcica in the cavernous sinus, and is formed chiefly by the internal division of the ascending branch from the superior cervical ganglion. It communicates with the third, the fourth, the ophthalmic division of the fifth, and the sixth nerves, and with the ophthalmic

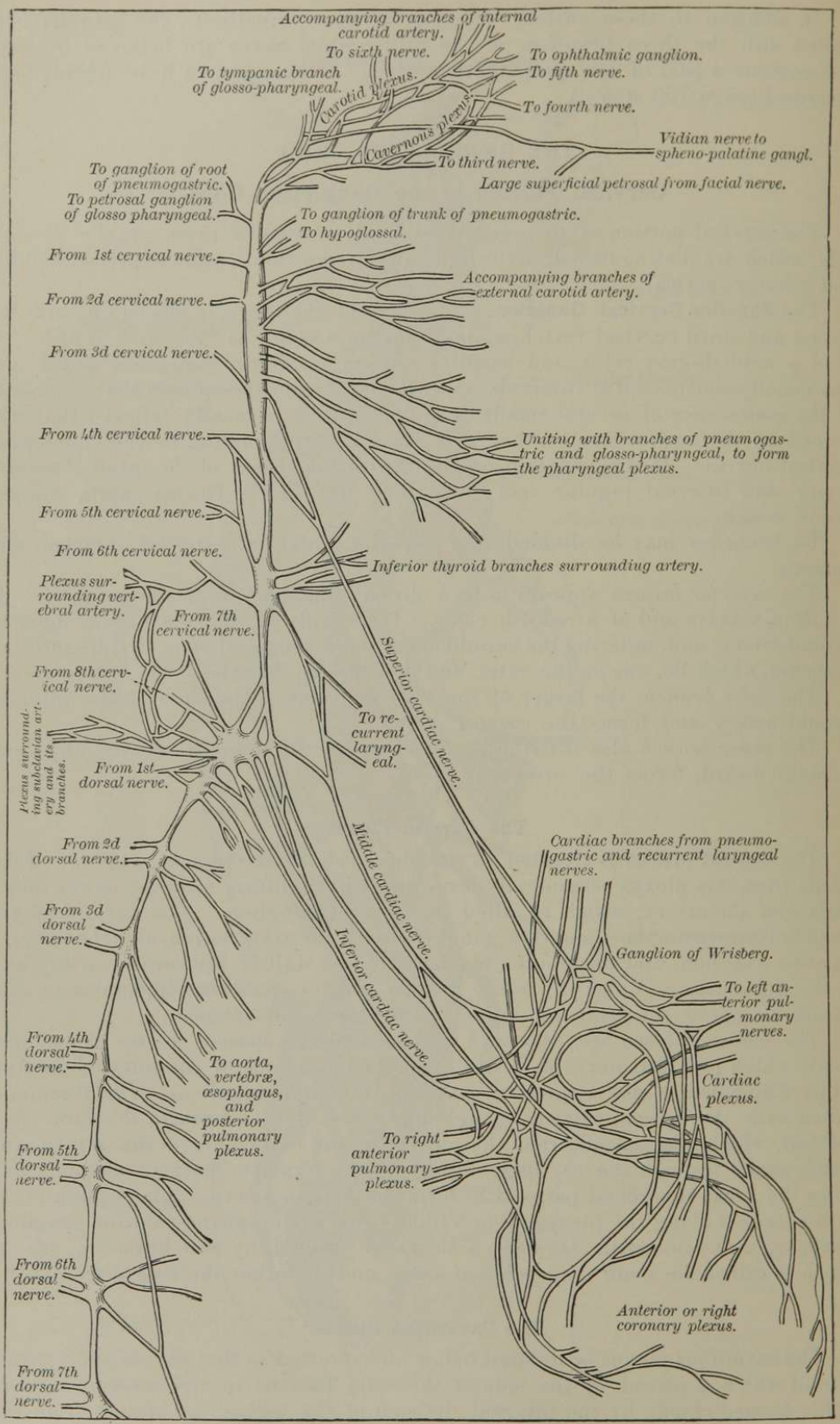

FIG. 513.—Plan of the cervical portion of the sympathetic. (After Flower.)

ganglion, and distributes filaments to the wall of the internal carotid. The branch of communication with the third nerve joins it at its point of division; the branch to the fourth nerve joins it as it lies on the outer wall of the cavernous sinus; other filaments are connected with the under surface of the trunk of the ophthalmic nerve; and a second filament of communication joins the sixth nerve.

The filament of connection with the ophthalmic ganglion arises from the anterior part of the cavernous plexus; it accompanies the nasal nerve or continues forward as a separate branch.

The terminal filaments from the carotid and cavernous plexuses are prolonged along the internal carotid, forming plexuses which entwine round the cerebral and ophthalmic arteries; along the former vessels they may be traced on to the pia mater; along the latter, into the orbit, where they accompany each of the subdivisions of the vessel, a separate plexus passing, with the arteria centralis retinæ, into the interior of the eyeball. The filaments prolonged on to the anterior communicating artery form a small ganglion, the *ganglion of Ribes*,[1] which serves, as mentioned above, to connect the sympathetic nerves of the right and left sides.

The **inferior** or **descending branch of the superior cervical ganglion** communicates with the middle cervical ganglion.

The **external branches** are numerous, and communicate with the cranial nerves and with the four upper spinal nerves. Sometimes the branch to the fourth spinal nerve may come from the cord connecting the upper and middle cervical ganglia. The branches of communication with the cranial nerves consist of delicate filaments, which pass from the superior cervical ganglion to the ganglion of the trunk of the pneumogastric and to the hypoglossal nerve. A separate filament from the cervical ganglion subdivides and joins the petrosal ganglion of the glosso-pharyngeal and the ganglion of the root of the pneumogastric in the jugular foramen.

The **internal branches** are three in number—the *pharyngeal*, *laryngeal*, and *superior cardiac nerve*. The *pharyngeal branches* pass inward to the side of the pharynx, where they join with branches from the glosso-pharyngeal, pneumogastric, and external laryngeal nerves to form the *pharyngeal plexus*. The *laryngeal branches* unite with the superior laryngeal nerve and its branches.

The *superior cardiac nerve* (*nervus superficialis cordis*) arises by two or more branches from the superior cervical ganglion, and occasionally receives a filament from the cord of communication between the first and second cervical ganglia. It runs down the neck behind the common carotid artery, lying upon the Longus colli muscle, and crosses in front of the inferior thyroid artery and recurrent laryngeal nerve.

The *right superior cardiac nerve*, at the root of the neck, passes either in front of or behind the subclavian artery, and along the arteria innominata, to the back part of the arch of the aorta, where it joins the deep cardiac plexus. This nerve, in its course, is connected with other branches of the sympathetic: about the middle of the neck it receives filaments from the external laryngeal nerve; lower down, one or two twigs from the pneumogastric; and as it enters the thorax it is joined by a filament from the recurrent laryngeal. Filaments from this nerve communicate with the thyroid branches from the middle cervical ganglion.

The *left superior cardiac nerve*, in the chest, runs by the side of the left common carotid artery and in front of the arch of the aorta to the superficial cardiac plexus, but occasionally it passes behind the aorta and terminates in the deep cardiac plexus.

The **anterior branches** ramify upon the external carotid artery and its branches, forming round each a delicate plexus, on the nerves composing which small ganglia are occasionally found. These ganglia have been named, according to their position, intercarotid[2] (placed at the angle of bifurcation of the common carotid), lingual, temporal, and pharyngeal. The plexuses accompanying some of these

[1] The existence of this ganglion is doubted by some observers.

[2] This ganglion is of the same structure as the coccygeal gland (Luschka).

arteries have important communications with other nerves. That surrounding the external carotid is connected with the branch of the facial nerve to the stylo-hyoid muscle; that surrounding the facial communicates with the submaxillary ganglion by one or two filaments; and that accompanying the middle meningeal artery sends offsets which pass to the otic ganglion and to the intumescentia ganglioformis of the facial nerve (external petrosal).

The **Middle Cervical Ganglion** (*thyroid ganglion*) is the smallest of the three cervical ganglia, and is occasionally altogether wanting. It is placed opposite the sixth cervical vertebra, usually upon, or close to, the inferior thyroid artery; hence the name, "thyroid ganglion," assigned to it by Haller. It is probably formed by the coalescence of two ganglia corresponding to the fifth and sixth cervical nerves.

Its *superior branches* ascend to communicate with the superior cervical ganglion.

Its *inferior branches* descend to communicate with the inferior cervical ganglion.

Its *external branches* pass outward to join the fifth and sixth spinal nerves. These branches are not constantly found.

Its *internal branches* are the thyroid and the middle cardiac nerve.

The *thyroid branches* are small filaments which accompany the inferior thyroid artery to the thyroid gland; they communicate, on the artery, with the superior cardiac nerve, and, in the gland, with branches from the recurrent and external laryngeal nerves.

The *middle cardiac nerve* (*nervus cardiacus magnus*), the largest of the three cardiac nerves, arises from the middle cervical ganglion or from the cord between the middle and inferior ganglia. On the right side it descends behind the common carotid artery, and at the root of the neck passes either in front of or behind the subclavian artery; it then descends on the trachea, receives a few filaments from the recurrent laryngeal nerve, and joins the deep cardiac plexus. In the neck it communicates with the superior cardiac and recurrent laryngeal nerves. On the left side the middle cardiac nerve enters the chest between the left carotid and subclavian arteries, and joins the left side of the deep cardiac plexus.

The **Inferior Cervical Ganglion** is situated between the base of the transverse process of the last cervical vertebra and the neck of the first rib on the inner side of the superior intercostal artery. Its form is irregular; it is larger in size than the preceding, and frequently joined with the first thoracic ganglion. It is probably formed by the coalescence of two ganglia which correspond to the two last cervical nerves.

Its *superior branches* communicate with the middle cervical ganglion.

Its *inferior branches* descend, some in front of, others behind, the subclavian artery, to join the first thoracic ganglion.

Its *internal branch* is the inferior cardiac nerve.

The *inferior cardiac nerve* (*nervus cardiacus minor*) arises from the inferior cervical or first thoracic ganglion. It passes down behind the subclavian artery and along the front of the trachea to join the deep cardiac plexus. It communicates freely behind the subclavian artery with the recurrent laryngeal and middle cardiac nerves.

The *external branches* consist of several filaments, some of which communicate with the seventh and eighth spinal nerves; others accompany the vertebral artery along the vertebral canal, forming a plexus round the vessel, supplying it with filaments, and communicating with the cervical spinal nerves as high as the fourth.

Thoracic Portion of the Gangliated Cord.

The thoracic portion of the gangliated cord consists of a series of ganglia which usually correspond in number to that of the vertebræ, but, from the occasional coalescence of two, their number is uncertain. These ganglia are placed on each side of the spine, resting against the heads of the ribs and covered by the

pleura costalis; the last two are, however, anterior to the rest, being placed on the side of the bodies of the eleventh and twelfth dorsal vertebræ. The ganglia are small in size and of a grayish color. The first, larger than the rest, is of an elongated form and frequently blended with the last cervical. They are connected together by cord-like prolongations from their substance.

The *external branches* from each ganglion, usually two in number, communicate with each of the dorsal spinal nerves.

The *internal branches from the six upper ganglia* are very small; they supply filaments to the thoracic aorta and its branches, besides small branches to the bodies of the vertebræ and their ligaments. Branches from the third and fourth, and sometimes also from the first and second ganglia, form part of the posterior pulmonary plexus.

The *internal branches from the six lower ganglia* are large and white in color; they distribute filaments to the aorta and unite to form the three splanchnic nerves. These are named the *great*, the *lesser*, and the *smallest* or *renal splanchnic*.

The *great splanchnic nerve* is of a white color, firm in texture, and bears a marked contrast to the ganglionic nerves. It is formed by branches from the thoracic ganglia between the sixth and tenth, receiving filaments (according to Dr. Beck) from all the thoracic ganglia above the sixth. These roots unite to form a large round cord of considerable size. It descends obliquely inward in front of the bodies of the vertebræ along the posterior mediastinum, perforates the crus of the Diaphragm, and terminates in the semilunar ganglion, distributing filaments to the renal and suprarenal plexus.

The *lesser splanchnic nerve* is formed by filaments from the tenth and eleventh ganglia and from the cord between them. It pierces the Diaphragm with the preceding nerve and joins the cœliac plexus. It communicates in the chest with the great splanchnic nerve, and occasionally sends filaments to the renal plexus.

The *smallest*, or *renal*, *splanchnic nerve* arises from the last ganglion, and, piercing the Diaphragm, terminates in the renal plexus and lower part of the cœliac plexus. It occasionally communicates with the preceding nerve.

A striking analogy appears to exist between the splanchnic and the cardiac nerves. The cardiac nerves are three in number; they arise from the three cervical ganglia, and are distributed to a large and important organ in the thoracic cavity. The splanchnic nerves, also three in number, are connected probably with all the dorsal ganglia, and are distributed to important organs in the abdominal cavity.

The Lumbar Portion of the Gangliated Cord.

The lumbar portion of the gangliated cord is situated in front of the vertebral column along the inner margin of the Psoas muscle. It consists usually of four ganglia, connected together by interganglionic cords. The ganglia are of small size, of a grayish color, shaped like a barleycorn, and placed much nearer the median line than the thoracic ganglia.

The *superior* and *inferior branches of the lumbar ganglia* serve as communicating branches between the chain of ganglia in this region. They are usually single and of a white color.

The *external branches* communicate with the lumbar spinal nerves. From the situation of the lumbar ganglia these branches are longer than in the other regions. They are usually two in number from each ganglion, but their connection with the spinal nerves is not so uniform as in other regions. They accompany the lumbar arteries around the sides of the bodies of the vertebræ, passing beneath the fibrous arches from which some of the fibres of the Psoas muscle arise.

Of the *internal branches*, some pass inward, in front of the aorta, and help to form the aortic plexus. Other branches descend in front of the common iliac arteries, and join over the promontory of the sacrum, helping to form the hypogastric plexus. Numerous delicate filaments are also distributed to the bodies of the vertebræ and the ligaments connecting them.

Pelvic Portion of the Gangliated Cord.

The pelvic portion of the gangliated cord is situated in front of the sacrum along the inner side of the anterior sacral foramina. It consists of four or five small ganglia on each side, connected together by interganglionic cords. Below, these cords converge and unite on the front of the coccyx by means of a small ganglion (the *coccygeal ganglion* or *ganglion impar*).

The *superior* and *inferior branches* are the cords of communication between the ganglia above and below.

The *external branches*, exceedingly short, communicate with the sacral nerves. They are two in number from each ganglion. The coccygeal nerve communicates either with the last sacral or coccygeal ganglion.

The *internal branches* communicate, on the front of the sacrum, with the corresponding branches from the opposite side; some, from the first two ganglia, pass to join the pelvic plexus, and others form a plexus which accompanies the middle sacral artery and sends filaments to the coccygeal gland.

THE GREAT PLEXUSES OF THE SYMPATHETIC.

The great plexuses of the sympathetic are the large aggregations of nerves and ganglia, above alluded to, situated in the thoracic, abdominal, and pelvic cavities respectively. From them are derived the branches which supply the viscera.

The Cardiac Plexus.

The cardiac plexus is situated at the base of the heart, and is divided into a *superficial part*, which lies in the concavity of the arch of the aorta, and a *deep part*, which lies between the trachea and aorta.

The **great** or **deep cardiac plexus** (*plexus magnus profundus*, Scarpa) is situated in front of the trachea at its bifurcation, above the point of division of the pulmonary artery and behind the arch of the aorta. It is formed by the cardiac nerves derived from the cervical ganglia of the sympathetic and the cardiac branches of the recurrent laryngeal and pneumogastric. The only cardiac nerves which do not enter into the formation of this plexus are the left superior cardiac nerve and the left inferior cervical cardiac branch from the pneumogastric.

The branches from the *right side* of this plexus pass, some in front of, and others behind, the right pulmonary artery; the former, the more numerous, transmit a few filaments to the anterior pulmonary plexus, and are then continued onward to form part of the anterior coronary plexus; those behind the pulmonary artery distribute a few filaments to the right auricle, and are then continued onward to form part of the posterior coronary plexus.

The branches from the *left side* of the deep cardiac plexus distribute a few filaments to the superficial cardiac plexus, to the left auricle of the heart, and to the anterior pulmonary plexus, and then pass on to form the greater part of the posterior coronary plexus.

The **superficial (anterior) cardiac plexus** lies beneath the arch of the aorta, in front of the right pulmonary artery. It is formed by the left superior cardiac nerve, the left (and occasionally the right) inferior cervical cardiac branches of the pneumogastric, and filaments from the deep cardiac plexus. A small ganglion (*cardiac ganglion of Wrisberg*) is occasionally found connected with these nerves at their point of junction. This ganglion, when present, is situated immediately beneath the arch of the aorta, on the right side of the ductus arteriosus. The superficial cardiac plexus forms the chief part of the anterior coronary plexus, and several filaments pass along the pulmonary artery to the left anterior pulmonary plexus.

The **posterior coronary plexus** is chiefly formed by filaments prolonged from the left side of the deep cardiac plexus, and by a few from the right side. It surrounds the branches of the coronary artery at the back of the heart, and its

filaments are distributed with those vessels to the muscular substance of the ventricles.

The **anterior coronary plexus** is formed chiefly from the superficial cardiac plexus, but receives filaments from the deep cardiac plexus. Passing forward between the aorta and pulmonary artery, it accompanies the left coronary artery on the anterior surface of the heart.

Valentin has described nervous filaments ramifying under the endocardium; and Remak has found, in several mammalia, numerous small ganglia on the cardiac nerves, both on the surface of the heart and in its muscular substance.

The Epigastric or Solar Plexus (Figs. 512, 514).

The **Epigastric** or **Solar plexus** supplies all the viscera in the abdominal cavity. It consists of a great network of nerves and ganglia, situated behind the stomach and in front of the aorta and crura of the Diaphragm. It surrounds the cœliac axis and root of the superior mesenteric artery, extending downward as low as the pancreas and outward to the suprarenal capsules. This plexus, and the ganglia connected with it, receive the great splanchnic nerve of both sides, and some filaments from the right pneumogastric. It distributes filaments which accompany, under the name of plexuses, all the branches from the front of the abdominal aorta.

The **semilunar ganglia of the solar plexus,** two in number, one on each side, are the largest ganglia in the body. They are large irregular gangliform masses formed by the aggregation of smaller ganglia, having interspaces between them. They are situated in front of the crura of the Diaphragm, close to the suprarenal capsules: the one on the right side lies beneath the inferior vena cava; the upper part of each ganglion is joined by the greater splanchnic nerve, and to the inner side of each the branches of the solar plexus are connected.

From the epigastric or solar plexus are derived the following:

Phrenic or Diaphragmatic plexus.
Suprarenal plexus.
Renal plexus.
Spermatic plexus.
Cœliac plexus { Gastric plexus. / Splenic plexus. / Hepatic plexus.
Superior mesenteric plexus.
Aortic plexus.

The **phrenic plexus** accompanies the phrenic artery to the Diaphragm, which it supplies, some filaments passing to the suprarenal capsule. It arises from the upper part of the semilunar ganglion, and is larger on the right than on the left side. It receives one or two branches from the phrenic nerve. In connection with this plexus, on the right side, at its point of junction with the phrenic nerve, is a small ganglion (*ganglion diaphragmaticum*). This ganglion is placed on the under surface of the Diaphragm, near the suprarenal capsule. Its branches are distributed to the inferior vena cava, suprarenal capsule, and hepatic plexus. There is no ganglion on the left side.

The **suprarenal plexus** is formed by branches from the solar plexus, from the semilunar ganglion, and from the phrenic and great splanchnic nerves, a ganglion being formed at the point of junction of the latter nerve. It supplies the suprarenal capsule. The branches of this plexus are remarkable for their large size in comparison with the size of the organ they supply.

The **renal plexus** is formed by filaments from the solar plexus, the outer part of the semilunar ganglion, and the aortic plexus. It is also joined by filaments from the lesser and smallest splanchnic nerves. The nerves from these sources, fifteen or twenty in number, have numerous ganglia developed upon them. They accompany the branches of the renal artery into the kidney, some filaments on the right side being distributed to the inferior vena cava, and others to the spermatic plexus on both sides.

The **spermatic plexus** is derived from the renal plexus, receiving branches from the aortic plexus. It accompanies the spermatic vessels to the testes.

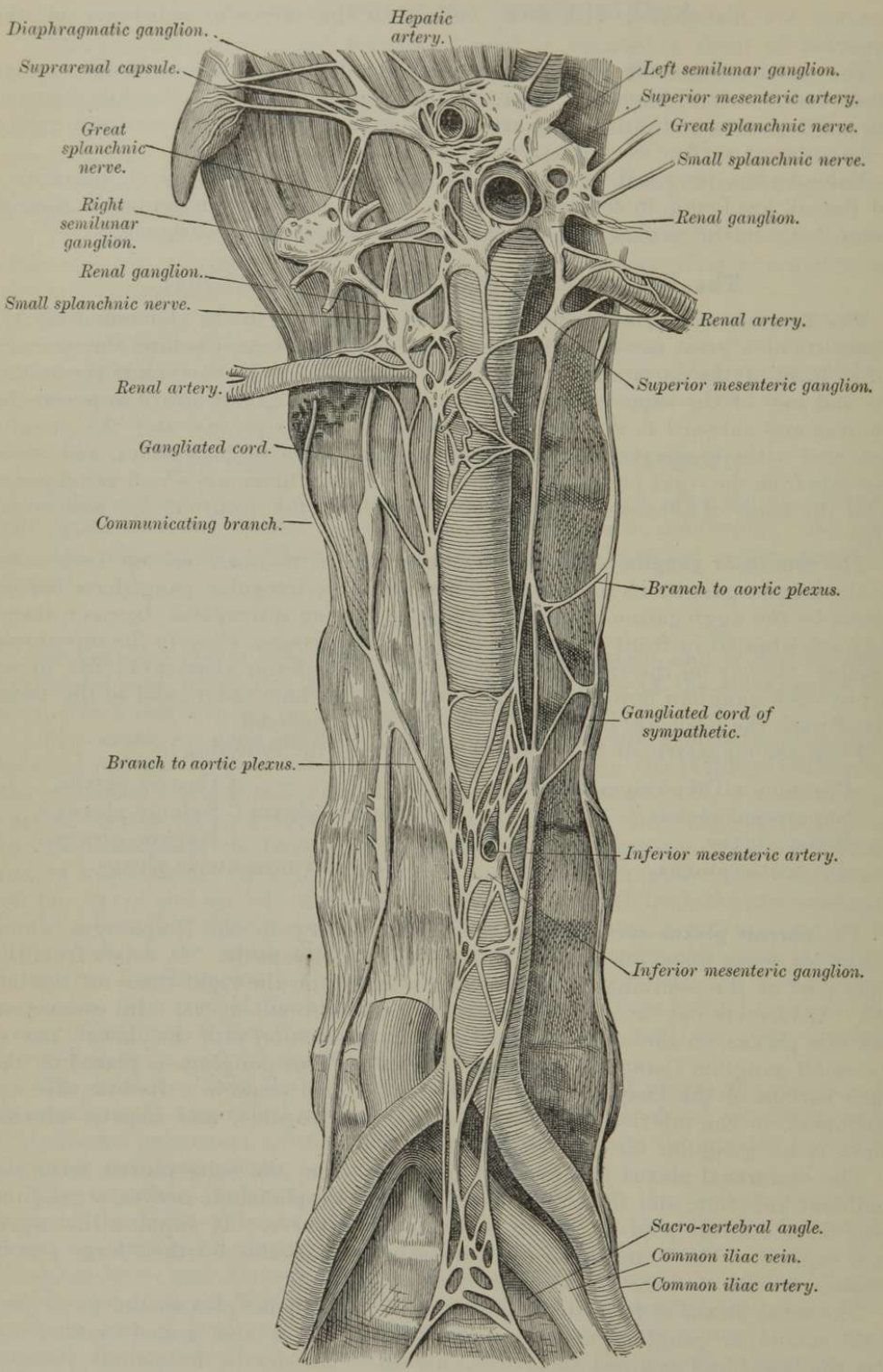

FIG. 514.—Lumbar portion of the gangliated cord, with the solar and hypogastric plexuses. (After Henle.)

In the female the **ovarian plexus** is distributed to the ovaries and fundus of the uterus.

The **cœliac plexus**, of large size, is a direct continuation from the solar plexus: it surrounds the cœliac axis and subdivides into the gastric, hepatic, and splenic

plexuses. It receives branches from the lesser splanchnic nerves, and, on the left side, a filament from the right pneumogastric.

The *gastric* or *coronary plexus* accompanies the gastric artery along the lesser curvature of the stomach, and joins with branches from the left pneumogastric nerve. It is distributed to the stomach.

The *hepatic plexus*, the largest offset from the cœliac plexus, receives filaments from the left pneumogastric and right phrenic nerves. It accompanies the hepatic artery, ramifying in the substance of the liver upon its branches and upon those of the vena portæ.

Branches from this plexus accompany all the divisions of the hepatic artery. Thus there is a *pyloric plexus* accompanying the pyloric branch of the hepatic, which joins with the gastric plexus and pneumogastric nerves. There is also a *gastro-duodenal plexus*, which subdivides into the pancreatico-duodenal plexus, which accompanies the pancreatico-duodenal artery, to supply the pancreas and duodenum, joining with branches from the mesenteric plexus; and a *gastro-epiploic plexus*, which accompanies the right gastro-epiploic artery along the greater curvature of the stomach and anastomoses with branches from the splenic plexus. A *cystic plexus*, which supplies the gall-bladder, also arises from the hepatic plexus near the liver.

The *splenic plexus* is formed by branches from the cœliac plexus, the left semilunar ganglia, and from the right pneumogastric nerve. It accompanies the splenic artery and its branches to the substance of the spleen, giving off, in its course, filaments to the pancreas (*pancreatic plexus*) and the *left gastro-epiploic plexus*, which accompanies the gastro-epiploica sinistra artery along the convex border of the stomach.

The **superior mesenteric plexus** is a continuation of the lower part of the great solar plexus, receiving a branch from the junction of the right pneumogastric nerve with the cœliac plexus. It surrounds the superior mesenteric artery, which it accompanies into the mesentery, and divides into a number of secondary plexuses, which are distributed to all the parts supplied by the artery—viz. pancreatic branches to the pancreas; intestinal branches, which supply the whole of the small intestine; and ileo-colic, right colic, and middle colic branches, which supply the corresponding parts of the great intestine. The nerves composing this plexus are white in color and firm in texture, and have numerous ganglia developed upon them near their origin.

The **aortic plexus** is formed by branches derived, on each side, from the solar plexus and the semilunar ganglia, receiving filaments from some of the lumbar ganglia. It is situated upon the sides and front of the aorta, between the origins of the superior and inferior mesenteric arteries. From this plexus arise part of the spermatic, the inferior mesenteric, and the hypogastric plexuses; and it distributes filaments to the inferior vena cava.

The *inferior mesenteric plexus* is derived chiefly from the left side of the aortic plexus. It surrounds the inferior mesenteric artery, and divides into a number of secondary plexuses, which are distributed to all the parts supplied by the artery—viz. the left colic and sigmoid plexuses, which supply the descending and sigmoid flexure of the colon; and the superior hæmorrhoidal plexus, which supplies the upper part of the rectum and joins in the pelvis with branches from the pelvic plexus.

The Hypogastric Plexus.

The **Hypogastric Plexus** supplies the viscera of the pelvic cavity. It is situated in front of the promontory of the sacrum, between the two common iliac arteries, and is formed by the union of numerous filaments, which descend on each side from the aortic plexus and from the lumbar ganglia. This plexus contains no ganglia, and bifurcates, below, into two lateral portions, which form the *pelvic plexuses*.

The Pelvic Plexus.

The **Pelvic Plexus** (sometimes called *inferior hypogastric*) supplies the viscera of the pelvic cavity, is situated at the side of the rectum and bladder in the male, and at the side of the rectum, vagina, and bladder in the female. It is formed by a continuation of the hypogastric plexus, by branches from the second, third, and fourth sacral nerves, and by a few filaments from the first two sacral ganglia. At the point of junction of these nerves small ganglia are found. From this plexus numerous branches are distributed to all the viscera of the pelvis. They accompany the branches of the internal iliac artery.

The **inferior hæmorrhoidal plexus** arises from the back part of the pelvic plexus. It supplies the rectum, joining with branches of the superior hæmorrhoidal plexus.

The **vesical plexus** arises from the fore part of the pelvic plexus. The nerves composing it are numerous, and contain a large proportion of spinal nerve-fibres. They accompany the vesical arteries, and are distributed at the side and base of the bladder. Numerous filaments also pass to the vesiculæ seminales and vas deferens; those accompanying the vas deferens join, on the spermatic cord, with branches from the spermatic plexus.

The **prostatic plexus** is continued from the lower part of the pelvic plexus. The nerves composing it are of large size. They are distributed to the prostate gland, vesiculæ seminales, and erectile structure of the penis. The nerves supplying the erectile structure of the penis consist of two sets, the small and large cavernous nerves. They are slender filaments, which arise from the fore part of the prostatic plexus, and, after joining with branches from the internal pudic nerve, pass forward beneath the pubic arch.

The *small cavernous nerves* perforate the fibrous covering of the penis near its roots.

The *large cavernous nerve* passes forward along the dorsum of the penis, joins with the dorsal branch of the pudic nerve, and is distributed to the corpus cavernosum and spongiosum.

The **vaginal plexus** arises from the lower part of the pelvic plexus. It is lost on the walls of the vagina, being distributed to the erectile tissue at its anterior part and to the mucous membrane. The nerves composing this plexus contain, like the vesical, a large proportion of spinal nerve-fibres.

The **uterine plexus** arises from the upper part of the pelvic plexus above the point where the branches from the sacral nerves join the plexus. Its branches accompany the uterine arteries to the side of the organ between the layers of the broad ligament, and are distributed to the cervix and lower part of the body of the uterus, penetrating its substance.

Other filaments pass separately to the body of the uterus and Fallopian tube.

Branches from the plexus accompany the uterine arteries into the substance of the uterus. Upon these filaments ganglionic enlargements are found.

THE ORGANS OF SENSE.

THE Organs of the Senses are five in number—viz. those of Touch, of Taste, of Smell, of Hearing, and of Sight. The skin, which is the principal seat of the sense of touch, has been described in the chapter on General Anatomy.

THE TONGUE.

The Tongue is the organ of the special sense of taste. It is situated in the floor of the mouth, in the interval between the two lateral portions of the body of the lower jaw.

Its base or root is directed backward, and connected with the os hyoides by the Hyo-glossi and Genio-hyo-glossi muscles and the hyo-glossal membrane; with the epiglottis by three folds of mucous membrane which form the *glosso-epiglottic ligaments;* with the soft palate by means of the anterior pillars of the fauces; and with the pharynx by the Superior constrictor and the mucous membrane. Its apex or tip, thin and narrow, is directed forward against the inner surface of the lower incisor teeth. The under surface of the tongue is connected with the lower jaw by the Genio-hyo-glossi muscles; from its sides the mucous membrane is reflected to the inner surface of the gums; and in front a distinct fold of that membrane, the *frænum linguæ*, is formed beneath its under surface.

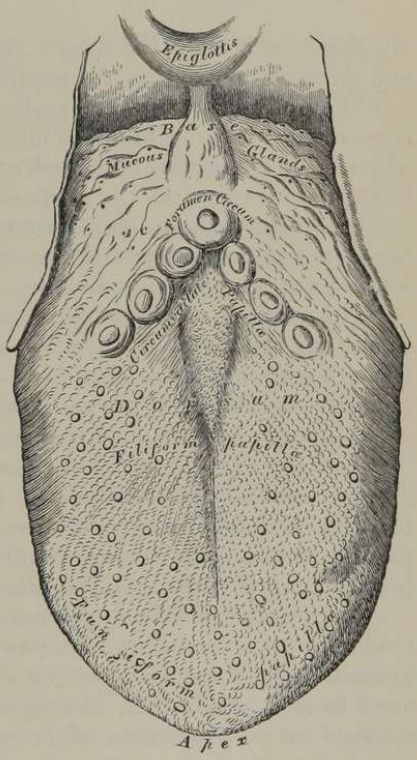

FIG. 515.—Upper surface of the tongue.

The *tip* of the tongue, part of the under surface, its sides and dorsum, are free.

The dorsum of the tongue is convex, marked along the middle line by a raphe, which divides it into symmetrical halves; this raphe terminates behind, about an inch from the base of the organ, in a depression, the *foramen cæcum*. The anterior two-thirds of this surface are rough and covered with papillæ; the posterior third is smoother, and covered by the projecting orifices of numerous muciparous glands.

Structure of the Tongue.—The tongue is partly invested by mucous membrane and a submucous fibrous layer. It consists of symmetrical halves, separated from each other, in the middle line, by a fibrous septum. Each half is composed of muscular fibres arranged in various directions, containing much interposed fat, and supplied by vessels and nerves.

The **mucous membrane** invests the entire extent of the free surface of the tongue. On the dorsum it is thicker behind than in front, and is continuous with the sheath of the muscles attached to it, through the submucous fibrous layer. On the under surface of the organ it can be traced on each side of the frænum through the ducts of the submaxillary and the sublingual glands. As it passes over the borders of the organ it gradually assumes its papillary character.

The **structure of the mucous membrane of the tongue** differs in different parts. That covering the under surface of the organ is thin, smooth, and identical in

structure with that lining the rest of the oral cavity. The mucous membrane on the anterior part of the dorsum of the tongue is thin and intimately adherent to the muscular tissue, whilst that at the root is much thicker and looser. It consists

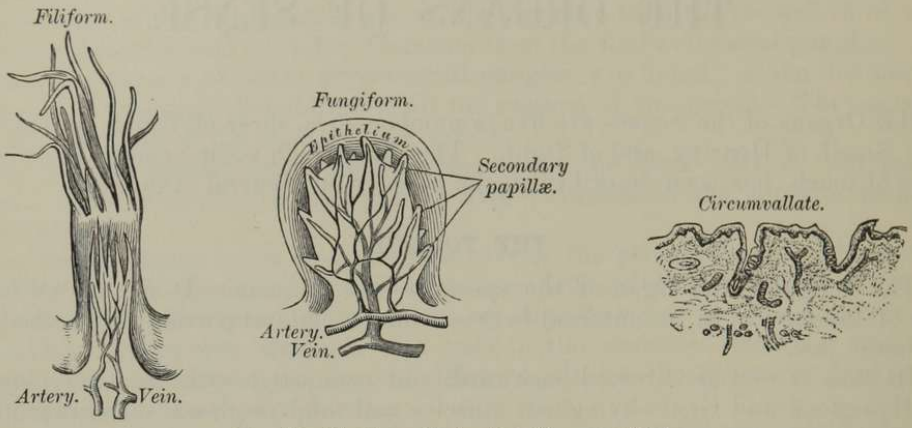

FIG. 516.—The three kinds of papillæ, magnified.

of a layer of connective tissue, the *corium* or *mucosa*, supporting numerous *papillæ* and covered, as well as the papillæ, with *epithelium*.

The epithelium is of the scaly variety, like that of the epidermis. It covers the free surface of the tongue, as may be easily demonstrated by maceration or boiling, when it can be easily detached entire: it is much thinner than on the skin: the intervals between the large papillæ are not filled up by it, but each papilla has a separate investment from root to summit. The deepest cells may sometimes be detached as a separate layer, corresponding to the rete mucosum, but they never contain coloring matter.

The *corium* consists of a dense feltwork of fibrous connective tissue, with numerous elastic fibres, firmly connected with the fibrous tissue forming the septa between the muscular bundles of the tongue. It contains the ramifications of the numerous vessels and nerves from which the papillæ are supplied, large plexuses of lymphatic vessels, and the glands of the tongue.

The Papillæ of the Tongue.—These are papillary projections of the corium. They are thickly distributed over the anterior two-thirds of its upper surface, giving to it its characteristic roughness. The varieties of papillæ met with are—the papillæ maximæ (*circumvallatæ*), papillæ mediæ (*fungiformes*), papillæ minimæ (*conicæ* or *filiformes*), and papillæ simplices.

The *papillæ maximæ* (circumvallatæ) are of large size, and vary from eight to twelve in number. They are situated at the back part of the dorsum of the tongue, near its base, forming a row on each side, which, running backward and inward, meet in the middle line, like the two lines of the letter V inverted. Each papilla consists of a projection of mucous membrane from $\frac{1}{20}$ to $\frac{1}{12}$ of an inch wide, attached to the bottom of a cup-shaped depression of the mucous membrane; the papilla is in shape like a truncated cone, the smaller end being directed downward and attached to the tongue, the broader part or base projecting on the surface and being studded with numerous small secondary papillæ, which, however, are covered by a smooth layer of the epithelium. The cup-shaped depression forms a kind of fossa round the papilla, having a circular margin of about the same elevation covered with smaller papillæ. At the point of junction of the two rows of papillæ is the deep depression, the *foramen cæcum*, mentioned above.

The *papillæ mediæ* (fungiformes), more numerous than the preceding, are scattered irregularly and sparingly over the dorsum of the tongue, but are found chiefly at its sides and apex. They are easily recognized among the other papillæ, by their large size, rounded eminences, and deep-red color. They are narrow at their attachment to the tongue, but broad and rounded at their free

extremities, and covered with secondary papillæ. Their epithelial investment is very thin.

The *papillæ minimæ* (conicæ or filiformes) cover the anterior two-thirds of the dorsum of the tongue. They are very minute, more or less conical or filiform in shape, and arranged in lines corresponding in direction with the two rows of the papillæ circumvallatæ, excepting at the apex of the organ, where their direction is transverse. They have projecting from their apices numerous filiform processes or secondary papillæ, which are of a whitish tint, owing to the thickness and density of the epithelium of which they are composed, and which has here undergone a peculiar modification, the cells having become cornified and elongated into dense, imbricated, brush-like processes. They contain also a number of elastic fibres, which render them firmer and more elastic than the papillæ of mucous membrane generally.

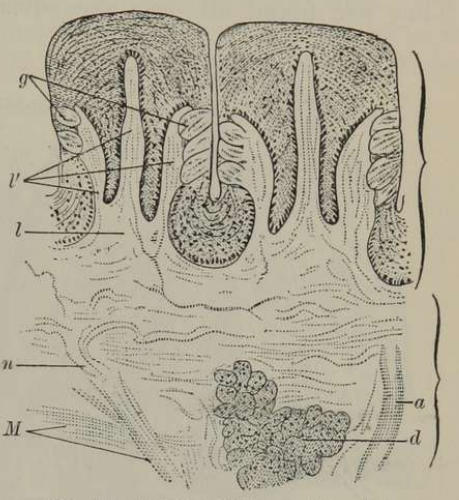

FIG. 517.—Circumvallate papillæ of tongue of rabbit, showing position of taste-goblets. (Stöhr.) *a*. Duct of gland. *d*. Serous gland. *g*. Taste-goblets. *l*. Primary septa, and *l'*, secondary septa, of papillæ. *n*. Medullated nerve. *M*. Muscular fibres.

Simple papillæ, similar to those of the skin, cover the whole of the mucous membrane of the tongue, as well as the larger papillæ. They consist of closely-set, microscopic elevations of the corium, containing a capillary loop, covered by a layer of epithelium.

Structure of the Papillæ.—The papillæ apparently resemble in structure those of the cutis, consisting of a cone-shaped projection of connective tissue, covered with a thick layer of squamous epithelium, and contain one or more capillary loops, amongst which nerves are distributed in great abundance. If the epithelium is removed, it will be found that they are not simple elevations like the papillæ of the skin, for the surface of each is studded with minute conical processes of the mucous membrane, which form secondary papillæ (Todd and Bowman). In the papillæ circumvallatæ the nerves are numerous and of large size; in the papillæ fungiformes they are also numerous, and terminate in a plexiform network, from which brush-like branches proceed; in the papillæ filiformes their mode of termination is uncertain. Buried in the epidermis of the papillæ circumvallatæ, and in some of the fungiformes, certain peculiar bodies called *taste-goblets* have been described.[1] They are flask-like in shape, their broad base resting on the corium, and their neck opening by an orifice between the cells of the epithelium. They are formed by two kinds of cells: the external (cortical) are arranged in several layers; they are long and flattened, with tapering ends, and in contact by their edges, the tapering extremities extending from the base to the apex of the organ. Their *apical* ends bound the orifice (gustatory pore) just mentioned. They thus enclose the central cells (gustatory cells), which are spindle-shaped and have a large spherical nucleus about the middle of the cell. Both extremities of a gustatory cell are filamentous; the inner process is described (denied by G. Retzius) as continuous with the terminal fibril of a nerve (glosso-pharyngeal), while the outer one projects as an extremely fine hair through the orifice of the taste-goblet.[2]

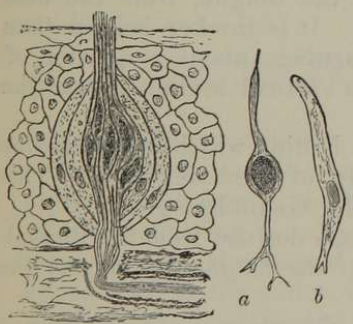

FIG. 518.—Taste-goblets. *a*. Central cell. *b*. Cortical cell.

[1] These bodies are also found in considerable numbers at the side of the base of the tongue, just in front of the anterior pillars of the fauces.

[2] See Englemann, in Stricker's *Handbook* (*New Syd. Soc. Trans.*), vol. iii. p. 2.

Glands of the Tongue.—The tongue is provided with mucous and serous glands and lymphoid follicles.

The *mucous glands* are similar in structure to the labial and buccal glands. They are found all over the surface of the mucous membrane of the tongue, especially at the back part, behind the circumvallate papillæ, but also at the apex and marginal parts. In connection with these glands a special one has been described by Blandin and Nuhn. It is situated near the apex of the tongue on either side of the frænum, and is covered over by a fasciculus of muscular fibre derived from the Stylo-glossus and Inferior lingualis. It is from half an inch to nearly an inch long and about the third of an inch broad. It has from four to six ducts, which open on the under surface of the apex.

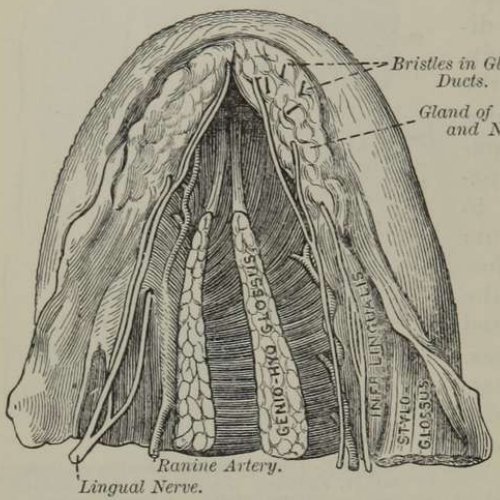

FIG. 519.—Under surface of tongue, showing position and relations of gland of Blandin and Nuhn. (From a preparation in the Museum of the Royal College of Surgeons.)

The *serous glands* occur only at the back of the tongue in the neighborhood of the taste-goblets, their ducts opening for the most part into the fossæ of the circumvallate papillæ. These glands are racemose, the duct branching into several minute ducts, which terminate in alveoli lined by a single layer of more or less columnar epithelium. Their secretion is of a watery nature, and probably assists in the distribution of the substance to be tasted over the taste-area (Ebner).

The Lymphoid Follicles.—The *lymphoid tissue* is situated, for the most part at the back of the tongue, between the epiglottis and the circumvallate papillæ, and is collected at numerous points into distinct masses known as *lymphoid follicles*. Here and there in this situation are depressions in the mucous membrane, surrounded by nodules of lymphoid tissue, similar to the structure found in the tonsil: into them open some of the ducts of the mucous glands.

The *fibrous septum* consists of a vertical layer of fibrous tissue, extending throughout the entire length of the middle line of the tongue, from the base to the apex, though not quite reaching the dorsum. It is thicker behind than in front, and occasionally contains a small fibro-cartilage about a quarter of an inch in length. It is well displayed by making a vertical section across the organ.

The **Hyo-glossal membrane** is a strong fibrous lamina which connects the under surface of the base of the tongue to the body of the hyoid bone. This membrane receives, in front, some of the fibres of the Genio-hyo-glossi.

Vessels of the Tongue.—The *arteries of the tongue* are derived from the lingual, the facial, and ascending pharyngeal. The *veins of the tongue* accompany the arteries.

Muscles of the Tongue.—The muscular fibres of the tongue run in various directions. These fibres are divided into two sets, Extrinsic and Intrinsic.

The *Extrinsic muscles of the tongue* are those which have their origin external to it, and only their terminal fibres contained in the substance of the organ. They are the Stylo-glossus, the Hyo-glossus, the Palato-glossus, the Genio-hyo-glossus, and part of the Superior constrictor of the pharynx (Pharyngo-glossus).

The *Intrinsic muscles* are those which are contained entirely within the tongue and form the greater part of its substance. Both sets have been already described (page 415).

The *lymphatic vessels from the tongue* pass to one or two small glands situated

on the Hyo-glossus muscle in the submaxillary region, and from thence to the deep glands of the neck.

The *nerves of the tongue* are four in number in each half: the lingual branch of the fifth, which is distributed to the papillæ at the fore part and sides of the tongue; the lingual branch of the glosso-pharyngeal, which is distributed to the mucous membrane at the base and side of the tongue and to the papillæ circum-

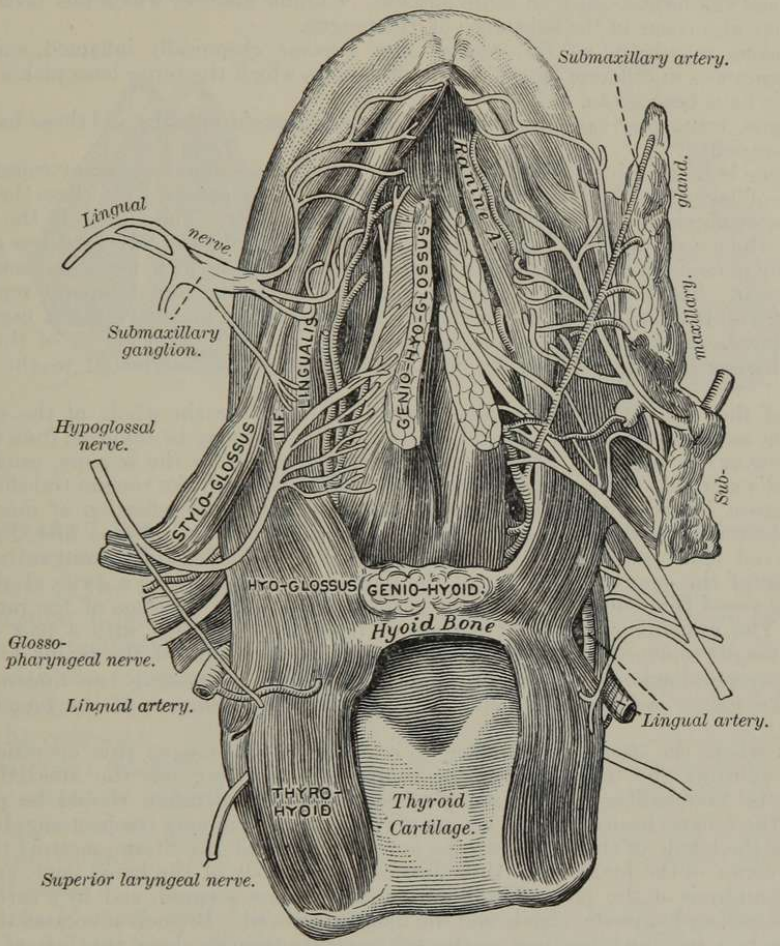

FIG. 520.—Under surface of the tongue, showing the distribution of nerves to this organ. (From a preparation in the Museum of the Royal College of Surgeons.)

vallatæ; the hypoglossal nerve, which is distributed to the muscular substance of the tongue; and the chorda tympani to the Lingualis muscle. Sympathetic filaments also pass to the tongue from the nervi molles on the lingual and other arteries supplying it. The glosso-pharyngeal branch is the special nerve of the sense of taste, the lingual (gustatory) is the nerve of common sensation, and the hypoglossal is the motor nerve of the tongue, except for the Inferior lingualis, which is supplied by the chorda tympani.

Surgical Anatomy.—The diseases to which the tongue is liable are numerous, and its surgical anatomy of importance, since any or all the structures of which it is composed—muscles, connective tissue, mucous membrane, glands, vessels, nerves, and lymphatics—may be the seat of morbid changes. It is not often the seat of congenital defects, though a few cases of vertical cleft have been recorded, and it is occasionally, though much more rarely than is commonly supposed, the seat of "tongue-tie," from shortness of the frænum. (See page 554.)

There is, however, one condition which must be regarded as congenital, though it does not sometimes evidence itself until a year or two after birth, which is not uncommon. This is an enlargement of the tongue which is due primarily to a dilatation of the lymph-channels and a greatly increased development of the lymphatic tissue throughout the tongue. This is often

aggravated by inflammatory changes induced by injury or exposure, and the tongue may assume enormous dimensions and hang out of the mouth, giving the child an imbecile expression. The treatment consists in excising a V-shaped portion and bringing the cut surfaces together with deeply-placed silver sutures. Compression has been resorted to in some cases and with success, but it is difficult to apply. Acute inflammation of the tongue, which may be caused by injury and the introduction of some septic or irritating matter, is attended by great swelling from infiltration of its connective tissue, which is in considerable quantity. This renders the patient incapable of swallowing or speaking, and may seriously impede respiration. It may run on to suppuration and the formation of an acute abscess. Chronic abscess, which has been mistaken for cancer, may also occur in the substance of the tongue.

The mucous membrane of the tongue may become chronically inflamed, and presents different appearances in different stages of the disease, to which the terms leucoplakia, psoriasis, and ichthyosis have been given.

The tongue, being very vascular, is often the seat of nævoid growths, and these have a tendency to grow rapidly.

The tongue is frequently the seat of ulceration, which may arise from many causes, as from the irritation of jagged teeth, dyspepsia, tubercle, syphilis, and cancer. Of these the cancerous ulcer is the most important, and probably also the most common. The variety is the squamous epithelioma, which soon develops into an ulcer with an indurated base. It produces great pain, which speedily extends to all parts supplied with sensation by the fifth nerve, especially to the region of the ear. The pain in these cases is conducted to the ear and temporal region by the lingual nerve, and from it to the other branches of the inferior maxillary nerve, especially the auriculo-temporal. Possibly pain in the ear itself may be due to implication of the fibres of the glosso-pharyngeal nerve, which by its tympanic branch is conducted to the tympanic plexus.

Cancer of the tongue may necessitate removal of a part or the whole of the organ, and many different methods have been adopted for its excision. It may be removed from the mouth by the écraseur or the scissors. Probably the better method is by the scissors, usually known as Whitehead's method. The mouth is widely opened with a gag, the tongue transfixed with a stout silk ligature, by which to hold and make traction on it and the reflection of mucous membrane from the tongue to the jaw, and the insertion of the Genio-hyo-glossus first divided with a pair of curved blunt scissors. The Palato-glossus is also divided. The tongue can now be pulled well out of the mouth. The base of the tongue is cut through by a series of short snips, each bleeding vessel being dealt with as soon as divided, until the situation of the ranine artery is reached. The remaining undivided portion of tissue is to be seized with a pair of Wells's forceps, the tongue removed, and the vessel secured. In the event of the ranine artery being accidentally injured hæmorrhage can be at once controlled by passing two fingers over the dorsum of the tongue as far as the epiglottis and dragging the root of the tongue forcibly forward.

In cases where the disease is confined to one side of the tongue this operation may be modified by splitting the tongue down the centre and removing only the affected half. In cases where the submaxillary glands are involved Kocher's operation should be performed. He removes the tongue from the neck, having performed a preliminary tracheotomy, by an incision from near the lobule of the ear, down the anterior border of the Sterno-mastoid to the level of the great cornu of the hyoid bone, then forward to the body of the hyoid bone, and upward to near the symphysis of the jaw. The lingual artery is now secured, and by a careful dissection the submaxillary lymphatic glands and the tongue removed. Regnoli advocated the removal of the tongue by a semilunar incision in the submaxillary triangle along the line of the lower jaw, and a vertical incision from the centre of the semilunar one backward to the hyoid bone. Care must be taken not to carry the first incision too far backward, so as to wound the facial arteries. The tongue is thus reached through the floor of the mouth, pulled out through the external incision, and removed with the écraseur or knife. The great objection to this operation is that all the muscles which raise the hyoid bone and larynx are divided, and that therefore the movements of deglutition and respiration are interfered with.

Finally, where both sides of the floor of the mouth are involved in the disease, or where very free access is required on account of the extension backward of the disease to the pillars of the fauces and the tonsil, or where the lower jaw is involved, the operation recommended by Syme must be performed. This is done by an incision through the central line of the lip, across the chin, and down as far as the hyoid bone. The lower jaw is sawn through at the symphysis, and the two halves of the bone forcibly separated from each other. The mucous membrane is separated from the bone, and the Genio-hyo-glossi detached from the bone, and the Hyo-glossi divided. The tongue is then drawn forward and removed close to its attachment to the hyoid bone. Any glands which are enlarged can be removed, and if the bone is implicated in the disease, it can also be removed by freeing it from the soft parts externally and internally, and making a second section with the saw beyond the diseased part.

Formerly many surgeons before removing the tongue performed a preliminary tracheotomy: (1) to prevent blood entering the air-passages; and (2) to allow the patient to breathe through the tube and not inspire air which had passed over a sloughy wound, and which was loaded with septic organisms and likely to induce septic pneumonia. By the judicious use of iodoform this secondary evil may be obviated, and the preliminary tracheotomy is now usually dispensed with.

THE NOSE.

The nose is the special organ of the sense of smell: by means of the peculiar properties of its nerves it protects the lungs from the inhalation of deleterious gases and assists the organ of taste in discriminating the properties of food.

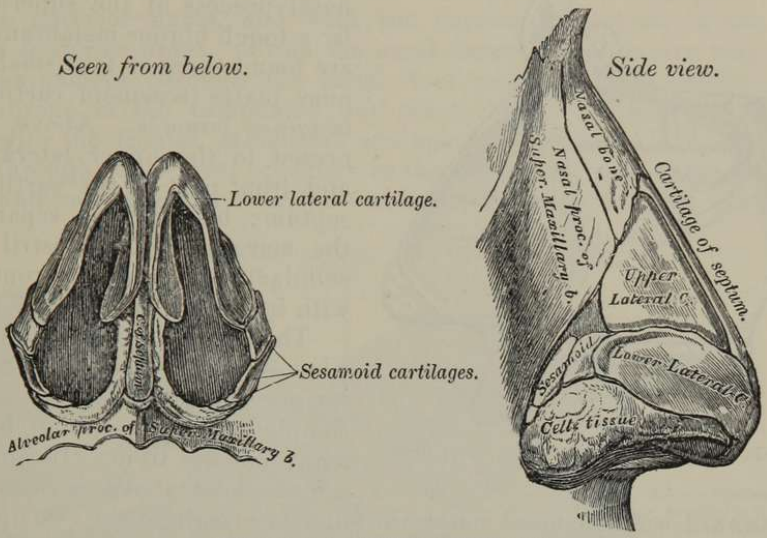

FIGS. 521, 522.—Cartilages of the nose.

The organ of smell consists of two parts—one external, the *nose;* the other internal, the *nasal fossæ.*

The *nose* is the more anterior and prominent part of the organ of smell. It is of a triangular form, directed vertically downward, and projects from the centre of the face immediately above the upper lip. Its summit or root is connected directly with the forehead. Its inferior part, the base of the nose, presents two elliptical orifices, the nostrils, separated from each other by an antero-posterior septum, the *columna.* The margins of these orifices are provided with a number of stiff hairs, or *vibrissæ*, which arrest the passage of foreign substances carried with the current of air intended for respiration. The lateral surfaces of the nose form, by their union, the *dorsum*, the direction of which varies considerably in different individuals. The dorsum terminates below in a rounded eminence, the *lobe of the nose.*

The nose is composed of a framework of bones and cartilages, the latter being slightly acted upon by certain muscles. It is covered externally by the integument, internally by mucous membrane, and supplied with vessels and nerves.

The *bony framework* occupies the upper part of the organ: it consists of the nasal bones and the nasal processes of the superior maxillary.

The *cartilaginous framework* consists of five pieces, the two upper and the two lower lateral cartilages and the cartilage of the septum.

The *upper lateral cartilages* are situated below the free margin of the nasal bones; each cartilage is flattened and triangular in shape. Its anterior margin is thicker than the posterior, and connected with the fibro-cartilage of the septum. Its posterior margin is attached to the nasal process of the superior maxillary and nasal bones. Its inferior margin is connected by fibrous tissue with the lower lateral cartilage: one surface is turned outward, the other inward toward the nasal cavity.

The *lower lateral cartilages* are two thin, flexible plates situated immediately below the preceding, and bent upon themselves in such a manner as to form the inner and outer walls of each orifice of the nostril. The portion which forms the inner wall, thicker than the rest, is loosely connected with the same part of the opposite cartilage, and forms a small part of the columna. Its inferior border, free, rounded, and projecting, forms, with the thickened integument and subja-

cent tissue and the corresponding parts of the opposite side, the tip of the nose. The part which forms the outer wall is curved to correspond with the ala of the nose; it is oval and flattened, narrow behind, where it is connected with the nasal process of the superior maxilla by a tough fibrous membrane, in which are found three or four small cartilaginous plates (sesamoid cartilages), *cartilagines minores*. Above, it is connected to the upper lateral cartilage and front part of the cartilage of the septum; below, it is separated from the margin of the nostril by dense cellular tissue; and in front, it forms, with its fellow, the lobe of the nose.

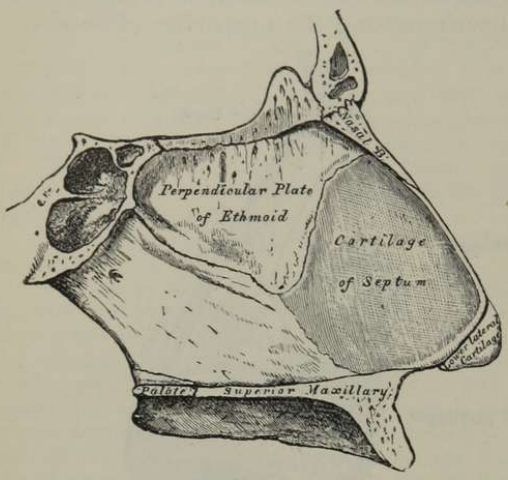

FIG. 523.—Bones and cartilages of septum of nose. Right side.

The *cartilage of the septum* is somewhat quadrilateral in form, thicker at its margins than at its centre, and completes the separation between the nasal fossæ in front. Its anterior margin, thickest above, is connected from above downward with the nasal bones, the anterior margin of the two upper lateral cartilages, and the inner portion of the two lower lateral cartilages. Its posterior margin is connected with the perpendicular lamella of the ethmoid, its inferior margin with the vomer and the palate processes of the superior maxillary bones.

These various cartilages are connected to each other and to the bones by a tough fibrous membrane, which allows the utmost facility of movement between them.

The *muscles of the nose* are situated immediately beneath the integument: they are (on each side) the Pyramidalis nasi, the Levator labii superioris alæque nasi, the Dilatator naris, anterior and posterior, the Compressor nasi, the Compressor narium minor, and the Depressor alæ nasi. They have been described above (page 399).

The *integument* covering the dorsum and sides of the nose is thin, and loosely connected with the subjacent parts, but where it forms the tip or lobe and the alæ of the nose it is thicker and more firmly adherent. It is furnished with a large number of sebaceous follicles, the orifices of which are usually very distinct.

The *mucous membrane* lining the interior of the nose is continuous with the skin externally and with that which lines the nasal fossæ within.

The *arteries of the nose* are the lateralis nasi from the facial, and the inferior artery of the septum from the superior coronary, which supply the alæ and septum, the sides and dorsum being supplied from the nasal branch of the ophthalmic and the infra-orbital.

The *veins of the nose* terminate in the facial and ophthalmic.

The *nerves of the nose* are branches from the facial, infra-orbital, and infra-trochlear, and a filament from the nasal branch of the ophthalmic.

Nasal Fossæ.

The nasal fossæ are two irregular cavities situated in the middle of the face and extending from before backward. They open in front by the two anterior nares, and terminate in the pharynx, behind, by the posterior nares. The *anterior nares* are somewhat pear-shaped apertures, each measuring about one inch vertically and half an inch transversely at their widest part. The *posterior nares* are two oval openings situated at the upper part of the anterior wall of the pharynx. They are smaller in the body than in the skeleton, because narrowed by the mucous membrane. Each opening measures an inch in the vertical and half an inch in the transverse direction in a well-developed adult skull.

The *mucous membrane* lining the nasal fossæ is called the *pituitary*, from the nature of its secretion; or *Schneiderian*, from Schneider, the first anatomist who showed that the secretion proceeded from the mucous membrane, and not, as was formerly imagined, from the brain. It is intimately adherent to the periosteum or perichondrium, over which it lies. It is continuous externally with the skin through the anterior nares, and with the mucous membrane of the pharynx through the posterior nares. From the nasal fossæ its continuity may be traced with the conjunctiva through the nasal duct and lachrymal canals; with the lining membrane of the tympanum and mastoid cells through the Eustachian tube; and with the frontal, ethmoidal, and sphenoidal sinuses, and the antrum of Highmore through the several openings in the meatuses. The mucous membrane is thickest and most vascular over the turbinated bones. It is also thick over the

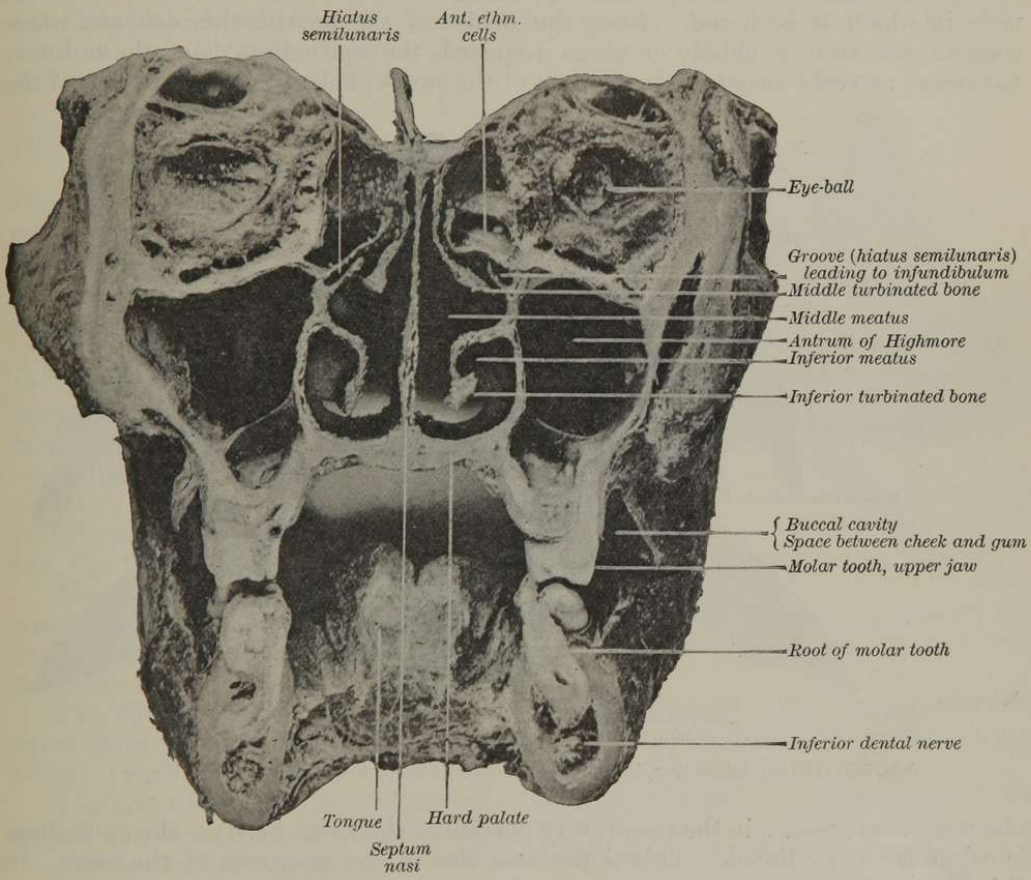

FIG. 524.—Transverse vertical section of the nasal fossæ. The section is made anterior to the superior turbinated bones. (Cryer.)

septum, but in the intervals between the spongy bones and on the floor of the nasal fossæ it is very thin. Where it lines the various sinuses and the antrum of Highmore it is thin and pale.

Owing to the great thickness of this membrane, the nasal fossæ are much narrower, and the turbinated bones, especially the lower ones, appear larger and more prominent than in the skeleton. From the same circumstance also the various apertures communicating with the meatuses are either narrowed or completely closed.

In the superior meatus the aperture of communication with the posterior ethmoidal cells is considerably diminished in size, and the spheno-palatine foramen completely covered in.

In the middle meatus the opening of the infundibulum is partially hidden by

a projecting fold of mucous membrane, and the orifice of the antrum is contracted to a small circular aperture, much narrower than in the skeleton.

In the inferior meatus the orifice of the nasal duct is partially hidden by either a single or double valvular mucous fold, and the anterior palatine canal either completely closed in or a tubular *cul-de-sac* of mucous membrane is continued a short distance into it. This *cul-de-sac* is termed the *organ of Jacobson*, and is present in all mammals as well as man. In the former it consists of a bilateral tube, situated in the nasal septum and supported by hyaline cartilage, the *cartilage of Jacobson*.

In the roof the opening leading to the sphenoidal sinus is narrowed, and the apertures in the cribriform plate of the ethmoid completely closed in.

Structure of the Mucous Membrane.—The epithelium covering the mucous membrane differs in its character according to the functions of the part of the nose in which it is found. Near the orifice of the nostril, the *vestibule*, where common sensation is chiefly or alone required, the epithelium is of the ordinary pavement or scaly variety. In the rest of the cavity, below the distribution of the

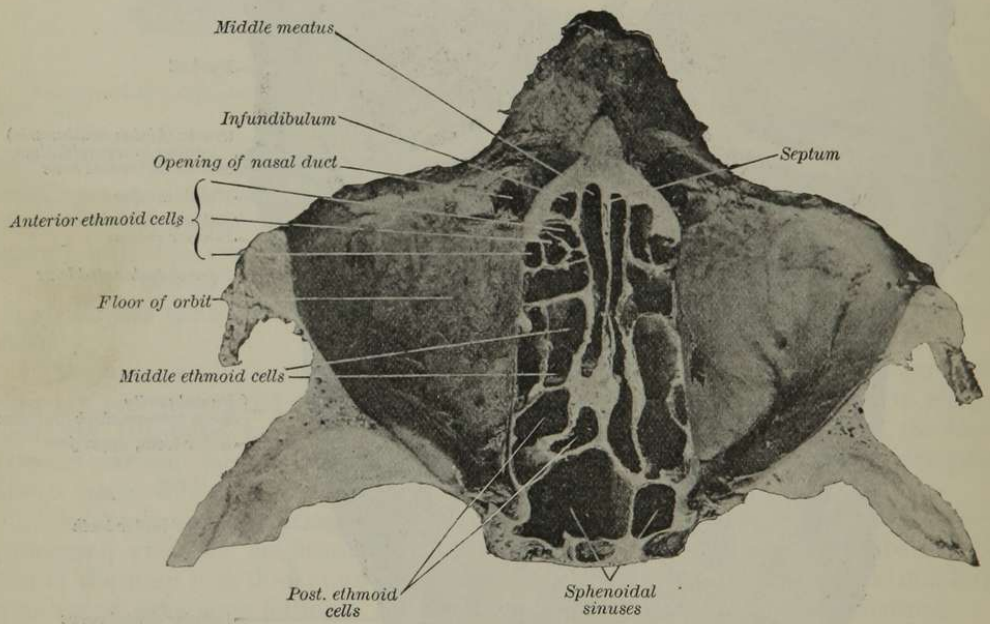

FIG. 525.—Horizontal section, high up, of the nasal fossæ, viewed from above. (Cryer.)

olfactory nerves—*i. e.* in the respiratory portion of the nasal cavity—the epithelium is columnar and ciliated. This is the case also in the meatuses of the nose. In this region, beneath the epithelium and its basement membrane, is a fibrous layer infiltrated with lymph-corpuscles, so as to form in many parts a diffuse adenoid tissue, and beneath this a nearly continuous layer of smaller and larger glands, some mucous and some serous, the ducts of which open upon the surface. In the olfactory region—*i.e.* the region in which the terminal filaments from the olfactory nerves are distributed (see page 889)—the epithelial cells are columnar and, for the most part, non-ciliated: their free surface presents a sharp outline, and their deep extremity is prolonged into a process which runs inward, branching to communicate with similar processes from neighboring cells, so as to form a network in the deep part of the mucous membrane. Lying between them are cells (termed by Max Schultze, *olfactory cells*), which consist of a nucleated body and two processes, of which one runs outward between the columnar epithelial cells and projects on the surface of the mucous membrane; the other (the deep) process runs inward, is frequently beaded like a nerve-fibre, and is believed by most observers to be in connection with one of the terminal filaments of the olfactory nerve. Amongst

the branched ends of the columnar cells there is a deep layer of epithelial cells of a conical shape, their broad end resting on the basement membrane, and their tapering extremity projecting between the other cells. Beneath the epithelium, extending through the thickness of the mucous membrane, is a layer of glands, the *glands of Bowman*, identical in structure with serous glands.

The mucous membrane is pigmented in the olfactory, but not in the other regions, being of a light yellow color, at least in the white races.[1]

The *arteries of the nasal fossæ* are the anterior and posterior ethmoidal, from the ophthalmic, which supply the ethmoidal cells, frontal sinuses, and roof of the nose; a minute twig from the small meningeal; the spheno-palatine, from the internal maxillary, which supplies the mucous membrane covering the spongy bones, the meatuses, and septum; the inferior artery of the septum from the superior coronary of the facial; and the alveolar branch of the internal maxillary, which supplies the lining membrane of the antrum. The ramifications of these vessels form a close, plexiform network beneath and in the substance of the mucous membrane.

The *veins of the nasal fossæ* form a close network beneath the mucous membrane. They pass, some with the veins accompanying the spheno-palatine artery, through the spheno-palatine foramen, and others through the alveolar branch, to join the facial vein; some accompany the ethmoidal arteries and terminate in the ophthalmic vein; and, lastly, a few communicate with the veins in the interior of the skull through the foramina in the cribriform plate of the ethmoid bone and the foramen cæcum.

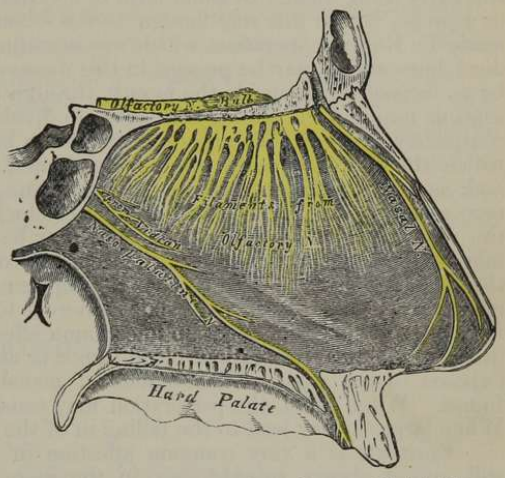

FIG. 526.—Nerves of septum of nose. Right side.

The *nerves* are—the olfactory, the nasal branch of the ophthalmic, filaments from the anterior dental branch of the superior maxillary, the Vidian, naso-palatine, descending anterior palatine, and nasal branches of Meckel's ganglion.

The *olfactory*, the special nerve of the sense of smell, is distributed over the upper third of the septum and over the surface of the superior and middle spongy bones.

The *nasal branch of the ophthalmic* distributes filaments to the fore part of the septum and outer wall of the nasal fossæ.

Filaments from the anterior dental branch of the superior maxillary supply the inferior meatus and inferior turbinated bone.

The *Vidian nerve* supplies the upper and back part of the septum and superior spongy bone, and the *upper anterior nasal branches* from the spheno-palatine ganglion have a similar distribution.

The *naso-palatine nerve* supplies the middle of the septum.

The *larger* or *anterior palatine nerve* supplies the middle and lower spongy bones.

Surgical Anatomy.—Instances of congenital deformity of the nose are occasionally met with, such as complete absence of the nose, an aperture only being present, or perfect development on one side, and suppression or malformation on the other; or there may be imperfect apposition of the nasal bones, so that the nose presents a median cleft or furrow. Deformities which have been acquired are much more common, such as flattening of the nose, the result of

[1] An interesting speculation has been suggested by Dr. W. Ogle, (*Med. Chir. Trans.*, vol. liii. p. 277) as to the possible connection between the presence and abundance of this pigment and the perfection of the sense of smell.

syphilitic necrosis, or imperfect development of the nasal bones in cases of congenital syphilis, or a lateral deviation of the nose may result from fracture.

The skin over the alæ and tip of the nose is thick and closely adherent to subjacent parts. Inflammation of this part is therefore very painful, on account of the tension. It is largely supplied with blood, and, the circulation here being terminal, vascular engorgement is liable to occur, especially in women at the menopause and in both sexes from disorders of digestion, exposure to cold, etc. The skin of the nose also contains a large number of sebaceous follicles, and these, as the result of intemperance, are apt to become affected and the nose reddened, congested, and irregularly swollen. To this the term "grog-blossom" is popularly applied. In some of these cases there is enormous hypertrophy of the skin and subcutaneous tissues, producing pendulous masses, termed lipomata nasi. Epithelioma and rodent ulcer may attack the nose, the latter being the more common of the two. Lupus and syphilitic ulceration frequently attack the nose, and may destroy the whole of the cartilaginous portion. In fact, lupus vulgaris begins more frequently on the ala of the nose than in any other situation.

Cases of congenital occlusion of one or both nostrils, or adhesion between the ala and septum may occur, and may require immediate operation, since the obstruction much interferes with sucking. Bony closure of the posterior nares may also occur.

To examine the nasal cavities, the head should be thrown back and the nose drawn upward, the parts being dilated by some form of speculum. It can also be examined with the little finger or a probe, and in this way foreign bodies detected. A still more extensive examination can be made by Rouge's operation, which was introduced for the cure of ozæna by the removal of any dead bone which may be present in this disease. The whole framework of the nose is lifted up by an incision made inside the mouth, through the junction of the upper lip with the bone; the septum nasi and the lateral cartilages are divided with strong scissors till the anterior nares are completely exposed. The posterior nares can be explored by reflected light from the mouth, by which the posterior nares can be illuminated. The examination is very difficult to carry out, and, as a rule, sufficient information regarding the presence of foreign bodies or tumors in the naso-pharynx can be obtained by the introduction of the finger behind the soft palate through the mouth. The septum of the nose may be displaced or deviate from the middle line: this may be the result of an injury or from some congenital defect in its development. Sometimes the deviation may be so great that the septum may come in contact with the outer wall of the nasal fossæ, and may even become adherent to it, thus producing complete obstruction. Perforation of the septum is not an uncommon affection, and may arise from several causes: syphilitic or tubercular ulceration, blood-tumor or abscess of the septum, and especially in workmen exposed to the vapor of bichromate of potash, from the irritating and corrosive action of the fumes. When small, the perforation may cause a peculiar whistling sound during respiration. When large, it may lead to the falling in of the bridge of the nose.

Epistaxis is a very common affection in children. It is rarely of much consequence, and will almost always subside, but in the more violent hæmorrhages of later life it may be necessary to plug the posterior nares. In performing this operation it is desirable to remember the size of the posterior nares. A ready method of regulating the size of the plug to fit the opening is to make it of the same size as the terminal phalanx of the thumb of the patient to be operated on.

Nasal polypus is a very common disease, and presents itself in three forms: the gelatinous, the fibrous, and the malignant. The first is by far the most common. It grows from the mucous membrane of the outer wall of the nasal fossa, where there is an abundant layer of highly vascular submucous tissue; rarely from the septum, where the mucous membrane is closely adherent to the cartilage and bone, without the intervention of much, if any, submucous tissue. Their most common seat is probably the middle turbinated bone. The fibrous polypus generally grows from the base of the skull behind the posterior nares or from the roof of the nasal fossæ. The malignant polypi, both sarcomatous or carcinomatous, may arise in the nasal cavities and the naso-pharynx; or they may originate in the antrum, and protrude through its inner wall into the nasal fossa.

Rhinoliths, or nose-stones, may sometimes be found in the nasal cavities, from the formation of phosphate of lime upon either a foreign body or a piece of inspissated secretion.

THE EYE.

The eyeball is contained in the cavity of the orbit. In this situation it is securely protected from injury, whilst its position is such as to ensure the most extensive range of sight. It is acted upon by numerous muscles, by which it is capable of being directed to any part; it is supplied by vessels and nerves, and is additionally protected in front by several appendages, such as the eyebrow, eyelids, etc.

The eyeball is imbedded in the fat of the orbit, but is surrounded by a thin membranous sac, the *capsule of Tenon*, which isolates it, so as to allow of free movement.

The **capsule of Tenon** (*tunica vaginalis oculi*) may be regarded as a distinct

serous membrane, consisting of a parietal and visceral layer. The latter invests the posterior part of the globe from the ciliary margin of the cornea backward to the entrance of the optic nerve, and is connected to it by very delicate connective tissue: the former (parietal) lines the hollow in the fat in which the eyeball is imbedded. Both layers are lined on their free surfaces by endothelial cells. The cavity between them is continuous with the spaces between the different layers of the sheath of the optic nerve—that is to say, with the *subarachnoidean* between the pia-matral and the arachnoid sheath, and the *subdural* between the arachnoid and dural sheath—and into it empty the lymphatic vessels of the sclerotic. The capsule is pierced by the muscles of the eyeball near their insertion, and sends tubular prolongations on them, which become continuous with the sheath of the muscles. From the outer surface of these sheaths expansions, consisting of elastic fibres and muscle-cells, are given off to the margin of the orbit, which serve to limit the degree of contraction of the muscles.[1]

The eyeball is composed of segments of two spheres of different sizes. The anterior segment is one of a small sphere, and forms about one-sixth of the eyeball. It is more prominent than the posterior segment, which is one of a much larger sphere, and forms about five-sixths of the globe. The segment of the larger sphere is opaque, and formed by the sclerotic, the tunic of protection to the eyeball; the smaller sphere is transparent, and formed by the cornea. The axes of the eyeballs are nearly parallel, and do not correspond to the axes of the orbits, which are directed outward. The optic nerves follow the direction of the axes of the orbits, and are therefore not parallel; they enter the eyeball a little to their inner or nasal side. The eyeball measures rather more in its transverse than in its antero-posterior and vertical diameters, the former amounting to about an inch, the latter to about nine-tenths of an inch.

The eyeball is composed of several investing tunics, and of fluid and solid refracting media, called *humors*.

The tunics are three in number:

1. Sclerotic and Cornea.
2. Choroid, Iris, and Ciliary Processes.
3. Retina.

The refracting media, or humors, are also three:

Aqueous. Crystalline (lens) and Capsule. Vitreous.

The sclerotic and cornea form the external tunic of the eyeball; they are essentially fibrous in structure, the sclerotic being opaque, and forming the posterior five-sixths of the globe; the cornea, which forms the remaining sixth, being transparent.

The **Sclerotic** (*σκληρός*, hard) (Fig. 527) has received its name from its extreme density and hardness; it is a firm, unyielding, fibrous membrane, serving to maintain the form of the globe. It is much thicker behind than in front. Its *external surface* is of a white color, quite smooth, except at the points where the Recti and Obliqui muscles are inserted into it, and covered, for part of its extent, by the conjunctival membrane; hence the whiteness and brilliancy of the front of the eyeball. Its *inner surface* is stained of a brown color, marked by grooves, in which are lodged the ciliary nerves, and connected by an exceedingly fine cellular tissue (*lamina fusca*) with the outer surface of the choroid. Behind, it is pierced by the optic nerve a little to its inner or nasal side, and is continuous with the fibrous sheath of the nerve, which is derived from the dura mater. At the point where the optic nerve passes through the sclerotic this membrane forms a thin cribriform lamina (the *lamina cribrosa*); the minute orifices in this layer serve for the transmission of the nervous filaments, and the fibrous septa dividing them from one another are continuous with the membranous processes which separate the bundles of nerve-fibres. One of these openings, larger than the rest, occupies

[1] See a paper by Mr. C. B. Lockwood (*Journal of Anatomy and Physiology*, vol. xx., part i. p. 1).

the centre of the lamella; it is called the *porus opticus*, and transmits the arteria centralis retinæ to the interior of the eyeball. Around the cribriform lamella are numerous small apertures for the transmission of the ciliary vessels and nerves In front the sclerotic is continuous with the cornea by direct continuity of tissue, but the opaque sclerotic overlaps the cornea rather more on its outer than on its inner surface.

Structure.—The sclerotic is formed of white fibrous tissue intermixed with fine elastic fibres, and of flattened connective-tissue corpuscles, some of which are pigmented, contained in cell-spaces between the fibres. These fibres are aggregated into bundles which are arranged chiefly in a longitudinal direction. It yields gelatin on boiling. Its vessels are not numerous, the capillaries being of small size, uniting at long and wide intervals. The existence of nerves in it is doubtful.

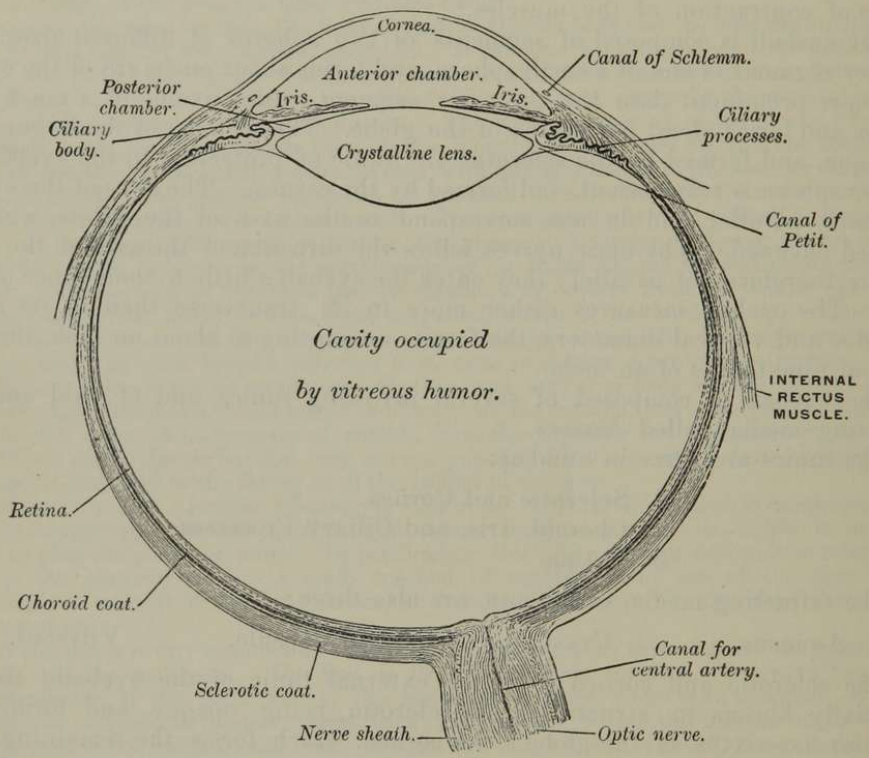

FIG. 527.—A horizontal section of the eyeball. (Allen.)

The **Cornea** is the projecting transparent part of the external tunic of the eyeball, and forms the anterior sixth of the globe. It is almost circular in shape, occasionally a little broader in the transverse than in the vertical direction. It is convex anteriorly, and projects forward from the sclerotic in the same manner that a watch-glass does from its case. Its degree of curvature varies in different individuals, and in the same individual at different periods of life, it being more prominent in youth than in advanced life, when it becomes flattened. The cornea is dense and of uniform thickness throughout; its posterior surface is perfectly circular in outline, and exceeds the anterior surface slightly in extent, from the latter being overlapped by the sclerotic.

Structure.—The cornea consists of four layers—namely, (1) several strata of epithelial cells, continuous with those of the conjunctiva; (2) a thick central fibrous structure, the *cornea proper;* (3) a homogeneous elastic lamina; and (4) a single layer of epithelial cells, forming part of the lining membrane of the anterior chamber of the eyeball. The name of *membrane of Descemet* or *Demours* is given to this posterior elastic lamina and its endothelial coating.

The *conjunctival epithelium*, which covers the front of the cornea proper, consists of several strata of epithelial cells. The lowermost cells are columnar: then follow two or three layers of polyhedral cells, some of which present ridges and furrows similar to those found in the cuticle. Lastly, there are three or four layers of scaly epithelium with flattened nuclei.

The *proper substance of the cornea* is fibrous, tough, unyielding, perfectly transparent, and continuous with the sclerotic, with which it is identical in structure. It is composed of about sixty flattened lamellæ, superimposed one on another. These lamellæ are made up of bundles of fibrous connective tissue, the fibres of which are directly continuous with the fibres of the sclerotic. The fibres of each lamella are for the most part parallel with each other; those of alternating lamellæ at right angles to each other. Fibres, however, frequently pass from one lamella to the next.

The lamellæ are connected with each other by an interstitial cement-substance, in which are spaces, the *corneal spaces*. The spaces are stellate in shape, and have numerous offsets by which they communicate with other spaces. Each space contains a cell, the *corneal corpuscle*, which resembles in form the space in which it is contained, but does not entirely fill it.

Immediately beneath the conjunctival epithelium the cornea proper presents certain characteristic differences, which have led some anatomists to regard it as a distinct membrane, and it has been named by Bowman the *anterior elastic lamina*. It differs, however, from the true elastic lamina or membrane of Descemet in many essential particulars, presenting evidence of fibrillar structure, and not having the same tendency to curl inward or to undergo fracture when detached from the other layers of the cornea. It consists of extremely closely interwoven fibrils, similar to those found in the rest of the cornea proper, but contains no corneal corpuscles. It seems, therefore, more proper to regard it as a part of the proper tissue of the cornea.[1]

The *posterior elastic lamina*, which covers the proper structure of the cornea behind, presents no structure recognizable under the microscope. It consists of a hard, elastic, and perfectly transparent homogeneous membrane, of extreme thinness, which is not rendered opaque by either water, alcohol, or acids. It is very brittle, but its most remarkable property is its extreme elasticity, and the tendency which it presents to curl up or roll upon itself, with the attached surface innermost, when separate from the proper substance of the cornea. Its use appears to be (as suggested by Dr. Jacob) "to preserve the requisite permanent correct curvature of the flaccid cornea proper."

At the margin of the cornea this posterior elastic membrane breaks up into fibres to form a reticular structure at the outer angle of the anterior chamber, the intervals between the fibres forming small cavernous spaces, the *spaces of Fontana*. These little recesses communicate with a somewhat larger space in the substance of the sclerotic close to its junction with the cornea. This is the *canal of Schlemm*, or *sinus circularis iridis*, and, according to some authors, is a lymph-canal, but according to others is a venous sinus. Some of the fibres of this reticulated structure are continued into the front of the iris, forming the ligamentum pectinatum iridis, while others are connected with the fore part of the sclerotic and choroid.

The *endothelial lining of the aqueous chamber* covers the posterior surface of the posterior elastic lamina. It consists of a single layer of polygonal flattened transparent nucleated cells, similar to those found lining other serous cavities.

Arteries and Nerves.—The cornea is a non-vascular structure, the capillary vessels terminating in loops at its circumference. Lymphatic vessels have not as yet been demonstrated in it, but are represented by the channels in which the bundles of nerves run; these are lined by an endothelium and are continuous with the cell-spaces. The nerves are numerous, twenty-four to thirty-six in

[1] This layer has been called by Reichert the "anterior limiting layer"—a name which appears more applicable to it than that of "anterior elastic lamina."

number (Kölliker), forty to forty-five (Waldeyer and Sümisch); they are derived from the ciliary nerves and enter the laminated tissue of the cornea. They ramify throughout its substance in a delicate network, and their terminal filaments form a firm and closer plexus on the surface of the cornea proper beneath the epithelium. This is termed the *subepithelial plexus*, and from it fibrils are given off which ramify between the epithelial cells, forming a network which is termed the *intra-epithelial plexus*.

Dissection.—In order to separate the sclerotic and cornea, so as to expose the second tunic, the eyeball should be immersed in a small vessel of water and held between the finger and thumb. The sclerotic is then carefully incised, in the equator of the globe, till the choroid is exposed. One blade of a pair of probe-pointed scissors is now introduced through the opening thus made, and the sclerotic divided around its entire circumference, and removed in separate portions. The front segment being then drawn forward, the handle of the scalpel should be pressed gently against it at its connection with the iris, and, these being separated, a quantity of perfectly transparent fluid will escape; this is the aqueous humor. In the course of the dissection the ciliary nerves may be seen lying in the loose cellular tissue between the choroid and sclerotic or contained in delicate grooves on the inner surface of the latter membrane.

Second Tunic.—This is formed by the choroid behind, the iris and ciliary processes in front, and by the Ciliary muscle, opposite the junction of the sclerotic and cornea.

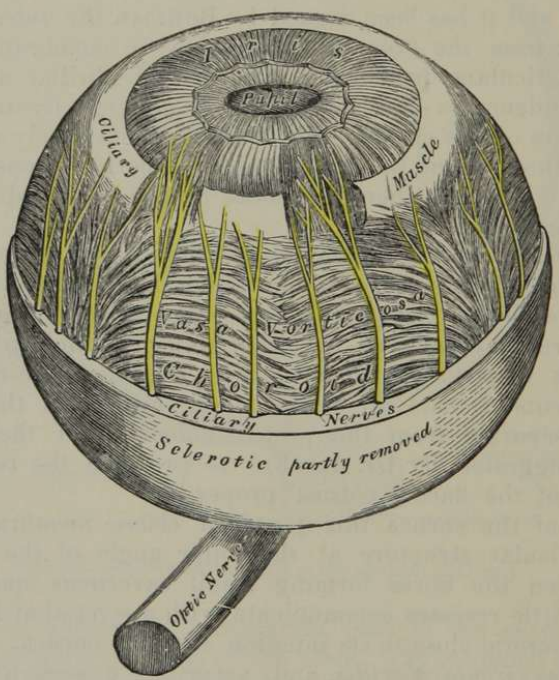

FIG. 528.—The choroid and iris. (Enlarged.)

The choroid is the vascular and pigmentary tunic of the eyeball investing the posterior five-sixths of the globe, and extending as far forward as the cornea, the ciliary processes being appendages of the choroid developed from its inner surface in front. The iris is the circular muscular septum which hangs vertically behind the cornea, presenting in its centre a large circular aperture, the *pupil*. The Ciliary muscle forms the white ring observed at the point where the choroid and iris join with each other and with the sclerotic and cornea.

The **Choroid** is a thin, highly vascular membrane, of a dark brown or chocolate color, which invests the posterior five-sixths of the central part of the globe. It is pierced behind by the optic nerve, and extends in front as far forward as the ciliary ligament, where it is connected with the iris, and bends inward, forming on its inner surface a series of folds or plaitings, the *ciliary processes*. It is thicker

behind than in front. Externally it is connected by a fine cellular web (*membrana fusca*) with the inner surface of the sclerotic. Its inner surface is smooth and lies in contact with the retina.

Structure.—The choroid consists mainly of a dense capillary plexus and of small arteries and veins, carrying the blood to and returning it from this plexus. On its external surface—*i. e.* the surface next the sclerotic—is a thin membrane of fine elastic fibres arranged in lamellæ, which are covered with endothelium and form spaces, which communicate by perforations in the sclerotic, through which the vessels and nerves enter, with the capsule of Tenon. This layer is named the *lamina suprachoroidea*, and is continuous with the lamina fusca of the sclerotic.

Internal to this is the *choroid proper*, and, in consequence of the small arteries and veins being arranged on the outer surface of the capillary network, it is customary to describe this as consisting of two layers, the outermost composed of small arteries and veins, with pigment-cells interspersed between them, and the

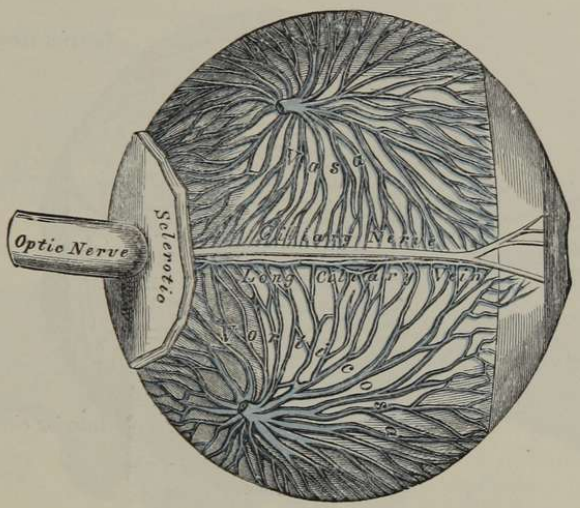

FIG. 529.—The veins of the choroid. (Enlarged.)

inner consisting of a capillary plexus. The *external layer* consists, in part, of the larger branches of the short ciliary arteries, which run forward between the veins before they bend inward to terminate in the capillaries; but is formed principally of veins, which are named, from their arrangement, *venæ vorticosæ*. They converge to four or five equidistant trunks, which pierce the sclerotic midway between the margin of the cornea and the entrance of the optic nerve. Interspersed between the vessels are lodged dark star-shaped pigment-cells, the fibrous offsets from which, communicating with similar branchings from neighboring cells, form a delicate network or stroma, which toward the inner surface of the choroid loses its pigmentary character. The *internal layer* consists of an exceedingly fine capillary plexus, formed by the short ciliary vessels, and is known as the *tunica Ruyschiana*. The network is close, and finer at the hinder part of the choroid than in front. About half an inch behind the cornea its meshes become larger, and are continuous with those of the ciliary processes. On the inner surface of this tunic is a very thin, structureless—or, according to Kölliker, faintly fibrous—membrane, called the *lamina vitrea;* it is closely connected with the stroma of the choroid, and separates it from the pigmentary layer of the retina.

The ciliary processes should now be examined. They may be exposed, either by detaching the iris from its connection with the Ciliary muscle, or by making a transverse section of the globe and examining them from behind.

The *ciliary processes* are formed by the plaiting and folding inward of the various layers of the choroid (*i. e.* the choroid proper and the lamina vitrea) at its anterior margin, and are received between corresponding foldings of the suspensory

ligament of the lens, thus establishing a connection between the choroid and inner tunic of the eye. They are arranged in a circle, and form a sort of plaited frill behind the iris round the margin of the lens. They vary between sixty and eighty in number, lie side by side, and may be divided into large and small; the latter, consisting of about one-third of the entire number, are situated in the spaces between the former, but without regular alternation. The larger processes are each about one-tenth of an inch in length, and are attached by their periphery to the Ciliary muscle, and are continuous with the layers of the choroid: the opposite margin is free, and rests upon the circumference of the lens. Their anterior surface is turned toward the back of the iris, with the circumference of which they are continuous. The posterior surface is closely connected with the suspensory ligament of the lens.

Structure.—The ciliary processes are similar in structure to the choroid, but the vessels are larger, and have chiefly a longitudinal direction. They are covered

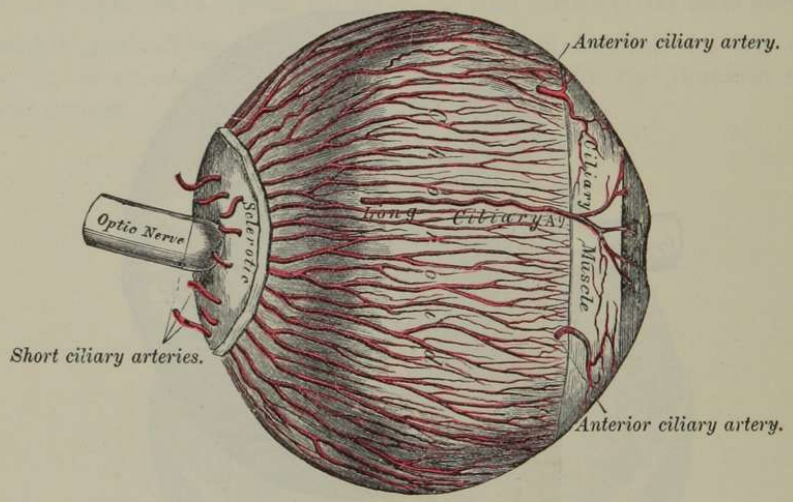

FIG. 530.—The arteries of the choroid and iris. The sclerotic has been mostly removed. (Enlarged.)

on their inner surface with a layer of black pigment-cells continuous with the cells of the pigmentary layer of the retina, and in their stroma are also other, stellate, pigment-cells, which, however, are not so numerous as in the choroid itself, and toward the free extremities of the folds are devoid of pigment.

The **Iris** (*iris*, a rainbow) has received its name from its various colors in different individuals. It is a thin, circular-shaped, contractile curtain, suspended in the aqueous humor behind the cornea and in front of the lens, being perforated a little to the nasal side of its centre by a circular aperture, the *pupil*, for the transmission of light. By its circumference it is intimately connected with the choroid; externally to this is the Ciliary muscle, by which it is connected to the sclerotic and cornea; its inner edge forms the margin of the pupil; its surfaces are flattened, and look forward and backward, the anterior surface toward the cornea, the posterior toward the ciliary processes and lens. The circumference of the iris is connected to the cornea by a reticular structure denominated the *ligamentum pectinatum iridis*. The anterior surface of the iris is variously colored in different individuals, and marked by lines which converge toward the pupil. The posterior surface is of a deep purple tint, from being covered by dark pigment; it is hence named *uvea*, from its resemblance in color to a ripe grape.

Structure.—The iris is composed of the following structures:

1. In front is a layer of polyhedral cells on a delicate hyaline basement membrane. This layer is continuous with the epithelial layer of the membrane of Descemet, and in men with dark-colored irides the cells contain pigment-granules.

2. *Stroma.*—The stroma consists of fibres and cells. The former are made up

of fine delicate bundles of fibrous tissue, of which some few fibres have a circular direction at the circumference of the iris, but the chief mass consists of fibres radiating toward the pupil. They form, by their interlacement, a delicate mesh, in which the vessels and nerves are contained. Interspersed between the bundles of connective tissue are numerous branched cells with fine processes. Many of them in dark eyes contain pigment-granules, but in blue eyes and the pink eyes of albinos they are unpigmented.

3. The *muscular fibre* is involuntary, and consists of circular and radiating fibres. The *circular fibres* (sphincter of the pupil) surround the margin of the pupil on the posterior surface of the iris, like a sphincter, forming a narrow band

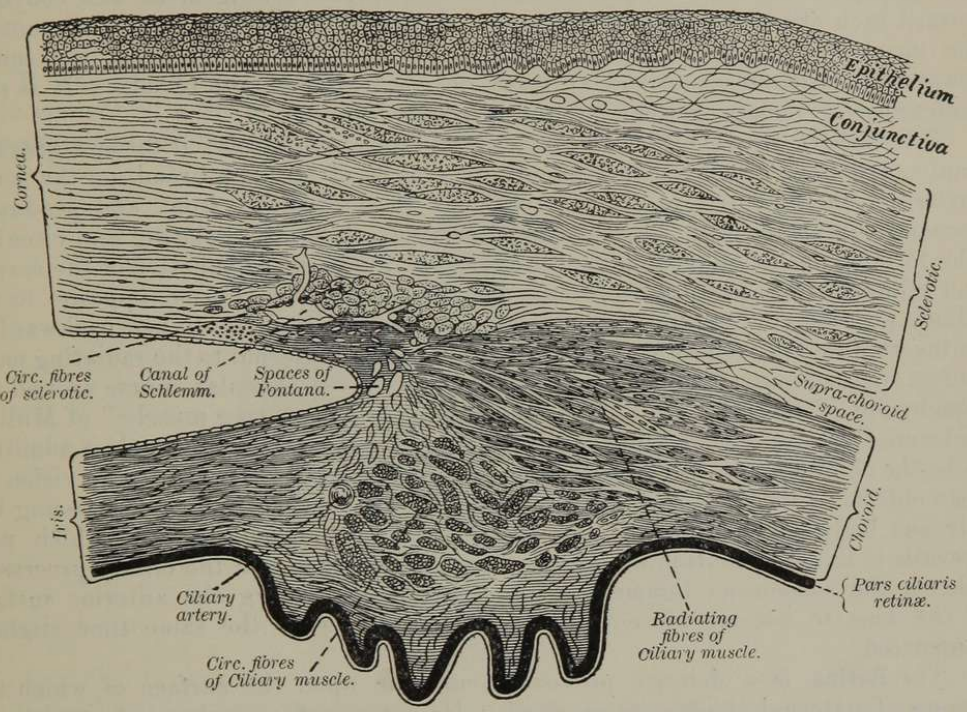

FIG. 531.—Section of the eye, showing the relations of the cornea, sclerotic, and iris, together with the Ciliary muscle and the cavernous spaces near the angle of the anterior chamber. (Waldeyer.)

about one-thirtieth of an inch in width, those near the free margin being closely aggregated; those more external somewhat separated, and forming less complete circles. The *radiating fibres* (dilator of the pupil) converge from the circumference toward the centre, and blend with the circular fibres near the margin of the pupil.

4. *Pigment.*—The situation of the pigment-cells differs in different irides. In the various shades of blue eyes the only pigment-cells are several layers of small round or polyhedral cells filled with dark pigment, situated on the posterior surface of the iris and continuous with the pigmentary lining of the ciliary processes. The color of the eye in these individuals is due to this coloring matter showing more or less through the texture of the iris. In the albino even this pigment is absent. In the gray, brown, and black eye there are, as mentioned above, pigment-granules to be found in the cells of the stroma and in the epithelial layer on the front of the iris, to which the color of the eye is due.

The *arteries of the iris* are derived from the long and anterior ciliary and from the vessels of the ciliary processes (see page 570).

The *nerves of the iris* are derived from the ciliary branches of the lenticular ganglion and the long ciliary from the nasal branch of the ophthalmic division of the fifth. After reaching the iris in the manner described above (page 797) they form a plexus around the attached margin of the iris; from this are derived non-

medullated fibres which terminate in the circular and radiating muscular fibres. Their exact mode of termination has not been ascertained. Other fibres from the plexus terminate in a network on the anterior surface of the iris. The fibres derived from the motor root of the lenticular ganglion (third nerve) supply the circular fibres, while those derived from the sympathetic supply the radiating fibres.

Membrana Pupillaris.—In the fœtus the pupil is closed by a delicate transparent vascular membrane, the *membrana pupillaris*, which divides the space into which the iris is suspended into two distinct chambers. This membrane contains numerous minute vessels, continued from the margin of the iris to those on the front part of the capsule of the lens. These vessels have a looped arrangement, and converge toward each other without anastomosing. Between the seventh and eighth months the membrane begins to disappear, by its gradual absorption from the centre toward the circumference, and at birth only a few fragments remain. It is said sometimes to remain permanent and produce blindness.

The *Ciliary muscle* (Bowman) consists of unstriped fibres: it forms a grayish, semitransparent, circular band, about one-eighth of an inch broad, on the outer surface of the fore part of the choroid. It is thickest in front, and gradually becomes thinner behind. It consists of two sets of fibres, radiating and circular. The former, much the more numerous, arise at the point of junction of the cornea and sclerotic, and, passing backward, are attached to the choroid opposite to the ciliary processes. One bundle, according to Waldeyer, is continued backward to be inserted into the sclerotic. The circular fibres are internal to the radiating ones, and to some extent unconnected with them, and have a circular course around the attachment of the iris. They are sometimes called the "ring muscle" of Müller, and were formerly described as the ciliary ligament. The Ciliary muscle is admitted to be the chief agent in accommodation—*i. e.* in adjusting the eye to the vision of near objects. Mr. Bowman believed that this was effected by its compressing the vitreous body, and so causing the lens to advance; but the view which now prevails is that the contraction of the muscle, by drawing on the ciliary processes, relaxes the suspensory ligament of the lens, thus allowing the anterior surface of the lens to become more convex. The pupil is at the same time slightly contracted.[1]

The **Retina** is a delicate nervous membrane upon the surface of which the images of external objects are received. Its outer surface is in contact with the choroid, the inner surface with the vitreous body. Behind it is continuous with the optic nerve; it gradually diminishes in thickness from behind forward, and in front extends nearly as far forward as the Ciliary muscle, where it terminates by a jagged margin, the *ora serrata*. It is soft, and semitransparent in the fresh state, but soon becomes clouded, opaque, and of a pinkish tint. Exactly in the centre of the posterior part of the retina, and at a point corresponding to the axis of the eye, in which the sense of vision is most perfect, is a round, elevated, yellowish spot, called, after its discoverer, the *yellow spot* or *limbus luteus* (*macula lutea*) of Sömmerring, having a central depression at its summit, the *fovea centralis*. The retina in the situation of the fovea centralis is exceedingly thin; so much so that the dark color of the choroid is distinctly seen through it; so that it presents more the appearance of a foramen, and hence the name "foramen of Sömmerring" at first given to it. It exists only in man, the quadrumana, and some saurian reptiles. About one-tenth of an inch to the inner side of the yellow spot is the point of entrance of the optic nerve (*porus opticus*); here the nervous substance is slightly raised so as to form an eminence (*colliculus nervi optici*); the arteria centralis retinæ pierces its centre. This is the only part of the surface of the retina from which the power of vision is absent.

Structure.—The retina is an exceedingly complex structure, and, when examined microscopically by means of sections made perpendicularly to its surface,

[1] See explanation and diagram in Power's *Illustrations of Some of the Principal Diseases of the Eye*, p. 590.

is found to consist of ten layers, which are named from within outward as follows:

1. Membrana limitans interna.
2. Fibrous layer, consisting of nerve-fibres.
3. Vesicular layer, consisting of nerve-cells.
4. Inner molecular, or granular, layer.
5. Inner nuclear layer.
6. Outer molecular, or granular, layer.
7. Outer nuclear layer.
8. Membrana limitans externa.
9. Layer of rods and cones (Jacob's membrane).
10. Pigmentary layer.

1. The *membrana limitans interna* is the most internal layer of the retina, and is in contact with the hyaloid membrane of the vitreous humor. It is derived from the supporting framework of the retina, with which tissue it will be described.

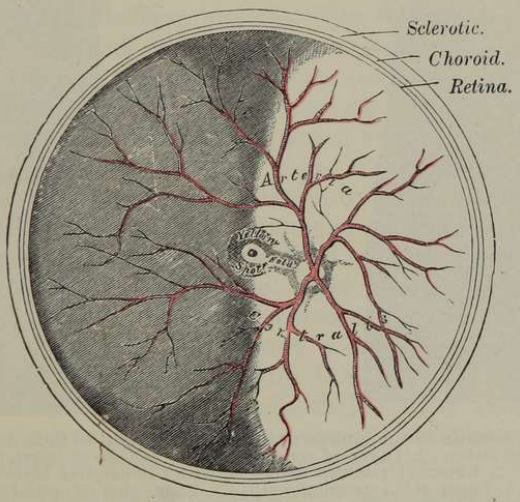

FIG. 532.—The arteria centralis retinæ, yellow spot, etc., the anterior half of the eyeball being removed. (Enlarged.)

2. The *fibrous layer* is made up of nerve-fibres, the direct continuation of the fibres of the optic nerve. This nerve therefore passes through all the other layers of the retina, except the one previously mentioned, to reach its destination in the fibrous layer. As the nerve passes through the lamina cribrosa of the sclerotic coat the fibres of which it is composed lay aside their medullary sheaths and are continued onward, through the choroid and retina, as simple axis-cylinders. When these non-medullated fibres reach the internal surface of the retina, they radiate from their point of entrance over the surface of the retina, grouped in bundles, and in many places, according to Michel, arranged in plexuses. The layer is thickest at the optic nerve entrance, and gradually diminishes in thickness toward the ora serrata.

3. The *vesicular layer* consists of a single layer of large ganglion-cells, except in the macula lutea, where there are several layers. The cells are somewhat flask-shaped; their rounded internal margin resting on the preceding layer, and sending off a single process, which is prolonged into the fibrous layer, and is believed to be continuous with a nerve-fibre. From the opposite extremity of the cell one or more thicker processes extend into the inner molecular layer, where they divide dichotomously and become lost in its reticulum, or, according to some, pass through this layer to reach the inner nuclear layer.

4. The *inner molecular layer* consists of a stratum of granular-looking substance, from which circumstance it is sometimes called the "inner granular" layer.

It is made up of a dense reticulum of minute fibrils, intermingled with the fine processes of the ganglion-cells and also processes derived from certain cells contained in the next layer, immediately to be described. No direct connection between these sets of processes has yet been demonstrated, but it is considered probable that they do communicate, and that there is therefore a direct connection between the ganglion-cells of the vesicular layer and the nuclear cells of the inner nuclear layer. Within the reticulum formed by these fibrils minute clear granules, of unknown nature, are imbedded.

5. The *inner nuclear layer* is made up of nuclear bodies, of which there are

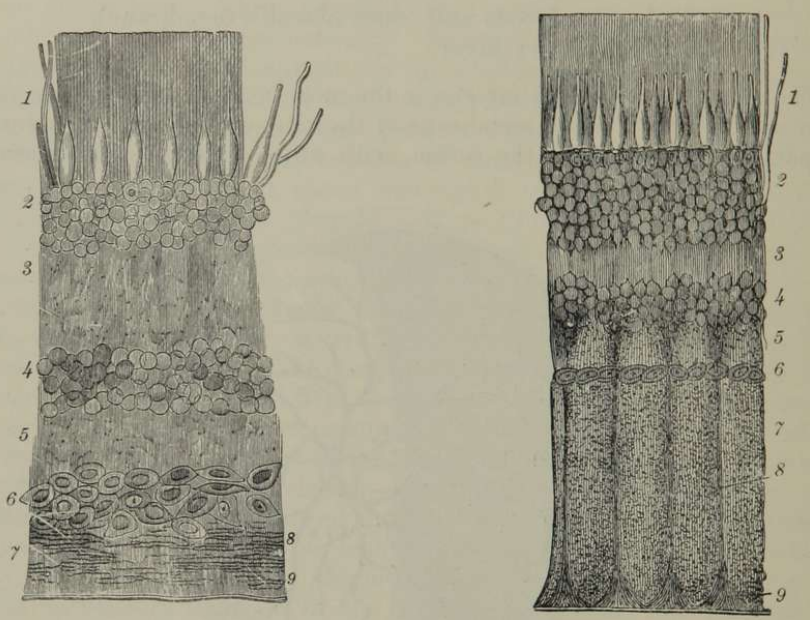

FIGS. 533, 534.—Vertical sections of the human retina. Fig. 533, half an inch from the entrance of the optic nerve. Fig. 534, close to the latter. 1. Layer of rods and cones (*columnar layer*), bounded underneath by the *membrana limitans externa*. 2. External nuclear layer. 3. Outer molecular layer. 4. Internal nuclear layer. 5. Inner molecular layer. 6. Layer of the ganglion-cells. 7. Expansion of optic fibres. 8. Sustentacular fibres of Müller. 9. Their attachment to the membrana limitans interna.

three different kinds: (1) A large number of oval nuclei, which are commonly regarded as bipolar nerve-cells, and are much more numerous than either of the other kind. They consist of a large oval nuclear body placed vertically to the surface, containing a distinct nucleolus: they are surrounded by a small amount of protoplasm, which is prolonged into two processes: one of these passes inward into the inner molecular layer, is varicose in appearance, and, as stated above, is believed to be continuous with the processes of the ganglion-cells. The other process passes outward into the outer molecular layer, and there bifurcates. According to some observers, the divisions thus formed communicate with the rod- and cone-fibres (Merkel). (2) At the innermost part of this inner nuclear layer is a stratum of cells which are not branched. (3) Some few cells are also found in this layer connected with the fibres of Müller, and will be described with those structures.

6. The *outer molecular layer* is much thinner than the inner molecular layer, but, like it, consists of a dense network of minute fibrils, and presents the same granular appearance. It differs, however, from the inner molecular layer in containing branched stellate cells, the processes of which are extremely fine and exhibit varicosities like nerve-fibrils. They are therefore considered by Schultze to be ganglion-cells.

7. *The Outer Nuclear Layer.*—Like the inner nuclear layer, this layer contains several strata of clear oval nuclear bodies; they are of two kinds, and, on account of their being respectively connected with the rods and cones of Jacob's membrane.

are named rod-granules and cone-granules. The *rod-granules* are much the more numerous, and are placed at different levels throughout the layer. They present a peculiar cross-striped appearance, and have prolonged from either extremity a fine process: the outermost is continuous with a single rod of Jacob's membrane; the innermost passes inward toward the outer molecular layer, and terminates in an enlarged extremity, from which are given off a number of minute fibrils, which enter the outer molecular layer. In its course it presents numerous varicosities.

The *cone-granules*, fewer in number than the rod-granules, are placed close to the membrana limitans externa, and are closely connected with the cones of Jacob's membrane. They do not present any cross-striping, but contain a pyriform nucleus, which almost completely fills the cell. From their inner extremity a thick process passes inward to the outer molecular layer, where, like the processes of the rod-cells, it terminates in an enlargement, from which are given off numerous fine fibrils which enter the outer molecular layer.

8. *The Membrana Limitans Externa.*—This layer, like the membrana limitans interna, is derived from the fibres of Müller, with which structures it will be described.

9. *Jacob's Membrane* (*bacillary layer*).—The elements which compose this layer are of two kinds, *rods* and *cones*, the former being much more numerous than the latter. The *rods* are solid, of nearly uniform size, and arranged perpendicularly to the surface. Each rod consists of two portions, an outer and inner, which are joined together by a cement-substance and are of about equal length. They differ from each other as regards refraction and in their behavior with coloring reagents, the inner portion becoming stained by carmine, iodine, etc., the outer portion remaining unstained. The outer portion of each rod is marked by transverse striæ, and is made up of a number of thin disks superimposed on one another. It also exhibits faint longitudinal markings. The inner portion of each rod at its inner extremity, where it is joined to the processes of the rod-granules, is indistinctly granular; at its outer extremity it presents a fine longitudinal striation, being composed of fine, bright, highly refracting fibrils.

The *cones* are conical or flask-shaped, their broad ends resting upon the membrana limitans externa, the narrow pointed extremity being turned to the choroid. Like the rods, they are made up of two portions, outer and inner; the outer portion being a short conical process, which, like the outer segment of the rods, presents transverse striæ. The inner portion resembles the inner portion of the rods in structure, presenting an outer striated and an inner granular appearance, but differs from it in size, being bulged out laterally and presenting a flask shape.

10. *The Pigmentary Layer, or Tapetum Nigrum.*—The most external layer of the retina, formerly regarded as a part of the choroid, consists of a single layer of hexagonal epithelium cells loaded with pigment-granules (Fig. 21). In the eyes of albinos the cells of the pigmentary layer are present, but they contain no coloring matter. In many of the mammals also, as in the horse, and many of the carnivora, there is no pigment in the cells of this layer, and the choroid possesses a beautiful iridescent lustre, which is termed the *tapetum lucidum*.

Connective-tissue Framework of the Retina.—Almost all these layers of the retina are connected together by a sort of supporting connective tissue, which has been named the *fibres of Müller, or radiating fibres*, from which the membrana limitans interna et externa are derived. These fibres are found stretched between the two limiting layers, "as columns between a floor and a ceiling," and passing through all the nervous layers except Jacob's membrane. They commence on the inner surface of the retina by a conical base, the edges of the bases of adjoining fibres being united, and thus forming a boundary-line which is the membrana limitans interna. As they pass through the various layers they present a roughness on their surface, as if a number of membranous processes had been abruptly broken off. By these they are continuous with the reticulum of the inner and outer molecular layer and with a sponge-like stroma, in which the nuclei of the inner nuclear layers are imbedded. In the inner nuclear layer each fibre of Müller

presents a clear oval nucleus, referred to above, which is sometimes situated at the side of, sometimes altogether within, the fibre. In the outer nuclear layer the fibre breaks up into fine lamellæ, which form a fenestrated or sponge-like tissue, in which the rod- and cone-granules are enclosed, and at the outer border of this layer these lamellæ unite along a definite line, forming the membrana limitans externa.

Macula Lutea and Fovea Centralis.—The structure of the retina at the yellow spot presents some modifications. In the macula lutea (1) the nerve-fibres are

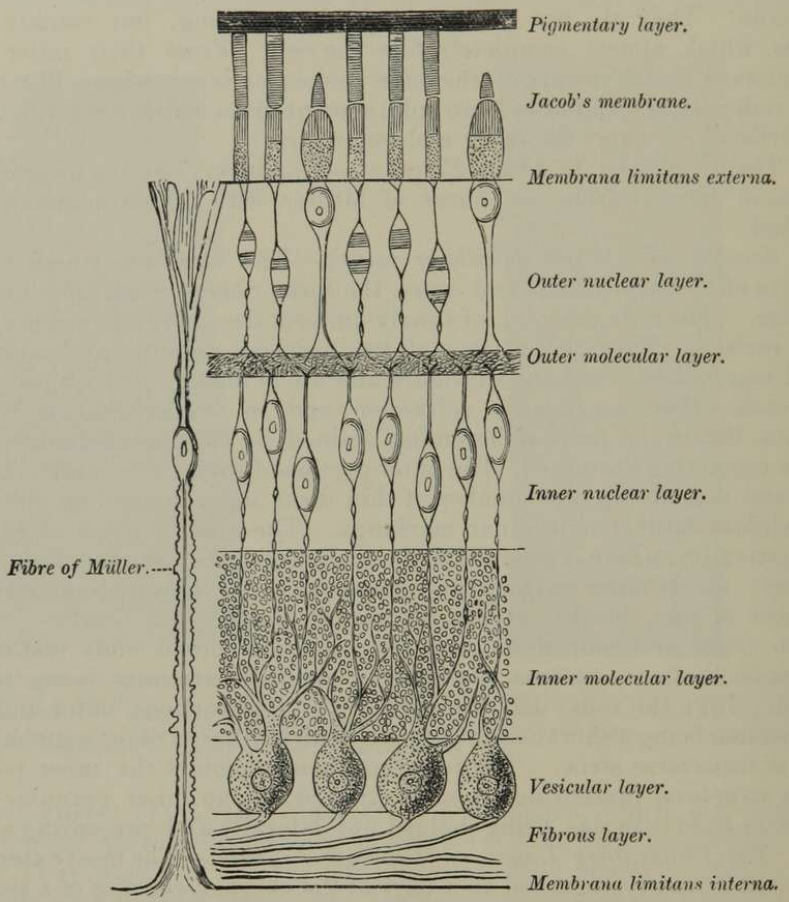

FIG. 535.—The layers of the retina (diagrammatic). (After Schultze.)

wanting as a continuous layer; (2) the vesicular layer consists of several strata of cells, instead of a single layer; (3) in Jacob's membrane there are no rods, but only cones, and these are longer and narrower than in other parts; and (4) in the outer nuclear layer there are only cone-fibres, which are very long and arranged in curved lines. At the fovea centralis the only parts which exist are the cones of Jacob's membrane, the outer nuclear layer, the cone-fibres of which are almost horizontal in direction, and an exceedingly thin inner granular layer. The color of the spot seems to imbue all the layers except Jacob's membrane; it is of a rich yellow, deepest toward the centre, and does not appear to consist of pigment-cells, but simply a staining of the constituent parts.

At the ora serrata the layers of the retina for the most part terminate abruptly, and the radiating fibres of Müller, covered by the pigmentary layer, can be traced forward, as the *pars ciliaris*, to the iris. The fibres of Müller here present the appearance of columnar epithelial cells arranged in a single stratum.

The *arteria centralis retinæ* and its accompanying vein pierce the optic nerve, and enter the globe of the eye through the porus opticus. It immediately divides

into four or five branches, which at first run between the hyaloid membrane and the nervous layer, but they soon enter the latter membrane, and pass forward, dividing dichotomously. From these branches a minute capillary plexus is given off, which does not extend beyond the inner nuclear layer. In the fœtus a small vessel passes forward, through the vitreous humor, to the posterior surface of the capsule of the lens.

Humors of the Eye.

The **aqueous humor** completely fills the anterior and posterior chambers of the eyeball. It is small in quantity (scarcely exceeding, according to Petit, four or five grains in weight), has an alkaline reaction, in composition is little more than water, less than one-fiftieth of its weight being solid matter, chiefly chloride of sodium.

The *anterior chamber* is a space bounded in front by the cornea, behind by the front of the iris. The *posterior chamber* was the name formerly given to a space which was believed to exist between the iris in front and the capsule of the lens, its suspensory ligament, and the ciliary processes behind. It is now known that the posterior surface of the iris is in immediate contact with the lens throughout the greater part of its extent. The only space which remains to represent the posterior chamber is a narrow chink between the peripheral part of the iris, the suspensory ligament, and the ciliary processes.

In the adult these two chambers communicate through the pupil; but in the fœtus in the seventh month, when the pupil is closed by the membrana pupillaris, the two chambers are quite separate.

The Vitreous Body.

The **vitreous body** forms about four-fifths of the entire globe. It fills the concavity of the retina, and is hollowed in front for the reception of the lens and its capsule. It is perfectly transparent, of the consistence of thin jelly, and is composed of an albuminous fluid enclosed in a delicate transparent membrane, the *hyaloid*. This membrane invests the surface of the vitreous body; at the *pars ciliaris retinæ* it splits into two layers, an anterior, the suspensory ligament of the lens, and a posterior, which passes over the front of the vitreous body. It has been supposed, by Hannover, that from its inner surface numerous thin lamellæ are prolonged inward in a radiating manner, forming spaces in which the fluid is contained. In the adult these lamellæ cannot be detected even after careful microscopic examination; but in the fœtus a peculiar fibrous texture pervades the mass, the fibres joining at numerous points, and presenting minute nuclear granules at their point of junction. In the centre of the vitreous humor, running from the position of the entrance of the optic nerve on the retina to the posterior surface of the lens, is a canal filled with fluid and lined by a prolongation of the hyaloid membrane. This is the *canal of Stilling*, and is the canal which in the embryonic vitreous humor conveyed the minute artery from the central artery of the retina to the back of the lens. The fluid from the vitreous body resembles nearly pure water; it contains, however, some salts and a little albumen.

The hyaloid membrane encloses the whole of the vitreous humor, that portion on its anterior surface, which is hollowed out for the reception of the lens, being the posterior layer just mentioned; while the anterior layer is the *suspensory ligament*. It is a delicate structureless membrane, except where it forms the suspensory ligament, where it contains longitudinal elastic fibres. Immediately beneath the hyaloid membrane are found small, granular, nucleated cells which are said to be possessed of amœboid movements.

In the fœtus the centre of the vitreous humor presents a tubular canal, through which a minute artery passes along the vitreous body to the capsule of the lens. *In the adult* no vessels penetrate its substance, so that its nutrition must be carried on by the vessels of the retina and ciliary processes situated upon its exterior.

The Crystalline Lens and its Capsule.

The crystalline lens, enclosed in its capsule, is situated immediately behind the pupil, in front of the vitreous body, and surrounded by the ciliary processes, which slightly overlap its margin.

The *capsule of the lens* is a transparent, highly elastic, and brittle membrane which closely surrounds the lens. It rests, behind, in a depression in the fore part of the vitreous body; in front it is in contact with the free border of the iris, this latter receding from it at the circumference, thus forming the posterior chamber of the eye; and it is retained in its position chiefly by the suspensory ligament of the lens. The capsule is much thicker in front than behind, structureless in texture, and when ruptured the edges roll up with the outer surface innermost, like the elastic lamina of the cornea. The anterior surface of the lens is connected to the inner surface of the capsule by a single layer of transparent, polygonal, nucleated cells. At the circumference of the lens these cells undergo a change in form: they become elongated, and Babucin states that he can trace the gradual transition of the cells into proper lens-fibres, with which they are directly continuous. There is no epithelium on the posterior surface.

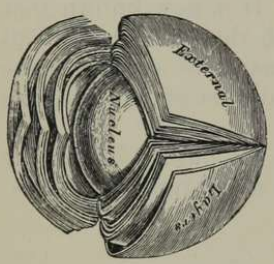

FIG. 536.—The crystalline lens, hardened and divided. (Enlarged.)

In the fœtus a small branch from the arteria centralis retinæ runs forward, as already mentioned, through the vitreous humor to the posterior part of the capsule of the lens, where its branches radiate and form a plexiform network which covers its surface, and they are continuous round the margin of the capsule with the vessels of the pupillary membrane and with those of the iris. In the adult no vessels enter its substance.

The *lens* is a transparent, double-convex body, the convexity being greater on the posterior than on the anterior surface. It measures about a third of an inch in the transverse diameter, and about one-fourth in the antero-posterior. It consists of concentric layers, of which the external in the fresh state are soft and easily detached; those beneath are firmer, the central ones forming a hardened nucleus. These laminæ are best demonstrated by boiling, or immersion in alcohol. The same reagents demonstrate that the lens consists of three triangular segments, the sharp edges of which are directed toward the centre, the bases toward the circumference. The laminæ consist of minute parallel fibres which are hexagonal prisms, the edges being dentated, and the dentations fitting accurately into each other; their breadth is about $\frac{1}{5000}$th of an inch. They run from the sutures or lines of junction of the triangular segments on the one surface to the periphery of the lens, and, curving round its margin, they terminate at the line of junction of the segments on the other. No fibres pass from pole to pole, but they are arranged in such a way that fibres which commence near the pole on the one aspect of the lens—that is to say, near the apex of the triangular segment—terminate near the peripheral extremity of the plane on the other, or near the base of the triangular segment, and *vice versâ*. The fibres of the outer layers of the lens each contain a nucleus, which together form a layer (nuclear layer) on the surface of the lens, most distinct toward its circumference. The meridians, or lines of junction of the three segments, are composed of an amorphous granular substance which sometimes becomes opaque, when the lines are seen forming a distinct star on the lens. The lines on one surface do not lie immediately opposite those on the other, but are intermediate.

The *changes produced in the lens by age* are the following:

In the fœtus its form is nearly spherical, its color of a slightly reddish tint, it is not perfectly transparent, and is so soft as to break down readily on the slightest pressure.

In the adult the posterior surface is more convex than the anterior; it is colorless, transparent, and firm in texture.

In old age it becomes flattened on both surfaces, slightly opaque, of an amber tint, and increases in density.

The *suspensory ligament of the lens* is a thin, transparent, membranous structure placed at first between the vitreous body and the ciliary processes of the choroid, and then passing from these same processes to the anterior surface of the lens near its circumference. It assists in retaining the lens in its position. Its outer surface presents a number of folds or plaitings in which the corresponding folds of the ciliary processes are received. These plaitings are arranged round the lens in a radiating form, and are stained by the pigment of the ciliary processes. The suspensory ligament is that part of the hyaloid membrane, which, as described above, is continued forward to the anterior part of the margin of the lens. It is covered on its outer surface by the pars ciliaris, or connective-tissue framework of the retina, prolonged forward from the ora serrata. That portion of this membrane which intervenes between the ciliary processes and the capsule of the lens forms part of the boundary of the posterior chamber of the eye. The posterior surface of this layer is turned toward the vitreous humor, being separated from it at the circumference of the lens by a space called the canal of Petit.

The *canal of Petit* is about one-tenth of an inch wide. It is bounded in front by the suspensory ligament; behind by the "posterior layer" of the hyaloid membrane, its base being formed by the capsule of the lens. When inflated with air it is sacculated at intervals, owing to the foldings on its anterior surface.

The *arteries of the globe of the eye* are the short, long, and anterior ciliary arteries and the arteria centralis retinæ. They have been already described (see page 570).

The *ciliary veins* are seen on the outer surface of the choroid, and are named, from their arrangement, the *venæ vorticosæ*. They converge to four or five equidistant trunks, which pierce the sclerotic midway between the margin of the cornea and the entrance of the optic nerve. Another set of veins accompany the anterior ciliary arteries and open into the ophthalmic vein.

The *ciliary nerves* are derived from the nasal branch of the ophthalmic and from the ciliary or ophthalmic ganglion.

Surgical Anatomy.—Foreign bodies frequently get into the conjunctival sac and cause great pain, especially if they come in contact with the corneal surface during the movements of the lid and the eye on each other. The conjunctiva is frequently involved in severe injuries of the eyeball, but is seldom ruptured alone; the most common form of injury to the conjunctiva alone is from a burn, either from fire, strong acids, or lime. In these cases union is liable to take place between the eyelid and the eyeball. The conjunctiva is often the seat of inflammation arising from many different causes, and the arrangement of the conjunctival vessels should be remembered as affording a means of diagnosis between this condition and injection of the sclerotic, which is present in inflammations of the deeper structures of the globe. The inflamed conjunctiva is bright red; the vessels are large and tortuous, and greatest at the circumference, shading off toward the corneal margin; they anastomose freely and form a dense network, and they can be emptied or displaced by gentle pressure.

From a surgical point of view the cornea may be regarded as consisting of three layers: (1) of an external epithelial layer, developed from the epiblast, and continuous with the external epithelial covering of the rest of the body, and therefore in its lesions resembling those of the epidermis and superficial layers of the derma; (2) of the cornea proper, derived from the mesoblast, and associated in its diseases with the fibro-vascular structures of the body; and (3) the posterior elastic layer with its endothelium, also derived from the mesoblast and having the characters of a serous membrane, so that inflammation of it resembles inflammation of the other serous and synovial membranes of the body.

The cornea contains no blood-vessels, except at its periphery, where numerous delicate loops, derived from the anterior ciliary arteries, may be demonstrated on the anterior surface of the cornea. The rest of the cornea is nourished by lymph, which gains access to the proper substance of the cornea and the posterior layer through the spaces of Fontana. This lack of a direct blood-supply renders the cornea very apt to inflame in the cachectic and ill-nourished. In cases of granular lids there is a peculiar affection of the cornea, called *pannus*, in which the anterior layers of the cornea become vascularized, and a rich network of blood-vessels may be seen on the cornea; and in interstitial keratitis new vessels extend into the cornea, giving it a pinkish hue, to which the term "salmon patch" is applied. The cornea is richly supplied with

nerves, derived from the ciliary, which enter the cornea through the fore part of the sclerotic and form plexuses in the stroma, terminating between the epithelial cells by free ends or in corpuscles. In cases of glaucoma the ciliary nerves may be pressed upon as they course between the choroid and sclerotic, and the cornea becomes anæsthetic. The sclerotic has very few blood-vessels and nerves. The blood-vessels are derived from the anterior ciliary, and form an open plexus in its substance. As they approach the corneal margin this arrangement is peculiar. Some branches pass through the sclerotic to the ciliary body; others become superficial and lie in the episcleral tissue, and form arches, by anastomosing with each other, some little distance behind the corneal margin. From these arches numerous straight vessels are given off, which run forward to the cornea, forming its marginal plexus. In inflammation of the sclerotic and episcleral tissue these vessels become conspicuous, and form a pinkish zone of straight vessels radiating from the corneal margin, commonly known as the zone of ciliary injection. In inflammation of the iris and ciliary body this zone is present, since the sclerotic speedily becomes involved when these structures are inflamed. But in inflammation of the cornea the sclerotic is seldom much affected, though the cornea and sclerotic are structurally continuous. This would appear to be due to the fact that the nutrition of the cornea is derived from a different source from that of the sclerotic. The sclerotic may be ruptured subcutaneously without any laceration of the conjunctiva, and the rupture usually occurs near the corneal margin, where the tunic is thinnest. It may be complicated with lesions of adjacent parts—laceration of the choroid, retina, iris, or suspensory ligament of the lens—and is then often attended with hæmorrhage into the anterior chamber, which masks the nature of the injury. In some cases the lens has escaped through the rent in the sclerotic, and has been found under the conjunctiva. Wounds of the sclerotic are always dangerous, and are often followed by inflammation, suppuration, and by sympathetic ophthalmia.

The function of the choroid is to provide nutrition for the retina and to convey vessels and nerves to the ciliary body and iris. Inflammation of the choroid is therefore followed by grave disturbance in the nutrition of the retina, and is attended with early interference with vision. In its diseases it bears a considerable analogy to those which affect the skin, and, like it, is one of the places from which melanotic sarcomata may grow. These tumors contain a large amount of pigment in their cells, and grow only from those parts where pigment is naturally present. The choroid may be ruptured without injury to the other tunics, as well as participating in general injuries of the eyeball. In cases of uncomplicated rupture the injury is usually at its posterior part, and is the result of a blow on the front of the eye. It is attended by considerable hæmorrhage, which for a time may obscure vision, but in most cases this is restored as soon as the blood is absorbed.

The iris is the seat of a malformation, termed *coloboma*, which consists in a deficiency or cleft, which in a great number of cases is clearly due to an arrest in development. In these cases it is found at the lower aspect, extending directly downward from the pupil, and the gap frequently extends through the choroid to the entrance of the optic nerve. In some rarer cases the gap is found in other parts of the iris, and is then not associated with any deficiency of the choroid. The iris is abundantly supplied with blood-vessels and nerves, and is therefore very prone to become inflamed. And when inflamed, in consequence of the intimate relationship which exists between the vessels of the iris and choroid this latter tunic is very apt to participate in the inflammation. And, in addition, inflammation of adjacent structures, the cornea and sclerotic, is apt to spread into the iris. The iris is covered with epithelium, and partakes of the character of a serous membrane, and, like these structures, is liable to pour out a plastic exudation when inflamed, and contract adhesions, either to the cornea in front (*synechia anterior*), or to the capsule of the lens behind (*synechia posterior*). In iritis the lens may become involved, and the condition known as secondary cataract may be set up. Tumors occasionally commence in the iris; of these, cysts, which are usually congenital and sarcomatous tumors, are the most common and require removal. Gummata are not unfrequently found in this situation. In some forms of injury of the eyeball, as the impact of a spent shot, the rebound of a twig, or a blow with a whip, the iris may be detached from the Ciliary muscle, the amount of detachment varying from the slightest degree to the separation of the whole iris from its ciliary connection.

The retina, with the exception of its pigment-layer and its vessels, is perfectly transparent, so as to be invisible when examined by the ophthalmoscope, so that its diseased conditions are recognized by its loss of transparency. In retinitis, for instance, there is more or less dense and extensive opacity of its structure, and not unfrequently extravasations of blood into its substance. Hæmorrhages may also take place into the retina from rupture of a blood-vessel without inflammation.

The retina may become displaced from effusion of serum between it and the choroid or by blows on the eyeball, or may occur without apparent cause in progressive myopia, and in this case the ophthalmoscope shows an opaque, tremulous cloud. Glioma, a form of sarcoma, and essentially a disease of early life, is occasionally met with in connection with the retina.

The lens has no blood-vessels, nerves, or connective tissue in its structure, and therefore is not subject to those morbid changes to which tissues containing these structures are liable. It does, however, present certain morbid or abnormal conditions of various kinds. Thus, variations in shape, absence of the whole or a part of the lens, and displacements are amongst its congenital defects. Opacities may occur from injury, senile changes, malnutrition, or errors in growth or development. Senile changes may take place in the lens, impairing its elasticity and render-

ing it harder than in youth, so that its curvature can only be altered to a limited extent by the Ciliary muscle. And, finally, the lens may be dislocated or displaced by blows upon the eyeball, and its relations to surrounding structures altered by adhesions or the pressure of new growths.

There are two particular regions of the eye which require special notice: one of these is known as the "filtration area," and the other as the "dangerous area." The *filtration area* is the circumcorneal zone immediately in front of the iris. Here are situated the cavernous spaces of Fontana, which communicate with the canal of Schlemm, through which the chief transudation of fluid from the eye is now believed to take place. The *dangerous area of the eye* is the region in the neighborhood of the ciliary body, and wounds or injuries in this situation are peculiarly dangerous; for inflammation of the ciliary body is liable to spread to many of the other structures of the eye, especially to the iris and choroid, which are intimately connected by nervous and vascular supplies. Moreover, wounds which involve the ciliary region are especially liable to be followed by sympathetic ophthalmia, in which destructive inflammation of one eye is excited by some irritation in the other.

The Appendages of the Eye.

The appendages of the eye (*tutamina oculi*) include the eyebrows, the eyelids, the conjunctiva, and the lachrymal apparatus—viz. the lachrymal gland, the lachrymal sac, and the nasal duct.

The **eyebrows** (*supercilia*) are two arched eminences of integument which surmount the upper circumference of the orbit on each side, and support numerous short, thick hairs, directed obliquely on the surface. In structure the eyebrows consist of thickened integument, connected beneath with the Orbicularis palpebrarum, Corrugator supercilii, and Occipito-frontalis muscles. These muscles serve, by their action on this part, to control to a certain extent the amount of light admitted into the eye.

The **eyelids** (*palpebræ*) are two thin, movable folds placed in front of the eye, protecting it from injury by their closure. The upper lid is the larger and the more movable of the two, and is furnished with a separate elevator muscle, the *Levator palpebræ superioris*. When the eyelids are opened an elliptical space (*fissura palpebrarum*) is left between their margins, the angles of which correspond to the junction of the upper and lower lids, and are called *canthi*.

The *outer canthus* is more acute than the inner, and the lids here lie in close contact with the globe; but the *inner canthus* is prolonged for a short distance inward toward the nose, and the two lids are separated by a triangular space, the *lacus lachrymalis*. At the commencement of the lacus lachrymalis, on the margin of each eyelid, is a small conical elevation, the *lachrymal papilla*, or tubercle, the apex of which is pierced by a small orifice, the *punctum lachrymale*, the commencement of the lachrymal canal.

The *eyelashes* (*cilia*) are attached to the free edges of the eyelids; they are short, thick, curved hairs, arranged in a double or triple row at the margin of the lids: those of the upper lid, more numerous and longer than the lower, curve upward; those of the lower lid curve downward, so that they do not interlace in closing the lids. Near the attachment of the eyelashes are the openings of a number of glands, *glands of Mohl*, arranged in several rows close to the free margin of the lid. They resemble in structure a portion of a sweat-gland, and are regarded as the modified sweat-glands of this region.

Structure of the Eyelids.—The eyelids are composed of the following structures, taken in their order from without inward:

Integument, areolar tissue, fibres of the Orbicularis muscle, tarsal plate (cartilage), and its ligament, Meibomian glands and conjunctiva. The upper lid has, in addition, the aponeurosis of the Levator palpebræ.

The *integument* is extremely thin, and continuous at the margin of the lids with the conjunctiva.

The *subcutaneous areolar tissue* is very lax and delicate, seldom contains any fat, and is extremely liable to serous infiltration.

The *fibres of the Orbicularis muscle*, where they cover the palpebræ, are thin, pale in color, and possess an involuntary action.

The *tarsal plates* (*cartilages*)[1] are two thin elongated plates of dense connective tissue about an inch in length. They are placed one in each lid, contributing to their form and support.

The *superior*, the larger, is of a semilunar form, about one-third of an inch in breadth at the centre, and becoming gradually narrowed at each extremity. Into the anterior surface of this plate the aponeurosis of the Levator palpebræ is attached.

The *inferior tarsal plate*, the smaller, is thinner and of an elliptical form.

The *free* or *ciliary margin* of these plates is thick, and presents a perfectly straight edge. The *attached* or *orbital margin* is connected to the circumference of the orbit by the fibrous membrane of the lids with which it is continuous. The outer angle of each plate is attached to the malar bone by the external palpebral or tarsal ligament. The inner angles of the two plates terminate at the commencement of the lacus lachrymalis, being fixed to the margins of the orbit by the tendo oculi.

The *tarsal ligament*, or *fibrous membrane of the lids*, is a layer of fibrous membrane beneath the Orbicularis, attached marginally to the edge of the orbit, where it becomes continuous with the periosteum, and centrally to the tarsal plate, near its ciliary margin, with the tissue of which it is continuous. It is thickest and densest at the outer part of the orbit. Upon its under surface is a layer of unstriped muscle, which in the upper lid passes from the aponeurosis of the Levator palpebræ muscle to the tarsal plate. This ligament serves to support the eyelids, and retains the tarsal plates in their position.

The *Meibomian glands* (Fig. 537) are situated upon the inner surface of the eyelids between the tarsal plates and conjunctiva, and may be distinctly seen through the mucous membrane on everting the eyelids, presenting the appearance of parallel strings of pearls. They are about thirty in number in the upper eyelid, and somewhat fewer in the lower. They are imbedded in grooves in the inner surface of the tarsal plates, and correspond in length with the breadth of each plate; they are, consequently, longer in the upper than in the lower eyelid. Their ducts open on the free margin of the lids by minute foramina, which correspond in number to the follicles. The peculiar parallel arrangement of these glands, side by side, forms a smooth layer adapted to the surface of the globe, over which they constantly glide. The use of their secretion is to prevent adhesions of the lids.

Structure of the Meibomian Glands.—These glands are a variety of the cutaneous sebaceous glands, each consisting of a single straight tube or follicle, having a cæcal termination, and with numerous small secondary follicles opening into it. The tubes consist of basement membrane, covered by a layer of scaly epithelium; the secondary follicles are lined by a layer of polyhedral cells continuous with the cells of the tube. The remainder of the follicle is filled with large polyhedral cells charged with fat. They are thus identical in structure with the sebaceous glands.

The **conjunctiva** is the mucous membrane of the eye. It lines the inner surface of the eyelids, and is reflected over the fore part of the sclerotic and cornea. In each of these situations its structure presents some peculiarities.

The *palpebral portion of the conjunctiva* is thick, opaque, highly vascular, and covered with numerous papillæ, its deeper parts presenting a considerable amount of lymphoid tissue. At the margin of the lids it becomes continuous with the lining membrane of the ducts of the Meibomian glands, and, through the lachrymal canals, with the lining membrane of the lachrymal sac and nasal duct. At the outer angle of the upper lid it may be traced along the lachrymal ducts into the lachrymal gland, and at the inner angle of the eye it forms a semilunar fold, the *plica semilunaris*. The folds formed by the reflection of the conjunctiva from the lids on to the eye are called the *superior* and *inferior palpebral folds*, the

[1] Recent observations have proved that the so-called "tarsal cartilages" do not contain any cartilage-cells, and that the name is a misnomer.

former being the deeper of the two. Upon the *sclerotic* the conjunctiva is loosely connected to the globe: it becomes thinner, loses its papillary structure, is transparent, and only slightly vascular in health. Upon the *cornea* the conjunctiva consists only of epithelium, constituting the anterior layer of the cornea (conjunctival epithelium) already described (see page 893). *Lymphatics* arise in the conjunctiva in a delicate zone around the cornea, from which the vessels run to the ocular conjunctiva.

At the point of reflection of the conjunctiva from the lid on to the globe of the eye, termed the *fornix conjunctivæ*, are a number of mucous glands which are much convoluted. They are chiefly found in the upper lid. Other glands, analogous to

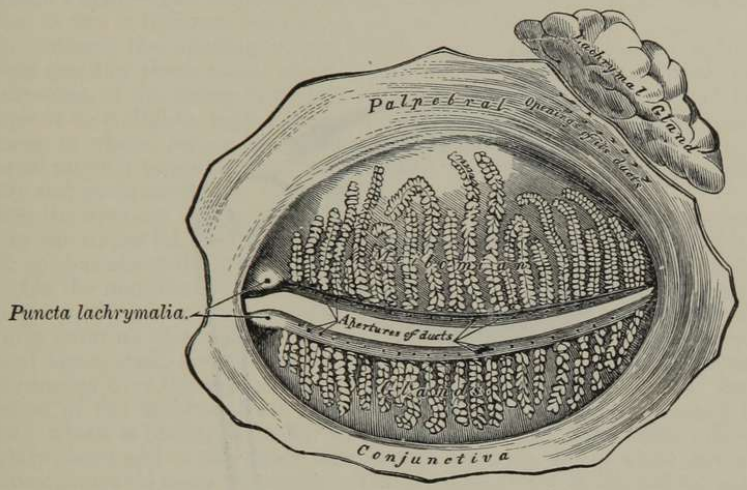

FIG. 537.—The Meibomian glands, etc., seen from the inner surface of the eyelids.

lymphoid follicles, and called by Henle *trachoma glands*, are found in the conjunctiva, and, according to Strohmeyer, are chiefly situated near the inner canthus of the eye. They were first described by Brush, in his description of Peyer's patches of the small intestines, as "identical structures existing in the under eyelid of the ox."

The nerves in the conjunctiva are numerous and form rich plexuses. According to Krause, they terminate in a peculiar form of tactile corpuscle, which he terms the "terminal bulb."

The *caruncula lachrymalis* is a small, reddish, conical-shaped body, situated at the inner canthus of the eye, and filling up the small triangular space in this situation, the *lacus lachrymalis*. It consists of a cluster of follicles similar in structure to the Meibomian, covered with mucous membrane, and is the source of the whitish secretion which constantly collects at the inner angle of the eye. A few slender hairs are attached to its surface. On the outer side of the caruncula is a slight semilunar fold of mucous membrane, the concavity of which is directed toward the cornea; it is called the *plica semilunaris*. Müller found smooth muscular fibres in this fold, and in some of the domesticated animals a thin plate of cartilage has been discovered. This structure is considered to be the rudiment of the third eyelid in birds, the *membrana nictitans*.

The Lachrymal Apparatus (Fig. 538).

The lachrymal apparatus consists of the lachrymal gland, which secretes the tears, and its excretory ducts, which convey the fluid to the surface of the eye. This fluid is carried away by the lachrymal canals into the lachrymal sac, and along the nasal duct into the cavity of the nose.

The **lachrymal gland** is lodged in a depression at the outer angle of the orbit, on the inner side of the external angular process of the frontal bone. It is of an

oval form, about the size and shape of an almond. Its upper convex surface is in contact with the periosteum of the orbit, to which it is connected by a few fibrous bands. Its under concave surface rests upon the convexity of the eyeball and upon the Superior and External recti muscles. Its vessels and nerves enter its posterior border, whilst its anterior margin is closely adherent to the back part of the upper eyelid, where it is covered to a slight extent by the reflection of the conjunctiva. The fore part of the gland is separated from the rest by a fibrous septum; hence it is sometimes described as a separate lobe, called the *palpebral portion of the gland* (*accessory gland of Rosenmüller*). Its ducts, about seven in number, run obliquely beneath the mucous membrane for a short distance, and, separating from each other, open by a series of minute orifices on the upper and outer half

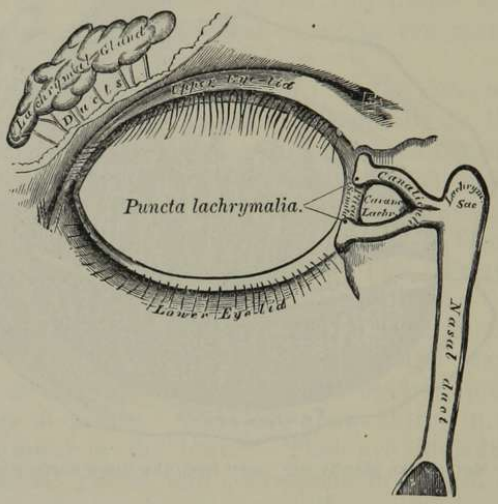

FIG. 538.—The lachrymal apparatus. Right side.

of the conjunctiva near its reflection on to the globe. These orifices are arranged in a row, so as to disperse the secretion over the surface of the membrane.

Structure of the Lachrymal Gland.—In structure and general appearance the lachrymal resembles the serous salivary glands (page 946). In the recent state the cells are so crowded with granules that their limits can hardly be defined. They contain an oval nucleus, and the cell-protoplasm is finely fibrillated.

The **lachrymal canals** commence at the minute orifices, *puncta lachrymalia*, on the summit of a small conical elevation, the *lachrymal papilla*, seen on the margin of the lids at the outer extremity of the lacus lachrymalis. The *superior canal*, the smaller and shorter of the two, at first ascends, and then bends at an acute angle, and passes inward and downward to the lachrymal sac. The *inferior canal* at first descends, and then, abruptly changing its course, passes almost horizontally inward to the lachrymal sac. These canals are dense and elastic in structure and somewhat dilated at their angle. The mucous membrane is covered with scaly epithelium.

The **lachrymal sac** is the upper dilated extremity of the nasal duct, and is lodged in a deep groove formed by the lachrymal bone and nasal process of the superior maxillary. It is oval in form, its upper extremity being closed in and rounded, whilst below it is continued into the nasal duct. It is covered by a fibrous expansion derived from the tendo oculi, and on the inner side it is crossed by the Tensor tarsi muscle (Horner's muscle, page 395), which is attached to the ridge on the lachrymal bone.

Structure.—It consists of a fibrous elastic coat, lined internally by mucous membrane, the latter being continuous, through the lachrymal canals, with the mucous lining of the conjunctiva, and, through the nasal duct, with the pituitary membrane of the nose.

The **nasal duct** is a membranous canal, about three-quarters of an inch in length, which extends from the lower part of the lachrymal sac to the inferior meatus of the nose, where it terminates by a somewhat expanded orifice, provided with an imperfect valve, the *valve of Hasner*, formed by the mucous membrane. It is contained in an osseous canal formed by the superior maxillary, the lachrymal, and the inferior turbinated bones, is narrower in the middle than at each extremity, and takes a direction downward, backward, and a little outward. It is lined by mucous membrane, which is continuous below with the pituitary lining of the nose. This membrane in the lachrymal sac and nasal duct is covered with ciliated epithelium as in the nose.

Surface Form.—The palpebral fissure, or opening between the eyelids, is elliptical in shape, and differs in size in different individuals and in different races of mankind. In the Mongolian races, for instance, the opening is very small, merely a narrow fissure, and this makes the eyeball appear small in these races, whereas the size of the eye is relatively very constant. The normal direction of the fissure is slightly oblique, in a direction upward and outward, so that the outer angle is on a slightly higher level than the inner. This is especially noticeable in the Mongolian races, in whom, owing to the upward projection of the malar bone and the shortness of the external angular process of the frontal bone, the tarsal plate of the upper lid is raised at its outer part and gives an oblique direction to the palpebral fissure.

When the eyes are directed forward, as in ordinary vision, the upper part of the cornea is covered by the upper lid, and the lower margin of the cornea corresponds to the level of the lower lid, so that about the lower three-fourths of the cornea is exposed under ordinary circumstances. On the margins of the lids, about a quarter of an inch from the inner canthus, are two small openings, the *puncta lachrymalia*, the commencement of the lachrymal canals. They are best seen by everting the eyelids. In the natural condition they are in contact with the conjunctiva of the eyeball, and are maintained in this position by the Tensor tarsi muscle, so that the tears running over the surface of the globe easily find their way into the lachrymal canals. The position of the lachrymal sac into which the canals open is indicated by a little tubercle (page 224), which is plainly to be felt on the lower margin of the orbit. The lachrymal sac lies immediately above and to the inner side of this tubercle, and a knife passed through the skin in this situation would open the cavity. The position of the lachrymal sac may also be indicated by the tendo oculi or internal tarsal ligament. If both lids be drawn outward, so as to tense the skin at the inner angle, a prominent cord will be seen beneath the tightened skin. This is the *tendo oculi*, which lies immediately over the lachrymal sac, bisecting it, and thus forming a useful guide to its situation. A knife entered immediately beneath the tense cord would open the lower part of the sac. A probe introduced through this opening can be readily passed downward through the duct into the inferior meatus of the nose. The direction of the duct is downward, outward, and backward, and this course should be borne in mind in passing the probe, otherwise the point may be driven through the thin bony walls of the canal. A convenient plan is to direct the probe in such a manner that if it were pushed onward it would strike the first molar tooth of the lower jaw on the same side of the body. In other words, the surgeon standing in front of his patient should carry in his mind the position of the first molar tooth, and should push his probe onward in such a way as if he desired to reach this structure.

Beneath the internal angular process of the frontal bone the pulley of the Superior oblique muscle of the eye can be plainly felt by pushing the finger backward between the upper and inner angle of the eye and the roof of the orbit; passing backward and outward from this pulley, the tendon can be felt for a short distance.

Surgical Anatomy.—The eyelids are composed of various tissues, and consequently are liable to a variety of diseases. The skin which covers them is exceedingly thin and delicate, and is supported on a quantity of loose and lax subcutaneous tissue which contains no fat. In consequence of this it is very freely movable, and is liable to be drawn down by the contraction of neighboring cicatrices, and thus produce an eversion of the lid known as *ectropion*. Inversion of the lids (*entropion*) from spasm of the Orbicularis palpebrarum or from chronic inflammation of the palpebral conjunctiva may also occur. The eyelids are richly supplied with blood, and are often the seat of vascular growths, such as nævi. Rodent ulcer also frequently commences in this situation. The loose cellular tissue beneath the skin is liable to become extensively infiltrated either with blood or inflammatory products, producing very great swelling. Even from very slight injuries to this tissue the extravasation of blood may be so great as to produce considerable swelling of the lids and complete closure of the eye, and the same is the case when inflammatory products are poured out. The follicles of the eyelashes or the sebaceous glands associated with these follicles may be the seat of inflammation, constituting the ordinary "sty." The Meibomian glands are affected in the so-called "tarsal tumor;" the tumor, according to some, being caused by the retained secretion of these glands; by others it is believed to be a neoplasm connected with the gland. The ciliary follicles are liable to become inflamed, constituting the disease known as *blepharitis ciliaris*, or "blear-eye." Irregular or disorderly growth of the eyelashes not unfrequently occurs, some of them being turned toward the eyeball and producing inflammation and ulceration of the cornea, and possibly eventually complete destruction of the eye. The Orbicularis palpebrarum may be the seat of spasm, either in the form of slight quiv-

ering of the lids or repeated twitchings, most commonly due to errors of refraction in children, or more continuous spasm, due to some irritation of the fifth or seventh cranial nerve. The Orbicularis may be paralyzed, generally associated with paralysis of the other facial muscles. Under these circumstances the patient is unable to close the lids, and, if he attempts to do so, rolls the eyeball upward under the upper lid. The tears overflow from displacement of the lower lid, and the conjunctiva and cornea, being constantly exposed and the patient being unable to wink, become irritated from dust and foreign bodies. In paralysis of the Levator palpebræ superioris there is drooping of the upper eyelid and other symptoms of implication of the third nerve. The eyelids may be the seat of bruises, wounds, or burns. In these latter injuries adhesions of the margins of the lids to each other or adhesion of the lids to the globe may take place. The eyelids are sometimes the seat of emphysema after fracture of some of the thin bones forming the inner wall of the orbit. If shortly after such an injury the patient blows his nose, air is forced from the nostril through the lacerated structures into the connective tissue of the eyelids, which suddenly swell up and present the peculiar crackling characteristic of this affection.

The lachrymal gland is occasionally, though rarely, the seat of inflammation, either acute or chronic; it is also sometimes the seat of tumors, benign or malignant, and for these may require removal. This may be done by an incision through the skin just below the eyebrow; and the gland, being invested with a special capsule of its own, may be isolated and removed without opening the general cavity of the orbit. The canaliculi may be obstructed, either as a congenital defect or by some foreign body, as an eyelash or a dacryolith, causing the tears to run over the cheek. The canaliculi may also become occluded as the result of burns or injury; overflow of the tears may in addition result from deviation of the puncta or from chronic inflammation of the lachrymal sac. This latter condition is set up by some obstruction to the nasal duct frequently occurring in tubercular subjects. In consequence of this the tears and mucus accumulate in the lachrymal sac, distending it. Suppuration in the lachrymal sac is sometimes met with; this may be the sequel of a chronic inflammation; or may occur after some of the eruptive fevers in cases where the lachrymal passages were previously quite healthy. It may lead to lachrymal fistula.

THE EAR.

The organ of hearing is divisible into three parts—the external ear, the middle ear or tympanum, and the internal ear or labyrinth.

The **external ear** consists of an expanded portion named *pinna* or *auricle*, and the auditory canal, or *meatus*. The former serves to collect the vibrations of the air by which sound is produced; the latter conducts those vibrations to the tympanum.

The **pinna**, or **auricle** (Fig. 539), is of an ovoid form, with its larger end directed upward. Its outer surface is irregularly concave, directed slightly forward, and presents numerous eminences and depressions which result from the foldings of its fibro-cartilaginous element. To each of these names have been assigned. Thus the external prominent rim of the auricle is called the *helix*. Another curved prominence, parallel with and in front of the helix, is called the *antihelix;* this bifurcates above, so as to enclose a triangular depression, the *fossa of the antihelix*. The narrow curved depression between the helix and antihelix is called the *fossa of the helix* (*fossa innominata* or *scaphoidea*); the antihelix describes a curve round a deep, capacious cavity, the *concha*, which is partially divided into two parts by the commencement of the helix. In front of the concha, and projecting backward over the meatus, is a small pointed eminence, the *tragus*, so called from its being generally covered on its under surface with a tuft of hair resembling a goat's beard. Opposite the tragus, and separated from it by a deep notch (*incisura intertragica*) is a small tubercle, the *antitragus*. Below this is the *lobule*, composed of tough areolar and adipose tissue, wanting the firmness and elasticity of the rest of the pinna.

Structure of the Pinna.—The pinna is composed of a thin plate of yellow fibro-cartilage covered with integument, and connected to the surrounding parts by the extrinsic ligaments and muscles, and to the commencement of the external auditory canal.

The *integument* is thin, closely adherent to the cartilage, and furnished with sebaceous glands, which are most numerous in the concha and scaphoid fossa.

The *cartilage of the pinna* consists of one single piece: it gives form to this part of the ear, and upon its surface are found all the eminences and depressions above described. It does not enter into the construction of all parts of the auricle: thus it does not form a constituent part of the lobule; it is deficient

also between the tragus and beginning of the helix, the notch between them being filled up by dense fibrous tissue. At the front part of the pinna, where the helix bends upward, is a small projection of cartilage, called the *process of the helix*. The cartilage of the pinna presents several intervals or fissures in its substance which partially separate the different parts. The fissure of the helix is a short vertical slit situated at the fore part of the pinna, immediately behind a small conical projection of cartilage, opposite the first curve of the helix (process of the helix). Another fissure, the fissure of the tragus, is seen upon the anterior surface of the tragus. The antihelix is divided below, by a deep fissure, into two parts: one part terminates by a pointed, tail-like extremity (*processus caudatus*); the other is continuous with the antitragus. The cartilage of the

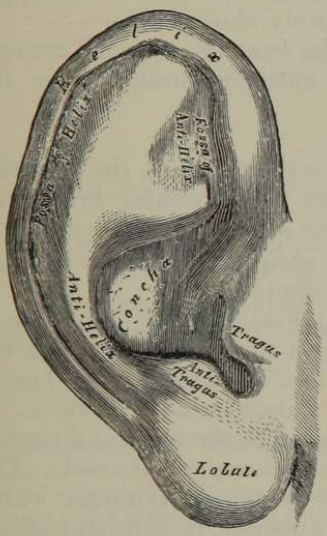

FIG. 539.—The pinna, or auricle. Outer surface.

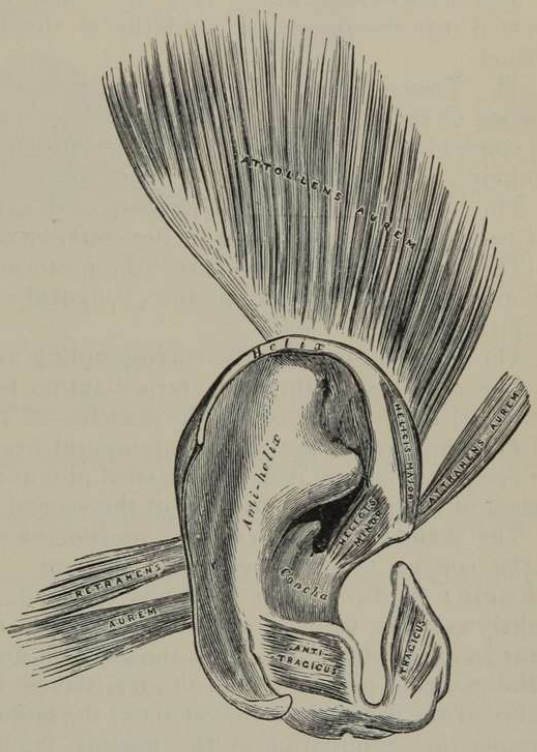

FIG. 540.—The muscles of the pinna.

pinna is very pliable, elastic, of a yellowish color, and belongs to that form of cartilage which is known under the name of yellow fibro-cartilage.

The *ligaments of the pinna* consist of two sets: 1. The extrinsic set, or those connecting it to the side of the head. 2. The intrinsic set, or those connecting the various parts of its cartilage together.

The *extrinsic ligaments*, the most important, are two in number, anterior and posterior. The *anterior ligament* extends from the process of the helix to the root of the zygoma. A few fibres connect the tragus to the root of the zygoma. The *posterior ligament* passes from the posterior surface of the concha to the outer surface of the mastoid process of the temporal bone.

The *intrinsic ligaments* are also two in number. Of these, one is a strong fibrous band stretching across from the tragus to the commencement of the helix, completing the meatus in front and partly encircling the boundary of the concha; the other extends between the concha and the processus caudatus.

The *muscles of the pinna* (Fig. 540) consist of two sets: 1. The *extrinsic*, which connect it with the side of the head, moving the pinna as a whole—viz. the Attollens, Attrahens, and Retrahens aurem (page 394); and 2. The *intrinsic*, which extend from one part of the auricle to another—viz.:

Helicis major.
Helicis minor.
Tragicus.
Antitragicus.
Transversus auriculæ.
Obliquus auris.

The *Musculus helicis major* is a narrow vertical band of muscular fibres, situated upon the anterior margin of the helix. It arises below from the process of the helix, and is inserted into the anterior border of the helix, just where it is about to curve backward. It is pretty constant in its existence.

The *Musculus helicis minor* is an oblique fasciculus, attached to that part of the helix which commences from the bottom of the concha.

The *Tragicus* is a short, flattened band of muscular fibres situated upon the outer surface of the tragus, the direction of its fibres being vertical.

The *Antitragicus* arises from the outer part of the antitragus: its fibres are inserted into the processus caudatus of the helix. This muscle is usually very distinct.

The *Transversus auriculæ* is placed on the cranial surface of the pinna. It consists of radiating fibres, partly tendinous and partly muscular, extending from the convexity of the concha to the prominence corresponding with the groove of the helix.

The *Obliquus auris* (Todd) consists of a few fibres extending from the upper and back part of the concha to the convexity immediately above it.

The *arteries of the pinna* are—the posterior auricular from the external carotid, the anterior auricular from the temporal, and an auricular branch from the occipital artery.

The *veins* accompany the corresponding arteries.

The *nerves* are—the auricularis magnus, from the cervical plexus; the posterior auricular, from the facial to the muscles of the pinna; the auricular branch of the pneumogastric; the auriculo-temporal branch of the inferior maxillary nerve; the occipitalis minor from the cervical plexus; and the occipitalis major or internal branch of the posterior division of the second cervical nerve.

The **Auditory Canal** (*meatus auditorius externus*) extends from the bottom of the concha to the membrana tympani. It is about an inch and a quarter in length; its direction is obliquely forward, inward, and downward. At first it slightly ascends, while in the middle portion it makes a sharp bend backward. It forms an oval cylindrical canal, the greatest diameter being in the vertical direction at the external orifice, but in the transverse direction at the tympanic end. The calibre of the canal is narrowest about the middle. The membrana tympani, which occupies the termination of the meatus, is obliquely directed, in consequence of which the floor of the canal is longer than the roof, and the anterior wall longer than the posterior. The auditory canal is formed partly by cartilage and membrane, and partly by bone, and is covered by skin.

The *cartilaginous portion* is about half an inch in length, being rather less than half the canal; it is formed by the cartilage of the concha and tragus, prolonged inward, and firmly attached to the circumference of the auditory process of the temporal bone. The cartilage is deficient at its upper and back part, its place being supplied by fibrous membrane. This part of the canal is rendered extremely movable by two or three deep fissures (*incisuræ Santorini*), which extend through the cartilage in a vertical direction.

The *osseous portion* is about three-quarters of an inch in length, and narrower than the cartilaginous portion. Its *inner end* is marked, except at its upper part, by a narrow groove (*sulcus tympanicus*) for the insertion of the membrana tympani. The bony ridge, external to the sulcus, is the remnant of the fœtal *tympanic ring*. It also is deficient above, and this deficiency is known as the *notch of Rivinus*. The *ends* of the incomplete ring bound the notch, and are known as the *anterior* and *posterior tympanic spines*. Its *outer end* is dilated, and rough, in the greater part of its circumference, for the attachment of the cartilage of the pinna. Its vertical transverse section is oval, the greatest diameter being from above downward. The front and lower parts of this canal are formed by a curved plate (tympanic plate) of bone, which, in the fœtus, exists as a separate ring (tympanic ring) incomplete at its upper part.

The *skin* lining the meatus is very thin, adheres closely to the cartilaginous

and osseous portion of the tube, and covers the surface of the membrana tympani, forming its outer layer. After maceration the thin pouch of epidermis, when withdrawn, preserves the form of the meatus. In the thick subcutaneous tissue of the cartilaginous part of the meatus are numerous ceruminous glands, which

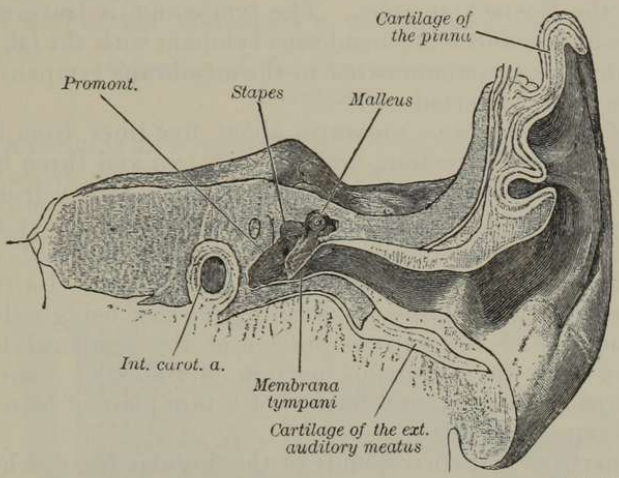

FIG. 541.—Transverse section of external auditory meatus and tympanum. Left side. (Gegenbaur.)

secrete the ear-wax. They resemble in structure sweat-glands, and their ducts open on the surface of the skin.

The *arteries* supplying the meatus are branches from the posterior auricular, internal maxillary, and temporal.

The *nerves* are chiefly derived from the auriculo-temporal branch of the inferior maxillary nerve.

Surface Form.—At the point of junction of the osseous and cartilaginous portions the tube forms an obtuse angle, which projects into the tube at its antero-inferior wall. This produces a sort of constriction in this situation, and renders it the narrowest portion of the canal—an important point to be borne in mind in connection with the presence of foreign bodies in the ears. The cartilaginous is connected to the bony part by fibrous tissue, which renders the outer part of the tube very movable, and therefore by drawing the pinna upward and backward the canal is rendered almost straight. At the external orifice are a few short, crisp hairs which serve to prevent the entrance of small particles of dust, or flies or other insects. In the external auditory meatus the secretion of the ceruminous glands serves to catch any small particles which may find their way into the canal, and prevent their reaching the membrana tympani, where their presence might excite irritation. In young children the meatus is very short, the osseous part being very deficient, and consisting merely of a bony ring (the *tympanic plate*), which supports the membrana tympani. In the fœtus the osseous part is entirely absent. The shortness of the canal in children should be borne in mind in introducing the aural speculum, so that it be not pushed in too far, at the risk of injuring the membrana tympani; indeed, even in the adult the speculum should never be introduced beyond the constriction which marks the junction of the osseous and cartilaginous portions. In using this instrument it is advisable that the pinna should be drawn upward, backward, and a little outward, so as to render the canal as straight as possible, and thus assist the operator in obtaining, by the aid of reflected light, a good view of the membrana tympani. Just in front of the membrane is a well-marked depression, situated on the floor of the canal and bounded by a somewhat prominent ridge; in this foreign bodies may become lodged. By aid of the speculum, combined with traction of the auricle upward and backward, the whole of the membrana tympani is rendered visible. It is a pearly-gray membrane, slightly glistening in the adult, placed obliquely, so as to form with the floor of the meatus a very acute angle, while with the roof it forms an obtuse angle. At birth it is more horizontal, situated in almost the same plane as the base of the skull. About midway between the anterior and posterior margins of the membrane, and extending from the centre obliquely upward, is a reddish-yellow streak; this is the handle of the malleus, which is inserted into the membrane. At the upper part of this streak, close to the roof of the meatus, a little white rounded prominence is plainly to be seen; this is the processus brevis of the malleus, projecting against the membrane. The membrana tympani does not present a plane surface; on the contrary, its centre is drawn inward, on account of its connection with the handle of the malleus, and thus the external surface is rendered concave.

Middle Ear, or Tympanum.

The **middle ear**, or **tympanum**, is an irregular cavity, compressed from without inward, and situated within the petrous bone. It is placed above the jugular fossa; the carotid canal lying in front, the mastoid cells behind, the meatus auditorius externally, and the labyrinth internally. It is filled with air, and communicates with the pharynx by the Eustachian tube. The tympanum is traversed by a chain of movable bones, which connect the membrana tympani with the labyrinth, and serve to convey the vibrations communicated to the membrana tympani across the cavity of the tympanum to the internal ear.

The *cavity of the tympanum* measures about five lines from before backward, three lines in the vertical direction, and between two and three in the transverse, being a little broader behind and above than it is below and in front. It is bounded externally by the membrana tympani and meatus, internally, by the outer surface of the internal ear, and communicates, behind, with the mastoid cells, and in front with the Eustachian tube and canal for the Tensor tympani. Its roof and floor are formed by thin osseous laminæ, the one forming the roof being a thin plate situated on the anterior surface of the petrous portion of the temporal bone, close to its angle of junction with the squamous portion of the same bone.

The **roof** is broad, flattened, and formed of a thin plate of bone which separates the cranial and tympanic cavities.

The **floor** is narrow, and corresponds to the jugular fossa, which lies beneath. It presents, near the inner wall, a small aperture for the passage of Jacobson's nerve.

The **outer wall** is formed mainly by the membrana tympani, partly by the ring of bone into which this membrane is inserted. Close to it are three small apertures—the iter chordæ posterius, the Glaserian fissure, and the iter chordæ anterius.

The *aperture of the iter chordæ posterius* is in the angle of junction between the posterior and external walls of the tympanum, immediately behind the membrana tympani and on a level with its centre; it leads into a minute canal, which descends in front of the aqueductus Fallopii and terminates in that canal near the stylo-mastoid foramen. Through it the chorda tympani nerve enters the tympanum.

The *Glaserian fissure* opens just above and in front of the ring of bone into which the membrana tympani is inserted; in this situation it is a mere slit about a line in length. It lodges the long process of the malleus and gives passage to some tympanic vessels.

The *aperture of the iter chordæ anterius* is seen just above the preceding fissure; it leads into a canal (*canal of Huguier*), which runs parallel with the Glaserian fissure. Through it the chorda tympani nerve leaves the tympanum.

The **internal wall of the tympanum** (Fig. 542) is vertical in direction and looks directly outward. It presents for examination the following parts:

Fenestra ovalis.	Ridge of the aqueductus Fallopii.
Fenestra rotunda.	Promontory.

The *fenestra ovalis* is a reniform opening leading from the tympanum into the vestibule; its long diameter is directed horizontally, and its convex border is upward. The opening in the recent state is occupied by the base of the stapes, which is connected to the margin of the foramen by an annular ligament.

The *fenestra rotunda* is an aperture placed at the bottom of a funnel-shaped depression leading into the cochlea. It is situated below and rather behind the fenestra ovalis, from which it is separated by a rounded elevation, the *promontory;* it is closed in the recent state by a membrane (*membrana tympani secundaria*, Scarpa). This membrane is concave toward the tympanum, convex toward the cochlea. It consists of three layers: the external, or mucous, derived from the mucous lining of the tympanum; the internal, or serous, from the lining membrane of the cochlea; and an intermediate, or fibrous layer.

The *promontory* is a rounded hollow prominence, formed by the projection outward of the first turn of the cochlea; it is placed between the fenestræ, and

is furrowed on its surface by three small grooves which lodge branches of the tympanic plexus.

The *rounded eminence of the aqueductus Fallopii*, the prominence of the bony canal in which the portio dura is contained, traverses the inner wall of the tympanum above the fenestra ovalis, and behind that opening curves nearly vertically downward along the posterior wall.

The **posterior wall of the tympanum** is wider above than below, and presents for examination the

Opening of the mastoid antrum.
Pyramid.

The mastoid antrum is an irregular cavity with several small apertures opening into it, situated above and behind the tympanum proper; the smaller openings lead into canals which communicate with large irregular cavities contained in the interior of the mastoid process. These cavities vary considerably in number,

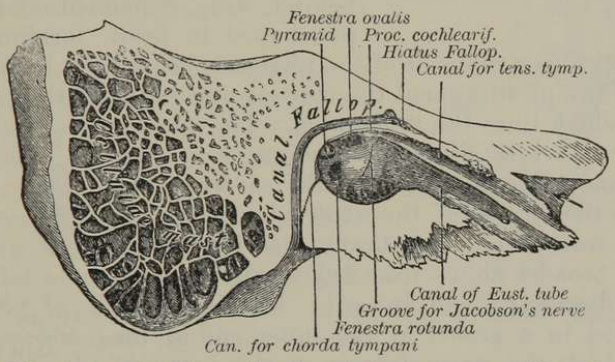

FIG. 542.—Antero-posterior section through the tympanum. (Gegenbaur.)

size, and form; they are lined by mucous membrane continuous with that lining the cavity of the tympanum. Just below the opening of the antrum is the pyramid. The antrum really opens into an upward and backward prolongation of the tympanum, known as the *attic* or *epitympanic recess*, in which are situated the head of the malleus and greater part of the incus (Fig. 543).

The *pyramid* is a conical eminence situated immediately behind the fenestra ovalis, and in front of the vertical portion of the Fallopian eminence above described; it is hollow in the interior, and contains the Stapedius muscle; its summit projects forward toward the fenestra ovalis, and presents a small aperture which transmits the tendon of the muscle. The cavity in the pyramid is prolonged into a minute canal, which communicates with the aqueductus Fallopii and transmits the nerve which supplies the Stapedius.

The **anterior wall of the tympanum** corresponds to the carotid canal, from which it is separated by a thin plate of bone. It presents the

Canal for the Tensor tympani muscle. Orifice of the Eustachian tube.
The processus cochleariformis.

The orifices of the canal for the Tensor tympani and of the Eustachian tube are separated from each other by a thin, delicate, horizontal plate of bone, the *processus cochleariformis*. These canals run from the tympanum, forward, inward, and a little downward, to the retiring angle between the squamous and petrous portions of the temporal bone.

The *canal for the Tensor tympani muscle* is the superior and the smaller of the two; it is rounded, and lies beneath the upper surface of the petrous bone, close to the hiatus Fallopii (Fig. 542).

The *Eustachian tube* is the channel through which the tympanum communicates with the pharynx. Its length is from an inch and a half to two inches, and its direction downward, forward, and inward. It is formed partly of bone, partly of cartilage and fibrous tissue.

The *osseous portion* is about half an inch in length. It commences in the lower part of the anterior wall of the tympanum, below the processus cochleariformis, and, gradually narrowing, terminates in an oval dilated opening at the angle of junction of the petrous and squamous portions, its extremity presenting a jagged margin which serves for the attachment of the cartilaginous portion.

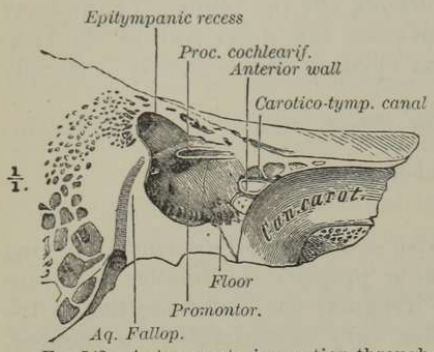

FIG. 543.—Antero-posterior section through the tympanum. (Gegenbaur.)

The *cartilaginous portion*, about an inch in length, is formed of a triangular plate of elastic fibro-cartilage, curled upon itself, an interval being left below, between the margins of the cartilage, which is completed by fibrous and muscular tissue. Its canal is narrow behind, wide, expanded, and somewhat trumpet-shaped in front, terminating by an oval orifice at the upper part and side of the pharynx, behind the back part of the inferior meatus. Through this canal the mucous membrane of the pharynx is continuous with that which lines the tympanum. The mucous membrane is covered with ciliated epithelium (Fig. 544).

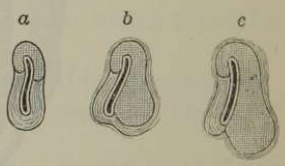

FIG. 544.—Transverse section of the Eustachian tube. *a*. Above. *b*. At about its middle. *c*. At its lower part.

The **membrana tympani** separates the cavity of the tympanum from the bottom of the external meatus. It is a thin, semi-transparent membrane, nearly oval in form, somewhat broader above than below, and directed very obliquely downward and inward. Its circumference is contained in a groove at the inner end of the meatus, which skirts the circumference of this part, excepting above. The portion filling in the *notch of Rivinus* (see above) is looser in texture than the remainder, and is known as the *membrana flaccida*. The handle of the malleus descends vertically between the inner and middle layers of this membrane as far down as its centre, where it is firmly attached, drawing the membrane inward, so that its outer surface is concave, its inner convex. The middle of the concavity is known as the *umbo*.

Structure.—This membrane is composed of three layers, an external (cuticular), a middle (fibrous), and an internal (mucous). The *cuticular lining* is derived from the integument lining the meatus. The *fibrous layer* consists of fibrous and elastic tissues; some of the fibres radiate from near the centre to the circumference; others are arranged, in the form of a dense circular ring, round the attached margin of the membrane. The *mucous lining* is derived from the mucous lining of the tympanum. The vessels pass to the membrana tympani along the handle of the malleus, and are distributed between its layers.

Ossicles of the Tympanum (Fig. 545).

The tympanum is traversed by a chain of movable bones three in number, the *malleus*, *incus*, and *stapes*. The former is attached to the membrana tympani, the latter to the fenestra ovalis, the incus being placed between the two, to both of which it is connected by delicate articulations.

The **Malleus**, so named from its fancied resemblance to a hammer, consists of a head, neck, and three processes—the handle or manubrium, the processus gracilis, and the processus brevis.

The *head* is the large upper extremity of the bone; it is oval in shape, and articulates posteriorly with the incus, being free in the rest of its extent.

The *neck* is the narrow contracted part just beneath the head, and below this is a prominence to which the various processes are attached.

The *manubrium* is a vertical process of bone which is connected by its outer margin with the membrana tympani. It decreases in size toward its extremity, where it is curved slightly forward, and flattened from within outward. On the

inner side, near its upper end, is a slight projection, into which the tendon of the Tensor tympani is inserted.

The *processus gracilis* is a long and very delicate process which passes from the eminence below the neck forward and outward to the Glaserian fissure, to which it is connected by bone and ligamentous fibres.

The *processus brevis* is a slight conical projection which springs from the root of the manubrium, and lies in contact with the membrana tympani.

The **Incus** has received its name from its supposed resemblance to an anvil, but it is more like a bicuspid tooth, with two roots, which differ in length and are widely separated from each other. It consists of a body and two processes.

The *body* is somewhat quadrilateral, but compressed laterally. On the anterior surface of its summit is a deeply concavo-convex facet, which articulates with the malleus; in the fresh state it is covered with cartilage and lined with synovial membrane.

The two processes diverge from one another nearly at right angles.

The *short process*, somewhat conical in shape, projects nearly horizontally backward, and is attached to the margin of the opening leading into the mastoid cells by ligamentous fibres.

The *long process*, longer and more slender than the preceding, descends nearly vertically behind and parallel to the handle of the malleus, and, bending inward, terminates in a rounded globular projection, the *os orbiculare*, or *lenticular process*, which is tipped with cartilage and articulates with the head of the stapes. In the fœtus the os orbiculare exists as a separate bone, but becomes united to the long process of the incus in the adult.

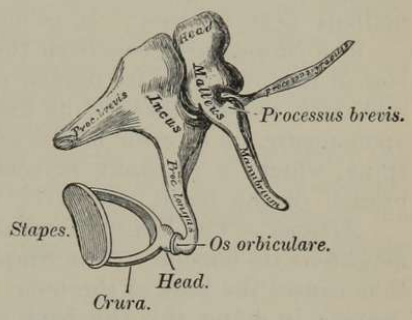

FIG. 545.—The small bones of the ear, seen from the outside. (Enlarged.)

The **Stapes**, so called from its close resemblance to a stirrup, consists of a head, neck, two branches, and a base. The *head* presents a depression, tipped with cartilage, which articulates with the os orbiculare. The *neck*, the constricted part of the bone below the head, receives the insertion of the Stapedius muscle. The *two branches* (*crura*) diverge from the neck, and are connected at their extremities by a flattened, oval-shaped plate (the *base*), which forms the foot of the stirrup, and is fixed to the margin of the fenestra ovalis by ligamentous fibres.

Ligaments of the Ossicula.—These small bones are connected with each other and with the walls of the tympanum by ligaments, and moved by small muscles. The articular surfaces of the malleus and incus and the orbicular process of the incus and head of the stapes are covered with cartilage, connected together by delicate capsular ligaments and lined by synovial membrane. The ligaments connecting the ossicula with the walls of the tympanum are four in number—two for the malleus, one for the incus, and one for the stapes.

The *anterior ligament of the malleus* was formerly described by Sömmerring as a muscle (*Laxator tympani*). It is now, however, believed by most observers to consist of ligamentous fibres only. It is attached by one extremity to the neck of the malleus, just above the processus gracilis, and by the other to the anterior wall of the tympanum, close to the Glaserian fissure, some of its fibres being prolonged through the fissure.

The *suspensory ligament of the malleus* is a delicate, round bundle of fibres which descends perpendicularly from the roof of the tympanum to the head of the malleus.

The *posterior ligament of the incus* is a short, thick, ligamentous band which connects the extremity of the short process of the incus to the posterior wall of the tympanum, near the margin of the opening of the mastoid cells.

The *annular ligament of the stapes* connects the circumference of the base of this bone to the margin of the fenestra ovalis.

A *suspensory ligament of the incus* has been described by Arnold, descending from the roof of the tympanum to the upper part of the incus, near its articulation with the malleus.

The **muscles of the tympanum** are two :

Tensor tympani. Stapedius.

The *Tensor tympani*, the larger, is contained in the bony canal above the osseous portion of the Eustachian tube, from which it is separated by the processus cochleariformis. It arises from the under surface of the petrous bone, from the cartilaginous portion of the Eustachian tube, and from the osseous canal in which it is contained. Passing backward through the canal, it terminates in a slender tendon which enters the tympanum and makes a sharp bend outward round the extremity of the processus cochleariformis, and is inserted into the handle of the malleus near its root. It is supplied by a branch from the otic ganglion.

The *Stapedius* arises from the side of a conical cavity hollowed out of the interior of the pyramid; its tendon emerges from the orifice at the apex of the pyramid, and, passing forward, is inserted into the neck of the stapes. Its surface is aponeurotic, its interior fleshy, and its tendon occasionally contains a slender bony spine, which is constant in some mammalia. It is supplied by the tympanic branch of the facial nerve.

Actions.—The Tensor tympani draws the membrana tympani inward and thus heightens its tension. The Stapedius draws the head of the stapes backward, and thus causes the base of the bone to rotate on a vertical axis drawn through its own centre: in doing this the back part of the base would be pressed inward toward the vestibule, while the fore part would be drawn from it. It probably compresses the contents of the vestibule.

The **mucous membrane of the tympanum** is thin, slightly vascular, and continuous with the mucous membrane of the pharynx through the Eustachian tube. It invests the ossicula and the muscles and nerves contained in the tympanic cavity, forms the internal layer of the membrana tympani, covers the foramen rotundum, and is reflected into the mastoid cells, which it lines throughout. In the tympanum and mastoid cells this membrane is pale, thin, slightly vascular, and covered with ciliated epithelium. In the osseous portion of the Eustachian tube the membrane is thin, but in the cartilaginous portion it is very thick, highly vascular, covered with laminar ciliated epithelium, and provided with numerous mucous glands.

The **arteries supplying the tympanum** are six in number. Three of them are larger than the rest—viz. the tympanic branch of the internal maxillary, which supplies the membrana tympani ; the Vidian and the stylo-mastoid branch of the posterior auricular, which supplies the back part of the tympanum and mastoid cells. The smaller branches are—the petrosal branch of the middle meningeal, which enters through the hiatus Fallopii ; a branch from the ascending pharyngeal, and another from the Vidian which pass up the Eustachian tube; and the tympanic branch from the internal carotid, given off in the carotid canal and perforating the thin anterior wall of the tympanum.

The **veins of the tympanum** terminate in the temporo-maxillary vein and in the superior petrosal sinus.

The **nerves of the tympanum** may be divided into—1, those supplying the muscles; 2, those distributed to the lining membrane; 3, branches communicating with other nerves.

Nerves to Muscles.—The Tensor tympani is supplied by a branch from the otic ganglion; the Stapedius, by the tympanic branch of the facial (Sömmerring).

The *nerves distributed to the lining membrane* are derived from the tympanic plexus.

The *communications* which take place in the tympanum are between the tympanic branch of the glosso-pharyngeal with the sympathetic and with filaments derived from the intumescentia ganglioformis of the facial.

The *tympanic branch of the glosso-pharyngeal* (Jacobson's nerve) enters the

tympanum by an aperture in its floor, close to the inner wall, and divides into branches which are contained in grooves upon the surface of the promontory forming the tympanic plexus.

Its *branches of distribution* are—one to the fenestra rotunda, one to the fenestra ovalis, and one to the lining membrane of the tympanum and Eustachian tube.

Its *branches of communication* are three, and occupy separate grooves on the surface of the promontory. One branch, the *small deep petrosal*, arches forward and downward to the carotid canal to join the carotid plexus. A second, the *long petrosal nerve*, runs forward through a canal close to or in the processus cochleariformis, and enters the foramen lacerum medium, where it joins the carotid plexus of the sympathetic, and generally the large superficial petrosal nerve. The third branch runs upward through the substance of the petrous portion of the temporal bone. In its course it passes by the gangliform enlargement of the facial nerve, and, receiving a connecting filament from it, becomes the *small superficial petrosal nerve*. It then enters the skull through a small aperture, situated external to the hiatus Fallopii on the anterior surface of the petrous bone, courses forward across the base of the skull, and emerges through a foramen in the middle fossa (sometimes through the foramen ovale) and joins the otic ganglion.

The *chorda tympani* leaves the facial about a quarter of an inch above the exit of the latter. It enters the tympanum through the *iter chordæ posterius*, and becomes invested with mucous membrane. It passes forward, between the handle of the malleus and vertical ramus of the incus, and leaves the tympanum through the iter chordæ anterius.

The Internal Ear, or Labyrinth (Fig. 546).

The **internal ear** has two main divisions, the *osseous* and *membranous* labyrinths. They are called **labyrinths** from the complexity of their shapes. The **osseous labyrinth** consists of three parts—the *vestibule*, *semicircular canals*, and *cochlea*. It is formed by a series of cavities channelled out of the substance of the petrous bone, communicating externally with the cavity of the tympanum through the fenestræ ovalis and rotunda, and internally with the meatus auditorius internus, by means of minute bony canals which contain the auditory nerve-filaments. Within the osseous labyrinth is contained the membranous labyrinth, upon which the ramifications of the auditory nerve are distributed.

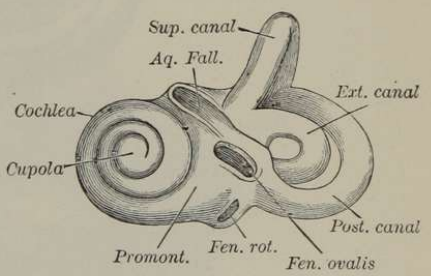

FIG. 546.—The bony labyrinth of the left ear, seen from the outer side and somewhat from below ⅔ (Gegenbaur).

The **Vestibule** (Fig. 547) is the common central cavity of communication between the parts of the internal ear. It is situated on the inner side of the tympanum, behind the cochlea, and in front of the semicircular canals. It is somewhat ovoidal in shape from before backward, flattened from within outward, and measures about one-fifth of an inch from before backward, as well as from above downward, being narrower from without inward. On its *outer* or *tympanic wall* is the fenestra ovalis, closed, in the recent state, by the base of the stapes and its annular ligament. On its *inner wall*, at the fore part, is a small circular depression, *fovea hemispherica*, which is perforated, at its anterior and inferior part, by several minute holes (*macula cribrosa*) for the passage of the filaments of the auditory nerve; and behind this depression is a vertical ridge, the *pyramidal eminence* (*crista vestibuli*). At the hinder part of the inner wall is the orifice of the *aqueductus vestibuli*, which extends to the posterior surface of the petrous portion of the temporal bone. It transmits a small vein, and contains a tubular prolongation (*ductus endolymphaticus*) which, derived from the saccule and utricle, in a manner to be described later, ends in a *cul-de-sac*. On the *upper wall* or *roof* is a transverse oval depression, *fovea semi-elliptica*, separated from the fovea hem-

ispherica by the pyramidal eminence already mentioned. Behind, the semicircular canals open into the vestibule by five orifices. In front is a large oval opening which communicates with the scala vestibuli of the cochlea by a single orifice, *apertura scalæ vestibuli cochleæ*.

The **Semicircular canals** are three bony canals situated above and behind the vestibule. They are of unequal length, compressed from side to side, and describe the greater part of a circle. They measure about one-twentieth of an inch in diameter, and each presents a dilatation at one end, called the *ampulla*, which measures more than twice the diameter of the tube. These canals open into the vestibule by five orifices, one of the apertures being common to two of the canals.

The *superior semicircular canal* is vertical in direction, and stretches across the petrous portion of the temporal bone, at right angles to its posterior surface; its arch forms a round projection on the anterior surface of the petrous bone. It describes about two-thirds of a circle. Its outer extremity, which is ampullated, commences by a distinct orifice in the upper part of the vestibule; the opposite end

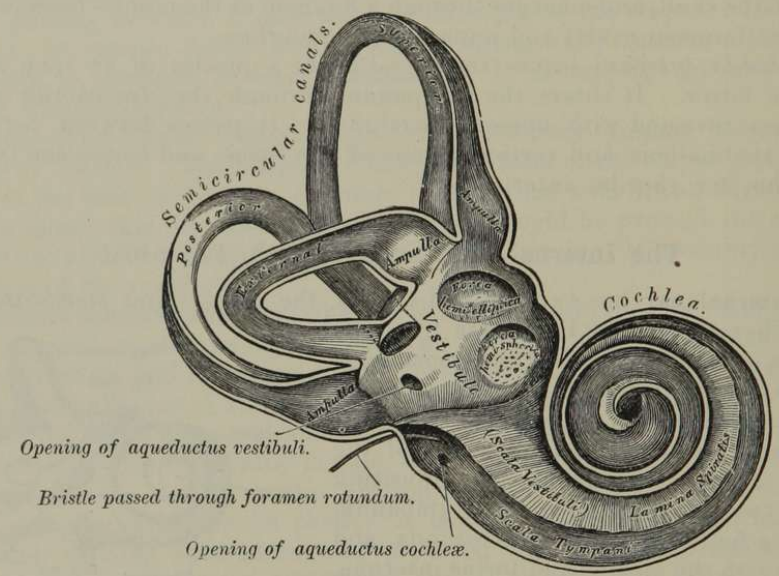

FIG. 547.—The osseous labyrinth laid open. (Enlarged.)

of the canal, which is not dilated, joins with the corresponding part of the posterior canal, and opens by a common orifice with it in the back part of the vestibule.

The *posterior semicircular canal*, also vertical in direction, is directed backward, nearly parallel to the posterior surface of the petrous bone; it is the longest of the three: its ampullated end commences at the lower and back part of the vestibule, its opposite end joining to form the common canal already mentioned.

The *external* or *horizontal canal* is the shortest of the three, its arch being directed outward and backward; thus each semicircular canal stands at right angles to the other two. Its ampullated end corresponds to the upper and outer angle of the vestibule, just above the fenestra ovalis; its opposite end opens by a distinct orifice at the upper and back part of the vestibule.

The **Cochlea** bears some resemblance to a common snail-shell: it forms the anterior part of the labyrinth, is conical in form, and placed almost horizontally in front of the vestibule; its apex is directed forward and outward toward the upper and front part of the inner wall of the tympanum; its base corresponds with the anterior depression at the bottom of the internal auditory meatus, and is perforated by numerous apertures for the passage of the cochlear branch of the

auditory nerve. It measures about a quarter of an inch in length, and its breadth toward the base is about the same. It consists of a conical-shaped central axis, the *modiolus* or *columella;* of a canal wound spirally round the axis for two turns and a half, from the base to the apex; and of a delicate lamina (the *lamina spiralis*) contained within the canal, which follows its windings and partially subdivides it into two.

The *central axis*, or *modiolus*, is conical in form, and extends from the base to the apex of the cochlea. Its base is broad, corresponds with the first turn of the cochlea, and is perforated by numerous orifices, which transmit filaments of the cochlear branch of the auditory nerve; the axis diminishes rapidly in size in the second coil, and terminates within the last half-coil, or *cupola*, in an expanded delicate, bony lamella, which resembles the half of a funnel divided longitudinally, and is called the *infundibulum;* the broad part of this funnel is directed toward the summit of the cochlea, and blends with the cupola or last half-turn of the spiral canal of the cochlea. At this point the two larger scalæ of the cochlea, the scala tympani and scala vestibuli, communicate by an opening called the *helicotrema*. The outer surface of the modiolus forms part of the wall of the spiral canal, and is dense in structure; but its centre is channelled, as far as the last half-coil, by numerous branching canals, which transmit nervous filaments in regular succession into the canal of the cochlea or on to the surface of the lamina spiralis. One of these, larger than the rest, occupies the centre of the modiolus, and is named the *canalis centralis modioli;* it extends from the base to the extremity of the modiolus, and transmits a small nerve and artery (*arteria centralis modioli*).

The *spiral canal* (Fig. 548) takes two turns and a half round the modiolus. It is about an inch and a half in length, measured along its outer wall, and

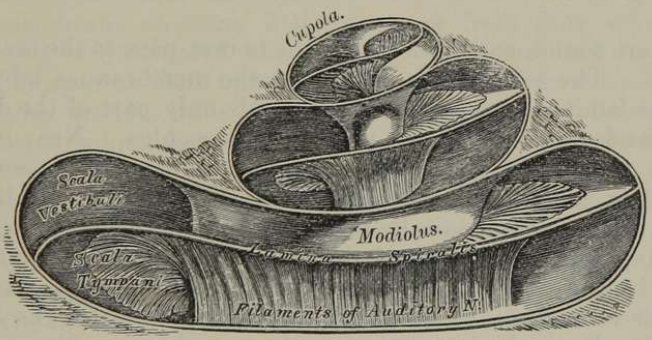

FIG. 548.—The cochlea laid open. (Enlarged.)

diminishes gradually in size from the base to the summit, where it terminates in a *cul-de-sac*, the *cupola*, which forms the apex of the cochlea. The commencement of this canal is about the tenth of an inch in diameter; it diverges from the modiolus toward the tympanum and vestibule and presents three openings. One, the *fenestra rotunda*, communicates with the tympanum; in the recent state this aperture is closed by a membrane, the *membrana tympani secundaria*. Another aperture, of an oval form, enters the vestibule. The third is the aperture of the *aqueductus cochleæ*, leading to a minute funnel-shaped canal, which opens on the basilar surface of the petrous bone and transmits a small vein.

The interior of the spiral canal (Fig. 549) is partially divided into two, in the dry state, by a thin bony plate, the *lamina spiralis*, which consists of two thin lamellæ of bone, between which are numerous canals for the passage of nerve-fibres. This lamina projects from the modiolus into the canal, but does not reach more than halfway toward the outer wall of the tube. From its extremity a thin membrane extends to the outer wall, and completes the division of the canal into an upper compartment, the *scala vestibuli*, and a lower one, the *scala tympani*.

By a second membrane a portion of the upper of these two canals is cut off from the rest, constituting the *scala media*. The lamina spiralis ends above in a hook-shaped process (*hamulus*) which partly bounds the helicotrema. At the point where the osseous lamina is attached to the modiolus is a small canal, which winds round the modiolus, and was denominated by Rosenthal the *canalis spiralis modioli;* it is occupied by a swelling of the cochlear nerve, the *ganglion spirale*, in which

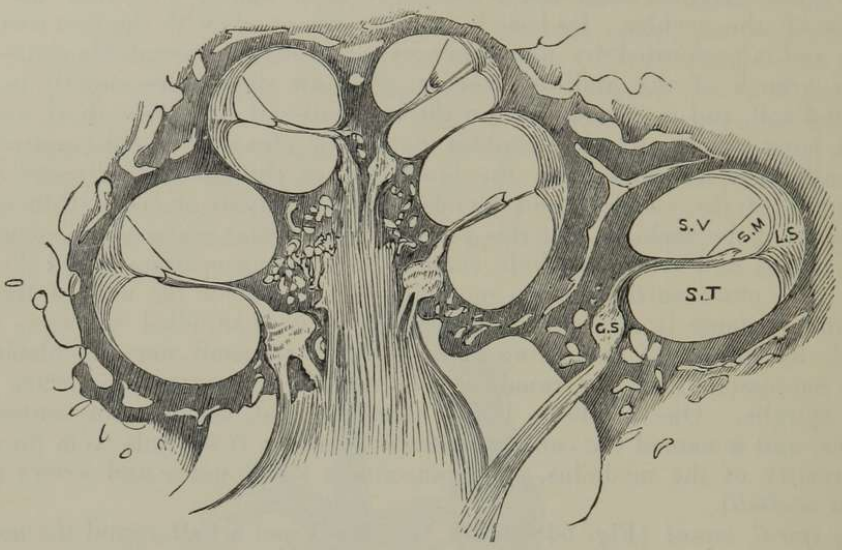

FIG. 549.—Longitudinal section of the cochlea, showing the relations of the scalæ, the ganglion spirale, etc. S. V. Scala vestibuli. S. T. Scala tympani. S. M. Scala media. L. S. Ligamentum spirale. G. S. Ganglion spirale.

ganglion-cells are found, and from which the nerves pass to the osseous lamina and organ of Corti. The *scala media* belongs to the membranous labyrinth.

The osseous lamina, as above stated, extends only part of the distance between the modiolus and the outer bony wall of the cochlea. Near its outer end the periosteum on the upper or vestibular surface of the lamina swells up into an elevation which is called the *limbus laminæ spiralis* ("denticulate lamina" of Todd and Bowman). The lamina spiralis terminates in a grooved extremity, the *sulcus spiralis*, which presents the form of the letter C: the upper part of the letter, being formed by the overhanging extremity of the limbus, is named the *labium vestibulare;* the lower part, prolonged and tapering, is called the *labium tympanicum* (Fig. 550). From the labium tympanicum a thin membrane extends over to the bony wall of the cochlea, completing the scala tympani. This membrane is called the *membrana basilaris*. At its outer attachment it swells out so as to form a thick triangular structure, which was regarded as a muscle by Todd and Bowman (cochlearis), but is now recognized as ligamentous—the *ligamentum spirale*. Between the labium vestibulare and the attachment of the membrane of Reissner, presently to be described, a very delicate membrane extends over to the outer wall of the cochlea, running nearly parallel to the membrana basilaris. It was described by Corti, and covers over the organ which is called after his name, and is therefore called *membrane of Corti*, or *membrana tectoria*. Farther inward, near the commencement of the limbus laminæ spiralis, another delicate membrane, the *membrane of Reissner*, is attached to the vestibular surface of the periosteum of the osseous lamina and stretches across to the outer wall of the cochlea. The canal which lies below the osseous lamina and membrana basilaris is the *scala tympani;* that which is bounded by the osseous lamina and membrane of Reissner, the *scala vestibuli;* while the space between the membrane of Reissner and membrana basilaris is generally described as the *Scala media*, *Canalis membranacea*, or *Canalis cochleæ*, and this is the nomenclature which will be used here. Others, however, apply the name *canalis cochleæ* only to the canal

lying between the membrane of Reissner and the membrana tectoria, which contains no object for description, while the space lying between the membrana tectoria and membrana basilaris is described by itself as a fourth canal—the *ductus cochlearis* or *ductus auditorius.*[1] The latter is the space in which the *organ of Corti*[2] is contained. This organ (Fig. 550) is situated upon the membrana basilaris, and appears at first sight as a papilla, winding spirally with the turns of this membrane throughout the whole length of the cochlea, from which circumstance it has been designated the *papilla spiralis.* More accurately viewed, it is seen to

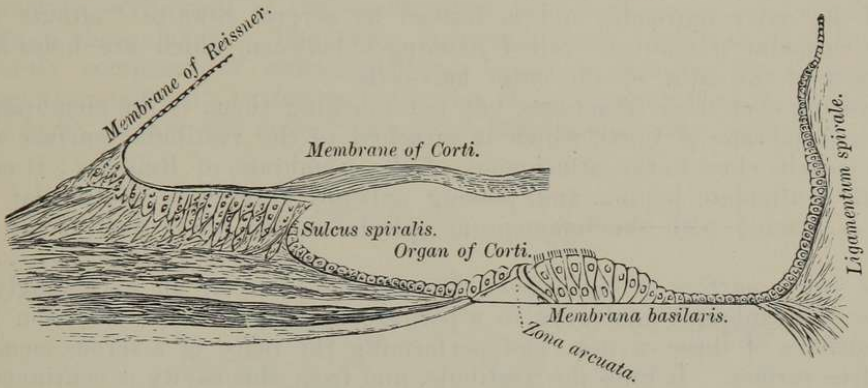

FIG. 550.—Floor of scala media, showing the organ of Corti, etc.

be composed of a remarkable arrangement of cells which may be likened to the keyboard of a pianoforte. Of these cells, the two central ones are rod-like bodies, and are called the inner and outer *rods of Corti.* They are placed erect on the basilar membrane at some little distance from each other, the space between them being denominated the *zona arcuata;* they are inclined toward each other, so as to meet at their opposite extremities and form a series of arches roofing over the zona arcuata, thus forming a minute tunnel between them and the basilar membrane, which ascends spirally through the whole length of the cochlea. They are estimated at over three thousand in number.

The inner rods, which are more numerous than the outer ones, rest on the basilar membrane, close to the labium tympanicum; they project obliquely forward and outward, and terminate above in expanded extremities, which resemble in shape the upper end of the ulna, with its sigmoid cavity, coronoid and olecranon processes. On the outer side of the rod, in the angle formed between it and the basilar membrane, is a protoplasmic cell, whilst on the inner side is a row of epithelial cells surmounted by a brush of fine, stiff, hair-like processes, these cells being continuous with the cubical cells lining the sulcus spiralis.

The outer rods also rest by a broad foot on the basilar membrane; they incline forward and inward, and their upper extremity resembles the head and bill of a swan, the head fitting into the concavity—the analogue of the sigmoid cavity—of one or more of the internal rods, and the bill resting against the phalanges of the lamina reticularis, presently to be described.

In the head of these outer rods is an oval portion, where the fibres of which the rod appears to be composed are deficient, and which stains more deeply with carmine than the rest of the rod. This is supposed to represent the nucleus of the cell from which the rod was originally developed. At the base of the rod, on its internal side—that is to say, in the angle formed by the rod with the basilar membrane—is a similar protoplasmic cell to that found on the outer side of the base of the inner rod, whilst external to the outer rod are three or four successive

[1] In reading the older descriptions of the organ of hearing the student must bear in mind that the membranes bounding the ductus auditorius, together with the organ contained between them, were described together as the "lamina spiralis membranacea," while the membrane of Reissner was not recognized, the parts being, in fact, as shown in the second turn of the cochlea on the right hand of Fig. 549.

[2] Corti's original paper is in the *Zeitschrift f. Wissen. Zool.*, iii. 109.

rows of epithelial cells, more elongated than those found on the internal side of the inner rod, but, like them, furnished with minute hairs or cilia. These are termed the *outer hair-cells*, in contradistinction to the inner set, which are termed the *inner hair-cells*. They are attached by their bases to the basilar membrane, whilst from the opposite extremity a brush of hairs or cilia projects through the reticular membrane. They are continuous externally with the cubical cells on the lateral part of the basilar membrane.

The *reticular lamina* or *membrane of Kölliker* is a delicate framework perforated by rounded holes. It extends from the inner rods of Corti to the external row of the outer hair-cells, and is formed by several rows of "minute fiddle-shaped cuticular structures," called *phalanges*, between which are holes for the projection of the ciliæ of the outer hair-cells.

Covering over these structures, but not touching them, is the membrana tectoria, or membrane of Corti, which is attached to the vestibular surface of the lamina spiralis close to the attachment of the membrane of Reissner; it courses over the denticulate lamina, and, passing outward parallel to the basilar membrane, is blended with the ligamentum spirale on the outer wall of the spiral canal.[1]

The *inner surface of the osseous labyrinth* is lined by an exceedingly thin fibro-serous membrane, analogous to a periosteum from its close adhesion to the inner surfaces of these cavities, and performing the office of a serous membrane by its free surface. It lines the vestibule, and from this cavity is continued into the semicircular canals and the scala vestibuli of the cochlea, and through the helicotrema into the scala tympani. This membrane is continued across the fenestræ ovalis and rotunda, and consequently has no communication with the lining membrane of the tympanum. Its attached surface is rough and fibrous, and closely adherent to the bone; its free surface is smooth and pale, covered with a layer of epithelium, and secretes a thin, limpid fluid, the *aqua labyrinthi*, *liquor Cotunnii*, or *perilymph* (Blainville).

The Membranous Labyrinth.

The membranous labyrinth (Fig. 551) is a closed sac, containing fluid, on the walls of which the ramifications of the auditory nerve are distributed. It has the same general form as the cochlea, vestibule, and semicircular canals in which it is enclosed, but is considerably smaller, and the vestibular and canalicular portions are more or less surrounded by the perilymph.

The *scala media*, already described in connection with the cochlea, is closed above and below. The upper blind extremity is attached to the cupola at the upper part of the helicotrema; the lower end fits into the angle at the commencement of the osseous lamina on the floor of the vestibule. Near this blind extremity the scala media receives the *canalis reuniens* (Fig. 551), a very delicate canal by which the ductus cochlearis is brought into continuity with the saccule.

The *vestibular portion* consists of two sacs, the utricle and the saccule.

The *utricle* is the larger of the two, of an oblong form, compressed laterally, and occupies the upper and back part of the vestibule, lying in contact with the fovea semi-elliptica. Numerous filaments of the auditory nerve are distributed on the wall of this sac, and its cavity communicates behind with the membranous semicircular canals by five orifices. It also sends off a minute canal into the aqueductus vestibuli, which unites with the *ductus endolymphaticus*, a similar but somewhat larger tubular prolongation from the saccule.

The *saccule* is the smaller of the two vestibular sacs; it is globular in form, lies in the fovea hemispherica near the opening of the vestibular scala of the cochlea, and receives numerous nervous filaments which enter from the bottom of the depression in which it is contained. Its cavity communicates with that of the scala media by means of the canalis reuniens and with that of the utricle in the manner just mentioned.

[1] In Fig. 550 only the inner half of the membrane is represented.

The *membranous semicircular canals* are about one-third the diameter of the osseous canals, but in number, shape, and general form they are precisely similar; they are hollow, and open by five orifices into the utricle, one opening being common to two canals. Their ampullæ are thicker than the rest of the tubes, and nearly fill the cavities in which they are contained.

Numerous fibrous bands stretch across between the membranous and bony labyrinths. These fibrous bands convey the blood-vessels and nervous filaments distributed to the utricle, to the saccule, and to the ampulla of each canal.

Structure.—The wall of the membranous labyrinth is semi-transparent, and consists of three layers. The *outer layer* is a loose and flocculent structure, apparently composed of ordinary fibrous tissue, containing blood-vessels and numerous pigment-cells analogous to those in the pigment-coat of the retina. The *middle layer*, thicker and more transparent, bears some resemblance to the hyaloid

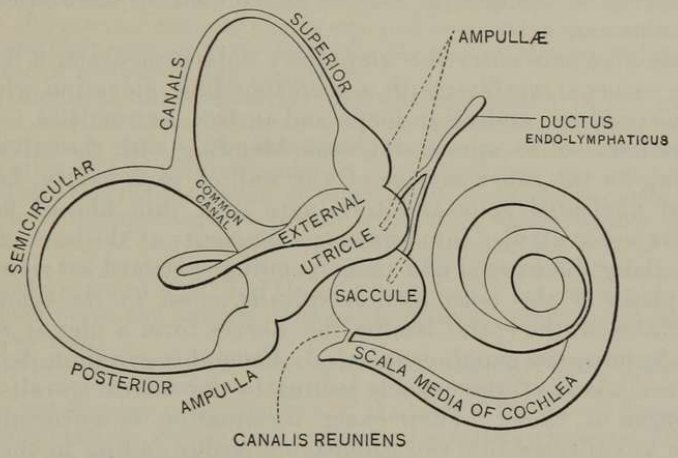

FIG. 551.—The membranous labyrinth. (Enlarged.)

membrane, but it presents on its internal surface numerous papilliform projections, and on the addition of acetic acid presents an appearance of longitudinal fibrillation and elongated nuclei. The *inner layer* is formed of polygonal nucleated epithelial cells, which secrete the endolymph.

The *endolymph* (*liquor Scarpæ*) is a limpid serous fluid which fills the membranous labyrinth; in composition it closely resembles the perilymph.

The *otoliths* are two small rounded bodies consisting of a mass of minute crystalline grains of carbonate of lime, held together in a mesh of delicate fibrous tissue, and contained in the walls of the utricle and saccule, opposite the distribution of nerves. A calcareous material is also, according to Bowman, sparingly scattered in the cells lining the ampulla of each semicircular canal.

The **arteries of the labyrinth** are—the internal auditory, from the basilar; the stylo-mastoid, from the posterior auricular; and, occasionally, branches from the occipital. The internal auditory divides at the bottom of the internal meatus into two branches, cochlear and vestibular.

The cochlear branch subdivides into from twelve to fourteen twigs, which traverse the canals in the modiolus, and are distributed, in the form of a capillary network, in the substance of the lamina spiralis.

The vestibular branches accompany the nerves, and are distributed, in the form of a minute capillary network, in the substance of the membranous labyrinth.

The **veins** (auditory) of the vestibule and semicircular canals accompany the arteries, and, receiving those of the cochlea at the base of the modiolus, terminate in the superior petrosal sinus.

The **auditory nerve**, the special nerve of the sense of hearing, divides, at the

bottom of the internal auditory meatus, into two branches, the cochlear and vestibular. The trunk of the nerve, as well as the branches, contains numerous ganglion-cells with caudate prolongations.

The *vestibular nerve*, the posterior of the two, divides into three branches—superior, middle, and inferior.

The superior vestibular branch, the largest, divides into numerous filaments, which pass through minute openings at the upper and back part of the *cul-de-sac* at the bottom of the meatus, and, entering the vestibule, are distributed to the utricle and to the ampulla of the external and superior semicircular canals.

The middle vestibular branch consists of numerous filaments, which enter the vestibule by a smaller cluster of foramina placed below those above mentioned, and which correspond to the bottom of the fovea hemispherica; they are distributed to the saccule.

The inferior and smallest branch passes backward in a canal behind the foramina for the nerves of the saccule, and is distributed to the ampulla of the posterior semicircular canal.

The nervous filaments enter the ampullary enlargements at a deep depression seen on their external surface, with a corresponding elevation when seen from within; the nerve-fibres ending in loops and in free extremities. In the utricle and saccule the nerve-fibres spread out, some blending with the calcareous matter; others, radiating on the inner surface of the wall of each cavity, become blended with a layer of nucleated cells and terminate in a thin fibrous film.

The *cochlear nerve* divides into numerous filaments at the base of the modiolus, which ascend along its canals, and then, bending outward at right angles, pass between the plates of the bony lamina spiralis, close to its tympanic surface. Between the plates of the spiral lamina the nerves form a plexus which contains ganglion cells forming the ganglion spirale. From this ganglion delicate filaments pass between the layers of the osseous lamina to the sulcus spiralis and pass outward to the organ of Corti. Their exact termination is uncertain. Waldeyer describes them as collected into two groups, one group ending in the outer and the other in the inner hair-cells.

The **bottom of the internal auditory meatus**, known as the *lamina cribrosa*, is subdivided by a horizontal ridge, the *crista falciformis*, into a superior and an inferior fossa. In the *superior fossa* is seen anteriorly the *foramen faciale* or orifice of the aqueductus Fallopii; and posteriorly is a group of foramina, *area cribrosa superior*, for the nerve-filaments to the *utricle*, *superior* and *external semicircular canals* (superior vestibular branch). In the *inferior fossa* are: (1) a group of foramina, *area cribrosa media*, for the filaments to the *saccule* (middle vestibular branch); (2) posteriorly, the *foramen singulare*, for the nerve to the *posterior semicircular canal* (inferior vestibular branch); (3) antero-inferiorly, the foramina for the filaments of the cochlear branch, grouped in a spiral, *tractus spiralis foraminulentus*, and at the end of the spiral is the *foramen centrale cochleæ* or orifice of the central canal of the modiolus.

Surgical Anatomy.—Malformations, such as imperfect development of the external parts, absence of the meatus, or supernumerary auricles, are occasionally met with. Or the pinna may present a congenital fistula which is due to defective closure of the first visceral cleft, or rather of that portion of it which is not concerned in the formation of the Eustachian tube, tympanum, and meatus. The skin of the auricle is thin and richly supplied with blood, but in spite of this it is frequently the seat of frost-bite, due to the fact that it is much exposed to cold, and lacks the usual covering of subcutaneous fat found in most other parts of the body. A collection of blood is sometimes found between the cartilage and perichondrium (*hæmatoma auris*), usually the result of traumatism, but not necessarily due to this cause. It is said to occur most frequently in the ears of the insane. Keloid sometimes grows in the auricle around the puncture made for earrings, and epithelioma occasionally affects this part. Deposits of urate of soda are often met with in the pinna in gouty subjects.

The external auditory meatus can be most satisfactorily examined by light reflected down a funnel-shaped speculum; by gently moving the latter in different directions the whole of the canal and membrana tympani can be brought into view. The points to be noted

are, the presence of wax or foreign bodies, the size of the canal, and the condition of the membrana tympani. The accumulation of wax is often the cause of deafness, and may give rise to very serious consequences, causing ulceration of the membrane and even absorption of the bony wall of the canal. Foreign bodies are not infrequently introduced into the ear by children, and, when situated in the first portion of the canal, may be removed with tolerable facility by means of a minute hook or loop of fine wire, with reflected light; but when they have slipped beyond the narrow middle part of the meatus, their removal is in no wise easy, and attempts to effect it, in inexperienced hands, may be followed by destruction of the membrana tympani and possibly the contents of the tympanum. The calibre of the external auditory canal may be narrowed by inflammation of its lining membrane, running on to suppuration; by periostitis; by polypi, sebaceous tumors, and exostoses. The membrana tympani, when seen in a healthy ear, "reflects light strongly, and, owing to its peculiar curvature, presents a bright spot of triangular shape at its lower and anterior portion." From the apex of this, proceeding upward and slightly forward, is a white streak formed by the handle of the malleus, while at the upper and middle part of the membrane may be seen a slight projection, caused by the short process of the malleus. In disease alterations in color, lustre, curvature or inclination, and perforation must be noted. Such perforations may be caused by a blow or a loud report or by a wound.

The upper wall of the meatus is separated from the cranial cavity by a thin plate of bone; the anterior wall is separated from the temporo-maxillary joint and parotid gland by the bone forming the glenoid fossa; and the posterior wall is in relation with the mastoid cells; hence inflammation of the external auditory meatus may readily extend to the membranes of the brain, to the temporo-maxillary joint, or to the mastoid cells; and, in addition to this, blows on the chin may cause fracture of the wall of the meatus.

The nerves supplying the meatus are the auricular branch of the pneumogastric, the auriculo-temporal, and the auricularis magnus. The connections of these nerves explain the fact of the occurrence, in cases of any irritation of the meatus, of constant coughing and sneezing from implication of the pneumogastric, or of yawning from implication of the auriculo-temporal. No doubt also the association of earache with toothache in cancer of the tongue is due to implication of the same nerve, a branch of the fifth, which supplies also the teeth and the tongue. The vessels of the meatus and membrana tympani are derived from the posterior auricular, temporal, and internal maxillary arteries. The upper half of the membrana tympani is much more richly supplied with blood than the lower half. For this reason, and also to avoid the chorda tympani nerve and ossicles, incisions through the membrane should be made at the lower and posterior part.

The principal point in connection with the surgical anatomy of the tympanum is its relations to other parts. Its roof is formed by a thin plate of bone, which, with the dura mater, is all that separates it from the temporo-sphenoidal lobe of the brain. Its floor is immediately above the jugular fossa behind and the carotid canal in front. Its posterior wall presents the openings of the mastoid cells. On its anterior wall is the opening of the Eustachian tube. Thus it follows that in disease of the middle ear we may get subdural abscess, septic meningitis, or abscess of the cerebrum or cerebellum from extension of the inflammation through the bony roof; thrombosis of the lateral sinus, with or without pyæmia, by extension through the floor; or mastoid abscess by extension backward. In addition to this, we may get fatal hæmorrhage from the internal carotid in destructive changes of the middle ear; and in throat disease we may get the inflammation extending up the Eustachian tube to the middle ear. The Eustachian tube is accessible from the nose. If the nose and mouth be closed and an attempt made to expire air, a sense of pressure with dulness of hearing is produced in both ears, from the air finding its way up the Eustachian tube and bulging out the membrana tympani. During the act of swallowing the pharyngeal orifice of the tube, which is normally closed, is opened, probably by the action of the Tensor tympani. This fact was employed by Politzer in devising an easy method of inflating the tube. The nozzle of an india-rubber syringe is inserted into the nostril; the patient takes a mouthful of water and holds it in his mouth; both nostrils are closed with the finger and thumb to prevent the escape of air, and the patient is then requested to swallow; as he does so the air is forced out of the syringe into his nose, and is driven into the Eustachian tube, which is now open. The impact of the air against the membrana tympani can be heard, if the membrane is sound, by means of a piece of india-rubber tubing, one end of which is inserted into the meatus of the patient's ear, the other into that of the surgeon. The direct examination of the Eustachian tube is made by the Eustachian catheter. This is passed along the floor of the nostril, with the curve downward, to the posterior wall of the pharynx. When this is felt, the catheter is to be withdrawn about half an inch, and the point rotated outward through a quarter of a circle, and pushed again slightly backward, when it will enter the orifice of the tube, and will be found to be caught, and air forced into the catheter will be heard impinging on the tympanic membrane if the ears of the patient and surgeon are connected by an india-rubber tube.

THE ORGANS OF DIGESTION.

THE Apparatus for the Digestion of the Food consists of the alimentary canal and of certain accessory organs.

The **alimentary canal** is a musculo-membranous tube, about thirty feet in length, extending from the mouth to the anus, and lined throughout its entire extent by mucous membrane. It has received different names in the various parts of its course: at its commencement, the mouth, we find provision made for the mechanical division of the food (*mastication*), and for its admixture with a fluid secreted by the salivary glands (*insalivation*); beyond this are the organs of deglutition, the pharynx and the œsophagus, which convey the food into that part of the alimentary canal (the stomach) in which the principal chemical changes occur, and in which the reduction and solution of the food take place; in the small intestines the nutritive principles of the food (the *chyle*) are separated, by its admixture with the bile and pancreatic fluid, from that portion which passes into the large intestine, most of which is expelled from the system.

Alimentary Canal.

Mouth.
Pharynx.
Œsophagus.
Stomach.
Small intestine { Duodenum. Jejunum. Ileum.
Large intestine { Cæcum. Colon. Rectum.

Accessory Organs.

Teeth.
Salivary glands { Parotid. Submaxillary. Sublingual.
Liver.
Pancreas.
Spleen.

THE MOUTH.

The **mouth** (oral or buccal cavity) (Fig. 552) is the vestibule to the alimentary canal. It is a nearly oval-shaped cavity, bounded in front by the lips, upon the sides by the cheeks, behind by the soft palate and fauces. The upper and lower dental arches, together with their alveolar processes, subdivide the general cavity into a lingual and a buccal cavity. The latter has as its inner wall the external faces of the teeth and gums of both jaws; its external wall is formed by the lips and cheeks. The lingual cavity is bounded anteriorly and laterally by the lingual surfaces of both dental arches; above, by the hard and the soft palates; below, by the floor of the mouth and the tongue.

The *mucous membrane* lining the mouth is continuous with the integument at the free margin of the lips and with the mucous lining of the fauces behind; it is of a rose-pink tinge during life, and very thick where it covers the hard parts bounding the cavity. It is covered by stratified epithelium.

The **lips** are two fleshy folds which surround the orifice of the mouth, formed externally of integument and internally of mucous membrane, between which are found the Orbicularis oris muscle, the coronary vessels, some nerves, areolar tissue, and fat, and numerous small labial glands. The inner surface of each lip is con-

nected in the middle line to the gum of the corresponding jaw by a fold of mucous membrane, the *frœnum labii superioris* and *inferioris*—the former being the larger of the two.

The *labial glands* are situated between the mucous membrane and the Orbicularis oris round the orifice of the mouth. They are rounded in form, about the size of small peas, their ducts opening by small orifices upon the mucous membrane. In structure they resemble the salivary glands.

The **cheeks** form the sides of the face and are continuous in front with the lips. They are composed externally of integument, internally of mucous membrane, and between the two of a muscular stratum, besides a large quantity of fat, areolar tissue, vessels, nerves, and buccal glands.

The *mucous membrane* lining the cheek is reflected above and below upon the gums, where its color becomes lighter; it is continuous behind with the lining mem-

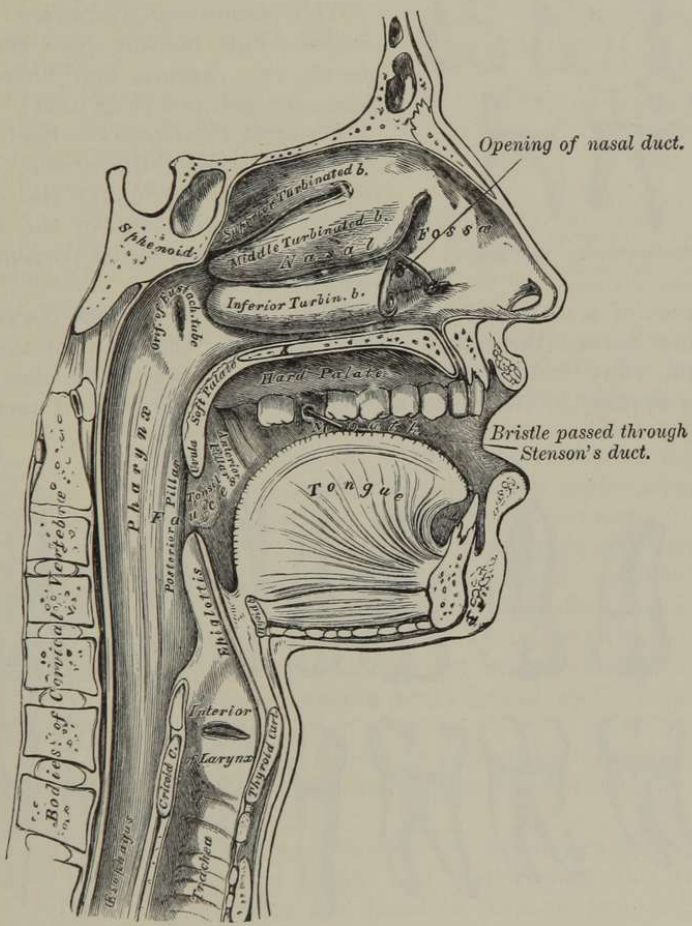

FIG. 552.—Sectional view of the nose, mouth, pharynx, etc.

brane of the soft palate. Opposite the second molar tooth of the upper jaw is a papilla, the summit of which presents the aperture of the duct of the parotid gland. The principal muscle of the cheek is the Buccinator, but numerous other muscles enter into its formation—viz. the Zygomatici, Risorius Santorini, and Platysma myoides.

The *buccal glands* are placed between the mucous membrane and Buccinator muscle: they are similar in structure to the labial glands. but smaller. Two or three of larger size than the rest are placed between the Masseter and Buccinator muscles; their ducts open into the mouth opposite the last molar tooth. They are called *molar glands*.

The **gums** are composed of a dense fibrous tissue closely connected to the

periosteum of the alveolar processes and surrounding the necks of the teeth. They are covered by smooth and vascular mucous membrane, which is remarkable for its limited sensibility. Around the necks of the teeth this membrane presents numerous fine papillæ. The deep fibrous layer is continuous with the periosteum lining the alveoli, (the pericementum).

THE TEETH.

The human subject is provided with two sets of teeth, which make their appearance at different periods of life. The first set appear in childhood, and are called the *temporary*, *deciduous*, or *milk teeth*. The second set are named *permanent*.

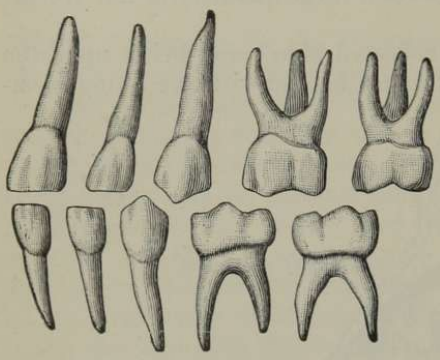

FIG. 553.—Deciduous teeth. Left side.

The *temporary teeth* are twenty in number—four incisors, two canine, and four molars, in each jaw (Fig. 553).

The *permanent teeth* are thirty-two in number—four incisors (two central and two lateral), two canines, four bicuspids, and six molars in each jaw (Fig. 554).

General Characters.—Each tooth consists of three portions: the *crown*, or *body*, projecting above the gum; the *root*, or *fang*, entirely concealed within the alveolus; and the *neck*, the constricted portion, between the root and crown.

The *surfaces* of a tooth are named thus: that which looks toward the lips is the *labial;* that toward the tongue is the *lingual;* that toward the mesial line, *proximal;* that away from the same, *distal;* that toward the cheek, the *buccal* surface. This applies to the roots as well as to the crowns of teeth.

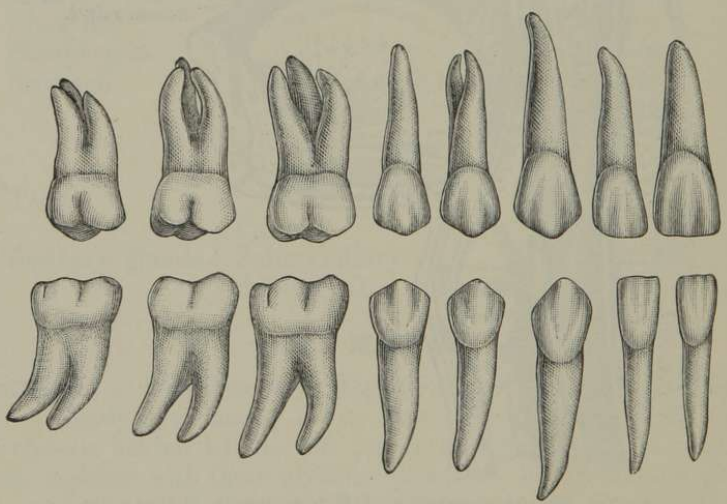

FIG. 554.—Permanent teeth. Right side (Burchard).

The *roots of the teeth* are firmly implanted within the alveoli (Fig. 558); these depressions are lined with periosteum (the pericementum) which is reflected on to the tooth at the point of the root and covers it as far as the neck. At the margin of the alveolus the periosteum becomes continuous with the fibrous structure of the gums.

Permanent Teeth (Figs. 555 and 556).

The **incisors**, or cutting teeth, are so named from their presenting a sharp cutting edge, adapted for incising the food. They are eight in number, and comprise the four front teeth in each jaw.

The *crown* is directed almost vertically and is spade-like in form; it has the form of a truncated cone whose top has been compressed into a sharp horizontal cutting edge. Before being subjected to attrition this edge presents three small elevations. *The labial* surface is convex, and marked by three longitudinal ridges extending from the edge tubercles toward the neck of the tooth. The *lingual* surface is concave, and is marked by two marginal ridges extending from an encircling ridge at the neck to the angles of the cutting edge of the tooth. The ridge at the neck is termed the cingulum or basal ridge.

The *mesial* and *distal surfaces* are triangular, the apex of the triangle at the cutting edge.

The *neck* of the tooth is constricted.

The *root* is long, single, and has the form of a transversely flattened cone, thicker before than behind. The root may be curved.

The *incisors of the upper jaw* are altogether larger and stronger than those of the lower jaw, the central incisors being larger and flatter than the laterals. They are directed obliquely downward and forward.

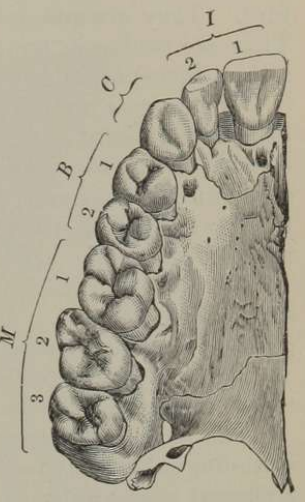

FIG. 555.—Right half of upper jaw (from below), with the corresponding teeth. The letters and numbers point to the classes of teeth and the numbers in classes.

The *incisors of the lower jaw* are smaller and flatter than the upper, and the elevations upon their lingual faces are not marked. The two central are smaller than the two lateral incisors, being the smallest of all the teeth. The roots of these teeth are flattened laterally.

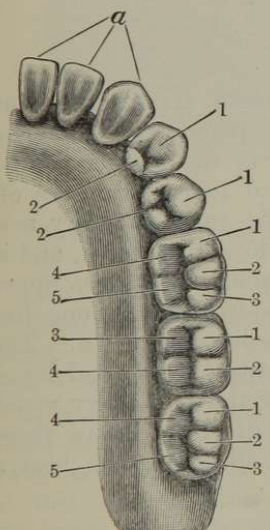

FIG. 556.—Right half of lower jaw, with the corresponding teeth. The letter and numbers point to the various cusps or their modifications on the different teeth (Burchard).

The *canine teeth* (cuspidati) are four in number, two in the upper, two in the lower jaw—one being placed distal to each lateral incisor. They are larger and stronger than the incisors, especially in the roots, which are deeply implanted and cause well-marked prominence of the process at the places of insertion.

The *crown* is large, of spear-head, form and its very convex labial surface is marked by three longitudinal ridges. The concave labial surface is also marked by three ridges which unite at a basal ridge. The point or cusp is longer than in the other teeth, and is the point of division between a short mesial and a long distal cutting edge.

The *root* is oval or elliptical in transverse section, and is longer and more prominent than the roots of the incisors.

The *upper canines* or cuspids (vulgarly called the eye teeth) are larger and longer than the two lower, and in occlusion are distal to them to the extent of half the width of the crown.

The *lower canines* (vulgarly called the stomach teeth) have the general form of the upper cuspids, but their lingual surfaces are much more flattened, owing to the absence of the elevations marking the upper. Their roots are more flattened and may be bifid at their apices.

The **bicuspid teeth** (premolars) are eight in number, four in each jaw; they are placed distal to the cuspid teeth, two upon each side. They are double cuspids in form.

The *crown* is surmounted by two cusps, one buccal and one lingual, separated by a groove, the buccal being more prominent and larger than the lingual. The lower bicuspids are not truly bicuspid, the first having but a primitive lingual cusp, the second having the lingual cusp divided into two sections—*i. e.* it is usually tricuspid.

The *necks* of the teeth are oval; the roots are laterally compressed, that of the

first upper bicuspid being frequently bifid. The first upper bicuspid is usually the largest of the series.

The **molar teeth** (*multicuspidati*; or grinders) are the largest teeth of the denture. They are adapted by their forms for the crushing and grinding of the food. They are twelve in number, six in each jaw, three being placed posterior to each second bicuspid.

The *crowns* are cuboidal in form, are convex buccally and lingually; they are flattened mesially and distally. They are formed by the fusion of three primitive cuspids in the upper and four in the lower. To these are added in the first and second upper molars a disto-lingual tubercle, and in the first and third molars of the lower jaw a disto-buccal tubercle. The unions of the primitive forms are marked by sulci. The necks of these teeth are large and rhomboidal in form.

The *roots* of the upper molars are three in number—one large lingual and two smaller buccal roots. In the lower, two roots are found, a mesial and a distal, each of which is much flattened from before backward.

The *first molar teeth* are the largest of the dental series: they have four cusps on the upper and five in the lower—three buccal and two lingual.

The *second molars* are smaller; the crown of the upper is compressed until the disto-lingual cusp is reduced. The crowns of the lower are almost rectangular, with a cusp at each angle.

The *third molars* are called the wisdom teeth (*dentes sapientiæ*) from their late eruption: they have three cusps upon the upper and five upon the lower. The three roots of the upper are frequently fused together, forming a grooved cone, which is usually curved backward. The roots of the lower, two in number, are compressed together and curve backward.

Temporary Teeth (Figs. 553 and 557).

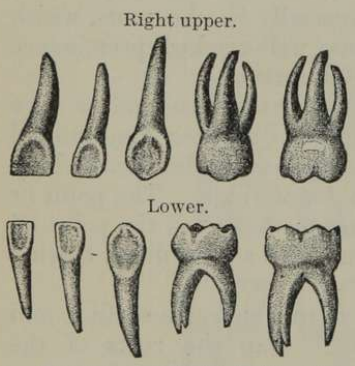

FIG. 557.—Deciduous teeth. Lingual view.

The **temporary** or **milk teeth** are smaller, but resemble in form those of the permanent set. The neck is more marked, owing to the greater degree of convexity of the labial and lingual surfaces of the crown. The hinder of the two temporary molars is the largest of all the deciduous teeth, and is succeeded by the second bicuspid. The first upper molar has only three cusps—two labial, one lingual; the second upper molar has four cusps. The first lower molar has four cusps; the second lower molar has five. The roots of the temporary molar teeth are smaller and more diverging than those of the permanent set, but in other respects bear a strong resemblance to them.

Arrangement of the Teeth.[1]

The human teeth are arranged in two parabolic arches, the upper arch being larger, its teeth overlapping the lower. The average distance between the centres of the condyles of the inferior maxillary bones is about four inches, which is also the distance from either of these points to the line of junction between the lower incisor teeth. Whether the jaw be large or small, the equilateral triangle indicated is included in it; the range of size is between $3\frac{1}{2}''$–$4\frac{1}{2}''$.

Owing to the smaller sizes of the lower incisors, the teeth of the lower jaw are each one half a tooth in advance of its upper fellow, so that each tooth of the dental series has two antagonists, with the exception of the lower central incisors and upper third molars (Figs. 558, 559).

The grinding faces of the upper bicuspids and molars curve progressively upward and point outward, the first molar being at the lowest point of the curve,

[1] After Dr. W. G. A. Bonwill.

the third molar at the highest. The curve of the lower dental arch is the reverse, the first molar at its deepest part, the third molar at its extremity. The greater the depth to which the upper incisors overlap the lower, the more marked this curve and the more pointed are the cusps of the grinding teeth.

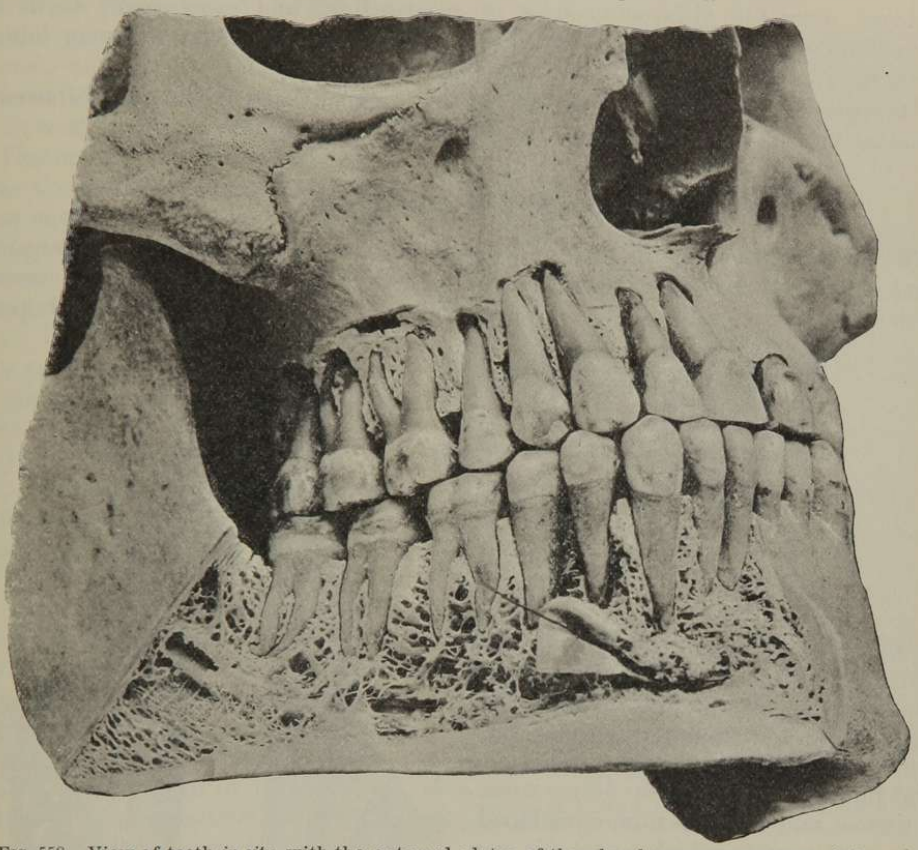

FIG. 558.—View of teeth *in situ*, with the external plates of the alveolar processes removed (Cryer).

The movement of the human mandible is forward and downward, the resultant of these directions being an oblique line, upon an average 35° from the horizontal plane.[1] When the lower jaw is advanced until the cutting edges of the incisors are in contact, the jaws are separated, but as the highest point of the lower arch, its third molar advances, it meets and rests upon a high point, second molar of the upper arch, and thus undue strain of the incisors is obviated.

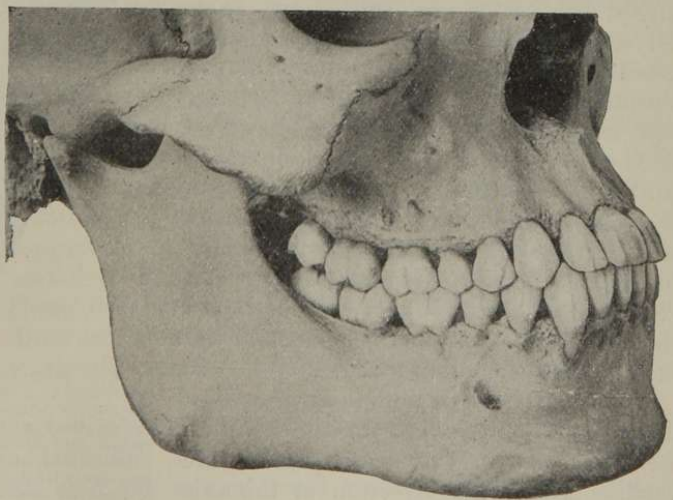

FIG. 559.—Front and side views of the teeth and jaws.

In the lateral movements of the mandible but one side is in effective action at one time; the oblique positions of the cusps of the opposite teeth are such that when either side is in action the other is balanced at two or more points.

[1] W. E. Walker, *Dental Cosmos*, 1896.

There is an anatomical correspondence between the forms and arrangement of the teeth, the form of the condyle of the inferior maxilla, and the muscular arrangement. Individuals who have teeth with long cusps have the head of the bone much rounded from before behind, and have a preponderance of the direct over the oblique muscles of mastication, and *vice versâ;* teeth with short or no cusps are associated with a flattened condyle and strong oblique muscles.

Very great aberrations in the dental arrangement are frequently followed by accomodative changes in the heads of the inferior maxilla.

Structure of the Teeth.

The Dental Pulp.—A longitudinal section of a tooth will show the presence of a central chamber having the general form of the crown of the tooth. Processes of the chamber pass from its body, one for each root and down each root, and open at

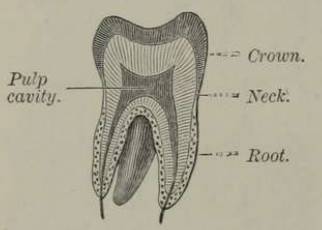

FIG. 560.—Vertical section of a molar tooth.

the apex by a minute orifice, the apical foramen. This cavity is known as the pulp-chamber, the minute canals the pulp-canals. The cavity contains a soft, vascular, and sensitive organ called the dental pulp. It is made up of myxomatous tissues, and contains numerous blood-vessels and nerves, which enter by way of the apical foramina. It does not possess lymphatics. The periphery of the pulp is bounded by a layer of cells arranged like columnar epithelium, each cell sending one or more branched processes through the basic substance of the dentine. These are the dentine-forming cells, the odontoblasts of Waldeyer. The blood-vessels break up into innumerable capillary loops which lie beneath the layer of odontoblasts. The nerve-fibrils break up into numberless non-medullary filaments, which spread out beneath the odontoblasts, and probably send terminal filaments to the extreme periphery of the pulp outside the odontoblasts.

The matrix cells and their processes are irregularly arranged in the body of the pulp, but in the canal portion the fibrillæ are in the direction of the axis of the root.

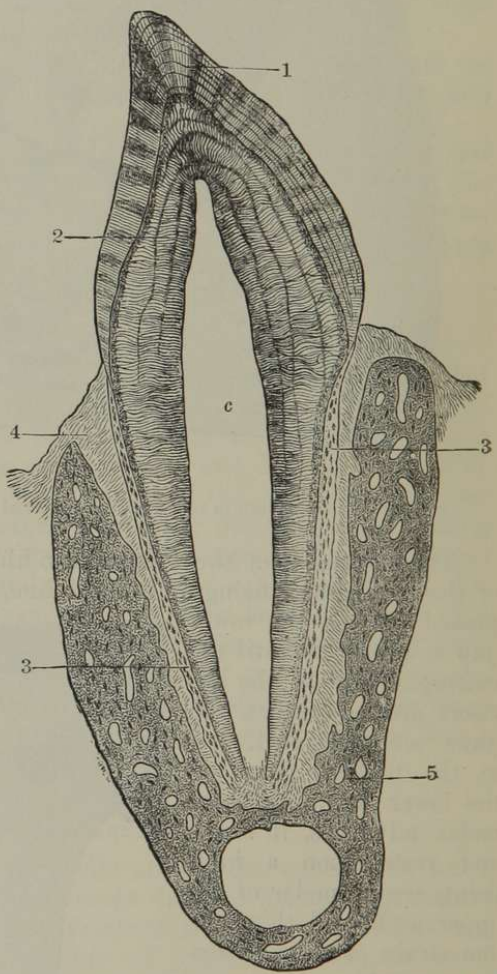

FIG. 561.—Vertical section of a tooth *in situ* (15 diameters). c is placed in the pulp-cavity, opposite the cervix or neck of the tooth; the part above is the crown, that below is the root (fang). 1. Enamel with radial and concentric markings. 2. Dentine with tubules and incremental lines. 3. Cement or crusta petrosa, with bon. corpuscles. 4. Dental periosteum. 5. Bone of lower jaw.

The section will exhibit three hard tissues in a tooth, one forming the greater mass of the tooth; hence its name *dentine* (the ivory). The dentine upon the crown is sheathed by a layer called the enamel; the dentine of the root is enclosed

in a distinct tissue, the cementum or crusta petrosa; both cementum and enamel are thinnest at the neck and thickest upon their distal portions.

The **solid portion** of the tooth consists of three distinct structures—viz. the proper dental substance, which forms the larger portion of the tooth, the *ivory* or *dentine;* a layer which covers the exposed part of the crown, the *enamel;* and a thin layer, which is disposed on the surface of the fang, the *cement* or *crusta petrosa.*

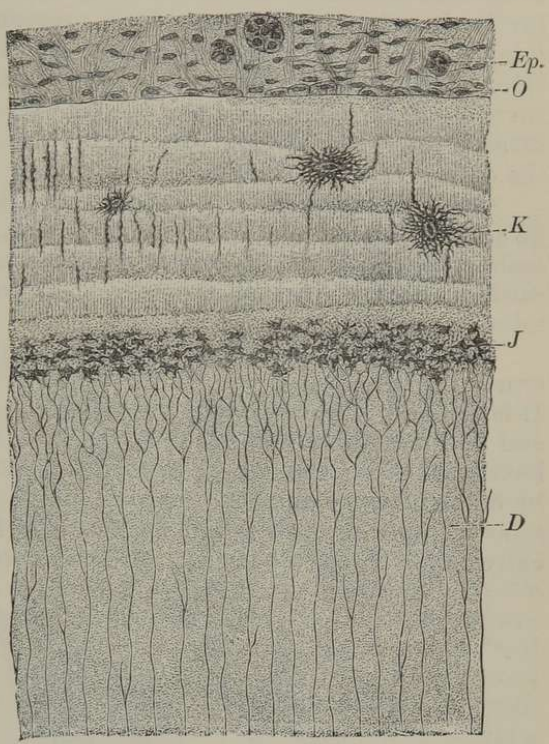

FIG. 562.—Ground section through the root of a human premolar: *D*, dentine; *K*, cement corpuscles; *O*, osteoblasts; *Ep.*, remains of Hertwig's epithelial sheath, 200 diameters; *J*, interglobular spaces (Röse).

The **ivory**, or **dentine** (Fig. 561), forms the principal mass of a tooth; in its central part is the cavity enclosing the pulp. It is a modification of osseous tissue, from which it differs, however, in structure. On microscopic examination it is seen to consist of a number of minute wavy and branching tubes having *distinct parietes.* They are called the *dentinal tubuli*, and are imbedded in a dense homogeneous substance, the *intertubular tissue.*

The *dentinal tubuli* (Fig. 562) are placed parallel with one another, and open at their inner ends into the pulp-cavity. In their course to the periphery they present two or three curves, and are twisted on themselves in a spiral direction. The direction of these tubes varies: they are vertical in the upper portion of the crown, oblique in the neck and upper part of the root, and toward the lower part of the root they are inclined downward. The tubuli, at their commencement, are about $\frac{1}{4500}$ of an inch in diameter; in their course they divide and subdivide dichotomously, so as to give to the cut surface of the dentine a striated appearance. From the sides of the tubes, especially in the root, ramifications of extreme minuteness are given off, which join together in loops in the intertubular substance, or terminate in small dilatations, from which branches are given off. Near the periphery of the dentine the finer ramifications of the tubuli terminate in a layer of irregular branched spaces which communicate with each other. These are called the *interglobular spaces of Czermak*, or the *granular layer of Tomes* (Fig. 562, *J*). The dentinal tubuli have comparatively thick walls, and contain slender cylindrical prolongations from the processes of the cells of the pulp-tissue already mentioned, and first described by Mr. Tomes and named Tomes's fibres or dentinal fibres. These dentinal fibres are analogous to the soft contents of the canaliculi of bone. Between Tomes's fibres and the ivory around the canals there is a tissue which is markedly resistant to the action of acids—the *dentinal sheath of Neumann.*

The *intertubular substance* or *tissue* is translucent, and contains the chief part of the earthy matter of the dentine. After the earthy matter has been removed by steeping a tooth in weak acid the animal basis remaining may be torn into laminæ which run parallel with the pulp-cavity across the direction of the tubules. These laminæ show the method of growth to be by deposition of successive strata of dentine. Fibrils have been found in the matrix of the intertubular substance, and are probably continuous with the dentinal fibres of Tomes. In a *dry* tooth a

section of dentine often displays a series of lines—the *incremental lines of Salter*—which are parallel with the laminæ above mentioned. These lines are caused by two facts: (1) The imperfect calcification of the dentinal laminæ immediately adjacent to the line; (2) The drying process, which reveals these defects in the calcification. These lines are wide or narrow according to the number of laminæ involved, and along their course, in consequence of the imperfection in the calcifying process, little irregular cavities are left, which are the *interglobular spaces* already referred to. They have received their name from the fact that they are surrounded by minute nodules or globules of dentine. Other curved lines may be seen parallel to the surface. These are the *lines of Schreger*, and are due to the optical effect of simultaneous curvature of the dentinal tubules.

Chemical Composition.—According to Berzelius and Bibra, dentine consists of 28 parts of animal and 72 of earthy matter. The animal matter is resolvable by boiling into gelatin. The earthy matter consists of phosphate and carbonate with calcium, with a trace of fluoride of calcium, phosphate of magnesia, and other salts.

The **enamel** is the hardest and most compact part of a tooth, and forms a thin crust over the exposed part of the crown as far as the commencement of the root. It is thickest on the grinding surface of the crown until worn away by attrition, and becomes thinner toward the neck. It consists of a congeries of minute hexagonal rods, columns, or prisms. They lie parallel with one another, resting by one extremity upon the dentine, which presents a number of minute depressions for their reception, and forming the free surface of the crown by the other extremity. These fibres are directed vertically on the summit of the crown,

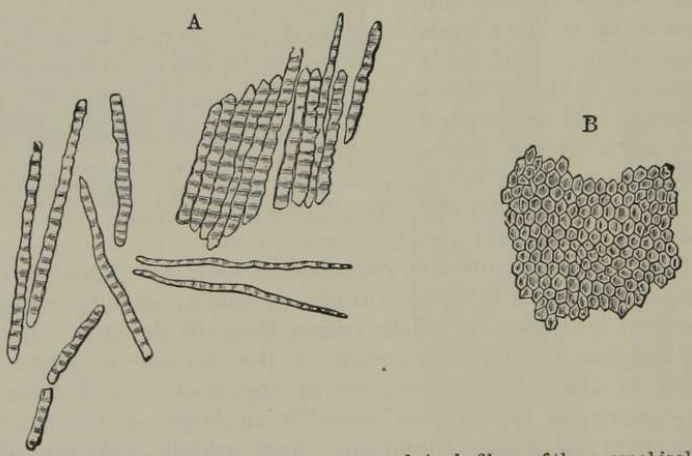

FIG. 563.—Enamel prisms (350 diameters). A. Fragments and single fibres of the enamel isolated by the action of hydrochloric acid. B. Surface of a small fragment of enamel, showing the hexagonal ends of the fibres.

horizontally at the sides; they are about the $\frac{1}{5500}$ of an inch in diameter, and pursue a more or less wavy course. Each enamel rod is crossed by a series of dark transverse lines, which mark the mode of the formation of the rods (Fig. 563). Another series of lines, having a brown appearance, and denominated the *parallel striæ of Retzius*, or the *colored lines*, are seen on a section of the enamel. These lines are concentric and *cross* the enamel rods. They are caused by the mode of enamel deposition. Inasmuch as the enamel columns, when near the dentine, cross each other and only become parallel farther away, a series of radial markings, light and dark alternately, is obtained (Fig. 561).

Numerous minute interstices intervene between the enamel-fibres near their dentinal surface. It is noted in rare cases that the dentinal fibres penetrate a certain distance between the rods of the enamel. No nutritive canals exist in the enamel.

Chemical Composition.—According to Bibra, enamel consists of 96.5 per cent. of earthy matter and 3.5 per cent. of animal matter. The earthy matter consists

of the phosphate with the carbonate of calcium, with traces of fluoride of calcium, phosphate of magnesia, and other salts.

The **cortical substance**, or **cementum** (*crusta petrosa*), is disposed as a thin layer on the roots of the teeth, from the termination of the enamel as far as the apex of the root, where it is usually very thick. In structure and chemical composition it resembles bone. It contains, sparingly, the lacunæ and canaliculi which characterize true bone; the lacunæ placed near the surface have the canaliculi radiating from the side of the lacunæ toward the periodontal membrane, *dental periosteum*, and those more deeply placed join with adjacent dentinal tubuli. In the thicker portions of the crusta petrosa the lamellæ and Haversian canals peculiar to bone are also occasionally found.

As age advances the cement increases in thickness, and gives rise to those bony growths, or exostoses, so common in the teeth of the aged; the pulp-cavity becomes also partially filled up by a hard substance intermediate in structure between dentine and bone (*osteo-dentine*, Owen; *secondary dentine*, Tomes). It is formed by the odontoblasts, the dental pulp lessening in volume.

Development of the Teeth.

The teeth are an evolution from the dermoid system, and not of the bony skeleton: they are developed from two of the blastodermic layers, the epiblast and mesoblast. From the former the enamel is developed, from the latter the dental pulp, dentine, cementum, and pericementum. It is customary to view the development of the permanent and temporary teeth as separate studies.

The earliest evidence of tooth-formation in the human embryo is observed in about the seventh week. The mucous membrane covering the embryonic jaws is seen to rise as a longitudinal ridge along the summit of each jaw.[1] A transverse section through the jaws will show the elevation to be due to a linear and outlined activity of the germinal epithelial layer: a corresponding epithelial growth is seen to sink as a band into the mesoblastic tissue beneath. The local cell-activity continues, and in its descent the band appears to meet with a resistance which causes a flattening of its extremity into a continuous lamina. From the inner (toward the tongue) edge of the lamina epithelial cords are given off, ten in number, one for each temporary tooth.

The growth of each cord continues, and each expands into a flask-like form, the walls covered by a layer of germinal cells, its interior by swollen mature cells. The ingrowing bulb is now seen to flatten upon its lower surface, as though it had met with an outlined resistance from the mesoblastic tissue beneath. The epithelial ingrowth assumes the general form of the several teeth; it is the enamel-organ of the tooth (Fig. 564). At this period the mesoblastic tissue around each enamel-organ is seen to become differentiated into fibrous tissue surrounding the enamel-organs, but at some distance from them. Islets of bone are also seen to be forming the beginning of the bony maxillæ.

The indentation of the base of the enamel-organ continues until it assumes the form of the future teeth. The cells bounding the organ assume a cylindrical form; the cells of the interior become much expanded, irregular in size and form.

The mesoblastic tissue underlying the enamel-organ is much condensed; evidences of cellular differentiation and a vascular system appear. Bone continues to develop until all of the tooth-follicles are embraced in a gutter of bone. From the lingual side of the cords of the temporary teeth epithelial buds are given off, which sink into the mesoblastic tissue and form the enamel-organs of the permanent teeth. The condensation of fibrous tissue continues until each embryonic tooth is enveloped in a sac, the dental sac; this, together with all of its contents, is called the dental follicle.

The cells of the enamel-organ now undergo a series of differentiations: the inner layer is arranged as columnar epithelium, and is called the ameloblastic or

[1] The maxillary rampart of Kolliker Waldeyer.

enamel-forming layer (Figs. 565 and 566). The cells of the outer wall remain cuboidal; the cells which lie between become much distended, and on account of

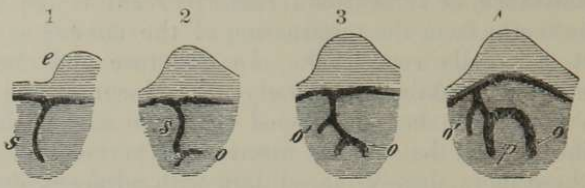

FIG. 564.—Diagram of method of development of the teeth. 1. Early stage. 4. Later stage. 2, 3. Intermediate stages. *s*. Common dental germ. *o*. Special dental germ (milk). *o'*. Special dental germ (permanent). *p*. Papilla. *e*. Dental furrow. (Gegenbaur.)

their appearance when seen in section this portion of the organ is called the stellate reticulum (the enamel-jelly). The layer of cells immediately contiguous to the ameloblasts form a layer called the stratum intermedium (Fig. 566A—*D*).

The enclosed mesoblastic papilla (the future dental pulp) has its peripheral cells differentiated into columnar bodies disposed as a layer, each cell having a large

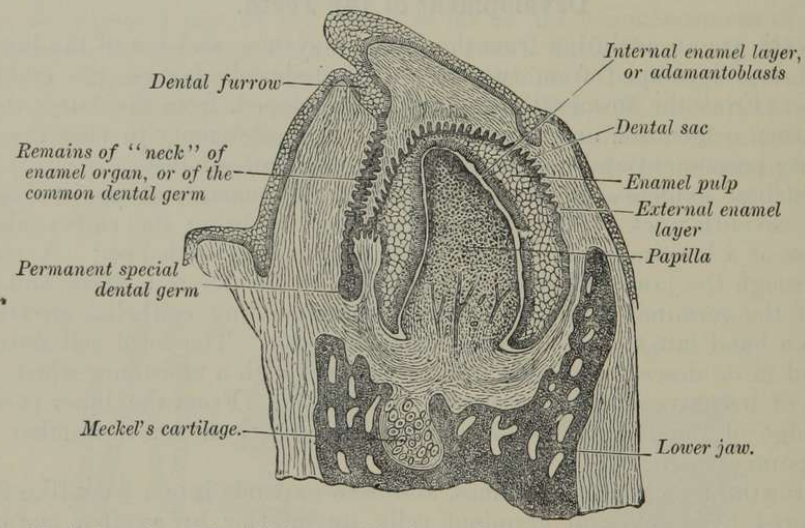

FIG. 565.—Vertical section of the inferior maxilla of an early human fœtus. (Magnified 25 diameters.)

nucleus. The vascular supply of the pulp is now well marked. A section of a follicle at this period will exhibit the follicular wall springing from the base of the dental papilla and having a well-marked blood-supply. The bony alveolar walls are well outlined, and evidences of a periosteum appear (Figs. 565 and 566).

Development of Enamel.—In point of time, the deposition of dentine actually begins before that of enamel, so that the first-formed layer of enamel is deposited against a layer of immature dentine. The enamel is built up of two distinct substances—globules of uniform size which are formed by the ameloblasts, and a cementing substance, probably an albuminate of calcium (calco-globulin), the basis of all the calcified tissues. At the ends of the ameloblasts, next to the dentine, the secretion calco-globulin is deposited, and into the plastic mass the enamel-globules are extruded, each globule remaining connected with the ameloblasts by plasmic strings, which also join the globules laterally.[1]

The first deposit of enamel begins in the tips of the cusps, and is quickly followed by a disappearance of the stellate reticulum at that point; the stellate reticulum now appears to atrophy, so that the vascular follicular wall is brought into direct apposition with the stratum intermedium, which becomes differentiated into a glandular (secreting) tissue which elaborates the calcic albuminous basis of the enamel. The secretion passes from the cells of the stratum intermedium through a membrane into the ameloblasts, where it is in part combined with the cellular

[1] J. L. Williams, *Dental Cosmos*, 1896.

globules, and irregular masses of it extruded as cementing substance. The deposition continues until the enamel-cap has its typical form. The deposition of the layers of globules is indicated by parallel lines transverse to the axes of the enamel-

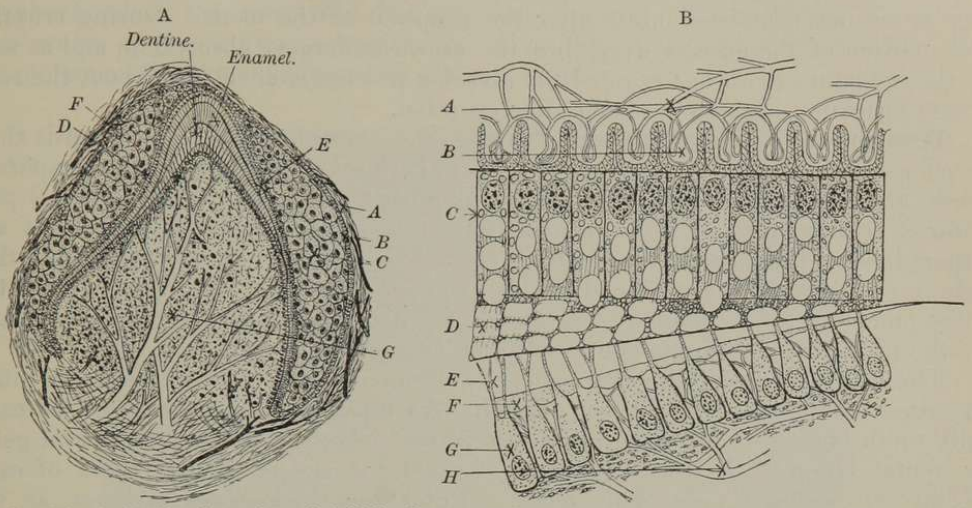

FIG. 566.—A. Section through tooth-follicle—human canine 7½ months: *A*, follicular wall: *B*, outer epithelial coat; *C*, stellate reticulum; *D*, stratum intermedium; *E*, ameloblasts; *F*, odontoblasts; *G*, pulp.
B. Diagram after Williams (*Dental Cosmos*, 1896), mode of enamel deposition: *A*, blood supply to *B*, secreting papillæ; *C*, layer of ameloblasts containing enamel globules and droplets of calcoglobulin; *D*, enamel-globules deposited; *E*, formed dentine; *F*, forming dentine; *G*, layer of odontoblasts; *H*, blood supply to odontoblastic layer.

rods. At the completion of amelification the ameloblasts are partially calcified and form the *cuticula dentis* or Nasmyth's membrane.

Formation of Dentine.—The layer of columnar cells bounding the periphery of the pulp (the odontoblasts) are in apposition with a plexus of capillary vessels (Fig. 566, *A*). Each cell is a secreting body which selects the material for dentine-building. Against the layer of ameloblasts covering the dental papilla the odontoblasts deposit globules of the calcium albuminate, and, receding as the deposits are made, leave one or more protoplasmic processes in the calcic deposit (Tomes's fibres). The process continues until the normal dentine thickness is formed. The deposit is laid down in a scaffolding of finely fibrillated tissue. The layer of formative cells remains constant.

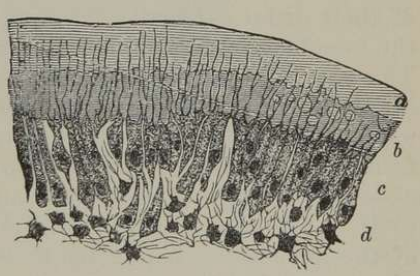

FIG. 567.—Part of section of developing tooth of young rat, showing the mode of deposition of the dentine (highly magnified). *a*. Outer layer of fully-calcified dentine. *b*. Uncalcified matrix with a few nodules of calcareous matter. *c*. Odontoblasts with processes extending into the dentine. *d*. Pulp. The section is stained with carmine, which colors the uncalcified matrix, but not the calcified part.

Formation of Cementum.—Hertwig asserts that the epithelial edge of the enamel-organ formed by the inner and outer epithelial layers of the organ grows downward, or rather the developing tooth grows upward until the future root-form of the tooth is outlined by a double layer of epithelial cells (the root-sheath of Hertwig). The growth of alveolar process is synchronous.

Upon the pulp side of the sheath a layer of odontoblasts is developed; upon the outer side the fibrous encasement becomes closely attached to the sheath and a layer of osteogenetic cells (cementoblasts) is differentiated. The growth of the dentine of the root is the same as in the crown. The epithelial sheath undergoes atrophic changes, leaving epithelial whorls which remain in the pericementum. The cementum is developed as subperiosteal bone. The cementum over the apex of the root is not formed until after the eruption of the tooth.

Formation of Alveoli.—By the time the crowns of the teeth have formed, each

is enclosed in a loculus of bone which has developed around it and at some distance from it; the loculus is open at the top toward the gums, where it is closed by fibrous tissue; the developing permanent tooth is contained in the same loculus, but is later separated from the temporary tooth by a growth of bone. The alveolar process is not completed until after the eruption of the teeth. During eruption that portion of the process overlying the crown undergoes absorption, and as soon as the immature tooth has erupted the alveolar process is developed about the root, whose formation is also completed after eruption.

Development of the Permanent Teeth.—The permanent teeth as regards their development may be divided into two sets: (1) those which replace the temporary teeth, and which, like them, are ten in number: these are the *successional permanent teeth;* and (2) those which have no temporary predecessors, but are superadded at the back of the dental series. These are three in number on either side in each jaw, and are termed the *superadded permanent teeth.* They are the three molars of the permanent set, the molars of the temporary set being replaced by the premolars or bicuspids of the permanent set.

The development of the *successional permanent teeth*—the ten anterior ones in either jaw—will be first considered. As already stated, the germ of each milk tooth is a special thickening of the "free" edge of the common dental germ or dental lamina. In like manner is formed the special dental germ of each of the successional permanent teeth. But these thickenings are not at the "free" edge of the dental lamina, but occur behind and lateral to each of the milk-tooth germs (Fig. 564). There are ten of these, and they appear in order, about the sixteenth week, on each side, the central incisor germs being the first.

These special dental germs now go through the same transformations (and become enamel-organs) as were described in connection with those of the milk teeth; that is, they recede into the substance of the gum behind the germs of the temporary teeth. As they recede they become flask-shaped, form an expansion of their distal extremity, and finally meet a papilla, which has been formed in the mesoblast, just in the same manner as was the case in the temporary teeth. The apex of the papilla indentates the dental germ, which encloses it, and forming a cap for it, undergoes analogous changes to those described in the development of the milk teeth, and becomes converted into the enamel, whilst the papilla forms the dentine, of the permanent tooth. In its development it becomes enclosed in a dentinal sac which adheres to the *back* of the sac of the temporary tooth. The sac of each permanent tooth is also connected with the fibrous tissue of the gum by a slender band or *gubernaculum*, which passes to the margin of the jaw behind the corresponding milk tooth (see above).

The *superadded permanent teeth*—three on each side in each jaw—arise from successive extensions backward—*i. e.* along the line of the jaw—of the common dental germ from the back part of the special dental germ of the immediately preceding tooth. During the fourth month or seventeenth week, in that portion of the common dental germ which lies behind—*i. e.* lateral to the special dental germ of the last temporary molar tooth, and which has hitherto remained unaltered, there is developed the special dental germ of the first permanent molar into which a papilla projects. In a similar manner, about the fourth month after birth the second molar is formed, and about the third year the third molar.

Eruption.—When the calcification of the different tissues of the *milk* tooth is sufficiently advanced to enable it to bear the pressure to which it will be afterward subjected, its eruption takes place, the tooth making its way through the gum. The gum is absorbed by the pressure of the crown of the tooth against it, which is itself pressed up by the increasing size of the fang. At the same time the septa between the dentinal sacs, at first fibrous in structure, ossify and thus form the loculi or alveoli; these firmly embrace the necks of the teeth and afford them a solid basis.

Previous to the *permanent teeth* penetrating the gum, the bony partitions which separate their sacs from the deciduous teeth are absorbed, the roots of the temporary teeth disappear by absorption through the agency of particular multinucleated cells, called *odontoclasts*, which are developed at the time in the neighborhood of the root, and the permanent teeth become placed under the loose crown of the deciduous teeth; the latter finally become detached, and the permanent teeth take their place in the mouth (Fig. 568).

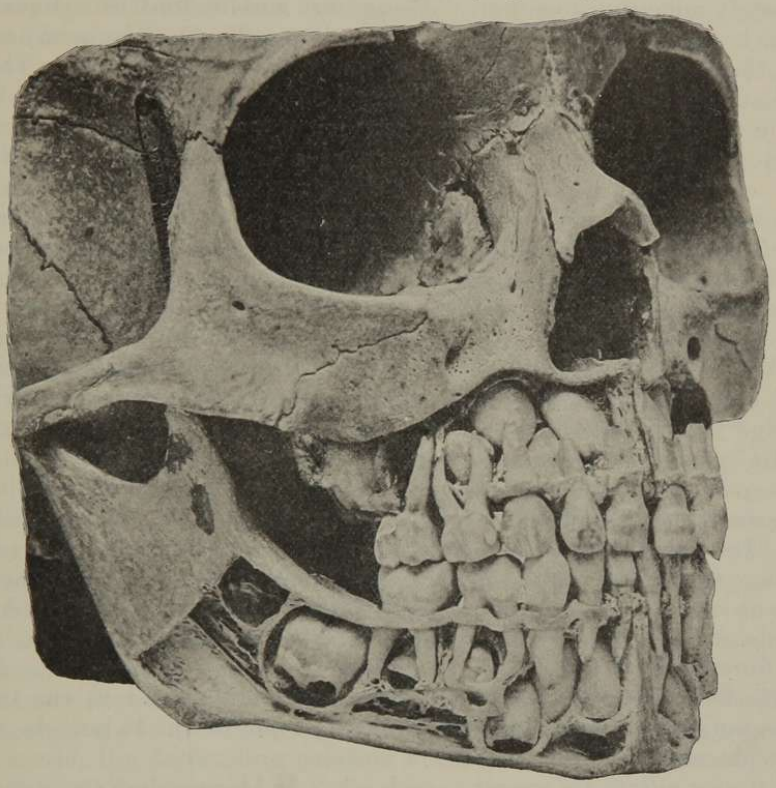

FIG. 568.—The milk-teeth in a child of about four years. The permanent teeth are seen in their alveoli. (Cryer.)

Calcification of the permanent teeth proceeds in the following order: First molar, soon after birth; the central incisor, lateral incisor, and cuspid, about six months after birth; the bicuspids, at the second year or later; second molar, end of second year; third molar, about the twelfth year.

The *eruption of the temporary teeth* commences at the seventh month, and is complete about the end of the second year.

The periods for the eruption of the temporary set are (C. S. Tomes)—

Lower central incisors	6 to 9 months.
Upper incisors	8 to 10 "
Lower lateral incisors and first molars	15 to 21 "
Canines	16 to 20 "
Second molars	20 to 24 "

The *eruption of the permanent teeth* takes place at the following periods, the teeth of the lower jaw preceding those of the upper by a short interval:

6½ years, first molars.
7th year, two middle incisors.
8th year, two lateral incisors.
9th year, first bicuspid.
10th year, second bicuspid.
11th to 12th year, canine.
12th to 13th year, second molars.
17th to 21st year, third molars.

THE PALATE.

The **palate** forms the roof of the mouth: it consists of two portions, the hard palate in front, the soft palate behind.

The **hard palate** is bounded in front and at the sides by the alveolar arches and gums; behind, it is continuous with the soft palate. It is covered by a dense structure formed by the periosteum and mucous membrane of the mouth, which are intimately adherent together. Along the middle line is a linear ridge or raphe, which terminates anteriorly in a small papilla (*incisive pad*) corresponding with the inferior opening of the anterior palatine fossa. This papilla receives filaments from the naso-palatine and anterior palatine nerves. On either side and in front of the raphe the mucous membrane is thick, pale in color, and corrugated; behind, it is thin, smooth, and of a deeper color: it is covered with squamous epithelium, and furnished with numerous glands (palatal glands), which lie between the mucous membrane and the surface of the bone.

The **soft palate** (*velum pendulum palati*) is a movable fold suspended from the posterior border of the hard palate, and forming an incomplete septum between the mouth and pharynx. It consists of a fold of mucous membrane enclosing muscular fibres, an aponeurosis, vessels, nerves, adenoid tissue, and mucous glands. When occupying its usual position (*i. e.* relaxed and pendent) its anterior surface is concave, continuous with the roof of the mouth, and marked by a median ridge or raphe, which indicates its original separation into two lateral halves. Its posterior surface is convex, and continuous with the mucous membrane covering the floor of the posterior nares. Its upper border is attached to the posterior margin of the hard palate, and its sides are blended with the pharynx. Its lower border is free.

Hanging from the middle of its lower border is a small, conical-shaped pendulous process, the *uvula*, and arching outward and downward from the base of the uvula on each side are two curved folds of mucous membrane, containing muscular fibres, called the *arches* or *pillars of the soft palate.*

The *anterior pillars* run downward, outward, and forward to the sides of the base of the tongue, and are formed by the projection of the Palato-glossi muscles, covered by mucous membrane.

The *posterior pillars* are nearer to each other and larger than the anterior; they run downward, outward, and backward to the sides of the pharynx, and are formed by the projection of the Palato-pharyngei muscles, covered by mucous membrane. The anterior and posterior pillars are separated below by a triangular interval in which the tonsil is lodged.

The space left between the arches of the palate on the two sides is called the *isthmus of the fauces.* It is bounded, above, by the free margin of the soft palate; below, by the back of the tongue; and on each side, by the pillars of the soft palate and the tonsil.

The *mucous membrane of the soft palate* is thin, and covered with squamous epithelium on its under surface, while on its superior surface the epithelium is columnar and ciliated.[1] Beneath the mucous membrane on the oral surface of the soft palate is a considerable amount of adenoid tissue. The palatine glands form a continuous layer on its posterior surface and round the uvula.

The *aponeurosis of the soft palate* is a thin but firm fibrous layer attached above to the posterior border of the hard palate, and becoming thinner toward the free margin of the velum. Laterally, it is continuous with the pharyngeal aponeurosis. It forms the framework of the soft palate, and is joined by the tendon of the Tensor palati muscle.

The *muscles of the soft palate* are five on each side: the Levator palati, Tensor palati, Azygos uvulæ, Palato-glossus, and Palato-pharyngeus (see page 421). The following is the relative position of these structures in a dissection of the soft

[1] According to Klein, the mucous membrane on the nasal surface of the soft palate is in the fœtus covered throughout by columnar ciliated epithelium, which subsequently becomes squamous.

palate from the posterior or nasal to the anterior or oral surface: Immediately beneath the nasal mucous membrane is a thin stratum of muscular fibres, the posterior fasciculus of the Palato-pharyngeus muscle, joining with its fellow of the opposite side in the middle line. Beneath this is the Azygos uvulæ, consisting of two rounded fleshy fasciculi, placed side by side in the median line of the soft palate. Next come the fibres of the Levator palati, joining with the muscle of the opposite side in the middle line. Fourthly, the anterior fasciculus of the Palato-pharyngeus, thicker than the posterior, and separating the Levator palati from the next muscle, the Tensor palati. This muscle terminates in a tendon which, after winding round the hamular process, expands into a broad aponeurosis in the soft palate, anterior to the other muscles which have been enumerated. Finally, we have a thin muscular stratum, the Palato-glossus muscle, placed in front of the aponeurosis of the Tensor palati, and separated from the oral mucous membrane by adenoid tissue.

The **tonsils** (*amygdalæ*) are two glandular organs, situated one on each side of the fauces, between the anterior and posterior pillars of the soft palate. They are of a rounded form, and vary considerably in size in different individuals. Externally the tonsil is in relation with the inner surface of the Superior constrictor, which separates it from the internal carotid and ascending pharyngeal arteries. It corresponds to the angle of the lower jaw. Its *inner surface* presents from twelve to fifteen orifices, leading into small recesses, from which numerous follicles branch out into the substance of the gland. These follicles are lined by a continuation of the mucous membrane of the pharynx, covered with epithelium; around each follicle is a layer of closed capsules imbedded in the submucous tissue. These capsules are analogous to those of Peyer's glands, consisting of adenoid tissue. No openings from the capsules into the follicles can be recognized. They contain a thick grayish secretion. Surrounding each follicle is a close plexus of lymphatic vessels. From these plexuses the lymphatic vessels pass to the deep cervical glands in the upper part of the neck, which frequently become enlarged in affections of these organs.

The *arteries* supplying the tonsil are the dorsalis linguæ from the lingual, the ascending palatine and tonsillar from the facial, the ascending pharyngeal from the external carotid, the descending palatine branch of the internal maxillary, and a twig from the small meningeal.

The *veins* terminate in the tonsillar plexus, on the outer side of the tonsil.

The *nerves* are derived from Meckel's ganglion and from the glosso-pharyngeal.

THE SALIVARY GLANDS (Fig. 569).

The principal salivary glands communicating with the mouth and pouring their secretion into its cavity are the parotid, submaxillary, and sublingual.

The **parotid gland**, so called from being placed near the ear (*παρά*, near; *οὖς*, *ὠτός*, the ear), is the largest of the three salivary glands, varying in weight from half an ounce to an ounce. It lies upon the side of the face immediately below and in front of the external ear. It is limited above by the zygoma; below, by the angle of the jaw and by a line drawn between it and the mastoid process: anteriorly, it extends to a variable extent over the Masseter muscle; posteriorly, it is bounded by the external meatus, the mastoid process, and the Sterno-mastoid and Digastric muscles, slightly overlapping the latter.

Its *anterior surface* is grooved to embrace the posterior margin of the ramus of the lower jaw, and advances forward beneath the ramus, between the two Pterygoid muscles and in front of the ramus over the Masseter muscle. Its *outer surface*, slightly lobulated, is covered by the integument and parotid fascia, and has one or two lymphatic glands resting on it. Its *inner surface* extends deeply into the neck by means of two large processes, one of which dips behind the styloid process and projects beneath the mastoid process and the Sterno-mastoid muscle; the other is

situated in front of the styloid process, and passes into the back part of the glenoid fossa, behind the articulation of the lower jaw. The structures passing through the parotid gland are—the external carotid artery, giving off its three terminal branches: the posterior auricular artery emerges from the gland behind; the temporal artery above; the transverse facial, a branch of the temporal, in front;

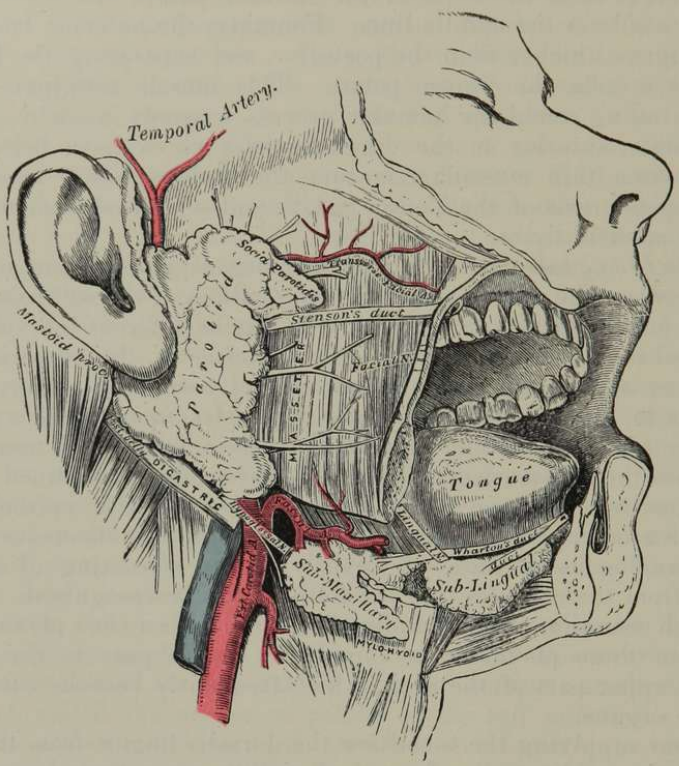

FIG. 569.—The salivary glands.

and the internal maxillary winds through it as it passes inward, behind the neck of the jaw. Superficial to the external carotid is the trunk formed by the union of the temporal and internal maxillary veins; a branch, connecting this trunk with the internal jugular, also passes through the gland. It is also traversed by the facial nerve and its branches, which emerge at its anterior border; branches of the great auricular nerve pierce the gland to join the facial, and the auriculo-temporal branch of the inferior maxillary nerve emerges from the upper part of the gland. The internal carotid artery and internal jugular vein lie close to its deep surface.

The **duct of the parotid gland** (*Stenson's*) is about two inches and a half in length. It commences by numerous branches from the anterior part of the gland, crosses the Masseter muscle, and at its anterior border dips down into the substance of the Buccinator muscle, which it pierces; it then runs for a short distance obliquely forward between the Buccinator and mucous membrane of the mouth, and opens upon the inner surface of the cheek by a small orifice opposite the second molar tooth of the upper jaw. While crossing the Masseter it receives the duct of a small detached portion of the gland, *socia parotidis*, which occasionally exists as a separate lobe, just beneath the zygomatic arch. In this position it has the transverse facial artery above it and some branches of the facial nerve below it.

Structure.—The parotid duct is dense, of considerable thickness, and its canal about the size of a crowquill; it consists of an external or fibrous coat, of considerable density, containing contractile fibres, and of an internal or mucous coat lined with short columnar epithelium.

Surface Form.—The direction of the duct corresponds to a line drawn across the face about a finger's breadth below the zygoma; that is, from the lower part of the tragus to midway between the free margin of the upper lip and the ala of the nose.

Vessels and Nerves.—The *arteries* supplying the parotid gland are derived from the external carotid, and from the branches given off by that vessel in or near its substance. The *veins* empty themselves into the external jugular through some of its tributaries. The *lymphatics* terminate in the superficial and deep cervical

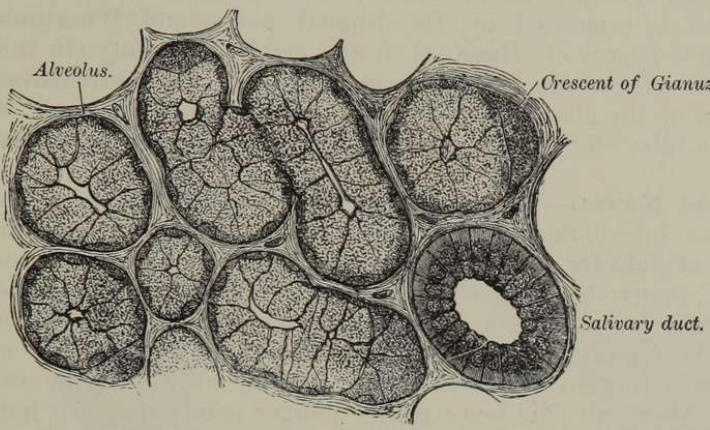

FIG. 570.—A highly magnified section of the submaxillary gland of the dog, stained with carmine. (Kölliker.)

glands, passing in their course through two or three lymphatic glands placed on the surface and in the substance of the parotid. The *nerves* are derived from the carotid plexus of the sympathetic, the facial, the auriculo-temporal, and great auricular nerves.

It is probable that the branch from the auriculo-temporal nerve is derived from the glosso-pharyngeal through the otic ganglion (which see). At all events, in some of the lower animals this has been proved experimentally to be the case.

The **submaxillary gland** is situated below the jaw, in the anterior part of the submaxillary triangle of the neck. It is irregular in form and weighs about two drachms (8–10 grammes). It is covered by the integument, Platysma, deep cervical fascia, and the body of the lower jaw, corresponding to a depression on the inner surface of the bone, and lies upon the Mylo-hyoid, Hyo-glossus, and Stylo-glossus muscles, a portion of the gland passing beneath the posterior border of the Mylo-hyoid. In front of it is the anterior belly of the Digastric; behind, it is separated from the parotid gland by the stylo-maxillary ligament, and from the sublingual gland in front by the Mylo-hyoid muscle. The facial artery lies imbedded in a groove in its posterior and upper border.

The **duct of the submaxillary gland** (*Wharton's*) is about two inches in length, and its walls are much thinner than those of the parotid duct. It commences by numerous branches from the deep portion of the gland, and passes forward and inward between the Mylo-hyoid and the Hyo-glossus and Genio-hyo-glossus muscles, then between the sublingual gland and the Genio-hyo-glossus, and opens by a narrow orifice on the summit of a small papilla at the side of the frænum linguæ. On the Hyo-glossus muscle it lies between the lingual and hypoglossal nerves, but at the anterior border of the muscle it crosses under the lingual nerve, and is then placed above it.

Vessels and Nerves.—The *arteries* supplying the submaxillary gland are branches of the facial and lingual. Its *veins* follow the course of the arteries. The *nerves* are derived from the submaxillary ganglion, through which it receives filaments from the chorda tympani of the facial and lingual branch of the inferior maxillary, from the mylo-hyoid branch of the inferior dental, and from the sympathetic.

The **sublingual gland** is the smallest of the salivary glands. It is situated beneath the mucous membrane of the floor of the mouth, at the side of the frænum linguæ, in contact with the inner surface of the lower jaw, close to the symphysis. It is narrow, flattened, in shape somewhat like an almond, and weighs about a drachm. It is in relation, *above*, with the mucous membrane; *below*, with the Mylo-hyoid muscle; *in front*, with the depression on the side of the symphysis of the lower jaw, and with its fellow of the opposite side; *behind*, with the deep part of the submaxillary gland; and *internally*, with the Genio-hyo-glossus, from which it is separated by the lingual nerve and Wharton's duct. Its excretory ducts (*ducts of Rivinus*), from eight to twenty in number, open separately into the mouth, on the elevated crest of mucous membrane caused by the projection of the gland, on either side of the frænum linguæ. One or more join to form a tube which opens into the Whartonian duct; this is called the *duct of Bartholin*.

Vessels and Nerves.—The sublingual gland is supplied with blood from the sublingual and submental arteries. Its nerves are derived from the lingual.

Structure of Salivary Glands.—The salivary are compound racemose glands, consisting of numerous lobes, which are made up of smaller lobules connected together by dense areolar tissue, vessels, and ducts. Each lobule consists of the ramifications of a single duct, "branching frequently in a tree-like manner," the branches terminating in dilated ends or alveoli, on which the capillaries are distributed. These alveoli, however, as Pflüger points out, are not necessarily spherical, though sometimes they assume that form; sometimes they are perfectly cylindrical, and very often they are mutually compressed. The alveoli are enclosed by a basement membrane which is continuous with the membrana propria of the duct. It presents a peculiar reticulated structure, having the appearance of a basket with open meshes, and consisting of a network of branched and flattened nucleated cells.

The alveoli of the salivary glands are of two kinds, which differ both in the appearance of their secreting cells, in their size, and in the nature of their secretion. The one variety secretes a ropy fluid which contains mucin, and has therefore been named the *mucous*, whilst the other secretes a thinner and more watery fluid, which contains serum-albumin, and has been named *serous* or *albuminous*. The sublingual gland may be regarded as an example of the former variety, the parotid of the latter. The submaxillary is of the mixed variety, containing both mucous and serous alveoli, the latter, however, preponderating.

Both alveoli are lined by cells, and it is by the character of these cells that the nature of the gland is chiefly to be determined. In addition, however, the alveoli of the serous glands are smaller than those of the mucous ones.

The **cells in the mucous alveoli** are spheroidal in shape, glassy, transparent, and dimly striated in appearance. The nucleus is usually situated in the part of the cell which is next the basement membrane, against which it is sometimes flattened. The most remarkable peculiarity presented by these cells is, that they give off an extremely fine process, which is curved in a direction parallel to the surface of the alveolus, lies in contact with the membrana propria, and overlaps the process of neighboring cells. The cells contain a quantity of mucin, to which their clear, transparent appearance is due.

Here and there in the alveoli are seen peculiar half-moon-shaped bodies lying between the cells and the membrana propria of the alveolus. They are termed the *crescents of Gianuzzi* or the *demilunes of Heidenhain* (Fig. 570), and are regarded by Pflüger as due to post-mortem change, but by most other later observers they are believed to be composed of polyhedral granular cells, which Heidenhain regards as young epithelial cells destined to supply the place of those salivary cells which have undergone disintegration. This view, however, is not accepted by Klein.

Serous Alveoli.—In the serous alveoli the cells almost completely fill the cavity,

so that there is hardly any lumen perceptible. Instead of presenting the clear, transparent appearance of the cells of the mucous alveoli, they present a granular appearance, due to distinct granules of an albuminous nature imbedded in a closely-reticulated protoplasm. The ducts which originate out of the alveoli are lined at their commencement by epithelium which differs little from the pavement type. As the ducts enlarge the epithelial cells change to the columnar type, and they are described by Pflüger as attached to the basement membrane by a brush of fine hair-like processes, which he believes to be continuous with the nerve-fibres. Other anatomists regard these cells as merely striated on their deep surface. The lobules of the salivary glands are richly supplied with blood-vessels which form a dense network in the interalveolar spaces. Fine plexuses of nerves are also found in the interlobular tissue.

Pflüger describes the nerves as being directly continuous with the salivary cells of the alveolus, the nerve sometimes passing through a ganglion-cell just before joining the alveolus (Fig. 571, A and B). This fact has not, however, been corroborated by other observers. There is no doubt that ganglia are to be found in some salivary glands in connection with the nerve-plexuses in the interlobular tissue; thus they are to be found in the submaxillary, but not in the parotid, but whether the ultimate fibrils are connected with the salivary cells, as asserted by Pflüger, remains to be proved.

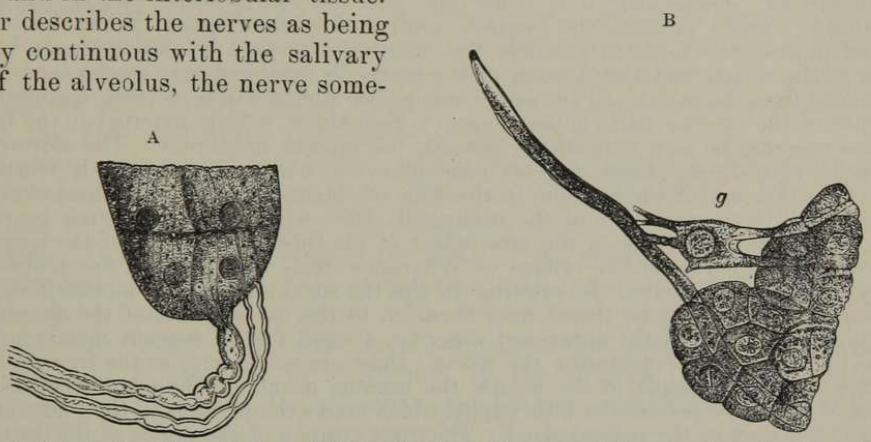

FIG. 571.—Illustrating Pflüger's views of the termination of the nerves in the alveolar cells. (From Stricker's "Handbook.") A. Direct passage of nerve into a salivary cell. B. By the medium of a multipolar ganglion-cell, *g*.

In the submaxillary and sublingual glands the lobes are larger and more loosely united than in the parotid.

Mucous Glands.—Besides the salivary glands proper, numerous other glands are found in the mouth. They appear to secrete mucus only, which serves to keep the mouth moist during the intervals of the salivary secretion, and which is mixed with that secretion in swallowing. Many of these glands are found at the posterior part of the dorsum of the tongue, behind the circumvallate papillæ, and also along its margins as far forward as the apex.[1] Others lie around and in the tonsil between its crypts, and a large number in the soft palate. These glands are of the ordinary compound racemose type.

Surface Form.—The orifice of the mouth is bounded by the lips, two thick, fleshy folds covered externally by integument and internally by mucous membrane, and consisting of muscles, vessels, nerves, areolar tissue, and numerous small glands. The size of the orifice of the mouth varies considerably in different individuals, but seems to bear a close relation to the size and prominence of the teeth. Its corners correspond pretty accurately to the outer border of the canine teeth. In the Mongolian tribes, where the front teeth are large and inclined forward, the mouth is large; and this, combined with the thick and everted lips which appear to be associated with prominent teeth, gives to the negro's face much of the peculiarity by which it is characterized. The smaller teeth and the slighter prominence of the alveolar arch of the

[1] It has recently been shown by Ebner that many of these glands open into the trenches around the circumvallate papillæ, and that their secretion is more watery than that of ordinary mucous glands. He supposes that they assist in the more rapid distribution of the substance to be tasted over the region where the special apparatus of the sense of taste is situated.

more highly civilized races render the orifice of the mouth much smaller, and thus a small mouth is an indication of intelligence, and is regarded as an evidence of the higher civilization of the individual.

Upon looking into the mouth, the first thing we may note is the tongue, the upper surface of which will be seen occupying the floor of the cavity. This surface is convex, and is marked along the middle line by a raphe which divides it into two symmetrical portions. The anterior two-thirds is rough and studded with papillæ; the posterior third smooth and tuberculated, covered by numerous glands which project from the surface. Upon raising the tongue the mucous membrane which invests the upper surface may be traced covering the sides of the under surface, and then reflected over the floor of the mouth on to the inner surface of the lower jaw, a part of which it covers. As it passes over the borders of the tongue it changes its character, becoming thin and smooth and losing the papillæ which are to be seen on the upper surface. In the middle line the mucous membrane on the under surface of the tip of the tongue forms a distinct fold, the *frænum linguæ*, by which this organ is connected to the symphysis of the jaw. Occasionally it is found that this frænum is rather shorter than natural, and, acting as a bridle, prevents the complete protrusion of the tongue. When this condition exists and an attempt is made to protrude the organ, the tip will be seen to remain buried in the floor of the mouth, and the dorsum of the tongue is rendered very convex, and more or less extruded from the mouth; at the same time a deep furrow will be noticed to appear in the middle line of the anterior part of the dorsum. Sometimes, a little external to the frænum, the ranine vein may be seen immediately beneath the mucous membrane. The corresponding artery, being more deeply placed, does not come into view, nor can its pulsation be felt with the finger. On either side of the frænum, in the floor of the mouth, is a longitudinal elevation or ridge, produced by the projection of the sublingual gland, which lies immediately beneath the mucous membrane. And close to the attachment of the frænum to the tip of the tongue may be seen on either side the slit-like orifices of Wharton's ducts, into which a fine probe may be passed without much difficulty. By everting the lips the smooth mucous membrane lining them may be examined, and may be traced from them on to the outer surface of the alveolar arch. In the middle line, both of the upper and lower lip, a small fold of mucous membrane passes from the lip to the bone, constituting the *frænæ;* these are not so large as the frænum linguæ. By pulling outward the angle of the mouth, the mucous membrane lining the cheeks can be seen, and on it may be perceived a little papilla which marks the position of the orifice of Stenson's duct—the duct of the parotid gland. The exact position of the orifice of the duct will be found to be opposite the second molar tooth of the upper jaw. The introduction of a probe into this duct is attended with considerable difficulty. The teeth are the next objects which claim our attention upon looking into the mouth. There are, as stated above, ten in either jaw in the temporary set, and sixteen in the permanent set. The gums, in which they are implanted, are dense, firm, and vascular.

At the back of the mouth is seen the *isthmus of the fauces*, or, as it is popularly called, "the throat:" this is the space between the pillars of the fauces on either side, and is the means by which the mouth communicates with the pharynx. Above, it is bounded by the soft palate, the anterior surface of which is concave and covered with mucous membrane, which is continuous with that lining the roof of the mouth. Projecting from the middle of its lower border is a conical-shaped projection, the *uvula*. On either side of the isthmus of the fauces are the anterior and posterior pillars, formed by the Palato-glossus and Palato-pharyngeus muscles respectively, covered over by mucous membrane. Between the two pillars on either side is situated the tonsil. By their external surface these glands are in close relationship with the internal carotid artery, being separated from this vessel only by the thin plane of muscular fibres forming the wall of the pharynx. It is stated that this vessel may be wounded in removing the tonsil. The extirpation of this glandular body is not unattended with danger of hæmorrhage from other sources. Dr. Weir has stated that he believes that when hæmorrhage occurs after their removal it arises from one of the palatine arteries having been wounded. These vessels are large: they lie in the muscular tissue of the palate, and when wounded are constantly exposed to disturbance from the contraction of the palatine muscles. The vessels of the tonsil, Dr. Weir states, are small and lie in the soft tissue, and readily contract when wounded.

When the mouth is wide open a prominent tense fold of mucous membrane may be seen and felt, extending upward and backward from the position of the fang of the last molar tooth to the posterior part of the hard palate. This is caused by the Pterygo-maxillary ligament, which is attached by one extremity to the apex of the internal pterygoid plate, and by the other to the posterior extremity of the mylo-hyoid ridge of the lower jaw. It connects the Buccinator with the Superior constrictor of the pharynx. The fang of the last molar tooth indicates the position of the lingual (gustatory) nerve, where it is easily accessible, and can with readiness be divided in cases of cancer of the tongue (see page 810). On the inner side of the last molar tooth we can feel the hamular process of the internal pterygoid plate of the sphenoid bone, around which the tendon of the Tensor palati plays. The exact position of this process is of importance in performing the operation of staphylorraphy. About one-third of an inch in front of the hamular process, and the same distance directly inward from the last molar tooth, is the situation of the opening of the posterior palatine canal, through which emerges the posterior or descending palatine branch of the internal maxillary artery and one of the descending palatine nerves from Meckel's ganglion. The exact position of the opening on the subject may

be ascertained by driving a needle through the tissues of the palate in this situation, when it will be at once felt to enter the canal. The artery emerging from the opening runs forward in a groove in the bone just internal to the alveolar border of the hard palate, and may be wounded in the operation for the cure of cleft palate. Under these circumstances the palatine canal may require plugging. By introducing the finger into the mouth the anterior border of the coronoid process of the jaw can be felt, and is especially prominent when the jaw is dislocated. By throwing the head well back a considerable portion of the posterior wall of the pharynx may be seen through the isthmus faucium, and on introducing the finger the anterior surface of the bodies of the upper cervical vertebræ may be felt immediately beneath the thin muscular stratum forming the wall of the pharynx. The finger can be hooked around the posterior border of the soft palate, and by turning it forward the posterior nares, separated by the septum, can be felt, or the presence of any adenoid or other growths in the naso-pharynx ascertained.

THE PHARYNX.

The **pharynx** is that part of the alimentary canal which is placed behind the nose, mouth, and larynx. It is a musculo-membranous sac, somewhat conical in form, with the base upward and the apex downward, extending from the under surface of the skull to the cricoid cartilage in front and the intervertebral disk between the fifth and sixth cervical vertebræ behind.

The pharynx is about four inches and a half in length, and broader in the transverse than in the antero-posterior diameter. Its greatest breadth is opposite the cornua of the hyoid bone; its narrowest point, at its termination in the œsophagus. It is limited, *above*, by the body of the sphenoid and basilar process of the occipital bone; *below*, it is continuous with the œsophagus; *posteriorly*, it is connected by loose areolar tissue with the cervical portion of the vertebral column and the Longi colli and Recti capitis antici muscles; *anteriorly*, it is incomplete, and is attached in succession to the internal pterygoid plate, the pterygo-maxillary ligament, the lower jaw, the tongue, hyoid bone, and thyroid and cricoid cartilages; *laterally*, it is connected to the styloid processes and their muscles, and is in contact with the common and internal carotid arteries, the internal jugular veins, and the glosso-pharyngeal, pneumogastric, hypoglossal, and sympathetic nerves, and above with a small part of the Internal pterygoid muscles.

It has seven openings communicating with it—the two posterior nares, the two Eustachian tubes, the mouth, larynx, and œsophagus.

The *posterior nares* are the two oval openings (see page 222) situated at the upper part of the anterior wall of the pharynx.

The *two Eustachian tubes* open one at each side of the upper part of the pharynx, at the back part of the inferior meatus. Below the posterior nares are the posterior surface of the soft palate and uvula, the large aperture of the mouth, the base of the tongue, the epiglottis, and the cordiform opening of the larynx.

The *œsophageal opening* is the lower contracted portion of the pharynx.

Structure.—The pharynx is composed of three coats—mucous, fibrous, and muscular.

The *pharyngeal aponeurosis*, or *fibrous coat*, is situated between the mucous and muscular layers. It is thick above, where the muscular fibres are wanting, and is firmly connected to the basilar process of the occipital and petrous portion of the temporal bones. As it descends it diminishes in thickness, and is gradually lost. It is strengthened posteriorly by a strong fibrous band which is attached above to the pharyngeal spine on the under surface of the basilar portion of the occipital bone, and passes downward, forming a median raphe, which gives attachment to the Constrictor muscles of the pharynx.

The *mucous coat* is continuous with that lining the Eustachian tubes, the nares, the mouth, and the larynx. It is covered by columnar ciliated epithelium, as low down as on a level with the floor of the nares; below that point the epithelium is of the squamous variety. Beneath the mucous membrane are found racemose mucous glands; they are especially numerous at the upper part of the pharynx around the orifices of the Eustachian tubes. Throughout the pharynx are also numerous crypts or recesses, the walls of which are surrounded by lymphoid tissue similar to what

is found in the tonsils. Across the back part of the pharyngeal cavity, between the two Eustachian tubes, a considerable mass of this tissue exists, and has been named the *pharyngeal tonsil*. Just below this in the middle line is the orifice of an irregular, flask-shaped recess of the mucous membrane, extending up as far as the basilar process of the occipital bone. It is known as the *bursa pharyngea*, and is the remains of the diverticulum of the alimentary canal, which is concerned in the development of the pituitary body (which see). It is only occasionally present in the adult.

The *muscular coat* has been already described (page 419).

Surgical Anatomy.—The internal carotid artery is in close relation with the pharynx, so that its pulsations can be felt through the mouth. It has been occasionally wounded by sharp-pointed instruments introduced into the mouth and thrust through the wall of the pharynx. In aneurism of this vessel in the neck the tumor necessarily bulges into the pharynx, as this is the direction in which it meets with the least resistance, nothing lying between the vessel and the mucous membrane except the thin Constrictor muscle, whereas on the outer side there is the dense cervical fascia, the muscles descending from the styloid process, and the margin of the Sterno-mastoid.

The mucous membrane of the pharynx is very vascular, and is often the seat of inflammation, frequently of a septic character, and dangerous on account of its tendency to spread to the larynx. On account of the tissue which surrounds the pharyngeal wall being loose and lax, the inflammation is liable to spread through it far and wide, extending downward into the posterior mediastinum along the œsophagus. Abscess may form in the connective tissue behind the pharynx, between it and the vertebral column, constituting what is known as post-pharyngeal abscess. This is most commonly due to caries of the cervical vertebræ, but may also be caused by suppuration of a lymphatic gland which is situated in this position opposite the axis, and which receives lymphatics from the nares, or by a gumma or by acute pharyngitis. The abscess may be most easily evacuated by an incision, with a guarded bistoury, through the mouth. It has recently been proposed to open the abscess aseptically by an incision in the neck behind the Sterno-mastoid. The operation, however, is a difficult one, unless the abscess is pointing laterally, and does not give such free access to the seat of disease for the removal of necrosed bone, if any exists, and does not appear to present sufficient advantages to warrant its performance.

Foreign bodies not unfrequently become lodged in the pharynx, and most usually at its termination at about the level of the cricoid cartilage, just beyond the reach of the finger, as the distance from the arch of the teeth to the commencement of the œsophagus is about six inches.

The position of the openings of the Eustachian tubes should be studied with a view to catheterism of these tubes. This is to be done by introducing the instrument through the anterior nares, so that its points rest on the floor of the nasal cavity close to the septum; it is then pushed gradually and slowly backward until the posterior wall of the pharynx is reached. Then having been slightly withdrawn so as to free the point from the wall of the pharynx, it is rotated outward and upward, so that the ring of the instrument is turned toward the external ear, and it can then be made to glide into the Eustachian tube.

THE ŒSOPHAGUS.

The **œsophagus,** or **gullet,** is a muscular canal, about nine inches (23 centim.) in length, extending from the pharynx to the stomach. When empty its lumen appears as a transverse slit. Its diameter varies from 1.8 to 2.4 centim. It commences at the upper border of the cricoid cartilage, opposite the intervertebral disk between the fifth and sixth cervical vertebræ, descends along the front of the spine through the posterior mediastinum, passes through the Diaphragm, and, entering the abdomen, terminates at the cardiac orifice of the stomach opposite the tenth dorsal vertebra or the intervertebral disk between the tenth and eleventh dorsal vertebræ. The general direction of the œsophagus is vertical, but it presents two or three slight curves in its course. At its commencement it is placed in the median line, but it inclines to the left side as far as the root of the neck, gradually passes to the middle line again, and finally again deviates to the left as it passes forward to the œsophageal opening of the Diaphragm. The œsophagus also presents an antero-posterior flexure, corresponding to the curvature of the cervical and thoracic portions of the spine. It is the narrowest part of the alimentary canal, being most contracted at its commencement and at the point where it passes through the Diaphragm.

Relations.—*In the neck* the œsophagus is in relation, *in front*, with the trachea, and at the lower part of the neck, where it projects to the left side, with

the thyroid gland and thoracic duct; *behind*, it rests upon the vertebral column and Longi colli muscles; *on each side*, it is in relation with the common carotid artery (especially the left, as it inclines to that side) and part of the lateral lobes of the thyroid gland; the recurrent laryngeal nerves ascend between it and the trachea.

In the thorax it is at first situated a little to the left of the median line; it then passes behind the left side of the aortic arch, and descends in the posterior mediastinum, along the right side of the aorta, nearly to the Diaphragm, where it passes in front and a little to the left of the artery, previous to entering the abdomen. It is in relation, *in front*, with the trachea, the arch of the aorta, left carotid, and left subclavian arteries, the left bronchus, and the posterior surface of the pericardium; *behind*, it rests upon the vertebral column, the Longi colli muscles, the thoracic duct (opposite middle dorsal vertebræ), the right intercostal vessels, and below, near the Diaphragm, upon the front of the aorta; *laterally*, it is covered by the pleuræ: the vena azygos major lies on the right and the descending aorta on the left side. The pneumogastric nerves descend in close contact with it on each side; lower down the right nerve passes behind, and the left nerve in front of it.

Structure.—The œsophagus has three coats—an external or muscular; a middle or areolar; and an internal or mucous coat.

The *muscular coat* is composed of two planes of fibres of considerable thickness, an external longitudinal and an internal circular.

The *longitudinal fibres* are arranged, at the commencement of the tube, in three fasciculi: one in front, which is attached to the vertical ridge on the posterior surface of the cricoid cartilage; and one at each side, which is continuous with the fibres of the Inferior constrictor: as they descend they blend together and form a uniform layer, which covers the outer surface of the tube.

Accessory slips of muscular fibres are described by Dr. Cunningham as passing between the œsophagus and the pleura, where it covers the thoracic aorta (almost always), or the root of the left bronchus (usually), or the back of the pericardium or corner of the mediastinum (more rarely), as well as other still more rare accessory fibres. In Fig. 572, taken from a dissection in the Museum of the Royal College of Surgeons, several of these accessory slips may be seen passing from the œsophagus to the pleura, and two slips to the back of the trachea just above its bifurcation.

The *circular fibres* are continuous above with the Inferior constrictor; their direction is transverse at the upper and lower parts of the tube, but oblique in the central part.

The muscular fibres in the upper part of the œsophagus are of a red color, and consist chiefly of the striped variety, but below they consist for the most part of involuntary muscular fibre.

The *areolar coat* connects loosely the mucous and muscular coats.

The *mucous coat* is thick, of a reddish color above and pale below. It is disposed in longitudinal folds, which disappear on distension of the tube. Its surface is studded with minute papillæ, and it is covered throughout with a thick layer of stratified pavement epithelium. Beneath the mucous membrane, between it and the areolar coat, is a layer of longitudinally arranged non-striped muscular fibres. This is the *muscularis mucosæ*. At the commencement it is absent, or only represented by a few scattered bundles; lower down it forms a considerable stratum.

The *œsophageal glands* are numerous small compound racemose glands scattered throughout the tube; they are lodged in the submucous tissue, and open upon the surface by a long excretory duct. They are most numerous at the lower part of the tube, where they form a ring round the cardiac orifice.

Vessels of the Œsophagus.—The arteries supplying the œsophagus are derived from the inferior thyroid branch of the thyroid axis of the subclavian, from the descending thoracic aorta, and from the gastric branch of the cœliac

axis from the abdominal aorta. They have for the most part a longitudinal direction.

Nerves of the Œsophagus.—The nerves are derived from the pneumogastric and from the sympathetic; they form a plexus in which are groups of ganglion-cells between the two layers of the muscular coats, and also a second plexus in the submucous tissue.

Surgical Anatomy.—The relations of the œsophagus are of considerable practical interest to the surgeon, as he is frequently required, in cases of stricture of this tube, to dilate the canal by a bougie, when it is of importance that the direction of the œsophagus and its relations to surrounding parts should be remembered. In cases of malignant disease of the œsophagus, where its tissues have become softened from infiltration of the morbid deposit, the greatest care is requisite in directing the bougie through the strictured part, as a false passage may easily be made, and the instrument may pass into the mediastinum, or into one or the other pleural cavity, or even into the pericardium.

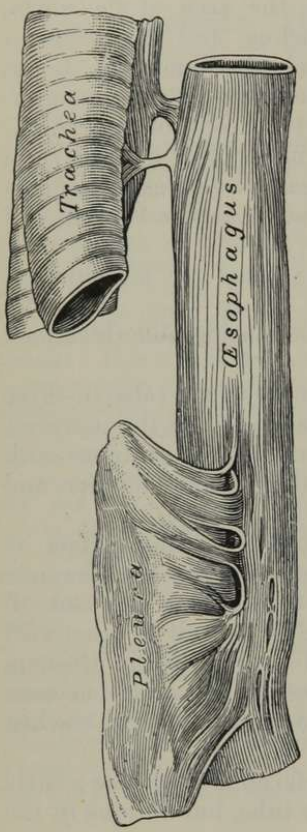

Fig. 572.—Accessory muscular fibres between the œsophagus and pleura, and œsophagus and trachea. (From a preparation in the Museum of the Royal College of Surgeons.)

The student should also remember that contraction of the œsophagus, and consequent symptoms of stricture, are occasionally produced by an aneurism of some part of the aorta pressing upon this tube. In such a case the passage of a bougie could only hasten the fatal issue.

In passing a bougie the left fore finger should be introduced into the mouth and the epiglottis felt for, care being taken not to throw the head too far backward. The bougie is then to be passed beyond the finger until it touches the posterior wall of the pharynx. The patient is now asked to swallow, and at the moment of swallowing the bougie is passed gently onward, all violence being carefully avoided.

It occasionally happens that a foreign body becomes impacted in the œsophagus which can neither be brought upward nor moved downward. When all ordinary means for its removal have failed, excision is the only resource. This, of course, can only be performed when it is not very low down. If the foreign body is allowed to remain, extensive inflammation and ulceration of the œsophagus may ensue. In one case the foreign body ultimately penetrated the intervertebral substance, and destroyed life by inflammation of the membranes and substance of the cord.

The operation of œsophagotomy is thus performed: The patient being placed upon his back, with the head and shoulders slightly elevated, an incision, about four inches in length, should be made on the left side of the trachea, from the thyroid cartilage downward, dividing the skin and Platysma. The edges of the wound being separated, the Omo-hyoid muscle should, if necessary, be divided, and the fibres of the Sterno-hyoid and Sterno-thyroid muscles drawn inward; the sheath of the carotid vessels, being exposed, should be drawn outward, and retained in that position by retractors: the œsophagus will now be exposed, and should be divided over the foreign body, which can then be removed. Great care is necessary to avoid wounding the thyroid vessels, the thyroid gland, and the laryngeal nerves.

The œsophagus may be obstructed not only by foreign bodies, but also by changes in its coats, producing stricture, or by pressure on it from without of new growths or aneurism, etc.

The different forms of stricture are: (1) the spasmodic, usually occurring in nervous women, and intermittent in character, so that the dysphagia is not constant; (2) fibrous, due to cicatrization after injuries, such as swallowing corrosive fluids or boiling water; and (3) malignant, usually epitheliomatous in its nature. This is situated generally either at the upper end of the tube, opposite to the cricoid cartilage, or at its lower end at the cardiac orifice, but is also occasionally found at that part of the tube where it is crossed by the left bronchus.

The operation of œsophagostomy has occasionally been performed in cases where the stricture in the œsophagus is at the upper part, with a view to making a permanent opening below the stricture through which to feed the patient, but the operation has been far from a successful one, and the risk of setting up diffuse inflammation in the loose planes of connective tissue deep in the neck is so great that it would appear to be better to perform gastrostomy.

THE ABDOMEN.

[By Fred J. Brockway, M. D.,
Asst' Demonstrator of Anatomy, College of Physicians and Surgeons (Columbia University) New York City.]

In the early stages of the embryo the "body-cavity" (pleuro-peritoneal cavity) is of large size. Anteriorly (*i. e.* superiorly in the erect posture) there is developed a comparatively enormous space, called the *pericardio-thoracic cavity* (Fig. 573, *A*, *B* and *C*). There also appears a *transverse fold* marking

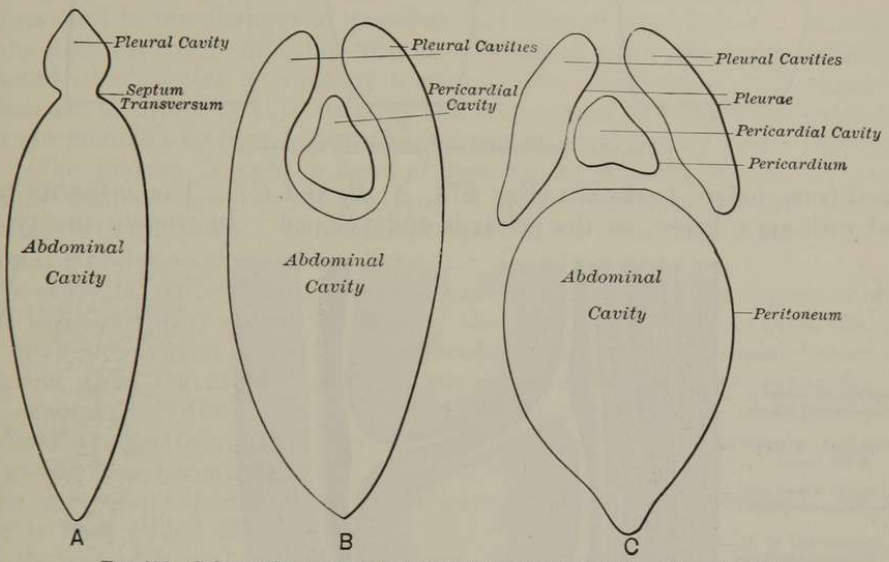

Fig. 573.—Schematic representation of the serous cavities. (Gegenbaur.)

off this cavity in part from the future *abdominal cavity*. This fold, associated with many large veins, is next developed into the *primary diaphragm*, but its dorsal part is incomplete. This is completed later, constituting the *diaphragm* as we know it in the adult. The diaphragm is thus made up of a ventral *younger part* and a dorsal *older part*. When this posterior part fails of development, there is an opportunity for the "congenital diaphragmatic hernia" to be present.

The superior or pericardio-thoracic cavity becomes separated into three distinct compartments (Fig. 573, *B* and *C*), the two lateral being continuous for a time with the abdominal cavity. Thus are formed the four large serous spaces of the body, each one lined with serous membrane. Two are *thoracic* or *pleural*, lined with *pleura*, one is *cardiac*, defined by the *pericardial sac*, and one is *abdominal*, lined with *peritoneum*.

The word *abdomen*[1] is applied to the part of the body lying between the thorax and pelvis; it refers to the largest cavity of the adult body, and is often applied incorrectly to the anterior wall of this cavity. It contains nearly all the digestive apparatus and a part of the urinary system.

Superficially the abdomen is marked from the thorax above by the costal arches, and below from the pelvis by the crests of the ilia, and from the thighs by Poupart's ligaments. These limits, however, do not correspond with those of the *abdominal cavity*. This extends high into the thorax to the cupola of the diaphragm. The lowest limit is the so-called "diaphragm of the pelvis" made by the Levator ani and Coccygeus muscles on either side. This great cavity shows a smaller artificial subdivision, the *pelvic cavity* (Fig. 577). The two are not separated, but the limit between them is taken as the brim of the true pelvis,

[1] Abdo'men comes perhaps from *abdĕre*, to conceal. Hyrtl says it is an ancient word applied to the belly of a pregnant pig. Cicero transferred it from swine to man in a sense of contempt. *Venter* and *alvus* were used for belly; *abdomen* and its adjective *abdominalis* finally came into general use.

the *linea innominata*. The larger upper cavity is called the *abdominal cavity proper*.

The *form* and *extent* of the abdomen vary with age and sex. In the *adult male* with intestines moderately distended it is barrel-shaped or oval, somewhat

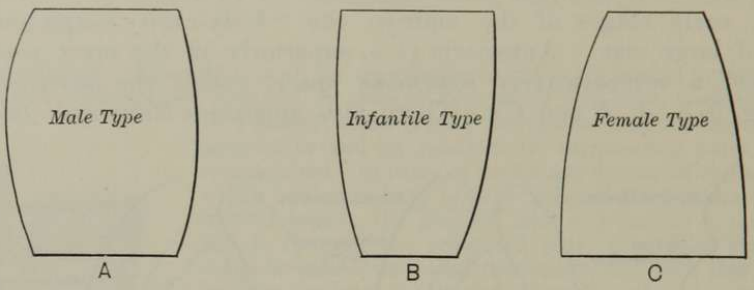

FIG. 574.—Schematic outlines of the abdomen.

flattened from before backward (Fig. 574, *A*, *B*, and *C*). The *infantile type* is conical with apex below, as the pelvis is undeveloped. In *woman* the type is a

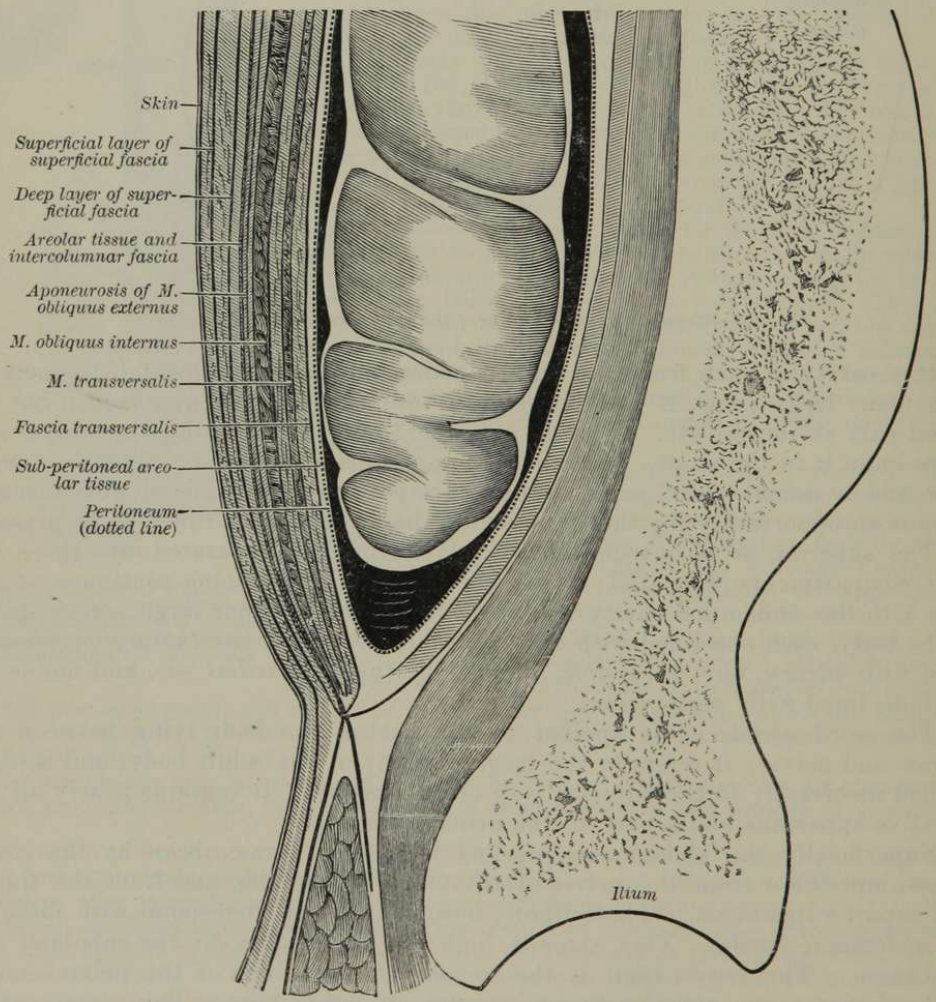

FIG. 575.—Antero-posterior vertical section through the outer third of Poupart's ligament, showing the layers of the abdominal walls. Schematic. (After Tillaux.)

reversed infantile, regardless of so-called civilized dress. The circumference of the fully-developed pelvis here is always larger than that of the lower end of the thorax.

Boundaries.—The *abdomen proper* is divided for description into the *abdominal wall* or *boundaries* and the *abdominal cavity* and *contents*. The boundaries are a *roof*, a *floor*, and the *wall*, which includes an *antero-lateral* and a *posterior* portion; the former is soft and contractile, muscular on the sides, fibrous and aponeurotic in the centre; the posterior wall is partly osseous, ligamentous and muscular.

Several facts depend on the character of the *antero-lateral wall*. It does not offer to the viscera and great vessels a passive protection as does the skull to its contents, but allows a mutual reaction which is of the greatest importance. It yields lightly to every pressure and corresponds to the changing volume of the intestines and to the changes of position and form of the viscera. Atmospheric pressure acts on every side, but this is overlooked when the many muscles are considered which exert a constant tension. The relations of each organ to its neighbor are modified by this tension, and soft organs like the liver, pancreas, or spleen are moulded by it and show the imprint of nearly every viscus that touches them. The tension is seen in cases of penetrating wounds, where the movable intestines tend to flow toward the spot of least resistance and are replaced or restrained with difficulty. The same pressure helps to develop herniæ and forces the portal circulation through the liver.

The *shape* of the soft antero-lateral wall depends upon the degree of distention of the alimentary canal, the size of the parenchymatous organs, and especially upon the deposit of fat in the subcutaneous tissue, in the peritoneal folds, and in the great omentum. All gradations occur between the great fat belly which depends over the thighs and the concave trough-like one of a thin person. The pliability and thinness of the wall allow palpation to be of more value here in diagnosis than percussion.

The component parts of the walls have already been discussed. A brief review is here added (Fig. 575).

In the antero-lateral wall from without inward are found in order:

1. Skin.
2. Superficial fascia, two layers.
3. Cellular tissue covering the External oblique muscle, and intercolumnar fascia from the external abdominal ring.
4. Muscles of the wall. Broad muscles—the External oblique and aponeurosis, the Internal oblique and aponeurosis, the Transversalis and aponeurosis. Longitudinal muscles—the Rectus and Pyramidalis.
5. Fascia transversalis.
6. Subperitoneal cellular tissue.
7. Peritoneum.

In this wall several regions are described: the inguinal, inguino-femoral, and umbilical.

The *arteries* of the antero-lateral wall are superficial and deep; the superficial epigastric and superficial circumflex-iliac from the femoral, the lower two intercostals from the thoracic aorta, the lumbar from the abdominal aorta, and ilio-lumbar from the internal iliac. Above are the superior epigastric and musculo-phrenic from the internal mammary—all forming the superficial set. Below are the deep circumflex-iliac and deep epigastric (inferior epigastric) from the external iliac. The latter is the most important and gives off the cremasteric artery, pubic and muscular branches. There is an anastomosis between the two lower epigastrics and between the deep epigastric and the internal mammary.

The *veins* are also divided into a superficial and deep set. Superficial are the superficial epigastric and superficial circumflex-iliac and another which passes subcutaneously along the side of the thorax, connecting above with the axillary vein and emptying below into either the superficial epigastric vein or into the femoral through the saphenous opening. It is dignified by the name *Vena thoracico-epigastrica longa tegumentosa* (Braune). The deep veins accompany their corresponding arteries and are usually double. The superficial veins do not

exactly correspond to their arteries, and are usually single. The superficial epigastric anastomoses with the deep epigastric, and both with the internal mammary.

Pressure upon the vena cava inferior forces blood into the superficial epigastric vein. A dilatation of the superficial abdominal veins to the size of the little finger (caput Medusæ) may thus be caused by cirrhosis of the liver. This is explained by the anastomosis between the superficial epigastric vein and the portal system: the superficial veins communicate with the deep epigastrics and these with the portal system by means of a little *vena parumbilicalis* running in the falciform ligament of the liver.

Depending upon the seat of obstruction, whether in the vena cava inferior or in the portal system, the course of the blood-stream in the dilated veins may be in one of two directions: toward the umbilicus in the former case, and from it in the latter.

The deep veins are the venæ comites of the deep epigastric and deep circumflex-iliac arteries. They communicate with the superficial set, the internal mammary, the portal system, and behind the sheath of the Rectus with a plexus in the parietal peritoneum.

The *superficial lymphatic* vessels above the umbilicus empty into the axillary glands, below the umbilicus into the inguinal glands. The *deep* lymphatics probably empty above into the sternal glands and below into the iliac glands.

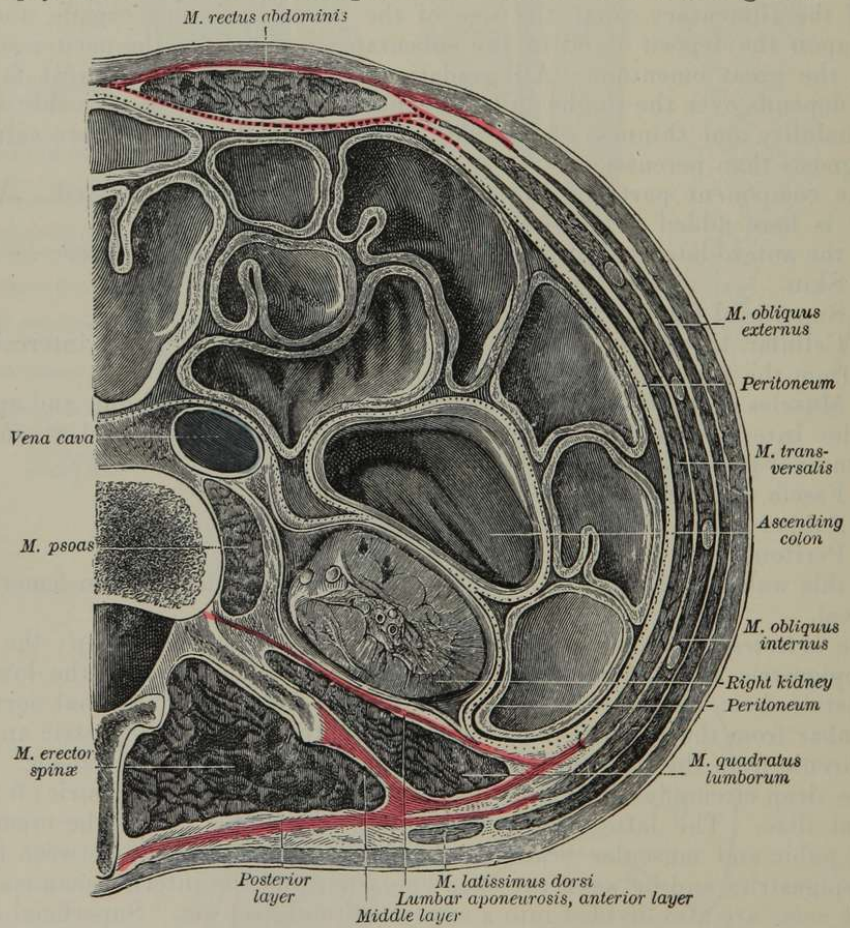

FIG. 576.—Horizontal section of the posterior abdominal wall through the second lumbar vertebra, right side. (Tillaux.)

The *nerves* supplying the whole musculature are the lower five intercostal, the anterior part of the first lumbar, viz. the ilio-hypogastric and ilio-inguinal. Twigs from the lower seven intercostal and from the ilio-hypogastric and ilio-inguinal furnish the sensory supply.

There may exist a congenital deformity in the anterior wall, a partial lack of development and an ununited symphysis pubis; with this the anterior wall of the bladder is lacking and its posterior wall, with ureters, exposed. This condition is called *exstrophy of the bladder.*

The *posterior wall* of the abdomen proper has no special line of demarcation from the antero-lateral wall; its vertical length is of much less extent than the latter (Fig. 576).

It is the part into which the skeleton enters, composed of the five lumbar vertebræ connected by ligaments and disks. Laterally are the Psoas and Quadratus lumborum muscles, and behind these the Sacro-spinalis mass (Erector spinæ muscle).

Through the lumbar region on either side of the vertebral column the following structures are met in order:

1. Skin.
2. Subcutaneous fascia and cellular tissue.
3. Lumbar aponeurosis, posterior layer.
4. Erector spinæ muscle.
5. Transverse process and lumbar aponeurosis, middle layer.
6. Quadratus lumborum muscle.
7. Lumbar aponeurosis, anterior layer.
8. Psoas muscle.
9. Visceral layer of kidney, cellular tissue, and colon.
10. Subperitoneal tissue and peritoneum.

This region presents the special districts, *lumbar* and *iliac*, already described. The *arteries*, *veins*, *nerves*, and *lymphatics* are all called *lumbar.*

The *roof* and *floor* of the abdomen are elsewhere described.

The *apertures* found in the walls of the abdomen for the transmission of structures to or from it are—the *umbilicus*, for the transmission (in the fœtus) of the umbilical vessels; the *caval opening* in the Diaphragm, for the transmission of the inferior vena cava; the *aortic opening*, for the passage of the aorta, vena azygos, and thoracic duct; and the *œsophageal opening*, for the œsophagus and pneumogastric nerves. *Below*, there are two apertures on each side, one for the passage of the femoral vessels, and the other for the transmission of the spermatic cord in the male and the round ligament in the female.

The Abdominal Cavity and Contents.

It must be carefully noted that there is a difference between the abdominal cavity proper and the peritoneal cavity. The peritoneum does not closely cover everywhere the abdominal walls, but is pushed in and out, leaving spaces and diverticula so that some organs will be extraperitoneal, others intraperitoneal, yet all will be inside the abdominal cavity.

Before studying the peritoneum it will be best to become more familiar with the names and location of the important viscera. This can be shown in a *topographical* way by dividing off the surface of the abdomen into districts and considering the chief organs lying in each.

Regions.

Many authors have devised many means for this subdivision, all of which consist in allowing two horizontal planes to cross two perpendicular ones; the edges of these planes are indicated by lines on the abdomen. An old way was to let the edge of one horizontal plane intersect the anterior extremities of the ninth ribs, and to let the lower plane pass through the highest points of the crests of the ilia. The perpendicular planes passed each one through the centre of Poupart's ligament.

The advantage of the following method (Joessel) is that all its planes pass through bony points and its two perpendicular planes through the brim of the

pelvis. Here the highest plane is *subcostal*, passing just under the lowest margin of the thorax in a line drawn through the cartilaginous ends of the *tenth ribs*. The lower plane is *interspinous* and passes through the anterior superior spines of the ilia (Fig. 577).

This marks off three *zones* or regions: 1. *Epigastric*. 2. *Mesogastric*. 3. *Hypogastric*. Each one is again subdivided into three parts by the two sagittal planes which pass through on either side the ileo-pectineal eminence and end on the horizontal line connecting the tenth ribs (Fig. 578).

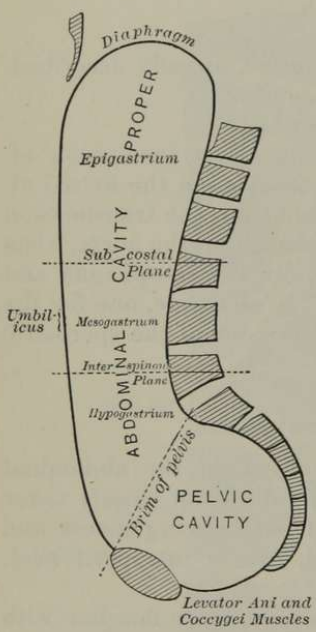

FIG. 577.—Outline of the abdominal cavity as seen in mesial section. The planes of subdivision are indicated by dotted lines. (Cunningham.)

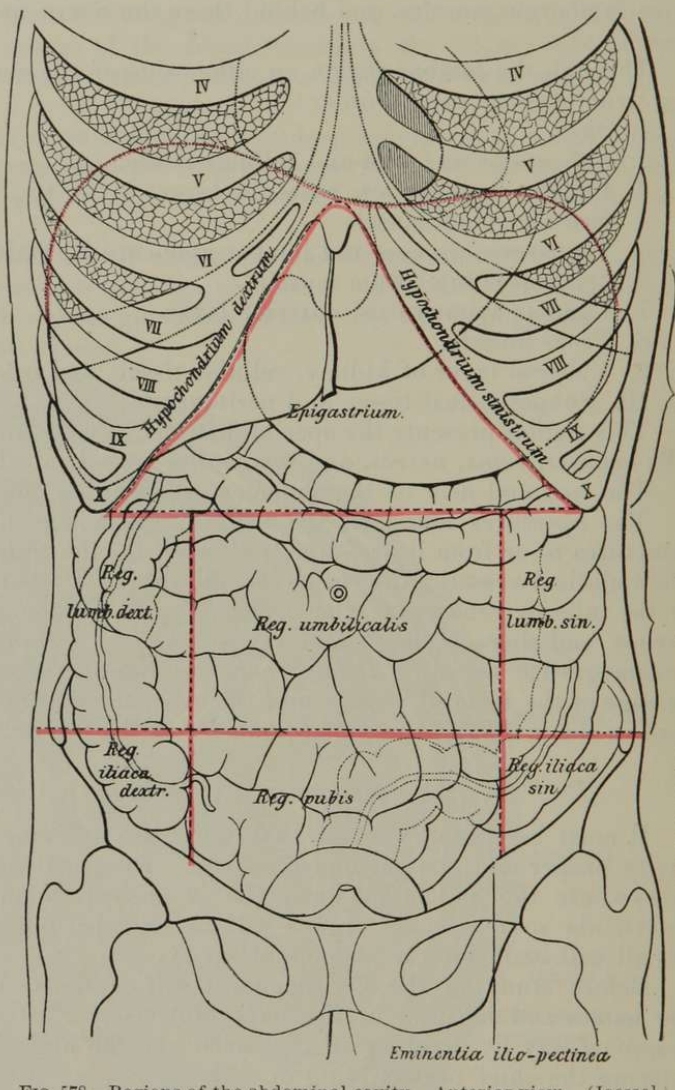

FIG. 578.—Regions of the abdominal cavity. Anterior view. (Joessel.)

The *epigastric zone* contains, in order, the *right hypochondrium* (ὑπό, under; χόνδροι, cartilages), *epigastrium* (ἐπί, upon; γαστήρ, stomach) and the *left hypochondrium*. The *mesogastric zone* contains the *right lumbar*, the *umbilical*, and the *left lumbar regions* (the lateral regions may be called lateral abdominal). The *hypogastric zone* contains the *right iliac*, the *pubic*, and *left iliac* regions. Sometimes the *iliac* regions are called inguinal; then a *subinguinal* region is distinguished below Poupart's ligament.

The limits of the *epigastric zone* are the diaphragm above and below the horizontal plane through the anterior ends of the tenth ribs. The lateral and posterior limits follow the eleventh and twelfth ribs to end with the last on the

spinal column. The epigastric surface of this region is triangular, placed between the costal arches and horizontal line below. The transverse colon corresponds to this horizontal line. Somewhat higher, opposite the ninth rib, is the greater curvature of the stomach in moderate distention. In the middle of the epigastrium farthest above is a depression called the *gastric* or *cardiac fossa* (scrobiculus cordis); corresponding to this place is the liver and pyloric end of stomach.

The *hypochondriac regions* include the spaces between the diaphragm superiorly, posteriorly, and externally, the costal cartilages internally, and the horizontal plane below. The right one is filled by the liver. The left one contains the spleen, the splenic flexure of the colon, the greater part of the stomach, and after distention of the stomach a large part of the great omentum.

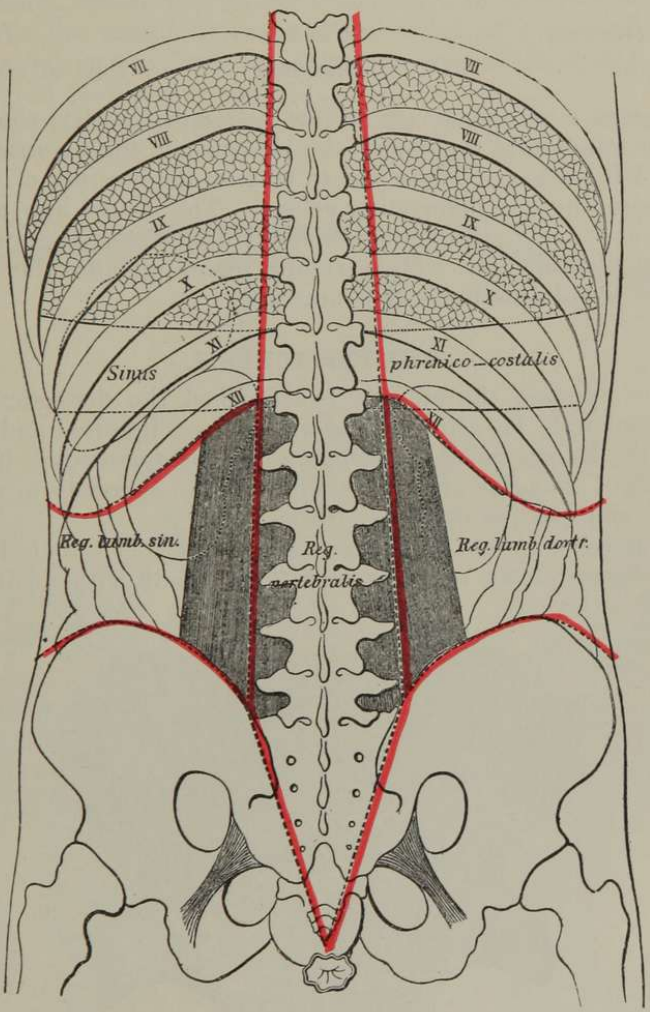

FIG. 579.—Regions of the abdominal cavity. Posterior view. (Joessel.)

The *mesogastric zone* is bounded above by the epigastric zone and below by the horizontal plane passing through the anterior superior spines of the ilia. Laterally and behind are the crests of the ilia. In the umbilical region lie the great omentum, the loops of small intestine, and their mesentery. In the *lumbar regions*, which extend from the perpendicular lines drawn through the ileo-pectineal eminences around to the vertebral column, are also small intestines, the kidneys, the ascending and descending colons.

The *hypogastric zone* is bounded above by the mesogastric and below by the brim of the true pelvis. The *pubic region* in the centre contains the bladder, the right iliac, the cæcum, and the left iliac, a part of the sigmoid flexure.

To recapitulate:

Right Hypochondrium.	*Epigastrium.*	*Left Hypochondrium.*
Liver.	Liver. Stomach.	Greater part of stomach. Spleen. Splenic flexure of colon. Great omentum.
Right Lumbar.	*Umbilical Region.*	*Left Lumbar.*
Right kidney. Small intestines. Ascending colon.	Great omentum. Small intestines. Mesentery.	Left kidney. Small intestines. Descending colon.
Right Iliac.	*Pubic.*	*Left Iliac.*
Cæcum.	Bladder.	Part of sigmoid flexure.

Fig. 579 gives a posterior view of the abdominal cavity, showing a *vertebral region* and the two lateral regions of the mesogastric zone continued posteriorly, the right and left lumbar. There are to be seen the outlines of the kidneys, the spleen, the ascending and descending colons. The dotted line meeting the vertebral column at the eleventh rib is the lower lung limit; the line at the twelfth rib is the lower pleural limit. The vertebral region includes the vertebral column and part of the Quadratus lumborum muscles.

THE PERITONEUM.

Let us now suppose the student has finished the dissection of the anterolateral abdominal wall, has studied the anatomy of inguinal and femoral hernia, the sheath of the Rectus muscle, and has seen the *adminiculum lineæ albæ*. The semilunar folds of Douglas are before him, and he is ready to incise the transversalis fascia and the parietal peritoneum.

The Recti muscles should have been cut transversely a little below the umbilicus and both turned down together from their sheath without dividing the linea alba.

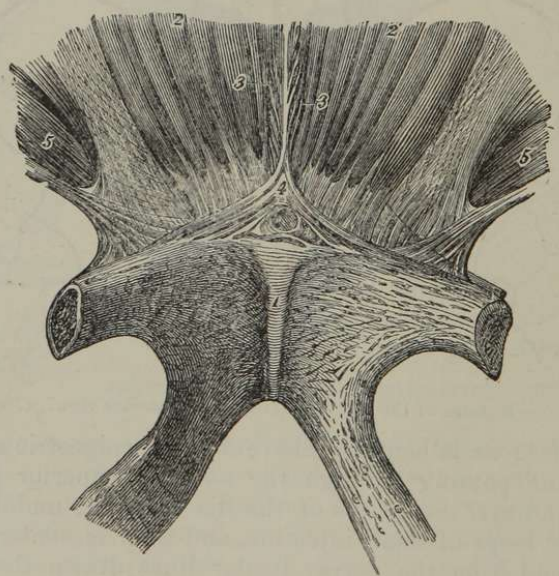

Fig. 580.—Posterior view of the Recti abdominis muscles. (Luschka.)

Behind the Recti on the lower and posterior part of the linea alba is a triangular band of fibrous tissue called *adminiculum lineæ albæ* (adminiculum, "prop on which a vine grows") (Fig. 580, 4). It passes up 4 or 5 cm. to strengthen the

white line, its apex being above and its base below. It rises from the crests of the pubic bones and arches over the upper edge of the symphysis pubis. This should not be mistaken for the urachus which lies behind it, separated by the transversalis fascia; both are outside the peritoneum.

Now open the peritoneal cavity. Do *not* make a median incision from the ensiform cartilage to the symphysis pubis. Start at the umbilicus and make two oblique cuts from it, one to each Poupart's ligament near the anterior superior spine of the ilium; make one more from the umbilicus to the ensiform cartilage. Make a transverse cut on either side when more room is desired. To the right of the upper incision will be seen a round cord passing from the umbilicus to the under surface of the liver and enclosed in a double layer of serous tissue. The latter is peritoneum, called the broad, suspensory, or *falciform ligament* of the liver; the cord is the *round ligament* of the liver, or a part of the *obliterated umbilical vein*, which in the fœtal state carried arterial blood from the placenta to the liver first and thence over the body.

Turn down the lower triangular flap and the view presented is shown in Fig. 581. Three distinct bands or cords are seen passing from below upward toward

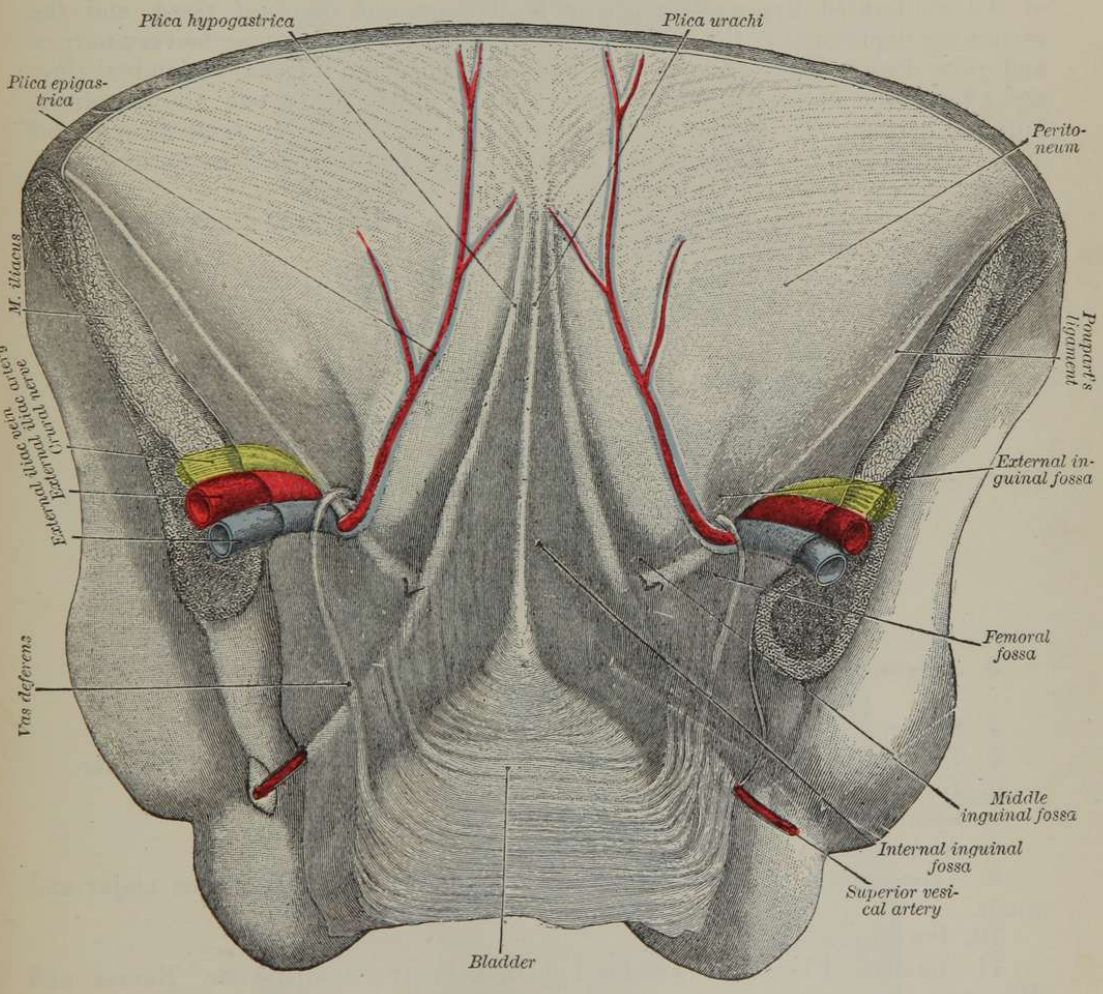

FIG. 581.—Posterior view of the anterior abdominal wall in its lower half. The peritoneum is in place, and the various cords are shining through. (After Joessel.)

the umbilicus. They are all fœtal structures. The middle one is the *urachus*, the remnant of the stalk of the allantois; it may remain pervious. The two lateral ones are the *obliterated hypogastric arteries* which conveyed venous blood

from the fœtus to the placenta for oxygenation which was returned, as we have seen, by the umbilical vein. The younger the subject under dissection, the bigger are these two cords. Near the umbilicus they subdivide into numerous threads which in part join the urachus, in part run free toward the umbilicus, and only the smallest part reaches it. The proximal part of this artery is still pervious after birth as far as the bladder under the name of superior vesical.

To either side of the three cords is seen the deep epigastric artery passing in behind the Rectus at the semilunar fold of Douglas. These five bands are covered posteriorly by peritoneum, which is thrown backward in five folds or ridges (*plica*, fold) forming in all six fossæ, or three to a side. Sometimes the obliterated hypogastric artery is identical in position with the deep epigastric, in which case folds and fossæ are less in number. The middle fold is called *plica umbilicalis media* or superior ligament of the bladder; the next on either side the *plica umbilicalis lateralis*, or lateral ligament of the bladder; the fold over the deep epigastric artery is the *plica epigastrica*. The simplest nomenclature is *plica urachi*, *plica hypogastrica*, *plica epigastrica*. The fossæ included between these folds are named—the most external, outside the epigastric artery and above Poupart's ligament, the *external inguinal fossa;* between the urachus and the cord of the obliterated hypogastric artery is the *internal inguinal fossa*, and the remaining depression is the *middle inguinal fossa*. This one may be very narrow and quite deep. The external fossa has on its floor the internal abdominal ring, and admits the oblique inguinal hernia; either of the other two allows a direct inguinal hernia. To the inner side of the femoral vein is the *femoral* or *crural fossa*, the site of femoral hernia. All the above points should be noticed when the abdomen is opened.

The structures now presented for study, more or less preliminary at first and in detail later, are here presented.

1. Peritoneum which lines the cavity and clothes the viscera.
2. Abdominal part of alimentary canal:

Small Intestine { Duodenum. Jejunum. Ileum.

Large Intestine { Cæcum. Ascending colon. Transverse colon. Descending colon. Sigmoid Flexure. Rectum.

3. Accessory Glands { Liver. Gall-bladder. Pancreas.
4. Spleen.
5. Two Kidneys, Ureters, Adrenals or Suprarenal Capsules, and Bladder.
6. *In female*, Uterus, Ovaries, and Fallopian Tubes.
7. Lymphatic Glands, Vessels, and beginning of Thoracic Duct.
8. Abdominal Aorta and nine sets of branches.
9. Vena cava inferior and tributaries; beginning of Vena azygos major and minor.
10. Portal venous system.
11. Lumbar Plexus of cerebro-spinal nerves; Sympathetic Nerves and Plexuses.

We get but a partial view of all when the viscera are undisturbed (Fig. 584). Like a curtain the *great omentum* conceals most of the small intestines, but it may be short or turned up or to one side. The parts to be seen are indicated in the diagram. To find the *transverse colon*, throw the great omentum and stomach well up over the ribs; now the whole colon can be traced, beginning in the

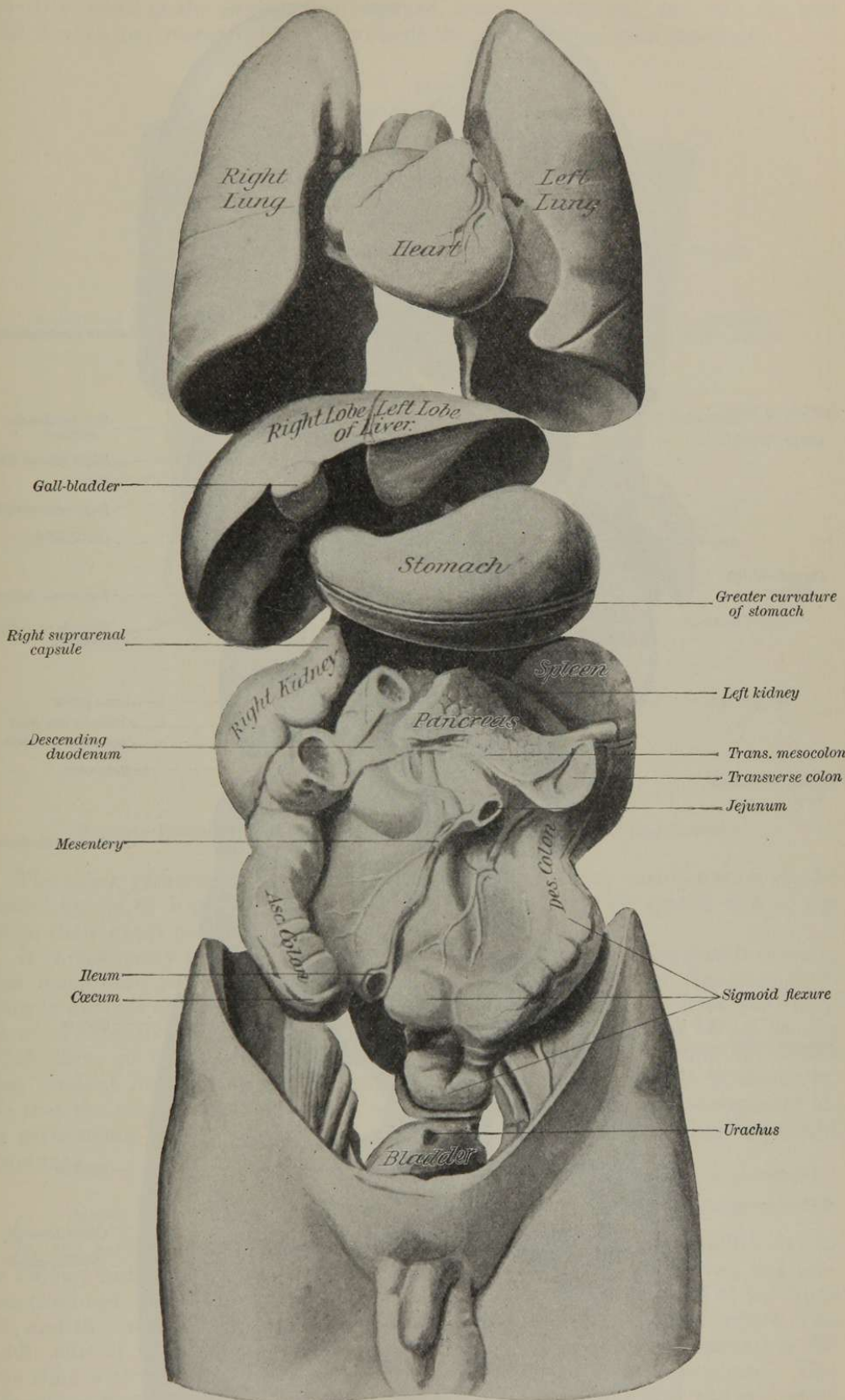

FIG. 582.—Anterior view of His' models of the abdominal contents. Drawn from photographs.

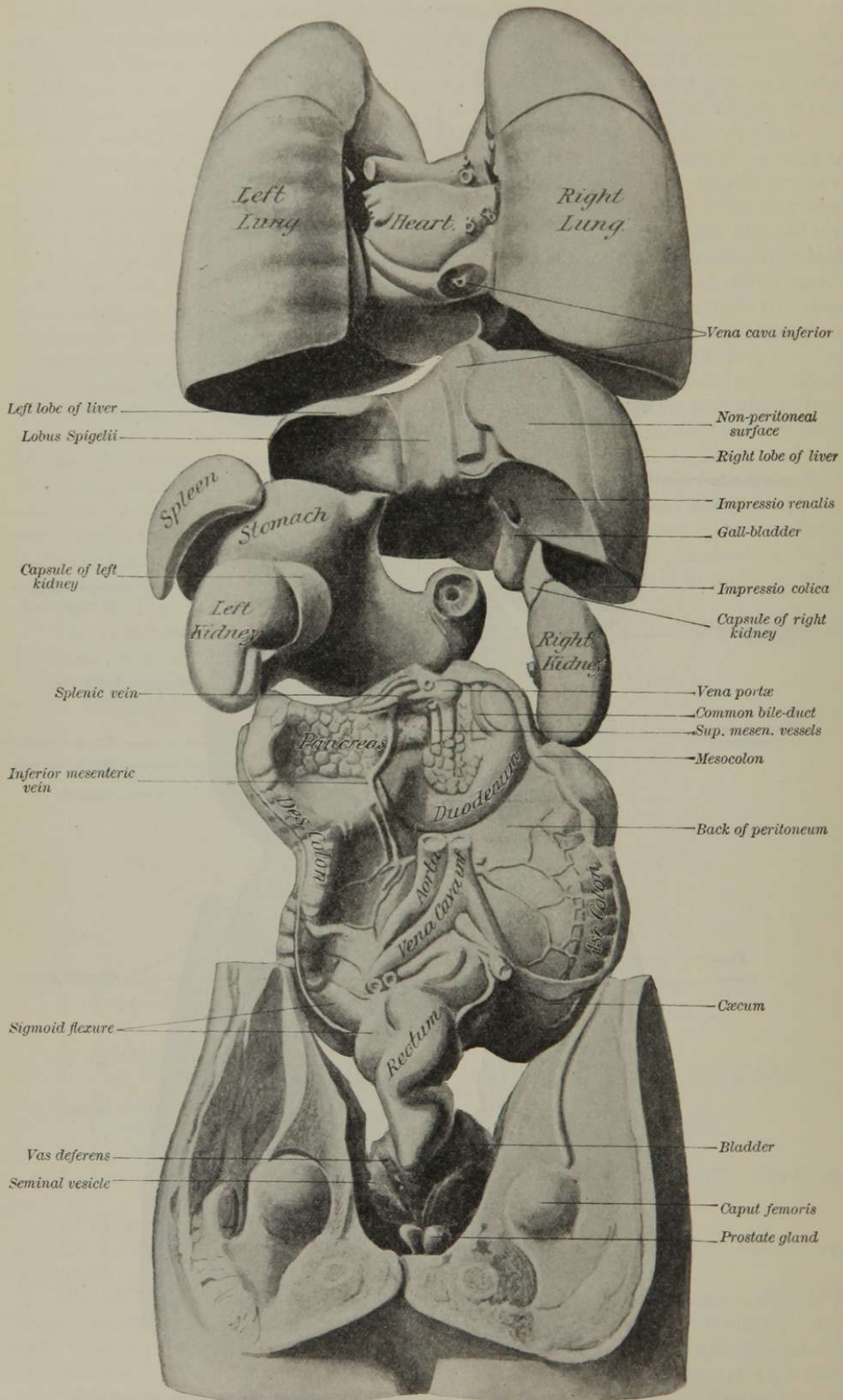

FIG. 583.—Posterior view of His' models. Drawn from photographs.

right iliac fossa at the *cæcum*, then upward, across, downward, and into the sigmoid flexure and rectum. This surrounds the coils of the small intestines.

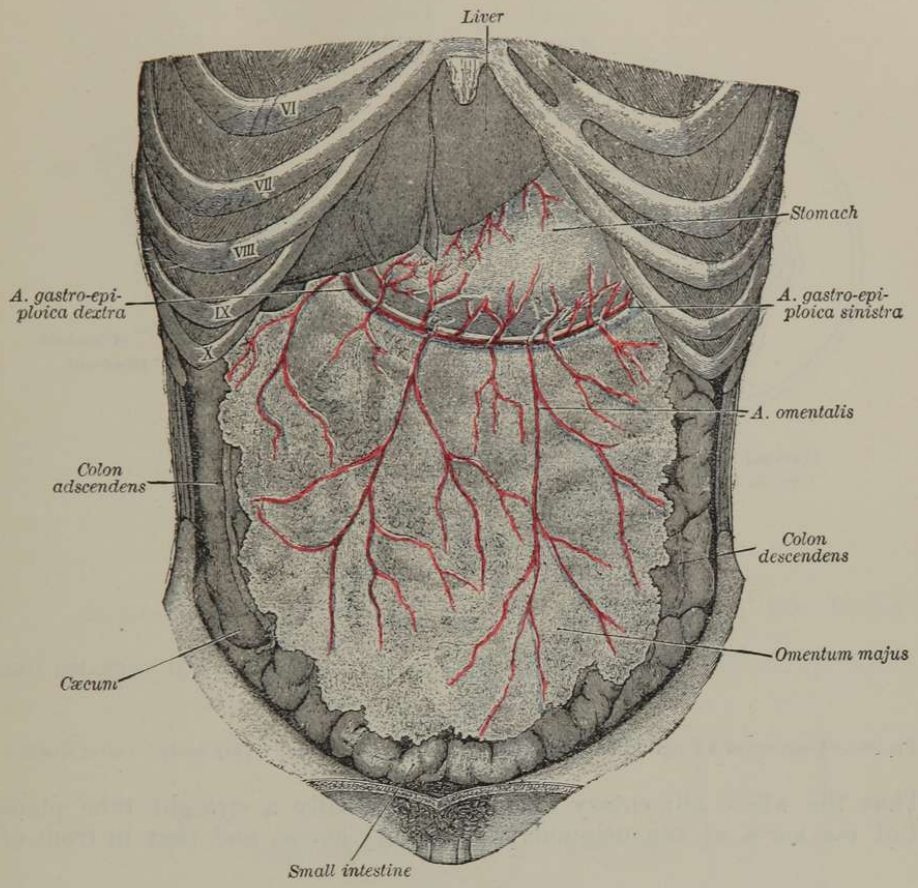

FIG. 584.—Position of abdominal organs in a state of moderate distention. (Joessel.)

The other structures not evident without dissection or manipulation can be located by aid of Figs. 582, 583. The organs there are all spaced and so are not in their exact positions.

It is customary to study the peritoneum before taking up the separate viscera. This membrane has quite a reputation. Whenever in Human Anatomy anything is difficult or obscure, one should leave the complex adult form and study the more primitive simple type of the embryo or new-born; if that be not wholly satisfactory, go to the lower animals (Comparative Anatomy), while the ambitious student investigates even fossil animals (Palæontology). It is meant by this that the medical student should first study something of the development of the peritoneum before opening the abdominal cavity and destroying important structures.

Some Essential Facts in the Development of the Peritoneum.

In the early development of the alimentary canal, before the twelfth day in the human embryo, all three germ-layers push forward, are folded over, and produce the head and the anterior part of the *fore-gut*. This is blind at the front end, and the *mouth* is developed later by an invagination from the exterior. The middle part of the future alimentary tract, *mid-gut*, is in free communication for some time with the blastodermic vesicle which is later called the *yolk-sac*. The approximation of the body-walls at the umbilicus gradually pinches the *yolk-stalk* off into the *vitelline duct*, so the sac finally lies wholly outside the body of the

embryo and that part of it enclosed within is the *pleuro-peritoneal cavity* (Fig. 585). Finally, at the caudal end a *hind-gut* is formed and an *anus* added by a process of invagination.

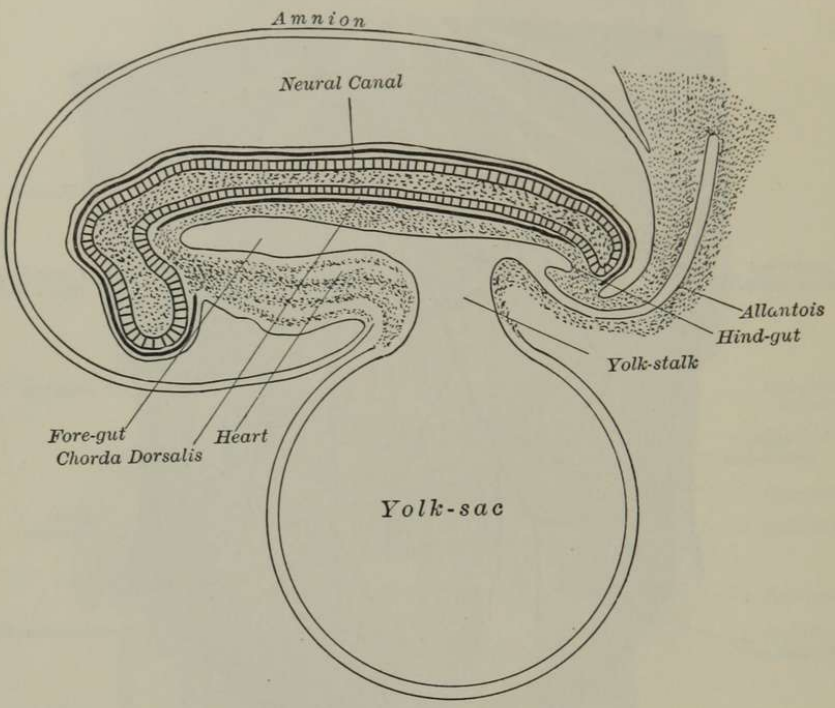

FIG. 585.—Diagram of a longitudinal section of a mammalian embryo. Very early. (After Quain.)

Thus the whole alimentary canal was originally a straight tube placed in front of the aorta, or the original two primary aortæ, and that in front of the

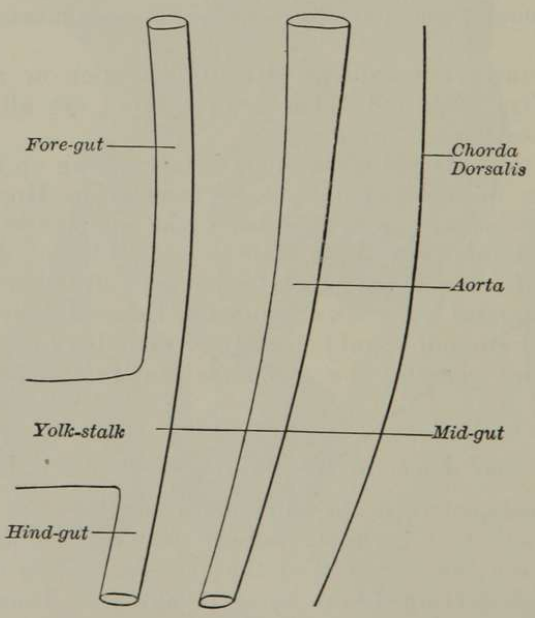

FIG. 586.—Schematic median section of a human embryo. (After Dexter.)

future vertebral column, the *chorda dorsalis* (Fig. 586). Along its middle region, the anterior wall is lacking as it opens here into the yolk-sac.

The fore-gut contracts to form the *œsophagus*, which is very short (Fig. 587). This gradually widens into a spindle-like dilatation indicating the *stomach*. The

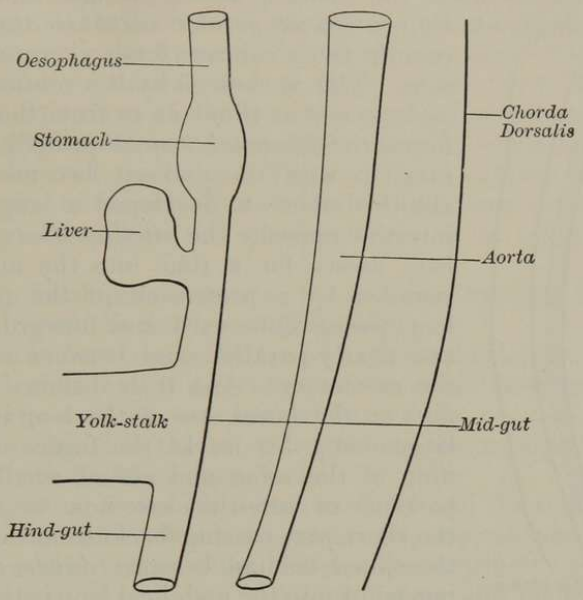

FIG. 587.—Schematic median section of a human embryo of fourth week. (After Dexter.)

small intestine is short and straight with a wide opening into the yolk-sac. Just

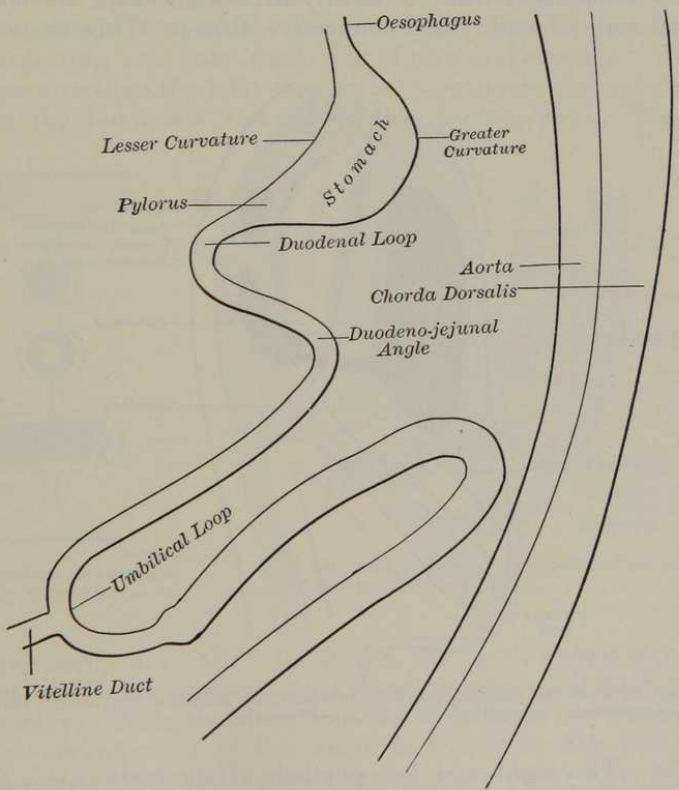

FIG. 588.—Schematic median section of a human embryo of fifth or sixth week. (After Dexter.)

below the stomach, the liver is budding out from the duodenum. This stage is attained in the fourth week in the human embryo. There are now five successive

districts in the whole canal, *mouth*, *throat* and *visceral clefts*, *œsophagus*, spindle-shaped *stomach*, and the remaining *tube* connected with the yolk-sac.

By the fifth or sixth week, the *stomach*, at first straight and parallel with the axis of the body, begins to show a convex *greater curvature* toward the vertebral column and a concave *lesser curvature* on the opposite side. This is covered by the voluminous liver. The *pyloric end* is tilted away from the column and this forms the *duodenal loop* (Fig. 588). As the communication with the yolk-sac becomes constricted and absorbed there is developed a long *umbilical loop* of intestine opposite the *vitelline duct*. The end of this loop passes for a time into the umbilical cord surrounded by a protrusion of the peritoneum. This loop passes downward and forward, and consists of two nearly parallel arms between which is stretched the mesentery. At a little distance from the vitelline duct on the lower arm of the loop is seen a small enlargement; this marks the future *cœcum* and beginning of the *colon* and end of small intestine. Five portions of intestine are now to be distinguished: the short part passing back from the stomach toward the spinal column becomes *duodenum;* at the turning-point into the umbilical loop is the *duodeno-jejunal junction;* the anterior descending arm and bend of the loop become *small intestine;* most of the ascending posterior arm becomes *colon*, and the terminal part, *sigmoid flexure* and *rectum*.

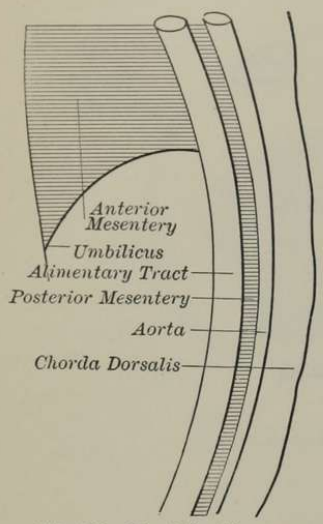

FIG. 589.—Fig. 586 with mesenteries added. (Dexter.)

At first the alimentary tract is mostly in contact with the chorda dorsalis held by a broad mass of embryonal connective tissue. This tissue contains two

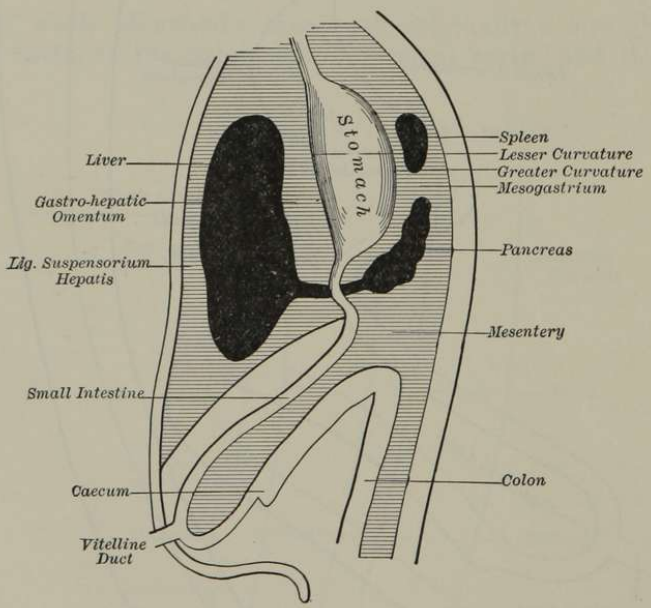

FIG. 590.—Diagram to show the original positions of the liver, stomach, duodenum, pancreas and spleen, and the mesenteries connected. A longitudinal section. (Hertwig.)

primitive aortæ. The right and left portions of the body-cavity approach each other and compress this tissue into a *mesentery*, which is attached to the whole length of the tube beginning with the stomach, connecting it with the chorda. The special part of this membrane attached to the stomach posteriorly is called *mesogastrium*, that to the small intestine is called *mesentery* (*medium intestinum*

or μέσον ἔντερον, middle intestine); that to the colon, the *mesocolon;* that to the sigmoid flexure, the *mesosigmoidea* or *sigmoid mesocolon;* and that to the rectum, the *mesorectum.* This has not been represented in the above figures for the sake of simplicity. There is also a *ventral mesentery*, but not of such extent as the dorsal. It extends along the front of the alimentary canal from the throat to the lower end of the duodenum and in front as far down as the umbilicus (Fig. 589). It almost makes the body-cavity a paired structure. In the upper part of this mesentery is developed the heart, the part enclosing it being called *mesocardium anterius* and *posterius.* The lower part extends from the stomach and duodenum to the anterior wall and has many names—*ventral gastric and duodenal mesentery*, *liver-ridge* and *prohepaticus;* it is never called anterior mesogastrium.

The *liver* is here developed anterior to the stomach, budding from the anterior part of the beginning of the duodenum (Fig. 590).

The *pancreas* buds from the posterior part of the duodenum, vertical at first and covered on both sides by the mesentery of the small intestine; it passes into the mesogastrium later and becomes transverse.

The *spleen* is developed in the second month in the mesogastrium and is not connected directly with the alimentary canal.

At this stage, passing from before backward, we find the structures arranged: anteriorly, liver; in the centre, stomach; posteriorly, spleen and pancreas. The anterior mesentery in front of the liver becomes the suspensory or *falciform ligament* of the liver, extending to the umbilicus below and embracing the intra-abdominal part of the umbilical vein. The anterior mesentery between the liver and stomach becomes the *lesser omentum* or *lig. hepato-gastro-duodenale.* The mesogastrium between stomach and spleen becomes *gastro-splenic omentum*, and that part between the spleen and vertebral column forms the *great omentum.*

Fig. 591 is a cross-section of the same embryo. Anteriorly are the two sacs of the liver projecting one into each side of the body-cavity. The right sac grows to a larger size than the left; they form respectively the right and left lobes. Behind these is the duodenum and behind that the pancreas. The intervening

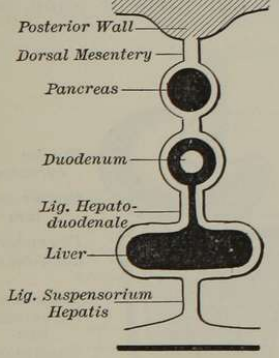

Fig. 591.—Cross section in duodenal region to show same structures as in Fig. 590. (Hertwig.)

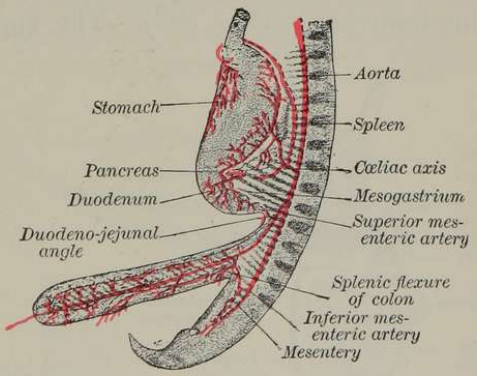

Fig. 592.—Schematic representation of the mesentery in a six-weeks' human embryo. (Toldt.)

parts of the mesentery are called ligaments, viz. first, *suspensory ligament* of liver, next *hepato-duodenal ligament*, next *duodeno-pancreatic ligament*, and lastly the dorsal mesentery. Note that pancreas and duodenum are wholly enclosed.

The *vascular arrangement* of this stage is shown in Fig. 592. The *cœliac axis*, the *superior mesenteric* and *inferior mesenteric arteries* have their points of supply definitely marked out even in the sixth week. They pass from the aorta between the two layers of the mesogastrium and mesentery to their destinations, which never change. The cœliac axis goes to the stomach, spleen, pancreas, liver and part of duodenum; the superior mesenteric, to part of duodenum, the

small intestines, and part of colon; the inferior mesenteric, to the remainder of the tube.

The length of the intestine continually increases, and it becomes more bent and tortuous, till from the third month on there occur two important changes, one

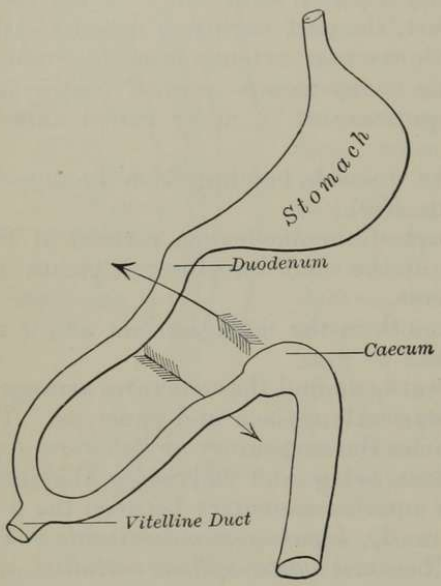

FIG. 593.—Torsion of the umbilical loop. Initial position. (Jonnesco.)

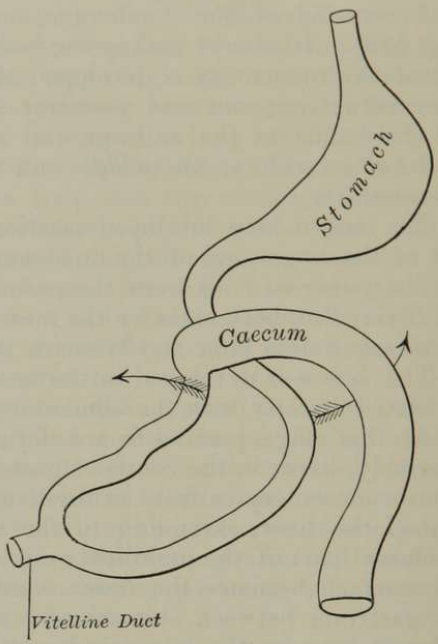

FIG. 594.—Torsion of the umbilical loop. Acquired position. (Jonnesco.)

in regard to a twist of the intestinal loop and one in regard to a change in position of the stomach. The ascending and descending arms of the umbilical loop have been lying side by side one above the other; now the lower arm, which becomes cæcum and colon, begins to pass over the upper arm and crosses the small intestine transversely (Fig. 593). The upper arm moves but little or none, as it

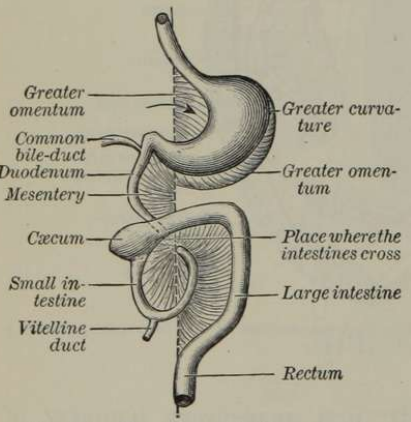

FIG. 595.—Development of human alimentary canal and mesentery. Earlier stage. (Hertwig.)

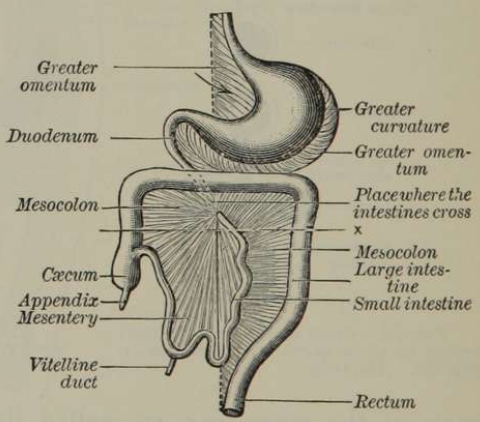

FIG. 596.—Development of human alimentary canal and mesentery. Later stage. (Hertwig.)

is already fixed to the vertebral column at its upper duodeno-jejunal end, perhaps by the muscle of Treitz.

The cæcum, which has already developed an appendix, is thus landed wholly on the right side of the body up under the liver (Figs. 594 and 596). At first there is no ascending colon, the transverse colon running across the duodenum inferior to the stomach and up to the spleen, making a splenic flexure; it passes through

the left lumbar region and is continued into the sigmoid flexure and rectum. The cæcum increases in length and, finding least resistance below, finally settles into the right iliac fossa, dragging down a short ascending colon.

The mesentery, seen in the loop of Fig. 592, makes a half rotation as does the loop, and its anterior surface becomes posterior, as may be inferred from Figs. 595 and 596.

Fig. 597 shows the arterial supply after the twist of the umbilical loop, with the cœliac axis behind the stomach, the superior mesenteric artery fastening the duodenum between itself and the aorta, and the inferior mesenteric coming off below.

During this period of intestinal torsion, the stomach has suffered a double change. First the stomach twists around an antero-posterior axis, so its cardiac or œsophageal end moves to the left and downward, while its pyloric end moves a little to the right and upward; and its vertical position becomes more transverse.

Secondly, its long axis having been parallel to the vertebral column, it originally presented a right and left surface, supplied respectively by the right and left vagus nerves. It now falls over so that its right side becomes posterior and its left side anterior, and the greater curvature becomes more inferior, and the lesser curvature more superior. The vagus nerves still supply the same surfaces, which have changed their positions: the right nerve now goes to the posterior surface and the left one to the anterior surface.

The lower end of the œsophagus also experiences the same torsion.

The *mesogastrium* is modified by this rotation to the right. In the anterior mesentery is the liver (Fig. 590), but in the adult we find it shifted to the right side of the body. The spleen was posterior to the stomach; in the adult it is to its left. So these three antero-posterior organs have become laterally placed, and from right to left are hereafter found: liver, stomach, spleen.

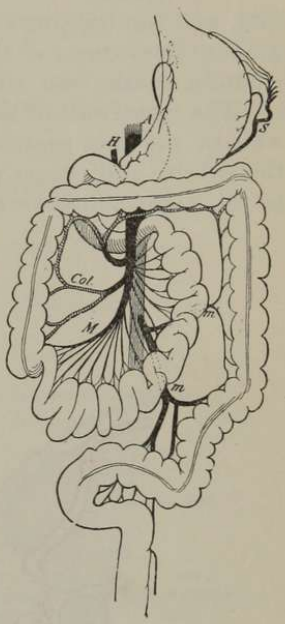

FIG. 597.—Final disposition of the intestines and their vascular relations. *A.* Aorta. *H.* Hepatic artery. *S.* Splenic artery. *M, Col.* Branches of superior mesenteric artery. *m, m'.* Branches of inferior mesenteric artery. (Jonnesco.)

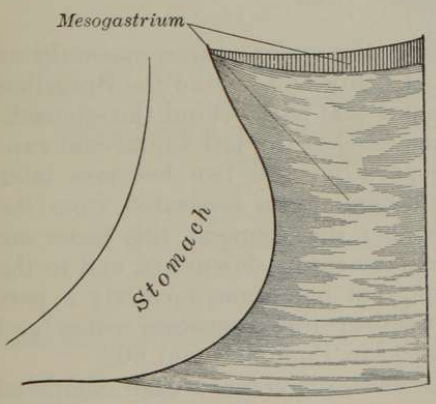

FIG. 598.—Wood and cloth to illustrate stomach and mesogastrium of two layers viewed from the side. (G. S. H.)

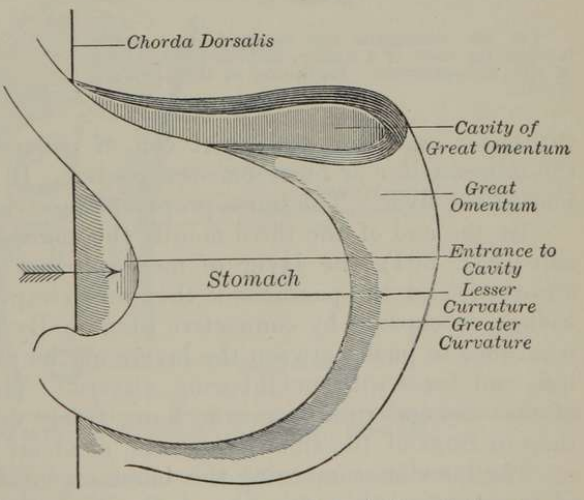

FIG. 599.—Stomach turned to right enclosing a space behind it, representing the great omentum and its cavity viewed from the front. (G. S. H.)

Again connected with this torsion of the stomach is associated the formation of the *great omentum*. To illustrate this, carve a piece of wood to represent the

stomach; let two layers of cloth attached to the posterior border represent the mesogastrium attached to the vertebral column (Fig. 598). This was the original condition (Fig. 592). Now turn the stomach to the right, allowing the cloth to fall loosely to the left, and immediately a cavity is formed included between two layers of cloth anteriorly and two layers posteriorly (Fig. 599). In the embryo a similar cavity is formed called the *cavity of the great omentum*, the *lesser sac of peritoneum*, *bursa omentalis;* and a similar fold of four layers is formed called the *great omentum* which in the embryo and infant contains this cavity.

The entrance to this cavity is indicated by the arrow in Figs. 595, 596, and 599, and the bulging of the great omentum is seen to the left of and below the greater curvature of the stomach. Compare the above with Fig. 600, and the position of the sac will be better understood.

The front wall of the bursa omentalis is formed by the stomach; the posterior wall by the mesogastrium, which at first completely invests the pancreas, touches the spleen, and covers part of the left suprarenal capsule. The opening is turned to the right and covered anteriorly by the lesser omentum. The space between

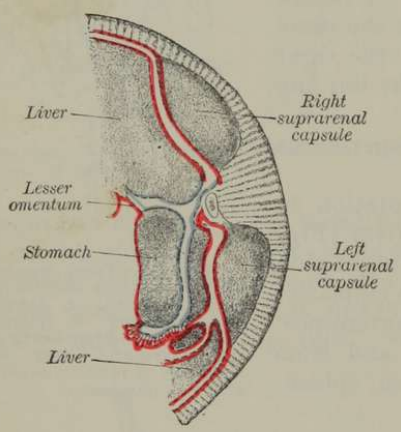

FIG. 600.—Schematic and enlarged cross section through the body of a human embryo in the region of the mesogastrium. Beginning of third month. (Toldt.)

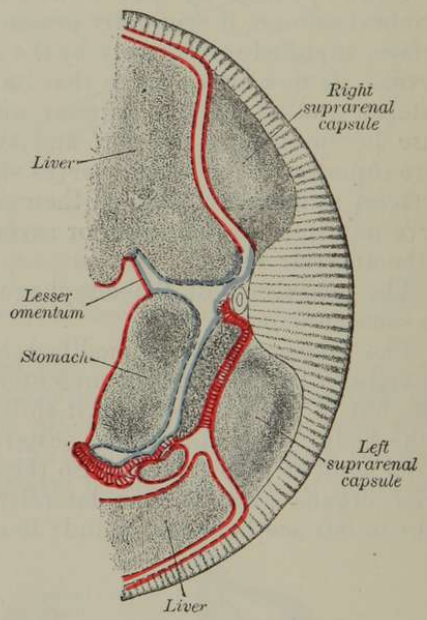

FIG. 601.—Same section as in Fig. 600, at end of third month. (Toldt.)

the lesser omentum and right end of pancreas is the *atrium bursæ omentalis* or the *antechamber* or *lesser omental pocket.* It lies below and behind the Spigelian lobe of the liver. The bursa proper, or lesser sac, is that part behind the stomach.

By the end of the third month the pancreas touches the left suprarenal capsule (Fig. 601), the layer of mesogastrium separating the two becomes later absorbed, and the pancreas is then an extraperitoneal organ separated from the kidney or capsule by connective tissue. By further development this lesser sac continues to push between the layers of the great omentum downward and to the left, and fuses with neighboring viscera. The great omentum, formerly a part of the mesogastrium, comes to hang freely down over the transverse colon and then in front of the small intestines, as about to do in Figs. 596 and 602.

The lamellæ composing the bursa omentalis or lesser sac are each composed of two layers; they are placed close together and are continuous below (Figs. 602 and 603). The more anterior one is attached to the greater curvature of the stomach and the posterior one lying on the intestines was originally attached to the vertebral column and enclosed most of the pancreas (Figs. 600 and 602). In many mammals no further change occurs. In man fusions follow: the pos-

terior lamella covers a large part of the posterior abominal wall, and its original line of vertebral attachment gets displaced to the left; it joins the diaphragm and forms the *lig. phreno-lienale*, suspensory ligament of the spleen. Below it becomes fused to the upper layer of the transverse mesocolon and to the transverse colon (Fig. 603). These two contiguous layers, *i. e.* the posterior layer of the mesogastrium and the upper layer of the transverse mesocolon, may present a fissure at birth in many mammals. During early infancy in the human species they form a single lamella with a deposit of fat (Fig. 603). In adult life no trace of the extra layer is seen.

There are then three types of relation of the posterior layer of the great omentum to the transverse mesocolon: *fœtal*, where they are separate (Fig. 602); *infantile*, where they are fused into one layer (Fig. 603); and *adult*, where all trace of this layer has disappeared and the posterior lamella of the great omentum seems to enclose the transverse colon (Fig. 606).

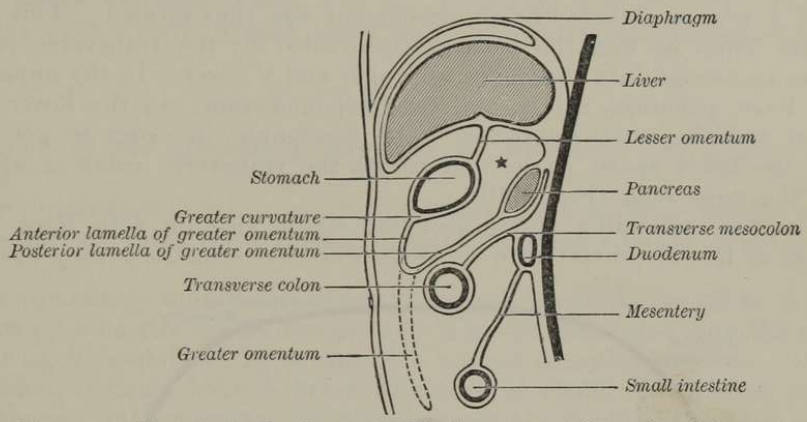

FIG. 602.—Diagram to illustrate the development of the bursa omentalis, cavity of the great omentum or lesser sac. Fœtal stage. *. Lesser sac. (Hertwig.)

The lesser sac of peritoneum (bursa omentalis) is still continuous with the greater sac or general peritoneal cavity, something like the two cavities of an hour-glass, only the upper cavity (lesser sac) is comparatively small and bent down behind the other. In Fig. 603 the cavity behind the stomach is connected

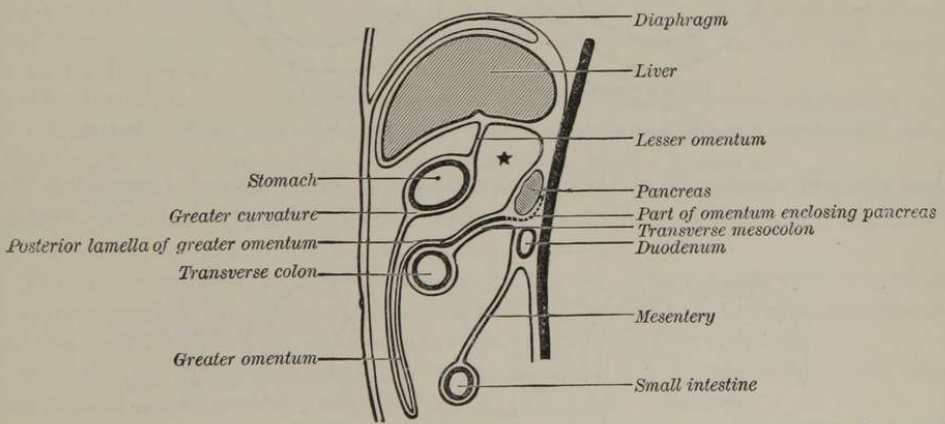

FIG. 603.—Development of bursa omentalis. Infantile stage. Great omentum covers the intestines and has fused with the transverse mesocolon. Pancreas is free of peritoneum posteriorly. (Hertwig.)

with the larger cavity in front of it by means of a foramen to the right of the lesser omentum. It is the *foramen of Winslow*, and is to be found just under the hilus (the black spot on a bean) of the liver to the right side of the neck of the gall-bladder.

After childhood the cavity of the lesser sac descending into the great omentum is obliterated and the four layers are fused into an *omental plate*.

Mesentery of the Small Intestine and Colon.

The mesentery is influenced by the increase in length of the small intestine. It becomes fan-shaped, and its length at its insertion into the intestine is many times that of its origin from the lumbar vertebræ; so it lies in folds and is called a *frill*. In man after the fourth month, this becomes more complicated by fusions with the posterior body-wall or neighboring viscera. It affects especially the mesentery of the duodenum and colon.

The duodenum at first is completely invested with peritoneum (Fig. 595); later other viscera growing faster are thought to pull it away and appropriate it, and so posteriorly it comes to lie on the posterior wall of the body and becomes an immovable organ (Fig. 603).

The large intestine possesses a suspensorium attached to the vertebral column and designated the *mesocolon*. When the twist of the umbilical loop occurred, the transverse colon and its mesocolon were drawn transversely across the duodenum, and a new secondary line of attachment was thus formed. This explains why in the adult we find the body-cavity divided by the transverse colon and transverse mesocolon into chambers, an upper and a lower. In the upper are the stomach, liver, pancreas, spleen and part of duodenum; in the lower, part of duodenum and the small intestines. The duodenum, in order to get from the upper to the lower space, passes underneath the transverse colon or apparently through the mesocolon (Fig. 596).

The cæcum, ascending and descending colon, also lie with their posterior walls more or less in contact with the body-wall, but sometimes they have a more

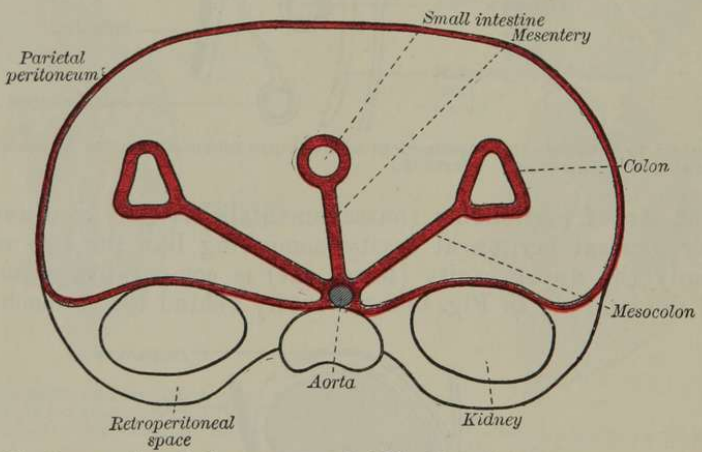

FIG. 604.—Cross section of alimentary canal of Fig. 596 to show mesenteries. (Dexter.)

or less distinct mesentery as they did originally. The original disposition can be seen by taking a cross section of the alimentary canal in Fig. 596 along the

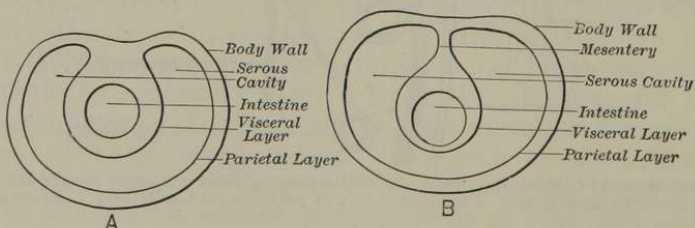

FIG. 605.—Schematic drawing of a cross section of a serous cavity. (Gegenbaur.)

line X. Each colon and the small intestine are fixed to the aorta and vertebral column by its special mesentery, which allows freedom of motion (Fig. 604). The *mesentery* is seen to be formed of two layers of peritoneum which surround an intestine completely, except at a posterior line where there is opportunity for

vessels, nerves, and lymphatics to enter or return. Two layers of peritoneal connective tissue, which lodge vessels, nerves, and lymphatics, constitute a mesentery. The intestine looks as though it had pushed its way into the sac of peritoneum as a finger enters a glove. That comparison is incorrect, for intestine and peritoneum are developed simultaneously. The intestine is not first made and then pushed, as would appear (Fig. 605).

The intestine and the two layers of peritoneum are formed together. As the intestine recedes, the serous membrane comes from the wall to it in a duplicature. The layer covering the intestine is called *visceral;* that reflected upon the parietes or wall is the *parietal layer*, and the passage from one to the other is the *mesentery.*

In the *adult* the small intestine is unchanged, but the mesentery of the right and left colon has been widely separated posteriorly, and it and some of the parietal peritoneum have been changed to connective tissue, so each colon becomes fixed and partly extraperitoneal, like the duodenum and pancreas (Fig. 603). The kidneys were always outside, being developed in the retroperitoneal space.

Summary.

Separation of the alimentary tube and its mesentery into distinct regions (Hertwig):

1. The alimentary canal is originally a straight tube from mouth to anus, near the middle of which the yolk-sac is attached by the vitelline duct (Figs. 586 and 587).

2. The alimentary tube is attached throughout its whole length to the vertebral column by a narrow dorsal mesentery; it is also connected with the anterior wall, as far as the umbilicus, by means of a ventral mesentery.

3. At some distance behind (below) the visceral clefts, the stomach arises as a spindle-shaped enlargement; its dorsal mesentery is designated as *mesogastrium.*

4. The portion which follows the stomach grows more rapidly in length than does the trunk, and therefore forms a loop with an upper, descending, narrower arm, which becomes the small intestine, and a lower ascending more capacious arm which produces the large intestine.

5. The stomach takes on the form of a sac and becomes so turned that its long axis coincides with the transverse axis of the body and that the line of attachment of the mesogastrium, or its greater curvature, which at first was dorsal, comes to lie below or caudad.

6. The intestinal loop undergoes such a twisting that its lower ascending arm (large intestine) is laid over (ventrad to) the upper descending arm (small intestine) from right to left and crosses it near its origin at the stomach.

7. The twisting of the intestinal loop explains why in the adult the duodenum, as it merges into the jejunum, passes under the transverse colon and through its mesocolon (crossing and crossed parts of the intestine).

8. The lower arm of the loop, during and after its twisting and crossing of the upper arm, assumes the form of a horseshoe, and permits one to distinguish the cæcum, the colon ascendens, colon transversum, and colon descendens.

9. Within the space bounded by the horseshoe, the upper arm of the loop becomes folded to form the convolutions of the small intestine.

10. The mesentery, which is at first common to the whole tube, becomes differentiated into separate regions and adapts itself to the different folds and elongations. It is elongated and here and there undergoes fusion with the peritoneum of the body-cavity, by means of which it acquires new points of attachment, or in certain tracts wholly disappears; some portions of the intestine are thus deprived of their mesentery (Fig. 614).

11. The mesentery of the duodenum, and in part that of the colon ascendens and descendens, fuses with the wall of the body.

12. The mesentery of the colon transversum acquires a new line of attachment running from right to left, and becomes differentiated from the mesentery as *mesocolon.*

13. The mesogastrium of the stomach follows the torsions of the latter, and is converted into the greater omentum, which grows out from the greater curvature of the stomach to cover all the viscera lying below.

14. Fusion of the walls of the omentum occur with the adjacent serous membranes: (1) on the posterior wall of the body, where its line of origin from the vertebral column is displaced to the left side of the body (Fig. 614); (2) with the transverse colon and mesocolon (Fig. 603); (3) anterior and posterior walls come into close contact and fuse into an *omental plate.*

Development of special organs out of the walls of the alimentary tube:

1. From the intestinal canal proper there are formed only two glands, developed from the duodenum, viz. the liver and pancreas.

2. The liver is developed as a branched tubular gland which becomes a network: (*a*) There grow out from the duodenum into the ventral mesentery or prehepaticus two liver-tubes, the fundaments of the right and left lobes of the liver. (*b*) The tubes form hollow or solid branches, the hepatic cylinders, which become in part bile-ducts and in part parenchyma of the liver. (*c*) The common bile-duct rises as an evagination of the wall of the duodenum receiving the two hepatic tubes, and at one place an evagination which becomes the gall-bladder and cystic duct.

3. From the ventral mesentery into which the liver grows are derived the suspensory ligament of the liver (falciform) and the lesser omentum.

4. The pancreas grows from the duodenum into the dorsal mesentery and into the mesogastrium.

The mesentery, which the pancreas originally possesses, disappears and fuses with the posterior body-wall. By reason of the twist of the stomach, the long vertical axis of the pancreas becomes transverse.

Adult Peritoneum.

During life and before dissection of the dead subject the abdominal cavity is *air-tight.* Atmospheric pressure and muscular tension allow no space to be vacant. The peritoneum (*περιτείνειν*, to extend around) is the shiny serous membrane lining the abdominal walls and posteriorly either lining the wall or covering the viscera. If one is asked to touch the liver or stomach it is the peritoneum covering those organs which is touched. The peritoneal cavity was opened when the anterior abdominal wall was incised, and does not exist till artificially produced by the surgeon or dissector.

In the male it is a *closed sac* with its two walls approximated, and consequently perfectly empty except for a small amount of yellowish-green lubricating fluid, *liquor peritonei.* Its *anterior wall* has already been opened and is called the *parietal peritoneum.* Its *posterior wall* is tucked into every crevice and corner around and between the viscera, which may be regarded as lying behind the whole sac. This layer is largely *visceral* and the spaces between single organs are only capillary. In the female, the peritoneum has two openings; there is a single region on either side where mucous membrane is continued into serous membrane, viz. where the Fallopian tube opens into the peritoneal cavity.

Other serous membranes are comparatively small, and, like the pleura, serous pericardium, or tunica vaginalis, surround one organ. In these it is very easy to trace the layer around the walls, then its reflection upon the viscus and off again to the starting-point. In the peritoneum, or really behind it, we have many organs involved, nearly all of which have experienced changes in size or position during fœtal life, so that the task is somewhat more complex. It is to trace the peritoneal layers from one organ to another or from an organ to a wall, and to show that the layers are continuous, making a closed sac.

We may say that the peritoneum has two surfaces, *i. e.* one attached to the wall or viscus and the other is free and shiny; there are two layers, parietal and visceral, and two sacs, since the large one has a posterior subdivision formed when the stomach rotated to the right in the embryo.

The various folds and bands formed by the peritoneum in passing from the different viscera or walls have definite names.

An **Omentum** means a fold of peritoneum which connects the stomach with other viscera, viz. *great* and *gastro-colic omentum*, *small* or *gastro-hepatic*, and *gastro-splenic*. These are situated respectively below, above, and to the left of the stomach.

A **Mesentery** is a fold of peritoneum connecting any part of the small intestine to the posterior wall. It is used also in a wider sense. The name of the fold connecting any part of the alimentary canal below the œsophagus to vertebral column or posterior abdominal wall may be found by prefixing the Greek adjective mesos (*μέσος*) or Latin *medium* to the Greek or Latin name of the part fixed, as *mesogastrium*, *mesoduodenum*, *mesentery*, *mesenteriolum* (*little mesentery* for vermiform appendix). There is no mesocæcum in the adult, but sometimes an ascending or descending mesocolon; always a transverse mesocolon, a sigmoid mesocolon, and a mesorectum.

Ligament is a term applied to folds connecting viscera not belonging to the intestinal canal, to the abdominal walls, or to folds which bind viscera to the diaphragm. The German anatomists apply this term also to omenta. There are ligaments of the bladder, uterus, and liver, and others, as lieno-renal, hepato-renal, and gastro-phrenic.

We will now trace the peritoneum in a vertical direction simply to show its continuity and to see from a side view how it surrounds viscera or forms bridges from one organ to another (Fig. 606).

We may begin anywhere, perhaps best at a point above the liver, where the parietal layer of peritoneum is reflected from the diaphragm to the liver, becoming visceral layer.

The student is supposed to have read carefully all the description of the peritoneal development. Now he follows by hand the parts in the subject and the diagram by eye. Lifting up the diaphragm the hand passes over the glistening superior surface of the liver in the middle line till it is stopped posteriorly by a fold called the *coronary ligament*. The peritoneum covers all the surface of the liver to its anterior acute margin. Next lift up the liver from the stomach and trace the layer backward on the under surface of the liver to the transverse fissure or hilus, and the hand is again stopped, this time by the peritoneum descending to the lesser curvature of the stomach, making one layer of the *lesser omentum;* or, giving the names of the viscera connected, *hepato-gastric omentum*. This layer now covers the anterior surface of the stomach and reaches the greater curvature; here it falls directly downward to a varying extent, usually to the pubic region, making the anterior superficial layer of the *great omentum*. Just below the stomach the transverse colon may be seen shining through. This layer in the fœtus and young child should not be attached to it, however. Now lift up the great omentum over the stomach and this layer may be seen to be reflected up to the under surface of the transverse colon, making the posterior superficial layer of the great omentum. Fig. 602 shows that the great omentum has not always been present; this layer we are now tracing used to pass *above* the transverse colon and go to the pancreas and then return, making two layers. Fig. 603 shows how these two layers united into one; and Fig. 606 shows how one has disappeared as such, and how this layer passes *beneath* the transverse colon and on to the vertebral column and anterior margin of the pancreas, making the lower layer of the *transverse mesocolon*.

This layer is closely connected with the vertebral column, aorta, and vena cava inferior, and on leaving the pancreas meets the superior mesenteric vessels and surrounds them. It covers only anteriorly the pre-aortic portion of the duode-

num, and makes another excursion to surround the small intestines and returns under the vessels forming the two layers of the *mesentery* proper. (Take a definite portion of the small intestine and prove this—that the mesentery has an upper and a lower layer and the intestine is fastened to the spinal colum by it.)

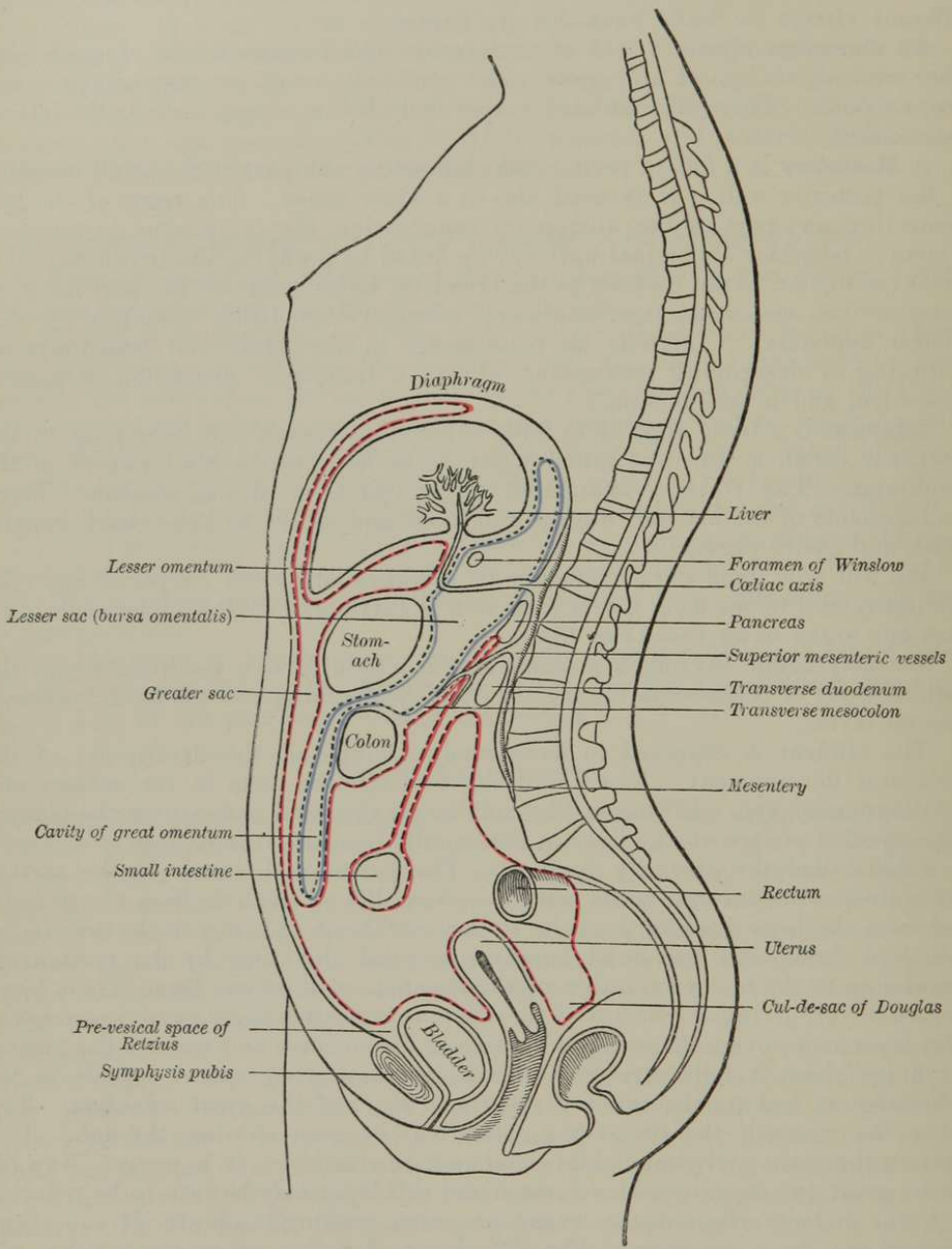

FIG. 606.—Diagram to illustrate the reflections and continuity of the peritoneum in a vertical direction in the female body. Section is a little to the right of a median plane. (After Allan Thomson.)

Next, this layer descends into the pelvis and forms a mesentery for the intestine, there surrounding it as low down as the middle of the third sacral vertebra. If anatomists agree to call that intestine the upper part of the rectum, the fold is *mesorectum*, but if the intestine be called the lower part of the sigmoid flexure, the fold is *sigmoid mesocolon*, and there is no mesorectum. Just at the third sacral vertebra the peritoneum leaves the posterior surface of the intestine, then the sides, and then the front, and is reflected in the female next upon the upper fifth

or fourth of the posterior wall of the vagina and then upon the uterus, covering its posterior wall, its fundus, its anterior surface, but it does not pass on to the vagina in front. About the level of the internal os it passes over the summit of the bladder as far as the urachus. The deep pouch behind the uterus and vagina is called the *recto-vaginal pouch*, or *cul-de-sac of Douglas*, or *recto-uterine pouch*. The more shallow anterior pouch is the *vesico-uterine*. In the male the peritoneum passes from the rectum directly upon the posterior wall and summit of the bladder to the urachus, forming behind the *recto-vesical pouch*. In either sex the peritoneum passes directly from the bladder to the anterior abdominal wall and does not cover the bladder anteriorly. The surgeon makes use of this fact in operating upon the bladder through this space below the peritoneum and above the symphysis pubis. It is called the *pre-vesical space of Retzius*, and is much increased in size by distending the bladder. By putting 420 c.c. of fluid into a rubber bag in the rectum and 500 c.c. into the bladder, the rectum will so push up the bladder and the bladder will so push up the peritoneum that a space of 8.5 cm. will exist between the lowest fold of peritoneum and the symphysis pubis.

This parietal layer is then simply traced, lining the anterior abdominal wall around to our starting-point between the liver and diaphragm. We see then that this is a closed sac and the parietal layer is continuous with the visceral. This is the cavity of the greater peritoneal sac.

We have not yet brought the peritoneum into contact with the Spigelian lobe of the liver or the posterior surface of the stomach or internal surface of the spleen. Behind the upper part of the large cavity and running into its lower part is another artificial cavity which we have not traced, viz. the *cavity of the lesser sac*, or the *bursa omentalis*. We have seen that these two sacs are continuous with each other through the foramen of Winslow. That is best shown in a cross section, but is indicated in the diagram.

The boundaries of the lesser sac cannot be well seen at this stage, and for the present must be mostly studied by diagram till the anterior parts are dissected. Remember the diagram is only true for the median line or near it, and nowhere else but in the region of the Spigelian lobe of the liver does the lesser sac reach up behind it as here represented. Imagine the hand introduced through the foramen of Winslow from right to left into the lesser sac; push the finger up behind the liver and in front of the diaphragm till stopped by the fornix made by the transition of parietal to visceral layer. This layer invests the Spigelian lobe only behind and inferiorly till the transverse fissure is reached; it then descends, as did the layer of greater sac in front of it, to the lesser curvature of the stomach forming the posterior layer of the lesser omentum. Next it descends behind the stomach and in front of the transverse colon into the great omentum, passing nearly to the free border of that apron. It now turns and ascends and covers the upper surface of the transverse colon and goes back to the vertebral column, forming the superior layer of the *transverse mesocolon*. It now covers the anterior surface of the pancreas, next the vertebral column and crura of diaphragm and great vessels to the reflection on to the liver.

It is advised that the above tracings for both sacs be followed in Fig. 607, which represents the organs in greater detail. This diagram shows two sections of the duodenum, one in its first and one in its second portion. A median section would show its third portion about at the root of the mesentery (Fig. 606).

We have traced the layers singly, and some new features may be presented if we take two layers together, beginning above at the liver.

Anteriorly, a layer passes back under the diaphragm and from behind another approaches it; one is from the greater sac and the other from the lesser (if section be near median line). They both turn down upon the liver, making these the anterior and posterior layers of the *coronary ligament*, including between them a small surface of liver directly connected to the diaphragm and uncovered by peritoneum. These two layers then surround the liver, forming its serous coat, and meet again at the transverse fissure. The two now descend to the

lesser curvature of the stomach, forming the lesser omentum or hepato-gastric omentum, the right free margin of which, also made of two layers, is called the *lig. hepato-duodenale*, because it passes between liver and duodenum. Between the two layers of this ligament to the right are the common bile-duct, the hepatic artery, and portal vein, all surrounded by connective tissue, the *capsule of Glisson*. These layers next invest the stomach, meeting at its greater curvature. They next pass down in front of the transverse colon and small intestines and form the anterior lamella of the great omentum; they turn on themselves and

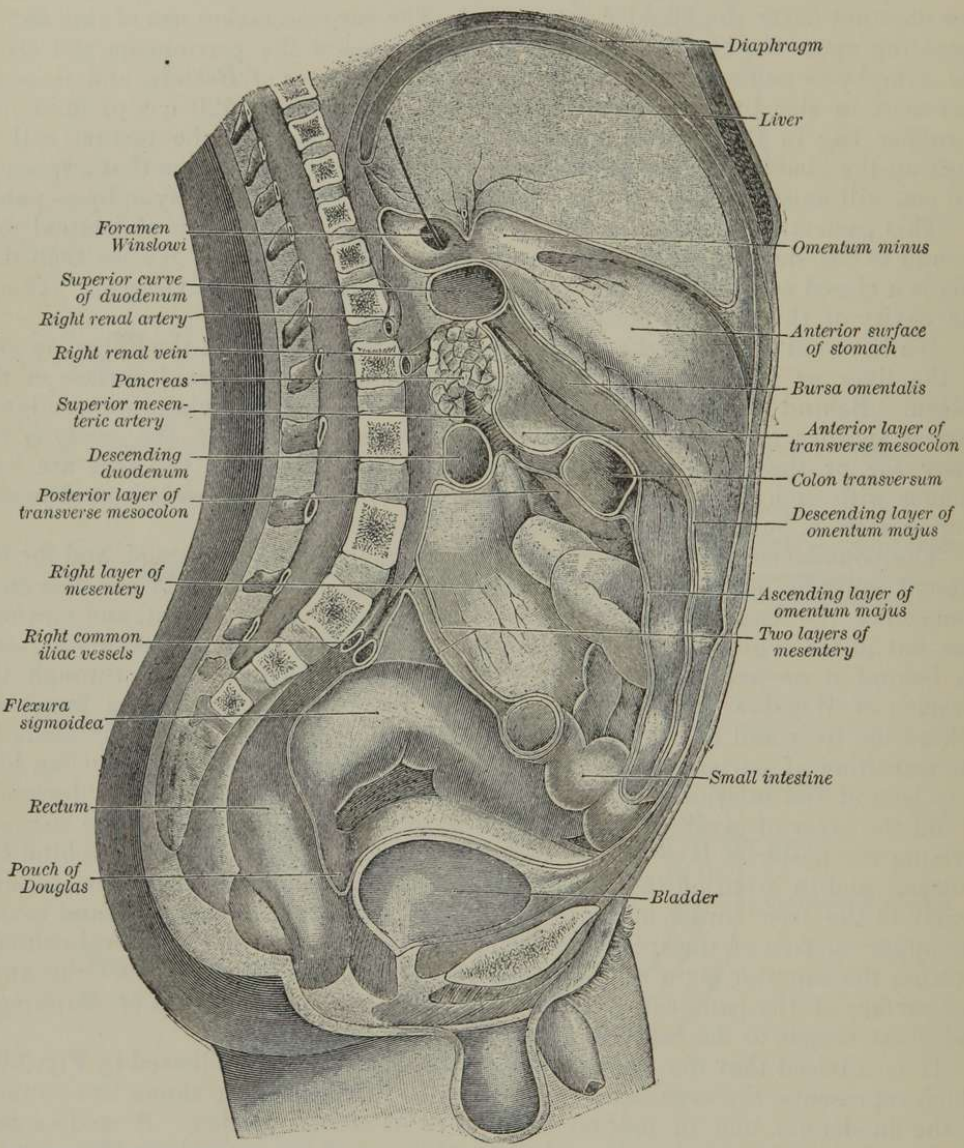

FIG. 607.—Sagittal section of abdominal cavity after Farabeuf. The cut runs a little to the right of the median line. A probe passes through the foramen of Winslow to the lesser sac.

reach the transverse colon, forming the posterior lamella of the great omentum, and next surround the transverse colon. Then they pass to the vertebral column, forming the transverse mesocolon with its upper and lower layers, and covering the anterior and inferior surfaces of the pancreas by their bifurcation, one layer passing upward and the other downward. These layers now diverge to complete their respective sacs, which have been traced, and meet again as the coronary ligaments of the liver at the starting-point.

So far we have seen the reflections and pouches in a longitudinal section in or near the median line.

It is the arrangement as found in the infant up to the age of two years; after that age the great omentum does not usually show a cavity.

We should next trace the peritoneum transversely in cross sections. This is simplest low down in the abdomen, where only the greater sac is involved. Let the section be made through the lumbar region somewhat above the level of the umbilicus (Fig. 608). Beginning at the linea alba, trace the parietal layer

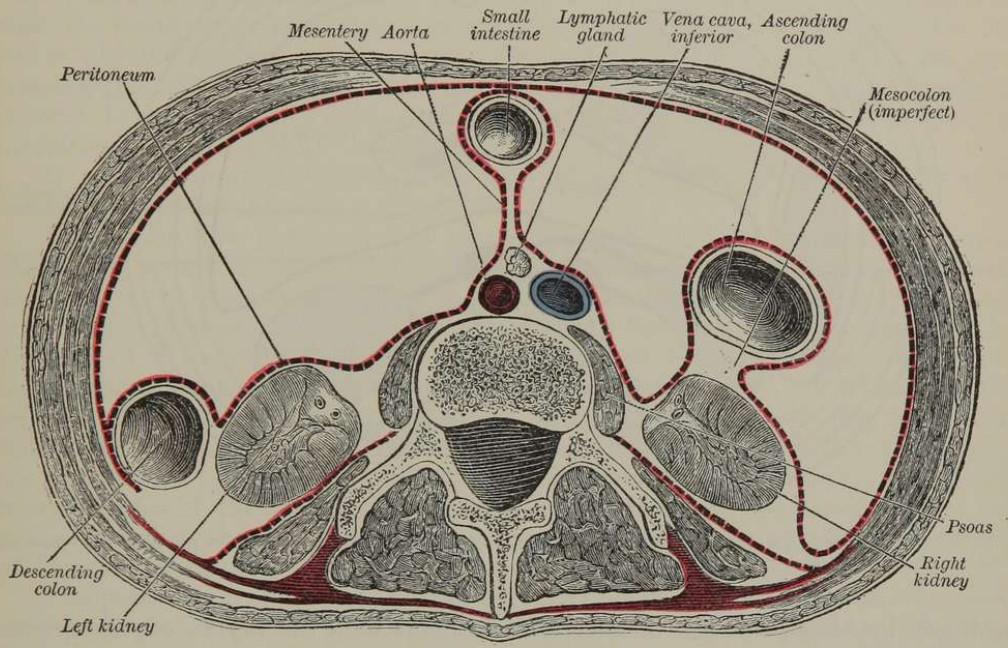

FIG. 608.—Peritoneal reflections in a transverse section of lumbar region below transverse colon. Seen from above. Schematic. (From Tillaux.)

around to the right until it nearly reaches the outer border of the Quadratus lumborum muscle. It then passes up over part of the anterior surface of the right kidney and meets the ascending colon. It partly surrounds it, forming sometimes a proper mesocolon, but usually leaving one-third of the posterior surface exposed. At birth only the anterior and external surfaces are covered.

This layer then passes from the right kidney over the Psoas muscle, over the vena cava, and, meeting the superior mesenteric vessels from the side, is led by them to surround the small intestine, enclosing blood-vessels, lacteals, lymphatics, and nerves in the mesentery proper. It next passes over the vertebral column and aorta, anterior to the left Psoas muscle and left kidney, and covers the anterior surface and sides of the descending colon, forming sometimes a true descending mesocolon. It next is reflected upon the antero-lateral abdominal wall and is continuous with itself at the linea alba.

Notice that the lower end of each kidney may be best felt by palpating to the right of each colon.

By taking a cross section higher up, just above the transverse colon, *both* cavities are involved, making the tracing more complex, but the continuity of one with the other is well seen. The spleen is met in this section, and all parts of the colon are below (Fig. 609). Begin again in front at the linea alba and trace to the right; soon the layer makes a fold open to the front and encloses the obliterated umbilical vein, now called the *round ligament* of the liver. The fold is a part of the fœtal anterior mesentery, now called *falciform* or *suspensory ligament* of the liver. The layer is a parietal one, passes to the posterior abdominal wall and covers the anterior surface of the right kidney and then passes in front

of the vena cava and behind the margin of the hepato-duodenal ligament which is the right free edge of the lesser omentum. This layer now forms the posterior

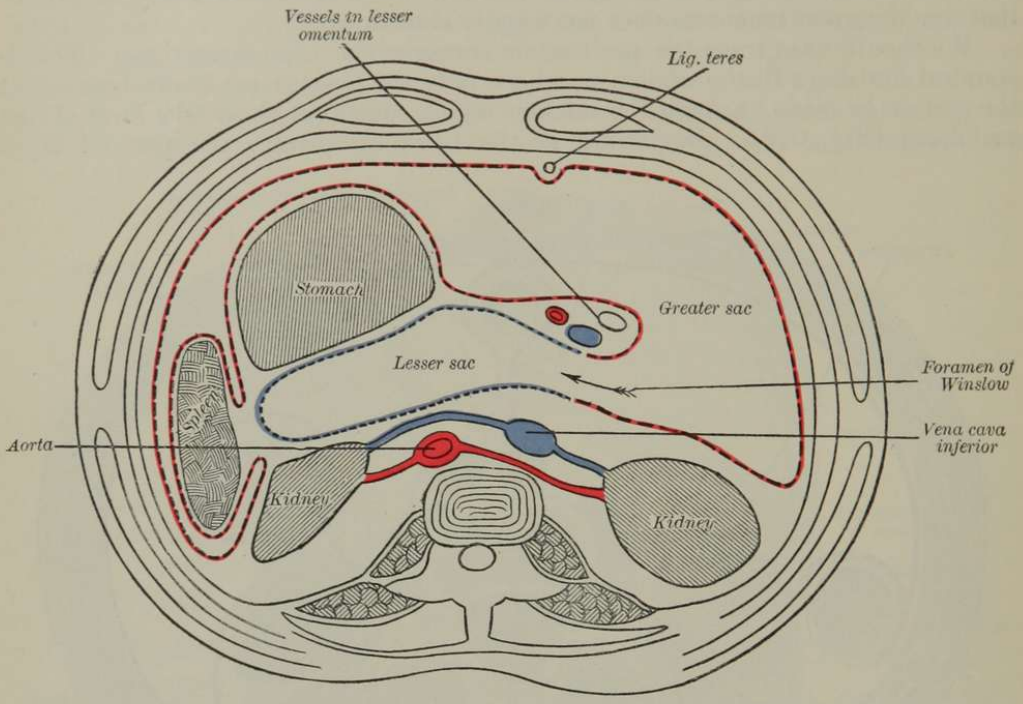

FIG. 609.—Transverse section of peritoneum above the transverse colon. The arrow points to the lesser sac and passes through the foramen of Winslow.

wall of the lesser sac and is directly continuous with the layers of the greater sac.

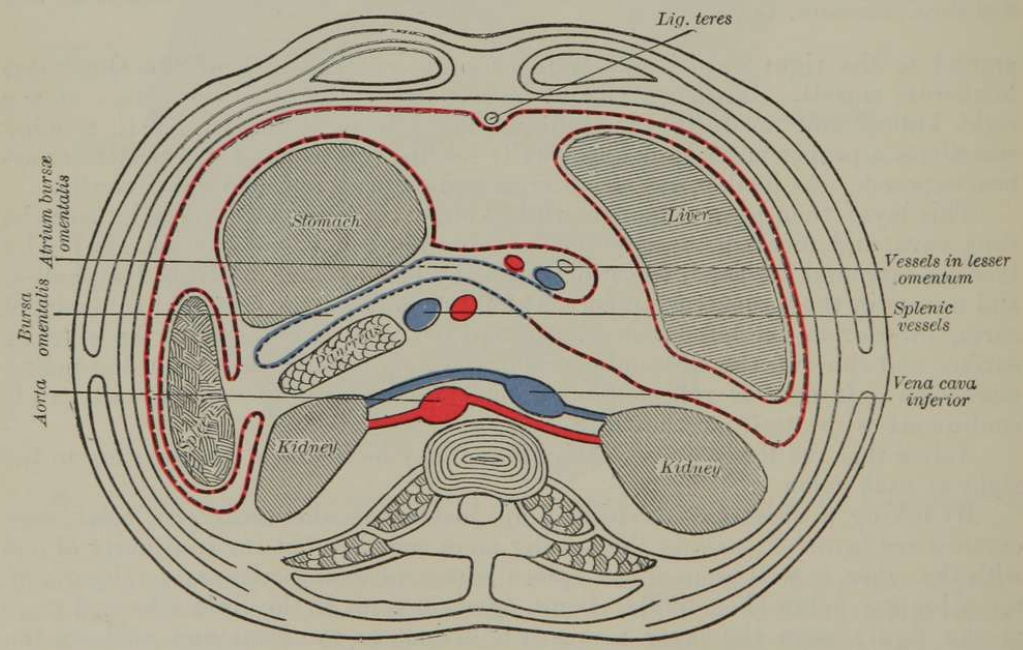

FIG. 610.—Horizontal section through the abdomen at the level of the foramen of Winslow. (Modified from Godlee.)

It passes over the vertebral column, the crura of the diaphragm and great vessels, in front of the left kidney to the hilus of the spleen, forming with the

greater sac, behind, a double fold, the *lieno-renal ligament* (*lien*, *liēnis*, spleen) in which run the splenic and pancreatic vessels. Anteriorly it forms with the greater sac another double fold, the *lieno-gastric ligament* or *gastro-splenic omentum*, in which pass the vasa brevia to the fundus of the stomach. This layer then covers the posterior surface of the stomach and makes the posterior layer of the lesser omentum, surrounding the three vessels and forming the anterior boundary of the foramen of Winslow. Now it forms a part of the greater sac and makes the anterior layer of the lesser omentum, covers the stomach anteriorly, dips down between it and the spleen to the anterior lip of the hilus to meet the lesser sac, and so forms the gastro-splenic omentum. It then covers the whole phrenic surface of the spleen, approaching the hilus from all sides, and meeting the lesser sac again from behind. Completing the lieno-renal ligament, it turns back on the left kidney to the abdominal wall and courses as parietal peritoneum to the middle line again.

If we trace a section through the level of the foramen of Winslow, the pancreas and liver are introduced (Fig. 610).

Here again the peritoneum is traced from the mid-line anteriorly where it invests the round ligament of the liver, then it covers the right abdominal wall and posteriorly touches the diaphragm, passes anterior to the right kidney and crosses the inferior vena cava, where it makes the posterior boundary of the foramen of Winslow. It then extends to the left as the posterior wall of the lesser sac, in front of the aorta, splenic vessels, pancreas and left kidney to the hilus of the spleen. Now the pancreas is interposed between this layer and the left kidney, and the splenic vessels pass behind or just above the pancreas in the lieno-renal ligament as before. The lesser sac makes a small blind pouch near the hilus of the spleen, and its peritoneum covers the posterior wall of the stomach, makes the posterior layer of the lesser omentum, bounds the foramen of Winslow anteriorly, and is then traced as in the last figure.

The peritoneum simply surrounds this section of the liver, not showing any coronary ligament. The peritoneal relations between stomach, kidney, pancreas, and spleen are shown in more detail in Fig. 611.

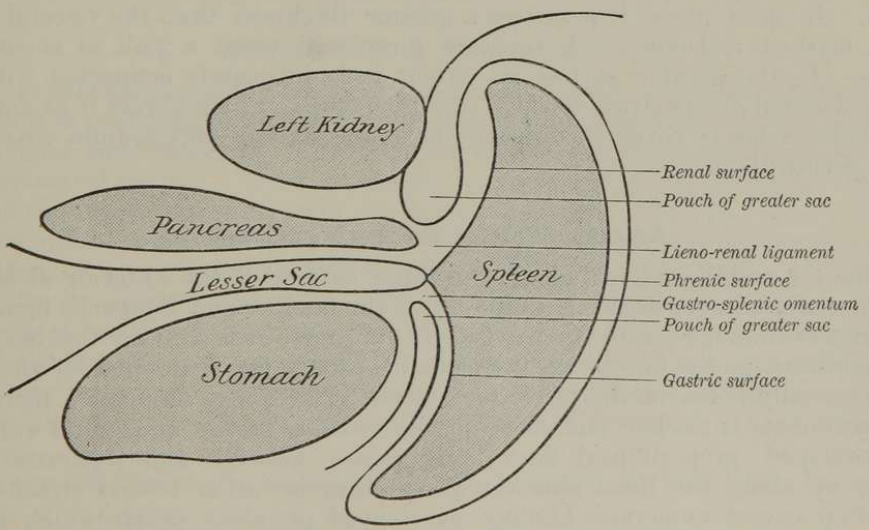

FIG. 611.—Horizontal section through the stomach, pancreas, spleen, and the left kidney to show peritoneal reflections at hilus of spleen. Schematic. (G. S. H.)

Here we see three pouches of peritoneum centering at the hilus of the spleen. Anteriorly and posteriorly are two from the greater sac and in the centre is the left blind extremity of the lesser sac. Should the structures at the hilus be grasped, the hand would enclose anteriorly a layer of the greater sac, then two of the lesser sac, then one of the greater, or four in all, and a section through them would show their cut edges standing out as two concentric rings (Fig. 612).

The layer of peritoneum covering the pancreas and attached to the spleen may be called the *lieno-pancreatic ligament;* it is really the anterior layer of the lieno-renal ligament.

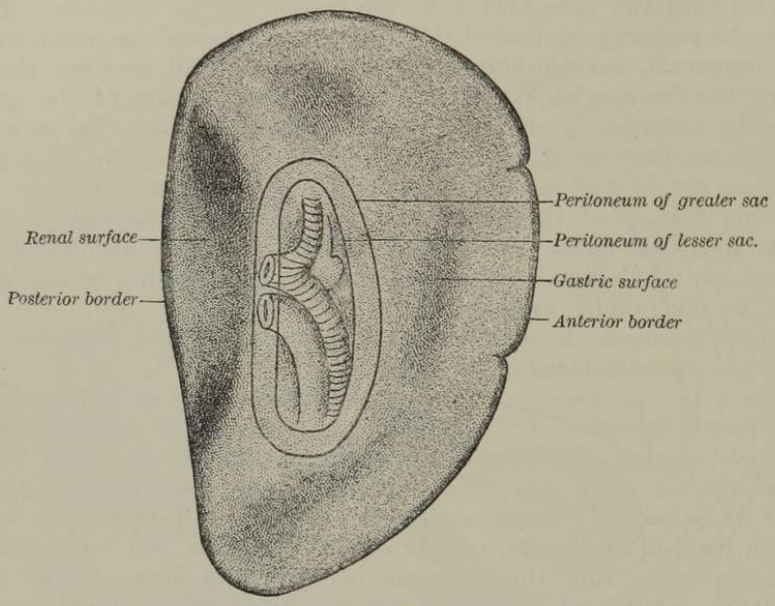

FIG. 612.—Inner surface of spleen, showing "peritoneal lines" at hilus. (From model of His.)

We are now prepared to follow a whole layer of peritoneum instead of tracing it in certain lines.

Parietal Peritoneum.

The wall-implanted peritoneum follows essentially the wall of the abdomen and that of the pelvis, being bound firmly to the latter and quite loosely to the former. In most places it possesses a greater thickness than the visceral layer and a marked resistance. A separate piece will resist a pull of about fifty pounds. In the greater part of its extent it is intimately connected with the endo-abdominal fascia (transversalis and iliac fascia) which covers it as does the endo-thoracic fascia cover the pleura; or as the fibrous pericardium covers the serous pericardium.

Anterior Wall of the Peritoneal Sac.

From the umbilicus down along the inner surface of the anterior abdominal wall the parietal layer descends to the top of the bladder and Poupart's ligaments, and extends from here into the pelvis. In its course it is thin on the linea alba and umbilicus, and is fused with the parts beneath. On both sides of the linea alba, especially below in the pubic region, and close above Poupart's ligaments, the peritoneum is thicker and does not lie so close to the abdomiual wall, as a well-developed properitoneal fatty layer comes between and separates them. Higher up along the linea alba the peritoneum is rather loosely attached and very often covers numerous, knobby, overlapped processes of fat which project inward, *plicæ adiposæ.*

Lower down the processes of the fatty layer project in the opposite direction toward the linea alba, and may push out through aponeurotic holes and make a fat hernia of variable size.

Above the umbilicus the peritoneum forms itself into a sheath which contains the beginning of the round ligament of the liver. It forms a pocket open from above which is in a position to receive a loop of intestine and to share in the formation of an umbilical hernia.

Below the umbilicus we have already noted the five longitudinal folds and the inguinal fossæ (p. 963).

The parietal layer passes from the anterior wall to the under surface of the diaphragm and clothes it up to the central tendon where the œsophagus and vena cava inferior pass through. From here it spreads out on one side to the liver, on the other to the stomach and spleen, and so changes into the visceral layer.

The parietal peritoneum of the *posterior abdominal wall* rests on small and limited spaces and passes over such structures as the kidneys, transverse duodenum, right and left colons, great vessel trunks, many lymph-glands and vessels and nerve-plexuses.

By means of a loose fatty connective tissue called *retroperitoneal cellular tissue* these structures fasten themselves together and themselves to the peritoneum. On this posterior wall to the left of the duodenum there may be as many as three infoldings or retroperitoneal pouches which will be described later.

Upper Wall of the Peritoneal Sac.

The lower surface of the diaphragm representing the roof of the abdomen is not covered wholly by peritoneum. Behind the central tendon it is partly free where the surface of the liver rests upon it and where the suprarenal capsules and kidneys come in contact with it. The greater part of the diaphragmatic covering is directly continuous with the anterior and lateral parietal layers, and is distinguished by its extreme delicacy and firm connection with the endo-abdominal fascia. In the cleft-like holes left between the costal and sternal parts of the diaphragm and between the costal and vertebral parts, peritoneum and pleura meet; these are called "weak places," and here a diaphragmatic hernia can be acquired.

A small surface of the diaphragm situated behind the lobus Spigelii gets a covering from the upper end of the posterior wall of the lesser sac which does not enter into continuity with the serous covering of either side, but on the left it turns into the mesial layer of the gastro-splenic omentum and on the right into the mesial layer of the hepatico-renal ligament.

Inferior Wall of the Peritoneal Sac.

This belongs in part to the false pelvis and in part to the true pelvis. In the former it is connected with the fascia iliaca. In the iliac fossa the peritoneum extends itself underneath and behind the cæcum so that that structure hangs free in the peritoneal cavity. There is usually no mesocæcum in the adult. Near the cæcum there are *pericæcal fossæ*, for later description. On the left side the peritoneum passes from within and without over the iliacus muscle and fascia to the formation of a very movable fold which surrounds the sigmoid flexure, the *mesosigmoidea* or *sigmoid mesocolon*. Where this attaches to the intestine, opposite the brim of the true pelvis, the peritoneum raises itself into a fold which has been called *lig. mesenterico-mesocolicum* (W. Gruber), which on one side runs into the mesentery proper and on the other into the mesocolon of this flexure. It seems to have the purpose of limiting the deep descent of the rectal limb of the sigmoid flexure.

In the left leaf of the *mesosigmoidea* is usually to be found the *fossa subsigmoidea* or *intersigmoidea*.

In the hollow of the true pelvis the peritoneum clothes that region of the lateral wall which in man extends between rectum and bladder, in woman between rectum and vagina, also between rectum and uterus. In the first it forms a pouch open above, *excavatio recto-vesicalis* or *recto-vesical pouch*. The mouth of the pouch is bounded by a crescentic fold of peritoneum on each side, the *plica semilunaris*. The left one is usually the larger. They form the *posterior false ligaments of the bladder*. The depth of this pouch extends to within one inch of the prostate or within about 8 cm. of the anal orifice.

In the female we have seen that two pouches exist at the lower end of the peritoneal sac; a shallow one between bladder and uterus, *excavatio vesico-uterina;* a posterior deep one between rectum behind and uterus and cervix and upper end of vagina in front. The deepest part is bounded on each side by a sharp semilunar fold as in the male, which folds are called *sacro-uterine ligaments*, or, according to some, *recto-uterine*. They pass from the upper part of the cervix in front and extend backward to the sides of the rectum toward the sacrum. This pouch has anteriorly the supravaginal cervix uteri and the upper fifth of the posterior wall of the vagina, and posteriorly the rectum and sacrum; it is the recto-vaginal pouch or the proper *cul-de-sac* of *Douglas*. The space above this, between rectum and uterus, is called the *recto-uterine pouch*.

On either side of the uterus the peritoneum forms a broad double layer passing to the side of the pelvis. It is called the *broad ligament*, and each contains three important structures, anteriorly the round ligament of the uterus, in the middle and highest up the Fallopian tube, and posteriorly the ovary.

In a distended condition of the pelvic organs the pouches are filled by them, otherwise coils of small intestines and usually a part of the sigmoid flexure fall into the pelvic cavity.

The Visceral Peritoneum.

By this term one understands in general the prolongations of the peritoneum into its own cavity, usually from behind, covering or nearly surrounding a viscus. It is also applied to prolongations from parietal layers and those which pass bridge-like from one organ to another.

In the middle line, the peritoneum accompanies in its course from the umbilicus to the diaphragm the extraperitoneal obliterated umbilical vein, forms a fold around it which on one hand follows the vein (lig. teres) to the under surface of the liver, and on the other continues itself to the upper surface of the liver, and from there passes to the diaphragm as the *lig. suspensorium hepatis*. It covers the concave surface of the diaphragm as far as the spot where the liver comes into direct contact with it and then passes upon the liver in a frontal direction as the anterior (or upper) layer of the *lig. coronarium hepatis* (coronary and lateral ligaments). The left leaf of the suspensory ligament passes out over the upper surface of the left lobe of the liver, meeting above the left part of the coronary ligament, and the right leaf passes over the upper surface of the right lobe in the same manner. After clothing the convex surface of the liver it advances over the anterior acute margin and then covers the quadrate lobe to the portal fissure, the gall-bladder except where adherent to the liver, and under surfaces of the right and left lobes, to turn finally back to the diaphragm, forming the lower layer of the coronary and lateral ligaments. There is but one place, the portal fissure, where this layer does not turn back. Here by the out- and ingoing vessels it is obliged to descend to the stomach.

Farther to the left the peritoneum goes from the diaphragm to the stomach (cardia) as the *lig. phrenico-gastricum* covering the anterior and left surfaces of the œsophagus; it descends from the diaphragm to the spleen as the *lig. phrenico-lienale* or suspensory ligament; and to the splenic flexure of the colon as the *lig. phrenico-colicum*.

From the fundus of the stomach, the peritoneum passes in a duplicature to the spleen as the *lig. gastro-lienale* (gastro-splenic omentum), which covers the gastric surface of the spleen and is continued over its phrenic and renal surfaces as we have seen.

This omentum descends over the splenic flexure of the colon and there may be called *omentum colicum;* thence it is connected with the posterior abdominal wall and descending colon.

The peritoneum leaves about one-third of the posterior surface of the left colon uncovered, forming no mesocolon usually; below, it surrounds the sigmoid flexure, forming a long mesentery, which follows it into the pelvis.

Turning to the right side and above, we have seen the right part of the coronary and lateral ligament descending in two layers from the diaphragm.

Below the liver, the peritoneum passes to the stomach and duodenum as the *lig. hepato-gastricum* and *lig. hepato-duodenale*, both of which make the lesser omentum of two layers. A part of the right edge of this omentum passes to the hepatic flexure of the colon, called *lig. hepato-colicum*. The peritoneum from the neck of the gall-bladder to the duodenum is the *lig. cystico-duodenale*. Behind the foramen of Winslow and beneath the neck of the gall-bladder another thin layer passes to the right kidney, *lig. hepato-renale* (Fig. 615). Farther down the

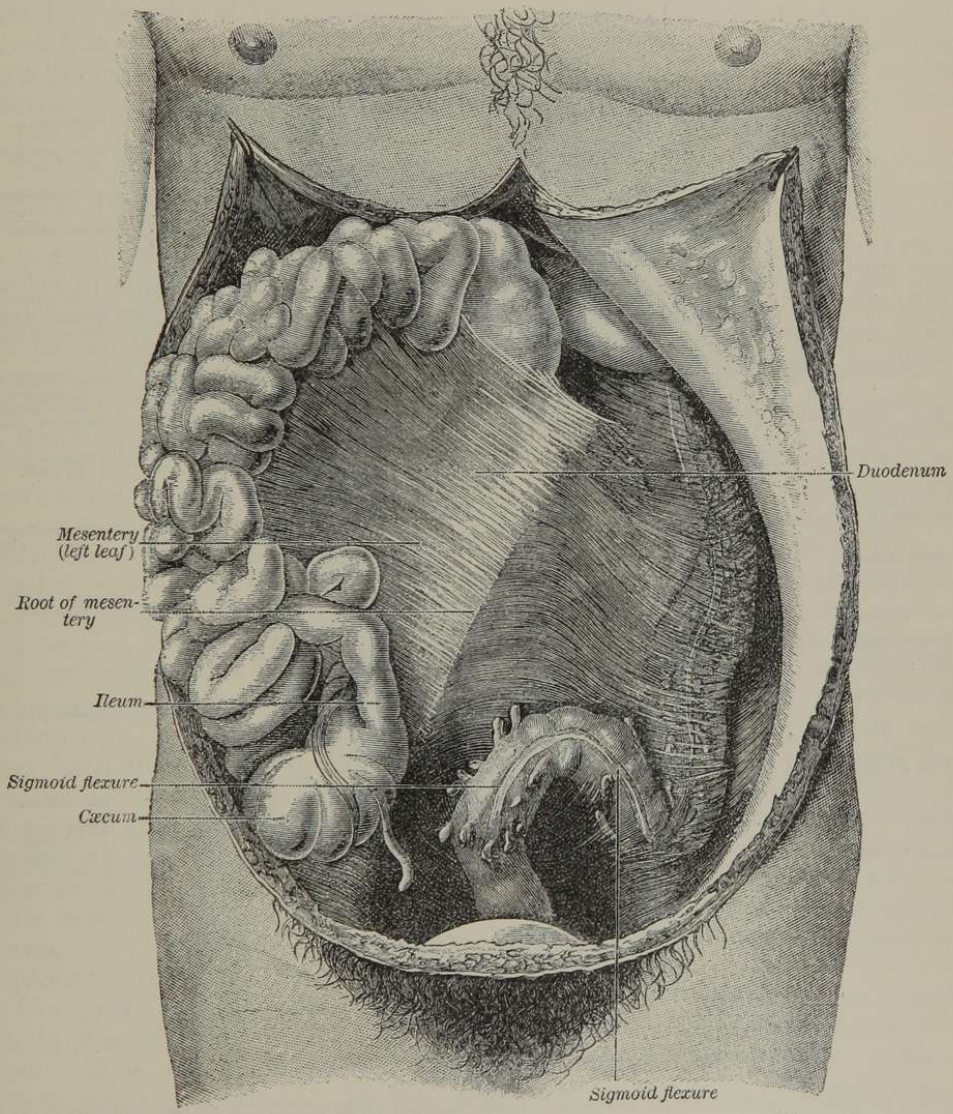

FIG. 613.—Mesentery. Small intestines pushed to the right and above. (Tillaux.)

peritoneum from the posterior abdominal wall, continuous with the hepato-colic ligament, covers about two-thirds of the ascending colon as on the left side, making no mesocolon, and covers the whole of the cæcum, making no meso-cœcum, because the layers have fused into a close-fitting pocket with no attachments except above. This, as the mesentery proper, forms a little mesentery for the appendix (mesenteriolum) and descends into the pelvis.

Mesentery.—When the peritoneum on the vertebral column reaches the ante-

rior surface of the superior mesenteric vessels, it follows them down to the loops of small intestine surrounding all the jejunum and ileum, but not the duodenum; it returns to the spinal column, constituting the *mesentery*. It has a right upper and a left lower layer, between which are the mesenteric arteries and veins, lacteals, lymphatics, and nerves, all fused together by fatty connective tissue. The point of origin of the two layers is called "root of the mesentery" (Radix mesenterii) (Fig. 613).

It runs obliquely from the left side of the body of the second lumbar vertebra across the vertebral column, aorta, vena cava inferior, and third part of the duo-

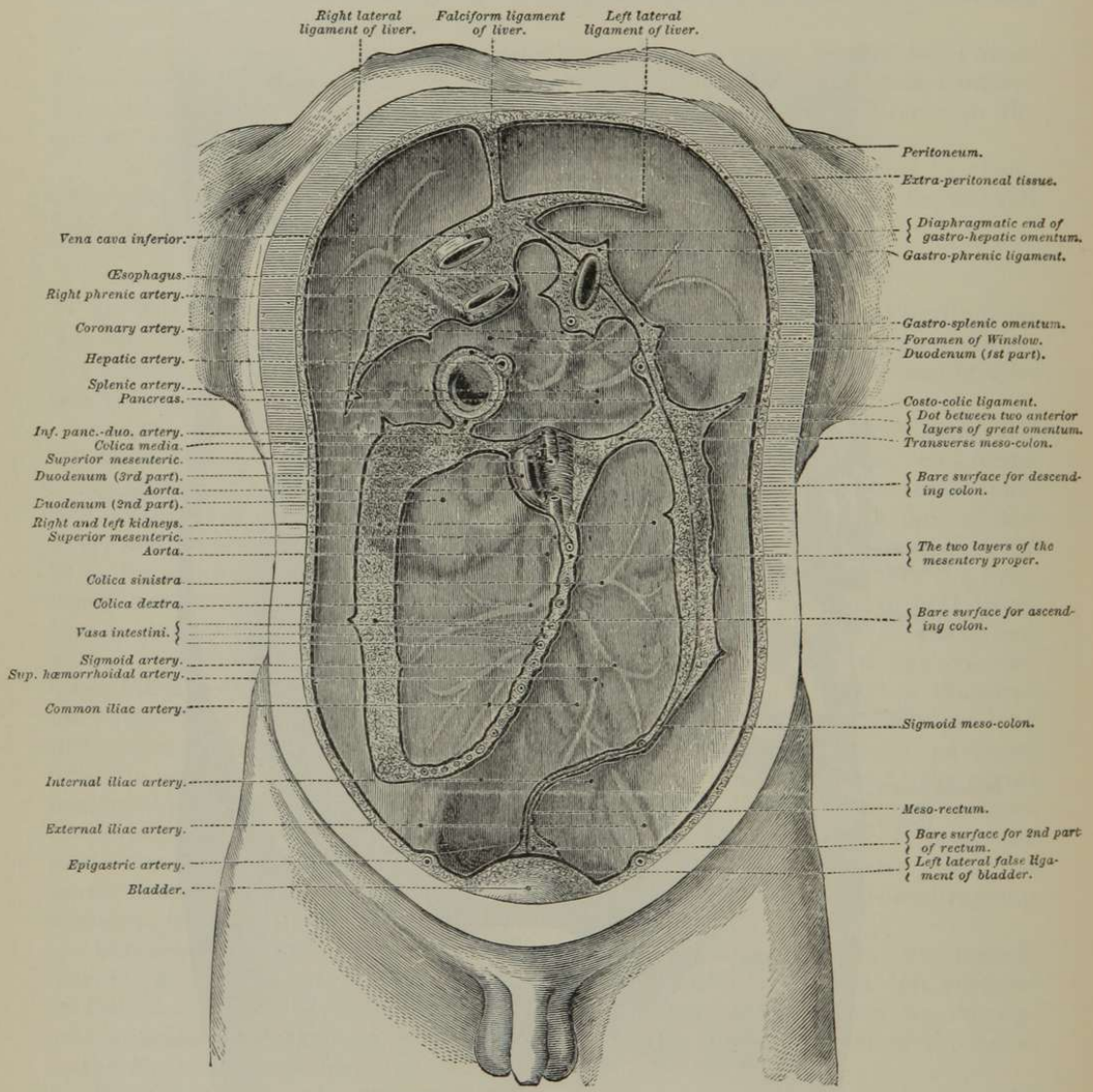

FIG. 614.—Diagram devised by Dr. Delépine to show the lines along which the peritoneum leaves the wall of the abdomen to invest the viscera.

denum to the right sacro-iliac articulation or to the right iliac fossa (Fig. 614). It is three-cornered or fan-shaped, with its root six inches long and its convex intestinal edge about twenty-one feet long; its average width is eight or nine inches. It is widest—*i. e.* gives greatest freedom to the intestine, 20 to 25 cm. above the cæcum, and then suddenly shortens. The middle and lower loops of intestine have the longest mesentery, and are more movable and more liable to hernia. They usually lie in the pelvis. From its obliquity, fluid exudate of any

kind on the right side would press upon the right inguinal region; if upon the left side, would have an inclination to gravitate to the true pelvic cavity. At the root, the right layer is continued into the lower layer of the transverse mesocolon; on both sides the layers continue themselves, one into the inner lamella of the left colon and the other into that one of the right colon. The left layer continues downward into the peritoneum, covering the lumbar vertebræ, which passes over the promontory to the pelvic organs.

The Omenta and Bursa Omentalis.

The *great omentum* we have seen consists of four layers formed by an anterior descending lamella of two and a posterior ascending lamella of two. It was derived from the mesogastrium (Fig. 599). Its two middle layers (Fig. 606) constitute the walls of the lesser sac and come from the right leaf of the mesogastrium; its two superficial layers belong to the greater peritoneal cavity and come from the left leaf of the mesogastrium.

Only in fœtal life could the first and second or third and fourth layers be separated and only up to about the age of two years does the cavity exist between the second and third layers. Before that age and sometimes in adults the cavity of the great omentum can be distended by air introduced through the foramen of Winslow or a finger could be inserted into it through an incision made just below the stomach dividing the two anterior layers. This finger would come in contact with another introduced from right to left through the foramen of Winslow. This can rarely be done in the adult without breaking down adhesions, for the reason that at about the age mentioned the anterior lamella of two layers fell back upon the transverse colon and became adherent to the posterior lamella, obliterating the cavity of the great omentum, which may now be called the *omental plate*. Figure 606 shows the opportunity. This arrangement gives the stomach a direct connection with the transverse colon and the two layers descending from the greater curvature cannot be lifted from it. Our former great omentum may now be called *gastro-colic* omentum; some speak of the layers between stomach and colon only as the *gastro-colic* part of the great omentum.

This part connects on the left with the gastro-splenic omentum and on the right with the hepatic flexure of the colon and descending colon, meeting there the hepato-colic ligament, and is distinguished at those points as *omentum colicum* (Haller). In later time, the great omentum is a four-cornered curtain which hangs down from the great curvature of the stomach in front of the small intestines fused with the transverse colon, ending usually in a free edge and descending a little lower on the left side as evidenced by its greater frequency in left herniæ. It may be tucked between the intestines or wholly pushed upward. It may accumulate much fat.

Its *vessels—vasa epiploica*—are chiefly derived from the art. gastro-epiploica sinistra, only the smallest part from the dextra. It is poorly supplied with *lymphatics*. Its *nerves* are from the cœliac plexus.

The *gastro-splenic omentum* we have seen (Figs. 610 and 611) as a double fold, dipping in between the fundus of the stomach and the gastric surface of the spleen. It is where the greater sac has opportunity to touch the lesser sac between these two organs. In this fold, made by two sacs, the splenic artery sends its vasa brevia to the stomach.

The *lesser omentum* (omentum minus) or *gastro-hepatic omentum* or *lig. hepatogastricum* passes nearly vertically between the transverse fissure of the liver and the lesser curvature of the stomach, continuous to the right upon the first part of the duodenum. This right free edge going to the duodenum, containing vessels, is called the lig. hepato-duodenale. The lesser omentum and hepato-duodenal ligament are made of two layers, one from the greater and one from the lesser sac. An index finger passed into the foramen of Winslow, if approximated to the thumb placed upon the anterior surface, includes the two layers, thin as they are. The

anterior layer at the right free border turns behind the vessels, now belongs to the lesser sac, and makes the posterior layer of the hepato-duodenal ligament and of the lesser omentum. These two layers below enclose the stomach, and to the left side form the gastro-splenic omentum. Above, the anterior layer is attached in front of the transverse fissure and then spreads over all the inferior surface of the liver. The posterior layer above is attached just behind the transverse fissure, and here separates from the anterior to pass backward and upward over the Spigelian lobule only. The combined layers leave the left end of the transverse fissure and run along the edges of the fissure for the ductus venosus, passing to the diaphragm and on that forward to the œsophagus, which the two layers partly surround, the anterior one covering its anterior and left side, the posterior one its posterior and right side, in part. The anterior one is the phrenico-gastric ligament. Between the two layers of the hepato-duodenal ligament at the right

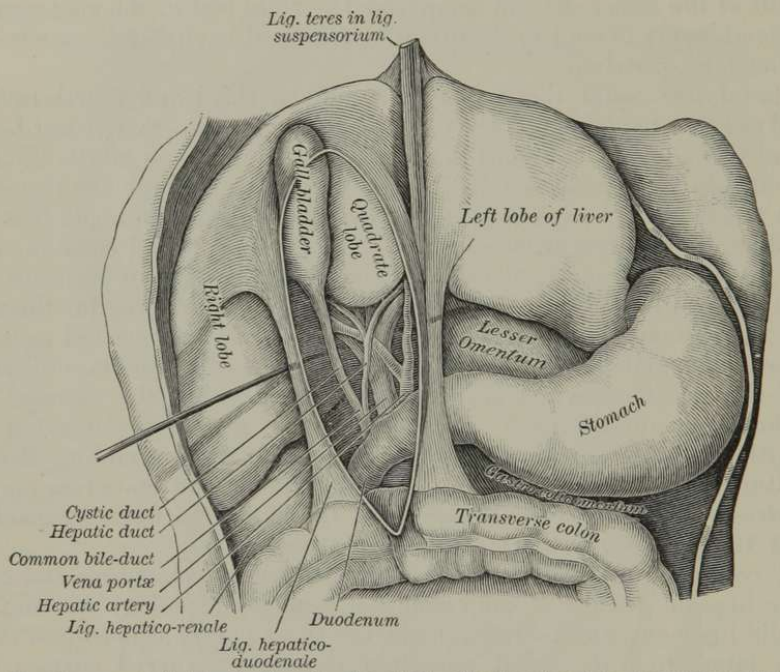

FIG. 615.—Upper part of abdominal cavity of a child. The liver has been drawn upward and the lig. hepato-duodenale, containing the hepatic vessels, has been put on the stretch; its anterior layer has been opened by a vertical incision. A probe passes behind it through the foramen of Winslow into the lesser sac. (Henle.)

edge of the lesser omentum, the outgoing and ingoing vessels are arranged as represented in Fig. 615.

Near the duodenum there are three vessels, the common bile-duct to the right, the hepatic artery to the left, and behind and between the two the portal vein. At the transverse fissure of the liver the artery and vein divide into right and left branches for the right and left lobes, and the common bile-duct receives the cystic duct and the hepatic ducts descending from the two lobes. Besides these are lymph-glands and vessels and nerves, all surrounded by connective tissue which is called *Glisson's capsule*.

The *foramen of Winslow* (J. B. Winslow, 1743) or *orificium epiploicum*, is the point of communication between the bursa omentalis (lesser sac) and the greater sac. It may be round in shape, triangular or semilunar. It should admit about two fingers. It is best shown when the liver is tilted upward and to the right, and the intestines, with the first part of the duodenum, downward and to the left. Its boundaries are—above, the caudate lobe of the liver; below, the first part of the duodenum and the first part of the hepatic artery as it passes forward; in front are the right free border of the lesser omentum, lig. hepato-duodenale, with its contained vessels, hepatic artery, vena portæ and common bile-duct; behind are the lig. hepato-renale and vena cava inferior.

As a result of closure of this foramen due to adhesive inflammation, a *hydrops saccatus* can be formed by a collection of serum in the lesser sac, and the stomach will rest on a sort of water-bed.

Another rare anomaly is a hernia through this foramen. A great part of the small intestines have worked their way through it by peristalsis into the lesser sac.

The Lesser Sac or Bursa Omentalis.—Between the mesogastrium and posterior wall of the stomach there was originally a three-cornered space with its apex turned to the left and base to the right (Figs. 599 and 600). During development the base has been narrowed to the foramen of Winslow. The cavity is called the lesser sac or omental bursa. Figure 606 shows that it sends a diverticulum up behind the Spigelian lobe of the liver, another downward known as the cavity of the great omentum, and in figure 610 we see the main chamber behind the stomach sending off a third pouch to the spleen and left kidney.

When the finger enters the foramen of Winslow it is able to mark out a circumscribed region confined by the Spigelian lobe anteriorly and the diaphragm behind. Push the finger to the left until it is obstructed and let it descend; at a level below the papillary tubercle of the liver it will slip under a prominent band, and can now ascend under the fundus of the stomach up to the posterior surface of the œsophagus; we can then push over to the spleen, or, if the subject be young enough, down into the great omentum.

The lesser sac seems to be subdivided. Huschke called the first portion, which receives the Spigelian lobe, the *bursa omenti minoris*, because it is just behind the lesser omentum.

The second large division going upward behind the stomach and downward into the omentum and over to the spleen was the *bursa omenti majoris*. Each

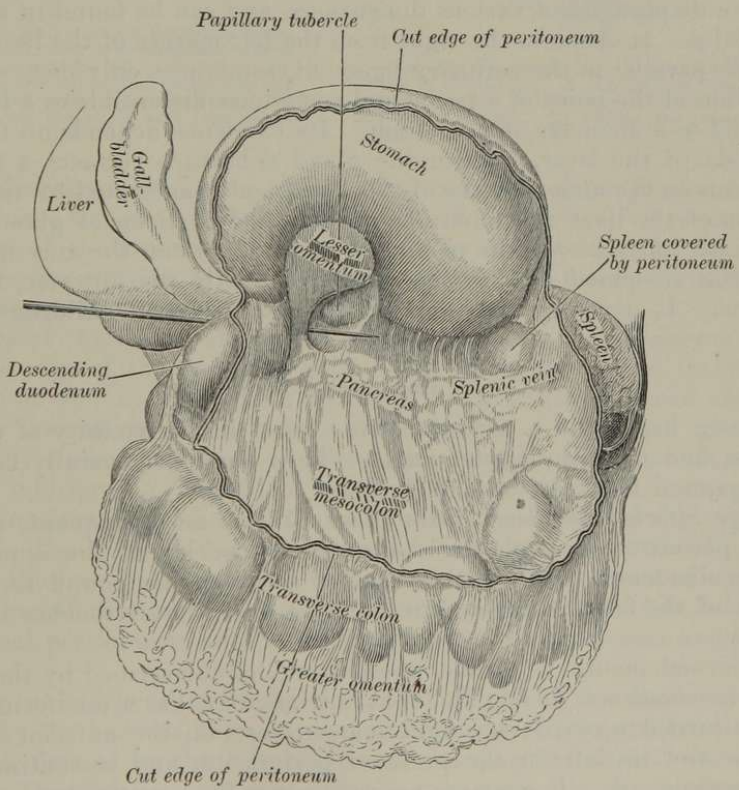

FIG. 616.—Bursa omentalis, opened from the front by an incision through the gastro-colic omentum. A probe passes through the foramen of Winslow and rests on the gastro-pancreatic ligament. (Henle.)

communicates with the other by the *foramen omenti majoris*. These subdivisions are still found, and the constricting band is still present, caused by the gastric

artery, throwing forward a fold of peritoneum in relief. This is called the *lig. gastro-pancreaticum* (Fig. 616).

The figure shows the posterior wall of the bursa lying in front of the pancreas. Through the opening to the right and above may be seen the papillary tubercle of the Spigelian lobe.

The connection of the two bursæ is narrowed by the tuber omentale of the pancreas and the gastro-pancreatic ligament which runs obliquely from the cardia to the anterior surface of the pancreas in about the middle line.

It is now proposed to call the first bursa the *atrium bursæ omentalis* or antechamber, and the second bursa the *bursa omentalis* proper.

The part behind the stomach persists throughout life. The surfaces are in immediate contact, and by their smoothness and moisture permit easy movements of the stomach in its various degrees of distention.

Recessus Peritonei or Retro-peritoneal Fossæ.

In four or five different parts of the abdominal cavity there are regions of surgical interest from the possibility of the occurrence of *retro-peritoneal herniæ*. One we have already noted, the foramen of Winslow, another is a *phrenico-hepatic fossa* at the left lobe of the liver. As many as three may occur at the upper end of the root of the mesentery: a *duodeno-jejunal* and *duodenal fossæ;* an *intersigmoid fossa* to the outer side of the sigmoid flexure, a *fossa iliaco-subfascialis* connected with a left Psoas minor muscle. Finally three fossæ may exist in the neighborhood of the cæcum.

Henle says of the first one, "It is remarkable that a hitherto overlooked pocket has been brought to light by Von Brunn, 1874. It is on the under surface of the diaphragm, of various dimensions, and can be found in about one-half of the adults. It opens to the right from the left margin of the liver and extends to the left, parallel to the coronary ligament, sometimes only deep enough for the introduction of the point of a probe and sometimes distensible to a length of 13 to 16 cm. and to a diameter of 3 to 4 cm. Its existence depends on the atrophy of the left lobe of the liver. When the gland substance retracts, a flat peritoneal fold remains on the under surface of the diaphragm, penetrated by vessels and vasa aberrantia of the liver and often lodging separate particles of gland tissue. The pocket *fossa phrenico-hepatis* originates therefore when the anterior or posterior edge of the atrophied lobe, by far most frequently the anterior, fuses with the diaphragm. It develops after birth. In new-born and children it is not to be found."

Duodenal Fossæ.

Jonnesco has found a series of three fossæ in the vicinity of the ascending duodenum and duodeno-jejunal angle. They have all generally been called the duodeno-jejunal fossa, or fossa of Treitz.

1. The *inferior duodenal fossa* (Fig. 617) is most frequent, and occurs in about 75 per cent. of cases. It is situated to the left of the upper part of the ascending duodenum and has the shape of a cornucopia bound to the intestine. The apex of the fossa is directed to the right and almost touches the root of the mesentery.

Its widened mouth is turned upward and circumscribed by the free edge of the *inferior duodenal fold.* This fold is triangular, has a falciform edge with its concavity turned upward; its right margin rests on the anterior surface of the duodenum and its left on the prerenal peritoneum and is continuous with the parietal peritoneum. It contains no vessels, nor fat, and the duodenum is readily seen through it. The boundaries of the fossa are—this fold to the front and left, the ascending duodenum to the right, and the left side of the third lumbar vertebra behind. Its tip may extend to the anterior surface of the fourth lumbar vertebra. The depth may attain 3 cm.; its orifice admits the tip of the index finger.

Sometimes the fold is bound to the intestine and the fossa is then apparently lacking.

The vascular relations of this fossa are not close. The inferior mesenteric vein is about one finger's breadth to the left and the art. colica sinistra is as far below. The vessels have no causal relations and the fossa is non-vascular. Jonnesco met one case where the artery and vein were related to the fold.

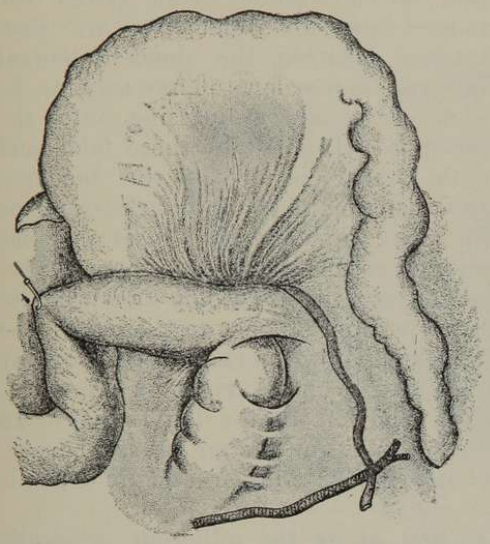

FIG. 617.—Inferior and superior duodenal fossæ. The inferior mesenteric vein is some distance from the inferior fossa but near the left border of the superior fossa. Transverse colon and mesocolon are turned up. On the left is the descending colon, ascending duodenum on the right, and jejunum is pulled to the right. (Jonnesco.)

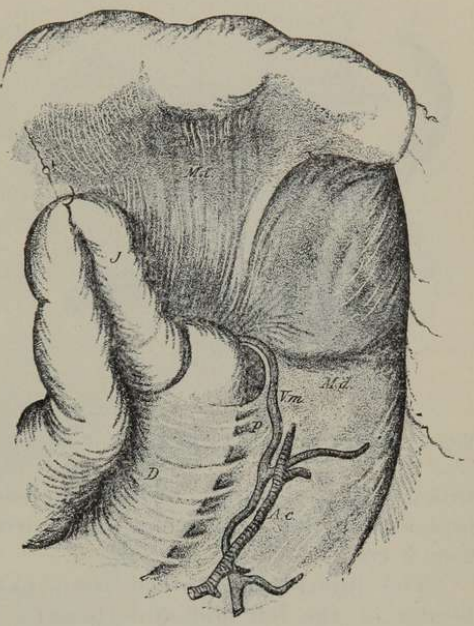

FIG. 618.—Duodeno-jejunal fossa of Treitz. (From Treitz in Jonnesco.) *D.* Ascending duodenum. *P.* Duodenal fold. *Vm.* Inferior mesenteric vein. *Ac.* Art. colica sinistra. *Mt.* Transverse mesocolon. *Md.* Descending mesocolon.

The fossa described by Treitz and known as the duodeno-jejunal fossa of Treitz is this one, but it is "vascular," in which the inferior mesenteric vein runs in the edge of the crescentic fold and the inferior extremity of the fossa is formed by the colica sinistra artery. Treitz regarded the formation of the fossa due to the presence of the vessels (Fig. 618).

"The orifice of the fossa was limited on the right by the duodenum, on the left by the free edge of the duodenal fold. The fossa lay on the third lumbar vertebra left side, and in the bottom of a depression of the posterior abdominal wall limited by the pancreas, left kidney and aorta."

2. The *superior duodenal fossa* is present in about 50 per cent. It often coexists with the inferior one (Fig. 617). It is always at the level of the superior extremity of the ascending duodenum, and its orifice looks downward, opposed to the preceding. The orifice is limited by the edge of the *superior duodenal fold*, which presents the free semilunar base turned below. The summit of the fold is lost above in the inferior layer of the transverse mesocolon, its left side passes over into prerenal peritoneum, and its right side on to the duodenum and left leaf of mesentery.

The fossa is limited in front by this fold, to the right by the duodenum and is stopped above by the body of the pancreas and rests on the second lumbar vertebra in the angle formed by the left renal vein crossing the aorta. Its greatest depth is 2 cm. This fossa is always vascular, *i. e.* is related to the inferior mesenteric vein which passes to its left along its adherent parietal border and disappears under the pancreas; sometimes it enters the free fold covering the orifice.

3. The *duodeno-jejunal or mesocolic fossa.* This is found in 16 per cent.; it does not coexist with any other. Its existence necessitates that the duodeno-

jejunal angle should penetrate the root of the transverse mesocolon. This occurs in two forms: (1) a single simple fossa (Fig. 619), and (2) a double fossa. Below the duodenum is the inferior mesenteric artery, giving off the colica sinistra; passing over the fossa is the inferior mesenteric vein. This was originally described by Huschke in 1844. In drawing the jejunum forward and to the right, the mesocolon being raised, the duodeno-mesocolic ligaments are seen stretched between the duodeno-jejunal angle and mesocolon. They seem to be layers of mesentery passing into the mesocolon. Limited by these folds and by the upper surface of the duodeno-jejunal angle and the inferior mesenteric vein there appears an almost circular opening leading into a deep fossa. This plunges into the mesocolon and occupies a retro-peritoneal space to the left of the second lumbar vertebra, limited above by the pancreas, on the right by the aorta, and on the left by the left kidney. In this cavity is the angle of the duodeno-jejunal flexure and higher up can be seen under it the left renal vein. The orifice admits the little finger and its depth is 2 or 3 cm.

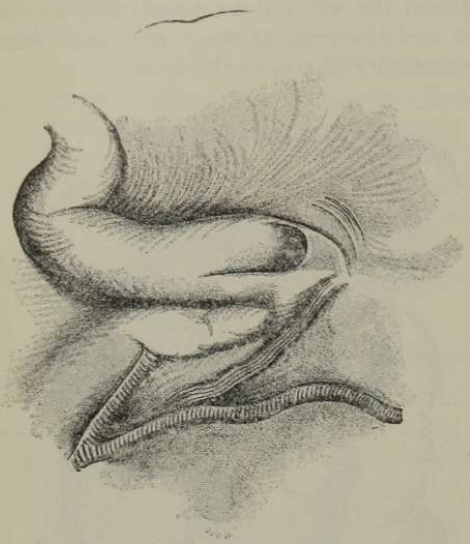

FIG. 619.—Simple duodeno-jejunal fossa. (Jonnesco.)

The inferior mesenteric vein passes at first along the adherent mesocolic border of the left fold and then its concavity crosses near the orifice.

Jonnesco has seen one case of a double duodeno-jejunal fossa where there were three ligaments. All these are related to the inferior mesenteric vein.

It is not believed that any of these are pathological. They are more or less developed in children and new-born.

Classification.

I. Duodenal fossæ (may coexist).	Inferior	Non-vascular most often. If vascular, is the fossa of Treitz.
	Superior	Always vascular, simple venous.
II. Duodeno-jejunal or mesocolic fossa (never coexists with the preceding).	Simple	Always vascular, venous.
	Double	

Fossa Intersigmoidea.

Under the name *intersigmoid* or *subsigmoid fossa*, Treitz described a funnel-shaped recess of the peritoneum, commonly found in the fœtus, next most often in the child, and rather rarely in the adult. Its mouth opens below in the left iliac fossa on the left side of the root of the mesentery of the sigmoid flexure. To find it, turn the flexure over to the right (Fig. 620).

The opening usually lies upon the left external iliac vessels at the interval between the edges of the Iliacus and Psoas muscles.

The pouch runs up under the parietal peritoneum of the posterior abdominal wall and ends blind at the point of division of the inferior mesenteric artery into the colica sinistra and its descending branch. More often the fossa is incompletely subdivided by a falciform projection of the wall. Sometimes two separate fossæ extend from a single opening. Probably the fossa is formed by the separation of the two layers of the peritoneum behind the descending colon which

formerly made the descending mesocolon. On the right side the *subcæcal fossa* is made in a similar way.

"The Psoas minor muscle can raise the peritoneum into a fold by the spreading out of its tendon of insertion into the fascia iliaca; at the side of this a peri-

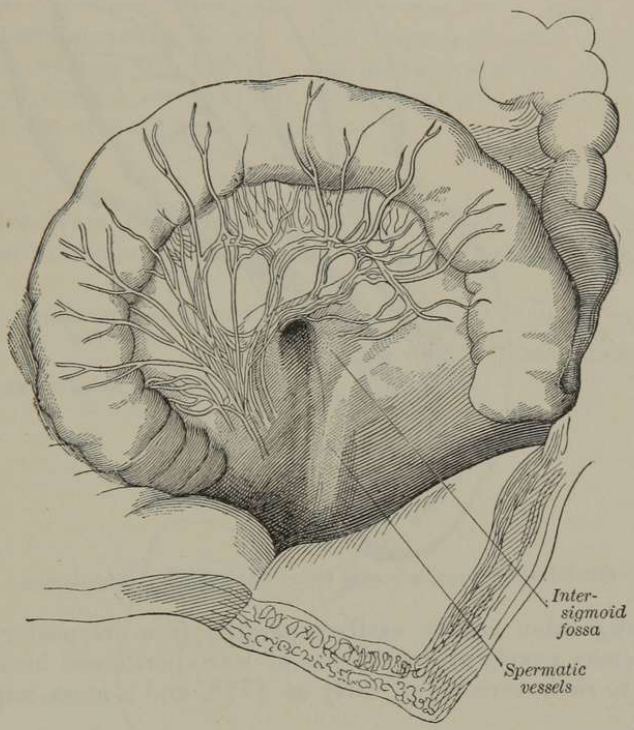

FIG. 620.—Fossa-intersigmoidea. Sigmoid flexure of a new-born, drawn upward. (Henle).

toneal fossa may exist which in some cases receives a part of the descending colon." Biesiadecki, who described it, gave it the name *fossa iliaco-subfascialis*. This fossa, of course, is of slight importance.

Pericæcal Fossæ.

At least three fossæ are to be found in the cæcal region. There is no agreement upon their frequency and nomenclature. Just above the ileo-colic junction between the end of the ileum and ascending colon, bounded in front by an ileo-colic fold may be the *ileo-colic fossa*, also called *superior ileo-cæcal*. (Luschka.)

It is just where the mesentery changes into the peritoneal coat of the ascending colon. It is smaller and less constant than the next.

Underneath the ileum, between it and the cæcum, is the *ileo-cæcal fossa*, which may be called the *inferior ileo-cæcal*, and has been described as the subcæcal. It lies between two definite folds of peritoneum, the formation of which requires explanation. Originally in the human fœtus there were three folds passing between the contiguous surfaces of the ileum and cæcum. These are normal in the spider monkey (Fig. 621).

They are called *anterior vascular*, *posterior vascular*, and intermediate *non-vascular folds*. In the human subject the anterior vascular and the middle non-vascular folds unite on the cæcum, but do not descend upon the appendix; the posterior vascular fold with its contained posterior ileo-cæcal artery passes to the appendix and forms its mesentery. The space left between this fold behind and the middle non-vascular fold in front is the ileo-cæcal fossa (Fig. 622).

The *subcæcal fossa* is directly behind the cæcum; it is really post-cæcal. Its fundus may pass up behind the ascending colon, *i. e.* the cæcum in descending

from its subhepatic position has never contracted extensive adhesions to the posterior abdominal wall, and a fossa is left between the layers of its mesocolon.

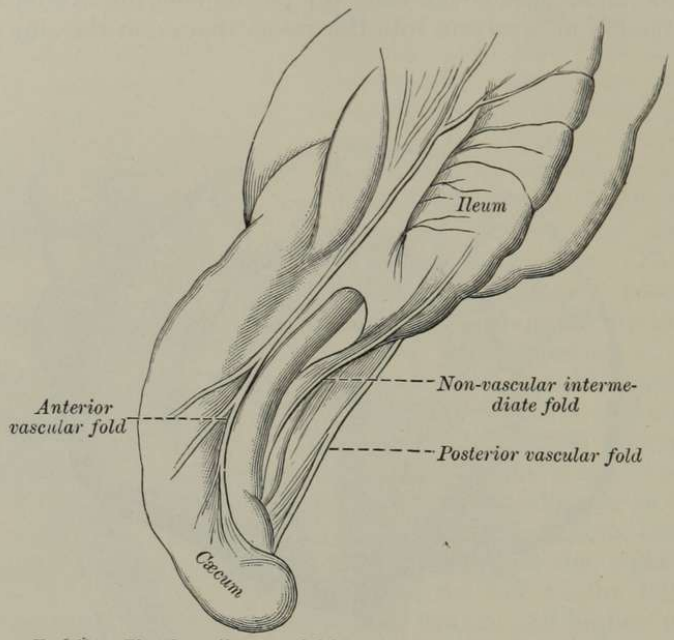

FIG. 621.—The three ileo-cæcal folds of Ateles ater. (Huntington.)

The ascending colon can be easily separated from its posterior connections. These fossæ may nearly all be the site of retro-peritoneal herniæ. Attention was first called to such herniæ as early as 1778, and a most important work on

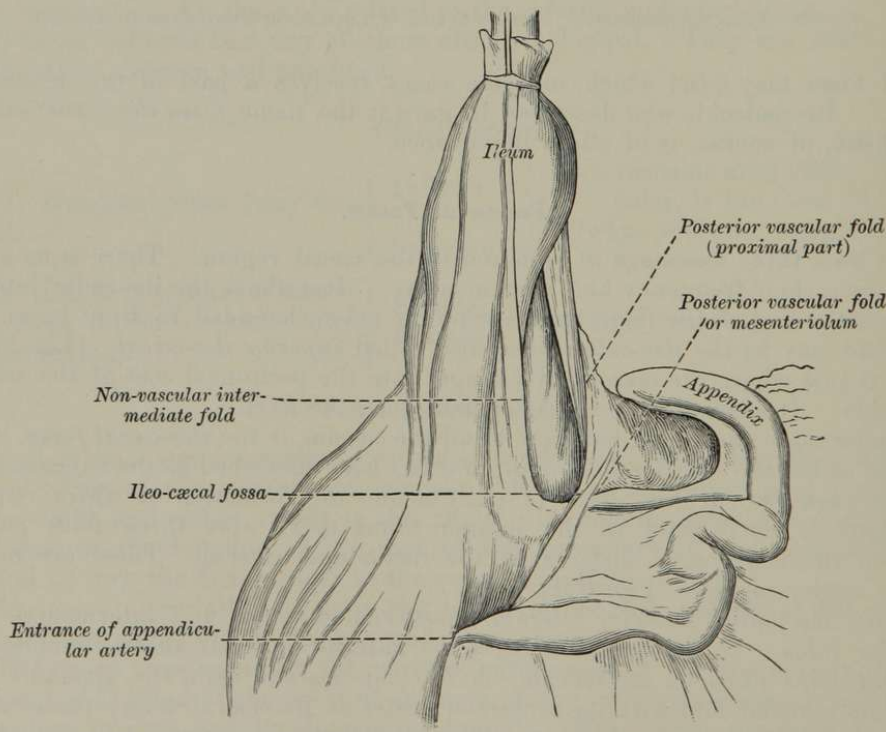

FIG. 622.—Human cæcum and ileo-colon, showing ileo-cæcal fossa. (Huntington.)

the subject appeared in 1857 by Treitz, who described the fossa of his name and reported cases of "retro-peritoneal" herniæ through his fossa.

Such cases are sometimes seen in the dissecting-room, say about 3 in 1000 subjects.

Contents of the Abdominal Cavity.

They are intra-peritoneal and retro-peritoneal, two groups. The stomach, small and large intestine, liver, and spleen receive a more or less complete investment of peritoneum, and are called intra-peritoneal organs. The other group, to which belong the kidneys, suprarenal capsules, pancreas, and great vessels are only covered on the side turned toward the abdominal cavity by parietal peritoneum and are retro-peritoneal.

THE STOMACH.

Form and Size (Figs. 623 and 624).—The stomach is a sac-like, pear-shaped dilatation of the alimentary canal placed between the œsophagus and beginning

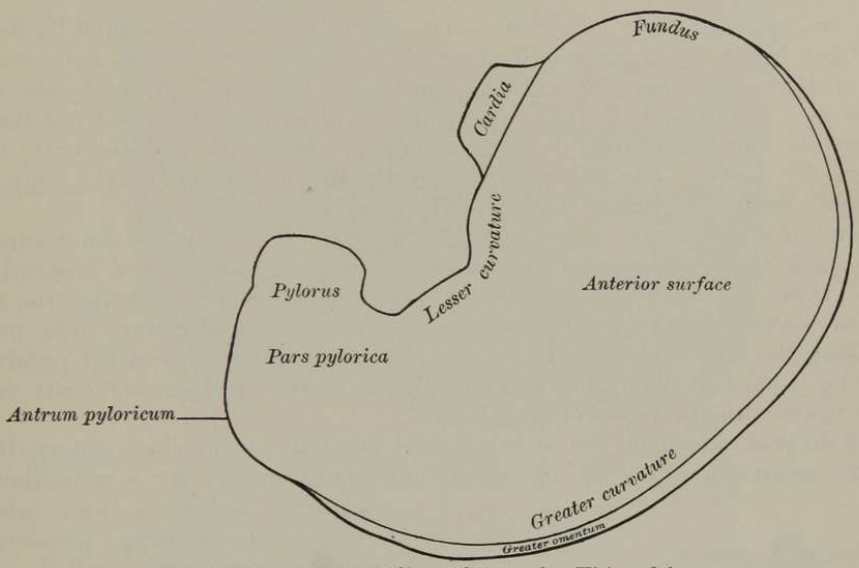

FIG. 623.—Anterior outlines of stomach. His' model.

of the small intestine. Its big end is directed above and to the left, to the diaphragm, its small end below and to the right. The beginning of the stomach or

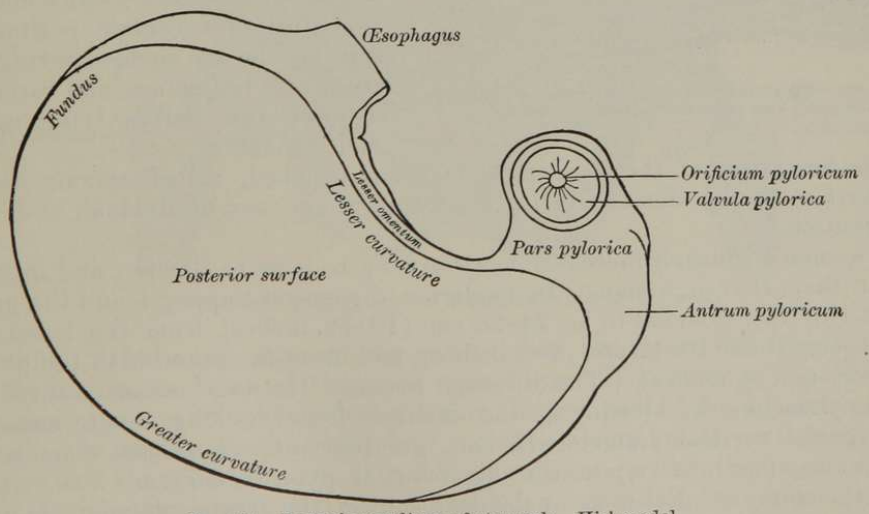

FIG. 624.—Posterior outlines of stomach. His' model.

its mouth is the *cardia* or *cardiac opening*, which passes from the œsophagus like

an inverted funnel without visible external limit. On the inner surface a definite line is seen between the œsophagus and cardia. Above the line the mucous membrane is whitish and made largely of pavement epithelium, while below the color is red and the mucous membrane shows characteristic cylindrical epithelium. Sometimes an external ring as well as an internal projection is found between cardia and the rest of the stomach, forming a kind of *antrum cardiacum*.

Passing from the cardia to the left and above, we find the first great pouch, the blind sac or *fundus*, whose relative size varies with age. In early youth it is slightly developed, in adult man it forms about one-fifth of the stomach.

This continues on the right into the *body of the stomach*, which has two surfaces—anterior and posterior—and two borders. The anterior surface looks upward and forward, the posterior backward and downward, and they are included between the borders *lesser curvature*, concave and turned to the right and above, and *larger curvature*, convex and three or four times as large as the lesser, turned to the left and below (Figs. 623 and 624).

At the right the body of the stomach gradually contracts toward its duodenal end. Then follows a second smaller part of the stomach, the *portio pylorica*, which includes the *antrum pyloricum*, whose form and size vary. Usually the antrum appears as a double pouch; the flatter one is higher and extends from the lesser curvature to the beginning of the duodenum. It is not very distinctly marked off from the body. The other lies laterally and is separated by a more or less deep notch from the greater curvature (Fig. 627).

Sometimes a third one is found under this last one. On the inner surface of the stomach there is sometimes a mucous fold, *plica præpylorica*, separating the antrum from the body of the stomach. The pouches representing the antrum pylori are caused by two flat ligamentous bands some millimeters wide, one running along the anterior wall, one on the posterior. They are called *pyloric ligaments* (lig. pyloricum) and lie between the muscular and serous coats and are closely fused with the latter (Fig. 627).

The division between the stomach and intestine is marked externally by a circular constriction, *sulcus pyloricus*, and more deeply by a muscular ring, *sphincter pyloricus*, and internally by a corresponding projection of mucous membrane called *valvula pylorica* or *pylorus* (Fig. 625).

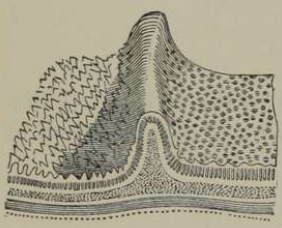

FIG. 625.—Diagrammatic view of coats of the stomach, duodenum, and pylorus. (Allan Thomson.)

The valve usually presents a round opening, bigger or smaller—*orificium duodenale*—which may have a central or eccentric position. It may not be an enclosing ring but a crescentic projection, and rarely consists of two halves lying opposite each other.

The first part of the duodenum is often pouched, called *antrum duodeni*.

The *size* of the stomach varies according to age, sex, individual, and degree of distention.

A woman's stomach increases more in length, is more slender, and in general smaller than that of a man. In moderate distention Sappey found the greatest diameter of the stomach to be 24–26 cm. (10–12 inches), from the lesser to the greater curvature 10–12 cm. (4–5 inches), and from the anterior to the posterior wall 8–9 cm. (3½ inches). The distance between the two orifices is three to six inches. Luschka, by blowing up the stomach, found its long axis to measure 34 cm., greatest vertical diameter 15 cm., greatest antero-posterior diameter 11.5 cm., and smallest antero-posterior diameter, at pylorus, 3.7 cm.

In the empty condition, as in the dead subject, the greatest diameter is reduced to 18–20 cm., the second diameter is 7–8 cm., and the third disappears as the two walls touch.

The weight of the freed stomach is in the male about four and a half ounces. Its normal capacity in the adult male is 2.5–4 litres (5–8 pints).

A blown-up stomach dried contained 5 pounds of water, female; and 8 pounds, male.

Position and Relations of the Stomach.

It lies in the epigastric region and left hypochondrium, rarely in the right hypochondrium, about five-sixths to the left of the median line, and one-sixth to

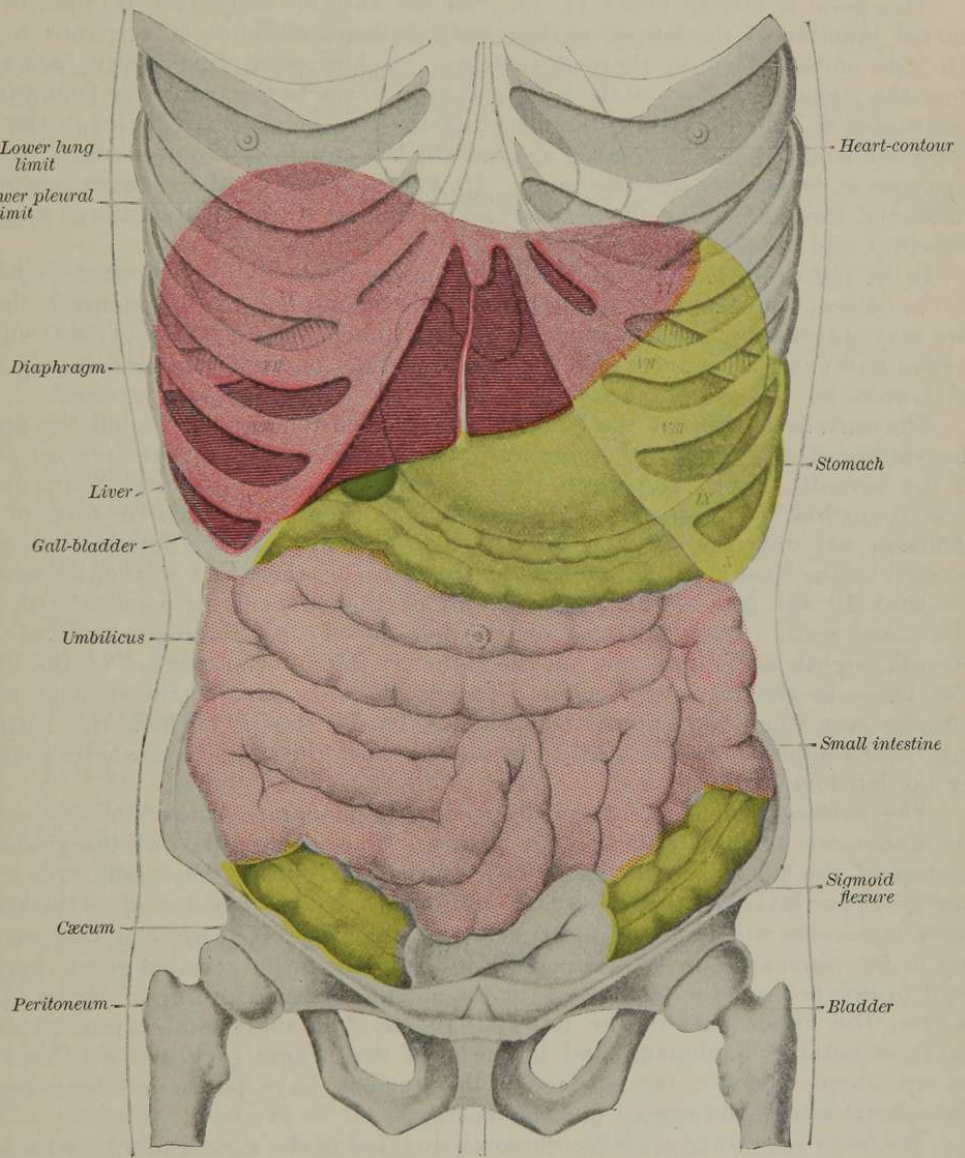

FIG. 626.—Relations of the abdominal viscera. (Joessel.)

the right. Of the left segment the greater part lies in the left hypochondrium, viz. the cardia, fundus, and the most curved part of the body; the rest of the body and a part of the pars pylorica fall in the left part of the epigastrium. The only part belonging to the right half includes a very small portion of the pars pylorica and the pylorus. The stomach then lies under the diaphragm and liver, above the jejunum, ileum, and transverse colon, extending its greater part into the left hypochondrium and smaller part into the epigastrium between the spleen on the left and gall-bladder on the right. It does not lie transversely nor yet so

vertically as Luschka puts it, unless in the infant or in the female deformed by corsets. It is directed from above and the left downward and forward to the right. An empty stomach may hang nearly vertically and present an anterior and a posterior surface, but there is usually some obliquity. If the small intestines are much distended it may be transverse, or if rigor mortis be rapid it may be cylindrical, especially below.

In moderate distention the *cardia* lies 2–3 cm. (1 inch) below the œsophageal opening of the diaphragm (Fig. 626).

This point is distant about 11 cm. from the anterior body-wall, is opposite the sternal junction of the left seventh costal cartilage, and that corresponds to the left side of the eleventh thoracic vertebra. A horizontal line drawn backward from the ziphoid cartilage to the vertebral column marks the transition from cardia to œsophagus. The fundus is 3–5 cm. higher than the cardia. It lies in the left hypochondrium and, if distended, against the left cupola of the diaphragm, which separates it from the overlying lung. Its highest point on the cadaver reaches a horizontal line connecting the sternal end of the left sixth costal cartilage and the vertebral end of the tenth rib.

In its full condition the fundus lies upon the upper half of the inner surface of the spleen, connected by the gastro-splenic omentum. A full stomach therefore may intrude upon respiration, or it may touch the left part of the central tendon and exert an influence on the heart's action, or may compress the big vessel trunks on the vertebral column.

The *anterior surface* of the body of the stomach touches on the left the posterior surface of the anterior thoracic wall, where it is covered by the anterior parts of the seventh, eighth and ninth ribs. The part of the lesser curvature lying next is covered by the liver. Thus one finds in the so-called *gastric fossa* of the abdomen not only the stomach but the liver in front of it. Between the part covered by the liver and that covered by the left ribs, there is a triangular section of about 40 sq. cm. of the anterior wall of the stomach in contact with the abdominal wall. It is bounded on the left by the cartilaginous ends of the seventh, eighth and ninth ribs, on the right by the anterior margin of the liver, and below by the transverse colon. This is the only part of the stomach to be actually seen when the subject is opened. This is the part which the surgeon can readily approach in operation. In the new-born the stomach is wholly covered by the left lobe of the liver.

The *posterior surface* of the body covers, in moderate distention, the end of the transverse colon and its splenic flexure. The greater part of the posterior surface of the stomach rests on a "bed" formed largely by the transverse colon and its upper layer of mesocolon. If the organs are hardened *in situ*, the transverse mesocolon will be found to present a concavity directed upward, corresponding to the convex shape of the stomach, and thus the latter receives great support. Still in this bed are the pancreas with the splenic vessels running along its upper border, the upper part of the left kidney, the left suprarenal capsule, spleen, bursa omentalis, duodenum, and left crus of diaphragm (Fig. 680). Cases are known where ulcers on this surface of the stomach have perforated branches of the splenic artery and caused fatal hæmorrhage.

The *lesser curvature*, with its concavity directed to the right and upward toward the under surface of the liver, descends in front of the vertebral portion of the diaphragm at first quite obliquely along the left side of the eleventh and twelfth thoracic vertebræ, then crosses the vertebral column at the level of the first lumbar vertebra, and then ascends into the pylorus. The *greater curvature* forms a convex arch directed below. In moderate distention it crosses the epigastrium in a line which connects the cartilages of the two ninth or tenth ribs. This line usually lies two fingers' breadth above the umbilicus. In great distention the great curvature can reach it, and in pathological cases can descend far below it. The portio pylorica, bent backward and outward, lying in the epigastrium, is covered by the quadrate lobe of the liver. The pylorus is to the right and some-

what below the ziphoid process between the sternal and parasternal lines on a level with the upper edge of the first lumbar vertebra. This may extend into the right hypochondrium. In an empty, fasting stomach these relations are all changed and the surfaces of contact are small. In a well-filled stomach a twist of the organ occurs, so that the anterior surface comes to be more superior and the posterior surface more inferior. The lesser curvature is more directed toward the vertebral column and the greater curvature toward the anterior abdominal wall. The pylorus also moves more to the right.

Relations of Stomach in Detail.

Cardia, opposite left 7th chondro-sternal junction.

Fundus reaches left 6th costal cartilage and left cupola of diaphragm.

Pylorus reaches upper border of 1st L. vertebra to the right of the median line.

Lowest edge of greater curvature in median line reaches to within two fingers' breadth of the umbilicus.

Anteriorly:

Diaphragm;
Thoracic wall formed by anterior parts of 7th, 8th, and 9th ribs;
Quadrate and left lobes of liver;
Anterior abdominal wall.

Posteriorly, or "bed:"

Diaphragm;
Left crus of diaphragm;
Aorta and vena cava inferior;
1st lumbar vertebra;
Cœliac axis;
Bursa omentalis (lesser sac);
Splenic flexure of colon;
Transverse colon;
Transverse mesocolon (upper layer);
Gastric surface of spleen;
Left kidney and capsule;
Pancreas;
Splenic vessels;
4th part of duodenum.

Right End:

Junction of transverse colon and under surface of liver.

Left End:

Spleen;
Diaphragm.

The peritoneal relations of the stomach have in general been described. It presents double "peritoneal lines" on both curvatures and fundus, showing the cut edges of peritoneum. Above, in front of the cardia is the attachment of the gastro-phrenic ligament running down along the lesser curvature as the anterior layer of the lesser omentum. Behind it, separated by a linear space where the stomach is uncovered, is the line for the posterior layer of the lesser omentum. Larger triangular spaces are left uncovered at either end of the stomach. On the greater curvature is the double line indicating the two layers of the anterior lamella of the great omentum running on the left into the two lines of the gastro-splenic omentum.

Points of Fixation of the Stomach.—It is a part very well secured, especially by the œsophagus fastened to the diaphragm and by the duodenum firmly bound

to the vertebral column. Some peritoneal folds also aid, as the lig. phrenico-gastricum connecting the cardia to the diaphragm. To the right this joins the lesser omentum, which is very thin, but farther to the right is the strong lig. hepato-duodenale, which confines the pylorus. The great omentum and gastro-splenic afford no fixation to the stomach. The spleen has no firmness of position, so the stomach gains nothing by that attachment. The great omentum hangs free in front of the intestines, and could only modify the position of the stomach when caught in a hernia.

Alterations in Position.—There is no organ in the body the position and connections of which present such frequent alterations as the stomach. *During inspiration* it is displaced downward by the descent of the Diaphragm, and elevated by the pressure of the abdominal muscles during expiration. Its position in relation to the surrounding viscera is also changed according to the empty or distended state of the organ. *When empty* it lies at the back part of the abdomen, some distance from the surface. The left lobe of the liver covers it in front, and the under surface of the heart rests upon it above and in front, being separated from it by the left lobe of the liver, besides the Diaphragm and pericardium. This close relation between the stomach and the heart explains the fact that in gastralgia the pain is generally referred to the heart, and is often accompanied by palpitation and intermission of the pulse. *When the stomach is distended* the greater curvature is elevated and carried forward, so that the anterior surface is turned upward and the posterior surface downward, and the stomach brought well against the anterior wall of the abdomen.[1] The Diaphragm at the same time is forced upward, contracting the cavity of the chest; hence the dyspnœa complained of, from inspiration being impeded. The heart is also displaced upward; hence the oppression in this region and the palpitation experienced in extreme distention of the stomach. *Pressure from without*, as from tight lacing, pushes the stomach down toward the pelvis. In disease also the position and connections of the organ may be greatly changed, from the accumulation of fluid in the chest or abdomen or from alteration in size of any of the surrounding viscera.

Structure.—Its walls are composed of four coats named in order—serous, muscular, submucous or areolar, and mucous.

The *serous coat*, peritoneum, is thin, smooth, and moist, allowing some mobility of the organ. It encloses the stomach between two layers, derived from the lesser omentum. Where the layers come upon the surface and leave it again—greater and lesser curvature—they lie loosely and leave a small interspace, in which blood-vessels, nerves, lymph-vessels and glands, take their course. Elsewhere the serous layer is held so tightly by *subserous tissue* to the muscular coat that it can only be removed artificially in small bits. There is a small posterior area near the cardia not covered by peritoneum which touches the diaphragm.

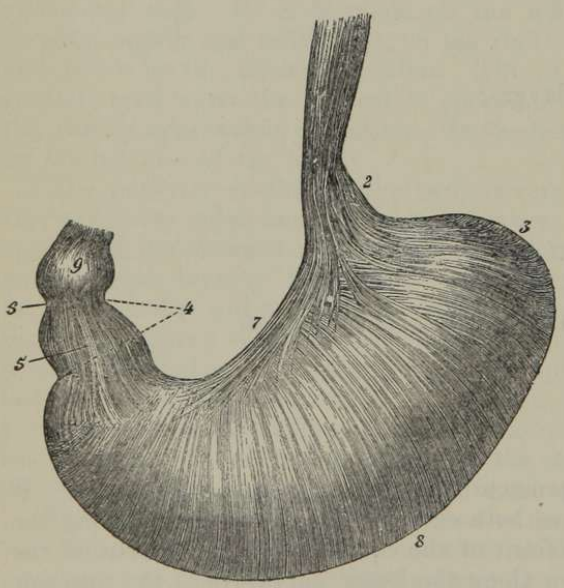

FIG. 627.—The external muscular coat of the stomach. (Luschka.) 1. Œsophagus. 2. Cardia. 3. Fundus. 4. Pars pylorica. 5. Lig. pyloricum. 6. Sulcus pyloricus. 7. Lesser curvature. 8. Greater curvature. 9. Antrum duodeni.

Musculature.—Three sets of unstriated muscular tissue are here included—longitudinal, circular, and oblique. Their purpose is to set the stomach contents in motion, to push them on, and to empty glandular secretion.

The external or *longitudinal layer* is very incomplete and is directly continuous with the longitudinal fibres of the œsophagus (Fig. 627). There is a connected layer on the outer side of the cardia, from which fibres

[1] This is denied by Dr. Lesshaft of St. Petersburg, who states that "if the stomach is enlarged, no one part can be alone displaced, but all parts are equally moved by the distention" (*Lancet*, March 11, 1882, p. 406).

stream outward in all directions with unequal lengths. They are thickest along the lesser curvature. At the fundus and anterior and posterior walls there are only a few delicate bundles which seem to pass deeply between the circular fibres. The substantial longitudinal layer is united at the pylorus, where it is firmly bound to the serous coat and wholly covers the circular layer. To this layer belong the *ligamenta pylorica*. This layer passes over the pylorus to the duodenal wall. The longitudinal layer stands in closest relation to the apertures of the stomach.

Circular fibres cover the whole length of the stomach in an uninterrupted layer, but they are not everywhere collected with the same thickness and strength (Fig. 628). They are fewest on the fundus, where there is a sort of whorl. They pass along the stomach in circles at right angles to its axis, and become thickest at the pylorus, where they form the sphincter pyloricus. On the margin of the duodenum they abruptly cease. Above they seem connected with the circular coat of the œsophagus. By this set the peristaltic movements of the stomach are produced, carrying the contents to the pyloric end, where is experienced a strong compression and after that a relaxation of the antrum pyloricum and of the pylorus, and then the longitudinal fibres can exercise their expulsive strength on the whole circumference.

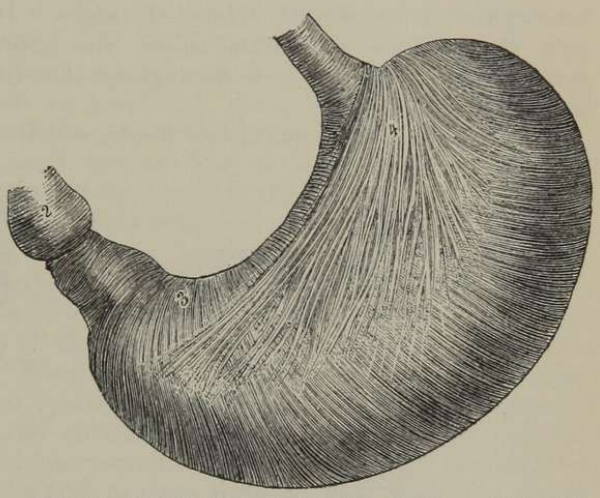

FIG. 628.—Musculature of the stomach from within. The stomach has been turned inside out. Circular and oblique fibres. (Luschka.) 1. Œsophagus. 2. Antrum duodeni. 3. Circular fibres. 4. Oblique fibres.

The *oblique fibres*, like the longitudinal, form an imperfect layer. They lie under the circular layer, and are thought to be derived from it. They can best be seen when the stomach is turned inside out and the mucous membrane is removed. This group is said to have no counterpart in any region of the digestive tract. They are not believed to represent the ring fibres of the œsophagus. They form a loose layer to the left of the cardia and pass superiorly and posteriorly toward the greater curvature. The upper edge of these fibres forms a raised ligamentous strip on either side of the lesser curvature, about a finger's breadth below it; this goes in a flat curve (seen on inner surface of stomach) from the left of the cardia on both sides toward the *portio pylorica*. At the apex of the fundus and toward the greater curvature the fibres grow smaller and paler. The bundles are apt to split into a sort of wicker-work, leaving longitudinal clefts. Delicate fibres run from these to the submucosa and to the circular fibres.

These fibres seem able to bring nearer together the cardia and pylorus, the greater and lesser curvatures, and also the contiguous surfaces of the anterior and posterior walls, resulting in the function of the pharyngeal groove in ruminants. A sort of half canal is formed along the lesser curvature, where fluid could be sent directly from œsophagus to pylorus or various juices could be sent in the opposite direction.

The *submucous coat* consists of loose, filamentous, areolar tissue, connecting the mucous and muscular layers, thus allowing free movement to the former. It supports the blood-vessels previous to their distribution to the mucous membrane. The rugæ of the stomach involve the mucous and submucous coats.

The *mucous membrane* is thick, its surface smooth, soft, and velvety. In the fresh state it is of a pinkish tinge at the pyloric end, and of a red or reddish-

brown color over the rest of its surface. In infancy it is of a brighter hue, the vascular redness being more marked. It is thin at the cardiac extremity, but thicker toward the pylorus. During the contracted state of the organ it is thrown into numerous plaits or rugæ, which for the most part have a longitudinal direction, and are most marked toward the lesser end of the stomach and along the greater curvature. These folds are entirely obliterated when the organ becomes distended.

Structure of the Mucous Membrane.—When examined with a lens the inner surface of the mucous membrane presents a peculiar honeycomb appearance, from being covered with small shallow depressions or alveoli of a polygonal or hexagonal form, which vary from $\frac{1}{100}$ to $\frac{1}{200}$ of an inch in diameter, and are separated by slightly elevated ridges. In the bottom of the alveoli are seen the orifices of minute tubes, the *gastric follicles*, which are situated perpendicularly side by side throughout the entire substance of the mucous membrane.

The gastric glands are of two kinds, which differ from each other in structure,

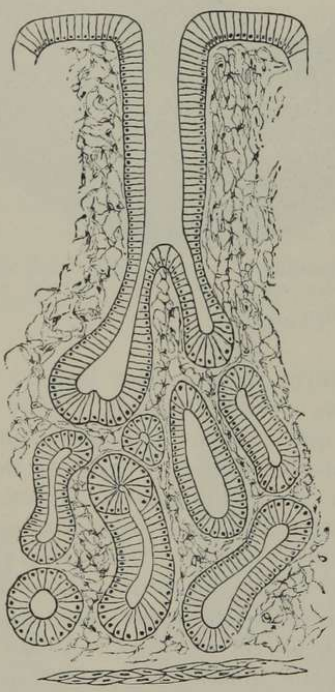

FIG. 629.—Pyloric gland.

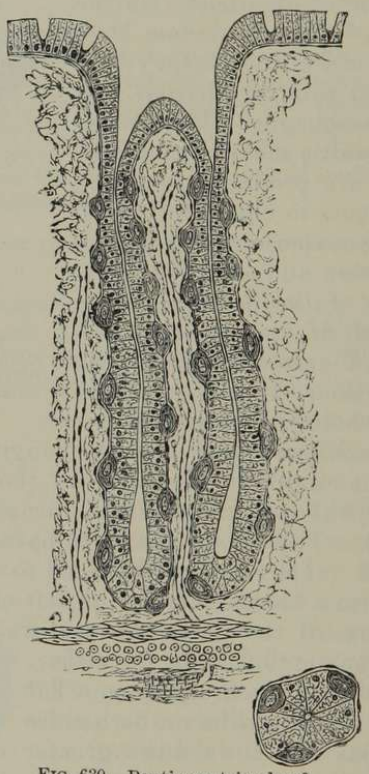

FIG. 630.—Peptic gastric gland.

and it is believed also in the nature of their secretion. They are named respectively *pyloric* and *peptic glands*. They are both tubular in character, and are formed of a delicate basement membrane, supporting epithelium. The basement membrane consists of flattened transparent endothelial cells, with processes which extend and support the epithelium. The *pyloric glands* (Fig. 629) are most numerous at the pyloric end of the stomach, and from this fact have received their name. They were formerly termed mucous glands, and were supposed to secrete mucus; but, as Klein points out, "the cells are serous, not mucous, and the secretion of the glands cannot therefore be mucus." They consist of two or three short closed tubes opening into a common duct, the external orifice of which is situated at the bottom of an alveolus. The cæcal tubes are wavy, and are of about equal length with the duct. The tubes and duct are lined throughout with epithelium, the duct being lined by columnar cells continuous with the epithelium lining the surface of the mucous

membrane of the stomach, the tubes with shorter and more cubical cells, which are finely granular. The *peptic glands* (Fig. 630) are found all over the surface of the stomach. Like the pyloric glands, they consist of a duct into which open two or more cæcal tubes. The duct, however, in these glands is shorter than in the other variety, sometimes not amounting to more than one-sixth of the whole length of the gland; it is lined throughout by columnar epithelium. At the point where the terminal tubes open into the duct, and which is termed the neck, the epithelium alters, the cells becoming much shorter and opaque: the lumen also becomes suddenly constricted, and is continued down to the bottom of the tubes as a very fine channel. Here also are found, between the epithelium and the basement membrane, large spheroidal, coarsely granular cells, which were formerly termed *peptic cells*, and which produce an outward bulging of the basement membrane. They are seen throughout the remainder of the tube at intervals, and give it a beaded or varicose appearance. Below the neck the terminal tubes, in addition to these isolated spheroidal cells, are occupied with finely granular, angular cells (columnar, Klein), leaving only a small channel in the centre. They are continuous with the short columnar cells of the neck, and are termed the *central* or *chief cells*, because they are believed to be principally concerned in the secretion of the gastric juice. The peptic cells, which were formerly supposed to possess this office, are now termed *parietal* or *oxyntic cells*. Between the glands the mucous membrane consists of a connective tissue framework, with lymphoid tissue. In places this latter tissue, especially in early life, is collected into little masses, which to a certain extent resemble the solitary glands of the intestine, and are by some termed the *lenticular* glands of the stomach. They are not, however, so distinctly circumscribed as the solitary glands. The epithelium lining the mucous membrane of the stomach and its alveoli is of the columnar variety. Beneath the mucous membrane, and between it and the submucous coat, is a thin stratum of involuntary muscular fibre (*muscularis mucosæ*), which in some parts consists only of a single longitudinal layer; in others, of two layers, an inner, circular, and an outer, longitudinal.

Vessels and Nerves.—The arteries supplying the stomach are—the gastric, the pyloric and right gastro-epiploic branches of the hepatic, the left gastro-epiploic and vasa brevia from the splenic. They supply the muscular coat, ramify in the submucous coat, and are finally distributed to the mucous membrane. The arrangement of the vessels in the mucous membrane is somewhat peculiar. The arteries break up at the base of the gastric tubules into a plexus of fine capillaries which run upward between the tubules, anastomosing with each other, and ending in a plexus of larger capillaries, which surround the mouths of the tubes and also form hexagonal meshes around the alveoli. From these latter the *veins* arise, and pursue a straight course backward between the tubules, to the submucous tissue, and terminate either in the splenic and superior mesenteric veins or directly in the portal vein. The *lymphatics* are numerous; they consist of a superficial and deep set, which pass through the lymphatic glands found along the two curvatures of the organ. The *nerves* are the terminal branches of the right and left pneumogastric, the former being distributed upon the back, and the latter upon the front part of the organ. A great number of branches from the sympathetic also supply the organ.

Surgical Anatomy.—Operations on the stomach are frequently performed. By "gastrotomy" is meant an incision into the stomach for the removal of a foreign body, the opening being immediately afterward closed—in contradistinction to "gastrostomy," the making of a more or less permanent fistulous opening. *Gastrotomy* is probably best performed by an incision in the linea alba, especially if the foreign body is large, by a cut from the ensiform cartilage to the umbilicus, but may be performed by an incision over the body itself, where this can be felt, or by one of the incisions for gastrostomy, to be mentioned immediately. The peritoneal cavity is opened, and the point at which the stomach is to be incised decided upon. This portion is then brought out of the abdominal wound and sponges carefully packed around. The stomach is now opened by a transverse incision and the foreign body extracted. The wound in the stomach is then closed by Lembert's sutures—*i. e.* by sutures passed through the peritoneal and muscular coats in such a way that the peritoneal surfaces

on each side of the wound are brought into apposition, and in this way the wound is closed. *Gastrostomy* is performed in two stages: The first stage consists in opening the peritoneal cavity and stitching the stomach to the abdominal wall. The second stage consists in opening the stomach after a few days have elapsed and adhesions formed between the peritoneal surfaces of the stomach and abdominal wall. The operation is usually performed by an oblique incision about one finger's breadth below and parallel with the margin of the left costal cartilages, commencing an inch and a half from the median line and being about three inches in length. Some surgeons prefer a straight incision, beginning opposite to the end of the eighth intercostal space, and passing down for three inches over the Rectus abdominis muscle. The skin, fasciæ, and muscles are to be severally divided down to the peritoneum. Howse recommends that the sheath of the Rectus should be opened longitudinally, and the fibres of this muscle separated, and not cut, in the same direction, so as to secure a sphincter-like action around the opening. After the peritoneum has been opened the stomach is recognized by its pink-red color and smooth surface. It is to be pulled up into the wound and sutured to the opening. This may be done in several ways, but in whatever way it is done the following points should be carefully attended to: (1) In taking up the stomach only to pass the needle through the serous and muscular coats, and avoid puncturing the mucous membrane. (2) To take up plenty of the muscular coat. (3) In passing the needle through the parietes of the abdomen to be careful to include the parietal peritoneum. (4) To enclose a circle of the stomach at least an inch in diameter. If the symptoms admit of it, the parts are now to be left quiet for four or five days, and a small puncture is then to be made through the exposed portion of the stomach, and a gum elastic catheter passed through it into the viscus, through which fluid can be injected, in small quantities at first. In more urgent cases it may be necessary to make the opening much earlier.

Excision of the pylorus has occasionally been performed, but the results of this operation are by no means favorable, and in cases of cancer of the pylorus gastro-enterostomy is generally preferred. The object of this operation is to make a fistulous communication between the stomach, on the cardiac side of the disease, and the small intestine, as high up as is possible.

THE INTESTINAL CANAL.

This, in the form of a curved tube, passes uninterruptedly from the pylorus to the anus. It has a remarkable length of about six times the height of its possessor, though in the adult it may be independent of the age, height, or weight. In this relation man stands midway between the herbivores, *e. g.* rabbit with very long intestine, and carnivores, *e. g.* lion, whose intestine is three times the length of its body. There is some evidence to prove that vegetarians may have a longer intestine than those living on a mixed or a flesh diet. The wall of the intestine offers throughout a serous, muscular and mucous coat presenting many modifications, by which the upper four-fifths is distinguished as *small intestine* and the lower fifth as *large intestine*.

The Small Intestine.

By this term is understood the part of the alimentary canal extending from the pylorus to the ileo-cæcal valve. Its average length is about 8 metres or (Luschka) 25 feet, or 6 metres longer than the whole body; Treves says 22½ feet, and Quain 22 feet. The extremes found are 34 feet and 8 feet. Its circumference decreases from the stomach toward the large intestine from 12.8 cm. to 9.5 cm. Its capacity, inflated and dried, is 15 pints. The wall of the ileum is so thin and translucent that a newspaper may be read through it.

The small intestine is divided into three parts:

1. Duodenum (12-finger intestine);
2. Jejunum (empty intestine);
3. Ileum (curved or twisted intestine).

The Duodenum.

The *duodenum* begins at the sulcus pyloricus and ends at the *duodeno-jejunal angle* or *flexure*, where it becomes jejunum. It was named by Herophilus, but it possesses neither the length nor the breadth of twelve fingers.

A better name would be *intestinum pancreaticum* (Luschka) on account of its intimate relation to the pancreas. In the adult male its axial length is 30 cm. (or 10–12 inches), and its usual circumference 12 or 13 cm. (1.5 to 2 inches in diameter). Authors fail to agree on its direction and form.

1. French authors give three portions, ending it at the superior mesenteric vessels; superior horizontal, vertical, and inferior horizontal parts.

2. To this third part Henle, Krause, Quain, and others add a fourth oblique part ascending from right to left.

3. Luschka, His, and Braune describe an annular form.

4. Cruvielhier, Young, and Treves describe a fourth portion 2 cm. long, coming forward at the end of duodenum, by joining the duodeno-jejunal junction. They are all described as different types, of which, according to Jonnesco,[1] there are three.

1. *Annular* or *circular type*, infantile;
2. U-*shaped type*, } adult, rare in infant
3. V-*shaped type*, }

(Figs. 632 and 633).

The typical *annular* form is always found in the child up to about the age of seven (Fig. 631).

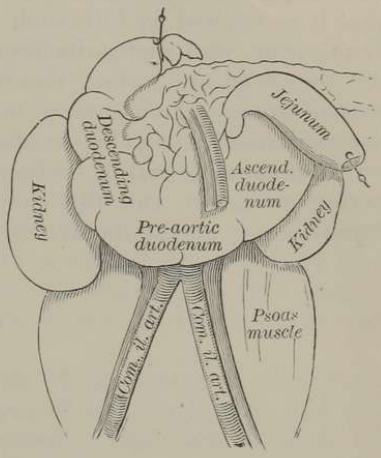

FIG. 631.—Annular duodenum. Infantile type, from boy of three years. (Jonnesco.)

The terminal point of this variety is strongly fixed to the left side of the first lumbar vertebra and is exactly on the same level as the beginning of the duodenum, and hence is behind the stomach (Fig. 634).

Between these points, the one fastened by the muscle of Treitz and the other by the hepato-duodenal ligament, the duodenum describes a regular curve in front of the vertebral column. This ring is filled and its margins overlapped by the

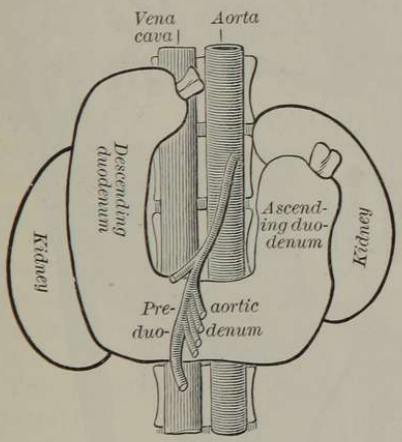

FIG. 632.—Duodenum in U. (Jonnesco.)

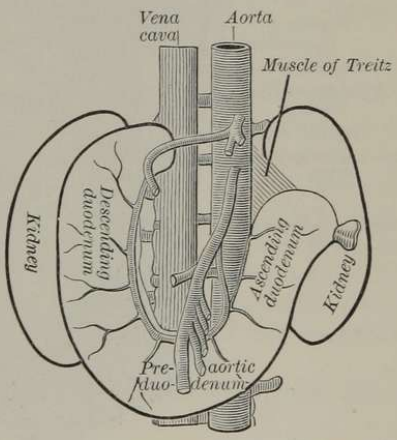

FIG. 633.—Duodenum in V. (Jonnesco.)

head of the pancreas, the neck of which is limited by the two extremities of the ring.

In the adult this type may be found, but the terminal point does not usually attain the same level that the origin has; it is pushed back more to the left as though the developing neck of the pancreas had forced the duodenal ring to open more widely for its lodgment.

Course of the Adult Duodenum.—Separated from the pylorus at the right of the upper edge of the first lumbar vertebra there is usually at first a bottle-shaped dilatation, the *antrum duodeni*. The direction of the *first portion* depends on the condition and length of the stomach and position of the pylorus. With an empty stomach the first part is nearly horizontal and transverse. With a distended stomach, it is nearly antero-posterior; its distal end is stationary and its proxi-

[1] "Anat. topographique du duodénum," Jonnesco, Paris, 1889.

mal end is not. In general, it is directed upward to the right and backward under the quadrate lobe of the liver and curves backward under the neck of the gall-bladder to make a sharp turn to the right surface of the lumbar column. This is the initial curve. It is so closely related to the liver and gall-bladder that it is stained by bile soon after death. Behind it are the common bile-duct, vena portæ, and gastro-duodenal artery. Behind and to the left is the neck of the pancreas, and below, the head of the pancreas. Its anterior surface and a part of its posterior surface near the pylorus are wholly covered by peritoneum, derived from the lig. hepato-duodenale. The length of this portion is so variable, "two inches" (Quain), "often almost inappreciable" (Jonnesco), that the latter author unites it and the curve which follows it under one name, the *superior hepatic curve* of the duodenum (Fig. 634). Placed on the vena cava inferior and

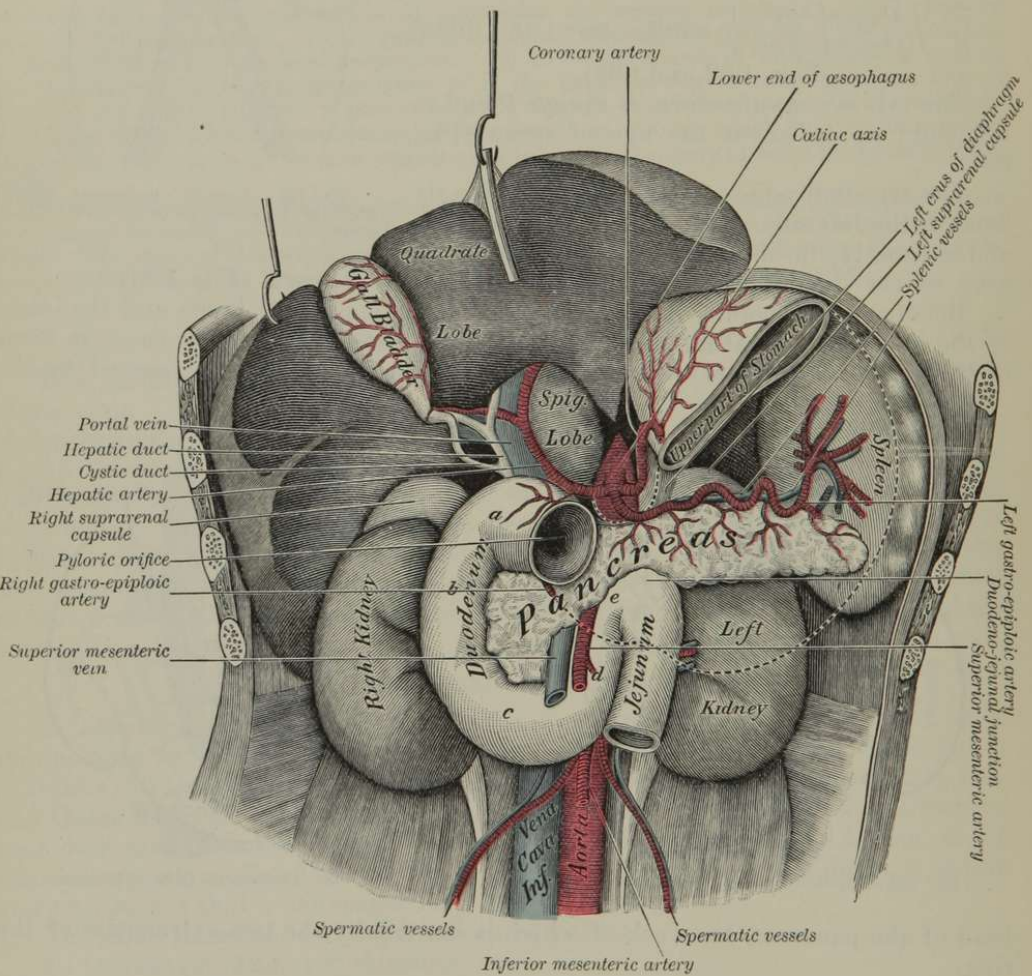

FIG. 634.—View of duodenum and its five parts, *a*, *b*, *c*, *d*, and *e*, and pancreas. The part of stomach removed is indicated by dotted lines. (Testut.)

right kidney, it next descends along the right side of the vertebral column a variable length, usually to the body of the fourth lumbar vertebra, starting from the right side of the first. This is called the *vertical*, *descending*, or *second portion*. It is three or four inches long and divided into two parts, *supracolic* and *infracolic*, since the transverse colon crosses its middle third. The two layers of transverse mesocolon (Fig. 679) leave an interspace uncovered by peritoneum where the approximated surfaces of duodenum and transverse colon touch except for a little areolar tissue. Above and below this place its anterior surface and

sides are covered with peritoneum. Above it is in contact with the right lobe of the liver, leaving its "impression." Posteriorly there is no peritoneum, areolar tissue connecting it with the kidney, vessels at its hilus, and vena cava. The pancreatic and common bile-ducts open into its postero-internal wall below the middle. The head of the pancreas is to its inner side.

Now the duodenum changes its direction and passes more or less horizontally from right to left in front of the great vessel-trunks and crura of the diaphragm, moulding itself over the third or fourth lumbar vertebra. This is the *transverse* or *pre-aortic portion* and is two or three inches long. The head of the pancreas is above it. It is crossed by the superior mesenteric vessels and mesentery. Its anterior surface is covered by the peritoneum of the mesentery, but is separated from it when the superior mesenteric vessels cross it from above. On the right its posterior surface has no peritoneal covering, but on the left the posterior layer of the mesentery may be prolonged behind it. In the middle line this part of the duodenum is situated at the point of divergence of the two layers of the root of the mesentery (Fig. 606).

Thence the duodenum ascends along the left side of the vertebral column and aorta, touches the left kidney, lies upon the left crus of the diaphragm, and ends at the left side of the second or first lumbar vertebra. This part is about two inches long and is called the *fourth* or *ascending portion.*

It often turns abruptly forward to unite with the jejunum and form the duodeno-jejunal angle. This terminal portion, about 2 cm. long (less than one inch), has been described as the fourth portion, but with the U-shaped duodenum it makes the *fifth* portion.

The duodenum begins with a short portion looking backward and ends with a short portion looking forward.

The five parts are—1. *Superior hepatic curve*, or pars superior horizontalis. 2. *Descending* or *vertical* portion. 3. *Pre-aortic* or *transverse* portion. 4. *Ascending* portion. 5. *Terminal* portion to form (6) the *duodeno-jejunal* angle.

When the above arrangement is complete, the duodenum has the form of the letter U, considering the second, third, and fourth portions (Figs. 632 and 634). When, however, the descending and ascending portions unite by a short curve or angle, the transverse portion is practically lacking, and the duodenum is then V-shaped (Fig. 633). The angle of the V is thrown to the right against the vena cava, and the ascending portion crosses the abdominal aorta at a sharp angle. The U-*shaped* duodenum usually descends to the fourth lumbar vertebra, and seems to occur in fœtal life when the ascending colon obstructs the way. The V-*shaped* duodenum usually descends to the fifth lumbar vertebra, and occurs when there is plenty of room and no obstruction by the descent of the ascending colon.

The lengths of the parts vary in the two types thus (measured from fifteen subjects):

	Duodenum— In U.	In V.
Superior curve	4 cm.	4 cm.
Descending portion	10.5 "	12 "
Pre-aortic portion	9.5 "	2 "
Ascending portion	7 "	13 "
	31	31

Peritoneal Relations of the Duodenum.—The duodenum is included among the extra-peritoneal viscera. In the fœtus it is completely invested, but the two layers of its mesentery have been separated or perhaps appropriated by the rapidly growing kidneys, and its posterior surface has adhered to the posterior abdominal wall. Its visceral layer has become parietal peritoneum. To get at this peritoneum it is necessary, on the cadaver, to practise certain manipulations: to disclose the initial superior parts, draw the hepatic flexure of the colon down and to the left, and lift up the anterior margin of the liver. The pylorus and supe-

rior curve of the duodenum can be seen attached to the liver by a ligament in which can be felt three cords, the *lig. hepato-duodenale*, and to the gall-bladder by a simple fold, the *lig. cystico-duodenale*.

Now pull toward the left this superior curve of the duodenum, and a deep space is formed bounded above by the right lobe of the liver. Below this is the right kidney, and to the left a series of organs all bound together by the same layer of peritoneum. The peritoneum covering the anterior surface of the right kidney passes from right to left, above, upon the vena cava inferior, thence behind an orifice, foramen of Winslow, into a large cavity which cannot be seen, the *atrium bursæ omentalis* (Fig. 635). As this layer covers the vena cava it passes to the posterior surface of the liver, and is the *lig. hepato-renale*. A little lower than this, where the vein is covered by the superior angle of the duodenum, the peritoneum from the kidney covers the right and anterior surface of the first portion and part of the surface of the descending portion, running below into the

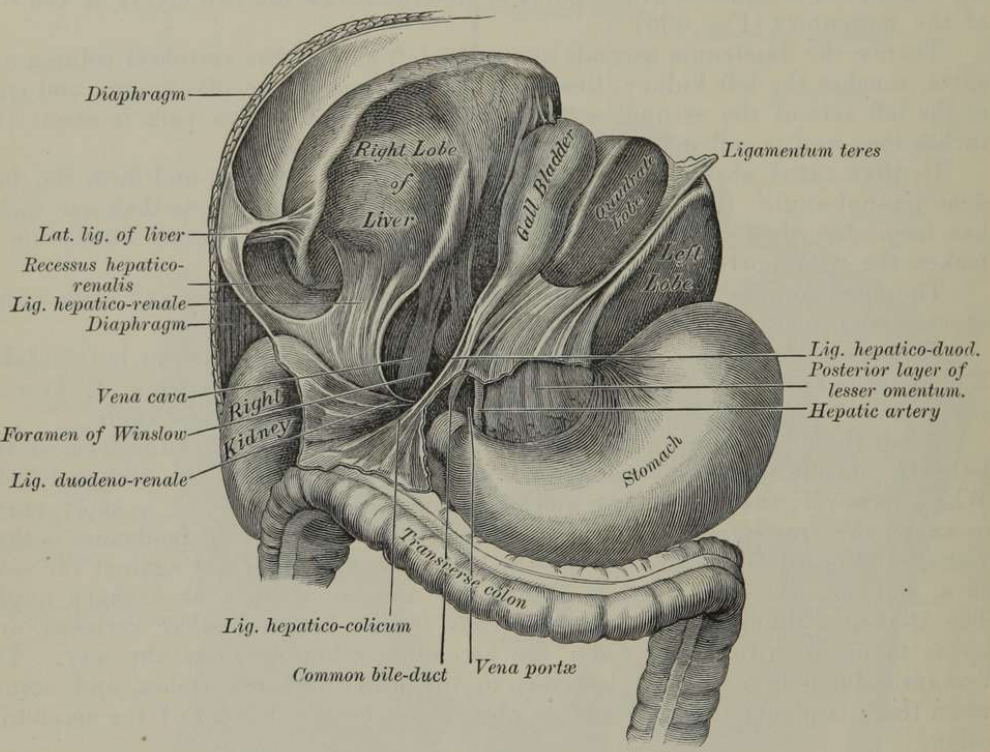

FIG. 635.—Peritoneal relations of the liver, first portion of duodenum, and entrance to the lesser sac. (Luschka).

gastro-colic part of the great omentum. Often the renal peritoneum passing to the first part of duodenum is raised into a fold, from the summit of the kidney to the summit of the curve of the duodenum, called *lig. duodeno-renale* (Huschke). Finally, still lower, where the hepatic flexure of the colon crosses about the middle of the descending duodenum, the renal peritoneum passes directly over the hepatic flexure of colon and fixes it. Three organs are thus bound together by a continuous layer, hepatic flexure of colon, duodenum, and right kidney. In other cases the hepatic flexure and ascending colon present a mesentery; here the renal peritoneum loses itself on the right leaf of this mesentery, which now covers in the descending duodenum. To see another side of the descending duodenum, incise the two anterior layers of the great omentum along the inner side of the duodenum and upper side of the transverse colon. This will open the bursa omentalis (Fig. 616). The large peritoneal surface which forms the posterior wall of this sac covers the pancreas and the left side of the descending duodenum. The rest of the duodenum still remains concealed under thick coverings. To see

the transverse and ascending portions and duodeno-jejunal angle, displace the intestines in two ways. Seize the lower end of the omentum and turn it and the transverse colon up over the chest-wall; then push the coils of the small intestine below and to the left. There is now uncovered a large peritoneal surface formed above by the lower layer of the transverse mesocolon, on the right by a layer of peritoneum to cover the ascending colon, on the left by the right layer of the mesentery, and below by the ileo-cæcal angle. Shining through this common layer one usually perceives a part of the duodenum, its inferior angle or transverse portion.

Sometimes none of it can be seen here; that means a low duodenum, and in order to disclose it, turn all the small intestines upward and to the right (Fig. 613). Then one sees perhaps a portion of the descending part, the pre-aortic part, and always the ascending part, and duodeno-jejunal angle, escaping from the mesocolon. It has been noticed that when the transverse colon is held vertically up above the body (the subject being supine) the transverse mesocolon forms a horizontal partition. It divides the peritoneal cavity into two chambers—a superior gastro-spleno-hepatic, and an inferior intestinal. The ceiling of the upper chamber is formed by the diaphragm, the sides by the inner surface of the short ribs, and the floor by the upper layer of the transverse mesocolon. The liver, spleen, and stomach form its contents. The inferior chamber is limited above by the lower layer of the transverse mesocolon, on the sides by the ascending and descending colons, below by the iliac fossæ, while the middle of this floor has been broken open to allow free communication between abdomen and pelvis. This chamber contains small intestines. The duodenum makes a bas-relief on the posterior walls of these two stories. The superior angle and a part of the descending portion is in the upper one; the rest of the descending portion, all the pre-aortic and ascending portion, and often the duodeno-jejunal angle, belong to the inferior story. Sometimes the duodeno-jejunal angle is in the thickness of the mesocolon forming the partition.

To describe the duodenal peritoneum of the lower chamber, reverse the great omentum as before, isolate the mesentery and hold it tense, then follow the course of its two layers. The left layer at first covers the part of the duodenum situated to the left of this mesentery and then proceeds to lose itself below in the right leaf of the sigmoid mesocolon, passing over the inferior mesenteric vessels; to the left it is continuous with the left prerenal peritoneum and right layer of peritoneum covering the descending colon; farther above, this layer passes over the left surface of the duodeno-jejunal angle and is continued into the inferior layer of the transverse mesocolon. The right leaf of the mesentery covers the duodenum to the right of this root and continues to cover the ascending colon; below it covers the ileo-cæcal angle. Above, it passes upon the inferior layer of the transverse mesocolon and on the right surface of the duodeno-jejunal angle. Sometimes the two leaves of the mesentery embrace the duodeno-jejunal angle, and, instead of immediately reuniting beyond, they leave a space between, forming the orifice of the duodeno-jejunal fossa. The duodenum is crossed by two mesenteries, the second portion by the transverse mesocolon, and the third or fourth portion by the root of the mesentery.

The first part of the duodenum is almost completely covered by peritoneum derived from the two layers of the lesser omentum. Only a part of its posterior surface near the vena cava and neck of the gall-bladder is uncovered. The supracolic part of the descending portion has no posterior covering. Its right and anterior surface are covered by peritoneum from the anterior surface of the right kidney; its left side is covered by peritoneum of the lesser sac. Next on its anterior surface is a non-serous region corresponding to the interspace between the layers of the transverse mesocolon. The infracolic part of the second portion is covered by the right leaf of the mesentery.

A part of the pre-aortic portion has only an anterior covering from the right leaf of the mesentery. Depending on the position of the radix mesenterii and

of the duodenum, the remaining parts would be covered anteriorly by the left leaf of mesentery until the intestine is called jejunum, when it is wholly invested by mesentery.

The different layers of mesocolon cannot be regarded as forming any covering in the above list, because their attachments are all secondary.

A persistence of the mesoduodenum is normal in many animals, abnormal in man.

Ligaments of the Duodenum.

These are peritoneal folds connecting it to neighboring viscera or to the posterior abdominal wall.

1. *Lig. suspensorium duodeni* or *lig. hepato-duodenale* is the right edge of the lesser omentum, and passes from the hilus of the liver to invest by two layers the first portion of the duodenum, except a part of its posterior surface.

2. *Lig. cystico-duodenale*, from the neck of the gall-bladder to the superior curve of the duodenum.

3. *Lig. duodeno-renale*, triangular in form, from the right surface of the superior curve of the duodenum to the summit of the right kidney. The lig. hepato-renale is posterior to this one.

4. On the left of the ascending duodenum, where the left layer of the mesentery runs into the lower layer of the transverse mesocolon or into prerenal peritoneum, one or two ligaments may limit certain fossæ: they are *lig. duodeno-mesocolica.*

For duodenal fossæ, see p. 994.

Relations of Duodenum.

The duodenum, occupying a fixed position against the posterior abdominal wall, comes into relation with all the abdominal organs except the spleen, which is fixed in the left cupola of the diaphragm. We may describe the relations with (1) Movable organs of the abdominal cavity, (2) Fixed organs of the posterior abdominal wall, (3) Lumbar skeleton.

(1) The relation with movable organs can be determined at once on opening the cavity. The *stomach*, in its empty state, touches by its antrum pylori the duodeno-jejunal angle (Braune), (Fig. 634). This occurs behind the posterior wall of the stomach, and the two are separated by the transverse mesocolon. If the stomach be distended the pylorus is deflected farther to the right, and the above relation is lost.

The *hepatic flexure of the colon* passes over the lower part of the anterior surface of the right kidney, and the beginning of the *transverse colon* over the middle part of the descending duodenum, as we have seen. The movable *small intestines*, being included in the ring of the colon, cover the duodenum as it lies in the lower chamber, and so render it almost inaccessible.

(2) The relations with fixed organs are with liver, the two kidneys, and the pancreas. The first and second portions are related to the *liver* and *neck of gall-bladder*. An impressio duodenalis is not always made on the quadrate lobe, although the first part of the duodenum passes under it. The initial curve is fixed at the inferior vena cava and neck of gall-bladder where the peritoneum is broken and the investment is incomplete. The *impressio duodenalis* is on the inferior surface of the right lobe to the right of the gall-bladder, to the left of the renal impression, and behind the colic impression.

In respect to the *kidneys*, not all authors speak of the left as being related. Luschka has always found the ascending duodenum related to the left kidney, as well as the descending duodenum to the right kidney, but the two duodenal parts always behave differently to their respective kidneys.

The descending duodenum is thrown strongly backward on the right of the lumbar column, and immediately meets the right kidney and suprarenal capsule as they all leave the liver. It then rests on the inner margin of the anterior surface

of the kidney and on the renal vessels at the hilus. Sometimes it only abuts against the inner margin, not covering its surface at all. This is thought to be due to a changed position of kidney and not of duodenum. The adhesion by connective tissue between the duodenum and kidney is especially close where the hepatic flexure crosses the kidney and then crosses the duodenum as transverse colon (Fig. 636).

In case the duodenum descends very low to the fifth lumbar vertebra, it then borders the lower extremity of the kidney. The relations of the ascending por-

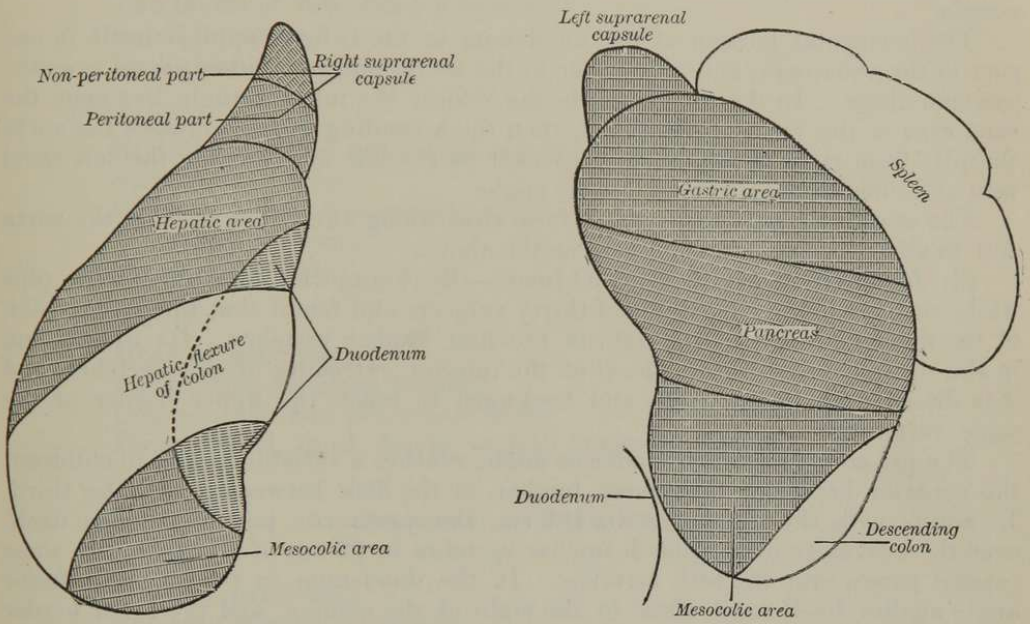

FIG. 636.—Diagram to show relations of duodenum to both kidneys.

tion with the left kidney are much more variable. A light traction from left to right displaces them. There are no adhesions, and the ascending duodenum glides easily over the subjacent tissue.

The annular or the U-shaped duodenum usually overlies the inner margin of the lower third or half of the left kidney; with the V-shaped duodenum, only the ascending portion or the duodeno-jejunal angle may touch the lower part of its inner margin. *Ureters* and *spermatic vessels* are covered on the two sides by the duodenal arch.

Between the duodenum and *pancreas* there exists not only a relation of contiguity but one of continuity of tissue, which is explained by the duodenal origin of the pancreas. The head of the pancreas fills the space limited by the duodenal arch and then escapes as the neck by the opening of the intestinal ring. It is to be noted that the head is always proportional in extent to the duodenum, and assumes the form allowed by that intestine. In the adult the head of the pancreas embraces the duodenum much as the parotid gland embraces the ramus of the lower jaw. It advances in front and behind, covering about one-half of the circumference of the intestinal wall, generally more anteriorly than posteriorly.

The second portion is much more enveloped than any other. Union between the intestine and pancreas is established by cellulo-fibrous tissue, by pancreatico-duodenal vessels, by excretory ducts, and perhaps by longitudinal muscular fibres from the intestines which run between the lobules of the gland. Verneuil and Treitz believe the duodenum holds the pancreas in place and not *vice versâ*.

By lifting all the viscera from the abdominal cavity, the vertebral column with its *prevertebral vessels* are disclosed behind the duodenum. There is the aorta, often a little to the left of the median line, which nearly always divides

at the fourth lumbar vertebra into its two primitive iliacs. A little to the right is the inferior vena cava, having just received the two common iliac veins. It also receives, behind the descending and ascending part of the duodenum, the renal veins—the right on the level of the lower part of the second lumbar vertebra, and the left a little higher on the level of the upper part of the same vertebra, having passed in front of the aorta.

The superior hepatic curve of the duodenum rests on the vena cava at the first lumbar vertebra right side. The descending portion covers about the two external thirds of the anterior surface of the vena cava and the right renal vessels.

The horizontal portion of the duodenum in the U-form applies itself in one part to the vena cava, and in another to the aorta, and sometimes passes over the common iliacs. In the duodenum in the V-form the inferior angle lies upon the vena cava to the right of the aorta, then the ascending portion crosses the aorta sharply, from right to left, then borders it on the left and crosses the left renal vein and ends in the duodeno-jejunal angle.

The ascending portion in the U-form runs along the left surface of the aorta and finally over the left renal vein as the above.

(3) *Relations to the Lumbar Column.*—By fixing the duodenum with pins while *in situ*, Jonnesco examined thirty subjects and found that the first portion of the duodenum lies to the right of the first lumbar vertebra. Its pyloric end in the median line is on the level of the inferior extremity of this vertebra, and it is directed up to the right and backward to reach the upper border of the same vertebra.

The pre-aortic portion, or inferior angle, reaches a variable point; in children, the superior border of the fourth lumbar, or the disk between it and the third. In adults with the duodenum in U-form, this pre-aortic portion moulds itself over the convexity of the fourth lumbar vertebra in 12 out of 20 cases. In some cases it passes over the fifth vertebra. In the duodenum in V-form the inferior angle applies itself most often to the right of the column, and the lower border of the fourth lumbar vertebra, in 5 out of 8 cases. Again it may go to the side of the fifth lumbar three times in 8 cases.

There may be three types: a *high type*, corresponding to the superior border of the fourth, or articulation between it and the third, seen in the child; *middle type*, to the body of the fourth lumbar; *low type*, to the body of the fifth lumbar, confined almost wholly to the V-type.

The duodeno-jejunal angle corresponds to the left of the vertebral column, may be to the first lumbar vertebra (infantile type), or to the second (adult type in U or V). In the first case the angle approaches the median line, in the latter it is thrown to the side of the column.

Relations of Duodenum in Detail.

Superior Hepatic Curve, First Portion.

Above and in front:

Quadrate lobe of liver;
Neck of gall-bladder;
Foramen of Winslow;
Hepatic artery.

Behind:

Common bile-duct;
Vena portæ;
Gastro-duodenal artery;
Vena cava inferior (at summit of curve);
First lumbar vertebra (on the left).

Below:

Neck of pancreas;
Head of pancreas.

Descending, or Second Portion.

Anteriorly:

Right lobe of liver (impressio duodenalis);
Right end of transverse colon;
Two layers of transverse mesocolon;
Small intestine;
Right leaf of mesentery.

Posteriorly:

Right kidney and suprarenal capsule (at times);
Structures at hilus;
Common bile and pancreatic ducts;
Vena cava inferior;
Spermatic vessels.

Internally:

Head of pancreas;
Pancreatico-duodenal vessels;
Common bile and pancreatic ducts;
First, second, third, fourth, or fifth lumbar vertebræ.

Pre-aortic, or Third Portion.

Superiorly:

Head of pancreas;
Superior mesenteric vessels.

Anteriorly:

Root of mesentery;
Right and left layers of mesentery;
Superior mesenteric vessels;
Small intestine.

Posteriorly:

Vena cava inferior;
Aorta;
Crura of diaphragm;
Third or fourth lumbar vertebra.

Ascending, or Fourth Portion.

Anteriorly:

Antrum pylori (at times);
Transverse colon;
Transverse mesocolon (lower layer);
Small intestine;
Left layer of mesentery.

Posteriorly:

Left Psoas muscle;
Left renal vessels;
Spermatic vessels;
Lower part of inner edge of left kidney.

Internally:

Head and neck of pancreas;
Aorta;
Fourth, third, and second lumbar vertebræ;
(Third, second, and first in child).

Terminal, or Fifth Portion.

Superiorly:

Body of pancreas.

Anteriorly:

Duodeno-jejunal angle;
Left layer of mesentery.

Externally:

Inner margin of left kidney.

Means of Fixation.—Neither peritoneal adhesions nor peritoneal ligaments really fix an organ; if the latter ever does, it is because it contains vessels and nerves and cellular tissue between its layers.

The means here are—1. Biliary and pancreatic ducts. 2. Arteries which are the conductors and support of fibro-nervous tissue. 3. Suspensory muscle of Treitz supporting the duodeno-jejunal angle. 4. A cellular fold under the pancreas. (Treitz.)

1. The *ducts* of the two glands, common bile-duct and the pancreatic, contribute to the fixation of the duodenum, yet the lig. hepato-duodenale must render service in resisting a downward pull, whereby the ducts would be stretched and their functions disturbed.

2. Two abdominal *arteries* are important in fixing the duodenum to the posterior wall: the cœliac axis above it and superior mesenteric above and in front, which have retained their original positions of fœtal life. There is a complete anastomosis or *arterial circle* between these vessels, connecting the posterior abdominal wall to the liver, stomach, pancreas, duodenum, and spleen.

3. Fibro-nervous investments accompany the arterial circle formed of cellular tissue and sympathetic nerve-plexuses. They have two rôles: first, innervation of the vessels, and secondly, support. The cœliac and solar plexuses support as one the duodenum and its neighboring organs the liver, stomach, and pancreas.

4. *Muscle of Treitz.*

In 1853 Treitz described a muscle running from the duodeno-jejunal angle to the diaphragm. Many have since described it for him. If the beginning of the jejunum be pressed down, after turning up the stomach and transverse colon, a ridge of peritoneum will be seen to extend from the duodeno-jejunal angle up under the pancreas to the left crus of the diaphragm. This ridge is called the *ligament of Treitz.* The original article[1] reads in substance thus—

"Raise the pancreas and detach it from the diaphragm. The duodeno-jejunal angle is seen attached to the posterior abdominal wall by a muscle (Fig. 637). This muscle is small and triangular and rises by its base from the superior border of the duodeno-jejunal curve and from a part of the ascending duodenum. It passes toward the aortic orifice of the diaphragm and near its centre continues into a tendon which becomes more narrow and loses itself in the tendinous tissue surrounding the superior mesenteric artery and cœliac trunk, enveloping the ganglia and nerves of the cœliac plexus. By traction these fibrous bands can be seen connected with the inner pillars of the diaphragm, and commonly with the right border of the œsophageal orifice. All subjects possess it; it is best developed in muscular individuals and with a low-placed duodenum. Its tendon is 1.5 mm. long; the muscle 1 mm. thick. As to its function, it does not merit the name Levator duodeni; its action is of little importance as a muscle; it plays the rôle of a suspensory ligament and ought to be called *Musculus suspensorius duodeni.*"

The muscle is continuous with the longitudinal muscular layer of the duodenum and is stronger the older the subject.

[1] *Prager Vierteljahresschrift*, 1853, s. 113.

Treitz indicates a cellular membrane (Fig. 637) stretching between the superior mesenteric artery on one side, the pylorus, duodeno-jejunal angle, and concavity of the duodenum on the other, which forms a floor to the posterior surface of the pancreas and represents the fœtal mesentery of the duodenum. He says on account of its tenuity it is unable to offer any fixation.

Such are the means of fixation in general. The duodenal ring is fixed in all its length, but unequally; it is suspended by two fixed extremities. Its superior hepatic angle is fixed by the total of organs attached to the liver and by the thick cellular tissue which fastens it to the inferior vena cava. There are also the structures forming the hepatic pedicle, artery, duct, and portal vein, all surrounded by fibro-nervous layers and all united into one by the serous membrane forming the lig. hepato-duodenale. Finally, the fibro-nervous tissue contained in the lig. cystico-duodenale serves to render the first part of the duodenum solid to the liver. The liver is fixed, not by peritoneal folds, as is commonly said, but by a thick cellular tissue and numerous subhepatic veins emptying into the inferior cava—nailed, so to speak, to the posterior abdominal wall. By such attachment to the vena cava and liver, the superior angle is secure.

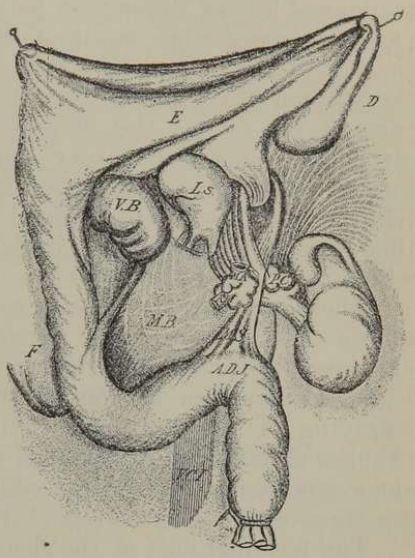

FIG. 637.—Muscle of Treitz. The large intestine, jejunum, mesentery, and pancreas are removed. (After Treitz in Jonnesco.) *D.* Inferior surface of diaphragm. *E.* Posterior surface of stomach. *F.* Liver. *Ls.* Spigelian lobe. *Vb.* Gall-bladder and duct. *VCI.* Vena cava. *Ac.* Cœliac axis. *Pc.* Cœliac plexus. *ADJ.* Duodeno-jejunal angle. *Ms.* Muscle of Treitz. *MB.* Original mesoduodenum.

The duodeno-jejunal angle is fixed by the muscle and ligament of Treitz. When this angle penetrates the thickness of the transverse mesocolon its fixation is still more assured. The branches of the superior mesenteric artery given to this angle reinforce the support. More than the ends of the duodenal arch must be supported or its lower part would separate from the posterior abdominal wall and come forward on a hinge-movement. As long as nothing presses this part of the duodenum backward this forward movement does occur, as in early human embryos or in case of a mesoduodenum, as in many animals.

Normally the adult human duodenum cannot separate from the posterior wall, owing to many agencies which come, in turn, to hold it down.

The descending duodenum is fixed to the inferior vena cava and right kidney by thick cellular tissue. This is further strengthened by the hepatic flexure and transverse colon, which apply themselves directly to the kidney and duodenum.

The pre-aortic portion is fixed by two agents—(*a*) by fibrous tissue between it and the aorta and vena cava inferior; (*b*) by the superior mesenteric artery surrounded by its fibro-nervous tissue, which forms the root of the mesentery and presses this part of the duodenum down upon the aorta. So the mesenteric artery and aorta, passing one behind the other, constitute a sort of vascular press, lessening the calibre to what may be called the *isthmus of the duodenum.*

The ascending portion is much less fixed than any other part to the posterior wall and left kidney. It is easily displaced from left to right, and peritoneal covering is its sole agency of fixation.

Résumé.—The duodenal ring is fixed against the posterior abdominal wall, or, better, against the fixed organs which cover it. This fixity is assured in part by the vascular system and by the fibro-nervous layers connected, and in another part by the muscle of Treitz.

Jejunum and Ileum (*Intestinum mesenteriale*).

Following the duodenum, about the upper two-fifths of the remaining small intestine is called jejunum and the lower three-fifths ileum There is no morphological line of distinction between these two, but there is considerable difference between the beginning of the jejunum and end of ileum. The diameter of the first is about one and a half inches; of the latter, one and one-fourth inches; the walls of the jejunum are thicker and a given length weighs more than the same of the ileum; the character of the mucous membrane and of the contents markedly changes, but very gradually. The ileum possesses none or poorly-formed valvulæ conniventes. The jejunum is usually in the umbilical region and left iliac fossa, while the coils of the ileum are more on the right side and right iliac fossa and true pelvis. Both these parts of the intestine retain the *mesentery*, which the duodenum does not.

There is but little *fixation* to the loops of the small intestine; the mesentery allows the freest motion. Every moment the coil must accommodate itself to changes in form and position of the peritoneal cavity or be prepared to fill some hole. Contraction of the diaphragm and abdominal muscles, the filling and emptying of viscera, presence of tumors, position of body, must all occasion changes of position in the small intestines. With this great motility, no definite shape can be ascribed for the coils, but frequently the upper loops of the jejunum are transverse and the lower of the ileum are more vertical.

The terminal part of the ileum is more fixed than any other, as its mesentery passing over the right Psoas muscle is very short. At the point of transition from the duodenum to the jejunum or from the small to the large intestine the various fossæ have been noticed (p. 994).

The vitelline duct coming from the original convexity of the intestinal loop (Fig. 588) may persist in adult life; it is then called *Meckel's diverticulum*. It is a blind intestine, having the same layers as the ileum, with the lumen of which it directly communicates. It is two or three inches long (one-half to seven inches), and rises about forty-three inches from the ileo-colic junction (from one to ten feet); originally it passes toward the umbilicus, but usually hangs free in the cavity. It may be connected with the umbilicus or other points by a solid band, which attains great firmness and is the enlarged remains of the omphalo-mesenteric vessels. It may be conical, cylindrical, or hour-glass in shape. It occurs about once in fifty cases, and may cause surgical complications.

Structure of the Wall of the Small Intestine.—Like the stomach, the wall is composed of four layers, serous, muscular, submucous, and mucous. It is much thinner than that of the stomach, only $\frac{3}{4}$–1 mm. thick.

The *external* or *serous* coat is peritoneum, which surrounds the whole of the ileum and jejunum except along the little interspace left at the *mesenteric border* of the intestine. Here a sort of linear hilus is left between the two layers where vessels, nerves, veins, and lymphatics have their entrance or exit. In case of the duodenum, each part is covered to a different degree.

The *muscular coat* consists of two layers; as usual for the alimentary canal, the external is made of longitudinal fibres, and the internal of circular fibres. The longitudinal fibres are best developed at the beginning of the duodenum and end of the ileum, and are here closely attached to the serous coat. They are most marked on the free border of the intestine, and may be wholly lacking on the mesenteric attachment. The circular set is three times thicker than the longitudinal, and consists of complete muscular rings which are pressed so closely together as to only leave clefts for the passage of vessels and nerves to deeper parts. This double coat gets thinner below, is pale, and made of unstriated muscular tissue. It produces *peristalsis*, by which food is pushed onward.

The *submucous coat* acts as a bed for the mucosa, is connected more closely with it than with the muscular coat, and is made of areolar tissue. Here are lymphatic vessels and nerve-plexuses, and the blood-vessels divide up for the mucosa.

The *mucous membrane* is thick, red, and highly vascular at the upper part of the intestine, but paler and thinner below. Its inner surface is shaggy like velvet; this is due to the presence of minute processes called *villi*. Next the submucous coat is a layer of unstriped muscle fibres, the *muscularis mucosæ*. This thin layer from the sheep makes the "catgut" of commerce. Internal to this is a quantity of retiform tissue containing goblet-cells and migratory leucocytes supporting tubular glands, blood-vessels, nerves, and lacteals. Most internally the mucosa is covered by a single layer of columnar epithelial cells resting upon a basement membrane. The prismatic cells contain granular protoplasm and oval nuclei. The free ends of the cells are invested by a cuticular zone or *basilar border*, a well-defined band exhibiting a fine vertical striation. Some interpret these as parallel canals for absorption of chyle.

The mucous membrane presents in its different parts the following structures:

Valvulæ conniventes;
Villi;
Intestinal true glands { *Glands of Lieberkühn;* *Glands of Brunner;*
Intestinal lymph-follicles { *Solitary glands;* *Agminated glands, or Peyer's patches.*

Valvulæ conniventes (valves of Kerkring, 1670), who gave the incorrect name, *conniventes* (*connivēre*, to close the eyelids) (Fig. 638) are permanent crescentic folds of mucous membrane and submucosa; each contains two layers of mucous membrane, placed back to back and separated by the submucosa. They contain no part of the muscular coats, and are not obliterated by distention of the intestine. They extend transversely across the axis of the tube for about one-half or two-thirds of its circumference. Some form complete circles and others spirals; the spirals rarely may

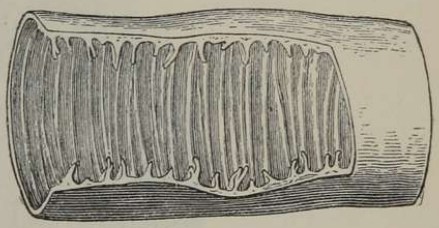

FIG. 638.—Diagram of valvulæ conniventes. (Brinton.)

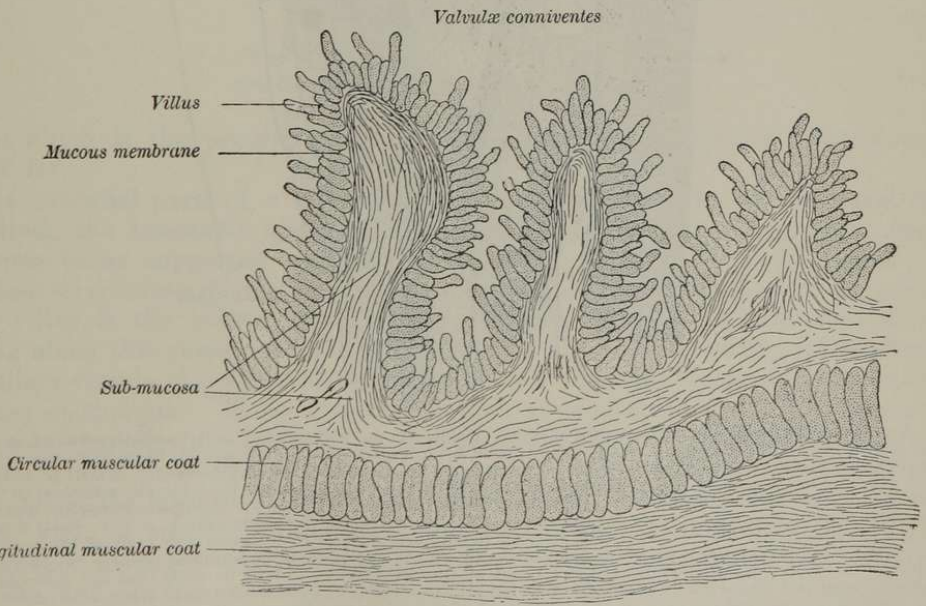

FIG. 639.—Longitudinal section of human small intestine to show relations of villi, valvulæ conniventes, and muscular coats. Schematic. (From Piersol.)

extend two or three times around the internal circumference. This is of interest, as a spiral valve is the characteristic of the intestine of certain fishes—*e. g.* the

shark family. The large folds project about one-third inch into the lumen, and often connect at one end obliquely with a smaller fold. Sometimes a valve terminates abruptly, or it bifurcates at one or both ends. They are so close that in a relaxed condition they cover the intestinal surface like roof-tiles. These valves are most abundant in the duodenum and jejunum; they decrease and disappear at the lower end of the ileum. Their total number is 800 or 900. They begin with the commencement of the descending duodenum, there being usually none in the first portion. Just beyond the point of entrance of the bile and pancreatic ducts they are very large and regular and closely packed. About two feet from the lower end of the ileum they cease. From this point up to the middle of the jejunum they are indistinct and irregular, smaller, and farther apart. They are seen at their best from the lower part of the descending duodenum through the upper half of the jejunum. Their function is to retard the passage of food and to afford an extensive absorptive surface.

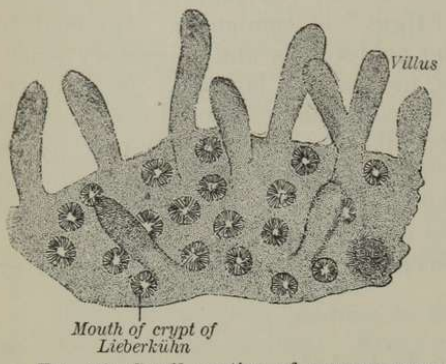

FIG. 640.—Small portion of mucous membrane of the small intestine. (Rauber.)

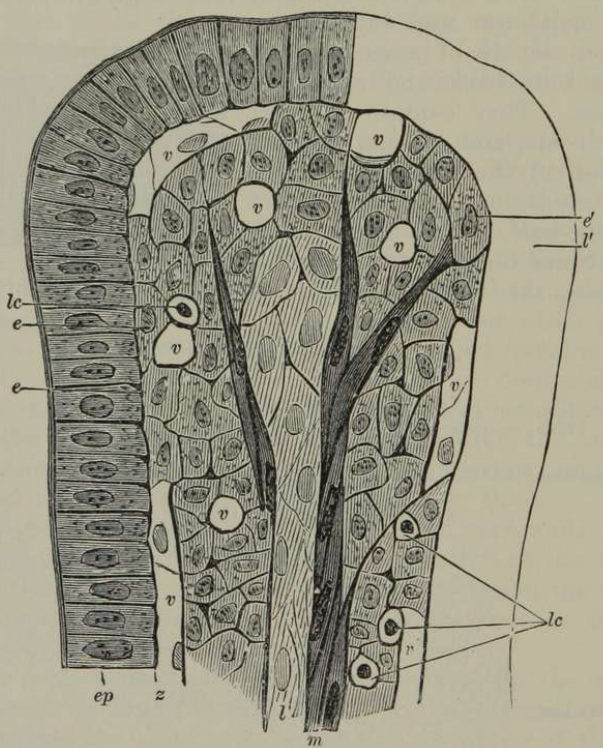

FIG. 641.—Diagrammatic section of a villus. (Watney.) *ep.* Epithelium only partially shaded in. *l.* Central chyle-vessel: the cells forming the vessel have been less shaded to distinguish them from the cells of the parenchyma of the villus. *m.* Muscle-fibres running up by the side of the chyle-vessel. It will be noticed that each muscle-fibre is surrounded by the reticulum, and by this reticulum the muscles are attached to the cells, forming the membrana propria, as at *e'*, or to the reticulum of the villus. *lc.* Lymph-corpuscles, marked by a spherical nucleus and a clear zone of protoplasm. *l'.* Upper limit of the chyle-vessel. *e, e, e'.* Cells forming the membrana propria. It will be seen that there is hardly any difference between the cells of the parenchyma, the endothelium of the *upper* part of the chyle-vessel, and the cells of the membrana propria. *v.* Blood-vessels. *z.* Dark line at the base of the epithelium formed by the reticulum. It will be seen that the reticulum penetrates between all the other elements of the villus. The reticulum contains thickenings or "nodal points." The diagram shows that the cells of the upper part of the villus are larger and contain a larger zone of protoplasm than those of the lower part. The cells of the upper part of the chyle-vessel differ somewhat from those of the lower part, in that they more nearly resemble the cells of the parenchyma.

The *villi* are minute vascular processes, consisting entirely of tissues of the mucosa, projecting from every part of the inner surface of the small intestine

over the valvulæ conniventes as well as between them (Fig. 639). They give to the surface its velvety appearance. Between the bases of the villi, wherever they are, the mouths of the glands of Lieberkühn are seen (Figs. 640 and 642). They are largest and most numerous in the duodenum and jejunum, resembling the valvulæ conniventes in distribution. They are smaller and fewer in the ileum, and stop abruptly at the ileo-cæcal orifice. There are none in the large intestine. They measure .5 to .7 mm. in length, and are present to the number of about four millions (Krause); 10 to 18 per sq. mm. in the upper intestine, and 8 to 14 to the same space in the ileum. They are apt to be leaf-shaped in the duodenum, tongue-shaped in the jejunum, and filiform in the ileum.

Structure of the Villi (Fig. 641).—The structure of the villi has been studied recently by many eminent anatomists. We shall here follow the description of Dr. Watney,[1] whose researches have a most important bearing on the physiology

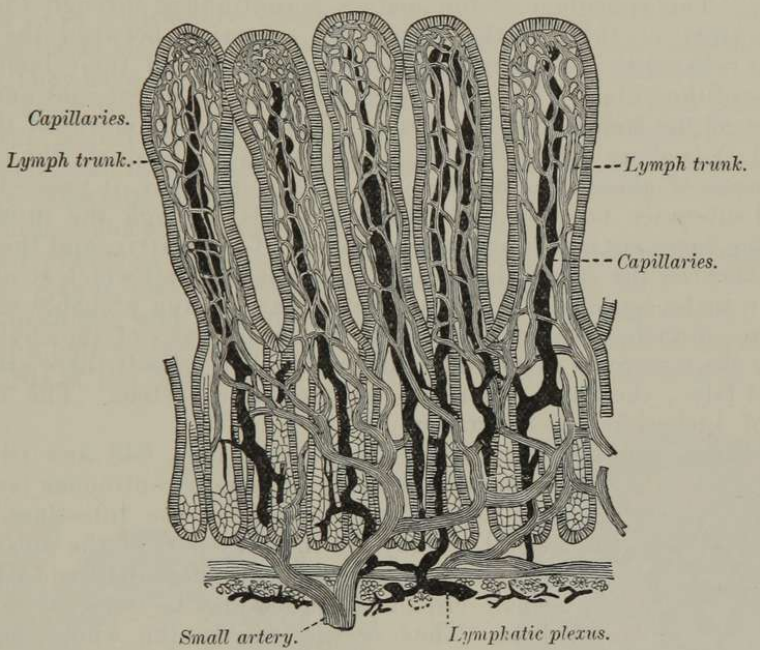

FIG. 642.—Villi of small intestine. (Cadiat.)

of that which is the peculiar function of this part of the intestine, the absorption of fat.

The essential parts of a villus are—the lacteal vessel, the blood-vessels, the epithelium, the basement membrane and muscular tissue of the mucosa, these structures being supported and held together by retiform lymphoid tissue.

These structures are arranged in the following manner: situated in the centre of the villus is the lacteal, terminating near the summit in a blind extremity; running along this vessel are unstriped muscular fibres; surrounding it is a plexus of capillary vessels, the whole being enclosed by a basement membrane, supporting columnar epithelium. Those structures which are contained within the basement membrane—namely, the lacteal, the muscular tissue, and the blood-vessels—are surrounded and enclosed by a delicate reticulum which forms the matrix of the villus, and in the meshes of which are found large flattened cells, with an oval nucleus, and, in smaller numbers, lymph-corpuscles. These latter are to be distinguished from the larger cells of the villus by their behavior with reagents, by their size, and by the shape of their nucleus, which is spherical. Transitional forms, however, of all kinds are met with between the lymph-corpuscle and the proper cells of the villus.

The *lacteals* are in some cases double, and in some animals multiple. Situated

[1] *Phil. Trans.*, vol. clxvi. pt. ii.

in the axis of the villi, they commence by dilated cæcal extremities near to, but not quite at, the summit of the villus. The walls are composed of a single layer of endothelial cells, the interstitial substance between the cells being continuous with the reticulum of the matrix.

The *muscular fibres* are derived from the muscularis mucosæ, and are arranged in bundles around the lacteal vessel, extending from the base to the summit of the villus, and giving off laterally, individual muscle-cells, which are enclosed by the reticulum, and by it are attached to the basement membrane.

The *blood-vessels* form a plexus between the lacteal and the basement membrane, and are enclosed in the reticular tissue; in the interstices of the capillary plexus, which they form, are contained the cells of the villus.

These structures are surrounded by the basement membrane, which is made up of a stratum of endothelial cells, and upon which is placed a layer of columnar epithelium. The reticulum of the matrix is continuous through the basement membrane (that is, through the interstitial substance between the individual endothelial cells) with the interstitial cement substance of the columnar cells on the surface of the villus. Thus we are enabled to trace a direct continuity between the interior of the lacteal and the surface of the villus by means of the reticular tissue, and it is along this path that, according to Dr. Watney, the chyle passes in the process of absorption by the villi. That is to say, it passes through the interstitial substance between the epithelium cells, through the interstitial substance of the basement membrane, the reticulum of the matrix, and the interstitial substance between the endothelial plates of the lacteal, all which structures have been shown to be continuous with one another, and, being probably semifluid, do not offer any obstacle to the passage of the molecular basis of the chyle.

Among the structures of the intestinal wall called *glands* there are two kinds —true and false; the latter belong to the lymphatic system. The true glands are those of Lieberkühn and Brunner.

The *follicles*, *crypts*, or *glands of Lieberkühn* (Figs. 643 and 644) are very numerous, forming an almost continuous layer of tubular depressions throughout the intestines, large and small. They are in every part of the small intestine, opening between the villi (Figs. 640 and 642). Their small circular mouths may be seen by the aid of a lens. They occupy nearly the whole depth of the mucosa, are upon the valvulæ conniventes, their blind ends approaching nearly perpendicularly the muscularis mucosæ. They consist of thin tubes, whose walls are made of basement membrane, lined by the columnar epithelium from the free surface. Many of these cells change to spherical secreting cells, some of which become goblet-cells (Fig. 644). They are 2 to 3 mm. long and about .04 mm. in diameter.

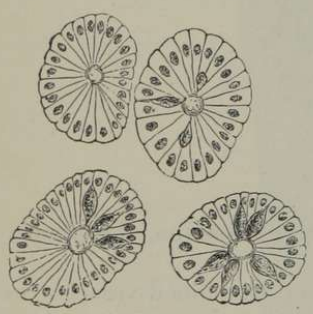

FIG. 643.—Transverse section of crypts of Lieberkühn. (Klein and Noble Smith.)

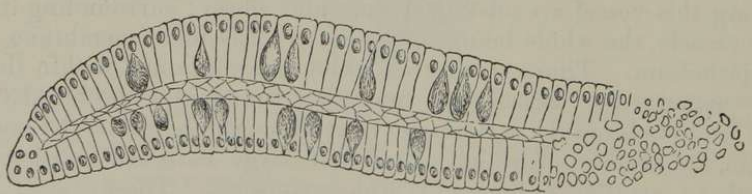

FIG. 644.—Longitudinal section of crypts of Lieberkühn. Goblet-cells seen among the columnar epithelial cells. (Klein and Noble Smith.)

The *duodenal* or *Brunner's glands* are limited to the duodenum and first part of the jejunum. They are most numerous in the first part of the duodenum, within one or two inches of the pylorus. They are small compound tubular glands, consisting of a number of tubular alveoli opening into a slender duct, much like

the salivary glands of the mouth, which are more compact. They are probably direct continuations and higher specializations of the pyloric glands. They are situated in the submucosa or in part in the mucous membrane. Their ducts penetrate the muscularis mucosæ, pass between the glands of Lieberkühn and open upon the inner surface of the intestine, or in some cases into the bases of the crypts.

The *solitary glands* (Fig. 645) are found scattered throughout the mucous membrane of the small intestine, but are most numerous in the lower part of the ileum. They are small, round, whitish and slightly prominent bodies 6 mm. to 3 mm. in diameter. They are formed on the mesenteric as well as free border, between and upon the valvulæ conniventes. The free surface of the follicle may have villi upon it, but at the centre or cupola they are lacking. Each gland is surrounded irregularly by the openings of the glands of Lieberkühn. These so-called glands have a structure similar to that of a lymph-node, consisting of dense retiform tissue closely packed with lymph-corpuscles, and permeated by fine capillaries. They have no ducts. The interspaces of the retiform tissue are continuous with larger lymph-spaces at the base of the gland by which they communicate with the lacteal system, or they may even hang into a lacteal sinus which may nearly surround the nodule. The base of the nodule is in the submucous tissue. They penetrate the muscularis mucosæ and enter the mucous membrane, where they form slight projections of its epithelial layer.

Agminated glands or *Peyer's glands* (1677) may be regarded as aggregations of the solitary glands, forming circular or oval patches (Fig. 646). They number from twenty to thirty, and vary in length from one-half to four inches; in width from one and a half to two inches. They are largest and most numerous in the lower two-thirds of the ileum. In the lower part of the jejunum they are small

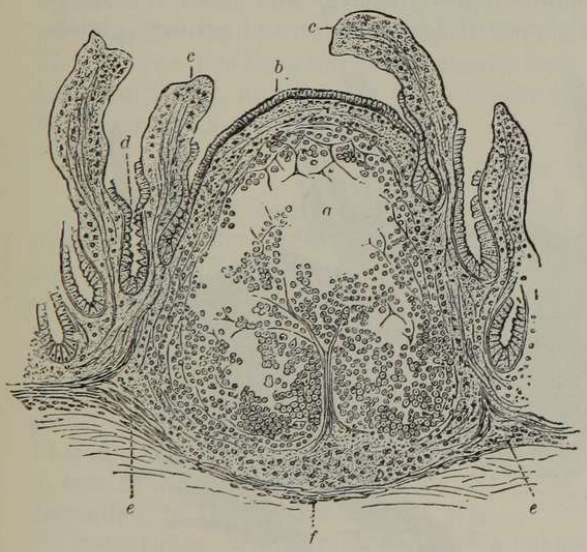

FIG. 645.—Section of a solitary gland of the small intestine. (Cadiat.) *a*. Solitary gland, which has become partly broken away. *b*. Epithelium of cupola. *c, c*. Villi. *d*. Crypt of Lieberkühn. *e, e*. Muscularis mucosæ. *f*. Submucous coat.



FIG. 646.—Patch of Peyer's glands from the ileum, slightly magnified. (Boehm.)

and few and of a circular form. They are occasionally seen in the lower duodenum. They are placed lengthwise to the intestine, covering that portion of the tube opposite the attachment of the mesentery, hence to see them well open the bowel along its mesenteric attachment.

Each patch is formed of a group of lymph-nodes which are similar to the solitary glands above described. Each follicle becomes somewhat pyramidal, due to pressure, and they lose much of their individuality, being most distinct along the

outer boundary. The surface of a patch is usually free from villi; it is surrounded by a row of the crypts of Lieberkühn. They are best marked in young subjects, where as many as 45 have been observed; they become indistinct in middle life and even disappear in old age. Their resemblance to lymph-glands is seen in any infectious disease of the intestines, especially in typhoid fever, where they may ulcerate and perforate to the peritoneal cavity, causing fatal hæmorrhage.

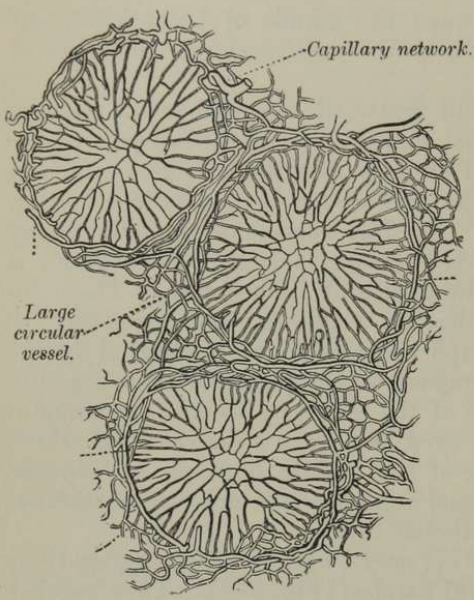

Fig. 647.—Transverse section through the equatorial plane of three of Peyer's follicles from the rabbit.

They have a large vascular supply which forms an abundant plexus around each follicle. This gives off fine capillaries, which, supported by the retiform tissue, converge toward the centre (Fig. 647). The lacteal plexuses, which are abundant throughout the small intestine, are especially so around the follicles of a Peyer's patch, often forming sinuses around them (Fig. 648).

Résumé.—The valvulæ conniventes and villi are most abundant in the upper part of the small intestine.

Brunner's glands are mostly in the duodenum.

Solitary glands and Peyer's patches are most abundant in the lower part of the small intestine.

The crypts of Lieberkühn are abundant in both large and small intestines.

The large intestine possesses the crypts of Lieberkühn and solitary glands.

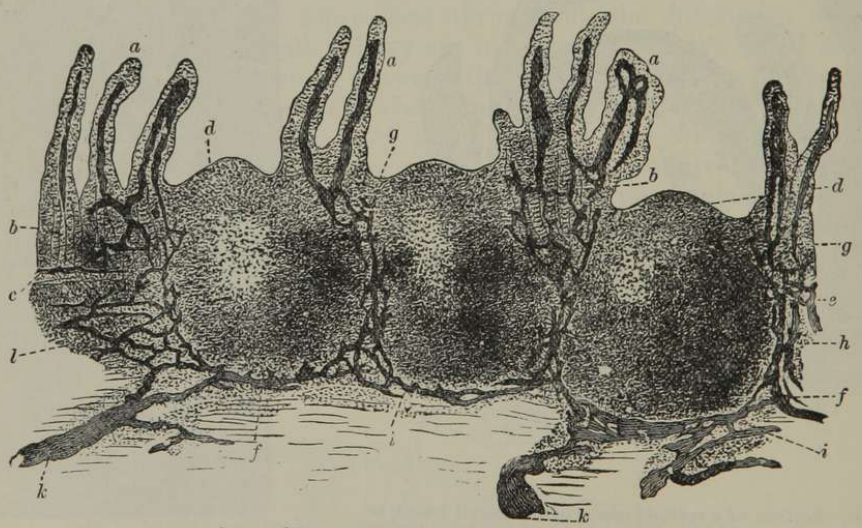

Fig. 648.—Vertical section of one of Peyer's patches from man, injected through its lymphatic canals. *a*. Villi with their chyle-passages. *b*. Follicles of Lieberkühn. *c*. Muscular mucosæ. *d*. Cupola or apex of solitary glands. *e*. Mesial zone of glands. *f*. Base of glands. *g*. Points of exit of the chyle-passages from the villi, and entrance into the true mucous membrane. *h*. Retiform arrangement of the lymphatics in the mesial zone. *i*. Course of the latter at the base of the glands. *k*. Confluence of the lymphatics opening into the vessels of the submucous tissue. *l*. Follicular tissue of the latter.

Vessels and Nerves of the Small Intestine.

The arteries supplying the duodenum are the pyloric, the superior pancreatico-duodenal, from the gastro-duodenal, all of which come from the hepatic, and the inferior pancreatico-duodenal, from the superior mesenteric.

The jejunum and ileum are supplied by the superior mesenteric artery, the

branches of which, having reached the attached border of the bowel, run between the serous and muscular coats, with frequent inosculations to the free border, where they also anastomose with other branches running round the opposite surface of the gut. From these vessels numerous branches are given off which pierce the muscular coat, supplying it and forming an intricate plexus in the submucous tissue. From this plexus minute vessels pass to the glands and villi of the mucous membrane. The veins have a similar course and arrangement to the arteries. Each artery has only one vein. The *lymphatics of the small intestine* (lacteals) are those of the mucous membrane and those of the muscular coat. The lymphatics of the villi commence in these structures in the manner described above, and form an intricate plexus in the mucous and submucous tissue, being joined by the lymphatics from the lymph-spaces at the bases of the solitary glands (Fig. 648), and from this pass to larger vessels at the mesenteric border of the gut. The lymphatics of the muscular coats are situated to a great extent between the two layers of muscular fibres, where they form a close plexus, and throughout their course communicate freely with the lymphatics from the mucous membrane, and empty themselves in the same manner into the commencement of the lacteal vessels at the attached border of the gut.

According to Sappey the vessels from a villus have two functions, one set is to carry chyle and the other lymph. The former either contains chyle only or is empty. After the vessels have entered the mesentery, then they interchangeably carry chyle or lymph. The *nerves of the small intestine* are derived from the plexuses of sympathetic nerves around the superior mesenteric artery. Those nerves come from the cœliac plexus, the semilunar ganglia, and largely from the right vagus nerve. From this source they run to a plexus of nerves and ganglia situated between the circular and longitudinal muscular fibres (Auerbach's plexus) from which the nervous branches are distributed to the muscular coats of the intestine. From this plexus a secondary plexus is derived (Meissner's plexus), which is formed by branches which have perforated the circular muscular fibres. This plexus lies between the muscular and mucous coats of the intestine. It is also gangliated, and from it the ultimate fibres pass to the muscularis mucosæ and to the mucous membrane.

The Large Intestine.

The large intestine extends from the termination of the ileum to the anal orifice. It differs from the small intestine in its larger size, more fixed position, saccular form and appendices epiploicæ. It is about five or six feet in length or one-fifth that of the whole intestinal canal (Sappey 1.68 m.). Its capacity in moderate distention averages twenty-two ounces per foot, or seven and a half to eight pints for the whole length. Its circumference decreases from beginning to end, except at the ampulla of the rectum; it measures 28.5 cm. at its widest part, junction of colon and cæcum, 20.5 cm. at the end of the ascending portion, 14.5 cm. in the descending portion. Diameter varies from two and a half inches to less than one inch. By accumulation of fæcal matter or gas the colon may be distended to double its normal size.

Sometimes in the fresh body of a robust suicide the descending colon or sigmoid flexure or even part of transverse colon may be contracted to the thickness of a thumb. The tube is hard and can scarcely be opened by inflation. It is not pathological, as coroners say, but a high degree of rigor mortis, which will disappear. In the greater part of the colon its external surface is very uneven from the presence of pouches or saccules, protrusions arranged in rows of three columns. These are separated by three ligamentous tapes about the width of the little finger.

In its course the large intestine describes a horseshoe-shaped arch which surrounds the convolutions of the small intestine. It begins in a blind sac in the right iliac fossa, ascends along the right posterior abdominal wall to the right hypochondrium, where it is in contact with the under surface of the liver. It here

bends to the left, and takes a transverse somewhat ascending course to the spleen. In the left hypochondrium it bends again and descends along the left posterior abdominal wall to the left iliac fossa, then becomes convoluted as the sigmoid flexure: it finally enters the pelvis and descends as the rectum along its posterior wall to the anus.

There are to be distinguished, then:

1. Cæcum (intestinum cæcum), or Caput coli;
2. Colon ascendens, or Right colon;
3. Hepatic flexure, or Flexura coli dextra;
4. Colon transversum;
5. Splenic flexure, or Flexura coli sinistra;
6. Colon descendens, or Left colon;
7. Flexura sigmoidea (Colon sigmoideum), or S. romanum.
8. Rectum (intestinum rectum).

Structure of the Large Intestine.

We find here the same four coats which have been seen in the canal above: serous, muscular, submucous, and mucous.

The *serous coat* is the peritoneal covering investing parts of the large intestine to a variable extent.

The cæcum is completely invested. The ascending and descending colons in the adult have usually only a third of the posterior surface left bare. It is a question when to declare the folds near enough to call them a mesocolon.

Treves says a mesocolon may be expected on the left side in 36 per cent. of all cases, on the right side in 26 per cent.

The transverse colon is almost completely invested, having a proper mesocolon; the great omentum is attached to its anterior surface.

The sigmoid flexure has a mesocolon, and the upper part of the rectum has a mesorectum. In the second part of the rectum the peritoneum covers its anterior surface and parts of the sides; its third portion loses it altogether. The peritoneum covering the internal tænia along the colon, especially the transverse and after part, is thrown into many external pouches containing fat in well-nourished people; they are called *appendices epiploicæ*, or *omentula*.

The *muscular coat* consists of an external longitudinal and an internal circular layer.

The *longitudinal fibres* are partly collected into three flat longitudinal bands, each about half an inch wide and one twenty-fifth inch thick. They are found on the cæcum and colon and each is called *ligamentum* or *tænia coli* Between these bands the longitudinal layer is present, but very thin. On the appendix the layer is uniform. These bands spread out from the root of the vermiform appendix to the cæcum. Thence they can be traced as far as the rectum, where they form two bundles. The *posterior* band passes along the mesenteric attachment of the intestine; another, the largest, runs along the *anterior* border of the ascending and descending colons and on the transverse colon corresponds to the attachment of the great omentum. The third or *internal* band runs along the inner borders of the ascending and descending colons, but becomes inferior on the transverse colon.

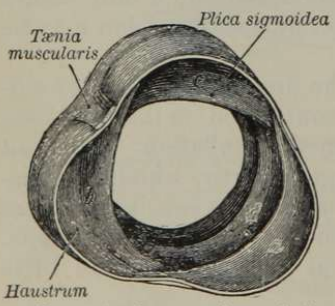

FIG. 649.—Cross-section of the colon. (Gegenbaur.)

The three bands are about one-half shorter than the real walls of the intestine and so form *sacculi* or *haustra* (buckets). If the bands be dissected away the sacculi will be wholly effaced and the colon becomes much elongated and cylindrical. The transverse constrictions seen on the outside of the intestine between the sacculi appear on the inside as sharp ridges

which separate the pouches, cellulæ, or haustra. The whole projection is made up of all the coats of the intestine and is called the *plica* or *valvula sigmoidea* (Fig. 649). A valve passes between two tæniæ where otherwise a transverse fold would exist. Only rarely do two or three valves lie in the same plane, so that they would be in position to effect a scissor-like motion and cut a mass of fæcal matter into scybalæ or round balls.

The *circular* fibres form a thin continuous layer and are especially collected in the constrictions between the sacculi. In the rectum they form the Internal sphincter muscle.

The *submucous coat* is in the same position and serves the same purpose as in the small intestine.

The *mucous membrane* is pale, smooth, destitute of villi and raised into crescentic folds, separating the pouches and corresponding to the external constrictions separating the sacculi.

As in the small intestine, the mucous membrane consists of a muscular layer, the muscularis mucosæ; of a quantity of retiform tissue, in which the vessels ramify; of a basement membrane and epithelium, which is of the columnar variety and exactly resembles the epithelium found in the small intestine. The mucous membrane of this portion of the bowel presents for examination crypts of Lieberkühn and solitary glands.

The *crypts of Lieberkühn* are tubular prolongations of the mucous membrane, arranged perpendicularly, side by side, over its entire surface; they are longer, more numerous, and placed in much closer apposition than those of the small intestine, and they open by minute rounded orifices upon the surface, giving it a cribriform appearance.

The *solitary glands* (Fig. 650) in the large intestine are most abundant in

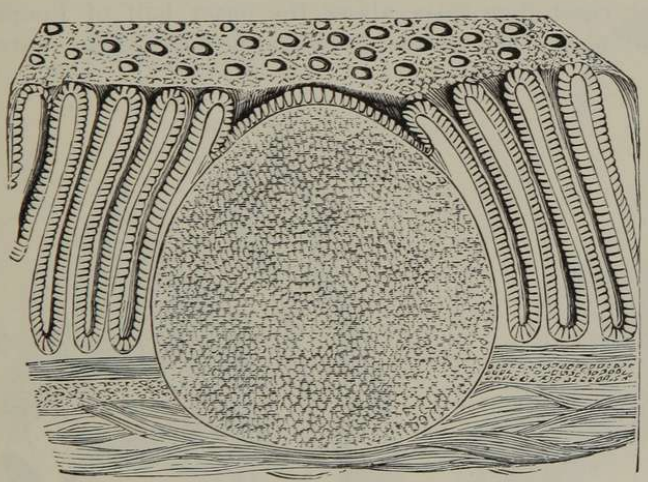

FIG. 650.—Minute structure of large intestine.

the *cæcum* and *appendix vermiformis*, but are irregularly scattered also over the rest of the intestine. They are similar to those of the small intestine.

Vessels and Nerves.—The arteries supplying the large intestine give off large branches, which ramify between the muscular coats, supplying them, and, after dividing into small vessels in the submucous tissue, pass to the mucous membrane. Those arteries are the ileo-colic, colica dextra, colica media from the superior mesenteric, colica sinistra and sigmoidea from the inferior mesenteric.

The lymphatic vessels consist of *two* layers; the deep set lie under the glands of Lieberkühn, and the superficial forms a wide-meshed network which penetrates the submucosa in all directions. The lymphatics of the ascending, transverse, and descending colons open into the mesenteric glands, those of the sigmoid flexure into the lumbar glands.

The *nerves* which supply the cæcum, ascending and right half of the transverse colon are sympathetic, coming from the superior mesenteric plexus derived from the cœliac plexus. Those which supply the left half of the transverse colon, the descending and sigmoid colon come from the inferior mesenteric plexus derived from the aortic plexus. In their course they accompany the arteries.

The **cæcum** (*cæcus*, blind) (Fig. 653) is the head of the colon, or that part of the large intestine situated below the ileo-cæcal valve, some say below the ileum. Its length and breadth are never equal, the breadth being always the greater. The opinions vary thus—

	Average length.	Average breadth.
Quain	2½ inches	3 inches
Berry	6 cm.	7 cm.
Treves	6 "	8 "
Struthers	6 "	6 "
Luschka	4–12 "	
Sappey	8–10 "	
Henle	5.5 "	

The discrepancies are due largely to methods of measurement. Treves takes as the upper limit of the cæcum the lower edge of the ileum. Berry states this is too short, and the upper limit of cæcum is on the level of the ileo-cæcal valve, or Struthers' "frænal furrows," which are continuations of the ileo-cæcal valve. If these furrows cannot be seen externally, take as the upper limit an "approximation line," drawn transversely across the colon from a point midway between the upper and lower edges of the ileum. In 100 cases this gave Berry's figures, 6 and 7 cm., for average length and breadth. "Sex has no influence upon size, but it varies with age, being absolutely and relatively larger in the adult. Cæca of insane persons are apt to be abnormal" (Berry).

The cæcum lies in the right iliac fossa above the outer half of Poupart's ligament, its point being at about the middle, immediately behind the anterior

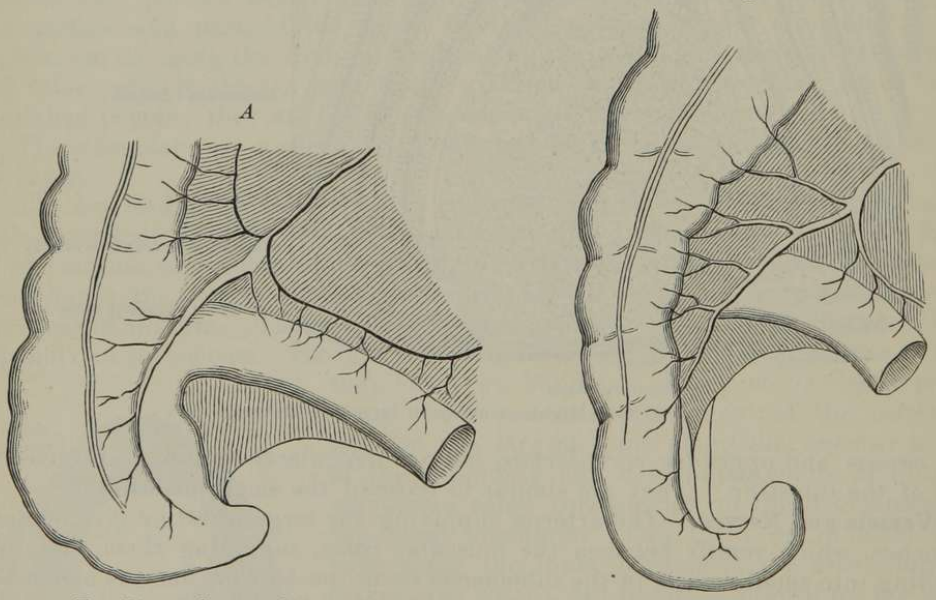

FIG. 651.—*A*. Cæcum of Mangabey monkey. *B*. Cæcum of spider monkey. (Treves.)

abdominal wall in front of the ilio-psoas muscle (Fig. 578). Should it be long it may extend more or less into the pelvic cavity (Fig. 626).

Many statements are made as to its peritoneal relations. Bardeleben first stated it was wholly invested by peritoneum; Luschka, Treves, very positively, Struthers and Jonnesco all agree. Quain states that in 5 per cent. of cases the

peritoneal covering is not complete, but is reflected just below its upper end, leaving the upper part of its posterior surface uncovered and connected to the iliac fascia by areolar tissue. Berry has seen the same thing in 6 per cent. of cases. The reflected peritoneum never makes a true mesocæcum. It may have sufficient motility or length to enter a right inguinal or femoral hernia, and in rare cases a left one. According to Treves, any human cæcum can be classified under one of four types (Fig. 652). In certain monkeys we see a primitive form

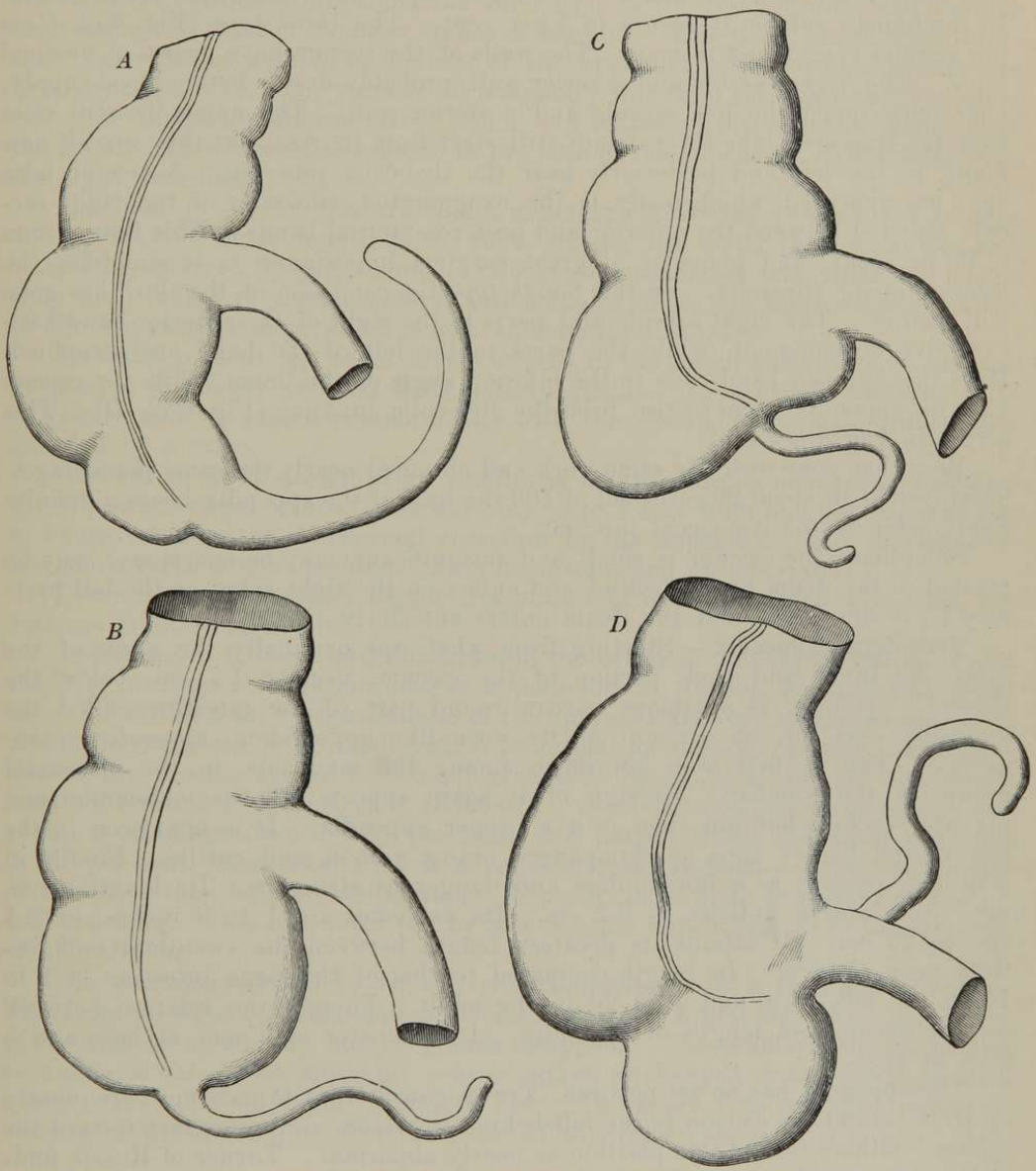

FIG. 652.—*A*, *B*, *C*, *D*, four types of human cæca. (Treves.)

where the cæcum is short, conical, and broad at the base, with its apex turned up and in toward the ileo-colic junction (Fig. 651, *A*). This type is seen early in the human fœtus. Next it grows in length more than in breadth, and this type is seen in the human fœtus in Fig. 651, *B*. As development goes on the lower part of the tube ceases to grow and the upper part becomes greatly increased, so that a narrow tube is formed hanging from a conical projection. The latter is the cæcum, and the small tube the *vermiform appendix*. This is the fœtal or *infantile* type (Fig. 652, *A*). It may persist throughout life. Treves found it

in adults to the extent of 2 per cent. The cæcum is conical, and the appendix rises from its apex in line with the axis of the colon. The three longitudinal bands of the colon start at the root of the fœtal appendix about equidistant, and pass up over the cæcum and colon as described, dividing them into three rows of sacculations. The *second* type (Fig. 652, *B*) has substituted the conical cæcum for a more quadrate one. The appendix is in the centre of two sacculi of equal size instead of at the apex of a cone. There is an equal extent of intestine on each side of the anterior band. The higher apes have this type—*e. g.* gibbon. In the human subject it occurs in 3 per cent. The *third type* (Fig. 652, *C*) is the normal type found in man. The walls of the cæcum have grown at unequal rates. The right saccule and anterior wall, probably due to better blood-supply, have outstripped the left saccule and posterior wall. The appendix still rises from the true apex, the three bands still start from its root, but they are all now found to the left and posteriorly near the ileo-colic junction. A new or false apex has appeared, which really is the exaggerated convexity of the right saccule situated between the anterior and postero-external bands. This form occurs in 90 per cent., and hence is of great surgical importance, as it simplifies the location of the appendix. In the *fourth type* the condition of the third has gone still farther. The right saccule and parts to the right of the anterior band have excessive development, while the parts to the left of the band are atrophied. Here the anterior band runs to the inferior angle of the ileum, while the cæcum and the appendix seem to rise from the ileo-colic junction (Fig. 652, *D*). This occurs in 4 or 5 per cent.

Berry has gone over the same work and obtained nearly the same percentages, proving that in about 90 cases out of 100 the base of the appendix bears a definite relationship to the ileo-cæcal junction.

Sometimes the cæcum is small and insignificant, may be enormous; may be rotated so the ileum passes behind and enters on the right side; or the left parts may be so developed that the ileum enters anteriorly.

Vermiform Appendix.—Starting from what was originally the apex of the tube, the inner and back portion of the cæcum, usually 1.7 cm. below the ileo-colic opening, is a famous narrow round part of the intestine called the *appendix cæci*, or, on account of its worm-like appearance, *appendix vermiformis*. This is first seen low down among the mammals, in the marsupial group, in the wombat. No sign of it again appears till the ichneumon and pig are reached, but not then is it a proper appendix. It is next seen in the lemurs and higher apes, as chimpanzee, orang, gibbon, and gorilla. Finally in man it is present as a functionless and dangerous structure. Its length, averaged from eleven authors, is 9.2 cm. Its extremes are 1 to 9 inches, or 3.1 cm. to 23 cm. It attains its greatest length between the twentieth and fortieth years (Berry). Its length compared to that of the large intestine is 1 to 10 in the new-born, and 1 to 20 in the adult. There is no relation between size of cæcum and length of appendix. Its diameter is 6 mm. at base and 5 mm. at apex.

The appendix has no set position. Treves considers it to pass most frequently up from behind the cæcum to the left behind the ileum and mesentery toward the spleen. Others regard this position as nearly abnormal. Turner of Russia finds it hanging into the true pelvis in 51 out of 83 cases, and transversely across the promontory in 20 more of those cases.

Berry gives order of frequency as: 1. Pelvic position; 2. Retro-cæcal; 3. Internal cæcal (toward spleen); 4. Variable.

The order of frequency found in this country by J. D. Bryant[1] was most often "inward," then "behind cæcum," "downward and inward," "into true pelvis."

The explanation of an up-turned or down-turned appendix is probably to be sought in fœtal life. If the distal end of the appendix gain adhesions with the

[1] *Ann. Surg.*, vol. 17, 1893, p. 164.

mesentery or abdominal wall when it is still high up beneath the liver, the cæcum will drag it down in an inverted position. If no such adhesions occur, then it will descend freely, and perhaps dip into the pelvis. It takes a somewhat spiral form, due to its short mesentery.

Relations to cæcum have been noted above under Cæcum, where the data are quite constant.

Relations to the anterior abdominal wall for clinical purposes do not agree. Clado draws two lines, one along the outer edge of the right Rectus, and another connecting the anterior superior spines of the ilia. The point where these intersect Clado uses as a guide to the base of the appendix, which brings it into the hypogastrium. McBurney draws an imaginary line from the right anterior superior spine to the umbilicus. His "point" is situated on this line two inches from the spine. This is used as a guide to the base of the appendix. This point is in the right iliac fossa.

Relations to peritoneum are that a mesentery is always present, but it does not extend the whole length of the tube, leaving the distal third or so free and completely covered by peritoneum. This *meso-appendix* is triangular and comes from the left leaf of the mesentery, and contains in its fold the posterior branch of the ileo-cæcal artery, which is derived from the ileo-colic.

Its walls present the same layers as seen in the colon, and its whole mucous membrane is closely studded with solitary glands. It is usually hollow to its extremity and its lumen communicates with the cæcum by a small orifice often guarded by a valve.

Gerlach in 1847 described a "semilunar fold of mucous membrane guarding the appendico-cæcal orifice." It was only .5 to 1 mm. high and was so turned as to cause retention of the normal secretion in the appendix. The existence of Gerlach's valve is now doubted. It is inconstant and unimportant.

There is usually another bigger crescentic fold near the orifice (Fig. 654), but with no function of a valve.

According to Ribbert and Zuckerkandl the cavity of the vermiform appendix tends to undergo obliteration, not as a pathological process, but a physiological one. In children the lymph-follicles of the appendix are very numerous and close. After the twentieth or thirtieth year it is normal for them to atrophy. Obliteration of the process occurs to some degree in 99 cases out of 400 (25 per cent.); total obliteration in 3.5 per cent. (Ribbert). Or obliteration occurred in 23.7 per cent.; total obliteration in 13.8 per cent., and partial (distal half most common) in 9.9 per cent. (Zuckerkandl). It never occurs in new-born. After sixty years of age more than half are obliterated. It occurs more often in a short process, 5 to 6 cm. long. One can never tell by macroscopic appearance as to the presence of obliteration.

The pathology seems to be an involution-change in a functionless organ. There are no signs of inflammation or cicatrices. As a first step there is atrophy of the mucous membrane, and its glands disappear. The submucosa thickens and accumulates fat. The muscular coat is either unchanged or becomes hypertrophied. The adenoid tissue is finally lost. There are four authentic cases of absence of the appendix. For the *fossæ* of this region see p. 997.

The Ileo-colic, Ileo-cæcal valve or Valvula Bauhini.

The end of the ileum passes obliquely upward and to the right, and opens into the large intestine on its postero-internal surface; it opens upon the summit of a plica sigmoidea which marks the junction between the cæcum and ascending colon.

This orifice appears as a transversely oblique or a double convex slit. It is often rounded on the left and presents a sharp apex to the right (Fig. 654). It is bounded by a valve having two semilunar segments, a colic and a cæcal one, which project into the lumen of the large intestine. The upper of these segments is more horizontal, the lower more concave and longer. At each end they

coalesce and are prolonged into *frœna* or *retinacula* of the valve. The segments are made by an invagination of parts of the wall of the ileum into those of the

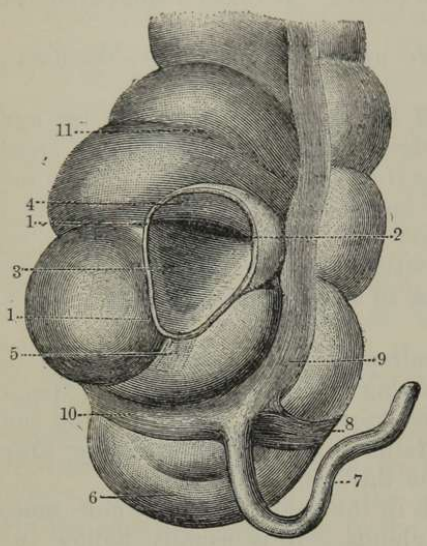

FIG. 653.—Cæcum and vermiform appendix. (Sappey.) 1. Ileum. 2. Orifice of valve. 3. Inf. segment. 4. Sup. segment. 5. Long muscular fibres from ileum. 6. Cul-de-sac of cæcum. 7. Appendix. 8. Post. tænia. 9. Int. tænia. 10. Ant. tænia. 11. Sacculus.

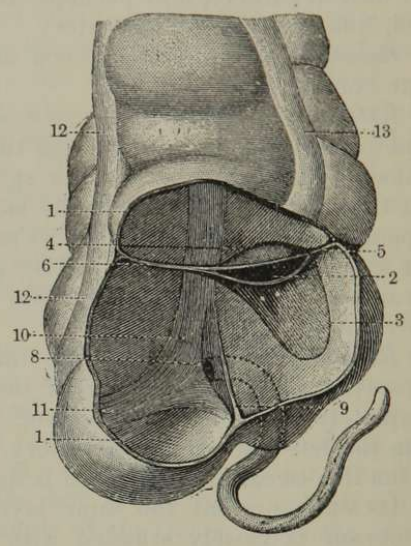

FIG. 654.—Ileo-cæcal valve. (Sappey.) 1. Edge of cæcum. 2. Orifice of valve. 3. Inf. segment. 4. Sup. segment. 5 and 6. Frœna. 7. Appendix. 8. Its mouth. 9. Semilunar fold. 10. Post. tænia. 11, 12, 12. Ant. tænia. 13. Int. tænia.

colon (Fig. 655). Each segment of the valve consists of two layers of mucous membrane continued around the free border, one from the small intestine and one from the large, including between them submucosa and circular muscular fibres; the longitudinal fibres and peritoneum are continued uninterruptedly across from one intestine to the other and do not enter their composition. If these two coats be incised and traction made on the ileum, these valves can be unfolded and drawn out of the colon, the ileum appearing to open into the intestine by a large funnel-shaped orifice. The opposed mucous surfaces of the segments looking toward the ileum are covered by villi and present the structure of the small intestine. In fœtal life the other two surfaces possessed villi too, but by birth the latter have disappeared. The surfaces turned toward the large intestine present the follicles and glands of Lieberkühn peculiar to the large intestine.

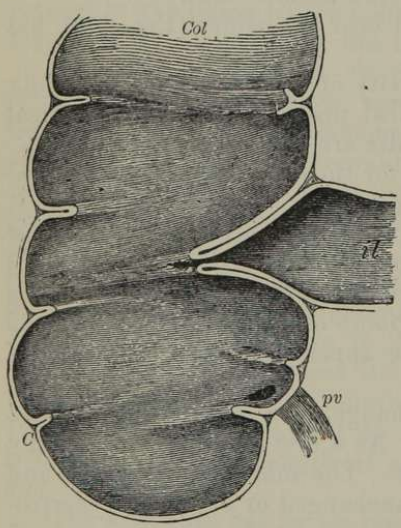

FIG. 655.—Vertical section through the cæcum and ileo-cæcal valve. (Gegenbaur.) *Col.* Colon. *C.* Cæcum. *pv.* Processus vermiformis.

The function of the valve is to prevent regurgitation of intestinal contents back into the small intestine. When the cæcum is distended, the segments are approximated. They act even in the cadaver, proving that muscular action is not essential. When in an experiment water was injected into the colon, not a drop passed through the valve; when the pressure was increased to a height of two or three metres the valves did not yield, but the walls ruptured. In intestinal obstruction there is evidence of a return of contents from the large intestine. This is probably due to a slow, gradual distention of the walls of the large intestine, and hence a relative insufficiency of the valve. High enemata may pass this valve in two out of three cases, but such a valve is regarded as imperfectly developed and incompetent from the first.

This valve has been named after nearly all the following men. It was discovered in 1573 by Varolius, who called it an *operculum*. Six years later Bauhin called it *valvula*. Fabricius in 1618 first tried its function by insufflation. Casserius, Tulpius, and Bartholin repeated the experiments. Morgagni in 1719 gave the best description. Winslow and Albinus followed him.

Colon.—As in the cæcum, the outer surface of the colon is prismatic and triangular. Four characteristics are observed: 1. Three tæniæ which start from the root of the appendix; 2. Three rows of sacculi between the bands; 3. Constrictions which separate the sacculi of each row; 4. Appendices epiploicæ. The internal surface has a reverse conformation, the projections between the pouches being called *plicæ sigmoideæ*.

The **ascending colon** is smaller than the cæcum, with which it is continuous, and larger than the transverse colon. It is very short. It passes up through the right lumbar region into the right hypochondrium until it reaches the inferior surface of the right lobe of the liver to the right of the gall-bladder, the *impressio colica*. It is retained in contact with the posterior abdominal wall by peritoneum which covers its anterior surface and sides, its posterior surface being connected by loose areolar tissue with the fascia covering the Quadratus lumborum and Transversalis muscles, and with the front of the lower and outer part of the right kidney. An abscess of the right kidney could thus break through into the ascending colon and not wound the peritoneum. It is *in relation* in front with the abdominal wall and convolutions of the ileum. Sometimes the peritoneum nearly surrounds the colon and forms a short mesocolon.[1] On the under surface of the liver in the region of the gall-bladder, the ascending colon forms a sharp angle from the posterior abdominal wall to the front and the left, becomes somewhat superficial, and continues into the transverse colon. This is the *hepatic* or *right colic flexure*, bound to the under surface of the liver by the *lig. hepato-colicum*.

The **transverse colon** is the longest part of the large intestine, averaging twenty inches, while the ascending colon is eight inches, and the descending, from the splenic flexure to the crest of the ilium, is eight and a half inches. It passes from the hepatic flexure in the right hypochondrium transversely and slightly upward from right to left along the anterior abdominal wall to the *splenic flexure* in the left hypochondrium (Fig. 626). Since the colon is longer than the width of the abdomen it describes an arch, *transverse arch of the colon*, with its convexity directed downward and forward.

It is the most movable part of the colon, for it has a very long mesentery, the *transverse mesocolon*, which allows it a variable position. Its usual position corresponds to the line separating the umbilical and epigastric regions. In four times out of five it is above the umbilicus. It is in relation by its *upper surface* with the under surface of the liver and gall-bladder, greater curvature of the stomach and lower end of the spleen; by its *under surface* with the small intestine; by its *anterior surface* with the great omentum and abdominal walls; by its *posterior surface* with the transverse mesocolon; on the right with the second part of the duodenum, and to the left of this with some convolutions of the small intestine. If this colon has a very direct and obliquely ascending course, the greater curvature of the stomach will be behind its left portion.

In some cases the transverse colon may present a V- or U-shaped bend descending as far as the pubes. These bends are always downward, abrupt, and angular. Treves thinks they are due to habitual distention or to congenital causes (Fig. 656). They are normal in many animals.

The **descending colon** is continuous with the transverse by the *splenic flexure*,

[1] Mr. Treves states that, after a careful examination of one hundred subjects, he found that in fifty-two there was neither an ascending nor a descending mesocolon. In twenty-two there was a descending mesocolon, but no trace of a corresponding fold on the other side. In fourteen subjects there was a mesocolon to both the ascending and the descending segments of the bowel, while in the remaining twelve there was an ascending mesocolon, but no corresponding fold on the left side. It follows, therefore, that in performing lumbar colotomy a mesocolon may be expected upon the left side in 36 per cent. of all cases, and on the right in 26 per cent. (*The Anatomy of the Intestinal Canal and Peritoneum in Man*, 1885, p. 55.)

or *left colic flexure*, which is higher up and farther back than the hepatic flexure. To this bend a fold of peritoneum is attached, rising from the diaphragm between the tenth and eleventh ribs. It is the *phreno-colic ligament*, rather than "costo-colic," as it does not touch a rib. The spleen happens to lie just above it, so it acts as a support to that organ though not connected with it, and thus receives a second name, *sustentaculum lienis* (supporter of the spleen). The colon then descends along the outer border of the left kidney, then turns in a little, and descends to the crest of the ilium or to a point where the peritoneum begins to surround the intestine and form a meso-colon for the sigmoid flexure.

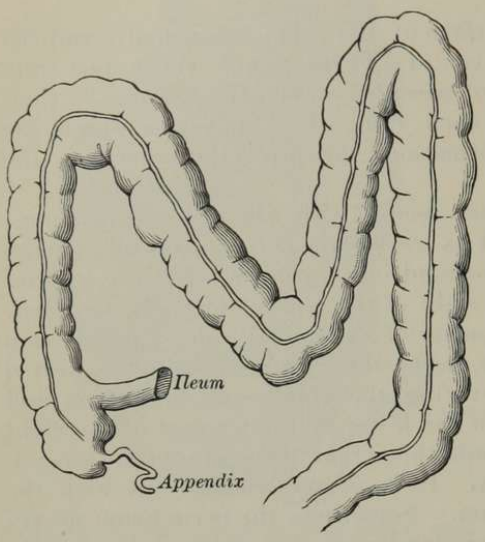

FIG. 656.—Extreme downward bend in the transverse colon. Found in four cases. (Treves.)

It has passed along the outer border of the Psoas muscle in front of part of the Quadratus lumborum, and more largely in front of the Transversalis muscle. The relations of the descending colon on the left side are much like those of the ascending on the right, only the former reaches a little higher and is placed more laterally, so it can be more easily reached through the posterior abdominal wall for the establishment of an artificial anus.

This colon is smaller and deeper than the ascending colon and more liable to have a mesocolon.

The **sigmoid colon** or **flexure** is in the left iliac fossa, commencing above at the iliac crest and ending below in the rectum at the brim of the true pelvis opposite the left sacro-iliac articulation, or just as often opposite the upper edge of the sacrum. In general it is described as an S-shaped curve in which can be distinguished an upper colic limb turned toward Poupart's ligament, and a lower rectal limb which hangs more or less into the true pelvis.

This first part usually passes downward, inward, and somewhat forward, approaching the anterior abdominal wall and outer part of Poupart's ligament. This portion may have peritoneum only in front and on the sides. The next part is more movable, its mesentery is about three inches long, and it constitutes the sigmoid loop proper. When it does not hang down into the pelvis, the bladder and rectum are distended and push it up, in rare cases as high as the umbilicus or even liver. This loop may lie in the iliac fossa outside the first part; if its mesocolon is short, it passes obliquely across the iliac fossa and is covered by small intestine.

The sigmoid mesocolon is inserted into a line running from the left at the crest of the ilium across the psoas muscle and left iliac vessels at right angles to the anterior surface of the sacral promontory, where it is continuous with the mesorectum (Fig. 614). In the left layer of this mesentery is the intersigmoid fossa (page 996). The position of the flexure in the new-born demands notice, for here the mesentery is very long and the flexure may reach over on the right to the cæcum. This flexure is usually filled with meconium.

Relations of Large Intestine in Detail.

Cæcum.

Anteriorly:

Anterior abdominal wall above outer half of Poupart's ligament.

Posteriorly:

Right ilio-psoas muscle; Origin of appendix.

Superiorly :

Ileo-cæcal valve ; and aperture.

Inner Side :

End of ileum.

Ascending Colon.

Anteriorly :

Ileum ;
Abdominal wall.

Posteriorly :

Quadratus lumborum muscle ;
Transversalis abdominis ;
Lower and outer part of the right kidney.

Superiorly :

Under surface right lobe of liver.

Transverse Colon.

Anteriorly :

Anterior abdominal wall ;
Great omentum.

Posteriorly :

Transverse mesocolon ;
Descending duodenum ;
Small intestine ;
Greater curvature of stomach (sometimes).

Superiorly :

Under surface of liver and gall-bladder ;
Greater curvature of stomach ;
Lower end of spleen ;
Tail of pancreas.

Inferiorly :

Small intestines.

Descending Colon.

Anteriorly :

Jejunum ;
Abdominal wall.

Posteriorly :

Quadratus lumborum muscle ;
Transversalis abdominis muscle ;
Outer margin of Psoas muscle ;
Lower part left edge of left kidney.

Superiorly :

Spleen ;
Phreno-colic ligament.

Sigmoid Colon.

Anteriorly :

Anterior abdominal wall ;
Small intestines.

Posteriorly :

Left ilio-psoas muscle ;
Posterior wall of pelvis ;
Rectum.

The **rectum** constitutes the terminal portion of the intestinal tube. It received its name *intestinum rectum* from its straight course in animals. In the human subject its course is nearly vertical, but it presents four curves and should be called *intestinum curvum* (Lisfranc).

The ancient and much-copied method of description divides it into three parts. We hesitate to introduce a change in old nomenclature, but will mention those proposed and allow the reader to make his choice.

Treves in 1885 called attention to the fact that there was no demarcation between the sigmoid flexure and the first part of the rectum at the brim of the pelvis. So he concludes the intestines should be called sigmoid flexure until the mesocolon is lost, *i. e.* until it reaches the third sacral vertebra. This rectum, therefore, has the two lower parts of the three usually described and no mesorectum. Cunningham and Quain take for the rectum the upper two of the three usually described, the third being regarded as a separate part called *anal canal.*

The rectum in three parts is situated in the pelvic cavity and on its floor. It is attached to its posterior wall, whose curve it follows. Its inferior limit is a circular line separating the skin from the mucous membrane—the *anal orifice.* Its superior limit cannot be determined precisely; it is continuous with the sigmoid flexure, but there is only an arbitrary line of demarcation. This is the pelvic brim, most usually opposite the left sacro-iliac articulation, quite often the sacro-vertebral angle, or rarely on the right of the base of the sacrum. Superiorly, it is united to the sacrum by a fold of peritoneum, the *mesorectum.* Lower down the peritoneum only covers the sides and front, much as in the case of the descending duodenum (Fig. 657). Still lower down, at a height of about one inch above the prostate gland, it entirely abandons the rectum and is reflected upon the neighboring organs, making, according to sex, the recto-vesical pouch or the recto-vaginal and recto-uterine. The height of the recto-vesical pouch in the male is never more than 8 cm. above the anus. The height of the recto-vaginal in the female is always less, about 6 cm. The *length* of the rectum, measured along its anterior wall (in the body), is 18 to 22 cm., or about eight inches. Outside the body it measures 25 cm. The *calibre* varies according to circumstances. When empty it is less than that of the other portions of the large intestine. When it contains a certain amount of fæcal matter its middle portion is more or less dilated, but not to the size of the cæcum. The calibre of the remainder, in general, is not circular. In the lower part of the rectum it presents a transverse slit, and the anterior and posterior walls lie upon each other, mainly from the pressure of the anterior organs forcing the rectum back on the sacrum and coccyx. Just at the turn of the rectum into its third portion, and especially

FIG. 657.—Relations of peritoneum to rectum and bladder. Outline of rectum. (Tillaux.)

marked anteriorly at the apex of the prostate, is the largest part, the *ampulla* of the rectum.

The lowest inch of the rectum, the *anal canal*, is an antero-posterior slit, the lateral walls resting on each other (Fig. 658). In pathological cases the calibre may be so distended as to occupy the whole pelvis.

The *direction* of the rectum, starting usually from the left of the base of the sacrum, is obliquely downward, backward, and to the right. When it comes to the level of the third sacral vertebra it has reached the middle line. It now passes that line a little and runs along the right lateral part of the fourth sacral vertebra. It again returns to the middle line at about the sacro-coccygeal junction and passes downward and forward, and may cross it a second time till it reaches the level of a transverse line drawn between the anterior parts of the ischial tuberosities. This point is also opposite the apex of the prostate gland (Fig. 657). This point is not opposite the lower end of the coccyx, as often stated, but fully one inch below that.

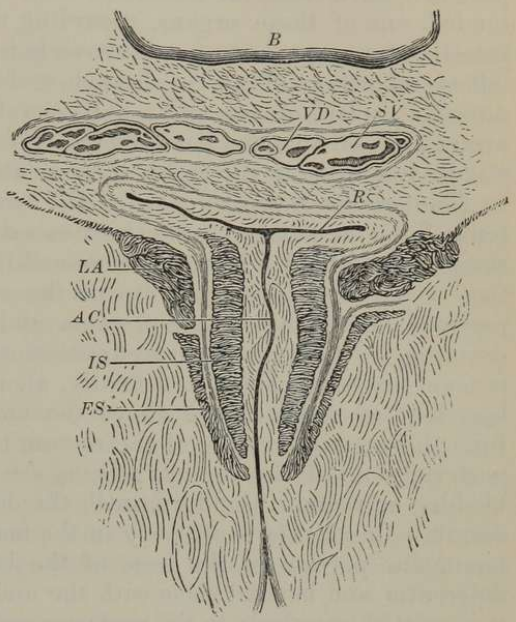

FIG. 658.—Coronal section through the anal canal. (Symington.) *B.* Cavity of bladder. *VD.* Vas deferens. *SV.* Seminal vesicle. *R.* Second part of rectum. *AC.* Anal canal. *LA.* Levator ani. *IS.* Internal sphincter. *ES.* External sphincter.

Sappey thus describes two *lateral curves*, and, with two antero-posterior curves, makes four altogether. The first turn of the rectum from left to right he does not consider a curve. The lateral curves are of little importance, and run into each other. The first is the more pronounced, and corresponds to the junction of the third and fourth pieces of the sacrum, with its concavity to the left. The second corresponds to the sacro-coccygeal junction, with its concavity to the right. They are best seen with an empty rectum, and are almost effaced when it is distended.

The *antero-posterior curves* are more pronounced and independent of the degrees of dilatation. The first or *sacral curve* is due to the conformation of the sacro-coccygeal column. It has its concavity forward, its convexity being most marked at the junction of the third and fourth sacral vertebræ. The second or *perineal curve* has its convexity forward, corresponding to the apex of the prostate gland in the male and posterior wall of the vagina in the female. Its concavity looks downward and backward. The sacral curve represents the arc of a circle. The last one is angular.

According to its direction, then, the rectum is divided into three parts—a *superior portion*, passing obliquely downward and backward; a *middle portion* passing obliquely downward and forward; an *inferior* or *anal portion*, passing obliquely downward and backward. They are not of equal lengths; that of the first is 8 to 9 cm.; second, 10 to 11 cm.; third, 2 to 3 cm. in the male, 1.5 to 2 cm. in the female. According to Quain, in order, the first part is five or four inches; second, three or four inches; anal canal, one-half to one inch. In the infant the rectum is straighter, less flexuous, and relatively larger than in the adult. In the female it is said to be larger and straighter than in the male.

The *first*, or *superior*, portion includes about half the length of the tube, and extends obliquely from the pelvic brim, opposite either the left sacro-iliac articulation or the sacro-vertebral angle or the right side of the base of the sacrum, to the body of the third sacral vertebra. It is almost completely surrounded by peritoneum, which is connected to the anterior surface of the sacrum by the

double fold called *mesorectum*. This is continued above with the sigmoid mesocolon, is triangular, and ends below in an apex at the third sacral vertebra. Some convolutions of the ileum, or a loop of the sigmoid flexure, usually lie in front of this part of the rectum. They separate it from the bladder in the male and posterior surface of the uterus in the female when the rectum is empty. If distended, one of these organs, according to sex, rests on its anterior surface, the intestine being pushed up. *Posteriorly* is the mesorectum, left Pyriformis muscle, left sacral plexus of nerves, branches of left internal iliac vessels, left portion of anterior surface of two and a half sacral vertebræ. To the left side are the left ureter and left internal iliac vessels. If this part of the rectum come down in the middle line or from the right, these relations will differ.

The *middle* or *second part* of the rectum is three or four inches long, and extends from the middle of the third sacral vertebra to a point opposite the apex of the prostate gland. Here the course of the rectum changes to a posterior one, and that is one inch below the tip of the coccyx. It is only partially covered by peritoneum. It has no mesorectum and its posterior surface has no peritoneal covering. At first it is covered anteriorly and laterally, but gradually the peritoneum leaves the sides, and finally, about one inch above the prostate or at the length of an index finger above the anus, never more than 8 cm., it is reflected from the anterior surface of the rectum to the bladder or to the upper fifth of the posterior wall of the vagina, making the pouches as above noted. Distention of bladder or rectum would diminish the depth of these pouches. This part of the rectum is in *relation anteriorly* in the male with the recto-vesical pouch, with the triangular portion of the base of the bladder, the vesiculæ seminales and vasa deferentia, and beyond them with the under surface of the prostate. In the female it is related anteriorly to the posterior wall of the vagina, with which it is adherent, with the recto-vaginal and recto-uterine pouches and small intestines therein.

The *posterior wall* lies upon the lower part of the sacrum, middle sacral artery, origin of Pyriformis muscles, coccyx and ano-coccygeal body, and Coccygei muscles. The ano-coccygeal body is a dense mass of musculo-fibrous tissue situated between the tip of the coccyx and anus.

The *lower portion* or *anal canal* is about one inch long when the rectum is empty; it is shorter when the rectum is distended. It turns downward and backward at the lower part of the prostate gland and ends at the anal orifice. It has no peritoneal covering. It is invested by the sphincter muscles and supported by the Levatores ani. *Behind* it is in relation to the ano-coccygeal body and Coccygei muscles; *on the sides* to the fat of the ischio-rectal fossæ and the Levatores ani muscles.

Anteriorly in the male is the bulb of the urethra and its membranous portion; in the female it is separated from the lower end of the vagina by the perineal body.

The skin about the anus is provided with a ring of sweat-glands called *circumanal glands*. The skin is also thrown into minute corrugations by means of little dermal muscles, the *Corrugator cutis ani*. The anal orifice is not situated alike in the sexes; it is farther forward in the female, and less concealed between the ischial tuberosities. It is 3 cm. in front of the coccyx or just at the bi-ischial line, a little elongated, and the skin is destitute of hair. In the male it is 2.5 cm. in front of the coccyx just behind the bi-ischial line and deeply placed. The skin is covered by hair more or less abundantly, and the orifice is circular and presents little skin folds vertically arranged like rays toward a centre. Between these, where they continue into the mucous membrane, linear excoriations may occur—*fissure* of the *anus*.

Structure of the Rectum.

Four coats are again met, but the muscular and mucous ones differ from those yet seen. The walls are 3 to 4 mm. thick, while those of the colon are 1 to 1.5 mm.

The *peritoneal coat* surrounds the first portion only and forms a mesorectum.

In the second portion it covers the upper part of the anterior surface, a part of the sides, and none of the posterior surface. The lower part is devoid of serous covering. The peritoneum of the upper part of the rectum is thrown into a few pouches, the *appendices epiploicæ*. In women, where the cul-de-sac is lower than in men, the peritoneum covers the whole of the anterior part of the middle portion.

The *muscular coat* is thick; the three bands of the colon do not spread out and form the uniform layer as described. The anterior band descends along the middle portion of the rectum and continues to the anus. The external band joins the anterior near the end of the sigmoid flexure and runs with it over the first part of the rectum. The internal band is most marked along the middle portion of the rectum and runs posteriorly to the anus. The three bands of the cæcum and colon are reduced to two on the rectum, an anterior and a posterior one. In proportion as they descend they get larger. The endings of these fibres are various: into pelvic fascia, anterior surface of coccyx, and deep surface of skin, just outside the anus. Tendencies to sacculation are described, as the longitudinal fibres are rather short. The longitudinal layer is more or less complete between the two bands.

The *circular* fibres are well developed and especially thick between the sacculations. Below, in the anal portion, they become much augmented as the *Internal sphincter*. This muscle is 3 cm. high, and 3 to 4 mm. thick; below it is precisely limited by the circular line, "white line," which marks the mucous membrane from the skin. It surrounds the whole length of the anal canal and ends very abruptly above in the thinner circular fibres. All these fibres are unstriated.

Posteriorly two Recto-coccygei muscles pass from the second or third vertebra of the coccyx to the posterior part of the anal canal.

The other muscles directly connected are the External sphincter, which descends a little lower than the Internal and surrounds the anal orifice (Fig. 658), and the Levator ani giving support on the sides. These have been described.

The *mucous membrane* of the rectum is thicker and more vascular than that of the colon, and, moving quite freely on the muscular coat, makes a kind of independent tube. When contracted it shows many folds of no special direction, most of which can be obliterated; some, however, are more permanent, and are

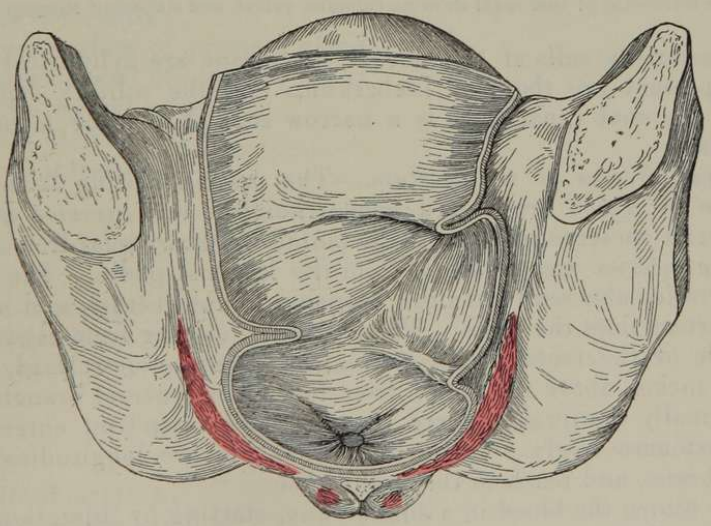

FIG. 659.—Coronal section of pelvis. Posterior wall of rectum seen from in front. (Henle.)

called *valves* of the *rectum*, or of *Houston*, or *plicæ recti*. Usually three are present, sometimes two or four. One of these, the largest and usually constant, is situated on the right side of the rectum, about at the point where the perito-

neum is reflected upon the bladder, *i. e.* 6 to 8 cm. above the anal orifice. It is historical, and has been described by Nélaton and Velpeau as *sphincter superior;* as Houston's "most frequent" *valve;* as Hyrtl's *sphincter tertius;* and Kohlrausch's *plica transversalis.* This extends from the right to the anterior wall of the rectum, and cannot be obliterated, as it does not contain longitudinal muscular fibres. It projects 15 mm. into the lumen of the gut and extends around one-half or two-thirds of its inner circumference (Fig. 659). There are generally two other folds on the left side, one about one inch above and the other one inch below, this one of the right side. These two contain all the coats of the wall and may be obliterated by distention. Note the tendency of the three to the formation of a spiral valve. They may all be called *valves* or *folds of Houston.* The dilatation between the lowest valve and the anal canal is the *rectal ampulla.* The presence of these valves may cause difficulty in the passage of bougies or in digital examinations. In function they seem to assist the sphincters and act as shelves in supporting the fæcal masses.

In the anal canal the mucous membrane is thrown into three to eight longitudinal folds containing muscular fibres, probably of the muscularis mucosæ; they are called *columnæ ani* or *columns of Morgagni.* They commence just above the anal orifice and extend 7 to 14 mm. up the anal canal, rising 1 to 2 mm. above the level of the mucous membrane. Stretched between these columns at their inferior extremities are *semilunar valves* or folds made of mucous membrane with concavities turned upward. They are unequal in length, varying inversely with the number of columns.

Behind each valve and between any two contiguous columns is a little concavity or *sinus* with mouth directed upward. Thus, there are *columns, valves,* and *sinuses of Morgagni* (Fig. 660).

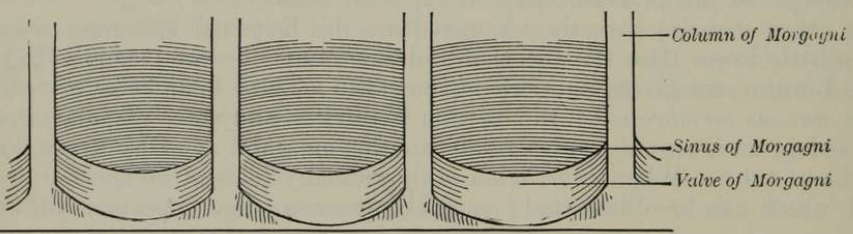

FIG. 660.—Mucous membrane of anal canal showing columns, valves, and sinuses of Morgagni. (Schematic.)

The characteristic cells of the mucous membrane are cylindrical epithelium. The glands present are those of Lieberkühn and the solitary lymph-follicles. Inferiorly on the anal canal there is a narrow zone of mucous membrane destitute of glands.

Vessels and Nerves of the Rectum.—The *arteries* spring from five or six sources, three of which are named hæmorrhoidal: the *superior hæmorrhoidal* from the inferior mesenteric artery; the *middle hæmorrhoidal* from the internal iliac; and the *inferior hæmorrhoidal* from the internal pudic. The *sacra media* and *sciatic* arteries also send unnamed branches to the rectum, and in the female the *vaginal* artery does the same. These arteries coming from above form loops on either side of the rectum with convexities pointing downward. These are three or four inches above the anus; from these loops several branches rise, and pass longitudinally downward, pierce the muscular coats and enter the submucosa, and anastomose freely. In the anal canal they are longitudinal in folds of mucous membrane, and reach to the anal orifice.

The *veins* return the blood in a similar way, starting by dilatations below and making a plexus higher up under the mucous membrane. Most of this blood is returned by the superior hæmorrhoidal vein to the inferior mesenteric vein and portal system. The rest of it reaches the systemic circulation and vena cava inferior. The rectum furnishes an anastomosis between these two systems. It is very strange that the anatomical text-books apply the term *hæmorrhoidal* to all vessels

connected with the rectum. Of course those vessels supply hæmorrhoids when the latter are present, but the implication is, they are always present. The term *rectal* would seem to be correct and the one intended.

The *lymphatics*, from mucous and from muscular coats, enter glands anterior to the sacrum. Those near the anus enter inguinal glands.

The *nerves* are from the sacral plexus (cerebro-spinal), and from the inferior mesenteric and hypogastric plexuses (sympathetic).

In animals the longitudinal muscular fibres have a motor supply from the sacral nerves.

Relations of the Rectum in Detail.

First Portion.

Anteriorly:

Small intestines;
Sigmoid flexure;
Posterior surface of bladder in *male;*
Posterior surface of uterus in *female.*

Posteriorly:

Mesorectum;
Left Pyriformis muscle;
Left sacral plexus;
Left internal iliac vessels;
Anterior surface of first two and a half sacral vertebræ.

Externally:

Left ureter;
Left internal iliac vessels.

Second Portion.

Anteriorly:

(*Male*) Recto-vesical pouch;
Small intestines;
Triangular portion of bladder;
Vesiculæ seminales;
Vasa deferentia;
Under surface of prostate gland.
(*Female*) Posterior wall of vagina;
Recto-vaginal pouch;
Recto-uterine pouch;
Small intestines.

Posteriorly:

Lower part of sacrum;
Coccyx;
Ano-coccygeal body;
Middle sacral vessels;
Origin of Pyriformis muscles.

Third Portion, or Anal Canal.

Anteriorly:

(*Male*) Bulb of urethra;
Membranous urethra.
(*Female*) Perineal body.

Posteriorly:

Ano-coccygeal body;
Coccygei muscles.

Laterally:

Fat of ischio-rectal fossæ;
Levatores ani muscles.

The other ways of describing the rectum (page 1038) only affect its method of subdivision.

Treves describes the two lower parts of the rectum and includes the first in the sigmoid flexure. This is doubtless an improvement on the old method. He says:[1] "The segments of the gut termed the sigmoid flexure and first part of the rectum form together a single loop which cannot be divided into parts. This loop begins where the descending colon ends, and ends at the spot where the mesorectum ceases opposite the third piece of the sacrum. This loop when unfolded describes a figure that may be compared to the capital omega" (Fig. 661).

"The average length of this adult omega loop is seventeen and a half inches, varying from six to twenty-seven. Its normal position is not in the left iliac fossa, but in the pelvis. Its most usual arrangement is this: the descending colon ends just at the outer border of the Psoas. The gut crosses the muscle at right

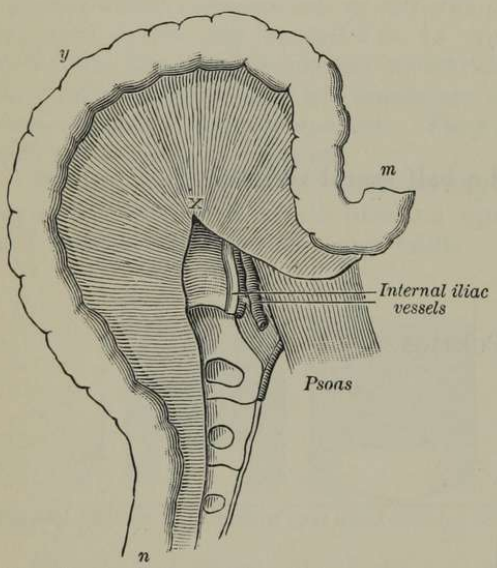

FIG. 661.—Omega loop of sigmoid flexure. (Treves.)

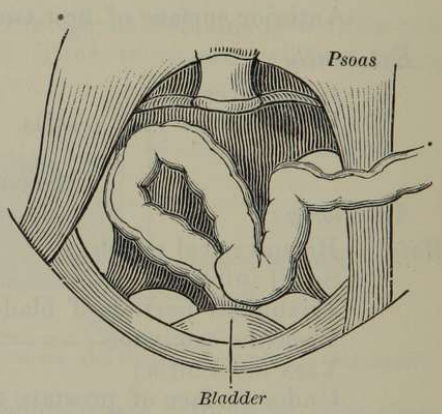

FIG. 662.—Usual course of the omega loop. (Treves.)

angles and descends vertically along the left pelvic wall, and may at once reach the pelvic floor. It then passes more or less horizontally and transversely across the pelvis from left to right and commonly comes into contact with the right pelvic wall. Here it is bent upon itself, and passing once more toward the left reaches the middle line and descends to the anus" (Fig. 662).

The line of attachment of the mesocolon that fastens the omega loop is as follows (Fig. 661): "It crosses the Psoas at a right angle, and then takes a slight curve upward so as to pass over the iliac vessels about at their bifurcation. The curve ends at the point *X*, which is most frequently at the bifurcation of the vessels. From here the line of attachment proceeds vertically down to terminate at *N*. Its course is to the left of the middle line, while its ending will be upon that line. At the point *X* the mesocolon is folded a little, and here there arises that part of the membrane which goes to the summit of the loop *Y*. Here the mesocolon attains its greatest length, and at this spot the sigmoid artery enters. The average length of the mesocolon is over the Psoas one and a half inches; at the point *X* three and a half inches; on the sacrum one and three-fourths inches. The distance between the ends of the loop *M* and *N* is three inches."

[1] *Hunterian Lectures*, 1885: "The Anatomy of the Intestinal Canal and Peritoneum in Man."

Surface Form.—The coils of the small intestine occupy the front of the abdomen below the transverse colon, and are covered more or less completely by the great omentum. For the most part the coils of the jejunum occupy the left side of the abdominal cavity—*i. e.* the left lumbar and inguinal regions and the left half of the umbilical region—whilst the coils of the ileum are situated to the right, in the right lumbar and inguinal regions, in the right half of the umbilical region, and also the hypogastric. The cæcum is situated in the right inguinal region. Its position varies slightly, but the mid-point of a line drawn from the anterior superior spinous process of the ilium to the symphysis pubis will about mark the middle of its lower border. It is comparatively superficial. From it the ascending colon passes upward through the right lumbar and hypochondriac regions, and becomes more deeply situated as it ascends to the hepatic flexure, which is deeply placed under cover of the liver. The transverse colon crosses the belly transversely on the confines of the umbilical and epigastric regions, its lower border being on a level slightly above the umbilicus, its upper border just below the greater curvature of the stomach. The splenic flexure of the colon is situated behind the stomach in the left hypochondrium, and is on a higher level than the hepatic flexure. The descending colon is deeply seated, passing down through the left hypochondriac and lumbar regions to the sigmoid flexure, which is situated in the left inguinal regions, and which can be felt in thin persons, with relaxed abdominal walls, rolling under the fingers when empty, and when distended forming a distinct tumor.

Surgical Anatomy.—The small intestines are much exposed to injury, but, in consequence of their elasticity and the ease with which one fold glides over another, they are not so frequently ruptured as would otherwise be the case. Any part of the small intestine may be ruptured, but probably the most common situation is the transverse duodenum, on account of its being more fixed than other portions of the bowel, and because it is situated in front of the bodies of the vertebræ, so that if this portion of the abdomen is struck by a sharp blow, as from the kick of a horse, it is unable to glide out of the way, but is compressed against the bone and so lacerated. Wounds of the intestine sometimes occur. If the wound is a small puncture, under, it is said, three lines in length, no extravasation of the contents of the bowel takes place. The mucous membrane becomes everted and plugs the little opening. The bowels, therefore, may be safely punctured with a fine capillary trocar, in cases of excessive distension of the intestine with gas, without fear of extravasation. A longitudinal wound gapes more than a transverse, owing to the greater amount of circular muscular fibres. The small intestine, and most frequently the ileum, may become strangulated by internal bands, or through apertures, normal or abnormal. The bands may be formed in several different ways: they may be old peritoneal adhesions from previous attacks of peritonitis; or an adherent omentum from the same cause; or the band may be formed by Meckel's diverticulum, which has contracted adhesions at its distal extremity; or the band may be the result of the abnormal attachment of some normal structure, as the adhesion of two appendices epiploicæ, or an adherent vermiform appendix or Fallopian tube. Intussusception or invagination of the small intestine may take place in any part of the jejunum and ileum, but the most frequent situation is at the ileo-cæcal valve, the valve forming the apex of the entering tube. This form may attain great size, and it is not uncommon in these cases to find the valve projecting from the anus. Stricture, the impaction of foreign bodies, and twisting of the gut (*volvulus*) may lead to intestinal obstruction.

Foreign bodies and small hardened masses of fæcal matter are very liable to become lodged in the vermiform appendix. Here they set up inflammation, often cause perforation of the appendix and formation of abscess in the loose connective tissue around. This may require operative interference, and in some cases of recurrent attacks of appendicitis this little diverticulum of the bowel has been removed. In external hernia the ileum is the portion of bowel most frequently herniated. When a part of the large intestine is involved, it is usually the cæcum, and this may occur even on the left side. In some few cases the vermiform appendix has been the part implicated in cases of strangulated hernia, and has given rise to serious symptoms of obstruction. Occasionally ulceration of the duodenal glands may occur in cases of burns, but is not a very common complication. The ulcer may perforate one of the large duodenal vessels, and may cause death from hæmorrhage, or it may perforate the coats of the intestine and produce fatal acute peritonitis. The diameter of the large intestine gradually diminishes from the cæcum, which has the greatest diameter of any part of the bowel, to the point of junction of the sigmoid flexure with the rectum, at or a little below which point stricture most commonly occurs and diminishes in frequency as one proceeds upward to the cæcum. When distended by some obstruction low down, the outline of the large intestine can be defined throughout nearly the whole of its course—all, in fact, except the hepatic and splenic flexures, which are more deeply placed; the distension is most obvious in the two flanks and on the front of the abdomen just above the umbilicus. The cæcum, however, is that portion of the bowel which is, of all, most distended. It sometimes assumes enormous dimensions, and has been known to be perforated from the pressure, causing fatal peritonitis. The hepatic flexure and the right extremity of the transverse colon is in close relationship with the liver, and abscess of this viscus sometimes bursts into the gut in this situation. The gall-bladder may become adherent to the colon, and gall-stones may find their way through into the gut, where they may become impacted or may be discharged per anum. The mobility of the sigmoid flexure renders it more liable to become the seat of a volvulus or twist than any other part of the intestine. It generally occurs in patients who have been the subjects of habitual constipation, and in whom, therefore, the meso-sigmoid flexure is elongated. The gut at this part being loaded with fæces, from its weight falls over the gut below, and so gives rise to the twist.

The surgical anatomy of the rectum is of considerable importance. There may be congenital malformation due to arrest or imperfect development. Thus, there may be no inflection of the epiblast (see page 134), and consequently a complete absence of the anus; or the hind-gut may be imperfectly developed, and there may be an absence of the rectum, though the anus is developed; or the inflection of the epiblast may not communicate with the termination of the hind-gut from want of solution of continuity in the septum which in early fœtal life exists between the two. The mucous membrane is thick and but loosely connected to the muscular coat beneath, and thus favors prolapse, especially in children. The vessels of the rectum are arranged, as mentioned above, longitudinally, and are contained in the loose cellular tissue between the mucous and muscular coats, and receive no support from surrounding tissues, and this favors varicosity. Moreover, the blood from these vessels is returned into the general circulation through two distinct channels—part through the systemic system and part through the portal system—so that they may be said to be placed between the portal and systemic circulations, and thus predisposed to congestion and consequent dilatation. In addition to this, there are no valves in the superior hæmorrhoidal veins, and the vessels of the rectum are placed in a dependent position, and are liable to be pressed upon and obstructed by hardened fæces. The anatomical arrangement, therefore, of the hæmorrhoidal vessels explains the great tendency to the occurrence of piles. Again, the presence of the Sphincter ani is of surgical importance, since it is the constant contraction of this muscle which prevents an ischio-rectal abscess from healing and causes it to become a fistula. Also, the reflex contraction of this muscle is the cause of the severe pain complained of in fissure of the anus. The relations of the peritoneum to the rectum are of importance in connection with the operation of removal of the lower end of the rectum for malignant disease. This membrane gradually leaves the rectum as it descends into the pelvis; first leaving its posterior surface, then the sides, and then the anterior surface to become reflected in the male on to the posterior wall of the bladder, forming the recto-vesical pouch, and in the female on to the posterior wall of the vagina, forming Douglas's pouch. The recto-vesical pouch of peritoneum extends to within three and a half or four inches from the anus, so that it is not safe to remove more than three inches of the entire circumference of the bowel for fear of the risk of opening the peritoneum. When, however, the disease is confined to the posterior surface of the rectum, or extends farther in this direction, a greater amount of the posterior wall of the gut may be removed, as the peritoneum does not extend on this surface to a lower level than five inches from the margin of the anus. The recto-vaginal or Douglas's pouch in the female extends somewhat lower than the recto-vesical pouch of the male, and therefore it is necessary to remove a less length of the tube in this sex.[1] Upon introducing the finger into the rectum the membranous portion of the urethra can be felt, if an instrument has been introduced into the bladder, exactly in the middle line; behind this the prostate gland can be recognized by its shape and hardness and any enlargement detected; behind the prostate the fluctuating wall of the bladder when full can be felt, and if thought desirable it can be tapped in this situation; on either side and behind the prostate the vesiculæ seminales can be readily felt, especially if enlarged by tubercular disease. Behind, the coccyx is to be felt, and on the mucous membrane one or two of Houston's folds. The ischio-rectal fossæ can be explored on either side, with a view to ascertaining the presence of deep-seated collections of pus. Finally, it will be noted that the finger is firmly gripped by the sphincter for about an inch up the bowel.

By gradual dilatation of the sphincter the whole hand can be introduced into the rectum so as to reach the descending colon. This method of exploration is rarely, however, required for diagnostic purposes.

The colon frequently requires opening in cases of intestinal obstruction, the descending colon being usually the portion of bowel selected for this operation. The operation of colotomy may be performed either without opening the peritoneum by an incision in the loin (lumbar colotomy), or by an opening through the peritoneum (inguinal colotomy). Lumbar colotomy is performed by placing the patient on the side opposite to the one to be operated on, with a firm pillow under the loin. A line is then drawn from the anterior superior to the posterior superior spine of the ilium, and the mid-point of this line (Heath) or half an inch behind the mid-point (Allingham) is taken, and a line drawn vertically upward from it to the last rib. This line represents, with sufficient correctness, the position of the normal colon. An oblique incision four inches in length is now made midway between the last rib and the crest of the ilium, so that its centre bisects the vertical line, and the following parts successively divided: (1) The skin, superficial fascia, with cutaneous vessels and nerves and deep fascia. (2) The posterior fibres of the External oblique and anterior fibres of the Latissimus dorsi. (3) The Internal oblique. (4) The lumbar fascia and the external border of the Quadratus lumborum. The edges of the wound are now to be held apart with retractors, and the transversalis fascia will be exposed. This is to be opened with care, commencing at the posterior angle of the incision. If the bowel is distended, it will bulge into the wound, and no difficulty will be found in dealing with it. If, however, the gut is empty, this bulging will not take place, and the colon will have to be sought for. The guides to it are the lower end of the kidney, which will be plainly felt, and the outer edge of the Quadratus lumborum. The bowel having been found, is to be drawn well up into the wound, and it may be opened at once and the margins of the openings stitched to the skin at the edge of the wound; or, if the case is not an urgent one, it may be retained in this position by two harelip pins passed through the muscular coat, the rest of the wound closed, and the

[1] Allingham says one inch less in the female.

bowel opened in three or four days, when adhesion of the bowel to the edges of the wound has taken place.

Inguinal colotomy is preferred by many surgeons in those cases where there is no urgent obstruction, and where, therefore, there is no necessity to open the bowel at once. The main reason for preferring this operation is that a spur-shaped process of the meso-colon can be formed which prevents any fæcal matter finding its way past the artificial anus and becoming lodged on the diseased structures below. The sigmoid flexure being almost entirely surrounded by peritoneum, a coil can be drawn out of the wound and the greater part of its calibre removed, leaving the remainder attached to the meso-colon, which forms a spur, much the same as in an artificial anus caused by sloughing of the gut after a strangulated hernia, and this prevents any fæcal matter finding its way from the gut above the opening into that below. The operation is performed by making an incision two or three inches in length from a point one inch internal to the anterior superior spinous process of the ilium, parallel to Poupart's ligament. The various layers of abdominal muscles are cut through, and the peritoneum opened and sewn to the external skin. The sigmoid flexure is now sought for, and pulled out of the wound and fixed by passing a needle threaded with carbolized silk through the meso-colon close to the gut and then through the abdominal wall. The intestine is now sewn to the skin all round, the suture passing only through the serous and muscular coats. The wound is dressed, and on the second to the fourth day, according to the requirements of the case, the protruded coil of intestine is opened and removed with scissors.

THE LIVER.

The **Liver** (Hepar) is a gland intended for the secretion of sugar and bile, remarkable for its size, equalling that of all the other glands put together, and for its connections with the system of the portal vein which ramifies in its substance. It may be described under two heads: (1) External conformation; (2) Structure or Histology. First we shall study its situation, its volume, its weight, its consistence and color, its form, its relations, and its means of fixation. This organ fills almost all the right hypochondrium, a great part of the epigastrium, and advances into the left hypochondrium as far as the mammary line in the neighborhood of the spleen. It is situated, consequently, *below* the diaphragm, which separates it from the lungs and heart; *above* the stomach, duodenum, transverse colon, and small intestines, which form a sort of pillow; and behind are the right false ribs, which protect it. In an embryo of three weeks this organ fills the greater part of the abdomen (Fig. 663). During the first half of intra-uterine life its anterior border is below the umbilicus. In a child of six or eight years it gets behind the free border of the right false ribs. In the adult its average transverse *dimension* is 28 cm. (eleven inches), its antero-posterior dimension is 20 cm. (eight inches), and vertical dimension is 6 cm. (two and a half inches) (Sappey). Quain's figures are—greatest vertical diameter on the right lobe, five to seven inches, greatest transverse is one or two inches more; its greatest antero-posterior diameter is above the right kidney, four to six inches, and in front of the vertebral column is two and a half to four inches. All this varies with the individual, the amount of blood contained, and the state of digestion and pathological state.

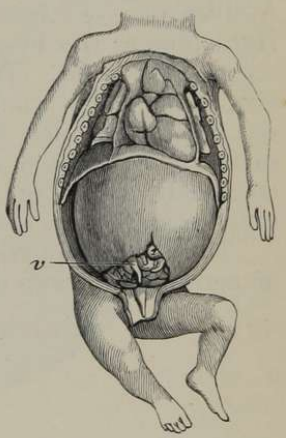

FIG. 663.—Embryo of twelve weeks with open thoracic and abdominal cavity in which the liver is seen, also cæcum and appendix. (Gegenbaur.)

Its *volume* is 90 to 100 cubic inches.

The *absolute weight* of the liver is proportional to its volume and amount of blood contained. The average is in bloodless livers 1.451 kg.; in physiological livers containing blood, 1.937 kg., or about one-thirty-second of the body-weight. At birth it is one-eighteenth of the body-weight. This is 50 or 60 ounces avoirdupois in the male, a little heavier than the brain, and 40 to 50 ounces in the female. Its specific gravity is 1.046. The *consistence* of the liver is soft, but harder than that of other glands. It has a certain friability. Its tissue is more easily crushed than depressed.

The physiological *color* is a dark, reddish brown. In the young it takes on a

brighter tone, due to the milk diet, and in later years may assume other shades, due to pathological changes. After death it may be red-brown at one place, yellow at another, with all variations; sometimes the colors occur in wavy lines. This means only unequal repletion of the vessels. The liver possesses no shape peculiar to itself. Like the lachrymal, or parotid gland, or pancreas, it is moulded to neighboring organs. Its general contour, however, is wedge-shaped, with the base to the right. Many compare it to the upper section of an ovoid cut by a plane passing from below upward to the left (Fig. 664). The right end is thick and the left end thin.

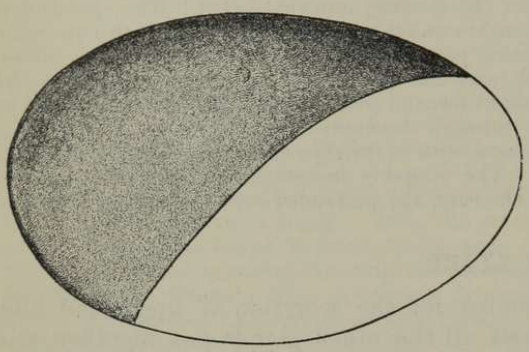

FIG. 664.—Figure to illustrate the shape of the liver.

The various *surfaces* ascribed to the liver are from two to five, resulting from the method of observation. A pathological, bloodless, decayed liver placed on the dissecting table as usually seen by the student, will always have two surfaces. It does not follow that that liver shows anything of its normal appearance during life. The inferior vena cava of this liver is horizontal on its inferior surface, yet we know that vessel runs vertically along the spinal column. A liver removed from the body and injected does not give the correct form. Hardening *in situ* by chromic acid or formalin injections leaves the shape of the viscera as in life. The liver treated thus shows three *surfaces*, a *superior*, *inferior*, and *posterior*; an *anterior border*, a *right*, and a *left extremity*. That which was formerly called the posterior blunt margin is now seen to be a posterior surface. Symington regards the shape of the liver as that of a right-angled triangular prism, and describes five surfaces, right basal or lateral, anterior, superior, posterior, and inferior.

The *convex*, upper, smooth *surface* of the liver is subdivided by a sagittal fold of peritoneum drawn down from the diaphragm, called the *suspensory*, *broad*, or

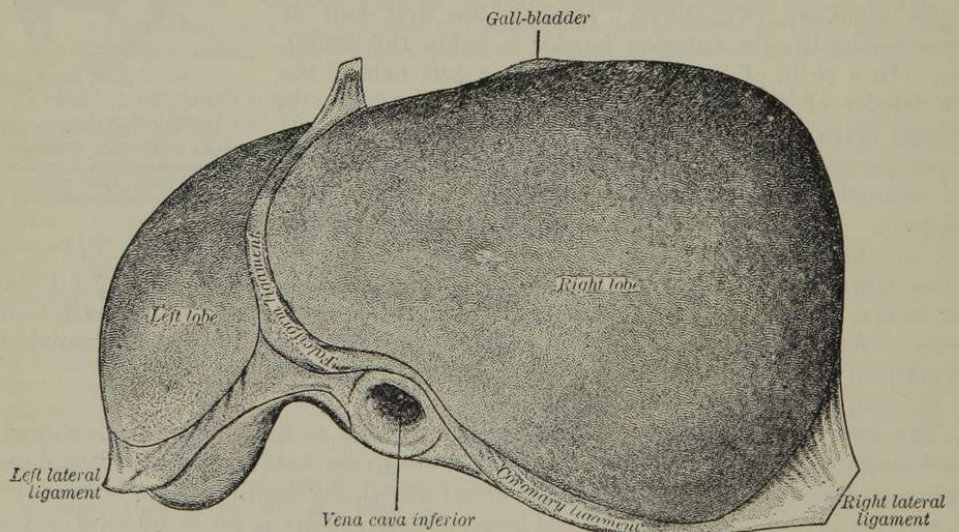

FIG. 665.—Superior surface of the liver. Drawn from His' models.

falciform ligament. To its right is a larger, broader convex lobe, and on the left a smaller, more slender, flatter lobe (Fig. 665). This broad ligament corresponds on the under concave surface of the liver to the left longitudinal fissure

(Fig. 666) running from before backward. This fissure also divides the *under* surface into a right and left lobe. The *left lobe* is variable, and usually constitutes one-sixth of the gland. Three more lobes are seen on the inferior and posterior surfaces of the right one, from before backward, the *quadrate*, the *caudate*, or *tuberculum caudatum*, and *Spigelian lobes*.

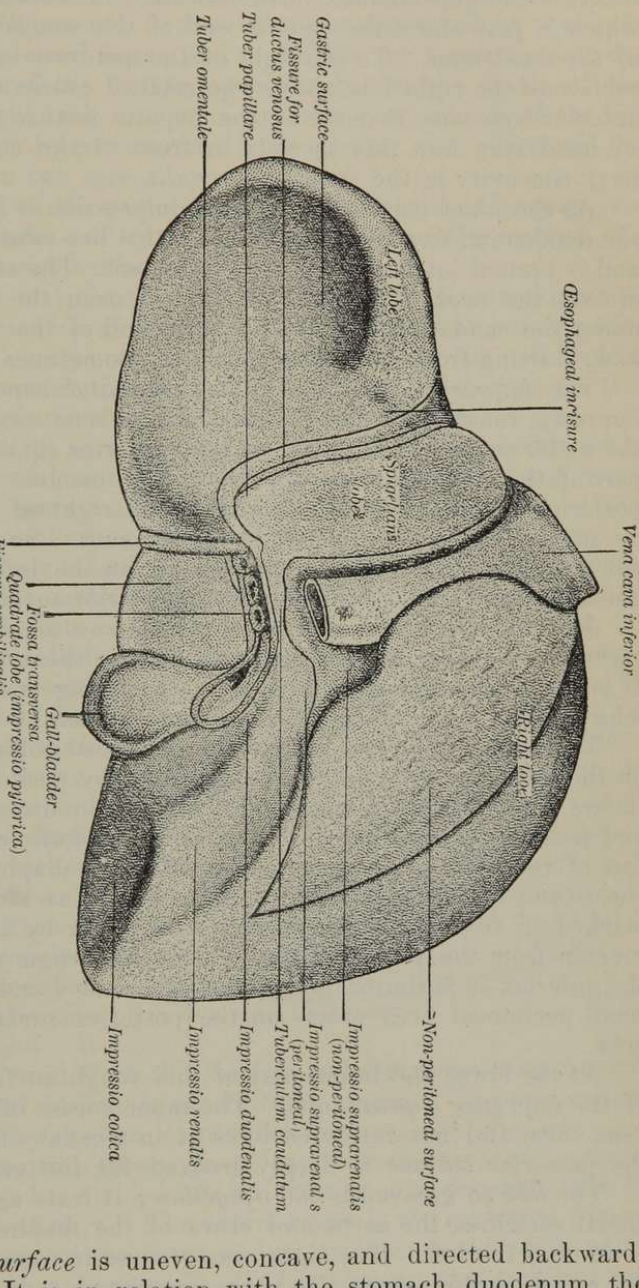

FIG. 666.—Posterior and inferior surfaces of the liver. Drawn from His' models.

Surfaces.—The *superior* or *phrenic surface* is convex, directed upward and forward and covered by peritoneum except for the linear space between the layers of the broad ligament. It includes the upper surface of the right and left lobes, the former being convex and the latter more flat. Between and upon the two is a shallow depression or flattening corresponding to the central tendon of the diaphragm and to the heart.

This separation of lobes continues below in the attachment of the falciform ligament and *incisura umbilicalis*, *umbilical* or *interlobular notch*.

To the right of the notch is a concavity intruding upon this surface, occupied by the fundus of the gall-bladder, the *incisura vesicalis*. This whole surface is in relation to the under surface of the diaphragm, and below to a small extent with the anterior abdominal wall.

The *inferior* or *visceral surface* is uneven, concave, and directed backward, downward, and to the left. It is in relation with the stomach, duodenum, the hepatic flexure of the colon, the right kidney, and suprarenal capsule. This surface, as we have seen, is divided into a right and left portion by the left longitudinal fissure. It is invested by peritoneum of the greater sac, except where the gall-bladder is adherent to it, and at the transverse fissure or hilus where the two layers of lesser omentum are attached.

The *under surface* of the *left lobe* is moulded over the cardia of the stomach. Near the centre and right part of this surface a result of moulding is seen in a large rounded tubercle, the *tuber omentale*, which fits into the concavity of the lesser curvature of the stomach. The whole tubercle is made from the under surface of the left lobe and the lower left corner of the Spigelian. It is in front of

the anterior layer of the lesser omentum. Here it meets another tuber omentale coming upward and forward from the pancreas.

The *under surface* of the *right lobe* has a middle piece cut off from it by the fossa for the gall-bladder, *fossa vesicalis*. This forms a *quadrate* or anterior lobe which is just above the pyloric end of the stomach and the superior curvature of the duodenum. To the right of the quadrate lobe and gall-bladder, the under surface of the right lobe shows two marked concavities separated by a ridge. The anterior concavity is made by the hepatic flexure of the colon, *impressio colica*; we have seen how this ascends in front of the right kidney, so posteriorly the next concavity is the *impressio renalis*.

At the inner border of the renal impression is another for the second part of the duodenum, *impressio duodenalis*; this lies outside the neck of the gall-bladder and is limited internally by the cystic duct. The superior curve of the duodenum crosses the neck of the gall-bladder or even the transverse fissure, and comes under the caudate lobe. The pyloric end of the stomach touches the quadrate lobe, starting from its anterior border. Sometimes there is an *impressio pylorica*.

The *impression* for the right *suprarenal capsule* is farther back than the impressio renalis and close to the inferior vena cava. Its basal part rests upon the under surface of the liver at the posterior tip of the renal impression. This part of the impression is covered by peritoneum. Its apex extends up on the posterior surface of the liver just to the right of the vena cava. This part of its impression is not covered by peritoneum. So the *impressio suprarenalis* has two parts, one covered with peritoneum on the inferior surface of the liver and one uncovered by peritoneum on the posterior surface.

Just anterior to the vena cava is a narrow area of liver tissue connecting the right lower corner of the Spigelian lobe to the under surface of the right lobe. It is the *tuberculum caudatum*, not always big enough to be called the caudate lobe (*cauda*, tail). This lies above the foramen of Winslow.

The *posterior surface* is rounded and broad behind the right lobe, but narrow on the left. To the right is not covered by peritoneum for a space about three inches broad and two inches high. This is in direct contact with the diaphragm and posterior abdominal wall, and is marked off from the upper surface by the line of reflection of the peritoneum from the diaphragm to the liver. This part constitutes the anterior layer of the coronary and right lateral ligaments. It is marked off from the under surface of the liver by a similar line of reflected peritoneum from the posterior part of the diaphragm to the liver, which here forms the inferior or posterior layer of the coronary and right lateral ligaments. A small peritoneal area exists on the posterior surface to the right of the rough area.

At the lower and inner part of this rough surface is the non-peritoneal part of the *impressio suprarenalis*. The inner border of the surface projects over the vena cava, and not rarely encloses it in a canal of liver tissue. The centre of the posterior surface is deeply grooved for the vertebral column and aorta.

The *lobe* so grooved is the *Spigelian*; it rests against the tenth and eleventh dorsal vertebræ, the aorta and crura of the diaphragm, but upon the right crus more than the left. The right crus grooves it from the right lower corner to the left upper corner; here also is the œsophagus. The end of the thoracic aorta lies behind the left lower corner separated by the diaphragm. To its right is the fossa or canal for the inferior vena cava; to its left is the furrow for the obliterated remains of the *ductus venosus Arantii*. In fœtal life this duct establishes communication between the vena umbilicalis and vena cava inferior. Still farther to the left of this is a groove for the œsophagus and beginning of the cardia.

The free surface of the Spigelian lobe looks backward, is nearly vertical, and is concave from side to side. Its superior border slopes toward the upper surface of the liver, but is separated from it by a double layer of peritoneum. Below, its inferior margin shows a slight notch separating a right part, which joins the caudate tubercle or lobe, and a left part called papillary tubercle, *tuber papillare*.

This is seen as the most prominent part of the lobe when the lesser omentum is divided in front. This lobe is the only part of the liver covered by the peritoneum of the lesser sac. The finger goes under the caudate lobe, through the foramen of Winslow, and passes up behind the Spigelian lobe. *Above*, it is limited by the posterior layer of the coronary ligament; to the *right* it is obstructed by the layer of the lesser sac attached to the caval fossa; and to the *left* the finger cannot pass over to the stomach by reason of the double layer attached to the fissure of the ductus venosus. All of the right lobe, except its posterior part, and all of the left and quadrate lobes are covered by peritoneum of the greater sac. That on the caudate is divided between the two sacs.

Finally, to the extreme left of the posterior surface we have the *thin posterior edge* of the *left lobe* sharply under-cut by the inferior surface. His regards the tuber omentale as on the posterior surface.

The *anterior border* is thin and sharp and marked opposite the attachment of the falciform ligament by the *umbilical notch* (incisura umbilicalis), and opposite the cartilage of the ninth rib by a second notch for the fundus of the gall-bladder (incisura vesicalis). In adult males this border usually corresponds with the free margin of the ribs; in women and children it may project below.

The *right extremity* of the liver is thick and rounded, convex from before backward and usually from above downward. Its upper and anterior *angles* are rounded. Below it forms an acute margin with the under surface.

The *left extremity* is thin and flattened from above downward.

The **fissures** of the liver closely follow the lines of the letter H (Meckel), supposing them projected upon a flat surface (Fig. 667). They are five in number, situated upon the inferior and posterior surfaces of the liver, often called *fossæ* instead of fissures. The *transverse fissure*, or *porta hepatis* (gate of the liver), is the most important, because the great vessels and nerves enter here and the hepatic ducts and lymphatics pass out. It is a short, deep fissure, 5 cm. long (two inches) and 12 to 15 mm. wide (one-half inch); it is on the under surface of the right lobe, passing transversely a little nearer the posterior surface than the anterior margin and nearer the left extremity than the right. It separates the quadrate lobe in front from the caudate and Spigelian lobes behind, and joins the two longitudinal fissures at nearly right angles. The two vertical arms of the H are represented by the two longitudinal fissures, right and left.

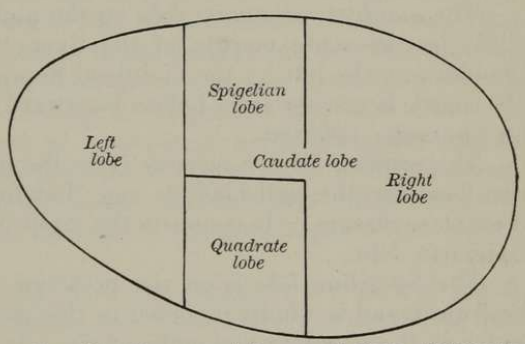

FIG. 667.—Diagram of fissures of liver. Schematic. Seen from behind and below.

The *left longitudinal*, or sagittal, *fissure* (fossa longitudinalis sinistra) separates the right from the left lobe, and is divided into an anterior and posterior part by its junction with the transverse fissure. The anterior part is the *umbilical fissure*, which contains the umbilical vein in the fœtus and its remains in the adult, which is then called the *round ligament* (Lig. teres). It lies between the quadrate and left lobes of the liver. This fissure, and the one for the ductus venosus, are often bridged over by liver tissue (*pons hepatis*), converting a fissure wholly or partially into a canal.

The posterior part of the left longitudinal fissure is not so marked as the anterior part; it passes between the lobe of Spigelius and the left lobe, and is called the *fissure of the ductus venosus*. In the fœtus it lodges a vein, but in the adult this vein becomes a slender cord, *lig. venosum*.

The *right longitudinal fissure* (fossa longitudinalis dextra) runs parallel to the left one, and has an anterior and posterior part. It meets one interruption just behind the transverse fissure, where the caudate lobe connects the Spigelian and

right lobe. The *posterior part* is the *fossa* of the *vena cava*, which separates the Spigelian from the right lobe, and is separated from the transverse fissure by the caudate lobe. It is a deep fossa, sometimes a canal; at its upper part the hepatic veins enter the floor of the fossa and end in the vena cava. The *anterior part* of this longitudinal fissure is the fossa for the gall-bladder, *fossa vesicalis*. The proposed name is fossa vesicæ felleæ. It is a shallow, oblong fossa on the under surface of the right lobe, and runs from the incisura vesicalis to near the right end of the transverse fissure.

The *transverse*, *umbilical*, and *vesical fissures* are on the under surface of the liver, and the *fissures* for the *ductus venosus* and *vena cava* are on the posterior surface.

Lobes.

We have seen five lobes, though one, the caudate, is very small. The boundaries between *right* and *left* are, superiorly, the attachment of the falciform ligament; anteriorly, the umbilical incisure; inferiorly, the lig. teres in the umbilical fissure; posteriorly, the lig. venosum in the fissure for the ductus venosus.

The *right lobe* is much larger than the left, and is of quadrate form. Three fissures are on its under and posterior surfaces: the transverse, and those for gall-bladder and vena cava. These separate three more lobes, all belonging to the right one. Three impressions are seen—*renal* and *suprarenal*, *colic*, and *duodenal*.

The *left lobe* is convex above, but less so than the right, and concave below, where it rests on the stomach. This impression is in front of the groove for the œsophagus, and is separated from the longitudinal fissure by the omental tuberosity which lies against the lesser omentum and lesser curvature of the stomach.

The *quadrate* or *square lobe* on the under surface of the right is bounded anteriorly by the acute margin of the liver; to the right by the fossa for the gall-bladder; to the left by the umbilical fissure and behind by the transverse fissure. Its length is greater from before backward than from side to side. It may present an *impressio pylorica*.

The *caudate lobe* or *tubercle* is on the under surface of the right lobe between the fossa for the gall-bladder and that for the vena cava, at the right end of the transverse fissure. It connects the right lobe with the right lower corner of the Spigelian lobe.

The *Spigelian lobe* is on the posterior surface of the right one, looks directly backward, and is wholly included in the *atrium bursæ omentalis*. It reaches below as far as the pancreas and cœliac axis. It is bounded above by the coronary ligament; to the right by the fossa for the vena cava; to the left by the fissure for the ductus venosus, and below by the transverse fissure. Its left upper angle is partly grooved for the œsophagus. Its *papillary tubercle* looks directly downward.

The *technical names* of the parts seen on the three surfaces of the liver are, in order from left to right—

Superior surface: Upper surface left lobe, umbilical incisure, attachment of falciform ligament, cardiac impression on both lobes, vesical incisure, upper surface of right lobe (Fig. 665).

Posterior surface: Thin margin of left lobe, œsophageal incisure, lig. venosum in fissure for ductus venosus, lobus Spigelii in front of the tenth and eleventh dorsal vertebræ; papillary tubercle; fossa for the vena cava and hepatic veins; non-peritoneal impression for part of the right suprarenal capsule; non-peritoneal surface of right lobe for the diaphragm (Fig. 666).

Inferior surface: Gastric impression on the under surface of left lobe; tuber omentale which includes lower left part of Spigelian lobe; umbilical fissure and lig. teres; quadrate lobe with impressio pylorica and duodenalis (first portion); fossa for gall-bladder; remainder of under surface of right lobe; impressio duodenalis (second portion); peritoneal impression for suprarenal capsule; impressio renalis posteriorly, and colica, anteriorly.

There are some *abnormal forms* of the liver. Frequently the left lobe is so

elongated it may reach the spleen or even be hooked around it or inseparably fused with it. The papillary tubercle may be so developed as to form a separate lobule. An accessory lobe may be attached to the left one, united by peritoneum and blood-vessels. Many times the number of lobes are diminished and the form becomes square or spherical. More often the number of lobes increases, separated by short deep clefts called *rimæ cæcæ*.

Besides congenital changes, others may be acquired by pressure. By excessive lacing in women the superficial part of the liver will become atrophic and the peritoneal coat will become thicker. On the convex surface of the liver a transverse furrow will be established dividing off an anterior portion, especially of the right lobe. This part will be pushed down into the abdominal cavity, and may become almost separated from the rest—the "corset liver." If the liver be more resistant, its surface may show the flat, stripe-like impressions occasioned by the ribs.

Ligaments and Peritoneal Relations.—The liver is connected in part by peritoneum to the roof of the abdominal cavity, to the anterior wall, to the stomach, duodenum, right kidney, and hepatic flexure of colon, whereby the following peritoneal folds or ligaments are to be distinguished. With one exception they are peritoneal folds.

The *coronary ligament* connects the posterior surface of the liver to the diaphragm. Its two layers surround the rough triangular surface seen on the posterior part of the right lobe, which is connected directly to the diaphragm by areolar tissue. These layers are reflections from the parietal peritoneum descending from the diaphragm. This ligament has three portions (Fig. 668). The *right part* is much the bigger and its layers are far apart, enclosing the posterior rough surface of the right lobe. The two layers are derived from the peritoneum of the greater sac. A *middle portion* is seen above the Spigelian lobe. The two layers are close together; the anterior one belongs to the greater sac, and the posterior one to the lesser. Farther to the *left* is a *third* narrow portion continued into the left lateral ligament. Both layers here belong to the greater sac. On either end of the coronary ligament the two layers of peritoneum gradually approach, and finally unite, thus forming the *right and left lateral ligaments* as prolongations of the coronary. As they enclose a triangular space, they are also called *triangular ligaments;* the left is the longer, and lies in front of the œsophagus. The right is often imperceptible.

The *suspensory*, *longitudinal*, *falciform*, or *broad* ligament is a part of the old anterior mesentery of the stomach and duodenum. The liver was developed in it, budding out from the duodenum, where its duct is still attached. This is a thin membrane which passes antero-posteriorly above the liver and below it. Above it meets the coronary ligament at right angles. By one of its margins it is connected with the posterior layer of the sheath of the right Rectus abdominis muscle as far as the umbilicus, and above to the under surface of the diaphragm, where it spreads out to the right and left. By its other margin it is attached along the upper surface of the liver, its left layer passing over the left lobe and continuing into the left part of the coronary and left lateral ligament. Its right layer passes over the right lobe and corresponding ligaments. The remaining margin is free and rounded, and passes from the interlobular notch to the transverse fissure of the liver. It contains between its two layers the intra-abdominal part of the umbilical vein of the fœtus, now a fibrous cord, the round ligament (lig. hepato-umbilicalis), which is lodged in the umbilical fissure. Also between the two layers run some branches of the epigastric veins anastomosing with the portal system, little twigs of the phrenic arteries, numerous lymphatics, and branches of the phrenic nerve which are destined for the serosa of the liver and for the peritoneum of the anterior abdominal wall. In its natural position the falciform ligament forms a pocket, which, with the diaphragm and abdominal wall, enclose the convex upper part of the left lobe of the liver. This ligament has no function of suspension.

Besides these there are others hardly less marked which we have noted in the study of the peritoneum. The *lesser omentum* (lig. gastro-hepaticum) with its

two layers attached to the anterior and posterior borders of the transverse fissure, descends to the lesser curvature of the stomach, containing between its layers some ascending branches of the left vagus nerve. The posterior layer descends behind the stomach as the anterior wall of the bursa omentalis, and arches behind the cardia into the posterior wall of this bursa. On the right both layers unite, forming a free edge, constituting the anterior margin of the foramen of Winslow.

This edge, whose layers separate below and nearly enclose the whole of the superior curve of the duodenum, constitutes the *lig. hepato-duodenale*, which contains the portal vein, hepatic artery, common bile-duct, lymphatics and nerves (not hepatic veins).

A part of this ligament passes on over the duodenum into the great omentum and reaches the transverse colon. This is the *hepato-colic ligament* (Fig. 635).

The *lig. hepato-renale* passes down from the under surface of the right lobe rising near the neck of the gall-bladder and vena cava and behind the foramen of Winslow to the upper part of the right kidney. It possesses a free edge directed forward. Between this and the right lateral ligament of the liver is often a recess, *recessus hepato-renalis*, into which fits the right end of the inferior and posterior surfaces of the liver. The posterior wall of this recess touches in part the right suprarenal capsule and in part the right kidney. That part of the hepato-duodenal ligament which rises from the gall-bladder is the *lig. cystico-duodenale.*

The ligaments of the liver are *coronary*, right and left *lateral* or *triangular*, *falciform* or suspensory, *round* or *lig. hepato-umbilicalis*, *lesser omentum*, which consists of *lig. hepato-gastricum* and *lig. hepato-duodenale*, *lig. cystico-duodenale*, *lig. hepato-colicum*, and *lig. hepato-renale* (Figs. 615 and 635).

Peritoneal Lines.—Beginning at the left, we see the space between the two layers of the left lateral ligament (Figs. 668 and 665). The anterior layer belongs wholly

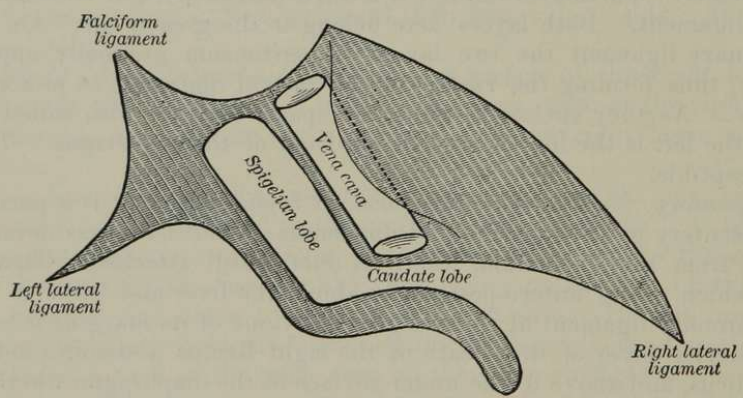

FIG. 668.—"Peritoneal lines" of the liver. Schematic.

to the greater sac. It passes from the left lateral ligament to the left layer of the falciform, forming a part of the coronary. This becomes continuous with the right layer at the umbilicus. The right layer runs along the upper margin of the liver, making the middle part of the coronary ligament, and then goes to the right, forming the rest of the coronary in front of the posterior rough surface on the liver, finally ending in the right lateral ligament. Taking the posterior layer from this point, we shall see it belongs mostly to the greater sac. It first completes the right lateral ligament, then runs behind the rough surface and enters into the impressio renalis, forming the lig. hepato-renale. It then passes under the rough impressio suprarenale in front of the vena cava and behind the tuberculum caudatum to the lobus Spigelii. It ascends on high to the left of the vena cava, surrounds the upper end of the Spigelian lobe, descends on its left side, turns in front of the papillary tubercle, follows the anterior edge of the caudate tubercle, and goes back to the right lobe. It here enters upon the under surface of the

gall-bladder and undergoes a more or less sharp bend, and passes to the anterior margin of the transverse fissure, following the posterior edge of the quadrate lobe to the left. It now reaches the tuber omentale, ascends on the left side of the fissure for the ductus venosus, and, making nearly a right angle, is prolonged above upon the left lobe. Here it forms the posterior edge of the lateral ligament. All the parts between the lines thus traced are not covered by peritoneum. This all belongs to the peritoneum of the greater sac except that which surrounds the Spigelian lobe; this belongs to the lesser sac or atrium of the omental bursa.

Relations of the Liver.

It lies in both hypochondria and in the epigastrium. It completely fills the right hypochondrium and sometimes enters the right lumbar region. Its entire right lobe lies in the right side of the abdominal cavity; only the left lobe reaches the left half of the body. The left longitudinal fissure and the attachment of the broad ligament, and the interlobar incisure which mark the limits between the right and left lobes, correspond almost always to the median line of the body (Fig. 626). Its convex upper surface fits itself to the concavity of the diaphragm, in which it glides as if in a joint-socket. The upper limit of the liver corresponds to that of the diaphragm. On the right side in the mammary line it is at the middle of the fourth intercostal space; on the left in the mammary line it is at the upper border of the fifth space. It does not usually go beyond this line. Above the right lobe rests the concave base of the right lung. In percussing the side of the chest downward three regions are noted—first, one of relative liver dulness, where it is covered by the lung; second, the region of costo-phrenic sinus, where diaphragm and not lung intervenes; third, absolute liver dulness below the diaphragm. A stab here could wound at the same time the pleura, right lung, diaphragm, peritoneum, and convex surface of the liver. Above the right and left lobes are the heart and then the left lung. The convex surface of the liver is covered on the right side by the greater part of the lower six or seven ribs, but usually stops at the eleventh. Anteriorly it is behind the fifth, sixth, seventh, eighth, and ninth costal cartilages and the ensiform cartilage. A part of the liver surface comes into direct contact with the anterior abdominal wall. From between the ninth and tenth rib cartilages the liver passes under the right costal arch into the epigastrium. Close under the ensiform process, at a spot usually called gastric fossa, lies a part of the liver which is turned forward and touches the abdominal wall more closely. In women with a "corset liver" the part in direct contact with the wall is much greater. Here some loops of intestine or transverse colon may intervene and a dulness will be found in percussing the mesogastrium, modified by a tympanitic sound.

The *under surface* of the liver is in contact by its right lobe directly with the upper two-thirds of the right kidney, and internal to that, with the descending duodenum, and above both, near the vena cava, with the suprarenal capsule which also touches the posterior surface (His). Lateral to the gall-bladder is the colon, internal to it the quadrate lobe with the portio pylorica of the stomach in relation. Going to the left and above, we find the tuber omentale, and still more laterally the whole concavity of the left lobe covering the lesser curvature, the cardia, and adjacent part of the anterior surface of the stomach. In an empty contracted stomach it may cover the fundus.

The *posterior edge* and *surface* rest against the tenth and eleventh dorsal vertebræ and the posterior ends of those ribs. This part also rests on the crura of the diaphragm, covers the œsophagus, and embraces the vena cava. Against it are the aorta, thoracic duct, nerves, and small vessels which rise from the vertebral column, but are separated from the liver by the diaphragm.

The anterior edge of the liver follows, in the right hypochondrium, the tenth and eleventh ribs, but normally does not extend over the anterior end of the last. Should one in quiet respiration feel the liver lower than this point, there is enlargement or displacement. Between the ninth and tenth ribs the anterior edge of the

liver leaves the costal arch and passes obliquely from right to left, ascending to the anterior end of the left eighth rib. In case of a thin abdominal wall this anterior edge of the liver can be felt as it passes through the epigastrium. This part can contract adhesions with the wall.

Relations in Detail.

Antero-superiorly:

Diaphragm;
Right and left lungs;
Pericardium and heart;
Anterior abdominal wall;
On the right { Six or seven lower ribs; / Fifth to ninth costal cartilage.

Inferiorly:

Right kidney and capsule;
Hepatic flexure of colon;
Descending duodenum;
Gall-bladder and cystic duct;
Vessels at portal fissure;
Pyloric end of stomach;
Superior curve of duodenum;
Cardia;
Lesser curvature of stomach;
Anterior surface stomach, small part (sometimes fundus of stomach).

Posteriorly:

Diaphragm;
Tenth and eleventh dorsal vertebræ;
End of tenth and eleventh ribs;
Crura of diaphragm;
Œsophagus;
Aorta;
Vena cava inferior;
Thoracic duct;
Non-peritoneal impression for right suprarenal capsule.

The Fixation of the Liver. — The liver, compared with other intraperitoneal organs, has a firm position, due to its fusion with the diaphragm. The peritoneal folds aid this fixation by connecting the liver to the concavity of the diaphragm. They are the falciform, or suspensory, coronary, and right and left lateral ligaments. In spite of this fixation, the liver experiences certain physiological changes and variations of position. It passes downward and forward in inspiration, and in expiration is pushed upward and backward. It moves up and down 1 to 1.5 cm. In inspiration Hasse finds a stretching of the liver; in expiration, a compression. These changes exert an influence over the circulation of the liver. The dilatation of the vessels accompanying the expansion of the liver during inspiration favors the influx of portal blood; during expiration and the accompanying compression the blood in the open hepatic veins is pressed into the vena cava.

Also the liver suffers small displacements occasioned by changes in the position of the body. In the horizontal supine position it falls back upon the diaphragm, and its anterior margin is more concealed behind the ribs. In the erect position the liver descends a little below the costal arch. The horizontal lateral position of body also has influence, displacing it a little toward the left or the right, as the case may be. Furthermore, by relaxation of ligaments, sometimes in women after childbirth, a "dislocation" of the liver results, or "wandering liver." Any pathological displacements of the diaphragm also affect the liver, as effusions into the thoracic cavity; also ascites, tympanites, or tumors in the abdominal cavity.

Vessels.—The blood-supply of the liver follows a double course through the *portal vein* and *hepatic artery*. The greatest amount of blood flowing through the liver, thus differing from other organs, comes from the veins of the digestive tract and of the spleen, which unite into a great vessel, *the vena portarum* or *portæ*.

The *hepatic artery* and *portal vein*, accompanied by numerous lymphatics and nerves, ascend to the transverse fissure between the layers of the gastro-hepatic omentum. The *hepatic duct*, lying in company with them, descends from the transverse fissure between the layers of the same omentum. The relative position of the three structures is as follows: the hepatic duct lies to the right, the hepatic artery to the left, and the portal vein behind and between the other two. They are enveloped in a loose areolar tissue, the capsule of Glisson, which accompanies the vessels in their course through the *portal canals* in the interior of the organ.

In the transverse fissure this portal vein splits into two trunks, the right and left, for lobes of the same name. At the point of division is an enlargement, the *sinus venæ portæ*. They enter the liver substance and subdivide dichotomously into smaller branches, which do not anastomose. They end in the interlobular connective tissue in three to five twigs, and form a rich plexus around each lobule, *interlobular veins*. These lose themselves in a capillary network, which penetrates the lobule in a ray-shaped manner, and are collected at its centre into a little vein, the *vena centralis* or *intralobular vein*. These are the roots of the hepatic veins.

The characteristic point of the blood-current of the portal system consists in this: it must first pass through a capillary circulation before it enters the inferior vena cava.

Accompanying the portal vein is the *hepatic artery*, a branch of the cœliac axis, which divides at the transverse fissure into a right and left branch. The twigs of the chief branches follow those of the portal vein, which accompany them singly or doubly. The hepatic artery supplies chiefly the connective tissue and the capsule of the liver. In the serous covering it anastomoses with the phrenic and internal mammary arteries.

The *intralobular veins* form, so to speak, the pedicles of the lobules, and, after their exit from each empty at an acute angle into bigger veins, the *sublobular*. These larger veins unite with each other and form numerous valveless *hepatic veins*, which, draining the blood from the circulation of the portal vein and hepatic artery, make their way to the posterior surface of the liver and empty, as three large trunks and a number of small ones, into the vena cava. These *hepatic veins* have no cellular investment, and their walls are directly adherent to the surrounding liver substance, while the branches of the portal vein, hepatic artery, and hepatic duct are enclosed by loose connective tissue, and the three go together in a *portal canal*.

When the arterial, portal, and biliary twigs are seen in the same connective tissue sheath, the portal twigs are the strongest, and the arteries have the smallest lumen.

On section of a piece of liver the open solitary holes are the cut hepatic veins, unable to collapse on account of their close relation to the liver-tissue. For this reason hemorrhage is so dangerous in wounds of the liver. The branches of the portal vein collapse on cross-section.

According to Sappey, there are five sets of *accessory portal veins*. The liver does not receive all its blood from the hepatic artery and vena portæ.

The *first group* occupies the lesser omentum, and consists of venules from the lesser curvature of the stomach. When the pyloric vein rises high it joins this group, which is distributed to the lobes just in front of and just behind the transverse fissure.

The *second group* is more important, and consists of twelve to fifteen little veins rising from the fundus of the gall-bladder and distributed to the fossa vesicalis. Two cystic veins here usually open into the right branch of the portal vein.

The *third group* includes all the venules rising in the walls of the portal vein, hepatic artery, and hepatic duct. They lose themselves in the subjacent lobules.

The *fourth group* consists of veins descending from the middle portion of the

diaphragm in the falciform ligament. They ramify in the lobes adjoining the ligament. They are almost capillary and anastomose with each other.

The *fifth group* is formed of veins passing from the subumbilical part of the abdominal wall to the left longitudinal fissure of the liver. They are situated in the inferior part of the falciform ligament. The most important end at the umbilical incisure of the liver; others end in the umbilical fissure; and others, very delicate, surround the round ligament: one or two constantly empty into the left portal branch. At their origin these veins communicate with the epigastric veins, internal mammary, and the tegumentary veins of the abdomen.

The fourth and fifth groups do not come from the alimentary tract, and hence establish an anastomosis between the portal and general venous systems. These branches would dilate in some chronic diseases of the liver and aid the obstructed portal system.

The *hepatic duct* is formed at the transverse fissure by two tributaries, one from the right and one from the left lobe. The calibre of each nearly equals that of the trunk formed. The tributaries to these two branches start from the interlobular spaces in company with the portal and arterial twigs.

The *lymph-vessels* form a superficial and deep set.

The superficial lymph-vessels of the *convex surface* belong either to the posterior half or to the anterior half of the liver. Those of the posterior half form several groups, and from right to left are found first on the right edge, a larger lymph-vessel which runs around to the right lateral ligament, and from there to the inferior surface, and empties into a gland on the head of the pancreas.

Then comes a series of lymph-vessels which go over to the coronary ligament, and from there to the posterior surface of the liver, and empty into the lymphatic glands which lie on the inferior vena cava just above the Diaphragm. Along the falciform ligament from the right as well as from the left lobe is developed a rich network of vessels which unite into several larger trunks. These run between both layers of the falciform ligament, and join finally to form a big trunk which pierces the Diaphragm and empties into glands situated above this at its point of fusion with the pericardium.

Those vessels springing more laterally from the left lobe of the liver empty into glands situated more to the right, lying on the vena cava; the vessels rising to the left of the left lateral ligament, and from it, empty into glands situated on the lower part of the œsophagus.

Those vessels springing from the anterior half of the convex surface arch around the anterior margin of the liver and run into the glands situated in the transverse fissure. The vessels of the under surface also pass to those same glands. Only a few twigs arising on the posterior surface of the liver end in the glands lying on the vena cava.

Of the *deeper* lymph-vessels, some accompany the portal veins, and others the hepatic veins. The first, fifteen or eighteen in number, empty into the glands surrounding the neck of the gall-bladder. The last accompany the hepatic veins to the vena cava, five or six in number, and pass through the foramen venæ cavæ of the Diaphragm, and empty into glands situated just above it.

Microscopically the lymphatics are seen in Glisson's capsule in the interlobular spaces, where they accompany the blood-vessels. They rise from lymph-spaces in the intralobular plexus.

The *nerves* come from two sources, left vagus and cœliac plexus. The left vagus after its passage through the œsophageal opening gives off twigs which turn from left to right along the lesser curvature of the stomach, between the two layers of the lesser omentum, to accompany the branches of the portal veins. Those twigs from the cœliac plexus are much more numerous, and come from three sources, right vagus, phrenic, and great sympathetic. They meet the hepatic artery and follow this to the transverse fissure. The nerves all divide into right and left sets, which accompany the branches of the artery, of the portal vein, and the tributaries of the hepatic duct. They terminate in fine tree-like endings, show-

ing varicosities, and are distributed to the blood-vessels and ducts, and to spaces between the liver-cells, and follow the biliary canaliculi (Berkeley). The phrenic nerves supply part of the external surface of the liver.

Structure.—The substance of the liver is composed of lobules held together by an extremely fine areolar tissue, and of the ramifications of the portal vein, hepatic duct, hepatic artery, hepatic veins, lymphatics, and nerves, the whole being invested by a serous and a fibrous coat.

The *serous coat* is derived from the peritoneum, and invests the greater part of the surface of the organ. It is intimately adherent to the fibrous coat.

The *fibrous coat* lies beneath the serous investment and covers the entire surface of the organ. It is difficult of demonstration, excepting where the serous coat is deficient. At the transverse fissure it is continuous with the capsule of Glisson, and on the surface of the organ with the areolar tissue separating the lobules.

The *lobules* form the chief mass of the hepatic substance; they may be seen either on the surface of the organ or by making a section through the gland.

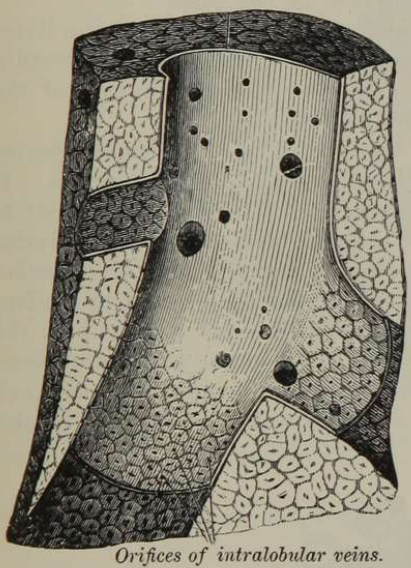

FIG. 669.—Longitudinal section of an hepatic vein. (After Kiernan.)

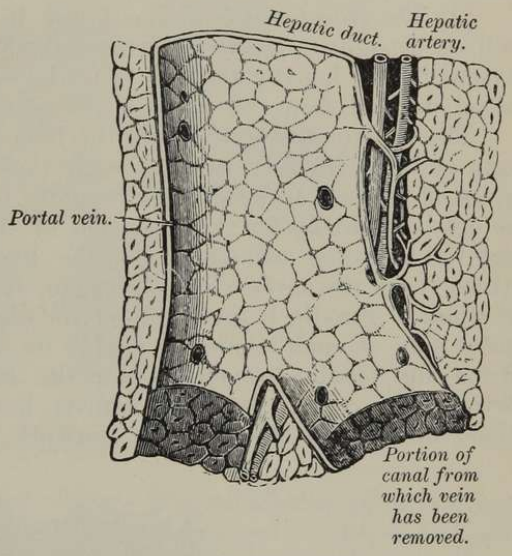

FIG. 670.—Longitudinal section of a small portal vein and canal. (After Kiernan.)

They are small granular bodies about the size of a millet-seed, measuring from one-twentieth to one-tenth of an inch in diameter. In the human subject their outline is very irregular, but in some of the lower animals (for example, the pig) they are well-defined, and when divided transversely have a polygonal outline. If divided longitudinally they are more or less foliated or oblong. The bases of the lobules are clustered round the smallest radicles (*sublobular*) of the hepatic veins, to which each is connected by means of a small branch which issues from the centre of the lobule (*intralobular*). The remaining part of the surface of each lobule is imperfectly isolated from the surrounding lobules by a thin stratum of areolar tissue in which is contained a plexus of vessels (the *interlobular plexus*) and ducts. In some animals, as the pig, the lobules are completely isolated one from another by this interlobular areolar tissue.

If one of the sublobular veins be laid open, the bases of the lobules may be seen through the thin wall of the vein on which they rest, arranged in the form of a tesselated pavement, the centre of each polygonal space presenting a minute aperture, the mouth of an intralobular vein (Figs. 669 and 671).

Microscopic Appearance.—Each lobule is composed of a mass of cells (*hepatic cells*) surrounded by a dense capillary plexus, composed of vessels which penetrate from the circumference to the centre of the lobule, and terminate in a single

straight vein, which runs through its centre, to open at its base into one of the radicles of the hepatic vein. Between the cells are also the minute commencements of the bile-ducts. Therefore in the lobule we have all the essentials of a secreting gland; that is to say: (1) *cells*, by which the secretion is formed; (2) *blood-vessels*, in close relation with the cells, containing the blood from which the secretion is derived; and (3) *ducts*, by which the secretion, when formed, is carried away. Each of these structures will have to be further considered.

(1) The *hepatic cells* are of more or less spheroidal form, but may be rounded, flattened, or many-sided from mutual compression. They vary in size from the $\frac{1}{1000}$ to the $\frac{1}{2000}$ of an inch in diameter. They consist of a honeycomb network (Klein) without any cell-wall, and contain one or sometimes two distinct nuclei. In the nucleus is a highly refracting nucleolus with granules. Embedded in the honeycomb network are numerous yellow particles, the coloring matter of the bile, and oil-globules. The cells adhere together by their surfaces so as to form rows, which radiate from the centre to the circumference of the lobules. As stated above, they are the chief agents in the secretion of the bile.

(2) *The Blood-vessels.*—The blood in the capillary plexus around the liver-cells is brought to the liver principally by the portal vein, but also to a certain extent by the hepatic artery. For the sake of clearness the distribution of the blood derived from the hepatic artery may be considered first.

The *hepatic artery*, entering the liver at the transverse fissure with the portal vein and hepatic duct, ramifies with these vessels through the portal canals. It gives off *vaginal branches* which ramify in the capsule of Glisson, and appear to be destined chiefly for the nutrition of the coats of the large vessels, the ducts, and the investing membranes of the liver. It also gives off *capsular branches* which reach the surface of the organ, terminating in its fibrous coat in stellate plexuses. Finally it gives off *interlobular branches* which form a plexus on the outer side of each lobule, to supply its wall and the accompanying bile-ducts. From this, lobular branches enter the lobule and end in the capillary network between the cells. Some anatomists, however, doubt whether it transmits any blood directly to the capillary network.

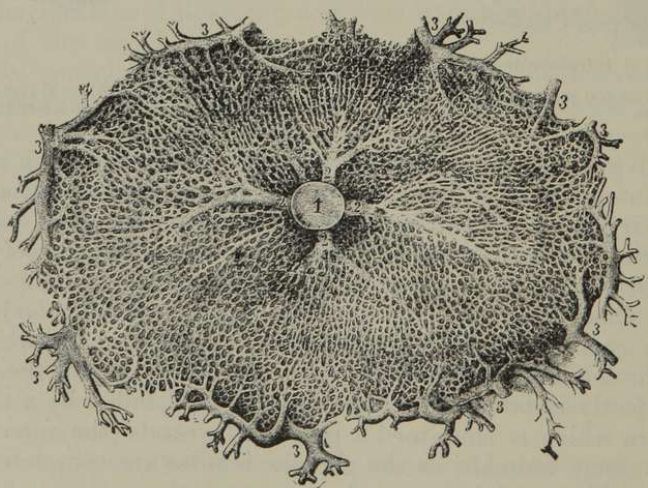

FIG. 671.—Cross section of a lobule of the human liver, showing capillary network between portal and hepatic veins. (Sappey.) 1. Section of intralobular vein. 2, 2. Tributaries from capillary net-work. 3, 3. Interlobular veins from vena portæ.

The *portal vein* (Fig. 670) also enters at the transverse fissure and runs through the portal canals, enclosed in Glisson's capsule, dividing into branches in its course, which finally break up into a plexus (the *interlobular plexus*) in the interlobular spaces between the lobules. In their course these branches receive the vaginal and capsular veins, corresponding to the vaginal and capsular

branches of the hepatic artery (Fig. 670). Thus it will be seen that all the blood carried to the liver by the portal vein and hepatic artery, except perhaps that derived from the interlobular branches of the hepatic artery, directly or indirectly finds its way into the interlobular plexus. From this plexus the blood is carried into the lobule by fine branches which pierce its wall and then converge from the circumference to the centre of the lobule, forming a number of longitudinal vessels which are connected by transverse or horizontal branches (Fig. 671). In the interstices of the network of vessels thus formed are situated, as before said, the liver-cells : and here it is that, the blood being brought into intimate connection with the liver-cells, the bile is secreted. Arrived at the centre of the lobule, all these minute vessels empty themselves into one vein, of considerable size, which runs down the centre of the lobules from apex to base and is called the *intralobular vein*. At the base of the lobule this vein opens directly into the *sublobular vein*, with which the lobule is connected, and which, as before mentioned, is a radicle of the hepatic vein (Fig. 672). The sublobular veins, uniting into larger and larger trunks, end at last in the hepatic veins, which do not receive any intralobular veins. Finally, the hepatic veins, as mentioned at page 1057, converge to form three large trunks which open into the inferior vena cava, while that vessel is situated in the fissure appropriated to it at the back of the liver.

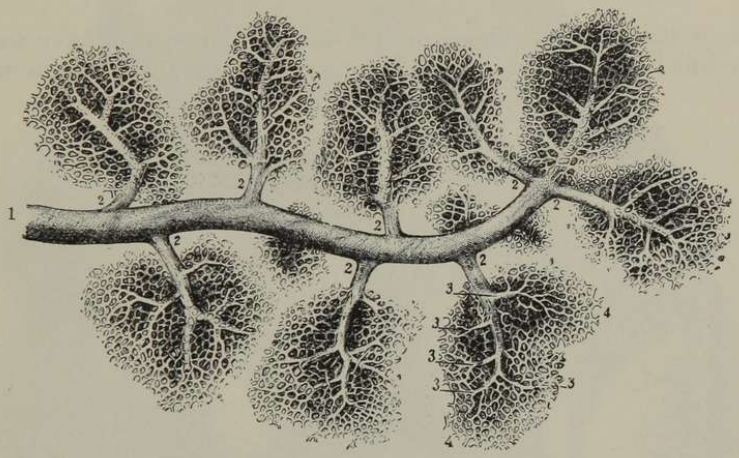

FIG. 672.—Origin of the hepatic veins. (Sappey.) 1. Sublobular vein. 2, 2. Intralobular veins. 3, 3. Tributaries to 2. 4, 4. Capillary network between portal and hepatic systems.

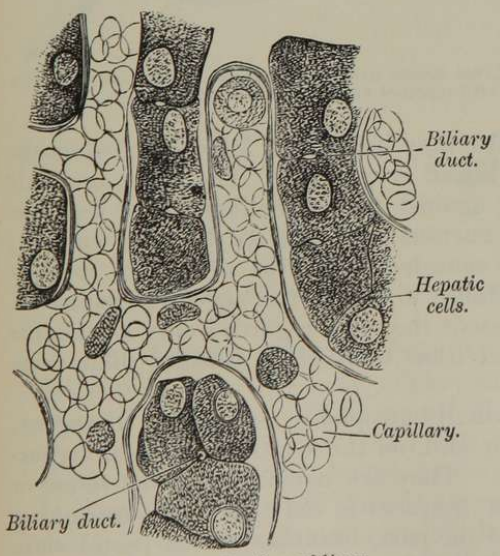

FIG. 673.—Section of liver.

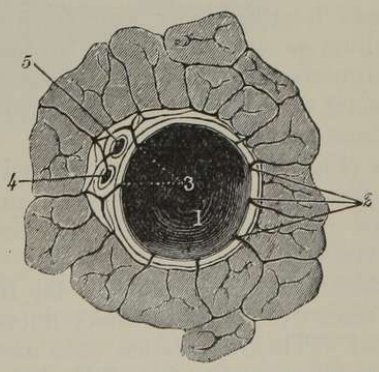

FIG. 674.—A transverse section of a small portal canal and its vessels. (After Kiernan.) 1. Portal vein. 2. Interlobular branches. 3. Vaginal branches. 4. Hepatic duct. 5. Hepatic artery.

(3) *The Ducts.*—Having shown how the blood is brought into intimate relation with the hepatic cells in order that the bile may be secreted, it remains now only to consider the way in which the secretion, having been formed, is carried away. Several views have prevailed as to the mode of origin of the hepatic ducts; it seems, however, to be clear that they commence by little passages which are formed between the cells, and which have been termed *intercellular biliary passages* or *bile-canaliculi* (Fig. 673). These passages are merely little channels or interspaces left between the contiguous surfaces of two cells or in the angle where three or more liver-cells meet, and it seems doubtful whether there is any delicate membrane forming the wall of the space. The channels thus formed radiate to the circumference of the lobule, and, piercing its wall, form a plexus (*interlobular*) between the lobules. From this plexus ducts are derived which pass into the portal canals, become enclosed in Glisson's capsule, and, accompanying the portal vein and hepatic artery (Fig. 674), join with other ducts to form two main trunks, which leave the liver at the transverse fissure, and by their union form the hepatic duct.

Structure of the Ducts.—Those in the interlobular spaces have walls of connective tissue lined by columnar epithelium. They probably contain muscle-cells

FIG. 675.—Blind tubules of the biliary ducts of a horse. (Sappey.)

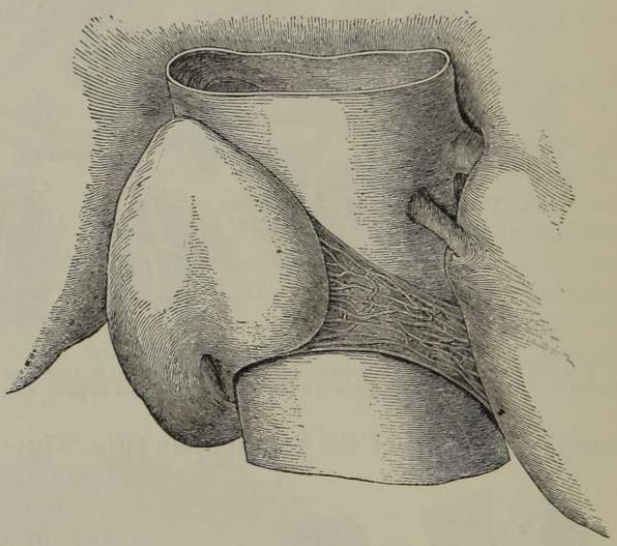

FIG. 676.—Liver tissue over the posterior surface of the vena cava inferior, with injected vasa aberrantia. (Henle.)

arranged longitudinally and circularly. As they lie in the lobule the columnar epithelium is very short and flat and the lumen very small. The bile-canaliculi open directly into them, liver-cells abutting against the epithelium. The ducts in the portal canals are larger, and present numerous openings on the inner surface, sometimes arranged in two rows. Sappey considers them the orifices of mucous glands (Fig. 675), and compares their appearance to that of the vegetable parasites. Their function is much discussed, and at present they are regarded only as tubular recesses. They occasionally anastomose, and from their sides saccular dilatations are given off.

Sometimes certain parts of the liver gradually atrophy or completely disappear, while the corresponding biliary ducts remain and, on the contrary, become hypertrophied. They are called *vasa aberrantia.* They are not found in the fœtus or child, are not rare in the adult, and are most frequent in old age. Accompanying them are all the other vessels which supplied the part, branches of the portal vein, hepatic vein, and artery. They are situated at either extremity of the liver, most often in the left lateral ligament, at the attachment of the falciform, or in the positions of atrophied "bridges," as over the left longitudinal fissure or vena cava (Fig. 676). They present certain common characteristics. All communicate with

the biliary ducts; they have a yellowish color, have epithelial lining, and fibrous coat, and in proportion as the lobe has atrophied, they have hypertrophied. They present the tubular recesses, and anastomose with each other. These vessels are found in certain mammals.

The Excretory Apparatus of the Liver.—This apparatus consists of the *bile-canaliculi* and *ducts*, which we have seen in and between the lobules; of the *hepatic duct* formed by the union of these; of a diverticulum or reservoir the *gall-bladder;* of the communicating tube, *cystic duct*, and of the united cystic and hepatic ducts, the *common bile-duct* or *ductus choledochus* (Fig. 677).

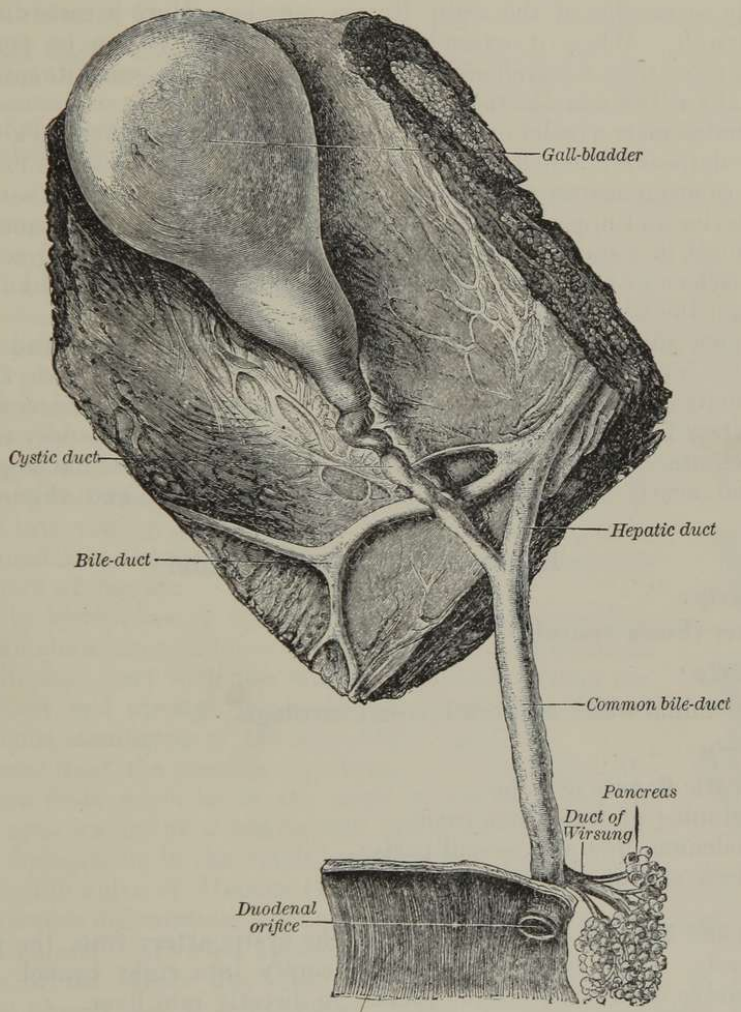

FIG. 677.—Biliary vessels and gall-bladder, dried and insufflated. (Tillaux.)

The **hepatic duct** is formed by the union of the right and left bile-ducts descending from the liver. They unite at an obtuse angle at the right end of the transverse fissure. Their point of union is usually near the spot where they emerge from the liver. Often this happens lower down and the hepatic duct is shortened. Its usual length is 3–5 cm. (one to two inches) and diameter 4 mm. It joins with the cystic duct at an acute angle to form the common bile-duct. It descends in the right margin of the gastro-hepatic omentum with the vena cava behind and the hepatic artery to the left. The passage of bile into the gall-bladder only occurs when its exit to the duodenum is closed. The bile then from the beginning of the common duct has a passage provided upward and backward to a reservoir which is the gall-bladder.

The **gall-bladder** is pear-shaped. It is directed, with its broader rounded end downward and forward and to the right to the anterior margin of the liver, and with its sharper end backward and upward toward the transverse fissure. It is 7 to 8 cm. long (three or four inches) and near the fundus 2.5–3 cm. broad (over an inch), and will contain 30–50 cc. of bile (1–1½ ounces). There are to be distinguished a *fundus*, a *body*, and a *neck*. It is fastened to the liver by connective tissue and vessels, and lies in the fossa vesicalis. The fundus extends beyond the anterior margin of the liver in the region of the incisura vesicalis. But in a normal position of the liver, the gall-bladder may be placed more or less behind this edge. The position of the fundus is usually at the lower edge of the ninth costal cartilage on the outer edge of the right Rectus muscle. Here it rests directly on the abdominal wall. When it extends beyond the liver it can be percussed. Its function is more than a storehouse. It forms some of the constituents of the bile. Exceptionally it lies more to the right or more to the left.

The fundus rests usually on the transverse colon and farther back on the upper end of the descending duodenum, or on the pylorus. This part is usually stained by biliary coloring matter after death. The neck of the bladder usually extends in the posterior and upper part of the vesical fossa close to the transverse fissure. It is continued in a spiral curve into the *cystic duct*. This curving corresponds on the inner surface to a constant more or less well developed screw-like valve which runs through the whole cystic duct, *Valvula Heisteri*.

The upper surface is attached to the liver by areolar tissue and vessels. Its under surface and fundus are covered by peritoneum reflected from the liver surface. Sometimes the peritoneum completely surrounds the bladder, suspending it by a mesentery from the under surface of the liver. The gall-bladder is not present in all vertebrates. It is lacking in some mammals and birds, but is present in all reptiles, and nearly all fishes. The ass, horse, elephant, and rhinoceros do not have it.

Relations of the Gall-bladder.

Superiorly:

Liver (Fossa vesicalis).

Anteriorly:

Abdominal wall; and ninth costal cartilage.

Inferiorly:

Hepatic flexure of colon;
Beginning of transverse colon;
Duodenum, first and second parts;
Pyloric end of stomach.

Vessels and Nerves.—It is supplied by the cystic artery from the right branch of the hepatic. Two cystic veins usually empty into right branch of the vena portæ. Twelve or fifteen from the fundus go directly into liver.

The *nerves* are from the cœliac plexus.

The *lymphatics* are numerous and empty into a gland on the neck of the bladder.

The **cystic duct**, the smallest of the three, running from the neck of the gall-bladder is 3–7 cm. long (one to three inches) and 2.3 mm. wide. Its course is toward the left, at first a little curved and then straight. It joins the hepatic duct at an acute angle to form the common duct. This is contained in the edge of the lesser omentum.

The **ductus choledochus** (*χολή*, bile, *δοχός*, which receives) is the largest of the three, and is the common excretory duct of both liver and gall-bladder and conveys the bile to the duodenum. The length is various depending upon the point of meeting of its two tributaries: 7–8 cm. (Sappey); 2–4.5 (Luschka); 6–7 cm., or about three inches (Joessel), and 5.6 mm. to 7.5 mm. wide (one-fourth inch). It

continues the course of the hepatic duct, running downward and backward in the hepato-duodenal ligament in front of the portal vein and to the right of the hepatic artery. It passes behind the first portion of the duodenum and then behind and to the inner side of the second portion, lying here in a furrow between duodenum and head of pancreas; or it may be enclosed by the pancreas till it meets the pancreatic duct. For a short space it is in contact with the right side of this duct. The two perforate the duodenal wall and run obliquely for three-fourths of an inch between the coats. They finally open into a little pouch and that upon a papilla of the mucous membrane by a common orifice, situated near the junction of middle and lower third of the duodenum on its posterior internal wall. This is three or four inches beyond the pylorns. (See Pancreas.)

When the gall-bladder is distended with bile or calculi, the fundus may be felt through the abdominal parietes, especially in an emaciated subject: the relations of this sac will also serve to explain the occasional occurrence of abdominal biliary fistulæ, through which biliary calculi may pass out, and of the passage of calculi from the gall-bladder into the stomach, duodenum, or colon, which occasionally happens.

Structure.—The gall-bladder consists of three coats—serous, fibrous and muscular, and mucous.

The *external* or *serous coat* is derived from the peritoneum; it completely invests the fundus, but covers the body and neck only on their under surface.

The *fibro-muscular coat* is a thin but strong layer which forms the framework of the sac, consisting of dense fibrous tissue which interlaces in all directions and is mixed with plain muscular fibres which are disposed chiefly in a longitudinal direction, a few running transversely.

The *internal* or *mucous coat* is loosely connected with the fibrous layer. It is generally tinged with a yellowish-brown color, and is everywhere elevated into minute rugæ, by the union of which numerous meshes are formed, the depressed intervening spaces having a polygonal outline. The meshes are smaller at the fundus and neck, being most developed about the centre of the sac.

The mucous membrane is covered with columnar epithelium and secretes an abundance of thick viscid mucus; it is continuous through the hepatic duct with the mucous membrane lining the ducts of the liver, and through the ductus communis choledochus with the mucous membrane of the alimentary canal.

In the *cystic duct* the mucous membrane is raised into oblique crescentic folds much as in the neck of the bladder. It presents the appearance of a continuous spiral valve of which we have seen indications in the small intestine and rectum (Fig. 678). This is the valve of Heister (1758). The outer surface of the duct presents indentations at the attachment of these folds, giving it a sacculated or twisted appearance (Fig. 677).

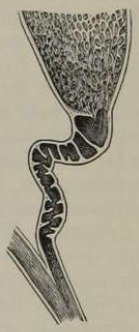

FIG. 678.—Section through the cystic duct and neck of gall-bladder. (Gegenbaur.)

The coats of the *larger ducts* are an external or fibrous and an internal or mucous. The fibrous coat is composed of strong fibro-areolar tissue, with a certain amount of muscular tissue arranged for the most part in a circular manner around the duct. The mucous coat is continuous with the lining membrane of the hepatic duct and gall-bladder, and also with that of the duodenum, and, like the mucous membrane of these structures, its epithelium is of the columnar variety. It is provided with numerous tubules, which are lobulated and open by minute orifices scattered irregularly (Fig. 675).

Surface Form.—The liver is situated in the right hypochondriac and the epigastric regions, and is moulded to the arch of the Diaphragm. In the greater part of its extent it lies under cover of the lower ribs and their cartilages, but in the epigastric region it comes in contact with the abdominal wall in the subcostal angle. The *upper limit of the right lobe of the liver* may be defined by a line drawn from the articulation of the fifth right costal cartilage to the sternum horizontally outward to a little below the nipple, and then inclined downward to reach the seventh rib at the side of the chest. The *upper limit of the left lobe* may be defined by continuing this line to the left, with an inclination downward as it crosses the gladiolus, to a point about

two inches to the left of the sternum on a level with the sixth left costal cartilage. The *lower limit of the liver* may be indicated by a line drawn half an inch below the lower border of the thorax on the right side as far as the ninth right costal cartilage, and thence obliquely upward across the subcostal angle to the eighth left costal cartilage. A slight curved line with its convexity to the left from this point—*i. e.* the eighth left costal cartilage—to the termination of the line indicating the upper limit will denote the left margin of the liver. The fundus of the gall-bladder approaches the surface behind the anterior extremity of the ninth costal cartilage, close to the outer margin of the Right rectus muscle.

It must be remembered that the liver is subject to considerable alterations in position, and the student should make himself acquainted with the different circumstances under which this occurs, as they are of importance in determining the existence of enlargement or other diseases of the organ.

Its position varies according to the posture of the body. In the erect position in the adult male the edge of the liver projects about half an inch below the lower edge of the right costal cartilages, and its anterior border can be often felt in this situation if the abdominal wall is thin. In the supine position the liver gravitates backward and recedes above the lower margin of the ribs, and cannot then be detected by the finger. In the prone position it falls forward, and can then generally be felt in a patient with loose and lax abdominal walls. Its position varies also with the ascent or descent of the Diaphragm. In a deep inspiration the liver descends below the ribs; in expiration it is raised behind them. Again, in emphysema, where the lungs are distended and the Diaphragm descends very low, the liver is pushed down; in some other diseases, as phthisis, where the Diaphragm is much arched, the liver rises very high up. Pressure from without, as in tight-lacing, by compressing the lower part of the chest, displaces the liver considerably, its anterior edge often extending as low as the crest of the ileum; and its convex surface is often at the same time deeply indented from the pressure of the ribs. Again, its position varies greatly according to the greater or less distension of the stomach and intestines. When the intestines are empty the liver descends in the abdomen, but when they are distended it is pushed upward. Its relations to surrounding organs may also be changed by the growth of tumors or by collections of fluid in the thoracic or abdominal cavities.

Surgical Anatomy.—On account of its large size, its fixed position, and its friability, the liver is more frequently ruptured than any of the abdominal viscera. The rupture may vary considerably in extent, from a slight scratch to an extensive laceration completely through its substance, dividing it into two parts. Sometimes an internal rupture without laceration of the peritoneal covering takes place, and such injuries are most susceptible of repair; but small tears of the surface may also heal; when, however, the laceration is extensive, death usually takes place from hæmorrhage, on account of the fact that the hepatic veins are contained in rigid canals in the liver-substance and are unable to contract, and are moreover unprovided with valves. The liver may also be torn by the end of a broken rib perforating the Diaphragm. The liver may be injured by stabs or other punctured wounds, and when these are inflicted through the chest-wall both pleural and peritoneal cavities may be opened up and both lung and liver be wounded. In cases of wound of the liver from the front, hernia of a part of this viscus may take place, but can generally easily be replaced. Abscess of the liver is of not unfrequent occurrence, and may open in many different ways on account of the relations of this viscus to other organs. Thus, it has been known to burst into the lungs, and the pus been coughed up, or into the stomach and the pus vomited; it may burst into the colon or into the duodenum; or, by perforating the Diaphragm, it may empty itself into the pleural cavity. Frequently it makes its way forward and points on the anterior abdominal wall, and finally it may burst into the peritoneal or pericardiac cavities. Abscesses of the liver frequently require opening, and this should be done preferably by an incision in the right semilunar line, in two stages: the peritoneal cavity being opened and the liver over the summit of the abscess being stitched to the parietal peritoneum on the first occasion, and three or four days subsequently the abscess being evacuated. Hydatid cysts are more often found in the liver than in any other of the viscera. The reason of this is not far to seek. The embryo of the egg of the tænia echinococcus, being liberated in the stomach by the disintegration of its shell, bores its way through the gastric walls, and usually enters a blood-vessel and is carried by the blood-stream to the hepatic capillaries, where its onward course is arrested, and where it undergoes development into the fully-formed hydatid.

When the *gall-bladder* is ruptured, or one of its main ducts, which may occur independently of laceration of the liver, the injury is necessarily fatal from peritonitis caused by the extravasation of bile into the peritoneal cavity.

The gall-bladder may become distended with bile in cases of obstruction of its duct or the common bile-duct, or from a collection of gall-stones within its interior, thus forming a large tumor. The swelling is pear-shaped, and projects downward and forward to the umbilicus. It moves with respiration, since it is attached to the liver. To relieve this condition the gall-bladder must be opened and the gall-stones removed. The operation is performed by an incision two or three inches long in the right semilunar line, commencing an inch below the costal margin. The peritoneal cavity is opened, and, the tumor having been found, sponges are packed round it to protect the peritoneal cavity, and it is aspirated. When the contained fluid has been evacuated the flaccid bladder is drawn out of the abdominal wound and its wall incised to the extent of an inch; any gall-stones in the bladder are now removed and the interior of the sac sponged dry. If the case is one of obstruction of the duct, an attempt must be made to dislodge

the stone by manipulation through the wall of the duct, or it must be crushed from without by carefully padded forceps. After all obstruction has been removed a drainage-tube is to be inserted and the external wound closed around it, the stitches being passed through the parietal peritoneum and also through the peritoneum covering the gall-bladder around the incision, so as to bring these two surfaces into apposition. The fistulous opening generally closes in the course of a few weeks.

THE PANCREAS.

Dissection.—The pancreas may be exposed for dissection in three different ways: 1. By raising the liver, drawing down the stomach, and tearing through the gastro-hepatic omentum and the ascending layer of the transverse meso-colon. 2. By raising the stomach, the arch of the colon, and great omentum, and then dividing the inferior layer of the transverse meso-colon and raising the ascending layer of the transverse meso-colon. 3. By dividing the two layers of peritoneum which descend from the great curvature of the stomach to form the great omentum, turning the stomach upward, and then cutting through the ascending layer of the transverse meso-colon (see Figs. 606 and 616).

The **pancreas** (*πᾶν-κρέας*, all flesh) or the abdominal salivary gland, is a compound racemose gland, similar in structure to the salivary glands, though softer and less compact. It is long and lies transversely across the posterior wall of the abdomen and when hardened *in situ* is prismatic, with three surfaces. But usually, when removed from the body, it appears flattened, with only two surfaces and two borders. It lies deep in the epigastrium at the level of the second lumbar vertebra; behind the stomach; between the duodenum on the right and the spleen on the left, so that for clinical and surgical purposes it is scarcely approachable. In shape, Meckel compared it to a sort of hammer; Verneuil, to a cross placed on its side, the short vertical arm representing the head. Winslow compared it to a dog's tongue. Its right extremity being broad is termed the *head;* then follows a constriction made by the two terminal parts of the duodenal loop called the *neck*, which connects head and body. The body is the free portion passing to the left, and finally it abuts against the spleen as the *tail* (Figs. 634 and 679).

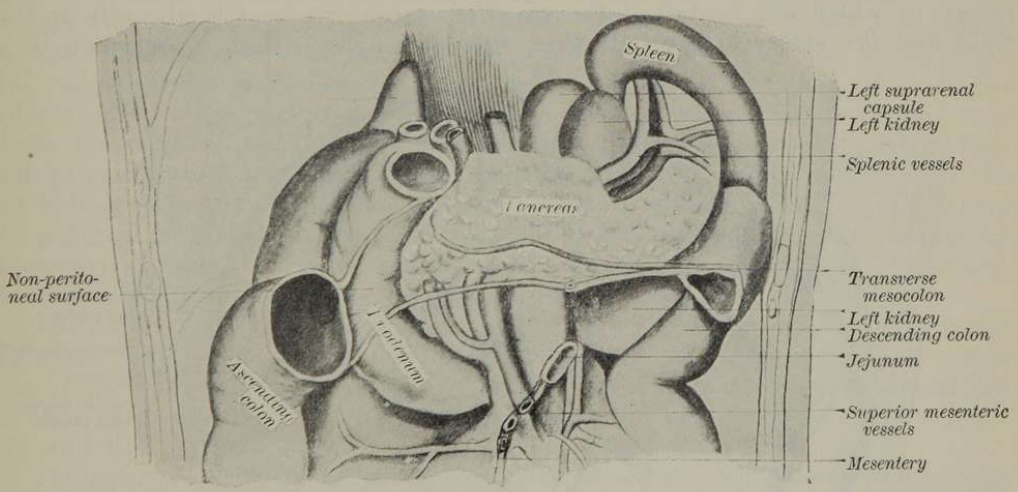

FIG. 679.—Pancreas and adjoining viscera from before. His' model. (F. E.)

In *color* the pancreas is grayish-white in the intervals of digestion, turning to a rosy hue during secretion.

Its *volume* presents many variations. In general it is bigger in man than in woman. It is usually 15-16 cm. long (six inches); its width is not one-fourth or one-fifth of its length; its thickness is 15-18 mm. (one-half to one inch). Length, 23 cm.; width, 4.5 cm.; thickness, 2.8 cm. (Luschka). Its volume is 54-90 c.c. Its weight is about 70 gm. in the male and 60 in the female, two and one-fourth to three and a half ounces. A maximum weight is 105 gm.

The *head* of the pancreas is called disc-shaped, or, since it is elongated both above and below, hammer-shaped. It is flattened from before backward, and conforms to the whole concavity of the duodenum made up of its four parts, and not *vice*

versâ. Its edges overlap the surface of the duodenum and may be connected by muscular tissue. There is an interruption at one place, below and to the left in

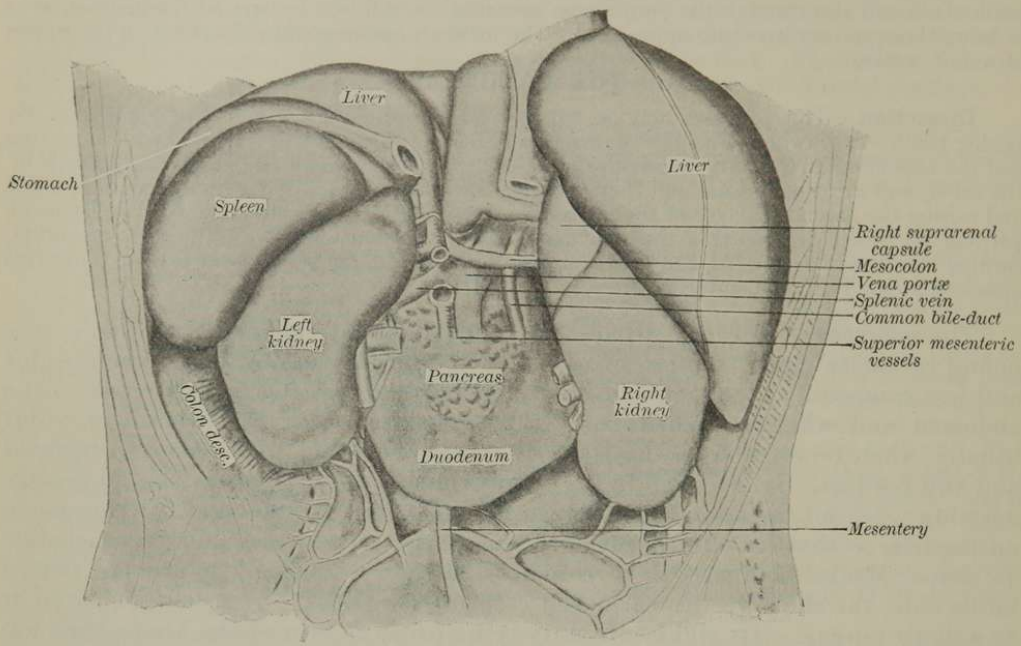

FIG. 680.—View of the abdominal viscera from behind, after removal of spinal column and posterior abdominal wall. (Drawn from His' model.)

front of the preaortic portion of the duodenum, where the root of the mesentery passes, in which are contained the superior mesenteric vessels, the vein to the right and the artery to the left (Figs. 634 and 679). Both vessels run in a

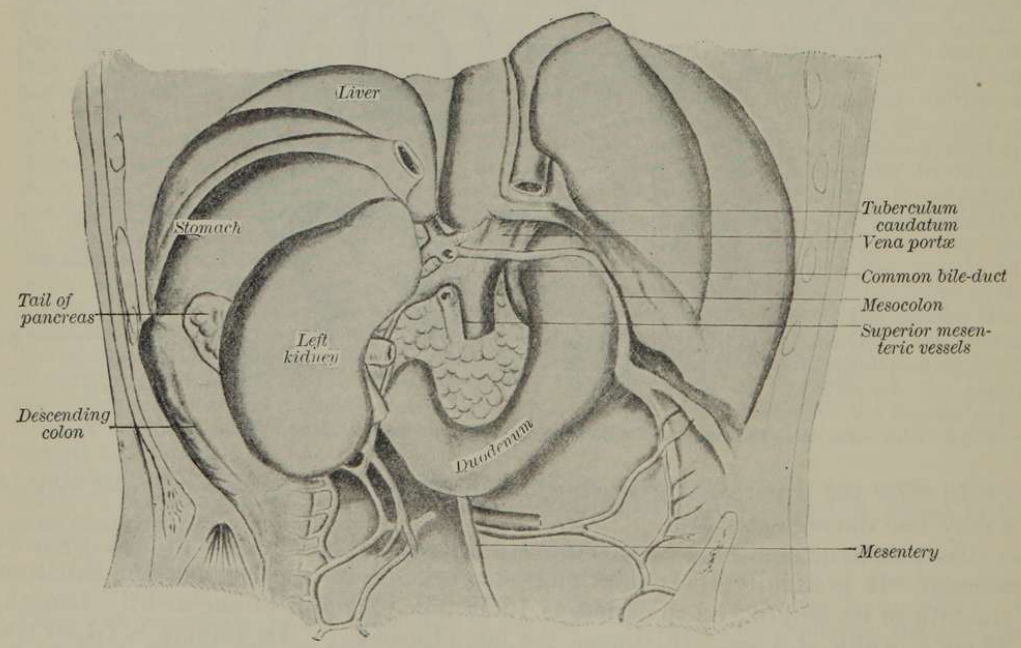

FIG. 681.—Same as previous figure, but with right kidney and spleen removed. (Drawn from His' model.)

groove on the posterior surface of the head, and near the descending duodenum in a groove or canal is the common bile-duct. A part of the pancreatic tissue is bent around behind the vessels, which is called the *lesser head*. The posterior

surface of the head is bound by loose tissue to and rests upon the inferior vena cava and right crus of diaphragm, cœliac plexus, left renal vein, and right renal vessels; the descending duodenum intervenes between it and the right kidney. Near its lower end it is crossed in front by the transverse colon and transverse mesocolon. The superior and inferior pancreatico-duodenal vessels are in front of the head.

The neck is about one inch long, passing upward and forward to the left; it is bounded above by the first part of the duodenum and below by the end of the ascending portion. The stomach, if distended, touches this portion by the posterior surface of the pylorus. Behind it is the junction of the superior mesenteric vein with the vena portæ (Fig. 681). To the right it is grooved by the gastro-duodenal and superior pancreatico-duodenal arteries.

The *body* and *tail* constitute the prismatic portion presenting three surfaces and three borders: *anterior*, *posterior*, and *inferior surfaces; superior* and two *inferior* borders. Some regard the surfaces as posterior, antero-superior, and antero-inferior, making an anterior border more distinct. This part of the pancreas passes from the right to the left and is moulded to different structures, following the example of the liver. Its anterior surface is fitted to the convexity of the filled stomach; its posterior surface is more flat except where it covers the left kidney; the tail passes upward and backward to the spleen. The *anterior surface* is concave, looks upward and forward; the posterior surface of the stomach lies upon it, separated by the bursa omentalis, or two layers of the lesser sac. Perforating ulcers of the stomach can reach the pancreas and result in fusion of these two organs, or in hemorrhage from the splenic vessels.

The *posterior surface* (Figs. 680 and 681) corresponds internally to the aorta and left crus of the diaphragm and the origin of the superior mesenteric artery. It crosses the second or third lumbar vertebra. Near the upper edge are two furrows—one for the somewhat tortuous splenic artery and a straight one for the splenic vein. The surface shows a shallow furrow for the splenic vein, which ascends from the middle of the lower edge toward the left to the upper edge. This edge carries a furrow from the middle along the left half, in which the splenic artery takes part of its course. The splenic vein in its outer half runs above the edge to reach the hilus of the spleen. To the left is the left kidney and its vessels, and sometimes the left suprarenal capsule. The relations to the left kidney show two types: one is seen in the His models and Fig. 636, where the pancreas runs directly over the hilus and centre of the kidney, exposing the suprarenal capsule, and a considerable part of the anterior kidney surface above, the tail touching the lower part of the spleen.

The other type is seen in Fig. 634. Here the pancreas is higher, and crosses the upper part of the kidney, leaving exposed above its edge the whole or only a part of the left suprarenal capsule. The tail touches the same part of the spleen in each case, showing it is also elevated with the pancreas. (Compare Figs. 634 and 679.)

The *inferior surface* is narrow, only 1 to 2 cm. broad, and shows, in the organ hardened *in situ*, internally a cavity and laterally a convexity, each directed downward. It rests by the concavity on the duodeno-jejunal flexure, and often on some coils of the jejunum, and to the left on the transverse colon.

The *superior border* of the body on the right is prominent, blunt, and flat; laterally, near the tail, it is narrower and sharper. The inner blunt elevation is covered by the lesser omentum, and fits into and behind the lesser curvature of the stomach; it is the *tuber omentale* of the pancreas. Between it and the tuber omentale of the liver is the lesser sac. This border is related above to the cœliac axis and solar plexus, and to two of the branches of the former, the hepatic artery passing to the right, the splenic to the left.

The *inferior* or *anterior border* is the dividing line for the two layers of the transverse mesocolon. The upper layer passes up over the anterior surface and here constitutes the posterior wall of the lesser sac. The lower layer passes down

over the narrow inferior surface (Fig. 679). Thus the posterior surface is devoid of peritoneum.

The tail of the pancreas rests upon the lower part of the inner surface of the spleen, or is bound to it by a fold of peritoneum, the *lig. pancreatico-lienale.* It crosses over the middle of the left kidney, or kidney and capsule, or capsule alone. In front of this portion is the left gastro-epiploic artery.

The *excretory duct* of the gland, *ductus pancreaticus* or *canal of Wirsung* runs (1643) from left to right in the long axis of the gland, sometimes approaching the anterior surface, but more often the posterior surface. It begins with a very small calibre, formed by union of small ducts from the lobules, in the tail part, and gradually increases in size on the receipt of tributaries from every side; so that near its mouth it attains the size of the classical quill, about one-ninth of an inch in diameter. It can be found by its white color and close relation to the large pancreatic artery. After reaching the neck it turns downward, backward, and to the right in the head, and reaches the left side of the common bile-duct, and both go to the descending duodenum.

It receives numerous branches in the head of the gland, a large one from below, and the *ductus pancreaticus accessorius* or *ductus Santorini* from above (1775) (Fig. 682).

This latter duct opens into the duodenum independently on a papilla about one inch above the orifice of the others.[1] The usual course of its contents, how-

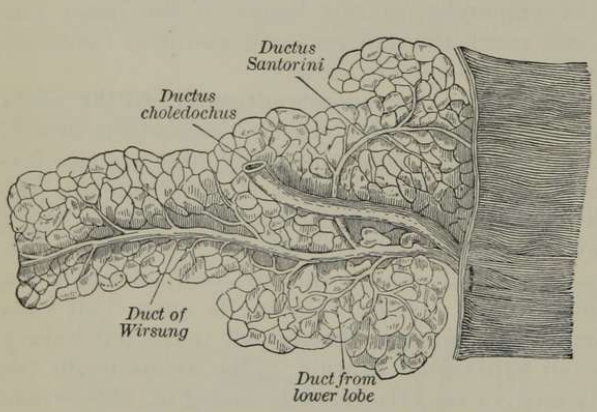

FIG. 682.—Pancreas and duodenum from behind. The pancreatic duct is dissected free and the posterior wall of the duodenum removed. (Henle.)

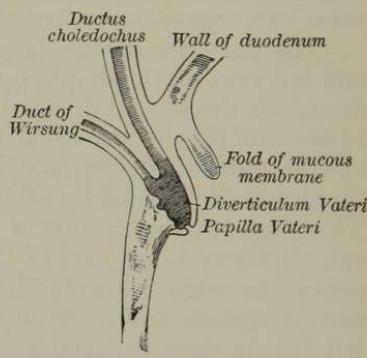

FIG. 683.—Section of duodenal wall through the papilla on which the bile and pancreatic ducts open. (Henle.)

ever, is below into the pancreatic duct. Should this become occluded near its orifice then a reverse flow might occur in the duct of Santorini.

The bile and pancreatic ducts do not unite outside the duodenal wall. They enter it obliquely and run obliquely a short distance between its coats and then unite at an acute angle and empty into a common receptacle just under the mucous membrane (Fig. 683). This little bladder-like pouch is called the *diverticulum Vateri* (1720). It throws up a papilla of mucous membrane situated on the free edge of one of the valvulæ conniventes. This is the *papilla of Vater.* It has a single opening, which can be best found by the presence of a drop of fluid intruded by pressure on the gall-bladder or pancreas. The papilla is still farther concealed by a mucous fold, which covers it from above (Fig. 683).

Abnormal forms occur; the descending duodenum may be surrounded by a ring of pancreatic tissue; the tail may be bifid; a part of the head curving around behind the mesenteric vessels may form the *lesser pancreas.* Accessory glands (pancreas accessorium) are found most often in the walls of the jejunum and in those of the stomach.

[1] This is of interest, as the pancreas originally budded from the duodenum as two outgrowths. At about the sixth week the processes and their ducts join, as here seen.

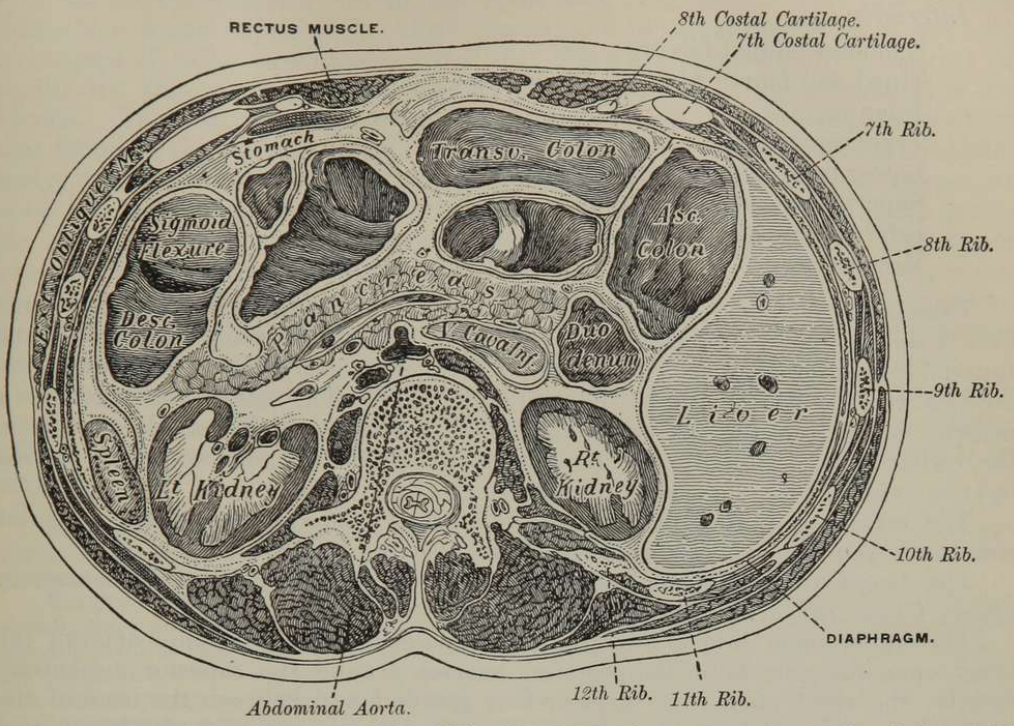

FIG. 684.—Transverse section through the middle of the first lumbar vertebra, showing the relations of the pancreas. (Braune.)

Relations in Detail (Fig. 684).

Superiorly:

First part of duodenum;
Cœliac axis, solar plexus;
Splenic and hepatic arteries;
Tuber omentale of liver.

Anteriorly:

Bursa omentalis (lesser sac);
Posterior surface of stomach;
Gastro-duodenal artery;
Pancreatico-duodenal arteries;
Upper layer of transverse mesocolon;
Transverse colon.

To right:

Concavity of duodenum.

To left:

Lower part of inner surface of spleen.

Posteriorly:

Second (third or first) lumbar vertebra;
Pancreatic and common bile-ducts;
Vena cava inferior;
Origin of thoracic duct;
Crura of diaphragm;
Cœliac plexus;
Aorta;
Sup. mesenteric artery;
Splenic, sup. and inf. mesenteric veins;
Vena portæ;
Right and left renal vessels;
Left kidney (or kidney and capsule or capsule alone).

Inferiorly:

Duodeno-jejunal flexure;
Third and fourth parts of duodenum;
Jejunum;
Transverse colon;
Lower layer of transverse mesocolon;
Superior mesenteric vessels;
Inferior mesenteric vein;
Mesentery.

Vessels and Nerves.—The pancreas is the only abdominal organ which does not have a special *artery* from the aorta. Its supply comes from the cœliac axis and superior mesenteric. The splenic artery gives the *pancreaticæ parvæ* and *pancreatica magna*, which supply the tail and body. The *pancreatico-duodenalis superior* comes from the gastro-duodenalis of the hepatic. These all come from the cœliac axis. The superior mesenteric gives off the *pancreatico-duodenalis inferior*, which, with the superior, supplies the head.

The *veins* are of the same names, and empty into the splenic and superior mesenteric veins, all belonging to the portal system.

The *lymphatic vessels* are numerous, divided, according to their course, in *upper*, *lower*, *right*, and *left* sets (Sappey).

The upper open into a row of lymph-glands along the splenic artery; the lower open into glands on the posterior surface around the superior mesenteric vessels; the right open into three or four glands found between the head of the pancreas and descending duodenum; the left, into a group of glands situated between the tail of the pancreas and spleen in the pancreatico-lienal ligament.

The *nerves* rise from the cœliac plexus, and probably have some elements of the right vagus, and accompany the vessels which supply the pancreas; the most of them go with the splenic artery. They are non-medullated and gangliated. In the gland they run independently of the vessels.

In *structure* the pancreas closely resembles the parotid gland. It differs in certain particulars, and is looser and softer in its texture. It is not enclosed in a

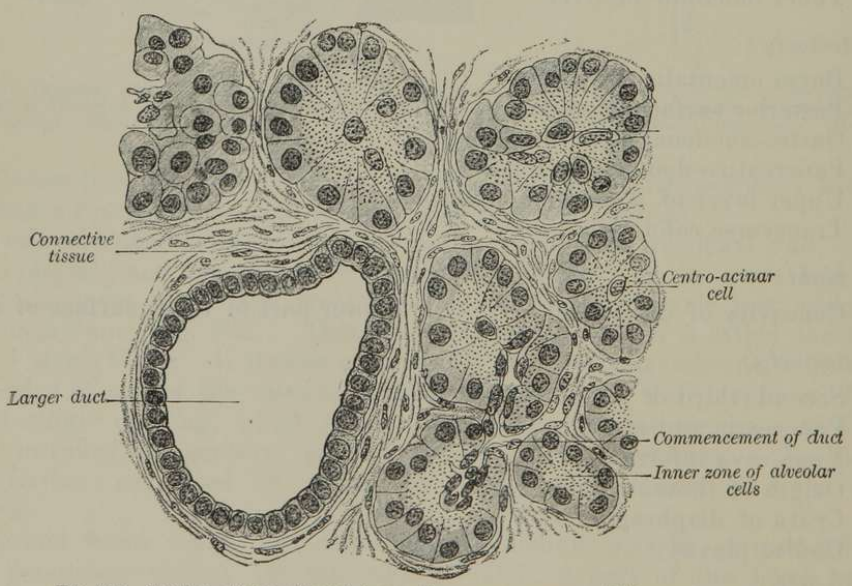

FIG. 685.—Section of alveoli and duct. Human pancreas. (Böhm and Davidoff.)

distinct capsule, but is surrounded by areolar tissue which dips down into its interstices and divides the gland tissue into lobes, and these are subdivided by septa into lobules which in turn are composed of groups of alveoli, connected

with one of the ramifications of the main duct (Fig. 685). This interalveolar connective tissue supports the blood-vessels, and in certain parts of it are seen collections of cells, *interalveolar cell-islets*. They are permeated by a network of capillaries, and are very characteristic of the pancreas. Their function is unknown. The minute ducts are lined by short columnar epithelium, shorter than that found in the salivary ducts, and with no striation. The alveoli are tubular, wavy, and convoluted, lined by columnar cells which presents two zones: an outer one presenting the nucleus, clear and faintly striated; and an inner granular one, next the lumen. These are the secreting cells; after their activity the granular zone occupies most of the cell, whereas, in the earliest stage of digestion, the clear zone did this. The lumen of the alveolus is hardly visible, being filled by spindle-shaped cells, the *centro-acinar* cells of Langerhaus. Piersol considers these as imperfectly developed acini, and calls them *bodies of Langerhaus*.

The *pancreatic duct* presents two coats, fibro-elastic and mucous. There is no sign of muscular tissue. Fine intercellular canaliculi have been seen, comparable to those of the liver, passing from between the cells to the lumen of an alveolus.

Surface Form.—The pancreas lies in front of the second lumbar vertebra, and can sometimes be felt, in emaciated subjects, when the stomach and colon are empty, by making deep pressure in the middle line about three inches above the umbilicus.

Surgical Anatomy.—The pancreas presents but little of surgical importance. It is occasionally the seat of cancer, which usually affects the head or duodenal end, and therefore often speedily involves the common bile-duct, leading to persistent jaundice. Cysts are also occasionally found in it, which may present in the epigastric region, above and to the right of the umbilicus, and may require opening and drainage. The fluid in them contains some of the elements of the pancreatic secretion and is very irritating, so that, if allowed to come in contact with the skin of the abdominal wall, it is likely to produce intractable eczema. It has been said that the pancreas is the only abdominal viscus which has never been found in a hernial protrusion; but even this organ has been found, in company with other viscera, in rare cases of diaphragmatic hernia. The pancreas has been known to become invaginated into the intestine, and portions of the organ have sloughed off. In cases of excision of the pylorus great care must be exercised to avoid wounding the pancreas, as the escape of the pancreatic fluid may be attended with serious results. According to Billroth, it is likely, in consequence of its peptonizing qualities, to dissolve the cicatrix of the stomach.

THE SPLEEN.

The **spleen** is the largest and most important ductless gland. It is probably related to the vascular system, yet its anatomical relations to the stomach and physiological relation to the liver, may allow it to be described as an accessory to the digestive tract.

It is placed deep in the left hypochondrium, between the fundus of the stomach and diaphragm, above the descending colon.

In *number* there is but one, yet various observations show it may be congenitally lacking, or may be multiple; as many as twenty-three in one body. These are called *accessory* or *supernumerary* spleens (*lienculi*), probably occasioned by the deep notching of the anterior margin and separation of the included parts. They may be connected with the mother-organ by thin bridges of splenic tissue or only by a portion of capsule. They are generally wholly isolated, and situated in the gastro-splenic omentum, great omentum, transverse mesocolon, or in the pancreas on a branch of the splenic artery. Frequently, one or two are in the region of the hilus. They are of the size of a hazelnut, red to almost black in color and of a rounded form.

No organ varies more in *volume* than the spleen. In children it is relatively well developed. In old age it is usually atrophied. It varies with the same individual, with sex, degree of fulness of portal vein, state of health or of disease, and with the influence of certain drugs. It is hypertrophied in all infectious diseases and in all depending upon malarial poison or leukæmia. It may be so large as to reach the pelvis and weigh many pounds.

Its average length in ten adult men was found to be 12 cm. (five or six

inches); breadth, 8 cm.; thickness, 3 cm. (Sappey). In children its proportion to body-weight is 1 to 350; in adults 1 to 320; in old age 1 to 700.

Its average cadaveric weight in the above ten specimens was 195 gm. If filled with blood its physiological weight would be 225 gm. (or 7 ounces). Its specific gravity is 1.054, showing greater density than the liver. Its volume is 200 to 300 cc.

Its *color* in the living animal is dark red and probably the same in living man. After death it is dark purple to a grayish red, due to the presence of venous blood.

In *consistence* it is soft and distensible and liable to laceration.

Form and Relations.—The spleen may be ellipsoid, tongue-shaped in length, or it may be rectilinear with its four corners rounded off. An internal view of the model by His (Fig. 612), shows it to be somewhat broader above than below, while typical forms presented by Luschka show two types both larger below. One is rectangular which is most frequent, and one is oval (Fig. 686).

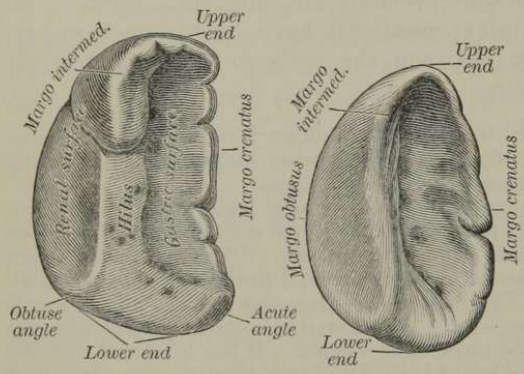

FIG. 686.—The two type-forms of the human spleen. *A*. Rhomboidal form of spleen. *B*. Oval form of spleen. (Luschka.)

Three *surfaces* may be distinguished, *phrenic* or *external*, *basal*, and *internal*, which is subdivided by the *intermediate ridge* (*margo intermedius*) into an anterior *gastric* portion (*superficies gastrica*), and a posterior *renal* portion (*superficies renalis*).

There are two *margins*, *anterior* or crenated (*margo crenatus*, and *posterior* (*margo obtusus*).

The spleen lies obliquely with its long axis placed deep in the left hypochondrium and nearly parallel to the ribs. It lies between the concave surface of the diaphragm, placed to the left, behind and above, and the fundus of the stomach, placed to the right and in front. It is above the left kidney and splenic flexure of colon (Fig. 680). This figure will repay study as we do not always appreciate that the suprarenal capsule and kidney and spleen rise nearly to the cardia with the pancreas, transverse colon, and splenic flexure in immediate contact.

Its large convex *phrenic surface* lies against the costal part of the diaphragm and looks upward, backward, and to the left or even a little inward above. It is covered by the ninth, tenth, and eleventh ribs, but separated from them by the peritoneum, diaphragm, costo-phrenic sinus, and in part by the left pleura and lung. In some cases the left lobe of the liver extends between this surface of the spleen and diaphragm. This is normal at birth when the hepatic surface of the spleen is the biggest of all.

The *internal surface* directed toward the abdominal cavity is divided by a prominent ridge into two parts, of which the posterior is narrow and the anterior broad.

The *hilus* of the spleen may be on the ridge, but is usually anterior to it. It is represented by an irregular longitudinal row of depressions, in which the arteries and nerves enter and through which the lymphatics and veins emerge.

The surface posterior to the ridge is the *renal surface*, flat and not reaching as high as the gastric surface, it is turned inward and downward toward the left crus of the diaphragm, and is in contact with the upper and outer margin of the left kidney, and usually the suprarenal capsule.

The *gastric surface*, broad and concave, is directed inward and forward. When the stomach is distended in the greater part of its extent, this surface lies

against the posterior wall of the fundus and body of the stomach (Fig. 680). Lower down it touches the tail of the pancreas.

The *basal surface* forms the lower and outer end of the spleen, and is triangular in shape. This does not rest on the left kidney, but frequently is in contact with the tail of the pancreas and *regularly* with the splenic flexure of the colon and phreno-colic ligament.

The *anterior* or *crenate margin* is sharp and thin and usually marked by a few, two to four, notches more or less deeply cut. It separates the internal from

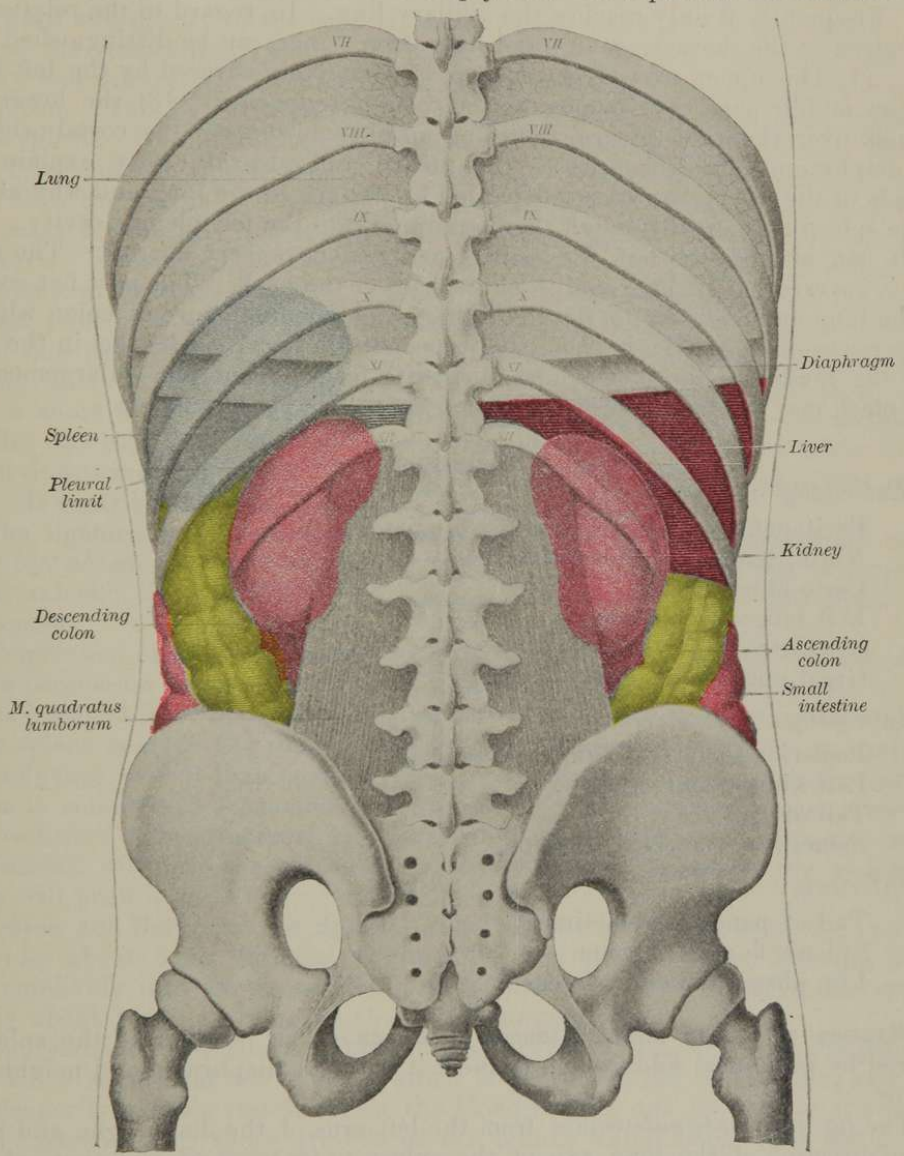

FIG. 687.—Relations of abdominal viscera. Posterior view. (Joessel.)

the phrenic surface. Traced from the upper end of the spleen, this border passes outward, convex above. This lies between the diaphragm and stomach nearly as high as the cardia. The border then passes downward and forward, and is in close contact with the chest-wall at the mid-axillary line.

The *inner* or *intermediate border* lies on the interior surface posterior to the hilus, and separates the gastric and renal surfaces. The *posterior* or *blunt border* separates the internal and phrenic surfaces. It dips in between the diaphragm and left kidney, and runs downward and outward along the lower border of the

eleventh rib. A *lower border* may be described between the phrenic and basal surfaces.

The *upper end* of the spleen lies on the level of the tenth dorsal vertebra. It approaches the vertebral column to within 2 or 3 cm., and often touches it. It is covered behind by the ribs and the great Sacro-spinalis muscle.

The *lower end* of the spleen extends more or less forward, but normally, even in deep inspiration, does not extend beyond the costo-clavicular line, which connects the left sterno-clavicular articulation to the anterior end of the eleventh rib. Frequently it only reaches the axillary line. In regard to the relations of the spleen to the thoracic cavity and lung three zones can be distinguished (Fig. 687): (1) The upper part of the spleen is completely covered by the left lung; (2) the middle part corresponds to the costo-phrenic sinus; (3) the lower part extends over the lower pleural limit and projects down over the costal origin of the diaphragm. Its relations to the pleura and pleural cavity explain why wounds of the spleen can be accompanied by wounds of the lung and why abscess of the spleen may open through the diaphragm into the left pleural cavity.

It can also be seen how the limit of percussion is very narrow. The upper part is covered by the lung and thick muscles of the back. The part not covered by the lung applies itself to the left kidney and splenic flexure of colon whereby the percussion note may be modified, especially if fæcal masses be in the colon or if the fundus of the stomach be filled with food. Abnormal enlargements of the spleen may be diagnosed by palpation as well as by percussion.

Relations.

Externally and above:

Peritoneum and left costal part of diaphragm;
Ninth, tenth, and eleventh ribs;
Costo-phrenic sinus;
Left lung and pleura;
(At birth) left lobe of liver;
Great muscles of back.

Internally:

Posterior surface of fundus of stomach;
Left kidney and capsule;
Tail of pancreas;
Sometimes vertebral column.

Inferiorly:

Tail of pancreas sometimes;
Splenic flexure of colon;
Lig. phreno-colicum; saccus lienalis.

Fixation of Spleen and Peritoneal Relations.—The position of the spleen is secured by peritoneal folds which connect it with the diaphragm and neighboring organs.

The *lig. phreno-lienale* comes from the left crus of the diaphragm, and passes in the direction of the long axis of the spleen to its point of insertion, which is directly behind the inner border (margo intermedius). The ligament consists of firm connective tissue strands, and deserves the name *suspensory ligament of the spleen* (lig. suspensorium lienis).

The *lig. gastro-lienale* or *gastro-splenic omentum* connects the hilus of the spleen with the fundus of the stomach. It consists of an anterior layer formed of peritoneum of the greater sac, and a posterior layer which helps form the anterior wall of the lesser sac (Fig. 611). It only receives a strong consistency by the presence of the vasa gastrica brevia, which run in this fold from the hilus of the spleen to the stomach. The insertion of the ligament into the fundus of the stomach has no firm hold and can offer but little fixation to the spleen, but

rather serves to fasten the fundus of the stomach, which, in an empty state, needs support.

The *lig. lieno-renale* (Fig. 611) is made of a posterior layer from the greater sac and an anterior layer which forms part of the posterior wall of the lesser sac. It contains the splenic vessels.

The *lig. phreno-colicum* (incorrectly costo-colic) contributes to the security of the spleen, although unconnected with it. It arises from the diaphragm opposite the anterior ends of the tenth and eleventh ribs, and passes below the spleen downward and inward to the splenic flexure of the colon and to the anterior surface of the descending colon. It forms a pocket, with its concavity directed upward and inward, the *saccus lienalis*, which, in the new-born, regularly receives the spleen. This ligament may also be called the *sustentaculum lienis*, supporter of the spleen. By the normal condition of the suspensory, and especially phreno-colic ligament, the spleen retains its position. Should the phreno-colic be relaxed then the spleen is displaced and its long axis becomes more vertical. In rare cases the normal spleen may sink deep into the abdominal cavity, even to the pelvis. This is called the "wandering spleen." It is liable to atrophy when the splenic artery suffers torsion. There are still two more inconstant ligaments, the *lig. pancreatico-lienale* and *colico-lienale*. The former is present when the tail of the pancreas does not reach the lower part of the inner surface of the spleen; then the visceral peritoneum from below and the lesser sac from above form a short band between these two organs, a part of the lig. lieno-renale.

The *lig. colico-lienale*, when present, passes from the basal surface of the spleen downward and outward to the descending colon and joins the great omentum. It contributes to the formation of the saccus lienalis.

The ligaments, altogether, are the *lig. gastro-lienale* or gastro-splenic omentum; *lig. phreno-lienale* or suspensory ligament; *lig. phreno-colicum* or supporter of the spleen; *lig. lieno-renale*, *lig. pancreatico-lienale*, and *lig. colico-lienale*, six in number.

Respiration exerts an influence upon the position of the spleen, and especially on the percussion limits. In inspiration it sinks somewhat, and its area of dulness is lessened from the overlapping of the lungs. Yet the respiratory motility of the spleen is much less than that of the liver, because the diaphragm exercises less influence over it than upon the liver. Hasse[1] states that in inspiration the spleen is compressed from above downward, and in expiration it passes upward and backward along the tenth rib. Pathological changes in the thoracic cavity, as effusions, will push the spleen down, or ascites and tumors in the abdominal cavity will push it up.

Vessels and Nerves of the Spleen.—The *arteries* are branches of the splenic; it divides about 3 cm. internal to the hilus into three or four branches which soon subdivide into twelve or fifteen twigs, which enter the gland. The *splenic vein* is about twice as large as the accompanying artery.

The *lymphatic vessels* are divided into a superficial and deep set. Sappey contends for a superficial set in man, which is proven in the horse, deer, and pig. The deeper lymphatic vessels follow the blood-vessels, one for each of the larger veins. At the hilus there are five or six trunks which empty into the glands situated there. In their farther course they follow the blood-vessels and unite with the lymphatics of the liver and stomach to form the thoracic duct.

The *nerves* come from the cœliac plexus and right vagus, and accompany, sparingly, the splenic artery.

Structure.—The spleen is invested by two coats—an external serous and an internal fibro-elastic coat (*tunica propria*).

The *external* or *serous coat* is derived from the peritoneum; it is thin, smooth, and in the human subject intimately adherent to the fibro-elastic coat. It invests almost the entire organ, being reflected from it, at the hilus, on to the great end of the stomach, and at the upper end of the organ on to the Diaphragm.

[1] *Arch. f. Anat. u. Phys.*, 1886, s. 208.

The *fibro-elastic coat* forms the framework of the spleen. It invests the exterior of the organ, and at the hilus is reflected inward upon the vessels in the form of vaginæ or sheaths. From these sheaths, as well as from the inner surface of the fibro-elastic coat, numerous small fibrous bands, *trabeculæ* (Fig. 688), are

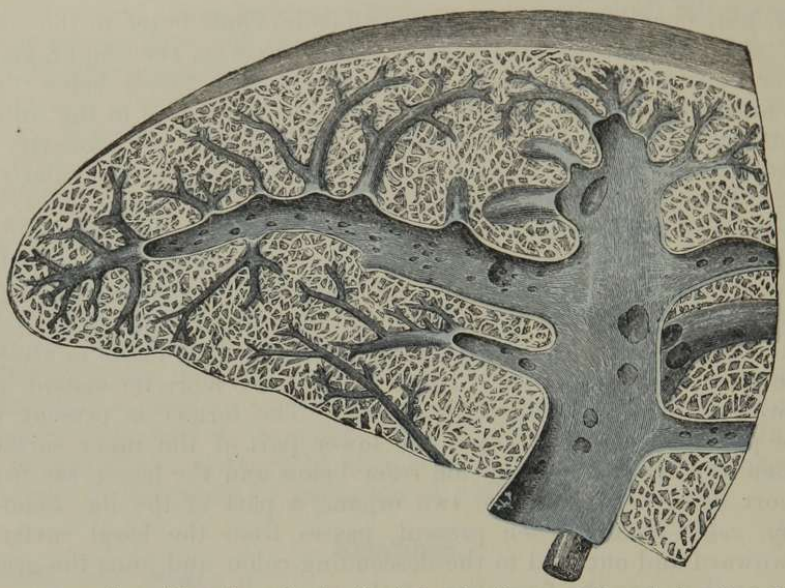

FIG. 688.—Transverse section of the spleen, showing the trabecular tissue and the splenic vein and its branches.

given off in all directions; these, uniting, constitute the areolar framework of the spleen. The framework of the spleen resembles, therefore, a sponge-like material, consisting of a number of small spaces or *areolæ*, formed by the trabeculæ which are given off from the inner surface of the capsule, or from the sheaths prolonged inward on the blood-vessels. And in these spaces or areolæ is contained the *splenic pulp*.

The proper coat, the sheaths of the vessels and the trabeculæ, consist of a dense mesh of white and yellow elastic fibrous tissues, the latter considerably predominating. It is owing to the presence of this tissue that the spleen possesses a considerable amount of elasticity, which allows of the very great variations in size that it presents under certain circumstances. In addition to these constituents of this tunic, there is found in man a small amount of non-striped muscular fibre, and in some mammalia (*e. g.* dog, pig, and cat) a very considerable amount, so that the trabeculæ appear to consist chiefly of muscular tissue. It is probably owing to this structure that the spleen exhibits, when acted upon by the galvanic current, faint traces of contractility.

The *proper substance of the spleen* or *spleen-pulp* is a soft mass of a dark reddish-brown color, resembling grumous blood. When examined, by means of a thin section, under a microscope, it is found to consist of a number of branching cells and an intercellular substance. The cells are connective-tissue corpuscles, and have been named the *sustentacular* or *supporting cells of the pulp*. The processes of these branching cells communicate with each other, thus forming a delicate reticulated tissue in the interior of the areolæ formed by the trabeculæ of the capsule; so that each primary space may be considered to be divided into a number of smaller spaces by the junction of these processes of the branching corpuscles. These secondary spaces contain blood, in which, however, the white corpuscles are found to be in larger proportions than they are in ordinary blood. The sustentacular cells are either small uni-nucleated or larger multi-nucleated cells; they do not become deeply stained with carmine, like the cells of the Malpighian bodies, presently to be described (W. Müller), but like them they possess amœboid movements (Cohnheim). In many of them may be seen deep red

or reddish-yellow granules of various sizes which present the characters of the hæmatin of the blood. Sometimes, also, unchanged blood-disks are seen included in these cells, but more frequently blood-disks are found which are altered both in form and color. In fact, blood-corpuscles in all stages of disintegration may be noticed to occur within them. Klein has recently pointed out that sometimes these cells in the young spleen contain a proliferating nucleus; that is to say, the nucleus is of large size, and presents a number of knob-like projections, as if small nuclei were budding from it by a process of gemmation. This observation is of importance, as it may explain one possible source of the colorless blood-corpuscles.

The interspaces or areolæ formed by the framework of the spleen are thus filled by a delicate reticulum of branched connective-tissue corpuscles the interstices of which are occupied by blood, and in which the blood-vessels terminate in the manner now to be described.

Blood-vessels of the Spleen.—The splenic artery is remarkable for its large size in proportion to the size of the organ, and also for its tortuous course.

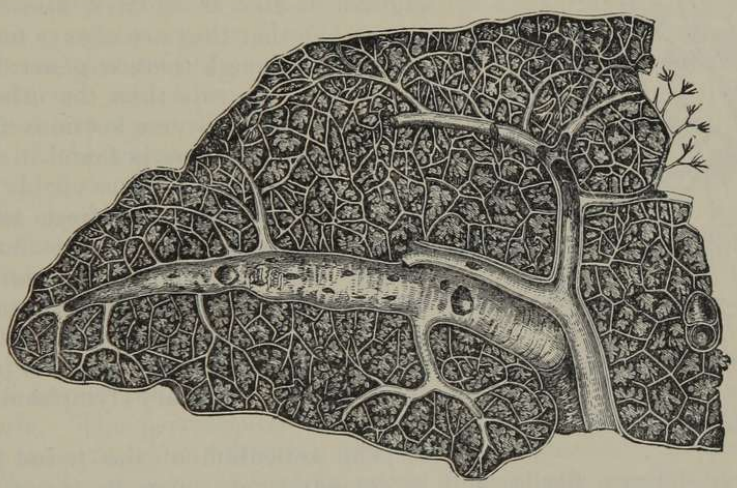

FIG. 689.—Transverse section of the human spleen, showing the distribution of the splenic artery and its branches.

It divides into twelve to fifteen branches, which enter the hilus of the spleen and ramify throughout its substance (Fig. 689), receiving sheaths from an involution of the external fibrous tissue. Similar sheaths also invest the nerves and veins.

Each branch runs in the transverse axis of the organ from within outward, diminishing in size during its transit, and giving off in its passage smaller branches, some of which pass to the anterior, others to the posterior part. These ultimately leave the trabecular sheaths, and terminate in the proper substance of the spleen in small tufts or pencils of minute arterioles, which open into the interstices of the reticulum formed by the branched sustentacular cells. Each of the larger branches of the artery supplies chiefly that region of the organ in which the branch ramifies, having no anastomosis with the majority of the other branches.

The *arterioles*, supported by the minute trabeculæ, traverse the pulp in all directions in bundles or penicilli of straight vessels. Their external coat, on leaving the trabecular sheaths, consists of ordinary connective tissue, but it gradually undergoes a transformation, becomes much thickened, and is converted into a lymphoid material.[1] This change is effected by the conversion of the connective tissue into a cystogenous tissue, the bundles of connective tissue becoming

[1] According to Klein, it is the sheath of the small vessel which undergoes this transformation, and forms a "solid mass of adenoid tissue which surrounds the vessel like a cylindrical sheath" (*Atlas of Histology*, p. 424).

looser and laxer, their fibrils more delicate, and containing in their interstices an abundance of lymph-corpuscles (W. Müller). This lymphoid material is supplied with blood by minute vessels derived from the artery with which they are in contact, and which terminates by breaking up into a network of capillary vessels.

The altered coat of the arterioles, consisting of lymphoid tissue, presents here and there thickenings of a spheroidal shape, the *Malpighian bodies of the spleen.* These bodies vary in size from about the $\frac{1}{100}$ of an inch to the $\frac{1}{25}$ of an inch in diameter. They are merely local expansions or hyperplasiæ of the lymphoid tissue of which the external coat of the smaller arteries of the spleen is formed. They are most frequently found surrounding the arteriole, which thus seems to tunnel them, but occasionally they grow from one side of the vessel only, and present the appearance of a sessile bud growing from the arterial wall. Klein, however, denies this, and says it is incorrect to describe the Malpighian bodies as isolated masses of adenoid tissue, but that they are always formed around an artery, though there is generally a greater amount on one side than the other, and that, therefore, in transverse sections the artery in the majority of cases is found in an eccentric position. These bodies are visible to the naked eye on the surface of a fresh section of the organ, appearing as minute dots of semi-opaque whitish color in the dark substance of the pulp. In minute structure they resemble the adenoid tissue of lymphatic glands, consisting of a delicate reticulum in the meshes of which lie ordinary lymphoid cells (Fig. 690).

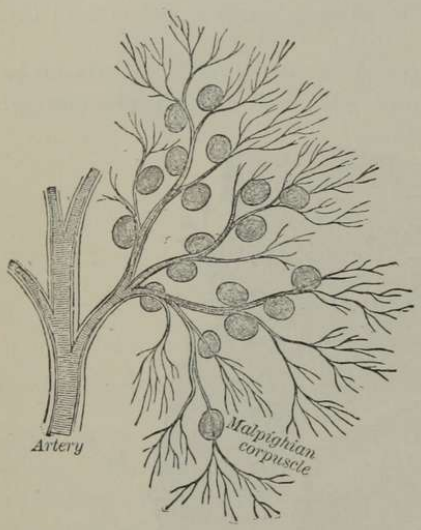

FIG. 690.—Artery from a dog's spleen, showing Malpighian corpuscles. (Kölliker.)

The reticulum of the tissue is made up of extremely delicate fibrils, and is comparatively open in the centre of the corpuscle, becoming closer at the periphery of the body. The cells which it encloses, like the supporting cells of the pulp, are possessed of amœboid move-

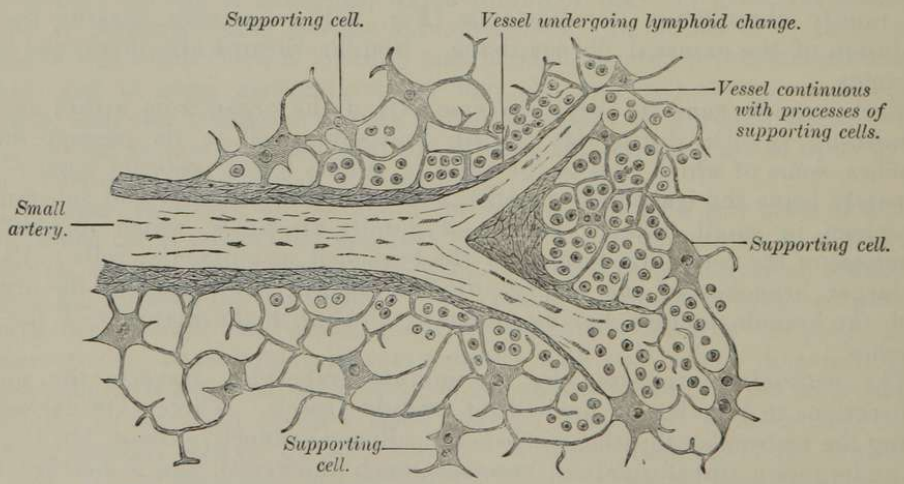

FIG. 691.—Section of spleen, showing the termination of the small blood-vessels.

ments, but when treated with carmine become deeply stained, and can thus easily be recognized from those of the pulp.

The arterioles terminate in capillaries, which traverse the pulp in all directions;

their walls become much attenuated, lose their tubular character, and the cells of the lymphoid tissue of which they are composed become altered, presenting a branched appearance and acquiring processes which are directly connected with the processes of the sustentacular cells of the pulp (Fig. 691). In this manner the capillary vessels terminate, and the blood flowing through them finds its way into the interstices of the reticulated tissue formed by the branched connective-tissue corpuscles of the splenic pulp. Thus the blood passing through the spleen is brought into intimate relation with the elements of the pulp, and no doubt undergoes important changes.

After these changes have taken place the blood is collected from the interstices of the tissue by the rootlets of the veins, which commence much in the same way as the arteries terminate. Where a vein is about to commence the connective-tissue corpuscles of the pulp arrange themselves in rows in such a way as to form an elongated space or sinus. They become changed in shape, being elongated and spindle-shaped, and overlap each other at their extremities. They thus form a sort of endothelial lining of the path or sinus, which is the radicle of a vein. On the outer surface of these cells are seen delicate transverse lines or markings which are due to minute elastic fibrillæ arranged in a circular manner around the sinus. Thus the channel obtains a continuous external investment, and gradually becomes converted into a small vein, which after a time presents a coat of ordinary connective tissue, lined by a layer of fusiform epithelial cells which are continuous with the supporting cells of the pulp. The smaller veins unite to form larger ones which do not accompany the arteries, but soon enter the trabecular sheaths of the capsule, and by their junction form from four to six branches which emerge from the hilum and, uniting, form the splenic vein, the largest radicle of the vena porta.

The veins are remarkable for their numerous anastomoses, while the arteries hardly anastomose at all.

The lymphatics originate in two ways—*i. e.* a *trabecular* set and a *perivascular* set. The former run on the trabeculæ and empty into the superficial network of the capsule. The perivascular is the deep set, rising in the lymphoid tissue surrounding the arteries and forming Malpighian corpuscles. At first they have no walls. They are seen to run with an artery in pairs and singly with each larger vein, forming many anastomoses. Both sets join at the hilus (see page 1077).

Surface Form.—The spleen is situated under cover of the ribs of the left side, being separated from them by the Diaphragm, and above by a small portion of the lower margin of the left lung. Its position corresponds to the ninth, tenth, and eleventh ribs. It is placed very obliquely. "It is oblique in two directions, viz. from above downward and outward, and also from above downward and forward" (Cunningham). "Its highest and lowest points are on a level respectively with the ninth dorsal and first lumbar spines; its inner end is distant about an inch and a half from the median plane of the body, and its outer end about reaches the mid-axillary line" (Quain).

Surgical Anatomy.—Injury of the spleen is less common than that of the liver, on account of its protected situation and connections. It may be ruptured by direct or indirect violence, torn by a broken rib, or injured by a punctured or gunshot wound. When the organ is enlarged the chance of rupture is increased. The great risk is hæmorrhage, owing to the great vascularity of the organ, and the absence of a proper system of capillaries. The injury is not, however, necessarily fatal, and this would appear to be due in a great measure to the contractile power of its capsule, which narrows the wound and prevents the escape of blood. In cases where the diagnosis is clear and the symptoms indicate danger to life laparotomy must be performed; and if the hæmorrhage cannot be stayed by ordinary surgical methods the spleen must be removed. The spleen may become displaced, producing great pain from stretching of the vessels and nerves, and this may require removal of the organ. The spleen may become enormously enlarged in certain diseased conditions, such as ague, syphilis, valvular disease of the heart, or without any obtainable history of previous disease. It may also become enlarged in lymphadenoma as a part of a general blood-disease. In these cases the tumor may sometimes fill the abdomen and extend into the pelvis, and may be mistaken for ovarian or uterine disease.

The spleen is sometimes the seat of cystic tumors, especially hydatids, and of abscess. These cases require treatment by incision and drainage; and in abscess great care must be taken if there are no adhesions between the spleen and abdominal cavity, to prevent the escape of any of the pus into the peritoneal cavity. If possible, the operation should be performed in two

stages, as in abscess of the liver. Sarcoma and carcinoma are occasionally found in the spleen, but very rarely as a primary disease.

Extirpation of the spleen has been performed for wounds or injuries, in floating spleen, in simple hypertrophy, and in leukæmic enlargement; but in these latter cases the operation is now regarded as unjustifiable, as every case in which it has been performed has terminated fatally. The incision is best made in the left semilunar line: the spleen is isolated from its surroundings, and the pedicle transfixed and ligatured in two portions, before the tumor is turned out of the abdominal cavity, if this is possible, so as to avoid any traction on the pedicle, which may cause tearing of the splenic vein. In applying the ligature care must be taken not to include the tail of the pancreas, and in lifting out the organ to avoid rupturing the capsule.

THE THORAX.

THE Thorax is a cone-shaped cavity containing and protecting the heart, enclosed in its membranous bag, the *pericardium*, and the lungs, invested by the pleura. Its shape and boundaries have already been described (see page 230).

The Cavity of the Thorax.—The size of the cavity of the thorax does not correspond with its apparent size externally, because (1) the space enclosed by the lower ribs is occupied by some of the abdominal viscera, and (2) the cavity extends above the first rib into the neck. The size of the cavity of the thorax is constantly varying during life with the movements of the ribs and Diaphragm and with the degree of distension of the abdominal viscera. From the collapsed state of the lungs in the dead body it would appear as if the viscera only partly filled the cavity of the thorax, but during life there is no vacant space, that which is seen after death being filled up by the expanded lungs.

The Upper Opening of the Thorax.—The parts which pass through the upper opening of the thorax are, from before backward in the middle line, the Sterno-hyoid and Sterno-thyroid muscles, the remains of the thymus gland, the trachea, œsophagus, thoracic duct, and the Longus colli muscle of each side; at the sides, the innominate artery, the left common carotid and left subclavian arteries, the internal mammary and superior intercostal arteries, the right and left innominate veins, and the inferior thyroid veins, the pneumogastric, cardiac, phrenic, and sympathetic nerves, the anterior branch of the first dorsal nerve, and the recurrent laryngeal nerve of the left side. The apex of each lung, covered by the pleura, also projects through this aperture, a little above the margin of the first rib.

The Lower Opening of the Thorax is wider transversely than from before backward. It slopes obliquely downward and backward, so that the cavity of the thorax is much deeper behind than in front. The Diaphragm (see page 444) closes in the opening, forming the floor of the thorax. The floor is flatter at the centre than at the sides, and is higher on the right side than on the left, corresponding in the dead body to the upper border of the fifth costal cartilage on the former, and to the corresponding part of the sixth costal cartilage on the latter. From the highest point on each side the floor slopes suddenly downward to the attachment of the Diaphragm to the ribs; this is more marked behind than in front, so that only a narrow space is left between it and the wall of the thorax.

For *measurements* of the thorax see page 1099.

THE PERICARDIUM.

The **Pericardium** (Figs. 692, 693) is a conical membranous sac in which the heart and the commencement of the great vessels are contained. It is placed behind the sternum and the cartilages of the third, fourth, fifth, sixth, and seventh ribs of the left side, in the interval between the pleuræ.

Its *apex* is directed upward, and surrounds the great vessels about two inches above their origin from the base of the heart. Its *base* is attached to the central tendon and part of the adjoining muscular structure of the Diaphragm, extending a little farther to the left than to the right side. *In front* it is separated from the sternum by the remains of the thymus gland above and a little loose areolar tissue below, and is covered by the margins of the lungs, especially the left. *Behind*, it rests upon the bronchi, the œsophagus, and the descending aorta. *Laterally*, it is covered by the pleuræ, the phrenic nerve with its accompanying vessels descending between the two membranes on either side.

Structure of the Pericardium.—The pericardium is a fibro-serous membrane, and consists, therefore, of two layers, an external fibrous and an internal serous.

The *fibrous layer* is a strong, dense membrane. Above, it surrounds the great vessels arising from the base of the heart, on which it is continued in the form of tubular prolongations which are gradually lost upon their external coat, the strongest being that which encloses the aorta. The pericardium may be traced over these vessels, to become continuous with the deep layer of the cervical fascia. On each side of the ascending aorta it sends upward a diverticulum: the one on

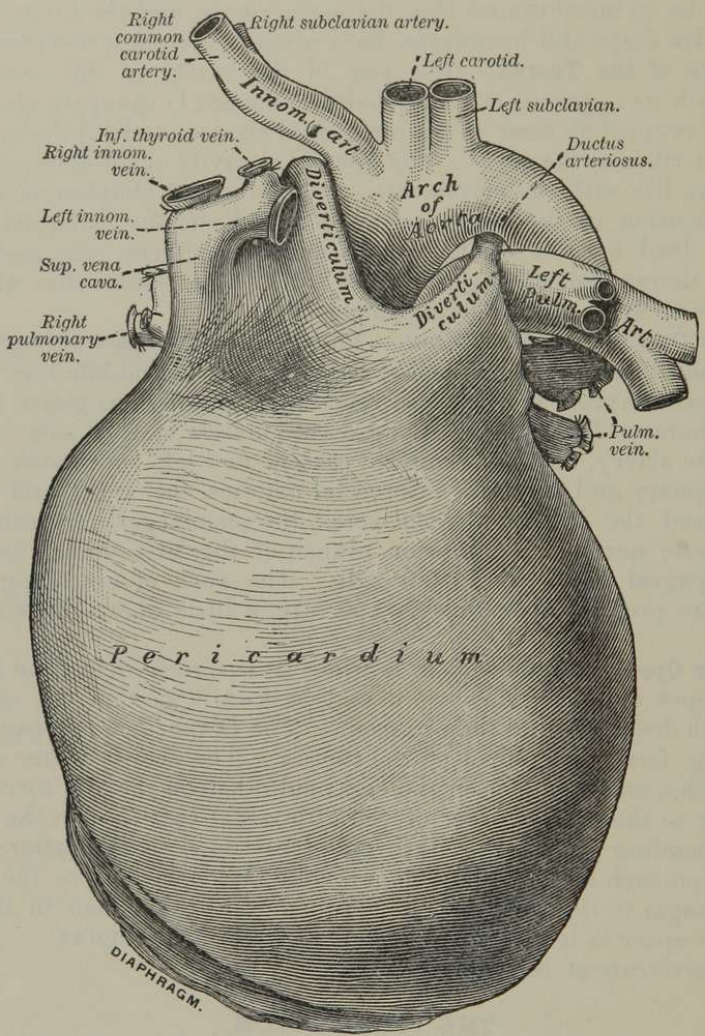

FIG. 692.—Pericardium, from in front. The sac has been distended with plaster. (From a preparation in the Museum of the Royal College of Surgeons.)

the left side, somewhat conical in shape, passes upward and outward, between the arch of the aorta and the left pulmonary artery, as far as the ductus arteriosus, where it terminates in a cæcal extremity, which is attached by loose connective tissue to the obliterated duct (Fig. 692). The one on the right side passes upward and to the right, between the ascending aorta and vena cava superior, and also terminates in a cæcal extremity. Below, the fibrous layer is attached to the central tendon of the Diaphragm, and on the left side to its muscular fibres. Anteriorly the pericardium is connected to the sternum by two variable bands of fascia, the *superior* and *inferior sterno-pericardial ligaments* of Luschka.

The vessels receiving fibrous prolongations are the aorta, the superior vena cava, the right and left pulmonary arteries, and the four pulmonary veins. As the inferior vena cava enters the pericardium, it receives no covering from the *fibrous* layer.

The *serous layer* invests the heart, and is then reflected on the inner surface of the pericardium. It consists, therefore, of a visceral and parietal portion. The former invests the surface of the heart and the commencement of the great vessels to the extent of one inch and a half from their origin; from these it is reflected upon the inner surface of the fibrous layer. The serous membrane encloses the aorta and pulmonary artery in a single tube; hence between these vessels and the auricles posteriorly is a passage, the *transverse pericardial sinus;* but it only partially covers the superior and inferior vena cava and the four pul-

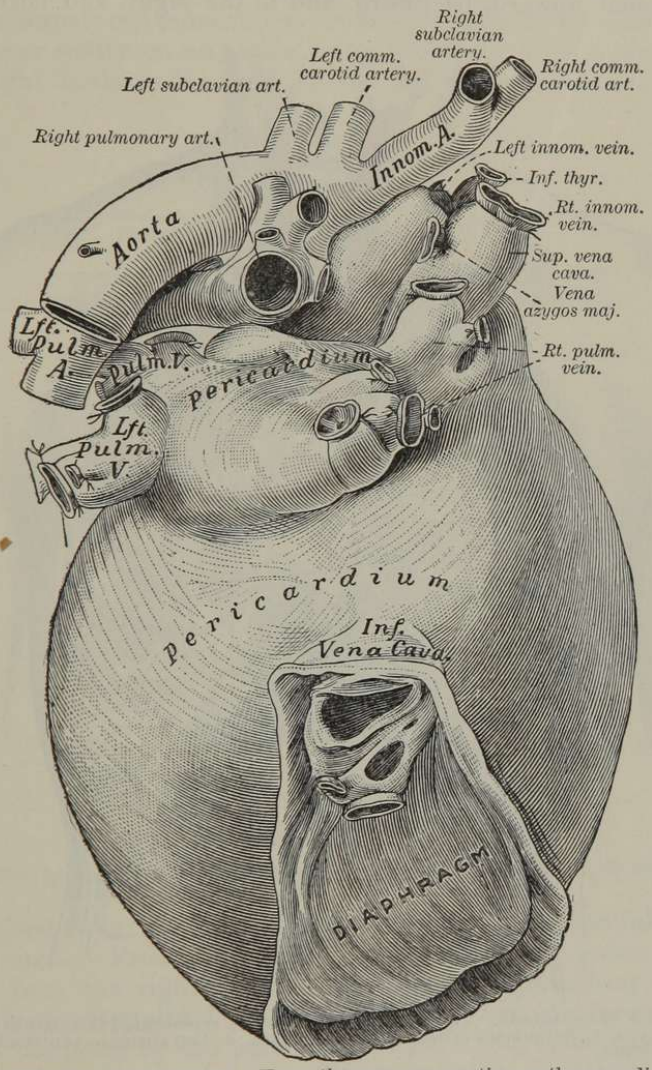

FIG. 693.—Pericardium, from behind. (From the same preparation as the preceding figure.)

monary veins. Its inner surface is smooth and glistening, and secretes a thin fluid which serves to facilitate the movements of the heart.

Arteries of the Pericardium.—These are derived from the internal mammary and its musculo-phrenic branch and from the descending thoracic aorta.

Nerves of the Pericardium.—These are branches from the vagus, the phrenic, and the sympathetic.

The Vestigial Fold of the Pericardium.—When the pericardium is opened there is seen lying between the left pulmonary artery and subjacent pulmonary vein a triangular fold (*vestigial fold of Marshall*) of the serous layer, which encloses between its layers the remains, a fibrous cord, of the *left* superior vena cava. This cord may sometimes be traced upward to the left superior intercostal vein.

Surgical Anatomy.—Paracentesis of the pericardium is sometimes required in cases of effusion into its cavity. The operation is best performed in the fifth intercostal space, one inch to the left of the sternum. The operation has been performed, however, in the fourth, sixth, and seventh spaces, and also on the right side of the sternum.

THE HEART.

The **Heart** is a hollow muscular organ, of a conical form, placed between the lungs and enclosed in the cavity of the pericardium.

Position.—The heart is placed obliquely in the chest: the broad attached end, or base, is directed upward, backward, and to the right, and corresponds to the

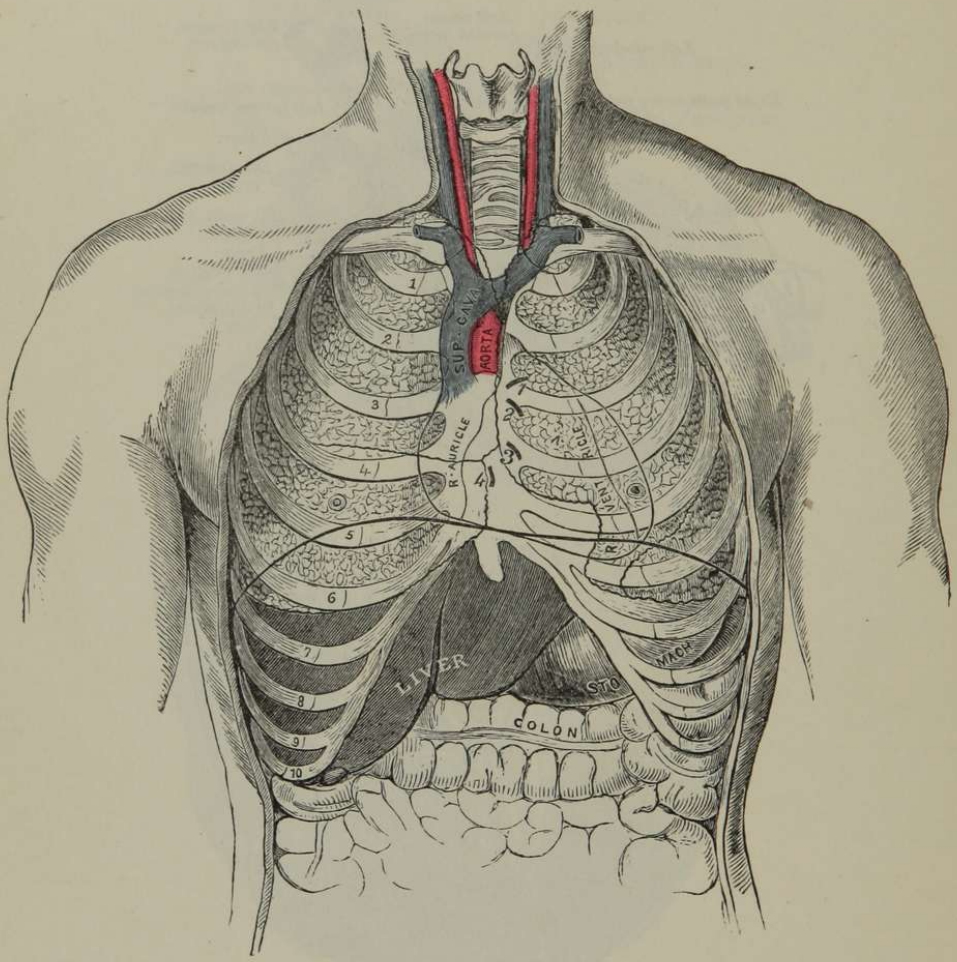

FIG. 694.—Front view of the thorax. The ribs and sternum are represented in relation to the lungs, heart, and other internal organs. 1. Pulmonary orifice. 2. Aortic orifice. 3. Left auriculo-ventricular orifice. 4. Right auriculo-ventricular orifice.

interval between the fifth and ninth dorsal vertebræ—that is, it lies opposite the sixth, seventh, and eighth vertebræ; the apex is directed downward, forward, and to the left, and corresponds to the space between the cartilage of the fifth and sixth ribs, three-quarters of an inch to the inner side and an inch and a half below the left nipple. The heart is placed behind the lower two-thirds of the sternum, and projects farther into the left than into the right cavity of the chest, extending from the median line about three inches in the former direction, and only one and a half in the latter. The anterior surface of the heart is round and convex, directed upward and forward, and formed chiefly by the right ventricle and part of the left. Its posterior surface is flattened and rests upon the Diaphragm, and is formed chiefly by the left ventricle. The right border is long, thin, and sharp; the left border short, but thick and round.

Size.—The heart in the adult measures five inches in length, three inches and a half in breadth in the broadest part, and two inches and a half in thickness. The prevalent weight, in the male, varies from ten to twelve ounces; in the female, from eight to ten: its proportions to the body being as 1 to 169 in males, 1 to 149 in females. The heart continues increasing in weight, and also in length, breadth, and thickness, up to an advanced period of life: this increase is more marked in men than in women.

Component Parts.—The heart is subdivided by a longitudinal muscular septum into two lateral halves, which are named respectively, from their position, right and left; and a transverse constriction subdivides each half of the organ into two cavities, the upper cavity on each side being called the *auricle*, the lower the *ventricle*. The right is the venous side of the heart, receiving into its auricle the

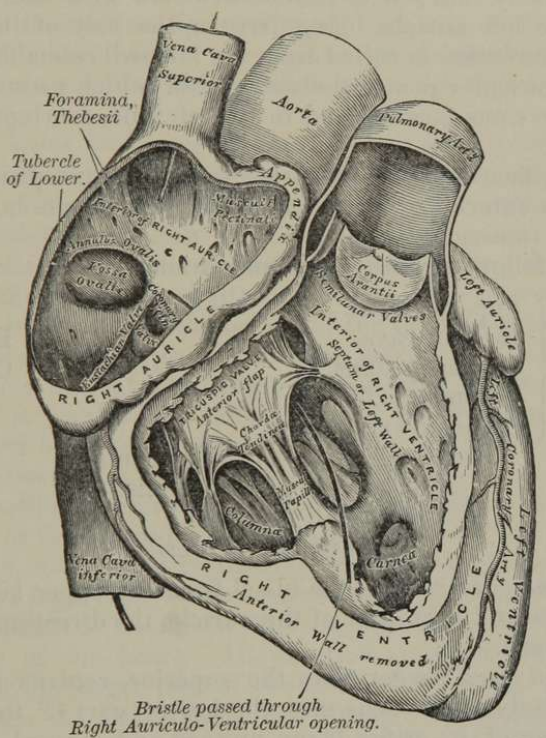

FIG. 695.—The right auricle and ventricle laid open, the anterior walls of both being removed.

dark venous blood from the entire body, by the superior and inferior vena cava and coronary sinus. From the right auricle the blood passes into the right ventricle, and from the right ventricle, through the pulmonary artery, into the lungs. The blood, arterialized by its passage through the lungs, is returned to the left side of the heart by the pulmonary veins, which open into the left auricle; from the left auricle the blood passes into the left ventricle, and from the left ventricle is distributed, by the aorta and its subdivisions, through the entire body. This constitutes the circulation of the blood in the adult.

The great transverse groove separates the auricles from the ventricles, and is called the *auriculo-ventricular groove*. It is deficient, in front, from being crossed by the root of the pulmonary artery. The two ventricles are also separated from each other on the surface by two longitudinal furrows, the *interventricular grooves*, which are situated one on the anterior, the other on the posterior surface; these extend from the base of the ventricle to a little to the right of the apex of the organ, where they are continuous, the former being situated nearer to the left border of the heart, and the latter to the right. It follows, therefore, that the right ventricle forms the greater portion of the anterior surface of the heart, and the left ventricle more of its posterior surface, while the apex is made up entirely of the left ventri-

cle. The grooves contain the coronary arteries, cardiac veins, lymphatics, nerves, and fat, all covered by the visceral layer of the serous pericardium.

Each of these cavities should now be separately examined.

To examine the interior of the right auricle, an incision should be made along its right border from the entrance of the superior vena cava to that of the inferior. A second cut is to be made from the centre of this first incision to the tip of the auricular appendix, and the flaps raised.

The **Right Auricle** is a little larger than the left, its walls somewhat thinner, measuring about one line, and its cavity is capable of containing about two ounces. It consists of two parts—a principal cavity, or *sinus venosus* or atrium, and an *appendix auriculæ*.

The *sinus* is the large quadrangular cavity placed between the two venæ cavæ; its walls are extremely thin; it is connected below with the right ventricle, and internally with the left auricle, being free in the rest of its extent.

The *appendix auriculæ*, so called from its fancied resemblance to a dog's ear, is a small conical muscular pouch the margins of which present a dentated edge. It projects from the sinus forward and to the left side, overlapping the root of the aorta.

The internal surface of the right auricle is smooth, except in the appendix and adjacent part of the anterior or right wall of the sinus venosus, where it is thrown into parallel ridges (*musculi pectinati*).

It presents the following parts for examination:

- Openings
  - Superior cava.
  - Inferior cava.
  - Coronary sinus.
  - Foramina Thebesii.
  - Auriculo-ventricular.
- Valves
  - Eustachian.
  - Coronary.
- Relics of fœtal structure
  - Annulus ovalis.
  - Fossa ovalis.
- Musculi pectinati.
- Tuberculum Loweri.

The *superior vena cava* returns the blood from the upper half of the body, and opens into the upper and back part of the auricle, the direction of its orifice being downward and forward.

The *inferior vena cava*, larger than the superior, returns the blood from the lower half of the body, and opens into the lowest part of the auricle near the septum, the direction of its orifice being upward and inward. The direction of a current of blood through the superior vena cava would consequently be toward the auriculo-ventricular orifice, whilst the direction of the blood through the inferior cava would be toward the auricular septum. This is the normal direction of the two currents in fœtal life.

The *tuberculum Loweri* is a small projection on the right wall of the auricle, between the two venæ cavæ. It is most distinct in the hearts of quadrupeds; in man it is scarcely visible. It was supposed by Lower to direct the blood from the superior cava toward the auriculo-ventricular opening.

The *coronary sinus* opens into the auricle, between the inferior vena cava and the auriculo-ventricular opening. It returns the blood from the substance of the heart, and is protected by a semicircular fold of the lining membrane of the auricle, the *coronary valve* (*valve of Thebesius*). The sinus, before entering the auricle, is considerably dilated—nearly to the size of the end of the little finger. Its wall is partly muscular, and at its junction with the great coronary vein is somewhat constricted and furnished with a valve consisting of two unequal segments.

The *foramini Thebesii* are numerous minute apertures, the mouths of small veins (*venæ cordis minimæ*), which open on various parts of the inner surface of the auricle. They return the blood directly from the muscular substance of the

heart. Some of these foramina are minute depressions in the walls of the heart, presenting a closed extremity.

The *auriculo-ventricular opening* is the large oval aperture of communication between the auricle and the ventricle, to be presently described.

The *Eustachian valve* is situated between the anterior margin of the inferior vena cava and the auriculo-ventricular orifice. It is semilunar in form, its convex margin being attached to the wall of the vein; its concave margin, which is free, terminating in two cornua, of which the left is attached to the anterior edge of the annulus ovalis, the right being lost on the wall of the auricle. The valve is formed by a duplicature of the lining membrane of the auricle containing a few muscular fibres.

In the fœtus this valve is of large size, and serves to direct the blood from the inferior vena cava, through the foramen ovale, into the left auricle.

In the adult it is occasionally persistent, and may assist in preventing the reflux of blood into the inferior vena cava; more commonly it is small, and its free margin presents a cribriform or filamentous appearance; occasionally it is altogether wanting.

The *coronary valve* (valve of Thebesius) is a semicircular fold of the lining membrane of the auricle, protecting the orifice of the coronary sinus. It prevents the regurgitation of blood into the sinus during the contraction of the auricle. This valve is occasionally double.

The *fossa ovalis* is an oval depression corresponding to the situation of the foramen ovale in the fœtus. It is situated at the lower part of the septum auricularum, above and to the left of the orifice of the inferior vena cava.

The *annulus ovalis* is the prominent oval margin of the foramen ovale. It is most distinct above and at the sides; below, it is deficient. A small slit-like valvular opening is occasionally found, at the upper margin of the fossa ovalis, which leads upward beneath the annulus into the left auricle, and is the remains of the aperture between the two auricles in the fœtus.

The *musculi pectinati* are small, prominent muscular columns which run across the inner surface of the appendix auriculæ and adjoining portion of the wall of the sinus. Posteriorly, they join a vertical ridge, the *crista terminalis* of His. They are called *pectinati* from their fancied resemblance to the teeth of a comb.

The **Right Ventricle** is triangular in form, and extends from the right auricle to near the apex of the heart. Its anterior or upper surface is rounded and convex, and forms the larger part of the front of the heart. Its under surface is flattened, rests upon the Diaphragm, and forms only a small part of the back of the heart. Its posterior wall is formed by the partition between the two ventricles, the *septum ventriculorum*, the surface of which is convex and bulges into the cavity of the right ventricle. Its upper and left angle is prolonged into a conical pouch, the *infundibulum* or *conus arteriosus*, from which the pulmonary artery arises. The walls of the right ventricle are thinner than those of the left, the proportion between them being as 1 to 3. The wall is thickest at the base, and gradually becomes thinner toward the apex. The cavity, which equals that of the left ventricle, is capable of containing about three fluidounces.[1]

To examine the interior of the right ventricle, an incision should be made a little to the right of the anterior interventricular groove from the pulmonary artery to the apex of the heart, and should be carried up from thence a little to the right of the posterior interventricular groove, as far as the auriculo-ventricular opening.

The following parts present themselves for examination:

Openings { Auriculo-ventricular.
Openings { Opening of the pulmonary artery.
Valves { Tricuspid.
Valves { Semilunar.

[1] Morrant Baker says that "taking the means of various estimates, it may be inferred that each ventricle is able to contain four to six ounces of blood" (Kirke's *Physiology*, 10th edition, p. 156).

And a muscular and tendinous apparatus connected with the tricuspid valve:

Columnæ carneæ. Chordæ tendineæ.

The *auriculo-ventricular orifice* is the large oval aperture of communication between the auricle and ventricle. It is situated at the base of the ventricle, near the right border of the heart. The opening is about an inch in diameter,[1] oval from side to side, surrounded by a fibrous ring, covered by the lining membrane of the heart, and rather larger than the corresponding aperture on the left side. It is guarded by the tricuspid valve.

The *opening of the pulmonary artery* is circular in form, and situated at the summit of the conus arteriosus, close to the septum ventriculorum. It is placed on the left side of the auriculo-ventricular opening, upon the anterior aspect of the heart, and, when viewed from above, on cross-section, the *aortic opening* is seen intervening. Its orifice is guarded by the pulmonary semilunar valves.

The *tricuspid valve* consists of three segments of a triangular or trapezoidal shape, formed by a duplicature of the lining membrane of the heart, reflected on both sides of a layer of fibrous tissue, which contains, according to Kurschner and Senac, muscular fibres. These segments are connected by their bases to the auriculo-ventricular orifice, and to one another, so as to form a continuous annular membrane which is attached round the margin of the auriculo-ventricular opening, their free margins and ventricular surfaces affording attachment to a number of delicate tendinous cords, the *chordæ tendineæ*. The largest and most movable segment, placed toward the left and anterior side of the auriculo-ventricular opening, is directed downward between that opening and the infundibulum (*left* or *infundibular* flap). Another segment corresponds to the front and right of the ventricle (*right flap*), and a third to its posterior wall (*posterior* or *septal flap*). The central part of each segment is thick and strong; the lateral margins are thin and indented. The *chordæ tendineæ* are connected with the segments of the valve in the following manner: 1. Three or four reach the attached margin of each segment, where they are continuous with the auriculo-ventricular tendinous ring. 2. Others, four to six in number, are attached to the central thickened part of each segment. 3. The most numerous and finest are connected with the marginal portion of each segment.

The *columnæ carneæ* are muscular columns which project from the inner surface, excepting near the opening of the pulmonary artery, where the wall becomes smooth. They may be classified into three sets: The first merely form prominent ridges; the second set (*trabeculæ*) are attached by their two extremities only; whilst the third set (*musculi papillares*) are attached by one extremity to the wall of the heart, the opposite extremity giving attachment to the *chordæ tendineæ*. There are two papillary muscles, anterior and posterior. The *chordæ tendineæ* of the former go to the left and right segments. Those of the latter, which is often replaced by two or three smaller ones, pass to the right and septal segments. There is still another set of chordæ which arise directly from the septum and pass to the septal and left segments.

The *semilunar valves*, three in number,[2] guard the orifice of the pulmonary artery. They consist of three semicircular folds, two anterior (right and left) and one posterior, formed by a fibrous membrane, covered above by the inner coat of the artery and below by a reflection of the endocardium. They are attached by

[1] In the *Pathological Transactions*, vol. vi. p. 119, Dr. Peacock has given some careful researches upon the weight and dimensions of the heart in health and disease. He states, as the result of his investigations, that in the healthy adult heart the right auriculo-ventricular aperture has a mean circumference of 54.4 lines, or $4\frac{2}{4}$ inches; the left auriculo-ventricular aperture, a mean circumference of 44.3 lines, or $3\frac{2}{4}$ inches; the pulmonic orifice, of 40 lines, or $3\frac{1}{4}$ inches; and the aortic orifice, of 35.5 lines, or $3\frac{4}{4}$ inches; but the dimensions of the orifices varied greatly in different cases, the auriculo-ventricular aperture having a range of from 45 to 60 lines, and the others in the same proportion.

[2] The pulmonary semilunar valves have been found to be two in number, instead of three (Dr. Hand, of St. Paul, Minn., in the *North-Western Med. and Surg. Jour.*, July, 1873), and the same variation is more frequently noticed in the aortic semilunar valves.

their convex margins to the wall of the artery at its junction with the ventricle, the straight border being free, and directed somewhat upward in the lumen of the vessel. The free margin of each is somewhat thicker than the rest of the valve, is strengthened by a bundle of tendinous fibres, and presents at its middle a small projecting thickened nodule called *corpus Arantii*.[1] From this nodule tendinous fibres radiate through the valve to its attached margin, and these fibres form a constituent part of its substance throughout its whole extent, excepting two narrow lunated portions (*lunulæ*) placed on each side of the nodule immediately behind the free margin; here the valve is thin and formed merely by the lining membrane. During the passage of the blood along the pulmonary artery these valves are pressed against the sides of the cylinder and the course of the blood along the tube is uninterrupted; but during the ventricular diastole, when the current of blood along the pulmonary artery is checked and partly thrown back by its elastic walls, these valves become immediately expanded and effectually close the entrance of the tube. When the valves are closed the lunated portions of each are brought into contact with one another by their opposed surfaces, the three corpora Arantii filling up the small triangular space that would be otherwise left by the approximation of the three semilunar valves.

Between the semilunar valves and the commencement of the pulmonary artery are three pouches or dilatations, one behind each valve. These are the pulmonary sinuses (*sinuses of Valsalva*). Similar sinuses exist between the semilunar valves and the commencement of the aorta; they are larger than the pulmonary sinuses. The blood, in its regurgitation toward the heart, finds its way into these sinuses, and so shuts down the valve-flaps.

In order to examine the interior of the left auricle, make an incision on the posterior surface of the auricle from the pulmonary veins on one side to those on the other, the incision being carried a little way into the vessels. Make another incision from the middle of the horizontal one to the appendix.

The **Left Auricle** is rather smaller than the right; its walls thicker, measuring about one line and a half; it consists, like the right, of two parts, a principal cavity, *atrium* or *sinus* and an *appendix auriculæ*.

The *sinus* is cuboidal in form, and concealed in front by the pulmonary artery and aorta; internally, it is separated from the right auricle by the septum auricularum; behind, it receives on each side two pulmonary veins, being free in the rest of its extent.

The *appendix auriculæ* is somewhat constricted at its junction with the auricle; it is longer, narrower, and more curved than that of the right side, and its margins are more deeply indented, presenting a kind of foliated appearance. Its direction is forward and toward the right side, overlapping the root of the pulmonary artery.

Within the auricle the following parts present themselves for examination:

The openings of the four pulmonary veins.
Auriculo-ventricular opening.
Musculi pectinati.

The *pulmonary veins*, four in number, open, two into the right, and two into the left side of the auricle. The two left veins frequently terminate by a common opening. They are not provided with valves.

The *auriculo-ventricular opening* is the large oval aperture of communication between the auricle and ventricle. It is rather smaller than the corresponding opening on the opposite side (see note, page 1090).

[1] In former editions, as well as in other text-books on anatomy, these little nodules have been described as fibro-cartilaginous in structure. At my request, Dr. Le Cronier Lancaster, Demonstrator of Anatomy at St. George's Hospital, has investigated this subject, and reports that the "corpora Arantii" appear to consist of bundles of interlacing connective-tissue fibres with branched connective-tissue cells, and some few elastic fibres. Occasionally a rounded cell, with indistinct capsule, resembling a cartilage-cell was seen; but there were not many of them. At the free edge of the corpus the structure is denser, there being a larger proportion of fibres to cells than in the central portion. He thinks the structure of the corpus should be put down as fibrous and not fibro-cartilaginous.

The *musculi pectinati* are fewer in number and smaller than on the right side; they are confined to the inner surface of the appendix.

On the inner surface of the septum auricularum may be seen a lunated impression bounded below by a crescentic ridge the concavity of which is turned upward. The depression is just above the fossa ovalis in the right auricle.

To examine the interior of the left ventricle, make an incision a little to the left of the anterior interventricular groove from the base to the apex of the heart, and carry it up from thence, a little to the left of the posterior interventricular groove, nearly as far as the auriculo-ventricular groove.

The **Left Ventricle** is longer and more conical in shape than the right ventricle. It forms a small part of the left side of the anterior surface of the

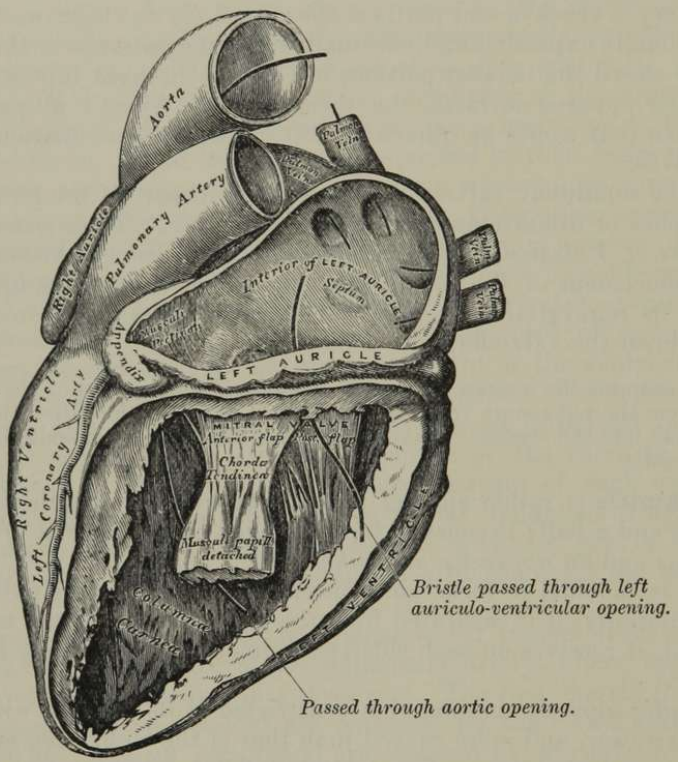

FIG. 696.—The left auricle and ventricle laid open, the posterior walls of both being removed.

heart, and a considerable part of its posterior surface. It also forms the apex of the heart by its projection beyond the right ventricle. Its walls are much thicker than those of the right side, the proportion being as 3 to 1. They are also thickest in the broadest part of the ventricle, becoming gradually thinner toward the base, and also toward the apex, which is the thinnest part.

The following parts present themselves for examination within the ventricle:

Openings { Auriculo-ventricular. / Aortic. } Valves { Mitral. / Semilunar. }

Chordæ tendineæ. Columnæ carneæ.

The *auriculo-ventricular opening* is placed below and to the left of the aortic orifice. It is a little smaller than the corresponding aperture of the opposite side, and, like it, is broader in the transverse than in the antero-posterior diameter. It is surrounded by a dense fibrous ring, covered by the lining membrane of the heart, and guarded by the mitral valves.

The *aortic opening* is a circular aperture in front and to the right side of the auriculo-ventricular, from which it is separated by one of the segments of the mitral valve. Its orifice is guarded by the semilunar valves.

The *mitral* or *bicuspid valve* is attached to the circumference of the auriculo-ventricular orifice in the same way that the tricuspid valve is on the opposite side. It is formed by fibrous membrane covered on both surfaces by endocardium, and contains a few muscular fibres. It is large in size, thicker, and altogether stronger than the tricuspid, and consists of two segments of unequal size. The large segment is placed in front and to the right, between the auriculo-ventricular and aortic orifices. Two smaller segments are usually found at the angles of junction of the larger. Similar segments are less constantly found between the main ones of the tricuspid valve. The mitral valve-flaps are furnished with chordæ tendineæ, the mode of attachment of which is precisely similar to that of those on the right side, but they are thicker, stronger, and less numerous.

The *semilunar valves* surround the orifice of the aorta; two are posterior (right and left), and one anterior; they are similar in structure and mode of attachment to the pulmonary valves. They are, however, larger, thicker, and stronger, the lunulæ are more distinct, and the corpora Arantii larger and more prominent. Between each valve and the cylinder of the aorta is a deep depression, the *sinus aortici* (sinuses of Valsalva); they are larger than those of the root of the pulmonary artery. The *right* coronary artery arises from the anterior; the *left* from the left posterior.

The *columnæ carneæ* admit of a subdivision into three sets, like those upon the right side, but they are smaller, more numerous, and present a dense interlacement, especially at the apex and upon the posterior wall. Those attached by one extremity only, the *musculi papillares*, are two in number, being connected one to

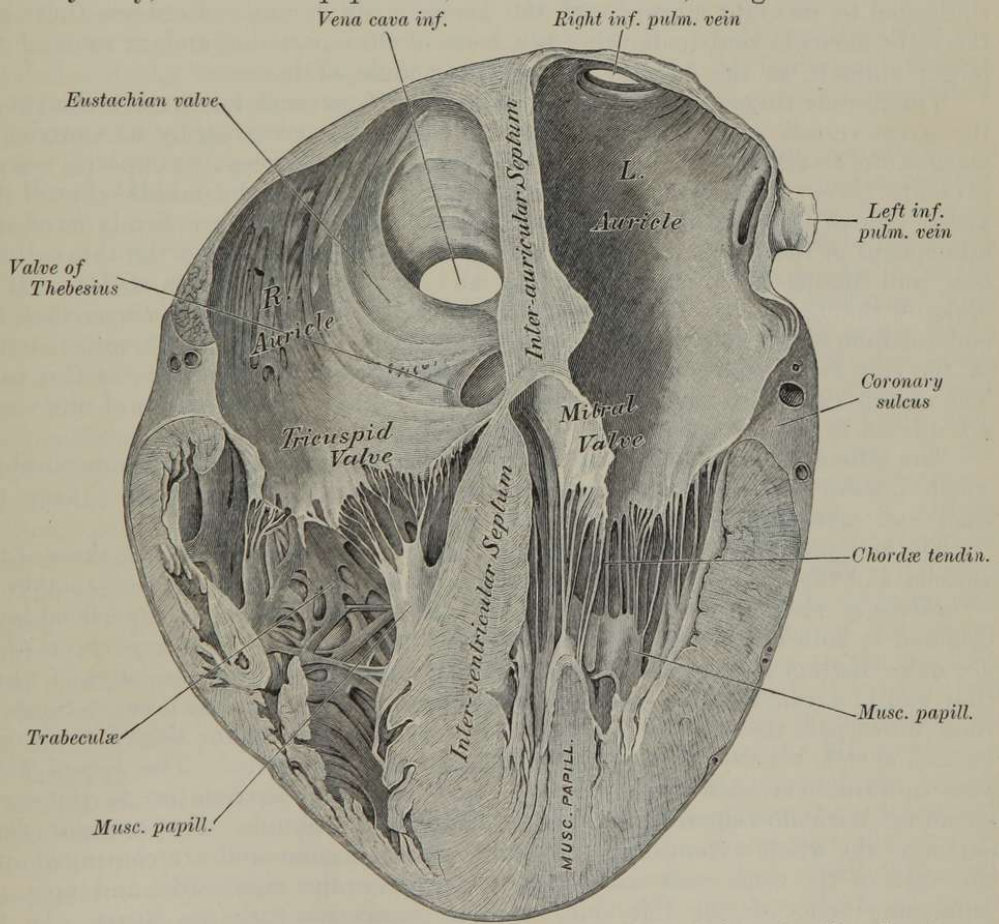

FIG. 697.—Section of the heart, showing the interarticular and interventricular septa. (Gegenbaur.)

the anterior, the other to the posterior wall; they are of large size, and terminate by free rounded extremities from which the chordæ tendineæ arise.

The septum between the two ventricles is thick, especially below (Fig. 697).

At its upper part it suddenly tapers off and loses its muscular fibres, consisting only of fibrous tissue covered by two layers of endocardium, and on the right side it is also, during diastole, in contact with the septal flap of the tricuspid valve. It continues upward, and forms the septum between the aortic vestibule and the right auricle. It is derived from the lower part of the aortic septum of the fœtus, and an abnormal communication may exist at this part owing to defective development. The *aortic vestibule* (Sibson) is a small portion of the ventricular cavity immediately under the root of the aorta.

The *Endocardium* is a thin membrane which lines the internal surface of the heart; it assists in forming the valves by its reduplications, and is continuous with the lining membrane of the great blood-vessels. It is a smooth, transparent membrane, giving to the inner surface of the heart its glistening appearance. It is more opaque on the left than on the right side of the heart, thicker in the auricles than in the ventricles, and thickest in the left auricle. It is thin on the musculi pectinati and on the columnæ carneæ, but thicker on the smooth part of the auricular and ventricular walls and on the tips of the musculi papillares.

Structure.—The heart consists of muscular fibres and of fibrous rings which serve for their attachment.

The *fibrous rings* surround the auriculo-ventricular and arterial orifices: they are stronger upon the left than on the right side of the heart. The auriculo-ventricular rings serve for the attachment of the muscular fibres of the auricles and ventricles, and also for the mitral and tricuspid valves; the ring on the left side is closely connected by its right margin with the aortic arterial ring. Between these and the right auriculo-ventricular ring is a mass of fibrous tissue, and in some of the larger animals, as the ox and elephant, a nodule of bone.

The fibrous rings surrounding the arterial orifices serve for the attachment of the great vessels and semilunar valves. Each ring receives, by its ventricular margin, the attachment of the muscular fibres of the ventricles; its opposite margin presents three deep semicircular notches, within which the middle coat of the artery (which presents three convex semicircular segments) is firmly fixed, the attachment of the artery to its fibrous ring being strengthened by the thin cellular coat and serous membrane externally and by the endocardium within. It is opposite the margins of these semicircular notches, in the arterial rings, that the endocardium by its reduplication, forms the semilunar valves, the fibrous structure of the ring being continued into each of the segments of the valve at this part. The middle coat of the artery in this situation is thin, and the sides of the vessel are dilated to form the sinuses of Valsalva.

The *muscular structure of the heart* (*myocardium*) consists of bands of fibres which present an exceedingly intricate interlacement. They are of a deep red color and marked with transverse striæ (page 65).

The muscular fibres of the heart admit of a subdivision into two kinds, those of the auricles and those of the ventricles, which are quite independent of one another.

Fibres of the Auricles.—These are disposed in two layers—a superficial layer common to both cavities, and a deep layer proper to each. The *superficial fibres* are more distinct on the anterior surface of the auricles, across the bases of which they run in a transverse direction, forming a thin, but incomplete layer. Some of these fibres pass into the septum auricularum. The *internal* or *deep fibres* proper to each auricle consist of two sets, looped and annular fibres. The *looped fibres* pass upward over each auricle, being attached by two extremities to the corresponding auriculo-ventricular rings in front and behind. The *annular fibres* surround the whole extent of the appendices auricularum, and are continued upon the walls of the venæ cavæ and coronary sinus on the right side, and upon the pulmonary veins on the left side, at their connection with the heart. In the appendices they interlace with the longitudinal fibres.

Fibres of the Ventricles.—These are arranged in an exceedingly complex manner, and the accounts given by various anatomists differ considerably. This is probably due partly to the fact that the various layers of muscular fibres of which the

heart is said to be composed are not independent, but their fibres are interlaced to a considerable extent, and therefore any separation into layers must be to a great extent artificial; and also no doubt partly due to the fact, pointed out by Henle, that there are varieties in the arrangement due to individual differences. If the *epicardium* (visceral layer of pericardium) and the subjacent fat is removed from a heart which has been subjected to prolonged boiling, so as to dissolve the connective tissues, the superficial fibres of the ventricles will be exposed. They will be seen to commence at the base of the heart, where they are attached to the tendinous rings around the orifices, and to pass obliquely downward toward the apex, with a direction from right to left. At the apex the fibres turn suddenly inward, forming what is called the *vortex*, into the interior of the left ventricle. On the back of the heart it will be seen that the fibres pass continuously from one ventricle to the other over the interventricular groove; and the same thing will be noticed on the front of the heart at the upper and lower end of the anterior interventricular groove, but in the middle portion of this groove the fibres passing from one ventricle to the other are interrupted by fibres emerging from the septum along the groove; many of the superficial fibres pass in also at this groove to the septum. The vortex is produced, as stated above, by the sudden turning inward of the superficial fibres in a peculiar spiral manner into the interior of the left ventricle. Those fibres which descended on the posterior surface of the heart enter, at the vortex, the left ventricle, and, ascending, form part of the inner layer of muscular fibres lining this cavity and the right (posterior) musculus papillaris; those fibres which descend on the front of the heart, and which pass to the apex, also pass, at the vortex, into the interior of the ventricle, where they also form the remainder of the innermost layer of the ventricle and the left (anterior) musculus papillaris. The fibres forming the inner layer of the wall of the ventricle ascend to be attached to the fibrous rings around the orifices.

By dissection these superficial fibres may be removed as a thin stratum, and it will then be found that the ventricles are made up of oblique fibres superimposed in layers one on the top of another, and assuming gradually a less oblique direction as they pass to the middle of the thickness of the ventricular wall, so that in the centre of the wall the fibres are transverse. Internal to this central transverse layer the fibres become oblique again, but in the opposite direction to the external ones. This division into distinct layers is, however, to a great extent artificial, as the fibres pass across from one layer to another, and have therefore to be divided in the dissection, and the change in the direction of the fibres is very gradual. These oblique fibres commence above at the fibrous rings at the base of the heart, and, descending toward the apex, they enter the septum near its lower end. In the septum the fibres which form the left ventricle may be traced in three directions: 1. Some pass upward to be attached to the central fibro-cartilage. 2. Others pass through the septum to become continuous with the fibres of the right ventricle. 3. The remainder pass through the septum to encircle the ventricle as annular fibres. Of the fibres of the right ventricle, some on entering the septum pass upward to be attached to the central fibro-cartilage; some, entering the septum from behind, pass forward to become continuous with the fibres on the anterior surface of the left ventricle; and others, entering in front, pass backward to join the fibres on the posterior wall of the left ventricle. The septum therefore consists of three varieties of fibres—viz. annular fibres, special to the left ventricle; ascending fibres, derived from both ventricles and ascending through the septum to the central fibro-cartilage; and decussating fibres, derived from the anterior wall of one ventricle and passing to the posterior wall of the other ventricle, or from the posterior wall of the right ventricle and passing to the anterior wall of the left. In addition to these fibres there are a considerable number which appear to encircle both ventricles and which pass across the septum without turning into it.

Vessels and Nerves.—The *arteries* supplying the heart are the left or anterior and right or posterior coronary (page 542).

The *veins* accompany the arteries, and terminate in the right auricle. They are

the great, the middle, anterior, and posterior, cardiac veins, the right or small and the left or great coronary sinuses, and the venæ cordis minimæ (*venæ Thebesii*) (p. 677).

The *lymphatics* terminate in the thoracic and right lymphatic ducts.

The *nerves* are derived from the cardiac plexuses, which are formed partly from the cranial nerves and partly from the sympathetic. They are freely distributed both on the surface and in the substance of the heart, the separate filaments being furnished with small ganglia.

Surface Form.—In order to show the extent of the heart in relation to the front of the chest, draw a line from the lower border of the second left costal cartilage, one inch from the sternum, to the upper border of the third right costal cartilage, half an inch from the sternum. This represents the base-line or upper limit of the organ. Take a point an inch and a half below and three-quarters of an inch internal to the left nipple—that is, about three and a half inches to the left of the median line of the body. This represents the apex of the heart. Draw a line from this apex-point, with a slight convexity downward, to the junction of the seventh right costal cartilage to the sternum. This represents the lower limit of the heart. Join the right extremity of the first line—that is, the base-line—with the right extremity of this line—that is, to the seventh right chondro-sternal joint—with a slight curve outward, so that it projects about an inch and a half from the middle line of the sternum. Lastly, join the left extremity of the base-line and the apex-point by a line curved slightly to the left.

The position of the various orifices is as follows: viz. the pulmonary orifice is situated in the upper angle formed by the articulation of the third left costal cartilage with the sternum; the aortic orifice is a little below and internal to this, behind the left border of the sternum, close to the articulation of the third left costal cartilage to this bone. The left auriculo-ventricular opening is behind the sternum, rather to the left of the median line, and opposite the fourth costal cartilages. The right auriculo-ventricular opening is a little lower, opposite the fourth interspace and in the middle line of the body.

A portion of the area of the heart thus mapped out is uncovered by lung, and therefore gives a dull note on percussion; the remainder, being overlapped by the lung, gives a more or less resonant note. The former is known as the area of superficial cardiac dulness; the latter as the area of deep cardiac dulness. The area of superficial cardiac dulness is included between a line drawn from the centre of the sternum, between the fourth costal cartilages, to the apex of the heart and a line drawn from the same point down the lower third of the middle line of the sternum. Below, this area merges into the dulness which corresponds to the liver. Dr. Latham lays down the following rule as a sufficient practical guide for the definition of the portion of the heart which is uncovered by lung or pleura: "Make a circle of two inches in diameter round a point midway between the nipple and the end of the sternum," that is, the gladiolus.

Peculiarities in the Vascular System of the Fœtus.

The chief peculiarities in the heart of the fœtus are the direct communication between the two auricles through the foramen ovale and the large size of the Eustachian valve. There are also several minor peculiarities. Thus, the position of the heart is vertical until the fourth month, when it commences to assume an oblique direction. Its size is also very considerable as compared with the body, the proportion at the second month being 1 to 50; at birth it is as 1 to 120; whilst in the adult the average is about 1 to 160. At an early period of fœtal life the auricular portion of the heart is larger than the ventricular, the right auricle being more capacious than the left; but toward birth the ventricular portion becomes the larger. The thickness of both ventricles is at first about equal, but toward birth the left becomes much the thicker of the two.

The *foramen ovale* is situated at the lower and back part of the septum auricularum, forming a communication between the auricles. It remains as a free oval opening from the time of the formation of the auricular septum (about the eighth week) until the middle period of fœtal life. About this period a fold grows up from the posterior wall of the auricle to the left of the foramen ovale, and advances over the opening so as to form a sort of valve, which allows the blood to pass only from the right to the left auricle, and not in the opposite direction.

The *Eustachian valve* is developed from the anterior border of the inferior vena cava at its entrance into the auricle. It is directed upward on the left side of the opening of this vein, and serves to direct the blood from the inferior vena cava through the foramen ovale into the left auricle.

The peculiarities in the arterial system of the fœtus are the communication between the pulmonary artery and the descending aorta by means of the *ductus*

arteriosus, and the communication between the internal iliac arteries and the placenta by means of the umbilical arteries.

The *ductus arteriosus* is a short tube, about half an inch in length at birth, and of the diameter of a goosequill. In the early condition it forms the continuation of the pulmonary artery, and opens into the descending aorta just below the origin of the left subclavian artery, and so conducts the chief part of the blood from the right ventricle into this vessel. When the branches of the pulmonary artery have become larger relatively to the ductus arteriosus, the latter is chiefly connected to the left pulmonary artery; and the fibrous cord, which is all that remains of the ductus arteriosus in later life, will be found to be attached to the root of that vessel.

The *umbilical* or *hypogastric arteries* arise from the internal iliacs, in addition to the branches given off from those vessels in the adult. Ascending along the sides of the bladder to its fundus, they pass out of the abdomen at the umbilicus, and are continued along the umbilical cord to the placenta, coiling round the umbilical vein. They return to the placenta the blood which has circulated in the system of the fœtus.

The peculiarity in the venous system of the fœtus is the communication established between the placenta and the liver and portal vein through the umbilical vein, and the inferior vena cava through the ductus venosus.

Fœtal Circulation.

The blood destined for the nutrition of the fœtus is carried from the placenta to the fœtus, along the umbilical cord, by the umbilical vein. The umbilical vein enters the abdomen at the umbilicus, and passes upward along the free margin of the suspensory ligament of the liver to the under surface of that organ, where it gives off two or three branches to the left lobe, one of which is of large size, and others to the lobus quadratus and lobulus Spigelii. At the transverse fissure it divides into two branches: of these, the larger is joined by the portal vein and enters the right lobe; the smaller branch continues onward, under the name of the ductus venosus, and joins the left hepatic vein at the point of junction of that vessel with the inferior vena cava. The blood, therefore, which traverses the umbilical vein reaches the inferior vena cava in three different ways: the greater quantity circulates through the liver with the portal venous blood before entering the vena cava by the hepatic veins; some enters the liver directly, and is also returned to the inferior cava by the hepatic veins; the smaller quantity passes directly into the vena cava by the junction of the ductus venosus with the left hepatic vein.

In the inferior cava the blood carried by the ductus venosus and hepatic veins becomes mixed with that returning from the lower extremities and wall of the abdomen. It enters the right auricle, and, guided by the Eustachian valve, passes through the foramen ovale into the left auricle, where it becomes mixed with a small quantity of blood returned from the lungs by the pulmonary veins. From the left auricle it passes into the left ventricle, and from the left ventricle into the aorta, by means of which it is distributed almost entirely to the head and upper extremities, a small quantity being probably carried into the descending aorta. From the head and upper extremities the blood is returned by the branches of the superior vena cava to the right auricle, where it becomes mixed with a small portion of the blood from the inferior cava. From the right auricle it descends over the Eustachian valve into the right ventricle, and from the right ventricle passes into the pulmonary artery. The lungs of the fœtus being solid and almost impervious, only a small quantity of the blood of the pulmonary artery is distributed to them by the right and left pulmonary arteries, and is returned by the pulmonary veins to the left auricle; the greater part passes through the ductus arteriosus into the commencement of the descending aorta, where it becomes mixed with a small quantity of blood transmitted by the left ventricle into the aorta.

Along this vessel it descends to supply the lower extremities and viscera of the abdomen and pelvis, the chief portion being, however, conveyed by the umbilical arteries to the placenta.

From the preceding account of the circulation of the blood in the fœtus it will be seen—

1. That the placenta serves the double purpose of a respiratory and nutritive

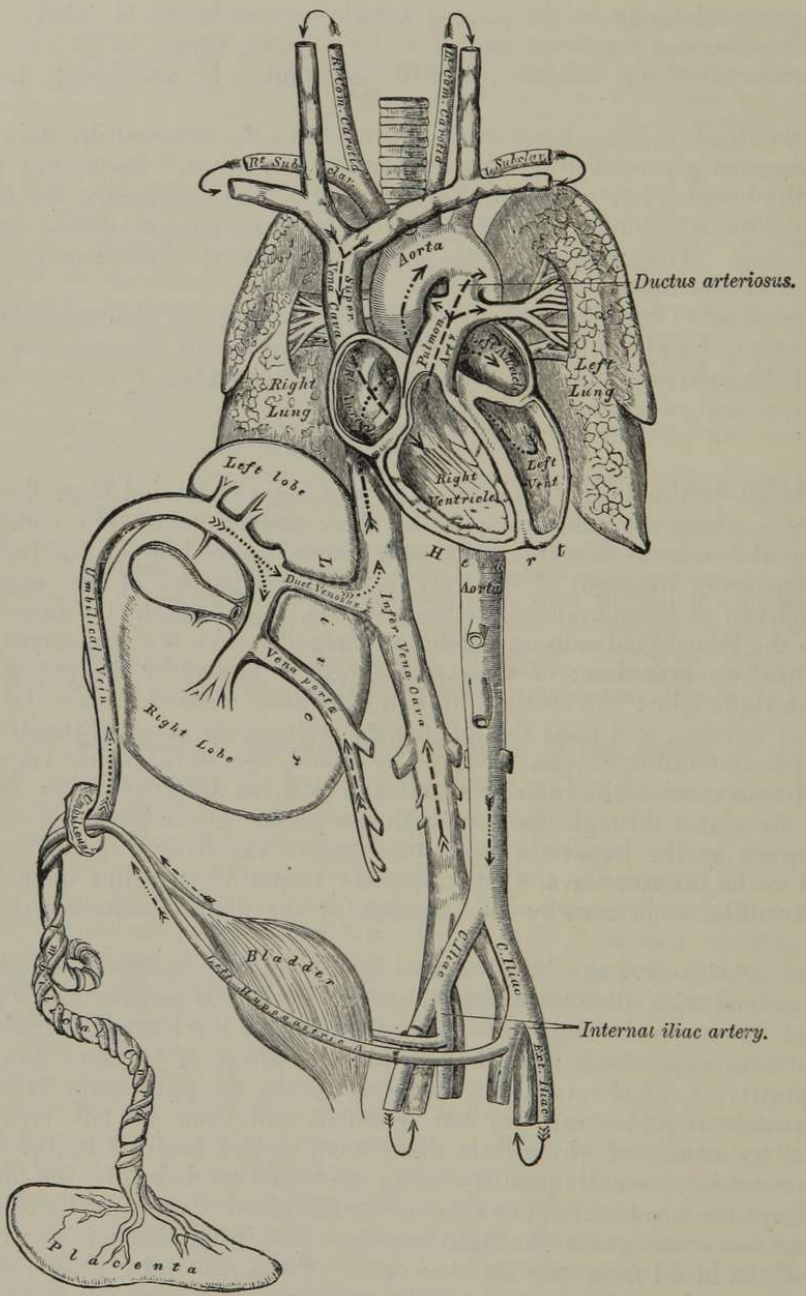

FIG. 698.—Plan of the fœtal circulation. In this plan the figured arrows represent the kind of blood, as well as the direction which it takes in the vessels. Thus, arterial blood is figured ≫—·····—>; venous blood, ≫———>; mixed (arterial and venous) blood, ≫·—·—>.

organ, receiving the venous blood from the fœtus, and returning it again re-oxygenated and charged with additional nutritive material.

2. That nearly the whole of the blood of the umbilical vein traverses the liver

before entering the inferior cava; hence the large size of this organ, especially at an early period of fœtal life.

3. That the right auricle is the point of meeting of a double current, the blood in the inferior cava being guided by the Eustachian valve into the left auricle, whilst that in the superior cava descends into the right ventricle. At an early period of fœtal life it is highly probable that the two streams are quite distinct, for the inferior cava opens almost directly into the left auricle, and the Eustachian valve would exclude the current along the vein from entering the right ventricle. At a later period, as the separation between the two auricles becomes more distinct, it seems probable that some mixture of the two streams must take place.

4. The blood carried from the placenta to the fœtus by the umbilical vein, mixed with the blood from the inferior cava, passes almost directly to the arch of the aorta, and is distributed by the branches of that vessel to the head and upper extremities; hence the large size and perfect development of those parts at birth.

5. The blood contained in the descending aorta, chiefly derived from that which has already circulated through the head and upper limbs, together with a small quantity from the left ventricle, is distributed to the lower extremities; hence the small size and imperfect development of these parts at birth.

Changes in the Vascular System at Birth.

At birth, when respiration is established, an increased amount of blood from the pulmonary artery passes through the lungs, which now perform their office as respiratory organs, and at the same time the placental circulation is cut off. The foramen ovale becomes gradually closed by about the tenth day after birth; the valvular fold above mentioned becomes adherent to the margins of the foramen for the greater part of its circumference, but above a slit-like opening is left between the two auricles which sometimes remains persistent.

The *ductus arteriosus* begins to contract immediately after respiration is established, becomes completely closed from the fourth to the tenth day, and ultimately degenerates into an impervious cord which serves to connect the left pulmonary artery to the descending aorta.

Of the *umbilical* or *hypogastric arteries*, the portion continued on to the bladder from the trunk of the corresponding internal iliac remains pervious as the superior vesical artery, and the part between the fundus of the bladder and the umbilicus becomes obliterated between the second and fifth days after birth, and projects into the peritoneal sac so as to form the two fossæ of the peritoneum spoken of in the section on the surgical anatomy of direct inguinal hernia.

The *umbilical vein* and *ductus venosus* become completely obliterated between the second and fifth days after birth, and ultimately dwindle to fibrous cords, the former becoming the round ligament of the liver, the latter the fibrous cord, which in the adult may be traced along the fissure of the ductus venosus.

Measurements of the Thorax.

Perimeters.

At the level of the highest point of the axilla	89.52 cm.
" " " nipple	86.64 cm.
" " " sterno-xiphoid articulation	81.88 cm.

Diameters.

Transverse, between the eighth intercostal spaces	28 cm.
Antero-posterior, at the level of the ensiform cartilage	20 cm.
Vertical, anterior wall	15.5 cm.
" posterior wall	31.5 cm.

(2.54 cm. = 1 inch.) (Joessel.)

THE ORGANS OF VOICE AND RESPIRATION.

THE LARYNX.

THE Larynx is the organ of voice, placed at the upper part of the air-passage. It is situated between the trachea and base of the tongue, at the upper and fore part of the neck, where it forms a considerable projection in the middle line. On either side of it lie the great vessels of the neck; behind, it forms part of the anterior boundary of the pharynx, and is covered by the mucous membrane lining that cavity.

The larynx is broad above, where it presents the form of a triangular box, flattened behind and at the sides, and bounded in front by a prominent vertical ridge. Below, it is narrow and cylindrical. It is composed of cartilages which are connected together by ligaments and moved by numerous muscles; the interior is lined by mucous membrane and supplied with vessels and nerves.

The **Cartilages of the Larynx** are nine in number, three single and three pairs:

Thyroid.	Two Arytenoid.
Cricoid.	Two Cornicula Laryngis.
Epiglottis.	Two Cuneiform.

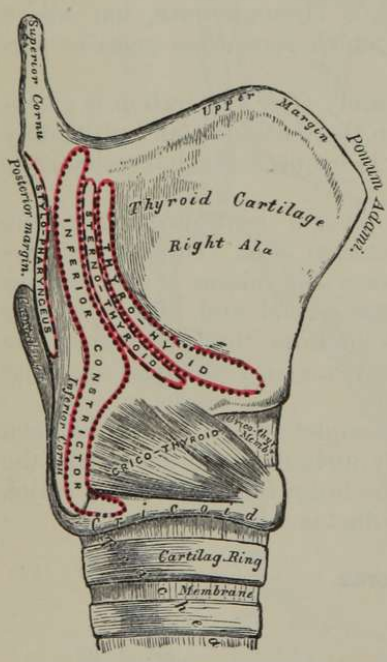

FIG. 699.—Side view of the thyroid and cricoid cartilages.

The **Thyroid** (*θυρεός*, a shield) is the largest cartilage of the larynx. It consists of two lateral lamellæ or alæ, united at an acute angle in front, forming a vertical projection in the middle line which is prominent above and called the *pomum Adami*. This projection is subcutaneous, more distinct in the male than in the female, and occasionally separated from the integument by a bursa mucosa.

Each lamella is quadrilateral in form. Its *outer surface* presents an oblique ridge which passes downward and forward from a tubercle situated near the root of the superior cornu. This ridge gives attachment to the Sterno-thyroid and Thyro-hyoid muscles, and the portion of cartilage included between it and the posterior border, to part of the Inferior constrictor muscle.

The *inner surface* of each ala is smooth, slightly concave, and covered by mucous membrane above and behind; but in front, in the receding angle formed by their junction, are attached the epiglottis, the true and false vocal cords, the Thyro-arytenoid and Thyro-epiglottidean muscles.

The *upper border of the thyroid cartilage* is sinuously curved, being concave at its posterior part, just in front of the superior cornu, and then rising into a convex outline, which dips, in front, to form the sides of a *notch* or *incisura* in the middle line immediately above the pomum Adami. This border gives attachment throughout its whole extent to the thyro-hyoid membrane.

From above the *lower border* posteriorly, there passes to the cricoid cartilage, in and on each side of the median line, the crico-thyroid membrane, on each side of which is the Crico-thyroid muscle.

The *posterior borders* terminate above in the *superior cornua*, and below in the *inferior cornua*. The two superior cornua, long and narrow, directed upward, backward, and inward, terminate each in a conical extremity which gives attachment to the lateral thyro-hyoid ligament. The two *inferior cornua* are short and thick; they pass downward, with a slight inclination forward and inward, and present each on its inner surface a small oval articular facet for articulation with the side of the cricoid cartilage. On the posterior border are inserted the Stylo-pharyngeus and Palato-pharyngeus muscles.

The **Cricoid Cartilage** is so called from its resemblance to a signet-ring (*κρίκος*, a ring). It is smaller, but thicker and stronger than the thyroid cartilage, and forms the lower part of the cavity of the larynx.

Its *anterior half* (*annulus*) is narrow, convex, affording attachment at the sides to the Crico-thyroid muscles, and behind to part of the Inferior constrictor.

Its *posterior half* (*lamina*) is very broad both from side to side and from above downward; it presents posteriorly in the middle line a vertical ridge (*linea eminens*) for the attachment of the longitudinal fibres of the œsophagus, and on either side a broad depression (*fovea*) for the Crico-arytenoideus posticus muscle.

At the point of junction of the two halves of the cartilage on either side is a small round elevated facet for articulation with the inferior cornu of the thyroid cartilage.

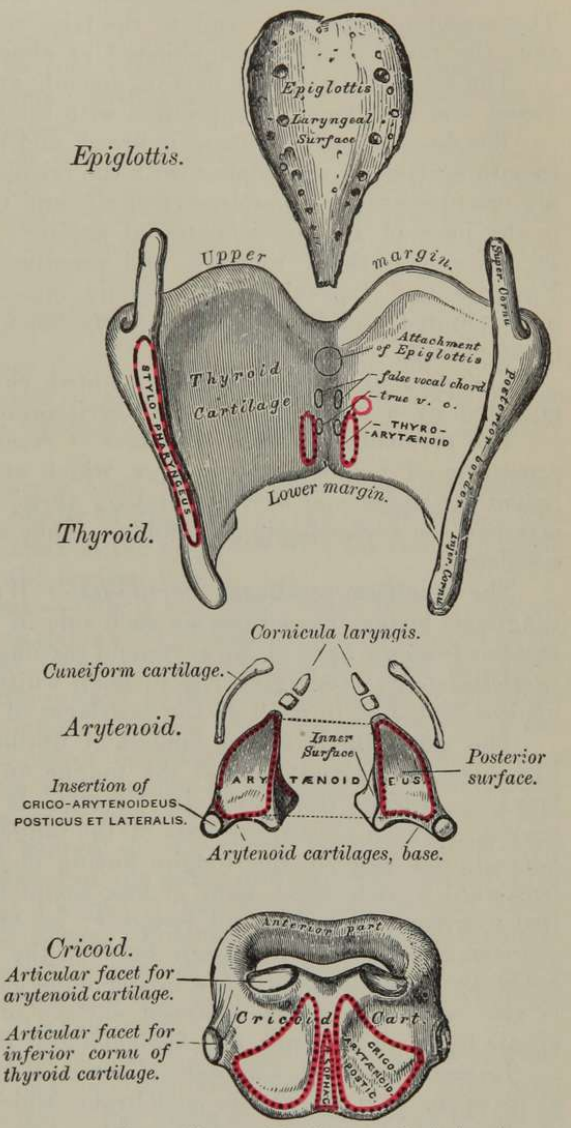

FIG. 700.—The cartilages of the larynx. Posterior view.

The *lower border of the cricoid cartilage* is horizontal and connected to the upper ring of the trachea by fibrous membrane.

Its *upper border* is directed obliquely upward and backward, owing to the height of the lamina. The upper border of the *lamina* is surmounted on each end by a smooth, oval facet for articulation with the arytenoid cartilage. Between these articular surfaces is a slight notch. To the rest of the upper border of the entire cartilage, all the way around from one arytenoid facet to the other, is attached the Crico-thyro-arytenoid ligament, and externally to this, at the sides, the lateral Crico-arytenoid muscle.

The *inner surface of the cricoid cartilage* is smooth and lined by mucous membrane.

The **Arytenoid Cartilages**, so called from ἀρύταινα, a ladle, are two in number, and each is situated at the end of the upper border of the lamina of the cricoid cartilage. Each cartilage is pyramidal in form, and presents for examination three surfaces, a base, and an apex.

The *posterior surface* is triangular, smooth, *concave*, and gives attachment to the Arytenoid muscle.

The *antero-external surface* is *convex* and rough. It gives attachment to the Thyro-arytenoid muscle; and to the false vocal cord immediately above a depression, the *fossa triangularis*, situated at about its centre.

The *internal surface* is narrow, smooth, and *flattened*, covered by mucous membrane, and lies almost in apposition with the cartilage of the opposite side.

The *base* of each cartilage is broad, and presents a concave (antero-posteriorly) smooth surface for articulation with the cricoid cartilage. Projecting from the base are *two* processes, one *postero-externally* and the other *anteriorly*. Between the two is the base of the antero-external surface. The *former*, known as the *muscular process*, is short, rounded, and prominent, and receives the insertion of the Posterior and Lateral crico-arytenoid muscles. The *latter* also prominent, but more pointed and flattened, gives attachment to the true vocal cord. This is the *vocal process*.

The *apex* of each cartilage is pointed, curved backward and inward, and surmounted by a small, cone-shaped, cartilaginous nodule, the *corniculum laryngis*.

The **cornicula laryngis** (*cartilages of Santorini*) are two small, conical nodules, consisting of yellow fibro-cartilage, which are attached to the summit of the arytenoid cartilages and serve to prolong them backward and inward. To them are attached the aryteno-epiglottic folds. They are sometimes united to the arytenoid cartilages.

The **cuneiform cartilages** (*cartilages of Wrisberg*) are two small, elongated, cartilaginous bodies, placed one on each side in the fold of mucous membrane, which extends from the apex of the arytenoid cartilage to the side of the epiglottis (*aryteno-epiglottic fold*); they give rise to small whitish elevations on the free edge of the mucous fold, just in front of the cartilages of Santorini.

The **epiglottis** is a thin lamella of fibro-cartilage, of a yellowish color, shaped like a leaf, and placed behind the tongue, in front of the superior opening of the larynx. During respiration its direction is vertically upward, its free extremity curving forward toward the base of the tongue; but when the larynx is drawn up beneath the base of the tongue during deglutition, it is carried downward and backward so as to close, more or less completely, the opening of the larynx. Its free extremity is broad and rounded; its attached end is long and narrow, and connected to the receding angle between the two alæ of the thyroid cartilage, just below the median notch, by a ligamentous band, the *thyro-epiglottic ligament*. It is also connected to the posterior surface of the body of the hyoid bone by an elastic ligamentous band, the *hyo-epiglottic ligament*.

Its *anterior* or *lingual surface* is curved forward toward the tongue, and covered at its upper part by mucous membrane, which is reflected on to the sides and base of the organ, forming a median and two lateral folds, the *glosso-epiglottic folds*.

Its *posterior* or *laryngeal surface* is smooth, concave from side to side, concavo-convex from above downward, and covered by mucous membrane; when this is removed the surface of the cartilage is seen to be studded with a number of little pits for the lodgment of mucous glands. To its sides the aryteno-epiglottic folds are attached. It is somewhat prominent just below its centre (*tubercle* or *cushion* of the epiglottis).

Structure.—The cornicula laryngis, cuneiform cartilages, and epiglottis are composed of yellow fibro-cartilage which shows little tendency to calcification, but the other cartilages are hyaline, becoming more or less calcified in old age.

Ligaments.—The ligaments of the larynx connect the thyroid cartilage and epiglottis with the hyoid bone, the cricoid cartilage with the trachea, and the several cartilages of the larynx to each other.

The Thyro-hyoid Ligaments.—These constitute the *thyro-hyoid membrane*, and the *middle* and two *lateral thyro-hyoid ligaments.*

The *middle thyro-hyoid ligament* consists of tough, yellowish fibro-elastic tissue. Its lower border is attached in the *thyroid notch;* its upper to the upper border of the posterior surface of the *body* of the hyoid bone, thus passing behind its posterior surface, and being separated from it by a synovial bursa (*sub-hyoid bursa*). When the thyro-hyoid membrane is removed, the lateral borders of this ligament are seen to be free.

The *two lateral thyro-hyoid ligaments* are rounded elastic cords, which pass between the superior cornua of the thyroid cartilage and the extremities of the greater cornua of the hyoid bone. A small cartilaginous nodule (*cartilago triticea*), sometimes bony, is frequently found in each.

The *thyro-hyoid membrane* fills in the interval between each lateral thyro-hyoid ligament and the free edge of the middle one. In this situation it is made up of two layers, cellular tissue externally and mucous membrane internally and, just in front of the lateral ligament, its cellular layer is pierced by the superior laryngeal vessels and nerve. The *cellular layer* is attached all the way around, above to the cornua and body of the hyoid bone, and below to the *entire* upper border, incisura as well, of the thyroid cartilage. It thus passes *in front* of the middle thyro-hyoid ligament, and here forms the anterior wall of the sub-hyoid bursa. At the free edge of the middle ligament the *mucous membrane* passes behind the epiglottis; at the lateral ligament it is reflected on to the posterior wall of the pharynx.

The **hyo-epiglottic ligament** is a fibrous band, which extends from the anterior surface of the epiglottis to the upper border of the body of the hyoid bone. The **thyro-epiglottic ligament** connects the apex of the epiglottis with the receding angle of the thyroid cartilage just beneath the median notch.

The Crico-thyro-arytenoid Ligament.—This is a strong fibrous lamina, bent on itself anteriorly. Its attachments are as follows: (1) Posteriorly, it is attached to the *vocal process* of one arytenoid cartilage, whence it extends as a *free edge* in a practically straight line, forward and a little inward, to the posterior aspect of the angle between the alæ of the thyroid cartilage. Here it bends on itself at an acute angle, is attached to the thyroid, and passes backward and a little outward, as a second *free edge*, to be attached to the vocal process of the other arytenoid cartilage. (2) From these two free edges, as an upper limit, the lamina passes downward, with an outward slope, to the curved sloping upper border of the cricoid cartilage which lies anterior to the *lamina* of the same, and becomes attached to it in its entire extent. The ligament, as a whole, is thus seen to be V-shaped above, apex forward, but of a curved outline below. Furthermore, its vertical diameter varies, being smallest behind and greatest in front at the middle line, this variation being due to the upper border of the cricoid, which slopes upward posteriorly until it almost reaches the vocal process of the arytenoid.

In the middle line the *angle* which is formed in front by the bending on itself of this ligament is acute above, but obtuse or "rounded" below. The *upper part* of this "angle" lies *behind* and *attached to* the angle of the thyroid cartilage, its upper limit (*i. e.* the angle of the free *edges*) being at some distance (almost halfway up) from the lower edge of the cartilage. The *lower* or "*rounded*" *part* is the direct continuation downward of the upper, and passes to the middle of the upper border of the cricoid. This last is known as the *crico-thyroid membrane*, is subcutaneous, and is crossed by a small anastomotic arterial arch from the two crico-thyroid arteries.

Laterally, there is a considerable interval between the *outer* surface of this ligament and the *inner* surface of the corresponding half of the thyroid cartilage, which is filled in by the Thyro-arytenoid and Lateral crico-arytenoid muscles.

The upper *free edges* of this ligament are thicker than the remainder, and are known as the *inferior thyro-arytenoid* ligaments. When covered with mucous membrane they constitute the *true vocal cords.* The *inner surfaces* of the crico-thyro-

arytenoid ligament are covered by mucous membrane prolonged from that of the true cords, and are the lateral boundaries of this portion of the cavity of the larynx.

The Crico-thyroid Ligaments.—These are *capsular ligaments* which enclose on each side the articulation of the inferior cornu of the thyroid with the cricoid cartilage. The articulation is lined by synovial membrane, and strengthened by accessory (kerato-cricoid) ligaments which pass from the tip of the cornu in various directions to the cricoid.

The **crico-arytenoid ligaments** are two *capsular* and two *posterior*. The *capsular* are thin and loose capsules attached to the margins of the articular surfaces; they are lined internally by synovial membrane. The *posterior* extend from the cricoid to the inner and back part of the base of the arytenoid cartilage.

The **crico-tracheal ligament** connects the cricoid cartilage with the first ring of the trachea. It resembles the fibrous membrane, which connects the rings of the trachea to each other.

Interior of the Larynx.—The *superior aperture of the larynx* (Fig. 701) is a cordiform opening, wide in front, narrow behind, and sloping obliquely downward and backward. It is bounded in front by the epiglottis, behind by the *inter-arytenoid fold* of mucous membrane passing between the arytenoid cartilages, and laterally, by a fold of mucous membrane enclosing areolar tissue and muscular fibres, stretched between the sides of the epiglottis and the apex of the arytenoid cartilages: these are the *aryteno-epiglottic folds*, on the margins of which the cuneiform cartilages and cornicula form more or less distinct whitish prominences.

The *cavity of the larynx* extends from the superior aperture to the lower border of the cricoid cartilage. It is divided into two parts by the projection inward of the true vocal cords; between the two cords is a long and narrow triangular fissure or chink, the *glottis*, of which the boundary is the *rima glottidis*. The portion of the cavity of the larynx above the true vocal cords is broad, and contains the false vocal cords, between each of which and the corresponding true vocal cord is the corresponding *ventricle* of the larynx. The portion below the true vocal cords is at first elliptical, and lower down circular, in form.

The *glottis* is the narrow fissure or chink between the inferior or true vocal cords in front (inter-ligamentous portion), and the vocal processes of the arytenoid cartilages behind (intercartilaginous portion). It is the narrowest part of the cavity of the larynx. Its length in the male measures rather less than an inch, its breadth when dilated varying at its widest part from a third to half an inch. The form of the glottis varies. In its half-closed condition it is a narrow fissure, a little enlarged and rounded behind. In quiet breathing it is somewhat triangular, the base of the triangle directed backward, and corresponding to the space between the arytenoid cartilages. When widely open it is lozenge-shaped. In forcible expiration it is smaller than during inspiration. When sound is produced it is more narrowed, the edges of the vocal cords being approximated and made parallel, the approximation and tension corresponding to the height of the note produced.[1]

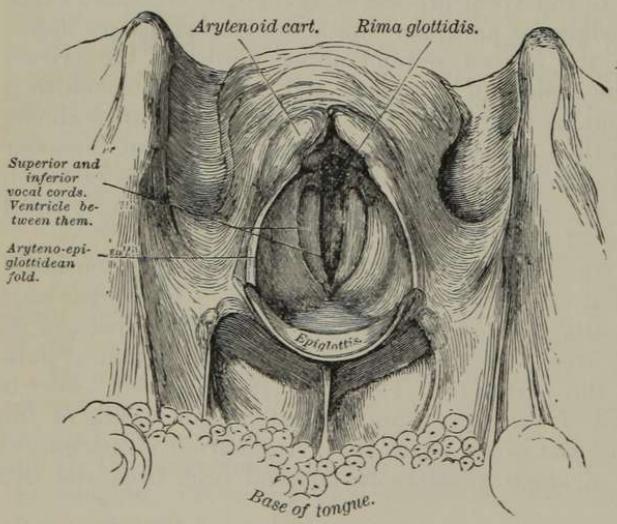

Fig. 701.—The larynx and adjacent parts, seen from above.

[1] On the shape of the rima glottidis in the various conditions of breathing and speaking, see Czermak, *On the Laryngoscope*, translated for the *New Sydenham Society*.

The *superior* or *false vocal cords*, so called because they are not directly concerned in the production of the voice, are two folds of mucous membrane, each enclosing a delicate rounded band, the *superior thyro-arytenoid ligament*. This ligament consists of areolar tissue, attached in front to the angle of the thyroid cartilage below the epiglottis, and behind to the antero-external surface of the arytenoid cartilage, just above the fossa triangularis. This ligament, enclosed in mucous membrane, forms a free margin, which constitutes the upper boundary of the corresponding ventricle of the larynx.

The *inferior* or *true vocal cords*, so called from their being concerned in the production of sound, are two strong fibrous bands (*inferior thyro-arytenoid ligaments*), covered on their surface by a thin layer of mucous membrane. These ligaments have already been described. Each forms the lower boundary of the corresponding ventricle of the larynx. Externally, the Thyro-arytenoideus (inner portion) muscle lies parallel with it.

The *ventricle of the larynx* is an oblong fossa situated between the superior and inferior vocal cords on each side, and extending nearly their entire length. This fossa is bounded above by the free crescentric edge of the superior vocal cord, below by the straight margin of the true vocal cord, externally by the mucous membrane covering the inner surface of the corresponding Thyro-arytenoideus muscle (outer portion). The anterior part of the ventricle leads up by a narrow opening into a cæcal pouch of mucous membrane of variable size called the *laryngeal pouch*.

The *sacculus laryngis*, or laryngeal pouch, is a membranous sac placed between the superior vocal cord and the inner surface of the thyroid cartilage, occasionally extending as far as its upper border; it is conical in form, and curved slightly backward. On the surface of its mucous membrane are the openings of sixty or seventy small follicular glands which are lodged in the submucous areolar tissue. This sac is enclosed in a fibrous capsule continuous below with the superior thyro-arytenoid ligament; its laryngeal surface is covered by muscular fibres derived from from those found in the aryteno-epiglottic fold (Aryteno-epiglottideus inferior muscle, *Compressor sacculi laryngis*, Hilton), whilst its exterior is covered by the Thyro-arytenoideus and Thyro-epiglottideus muscles.

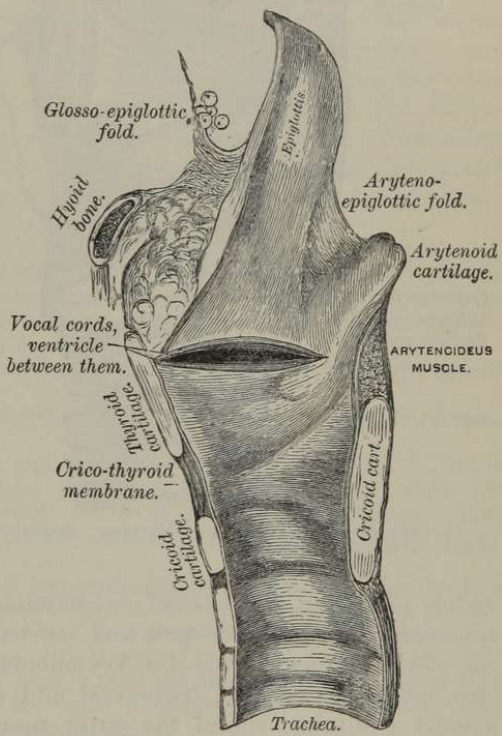

FIG. 702.—Vertical section of the larynx and upper part of the trachea.

Muscles.—The muscles of the larynx are eight in number, and are as follows:

The *Cricoid-thyroid* is triangular in form, and situated at the fore part and side of the cricoid cartilage. It arises from the front and lateral part of the cricoid cartilage; its fibres diverge, passing obliquely upward and outward to be inserted into the lower border of the thyroid cartilage and into the anterior border of the lower cornua.

The inner borders of these two muscles are separated in the middle line by a triangular interval occupied by the crico-thyroid membrane.

The *Crico-arytenoideus posticus* arises from the broad depression occupying each lateral half of the posterior surface of the lamina of the cricoid cartilage; its fibres pass upward and outward, converging to be inserted into the muscular pro-

cess of the base of the arytenoid cartilage. The upper fibres are nearly horizontal, the middle oblique, and the lower almost vertical.[1]

The *Crico-arytenoideus lateralis* is smaller than the preceding, and of an oblong form. It arises from the upper border of the side of the cricoid cartilage, and, passing obliquely upward and backward, is inserted into the muscular process of the base of the arytenoid cartilage in front of the preceding muscle.

The *Arytenoideus* is a single muscle filling up the posterior concave surface of the arytenoid cartilages. It arises from the posterior surface and outer border of one arytenoid cartilage, and is inserted into the corresponding parts of the opposite cartilage. It consists of three planes of fibres, two oblique and one transverse. The *oblique fibres*, the most superficial, form two fasciculi,

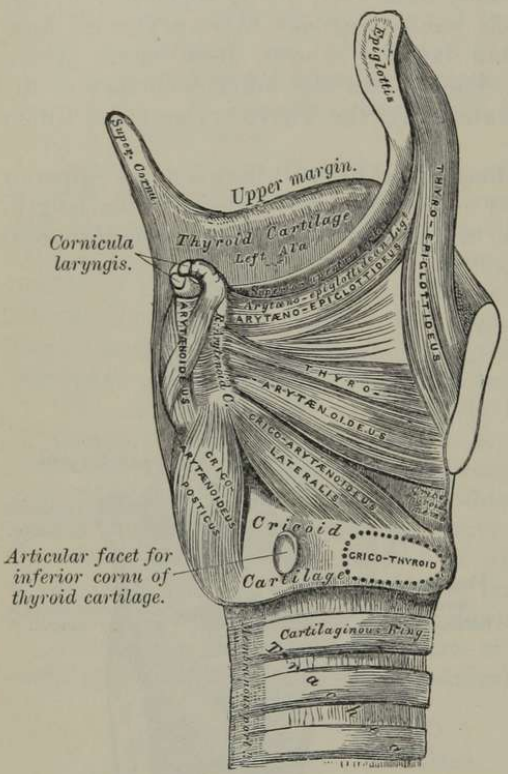

FIG. 703.—Muscles of larynx. Side view. Right ala of thyroid cartilage removed.

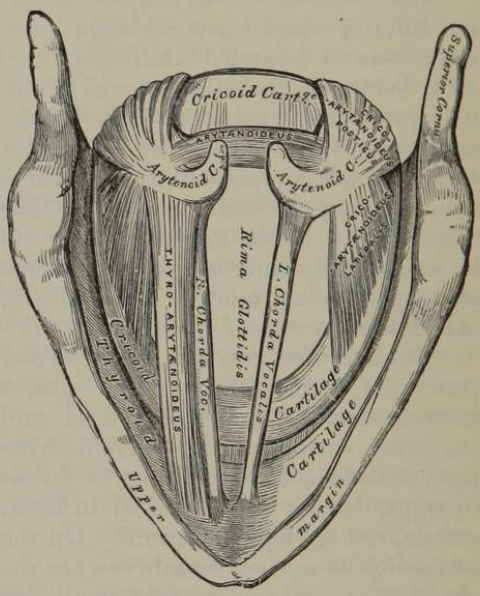

FIG. 704.—Interior of the larynx, seen from above. (Enlarged.)

which pass from the base of one cartilage to the apex of the opposite one. The *transverse fibres*, the deepest and most numerous, pass transversely across between the two cartilages; hence the Arytenoideus was formerly considered as several muscles, under the name of *transversi* and *obliqui*. A few of the oblique fibres are usually continued round the outer margin of the cartilage, and blend with the Thyro-arytenoid or the Aryteno-epiglottideus superior muscle.[2]

The *Thyro-arytenoideus* is a broad, flat muscle, which lies parallel with the outer side of the true vocal cord. It arises in front from the lower half of the receding angle of the thyroid cartilage and from the crico-thyroid membrane. Its fibres pass backward and outward, to be inserted into the arytenoid cartilage. This muscle consists of two fasciculi. The *inner portion*, the thicker, is inserted into the vocal process of the base of the arytenoid cartilage and into the adjacent por-

[1] Dr. Merkel of Leipsic has described a muscular slip which occasionally extends between the outer border of the posterior surface of the cricoid cartilage and the posterior margin of the inferior cornu of the thyroid; this he calls the "Musculus kerato-cricoideus." It is not found in every larynx, and when present exits usually only on one side, but is occasionally found on both sides. Sir William Turner (*Edinburgh Medical Journal*, Feb., 1860) states that it is found in about one case in five. Its action is to fix the lower horn of the thyroid cartilage backward and downward, opposing in some measure the part of the Crico-thyroid muscle which is connected to the anterior margin of the horn.

[2] The *arytenoideus rectus* (Luschka) is a small slip passing between the posterior surface of the arytenoid cartilage below to the cartilage of Santorini (corniculum) above. *Anatomy*, Hyrtl, p. 718.

tion of its antero-external surface; it lies parallel with the true vocal cord, to which it is adherent. The *outer* or *superior fasciculus*, the thinner, is inserted into the muscular process and outer border of the arytenoid cartilage above the preceding fibres; it lies on the outer side of the sacculus laryngis.[1]

The *Thyro-epiglottideus* is a delicate fasciculus which arises from the angle of the thyroid cartilage, close to the origin of the Thyro-arytenoid, and spreads out upon the outer surface of the sacculus laryngis; some of its fibres are lost in the aryteno-epiglottic fold, whilst others pass to the margin of the epiglottis (*Depressor epiglottidis*).

The *Aryteno-epiglottideus superior* consists of a few delicate fasciculi, which arise from the apex of the arytenoid cartilage and become lost in the aryteno-epiglottic fold.

The *Aryteno-epiglottideus inferior* (*Compressor sacculi laryngis*, Hilton), arises from the arytenoid cartilage just below the preceding; and passes forward and upward, it spreads out upon the inner surface of the laryngeal pouch.[2]

Actions.—In considering the action of the muscles of the larynx, they may be conveniently divided into two groups, viz.: 1. Those which open and close the glottis. 2. Those which regulate the degree of tension of the vocal cords.

1. The muscles which open the glottis are the Crico-arytenoidei postici; and those which close it are the Arytenoideus and the Crico-arytenoidei laterales. 2. The muscles which regulate the tension of the vocal cords are the Crico-thyroidei, which tense and elongate them; and the Thyro-arytenoidei, which relax and shorten them. The Thyro-epiglottideus is a depressor of the epiglottis, and the Aryteno-epiglottidei constrict the superior aperture of the larynx, compress the sacculi laryngis, and empty them of their contents.

The *Crico-arytenoidei postici* separate the chordæ vocales, and consequently open the glottis, by rotating the arytenoid cartilages outward around a vertical axis passing through the crico-arytenoid joints, so that their anterior angles and the ligaments attached to them become widely separated, the vocal cords at the same time being made tense.

The *Crico-arytenoidei laterales* close the glottis by rotating the arytenoid cartilages inward so as to approximate their anterior angles.

The *Arytenoideus muscles* approximate the arytenoid cartilages, and thus close the opening of the glottis, especially at its back part.

The *Crico-thyroid muscles* produce tension and elongation of the vocal cords. This is effected as follows: the thyroid cartilage is fixed by the Thyro-hyoid muscles; then the Crico-thyroid muscles, when they act, draw upward the front of the cricoid cartilage, and so depress the posterior portion, which carries with it the arytenoid cartilages, and thus elongate the vocal cords.

The *Thyro-arytenoidei muscles*, consisting of two parts having different attachments and different directions, are rather complicated as regards their action. Their main use is to draw the arytenoid cartilages forward toward the thyroid, and thus shorten and relax the vocal cords. But, owing to the connection of the inner portion with the vocal cord, this part, if acting separately, is supposed to modify its elasticity and tension, and the outer portion, being inserted into the outer part of the anterior surface of the arytenoid cartilage, may rotate it inward, and thus narrow the rima glottidis by bringing the two cords together.

The *Thyro-epiglottidei* depress the epiglottis and assist in compressing the sacculi laryngis. The Aryteno-epiglottideus superior constricts the superior aperture of the larynx, when it is drawn upward, during deglutition, and the opening closed by the epiglottis. The Aryteno-epiglottideus inferior, together with some fibres of the Thyro-arytenoidei, compress the sacculus laryngis.

The **Mucous Membrane of the Larynx** is continuous above with that lining the mouth and pharynx, and is prolonged through the trachea and bronchi into the lungs. It lines the posterior and upper part of the anterior surface of the epiglottis, to which it is closely adherent, and forms the aryteno-epiglottic folds which

[1] Henle describes these two portions as separate muscles, under the names of External and Internal thyro-arytenoid.

[2] MUSCULUS TRITICEO-GLOSSUS. Bochdalek, jun. (*Prager Vierteljahrsschrift*, 2d part, 1866), describes a muscle hitherto entirely overlooked, except a brief statement in Henle's *Anatomy*, which arises from the nodule of cartilage (*corpus triticeum*) in the posterior thyro-hyoid ligament, and passes forward and upward to enter the tongue along with the Hyo-glossus muscle. He met with this muscle eight times in twenty-two subjects. It occurred in both sexes, sometimes on both sides, at others on one only.

encircle the superior aperture of the larynx. It lines the whole of the cavity of the larynx; forms, by its reduplication, the chief part of the superior or false vocal cord; and, from the ventricle, is continued into the sacculus laryngis. It is then reflected over the true vocal cords, where it is thin and very intimately adherent; covers the inner surface of the crico-thyroid membrane and cricoid cartilage; and is ultimately continuous with the lining membrane of the trachea. It is covered with columnar ciliated epithelium below the superior vocal cord, but above this point the cilia are found only in front, as high as the middle of the epiglottis. In the rest of its extent the epithelium is of the squamous variety; as is also that covering the true vocal cords.

Glands.—The mucous membrane of the larynx is furnished with numerous muciparous glands, the orifices of which are found in nearly every part; they are very numerous upon the epiglottis, being lodged in little pits in its substance; they are also found in large numbers along the posterior margin of the aryteno-epiglottidean fold, in front of the arytenoid cartilages, where they are termed the *arytenoid glands*. They exist also in large numbers upon the inner surface of the sacculus laryngis. None are found on the vocal cords.

Vessels and Nerves.—The *arteries of the larynx* are the laryngeal branches derived from the superior and inferior thyroid. The *veins* accompany the arteries: those accompanying the superior laryngeal artery join the superior thyroid vein which opens into the internal jugular vein; while those accompanying the inferior laryngeal artery join the inferior thyroid vein which opens into the innominate vein. The *lymphatics* terminate in the deep cervical glands. The *nerves* are the superior laryngeal and the inferior or recurrent laryngeal branches of the pneumogastric nerves, joined by filaments from the sympathetic. The superior laryngeal nerves supply the mucous membrane of the larynx and the Crico-thyroid muscles. The inferior laryngeal nerves supply the remaining muscles. The Arytenoid muscle is supplied by both nerves.

THE TRACHEA (Fig. 705).

The **Trachea**, or **Windpipe**, is a cartilaginous and membranous cylindrical tube, flattened posteriorly, which extends from the lower part of the larynx, on a level with the sixth cervical vertebra, to opposite the fourth, or sometimes the fifth, dorsal, where it divides into the two bronchi, one for each lung. The trachea measures about four inches and a half in length (10–11 cm.); its diameter, from side to side, is from three-quarters of an inch to an inch (2–2½ cm.), being always greater in the male than in the female.

Relations.—The anterior surface of the trachea is convex, and covered *in the neck*, from above downward, by the isthmus of the thyroid gland, the inferior thyroid veins, the arteria thyroidea ima (when that vessel exists), the Sterno-hyoid and Sterno-thyroid muscles, the cervical fascia, and more superficially, by the anastomosing branches between the anterior jugular veins: *in the thorax* it is covered from before backward by the first piece of the sternum, the remains of the thymus gland, the left innominate vein, the arch of the aorta, the innominate and left common carotid arteries, and the deep cardiac plexus. Posteriorly, it is in relation with the œsophagus; laterally, *in the neck*, it is in relation with the common carotid arteries, the lateral lobes of the thyroid gland, the inferior thyroid arteries, and recurrent laryngeal nerves; and *in the thorax* it lies in the space between the pleuræ (superior mediastinum); having the pneumogastric nerve on each side of it.

The **Right Bronchus**, wider, shorter, and more horizontal in direction than the left, is about an inch in length, and enters the right lung opposite the fifth dorsal vertebra. The vena azygos major arches over it from behind, and the right pulmonary artery lies below and then in front of it. About three-quarters of an inch from its origin it gives off a branch to the *upper lobe* of the right lung. This branch is known as *eparterial* because it is given off *above* the right pulmonary artery, *below* which the main bronchus now passes and is known as *hyparterial;*

this subdivides into two branches for the middle and lower lobes of the right lung.

The **Left Bronchus** is smaller, longer, and more oblique than the right, being nearly two inches in length. It enters the root of the left lung opposite the sixth dorsal vertebra, about an inch lower than the right bronchus. It passes beneath the arch of the aorta, crosses, in front of the œsophagus, the thoracic duct and

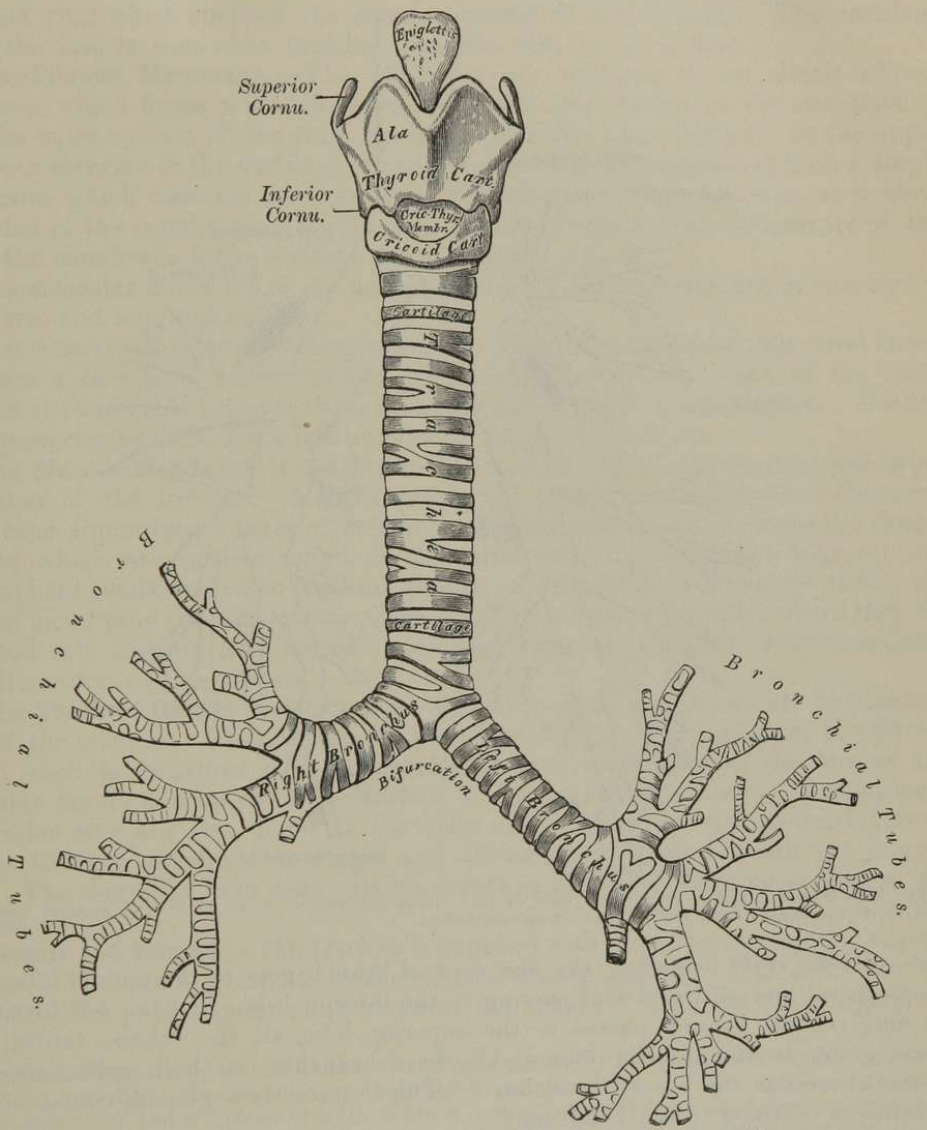

FIG. 705.—Front view of cartilages of larynx; the trachea and bronchi.

the descending aorta, and has the left pulmonary artery lying at first above and then in front of it. It is entirely *hyparterial*, having no *eparterial* branch, and divides into two branches for the upper and lower lobes of the left lung. If a transverse section is made across the trachea a short distance above its point of bifurcation, it is seen, in many cases, on looking down the tube that the right bronchus appears to continue the direction of the trachea more directly than does the left.

Subdivisions of the Bronchi.—According to Aeby, whose observations are based on casts of the trachea and bronchi made with Roser's fusible alloy, the following is the arrangement of the bronchi and larger bronchial tubes (Fig. 706): The *right bronchus*, after giving off the *eparterial branch*, becomes hyparterial, which the left bronchus is from the beginning. Each bronchus then passes downward and back-

ward, constantly diminishing in calibre until it ends, as such, in the lower and posterior part of the inferior lobe of the corresponding lung. In its course each bronchus gives off *four ventral* and *four dorsal branches*, the right bronchus also giving off an additional or *accessory bronchus*, the so-called "heart-bronchus" which passes mesially and dorsally into the inferior lobe. Its name comes from the fact that it is the homologue of a bronchus which, in certain animals, runs to the infracardiac

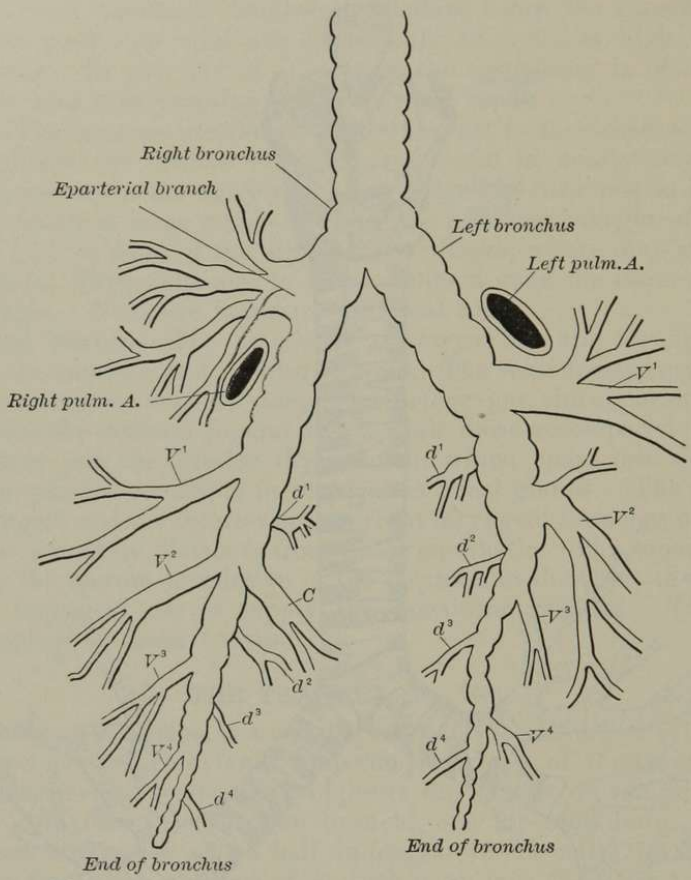

FIG. 706.—Diagram (after Aeby) of a cast of the "bronchial-tree:" v^1, v^2, v^3, v^4, the ventral branches; d^1, d^2, d^3, d^4, the dorsal branches; C, the "heart-bronchus."

lobe. Of the *right* bronchus, the *first ventral* branch goes to the middle lobe; the other ventral and all the dorsal passing to the inferior lobe. Of the *left* bronchus, the *first ventral* branch passes to the superior lobe, all the others, ventral and dorsal, going to the inferior lobe. All these branches, on both sides, are hyparterial as well as the "heart-bronchus." The characteristic general course of each bronchus is outlined in the Diagram.

Structure.—The trachea is composed of imperfect cartilaginous rings, fibrous membrane, muscular fibres, mucous membrane, and glands.

The **cartilages** vary from sixteen to twenty in number; each forms an imperfect ring which surrounds about two-thirds of the cylinder of the trachea, which is completed behind by fibrous membrane. The cartilages are placed horizontally above each other, separated by narrow membranous intervals. They measure about two lines in depth and half a line in thickness. Their outer surfaces are flattened, but internally they are convex from being thicker in the middle than at the margins. Two or more of the cartilages often unite partially or completely, and are sometimes bifurcated at their extremities. They are highly elastic, but sometimes become calcified in advanced life. In the right bronchus the cartilages vary in number from six to eight; in the left, from nine to twelve. They are shorter and narrower than those of the trachea.

The *first cartilage* is broader than the rest, and sometimes divided at one end; it is connected by fibrous membrane with the lower border of the cricoid cartilage, with which or with the succeeding cartilage it is sometimes blended.

The *last cartilage* is thick and broad in the middle, in consequence of its lower border being prolonged into a triangular hook-shaped process which curves downward and backward between the two bronchi. It terminates on each side in an imperfect ring which encloses the commencement of the bronchi. The cartilage above the last is somewhat broader than the rest at its centre.

The Fibrous Membrane.—The cartilages are enclosed in an elastic fibrous membrane which forms a double layer, one layer, the thicker of the two, passing over the outer surface of the ring, the other over the inner surface; at the upper and lower margins of the cartilages these two layers blend together to form a single membrane, which connects the rings one with another. They are thus, as it were, imbedded in the membrane. In the space behind, between the extremities of the rings, the membrane forms a single distinct layer.

The **muscular fibres** are of the unstriped variety and are disposed in two layers, transverse and longitudinal.

The *transverse fibres* (Trachealis muscle, Todd and Bowman), the most internal, form a thin layer which extends transversely between the ends of the cartilages in the intervals between them at the posterior part of the trachea. Outside of or posterior to these are a few bundles of longitudinal fibres.

The **Mucous Membrane** is continuous above with that of the larynx, and below with that of the bronchi. Microscopically, it presents a well-marked basement membrane supporting a layer of columnar ciliated epithelium, between the deeper ends of which are smaller round or elongated cells. It contains a large amount of lymphoid tissue and some tracheal glands. Next to the submucous tissue, the mucous membrane contains *elastic fibres*, most abundant posteriorly, where they are collected into distinct longitudinal bundles. They are especially numerous about the bifurcation of the trachea.

The **Tracheal Glands** (racemose) are found in great abundance at the posterior part of the trachea. They are small, placed upon the outer surface of the fibrous layer; each is furnished with an excretory duct, which pierces the fibrous and muscular layers and opens on the surface of the mucous membrane. Some glands of smaller size are also found at the sides of the trachea, between the layers of fibrous tissue connecting the rings, and others immediately beneath the mucous coat. The secretion from these glands serves to lubricate the inner surface of the trachea.

Vessels and Nerves.—The trachea is supplied with blood by the inferior thyroid arteries. The *veins* terminate in the thyroid venous plexus. The *nerves* are derived from the pneumogastric and its recurrent branches and from the sympathetic.

Surface Form.—In the middle line of the neck some of the cartilages of the larynx can be readily distinguished. In the receding angle below the chin the hyoid bone can easily be made out (see page 230), and a finger's breadth below it is the pomum Adami, the prominence between the upper borders of the two alæ of the thyroid cartilage. About an inch below this, in the middle line, is a depression corresponding to the crico-thyroid space, in which the operation of laryngotomy is performed. This depression is bounded below by a prominent arch, the anterior ring of the cricoid cartilage, below which the trachea can be felt, though it is only in the emaciated adult that the separate rings can be distinguished. The lower part of the trachea is not easily made out, for as it descends it is farther removed from the surface. The level of the vocal cords corresponds to the middle of the anterior margin of the thyroid cartilage.

With the laryngoscope the following structures can be seen: The base of the tongue and the upper surface of the epiglottis, with the glosso-epiglottic folds, the superior aperture of the larynx, bounded on either side by the aryteno-epiglottic folds, in which may be seen two rounded eminences corresponding to the cornicula and cuneiform cartilages. Beneath these, the true and false vocal cords, with the ventricle between them. Still deeper, the cricoid cartilage and some of the anterior parts of the rings of the trachea, and sometimes, in deep inspiration, the bifurcation of the trachea.

Surgical Anatomy.—*Foreign bodies* often find their way into the air-passages. These may be large substances, as a piece of meat, which becomes lodged in the upper aperture of the larynx or in the rima glottidis, and cause speedy suffocation unless rapidly got rid of or unless

an opening is made into the air-passages below. Smaller bodies, such as cherry- or plum-stones, small pieces of bone, buttons, etc., may find their way into the trachea or bronchus, or may become lodged in the ventricle of the larynx. The dangers then depend not so much upon the mechanical obstruction as upon the spasm of the glottis which they excite. When lodged in the ventricle of the larynx they may produce very few symptoms beyond sudden loss of voice or alteration in the voice sounds immediately following the inhalation of the foreign body. When, however, they are situated in the trachea, they are constantly striking against the vocal cords during expiratory efforts, and produce attacks of dyspnœa from spasm of the glottis. When lodged in the bronchus they usually become fixed there, and, occluding the lumen of the tube, cause a loss of the respiratory murmur on the affected side, which is usually the right.

Beneath the mucous membrane of the upper part of the air-passages there is a considerable amount of submucous tissue which is liable to become much swollen from effusion in inflammatory affections, constituting the disease known as "œdema of the glottis." This effusion does not extend below the level of the vocal cords, on account of the mucous membrane being closely adherent to these structures. So that in cases of this disease the operation of laryngotomy is sufficient.

Chronic laryngitis, which occurs in those who speak much in public, is known as "clergyman's sore throat." It is due to the large amount of cold air drawn into the air-passages during prolonged speaking.

Ulceration of the larynx may occur from syphilis, either superficial or from the softening of a gumma, from tubercular disease (laryngeal phthisis), or from malignant disease (epithelioma).

The air-passages may be opened in two different situations: through the crico-thyroid membrane (*laryngotomy*), or in some part of the trachea (*tracheotomy*); and to these some surgeons have added a third method, by opening the crico-thyroid membrane and dividing the cricoid cartilage with the upper ring of the trachea (*laryngo-tracheotomy*).

Laryngotomy is the most simple, and should always be preferred when particular circumstances do not render the operation of tracheotomy absolutely necessary. The crico-thyroid membrane is very superficial, being covered only in the middle line by the skin, superficial fascia, and the deep fascia. On each side of the middle line it is also covered by the Sterno-hyoid and Sterno-thyroid muscles, which diverge slightly from each other at their upper parts, leaving a slight interval between them. On these muscles rests the anterior jugular vein. The only vessel of any importance in connection with this operation is the crico-thyroid artery, which crosses the crico-thyroid membrane, and which may be wounded, but rarely gives rise to any trouble. The operation is performed thus: The crico-thyroid depression having been felt for and found, a vertical incision is then made through the skin in the middle line over this spot, and carried down through the fascia until the crico-thyroid membrane is exposed. A cross cut is then made through the membrane, close to the upper border of the cricoid cartilage, so as to avoid, if possible, the crico-thyroid artery, and a tracheotomy-tube introduced.

Tracheotomy may be performed either above or below the isthmus of the thyroid body, or this structure may be divided and the trachea opened beneath it.

The isthmus of the thyroid gland usually crosses the second and third rings of the trachea; along its upper border is frequently to be found a large transverse communicating branch between the superior thyroid veins; and the isthmus itself is covered by a venous plexus formed between the thyroid veins of the opposite sides. Theoretically, therefore, it is advisable to avoid dividing this structure in opening the trachea.

Above the isthmus the trachea is comparatively superficial, being covered by the skin, superficial fascia, deep fascia, Sterno-hyoid and Sterno-thyroid muscles, and a second layer of the deep fascia, which, attached above to the lower border of the hyoid bone, descends beneath the muscles to the thyroid body, where it divides into two layers and encloses the isthmus.

Below the isthmus the trachea lies much more deeply, and is covered by the Sterno-hyoid and the Sterno-thyroid muscles and a quantity of loose areolar tissue in which is a plexus of veins, some of them of large size; they converge to two trunks, the inferior thyroid veins, which descend on either side of the median line on the front of the trachea and open into the innominate veins. In the infant the thymus gland ascends a variable distance along the front of the trachea, and opposite the episternal notch the windpipe is crossed by the left innominate vein. Occasionally also, in young subjects, the innominate artery crosses the tube obliquely above the level of the sternum. The thyroidea ima artery, when that vessel exists, passes from below upward along the front of the trachea.

From these observations it must be evident that the trachea can be more readily opened above than below the isthmus of the thyroid body.

Tracheotomy above the isthmus is performed thus: An incision is made from an inch and a half to two inches in length exactly in the median line of the neck from the top of the cricoid cartilage. After the superficial structures have been divided the interval between the Sterno-hyoid muscles must be found, the raphe divided, and the muscles drawn apart. The lower border of the cricoid cartilage must now be felt for, and the upper part of the trachea exposed from this point downward in the middle line. Bose has recommended that the layer of fascia in front of the trachea should be divided transversely at the level of the lower border of the cricoid cartilage, and, having been seized with a pair of forceps, pressed downward with the handle of the scalpel. By this means the isthmus of the thyroid gland is depressed, and is saved from all danger of being wounded, and the trachea cleanly exposed. The trachea is now transfixed with a sharp hook and drawn forward in order to steady it, and is then opened by

inserting the knife into it and dividing the two or three upper rings from below upward. If the trachea is to be opened below the isthmus, the incision must be made from a little below the cricoid cartilage to the top of the sternum.

In the child the trachea is smaller, more deeply placed, and more movable than in the adult.

A portion of the larynx or the whole of it has been removed for malignant disease, *laryngectomy*. The results which have been obtained from the removal of the whole of it have not been very satisfactory, and the cases in which the operation is justifiable are very few. It may be removed by a median incision through the soft parts, freeing the cartilage from the muscles and other structures in front, separating the larynx from the trachea below, and dissecting off the deeper structure from below upward.

THE PLEURÆ.

Each lung is invested, upon its external surface, by an exceedingly delicate serous membrane, the **pleura,** which encloses the organ as far as its root, and is then reflected upon the inner surface of the thorax. The portion of the serous membrane investing the surface of the lung is called the *pleura pulmonalis* (visceral layer of pleura), while that which lines the inner surface of the chest is called the *pleura costalis* (parietal layer of pleura). The space between these two layers is called the *cavity of the pleura*, but it must be borne in mind that in the healthy condition the two layers are in contact, and there is no real cavity until the lung becomes collapsed and a separation of it from the wall of the chest takes place. Each pleura is therefore a shut sac, one occupying the right, the other the left half of the thorax, and they are perfectly separate, not communicating with each other. The two pleuræ do not meet in the middle line of the chest, excepting anteriorly opposite the upper part of the second piece of the sternum—a space being left between them, which contains all the viscera of the thorax excepting the lungs: this is the *mediastinum*.

Reflections of the Pleura (Fig. 707).—Commencing at the sternum, the pleura passes outward, covers the costal cartilages, the inner surface of the ribs and

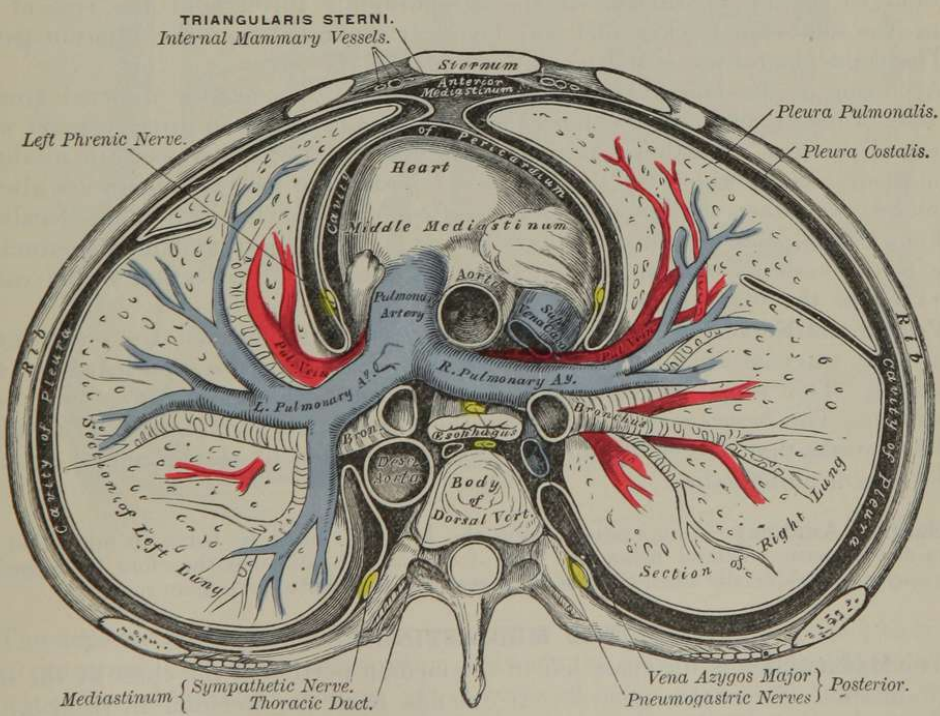

FIG. 707.—A transverse section of the thorax, showing the relative position of the viscera and the reflections of the pleuræ.

Intercostal muscles, and at the back part of the thorax passes over the thoracic ganglia and their branches, and is reflected upon the sides of the bodies of the

vertebræ, where it is separated by a narrow interval, the *posterior mediastinum*, from the opposite pleura. From the vertebral column the pleura passes to the side of the pericardium, which it covers to a slight extent; it then covers the back part of the root of the lung, from the lower border of which a triangular fold descends vertically by the side of the posterior mediastinum to the Diaphragm. This fold is the broad ligament of the lung, the *ligamentum latum pulmonis*, and serves to retain the lower part of that organ in position. *From the root* the pleura may be traced over the convex surface of the lung, the summit and base, and also over the sides of the fissures between the lobes on to its anterior surface and the front part of its root; from this it is reflected upon the side of the pericardium to the inner surface of the sternum. *Below*, it covers the upper surface of the Diaphragm, and extends in front as low as the costal cartilage of the seventh rib; at the side of the chest, as low as the tenth rib on the left side and the ninth on the right side; and behind, it reaches as low as the twelfth rib, and sometimes even beyond it, as low as the transverse process of the first lumbar vertebra. *Above*, its apex projects, in the form of a *cul-de-sac*, through the superior opening of the thorax into the neck, extending from one to two inches above the margin of tha first rib, and receives the summit of the corresponding lung; this sac is strengthened, according to Dr. Sibson, by a dome-like expansion of fascia, attached in front to the posterior border of the first rib, and behind to the anterior border of the transverse process of the seventh cervical vertebra. This is covered and strengthened by a few spreading muscular fibres derived from the Scaleni muscles.

A little above the middle of the sternum, the contiguous surfaces of the two pleuræ are sometimes in contact for a slight extent; but above and below this point the interval left between them forms part of the mediastinum.

The inner surface of the pleura is smooth, polished, and moistened by a serous fluid; its outer surface is intimately adherent to the surface of the lung and to the pulmonary vessels as they emerge from the pericardium; it is also adherent to the upper surface of the Diaphragm: throughout the rest of its extent it is somewhat thicker, and may be easily separated from the adjacent parts.

The right pleural sac is shorter and wider than the left.

A portion of the Diaphagm below and behind, *i. e.* a narrow interval around this part of its circumference, is not covered by pleura and is in direct contact with the costal parietes. Furthermore, it is to be noted that there are certain localities in the pleural sac in which the surfaces of two portions of parietal pleura are always in contact, even when the lung is in a state of complete inspiration. These localities are known as *sinuses* or complementary spaces. The largest and most distinct of these is the *costo-phrenic sinus*, which follows the line of reflection of the costal pleura on to the diaphragm.

Vessels and Nerves.—The *arteries of the pleura* are derived from the intercostal, the internal mammary, the musculo-phrenic, thymic, pericardiac, and bronchial. The *veins* correspond to the arteries. The *lymphatics* are very numerous. The *nerves* are derived from the phrenic and sympathetic (Luschka). Kölliker states that nerves accompany the ramification of the bronchial arteries in the pleura pulmonalis.

Surgical Anatomy.—In operations upon the kidney it must be borne in mind that the pleura may sometimes extend below the level of the last rib, and may therefore be opened in these operations, especially when the last rib is removed in order to give more room.

THE MEDIASTINUM.

The **Mediastinum** is the space left in the median portion of the chest by the non-approximation of the two pleuræ. It extends from the sternum in front to the spine behind, and contains all the viscera in the thorax excepting the lungs. The mediastinum may be divided for purposes of description into two parts—an upper portion, above the upper level of the pericardium, which is named the *Superior mediastinum* (Struthers); and a lower portion, below the upper level of the pericardium. This lower portion is again subdivided into three—that part

which contains the pericardium and its contents, the *middle mediastinum;* that part which is in front of the pericardium, the *anterior mediastinum;* and that part which is behind the pericardium, the *posterior mediastinum.*

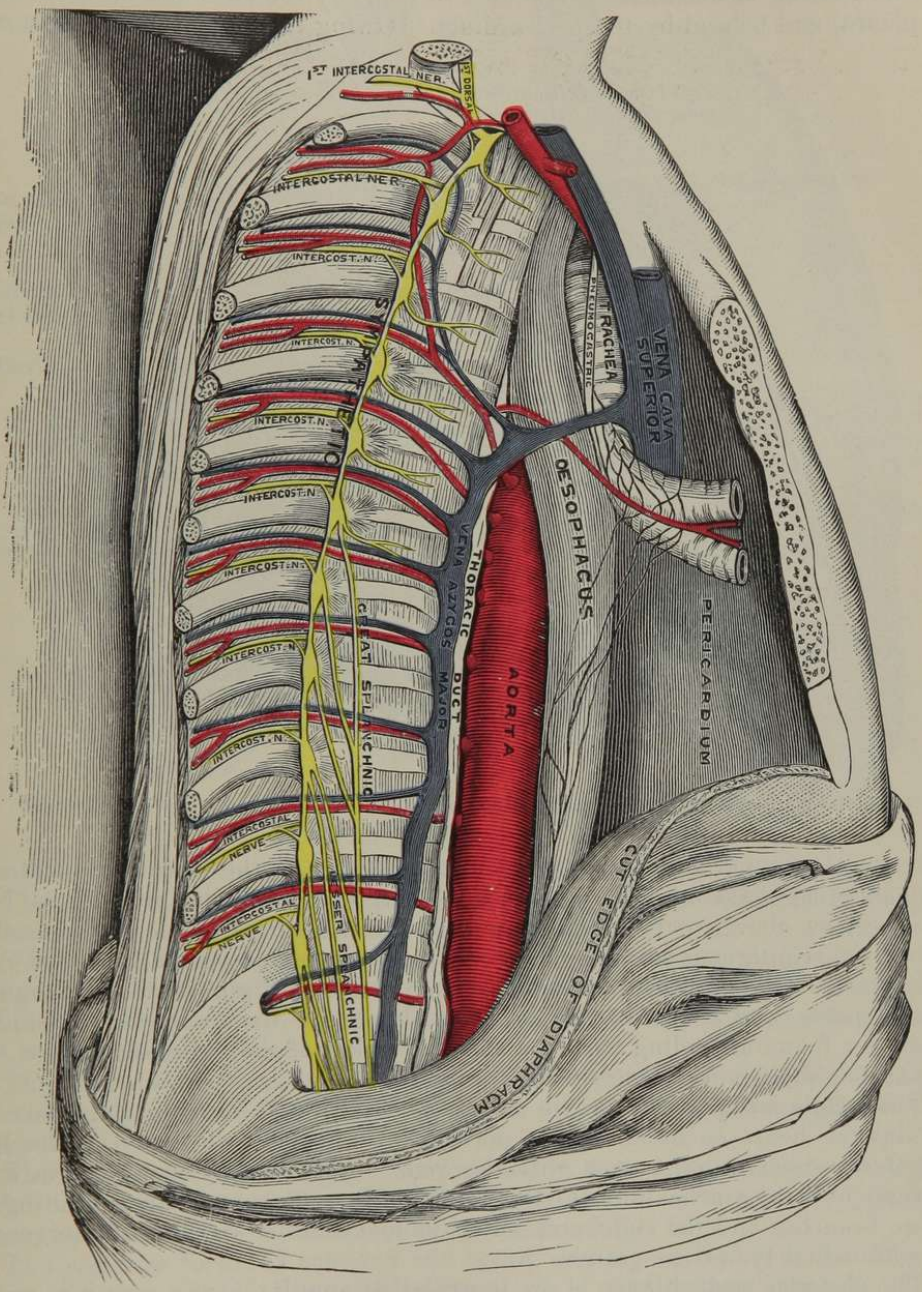

FIG. 708.—The posterior mediastinum.

The **superior mediastinum** is that portion of the interpleural space which lies above the upper level of the pericardium, between the manubrium sterni in front and the upper dorsal vertebræ behind. It is bounded below by a plane passing backward from the junction of the manubrium and gladiolus sterni to the lower part of the body of the fourth dorsal vertebra. It contains the origins of the Sterno-hyoid and Sterno-thyroid muscles and the lower ends of the Longi colli muscles; the transverse portion of the arch of the aorta; the innominate, the thoracic portion of the left carotid and subclavian arteries; the upper half of the superior

vena cava and the innominate veins, and the left superior intercostal vein; the pneumogastric, cardiac, phrenic, and left recurrent laryngeal nerves; the trachea, œsophagus, and thoracic duct; the remains of the thymus gland and lymphatics.

The **anterior mediastinum** is bounded in front by the sternum, on each side by the pleura, and behind by the pericardium. Owing to the oblique position of the

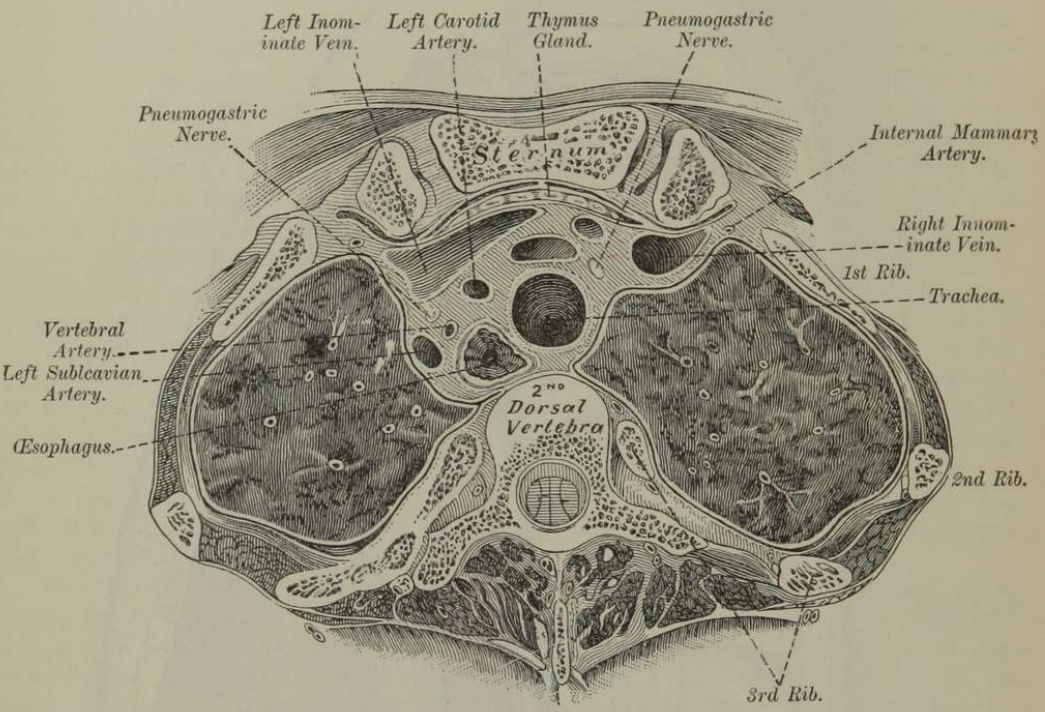

FIG. 709.—Transverse section through the upper margin of the third dorsal vertebra. (Braune.)

heart toward the left side, this space is not parallel with the sternum, but directed obliquely from above downward and to the left of the median line; it is broad below, narrow above, very narrow opposite the first segment of the gladiolus of the sternum, the contiguous surfaces of the two pleuræ being occasionally united over a small space. The anterior mediastinum contains the origins of the Triangularis sterni muscles, and a quantity of loose areolar tissue in which some lymphatic vessels are found ascending from the convex surface of the liver, and two or three lymphatic glands (anterior mediastinal glands).

The **middle mediastinum** is the broadest part of the interpleural space. It contains the heart enclosed in the pericardium, the ascending aorta, the lower half of the superior vena cava, with the vena azygos major opening into it, the bifurcation of the trachea and the two bronchi, the pulmonary artery dividing into its two branches and the right and left pulmonary veins, the phrenic nerves, and some bronchial lymphatic glands.

The **posterior mediastinum** is an irregular triangular space running parallel with the vertebral column; it is bounded in front by the pericardium and roots of the lungs, behind by the vertebral column from the lower border of the fourth dorsal vertebra, and on either side by the pleura. It contains the descending thoracic aorta, the greater and lesser azygos veins, the pneumogastric and splanchnic nerves, the œsophagus, thoracic duct, and some lymphatic glands.

THE LUNGS.

The **Lungs** are the essential organs of respiration; they are two in number, placed one on each side of the chest, separated from each other by the heart and

other contents of the mediastinum. Each lung is conical in shape, and presents for examination an apex, a base, two borders, and two surfaces (Fig. 710).

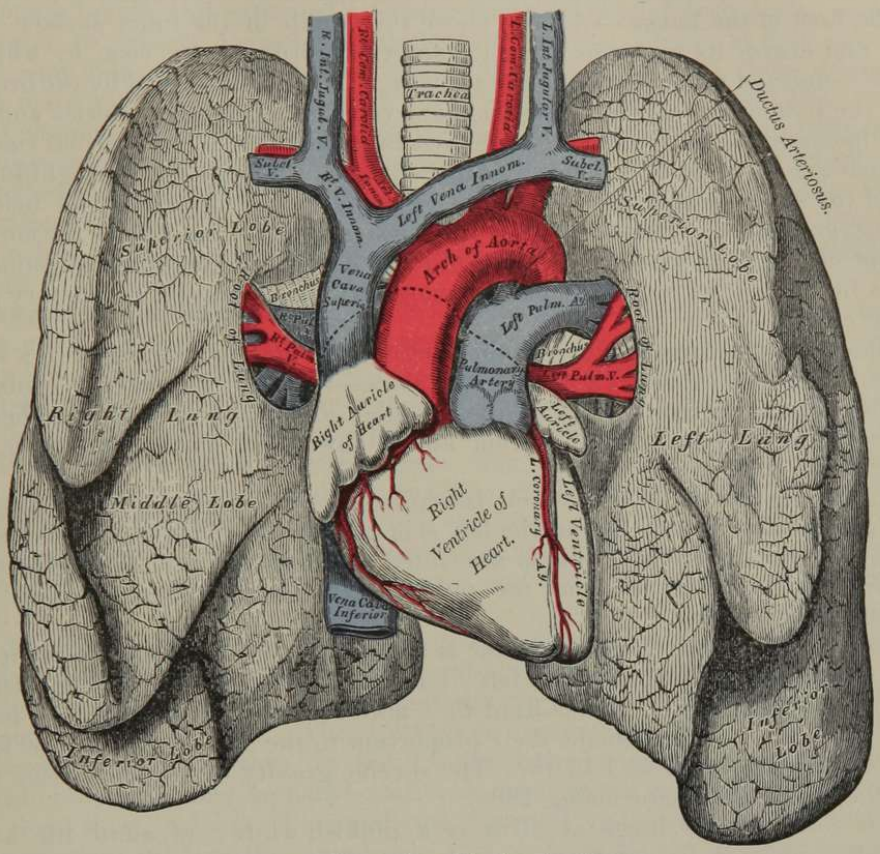

FIG. 710.—Front view of the heart and lungs.

The *apex* forms a tapering cone which extends into the root of the neck about an inch to an inch and a half above the level of the first rib.

The *base* is broad, concave, and rests upon the convex surface of the Diaphragm; its circumference is thin, and fits into the space between the lower ribs and the costal attachment of the Diaphragm, extending lower down externally and behind than in front.

The *external* or *thoracic surface* is smooth, convex, of considerable extent, and corresponds to the form of the cavity of the chest, being deeper behind than in front.

The *inner surface* is concave. It presents in front a depression corresponding to the convex surface of the pericardium, and behind a deep fissure (the hilum pulmonis) which gives attachment to the root of the lung.

The *posterior border* is rounded and broad, and is received into the deep concavity on either side of the spinal column. It is much longer than the anterior border, and projects below between the ribs and the Diaphragm.

The *anterior border* is thin and sharp, and overlaps the front of the pericardium.

Each lung is divided into two lobes, an upper and lower, by a long and deep fissure which extends from the upper part of the posterior border of the organ, about three inches from its apex, downward and forward to the lower part of its anterior border. This fissure penetrates nearly to the root. In the right lung the upper lobe is partially subdivided by a second and shorter fissure which extends from the middle of the preceding, forward and slightly upward, to the anterior margin of the organ, marking off a small triangular portion, the middle lobe.

The *right lung* is the larger and heavier; it is broader than the left, owing to the inclination of the heart to the left side; it is also shorter by an inch, in consequence of the Diaphragm rising higher on the right side to accommodate the liver.

The Root of the Lungs.—A little above the middle of the inner surface of each lung, and nearer its posterior than its anterior border, is its root, by which the lung is connected to the heart and the trachea. The root is formed by the bronchial tube, the pulmonary artery, the pulmonary veins, the bronchial arteries and veins, the pulmonary plexus of nerves, lymphatics, bronchial glands, and areolar tissue, all of which are enclosed by a reflection of the pleura. The root of the right lung lies behind the superior vena cava and ascending portion of the aorta and below the vena azygos major. That of the left lung passes beneath the arch of the aorta and in front of the descending aorta; the phrenic nerve and the anterior pulmonary plexus lie in front of each, and the pneumogastric and posterior pulmonary plexus behind each.

The chief structures composing the root of each lung are arranged in a similar manner from before backward on both sides—viz. the pulmonary veins most anterior; the pulmonary artery in the middle; and the bronchus, together with the bronchial vessels, behind. From above downward, on the two sides, their arrangement differs, thus:

On the right side their position is—bronchus (undivided portion), pulmonary artery, pulmonary veins; but on the left side their position is—pulmonary artery, bronchus, pulmonary veins; this is accounted for by the bronchus being placed on a lower level on the left than on the right side, in order that it may pass under the arch of the aorta.

The *weight* of both lungs together is about forty-two ounces, the right lung being two ounces heavier than the left; but much variation is met with according to the amount of blood or serous fluid they may contain. The lungs are heavier in the male than in the female, their proportion to the body being in the former as 1 to 37, in the latter as 1 to 43. The specific gravity of the lung-tissue varies from 0.345 to 0.746, water being 1000.

The *color* of the lungs at birth is a pinkish-white; in adult life a dark slate-color, mottled in patches; and as age advances this mottling assumes a black color. The coloring matter consists of granules of a carbonaceous substance deposited in the areolar tissue near the surface of the organ. It increases in quantity as age advances, and is more abundant in males than in females. The posterior border of the lung is usually darker than the anterior.

The *surface* of the lung is smooth, shining, and marked out into numerous polyhedral spaces, indicating the lobules of the organ; the area of each of these spaces is crossed by numerous lighter lines.

The *substance* of the lung is of a light, porous, spongy texture; it floats in water and crepitates when handled, owing to the presence of air in the tissue; it is also highly elastic; hence the collapsed state of these organs when they are removed from the closed cavity of the thorax.

Structure.—The lungs are composed of an external serous coat, a subserous areolar tissue, and the pulmonary substance or parenchyma.

The *serous coat* is the visceral layer of the pleura.

The *subserous areolar tissue* contains a large proportion of elastic fibres; it invests the surface of the lung, and extends inward between the lobules.

The *parenchyma* is composed of lobules which, although closely connected together by an interlobular areolar tissue, are quite distinct from one another, and may be teased asunder without much difficulty in the fœtus. The lobules vary in size; those on the surface are large, of pyramidal form, the base turned toward the surface; those in the interior, smaller and of various forms. Each lobule is composed of one of the ramifications of a bronchial tube and its terminal air-cells, and of the ramifications of the pulmonary and bronchial vessels, lymphatics, and nerves, all of these structures being connected together by areolar tissue.

The *bronchus*, upon entering the substance of the lung, divides and subdivides

dichotomously, or rather bipinnately, throughout the entire organ. Sometimes three branches arise together, and occasionally small lateral branches are given off from the sides of a larger. Each of the smaller subdivisions of the bronchi enters a pulmonary lobule, and is termed a *lobular bronchial tube* or *bronchiole*. Its wall now begins to present irregular dilatations, *air-cells* or *alveoli*, at first sparingly and on one side of the tube only, but as it proceeds onward these dilatations become more numerous and surround the tube on all sides, so that it loses its cylindrical character. The *lobular bronchiole* now becomes enlarged, and is known as the *atrium* or *alveolar passage*. From the atrium are now given off in all directions somewhat elongated blind pouches (1 mm. in diameter), the *infundibula*. Each infundibulum is, in its turn, closely beset with *alveoli*. Within the lungs the bronchial tubes are circular, not flattened, and present certain peculiarities of structure.

Changes in the Structure of the Bronchi.—As the bronchial tubes become smaller and smaller the following changes take place: The *cartilages* consist of thin laminæ, of varied form and size, scattered irregularly along the sides of the tube, being most distinct at the points of division of the tubes. They may be traced into tubes the diameter of which is only one-fourth of a line. Beyond this point the tubes are wholly membranous. The fibrous coat and the longitudinal elastic fibres are continued into the smallest ramifications of the bronchi. The muscular coat is disposed in the form of a continuous layer of annular fibres, which may be traced upon the smallest bronchial tubes. The mucous membrane lines the bronchi and its ramifications throughout, and is covered with columnar ciliated epithelium.

In the *lobular bronchial tubes* and in the infundibula the following changes take place: The muscular tissue begins to disappear; the longitudinal elastic fibres begin to break up, so that in the infundibula they form an interlacement around the mouths of the air-cells. The *epithelium* becomes non-ciliated and flattened. This occurs gradually; thus, in the lobular bronchioles patches of non-ciliated flattened epithelium may be found scattered amongst the columnar ciliated epithelium; then these patches of non-ciliated flattened epithelium become more and more numerous, until in the infundibula and air-cells all the epithelium is of the non-ciliated pavement variety. In addition to these flattened cells, there are small polygonal granular cells in the air-sacs, in clusters of two or three, between the others.

The air-cells are small, polyhedral, recesses composed of a fibrillated connective tissue and surrounded by a few involuntary muscular and elastic fibres. Free within their cavities are granular leucocytes, often containing carbonaceous particles. The air-cells are well seen on the surface of the lung, and vary from $\frac{1}{200}$th to $\frac{1}{70}$th of an inch in diameter, being largest on the surface at the thin borders and at the apex, and smallest in the interior.

The *pulmonary artery* conveys the venous blood to the lungs; it divides into branches which accompany the bronchial tubes, and terminates in a dense capillary network upon the walls of the intercellular passages and air-cells. In the lung the branches of the pulmonary artery are usually above and behind a bronchial tube, the vein below and in front.

The *pulmonary capillaries* form plexuses which lie immediately beneath the mucous membrane in the walls and septa of the air-cells and of the infundibula. In the septa between the air-cells the capillary network forms a single layer. The capillaries form a very minute network, the meshes of which are smaller than the vessels themselves;[1] their walls are also exceedingly thin. The arteries of neighboring lobules are distinct from each other, and do not anastomose, whereas the corresponding venous anastomosis is extremely free.

The radicles of the *pulmonary veins* commence in the pulmonary capillaries, and coalesce into larger branches, which accompany the arteries and return the

[1] The meshes are only 0.002‴ to 0.008‴ in width, while the vessels are 0.003‴ to 0.005‴ (Kölliker, *Human Microscopic Anatomy*).

oxygenated blood to the left auricle of the heart. The radicles come together in the septa between the infundibula, entirely separate from the small arterial ramifications. Those which are near the surface of the lung have an undivided course for some distance and then either unite with some deeper lying vein or form, with their companions, a wide-meshed superficial plexus.

The *bronchial arteries* supply blood for the nutrition of the lung: they are derived from the thoracic aorta, and, accompanying the bronchial tubes, are distributed to the bronchial glands and upon the walls of the larger bronchial tubes and pulmonary vessels. Those supplying the bronchial tubes form a capillary plexus in the muscular coat, from which branches are given off to form a second plexus in the mucous coat. This plexus in the lobular branchioles is continuous with that of the pulmonary artery, and the blood which the bronchial artery brings is thus carried back by the pulmonary vein. Others are distributed in the interlobular areolar tissue, and terminate partly in the deep, partly in the superficial, bronchial veins. Lastly, some ramify upon the surface of the lung beneath the pleura, where they form a capillary network.

The *bronchial vein* is formed at the root of the lung, receiving superficial and deep veins corresponding to branches of the bronchial artery. It does not, however, receive all the blood supplied by the artery, as some of it passes into the pulmonary vein. It terminates on the right side in the vena azygos major, and on the left side in the superior intercostal or left upper azygos vein. Some authorities, especially Zuckerkandl, state that, in other parts of the lung than in the lobular branchioles, *bronchial veins*, even those coming from the larger bronchial tubes, join more or less freely with pulmonary veins. The intercostal arteries give small branches to the surface of the lung, by way of the ligamentum latum pulmonis. (Turner.)

The **lymphatics** consist of a superficial and deep set: they terminate at the root of the lung, in the bronchial glands.

Nerves.—The lungs are supplied from the anterior and posterior pulmonary plexuses, formed chiefly by branches from the sympathetic and pneumogastric. The filaments from these plexuses accompany the bronchial tubes, upon which they are lost. Small ganglia are found upon these nerves.

Surface Form.—The apex of the lung is situated in the neck, behind the interval between the two heads of origin of the Sterno-mastoid. The height to which it rises above the clavicle varies very considerably, but is generally about one inch. It may, however, extend as much as an inch and a half or an inch and three-quarters, or, on the other hand, it may scarcely project above the level of this bone. In order to mark out the anterior margin of the lung, a line is to be drawn from the apex-point, one inch above the level of the clavicle, and rather nearer the posterior than the anterior border of the Sterno-mastoid muscle, downward and inward across the sterno-clavicular articulation and first piece of the sternum until it meets, or almost meets, its fellow of the other side opposite the articulation of the manubrium and gladiolus. From this point the two lines are to be drawn downward, one on either side of the mesial line and close to it, as far as the level of the articulation of the fourth costal cartilages to the sternum. From here the two lines diverge; the left is to be drawn at first passing outward with a slight inclination downward, and then taking a bend downward with a slight inclination outward to the apex of the heart, and thence to the sixth costo-chondral articulation. The direction of the anterior border of this part of the left lung is denoted with sufficient accuracy by a curved line with its convexity directed upward and outward from the articulation of the fourth right costal cartilage of the sternum to the fifth intercostal space, an inch and a half below and three-quarters of an inch internal to the left nipple. The continuation of the anterior border of the right lung is marked by a prolongation of its line from the level of the fourth costal cartilages vertically downward as far as the sixth, when it slopes off along the line of the sixth costal cartilage to its articulation with the rib.

The lower border of the lung is marked out by a slightly curved line with its convexity downward from the articulation of the sixth costal cartilage to its rib to the spinous process of the tenth dorsal vertebra. If vertical lines are drawn downward from the nipple, the mid-axillary line, and the apex of the scapula, while the arms are raised from the sides, they should intersect this convex line, the first at the sixth, the second at the eighth, and the third at the tenth rib. It will thus be seen that the pleura (see page 1114) extends farther down than the lung, so that it may be wounded, and a wound pass through its cavity into the Diaphragm, and even injure the abdominal viscera, without the lung being involved.

The posterior border of the lung is indicated by a line drawn from the level of the spinous

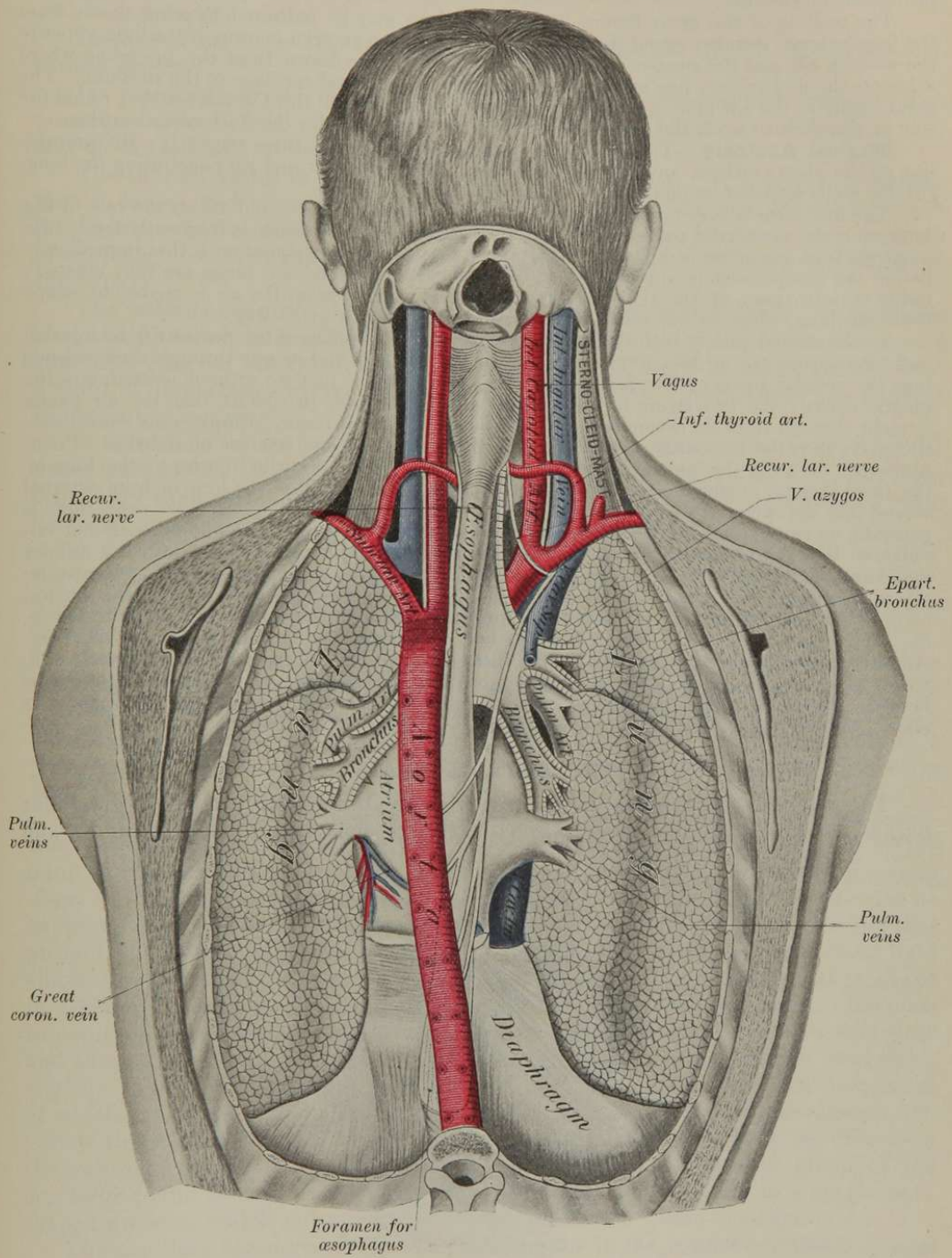

FIG. 711.—Thoracic contents seen from behind. (Joessel.)

process of the seventh cervical vertebra, down either side of the spine, corresponding to the costo-vertebral joints as low as the spinous process of the tenth dorsal vertebra. The trachea bifurcates opposite the spinous process of the fourth dorsal vertebra, and from this point the two bronchi are directed outward, the right one almost horizontally, the left with a considerable inclination downward.

The position of the great fissure in the right lung may be indicated by a line drawn from the fourth dorsal vertebra round the side of the chest to the anterior margin of the lung opposite the seventh rib, and the smaller or secondary fissure by a line drawn from the preceding where it bisects the mid-axillary line to the junction of the fourth costal cartilage to the sternum. The great fissure in the left lung is a little higher, extending from the third dorsal vertebra round the side of the chest to reach the anterior margin of the lung opposite the sixth costal cartilage.

Surgical Anatomy.—The lungs may be wounded or torn in three ways: (1) By compression of the chest, without any injury to the ribs. (2) By a fractured rib penetrating the lung. (3) By stabs, gunshot wounds, etc.

The first form is very rare, and usually occurs in young children, and affects the root of the lung—*i. e.* the most fixed part—and thus, implicating the great vessels, is frequently fatal. Its exact mode of causation is difficult to interpret. The probable explanation is that immediately before the compression is applied a deep inspiration is taken and the lungs are fully inflated; owing then to spasm of the glottis at the moment of compression, the air is unable to escape from the lung, which is not able to recede, and consequently gives way.

In the second variety both the pleura costalis and pulmonalis must necessarily be injured, and consequently the air taken into the wounded air-cells may find its way through these wounds into the cellular tissue of the parietes of the chest. This it may do without collecting in the pleural cavity; the two layers of the pleura are so intimately in contact that the air passes straight through from the wounded lung into the subcutaneous tissue. Emphysema constitutes, therefore, the most important sign of injury to the lung in cases of fracture of the ribs. Pneumothorax, or air in the pleural cavity, is much more likely to occur in injuries to the lung of the third variety, in which cases air passes either from the wound of the lung or from external wound into the cavity of the pleura during the respiratory movements. In these cases there is generally no emphysema of the subcutaneous tissue unless the external wound is small and valvular, so that the air drawn into the wound during inspiration is then forced into the cellular tissue around during expiration because it cannot escape from the external wound. Occasionally in wounds of the parietes of the chest no air finds its way into the cavity of the pleura, because the lung at the time of the accident protrudes through the wound and blocks the opening. This occurs where the wound is large, and constitutes one form of *hernia* of the lung. Another form of hernia of the lung occurs, though very rarely, after wounds of the chest-wall, when the wound has healed and the cicatrix subsequently yields from the pressure of the viscus behind. It forms a globular, elastic, crepitating swelling, which enlarges during expiratory efforts, falls in during inspiration, and disappears on holding the breath.

THE THYROID GLAND.

The **thyroid gland** bears much resemblance in structure to other glandular organs, and is classified, together with the thymus, suprarenal capsules, and

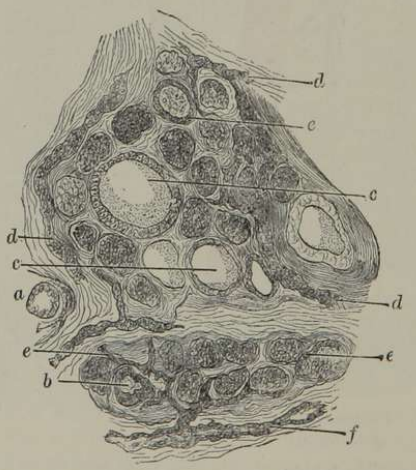

FIG. 712.—Two lobules from the thyroid of an infant. *a*. Small glandular vesicles with their cells. *b*. The same, with incipient colloid metamorphosis, more strongly marked at *c*. *d*. Coarse lymph-canals. *e*. Fine radicles of the same. *f*. An efferent vessel of considerable size.

spleen, under the head of *ductless glands*, since when fully developed it has no excretory duct. From its situation in connection with the trachea and larynx, the thyroid body is usually described with those organs, although it takes no part

in the function of respiration. It is situated at the upper part of the trachea, and consists of two *lateral lobes*, placed one on each side of that tube and connected together by a narrow transverse portion, the *isthmus*.

Its *anterior surface* is convex, and covered by the Sterno-hyoid, Sterno-thyroid, and Omo-hyoid muscles.

Its *lateral surfaces*, also convex, lie in contact with the sheath of the common carotid artery.

Its *posterior surface* is concave, and embraces the trachea and larynx. The posterior borders of the gland extend as far back as the lower part of the pharynx, and on the left side to the œsophagus.

The thyroid varies in weight from one to two ounces. It is larger in females than in males, and becomes slightly increased in size during menstruation. Each lobe is somewhat conical in shape, about two inches in length, and three-quarters of an inch to an inch and a quarter in breadth, the right lobe being the larger of the two.

The *isthmus* connects the lower third of the two lateral lobes; it measures about half an inch in breadth and the same in depth, and usually covers the second and third rings of the trachea. Its situation presents, however, many variations—a point of importance in the operation of tracheotomy. Sometimes the isthmus is altogether wanting.

A third lobe, of conical shape, called the *pyramid*, occasionally arises from the upper part of the isthmus or from the adjacent portion of either lobe, but most commonly the left, and ascends as high as the hyoid bone. It is occasionally quite detached, or divided into two parts, or altogether wanting.

A few muscular bands are occasionally found attached above to the body of the hyoid bone, and below to the isthmus of the gland or its pyramidal process. These form a muscle which was named by Sömmerring the *Levator glandulæ thyroideæ*.

Structure.—The thyroid body is invested by a thin capsule of connective tissue which projects into its substance and imperfectly divides it into masses or lobules of irregular form and size. When the organ is cut into it is of a brownish-red color, and is seen to be made up of a number of closed vesicles containing a yellow glairy fluid and separated from each other by intermediate connective tissue.

According to Dr. Baber, who has recently published some important observations on the minute structure of the thyroid,[1] the vesicles of the thyroid of the adult animal are generally closed cavities; but in some young animals (*e. g.* young dogs) the vesicles are more or less tubular and branched. This appearance he supposes to be due to the mode of growth of the gland, and merely indicating that an increase in the number of vesicles is taking place. Each vesicle is lined by a single layer of epithelium, the cells of which, though differing somewhat in shape in different animals, have always a tendency to assume a columnar form. Between the epithelial cells exists a delicate reticulum. The vesicles are of various sizes and shapes, and contain as a normal product a viscid, homogeneous, semi-fluid, slightly yellowish material which frequently contains blood, the red corpuscles of which are found in it in various stages of disintegration and decolorization, the yellow tinge being probably due to the hæmoglobin, which is thus set free from the colored corpuscles. Baber has also described in the thyroid gland of the dog large round cells ("parenchymatous cells"), each provided with a single oval-shaped nucleus, which migrate into the interior of the gland-vesicles.

The capillary blood-vessels form a dense plexus in the connective tissue around the vesicles, between the epithelium of the vesicles and the endothelium of the lymph-spaces, which latter surround a greater or smaller part of the circumference of the vesicle. These lymph-spaces empty themselves into lymphatic vessels which run in the interlobular connective tissue, not uncommonly surrounding the arteries which they accompany, and communicate with a network in the capsule

[1] "Researches on the Minute Structure of the Thyroid Gland," *Phil. Trans.*, part iii., 1881.

of the gland. Baber has found in the lymphatics of the thyroid a viscid material which is morphologically identical with the normal constituent of the vesicle.

Vessels and Nerves.—The *arteries* supplying the thyroid are the superior and inferior thyroid, and sometimes an additional branch (thyroidea media or ima)

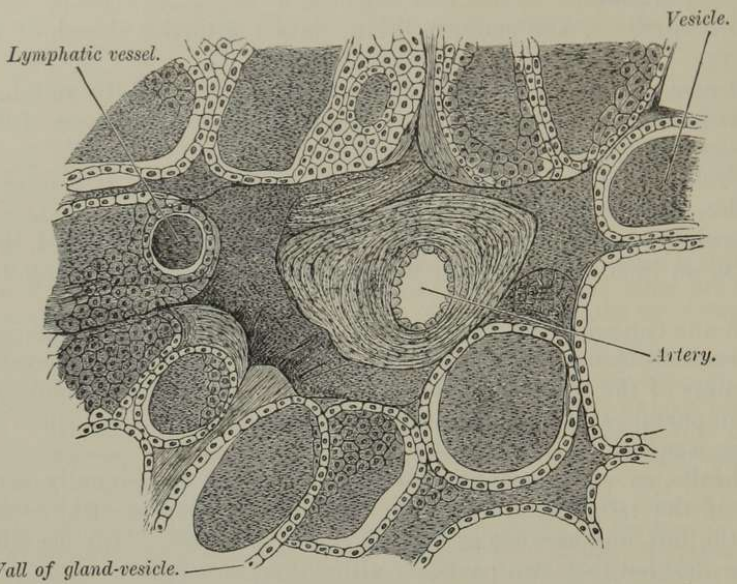

FIG. 713.—Minute structure of thyroid. From a transverse section of the thyroid of a dog. (Semi-diagrammatic.) (Baber.)

from the innominate artery or the arch of the aorta, which ascends upon the front of the trachea. The arteries are remarkable for their large size and frequent anastomoses. The *veins* form a plexus on the surface of the gland and on the front of the trachea, from which arise the superior, middle, and inferior thyroid veins, the two former terminating in the internal jugular, the latter in the innominate vein. The *lymphatics* are numerous, of large size, and terminate in the thoracic and right lymphatic ducts. The *nerves* are derived from the middle and inferior cervical ganglia of the sympathetic.

Surgical Anatomy.—The thyroid gland is subject to enlargement, which is called goitre. This may be due to hypertrophy of any of the constituents of the gland. The simplest (parenchymatous goitre) is due to an enlargement of the follicles. The *fibroid* is due to increase of the interstitial connective tissue. The *cystic* is that form in which one or more large cysts are formed from dilatation and possibly coalescence of adjacent follicles. The *pulsating goitre* is where the vascular changes predominate over the parenchymatous, and the vessels of the gland are especially enlarged. Finally, there is *exophthalmic goitre* (Graves's disease), where there is great vascularity and often pulsation, accompanied by exophthalmos, palpitation, and rapid pulse.

For the relief of these growths various operations have been resorted to, such as injection of tincture of iodine or perchloride of iron, especially applicable to the cystic form of the disease, ligature of the thyroid arteries, excision of the isthmus, and extirpation of the whole or a part of the gland. This latter operation is one of difficulty, and when the entire gland has been removed the operation has been followed by a condition resembling myxœdema. In removing the organ great care must be taken to avoid tearing the capsule, as if this happens the gland-tissue bleeds profusely. The thyroid arteries should be ligatured before an attempt is made to remove the mass, and in ligaturing the inferior thyroids the position of the recurrent laryngeal nerve must be borne in mind, so as not to include it in the ligature.

THE THYMUS GLAND.

The **thymus gland** presents much resemblance in structure to other glandular organs, and is another of the organs which are denominated *ductless glands*.

The thymus gland is a temporary organ, attaining its full size at the end of the second year, when it ceases to grow, and gradually dwindles, until at puberty it has almost disappeared. If examined when its growth is most active, it will be

found to consist of two lateral lobes placed in close contact along the middle line, situated partly in the superior mediastinum, partly in the neck, and extending from the fourth costal cartilage upward as high as the lower border of the thyroid gland. It is covered by the sternum and by the origins of the Sterno-hyoid and Sterno-thyroid muscles. Below, it rests upon the pericardium, being separated from the arch of the aorta and great vessels by a layer of fascia. In the neck it lies on the front and sides of the trachea, behind the Sterno-hyoid and Sterno-thyroid muscles. The two lobes generally differ in size; they are

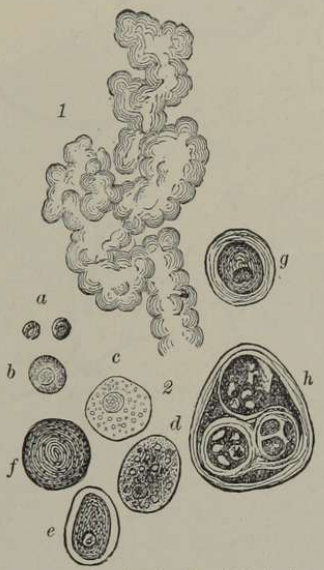

FIG. 714.—1. Upper portion of the thymus of a fœtal pig of 2″ in length, showing the bud-like lobuli and glandular elements. 2. Cells of the thymus, mostly from a man. *a*. Free nuclei. *b*. Small cells. *c*. Larger. *d*. Larger, with oil-globules, from the ox. *e*, *f*. Cells completely filled with fat, at *f* without a nucleus. *g*, *h*. Concentric bodies. *g*. An encapsulated nucleated cell. *h*. A composite structure of a similar nature.

occasionally united so as to form a single mass, and sometimes separated by an intermediate lobe. The thymus is of a pinkish-gray color, soft, and lobulated on its surfaces. It is about two inches in length, one and a half in breadth below, and about three or four lines in thickness. At birth it weighs about half an ounce.

Structure.—Each lateral lobe is composed of numerous lobules held together by delicate areolar tissue, the entire gland being enclosed in an investing capsule of a similar but denser structure. The primary lobules vary in size from a pin's head to a small pea, and are made up of a number of small nodules or follicles which are irregular in shape and are more or less fused together, especially toward the interior of the gland. According to Watney, each follicle consists of a medullary and cortical portion, which differ in many essential particulars from each other. The *cortical portion* is mainly composed of lymphoid cells supported by a delicate reticulum. In addition to this reticulum, of which traces only are found in the medullary portion, there is also a network of finely-branched cells which is continuous with a similar network in the medullary portion. This network forms an adventitia to the blood-vessels. In the *medullary portion* there are but few lymphoid cells, but there are, especially toward the centre, granular cells and concentric corpuscles. The granular cells are rounded or flask-shaped masses attached (often by fibrillated extremities) to blood-vessels and to newly-formed connective tissue. The concentric corpuscles are composed of a central mass consisting of one or more granular cells, and of a capsule which is formed of epithelioid cells which are continuous with the branched cells forming the network mentioned above.

Each follicle is surrounded by a capillary plexus from which vessels pass into the interior and radiate from the periphery toward the centre, and form a second zone just within the margin of the medullary portion. In the centre of the medulla there are very few vessels, and they are of minute size.

Dr. Watney has recently made the important observation that hæmoglobin is found in the thymus either in cysts or in cells situated near to or forming part

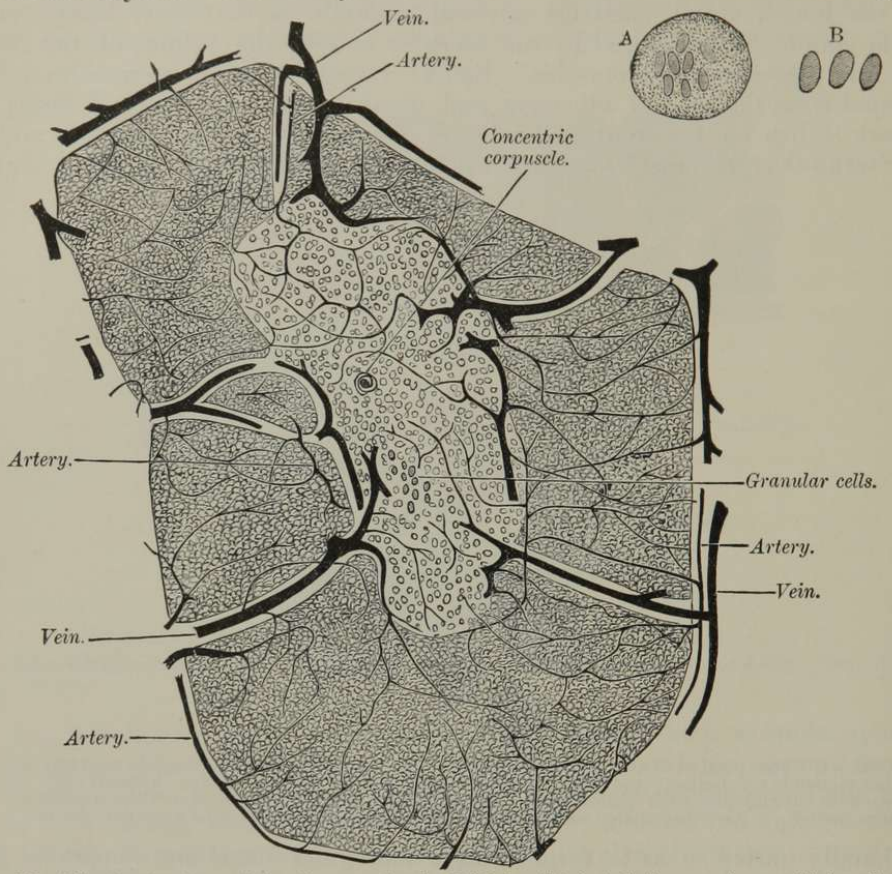

FIG. 715.—Minute structure of the thymus gland. Follicle of injected thymus from calf, four days old, slightly diagrammatic, magnified about 50 diameters. The large vessels are disposed in two rings, one of which surrounds the follicle, the other lies just within the margin of the medulla. (Watney.) A and B. From thymus of camel, examined without addition of any reagent. Magnified about 400 diameters. A. Large colorless cell containing small oval masses of hæmoglobin. Similar cells are found in the lymph-glands, spleen, and medulla of bone. B. Colored blood-corpuscles.

of the concentric corpuscles. This hæmoglobin varies from granules to masses exactly resembling colored blood-corpuscles, oval in the bird, reptile, and fish; circular in all mammals except in the camel. Dr. Watney has also discovered in the lymph issuing from the thymus similar cells to those found in the gland, and, like them, containing hæmoglobin either in the form of granules or masses. From these facts he arrives at the physiological conclusion that the thymus is one source of the colored blood-corpuscles.

Vessels and Nerves.—The *arteries* supplying the thymus are derived from the internal mammary and from the superior and inferior thyroid. The *veins* terminate in the left innominate vein and in the thyroid veins. The *lymphatics* are of large size, arise in the substance of the gland, and are said to terminate in the internal jugular vein. The *nerves* are exceedingly minute; they are derived from the pneumogastric and sympathetic. Branches from the descendens hypoglossi and phrenic reach the investing capsule, but do not penetrate into the substance of the gland.

THE URINARY ORGANS.

THE KIDNEYS.

THE Kidneys, two in number, are situated in the back part of the abdomen, and are for the purpose of separating from the blood certain materials which, when dissolved in a quantity of water, also separated from the blood by the kidneys, constitute the urine.

They are placed in the loins, one on each side of the vertebral column, behind the peritoneum, and surrounded by a mass of fat and loose areolar tissue. Their upper extremity is on a level with the upper border of the twelfth dorsal vertebra, their lower extremity on a level with the third lumbar. The right kidney is usually on a slightly lower level than the left, probably on account of the vicinity of the liver.

The kidneys rest on the lower part of the Diaphragm and the fascia covering the Quadratus lumborum and the Psoas magnus muscles. The right is covered in front by right lobe of liver, peritoneum intervening, the descending portion of the duodenum, and the beginning of the transverse colon; the left has in front the fundus of the stomach, the tail of the pancreas, and the descending colon (upper part).

Each kidney is about four inches in length, two to two and a half in breadth, and rather more than one inch in thickness. The left is somewhat longer, though narrower, than the right. The weight of the kidney in the adult male varies from 4½ ounces to 6 ounces, in the adult female from 4 ounces to 5½ ounces. The combined weight of the two kidneys in proportion to the body is about 1 in 240.

The kidney has a characteristic form. It is flattened and presents at one part of its circumference a hollow. It is larger at its upper than at its lower extremity. It has two surfaces, two borders, and an upper and lower extremity.

Its *anterior surface* is convex, looks forward and outward, and is covered by peritoneum. The upper part of this surface on the right side is in contact with the under surface of the right lobe of the liver, on which it produces a slight concave impression, the *impressio renalis;* below this the descending portion of the duodenum and the hepatic flexure of the colon are connected to this surface, the former by areolar tissue and the latter by its mesocolon. On the left side the upper part of the anterior surface of the kidney (covered by peritoneum of lesser sac) is in contact with the under surface of the stomach, and below this with the left extremity of the pancreas, whilst the lower part has anteriorly the splenic flexure of the colon, and internally the last portion of the duodenum.

The *posterior surface* is flatter than the anterior, and is imbedded in areolar tissue, which separates it from the Diaphragm and from the anterior lamella of the lumbar fascia covering the Quadratus lumborum and Psoas magnus muscle. It is also in relation with the last dorsal, ilio-inguinal, and ilio-hypogastric nerves.

The *external border* is convex, and is directed outward and backward. On the left side it is in contact, at its upper half or more, with the spleen, and below with the descending colon. On the right side, upper two-thirds, liver; below, ascending colon.

The *internal border* is concave, and is directed forward and a little downward. It presents a deep longitudinal fissure bounded by prominent anterior and posterior lip. This fissure is the *hilum*, and allows of the passage of the vessels, nerves, and ureter.

The *superior extremity*, directed slightly inward as well as upward, is thick

and rounded, and is surmounted by the suprarenal capsule, which covers also a small portion of the anterior surface.

The *inferior extremity*, directed a little outward as well as downward, is smaller and thinner than the superior. It extends to within two inches of the crest of the ilium.

At the hilum of the kidney the relative position of the main structures passing into and out of the kidney is as follows: the vein is in front, the artery in the middle, and the duct or ureter behind and toward the lower part. By a knowledge of these relations the student may distinguish between the right and left kidney. The kidney is to be laid on the table before the student on its posterior surface, with its lower extremity toward the observer—that is to say, with the ureter *behind* and *below* the other vessels; the hilum will then be directed to the side to which the kidney belongs.

General Structure of the Kidney.—The kidney is surrounded by a distinct investment of fibrous tissue which forms a firm, smooth covering to the organ. It closely invests it, but can be easily stripped off, in doing which, however, numerous fine processes of connective tissue and small blood-vessels are torn through. Beneath this coat a thin wide-meshed network of unstriped muscular fibre forms an incomplete covering to the organ. When the fibrous coat is stripped off, the surface of the kidney is found to be smooth and even and of a deep-red color.

In infants fissures extending for some depth may be seen on the surface of the organ, a remnant of the lobular construction of the gland. The kidney is dense in texture, but is easily lacerable by mechanical force. In order to obtain a knowledge of the structure of the gland, a vertical section must be made from its convex to its concave border, and the loose tissue and fat removed from around the vessels and the excretory duct (Fig. 716). It will be then seen that the kidney consists of a central cavity surrounded at all parts but one by the proper kidney-substance. This central cavity is called the *sinus*, and is lined by a prolongation of the fibrous coat of the kidney, which enters through a longitudinal fissure, the *hilum* (before mentioned), which is situated at that part of the cavity which is not surrounded by kidney-structure. Through this fissure the blood-vessels of the kidney and its excretory duct pass, and therefore these structures, upon entering the kidney, are contained within the sinus. The excretory duct, or *ureter*, after entering, dilates into a wide, funnel-shaped sac named the *pelvis*. This divides into two or three tubular divisions, which subdivide into several short, truncated branches named *calices* or *infundibula*, all of which are contained in the central cavity of the kidney. The blood-vessels of the kidney, after passing through the hilum, are contained in the sinus or central cavity, lying between its lining membrane and the excretory apparatus, before entering the kidney-substance.

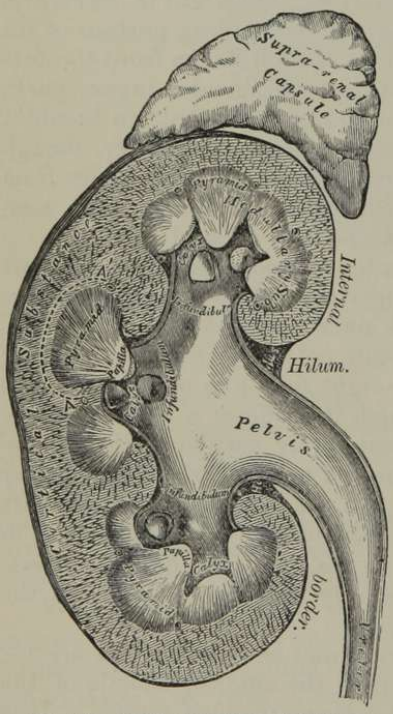

FIG. 716.—Vertical section of kidney.

This central cavity, as before mentioned, is surrounded on all sides except at the hilum by the substance of the kidney, which is at once seen to consist of two parts—viz. of an external granular investing part, which is called the *cortical portion;* and of an internal part, the *medullary portion*, made up of a number of dark-colored pyramidal masses, with their bases resting on the cortical part and their apices converging toward the centre, where they form prominent papillæ which project into the interior of the calices.

The cortical substance is of a bright reddish-brown color, soft, granular, and easily lacerable. It is found everywhere immediately beneath the capsule, and is seen to extend in an arched form over the base of each medullary pyramid. The part separating the sides of any two pyramids through which the arteries and nerves enter, and the veins and lymphatics emerge, from the kidney, is called a *cortical column* or *column of Bertin* (A, A′, Fig. 716); whilst that portion which stretches from one cortical column to the next, and intervenes between the base of the pyramid and the capsule (marked by the dotted line from A to A′ in Fig. 716), is called a *cortical arch*, the depth of which varies from a third to half an inch.

The *medullary substance*, as before stated, is seen to consist of pale red-colored, striated, conical masses, the *pyramids of Malpighi*, the number of which, varying from eight to eighteen, correspond to the number of lobes of which the organ in the fœtal state is composed. The base of each pyramid is surrounded by a cortical arch, and directed toward the circumference of the kidney; the sides are contiguous with the cortical columns; whilst the apex, known as the *papilla* or *mammilla* of the kidney, projects into one of the calices of the ureter, one calyx receiving two or three papillæ.

These two parts, *cortical* and *medullary*, so dissimilar in appearance, are very similar in structure, being made up of urinary tubes and blood-vessels united and bound together by a connecting matrix or stroma.

Minute Anatomy.—The *tubuli uriniferi*, of which the kidney is for the most part made up, commence in the cortical portion of the kidney, and, after pursuing a very circuitous course through the cortical and medullary parts of the kidney, finally terminate at the apices of the Malpighian pyramids by open mouths (Fig. 717), so that the fluid which they contain is emptied into the dilated extremity of the ureter contained in the sinus of the kidney. If the surface of one of the papillæ is examined with a lens, it will be seen to be studded over with a number of small depressions from sixteen to twenty in number, and in a fresh kidney, upon pressure being made, fluid will be seen to exude from these depressions. They are the orifices of the tubuli uriniferi, which terminate in this situation. They commence in the cortical portion of the kidney as the *Malpighian bodies*, which are small rounded masses, varying in size, but of an average of about $\frac{1}{120}$ of an inch in diameter. They are of a deep-red color, and are found only in the cortical portion of the kidney. Each of these little bodies is composed of two parts—a central glomerulus of vessels, called a *Malpighian tuft*, and a membranous envelope, the *Malpighian capsule*, or *capsule of Bowman*, which latter is a small pouch-like commencement of a uriniferous tubule.

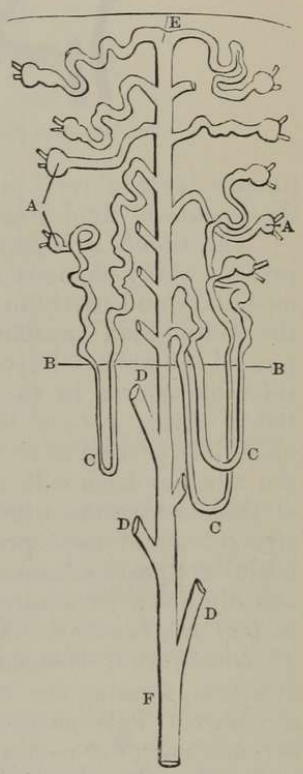

FIG. 717.—A, A. Malpighian bodies. B, B. Margin of medullary structure. C, C, C. Loops of Henle. D, D, D. Straight tubes cut off. E. Commencing straight tubes. F. Termination of straight tube.

The *Malpighian tuft*, or vascular glomerulus, is a network of convoluted capillary blood-vessels held together by scanty connective tissue and grouped into from two to five lobules. This capillary network is derived from a small arterial twig, the *afferent vessel*, which pierces the wall of the capsule, generally at a point opposite that at which the latter is connected with the tube; and the resulting vein, the *efferent vessel*, emerges from the capsule at the same point. The afferent vessel is usually the larger of the two (Fig. 718). The *Malpighian* or *Bowman's capsule*, which surrounds the glomerulus, is formed of a hyaline membrane supported by a small amount of connective tissue which is continuous with the connective tissue of the tube. It is lined on its inner surface by a layer of squa-

mous epithelial cells which are reflected from the lining membrane on to the glomerulus at the point of entrance or exit of the afferent and efferent vessels. The whole surface of the glomerulus is covered with a continuous layer of the same cells on a delicate supporting membrane, which with the cells dips in between the lobules of the glomerulus, closely surrounding them (Fig. 719). Thus, between the glomerulus and the capsule a space is left, forming a cavity lined by a con-

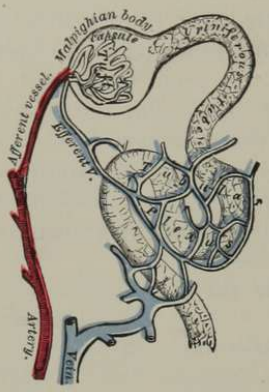

FIG. 718.—Minute structure of kidney.

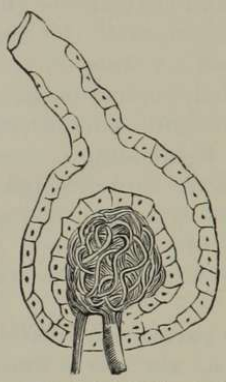

FIG. 719.—Malpighian body.

tinuous layer of cells, which varies in size according to the state of secretion and the amount of fluid present in it. The cells are squamous or flattened.

The *tubuli uriniferi*, commencing in the Malpighian bodies, in their course present many changes in shape and direction, and are contained partly in the medullary and partly in the cortical portions of the organ. At their junction with the Malpighian capsule they present a somewhat constricted portion which is termed the *neck*. Beyond this the tube becomes convoluted, and pursues a considerable course in the cortical structure, constituting the *proximal convoluted tube*. After a time the convolutions disappear, and the tube approaches the medullary portion of the kidney in a more or less spiral manner. This section of the tube has been called the *spiral tube of Schachowa*. Throughout this portion of their course the tubuli uriniferi have been contained entirely in the cortical structure, and have presented a pretty uniform calibre. They now enter the medullary portion, and suddenly become much smaller, quite straight in direction, and dip down for a variable depth into the pyramids, constituting the *descending limb of Henle's loop*. Bending on themselves, they form a kind of loop, the *loop of Henle*, and, reascending, become suddenly enlarged and again spiral in direction, forming the *ascending limb of Henle's loop*, and re-enter the cortical structure. This portion of the tube does not present a uniform calibre, but becomes narrower as it ascends and irregular in outline. As a narrow tube it now is found in the cortex along the *medullary ray* and ascends for a short distance, when it again becomes dilated, irregular, and angular, and leaves the medullary ray to enter the *labyrinth* of the cortex. This section is termed the *irregular tubule;* it terminates in a convoluted tube which exactly resembles the proximal convoluted tubule, and is called the *distal convoluted tubule*. This again terminates in a narrow *curved* or junctional *tube*, which enters the straight or collecting tube.

Each *straight*, otherwise called a *collecting* or *receiving*, *tube* commences by a small orifice on the summit of one of the papillæ, thus opening and discharging its contents into the interior of one of the calices. Traced into the substance of the pyramid, these tubes are found to run from apex to base, dividing dichotomously in their course and slightly diverging from each other. Thus dividing and subdividing, they reach the base of the pyramid, and enter the cortical structure greatly increased in number. Upon entering the cortical portion they continue a straight course for a variable distance, and are arranged in groups called *medullary rays*, several of these groups corresponding to a single pyramid. The tubes in the

centre of the group are the longest, and reach almost to the surface of the kidney, while the external ones are shorter, and advance only a short distance into the

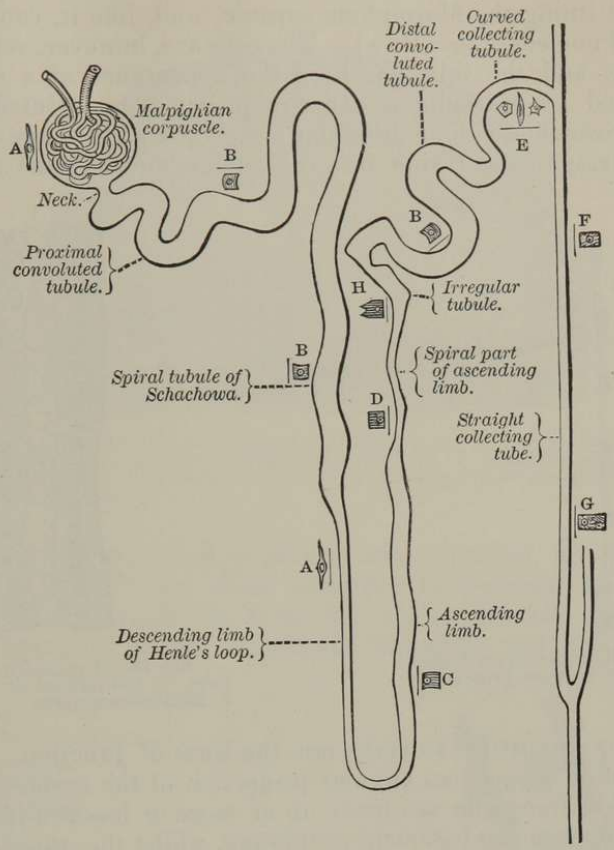

FIG. 720.—Uriniferous tube. For the sake of clearness the epithelial cells have been represented more highly magnified than the tubes in which they are contained.

cortex. In consequence of this arrangement the cortical portion presents a number of conical masses, the apices of which reach the periphery of the organ, and the bases are applied to the medullary portion. These are termed the *pyramids of Ferrein*. As they run through the cortical portion the straight tubes receive on either side the curved extremity of the convoluted tubes, which, as stated above, commence at the Malpighian bodies. The portions of the cortex between the medullary rays are known as the *labyrinth* of the cortex.

It will be seen from the above description that there is a continuous series of tubes from their commencement in the Malpighian bodies to their termination at the orifices on the apices of the pyramids of Malpighi, and that the urine, the secretion of which commences in the capsule, finds its way through these tubes into the calices of the kidney, and so into the ureter. To recapitulate: the tube first presents a constricted portion, (1) the *neck*. 2. It forms a wide convoluted tube, the *proximal convoluted tube*. 3. It becomes spiral, the *spiral tubule of Schachowa*. 4. It enters the medullary structure as a narrow, straight tube, the *descending limb of Henle's loop*. 5. Forming a loop and becoming dilated, it ascends somewhat spirally, and, gradually diminishing in calibre, again enters the cortical structure, the *ascending limb of Henle's loop*. 6. It now becomes irregular and angular in outline, the *irregular tubule*. 7. It then becomes convoluted, the *distal convoluted tubule*. 8. Diminishing in size, it forms a curve, the *curved tubule*. 9. Finally, it joins a straight tube, the *straight collecting tube*, which is continued downward through the medullary substance to open at the apex of a pyramid.

The Tubuli Uriniferi: their Structure.—The tubuli uriniferi consist of base-

ment membrane lined with epithelium. The epithelium varies considerably in different sections of the uriniferous tubes. In the neck the epithelium is continuous with that lining the Malpighian capsule, and, like it, consists of flattened cells with an oval nucleus (Fig. 720 A). The cells are, however, very indistinct and difficult to trace, and the tube has here the appearance of a simple basement membrane unlined by epithelium. In the proximal convoluted tubule and the spiral tubule of Schachowa the epithelium is polyhedral in shape, the sides of the cells not being straight, but fitting into each other, and in some animals so fused

FIG. 721.[1]—Longitudinal section of Henle's descending limb. *a*. Membrana propria. *b*. Epithelium.



FIG. 722.—Longitudinal section of straight tube. *a*. Cylindrical or cubical epithelium. *b*. Membrana propria.

together that it is impossible to make out the lines of junction. In the human kidney the cells often present an angular projection of the surface next the basement membrane. These cells are made up of more or less rod-like fibres, which rest by one extremity on the basement membrane, whilst the other projects toward the lumen of the tube. This gives to the cells the appearance of distinct striation (Heidenhain) (Fig. 720 B). In the descending limb of Henle's loop the epithelium resembles that found in the Malpighian capsule and the commencement of the tube, consisting of flat transparent epithelial plates with an oval nucleus (Figs. 720 A, 721). In the ascending limb, on the other hand, the cells partake more of the character of those described as existing in the proximal convoluted tubule, being polyhedral in shape and presenting the same appearance of striation. The nucleus, however, is not situated in the centre of the cell, but near the lumen (Fig. 720 C). After the ascending limb of Henle's loop becomes narrower upon entering the cortical structure, the striation appears to be confined to the outer part of the cell; at all events, it is much more distinct in this situation, the nucleus, which appears flattened and angular, being still situated near the lumen (Fig. 720 D). In the irregular tubule the cells undergo a still farther change, becoming very angular, and presenting thick bright rods or markings, which render the striation much more distinct than in any other section of the urinary tubules (Fig. 720 H). In the distal convoluted tubule the epithelial cells are long in shape, are highly refractive, and their nuclei are comparatively large. In other respects they resemble those in the proximal convoluted tubule (Fig. 720 B). In the curved tubule, just before its entrance into the straight collecting tube, the epithelium varies greatly as regards the shape of the cells, some being angular with short processes, others spindle-shaped, others polyhedral (Fig. 720 E).

In the straight tubes the epithelium is more or less columnar; in its papillary portion the cells are distinctly columnar and transparent (Figs. 722, 723), but as the tube approaches the cortex the cells are less uniform in shape; some are polyhedral, and others angular with short processes (Fig. 720 F and G).

[1] From the *Handbook for the Physiological Laboratory*.

The Renal Blood-vessels.—The kidney is plentifully supplied with blood by the renal artery, a large offset of the abdominal aorta. Previously to entering

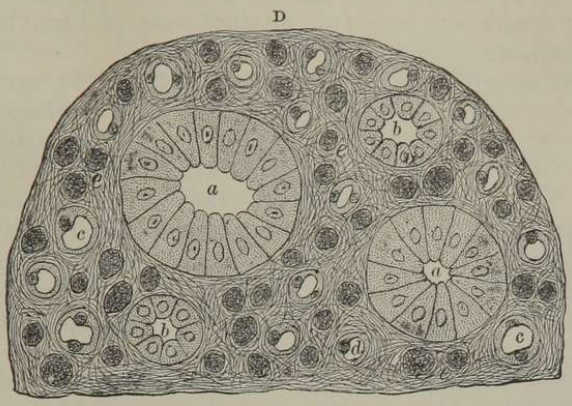

FIG. 723.—Transverse section of pyramidal substance of kidney of pig, the blood-vessels of which are injected. *a*. Large collecting tube cut across, lined with cylindrical epithelium. *b*. Branch of collecting tube cut across, lined with epithelium with shorter cylinders. *c* and *d*. Henle's loops cut across. *e*. Blood-vessels cut across. D. Connective-tissue ground-substance.

the kidney, each artery divides into four or five branches, which are distributed to its substance. At the hilum these branches lie between the renal vein and ureter, the vein being usually in front, the ureter behind. Each vessel gives off some small branches to the suprarenal capsules, the ureter, and the sur-

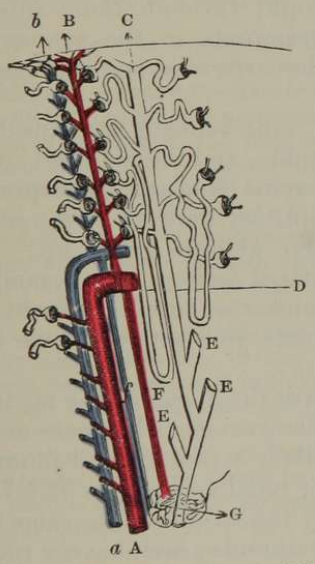

FIG. 724.–Diagrammatical sketch of kidney.

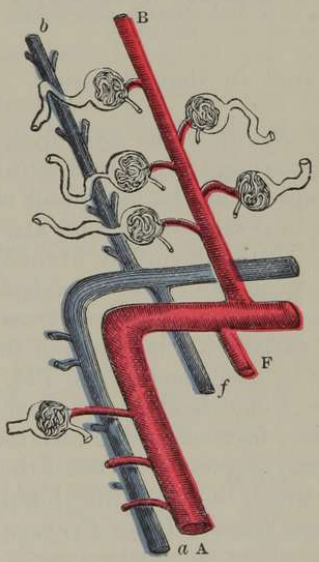

FIG. 725.—A portion of Fig. 593 enlarged. (The references are the same.)

A, *a*. Proper renal artery and vein, the former giving off the renal afferents, the latter receiving the renal efferents. B, *b*. Interlobular artery and vein, the latter commencing from the stellate veins, and receiving branches from the plexus around the tubuli contorti, the former giving off renal afferents. C. Straight tube, surrounded by tubuli contorti, with which it communicates, as more fully shown in Fig. 586. D. Margin of medullary substance. E, E, E. Receiving tubes cut off. F, *f*. Arteriolæ et venæ rectæ, the latter arising from (G) the plexus at the medullary apex.

rounding cellular tissue and muscles. Frequently there is a second renal artery, which is given off from the abdominal aorta at a lower level, and supplies the lower portion of the kidney. It is termed the *inferior renal artery*. The branches of the renal artery whilst in the sinus give off a few twigs for the nutrition of the surrounding tissues, and terminate in the *arteriæ propriæ renales*, which enter the kidney proper in the columns of Bertin. Two of these pass to each pyramid of Malpighi and run along its sides for its entire length,

giving off as they advance the afferent vessels of the Malpighian bodies in the columns. Having arrived at the bases of the pyramids, they make a bend in their course, so as to lie between the bases of the pyramids and the cortical arches, where they break up into two distinct sets of branches devoted to the supply of the remaining portions of the kidney.

The *first set*, the *interlobular arteries* (Figs. 724, 725 B), are given off at right angles from the side of the arteriæ propriæ renales looking toward the cortical substance, and, passing directly outward between the pyramids of Ferrein, they reach the capsule, where they terminate in the capillary network of this part. In their outward course they give off lateral branches; these are the *afferent vessels* for the Malpighian bodies (see page 1130), and, having pierced the capsule, end in the Malpighian tufts. From each tuft the corresponding renal efferent arises, and, having made its egress from the capsule near to the point where the afferent vessel entered, anastomoses with other efferents from other tufts, and contributes to form a dense *venous plexus* around the adjacent urinary tubes (Fig. 726).

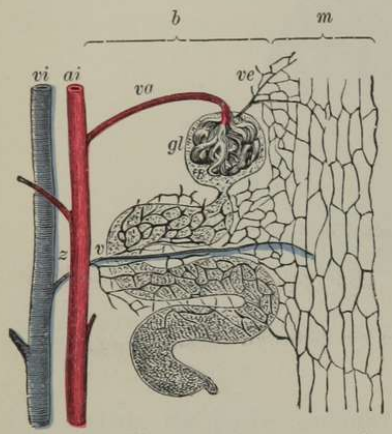

FIG. 726.—Diagrammatic representation of the blood-vessels in the substance of the cortex of the kidney. *m*. Region of the medullary ray. *b*. Region of the tortuous portion of the tubules. *ai*. Arteria interlobularis. *vi*. Vena interlobularis. *va*. Vas afferens. *gl*. Glomerulus. *ve*. Vas efferens. *vz*. Venous twig of the interlobularis. (From Ludwig, in Stricker's *Handbook*.)

The *second set of branches* from the arteriæ propiæ renales are for the supply of the medullary pyramids, which they enter at their bases; and, passing straight through their substance to their apices, terminate in the venous plexuses found in that situation. They are called the *arteriolæ rectæ* (Figs. 724, 725 F).

The *Renal Veins* arise from *three sources*—the veins beneath the capsule, the plexuses around the tubuli contorti in the cortical arches, and the plexuses situated at the apices of the pyramids of Malpighi. The veins beneath the capsule are stellate in arrangement, and are derived from the capillary network of the capsule, into which the terminal branches of the interlobular arteries break up. These join to form the *venæ interlobulares*, which pass inward *between* the pyramids of Ferrein, receive branches from the plexuses around the tubuli contorti, and, having arrived at the bases of the Malpighian pyramids, join with the venæ rectæ, next to be described (Figs. 724, 725 *b*).

The *Venæ Rectæ* are branches from the plexuses at the apices of the medullary pyramids, formed by the terminations of the arteriolæ rectæ. They pass outward in a straight course between the tubes of the medullary structure, and joining, as above stated, the venæ interlobulares, form the proper renal veins (Figs. 724, 725 *f*).

These vessels, *Venæ Propriæ Renales*, accompany the arteries of the same name, running along the entire length of the sides of the pyramids; and, having received in their course the efferent vessels from the Malpighian bodies in the cortical structure adjacent, quit the kidney substance to enter the sinus. In this cavity they inosculate with the corresponding veins from the other pyramids to form the *renal vein*, which emerges from the kidney at the hilum and opens into the inferior vena cava, the left being longer than the right, from having to cross in front of the abdominal aorta.

Nerves of the Kidney.—The nerves of the kidney, although small, are about fifteen in number. They have small ganglia developed upon them, and are derived from the renal plexus, which is formed by branches from the solar plexus, the lower and outer part of the semilunar ganglion and aortic plexus, and from the lesser and smallest splanchnic nerves. They communicate with the spermatic plexus, a circumstance which may explain the occurrence of pain in the testicle in affections of the kidney. So far as they have been traced, they seem to accompany

the renal artery and its branches, but their exact mode of termination is not known.

The *lymphatics* consist of a superficial and deep set which terminate in the lumbar glands.

Connective Tissue, or Intertubular Stroma.—Although the tubules and vessels are closely packed, a certain small amount of connective tissue, continuous with the capsule, binds them firmly together. This tissue was first described by Goodsir, and subsequently by Bowman. Ludwig and Zawarykin have observed distinct fibres passing around the Malpighian bodies, and Henle has seen them between the straight tubes composing the medullary structure.

Surface Form.—The kidneys, being situated at the back part of the abdominal cavity and deeply placed, cannot be felt unless enlarged or misplaced. They are situated on the confines of the epigastric and umbilical regions internally, with the hypochondriac and lumbar regions externally. The left is somewhat higher than the right. According to Morris, the position of the kidney may be thus defined: *Anteriorly:* "1. A horizontal line through the umbilicus is below the lower edge of each kidney. 2. A vertical line carried upward to the costal arch from the middle of Poupart's ligament has one-third of the kidney to its outer side and two-thirds to its inner side—*i. e.* between this line and the median line of the body." In adopting these lines it must be borne in mind that the axes of the kidneys are not vertical, but oblique, and if continued upward would meet about the ninth dorsal vertebra. *Posteriorly:* The upper end of the left kidney would be defined by a line drawn horizontally outward from the spinous process of the eleventh dorsal vertebra, and its lower end by a point two inches above the iliac crest. The right kidney would be half to three-quarters of an inch lower. Morris lays down the following rules for indicating the position of the kidney on the posterior surface of the body: "1. A line parallel with, and one inch from, the spine, between the lower edge of the tip of the spinous process of the eleventh dorsal vertebra and the lower edge of the spinous process of the third lumbar vertebra. 2. A line from the top of this first line outward at right angles to it for $2\frac{3}{4}$ inches. 3. A line from the lower end of the first transversely outward for $2\frac{3}{4}$ inches. 4. A line parallel to the first and connecting the outer extremities of the second and third lines just described."

The hilum of the kidney lies about two inches from the middle line of the back, at the level of the spinous process of the first lumbar vertebra.

Surgical Anatomy.—The kidney is imbedded in a large quantity of loose fatty tissue, and is but slightly covered by peritoneum; hence rupture of this organ is not nearly so serious an accident as rupture of the liver or spleen, since the extravasation of blood and urine which follows is outside the peritoneal cavity. Occasionally the kidney may be bruised by blows in the loin or by being compressed between the lower ribs and the ilium when the body is violently bent forward. This is followed by a little transient hæmaturia, which, however, speedily passes off. Occasionally, when rupture involves the pelvis of the kidney or the commencement of the ureter, this duct may become blocked, and hydronephrosis follow.

The loose cellular tissue around the kidney may be the seat of suppuration, constituting *perinephritic abscess.* This may be due to injury, to disease of the kidney itself, or to extension of inflammation from neighboring parts. It may burst into the pleura, constituting empyema; into the colon or bladder; or may point externally in the groin or loin. Tumors of the kidney, of which, perhaps, sarcoma in children is the most common, may be recognized by their position and fixity; by the resonant colon lying in front of it; by their not moving with respiration; and by their rounded outline, not presenting a notched anterior margin like the spleen, with which they are most likely to be confounded. The examination of the kidney should be bimanual; that is to say, one hand should be placed in the flank and firm pressure made forward, while the other hand is buried in the abdominal wall just external to the semilunar line. Manipulation of the kidney frequently produces a peculiar sickening sensation, with sometimes faintness.

The kidney is mainly held in position by the mass of fatty matter in which it is imbedded and over which the peritoneum is stretched. If this fatty matter is loose or lax or is absorbed, the kidney may become movable and may give rise to great pain. This condition occurs, therefore, in badly-nourished people or in those who have become emaciated from any cause, and is more common in women than in men. It must not be confounded with the *floating kidney:* this is a congenital condition due to the development of a meso-nephron, which permits the organ to move more or less freely. The two conditions cannot, however, be distinguished until the abdomen is opened or the kidney explored from the loin.

The kidney has, of late years, been frequently the seat of surgical interference. It may be exposed for exploration or the evacuation of pus (nephrotomy); it may be incised for the removal of stone (nephro-lithotomy); it may be sutured when movable or floating (nephrorraphy); or it may be removed (nephrectomy).

The kidney may be exposed either by a lumbar or abdominal incision. The lumbar operation is the one which is generally adopted, unless in cases of very large tumors or of wandering kidneys with a loose meso-nephron, on account of the advantages which it possesses of not opening the peritoneum and of affording admirable drainage. It may be performed either by an oblique, a vertical, or a transverse incision. Perhaps the preferable, as affording the best

means for exploring the whole surface of the kidney, is an incision from the tip of the last rib backward to the edge of the Erector spinæ. This incision must not be quite parallel to the rib, but its posterior end must be at least three-quarters of an inch below it, lest the pleura be wounded. This cut is quite sufficient for an exploration of the organ. Should it require removal, a vertical incision can be made downward to the crest of the ilium, along the outer border of the Quadratus lumborum. The structures divided are the skin, the superficial fascia with the cutaneous nerves, the deep fascia, the posterior border of the External oblique muscle of the abdomen, and the outer border of the Latissimus dorsi; the Internal oblique and the posterior aponeurosis of the Transversalis muscle; the outer border of the Quadratus lumborum, and the deep layer of the transversalis aponeurosis, and the transversalis fascia. The fatty tissue around the kidney is now exposed to view, and must be separated by the fingers or a director in order to reach the kidney.

The abdominal operation is best performed by an incision in the linea semilunaris on the side of the kidney to be removed, as recommended by Langenbuch. The incision is made of varying length according to the size of the kidney; its mid-point should be on a level with the umbilicus. The abdominal cavity is opened. The intestines are then held aside and the outer layer of the meso-colon opened, so that the fingers can be introduced behind the peritoneum and the renal vessels sought for. These are then to be ligatured; if tied separately, care must be taken to ligature the artery first. The kidney must now be enucleated, and the vessels and ureter divided, and the latter tied or, if thought necessary, stitched to the edge of the wound.

THE URETERS.

The **Ureters** are the two tubes which conduct the urine from the kidneys into the bladder. They commence within the sinus of the kidney by a number of short truncated branches, the *calices* or *infundibula*, which unite either directly or indirectly to form a dilated pouch, the *pelvis*, from which the ureter, after passing through the hilum of the kidney, descends to the bladder. The *calices* are cup-like tubes encircling the apices of the Malpighian pyramids; but inasmuch as one calyx may include two or even more papillæ, their number is generally less than the pyramids themselves, the former being from seven to thirteen, whilst the latter vary from eight to eighteen. These calices converge into two or three tubular divisions which by their junction form the *pelvis* or dilated portion of the ureter. The portion last mentioned, where the pelvis merges into the ureter proper, is found opposite the spinous process of the first lumbar vertebra, in which situation it is accessible behind the peritoneum.

The *ureter proper* is a cylindrical membranous tube, about sixteen inches in length and of the diameter of a goosequill, extending from the pelvis of the kidney to the bladder. Its course is obliquely downward and inward through the lumbar region into the cavity of the pelvis, where it passes downward, forward, and inward across that cavity to the base of the bladder, into which it then opens by a constricted orifice, after having passed obliquely for nearly an inch between its muscular and mucous coats.

Relations.—In its course it rests upon the Psoas muscle, being covered by the peritoneum, and crossed obliquely, from within outward, by the spermatic vessels; the right ureter lying close to the outer side of the inferior vena cava. Opposite the first piece of the sacrum it crosses either the common or external iliac artery, lying behind the ileum on the *right* side and the sigmoid flexure of the colon on the *left*. In the pelvis it enters the posterior false ligament of the bladder below the obliterated hypogastric artery, the vas deferens in the male passing between it and the bladder. In the female the ureter passes along the side of the cervix of the uterus and upper part of the vagina. At the level of the external os it is three-fifths of an inch external to the cervix, and is crossed by the uterine artery, a venous plexus intervening (Holl). At the base of the bladder it is situated about two inches from its fellow, lying, in the male, about an inch and a half behind the prostate.

Structure.—The *ureter* has three coats—a fibrous, muscular, and mucous.

The *fibrous coat* is the same throughout the entire length of the duct, being continuous at one end with the capsule of the kidney at the floor of the sinus, whilst at the other it is lost in the fibrous structure of the bladder.

In the pelvis of the kidney the muscular coat consists of two layers, longitudinal and circular: the longitudinal fibres become lost upon the sides of the papillæ at

the extremities of the calices; the circular fibres may be traced surrounding the medullary structure in the same situation. In the ureter proper the muscular fibres are very distinct, and are arranged in three layers—an external longitudinal, a middle circular, and an internal layer, less distinct than the other two, but having a general longitudinal direction. According to Kölliker, this internal layer is only found in the neighborhood of the bladder.

The *mucous coat* is smooth, and presents a few longitudinal folds which become effaced by distension. It is continuous with the mucous membrane of the bladder below, whilst it is prolonged over the papillæ of the kidney above. Its epithelium is of a peculiar character, and resembles that found in the bladder. It is known by the name of "transitional" epithelium. It consists of several layers of cells, of which the innermost—that is to say, the cells in contact with the urine—are quadrilateral in shape, with a concave margin on their outer surface, into which fits the rounded end of the cells of the second layer. These, the intermediate cells, more or less resemble columnar epithelium, and are pear-shaped, with a rounded internal extremity which fits into the concavity of the cells of the first layer, and a narrow external extremity which is wedged in between the cells of the third layer. The external or third layer consists of conical or oval cells varying in number in different parts, and presenting processes which extend down into the basement membrane.

The *arteries* supplying the ureter are branches from the renal, spermatic, internal iliac, and inferior vesical.

The *nerves* are derived from the inferior mesenteric, spermatic, and pelvic plexuses.

THE SUPRARENAL CAPSULES.

The **Suprarenal Capsules** are classified, together with the spleen, thymus, and thyroid, under the head of "ductless glands," as they have no excretory duct. They are two small flattened glandular bodies, of a yellowish color, situated at the back part of the abdomen, behind the peritoneum and immediately above and a little in front of the upper part of each kidney; hence their name. The right one is somewhat triangular in shape, bearing a resemblance to a cocked hat; the left is more semilunar, and usually larger and higher than the right. They vary in size in different individuals, being sometimes so small as to be scarcely detected; their usual size is from an inch and a quarter to nearly two inches in length, rather less in width, and from two to three lines in thickness. Their average weight is about a drachm each.

Relations.—The relations of the suprarenal capsules differ on the two sides of the body. The *right suprarenal* presents on its anterior surface two areas: along its upper and inner borders a depressed area, which is in contact in front with the under surface of the right lobe of the liver, and along its inner border with the inferior vena cava (Rolleston), and behind rests on the crus of the Diaphragm; over the remainder of the anterior surface is an elevated area, which is covered in front by peritoneum passing from the upper part of the kidney to the under surface of the liver, and behind rests on the upper and inner part of the kidney. The left suprarenal is in contact by its anterior surface, superiorly, with the spleen; below and internal to this it is in contact with the peritoneum forming the lesser sac, which separates it from the cardiac extremity of the stomach; and at its lower part it is covered by the pancreas and splenic artery, and is therefore not in contact with the peritoneum. By its posterior surface, at its outer and back part, it rests upon the kidney, whilst below and internally it is in contact with the left crus of the Diaphragm.

Structure.—The surface of the suprarenal gland is surrounded by areolar tissue containing much fat, and closely invested by a thin fibrous coat, which is difficult to remove on account of the numerous fibrous processes and vessels which enter the organ through the furrows on its anterior surface and base.

Small accessory suprarenals are often to be found in the connective tissue

around the suprarenals. The smaller of these, on section, show a uniform surface, but in some of the larger a distinct medulla can be made out.

On making a perpendicular section, the gland is seen to consist of two substances—external or cortical and internal or medullary. The former, which constitutes the chief part of the organ, is of a deep-yellow color. The medullary substance is soft, pulpy, and of a dark-brown or black color, whence the name *atrabiliary capsules* formerly given to these organs. In the centre is often seen a space, not natural, but formed by the breaking down after death of the medullary substance.

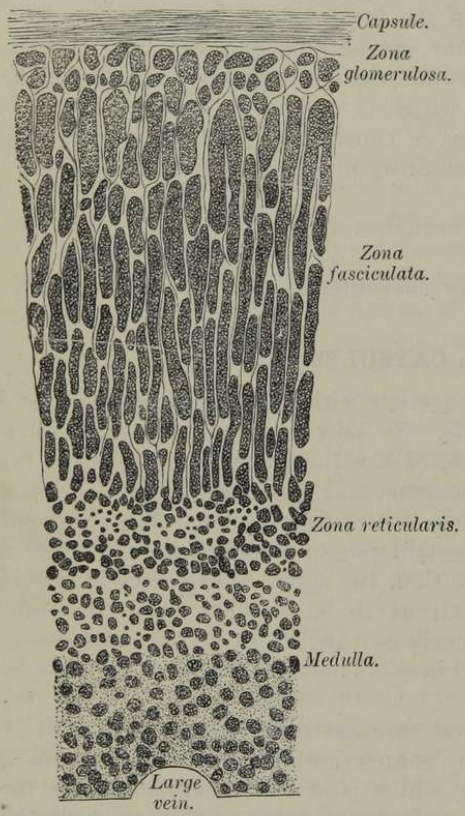

FIG. 727.—Vertical section of the suprarenal capsule. From Elberth, in Stricker's *Manual*.

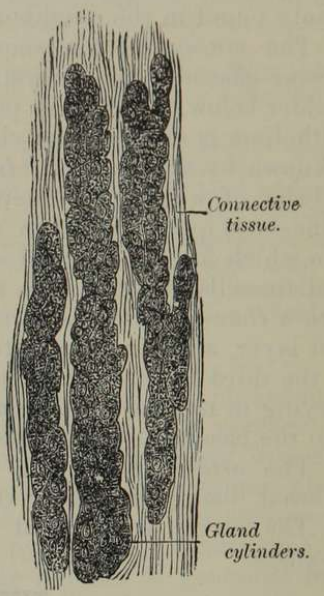

FIG. 728.

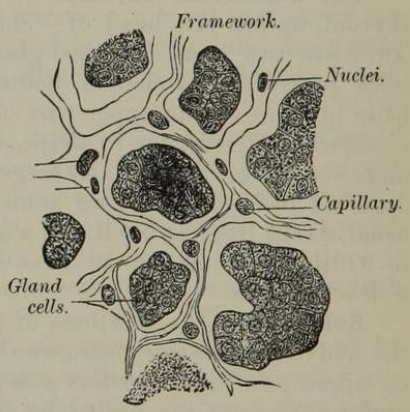

FIG. 729.

The **cortical portion** consists chiefly of narrow columnar masses placed perpendicularly to the surface. This arrangement is due to the disposition of the capsule, which sends into the interior of the gland processes passing in vertically and communicating with each other by transverse bands so as to form spaces which open into each other. These spaces are of slight depth near the surface of the organ, so that there the section somewhat resembles a net; this is termed the *zona glomerulosa*; but they become much deeper or longer farther in, so as to resemble pipes or tubes placed endwise, the *zona fasciculata*. Still deeper down, near the medullary part, the spaces become again of small extent; this is named the *zona reticularis*. These processes or trabeculæ, derived from the capsule and forming the framework of the spaces, are composed of fibrous connective tissue with longitudinal bundles of unstriped muscular fibres. Within the interior of the spaces are contained groups of polyhedral cells, which are finely granular in appearance, and contain a spherical nucleus, and not unfrequently fat-molecules. These groups of cells do not entirely fill the spaces in which they are contained,

but between them and the trabeculæ of the framework is a channel which is believed to be a lymph-path or sinus, and which communicates with certain passages between the cells composing the group. The lymph-path is supposed to open into a plexus of efferent lymphatic vessels which are contained in the capsule.

In the **medullary portion** the fibrous stroma seems to be collected together into a much closer arrangement, and forms bundles of connective tissue which are loosely applied to the large plexus of veins of which this part of the organ mainly consists. In the interstices lie a number of cells compared by Frey to those of columnar epithelium. They are coarsely granular, do not contain any fat-molecules, and some of them are branched. Luschka has affirmed that these branches are connected with the nerve-fibres of a very intricate plexus which is found in the medulla: this statement has not been verified by other observers, for the tissue of the medullary substance is less easy to make out than that of the cortical, owing to its rapid decomposition.

The numerous arteries which enter the suprarenal bodies from the sources mentioned below penetrate the cortical part of the gland, where they break up into capillaries in the fibrous septa, and these converge to the very numerous veins of the medullary portion, which are collected together into the suprarenal vein, which usually emerges as a single vessel from the centre of the gland.

The *arteries* supplying the suprarenal capsules are numerous and of large size; they are derived from the aorta, the phrenic, and the renal; they subdivide into numerous minute branches previous to entering the substance of the gland.

The *suprarenal vein* returns the blood from the medullary venous plexus, and receives several branches from the cortical substance; it opens on the right side into the inferior vena cava, on the left side into the renal vein.

The *lymphatics* terminate in the lumbar glands.

The *nerves* are exceedingly numerous: they are found chiefly, if not entirely, in the medulla, and are derived from the solar and renal plexuses, and, according to Bergmann, from the phrenic and pneumogastric nerves. They have numerous small ganglia developed upon them, from which circumstance the organ has been conjectured to have some function in connection with the sympathetic nervous system.

THE CAVITY OF THE PELVIS.

The **cavity of the pelvis** is that part of the general abdominal cavity which is below the level of the linea ilio-pectinea and the promontory of the sacrum.

Boundaries.—It is bounded behind by the sacrum, the coccyx, the Pyriformis muscle, and the great sacro-sciatic ligaments; in front and at the sides by the ossa pubis and ischia, covered by the Obturator muscles; above, it communicates with the cavity of the abdomen; and below, the outlet is closed by the triangular ligament, the Levatores ani and Coccygei muscles, and the visceral layer of the pelvic fascia, which is reflected from the wall of the pelvis on to the viscera.

Contents.—The viscera contained in this cavity are—the urinary bladder, the rectum, and some of the generative organs peculiar to each sex, and some convolutions of the small intestines; they are partially covered by the peritoneum, and supplied with blood-vessels, lymphatics, and nerves.

THE BLADDER.

The **bladder** is the reservoir for the urine. It is a musculo-membranous sac situated in the pelvis, behind the pubes, and in front of the rectum in the male, the cervix uteri and upper part of the vagina intervening in the female. The shape, position, and relations of the bladder are greatly influenced by age, sex, and the degree of distention of the organ. *During infancy* it is conical in shape, and projects above the upper border of the os pubis into the hypogastric region. *In the adult*, when quite empty and contracted, it, together with the urethra, in a median

vertical section, is Y-shaped, the urethra forming the stem of the Y. It is placed deeply in the pelvis, flattened from before backward, the anterior limb of the Y reaching as high as the upper border of the symphysis pubis. When slightly distended it has a rounded form, and is still contained within the pelvic cavity; and when fully distended it is ovoid in shape, and rises into the abdominal cavity. When greatly distended it may reach nearly as high as the umbilicus. It is larger in its vertical diameter than from side to side, and its long axis is directed from above obliquely downward and backward, in a line directed from some point between the os pubis and umbilicus (according to its distention) to the end of the coccyx. The bladder, when distended, is slightly curved forward toward the anterior wall of the abdomen, so as to be more convex behind than in front. In the female it is larger in the transverse than in the vertical diameter, and its capacity is

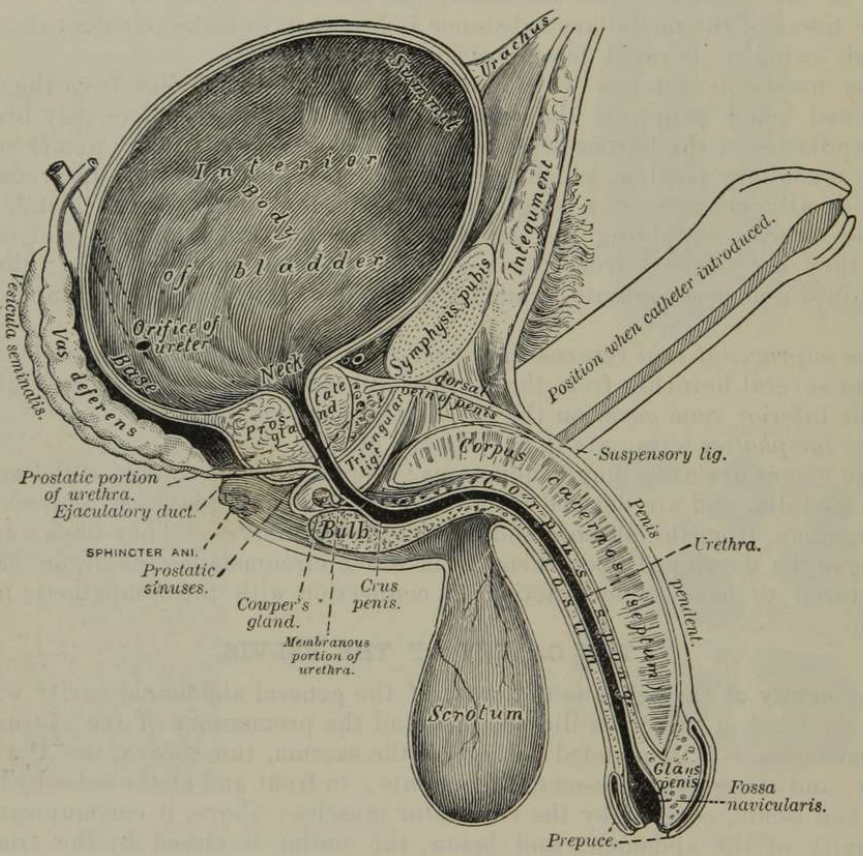

FIG. 732.—Vertical section of bladder, penis, and urethra.

said to be greater than in the male.[1] When moderately distended it contains about a pint.

The bladder has a *summit* and five surfaces, *superior* or *abdominal*, *postero-inferior* or *base*, *antero-inferior* or *pubic*, and two *lateral* or *sides*.

The *summit* or apex of the bladder looks forward and upward; it is connected to the abdominal wall by a fibro-muscular cord, the *urachus*, which is the obliterated remains of a tubular canal which, in the embryo, prolongs the cavity of the bladder into the *allantois*. It passes upward from the apex of the bladder between the transversalis fascia and peritoneum to the umbilicus, becoming thinner as it ascends. On each side of it is placed a fibrous cord, the obliterated portion of the hypogastric artery, which, passing upward from the side of the bladder, approaches the urachus above its summit. In the infant, at birth, the urachus is sometimes found per-

[1] According to Henle, the bladder is considerably smaller in the female than in the male.

vious, so that the urine escapes at the umbilicus, and calculi have been found in its canal.

The *superior* or *abdominal surface* is free, and extends antero-posteriorly from the summit to the base; laterally, it reaches to the *sides* of the bladder from which it is approximately marked off by the obliterated hypogastric arteries. This surface is entirely covered by peritoneum, and is in relation with the uterus, in the female, the sigmoid flexure, in the male, and in either sex with some loops of the small intestine. Posteriorly on each side, beneath the peritoneum, is, in the male, a part of the vas deferens.

The *antero-inferior* or *pubic surface* is not covered in front by peritoneum, but is in relation with the triangular ligament, the posterior surface of the symphysis pubis, the anterior parts of Levator ani and Internal obturator muscles,

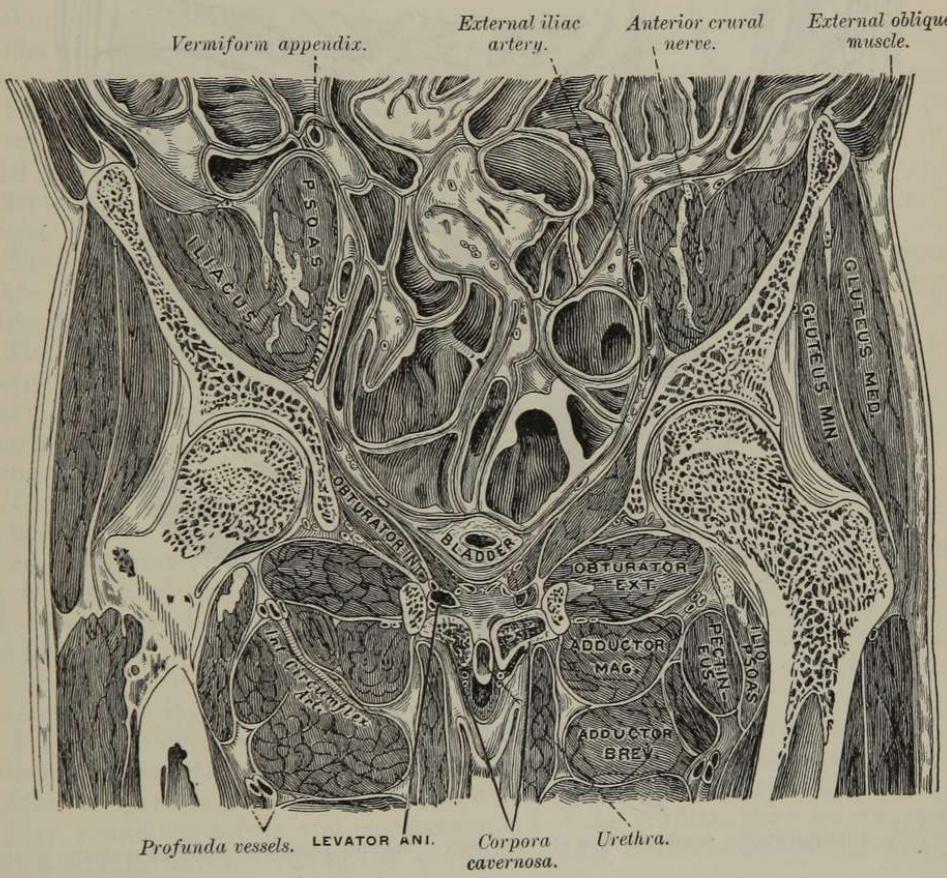

FIG. 731.—Frontal section of the lower part of the abdomen. Viewed from the front. (Braune.)

and, when distended, with the abdominal parietes, recto-vesical fascia being interposed.

The *side* of the bladder is crossed obliquely from below, upward and forward, by the obliterated hypogastric artery; above and behind this cord the side of the bladder is covered by peritoneum, but below and in front of it the serous covering is wanting, and it is connected to the recto-vesical fascia. The vas deferens passes, in an arched direction, from before backward, along the posterior portion (subperitoneal) of the side of the bladder, toward its base, crossing the obliterated hypogastric artery, and passing along the inner side of the ureter. The *space* occupied by recto-vesical fascia, which lies between the pubic surface and those portions of the sides of the bladder which are uncovered by peritoneum on the one hand, and their antero-inferior relations on the other, is known as the Cavum Retzii or space of Retzius.

The *base* (*fundus*) *of the bladder* is directed downward and backward. It varies in extent according to the state of distention of the organ, being very broad when full, but much narrower when empty. *In the male* it rests upon the second portion of the rectum, from which it is separated by a reflection of the recto-vesical fascia. It is covered superiorly, for a slight extent, by the peritoneum, which is reflected from it upon the rectum, forming the recto-vesical fold. The portion of the bladder in relation with the rectum corresponds to a triangular space bounded in front by the prostate gland, and on each side by the vesicula seminalis and vas deferens. *In the female* the base of the bladder lies in contact with the cervix

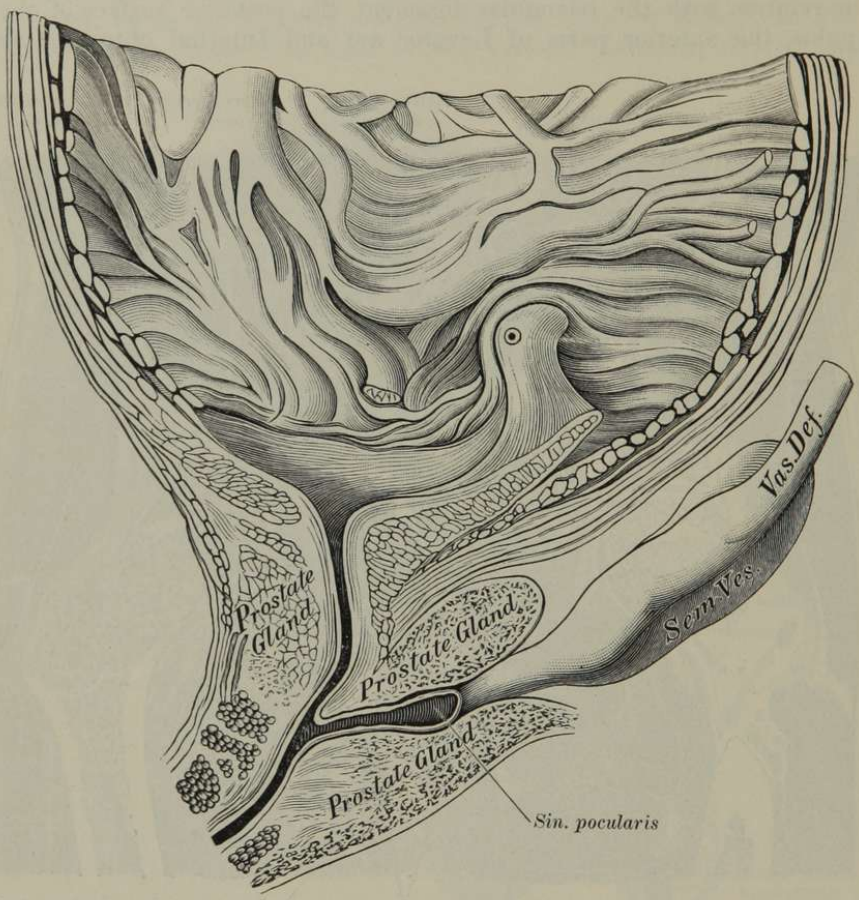

FIG. 732.—Antero-posterior median section of lower part of bladder, prostate gland, and prostatic urethra. (Henle.)

uteri and upper part of the anterior wall of the vagina. Above this connection is the peritoneal utero-vesical pouch.

The so-called *neck of the bladder* is the point of commencement of the urethra. The portion of the bladder immediately surrounding it is in relation with the prostate gland.

Ligaments.—The bladder is retained in its place by ligaments which are divided into true and false. The true ligaments are five in number: two anterior, two lateral, and the urachus. The false ligaments, also five in number, are formed by folds of the peritoneum.

The *anterior ligaments* (*pubo-prostatic*) extend from the back of the os pubis, one on each side of the symphysis, to the pubic surface of the bladder, over the upper surface of the prostate gland. These ligaments are formed by the recto-vesical fascia, and contain muscular fibres prolonged from the bladder.

The *lateral ligaments*, also formed by the recto-vesical fascia, are broader and thinner than the preceding. They are attached to the lateral parts of the prostate and to the sides of the bladder and the pelvic wall. The posterior prolongation of this ligament is known as the *ligament of the rectum.*

The *urachus* is the fibro-muscular cord already mentioned, extending between the summit of the bladder and the umbilicus. It is broad below, and becomes narrower as it ascends.

The *false ligaments of the bladder* are—two posterior, two lateral, and one superior.

The *two posterior* pass forward, in the male, from the sides of the rectum; in the female, from the sides of the uterus to the posterior and lateral aspect of the bladder; they form the lateral boundaries of the recto-vesical cul-de-sac of the peritoneum, and contain the obliterated hypogastric arteries and the ureters, together with vessels and nerves.

The *two lateral ligaments* are reflections of the peritoneum from the iliac fossæ to the sides of the bladder, along the line of the obliterated hypogastric arteries.

The *superior ligament* is the prominent fold of the peritoneum extending from the summit of the bladder to the umbilicus. It covers the urachus and the obliterated hypogastric arteries.

Structure.—The bladder is composed of four coats—serous, muscular, submucous, and mucous.

The *serous coat* is derived from the peritoneum. It invests the entire superior surface, the upper part of the base, and each *side*, above and behind the "hypogastric cord," and is reflected on to the abdominal and pelvic walls.

The *muscular coat* consists of three layers of unstriped muscular fibre: an external layer, composed of fibres having for the most part a longitudinal arrangement; a middle layer, in which the fibres are arranged, more or less, in a circular manner; and an internal layer, in which the fibres have a general longitudinal arrangement.

The *fibres of the external longitudinal layer* arise from the posterior surface of the body of the os pubis in both sexes (*musculi pubo-vesicalis*), and in the male from the adjacent part of the prostate gland and its capsule. They pass, in a more or less longitudinal manner, up the anterior surface of the bladder, over its apex, and then descend along its posterior surface to its base, where they become attached to the prostate in the male and to the front of the vagina in the female. At the sides of the bladder the fibres are arranged obliquely and intersect one another. This layer has been named the *detrusor urinæ muscle.*

The *middle circular layers* are very thinly and irregularly scattered on the body of the organ, and, though to some extent placed transversely to the long axis of the bladder, are for the most part arranged obliquely. Toward the lower part of the bladder, round the cervix and commencement of the urethra, they are disposed in a thick circular layer, forming the *sphincter vesicæ*, which is continuous with the muscular fibres of the prostate gland.

The *internal longitudinal layer* is thin, and its fasciculi have a reticular arrangement, but with a tendency to assume for the most part a longitudinal direction.

Two bands of oblique fibres, originating behind the orifices of the ureters, pass between these orifices and also converge to the back part of the prostate gland, and are inserted, by means of a fibrous process, into the middle lobe of that organ. They are the *muscles of the ureters,* described by Sir C. Bell, who supposed that during the contraction of the bladder they served to retain the oblique direction of the ureters, and so prevent the reflux of the urine into them.

The *submucous coat* consists of a layer of areolar tissue connecting together the muscular and mucous coats, and intimately united to the latter.

The *mucous coat* is thin, smooth, and of a pale rose color. It is continuous through the ureters with the lining membrane of the uriniferous tubes, and below with that of the urethra. It is connected loosely to the muscular coat by a layer

of areolar tissue, excepting at the trigone, where its adhesion is more close. It is provided with mucous follicles, more numerous than elsewhere near the neck of the organ, but which are not regarded as definite glands. The epithelium covering it is of the transitional stratified variety, consisting of a superficial layer of polyhedral, flattened cells, each with one, two, or three nuclei; beneath these a stratum of large club-shaped cells, with the narrow extremity directed downward

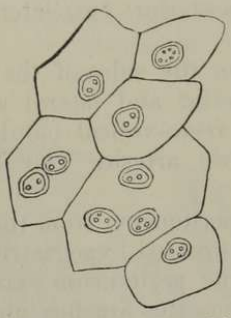

FIG. 733.—Superficial layer of the epithelium of the bladder. Composed of polyhedral cells of various sizes, each with one, two, or three nuclei. (Klein and Noble Smith.)

FIG. 734.—Deep layers of epithelium of bladder showing large club-shaped cells above, and smaller, more spindle-shaped cells below, each with an oval nucleus. (Klein and Noble Smith.)

and wedged in between smaller spindle-shaped cells, containing an oval nucleus (Figs. 733, 734).

Objects Seen on the Inner Surface.—Upon the inner surface of the bladder are seen the orifices of the ureters, the trigone, and the orifice of the urethra.

The Orifices of the Ureters.—These are situated at each end of the base of the trigone, being distant from each other by less than two inches; they are about an inch and a half from the base of the prostate and the commencement of the urethra.

The *trigonum vesicæ* (Lieutaud), or *trigone vesicale*, is a triangular smooth surface, with the apex directed forward, situated in the base of the bladder immediately behind the urethral orifice. It is paler in color than the rest of the mucous membrane, and never presents any rugæ, even in the collapsed condition of the organ, owing to its intimate adhesion to the subjacent tissue. It is bounded at each posterior angle by the orifice of the ureter. Its antero-inferior angle is occupied by the orifice of the urethra. Between the orifices of the ureters is seen an arched fold (*plica ureterica*) of mucous membrane caused by the projection of muscular fibres which have a similar direction (see preceding page). Projecting from the lower and anterior part and reaching to the orifice of the urethra is a slight elevation of mucous membrane called the *uvula vesicæ*. It is formed by a thickening of the submucous tissue. In the female, the uvula vesicæ and trigonum are small and ill-defined.

The *arteries* supplying the bladder are the superior, middle, and inferior vesical in the male, with additional branches from the uterine and vaginal in the female. They are all derived from the anterior trunk of the internal iliac. The obturator and sciatic arteries also supply small visceral branches to the bladder.

The *veins* form a complicated plexus round the neck, sides, and base of the bladder, and terminate in the internal iliac vein.

The *lymphatics* accompany the blood-vessels, passing through the glands surrounding them.

The *nerves* are derived from the pelvic plexus of the sympathetic and from the third and the fourth sacral nerves; the former supplying the upper part of the organ, the latter its base and neck. According to F. Darwin, the sympathetic fibres have ganglia connected with them, which send branches to the vessels and muscular coat.

Surface Form.—The surface form of the bladder varies with its degree of distension and under other circumstances. In the young child it is represented by a conical figure, the apex

of which, even when the viscus is empty, is situated in the hypogastric region, about an inch above the level of the symphysis pubis. In the adult, when the bladder is empty, its apex does not reach above the level of the upper border of the symphysis pubis, and the whole organ is situated in the pelvis; the neck, in the male, corresponding to a line drawn horizontally backward through the symphysis a little below its middle. As the bladder becomes distended it gradually rises out of the pelvis into the abdomen, and forms a swelling in the hypogastric region which is perceptible to the hand as well as to percussion. In extreme distension it reaches into the umbilical region. Under these circumstances it is closely applied to the abdominal wall, without the intervention of peritoneum, so that it can be tapped by an opening in the middle line just above the pubes without any fear of wounding the serous membrane. When the rectum is distended the prostatic portion of the urethra is elongated and the bladder lifted out of the pelvis and the peritoneum pushed upward. Advantage is taken of this in performing the operation of suprapubic cystotomy. The rectum is distended by an india-rubber bag, which is introduced into this cavity empty, and then filled with ten or twelve ounces of water. If now the bladder is injected with about half a pint of some antiseptic fluid, it will appear above the pubes, plainly perceptible to the sight and touch. The peritoneum will be pushed out of the way, and an incision three inches long may be made in the linea alba from the symphysis pubis upward without any great risk of wounding the peritoneum.

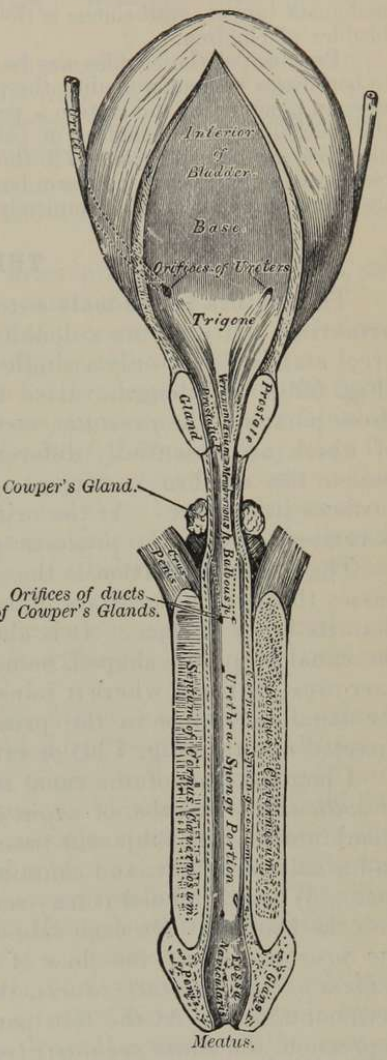

FIG. 735.—The bladder and urethra laid open. Seen from above.

When distended the bladder can be felt in the male, from the rectum, behind the prostate, and fluctuation can be perceived by a bimanual examination, one finger being introduced into the rectum and the distended bladder tapped on the front of the abdomen with the finger of the other hand. This portion of the bladder—that is, the portion felt in the rectum by the finger—is also uncovered by peritoneum, and the bladder may here be punctured from the rectum, in the middle line, without risk of wounding the serous membrane.

Surgical Anatomy.—A defect of development in which the bladder is implicated is known under the name of *extroversion of the bladder*. In this condition the lower part of the abdominal wall and the anterior wall of the bladder are wanting, so that the posterior surface of the bladder presents on the abdominal surface, and is pushed forward by the pressure of the viscera within the abdomen, forming a red vascular tumor on which the openings of the ureters are visible. The penis, except the glans, is rudimentary and is cleft on its dorsal surface, exposing the floor of the urethra—a condition known as *epispadias*. The pelvic bones are also arrested in development (see page 283).

The bladder may be ruptured by violence applied to the abdominal wall, when the viscus is distended without any injury to the bony pelvis, or it may be torn in cases of fracture of the pelvis. The rupture may be either intraperitoneal or extraperitoneal—that is, may implicate the superior surface of the bladder in the former case, or one of the other surfaces in the latter. Rupture of the anterior surface alone is, however, very rare. Until recently intraperitoneal rupture was uniformly fatal, but now abdominal section and suturing the rent with Lembert's suture is resorted to, with a very considerable amount of success. The sutures are inserted only through the peritoneal and muscular coats in such a way as to bring the serous surfaces at the margins of the wound into apposition, and one is inserted just beyond the end of the wound. The bladder should be tested as to whether it is water-tight before closing the external wound.

The muscular coat of the bladder undergoes hypertrophy in cases in which there is any obstruction to the flow of urine. Under these circumstances the bundles of which the muscular coat consists become much increased in size, and, interlacing in all directions, give rise to what is known as the *fasciculated bladder*. Between these bundles of muscular fibres the mucous membrane may bulge out, forming sacculi, constituting the *sacculated bladder*, and in these little pouches phosphatic secretions may collect, forming *encysted calculi*. The mucous membrane is very loose and lax, except over the trigone, to allow of the distension of the viscus.

Various forms of tumor have been found springing from the wall of the bladder. The

innocent tumors are the papilloma and the mucous polypus, arising from the mucous membrane; the fibrous, from the submucous tissue; and the myoma, originating in the muscular tissue; and, very rarely, dermoid tumors, the exact origin of which it is difficult to explain. Of the malignant tumors, epithelioma is the most common, but sarcomata are occasionally found in the bladder of children.

Puncture of the bladder may be performed either above the pubes or through the rectum, in both cases without wounding the peritoneum. The former plan is generally to be preferred, since in puncture by the rectum a permanent fistula may be left from abscess forming between the rectum and the bladder; or pelvic cellulitis may be set up; moreover, it is exceedingly inconvenient to keep a cannula in the rectum. In some cases in performing this operation the recto-vesical pouch of peritoneum has been wounded, inducing fatal peritonitis. The operation, therefore, has been almost completely abandoned.

THE MALE URETHRA.

The **urethra in the male** extends from the neck of the bladder to the meatus urinarius. It presents a double curve in the flaccid state of the penis, but in the erect state it forms only a single curve, the concavity of which is directed upward (Fig. 599). Its length varies from eight to nine inches, and it is divided into three portions, the *prostatic*, *membranous*, and *spongy*, the structure and relations of which are essentially different. Except during the passage of the urine or semen the urethra is a mere transverse cleft or slit, with its upper and under surfaces in contact. At the orifice of the urethra at the end of the penis the slit is vertical, and in the prostatic portion somewhat arched.

The **Prostatic Portion** is the widest and most dilatable part of the canal. It passes through the prostate gland, from its base to its apex, lying nearer its upper than its lower surface. It is about an inch and a quarter in length; the form of the canal is spindle-shaped, being wider in the middle than at either extremity, and narrowest in front, where it joins the membranous portion. A transverse section of the canal as it lies in the prostate is horseshoe in shape, the convexity being directed upward (Fig. 736) or rather forward, since its direction is nearly vertical.

Upon the floor of the canal is a narrow longitudinal ridge, the *verumontanum*, or *colliculus seminalis*, or *caput gallinaginis*, formed by an elevation of the mucous membrane and its subjacent tissue. It is eight or nine lines in length and a line and a half in height, and contains, according to Kobelt, muscular and erectile tissues. When distended it may serve to prevent the passage of the semen backward into the bladder. On each side of the verumontanum is a slightly depressed fossa, the *prostatic sinus*, the floor of which is perforated by numerous apertures, the *orifices of the prostatic ducts*, the ducts of the middle lobe opening behind the verumontanum. At the fore part of the verumontanum, in the middle line, is a depression, the *sinus pocularis* (*vesicula prostatica*), and upon or within its margins are the slit-like openings of the ejaculatory ducts. The sinus pocularis forms a *cul-de-sac* about a quarter of an inch in length, which runs upward and backward in the substance of the prostate beneath the middle lobe; its prominent upper wall partly forms the verumontanum. Its walls are composed of fibrous tissue, muscular fibres, and mucous membrane, and numerous small glands open on its inner surface. It has been called by Weber, who discovered it, the *uterus masculinus*, from its being developed from the united ends of the rudimentary Müllerian ducts, and therefore homologous with the uterus in the female.

The **Membranous portion of the urethra** extends between the apex of the prostate and the bulb of the corpus spongiosum. It is the narrowest part of the canal (excepting the orifice), and measures three-quarters of an inch along its anterior and half an inch along its posterior surface, in consequence of the bulb projecting backward beneath it. Its anterior concave surface is placed about an inch beneath the pubic arch, from which it is separated by the dorsal vessels and nerves of the penis and some muscular fibres. Its posterior convex surface is separated from the rectum by a triangular space, which is part of the perinæum. The membranous portion of the urethra perforates both the anterior and posterior layers of the deep perineal fascia, and receives an investment from them. As it pierces the posterior layer, the fibres around the opening are prolonged backward

over the posterior part of the membranous portion of the urethra, and as it pierces the anterior layer, a similar prolongation takes place in the opposite direction, investing the anterior part of the membranous portion. It is also surrounded by the Compressor urethræ muscle.

The **Spongy portion** is the longest part, and is contained in the corpus spongiosum. It is about six inches in length, and extends from the termination of the membranous portion of the meatus urinarius. Its direction at first is downward and forward then upward for a short distance and then downward again. It is narrow and of uniform size in the body of the penis, measuring about a quarter of an inch in diameter, being dilated behind, within the bulb, and again anteriorly within the glans penis, where it forms the *fossa navicularis*.

The *Bulbous portion* is a name given, in some descriptions of the urethra, to the posterior part of the spongy portion contained within the bulb.

The *meatus urinarius* is the most contracted part of the urethra; it is a vertical slit, about three lines in length, bounded on each side by two small labia.

The inner surface of the lining membrane of the urethra, especially on the floor of the spongy portion, presents the orifices of numerous mucous glands and follicles situated in the submucous tissue, and named the *glands of Littre*. They vary in size, and their orifices are directed forward, so that they may easily intercept the point of a catheter in its passage along the canal. One of these lacunæ, larger than the rest, is situated in the upper surface of the fossa navicularis, about an inch and a half from the orifice; it is called the *lacuna magna*. Into the bulbous portion are found opening the ducts of Cowper's glands.

Structure.—The urethra is composed of a continuous mucous membrane, supported by a submucous tissue which connects it with the various structures through which it passes.

The *mucous coat* forms part of the genito-urinary mucous membrane. It is continuous with the mucous membrane of the bladder, ureters, and kidneys; externally with the integument covering the glans penis; and is prolonged into the ducts of the glands which open into the urethra—viz. Cowper's glands and the prostate gland—and into the vasa deferentia and vesiculæ seminales through the ejaculatory ducts. In the spongy and membranous portions the mucous membrane is arranged in longitudinal folds when the organ is contracted. Small papillæ are found upon it near the orifice, and its epithelial lining is of the columnar and stratified variety, excepting near the meatus, where it is squamous.

The *submucous tissue* consists of a vascular erectile layer, outside which is a layer of unstriped muscular fibres, arranged in a circular direction, which separates the mucous membrane and submucous tissue from the tissue of the corpus spongiosum.

Surgical Anatomy.—The urethra may be ruptured by the patient falling astride of any hard substance and striking his perinæum, so that the urethra is crushed against the pubic arch. Bleeding will at once take place from the urethra, and this, together with the bruising in the perinæum and the history of the accident, will at once point to the nature of the injury.

The surgical anatomy of the urethra is of considerable importance in connection with the passage of instruments into the bladder. Otis was the first to point out that the urethra is capable of great dilatability, so that, excepting through the external meatus, an instrument corresponding to 18 English gauge (29 French) can usually be passed without damage. The orifice of the urethra is not so dilatable, and therefore frequently requires slitting. A recognition of this dilatability caused Bigelow to very considerably modify the operation of lithotrity and introduce that of litholapaxy. In passing catheters, especially fine ones, the point of the instrument should be kept as far as possible along the upper wall of the canal, as the point is otherwise very liable to enter one of the lacunæ. Stricture of the urethra is a disease of very common occurrence, and is generally situated in the spongy portion of the urethra, most commonly in the bulbous portion, just in front of the membranous urethra, but in a very considerable number of cases in the penile or ante-scrotal part of the canal.

MALE GENERATIVE ORGANS.

THE PROSTATE GLAND.

THE **Prostate Gland** (*προϊστημι*, to stand before) is a firm, muscular, glandular body, which is placed immediately in front of the neck of the bladder and around the commencement of the urethra. It is placed in the pelvic cavity, behind and below the symphysis pubis, posterior to the deep perineal fascia, and rests upon

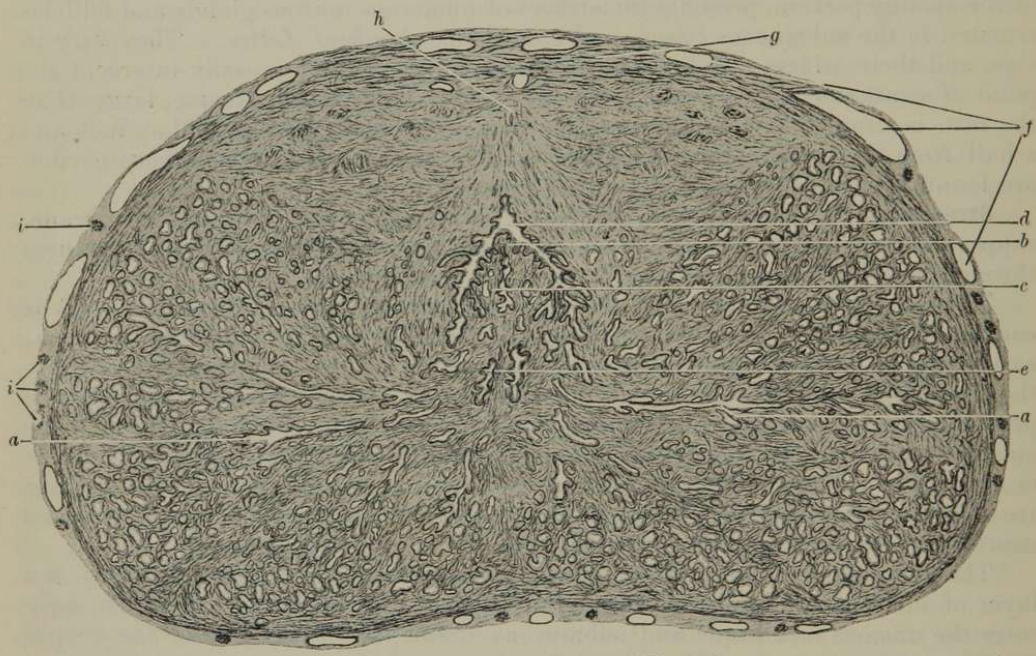

FIG. 736.—Transverse section of normal prostate through the middle of the verumontanum, from a subject aged nineteen years. (Taylor.) *a*, Longitudinal sections of ducts leading from the lobules of the prostatic glands; *b*, verumontanum; *c*, sinus pocularis; *d*, urethra; *e*, ejaculatory ducts; *f*, arteries, veins, and venous sinuses in capsule of prostate; *g*, nerve trunks in capsule; *h*, point of origin of fibro-muscular bands encircling urethra; *i*, zone of striated voluntary muscle on superior surface. (Drawn from Erdinger projection apparatus.)

the rectum, through which it may be distinctly felt, especially when enlarged. In shape and size it is said to resemble a chestnut.

Its *base* is directed upward and backward and rests against the neck of the bladder.

Its *apex* is directed downward and forward to the deep perineal fascia, which it touches.

Its *posterior surface* is smooth and flat, marked by a slight longitudinal furrow, and rests on the rectum, to which it is connected by dense areolar tissue.

Its *anterior surface* is convex, and is placed about three-quarters of an inch behind the lower part of the pubic symphysis.

It measures about an inch and a half in its transverse diameter at the base, an inch in its antero-posterior diameter, and three-quarters of an inch in depth. Its weight is about five drachms. It is held in its position by the anterior ligaments of the bladder (*pubo-prostatic*); by the posterior layer of the deep perineal fascia, which invests the commencement of the membranous portion of the urethra and

prostate gland; and by the anterior portion of the Levator ani muscle (*levator prostatæ*), which passes down on each side from the symphysis pubis and anterior ligament of the bladder to the *sides* of the prostate.

The prostate consists of two lateral lobes and a middle lobe.

The *two lateral lobes* are of equal size, separated by a deep notch behind, and by a slight furrow upon the anterior and posterior surfaces of the gland, which indicates the bilobed condition of the organ in some animals.

The third, or *middle lobe*, is a small transverse band, occasionally a rounded or triangular prominence, placed between the two lateral lobes at the posterior part of the organ. It lies immediately beneath the neck of the bladder, behind the commencement of the urethra, and above and between the ejaculatory ducts. Its existence is not constant, but it is occasionally found at an early period of life, as well as in adults and in old age.

The prostate gland is perforated by the urethra and the ejaculatory ducts. The urethra usually lies about one-third nearer its posterior than its anterior surface; occasionally, the prostate surrounds only the lower three-fourths of the tube, and more rarely the urethra runs through the lower instead of the upper part of the gland. The ejaculatory ducts pass forward obliquely between the middle and each lateral lobe of the prostate and open into the prostatic portion of the urethra.

Structure.—The prostate is enclosed in a thin but firm fibrous capsule, distinct from that derived from the posterior layer of the deep perineal fascia, and separated from it by a plexus of veins. Its substance is of a pale reddish-gray color, of great density and not easily torn. It consists of glandular substance and muscular tissue.

The muscular tissue, according to Kölliker, constitutes the proper stroma of the prostate, the connective tissue being very scanty, and simply forming thin trabeculæ between the muscular fibres, in which the vessels and nerves of the gland ramify. The muscular tissue is arranged as follows: Immediately beneath the fibrous capsule is a dense layer, which forms an investing sheath for the gland; secondly, around the urethra, as it lies in the prostate, is another dense layer of circular fibres, continuous behind with the internal layer of the muscular coat of the bladder, and in front blending with the fibres surrounding the membranous portion of the urethra. Between these two layers strong bands of muscular tissue, which decussate freely, form meshes in which the glandular structure of the organ is imbedded. In that part of the gland which is situated above the urethra the muscular tissue is especially dense, and there is here little or no gland tissue; while in that part which is below the urethra the muscular tissue presents a wide-meshed structure, which is densest at the upper part of the gland—that is, near the bladder—becoming looser and more sponge-like toward the apex of the organ.

The *glandular substance* is composed of numerous follicular pouches, opening into elongated canals, which join to form from twelve to twenty small excretory ducts. The follicles are connected together by areolar tissue, supported by prolongations from the fibrous capsule and muscular stroma, and enclosed in a delicate capillary plexus. The epithelium lining of both the canals and the terminal vesicles is of the columnar variety. The prostatic ducts open into the floor of the prostatic portion of the urethra.

Vessels and Nerves.—The *arteries* supplying the prostate are derived from the internal pudic, vesical, and hæmorrhoidal. Its *veins* form a plexus around the sides and base of the gland; they receive in front the dorsal vein of the penis, and terminate in the internal iliac vein. The *nerves* are derived from the pelvic plexus.

Surgical Anatomy.—The relation of the prostate to the rectum should be noted: by means of the finger introduced into the gut the surgeon detects enlargement or other disease of this organ; he can feel the apex of the gland, which is the guide to Cock's operation for stricture; he is enabled also by the same means to direct the point of a catheter when its introduction is attended with difficulty either from injury or disease of the membranous or prostatic portions of

the urethra. When the finger is introduced into the bowel the surgeon may, in some cases, especially in boys, learn the position, as well as the size and weight, of a calculus in the bladder; and in the operation for its removal, if, as is not unfrequently the case, it should be lodged behind an enlarged prostate, it may be displaced from its position by pressing upward the base of the bladder from the rectum. The prostate gland is occasionally the seat of suppuration, either due to injury, gonorrhœa, or tuberculous disease. The gland, being enveloped in a dense unyielding capsule, determines the course of the abscess, and also explains the great pain which is present in the acute form of the disease. The abscess most frequently bursts into the urethra, the direction in which there is least resistance, but may occasionally burst into the rectum, or more rarely in the perinæum. In advanced life the prostate becomes considerably enlarged, and projects into the bladder so as to impede the passage of the urine. According to Dr. Messer's researches, conducted at Greenwich Hospital, it would seem that such obstruction exists in 20 per cent. of all men over sixty years of age. In some cases the enlargement affects principally the lateral lobes, which may undergo considerable enlargement without causing much inconvenience. In other cases it would seem that the middle lobe enlarges most, and even a small enlargement of this lobe may act injuriously, by forming a sort of valve over the urethral orifice, preventing the passage of the urine, and blocking more completely the orifice the more the patient strains. In consequence of the enlargement of the prostate a pouch is formed at the base of the bladder behind the projection, in which water collects and cannot be entirely expelled. It becomes decomposed and ammoniacal, and leads to cystitis. For this condition "prostatectomy" is sometimes done. The bladder is opened by an incision above the symphysis pubis, the mucous membrane incised, and the enlarged and projecting middle lobe enucleated.

COWPER'S GLANDS.

Cowper's Glands are two small rounded and somewhat lobulated bodies of a yellow color, about the size of peas, placed behind the fore part of the membranous portion of the urethra, between the two layers of the deep perineal fascia. They lie close above the bulb, and are enclosed by the transverse fibres of the Compressor urethræ muscle. Their existence is said to be constant: they gradually diminish in size as age advances.

Structure.—Each gland consists of several lobules held together by a fibrous investment. Each lobule consists of a number of acini lined by columnar epithelial cells, opening into one duct, which, joining with the ducts of other lobules outside the gland, form a single excretory duct. The excretory duct of each gland, nearly an inch in length, passes obliquely forward beneath the mucous membrane, and opens by a minute orifice on the floor of the bulbous portion of the urethra. Their existence is said to be constant; they gradually diminish in size as age advances.

THE PENIS.

The **Penis** is the organ of copulation. It consists of a root, body, and extremity, or *glans penis*.

The *root* is firmly connected to the rami of the os pubis and ischium by two strong tapering, fibrous processes, the *crura*, and to the front of the symphysis pubis by the *suspensory ligament*, a strong band of fibrous tissue which passes downward from the front of the symphysis pubis to the upper surface of the root of the penis, where it blends with the fascial sheath of the organ.

The *extremity* or *glans penis*, presents the form of an obtuse cone, flattened from above downward. At its summit is a vertical fissure, the orifice of the urethra (*meatus urinarius*). The base of the glans forms a rounded projecting border, the *corona glandis*, and behind the corona is a deep constriction, the *cervix*. Upon both of these parts numerous small sebaceous glands are found, the *glandulæ Tysonii odoriferæ*. They secrete a sebaceous matter of very peculiar odor, which probably contains caseine and becomes easily decomposed.

The *body of the penis* is the part between the root and extremity. In the flaccid condition of the organ it is cylindrical, but when erect has a triangular prismatic form with rounded angles, the broadest side being turned upward, and called the *dorsum*. The body is covered by integument, and contains in its interior a large portion of the urethra. The integument covering the penis is remarkable for its thinness, its dark color, its looseness of connection with the deeper parts of the organ, and its containing no adipose tissue. At the root of the penis the

integument is continuous with that upon the pubes and scrotum, and at the neck of the glans it leaves the surface and becomes folded upon itself to form the *prepuce*.

The internal layer of the prepuce is attached behind to the cervix, and approaches in character to a mucous membrane; from the cervix it is reflected over the glans penis, and at the meatus urinarius is continuous with the mucous lining of the urethra.

The mucous membrane covering the glans penis contains no sebaceous glands, but projecting from its free surface are a number of small, highly sensitive papillæ. At the back part of the meatus urinarius a fold of mucous membrane passes backward to the bottom of a depressed raphe, where it is continuous with the prepuce; this fold is termed the *frænum præputii*.

Structure of the Penis.—The penis is composed of a mass of erectile tissue enclosed in three cylindrical fibrous compartments. Of these, two, the *corpora cavernosa*, are placed side by side along the upper part of the organ; the third, or *corpus spongiosum*, encloses the urethra and is placed below.

The **Corpora Cavernosa** form the chief part of the body of the penis. They consist of two fibrous cylindrical tubes, placed side by side, and intimately connected along the median line for their anterior three-fourths, whilst at their back part they separate from each other to form the *crura*, which are two strong tapering fibrous processes firmly connected to the rami of the os pubis and ischium. Each crus commences by a blunt-pointed process in front of the tuberosity of the ischium, and before its junction with its fellow to form the body of the penis it presents a slight enlargement, named by Kobelt the *bulb of the corpus cavernosum*. Just beyond this point they become constricted, and retain an equal diameter to their anterior extremity, where they form a single rounded end which is received into a fossa in the base of the glans penis. A median groove on the upper surface lodges the dorsal vein of the penis, and the groove on the under surface receives the corpus spongiosum. The root of the penis is connected to the symphysis pubis by the suspensory ligament.

Structure.—The corpora cavernosa are surrounded by a strong fibrous envelope, consisting of two sets of fibres—the one, longitudinal in direction, being common to the two corpora cavernosa, and investing them in a common covering; the other, internal, being circular in direction, and being proper to each corpus cavernosum. The internal circular fibres by their junction at one part form an incomplete partition or septum between the two bodies.

The *septum* between the two corpora cavernosa forms an imperfect partition; it is thick and complete behind, but in front it is incomplete, and consists of a number of vertical bands, which are arranged like the teeth of a comb, whence the name which it has received. *septum pectiniforme*. These bands extend between the dorsal and the urethral surface of the corpora cavernosa. This fibrous investment is extremely dense, of considerable thickness, and consists of bundles of shining white fibres, with an admixture of well-developed elastic fibres, so that it is possessed of great elasticity.

From the internal surface of the fibrous envelope, as well as from the sides of the septum, are given off a number of bands or cords which cross the interior of the corpora cavernosa in all directions, subdividing them into a number of separate compartments, and giving the entire structure a spongy appearance. These bands and cords are called *trabeculæ*, and consist of white fibrous tissue, elastic fibres, and plain muscular fibres. In them are contained numerous arteries and nerves.

The component fibres of which the trabeculæ are composed are larger and stronger round the circumference than at the centre of the corpora cavernosa; they are also thicker behind than in front. The interspaces, on the contrary, are larger at the centre than at the circumference, their long diameter being directed transversely; they are largest anteriorly. They are occupied by venous blood, and are lined by a layer of flattened cells similar to the endothelial lining of veins.

The whole of the structure of the corpora cavernosa contained within the fibrous sheath consists, therefore, of a sponge-like tissue of areolar spaces freely communicating with each other and filled with venous blood. The spaces may therefore be regarded as large cavernous veins.

The arteries bringing the blood to these spaces are the arteries of the corpora cavernosa and branches from the dorsal artery of the penis, which perforate the fibrous capsule, along the upper surface, especially near the fore part of the organ.

These arteries on entering the cavernous structure divide into branches which are supported and enclosed by the trabeculæ. Some of these terminate in a capillary network, the branches of which open directly into the cavernous spaces; others assume a tendril-like appearance, and form convoluted and somewhat dilated vessels, which were named by Müller *helicine arteries*. They project into the spaces, and from them are given off small capillary branches to supply the trabecular structure. They are bound down in the spaces by fine fibrous processes, and are more abundant in the back part of the corpora cavernosa (Fig. 737).

The blood from the cavernous spaces is returned by a series of vessels, some of which emerge in considerable numbers from the base of the glans penis and

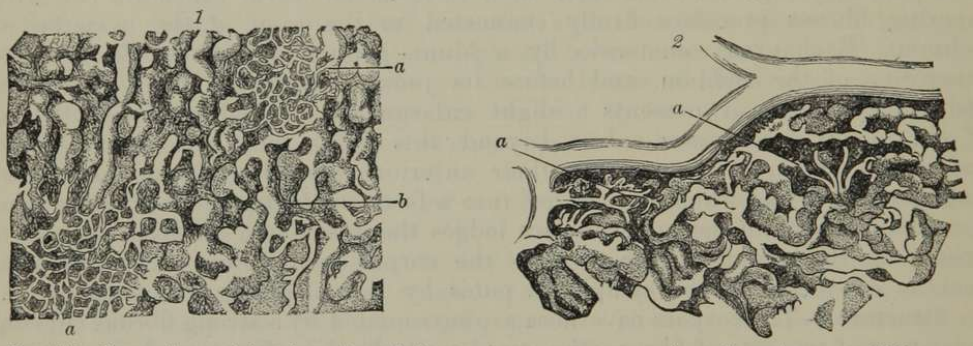

FIG. 737.—From the peripheral portion of the corpus cavernosum penis under a low magnifying power. (Copied from Langer.) 1. *a*. Capillary network. *b*. Cavernous spaces. 2. Connection of the arterial twigs (*a*) with the cavernous spaces.

converge on the dorsum of the organ to form the dorsal vein; others pass out on the upper surface of the corpora cavernosa and join the dorsal vein; some emerge from the under surface of the corpora cavernosa, and, receiving branches from the corpus spongiosum, wind round the sides of the penis to terminate in the dorsal vein; but the greater number pass out at the root of the penis and join the prostatic plexus.

The **Corpus Spongiosum** encloses the urethra, and is situated in the groove on the under surface of the corpora cavernosa. It commences posteriorly in front of the deep perineal fascia, between the diverging crura of the corpora cavernosa, where it forms a rounded enlargement, the *bulb*, and terminates anteriorly in another expansion, the *glans penis*, which overlaps the anterior rounded extremity of the corpora cavernosa. The central portion, or body of the corpus spongiosum, is cylindrical, and tapers slightly from behind forward.

The *bulb* varies in size in different subjects; it receives a fibrous investment from the anterior layer of the deep perineal fascia, and is surrounded by the Accelerator urinæ muscle. The urethra enters the bulb nearer its upper than its lower surface, being surrounded by a layer of erectile tissue, a thin prolongation of which is continued backward round the membranous and prostatic portions of the canal to the neck of the bladder, lying between the two layers of muscular tissue. The portion of the bulb below the urethra presents a partial division into two lobes, being marked externally by a linear raphe, whilst internally there projects inward, for a short distance, a thin fibrous septum, more distinct in early life.

Structure.—The corpus spongiosum consists of a strong fibrous envelope, enclosing a trabecular structure, which contains in its meshes erectile tissue. The fibrous envelope is thinner, whiter in color, and more elastic than that of the corpora cavernosa. The trabeculæ are delicate, uniform in size, and the meshes between them small, their long diameter, for the most part, corresponding with that of the penis. The external envelope or outer coat of the corpus spongiosum is formed partly of unstriped muscular fibre, and a layer of the same tissue immediately surrounds the canal of the urethra.

The *lymphatics of the penis* consist of a superficial and deep set; the former are derived from a dense network on the skin of the glans and prepuce and from the mucous membrane of the urethra, and terminate in the superficial inguinal glands; the latter emerge from the corpora cavernosa and corpus spongiosum, and, passing beneath the pubic arch, join the deep lymphatics of the pelvis.

The *nerves* are derived from the internal pudic nerve and the pelvic plexus. On the glans and bulb some filaments of the cutaneous nerves have Pacinian bodies connected with them, and, according to Krause, many of them terminate in a peculiar form of end-bulb.

Surgical Anatomy.—The penis occasionally requires removal for malignant disease. Usually, removal of the ante-scrotal portion is all that is necessary, but sometimes it is requisite to remove the whole organ from its attachment to the rami of the os pubis and ischium. The former operation is performed either by cutting off the whole of the anterior part of the penis with one sweep of the knife, or, what is better, cutting through the corpora cavernosa from the dorsum, and then separating the corpus spongiosum from them, dividing it at a level nearer the glans penis. The mucous membrane of the urethra is then slit up, and the edges of the flap attached to the external skin, in order to prevent contraction of the orifice, which would otherwise take place. The vessels which require ligature are the two dorsal arteries of the penis, the arteries of the corpora cavernosa, and the artery of the septum. When the entire organ requires removal the patient is placed in the lithotomy position, and an incision is made round the root of the penis, and carried down the median line of the scrotum as far as the perinæum. The two halves of the scrotum are then separated from each other, and, a catheter having been introduced into the bladder as a guide, the membranous portion of the urethra is separated from the corpus spongiosum and divided, the catheter having been withdrawn, just behind the bulb. The suspensory ligament is now severed, and the crura separated from the bone with a periosteum scraper, and the whole penis removed. The membranous portion of the urethra, which has not been removed, is now to be attached to the skin at the posterior extremity of the incision in the perinæum. The remainder of the wound is to be brought together, free drainage being provided for.

THE TESTES AND THEIR COVERINGS (Fig. 738).

The **Testes** are two glandular organs, which secrete the semen; they are situated in the scrotum, being suspended by the spermatic cords. At an early period of fœtal life the testes are contained in the abdominal cavity, behind the peritoneum. Before birth they descend to the inguinal canal, along which they pass with the spermatic cord, and, emerging at the external abdominal ring, they descend into the scrotum, becoming invested in their course by numerous coverings derived from the serous, muscular, and fibrous layers of the abdominal parietes, as well as by the scrotum. The coverings of the testes are—the

Skin, Dartos } Scrotum.
Intercolumnar, or External spermatic fascia.
Cremasteric fascia.
Infundibuliform, or Fascia propria (Internal spermatic fascia).
Tunica vaginalis.

The **Scrotum** is a cutaneous pouch which contains the testes and part of the spermatic cords. It is divided superficially into two lateral halves by a median line, or *raphe*, which is continued forward to the under surface of the penis and backward along the middle line of the perinæum to the anus. Of these two lateral portions, the left is longer than the right, and corresponds with the greater length of the spermatic cord on the left side. Its external aspect varies under different circumstances:

thus, under the influence of warmth and in old and debilitated persons it becomes elongated and flaccid, but under the influence of cold and in the young and robust it is short, corrugated, and closely applied to the testes.

The scrotum consists of two layers, the integument and the dartos.

The **integument** is very thin, of a brownish color, and generally thrown into folds or rugæ. It is provided with sebaceous follicles, the secretion of which has a peculiar odor, and is beset with thinly-scattered, crisp hairs, the roots of which are seen through the skin.

The **dartos** is a thin layer of loose reddish tissue, endowed with contractility: it forms the proper tunic of the scrotum, is continuous, around the base of the scrotum, with the two layers of the superficial fascia of the groin and perinæum,

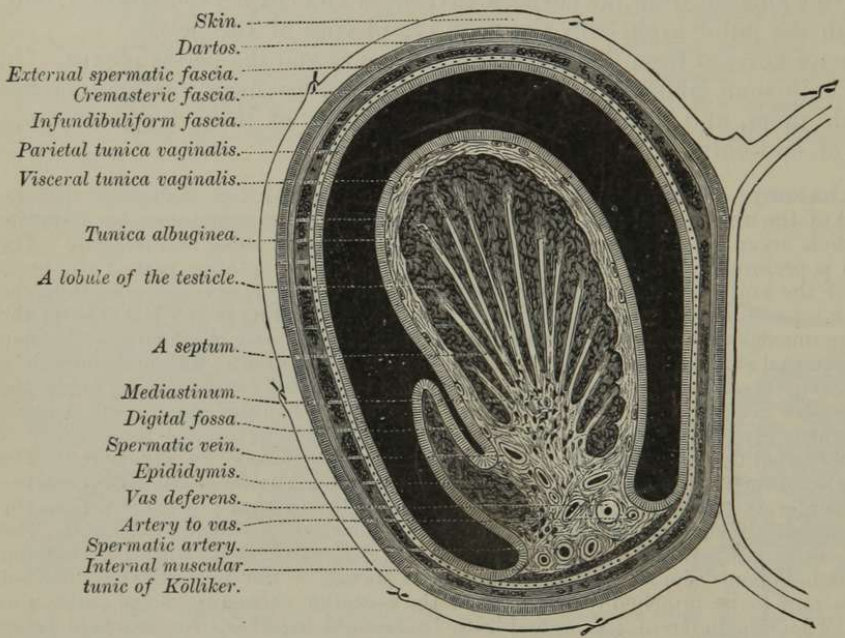

FIG. 738.—Transverse section through the left side of the scrotum and the left testicle. The sac of the tunica vaginalis represented in a distended condition. (Delépine.)

and sends inward a distinct septum, *septum scroti*, which divides it into two cavities for the two testes, the septum extending between the raphe and the under surface of the penis as far as its root.

The dartos is closely united to the skin externally, but connected with the subjacent parts by delicate areolar tissue, upon which it glides with the greatest facility. The dartos is very vascular, and consists of a loose areolar tissue containing unstriped muscular fibre, but no fat. Its contractility is slow, and excited by cold and mechanical stimuli, but not by electricity.

The **intercolumnar fascia** is a thin membrane derived from the margin of the pillars of the external abdominal ring, during the descent of the testes in the fœtus, which is prolonged downward around the surface of the cord and testis. It is separated from the dartos by loose areolar tissue, which allows of considerable movement of the latter upon it, but is intimately connected with the succeeding layers.

The **cremasteric fascia** consists of scattered bundles of muscular fibres (*Cremaster muscle*) connected together into a continuous covering by intermediate areolar tissue. The muscular fibres are continuous with the lower border of the Internal oblique muscle of the abdomen.

The **fascia propria** is a thin membranous layer which loosely invests the surface of the cord. It is a continuation downward of the infundibuliform process of the fascia transversalis and the subperitoneal areolar tissue, and is acquired during the descent of the testis in the fœtus.

The **tunica vaginalis** is described with the proper covering of the testis.

Vessels and Nerves.—The *arteries* supplying the coverings of the testis are: the superficial and deep external pudic, from the femoral; the superficial perineal branch of the internal pudic; and the cremasteric branch from the epigastric. The *veins* follow the course of the corresponding arteries. The *lymphatics* terminate in the inguinal glands. The *nerves* are: the ilio-inguinal branch of the lumbar plexus, the two superficial perineal branches of the internal pudic nerve, the inferior pudendal branch of the small sciatic nerve, and the genital branch of the genito-crural nerve.

The **Spermatic Cord** extends from the internal abdominal ring, where the structures of which it is composed converge, to the back part of the testicle. In the abdominal wall the cord passes obliquely along the inguinal canal, resting on Poupart's ligament. It lies at first between the Internal oblique and the fascia transversalis; but nearer the pubes it has the aponeurosis of the External oblique in front of it and the conjoined tendon behind it. It then escapes at the external ring, and descends nearly vertically into the scrotum. The left cord is rather longer than the right, consequently the left testis hangs somewhat lower than its fellow.

Structure of the Spermatic Cord.—The spermatic cord is composed of arteries, veins, lymphatics, nerves, the excretory duct of the testicle, and a thin fibrous cord, the *remains* of the *peritoneal pouch*, caused by the descent of the testicle. These structures are connected together by areolar tissue, and invested by the fasciæ brought down by the testicle in its descent.

The *arteries of the cord* are: the spermatic, from the aorta; the artery of the vas deferens, from the superior vesical; the cremasteric, from the deep epigastric.

The *spermatic artery*, a branch of the abdominal aorta, escapes from the abdomen at the internal or deep abdominal ring, and accompanies the other constituents of the spermatic cord along the inguinal canal and through the external abdominal ring into the scrotum. It then descends to the testicle, and, becoming tortuous, divides into several branches, two or three of which accompany the vas deferens and supply the epididymis, anastomosing with the artery of the vas deferens; others pierce the back of the tunica albuginea and supply the substance of the testis.

The *cremasteric artery* is a branch of the deep epigastric artery. It accompanies the spermatic cord and supplies the Cremaster muscle and other coverings of the cord, anastomosing with the spermatic artery.

The *artery of the vas deferens*, a branch of the superior vesical, is a long slender vessel which accompanies the vas deferens, ramifying upon the coats of that duct, and anastomosing with the spermatic artery near the testis.

The spermatic veins emerge from the back of the testis and receive tributaries from the epididymis; they unite and form a convoluted plexus (*plexus pampiniformis*), which forms the chief mass of the cord: the vessels composing this plexus are very numerous, and ascend along the cord in front of the vas deferens; below the external or superficial abdominal ring they unite to form three or four veins, which pass along the spermatic canal, and, entering the abdomen through the internal or deep abdominal ring, coalesce to form two veins. These again unite to form a single vein, which opens on the right side into the inferior vena cava at an acute angle, and on the left side into the renal vein at a right angle.

The *lymphatic vessels* terminate in the lumbar glands.

The *nerves* are the spermatic plexus from the sympathetic, joined by filaments from the pelvic plexus which accompany the artery of the vas deferens.

Surgical Anatomy.—The scrotum forms an admirable covering for the protection of the testicle. This body, lying suspended and loose in the cavity of the scrotum and surrounded by a serous membrane, is capable of great mobility, and can therefore easily slip about within the scrotum, and thus avoid injuries from blows or squeezes. The skin of the scrotum is very elastic and capable of great distension, and on account of the looseness and amount of subcutaneous tissue the scrotum becomes greatly enlarged in cases of œdema, to which this part is especially liable on account of its dependent position. The scrotum is frequently the seat of

epithelioma; this is no doubt due to the rugæ on its surface, which favor the lodgment of dirt, and this, causing irritation, is the exciting cause of the disease, which is especially common in chimney-sweeps from the lodgment of soot. The scrotum is also the part most frequently affected by elephantiasis.

On account of the looseness of the subcutaneous tissue considerable extravasations of blood may take place from very slight injuries. It is therefore generally recommended never to apply leeches to the scrotum, since they may lead to considerable ecchymosis, but rather to puncture one or more of the superficial veins of the scrotum in cases where local bloodletting from this part is judged to be desirable. The muscular fibre in the dartos causes contraction and considerable diminution in the size of a wound of the scrotum, as after the operation of castration, and is of assistance in keeping the edges together and covering the exposed parts.

THE TESTES.

The **Testes** are suspended in the scrotum by the spermatic cords. As the left spermatic cord is rather longer than the right one, the left testicle hangs somewhat lower than its fellow. Each gland is of an oval form, compressed laterally, and having an oblique position in the scrotum, the upper extremity being directed forward and a little outward, the lower, backward and a little inward; the anterior convex border looks forward, outward, and downward; the posterior or straight border, to which the cord is attached, inward, backward, and upward.

The anterior border and lateral surfaces, as well as both extremities of the organ, are convex, free, smooth, and invested by the tunica vaginalis. The posterior border, to which the cord is attached, receives only a partial investment from that membrane. Lying along this posterior border is a long, narrow, flattened body, named from its relation to the testis, the epididymis (*δίδυμος*, testis). It consists of a central portion, or *body;* an upper enlarged extremity, the *globus major*, or head; and a lower pointed extremity, the tail, or *globus minor*. The globus major is intimately connected with the upper end of the testicle by means of its efferent ducts, and the globus minor is connected with its lower end by cellular tissue and a reflection of the tunica vaginalis. The outer surface and upper and lower ends of the epididymis are free and covered by serous membrane; the body is also completely invested by it, excepting along its posterior border. The epididymis is connected to the back of the testis by a fold of the serous membrane. Attached to the upper end of the testis or to the epididymis are one or more small pedunculated bodies. One of them is pretty constantly found between the globus major of the epididymis and the testicle, and is believed to be the remains of the upper extremity of the Müllerian duct (page 136). It is termed the *hydatid of Morgagni*. When the testicle is removed from the body, the position of the vas deferens, on the posterior surface of the testicle and inner side of the epididymis, marks the side to which the gland has belonged.

Size and Weight.—The average dimensions of this gland are from one and a half to two inches in length, one inch in breadth, and an inch and a quarter in the antero-posterior diameter, and the weight varies from six to eight drachms, the left testicle being a little the larger.

The testis is invested by three tunics—the tunica vaginalis, tunica albuginea, and tunica vasculosa.

The **Tunica Vaginalis** is the serous covering of the testis. It is a pouch of serous membrane, derived from the peritoneum during the descent of the testis in the fœtus from the abdomen into the scrotum. After its descent that portion of the pouch which extends from the internal ring to near the upper part of the gland becomes obliterated, the lower portion remaining as a shut sac, which invests the outer surface of the testis, and is reflected on to the internal surface of the scrotum; hence it may be described as consisting of a visceral and parietal portion.

The *visceral portion* (*tunica vaginalis propria*) covers the outer surface of the testis, as well as the epididymis, connecting the latter to the testis by means of a distinct fold forming a depression, the digital fossa. From the posterior border of the gland it is reflected on to the internal surface of the scrotum.

The *parietal portion of the serous membrane* (*tunica vaginalis reflexa*) is far more extensive than the visceral portion, extending upward for some distance in front and on the inner side of the cord, and reaching below the testis. The inner surface of the tunica vaginalis is free, smooth, and covered by a layer of endothelial cells. The interval between the visceral and parietal layers of this membrane constitutes the cavity of the tunica vaginalis.

The obliterated portion of the pouch may generally be seen as a fibro-cellular thread lying in the loose areolar tissue around the spermatic cord; sometimes this may be traced as a distinct band from the upper end of the inguinal canal, where it is connected with the peritoneum, down to the tunica vaginalis; sometimes it gradually becomes lost on the spermatic cord. Occasionally no trace of it can be detected. In some cases it happens that the pouch of peritoneum does not become obliterated, but the sac of the peritoneum communicates with the tunica vaginalis. This may give rise to one of the varieties of oblique inguinal hernia (page 1191). Or in other cases the pouch may contract, but not become entirely obliterated; it then forms a minute canal leading from the peritoneum to the tunica vaginalis.[1]

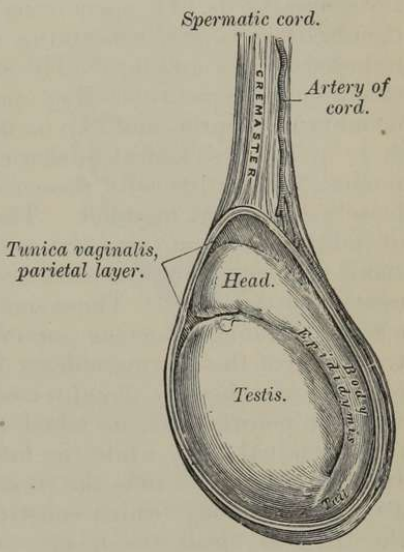

FIG. 739.—The testis *in situ*, the tunica vaginalis having been laid open.

The **Tunica Albuginea** is the fibrous covering of the testis. It is a dense fibrous membrane, of a bluish-white color, composed of bundles of white fibrous tissue, which interlace in every direction. Its outer surface is covered by the tunica vaginalis, except along its posterior border, at the points of attachment of the epididymis; hence the tunica albuginea may be considered as a fibro-serous membrane, like the pericardium. This membrane surrounds the glandular structure of the testicle, and at its posterior border is reflected into the interior of the gland, forming an incomplete vertical septum, called the *mediastinum testis* (*corpus Highmorianum*).

The *mediastinum testis* extends from the upper, nearly to the lower, border of the gland, and is wider above than below. From the front and sides of this septum numerous slender fibrous cords and imperfect septa (*trabeculæ*) are given off, which radiate toward the surface of the organ, and are attached to the inner surface of the tunica albuginea. They therefore divide the interior of the organ into a number of incomplete spaces, which are somewhat cone-shaped, being broad at their bases at the surface of the gland, and becoming narrower as they converge to the mediastinum. The mediastinum supports the vessels and ducts of the testis in their passage to and from the substance of the gland.

The **Tunica Vasculosa** (*pia mater testis*) is the vascular layer of the testis, consisting of a plexus of blood-vessels held together by a delicate areolar tissue. It covers the inner surface of the tunica albuginea and the different septa in the interior of the gland, and therefore forms an internal investment to all the spaces of which the gland is composed.

Structure.—The glandular structure of the testis consists of numerous lobules (*lobuli testis*). Their number, in a single testis, is estimated by Berres at 250, and by Krause at 400. They differ in size according to their position, those in the middle of the gland being larger and longer. The lobules are conical in shape, the base being directed toward the circumference of the organ, the apex toward the

[1] It is recorded that in the post-mortem examination of Sir Astley Cooper this minute canal was found on both sides of the body. Sir Astley Cooper states that when a student he suffered from inguinal hernia; probably this was of the congenital variety, and the canal found after death was the remains of the one down which the hernia travelled (*Lancet*, vol. ii., 1824, p. 116).

mediastinum. Each lobule is contained in one of the intervals between the fibrous cords and vascular processes which extend between the mediastinum testis and the tunica albuginea, and consists of from one to three or more minute convoluted tubes, the *tubuli seminiferi*. The tubes may be separately unravelled by careful dissection under water, and may be seen to commence either by free cæcal ends or by anastomotic loops. The total number of tubes is considered by Munro to be about 300, and the length of each about sixteen feet; by Lauth their number is estimated at 840, and their average length two feet and a quarter. The diameter varies from $\frac{1}{200}$ to $\frac{1}{150}$ of an inch. The tubuli are pale in color in early life, but in old age they acquire a deep yellow tinge from containing much fatty matter. They consist of a membrana propria, inside which are several layers of epithelial cells, the *seminal cells*. The membrana propria is a hyaline structure, consisting of several membranous layers, containing oval flattened nuclei at regular intervals, superimposed on one another. The seminal cells or lining epithelium differ in different tubules. In some tubes they may be seen to consist of an outer layer, next the membrana propria, and two or more layers of inner cells. The former cells are more or less polyhedral in shape, uniform in size, and contain an oval or spherical nucleus; the latter cells, those comprising the inner layers, are spherical and more loosely connected together. The nucleus of most or all of them is in the process of indirect division (*karyokinesis*, page 40), and in consequence of this numerous small spherical daughter-cells are to be seen, lying nearest to the lumen and closely connected together. These small daughter-cells are named *spermatoblasts*, and by a series of changes become converted into spermatozoa. In other tubes the gradual transition of the spermatoblasts into spermatozoa may be traced. In some tubes or parts of tubes the daughter-cells may be seen to have assumed a pear shape, with the pointed end, in which the nucleus is to be found, directed toward the inner seminal cells, while the broad part is directed into the lumen of the tube. In other parts of a tube the broad end may be seen to have become elongated into a rod-shaped body, which constitutes the middle piece of the spermatozoon, while the nucleus forms the head. Again, in other parts of the tubes these young spermatozoa may be seen collected together into fan-shaped groups, and from their distal end—that is to say, the end projecting into the lumen of the tube—a thin long filament, called the tail, is growing out. In the young subject the seminal cells present somewhat the appearance of an epithelial lining, and do not almost fill the tube, as in the adult testis.

The tubules are enclosed in a delicate plexus of capillary vessels, and are held together by an intertubular connective tissue, which presents large interstitial spaces lined by endothelium, which are believed to be the rootlets of lymphatic vessels of the testis.

In the apices of the lobules the tubuli become less convoluted, assume a nearly straight course, and unite together to form from twenty to thirty larger ducts, of about $\frac{1}{50}$ of an inch in diameter, and these, from their straight course, are called *vasa recta* or *tubuli recti*.

The *vasa recta* enter the fibrous tissue of the mediastinum, and pass upward and backward, forming, in their ascent, a close network of anastomosing tubes, which are merely channels in the fibrous stroma, having no proper walls; this constitutes the *rete testis*. At the upper end of the mediastinum the vessels of the rete testis terminate in from twelve to fifteen or twenty ducts, the *vasa efferentia*: they perforate the tunica albuginea, and carry the seminal fluid from the testis to the epididymis. Their course is at first straight; they then become enlarged and exceedingly convoluted, and form a series of conical masses, the *coni vasculosi*, which, together, constitute the globus major of the epididymis. Each cone consists of a single convoluted duct from six to eight inches in length, the diameter of which gradually decreases from the testis to the epididymis. Opposite the bases of the cones the efferent vessels open at narrow intervals into a single duct, which constitutes, by its complex convolutions, the body and globus minor of the epididymis. When the convolutions of this tube are unravelled it

measures upward of twenty feet in length, and increases in breadth and thickness as it approaches the vas deferens. The convolutions are held together by fine areolar tissue and by bands of fibrous tissue.

The vasa recta are of smaller diameter than the seminal tubes, and have very thin parietes. They, as well as the channels of the rete testis, are lined by a single layer of flattened epithelium. The vasa efferentia and the tube of the epididymis have walls of considerable thickness, on account of the presence in them of muscular tissue, which is principally arranged in a circular manner. These tubes are lined by columnar ciliated epithelium.

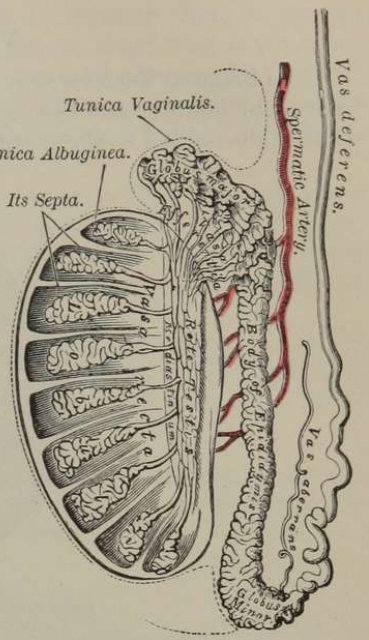

FIG. 740.—Vertical section of the testicle, to show the arrangement of the ducts.

The **Vas Deferens**, the excretory duct of the testis, is the continuation of the epididymis. Commencing at the lower part of the globus minor, it ascends along the posterior border of the testis and inner side of the epididymis, and along the back part of the spermatic cord, through the spermatic canal to the internal or deep abdominal ring. From the ring it curves round the outer side of the epigastric artery, crosses the external iliac vessels, and descends into the pelvis at the side of the bladder; it arches backward and downward to its base, crossing over the obliterated hypogastric artery and to the inner side of the ureter. At the base of the bladder it lies between that viscus and the rectum, running along the inner border of the vesicula seminalis. In this situation it becomes enlarged and sacculated, forming the *ampulla*, and then, becoming narrowed at the base of the prostate, unites with the duct of the vesicula seminalis to form the ejaculatory duct. The vas deferens presents a hard and cord-like sensation to the fingers; it is about two feet in length, of cylindrical form, and about a line and a quarter in diameter. Its walls are dense, measuring one-third of a line, and its canal is extremely small, measuring about half a line.

Structure.—The vas deferens consists of three coats: 1. An external or cellular coat. 2. A muscular coat, which in the greater part of the tube consists of two layers of unstriped muscular fibre: an outer, longitudinal in direction, and an inner, circular; but in addition to these, at the commencement of the vas deferens, there is a third layer, consisting of longitudinal fibres, placed internal to the circular stratum, between it and the mucous membrane. 3. An internal or mucous coat, which is pale, and arranged in longitudinal folds; its epithelial covering is of the columnar variety.

A long narrow tube, the *vas aberrans of Haller*, is occasionally found connected with the lower part of the canal of the epididymis or with the commencement of the vas deferens. It extends up into the cord for about two or three inches, where it terminates by a blind extremity, which is occasionally bifurcated. Its length varies from an inch and a half to fourteen inches, and sometimes it becomes dilated toward its extremity; more commonly it retains the same diameter throughout. Its structure is similar to that of the vas deferens. Occasionally it is found unconnected with the epididymis. (For organ of Giraldès or paradidymis see page 136).

Surgical Anatomy.—The testicle frequently requires removal for malignant disease; in tuberculous disease, to prevent systemic infection; in cystic disease; in cases of large hernia testis, and in some instances of incompletely descended or misplaced testicle, and for prostatic hypertrophy. The operation is a comparatively simple one. An incision is made from the external ring to the bottom of the scrotum into the tunica vaginalis. The coverings are shelled off the organ, and the mesorchium, stretching between the back of the testicle and the scrotum, divided. The cord is then isolated, and an aneurism needle, armed with a double ligature,

passed under it, as high as is thought necessary, and the cord tied in two places, and divided between the ligatures. Sometimes, in cases of malignant disease, it is desirable to open the inguinal canal and tie the cord as near the internal abdominal ring as possible.

VESICULÆ SEMINALES.

The **Seminal Vesicles** are two lobulated membranous pouches placed between the base of the bladder and the rectum, serving as reservoirs for the semen, and secreting a fluid to be added to the secretion of the testicles. Each sac is somewhat pyramidal

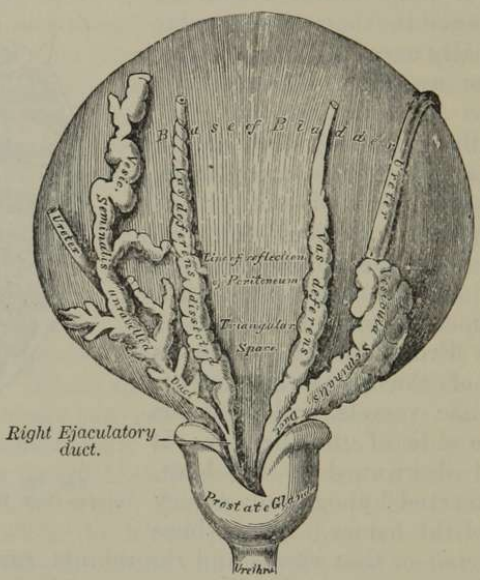

FIG. 741.—Base of the bladder, with the vasa deferentia and vesiculæ seminales.

in form, the broad end being directed backward and the narrow end forward toward the prostate. They measure about two and a half inches in length, about five lines in breadth, and two or three lines in thickness. They vary, however, in size, not only in different individuals, but also in the same individual on the two sides. Their *upper surface* is in contact with the base of the bladder, extending from near the termination of the ureters to the base of the prostate gland. Their *under surface* rests upon the rectum, from which they are separated by the recto-vesical fascia. Their *posterior extremities* diverge from each other. Their *anterior extremities* are pointed, and converge toward the base of the prostate gland, where each joins with the corresponding vas deferens to form the ejaculatory duct. Along the inner margin of each vesicula runs the enlarged and convoluted vas deferens. The inner border of the vesiculæ and the corresponding vas deferens form the lateral boundaries of a triangular space, limited behind by the recto-vesical peritoneal fold; the portion of the bladder included in this space rests on the rectum, its antero-inferior portion corresponding with the trigonum vesicæ in its interior.

Each vesicula consists of a single tube, coiled upon itself and giving off several irregular cæcal diverticula, the separate coils, as well as the diverticula, being connected together by fibrous tissue. When uncoiled this tube is about the diameter of a quill, and varies in length from four to six inches; it terminates posteriorly in a *cul-de-sac;* its anterior extremity becomes constricted into a narrow straight duct, which joins on its inner side with the corresponding vas deferens, and forms the ejaculatory duct.

The **ejaculatory ducts,** two in number, one on each side, are formed by the junction of the ducts of the vesiculæ seminales with the vasa deferentia. Each duct is about three-quarters of an inch in length; it commences at the base of the prostate, and runs forward and downward between the middle and lateral lobes, and along the side of the sinus pocularis, to terminate by a separate slit-like orifice close

to or just within the margins of the sinus (verumontanum). The ducts diminish in size and converge toward their termination.

Structure.—The vesiculæ seminales are composed of three coats: an *external* or *fibro-cellular;* a *middle* or *muscular coat*, which is thinner than in the vas deferens: the muscular fibres are arranged in three layers, consisting of an inner and outer longitudinal stratum and an intermediate layer of circular fibres; and an *internal* or *mucous coat*, which is pale, of a whitish-brown color, and presents a delicate reticular structure, like that seen in the gall-bladder, but the meshes are finer. The epithelium is columnar.

The coats of the ejaculatory ducts are extremely thin. They are: an *outer fibrous layer*, which is almost entirely lost after their entrance into the prostate; a *layer of muscular fibres*, consisting of an outer thin circular and an inner longitudinal layer; and the *mucous membrane*, forming the only constituents of the tubes.

Vessels and Nerves.—The *arteries* supplying the vesiculæ seminales are derived from the middle and inferior vesical and middle hæmorrhoidal. The *veins* and *lymphatics* accompany the arteries. The *nerves* are derived from the pelvic plexus.

Surgical Anatomy.—The vesiculæ seminales are often the seat of an extension of the disease in cases of tuberculous disease of the testicle, and should always be examined from the rectum before coming to a decision with regard to castration in this affection.

Descent of the Testes.

The testes at an early period of fœtal life are placed at the back part of the abdominal cavity, behind the peritoneum, in front and a little below the kidneys. The anterior surface and sides are invested by peritoneum. At about the third month of intra-uterine life a peculiar structure, the *gubernaculum testis*, makes its appearance. This structure is at first a slender band which extends from the situation of the internal ring to the epididymis and body of the testicle, and is then continued upward in front of the kidney toward the Diaphragm. As development advances the peritoneum covering the testicle encloses it and forms a mesentery, the *mesorchium*, which also encloses the gubernaculum and forms two folds—one above the testicle, and the other below it. The one above the testicle is the *plica vascularis*, and contains ultimately the spermatic vessels; the one below, the *plica gubernatrix*, contains the lower part of the gubernaculum, which has now grown into a thick cord; it terminates below at the internal ring in a tube of peritoneum, the *processus vaginalis*, which now lies in the inguinal canal. The lower part of the gubernaculum by the fifth month has become a thick cord, whilst the upper part has disappeared. The lower part can now be seen to consist of a central core of unstriped muscle-fibre, and outside this of a firm layer of striped elements, connected, behind the peritoneum, with the abdominal wall. Later on, about the sixth month, the lower end of the gubernaculum can be traced into the inguinal canal, extending to the pubes, and, at a later period, to the bottom of the scrotum. The fold of peritoneum constituting the *processus vaginalis* projects itself downward into the inguinal canal, forming a gradually elongating depression or *cul-de-sac*, which eventually reaches the bottom of the scrotum. This *cul-de-sac* is now invaginated by the testicle, as the body of the fœtus *grows*, for the gubernaculum does not grow commensurately with the growth of other parts, and therefore the testicle, being attached by the gubernaculum to the bottom of the scrotum, is prevented from rising as the body grows, and is drawn first into the inguinal canal, and eventually into the scrotum. By the eighth month the testicle has reached the scrotum, preceded by the lengthened pouch of peritoneum, the processus vaginalis, which communicates by its upper extremity with the peritoneal cavity. Just before birth the upper part of the pouch usually becomes closed, and this obliteration extends gradually downward to within a short distance of the testis. The process of peritoneum surrounding the testis, which is

now entirely cut off from the general peritoneal cavity, constitutes the *tunica vaginalis*.[1]

In the female, a small cord, corresponding to the gubernaculum in the male, descends to the inguinal region, and ultimately forms the round ligament of the uterus. A pouch of peritoneum accompanies it along the inguinal canal, analogous to the processus vaginalis in the male: it is called the *canal of Nuck*.

Surgical Anatomy.—Abnormalities in the formation and in the descent of the testicle may occur. The testicle may fail to be developed, or the testicle may be fully developed and the vas deferens may be undeveloped in whole or part; or, again, both testicle and vas deferens may be fully developed, but the duct may not become connected to the gland. The testicle may fail in its descent (*cryptorchismus*), or it may descend into some abnormal position. Thus it may be retained in the position where it was primarily developed, below the kidney; or it may descend to the internal abdominal ring, but fail to pass through this opening; it may be retained in the inguinal canal, which is perhaps the most common position; or it may pass through the external abdominal ring and remain just outside it, failing to pass to the bottom of the scrotum. On the other hand, it may get into some abnormal position: it may pass the scrotum and reach the perinæum, or it may fail to enter the inguinal canal, and may find its way through the femoral ring into the crural canal, and present itself on the thigh at the saphenous opening. There is still a third class of cases of abnormality of the testicle, where the organ has descended in due course into the scrotum, but is malplaced. The most common form of this is where the testicle is *inverted;* that is to say, the organ is rotated, so that the epididymis is connected to the front of the scrotum, and the body, surrounded by the tunica vaginalis, is directed backward. In these cases the vas deferens is to be felt in the front of the cord. The condition is of importance in connection with hydrocele and hæmatocele, and the position of the testicle should always be carefully ascertained before performing any operation for these affections. Again, more rarely, the testicle may be *reversed*. This is a condition in which the top of the testicle, indicated by the globus major of the epididymis, is at the bottom of the scrotum, and the vas deferens comes off from the summit of the organ.

[1] The obliteration of the process of peritoneum which accompanies the cord, and is hence called the *funicular process*, is often incomplete. See section on Inguinal Hernia.

THE FEMALE GENERATIVE ORGANS.

EXTERNAL ORGANS.

THE **External Organs of Generation in the Female** are: the mons Veneris, the labia majora and minora, the clitoris, the meatus urinarius, and the orifice of

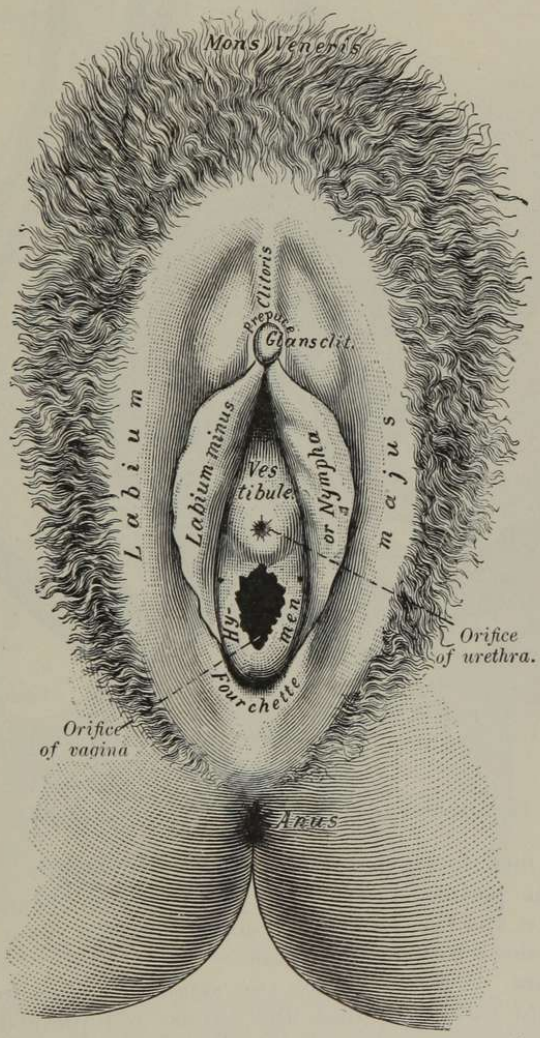

FIG. 742.—The vulva. External female organs of generation.

the vagina. The term "vulva" or "pudendum," as generally applied, includes all these parts.

The **Mons Veneris** is the rounded eminence in front of the pubic symphysis, formed by a collection of fatty tissue beneath the integument. It surmounts the vulva, and becomes covered with hair at the time of puberty.

The **Labia Majora** are two prominent longitudinal cutaneous folds extending downward from the mons Veneris to the anterior boundary of the perinæum, and

enclosing the common urino-sexual opening. Each labium is formed of two folds of integument: covered with hair externally; internally, smooth and pinkish. The inner fold is continuous with the genito-urinary mucous tract. Between the two folds is a quantity of areolar tissue, fat, and a tissue resembling the dartos of the scrotum, besides vessels, nerves, and glands. The labia are thicker in front, where they form by their meeting the *anterior commissure*. Posteriorly they are not really joined, but appear to become lost in the neighboring integument, terminating close to, and nearly parallel with, each other. Together with the connecting skin between them, they form the posterior commissure or posterior boundary of the vulval orifice. The interval between the posterior commissure and

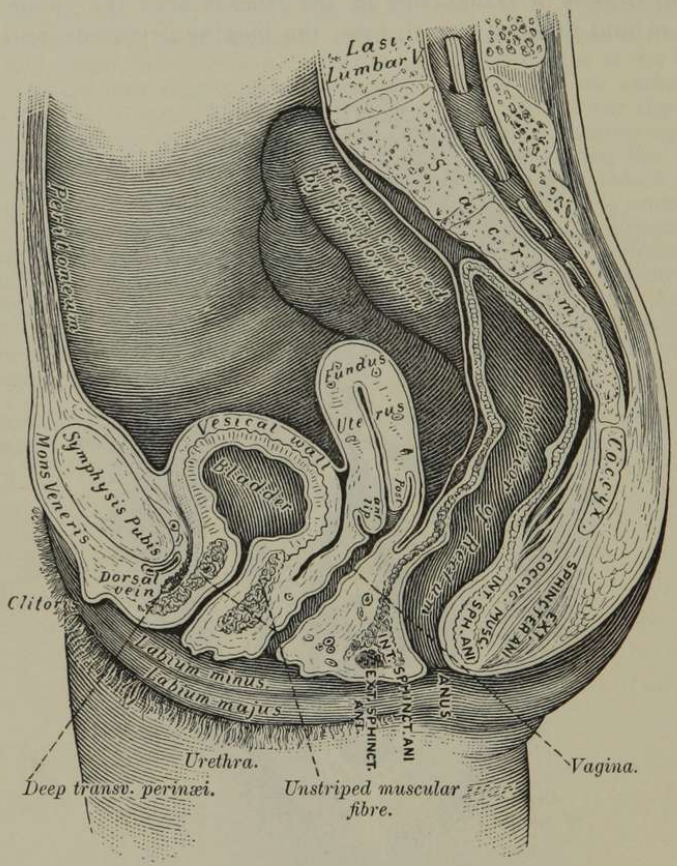

FIG. 743.—Vertical median section of the female pelvis.

the anus, about an inch to an inch and a quarter in length, constitutes the perinæum or base of the perineal body. The *fourchette* is the anterior edge of the latter, and between it and the hymen is a depression, the *fossa navicularis*. The labia correspond to the scrotum in the male.

The **Labia Minora**, or **Nymphæ**, are two small cutaneous folds, situated within the labia majora, and extending from the clitoris obliquely downward, outward, and backward for about an inch and a half on each side of the orifice of the vagina, between which and the labia majora they are lost. Anteriorly, the two labia minora meet and form the *frænum of the clitoris*. The *prepuce* of the clitoris, passing backward on each side, is inserted, as it were, into each labium minus. The nymphæ are really modified skin. Their internal surfaces have numerous sebaceous follicles.

The **Clitoris** is an erectile structure analogous to the corpora cavernosa of the penis. It is situated beneath the anterior commissure, partially hidden between the anterior extremities of the labia minora. It is connected to the rami of the os pubis

and ischium on each side by a crus; the body is short and concealed beneath the labia; the free extremity, or *glans clitoridis*, is a small rounded tubercle, consisting of spongy erectile tissue, and highly sensitive. It is provided, like the penis, with a suspensory ligament, and with two small muscles, the Erectores clitoridis, which are inserted into the crura of the clitoris. The clitoris consists of two corpora cavernosa, composed of erectile tissue enclosed in a dense layer of fibrous membrane, united together along their inner surfaces by an incomplete fibrous pectiniform septum.

Between the clitoris and the entrance of the vagina is a triangular smooth surface, bounded on each side by the nymphæ; this is the *vestibule*.

The orifice of the urethra (**meatus urinarius**) is situated at the back part of the vestibule, about an inch below the clitoris and near the margin of the vagina, surrounded by a prominent elevation of the mucous membrane. Below the meatus urinarius is the orifice of the vagina, more or less closed in the virgin by a membranous fold, the *hymen*.

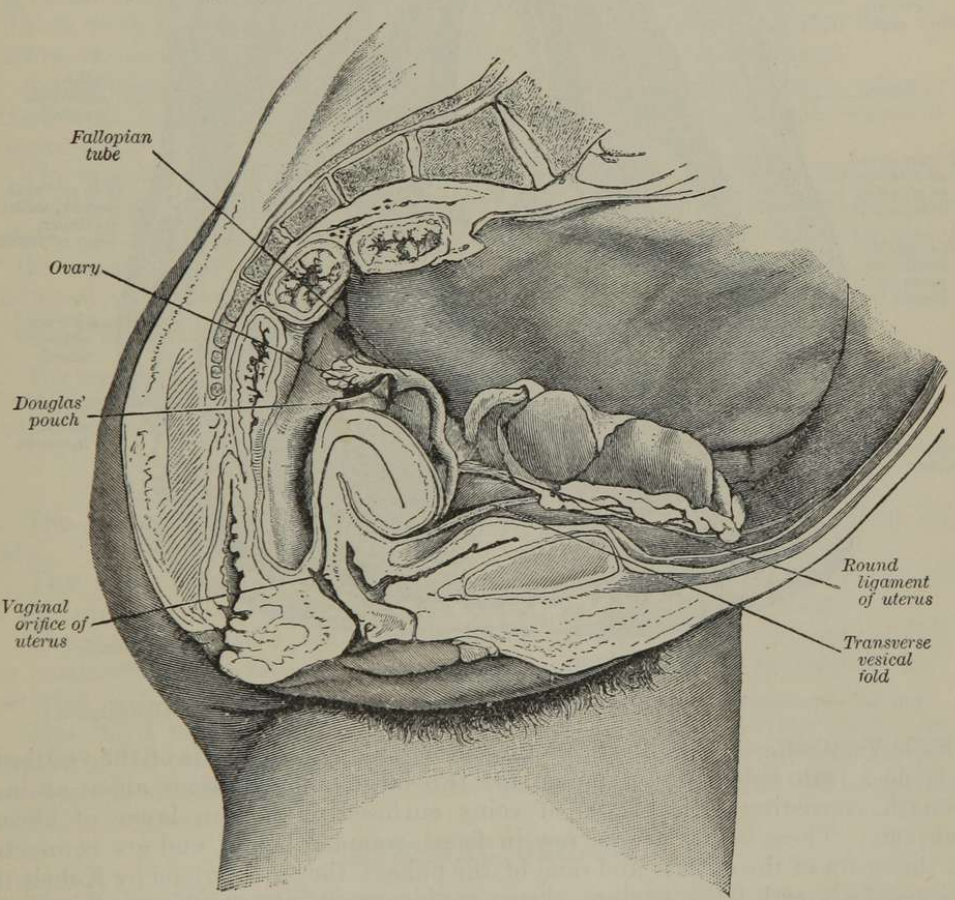

FIG. 744.—Longitudinal section through the pelvis of a young woman. (Bardeleben.)

The **Hymen** is a membranous fold which closes to a greater or less extent the opening of the vagina. It varies much in shape. Its commonest form is that of a ring, generally broadest posteriorly: sometimes it is represented by a semilunar fold, with its concave margin turned toward the pubes. A complete septum stretched across the lower part of the vaginal orifice is called "imperforate hymen." Occasionally it is cribriform, or its free margin forms a membranous fringe, or it may be entirely absent. It may persist after copulation, so that it cannot be considered as a test of virginity. After parturition the small rounded elevations known as the *carunculæ myrtiformes* are found as the remains of the hymen.

Glands of Bartholin.—On each side of the commencement of the vagina, and

behind the hymen, is a round or oblong body, of a reddish-yellow color, and of the size of a horse-bean, analogous to Cowper's gland in the male. It is called the *gland of Bartholin*. Each gland opens by means of a long single duct on each side external to the hymen.

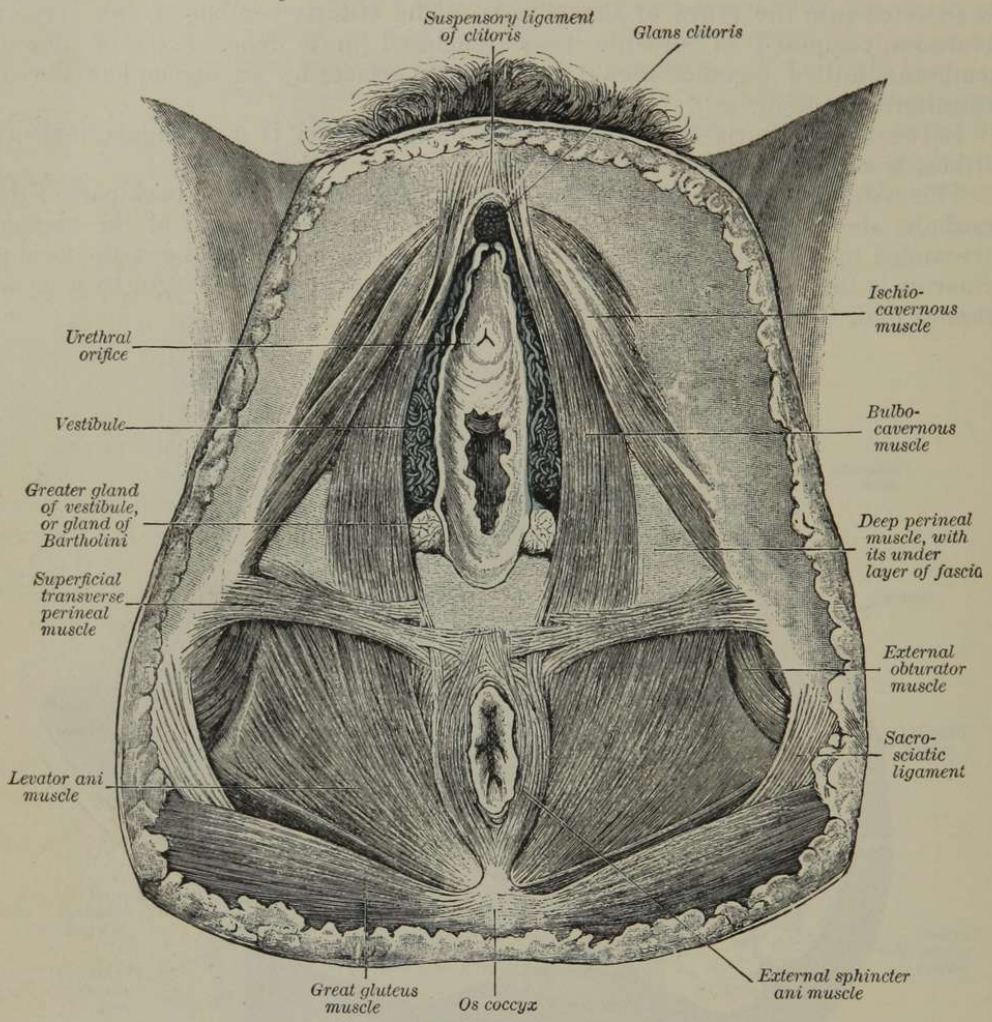

FIG. 745.—The female perinæum after removal of the skin and superficial fascia. (Bardeleben.)

Bulbi Vestibuli.—Extending from the clitoris, along either side of the vestibule, and lying a little behind the nymphæ, are two large oblong masses, about an inch in length, consisting of a plexus of veins enclosed in a thin layer of fibrous membrane. These bodies are narrow in front, rounded below, and are connected with the crura of the clitoris and rami of the pubes: they are termed by Kobelt the *bulbi vestibuli*, and he considers them analogous to the bulb of the corpus spongiosum in the male. Immediately in front of these bodies is a smaller venous plexus, continuous with the bulbi vestibuli behind and the glans clitoridis in front: it is called by Kobelt the *pars intermedia*, and is considered by him as analogous to that part of the body of the corpus spongiosum which immediately succeeds the bulb.

RELATIONS OF THE BLADDER.

The **Bladder** is situated at the anterior part of the pelvis. It is in relation, *in front*, with the symphysis pubis; *behind*, with the utero-vesical pouch of peritoneum, which separates it from the body of the uterus; its *base* lies in contact with the connective tissue in front of the cervix and upper part of the vagina. *Laterally*, is the recto-vesical fascia. The bladder is said by some anatomists to be larger in

the female than in the male. At any rate, it does not rise above the symphysis pubis till more distended than in the male, but this is perhaps owing to the more capacious pelvis rather than to its being of actually larger size.

THE URETHRA.

The **Urethra** is a narrow membranous canal, about an inch and a half in length, extending from the neck of the bladder to the meatus urinarius. It is placed beneath the symphysis pubis, imbedded in the anterior wall of the vagina; and its direction is obliquely downward and forward, its course being slightly curved, the concavity directed forward and upward. Its diameter when undilated is about a quarter of an inch. The urethra perforates the triangular ligament precisely as in the male.

Structure.—The urethra consists of three coats: muscular, erectile, and mucous.

The *muscular coat* is continuous with that of the bladder; it extends the whole length of the tube, and consists of a circular stratum of muscular fibres. In addition to this, between the two layers of the triangular ligament, the female urethra is surrounded by the Compressor urethræ, as in the male.

A *thin layer of spongy erectile tissue*, containing a plexus of large veins intermixed with bundles of unstriped muscular fibre, lies immediately beneath the mucous coat.

The *mucous coat* is pale, continuous externally with that of the vulva, and internally with that of the bladder near which it contains many tubular mucous glands. It is thrown into longitudinal folds, one of which placed along the floor of the canal, resembles the verumontanum in the male urethra. It is lined by laminated epithelium, which becomes transitional near the bladder. Its external orifice is surrounded by a few mucous follicles.

The urethra, from not being surrounded by dense resisting structures, as in the male, admits of considerable dilatation, which enables the surgeon to remove with considerable facility calculi or other foreign bodies from the cavity of the bladder.

THE RECTUM.

The **Rectum** is more capacious and less curved in the female than in the male.

The *first portion* extends from the left sacro-iliac articulation to the middle of the sacrum. Its connections are similar to those in the male.

The *second portion* extends to the tip of the coccyx. It is covered in front by the peritoneum for a short distance, at its upper part: it is in relation with the posterior wall of the vagina.

The *third portion* curves backward from the vagina to the anus, leaving a space which corresponds on the surface of the body to the perinæum. Its extremity is surrounded by the Sphincter muscles, and its sides are supported by the Levatores ani.

INTERNAL ORGANS.

The **Internal Organs of Generation** are—the vagina, the uterus and its appendages, the Fallopian tubes, the ovaries and their ligaments, and the round ligaments.

The **Vagina** extends from the vulva to the uterus. It is situated in the cavity of the pelvis, behind the bladder and in front of the rectum. Its direction is curved upward and backward, at first in the line of the outlet, and afterward in that of the axis of the cavity of the pelvis. Its walls are ordinarily in contact, and its usual shape on transverse section is that of an **H**, the transverse limb being slightly curved forward or backward, whilst the lateral limbs are somewhat convex toward the median line. Its length is about two and a half inches along its anterior wall, and three and a half inches along its posterior wall. It is constricted at its commencement, and becomes dilated medially, and narrowed near its uterine extremity; it surrounds the vaginal portion of the cervix uteri, a short

distance from the os, its attachment extending higher up on the posterior than on the anterior wall of the uterus.

Relations.—Its *anterior surface* is in relation with the base of the bladder and with the urethra. Its *posterior surface* is connected for the lower three-fourths of its extent to the anterior wall of the rectum, the upper fourth being separated from that tube by the recto-vaginal fold of peritoneum, which forms a *cul-de-sac* between the vagina and rectum. Its sides give attachment superiorly to the broad ligaments, and inferiorly to the Levatores ani muscles and recto-vesical fascia.

Structure.—The vagina consists of an internal mucous lining, of a muscular coat, and between the two of a layer of erectile tissue.

The *mucous membrane* is continuous above with that lining the uterus. Its inner surface presents, along the anterior and posterior walls, a longitudinal ridge or raphe, called the *columns of the vagina*, and numerous transverse ridges or rugæ, extending outward from the raphe on either side. These rugæ are divided by furrows of variable depth, giving to the mucous membrane the appearance of being studded over with conical projections. There are also microscopic papillæ; the projections are most numerous near the orifice of the vagina, especially in females before parturition. The epithelium covering the mucous membrane is of the squamous variety. The submucous tissue is very loose and contains numerous large veins, which by their anastomoses form a plexus, together with smooth muscular fibres derived from the muscular coat; it is regarded by Gussenbauer as an erectile tissue. It contains a number of mucous crypts, but no true glands.

The *muscular coat* consists of two layers: an external longitudinal, which is far the stronger, and an internal circular layer. The longitudinal fibres are continuous with the superficial muscular fibres of the uterus. The strongest fasciculi are those attached to the recto-vesical fascia on each side. The two layers are not distinctly separable from each other, but are connected by oblique decussating fasciculi which pass from the one layer to the other. In addition to this the vagina at its lower end is surrounded by a band of striped muscular fibres, the *sphincter vaginæ* (see page 464).

External to the muscular coat is a layer of connective tissue containing a large plexus of blood-vessels.

The *erectile tissue* consists of a layer of loose connective tissue situated between the mucous membrane and the muscular coat; imbedded in it is a plexus of large veins, and numerous bundles of unstriped muscular fibres derived from the circular muscular layer. The arrangement of the veins is similar to that found in other erectile tissues.

THE UTERUS.

The **Uterus** is the organ of gestation, receiving the fecundated ovum in its cavity, retaining and supporting it during the development of the fœtus, and becoming the principal agent in its expulsion at the time of parturition.

In the virgin state it is pear-shaped, flattened from before backward, and situated in the cavity of the pelvis between the bladder and the rectum; it is retained in its position by the round and broad ligaments on each side, and projects into the upper end of the vagina below. Its upper end, or base, is directed upward and forward; its lower end, or apex, downward and backward, in the line of the axis of the inlet of the pelvis. It therefore forms an angle with the vagina, since the direction of the vagina corresponds to the axis of the cavity and outlet of the pelvis. The uterus measures about three inches in length, two in breadth at its upper part, and nearly an inch in thickness, and it weighs from an ounce to an ounce and a half.

It consists of two parts: (1) the *body*, with its upper broad extremity, the *fundus*; and (2) the *cervix*, or *neck*, which is partly above the vagina and partly in the vagina. The fundus is placed on a line below the level of the brim of the pelvis, being directed forward behind the upper portion of the anterior pelvic wall.

The division between the body and cervix is indicated externally by a slight constriction, and by the reflection of the peritoneum from the anterior surface of the uterus on to the bladder, and internally by a narrowing of the canal, called the *internal os*.

The *body* gradually narrows from the fundus to the neck. Its anterior surface is flattened, compared to the posterior, covered by peritoneum throughout, and

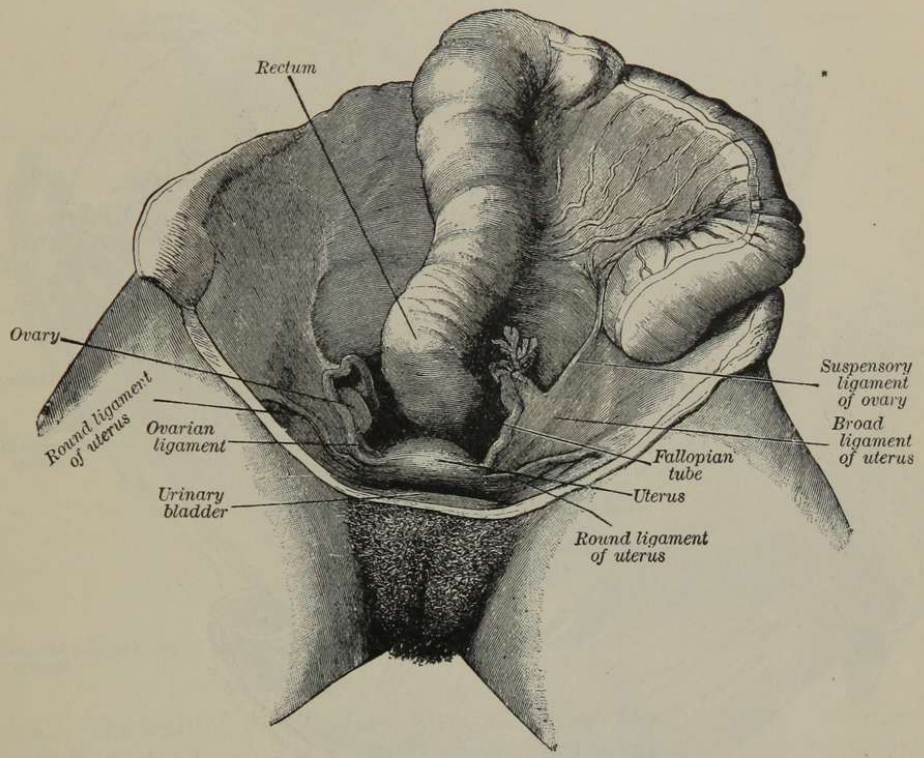

FIG. 746.—Female pelvic organs *in situ* (seen from above). (Bardeleben.)

separated from the bladder by the utero-vesical pouch. Its *posterior surface* is convex transversely, covered by peritoneum throughout, and separated from the rectum by some convolutions of the intestine. Its *lateral margins* are concave, and give attachment to the Fallopian tube above, the round ligament below and in front of this, and the ligament of the ovary behind both of these structures.

The *cervix* is the lower constricted segment of the uterus; around its circumference is attached the upper end of the vagina, which extends upward a greater distance behind than in front.

The supravaginal portion is not covered by peritoneum in front; a pad of cellular tissue is interposed between it and the bladder. Behind, the peritoneum is extended over its upper part. The vaginal portion is the rounded lower end projecting into the vagina. On its surface is a small aperture, the *os uteri*, generally circular in shape, but sometimes oval or almost linear. The margin of the opening is, in the absence of past parturition or disease, quite smooth.

Ligaments.—The ligaments of the uterus are eight in number: one anterior; one posterior; two lateral or broad; two sacro-uterine,—all these being formed of peritoneum—and, lastly, two round ligaments.

The *anterior ligament* (vesico-uterine) is reflected on to the bladder from the front of the uterus, at the junction of the supravaginal cervix and body.

The *posterior ligament* (recto-uterine) passes from the posterior wall of the uterus over the upper fourth of the vagina, and thence on to the rectum and sacrum. It thus forms a pouch called *Douglas's pouch* (Fig. 747), the boundaries of which are, in front, the posterior wall of the uterus, the supravaginal cervix, and the upper

fourth of the vagina; behind, the rectum and sacrum; above, the small intestine; and, laterally, the sacro-uterine ligaments investing recto-vesical fascia.

The *two lateral* or *broad ligaments* pass from the sides of the uterus to the lateral walls of the pelvis, forming a septum across the pelvis, which divides that cavity into two portions. In the anterior part are contained the bladder,

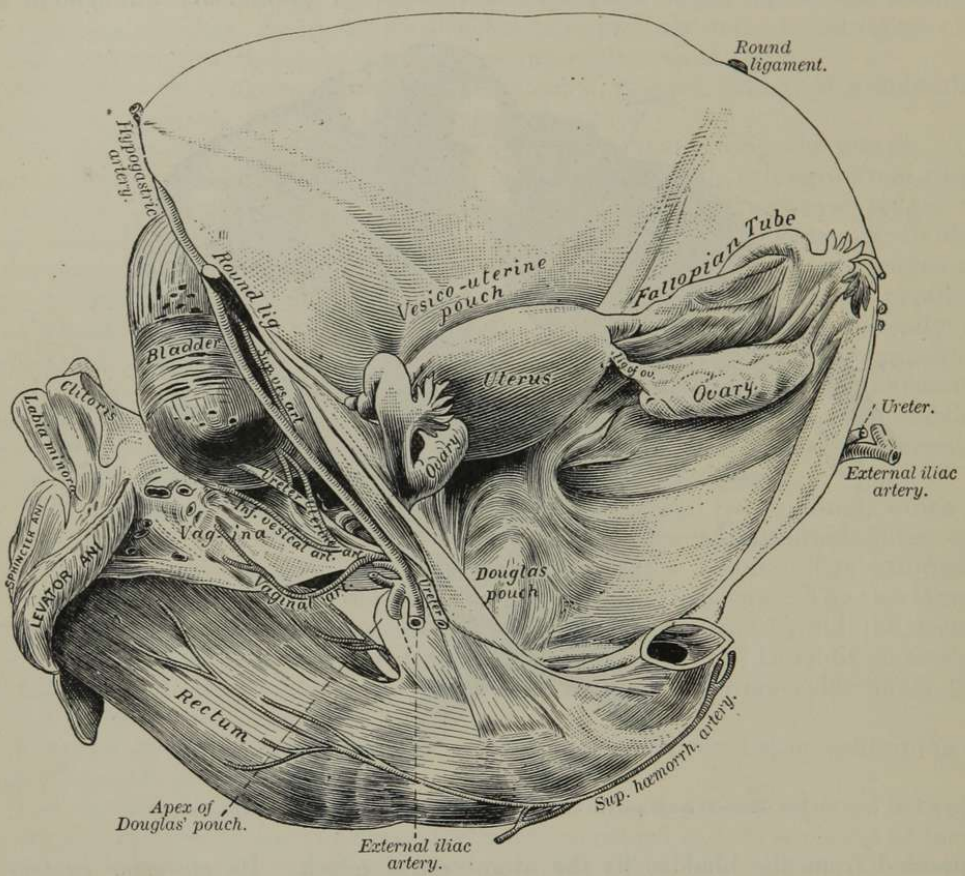

FIG. 747.—Douglas's pouch. (From a preparation in the Museum of the Royal College of Surgeons.)

urethra, and vagina; in the posterior part, the rectum. Between the two layers of each broad ligament are contained—(1) the Fallopian tubes superiorly; (2) the round ligament; (3) the ovary and its ligament; (4) the parovarium, or organ of Rosenmüller; (5) connective tissue; and (6) unstriped muscular fibre. Between the fimbriated extremity of the tube and the lower attachment of the broad ligament is a concave rounded margin called the *infundibulo-pelvic ligament* (Fig. 752). The upper border is often known as the mesosalpinx.

The *sacro-uterine ligaments* pass from the second and third bones of the sacrum, downward and forward, to be attached one on each side of the uterus at the junction of the supravaginal cervix and the body, this point corresponding internally to the position of the os internum. (For the *round ligaments*, see page 1177.)

The **cavity of the uterus** is small in comparison with the size of the organ; that portion of the cavity which corresponds to the body is triangular, flattened from before backward, so that its walls are closely approximated, and having its base directed upward toward the fundus. At each superior angle is a funnel-shaped cavity, which constitutes the remains of the division of the body of the uterus into two cornua, and at the bottom of each cavity is the minute orifice of the Fallopian tube. At the inferior angle of the uterine cavity is a small constricted opening, the internal orifice (*ostium internum*), which leads into the cavity of the cervix.

The **cavity of the cervix** is somewhat fusiform, flattened from before backward, broader at the middle than at either extremity, and communicates below with the

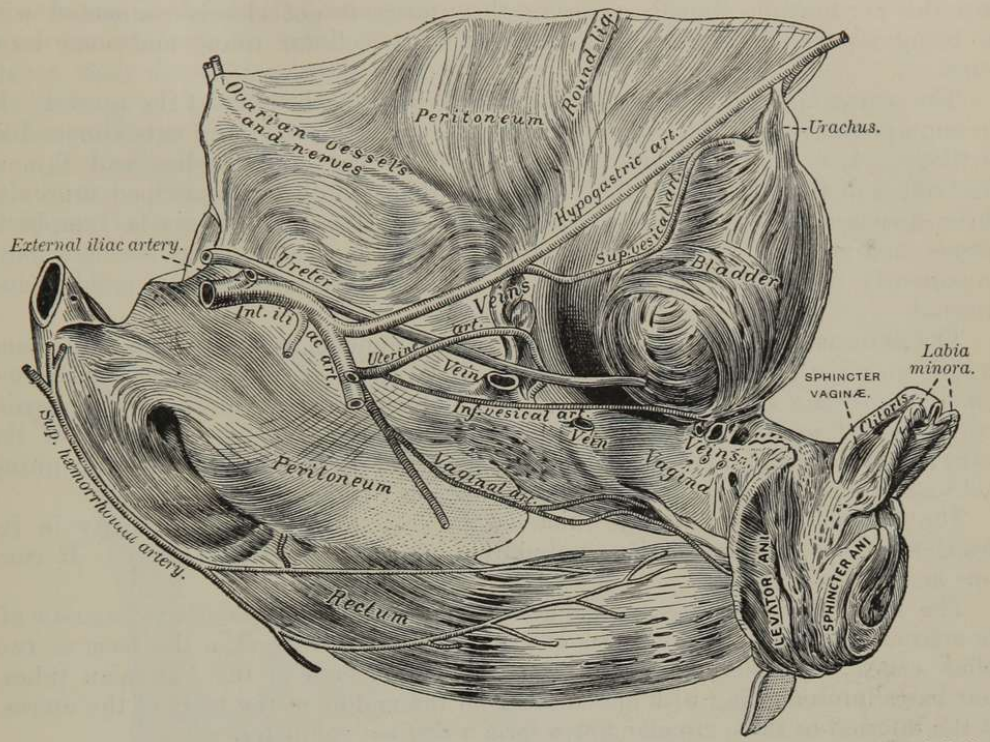

FIG. 748.—Side view of the female pelvic organs. (From a preparation in the Museum of the Royal College of Surgeons.)

vagina. The wall of the canal presents, anteriorly and posteriorly, a longitudinal column, from which proceed a number of small oblique columns, giving the appearance of branches from the stem of a tree; and hence the name *arbor vitæ uterina*

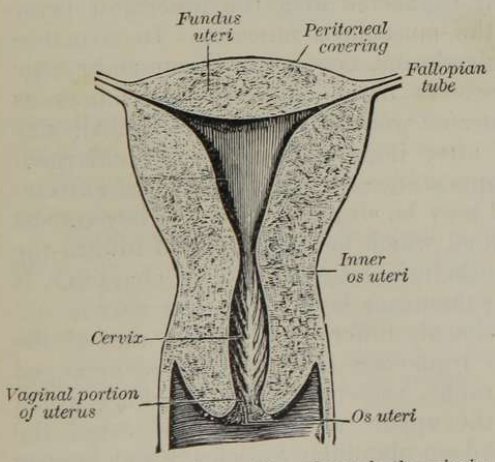

FIG. 749.—Anterior section through the virgin uterus. (Bardeleben.)

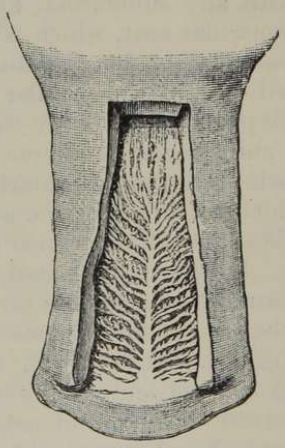

FIG. 750.—Opening in the wall of the cervical canal in a human uterus, showing the plicæ palmatæ. (Bardeleben.)

(plicæ palmatæ) applied to it. These folds usually become very indistinct after the first labor (Fig. 750).

Structure.—The uterus is composed of three coats—an external serous coat, a middle or muscular, and an internal mucous coat.

The *serous coat* is derived from the peritoneum; it invests the fundus and the whole of the posterior surface of the body of the uterus, but only the upper three-fourths of its anterior surface. In the lower fourth of the posterior surface the peritoneum, though covering the uterus, is not closely connected with it, being separated from it by a layer of loose cellular tissue and some large veins.

The *muscular coat* forms the chief bulk of the substance of the uterus. In the unimpregnated state it is dense, firm, of a grayish color, and cuts almost like cartilage. It is thick opposite the middle of the body and fundus, and thin at the orifices of the Fallopian tubes. It consists of bundles of unstriped muscular fibres, disposed in layers, intermixed with areolar tissue, blood-vessels, lymphatic vessels, and nerves. In the impregnated state the muscular tissue becomes more prominently developed, and is disposed in three layers—external, middle, and internal.

The external layer is placed beneath the peritoneum, disposed as a thin plane on the anterior and posterior surfaces. It consists of fibres which pass transversely across the fundus, and, converging at each superior angle of the uterus, are continued on the Fallopian tube, the round ligament, the ligament of the ovary: some passing at each side into the broad ligament, and others running backward from the cervix into the sacro-uterine ligaments.

The middle layer of fibres, which is thickest, presents no regularity in its arrangement, being disposed longitudinally, obliquely, and transversely. It contains most blood-vessels.

The internal or deep layer is the greatly hypertrophied *muscularis mucosæ* of the mucous membrane. It consists of circular fibres arranged in the form of two hollow cones, the apices of which surround the orifices of the Fallopian tubes, their bases intermingling with one another on the middle of the body of the uterus. At the internal os these circular fibres form a distinct sphincter.

The *mucous membrane* is smooth, and closely adherent to the subjacent tissue. It is continuous, through the fimbrinated extremity of the Fallopian tubes, with the peritoneum, and through the os uteri with the lining of the vagina.

In the *body* of the uterus it is smooth, soft, of a pale red color lined by columnar ciliated epithelium, and presents, when viewed with a lens, the orifices of numerous tubular follicles arranged perpendicularly to the surface. It is unprovided with any submucosa, but is intimately connected with the innermost layer of the muscular coat, which is regarded as the muscularis mucosæ. In structure its *corium* differs from ordinary mucous membrane, consisting of an embryonic nucleated and highly cellular form of connective tissue in which run numerous large lymphatics. In it are the tube-like *uterine glands*, which are of small size in the unimpregnated uterus, but shortly after impregnation become enlarged, elongated, presenting a contorted or waved appearance toward their closed extremities, which reaches into the muscularis, and may be single or bifid. They consist of a delicate membrane, lined by an epithelium, which becomes ciliated toward the orifices. In the impregnated uterus the epithelium loses its ciliated character, is thicker and tougher, and is provided with a submucous layer of areolar tissue.

In the *cervix* the mucous membrane is sharply differentiated from that of the uterine cavity. It is thrown into numerous transverse folds, which are arranged along an anterior and posterior longitudinal raphe, presenting an appearance which has received the name of *arbor vitæ*. In the upper two-thirds of the canal the mucous membrane is provided with numerous deep glandular follicles, which secrete a clear viscid alkaline mucus; and in addition, extending through the whole length of the canal, are a variable number of little cysts, presumably follicles, which have become occluded and distended with retained secretion. They are called the *ovula Nabothi*. The mucous membrane covering the lower half of the cervical canal presents numerous papillæ. The epithelium of the upper two-thirds is columnar and ciliated, but below this it loses its cilia, and gradually changes to squamous epithelium close to the external os.

Vessels and Nerves.—The *arteries of the uterus* are the uterine, from the internal iliac, and the ovarian, from the aorta. They are remarkable for their tortuous course in the substance of the organ and for their frequent anastomoses. The termination of the ovarian artery meets the termination of the uterine artery, and forms an anastomotic trunk from which branches are given off to supply the uterus, their disposition being, as shown by John Williams, circular. The *veins* are of large size, and correspond with the arteries. In the impregnated uterus these vessels are termed the *uterine sinuses*, consisting of the lining membrane of the veins adhering to the walls of the canal channelled through the substance of the uterus. They terminate in the uterine plexuses. The *lymphatics* of the body terminate in the lumbar glands, those of the cervix in the pelvic glands. The

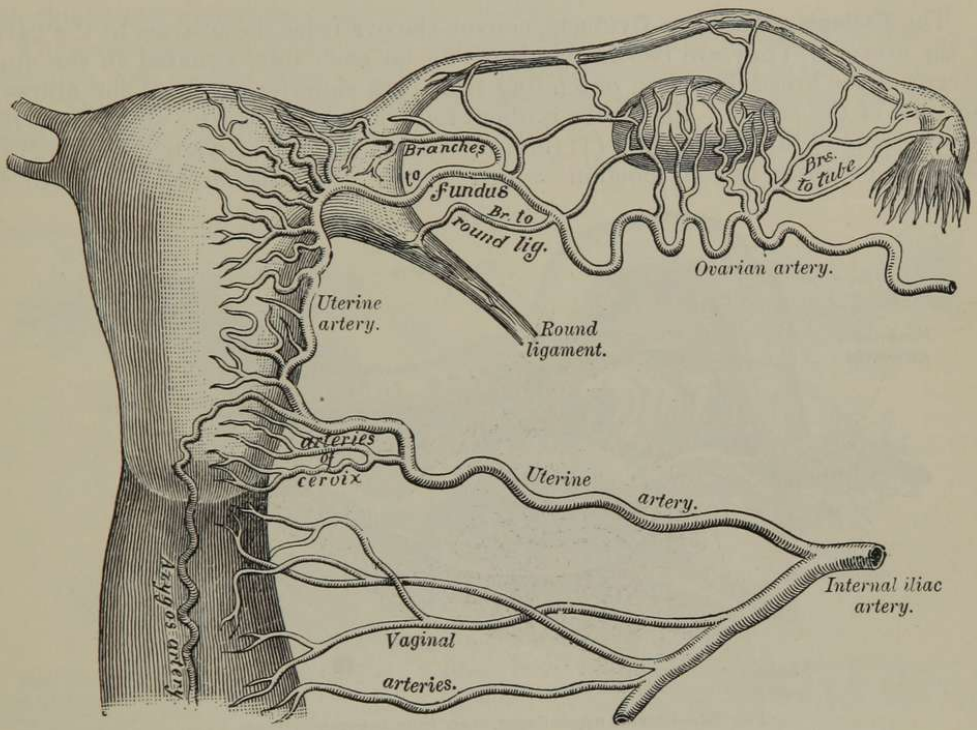

FIG. 751.—The arteries of the internal organs of generation of the female, seen from behind. (After Hyrtl.)

nerves are derived from the inferior hypogastric and ovarian plexuses, and from the third and fourth sacral nerves.

The form, size, and situation of the uterus vary at different periods of life and under different circumstances.

In the fœtus the uterus is contained in the abdominal cavity, projecting beyond the brim of the pelvis. The cervix is considerably larger than the body.

At puberty the uterus is pyriform in shape, and weighs from eight to ten drachms. It has descended into the pelvis, the fundus being just below the level of the brim of this cavity. The arbor vitæ is distinct, and extends to the upper part of the cavity of the organ.

During menstruation the organ is enlarged, and more vascular, its surfaces rounder; the os externum is rounded, its labia swollen, and the lining membrane of the body thickened, softer and of a darker color. According to J. Williams, at each recurrence of menstruation a molecular disintegration of the mucous membrane takes place, which leads to its complete removal, only the bases of the glands imbedded in the muscle being left. At the cessation of menstruation by a proliferation of the remaining structures a fresh mucous membrane is formed.

During pregnancy the uterus becomes enormously enlarged, and in the ninth month reaches the epigastric region. The increase in size is partly due to growth of pre-existing muscle and partly to development of new fibres.

After parturition the uterus nearly regains its usual size, weighing about an ounce and a half; but its cavity is larger than in the virgin state, the external orifice is more marked, its edges present a fissured surface, its vessels are tortuous, and its muscular layers are more defined.

In old age the uterus becomes atrophied, and paler and denser in texture; a more distinct constriction separates the body and cervix. The ostium internum and, occasionally, the vaginal orifice often become obliterated, and its labia almost entirely disappear.

APPENDAGES OF THE UTERUS.

The **appendages of the uterus** are the Fallopian tubes, the ovaries and their ligaments, and the round ligaments. They are placed in the following order: in front is the round ligament; the Fallopian tube occupies the upper margin of the broad ligament; the ovary and its ligament are behind and below both.

THE FALLOPIAN TUBES.

The **Fallopian Tubes,** or **Oviducts,** convey the ova from the ovaries to the cavity of the uterus. They are two in number, one on each side, situated in the upper margin of the broad ligament, extending from each superior angle of the uterus to the sides of the pelvis. Each tube is about four inches in length; and is described as consisting of three portions: (1) the *isthmus*, or inner constricted half; (2) the *ampulla*, or outer dilated portion, which curves over the ovary; and (3) the

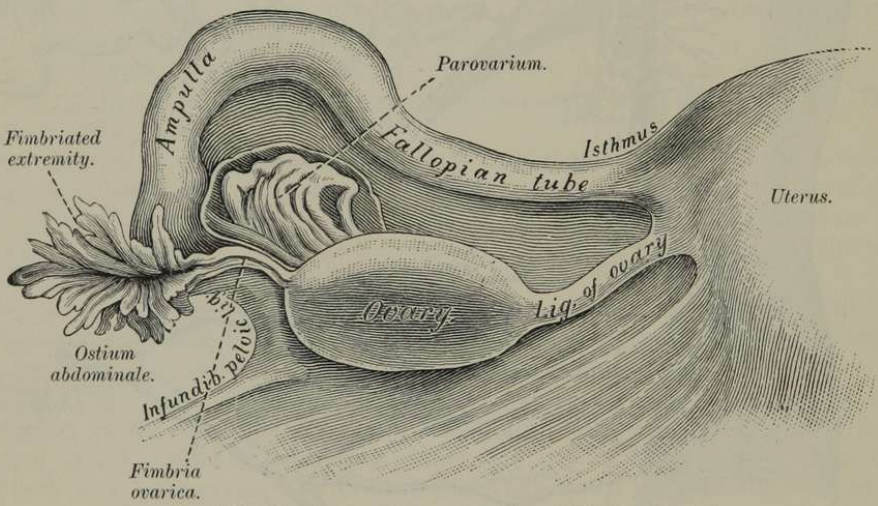

FIG. 752.—Uterine appendages, seen from behind. (Henle.)

infundibulum with its *ostium abdominale*, surrounded by fimbriæ, one of which is attached to the ovary, the *fimbria ovarica*. The general direction of the Fallopian tube is outward and upward, backward and downward. The uterine opening is minute, and will only admit a fine bristle; the abdominal opening is comparatively much larger. In connection with the fimbriæ of the Fallopian tube or with the broad ligament close to them there is frequently one or more small vesicles floating on a long stalk of peritoneum. These are termed the *hydatids of Morgagni*, and are probably of peritoneal origin.

Structure.—The Fallopian tube consists of three coats—serous, muscular, and mucous.

The *external* or *serous coat* is peritoneal.

The *middle* or *muscular coat* consists of an external longitudinal and an internal circular layer of muscular fibres continuous with those of the uterus.

The *internal* or *mucous coat* is continuous with the mucous lining of the uterus and, at the free extremity of the tube, with the peritoneum. It is thrown into longitudinal folds, which in the outer, larger part of the tube, or ampulla, are much more extensive than in the narrow canal of the isthmus. The lining epithelium is columnar ciliated. This form of epithelium is also found on the inner surface of the fimbriæ, while on the outer or serous surfaces of these processes the epithelium gradually merges into the endothelium of the peritoneum.

THE OVARIES.

The **Ovaries** (*testes muliebres*, Galen) are analogous to the testes in the male. They are oval-shaped, flattened bodies of an elongated form, situated one on each side of the uterus, connected to the posterior layer of the broad ligament behind and below the Fallopian tubes. Each ovary is connected by its anterior straight margin to the broad ligaments; by its lower extremity to the uterus by a proper ligament, the *ligament of the ovary;* and by its upper end to the fimbriated extremity of the Fallopian tube by the ovarian fimbria; its mesial and lateral surfaces and posterior convex border are free. The ovaries are of a grayish-pink color, and present either a smooth or puckered, uneven surface. They are each about an inch and a half in length, three-quarters of an inch in width, and about a third of an inch thick, and weight from one to two drachms.

The exact position of the ovary has been the subject of considerable difference of opinion, and writers differ much as to what is to be regarded as the normal position. The fact appears to be that it is differently placed in different individuals. Hasse has described it as being situated with its long axis transverse, or almost transverse, to the pelvic cavity. Schultze, on the other hand, believes that its

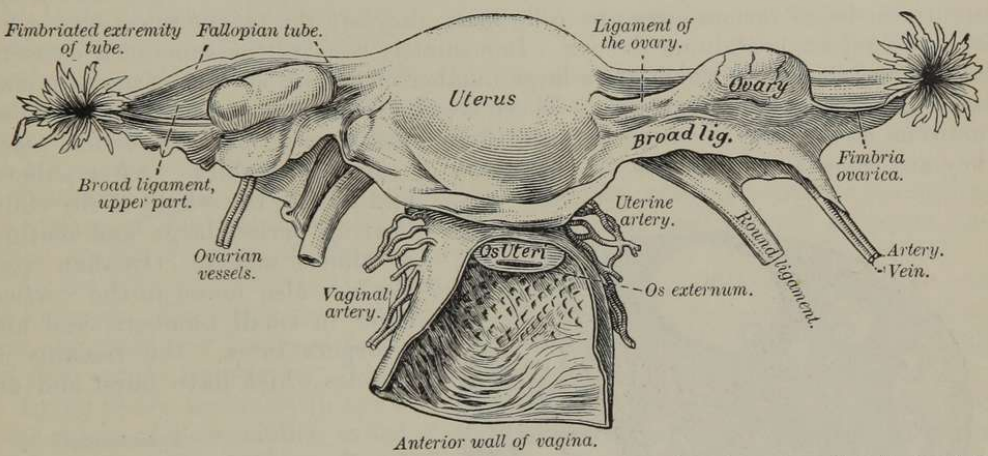

FIG. 753.—The uterus and its appendages. Posterior view. The parts have been somewhat displaced from their proper position in the preparation of the specimen; thus the right ovary has been raised above the Fallopian tube, and the fimbriated extremities of the tubes have been turned upward and outward. (From a preparation in the Royal College of Surgeons.)

long axis is antero-posterior. Kölliker asserts that the truth lies between these two views, and that the ovary is placed obliquely in the pelvis, its long axis lying parallel to the external iliac vessels, with its surface directed inward and outward, and its convex free border upward. His has made some important observations on this subject, and his views are largely accepted. He teaches that the uterus rarely lies symmetrically in the middle of the pelvic cavity, but is generally inclined to one or other side, most frequently to the left, in the proportion of three to two. The position of the two ovaries varies according to the inclination of the uterus. When the uterus is inclined to the left, the ovary of this side lies with its long axis vertical and with one side closely applied to the outer wall of the pelvis, while the ovary of the opposite side, being dragged upon by the inclination of the uterus, lies obliquely, its outer extremity being retained in close apposition to the side of the pelvis by the infundibulo-pelvic ligament (page 1170). When, on the other hand, the uterus is inclined to the right, the position of the two ovaries is exactly reversed, the right being vertical and the left oblique. In whichever position the ovary is placed, the Fallopian tube forms a loop around it, the uterine half ascending obliquely over it, and the outer half, including the dilated extremity, descending and bulging freely behind it. From this extremity the fimbriæ pass upward on to the ovary and closely embrace it.

Structure.—The ovary consists of a number of Graafian vesicles imbedded in

the meshes of a stroma or framework, and invested by a serous covering derived from the peritoneum.

Serous Covering.—Though the investing membrane of the ovary is derived from the peritoneum, it differs essentially from that structure, inasmuch as its epithelium consists of a single layer of columnar cells, instead of the flattened endothelial cells of other parts of the membrane; this has been termed the *germinal epithelium of Waldeyer*, and gives to the surface of the ovary a dull gray aspect instead of the shining smoothness of serous membranes generally.

Stroma.—The stroma is a peculiar soft tissue, abundantly supplied with blood-vessels, consisting for the most part of spindle-shaped cells, with a small amount of ordinary connective tissue. These cells have been regarded by some anatomists as unstriped muscle-cells, which, indeed, they most resemble (His); by others as connective-tissue cells (Waldeyer, Henle, and Kölliker). On the surface of the organ this tissue is much condensed, and forms a layer composed of short connective-tissue fibres, with fusiform cells between them. This was formerly regarded as a distinct fibrous covering, and was termed the *tunica albuginea*, but is nothing more than a condensed layer of the stroma of the ovary.

Graafian Follicles.—Upon making a section of an ovary numerous round transparent vesicles of various sizes are to be seen; they are the *Graafian vesicles* or *follicles*, the ovisacs containing the ova. Immediately beneath the superficial covering is a layer of stroma, in which are a large number of minute vesicles of uniform size, about $\frac{1}{100}$ of an inch in diameter. These are the Graafian vesicles in their earliest condition, and the layer where they are found has been termed the *cortical layer*. They are especially numerous in the ovary of the young child. After puberty and during the whole of the child-bearing period large and mature, or almost mature, Graafian vesicles are also found in the cortical layer in small numbers, and also "corpora lutea," the remains of vesicles which have burst and are

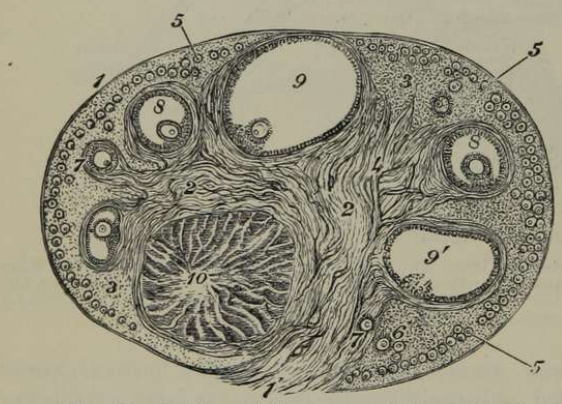

FIG. 754.—Section of the ovary. (After Schron.) 1. Outer covering. 1′. Attached border. 2. Central stroma. 3. Peripheral stroma. 4. Blood-vessels. 5. Graafian follicles in their earliest stage. 6, 7, 8. More advanced follicles. 9. An almost mature follicle. 9′. Follicle from which the ovum has escaped. 10. Corpus luteum.

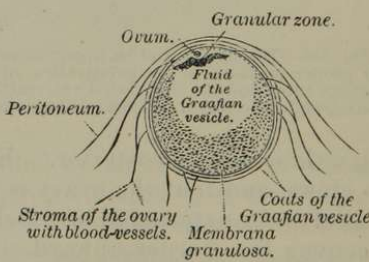

FIG. 755.—Section of the Graafian vesicle. (After Von Baer.)

undergoing atrophy and absorption. Beneath this superficial stratum other large and more mature Graafian vesicles are found imbedded in the ovarian stroma. These increase in size as they recede from the surface toward a highly vascular stroma in the centre of the organ, termed the *medullary substance* (*zona vasculosa*, Waldeyer). This stroma forms the tissue of the hilum by which the ovary is attached, and through which the blood-vessels enter; it does not contain any Graafian vesicles.

The larger *Graafian follicles* consist of an external fibro-vascular coat connected with the surrounding stroma of the ovary by a network of blood-vessels; and an internal coat, named *ovicapsule*, which is lined by a layer of nucleated cells, called the *membrana granulosa*. The fluid contained in the interior of the vesicles is transparent and albuminous, and in it is suspended the ovum. In that part of the mature Graafian vesicle which is nearest the surface of the ovary the cells of the membrana granulosa are collected into a mass which projects into the cavity

of the vesicle. This is termed the *discus proligerus*, and in this the ovum is imbedded.[1]

The ova are formed from the germ-epithelium on the surface of the ovary: the cells become enlarged and involuted, forming little depressions on the surface of the ovary. As they sink deeper into the tissue they become enclosed by the outgrowth of processes from the stroma of the ovary, and, becoming surrounded, their connection with the surface is cut off, and the germ-epithelium forming the involution is contained in a cavity, the future Graafian follicle. The germ-cell or cells now form the ovum; the cell-wall forms the vitelline membrane; the nucleus, the germinal area or vesicle; and a nucleolus, which soon appears, the germinal spot. A clear homogeneous protoplasm is formed within the cell, constituting the yelk, and thus the primordial ovum is developed. According to Dr. Foullis, the cells of the membrana granulosa are formed out of the nuclei of the fibro-cellular stroma of the ovary.[2]

The development and maturation of the Graafian vesicles and ova continue uninterruptedly from puberty to the end of the fruitful period of woman's life, while their formation commences before birth. Before puberty the ovaries are small, the Graafian vessels contained in them are disposed in a comparatively thick layer in the cortical substance; here they present the appearance of a large number of minute closed vesicles, constituting the early condition of the Graafian vesicle; many, however, never attain full development, but shrink and disappear, their ova being incapable of impregnation. At puberty the ovaries enlarge, are more vascular, the Graafian vesicles are developed in greater abundance, and their ova are capable of fecundation.

Discharge of the Ovum.—The Graafian vesicles, after gradually approaching the surface of the ovary, burst: the ovum and fluid contents are liberated, and escape on the exterior of the ovary, passing thence into the Fallopian tube.[3]

In the fœtus the ovaries are situated, like the testes, in the lumbar region, near the kidneys. They may be distinguished from those bodies at an early period by their elongated and flattened form, and by their position, which is at first oblique and then nearly transverse. They gradually descend into the pelvis.

Lying above the ovary in the broad ligament between it and the Fallopian tube is the **organ of Rosenmüller**, called also the *parovarium*. This is the remnant of a fœtal structure, described at page 137. In the adult it consists of a few closed convoluted tubes lined with epithelium, which converge toward the ovary, but which are connected at their opposite extremities with a longitudinal tube, the duct of Gartner (*epöophoron*), which ends in a bulbous or hydated swelling. The parovarium is connected at its uterine extremity with the remains of the Wolffian duct.

The *paröophoron* corresponds to the paradidymis of the male, and is found, when present, near the uterus.

The **Ligament of the Ovary** is a rounded cord which extends from each superior angle of the uterus to the lower extremity of the ovary; it consists of fibrous tissue and a few muscular fibres derived from the uterus.

The **Round Ligaments** are two rounded cords, between four and five inches in length, situated between the layers of the broad ligament in front of and below the Fallopian tube. Commencing on each side at the superior angle of the uterus, this ligament passes forward, upward, and outward through the internal abdominal ring, along the inguinal canal, to the labia majora, in which it becomes lost. The round ligament consists principally of muscular tissue prolonged from the uterus; also of some fibrous and areolar tissue, besides blood-vessels and nerves, enclosed in a duplicature of peritoneum, which in the fœtus is prolonged in the form of a tubular process for a short distance into the inguinal canal. This process is called the *canal of Nuck*. It is generally obliterated in the adult, but sometimes remains

[1] For a description of the ovum, see page 100.

[2] *Proceedings of the Royal Society of Edinburgh*, April, 1875.

[3] This is effected either by application of the tube to the ovary, or by a curling upward of the fimbriated extremity, so that the ovum is caught as it falls.

pervious even in advanced life. It is analogous to the peritoneal pouch which accompanies the descent of the testis.

Vessels and Nerves.—The *arteries of the ovaries and Fallopian tubes* are the ovarian from the aorta. They enter the attached border, or hilum, of the ovary. The *veins* follow the course of the arteries; they form a plexus near the ovary, the *pampiniform plexus*. The *nerves* are derived from the inferior hypogastric or pelvic plexus, and from the ovarian plexus, the Fallopian tube receiving a branch from one of the uterine nerves.

THE MAMMARY GLANDS.

The **mammæ,** or breasts, are accessory glands of the generative system, which secrete the milk. They exist in the male as well as in the female, but in the former only in the rudimentary state, unless their growth is excited by peculiar circumstances. In the female they are two large hemispherical eminences situated

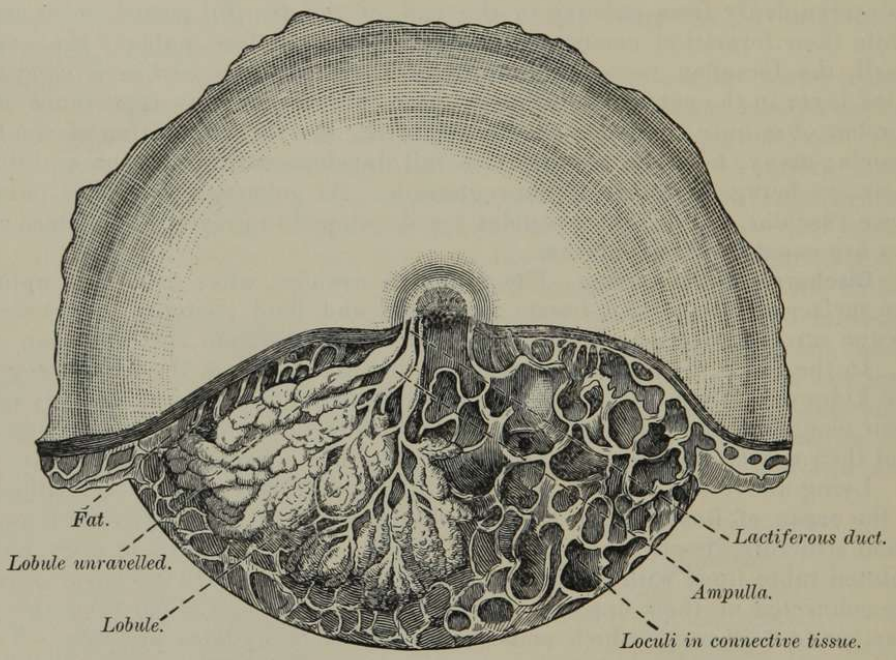

FIG. 756.—Dissection of the lower half of the female breast during the period of lactation. (From Luschka.)

toward the lateral aspect of the pectoral region, corresponding to the intervals between the third and sixth or seventh ribs, and extending from the side of the sternum to the axilla. Their weight and dimensions differ at different periods of life and in different individuals. Before puberty they are of small size, but enlarge as the generative organs become more completely developed. They increase during pregnancy, and especially after delivery, and become atrophied in old age. The left mamma is generally a little larger than the right. Their base is nearly circular, flattened or slightly concave, and has its long diameter directed upward and outward toward the axilla; they are separated from the Pectoral and Serratus magnus muscles by a layer of fascia. The outer surface of the mamma is convex, and presents, just below the centre, a small conical prominence, the nipple (*mammilla*). The surface of the nipple is dark-colored and surrounded by an areola having a colored tint. In the virgin the areola is of a delicate rosy hue; about the second month after impregnation it enlarges and acquires a darker tinge, which increases as pregnancy advances, becoming in some cases of a dark-brown or even black color. This color diminishes as soon as lactation is over, but is never entirely lost throughout life. These changes in the color of the areola are of importance in forming a conclusion in a case of suspected first pregnancy.

The **nipple** is a cylindrical or conical eminence capable of undergoing a sort of erection from mechanical excitement, a change mainly due to the contraction of its muscular fibres. It is of a pink or brownish hue, its surface wrinkled and provided with papillæ, and it is perforated at the tip by numerous orifices, the apertures of the lactiferous ducts. Near the base of the nipple and upon the surface of the areoli are numerous sebaceous glands, which become much enlarged during lactation, and present the appearance of small tubercles beneath the skin. These glands secrete a peculiar fatty substance, which serves as a protection to the integument of the nipple during the act of sucking. The nipple consists of numerous vessels, intermixed with plain muscular fibres, which are principally arranged in a circular manner around the base, some few fibres radiating from base to apex.

Structure.—The mamma consists of gland-tissue ; of fibrous tissue, connecting its lobes ; and of fatty tissue in the intervals between the lobes. The gland-tissue, when freed from fibrous tissue and fat, is of a pale reddish color, firm in texture, circular in form, flattened from before backward, thicker in the centre than at the circumference, and presenting several inequalities on its surface, especially in front. It consists of numerous lobes, and these are composed of lobules connected together by areolar tissue, blood-vessels, and ducts. The smallest lobules consist of a cluster of rounded alveoli, which open into the smallest branches of the lactiferous ducts ; these ducts, uniting, form larger ducts, which terminate in a single canal, corresponding with one of the chief subdivisions of the gland. The number of excretory ducts varies from fifteen to twenty : they are termed the *tubuli lactiferi*, or *galactophori*. They converge toward the areola, beneath which they form dilatations, or *ampullæ*, which serve as reservoirs for the milk, and at the base of the nipple become contracted and pursue a straight course to its summit, perforating it by separate orifices considerably narrower than the ducts themselves. The ducts are composed of areolar tissue, with longitudinal and transverse elastic fibres and longitudinal muscular fibres : their mucous lining is continuous, at the point of the nipple, with the integument. The epithelium of the mammary gland differs according to the state of activity of the organ. In the gland of a woman who is not pregnant or suckling the alveoli are very small and solid, being filled with a mass of granular polyhedral cells. During pregnancy the alveoli enlarge and the cells undergo rapid multiplication. At the commencement of lactation the cells in the centre of the alveolus undergo fatty degeneration, and are eliminated in the first milk as *colostrum-corpuscles*. The peripheral cells of the alveolus remain, and form a single layer of granular, short columnar cells, with a spherical nucleus, lining the limiting membrana propria. These cells during the state of activity of the gland are capable of forming, in their interior, oil-globules, which are then ejected into the lumen of the alveolus and constitute the milk-globules.

The *fibrous tissue* invests the entire surface of the breast, and sends down septa between its lobes, connecting them together.

The *fatty tissue* surrounds the surface of the gland and occupies the interval between its lobes. It usually exists in considerable abundance, and determines the form and size of the gland. There is no fat immediately beneath the areola and nipple. (The colostrom-corpuscles may be emigrated white corpuscles.)

Vessels and Nerves,—The *arteries* supplying the mammæ are derived from the thoracic branches of the axillary, the intercostals, and internal mammary. The *veins* describe an anastomotic circle round the base of the nipple, called by Haller the *circulus venosus*. From this large branches transmit the blood to the circumference of the gland and end in the axillary and internal mammary veins. The *lymphatics*, for the most part, run along the lower border of the Pectoralis major to the axillary glands ; some few, from the inner side of the breast, perforate the intercostal spaces and empty themselves into the anterior mediastinal glands. The *nerves* are derived from the anterior and lateral cutaneous nerves of the thorax.

THE SURGICAL ANATOMY OF HERNIA.

Dissection (Fig. 757).—For dissection of the parts concerned in inguinal hernia a male subject, free from fat, should always be selected. The body should be placed in the supine position, the abdomen and pelvis raised by means of blocks placed beneath them, and the lower extremities rotated outward, so as to make the parts as tense as possible. If the abdominal walls are flaccid, the cavity of the abdomen should be inflated by an aperture through the umbilicus. An incision should be made along the middle line from the umbilicus to the symphysis pubis, and continued along the front of the scrotum, and a second incision from the anterior superior spine of the ilium to just below the umbilicus. These incisions should divide the integument, and the triangular-shaped flap included between them should be reflected downward and outward, when the superficial fascia will be exposed.

The Superficial Fascia of the Abdomen.—This, over the greater part of the abdominal wall, consists of a single layer of fascia, which contains a variable amount of fat; but as it approaches the groin it is easily divisible into two layers, between which are found the superficial vessels and nerves and the superficial inguinal lymphatic glands.

The *superficial layer* is thick, areolar in texture, containing adipose tissue in its meshes, the quantity of which varies in different subjects. Below, it passes over Poupart's ligament, and is continuous with the outer layer of the superficial fascia of the thigh. In the male this fascia is continued over the penis and over the outer surface of the cord to the scrotum, where it helps to form the dartos. As it passes to the penis and over the cord to the scrotum it changes its character, becoming thin, destitute of adipose tissue, and of a pale reddish color; and in the scrotum it acquires some involuntary muscular fibres. From the scrotum it may be traced backward, to be continuous with the superficial fascia of the perinæum. In the female this fascia is continued into the labia majora.

The *hypogastric branch of the ilio-hypogastric nerve* perforates the aponeurosis of the External oblique muscle about an inch above and a little to the outer side of the external abdominal ring, and is distributed to the integument of the hypogastric region.

The *ilio-inguinal nerve* escapes at the external abdominal ring, and is distributed to the integument of the upper and inner part of the thigh, to the scrotum in the male and to the labium in the female.

The *superficial epigastric artery* arises from the femoral about half an inch below Poupart's ligament, and, passing through the saphenous opening in the fascia lata, ascends on to the abdomen, in the superficial fascia covering the External oblique muscle, nearly as high as the umbilicus. It distributes branches to the superficial inguinal lymphatic glands, the superficial fascia, and the integument, anastomosing with branches of the deep epigastric and internal mammary arteries.

The *superficial circumflex iliac artery*, the smallest of the cutaneous branches, arises close to the preceding, and, piercing the fascia lata, runs outward, parallel with Poupart's ligament, as far as the crest of the ilium, dividing into branches which supply the superficial inguinal lymphatic glands, the superficial fascia, and the integument, anastomosing with the deep circumflex iliac and with the gluteal and external circumflex arteries.

The *superficial external pudic* (*superior*) *artery* arises from the inner side of the femoral artery close to the preceding vessels, and, after passing through the saphenous opening, courses inward across the spermatic cord, to be distributed to the integument on the lower part of the abdomen, the penis and scrotum in the male, and the labium in the female, anastomosing with branches of the internal pudic.

The Superficial Veins.—The veins accompanying these superficial vessels are

usually much larger than the arteries; they terminate in the internal saphenous vein.

The *superficial inguinal lymphatic glands* are placed immediately beneath the integument, are of large size, and vary from eight to ten in number. They are divisible into two groups: an upper, disposed irregularly along Poupart's ligament, which receive the lymphatic vessels from the integument of the scrotum, penis, parietes of the abdomen, perineal and gluteal regions, and the mucous membrane of the urethra; and an inferior group, which surround the saphenous opening in the fascia lata, a few being sometimes continued along the saphenous

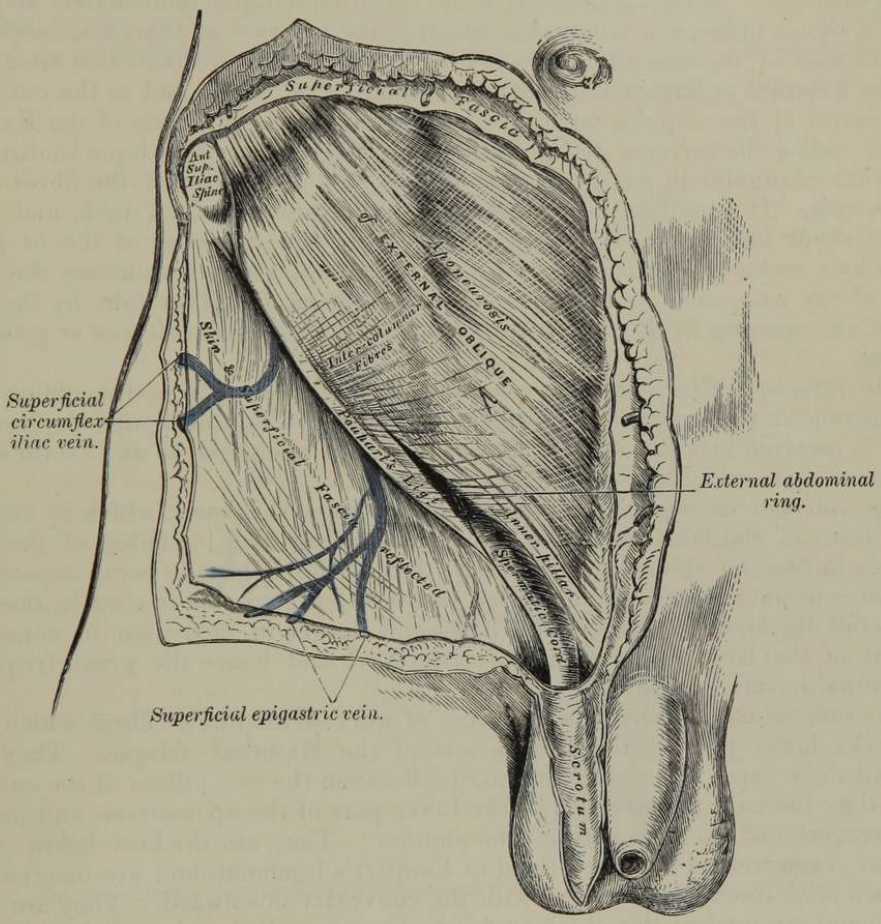

FIG. 757.—Inguinal hernia. Superficial dissection.

vein to a variable extent. This latter group receive the superficial lymphatic vessels from the lower extremity.

The *deep layer of the superficial fascia* (*fascia of Scarpa*) is thinner and more membranous in character than the superficial layer. In the middle line it is intimately adherent to the linea alba; above, it is continuous with the superficial fascia over the rest of the trunk; below, it is connected with the fascia lata (thigh) a little below Poupart's ligament; below and internally, in the male, it is continued over the penis and over the outer surface of the cord to the scrotum, where it helps to form the dartos. From the scrotum it may be traced backward to be continuous with the *deep layer* of the superficial fascia of the perineum. In the female it is continuous with the labia majora.

The scrotum is a cutaneous pouch which contains the testes and part of the spermatic cords, and into which an inguinal hernia frequently descends (see page 1153).

The Aponeurosis of the External Oblique Muscle.—This is a thin but strong

membranous aponeurosis, the fibres of which are directed obliquely downward and inward. That portion of the aponeurosis which extends between the anterior superior spine of the ilium and the spine of the os pubis is a broad band, folded inward and continuous below with the fascia lata; it is called *Poupart's ligament*. The portion which is reflected from Poupart's ligament at the spine of the os pubis, along the pectineal line, is called *Gimbernat's ligament*. From the point of attachment of the latter to the pectineal line a few fibres pass upward and inward, behind the inner pillar of the ring, to the linea alba. They diverge as they ascend, and form a thin, triangular, fibrous band, which is called the *triangular ligament of the abdomen*. In the aponeurosis of the External oblique, immediately above the crest of the os pubis, is a triangular opening, the *external* or *superficial abdominal ring*, formed by the separation of the fibres of the aponeurosis in this situation.

The External or Superficial Abdominal Ring.—Just above and to the outer side of the crest of the os pubis an interval is seen in the aponeurosis of the External oblique, called the *external abdominal ring*. This aperture is oblique in direction, somewhat triangular in form, and corresponds with the course of the fibres of the aponeurosis. It usually measures from base to apex about an inch, and transversely about half an inch. It is bounded below by the crest of the os pubis; above, by a series of curved fibres, the *intercolumnar*, which pass across the upper angle of the ring, so as to increase its strength; and on either side, by the margins of the opening in the aponeurosis, which are called the *columns* or *pillars of the ring*.

The *external pillar*, which at the same time is *inferior* from the obliquity of its direction, is the stronger; it is formed by that portion of Poupart's ligament which is inserted into the spine of the os pubis; it is curved, so as to form a kind of groove, upon which the spermatic cord rests.

The *internal* or *superior pillar* is a broad, thin, flat band, which is attached to the front of the body of the os pubis, interlacing with its fellow of the opposite side in front of the symphysis pubis, that of the right side being superficial.

The external abdominal ring gives passage to the spermatic cord in the male and round ligament in the female; it is much larger in men than in women, on account of the large size of the spermatic cord, and hence the great frequency of inguinal hernia in men.

The *intercolumnar fibres* are a series of curved tendinous fibres which arch across the lower part of the aponeurosis of the External oblique. They have received their name from stretching across between the two pillars of the external ring; they increase the strength of the lower part of the aponeurosis and prevent the divergence of the pillars from one another. They are thickest below, where they are connected to the outer third of Poupart's ligament, and are inserted into the linea alba, describing a curve, with the convexity downward. They are much thicker and stronger at the outer angle of the external ring than internally, and are more strongly developed in the male than in the female. These intercolumnar fibres, as they pass across the external abdominal ring, are themselves connected together by delicate fibrous tissue, thus forming a fascia which, as it is attached to the pillars of the ring, covers it in, and is called the *intercolumnar fascia*. This intercolumnar fascia is continued downward as a tubular prolongation around the outer surface of the cord and testis, and encloses them in a distinct sheath; hence it is also called the *external spermatic fascia*. The sac of an inguinal hernia in passing through the external abdominal ring receives an investment from the intercolumnar fascia.

If the finger is introduced a short distance into the external ring, and then, if the limb is extended and rotated outward, the aponeurosis of the External oblique, together with the iliac portion of the fascia lata, will be felt to become tense and the external ring much contracted; if the limb is, on the contrary, flexed upon the pelvis and rotated inward, this aponeurosis will become lax, and the external ring sufficiently enlarged to admit the finger with comparative ease; hence the patient should always be put in the latter position when the taxis is applied for the reduc-

tion of an inguinal hernia, in order that the abdominal walls may be relaxed as much as possible.

The aponeurosis of the External oblique should be removed by dividing it across in the same direction as the external incisions, and reflecting it downward and outward: great care is requisite in separating it from the aponeurosis of the muscle beneath. The lower part of the Internal oblique and the Cremaster are then exposed, together with the inguinal canal, which contains the spermatic cord (Fig. 758). The mode of insertion of Poupart's and Gimbernat's ligaments into the os pubis should also be examined.

Poupart's ligament, or the crural arch, is the lower border of the aponeurosis of the External oblique muscle, which extends from the anterior superior spine of the ilium to the spine of the os pubis. From this latter point it is reflected outward to be attached to the pectineal line for about half an inch, forming

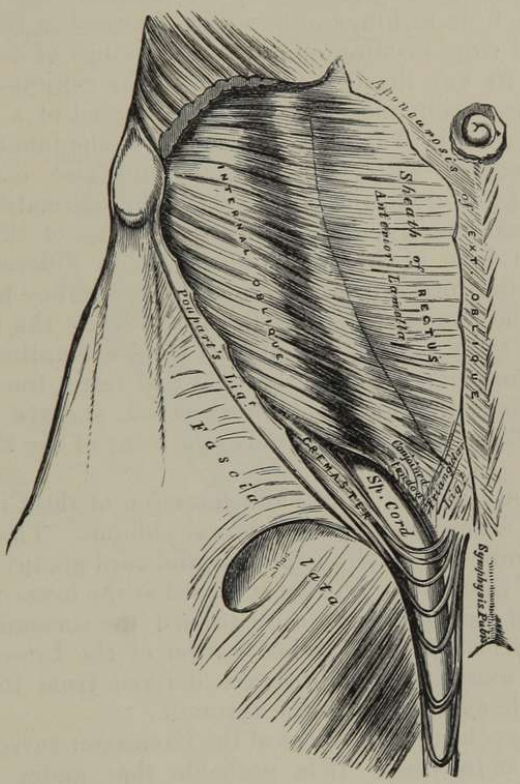

FIG. 758.—Inguinal hernia, showing the Internal oblique, Cremaster, and spermatic canal.

Gimbernat's ligament. Its general direction is curved downward toward the thigh, where it is continuous with the fascia lata. Its outer half is rounded and oblique in direction; its inner half gradually widens at its attachment to the os pubis, is more horizontal in direction, and lies beneath the spermatic cord.

Gimbernat's ligament (Fig. 765) is that portion of the External oblique muscle which is reflected downward and outward from the spine of the os pubis to be inserted into the pectineal line. It is about half an inch in length, larger in the male than in the female, almost horizontal in direction in the erect posture, and of a triangular form, with the base directed outward. Its base or outer margin is concave, thin, and sharp, and lies in contact with the crural sheath, forming the inner boundary of the crural ring (see Fig. 766). Its apex corresponds to the spine of the os pubis. Its posterior margin is attached to the pectineal line, and is continuous with the pubic portion of the fascia lata. Its anterior margin is continuous with Poupart's ligament.

The **triangular ligament of the abdomen** is a band of tendinous fibres, of a triangular shape, which is attached by its apex to the pectineal line, where it is

continuous with Gimbernat's ligament. It passes inward beneath the spermatic cord, and expands into a somewhat fan-shaped fascia, lying behind the inner pillar of the external abdominal ring and in front of the conjoined tendon, and interlaces with the ligament of the other side at the linea alba.

The **Internal oblique muscle** has been previously described (page 451). The part which is now exposed is partly muscular and partly tendinous in structure. Those fibres which arise from Poupart's ligament, few in number and paler in color than the rest, arch downward and inward across the spermatic cord, and, becoming tendinous, are inserted, conjointly with those of the Transversalis, into the crest of the os pubis and pectineal line, forming what is known as the conjoined tendon of the Internal oblique and Transversalis. This tendon is inserted immediately behind the external abdominal ring, serving to protect what would otherwise be a weak point in the abdominal wall. Sometimes this tendon is insufficient to resist the pressure from within, and is carried forward in front of the protrusion through the external ring, forming one of the coverings of direct inguinal hernia, or the hernia forces its way through the fibres of the conjoined tendon.

The **Cremaster** is a thin muscular layer composed of a number of fasciculi which arise from the middle of Poupart's ligament at the inner side of the Internal oblique, being connected with that muscle and also occasionally with the Transversalis. It passes along the outer side of the spermatic cord, descends with it through the external ring upon the front and sides of the cord, and forms a series of loops which differ in thickness and length in different subjects. Those at the upper part of the cord are exceedingly short, but they become in succession longer and longer, the longest reaching down as low as the testicle, where a few are inserted into the tunica vaginalis. These loops are united together by areolar tissue, and form a thin covering over the cord and testis, the *fascia cremasterica*. The fibres ascend along the inner side of the cord, and are inserted by a small pointed tendon into the crest of the os pubis and front of the sheath of the Rectus muscle.

It will be observed that the origin and insertion of the Cremaster is precisely similar to that of the lower fibres of the Internal oblique. This fact affords an easy explanation of the manner in which the testicle and cord are invested by this muscle. At an early period of fœtal life the testis is placed at the lower and back part of the abdominal cavity, but during its descent toward the scrotum, which takes place before birth, it passes beneath the arched border of the Internal oblique. In its passage beneath this muscle some fibres are derived from its lower part which accompany the testicle and cord into the scrotum.

It occasionally happens that the loops of the Cremaster surround the cord, some lying behind as well as in front. It is probable that under these circumstances the testis in its descent passes through, instead of beneath, the fibres of the Internal oblique.

In the descent of an oblique inguinal hernia, which takes the same course as the spermatic cord, the Cremaster muscle forms one of its coverings. This muscle becomes largely developed in cases of hydrocele and large old scrotal herniæ. No such muscle exists in the female, except a few fibres on the surface of the round ligament, but an analogous structure is developed in those cases where an oblique inguinal hernia descends beneath the margin of the Internal oblique.

The Internal oblique should be detached from Poupart's ligament, separated from the Transversalis to the same extent as in the previous incisions, and reflected inward on to the sheath of the Rectus (Fig. 759). The circumflex iliac vessels, which lie between these two muscles, form a valuable guide to their separation.

The **Transversalis muscle** has been previously described (page 453). The part which is now exposed is partly muscular and partly tendinous in structure; this portion arises from the outer third of Poupart's ligament, its fibres curve downward and inward, and are inserted, together with those of the Internal oblique, into the lower part of the linea alba, into the crest of the os pubis and pectineal line, forming what is known as the conjoined tendon of the Internal oblique and

Transversalis. Between the lower border of this muscle and Poupart's ligament a space is left in which is seen the fascia transversalis.

The **inguinal** or **spermatic canal** contains the spermatic cord in the male and the round ligament in the female. It is an oblique canal, about an inch and a half in length, directed downward and inward and placed parallel with, and a little above, Poupart's ligament. It commences above at the internal abdominal ring, which is the point where the cord enters the spermatic canal, and terminates below at the external ring. It is bounded, *in front*, by the integument and superficial fascia, by the aponeurosis of the External oblique throughout its whole length, and by the Internal oblique for its outer third; *behind*, by the triangular ligament, the conjoined tendon of the Internal oblique and Transversalis, transversalis fascia, and the subperitoneal fat and peritoneum; *above*, by the arched fibres of the Internal oblique and Transversalis; *below*, by the union of the fascia transversalis with Poupart's ligament. That form of protrusion in which the

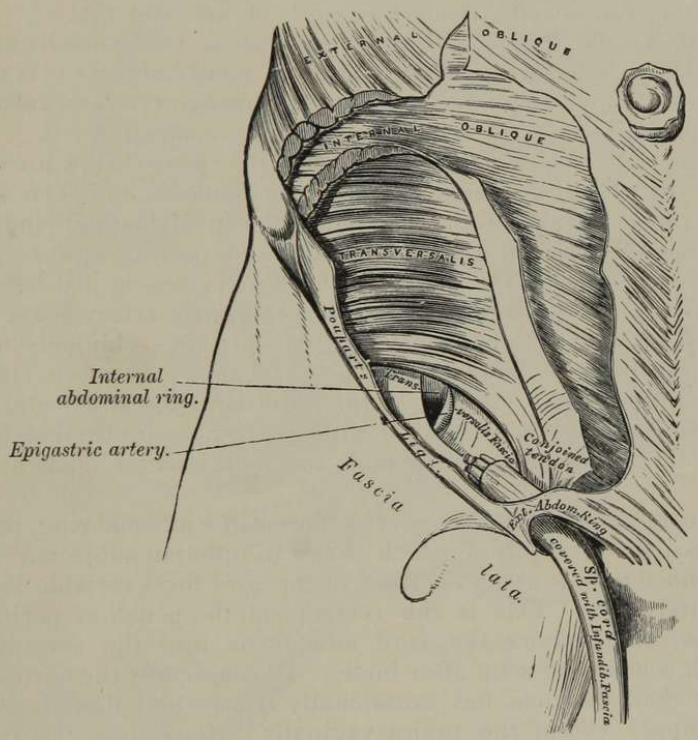

FIG. 759.—Inguinal hernia showing the Transversalis muscle, the transversalis fascia, and the internal abdominal ring.

intestine follows the course of the spermatic cord along the spermatic canal is called *oblique inguinal hernia.*

The **fascia transversalis** is a thin aponeurotic membrane which lies between the inner surface of the Transversalis muscle and the peritoneum. It forms part of the general layer of fascia which lines the interior of the abdominal and pelvic cavities, and is directly continuous with the iliac and pelvic fasciæ.

In the inguinal region the transversalis fascia is thick and dense in structure, and joined by fibres from the aponeurosis of the Transversalis muscle; but it becomes thin and cellular as it ascends to the Diaphragm. Below, it has the following attachments: external to the femoral vessels it is connected to the posterior margin of Poupart's ligament, and is there continuous with the iliac fascia. Internal to the vessels it is thin, and attached to the os pubis and pectineal line behind the conjoined tendon, with which it is united; and, corresponding to the points where the femoral vessels pass into the thigh, this fascia descends in front of them, forming the anterior wall of the crural sheath. The spermatic cord

in the male and the round ligament in the female pass through this fascia; the point where they pass through is called the internal or deep abdominal ring. This opening is not visible externally, owing to a prolongation of the transversalis fascia on these structures, forming the infundibuliform process.

The **internal** or **deep abdominal ring** is situated in the transversalis fascia, midway between the anterior superior spine of the ilium and the symphysis pubis, and about half an inch above Poupart's ligament. It is of an oval form, the extremities of the oval directed upward and downward; it varies in size in different subjects, and is much larger in the male than in the female. It is bounded above and externally by the arched fibres of the Transversalis muscle, below and internally by the deep epigastric vessels. It transmits the spermatic cord in the male and the round ligament in the female. From its circumference a thin, funnel-shaped membrane, the *infundibuliform fascia*, is continued round the cord and testis, enclosing them in a distinct pouch. When the sac of an oblique inguinal hernia passes through the internal or deep abdominal ring, the infundibuliform process of the transversalis fascia forms one of its coverings.

The Subperitoneal Areolar Tissue.—Between the fascia transversalis and the peritoneum is a quantity of loose areolar tissue. In some subjects it is of considerable thickness and loaded with adipose tissue. Opposite the internal ring it is continued round the surface of the cord, forming a loose sheath for it.

The *deep epigastric artery* arises from the external iliac artery a few lines above Poupart's ligament. It at first descends to reach this ligament, and then ascends obliquely along the inner margin of the internal or deep abdominal ring, lying between the transversalis fascia and the peritoneum, and passing upward pierces the transversalis fascia and enters the sheath of the Rectus muscle just below the semilunar fold of Douglas. Consequently the deep epigastric artery bears a very important relation to the internal abdominal ring as it passes obliquely upward and inward from its origin from the external iliac. In this part of its course it lies along the lower and inner margin of the internal ring and beneath the commencement of the spermatic cord. As it winds round the internal abdominal ring it is crossed by the vas deferens in the male and by the round ligament in the female.

The **peritoneum,** corresponding to the inner surface of the internal ring, presents a well-marked depression, the depth of which varies in different subjects. A thin fibrous band is continued from it along the front of the cord for a variable distance, and becomes ultimately lost. This is the remains of the pouch of peritoneum which, in the fœtus, accompanies the cord and testis into the scrotum, the obliteration of which commences soon after birth. In some cases the fibrous band can only be traced a short distance, but occasionally it may be followed, as a fine cord, as far as the upper end of the tunica vaginalis. Sometimes the tube of peritoneum is only closed at intervals and presents a sacculated appearance, or a single pouch may extend along the whole length of the cord, which may be closed above, or the pouch may be directly continuous with the peritoneum by an opening at its upper part.

In the female (in the fœtus) the peritoneum is also prolonged in the form of a tubular process for a short distance into the inguinal canal. This process is called the canal of Nuck. It is generally obliterated in the adult, but sometimes it remains pervious even in advanced life. It is analogous to the peritoneal pouch which accompanies the descent of the testis.

INGUINAL HERNIA.

Inguinal hernia is that form of protrusion which makes its way through the abdomen in the inguinal region.

There are two principal varieties of inguinal hernia—external or oblique, and internal or direct.

External or *oblique inguinal hernia*, the more frequent of the two, takes the

same course as the spermatic cord. It is called *external* from the neck of the sac being on the outer or iliac side of the deep epigastric artery.

Internal or *direct inguinal hernia* does not follow the same course as the cord, but protrudes through the abdominal wall on the inner or pubic side of the deep epigastric artery.

Oblique Inguinal Hernia.

In **oblique inguinal hernia** the intestine escapes from the abdominal cavity at the internal ring, pushing before it a pouch of peritoneum, which forms the hernial

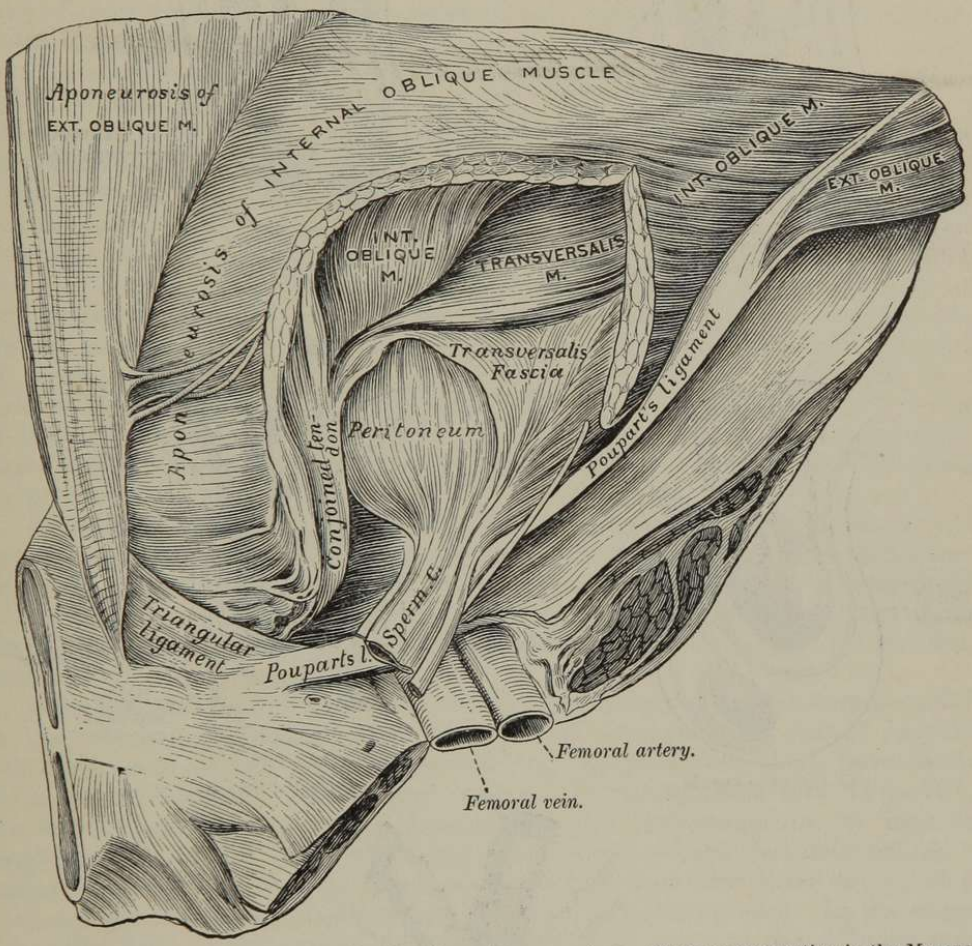

FIG. 760.—Oblique inguinal hernia, showing its various coverings. (From a preparation in the Museum of the Royal College of Surgeons.)

sac (Fig. 761, A). As it enters the inguinal canal it receives an investment from the subserous areolar tissue, and is enclosed in the infundibuliform process of the transversalis fascia. In passing along the inguinal canal it displaces upward the arched fibres of the Transversalis and Internal oblique muscles, and is surrounded by the fibres of the Cremaster. It then passes along the front of the cord, and escapes from the inguinal canal at the external ring, receiving an investment from the intercolumnar fascia. Lastly, it descends into the scrotum, receiving coverings from the superficial fascia and the integument.

The coverings of this form of hernia, after it has passed through the external ring, are, from without inward, the integument, superficial fascia, intercolumnar fascia, Cremaster muscle, infundibuliform fascia, subserous areolar tissue, and peritoneum.

This form of hernia lies in front of the vessels of the spermatic cord and

seldom extends below the testis, on account of the intimate adhesion of the coverings of the cord to the tunica vaginalis.

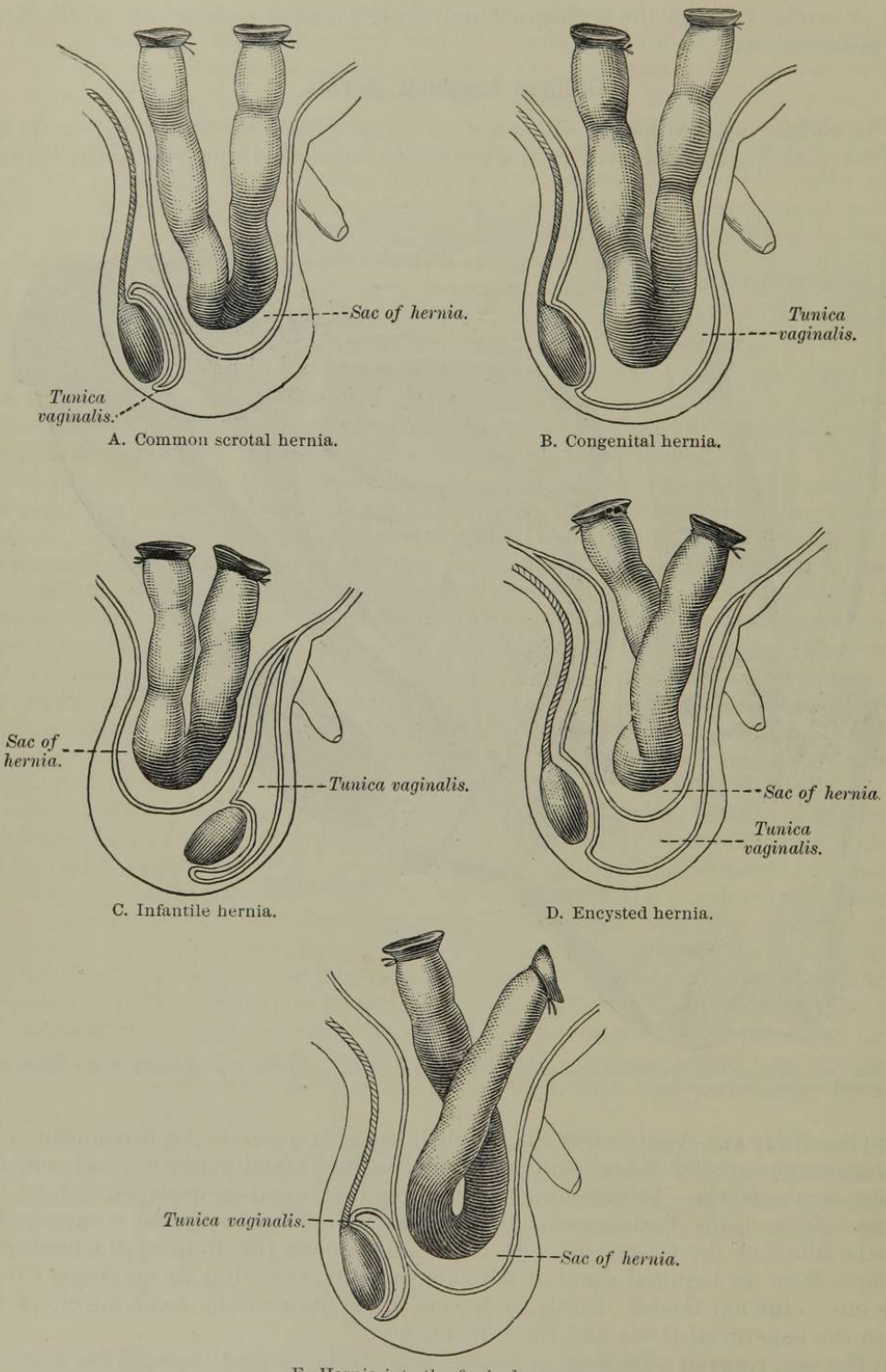

A. Common scrotal hernia.

B. Congenital hernia.

C. Infantile hernia.

D. Encysted hernia.

E. Hernia into the funicular process.

FIG. 761.—Varieties of oblique inguinal hernia.

The *seat of stricture* in oblique inguinal hernia is either at the external ring, in the inguinal canal, caused by the fibres of the Internal oblique or Trans-

versalis; or at the internal ring, most frequently in the latter situation. If it is situated at the external ring, the division of a few fibres at one point of its circumference is all that is necessary for the replacement of the hernia. If in the inguinal canal or at the internal ring, it may be necessary to divide the aponeurosis of the External oblique so as to lay open the inguinal canal. In dividing the stricture the direction of the incision should be upward.

When the intestine passes along the spermatic canal and escapes from the external ring into the scrotum, it is called *complete oblique inguinal* or *scrotal hernia*. If the intestine does not escape from the external ring, but is retained in the inguinal canal, it is called *incomplete inguinal hernia*, or *bubonocele*. In each of these cases the coverings which invest it will depend upon the extent to which it descends in the inguinal canal.

There are some other varieties of oblique inguinal hernia depending upon congenital defects in the processus vaginalis. The testicle in its descent from the abdomen into the scrotum is accompanied by a pouch of peritoneum, which about the period of birth becomes shut off from the general peritoneal cavity by a closure of that portion of the pouch which extends from the internal abdominal ring to near the upper part of the testicle, the lower portion of the pouch remaining persistent as the tunica vaginalis. It would appear that this closure commences at two points—viz. at the internal abdominal ring and at the top of the epididymis—and gradually extends until, in the normal condition, the whole of the intervening portion is converted into a fibrous cord. From failure in the completion of this process variations in the relation of the hernial protrusion to the testicle and tunica vaginalis are produced, which constitute distinct varieties of inguinal hernia, and which have received separate names and are of surgical importance. These are congenital, infantile, encysted, and hernia of the funicular process.

Congenital Hernia (Fig. 761, B).—Where the pouch of peritoneum which accompanies the cord and testis in its descent remains patent throughout and is unclosed at any point, the cavity of the tunica vaginalis communicates directly with the peritoneum. The intestine descends along this pouch into the cavity of the tunica vaginalis, which constitutes the sac of the hernia, and the gut lies in contact with the testicle.

Infantile and Encysted Hernia.—Where the pouch of peritoneum is occluded at the internal ring only, and remains patent throughout the rest of its extent, two varieties of oblique inguinal hernia may be produced, which have received the names of infantile and encysted hernia. In the *infantile* form (Fig. 761, C) the bowel, pressing upon the septum and the peritoneum in its immediate neighborhood, causes it to yield and form a sac, which descends behind the tunica vaginalis, so that in front of the bowel there are three layers of peritoneum, the two layers of the tunica vaginalis and its own sac. In the *encysted* form (Fig. 761, D) pressure in the same position—namely, at the occluded spot in the pouch—causes the septum to yield and form a sac which projects *into* and not *behind* the tunica vaginalis, as in the infantile form, and thus it constitutes a sac within a sac, so that in front of the bowel there are two layers of peritoneum—one layer of the tunica vaginalis and its own sac.

Hernia into the Funicular Process (Fig. 761, E).—Where the pouch of peritoneum is occluded at the lower point only—that is, just above the testicle—the intestine descends into the pouch of peritoneum as far as the testicle, but is prevented from entering the sac of the tunica vaginalis by the septum which has formed between it and the pouch, so that it resembles the congenital form in all respects, except that, instead of enveloping the testicle, that body can be felt below the rupture.

Direct Inguinal Hernia.

In **direct inguinal hernia** the protrusion makes its way through some part of the abdominal wall internal to the epigastric artery.

At the lower part of the abdominal wall is a triangular space (*Hesselbach's triangle*), bounded externally by the deep epigastric artery covered by peritoneum (*plica epigastriea*), internally by the margin of the Rectus muscle, below by Poupart's ligament. The conjoined tendon is stretched across the inner two-thirds of this space, the remaining portion of the space having only the subperitoneal areolar tissue and the transversalis fascia between the peritoneum and the aponeurosis of the External oblique muscle.

In some cases the hernial protrusion escapes from the abdomen on the outer side of the conjoined tendon, pushing before it the peritoneum, the subserous areolar tissue, and the transversalis fascia. It then enters the inguinal canal, passing along nearly its whole length, and finally emerges from the external ring, receiving an investment from the intercolumnar fascia. The coverings of this form of hernia are precisely similar to those investing the oblique form, with the insignificant difference that the infundibuliform fascia is replaced by a portion derived from the general layer of the fascia transversalis.

In other cases—and this is the more frequent variety—the hernia is either forced through the fibres of the conjoined tendon or the tendon is gradually distended in front of it so as to form a complete investment for it. The intestine then enters the lower end of the inguinal canal, escapes at the external ring lying on the inner side of the cord, and receives additional coverings from the superficial fascia and the integument. This form of hernia has the same coverings as the oblique variety, excepting that the conjoined tendon is substituted for the Cremaster, and the infundibuliform fascia is replaced by a portion derived from the general layer of the fascia transversalis.

The difference between the position of the neck of the sac in these two forms of direct inguinal hernia has been referred, with some probability, to a difference in the relative positions of the obliterated hypogastric artery and the deep epigastric artery. When the course of the obliterated hypogastric artery corresponds pretty nearly with that of the deep epigastric—which is regarded as the normal arrangement—the projection of these arteries toward the cavity of the abdomen produces two fossæ in the peritoneum. The bottom of the external fossa of the peritoneum corresponds to the position of the internal abdominal ring, and a hernia which distends and pushes out the peritoneum lining this fossa is an oblique hernia. When, on the other hand, the obliterated hypogastric artery lies considerably to the inner side of the deep epigastric artery, corresponding to the outer margin of the conjoined tendon, the projection of the peritoneum over it (*plica hypogastrica*) divides the triangle of Hesselbach into two parts, so that three depressions will be seen on the inner surface of the lower part of the abdominal wall—viz. an external one, on the outer side of the deep epigastric artery; a middle one, between the deep epigastric and the obliterated hypogastric arteries; and an internal one, on the inner side of the obliterated hypogastric artery. In such a case a hernia may distend and push out the peritoneum forming the bottom of the external fossa, it is an oblique or external inguinal hernia. These fossæ are the *inguinal fossæ*.

When the hernia distends and pushes out the peritoneum forming the bottom of either the middle or the internal fossa, it is a direct or internal hernia.

The anatomical difference between these two forms of direct or internal inguinal hernia is that, when the hernia protrudes through the middle fossa—that is, the fossa between the deep epigastric and the obliterated hypogastric arteries—it will enter the upper part of the inguinal canal; consequently its coverings will be the same as those of an oblique hernia, with the insignificant difference that the infundibuliform fascia is replaced by a portion derived from the general layer of the fascia transversalis, whereas when the hernia protrudes through the internal fossa it is either forced through the fibres of the conjoined tendon or the tendon is gradually distended in front of it so as to form a complete investment for it. The intestine then enters the lower part of the inguinal canal, and escapes from the external abdominal ring lying on the inner side of the cord.

This form of hernia has the same coverings as the oblique variety, excepting that the conjoined tendon is substituted for the Cremaster, and the infundibuliform fascia is replaced by a portion derived from the general layer of the fascia transversalis.

The *seat of stricture* in both varieties of direct hernia is most frequently at the neck of the sac or at the external ring. In that form of hernia which perforates the conjoined tendon it not unfrequently occurs at the edges of the fissure through which the gut passes. In dividing the stricture the incision should in all cases be directed upward.[1]

If the hernial protrusion passes into the inguinal canal, but does not escape from the external abdominal ring, it forms what is called *incomplete direct hernia.* This form of hernia is usually of small size, and in corpulent persons very difficult of detection.

Direct inguinal hernia is of much less frequent occurrence than the oblique, their comparative frequency being, according to Cloquet, as one to five. It occurs far more frequently in men than in women, on account of the larger size of the external ring in the former sex. It differs from the oblique in its smaller size and globular form, dependent most probably on the resistance offered to its progress by the transversalis fascia and conjoined tendon. It differs also in its position, being placed over the os pubis and not in the course of the inguinal canal. The deep epigastric artery runs on the outer or iliac side of the neck of the sac, and the spermatic cord along its external and posterior side, not directly behind it, as in oblique inguinal hernia.

FEMORAL HERNIA.

The dissection of the parts comprised in the anatomy of femoral hernia should be performed, if possible, upon a female subject free from fat. The subject should lie upon its back; a block is first placed under the pelvis, the thigh everted, and the knee slightly bent and retained in this position. An incision should then be made from the anterior superior spinous process of the ilium along Poupart's ligament to the symphysis pubis; a second incision should be carried transversely across the thigh about six inches beneath the preceding; and these are to be connected together by a vertical one carried along the inner side of the thigh. These several incisions should divide merely the integument; this is to be reflected outward, when the superficial fascia will be exposed.

The **superficial fascia** forms a continuous layer over the whole of the thigh, consisting of areolar tissue, containing in its meshes much fat, and capable of being separated into two or more layers, between which are found the superficial vessels and nerves. It varies in thickness in different parts of the limb. In the groin it is thick, and the two layers are separated from one another by the superficial inguinal lymphatic glands, the internal saphenous vein, and several smaller vessels. One of these layers, the superficial, is continuous with the superficial fascia of the abdomen.

The superficial layer should be detached by dividing it across in the same direction as the external incisions; its removal will be facilitated by commencing at the lower and inner angle of the space, detaching it at first from the front of the internal saphenous vein, and dissecting it off from the anterior surface of that vessel and its tributaries; it should then be reflected outward in the same manner as the integument. The cutaneous vessels and nerves and superficial inguinal glands are then exposed, lying upon the deep layer of the superficial fascia. These are the internal saphenous vein and the superficial epigastric, superficial circumflex iliac, and superficial external pudic vessels, as well as numerous lymphatics, ascending with the saphenous vein to the inguinal glands.

The *internal* or *long saphenous vein* ascends along the inner side of the thigh, and, passing through the saphenous opening in the fascia lata, terminates in the femoral vein about an inch and a half below Poupart's ligament. This vein

[1] In all cases of inguinal hernia, whether oblique or direct, it is proper to divide the stricture directly upward: the reason of this is obvious, for by cutting in this direction the incision is made parallel to the deep epigastric artery—either external to it in the oblique variety, or internal to it in the direct form of hernia—and thus all chance of wounding the vessel is avoided. If the incision was made outward, the artery might be divided if the hernia was direct; and if made inward, it would stand an equal chance of injury if the case was one of oblique inguinal hernia.

receives at the saphenous opening the superficial epigastric, the superficial circumflex iliac, and the superficial external pudic veins.

The *superficial external pudic artery* (superior) arises from the inner side of the femoral artery, and, after passing through the saphenous opening, courses inward across the spermatic cord, to be distributed to the integument on the lower part of the abdomen, the penis and scrotum in the male and the labium in the female, anastomosing with branches of the internal pudic.

The *superficial epigastric artery* arises from the femoral about half an inch below Poupart's ligament, and, passing through the saphenous opening in the fascia lata, ascends on to the abdomen, in the superficial fascia covering the

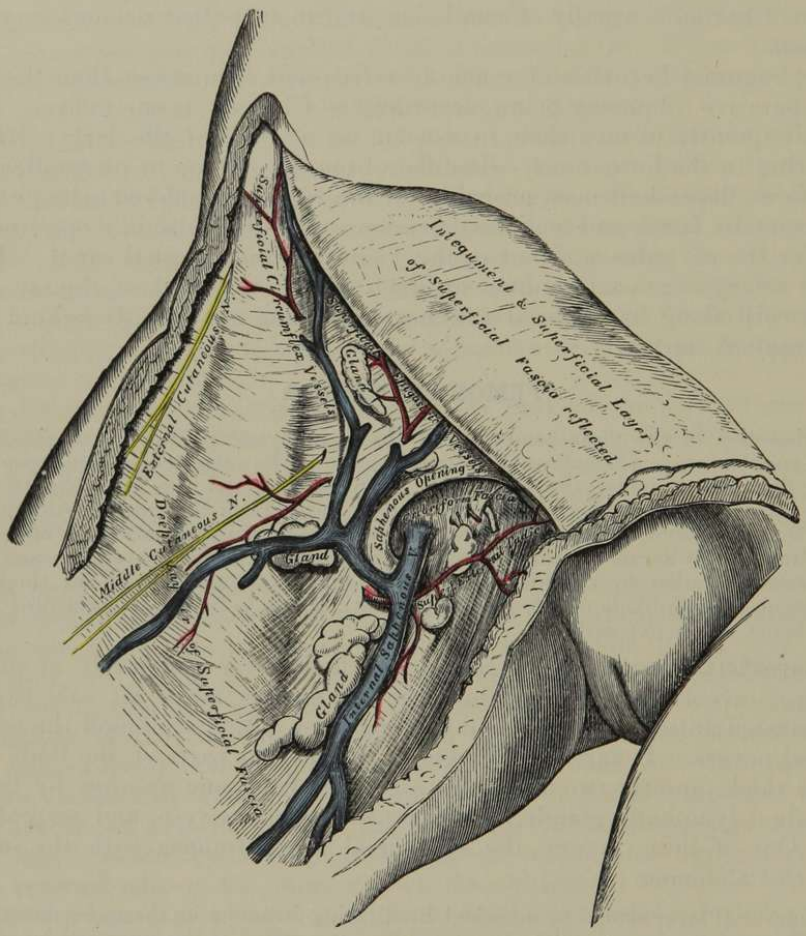

FIG. 762.—Femoral hernia. Superficial dissection.

External oblique muscle, nearly as high as the umbilicus. It distributes branches to the superficial inguinal lymphatic glands, the superficial fascia, and the integument, anastomosing with branches of the deep epigastric and internal mammary arteries.

The *superficial circumflex iliac artery*, the smallest of the cutaneous branches, arises close to the preceding, and, piercing the fascia lata, runs outward, parallel with Poupart's ligament, as far as the crest of the ilium, dividing into branches which supply the superficial inguinal lymphatic glands, the superficial fascia, and the integument of the groin, anastomosing with the deep circumflex iliac, and with the gluteal and external circumflex arteries.

The Superficial Veins.—The veins accompanying these superficial arteries are usually much larger than the arteries: they terminate in the internal or long saphenous vein at the saphenous opening.

The *superficial inguinal lymphatic glands*, placed immediately beneath the integument, are of large size and vary from eight to ten in number. They are divisible into two groups: an upper, disposed irregularly along Poupart's ligament, which receive the lymphatic vessels from the integument of the scrotum, penis, parietes of the abdomen, perineal and gluteal regions, and the mucous membrane of the urethra; and an inferior group, which surround the saphenous opening in the fascia lata, a few being sometimes continued along the saphenous vein to a variable extent. This latter group receive the superficial lymphatic vessels from the lower extremity.

The *ilio-inguinal nerve* arises from the first lumbar nerve. It escapes at the external abdominal ring, and is distributed to the integument of the upper and inner part of the thigh—to the scrotum in the male and to the labium in the female. The size of this nerve is in inverse proportion to that of the ilio-hypogastric. Occasionally it is very small, and ends by joining the ilio-hypogastric: in such cases a branch of the ilio-hypogastric takes the place of the ilio-inguinal, or the latter nerve may be altogether absent. The *crural branch of the genito-crural nerve* passes along the inner margin of the Psoas muscle, beneath Poupart's ligament, into the thigh, entering the sheath of the femoral vessels, and lying superficial and a little external to the femoral artery. It pierces the anterior layer of the sheath of the vessels, and, becoming superficial by passing through the fascia lata, it supplies the skin of the anterior aspect of the thigh as far as midway between the pelvis and knee. On the front of the thigh it communicates with the outer branch of the middle cutaneous nerve, derived from the anterior crural.

The *deep layer of the superficial fascia* is a very thin fibrous layer, best marked on the inner side of the long saphenous vein and below Poupart's ligament. It is placed beneath the subcutaneous vessels and nerves, and upon the surface of the fascia lata, to which it is intimately adherent at the lower margin of Poupart's ligament. It covers the saphenous opening in the fascia lata, is closely united to its circumference, and is connected to the sheath of the femoral vessels corresponding to its under surface. The portion of fascia covering this aperture is perforated by the internal saphenous vein and by numerous blood- and lymphatic vessels; hence it has been termed the *cribriform fascia*, the openings for these vessels having been likened to the holes in a sieve. The cribriform fascia adheres closely both to the superficial fascia and to the fascia lata, so that it is described by some anatomists as a part of the fascia lata, but it is usually considered (as in this work) as belonging to the superficial fascia. It is not till the cribriform fascia has been cleared away that the saphenous opening is seen, so that this opening does not in ordinary cases exist naturally, but is the result of dissection. A femoral hernia in passing through the saphenous opening receives the cribriform fascia as one of its coverings.

The deep layer of superficial fascia, together with the cribriform fascia, having been removed, the fascia lata is exposed.

The **Fascia Lata** has been already described with the muscles of the front of the thigh (page 506). At the upper and inner part of the thigh, a little below Poupart's ligament, a large oval-shaped aperture is observed after the superficial fascia has been cleared away; it transmits the internal saphenous vein and other smaller vessels, and is called the *saphenous opening*. In order the more correctly to consider the mode of formation of this aperture, the fascia lata in this part of the thigh is described as consisting of two portions, an iliac portion and a pubic portion.

The *iliac portion* is all that part of the fascia lata on the outer side of the saphenous opening. It is attached externally to the crest of the ilium and its anterior superior spine; to the whole length of Poupart's ligament as far internally as the spine of the os pubis; and to the pectineal line in conjunction with Gimbernat's ligament. From the spine of the os pubis it is reflected downward and outward, forming an arched margin, the outer boundary or falciform process or superior cornu of the saphenous opening. This margin overlies and is adherent to the anterior layer of the sheath of the femoral vessels; to its edge is attached the

cribriform fascia, and below it is continuous with the pubic portion of the fascia lata.

The *pubic portion of the fascia lata* is situated at the inner side of the saphenous opening: at the lower margin of this aperture it is continuous with the iliac portion: traced upward, it covers the surface of the Pectineus, Adductor longus, and Gracilis muscles; and, passing behind the sheath of the femoral vessels, to which it is closely united, is continuous with the sheath of the Psoas and Iliacus muscles, and is attached above to the ilio-pectineal line, where it becomes continuous with the fascia covering the Iliacus muscle. From this description it may be observed that the iliac portion of the fascia lata passes in front of the femoral vessels and the pubic portion behind them, so that an apparent aperture

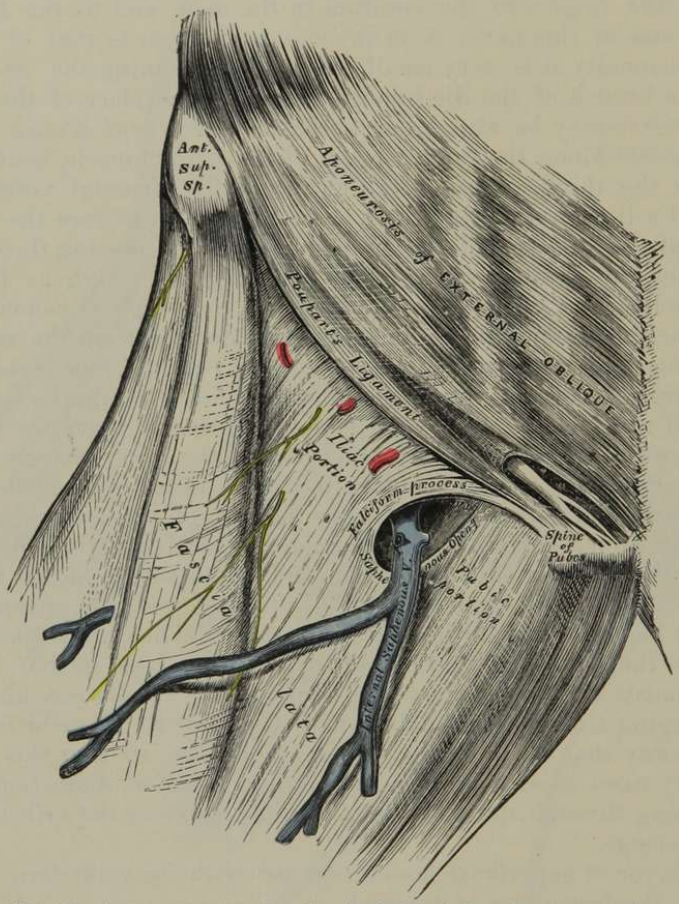

FIG. 763.—Femoral hernia, showing fascia lata and saphenous opening.

consequently exists between the two, through which the internal saphenous joins the femoral vein.

The **Saphenous Opening** is an oval-shaped aperture measuring about an inch and a half in length and half an inch in width. It is situated at the upper and inner part of the front of the thigh, below Poupart's ligament, and is directed obliquely downward and outward.

Its *outer margin* is of a semilunar form, thin, strong, sharply defined, and lies on a plane considerably anterior to the inner margin. If this edge is traced upward, it will be seen to form a curved elongated process, the *falciform process* or *superior cornu*, which ascends in front of the femoral vessels, and, curving inward, is attached to Poupart's ligament and to the spine of the os pubis and pectineal line, where it is continuous with the pubic portion. If traced downward, it is found continuous with another curved margin, the concavity of which is directed upward and inward: this is the inferior cornu of the saphenous

opening, and is blended with the pubic portion of the fascia lata covering the Pectineus muscle.

The *inner boundary of the opening* is on a plane posterior to the outer margin and behind the level of the femoral vessels; it is much less prominent and defined than the outer, from being stretched over the subjacent Pectineus muscle. It is through the saphenous opening that a femoral hernia passes after descending along the crural canal.

If the finger is introduced into the saphenous opening while the limb is moved in different directions, the aperture will be found to be greatly constricted on extending the limb or rotating it outward, and to be relaxed on flexing the limb

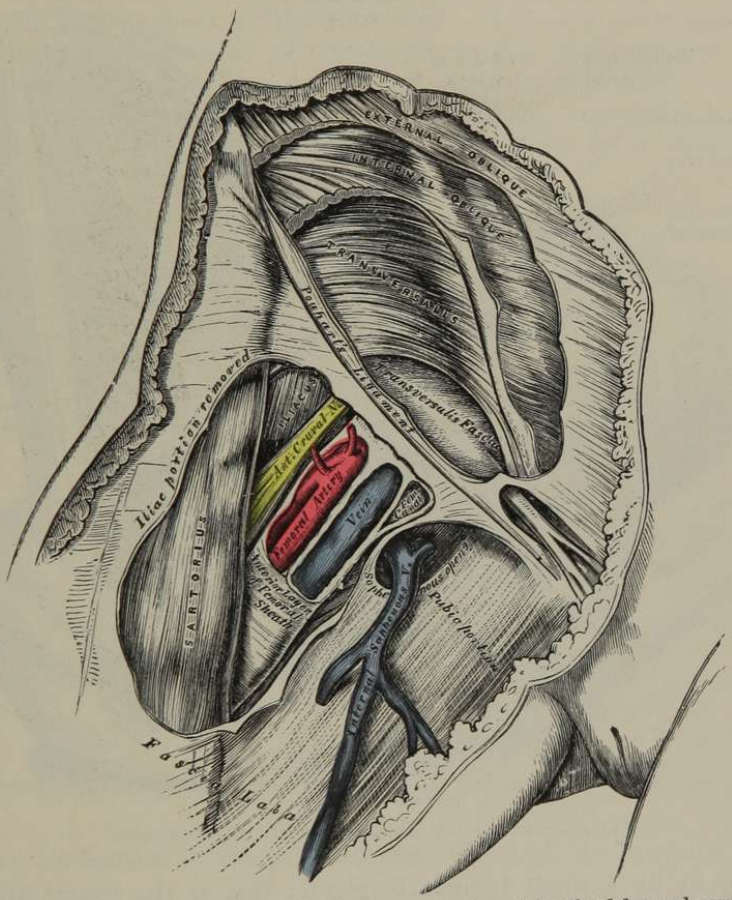

FIG. 764.—Femoral hernia. Iliac portion of fascia lata removed, and sheath of femoral vessels and femoral canal exposed.

and inverting it: hence the necessity for placing the limb in the latter position in employing the taxis for the reduction of a femoral hernia.

The iliac portion of the fascia lata, but not its falciform process, should now be removed by detaching it from the lower margin of Poupart's ligament, carefully dissecting it from the subjacent structures, and turning it inward, when the sheath of the femoral vessels is exposed, descending beneath Poupart's ligament (Fig. 764).

Poupart's Ligament, or the **Crural Arch,** is the lower border of the aponeurosis of the External oblique muscle, which extends from the anterior superior spine of the ilium to the spine of the os pubis. From this latter point it is reflected outward, to be attached to the pectineal line for about half an inch, forming Gimbernat's ligament. Its general direction is curved downward toward the thigh, where it is continuous with the fascia lata. Its outer half is rounded and oblique in direction. Its inner half gradually widens at its attachment to the os pubis, is more horizontal in direction, and lies beneath the spermatic cord. Nearly the

whole of the space included between the crural arch and innominate bone is filled in by the parts which descend from the abdomen into the thigh. The outer half of the space is occupied by the Iliacus and Psoas muscles, together with the external cutaneous and anterior crural nerves. The pubic half of the space is occupied by the femoral vessels included in their sheath, a small oval-shaped interval existing between the femoral vein and the inner wall of the sheath, which is occupied merely by a little loose areolar tissue, a few lymphatic vessels,

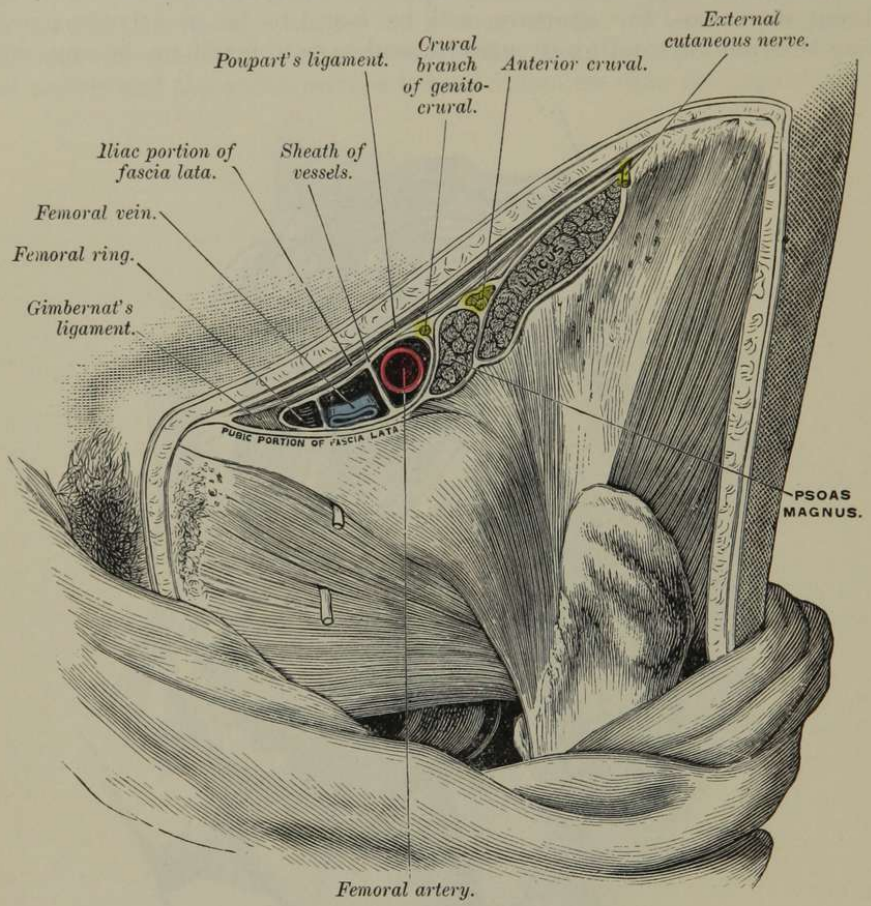

FIG. 765.—Structures which pass beneath the crural arch.

and occasionally by a small lymphatic gland: this is the crural ring, through which the gut descends in femoral hernia.

Gimbernat's Ligament (Fig. 766) is that part of the aponeurosis of the External oblique muscle which is reflected downward and outward from the spine of the os pubis, to be inserted into the pectineal line. It is about half an inch in length, larger in the male than in the female, almost horizontal in direction in the erect posture, and of a triangular form, with the base directed outward. Its *base*, or outer margin, is concave, thin, and sharp, and lies in contact with the crural sheath. Its *apex* corresponds to the spine of the os pubis. Its *posterior margin* is attached to the pectineal line, and is continuous with the pubic portion of the fascia lata. Its *anterior margin* is continuous with Poupart's ligament.

Crural Sheath.—The femoral or crural sheath is a continuation downward of the fasciæ that line the abdomen, the transversalis fascia passing down in front of the femoral vessels, and the iliac fascia descending behind them; these fasciæ are directly continuous on the iliac side of the femoral artery, but a small space exists between the femoral vein and the point where they are continuous on the pubic side of that vessel, which constitutes the femoral or crural canal. The

femoral sheath is closely adherent to the contained vessels about an inch below the saphenous opening, being blended with the areolar sheath of the vessels, but opposite Poupart's ligament it is much larger than is required to contain them; hence the funnel-shaped form which it presents. The outer border of the sheath is perforated by the genito-crural nerve. Its inner border is pierced by the internal saphenous vein and numerous lymphatic vessels. In front it is covered by the iliac portion of the fascia lata; and behind it is the pubic portion of the same fascia.

If the anterior wall of the sheath is removed, the femoral artery and vein are seen lying side by side, a thin septum separating the two vessels, while another septum may be seen lying just internal to the vein, and cutting off a small space between the vein and the inner wall of the sheath. The septa are stretched between the anterior and posterior walls of the sheath, so that each vessel is enclosed in a separate compartment. The interval left between the vein and the inner wall of the sheath is not filled up by any structure, excepting a little loose areolar tissue, a few lymphatic vessels, and occasionally by a small lymphatic

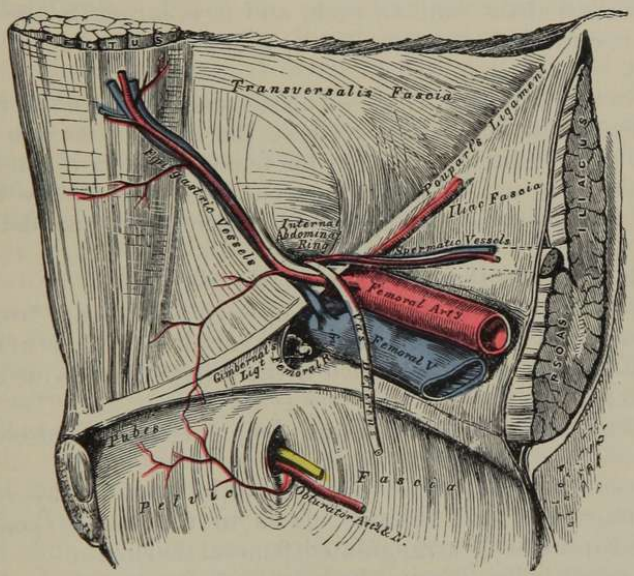

FIG. 766.—Hernia. The relations of the femoral and internal abdominal rings, seen from within the abdomen. Right side.

gland: this is the femoral or crural canal, through which the intestine descends in femoral hernia.

Deep Crural Arch.—Passing across the front of the crural sheath on the abdominal side of Poupart's ligament, and closely connected with it, is a thickened band of fibres called the *deep crural arch*. It is apparently a thickening of the fascia transversalis, joining externally to the centre of Poupart's ligament, and arching across the front of the crural sheath, to be inserted by a broad attachment into the pectineal line behind the conjoined tendon. In some subjects this structure is not very prominently marked, and not unfrequently it is altogether wanting.

The **crural canal** is the narrow interval between the femoral vein and the inner wall of the crural sheath. It exists as a distinct canal only when the sheath has been separated from the vein by dissection or by the pressure of a hernia or tumor. Its length is from a quarter to half an inch, and it extends from Gimbernat's ligament to the upper part of the saphenous opening.

Its *anterior wall* is very narrow, and formed by a continuation downward of the fascia transversalis, under Poupart's ligament, covered by the falciform process of the fascia lata.

Its *posterior wall* is formed by a continuation downward of the iliac fascia covering the pubic portion of the fascia lata.

Its *outer wall* is formed by the fibrous septum separating it from the inner side of the femoral vein.

Its *inner wall* is formed by the junction of the processes of the transversalis and iliac fasciæ, which form the inner side of the femoral sheath, and lies in contact at its commencement with the outer edge of Gimbernat's ligament.

This canal has two orifices—an upper one, the *femoral* or *crural ring*, closed by the septum crurale; and a lower one, the *saphenous opening*, closed by the cribriform fascia.

The **femoral** or **crural ring** (Fig. 766) is the upper opening of the femoral canal, and leads into the cavity of the abdomen. It is bounded in front by Poupart's ligament and the deep crural arch; behind, by the os pubis, covered by the Pectineus muscle and the pubic portion of the fascia lata; internally, by the base of Gimbernat's ligament, the conjoined tendon, the transversalis fascia, and the deep crural arch; externally, by the fibrous septum lying on the inner side of the femoral vein. The femoral ring is of an oval form; its long diameter, directed transversely, measures about half an inch, and it is larger in the female than in the male, which is one of the reasons of the greater frequency of femoral hernia in the former sex.

Position of Parts around the Ring.—The spermatic cord in the male and round ligament in the female lie immediately above the anterior margin of the femoral ring, and may be divided in an operation for femoral hernia if the incision for the relief of the stricture is not of limited extent. In the female this is of little importance, but in the male the spermatic artery and vas deferens may be divided.

The *femoral vein* lies on the outer side of the ring.

The *deep epigastric artery* in its passage upward and inward from the external iliac artery passes across the upper and outer angle of the crural ring, and is consequently in danger of being wounded if the stricture is divided in a direction upward and outward.

The *communicating branch* between the deep epigastric and obturator lies in front of the ring.

The circumference of the ring is thus seen to be bounded by vessels in every part, excepting internally and behind. It is in the former position that the stricture is divided in cases of strangulated femoral hernia.

The *obturator artery*, when it arises by a common trunk with the deep epigastric, which occurs once in every three subjects and a half, bears a very important relation to the crural ring. In some cases it descends on the inner side of the external iliac vein to the obturator foramen, and will consequently lie on the outer side of the crural ring, where there is no danger of its being wounded in the operation for dividing the stricture in femoral hernia (see Fig. 373, page 623, fig. A). Occasionally, however, the obturator artery curves along the free margin of Gimbernat's ligament in its passage to the obturator foramen: it would consequently skirt along the greater part of the circumference of the crural ring, and could hardly avoid being wounded in the operation (see Fig. 373, page 623, fig. B).

Septum Crurale.—The femoral ring is closed by a layer of condensed areolar tissue called, by J. Cloquet, the *septum crurale*. This serves as a barrier to the protrusion of a hernia through this part. Its upper surface is slightly concave (*fovea femoralis*), and supports a small lymphatic gland by which it is separated from the subserous areolar tissue and peritoneum. Its under surface is turned toward the femoral canal. The septum crurale is perforated by numerous apertures for the passage of lymphatic vessels connecting the deep inguinal lymphatic glands with those surrounding the external iliac artery.

The size of the femoral canal, the degree of tension of its orifices, and consequently the degree of constriction of a hernia, vary according to the position of the limb. If the leg and thigh are extended, abducted, or everted, the femoral

canal and its orifices are rendered tense from the traction on these parts by Poupart's ligament and the fascia lata, as may be ascertained by passing the finger along the canal. If, on the contrary, the thigh is flexed upon the pelvis, and at the same time adducted and rotated inward, the femoral canal and its orifices become considerably relaxed; for this reason the limb should always be placed in the latter position when the application of the taxis is made in attempting the reduction of a femoral hernia.

The *subperitoneal areolar tissue* is continuous with the subserous areolar tissue of surrounding parts. It is usually thickest and most fibrous where the iliac vessels leave the abdominal cavity. It covers over the small interval (crural ring) on the inner side of the femoral vein. In some subjects it contains a considerable amount of adipose tissue. In such cases, where it is protruded forward in front of the sac of a femoral hernia, it may be mistaken for a portion of omentum. The peritoneum lining the portion of the abdominal wall between Poupart's ligament and the brim of the pelvis is similar to that lining any other portion of the abdominal wall, being very thin. It has here no natural aperture for the escape of intestine.

Descent of the Hernia.—From the preceding description it follows that the femoral ring must be a weak point in the abdominal wall: hence it is that when violent or long-continued pressure is made upon the abdominal viscera a portion of intestine may be forced into it, constituting a femoral hernia; and the changes in the tissues of the abdomen which are produced by pregnancy, together with the larger size of this aperture in the female, serve to explain the frequency of this form of hernia in women.

When a portion of the intestine is forced through the femoral ring, it carries before it a pouch of peritoneum, which forms what is called the *hernial sac;* it receives an investment from the subserous areolar tissue and from the septum crurale, and descends vertically along the crural canal in the inner compartment of the sheath of the femoral vessels as far as the saphenous opening; at this point it changes its course, being prevented from extending farther down the sheath on account of the narrowing of the sheath and its close contact with the vessels, and also from the close attachment of the superficial fascia and crural sheath to the lower part of the circumference of the saphenous opening; the tumor is consequently directed forward, pushing before it the cribriform fascia, and then curves upward on to the falciform process of the fascia lata and lower part of the tendon of the External oblique, being covered by the superficial fascia and integument. While the hernia is contained in the femoral canal it is usually of small size, owing to the resisting nature of the surrounding parts; but when it has escaped from the saphenous opening into the loose areolar tissue of the groin, it becomes considerably enlarged. The direction taken by a femoral hernia in its descent is at first downward, then forward and upward; this should be borne in mind, as in the application of the taxis for the reduction of a femoral hernia pressure should be directed in the reverse order.

Coverings of the Hernia.—The coverings of a femoral hernia, from within outward, are—peritoneum, subserous areolar tissue, the septum crurale, crural sheath, cribriform fascia, superficial fascia, and integument.[1]

Varieties of Femoral Hernia.—If the intestine descends along the femoral canal only as far as the saphenous opening, and does not escape from this aperture, it is called *incomplete femoral hernia.* The small size of the protrusion in this form of hernia, on account of the firm and resisting nature of the canal in which it is contained, renders it an exceedingly dangerous variety of the disease, from the

[1] Sir Astley Cooper has described an investment for femoral hernia, under the name of "fascia propria," lying immediately external to the peritoneal sac, but frequently separated from it by more or less adipose tissue. Surgically, it is important to remember the existence (at any rate, the occasional existence) of this layer, on account of the ease with which an inexperienced operator may mistake the fascia for the peritoneal sac and the contained fat for omentum. Anatomically, this fascia appears identical with what is called in the text "subserous areolar tissue," the areolar tissue being thickened and caused to assume a membranous appearance by the pressure of the hernia.

extreme difficulty of detecting the existence of the swelling, especially in corpulent subjects. The coverings of an incomplete femoral hernia would be, from without inward, integument, superficial fascia, falciform process of fascia lata, crural sheath, septum crurale, subserous areolar tissue, and peritoneum. When, however, the hernial tumor protrudes through the saphenous opening and directs itself forward and upward, it forms a *complete femoral hernia*. Occasionally the hernial sac descends on the iliac side of the femoral vessels or in front of these vessels, or even sometimes behind them.

The *seat of stricture of a femoral hernia* varies: it may be in the peritoneum at the neck of the hernial sac; in the greater number of cases it would appear to be at the point of junction of the falciform process of the fascia lata with the lunated edge of Gimbernat's ligament, or at the margin of the saphenous opening in the thigh. The stricture should in every case be divided in a direction upward and inward, and the extent necessary in the majority of cases is about two or three lines. By these means all vessels or other structures of importance in relation with the neck of the hernial sac will be avoided.

SURGICAL ANATOMY OF THE ISCHIO-RECTAL REGION AND PERINÆUM.

Dissection.—The student should select a well-developed muscular subject, free from fat, and the dissection should be commenced early, in order that the parts may be examined in as recent a state as possible. A staff having been introduced into the bladder and the subject placed in the position shown in Fig. 767, the scrotum should be raised upward, and retained in that position, and the rectum moderately distended with tow.

The space which is now to be examined corresponds to the inferior aperture or outlet of the pelvis. Its deep boundaries are, in front, the pubic arch and subpubic ligament; behind, the tip of the coccyx; and on each side, the rami of the pubes and ischium, the tuberosities of the ischium, and great sacro-sciatic ligaments. The space included by these boundaries is somewhat lozenge-shaped, and is limited on the surface of the body by the scrotum in front, by the buttocks behind, and on each side by the inner side of the thighs. A line drawn transversely between the anterior part of the tuberosity of the ischium on each side, in front of the anus, divides this space into two portions. The anterior portion contains the penis and urethra, and is called the *perinæum*. The posterior portion contains the termination of the rectum, and is called the *ischio-rectal region*.

THE ISCHIO-RECTAL REGION.

The ischio-rectal region corresponds to the portion of the outlet of the pelvis situated immediately behind the perinæum: it contains the termination of the rectum and a deep fossa, filled with fat, on each side of the intestine, between it and the tuberosity of the ischium: this is called the *ischio-rectal fossa*.

The **ischio-rectal region** presents in the middle line the *aperture of the anus:* around this orifice the integument is thrown into numerous folds, which are obliterated on distension of the intestine. The integument is of a dark color, continuous with the mucous membrane of the rectum, and provided with numerous follicles, which occasionally inflame and suppurate, and may be mistaken for fistulæ. The veins around the margin of the anus are occasionally much dilated, forming a number of hard pendent masses, of a dark bluish color, covered partly by mucous membrane and partly by the integument. These tumors constitute the disease called *external piles*.

Dissection (Fig. 767).—Make an incision through the integument, along the median line, from the base of the scrotum to the anterior extremity of the anus: carry it round the margins of this aperture to its posterior extremity, and continue it backward to about an inch behind the tip of the coccyx. A transverse incision should now be carried across the base of the scrotum, joining the anterior extremity of the preceding; a second, carried in the same direction, should be made in front of the anus; and a third at the posterior extremity of the first incision. These incisions should be sufficiently extensive to enable the dissector to raise the integument from the inner side of the thighs. The flaps of skin corresponding to the ischio-rectal region should now be removed. In dissecting the integument from this region great care is required, otherwise the Corrugator cutis ani and External sphincter will be removed, as they are intimately adherent to the skin.

The **superficial fascia** is exposed on the removal of the skin: it is very thick, areolar in texture, and contains much fat in its meshes. In it are found ramifying two or three cutaneous branches of the small sciatic nerve; these turn round the inferior border of the Gluteus maximus and are distributed to the integument around the anus.

In this region, and connected with the lower end of the rectum, are four muscles: the Corrugator cutis ani; the two Sphincters, External and Internal; and the Levator ani.

These muscles have been already described (see pages 458 and 459).

The **ischio-rectal fossa** is situated between the end of the rectum and the tuberosity of the ischium on each side. It is triangular in shape; its base, directed to the surface of the body, is formed by the integument of the ischio-rectal region; its *apex*, directed upward, corresponds to the point of division of the obturator fascia and the thin membrane given off from it, which covers the outer surface of the Levator ani (ischio-rectal or anal fascia). Its dimensions are about an inch in breadth at the base and about two inches in depth, being deeper behind than in front. It is bounded, *internally*, by the Sphincter ani, Levator ani, and Coccygeus muscles; *externally*, by the tuberosity of the ischium and the obturator fascia, which covers the inner surface of the Obturator internus muscle; *in front*, it is limited by the line of junction of the superficial and deep perineal fasciæ; and *behind*, by the margin of the Gluteus maximus and the great sacro-sciatic ligament. This space is filled with a large mass of adipose tissue, which explains the frequency with which abscesses in the neighborhood of the rectum burrow to a considerable depth.

If the subject has been injected, on placing the finger on the outer wall of this fossa the internal pudic artery, with its accompanying veins and nerve, will be felt about an inch and a half above the margin of the ischiatic tuberosity, but approaching nearer the surface as they pass forward along the inner margin of the pubic arch. These structures are enclosed in a sheath (canal of Alcock) formed by the obturator fascia, the pudic nerve lying below the artery (Fig. 374). Crossing the space transversely, about its centre are the inferior hæmorrhoidal vessels and nerves, branches of the internal pudic; they are distributed to the integument of the anus and to the muscles of the lower end of the rectum. These vessels are occasionally of large size, and may give rise to troublesome hæmorrhage when divided in the operation of lithotomy or of fistula in ano. At the back part of this space may be seen a branch of the fourth sacral nerve, and, at the fore part of the space the superficial perineal vessels and nerves can be seen for a short distance.

THE PERINÆUM IN THE MALE.

The perineal space is of a triangular form; its deep boundaries are limited, laterally, by the rami of the pubic bones and ischia, meeting in front at the pubic arch; behind, by an imaginary transverse line extending between the tuberosities of the ischia. The lateral boundaries are, in the adult, from three inches to three inches and a half in length, and the base from two to three inches and a half in breadth, the average extent of the space being two inches and three-quarters.

The variations in the diameter of this space are of extreme interest in connection with the operation of lithotomy and the extraction of a stone from the cavity of the bladder. In those cases where the tuberosities of the ischia are near together it would be necessary to make the incisions in the lateral operation of lithotomy less oblique than if the tuberosities were widely separated, and the perineal space consequently wider. The perinæum is subdivided by the median raphe into two equal parts. Of these, the left is the one in which the operation of lithotomy is performed.

In the middle line the perinæum is convex, and corresponds to the bulb of the urethra. The skin covering it is of a dark color, thin, freely movable upon the subjacent parts, and covered with sharp crisp hairs, which should be removed before the dissection of the part is commenced. In front of the anus a prominent line commences, the *raphe*, continuous in front with the raphe of the scrotum.

Upon removing the skin and superficial structures from this region, in the manner shown in Fig. 767, a plane of fascia will be exposed, covering in the triangular space and stretching across from one ischio-pubic ramus to the other. This is the *deep layer of the superficial fascia* or *fascia of Colles*. It has already

been described (page 460). It is a layer of considerable strength, and encloses and covers a space in which are contained muscles, vessels, and nerves. It is continuous in front with the dartos of the scrotum; on each side it is firmly attached to the margin of the ischio-pubic ramus and to the tuberosity of the ischium; and posteriorly it curves down behind the Transversus perinæi muscles to join the lower margin of the deep perineal fascia.

It is between this layer of fascia and the next layer, the superficial layer of the deep perineal fascia, that extravasation of urine most frequently takes place in cases of rupture of the urethra. The superficial layer of the deep perineal fascia (see page 463) is also attached to the ischio-pubic rami, and in front to the subpubic ligament. It is clear, therefore, that when extravasation of fluid takes place between these two layers, it cannot pass backward, because the two layers are continuous with each other around the Transversus perinæi muscles; it cannot extend laterally, on account of the connection of both these layers to the rami of the os pubis and ischium; it cannot find its way into the pelvis, because the opening into this cavity is closed by the deep perineal fascia; and therefore, so long as these two layers remain intact, the only direction in which the fluid can make its way is forward into the areolar tissue of the scrotum and penis, and from thence on to the anterior wall of the abdomen.

When the deep layer of the superficial fascia is removed, a space is exposed between this fascia and the deep perineal fascia in which are contained the peri-

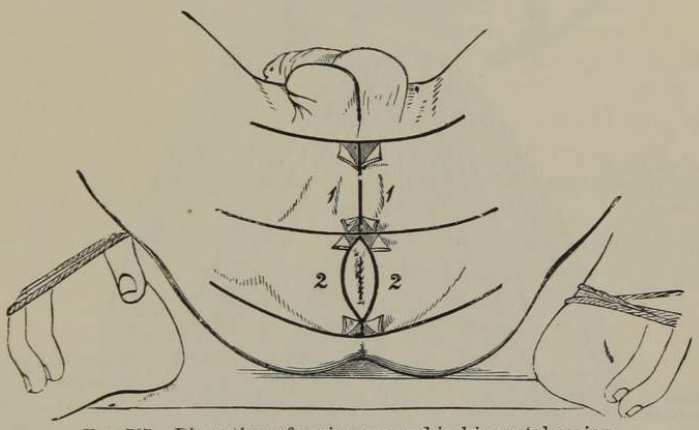

FIG. 767.—Dissection of perinæum and ischio-rectal region.

neal branches of the internal pudic artery, with their accompanying veins; the perineal branches of the internal pudic nerve; some of the muscles connected with the penis and urethra;—in the middle line, the Accelerator urinæ; on each side, the Erector penis; and behind, the Transversus perinæi;—the crura of the corpora cavernosa; and the bulb of the corpus spongiosum. Here also is seen the *central tendinous point of the perinæum.* This is a fibrous point in the middle line of the perinæum between the urethra and the rectum, being about half an inch in front of the anus. At this point five muscles converge and are attached—viz. the External sphincter ani, the Acceleratores urinæ, and the two Transversi perinæi muscles—so that by the contraction of these muscles, which extend in opposite directions, it serves as a fixed point of support.

The Accelerator urinæ, the Erector penis, and the Transversus perinæi muscles have been already described (page 461). They form a triangular space, bounded internally by the Accelerator urinæ, externally by the Erector penis, and behind by the Transversus perinæi. The floor of this space is formed by the triangular ligament of the urethra (deep perineal fascia), and running from behind forward in it are the superficial perineal vessels and nerves, and the transverse perineal artery coursing along the posterior boundary of the space on the Transversus perinæi muscle. The two terminal branches of the internal pudic artery are not to be seen in this space, as they as well as the dorsal nerve of the penis are dorsal to the superficial layer of the triangular ligament: the dorsal artery of the penis ascending between the two layers of the ligament; and the artery to the corpus cavernosum entering the crus immediately after piercing from above downward

the lower layer. The dorsal nerve of the penis is also contained within the two layers, accompanying the dorsal artery along the ischio-pubic ramus, and with it piercing the anterior layer and the suspensory ligament to be distributed to the penis.

The Accelerator urinæ and Erector penis should now be removed, when the deep perineal fascia will be exposed, stretching across the front part of the outlet of the pelvis. The urethra is seen perforating its centre just behind the bulb, and on each side is the crus penis, connecting the corpus cavernosum with the rami of the ischium and os pubis.

The **deep perineal fascia** (*triangular ligament*), which has already been described (see page 463), consists of two layers, the inferior or superficial layer of which, sometimes called the *anterior layer of the triangular ligament*, is now exposed. It is united to the superior or deep layer behind, but is separated in front by a subfascial space, in which are contained certain structures.

The *superficial layer of the deep perineal fascia* consists of a strong fibrous membrane, the fibres of which are disposed transversely, which stretches across

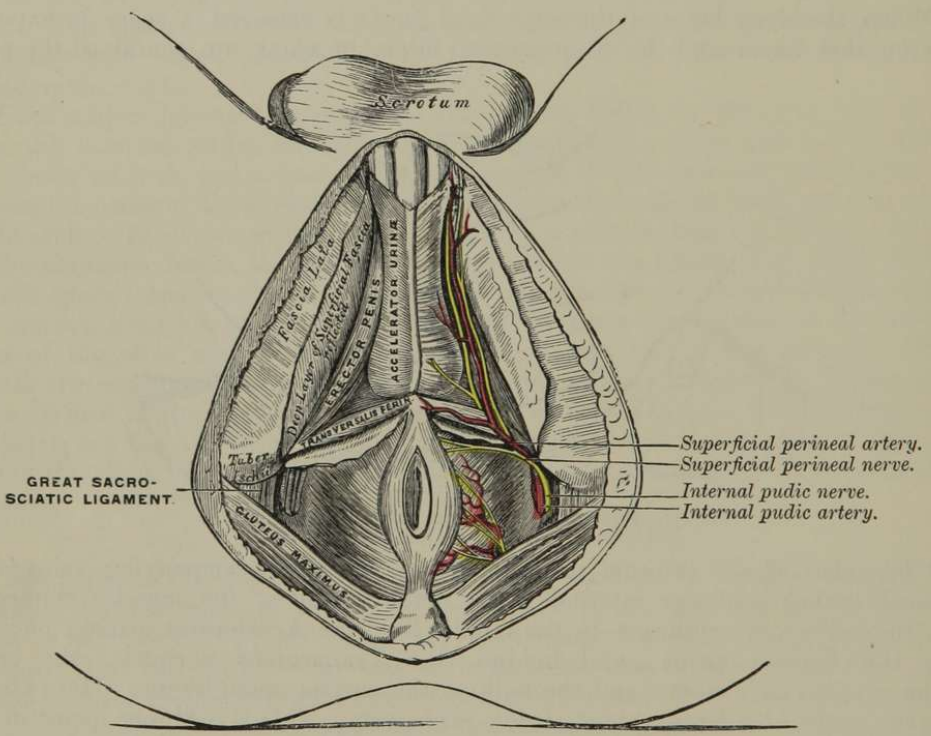

FIG. 768.—The superficial muscles and vessels of the perinæum.

from one ischio-pubic ramus to the other and completely fills in the pubic arch; it is attached in front to the subpubic ligament, except just in the centre, where a small interspace is left for the dorsal vein of the penis. In the erect position of the body it is almost horizontal. It is perforated by the urethra in the middle line, and on each side by the ducts of Cowper's glands. It is pierced also by the dorsal artery of the penis close to the base of the ligament; by the artery to the corpus cavernosum more anteriorly and in the opposite direction, close to the lateral margin of the ligament; and by the artery to the bulb also from above downward in front of the opening for Cowper's duct. The dorsal nerve of the penis also passes through the ligament in company with the artery of the same name. The *crura penis* are exposed, lying superficial to this ligament. They will be seen to be attached by blunt-pointed processes to the rami of the os pubis and ischium, in front of the tuberosities, and passing forward and inward, joining to form the body of the penis. In the middle line is the bulb and corpus spongiosum, exposed by the removal of the Accelerator urinæ muscle.

If the superficial layer of the deep perineal fascia is detached on either side, the deep perineal interspace will be exposed and the following parts will be seen between it and the deep layer of the fascia: the subpubic ligament in front, close to the symphysis pubis; the dorsal vein of the penis; the membranous portion of the urethra and the Compressor urethræ muscle; Cowper's glands and their ducts; the dorsal artery and the dorsal nerve of the penis; the artery and nerve of the bulb and a plexus of veins.

The *superior* or *deep layer of the deep perineal fascia* is derived from the obturator fascia or is continuous with it along the pubic arch. Behind, it joins with the superficial layer of the deep perineal fascia and is continuous with the anal fascia. Above it is the recto-vesical fascia, separated from it on each side by the anterior fibres of the Levator ani, but in the median line these two layers of fascia are continuous and form a median septum, in consequence of the recto-vesical fascia dipping down to join the deep layer of the deep perineal fascia. Thus on each

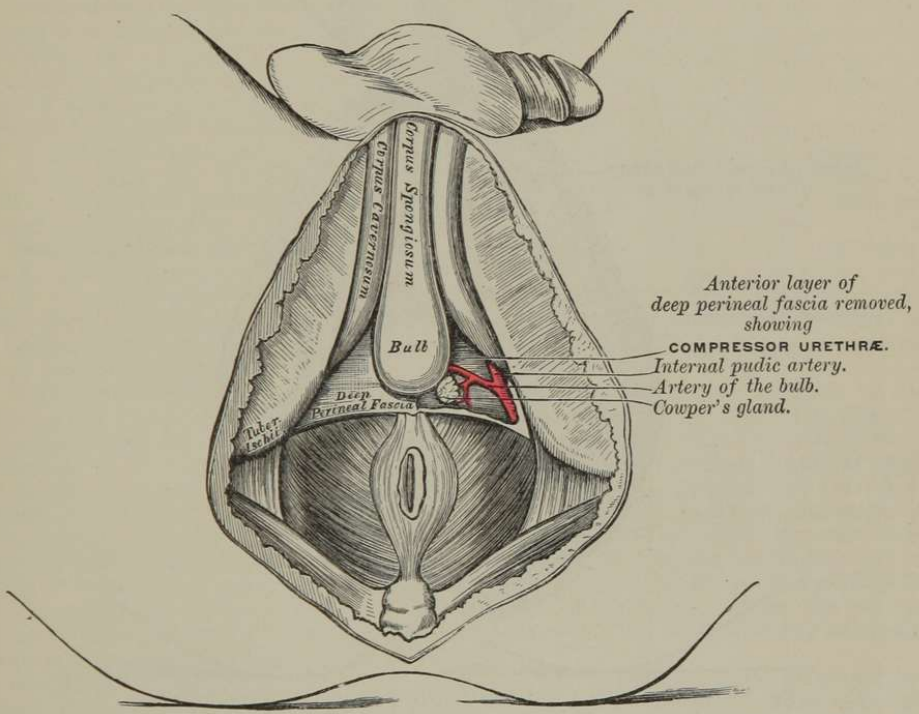

FIG. 769.—Deep perineal fascia. On the left side the anterior layer has been removed.

side of the middle line, beneath this fascia, is a little interspace in which is contained the anterior fibres of the Levator ani (Levator prostatæ). It is bounded, below, by the deep layer of the deep perineal fascia; above, by the recto-vesical fascia, and is separated internally from the space on the other side by the median septum. The deep layer of the deep perineal fascia is pierced by the urethra, and is continued backward around the posterior part of the membranous portion of the urethra and the outer surface of the prostate gland.

The **Compressor urethræ** has already been described (page 464). In addition to this muscle and immediately beneath it *circular muscular fibres* surround the membranous portion of the urethra from the bulb in front to the prostate behind, and are continuous with the muscular fibres of the bladder. These fibres are involuntary.

Cowper's glands are situated immediately below the membranous portion of the urethra, close behind the bulb, and below the artery of the bulb.

The **dorsal artery** and **dorsal nerve of the penis** are placed along the inner margin of the pubic arch (pages 623 and 861).

The **artery of the bulb** passes transversely inward, from the internal pudic along the base of the triangular ligament, between its two layers of fascia,

accompanied by a branch of the pudic nerve (page 861). If the posterior layer of the deep perineal fascia is removed and the crus penis of one side detached from the bone, the under or perineal surface of the Levator ani is brought fully into view. This muscle, with the triangular ligament in front and the Coccygeus and Pyriformis behind, closes the outlet of the pelvis.

The Levator ani and Coccygeus muscles have already been described (page 459).

Position of the Viscera at the Outlet of the Pelvis.—Divide the central tendinous point of the perinæum, separate the rectum from its connections by dividing the fibres of the Levator ani, which descend upon the sides of the prostate gland, and draw the gut backward toward the coccyx, when the under surface of the prostate gland, the neck and base of the bladder, the vesiculæ seminales, and the vasa deferentia will be exposed.

The **Prostate Gland** is a pale, firm, glandular body which is placed immediately in front of the neck of the bladder around the commencement of the urethra. It is

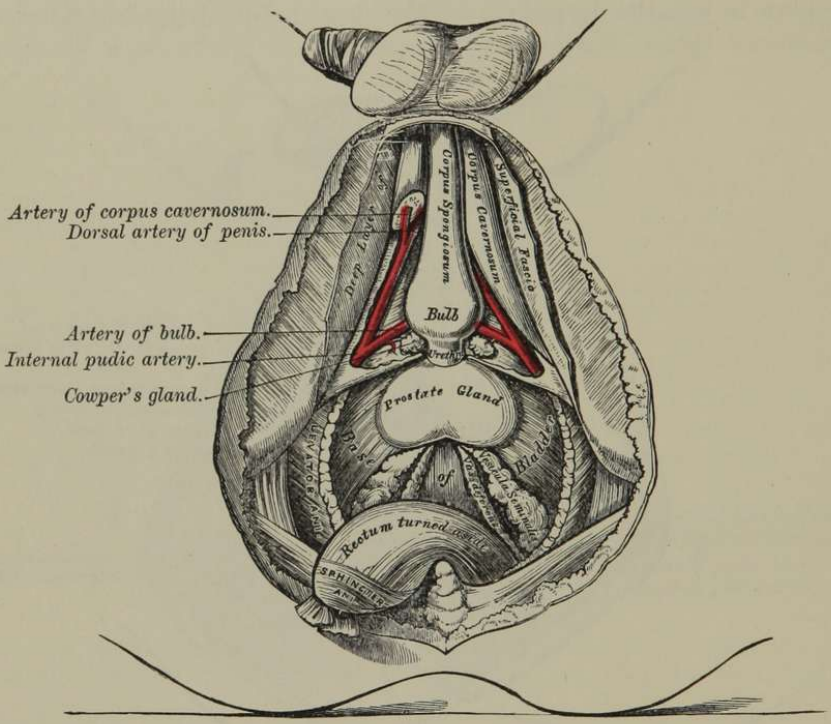

FIG. 770.—A view of the position of the viscera at the outlet of the pelvis.

placed in the pelvic cavity, behind and below the symphysis pubis, posterior to the deep perineal fascia, and rests upon the rectum, through which it may be distinctly felt, especially when enlarged. In shape and size it resembles a chestnut. Its base is directed backward toward the neck of the bladder. Its apex is directed forward to the deep perineal fascia, which it touches.

Its posterior surface is smooth, marked by a slight longitudinal furrow, and rests on the rectum, to which it is connected by areolar tissue. Its anterior surface is flattened, marked by a slight longitudinal furrow, and placed about three-quarters of an inch below the pubic symphysis. It measures about an inch and a half in its transverse diameter at the base, an inch in its antero-posterior diameter, and three-quarters of an inch in depth. Hence the greatest extent of incision that can be made in it without dividing its substance completely across is obliquely backward and outward. This is the direction in which the incision is made in it in the lateral operation of lithotomy.

Behind the prostate is the posterior surface of the neck and base of the bladder, a small triangular portion of the bladder being seen, bounded, in front, by the prostate gland; behind, by the recto-vesical fold of the peritoneum; on each side, by the vesicula seminalis and the vas deferens. It is separated from direct contact

with the rectum by the recto-vesical fascia. The relation of this portion of the bladder to the rectum is of extreme interest to the surgeon. In cases of retention of urine this portion of the organ is found projecting into the rectum, between three and four inches from the margin of the anus, and may be easily perforated without injury to any important parts: this portion of the bladder is, consequently, occasionally selected for the performance of the operation of tapping the bladder.

Surgical Anatomy.—The student should consider the position of the various parts in reference to the lateral operation of lithotomy. This operation is performed on the left side of the perinæum, as it is most convenient for the right hand of the operator. A staff having been introduced into the bladder, the first incision is commenced midway between the anus and the back of the scrotum (*i. e.* in an ordinary adult perinæum about an inch and a half in front of the anus) a little on the left side of the raphe, and carried obliquely backward and outward to midway between the anus and tuberosity of the ischium. The incision divides the integument and superficial fascia, the inferior hæmorrhoidal vessels and nerves, and the superficial and transverse perineal vessels. If the forefinger of the left hand is thrust upward and forward into the wound, pressing at the same time the rectum inward and backward, the staff may be felt in the membranous portion of the urethra. The finger is fixed upon the staff, and the structures covering it are divided with the point of the knife, which must be directed along the groove toward the bladder, the edge of the knife being turned outward and backward, dividing in its course the membranous portion of the urethra and part of the left lobe of the prostate gland to the extent of about an inch. The knife is then withdrawn, and the forefinger of the left hand passed along the staff into the bladder. The position of the stone having been ascertained, the staff is to be withdrawn, and the forceps is introduced over the finger into the bladder. If the stone is very large, the opposite side of the prostate may be notched before the forceps is introduced: the finger is now withdrawn, and the blades of the forceps opened and made to grasp the stone, which must be extracted by slow and cautious undulating movements.

Parts Divided in the Operation.—The various structures divided in this operation are as follows: the integument, superficial fascia, inferior hæmorrhoidal vessels and nerves, and probably the superficial perineal vessels and nerves, the posterior fibres of the Accelerator urinæ, the Transversus perinæi muscle and artery, the deep perineal fascia, the anterior fibres of the Levator ani, part of the Compressor urethræ, the membranous and prostatic portions of the urethra, and part of the prostate gland.

Parts to be Avoided in the Operation.—In making the necessary incisions in the perinæum for the extraction of a calculus the following parts should be avoided: The primary incision should not be made too near the middle line, for fear of wounding the bulb of the corpus spongiosum or the rectum; nor too far externally, otherwise the pudic artery may be implicated as it ascends along the inner border of the pubic arch. If the incisions are carried too far forward, the artery of the bulb may be divided; if carried too far backward, the entire breadth of the prostate and neck of the bladder may be cut through, which allows the urine to become infiltrated behind the pelvic fascia into the loose areolar tissue between the bladder and rectum, instead of escaping externally; diffuse inflammation is consequently set up, and peritonitis, from the close proximity of the recto-vesical peritoneal fold, is the result. If, on the contrary, the prostate is divided in front of the base of the gland, the urine makes its way externally, and there is less danger of infiltration taking place.

During the operation it is of great importance that the finger should be passed into the bladder *before* the staff is removed; if this is neglected, and if the incision made in the prostate and neck of the bladder is too small, great difficulty may be experienced in introducing the finger afterward; and in the child, where the connections of the bladder to the surrounding parts are very loose, the force made in the attempt is sufficient to displace the bladder upward into the abdomen, out of the reach of the operator. Such a proceeding has not unfrequently occurred, producing the most embarrassing results and total failure of the operation.

It is necessary to bear in mind that the arteries in the perinæum occasionally take an abnormal course. Thus the artery of the bulb, when it arises, as sometimes happens, from the pudic opposite the tuber ischii, is liable to be wounded in the operation for lithotomy in its passage forward to the bulb. The accessory pudic may be divided near the posterior border of the prostate gland, if this is completely cut across; and the prostatic veins, especially in people advanced in life, are of large size, and give rise, when divided, to troublesome hæmorrhage.

THE FEMALE PERINÆUM.

The **female perinæum** presents certain differences from that of the male, in consequence of the whole of the structures which constitute it being perforated in the middle line by the vulvo-vaginal passage.

The **superficial fascia,** as in the male, consists of two layers, of which the superficial one is continuous with the superficial fascia over the rest of the body, and the deep layer, corresponding to the fascia of Colles in the male, is like it attached to the ischio-pubic ramus, and in front is continued forward through

the labia majora to the inguinal region. It is of less extent than the male, in consequence of being perforated by the aperture of the vulva.

On removing this fascia the muscles of the female perinæum, which have already been described (page 464), are exposed. The Sphincter vaginæ, corresponding to the Accelerator urinæ in the male, consists of an attenuated plane of fibres, forming an orbicular muscle around the orifice of the vagina, instead of being united in a median raphe, as in the male. The Erector clitoridis is proportionately reduced in size, but differs in no other respect, and the Transversus perinæi is similar to the muscle of the same name in the male.

The *deep perineal fascia* is not so strongly marked as in the male. It transmits the urethra, and is wide, separated in the median line by the aperture of the vagina.

The **Compressor Urethræ** (*Transversus perinæi profundus*) is the analogue of the Compressor urethræ in the male. It arises from the ischio-pubic ramus, and, passing inward, its anterior fibres blend with the muscle of the opposite side, in front of the urethra; its middle fibres, the most numerous, are inserted into the side of the vagina, and the posterior fibres join the central point of the perinæum.

The distribution of the internal pudic artery is the same as in the male (see page 625), and the pudic nerve has also a similar arrangement, the dorsal nerve being, however, very small and supplying the clitoris.

The corpus spongiosum is divided into two lateral halves, which are represented by the *bulbi vestibuli* and *partes intermediales* (see page 1165).

The **perineal body** fills up the interval between the lower part of the vagina and the rectum. Its base is covered by the skin lying between the anus and

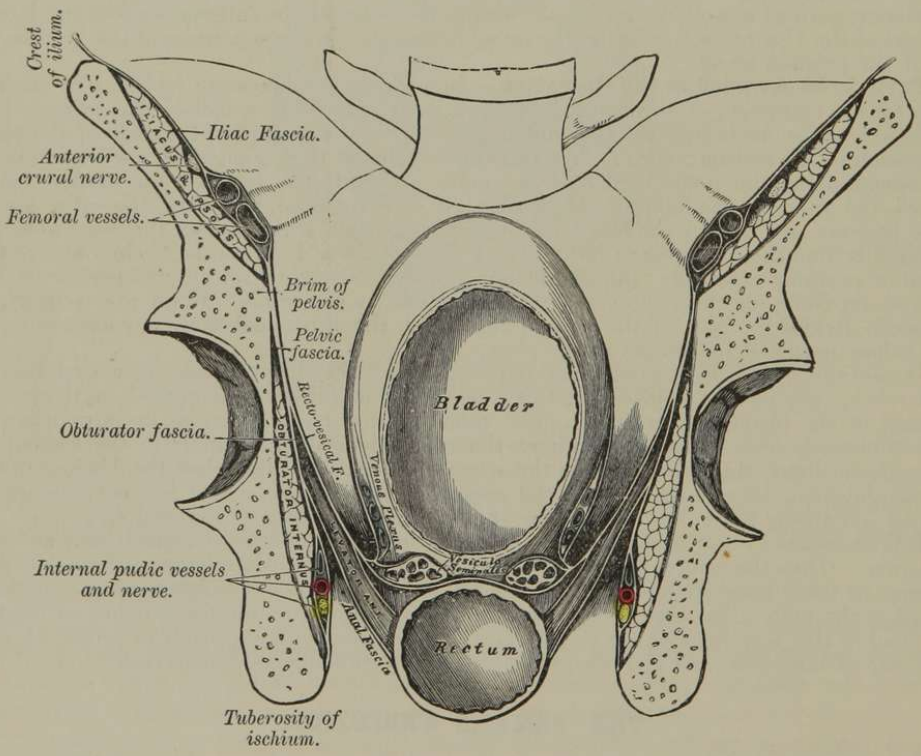

FIG. 771.—A transverse section of the pelvis, showing the pelvic fascia from behind.

vagina on what is called the "perinæum." Its anterior surface lies behind the posterior vaginal wall, and its posterior surface lies in front of the anterior rectal wall and the anus. It measures about an inch and a quarter from before backward, and laterally extends from one tuberosity of the ischium to the other. In it are attached the muscles belonging to the external organs of generation. Through its

centre runs the transverse perineal septum, which is of great strength in women, and forms on either side, behind the posterior commissure, a hard, ill-defined body, consisting of connective tissue, with much yellow elastic tissue and interlacing bundles of involuntary muscular fibres, in which the voluntary muscles of the perinæum are inserted.

PELVIC FASCIA.

The **Pelvic fascia** (Fig. 772) is a thin membrane which lines the whole of the cavity of the pelvis and is continuous with the transversalis and iliac fasciæ. It is attached to the brim of the pelvis, for a short distance, at the side of the cavity, and to the inner surface of the bone round the attachment of the Obturator internus. At the posterior border of this muscle it is continued backward as a very thin membrane in front of the Pyriformis muscle and sacral nerves to the front of the sacrum. In front it follows the attachment of the Obturator internus to the bone, arches beneath the obturator vessels, completing the orifice of the obturator canal, and at the front of the pelvis is attached to the lower part of the symphysis pubis. At the level of a line extending from the lower part of the symphysis pubis to the

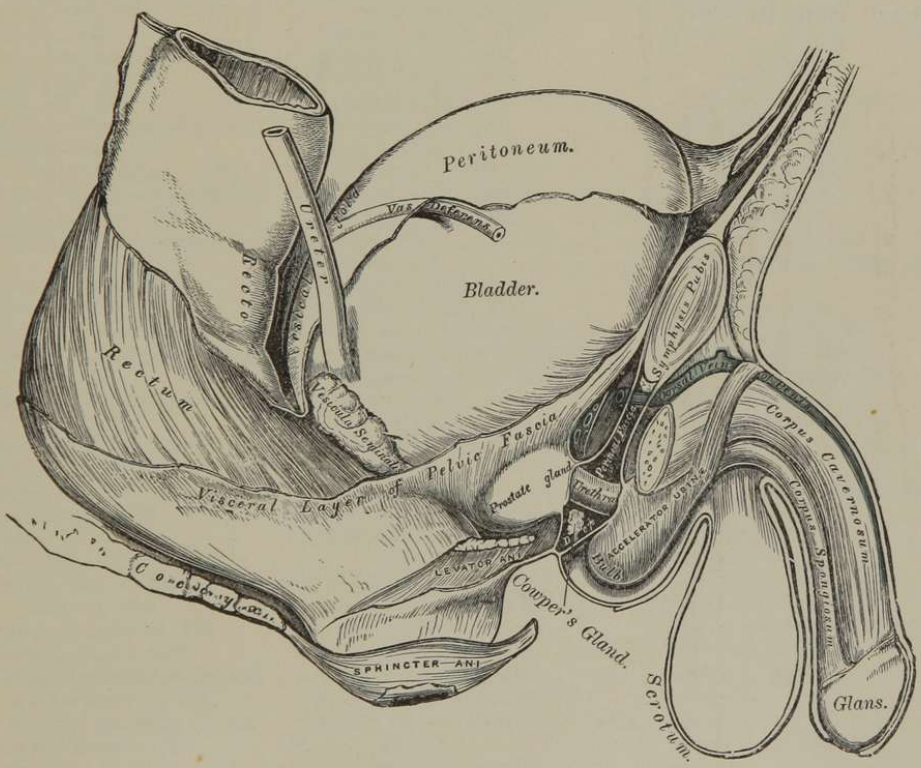

FIG. 772.—Side view of the pelvic viscera of the male subject, showing the pelvic and perineal fasciæ.

spine of the ischium is a thickened whitish band; this marks the attachment of the Levator ani muscle to the pelvic fascia, and corresponds to its point of division into two layers, the *obturator* and *recto-vesical.*

The **obturator fascia** descends and covers the Obturator internus muscle. It is a direct continuation of the pelvic fascia below the white line above mentioned, and is attached to the pubic arch and to the margin of the great sacro-sciatic ligament. From its attachment to the rami of the os pubis and ischium a process is given off which is continuous with a similar process from the opposite side, so as to close the front part of the outlet of the pelvis, forming the superior layer of the triangular ligament. This fascia forms a canal for the pudic vessels and nerve in their passage forward to the perinæum, and gives off a thin membrane

which covers the perineal aspect of the Levator ani muscle, called the *ischio-rectal* (*anal*) *fascia*.

The **recto-vesical fascia** (*visceral layer of the pelvic fascia*) descends into the pelvis upon the upper surface of the Levator ani muscle, and invests the prostate, bladder, and rectum. From the inner surface of the symphysis pubis a short rounded band is continued to the anterior surface of the prostate and neck of the bladder, forming the pubo-prostatic or anterior true ligaments of the bladder. At the side this fascia is connected to the side of the prostate, enclosing this gland and the vesico-prostatic plexus of veins, and is continued upward on the side of the bladder, forming the lateral true ligaments of the organ. Another prolongation invests the vesiculæ seminales, and passes across between the bladder and rectum, being continuous with the same fascia of the opposite side. Another thin prolongation is reflected round the surface of the lower end of the rectum. The Levator ani muscle arises from the point of division of the pelvic fascia, the visceral layer of the fascia descending upon and being intimately adherent to the upper surface of the muscle, while the under surface of the muscle is covered by a thin layer derived from the obturator fascia, called the *ischio-rectal* or *anal fascia*. In the female the vagina perforates the recto-vesical fascia, and receives a prolongation from it.

INDEX.

A.

Abdomen, 955
  contents of, 959, 999
  lymphatics of, 689
  muscles of, 447
  regions of, 959
Abdominal aorta, 608
    branches of, 609
    surface-marking of, 609
    surgical anatomy of, 609
  cavity, 955, 959
  muscles, 447
  ring, external, 449
    internal, 1186
  wall, 957, 959
Abdomino-thoracic arch, 237
Abducent nerve, 810
    surgical anatomy of, 811
Abductor hallucis muscle, 530
  indicis muscle, 496
  minimi digiti muscle, foot, 531
      hand, 494
Absorbent glands, 679
Absorbents, 679
Accessorii orbicularis oris, 402
Accessorius ad ilio-costalem muscle, 436
Accessory descending palatine canals, 197
  obturator nerve, 854
  portal vein, 1057
  processes, 152
  pudic artery, 623
  spleen, 1073
Acetabulum, 278
Acromial end of clavicle, fracture of, 500
  region, muscles of, 471
  thoracic artery, 592
Acromio-clavicular joint, 342
    surface form of, 344
    surgical anatomy of, 344
Acromion process, 244
    fracture of, 500
Actions of muscles. See each group of muscles.
Adamantoblasts, 940
Adductor brevis muscle, 512
  longus muscle, 512
  magnus muscle, 513
  obliquus hallucis, 533
    pollicis, 493
  transversus hallucis, 533
    pollicis, 493
  tubercle, 287
Adenoid connective tissue, 49
Adipose tissue, 49
Adminiculum lineæ albæ, 962
Afferent nerves, 75
  vessels of kidney, 1134
After-brain, 707
Agminated glands, 1025
Air-cells, 1119
Ala cinerea, 724
Alæ of cerebellum, 729, 730
  of vomer, 201
Alar ligaments, 326
    of knee, 372
  thoracic artery, 592
Alcock, canal of, 1202
Alimentary canal, 930
    development of, 132
    subdivisions of, 930
Allantoic vesicle, 113
Allantois, 113, 1140
Alveolar artery, 562
  passage, 1119
  process, 193, 203
Alveoli, 1119
  formation of, 941
  of lower jaw, 203
  of upper jaw, 193
Alveus, 763
Amnion, 111
Amniotic cavity, 112
Amphiarthrosis, 315
Ampullæ of rectum, 1039
  of semicircular canals, 922
  of tubuli lactiferi, 1179
Amygdalæ, 945
  of cerebellum, 732
Anal canal, 1038, 1040
  fascia, 1210
  orifice, 1038
Anastomosis of arteries, 539
Anastomotica magna of brachial, 596
    of femoral, 637
Anatomical neck of humerus, 248
      fracture of, 253
Anconeus muscle, 486
Andersch, ganglion of, 816
Aneurisms of abdominal aorta, 609
  of arch of aorta, 544
  of thoracic aorta, 606
Angle of floor of fourth ventricle, 723
  inferior lateral, of sacrum, 157
  of jaw, 206
  lateral, 738
  of rib, 233
  sacro-vertebral, 155
Angular artery, 556
  process, external, 171
    internal, 171
  vein, 651
Ankle-joint, 377
  relations of tendons and vessels to, 379
  surface form of, 379
  surgical anatomy of, 379
Annular ligament of ankle, anterior, 528
      external, 529
      internal, 528
    of radius and ulna, 353
    of stapes, 919
    of wrist, anterior, 489
      posterior, 490
Annulus, 1101
  ovalis, 1089
Ansa lenticularis, 747
  pedunclaris, 747
Anterior annular ligament, ankle, 528
      wrist, 489
  chamber of eye, 903
  crural nerve, 855
      surgical anatomy of, 866
  dental canal, 190
  ethmoidal cells, 186
  fontanelle, 188
  fossa of skull, 208
  and internal frontal artery, 572
  nasal spine, 194
  palatine canal, 194
    fossa, 194, 213
  perforated space, 784
  region of skull, 217
  triangle of neck, 563
Antero-lateral ganglionic artery, 572
Antero-median ganglionic artery, 571
Antihelix, 912
  fossa of, 912
Antitragicus muscle, 914
Antitragus, 912
Antrum duodeni, 1000
  of Highmore, 190
  pyloricum, 1000
Anus, 1201
  development of, 134
  muscles of, 458
Aorta, 541
  abdominal, 608
    branches of, 609
    development of, 128
    surgical anatomy of arch of, 544
  arch of, 543
    branches of, 545
    peculiarities of, 543
      branches of, 545
    sinuses of, 542
    surgical anatomy of, 544
  descending, 605
  thoracic, 605
    branches of, 606
    sinuses of, 542
    surgical anatomy of, 606
  transverse, 541, 543

Aortic opening of diaphragm, 446
of heart, 1092
plexus, 878
semilunar valves, 1093
sinuses, 1093
vestibule, 1094
Apertura scalæ vestibuli cochleæ, 922
Aponeurosis, 389
of deltoid, 471
of external oblique in inguinal region, 448
of occipito-frontalis, 393
posterior, of transverse muscle, 453, 458
of soft palate, 944
suprahyoid, 413
Apophysis, 144
Apparatus ligamentosus coli, 326
Appendages of eye, 907
surgical anatomy of, 911
of skin, 89
of uterus, 1174
Appendices epiploicæ, 1028, 1041
Appendix of left auricle, 1091
of right auricle, 1088
vermiformis, 1032
Aqua labyrinthi, 926
Aquæductus cochleæ, 178, 923
Fallopii, 177, 919
Sylvius, 707, 741, 744
vestibuli, 177, 921
Aqueous humor, 903
Arantii corpora, 1091
Arbor uterina, 1171
vitæ, 734
Arch of aorta, 543
branches of, 545
peculiarities of, 543
surgical anatomy of, 544
crural or femoral, 1195
deep, 598
of os pubis, 283
plantar, 647
supraorbital, 171
of a vertebra, 144
zygomatic, 216
Arches, aortic, fœtal, 129
Archoplasm apheres, 40
Arciform fibres, deep, 719
external or superficial, 710, 712, 718
internal, 719
superficial or external, 710, 712, 718
Area of Broca, 783
cribrosa, media, 928
superior, 928
germination, 103
Areas of Cohnheim, 66
of medulla, 712, 713, 714
Areola of breast, 1178
Areolæ of bone, primary, 60
secondary, 61
Areolar tissue, 46
Arm, arteries of, 576
back of, muscles of, 477
bones of, 248
fascia of, 475
front of, muscles of, 475
lymphatic glands of, 681
lymphatics of, 684
superficial fascia of, 471
veins of, 662
Arnold's ganglion, 807
nerve, 821
canal for, 178
Arrectores pili, 94
Arteria centralis retinæ, 570
Arteriæ propriæ renales, 1133
receptaculi, 568
Arteries, development of, 128
anastomoses of, 539
capillary, 82
distribution of, 539
mode of division, 539
of origin of branches, 539
nerves of, 82
sheath of, 82
structure of, 80
subdivision of, 539
systemic, 539
vessels of, 82
Arteries or artery, accessory pudic, 623
acromial, thoracic, 592
alar thoracic, 592
alveolar, 562
anastomotica magna of brachial, 597
of femoral, 637
angular, 556
anterior cerebral, 570
ciliary, 570
communicating, 572
inferior cerebellar, 583
intercostal, 586
and internal frontal, 670
spinal, 582
antero-lateral ganglionic, 572
antero-median ganglionic, 571
aorta, 541
abdominal, 608
arch of, 543
ascending part, 542
descending part, 605
thoracic, 605
articular, knee, 639
ascending cervical, 584
pharyngeal, 558
auditory, 583, 927
auricular anterior, 559
posterior, 557
axillary, 589
accessory external mammary, 592
cutaneous, 593
external mammary, 592
accessory, 592
humeral branch, 592
azygos of knee, 641
basilar, 583
brachial, 593
bronchial, 606, 1120
buccal, 562
of bulb, 625
calcanean, external, 647
internal, 647
carotid, common, 547
external, 551
internal, 565
carpal, radial, 599
ulnar, 603
of cavernous body, 625
centralis retinæ, 570
cerebellar, 583
cerebral, 570, 572, 583
ascending cervical, 584
princeps, 557
Arteries or artery, cerebral profunda, 587
superficial cervical, 585
choroid anterior, 573
posterior, 584
ciliary, 570
circle of Willis, 573, 584
circumflex, of arm, 593
of iliac, superficial, 635
of thigh, 636
coccygeal, 626
cochlear, 927
cœliac axis, 610
colica dextra, 614
media, 614
sinistra, 614
comes nervi ischiadici, 626
phrenici, 586
common carotid, 547
iliac, 618
communicating, anterior cerebri, 572
branch of ulnar, 604
posterior cerebri, 573
coronary, descending, 542, 543
of heart, 542
infundibular, 542
of lip, 556
marginal, 542
transverse, 542, 543
cremasteric, 629
crico-thyroid, 552
cystic, 611
deep branch of ulnar, 605
cervical, 587
temporal, 561
dental anterior, 562
inferior, 561
posterior, 562
descending aorta, 605
palatine, 562
digital plantar, 648
of ulnar, 604
dorsal, of penis, 624
of scapula, 592
dorsalis hallucis, 643, 644
indicis, 600
linguæ, 553
pedis, 643
communicating, 643, 644
first dorsal interosseous, 643, 644
plantar digital, 643, 644
pollicis, 600
epigastric, deep, 629
superficial, 635
superior, 587
ethmoidal, 569
external carotid, 551
iliac, 628
plantar, 647
anterior perforating, 644, 648
facial, 554
femoral, 630
deep, 635
frontal, 570
gastric, 611, 612
gastro-duodenalis, 611
gastro-epiploica dextra, 611
sinistra, 612
gluteal, 627
inferior, 626
helicine, 1152
hæmorrhoidal inferior, 625

Arteries or artery, hæmorrhoidal, middle, 622
superior, 615
hepatic, 611, 1057
hyoid branch of lingual, 553
of superior thyroid, 552
hypogastric, in fœtus, 621, 1097
ileo-colic, 614
iliac, common, 618
external, 628
internal, 620
ilio-lumbar, 626
inferior cerebellar, 583
dental, 561
labial, 555
laryngeal, 584
mesenteric, 614
profunda, 596
pyloric, 611
thyroid, 584
infraorbital, 562
innominate, 545
intercostal, 606
anterior, 586
superior, 587
internal auditory, 927
carotid, 565
iliac, 620
mammary, 586
maxillary, 559
plantar, 647
interosseous, of foot, 644
of hand, 602
ulnar, 602
intestini tenuis, 614
labial inferior, 555
lachrymal, 568
laryngeal inferior, 584
superior, 552
lateral sacral, 627
spinal, 582
lateralis nasi, 556
lingual, 553
long ciliary, 570
thoracic, 592
lumbar, 617
malleolar, 643
mammary, internal, 586
masseteric, 562
maxillary, internal, 559
median, of forearm, 603
of spinal cord, 583
mediastinal, 586
posterior, 606
meningeal anterior, 568
middle, 560
small, 561
from occipital, 557
from pharyngeal, 558
from vertebral, 581
mesenteric inferior, 614
superior, 613
metacarpal, 600
metatarsal, 644
middle cerebral, 572
sacral, 617
musculo-phrenic, 586
mylo-hyoid, 561
nasal, of ophthalmic, 570
of septum, 556
inferior, 556
superior, 562
nutrient, of fibula, 646
humerus, 586
radius and ulnar, 602
Arteries or artery, radius and tibia, 646
obturator, 622
occipital, 556
œsophageal, 606
ophthalmic, 568
orbital, 562
ovarian, 616
palatine, ascending, 555
descending, 562
palmar arch, deep, 604
superficial, 604
of pharyngeal, 558
palmar interossei, 601
palpebral, 570
pancreatic, 612
pancreatico-duodenalis, 611
inferior, 613
perforating, of foot, 648
of hand, 601
of intercostal, 586
of thigh, 636
pericardiac, 586, 606
perineal, superficial, 625
transverse, 625
peroneal, 646
anterior, 646
posterior, 646
phrenic, 616
plantar, 647
popliteal, 638
posterior auricular, 557
carpal, inferior perforating of radial, 600
cerebral, 583
communicating, 573
meningeal, from vertebral, 582
tibial, 644
princeps cervicis, 557
pollicis, 600
profunda of arm, inferior, 596
superior, 596
cervicis, 587
femoris, 635
pterygoid, 562
pterygo-palatine, 562
pudic, deep external, 635
superficial external, 635
internal, 623
pulmonary, 540, 1119
pyloric inferior, 611
of hepatic, 611
radial, 597
posterior carpal, inferior perforating, 600
radialis indicis, 601
ranine, 553
recurrent interosseous, 603
radial, 599
tibial, 642
posterior, 642
ulnar, anterior, 602
posterior, 602
renal, 616
sacral lateral, 627
middle, 617
scapular, posterior, 585
sciatic, 626
short ciliary, 570
sigmoid, 614
spermatic, 616, 1155
spheno-palatine, 562
spinal, anterior, 582
lateral, 582
Arteries or artery, spinal, median, 583
posterior, 582
splenic, 611
sterno-mastoid, 557
stylo-mastoid, 557
subclavian, 576
sublingual, 553
submaxillary, 555
submental, 555
subscapular, 592
superficial cervical, 585
circumflex iliac, 630
palmar arch, 604
perineal, 625
superficialis volæ, 599
superior cerebellar, 583
epigastric, 587
hæmorrhoidal, 615
intercostal, 587
laryngeal, 552
mesenteric, 613
profunda, 596
thoracic, 592
thyroid, 554
supraorbital, 569
suprarenal, 615
suprascapular, 585
sural, 639
tarsal, 644
temporal, 558
anterior, 558
deep, 561
middle, 559
posterior, 558
thoracic, acromial, 592
alar, 592
aorta, 605
long, 592
superior, 592
thyroid axis, 584
inferior, 584
superior, 552
thyroidea ima, 545
tibial anterior, 641
posterior, 644
recurrent, 642
tonsillar, 555
transverse facial, 559
transversalis colli, 585
tympanic, from internal carotid, 568
from internal maxillary, 500
ulnar, 601
recurrent anterior, 602
posterior, 602
umbilical in fœtus, 621, 1099
uterine, 622
vaginal, 622
vasa aberrantia of arm, 595
brevia, 612
intestini tenuis, 614
vertebral, 581
vesical inferior, 622
middle, 622
superior, 622
vestibular, 927
Vidian, 562
Arteriolæ rectæ, 1134
Arthrodia, 316
Articular arteries (knee), from popliteal, 641
cartilage, 143
end-bulbs, 76
lamella of bone, 313

Articular processes of vertebræ, 146
Articulations, acromio-clavicular, 342
ankle, 377
astragalo-calcanean, 381
navicular, 382
atlanto-axial, 323
calcaneo-astragaloid, 381
-cuboid, 381
navicular, 382
carpal, 357
carpo-metacarpal, 359
chondro-sternal, 334
classification of, 314
coccygeal, 339
costo-central, 330
-transverse, 331
of cuboid with external cuneiform, 384
of cuneiform with each other, 383
different kinds of, 34
elbow, 349
femoro-tibial, 368
in general, 313
hip, 362
immovable, 314
knee, 368
metacarpal, 357
metacarpo-phalangeal, 361
metatarsal, 385
metatarso-phalangeal, 386
mixed, 315
movable, 315
movements of, 316
naviculo-cuboid, 383
-cuneiform, 383
occipito-atlantal, 325
-axial, 326
pelvis, 336
with spine, 336
phalanges, 362
pubic, 339
radio-carpal, 356
-ulnar, inferior, 355
middle, 354
superior, 353
sacro-coccygeal, 339
-iliac, 337
-sciatic, 337, 338
-vertebral, 336
scapulo-clavicular, 343
-humeral, 345
shoulder, 345
sterno-clavicular, 341
of sternum, 336
tarsal, 380
tarso-metatarsal, 384
temporo-maxillary, 327
tibio-fibular, inferior, 376
middle, 376
superior, 376
of tympanic bones, 918
vertebral column, 319
wrist, 356
Articular nerve, 842
Arytæno-epiglottic folds, 1104
Arytæno-epiglottideus, inferior, 1107
superior, 1107
Arytenoid cartilages, 1102
glands, 1108
muscle, 1106
Arytenoideus rectus, 1106
Ascending colon, 1035
cutaneous nerve, 862
frontal artery, 572
oblique muscle of abdomen, 451
palatine artery, 556
parietal artery, 572
pharyngeal artery, 558
surgical anatomy of, 558
Astragalus, 303
development of, 308
Atlanto-axial articulation, 323
-odontoid joint, 323
Atlas, 146
development of, 153
Atrabiliary capsules, 1137
Atrium, 1088, 1091, 1119
bursæ omentalis, 974, 994, 1012, 1052
Attic, 917
Attollens aurem muscle, 394
Attrahens aurem muscle, 393
Auditory artery, 927
canal, 914
meatus, external, 177
internal, 177
nerve, 815
surgical anatomy of, 816
process, 177
veins, 927
vesicle, 124
Auricle of ear, 912
cartilage of, 912
ligaments of, 913
of heart, left, 1091
appendix of, 1091
septum, 1092
sinus of, 1091
right, 1088
openings in, 1088
septum of, 1089
sinus of, 1088
valves in, 1089
Auricular artery, anterior, 559
posterior, 557
fissure, 179, 214
lymphatic glands, 681
nerve of vagus, 821
posterior from facial, 813
surface of sacrum, 157
veins, anterior, 652
posterior, 653
Auricularis anterior muscle, 393
magnus nerve, 831
posterior muscle, 394
superior muscle, 394
Auriculo-temporal nerve, 806
Auriculo-ventricular groove of heart, 1087
opening, left, 1092
right, 1089
Axes of the pelvis, 282
Axilla, 587
dissection of, 466
surgical anatomy of, 589
Axillary artery, 589
branches of, 592
lymphatic glands, 684
peculiarities of, 590
space, 587
surface-marking of, 591
surgical anatomy of, 591
vein, 664
surgical anatomy of, 665
Axis, or second vertebra, 147
Axis, cerebro-spinal, 693
cœliac, 610
development of, 154
thyroid, 584
Axis-cylinder of nerve-tubes, 71
Azygos artery, articular, 641
uvulæ muscle, 422
veins, 667

B.

Bacillary layer of retina, 901
Back, muscles of, fifth layer, 437
first layer, 428
fourth layer, 434
second layer, 431
third layer, 432
Ball-and-socket joint. See *Enarthrodia.*
Bartholin, duct of, 948
glands of, 1165
Basal ridge, 933
Base of brain, 784
of skull, 208
external surface, 211
internal surface, 208
Basement membranes, 49
Basi-hyal of hyoid bone, 227
Basilar artery, 583
groove, 720, 721
membrane of cochlea, 924
process, 165
suture, 207
Basilic vein, 663
median, 663
Basis vertebrarum venæ, 668
Bauhin, valve of, 1033
Beaunis et Bouchard, Table of Development of Fœtus from, 141
Belly-stalk, 113
Bend of elbow, 593
Biceps flexor cruris, 518
cubiti, 476
Bicipital fascia, 476
groove, 248
ridges, 248
tuberosity, 259
Bicuspid teeth, 933
Biliary ducts, 1062, 1063
Biventer cervicis muscle, 437
Bladder, 1139
exstrophy of, 959
female, 1166
ligaments of, 1142
surface form of, 1144
surgical anatomy of, 1145
trigone of, 1144
vessels and nerves of, 1144
Blastodermic vesicle, 103
Blood, circulation of, in adult, 1087
in fœtus, 1097
gases of, 37
general composition of, 33
Blood-cells, 127
Blood-corpuscles, 34
Blood-crystals, 37
Blood-globules, 34
Blood-plaques, 36
Blood-vessels of brain, 573
Bochdalek, cavity, 955
ganglion of, 802, 804
on musculus triticeo-glossus, 1107, *note.*

Body of lateral ventricle, 757
perineal, 1164
of a tooth, 932
of a vertebra, 145
Bone, animal constituent of, 58
apophysis of, 144
articular lamella of, 313
canaliculi of, 56
cancellous tissue of, 54
cells, 58
chemical analysis of, 58
compact tissue of, 54
development of, 59
diploë of, 144
earthy constituent of, 59
eminences and depressions of, 144
epiphysis of, 144
growth of, 63
Haversian canals of, 56
systems of, 56
inorganic constituent of, 59
lacunæ of, 58
lamellæ of, 57
lymphatics of, 56
marrow of, 55
medullary canal of, 54, 143
membrane of, 54
microscopic appearances, 55
nerves of, 55
organic constituent of, 59
ossific centres, number of, 64
ossification of, 60
periosteum of, 54
spongy tissue of, 143
structure of, 54
vessels of, 55
Bones, forms of, viz. long, flat, short, mixed, irregular, 143
number of, in the body, 143
Bones or bone, astragalus, 303
atlas, 146
axis, 147
calcaneum, 299
carpal, 262
clavicle, 238
coccyx, 159
cranial, 164
cuboid, 303
cuneiform, of carpus, 264
of tarsus, 305
descriptive anatomy of, 143
ear, 916
ethmoid, 185
facial, 188
femur, 284
fibula, 297
frontal, 170
hand, 262
humerus, 248
hyoid, 227
ilium, 272
incus, 919
inferior maxillary, 201
turbinated, 200
innominate, 272
ischium, 272, 275
lachrymal, 195
lesser lachrymal, 195
lingual, 227
magnum, 266
malar, 196
malleus, 919
maxillary, inferior, 201
Bones or bone, maxillary, superior, 189
metacarpal, 267
metatarsal, 306
nasal, 189
navicular, 304
occipital, 164
palate, 197
parietal, 168
patella, 291
pelvic, 279
phalanges of foot, 308
of hand, 270
pisiform, 264
pubic, 277
radius, 259
ribs, 232
sacrum, 155
scaphoid, 262
scapula, 242
semilunar, 266
sesamoid, 312
sphenoid, 180
sphenoidal, spongy, 184
stapes, 919
sternum, 228
superior maxillary, 189
tarsal, 299
temporal, 173
tibia, 293
trapezium, 266
trapezoid, 266
triquetral, 188
turbinate, inferior, 200
middle, 186
superior, 187
tympanic, 179
ulna, 254
unciform, 267
vertebra prominens, 149
vertebræ, cervical, 145
dorsal, 149
lumbar, 151
vomer, 201
Wormian, 188
Bowman, glands of, 889
sarcous elements of, 66
Bowman's capsule, 1129
Brachial artery, 593
branches of, 596
peculiarities of, 596
surface marking of, 595
surgical anatomy of, 595
lymphatic glands, 684
plexus, 834
surgical anatomy of, 844
region, anterior, muscles of, 479, 481
posterior, muscles of, 485
veins, 664
Brachialis anticus muscle, 477
Brachio-cephalic artery. See *Innominate.*
Brachium, anterior, 743
posterior, 743
Brain, 706
development of, 120
general anatomy of, 93
membranes and dissection, 702
subdivision into parts, 706
Branchial clefts, 118
Breasts, 1178
Bregma, 208
Brim of pelvis, 281
Broad ligament, 988
Broad ligament of liver, 1053
of uterus, 1169
Broca, area of, 783
Bronchi, 1110
dorsal, 1110
right and left, 1108, 1109
septum of, 1111
in lung, 1119
subdivisions of according to Aeby, 1119
ventral, 1110
Bronchial arteries, 606, 1120
lymphatic glands, 692
septum, 1111
tubes. See *Bronchi.*
veins, 668, 1120
Bronchiole, 1119
Bronchus, accessory, 1110
eparterial, 1108, 1109
heart, 1110
hyparterial, 1108, 1109
Brunner's glands, 1024
Bubonocele, 1189
Buccal arteries, 562
cavity, 930
development of, 133
glands, 931
lymphatic glands, 681
nerve of facial, 815
of inferior maxillary, 806
Buccinator muscle, 402
Bulb, artery of, 625
of corpus cavernosum, 1151
spongiosum, 1152
olfactory, 782, 788
posterior cornu, 758
spinal, 708
Bulbi vestibuli, 1166
Bulbous portion of the urethra, 1147
Bundle of Vicq d'Azyr, 748, 750
Burdach's column, 700
Bursa omentalis, 974, 981, 993
Bursæ of knee, 372
mucosæ, 314
of shoulder, 346
synoviæ, 314
Bursal synovial membranes, 314

C.

Cæca, types of, 1031
Cæcum, 1030
Calcanean arteries, external, 647
internal, 647
Calcaneo-astragaloid ligaments, 381
Calcaneo-cuboid ligaments, 381
Calcaneo-navicular ligaments, 382
Calcaneum, 299
Calcaneus scriptorius, 724
Calcar avis, 758
femorale, 289
Calices of kidney, 1128
Camper's ligament. See *Triangular Ligament of Urethra.*
Canals or canal, accessory palatine, 197
alimentary, 929
anal, 1038, 1040
anterior, for Arnold's nerve, 178
dental, 191
palatine, 194

Canals or canal, auditory, 914
carotid, 178
for chorda tympani, 916
of cochlea, 923
central, of modiolus, 923
crural, 1197
dental, posterior, 190
ethmoidal, 172
Haversian, of bone, 56
of Huguier, 175
incisive, 213
inferior dental, 203
infraorbital, 191
inguinal, 1185
intestinal, 1008
for Jacobson's (tympanic) nerve, 178
lachrymal, 910
of modiolus, 923
naso-palatine, 194
of Nuck, 1162, 1177
of Petit, 905
palatine, anterior, 194
posterior, 191
portal, 1057
pterygo-palatine, 182
sacral, 157
of Schlemm, 893
semicircular, 922
spermatic, 1185
of spinal cord, 121
spiral, of cochlea, 923
of Stilling, 903
temporo-malar, 197
for tensor tympani, 179, 895
vertebral, 162
Vidian, 183
of Wirsung, 1070
Canaliculi of bone, 58
Canalis centralis modioli, 924
spiralis modioli, 924
Cancellous tissue of bone, 53
Canine eminence, 190
fossa, 190
teeth, 933
Canthi of eyelids, 907
Capillaries, 82
structure of, 83
Capitellum of humerus, 251
Capsular ligament of hip, 362
of knee, 368
of shoulder, 346
of thumb, 359
of vertebræ, 321
Capsule, external, of brain, 759, 760
in fœtus, 124
of Glisson, 982, 992
internal, of brain, 759, 760
of kidney, 1128
of lens, 904
of Tenon, 890
Capsules, suprarenal, 1137
Caput cornu posterioris, 700
gallinaginis, 1146
Cardia, 999
Cardiac lymphatics, 692
nerves, 871
from pneumogastric, 822
plexus of nerves, deep, 874
superficial, 874
veins, 677
Cardinal veins, fœtal, 131
Carotid artery, common, 547
Carotid artery, common, branches of (occasional), 549
peculiarities of, 549
surface-marking of, 549
surgical anatomy of, 549
external, 551
branches of, 552
surface-marking of, 551
surgical anatomy of, 551
internal, 565
branches of, 568
peculiarities of, 567
surgical anatomy of, 568
tubercle, 146
branch of Vidian, 804
canal, 178
ganglion, 869
groove, 181
plexus, 869
triangle, anterior, 563
inferior, 563
superior, 564
Carpal arteries, from radial, 599
from ulnar, 603
ligaments, 357
Carpo-metacarpal articulations, 359
Carpus, 262
articulations of, 357
development of, 271
surface form of, 270
surgical anatomy of, 271
Cartilage, articular, 52
arytenoid, 1102
of auricle, 912
of bronchi, 1110
cellular, 51
costal, 52, 236
cricoid, 1101
cuneiform, 1102
descriptive anatomy of, 51
of ear, 912, 914, 918
ensiform, 228
of epiglottis, 1102
fibro-, 52, 53
hyaline, 51
intercellular substance of, 51
of larynx, 1100
of the nose, 885
of the pinna, 912
reticular, 53
of Santorini, 1102
semilunar, of knee, 370
of septum of nose, 885
structure of, 52
tarsal, 908
temporary, 54
thyroid, 1200
of trachea, 1110
white fibro-, 52
of Wrisberg, 1202
yellow elastic, 53
xiphoid, 228
Cartilage-cells, 51
Cartilage-lacunæ, 51
Cartilagines minores, 886
Cartilago triticea, 1103
Caruncula lachrymalis, 909
Carunculæ myrtiformes, 1165
Cauda equina, 693
Caudate lobe of liver, 1052
Cava, inferior, 673
peculiarities of, 674
superior, 667
Cavernous body, artery of, 625
Cavernous groove, 181
nerves of penis, 878
plexus, 869
sinus, 659
nerves in, 810
surgical anatomy of, 659
Cavity, abdominal, 955, 959
body, 955
cotyloid, 278
glenoid, 245
pelvic, 955
of pelvis, 281
pericardial, 955
pericardio-thoracic, 955
pleural, 955
sigmoid, 256
Cavum Meckelii, 797
Retzii, 1141
Cells, 38
of bone, 58
definition of, 38
division of, direct, 41
indirect, 39
ethmoidal, 186
fusiform, 787
hepatic, 1060
mastoid, 176
mitral, 788
polymorphous, 787
prickle, 43
pyramidal, 787
reproduction of, 40
structure of, 38
wall, 41
Cement of teeth, 941
formation of, 941
Central canal of cord, 698
ganglionic vessels of brain, 574
lobule, 729
Centres of ossification, 63
Centrifugal nerve-fibres, 75
Centripetal nerve-fibres, 75
Centrosomes, 40
Centrum ovale majus, 756
minus, 755
vertebra, 145
Cephalic vein, 63
median, 663
Cerato-hyal of hyoid bone, 227
Cerebellar arteries, anterior, 583
inferior, 583
superior, 583
column, 700
tract, 700
direct, 710
veins, 657
Cerebellum, 725, 737
gray matter, 735–737
cortical, 735–737
peduncles, inferior, 712
middle, 720
superior, 720
weight of, 725
white matter, 733–735
Cerebral arteries, 570
anterior, 570
middle, 572
posterior, 583
localization, 789–791
lymphatics, 682
topography, 789–791
veins, 656
vesicles, 706
Cerebro-spinal axis, 693
nerves, 69

Cerebro-spinal system, 69
Cerebrum, 706
gray matter of, 73
Cervical artery, ascending, 584
superficial, 585
fascia, 407
ganglion, inferior, 872
middle, 872
superior, 869
lymphatic glands, deep, 684
superficial, 684
nerves, 828
anterior divisions of, 830
posterior divisions of, 828
plexus, 831
deep branches of, 833
posterior branches of, 828
superficial branches of, 831
veins, deep, 655
vertebræ, 145
surgical anatomy of, 327
Cervicalis ascendens muscle, 436
Cervicis princeps, 557
profunda, 587
Cervico-facial nerve, 815
Cervix cornu posterioris, 701
uteri, 1171
Chalice cells, 43
Chambers of the eye, 903
Check ligaments, 326
Cheek, muscles of, 401
Cheeks, structure of, 931
Chest, muscles of front, 467
of side, 470
surface form of, 236
surgical anatomy of, 237
Chiasma, or optic commissure, 793
Chondro-glossus muscle, 416
Chondro-sternal ligaments, 334
Chondro-xiphoid ligament, 334
Chorda dorsalis, 107, 115, 968
tympani nerve, 812, 921
Chordæ tendineæ, of left ventricle, 1092
of right ventricle, 1090
vocales, 1105
Willisii, 657
Chorion, 112
Choroid arteries, anterior, 573
posterior, 584
coat of eye, 894
plexus, 766, 769, 770
of fourth ventricle, 740
of lateral recess, 740
of ventricle, 749
veins of brain, 656
Choroidal fissure, 123
Chyle, 38
Chyli receptaculum, 680
Cilia, or eyelashes, 907
Ciliary arteries, 570, 905
ganglion, 799
muscle, 898
nerves, long, 799
short, 800
processes of eye, 895
Cingulum, 786, 933
Circle of Willis, 584
Circular sinus, 660
Circulation of blood in adult, 1087
in fœtus, 1097
Circumanal glands, 1040
Circumduction, 322
Circumferential fibro-cartilage, 53
Circumflex artery of arm, anterior, 593
posterior, 593
of thigh, external, 636
internal, 636
iliac artery, 630
superficial, 635
nerve, 839
surgical anatomy of, 844
vein, 672
superficial, 670
Circumflexus palati muscle, 422
Circumvallate papillæ of tongue, 880
Clava, 711, 714, 715
Clavicle, 238
development of, 241
fracture of, 499
peculiarities in sexes, 241
surface form of, 241
surgical anatomy of, 241
Cleft palate, 423
Clinoid processes, anterior, 183
middle, 180
posterior, 181
Clitoris, 1164
frænum of, 1164
lymphatics of, 689
muscles of, 465, 1165
prepuce of, 1165
Clivus, 181, 730
Coccygeal artery, 626
gland, 617
nerves, 858
Coccygeus muscle, 460
Coccyx, 159
development of, 160
Cochlea, 922
aqueduct of, 178
arteries of, 927
central axis of, 923
cupola of, 923
denticulate lamina of, 924
infundibulum of, 923
lamina spiralis of, 923
nerves of, 928
scalæ of, 924
spiral canal of, 923
veins of, 928
Cochlear artery, 928
nerve, 928
Cochleariform process, 179, 916
Cœliac axis, 610
plexus, 876
Colica dextra artery, 614
media, 614
sinistra, 614
Collateral branches of nerve fibres, 70
circulation. See *Surgical Anatomy of each Artery.*
ulnaa nerve, 843
Collaterals, 700, 787
Collecting tubes of kidney, 1130
Colliculus nervi optici, 898
seminalis, 1146
Colon, 1035
Colostrum corpuscles, 1179
Colotomy, 1046, 1047
Columella cochleæ, 923
Column of Burdach, 700
cerebellar, 700
Column, Clarke's vesicular, of spinal cord, 701
of Goll, 700
mixed lateral, 700
of Morgagni, 1042
vesicular, of anterior cornu, 701
Columnæ ani, 1042
carneæ of left ventricle, 1093
fornicis, anterior pillars, 761
of right ventricle, 1090
papillaries, 1090, 1093
Columns of abdominal ring, 1182
of spinal cord, 697, 700
antero-lateral, 697, 700
postero-lateral, 697, 700
postero-median, 697, 700
of vagina, 1168
Comes nervi ischiadici artery, 626
phrenici artery, 586
Commissures of brain, anterior, 753, 762, 786
middle or soft, 751
posterior, 748
of Gudden, 793
optic, 752
of spinal cord, 697, 698
gray, 698
white, 697
Common ligaments of vertebræ, 319
dental germ, 938
Communicans hypoglossi nerve, 833
peronei, 865
Communicating artery of brain, anterior, 572
posterior, 573
from dorsalis pedis, 643
ulnar, 604
Compact tissue of bone, 54, 143
Complexus muscle, 437
Compressor narium minor, 399
nasi, 399
sacculi laryngis, 1107
urethræ, 464
in female, 1208
Conarium, 748
Conception, where effected, 100
Concha, 912
Condyles of bones. See *Bones.*
Condyloid articulations, 316
process, 204
veins, posterior, 657
Congenital fissures in cranium, 188
hernia, 1189
Conglobate glands, 679
Coni vasculosi, 1042
Conjoined tendon of internal oblique and transversalis, 451, 1184
Conjunctiva, 908
Connecting fibro-cartilages, 53
Connective tissue, 45
development of, 48
lymphatics of, 48
lymphoid, 48
mucoid, 48
nerves of, 48
retiform, 48
Conoid ligament, 344
tubercle, 239
Constrictor inferior muscle, 419
isthmi faucium, 420

Constrictor medius muscle, 420
superior muscle, 420
urethræ, 464
Contents of abdomen, 959, 999
Contractile fibre-cells, 68
Conus terminalis, 693
Convolutions, 772, 773
angular, 777
annectant, 777, 779
frontal, 775
ascending, 775
inferior, 775, 776
superior, 775, 776
hippocampal, 781
infracalcarine, 780
marginal, 780
occipital, 777
orbital, 775
parietal, 776, 777
ascending, 776, 777
superior, 777
supramarginal, 777
temporal, 778, 779, 781
Coraco-acromial ligament, 344
Coraco-brachialis muscle, 476
nerve, 837, 839
Coraco-clavicular ligament, 343
Coraco-humeral ligament, 346
Coracoid ligament, 345
process, 245
fracture of, 500
Cord, spermatic, 1155
umbilical, 115
Cords, vocal, 1103, 1105
Cordiform tendon of diaphragm, 445
Corium of skin, 89
of tongue, 880
Cornea, 892
Corneal corpuscles, 893
spaces, 893
Cornu Ammonis, 763
formation of, 788
lateral ventricles, anterior, 758
descending, 758
middle, 758
posterior, 758
Cornua of the coccyx, 159
of hyoid bone, 227
of lateral ventricles, 755
radiata, 760
of the sacrum, 156
Corona glandis, 1150
radiata, 785
Coronal suture, 206
Coronaria ventriculi artery, 611
Coronary arteries of lip, 556
of heart, 542
peculiarities of, 543
ligament, 979, 981, 988
of liver, 1053
ligaments of knee, 371
plexus, anterior, 875
posterior, 874
sinus, 677
opening of, 1088
valve, 678, 1090
Coronoid depression, 251
process of jaw, 204
of ulna, 254
Corpora albicantia, 750
Arantii, 1091
cavernosa penis, 1151
crura of, 1151
geniculata, 743
Corpora geniculata, external, 743, 744, 746
internal, 743, 744, 746
mamillaria, 750
quadrigemina, 743
third ventricle, 751
veins of, 657
Corpus callosum, 753, 772, 786
fimbriatum, 763, 768
genu of, 756, 758
peduncles of, 757
rostrum of, 756
splenium of, 757
cavernosum, artery of, 525
dentatum of cerebellum, 737
fimbriatum, 759
Highmorianum, 1157
spongiosum, 1152
striatum, 759
Corpuscles, blood-, 34
colored, 34
development of, 126
of Herbst, 77
Malpighian, of kidney, 1129
of Purkinje, 736
of spleen, 1080
tactile, 76
of Vater, 77, *note.*
white, 35
Corrugator cutis ani, 458, 1040
supercilii muscle, 395
Corset-liver, 1053
Cortex of hemispheres, 786
layers, 787
white centre, 787
Corti, membrane of, 924
organ of, 925
rods of, 925
Cortical arches, 1129
arteries of brain, 574
columns, 1129
substance of kidney, 1129
of suprarenal capsules, 1138
Costal cartilages, 52, 236
connection with ribs, 334
process, 146
vertebral ligaments, 330
Costo-chrondral articulation, 335
Costo-clavicular ligament, 341
Costo-colic ligament, 1077
Costo-coracoid fascia, 468
ligament, 468
Costo-phrenic sinus, 1114
Costo-transverse articulations, 331
Costo-vertebral articulations, 330
Cotunnius, nerve of, 805
Cotyloid cavity, 278
ligament, 364
notch, 278
Coverings of direct inguinal hernia, 1190
of femoral hernia, 1199
of oblique, 1187
of testis, 1156
Cowper's glands, 1150, 1205
Cranial bones, 163
articulations of, 208
fossæ, 208
nerves, 792
development of, 117
eighth, 815
eleventh, 823
fifth, 796
first pair, 792
Cranial nerves: fourth, 796
ninth, 816
second, 793
seventh, 811
sixth, 810
tenth, 819
third, 794
twelfth, 823
sutures, 205
Cranium, 164
congenital fissures in, 188
development of, 187
lymphatics of, 682
Cremaster muscle, 452
formation of, 1184
Cremasteric artery, 629
fascia, 452
Crescents of Gianuzzi, 948
Crest, frontal, 171
of ilium, 272
lachrymal, 195
nasal, 189
occipital, 164
internal, 166
supra-mastoid, 174
turbinated, of palate, 198
of pubes, 277
of the superior maxillary, 192
of tibia, 293, 294
Cribriform fascia, 1193
plate of ethmoid, 185
Crico-arytenoid ligament, 1104
Crico-arytenoideus lateralis muscle, 1106
Crico-thyro-arytenoid ligament, 1103
Crico-thyroid artery, 552
ligament, 1104
membrane, 1103
muscle, 1105
Crico-tracheal ligament, 1104
Cricoid cartilage, 1101
Crista falciformis, 177, 928
galli, 185, 208
pubis, 277
terminalis, 1089
vestibuli, 921
Crossed pyramidal tract, 710
Crown of a tooth, 933
Crucial anastomosis, 636
ligaments of knee, 369
Cruciform ligament, 324
Crura of corpora cavernosa, 1151
of diaphragm, 445
of fornicis, posterior pillars, 761
Crural arch, 450, 1195
deep, 457, 1197
canal, 1197
nerve, anterior, 855
surgical anatomy of, 866
ring, 1198
sheath, 1196
septum, 1198
Crureus muscle, 510
Crus cerebri, 740, 742
penis, 1151
Crusta, 741, 742, 785
petrosa of teeth, 936
Cryptorchismus, 1162
Crypts of Lieberkühn, 1024, 1029
Crystalline lens, 904
Crystals, blood, 37

Cuboid bone, 303
Cul-de-sac of Douglas, 981
Culmen, 730
Cuneiform bone, foot, external, 306
internal, 305
middle, 305
hand, 264
cartilages, 1102
Cupola of cochlea, 923
Curvatures of the spine, 161
Curves of rectum, 1039
Cuspidate teeth, 933
Cutaneous branches of accessory obturator, 855
of anterior tibial nerve, 865
of arm, musculo-cutaneous, 839
internal, 839
lesser internal, 840
of buttock and thigh, 862
of cervical plexus, 831
of circumflex, 839
of dorsal nerve of penis, 861
of dorsal nerves, 848
of external popliteal, 865
of ilio-hypogastric, 851
of ilio-inguinal, 851
of inferior hæmorrhoidal nerve, 861
of inguinal region, 1193
of intercostal nerves, 848
of internal popliteal, 863
of ischio-rectal region, 1201
from obturator, 854
of lesser sciatic nerve, 862
of lumbar nerves, 849
of median, 841
of musculo-spiral, 844
of patella, 856
of perineal nerve, 861
of plantar nerve, 864
of posterior tibial, 863
of radial, 844
of sacral nerves, 857
of thigh, external, 852
internal, 856
middle, 856
of ulnar nerve, 842
Cuticle of skin, 89
Cuticula dentis, 940
Cutis vera, 91
Cuvier, ducts of, 131
Cystic artery, 611
duct, 1064, 1065
valve of, 1065
plexus of nerves, 877
veins, 677

D.

Dartos, 1154
Decidua, 114
reflexa, 114
serotina, 114
vera, 114
Deciduous teeth, 932
Decline, 730
Decussation of fillet, 719
of optic nerves, 794
of pyramids, 710
Deep crural arch, 457, 1197
palmar arch, 598
perineal fascia, 463, 1204
Deferent artery, 622
Deglutition, actions of, 423
Deltoid aponeurosis, 471
muscle, 471
tubercle, 239
Demilunes of Heidenhain, 948
Démours, membrane of, 892
Dendrites, 70, 737, 787, 788
Dental artery, anterior, 562
inferior, 561
posterior, 562
canal, anterior, 191
inferior, 203
posterior, 190
furrow, 938
germ, common, 938
special, 939
groove, 938
lamina, 938
nerves, anterior, 802
inferior, 807
middle, 802
posterior, 802
pulp, 935
ridges, 938
sacs, 940
tubuli, 936
vein, inferior, 653
Dentate nucleus, 710, 717
Denticulate lamina of cochlea, 924
Dentinal sac, 942
sheath, 937
Dentine, 935
formation of, 941
Depressions of Pacchionian bodies, 169
Depressor alæ nasi, 399
anguli oris, 401
epiglottidis, 1107
labii inferioris, 401
Derma, or true skin, 91
Descemet, membrane of, 892
Descendens, hypoglossi nerve, 825
Descending aorta, 605
colon, 1035
oblique muscle of abdomen, 448
Descent of testicle, 1161
Development of alimentary canal and its appendages, 132
arteries, 128
atlas, 153
axis, 154
bone, 59
carpus, 271
clavicle, 241
coccyx, 160
cranium, 117, 187
ear, 124
ethmoid, 187
eye, 122
face, 117
femur, 290
fibula, 298
foot, 308
frontal bone, 173
genital organs, 137
hand, 271
heart, 126
humerus, 252
hyoid bone, 227
inferior turbinated bone, 200
lachrymal bone, 196
lens, 122
Development of lower jaw, 204
lumbar vertebræ, 152
malar bone, 197
mammæ, 125
metacarpus, 272
metatarsus, 309
muscles, 126
nasal bone, 189
nervous centres, 120
nose, 125
occipital bone, 167
os innominatum, 278
Organs, Chronological Table of, 141
palate, 119
bone, 199
parietal bone, 170
patella, 292
peritoneum, 967
permanent teeth, 942
phalanges of foot, 309
of hand, 272
radius, 260
ribs, 235
sacrum, 158
scapula, 246
seventh cervical, 154
skin, 125
sphenoid, 184
spine, 115
sternum, 231
superior maxillary bone, 194
tarsus, 308
temporal bone, 179
temporary teeth, 938
tibia, 296
ulna, 258
veins, 130
vertebræ, 152
vomer, 201
Wormian, 188
Diameters of pelvis, 280
Diaphragm, 444, 995
development of, 134
lymphatics of, 692
Diaphysis, 64
Diarthrosis, 315
Digastric fossa, 176
muscle, 413
nerve, from facial, 813
Digestion, organs of, 930
Digital arteries from plantar, 647
from ulnar, 604
fossa, 285, 1156
nerves, from median, 841
from radial, 844
from ulnar, 842
Dilatator naris, anterior, 399
posterior, 399
Diploë, 144
veins of, 655
Direct inguinal hernia, 1189
course of, 1190
coverings of, 1190
pyramidal tract, 710
Discus proligerus, 100, 1177
Disks, blood, 36
Dissection of abdominal muscles, 447
arm, 475
auricular region, 393
axilla, 466
back, 428
epicranial region, 391
eye, 894

Dissection of face, 394
femoral hernia, 1190
foot, 528
forearm, 478
gluteal region, 514
hand, 489
heart, left auricle, 1091
left ventricle, 1092
right auricle, 1088
right ventricle, 1089
hernia, femoral, 1191
inguinal, 1180
iliac region, 503
inferior maxillary region, 400
infrahyoid region, 411
inguinal hernia, 1180
intermaxillary region, 401
ischio-rectal region, 1201
leg, 520
lingual region, 415
neck, 406
orbit, 396
palatal region, 421
palm of hand, 490
palpebral region, 394
pancreas, 1067
pectoral region, 466
perineum, 1201
pharynx, 419
pterygoid muscles, 404
radial region, 483
scalp, 391
sole of foot, 529
spinal cord and membranes, 693
suprahyoid region, 413
temporal muscle, 403
thigh, back of, 518
front of, 505
inner side of, 511
Diverticulum, Vateri, 1070
Division of cells, 39
direct, 41
indirect, 41
Dorsal artery of penis, 624
nerve of penis, 861
nerves, 845
anterior divisions of, 846
peculiar, 848
posterior divisions of, 845
roots of, 845
vein of penis, 673
vertebræ, 149
peculiar, 151
Dorsales pollicis arteries, 600
Dorsalis chorda, 968
hallucis artery, 644
indicis, 600
linguæ, 553
pedis, 643
branches of, 644
peculiarities of, 643
surface marking of, 643
surgical anatomy of, 643
scapulæ, 592
Dorsi-lumbar nerve, 849
Dorsi-spinal veins, 668
Dorsum of scapula, 243
ephippii or sellæ, 181
Douglas, pouch of, 981, 988
semilunar fold of, 455
Ducts or duct, of Bartholin, 948
biliary, 1062, 1063
common bile-, 1064
of Cowper's glands, 1147
Ducts or duct of Cuvier, 131
cystic, 1064, 1065
ejaculatory, 1160
galactophorous, 1179
of gall-bladder, 1865
of Gartner, 139
hepatic, 1057, 1063
of kidney, 1134
lactiferous, 1179
lymphatics, 681
nasal, 911
of pancreas, 1070
parotid, 945
Rivini, 948
seminal, 1160
Stenson's, 946
thoracic, 680
vitelline, 967, 970
Wharton's, 947
Ductless glands:
spleen, 1073
suprarenal capsule, 1137
thyroid, 1122
thymus, 1124
Ductus arteriosus, 540, 1097
how obliterated in fœtus, 1099
choledochus, 1064
endolymphaticus, 921, 926
pancreaticus, 1070
accessorius, 1070
Rivini, 948
Santorini, 1070
venosus, Arantii, 1050
how obliterated, 1099
Duodenal fossæ, 994
glands, 1024
loop, 969
Duodeno-jejunal flexure, 1008
fossa, 995
Duodenum, 1008
fixation of, 1018
relations of, 1011, 1014
types of, 1009
Dura mater of cord, 693
peculiarities of, 693

E.

Ear, 912
arteries of, 915, 920, 927
auditory canal, 914
cochlea, 922
internal, or labyrinth, 921
membranous labyrinth, 926
muscles of auricle, 913
of tympanum, 918
ossicula of, 918
pinna, or auricle of, 912
semicircular canals, 922
surface form of, 915
surgical anatomy of, 928
tympanum, 916
vestibule, 921
Earthy constituents of bone, 59
Ectoderm, 104
Efferent nerves, 75
Eighth nerve, 815
surgical anatomy of, 816
Ejaculator seminis muscle, 461
Ejaculatory ducts, 1160
Elastic lamina of cornea, 893
Elbow, anastomoses around, 597
bend of, 593
joint, 349
Elbow, surface form of, 352
surgical anatomy of, 352
vessels and nerves of, 351
Eleidin, 90
Eleventh nerve, 823
surgical anatomy of, 823
Embryo, first rudiments of, 107
Eminence of aquæductus Fallopii, 917
canine, 190
frontal, 171
ilio-pectineal, 277
nasal, 171
parietal, 168
Eminences and depressions of bones, 144
Eminentia articularis, 174
cinerea, 724
collateralis, 759, 765
Emissary veins, 661
Enamel epithelium, 940
germ, 939
neck of, 939
organ, 939, 940
pulp, 940
of teeth, 937
formation of, 940
Enarthrosis, 317
Encephalon, 706
weight of, 789
End-bulbs of Krause, 76
End-plates, motorial, of Kühne, 78
Endolymph, 927
Endomysium, 65
Endoneurism, 74
Endothelium, 44
Ensiform appendix, 228
Entoderm, 104
Epencephalon, 706
Ependyma, 755
Epiblast, 104
Epidermis, development of, 125
structure of, 89
Epididymis, 1159
development of, 125
Epigastric artery, deep, 629
peculiarities, 630
relation to femoral ring, 1198
with internal ring, 1186
superficial, 635
superior, 587
plexus, 875
region, 955
vein, 672
superficial, 670
Epigastrium, 960
Epiglottic glands, 1108
Epiglottis, 1102
tubercle or cushion of, 1102
Epimysium, 65
Epineurium, 74
Epiphysial cartilage, 64
Epiphysis, 64, 144
cerebri, 748
Epithelial floor of ventricle, 768
sheath of Hertwig, 941
wall of descending cornu, 768
Epithelium, 41
ciliated, 43
columnar, 43
enamel, 940
external, 940
internal, 940

Epithelium pavement, 42
spheroidal or glandular, 43. See *Various Organs.*
stratified, 44
Epoöphoron, 1177
Erectile tissue of penis, 1151
its structure, 1151
Erector clitoridis, 465
penis, 462
spinæ, 434
Eruption of the teeth, 942
Erythroblasts, 55
Ethmo-frontal suture, 208
Ethmo-sphenoidal suture, 208
Ethmoid bone, 185
articulations of, 187
cribriform plate of, 185
development of, 187
lateral masses of, 186
os planum of, 186
perpendicular plate of, 186
unciform process of, 186
Ethmoidal artery, 569
canal, anterior, 172
posterior, 172
cells, 186
notch, 172, 186
process of inferior turbinated, 200
spine, 180
Eustachian tube, 179, 917
surgical anatomy of, 952
valve, 1089
in fœtal heart, 1096
Excretory apparatus of liver, 1063
Expiration, muscles of, 444
Exstrophy of bladder, 959
Extensor brevis digitorum muscle, 530
carpi radialis brevior, 484
longior, 484
ulnaris, 486
coccygis, 438
communis digitorum (hand), 485
indicis, 488
longus digitorum (foot), 521
minimi digiti, 483
ossis metacarpi pollicis, 486
proprius hallucis, 521
pollicis, 488
External abdominal ring, 457, 1182
annular ligament, 529
and inferior frontal artery, 572
inguinal hernia, 1186
orbital foramina, 183
pterygoid plate, 183
spermatic fascia, 1182
sphincter ani, 458
Extrinsic muscles of tongue, 417
Eye, 890
appendages of, 907
aqueous humors of, 903
chambers of, 903
ciliary muscle, 898
processes of, 895
choroid, 894
conjunctiva, 908
cornea, 892
crystalline lens, 904
elastica lamina of cornea, 893
hyaloid membrane, 903
Eye, humors of, 903
iris, 896
Jacob's membrane, 901
membrana pupillaris, 898
pupil of, 896
retina, 898
sclerotic, 891
surgical anatomy of, 905
tunics of, 890
uvea of, 896
vessels of globe of, 905
vitreous humors of, 903
Eyeball, muscles of, 396
nerves of, 905
vessels of, 905
Eyebrows, 907
Eyelashes, 907
Eyelids, 907
cartilages or plates of, 908
Meibomian glands of, 908
muscles of, 390
tarsal ligament of, 908
Eye-teeth, 932

F.

Face, arteries of, 554
bones of, 163, 188
development of, 117
lymphatics of, 682
muscles of, 390
nerves of, 811
veins of, 650
Facial artery, 554
peculiarities of, 556
surgical anatomy of, 556
transverse, 559
bones, 188
nerve, 811
surgical anatomy of, 815
vein, 652
surgical anatomy of, 652
Falciform ligament of liver, 971, 1053
process of fascia lata, 508
Fallopian tubes, 1174
development of, 138
fimbriated extremity of, 1174
lymphatics of, 689
nerves of, 1178
structure of, 1174
vessels of, 1178
False ligaments of bladder, 1143
pelvis, 280
ribs, 232
Fangs of teeth, 932
Fascia, anal, 1210
dentata, 763, 765
Fasciæ of arm, 475
cervical, deep, 407
superficial, 407
of Colles, 460
costo-coracoid, 468
of cranial region, 391
cremasteric, 452
cribriform, 1193
deep, 390
dorsal, of foot, 530
fibro-areolar, its structure, 389
general description of, 388
iliac, 503
infundibuliform, 1186
intercolumnar, 452, 1182
intercostal, 441
intermuscular, of arm, 475
Fasciæ, intermuscular, of foot, 529
ischio-rectal, 1210
lata, 1193
falciform process of, 1194
iliac portion, 508, 1193
pubic portion, 508, 1194
of leg, 521
deep transverse, 524
lumborum, 433
of mamma, 465
masseteric, 403
of neck, 406
obturator, 1209
palmar, 490
parotid, 403, 408
pelvic, 1209
perineal, deep, 1204
superficial, 1204
plantar, 529
of foot, 529
of forearm, 478
of hand, 490
propria of femoral hernia 1191
recto-vesical, 1210
spermatic, 450, 1182
superficial, 389
of inguinal region, 1180
of ischio-rectal region, 1201
of thigh, 506
temporal, 403
of thigh, deep, 506
superficial, 506
of thorax, 441, 466
visceral layer of pelvic, 121
Fasciculus, 700
longitudinal, inferior, 786
superior, 786
perpendicular, 786
of Turck, 700
uncinate, 786
Fasciola cinerea, 765
Fat, 50
Fat-cells, 50
Fauces, isthmus of, 944
Fecundation of ovum, 107
Female organs of generation:
bulbi vestibuli, 1166
carunculæ myrtiformes, 1165
clitoris, 1164
development of, 138
fossa navicularis, 1164
glands of Bartholin, 1165
hymen, 1165
labia majora, 1163
minora, 1164
nymphæ, 1164
uterus, 1167
vagina, 1166
vestibule, 1165
Femoral artery, 630
branches of, 635
common, 631
deep, 635
peculiarities of, 633
superficial, 632
surface marking of, 633
surgical anatomy of, 633
or crural canal, 1198
variation in size of, according to position of limb, 1198
cutaneous nerve, 862
hernia, complete, 1200

Femoral hernia, coverings of, 1199
descent of, 1199
dissection of, 1191
incomplete, 1199
seat of stricture, 1200
surgical anatomy of, 1191
position of surrounding parts, 1198
region, muscles of, anterior, 505
internal, 511
posterior, 518
ring, 1198
sheath, 1196
spur, 289
vein, 672
relation of femoral ring, 1198
Femur, 284
articulations of, 290
attachment of muscles to, 290
condyles of, 288
development of, 290
fracture of, above condyles, 537
below trochanters, 537
head of, 284
neck of, 284
structure of, 288
surface form of, 290
surgical anatomy of, 290
trochanters of, 285
Fenestra ovalis, 916
rotunda, 916, 923
Fenestrated membrane of Henle, 81
Ferrein, pyramids of, 1131
Fibre-cells, contractile, 68
Fibres, association, 785, 786
of cerebellum, 735
collateral, 700, 787
commissural, 785, 786
of Müller, 901
of muscle, 67
of nerves, 69
peduncular, 785
projection, 785
Fibrin, 33
ferment, 33
Fibrinogen, 33
Fibro-cartilage, 52
circumferential, 53
connecting, 53
interarticular, 53
stratiform, 53
yellow, 53
Fibro-cartilages, acromio-clavicular, 343
intervertebral, 320
of knee, 371
of lower jaw, 329
pubic, 340
radio-ulnar, 355
sacro-coccygean, 339
Fibro-serous membranes, 96
Fibrous cartilage, 52
connective tissue, 45
nervous matter, 69
rings of heart, 1094
tissue, white, 45
yellow, 45
Fibula, 297
articulations of, 298
attachment of muscles to, 299
development of, 298
Fibula, fracture of, with dislocation of the tibia, 538
surface form of, 299
Fibular region, muscles of, 527
Fifth nerve, 796
surface marking of, 809
surgical anatomy of, 809
Filiform papillæ of tongue, 880
Fillet, 718, 742, 743
Filum terminale of cord, 693, 695
Fimbriæ of Fallopian tube, 1174
First nerve, 792
surgical anatomy of, 793
Fissura prima, 783
Fissure or Fissures, auricular, 179
brain, 772
calcarine, 779
calloso-marginal, 778
cerebellum, 727–733
interlobular, 727, 728
collateral, 765, 779
congenital, in cranium, 188
dentate, 779
of ductus venosus, 1051
frontal, inferior, 791
superior, 791
Glaserian, 175, 916
great horizontal, of cerebellum, 727
longitudinal, of cerebrum, 772, 784
hippocampal, 763, 779
intraparietal, 791
left longitudinal, 1051
of liver, 1051
longitudinal, 790
parieto-occipital, 774, 779, 791
post-limbic, 780
precental, 778
pterygo-maxillary, 216
right longitudinal, 1051
of Rolando, 774, 790
sphenoidal, 182
spheno-maxillary, 216
spinal cord, 696, 697
antero-lateral, 697
-median, 696
lateral, 697
posterior intermediate, 697
postero-lateral, 697
-median, 696, 697
of Sylvius, 755, 774, 790
transverse, of cerebrum, 770
of liver, 1051
umbilical, 1051
for vena cava, 1052
vesical, 1052
Fixation of duodenum, 1018
of liver, 1056
of small intestine, 1020
of spleen, 1026
of stomach, 1003
Flat bones, 143
Flexor accessorius muscle, 532
brevis digitorum, 530
hallucis, 532
minimi digiti (foot), 533
(hand), 495
pollicis, 492
carpi radialis, 479
ulnaris, 480
digitorum sublimis, 480
profundus, 481
longus digitorum, 527
Flexor longus hallucis, 525
pollicis (hand), 482
ossi metacarpi pollicis, 494
Flexure, duodeno-jejunal, 1008
hepatic, 1035
sigmoid, 1036, 1044
splenic, 1036
Floating ribs, 232
Flocculus, 732
Flood's ligament, 346
Floor, epithelial, of ventricle, 768
of fourth ventricle, 711, 720, 723
of third ventricle, 745, 750
Fluids of the body, 33
Fœtus, circulation in, 1097
Eustachian valve in, 1096
foramen ovale in, 128, 1096
liver of, distribution of its vessels, 1097
ovaries in, 138
vascular system in, peculiarities, 1097
Fold of Douglas, 455
Folds, aryteno-epiglottic, 1104
genital, 140
of Houston, 1041
interarytenoid, 1104
recto-uterine, 1169
recto-vesical, 1142
vesico-uterine, 1169
Folium cacuminis, 730
Follicle of hair, 93
Follicles, Graafian, 1176
sebaceous, 94
Fontana, spaces of, 893
Fontanelles, 167, 188
Foot, arteries of, 643
bones of, 299
development of, 308
dorsum, muscles of, 530
fascia of, 530
ligaments of, 528, 529
nerves of, 863
sole of, muscles of, 529
fascia of, 529
surface form of, 310
surgical anatomy of, 311
veins of, 670
Foramen cæcum, 709
of frontal bone, 171, 208
of tongue, 880
carotid, 178
centrale cochleæ, 928
condyloid, 165
dental inferior, 203
ethmoidal, 209
faciale, 928
incisive, 213
infraorbital, 190
jugular, 211
lacerum anterius, 210
posterius, 211
magnum, 165
of Majendie, 740
mastoid, 175
medium, 211
mental, 202
of Monro, 708, 751, 752, 761
obturator, 278
optic, 183, 210
ovale of sphenoid, 182
palatine, anterior, 194, 211
posterior, 198, 213

Foramen, parietal, 169
pterygo-palatine, 182
rotundum, 182, 210
sacro-sciatic, 275, 337
of Scarpa, 194, 213
of Sömmerring, 898
spheno-palatine, 199, 221
spinosum, 182, 210
of Stenson, 194, 213
sternal, 229
stylo-mastoid, 178
supraorbital, 171
thyroid, 278
Vesalii, 182, 210
of Winslow, 975, 992
Foramina of diaphragm, 446
external orbital, 182
malar, 196
olfactory, 185
sacral, 156
Thebesii, 678, 1088
Forceps, major, 757, 758
minor, 757, 758
Forearm, arteries of, 597
bones of, 254
fascia of, 478
lymphatics of, 684
muscles of, 478
nerves of, 838
veins of, 662
Fore-brain, 706, 707
Form of bones, 143
Formatio reticularis of medulla, 713, 714, 715, 718
of pons, 721
Fornix, 753, 760–762
anterior pillar, 748, 750, 761
conjunctivæ, 908
Fossa acetabuli, 278
of antihelix, 912
canine, 190
condyloid, 165
digastric, 176
digital, 285, 1156
duodeno-jejunal, 995
glenoid, 174
of helix, 912
ileo-cæcal, 997
ileo-colic, 997
iliac, 274
incisive, 190, 202
infra- and supraspinous, 244
inguinal, 964, 1190
innominata, 912
intersigmoid, 996
ischio-rectal, 1201
jugular, 179
lachrymal, 172
myrtiform, 190
navicularis of urethra, 1146
of vulva, 1164
occipital, 165
olfactory, of fœtus, 125
ovalis, 1089
palatine, anterior, 194
pericæcal, 997
phrenico-hepatic, 994
pituitary, 180
pterygoid, of sphenoid, 183
of lower jaw, 204
rhomboidalis, 723
scaphoid, 183
scaphoidea, 912
sigmoidea, 176
singulare, 928
Fossa of skull, anterior, 208
middle, 210
posterior, 211
spheno-maxillary, 216
subcæcal, 997
sublingual, 202
submaxillary, 203
subscapular, 243
subsigmoid, 996
temporal, 215
of Trietz, 995
triangularis, 1102
trochanteric, 285
venæ cavæ, 1052
vesicalis, 1050, 1052
zygomatic, 216
Fossæ, duodenal, 994
nasal, 219, 889
retro-peritoneal, 994
of skull, 208
Fourchette, 1164
Fourth nerve, 796
surgical anatomy of, 796
ventricle, 708, 737–740
Fovea, boundaries of, 738
centralis retinæ, 898
femoralis, 1198
hemispherica, 921
inferior, 724
larynx, 1101
roof of, 738
semi-elliptica, 921
superior, 724
Fracture of acromial end of clavicle, 500
acromion process, 500
centre of clavicle, 499
coracoid process, 500
coronoid process of ulna, 501
femur above condyles, 537
below trochanters, 537
fibula, with dislocation of tibia, 538
humerus, anatomical neck, 500
shaft of, 500
non-union of, 253
surgical neck, 500
neck of femur, 537
olecranon process, 501
patella, 537
Pott's, 538
radius, 501
lower end of, 502
neck of, 501
shaft of, 501
and ulna, 502
Frænula cerebellum, 729
Frænulum cerebellum, 734
Frænum clitoridis, 1164
labii superioris et inferioris, 931
linguæ, 879
præputii, 1151
Frontal artery, 570
bone, 170
articulations of, 173
attachment of muscles to, 173
development of, 173
structure of, 173
crest, 171
eminence, 171
nerve, 798
process of malar, 196
sinuses, 173
Frontal suture, 171, 173
vein, 651
Fronto-nasal process, 119
Fronto-sphenoidal suture, 206, 207
Fundus of bladder, 1142
of uterus, 1168
Fungiform papillæ of tongue, 880
Funiculi of nerve, 73
Funiculus cuneatus, 710, 711, 714
gracilis, 710, 711, 714
of Rolando, 710, 711, 714
solitarius, 718
teres, 724
Furrow, auriculo-ventricular, 1087
dental, 938
genital, 140
interventricular, 1087
labio-dental, 938
posterior intermediate, 697

G.

Galactophorous ducts, 1179
Galen, veins of, 657
Gall-bladder, 1064
development of, 134
ducts of, 1065
nerves of, 1064
relations of, 1064
structure of, 1065
surface form of, 1065
vessels of, 1064
Ganglion or ganglia, general anatomy of, 79
of Andersch, 816
Arnold's, 807
of Bochdalek, 802, 804
cardiac, 874
carotid, 869
cephalic, 799
cervical inferior, 892
middle, 892
superior, 869
ciliary, 799
on circumflex nerve, 839
diaphragmatic, 875
on facial nerve, 811
of fifth nerve, 799
Gasserian, 797
of glosso-pharyngeal, 816
impar, 867, 874
intercarotid, 872
jugular, 816
lateral root of eighth nerve, 815
lenticular, 799
lingual, 872
lumbar, 873
Meckel's, 803
mesenteric, 877
ophthalmic, 799
otic, 807
petrous, 817
pharyngeal, 871
of pneumogastric, 819
of portio dura, 811
on posterior interosseous nerve, 844
of Ribes, 871
of root of vagus, 820
sacral, 871

Ganglion or ganglia, semilunar, of abdomen, 875
of fifth nerve, 797
spheno-palatine, 803
of spinal nerves, 827
spirale, 928
submaxillary, 808
suprarenal, 875
of sympathetic nerve, 867
temporal, 872
thoracic, 872
thyroid, 872
of trunk of vagus, 820
of Wrisberg, 874
Ganglionic branch of nasal nerve, 799
Gartner, duct of, 139
Gases of the blood, 37
Gasserian ganglion, 797
Gastric arteries (vasa brevia), 612
artery, 611
follicles, 1006
glands, 1006
nerves from vagus, 822
plexus, 877
vein, 676
Gastrocnemius muscle, 522
Gastro-colic omentum, 991
Gastro-duodenal artery, 611
plexus, 877
Gastro-epiploic plexus, 877
veins, 676
Gastro-epiploica dextra artery, 611
sinistra, 612
Gastro-splenic omentum, 971, 991, 1076
Gelatinous connective tissue, 48
nerve-fibres, 72
Gemellus inferior muscle, 517
superior muscle, 517
Generative organs, development of, 137
female, 1163
male, 1148
Genial tubercles, 202
Geniculate bodies, 743
ganglion, 811
Genio-hyo-glossus muscle, 415
Genio-hyoid muscle, 414
Genital cord, 136
corpuscles, 76
folds, 140
furrow, 140
tubercle, 140
Genito-crural nerve, 852
Genu of the corpus callosum, 756, 758
of the internal capsule, 760
Gerlach's nerve network, 702
Germ, common dental, 938
special dental, 939
Germinal area, 103
disk, 103
spot, 101
vesicle, 101
Giacemini, band of, 765
Giant cells, 55
Gianuzzi, crescents of, 948
Gimbernat's ligament, 448, 1183
Ginglymus, 316
Giraldès, organ of, 139
Girdle, pelvic, 238
shoulder, 238
Glabella of frontal bone, 171, 217
Gladiolus, 229
Gland or glands, accessory, of parotid, 947
agminated, 1025
arytenoid, 1108
of Bartholin, 1165
Brunner's, 1024
buccal, 931
circumanal, 1040
coccygeal, 617
Cowper's, 1150, 1205
development of, 125
ductless, spleen, 1073
suprarenal, 1137
thymus, 1124
thyroid, 1122
duodenal, 1024
epiglottic, 1108
gastric, 1006
of Havers, 314
labial, 931
lachrymal, 909
of larynx, 1108
of Lieberkühn, 1024
lingual, 882
of Littré, 1147
of Luschka, 617
lymphatic, 87
mammary, 1178
Meibomian, 908
mucilaginous, of Havers, 314
odoriferæ, 1150
œsophageal, 953
of Pacchioni, 657
palatal, 944
parotid, 945
peptic, 1006
Peyer's, 1025
pharyngeal, 951
prostate, 1148
pyloric, 1006
salivary, 945
sebaceous, 94
secreting, 98
solitary, 1025, 1029
sublingual, 948
submaxillary, 947
sudoriferous, 95
suprarenal, 1137
thymus, 1124
thyroid, 1122
tracheal, 1111
of Tyson, 1150
uterine, 1172
of vulva, 1166
Glandulæ odoriferæ, 1150
Pacchioni, 657
Glans penis, 1150
clitoridis, 1165
Glaserian fissure, 174, 916
Glenoid cavity, 245
fossa, 174
ligament of Cruveilhier, 361
of phalanges, 361
of shoulder, 346
Gliding movement, 318
Glisson's capsule, 982, 992
Globules, blood-, 34
development of, 127
Globus major of epididymus, 1158
minor, 1158
pallidus, 760
Glosso-epiglottidean ligaments, 879,
Glosso-pharyngeal nerve, 816
Glottis, rima of, 1104
Gluteal aponeurosis, 515
artery, 627
inferior, 626
lines, 272, 273
lymphatic glands, 686
nerve, inferior, 861
superior, 861
region, lymphatics of, 689
muscles of, 514
ridge, 286
Gluteus maximus muscle, 514
medius, 515
minimus, 516
Goblet cells, 43
Golgi, organs of, 78
Goll's column, 700
Gomphosis, 315
Graafian follicles, 1176
membrana granulosa of, 1176
ovicapsule of, 1176
structure of, 1176
Gracilis muscle, 511
Gray nervous matter, 69
of spinal cord, 701
Great omentum, 971, 973, 975, 991
sciatic nerve, 862
surgical anatomy of, 866
Greater wings of sphenoid, 182
Groove, auriculo-ventricular, 1087
basilar, 720, 721
bicipital, 248
cavernous, 181
dorso-lateral, 709, 717
infraorbital, 191
lachrymal, 192
longitudinal, floor of fourth ventricle, 723
mylo-hyoid, 203
nasal, 189
occipital, 176
optic, 180
primitive dental, 938
subclavian, 234
ventro-lateral, 709, 717
Grooves in the radius, 260
interventricular, 1087
Growth of bones, 63
Gubernaculum dentis, 942
testis, 1161
Gudden, commissure of, 793
Gums, 932
Gustatory nerve, 807
Gyrus or Gyri, 772, 773
dentate, 782
fornicatus, 779, 792
fillet of, 786
operati, 778
supracallosal, 782
uncinate, 781

H.

Habenula, 749
Hæmatoidin crystals, 37
Hæmin crystals, 37
Hæmoglobin, 34
crystals, 37
Hæmorrhoidal artery, inferior, 625
middle, 622
superior, 615

Hæmorrhoidal nerve, inferior, 861
plexus of nerves, 878
veins, inferior, 672
middle, 672
superior, 672
venous plexus, 674, 675
surgical anatomy of, 672
Hair-cells of internal ear, 926
Hair-follicles, 93
Hairs, 93
root-sheath of, 93
shaft of, 94
structure of, 93
Hamstring tendons, surgical anatomy of, 520
Hamular process of humerus, 250, *note*.
of lachrymal, 195
of sphenoid, 183
Hamulus, 924
Hand, arteries of, 601
bones of, 262
fascia of, 489
ligaments of, 356, 357
muscles of, 489
nerves of, from median, 839
from radial, 844
from ulnar, 841
surface form of, 270, 497
veins of, 662
Hard palate, 944
Hasner, valve of, 911
Haustrum, 1028
Havers, glands of, 314
Haversian canals of bone, 56
Head, lymphatics of, 681
muscles of, 390
veins of, 650
Heart, 1086
annular fibres of auricles, 1094
arteries of, 545, 1095
deep fibres of auricles, 1094
development of, 126
endocardium, 1094
fibres of the auricles, 1094
of the ventricles, 1094
fibrous rings of, 1094
fœtal relics in, 1088
infundibulum of, 1089
left auricle, 1091
ventricle, 1092
looped fibres of auricles, 1094
lymphatics of, 692, 1096
muscular fibres of, 67
structure of, 1094
nerves of, 821, 874, 1095
position of, 1086
right auricle, 1088
ventricle, 1089
septum ventriculorum, 1089
size and weight, 1087
structure of, 1094
subdivision into cavities, 1087
superficial fibres of auricles, 1094
surface-marking of, 1096
veins of, 677
vortex of, 1095
Heidenhain, demilunes of, 948
Helicis major muscle, 914
minor, 914
Helicotrema of cochlea, 923
Helix, 912
fossa of, 912
Helix, muscles of, 913
process of, 913
Hemisphere vesicles, 707
Hemispheres, cerebellum, 725, 727
cerebrum, 752
development, 752
gray matter, 786
cortex, 786
structure, 785–788
surface aspect, 771–785
white matter, 785, 786
Henle, looped tubes of, 1130
Henle's layer of hair-follicle, 94
Hepatic artery, 611, 1057
cells, 1060
duct, 1057, 1063
flexure, 1035
plexus, 877
veins, 675, 1057, 1061
Hepatico-gastric omentum, 979, 991
-renalis recessus, 1012
Hernia, congenital, 1189
direct inguinal, 1189
dissection of, 1190
encysted, 1189
femoral, coverings of, 1199
descent of, 1199
of funicular process, 1189
infantile, 1189
inguinal, 1180
dissection of, 1186
oblique inguinal, 1187
scrotal, 1189
Hesselbach's triangle, 1190
Hiatus Fallopii, 177
Highmore, antrum of, 192
Hilton's muscle, 1107
Hilum of kidney, 1128
Hind-brain, 706, 724
Hinge-joint, 316
Hip-joint, 362
muscles of, 514
in relation with, 365
surface form of, 366
surgical anatomy of, 366
Hippocampus major, 759, 763
minor, 758
Horizontal plate of ethmoid, 185
of palate, 197
Horner's muscle, 395
Houston's folds of rectum, 1041
Howship's lacunæ, 55
Huguier, canal of, 175
Humerus, 248
anatomical neck, fracture of, 500
articulations of, 252
attachment of muscles to, 252
development of, 252
head of, 248
neck of, 248
nutrient artery of, 596
shaft of, fracture of, 500
surgical anatomy of, 253
tuberosities of, greater and lesser, 248
Humors of the eye, 903
Hunter's canal, 630
Huxley's layer of hair-follicle, 94
Hyaline cartilage, 51
Hyaloid membrane of eye, 903
Hydatid of Morgagni, 138
Hymen, 1165
Hyo-epiglottic ligament, 1103
Hyo-glossal membrane, 882
Hyo-glossus muscle, 416
Hyoid arch (fœtal), 119
artery of superior thyroid, 552
bone, 227
attachment of muscles to, 227
cornua of, 227
development of, 227
branch of lingual artery, 553
region, muscles of, infra-, 411
supra-, 413
Hypertrophy of prostate, 1159
Hypoblast, 104
Hypochondriac regions, 955
Hypogastric arteries in fœtus, 620, 1097
how obliterated, 1099
plexus, 877
Hypogastrium, 961
Hypoglossal nerve, 823
surgical anatomy of, 825
Hypophysis cerebri, 751
of pituitary body, 121

I.

Ileo-cæcal fossa, 997
valve, 1033
Ileo-colic artery, 614
fossa, 997
valve, 1033
Ileum, 1020
Iliac arteries, common, 618
peculiarities of, 618
surface-marking of, 619
surgical anatomy of, 619
external, 628
surface-marking of, 628
surgical anatomy of, 628
internal, 620
at birth, 621
peculiarity in the fœtus, 621
surgical anatomy of, 621
fascia, 503
fossa, 274
lymphatic glands, 689
portion of fascia lata, 503
region, muscles of, 503
veins, common, 673
peculiarities of, 673
external, 672
internal, 672
Iliacus muscle, 504
Ilio-costalis muscle, 434
Ilio-femoral ligament, 363
Ilio-hypogastric nerve, 851
Ilio-inguinal nerve, 851
Ilio-lumbar artery, 626
ligament, 336
vein, 674
Ilio-pectineal eminence, 277
Ilio-tibial band, 507
Ilium, 272
crest of, 275
dorsum of, 272
spines of, 272
venter of, 274
Impressio colica, 1050, 1052
duodenalis, 1050, 1052
gastrica, 1052
pylorica, 1050
renalis, 1050, 1052
suprarenalis, 1050, 1052

Incisive foramina, 213
fossa, 191, 202
pad, 944
Incisor teeth, 932
Incisura, 1100
cerebellum, 726
intertragica, 912
œsophageal, 1052
Santorini, 914
umbilicalis, 1049, 1052
vesicalis, 1049, 1052
Incremental lines of dentine, 937
Incus, 919
development of, 125
ligament of, 919
suspensory, 919
Infantile hernia, 1189
Inferior dental artery, 561
canal, 203
maxillary bone, 201
changes produced by age in, 204
meatus of nose, 221
occipital fossa, 166
peduncle of cerebellum, 702
profunda artery, 596
turbinated bones, 200
articulations of, 200
development of, 200
ethmoidal process of, 200
lachrymal process of, 200
maxillary process of, 200
vena cava, 673
Infracostal muscles, 442
Infraglenoid tubercle, 245
Inframaxillary nerves from facial, 815
Infraorbital artery, 562
branches of facial nerve, 814
canal, 191
foramen, 190
groove, 191
plexus of nerves, 801
Infraspinatus muscle, 473
Infraspinous fascia, 473
fossa, 244
Infratrochlear nerve, 799
Infundibula, 1119
of kidney, 1128
Infundibuliform fascia, 457, 1186
Infundibulum of brain, 750
of cochlea, 923
of ethmoid, 187
of heart, 1089
Ingrassias, processes of, 183
Inguinal canal, 1185
fossa, 964, 1190
glands, deep, 686
superficial, 686, 1181
hernia, 1186
dissection of, 1180
Inlet of pelvis, 281
Innominate artery, 545
peculiarities of, 546
surgical anatomy of, 546
bone, 272
articulations of, 278
attachment of muscles to, 279
development of, 278
veins, 665
peculiarities of, 665
Inorganic constituents of bone, 59
Inspiration, muscles of, 444
Interarticular fibro-cartilage, 53
of acromio-clavicular joint, 343
of jaw, 329
of knee, 370, 371
of radio-ulnar joint, 355
ligament of ribs, 334
Interarytenoid fold, 1104
Inter-brain, 706, 745–752
Intercarotid ganglion, 872
Intercellular substance of cartilage, 51
Interchondral ligaments, 334
Interclavicular ligaments, 341
Intercolumnar fascia, 450
fibres, 450, 1182
Intercondyloid notch, 288
Intercostal arteries, 606
anterior, 607
superior, 587
fasciæ, 442
lymphatic glands, 691
lymphatics, 692
muscles, 442
nerves, 846
spaces, 228
veins, superior, 666
Intercosto-humeral nerves, 840, 848
Interglobular spaces, 937
Interlobular arteries of kidney, 1134
biliary plexus, 1061
notch, 1049
vein, 1057, 1061
Intermaxillary suture, 217
Intermediate disk of muscular fibre, 66
Intermembranous ossification, 63
Internal annular ligament, 528
capsule, 785
carotid artery, 565
cutaneous nerve, 840
inguinal hernia, 1187
mammary artery, 586
vein, 666
maxillary artery, 559
branches of, 560
peculiarities of, 559
surgical anatomy of, 561
occipital crest, 166
pterygoid plate, 183
sphincter, 1041
Internasal suture, 217
Internodal segment of nerves, 71
Internodia or phalanges, 270
Interossei muscles, dorsal, of foot, 534
of hand, 496
palmar, 496
plantar, 534
Interosseous artery of foot, 644
of forearm, 601
membrane of forearm, 354
of leg, 377
nerve, anterior, 841
posterior, 844
veins of forearm, 664
Intersigmoid fossa, 896
Interspinales muscles, 438
Interspinous ligaments, 322
Intertransversales muscles, 438
Intertransverse ligaments, 322
Intertubular stroma of kidney, 1135
Intervertebral notches, 145
substance, 320
Intestinal canal, 1008
Intestine, development of, 133
large, coats of, 1027
lymphatics of, 691
small, 970, 1008
surface form of, 1045
surgical anatomy of, 1045
torsion of, 972
Intracartilaginous ossification, 60
Intralobular veins, 1057
Intrinsic muscle of tongue, 417
Intumescentia gangliformis, 811
Investing mass of Rathke, 118
Involuntary muscle, 78
Iris, 896
Irregular bones, 144
Ischiatic lymphatic glands, 686
Ischio-rectal fascia, 1210
fossa, 1202
position of vessels and nerves in, 1202
region, surgical anatomy of, 1201
Ischium, 275
body of, 275
ramus of, 276
spine of, 276
tuberosity of, 276
Island of Reil, 778
Isthmus cerebri, 740
of the fauces, 944
of thyroid gland, 1123
Iter a tertio ad quartum ventriculum, 744, 752
chordæ anterius, 916
posterius, 916
Ivory of tooth, 935

J.

Jacob's membrane, 901
Jacobson's cartilage, 888
nerve, 818, 921
canal for, 178
organ, 888
Jaw, lower, 201
articulations of, 204
attachment of muscles to, 204
changes produced in, by age, 204
condyle of, 204
development of, 204
ligaments of, 327, 328
oblique line of, 202
pterygoid fossa of, 204
rami of, 203
sigmoid notch of, 204
symphysis of, 202
upper. See *Maxillary Bone.*
Jejunum, 1020
Joint. See *Articulations.*
Jugular foramen, 211
fossa, 179
ganglion, 816
surface, 178
vein, anterior, 654
external, 653
surgical anatomy of, 653
internal, 654
sinus or gulf of, 654
surgical anatomy of, 655
posterior, external, 654

K.

Karyokinesis, 39
Karyomitosis, 39
Kidney, 1127
  calices, 1128
  cortical substance of, 1129
  development of, 135
  hilum of, 1128
  infundibula of, 1128
  labyrinth of cortex of, 1131
  lymphatics of, 690, 1135
  Malpighian bodies of, 1129
  mammillæ of, 1129
  medullary substance, 1129
  nerves of, 1134
  papillæ of, 1129
  pelvis of, 1128
  pyramids of Ferrein, 1131
  renal artery, 616, 1133
  sinus of, 1128
  surface-marking of, 1135
  surgical anatomy of, 1135
  tubuli uriniferi, 1130
  veins of, 675, 1134
  weight and dimensions, 1127
Knee-joint, 368
  surface form of, 374
  surgical anatomy of, 374
Krause's membrane, 66
  end-bulbs of, 76
Kühne's views on the terminations of motor nerves, 78

L.

Labia cerebri, 756
  pudendi majora, 1163
    minora, 1164
Labial artery, 556
  glands, 931
  veins, inferior, 652
    superior, 652
Labio-dental furrow, 938
  strand, 938
Labyrinth, 921
  arteries of, 927
  cortex of kidney, 1131
  fibro-serous membrane of, 926
Lachrymal apparatus, 909
  artery, 568
  bone, 195
    articulations of, 196
    attachment of muscles to, 196
    development of, 196
  canals, 910
  caruncula, 909
  crest, 195
  fossa, 172
  gland, 909
  groove, 192
  nerve, 798
  notch, 191
  papilla, 907, 910
  process of inferior turbinated bone, 200
  puncta, 910
  sac, 910
  tubercle, 193
Lacteals, 679
Lactiferous ducts, 1179
Lacuna magna, 1147
Lacunæ of bone, 58
  Howship's, 55
Lacus lachrymalis, 909
Lambda, 208
Lambdoid suture, 206
Lamella of bone, articular, 313
  horizontal, of ethmoid, 185
  perpendicular, of ethmoid, 186
Lamellæ of bone, 57
Lamina, 1101
  cinerea, 751
  of cornea, elastic, 893
  cribrosa, 177, 928
    of sclerotic, 893
  dental, 938
  fusca, 891
  medullary, 747
  posterior perforated, 745, 750
  quadrigemina, 743
  spiralis ossea of cochlea, 923
    membranacea, 925, *note.*
  suprachoroidea, 895
  terminalis, 751
  of the vertebræ, 144
  vitrea, 895
Laminæ dorsales, 107
Lancisi, nerves of, 757
Lanugo (fœtal hairs), 125
Large intestine, 1027
    cæcum, 1030
    colon, 1035
    ileo-cæcal valve, 1033
    muscular coat, 1041
    rectum, 1038
    relations of, 1036
    structure of, 1028
    vessels of, 1029
Laryngeal artery, inferior, 584
    superior, 552
  nerve, external, 821
    internal, 821
    recurrent, 821
    superior, 821
    surgical anatomy of, 822
    from sympathetic, 871
  pouch, 1105
  veins, 666
Laryngectomy, 1113
Laryngo-tracheotomy, 1112
Laryngotomy, 1112
Larynx, 1100
  actions of muscles of, 1107
  arteries of, 1108
  cartilages of, 1100
  cavity of, 1104
  glands of, 1108
  interior of, 1103
  ligaments of, 1102
  lymphatics of, 1108
  mucous membrane of, 1107
  muscles of, 1105
  nerves of, 1108
  rima glottidis, 1104
  superior aperture of, 1103
  surface form of, 1111
  surgical anatomy of, 1111
  veins of, 1108
  ventricle of, 1104
Lateral disk of muscular fibre, 66
  horn of spinal cord, 701
  ligaments of liver, 1053
  masses of ethmoid, 186
  recess, 734, 738, 739
  region of skull, 214
  sinus of brain, 658
  tract of medulla oblongata, 710
  ventricles, 755
Lateralis nasi artery, 556
Latissimus dorsi muscle, 430
Left lobe of liver, 1052
  longitudinal fissure of liver, 1051
Leg, arteries of, 641
  bones of, 291
  fascia of, 520
    deep transverse, 524
  ligaments of, 362
  lymphatics of, 686
  muscles of, 520
    back of, 522
    front of, 521
  nerves of, 859
  veins of, 670
Lemniscus, 718
Lens, 904
  changes produced in, by age, 904
  suspensory ligament of, 905
Lenticular ganglion, 799
Lesser lachrymal bone, 195
  omentum, 971, 991, 1053
  pancreas, 1070
  sac, 993
  sciatic nerve, 862
  wings of sphenoid, 183
Levator anguli oris, 400
    scapulæ, 431
  ani, 459
  glandulæ thyroidæ, 1123
  labii inferioris, 400
    superior alæque nasi, 400
    superioris, 400
  menti, 400
  palati, 421
  palpebræ, 395
Levatores costarum, 442
Lieberkühn, crypts of, 1024, 1029
  glands of, 1024
Lienculi, 1073
Ligament, structure of, 313
  acromio-clavicular, inferior, 343
    superior, 343
  alar, of knee, 372
  of ankle, anterior, 377
    lateral, 378
  annular, of ankle, 377
      external, 378
      internal, 378
    of radius, 353
    of wrist, anterior, 356
      posterior, 357
  anterior, of knee, 368
  arcuate, 444
  aryteno-epiglottic, 1102
  astragalo-navicular, 383
  atlanto-axial, anterior, 323
    posterior, 323
  of bladder, false, 1143
    true, 1142
  broad, of liver, 988, 1053
  calcaneo-astragaloid, external, 381
    internal, 381
    interosseous, 381
    posterior, 381
  calcaneo-cuboid, internal, 381
    long, 381
    short, 381
    superior, 381
  calcaneo-navicular, inferior, 382

Ligament, calcaneo-navicular, superior, 382
capsular. See *Individual Joints.*
carpo-metacarpal, dorsal, 357
interosseous, 358
palmar, 357
of carpus, 357
central, of spinal cord, 695
check, 326
chondro-sternal, anterior, 334
posterior, 334
common vertebral, anterior, 319
posterior, 319
conoid, 344
coraco-acromial, 344
coraco-clavicular, 343
coraco-humeral, 346
coracoid, 345
coronary, of liver, 979, 981, 988, 1053
costo-central, 330
anterior, 330
costo-colic, 1077
costo-transverse, 331
posterior, 332
superior, 331
anterior, 331
posterior, 331
costo-vertebral, or stellate, 330
cotyloid, 364
crico-arytenoid, 1104
crico-thyro-arytenoid, 1103
crico-thyroid, 1104
crico-tracheal, 1104
crucial, of knee, 369
cruciform, 324
deltoid, 378
dorsal. See *Individual Joints.*
of elbow, 349
anterior, 349
external lateral, 350
internal lateral, 350
posterior, 350
falciform, of liver, 971, 1053
Flood's, 346
Gimbernat's, 448, 1183, 1196
glenoid, 346
glosso-epiglottidean, 1102
of hip, 362
hyo-epiglottic, 1103
ilio-femoral, 363
ilio-lumbar, 336
of incus, 919
interarticular, of ribs, 331
interclavicular, 341
interchondral, 334
interosseous. See *Individual Joints.*
interspinous, 322
intertransverse, 322
intervertebral, 320
of jaw, 327
kerato-cricoid, 1104
of knee, 368
of larynx, 1102
lateral. See *Individual Joints.*
longitudinal, of liver, 1053
long plantar, 381
lumbo-iliac, 336
lumbo-sacral, 336
of Luschka, 1084
of malleus, 919
metacarpal, 361
metacarpo-phalangeal, 361
Ligament, metatarsal, 385
metatarso-phalangeal, 386
mucosum, of knee, 368
nuchæ, 430
oblique, 354
obturator, 516
occipito-atlantal, anterior, 325
lateral, 325
posterior, 325
occipito-axial, 326
odontoid, 326
lateral, 326
middle, 326
orbicular, 353
of ossicula, 919
of ovary, 1175
palpebral or tarsal, 908
of patella, 368
of pelvis, 336
of the phalanges, (foot), 387 (hand), 362
phreno-colic, 1036
of the pinna, 373
plantar, 385
posterior of knee, or posticum Winslowii, 368
Poupart's, 448, 1183, 1195
pterygo-maxillary, 402
pubic, anterior, 340
posterior, 340
superior, 340
radio-carpal, 356
radio-ulnar joint, inferior, 355
middle, 354
superior, 353
recto-uterine, 1169
of rectum, 1143
rhomboid, 341
round, of hip, 363
of liver, 983, 1053
of radius and ulna, 354
of uterus, 1177
sacro-coccygeal, anterior, 339
interarticular, 339
lateral, 339
posterior, 339
deep, 339
superficial, 339
sacro-iliac, anterior, 337
oblique, 337
posterior, 337
sacro-sciatic, greater, 337
lesser, 338
sacro-uterine, 1169
sacro-vertebral, 336
of scapula, 344
Schlemm's, 346
of shoulder-joint, gleno-humeral, 346
inferior, 346
middle, 346
superior, 346
stellate, 330
sterno-clavicular, anterior, 341
posterior, 341
sterno-pericardial, 1084
of sternum, 336
stylo-maxillary, 328
subpubic, 340
supraspinous, 321
suspensory, of incus, 919
of lens, 905
of liver, 1053, 1076
of malleus, 919
of mamma, 466
Ligament, suspensory, of spleen, 1150
sutural, 313
tarsal, of eyelids, 908
tarso-metatarsal, 384
of tarsus, 380
of thumb, 359
thyro-arytenoid, inferior, 1103
superior, 1105
thyro-epiglottic, 1103
thyro-hyoid, 1103
tibio-tarsal, 377
transverse, of atlas, 323
of hip, 361
of knee, 371
of scapula, 345
trapezoid, 344
of Treitz, 1018
triangular, of liver, 1053
of urethra, 1024
of tympanic bones, 919
of uterus, 1169
of vertebræ, 320
vesico-uterine, 1169
of Winslow, 368
of wrist, anterior, 356
lateral external, 356
internal, 356
posterior, 357
of Zinn, 397
Ligamenta alaria, 372
subflava, 321
suspensoria of mamma, 466
Ligamentum arcuatum externum, 445
internum, 444
coli, 1028
colico-lienale, 1077
coronarium hepatis, 988
cystico-duodenale, 989, 1012, 1054
denticulatum, 695
duodeno-mesocolicum, 1014
-pancreaticum, 971
-renale, 1012
gastro-hepaticum, 1053
-lienale, 1076
-pancreaticum, 994
hepato-colicum, 989, 1054
-duodenale, 971, 982, 989, 1000, 1054
-gastricum, 989
-gastro-duodenale, 971
-renale, 989, 1012, 1054
-umbilicalis, 1053
latum pulmonalis, 1114
lieno-gastricum, 985, 988
-pancreaticum, 986
-renale, 985, 1077
mesenterico-mesocolicum, 987
mucosum, 371
nuchæ, 430
pancreatico-lienale, 1077
patellæ, 368
pectinatum iridis, 896
phrenico-colicum, 988, 1077
-gastricum, 988
phreno-lienale, 975, 988, 1076
posticum Winslowii, 368
pyloricum, 1000, 1005
suspensorium, 326
duodeni, 1014
hepatis, 971, 988
lienis, 1076
teres, 364

Ligamentum venosum, 1051
Ligature of arteries. See each *Artery*.
Limbs, development of, 125
Limbus laminæ spiralis, 924
luteus, 898
Linea aspera, 286
eminens, 1101
gluteal, inferior, 273
middle, 273
superior, 272
ilio-pectinea, 274
quadrati, 286
splendens, 695
supracondylar, 287
suprema, 165
Lineæ semilunares, 456
transverse of abdomen, 456
Lingual artery, 553
surgical anatomy of, 553
bone, 227
ganglion, 872
nerve, 807
veins, 654
Lingualis muscle, inferior, 418
superior, 417
transverse, 418
vertical, 418
Lingula, 729
of sphenoid, 181
Lips, 930
arteries of, 556
Liquor amnii, 112
Cotunnii, 926
Scarpæ, 927
sanguinis, 36
Lissauer, tract of, 700
Lithotomy, parts avoided in operation, 1207
concerned in operation of, 1207
divided, in operation, 1207
Littré, glands of, 1147
Liver, 971, 1047
corset, 1053
development of, 134
distribution of vessels to, in fœtus, 1097
ducts of, 1064, 1065
excretory apparatus of, 1063
fissures of, 1051
fixation of, 1056
hepatic artery, 611, 1058
cells, 1058
duct, 1058
veins, 675, 1057
ligaments of, 1053
broad, 1053
coronary, 1053
falciform, 1853
lateral, 1053
longitudinal, 1053
round, 1053
suspensory, 1053, 1076
triangular, 1053
lobes of, 1052
caudate, 1052
left, 1052
quadrate, 1052
right, 1052
lobules of, 1059
lymphatics of, 690, 1058
nerves of, 877, 1058
peritoneal relations of, 1054
portal vein, 675
Liver, relations of, 1055
structure of, 1059
surface form of, 1065
surfaces of, 1049
surgical anatomy of, 1066
vessels of, 1060
Lobe or lobes, central, 729, 778
caudate, 1052
cuneate, 780
frontal, 753, 775
of kidney, 1128
limbic, 781
of liver, 1052
of lung, 1118
occipital, 753, 777, 780
olfactory, 782, 784
orbital, 775
paracentral, 780
parietal, 753, 776
of prostate, 1149
quadrate, 730, 780
of liver, 1052
of prostate, 730, 780
Spigelian, 1050, 1050
of testis, 1158
of thymus, 1125
of thyroid, 1123
temporal, 754, 777
temporo-sphenoidal, 777
Lobular bronchial tube, 1119
Lobule, 729
anterior crescentic, 730
slender, 731
biventral, 731
digastric, 731
of the ear, 912
fusiform, 781
inferior semilunar, 730
lingual, 781
pneumogastric, 733
posterior crescentic, 730
slender, 731
postero-inferior, 730
-superior, 730
quadrangular, 730
superior semilunar, 730
Lobules of cerebellum, 728–733
structure of, 728
of kidney, 1128
of liver, 1059
of lung, 1119
Lobuli testes, 1158
Lobulus centralis, 729
Locus cœruleus, 724
niger, substantia nigra, 744
Long bones, 143
saphenous nerve, 856
Longissimus dorsi muscle, 436
Longitudinal fissure of liver, 1051
ligament of liver, 1053
sinus of brain, inferior, 658
superior, 657
Loop, duodenal, 969
omega, 1044
umbilical, 969
Looped tubes of Henle, 1131
Lower extremity, arteries of, 630
bones of, 272
fascia of, 502
ligaments of, 362
lymphatics of, 686
muscles of, 502
nerves of, 849
surface form of, 535
Lower extremity, veins of, 670
Lower, tubercle of, 1088
Lumbar arteries, 617
fascia, 433
ganglia, 873
glands, 688
nerves, 849
anterior divisions of, 850
posterior divisions of, 849
roots of, 849
surgical anatomy of, 866
plexus of nerves, 850
vein, ascending, 674
veins, 674
vertebræ, 151
development of, 152
Lumbo-iliac ligament, 336
Lumbo-sacral ligament, 336
nerve, 850
Lumbricales muscles (foot), 532
(hand), 496
Lungs, 1116
air-cells of, 1119
bronchial arteries, 1120
veins, 1120
capillaries of, 1119
development of, 134
in fœtus, 1097
lobes and fissures of, 1117
lobules of, 1119
lymphatics of, 692, 1120
nerves of, 1120
pulmonary artery, 1119
veins, 1119
root of, 1118
structure of, 1118
surface-marking, 1120
weight, color, etc., 1118
Lunulæ, 1091
of nails, 92
Luschka's gland, 617
ligaments, 1084
Lymph, 37
path or sinus, 88
-vessels of liver, 1058
of pancreas, 1072
Lymphatic or lymphatics, structure of, 85
bone, 56
origin of, 86
plexus of, 86
subdivision into deep and superficial, 679
terminations of, 87
valves of, 86
descriptive anatomy:
abdomen, 687
arm, 684
bladder, 689
broad ligaments, 689
cardiac, 692
cerebral, 682
cervical, superficial and deep, 683
chest, 692
of clitoris, 689
of cranium, 682
diaphragm, 692
duct, right, 681
face, deep, 682
superficial, 682
Fallopian tubes, 689
glands, structure of, 87
anterior mediastinal, 691

Lymphatic or lymphatics, descriptive anatomy:
glands, auricular posterior, 681
axillary, 684
brachial, 684
bronchial, 692
buccal, 681
cervical, deep, 683
superficial, 683
in front of elbow, 684
gluteal, 686
of head, 681
iliac, external, 687
internal, 688
inguinal, deep, 686
superficial, 686
intercostal, 691
internal mammary, 691
ischiatic, 686
of large intestine, 691
of lower extremity, 686
lumbar, 688
of neck, 684
occipital, 681
parotid, 681
of pelvis, 687
popliteal, 686
radial, 684
sacral, 688
of small intestines, 691
of spleen, 690
of stomach, 690
submaxillary, 681
of thorax, 691
tibial anterior, 686
of upper extremity, 684
zygomatic, 681
gluteal region, 689
head, superficial, 681
heart, 692
intercostal, 691
internal mammary, 692
intestines, 691
kidneys, 690
labia, 690
lacteals, 691
large intestine, 691
leg, 686
liver, 690
lower extremity, 686
lung, 692
lymphatic duct, 681
meningeal, 682
mouth, 682
neck, 681
nose, 682
œsophagus, 692
ovaries, 690
pancreas, 690
pelvis, 689
penis, 689
perinæum, 689
pharynx, 683
pia mater, 682
prostate, 689
rectum, 689
scrotum, 689
small intestine, 691
spleen, 690
stomach, 690
testicle, 690
thoracic duct, 680
thorax, 691
thymic, 692
thyroid, 692
Lymphatic or lymphatics, descriptive anatomy:
upper extremity, 685
deep, 686
superficial, 685
uterus, 689
vagina, 689
Lymphoid connective tissue, 49
of tongue, 882

M.

Macula cribrosa, 921
lutea, 902
Magnum of carpus, 266
Majendie, foramen of, 694
Malar bone, 196
articulations of, 197
attachment of muscles to, 197
development of, 197
frontal process of, 196
maxillary process of, 197
orbital process of, 197
zygomatic process of, 197
canals, 196
nerves, from fascial, 814
process of superior maxillary, 192
Male urethra, 1146
Malleolar arteries, external and internal, 643
Malleolus, external, 297
internal, 297
Malleus, 918
development of, 125
suspensory ligament of, 919
Malpighi, pyramids of, 1129
Malpighian bodies of kidney, 1129
capsules, 1129
corpuscles of spleen, 1080
tufts, 1129
Mamma, areola of, 1178
lobules of, 1179
nerves of, 1179
nipple or mammilla of, 1179
vessels of, 1179
Mammæ, development of, 125
Mammary artery, internal, 586
glands, 1178
lymphatic glands, 681
veins, internal, 666
Mammilla of breast, 1178
of kidney, 1129
Mammillary processes, 152
Manubrium of malleus, 918
of sternum, 228
Margo, crenatus, 1074
intermedius, 1074
obtusus, 1074
Marrow of bone, 55
Marshall, vestigial fold of, 666
Masseter muscle, 403
Masseteric arteries, 562
nerve, 805
veins, 652
Mastoid cells, 176
foramen, 175
portion of temporal bone, 175
process, 176
vein, 653
Masto-occipital suture, 207
Masto-parietal suture, 207
Matrix of nail, 92
Maxillary arch, fœtal, 119
artery, internal, 559
bone, inferior, 201
superior, 189
development of, 194
nerve, inferior, 805
superior, 801
process of inferior turbinated, 200
of malar bone, 197
processes, fœtal, 119
tuberosity, 190
vein, internal, 652
Measurements of thorax, 1083, 1099
Meatus auditorius externus, 177
internus, 177
of nose, inferior, 221, 888
middle, 221, 887
superior, 221, 887
urinarius, female, 1165
male, 1147
Meatuses of the nose, 221, 887, 888
Meckel's cartilage, 119
cavum, 797
ganglion, 803
Median artery of forearm, 603
of spinal cord, 583
disk of Hensen, 67
nerve, 840
surgical anatomy of, 844
vein, 663
Mediastinal arteries, from internal mammary, 586
posterior, from aorta, 606
lymphatic glands, 651
Mediastinum, anterior, 1116
middle, 1116
posterior, 1116
superior, 1115
testis, 1157
Medio-tarsal joint, 379
Medulla, closed part of, 713
gray matter of, 713, 715
oblongata, 706–719
open part, 715
spinalis, 695
Medullary canal of bone, 62, 143
formation of, 63
of spine, development of, 120
membrane of bone, 54
plates, 107
sheath of nerve-fibres, 71
spaces of bone, 71
of kidney, 1128
of suprarenal capsules, 1139
velum, inferior of cerebellum, 733, 734, 738
superior, 733, 734, 738
Medullated nerve-fibres, 71
Medullo-spinal veins, 668
Meibomian glands, 908
Membrana basilaris, 924
fusca, 891
flaccida, 918
granulosa, of Graafian vesicle, 1176
limitans of retina, 899
pupillaris, 898
sacciformis, 360
tectoria, 924
tympani, 918
secundaria, 923

Membrane of aqueous chamber, 893
arachnoid, spinal, 694
choroid, 894
of Corti, 924
costo-coracoid, 468
crico-thyroid, 1103
of Descemet, 892
fenestrated, 80
hyaloid, 903
Jacob's, 901
limiting, 899
pituitary, 887
pupillary, 898
of Reissner, 924
Schneiderian, 887
thyro-hyoid, 1103
Membranes of spinal cord, 693
Membranous labyrinth, 926
portion of urethra, 1146
semicircular canals, 926
Meningeal artery, from ascending pharyngeal, 558
anterior, from internal carotid, 568
middle, from internal maxillary, 560
from occipital, 557
posterior, from vertebral, 582
small, from internal maxillary, 561
lymphatics, 682
Meninges. See *Membranes.*
Mental foramen, 202, 217
process, 202
spines, 202
tubercles, 202
Mesencephalon, 121, 706, 740
Mesenteric artery, inferior, 614
superior, 613
glands, 691
plexus of nerves, inferior, 877
superior, 877
vein, inferior, 675
superior, 675
Mesenteriolum, 989
Mesentery, 970, 976, 979, 989
Mesoblast, 104
Mesoblastic somites, 107
Mesocolon, 979
transverse, 979
Mesoderm, 104
Mesogastric zone, 961
Mesogastrium, 970, 973
Mesonephros, 135
Mesorchium, 137
Mesorectum, 1038
Mesosalpinx, 1170
Mesosternum, 229
Mesovarium, 137
Metacarpal artery, 600
articulations, 361
Metacarpo-phalangeal articulations, 361
Metacarpus, 267
common characters of, 267
development of, 272
peculiar bones of, 268
Metanephros, 135
Metasternum, 229
Metatarsal artery, 644
articulations, 385
bones, 306
Metatarso-phalangeal articulations, 386
Metatarsus, 306
development of, 308
Metencephalon, 120, 706
Mid-brain, 706, 740–745
Middle and internal frontal artery, 572
clinoid processes, 180
ear, or tympanum, 916
fossa of skull, 210
meatus, 221, 887
Mid-frontal process, fœtal, 119
Milk teeth, 935
Mitral valve, 1093
Mixed bones, 144
Modiolus of cochlea, 923
Mohl, glands of, 907
Molar glands, 931
teeth, 933
Monro, foramen of, 708, 751, 752, 761
Monticulus, 730
Morgagni, column of, 1042
hydatid of, 138
sinus of, 420, 1042
valves of, 1042
Motor nerves, 78
oculi nerve, 794
surgical anatomy of, 795
Motorial end-plates, 78
Mouth, 930
mucous membrane of, 931
muscles of, 400
surface form of, 949
Movement admitted in joints, 316
Mucilaginous glands, 314
Mucoid connective tissue, 48
Mucous glands of tongue, 882
membrane, 97
Müller, duct of, 136
fibres of, 902
Multicuspidati teeth, 933
Multifidus spinæ muscle, 438
Muscle, general anatomy of, 64
of animal life, 64
arrangement of fibres of, 65
bipenniform, 388
blood-vessels of, 67
chemical composition of, 68
derivation of names, 388
development of, 126
fasciculi of, 65
fibres of, 65
fibrils of, 65
form of, 388
involuntary, 78
lymphatics of, 68
meaning of the terms "origin" and "insertion," 389
mode of connection of, with bone, cartilage, skin, etc., 389
nerves of, 68, 78
of organic life, 78
sarcous elements of, 66
sheath of, 65
size of, 388
striped, 65
structure of, 65
tendons of, 389
triangular, 388
unstriped, 68
voluntary, 64
Muscles or muscle, descriptive anatomy:
of abdomen, 447
abductor hallucis, 530
indicis, 496
minimi digiti (foot), 531
(hand), 494
pollicis (hand), 492
accelerator urinæ, 461
accessorii orbicularis oris, 401
accessorius pedis, 532
ad ilio-costalem, 436
adductor brevis, 512
longus, 512
magnus, 513
obliquus hallucis, 533
pollicis (hand), 493
transversus hallucis, 533
pollicis, 493
anconeus, 486
antitragicus, 914
aryteno-epiglottideus, inferior, 1107
superior, 1107
arytenoideus, 1106
attollens aurem, 394
attrahens aurem, 393
azygos uvulæ, 422
biceps (arm), 476
(thigh), 518
biventer cervicis, 437
brachialis anticus, 477
buccinator, 402
bulbo-cavernosus, 461
cervicalis ascendens, 436
chondro-glossus, 416
ciliary, of eye, 898
circumflexus palati, 422
coccygeus, 460
complexus, 437
compressor narium minor, 399
nasi, 399
sacculi laryngis, 1107
urethræ, 465
in female, 1208
constrictor isthmi faucium, 416
pharyngeus inferior, 419
medius, 420
superior, 420
coraco-brachialis, 476
corrugator of cranial region, 391
cutis ani, 1040
supercilii, 395
cremaster, 452
crico-arytenoideus lateralis, 1106
posticus, 1105
crico-thyroid, 1105
crureus, 510
cutis ani, 458
deltoid, 471
depressor alæ nasi, 399
anguli oris, 401
labii inferioris, 401
diaphragm, 444
digastric, 413
dilatator naris, anterior, 399
posterior, 399
erector clitoridis, 465
penis, 462
spinæ, 434
of external ear, 394
sphincter, 458
extensor brevis digitorum, 530

Muscles or muscle, descriptive anatomy:
extensor brevis pollicis, 488
carpi longior, 484
radialis brevior, 484
ulnaris, 486
coccygis, 438
digitorum communis, 485
indicis, 488
longus digitorum, 521
pollicis, 488
minimi digiti, 485
ossi metacarpi pollicis, 486
primi internodii pollicis, 488
proprius hallucis, 521
of face, 394
femoral region, anterior, 505
internal, 511
posterior, 518
fibular region, 527
flexor accessorius, 532
brevis digitorum, 530
hallucis, 532
minimi digiti (foot), 533
(hand), 494
pollicis (hand), 492
carpi radialis, 479
ulnaris, 480
digitorum sublimis, 480
longus digitorum, 525
hallucis, 525
pollicis (hand), 482
ossis metacarpi pollicis, 492
profundus digitorum, 481
fusiform, 388
gastrocnemius, 522
gemellus inferior, 517
superior, 517
genio-hyo-glossus, 415
genio-hyoid, 414
gluteus maximus, 514
medius, 515
minimus, 516
gracilis, 511
of hand, 492
of head and face, 390
helicis, major, 914
minor, 914
Hilton's, 1107
of hip, 514
Horner's 395
hyo-glossus, 416
iliac region, 503
iliacus, 504
ilio-costalis, 434
infracostal, 442
infraspinatus, 473
intercostal, 441
internal sphincter, 459, 1041
interossei of foot, 534
of hand, 496
interspinales, 438
intertransversales, 438
ischio-cavernous, 462
labial, 400
of larynx, 1105
latissimus dorsi, 430
of leg, 520
levator anguli oris, 400
ani, 414
glandulæ thyroideæ, 1123
labii inferioris, 400
menti, 400
superioris, 400
Muscles or muscle, descriptive anatomy:
levator labia superioris alæque nasi, 399
palati, 421
palpebræ, 395
prostatæ, 460
levatores costarum, 442
lingualis, 415
longissimus dorsi, 436
longus colli, 425
lumbricales (foot), 532
(hand), 496
masseter, 403
multifidus spinæ, 438
musculus accessorius ad ilio-costalem, 436
mylo-hyoid, 414
naso-labialis, 399
of neck, 406
obliquus abdominus externus, 448
internus, 451
auris, 914
capitis inferior, 439
superior, 439
obturator, externus, 518
internus, 516
occipito-frontalis, 391
oculi, inferior, 397
superior, 397
omo-hyoid, 412
opponens minimi digiti, 495
pollicis, 492
orbicularis oris, 401
palpebrarum, 394
palate, 421
palato-glossus, 422
palato-pharyngeus, 422
palmaris brevis, 494
longus, 480
pectineus, 511
pectoralis, major, 467
minor, 469
penniform, 388
of perineum, female, 464
male, 458
peroneus brevis, 527
longus, 527
tertius, 522
of pharynx, 419
plantaris, 524
platysma myoides, 407
popliteus, 524
pronator quadratus, 483
radii teres, 479
psoas magnus, 504
parvus, 504
pterygoid, external, 404
internal, 405
pyramidalis abdominis, 455
nasi, 399
pyriformis, 516
quadratus femoris, 517
lumborum, 458
menti, 401
quadriceps extensor cruris, 509
quadrilateral, 388
recto-coccygeus, 1041
rectus abdominis, 453
capitis anticis major, 424
minor, 424
femoris, 509
lateralis, 425
Muscles or muscle, descriptive anatomy:
rectus oculi, externus, superior, inferior, and internus, 397
posticus major, 439
minor, 439
retrahens aurem, 394
rhomboidal, 388
rhomboides major, 431
minor, 431
risorius, 402
rotatores spinæ, 438
sacro-lumbalis, 434
salpingo-pharyngeus, 423
sartorius, 508
scalenus anticus, 425
medius, 425
posticus, 426
scapulæ, 431
semimembranosus, 519
semispinalis colli, 437
dorsi, 437
semitendinosus, 519
serratus magnus, 470
posticus, inferior, 432
superior, 432
sole of foot, 529
first layer, 530
fourth layer, 534
second layer, 532
third layer, 532
soleus, 523
sphincter, external, 458
internal, 459
tertius, 1042
vaginæ, 464
spinalis colli, 436
dorsi, 436
splenius, 433
capitis, 433
colli, 433
stapedius, 920
sterno-cleido-mastoid, 409
sterno-hyoid, 409
sterno-thyroid, 409
stylo-glossus, 416
stylo-hyoid, 413
stylo-pharyngeus, 420
subanconeus, 478
subclavius, 469
subcrureus, 510
subscapularis, 472
supinator brevis, 486
longus, 483
supraspinales, 438
supraspinatus, 473
temporal, 403
tensor palati, 422
tarsi, 395
tympani, 920
vaginæ femoris, 508
teres major, 474
minor, 474
thyro-arytenoideus, 1106
thyro-epiglottic, 1107
thyro-hyoid, 411
tibialis anticus, 521
posticus, 526
of tongue, 416
trachelo-mastoid, 436
tragicus, 914
transversalis abdominis, 453
colli, 436
transversus auriculæ, 914
perinæi, 461

Muscles or muscle, descriptive anatomy:
transversus perinæi (female), 464
profundus, 1208
trapezius, 428
of Treitz, 1018
triangular, 388
triangularis sterni, 442
triceps, extensor cruris, 509
cubiti, 477
femoralis, 510
of tympanum, 920
of ureters, 1146
vastus externus, 509
internus and crureus, 510
zygomaticus major, 400
minor, 400
Muscles of inspiration and expiration, 444
Muscular columns, 66
fibres of heart, 67
process, 1102
Muscularis mucosæ, 97
Musculi papillares, left ventricle, 1093
right ventricle, 1090
pectinati in left auricle, 1092
in right auricle, 1089
Musculo-cutaneous nerve of arm, 839
from peroneal, 864
Musculo-spiral groove, 250
surgical anatomy of, 844
nerve, 842
Musculo-phrenic artery, 586
Musculus accessorius ad ilio-costalem, 436
Myelo-plaques, 55
Mylo-hyoid artery, 561
groove, 203
muscle, 414
nerve, 807
ridge, 203
Myocardium, 1094
Myrtiform fossa, 190

N.

Nails, 92
Nares, anterior, 222, 886
posterior, 222, 886, 951
septum of, 220, 886
Nasal angle, 189
artery, of internal maxillary, 562
of ophthalmic, 570
of septum, 556
bones, 189
articulations of, 189
development of, 189
cartilages, 885
crest, 189
duct, 911
eminence, 171
fossæ, 219, 886
arteries of, 889
mucous membrane of, 888
nerves of, 889
surgical anatomy of, 889
veins of, 889
groove, 189
nerve, 798
nerves from Meckel's ganglion, 804
Nasal notch, 171
process, 192
spine, 171
anterior, 194, 217
posterior, 196
venous arch, 651
Nasion, 217
Nasmyth's membrane, 940
Naso-maxillary suture, 217
Naso-palatine nerve, 803
Navicular bone, 304
articulations of, 305
attachment of muscles to, 305
tuberosity of, 304
Neck, glands of, 683
lymphatics of, 681
muscles of, 406
triangle of, anterior, 563
posterior, 565
veins of, 653
Nerve-cells, 70
Nerve-epithelium cells, 78
Nerves, structure of, 73
cerebro-spinal, 73
endoneurium, 74
epineurium, 74
funiculi of, 73
origin of, 75
perineum, 74
plexus of, 75
sheath of, 74
sympathetic, 75
termination of, 75
vessels of, 74
Nerves or nerve, descriptive anatomy:
of abducens, 810
accessory obturator, 854
anterior crural, 855
articular, 842
ascending cutaneous, 862
auditory, 815
roots of lateral, 815
mesial, 815
auricular, posterior, 813
of vagus, 821
auricularis magnus, 831
of auriculo-temporal, 806
of brachial plexus, 834
buccal, 806
of facial, 815
cardiac, 872
inferior, 872
middle, 872
plexus, deep, 874
superficial, 874
of pneumogastric, 819
superior, 871
cavernous, of penis, 878
cervical, anterior, 830
posterior, 828
superficial, 831
cervico-facial, 815
chorda tympani, 812, 921
ciliary, long, 799
short, 799
circumflex, 839
coccygeal, 858
cochlear, 928
communicans hypoglossi, 833
peronei, 863
coraco-brachialis, 837, 839
of Cotunnius, 805
cranial, 792
Nerves or nerve, descriptive anatomy:
crural anterior, 855
cutaneous. See *that heading.*
deep palmar, 842
temporal, 805
dental anterior, 802
inferior, 807
posterior, 802
descendens hypoglossi, 825
digastric, from facial, 813
digital, 865
foot, 864
hand, 841, 842
dorsal (hand), 845
peculiar, 848
of penis, 861
spinal, 846
dorsi-lumbar, 848
eighth pair, 815
eleventh pair, 823
of eyeball, 793
facial, 811
femoral cutaneous, 862
fifth, 796
fourth, 796
frontal, 798
ganglionic branch of nasal, 799
gastric branches of vagus, 877
genito-crural, 852
glosso-pharyngeal, 816
gluteal, inferior, 861
superior, 861
great petrosal, 804
splanchnic, 873
gustatory, 807
hæmorrhoidal, inferior, 861
of heart. See *Cardiac.*
hepatic, 877
hypoglossal, 823
ilio-hypogastric, 851
ilio-inguinal, 851
incisive, 807
inferior maxillary, 805
inframaxillary, of facial, 815
infraorbital, of facial, 815
infratrochlear, 799
intercostal, 848
intercosto-humeral, 848
interosseous, anterior, 841
posterior, 844
ischiadic, great, 862
small, 862
Jacobson's, 818
labial, 803
of labyrinth, 927
lachrymal, 798
large cavernous, 878
laryngeal, external, 821
internal, 821
recurrent, 821
superior, 821
lesser splanchnic, 873
lingual of fifth, 807
of glosso-pharyngeal, 818
of liver, 1058
long ciliary, 799
saphenous, 856
thoracic, 837
lumbar, 849
lumbo-sacral, 850
malar branch of orbital nerve, 801
of facial, 814

Nerves or nerve, descriptive anatomy:
masseteric, 805
maxillary, inferior, 805
superior, 801
median, 840
mental, 807
middle cardiac, 872
motor of the eye, common, 794
external, 808
musculo-cutaneous, of arm, 839
leg, 865
musculo-spiral, 842
mylo-hyoid, 807
nasal, from Meckel's ganglion, 803
from ophthalmic, 798
from Vidian, 803
naso-palatine, 805
ninth, 816
obturator, 854
occipital, of facial, 813
great, 828
small, 831
of third cervical, 829
œsophageal, 822
olfactory, 792
ophthalmic, 797
optic, 793
orbital nerves in cavernous sinus, 810
in orbit, 811
their relation, 810
in sphenoidal fissure, 810
of superior maxillary, 801
palatine, anterior or large, 804
external, 804
posterior or small, 804
palmar, cutaneous, of median, 841
ulnar, 842
palpebral, 803
of pancreas, 1022
par vagum, 819
pathetic, 796
pectineus, 855
perforans Casserii, 839
perforating cutaneous, 861
perineal, 861
cutaneous, 862
superficial, 861
peroneal, 864
petrosal, deep large, 804
small, 816
long, 816
superficial, external, or large, 804
small, 816
pharyngeal, of external laryngeal, 821
of glosso-pharyngeal, 818
of Meckel's ganglion, 805
of pneumogastric, 821
of sympathetic, 871
phrenic, 833
plantar, cutaneous, 863
external, 864
internal, 863
pneumogastric, 819
lingual branch, 821, 824
popliteal, external, 864
internal, 863
portia dura, 811
inter duram et mollem, 811
mollis, 811
Nerves or nerve, descriptive anatomy:
posterior auricular, 813
pterygoid, 805
pterygo-palatine, 805
pudendal, inferior, 862
pudic, 861
pulmonary, from vagus, 822
radial, 844
of rectum, 1042
recurrent laryngeal, 821
to tentorium, 796
renal splanchnic, 873
respiratory, external, 837
internal, 833
sacral, 857
plexus, 859
saphenous, long or internal, 856
short or external, 863
sartorius, 855
sciatic, great, 862
of second cervical, 828
small, 862
short ciliary, 799
sixth, 810
small cavernous, 878
occipital, 831
spinal, 826
accessory, 823
recurrent branch, 827
roots of, 826
splanchnic, great, 873
small, 873
smallest, 873
of stomach, 1007
stylo-hyoid of facial, 813
subclavian, 873
subcostal, 848
suboccipital, 828
posterior branch of, 828
subscapular, 838
superficialis colli, 831
superior cardiac, 872
maxillary, 801
supra-acromial, 832
supraclavicular, 832
supramaxillary of facial, 815
supra-orbital, 798
suprascapular, 837
suprasternal, 732
supratrochlear, 798
sympathetic, 867
temporal, of auriculo-temporal, 806
deep, 805
of facial, 814
temporo-facial, 813
temporo-malar, 801
tenth, 819
third, or motor oculi, 794
thoracic anterior, 838
posterior, 837
thyro-hyoid, 825
tibial, anterior, 865
posterior, 863
of tongue, 883
trifacial or trigeminus, 796
twelfth, 823
tympanic of facial, 812
of glosso-pharyngeal, 816
ulnar, 841
collateral, 843
uterine, 878
vaginal, 878
Nerves or nerve, descriptive anatomy:
vagus, 819
vestibular, 928
Vidian, 804
sphenoidal filament, 804, 808
of Wrisberg, 840
Nervi clunium, inferiores, 862
medii, 857
superiores, 850
-nervorum, 74
tentorii, 797
Nervous fibrous matter, 70
ganglia, 79
gelatinous fibres, 72
layer of retina, 899
substance, chemical analysis, 72
gray, 69
white, 70
sympathetic, 73
composition of, 73
system, general anatomy of, 69
white, or medullary substance, 70
Nervus cardiacus magnus, 872
minor, 872
petrosus profundus, 804
superficialis cordis, 871
Neumann, dentinal sheath of, 937
Neuroblasts, 121
Neurokeratin, 73
Neurilemma, 71, *note.*
Neuroglia, 73
of cord, 698
Neuron, 69
Ninth nerve, 816
Nipple, 1179
Nodes of Ranvier, 71
Nodulus, 732
Non-medullated nerve-fibres, 72
Nose, 885
arteries of, 886
bones of, 189
cartilage of septum of, 886
cartilages of, 885
development of, 125
fossæ of, 219, 886
mucous membrane of, 886
muscles of, 398
nerves of, 886
surgical anatomy of, 889
veins of, 886
Notch, anterior cerebellar, 726
cotyloid, 278
ethmoidal, 173, 185
great scapular, 244
intercondyloid, 288
interlobular, 1049
nasal, 171
posterior cerebellar, 726
Rivini, 914
sacro-sciatic, greater, 276
lesser, 276
sigmoid, 204
spheno-palatine, 199
supra-orbital, 171
suprascapular, 245
thyroid, 1100
umbilical, 1049, 1051
Notochord, 107, 115
Nuck, canal of, 1162, 1177
Nuclei of medulla, 515

Nuclei of optic thalamus, 747, 748
pontis, 721
Stilling, 737
Nucleus, 717
amygdalæ, 760
of auditory nerve, 716, 722
accessory, 815
dorsal, 815
ventral, 815
caudatus, 759
of a cell, 39
cuneatus, 714
accessorius, 714
dentate, of medulla, 710, 717
facial nerve, 722
fifth nerve, 722
fourth nerve, 744
glosso-pharyngeal nerve, 716
gracilis, 714
hypoglossal nerve, 716
lenticularis, 759
Luys, 745
olivary, 710, 743
red, 743
Rolando, 711
sixth nerve, 722
spinal accessory nerve, 716
superior olivary, 722
third nerve, 744
vagus nerve, 716
Nutrient artery of bone, 55
Nymphæ, 1164
lymphatics of, 689

O.

Obelion, 208
Obex, 740
Oblique inguinal hernia, 1187
coverings of, 1187
ligament, 354
line of the clavicle, 239
of lower jaw, 202
of radius, 259
ridge of ulna, 256
Obliquus auris muscle, 914
externus abdominis, 448
inferior capitis, 439
oculi, 397
internus abdominis, 449
superior capitis, 439
oculi, 397
Obturator artery, 622
peculiarities of, 623
relation of, to femoral ring, 1123
externus muscle, 518
fascia, 1209
foramen, 278
internus muscle, 516
ligament or membrane, 516
nerve, 854
accessory, 854
surgical anatomy of, 866
veins, 673
Occipital artery, 556
bone, 164
articulations of, 168
attachment of muscles to, 168
development of, 167
crests, 164, 166
protuberances, 164, 166
fossæ, 165
lymphatic glands, 681
Occipital lymphatic groove, 176
sinus, 659
triangle, 565
vein, 653
Occipito-atlantal articulation, 325
Occipito-axial articulation, 326
Occipito-frontalis muscle, 391
Occiput, arteries of, 556
Ocular cleft, 123
cup, 123
vesicle, primitive, 123
secondary, 123
Odontoblasts, 935
Odontoclasts, 943
Odontoid ligaments, 326
process of axis, 148
Œsophageal arteries, 606
branches of vagus nerve, 822
glands, 953
incisure, 1052
opening of diaphragm, 446
plexus, 822
Œsophagus, 952
lymphatics of, 692
nerves of, 954
structure of, 953
surgical anatomy of, 954
vessels of, 953
Olecranon process, 254
fracture of, 501
Olfactory bulb, 782, 788
cells, 888
foramina, 185
fossæ, fœtal, 125
lobe, 782
lobule, anterior, 782
posterior, 784
nerve, 792
roots, 784
sulcus, 792
surgical anatomy of, 793
tract, 782, 783
Olivary bodies of medulla oblongata, 710, 717
nucleus, 710
peduncle, 715
process, 180
Olive, 710
Omega loop, 1044
Omental plate, 975
Omentula, 1028
Omentum colicum, 988, 991
gastro-colic, 991
gastro-splenic, 971, 991, 1076
great, 971, 973, 975, 991
hepato-gastric, 971, 991
lesser, 971, 991, 1053
Omo-hyoid muscle, 412
Omphalo-mesenteric arteries, fœtal, 127
duct, 109
veins, 127
Opening of aorta in left ventricle, 1092
aortic, in diaphragm, 446
canal, in diaphragm, 446
of coronary sinus, 1089
of inferior cava, 1088
left auriculo-ventricular, 1092
of pulmonary artery, 1090
veins, 1091
right auriculo-ventricular, 1092
saphenous, 507, 1092
Opening of superior cava, 1090
Operations:
amputations of foot, 311
of penis, 1037
arteries, ligature of, abdominal aorta, 609
axillary, 591
brachial, 596
carotid, common, 550
external, 551
internal, 568
femoral, 633
iliac, common, 619
external, 628
internal, 621
innominate, 546
lingual, 553
popliteal, 638
radial, 598
subclavian, 579
thyroid, inferior, 585
tibial, anterior, 642
posterior, 645
ulnar, 602
catheterism of Eustachian tube, 952
cholecystotomy, 1066
for cleft palate, 423
colotomy, 1047
division of nerves, facial, 815
infraorbital, 809
lingual, 809
sciatic, great, 866
spinal accessory, 822
supra-orbital, 809
excision of ankle, 380
elbow, 353
hip, 367
knee, 375
of shoulder, 349
extirpation of spleen, 1082
of thyroid, 1124
gastrostomy, 1008
gastrotomy, 1007
hamstring tendons, division of, 520
laryngotomy, 1112
lithotomy, 1207
nephrotomy and nephrectomy, 1135
œsophagotomy, 954
paracentesis of pericardium, 1086
prostatectomy, 1150
puncture of the bladder, 1145
removal of the bladder, 241
lower jaw, 226
scapula, 247
testis, 1159
tongue, 418, 883
upper jaw, 226
for strabismus, 398
tapping chest, 238
for torticollis, 411
tracheotomy 1112
venesection, 663
Opercular, 778
Ophthalmic artery, 568
ganglion, 799
nerve, 797
vein, 659
Opponens minimi digiti muscle, 495
pollicis muscle, 492
Optic commissure, 752

Optic foramen, 180, 210
groove, 180, 210
nerve, 793
intercerebral fibres of, 793
interretinal fibres of, 793
surgical anatomy of, 794
recess, 751
thalamus, 746–748
tract, 752
vesicle, 752
Ora serrata, 898
Oral cavity, 930
sinus, 119
Orbicular bone, 919
ligament, 353
Orbicularis oris muscle, 401
palpebrarum, 394
Orbit, 217
arteries of, 569
muscles of, 396
relation of nerves in, 811
Orbital artery, 562
foramina, 183
nerve, 801
process of malar, 197
of palate, 199
Organic constituent of bone, 60
Organs of Golgi, 78
Orifice, anal, 1038
Os calcis, 299
development of, 308
hyoids, 227
innominatum, 272
development of, 278
magnum of carpus, 266
orbiculare, 919
planum, 186
unguis, 195
uteri, 1169
Ossa triquetra, 188
Ossicula auditus, 919
ligaments of, 919
Ossification of bone, 60
defects in, 163
intracartilaginous, 60
intramembranous, 63
period of, 64
of spine, progress in, 154
subperiosteal, 59
Osteoblasts, 60
Osteoclasts, 55
Osteology, 143
Ostium abdominale of Fallopian tube, 1174
internum or uterinum, 1170
Otic ganglion, 807
Otoliths, 927
Outlet of pelvis, 281
Ovarian arteries, 616
plexus of nerves, 876
veins, 674
Ovary, 1175
development of, 137
Graafian follicles of, 1176
ligament of, 1177
lymphatics of, 690
nerves of, 1178
ovicapsule of, 1176
shape, position, and dimensions, 1175
stroma of, 1176
tunica albuginea of, 1176
vessels of, 1178
Ovicapsule of Graafian follicles, 1176
Oviducts, 1174
Ovisacs of ovary, 1176
Ovula of Naboth, 1172
Ovum, 100
cleavage of, 102
discharge of, 1177
discus proligerus of, 100
fecundation of, 102
germinal spot of, 101
vesicle of, 101
vitelline membrane of, 100
yolk of, 101
zona pellucida of, 100
Oxyntic cells of peptic glands, 1007

P.

Pacchionian depressions, 169
glands, 657
Pacinian corpuscles, 77
Pad, incisive, 944
Palatal glands, 944
Palate, aponeurosis of, 422
arches of, 944
bone, 197
articulations of, 200
attachment of muscles to, 200
development of, 199
horizontal plate of, 197
orbital process of, 199
process of superior maxillary, 193
sphenoidal process of, 199
turbinated crest of, 198
vertical plate of, 198
development of, 119
hard, 944
muscles of, 421
soft, 944
Palatine artery, ascending, 555
descending or posterior, 562
canal, accessory, 197
anterior, 194
posterior, 197
fossa, anterior, 194
nerves, 804
process of superior maxillary, 193
Palato-glossus muscle, 416, 422
Palato-pharyngeus, 422
Palmar arch, superficial, 604
branches of, 604
surface-marking of, 604
cutaneous nerve, 841, 842
fascia, 490
interossei arteries, 601
nerve, deep, of ulnar, 842
superficial, of ulnar, 842
veins, 663
Palmaris brevis muscle, 494
longus muscle, 480
Palpebræ, 907
Palpebral arteries, 570
cartilages or plates, 907
fissures, 907
surface form of, 911
folds of conjunctiva, 908
ligaments, 908
muscles, 394
veins, inferior, 652
superior, 652
Pampiniform plexus of veins, 674, 1155, 1178
Pancreas, 971, 1067
development of, 134
lesser, 1070
lymph-vessels of, 1072
lymphatics of, 690
relations of, 1071
structure of, 1072
surface form of, 1073
surfaces of, 1069
surgical anatomy of, 1073
vessels and nerves of, 1072
Pancreatic arteries, 612
duct, 1070
plexus of nerves, 877
veins, 675
Pancreatica magna artery, 612
Pancreatico-duodenal artery, inferior, 613
superior, 611
plexus of nerves, 877
Papilla lachrymalis, 910
spiralis, 925
Vateri, 1070
Papillæ conicæ vel filiformes, 881
fungiformes (mediæ), 880
maximæ (circumvallatæ), 880
of skin, 91
of teeth, 939, 941
of tongue, 880
Papillary layer of skin, 91
Par vagum, 819
Paraglobulin, 36
Paramastoid process, 165
Parietal bones, 168
articulations of, 170
attachment of muscles to, 170
development of, 170
cells of peptic glands, 1007
eminence, 168
foramen, 169
veins, 131
Parieto-sphenoid artery, 573
Paroöphoron, 138, 1177
Parotid fascia, 403, 408
gland, 945
accessory portion of, 947
duct of, 946
nerves of, 947
vessels of, 947
lymphatic glands, 681
veins, 652
Parovarium, 138, 1177
Pars pylorica, 1000
Patella, 291
articulations of, 292
attachment of muscles to, 292
development of, 292
fracture of, 537
structure of, 292
surface form of, 292
surgical anatomy of, 292
Pecquet, reservoir of, 680
Pectineus muscle, 511
nerve, 855
Pectiniform, septum, 1151
Pectoral region, dissection of, 467
ridge, 248
Pectoralis major, 467
minor, 469
Peculiar dorsal vertebræ, 151
Pedicles of a vertebra, 144
Peduncles of cerebellum, inferior, 734, 735, 738
middle, 734, 735, 738
superior, 734, 735, 738

Peduncles, inferior, of cerebellum, 712
middle, of cerebellum, 720
olivary, 715
superior, of cerebellum, 720
Pedunculi cerebri, 742
Pelvic cavity, 955
fascia, 1209
parietal or obturator layer, 1209
visceral layer, 1210
girdle, 238
plexus, 878
Pelvis, 279
arteries of, 620
articulations of, 336
axes of, 282
boundaries of, 279
brim of, 280
cavity of, 281
diameters of, 282
false, 280
inlet of, 281
of kidney, 1128
ligaments of, 336
lymphatics of, 687
male and female, differences of, 282
outlet of, 281
position of, 282
of viscera at outlet of, 1206
surface form of, 283
surgical anatomy of, 283
Penis, 1150
arteries of, 1152
body of, 1150
corpora cavernosa, 1151
corpus spongiosum, 1152
development of, 140
dorsal artery of, 624
nerve of, 861
vein of, 673
lymphatics of, 689, 1153
muscles of, 462
nerves of, 1153
prepuce of, 1151
root of, 1151
structure of, 1153
surgical anatomy of, 1153
suspensory ligament, 1150
Penniform muscle, 388
Peptic glands, 1006
Perforans Casserii nerve, 839
Perforating arteries of hand, 601
from mammary artery, 586
from plantar, 647
from profunda, 636
cutaneous nerve, 861
Pericæcal fossæ, 997
Pericardiac arteries, 586, 606
Pericardial cavity, 955
Pericardio-thoracic cavity, 955
Pericardium, diverticula of, 1084
fibrous layer of, 1084
nerves of, 1085
relations of, 1083
serous layer of, 1085
structure of, 1084
vessels of, 1085
vestigial fold of, 1085
Perichondrium, 51
Perilymph, 926
Perimysium, 65
Perineal artery, superficial, 625
transverse, 625
Perineal body, 1164
fascia, deep, 463, 1204
superficial, 460
nerve, 861
cutaneous, 862
superficial, 861
Perineum, 1201
abnormal course of arteries in, 1208
deep boundaries of, 1203
development of, 140
in the female, 1207
lymphatics of, 689
in the male, 1202
muscles of, 458
surgical anatomy of, 1201
Perineurium, 74
Periosteum, 54
of teeth, 932
Peripheral termination of nerves, 76
Peritoneal relations of liver, 1054
spleen, 986, 1076
sac, 986
Peritoneum, 955, 962, 978
development of, 967
parietal, 986
visceral, 988
Perivascular lymph-sheaths, 87, 657
Permanent cartilage, 51
teeth, 932
Peroneal artery, 646
anterior, 646
peculiarities of, 646
nerve, 864
ridge, 301
veins, 671
Peroneus brevis muscle, 527
longus muscle, 527
tertius muscle, 522
Perpendicular plate of ethmoid, 186
line of ulna, 258
Pes accessorius, 759, 765
anserinus, 812
hippocampi, 759
Petit, canal of, 905
triangle of, 449
Petrosal nerve, deep large, from Vidian, 804
small, 818
long, 818
small superficial, 818
superficial large, 804
sinus inferior, 660
superior, 660
Petro-mastoid portion of temporal bone, 179
Petro-occipital suture, 207
Petro-sphenoidal suture, 207
Petrous ganglion, 817
portion of temporal bone, 176
Peyer's glands, 1025
Phalanges, hand, 270
articulations of, 270, 362
development of, 272
foot, 308
articulations of, 308, 387
development of, 308
Pharyngeal aponeurosis, 951
artery, ascending, 558
ganglion, 871
glands, 951
Pharyngeal nerve, from external laryngeal, 821
from glosso-pharyngeal, 818
from Meckel's ganglion, 805
from sympathetic, 871
from vagus, 821
plexus of nerves, 821, 871
spine, 165
tonsil, 953
vein, 654
Pharynx, 951
aponeurosis of, 951
arteries of, 558
development of, 132
mucous membrane of, 951
muscles of, 419
surgical anatomy of, 952
Phleboliths, 673
Phrenic arteries, 616
nerve, 833
plexus of nerves, 875
veins, 675
Phrenico-hepatic fossa, 994
Phreno-colic ligament, 1036
Pia mater of cord, 705
Pigment, 50
of iris, 897
of skin, 91
Pigmentary layer of retina, 901
Pillars of diaphragm, 446
of external abdominal ring, 449, 1182
of fauces, 944
Pineal gland, 748
recess, 748
arteries of, 914
Pinna of ear, 912
cartilage of, 912
ligaments of, 913
muscles of, 913
nerves of, 914
structure of, 912
vessels of, 914
Pisiform bone, 264
Pituitary body, 751
development of, 119
fossa, 180
membrane, 887
Pivot-joint, 316
Placenta, 115
Placental sinus, 115
circulation, 129
Plantar artery, external, 647
internal, 647
cutaneous nerve, 863
fascia, 529
ligaments, 381
nerve, external, 864
internal, 863
veins, external, 671
internal, 671
Plantaris muscle, 524
Plasma, 36
Plates, omental, 975
tarsal, 908
tympanic, 914
Platysma myoides, 407
Pleura, 955, 1113
cavity of, 955, 1113
costalis, 1113
pulmonalis, 1113
reflections of, traced, 1113
surgical anatomy of, 1114
vessels and nerves of, 1114
Pleural cavity, 955

Pleural sinuses, 1114
Plexus of nerves, 75
brachial, 834
cardiac, deep, 874
superficial, 874
carotid, 869
external, 869
cavernous, 869
cervical, 831
superficial, 831
choroid, 766, 769, 770
cœliac, 876
coronary, anterior, 875
posterior, 874
cystic, 877
diaphragmatic, 875
epigastric or solar, 875
facial, 871
gastric, 877
gastro-duodenal, 877
gastro-epiploic, 877
left, 877
great cardiac, 874
hæmorrhoidal, inferior, 978
superior, 878
hepatic, 877
hypogastric, 877
inferior, 878
lumbar, 850
mesenteric, inferior, 877
superior, 877
œsophageal, 822
ophthalmic, 869
ovarian, 876
pancreatic, 877
pancreatico-duodenal, 877
patellæ, 856
pharyngeal, 821, 871
phrenic, 875
prostatic, 878
pulmonary, anterior, 822
posterior, 822
pyloric, 877
renal, 875
sacral, 857
sigmoid, 877
solar, 875
spermatic, 875
splenic, 877
superficial cardiac, 874
suprarenal, 875
tonsillar, 818
tympanic, 810
uterine, 878
vaginal, 878
vertebral, 872
vesical, 878
Plexus magnus profundus, 874
of veins. See *Veins.*
Plica epigastrica, 964, 1190
hypogastrica, 964, 1190
præpylorica, 1000
recti, 1041
semilunaris, 909, 987
transversalis, 1042
urachi, 964
ureterica, 1144
Plicæ adiposæ, 986
palmatæ, 1171
Pneumogastric nerve, 819
Polar globules of Robin, 101
Pomum Adami, 1100
Pons, gray matter of, 721
hepatis, 1051, 1062
nuclei of, 721
Pons, raphe of, 721
Tarini, 750
Varolii, 719, 724
Ponticulus, 710
Popliteal artery, 637
branches of, 639
peculiarities of, 638
surface-marking of, 638
surgical anatomy of, 638
unusual branches, 638
lymphatic glands, 686
nerve, external, 864
surgical anatomy of, 866
internal, 863
space, 637
surface of femur, 286
vein, 671
Popliteus muscle, 524
Pores of the skin, 95
Portal canals, 1057
vein, 674, 1057
Portio dura of seventh nerve, 811
inter durem et mollem, 811
mollis, 811
Porus opticus of sclerotic, 892
Posterior. See *under each separate head.*
Posterior glenoid process, 174
and interior choroid artery, 584
frontal artery, 572
longitudinal bundle, 718, 742
Postero-lateral ganglionic arteries, 584
median ganglionic arteries, 584
Post-glenoid process, 174
Post-patellar bursa, 510
Pott's fracture, 538
Pouch of Douglas, 971, 988
recto-uterine, 981
recto-vaginal, 981
recto-vesical, 981, 987
vesico-uterine, 981, 988
Pouches, laryngeal, 1105
Poupart's ligament, 1183, 1195
Precuneus, 780
Prepatellar bursa, 510
Prepuce, 1151
of clitoris, 1164
Presternal notch, 229
Presternum, 229
Prevertebral fascia, 409
Prevesical space of Retzius, 981
Prickle cells, 43
Primary areolæ of bone, 60
Primitive aorta, 127
fibrillæ of Schultze, 71
jugular veins, 132
otic vesicle, 124
sheath of nerve-fibre, 71
trace, 104
Princeps cervicis artery, 557
pollicis artery, 600
Processes or process: acromion, 244
alveolar, 193
angular, external, 171
internal, 171
auditory, 177
ciliary, 895
clinoid, anterior, 183
middle, 180
posterior, 181
cochleariform, 179, 917
condyloid of lower jaw, 204
coracoid, 245
Processes or process: coronoid, of lower jaw, 204
of ulna, 254
costal, 146
ethmoidal of inferior turbinated, 200
frontal of malar, 196
hamular of lachrymal, 195
of sphenoid, 183
of helix, 913
of Ingrassias, 183
jugular, 166
lachrymal, of inferior turbinated bone, 200
malar, 192
of malar bone, 196
mammillary, 152
mastoid, 176
maxillary, of inferior turbinated, 200
mental, 202
muscular, 1102
nasal, 192
odontoid of axis, 147
olecranon, 254
olivary, 180
orbital, of malar, 196
of palate, 199
palatine, of superior maxillary, 193
post-glenoid, 174
pterygoid, of palate bone, 198
of sphenoid, 183
sphenoidal, of palate, 199
spinous of ilium, 275
of sphenoid, 182
of tibia, 293
styloid, of radius, 260
of temporal, 178
of ulna, 258
unciform, 267
of ethmoid, 186
vaginal, of sphenoid, 182
of temporal, 178
vermiform, of cerebellum, 727
inferior, 727
vocal, 1102
zygomatic, 197
Processus brevis of malleus, 919
caudatus, 913
cochleariformis, 179, 917
gracilis of malleus, 919
Profunda cervicis artery, 587
femoris artery, 635
inferior artery of arm, 596
superior artery of arm, 596
vein, 672
Projection fibres, 785, 786
Promontory of sacrum, 155
of tympanum, 916
Pronator quadratus muscle, 483
radii teres muscle, 479
ridge, 256
Pronephros, 135
Pronucleus, female, 103
male, 103
Prosencephalon, 121, 706, 751
Prostate, hypertrophy of, 1159
gland, 1148
levator muscle of, 460
lobes of, 1149
lymphatics of, 689
surgical anatomy of, 1149
vessels and nerves of, 1149
Prostatic plexus of nerves, 878

Prostatic plexus of veins, 673
portion of urethra, 1146
sinus, 1146
Protoplasm, 39
Protoplasmic process of nerve-cells, 70
Protovertebræ, 107
Protovertebral column, 116
somites, 107
Protuberance, occipital, external, 164
internal, 166
Psoas magnus muscle, 504
surgical anatomy of, 505
parvus, 504
Pterion ossicle, 188
Pterygoid arteries, 562
fossa of lower jaw, 204
of sphenoid, 183
muscles, 404
nerve, 806
plexus of veins, 652
process of palate bone, 198
processes of sphenoid, 183
ridge, 182
Pterygo-maxillary fissure, 216
ligament, 402
Pterygo-palatine artery, 562
canal, 182
nerve, 805
Pubes, angle of, 277
crest of, 277
os, 277
spine of, 277
symphysis of, 277, 339
Pubic arch, 281
articulations of, 339
portion of fascia lata, 508
Pubo-prostatic ligaments, 1142
Pudendum, 1163
Pudic artery, accessory, 624
deep external, 635
internal, 623
in female, 625
in male, 624
peculiarities of, 624
superficial external, 635
nerve, 861
vein, external, 670
internal, 672
Pulmonary artery, 540, 1119
opening of, in right ventricle, 1090
capillaries, 1119
sinuses, 1091
veins, 649, 650, 1119
openings of, left auricle, 1091
Pulp-cavity of tooth, 935
enamel, 940
formative, 941
permanent, 941
of teeth, development of, 943
Pulvinar, 746, 758
Puncta lachrymalia, 911
vasculosa, 755
Pupil of eye, 896
membrane of, 898
Purkinje, axis-cylinder of, 71
corpuscles of, 736
granular layer of, 936
vesicle of, 101
Putamen, 760
Pyloric artery, 611
glands, 1006
Pyloric plexus, 877
Pylorus, 1000
Pyramid, 716
of cerebellum, 731
of thyroid gland, 1123
of tympanum, 916
in vestibule, 921
Pyramidal tract, 700
crossed, 710
direct, 710
Pyramidalis muscle, 455
nasi, 399
Pyramids of Ferrein, 1131
of Malpighi, 1129
of medulla, 709
decussation of, 710
of the spine, 161
Pyriformis muscle, 516

Q.

Quadrate lobe of liver, 1052
Quadratus femoris muscle, 517
lumborum, 458
fascia covering, 458
menti, 401
Quadriceps extensor cruris muscle, 509

R.

Racemose glands, 99
Recessus peritonei, 994
Radial artery, 597
branches of, 599
peculiarities of, 598
surface-marking of, 598
surgical anatomy of, 598
lymphatic glands, 684
nerve, 844
recurrent artery, 599
region, muscles of, 483
vein, 663
Radialis indicis artery, 601
Radiations, optic, 747
Radicular zone, anterior, 700
Radio-carpal articulation, 356
surface form of, 357
surgical anatomy of, 357
Radio-ulnar articulations, inferior, 355
middle, 354
superior, 353
Radius, 259
articulations of, 261
development of, 260
fracture of, 501
grooves in lower end of, 260
muscles attached to, 261
oblique line of, 259
sigmoid cavity of, 260
surface form of, 261
surgical anatomy of, 261
tuberosity of, 259
and ulna, fracture of, 502
Radix mesenterii, 990
Rami of the lower jaw, 203
Ramus, horizontal, of pubes, 277
of ischium, 276
descending, 277
of pubes, 277
Ranine artery, 553
vein, 652, 654
Ranvier, nodes of, 71
Raphe of medulla, 712, 719
Raphe of perineum, 1202
of pons, 721
of scrotum, 1153
Receiving tubes of kidney, 1130
Receptaculi arteriæ, 568
Receptaculum chyli, 680
Recess, epitympanic, 917
lateral, 734, 738, 739
optic, 751
Recessus hepato-renalis, 1054
labyrinthi, 124
Recto-coccygeus muscle, 1041
Recto-uterine ligaments, 1169
pouch, 981
Recto-vaginal pouch, 981
Recto-vesical fascia, 1210
fold, peritoneal, 1142
pouch, 981, 987
Rectum, 1038
ampulla of, 1039
curves of, 1039
development of, 133
lymphatics of, 689
nerves of, 1042
relations of, 1043
structure of, 1040
surgical anatomy of, 1045
valves of, 1041
vessels of, 1042
Rectus abdominis, 453
capitis anticus major, 424
minor, 424
lateralis, 425
femoris muscle, 509
surgical anatomy of, 511
oculi, internus, superior, inferior, and externus, 397
posticus major, 439
minor, 439
Recurrent artery, interosseous, 603
radial, 599
tibial, anterior, 642
posterior, 642
ulnar, anterior, 602
posterior, 602
laryngeal nerve, 821
nerves to tentorium, 797
Region, abdominal, 959
muscles of, 447
acromial, muscles of 471
auricular, 393
back, muscles of, 427
brachial, anterior, 479
cervical superficial, muscles of, 407
diaphragmatic, 444
epicranial, muscles of, 391
epigastric, 955
femoral, muscles of, anterior, 505
internal, 511
posterior, 518
fibular, 527
foot, dorsum of, 530
sole of, 530
gluteal, muscles of, 514
of hand, muscles of, 489
humeral, anterior, 475
posterior, 477
hypochondriac, 955
iliac, muscles of, 503
infrahyoid, 411
inguinal, 1189
intermaxillary, muscles of, 401

Region, ischio-rectal, 1201
laryngo-tracheal, surgical anatomy of, 1112
lingual, muscles of, 415
maxillary, muscles of, inferior, 400
superior, 400
nasal, muscles of, 398
orbital, muscles of, 396
palatal, muscles of, 421
palmar, 489
palpebral, 394
perineum, 1201
pharyngeal, muscles of, 419
popliteal, 637
pterygo-maxillary, muscles of, 404
radial, muscles of, 483
radio-ulnar, posterior, muscles of, 485
scapular, muscles of, anterior, 472
posterior, 473
Scarpa's triangle, 630
suprahyoid, muscles of, 413
temporo-maxillary, muscles of, 403
thoracic, 441
anterior, 467
lateral, 470
tibio-fibular, anterior, 521
posterior, 522
ulnar, 494
vertebral, muscles of, anterior, 424
lateral, 425
Reil, island of, 778
Relations of duodenum, 1011, 1014
of gall-bladder, 1064
of large intestine, 1036
of liver, 1055
of pancreas, 1071
of rectum, 1043
of spleen, 1076
of stomach, 1001
of vermiform appendix, 1032
Remak, fibres of, 72
Renal afferent vessels, 1129, 1134
artery, 616, 1133
efferent vessels, 1129, 1134
plexus, 875
veins, 675, 1134
Respiration, muscles of, 444
organs of, 1100
Respiratory nerves of Bell, external, 837
internal, 833
organs, development of, 134
Rete Malpighii, 90
mucosum of skin, 90
testis, 1158
Reticular cartilage, 53
formation, 713, 714
layer of skin, 91
lamina of Kölliker, 926
Retiform body, 712, 717, 735, 738
connective tissue, 48
Retina, 898
arteria centralis of, 570, 902
fovea centralis of, 902
limbus luteus of, 898
membrana, layers of, 899, 900
limitans externa, 901
Retina membrana, limitans interna, 899
structure of, 899
Retrahens aurem muscle, 394
Retro-peritoneal fossæ, 994
Retzius, prevesical space of, 981
space of, 1141
Rhomboid impression, 240
ligament, 341
Rhomboidal sinus, 120
Rhomboideus major, 431
minor, 431
Ribes, ganglion of, 867
Ribs, 232
angle of, 233
articulations of, 330
attachment of muscles to, 235
development of, 117, 235
false, 232
floating, 232
head of, 233
ligaments of, 330, 331
neck of, 233
peculiar, 234
true, 232
tuberosity of, 233
Ridge, basal of teeth, 933
internal occipital, 166
mylo-hyoidean, 202
pectoral, 248
pterygoid, 182
superciliary, 171
supracondylar, 250
temporal, 173, 174, 215
Right lobe of liver, 1052
longitudinal fissure of liver, 1051
Rima glottidis, 1104
Rimæ cæcæ, 1053
Ring, abdominal, external, 449, 1182
internal, 1186
femoral or crural, 1198
fibrous, of heart, 1094
Risorius muscle, 402
Rivini, ducts of, 948
notch of, 914, 918
Robin, polar globules of, 101
Rods of Corti, 925
Rolando, funiculus of, 710
nucleus of, 711
tubercle of, 711, 715
Roof of fourth ventricle, 738, 739
of third ventricle, 748–750
Root, ascending, of fifth nerve, 723
of auditory nerve, 815
descending, of fifth nerve, 723
of lung, 1118
of olfactory nerve, 784
of spinal nerves, 826
of teeth, 934
of zygomatic process, 174
Rosenmüller, accessory gland of, 910
organ of, 138, 1177
Rostrum of sphenoid bone, 182
Rotation, 318
Rotatores spinæ muscles, 438
Round ligaments of uterus, 1177
relations of, to femoral ring, 1198
of liver, 983, 1053
Rugæ of vagina, 1168
Rupture of urethra, course taken by urine in, 1203

S.

Sac, lachrymal, 910
Saccular secretory glands, 98
Saccule of vestibule, 926
Saccus lienalis, 1077
Sacra-media artery, 617
Sacral arteries, lateral, 627
canal, 157
cornua, 156
foramina, 155
ganglia, 874
groove, 156
lymphatic glands, 688
nerves, 851
anterior divisions of, 858
posterior divisions of, 857
roots of, 857
plexus, 859
vein, lateral, 673
middle, 673
peculiarities of, 673
Sacro-coccygeal ligaments, 339
Sacro-iliac articulation, 337
Sacro-lumbalis muscle, 434
Sacro-sciatic foramen, greater, 276, 337
lesser, 276, 338
ligaments, 337
notch, greater, 276
lesser, 276
Sacro-uterine ligament, 1171
Sacro-vertebral angle, 155
ligament, 337
Sacrum, 155
ala of, 157
articulations of, 159
attachment of muscles to, 159
development of, 158
peculiarities of, 158
structure of, 158
Sacs, dental, 940
Saddle-joint, 316
Sagittal suture, 206
Salivary glands, 945
structure of, 948
Salpingo-pharyngeus, 423
Salter, incremental lines of, 937
Santorini, cartilages of, 1102
Saphena veins, surgical anatomy of, 671
Saphenous nerve, long or internal, 856
short, 862
opening, 507, 1194
vein, external or short, 672
internal or long, 670, 1190
surgical anatomy of, 671
Sarcolemma, 65
Sarcoplasm, 66
Sarcostyles, 66
Sarcous elements of muscle, 66
Sartorius muscle, 508
Scala media, 924
tympani of cochlea, 923
vestibuli of cochlea, 923
Scalæ of cochlea, 924
Scalenus anticus, 425
medius, 425
posticus, 426
Scaphoid bone (foot), 304
(hand), 262

Scaphoid fossa of sphenoid, 183
Scapula, 242
articulations of, 247
attachment of muscles to, 247
development of, 246
dorsum of, 243
glenoid cavity of, 245
head of, 469
ligaments of, 344, 345
muscles of, 472, 473
spine of, 244
surface form of, 247
surgical anatomy of, 247
venter of, 242
Scapular artery, posterior, 585
region, muscles of, anterior, 472
posterior, 473
veins, 666
Scarfskin, 89
Scarpa, foramina of, 194, 213
Scarpa's triangle, 630
Schachowa, spiral tubes of, 1130
Schindylesis, 315
Schlemm, canal of, 893
ligaments, 346
Schneiderian membrane, 887
Schreger, lines of, 937
Schultze, cells of, 792
primitive fibrillæ of, 71
Schwann, white substance of, 71
Sciatic artery, 626
nerve, greater, 862
surgical anatomy of, 866
lesser, 862
veins, 673
Sclerotic, 891
Scrobiculus cordis, 237
Scrotal hernia, 1189
Scrotum, 1153
dartos of, 1154
development of, 140
lymphatics of, 689
nerves of, 1155
septum of, 1153
surgical anatomy of, 1155
vessels of, 1155
Sebaceous glands, 94
Second nerve, 793
surgical anatomy of, 794
Secreting glands, 98
Segmental duct, 135
Segmentation spherules, 103
Sella Turcica, 180
Semicircular canals, 922
Semilunar bone, 264
cartilages of knee, 370
fascia, 476
fold of Douglas, 455
ganglion of abdomen, 872
of fifth nerve, 797
valves, aortic, 1093
pulmonic, 1090
Semimembranosus muscle, 519
Seminal cells, 1158
tubes, 1158
vesicles, 1160
Semispinalis muscle, 437
Semitendinosus muscle, 519
Senses, organs of the, 879
Septum, cartilage of, 886
crurale, 1198
lucidum, 754, 762
of medulla, 712
of nose, 221
Septum pectiniforme, 1151
of pons, 721
scroti, 1153
subarachnoid, 694
of tongue, 882
ventriculorum, 1089
Septum between bronchi, 1109
Serous glands of tongue, 882
membranes, 96
Serratus magnus, 470
posticus, inferior, 432
superior, 432
Serum, 33
albumen, 36
globulin, 36
Sesamoid bones, 312
cartilages, 886
Seventh nerve, 814
surgical anatomy of, 815
Shaft of a bone, its structure, 143
Sheath of arteries, 81
epithelial, of Hertwig, 941
of femoral or crural, 1196
of muscles, 65
of nerves, 74
of rectus muscle, 454
Shin, 294
Short bones, 143
Shoulder girdle, 238
joint, 345
surface form of, 348
surgical anatomy of, 348
muscles of, 467
vessels and nerves of, 347
Sigmoid artery, 614
cavity, greater and lesser, of radius, 260
ulna, 256
flexure of colon, 1036
of rectum, 1044
notch of lower jaw, 204
Sinus circularis iridis, 893
coronary, great, 677
left, 677
right, 677
small, 677
costo-phrenic, 1114
of external jugular vein, 653
of internal jugular vein, 654
of kidney, 1128
of Morgagni, 420, 1042
pocularis, 1146
prostaticus, 137, 1146
transverse pericardial, 1085
venæ portæ, 1057
venosus, 130
Sinuses, cavernous, 659
circular, 660
of coronary vein, 677, 1088
cranial, 171, 650, 657
ethmoidal, 185
frontal, 171
of heart, of left auricle, 1091
of right auricle, 1088
lateral, 658
longitudinal inferior, 658
superior, 657
maxillary, 192
of nose, 171
occipital, 659
petrosal, inferior, 660
superior, 660
plural, 1114
pulmonary, 1091
Sinuses, sphenoidal, 181
straight, 658
transverse, 661
of Valsalva, 542, 1093
Sixth nerve, 810
surgical anatomy of, 811
Skeleton, 143
number of its pieces, 143
Skin, appendages of, 92
arteries of, 92
corium of, 91
cuticle of, 89
derma, or true skin, 91
development of, 125
epidermis of, 89
furrows of, 91
hairs, 93
muscular fibres of, 94
nails, 92
nerves of, 92
papillary layer of, 91
rete mucosum of, 90
sebaceous glands of, 94
structure of, 89
sudoriferous or sweat-glands of, 95
tactile corpuscles of, 76
vessels of, 92
Skull, 163, 208
anterior region, 217
base of, external surface, 208
internal surface, 208
fossa of, anterior, 208
middle, 210
posterior, 211
lateral region of, 214
surface-marking of, 222
tables of, 143
vertex of, 208
vitreous table of, 144
Small intestine, 1008
fixation of, 1020
structure of, 1020
valvulæ conniventes, 1021
villi of, 1022
vessels of, 1026
Soft palate, 944
aponeurosis of, 944
arches or pillars of, 944
muscles of, 422
structure of, 944
Solar plexus, 875
Sole of foot, muscles of, first layer, 530
fourth layer, 534
second layer, 532
third layer, 532
Soleus muscle, 523
Solitary glands, 1025, 1029
Somatopleure, 108
Sömmerring, yellow spot of, 898
Space, anterior perforated, 784
axillary, 587
intercostal, 232
interpeduncular, 784
popliteal, 637
posterior perforated, 750
of Retzius, 1141
Spaces of Fontana, 893
Spermatic artery, 616, 1155
canal, 1185
cord, 1155
arteries of, 1155
course of, 1155
lymphatics of, 1155

Spermatic cord, nerves of, 1155
fascia, external, 450, 1182
plexus of nerves, 875
of veins, 674
relation to femoral ring, 1198
of, in inguinal canal, 1155, 1185
veins, 674, 1155
surgical anatomy of, 674
Sphenoid bone, 180
articulations of, 185
attachment of muscles to, 185
body of, 180
development of, 184
greater wings of, 182
lesser wings of, 183
pterygoid processes of, 183
rostrum of, 182
spinous processes of, 182
vaginal processes of, 182
Sphenoidal fissure, 183
nerves in, 810
process of palate, 199
sinuses, 181
spongy or turbinated bones, 184
Spheno-maxillary fissure, 216
fossa, 216
Spheno-palatine artery, 562
foramen, 199
ganglion, 803
nerves, 803
notch, 199
Spheno-parietal suture, 207
Sphincter muscle of bladder, 1143
pyloricus, 1000
of rectum, external, 458
internal, 459
tertius, 1042
of vagina, 464
Spigelian lobe, 1050, 1052
Spina bifida, 162
Spinal accessory nerve, 823
surgical anatomy of, 823
arteries, anterior, 582
lateral, 582
median, 582
posterior, 582
bulb, 708
canal, 162
cord, 695–702
arachnoid of, 694
arrangement of gray and white matter in, 699
central canal of, 698
ligament of, 695
columns of, 697
commissures of, 697, 698
development of, 115
dura mater of, 693
fissures of, 696, 697
fœtal, peculiarity of, 695
gray commissure of, 697
internal structure of, 697
ligamentum denticulatum of, 695
membranes of, 693
minute structure of, 698
neuroglia of, 698
pia mater of, 695
sections of, 696
structure of, 697
white commissure of, 697
Spinal cord, white matter of, 699
foramen, 145
nerves, 826
arrangement into groups, 826
development of, 122
distribution of, 827
divisions of, anterior, 827
posterior, 827
origin of, in cord, 702
of roots, anterior, 826
posterior, 826
points of emergence of, 827
veins, 668
longitudinal, anterior, 669
posterior, 669
Spinalis colli muscle, 436
dorsi muscle, 436
Spine, 144
articulations of, 319
development of, 115
general description of, 160
ossification of, 154
Spines of bones, ethmoidal, 180
of ischium, 276
mental, 202
nasal, 171
anterior, 194
posterior, 197
of os pubis, 277
pharyngeal, 165
of scapula, 244
tympanic, 914
Spinous process of ilium, 275
of sphenoid, 182
of tibia, 293
of vertebræ, 145
Spiral canal of cochlea, 923
Splanchnic nerve, greater, 873
lesser, 873
smallest or renal, 873
Splanchnopleure, 108
Spleen, 971, 1073
accessory, 1073
fixation of, 1076
lymphatics of, 690, 1077, 1081
nerves of, 1077
peritoneal relations of, 986, 1076
pulp of, 1078
relations of, 1076
structure of, 1077
surface-marking of, 1081
surfaces of, 1074
surgical anatomy of, 1081
vessels of, 1077, 1079
Splenic artery, 611
flexure, 1036
plexus, 877
vein, 675
Splenius muscle, 433
Spongioblasts, 121
Spongy portion of urethra, 1147
tissue of bone, 143
Squamo-parietal suture, 207
Squamo-sphenoidal suture, 207
Squamo-zygomatic portion of temporal bone, 179
Squamous portion of temporal bone, 173
Stapedius muscle, 920
Stapes, 919
annular ligament of, 919
development of, 125
Stellate ligament, 330
plexus of kidney, 1134
Stenson, foramina of, 194, 213
Stenson's duct, 946
Sternal end of clavicle, fracture of, 499
foramen, 231
furrow, 236
ligaments, 336
Sterno-clavicular articulation, 341
surface form of, 342
surgical anatomy of, 342
Sterno-hyoid muscle, 411
Sterno-mastoid muscle, 409
artery, 557
Sterno-pericardial ligament, 1084
Sterno-thyroid muscle, 411
Sternum, 228
articulations of, 232
attachment of muscles to, 232
development of, 117, 231
ligaments of, 336
structure of, 231
Stilling, canal of, 903
Stomach, 969, 999
alteration in position of, 1004
development of, 133
fixation of, 1003
lymphatics of, 690
mucous membrane of, 1005
peptic glands of, 1007
position of, 1004
pyloric end of, 1006
glands of, 1006
pylorus, 1000
relations of, 1001
structure of, 1004
submucous coat of, 1005
surgical anatomy of, 1007
torsion of, 973
vessels and nerves of, 1007
Stomodœum, 120
Straight sinus, 658
tubes of kidney, 1130
Strand, labio-dental, 938
Stratiform fibro-cartilage, 53
Stratum cinereum, 743
corneum, 90
dorsale, 745
lucidum, 91
opticum, 743
zonale, 747
Striæ acusticæ, 724
laterales, 757
longitudinales, 757
of muscle, 66
Striped muscle, 64
Stroma of ovary, 1176
Structure of gall-bladder, 1065
of large intestine, 1028
of liver, 1059
of pancreas, 1072
of rectum, 1040
of a villus, 1023
Stylo-glossus muscle, 416
Stylo-hyoid ligament, 414
muscle, 413
nerve from facial, 813
Stylo-mastoid artery, 557
foramen, 178
vein, 653
Stylo-maxillary ligament, 328
Stylo-pharyngeus muscle, 420
Styloid process of radius, 260

Styloid process of temporal bone, 178
of ulna, 258
Subanconeus muscle, 478
Subarachnoid of cord, 694
of septum, 694
tissue, 694
Subcæcal fossa, 997
Subclavian arteries, 576
branches of, 581
first part of, left, 577
right, 577
peculiarities of, 579
second portion of, 578
surface form of, 579
surgical anatomy of, 579
third portion of, 578
groove, 234
triangle, 565
vein, 665
Subclavius muscle, 469
Subcostal angle, 228
muscle, 442
nerve, 848
Subcrureus muscle, 510
Subdural space, 694
Sublingual artery, 553
fossa, 202
gland, 948
vessels and nerves of, 948
Sublobular veins, 1057, 1061
Submaxillary artery, 555
fossa, 203
ganglion, 808
gland, 947
nerves of, 947
vessels of, 947
lymphatic gland, 683
triangle, 564
vein, 652
Submental artery, 555
Suboccipital nerve, 826
posterior branch of, 826
triangle, 582
Subpleural mediastinal plexus, 586
Subpubic ligament, 340
Subscapular angle, 243
artery, 592
fascia, 472
fossa, 242
nerves, 838
Subscapularis muscle, 472
Subsigmoid fossa, 996
Substantia cinerea gelatinosa, 701
ferruginea, 724
nigra, 741, 742, 744
Subthalmic region, 745
Sudoriferous glands, 95
Sulci of brain, 772
frontal, 775
intraparietal, 776
occipital, 777
parallel, 778
post-central, 776
precentral, 775
of Reil, 778
temporal, 778
Sulcus basilaris, 721
callosal, 780
centralis insulæ, 778
lateralis, 741, 742
oculo-motorius, 741
for olfactory tract, 775, 783
Sulcus, orbital, 775
precentral, 791
pyloricus, 1000
spiralis, 924
tympanicus, 914
vallecutæ, 726
Supercilia, 907
Superciliary ridge, 171
Superficial cervical artery, 585
circumflex iliac artery, 635
epigastric artery, 635
external pudic artery, 635
palmar arch, 604
perineal artery, 625
temporal artery, 558
surgical anatomy of, 559
transverse ligament of fingers, 492
Superficialis colli nerve, 831
volæ artery, 599
Superior maxillary bone, 189
articulations of, 195
attachment of muscles to, 195
changes in, produced by age, 195
development of, 194
nerve, 801
meatus, 221
mediastinum, 1115
profunda artery, 596
thyroid artery, 552
surgical anatomy of, 552
turbinated crest, 192
of palate, 198
vena cava, 667
Supinator brevis muscle, 486
longus muscle, 483
Supracondylar line, 287
Suprahyoid aponeurosis, 413
Supramastoid crest, 174
Supramaxillary nerves from facial, 815
Supraorbital arch, 171
artery, 569
foramen, 171, 217
nerve, 798
notch, 171
Suprarenal arteries, 615
capsules, 1137
nerves of, 1139
vessels of, 1139
plexus, 875
veins, 675
Suprascapular artery, 585
nerve, 838
notch, 245
Supraspinales muscles, 438
Supraspinatus muscle, 473
Supraspinous fascia, 473
fossa, 244
ligaments, 321
Supratrochlear foramen, 251
nerve, 798
Sural arteries, 639
veins, 672
Surface form or marking of abdominal aorta, 609
of acromio-clavicular joint, 344
of ankle-joint, 379
of anterior tibial artery, 642
of axillary artery, 591
of back, 440
of bladder, 1144
Surface form or marking of brachial artery, 595
of branches of internal iliac artery, 627
of carpus, 270
of clavicle, 241
of common carotid artery, 549
iliac artery, 619
of cranium, 222
of dorsalis pedis artery, 643
of elbow, 352
of external auditory meatus, 915
carotid artery, 551
iliac artery, 619
of femoral artery, 633
of femur, 290
of fibula, 299
of fifth cranial nerve, 809
of foot, 310
of head and face, 406
of heart, 1096
of hip-joint, 386
of humerus, 253
of hyoid bone, 228
of intestines, 1045
of kidney, 1135
of knee-joint, 374
of knuckles, 362
of larynx, 1111
of liver, 1065
of lower extremity, 535
of lungs, 1120
of mouth, 949
of muscles of abdomen, 457
of neck, 427
of palmar arches, 604
of palpebral fissure, 911
of pancreas, 1073
of patella, 292
of pelvis, 283
of plantar arch, 648
of popliteal artery, 638
of posterior tibial artery, 645
of radial artery, 598
of radio-ulnar joint, inferior, 356
superior, 353
of radius, 261
of scapula, 247
of shoulder-joint, 348
of skull, 222
of spleen, 1081
of spine, 162
of sterno-clavicular joint, 342
of sterno-mastoid, 411
of stomach, 1007
of subclavian artery, 579
of tarsus and foot, 310
of temporo-maxillary joint, 330
of thorax, 236
of tibia, 296
of ulna, 259
of ulnar artery, 802
of upper extremity, 497
of vertebral column, 162
of wrist and hand, 270
of wrist-joint, 357
Surfaces of liver, 1049
of pancreas, 1069
of popliteal of femur, 286
of spleen, 1074

Surgical anatomy of abdominal aorta, 609
of abducent nerve, 811
of acromio-clavicular joint, 344
of adductor longus muscle, 513
of ankle-joint, 379
of anterior tibial artery, 642
of arch of aorta, 544
of artery of the bulb, 625
of ascending pharyngeal artery, 558
of auditory nerve, 816
of axilla, 589
of axillary artery, 591
glands, 684
vein, 665
of azygos veins, 668
of base of bladder, 1207
of bend of elbow, 593
of bones of face, 224
of brachial artery, 595
plexus, 844
of branches of internal iliac, 628
of cavernous sinus, 659
of cervical glands, 684
vertebræ, 327
of clavicle, 241
of club-foot, 528
of common carotid, 549
iliac, 619
of deep epigastric, 630
of deltoid muscle, 472
of descending aorta, 606
of dorsalis pedis artery, 643
of elbow-joint, 352
of Eustachian tube, 952
of extensor muscles of thumb, 489
of external carotid artery, 551
ear, 928
iliac artery, 619
of jugular vein, 653
of eye, 905
of facial artery, 556
nerve, 815
vein, 652
of femoral artery, 653
hernia, 1190
of femur, 290
of foot, bones of, 311
of forearm, bones of, 261
of gluteal artery, 627
of hæmorrhoidal veins, 672
of hamstrings, 520
of hand, bones of, 271
of hip-joint, 366
of humerus, 253
of hyoid bone, 228
of hypoglossal nerve, 825
of iliac fascia, 505
of inferior thyroid artery, 585
vena cava, 668
of inguinal hernia, 1180
glands, 686
of innominate artery, 546
of intercostal nerves, 848
of internal carotid artery, 568
iliac artery, 621
jugular vein, 655
Surgical anatomy of internal mammary artery, 687
pudic artery, 624
of intestines, 1045
of ischio-rectal region, 1201
of joints of cervical vertebræ, 327
of kidneys, 1135
of knee-joint, 374
of lachrymal apparatus, 911
of laryngeal nerves, 822
of laryngo-tracheal region, 1111
of larynx, 1111
of leg, bones of, 299
of lingual artery, 553
of liver, 1066
of lumbar plexus, 866
of lungs, 1122
of middle meningeal artery, 561
of motor oculi nerve, 795
of muscles of eye, 398
of lower extremity, 537
of soft palate, 423
of upper extremity, 499
of musculo-spiral nerve, 844
of nasal fossæ, 889
of nose, 889
of œsophagus, 954
of olfactory nerve, 793
of optic nerve, 794
of palmar arch, 605
fascia, 492
of pancreas, 1073
of patella, 292
of pelvis, bones of, 283
of penis, 1153
of perinæum, 1201
of peroneal or external popliteal nerve, 866
of pharynx, 952
of plantar arch, 648
ligaments, 382
of pleura, 1114
of popliteal artery, 638
of posterior tibial, 645
of pronator radii teres muscle, 479
of prostate gland, 1149
of psoas magnus, 505
of radial artery, 598
of radio-ulnar joint, 354
of rectum, 1046
of rectus femoris muscle, 511
of ribs, 237
of saphena veins, 671
of scapula, 247
of Scarpa's triangle, 630
of sciatic artery, 628
nerve (great), 866
of scrotum, 1155
of serratus magnus muscle, 471
of shoulder-joint, 348
of skull, 224
of spermatic veins, 674
of spinal accessory nerve, 823
of spine, 162
of spleen, 1081
of sterno-clavicular joint, 342
of sterno-mastoid muscle, 411
of sternum, 237
Surgical anatomy of stomach 1007
of subclavian artery, 579
of superior thyroid artery, 552
of synovial sheaths of tendons of wrist, 490
of talipes, 528
of tarsal joints, 382, 384
of temporal artery, 559
of temporo-maxillary joint, 330
of testis, 1159
of thoracic aorta, 606
of thorax, 237
of thyroid gland, 1124
of tongue, 418, 883
of triangles of neck, 563
of triceps, 478
of trifacial nerve, 809
of trochlear nerve, 796
of ulnar artery, 602
of upper extremity, 499
of urethra, 1147
of vertebral artery, 583
of vesico-prostatic plexus, 673
of vesiculæ seminales, 1161
of wrist-joint, 357
Suspensory ligament of incus, 920
of lens, 905
of liver, 1053, 1076
of malleus, 919
of penis, 1151
Sustentaculum lienis, 1036, 1077
tali, 301
Sutura, 315
dentata, 315
false, 715
harmonia, 315
limbosa, 315
notha, 315
serrata, 315
squamosa, 315
vera, 315
Suture, basilar, 207
coronal, 206
cranial, 206
frontal, 206
fronto-parietal, 206
fronto-sphenoidal, 206, 207
intermaxillary, 217
internasal, 217
interparietal, 206
lambdoid, 206
masto-occipital, 207
masto-parietal, 207
occipito-parietal, 206
petro-occipital, 207
petro-sphenoidal, 207
sagittal, 206
spheno-parietal, 207
squamo-parietal, 207
squamo-sphenoidal, 207
temporal, 177
transverse facial, 207
Sweat-glands, 95
Sylvius, aqueduct of, 707, 741, 744
fissure of, 755
Sympathetic nerve, 75, 867
cervical portion, 869
cranial portion, 869
lumbar portion, 873

Sympathetic nerve, pelvic portion, 874
thoracic portion, 872
plexuses, 874
cardiac, 874
epigastric, 875
hypogastric, 877
pelvic, 878
solar, 875
Symphysis, 315, 317
of jaw, 202
pubis, 277, 339
Synarthrosis, 314
Synchondrosis, 315, 317
Syndesmo-odontoid joint, 323
Syndosmosis, 315, 317
Synostosis, 315
Synovia, 314
Synovial membrane, 96, 313
articular, 313
bursal, 314
vaginal, 314. See also *Individual Joints.*
System, Haversian, 56
Systemic arteries, 539
veins, 649

T.

Tables of the skull, 143
Tactile corpuscles, 76
of Grandy, 77
Tænia coli, 1028
hippocampi, 763
semicircularis, 760, 768
tectæ, 757
Tapetum, 757
lucidum, 901
nigrum, 901
Tarsal artery, 643
bones, 299
ligament of eyelid, 908
ligaments, 380
plates of eyelid, 908
Tarso-metatarsal articulations, 384
Tarsus, 299
articulations of, 380
surface form of, 310
surgical anatomy of, 311
synovial membranes of, 381
development of, 308
Taste-goblets, 881
Teeth, 932
bicuspid, 933
body of, 932
canine, 933
cement of, 937
cortical substance of, 938
crown of, 932
crusta petrosa of, 938
cuspidate, 933
deciduous, 932
dental tubuli of, 936
dentine of, 935
development of, 938
enamel of, 938
eruption of, 944
eye, 932
false molars, 933
fang of, 933
general characters of, 932
growth of, 942
incisors, 932
intertubular substance of, 937
Teeth, ivory of, 935
milk, 932, 935
molar, 933
multicuspidate, 933
permanent, 932
pulp-cavity of, 935
root of, 932
structure of, 935
temporary, 932, 935
true or large molars, 933
wisdom, 935
Tegmen tympani, 177
Tegmentum, 741, 742, 785
Tela choroidea, inferior, 738, 739
superior, 750
Temporal artery, 558
anterior, 558
deep, 561
middle, 559
posterior, 558
surgical anatomy of, 559
bone, 173
articulations of, 180
attachment of muscles to, 180
development of, 179
mastoid portion, 175
petrous portion, 176
squamous portion, 173
structure of, 179
fascia, 403
fossæ, 215
ganglion, 871
muscle, 403
nerves of auriculo-temporal, 806
deep, 806
of facial, 814
ridge, 171, 173, 174, 215
suture, 177
veins, 652
Temporary cartilage, 51
teeth, 932, 935
Temporo-facial nerve, 813
Temporo-malar nerve, 801
Temporo-maxillary articulation, 327
surface form of, 330
surgical anatomy of, 330
vein, 653
Tendo Achillis, 523
palpebrarum or oculi, 395
Tendon, central or cordiform, of diaphragm, 445
conjoined, of internal, oblique and transversalis, 452, 1184
structure of, 389
of wrist, relation of, 490
Tenon, capsule of, 890
Tensor palati muscle, 422
tarsi muscle, 395
tympani muscle, 920
canal for, 179, 917
vaginæ femoris muscle, 508
Tent, 734
Tenth nerve, 819
surgical anatomy of, 822
Teres major muscle, 474
minor muscle, 474
Testes, 1156
coni vasculosi of, 1158
coverings of, 1153
development of, 137
gubernaculum testis, 1161
lobules of, 1158
Testes, lymphatics of, 689
mode of descent, 1161
rete testis, 1158
size and weight of, 1156
structure of, 1157
surgical anatomy of, 1159
tubuli seminiferi of, 1158
tunica albuginea, 1157
vaginalis, 1156
vasculosa, 1157
vas aberrans of, 1159
vas deferens of, 1159
vas recta of, 1158
vasa efferentia of, 1158
Testes muliebres, 1175
Thalamencephalon, 121, 706, 745
Thalamus opticus, 746–748
Thebesii foramina, 678
valve of, 1088
venæ, 678
Thigh, deep fascia, fascia lata, 506
muscles of back of, 518
of front of, 507
superficial fascia of, 506, 1190
Third nerve, 794
surgical anatomy of, 795
ventricle of the brain, 707, 745, 748
Thoracic aorta, 605
surgical anatomy of, 606
artery, acromial, 592
alar, 592
long, 592
superior, 592
duct, 680
ganglia of sympathetic, 872
nerves, anterior, 838
posterior, or long, 837
region, muscles of anterior, 467
lateral, 470
Thorax, base of, 1083
bones of, 228
boundaries of, 1083
cavity of, 1083
cutaneous nerves of, anterior, 848
lateral, 848
fasciæ of, 441
general description of, 1083
lymphatics of, 691
measurements of, 1083, 1099
muscles of, 441
parts passing through upper opening of, 1083
surface form of, 236
Thumb, articulation of, with carpus, 359
muscles of, 492
Thymus gland, 1124
lobes of, 1125
lymphatics of, 1126
Thyro-arytenoideus muscle, 1106
Thyro-epiglottic ligament, 1102
Thyro-epiglottideus muscle, 1107
Thyro-hyal of hyoid bone, 227
Thyro-hyoid arch (fœtal), 1119
ligaments, 1103
membrane, 1103
muscle, 411
nerve, 825
Thyroid artery, inferior, 584
superior, 552
surgical anatomy of, 552
axis, 584

Thyroid branches of sympathetic, 872
cartilage, 1100
foramen, 278
ganglion, 872
gland, 1122
isthmus of, 1123
lymphatics of, 692
notch, 1100
veins, inferior, 666
middle, 655
superior, 654
Thyroidea ima artery, 545
Tibia, 293
articulations of, 296
attachment of muscles to, 296
crest of, 293, 294
development of, 296
fracture of shaft of, 538
nutrient artery of, 646
spinous process of, 293
surface form of, 296
surgical anatomy of, 299
tubercle of, 293
tuberosities of, 293
Tibial artery, anterior, 641
branches of, 642
peculiarities of, 642
surface-marking of, 642
surgical anatomy of, 642
lymphatic glands, 686
nerve, anterior, 865
posterior, 863
recurrent artery, 642
veins, anterior, 671
posterior, 671
Tibialis anticus muscle, 521
posticus muscle, 526
Tibio-fibular articulations, 376
region, anterior, muscles of, 521
posterior, muscles of, 522
Tibio-tarsal ligament, 377, 378
Tongue, 879
arteries of, 882
fibrous septum of, 882
frænum of, 879
mucous glands of, 882
membrane of, 879
muscles of, 416
nerves of, 883
papillæ of, 880
serous glands of, 882
surgical anatomy of, 883
Tonsillar artery, 555
nerves, 818
Tonsils, 945
of cerebellum, 732
nerves of, 945
vessels of, 945
Torcular Herophili, 166, 658
Torsion of intestine, 972
of stomach, 972
Trabeculæ, 1090
of corpus cavernosum, 1151
of fœtal skull, 118
of testis, 1157
Trachea, 1108
cartilages of, 1110
glands of, 1111
relations of, 1108
structure of, 1110
surface form of, 1111
surgical anatomy of, 1111
vessels and nerves of, 1111
Trachelo-mastoid muscle, 436
Tracheotomy, 1092
Trachoma glands, 909
Tract, antero-lateral ascending cerebellar, 700, 710, 717
descending cerebellar, 700, 710, 717
direct cerebellar, 700, 710
sensory, 742
lateral, 710
of Lissauer, 700
olfactory, 782, 783
optic, 752
pyramidal, 710, 742
crossed, 700
direct, 700
Tractus intermedio-lateralis, 702
opticus, 793
spiralis foramenulentus, 928
Tragicus muscle, 914
Tragus, 912
Transversalis colli artery, 585
muscle, 436
fascia, 1185
muscle, 453
humeri artery, 585
Transverse arteries of basilar, 583
colon, 1035
disks of muscular fibre, 66
facial artery, 559
vein, 652
fissure of brain, 770
of liver, 1051
joint of foot, 379
ligament of atlas, 323
of hip, 364
of knee, 371
of scapula, 345
of shoulder, 346
superficial, of fingers, 492
tibio-fibular, 377
pericardial sinus, 1085
process of a vertebra, 145
sinus, 661
suture, 207
Transversus auriculæ, 914
perinæi, 461
(in female), 464
Trapezium, 816
bone, 266
of pons, 721
Trapezius muscle, 428
Trapezoid bone, 266
ligament, 344
Treitz, fossa of, 995
ligament of, 1018
muscle of, 1018
Triangle of elbow, 593
of Hesselbach, 1190
inferior carotid, 563
of neck, anterior, 563
posterior, 565
occipital, 565
Scarpa's, 630
subclavian, 565
submaxillary, 564
suboccipital, 582
superior carotid, 564
Triangular interarticular fibro-cartilage, 355
ligament of abdomen, 448, 1183
of liver, 1053
of urethra, 463, 1204
Triangularis sterni muscle, 442
Triceps extensor cruris, 509
cubiti, 477
Tricuspid valves, 1090
Trifacial or trigeminus nerves, 796
surface-marking of, 809
surgical anatomy of, 809
Trigone of bladder, 1144
Trigonum, acustici, 724
habenulæ, 749
hypoglossi, 724, 823
olfactorium, 783, 784
vagi, 724
ventriculi, 758
Trochanter, greater, 285
lesser, 286
Trochanteric fossa, 285
Trochlea, 397
of femur, 288
of humerus, 251
Trochlear nerve, 796
surgical anatomy of, 796
Trochoides, 316
True ligaments of bladder, 1142
pelvis, 280
ribs, 232
Trunk, articulations of, 319
muscles of, 427
Tube, Eustachian, 916
Fallopian, 1174
Tuber annulare, 720
cinereum, 750
omentale, 1049, 1069
papillare, 1050
valvulæ, 730
Tubercle, carotid or Chassaignac's, 146
of the clavicle, 239
cuneate, 711, 715
of the femur, 286
genial, 202
genital, 140
of hyoid bone, 227
lachrymal, 193
of Lower, 1088
mamillary, 750
mental, 202
of navicular, 304
for odontoid ligaments, 165
of optic thalamus, 746
of ribs, 233
of Rolando, 711, 715
of scaphoid of carpus, 262
of tibia, 293
of ulna, 254, 256
of zygoma, 174
Tubercula quadrigemina, 743
Tuberculum caudatum, 1052
Tuberosities of humerus, greater and lesser, 248
of tibia, 293
Tuberosity, cuboid, 304
of ischium, 276
maxillary, 190
of palate bone, 199
of radius, 259
of ribs, 233
Tubes, bronchial, 1108
structure of, in lung, 1119
Tubular secreting glands, 98
substance of kidney, 1129
Tubuli, dental, 936
of Ferrein, 1131
lactiferi, 1179

Tubuli recti, 1158
seminiferi, 1158
uriniferi, 1129
Tuft, vascular, in Malpighian bodies of kidney, 1129
Tunica adventitia, 81
albuginea, 1157
of eye, 397
intima, of arteries, 80
media, 81
of ovary, 1175
Ruyschiana, 895
vaginalis, 1156
oculi, 891
propria, 1156
reflexa, 1156
vasculosa testis, 1158
Turbinated bone, inferior, 200
middle, 186
superior, 187
crest, inferior, 192
superior, 192
Tutamina oculi, 907
Twelfth nerve, 823
Tympanic artery, from internal carotid, 568
maxillary, 560
nerve, 818, 920
of facial, 812
plate, 175, 914
ring, 914
spines, 913
Tympanum, 916
arteries of, 920
cavity of, 916
membrane of, 918
mucous membrane of, 920
muscles of, 920
nerves of, 920
ossicula of, 918
veins of, 920
Types of cæca, 1031
of duodenum, 1009

U.

Ulna, 254
articulations of, 258
coronoid process of, 254
development of, 258
fracture of coronoid process of, 501
muscles attached to, 258
of olecranon, 501
process of, 254
of shaft, 501
sigmoid cavities of, 256
styloid process of, 258
surface form of, 259
surgical anatomy of, 261
tubercle of, 254, 256
Ulnar artery, 601
branches of, 602
peculiarities of, 601
recurrent, anterior, 602
posterior, 602
surface-marking of, 602
surgical anatomy of, 602
collateral nerve, 843
nerve, 841
surgical anatomy of, 844
vein, anterior, 663
posterior, 663
Umbilical arteries in fœtus, 130, 1097
Umbilical arteries in fœtus, how obliterated, 1099
cord, 115
fissure of liver, 1051
loop, 969
notch, 1049, 1051
vein, 130
vesicle, 109
Umbilicus, 109
Unciform bone, 267
process of ethmoid, 186
Uncus, 781
Ungual phalanges, 270
Unstriped muscle, 68
Upper extremities, arteries of, 575
bones of, 238
fascia of, 465
ligaments of, 340
lymphatics of, 684
muscles of, 465
nerves of, 837
surface form of, 497
surgical anatomy of, 499
veins of, 662
Urachus, 113, 963, 1143
Ureters, 1036
muscles of, 1137
nerves of, 1137
vessels of, 1137
Urethra, bulbous portion of, 1147
caput gallinaginis, 1146
development of, 140
female, 1167
male, 1146
membranous portion, 1146
prostatic portion, 1146
sinus of, 1146
rupture of, course taken by urine, 1203
sinus pocularis of, 1146
spongy portion of, 1147
structure of, 1147
surgical anatomy of, 1147
verumontanum, 1146
Urinary organs, 1127
development of, 135
Urogenital sinus, 140
Uterine arteries, 622
plexus, 878
of veins, 673
Uterus, 1168
after parturition, 1173
appendages of, 1174
arbor vitæ of, 1172
broad ligaments of, 1171
cavity of, 1172
development of, 137
during menstruation, 1173
pregnancy, 1173
in fœtus, 1073
fundus, body, and cervix of, 1168
ganglia of, 878
nerves of, 878
ligaments of, 1169
lymphatics of, 689
masculinus, 138, 1146
nerves of, 1173
in old age, 1174
at puberty, 1173
round ligaments of, 1177
shape, position, dimensions, 1168
Uterus, structure of, 1170
vessels, 1173
Utricle of vestibule, 926
Uvea, 896
Uvula of cerebellum, 732
of throat, 944
vesicæ, 1144

V.

Vagina, 1167
columns of, 1168
lymphatics of, 689
orifice of, 1163
Vaginal arteries, 622
plexus of nerves, 878
of veins, 673
process of temporal, 175, 178
processes of sphenoid, 182
synovial membranes, 313
Vagus, ganglion of root of, 819
nerve, 819
of trunk of, 819
Vallecula, 726
Sylvii, 774, 784
Valsalva, sinuses of, 542, 1091, 1094
Valve, coronary, 1088
Eustachian, 1089
of Gerlach, 1033
of Hasner, 911
ileo-cæcal, 1033
ileo-colic, 1033
mitral, 1093
of Morgagni, 1042
of Thebesius, 1088
tricuspid flaps, infundular, 1090
right, 1090
septal, 1090
of Vieussens, 720, 733, 734
Valves of lymphatics, 86
pulmonic, 1089
of rectum, 1041
in right auricle, 1088
semilunar aortic, 1093
of veins, 84
Valvula Bauhini, 1033
Heisteri, 1064
pylorica, 1000
Valvulæ conniventes, 1021
Vas aberrans, 1159
deferens, 1159
structure of, 1159
Vasa aberrantia, 1062
from brachial artery, 595
afferentia of lymphatic glands, 680
brevia arteries, 612
veins, 675
efferentia of testis, 1158
of lymphatic glands, 680
intestini tenuis, 1158
recta, 1158
vasorum of arteries, 82
of veins, 85
Vascular system, changes in, at birth, 1099
general anatomy of, 80
peculiarities in the fœtus, 1097
Vaso-motor nerves, 74
Vastus externus muscle, 509
internus and crureus, 510
Vater, corpuscles of, 77, *note.*

Vater, diverticulum of, 1070
papilla of, 1070
Veins, structure of, 84
anastomoses of, 649
of bone, 56
coats of, 84
development of, 130
muscular tissue of, 84
plexuses of, 649
size, form, etc., 649
structure of, 84
valves of, 84
vessels and nerves of, 85
Veins or Vein, descriptive anatomy of, 649
accessory portal, 1057
of alæ nasi, 652
angular, 651
articular, of knee, 672
auditory, 927
auricular anterior, 652
posterior, 653
axillary, 664
azygos, left lower, 667
left upper, 667
right, 667
basilic, 664
basi-vertebral, 669
brachial, 664
brachio-cephalic or innominate, 665
bronchial, 668
buccal, 653
cardiac, 677
anterior, 677
great, 677
left, 677
middle, 677
posterior, 677
right, 677
cardinal, 131
cava inferior, 673
superior, 667
cephalic, 663
cerebellar, 657
cerebral, 657
cervical, ascending, 655
deep, 655
choroid of brain, 657
circumflex, iliac, 672
superficial, 670
condyloid posterior, 655, 659
of corpora cavernosa, 1152
of corpus spongiosum, 673
striatum, 657
deep, or venæ comites, 649
dental inferior, 653
digital, of hand, 663
of diploë, 655
dorsal of penis, 673
dorsi-spinal, 668
emissary, 661
surgical anatomy of, 662
epigastric, 672
superficial, 670
of eyeball, 905
facial, 652
femoral, 672
first intercostal, 655
frontal, 651
of Galen, 657
gastric, 676
gluteal, 672
hæmorrhoidal, 672
of head, 650
Veins or vein, hepatic, 675, 1057, 1061
iliac, common, 673
external, 672
internal, 672
ilio-lumbar, 674
inferior cava, 673
innominate, 665
intercostal, first, 655
superior, 666
interlobular, of kidney, 1134
of liver, 1057
interosseous, of forearm, 664
intralobular, of liver, 1057
jugular, anterior, 654
external, 653
internal, 654
posterior, 654
of kidney, 1134
labial, inferior, 652
superior, 652
laryngeal, 666
lateral sacral, 673
lingual, 654
of liver, 1057
longitudinal inferior, 658
lumbar, 674
ascending, 674
mammary internal, 666
masseteric, 652
mastoid, 653
maxillary internal, 652
median basilic, 663
cephalic, 663
medulli-spinal, 668
meningeal, 653
meningo-rachidian, 668
mesenteric inferior, 675
superior, 675
nasal, 650
oblique, 677
occipital, 653
œsophageal, 667
ophthalmic, 659
ovarian, 674
palmar, deep, 664
parotid, 652
parumbilicalis, 958
peroneal, 671
pharyngeal, 654
phrenic, 675
plantar, external, 671
internal, 671
popliteal, 671
plexuses of ovarian, 1178
pampiniform, 674, 1155, 1178
pharyngeal, 654
pterygoid, 652
spermatic, 674, 1155
uterine, 673
vaginal, 873
vesico-prostatic, 655
portal, 649, 677, 1057, 1060
profunda femoris, 672
pterygoid plexus, 652
pubic, external, 670
internal, 672
pulmonary, 650
radial, 663
ranine, 652, 654
renal, 675, 1134
sacral, lateral, 673
middle, 673
Salvatella, 663
Veins or vein, saphenous, external, or short, 670
internal, or long, 670, 1190
sciatic, 672
spermatic, 674
spheno-palatine, 655
spinal, 668
splenic, 675
stylo-mastoid, 653
subclavian, 665
sublobular, 1057, 1061
submaxillary, 652
submental, 654
superficial, 649
supraorbital, 651
suprarenal, 675
suprascapular, 654
sural, 672
systemic, 649
temporal, 654
middle, 652
temporo-maxillary, 653
thoracico-epigastrica, 957
thyroid inferior, 666
middle, 655
superior, 654
tibial anterior, 671
posterior, 671
transverse cervical, 654
facial, 652
ulnar anterior, 663
common, 663
deep, 664
posterior, 663
umbilical, 1099
vertebral, 655
first intercostal, 655
Vidian, 654
Velum medullary, inferior, 733, 734, 738
superior, 733, 734, 738
pendulum palati, 944
interpositum, 749, 766, 769
Vena cava, fissure for, 1052
inferior, 673
peculiarities of, 674
superior, 667
Venæ comites, 649
hepaticæ advehentes, 131
revehentes, 131
interlobulares of kidney, 1134
rectæ of kidney, 1134
Thebesii, or minimæ cordis, 678, 1088
vorticosæ, 895
Venesection, 663
Venter of ilium, 274
Ventricle of brain, fifth, 763
fourth, 708, 737–740
floor of, 720, 723
third, 707, 745, 748
of corpus callosum, 756
of heart, left, 1092
right, 1089
of larynx, 1105
lateral, 704, 755
Vermicular motion, 68
Vermiform appendix, 1032
relations of, 1033
process of cerebellum, inferior, 727
superior, 727
Vernix caseosa, 125
Vertebra prominens, 149
development of, 152

Vertebræ, 144
cervical, 145
development of, 152
dorsal. 149
general characters, 144
ligaments of, 319
lumbar, 151
sacral, 155
structure of, 152
Vertebral aponeurosis, 433
artery, 581
column, 160
articulation of, 319
ossification of, 152
surface form of, 162
ligaments, 319
region, muscles of, anterior 424
lateral, 425
vein, 655
Vertex of skull, 208
Vertical plate of palate bone, 198
Verumontanum, 1146
Vesical artery, inferior, 622
middle, 622
superior, 622
plexus of nerves, 878
Vesicle, auditory, 124
cerebral, 119, 706
fissure, 1052
germinal, 101
hemisphere, 707
ocular, 123
optic, 752
of Purkinje, 101
umbilical, 109
Vesicles, Graafian, 1176
Vesico-prostatic plexus of veins 673
Vesico-uterine ligaments, 1169
pouch, 981, 988
Vesicula prostatica, 1146
Vesiculæ seminales, 1160
surgical anatomy of, 1161
vessels and nerves of, 1161
Vesicular column of anterior cornu of spine, 702
Vessels of large intestine, 1029
of liver, 1060
of rectum, 1042
of small intestine, 1026
of spleen, 1077, 1079
Vessels of stomach, 1007
Vestibular artery, 927
nerve, 927
Vestibule, aortic, 1094
of ear, 921
aqueduct of, 177, 921
Vestigial fold of pericardium, 666
Vibrissæ, 885
Vidian artery, 562
canal, 184
nerve, 804
sphenoidal filament, 804, 808
Vieussens, valve of, 733, 734, 796
Villi, 1022
structure of, 1023
Viscera, pelvic position of, at outlet of pelvis, 1206
Visceral clefts, 118
Vitelline circulation, 126
duct, 967, 970
membrane, 100
Vitellus, 100
Vitreous humor of the eye, 903
table of the skull, 144
Vocal cords, inferior or true, 1103
superior or false, 1105
process, 1102
Voice, organs of, 1100
Voluntary muscles, 64
Vomer, 201
alæ of, 201
articulations of, 201
development of, 201
Vortex of heart, 1095
Vulva, 1163
development of, 140

W.

Wagner, tactile corpuscles of, 76
Wall, abdominal, 957, 959
Watney on the structure of thymus, 1126
Weight of organs. See *Individual Organs.*
Wharton's duct, 947
White fibrous tissue, 45
nerve-matter, 69
substance of cord, 699
of Schwann, 71
Willis, circle of, 573, 584
Winslow, foramen of, 975, 992
ligament of, 368
Wirsung, canal of, 1070
Wisdom tooth, 935
Wolffian duct, 135
Womb. See *Uterus.*
Worm of cerebellum, 725, 727
Wormian bones, 188
Wrisberg, cartilages of, 1102
ganglion of, 874
nerve of, 840
Wrist-joint, 356
surface form of, 270, 357
surgical anatomy of, 357
Wry-neck, 411

X.

Xiphoid appendix, 229

Y.

Y-ligament, 364
Y-shaped centre of acetabulum, 278
Yellow cartilage, 53
elastic fibrous tissue, 45
spot of retina, 898
Yolk, 101
sac. 109. 967
stalk, 967

Z.

Zinn, ligament of, 397
Zona arcuata, 925
fasciculata, 1138
glomerulosa, 1138
incerta, 745
mesogastric, 961
pellucida, 101
radiata, 101
reticularis, 1138
vasculosa, 1176
Zygoma, 174
roots of, 174
tubercle of, 174
Zygomatic arch, 216
fossæ, 216
lymphatic glands, 681
process of malar. 197
Zygomaticus major muscle, 400
minor, 400

Catalogue of Books

PUBLISHED BY

Lea Brothers & Company,

706, 708 & 710 Sansom St., Philadelphia.
111 Fifth Avenue, New York.

The books in the annexed list will be sent by mail, post-paid, to any Post-Office in the United States, on receipt of the printed prices. No risks of the mail, however, are assumed either on money or books. Intending purchasers will therefore in most cases find it more convenient to deal with the nearest bookseller.

STANDARD MEDICAL PERIODICALS.

Progressive Medicine.

A Quarterly Digest of New Methods, Discoveries and Improvements in the Medical and Surgical Sciences by Eminent Authorities. Edited by Dr. Hobart Amory Hare. In four abundantly illustrated, cloth bound, octavo volumes of 400–500 pages each, issued quarterly, commencing March 1, 1899. Per annum (4 volumes), $10.00, delivered.

The Medical News.

WEEKLY, $4.00 PER ANNUM.

Each number contains 32 quarto pages, abundantly illustrated. A crisp, fresh weekly professional newspaper.

The American Journal of the Medical Sciences.

MONTHLY, $4.00 PER ANNUM.

Each issue contains 128 octavo pages, fully illustrated. The most advanced and enterprising American exponent of scientific medicine.

The Medical News Visiting List for 1900.

Four styles, Weekly (dated for 30 patients); Monthly (undated, for 120 patients per month); Perpetual (undated, for 30 patients weekly per year; and Perpetual (undated, for 60 patients weekly per year). Each style in one wallet-shaped book, leather bound, with pocket, pencil and rubber. Price, each, $1.25. Thumb-letter index, 25 cents extra.

The Medical News Pocket Formulary for 1900.

Containing 1700 prescriptions representing the latest and most approved methods of administering remedial agents. Strongly bound in leather, with pocket and pencil. Price, $1.50, *net.*

COMBINATION RATES.

Per Annum

	ALONE.	IN COMBINATION
American Journal of the Medical Sciences	$4.00	$7.50
Medical News	4.00	
Progressive Medicine	10.00	$15.00
Medical News Visiting List	1.25	
Medical News Formulary	1.50, net.	

In all $20.75 for $16.00

First four above publications in combination.....$15.75
All above publications in combination..... 16.00
Other Combinations will be quoted on request. Full Circulars and Specimens free.

ABBOTT (A. C.). *PRINCIPLES OF BACTERIOLOGY:* a Practical Manual for Students and Physicians. New (5th) edition enlarged and thoroughly revised. In one handsome 12mo. volume of 585 pages, with 109 engravings, of which 26 are colored. *Just ready.* Cloth, $2.75, *net.*

ALLEN (HARRISON). *A SYSTEM OF HUMAN ANATOMY; WITH AN INTRODUCTORY SECTION ON HISTOLOGY,* by E. O. SHAKESPEARE, M.D. Comprising 813 double-columned quarto pages, with 380 engravings on stone on 109 full-page plates, and 241 woodcuts. One volume, cloth, $23. *Sold by subscription only.*

A TREATISE ON SURGERY BY AMERICAN AUTHORS. *FOR STUDENTS AND PRACTITIONERS OF SURGERY AND MEDICINE.* Edited by ROSWELL PARK, M.D. New condensed edition. In one large octavo volume of 1261 pages, with 625 engravings and 38 plates. *Just ready.* Cloth, *net,* $6.00; leather, *net,* $7.00.
☞This work is published also in a large edition, comprising two octavo volumes. Vol. I., *General Surgery,* 799 pages, with 356 engravings and 21 full-page plates in colors and monochrome. Vol. II., *Special Surgery,* 796 pages, with 451 engravings and 17 full-page plates in colors and monochrome. Price per volume, cloth, $4.50; leather, $5.50, *net.*

AMERICAN SYSTEM OF PRACTICAL MEDICINE. *A SYSTEM OF PRACTICAL MEDICINE.* In Contributions by Eminent American Authors. Edited by ALFRED L. LOOMIS, M.D., LL.D., and W. GILMAN THOMPSON, M.D. In four very handsome octavo volumes of about 900 pages each, fully illustrated. *Complete work now ready.* Per volume, cloth, $5; leather, $6; half Morocco, $7. *For sale by subscription only.* Prospectus free on application.

AMERICAN SYSTEM OF DENTISTRY. *IN TREATISES BY VARIOUS AUTHORS.* Edited by WILBUR F. LITCH, M.D., D.D.S. In four very handsome super-royal octavo volumes, containing about 4000 pages, with about 2200 illustrations and many full-page plates. Volume IV., *preparing.* Per volume, cloth, $6; leather, $7; half Morocco, $8. *For sale by subscription only.* Prospectus free on application to the Publishers.

AMERICAN TEXT-BOOK OF ANATOMY. See *Gerrish,* page 7.

AMERICAN TEXT-BOOKS OF DENTISTRY. *IN CONTRIBUTIONS BY EMINENT AMERICAN AUTHORITIES.* In two octavo volumes of 600–800 pages each, richly illustrated:

—— *PROSTHETIC DENTISTRY.* Edited by CHARLES J. ESSIG, M.D., D.D.S., Professor of Mechanical Dentistry and Metallurgy, Department of Dentistry, University of Pennsylvania, Philadelphia. 760 pages, 983 engravings. Cloth, $6; leather, $7, *net.*

—— *OPERATIVE DENTISTRY.* Edited by EDWARD C. KIRK, D.D.S., Professor of Clinical Dentistry, Department of Dentistry, University of Pennsylvania. 700 pages, 751 engravings. Cloth, $5.50; leather, $6.50, *net.*

AMERICAN SYSTEMS OF GYNECOLOGY AND OBSTETRICS. In treatises by the most eminent American specialists. Gynecology edited by MATTHEW D. MANN, A.M., M.D., and Obstetrics edited by BARTON C. HIRST, M.D. In four large octavo volumes comprising 3612 pages, with 1092 engravings, and 8 colored plates. Per volume, cloth, $5; leather, $6; half Russia, $7. *For sale by subscription only.* Prospectus free.

ASHHURST (JOHN, JR.). *THE PRINCIPLES AND PRACTICE OF SURGERY.* For the use of Students and Practitioners. Sixth and revised edition. In one large and handsome 8vo. volume of 1161 pages, with 656 engravings. Cloth, $6; leather, $7.

A SYSTEM OF PRACTICAL MEDICINE BY AMERICAN AUTHORS. Edited by WILLIAM PEPPER, M.D., LL.D. In five large octavo volumes, containing 5573 pages and 198 illustrations. Price per volume, cloth, $5; leather, $6; half Russia, $7. *Sold by subscription only.* Prospectus free on application to the Publishers.

A PRACTICE OF OBSTETRICS BY AMERICAN AUTHORS. See *Jewett,* page 9.

ATTFIELD (JOHN). *CHEMISTRY; GENERAL, MEDICAL AND PHARMACEUTICAL.* New (16th) edition, specially revised by the Author for America. In one handsome 12mo. volume of 784 pages, with 88 illustrations. Cloth, $2.50, *net*

BACON (GORHAM). *ON THE EAR.* One 12mo. volume, 398 pages, with 109 engravings and one colored plate. Cloth, $2, *net.*

BARNES (ROBERT AND FANCOURT). *A SYSTEM OF OBSTETRIC MEDICINE AND SURGERY, THEORETICAL AND CLINICAL.* The Section on Embryology by PROF. MILNES MARSHALL. In one large octavo volume of 872 pages, with 231 illustrations. Cloth, $5; leather, $6.

BARTHOLOW (ROBERTS). *CHOLERA; ITS CAUSATION, PREVENTION AND TREATMENT.* In one 12mo. volume of 127 pages, with 9 illustrations. Cloth, $1.25.

BILLINGS (JOHN S.). *THE NATIONAL MEDICAL DICTIONARY.* Including in one alphabet English, French, German, Italian and Latin Technical Terms used in Medicine and the Collateral Sciences. In two very handsome imperial octavo volumes, containing 1574 pages and two colored plates. Per volume, cloth, $6; leather, $7; half Morocco, $8.50. *For sale by subscription only.* Specimen pages on application.

BLACK (D. CAMPBELL). *THE URINE IN HEALTH AND DISEASE, AND URINARY ANALYSIS, PHYSIOLOGICALLY AND PATHOLOGICALLY CONSIDERED.* In one 12mo. volume of 256 pages, with 73 engravings Cloth, $2.75.

BLOXAM (C. L.). *CHEMISTRY, INORGANIC AND ORGANIC.* With Experiments. New American from the fifth London edition. In one handsome octavo volume of 727 pages, with 292 illustrations. Cloth, $2; leather, $3.

BROCKWAY (FRED. J.). *A POCKET TEXT-BOOK OF ANATOMY.* 12mo. of about 400 pages, richly illustrated. *Shortly.*

BRUCE (J. MITCHELL). *MATERIA MEDICA AND THERAPEUTICS.* New (6th) edtion. In one 12mo. volume of 600 pages. *Just ready.* Cloth, $1.50, *net.* See *Students' Series of Manuals*, page 14.

——— *PRINCIPLES OF TREATMENT.* In one octavo volume of 625 pages. *Just Ready.* Cloth, $3.75, *net.*

BRYANT (THOMAS). *THE PRACTICE OF SURGERY.* Fourth American from the fourth English edition. In one imperial octavo volume of 1040 pages, with 727 illustrations. Cloth, $6.50; leather, $7.50.

BUMSTEAD (F. J.) AND TAYLOR (R. W.). *THE PATHOLOGY AND TREATMENT OF VENEREAL DISEASES.* See *Taylor on Venereal Diseases*, page 15.

BURCHARD (HENRY H.). *DENTAL PATHOLOGY AND THERAPEUTICS, INCLUDING PHARMACOLOGY.* Handsome octavo, 575 pages, with 400 illustrations. Cloth, $5; leather, $6, *net.*

BURNETT (CHARLES H.). *THE EAR: ITS ANATOMY, PHYSIOLOGY AND DISEASES.* A Practical Treatise for the Use of Students and Practitioners. Second edition. In one 8vo. volume of 580 pages, with 107 illustrations. Cloth, $4; leather, $5.

CARTER (R. BRUDENELL) AND FROST (W. ADAMS). *OPHTHALMIC SURGERY.* In one pocket-size 12mo. volume of 559 pages, with 91 engravings and one plate. Cloth, $2.25. See *Series of Clinical Manuals*, page 13.

CASPARI (CHARLES, JR.). *A TREATISE ON PHARMACY.* For Students and Pharmacists. In one handsome octavo volume of 680 pages, with 288 illustrations. Cloth, $4.50.

CHAPMAN (HENRY C.). *A TREATISE ON HUMAN PHYSIOLOGY.* New (2d) edition. In one octavo volume of 921 pages, with 595 illustrations. *Just ready.* Cloth, $4.25; leather, $5.25, *net.*

CHARLES (T. CRANSTOUN). *THE ELEMENTS OF PHYSIOLOGICAL AND PATHOLOGICAL CHEMISTRY.* In one handsome octavo volume of 451 pages, with 38 engravings and 1 colored plate. Cloth, $3.50.

CHEYNE (W. WATSON). *THE TREATMENT OF WOUNDS, ULCERS AND ABSCESSES.* In one 12mo. volume of 207 pages. Cloth, $1.25.

CHEYNE (W. WATSON) AND BURGHARD (F. F.). *SURGICAL TREATMENT.* In seven octavo volumes, illustrated. Volume I, *just ready.* 299 pages and 66 engravings. Cloth, $3.00, *net.* Volume II, *just ready.* 382 pages, 141 engravings. Cloth, $4.00, *net.* Volume III. *Just Ready.* 300 pages, 100 engravings. Cloth, $3.50, *net.* Vol. IV. *In Press.*

CLARKE (W. B.) AND LOCKWOOD (C. B.). *THE DISSECTOR'S MANUAL.* In one 12mo. volume of 396 pages, with 49 engravings. Cloth, $1.50. See *Students' Series of Manuals*, page 14.

CLELAND (JOHN). *A DIRECTORY FOR THE DISSECTION OF THE HUMAN BODY.* In one 12mo. volume of 178 pages. Cloth, $1.25.

CLINICAL MANUALS. See *Series of Clinical Manuals*, page 13.

CLOUSTON (THOMAS S.). *CLINICAL LECTURES ON MENTAL DISEASES.* New (5th) edition. Crown 8vo., of 736 pages with 19 colored plates. Cloth, $4.25, *net.*

☞ FOLSOM'S *Abstract of Laws of U. S. on Custody of Insane*, octavo, $1.50, is sold in conjunction with *Clouston on Mental Diseases* for $5.00, *net*, for the two works.

CLOWES (FRANK). *AN ELEMENTARY TREATISE ON PRACTICAL CHEMISTRY AND QUALITATIVE INORGANIC ANALYSIS.* From the fourth English edition. In one handsome 12mo. volume of 387 pages, with 55 engravings. Cloth, $2.50.

COAKLEY (CORNELIUS G.). *THE DIAGNOSIS AND TREATMENT OF DISEASES OF THE NOSE, THROAT, NASO-PHARYNX AND TRACHEA.* In one 12mo. volume of 526 pages, with 92 engravings, and 2 colored plates. Cloth, $2.75, *net.*

COATES (W. E., Jr.). *A POCKET TEXT-BOOK OF BACTERIOLOGY AND HYGIENE.* 12mo., of about 350 pages with many illustrations. *Shortly.*

COATS (JOSEPH). *A TREATISE ON PATHOLOGY.* In one volume of 829 pages, with 339 engravings. Cloth, $5.50; leather, $6.50.

COLEMAN (ALFRED). *A MANUAL OF DENTAL SURGERY AND PATHOLOGY.* With Notes and Additions to adapt it to American Practice. By THOS. C. STELLWAGEN, M.A., M.D., D.D.S. In one handsome octavo volume of 412 pages, with 331 engravings. Cloth, $3.25.

COLLINS (C. P.). *A POCKET TEXT-BOOK OF MEDICAL DIAGNOSIS.* 12mo. of about 350 pages. *Shortly.*

COLLINS (H. D.) AND ROCKWELL (W. H., JR.). *A POCKET TEXT-BOOK OF PHYSIOLOGY.* 12mo., of 316 pages, with 153 illustrations. *Just Ready.* Cloth, $1.50, *net;* flexible red leather, $2.00, *net.*

CONDIE (D. FRANCIS). *A PRACTICAL TREATISE ON THE DISEASES OF CHILDREN.* Sixth edition. 8vo. 719 pages. Cloth, $5.25; leather, $6.25.

CORNIL (V.). *SYPHILIS: ITS MORBID ANATOMY, DIAGNOSIS AND TREATMENT.* Translated, with Notes and Additions, by J. HENRY C. SIMES, M.D., and J. WILLIAM WHITE, M.D. In one 8vo. volume of 461 pages, with 84 illustrations. Cloth, $3.75.

CROCKETT (M. A.). *A POCKET TEXT-BOOK OF DISEASES OF WOMEN.* 12mo. of 368 pages, with 107 illustrations. *Just Ready.* Cloth, $1.50, *net.* Flexible Red Leather, $2.00, *net.*

CROOK (JAMES K.). *MINERAL WATERS OF UNITED STATES.* Octavo 574 pages. *Just ready.* Cloth, $3.50, *net.*

CULBRETH (DAVID M. R.). *MATERIA MEDICA AND PHARMACOLOGY* In one handsome octavo volume of 812 pages, with 445 engravings. Cloth, $4.75.

CUSHNY (ARTHUR R.) *A TEXT-BOOK OF PHARMACOLOGY AND THERAPEUTICS.* Octavo of 728 pages, with 47 illustrations. *Just ready.* Cloth, $3.75, *net.*

DALTON (JOHN C.). *A TREATISE ON HUMAN PHYSIOLOGY.* Seventh edition, thoroughly revised. Octavo of 722 pages, with 252 engravings. Cloth, $5; leather, $6.

——— *DOCTRINES OF THE CIRCULATION OF THE BLOOD.* In one handsome 12mo. volume of 293 pages. Cloth, $2.

DAVENPORT (F. H.). *DISEASES OF WOMEN.* A Manual of Gynecology. For the use of Students and General Practitioners. New (3d) edition. In one handsome 12mo. volume, 387 pages and 150 engravings. Cloth, $1.75, *net.*

DAVIS (F. H.). *LECTURES ON CLINICAL MEDICINE.* Second edition. In one 12mo. volume of 287 pages. Cloth, $1.75.

DAVIS (EDWARD P.). *A TREATISE ON OBSTETRICS.* For Students and Practitioners. In one very handsome octavo volume of 546 pages, with 217 engravings, and 30 full-page plates in colors and monochrome. Cloth, $5; leather, $6.

DE LA BECHE'S *GEOLOGICAL OBSERVER.* In one large octavo volume of 700 pages, with 300 engravings. Cloth, $4.

DENNIS (FREDERIC S.) AND BILLINGS (JOHN S.). *A SYSTEM OF SURGERY.* In Contributions by American Authors. In four very handsome octavo volumes, containing 3652 pages, with 1585 engravings, and 45 full-page plates in colors and monochrome. Per volume, cloth, $6; leather, $7; half Morocco, gilt back and top, $8.50. *For sale by subscription only.* Full prospectus free.

DERCUM (FRANCIS X.), Editor. *A TEXT-BOOK ON NERVOUS DISEASES.* By American Authors. In one handsome octavo volume of 1054 pages, with 341 engravings and 7 colored plates. Cloth, $6; leather, $7, *net.*

DE SCHWEINITZ (GEORGE E.). *THE TOXIC AMBLYOPIAS; THEIR CLASSIFICATION, HISTORY, SYMPTOMS, PATHOLOGY AND TREATMENT.* Very handsome octavo, 240 pages, 46 engravings, and 9 full-page plates in colors. Limited edition, de luxe binding, $4, *net.*

DRAPER (JOHN C.). *MEDICAL PHYSICS.* A Text-book for Students and Practitioners of Medicine. Octavo of 734 pages, with 376 engravings. Cloth, $4.

DRUITT (ROBERT). *THE PRINCIPLES AND PRACTICE OF MODERN SURGERY.* A new American, from the twelfth London edition, edited by STANLEY BOYD, F.R.C.S. Large octavo, 965 pages, with 373 engravings. Cloth, $4; leather, $5.

DUANE (ALEXANDER). *A DICTIONARY OF MEDICINE AND THE ALLIED SCIENCES.* Comprising the Pronunciation, Derivation and Full Explanation of Medical, Dental, Pharmaceutical and Veterinary Terms. Together with much Collateral Descriptive Matter, Numerous Tables, etc. New (3d) edition. Square octavo volume of 652 pages with 8 colored plates. *Just Ready.* Cloth, $3.00, *net;* limp leather, $4.00, *net.*

DUDLEY (E. C.). *A TREATISE ON THE PRINCIPLES AND PRACTICE OF GYNECOLOGY.* For Students and Practitioners. New (2d) edition. In one very handsome octavo volume of 717 pages, with 453 engravings, of which 47 are colored, and 8 full page plates in colors and monochrome. *Just Ready.* Cloth, $5.00, *net;* leather, $6.00, *net;* half morocco, $6.50, *net.*

DUNCAN (J. MATTHEWS). *CLINICAL LECTURES ON THE DISEASES OF WOMEN.* Delivered in St. Bartholomew's Hospital. In one octavo volume of 175 pages. Cloth, $1.50.

DUNGLISON (ROBLEY). *A DICTIONARY OF MEDICAL SCIENCE.* Containing a full Explanation of the Various Subjects and Terms of Anatomy, Physiology, Medical Chemistry, Pharmacy, Pharmacology, Therapeutics, Medicine, Hygiene, Dietetics. Pathology, Surgery, Ophthalmology, Otology, Laryngology, Dermatology, Gynecology, Obstetrics, Pediatrics, Medical Jurisprudence, Dentistry, etc., etc. By ROBLEY DUNGLISON, M.D., LL.D., late Professor of Institutes of Medicine in the Jefferson Medical College of Philadelphia. Edited by RICHARD J. DUNGLISON, A.M., M.D. Twenty-second edition, thoroughly revised and greatly enlarged and improved, with the Pronunciation, Accentuation and Derivation of the Terms. With Appendix. Imperial octavo of about 1400 pages. *Shortly.*

DUNHAM (EDWARD K.). *MORBID AND NORMAL HISTOLOGY.* Octavo, 450 pages, with 360 illustrations. Cloth, $3.25, *net.*

——— *NORMAL HISTOLOGY.* New (2d) edition. Octavo, 319 pages, with 244 illustrations. *Just Ready.* Cloth, $2.50, *net.*

EDES (ROBERT T.). *TEXT-BOOK OF THERAPEUTICS AND MATERIA MEDICA.* In one 8vo. volume of 544 pages. Cloth, $3.50; leather, $4.50.

EDIS (ARTHUR W.). *DISEASES OF WOMEN.* A Manual for Students and Practitioners. In one handsome 8vo. volume of 576 pages, with 148 engravings. Cloth, $3; leather, $4.

EGBERT (SENECA). *HYGIENE AND SANITATION.* In one 12mo. volume of 359 pages, with 63 illustrations. Cloth, $2.25, *net.*

ELLIS (GEORGE VINER). *DEMONSTRATIONS IN ANATOMY.* Being a Guide to the Knowledge of the Human Body by Dissection. From the eighth and revised English edition. Octavo, 716 pages, with 249 engravings. Cloth, $4.25; leather, $5.25.

EMMET (THOMAS ADDIS). *THE PRINCIPLES AND PRACTICE OF GYNÆCOLOGY.* For the use of Students and Practitioners. Third edition, enlarged and revised. 8vo. of 880 pages, with 150 original engravings. Cloth, $5; leather, $6.

ERICHSEN (JOHN E.). *THE SCIENCE AND ART OF SURGERY.* A new American from the eighth enlarged and revised London edition. In two large octavo volumes containing 2316 pages, with 984 engravings. Cloth, $9; leather, $11.

ESSIG (CHARLES J.). *PROSTHETIC DENTISTRY.* See *American Text-books of Dentistry*, page 2.

EVANS (DAVID J.). *A POCKET TEXT-BOOK OF OBSTETRICS.* 12mo. of about 300 pages, amply illustrated. *Shortly.*

FARQUHARSON (ROBERT). *A GUIDE TO THERAPEUTICS.* Fourth American from fourth English edition, revised by FRANK WOODBURY, M.D. In one 12mo. volume of 581 pages. Cloth, $2.50.

FIELD (GEORGE P.). *A MANUAL OF DISEASES OF THE EAR.* Fourth edition. Octavo, 391 pages, with 73 engravings and 21 colored plates. Cloth, $3.75.

FLINT (AUSTIN). *A TREATISE ON THE PRINCIPLES AND PRACTICE OF MEDICINE.* New (7th) edition, thoroughly revised by FREDERICK P. HENRY, M.D. In one large 8vo. volume of 1143 pages, with engravings. Cloth, $5; leather, $6.

——— *A MANUAL OF AUSCULTATION AND PERCUSSION;* of the Physical Diagnosis of Diseases of the Lungs and Heart, and of Thoracic Aneurism. Fifth edition, revised by JAMES C. WILSON, M.D. In one handsome 12mo. volume of 274 pages, with 12 engravings.

——— *A PRACTICAL TREATISE ON THE DIAGNOSIS AND TREATMENT OF DISEASES OF THE HEART.* Second edition, enlarged. In one octavo volume of 550 pages. Cloth, $4.

——— *A PRACTICAL TREATISE ON THE PHYSICAL EXPLORATION OF THE CHEST, AND THE DIAGNOSIS OF DISEASES AFFECTING THE RESPIRATORY ORGANS.* Second and revised edition. In one octavo volume of 591 pages. Cloth, $4.50.

——— *MEDICAL ESSAYS.* In one 12mo. volume of 210 pages. Cloth, $1.38.

——— *ON PHTHISIS: ITS MORBID ANATOMY, ETIOLOGY, ETC.* A Series of Clinical Lectures. In one 8vo. volume of 442 pages. Cloth, $3.50.

FOLSOM (C. F.). *AN ABSTRACT OF STATUTES OF U. S. ON CUSTODY OF THE INSANE.* In one 8vo. volume of 108 pages. Cloth, $1.50. With *Clouston on Mental Diseases* (see page 4), at $5.00, *net*, for the two works.

FORMULARY, THE NATIONAL. See *Stillé, Maisch & Caspari's National Dispensatory*, page 14.

FORMULARY, POCKET. See page 1.

FOSTER (MICHAEL). *A TEXT-BOOK OF PHYSIOLOGY.* New (6th) and revised American from the sixth English edition. In one large octavo volume of 923 pages, with 257 illustrations. Cloth, $4.50; leather, $5.50.

FOTHERGILL (J. MILNER). *THE PRACTITIONER'S HAND-BOOK OF TREATMENT.* Third edition. In one handsome octavo volume of 664 pages. Cloth, $3.75; leather, $4.75.

FOWNES (GEORGE). *A MANUAL OF ELEMENTARY CHEMISTRY (INORGANIC AND ORGANIC).* Twelfth edition. Embodying WATTS' *Physical and Inorganic Chemistry.* In one royal 12mo. volume of 1061 pages, with 168 engravings, and 1 colored plate. Cloth, $2.75; leather, $3.25.

FRANKLAND (E.) AND JAPP (F. R.). *INORGANIC CHEMISTRY.* In one handsome octavo volume of 677 pages, with 51 engravings and 2 plates. Cloth, $3.75; leather, $4.75.

FULLER (EUGENE). *DISORDERS OF THE SEXUAL ORGANS IN THE MALE.* In one very handsome octavo volume of 238 pages, with 25 engravings and 8 full-page plates. Cloth, $2.

FULLER (HENRY). *ON DISEASES OF THE LUNGS AND AIR-PASSAGES.* Their Pathology, Physical Diagnosis, Symptoms and Treatment. From second English edition. In one 8vo. volume of 475 pages. Cloth, $3.50.

GALLAUDET (BERN B.). *A POCKET TEXT-BOOK ON SURGERY.* 12mo. of about 400 pages, with many illustrations. *Shortly.*

GANT (FREDERICK JAMES). *THE STUDENT'S SURGERY.* A Multum in Parvo. In one square octavo volume of 845 pages, with 159 engravings. Cloth, $3.75.

GERRISH (FREDERIC H.). *A TEXT-BOOK OF ANATOMY.* By American Authors. Edited by FREDERIC H. GERRISH, M.D. In one imp. octavo volume of 915 pages, with 950 illustrations in black and colors. Cloth, $6.50; flexible water-proof, $7; sheep, $7.50, *net.*

GIBBES (HENEAGE). *PRACTICAL PATHOLOGY AND MORBID HISTOLOGY.* Octavo of 314 pages, with 60 illustrations, mostly photographic. Cloth, $2.75.

GOULD (A. PEARCE). *SURGICAL DIAGNOSIS.* In one 12mo. volume of 589 pages. Cloth, $2. See *Students' Series of Manuals*, page 14.

GRAY (HENRY). *ANATOMY, DESCRIPTIVE AND SURGICAL.* New American edition thoroughly revised. In one imperial octavo volume of 1239 pages, with 772 large and elaborate engravings. Price with illustrations in colors, cloth, $7; leather, $8. Price, with illustrations in black, cloth, $6; leather, $7.

GREEN (T. HENRY). *AN INTRODUCTION TO PATHOLOGY AND MORBID ANATOMY.* New (8th) American from eighth and revised English edition. Oct. 595 pages, with 215 engravings and a colored plate. Cloth, $2.50, *net.*

GREENE (WILLIAM H.). *A MANUAL OF MEDICAL CHEMISTRY.* For the Use of Students. Based upon BOWMAN'S *Medical Chemistry.* In one 12mo. volume of 310 pages, with 74 illustrations. Cloth, $1.75.

GRINDON (JOSEPH). *A POCKET TEXT-BOOK OF SKIN DISEASES.* 12mo. of 350 pages, with many illustrations. *Shortly.*

GROSS (SAMUEL D.). *A PRACTICAL TREATISE ON THE DISEASES, INJURIES AND MALFORMATIONS OF THE URINARY BLADDER, THE PROSTATE GLAND AND THE URETHRA.* Third edition, revised by SAMUEL W. GROSS, M.D. Octavo of 574 pages, with 170 illustrations. Cloth, $4.50.

HABERSHON (S. O.). *ON THE DISEASES OF THE ABDOMEN*, comprising those of the Stomach, Œsophagus, Cæcum, Intestines and Peritoneum. Second American from the third English edition. In one octavo volume of 554 pages, with 11 engravings. Cloth, $3.50.

HALL (**WINFIELD S.**). *TEXT-BOOK OF PHYSIOLOGY.* Octavo, 672 pages, with 343 engravings and 6 colored plates. *Just Ready.* Cloth, $4.00, *net;* leather, $5.00, *net.*

HAMILTON (**ALLAN McLANE**). *NERVOUS DISEASES, THEIR DESCRIPTION AND TREATMENT.* Second and revised edition. In one octavo volume of 598 pages, with 72 engravings. Cloth, $4.

HARDAWAY (**W. A.**). *MANUAL OF SKIN DISEASES.* New (2d) edition. In one 12mo. volume, 560 pages with 40 illustrations and 2 colored plates. Cloth, $2.25, *net.*

HARE (**HOBART AMORY**). *A TEXT-BOOK OF PRACTICAL THERAPEUTICS,* with Special Reference to the Application of Remedial Measures to Disease and their Employment upon a Rational Basis. With articles on various subjects by well-known specialists. New (8th) and revised edition. In one octavo volume of 796 pages, with 37 engravings and 3 colored plates. *Just Ready.* Cloth, $4.00, *net;* leather, $5.00, *net.*

——— *PRACTICAL DIAGNOSIS.* The Use of Symptoms in the Diagnosis of Disease. New (4th) edition, revised and enlarged. In one octavo volume of 623 pages, with 205 engravings, and 14 full-page plates. Cloth, $5, *net.*

——— **Editor.** *A SYSTEM OF PRACTICAL THERAPEUTICS.* By American and Foreign Authors. In a series of contributions by eminent practitioners. In four large octavo volumes comprising 4600 pages, with 476 engravings. Vol. IV., *now ready.* Regular price, Vol. IV., cloth, $6; leather, $7; half Russia, $8. Price Vol. IV. to former or new subscribers to complete work, cloth, $5; leather, $6; half Russia, $7. Complete work, cloth, $20; leather, $24; half Russia, $28. *For sale by subscription only.* Full prospectus free on application to the publishers.

——— *ON THE MEDICAL COMPLICATIONS AND SEQUELÆ OF TYPHOID FEVER.* Octavo, 276 pages, 21 engravings, and2 full-page plates. Cloth, $2.40, *net.*

HARTSHORNE (**HENRY**). *ESSENTIALS OF THE PRINCIPLES AND PRACTICE OF MEDICINE.* Fifth edition. In one 12mo. volume, 669 pages, with 144 engravings. Cloth, $2.75; half bound, $3.

——— *A HANDBOOK OF ANATOMY AND PHYSIOLOGY.* In one 12mo. volume of 310 pages, with 220 engravings. Cloth, $1.75.

——— *A CONSPECTUS OF THE MEDICAL SCIENCES.* Comprising Manuals of Anatomy, Physiology, Chemistry, Materia Medica, Practice of Medicine, Surgery and Obstetrics. Second edition. In one royal 12mo. volume of 1028 pages, with 477 illustrations. Cloth, $4.25; leather, $5.

HAYDEN (**JAMES R.**). *A MANUAL OF VENEREAL DISEASES.* New (2d) edition. In one 12mo. volume of 304 pages, with 54 engravings. Cloth, $1.50, *net.*

HAYEM (**GEORGES**) **AND HARE** (**H. A.**). *PHYSICAL AND NATURAL THERAPEUTICS.* The Remedial Use of Heat, Electricity, Modifications of Atmospheric Pressure, Climates and Mineral Waters. Edited by Prof. H. A. HARE, M.D. In one octavo volume of 414 pages, with 113 engravings. Cloth, $3.

HERMAN (**G. ERNEST**). *FIRST LINES IN MIDWIFERY.* 12mo., 198 pages, with 80 engravings. Cloth, $1.25. See *Students' Series of Manuals,* page 14.

HERMANN (**L.**). *EXPERIMENTAL PHARMACOLOGY.* A Handbook of the Methods for Determining the Physiological Actions of Drugs. Translated by ROBERT MEADE SMITH, M.D. In one 12mo. vol. of 199 pages, with 32 engravings. Cloth, $1.50.

HERRICK (**JAMES B.**). *A HANDBOOK OF DIAGNOSIS.* In one handsome 12mo. volume of 429 pages, with 80 engravings and 2 colored plates. Cloth, $2.50.

HILL (**BERKELEY**). *SYPHILIS AND LOCAL CONTAGIOUS DISORDERS.* In one 8vo. volume of 479 pages. Cloth, $3.25.

HILLIER (**THOMAS**). *A HANDBOOK OF SKIN DISEASES.* Second edition. In one royal 12mo. volume of 353 pages, with two plates. Cloth, $2.25.

HIRST (**BARTON C.**) **AND PIERSOL** (**GEORGE A.**). *HUMAN MONSTROSITIES.* Magnificent folio, containing 220 pages of text and illustrated with 123 engravings and 39 large photographic plates from nature. In four parts, price each, $5. *Limited edition. For sale by subscription only.*

HOBLYN (RICHARD D.). *A DICTIONARY OF THE TERMS USED IN MEDICINE AND THE COLLATERAL SCIENCES.* New (13th) edition. In one 12mo. volume of 845 pages. *Just Ready.* Cloth, $3.00, *net.*

HODGE (HUGH L.). *ON DISEASES PECULIAR TO WOMEN, INCLUDING DISPLACEMENTS OF THE UTERUS.* Second and revised edition. In one 8vo. volume of 519 pages, with illustrations. Cloth, $4.50.

HOFFMANN (FREDERICK) AND POWER (FREDERICK B.). *A MANUAL OF CHEMICAL ANALYSIS,* as Applied to the Examination of Medicinal Chemicals and their Preparations. Third edition, entirely rewritten and much enlarged. In one handsome octavo volume of 621 pages, with 179 engravings. Cloth, $4.25.

HOLMES (TIMOTHY). *A TREATISE ON SURGERY.* Its Principles and Practice. A new American from the fifth English edition. Edited by T. PICKERING PICK, F.R.C.S. In one handsome octavo volume of 1008 pages, with 428 engravings. Cloth, $6; leather, $7.

——— *A SYSTEM OF SURGERY.* With notes and additions by various American authors. Edited by JOHN H. PACKARD, M.D. In three very handsome 8vo. volumes containing 3137 double-columned pages, with 979 engravings and 13 lithographic plates. Per volume, cloth, $6; leather, $7; half Russia, $7.50. *For sale by subscription only.*

HORNER (WILLIAM E.). *SPECIAL ANATOMY AND HISTOLOGY.* Eighth edition, revised and modified. In two large 8vo. volumes of 1007 pages, containing 320 engravings. Cloth, $6.

HUDSON (A.). *LECTURES ON THE STUDY OF FEVER.* In one octavo volume of 308 pages. Cloth, $2.50.

HUTCHISON (ROBERT) AND RAINY (HARRY). *CLINICAL METHODS.* An Introduction to the Practical Study of Medicine. In one 12mo. volume of 562 pages, with 137 engravings and 8 colored plates, Cloth, $3.00.

HYDE (JAMES NEVINS). *A PRACTICAL TREATISE ON DISEASES OF THE SKIN.* New (5th) edition, thoroughly revised. Octavo, 866 pages, with 111 engravings and 24 full-page plates, 8 of which are colored. *Just Ready.* Cloth, $4.50, *net;* leather, $5.50, *net;* half morocco, $6.00, *net.*

JACKSON (GEORGE THOMAS). *THE READY-REFERENCE HANDBOOK OF DISEASES OF THE SKIN.* New (3d) edition. 12mo. volume of 637 pages, with 75 engravings, and one colored plate. Cloth, $2.50, *net.*

JAMIESON (W. ALLAN). *DISEASES OF THE SKIN.* Third edition. Octavo, 656 pages, with 1 engraving and 9 double-page chromo-lithographic plates. Cloth, $6.

JEWETT (CHARLES). *ESSENTIALS OF OBSTETRICS.* In one 12mo. volume of 356 pages, with 80 engravings and 3 colored plates. Cloth, $2.25.

——— *THE PRACTICE OF OBSTETRICS.* By American Authors. One large octavo volume of 763 pages, with 441 engravings in black and colors, and 22 full-page colored plates. Cloth, $5.00, *net*; leather, $6.00, *net*; half morocco, $6.50, *net.*

JONES (C. HANDFIELD). *CLINICAL OBSERVATIONS ON FUNCTIONAL NERVOUS DISORDERS.* Second American edition. In one octavo volume of 340 pages. Cloth, $3.25.

JULER (HENRY). *A HANDBOOK OF OPHTHALMIC SCIENCE AND PRACTICE.* Second edition. In one octavo volume of 549 pages, with 201 engravings, 17 chromo-lithographic plates, test-types of Jaeger and Snellen, and Holmgren's Color-Blindness Test. Cloth, $5.50; leather, $6.50.

KIRK (EDWARD C.). *OPERATIVE DENTISTRY.* See *American Text-books of Dentistry,* page 2.

KING (A. F. A.). *A MANUAL OF OBSTETRICS.* New (8th) edition. In one 12mo. volume of 612 pages, with 264 illustrations. *Just Ready.* Cloth, $2.50, *net.*

KLEIN (E.). *ELEMENTS OF HISTOLOGY.* New (5th) edition. In one pocket-size 12mo. volume of 506 pages, with 296 engravings. Cloth, $2.00, *net.*
See *Students' Series of Manuals,* page 14.

LANDIS (HENRY G.). *THE MANAGEMENT OF LABOR.* In one handsome 12mo. volume of 329 pages, with 28 illustrations. Cloth, $1.75.

LA ROCHE (R.). *YELLOW FEVER.* In two 8vo. volumes of 1468 pages. Cloth, $7.

LAURENCE (J. Z.) AND MOON (ROBERT C.). *A HANDY-BOOK OF OPHTHALMIC SURGERY.* Second edition. In one octavo volume of 227 pages, with 66 engravings. Cloth, $2.75.

LEA (HENRY C.). *CHAPTERS FROM THE RELIGIOUS HISTORY OF SPAIN; CENSORSHIP OF THE PRESS; MYSTICS AND ILLUMINATI; THE ENDEMONIADAS; EL SANTO NINO DE LA GUARDIA; BRIANDA DE BARDAXI.* In one 12mo. volume of 522 pages. Cloth, $2.50.

——— *A HISTORY OF AURICULAR CONFESSION AND INDULGENCES IN THE LATIN CHURCH.* In three octavo volumes of about 500 pages each. Per volume, cloth, $3. *Complete work just ready.*

——— *FORMULARY OF THE PAPAL PENITENTIARY.* In one octavo volume of 221 pages, with frontispiece. Cloth, $2.50.

——— *STUDIES IN CHURCH HISTORY.* The Rise of the Temporal Power—Benefit of Clergy—Excommunication. New edition. In one handsome 12mo. volume of 605 pages. Cloth, $2.50.

——— *SUPERSTITION AND FORCE; ESSAYS ON THE WAGER OF LAW, THE WAGER OF BATTLE, THE ORDEAL AND TORTURE.* Fourth edition, thoroughly revised. In one royal 12mo. volume of 629 pages. Cloth, $2.75.

——— *AN HISTORICAL SKETCH OF SACERDOTAL CELIBACY IN THE CHRISTIAN CHURCH.* Second edition. In one handsome octavo volume of 685 pages. Cloth, $4.50.

LOOMIS (ALFRED L.) AND THOMPSON (W. GILMAN), Editors. *A SYSTEM OF PRACTICAL MEDICINE.* In Contributions by Various American Authors. In four very handsome octavo volumes of about 900 pages each, fully illustrated in black and colors. *Complete work now ready.* Per volume, cloth, $5; leather, $6; half Morocco, $7. *For sale by subscription only.* Full prospectus free on application to the Publishers.

LUFF (ARTHUR P.). *MANUAL OF CHEMISTRY,* for the use of Students of Medicine. In one 12mo. volume of 522 pages, with 36 engravings. Cloth, $2. See *Students' Series of Manuals,* page 14.

LYMAN (HENRY M.). *THE PRACTICE OF MEDICINE.* In one very handsome octavo volume of 925 pages with 170 engravings. Cloth, $4.75; leather, $5.75.

LYONS (ROBERT D.). *A TREATISE ON FEVER.* In one octavo volume of 362 pages. Cloth, $2.25.

MACKENZIE (JOHN NOLAND). *THE DISEASES OF THE NOSE AND THROAT.* Octavo, of about 600 pages, richly illustrated. *Preparing.*

MAISCH (JOHN M.). *A MANUAL OF ORGANIC MATERIA MEDICA.* New (7th) edition, thoroughly revised by H. C. C. Maisch, Ph.G., Ph.D. In one very handsome 12mo. of 512 pages, with 285 engravings. Cloth, $2.50, *net.*

MALSBARY (GEO. E.). *A POCKET TEXT-BOOK OF THEORY AND PRACTICE OF MEDICINE.* 12mo. 405 pages, with 45 illustrations. *Just Ready.* Cloth, $1.75, *net;* flexible red leather, $2.25, *net.*

MANUALS. See *Students' Quiz Series,* page 14, *Students' Series of Manuals,* page 14, and *Series of Clinical Manuals,* page 13.

MARSH (HOWARD). *DISEASES OF THE JOINTS.* In one 12mo. volume of 468 pages, with 64 engravings and a colored plate. Cloth, $2. See *Series of Clinical Manuals,* page 13.

MARTIN (EDWARD.) *SURGICAL DIAGNOSIS.* One 12mo. volume of 400 pages, richly illustrated. *Preparing.*

MARTIN (WALTON) AND ROCKWELL (W. H., JR.). *A POCKET TEXT-BOOK OF CHEMISTRY AND PHYSICS.* 12mo. 366 pages, with 137 illustrations. *Just ready.* Cloth, $1.50, *net;* flexible red leather, $2.00, *net.*

MAY (C. H.). *MANUAL OF THE DISEASES OF WOMEN.* For the use of Students and Practitioners. Second edition, revised by L. S. RAU, M.D. In one 12mo. volume of 360 pages, with 31 engravings. Cloth, $1.75.

MEDICAL NEWS POCKET FORMULARY. See page 1.

MITCHELL (JOHN K.). *REMOTE CONSEQUENCES OF INJURIES OF NERVES AND THEIR TREATMENT.* In one handsome 12mo. volume of 239 pages, with 12 illustrations. Cloth $1.75.

MITCHELL (S. WEIR). *CLINICAL LESSONS ON NERVOUS DISEASES.* In one very handsome 12mo. volume of 299 pages, with 17 engravings and 2 colored plates. Cloth, $2.50.

MORRIS (MALCOLM). *DISEASES OF THE SKIN.* New (2d) edition. In one 12mo. volume of 601 pages, with 10 chromo-lithographic plates and 26 engravings. Cloth, $3.25, *net.*

MULLER (J.). *PRINCIPLES OF PHYSICS AND METEOROLOGY.* In one large 8vo. volume of 623 pages, with 538 engravings. Cloth, $4.50.

MUSSER (JOHN H.). *A PRACTICAL TREATISE ON MEDICAL DIAGNOSIS,* for Students and Physicians. New (3d) edition. In one octavo volume of 1082 pages, with 253 engravings and 48 full-page colored plates. *Just Ready.* Cloth, $6.00, *net;* leather, $7.00, *net.*

NATIONAL DISPENSATORY. See *Stillé, Maisch & Caspari,* page 14.

NATIONAL FORMULARY. See *National Dispensatory,* page 14.

NATIONAL MEDICAL DICTIONARY. See *Billings,* page 3.

NETTLESHIP (E.). *DISEASES OF THE EYE.* New (6th) American from sixth English edition. Thoroughly revised. In one 12mo. volume of 562 pages, with 192 engravings, 5 colored plates, test-types, formulæ and color-blindness test. *Just Ready.* Cloth, $2.25, *net.*

NICHOLS (JOHN B.) AND VALE (F. P.). *A POCKET TEXT-BOOK OF HISTOLOGY AND PATHOLOGY.* 12mo. of 459 pages, with 213 illustrations. *Just ready.* Cloth, $1.75, *net;* flexible red leather, $2.25, *net.*

NORRIS (WM. F.) AND OLIVER (CHAS. A.). *TEXT-BOOK OF OPHTHALMOLOGY.* In one octavo volume of 641 pages, with 357 engravings and 5 colored plates. Cloth, $5; leather, $6.

OWEN (EDMUND). *SURGICAL DISEASES OF CHILDREN.* In one 12mo. volume of 525 pages, with 85 engravings and 4 colored plates. Cloth, $2. See *Series of Clinical Manuals,* page 13.

PARK (WILLIAM H.). *BACTERIOLOGY IN MEDICINE AND SURGERY.* 12mo. 688 pages, with 87 engravings in black and colors and 2 colored plates. *Just Ready.* Cloth, $3.00, *net.*

PARK (ROSWELL), Editor. *A TREATISE ON SURGERY,* by American Authors. For Students and Practitioners of Surgery and Medicine. New condensed edition. In one large octavo volume of 1261 pages, with 625 engravings and 38 plates. *Just Ready.* Cloth, *net,* $6.00; leather, *net,* $7.00. ☞This work is published also in a large edition, comprising two octavo volumes. Vol. I., *General Surgery,* 799 pages, with 356 engravings and 21 full-page plates in colors and monochrome. Vol. II., *Special Surgery,* 796 pages, with 451 engravings and 17 full-page plates in colors and monochrome. Price per volume, cloth, $4.50; leather, $5.50, *net.*

PARVIN (THEOPHILUS). *THE SCIENCE AND ART OF OBSTETRICS.* Third edition. In one handsome octavo volume of 677 pages, with 267 engravings and 2 colored plates. Cloth, $4.25; leather, $5.25.

PEPPER'S *SYSTEM OF MEDICINE.* See page 2.

PEPPER (A. J.). *SURGICAL PATHOLOGY.* In one 12mo volume of 511 pages, with 81 engravings. Cloth, $2. See *Students' Series of Manuals*, page 14.

PICK (T. PICKERING). *FRACTURES AND DISLOCATIONS.* In one 12mo. volume of 530 pages, with 93 engravings. Cloth, $2. See *Series of Clinical Manuals*, p. 13.

PLAYFAIR (W. S.). *A TREATISE ON THE SCIENCE AND PRACTICE OF MIDWIFERY.* New (7th) American from the Ninth English edition. In one octavo volume of 700 pages, with 207 engravings and 7 full page plates. Cloth, $3.75, *net;* leather, $4.75, *net.*

——— *THE SYSTEMATIC TREATMENT OF NERVE PROSTRATION AND HYSTERIA.* In one 12mo. volume of 97 pages. Cloth, $1.

OLITZER (ADAM). *A TEXT-BOOK OF THE DISEASES OF THE EAR AND ADJACENT ORGANS.* Second American from the third German edition. In one octavo volume of 748 pages, with 330 original engravings.

POCKET FORMULARY. See page 1.

POCKET TEXT-BOOKS Cover the entire domain of medicine in sixteen volumes of 350 to 450 pages each, written by teachers in leading American medical colleges. Issued under the editorial supervision of BERN B. GALLAUDET, M.D., of the College of Physicians and Surgeons, New York. Thoroughly modern and authoritative, concise and clear, amply illustrated with engravings and plates, handsomely printed and bound. The series is constituted as follows: Anatomy (*preparing*), Physiology (*ready*), Chemistry and Physics (*ready*), Histology and Pathology (*ready*), Materia Medica, Therapeutics, Medical Pharmacy, Prescription Writing and Medical Latin (*ready*), Practice (*ready*), Diagnosis (*shortly*), Nervous and Mental Diseases (*ready*), Surgery (*preparing*), Genito-Urinary and Venereal Diseases (*preparing*), Skin Diseases (*preparing*), Eye, Ear, Nose and Throat (*shortly*), Obstetrics (*shortly*), Gynecology (*ready*), Diseases of Children (*ready*), Bacteriology and Hygiene (*shortly*). For further details see under respective authors in this catalogue. Special circular free on application.

POTTS (CHAS. S.). *A POCKET TEXT-BOOK OF NERVOUS AND MENTAL DISEASES.* 12mo. of 455 pages, with 88 illlustrations. *Just ready.* Cloth, $1.75, *net;* flexible red leather, $2.25, *net.*

PROGRESSIVE MEDICINE. See page 1.

PURDY (CHARLES W.). *BRIGHT'S DISEASE AND ALLIED AFFECTIONS OF THE KIDNEY.* In one octavo volume of 288 pages, with 18 engravings. Cloth, $2.

PYE-SMITH (PHILIP H.). *DISEASES OF THE SKIN.* In one 12mo. volume of 407 pages, with 28 illustrations, 18 of which are colored. Cloth, $2.

QUIZ SERIES. See *Students' Quiz Series*, page 14.

RALFE (CHARLES H.). *CLINICAL CHEMISTRY.* In one 12mo. volume of 314 pages, with 16 engravings. Cloth, $1.50. See *Students' Series of Manuals*, page 14.

RAMSBOTHAM (FRANCIS H.). *THE PRINCIPLES AND PRACTICE OF OBSTETRIC MEDICINE AND SURGERY.* Imperial octavo, of 640 pages, with 64 plates and numerous engravings in the text. Leather, $7.

REMSEN (IRA). *THE PRINCIPLES OF THEORETICAL CHEMISTRY.* New (5th) edition, thoroughly revised. In one 12mo. volume of 326 pages. Cloth, $2.

RICHARDSON (BENJAMIN WARD). *PREVENTIVE MEDICINE.* In one octavo volume of 729 pages. Cloth, $4; leather, $5.

ROBERTS (JOHN B.). *THE PRINCIPLES AND PRACTICE OF MODERN SURGERY.* New (2d) edition. In one octavo volume of 838 pages, with 474 engravings and 8 plates. *Just Ready.* Cloth, $4.25, *net;* leather, $5.25, *net.*

——— *THE COMPEND OF ANATOMY.* For use in the Dissecting Room and in preparing for Examinations. In one 16mo. volume of 196 pages. Limp cloth, 75 cents.

ROSS (JAMES). *A HANDBOOK OF THE DISEASES OF THE NERVOUS SYSTEM.* In one handsome octavo volume of 726 pages, with 184 engravings. Cloth, $4.50; leather, $5.50.

SCHAFER (EDWARD A.). *THE ESSENTIALS OF HISTOLOGY, DESCRIPTIVE AND PRACTICAL.* For the use of Students. New (5th) edition. In one handsome octavo volume of 350 pages, with 325 illustrations. Cloth, $3, *net.*

——— *A COURSE OF PRACTICAL HISTOLOGY.* Second edition. In one 12mo. volume of 307 pages, with 59 engravings. Cloth, $2.25.

SCHLEIF (WM.). *A POCKET TEXT-BOOK OF MATERIA MEDICA, THERAPEUTICS, PRESCRIPTION WRITING. MEDICAL LATIN AND MEDICAL PHARMACY.* 12mo. 352 pages. *Just Ready.* Cloth, $1.50, *net;* flexible red leather, $2.00, *net.*

SCHMITZ AND ZUMPT'S CLASSICAL SERIES.
ADVANCED LATIN EXERCISES Cloth, 60 cents; half bound, 70 cents.
SCHMITZ'S ELEMENTARY LATIN EXERCISES. Cloth, 50 cents.
SALLUST. Cloth, 60 cents; half bound, 70 cents.
NEPOS. Cloth, 60 cents; half bound, 70 cents.
VIRGIL. Cloth, 85 cents; half bound, $1.
CURTIUS. Cloth, 80 cents; half bound, 90 cents.

SCHOFIELD (ALFRED T.). *ELEMENTARY PHYSIOLOGY FOR STUDENTS.* In one 12mo. volume of 380 pages, with 227 engravings and 2 colored plates. Cloth, $2.

SCHREIBER (JOSEPH). *A MANUAL OF TREATMENT BY MASSAGE AND METHODICAL MUSCLE EXERCISE.* Translated by WALTER MENDELSON, M.D., of New York. In one handsome octavo volume of 274 pages, with 117 fine engravings.

SENN (NICHOLAS). *SURGICAL BACTERIOLOGY.* Second edition. In one octavo volume of 268 pages, with 13 plates, 10 of which are colored, and 9 engravings. Cloth, $2.

SERIES OF CLINICAL MANUALS. A Series of Authoritative Monographs on Important Clinical Subjects, in 12mo. volumes of about 550 pages, well illustrated. The following volumes are now ready: YEO on Food in Health and Disease, new (2d) edition, $2.50; CARTER and FROST'S Ophthalmic Surgery, $2.25; MARSH on Diseases of the Joints, $2; OWEN on Surgical Diseases of Children, $2; PICK on Fractures and Dislocations, $2.
For separate notices, see under various authors' names.

SERIES OF POCKET TEXT-BOOKS. See page 12.

SERIES OF STUDENTS' MANUALS. See next page.

SIMON (CHARLES E.). *CLINICAL DIAGNOSIS, BY MICROSCOPICAL AND CHEMICAL METHODS.* New (3d) and revised edition. In one handsome octavo volume of 563 pages, with 138 engravings and 18 full-page plates in colors. *Just Ready.* Cloth, $3.50, *net.*

SIMON (W.). *MANUAL OF CHEMISTRY.* A Guide to Lectures and Laboratory Work for Beginners in Chemistry. A Text-book specially adapted for Students of Pharmacy and Medicine. New (6th) edition. In one 8vo. volume of 536 pages, with 46 engravings and 8 plates showing colors of 64 tests. Cloth, $3.00, *net.*

SLADE (D. D.). *DIPHTHERIA; ITS NATURE AND TREATMENT.* Second edition. In one royal 12mo. volume, 158 pages. Cloth, $1.25.

SMITH (EDWARD). *CONSUMPTION; ITS EARLY AND REMEDIABLE STAGES.* In one 8vo. volume of 253 pages. Cloth, $2.25.

SMITH (J. LEWIS). *A TREATISE ON THE DISEASES OF INFANCY AND CHILDHOOD.* Eighth edition, thoroughly revised and rewritten and greatly enlarged. In one large 8vo. volume of 983 pages, with 273 illustrations and 4 full-page plates. Cloth, $4.50; leather, $5.50.

SMITH (STEPHEN). *OPERATIVE SURGERY.* Second and thoroughly revised edition. In one octavo vol. of 892 pages, with 1005 engravings. Cloth, $4; leather, $5

SOLLY (S. EDWIN). *A HANDBOOK OF MEDICAL CLIMATOLOGY.* In one handsome octavo volume of 462 pages, with engravings and 11 full-page plates, 5 of which are in colors. Cloth, $4.00.

STILLE (ALFRED). *CHOLERA: ITS ORIGIN, HISTORY, CAUSATION, SYMPTOMS, LESIONS, PREVENTION AND TREATMENT.* In one 12mo. volume of 163 pages, with a chart showing routes of previous epidemics. Cloth, $1.25.

—— *THERAPEUTICS AND MATERIA MEDICA.* Fourth and revised edition. In two octavo volumes, containing 1936 pages. Cloth, $10; leather, $12.

STILLE (ALFRED), MAISCH (JOHN M.) AND CASPARI (CHAS. JR.). *THE NATIONAL DISPENSATORY:* Containing the Natural History, Chemistry, Pharmacy, Actions and Uses of Medicines, including those recognized in the latest Pharmacopœias of the United States, Great Britian and Germany, with numerous references to the French Codex. Fifth edition, revised and enlarged in accordance with and embracing the new *U. S. Pharmacopœia*, Seventh Decennial Revision. With Supplement containing the new edition of the *National Formulary*. In one magnificent imperial octavo volume of 2025 pages, with 320 engravings Cloth, $7.25; leather, $8. With ready reference Thumb-letter Index. Cloth, $7.75; leather, $8.50.

STIMSON (LEWIS A.). *A MANUAL OF OPERATIVE SURGERY.* New (4th) edition. In one royal 12mo. volume of 581 pages, with 293 engravings. Cloth, $3.00, *net. Just Ready.*

—— *A TREATISE ON FRACTURES AND DISLOCATIONS.* In one handsome octavo volume of 831 pages, with 326 engravings and 20 full-page plates. Cloth, $5; leather, $6, *net.*

STUDENTS' QUIZ SERIES. A New Series of Manuals in question and answer for Students and Practitioners, covering the essentials of medical science. Thirteen volumes, pocket size, convenient, authoritative, well illustrated, handsomely bound in limp cloth, and issued at a low price. 1. Anatomy (double number); 2. Physiology; 3. Chemistry and Physics; 4. Histology, Pathology and Bacteriology; 5. Materia Medica and Therapeutics; 6. Practice of Medicine; 7. Surgery (double number); 8. Genito-Urinary and Venereal Diseases; 9. Diseases of the Skin; 10. Diseases of the Eye, Ear, Throat and Nose; 11. Obstetrics; 12. Gynecology; 13. Diseases of Children. Price, $1 each, except Nos. 1 and 7, *Anatomy and Surgery*, which being double numbers are priced at $1.75 each. Full specimen circular on application to publishers.

STUDENTS' SERIES OF MANUALS. A Series of Fifteen Manuals by Eminent Teachers or Examiners. The volumes are pocket-size 12mos. of from 300–540 pages, profusely illustrated, and bound in red limp cloth. The following volumes may now be announced: HERMAN'S First Lines in Midwifery, $1.25; LUFF'S Manual of Chemistry, $2; BRUCE'S Materia Medica and Therapeutics (sixth edition), $1.50, *net;* GOULD'S Surgical Diagnosis, $2; KLEIN'S Elements of Histology (5th edition), $2.00, *net;* PEPPER'S Surgical Pathology, $2; TREVES' Surgical Applied Anatomy, $2; RALFE'S Clinical Chemistry, $1.50; and CLARKE and LOCKWOOD'S Dissector's Manual, $1.50.
For separate notices, see under various authors' names.

STURGES (OCTAVIUS). *AN INTRODUCTION TO THE STUDY OF CLINICAL MEDICINE.* In one 12mo. volume. Cloth, $1.25.

SUTTON (JOHN BLAND). *SURGICAL DISEASES OF THE OVARIES AND FALLOPIAN TUBES.* Including Abdominal Pregnancy. In one 12mo. volume of 513 pages, with 119 engravings and 5 colored plates. Cloth, $3.

TAIT (LAWSON). *DISEASES OF WOMEN AND ABDOMINAL SURGERY* Vol. I. contains 554 pages, 62 engravings, and 3 plates. Cloth, $3.

TANNER (THOMAS HAWKES). *ON THE SIGNS AND DISEASES OF PREGNANCY.* From the second English edition. In one octavo volume of 490 pages, with 4 colored plates and 16 engravings. Cloth, $4.25.