ANNEX

ARMY MEDICAL LIBRARY
FOUNDED 1836



ANNEX
ANNEX
WASHINGTON, D.C.
ANNEX

DUE TWO WEEKS FROM LAST DATE

OCT 3 - 1963

868

NUOVE DIMOSTRAZIONI

DI OSTETRICIA

CON INCISIONI IN RAME

ED UN TESTO RAGIONATO ADATTATO A FACILITARNE
LA SPIEGAZIONE

DI G. P. MAYGRIER

DOTT. DI MEDIC. DELLA FACOLTA' DI PARIGI, P. D'OSTETRICIA; DI MALATTIE DELLE DONNE E DEI BAMBINI, MEDICO DELL'UFFIZIO DI CARITA' DEL DECIMO CIRCONDARIO, MEMBRO DI VARIE SOCIETA' MEDICHE.

PRIMA VERSIONE ITALIANA

CON ANNOTAZIONI ED AGGIUNTE

DEL CHIRURGO MARCO FOSCARINI

MAESTRO OPERATORE D'OSTETRICIA NELL'I. E R. SPEDALE DI PISA.

Prima Dispensa

SURGEON GENERAL'S OFFICE
114196
LIBRARY

PISA

TIPOGRAFIA NISTRI E C.

1831.

23 29

WQ
M467n
1831
atlas

Tav. I

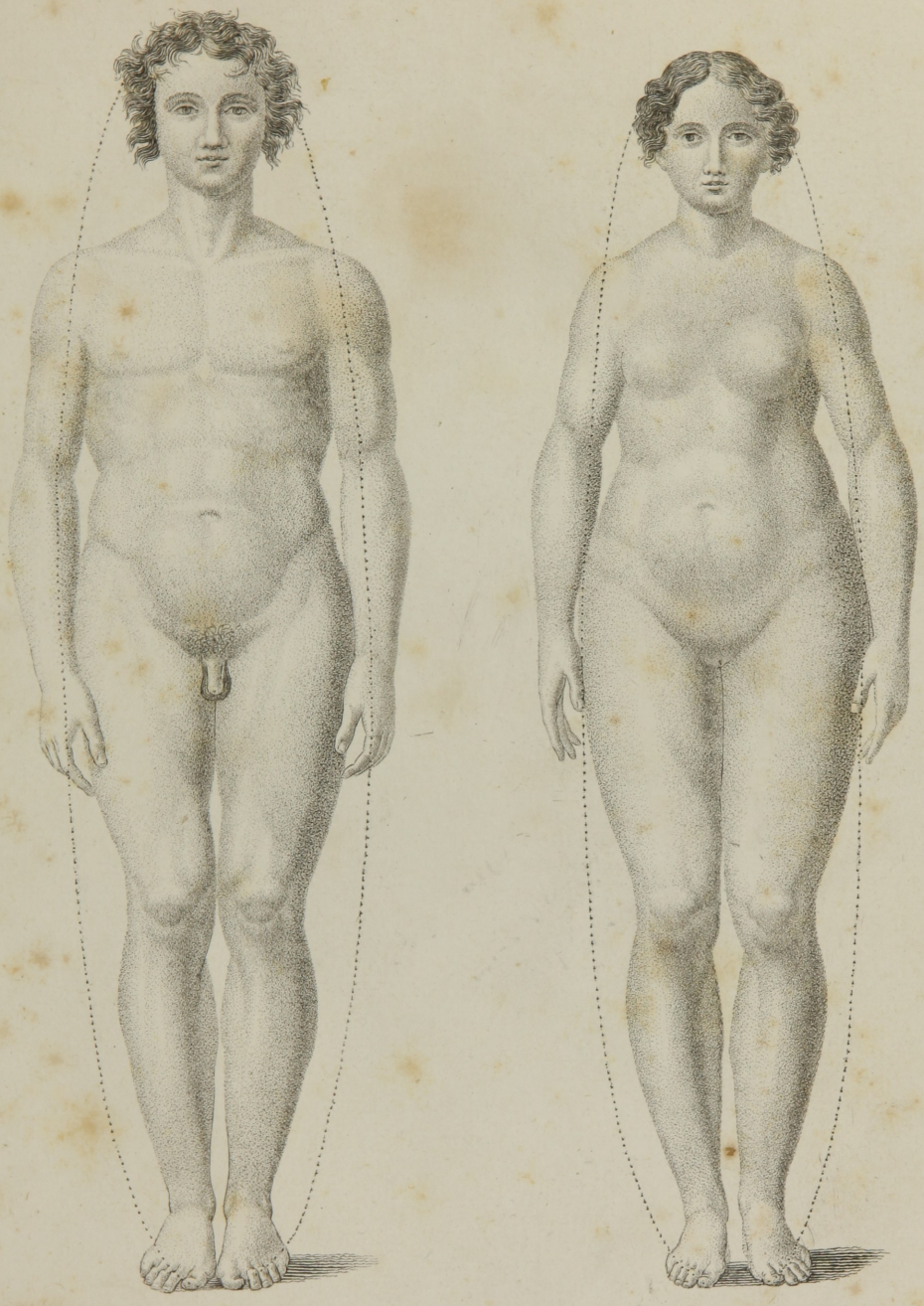

SURGEON GEN'LS OFFICE
114176.
LIBRARY

114176

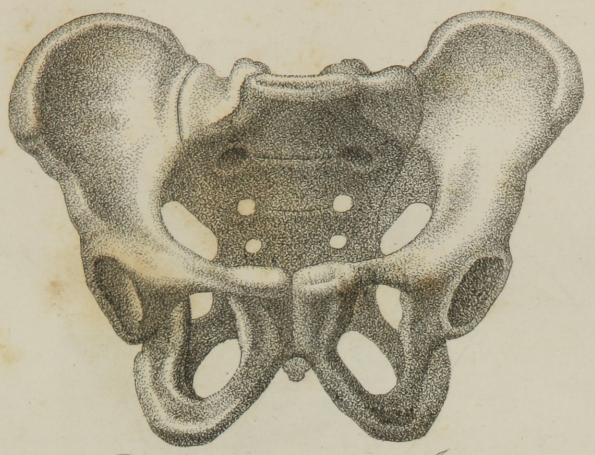

Bacino d'Uomo Adulto.

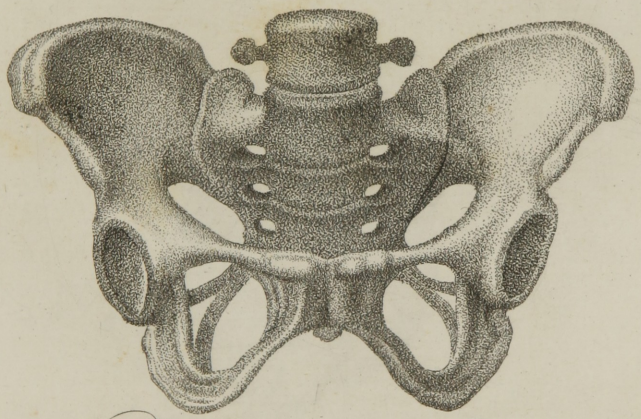

Bacino di Donna Adulta.

Bacino di Feto a Termine.

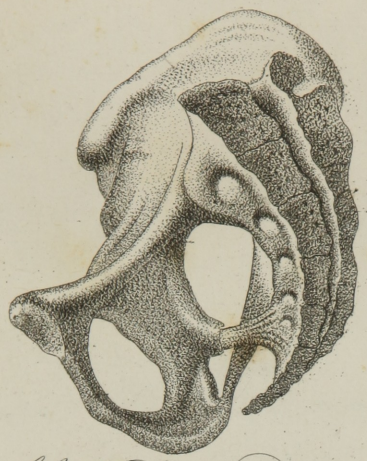

Profilo di Bacino d'Uomo.

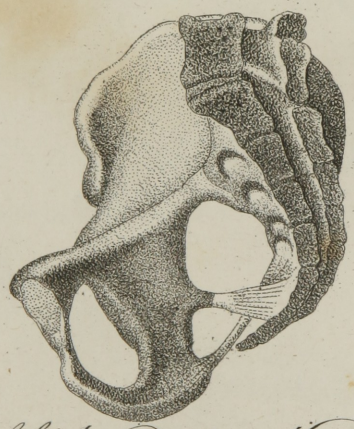

Profilo di Bacino di Donna.

Profilo di Bacino di Feto.

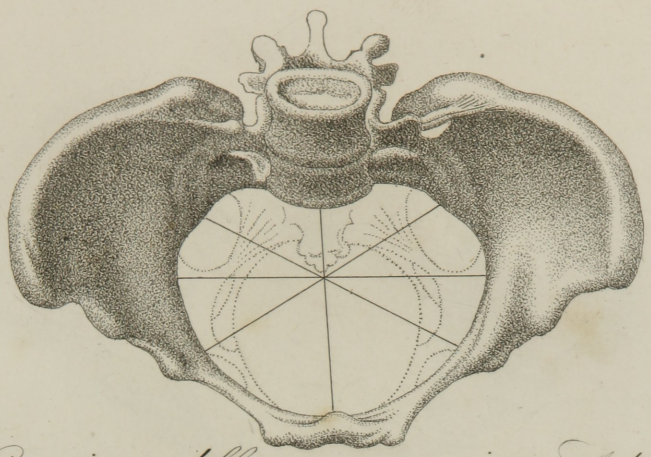

Dimensione dello Stretto superiore o Addominale.

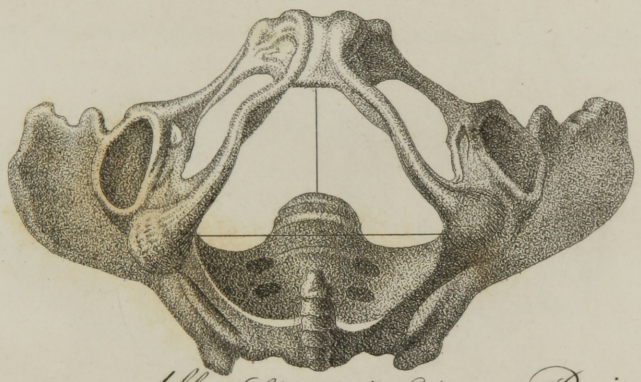

Dimensione dello Stretto inferiore o Perineale.

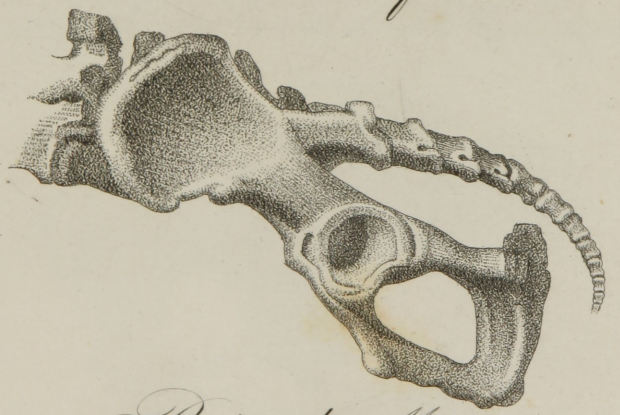

Bacino di Mammifero.

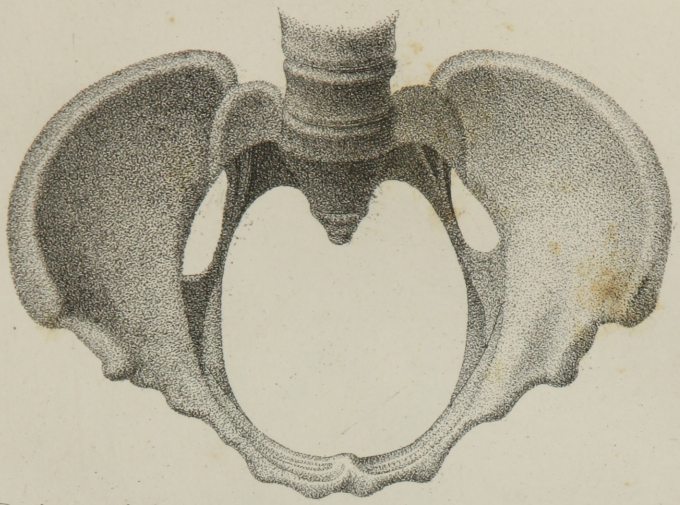

Bacino viziato per eccesso di grandezza regolare.

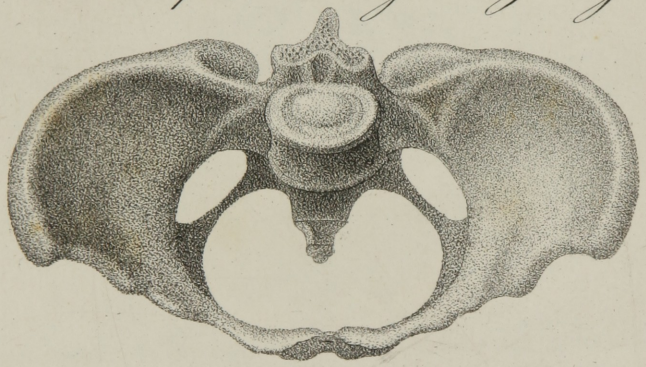

Bacino viziato per eccesso di Strettezza regolare

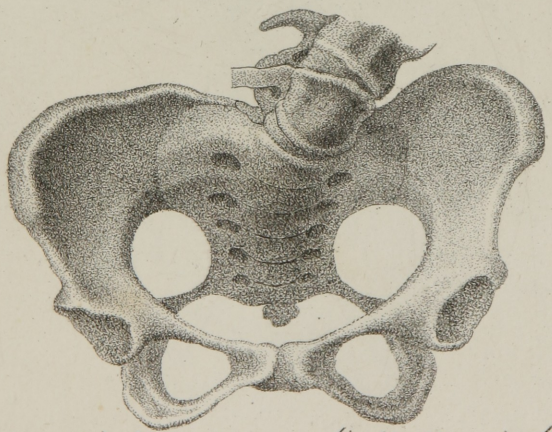

Bacino viziato per eccesso di Strettezza difforme.

Fig. 1

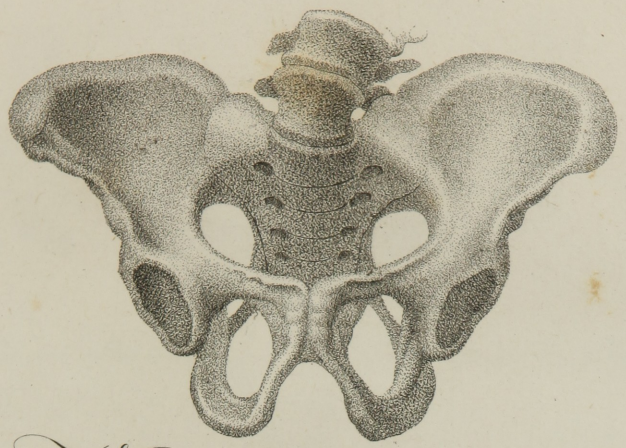

Vizi dello Stretto perineale.

Fig. 2

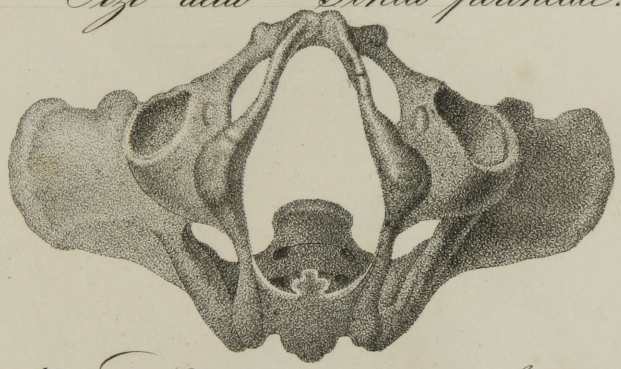

Il medesimo Bacino veduto per la parte disotto.

Fig. 3

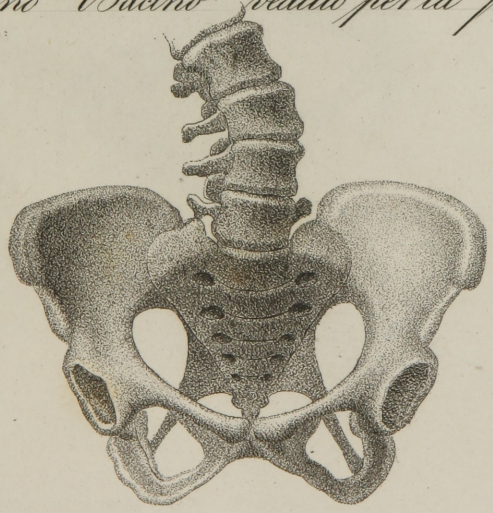

Bacino regolare con colonna deviata

Fig. 1

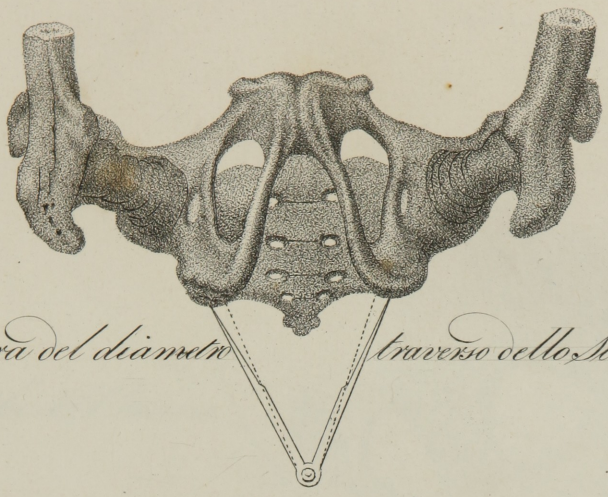

Misura del diametro traverso dello Stretto inferiore.

Fig. 3

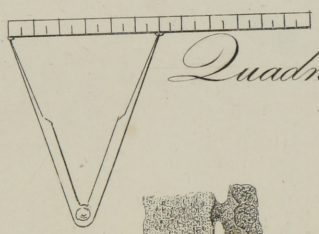

Quadrante.

Fig. 2

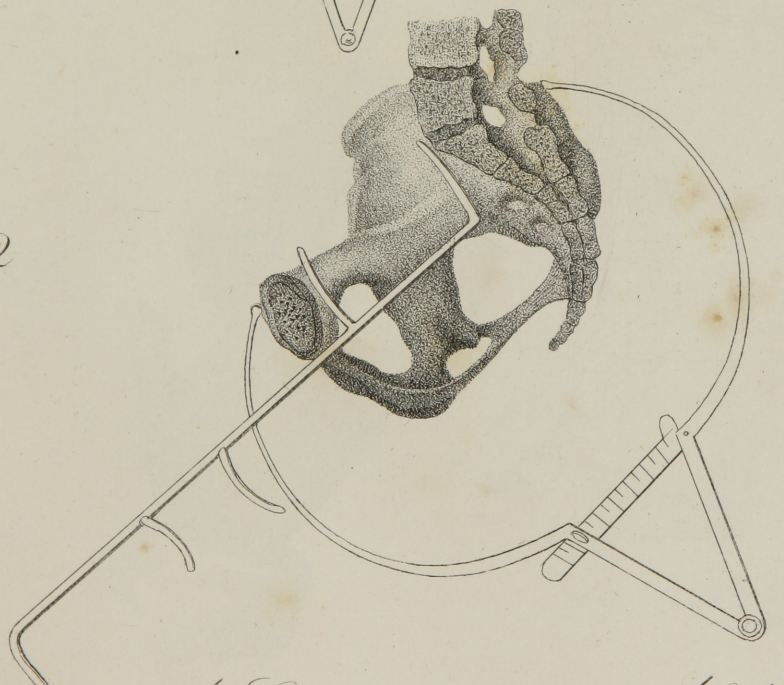

Applicazione del Compasso a grossezza e del pelvi-metro.

Fig. 1.

Direzione ed Assi del Bacino.

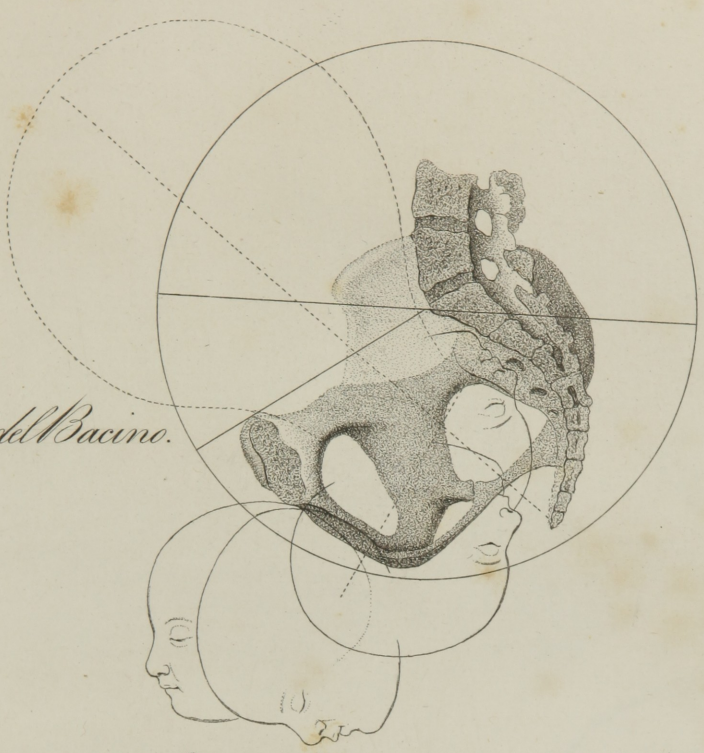

Fig. 2.

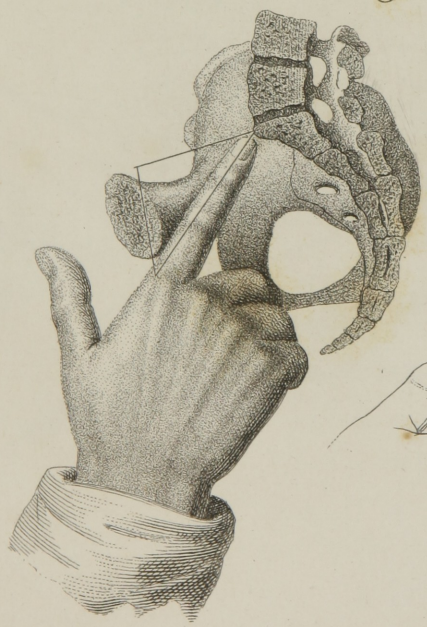

Situazione del dito indice per misurare il diametro Sacro pubiano.

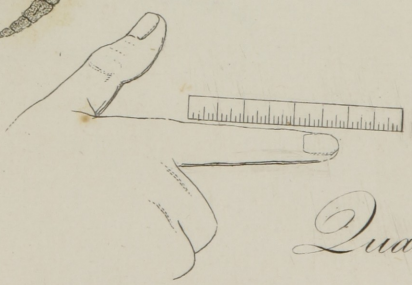

Fig. 3.

Quadrante

TAV. IX.

G. Ciuti Inc.

TAV. X.

Fig. 1.

Fig. 2.

Fig. 3.

Fig. 4.

G. Giuli Inc.

TAV. XI.

Fig. 1.

Fig. 2.

G. Ciuti Incise

TAV. XII.

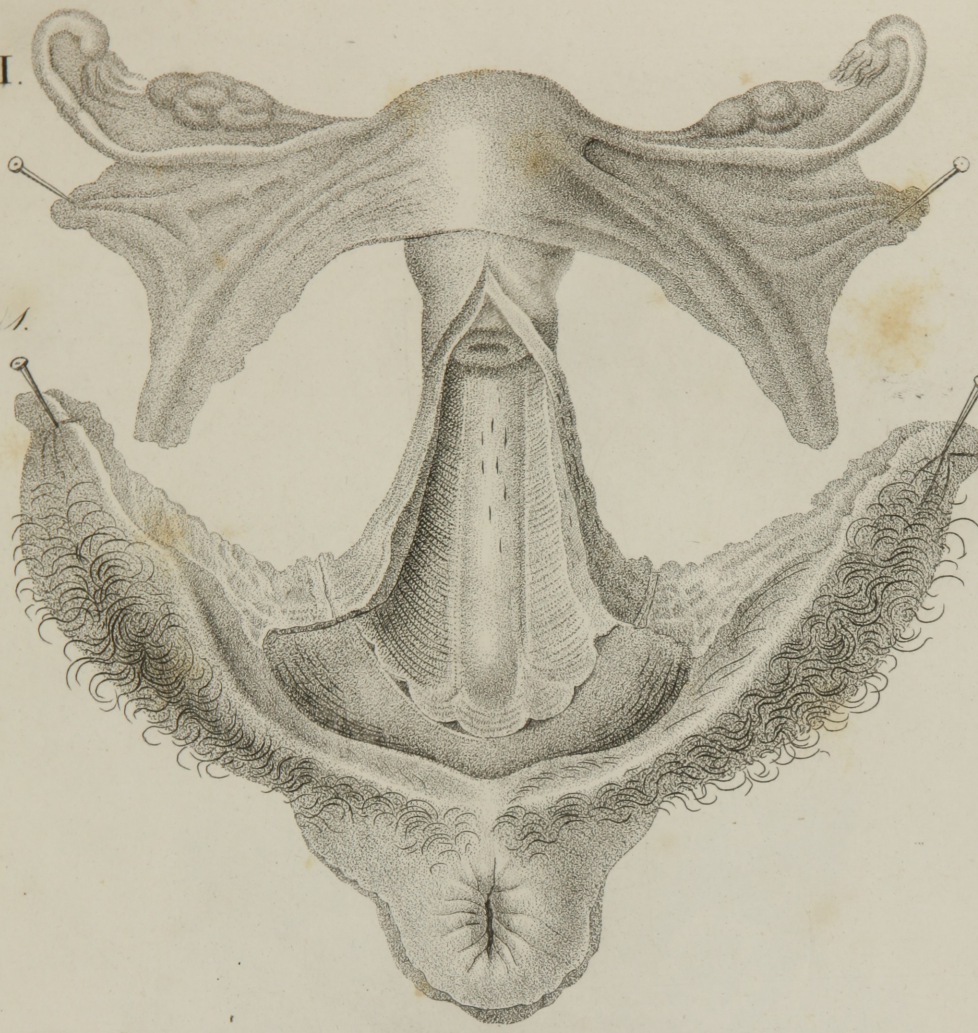

Fig. 1.

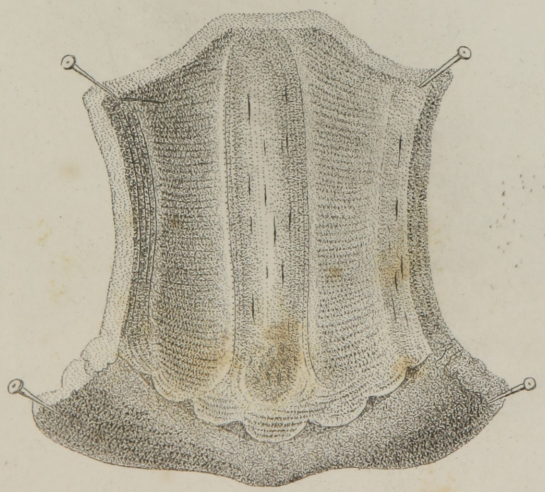

Fig. 2.

G. Ciuti Inise

Fig. 1.

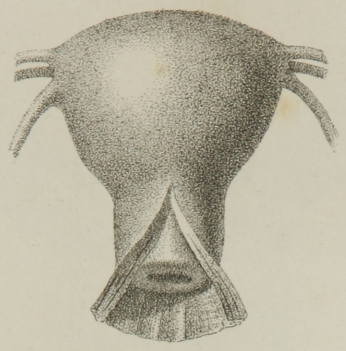

Utero isolato

Fig. 2.

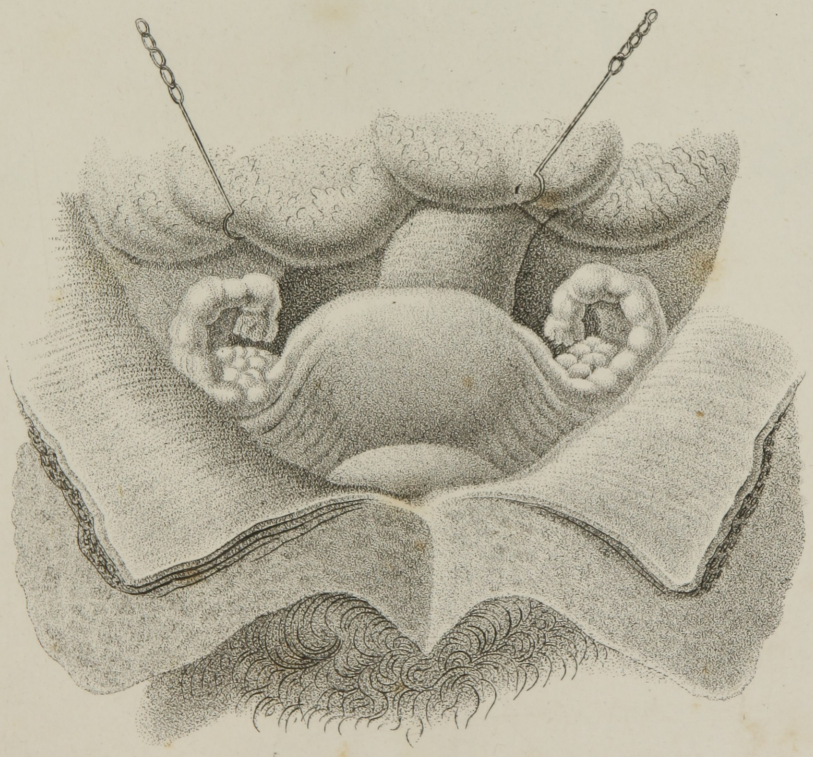

Rapporti dell'utero colla vescica e coll' intestino retto

G. Ciuti Incise

TAV. XIV.

Fig. 1.

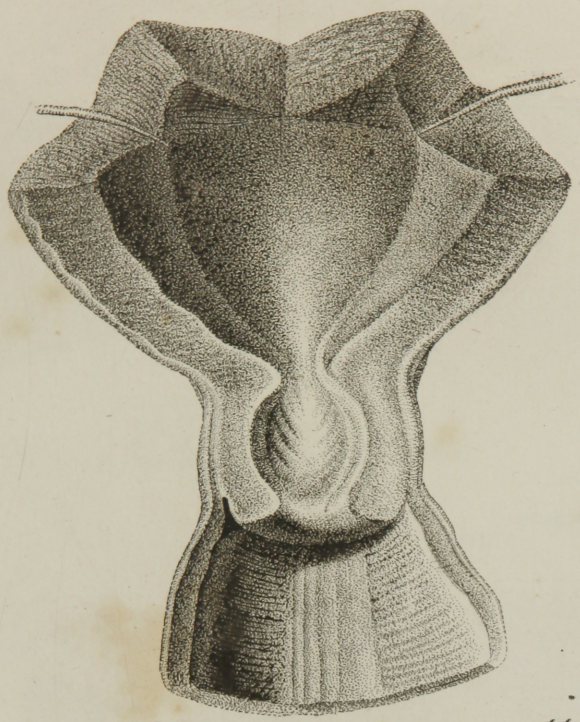

Parte interna dell' utero messa allo Scoperto

Fig. 2.

Utero diviso verticalmente

Fig. 1.

Tuba Sviluppata

Fig. 2.

Gravidanza estrauterina della Tuba

Fig. 3.

Fig. 4.

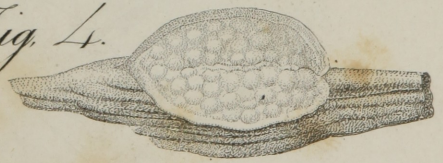

Profilo longitudinale dell'Ovaja

G. Ciuti Incise

TAV. XVI.

Fig. 1.

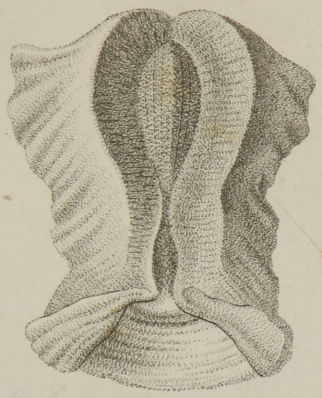

Utero doppio

Fig. 2.

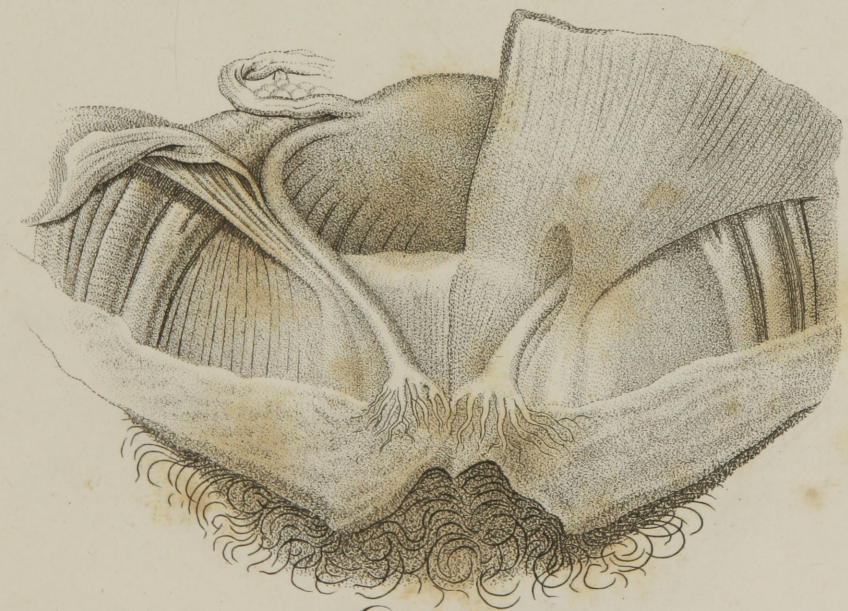

Veduta dei Ligamenti rotondi

G. Cioli Firenze

15 Giorni.

Fig 1.

Fig 2.

21 Giorni.

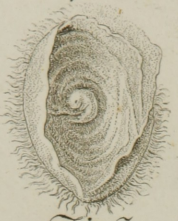

Fig 3.

1/5 Giorni.

Fig 4.

2 Mesi.

Fig. 5

3 Mesi.

Fig. 6.

4. Mesi.

Fig. 7.

5 Mesi.

Fig. 8.

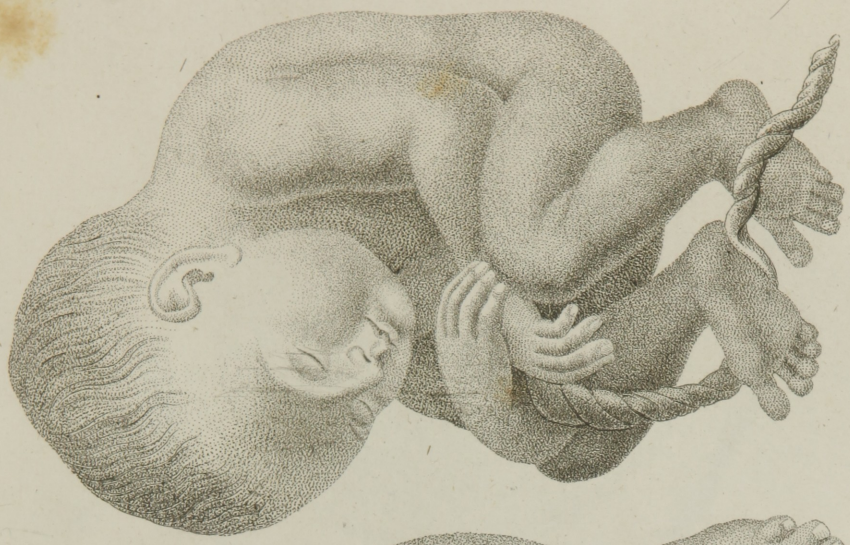

Fig. 1. *7 Mesi.*

Fig. 2. *9 Mesi.*

Guida incise

Fig. 1.

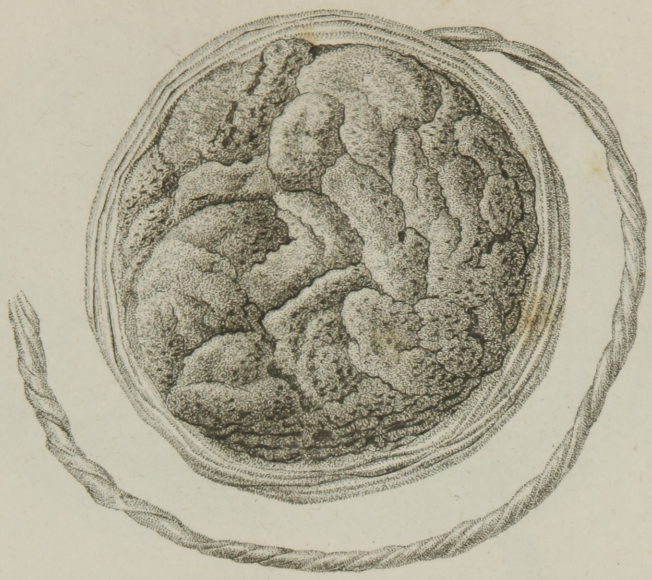

Faccia Uterina.

Placenta

Fig. 2.

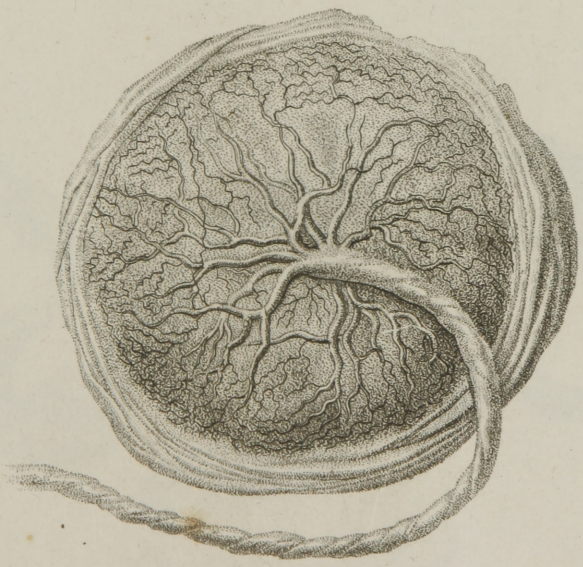

Faccia Fetale.

Ciuti inciso

Fig. 1.

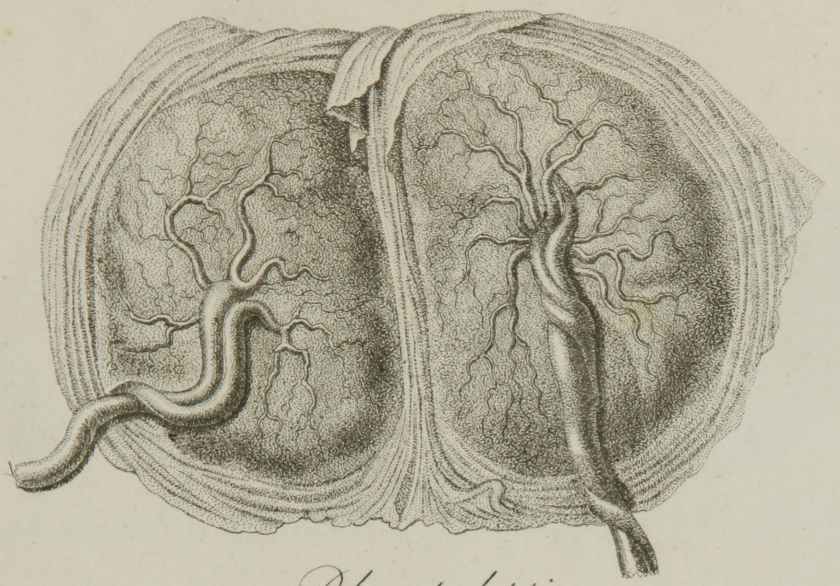

Placenta doppia.

Fig. 2.

Cordone ombelicale.

Ciuti inciso

Circolazione del Feto.

Fig. 2.

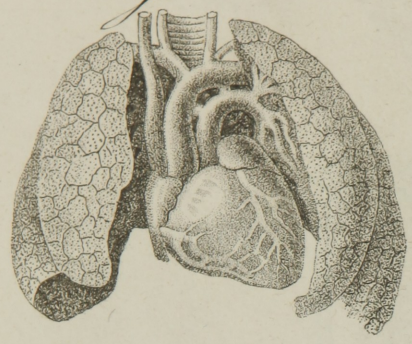

Disposizione del Canal Arterioso.

Fig. 1.

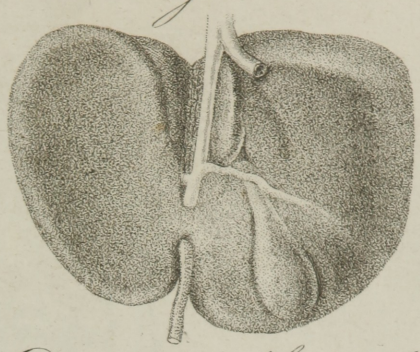

Disposizione del Canale Venoso.

Fig. 3.

Situazione del foro Botale.

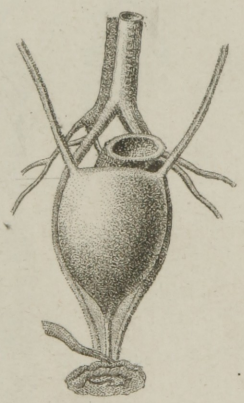

Fig. 4.

Disposizione dell' Arterie Ombelicale.

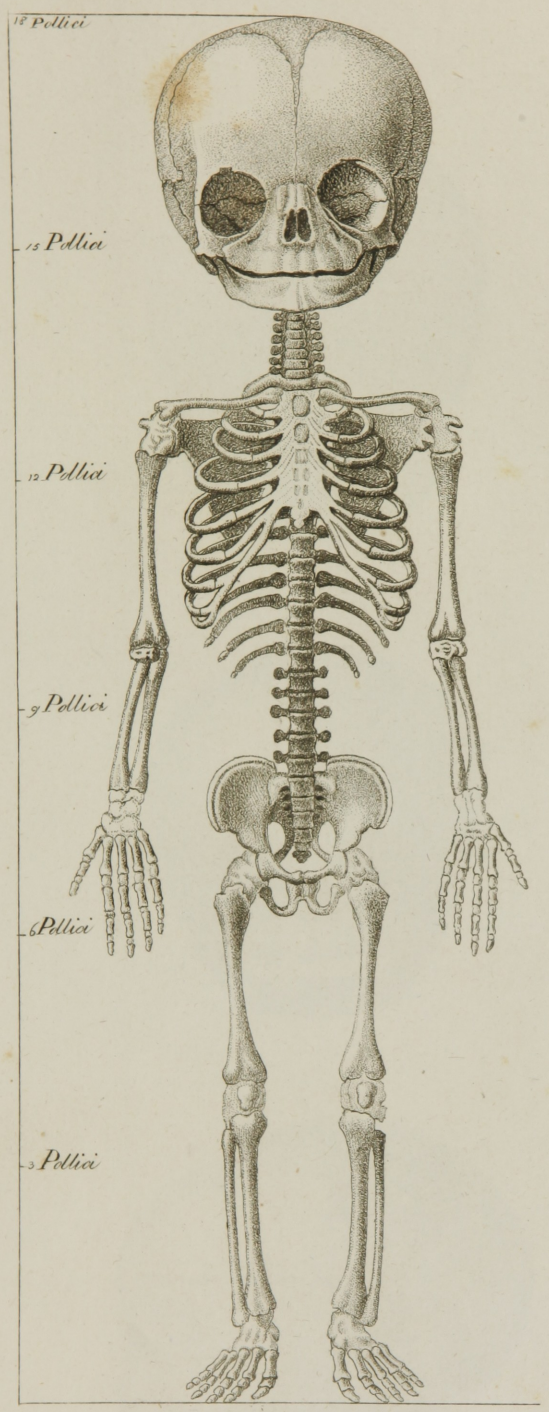

Scheletro di Feto.

Cuelli incise

Fig. 1.

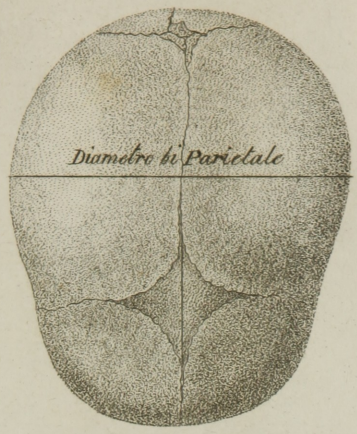

Fig. 2.

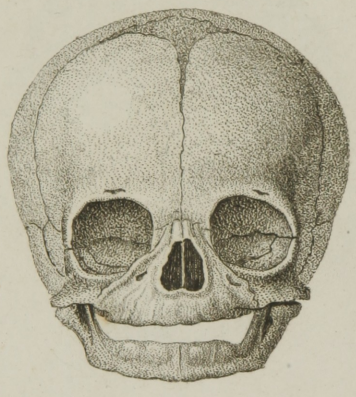

Fig. 3.

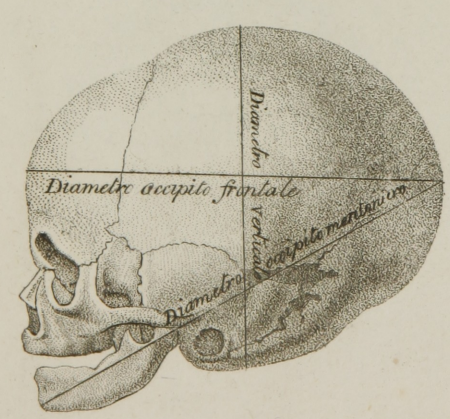

Fig. 1.

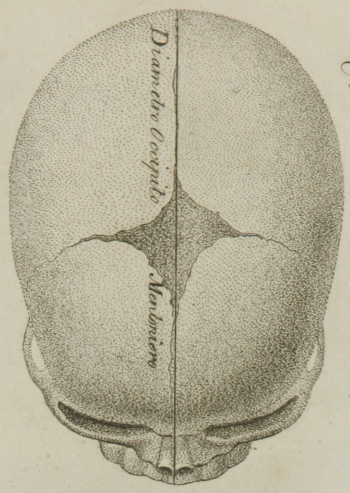

Fig. 2.

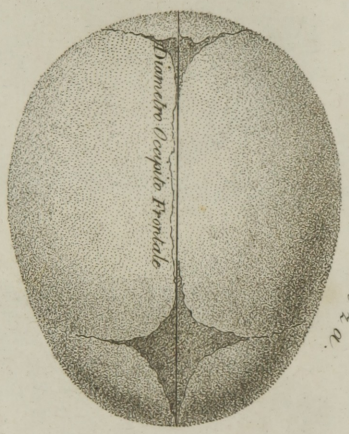

Fig. 3.

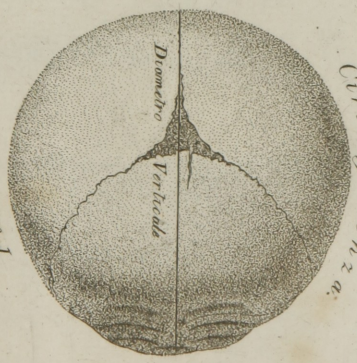

Ciuli incise

TAV. XXV.

Istoria della Gravidanza.

Stato naturale.

Fig. 1.

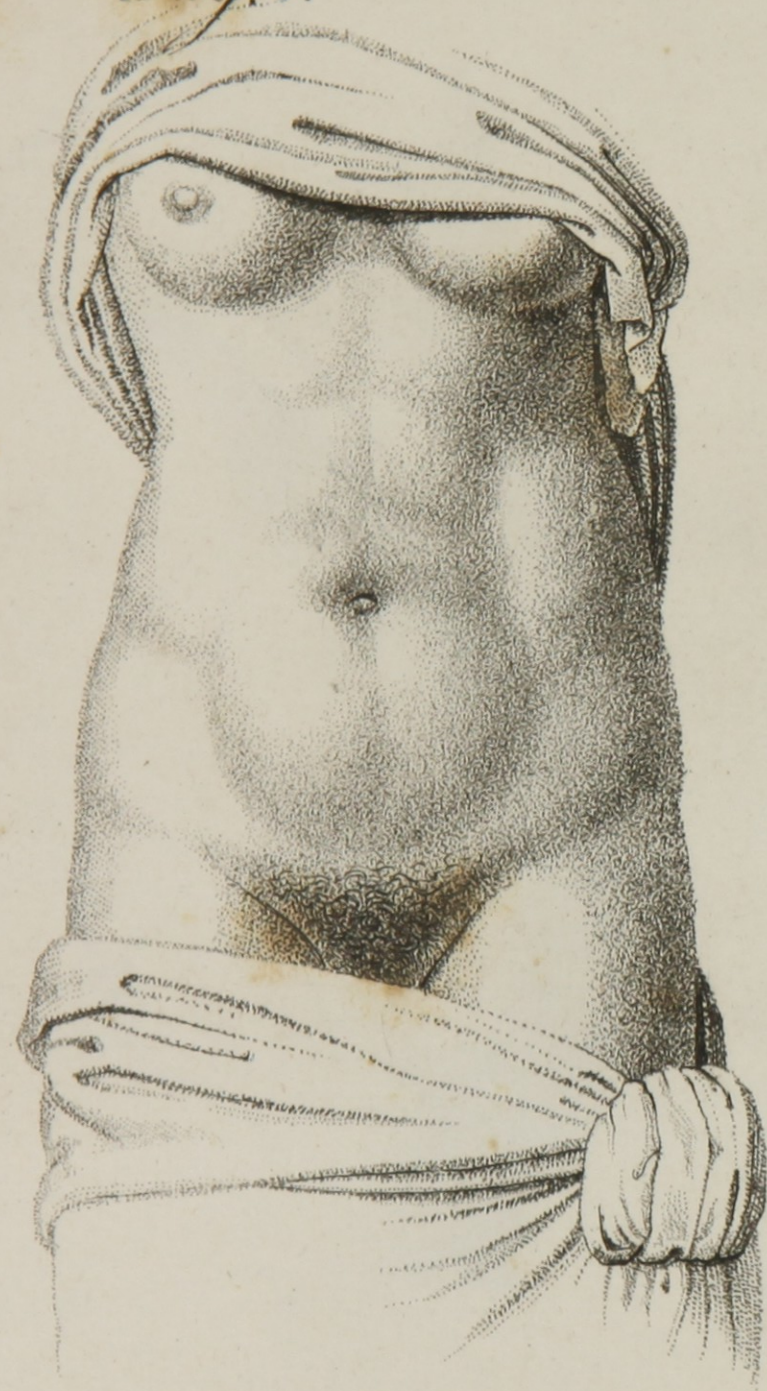

3. Mesi.

Fig. 2.

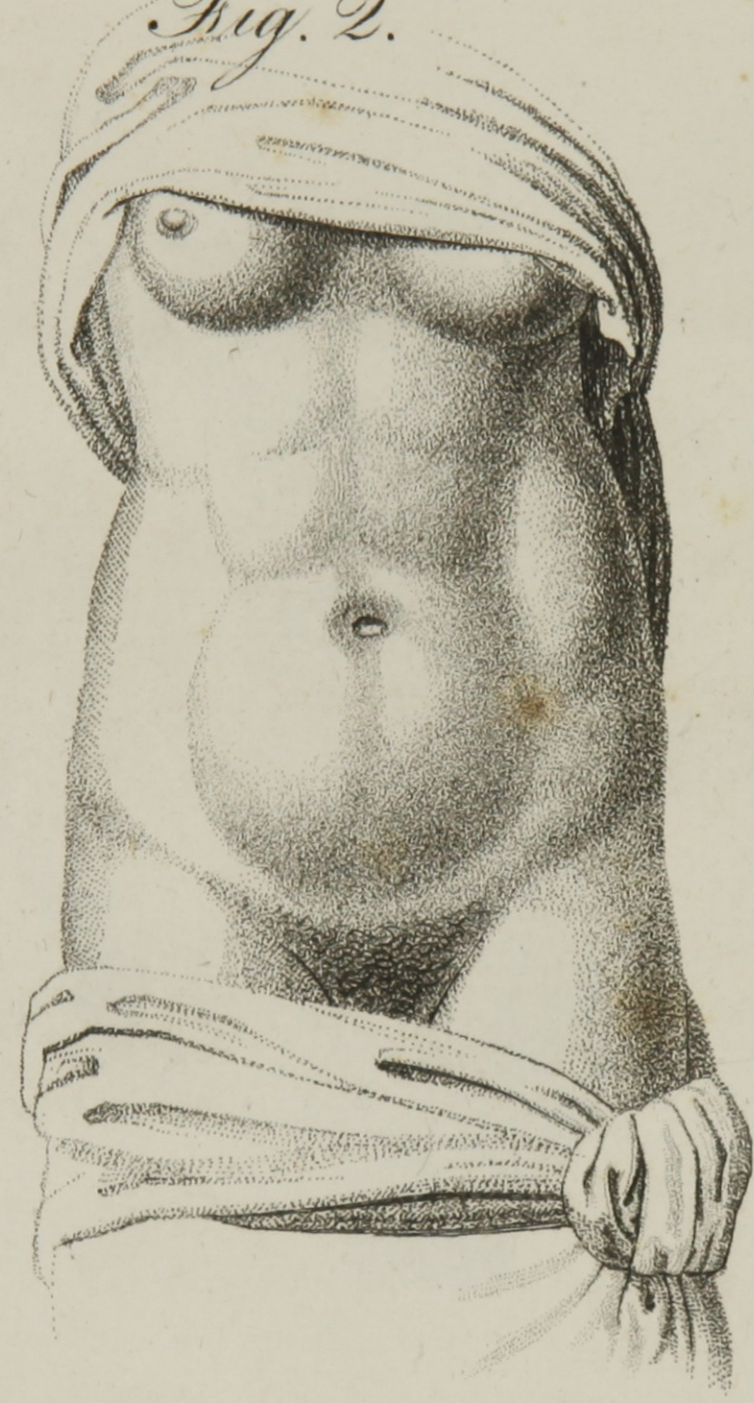

6. Mesi.

Fig. 3.

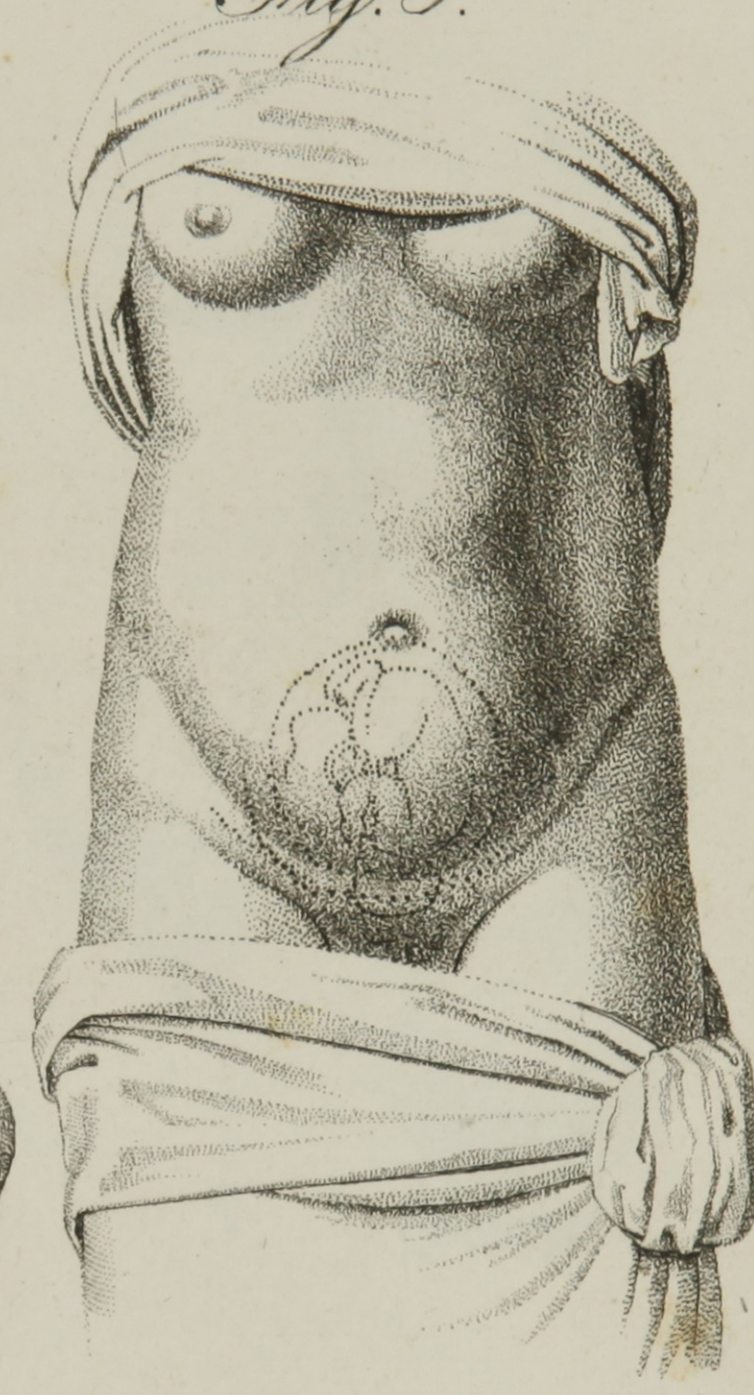

9. Mesi.

Fig. 4.

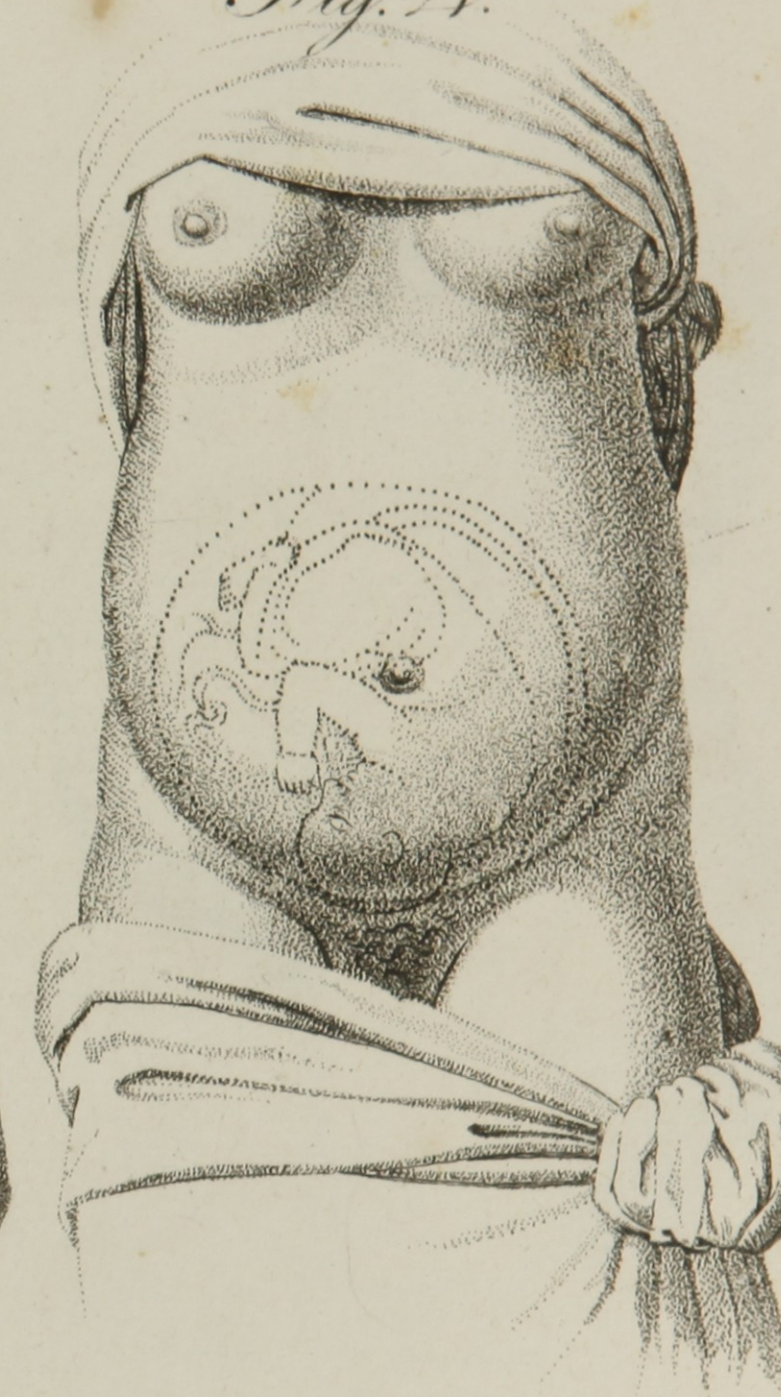

Ciutli incise

Stato naturale.

Fig. 1

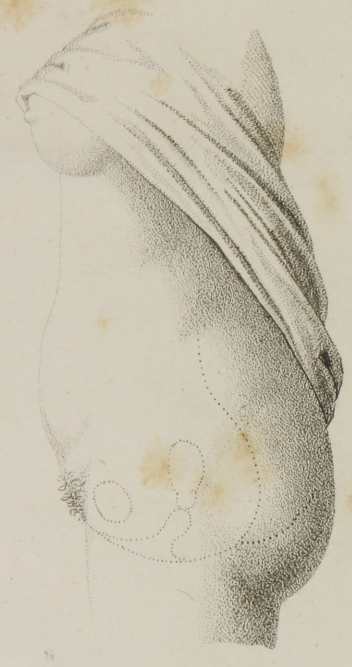

3. Mesi.

Fig. 2

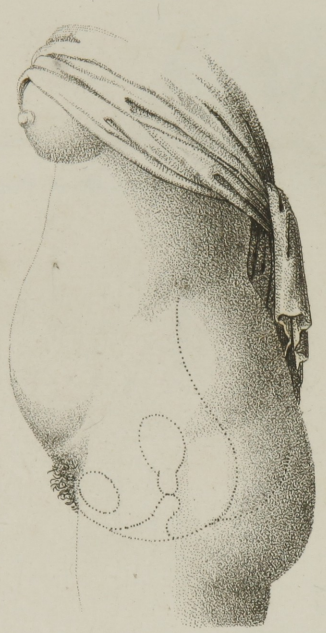

6. Mesi.

Fig. 3

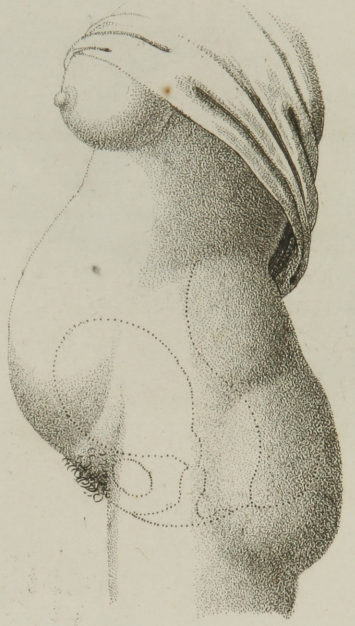

9. Mesi.

Fig. 4

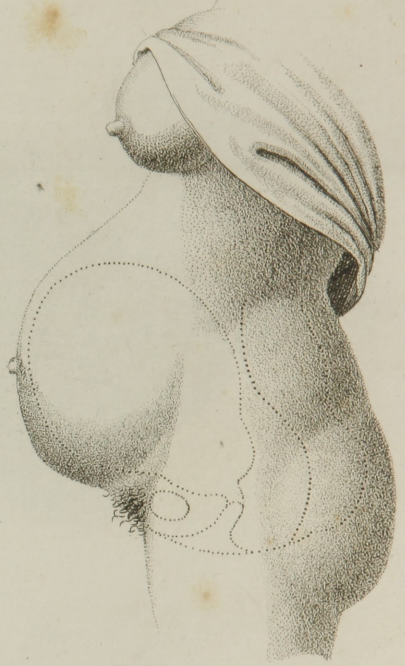

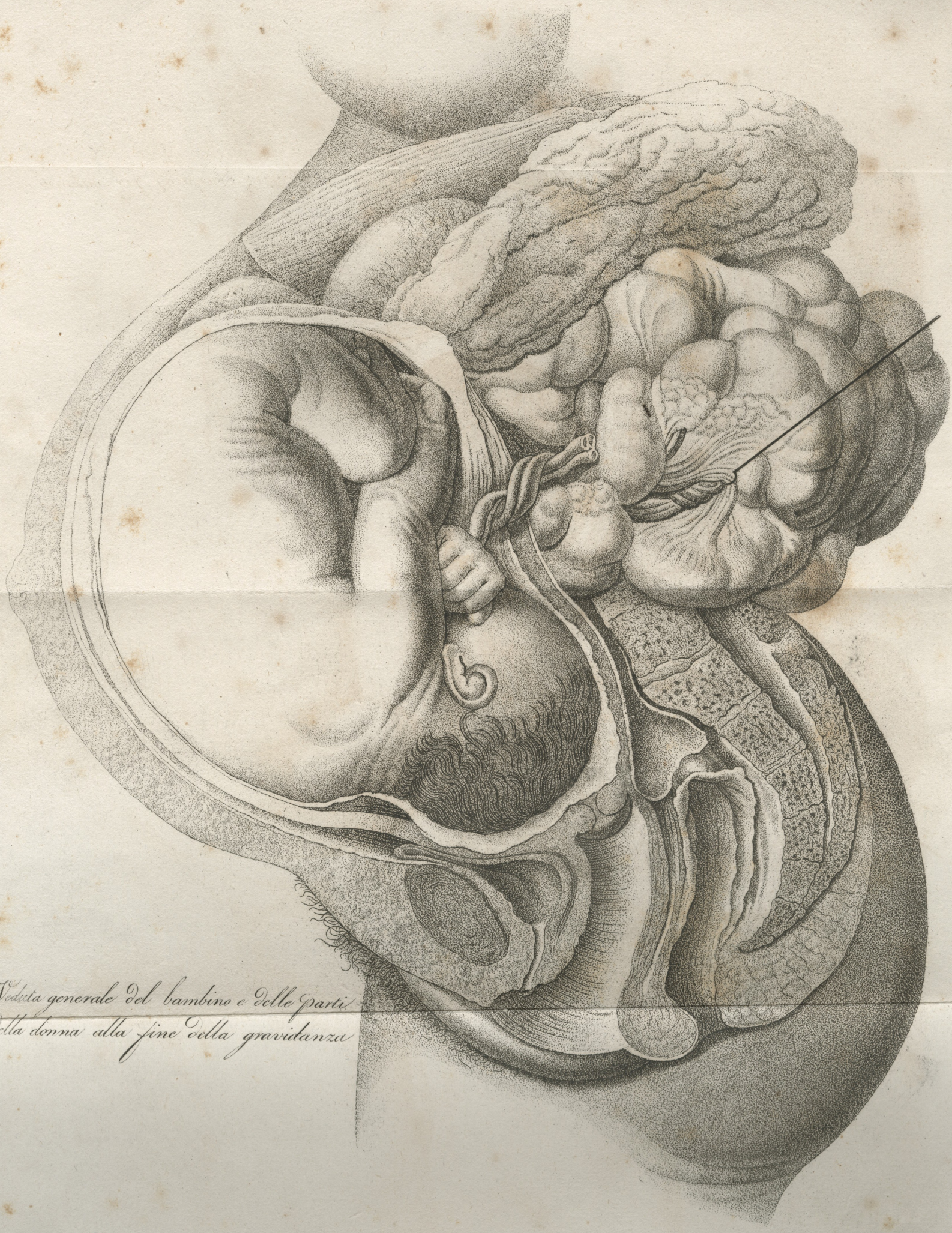

Veduta generale del bambino e delle parti della donna alla fine della gravidanza

Ciuti inciso

Storia generale dell' esplorazione.

Esplorazione in piedi.

Cialli incise

Esplorazione in posizione orizzontale

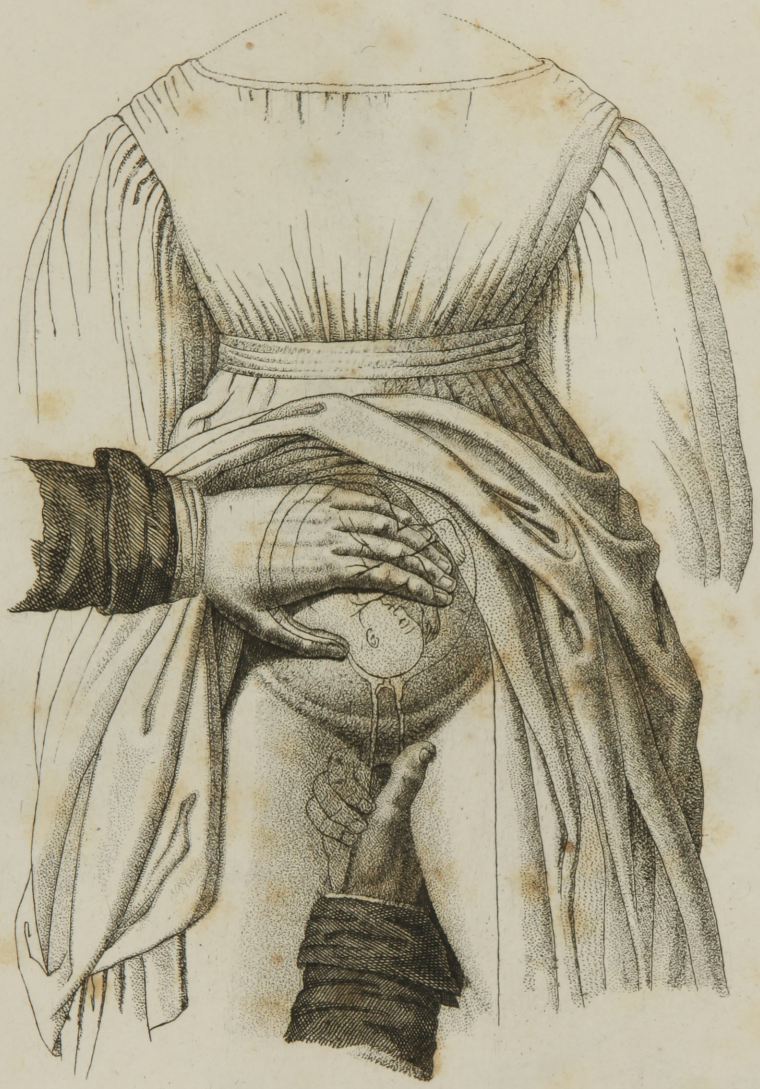

Esplorazione per eseguire il ballottamento

Carli inc.ve

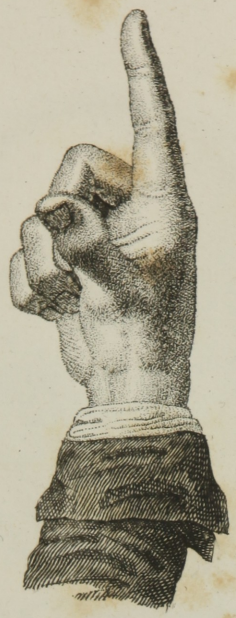

Fig. 1

Posizione del dito per l'esplorazione

Fig. 2

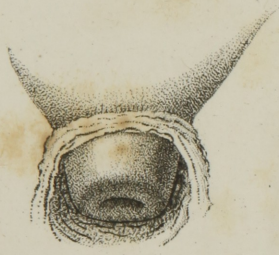

Stato del Collo a 3 mesi

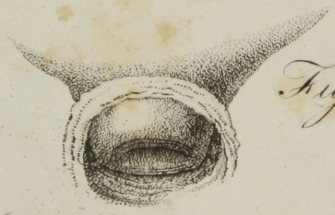

Fig. 3

Stato del Collo a 6 mesi

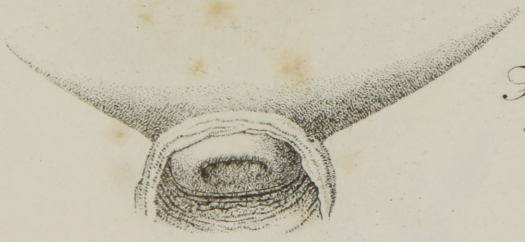

Fig. 4

Stato del Collo a 9 mesi

1.ª Posizione della Testa

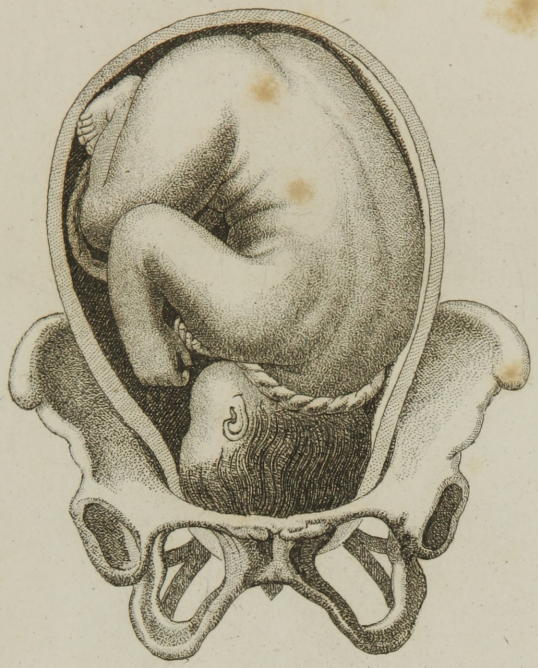

Fig. 1.

2.ª Posizione della Testa.

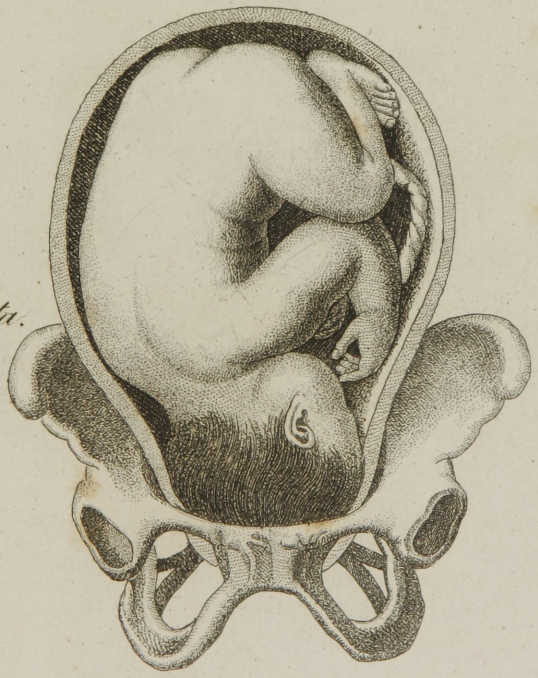

Fig. 2.

Ciuti inc.

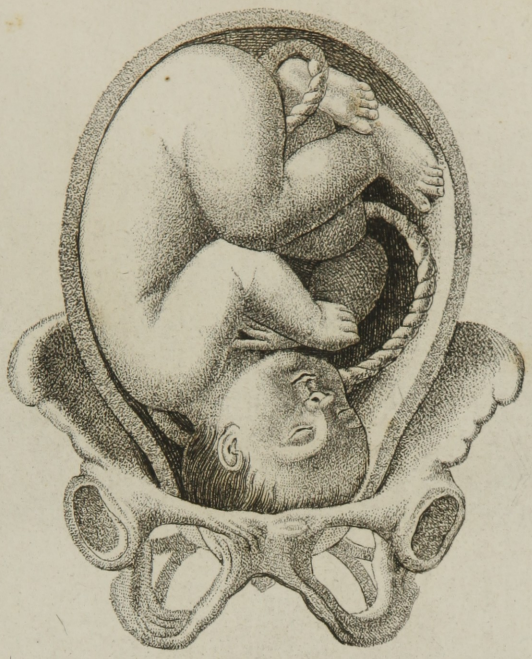

Fig. 1. *3.ª posizione della testa.*

Fig. 2. *4.ª posizione della testa.*

Curti inc.

Fig. 1. *Uscita della Testa. coll'occipite in Alto*

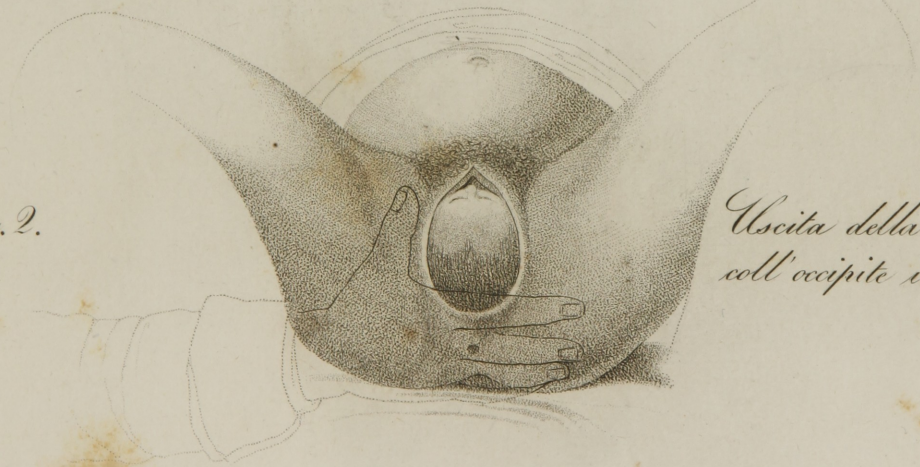

Fig. 2. *Uscita della Testa coll'occipite in basso.*

Ciuli inc.

Fig. 1. *Posizione dei piedi.*

Fig. 2. *Posizione delle natiche.*

Cauti inc.

Fig. 1.

Prendere i piedi in 1.° posizione.

Fig. 2.

Prendere il tronco.

Cuti inc.

Estrazione delle Braccia

Fig. 1.

Estrazione della Testa

Fig. 2.

Fig. 1.

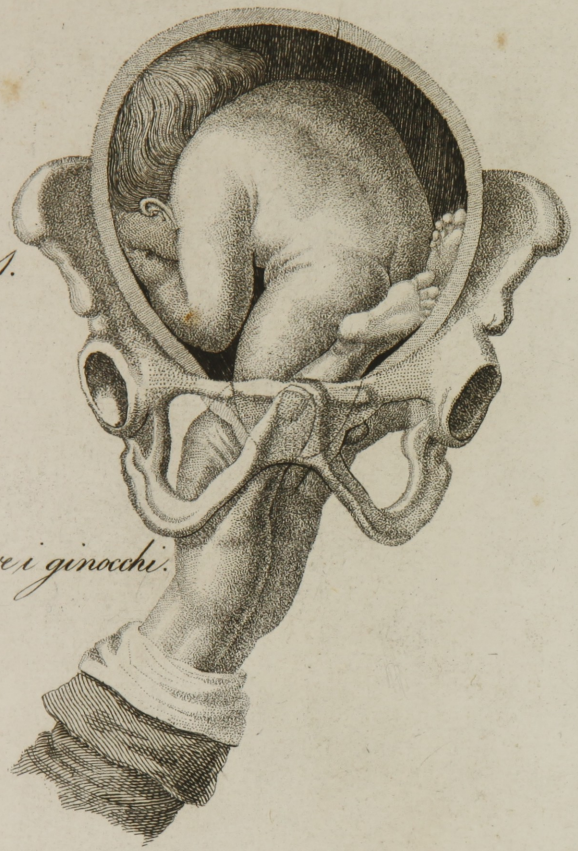

Prendere i ginocchi.

Fig. 2.

Applicazione del laccio.

Fig. 1.

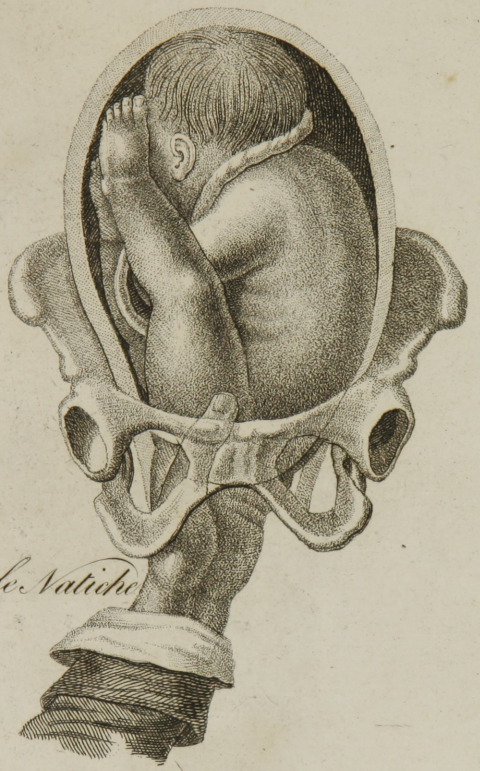

Prendere le Natiche

Fig. 2.

Disimpegnare i Piedi

Fig. 1.

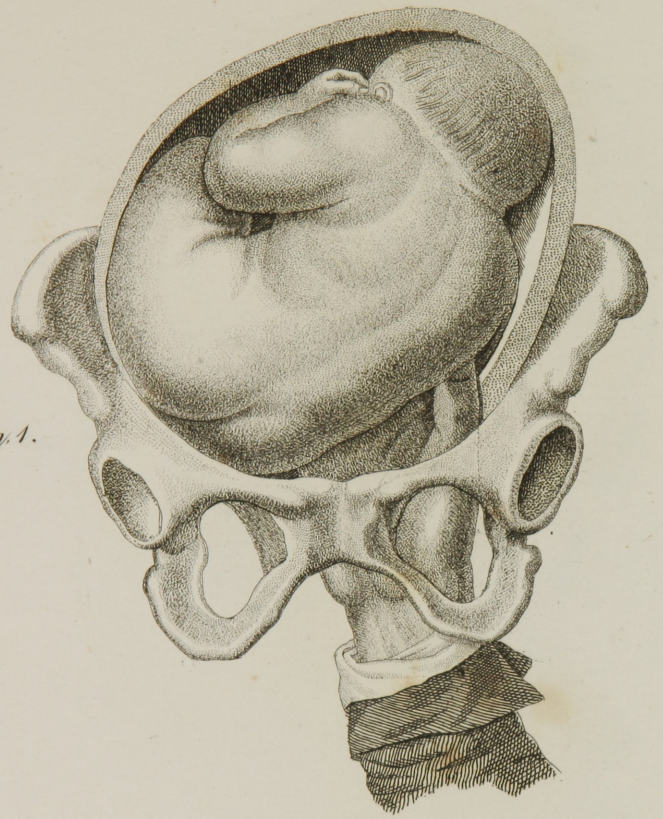

1.ma Posizione del dorso.

Fig. 2.

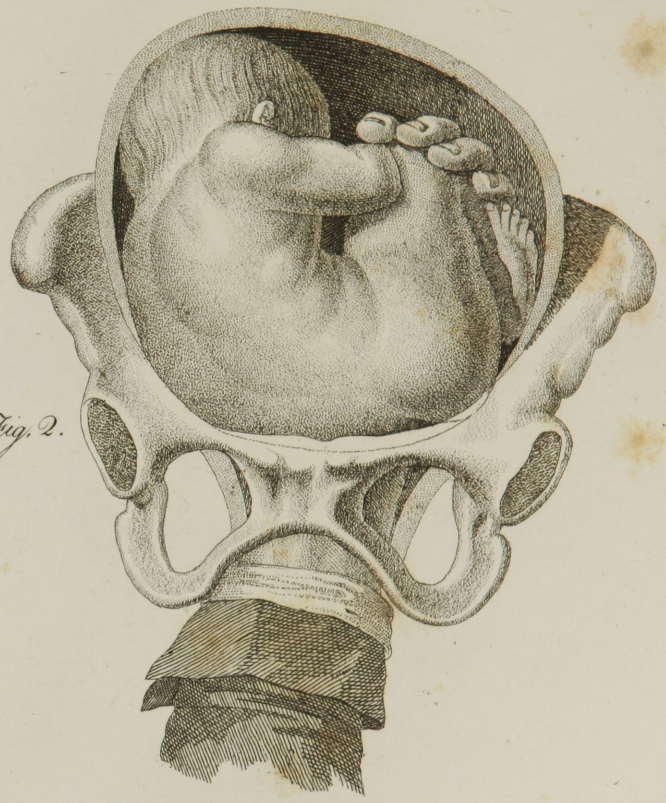

2.da Posizione del dorso.

Fig. 1.

1.ma Posizione del Ventre

Fig. 2.

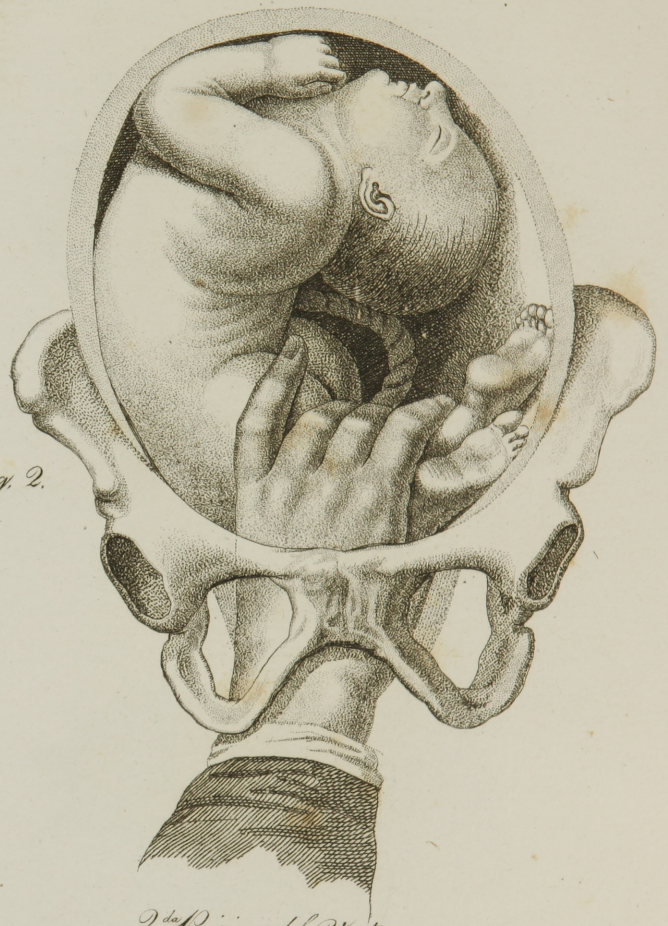

2.da Posizione del Ventre.

2.da Posizione del petto.

Fig. 1.

1.ma Posizione del petto.

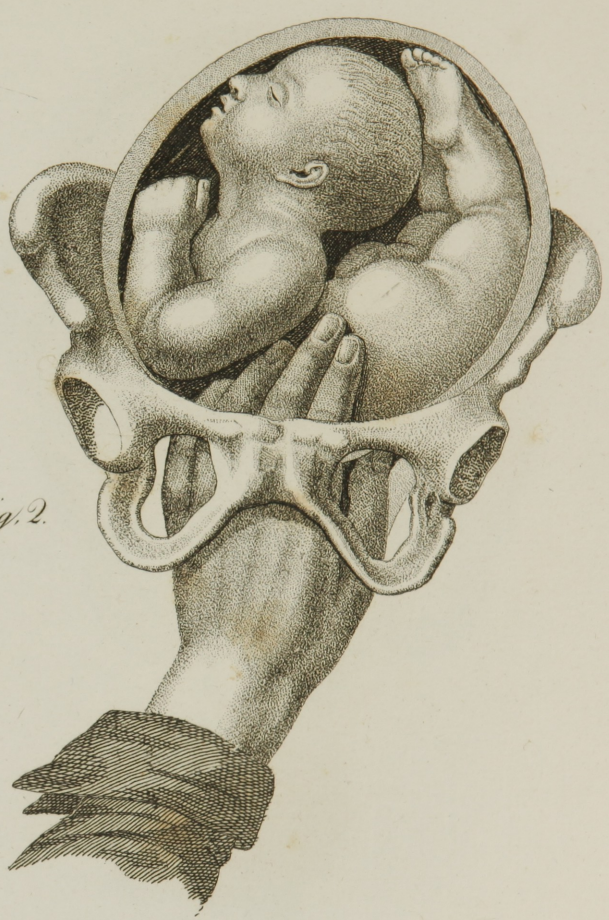

Fig. 2.

Fig. 1

1.ma Posizione dell' Anca destra.

Fig. 2

2.da Posizione dell' Anca destra.

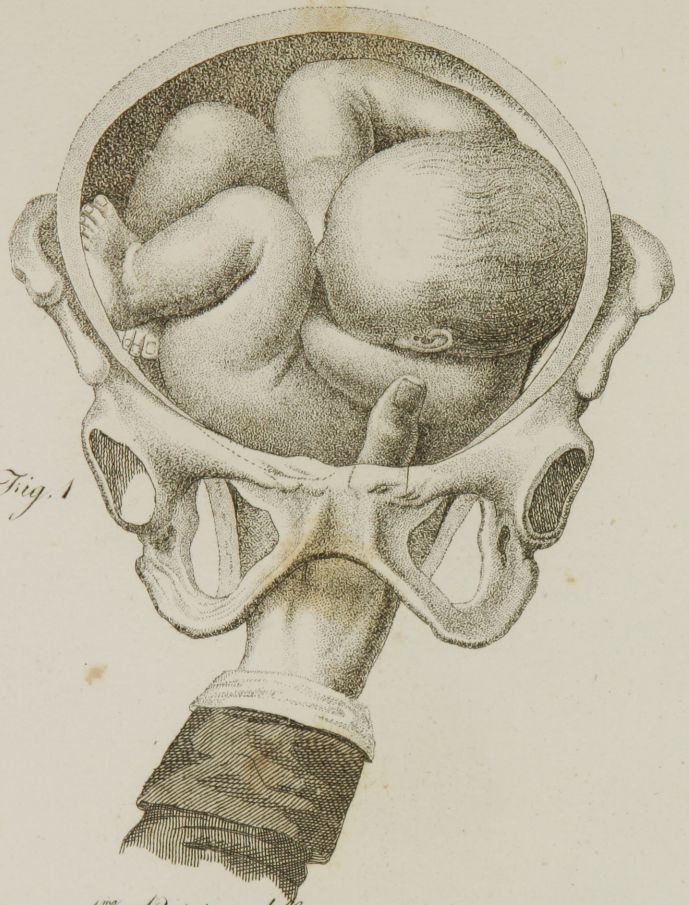

Fig. 1

1.ma Posizione dell' Anca Sinistra.

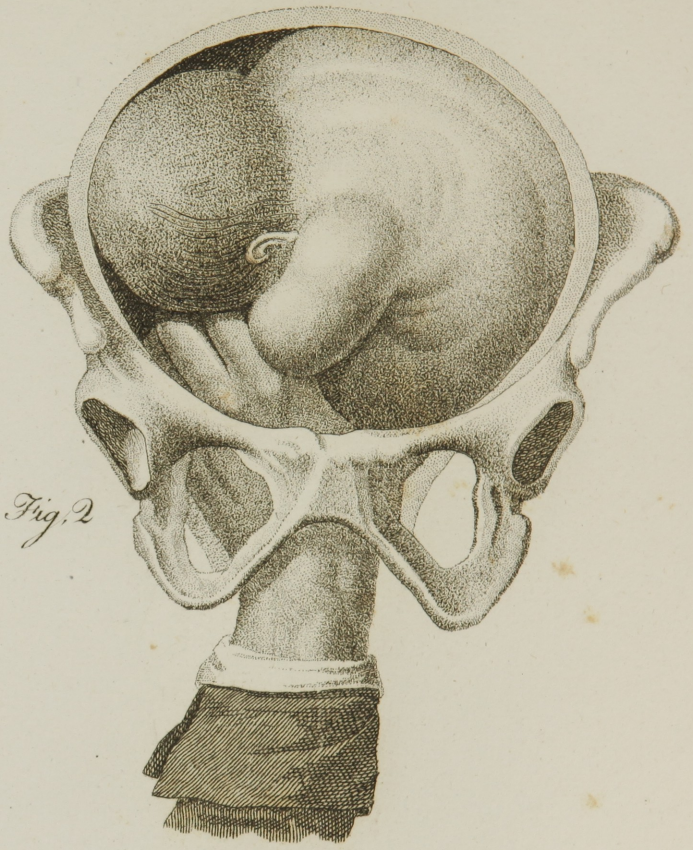

Fig. 2

2.da Posizione dell' Anca Sinistra.

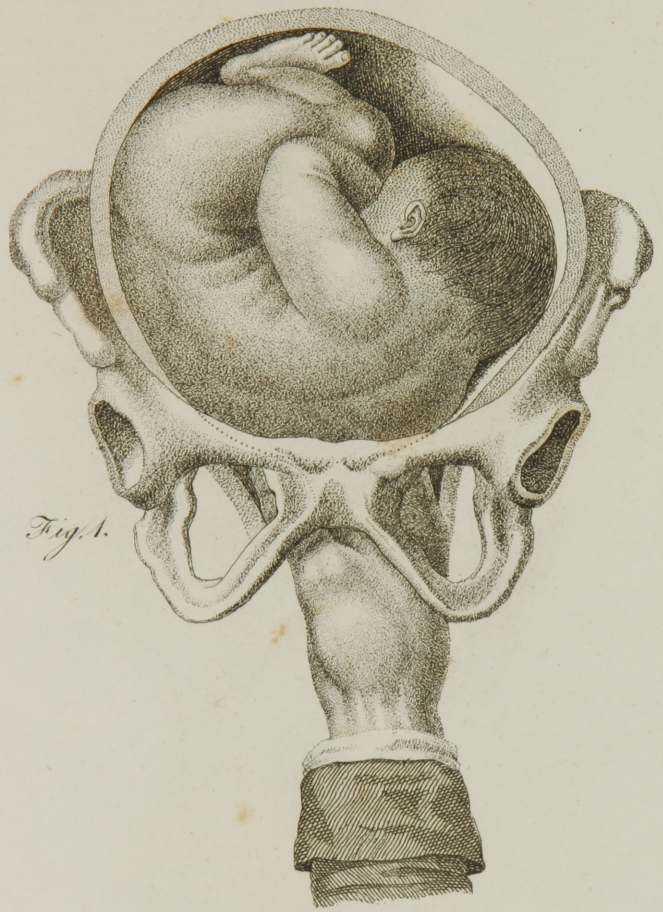

Fig. 1.

1.ª Posizione della Spalla destra

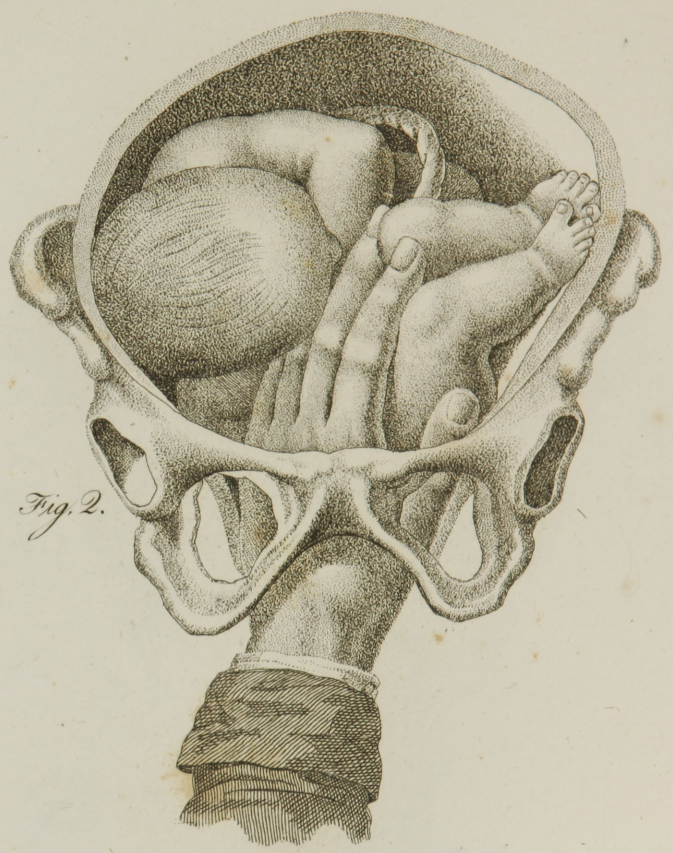

Fig. 2.

2.ª Posizione della Spalla destra

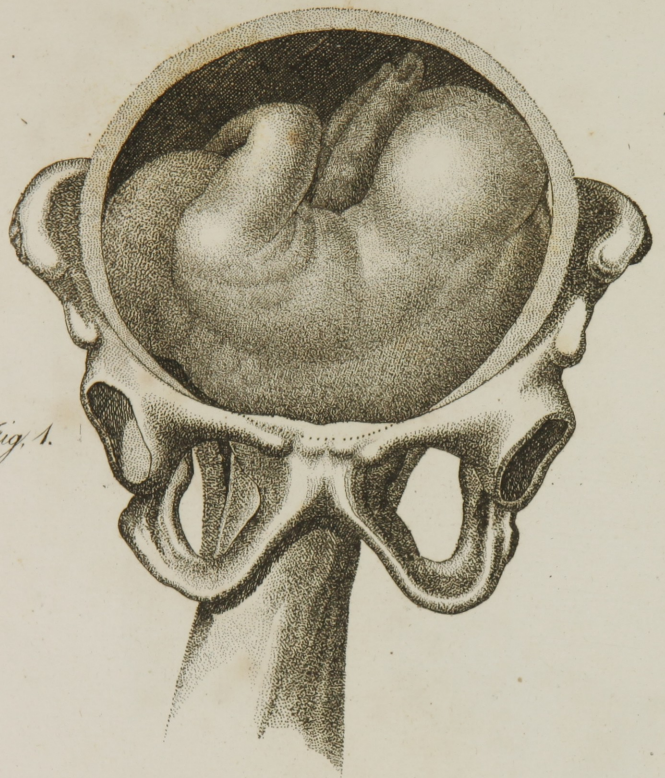

Fig. 1.

2.° Posizione della Spalla sinistra.

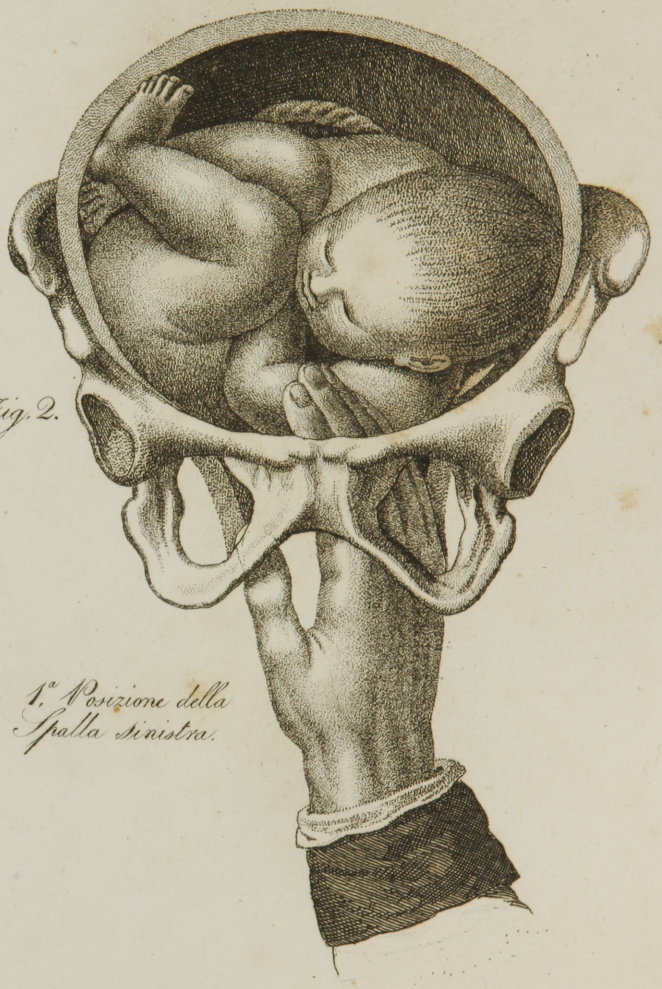

Fig. 2.

1.° Posizione della Spalla sinistra.

Fig. 1.

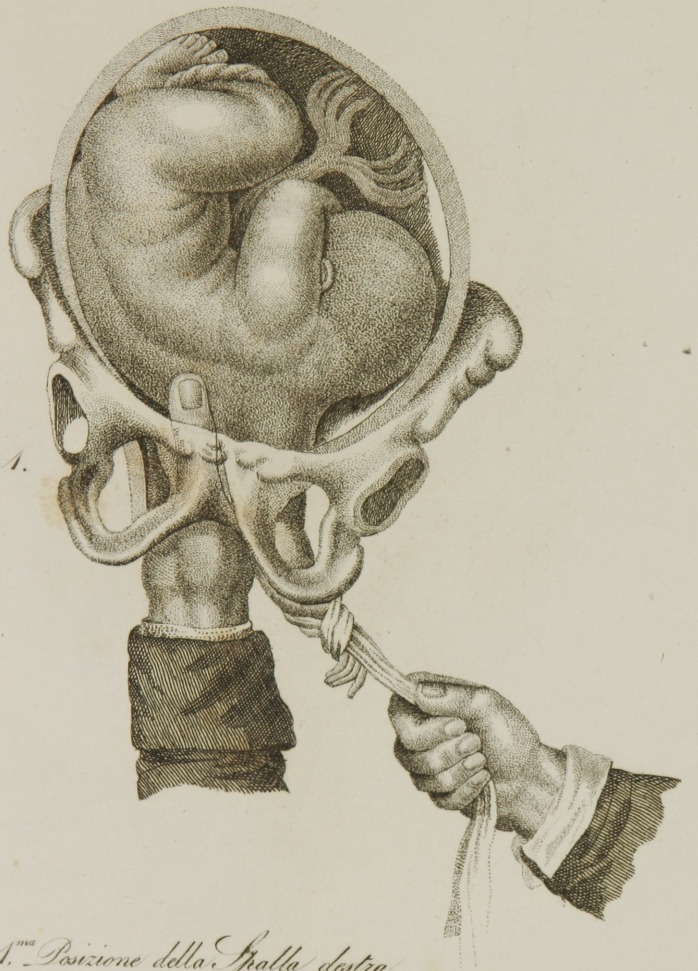

1.ma Posizione della Spalla destra.
con uscita di un braccio allacciato.

Fig. 2.

La stessa posizione col braccio uscito.

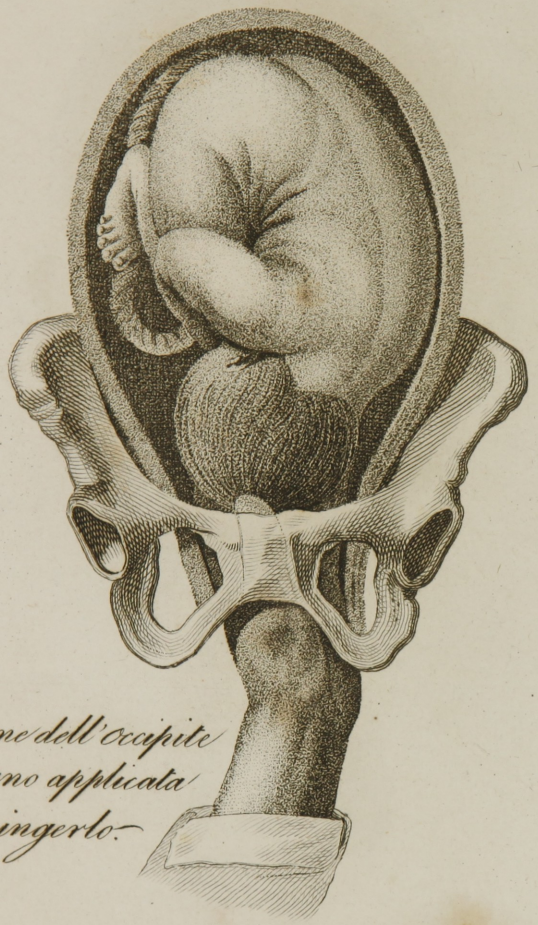

Fig. 1.ª

1.ª Posizione dell'occipite colla mano applicata per respingerlo.

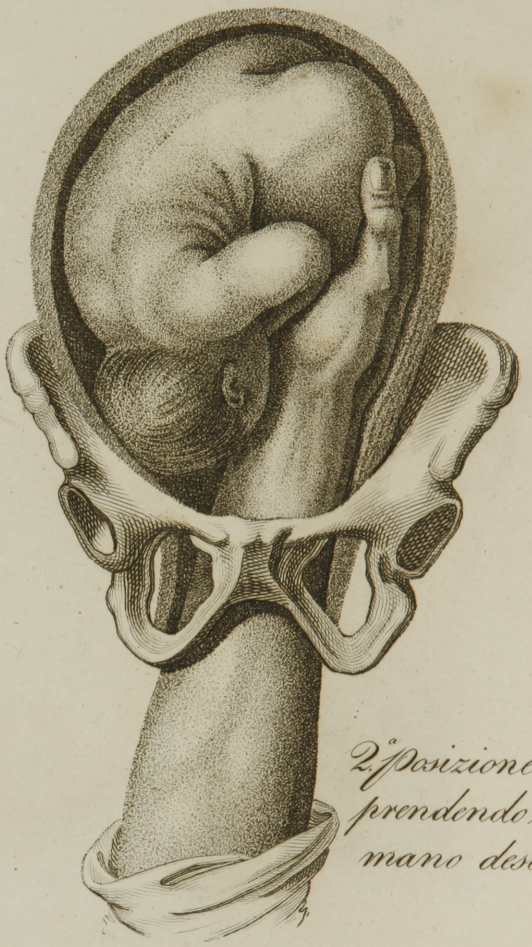

Fig. 2.ª

2.ª posizione dell'occipite prendendo i piedi colla mano destra.

Fig. 1.

Estrazione dei piedi in una delle posizioni della Testa.

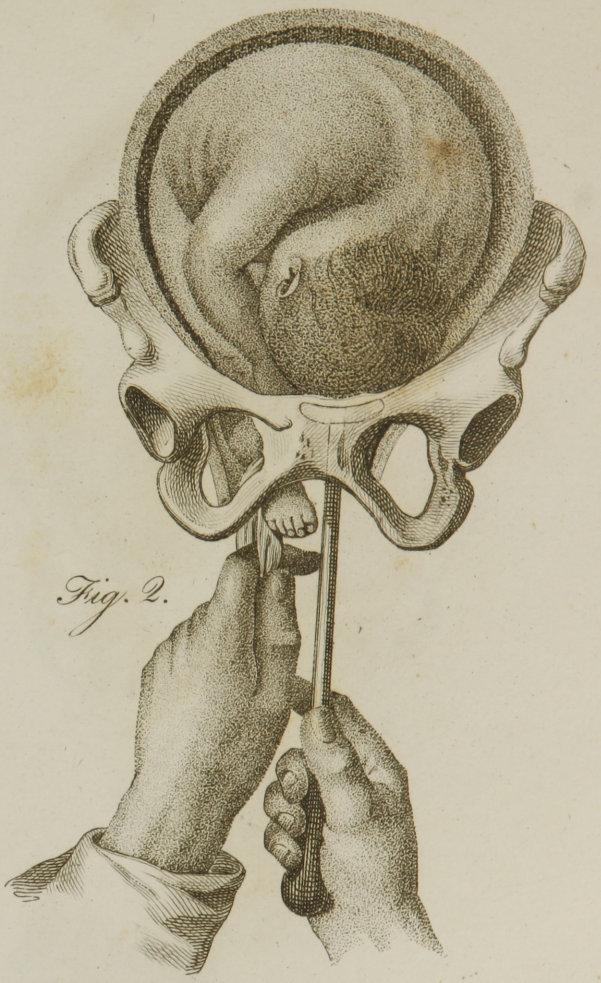

Fig. 2.

Applicazione del Depressore.

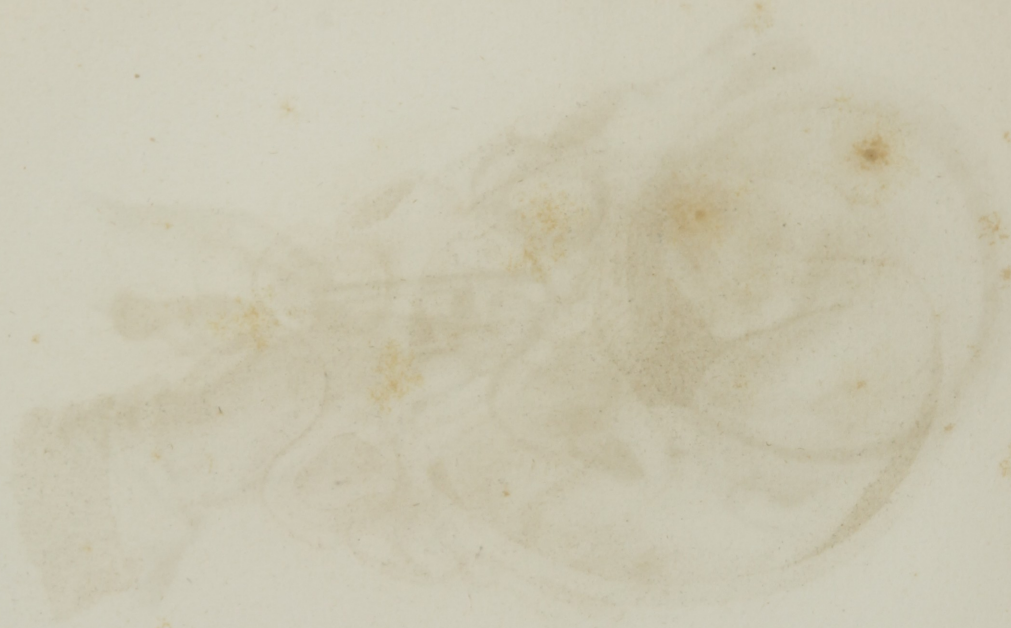

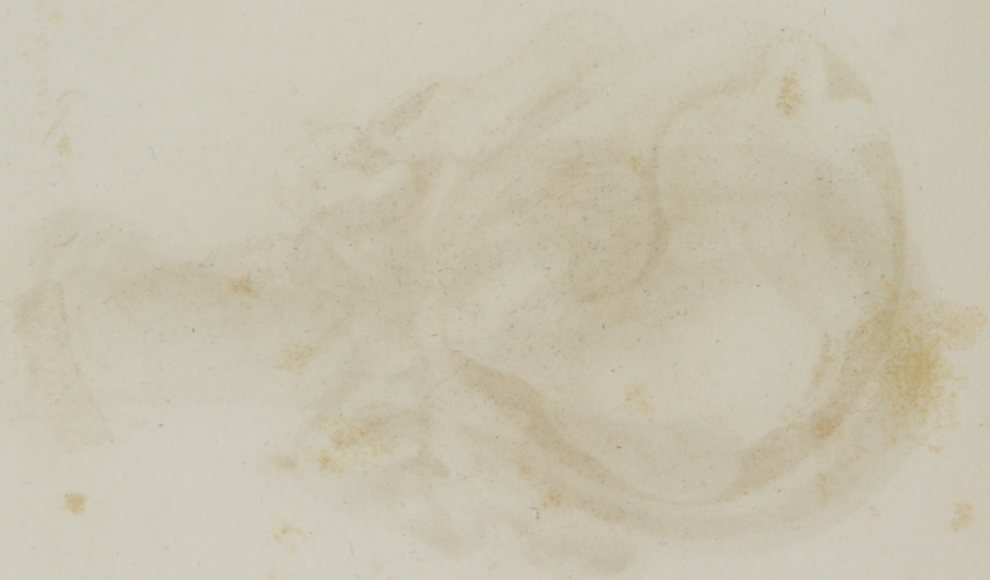

Fig. 1.

Fig. 2.

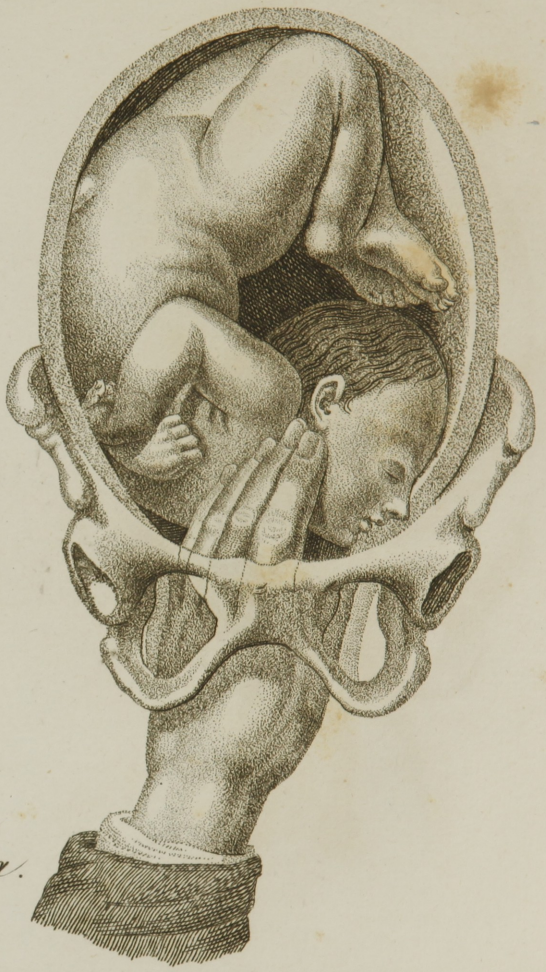

Posizione della Faccia.

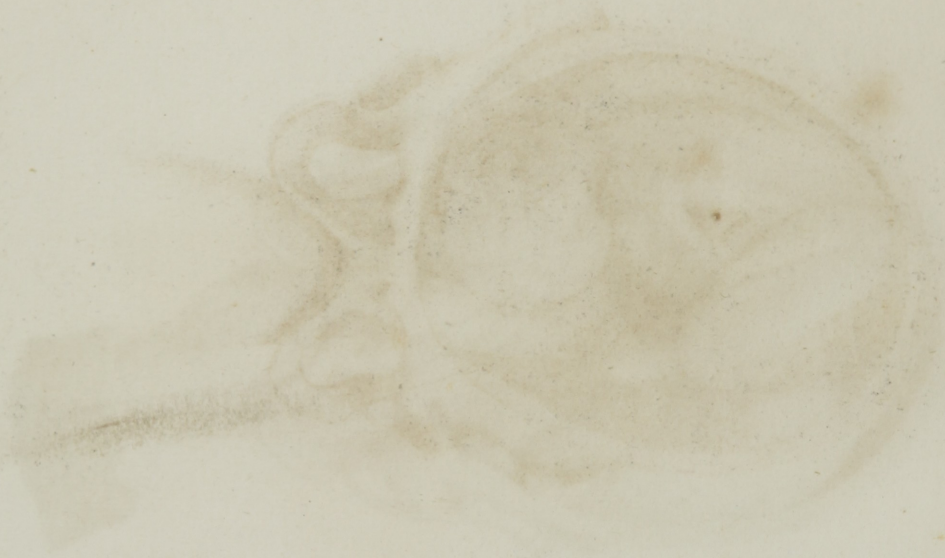

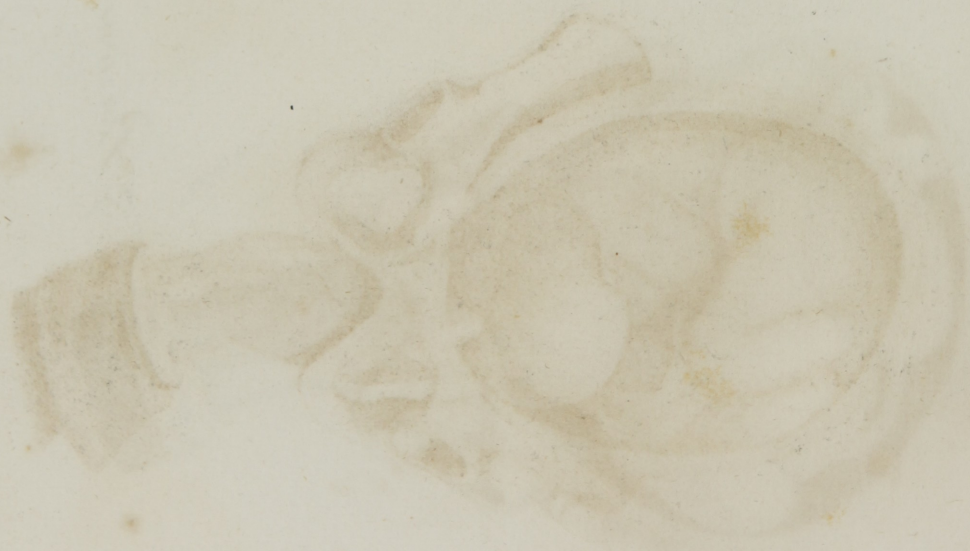

Fig. 1

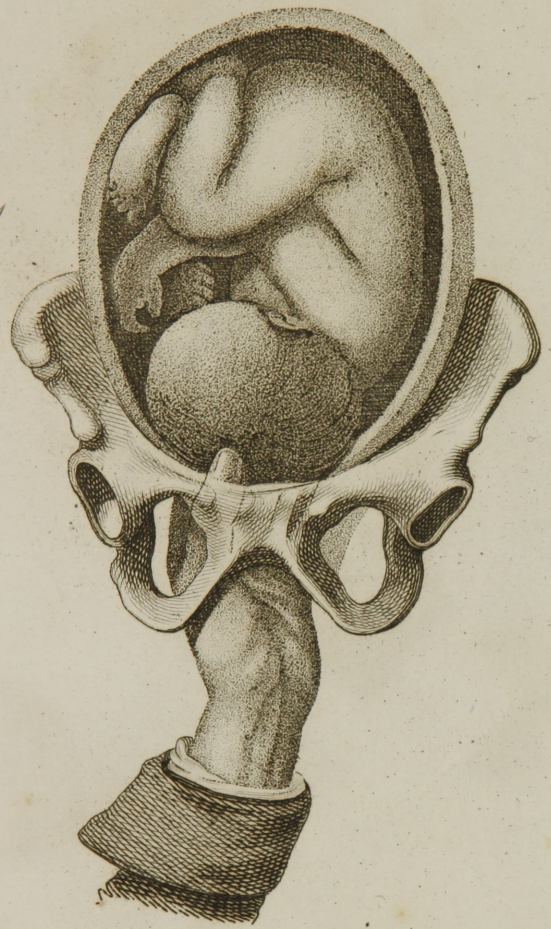

Posizione del lato della testa, applicazione della mano.

Fig. 2.

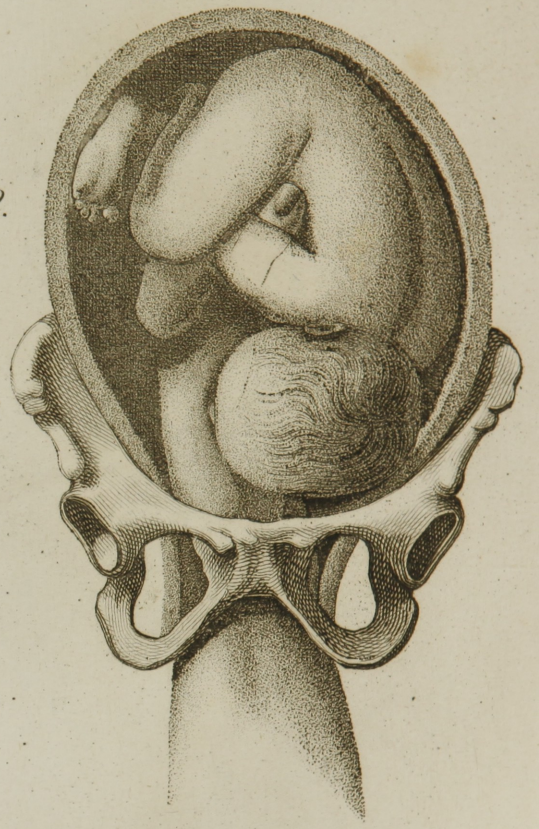

Medesima posizione, introduzione della mano fino ai piedi.

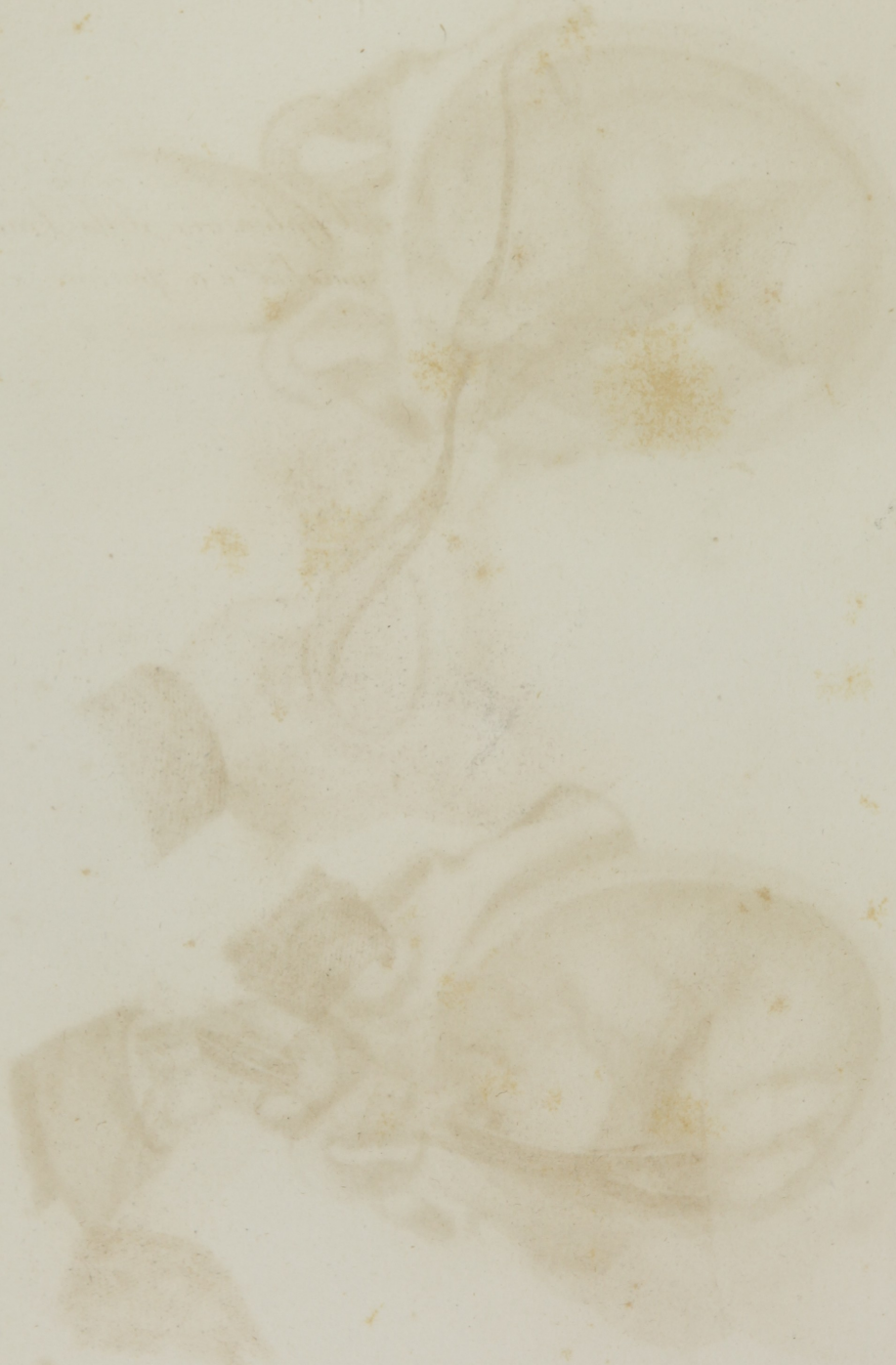

Applicazione della branca maschia o a pernio.

Fig. 1.

Fig. 2.

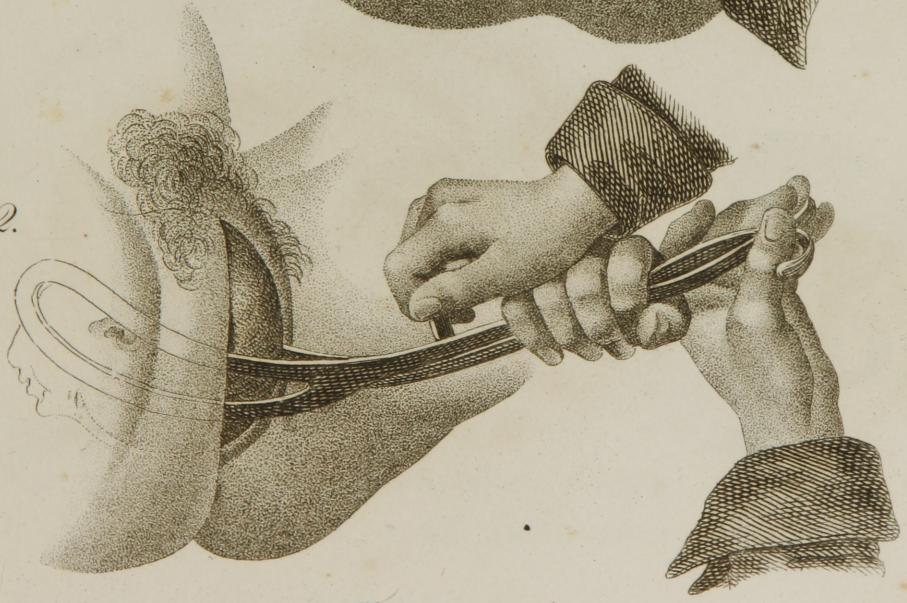

Forcipe applicato.

Fig. 1.

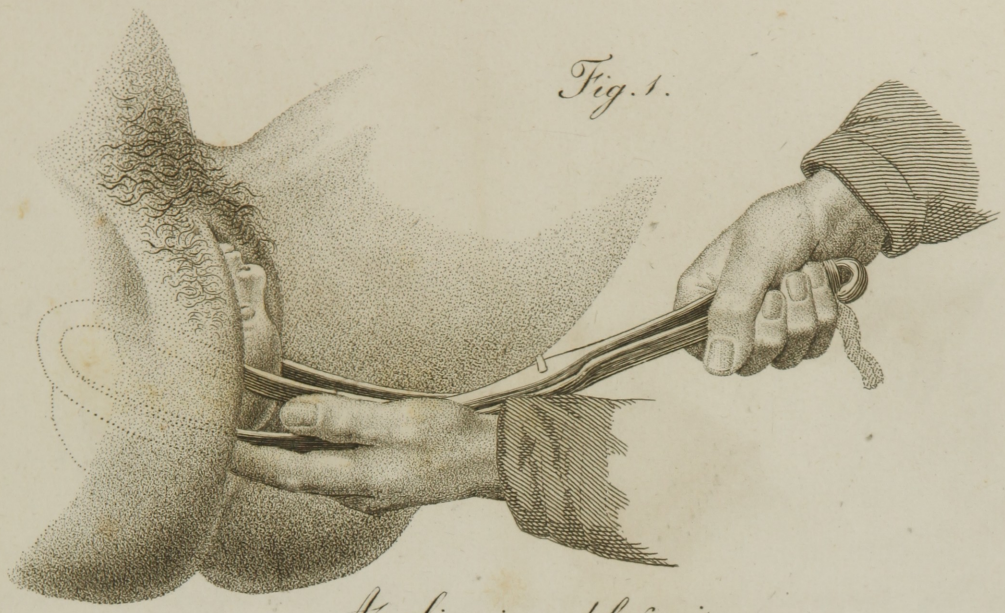

Applicazione del forcipe
Faccia voltata in alto

Fig. 2.

Applicazione del forcipe
Faccia voltata Lateralmente

Ciuti Inc.



Fig. 1.

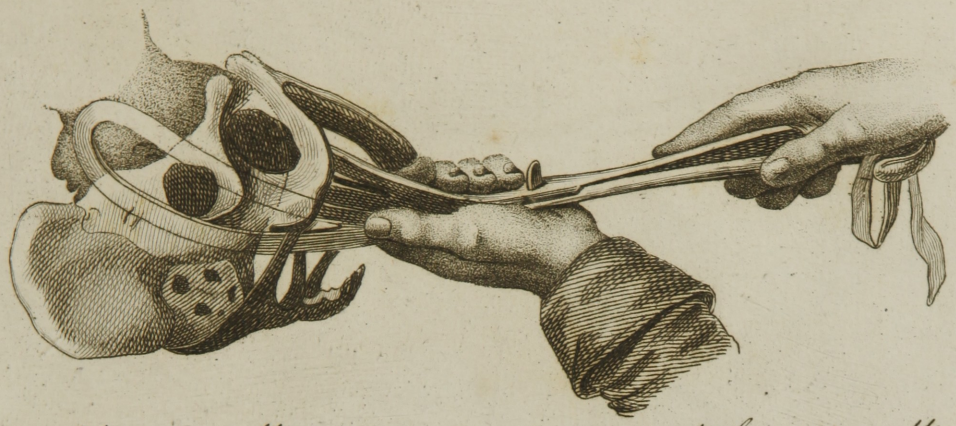

Applicazione del forcipe allo Stretto superiore essendo l'occipite all' insù.

Fig. 2.

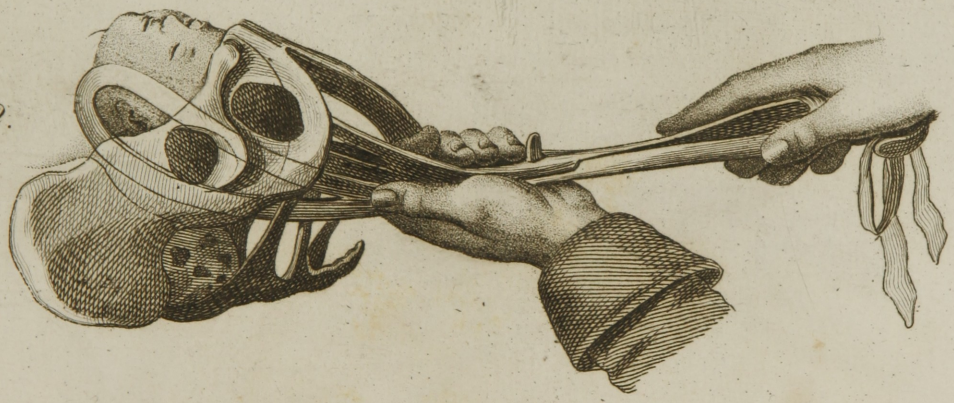

Applicazione del forcipe allo Stretto superiore essendo l'occipite all' ingiù.

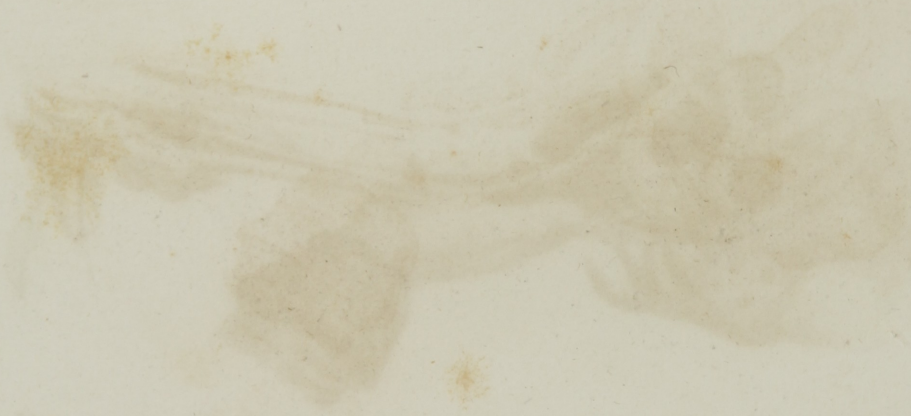



Applicazione del forcipe sopra la Testa, situata sui lati, ed inchiodata.

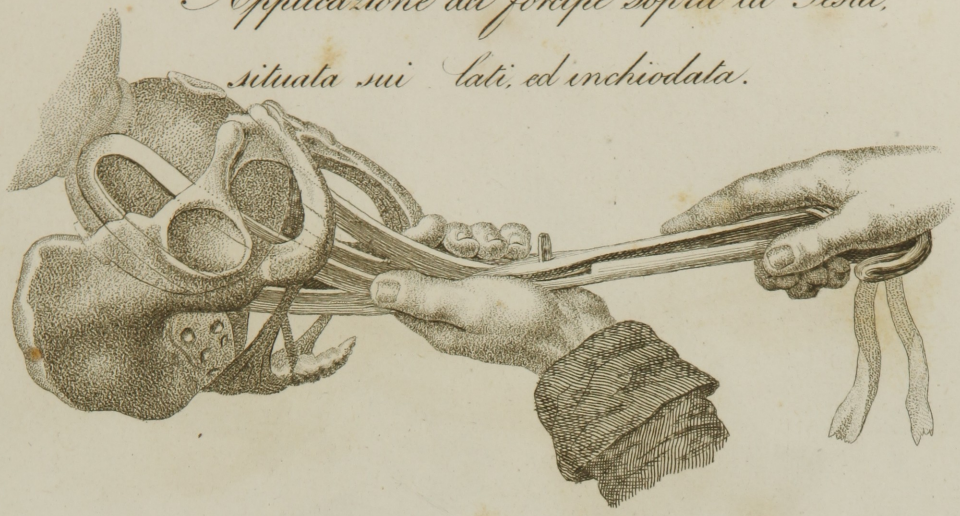

Fig. 2.

Fig. 1.

Applicazione del forcipe, essendo uscito il tronco.

Incisione degli Integumenti per l'Operazione della Sinfisi.

Rapporti della testa col bacino nel momento della sua uscita.

Fig. 1.

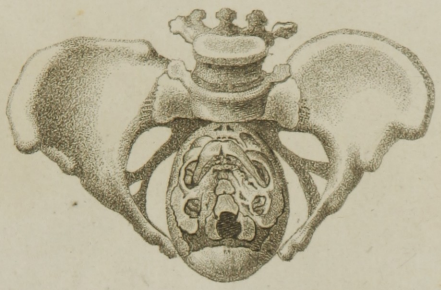

Fig. 2.

Estrazione della testa col forcipe.

Divaricamento dei pubi dopo la sezione della fibro-cartilagine.

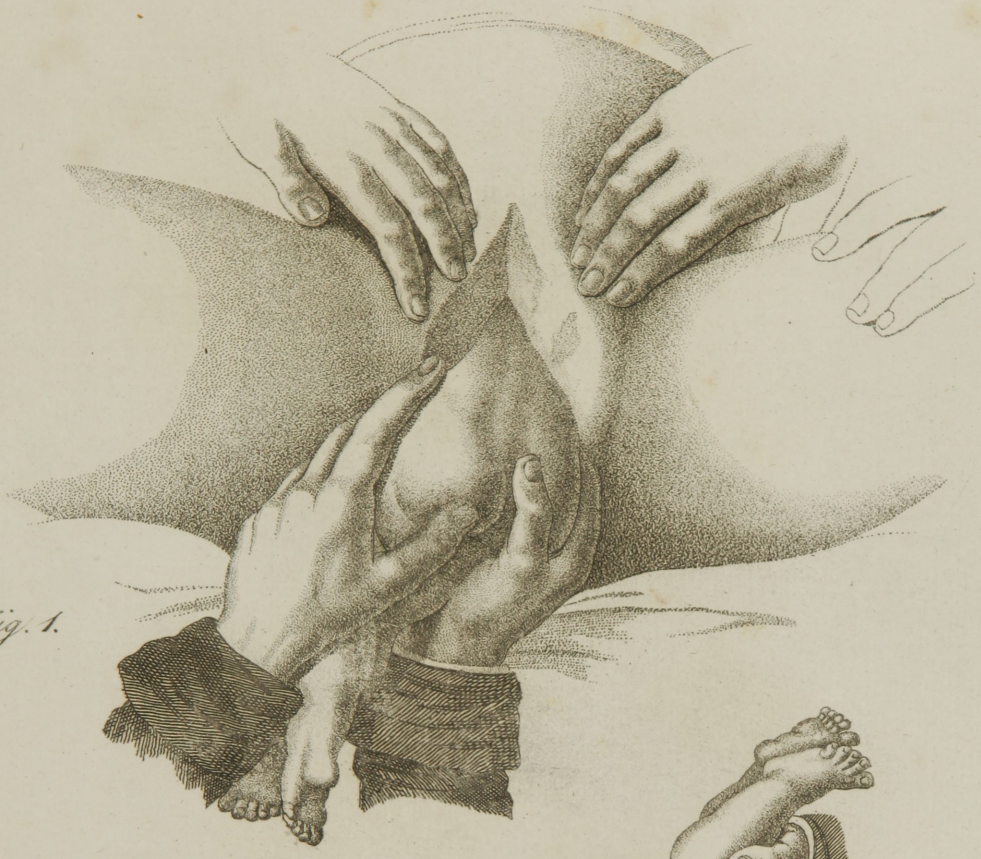

Fig. 1.

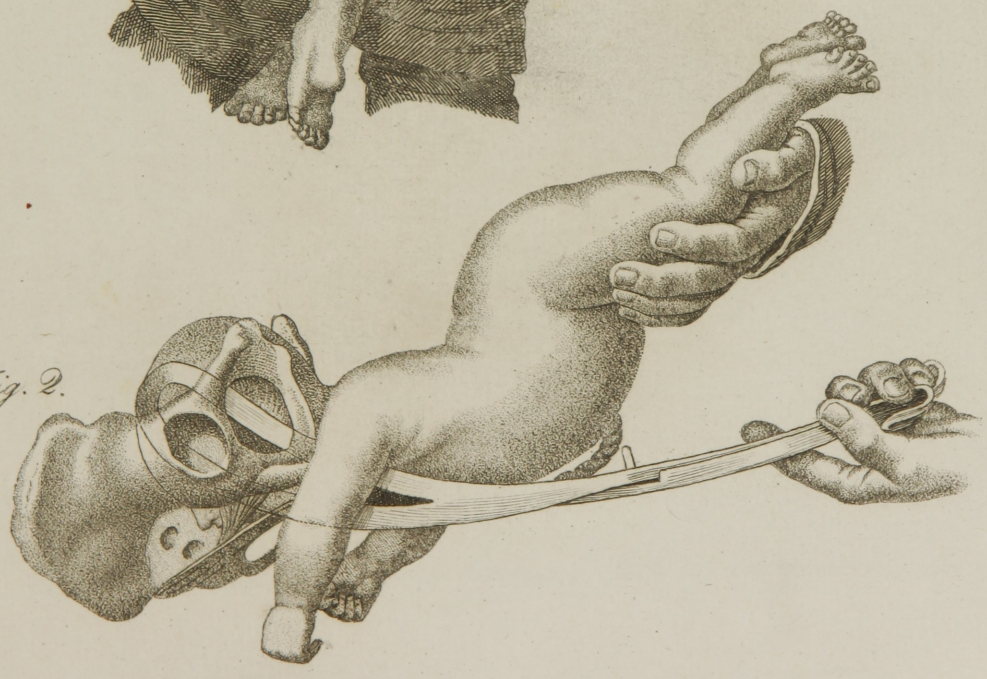

Fig. 2.

Estrazione della testa col forcipe dopo l'operazione della Sinfisi.

Fig. 1.

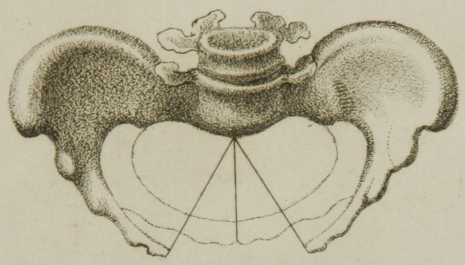

Divaricamento sopra un bacino viziato ma regolare

Fig. 2.

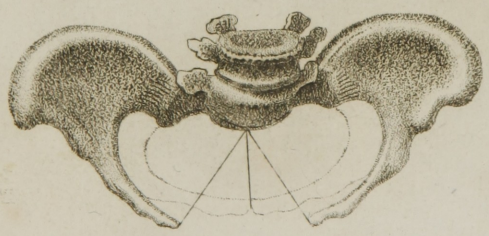

Divaricamento sopra un bacino viziato e irregolare.

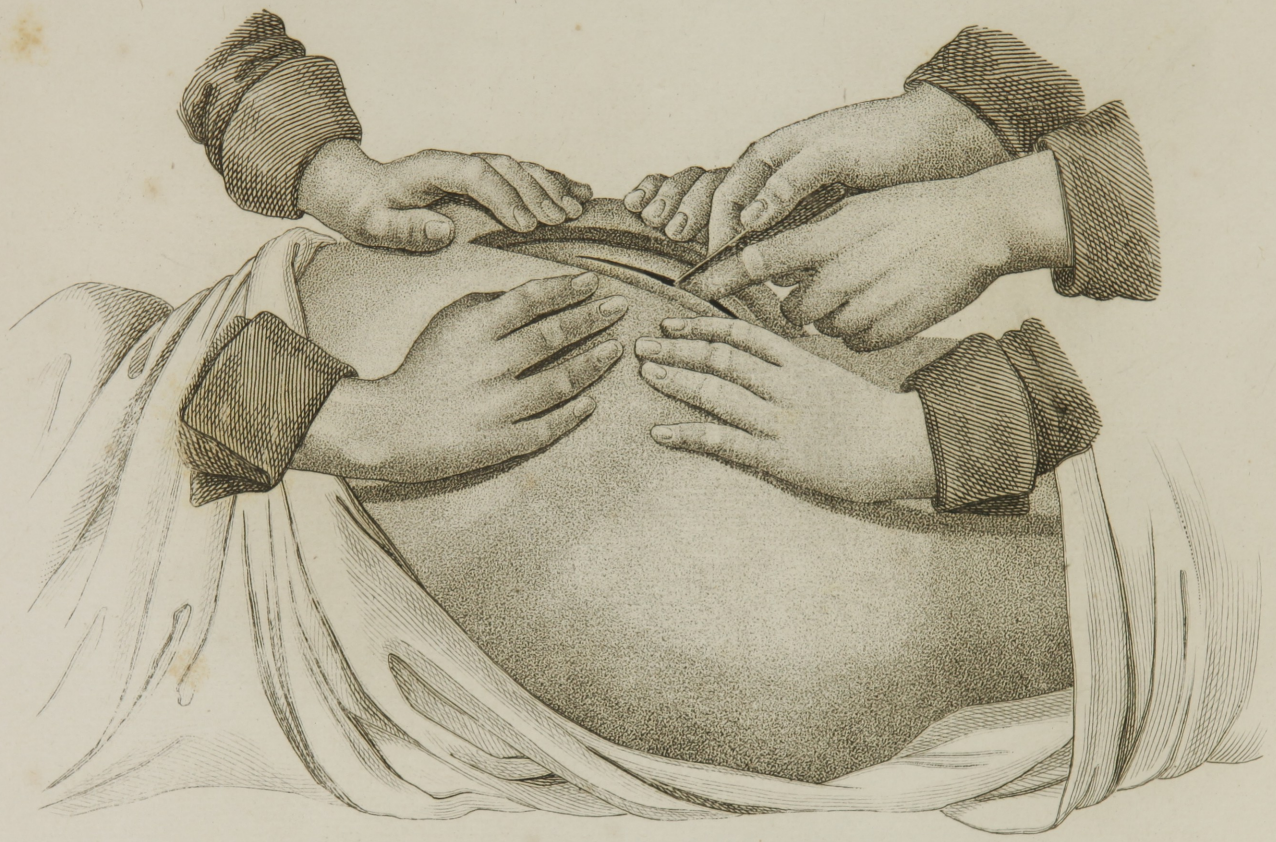

Operazione Cesarea_Metodo degli Antichi.

Operazione Cesarea.

Estrazione del Bambino.

Operazione Cesarea.

Passaggio del Cordone per l'estrazione della Placenta.

Procédé de Lauverjat.

Procédé de Baudelocque.

Azione del Cefalotomo.

Fig. 1.

Fig. 2.

Azione delle cesoje di Smellie.



Fig. 2.

Fig. 1.

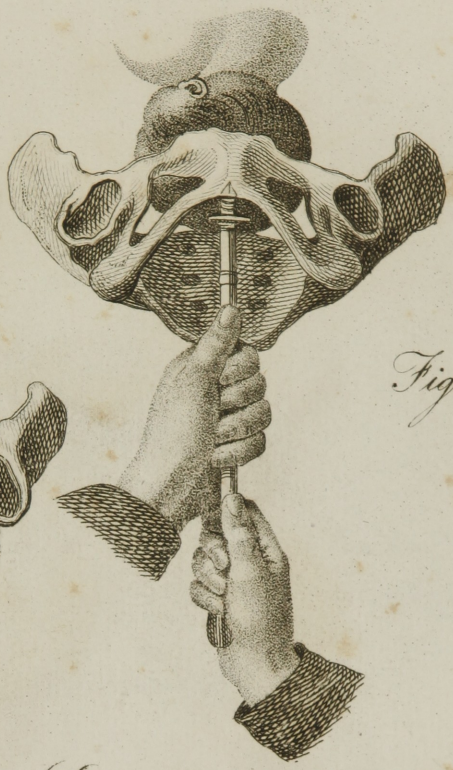

Estrazione del bambino col tira-testa di Baudelocque.

Estrazione del Bambino col Forcipe uncinato.

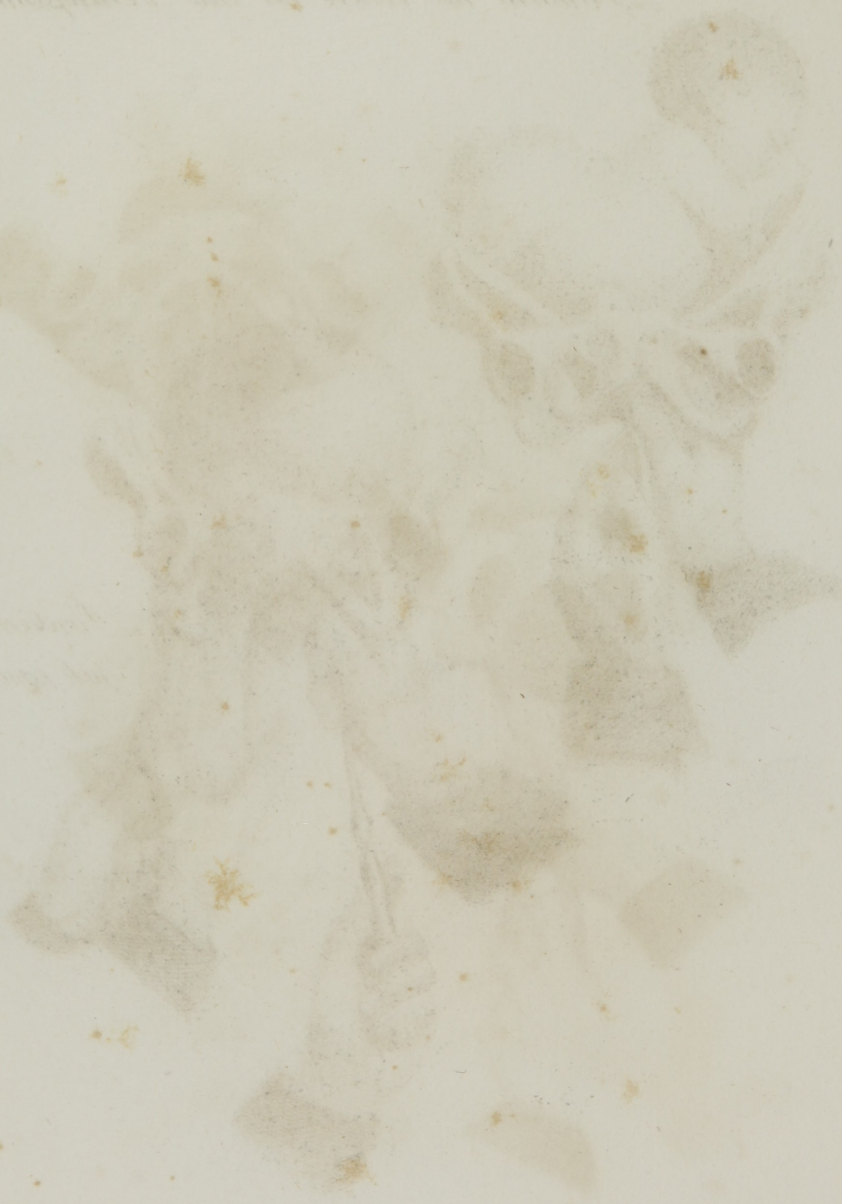

Puntura del ventre nel caso d'Idropisia.

Puntura della Testa nel caso d'Idrocefalo.



Estrazione della Testa col nuovo tira-testa.

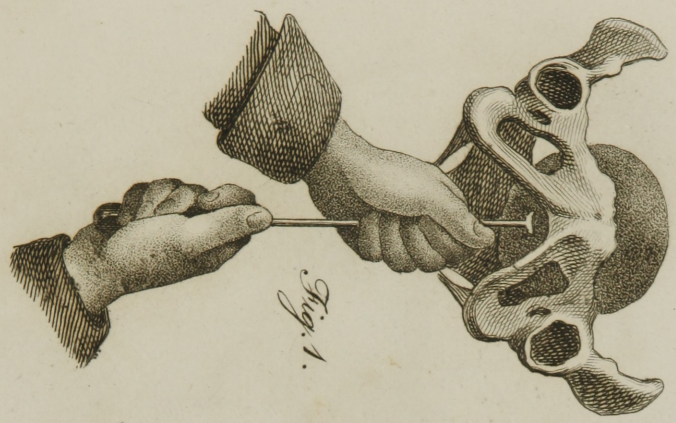

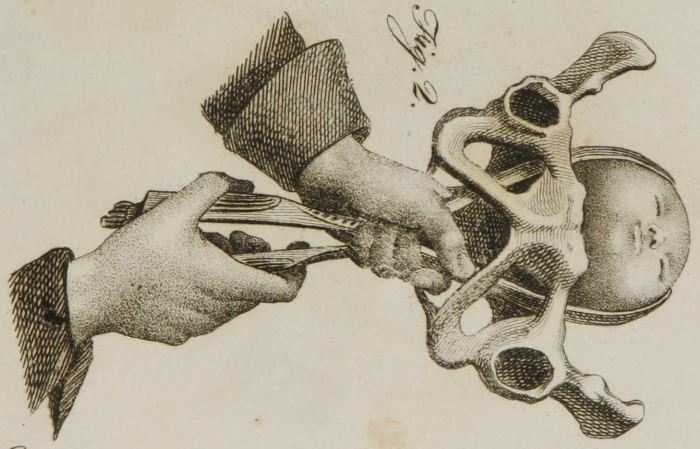

Estrazione della Testa con il Forcipe uncinato.

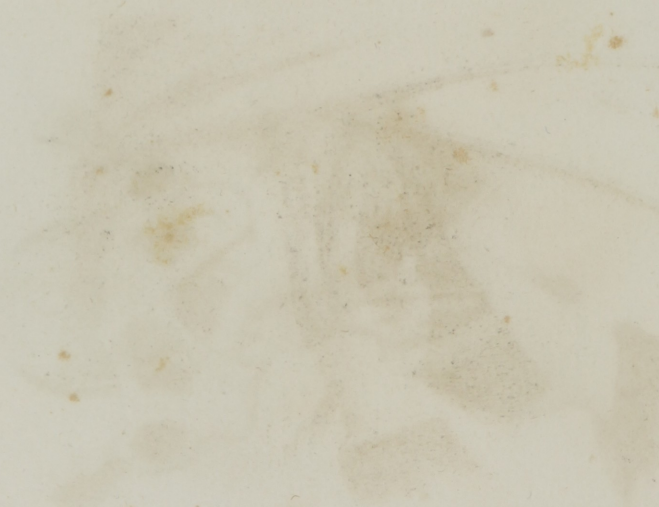

Liberazione naturale.

Fig. 1.

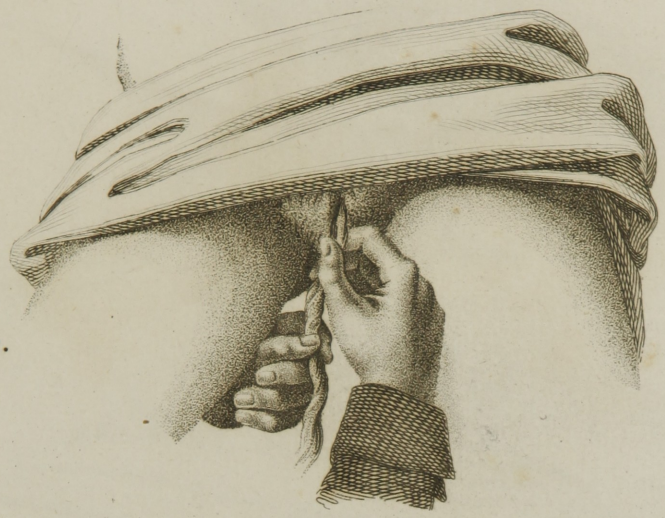

Primo tempo.

Fig. 2.

Secondo tempo.

Fig. 1.



Estrazione della Placenta
dopo la rottura del Cordone.

Fig. 2.

Estrazione della Placenta
con la tanaglia a mola.

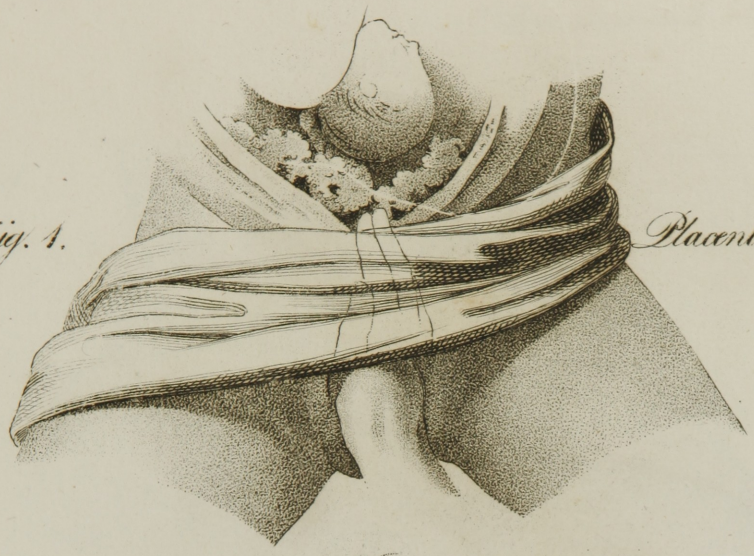

Fig. 1. *Placenta sull' Orifizio.*

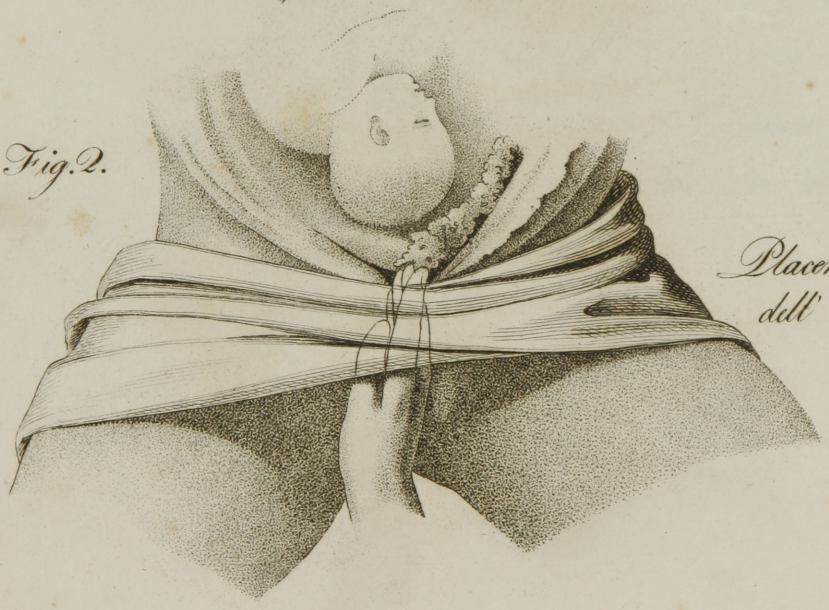

Fig. 2. *Placenta sui bordi dell' Orifizio.*



Estrazione della Placenta aderente.

Fig. 1.

Fig. 2.

Estrazione della Placenta Saccata.



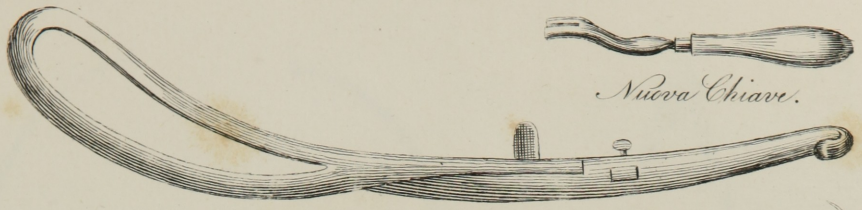

Nuova Chiave.

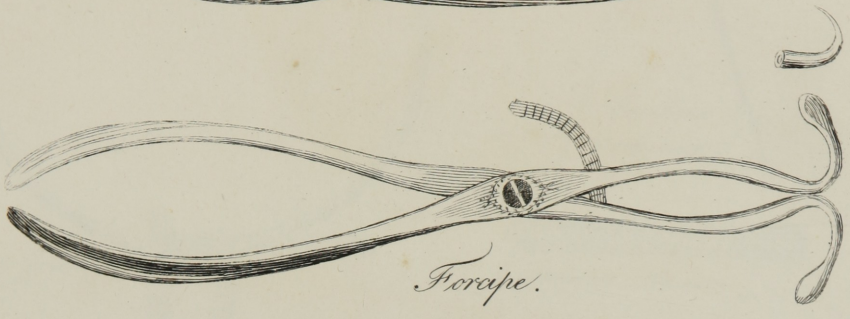

Forcipe.

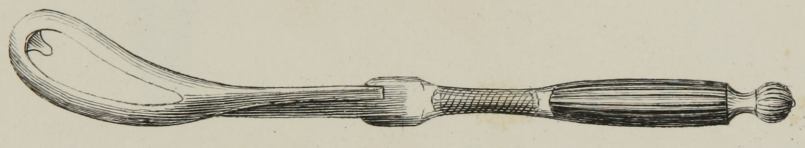

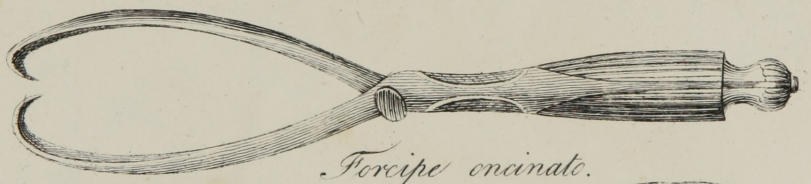

Forcipe ancinato.

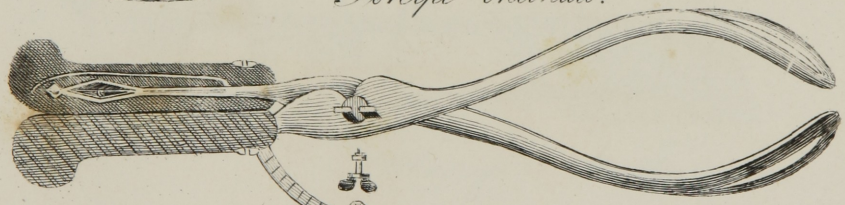

Forcipe del S.r D.r Guillon.



Leva.

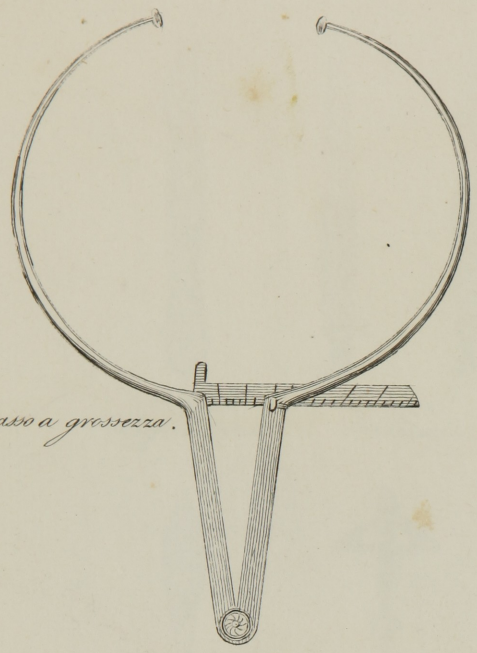

Compasso a grossezza.

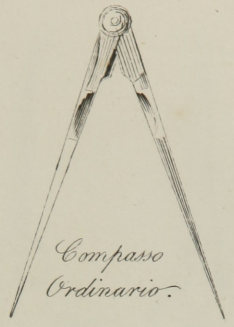

Compasso Ordinario.



Misura Lineare.

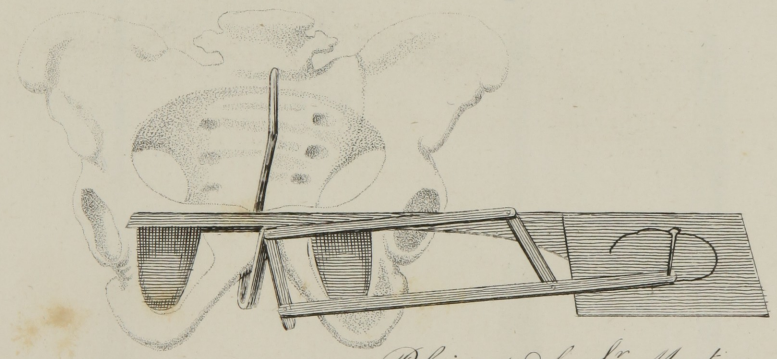

Pelvigrafo del Sr. Martin.



Pelvimetro di Coutuly.

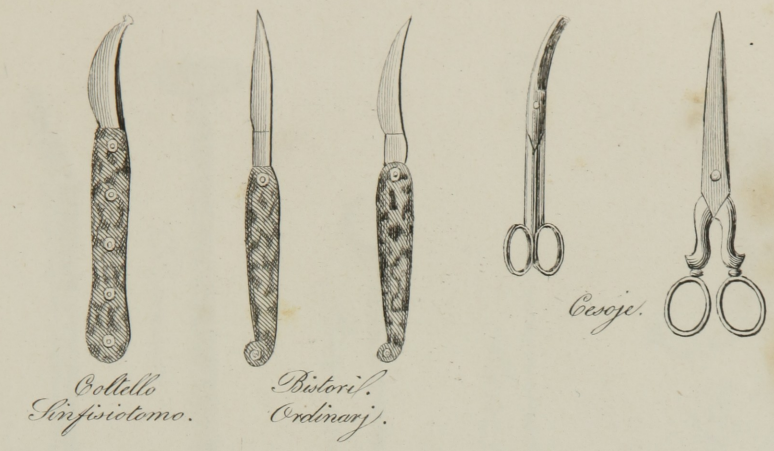

Coltello Sinfisiotomo.

Bistori. Ordinarj.

Cesoje.



Tira-Testa.

3/4

Nuovo Tira-Testa.

Cesoje di Smellie.

Tubo Laringeo.



Applicazione del Laccio.



Porta-Cordone di Ducamp.



Porta-Cordone del Dr. Guillon.

Dilatatore.



Tenta per la Liberazione.

Pinzetta per l'istrazione della Mola.



Tenta ordinaria.

Allattamento.

Fig. 1.

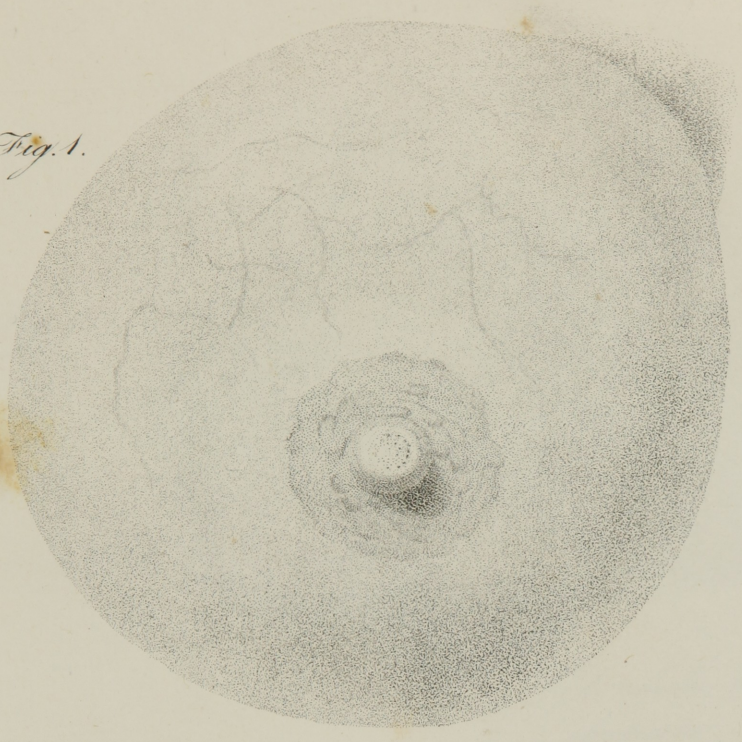

Mammella gonfiata dal Latte.

Fig. 4.

Porzione staccata dell' areola.

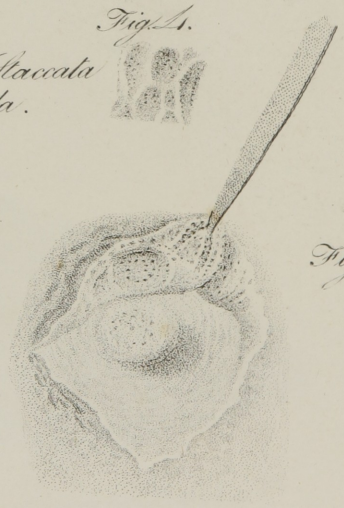

Fig. 3.

Fig. 2.

Papilla d'una donna che allatta.

Preparazione speciale dell' areola.

Fig. 1.

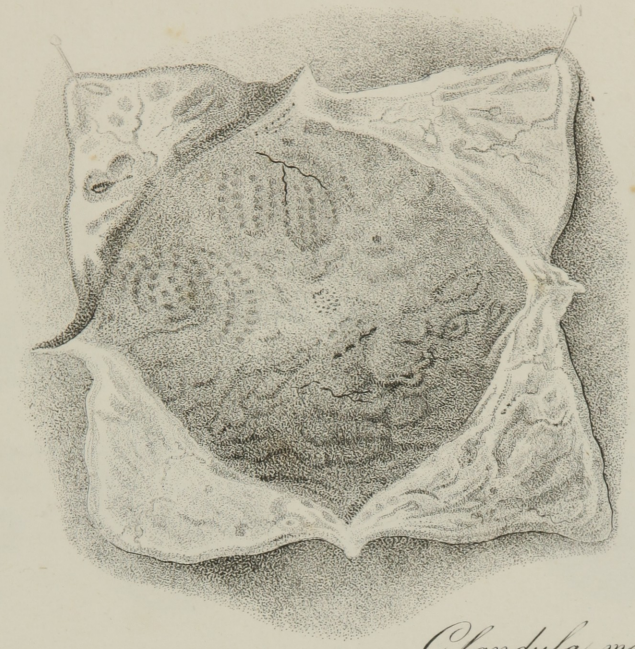

Glandula mammaria scoperta.

Fig. 2.

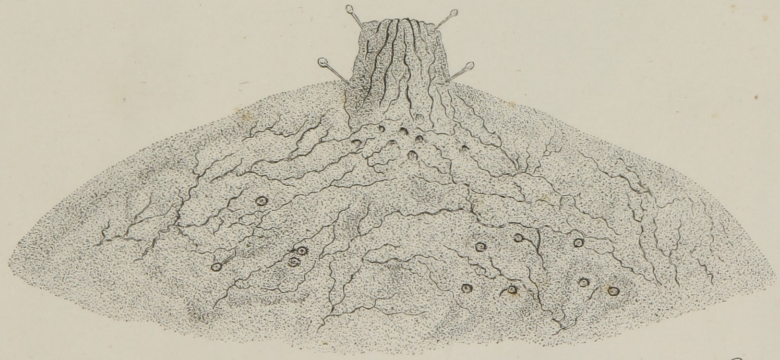

Vizio dei vasi sanguigni e galattofori



Fig. 1. Poppajola di vetro.

Fig. 2. Cappelletti in cera.

Fig. 3.

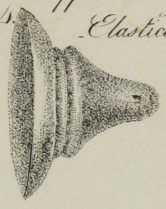

Fig. 4. Cappelletti di Gomma Elastica.

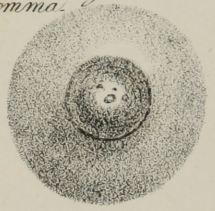

Fig. 5.



Fig. 6. Cappelletto di Bosso.

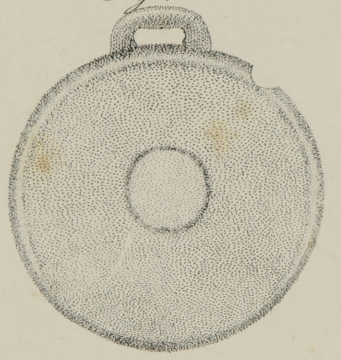

Fig. 7. Cappelletto di Vetro.

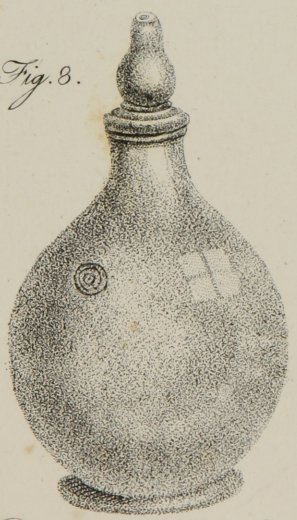

Fig. 8. Boccia della S.ra Lebreton.

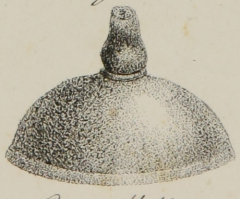

Fig. 9. Cappelletto col capezzolo di Vacca.

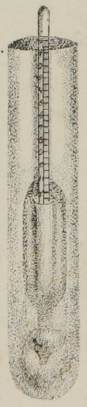

Fig. 10. Galactometro o pesa Latte.

SURGEON GENERAL'S OFFICE LIBRARY