WE
7
qM117c
Bk.3
1925

WE 7 qM117c

35830140R

NLM 05174767 1

NATIONAL LIBRARY OF MEDICINE

ARMY MEDICAL LIBRARY

WASHINGTON

Founded 1836



Section .....

Number 366163

0 P O 3—10543 FORM 113c, W. D., S. G. O. (Revised June 13, 1936)

219
MacAusland, W R
WO 910
W 91
1925

A COLLECTION OF ORTHOPEDIC PAPERS

BOOK THREE

1. Mobilization of Ankylosed Joints
2. Recurrent Dislocation of the Patella
3. Transplantation of the Entire Fibula in Cases of Loss of Tibia from Osteomyelitis
4. Ankylosis : Treatment by Arthroplasty
5. Intrinsic Splint Traction
6. Astragalectomy (The Whitman Operation) in Paralytic Deformities of the Foot
7. Recurrent Dislocation of the Shoulder
8. Injuries to the Musculospiral Nerve
9. Mobilization of the Elbow by Free Fascia Transplantation with Report of Thirty-One Cases
10. Backache

1925

ARMY MEDICAL LIBRARY AUG 21 1944
LSC

WE
7
M117c
Bk.3
1925

032.1

Reprint from
SURGERY, GYNECOLOGY AND OBSTETRICS
September, 1923, pages 255-309

MOBILIZATION OF ANKYLOSED JOINTS[1]

By W. RUSSELL MacAUSLAND, M.D., Boston
Surgeon-in-Chief, Orthopedic Department, Carney Hospital

Introduction

MUCH progress has been made in the surgery of bones and joints in recent years, due largely to the extraordinary perfection of technical methods and the persistent efforts of a few able leaders. Probably no section of this field has occupied so much interest and effort as the surgery of stiff joints.

The best teaching, until very recent years, dealt almost entirely with the proper position in which a joint should be allowed to ankylose so as to permit the best function. The shoulder *stiff in abduction* is certainly much better functionally than the shoulder stiff at the side of the body; the knee *stiff in almost full extension* is undoubtedly far less of a disability than the knee fixed in marked flexion. And yet, with the gradual development of surgical technique, certain pioneers in joint surgery have tried to increase function by different methods.

Although the mobilization of ankylosed joints was at first, and is even now, attempted by only a few surgeons, several good results arising in a sea of failures led the pioneers onward to develop this new field of surgery. Foremost among them is the late John B. Murphy, of Chicago, to whom we pay a tribute of admiration for his constructive efforts founded on a vast accumulation of clinical and scientific material. The results of operations have been sufficiently definite so that various methods may be presented with the assurance that they will continue to be more or less standard in future work. Today Payr, Putti, and Baer, persisting in the face of adversity, have opened this limited field of surgery so that carefully trained operators with highly developed technical skill can now present results which show only a small percentage of failures. The risk to life is very low and the margin of good results reasonably certain.

Arthroplasty not an Excision

Arthroplasty, or the operation of mobilizing ankylosed joints, is not an excision. Murphy has well said: "Arthroplasty to be functional must be stable, and excision of joints results always in flail joints." A flail joint cannot be considered a proper result from a plastic operation. Excision has no place in the surgery of weight-bearing joints, save to obtain ankylosis, nor would it be used in non-weight-bearing joints if it were not that flail joints may be stabilized by means of light apparatus.

Those who attempt to mobilize ankylosed joints must approach the work well trained, must show great technical skill, and, above all, must exercise judgment in their selection of cases, if they would qualify for this work.

I present the subject of arthroplasty to you, therefore, in order to stress these important points:

[1] Presented before the International Congress of Surgery, London, July 18, 1923.

1. That excision of a joint does not constitute an arthroplasty;
2. That highly developed technical skill is absolutely necessary;
3. That the judgment in the selection of cases is very difficult.

Types of Ankylosis—Infectious, Non-Tuberculous, Traumatic

Ankylosis is the result of an infectious process or traumatism. The latter is usually a fracture dislocation with wide separation of fragments, followed by excessive callus. The ankylosis in these traumatic cases is usually a firm fibrous formation, although occasionally a true bony ankylosis may result.

The infectious process may be either acute or chronic. In the former case the causative agent is usually the streptococcus, the pneumococcus, or the gonococcus. In these infections the onset is sudden, and the course severe, ending usually in a bony ankylosis. We may, on the other hand, have a slow, insidious, polyarthritic process. The focus of infection is situated elsewhere and the joint condition is caused by the hæmotogenous deposits in the joint, either of attenuated bacteria or of toxins. The primary focus is often difficult to locate. The ankylosis results from adhesions both within and without the joint, and is, at least at first, fibrous in character.

Murphy (120, b) believed every type of non-traumatic joint inflammation to be the metastatic manifestation of primary infection in some other part of the body. Sometimes long periods elapse between the primary infection and the secondary arthritides. Gonococci metastases usually occur in 18 to 20 days, staphylococci in 10 to 14 days, and streptococci and colon bacilli in 8 to 10 days. These metastatic joint infections are initiated with a chill, and are not rheumatic in character.

The synovia is first involved; the serous surface of the membrane is destroyed in large and small areas. Up to a certain extent it may be repaired. In extreme erosions subserous tissues bridge over the spaces between the serous erosions, and adhesions result. The gonococcus, pneumococcus, and streptococcus may produce this condition. Pathology shows thick, porky infiltrations of the synovial membrane, œdema of the subserous surfaces, and injection of the surface toward the joint. The cartilage is not affected at an early date. In repair, the proliferated epitheloid cells become obliterated.

Causes and Extent of Ankylosis in Relation to Mobilization

It is important to emphasize the necessity of determining the cause of ankylosis, for it makes a great difference whether the ankylosed joint is the result of fracture or of disease, or whether it is congenital.

Infections, either acute or chronic, do not constitute a contra-indication to the operation, provided that the process has not been tuberculous or is not active. It is well to point out that many joints, apparently firmly ankylosed even by a bony bridge, may retain active infectious agents for a year or even two years. A tuberculous joint, even when ankylosed firmly, may retain small walled-off foci throughout life, and, therefore, except in cases of great rarity, should be considered a direct contra-indication to any mobilizing.

Certain infections cause great destruction of bone and injury to the soft structures of the joint. Where such destruction is extensive, or where there is marked scarring of the tissues, a difficult operation may be expected.

Occasionally deformity of such extent is present as to warrant the correction of the deformity before arthroplasty is attempted. The hip, for instance, ankylosed in marked flexion and adduction, will present a very difficult operative problem, unless the deformity is first corrected by a preliminary procedure. Marked flexion of the knee, although not so important, may also necessitate a preliminary intervention.

In general, I have found bony ankylosis easier to deal with than partial or the so-called fibrous type.

Indications and Contra-Indications for Arthroplasty

Any ankylosed joint might be considered for arthroplastic procedure, but there are definite limitations, and therefore we come to have certain fundamental indications for arthroplasty.

Major joints. First, two stiff hips will indicate arthroplasty on one hip, or possibly both. Second, two stiff elbows will present the same indication. Third, two stiff knees will present a definite indication for an arthroplasty on one side, at least. Fourth, combinations of hips and knees in the same individual, a condition not infrequently seen in multiple arthritis, is a very definite indication for attempting to mobilize one or more joints. The surgeon considers in all of the above indications the anatomical and occupational status of the patient.

Minor joints. Among the lesser joints which may be considered properly a subject for intervention are: first, stiff shoulders; second, stiff fingers; third, stiff wrist (a very rare subject for arthroplasty); fourth, the jaw, which demands arthroplasty.

In general it may be said that definite indications naturally rest with the judgment of the surgeon, but must depend to a large degree upon the patient. One stiff elbow, for instance, in some individuals is a very slight disability; in others, it is of supreme importance. It is necessary, therefore, that each case be considered upon its merits and not upon the mere desire of a patient to be able to move a joint. There should be considered constantly the question of whether the deformity may be actually the principal source of disability, and whether, as has been mentioned before, correction of deformity may not give sufficient relief to the patient.

Methods of Treatment—General Survey Prior to Arthroplasty

Many means have been used to gain mobility in ankylosed joints. Previous to 1860, *brisement forcé* was the general method of treatment. It is still in use, and in properly selected cases the results are good.

J. Rhea Barton (11), of Philadelphia, in 1826, first attempted pseudoarthrosis in the case of ankylosis of the hip joint. The operation consisted of an osteotomy through the femur above the trochanter and the attempt to prevent bony union by movement. The patient lived 6 years with a good weight-bearing leg and some motion in all directions.

Rodgers (155), of New York, modified this method in 1830 by removing a disc of bone from between the trochanters. He obtained a more satisfactory result. Bérard (13), Esmarch and Rizzoli, both reported by Murphy (120, g), and McIlhenney (114) used similar methods for treatment of the jaw.

In 1880, Wolff (197) recommended a method which he called arthrolysis, which consisted of chiseling through and dividing all fibrous or bony adhesions, without resection of the articular extremities that had been restored to their normal position. Wolff claims favorable results in nine cases, four of ankylosis of the fibrous type and five of the bony type. It is probable that he did not treat a true bony ankylosis.

Kocher (103) suggested dislocating the joint for a short period after arthrolysis. No success is reported.

Actual resection has a few advocates. Good functional results have been reported in a proportion of cases of ankylosis of the jaw, elbow, and hip. Koenig (104) recommended resection in wide luxation. Textor (178) in 1843 reported a case of ankylosis of the elbow in which there was full range of motion 6 years later. Ferguson (63) secured a weight-bearing limb by resection of the knee. Dautrelepont (45), Czerny (42), and others observed that a new joint cavity with synovial membrane and articular cartilage formed 3 years after resection. Sayre (161) and Defontaine (47) tried to fit bony ends after the fashion of an articulation. They obtained stability, but adhesions formed again. Dartignes (44) described a trochleariform osteotomy; he resected the joint surfaces with preservation of their form. The result was ankylosis again. Cavazzani (29) liked to spare the bone and soft parts for the preservation of the physiological function. He emphasized a transverse incision.

Painter (133) recommended excision, for in arthroplasty he feared the extrusion of the interposed material, or infection. Resection cannot, however, increase function in a weight-bearing joint, as the one essential—stability—is lacking, and, while resection in the upper extremity is practised and is as good as a poor arthroplasty, it does not measure up with a

good arthroplasty either in surgical technique or in functional result.

Very little has yet been done in the transplantation of half or whole joints. Lexer's (110) first case was to implant in a stiff elbow of gonorrhœal origin the patellar surface of the femur. The result was fibrous ankylosis. His next step was to use a transplant of the entire knee joint. The knee joint was fixed in acute flexion in bony ankylosis, resulting from articular suppuration after purulent osteomyelitis of the femur. He made an anterior flap incision, the soft parts remaining in contact with the flap. All lateral and posterior coverings were detached. A new joint, obtained from a limb amputated simultaneously for senile gangrene (without phlegmon), was fitted in. In this case he neglected to place tissue beneath the patella, thus necessitating a second interference. Fixation by plaster cast from toes beyond the iliac crest followed. Three months later the epiphyses were in firm union, the semilunar cartilage preserved, and the articular cartilage was smooth. A small spicule of bone was later excised and analyzed. The transplanted portion had become a part of the new organism.

The second case Lexer reported was a transplantation for bony ankylosis of a tuberculous knee joint. The entire joint was again taken from a freshly amputated limb. In both cases the extremity was somewhat shorter. The knee joint was in normal extension. Lateral motion was present in the second case. Both patients could bear their weight well when walking or standing. Lexer then aimed to obtain function by muscle plastic elongation of the efficient non-atrophic muscles.

Herzberg (83) reported four cases in which transplantation of joints was done after resection. Three of the cases were children.

Eloesser (60) reported a case of implanting a cadaveric joint consisting of three inches of tibia, fibula, and astragalus. The attendant dropped the implant during the operation, which necessitated heating it. Suppuration developed and the foot was amputated. Examination showed the tibia was invaded by new bone in all stages of formation. In a case of implanting a finger joint from the cadaver, 35 degrees active motion and 60 degrees passive were secured. Movement was improving at the time of the report.

Goebell (72) implanted a toe joint into a finger resected for severe arthritis deformans. A good movable finger resulted, and the patient, a violinist, resumed her profession.

G. T. Vaughan (185), of Washington, was unsuccessful in replacing a knee taken from the cadaver. The graft became the site of suppuration.

Kuettner (106) reported two cases of implantation of femoral neck and head, using the cadaver as the source of material. One patient walked without a cane and had considerable motion. An autopsy at death from vertebral metastasis, 1 year and 1 month after operation, showed the joint fixed to the femoral shaft by a narrow ring of bony callus. The whole graft was covered by a membrane similar to periosteum. The second case remained cured 3 years and 2 months. Local recurrence necessitated disarticulation of the hip.

Deutschlander (52) tried transplanting in a child of thirteen a graft containing the joint extremities of the femur and tibia with the greatest part of the joint capsule, menisci, and ligamentous apparatus. Ten months after the operation, the transplant was luxated and removed.

Oehlecker (126), in 1922, reported the outcome, after 6 years, of eight cases in which an entire joint was transplanted into a finger. In four cases the joint was taken from the patient himself and in others from another person. The results in the autoplastic cases were more successful.

Work with whole and half joints has been done by Sievers (169), Petraschewskaja (137), Katzenstein (97), and Buchmann (24).

There is much discussion in regard to the regeneration process. Axhausen (8) in 1907 proved that periosteum and endosteum of implants remained alive. Eloesser (60) believes regeneration takes place in part from the elements of the graft itself.

The cadaver material is easier to obtain than a living graft, but infection must be avoided. The joint is removed within 12 hours after death. The Wassermann test is used on the blood and part of the bone marrow

is incubated in broth. The joint is implanted in Ringer's solution for 24 hours. It is then freed of all adherent tissue and muscle.

In the operation a horseshoe flap is outlined and the bone is sawed close to the joint. The new joint is inserted by mortising and held in place by catgut. Traction is secured by adhesive plaster strips. A plaster-of-Paris splint is then applied. General passive motion is instituted in a week.

This surgical procedure seems at once radical and dangerous, and has not been generally accepted. Simple arthroplasty, without the use of bone transplants and with little use of any foreign heterogeneous material, has supplanted all such extravagant measures. Their interest is chiefly historical.

Various non-absorbable materials have been tried as the interposed material. Carnochan (27), of New York, in 1840, inserted a piece of wood in an ankylosed jaw. Orlow (130) in 1901 used gilded aluminum plates in two jaw cases. Roser (158), Pupovac (144), Huebscher (93), Hoffa (86), and others used magnesium plates and silver. Chlumsky (33) tried zinc and rubber, but reported no permanent results. Later he used absorbable plates of decalcified bone, ivory, and magnesium, but the results, on the whole, were not satisfactory. Gluck (70) and others inserted ivory pegs. Besides these materials, celluloid, gutta percha, and temporary packings of gauze have been used. Foederl (65) in 1903 used animal membrane or walls of ovarian cysts, but found that they caused suppuration, and re-ankylosis occurred.

Rechet (148) covered the ends of the resected bones in various joints with periosteal flaps.

Hofmann (87, a), in 1906, reported a case in which he transplanted periosteal flaps from the tibia to the resected ends of the bones of the elbow. He obtained full extension and flexion to 80 degrees.

Von Frisch (66) used periosteal grafts from the tibia in an elbow ankylosed from gonorrhœal arthritis. Only 25 degrees motion was obtained. The author attributed the result to lack of after-treatment.

Greiffenhagen (75) reported three cases in which periosteum was used in elbow joints.

A graft of joint cartilage was first used with success by Tuffier (183) in 1901 for a comminuted fracture of the upper end of the humerus. Judet (96) doubled the cartilage with a layer of bone.

Mauclaire (112) used cartilage from the astragalus to cover the rough ends. Later the X-ray showed these fused to the bone.

Weglowski (189), in 1907, reported a case in which he successfully used cartilage from the rib in an ankylosed elbow.

More recently cartilage grafts were used by Delagenière (48) after a resection had been done. The operation showed no advantage over excision, as some instability of the joint followed.

Gluck (70), in 1902, used skin flaps.

Diel (53) reported the use of reindeer tendon and the epiploon of a rabbit in a case of femoral-patellar ankylosis. In 10 months the patient could walk easily without a cane.

ARTHROPLASTY

History

Foreign substances are no longer used, and since 1900, fat, muscle, fascia, or specially prepared membranes have been inserted in the joints.

The first case of muscle interposition was in the jaw, where immobility often interferes with life. In 1860, Verneuil (186) interposed a piece of temporal muscle and fascia between the condyle and glenoid after resection. Helferich (80) and Ollier (129) developed the technique of muscle implantation and gave it general notice. In 1893, Helferich exhibited a child who had regained motion in an ankylosed jaw by use of a flap of temporal muscle. Lentz (108), Henle (82), and others repeated the operation, using muscle flaps. Both coronoid process and condyle of the inferior maxillary were removed by Bilczynski (17) and Hoffa (86), and a flap of temporal muscle inserted.

In 1895, Mikulicz (118) used a flap from the masseter muscle instead of from the temporal. Kusnetsoff (107) repeated the operation per-

formed by Hoffa and Bilczynski, using a masseter flap as the interposed substance. Rochet (154) and Schmidt (165), after the removal of the entire ramus, interposed a masseter flap.

Operations on other joints followed those of the jaw. In the treatment of the elbow, Quénu (146), Albarran (2), Nélaton (123), Delbet (50a), Murphy (120), Hoffa (86), and Schanz (162) used flaps from a muscle contiguous to the joint. Berger (15) in 1903 mobilized a fibrous ankylosis by inserting a flap of the anconeus which he sutured to the brachialis anticus. Huguier (94b) introduced in the radio-ulnar joint a layer of the posterior ulna.

Muscle flaps were then used by Rochet (154), Nélaton (123), and Hoffa (86) in ankylosis of the hip, and others used them in the knee.

Experimental Methods

Unfortunately the experimental work in arthroplasties on animals has been relatively small.

Experiments with living tissue have shown that it degenerates or is replaced by a fibrous tissue. Small cavities are formed during this process. Allison and Brooks (4) found that the end-results of simple resection of joint surfaces without interposition of a substance do not differ materially from cases in which the substance was inserted.

Murphy (120, g) destroyed joint surfaces and interposed flaps of fat and fascia. He claimed that the fat undergoes connective-tissue changes which facilitate the bursa formation.

Neff (122) reports only one successful case of four arthroplasties on dogs, using free transplants from the rectus aponeurosis. Three cases were ruined by wound infection. The successful operation on the knee showed new capsule had formed connective tissue between the tibia and femur, and that two bursal sacs had developed.

Davis (46) in his experiments on a dog found, at autopsy, that free fascia in the knee joint was adherent to the end of the femur and the material was viable. Putti (145, d) also used free fascia, and found the substance retained normal characteristics.

Kolazek (105) in five experiments on dogs excised a portion of the capsule and inserted homo-transplants of peritoneum. They healed and formed no adhesions.

Sumita (175) destroyed the joint surfaces of the knee, hip, and ankle of twenty dogs and interposed pedicled flaps of muscle, fascia, and tendon. The dogs were observed for periods of 21 to 244 days. Fibrous tissue and small cavities had formed, but the largest cavity measured only 1.5 centimeters in diameter.

Bolognesi (20), in a long series of experiments, followed the process of formation of periarticular nearthrosis. He believed that an enarthrosis or a true diarthrosis can be formed only when a foreign element is interposed, and that the means of covering the cavity had origin in the cartilage of the neoformation which covered the free fragments of the fracture.

Segale (167), in 1913, in experiments found that the joint capsule in a rabbit or dog reproduces itself from the surrounding tissues and forms a new capsule which limits the joint cavity and contains synovia. The reproduction of the joint surroundings is closely connected with the operative technique which provides for the preservation of those parts which assure a correct joint mechanism.

Ely (61) experimented on nineteen dogs, using no interposing material. Bony ankylosis developed in one case in 432 days.

Hohmeier and Magnus (90), in a series of experiments on dogs, found the end-results were the same with or without interposing substances.

Beye and Steindler (174) experimented on dogs and found no adhesions formed after mere scraping of the cartilage covering and inserting of fascia. Pedunculated muscle fascia was transformed into a connective-tissue pannus adherent to denuded areas of bone. There was complete transformation into connective tissue and no traces of original muscle fibers existed.

Experiments were then made using non-absorbable materials, but they were discarded.

Allison and Brooks (4) found that the chromicized pig's bladder suggested by Baer caused reaction in the surrounding tissues,

and adhesions formed. They experimented with silver impregnated fascia and found relatively little reaction in the surrounding tissues.

Phemister and Miller (139) obtained similar results in the elbows and knees of dogs, with or without the interposition of free or pedunculated flaps. The flaps largely broke down, and the resulting joints were alike in the three types of operation. They did not see how any appreciable amount of nutrition can be furnished by the circulation through the pedicle. They believed that the circulation in the surviving portions is through adhesions to the parts with which they come in contact.

Present Clinical Methods

The methods in use today, as outlined by Murphy (120), Payr (134), Baer (9), Allison and Brooks (4), Putti (145), and the writer (111), have in common the exposing of the joint surfaces, modeling of the bone-ends after the conformation of the normal joint, and the interposition of a substance to obstruct effectively bony union. They differ particularly in the substance interposed.

The two essential features of the Murphy treatment are the interposition of the pedicled fat and fascia flap and the application of traction. Murphy (120) emphasized the inclusion of the fat, as he believed it essential to a new joint foundation. It was his belief, too, that the flap was nourished through the pedicle. His technique in the different joints varied, not in principle, but as necessitated by the different joints. It will accordingly be treated later under each joint. The writer believes that pedunculated flaps are entirely unnecessary, and when covered with fat they interfere with the highest technique.

Baer (9) objects to the interposition of muscle or fascia for several reasons. He maintains that the structure of the joint is interfered with when a bulky substance is inserted; that too large an excision is required; that, if too little muscle or fat is interposed, ankylosis results; that the pain is severe, due to the pressure on the nerve-endings; that the motion obtained is generally unnatural in character; and that periarticular tissues are interfered with.

Baer advised chromicized pig's bladder as the transplanted medium. It is thin and flexible and conforms accurately to the surfaces of the modeled bones, and is tenacious enough to withstand disintegration for a period of from 60 to 100 days.

The use of Baer's membrane has not become universal on account of numerous failures and sloughing out of membrane, often weeks and months after the healing of wounds. Allison and Brooks (4) found that with Baer's membrane the reaction of the surrounding tissues was of such intensity that adhesions formed. In 1913 they recommended the use of silver impregnated fascia from which there was relatively little reaction.

In the use of the "free flap" as the interposing material, there is an opportunity to obtain the correct size, to determine the presence of a bursa, and to secure a good layer of fatty tissue. Putti (145) states that fascia will live after transplantation; there is, therefore, no need to use pedunculated flaps. He believes that the free fascia grows and is transformed into a tissue like the synovia. He covers the epiphysis completely with free aponeurotic flaps from fascia lata. One difficulty he has met in the use of these flaps is necrosis of the edges, a condition existing even in satisfactory cases.

Putti has been particularly successful in his operations on the knee. I shall treat his technique under the division on the knee joint.

Payr (134, b) advises the careful extfrpation of the capsular tube leading to the nerve-endings; the removal of the masses of connective tissue is not enough. Under the influence of the rapidly resumed function, there develop in and between the interposed soft portion (fat or fascia, etc.) at first multiple, and later connected interstitial spaces which finally form a joint space. A new satisfactory capsular tube is formed out of the periarticular connective tissue in which other accessory ligaments may develop by simple mechanical exercises. The new joint contains a synovial-like fluid.

Payr has obtained the best results with pedunculated flaps and freely transplanted fat. In all cases Payr has found that the opera-

tion has increased the breadth of excursion of the joint motion. Patients with an ankylosed knee, leaving the hospital with 65 degrees active mobility, showed 90 degrees or more after a year or so. The movement is usually smooth and painless. The X-ray showed the newly formed joint to be smooth and sharply defined; there are no free bodies. From a functional point of view also the new joints are satisfactory. He advises being careful in operating for ankylosis of tuberculous origin.

Payr's technique is recommended by Wollenberg (196), who, however, warns against the general use of arthroplasty, as too often mobility is purchased at the cost of an unstable joint.

The writer (111, a) first used free fascia in an ankylosed elbow in 1908. In 1914 four cases of free fascia transplants with excellent stable joints resulting were reported before the Orthopedic Section of the American Medical Association in Detroit. A series of thirty-one cases of elbow arthroplasties was reported in 1921.

Ritter (reported by Thom, 179), Behn, reported by Harris (79), Kirschner (100), and others have also used free flaps.

ELBOW

Most joints, when stiff, can be placed in a position to function well. The position in which maximum function is obtained in the elbow is near 90°, and many surgeons advocate it in preference to a mobilized joint. But ankylosis of the elbow joint, even at this most satisfactory angle, has very objectionable features.

While function may be present if the elbow joint is ankylosed in flexion, it is never good function, and the arm is always in the way. Usually, too, ankylosis is found in extension of about 160 degrees, in which position the arm is awkward, although not unsightly. Given, then, an ankylosis of the elbow joint from any cause except tuberculosis, some type of mobilization operation may be considered indicated.

Resection, which is performed for the tuberculous joint in adult patients, is the operation which is usually thought of first. The results from this procedure are very unsatisfactory, as the joint becomes flail, weak, and usually requires external support in the form of a leather armlet with limited elbow-joint motion. Excision, therefore, is rather a crude surgical procedure, and the ultimate results from its use do not warrant its being considered for any condition except tuberculosis of the elbow.

For many years the writer has been working to improve the method of procedure in these cases, and has found that, with each improvement in the technique, a definite improvement in the function of the elbow-joint motion is obtained, until finally the operation which is at present employed, namely, a true arthroplasty, has been evolved.

A good arthroplasty gives a smooth gliding joint, so frequently emphasized by the late John B. Murphy. The range of motion is excellent, the strength approaches normal, the stability is normal, and the joint is painless and tends to stand rather severe work without showing arthritic changes.

To my mind, therefore, the operation of arthroplasty on the elbow is to be considered in a different category from the old operation of excision. However, I wish to emphasize four important points: first, the necessity for the proper selection of the case; second, careful preparation for operation; third, strict adherence to the technique of the operation; and, fourth, proper after-care. No arthroplastic method should be attempted until 2 years after an infectious process has been quieted down, and until at least 1 year after a traumatic ankylosis. These two groups include fractures, infectious arthritis, and a few neisserian joints.

Ankylosis of tuberculous origin requires other treatment, and arthroplasty is indicated in only the most unusual case.

There have been more arthroplasties on the elbow than on any other joints. One of the early cases of arthroplasty using a muscle flap was reported by Albarran (2). Ankylosis had followed operative reposition. A partial resection was done by which a good immediate result was obtained, but later ankylosis occurred again. A third operation was undertaken, which consisted of a resection of the olecranon and interposition of a muscle-fascia

flap of the triceps. After 2 years there was a range of motion from 65 to 115 degrees.

Nélaton (123), in a case of ankylosis following neisserian infection, resected an elbow and interposed a flap of the brachialis anticus. Two years after the operation, flexion and extension were normal, but pronation and supination were much decreased. Active extension required the weight of gravity.

In 1903, Quénu (146b) reported an arthroplasty of the elbow for an ankylosis following a severe trauma of the arm, consisting of a fracture of both bones of the forearm and destruction of the soft parts. After resection he interposed a tendon fascia flap. There resulted flexion to a right angle and good but incomplete extension. There was good pronation, but difficulty in maintaining an intermediate position. The patient died of pulmonary tuberculosis a few months after the operation.

Delbet (50, a) also reported mobilizing, in a girl of six, an elbow which had become ankylosed in infancy, resulting in complete atrophy of the arm. At his first operation he resected the joint without breaking up the ankylosis. Two months later, after re-ankylosis, he intervened again, removing the bony spicules that had formed 0.5 centimeter thick, from the humerus, radius, and ulna. Some fibers of the flexor carpi ulnaris were interposed. Chloroform mobilization was necessary a month later, but the final result was good, with flexion to a right angle and extension nearly complete.

Schanz (162), in 1904, reported a mobilization of a bony ankylosis following rheumatism. After chiseling through the joint, he enlarged the sigmoid fossa, removed a piece of the trochlea, and interposed a flap of fat from the under side of the forearm. Three months after the operation the arm could be used for ordinary purposes.

Murphy (120, a) first mobilized the elbow by his method in 1904, in a case of ankylosing arthritis. A pyriform flap of deep fascia was dissected from the posterior surface of the triceps. The flap was 4½ inches long by 2 inches wide at its upper end, and received its blood supply from a broad pedicle which remained attached to the muscle and fascia just below the level of the olecranon. After the bony parts had been remodeled, the fascia was drawn down and turned into the joint around the inner margin of the olecranon. The proximal portion of the flap covered the trochlea, lined the olecranon depression and the lesser sigmoid cavity, while the distal portion covered the external condyle. Subsequent events showed that the flap was not carried sufficiently high on the anterior surface of the humerus to permit adequate flexion of the joint. Five months later, the patient could pass his hand through an arc of 5 inches. Pronation and supination were about one-half normal. His second case was reported 2 months after operation. The hand could be moved through an arc of 3 inches and the elbow forcibly flexed to an acute angle and extended to 160 degrees. Pronation and supination were approaching normal.

Hoffa (86), in 1906, reported a series of arthroplasties, seven of which were on the elbow. One, using a magnesium plate, was unsuccessful, owing to formation of gas in the joint. A fistula resulted which closed only when the plate was removed. The operations in which fat, fat and fascia, and fascial flaps were used were all successful. In two of them, ankylosis followed scarlatina; in the others, gonorrhœal infection.

In 1905, Quénu (146, c) reported a third case in which there was great atrophy of the muscles. He used for a flap the inner part of the triceps sutured to the anterior ligament. Passive movements were begun in 10 days, and later electrical treatment was used. As active movement was incomplete at the end of 2 months, he made a second intervention to recover a part of the tendon of the triceps, of which a large portion had been sacrificed. He cut the portion interposed close to the bone. He could then ascertain that there was no adherence between the superior surface of the interposed segment and the inferior cut surface of the humerus. The same condition existed on the inferior surface. The tendinous segment had left a distinct cavity. The tendon of the triceps was sectioned and reinserted on a little fibrous flap previously dissected on forearm. Patient gained not quite complete extension, and flexion to right angle.

Dupuy (56), in 1905, reported five arthroplasties. Three were done by Jeannel, one by Kirmisson, and one by Launay. Jeannel used flaps of the brachialis anticus; Kirmisson, of the biceps; Launay, a flap from the anterior ligament and the brachialis anticus. In all cases good results were obtained.

Huguier (94, a), in 1905, reported two cases operated on by Nélaton with the interposition of a muscle flap. In one case he gained good motion. Huguier reported a third case by Ombrédanne, using the same method.

Pereira (135), in 1906, in an unreduced subluxation, resected the ends of the bones and interposed a flap of triceps muscle, with an almost perfect functional result.

Scudder (166), in 1906, 1907, and 1908, reported several successful cases in which he used Murphy's method.

In 1907, Bazy (12) reported a case in which he used a flap from the brachialis anticus. Nine months later, the function of the arm was almost perfect.

Ameyaga (5), in 1907, brought his method of treatment to general attention. The two main factors of his technique are the formation of a new socket in the humerus and the firm grasp of the humerus by the hook of the ulna. One difficult case he reported had a good success, the patient in 3 years working in a factory and carrying heavy weights.

Stein (173), 1907, cited three successful cases from Bier's clinic. Triceps flaps were used.

Wiener (194), in 1909, treated an elbow ankylosed as a result of fracture. A flap of fascia and subcutaneous fatty tissue from the triceps was inserted. Twenty days after operation, he broke up the adhesions. Eighteen months later, the patient could carry heavy bundles, and motion was improving.

Huguier (94, b), in the same year, mobilized an elbow, using a flap of brachialis anticus. In 16 months, the patient could touch his shoulder with the hand and extend the forearm to 150 degrees.

Cifuentes (35) reported, in the same year, a similar arthroplasty in which, 1 month after the operation, he obtained a good functional result, with normal movements.

Reiner (149), in 1910, reported a series of twenty-eight arthroplasties, twenty-five of which were given in full, with the after-results. Two others, recent cases, were reported with good immediate results. In three cases the histories were unknown. Of the others, nineteen had useful arms, although one was a flail joint which lacked power, but could be controlled by the muscles. The poor results in the other cases were due to extreme atrophy of the muscles, and to extensive resection of the diseased tissue. Re-ankylosis occurred in two cases. In one, it was due to operation too soon after trauma, a fracture luxation, and lack of after-treatment. In the other case, Reiner attributes the result to the disease, myositis ossificans.

Thom (179), in 1910, reported a case of ankylosed elbow operated on by Ritter. He used freely transplanted fascia lata as an insert after the parts had been made freely movable. On discharge there was 65 degrees flexion and 100 degrees extension. Pronation and supination, which were very slight before the operation, were unchanged.

Wille (195), in 1911, interposed supinator longus fascia, with good results, gaining 95 degrees motion.

Osgood (131), in 1911, reported a case of elbow operation, using Baer's membrane. Four months after operation, extension was complete, there was voluntary flexion to 120 degrees, and a little more than normal "lateral mobility." (Just what Osgood means by "lateral mobility" is hard to understand, as a good arthroplasty has none.)

Whitman (193) reported two cases of arthroplasty of the elbow in which he used Murphy's method.

Edmunds (59), in 1912, reported an elbow ankylosis following fracture, in which this method was also used. At the time of the report, active motion was not possible, on account of the great atrophy of the muscles.

Denk (51) reported two of von Eiselberg's cases, in which elbow joints were mobilized with free fascia transplants, with good functional results.

Neff (122) reported a case in which he interposed a pedunculated triceps aponeurosis flap between the humerus and ulna and the radius and ulna. Seven months after the operation, there was active painless motion of 180 degrees

and 30 degrees, and only slight lateral mobility. The joints of the wrist and hand, which were previously partially ankylosed, regained from one-third to one-half their normal range of mobility, with the return of function to the elbow.

Delbert (49), in 1912, reported having done nine resections of the elbow with articular grafts. Most of these were too recent to determine the results, but he reported in detail two cases of a year's duration in which the results appeared to be permanent. In one of these, he used cartilage from an ankle joint; in the other, cartilage from an elbow. Both gave good functional results.

Chaput (32, a) reported three cases in which he resected from the thigh a flap of fat the size of the palm, and encapsulated the lower end of the humerus with it, suturing it to the neighboring muscles by anteroposterior and lateral sutures.

Conrad (37), in 1912, published a dissertation on the use of muscle flaps as interposing material. I have been unable to obtain a copy of this thesis.

Pomponi (141) advocated the use of a pedunculated fascial flap by the method of Durante. He cited one case in which he gained complete pronation and supination, nearly normal extension, and flexion to 60 degrees.

Murphy (120, b) reported twelve arthroplasties on the elbow, using pedunculated fat and fascia flap.

Mauclaire (112) mobilized an elbow, using cartilage from the astragalus to cover the defects. One fragment was put on the lower end of the humerus and another between the radius and ulna. A roentgenogram later showed these grafts fused to the bone.

Putti (145, a), in 1913, reported his arthroplasties to date. These included twelve elbow cases in which he used Kocher's incision and a free flap of fascia lata. He obtained stable joints, with a useful degree of motion.

Roepke (156) reported ten cases of ankylosis of the elbow in which he did arthroplasties, using free fat flaps to interpose between the joints. He advised against beginning passive motion too soon. One case of arthritis deformans was shown in 1911 before the Medical Society of Jena. In others, the ankylosis had resulted from trauma, neisserian infection, and tuberculosis.

Exner (62) reported a case 14 months after an arthroplasty in which a free flap of fascia lata was interposed. The arm was somewhat unstable, but gave good function. The patient could lift heavy weights. At the same time Pupovac reported a second case by the same method.

Darling (43) reported an arthroplasty with the use of a pedunculated flap done in the presence of active infection. The immediate result was good.

Harris (79), in 1914, reported two elbow cases by the Murphy method. In one he gained 75 degrees motion. In the other there was 60 degrees motion.

Turner (184) reported an arthroplasty of the elbow for an ankylosis following a severe osteomyelitis. There had been a musculospiral paralysis from which the patient made a perfect recovery. The elbow had entirely healed, but, at the time of operation, a small area of latent infection was found. Turner used a posterior skin incision and inserted a flap of fascia lata. The elbow was put up in extension. The next day there was a recurrence of the paralysis with signs of local infection. Later, fearing re-ankylosis, he manipulated the elbow under ether into extreme flexion. Six months later, the boy had motion from 50 degrees to 120 degrees, and a useful arm, though the muscles were still atrophied.

Murphy (120, c), in the same year, cited two cases operated on by his usual method. One patient left the hospital in 5 weeks, with free flexion and extension within an arc of about 45 degrees. The other patient, one year after the operation, had motion to 120 degrees.

Vulpius (188) prefers pedunculated flaps, but also uses free flaps of fat, or fascia and fat, or Baer's membrane.

Durante (58), in 1914, interposed a flap of the sturdy aponeurosis taken from the forearm. This method is indicated particularly in extended and hyperextended ankylosis and in cases at a right angle.

Simon (171), in 1914, in operating for ankylosis in a position of extension of about 170 degrees, used a longitudinal incision and a

pedunculated flap from the fascia of the upper arm. The result was the ability to bend the elbow almost to a right angle and to extend it at least to 170 degrees.

Payr (134, a) emphasizes the importance of removing the capsule, or at least the synovia as well as the fibrous cartilage. He has met with secondary dislocations and loose joints only in some of his first knee cases. The initial gain in motion is preserved, or even increased, with use. He had trouble with persistent swelling, especially in cases where this had existed for a considerable time before operation, or had been marked. He believes convalescence is shortened by waiting until the swelling has subsided. If re-operation is needed, he advises waiting at least 6 months. In 1914, his first case was 4 years old. He reports twenty-two arthroplasties, of which three were elbows, one with a good result and two with very good results. He believes that, if the indications are correct and the technique and after-treatment good, a favorable result is to be expected in 70 to 80 per cent of the operations.

Pupovac (144) reported a case of a girl of nineteen whose elbow had become ankylosed at 130 degrees as the result of a severe arthritis. He did an arthroplasty, using a posterior incision and a free fascial flap, and gained motion from 105 degrees to 140 degrees. Five months later, he reopened the joint and removed some exuberant bone that united the humerus with the ulna. He gained 70 degrees to 130 degrees motion.

Davis (46) thinks that we should be conservative about opening a joint ankylosed by tuberculosis. He finds the elbow one of the most satisfactory joints for an arthroplasty, as well as for an excision, but the results with the former are much more satisfactory. An excision requires the removal of 1 to 1.5 inches of bone to ensure movement, but, with an arthroplasty, only sufficient bone need be removed to interpose the flap, and it is almost certain to give a stable joint. He used two pedunculated flaps, one from either side. The joint, he believes, should have drainage.

Murphy (120, a) reported in 1915 a case of ankylosis following fracture. The elbow was ankylosed at about 150 degrees with a few degrees of motion. Seven weeks after operation, there was good pronation and supination, and perfect freedom of motion.

Ashhurst (7) uses an incision along the external supracondylar line and the external condyle, detached from the humerus with an osteotome. A pedunculated flap is inserted, and the external condyle replaced by means of a Lambotte self-boring screw. He reports five cases. In these cases there were three good end-results. One case had a flail joint with very slight power of extension. The fifth case had a limited motion, but the patient refused forcible manipulation.

Gilbert (68) cited a case of dislocation of the elbow which had existed 3 months. Good use of the joint was obtained after a Murphy arthroplasty.

Tubby (182, a) reported one elbow case in which he used a muscle flap. At the time of the arthroplasty, insufficient bone was removed and re-ankylosis took place. Eight months later, he did a secondary operation to remove the mass of new bone. After this intervention, all movements were free, but the elbow was slightly flail.

Chaput (32, b) reported a case of arthroplasty for ankylosis following luxation of the elbow. He used two lateral pedunculated flaps and sewed the skin up tight. The arm was put up in a sterile dressing in extension. The following day the arm was flexed, and flexion was complete and vigorous. He attributes the good result to sewing up the wound without drainage and to the immediate mobilization.

Graff (73) described a case in which he interposed a flap of triceps muscle with almost complete return of normal motion.

Kennedy (98) cited a case in which a pedunculated flap was used. The end-result is not reported.

Murphy (120, d) reported a case showing perfect motion 7 months after arthroplasty for ankylosis from a fracture. A second ankylosis from tuberculosis showed a good end-result.

Whitman (193) exhibited before the New York Surgical Society a case in which an arthroplasty had been done for a fibrous ankylosis following tuberculosis. Four years before, an arthroplasty had been done using a

pedunculated flap. At the second operation, the fibrous ankylosis was found to have become bony. Whitman used a flap of fascia lata at this operation. He believes that, in an ankylosis following tuberculosis, a free fascial transplant is essential to success, as the tissues about the joint are atrophied. His case showed a perfect end-result, with normal flexion and 165 degrees of extension.

Brown (22) gained 80 to 150 degrees of motion in an arthroplasty by the Murphy method. The arm had been ankylosed in extension following acute metastatic arthritis.

Rovsing (159) reported before the Northern Surgical Society two successful cases in which the Murphy method was used. The ankylosis was the result of fracture. In the discussion, Bergman and Haglund expressed the opinion that mobilization of the knee should not be attempted.

Moszkowicz (119), in his report in 1916 on his operation on war injuries to joints, gives among other cases six elbow arthroplasties. In all of these a useful degree of motion was gained.

Ringel (151), in 1916, mobilized five cases of complete ankylosis of the elbow and implanted fat and fascia flaps. One good result was obtained; three cases were being treated when he reported, and in the other case suppuration developed.

Four cases of mobilization of the elbow, in which flaps of fat were interposed, were reported by Werde (190), in 1916. He obtained normal motion in all cases.

Steindler (174), in 1916, reported two operations. In one of ankylosis of the humerus, a pedunculated muscle flap was used. Mobility was good as long as the patient was under observation. The end-result is not reported. The other case followed fracture of the head of the radius, resulting in partial ankylosis. A pedunculated fascia flap was inserted. In two weeks range of motion was about normal.

Crosti (41), in 1916, presented a case in which he had interposed an aponeurosis flap taken posteriorly from the forearm. Complete bony union at an angle of 130 degrees was a result of fracture from a shell. There was a vast amount of cicatrix. The olecranon was temporarily detached according to Durante's process. To ensure pronation and supination, he interposed a small muscular flap between the radius and ulna according to the process of Huguier. The olecranon was nailed in place. Movements were started in 10 days. In 8 months there was complete active extension, flexion at an angle of 40 degrees, good movement, pronation was somewhat fettered, and supination was restored.

Plummer (140) reported two arthroplasties in which he used pedunculated fat and fascia flaps. One of his cases became infected, and subsequently a portion of the end of the humerus had to be removed. The resulting joint was somewhat flail, but gave good function. His second case also had good motion, but facility for moving joint was not good.

Ryerson (160) gives in detail his operative technique in arthroplasty on the elbow joint. He uses a long posterior incision, avoiding the olecranon. The triceps tendon is cut and a thin shell of bone is removed from the external condyle, taking the origin of the extensor with it. Then a shell from the internal condyle is removed. The joint is dislocated. After it is remodeled, a flap of fascia lata is interposed.

Thomson (180) reports the end-results in an elbow arthroplasty by the Murphy method. Ankylosis was the result of sepsis following a fracture. Seven months later, elbow motion was good, but somewhat restricted. His successful cases have all been traumatic. He believes that neisserian infection is a contraindication to arthroplasty, as it stimulates bone formation. Tuberculosis is also a contraindication, on account of the recrudescence of the disease.

A brief mention is made by Prando (142) of a case using a modification of the Murphy method. He did not use an Esmarch bandage, and enveloped the ulnar nerve in a flap of muscle taken from the triceps. He is satisfied with his results. He also reports a case in which Padman followed the Murphy method. Satisfactory motion was obtained, but later the joint re-ankylosed. Prando believes that the Murphy method is very good, although it cannot be so successful as orthopedic resection, on account of the great danger which the slightest negligence involves.

Ceccarelli (31) used strips of fascia lata in an arthroplasty on a post-traumatic ankylosed elbow. The end-result was perfect flexion, extension to 165°, and almost normal pronation and supination.

Olivieri (128) reports two arthroplasties with interposition of strips of brachialis anticus. The end-results were perfect.

Hohmann (89), in 1918, reported five elbow arthroplasties in which he inserted part of the triceps with good immediate results. Lange at the same time showed six cases in which useful joints were obtained and the patients were enabled to resume their old occupations. He used fat or muscle flaps.

Baer (9,a), in 1918, reported having done to date three arthroplasties on the elbow joint. In one, re-ankylosis occurred, one patient died, and the third showed 25 degrees motion. He believes that the elbow is the least favorable joint for arthroplasty, and that the success from the interposition of muscle or fascial flaps is due to the amount of bone removed rather than to the flap itself, and that these operations are in fact only excisions. In the discussion of this paper, Galloway and Freiberg express the opinion that an arthroplasty has no advantage over an excision. Davis states that with an arthroplasty a more stable joint is obtained.

Albee (3) uses a vertical incision directly over the olecranon. After retracting the ulnar nerve and dissecting the soft tissues, he saws through the olecranon from within outward. He remodels the joint and interposes a flap of fascia lata containing as much fatty tissue as possible. The arm is put in plaster at right angles. After 10 days, passive motion is begun.

Henderson (81), in 1918, tabulated the end-results of the forty-three arthroplasties done at the Mayo Clinic. Twenty-one of these were on the elbow. He found the prognosis most favorable in the jaw and next in the elbow. The knee was the most unfavorable position. In reports from other surgeons he found a general agreement as to prognosis.

Kleinschmidt (102), in 1919, demonstrated two cases in which he secured mobility, using Payr's method. One case of complete ankylosis had resulted from a shot wound and the other from acute rheumatism. Good active and passive motion to a sharp angle were secured, extension was complete, and pronation and supination amounted to 60 degrees.

Grange (74), in 1920, used a flap of fat from the posterior surface of the triceps and a piece of cargile membrane on each side of the flap in an arthroplasty for complete ankylosis of the elbow at an angle of 90 degrees. The joint was reached through an incision 4 inches long on the outer and inner side of the joint and a transverse incision across the arm above the olecranon. The ulnar nerve was dissected, the triceps muscle divided, and the humerus exposed. Flexion of 30 degrees beyond a right angle and extension of 45 degrees from a right angle were secured. The pronation and supination amounted to about 30 degrees, due perhaps to too little excision of bone.

Kerr (99) cited a case of complete ankylosis of the elbow following arthritis. He used Kocher's incision and inserted periarticular fascia. The result was a movable, useful joint, with no atrophy of the muscles.

Verral (187), in 1920, described his method of operation. He makes an eight-inch incision along back of the elbow. The triceps tendon is divided in two layers to overlap when sutured. A fascia flap is sutured over the end of the humerus. The elbow is put at about 120 degrees.

Rocher (153), in 1920, applied Putti's technique, using a flap of aponeurosis fascia lata in operating for a case of fibrous ankylosis of the elbow in an almost rectilinear position. He secured a perfect functional result of voluntary flexion to 80 degrees and pronation of 45 degrees.

Silfverskiöld (170), in 1922, reported an arthroplasty, using flap of fascia lata. In eight months the patient showed full active capacity for flexion and extension.

Campbell (26,b) has just published his method for arthroplasty of the elbow, which is evolved from his method for reduction of old dislocations. An incision 6 to 8 inches long is made on the posterior aspect of the arm and forearm. The skin and fascia are incised and the deep fascia dissected laterally about one inch. The suture is then dissected downward, making a long tongue flap.

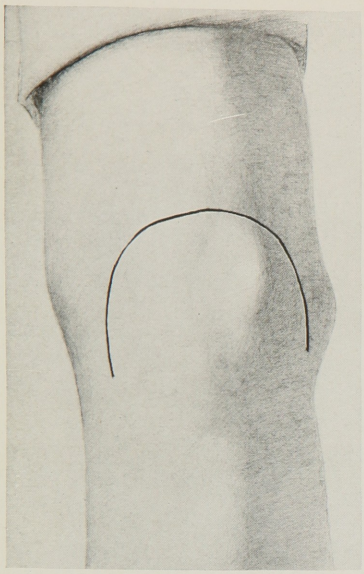

Fig. 1. Line of incision used by the author.

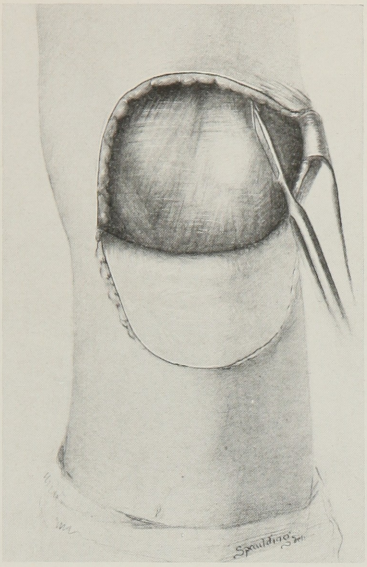

Fig. 2. Dissecting out the ulnar nerve.

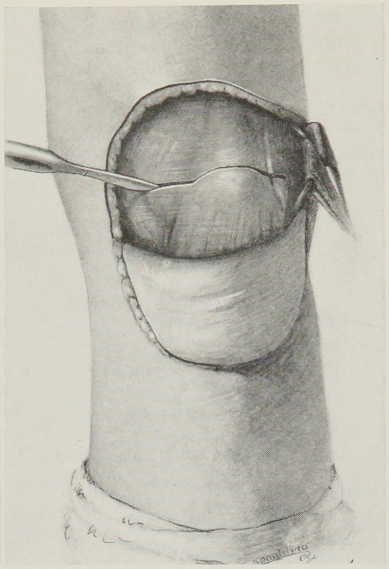

Fig. 3. Cutting through the muscle and fascia down to the joint.

Through a further incision the periosteum is stripped from the lower third of the humerus. A half-inch of bone is removed from the humerus and the end modeled into a surface convex from before backward. A half-inch of bone is then removed from the tip of the olecranon process. The surface of the head of the radius is made the same level as the coronoid process. The periosteum and triceps are dissected into a double flap, which is stitched to the anterior capsule. One case of ankylosis as a result of acute infectious arthritis, operated on by the above method, in 6 months resulted in complete extension

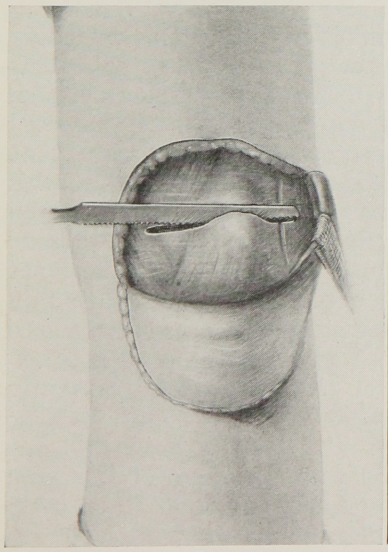

Fig. 4. Sawing through olecranon and end of humerus.

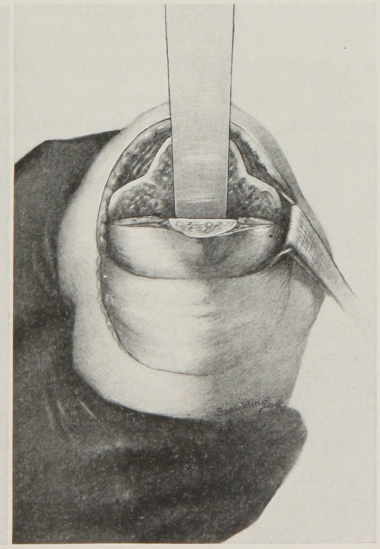

Fig. 5. Splitting off tip of olecranon with chisel.

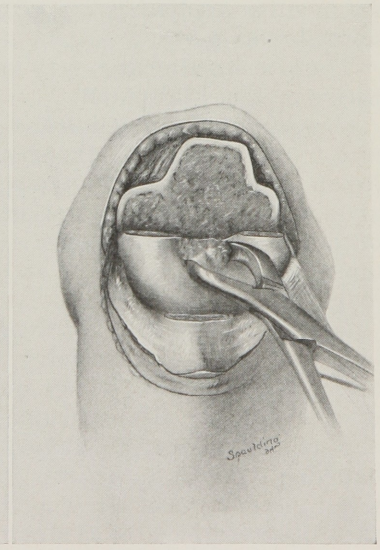

Fig. 6. Removing with rongeur forceps bit of olecranon tip left in humerus.

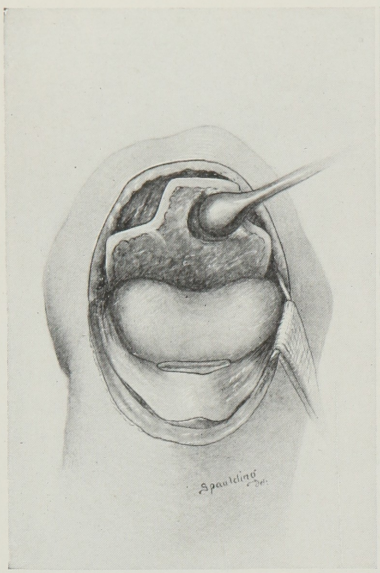

Fig. 7. Scooping out ulna and radius with curette.

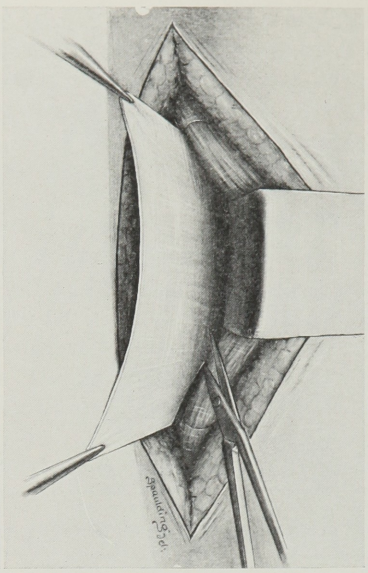

Fig. 8. Cutting fascia lata from thigh.

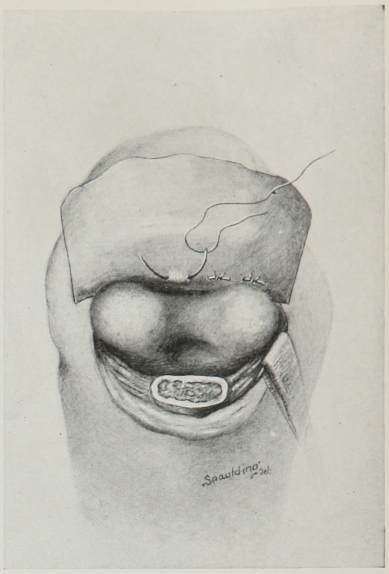

Fig. 9. Sewing flap of fascia lata to elbow joint anteriorly.

with flexion to 60 degrees. Physiotherapy is being used to increase the flexion.

In case of a normal radio-humeral joint with bony ankylosis between the ulna and humerus, a hemi-arthroplasty is done between the humerus and ulna and a broad aponeurotic tongue flap from the triceps interposed. The one case reported, of solid bony ankylosis, in six months resulted in 50 per cent of the normal motion.

The after-treatment is very important, and active motion is essential.

Operative technique—author's method. The arm from the wrist to the shoulder and the leg on the same side, from the hip to the knee, are given a two-day preparation. At the time of the operation, a tourniquet is applied to the upper third of the arm and an application of iodine made to the skin.

A semicircular incision is then made, beginning over the external condyle (Fig. 1), running down about two inches and up over the internal condyle. The wound is sponged with alcohol and carefully clamped off to avoid handling the skin during the operation. The flap containing skin and superficial fascia is then dissected back to the base line and retracted. The ulnar nerve is isolated and dissected out of its sheath (Fig. 2). It is sometimes difficult to find this nerve, but it is always to be sought at the inner side of the internal condyle. It should be dissected out carefully with a blunt dissector so as not to injure it. After it has been freed for one and one-half inches, gauze is passed beneath the nerve, and it is retracted to the ulnar side. It is then freed further by blunt dissection with gauze.

A transverse incision is then made extending down through the periosteum (Fig. 3). This incision follows in direction the superficial one, and outlines a flap which is to be dissected back and preserved *in toto* for subsequent covering for the joint. The pulling back of this flap is a hard and tedious process until it is well started, after which it can be peeled back readily by blunt dissection. It is the inner side that is the hard part, as the layer is thin here, and one must exercise great care not to buttonhole it. The olecranon is then sawed through (Fig. 4). After this, it is frequently possible to break open the old joint. In some cases, however, ankylosis is bony and the joint cavity obliterated. Cases of this kind are the most difficult. It is in these cases necessary to saw through the joint. The tip of the olecranon has to be chiseled out and dissected back with its posterior flap. Usually

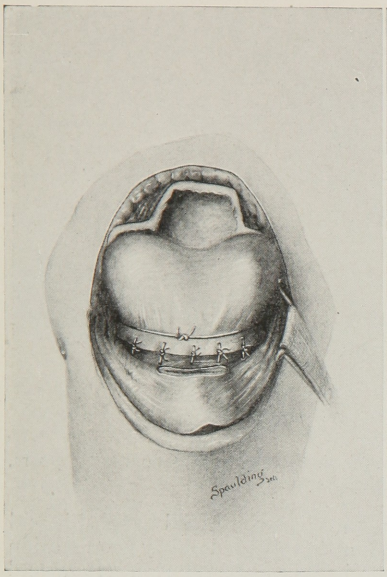

Fig. 10. Fascia sewed over humerus; tied with chromic catgut suture.

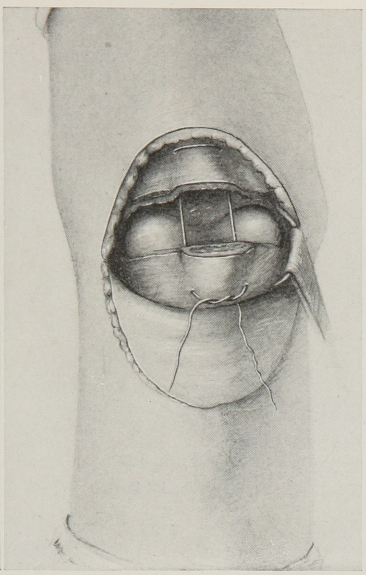

Fig. 11. Kangaroo suture through ulna and olecranon tip.

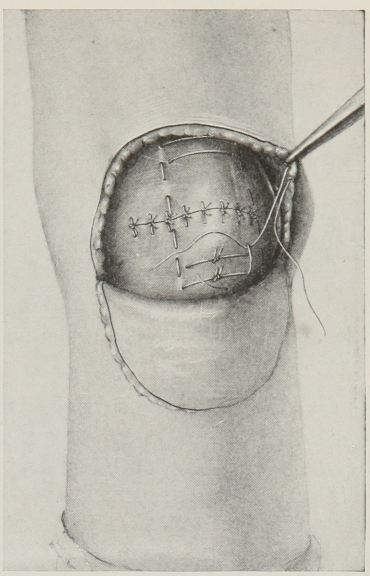

Fig. 12. Stay sutures.

the olecranon is too large, and it is well to take off a little of it (Fig. 5).

The capsule, fascia, and ligaments are then dissected back so as to allow the lower end of the humerus to protrude into the wound. Then its edges are snipped off with rongeur forceps and a new trochlear or intercondylar surface formed (Fig. 6). A shoemaker's rasp is used in filing the extremity as near like the normal humeral end as possible. After this modeling, a piece is removed corresponding to the olecranon fossa in the normal humerus. One has to be careful about making this cup, as the success of the operation depends largely upon attention to such small details (Fig. 7). This modeling is largely done with a saw and a file.

To ensure good function, the joint surfaces should fit accurately before the fascia is applied, but the joint should not be too loose. Only sufficient bone must be removed to give free motion. If too much of the ends of the bones is removed, a flail joint will result, giving the operation no advantage over an excision. When this mortising is completed, the fascial flap is dissected from the leg (Fig. 8). An incision is made on the outer side of the thigh, a little below the middle, extending down to the fascia lata. After a flap of fascia 5 to 7 inches by 4 to 5 inches wide is dissected out, the wound is closed.

This fascia, which is free from all fat, is placed about the newly fashioned humeral condyles and attached anteriorly to the capsule (Fig. 9) and posteriorly to the periosteum of the lower end of the shaft of the humerus with interrupted chromic catgut sutures No. 2 (Fig. 10). Chromic catgut No. 2 is then loosely wound twice around the shaft just below the interrupted suture line.

The forearm is placed in apposition to the condyles. Two drill holes are then made in the olecranon process and two others opposite them in the shaft of the ulna. Through these kangaroo tendon is passed and tied (Fig. 11). The inner layer is now sutured with chromic catgut No. 2 and the skin and fascia with plain catgut No. 2 (Fig. 12). Dry sterile dressings are applied and the arm put up in plaster beyond a right angle.

After-treatment. If there is no evidence of infection, the cast should remain on for a week. It is then split and the dressing changed. If there is a persistent temperature, a window should be cut in the cast and the wound inspected.

Passive motions are begun in about 10 days, if normal healing has taken place. The arm is

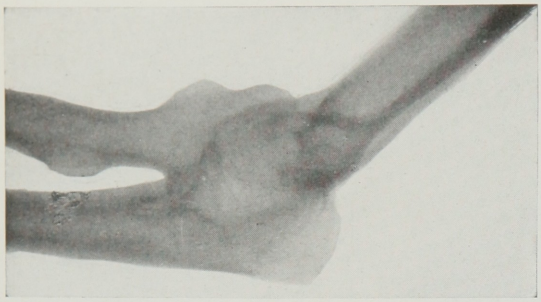

Fig. 13. Case 1. E. S. Roentgenogram showing position of ankylosis before arthroplasty.

always kept above a right angle. After 3 weeks, gentle massage is applied. Baking is begun in 6 weeks, three or four times a week.

The ultimate success in these cases depends very largely on the after-treatment. The patients should be under observation for a long period of time. Frequent X-rays should be taken so that we may follow the bony changes in the joint. If motion begins to shut down, the arm should be manipulated under an anæsthetic and the elbow put up in acute flexion. Occasionally motion becomes limited, due to an exuberant growth of new bone. In this case, a secondary operation should be done to remove this, but it should not be undertaken for at least 3 months after the original operation.

Case 1. E. S. was admitted to the Carney Hospital, August 11, 1913, for immobility of the right elbow and right knee. Six years previously, the patient had had an acute illness accompanied by fever and pain and swelling in the joints, for which she was treated in her home, without relief. At the end of 8 months, the pain and swelling had disappeared from her left shoulder and elbow so that she was able to feed herself, but she remained in bed for 12 months and after this was in a wheel-chair

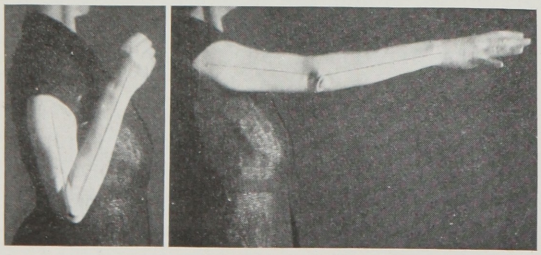

Fig. 14. Case 1. E. S. End-result, 5 years and 10 months after arthroplasty. At left, voluntary flexion; at right, voluntary extension.

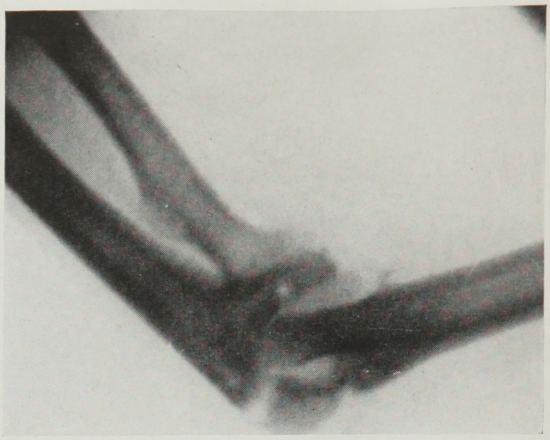

Fig. 15. Case 1. E. S. Lateral roentgenogram, 5 years, 10 months after arthroplasty.

for 2 years. The symptoms continued to subside and the pain and swelling disappeared; fairly good motion returned to all the joints except the right elbow and the right knee, in which pain and stiffness continued at the end of the fourth year, and no motion was possible. This condition continued up to the time of admission.

August 14, 1913, roentgenoscopy revealed an ankylosis of the elbow joint and of the patella to the femur (Fig. 13).

August 20, 1913, I did an arthroplasty of the right elbow using a flap of fascia lata. A light plaster cast was applied. Following the operation, the patient made a good ether recovery. There was slight pain in the elbow.

August 27, 1913, the cast was split for dressing.

September 1, 1913, the wound had healed by first intention except for a slight discharge on the upper border.

September 4, 1913, daily manipulation of the elbow was ordered.

September 10, 1913, the arm could be extended completely and flexed to 15 degrees beyond a right angle.

September 15, 1913, traction was applied for flexing and extending the arm.

October 1, 1913, active motion was possible.

October 15, 1913, I manipulated the arm under ethyl chloride.

May 15, 1919, 5 years and 10 months after operation, she writes: "The arm is doing excellent work." Photographs taken at this time show practically full extension and flexion (Figs. 14 and 15).

Case 2. E. S. sustained a fracture of the right elbow on October 4, 1913, as the result of a fall of 42 feet. The roentgenogram showed a transverse fracture of both condyles with the radial head dislocated laterally and anteriorly.

Physical examination was negative except for the right arm. The shoulder appeared normal. The elbow was held at 150 degrees extension with less

than 3 degrees motion. Supination was limited one-fourth. The wrist showed a Colles fracture unreduced. Flexion and extension were both one-half normal. Eversion was limited three-fourths and inversion four-fifths (Fig. 16).

On March 25, 1914, I did an arthroplasty on the right elbow, using a flap of fascia from the thigh. When the joint cavity was opened, it was found that the synovial tissue was hypertrophied, and there was much fibrous callous formation infiltrating the articular surfaces. A transverse fracture of both condyles was noted. The head of the radius was impacted, and was surrounded by callous formation.

Five-eighths of an inch of the condyles was sawed off square at right angles to the shaft of the humerus. The joint surfaces were smoothed off and the operation completed according to my usual method. The arm was put up in plaster in an extended position. The patient made a good ether recovery, but suffered considerably from pain, for which morphia was ordered, and the following day the arm was put up in suspension. He continued to suffer considerable pain for 4 days, after which it abated.

On March 29, 1914, the wound was dressed, and was found clean except for some serous discharge.

March 30, 1914, the cast was split and a voluminous dressing applied with splints to the forearm.

March 31, 1914, the patient was seen in consultation by Dr. Courtney, who reported a tourniquet paralysis, and advised electricity and massage.

April 1, 1914, the wound was dressed, and found clean and healing by second intention. Electricity and massage daily.

April 5, 1914, the patient was out of bed and walking about the ward. When dressed, the wound was found clean.

April 10, 1914, the wound was dressed. The motion in the elbow was good, with supination and about 45 degrees motion in flexion. A nerve report was ordered.

April 15, 1914, the nerves were reported responding to the faradic current. The prognosis was considered good. Massage was advised.

April 18, 1914, the patient was discharged from the hospital to report daily at my office.

November 30, 1914, the patient re-entered the hospital for operative interference in an attempt to gain increased motion. Both bones of the forearm had dislocated backward and the head of the radius was very much enlarged. Motion was from 150 degrees extension to 50 degrees flexion with the carrying angle markedly increased.

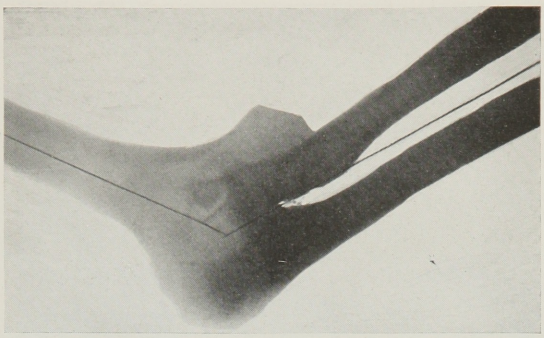

Fig. 16. Case 2. E. S. Roentgenogram showing ankylosis before arthroplasty.

On December 2, 1914, after the usual preparation, a four-inch incision was made over the external condyle. The removal of the enlarged head of the radius caused a marked increase in motion, but the posterior dislocation was not improved. The internal condyle was chiseled loose and removed through a small incision over the fragment. After the end of the humerus was smoothed as much as possible with a rasp, the wound was closed and a cast applied with the arm at right angles. A good ether recovery followed.

After the operation, the patient suffered considerably and showed some swelling of the arm. On the fourth day, the cast was split, and the patient experienced relief.

On the seventh, the patient was comfortable and out of bed. The following day he was discharged, to report to my office.

The end-result shows nearly normal range of motion with a stable, useful joint.

On October 29, 1920, he writes: "I can crank a Ford. I can do anything that I ever could. My work is driving and repairing automobiles, and I have had to change 38-7 tires on the road, which requires the use of two good arms." (Fig. 17.)

Case 3. F. D. In 1910, the right elbow became swollen and tender. At this time an open operation

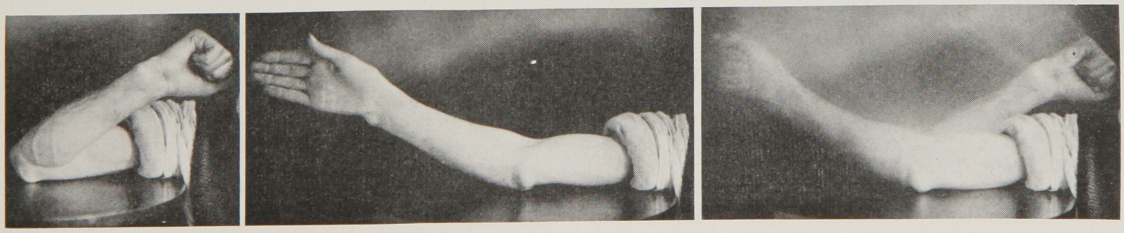

a. b. c.

Fig. 17. Case 2. E. S. End-result, 6 years, 6 months after arthroplasty. a, voluntary flexion; b, voluntary extension; c, range of motion.

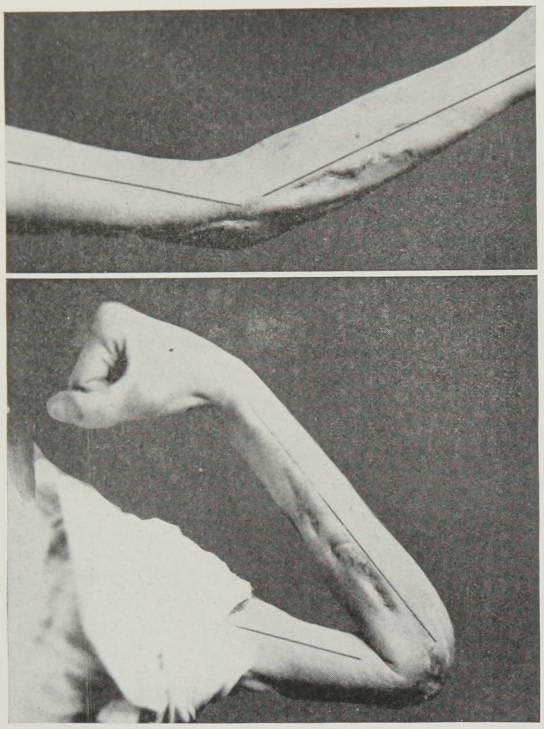

Fig. 18. Case 3. F. D. End-result, 1 year and 4 months after arthroplasty. Below, voluntary flexion; above, voluntary extension.

was done on the joint. Six months later, another operation was done after which the elbow drained for 4 years and the patient lost the entire use of the arm. There were numerous scars above and about the elbow. The elbow was ankylosed at 180 degrees. Finger and shoulder motions were normal.

On August 10, 1918, by the usual method, I did an arthroplasty on his elbow. He made a good recovery and had a normal convalescence. Two weeks later, he was discharged to have daily dressings done by the family doctor. Motion at this time was from 80 degrees to 100 degrees without pain.

He reported at my office on August 30, 1918. At this time the wound was quite healed. The elbow showed 30 degrees motion. He was then seen about every 6 weeks. On October 18, 1918, the wound was found healed. Motion gradually increased

On December 9, 1919, he showed motion from 35 degrees to 145 degrees, with full supination. The elbow was stable, with no lateral motion. He has no pain, works as a telegraph operator, and "lifts anything." (Figs. 18 and 19.)

Case 4. E. M. This patient's trouble started slowly with general poor health. Two years ago, she became ill with infectious arthritis, which at first affected the knees. There was no history of a neisserian infection. The patient was very much

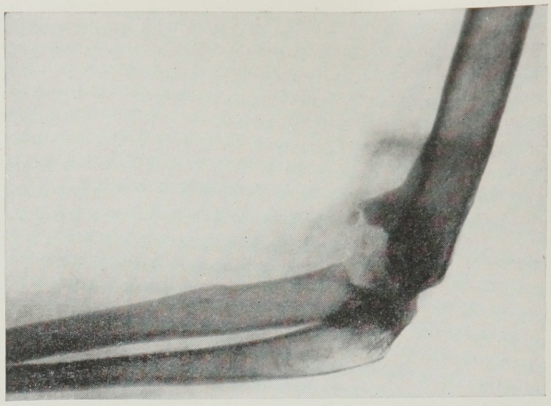

Fig. 19. Case 3. F. D. End-result, 1 year and 4 months after arthroplasty. Voluntary extension.

constipated and suffered more or less from tonsillitis. Later, the elbows became painful and could not be straightened out.

Physical examination showed a thickening of the capsule of the left elbow, with about 35 degrees limitation in motion. The left knee showed extension to within 15 degrees of full extension. The patient walked with a marked limp, and flexed knees. General treatment was prescribed, with forcible extension of the knees. As motion in the arm had shut down leaving it ankylosed at 100 degrees, an arthroplasty on this joint was advised.

February 25, 1913, I did an arthroplasty, using my fascia lata method.

March 24, 1913, the arm showed no swelling. There was little pain and the patient's general condition was fair. There was about 15 degrees motion. Gentle manipulation was ordered.

December 16, 1913, the wound had healed by first intention; supination was three-quarters normal, extension was to 170 degrees and flexion to 10 degrees to 15 degrees beyond a right angle. The patient could reach the opposite shoulder with the thumb with ease, but could not dress the lower part of the hair. The muscular power was as good as in the right arm. To gain more motion, a forcible manipulation was advised.

December 29, 1913, under ether, extension to within 5 degrees of straight was obtained and flexion to 45 degrees.

January 26, 1914, examination of the arm showed no lateral mobility and no crunching crepitation. Mobility was from 55 degrees to 145 degrees. (Figs. 20 and 21.)

Case 5. S. S. This patient was first admitted to the Burbank Hospital, Fitchburg, December 5, 1917, with a subacute neisserian infection. Five years previously the right knee had become swollen, and remained so for 3 months. A month later, the right elbow became swollen and painful. The Wassermann test was positive. She remained in the hospital 38 days, receiving general treatment, and was discharged relieved.

She returned to the out-patient department July 1, 1918. The arm was then put up in plaster from wrist to shoulder to remain on 2 months. She was told that her elbow would probably become stiff and would require an arthroplasty later.

On January 9, 1919, the patient was advised to have an arthroplasty done as her elbow had become stiff. Following the operation on February 6, she had an uneventful recovery. The cast was removed in 2 weeks, after which passive motion was begun. She was discharged March 18, 1919 (Figs. 22 and 23).

Case 6. M. R. For 13 years this patient had had attacks of rheumatism affecting the ankles, elbows, and knees. The physical examination was negative except for the joints. Both knees were slightly flexed and the right one was ankylosed, showing scars on either side. The right ankle showed some contraction of the tendo-achillis. The left elbow showed good motion except for 10 degrees limitation in extension; the right was ankylosed at 125 degrees.

The patient was admitted to the orthopedic service of the Carney Hospital, September 6, 1910, where very slight improvement took place in the knees and feet under conservative treatment. In October, 1910, on account of the swelling and boggi-ness of the left knee, an arthrotomy was advised. This was done October 19, 1910. Daily manipulations were begun on the fifth day, and an uneventful recovery took place as regards the knee.

As the elbow was stiff and in an ungainly position, operation on this joint was advised. On November 5, 1910, an arthroplasty by the Murphy method was done on this joint.

November 10, 1910, the right hand was consider-ably swollen and painful, for which pressure and hot fomentations were applied. The skin on the upper part of the arm became somewhat necrotic from poor circulation and later sloughed.

November 30, 1910, passive motion was begun and repeated daily. The first attempt at motion was made and 30 degrees attained. Following this, progress was continuous and a gradual gain in motion was made. Later, massage was ordered for the hand, forearm, and shoulder.

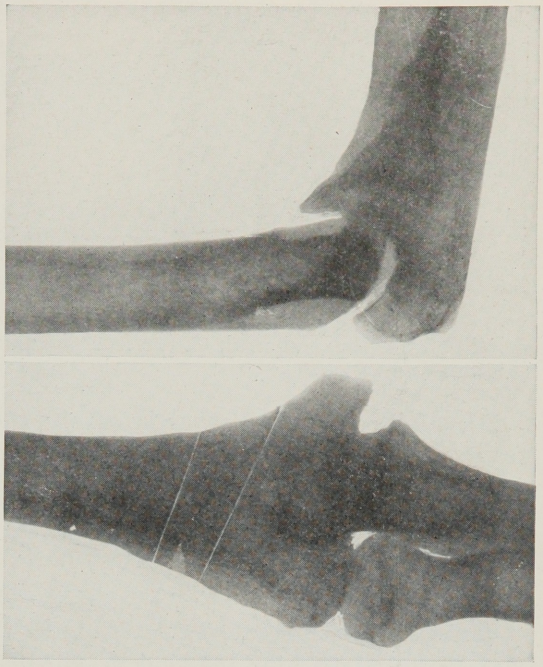

Fig. 20. Case 4. E. M. Above, lateral roentgenogram 10 months after arthroplasty; below, anteroposterior roentgenogram.

January 11, 1911, about 30 degrees to 40 degrees of motion in flexion and extension were obtained. The wound showed heavy granulation tissue. A week later she was discharged from the hospital. Dressings were to be done at home.

February 28, 1911, she was readmitted to the hospital for manipulation. Normal motion was ob-tained. Since this time, she has been seen in the out-patient department. There is practically no lateral

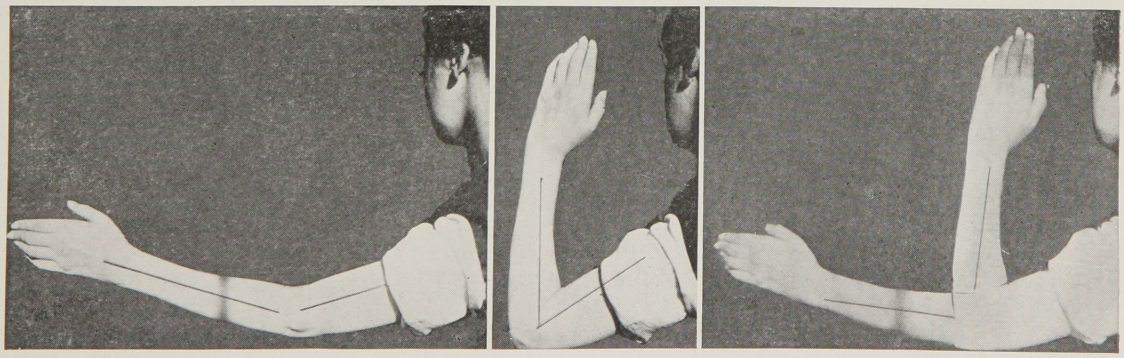

a. b. c.

Fig. 21. Case 4. E. M. End-result, 10 months after arthroplasty. a voluntary extension; b, voluntary flexion; c, range of motion (not in full range).

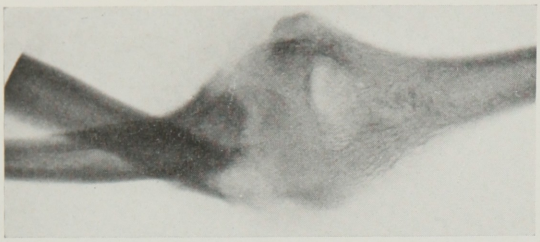

Fig. 22. Case 5. S. S. Roentgenogram showing ankylosis before arthroplasty.

mobility and the end-result is perfect function (Figs. 24 and 25).

For a full report of elbow arthroplasty, the reader is referred to the author's (111) articles appearing in *Clinics of North America*, *Journal of the American Medical Association*, and SURGERY, GYNECOLOGY AND OBSTETRICS.

KNEE

The knee joint presents a greater barrier to good arthroplastic work than any of the other large joints. Lateral stability and security in the knee must be almost absolute. Without stability, a brace is necessary to permit walking; even the use of a brace will not prevent the progress of overgrowth of bone (a direct result of undue strain), with its accompanying pain and soreness. A stiff knee, on the other hand, is a good functional member if the ankylosis is firm and in good position (5 degrees to 8 degrees of flexion). (Figs. 26 and 27.)

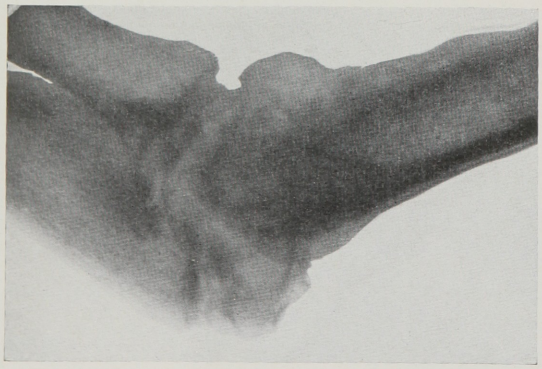

Fig. 24. Case 6. M. R. Roentgenogram showing ankylosis before arthroplasty.

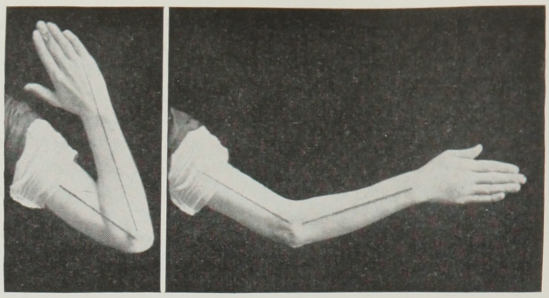

Fig. 23. Case 5. S. S. End-result, 1 year and 4 months after arthroplasty. At left, voluntary flexion; at right, voluntary extension.

If we consider arthroplastic measures in a single ankylosis of the knee, they must be cautiously advised, even in face of the advances that have been made, largely by the splendid work of Professor V. Putti, of Bologna. Arthroplasty must be done with the assurance of stability and freedom from sensitiveness and pain. In other words, we must increase function in order to classify the result as good or improved.

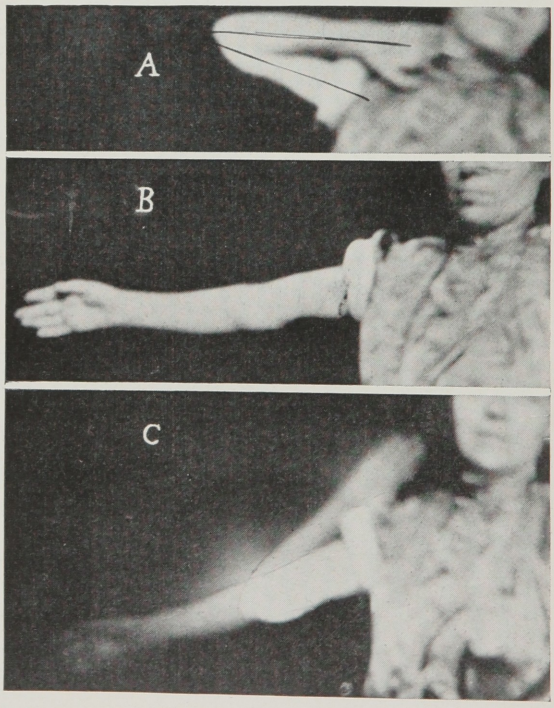

Fig. 25. Case 6. M. R. End-result, 1 year and 3 months after operation. a, voluntary flexion; b, voluntary extension; c, range of motion.

Progress is fast being made, and, although undoubtedly the last 5 years have seen a great advance in the number of functional results, we expect better ones in the future.

Generally speaking, an ankylosis, bony in character, lends itself best to mobilization, as it is more free from the results of tissue infection. Such a condition is true of all joints.

In general, the results of fascia transplantation have proved most successful, and the technique as advised by Putti has given the most consistent results. I differ from his technique only in believing it advisable not to sever or disturb the patella tendon or its attachment.

Operative technique—author's method. The usual preparation is given both legs from the ankle to the groin. I feel it is best to remove the fascia from the opposite leg, thereby minimizing the extent of the operation on the ankylosed leg as well as making it possible to remove more fascia without disturbing the external support of the joint.

The incision is made from just below the inner attachment of the patella tendon, curving slowly over this point to the middle of the external cartilage, and then directly up the outer side of the leg just above the mid-horizontal line, a distance of 5 to 10 inches from the joint proper (Fig. 28). As much fat as possible is taken with this incision. After clamping the skin-edges with towels, the skin is dissected to the inner side of the leg, exposing the patella tendon, patella, and tibial tubercle.

A curved incision is then made through the fascia, beginning in the mid-anterior line, about 5 inches above the patella, and running between the patella and outer condyle to just below the knee joint.

The quadriceps tendon is then exposed and elongated. This elongation not only allows better joint exposure, but affords a proper lengthening when we later place the leg in flexion in plaster. This lengthening may also be done by the Bennett method (Fig. 29). The patella is then raised from the femur, taking the lower cut portion of the quadriceps tendon, and forcibly retracted to the inner side of the knee, with its inner ligament attachments intact. Some surgeons detach a

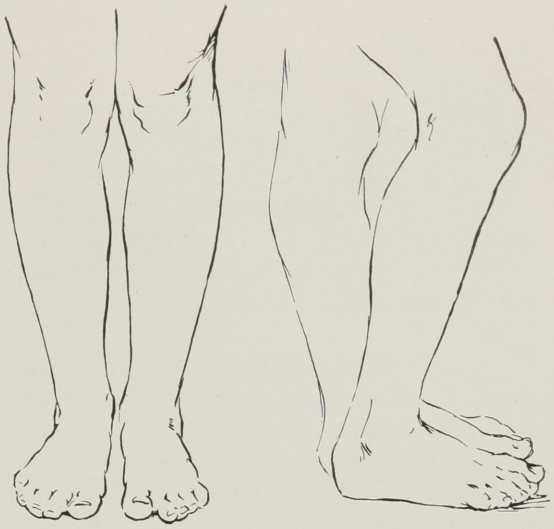

Fig. 26 (at left). Ankylosis of knee, normal position.
Fig. 27. Ankylosis of knee, 30 degrees flexion.

piece of the tibial tubercle in order to increase exposure, but I have found this unnecessary when the quadriceps tendon is elongated in the beginning. There are also many difficulties when this piece is removed, such as delayed or faulty union, which complicate the convalescence (Fig. 31, see frontispiece).

The patella in these cases is often found hypertrophied and should be narrowed laterally, as well as thinned and smoothed with a shoemaker's rasp.

The joint being then exposed, a careful study of it is made from X-rays, and great care is taken to follow the contour carefully. Putti instruments are admirable for this purpose (Fig. 30).

Several important requirements must be observed:

1. Be sure to leave a well-defined spine between the tibia condyle, as well as cup out the upper tibia surface, which will help stabilize lateral mobility (Figs. 32 and 33).

2. Carefully round the condyle with a Putti instrument and a shoemaker's rasp, making a concavity to fit over the newly formed spine.

3. Actually replace these opposing surfaces, and mold carefully, without any irregular hitches during attempts to flex.

4. Cup out a space into which the patella will articulate. Great care should be taken with this modeling.

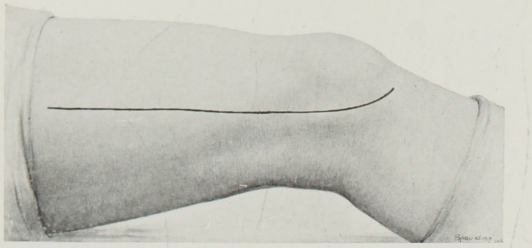

Fig. 28. Kocher's incision as used in technique employed by author.

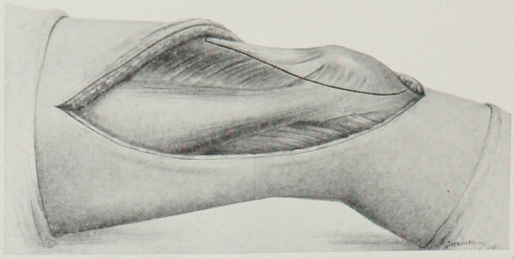

Fig. 29. Incision through fascia and capsule including division of the quadriceps tendon.[1]

5. Remove a large piece of fascia lata ample enough to cover both condyles. The fascia nearest the knee on the outer side is thickest and most serviceable. When this is removed, sew the fascia over the condyle, covering all exposed bone well. Sew posteriorly 2 inches above the articular surface (Figs. 34 and 35). The femur is then adjusted to the tibia, and the patella is replaced. The outer fascia is united with interrupted chromic catgut.

The elongated quadriceps is then strongly sutured and the skin closed with interrupted catgut (Fig. 36). A plaster is applied from the toe to the groin with the knee in 35 degrees to 40 degrees flexion and the leg placed in an elevated position in bed. Opiates are often necessary and may be freely used.

After-treatment. The temperature, pulse, and pain are carefully watched for any signs of infection.



Fig. 30. Putti instruments.

The cast is split for dressing in 2 weeks and the leg put in a ring caliper with 35 degrees flexion, so arranged that this can be changed and passive motion slowly started. Traction is also applied with this caliper which remains on day and night. Gentle passive motions are started and increased gently, guided by pain and sensitiveness, which always should be minimized. Massage is started in 5 to 6 weeks for thigh and calf, and the patient may usually walk with crutches about the sixth week. By means of an overhead extension, the patient may also use passive motions in bed, two or three times a day.

Active motions are started or attempted about the tenth week, preferably with the leg submerged in a tub of water. No actual weight-bearing is allowed until the lateral ligaments have tightened, and a caliper may be applied to assist weight-bearing, depending wholly upon the sensitiveness and pain on use.

CASE 1. F. O. K., age 31. In 1909, patient had an acute neisserian infection in the left knee. The opening of the joint resulted in an ankylosis. The knee was in good position, but there was no motion between the tibia and the femur. The patella was ankylosed to the femur. Manipulations were unsuccessful in obtaining motion. Arthroplasty was advised.

December 14, 1910, arthroplasty on left knee according to the technique as described.

December 23, 1910, out of bed. Daily dressings.

January 5, 1911, cast removed. Posterior shell applied.

January 7, 1911, small amount of weight-bearing. Crutches.

January 19, 1911, patient discharged from hospital. In a leather leglet with limited motion. He is to continue stretching and daily hot fomentations.

January 3, 1923, now 12 years since arthroplasty. Patient has no pain and has had no trouble. "No

[1] Figures 31 to 36, detailing further points in author's technique, shown in frontispiece.

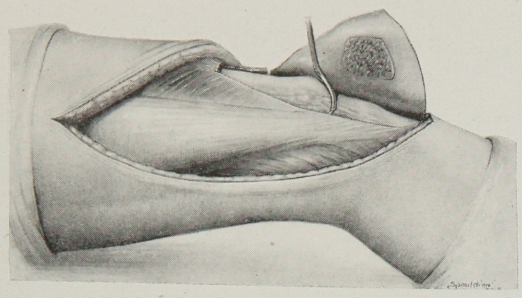

Fig. 31.

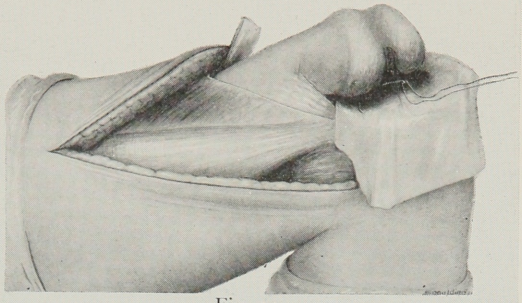

Fig. 34.

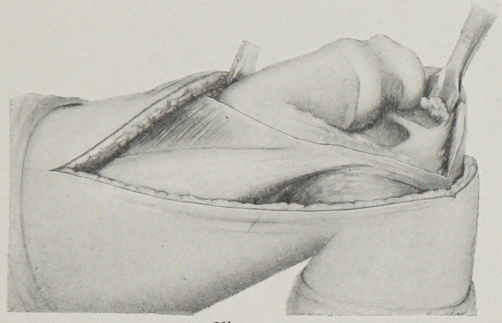

Fig. 32.

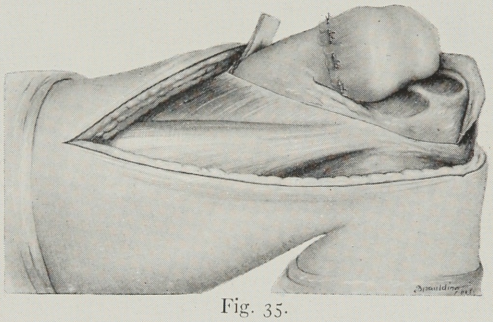

Fig. 35.

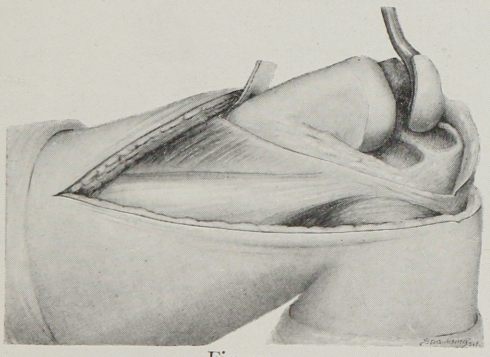

Fig. 33.

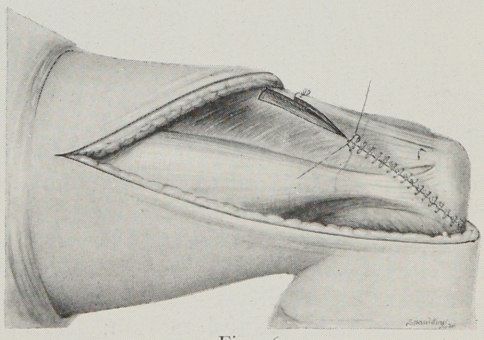

Fig. 36.

Fig. 31. Displacement of the patella with inner capsule inward and division of ankylosis.

Figs. 32 and 33. Luxation of the joint and remodeling of the femoral and tibial surfaces. Note the exaggeration of the spine of the tibia.

Fig. 34. Attachment of the fascial flap to the posterior capsule.

Fig. 35. Completion of the suture about femoral end.

Fig. 36. Suture of the capsule and elongated quadriceps.



Fig. 37. Case 1. F. O'K. Weight-bearing, 12 years after arthroplasty.

Fig. 38. Case 1. F. O'K. Weight-bearing, 12 years after arthroplasty.

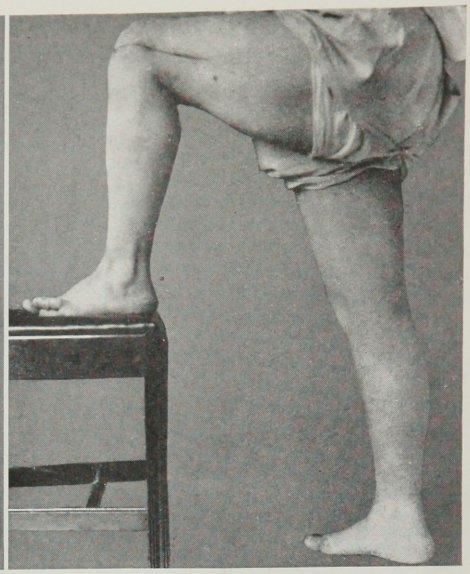

Fig. 39. Case 1. F. O'K. 95 degrees flexion, 12 years after arthroplasty.

bother at all and can do everything. Sometimes has to stop and think which is the knee operated upon." Has gained 40 to 50 pounds. The leg is straight. He has good power in quadriceps. Complete extension is possible and he has 95 degrees motion in flexion. He has absolutely no lateral mobility. (Figs. 37, 38, 39, 40, 41.)

The use of the muscle flap from the vastus internus in operations of the knee joint was suggested by Helferich (80, b). Cramer (40) followed his proposal, and in 1901 reported ten operations of ankylosis of the patella by interposition of a piece of the vastus internus. Six of these were successful. Hoffa (86) reports eight tibiofemoral cases of his own. He used fatty flaps. One case resulted in 15 degrees motion and ability to walk, the second in 15 degrees and painful motion, and the third in good motion, but with slight limping. In three cases ankylosis recurred. The seventh case had good walking ability and the eighth had 15 degrees motion 7 months after the operation. One patella case had 10 degrees motion 2 years after the operation. Hoffa believes his results are due to shortening and the contraction and atrophy of the extensor muscles. It is his opinion that the tendon should be lengthened by plastic operation or the tuberosity chiseled and attached higher up.

Murphy (120, a) first used his fascia method in 1901 on the knee joint. A large layer of fascia lata, with a thin layer of muscle attached, was dissected from the outer surface of the vastus externus, with its base below and anterior. A small flap of fascia covering the vastus internus was dissected free and

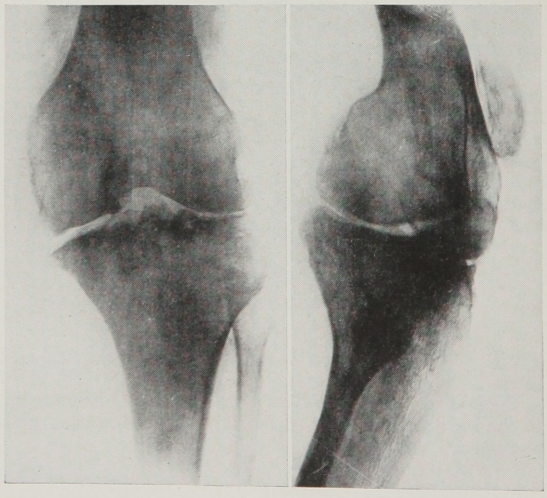

Fig. 40 (at left). Case 1. F. O'K. Anteroposterior roentgenogram 12 years after arthroplasty.

Fig. 41. Case 1. F. O'K. Lateral roentgenogram 12 years after arthroplasty.

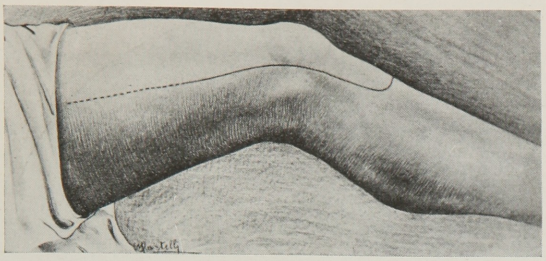

Fig. 42. Line of Kocher's incision. The dotted line shows the prolongation of the incision which is necessary to obtain the flap for transplant. (Putti.)

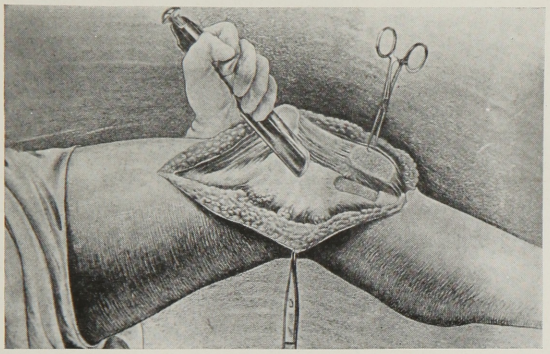

Fig. 43. Detachment of the tibial tubercle and the arthrolysis. (Putti.)



Fig. 44. Luxation of the joint surfaces. (Putti.)

placed between the patella and the femur. Between 1912 and 1916, Murphy reported fourteen operations. While at first he used fascia lata from vastus externus, he later used two implants of fat and fascia, one lifted from the inner and one from the outer aspect of the knee. He also changed his incision from two vertical cuts to a U-incision. The patella was treated in four different ways; by placing a flap under it, by turning it turtle, by rotating,

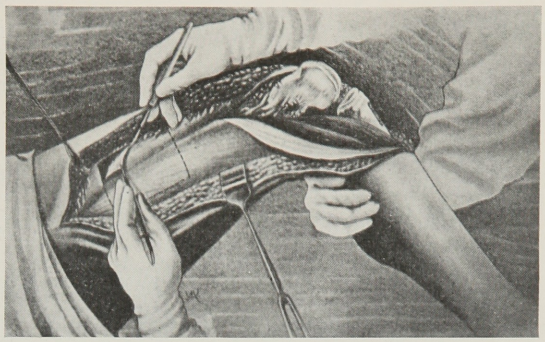

Fig. 45. Preparation of fascia lata flap. (Putti.)

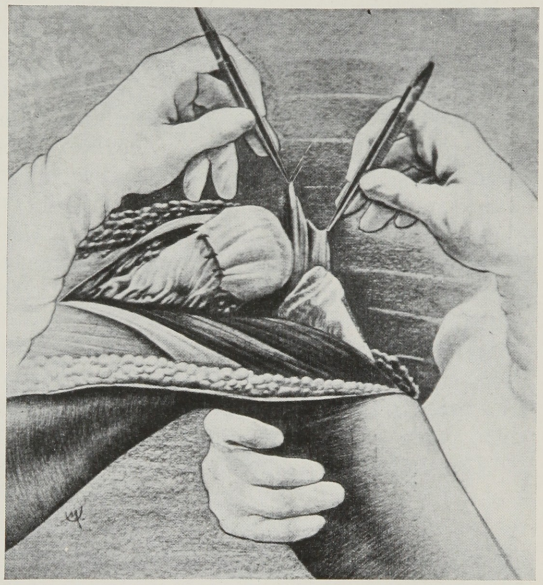

Fig. 46. Attachment of the flap on the resectioned surfaces. (Putti.)

or by transplanting a detached flap of the trochanter. Of the fourteen cases, there were two splendid results, six good weight-bearing legs, one showed good flexion and extension improving, and three records are incomplete. In one, a sheet of paraffin was inserted beneath the patella.

Since 1901 many attempts to mobilize the knee, using Baer's membrane, Cargile membrane, free and pedunculated flaps of fascia, have been reported.

McCurdy (113) and Osgood (131) used Baer's membrane. The former did not report on his result, but Osgood found that, although

good or fair motion resulted, there was some lateral motion. These results, I feel, clearly show the loss of stability so dangerous to function, and do not represent arthroplastic, but rather flail joints.

Tubby (182, a) in 1914 interposed Cargile membrane in three cases with one good result. In the other cases the patients refused the after-treatment.

Schmerz (164) has had good results in the interposition of amnion membrane which he claims surpasses the fascia transplantation in simplicity and safety.

Whitacre (192), Neff (122), Owen (132), Quigley (147), Tubby (182, a), Pringle (143), McKenna (115), Thomson (180), Wheeler (191), Hohlbaum (88), Zeller (199), and Finochietto (64) have used pedunculated flaps of fascia. In general, good serviceable knees were secured; in two cases there occurred lateral motion and one case re-ankylosed. Of eighty-five cases on which Hohlbaum (88) reported, using free and pedunculated flaps, there were 78 per cent good results and 22 per cent poor.

Steindler (174), Thomson (180), Brandstrup (21), Hessert (85), and Goddu (71) reported the use of free fascia flaps with good results.

Whitacre (192), Appel (6), Ogilvy (127), and Hoerhammer (92) secured good motion by the interposition of fascia and fat flaps.

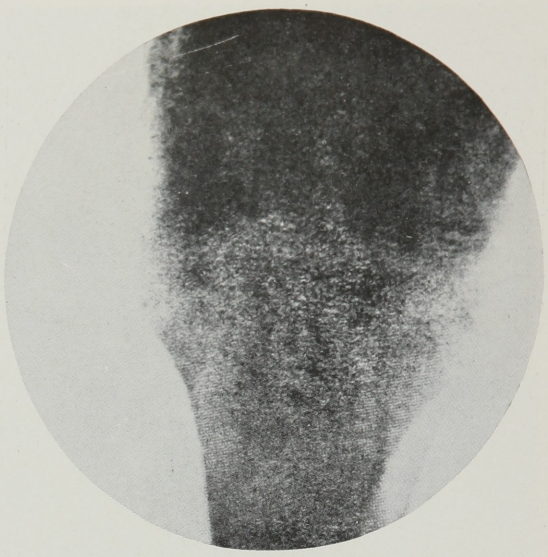

Fig. 47. Before mobilization. (Putti.)

Kirschner (100) and Osgood (131) followed Payr's method, using free fascia flaps, but in Kirschner's cases adhesions formed, and Osgood's result was only fair and necessitated the wearing of a splint. Simon (171) and Schloffer (163), however, secured good results by the same process. Tavernier (176) and Leriche (109) followed Putti's method. The former secured good motion, but Leriche's result was an unserviceable leg.

Flaps of tissue were tried by Hoke and Andrews (91) without success. Hofmann

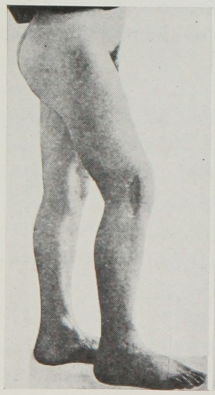

Fig. 48.

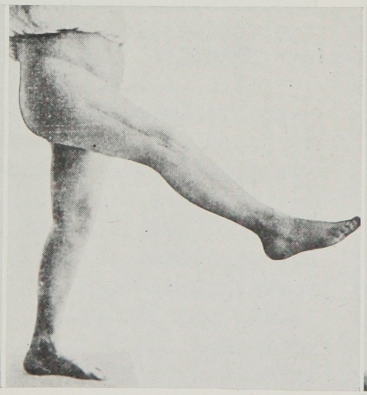

Fig. 49.

Fig. 48. After mobilization, showing weight bearing. (Putti.)

Fig. 49. After mobilization, showing active extension. (Putti.)

Fig. 50.

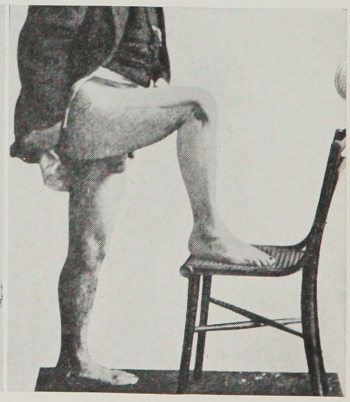

Fig. 51.

Fig. 50. After mobilization, showing weight bearing. (Putti.)

Fig. 51. Eighty-five degrees flexion. (Putti.)

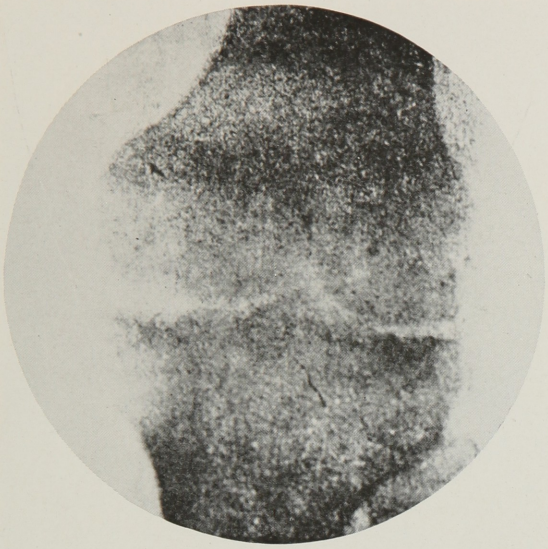

Fig. 52. Anteroposterior roentgenogram taken 27 months after intervention. (Putti.)

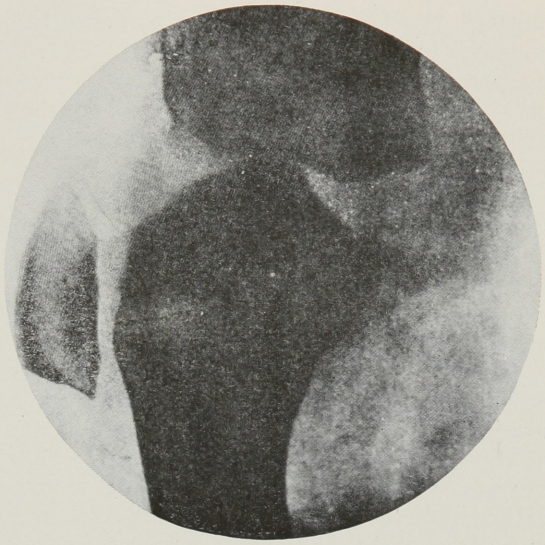

Fig. 53. Lateral roentgenogram taken 27 months after intervention. (Putti.)

(87, b), by the use of free periosteal flaps, obtained only an active motion of 15 degrees. Fascia lata and strips of subcutaneous tissue were used by Verral (187). Roeren (157) secured immediate good results with the interposition of flaps of fat, but the development of lateral motion made necessary the application of an apparatus. Cotton (39) secured a good result by the interposition of a muscle flap.

Campbell (26, a) based his report on twenty-four knee-joint cases. In ten cases using fascia flap, one resulted in 40 degrees motion, one in 30 degrees, six re-ankylosed, and on one there has not been time to report. He used Baer's membrane in nine cases; in one he obtained practically perfect motion; in one, 70 degrees of free motion; in four, the membrane extruded, and in two, of osteomyelitis, good results could not be expected. Two cases, in which free fascia from the thigh was inserted, were failures. In three operations in which prepatellar bursæ were inserted, one resulted in 15 degrees flexion and voluntary extension, the second in 20 degrees flexion and voluntary extension; it was too early to report on the third case. Of twenty of the cases on which there has been sufficient time to record the end-results, thirteen had definite voluntary motion, four did not obtain motion of sufficient value, and three were not successful, as dense bone was involved.

Campbell does not consider his work on the whole satisfactory. He recommends operations for ankylosis of complete destruction of the articular surfaces and adjoining bone, and solid union of bony surfaces. In cases of complete fibrous ankylosis, irregular scattered bands, or irregular fibrous union with areas of destruction, operation is also advised.

Up to 1917, Baer (9, b) had reported twenty-eight cases of arthroplasties on knee joints. He obtained serviceable motion only in cases of fibrous ankylosis between femur and patella or femur and tibia, of which there were seven cases; four gave 75 degrees, 40 degrees, 50 degrees, and 55 degrees of motion, respectively, and good function; three were failures—active tuberculosis set up. In five cases of bony ankylosis between patella and femur and fibrous ankylosis between tibiofemoral joint, excellent results were obtained. In sixteen cases of bony ankylosis between the patella and femur and femur and tibia, 19 per cent secured motion, 7 per cent had no ultimate motion, 6 per cent had 20 degrees, 2 per cent had 30 degrees, and 1 per cent, 45 degrees.

In his early cases Baer made two lateral incisions, one on each side of the patella,

chiseled the bones apart, and modeled the ends of joint surfaces. The first piece of membrane was carried through the opening on one side of the patella to the other side. The second piece overlapped the first; the joint was covered as far as the top of the subquadriceps bursa. Baer later used the horseshoe incision.

The writer believes that the general opinion is that lateral incisions do not give sufficient exposure to model the femur and tibia properly.

In 1920, Putti (145, f) reported on ten cases of knee arthroplasty. The largest range of motion obtained was 100 degrees, the smallest 50 degrees, and the average 82 degrees. The average age was 22 years. Putti thinks arthroplasty of the knee should be executed more frequently, and that the restoration of the knee joint can give the greatest satisfaction to the patient. There is more than an æsthetic value obtained by these operations.

Fig. 54 (at left). Ankylosis of the hip. Note flexion adduction, and inward rotation usually found in this condition untreated.

Fig. 55. Ankylosis of the hip. Note proper position, *i.e.* abduction 10 degrees—slight flexion (10 degrees) and slight external rotation.

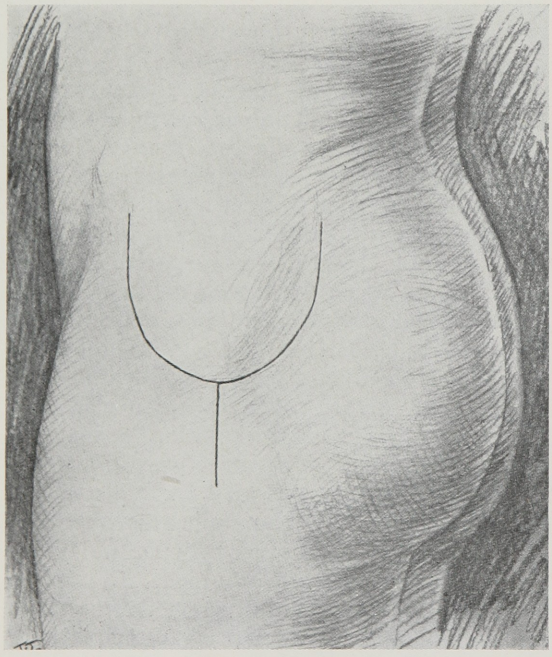

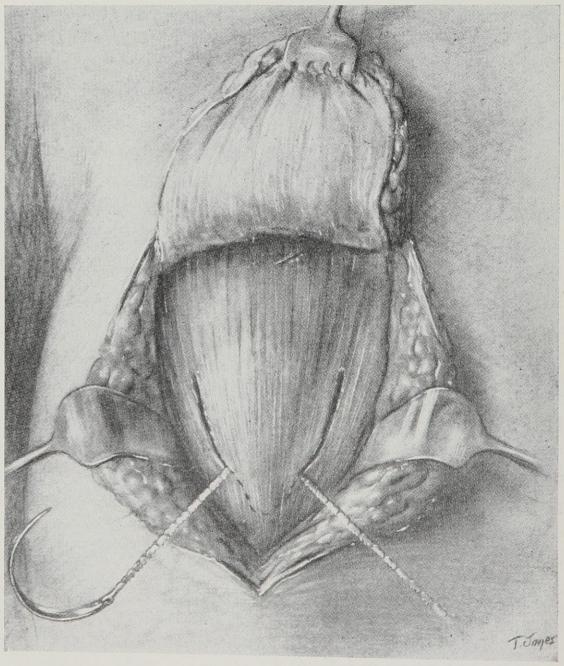

Fig. 56. "Goblet" incision through the skin and fascia lata down to the muscles and trochanter. The lower tip of the upper flap is placed just below the trochanter. The downward prolongation lies along the outer surface of the femur. (Murphy.)

Fig. 57. The flap of skin, fat, or fascia lata has been retracted upward; anterior and posterior borders of wound are retracted, exposing great trochanter with its attached muscles. The chain saw is passed on needle underneath superior muscle group, chiefly gluteus medius, down to capsule of joint, and trochanter with muscles attached is being sawed off in direction indicated by the dotted line. (Murphy.)

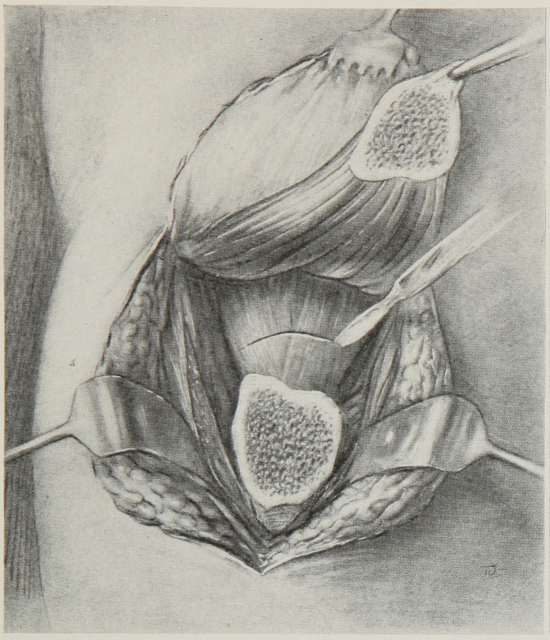

Fig. 58. The trochanter with its attached muscles is drawn upward, the anterior fibers of the gluteus medius muscle having been cut. The capsule of the joint is being incised at right angles to the direction of its fibers. In this operation it was not necessary to cut either the pyriformis or abdurator externus muscles. (Murphy.)

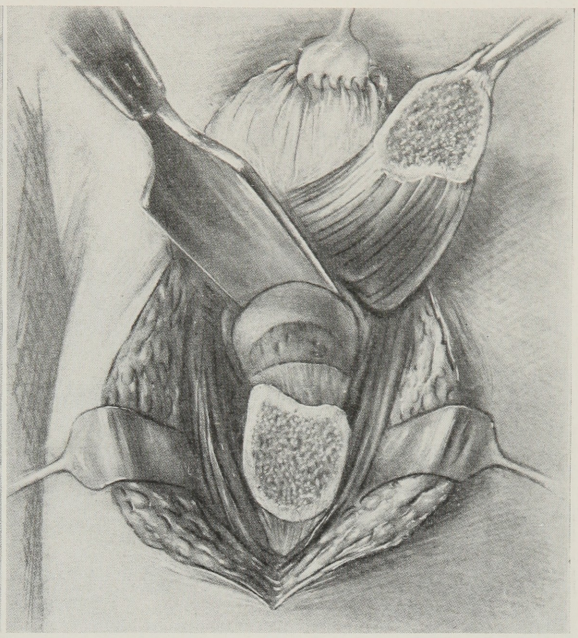

Fig. 59. The large gouge is being driven between the head of the femur and the acetabulum to divide the bony ankylosis between the two. A gouge has been selected the curve of which fits the normal curve of the head of the femur and the acetabulum, so that minimum amount of reshaping is necessary after division of ankylosis. (Murphy.)

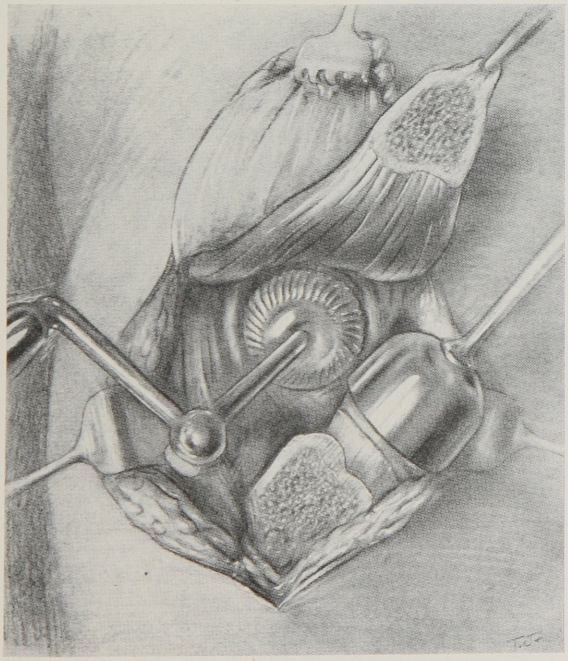

Fig. 60. Reshaping and smoothing the head of the femur and the acetabular cavity with Murphy's end-mill and reamers. Head of the femur is dislocated backward from acetabulum preceding this step. (Murphy.)

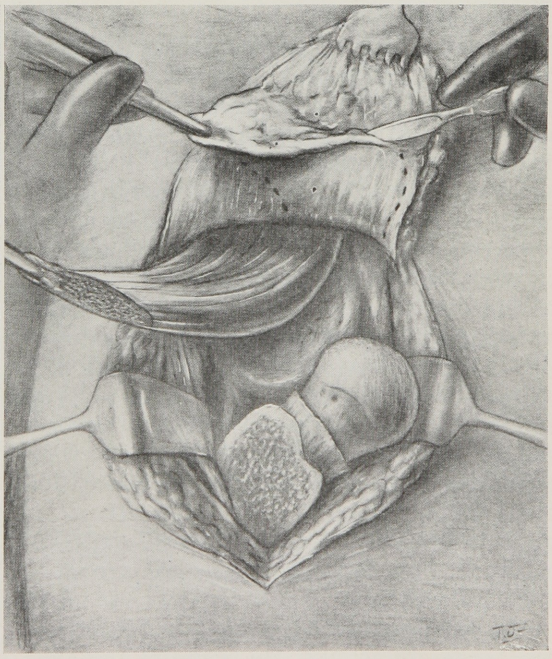

Fig. 61. Preparation from under surface of the skin-flap of the Murphy pedicled fascia and fat flap for interposition between the freshened ends of the bones. The dotted lines indicate the extent of the flap. (Murphy.)

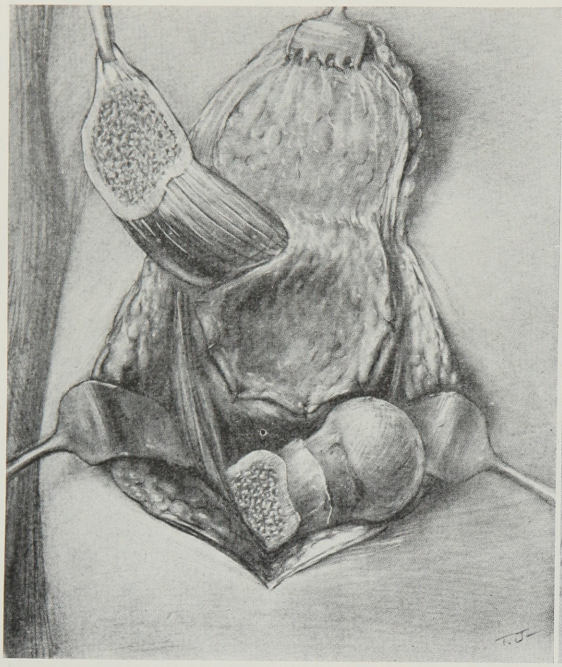

Fig. 62. The interposing pedicled flap of fascia and fat has been passed around the gluteus medius muscle posterior to its attachment, and dropped down over the acetabulum, to the rim of which it has been sutured with chromicized catgut. The head of the femur, when replaced, will lie on this flap. (Murphy.)

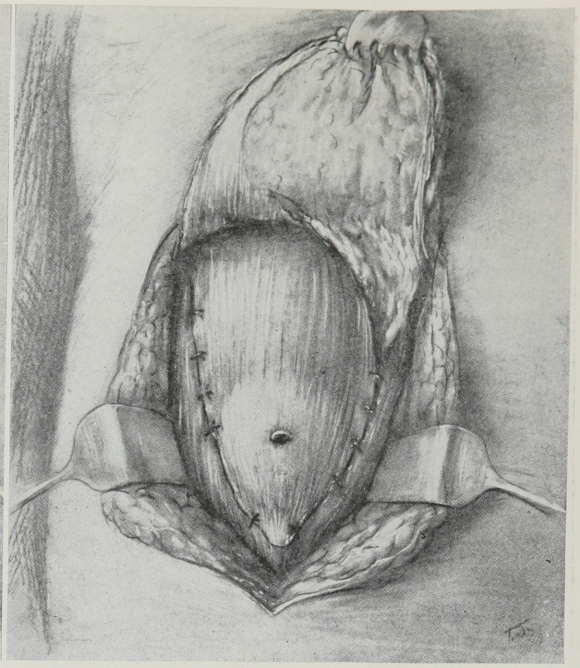

Fig. 63. The trochanter has been nailed back in place and the cut end of the muscles sutured. Usually Murphy used a continuous suture of phosphor bronze wire to reunite the muscles. The skin is sutured with horsehair and two or three sutures of silkworm-gut are inserted, if necessary. (Murphy.)

Putti uses the method set forth by Ollier of resecting the articulating surfaces, interposing membrane (Figs. 45 and 46), and preserving all the periarticular structures, particularly ligamentous. A modification of the Kocher incision is used; the cut is prolonged below to round the tibial tubercle (Fig. 42). This allows rolling in the skin after the insertion of the patellar tendon has been removed with the tibial tubercle. A piece of bone 4 by 3 centimeters and 1 centimeter deep is removed (Fig. 43). Solid union of this afterward is very important. As there is sometimes difficulty in making this union, this constitutes the weak point of Kocher's incision. Putti also uses the procedure of plastic elongation by an incision in a Z-form of the quadriceps tendon to overcome strong contraction of the extensor apparatus. This incision gives good access to joint surfaces.

The joint exposed (Fig. 44), the femur and tibia ends are shaped, the spine of the tibia made sharp, and the intercondyloid groove deepened. The transverse diameter of the condyles is preserved, but the sagittal diameter is decreased. In this way the loss of the crucial ligaments is compensated. The ankylosis is freed by a chisel to the posterior side. He uses manipulation to break up the bony lamellæ, smooths resected surfaces by files, and removes any cicatricial mass. He advises against using patella flaps, as he found the patella nearly always increases in thickness. The patella should never be completely removed. The ligamentum patellæ and tibial tubercle are nailed in place by a double-headed nail which is usually removed in a month. If necessary for flexion the quadriceps tendon is lengthened by the "Z" method.

For 15 days the whole leg is in a plaster gutter splint in semi-flexion; 4 to 5 kilograms traction is applied. After the removal of the stitches, the knee is suspended to an overhead frame with strap and pulley. The amount of exercise depends on the patient's strength, ability to stand pain, and the reaction of the

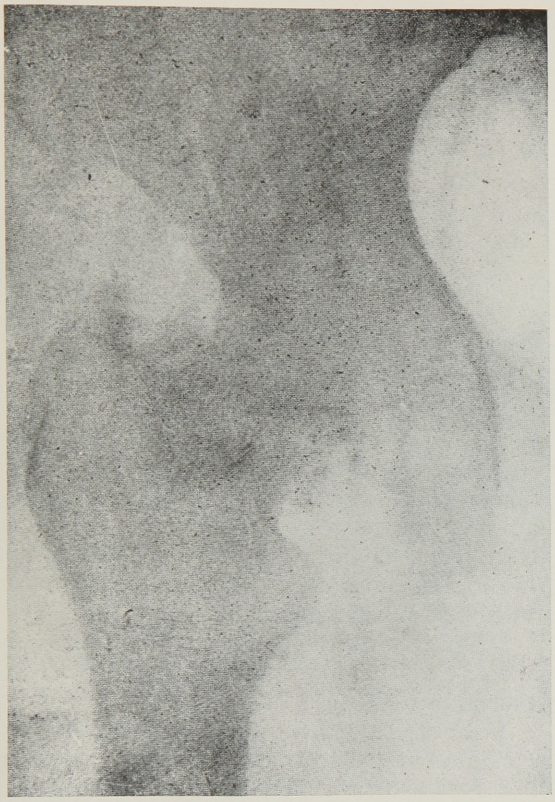

Fig. 64. Complete bony ankylosis of left hip with rotation of leg inward and abduction beyond pelvic inlet. (Murphy.)

joint. With the patient on the edge of the bed, the limb hangs out and flexion is obtained by gravity. In a month, massage, faradism, heat, and mechanotherapy (Bonnet's apparatus) are used. Auto-immobilization is essential. In 6 weeks a stiff leg brace is applied. The patient should have good use of the limb in 3 months.

Among his cases, Putti (145, d) reported one of complete bony ankylosis of the knee at an angle of 140 degrees. Suppurative arthritis had caused wounds to be open 5 months, and resulted in deep cicatrix. There was bony ankylosis between the femur and the tibia and between the femur and patella, and periarticular ossification (Fig. 47). Putti used his regular technique in operation, prolonging Kocher's incision at the base to encircle the tibial protuberance. One month after the operation there was 40 degrees motion, no pain, and complete extension. In 5 months the patient could walk long distances, had complete extension, and flexion to 110 degrees. There was slight lateral movement. In 7 months the flexion was 85 degrees and there was more lateral movement. The leg was serviceable. Fourteen months after the operation the patient returned to the hospital because of severe pain in the knee. The joint was flexed in the position of semiflexion and could not be extended. After traction and hot air applications, the joint improved. The patient walked again, and 27 months after the first intervention he could flex his knee to an angle of 85 degrees, had a movable patella, and *no* lateral mobility (Figs. 49, 50, 51, 52, and 53).

HIP

Ankylosis of the hip practically always is seen in the position of deformity; that is, flexion and adduction (Fig. 54). The correction of this deformity results in a functional limb for working use (Fig. 55). It has, however, a distinct disadvantage in sitting, stooping, going up and down stairs, etc., as well as somewhat interfering with the gait. As the joint is rotary, it lends itself to arthroplastic measures. In single ankylosis, interference is decided upon with caution and judgment. In double ankylosis, the decision is easier.

Any increase in motion in this joint improves the knee-joint action, and this, together with the hypermobility of the lumbar spine, distinctly increases function. One must, however, remember that stability is very necessary, and unfortunate results, such as dislocation, have followed arthroplasty of the hip where stability has not been obtained.

Hoffa's (86) statistics in 1906 recorded three operations on the hip by Rochet and two by Nélaton, using muscle interposition. One of the five cases showed a mobility of 40 degrees in 1 year, the other a good function of 45 degrees in 8 months. One case had good mobility at first, but it diminished later. The fourth case had good motion 5 years after the operation, and the fifth case resulted in poor function 9 months after intervention.

Hoffa (86) reported one of his own cases in which he used a flap of fatty tissue. Seven-

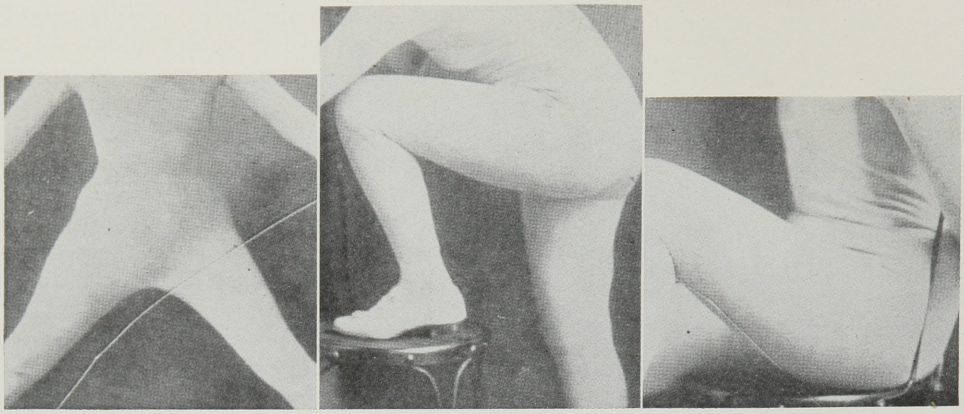

Figs. 65, 66, and 67. One year after operation, showing that patient has a full normal range of motion. (Murphy.)

teen months after the operation the patient walked, but active mobility was somewhat restricted.

Stein (173), in 1907, in Bier's clinic, interposed a flap of the sartorius muscle in a case of double ankylosis of the hip. In 5 months there was 30 per cent of normal flexion, and extension and abduction of 10 per cent of normal.

Ahrens (1), in 1908, used the gluteus maximus muscle. The patient walked in eleven weeks.

Meyer (117), in 1909, cited a case of using a flap of fatty tissue with a thin layer of muscle on a hip ankylosed from spondylitis. The thigh was flexed on the pelvis at 150 degrees. After the operation the patient had passive motion to 60 degrees, extension to normal, adduction 30 degrees, and abduction 45 degrees.

Durán (57), in 1910, used membrane, and he was able to obtain motion of 50 per cent of normal.

Murphy (120, b) found that the hip joint gave him the best results in arthroplasty. He used three incisions; the original one was U-shaped, beginning 1.5 inches above the trochanter and 1 inch behind it, extending down 2 inches below and passing under and in front of it up to a point opposite the commencement. Sometimes the skin was divided down at the lowest point of the U to form the large interposed flap. The second incision was along the iliotrochanter line 1 inch below and in front of the trochanter and upward for about 5 inches in a straight line with the anterior superior spine of the ilium. The third was a modification of the second, in that the incision was curved and convexed backward behind the trochanter (Fig. 56).

His next step was to free the trochanter by a chain saw and retract it upward with attached muscles (Figs. 57 and 58).

The ankylosed head of the femur was severed from the ilium, as near the anatomical line as possible, with a carpenter's and cabinet curved chisel (Fig. 59). It was drawn obliquely into the acetabular cavity for 1 inch. The head was fractured out and a special globular burr fashioned the acetabular cavity. A cup-shaped well conformed the femoral head (Fig. 60).

A flap of fat and fascia, fascia lata, and subcutaneous fatty tissue (one-fourth inch thick) was inserted behind the head and neck of the femur, and the edge was sutured to the acetabular margin and to the capsular ligament with phosphor bronze wire (Figs. 61 and 62). The head was replaced. The trochanter was nailed in place (Fig. 63). The fascia was re-approximated by chromic catgut and the skin sutured with silkworm or horsehair. No drainage was used.

The field operated upon was dusted with bismuth subiodide powder and the wound sealed with gauze saturated with collodion. A pad of plain sterile gauze, moistened with 95 per cent alcohol and 61 per cent phenol, was placed over the hip 4 or 5 inches beyond the line of incision on either side. A Rainey

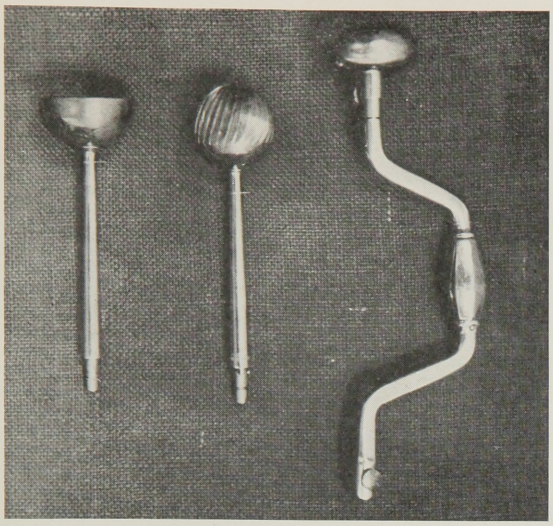

Fig. 68. Murphy instruments.

travois splint and Buck's extension with 20 to 25 pounds were applied. Both legs were dressed in an abducted position.

Passive motion was instituted in 3 or 4 weeks.

In the majority of cases of ankylosis of the hip reported by Murphy, there resulted a good range of motion and ability to walk without support. Among them was one case of metastatic origin, of complete bony ankylosis of the left hip with rotation of the leg inward and adduction beyond the pelvic inlet (Fig. 64). The usual technique was followed in the operation. The patient made an excellent recovery. In 1 year she could walk without support and had full flexion (Figs. 65, 66, 67).

Pettis (138), Torrey (181), Clark (36), Gibby, reported by McCurdy (113), Ceballos (30), Prando (142), Thomson (180), and Burlew (25) reported cases in which they had followed the technique of Murphy, using pedunculated flaps. Several good results were recorded. Thomson believes his case re-ankylosed because he removed too little bone.

McKenna (115) outlined his technique as a modification of the Murphy goblet-shaped incision. The cut was carried farther back to secure a fat and fascia flap that comes directly under the gluteus muscle. This fits into the acetabular cavity without cutting the pedicle of the flap.

Perthes (136), in 1919, mobilized a hip joint ankylosed in the position of adduction. After the freeing of the ankylosis two pedunculated fat and fascia flaps were interposed. In spite of ankylosis of the other hip joint and of the two knees and of paralysis of the sciatic nerve, walking was possible.

Baer (9,b), in 1917, reported his series of fifty cases of bony ankylosis of the hip in which an arthroplasty was done with the use of the chromicized pig's bladder. The resulting motion in nine cases of gonorrhœal arthritis was active motion in 89 per cent. Two cases operated on in 1909 resulted in 20 degrees and 40 degrees motion, respectively. Infection was the cause of failure in one case; in the other, the periarticular tissues needed stretching. In twenty-one cases of tubercular origin, 66 per cent good voluntary motion, utility and good walking ability were secured. One hundred per cent good serviceable motion resulted in fifteen cases of infectious arthritis. In five cases of arthritis deformans involving spine, hip, knees, and ankles, 60 per cent motion was obtained.

Baer makes his incision from the anterior superior spine, down the thigh, parallel to the femur, between the tensor femoris muscle on the outer side and the sartorius on the inner. The capsule is stripped back, the ends of the bones shaped, and the membrane thrown around the femoral head.

Baldwin (10), in 1915, reported a successful result, using Baer's membrane.

Neff (122) used a U-incision with reflexion of the flap upward for the formation of a long, broad flap of fascia lata. If enough capsule was available, it was used for flaps; if not, fascia was interposed.

In 1913, Osgood (131) reported on five cases; in one, using the capsule for a flap, the result was poor; in the second case, using tissue flap, the outcome was fair; in the third case of excision, death resulted; in the fourth case of fibrous ankylosis, in which free fascia was used, the result was good; and in the fifth case of fibrous type, doing a part excision according to Baer's method, the result was fair and improving.

Two methods are used by Payr (134, b) on the hip. One consists of the separating of the

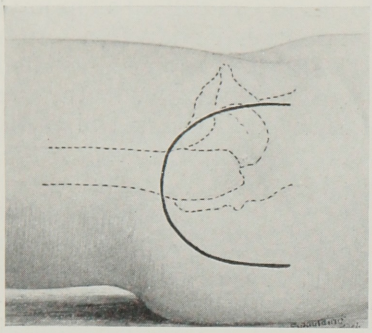

Fig. 69. U-shaped skin incision as used by author.

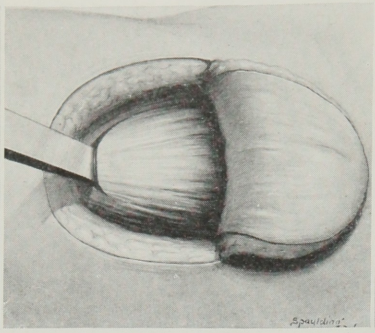

Fig. 70. Line of fascia incision preparatory to removal of great trochanter.

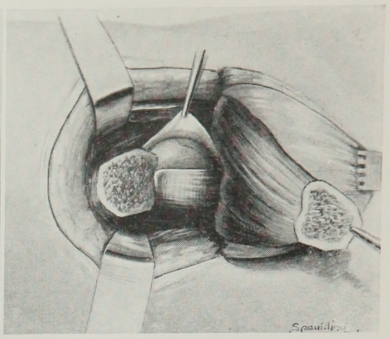

Fig. 71. Incision through capsule parallel to and in center of femoral neck.

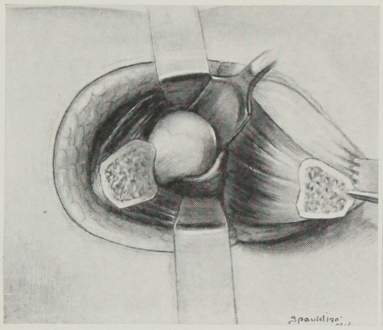

Fig. 72. Separation of the femur from the acetabulum.

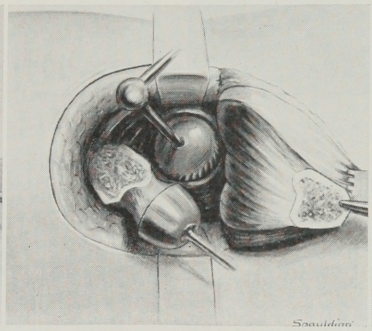

Fig. 73. Reaming out of acetabulum and rounding of head with Murphy male and female rasps.

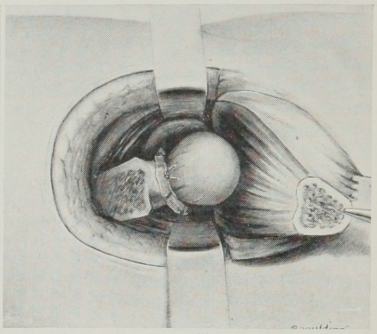

Fig. 74. The fascia flap sewed around neck of femur with interrupted sutures and tied with a purse string.

ankylosis, smoothing off of the head of the bone or building a new rounded epiphysis out of the neck of the femur, with interposition of fat (free or pedunculated) or a flap from the tractus iliotibialis. The second process is the formation of a pseudoarthrosis as near as possible to the acetabular margin, likewise with the interposition of soft parts. Payr tries to form the pseudoarthrosis after the manner of a saddle joint, simulating the carpometacarpal joint.

Corner (38), Steindler (174), and Hallopeau (76) reported the use of fascia lata in the hip. Corner and Steindler did not record their results, but Hallopeau secured a good weight-bearing leg after operation for double bony ankylosis of 4 years' standing.

Grange (74), in 1920, reported three cases of arthroplasty. In one, of bony ankylosis with internal rotation of the thigh, of traumatic origin, a curved incision was made between the crest of the ilium and the great

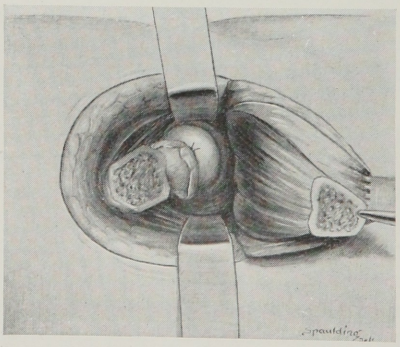

Fig. 75. Reduction of femoral head.

trochanter, the femur was divided at the neck and a flap of gluteus medius sutured over the raw end of the neck of the femur and a loose flap of fat from the buttock placed in the cup in the head of the femur. Within 2 months the patient could flex his hip to a right angle.

Hohlbaum (88), in 1921, reported twenty cases of hip ankylosis of tubercular, rheumatic,

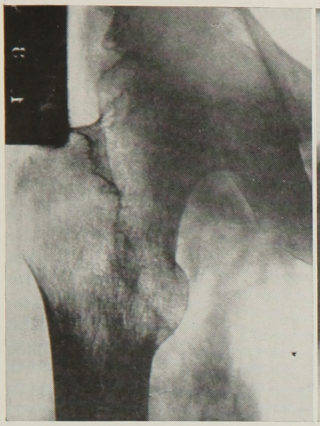

Fig. 76.

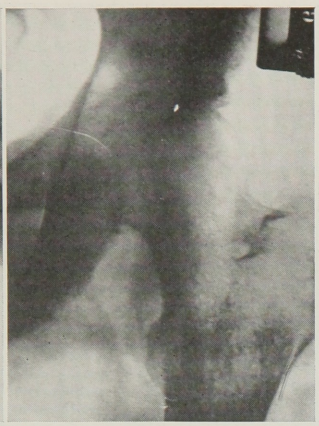

Fig. 77.

Fig. 76. Case 1. O. P. Roentgenogram of right hip before arthroplasty. March, 1916.

Fig. 77. Case 2. O. P. Roentgenogram of left hip before arthroplasty. March, 1916.

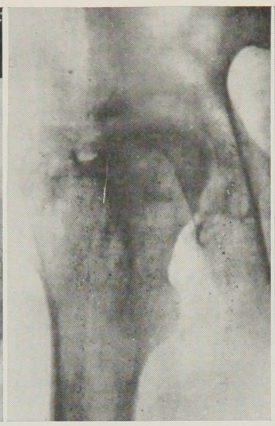

Fig. 78.

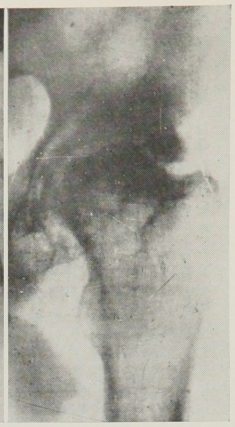

Fig. 79.

Fig. 78. Case 1. O. P. Roentgenogram of right hip 2 years after arthroplasty.

Fig. 79. Case 2. O. P. Roentgenogram of left hip 1½ years after anthroplasty.

gonorrhœal, arthritic, and other origins. Free fascia and pedunculated flaps were interposed. In his series there were six very good results; five good results; six cases re-ankylosed; two patients died; and in one the result was unknown.

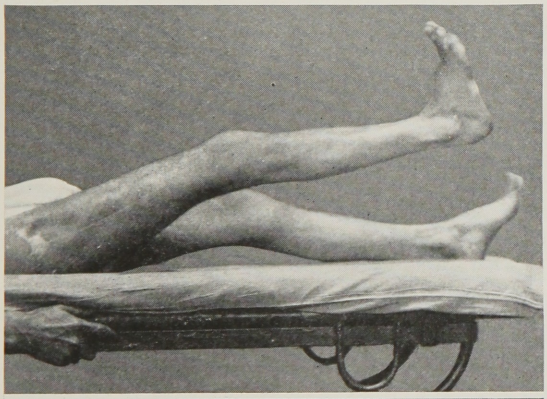

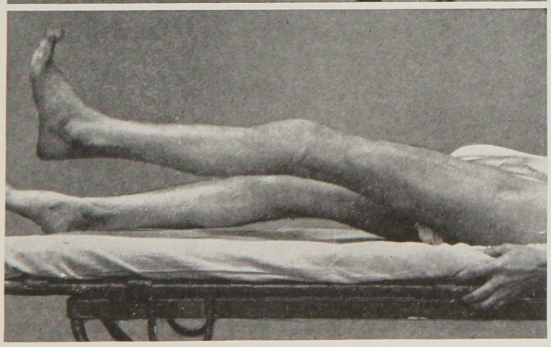

Fig. 80 (above). Case 1. O. P. Motion in right hip 1½ years after arthroplasty.

Fig. 81. Case 2. O. P. Motion in left hip 1½ years after arthroplasty.

Author's technique. In operation on the hip I use the following technique:

The patient is given a very careful two-day preparation of the hip from the rib-line to below the knee.

A skin incision is made beginning at the anterior superior spine and running in a horizontal plane to about 2 inches below the level of the trochanter, at which point it curves over the femur, 3 to 4 inches below the trochanter in a U-shaped fashion (Fig. 69). This flap, with considerable fatty issue attached, is elevated, raised to its base line, and retracted.

A similar incision is made through the fascia external to the sartorius and sweeps around about 3 inches below the trochanter, at which point it reaches the base of the femur (Fig. 70). The periosteum is separated downward one-half inch and then upward to the base of the trochanter.

With a two-inch osteotome the entire trochanter is removed and elevated, taking with it all the muscle attachments.

An incision is then made through the capsule beginning on the ilium and passing parallel to, and in the center of, the femoral neck to the base of the detached trochanter (Fig. 71). At the attachment of the capsule

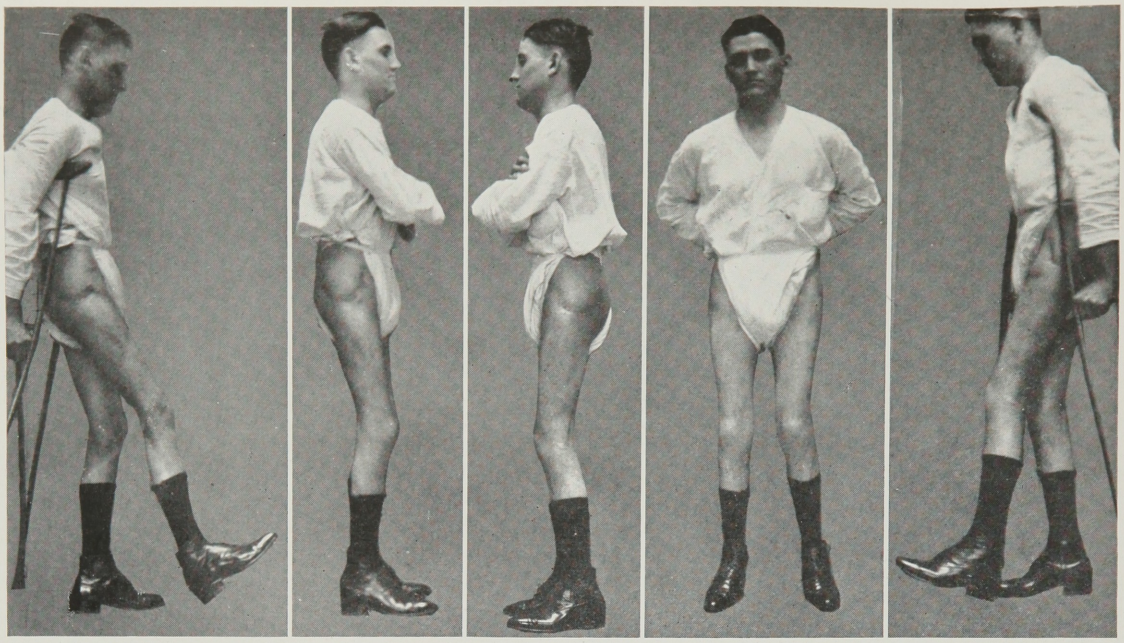

Fig. 82. Fig. 83. Fig. 84. Fig. 85. Fig. 86.

Fig. 82. Case 1. O. P. Motion in right hip 1½ years after arthroplasty.

Figs. 83 and 84. Cases 1 and 2. O. P. Lateral view, standing after arthroplasty.

Fig. 85. Cases 1 and 2. O. P. Anteroposterior view, standing, after arthroplasty.

Fig. 86. Case 2. O. P. Motion in left hip 1½ years after anthroplasty. (Patient has about twice this motion but is handicapped in further flexion by double ankylosis of the knee.

to the femoral neck, it is cut off around on both sides for a distance of 1.5 inches and retracted. A blunt dissector then frees the capsule from the neck as much as it is possible to free it.

A study of the junction between the head and the ilium is made, and then with a curved chisel, covering a small space at a time, the femur is separated from the acetabulum. Care should be taken to follow the outline of the acetabulum, as this is always hard, while the head is usually atrophied (Fig. 72).

Finally the head is freed and dislocated. With the Murphy male and female rasp (Fig. 68), the acetabulum is thoroughly reamed out and the head is thoroughly rounded (Fig. 73). Great care should be taken to remove all spicules of bone.

A piece of free fascia lata from the outer side of the opposite leg is removed and sewed around the neck of the femur by interrupted sutures. Then a purse-string suture is tied about it tightly (Fig. 74).

The head is reduced (Fig. 75). The old capsule is returned and sewed together and to the old attachments as nearly as possible. I feel that this very materially adds to stability and ensures against dislocation or a wabbly, unstable joint.

The trochanter is then pulled down to its old position and held by resuture of the periosteum with fascia originally elevated. The skin is closed and the leg placed in plaster-of-Paris cast from the nipple line to the toe, with the leg in 10 degrees abduction, complete extension, and with a little pressure over the trochanter.

The cast remains on 2½ weeks and is then removed and traction applied. Passive motions are started at the third week and should always be within the limits of pain. The patient is encouraged voluntarily to contract the thigh muscles and thereby get voluntary control early.

The patient may walk with crutches in 6 weeks and bear a little weight in about 8

weeks. Convalescence as regards motion varies with the type of individual, but all motion should be within the pain limits.

Case 1. O. P., age 24. Patient had an ankylosis of 3 years' duration involving both hips and knees, due to an infectious process, probably neisserian in origin. (Figs. 76 and 77.)

April 12, 1920. Arthroplasty of right hip by Dr. Andrew R. MacAusland, using the technique as outlined. It was then about 3 years since the original infection. The operation was followed by some shock. The wound healed perfectly. A cast was applied.

May 17, 1920. The cast was removed and passive movements encouraged.

June 5, 1920. Patient out of bed with crutches.

June 10, 1920. He walked with crutches.

June 12, 1920. Discharged from hospital.

January 13, 1923. No pain. Motion in flexion 40 degrees. Motion in adduction and abduction in arc of 15 degrees to 20 degrees. (Figs. 78, 80, 82, 83, 84, and 85.)

Case 2. O. P., age 24. The previous history of this case was reported under Case 1. Both hips were ankylosed. (Figs. 76 and 77.)

November 2, 1920. Seven months after the operation on the right hip, Dr. Andrew R. MacAusland did an arthroplasty of the left hip, using the regular technique.

November 29, 1920. The cast was removed. The wound healed by first intention.

December 6, 1920. Passive motions were started.

December 17, 1920. Patient was up in wheelchair. He had some sensitiveness. Motion was omitted for 1 week.

December 26, 1920. Passive motion renewed.

January 4, 1921. He walked with crutches.

January 22, 1921. He was discharged from hospital.

January 12, 1923. No pain. Motion in flexion 40 degrees. Good abduction and adduction. Excellent functional result. (Figs. 79, 86, 81, 83, 84 and 85.)

JAW

Ankylosis or greatly limited motion in the temporomaxillary articulations early assumes dangerous proportions, because of the inability of the patient to take nourishment. In young children this condition is complicated by the dangers from swelling during throat infections, so common in this type of case. Much of this infection undoubtedly arises from the inability to give proper hygienic care to the mouth and teeth. Arthroplasty is indicated in all of these cases, and, although the mortality is high in young children and the dangers of infection considerable, the relief is at times a matter of necessity. The method as described by Murphy has been accepted as standard.

An incision is made in front of the ear from one-half inch below the root of the zygoma up to the hair line. The incision may be curved in, convexed backward, passing forward under the zygoma to 1 inch in front of the ear, 2 inches above the zygoma. The L-incision gives the best access (Fig. 87).

The ankylosis is divided and a flap of temporomaxillary muscle aponeurosis dropped over the zygoma. (Figs. 88, 89, 90, 91, and 92.)

Murphy (120, b), in 1913, brought to our attention his series of nine arthroplasties of the jaw, seven for bony ankylosis and two for extra-articular fibrous fixation. The first case, of a boy with fibrous ankylosis of the left temporomandibular joint and bony ankylosis of the right, resulted in the ability to open his mouth 1 inch, 4 weeks after the operation. Now he can put an apple between his teeth. An operation on a case of fibrous ankylosis allowed the opening of the jaws to 1.5 inches 3 months after the operation.

Another patient who had fibrous ankylosis could open his mouth 1 inch in 5 weeks after the operation.

As the impairment of health is involved in an ankylosed jaw, early attempts at operation were made.

Hoffa (86) collected eighteen cases: Helferich one, Lentz one, Mikulicz one, Henle one, Bilczynski one, Kusnetsoff one, Gluck two, Rochet four, Schmidt one, Foederl one, Orlow two, Meyer one, and Beresowski one. In thirteen cases in which muscle flaps were used, good results were secured, and the average separation of the incisor teeth in ten cases was 2.6 centimeters. Good results were obtained in two cases using skin flaps. In one, inserting hog's bladder, the incisors were separated 2.6 centimeters, and in two cases, using gilded plates, 2 and 1.75 centimeters.

Hoffa (86) reported two of his own cases; one of simple resection resulted in a separation of 2 centimeters and the other, using a temporal muscle flap, allowed the placing of two fingers between the jaws.

Biermann (16), in 1909, reported using a flap of the temporal muscle and obtaining a good result.

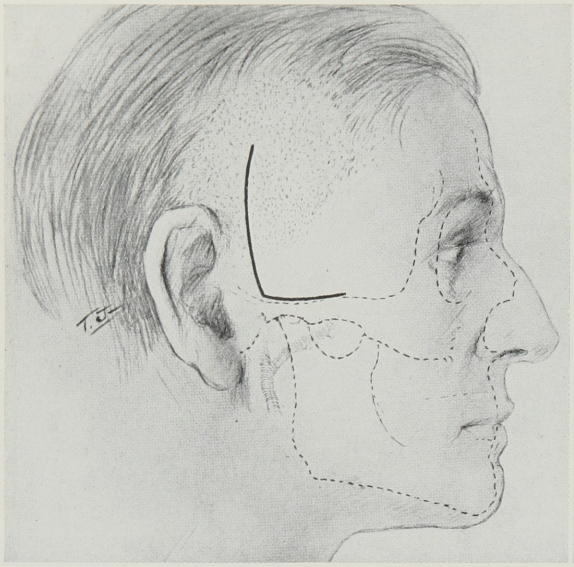

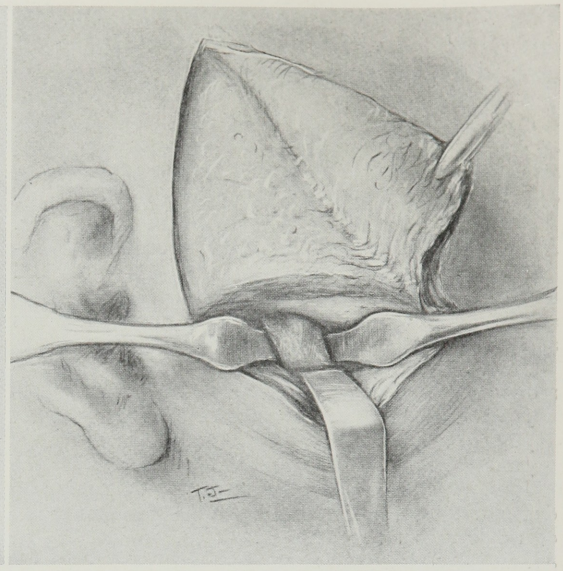

Fig. 87 (at left). L-shaped skin incision above the zygoma and in front of the ear, so placed to avoid injury to the facial nerve. (Murphy.)

Fig. 88. Skin flap retracted and zygoma and neck of mandible exposed. Two curved periosteal elevators are shown closely applied to the posterior surface of the neck of the mandible, thus protecting the internal maxillary artery from injury during division of the bone. (Murphy.)

Stein (173), in the same year, obtained a perfect recovery of a case using muscle flaps.

Baer (9, b), in 1917, recorded his series of nine cases in which eleven operations on temporomaxillary jaws had been done. One excellent result was secured in which a boy had even more motion than normal. The other cases showed good results. In Case 8, the patient could open his mouth only 3 centimeters; this case had been operated on twice by other methods and had been ankylosed 23 years.

An arthroplasty on another case of marked cicatricial changes allowed the opening of the mouth to the extent of 0.5 centimeter. A baby, 18 months old and in weakened condition, died from the effects of the operation.

Baer, in his technique, first scrubs the place of operation, using potassium permanganate, oxide, and bichloride of mercury, ether, and alcohol. The incision is made parallel to the zygoma and along its lowest border; the fibers of the external pterygoid muscle are separated and the temporal muscle retracted forward. He then cuts through the periosteum of the ramus of the inferior maxillary bone and exposes the condyle. This is separated from the ramus and the temporal bone. The bones are shaped and a cuff of membrane sewed to the periosteum of the bone. The muscle is brought together and sewed, and the wound is closed. After 2 weeks the patient is encouraged to use his mouth, and movements are regulated by graduated corks.

An arthroplasty, using Baer's membrane, was reported by Osgood (131), in 1911, for complete bony ankylosis of the jaws of 2 years' duration. A slight pus discharge made necessary an incision and the removal of the membrane. Four months after the intervention the motion was good.

Neff (122) used a curved incision beginning in front of the tragus and carried up over the zygoma. Fascia was stripped from the zygoma subperiosteally. The condyle was separated from the glenoid fossa and the joint mobilized. A flap from the temporal fascia or masseter was sutured to the capsule on the inside.

Putti (145, a), in 1913, reported three jaw arthroplasties. In operation, he used Abbe's incision, resected enough bone to allow opening the jaw and interposed a free flap of fascia lata 6 by 8 centimeters, taken from the base of the great trochanter. In the post-

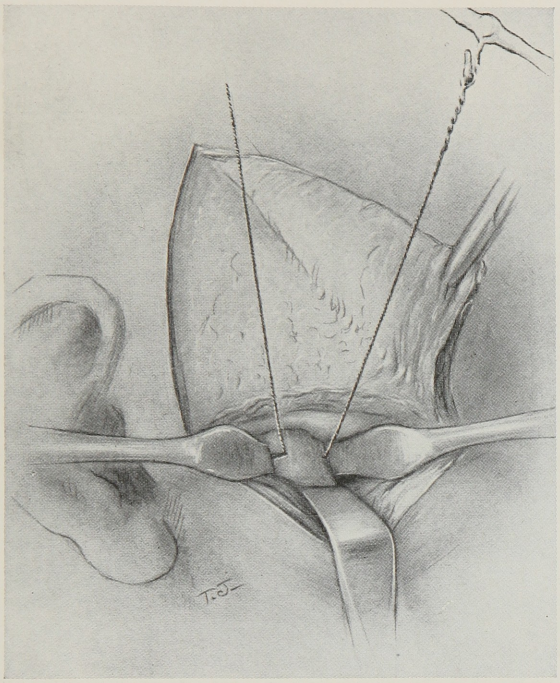

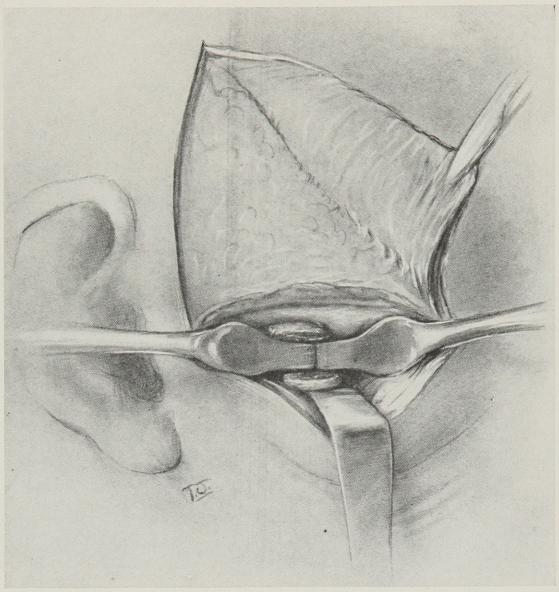

Fig. 89. Dividing the neck of the mandible with the Gigli saw. In actual operation the saw is not allowed to make so acute an angle as shown in the illustration, because of its great tendency to break when sharply bent. (Murphy.)

Fig. 90. The neck of the mandible has been divided, the cut ends of the bone separated by traction on the lower fragment and space thus provided for the interposing fascia and fat flap. The curved periosteal elevators still protect the internal maxillary artery from trauma. (Murphy.)

operative treatment, the passive exercises are regulated by means of wooden wedges.

Four months after intervention in the first case of total bilateral ankylosis of blennorrhœal origin, the patient had nearly normal motion. The after-treatment had been neglected, which accounted for lack of complete mobility. In 1 month after operation in the second case of complete congenital ankylosis of the right temporal jaw, the child could open his mouth to allow a space of 2.5 centimeters between the incisors. The third case, one of complete ankylosis between the condyle and glenoid on the left side, showed in 1 year the ability to open the mouth fully.

Blair (18), in 1914, found a flap of subcutaneous temporal fascia admirably adapted for interposition. His incision was almost completely within the hair line. Enough bone was removed to leave a space 0.5 inch wide. The immediate result was 0.75 to 1 inch opening, and this, by the use of a rubber bottle-stopper, was increased further.

Carr (28), in 1917, obtained three good results, using a modification of the Murphy method. He was unacquainted with the Murphy process at the time, but he would use it on future cases. In 18 months one patient, who had had complete fixation for years, could separate his teeth 1.25 inches. The second patient, in 3 weeks, could open and close his mouth without discomfort, and the third patient could eat in 3 days, as the muscles had not been greatly contracted.

The same year Prando (142) applied the Murphy method in a case. Although it became gangrenous, the case turned out well and the patient can open his mouth and talk clearly.

Henderson and New (81), in 1918, tabulated twenty-three cases of ankylosis of the lower jaw operated on in the Mayo Clinic during a period of 8 years. They divided the ankylosis into articular, extra-articular, and articular-extra-articular types, depending on the location of the fixation. Fifteen cases were articu-

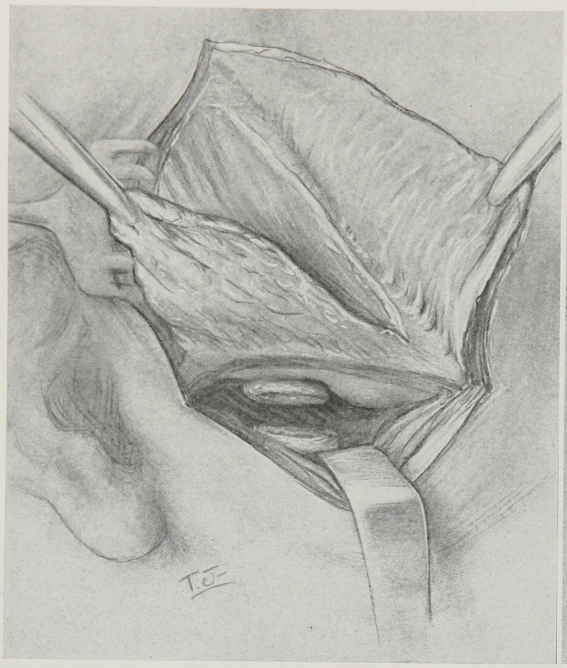

Fig. 91. The pedicled fascia and fat flap is dissected from temporal fascia and free end of flap is turned inward between divided ends of mandible and sutured securely in place with tacking stitches. (Murphy.)

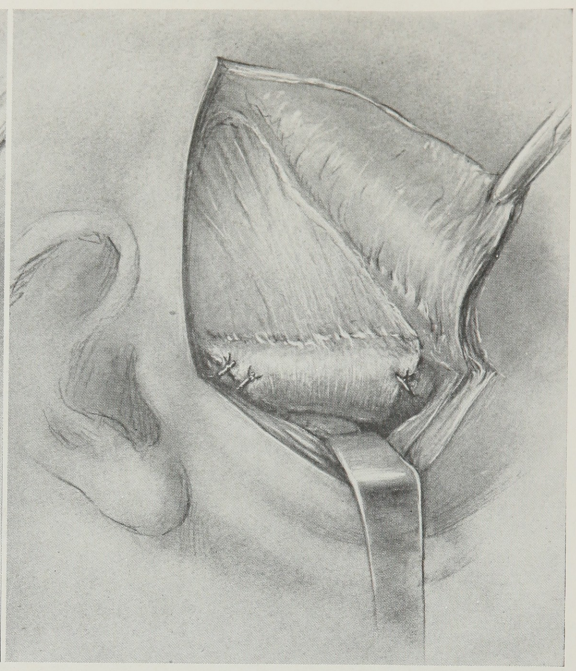

Fig. 92. The flap is now in place and the wound ready for closure. (Murphy.)

lar, five extra-articular, and the remainder articular-extra-articular. The average age of the patients was under 10 years. Excision was the basic principle of each operation, and no interposing substance was used.

The fifteen cases did well, and from 1 inch to 1.75 inches separation was obtained. In the extra-articular types the best results were secured by forcible stretching. In the articular-extra-articular type the scarring of the muscles prevented wide separation, but all the patients secured an opening of an inch.

Douglas (54), in 1919, operated for complete bony ankylosis of the left temporomaxillary joint. A horizontal incision was made just above the zygoma, the bones were separated and a flap of the temporal fascia with overlying fat interposed. The final result was excellent, although after-treatment was not carried out.

Woolsey (198) also did a similar operation and obtained a good result. He kept the jaws apart for some time after the operation.

Kerr (99), in 1920, cited four successful cases. One patient could open his mouth one-sixth inch and the second one-fourth inch. A curved, L-shaped incision was made, beginning 2 inches above and 0.5 inch in front of the ear and down to the external auditory opening, then anteriorly for 1.5 inches. The facial nerve was avoided. The condyle of the mandible was sawed off with a chain saw and a flap of temporal muscle inserted. Both patients can masticate normally. The third patient, suffering from fibrous and bony ankylosis of both joints of the mandible, with contractions of the periarticular muscles and fascia, after operation could masticate solid food. He had to guard against muscle contractions. Fourth patient after operation could open her mouth normally and masticate food.

Ritchie (152), in 1920, emphasized the importance of the after-treatment in the form of continual motion during waking hours, and wearing a rubber gag at night. He reported two cases using flaps of temporal muscle. In one case the flap was cut too short and pulled off when applied as a free flap. It was ex-

truded on the fifth day. In the other case the flap was cut large enough. The end-results of both cases were equally complete.

Chubb (34), in 1920, reported a method which he had found very successful. He divided the operation for ankylosis of the jaw into two groups according as the bone is resected from the region of the condyle or from the horizontal ramus.

The bony or fibrous ankylosis in the five cases he described was between the anterior border of the coronoid and the pterygoid aspect of the maxilla. Four cases were traumatic. One was infective in origin, and followed a bilateral suppurative arthritis of the temporomandibular joints in infancy.

In operation, the incision started in the preauricular fold at the lower level of the external auditory meatus, passing vertically upward to the level of the tip of the pinna, and curving forward below the superior temporal crest to terminate anteriorly within the hair region. The zygoma was exposed and the necessary bone removed piecemeal. The whole coronoid process was removed.

In the case of infective origin of 15 years' standing, the condylar neck region and coronoid of the left and right sides were resected. The operation was completed by a flap of temporal fascia and muscle.

The result in all cases was a gap of at least 2.5 centimeters and a very satisfactory power of mastication.

Imbert (95), in 1921, emphasized regulating the dimensions of the incisions for ankylosis of the jaw by the crossing of the facial nerve on the neck of the condyle. The upper extremity of the incision should be about 2 centimeters above the most prominent part of the tragus. The resection of the condyle is made by means of scissors and is at least 0.5 centimeter in height. He recommended the interposition of soft parts.

Dufourmentel and Darcissa (55), in 1921, presented two cases. In one, of complete temporomaxillary ankylosis of gonococcic origin, the thickness of bone was destroyed and a piece of rubber inserted. Their special apparatus was used in the after-treatment. Three months after the operation, the power and amplitude of the jaw was normal. A second case, using a muscular aponeurotic flap, failed; resection, with no interposition of rubber, resulted in a normal joint.

Bockenheimer (19), in 1922, used an incision behind the ear in freeing bony ankylosis of the jaw, of inflammatory origin. After resection, a flap of fat and fascia was interposed. In 15 months the patient could open her mouth normally. This incision had the advantage of avoiding the facial nerve and of hiding the scars.

Gilpatrick (69) recently (1922) reported a severe case of ankylosis of the jaw very similar to a case reported by Murphy. The patient had had almost complete ankylosis of the inferior maxilla for 14 years as a result of scarlet fever, complicated by an infection of both mastoids. The food had to be macerated in the plate and the boy could talk only through clenched teeth.

The right side was attacked first in operation. An incision 1.5 inches long was made in front of the right ear from a point 0.5 inch below the zygoma upward. All new bone was removed. The jaw could then be opened so that the left side was not touched. A flap of fat and fascia from the skin anterior to the original incision was interposed. In 10 days the patient could eat.

SHOULDER

The shoulder joint is rarely the seat of troublesome ankylosis. The mobility of the scapula replaces the lost motion, especially when ankylosis has occurred in the position of election; that is, abduction of 50 degrees to 70 degrees and flexion of about 15 degrees to 20 degrees forward of the frontal plane, in which position the shoulder function closely simulates normal. (Figs. 93 and 94.)

No arthroplastic measure can be considered in the absence of the deltoid muscle.

The first arthroplasty of the shoulder was reported by Nélaton (123), in 1903. The operation was done by Caville. A four-inch incision was made below the clavicle, passing externally to the coracoid process, down along the arm following the fibers of the deltoid. The head of the humerus was divided at the level of the anatomical neck. A piece of deltoid obtained by a transverse section was interposed between the surface of the humerus and

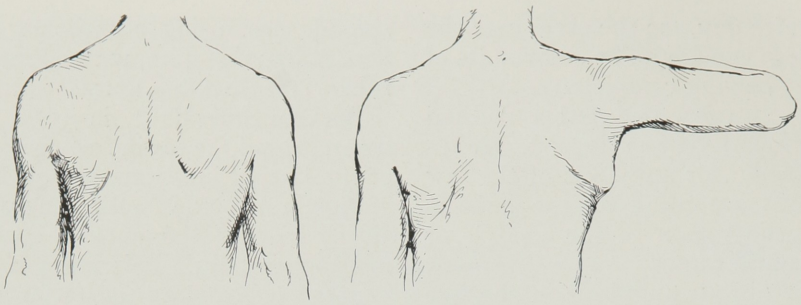

Fig. 93 (at left). Ankylosis of shoulder. Position of rest; note rotation of scapula with full rest position of arm.
Fig. 94. Ankylosis of shoulder. Full abduction obtained by rotation of scapula.

the glenoid cavity. A counter-incision was made at the same level and a thread passed through the opening, surrounding in loop form the extremity of the muscular strip. By tightening, the muscle was applied in the articular cavity. The result was good; there was passive motion in 3 days. The patient can sew. Abduction is limited.

Hofmann (87, b), in 1908, used periosteal transplants rom the tibia. The results were excellent; 1 year after the operation the rotary movements were almost normal. There was active abduction with fixed scapula up to 45 degrees, after which the scapula moved with the arm.

Ochsner (125), always conservative in advising arthroplasties in ankylosis with deformity, makes a vertical incision over the middle of the deltoid muscle, and separates the fibers by the Kocher dissector. A vertical incision is made in the capsule to expose the head of the humerus. This is severed by cutting the neck with a chain saw. Strands of silkworm gut are inserted for drainage. The arm is bandaged snugly to the side and the forearm placed in a sling. He has not found it necessary to use a fascial flap. All of his patients, within a few months, have been able to use the arm as before ankylosis; they can comb their hair, etc.

In the treatment of ankylosis without deformity, in the finger, ankle, shoulder joint, or wrist, Ochsner does not consider arthroplasty indicated. In the knee, elbow, and hip, the subject is debatable. On the knee, he uses the resection method; on the hip, subtrochanteric osteotomy; and on the elbow, force only. He commends the Murphy method.

Neff (122) believed that operation in the shoulder is rarely indicated, as the scapular muscles provide good function. In case of intervention he advised reaching the joint through an incision 3.5 inches long, extending from the base of the coracoid and on a level with it, down on a line with the bicipital groove. The cephalic vein serves as a guide. The greater tuberosity is divided by means of a Gigli saw and retracted upward. The remainder of the operation is like that on the hip. Fascia or capsule may be used as flaps.

Murphy (120, e) did not report an arthroplasty of the shoulder, but in 1913 he outlined his technique on the cadaver as follows: The skin and deltoid are split and the fascia separated along the anterior margin for 4 inches. It is then elevated to expose the coracoid process with the head of the biceps and coracobrachialis. The process is divided three-fourths inch from the tip and displaced outward. The ankylosis is chiseled between the glenoid fossa and the head of the humerus, and an additional excavation of the glenoid fossa made. An incision at a right angle to the original incision is made across the chest, over the middle pectoralis major muscle. A flap of fat, aponeurosis, and pedunculated muscle is placed between the head of the humerus and the glenoid fossa. The anterior portion of the deltoid may also be used as a flap.

W. L. and C. P. Brown (23), in 1914, reported the use of a portion of the short head of the biceps for the interposed flap. It is located correctly anatomically and covered with a tendinous sheath; its attachment to the coracoid process gives the pedicle the right

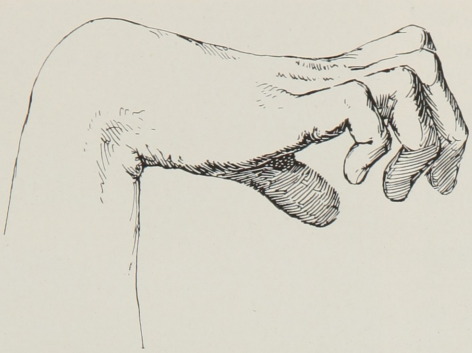

Fig. 95 (at left). Ankylosis of wrist. Position of weakness (flexion); note compensatory contraction of phalanges.
Fig. 96. Ankylosis of wrist. In position of strength, a most important factor in all wrist cases.

location. An incision in the shape of a reversed "S" is made from the junction of the middle and outer thirds of the clavicle, forward and downward below the acromion process. The muscle fibers of the sulcus should be separated, coming down directly on the tendinous attachment of the inner head of the biceps. The tendon of the pectoralis major should be transfixed with a linen thread and then cut loose from the humerus; the attachment of the inner fibers of the deltoid is transfixed and severed from the humerus, which will facilitate its retraction. The forefinger of the left hand is passed beneath the inner head of the biceps, separating it from the coracobrachialis and then its sheath and fibers cut across 4.5 inches below its attachment at the glenoid cavity. About one-half the muscle, of fan-shape, 4.5 by 3.5 inches, is taken. The capsule of the joint is opened and the head of the humerus is separated from the glenoid fossa, preserving the head of the biceps if possible. Enough capsule is removed to mobilize the joint. The flap is drawn in place by three No. 1 chromicized catgut sutures, guided by the finger. If the capsule allows good motion, it should be sutured; otherwise, it should be free. If the pectoralis major has contracted, it should not be re-attached to the humerus unless it is lengthened.

The arm is put in a cast at right angles to the body with the forearm flexed, if the head of the biceps is severed. The cast is removed in 10 days.

The case of infectious origin on which the operation was done resulted in perfect motion. The patient, a carpenter, resumed his trade in 6 weeks. There was some restriction of the arc of motion because of periarticular contraction, but 2 years after intervention the patient had practically recovered the arc of motion.

Ringel (151) demonstrated a case, in which there had been a complete shattering of the shoulder region, treated by freeing of the joint and interposing a pedunculated muscle flap from the deltoid. The immediate result was so good that the patient returned to the army. Later it was found that the flap had sloughed and new bone formed. In the second operation, a broad fat and fascia flap from the thigh was fixed over the humerus. Free motion in all directions was obtained; the arc of motion was limited because of the great atrophy of the deltoid.

Thomson (180) reported a case in 1917. He made an anterior incision, removed the greater part of the head of the humerus and stitched in a piece of fascia lata from the thigh. The limb was put in the position of right angle abduction. A sufficient range of movement was secured.

Verrall (187) believes he was justified in operating on a shoulder adducted and having a small degree of painful motion, as he did not jeopardize arthrodesis in a good position. He exposed the joint along the anterior border of the deltoid and dislocated the humerus

through the wound. The glenoid was hollowed into shape and three-fourths of the humerus removed. A flap of subcutaneous tissue from over the deltoid was turned over the glenoid. He does not report his result.

Grange (74), in 1920, did an arthroplasty for ankylosis of the shoulder joint in a slightly abducted position with a good deal of destruction of the head and great tuberosity. In the operation, an incision was made along the lower border of the clavicle and down the front of the arm for 3 inches; another was made just below the acromion process to meet the first, and a third was made along the lower border of the pectoralis major. This was divided where it crosses the axilla, and the anterior half of the deltoid was cut through 0.5 inch below the acromion process, and turned down. The short head of the biceps and coracobrachialis were then divided. The humerus was exposed and rounded, and a large flap of superficial fascia turned in from the surface of the pectoralis major. The wound was closed and the arm put up with the shoulder abducted 45 degrees. Active abduction to 45 degrees, flexion to 45, and 60 degrees rotation resulted. Passive abduction and flexion could be obtained to 90 degrees.

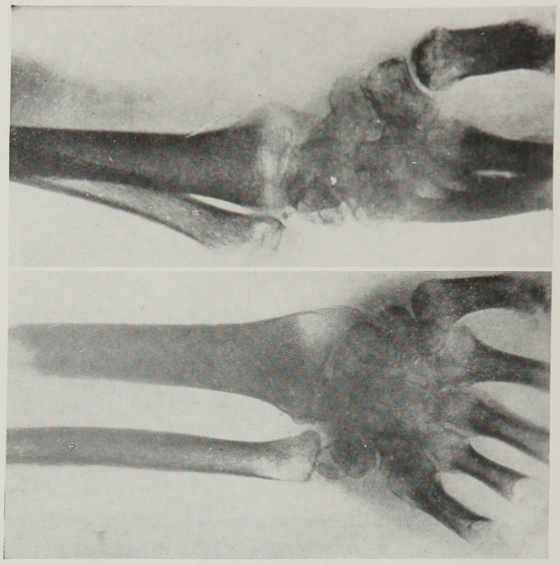

Fig. 97 (above). Case 1. E. M. Lateral roentgenogram showing ankylosis before arthroplasty.
Fig. 98. Case 1. E. M. Anteroposterior roentgenogram showing ankylosis before arthroplasty.

WRIST

For most purposes, a wrist ankylosed in hyperextension permits satisfactory function with undiminished strength in the fingers. (Figs. 95 and 96.) Occasionally, however, lateral and flexed motions are desirable, in which case mobilization may be attempted.

Only a few cases of arthroplasties of the wrist have been reported.

Hoffa (86) records a case done by Nélaton and Ombrédanne (124) in 1905. They resected the first row of carpal bones and interposed a tendon-muscular flap. The outcome was poor; ankylosis recurred in four months.

Hoffa (86), himself, did two wrist arthroplasties. In one he inserted a magnesium plate. A fistula resulted, which necessitated the removal of the plate; ankylosis recurred. In the other operation he resected the first row of carpal bones and inserted a fat and fascia flap taken from the proximal side of the wound. Two months after the operation, there was free motion of several degrees. Nine months later there was good mobility in the wrist and excellent function.

Stein (173), in 1907, in Bier's clinic, did an arch-shaped resection of the bones and interposed a muscle flap. In 2 years the passive motion was good, but the function was unsatisfactory, due to the patient's cutting the flexor tendons.

Baer (9, c), in 1909, reported a case of congenital union between the head of the radius and the ulna. Chromicized pig's bladder was interposed. Three months after the operation, supination was possible to 100 degrees, but a twist in the radius prevented it going farther.

Two more cases were cited by Baer (9, a) in 1918. One of congenital synostosis of the radial head and ulna, in which the animal membrane was used, gave voluntary motion of 110 degrees. Marked curvature of the radius made normal conditions impossible. The other case of bony ankylosis between the ulna and radius, when chiseled apart, gave 90 degrees supination and pronation.

L. Durán (57), in 1910, did an arthroplasty, using Baer's membrane. Painless mobility of about 50 per cent of normal resulted in 1 month.

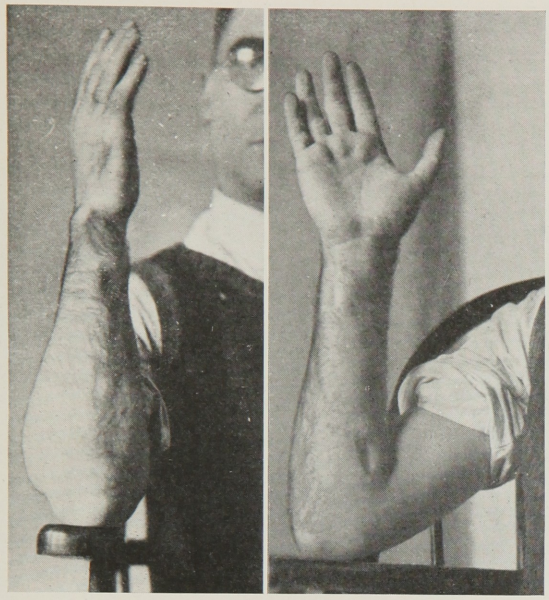

Figs. 99 and 100. Case 1. E. M. Ankylosis before arthroplasty.

Fig. 101 (above). Case 1. E. M. Anteroposterior roentgenogram after manipulation. (MacAusland.)
Fig. 102. Case 1. E. M. Lateral roentgenogram after manipulation. (MacAusland.)

Mention has been made of an arthroplasty by Whitman (193) in 1911, in which a section representing the first row of carpal bones was removed and the deformity corrected. The record is incomplete.

Neff (122), in 1912, outlined his technique of operation on the wrist: A convex incision with the convexity downward through the skin, on the dorsum of the wrist, extending from the ulnar to the radial side; division of the posterior annular ligament and retraction of the extensor tendons laterally; division of the capsule transversely, low down on the carpal bones and dissection of it upward, leaving it attached to the radius and ulna; resection of the first row of carpal bones in an arched direction with convexity upward; inversion of the posterior capsular flap between the articular surfaces. If there is not sufficient capsule a fascia lata flap or rectus aponeurosis may be used. The wound is sutured, and passive and active motion and massage begun on the eighth day.

Murphy (120, f), in 1913, reported three wrist arthroplasties. In one, of infection, an incision was made over the end of the radius on the back of the arm, and a flap of superficial fat and fascia interposed between the radius and the scaphoid. Limited motion resulted; ankylosis did not recur. The second case was that of a woman who had multiple arthritis of 6 years' duration. Elbows, ankles, knees, and hips were involved. On one wrist he made a longitudinal incision over the ulnar styloid process, dissected down on the ulna, and with an elevator separated the muscles, tendons, and arteries. Care was taken not to dissect the periosteum from the bones. A pedicled ulnar flap from the outer surface of the wrist was passed over the ends of the bones, and the tip was brought to the radial side of the joint, where it was fastened. A radial flap was interposed in like manner. The arm was dressed in slight anterior flexion and held in an elevated position.

Five weeks later, Murphy operated on the other wrist, the carpal bones and ulna and radius of which were completely ankylosed. Only a radial incision was made. The lower ends of the ulna and radius were resected about five-eighths inch to three-fourths inch. The division of the ankylosis was semicircular with concavity upward. A flap from the dorsum of the radial side of the forearm was interposed and fastened to the joint capsule on the ulnar side.

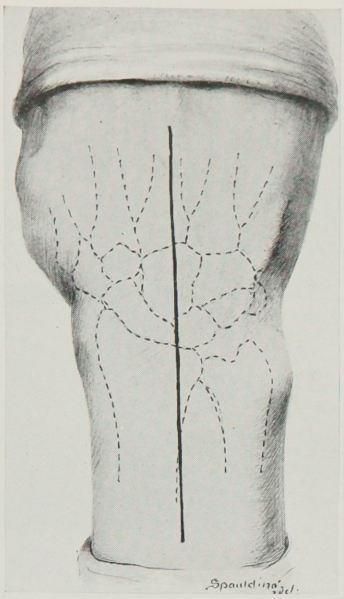

Fig. 103. Line of incision used in author's technique.

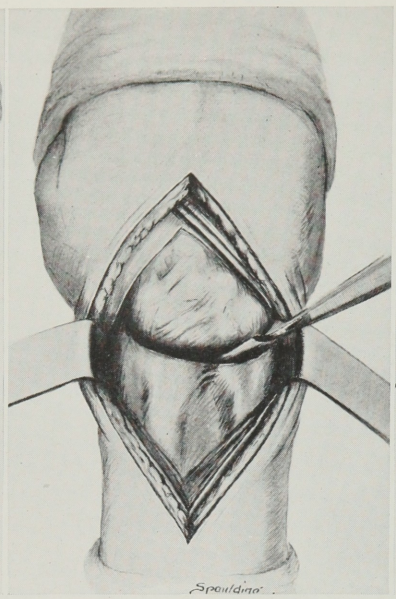

Fig. 104. Cutting out the joint line with curved chisel and removal of a small amount of bone.

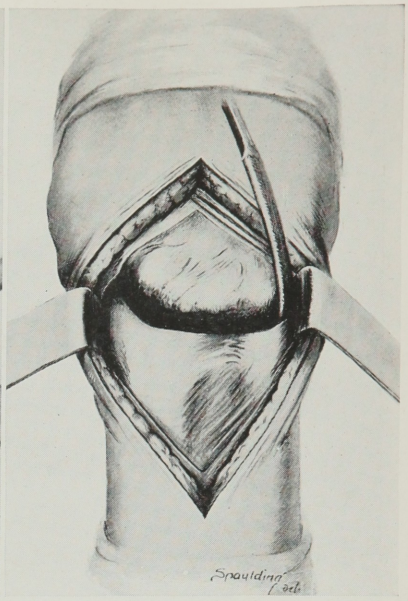

Fig. 105. Making convex and concave surfaces smooth with file.

The right wrist had an almost normal conformation; the left wrist luxated slightly.

In 1922 I did an arthroplasty in the following case:

Case 1. E. M. On May 12, 1922, patient fell through a pane of glass, cutting the right wrist. This was followed by infection, resulting in ankylosis in deformity of 25 degrees flexion. Scars from numerous incisions during sepsis were present.

When I first saw the patient, he had power in all tendon groups, but was unable to make a fist, and the wrist was ankylosed in 25 degrees flexion deformity. Roentgenograms showed considerable atrophy and periarthritic changes with some posterior displacement of the tip of the ulna (Figs. 97 and 98). Manipulation into the hyperextended position was done in August, 1922, and a plaster applied.

August 23, 1922. Patient could bend fingers. Use encouraged while in plaster.

September 25, 1922. Plaster cast removed and hyperextension splint applied. Baking and massage daily. Wrist in good position and, although motion of fingers had increased and the wrist was in hyperextended position, there was no wrist-joint motion (Figs. 99 and 100).

October 30, 1922. Roentgenogram shows ankylosis between the scaphoid, semilunar, and the end of the radius (Figs. 101 and 102). Arthroplasty of the wrist was advised.

November 7, 1922. Operation.

Operative technique—author's method. Posterior incision 5 inches long (Fig. 103). Skin and superficial fascia clamped off with towels. Incision then made over fascia and posterior ligament and both retracted. Common extensors retracted outward, and the extensors of the thumb were retracted inward. An incision was then made over the capsule of the old joint, which was carefully saved and retracted laterally. With a curved chisel the scaphoid and semilunar were separated by osteotomy from the radius. The lower end of the radius was re-shaped and made to approximate as near as possible the normal radial end. One-fourth inch of the carpus was removed and the carpus very carefully rounded to conform to the opposing radial end (Figs. 104 and 105). A piece of fascia was then removed from the outer side of the lower thigh of the right leg and sewed between these surfaces with interrupted chromic gut. It was sutured first to the anterior capsule of the joint, then to the posterior capsule, well over the head of the radius (Figs. 106 and 107). The old capsule of the joint was then closed with interrupted chromic catgut and the skin was closed with continuous catgut. The hand

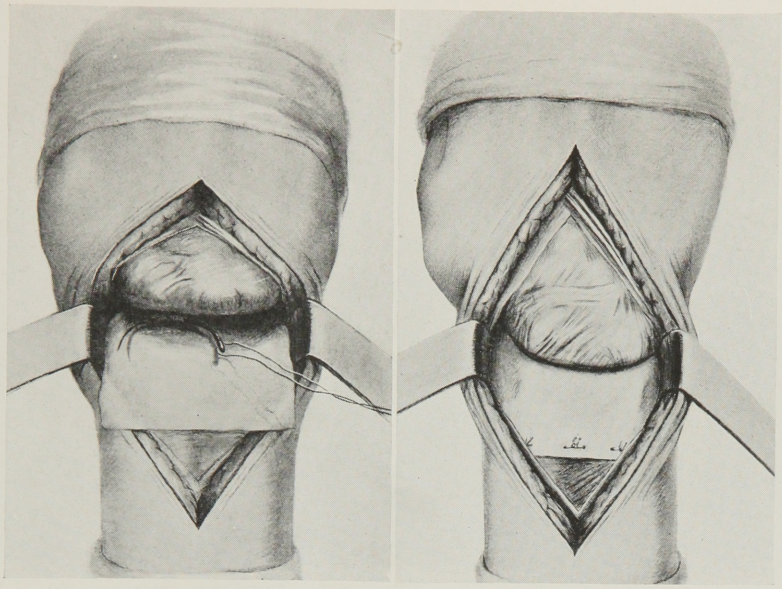

Fig. 106 (at left). Suture of fascia lata to anterior capsule.
Fig. 107. Suture of fascia lata to posterior capsule.

was placed in a cast in hyperextension. The plaster was allowed to remain on 3 weeks and then was split down the side and gentle passive motions begun (Figs. 108 and 109). Active motions were encouraged.

November 20, 1922. Treatment continued. There was no discharge. An X-ray showed separation between carpus and radius as a result of arthroplasty (Figs. 110 and 111).

November 27, 1922. Hand was in good condition. No pain, and use of the fingers had increased. Hyperextension splint applied. To have daily baking and massage with motion.

January 22, 1923. There was 10 degrees lateral motion in the wrist, hand flexion 5 degrees, hyperextension 35 degrees to 40 degrees (Figs. 112 and 113). The patient could almost make a fist. His inability completely to close fingers was due to the old sepsis involving the sheaths of the tendons. He has no pain and wishes to go to work.

I feel that the function will increase as time goes on.

FINGERS

Unfortunately, the phalangeal joints lend themselves poorly to plastic work, due to the fact that, in most cases, the injury which causes the ankylosis also damages the tendon sheaths and the tendons. As a result rapid and extensive atrophy follows, rendering the skin and subcutaneous tissue very delicate. So tender are all the structures with which the operator comes in contact that, even though he uses the best technique, he is baffled. Not until the metacarpal row is reached can the operator feel that the chances of success favor plastic work, and here only in the presence of intact tendons and sheaths.

In 1908, Hofmann (87, b) reported a case of fibrous ankylosis of two interphalangeal joints of the same hand, in which he interposed periosteal transplants from the tibia. Six weeks after the operation there was good passive but no active mobility.

Eloesser (60) secured a good result by implanting a finger joint from the cadaver.

Goebell (72) also obtained a good movable joint by implanting a toe joint in a finger resected for severe arthritis deformans.

Hammesfahr (78), in 1912, reported transplanting the joint of the second toe with capsule and ligaments between the proximal phalanx of the middle hand bone. The result has been very satisfactory; the patient can move the joint freely in all directions; there is only slight lack of bending ability.

In 1922, Oehlecker (126) reported good results, after 6 years, in transplanting the entire finger joints taken from the patients

ARMY MEDICAL LIBRARY
36163
WASHINGTON, D. C. U.S.A.

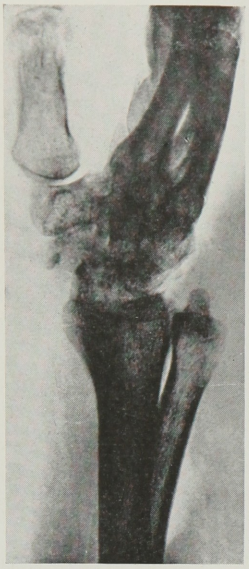

Fig. 108.

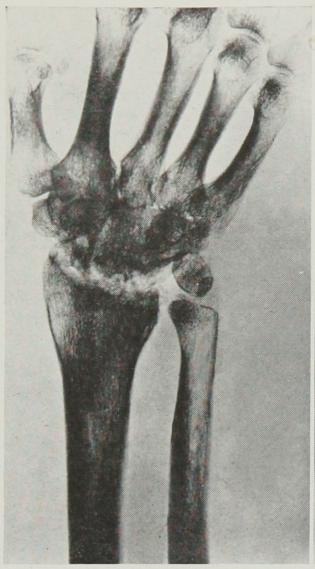

Fig. 109.

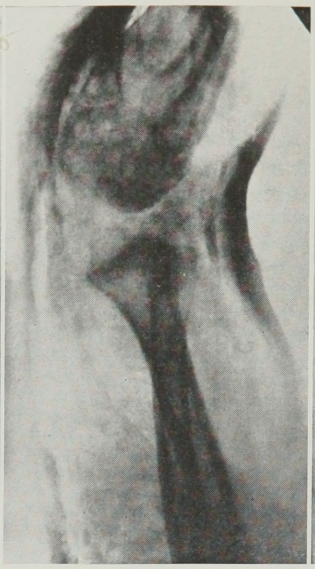

Fig. 110.

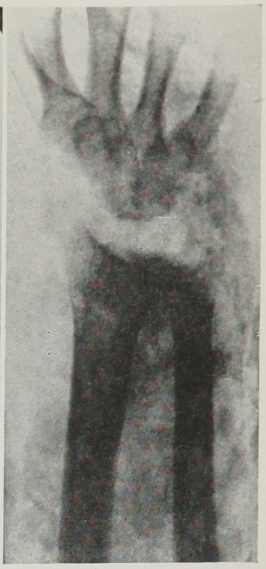

Fig. 111.

Fig. 108. Case 1. E. M. Lateral roentgenogram 2 months after arthroplasty.

Fig. 109. Case 1. E. M. Anteroposterior roentgenogram 2 months after arthroplasty.

Fig. 110. Case 1. E. M. Roentgenogram after arthroplasty. (In plaster.)

Fig. 111. Case 1. E. M. Roentgenogram after arthroplasty. (In plaster.)

themselves and from other persons. The results in the autoplastic cases were the better.

Roepke (156), in 1913, operated for finger-joint ankylosis and mentioned that he had success with free fat transplantation.

Payr (134, b), in 1914, recommended arthroplasty of the fingers, using pedunculated implants of flaps of tendon sheath from the palmar side of the hand. He reported two arthroplasties of the interphalangeal joints with favorable results.

Gallagher (67), in 1915, reported the result of an arthroplasty for traumatic bony ankylosis of a proximal interphalangeal joint of the fourth finger. He does not describe his method. In 2 months the patient could lift and carry on the joint 7.75 pounds. There was voluntary flexion to about 45 degrees and extension to about 170 degrees. He has devised a simple apparatus to give proper exercise to the joint.

Hamilton (77) reported success in arthroplasties on the phalangeal and metacarpophalangeal joints. The same principles are involved as in arthroplasty on the larger joints. The incision for all phalangeal joints is made parallel to the long axis of the finger. A mid-lateral incision is made on either side down to the capsular ligament. For metacarpophalangeal joints an incision is made at the junction of the posterior and lateral surfaces on either side. The bones are mobilized by sawing two nicks about one-sixth inch apart. All fragments of capsular ligament are removed. In the thumb he recommends the use of a free flap. Extension is applied by means of a splint and adhesive plaster. Passive motion is instituted after 2 or 3 weeks. A case is cited of virulent polyarthritis which left a man with bony ankylosis of the thumb joint and proximal phalangeal joint of the index finger of the right hand. Within 6 months after arthroplasty the patient was accepted as a naval recruit by the United States Navy.

Verral (187), in 1920, reported his belief that the proximal joints can be treated by arthroplasty, using free fascial graft. Metacarpophalangeal joints afford a good field; for the first, second, and fifth fingers enough subcutaneous tissues can be obtained locally; for the third and fourth fingers he used fascia lata. The flap is cut in a strip 3 inches by 1 inch, folded in half and sewed up into a bag which is slipped over the metacarpal head and secured by catgut.

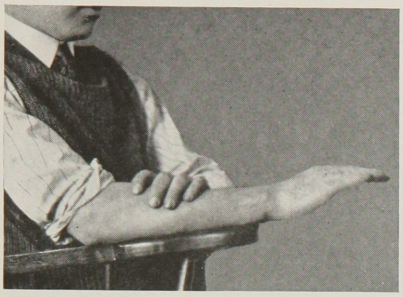

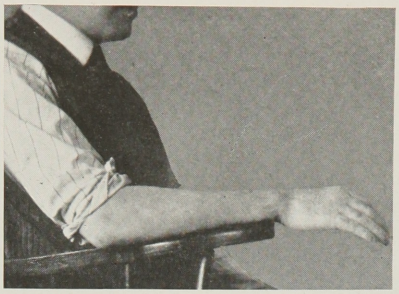

Fig. 112 (at left). Case 1. E. M. End-result 2 months after arthroplasty. Voluntary hyperextension 35 to 40 degrees.
Fig. 113. Case 1. E. M. End-result plantar flexion, 2 months after arthroplasty.

Hesse (84), in 1922, reported on fourteen cases of finger mobilization. On the middle joint, he made a lateral incision, resected the head of the basal phalanx after separation of the lateral ligaments. In two cases, a layer of periosteum from the tibia was placed over the resected end. In 10 months, one patient had complete working ability of the finger. In 3½ months, the other patient had active mobility of 120 degrees and normal extension. In the twelve other cases, free fascia lata transplantation was used. In ten cases, the patients were benefited, securing satisfactory mobility. In one case, the fascia sloughed and there was no betterment. In another case, there was shortening to about 2 centimeters, active motion in the basal joint 100 degrees, but no movement in the middle joint and strong lateral motion. In four of the cases, it was necessary to remove the fascia.

ANKLE

Ankylosis of the tibio-astragaloid joint, if at a right angle without varus or valgus, is a functional joint with which, in my opinion, we should not interfere. Although a weight-bearing joint may be obtained from arthroplasty, instability, pain, and sensitiveness may result.

In a slight ankylosis of the ankle in good position, there is only a slight limp. If, after experience in years to come, stability may be assured with an arc of motion without pain and sensitiveness, then and only then will arthroplasty be indicated.

Ochsner (125), in 1912, reported that in case operation was necessary for ankle deformities he used the resection method, removing the necessary amount of bone in a transverse line. His cases have been successful, and the patients can usually walk in 2 weeks. In case of severe ankylosis without deformity, he is opposed to arthroplasty.

Ashhurst (7), in 1915, cited the case of a boy with bony ankylosis of the right ankle, with the foot in a position of equinus at 140 degrees with the leg. There were deep scars on the leg and foot. Ashhurst incised down to the bone on the outer side of the tarsus from below the external malleolus to the extensor tendons. The soft parts were raised from the bones. Another incision 1 inch long was made on the inner side of the ankle joint in front of the internal malleolus and parallel to the tibia. The wounds were joined by burrowing. A wedge of bone, cut with its base on the dorsum of the tarsus and its apex at the posterior surface of the ankle joint, rendered the foot movable. Fascia lata from the left thigh was inserted. The result was free voluntary motion of about 10 degrees, with the foot not quite at a right angle. The hallux valgus caused extreme deformity.

A second operation was performed in which the head of the metatarsal was removed and the toe put in position. The tendon of abduction hallucis was inserted. The tendo achillis was lengthened by the "Z" operation. One month later there was free voluntary motion in the ankle from 85 degrees to 95 degrees and passive motion from 85 degrees to 110 degrees. Dr. Ashhurst looked for further improvement.

One would hardly feel that 10 degrees motion in an ankle warranted the attempt to mobilize it. An ankylosis, corrected into proper position, would be useful and mobili-

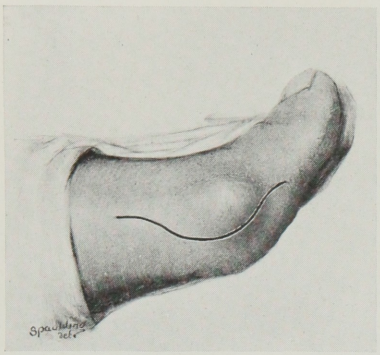

Fig. 114. Line of incision as used by author.

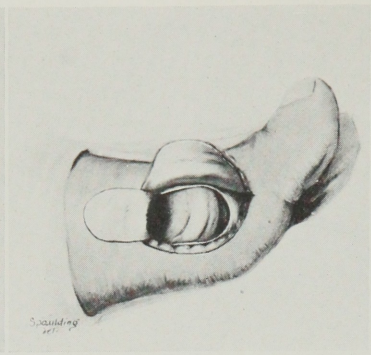

Fig. 115. Flap dissected back.

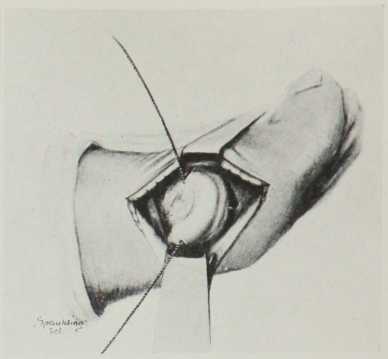

Fig. 116. Excision of small amount of bone.

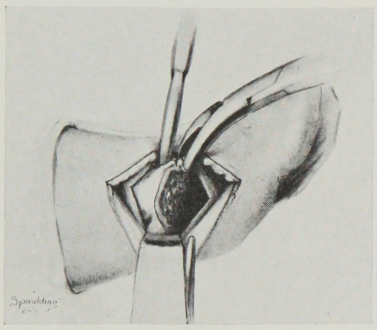

Fig. 117. Rounding of distal end of metatarsus.

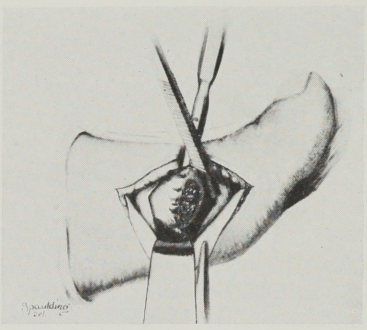

Fig. 118. Filing and smoothing of metatarsal shaft.

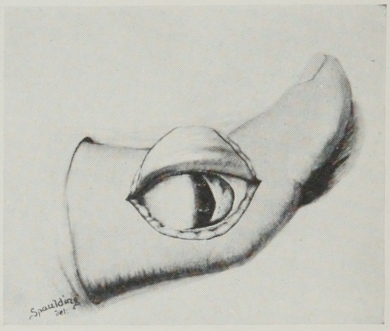

Fig. 119. Flap sewn in place.

zation might result in a sore and painful joint.

Steindler (174), in 1916, reported two cases in which pedunculated fascia flaps were used. One case was the result of a fracture of the astragalus and collum astragali, with supination deformity, and the other the result of fracture of the internal and external malleolus and impingement of the body of the astragalus on the fractured end of the tibia and fibula. No results were recorded.

Ceballos (30), in 1917, used a free flap of fascia lata in a case of complete tibiotarsal ankylosis in a right angle. No result is given.

Baer's (9, a) one case of arthroplasty on the ankle was reported in 1918. It is of interest, as a bone graft of fibula was inserted before the arthroplasty could be made. The membrane was inserted between the astragalus and the fibula. Voluntary motion of 30 degrees was obtained, and the patient walks with comfort.

Reich (150), in 1919, issued his views on arthroplasty of the ankle joint, which he considered one of the most satisfactory mobilizations. Observations were made in various cases operated upon, which showed that the desired 20 degrees to 30 degrees range of mobility was not obtained. This, Reich believed, was because in operation the tibia was again made concave and the astragalus convex. As the mobility attained by the natural joint is closely connected with the height of the astragalus over the posterior segment of the foot, the slightest diminution of this height interferes with the movement, for the margins of the concave plane of the tibia strike against the astragalus anteriorly and posteriorly. In arthroplasty a decrease in the height of the astragalus seems unavoidable.

Reich recommended an inversion of the natural form of the portions of the joint, making the surface of the tibia convex and the astragalus concave. The flaps of fat are laid

Fig. 120. Case 1. D. R. Anteroposterior roentgenogram 20 months after arthroplasty.

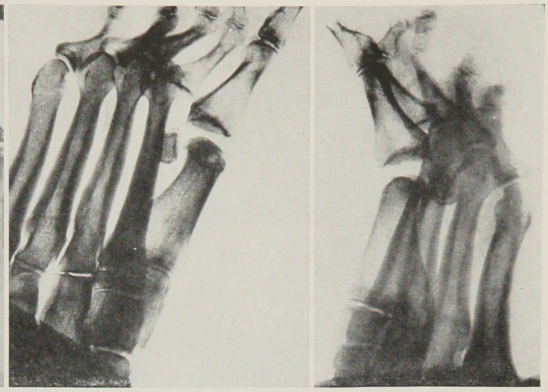

Fig. 121. Case 1. D. R. Lateral roentgenogram 20 months after arthroplasty.

between the surfaces. With this inversion, the axis of the joint mobility will be changed downward without the lateral ligaments being adapted to it, but this new mobility is not so much of the joint as of the rocking motion which furnishes a useful substitute for the former.

METATARSOPHALANGEAL JOINTS

The metatarsophalangeal joints, with the exception of the first metatarsophalangeal joint, never call for arthroplastic measures. These joints, in fact, are rarely stiff. The fascia-flap method gives an excellent result in the operation on the first metatarsophalangeal joint.

Operative technique—author's method. After thorough preparation of the part and the application of a tourniquet, an incision is made, beginning on the lateral aspect of the first phalanx and extending parallel to the shaft, curving to the lateral dorsal surface over the region of the joint and then back to the lateral aspect of the first metatarsal (Fig. 114). This flap is then dissected down and retracted with double hooks. A curved incision is then made through all remaining tissue, including bursa, capsule, and fascia. This incision begins near the base of the first metatarsal on the lateral plantar surface and sweeps about one-fourth inch over the base of the first phalanx to a corresponding position on the lateral dorsal aspect of the first metatarsal. The flap is dissected back, exposing the old joint (Fig. 115). About five-eighths inch of the head of the first metatarsal is then removed and all edges smoothed with a file or shoemaker's rasp (very important) (Figs. 116, 117, 118). A chromic suture is then passed from the plantar surface into the cavity and through the flap, making a mattress suture, and then the needle is passed through the cavity to the outer plantar surface and the flap firmly pulled into the cavity over the end of the metatarsal head (Fig. 119). The skin is closed with continuous catgut and a dry dressing applied. The toe is bandaged in inversion and slight plantar flexion, opposite to the usual deformity.

Weight-bearing is allowed in 2 or 3 weeks, at which time passive motion and hydrotherapy are of use. Activity depends upon the amount of swelling and pain, and motion is limited accordingly. The results of mobilization of the joint are excellent.

Case 1. D. R., age 45. In February, 1921, I operated for a case of double hallux valgus, using the technique I have outlined.

For years this patient had complained of increasing pain and stiffening in the toe joints. More recently she complained of loss of motion and enlargement of the joints. Physical examination showed a marked exostosis on the top and inside of both toe joints, with limited motion. Excision of the distal head of the first metatarsus and insertion of a bursal flap was advised.

February, 1921. In the operation 0.5 inch of the distal head of the first metatarsus was removed.

April 8, 1921. Good motion. Anterior arch padding. Subsequent convalescence without pain or swelling. Elastic cuffs advised.

November 17, 1922. Motion perfect. (Figs. 120 to 125.)

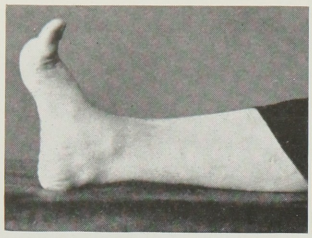

Fig. 122.

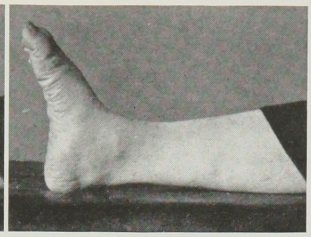

Fig. 123.

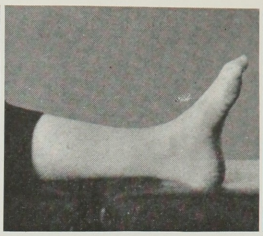

Fig. 124.

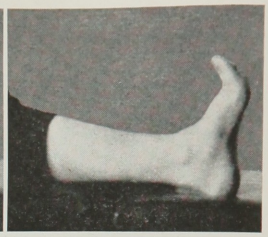

Fig. 125.

Fig. 122. Case 1. D. R. Toes of right foot in dorsi-flexion 21 months after arthroplasty.

Fig. 123. Case 1. D. R. Toes of right foot in plantar flexion 21 months after arthroplasty.

Fig. 124. Case 1. D. R. Toes of left foot in plantar flexion 21 months after arthroplasty.

Fig. 125. Case 1. D. R. Toes of left foot in dorsi-flexion 21 months after arthroplasty.

Murphy (120, b), in 1913, secured good motion in 18 days in a case of ankylosis of the phalangeal and metatarsophalangeal joints. Leucorrhœa of 4 years' duration had been the cause of stiffness. Murphy made an incision on the dorsum of the toe and used a flap of fat and fascia from the inner side of the foot with base upward.

In 1916, Murphy (120, b) outlined his operative technique for hallux rigidus as follows: A curved incision with convexity outward along the extensor tendon; incision of the tendon to elongate it; metatarsal head resected and bursal capsule used as the interposing flap.

Putti (145, a), in 1913, reported an arthroplasty on an ankylosed metatarsal phalanx of the hallux. He made a longitudinal cut on the internal side of the metatarsal phalanx, removed two large sesamoids that contributed to the stiffness, removed all capsule, and interposed a flap of fascia lata, wrapping the two surfaces. The extensor tendon was shortened. A plaster cast was applied to keep the hallux in a dorsal position. The postoperative treatment was regular. The stitches were removed on the ninth day, and gentle passive movement was begun.

BIBLIOGRAPHY

1. Ahrens. Muenchen. med. Wchnschr., 1908, iv, 2138.
2. Albarran. Cited by Hoffa, loc. cit.
3. Albee. Orthopedic and Reconstruction Surgery. 1918, p. 965.
4. Allison and Brooks. Surg., Gynec. & Obst., 1913, xvii, 645.
5. Ameyaga, G. de. Ann. Surg., 1907, xlvi, 617.
6. Appel. Deutsche Ztschr. f. Chir., 1916, cxxxvi, 508.
7. Ashhurst. Ann. Surg., 1915, lxii, 302; 378.
8. Axhausen, G. Beihefte z. med. Klin., Berl., 1908, iv, 23.
9. Baer. (a) Am. J. Surg., 1918, xvi, 170. (b) Tr. South. Surg. Ass., 1916, 1917, xxx, 126. (c) Johns Hopkins Hosp. Bull., 1909, xx, 271.
10. Baldwin. West London M. J., 1915, xx, 111.
11. Barton, J. Rhea. N. Am. M. & S. J., Phila., 1827.
12. Bazy. Bull. et mém. Soc. chir., Par., 1907, xxxii, 520.
13. Bérard. Dict. de méd., 1838, xxiii, 440.
14. Beresowski. Cf. Orlow, Deutsche Ztschr. f. Chir., 1903, xxxvi, 400.
15. Berger. Bull. et mém. Soc. chir., Par., 1901, xxix, 998.
16. Biermann, Karl. Die funktionellen Resultate der Gelenkresectionen mit besonderer Berucksichtigung der Methoden zur Erhaltung der Beweglichkeit. Dissertation, Berlin, 1909.
17. Bilczynski. Zentralbl. f. Chir., 1898.
18. Blair. Tr. South. Gynec. Ass., 1914, xxvi, 435.
19. Bockenheimer. Deutsche med. Wchnschr., 1922, xlviii, 729.
20. Bolognesi. Arch. internat. de chir., Gand, 1912–13, vi, 69.
21. Brandstrup. Hosp.-Tied., Københ., 1917, No. 27, 663.
22. Brown. California State J. M., 1916, xiv, 146.
23. Brown, W. L., and C. P. J. Am. M. Ass., Chicago, 1914, lxii, 1389.
24. Buchmann. Zentralbl. f. Chir., 1908, No. 19.
25. Burlew. California State J. M., 1918, xvi, 237.
26. Campbell. (a) J. Orthop. Surg., 1921, iii, 430. (b) Ann. Surg., 1922, Nov., 615.
27. Carnochan. Arch. de méd., 1860, p. 284.
28. Carr. Tr. South. Surg. Ass., 1917, p. 161.
29. Cavazzani. Gazz. d. osp., Milano, 1899, p. 37.
30. Ceballos. Prensa méd. argentina, Buenos Aires, 1917, iv, 400.
31. Ceccarelli. Riforma med., Napoli, 1917, xxxiii, 1173.
32. Chaput. (a) Bull. et mém. Soc. chir. Par., 1912, n.s., xxxviii, 452. (b) 1915, xli, 1540.
33. Chlumsky. Zentralbl. f. Chir., 1900, xxvii, 921.
34. Chubb. Brit. M. J., 1920, i, 256.
35. Cifuentes. Rev. de espec. méd., Madrid, 1909, xii, 73.
36. Clark. Med. Press. & Circ., Lond., 1914, n.s. xcvii, 30.
37. Conrad. Dissertation, Kiel, 1912.
38. Corner. Med. Press. & Circ., London, 1913, n.s. cxvi, 723.
39. Cotton. Surg. Clin., North America, 1922, ii.
40. Cramer. Arch. f. klin. Chir., 1901.
41. Crosti. Atti d. Soc. lomb. di sc. med. e biol., Milano, 1916–17, vi, 48.

42. Czerny. Arch. f. klin. Chir., 1872, xiii, 227.
43. Darling. Physician & Surg., 1913, xxxv, 71.
44. Dartignes. Rev. d'orthop., 1900, xi.
45. Dautrelpont. Arch. f. klin. Chir., 1868, ix, 917.
46. Davis. Johns Hopkins Hosp. Bull., 1911, Oct.
47. Defontaine. Rév. de chir., 1887, No. 9.
48. Delagenière. Bull. et mém. Soc. de chir. de Par., 1917, xliii, 2195.
49. Delbert. Gaz. méd. d. Par., 1912, lxxxiii, 117.
50. Delbet. (a) Bull. et mém. Soc. de chir. de Par., 1903, xxix, 1172. (b) Ann. de la Policlin. de Par., 1912, xxiii, 284.
51. Denk. Arch. f. klin. Chir., 1912, xcvii, 458.
52. Deutschlander. Soc. des chir. de l'allemagne du sud-ouest, 1911, Nov.
53. Diel. Gaz. d. hôp., Par., 1913, lxxxvi, 1727.
54. Douglas. Ann. Surg., 1920, lxxii, 636.
55. Dufourmentel, L., and Darcissa. Bull. Soc. de pédiat. de Par., 1921, xix, 62.
56. Dupuy. Thèse de doct., Toulouse, 1903.
57. Durán, L. Rev. Ibero-Am. de cien. méd., Madrid, 1910, xxii, 366.
58. Durante. Trattado di Medicina Operatoria di Durante e Leotta, vol. ii, Chirugia degli Arti, 113.
59. Edmunds. Med. Press & Circ., 1912, xciv, 574.
60. Eloesser. California State J. M., 1913, xi, 485.
61. Ely. Bone and Joint Studies. Leland Stanford Junior Univ. Publications, 1916.
62. Exner. Wien. klin. Wchnschr., 1913, xxvi, 1821.
63. Ferguson. Med. Times & Gaz., 1861, i, 601.
64. Finochietto. Semana méd., Buenos Aires, 1918, xxv, 590.
65. Foederl. Prag. Ztschr. f. Heilk., xvi, No. 4. Zentralbl. f. Chir., 1896, No. 5.
66. Frisch, von. Wien. klin. Wchnschr., 1911, xxiv, p. 922.
67. Gallagher, P. J. Am. M. Ass., 1915, lxv, 1180.
68. Gilbert. Texas State M. J., 1915, xxxi, 226.
69. Gilpatrick. Boston M. & S. J., 1922, clxxxvi 374.
70. Gluck, Th. Deutsche méd. Presse, vii, 1.
71. Goddu. Boston M. & S. J., 1921, clxxxiv, 198.
72. Goebell, W. Muenchen. med. Wchnschr., 1913, lx, 356.
73. Graff. Deutsche med. Wchnschr., 1915, xli, 1502.
74. Grange, C. D'O. Lancet, Lond., 1920, ii, 554.
75. Greiffenhagen. St. Petersb. med. Ztschr., 1913, xxxviii, 93.
76. Hallopeau, P. Bull. et mém. Soc. de chir. de Par., 1920, xlvi, 1447.
77. Hamilton, G. Texas State J. M., Fort Worth, 1919, xiv, 353.
78. Hammesfahr. Deutsche med. Wchnschr., 1912, xxxviii, 390.
79. Harris. Texas State J. M., Fort Worth, 1913, ix, 213.
80. Helferich. (a) Verhandl. d. deutsch. Gesellsch. f. Chir., 1894, xxiii, 504. (b) Zentralbl. f. Chir., 1894, suppl., p. 35.
81. Henderson. Am. J. Surg., 1918, xvi, 30.
82. Henle. Dissertation A. Lesser, Tuebingen, 1898.
83. Herzberg. Dissertation, Berlin, 1913.
84. Hesse, E. Arch. f. klin. Chir., 1922, cix, Jan. 1.
85. Hessert. Surg. Clin., Chicago, 1918, ii, 129.
86. Hoffa. Ztschr. f. orthop. Chir., 1906, xvii, 1.
87. Hofmann. (a) Ztschr. f. orthop. Chir., 1906, xvii, 1. (b) Beitr. z. klin. Chir., Tuebingen, 1918, lix, 717.
88. Hohlbaum. Arch. f. klin. Chir., 1922, cxvii, 647.
89. Hohmann. Berl. klin. Wchnschr., 1918, lv, 222.
90. Hohmeier and Magnus. Verhandl. d. deutsch. Gesellsch. f. Chir., 1914.
91. Hoke and Andrews. Atlanta J.-Rec. Med., 1908, x, 132.
92. Hoerhammer. Muenchen. med. Wchnschr., 1917, lxiv, 1338.
93. Huebscher, C. Corres.-bl. f. schweiz. Aerzte, xxxi, 785.
94. Huguier. (a) Thèse de doct., Par., 1905. (b) Tribune méd. Par., n.s., 1909, xli, 197.
95. Imbert, L. Lyon chir., 1921, xviii, 572.
96. Judet. Recherches de chir. experimentale. Paris: Baillere, 1908.
97. Katzenstein. Berl. klin. Wchnschr., 1916, No. 24.
98. Kennedy. Tr. Roy. Acad. M. Ireland, Dublin, 1915, xxxiii, 223.
99. Kerr. Surg., Gynec. & Obst., 1920, xxx, 518.
100. Kirschner. Verhandl. d. deutsch. Gesellsch. f. orthop. Chir., X Kong., Berl., 1910, 222.
101. Klapp, R. Zentralbl. f. Chir., Leipz., 1909, xxvi, 1196.
102. Kleinschmidt. Muenchen. med. Wchnschr., 1919, lxvi, 520.
103. Kocher. Chirurg. Operations Lehre.
104. Koenig. Lehrb. d. Chir., 1894.
105. Kolazek. Beitz. klin. Chir., 1912, lxxviii, 155.
106. Kuettner. Beitr. z. klin. Chir., Tuebingen, 1911, lxxv, 1.
107. Kusnetsoff. Vrach. St. Petersburg, 1898, xix, 1275; 1311.
108. Lentz. Cong. franç. de chir., 1895.
109. Leriche, M. R. Lyon chir., 1921, xviii, 547.
110. Lexer. Surg., Gynec. & Obst., 1908, vi, 601.
111. MacAusland. (a) J. Am. M. Ass., 1915, lxiv, 312. (b) Surg. Clin., N. A., 1922, ii, 959. (c) Surg., Gynec. & Obst., 1921, xxxiii, 223.
112. Mauclaire. Bull. méd. Par., 1913, xxvii, 66.
113. McCurdy. Pennsylvania. M. J., Athens, 1914–15, xviii, 606.
114. McIlhenney. New Orleans M. J., 1901.
115. McKenna. J. Am. M. Ass., 1917, lxix, 891.
116. Meyer. Klin. Abend 18, October, 1895.
117. Meyer, O. Deutsche med. Wchnschr., 1909, xxxv, 1931.
118. Mikulicz. Verhandl. d. deutsch. Gesellsch. f. Chir., Berl., 1895, xxiv, 350.
119. Moszkowicz. Berl. Ztschr. f. Chir., 1917, cv, 168.
120. Murphy. (a) Tr. Am. Surg. Ass., 1904, xxii, 313. (b) Ann. Surg., 1913, lvii, 593. (c) Murphy's Clin., 1914, iii, 523, 1159. (d) J. Am. M. Ass., 1915, 851. (e) Murphy's Clin., 1916, v, 641, 189. (f) Tr. Am. Surg. Ass., 1913, xxxi, 67. (g) J. Am. M. Ass., 1905, xliv, 1479, 1573, 1671.
121. Narath. Zentralbl. f. Chir., 1896.
122. Neff. Surg., Gynec. & Obst., 1912, xv, 552; 592.
123. Nélaton. Bull. et. mém. Soc. de chir. de Par., 1902, xxviii, 687.
124. Nélaton and Ombrédanne. Rév. d. Orthop., 1905, 25, vi, 39.
125. Ochsner. Illinois M. J., 1912, xxxi, 596.
126. Oehlecker. J. Am. M. Ass., 1922, lxxix, 778.
127. Ogilvy. New York M. J., 1921, cxiv, 566.
128. Olivieri. Semana méd., Buenos Aires, 1917, xxiv, 127.
129. Ollier. Traite des resections et des operations conservatrices, etc., Paris, 1885.
130. Orlow, L. W. Deutsche Ztschr. f. Chir., Leipzig., lxvi, 399.
131. Osgood. Boston M. & S. J., 1911, clxv, 86.
132. Owen. Ann. Surg., 1914, lix, 426.
133. Painter. Canada Lancet, Toronto, 1912–13, xlvi, 332.

134. PAYR. (a) Deutsche Ztschr. f. Chir., 1914, cxxix, 341. (b) Arch. f. klin. Chir., Berl., 1914, cvi, 235.
135. PEREIRA. Brazil-méd., Rio de Jan., 1906, xx, 361.
136. PERTHES. Muenchen. med. Wchnschr., 1917, lxiv, 919.
137. PETRASCHEWSKAJA. Verhandl. d. wiss. Ver. d. Aerzte d. stadt Obuchow-Krankenh. in St. Petersburg, 22, 1913.
138. PETTIS. Physician & Surg., 1913, xxxv, 352.
139. PHEMISTER and MILLER. Surg., Gynec. & Obst., 1918, xxvi, 400.
140. PLUMMER. Surg., Gynec. & Obst., 1917, xxiv, 509.
141. POMPONI. Gior. di med. mil., Roma, 1912, lx, 418.
142. PRANDO. Prensa méd. argentina, Buenos Aires, 1917–18, iv, 399.
143. PRINGLE. Tr. Roy. Acad. M., Ireland, Dublin, 1915, xxxiii, 220.
144. PUPOVAC. Wien. med. Wchnschr., 1914, xxvii, 151.
145. PUTTI. (a) Arch. d. orthop., Milano, 1913, xxx, 1; 205. (b) Chir. d. organi di movimento, Bologna, 1919, iii, 627. (c) J. Orth. Surg., 1912, iii, 421. (d) Chir. d. orig. di movimento, Bologna, 1917, i, 1. (e) Arch. d. orthop., Milano, 1919, xxxv, 272. (f) J. Orth. Surg., Lincoln, Nebraska, 1920, ii, 530.
146. QUÉNU. (a) Bull. et mém. Soc. chir., Par., 1902, xxviii, 724. (b) Ibid., 1903, xxix, 112. (c) Ibid., 1905, xxxi, 622.
147. QUIGLEY, D. T., and STEVENSON, E. C. West M. Rev., Omaha, 1913, xviii, 137.
148. RECHET. VIII Cong. chir., Lyon, 1894; Arch. prov. Chir., 1896.
149. REINER. Deutsch. Ztschr. f. Chir., 1910, xiv, 209.
150. REICH, A. Zentralbl. f. Chir., 1919, xlvi, No. 6, 97.
151. RINGEL. Deutsche med. Wchnschr., 1916, xlii, 713.
152. RITCHIE. J.-Lancet, 1920, xl, 479.
153. ROCHER. J. de méd. de Bordeaux, 1920, i, 215.
154. ROCHET. Thèse de Fondet, 1895.
155. RODGERS. New York J. M. & S., 1840.
156. ROEPKE. Deutsche chir. Kong., 1913, 116.
157. ROEREN. Arch. f. Orthop., Muenchen. u. Berl., 1922, xx, 36.
158. ROSER. Zentralbl. f. Chir., 1886, p. 36.
159. ROVSING. Tr. XI North Surg. Cong., Gothenburg, 1916.
160. RYERSON. Surg. Clin., Chicago, 1917, i, 197.
161. SAYRE. A New Operation for Hip Joint in Bony Ankylosis. New York, 1869.
162. SCHANZ. Muenchen. med. Wchnschr., 1904, p. 2228.
163. SCHLOFFER. Deutsche med. Wchnschr., 1917, xliii, 1183.
164. SCHMERZ. Beitr. z. klin. Chir., Tuebingen, 1911, lxxvi, 261.
165. SCHMIDT. Khirurgia, Moscow, 1899.
166. SCUDDER. Boston M. & S. J., 1906, clv, 375; Ann. Surg., 1907, xlv, 297; 1908, xlvii, 711.
168. SEGALE. Beitr. z. klin. Chir., Tuebingen, 1913, lxxxi, 259.
168. SEXSMITH. J. Med. Soc. N. J., 1920, xviii, 333.
169. SIEVERS. Freie Vereinigung der Chirurgen Sachsens, Leipzig, x, 1912; Zentralbl. f. Chir., 1913, No. 23.
170. SILFVERSKIÖLD, N. J. Am. M. Ass., 1922, lxxviii, 856.
171. SIMON. Berl. klin. Wchnschr., 1914, li, 235.
172. SOURDAT. Méd. prat., Par., 1910, vi, 806.
173. STEIN. Dissertation, Bonn, 1907.
174. STEINDLER, A. J. Iowa State M. J., 1916, vi, 284.
175. SUMITA. Arch. f. klin. Chir., Berl., 1912, xcix, 755.
176. TAVERNIER. Lyon chir. 1920, xvi, 527.
177. TAYLOR. Pennsylvania M. J., 1912, xvi, 294.
178. TEXTOR. Wurzburg, 1843, viii, 4.
179. THOM, V. Deutsche Ztschr. f. Chir., Leipz., 1910–11, cviii, 424.
180. THOMSON. Edinburgh M. J., 1917, xix, 176.
181. TORREY. J. Michigan M. Soc., 1913, xii, 318.
182. TUBBY. (a) Am. J. Orthop. Surg., 1914–15, xii, 433; 377. (b) Med. Press & Circ., Lond., 1914, n.s. xcviii, 324.
183. TUFFIER. Soc. de chir. de R., 1901.
184. TURNER. Edinburgh M. J., 1914, n.s. xii, 433.
185. VAUGHAN. G. T. Surg., Gynec. & Obst., 1911, xiii, 80.
186. VERNEUIL. Arch. de méd., 1860.
187. VERRALL, P. J. Clin. J., Lond., 1920, xlix, 76.
188. VULPIUS. Muenchen. med. Wchnschr., 1914, Mar. 17.
189. WEGLOWSKI. Zentralbl. f. Chir., 1907, Apr. 27.
190. WERDE. Deutsche med. Wchnschr., 1916, xlii, 1287.
191. WHEELER, W. I. de C. Brit. J. Surg., Bristol, 1921, ix, 242.
192. WHITACRE. Lancet-Clin., Cincin., 1908, xcix, 424.
193. WHITMAN. Ann. Surg., 1911, liv, 860; 1916, lxiii, 503.
194. WIENER. Am. J. Surg., N. Y., 1911, xxv, 281.
195. WILLE. Norsk. Mag. f. Lægevidensk., Kristiania, 1911, ix, 40.
196. WOLLENBERG. Ztschr. f. aerztl. Fortbild., Jena, 1915, xii, 267.
197. WOLFF. Verhandl. d. deutsch. Gesellsch. f. Chir., 1882.
198. WOOLSEY. Ann. Surg., 1920, lxxii, 636.
199. ZELLER. Jahresk. f. aerztl. Fortbild., Muenchen, 1919, xii, Hft. 25.

NOTE.— Figures 56 to 63 and 87 to 92 are reproduced from the *Surgical Clinics of John B. Murphy;* Figures 64 to 67 from *Ann. Surg.;* Figures 42 to 53 from *Chir. d. org. di Movimento.*

Reprint from SURGERY, GYNECOLOGY AND OBSTETRICS, July, 1922, pages 35-41

RECURRENT DISLOCATION OF THE PATELLA

With Report of Sixteen Cases

By W. RUSSELL MacAUSLAND, M.D., Boston
Surgeon-in-Chief, Orthopedic Department, Carney Hospital
AND
ARTHUR F. SARGENT, M.D., Boston
Assistant Surgeon, Orthopedic Department, Carney Hospital

A NUMBER of factors play important rôles in recurrent dislocation of the patella. Trauma is unquestionably important and frequent in the initial displacement. It is less important in recurrences. There is an inward twisting at the knee together with a blow or pressure on the outer side of the leg, and associated with this is always a strong sudden contraction of the quadriceps muscle.

Recurrent outward displacement of the patella is a lesion peculiar to young girls during their growing period and tends to persist into adult life. Usually the first displacement occurs between the ages of 12 and 18 years and this initial displacement is more painful and disabling than subsequent ones. Injury and excessive knock-knee are the chief etiological factors. The displacement occurs with the strong contraction of the quadriceps muscle, usually early in the act of knee flexion, since in ten to twenty degrees' flexion, the femur easily rotates inward on the tibia and an exaggeration of the knock-knee takes place.

There is a long line of contributing factors which aid these recurrences. Among these are found so many common postural conditions affecting the knee joint that it seems improbable that they alone can be the exciting etiological factor. The most constant contributing factors are:

1. Heredity. Abnormal mobility and laxity of the knee, associated with poor general posture are occasionally hereditary peculiarities.

2. Weakness of the quadriceps extensor muscle with resultant laxity of structures about the knee joint.

3. Static defects. Knock-knee has been long associated with this lesion but the frequency of knock-knee and the infrequent number of slipping patellæ rather weaken this as a strong etiological factor. It is necessary that the outer ridge of femoral condyles be poorly developed. Probably all postural defects act as factors only secondarily through this associated developmental defect.

4. Flat feet give static strain on the inner side of the knee joint and may contribute that additional twist which aids displacement.

5. Elongated patella tendon with relaxed synovial membrane and capsule, both usually due to chronic synovitis. The distention of the joint causes stretching of all the retaining structures.

6. Imperfect development in size and shape of the patella in relation to the external condyle will allow the patella to slip more easily to the outer side.

7. Imperfect development in the size and shape of the external condyle is important. Graser (9) did a supracondylar osteotomy in one case in which he felt this faulty relation required correction.

That the external condyle is occasionally underdeveloped and does not thereby offer a bony resistance to the displacement, is acknowledged by Albee (2) who has used a bone graft to correct this anatomic defect, tilting the outer rim of patellar surface of the femur to block the lateral thrust of the patella.

Of the above lesions, the lateral tendon attachment and the faulty condylar development are the most constant pathological findings. Static defects and capsule relaxation are important in releasing the normal factors restraining displacement.

DIAGNOSIS

The patient usually makes the diagnosis, giving the history of (a) severe initial displacement, (b) recurrences, (c) constant fear

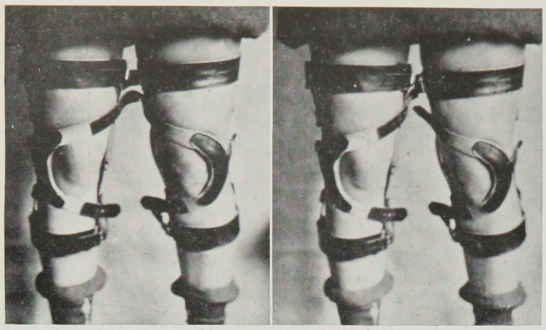

Figs. 1 and 2. Jones knee brace with pad attached.

lest displacement recur—with resultant inactivity.

The initial attack is most painful. The knee is flexed and the patella is found on the outer side of the condyle. Following reduction, expecially in the initial attack, an acute synovitis develops.

TREATMENT

A. *Acute attack.* The treatment of the initial attack calls for immediate reduction of the displacement. This can usually be accomplished by sudden extension of the leg with pressure of one hand against the outer condyle, pushing the patella to the median line. The injury calls for immobilization by means of plaster for 3 weeks, and were this done following the original injury recurrences would be less frequent.

B. *Recurrent attacks.* The treatment of recurrent attacks may be divided into (1) supportive, (2) stimulative, (3) correction of static errors, (4) operative.

1. Supportive treatment in the earlier attacks usually gives the patient confidence. This may be obtained by the use of a split knee cap with a crescentic pressure pad to aid in holding the patella in place or it may require a Jones knee brace with a pad attached (Fig. 1). These should not be used without stimulative treatment, and if used too long are apt to cause varicose veins and œdema of lower leg from constricting straps.

2. Stimulative treatment consists of (a) baking and massage, which will to a degree give tone to the relaxed ligaments; (b) exercises to strengthen muscles and ligaments and to develop postural strength.

3. The correction of static errors is most important. In many of these cases there is marked abduction of the feet (weak or flat feet). This should be corrected in all cases by the Whitman type of foot brace. This correction counteracts in a mild degree a moderate knock-knee. In spite of conservative measures, the knee frequently remains not dependable. In such cases operation should be considered.

4. *Operative methods.* The operative methods are (a) capsulorrhaphy, (b) transplantation of part of patella tendon, (c) transplantation of bony insertion of patella tendon.

Capsulorrhaphy. Alone this operation has been a distinct failure. In conjunction with other procedures, it might be used, provided the length of time of the disability has been such as to cause the inner capsule to relax markedly and secondary deformities to develop. The authors have never done this, however, either alone or in conjunction with the following methods.

Transplantation of part of patella tendon. In the early cases of the authors, this procedure was followed, all cases showing good results. The objections, however, are—

1. Twisting of half of the patella tendon, which, although bringing more tautness between outer side of patella and external condyle, is open to the danger that relaxation of this tendon may take place. In general, a muscle cannot function in two places at once.

2. Splitting of tendon, sewing and handling ends cause them to fray and make it impossible to secure a clean, firm anatomic attachment, whether subperiosteal or into a bony cavity. The patella tendon is surprisingly thin and, on account of this tendency to fray, it is almost impossible to suture. We have, therefore, come to use only the bony transplant operations.

Technique of transplantation of patella tendon (Figures 3, 4, 5, 6 and 7). Usual two-day preparation. Tourniquet.

A curved incision is made from the inner side of the patella well down over the attachment of the patella tendon (Fig. 3). The skin is clamped off with towels. The patella tendon is exposed to view. An incision is made

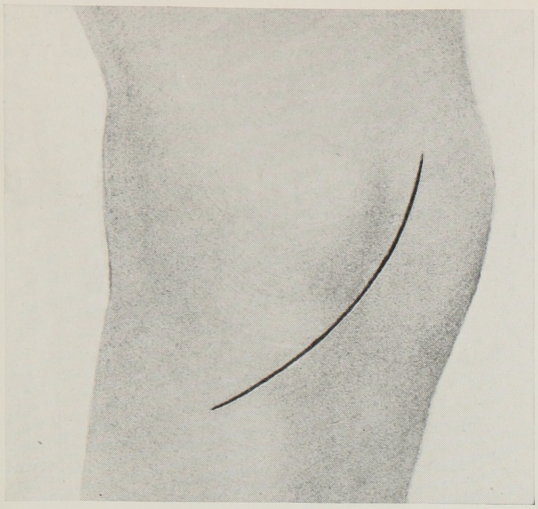

Fig. 3. Drawing showing line of incision.

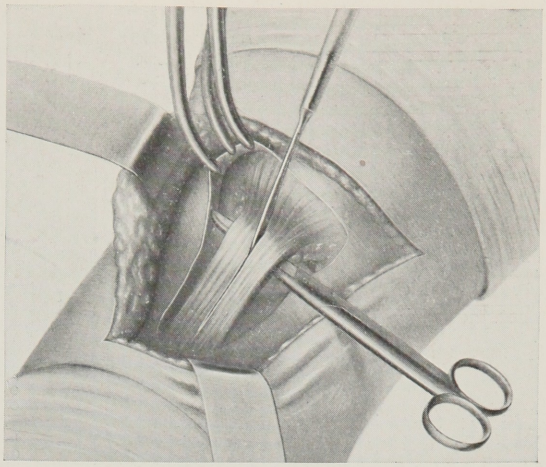

Fig. 4. Cutting outer half of patella tendon in slipping patella.

through the thin fibrous covering of the tendon which is then gently retracted and preserved as far as possible for resuture (Fig. 4). An incision through the center of the patella tendon is then made from the patella to the tubercle (Fig. 5), cutting it off at this point on the outer half. This half is then quilted with chromic catgut No. 3, turned in under the inner remaining half and sutured in a bony groove as far as possible to the inner side, on the inner face of the tibia (Fig. 6). The periosteum is then pulled over this insertion and the thin capsule pulled over these tendons (Fig. 7). The skin is closed with continuous catgut No. 2. Dry dressing is applied, followed by plaster from the toe to the groin. This plaster remains on for 10 weeks and is followed by gentle passive movements, baking and massage of thigh and calf, and increasing use. (See report of cases by authors, 1, 2, 3, 7, 8, and our cases 12, 14, and 15.)

Transplantation of the bony insertion of the patella tendon. (Figs. 3, 8, 9.) This procedure appeals from an anatomic standpoint as well as being practical and simple. The tendon is neither weakened nor traumatized. There is no suture through tendon and tendon strength is preserved. Results are excellent. (Cases from literature, 4, 8, our cases 13 and 16.)

Operative technique. Two-day preparation. Tourniquet.

A long curved incision is made halfway between the inner condyle and patella, curving over the tibial tubercle. The skin wounds are clamped off with towels, and the patella tendon with fascial covering is exposed. A light incision is made through the fascia from the inner border of patella to below the tibial tubercle; this covering is dissected, quickly clamped and retracted to right and left to be resutured later over the tendon. A wedge of bone the size of a thumb-nail is then removed, including the attachment of the inner half of the patella tendon. The patella tendon is split in half and a similarly symmetrical bony wedge removed from the inner surface of the tibia at a point that will take the tendon bone graft. The bony transplant is forcibly wedged into its new bed, the periosteum sutured with fine chromic gut, the light fascial covering resutured, and the skin closed with continuous catgut No. 2. Plaster is applied from ankle to groin and should remain on for 10 weeks. Following this, gentle motions, use, and massage should be conscientiously carried out.

CASE ABSTRACTS

Case 1. K. A., age 18, first seen March, 1915. The left knee cap had slipped out of place 3 or 4 years ago following injury to knee. Four months later while playing tennis "knee went out" again. Since then this has recurred at intervals. Physical examination was negative except for local condition. Any attempt to move left patella is received in a very

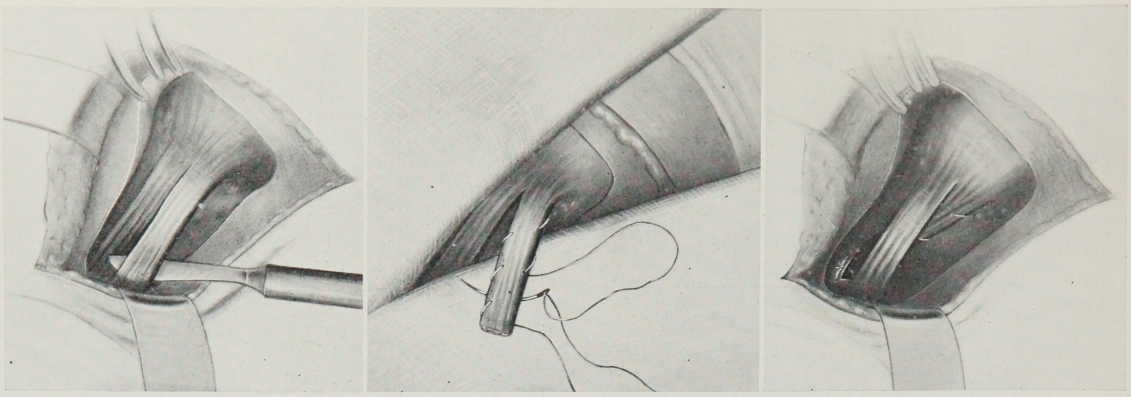

Fig. 5. Operation for transplantation of patella tendon. Note skin incision and the incision through the fascia covering tendon. Note longitudinal division of tendon.

Fig. 6. Running a line of silk sutures up and down the upper half of the patella tendon.

Fig. 7. Note the external half of the patella tendon has been sutured, passed under the internal half and is sutured subperiosteally. The wound is closed in the usual manner with continuous catgut suture.

apprehensive manner by the patient, especially when it approaches the external condyle. Slight pronation of both feet. X-rays of knee are negative.

Diagnosis. Slipping patella, and operation is recommended.

Operation. Transplantation of the outer half of the patella tendon into the periosteum of the tibia.

Result. Up to March, 1920 (5 years), there had been no recurrence. Perfect function.

CASE 2. Miss R., age 17, first seen August, 1912. Fourteen years ago patient fell against an oil stove and pushed the patella out. Since then this has slipped out at various intervals. Physical examination showed very relaxed capsule on the inner side. Any attempt to displace patella is very painful.

Diagnosis. Slipping patella, and operation is recommended.

Operation. Transplantation of the outer half of patella tendon into the periosteum of the tibia.

Result. Perfect function of knee. No recurrence to date (9 years).

CASE 3. T. K., age 23, first seen in April, 1918. About 5 years ago following an injury to the right knee, the right patella began dropping to one side. Has been treated with plaster casts, etc. Since the first attack the patella has slipped out seven different times. Physical examination was negative, except for local examination. The right knee is slightly swollen. All motions are limited and very painful. No surface heat.

Diagnosis. Slipping patella, and operation is recommended.

Operation. Transplantation of the bony insertion of patella tendon into tibia.

Result. Perfect function. No recurrence to date (3½ years).

CASE 4. I. H., first seen February, 1917. Since childhood has had a weak right knee which often twisted without warning, causing patient to fall to the ground, after which knee would be swollen and very painful. Following a fall, 3 years ago, right knee has been limited in motion. Physical examination was negative except for local condition. The right knee is swollen and tender. Patella approaches outer side of knee. Extension is normal, flexion is painful and limited. The patella slips to outer side of knee when knee is flexed. Some grating under patella on motion.

Diagnosis. Slipping patella, and operation is recommended.

Operation. Transplantation of bony insertion of patella tendon into inner side of tibia.

Result. Good function, no recurrence. January, 1921: "On the whole it seems to be greatly improved. There is no slipping of the knee-cap and, although it is somewhat weak and occasionally wrenches enough to throw me, it does not hurt as it used to and no swelling follows. I have a little more than half motion, but do not limp at all."

CASE 5. A. C., first seen June, 1911. Fifteen years ago patient fell through a piazza, striking on left knee. Since then has had attacks of patella slipping toward the outside of the knee, causing extreme pain and discomfort often lasting several hours. Last attack 2 years ago and since then knee-cap has been very loose. Physical examination shows left patella freely movable and can be carried well beyond median line on outer side.

Diagnosis. Slipping patella, and operation is recommended.

Operation. Capsulorrhaphy (by another surgeon).

Result. (?) Case has been lost.

CASE 6. W. T., first seen July, 1906. Four years ago patient fell, striking on the outer side of the left foot, bending the knee inward. After that the knee has often "given out from under him." Feels insecure and has been wearing knee-cap and bandage.

The patella tendon is loose and attached toward the outer side of the median line of leg. It is also tilted down to the outer side of the knee. The

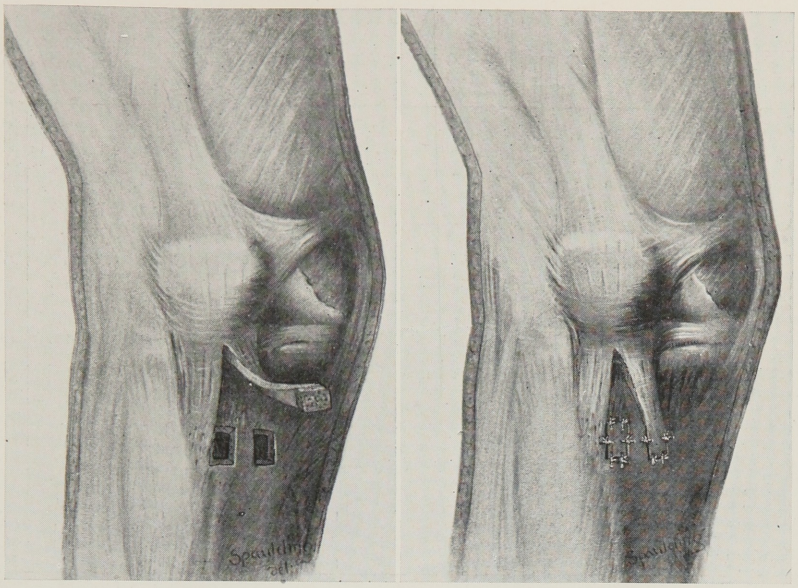

Figs. 8 and 9. Showing method of transplanting bony insertion of patella tendon.

internal condyle is prominent. The leg cannot be fully extended and there is slight crepitation under the patella.

Diagnosis. Slipping patella, and operation is recommended.

Operation. Transplantation of the outer half of the patella tendon into periosteum of tibia.

Result. Not satisfactory. Previous operation did not accomplish all that was desired so about 8 months later a rotation osteotomy was done just above adductor tubercle, the condyles being placed in their normal relationship. This operation resulted in normal function of the knee.

Case 7. B. D., first seen July, 1908. Knees have always turned in. Left knee has "given way under her" when walking. Has had several attacks during the last few years. Physical examination shows knees in semi-valgus position. There is also about 5 degrees' lateral mobility in full extension. Both patellæ are abnormally movable. The tibial tubercle is congenitally misplaced, being nearer the external edge of tibia than is normal.

Diagnosis. Slipping patella, and operation is recommended.

Operation. Transplantation of outer half of patella into periosteum of tibia.

Result. Immediate result good but patient has since disappeared.

Case 8. J. M., first seen November, 1904. About 12 years ago patient's knees began to "give way" from beneath her. The attacks came suddenly and she would fall. These occurred at intervals of weeks, always associated with swelling of the knee and "it always felt as if something came out from the inside of her knees." Physical examination was negative, except for local condition. Motions of knees are normal. On complete flexion, the patellæ move toward outer aspect of knee. Patient has a slight knock-knee.

Diagnosis. Slipping patella, and operation is recommended.

Operation. Transplantation of the outer half of patella tendon into periosteum of tibia.

Result. Normal function. No recurrence to date (17 years).

Case 9. Mrs. T. C. K., first seen March, 1912. Patient has had trouble with her feet for years. At the age of 10 years her left knee began to slip out at frequent intervals. Six years later her knee was operated upon by another surgeon, a reef being taken in the capsule. The knee remained well for 4 years when it began to slip out again in spite of the leather braces and knee-caps she had been wearing.

Diagnosis. Slipping patella.

Treatment. Capsulorrhaphy (by another surgeon).

Result. Failure.

Case 10. A. B., first seen August, 1915. About 19 years ago, left knee-cap slipped out for the first time. This has since recurred at frequent intervals. Four years ago, this knee was operated upon for this condition. Several hours (?) ago the patient tripped, fully flexing the knee. The patella was displaced laterally forcing the femoral condyles through the inner capsule, the tear being from the inner tuberosity and the front of the tibia. Patella tendon is intact.

Diagnosis. Recurrent dislocation of left patella and ruptured internal lateral ligament.

Treatment. Light plaster cast. Operation later.

Result. Good function.

SUMMARY OF AUTHOR'S CASES

No.	Name	Date First Seen	Original Injury	Static Defects	Treatment	Result	Remarks
1	K. R.	Mar., 1915	Slight trauma	Weak feet.	Tendon transplantation	Good	No recurrence
2	Miss R.	Aug., 1912	Dislocation of patella	?	Tendon transplantation	Good	No recurrence
3	T. K.	Apr., 1918	Contusion	?	Tendon bone transplantation	Good	No recurrence
4	I. H.	Feb., 1917	Twist	?	Tendon bone transplantation	Good	No recurrence
5	A. C.	June, 1911	Contusion	?	Capsulorrhaphy	?	
6	W. T.	July, 1906	Contusion	?	Tendon transplantation	Poor	Eight months later osteotomy done and condyles placed in normal relationship Good result then.
7	B. D.	July, 1908	None	Tibial tubercle misplaced outward.	Tendon transplantation	Patient lost track of	Immediate result good.
8	J. M.	Nov., 1904	None	Slight knock-knee.	Tendon transplantation	Good	No recurrence
9	Mrs. T.C.K.	Mar., 1912	None		Conservative capsulorrhaphy	Poor	This case previously operated upon by another surgeon and capsule reefed without improvement.
10	A. B.	Aug., 1915	None	None	Conservative	Good function	
11	Mrs T. S. M.	Oct., 1919	None	Flat feet	Conservative	No improvement	Operation later
12	E. H. T.	Oct., 1904	Contusion		Tendon transplantation	Good function	No recurrence
13	L. D.	Nov., 1919	Twist	None	Bone transplantation	Excellent	No recurrence
14	L. A. S.	Oct., 1911	Contusion		Tendon transplantation	Function normal	No recurrence
15	M. H.	Nov., 1908	None	None	Tendon transplantation	Function normal	No recurrence
16	Miss M. R.	Aug., 192c	Contusion	None	Bone transplantation	Function normal	No recurrence

Case 11. Mrs. T. S. M., first seen October, 1919. For the last 24 years both knee-caps have been slipping out. These attacks come on very suddenly and are very painful. The patient has been wearing supports for the knees. Physical examination shows both feet slightly flattened with a moderate hallux valgus. The patient is wearing very tight split knee-caps which are causing swelling of the lower legs.

Diagnosis. Slipping patellæ (double).

Treatment. Conservative. Operation later.

Result. No improvement. Refuses operation and still has recurrent displacements.

Case 12. E. H. T., first seen October, 1904. About 4 years ago, patient fell on knee and was confined to bed for a month with leg in splints. Two and one-half years ago she fell again, and remained in bed 2 months. Three months ago, she again fell and had to push patella back in place. Cast worn one month. Physical examination negative except for local condition. The entire musculature of the right leg is flabby and the power in this limb is considerably diminished. Both patellæ are more movable than normal.

Diagnosis. Slipping patella, and operation is recommended.

Operation. Transplantation of outer half of the patella tendon into periosteum of tibia.

Result. Function normal. No recurrence to date.

Case 13. L. D., first seen November, 1919. Five years ago patient twisted the left knee. Laid up a week. One year later fell again, this time striking on the right knee. A year later her knee slipped out five or six times, always accompanied by pain and swelling. Physical examination shows a moderate amount of fluid in the right knee and any attempt to push the patella to the outer side is very painful.

Diagnosis. Slipping patellæ, and operation is recommended.

Operation. Transplantation of the bony insertion of the patella tendon in tibia.

Result. No recurrence; excellent function; no subjective symptoms.

Case 14. L. A. S., first seen October, 1911. Nine years ago the patient injured the knee which became swollen and painful. Patient was unable to walk. Knee-cap has slipped out twice in the last 2 years. Physical examination shows patella unusually mobile. Can almost be thrown off to outer side with ease.

Diagnosis. Slipping patella, and operation is recommended.

Operation. Transplantation of outer half of patella tendon into periosteum of tibia.

Result. No recurrence. Function normal to date.

Case 15. M. H., first seen November, 1908. Left knee-cap has slipped out many times within the last 3 years. Physical examination was negative except for local condition. Left knee is moderately swollen. Fossæ on either side obliterated. Slight increase in surface temperature. Complete extension of knees possible with difficulty. Both patellæ tendons are elongated, those on the left more than the right. Tibial tubercle is external to mid-line of patella; the pull of the patella tendon is, therefore, obliquely outward, the patella being tilted.

Diagnosis. Slipping patella, and operation is recommended.

Operation. Transplantation of outer half of patella tendon into periosteum of tibia.

Result. No recurrence. Function normal.

Case 16. Miss M. H., age 28, first seen August, 1920. In 1915, patient struck right knee against a chair sustaining an injury which kept her in bed for

6 weeks. After that she was unable to use the knee even with a knee-cap and "it kept slipping out." Following each attack she was "laid up" from 6 to 8 weeks. Last attack July 7, 1920, following which she was confined to bed until September 6, 1920. Physical examination was negative, except for condition of right knee, which is swollen. All motions are painful, especially on moving the patella outward.

Diagnosis. Slipping patella, and operation is recommended.

Operation. Transplantation of bony insertion of patella tendon.

Result. Excellent function.

BIBLIOGRAPHY ABSTRACTS

Goldthwait in February, 1904, reported 11 cases of slipping patellæ with the following results: 1 case where tendon was transplanted with its bony insertion with good result; 5 cases where tendon was transplanted into periosteum with good result; 2 cases where tendon was transplanted into periosteum, not good result; 2 cases where capsule was quilted with not good result.

Krogius in *Zentralbl. f. Chir.*, Mar. 5, 1904, reported 2 cases (one double) where patella was drawn outward by tense outer portion of the capsule. He operates as follows: (1) approach the knee by Kocher incision; (2) incision from slightly above the patella, down a few inches in front of its outer edge to insertion of ligamentum patellæ; through the iliotibial band, tendinous expansion of vastus externus and fibrous capsular wall; (3) formation of bridge-shaped flap on inner side of patella connecting below with the tendinous expansion of vastus internus and fibrous capsule and above with muscle and fascia; (4) transplantation of the flap, left attached at both sides, across patella at its outer edge.

Result. First case: after 6 months patella slipped out again. Second case: result perfect after 3 months.

Whitlock in *British Journal of Surgery*, July, 1914, gives technique as follows: (1) reefing medial side of capsule with or without opening joint; (2) transplanting insertion of patellar ligament medially; (3) reinforcing the patellar ligament by grafting tendon of gracilis into it.

Dumferline in Surgery, Gynecology and Obstetrics, April, 1912, describes his technique as follows: patellar ligament is split, portion is turned up and sutured to the cut end of the tendon of the semitendinosus with chromic catgut. Capsule and fascia are then reefed.

Murphy's technique is given in Murphy's *Clinics* vol. iii, No. 4, August, 1914, as follows; Joint exposed freely by two longitudinal incisions, one on either side of the patella, turning the patella with the ligamentum patellæ to one side. Segment of bone between condyles removed to deepen the groove. Flap of fat and fascia then turned in from above and sutured over the denuded bone area to prevent ankylosis of patella to femur. Patella then replaced.

Graser in *Deutsche Gesellsch. f. Chir., and Zentralbl. f. Chir.*, July 9, 1904, reports a case where outer condyle of femur stood considerably farther backward than inner condyle when leg rotated outward. He operated by doing a supracondyloid osteotomy of femur and twisting the condyles so as to bring outer portion forward and inner condyle farther back.

Albee in *Orthopedic and Reconstruction Surgery* describes his technique as follows:

"A semilunar skin incision is made at the outer border of the patella sufficiently long to reach below the tibial tubercle and to a point above the external condyle. Avoiding undue disturbance of the underlying joint structures, the external condyle is penetrated with a broad thin osteotome on its external surface, making a bone incision from 1½ to 2 inches long, and situated about 1½ to ¾ inches below its anterior articulated surface and nearly in line with the long axis of the femur. This bone incision allows the anterior surface of the external condyle to be elevated to a plane above the internal condyle, by producing a greenstick fracture near the intercondylar groove, the object being to place a permanent and rigid obstacle in the way of outward displacement of the patella.

"When the anterior segment of the external condyle has been obliquely elevated to a sufficient degree to secure the desired obstructing effect, the width of the bone-gap thus formed is measured, and a section of bone sufficiently large to fill this cuneiform opening is removed from the crest of the tibia through the lower portion of the original skin incision, extended below the tubercle for this purpose. This bone-graft wedge can be easily and quickly procured by the use of the motor-saw. Before the graft is removed, it is drilled obliquely in one or two places with a motor-drill so that it may be pegged to the under portion of the external condyle after it has been put in position. Dowel pins, made from an additional portion of the bone removed from the crest of the tibia at the time the graft is obtained, and rounded by the motor-lathe to fit the drill holes in the graft, are driven into place.

"The cancellous structure of the condyle is easily penetrated by the bone-graft pins, but if any difficulty is encountered, the motor-drill can again be inserted into the holes already made in the graft and these prolonged into the external condyle. The ligaments and tendinous expansions are sutured over the graft with kangaroo tendon, thus securely holding the elevated portion of the condyle. The skin wound is closed with a continuous mattress suture of plain catgut, without drainage, and the leg from toes to groin is encased in a plaster-of-Paris splint in which it is allowed to remain for 3 weeks; at the end of this time passive motion and massage are begun.

"The advantages of this procedure are that with no sacrifice of joint cartilage, a minimal amount of joint injury is produced at the time of operation, thereby greatly lessening the dangers of limitation of motion and the formation of adhesions, and that the permanent blocking of any further tendency to displacement of the patella is effected by the actual elevation of the external condyle or an actual restoration of the normal mechanico-anatomical conditions. The soft parts are not interfered with. The only further suggestion in the case of extremely lax and stretched internal capsular ligaments is their plication with kangaroo tendon; this, however, is usually unnecessary, for if the external condyle is propped well forward, all requirements are fulfilled."

BIBLIOGRAPHY

1. Tubby, A. G. Deformities Including Diseases of the Bones and Joints. Vol. i, chap. ii, p. 313.
2. Albee, F. G. Orthopedic and Reconstruction Surgery. Philadelphia: Saunders Co., 1919, p. 624–630.
3. Goldthwaite, Joel E. Slipping or recurrent dislocation of patella. Boston M. & S. J., 1904, cl, 169.
4. Idem. Permanent dislocation of the patella. Ann. Surg., 1899, Jan.
5. Krogius. Zentralbl. f. Chir., 1904, Mar. 5.
6. Whitlock. Brit. J. S., 1914, July.
7. Dumferline. Surg., Gynec. & Obst., 1912, April.
8. Murphy. Murphy's Clinics, 1914, iii.
9. Graser. Deutsche Gesellsch. f. Chir. and Zentralbl. f. Chir., 1904, July 9.

REPRINTED FROM

ANNALS OF SURGERY

227 South Sixth Street, Philadelphia, Penna.

July, 1922.

TRANSPLANTATION OF THE ENTIRE FIBULA IN CASES OF LOSS OF TIBIA FROM OSTEOMYELITIS

By W. Russell MacAusland, M.D.

of Boston, Mass.

SURGEON-IN-CHIEF, ORTHOPÆDIC DEPT., CARNEY HOSPITAL

AND

Arthur F. Sargent, M.D.

ASSISTANT SURGEON

In April, 1912, the author [1] reported the results of the transplantation of the entire fibula as a substitute for the loss of the tibia in the same leg following osteomyelitis. The values of such transplants are several: First, the dangers from infection following a small exposure are largely minimized, as compared with a tibial graft. Second, failure is practically impossible, owing to the fact that the blood supply of the fibula is not disturbed. Third, the bone rapidly hypertrophies to take up the added weight and leaves no defect from the absence of the fibula. Fourth, fracture of graft is impossible.

The entire transplantation is, of course, used only in those cases following osteomyelitis of the tibia where no regeneration has occurred and the disability therefore is complete.

In practically all cases of osteomyelitis of the tibia, the upper and lower epiphyses remain the limiting barriers and are undisturbed so that the growing portions are not usually totally destroyed.

Technic of Transplantation.—Following careful preparation of the leg, an incision three inches long is made between the head of the fibula and the head of the tibia (see Drawing No. 1A) (Fig. 11) being careful not to injure or divide the peroneal nerve as it passes over the fibula.

The remaining tibia is then cupped out to take the fibula graft.

A longitudinal slit is then made in the periosteal covering of the upper fibula and the outer half gently freed from the fibula. The fibula is then osteomized as high as thought practical and by means of heavy traction is pried into this tibial cup. It is usually best to deepen this cup a little, thereby gaining better and quicker union. (See Drawing No. 1B.) (Fig. 12).

By leaving the periosteum on the outer side of the fibula intact both to the remaining fibula head and to the outer transplanted shaft, we gain a periosteal bridge which will often develop a bony bridge, thus more efficiently uniting the fibula and tibia. (See Cases I, II and III.)

The use of wire is unwise as union is always delayed in the presence of a foreign material. The wound is closed in the usual manner and a plaster applied from the toe to well above the knee. This remains on for two months, after which, a similar operation is performed on the lower leg. (See Drawing No. 2A and 2B) (Figs. 13 and 14) and diagrammatic sketch. (Fig. 10).

Usually two months following the second operation, weight-bearing is permitted, and either plaster or a caliper brace is used for a period of six to eight months.

It is surprising how quickly bone hypertrophy follows in the fibula with this added responsibility.

Note that the hypertrophy in Case I reached nearly the proportion of a normal tibia.

Observations.—1. Union is solid and takes place in record time.

2. The fibula hypertrophies, as seen in Case I of seven years' standing, and in Cases II and III of four and a half years and nine years.

3. Growth of leg continues and does not seem to be retarded.

Case I.—A. L. This was a case of a young girl who in January, 1915, had an osteomyelitis of the left tibia and the right femur. She was admitted to the hospital on June 10, 1912.

Physical Examination.—Negative except for the local examination, which showed many discharging sinuses over the left tibia and the right femur. Wassermann negative.

On June 25, 1915, the entire tibia was removed from the epiphysis to epiphysis and plaster cast applied from groin to toes. Femur curetted, troughed and packed.

On March 1, 1917, there was no regeneration of the tibia—all wounds healed.

February, 1918, upper end of fibula transplanted into upper epiphysis of tibia—wound healed with only slight discharge in three weeks.

November 4, 1920, lower end of fibula transplanted into lower tibial epiphysis.

Wound healed in three weeks. Plaster case applied following each transplant from toes to groin. (See X-rays, Figs. 1, 2, 3, and 4.)

Functional result excellent seven years after operation.

Case II.—N. G. This is the case of a young boy who had an acute osteomyelitis of the tibia in April, 1917, which resulted in marked destruction of the greater part of the tibia. This osteomyelitis was treated up to November, 1917, when the wound was healed. On May 23, 1918, the fibula was transplanted into the epiphyses of the tibia as in the previous case.

March 17, 1919, X-rays show hypertrophy of the fibula. (See X-rays, Figs. 5 and 6.)

Functional result excellent four years following transplantation.

Case III.—L. B. This young girl, at the age of thirteen, was seen by her physician for pain and discharge of the lower leg. Two years' duration. At the first onset the pain had been sudden, accompanied by temperature ranging from 101 degrees to 104 degrees. Three operations were performed, each consisting of the removal of a portion of the tibia.

April 15, 1909, this case was seen by one of the writers and the examination showed four discharging sinuses along the tibia. A diagnosis of chronic osteomyelitis was made and X-ray showed the whole tibia honeycombed and practically sequestrated.

Operation.—May, 1909, the whole tibia excised, only the epiphysis remaining. The periosteum resutured.

November, 1909, as there was no evidence of an attempt to regenerate a new tibia, the upper end of fibula was transplanted into the upper epiphysis of the tibia; the wound healed in two weeks.

December 31, 1909, the lower end of the fibula was transplanted into the

lower epiphysis of the tibia. The wound healed in two weeks. (See X-rays, Figs. 7 and 8.)

Functional result excellent twelve years following transplantation.

Case IV.—C. W. M. Two years previous this man had a compound comminuted fracture of both bones in the right lower leg, with the loss of two and one-half to three inches of bone. He had four operations. Examination on August 22, 1921, showed a two and one-half inch gap at the junction of the middle and lower third of the tibia with a tendency to varus. The wound has since February, 1921, been healed.

Diagnosis.—Non-union of old fracture of the tibia.

August 26, 1921, lower end of the fibula transplanted into the lower end of the tibia. Wound healed in two weeks. (See X-ray, Fig. 9.)

September 20, 1921, upper end of fibula transplanted into the upper end of the tibia. (See X-ray, Fig. 9.)

December 28, 1921, lower fragment solid, upper fragment has slipped. To have another operation in two months.

February 14, 1922, upper end of fibula placed in approximation with tibia and then sutured with kangaroo tendon. Convalescence thus far uneventful. (See X-ray, Fig. 9.)

Clinically, one can see no reason why a perfect functional result should not follow.

LITERATURE

Campbell, W. C.[2]: Transference of the fibula as an adjunct to free bone graft in tibial deficiency. J. Orth. Surg., October, 1919, vol. i, pp. 625–631.

Three cases are reported by the author. In order to make the success more certain in this condition, Campbell uses the following technic: An incision in the skin about four inches in length is made over the lateral aspect of the head of the fibula, the deep fascia is incised, then the capsule of the tibio-fibular joint. All cartilage and fibrous tissue is removed from the head of the fibula, being careful not to injure external popliteal or peroneal nerves. Next a cavity is made in the inferior and external aspect for the reception of the denuded head of the fibula. Heavy traction will place the head of the fibula within the cavity, provided scar tissue between tibial fragments does not prevent. When such difficulties arise these tough bands are excised or severed, the periosteum of the fibula is sewed to the periosteum of the tibia and the wound closed with catgut throughout. The final step is to do the inlay graft in the usual manner, which needs no description. This method has been successfully employed in the three cases. The advantages of the procedure are: 1st: It is possible to lengthen the limb one and one-quarter inches. 2nd: Early transference of head will stabilize limb and prevent shortening; 3rd: At the end of eight weeks we have a stabile limb in which no false motion is possible between knee and ankle. 4th: Early stability prevents motion and facilitates the development of the free graft. 5th: New blood supply is added to the tibia through the medium of the fibula, promoting nutrition. 6th: Greater chances of complete success. One point that Campbell especially desires to emphasize is that a two-stage operation should be done in all cases where there is much difficulty in making the limb straight from contraction of dense scar tissue. Most patients will readily submit to the second operation when such marked improvement follows the first.

C. J. Bond[3]: Transplantation of the fibula; osteomyelitis. Brit. J. Surg., vol. i, p. 610, April, 1914.

Case I.—Little girl, aged four years. Shaft of right tibia had been destroyed by osteomyelitis in June, 1904. The right fibula was cut across just below the head of the bone and this portion, with the epiphysial cartilage, was left in normal

position. The divided end of the shaft of the fibula was then pushed over to the inner side and inserted into the freshened lower surface of the tibial epiphysis, to which it was wired in position.

Within the next two months firm, bony union had taken place. Bony outgrowth took place from the isolated upper fragment of the fibula. The upper end of the shaft of the fibula began to assume the outline characteristic of the normal tibia. In March, 1907, fibula was divided just above external malleolus and lower end of shaft was displaced inward and inserted into soft cancellous tissues of the lower tibial extremity. The child now walks and runs with the aid of a high-soled boot without any noticeable limp.

Case II.—A boy, in whom the shaft of the right tibia was destroyed by osteomyelitis in 1907. This was removed as a sequestrum in November of that year when the boy was ten years old. The place of the lost tibia was supplied by transplanting the shaft of the fibula in two stages, as in Case I. At the first operation, in March, 1908, the shaft of the bone was divided just below the head. It was then displaced inwards and the cut surface wired to the freshened tibial extremity somewhat to its outer edge. In May, 1908, the lower end of the shaft was divided above the external malleolus and embedded in the cancellous tissue of the lower tibial epiphysis.

Owing to the contraction of the soft tissues of the limb, due to the absence of the tibial framework, considerable pressure was exerted on the lower end of the shaft and this gradually forced the end of the bone deeper into the spongy tissue until it eventually passed right through the epiphysis, almost passing through into the joint. Unfortunately, in this case, the disease affected the left tibia, destroying about two inches of the bone and producing a bad anterior posterior deformity of the limb at this spot; about one and one-half inches of soft bone were removed and ends of divided shaft wired together. This necessitated a subperiosteal division of the fibula at the corresponding level. A year after the operation shows a restored shaft with a single central medullary canal and no callus. It is impossible from an examination of the limb on the skiagram to say that the fracture had occurred at this spot.

H. Schloffer[4]: Zur Osteoplastik bei Defekten der Tibia. Bruns. Beitr. zur klin. Chir., vol. xxv, 1899, p. 76.

The transplantation of a graft from the fibula to the tibia was first practiced by Hahn.

Lilienthal writes of a wonderfully successful operation of this nature in a boy of nine years with absence of bony matter from the tibia due to fracture. The surgeon severed the fibula and fitted the upper end of the shaft into the tibial fragment. Within four months consolidation took place. McBurney simply sutured the head of the fibula to the tibia with favorable results.

Gangolphe[5]: Considerations sur la resection du tibia pour osteosarcomes et sur l'utilisation du perone. Lyon Med., 1909, vol. cxiii, pp. 749–751.

Patient suffering from suppurating tibia following fracture and which the author suspected of being an epithelioma. The author decided to make a large diaphyseal resection of the tibia, causing the patient to support his weight on the fibula. If the weight of the body does not exceed sixty kilometres this is possible. The author advises the use of the fibula of the other leg as, in case of some mishap in the operation, the patient stands more chance of recovery. The patient mentioned was operated on successfully by this method by another surgeon.

M. Brandes[6]: Die Heilung grösster Tibiadefkte durch Transplantation. Med. klin. Berl., 1913, vol. ix, p. 1493.

The author advises the use of the fibula of the same leg for transplantation because it is the material nearest at hand and, being usually strong and hypertrophic, is splendid material for bridging the tibial deficiency. The head of the fibula

is split and the upper end of the fibular shaft implanted in the upper fragment of the tibia and then the lower end of the fibula is implanted in the lower fragment of the tibia. The result is a fusion of the tibia and fibula into a new bone formation which permits the movement of the leg. Two children, having undergone this operation, walk easily.

Berard[7]: Greffe d'une portion du perone gauche dans une perte de substance de ten cm. du tibia droite, consecutive a une fracture pathologique avec dystrophie osseuse. Lyon Chir., 1913, vol. ix, pp. 574–8.

The patient, twenty-seven years old, had three successive fractures in the same place in seven years. The first two fractures consolidated normally. The third left the leg impotent, shortened by about three cm., curved slightly inward, and with pains. The author uncovered the tibial focus, which presented a swelling which had the appearance and consistency of an egg shell.

In the interior of this cavity was a little serosanguineous liquid and some pimples forming an interrupted membrane. After ablation of the entire diseased bony area, the author realized a loss of bony tissue amounting to nine or ten cm. at the two poles of which the medullary canal was closed by a bony shell. The author then resorted to ablation of the left fibula, without its periosteum, to a length of twelve cm. The fragment of the fibula was inserted into the medullary canal of the tibial fragments. The operative results were uncomplicated. After five months the right leg was consolidated. The patient walked easily with a metal support.

Lapeyre[8]: Autogreffe de la diaphyse peroneale pour remplacer la diaphyse tibiale necrosee et sequestree osteomyelite. Réstauration du tibia autour de la greffe. Guérison avec résultat fonctionnel excellent. Bull. et Mem. de Soc. de Chir. de Paris, 1914, n.s. vol. xl, pp. 182–90.

A child of three years came for treatment July 16, 1912, for an acute affection of the lower leg which had begun November 27, 1911. Upon the author's first examination the tibia seemed in a necrotic state, which seemed to involve nearly the whole diaphyses. The upper and lower epiphyses were curetted and cleaned. Fifteen centimetres separated the two osseous extremities. Suppuration persisted. It was vain to hope for a spontaneous reparation. On February 2, 1913, the author performed the fibular transplantation.

1. Careful curettage of the area to which the fibula was to be transplanted and extirpation of fungosities.

2. The section of the fibula at its lower extremity. The length of the graft was about thirteen cm.

The author did not dare to insert the two extremities of the fibula into the same epiphysis on account of the inflamed condition of the latter and decided to use two ivory pegs. For two or three months suppuration persisted at the upper end. At the end of three months consolidation was in progress. On September 10th the leg appeared solid. It had taken seven months to obtain this result. From a radiograph taken on this date the transplanted fibula showed itself to be completely surrounded by new bony tissue, irregular but solid. Suppuration had ceased. On December 10th, when the child left the hospital, he could walk with one cane. Thus transplantation of the fibula had saved a leg from amputation and reconstructed a useless member into a solid construction with splendid functional result.

Michon[9]: Perte de substance du tibia, consecutive a une blessure par eclat d'obus; transplantation du perone; guerison avec bon resultat fonctionnel. Bull. et Mémoires de la Société de Chirurgie de Paris, vol. 422, 1916, pp. 1719–22.

M. M. Sub-lieutenant, wounded by shell explosion on June 23, 1915, which resulted in a serious wound in the right leg. (1) A foot wound with tarsal fracture. (2) A fracture of the inner malleolus with a hole in the tibio-tarsal articulation. (3) A comminuted fracture of the medium tibia with important loss

of bony substance covering about three cm. The limb was immobilized. The inferior wounds cicatrized after prolonged suppuration. The malleolar fracture was consolidated with tibio-tarsal ankylosis and a slight degree of equinism. On January 22, 1916, seven months after the accident, the author performed a transplantation of the fibula of the same leg, following the technic of Barbet.

The operation consisted of the liberation and resection of the two tibial extremities by an internal incision and a section of the fibula by external incision. The fragment of the fibula, obtained by double section and adhering always to the interosseous membrane serving as pedicle, was thrust between these and the muscles of the anterior leg; the two extremities, bevelled, were both introduced into the medullary canal of the corresponding tibial fragment. The operation was long and tedious. The operative results were accompanied by suppuration and fever. The final results were satisfactory.

The leg is solid. The grafting is surrounded by new bony matter according to radiographs. The lower fragment of the fibula was welded to the tibia. The upper fragment was loose but caused no discomfort. The patient could walk with a cane.

P. Mauclaire [10]: Grosse perte de substance du tibia; greffon emprunte au perone du cote oppose. Bull. et Mem. de Soc. Chir. de Paris, 1916, n.s. 12, 1864–66.

Case of a soldier who was wounded by a bullet, leaving a large wound in the tibia. This produced an arterial aneurism, osteitis of the calcaneum and violent retraction of the Achillis tendon. The wound suppurated for a long period. Three months after cicatrization the author transplanted a graft from the fibula of the other leg. Above he sunk the graft into the medullary canal. Below he fastened it to the tibial groove with catgut. The author does not feel ready to advise the maximum length of bone to be taken for grafting. In the present case he used seven cm. of the fibula. In this patient the consolidation was rapid and the patient walks easily. The leg from which the graft was taken is in good condition. The tibia suffices by itself for the functions of the leg, if judged from the six cases of fibular grafts made by the author.

For good consolidation it is necessary to sink the graft in the medullary canal as soon as possible. After the grafting the author sectioned the Achilles tendon to correct the equinism, then he scraped the necrotic calcaneum. The author states his intention of getting X-ray picture of this operation after one year has elapsed.

Pierre Barbet [11]: Revue general de la reconstitution du tibia detruit par transposition du perone voisin. La Clin. Par., vol. vii, 1912, pp. 65–69.

It is evident that the Hahn-Huntington operation is beneficial. It furnishes almost certain results (showing only two partial failures in twenty-seven cases). From the functional standpoint it seems superior to other grafts. The cases show almost identical post-operative history: rapid consolidation, return of muscular vitality, progressive hypertrophy of the transplanted fibula.

This operation is then preferred before all others. (1) In cases of destruction of the bony tissue due to osseous necrosis with death or insufficiency of regenerating periosteum. (2) After periosteal resection of an osteosarcoma of the tibial diaphysis. (3) After resection of the foci of old pseudo-arthrosis, followed by fracture with atrophy of the fragments.

Bond, C. J.[12]: On the late results of three cases of transplantation of the fibula, with remarks on the process of growth and the physiological development of transplanted bone. Brit. J. Surg., April, 1914, vol. i, pp. 610–624.

Bond gives credit to Huntington as being the first surgeon to publish a case in which a successful attempt had been made to replace the whole shaft of the tibia by transplanting the shaft of the fibula into its place. The surgical results of the author's first two cases are as follows: The end results of bone transplantation in both cases (in one of which amputation had been suggested) Bond thinks

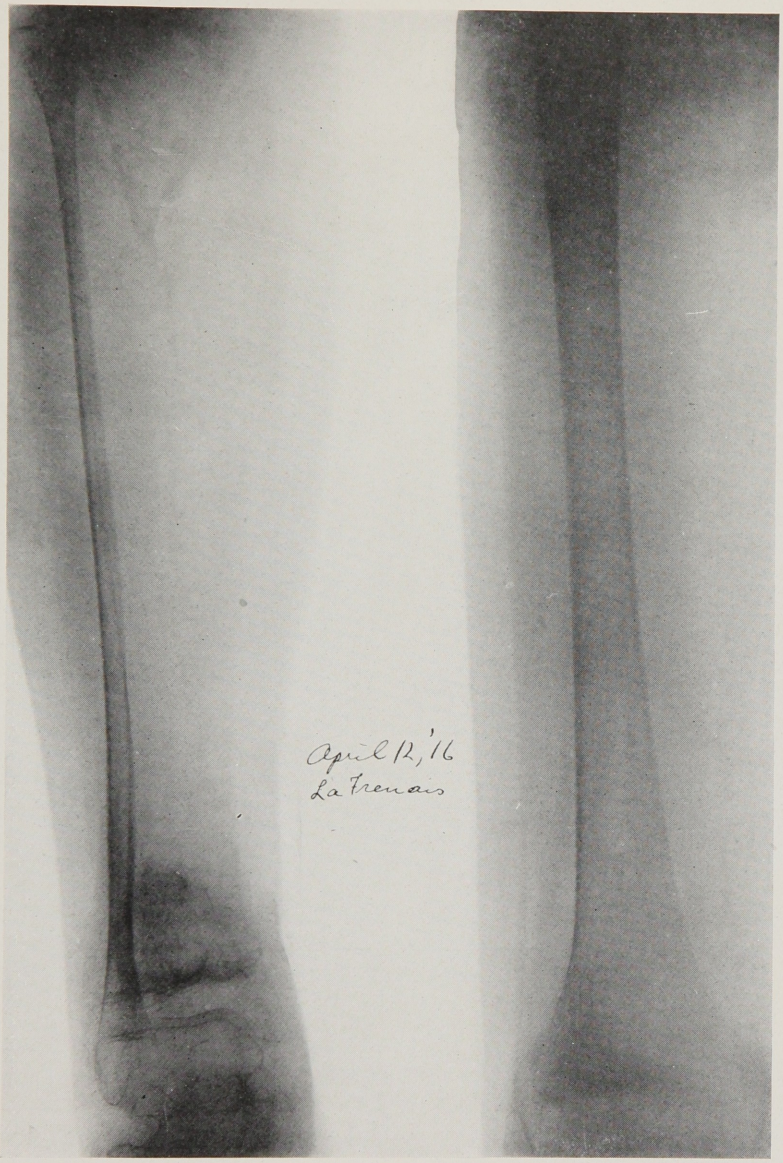

FIG. 1.—Case I, A. B., taken April 12, 1916, before operation for transplantation of the fibula (A-P view).

FIG. 2.—Case I, A. L., lateral view taken April 12, 1916, before transplantation of fibula.

FIG. 3.—Case IV, Moulton. Radiogram taken five months following lower transplantation and one week following upper transplantation.

FIG. 4.—Case I, A. L., post-operative radiogram, January, 1922.

Fig. 5.—Case II, N. Y.

FIG. 6.—Case II, N. Y. Post-operative radiogram, taken January, 1922.

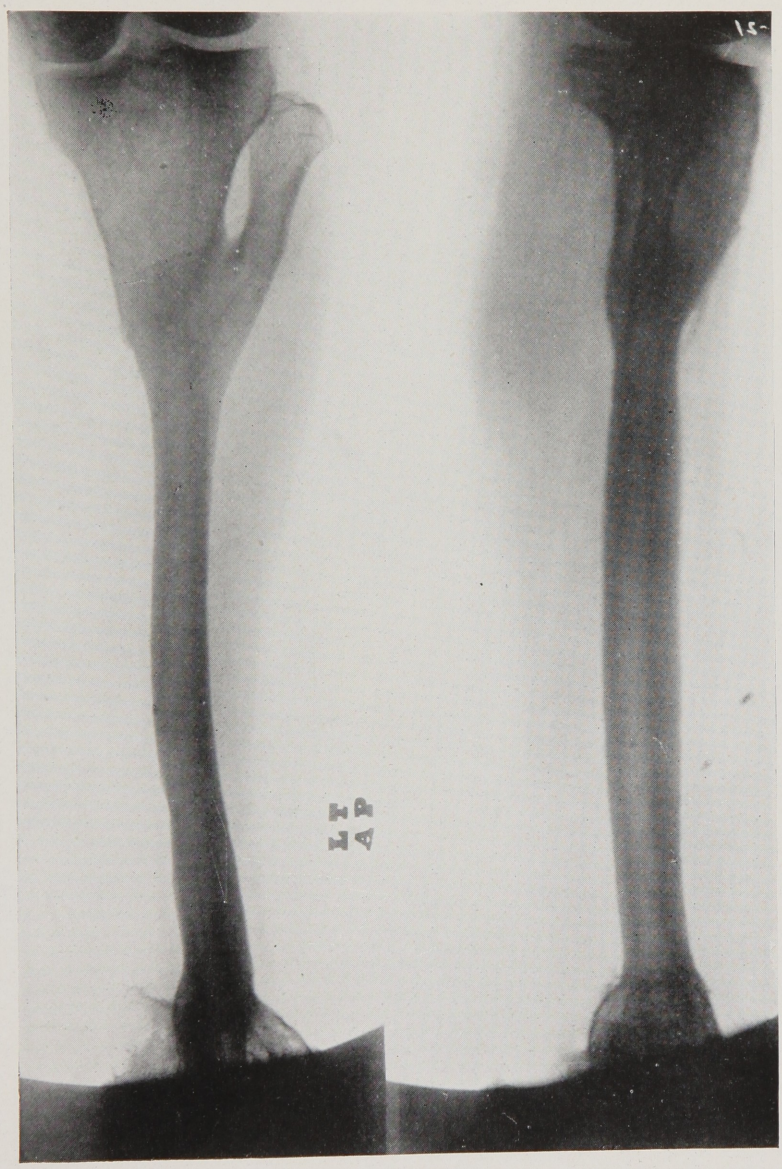

FIG. 7.—Case III. L. B. Radiogram taken twelve years after operation

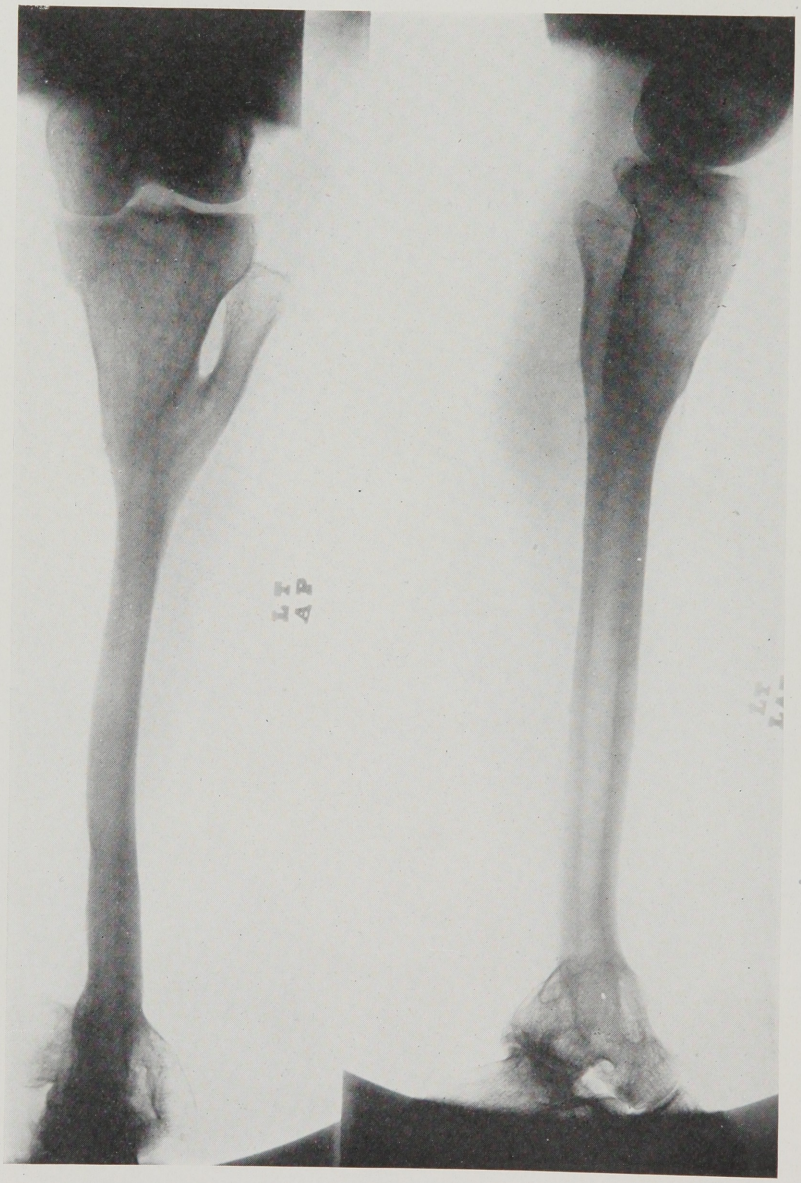

FIG. 8.—Case III, L. B. Radiogram taken twelve years after operation.

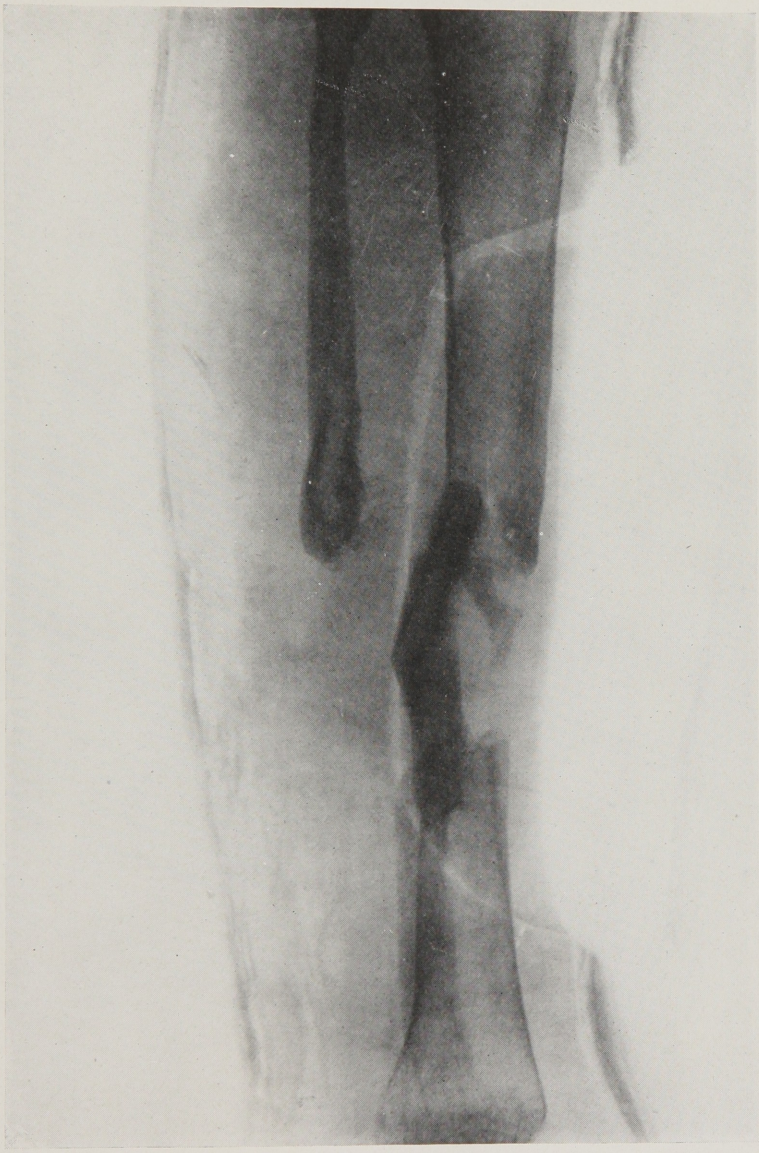

FIG. 9.—Case IV, C. W. M. Showing transplant of fibula into tibia.

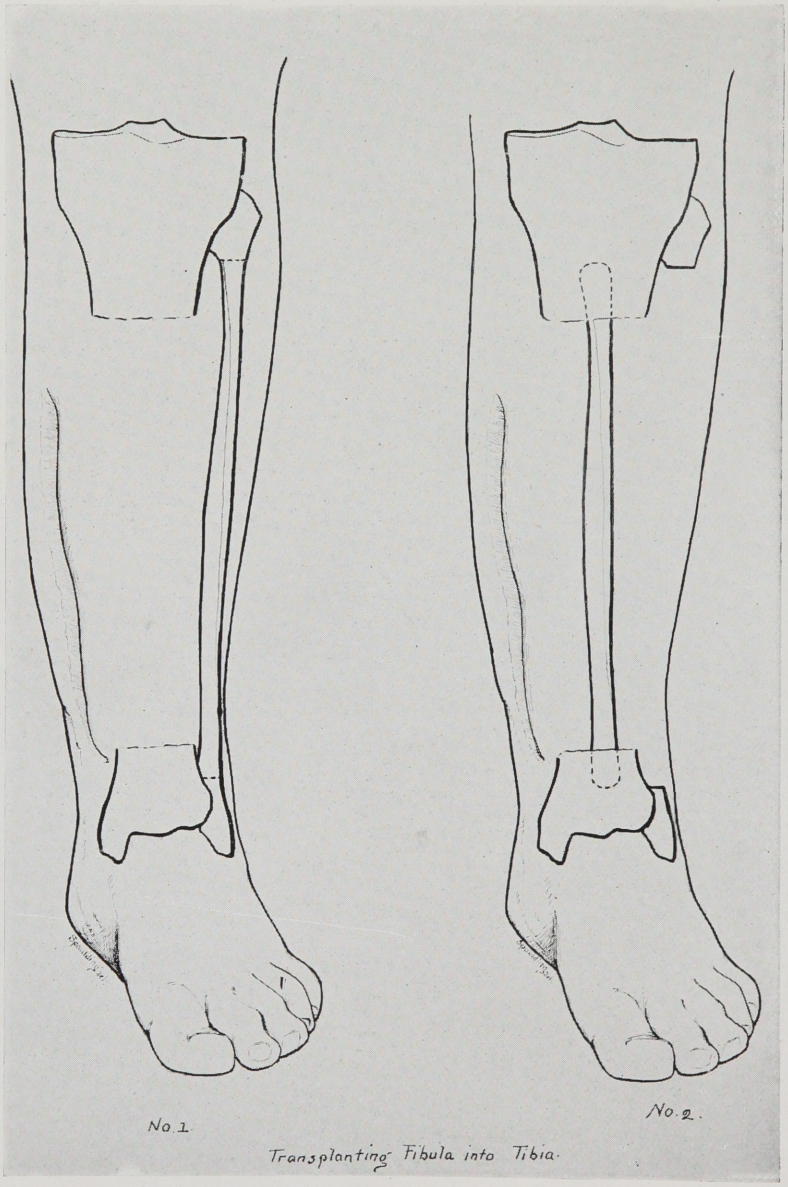

FIG. 10.—Diagrammatic sketch showing result of transplant.

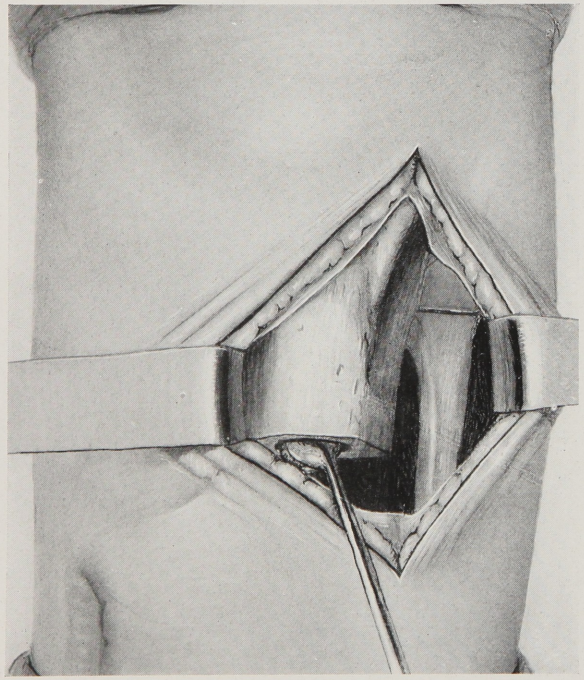

FIG. 11.—Drawing 1A, showing point of division of fibula preparatory to transplantation.

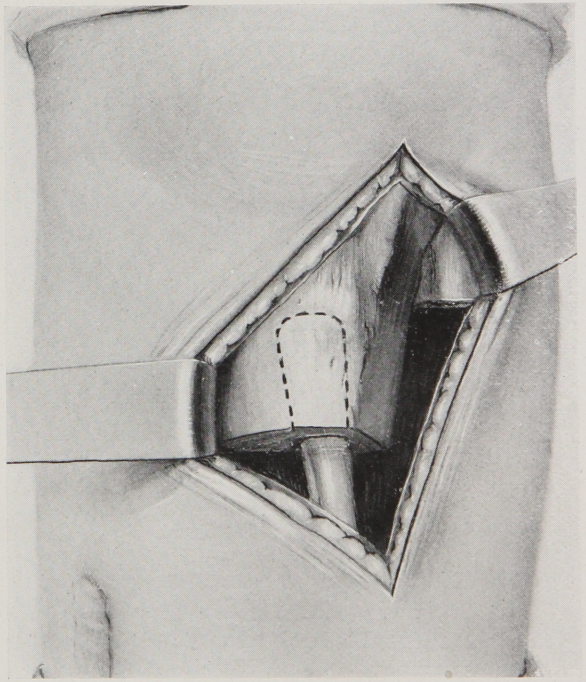

FIG. 12.—Drawing 1B. Transplantation in place.

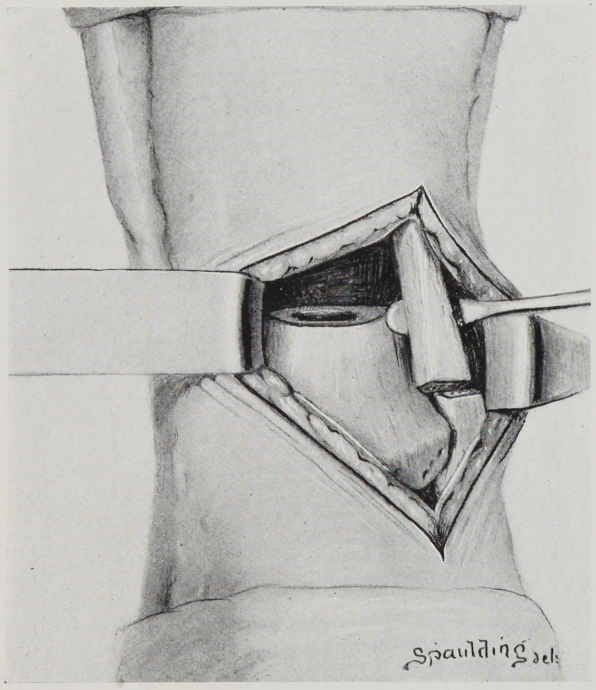

FIG. 13.—Drawing 2A, showing point of division of lower fibula preparatory to transplantation.

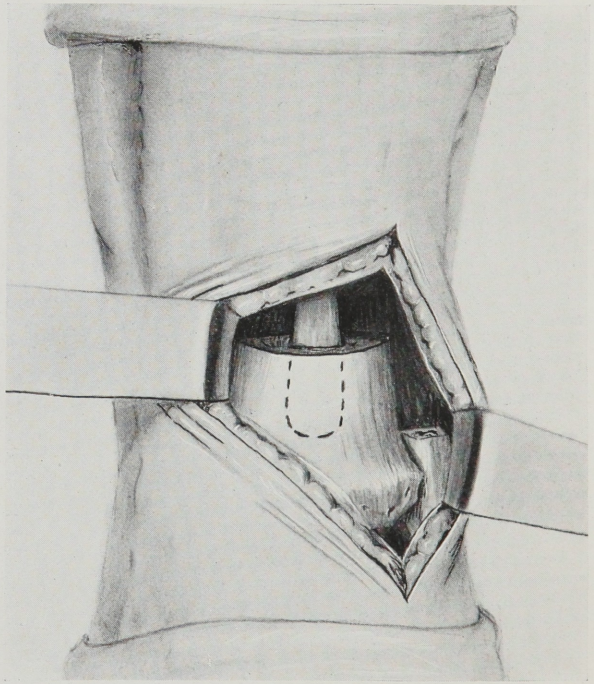

FIG. 14.—Drawing 2B, showing transplantation of lower fibula in place.

can be called satisfactory). The functional result is good. Both children can walk and run well without assistance, one without any noticeable limp and the other with only a slight one. From the surgical point of view the problem is how to secure the continuous growth in length of transplanted shaft and how thus to prevent the shortening of the limb, which occurred in both these, as in other recorded cases. In regard to this question of stunted growth, no doubt, much will depend on the extent to which the disease which destroys the original shaft also damages the osteogenetic capacity of the epiphysial cartilages, especially the one which exercises the greatest influence on the growth of the leg bones.

It was with the double object of restoring this capacity of bone formation to the damaged epiphysial cartilage and of counteracting the deformity of the limb caused by the unopposed growth of the fibula that Bond performed another operation on his third case. This case was a child aged four, who in 1903 developed a tuberculous focus in the upper epiphysis of the left tibia which partly destroyed the epiphysial growing line. After abscess formation and recovery a considerable deformity was left and the limb was carried inwards at a sharp angle below the knee by the unopposed growth of the fibula on its outer side. In November, 1905, the left fibula was divided just below the head of the bone and this with the epiphysis was removed. A V-shaped portion of bone was then removed from the inner side of the head of the deformed tibia in the situation of the normal epiphysial junction. The deformity was then corrected by forcibly straightening the shaft of the bone. The removed head of the fibula was now cut down to a V-shape and was inserted into the wedge-shaped gap in the head of the tibia so formed and the wound was closed. The grafted cartilage healed well in its new position. The child now walks fairly well. There is, however, still some shortening of the limb and some internal rotation of the foot, showing that the growth of the tibia has not kept pace with that in the opposite limb. The author's first two cases showed no increased growth; it made no attempt to take on new developments as long as it was connected with its own epiphyses, even though the tibia had been destroyed and it was exposed to new strains, but as soon as the shaft of this fibula became attached to tibial epiphyses, it began at once to assume a new outline and grow like the tibia. This fact suggests that it was the influence of osteoblasts from the tibial epiphyses which brought about the change and started the growth of the transplanted bone along tibial lines; it being a fact that in Bond's, as well as in other cases, the transplanted fibular shaft did develop into a bone of the size and shape of the tibia, shows that the failure to do so in some cases is not due primarily to the fact that the transplanted bone is "naturally" a smaller bone, but to the fact that it is not sufficiently taken over, or its growth is not sufficiently stimulated, by osteoblasts of tibial origin.

Torrance, Gaston[13]: Excision of the whole shaft of the tibia; replaced by transplanting the fibula. Surg., Gyn. and Obst., Feb., 1912, vol. xiv, pp. 184–186.

This case was a boy, six years of age, admitted to hospital May 15, 1908, with the history of having struck his right leg with a hammer over the middle of the tibia. An abscess formed at the point of injury, which was incised and curetted and healed up but reopened, and was operated again a few weeks later. Congenital syphilis was suspected, but no history could be elicited to confirm this. A considerable portion of the shaft had been chiseled out at different times, leaving a persistent sinus. When patient came under Torrance's care, about three months after admission, he was very much emaciated and ran a constant temperature. A skiagraph showed the tibia much enlarged and in an unhealthy condition.

Excision of the tibia was proposed. Under ether an incision was made along the anterior border of the tibia and the bone was sawed in two with a Gigli saw, leaving about an inch of bone at either end; the shaft was removed without any attempt being made to preserve the periosteum; the fibula was then sawed in two

at the upper end and transplanted to the stump of the tibia and was held in place by suturing the muscles up snugly around it. The leg was placed in a wire splint. A skiagraph, made a week later, showed the fibula to be in good position. His general condition began to improve at once. He was allowed to be up on crutches at the end of four weeks and was in good physical condition. Two months after operation two large ulcers developed near the point of the original injury and grew larger and deeper under local treatment.

He was put on potassium iodide and the dose rapidly increased to forty drops of the saturated solution, three times daily. He bore this treatment well and the ulcers healed rapidly. On questioning the father again he admitted that the child had contracted syphilis from kissing a relative at two years of age and had been treated for about a year. A skiagraph, made five months after operation, showed that the fibula had about doubled in size and that the union with the tibia was rounded off, resembling a joint "wiped" by a plumber. A few weeks later he was walking on the limb without a splint or crutch; the only difficulty he experienced was a slight tilting of the ankle. The lower end of the fibula was transplanted ten months after the first operation. He was allowed to walk about on crutches for two months and then lateral splints were applied and he was allowed to put some weight on the leg.

He was again seen in August, 1911, when a photograph and the last skiagraph was made. The muscles of the leg are well developed and there is no shortening; while the skiagraph shows some bowing of the shaft, the general lines of the leg are almost perfect and when standing with long stockings on it is not possible to tell which is the operated leg. He runs, jumps and plays with the other children and has perfect use of the leg.

T. W. Huntington[14]: Case of bone transference. Use of a segment of fibula to supply a defect in the tibia. Annals of Surgery, February, 1905, vol. xli, pp. 249–251.

Huntington's case illustrates the possibility of supplying a tibial defect amounting to absence of nearly the entire diaphysis by the appropriation of corresponding portion of the fibula. The early history of the case is that of an acute, infectious osteomyelitis of the left tibia. The patient, a boy of seven, entered the hospital in May, 1902. The trouble began a few days before. While at play he sustained a slight injury to the left leg just below the knee. Leg became swollen, tense and acutely tender. There was high temperature succeeding a chill. The attending physician made a small incision about three inches below the knee, from which, at time of admission, there flowed a small amount of clear yellow fluid. Tibia was extensively denuded and near the ankle there were two red fluctuating areas. An incision along the spine of the tibia from the tubercle to one inch above the ankle-joint revealed the fact that nearly the entire shaft was disintegrated. Pus oozed through several sinuses leading to the medullary cavity. On stripping the periosteum, the cortical portion of bone was readily scooped out with a curette, leaving a trough of periosteum. Having in mind the possibility of bone reproduction, the periosteum was stitched into a tube of small calibre. The wound was drained, partly closed and the leg laid upon a posterior splint. For three months there was gradual and satisfactory progress and the wound was fully healed. Six months later, despite an apparent effort on the part of nature to reproduce the tibia, there was still an interval of about five inches between the upper and lower fragments and progress here seemed to be practically suspended. The leg could not be extended upon the thigh, but hung loose, flail-like, and utterly useless. On January 27, 1903, Huntington finally determined to supply the defect by sawing the fibula at a point opposite the lower end of the upper tibial fragment and attaching it thereto. This was done without

difficulty and the divided end of the fibula was firmly planted in a cup-shaped depression in the tibia.

At this time the diameter of the fibula was about that of an ordinary lead-pencil. Union was tolerably slow but solidification was finally noted six months later. In September, 1903, the lad walked with the limb encased in two lateral splints as a support to the ankle-joint, there being a tendency for the foot to evert when the patient stands upon the affected member. Not satisfied, Huntington concluded to transfer the lower end of the fibula to the lower fragment of the tibia, which was done October 6, 1903. The wound healed kindly and on February 15, 1904, perfect bony union was secured. Since that time the patient has progressed admirably. The limb, though three-quarters of an inch short, has assumed the dimensions and in a general way the contour of the normal member. The transferred portion of the fibula shows that its diameter is now three-quarters of an inch, or practically the same as the opposite tibia. The lad joins in the ordinary sports of other boys and, despite the lateral deformity and slight shortening, he walks without support and with only the suggestion of a limp. In a similar case Huntington would insist upon the affected member being kept at rest until the second transposition could be effected; thereby avoiding the deformity, which is the only serious defect in this case. Considering the extensive destruction of the tibia which occurred before patient was seen by the author, he can conceive of no other method which would have offered a result so satisfactory as the one adopted.

J. S. Stone[15]: Partial loss of the tibia replaced by transfer of the fibula, with maintenance of malleoli of the ankle. Annals of Surgery, October, 1907, vol. xlvi, pp. 628–632.

The author's case was a boy five years old, who in June, 1904, had an acute dissecting periostitis beginning at the lower end of the right tibia and in six days stripping the bone nearly as far as the patellar tubercle. Owing to sloughing of the periosteum after removal of the shaft the tibia regenerated very imperfectly. Nine months after the onset of the trouble the bone had reformed for about one and one-quarter inches from the upper end. There was then a gap of about an inch. The fibula was normal. Thirteen months after the onset of the trouble he was admitted for operation. Since ten weeks after the trouble began he had been going about with a plaster bandage and Thomas knee-splint. The attachment of the upper end of the fibula had become loose so that the head of the bone could be shoved upward slightly and the foot moved inward for about two and one-half inches. There was marked shortening of the leg and the foot was a little smaller than on the sound side. The fibula had become somewhat hypertrophied, particularly at the middle of the shaft. All wounds were healed.

It was decided to transfer the fibula into the gap in the tibia. The upper end was transferred first. A vertical incision about three inches long was made directly over the lower end of the upper sound portion of the tibia. The cut was made directly through the periosteum which was separated on the fibular side for a vertical distance of about two inches. In order to reach the fibula more readily a second incision of one and one-half inches long was made directly down onto the bone on the outside of the leg. At about two inches from the upper end the fibula was then cut across with a chain saw. The upper end of the lower fragment was then inserted into a mortise cut in the tibia. The periosteum was reflected from that side of the fibula which rested in the mortise. The reflected periosteum of tibia and fibula were then sutured together with chromic catgut to maintain close apposition and the reflected periosteum of the tibia was further sutured as a cuff around the upper end of the fibula to hold it more securely in position. The incisions were closed with drainage. A sterile dressing and plaster bandage were applied. The boy was readmitted to the hospital five months after-

wards. The union between the upper end of the tibia and the fibula had become absolutely solid and the shaft of the fibula had materially increased in thickness. Five and a half months after the first operation a longitudinal incision was made anteriorly over the outer part of the lower end of the tibia. The bone was exposed. By careful dissection the lower end of the fibula was then exposed through the same incision and split horizontally with a chisel for a distance nearly four inches. A small pocket was cut in the cartilage covering the end of the tibial epiphysis just large enough to receive the inner half of the fibula.

The inner half of the fibula was then sprung into its new position in the tibia. Closure was made without drainage. A plaster bandage from the toes to the thigh completed the dressing. Three months later plaster was removed. A small granulating spot was found at the lower end of incision. Bony union was solid. Five days later a small piece of necrotic bone about three-quarters inch long was discharged. After this the skin healed solidly. A month later the boy began to walk on his leg, and ever since has used it without restraint. The problem presented in this case was the restoration to usefulness of a leg in which the fibula was sound, the upper end of the fibula was sound and in which the lower epiphysis of the tibia remained, but without any shaft for a distance of nearly five inches. The continued increase in the size of the transferred bone is most striking and corresponded in amount with the freedom of use which was allowed. In any similar case more prompt transfer of the bone would seem advisable. The length of time allowed between the steps of the operation might also have been shortened.

A. Keith[16]: Fibula transplantation to replace the necrosed shaft of the tibia. Menders of the Maimed. London, 1919, p. 273.

Keith states that the most instructive examples of bone transplantation are those in which the fibula has been used to replace the necrosed shaft of the tibia. The case he wishes to call attention to is that of Bond (*Brit. J. Surg.*, 1914, vol. i, p. 610), who operated in May, 1905. He also cites Professor Huntington as having carried out the first successful substitution of fibula for tibia, publishing an account of it in 1905 (Annals of Surgery, 1905, vol. xli, p. 249). The same problem had presented itself to two men situated on opposite sides of the earth and both had adopted the same method of solving it.

BIBLIOGRAPHY

[1] W. Russell MacAusland: Surg., Gyn. and Obst., April, 1912.
[2] W. C. Campbell: J. Orthop. Surg., vol. i, p. 625, Oct., 1919.
[3] C. J. Bond: Brit. J. Surg., vol. i, p. 610, Apr., 1914.
[4] H. Schloffer: Bruns. Beite. zur clin. Chir., vol. xxv, 1899, p. 76.
[5] Gangolphe: Lyon Med., 1909, vol. cxiii, pp. 749–751.
[6] M. Brandes: Med. klin. Berl., 1913, vol. ix, p. 1493.
[7] M. Berard: Lyon Chir., 1913, vol. ix, pp. 574–8.
[8] L. Lapeyre: Bull. et Mem. de Soc. de Chir. de Paris, 1914, n.s. vol. xl, pp. 182–90.
[9] Ed. Michon: Bull. et Mémoires de la Société de Chirurgie de Paris, vol. 422, 1916, pp. 1719–22.
[10] P. Mauclaire: Bull. et Mem. de soc. Chir. de Paris, 1916, n.s. 12, pp. 1864–66.
[11] Pierre Barbet: La Clin. Par., vol. vii, 1912, pp. 65–69.
[12] C. J. Bond: Brit. J. Surg., April, 1914, vol. i, pp. 610–624.
[13] Gaston Torrance: Surg., Gyn. and Obst., Feb., 1912, vol. xiv, pp. 184–186.
[14] T. W. Huntington: Annals of Surgery, Feb., 1905, vol. xli, pp. 249–251.
[15] J. S. Stone: Annals of Surgery, October, 1907, vol. xlvi, pp. 628–632.
[16] A. Keith: Menders of the Maimed. London, 1919, p. 273.

Reprinted from the New York State Journal of Medicine, September, 1923

ANKYLOSIS; TREATMENT BY ARTHROPLASTY.*

By W. RUSSELL MacAUSLAND, M.D.,
BOSTON, MASS.

INJURY to the smooth resilient cartilage which lines the normal joint, whether due to disease or external violence, results in a lessened range of motion, and, if severe enough, in complete loss of motion. A bony bridge, or fibrous tissue develops and may entirely replace the joint space, giving rise to bony or fibrous ankylosis.

Ankylosis of a joint causes varying degrees of disability, depending (1) on the joint involved, (2) on the stabiltiy of the ankylosis, and (3) on the deformity present. For instance (1) loss of motion in a spinal joint may take place without the individual's being aware that he has lost any function. This observation is frequently made in chronic arthritic cases. Occasionally a striking loss of motion may be observed in the whole lumbar spine without the patient's being aware that function has been lost. A wrist joint may be stiff with only the slightest disability. One knee joint without motion may be disabling only in a mild degree. The second factor, (2) *stability,* must be kept constantly in mind. To return to the example of the stiff knee joint—the disability and pain may be considerable if there is a fibrous ankylosis which is susceptible to joint strain; on the other hand, if the ankylosis is bony, the patient may suffer no pain and only slight disability. It is in weight-bearing joints that this factor is of more importance.

(3) There is a direct relation between the deformity present and the amount of disability in most joints, and it is with this factor more than any other that the surgeon must deal. A hip joint with flexion and adduction deformity may be very disabling, but if the hip is ankylosed in a good position, there is little loss of function. Similarly, a shoulder joint ankylosed with the proper degree of abduction may show a range of usefulness which closely approaches normal.

It is important for the surgeon to be familiar with these facts concerning ankylosis, before he approaches the subject of arthroplasty, or the mobilization of ankylosed joints by operation. Each individual case must be considered singly and not infrequently the surgeon must base his final decision upon a minor factor, which without careful consideration might be overlooked. It is not merely the fact that the joint is stiff that leads one to advise operation.

Indications for Arthroplasty.

What may be considered, then, the definite indications for operation? In general, only certain joints are to be considered for operation, and these in the following order of frequency: (1) the elbow, (2) the hip, (3) the knee, (4) the temporo-maxillary (jaw), (5) the wrist and fingers. Other joints are not included for the reason that the ankylosed joint in good position will give good function. The shoulder, as has been mentioned before, functions well in a good position. The ankle stiff at a right angle functions well. Further indications for mobilization should be considered for each separate joint which I shall take up in order.

(1) *The elbow*—

(a) When both elbows are stiff, arthroplasty is always indicated on one joint, at least.

(b) Arthoplasty is always indicated when the loss of function in the joint is a serious disability in a patient's occupation.

(c) Arthroplasty is indicated when the elbow is stiff in a bad position. By this, I mean that if an elbow is stiff at 180°, it is absolutely necessary to change the position for functional purposes and, since an operation is required to do this, the procedure may well be an attempt to mobilize rather than a simple osteotomy.

(2) *The hip*—

(a) Two stiff hips may be considered a definite indication for an attempt to mobilize one of them.

(b) A stiff hip associated with a stiff knee in either leg may be considered a definite indication for mobilization.

(c) A stiff hip in bad position requiring an osteotomy rarely may be considered an indication for arthroplasty.

(3) *The knee*—

(a) Two stiff knees alone or associated with one or two stiff hips may be considered an indication for an attempt at mobilization of one and rarely both knees.

(4) *Temporo-maxillary*—Always must be mobilized.

(5) *Wrist and fingers*—

(a) The general indications for arthroplasty are rare because of the fact that in hyperextension a stiff wrist causes very little loss of function. For patients who require wrist-joint motion in their work, an attempt at arthroplasty is permissible, but the procedure is rarely found necessary. In finger joints, also, operation is seldom applicable, and the judgment of the surgeon depends solely on the patient's individual circumstances.

Contra-indications to Arthroplasty.

(1) The tubercular joint rarely, if ever, lends itself properly to operative interference.

(2) No joint should be mobilized in which a stiff joint is of slight disability.

(3) No joint should be mobilized when operation is contra-indicated by age or the patient's general condition.

* Read at the Annual Meeting of the Medical Society of the State of New York at New York City, May 23, 1923.

A Short History of the Mobilization of Joints.

The mobilization of stiff joints was first attempted by J. Rhea Barton in Philadelphia in 1826, who produced a pseudo-arthrosis in a case of ankylosis of the hip joint. From this time many writers who have advocated various methods have written on this subject. The great advances in the work have been due to such men as the late Dr. John B. Murphy of Chicago, Dr. Putti of Bologna, Dr. Baer of Baltimore and Dr. Neff of Chicago. By the untiring and earnest efforts of these leaders much has been done to advance this work and to so stabilize surgical technique in its application to ankylosed joints that, at the present time, the surgeon who is devoting his attention to this special branch may justifiably and without hesitation recommend arthroplastic measures in certain joints. Various substances have been advocated as interposing material; fat, muscle, fascia, and specially prepared membranes. The concensus of opinion, however, is that free fascia transplants give us the best and most consistent results.

Arthroplasty not an Excision.

It is necessary to point out quite definitely the difference between arthroplasty and excision. Literature is filled with various reports of cases in which the procedure, *an excision,* resulted in the unstable joint that one expects from a careless removal of bone. Excision does not result in stability; arthroplasty does. Excision is a crude surgical procedure, the ultimate results of which do not warrant its use in any conditions save in serious joint infections, usually of tubercular origin.

A good arthroplasty gives a good sliding joint. The late Dr. John B. Murphy has emphasized this point over and over again. The range of motion in the joint is always good and its strength approaches normal. Stability is an absolute essential. The joint should also be painless and able to stand hard use without showing arthritic changes. To summarize: An arthroplasty results in good permanent motion, good strength, and good stability, without pain.

Technique for Arthroplasty.

In the technique for arthroplasty for various joints, the approach and exposure to enable proper remodeling of the joint, as well as the proper interposition of tissue, seem to me to be the two fundamental factors to be considered. With these in view, the following technique for elbow-joint arthroplasties has been evolved. It will be readily seen that the posterior exposure has many advantages over the double lateral exposure, in that perfect remodeling and interposition of tissue may be obtained.

Operative Technique.

The Elbow Joint—

The arm from the wrist to the shoulder and the leg on the same side, from the hip to the knee, are given a two-day preparation. At the time of the operation, a tourniquet is applied to the upper third of the arm and an application of iodine made to the skin.

A semicircular incision is then made, beginning over the external condyle and running down about two inches and up over the internal condyle. The wound is sponged with alcohol and carefully clamped off to avoid the handling of the skin during the operation. The flap containing skin and superficial fascia is then dissected back to the base line and retracted. The ulnar nerve is isolated and dissected out of its sheath. It is sometimes difficult to find this nerve, but it is always to be sought at the inner side of the internal condyle. It should be dissected out carefully with a blunt dissector so as not to break or injure it. After it has been freed for one and one-half inches, gauze is passed beneath the nerve, and it is retracted to the ulnar side. It is then freed further by blunt dissection with gauze.

A transverse incision is then made extending down through the periosteum. This incision follows in direction the superficial one, and outlines a flap which is to be dissected back and preserved *in toto* for subsequent covering for the joint. The pulling back of this flap is a hard and tedious process until it is well started, after which it can be peeled back readily by blunt dissection. It is the inner side that is the hard part, as the layer is thin here, and one must exercise great care not to buttonhole it. The olecranon is then sawed through. After this, it is frequently possible to break open the old joint. In some cases, however, ankylosis is bony and the joint cavity obliterated. Cases of this kind are the most difficult and in these it is necessary to saw through the joint. The tip of the olecranon has to be chiseled out and dissected back with its posterior flap. Usually the olecranon is too large, and it is well to take off a little of it.

The capsule, fascia, and ligaments are then dissected back so as to allow the lower end of the humerus to protrude into the wound. Then its edges are snipped off with rongeur forceps and a new trochlear or intercondylar surface formed. A shoemaker's rasp is used in filing the extremity as near like the normal humeral end as possible. After this modeling, a piece is removed corresponding to the olecranon fossa in the normal humerus. One has to be careful about making this cup, as the success of the operation depends largely upon attention to such small details. This modeling is largely done with a saw and a file.

To ensure good function, the joint surfaces should fit accurately before the fascia is applied, but the joint should not be too loose. Only sufficient bone must be removed to give free motion. If too much bone is removed from the ends, a flail joint will result, giving the operation no advantage over an excision. When this mortising is completed, the fascial flap is dissected from the leg. An incision is made on the outer side of the thigh, a little below the middle, extending down to the fascia lata. After a flap of fascia five to

seven inches by four to five inches is dissected out, the wound is closed.

This fascia, which is free from all fat, is placed about the newly fashioned humeral condyles and attached anteriorly to the capsule and posteriorly to the periosteum of the lower end of the shaft of the humerus with interrupted chromic catgut sutures No. 2. Chromic catgut No. 2 is then loosely wound twice around the shaft just below the interrupted suture line.

The forearm is placed in apposition to the condyles. Two drill holes are then made in the olecranon process and two others opposite them in the shaft of the ulna. Through these, kangaroo tendon is passed and tied. The inner layer is now sutured with chromic catgut No. 2 and the skin and fascia with plain catgut No. 2. Dry sterile dressings are applied and the arm put up in plaster beyond a right angle.

After-treatment.

If there is no evidence of infection, the cast should remain on for a week. It is then split and the dressing changed. If there is a persistent temperature, a window should be cut in the cast and the wound inspected.

If normal healing takes place, passive motions are begun in about ten days. The arm is always kept above a right angle. After three weeks, gentle massage is applied. Baking is begun in six weeks and practised three or four times a week.

The ultimate success in these cases depends very largely on the after-treatment. The patients should be under observation for a long period of time. Frequent X-Rays should be taken so that we may follow the bony changes in the joint. If motion begins to shut down, the arm should be manipulated under an anæsthetic and the elbow put up in acute flexion. Occasionally motion becomes limited, due to an exuberant growth of new bone. In this case, a secondary operation should be done to remove the new bone, but it should not be undertaken for at least three months after the original operation.

Case I. W. D. was referred to me by Dr. A. W. Shea of Nashua, New Hampshire, and was operated on before the New Hampshire Surgical Club. On March 25, 1911, he had received a contused wound of the left thumb, which became septic. Sepsis became general and in a week he entered the hospital. Five incisions were made in the left hand, two in the left wrist, one close to the left elbow-joint and one in the left hip. All had drains put in. A student in the hospital opened a swelling near the right elbow and cut into the joint. At the end of twenty-one weeks the patient was discharged from the hospital with bony ankylosis of the right elbow and with only a few degrees of motion in the left elbow. Both joints were slightly flexed. The left wrist had a sinus which still drained a little. The patient had little motion in the fingers, being unable to flex them to a right angle with the palm of the hand. He was unable to feed himself or to touch his head with either hand.

He entered St. Joseph's Hospital, and I did an arthroplasty on the right elbow, in March, 1912, using a flap of fascia lata for interposition. A hard bony ankylosis was found. The skin was closed with silkworm-gut and a voluminous dressing applied with the arm at a right angle. Arm and forearm were placed on pillows with heavy dressings but no splint. Passive motion was begun on the fifth day. Primary union took place in the wounds of the elbow and thigh. Passive motions were continued and increased, but at the end of six weeks it was found that he could not use either biceps or triceps muscles, as he had lost all power from long disuse. However, after several weeks he trained the muscles by counting and attempting contraction at the same time. Finally he was able to flex the forearm himself, and since that time improvement has continued.

He has now full motion in flexion, extension, and rotation, and is able to feed himself, put on his own clothes, and to do chores about the house.



Fig. 1, Case I, W. D. Ankylosis elbow. Six months after operation, showing voluntary flexion and extension and power of biceps.

Previous to the operation, he was entirely helpless, and unable to care for himself in any way.

Case II. W. D. The previous history of this case is given under Case I. After the arthroplasty on the right elbow, the patient requested that a similar operation be done on the left elbow. The roentgenogram showed a bony ankylosis at 90°. On January 31, 1914, I did an arthroplasty on the elbow, using the same method as applied on the

right elbow. The end-result was a stable useful elbow, with motion from 60° to 160°.

Case III. I. H. had fallen on her elbow four months before she entered the hospital. She had suffered considerably from pain and was unable to use her arm. At this time, I manipulated her elbow under ether and later manipulated it every two weeks in the Carney out-patient department. On account of the limitation in motion, an arthroplasty was advised.

She entered the Carney Hospital on June 22, 1915. At this time, the elbow was slightly tender and motion was limited to 40°. There was no

Fig. 2, Case II, I. H. Ankylosis of elbow, showing voluntary motion in flexion and extension, eight months after operation.

pain, but the joint was somewhat enlarged and the bones felt rough. The roentgenogram showed an old fracture of the lower end of the humerus.

On June 23d, I did an arthroplasty of the elbow-joint, using a free flap of fascia lata. The patient made a good ether recovery. The following day, the plaster was trimmed about the fingers. The fever and swelling of the hand continued for several days until, on the 28th, after the cast was bivalved, the temperature dropped and the œdema disappeared.

On July 3d, the patient was up in a chair. On the 6th, the dressing showed a slight superficial sepsis. The motion of the arm was very much increased. She was discharged from the hospital on July 15th to report to the out-patient department. There was a gradual return of motion.

Case IV. W. M. had fractured his olecranon as the result of a fall. After an open operation in which the olecranon was fastened in place with silver wire, the elbow gave him no further trouble until a year later following a second injury. A box had fallen and hit him on the elbow. Two weeks later, when he reported to the hospital, he was in great pain and showed a discharging sinus from which a piece of wire, which was protruding, was easily removed. Free drainage was established and later the arm was twice curetted.

He was discharged March 21st after a tempestuous illness, to report to the out-patient department for dressings. In July the wounds had healed and the patient was discharged to return in six months for an arthroplasty.

This I did on July 9, 1919, and on his discharge from the hospital on September 4th, he was able to flex and rotate his arm voluntarily. On October 18, 1919, he had voluntarily motion from 158° to 105°. On October 30, 1920, he had voluntary motion from 60° to 135°.

Case V. E. M. The patient's trouble started slowly with general poor health. Two years ago, she became ill with infectious arthritis, which at first affected the knees. There was no history of a neisserian infection. The patient was very much constipated and suffered more or less from tonsillitis. Later, the elbows became painful and could not be straightened out.

Physical examination showed a thickening of the capsule of the left elbow, with about 35° limitation in motion. The left knee showed extension to within 15° of full extension. The patient walked with a marked limp, and flexed knees. General treatment was prescribed, with forcible extension of the knees. As motion in the arm had shut down, leaving it ankylosed at 100°, an arthroplasty on this joint was advised.

February 25, 1913, I did an arthroplasty, using my fascia lata method.

March 24, 1913, the arm showed no swellings. There was little pain, and the patient's general condition was fair. There was about 15° motion. Gentle manipulation was ordered.

December 16, 1913, the wound had healed by first intention; supination was three-quarters normal, extension was possible to 170° and flexion to 10° to 15° beyond a right angle. The patient could reach the opposite shoulder with the thumb with ease, but could not dress the lower part of the hair. The muscular power was as good as in the right arm. To gain more motion, a forcible manipulation was advised.

December 29, 1913, under ether, extension to within 5° of straight was obtained and flexion to 45°.

January 26, 1914, examination of the arm showed no lateral mobility and no crunching crepitation. Mobility was possible from 150° to 70°.

B A C

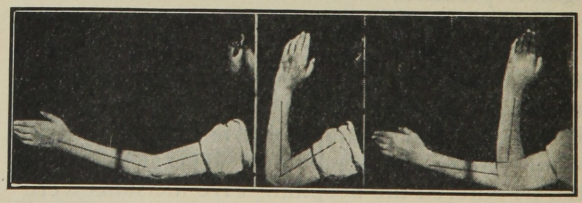

Fig. 3, Case V, E. M. End-result, ten months after arthroplasty.
A. Voluntary flexion.
B. Voluntary extension.
C. Range of motion (not full motion).

Case VI. S. S. This patient was first admitted to the Burbank Hospital, Fitchburg, December 5, 1917, with a subacute neisserian infection. Five years previously the right knee had become swollen and remained so for three months. A month later, the right elbow became swollen and painful. The Wassermann test was positive.

She remained in the hospital thirty-eight days, receiving general treatment and was discharged relieved.

She returned to the out-patient department, July 1, 1918. The arm was then put in plaster from wrist to shoulder, to remain on two months. She was told that her elbow would probably become stiff and would require an arthroplasty later.

On January 9, 1919, the patient was advised to have an arthroplasty done, as her elbow had become stiff. Following the operation on February 6th, she had an uneventful recovery. The cast

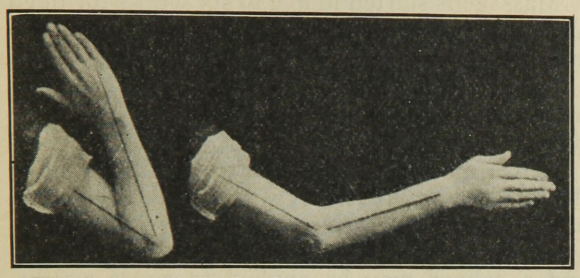

Fig. 4, Case VI, S. S. End-result, three months after arthroplasty.
At left, voluntary flexion.
At right, voluntary extension.

was removed in two weeks, after which passive motion was begun. She was discharged March 18, 1919.

Case VII. M. R. For thirteen years this patient had had attacks of rheumatism affecting the ankles, elbows, and knees. The physical examination was negative except for the joints. Both knees were slightly flexed and the right one was ankylosed, showing scars on either side. The right ankle showed some contraction of the tendo-achillis. The left elbow showed good motion except for 10° limitation in extension; the right was ankylosed at 125°.

The patient was admitted to the orthopedic service of the Carney Hospital, September 6, 1910, where very slight improvement took place in the knees and feet under conservative treatment. In October, 1910, on account of the swelling and bogginess of the left knee, an arthrotomy was advised. This was done October 19, 1910. Daily manipulations were begun on the fifth day, and an uneventful recovery took place as regards the knee.

As the elbow was stiff and in an ungainly position, operation on this joint was advised. On November 5, 1910, an arthroplasty by the Murphy method was done on this joint.

November 10, 1910, the right hand was considerably swollen and painful, for which pressure and hot fomentations were applied. The skin on the upper part of the arm became somewhat necrotic from poor circulation and later sloughed.

November 30, 1910, passive motion was begun and repeated daily. The first attempt at motion was made and 30° attained. Progress was continuous and a gradual gain in motion was made. Later, massage was ordered for the hand, forearm, and shoulder.

January 11, 1911, about 30° to 40° motion in flexion and extension were obtained. The wound showed heavy granulated tissue. A week later she was discharged from the hospital. Dressings were to be done at home.

February 28, 1911, she was re-admitted to the hospital for manipulation. Normal motion was obtained. Since this time, she has been seen in the out-patient department. There is practically no lateral mobility and the end-result is perfect function.

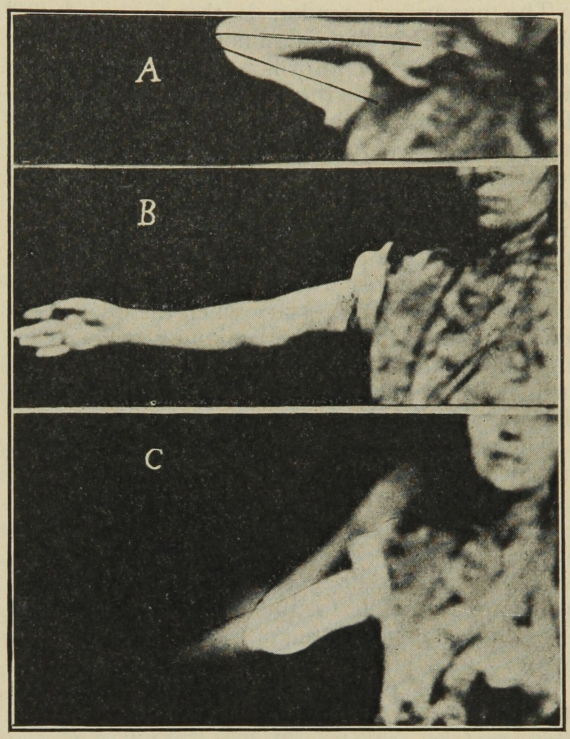

Fig. 5, Case VII, M. R. End-result, fourteen months after arthroplasty.
A. Voluntary flexion.
B. Voluntary extension.
C. Range of motion.

The Knee Joint.

Knee-joint technique, I feel, has been perfected to its highest degree by Putti. My technique differs, in that division of the patellar tendon or elevation of the tibial tubercle with the patella is not done, as these seriously complicate convalescence. The Kocher incision is used and the joint exposed and remodeled in the following manner:

Operative Technique.

The usual preparation is given both legs from the ankle to the groin. I feel it is best to remove the fascia from the opposite leg, thereby minimizing the extent of the operation on the ankylosed leg as well as making it possible to remove more fascia without disturbing the external support of the joint.

The incision is made from just below the inner attachment of the patella tendon, curving slowly over this point to the middle of the external cartilage, and then directly up the outer side of

the leg just above the mid-horizontal line, a distance of five to ten inches from the joint proper. As much fat as possible is taken with this incision. After clamping the skin-edges with towels, the skin is dissected to the inner side of the leg, exposing the patella tendon, patella, and tibial tubercle.

A curved incision is then made through the fascia, beginning in the mid-anterior line, about five inches above the patella, and running between the patella and outer condyle to just below the knee-joint.

The quadriceps tendon is then exposed and elongated. This elongation not only allows better joint exposure, but affords a proper lengthening when we later place the leg in flexion in plaster. This lengthening may also be done by the Bennet method. The patella is then raised from the femur, taking the lower cut portion of the quadriceps tendon, and forcibly retracted to the inner side of the knee, with its inner ligament attachments intact. Some surgeons detach a piece of the tibial tubercle in order to increase exposure, but I have found this unnecessary when the quadriceps tendon is elongated in the beginning. There are also many difficulties when this piece is removed, such as delayed or faulty union, which complicate the convalescence.

The patella in these cases is often found hypertrophied and should be narrowed laterally, as well as thinned and smoothed with a shoemaker's rasp.

The joint being then exposed, a careful study of it is made from X-Rays, and great care is taken to follow the contour carefully. Putti instruments are admirable for this purpose.

Several important requirements must be observed:

1. Be sure to leave a well-defined spine between the tibia condyle, as well as cupping out the upper tibia surface, which will help stabilize lateral mobility.
2. Carefully round the condyle with a Putti instrument and a shoemaker's rasp, making a concavity to fit over the newly formed spine.
3. Actually replace these opposing surfaces, and mould carefully, without any irregular hitches during attempts to flex.
4. Cup out a space into which the patella will articulate. Great care should be taken with this modeling.
5. Remove a large piece of fascia lata ample enough to cover both condyles. The fascia nearest the knee on the outer side is thickest and most serviceable. When this is removed, sew the fascia over the condyle, covering all exposed bone well. Sew posteriorly two inches above the articular surface. The femur is then adjusted to the tibia and the patella is replaced. The outer fascia is united with interrupted chromic catgut.

The elongated quadriceps is then strongly sutured and the skin closed with interrupted catgut. A plaster is applied from the toe to the groin with the knee in 35° to 40° flexion and the leg placed in an elevated position in bed. Opiates are often necessary and may be freely used.

After-treatment.

The temperature, pulse, and pain are carefully watched for any signs of infection.

The cast is split for dressing in two weeks and the leg placed into a ring caliper with 35° flexion, so arranged that this can be changed and passive motion slowly started.

Traction is also applied with this caliper which remains on day and night.

Gentle passive motions are started and increased gently, guided by pain and sensitiveness, which always should be minimized.

Massage is started in five to six weeks for thigh and calf, and the patient may usually walk with crutches about the sixth week.

By means of an overhead extension, the patient may also use passive motions in bed, two or three times a day.

Active motions are started or attempted about the tenth week, preferably with the leg submerged in a tub of water. No actual weight-bearing is allowed until the lateral ligaments have tightened, and a caliper may be applied to assist weight-bearing, depending wholly upon the sensitiveness and pain on use.

Case I. F. O. K. Age 31 years. In 1909, patient had an acute neisserian infection in the left knee. The opening of the joint resulted in an ankylosis. The knee was in good position, but there was no motion between the tibia and the femur. The patella was ankylosed to the femur. Manipulations did not result in a gain in motion. Arthroplasty was advised.

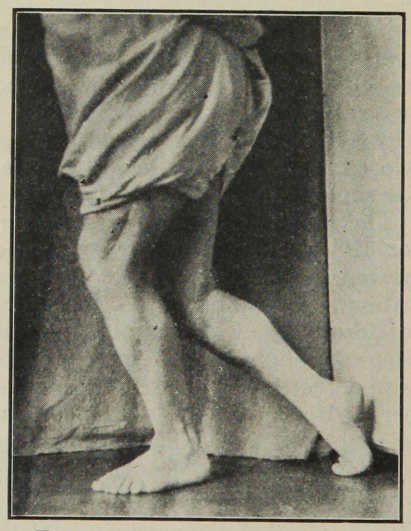

Fig. 6, Case I, F. O'K. Twelve years after mobilization, showing weight-bearing, January, 1923.

December 14, 1910, arthroplasty on left knee according to the technique as described.

December 23, 1910, out of bed. Daily dressings.

January 5, 1911, cast removed. Posterior shell applied.

January 7, 1911, small amount of weight-bearing. Crutches.

January 19, 1911, patient discharged from hospital. In a leather leglet with limited motion.

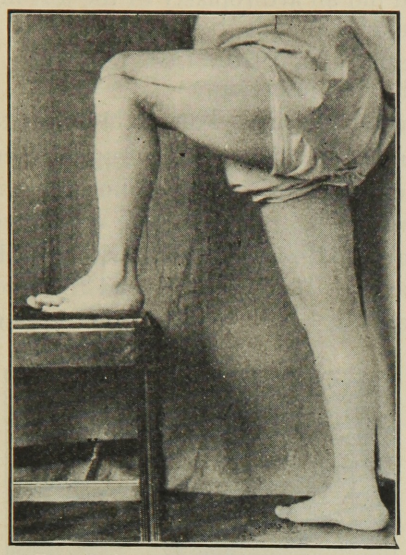

Fig. 7, Case I, F. O'K. 95° flexion. Twelve years after arthroplasty, January, 1923.

To continue stretching and daily hot fomentations.

January 3, 1923, now twelve years since arthroplasty. No pain and has had no trouble. "No bother at all and can do everything. Sometimes has to stop and think which is the operated knee." Has gained forty to fifty pounds. Leg straight. Good power in quadriceps. Complete extension

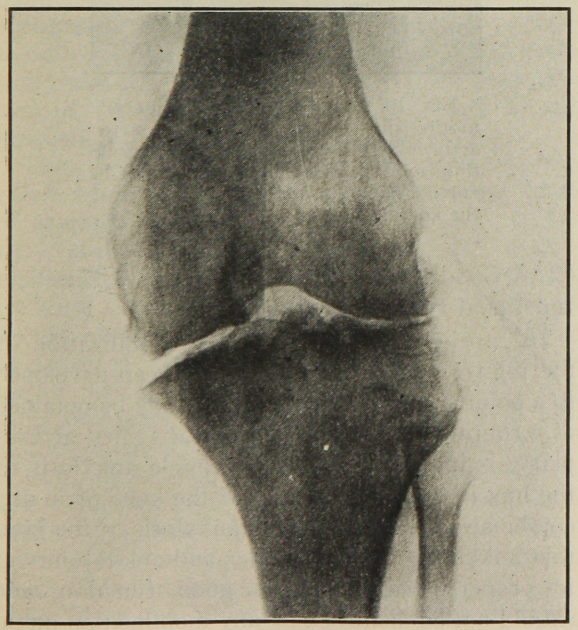

Fig. 8, Case I, F. O'K. Antero-posterior roentgenogram twelve years after arthroplasty, January, 1923.

and 95° motion in flexion possible. Absolutely no lateral mobility. (Figs. 6, 7, 8.)

The Hip Joint.

In the hip joint, the method as originally planned by the late Dr. John B. Murphy is substantially the same as that being used today, with the exception that a free fascia transplant is used and that the transplant is placed around the head and neck of the femur, instead of over the acetabulum. Great care is taken to save the old capsule and resuture it over and above the head of the femur. The technique is as follows:

Operative Technique.

The patient is given a very careful two-day preparation of the hip from the rib-line to below the knee. A skin incision is made beginning at the anterior superior spine and running in a horizontal plane to about two inches below the level of the trochanter, at which point it curves over the femur three to four inches below the trochanter in a U-shaped fashion. This flap, with considerable fatty tissue, is elevated, raised to its base line and retracted.

A similar incision is made through the fascia external to the sartorius and sweeps around about three inches below the trochanter, at which point it reaches the base of the femur. The periosteum is separated downward one-half inch and then upward to the base of the trochanter.

With a two-inch osteotome the entire trochanter is removed and elevated, taking with it all the muscle attachments.

An incision is then made through the capsule beginning on the ilium and passing parallel to and in the center of the femoral neck to the base of the detached trochanter. At the attachment of the capsule to the femoral neck it is cut off on both sides for a distance of one and one-half inches and retracted. A blunt dissector then frees the capsule from the neck as much as possible.

A study of the junction between the head and the ilium is made, and then with a curved chisel, covering a small space at a time, the femur is separated from the acetabulum. Care should be taken to follow the outline of the acetabulum, as this is always hard, while the head is usually atrophied.

Finally the head is freed and dislocated. With the Murphy male and female rasp the acetabulum is thoroughly reamed out and the head is thoroughly rounded. Great care should be taken to remove all spicules of bone.

A piece of free fascia lata from the outer side of the opposite leg is removed and sewed around the neck of the femur by interrupted sutures. Then a purse string is tied about it tightly.

The head is reduced. The old capsule is returned and sewed together and to the old attachments as nearly as possible. I feel that this very materially adds to stability and ensures against dislocation or a wabbly, unstable joint.

The trochanter is then pulled down to its old position and held by resuture of the periosteum with fascia originally elevated. The skin is closed and the leg placed in plaster from the nipple line to the toe, with the leg in 10° abduction, complete

extension, and a little pressure over the trochanter.

The cast remains on two and one-half weeks and is then removed and traction applied. Passive motions are started at the third week and should always be within the limits of pain. The patient is encouraged to voluntarily contract the thigh muscles and thereby get voluntary control early.

The patient may walk with crutches in six weeks and bear a little weight in about eight weeks. Convalescence as regards motion varies with the type of individual, but all motion should be within the pain limits.

Case I. O. P. Age 24 years. Patient had an ankylosis of three years' duration involving both hips and knees, due to an infectious process, probably neisserian in origin.

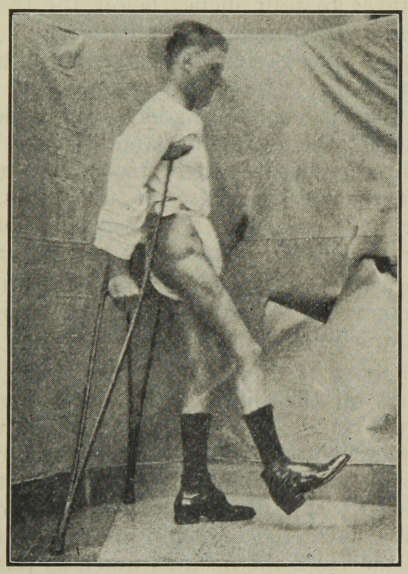

Fig. 9, Case I, O. P. Voluntary motion in right hip two and a half years after arthroplasty. (Patient has about twice this motion, but is handicapped in further flexion by double ankylosis of the knee.)

April 12, 1920. Arthroplasty of right hip by Dr. Andrew R. MacAusland, using the technique as outlined. It was then about three years since the original infection. The operation was followed by some shock. Perfect healing of the wound. Cast applied.

May 17, 1920. Cast removed and passive movements encouraged.

June 5, 1920. Out of bed with crutches.

June 10, 1920. Walking with crutches.

June 12, 1920. Discharged from hospital.

January 13, 1923. No pain. Motion in flexion 40°. Motion in adduction and abduction in arc of 15° to 20°. (Fig. 9.)

Case II. O. P. Age 24 years. The previous history of this case was reported under Case I. Both hips were ankylosed.

November 2, 1920. Seven months after the operation on the right hip, Dr. Andrew R. MacAusland did an arthroplasty of the left hip, using the regular technique.

November 29, 1920. Cast removed. Wound healed by first intention.

December 6, 1920. Passive motions started.

December 17, 1920. Patient up in wheel-chair. Some sensitiveness. Omit motion for one week.

December 26, 1920. Passive motion renewed.

January 4, 1921. Walking with crutches.

January 22, 1921. Discharged from hospital.

January 12, 1923. No pain. Motion in flexion 40°. Good abduction and adduction. Excellent functional result. (Fig. 10.)

Fig. 10, Case II, O. P. Voluntary motion in left hip two years after arthroplasty. (Patient has about twice this motion, but is handicapped in further flexion by double ankylosis of the knee.)

In conclusion, I consider that mobilization of the joints in its present stage has been developed to a point where excellent results may be obtained as a routine in elbow-joint ankylosis; that arthroplasty is indicated always in double ankylosis of the hip, in double ankylosis of the knee or in any combination of these, and in ankylosis of the jaw; that ankylosis of the shoulder and ankle joints, if in proper position, allows good function, and should not be disturbed by any mobilization methods. In ankylosis of a single hip-joint or a single knee-joint, mobilizing methods should be advised with caution and judgment, and should be attempted only by highly trained technical operators who have had considerable experience in mobilizing methods.

BROOKLYN EAGLE PRESS

[Reprinted from the Boston Medical and Surgical Journal, Vol. 190, No. 7, pp. 242-244, Feb. 14, 1924.]

Intrinsic Splint Traction

BY J. WARREN WHITE, M.D., BOSTON

The purpose of this paper is to report a simple type of intrinsic traction, which, in my experience, has proved of value, and which has not been employed, to my knowledge, in the form described below. Although a casual search of the literature has revealed no type of apparatus embodying its three main principles, it undoubtedly has been used by others. These principles may be briefly stated as follows: First, facility in maintaining a desired amount of traction; second, comparatively accurate mensuration of force employed; and third, ease of application, adjustment and transportation.

This method of producing extension was the result of working with the early ice-tong type of skelatile traction, where the necessity existed of maintaining a continuous pull for considerable periods of time. The mechanics of the ice tong in the hands of the iceman applies to its use on the femoral condyles; that is, as long as force is maintained in lifting the cake of ice or exerting traction on the skeleton, the tong will stay in place. If this force is not continued in either case, there is a probability of slipping and displacement of the instrument. The necessity of a more or less fool-proof and stable apparatus was therefore apparent. With the adjustable tongs being made now, the need of continuous traction is not so imperative.

As its name indicates, the traction is produced and applied within the limits of the splint. A Thomas leg splint, or some such modification as would be necessary in employing it with an upper extremity, is the basis of the apparatus. This splint should be sufficiently long to allow for at least two feet between its distal tip and the distal end of the arrangement that is fixed to the extremity, whether is be tong, if skelatile traction is used, or "adhesive spreader" or its equivalent, if "skin traction" is utilized. The advantage of this type of traction over the weight-and-pulley arrangement will be taken up later on in this paper and I will now describe the mechanical details upon which it depends.

The pull is exerted and maintained by three elements arranged in series, one end of which applied to the distal extremity of the splint and the other end to the distal extremity of the arrangement fixed to the point at which traction is desired. The proximal element in this series is a bunch of rubber bands of thickness and number suitable to the space available and to the amount of traction deemed necessary. To these india-rubber bands is fastened a spring balance of about twenty-five pounds capacity, of the type used for weighing infants. A small, nicely nickeled spring balance, as above, can be obtained at most surgical supply houses for about a dollar, which will be satisfactory for this purpose. I have found that they retain their accuracy, although they do stretch out to some extent, even after being used on a constant traction varying from seventeen to seven or eight pounds for six weeks or more. To the other end of this scale is hooked a metal chain of the type now used in heavy windows instead of window cord. This chain is passed about the distal end of the splint and hooked back on the scale through a link that will give the traction desired, which is read directly on this scale. It has been found that the combination of the india-rubber bands and the balance makes it possible by its elasticity to maintain a given

traction for an indefinite period with little need for adjustment. Rarely has more than twenty pounds traction been found necessary to effect correction of overriding in fractured femurs, and in recent cases I have never had to use more than twenty-five. It might be stated here that I have found it better to employ many small rubber bands than a few of the larger type, as they can be handled more easily and it makes little difference if two or three should snap.

The usual form of intrinsic traction commonly described depends for its action on the principle of the Spanish windlass. This has been found to be impracticable except in emergencies, as there is no way of measuring the amount of traction applied or maintaining it at a constant amount. The relative lack of elasticity results in either too much or too little traction, producing discomfort and pressure sores in the former event and no correction in the latter. Any slight variation in the distance from the point at which traction is applied on the limb and the distal extremity of the splint produces a great amount of variation in the force exerted. The stretching of the rope used in the windlass also tends to reduce the amount of traction in a short time.

While this apparatus is used most commonly on the lower extremity, it can be almost equally well employed with a Jones humerus extension splint, the Thomas traction arm splint, or even in forearm conditions where a Jones splint is used and traction desired. While I stated above, two feet is wanted where possible, this type of traction may be employed within a space of ten inches.

The leg is supported by the usual transverse slings attached to the bars of the splint, which itself is supported by some form of adjustable upright fixed to the foot of the bed or the Bradford frame, the latter being most convenient in handling these cases, which are necessarily bedridden, while active traction is being employed. If the pressure on the ischial tuberosity and pubic ramus becomes uncomfortable, the foot of the bed may be elevated, allowing the body to pull slightly away from the ring. This, naturally, increases the amount of traction, which is immediately noted on the scale, and the necessary adjustment can be made. The apparatus

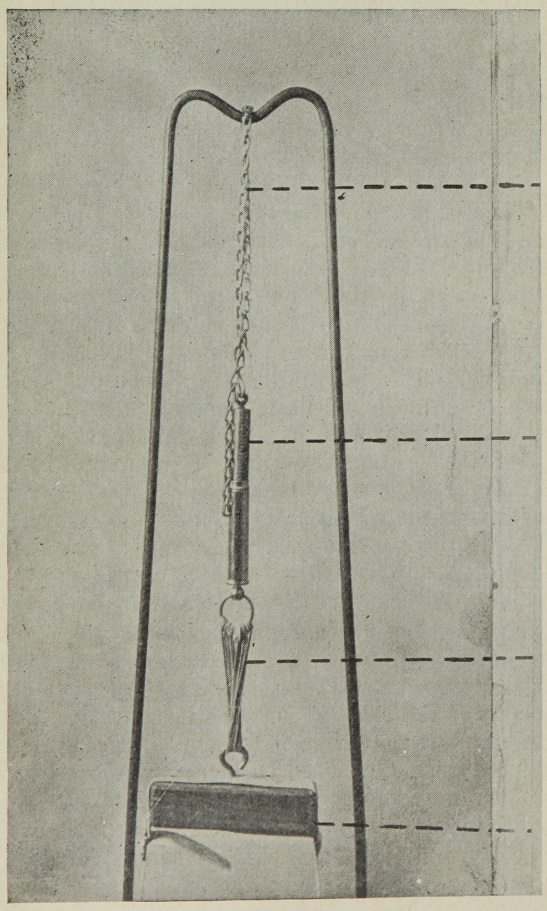

FIG. I.—Showing arrangement of the three elements producing the traction, one end attached to an adhesive "spreader" and the other to the distal extremity of a Thomas splint.

is so stable that no risk is run in moving the patient on the frame to another bed, or to a truck for ease in transportation outdoors or to the x-ray department. The fact that the entire apparatus is a unit on the frame and cannot be easily disarranged is an argument in its favor when one compares it with the cumbersomeness of the weight-and-pulley mechanism usually necessitating the Balkan frame. The ease in obtaining x-rays is of great value in effecting and maintaining position with a minimum of traction. This in itself predisposes good results. Excessive traction that tends to separate the fragments must be avoided as it is undoubtedly a cause of delayed union. Sufficient force to maintain position is all that is desired.

The efficiency of this arrangement will appeal to the man who has had to care for fractured femurs on a busy ward surgical service, where it is difficult to give these cases the necessary personal attention that will insure the proper functioning of the extension apparatus. The usual way of treating the average fractured femoral shaft at present is by extrinsic weight-and-pulley traction with suspension of the extremity. This is, of course, more efficient than the old Buck's extension, even if a Volkman's sliding rest is used to minimize the friction of the lower leg on the bed. Not infrequently the morning hospital visit finds cases, supposed to be "on traction," without a pound's pull being exerted. A few of the commoner reasons for this are: sliding the patient in bed, bringing the "spreader" against the upright holding the pulley, the rope being off the pulley and wedged down beside it, the pulley itself being jammed for some reason or other, the weights resting either on the floor or on a crossbar at the foot of the bed, slipping a knot in the rope against the pulley, and so on.

It is not only for reducing and maintaining fractures in apposition that this form of traction is useful, but it is for any condition where traction is indicated, such as in the correction of flexion deformities, immobilization in acute or chronic arthritis or septic joints, including cervical caries or arthritis, where the Bradford frame is used as a splint, and in arthroplasties, particularly of the hip and knee. The convenience and efficiency of this type of apparatus suggests its use where the more cumbersome and complicated weight-and-pulley traction would not be considered.

240 Newbury Street.

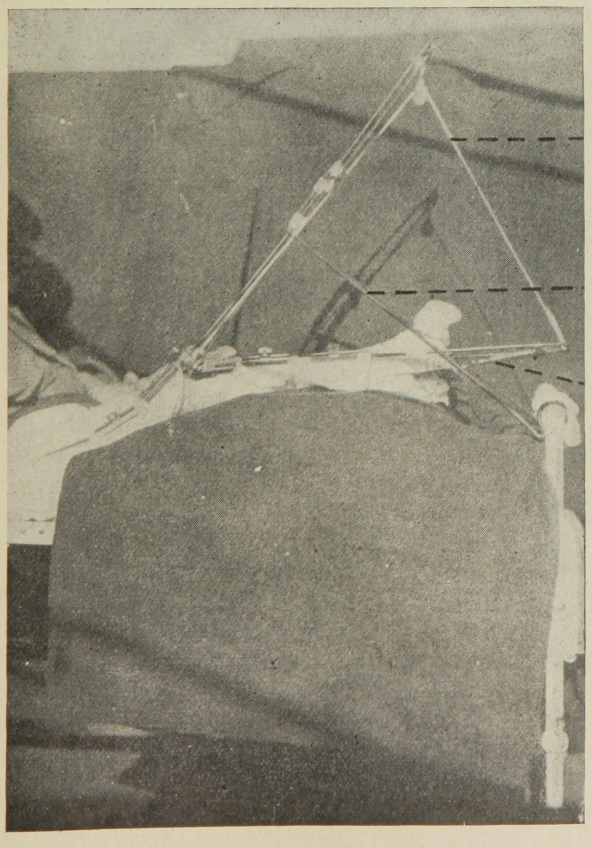

Cord regulating passive motion under control of patient.

Upright holding splint in anti-aircraft position, resting on foot of bed.

Traction without using chain because of lack of space, amount used obtained by employing proper number of rubber bands.

FIG. II.—Intrinsic splint traction being used in postoperative care of an arthroplasty on a knee. Ten pounds traction is used and early passive motions under control of patient within the limits of pain urged.

PRESS OF JAMAICA PRINTING COMPANY, BOSTON, MASS., U. S. A.

REPRINTED FROM
ANNALS OF SURGERY
227 South Sixth Street, Philadelphia, Penna.
DECEMBER, 1924.

ASTRAGALECTOMY (THE WHITMAN OPERATION) IN PARALYTIC DEFORMITIES OF THE FOOT

BY W. RUSSELL MACAUSLAND, M.D.
SURGEON-IN-CHIEF, ORTHOPŒDIC DEPARTMENT, CARNEY HOSPITAL
AND
ANDREW R. MACAUSLAND, M.D.
OF BOSTON, MASS.

IN 1916, one of the writers [11] read before the Orthopædic Section of the American Medical Association a paper on "Astragalectomy in Infantile

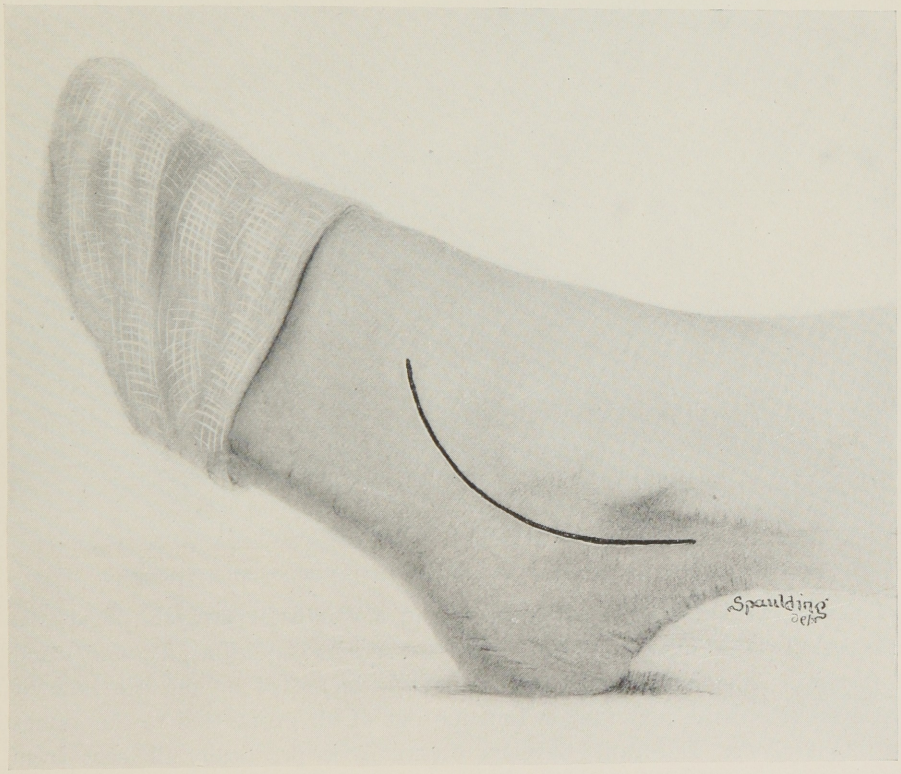

FIG. 1.—Astragalectomy—the Whitman operation. Line of incision.

Paralysis," which included a review of the literature of the subject up to that time, and covered a series of one hundred and thirty-five cases. In 1920, J. W. Sever [18] published an article in the *Journal of the American Medical Association*, reporting two hundred and seventeen cases of astragalectomy done at the Boston Children's Hospital, by eight surgeons. The results recorded by Sever are so diametrically opposite to those which were reported in the above paper that, in justice to the classical operation described by

Whitman,[22] we believe it necessary to make a further report of a series of two hundred and forty-seven of our own cases.

The Importance of Muscle Balance in the Foot.—The normal foot is balanced by muscles which work in perfect coördination, assisted by ligaments which check the extremes of motion. When paralysis involves the foot, the resultant damage varies from a slight, almost unrecognizable lack of muscle

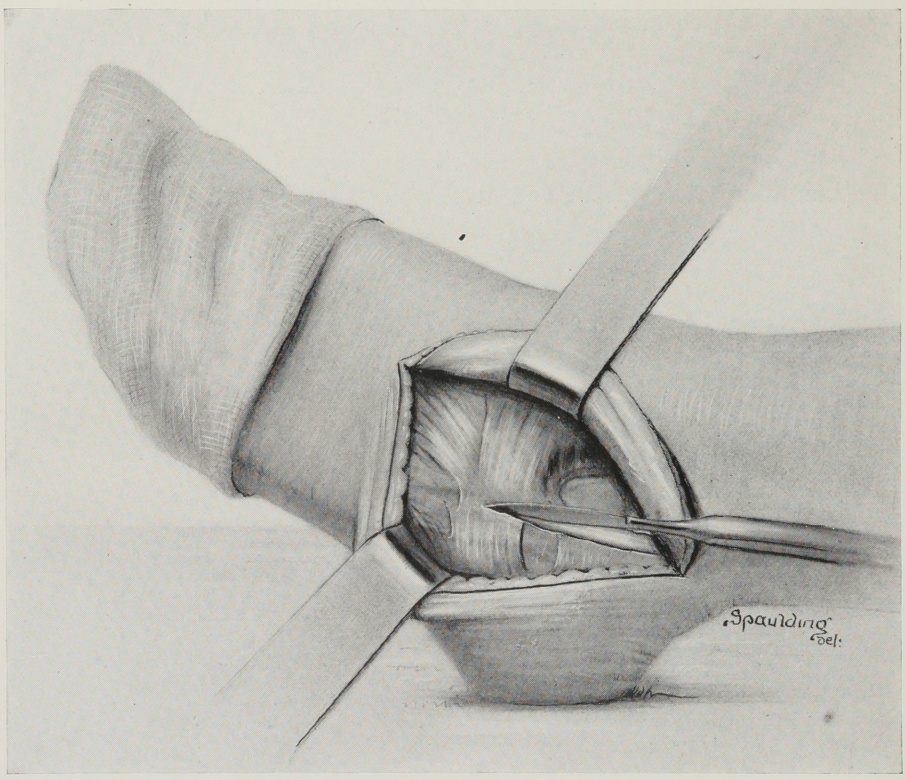

FIG. 2.—Tendon of peroneus longus exposed; tendon of peroneus brevis being exposed.

balance or weakness of a single group, to a complete paralysis of all the muscles. Lack of muscle balance causes two serious conditions, *instability* and *deformity*. The instability, which is greatly increased by the presence of paralysis elsewhere, may impair function out of all proportion to the extent of the paralysis. Deformity develops eventually in practically all cases from unopposed muscle pull. The recognition of this fact and the prevention of deformity are most important, since no reconstructive surgery can be done until all deformity has been corrected.

The Relation of Shortening (and Atrophy) to the Extent of Paralysis.—Instability, particularly with the additional handicap of deformity, is the major factor in determining the amount of shortening. The authors observed long ago that many severe and extensive paralyses developed only one or two

inches of shortening, whereas many cases with a single paralyzed group of muscles had as much as two to four inches. Analysis showed that patients using the leg well in walking developed less shortening than those using the leg poorly. Further, it was apparent that insecurity or instability of the foot caused the patients in the latter group to hop quickly over the weak leg, using it as little as possible. This explains perfectly why calcaneovalgus is asso-

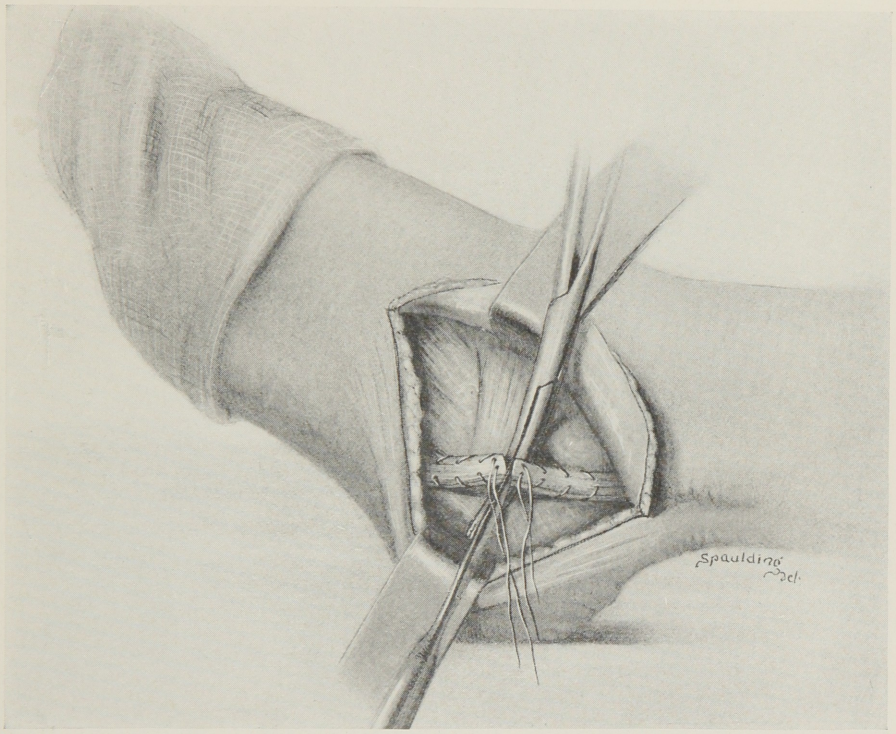

FIG. 3.—Peroneal tendons sutured and divided.

ciated with more shortening than one would expect from a single group paralysis; and, conversely, why almost flail legs vigorously used, show less shortening than one would expect. It becomes unnecessary to fall back on the term "trophic" to explain shortening.

Early "stabilizing" operations are amply justified to avoid shortening.

The Object of Astragalectomy.—The object of astragalectomy is to make a new ankle-joint (an arthroplasty) which, with such muscle as is present, will be stable and well balanced. When properly done, an astragalectomy shifts the weight-bearing line to the front by the forward displacement of the tibia and the fibula, thereby obtaining a so-called "rocking-horse foot," with the weight-bearing near the middle—the point of advantage—rather than on the "backstep of the rocking horse" as is clinically seen in a case of calcaneovalgus. The fulcrum is increased by the lengthening of the posterior arm or the distance between the weight-bearing line of the tibia and fibula

and the back of the heel. This change in weight-bearing is particularly efficient when the peronei are transplanted into the Achilles tendon, in which position they not only tend to prevent recurrence of calcaneous but in most cases may even assist in plantar flexion.

Astragalectomy not for Ankylosis but for Mobility (Arthroplasty).—There seems to be a widespread impression that the operation results in anky-

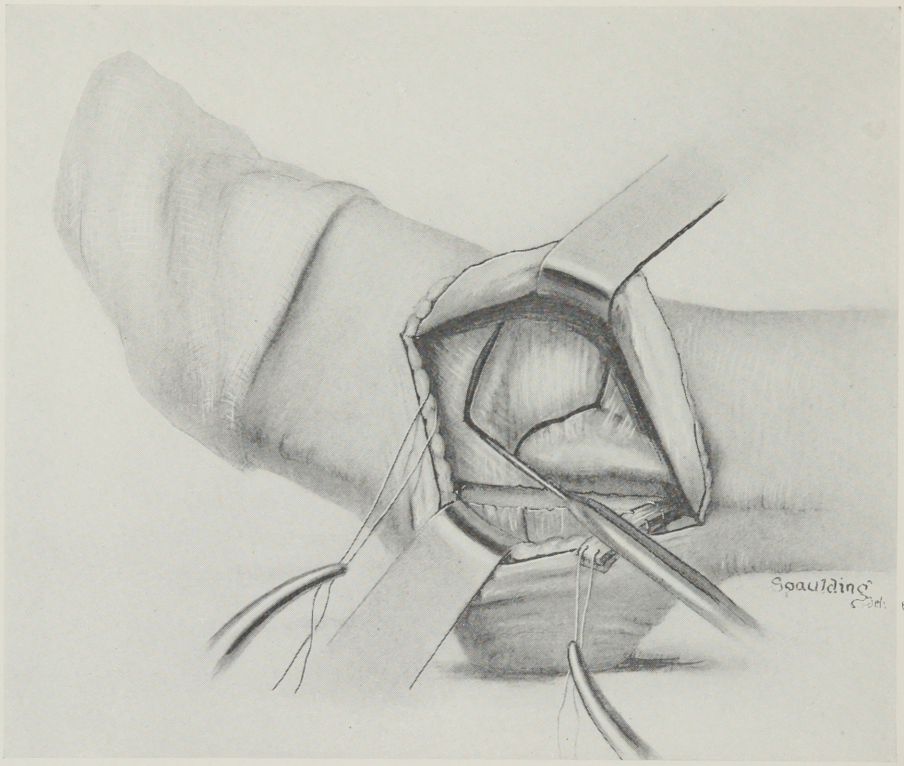

FIG. 4.—External lateral ligament divided; tibio-astragaloid ligament divided; interosseus and external talocalcaneal ligaments being divided.

losis, but ankylosis is neither sought nor expected, and if it does occur should be regarded as an unfortunate result. Astragalectomy has a distinct advantage over arthrodesis, in that it not only *stabilizes* but also *preserves motion.*

Indications and Contra-indications.—Astragalectomy should never be done in the presence of any structural deformity. This, if present, should be corrected by manipulative methods and the foot held in overcorrection for several months (walking being allowed) before astragalectomy. This necessary principle may have been overlooked in some of the many failures reported in the series from the Boston Children's Hospital.

Astragalectomy is indicated in *calcaneus deformities,* especially in valgus, for which it was originally devised by Whitman.[22] In calcaneovarus, it is important first to eliminate all varus deformity by repeated stretchings and by

retention of the foot in overcorrection. After months of overcorrection, astragalectomy may be done with safety.

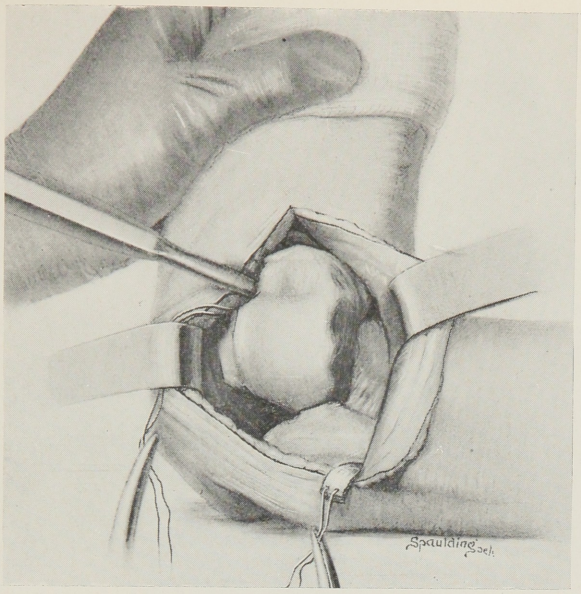

FIG. 5.—Dislocation of astragalus by strong inversion of foot. Note heavy dissector under neck by which astragalus is pried loose head first.

In *dangle-foot* astragalectomy results in stability, the weight being transferred to the centre of the foot, the arch elongated, and the os calcis made more horizontal. In cases in which only the plantar flexors remain, great care must be taken to prevent the deformity of equinis.

In *equinis* deformities (with no power in the anterior group) astragalectomy is useful in increasing stability, but great care must be taken to prevent a recurrent deformity. In severe *equinovarus,* after repeated stretching, the removal of the astragalus is frequently the coup-de-gras needed to complete and maintain a serviceable foot without deformity.

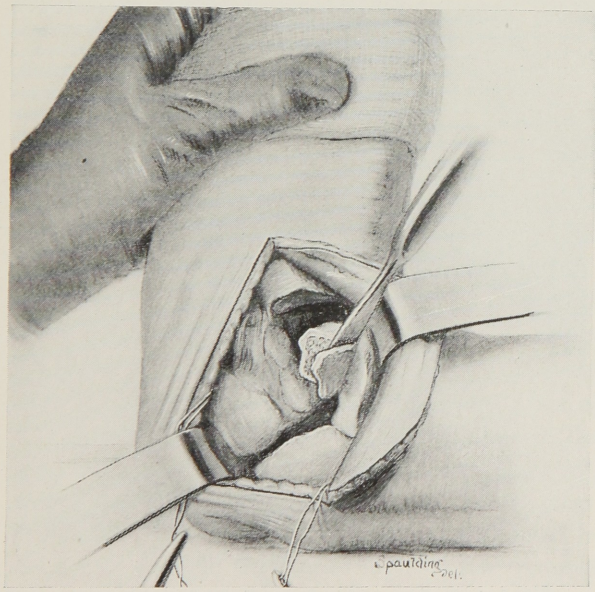

FIG. 6.—Widening tibia-fibular articulation by removal of thin slice of cartilage from internal malleolus.

Astragalectomy is very valuable in severe *claw-foot.* The great relaxation of the soft tissues occasioned by the removal of the astragalus gives the opportunity to save many feet that otherwise would be amputated. Slight or moderate varus and equinovarus may be treated by other methods.

Formerly we have included a few cases of *equinovalgus* in our list of astragalectomies, but the recent addition of the "loop" operation, also devised by Whitman, is replacing astragalectomy or astragalo-scaphoid arthro-

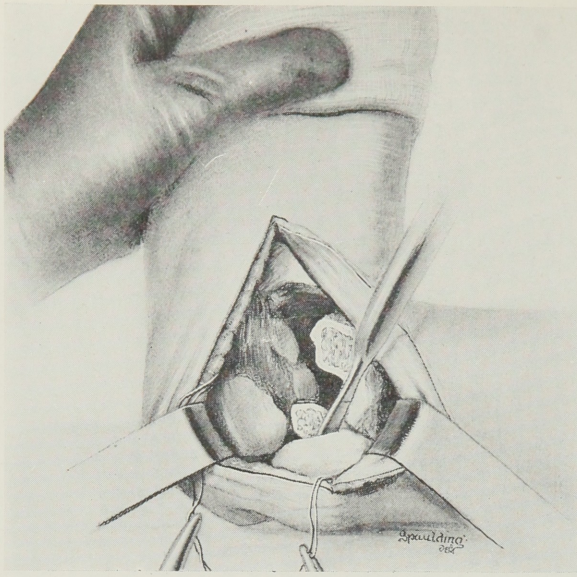

FIG. 7.—Widening the tibia-fibula articulation by removal of thin slice of cartilage from one or both; the internal lateral ligament has been dissected up to sharpen the malleolus.

desis in paralysis of the anterior tibial.

Age.—Any operative interference should be withheld until two years have elapsed since the original paralysis. It is neither necessary nor advisable to do an astragalectomy before this period. Also, we do not advise an astragalectomy before the age of six years, and it is better to wait until the child is eight years old. The ages between eight and sixteen years have been found the best, for in this period *motion is easily preserved.*

Operative Technic.—Asepsis should be guarded carefully and all manipulations should be gentle. A tourniquet is applied after the Esmarch bandage.

A curved or L-shaped incision is made around the external malleolus extending forward over the head of the astragalus. (Fig. 1.) The upper flap is then dissected upward, exposing the tendons of the peroneus longus and brevis, which are dissected free and severed at the fibular tip. The ends are sutured with No. 2 catgut and retracted. (Figs. 2 and 3.) An incision is then made through the external ligaments around the astragalus, special care being taken about the head of the astragalus. (Fig. 4.) The foot is then strongly inverted. By means of a blunt dissector placed under the neck of the astragalus the bone is pried out of position, head first,

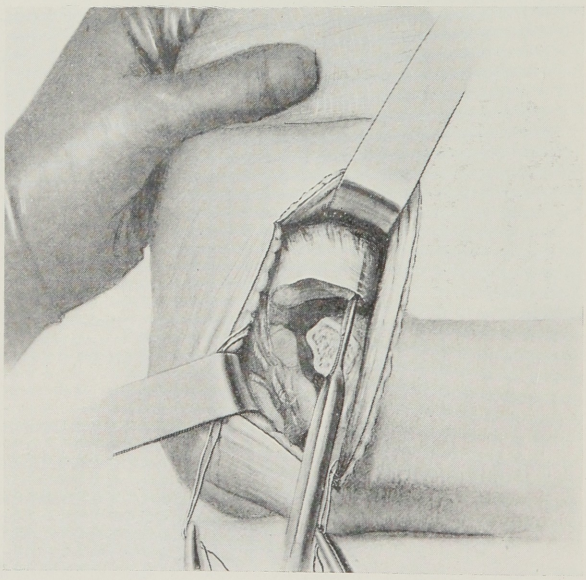

FIG. 8.—The new articulation for internal malleolus. Note removal of inner one-fourth to one-sixth from inner side of scaphoid, thus forming pocket for sharpened internal malleolus.

and removed—a veritable coup-de-main when well done, taking less than thirty seconds. (Fig. 5.) The ease with which the foot may be displaced backward will be appreciated at once, but in order to ensure a good, stable joint a certain amount of careful modelling must be done.

The internal lateral ligament is dissected upward from the internal malleolus, more in cases of equinovarus than in other cases. If necessary, a strip of cartilage is removed from both tips to allow spanning of the scaphoid and cuboid. (Figs. 6 and 7.) A thin slice of bone is then excised from the sides of the scaphoid and cuboid to form pockets for the malleoli. (Figs. 8 and 9.) The foot is displaced backward and held carefully in this position to ensure the proper relations in the new joint. This backward displacement of the foot which checks lateral movements by actual bony contact between the scaphoid and the tibia, is the essential feature of the Whitman operation. A moderate equinovalgus ensures stability while holding. (Figs. 10, 11 and 12.) The peronei are disposed of by (*a*) suture to the Achilles tendon, by (*b*) tendon fixation to the fibula, or by (*c*) resuture to the tendons of the peronei, as indicated in the given case. (Figs. 13, 14, and 15.) The skin is closed with catgut, and plaster is applied from the toes to the mid-thigh with the knee flexed and the foot in slight equinovalgus. (Fig. 16.) The leg is kept elevated for a period of ten days, after which crutches may be used. The first change of plaster case takes place in three or four weeks, at which time the equinus is corrected to a right angle in cases where the quadriceps is present, or is left in 5° to 8° equinus in cases in which the quadriceps is paralyzed. The mechanical value of this must be apparent. Valgus should persist to a slight degree throughout the treatment.

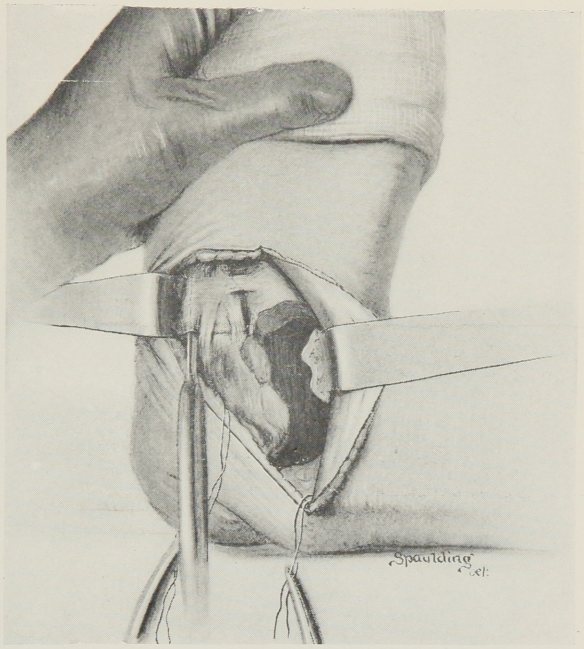

FIG. 9.—Dissection of ligaments up to make pocket for fibula by the cuboid.

A leather shoe is then put over the plaster and the child is allowed to walk, changing the plaster as necessary during the next five or six months. After its removal, a shoe with a lift on the outer side of the sole is used to maintain valgus. A one-half or three-quarters inch cork lift worn

under the heel throughout life will compensate for the shortening of the leg and improve the gait. Circulation improves rapidly with the return of active use, loss of growth ceases, and the paralyzed leg begins to grow at a rate equal to that of the well side.

After the removal of the plaster, it is sometimes advisable for older patients to wear a limited motion ankle brace, either in the form of an ortho-

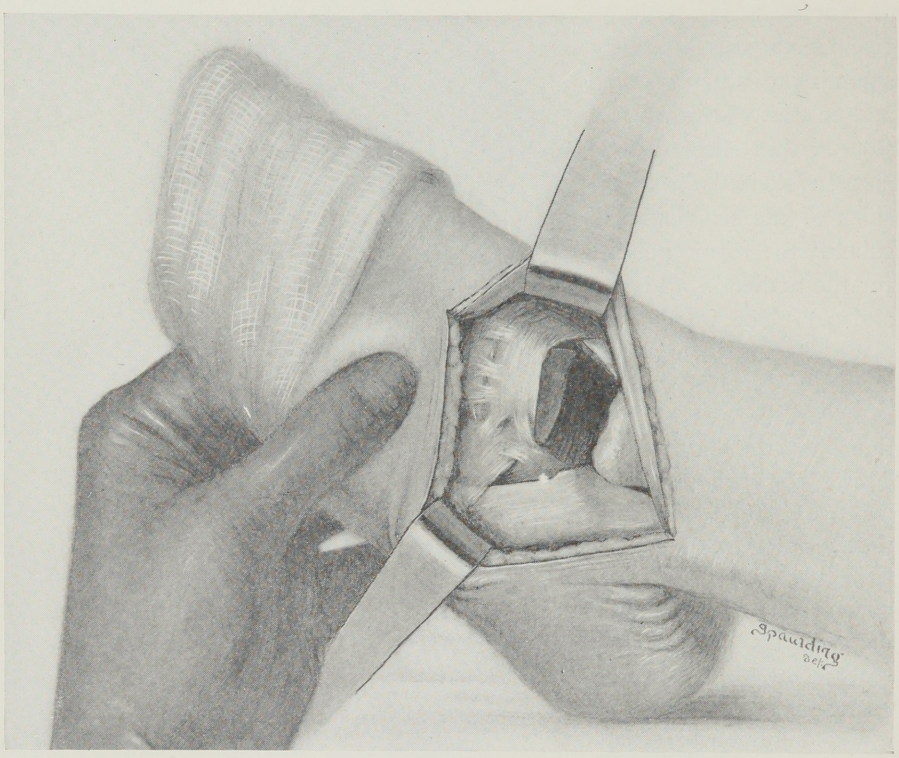

FIG. 10.—Fibula and tibia being inserted into pocket.

pædic shoe or an inner or outer upright to protect the foot from strain during the early months of weight-bearing.

Steps in Technic.—1. Correct all existing deformities before open operation.

2. Astragalectomy may be done with or without tendon transplantation, tendon fixation of the peroneals or transplantation through the Achilles and resuture, with strong displacement of the foot backward.

3. Proper after-care. This should be followed by the operator and not by untrained assistants.

4. Prevention of Complications. Recurrent deformity is due to improper post-operative care.

Lack of posterior displacement is due to careless or improper operative technic, such as failure to remove head of astragalus. (See reproductions of X-rays accompanying Sever's [18] paper.)

We recently examined two hundred forty-seven cases operated from two to ten years ago. The majority of the cases were calcaneovalgus deformities, but varus, equinovarus, equinovalgus, and dangle-foot types were also represented. The age of the patients varied from three to twenty years, with an average age of eight to ten years.

In all cases of calcaneovalgus the peroneals were transplanted into the Achilles, with resulting increased function. In twelve cases, the peronei were

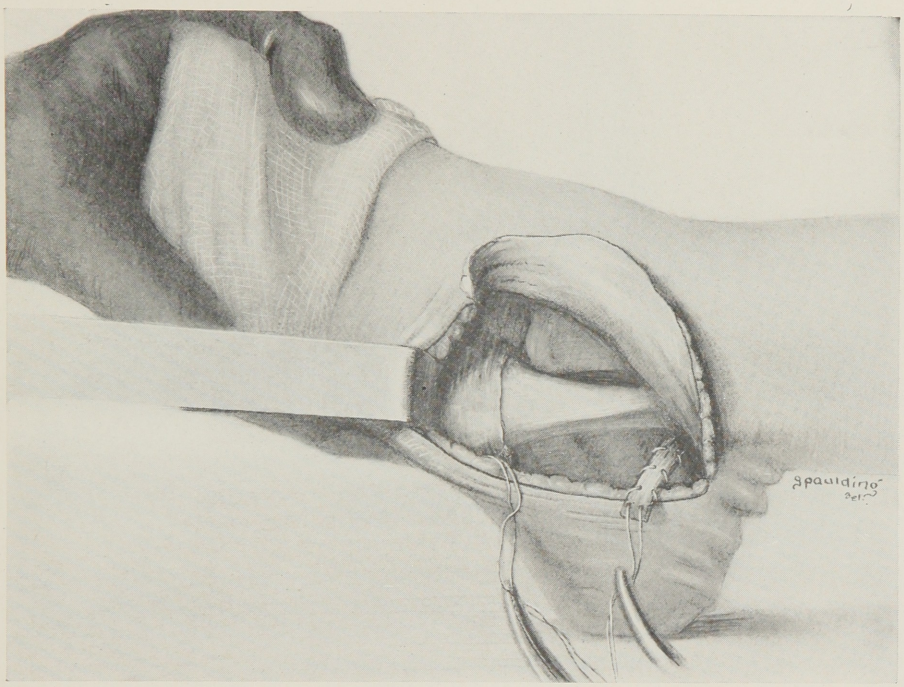

FIG. 11.—The external malleolus rests in a similar socket over calcaneo-cuboid joint. Note.—1, backward displacement of foot. 2, fibula carried well forward.

fixed to the fibula with satisfactory results. The foot was kept in plaster for an average of five months.

Out of the two hundred forty-seven cases, post-operative deformity developed in twelve, and of these varus developed in seven. In the later group, one patient refused after-treatment following astragalectomy; one insisted that the family physician change the cast; and the remaining five developed deformities from improper after-care in our hands. These, however, were corrected in every case before the patient was finally discharged.

One case of equinovarus deformity recurred. The patient did not return to the clinic for after-care.

There was one case of sloughing of the toe from swelling which developed because the patient was taken home and no attempt was made to keep the leg elevated; the end result was good.

The satisfactory results we have obtained lead us to recommend the Whitman operation in most cases in which stability with motion is desired.

ILLUSTRATIVE CASE ABSTRACTS

Case I.—F. H. Age thirteen. Calcaneovalgus deformity. *Complaint:* Limp of the left leg. *Duration:* Nine years. *Cause:* Infantile paralysis. At four years of age, this patient had a " fever " resulting in paralysis of the left leg.

Physical Examination.—The left foot was held in calcaneovalgus deformity. There

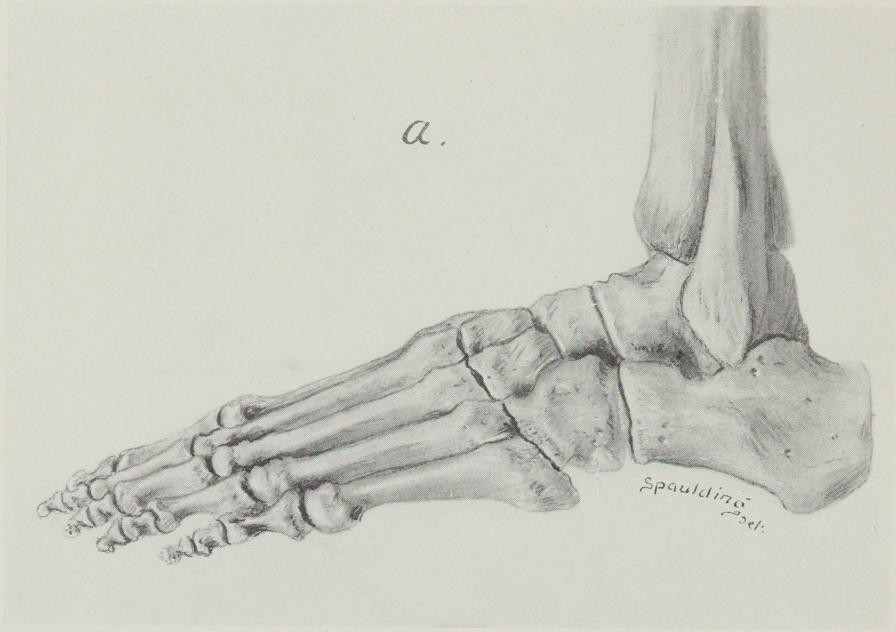

Fig. 12a.—Normal relation of tarsal bones.

was power in the peronei and the outer dorsal flexors, but there was no power in the posterior or inner groups. There was one and three-fourths inches shortening, mostly in the lower leg. The quadriceps was present, although weak.

Treatment: October 14, 1919.—An astragalectomy was performed according to the usual technic. Plaster was applied with the foot in about 5° plantar flexion. The case above the knee was removed at the end of three weeks. New cases were applied on November 29, 1919 and February 24, 1920. About the fifth week, felt was put under the heel and the patient was allowed to walk on the plaster case.

March 20, 1920.—The cast was removed and a flannel bandage applied.

March 31, 1920.—The foot was in excellent position and the patient was advised to wear a three-eighths inch lift under the heel inside the shoe.

October 18, 1920.—The position of the foot was excellent, and there was good motion. A one and three-fourths inch lift was worn under the heel, a one and one-half inch lift under the sole, and a one and one-fourth inch lift at the toe. Of this amount, one-half inch was put inside the shoe at the heel and one-fourth inch at the sole.

April 16, 1923.—The foot was in excellent condition. *Result:* Good function.

Case II.—J. Hart. Age ten. Calcaneovalgus deformity. *Complaint:* Lameness. *Duration:* Since seven months old. *Cause:* Infantile paralysis. The onset was sudden.

When seven months old the patient had infantile paralysis, and was in bed three weeks. At first both legs were affected, but later only the feet were in bad condition.

Physical Examination.—Calcaneovalgus of the left foot. Outer hamstrings absent; left thigh and gluteal muscles about one-half normal. No power in the calf muscles or in the extensors of the toes.

Treatment: May 27, 1919.—An astragalectomy was performed according to the

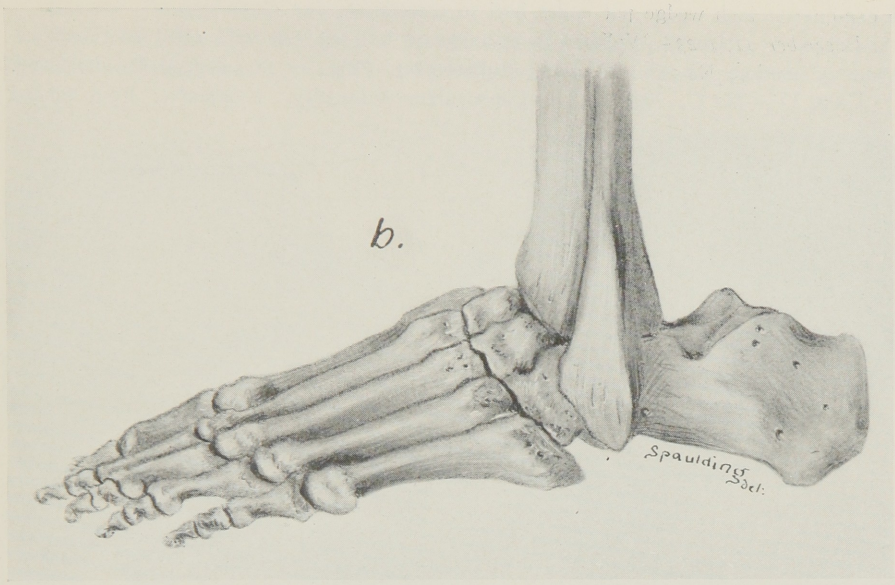

FIG. 12b.—Relations following the properly done astragalectomy.

usual technic and a plaster case applied with the foot displaced backward, and in slight valgus and equinus.

June 24, 1919.—The case above the knee was removed.

July 22, 1919.—A light plaster case was applied from the toe to the knee, and the sole reinforced with the foot at a right angle.

September 2, 1919.—A new case was applied. This was removed on October 28, 1919.

January 6, 1920.—The left leg was one and one-half inches shorter than the right. A one and one-fourth inch lift was worn under the heel, one-half inch of which was on the inside of the shoe. A one-inch lift with one-fourth inch inside the shoe was worn on the sole.

Result: March 1, 1921.—Examination showed an excellent result.

CASE III.—B. P. Age seven. Calcaneovalgus deformity. *Complaint:* Slight limp and turning of left ankle. *Duration:* Three to four years. *Cause:* Infantile paralysis. When the patient began to walk she had difficulty with balance.

Physical Examination.—Walked with marked pronated feet and heel was wabbly. Good dorsiflexors. Excellent peronei. No inner or posterior group. Astragalectomy with transplanting of peronei into the Achilles advised.

Treatment: May 1, 1923.—Astragalectomy was performed without transferring the peroneal tendons. Plaster applied in toe-drop, to be changed in three weeks.

May 31, 1923.—Case was removed and a new one applied. There was a slight serous discharge.

June 21, 1923.—There was still some sloughing. The patient began to walk on the case and bend the knee.

August 21, 1923.—The case had been removed when the scab fell off, and was replaced by a flannel bandage. The foot was at a right angle. There was 10° to 15° motion.

November 13, 1923.—Foot at a right angle. Massage advised to increase circulation. A one-quarter inch wedge put under heel to compensate for shortening.

December 11, 1923.—Walks with eversion of left leg, but with good foot balance. About 25° motion. No pain. Excellent displacement. (Figs. 17, 18, and 19.) *Result:* Good.

CASE IV.—M. C., Age six. Calcaneovalgus deformity. *Complaint:* Foot turned

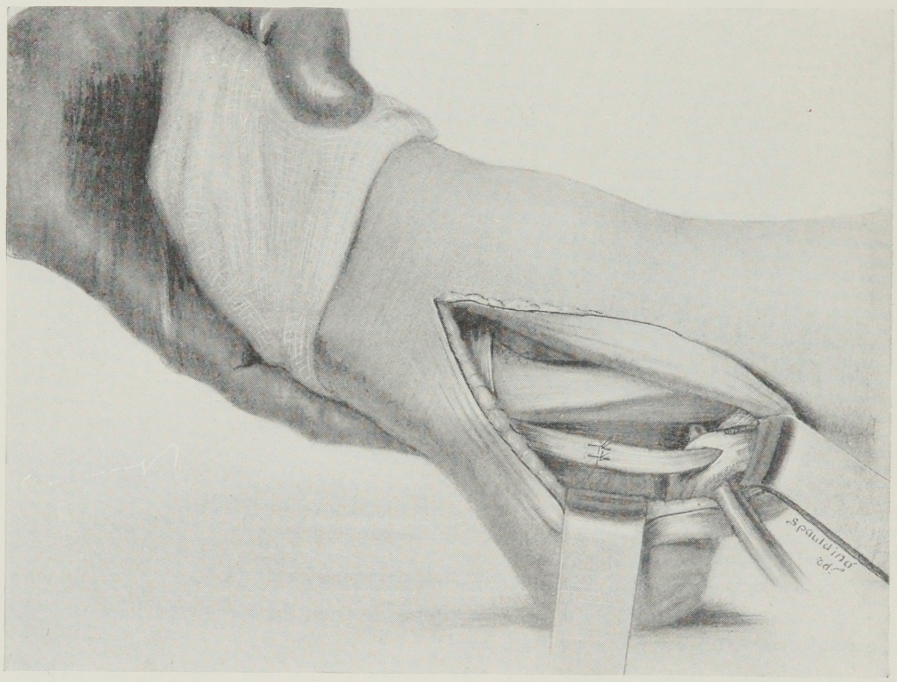

FIG. 13.—Disposition of the tendons of the peronei into the tendo-Achillis.

out. *Duration:* Three years. *Cause:* At three years of age patient had infantile paralysis which left her unable to walk. She gradually recovered, but the left foot did not respond to treatment and its condition grew worse.

Physical Examination.—The child walked with marked valgus of the left foot. The anterior tibial and peronei were present, although the former was weak. There was no Achilles or posterior tibialis. The left leg was one-half inch shorter than the right.

Treatment: May 24, 1913.—An astragalectomy and transplantation of the peroneals into the tendo-Achillis was performed according to the usual technic.

Result: December 22, 1914.—The functional result was good. The left foot was in good position.

CASE V.—M. O'B. Age eight years. Calcaneovalgus deformity. *Complaint:* Deformity of the right foot. *Duration:* Six years. *Cause:* Infantile paralysis.

P. I.—July, 1913. The patient entered the out-patient department with history of having had anterior poliomyelitis six years before. When first seen she complained of a limp and deformity of the right foot.

Physical Examination.—Negative except for the deformity of the right foot. The examination showed the absence of the inner and posterior groups of muscles. (Fig. 24.)

The patient was advised to enter the hospital for operation. A regular astragalectomy was performed, including the transplantation of the peroneal tendons into the Achilles and os calcis.

The convalescence was managed in the routine manner, and was uneventful.

Result.—The end-result was excellent.

Case VI.—E. D. Age eight years. Calcaneovalgus deformity. *Complaint:* Deformity of the left foot. *Duration:* Four years. *Cause:* Infantile paralysis.

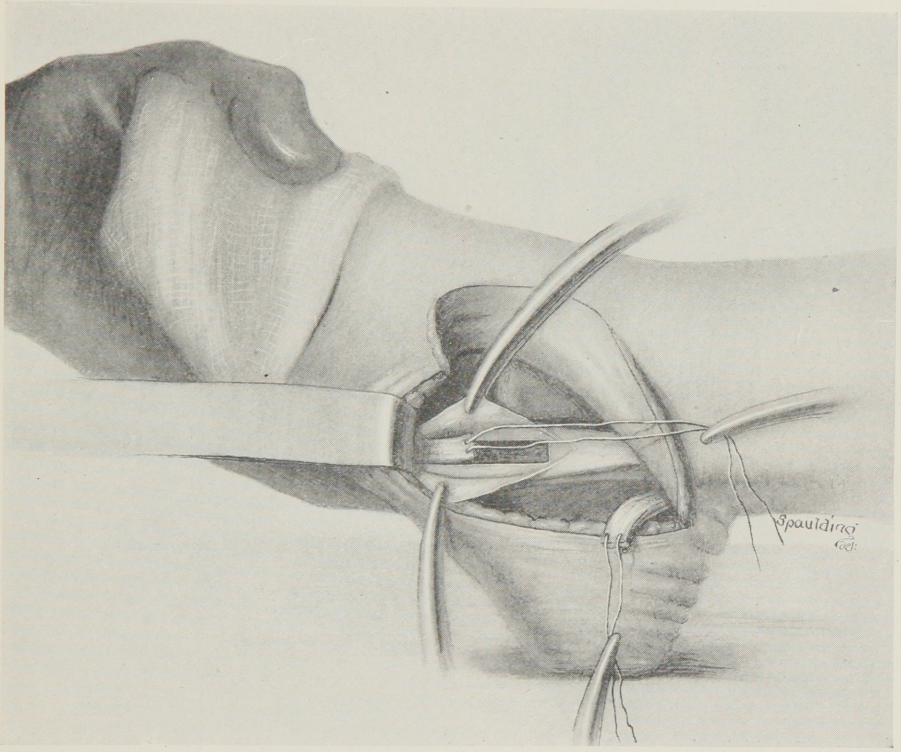

Fig. 14.—Disposition of tendons of peronei into the Achilles tendon and resuture and tendon fixation (Galli operation).

Physical Examination.—There were no contractures. The gastrocnemius and plantar flexors were absent. The quadriceps, anterior tibial and peroneal muscles were in good condition. There was shortening of one and one-half inches. The left foot was in calcaneovalgus deformity.

Treatment.—In December, 1914, an astragalectomy and transplantation of the peroneal tendons into the tendo-Achillis were done.

Result: January 22, 1924.—The foot was at a right angle and in excellent posterior displacement and good alignment. There was 10° motion in the mid-tarsal joint. The patient was wearing a lift under the heel and sole of shoe.

Case VII.—C. V. A. Calcaneovalgus deformity. This patient had a calcaneovalgus deformity on the left foot, due to infantile paralysis. A regular astragalectomy was done.

Result.—The result was good, with posterior displacement of foot in good alignment.

Case VIII.—K. M. Age four. Valgus deformity. *Complaint:* Left foot deformed. *Duration:* One year.

Cause.—Infantile paralysis. The onset was sudden; the patient on getting out of bed was unable to walk.

Physical Examination.—The child walked with a marked valgus of the left foot. The peronei were present. There was no anterior tibial. The tendo-Achillis was slightly

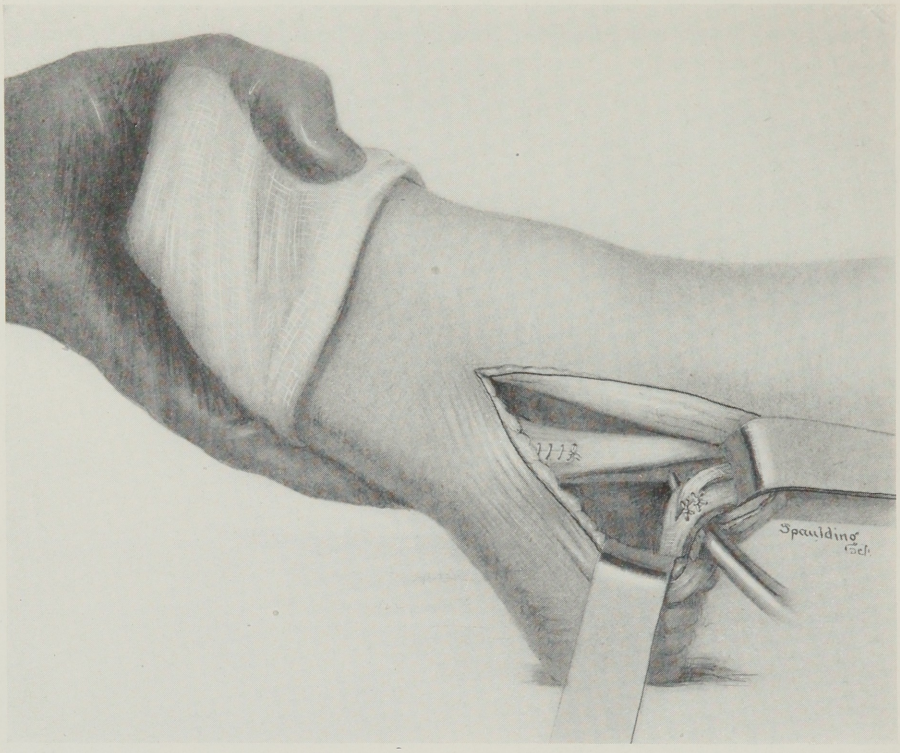

Fig. 15.—Disposition of tendons of peronei into Achilles tendon, and resuture of ends.

contracted. Abduction of the foot was not possible. The entire left leg was markedly atrophied.

Treatment: April 19, 1913.—A regular astragalectomy with transplantation of the peronei into the os calcis was done.

Result: June 4, 1915.—An excellent functional result was obtained. She walked well; motion from 85° to almost 180° was possible.

Case IX.—J. H. Age thirteen. Valgus deformity. *Complaint:* Walked with left limp. *Duration:* About twelve years. *Cause:* Infantile paralysis at the age of twenty-two months.

Physical Examination.—Left foot in marked valgus. Slight power in the extensors and Achilles tendon. No power in the tibialis anticus. (Fig. 20.) Glutei very weak.

Treatment: June 24, 1919.—Astragalectomy according to the regular technic.

August 5, 1919.—New case applied with the foot at a right angle. Patient began to bear weight.

November 18, 1919.—Case removed.

December 19, 1919.—Foot in fine condition. The patient was wearing a shoe with a one and one-half inch lift under the heel.

March 20, 1920.—The patient stood with the foot in slight valgus. The leg was two and one-half inches shorter than the right. A one and one-fourth inch bevelled lift was worn under the sole of the shoe, of which one-fourth was worn inside the shoe.

May 25, 1920.—The patient walked very well with shoe. Exercises begun.

Result: June 21, 1921.—An excellent result. The foot was at right angles, and there was good displacement and good control. There was flexion of 25°. (Figs. 21 and 22.)

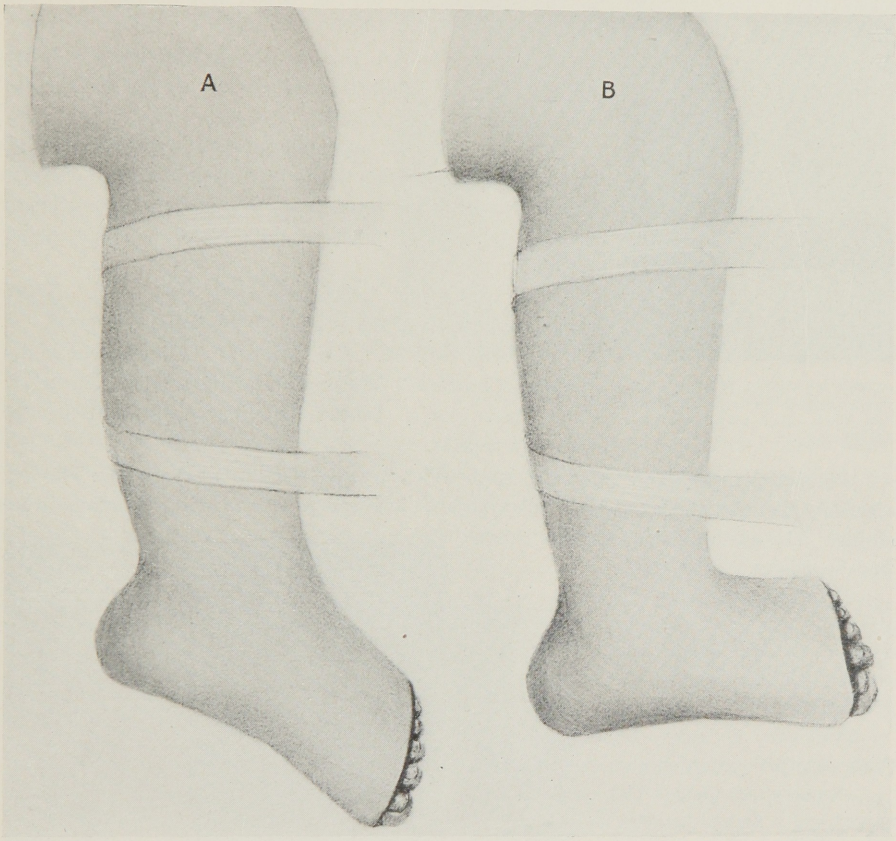

FIG. 16.—In plaster, following operation.

CASE X.—C. H. Age nine. Varus deformity. *Complaint:* Lameness. *Duration:* Six years. *Cause:* Infantile paralysis.

At three years of age this child had a fever which was followed by paralysis of the right foot that resulted finally in a varus deformity.

The foot was manipulated and the deformity corrected into a slight valgus.

On account of the general muscular weakness of the foot, as well as the absence of the peronei and the anterior muscle group, as astragalectomy was performed.

Two years later there was 25° motion in the ankle-joint. The foot was in good position and the patient walked splendidly. There was good stability and no pain.

CASE XI.—C. S. Age sixteen. Talipes equinus (extreme). *Complaint:* Lameness. *Duration:* Thirteen years. *Cause:* Infantile paralysis.

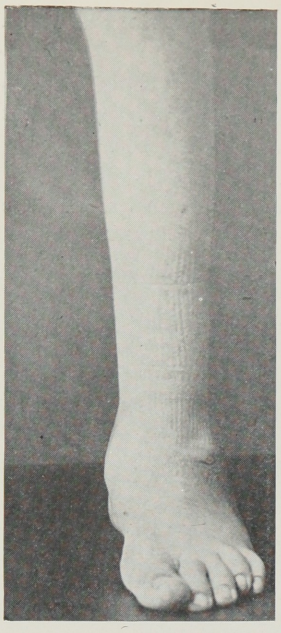

FIG. 17.—Case III, B. P., calcaneo-valgus deformity. Anterior view after astragalectomy (Whitman).

At three years of age this patient had a "fever" resulting in loss of use of the right leg. Improvement followed, but the right foot remained in extreme deformity.

Physical Examination.—Negative except for the contraction of plantar fascia and the Achilles. The peronei were present. The leg was one and three-eighths inches shorter than the left leg. The diagnosis was made of extreme talipes equinus, due to anterior poliomyelitis. The foot was manipulated and the plantar fascia contraction was first corrected.

May 19, 1914.—A regular astragalectomy was done, followed by the application of plaster from toe to just above the knee.

June 30, 1914.—A new plaster case was applied from the toe to the knee with the foot at a right angle. Several changes were made later, and the patient was allowed to walk on plaster with a three-eighths wedge under the heel.

July, 1913.—The functional result was good. There was good valgus, and the motion at the ankle was good.

CASE XII.—L. M. Age fourteen. Calcaneocavus deformity. *Complaint:* Walks with left heel limp. *Duration:* About twelve years. *Cause:* Infantile paralysis at the age of twenty months.

Physical Examination: August 7, 1923.—The left foot was in slight cavus. The leg, especially the calf, was atrophied. The iliopsoas, quadriceps and the tibialis anticus were strong. The gastrocnemius and the peronei had no power. (Fig. 23.)

Treatment: October 17, 1923.—Astragalectomy was done together with tendon fixation of the flexor longus hallucis to prevent plantar flexion deformity of the great toe.

November 27, 1923.—Ninety degrees to thirty degrees extension was possible.

January 22, 1924.—The case was removed and a flannel bandage applied. Massage of the calf was begun. The patient began to bear weight and was to begin walking as soon as possible, without a lift in the shoe. (Fig. 23.) Note posterior displacement.

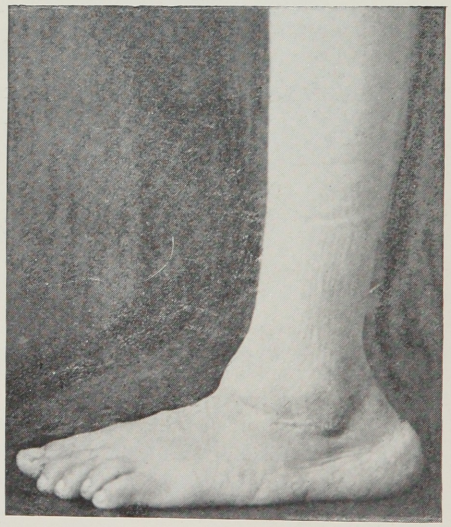

FIG. 18.—Case III, B. P., calcaneo-valgus deformity Lateral view after astragalectomy. (Whitman.)

Discussion of Doctor Sever's Report of Cases.—Our end-results are so different from those reported in Doctor Sever's [18] series, that it is interesting to try to explain the factors which account for the differences. We believe there are three:

1. *Failure to correct the structural deformity before operation.* One hundred and eighty-eight cases had deformity, but no mention is made of its correction before astragalectomy. Sixty-five cases had varus deformity, which should always be corrected before operation.

2. *Lack of proper operative technic.*—(a) Failure to remove the head of the astragalus. X-rays accompanying the report show that the head of the astragalus has not been removed. This fact is not noted in the report.

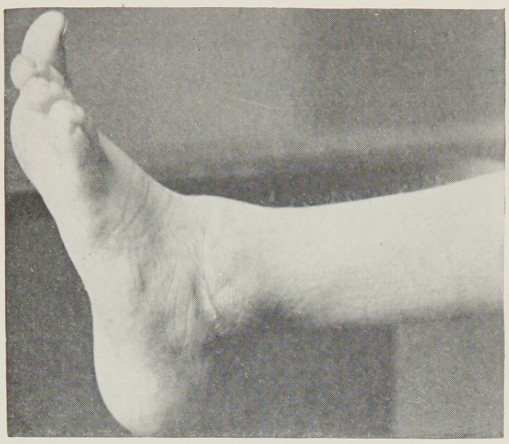

FIG. 19.—Case III, B. P., calcaneo-valgus deformity. Degree of motion after astragalectomy (Whitman).

(b) Failure to displace the foot properly. Sever admits failure due to lack of displacement in thirty-five per cent. of the fifty-four cases on which there is a note.

3. There are several factors in the operative technic on which Doctor Sever did not seem to be clear. The operation was originally designed for the calcaneus type of deformity, yet only fifty-two of the two hundred seventeen cases were of this type. The operation was also designed for cases involving paralysis of the gastrocnemius, but it was used in sixty-nine cases in which the gastrocnemius was active. Sever also appears to have anticipated a stiff ankle, which is not the aim of astragalectomy. Sever believed that the equinus position was the one sought by the operator, but this is true only in the absence of a quadriceps and even then only 5° to 8° toe-drop is advisable. In "Table No. 5" Sever records one hundred eight cases as having good "lateral movement." The object of the operation is to establish stability by limiting the lateral motion.

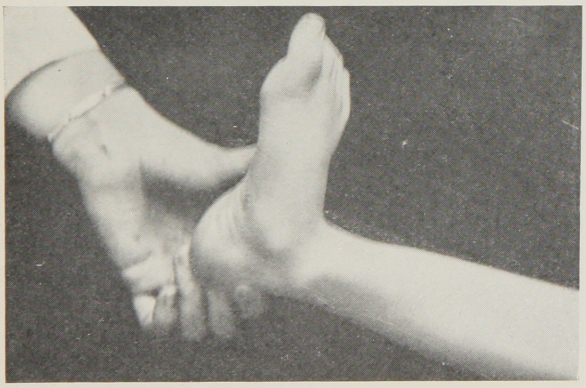

FIG. 20.—Case IX, J. H., valgus deformity. Lateral view before astragalectomy (Whitman).

Sever and his operators have failed in all the above essentials and their end-results might have been anticipated. We believe, as does Whitman, that the end-results and tabulations reported by Sever are of little value.

Literature.—Astragalectomy was first reported in the records of the Hospital for Ruptured and Crippled Children in 1897. Whitman [22] designed

it for calcaneus deformities of advanced degree, but its application has been broadened extensively and in a series of sixty cases reported more recently by Doctor Whitman [23] only sixteen were calcaneus deformities.

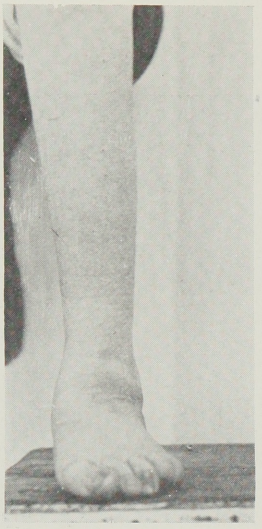

FIG. 21.—Case IX, J. H., valgus deformity. Anterior view after astragalectomy (Whitman).

Whitman's results certainly corroborate the value of this operation. Armitage Whitman,[23] in 1922, issued his report on a series of sixty cases, extending over a period of five years. Twenty-eight of these cases were operated upon by Royal Whitman and thirty-two cases by other surgeons. Ninety per cent. of the patients were satisfied with the results; sixty-five per cent. discarded braces. The best results were secured in calcaneus deformities. The causes of failure in their order of frequency were: insufficient backward displacement of the foot, varus deformity from faulty technic, persistence of the original deformity, and removal of the support of the head of the astragalus from the scaphoid.

Doctor Whitman bases the success of his operation on the proper selection of the cases, a thorough understanding of the mechanical principles on which the operation is based, exact operative technic, and appreciation of the deformity before operation, and of the recurrent distortion.

The Whitman operation has many advocates. Dane and Townsend [4] have reported three successful results, one for calcaneus deformity, and two for calcaneovalgus deformity. Gibney,[6] Taylor [20] and Albee [1] are in favor of it. Bradford [2] has found in his experience in the Boston Children's Hospital that the Whitman operation has given the best results.

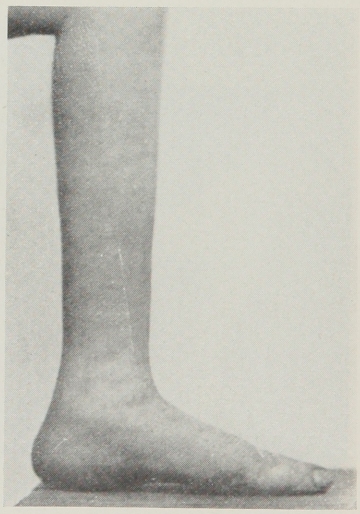

FIG. 22.—Case IX, J. H., valgus deformity. Lateral view after astragalectomy (Whitman).

Tubby,[21] Lord,[10] Reed,[15] Campbell,[3] Rogers,[17] Orr,[13] and Gillette and Chatterton,[7] and Henderson [8] endorse the Whitman operation enthusiastically, particularly for talipes calcaneus.

Other surgeons have found astragalectomy of value in other deformities. Nathan,[12] and Henderson [8] consider that calcaneovalgus is corrected most efficiently by the Whitman operation. Gallie,[5] too, recommended it for extreme cases of calcaneovalgus and also for dangle-foot; Roberts [16] has secured many good results in typical dangle-foot. Stern and Cook [19] have reported that out of two hundred fifty

FIG. 23.—Case XII. L. M., calcaneocavus deformity. a, lateral view before astragalectomy. b, anterior view after astragalectomy. c, lateral view after astragalectomy (Whitman).

cases of astragalectomy that they investigated, only twenty relapsed and these could be corrected by a secondary operation. They recommend the operation particularly for paralytic talipes, talipes calcaneocavus, flail and dangle-feet in children ten to fourteen years of age. Packard [14] reported eight successful cases, six of flail ankles, one of marked calcaneovalgus, one of everted foot with toe-drop.

In discussion of Hoke's paper [9] on the arthrodesis operation, Wallace advocated the Whitman operation, particularly for calcaneous, calcaneovalgus, and dangle-foot. He has used or observed it in one hundred fifty to two hundred fifty cases and there has not been a case in which the patient was not materially benefited. He does not consider age a barrier to the operation, but believes that interference should be made two or three years after the original onset.

The many good functional and cosmetic results obtained from properly performed astragalectomy account for its acceptance as the operation of preference. It has gradually replaced many other operative procedures that have been devised to increase function in paralytic conditions of the foot.

BIBLIOGRAPHY

[1] Albee: Orthopædic and Reconstructive Surgery, 1919, p. 776.
[2] Bradford: In Discussion of Whitman's Paper, 1908.
[3] Campbell: J. A. M. A., Oct. 11, 1913.
[4] Dane and Townsend: Am. J. Orthop. Surg., vol. ii, 1904–5, p. 38.
[5] Gallie: Am. J. Orthop. Surg., Phila., 1916, vol. xiv, p. 18.
[6] Gibney: In Discussion of Whitman's Paper, 1908.
[7] Gillette and Chatterton: Journal-Lancet, Minneap., 1917, vol. xxxvii, p. 691.
[8] Henderson: St. Paul M. J., 1917, vol. xix, p. 365.
[9] Hoke: J. Orthop. Surg., vol. iii, p. 494, Oct. 19, 1921.
[10] Lord: J. A. M. A., Oct. 11, 1913, p. 1374.
[11] MacAusland, W. R.: J. A. M. A., vol. lxviii, 1917, p. 239.
[12] Nathan: Am. J. Orthop. Surg., 1914–15, vol. xii, p. 444.
[13] Orr: Am. J. Orthop. Surg., Bost., 1916, vol. xiv, p. 336.
[14] Packard: Colorado Med., Denver, 1916, vol. xiii, p. 93.
[15] Reed: J. A. M. A., Oct. 11, 1913.
[16] Roberts: N. Y. M. J., 1916, vol. ciii, p. 826.
[17] Rogers: Am. J. Orthop. Surg., Bost., 1916, vol. xiv, p. 381.
[18] Sever: J. A. M. A., vol. lxxv, p. 1200, Oct. 30, 1920.
[19] Stern and Cook: J. Orthop. Surg., vol. iii, pp. 437–444, Sept., 1921.
[20] Taylor: Am. J. Orthop. Surg., Boston, 1916, vol. xiv, p. 394.
[21] Tubby: Clinical Journal, vol. xl, June 19, 1912, p. 164.
[22] Whitman, R.: A Treatise on Orthopædic Surgery, N. Y., Lea and Febiger, 1919, p. 806.
[23] Whitman, A.: J. Bone and Joint Surg., Bost., 1922, vol. iv, p. 266.

Reprint from SURGERY, GYNECOLOGY AND OBSTETRICS, June, 1924, pages 739--747

RECURRENT DISLOCATION OF THE SHOULDER

With Report of Cases

By W. RUSSELL MacAUSLAND, M.D., Boston, Massachusetts
Surgeon-in-Chief, Orthopedic Department, Carney Hospital

RECURRENT dislocation of the humeral head occurs most frequently in early adolescence. It is generally preceded by a history of trauma, the original injury having been sufficient to produce a subglenoid or subcoracoid dislocation of the head. Men are more prone to the affliction than women and it is found more commonly in the relaxed type of individual. Epileptics are particularly subject to it. Only rarely is there a case of double dislocation.

PATHOLOGY

The pathology varies widely in different individuals.

Capsule. The most constant lesion, which may be of several varieties, is located in the capsule. In some cases there is actual avulsion of the capsule from its attachment, while in most cases it is raggedly torn, usually in its anterior and inferior parts, and stretched to a point where, even in repair, an actual pouch is found on the inferior and anterior surface. As this portion of the capsule is not supported by muscle it is easy for the head to slip out. The pouch acts as a receptacle for the head, when the patient's arm is abducted or elevated.

Some operators have described a capsular-periosteal separation, in which the capsule and a part of the glenoid pad are continuous with the periosteum detached from the scapula.

Bone. Chief among the bony abnormalities that have been observed, is the defect of the humeral head. Many surgeons since the time of Joessel (35), Cramer (10), and Loebker (43) have demonstrated by resections on both the cadaver and on the living that the humeral head is normal in only its anterior part. A wedge-shaped notch exists on its posterior side, which is caused by the striking of the head against the glenoid margin when luxation occurs. Grégoire (26) considered that this groove in the head was the main cause of recurrent dislocation.

In some cases the lower glenoid margin is found worn off. In others there may be loose bodies or avulsion of the great tuberosity. In some of the severer cases an actual pulling away of the inferior capsular ligament with its bone attachment may take place, thus lessening the ridge of the glenoid cavity and making displacement easy.

Muscle. Occasionally the muscles supporting the joint and holding the head against the glenoid cavity are found torn or atrophied. The resulting altered muscle tension is undoubtedly connected with dislocation. The pectoralis major, the latissimus dorsi, and the teres major keep the head pressed against the glenoid surface, while the supraspinatus, infraspinatus, and the teres minor act as the lateral rotators, and the subscapularis as the medial rotator. In a posterior dislocation, the detachment or rupture of the subscapularis contributes to the loss of support. In cases in which the insertions of the supraspinatus and infraspinatus are torn off at the first luxation, relaxation and loss of tone result. The teres major and latissimus dorsi then tend to pull the head downward and when the muscles contract, the head slips over the glenoid margin.

SYMPTOMS

The main complaint in all cases is the fear that displacement will occur on abduction of the arm. This fear seriously handicaps the patient in any occupation that involves the possibility of arm elevation and is a serious obstacle in sports.

The frequency of recurrence varies in different cases. Some dislocations recur only once in several months, while others may occur daily. Occupation has much to do with the frequency. Sometimes turning in bed will produce a dislocation. Fortunately cases that have luxated several times may be reduced easily.

Some muscular atrophy of the coracobrachialis, triceps, deltoid, and especially the

Published by Surgical Pub. Co., Chicago, U.S.A.

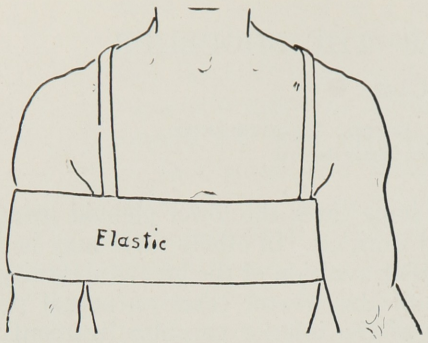

Fig. 1. An elastic surcingle.

posterior part of the supraspinatus and infraspinatus may be observed. There may be a slight limitation of motion, frequently in abduction.

Pain is usually present just after actual displacement.

The diagnosis is made purely on subjective symptoms, voluntary spasm, and protection against dislocation on any attempts at abduction, together with the history of recurrent attacks without trauma.

CONSERVATIVE TREATMENT

After the initial displacement the shoulder is reduced and held to the side for a period of at least 2 weeks. In recurrent cases an elastic surcingle 3 to 4 inches wide is placed around the chest and over the affected arm several inches below the shoulder. This serves as a constant reminder and resists the abduction of the arm (Fig. 1). The surcingle should be worn constantly for 6 months, and during this time local therapeutic measures, baking and massage should be practised. If only two or three displacements have occurred, this treatment often succeeds.

When displacement has recurred too many times, and especially when the displacement recurs only on slight exertion, conservative treatment is of no avail. Operative interference offers the only means of overcoming the difficulty.

OPERATIVE TREATMENT

Usual Two-day Preparation

The arm is abducted to an angle of 90 degrees with the body. The humeral head is then easily felt as prominent in the axilla. The vessels are located and a 4-inch incision

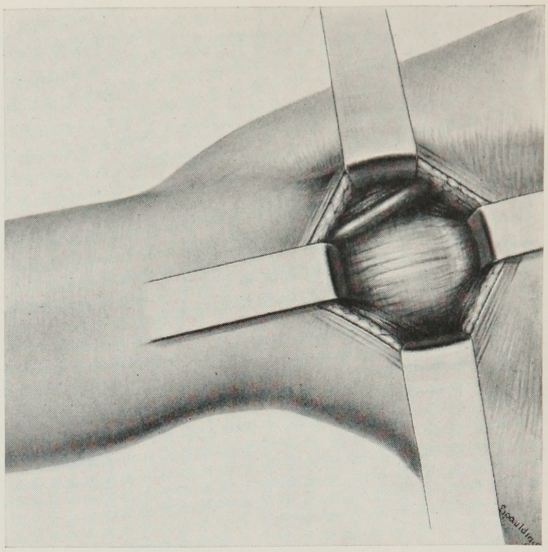

Fig. 2. The 4-inch incision made posterior to the vessels and parallel with the arm.

made posterior to them and parallel with the arm (Fig. 2). A plexus of veins is usually found over the head and these are cut and retracted. The subscapular muscle is then exposed directly over the humeral head. It may be retracted as a whole or it may be divided in the direction of its fibers and the portion overhead retracted. The capsule over the head is then in view, and a complete exposure of the capsule should be obtained. About halfway between the glenoid and the middle of the humeral head, a curved incision is made parallel to the glenoid. After the head is examined and the pathology studied, it is replaced. The capsule is overlapped well and the sutures placed, but not actually tied until the arm is brought down to an angle of about 45 degrees from the body (Fig. 4.) Chromic gut is usually used for this purpose. The subscapular muscle is then returned to normal and the skin closed with interrupted catgut No. 1. Dry dressing is applied and the arm held at the side for 6 weeks without motion. Then restricted use is allowed, taking care to protect the arm from forced abduction for a period of 3 to 4 months (Fig. 2).

REPORT OF CASES

CASE 1. R. M., an epileptic suffered from dislocation of both shoulders. When I saw the patient in January, 1921, he reported that the right shoulder

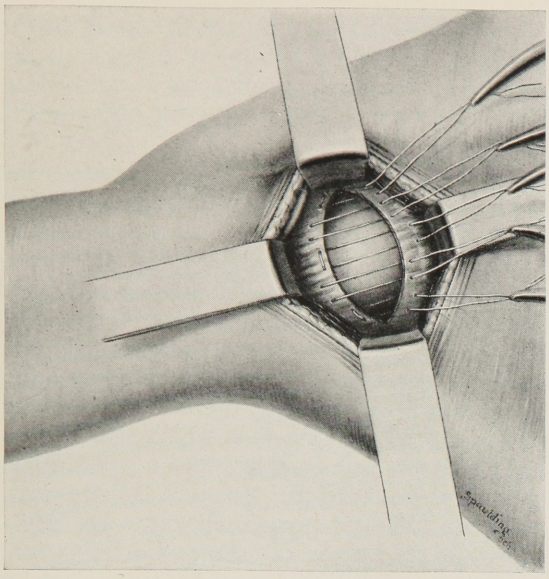

Fig. 3. Capsule overlapped and sutures in place.

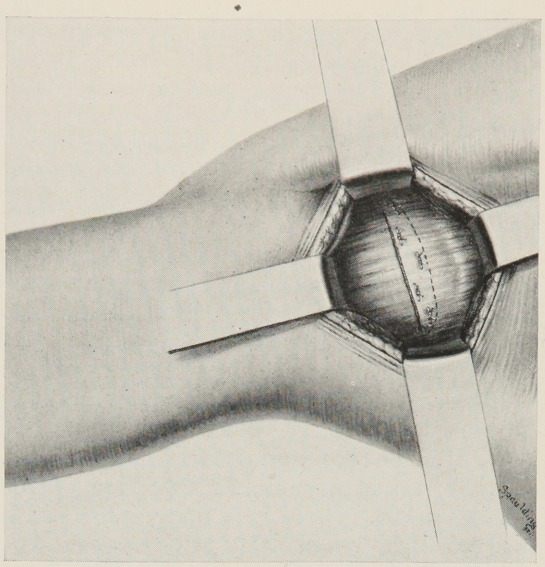

Fig. 4. Capsule overlapped and sutures tied.

was dislocated about twenty times during the previous year. Abduction of the shoulder was limited by spasm. The left shoulder first slipped out 4 years ago and dislocation had recurred about forty times. The left shoulder was operated on elsewhere twice without relief, and a third operation prevented the shoulder from slipping out again, but resulted in a considerable limitation of motion.

Treatment. An operation following the technique described was performed on the right shoulder in March, 1921. Six weeks later the anteroposterior motions were normal and abduction was one-half normal.

In June, 1921, 3 months after intervention, the patient, in falling, displaced the right shoulder anteriorly. Another operation was done in August, 1921. After several falls during epileptic attacks, resulting in dislocation, an excision of the head of the humerus was done in September, 1922.

Result. In June, 1923, when I examined the patient, abduction of 80 degrees was possible in the left shoulder, rotation in adduction was normal, rotation in abduction was possible for a few degrees each way. There had been no recurrence. The patient had wrenched the right shoulder 1 week before. Abduction without pain was impossible beyond 50 degrees. A few degrees of internal and external rotation were possible. There was marked atrophy of the deltoid. There had been no recurrence.

Case 2. E. R., dislocated his left shoulder while playing football in 1908. From then up to the time of admission to the hospital (February, 1911) the shoulder was dislocated fifteen times.

Treatment. An open reduction, using the usual technique was performed in 1911.

Result. Twelve years later the patient wrote me that he had never had any trouble with the shoulder and he used it as freely as the other one.

Case 3. E. D., dislocated both shoulders while playing football in 1912. When I saw the patient 3 years later, the right shoulder gave no symptoms, but the left had slipped out repeatedly since the injury. The shoulder was dislocated eight times during 3 months, once while sleeping.

Treatment. An operation following the usual technique was performed in 1915.

Result. Up to December, 1921, there was no recurrence nor any disability, except for a slight weakness in doing heavy physical work. Late in December the shoulder came out once during gymnastic exercises. Up to the present time (June, 1923) there has been no further trouble, but the patient uses the arm with caution.

Case 4. E. L., while playing football in 1911, dislocated his left shoulder. Recurrence took place six times after the original dislocation, often during sleep.

Treatment. An open operation was done, following the usual technique.

Result. About 9 months later the patient reported having no trouble, except that the arm was not as strong as the other.

Case 5. S. S. fell from a horse in 1913 and injured her shoulder. Dislocation had recurred repeatedly, once while dancing, once while swimming.

Treatment. An open operation following my usual technique was done in May, 1916.

Result. The patient wrote several years after the operation that she had had no trouble with the shoulder, although at times it felt weak. She is a counsellor in a camp.

Case 6. L. R., while wrestling, dislocated his left shoulder and 6 months later the shoulder came out again. Before I saw the patient in 1915, dislocation had recurred fifteen times.

Treatment. An open operation was done in which the capsule was quilted.

Result. Two years after the intervention, the patient showed a perfect result and the arm had never given him any trouble.

HISTORY

Prior to capsulorrhaphy, braces and bandages were first used in treatment, but as they allowed only limited motion, they were finally disregarded.

Hippocrates (32) tried to form a cicatrix to contract the joint space, by entering the articular cavity with a red hot iron. Malgaigne (46) and others practised myotomy in the hope of producing an inflammatory condition.

Albert (2), in 1879, first tried arthrodesis; he was followed by Wolff (84), Karewski (36), Mueller (50), and others. Cramer (10), in 1882, made a complete resection of the humeral head. There were many imitators of his technique, particularly in Germany.

But all these methods were finally abandoned because they resulted in diminution of function or were considered unsurgical.

Capsulorrhaphy without arthrotomy. In opening the joint for resection, the dilated condition of the capsule attracted the attention of the operators. Several methods, with or without arthrotomy or capsulotomy were then devised to obtain a diminution of the capsule. Ricard (59), in 1892, first tried capsule reefing without opening the joint, by forming a permanent fold in the anterior portion of the capsule by means of three silk sutures placed vertically. No relapse followed and normal mobility resulted in two cases.

Many surgeons followed his technique or modifications of it. Certain operators used a posterior incision instead of the anterior one Steinthal (74), Paladini (54), Mueller (50) Francke (22), Payr (55), Lardennois (41)' Nélaton (51), and Thomas (76) operated in a similar manner.

Dehner (13) and Krumm (39) used a posterior vertical incision to bring the humeral head to the posterior cavity rim and then contracted the capsule at about the approach of the head into the rim.

Beck (5), in 1903, plicated the capsule on its anterior surface and in addition carried a silver wire through a hole drilled in the head of the humerus and in the acromion. The wire was removed in 5 weeks. The result was perfect.

Mauclaire (47) and Berger (6) modified the method, Berger by fixing the capsule to the tip of the acromion to reinforce it, and Mauclaire by making two plications, one vertical and one horizontal.

Trethowan (77) successfully plicated the capsule in a case, but he found the operation very difficult.

Picqué's (57) method differed from Ricard's in that he formed a fibrous-muscular capitonnage on the anterior face of the joint by passing three sutures of horsehair or silk through the capsule. He discriminated between the cases in which there was a swelling of the capsule and those in which there was a notch in the humeral head and a capsular-periosteal separation. In the latter cases, resection followed capsulorrhaphy. De Fourmestraux (21) made the same discrimination.

Legueu (42) relieved an epileptic patient by reefing the capsule with horsehair. Three months after the operation, the patient fell, causing a new luxation. Picqué (57) used his method on the case and obtained a successful result.

Bliss (7), in 1906, tightened the capsule in a case in which there had been fifty recurrences, by means of including an elliptical portion in silk strand sutures. A perfect result was obtained.

In 1908, Stimson (75) used Ricard's method successfully, making a permanent fold by means of three silk sutures placed vertically. Meyer (48) used the same procedure in one case.

The same year, Dahlgren (11) traced the efficacy of simple capsule contraction and found there had been no relapse in twenty-five of the forty-one cases which he collected from literature. All of these cases had not been due to the enlargement of the capsule, but to other causes such as the tearing off of the muscles, especially the outward rotators.

Wilmanns (82) had two interesting cases in which he obtained perfect cures through simple interference and contracture.

Kosloff (37) herself, suffered from a recurrent dislocation of the shoulder. She was operated on by Duval, who sutured the capsule vertically with linen thread. The patient, after 4 years, used the arm with the same facility as the sound one. Kosloff believed capsulorrhaphy was justified in cases

where, aside from the laxity of the capsule, there existed a capsular tear, a capsular-periosteal separation, or a lesion of the anterior edge of the glenoid.

Walther (78), in 1918, plicated the capsule by means of three horsehair sutures passed from the inner side outward through the entire length of the capsule. His patient could pursue his occupation, although there was some limitation of motion.

Rivière (61) secured a perfect result by suturing the capsule and fixing it to the subscapularis without opening the joint.

Durand (17), in 1919, reported a case in which he made a vertical and horizontal fold in the capsule. No relapse followed and the patient had normal motion.

Capsulorrhaphy following arthrotomy. As these methods did not permit the exploration of the joint, which several surgeons believed to be important, Samter (64) and Mikulicz (49) then recommended the splitting of the capsule vertically and the drawing of the medial part over the lateral part.

Grothe (27) incised the anterior portion of the capsule and narrowed it by overlapping the edges of the incision.

MacKinnon (45), in 1907, in the case of a farmer whose shoulder dislocated frequently in sleep, introduced mattress sutures into one margin of the incised capsule and tied the sides in such a way that one flap came under the other. The patient made a complete recovery. In discussion of this report, Dr. Wright said he had successfully quilted the capsule transversely in the case of an epileptic patient.

Steeg (73), in 1910, reported a case in which, after exploration of the joint, he introduced four sutures of catgut vertically into the capsule. The result was successful; the patient had full function of his arm.

Schultze (67) in his operation, after blunt dissection of the deltoid on the outside, freed the capsule and drew the edges of the wound one over the other. In this way he doubled the anterior capsule.

Worcester (85) overlapped the edges of the capsule in three patients, with successful results.

Henderson (29), in 1921, issued a report of nineteen cases treated in the Mayo Clinic. The method used was based on the principle that the anterior inferior portion of the capsule is torn and as this portion is unsupported by muscular insertions, recurrence is easy. Therefore, this section of the capsule was strengthened. In some cases the pectoralis major was lengthened. The condition of sixteen patients was decidedly improved; 50 per cent of these were cured. It was too early to report on the other three cases.

Of a group of eight patients on whom he reported in 1917, one had dislocation nearly 6 years after the operation and another patient had relapse in 5 years. Both, however, were better than before the operation.

Dreesmann (15), Goldmann (25), Wilmanns (82), Samosch (63), Hildebrand (31), and Schultze (67) tried capsule doubling or reinforcing. Wiesinger (81) used the incision of the capsule and tamponade to secure reduction.

Capsulorrhaphy after excision. The first capsulorrhaphy after excision was tried by Gerster (23) in 1883. He removed a piece of capsule by a semi-elliptical incision and united the capsular wall, as well as the muscles and skin, by three tiers of interrupted catgut. The patient was cured.

Bardenheuer (4), in 1886, excised two pieces of capsule, and secured good results.

In 1895, Burrell and Lovett (8) removed an elliptical piece and sutured the capsule to shorten it. A second case was reported in 1897. They believed it important to divide the tendon of the insertion of the pectoralis major for three-fourths its breadth, to allow uncovering the capsule.

Warren (79), Dawborn (12), Baldwin (3), and Albee (1) secured good results using Burrell and Lovett's procedure.

Mueller (50), Haegler (28), Kuh (40), Kronacher (38), Goldmann (25), and Donati (14) reported cases in which they excised pieces of the capsule. Some surgeons combined the methods of Gerster and Mikulicz.

Between 1909 and 1921 Thomas (76) issued several reports summarizing his cases and describing his technique. The capsule was contracted by sutures, by overlapping, or by excision. At first he used an anterior axillary incision, but later recommended the posterior route, as he found the capsule could be approached more easily in this way. Also the wound was smaller, and motion returned

more rapidly. In the cases in which the method of excision was employed, Thomas allowed cicatrization across the gap made in the capsule, then contracted the portion to within normal length, and stretched it by suitable exercises. In all cases he found evidence of wearing in the posterior part of the head and glenoid. In some it was necessary to do a partial excision of the head.

Because of this wearing, which will prevent complete return of the joint to normal, Thomas considered the terms of success only relative. In 1921, he issued a report covering the accumulation of 4 years' observations. Of forty-four shoulders which he had treated, eighteen had been epileptic cases. There had been no dislocation in eleven cases after capsulorrhaphy, done in the most recent case 4 years before the time of the report, and in the first case 11½ years before. Another case had been successful after excision of part of the humeral head. Three were failures. In the non-epileptic group, there were twenty-two successful cases after capsulorrhaphy, done in the first case 13 years before, and in the last case 3 months before. There were two failures.

Capsulorrhaphy plus treatment of other lesions. Some surgeons did not consider capsulorrhaphy sufficient as they found other lesions present and believed it necessary to do a simultaneous operation to give the joint support.

Winiwater (83), in 1905, presented a young man on whom he had operated 2 years before. One incision was made along the upper edge of the clavicle, and a second made obliquely between the major pectoralis and the deltoid muscle. Two folds were made in the capsule by means of sutures. Then, to oppose dislocation of the head, he united the upper edge of the subscapularis to the lower edge of the minor pectoralis by a series of sutures, thus stretching the two muscles over the capsule. The major pectoralis was returned to its place and sutured at its clavicular and deltoid insertion. The functional result was excellent; in 4 months the patient had complete use of his arm.

Other surgeons strengthened the capsule by nailing the head of the biceps on the lesser tuberosity to strengthen the restraining apparatus in front of the joint. Werndorff (80) used this method in connection with capsular plication.

Seidel (68), in 1913, reported a case in which he separated the subscapularis muscle, took out an oval piece of capsule and sutured the edges of the capsule together. He then covered the entire front of the joint with a piece of transplanted fascia and sutured it to the deltoid and subscapularis. The patient died some time later and examination showed the flap had been preserved. Payr (55) also reported one case using this technique. Schultze (67) was of the opinion the fascia flaps were necessary.

Still others reduced the capsule and sutured the outward rotators. These operations treating the muscles are chaotic. Mueller (50) tried to revise the external rotators at their appendage behind the deltoid or subscapularis.

Perthes (56) twice used reefing of the capsule and firm fixing of the torn external rotators on the great tuberosity. In the four cases reported, he varied his technique, according as the muscles were torn, the cavity rim broken, or the capsule dilated. If the muscles were torn from the tuberculum majus, he replaced their insertions on the head of the humerus by means of V-shaped nails. The tendons were nailed directly to the bony surface or attached to the bows of the nails with silk. If the glenoid rim was torn, it also could be fixed by means of V-shaped nails driven into the neck of the scapula.

Hildebrand's (31) operation was concerned with the changes of the joint cartilage. He deepened the cavity with a sharp curette, and thus obtained a prominence of the medial glenoid edge.

Besides capsulorrhaphy, other methods were tried, some to change the tension of the dilated capsule or others to construct a ligament to hold the joint in place.

Roepke (62) reefed the tendon of the subscapularis muscle to secure better support around the capsule. This was handled by an incision on the outside axillary border. Selig (69) proposed reefing the supraspinatus tendon as he considered this muscle played an important part in dislocation. Sever (71) recommended suturing the subscapularis tendon and dividing the pectoralis major tendon. Capsulorrhaphy may be performed in con-

nection with these steps, but it is not necessary. Complete revision of the pectoralis major was done in forty cases. There were no relapses or loss of motion.

Joseph (34) used fascia lata strips to construct a ligament that would prevent luxation of the head. In two cases, the results were satisfactory and motion, which he had feared might be lost, was good. Schmieden (66) also secured a favorable result by this method.

Semken (70) made a vertical incision 1 inch external to the anterior border of the deltoid. A tunnel was made under the subscapularis and a graft of fascia lata from the thigh drawn through and its upper end fastened with interrupted catgut sutures to the upper part of the capsule and its lower end to the subscapular head of the triceps muscle. This flap thickened and contracted and hindered the anterior excursion of the humeral head.

Loeffler (44), Sandes (65), and Herforth (30) advocated fascia flaps to gain security. Evatt (19) recommended a silk cord to connect the humerus and the axillary border of the scapula.

Treatment of muscular contraction Several surgeons believe that operation should be directed to the relief of the disturbance of the co-ordination in the muscular contraction. At the surgical congress in Germany in 1909, Clairmont and Ehrlich (9) proposed a new method—myoplasty—to struggle against the action of the deltoid. The opposing muscular traction was obtained through the formation of a flap on the inner portion of the deltoid muscle which was passed from behind forward under the neck of the humerus, and its end sutured to the same muscle in front. This flap acted as a sling to hold the joint in place.

Clairmont reported four cases; Major Dunn (16), one case; Platt (58), one case; and Thomas (76), three cases. Only one of these cases (Clairmont's) relapsed. Seven cases by Gibson (24) gave favorable results.

R. Jones (33), in 1912, is reported to have done two of these operations. The flap was carried through the quadrilateral axillary space and fastened to make a sphincterlike ring about the neck of the humerus. Immobility for 2 months followed. One case recurred from lack of immobility or insufficient fixation of muscle. The second was a success.

Finsterer (20) secured satisfactory results in seven cases, using muscle flaps. Ollerenshaw (52) advocated this procedure.

Other surgeons attempted the division of the tendon of the subscapularis muscle. Spencer (72) reported one successful case and Openshaw (53), three satisfactory cases.

Another type of operation was based on changing the leverage of the two powerful muscles which act as the dislocating force. Young (86) was the advocator of this method, which was suggested by Allis. The incision was made in the space between the deltoid and pectoralis major muscles. The attachment of the latter muscle was divided at its lower half. Through a second incision the latissimus dorsi muscle was reached and the lower half divided. The arm was put in wide abduction for 10 days.

Eden (18) found that in many cases the tearing of the capsule with bone from the cavity rim was ground for the return of the luxation. In these cases, he considered that capsule reefing, suturing of the external rotators or muscle plastic, could not prevent recurrence. The joint capsule must be fastened into position and the shape of the cavity restored. This was obtained by building a hindrance of a piece of bone from the tibia. The torn capsule was fastened in its old place by sutures. Two patients have had no relapse after 3 years.

CONCLUSION

From a study of the literature of this subject, it appears that the treatment of recurrent dislocation of the shoulder has been one of varying technique. No consistent method, adaptable to a large number of cases, has been reported. On the contrary, each treatment differs according to the importance attributed by the surgeon to the pathological condition of the bone, capsule, and muscle. The majority of cases have been treated by some form of capsulorrhaphy, and in most of them satisfactory results have been obtained.

BIBLIOGRAPHY

1. Albee. Am. J. Surg., 1908, xxii, 210.
2. Albert. Intern. klin. Rundschau, 1888, No. 9.
3. Baldwin. Ohio M. J., 1907-08, iii, 161.
4. Bardenheuer. Deutsche Chir., 1886, lxiiia.
5. Beck. New York M. J., 1903, lxxviii, 64.
6. Berger. Bull. Soc. de chir., 1905.

7. Bliss. J. Roy. Army M. Corps, London, 1906, vii, 507.
8. Burrell and Lovett. Am. J. M. Sc., 1897, Aug.
9. Clairmont and Ehrlich. Wien. klin. Wchnschr., 1917, xxx, 1507.
10. Cramer. Berl. klin. Wchnschr., 1882, p. 21.
11. Dahlgren. Nord. med. Ark., 1908, i, 33.
12. Dawborn. Reported by Baldwin, Ohio M. J., 1907–08, iii, 161.
13. Dehner. Muenchen. med. Wchnschr., 1889, No. 5, 165.
14. Donati. Bull. d. sc. méd. di Bologna, 1907, vii, 201.
15. Dreesmann. Muenchen. med. Wchnschr., 1900, No. 19, 650.
16. Dunn. Reported by Thomas. Surg., Gynec. & Obst., 1921, xxxii, 291.
17. Durand. Lyon chir., 1919, xvi, 404.
18. Eden. Deutsche Ztschr. f. Chir., 1918, cxliv, 268.
19. Idem. Zentralbl. f. Chir., 1920, xlvii, 1002.
19. Evatt. Dublin J. M. Sc. incl. Tr. Roy. Acad. Med., Ireland, 1921, 4. s., 161.
20. Finsterer. Muenchen. med. Wchnschr., 1917, lxiv, 360; Deutsche med. Wchnschr., 1917, xliii, 800.
21. de Fourmestraux. Bull. et mém. Soc. anat. de Par., 1906, lxxxi, 433; 671.
22. Francke. Deutsche Ztschr. f. Chir., 1898, xlviii, 399.
23. Gerster. New York M. J., 1884.
24. Gibson. Canadian M. Ass. J., Toronto, 1921, xi, 194.
25. Goldmann. Zentralbl. f. Chir., 1909, No. 12, 429.
26. Grégoire. Rev. d'orthop., Par., 1913, 3. s., iv, 15.
27. Grothe. Muenchen. med. Wchnschr., 1900, No. 19.
28. Haegler. Reported by Finsterer. Muenchen. med. Wchnschr., 1917, lxiv, 360. Deutsche med. Wchnschr., 1917, xliii, 800.
29. Henderson. Surg., Gynec. & Obst., 1921, xxxiii, 1.
30. Herforth. Zentralbl. f. Chir., 1922, xlix, 1140.
31. Hildebrand. Arch. f. clin. chir., 1902, lxvi, 360.
32. Hippocrates. The Genuine Works of Hippocrates, translated by F. Adams. 1886, ii, 95.
33. Jones, R. Reported by Armour. Liverpool Med.-Chir. J., 1914, xxxiv, No. 65, 100.
34. Joseph. Berl. klin. Wchnschr., 1917, liv, 525; 1919, lvi, 779.
35. Joessel. Deutsche Ztschr. f. Chir., 1874, iv, 124.
36. Karewski. Reported by Donati. Bull. d. sc. méd. di Bologna, 1907, 8. s., vii, 201.
37. Kosloff. Contribution à l'étude de la luxation récidivante de l'épaule. Paris, 1911, Jouve & Cie.
38. Kronacher. Reported by Finsterer. Muenchen. med. Wchnschr., 1917, lxiv, 360. Deutsche med. Wchnschr., 1917, xliii, 800.
39. Krumm. Muenchen. med. Wchnschr., 1899, No. 30, 986.
40. Kuh. Prag. med. Wchnschr., 1903, xxviii, 599.
41. Lardennois. Union méd. du nord-est, Reims, 1905, xxix, 125.
42. Legueu. Bull. et mém. Soc. de chir. de Par., 1905, n.s. xxxi, 573.
43. Loebker. Klin. Chir., 1887, xxxiv, 657.
44. Loeffler, T. Zentralbl. f. Chir., 1920, xlvii, 324.
45. MacKinnon. Med. Herald, 1904, xxiii, 566.
46. Malgaigne. Traité des Luxations.
47. Mauclaire. Bull. et mém. Soc. de chir. de Par., 1905, xxxi, 10.
48. Meyer. Ann. Surg., 1918, May, 811.
49. Mikulicz. Beitr. f. klin. Chir., 1896.
50. Mueller. Ueber habituelle Schulterluxation. 27. Chirurgencongress. Berlin, 1898.
51. Nélaton. Traité de Chirurgie. Duplay et Reclus, 1897, iii.
52. Ollerenshaw. J. orthop. Surg., 1920, ii, 255.
53. Openshaw. Proc. Roy. Soc. Med., Lond., 1907-08, i, Clin. Sect., 29.
54. Paladini. Riforma med., 1895.
55. Payr. Reported by Finsterer. Deutsche Ztschr. f. Chir., 1917, cxli, 354.
56. Perthes. Deutsche Ztschr. f. Chir., 1906, lxxxv, 199.
57. Picqué. Bull. et mém. Soc. de chir. de Par., 1905, xxxi, 564; 963.
58. Platt. Reported by Thomas. Surg., Gynec. & Obst., 1921, xxxii, 291.
59. Ricard. Bull de l'Acad. de Méd., 1892. Thèse Boulakia.
60. Rich. Northwest med., 1917, xvi, 114.
61. Rivière. Lyon chir., 1918, xv, 437.
62. Roepke. Verhandl. d. deutsch. Gesellsch. f. Chir., Berl., 1912, xlii, 351.
63. Samosch. Beitr. z. klin. Chir., 1896, xvii, 803.
64. Samter. Arch. f. klin. chir., 1900, lxii, 115.
65. Sandes. Brit. M. J., Lond., 1921, ii, 321.
66. Schmieden. Reported by Joseph. Berl. klin. Wchnschr., 1919, lvi, 779.
67. Schultze. Arch. f. klin. Chir., Berl., 1914, civ, 138.
68. Seidel. Zentralbl. f. Chir., 1913, No. 34, 1344.
69. Selig. Deutsche Ztschr. f. Chir., 1915, cxxxii, 581.
70. Semken. Med. Rec., N. Y., 1917, xci, 435.
71. Sever. J. Am. M. Ass., 1921, lxxvi, 925.
72. Spencer. Proc. Roy. Soc. Med., Lond., 1909–10, iii, Clin. Sect., 20.
73. Steeg. Rev. méd. de Normandie, Rouen, 1910, 62.
74. Steinthal. Wuertemberg. Corres.-Bl., 1895.
75. Stimson. Fractures and Dislocations. 1917, 678.
76. Thomas. J. Am. M. Ass., Chicago, 1910, liv, 834. Internat. Clin., Phila., 1910, ii, 277. Am. J. M. Sc., 1909, cxxxvii, 299; 367. Univ. Penn. M. Bull., 1909–10, xxii, 16. Surg., Gynec. & Obst., 1914, xviii, 107. Ann. Surg., 1921, lxxiii, 639. Surg., Gynec. & Obst., 1921, xxxii, 291.
77. Trethowan. Reported by Thomas. Surg., Gynec. & Obst., 1921, xxxii, 291.
78. Walther. Bull. et mém. Soc. de chir. de Par., 1918, xliv, 48.
79. Warren. Boston M. & S. J., 1903, cxlviii, 285.
80. Werndorff. Ztschr. f. orthop. Chir., 1907, xix, 224
81. Wiesinger. Deutsche med. Wchnschr., 1895, Vereinsbeilage No. 17, 116.
82. Wilmanns. Zentralbl. f. Chir., 1909, xxxvi, 429.
83. Winiwater. Ann. Soc. méd.-chir. de Liège, 1905, xliv, 134.
84. Wolff. Reported by Donati. Bull. delle sc. med., Bologna, 1907, 201.
85. Worcester. Med. Rec., N. Y., 1920, xcviii, 80.
86. Young. Ann. Surg., 1916, lxiii, 375. Interstate M. J., St. Louis, 1916, xxiii, 312. Am. J. Orthop. Surg., 1913, xi, 243.

Extracted from the American Journal of the Medical Sciences,
January, 1925, No. 1, vol. clxix, p. 1

INJURIES TO THE MUSCULOSPIRAL NERVE.

By W. Russell MacAusland, M.D.,
SURGEON-IN-CHIEF, ORTHOPEDIC DEPARTMENT, CARNEY HOSPITAL.
AND
Andrew R. MacAusland, M.D.,
ORTHOPEDIC SURGEON, CARNEY HOSPITAL, BOSTON, MASS.

The musculospiral nerve is frequently involved in injuries of the upper extremity, due largely to the close approximation of the nerve to the shaft of the humerus in its middle third. von Busch,[10] in 1863, was the first to describe the paralysis resulting from injury of the musculospiral nerve in fractures of the humerus. Since his discovery many attempts have been made to restore the anatomical continuity of the nerve. In the World War, operative procedures were used with an appreciable measure of success in cases of paralysis of the musculospiral nerve resulting from wounds or fractures.

Slight injuries to the musculospiral nerve are frequently overlooked, especially as the paralytic symptoms may disappear rapidly after reduction of the fracture. In some cases, however, paralysis follows injury to the nerve trunk, due to the original trauma or to subsequent pressure upon the nerve from bony callus or scar tissue. These injuries demand early recognition and treatment, for such damage unrecognized often leads to a serious loss of function.

Very little has appeared in American literature on this important subject. It is our purpose to review the literature, particularly that of foreign countries, and to present our personal experiences with several of the more severe types of these injuries.

Anatomy of the Nerve. The musculospiral nerve is the principal continuation of the posterior cord of the brachialis plexus, and the only branch prolonged into the arm. It arises behind the axillary vessels, turns backward with the superior profunda artery between the long and internal heads of the triceps, and runs beneath the external head of the muscle in the musculospiral groove of the humerus, to the outer side of the arm. It pierces the external intermuscular septum, and descends between the brachialis anticus and the supinator longus to the front of the external condyle, where

it divides into the radial and posterior interosseous nerves. The radial is a cutaneous nerve, supplying the outer side of the thumb and the skin of two and a half fingers. The posterior interosseous supplies all the muscles on the back of the forearm except the anconeus.

The branches of the musculospiral nerve, arising on the inner side of the humerus, consist of the muscular branches supplying the long and inner heads of the triceps, and the internal cutaneous branch which passes backward beneath the intercosto-humeral nerve and supplies filaments to the skin over the long head of the triceps. The posterior branches of the musculospiral nerve consist of a fasciculus of muscular branches which supply the outer and inner heads of the triceps muscle and the anconeus. The external branches consist of the external cutaneous branches and the muscular branches. The external cutaneous branches distribute filaments to the lower half of the arm on its outer and anterior aspect and the branch descending to the wrist distributes offsets to the lower half of the arm and forearm, on their posterior aspect. The muscular branches supply the supinator longus, the extensor carpi radialis longior and frequently a small branch to the outer part of the brachialis anticus (Quain[63]).

Symptoms. The symptoms of injury to the musculospiral nerve vary in degree and duration according to the severity of the trauma and the resultant pathology. If, in a fracture of the humerus, the pressure on, or the stretching of the nerve is slight, any symptoms traceable to nerve injury may disappear in a few minutes. If continuity is interfered with, certain motor and sensory changes make their appearance.

Motor Changes. The wrist drops and the power of extension of the hand is lost. The hand is held pronated and half-flexed with the palmar surface slightly concave. If the hand is placed on a resistant surface, the lateral movements are impossible. If this deformity has existed for some time, there is a marked prominence on the dorsum of the hand, due to the stretching of the dorsal ligament of the wrist and the subluxation of the carpus. Extension of the fingers at the metacarpophalangeal joints as well as extension of the terminal phalanx of the thumb is lost.

The forearm is half-flexed and no extension is possible at the elbow. Supination is entirely lost when the forearm is extended on the arm, but if the forearm is flexed, a moderate degree of supination is possible through the action of the biceps.

Sensory Changes. There may or may not be any loss of sensibility. The area of loss when the nerve is divided extends roughly over the dorsum of the hand and lower wrist. There is no loss of sensibility in the forearm beyond a slight impairment of a very small area to the faradic current, and even this is doubtful.

Several theories have been expounded to explain the slight changes in sensibility. Létiévant[45] attributes it either to the abundant anastomoses between the median and ulnar nerves which undertake regeneration when the radial nerve is injured, or to the newly-formed nerve fibers from the uninjured parts which grow into the anesthetic region and produce regeneration. Fessler[24] does not support this theory, but believes the fibers of the radial are important in the retention of the sensibility.

Pain. In complete division of the nerve no pain is experienced. If the nerve is injured or compressed by organized callus or scar tissue, the sensation of pain is most evident a few days after the injury.

Clinical Examination. In determining the extent of the injury it is necessary to obtain a careful history of the accident and symptoms, as well as to examine the injured parts and test all muscle groups and sensory areas.

If possible, it should be decided whether the nerve is completely divided or merely traumatized. The function may be lost below the seat of the injury, either because the nerve has been divided, traumatized, or compressed by callus. It is frequently difficult to judge the exact condition, particularly if the injured part is examined immediately after the accident, when the symptoms are severe. In such cases, the sensory examination is very frequently ineffective as numerous anastomoses exist in the hand, and the maximum puncture may be of no value. An electrical excitability test does not give deciding data, as it is rendered difficult through swelling, and excitability of the peripheral nerves may still be possible. The presence of motor signs may be of no value, as they may show remaining power or may indicate the beginning of repair.

Muscles. All the muscles supplied by the musculospiral nerve should be tested for movement, tone, reflexes and atrophy. The power of the extensors of the wrist should be tested with the fingers flexed on the palm, as any slight contraction in the extensors of the wrist may then be felt. The extension of the proximal phalanges should be noted. The extension of the thumb must be carefully distinguished from the movement of abduction, the latter being controlled by the median nerve. If the examiner discerns a slight trace of movement, spontaneous recovery may be expected.

Electrical Diagnosis. In making the electrical examination, the use of the Victor Multi-plex Sinusoidal apparatus with a diagnostic electrode and 6 by 8-inch disbursing indifferent electrode is recommended in the U. S. A. Manual of Neuro-Surgery. The indifferent electrode is moistened and placed over the abdomen or back. The diagnostic electrode is applied over the motor point of each muscle to be tested. Sufficient current is used to obtain a contraction but not enough to stimulate the adjoining muscles. The patient lies

relaxed. The faradic current is first used if a normal reaction to electrical stimuli is obtained. The presence of faradic irritability after ten to fourteen days means that the nerve will recover spontaneously, since it shows at once that reaction of degeneration is not present. If faradic irritability is diminished, then galvanic current is used and the speed of muscle contraction and the amount of current required, are noted. A feeble, sluggish contraction is an indication that the nerve has degenerated. A brisk galvanic reaction, even though faradic excitability is absent, is an indication to adopt an expectant line of treatment.

Skin. Methods for the examination of the sensory conditions have been outlined in the U. S. A. Manual of Neuro-Surgery. The epicritic sense is tested by shaving the skin and turning a camel's-hair brush over it. The protopathic sense is tested with a sharp pin on the end of a 6-inch stick. Deep sensibility is determined by the pressure of a pencil. It is rarely that some definite area of sensibility is not found following lesions of the musculospiral nerve.

Hamilton[32] studied 55 cases at the Walter Reed Hospital to determine the areas of sensibility to pressure, pin-prick, and cotton or camel's-hair touch. He found that the patient fails to recognize subjectively and with any degree of accuracy the area of sensory loss, especially of the epicritic sense. Twenty-seven cases showed a definite area of sensory involvement in the forearm and hand. There was only 1 case in which the musculospiral nerve had been injured sufficiently high to produce loss of sensation corresponding to all three branches.

Vasomotor and trophic changes in the condition of the skin, nails, muscles, joints and bones should also be noted.

Types of Injuries. Injuries to the musculospiral nerve may be divided into two groups.

1. Immediate loss of function from traumatism.

2. Loss of function from pressure, callus, or scar tissue, usually associated with fractures, and occasionally following crushing injuries.

In primary division the onset of the paralysis is sudden. In secondary cases the paralysis develops insidiously and the functional loss increases as compression takes place. In case of injury coincident with or immediately following a fracture, the nerve may be bruised, stretched, compressed between the bone fragments or impaled by a spicule of bone. The nerve may be completely divided or the fibers may be crushed without damage of the nerve sheath. Goldstein[29] found 12 cases of complete division out of 20 cases of paralysis due to injury at the time of fracture, and he believes that complete division usually occurs at the time of primary injury.

Complete division of the nerve results from fractures or from direct injuries such as occur in stabbing accidents. Such cases should

be sutured as soon as possible. This type is illustrated by the following case.

CASE I. In the course of a fight this patient, T. G., had been stabbed in the right arm. Two months later he began to notice that he could not close his hand or pick up things. When we first saw him, four months after the injury, he had right wrist-drop, no sensation in the posterior radial side of the hand, and no power in the supinator longus or extensor groups. Operative interference was advised.

Operation. After a careful preparation, a 5-inch incision was made on the outer side of the arm. Upon exposure of the nerve, the upper end revealed a bulb almost as large as the end of the little finger, and the lower end was entirely separated and involved in scar tissue. By means of a safety-razor blade, $\frac{3}{8}$ of an inch was removed from each end. The nerve sheath was sutured with interrupted linen, and the nerve surrounded by fat. The muscles were sutured together loosely. The skin was closed with silkworm gut and the arm strapped in 45° flexion. A hyperextension splint was applied to the forearm and hand. This position was maintained for three months.

Six months after operation, power began to return in the wrist. Baking, massage and gentle movements were advised. Fourteen months after the operation, Dr. Earle E. Hussey, of Fall River, examined the patient and sent the following report:

At the elbow-joint, all motions were free and unlimited. The muscular power to flex and extend the forearm was very good. The patient complained of an aching sensation in the upper third of the forearm, but there was neither tenderness nor loss of sensation.

At the wrist-joint, the patient could move the hand freely in all directions. He could dorsiflex the wrist and had good power in the flexor and extensor muscles.

The Fingers. He could make a good fist; his hand grip was about one-half power. The power of flexion and extension was good. The terminal joints of all four fingers were stiff; all the other joints were free.

Loss of function may occur from hemorrhage which has become organized into scar tissue, which in turn involves the nerve and constricts the trunk.

CASE II. B. M., hurt her arm in an automobile accident in November, 1921. She suffered a deep muscle injury about 4 inches above and anterior to the external condyle. The wound healed in three weeks, but the patient was unable to dorsiflex the wrist and fingers. She was seen from the first time on December

27, 1921. There was a deep adherent scar, and considerable numbness over the lower external humeral region. The biceps and triceps were present and the patient could make a fist. There was no power in extension of the wrist or fingers, in spite of their having been held in hyperextension for six weeks. The patient had suffered also a fracture of the left clavicle and numerous other injuries. She was advised to enter the hospital for an exploratory operation.

Operation. January, 1922: After a careful preparation, the musculospiral nerve was exposed by a curved incision. The nerve was found to pass through scar tissue that had developed at the site of the wound. This scar tissue was excised and the nerve thoroughly freed. It was found intact and there was no bulbous end. The nerve was placed in a new muscle bed. The arm was kept at a right angle without motion for eight to ten weeks. The temperature remained normal. The wound was dressed for the first time on the fifth day. Seven weeks after the operation the patient was measured for a hyperextension splint for the fingers.

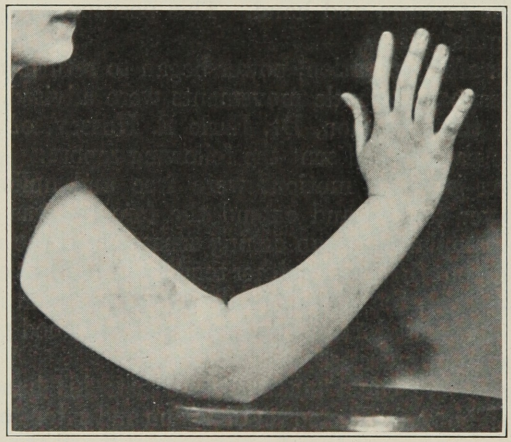

FIG. 1.—Case II. B. M. Showing return of voluntary power in extension of wrist and fingers, one year and three months after freeing nerve from scar tissue.

April 18, 1922. There was slight power in the extensors of the wrist.

May 16, 1922. The patient had regained power in the extensors on the radial side, but not on the ulnar. There were 20° of motion in flexion and limited extension in the elbow-joint, and it was expected that these motions would increase. The patient was advised to continue massage.

August 4, 1922. The arm was greatly improved. The extensor return, except the extensor pollicis, was very good. Patient was

advised to continue wearing the splint and to exercise the fingers daily for fifteen minutes.

September 6, 1922. The restoration of muscle control in the wrist was complete except for the extensor of the first metacarpal. The brace was discarded.

March 20, 1923. One year and two months after the operation, there was perfect flexion and extension at the elbow, good supination and pronation, and complete return of the musculospiral nerve distribution. The patient could separate the fingers. The thumb and index finger were slightly numb and the hand showed a little atrophy of the thenar eminence. The patient could not make a strong grip. (Fig. 1.)

Loss of function from pressure occurs following fractures of the humerus in which the nerve root is usually enveloped by callus or scar tissue that forms about the site of the fracture or injury.

Case III. This was a case (J. L.) of injury to the musculospiral nerve following a comminuted fracture at the middle and the lower end of the left humerus with non-union. The nerve was compressed and caught in callus and scar tissue.

October 4, 1921. One year and six months after the injury, the patient was seen for the first time, and advised to have an immediate operation.

Operation. A lateral incision was made, exposing the field of non-union. The upper end of the musculospiral nerve where it enters the groove was located and dissected free from the groove for a short distance. As it then entered dense scar tissue it was necessary to locate the lower end of the nerve which was dissected upward from below. This lower end also entered the scar tissue, and it was only by careful and tedious dissection that the nerve was freely removed from this area without damage. (Fig. 2.)

The nerve was carefully examined and although there were a few areas of local swelling, no definite division had taken place, and there were no bulbous masses within the sheath.

The area of non-union was then explored and a graft removed from the tibia, was inserted and held in the humerus by kangaroo suture. A new bed was made for the musculospiral nerve and the wound closed.

A plaster was applied from the fingers over the shoulder and about the chest. The wrist was held in hyperextension.

January 24, 1922. As the radiogram showed no union, the cast was not removed.

March 27, 1922. Callus formation was beginning and the graft was firm. The plaster was taken off (now six months), but protection was continued.

January 22, 1924. Union was solid. The shoulder was normal.

Flexion and extension were perfect. Supination was limited a few degrees. The patient could make a fist, but the fourth and fifth fingers were contracted at the second phalangeal joints. There was complete regeneration of the extensor control. The patient was back at work and had a very functional hand.

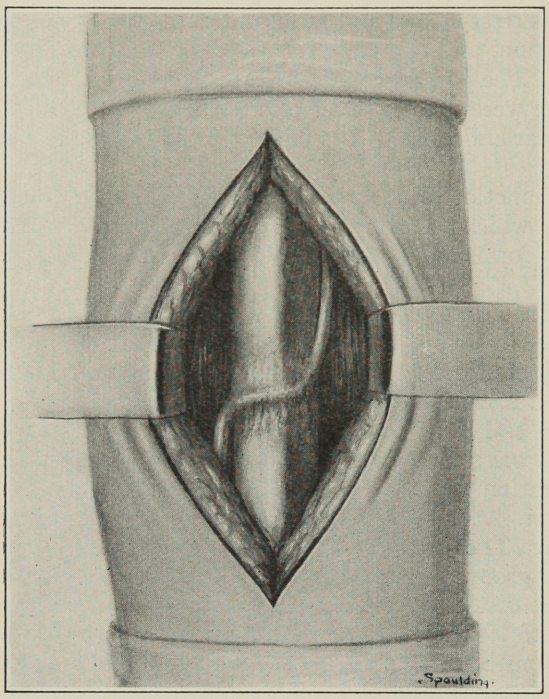

FIG. 2.—Case III. J. L. Showing area of non-union with musculospiral nerve caught in cicatricial tissue.

Prognosis. In general, operative results have been satisfactory. Kramer[43] reported 35 cases with only 3 poor results. Blenke[5] reported 58 cases, 41 of which made complete recovery, 6 partial recovery, 8 improved, and 3 showed little improvement. In some cases failures have been due to neglect of aseptic requirements or to lack of postoperative care.

Surgeons disagree as to whether recovery is better after nerve suturing for primary injuries, or following operation for paralysis due to the involvement of the nerve in scar tissue or callus formation. Sherren[73] and others have found that recovery may be perfect after a primary suture, but that it is not so good following secondary operations, as sensory recovery is rarely perfect. Borchard,[6] on the other hand, claims that operation for secondary injuries results

more favorably because in primary suture any neglect of aseptic requirements is followed by failure of nerve suture.

Although the prognosis is better if the interval between the injury and operation is short, still there is a chance of complete recovery after a long period of paralysis. Cases operated after sixteen months or even after three and a half years following fracture have resulted in complete restoration of function.

The establishment of continuity by end-to-end suture offers a greater chance of success than any other operative procedures such as grafting, implantation, or transplantation of nerve.

Indications for Exploration. Any open wound over the musculospiral nerve accompanied by wrist-drop, should be enlarged and the nerve examined. If a division of the nerve is present, a suture should be done at once.

If the nerve is injured from a blow in which it seems probable that complete division has taken place, suturing should be done early. Sometimes, however, the bruised condition of the soft parts is such that it is necessary to postpone a needed operation until the hemorrhage is reabsorbed, and a favorable opportunity offered for the healing of the wound. If the exact condition of the nerve cannot be determined, it is well to wait to see if power returns spontaneously. During this period, however, the fingers and wrist should be held in hyperextension, which position always favors the return of muscle power.

In the presence of fractures accompanied by radial paralysis in which it is impossible to determine whether paralysis is due to contusion or sectioning, it is best to first obtain reduction of the fracture and apply plaster. The muscles should then be watched for signs of atrophy and the fingers and the thumb should be exercised daily. If, after three or four months, paralysis still persists, exporatory operation should be performed.

Operative Technic. The method of treating the nerve must vary according to the pathological findings. If the nerve is found intact, often only a simple operation, such as removing the bone over which the nerve is stretched, or removing scar tissue or excessive callus, may be necessary to give relief.

Frequently, however, the nerve may be completely divided, constricted, torn, or bulbous at one end. In such cases, the usual procedure is to excise the affected portion, freshen the nerve ends, and establish continuity by suture. Nerve sutures have given very gratifying results and are recommended by many operators, including McCurdy,[48] Keen,[42] Cheyne,[13] Eve,[22] Ashhurst,[1] Auvray,[2] and many others.

Author's Technic. The approach to the part of the nerve involved is most successful if the upper and lower parts outside the field of injury are located and a dissection made up and down to

the seat of damage. This approach is not only much safer but quicker than other method. When the ends of the nerve are found bulbous, or a distinct swelling or constriction is felt in the nerve trunk, it is best to cut out this section by means of a safety-razor blade. The ends are then approximated and the entire sheath about the nerve sutured with linen. In cases of division of the nerve in which retraction has taken place it is often necessary to place the arm in flexion to gain approximation. It is rarely necessary to shorten the humerus.

After the ends have been sutured, the nerve should be placed in a new non-scar tissue bed, usually between layers of fat or muscle. There is some discussion as to whether fat is the best substance to prevent the formation of adhesions. Henle,[35] Morris[50] Williams,[81] and many others approve its use. Other operators believe that the fat atrophies, and they recommend the method used by Fessler[24] and Grisson,[31] of wrapping the nerve in a muscle flap of the triceps or of the brachialis.

The elbow should be held in flexion for at least five to six weeks, and then gentle passive motions may be started. The wrist and fingers must be held in hyperextension to avoid flexion contraction, to favor muscle regeneration, and to prevent the stretching of the extensors which, in itself is an important factor in hindering the return of muscle power.

As soon as motion begins to return, graduated massage and muscle training are of great advantage. The time when improvement begins varies from a week to several months. Motion usually begins to return in three or four months and it is usually a year before restoration is complete.

It may happen that after excision of the affected portion of the nerve, too large a gap exists to allow the approximation of the nerve ends. Such a condition is not frequently found in civil life, but war injuries often destroy a large part of the nerve. Several means have been used to bridge the space.

Piper,[60] Morton,[51] and Sherren[73] advised the manual stretching of the nerve and suture after the ends were in apposition.

Plastic neurotomy was used with success by Harrison[33] who turned into the space a flap from the upper end of the nerve which was bulbous. Dawbarn and Byrne[15] bridged a 3-inch gap by splitting the nerve at a low point of its distal portion and swinging the long shaft thus made into the space. Sherren[73] believed a flap should be used as rarely as possible, because such an operation necessarily is technically complicated.

Implantation of nerve, the method of attaching the stump of the distal end of the severed nerve to a healthy nerve, was first proposed by Lobker.[46] Roques de Fursac[70] implanted the musculospiral nerve in the median. Barkley[3] anastomosed the proximal

and distal ends with the median. Auvray[2] formed an anastomosis of the lower end of the radial with the internal brachialis cutaneous nerve. These procedures are of little value if the fibers of the healthy nerve are not separated and such an operation is difficult.

A few successful results from nerve grafting have been reported. Auvray[2] transplanted successfully a portion of the internal brachialis nerve 10 to 12 cm. long between the two freshened extremities of the musculospiral nerve. Sherren[73] suggested using for grafts the internal saphenous nerve obtained from the patient or from a recently amputated limb. Neuhof,[57] in a recent article on the transplantation of nerves in general, stated that as yet it was impossible to estimate the value of nerve transplantation. Only a few successful results have been obtained and the cases in literature have been recorded too early to judge the final result.

Still other means of bridging the gap have been suggested. A tubular suture has been proposed by some surgeons. Sherren[73] preferred a tube composed of one of the patient's superficial veins. Foreign materials have also been used. Keen[42] applied catgut threads, and Morris[50] bridged a gap of 3 cm. with silk thread. Magnesium was tried, but it was found to harden. Reisinger[68] proposed sinking the nerve in the triceps muscle and fixing it there.

Resection of the humerus as a means of allowing the approximation of the nerve ends is justifiable only in cases of ununited fractures complicated by division of the nerve. Ollier[59] has reported early cases of resection. Keen[42] reported using this method in 1 case and Riethus[69] in 3 cases.

If the damage to the musculospiral nerve is irreparable by the use of any of the methods mentioned, or if a case has not been relieved by end-to-end suture, then tendon transplantation is a commendable procedure. Its object is the improvement and restoration of muscle balance in the hand.

As the extensors of the wrist and fingers have lost their power, the problem is to transpose some of the muscles on the flexor aspect of the forearm without interfering with the power of flexion. The flexor carpi radialis, the flexor carpi ulnaris, and the pronator radii may be relied upon for this procedure.

Author's Technic. The attachment of the flexor carpi radialis is severed through a 1-inch incision made directly over it on the anterior surface of the wrist. A second incision is made half way up the forearm along the course of the flexor carpi radialis tendon, and the tendon pulled up. A long L-shaped incision is made across the back of the wrist and up the side of the ulna. The flap is dissected upward, the tendon of the flexor carpi radialis is thrust obliquely over the edge of the radius and made to appear over the back of the lower end of the radius. (Fig. 3). The ulnar tendon is severed at its attachment, carefully dissected upward as far as the

incision permits, and the whole muscle turned over, so that the tendon lies along the back of the lower end of the ulna.

During the completion of the operation the wrist and fingers are held in hyperextension. All the extensors are split to receive

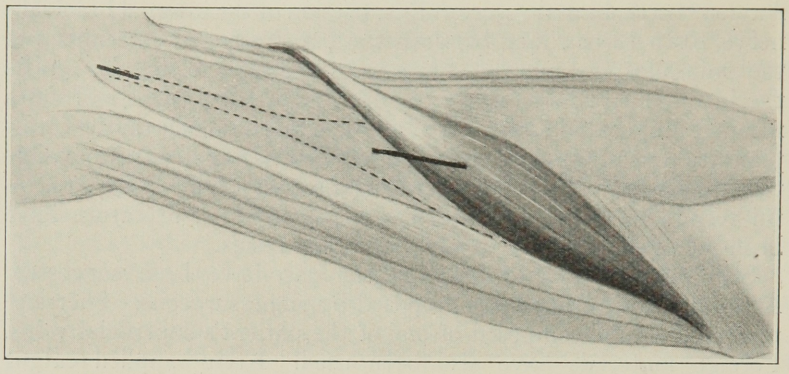

FIG. 3.—Showing incisions over attachment of flexor radialis and along the course of the tendon. The tendon is thrust obliquely over the edge of the radius.

these tendons, which are crossed through them (Fig. 4.). The thumb extensors are also included in those cases in which special provision has not been made for the extension of the thumb by the use of the pronator radii teres or the palmaris longus.

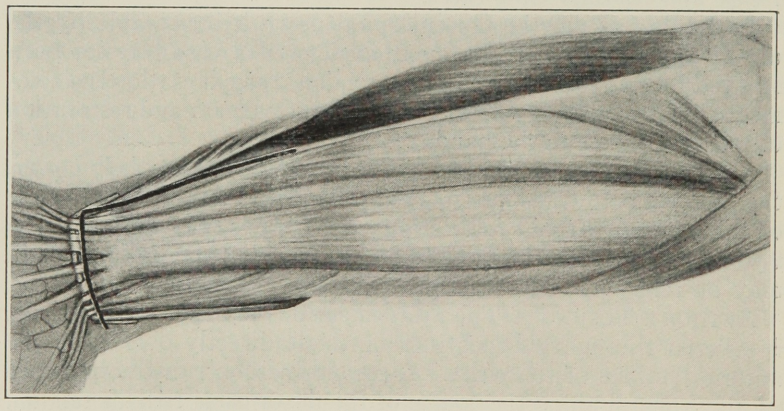

FIG. 4.—Showing the L-shaped incision across the back of wrist and up the side of ulna. The ulnar tendon has been severed at its attachment and the whole muscle turned over. The radial and ulnar tendons are seen running through the extensors which are slit to receive them.

The wound is closed. A splint is applied with the wrist and fingers held in hyperextension. This is worn for six to eight weeks during which time massage and passive motion are carried out.

Case IV. F. A., was ill in 1916 with acute arthritis of the shoulder. After an operation in which some dead bone was removed, wrist-drop and loss of elbow motion were noticed.

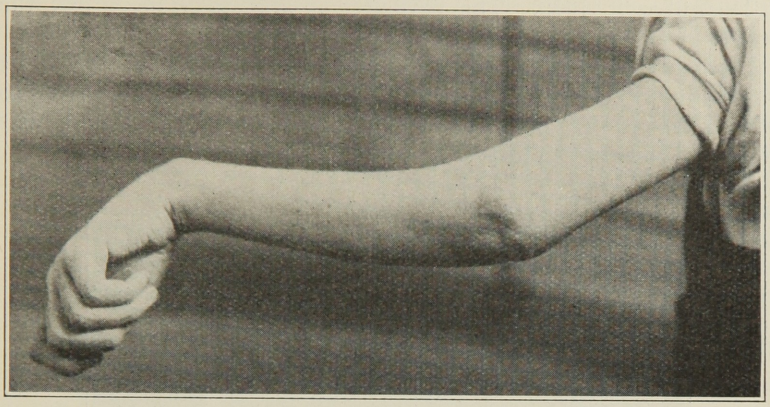

Fig. 5.—Case IV. F. A. Showing wrist-drop and hand deformity before tendon transplantation.

January, 1917. The patient was seen for the first time. Radiograms showed a diffuse osteomyelitic process involving the whole humerus. The shaft was opened *in toto* and four days later the patient was able to extend the fingers, showing some power in the radial nerve.

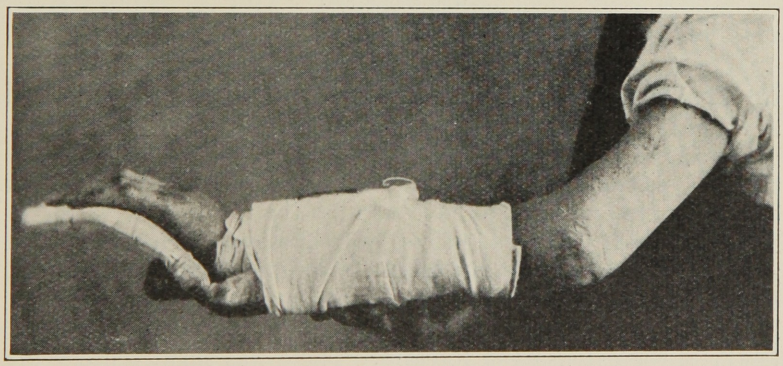

Fig. 6.—Case IV. F. A. Hand in splint after tendon transplantation.

September, 1917. The patient discarded the leather brace he had been wearing and a small hyperextension hand splint was applied. A radiogram later showed complete regeneration of the humerus. Daily olive oil massage and constant use of the hand were advised.

November 5, 1919. The power of extension of the wrist had not been regained (Fig. 5). A tendon transplantation was performed according to the above technic.

November 29, 1919. Massage and muscle training were started.

December 8, 1919. The patient was able to hyperextend the wrist.

September 8, 1920. He had voluntary extension of the wrist to within 15° of normal, and voluntary extension of the fingers to within 20° to 40° of normal. The extension of the thumb was deficient, but satisfactory (Fig. 6).

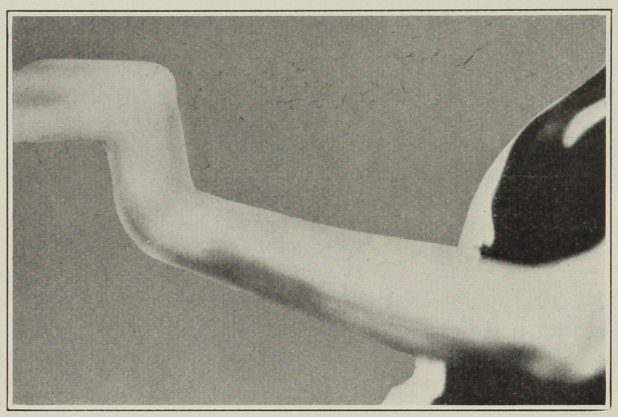

FIG. 7.—Case IV. F. A. Voluntary extension four years after tendon transplantation.

CASE V. M., admitted to the Alder Hey Hospital September 26, 1917, had suffered a compound fracture of the right humerus and severance of the musculospiral on May 9, 1915.

History. He had been treated in France, having had 7 operations for removal of shrapnel and cleaning of wound. The last operation was supposed to have been on the nerve.

Examination. The wound had been healed eight months. The present complaint was wrist-drop. Two long scars were attached to the bone in the upper arm. The humerus was shortened and irregularly thickened in middle and lower thirds. There was no power in the extensors of forearm. There was slight sensory loss over first phalanx of thumb. From the depth of the density of the scars, a wide gap of nerve seemed probable.

Electrical Reactions. The median and ulnar sensations were not affected. The radial sensation, E. and P. was impaired on the whole dorsal surface of the thumb, and slightly over the knuckle of the index finger. The forearm sensation was not affected over the musculospiral area. The extensors of the thumb, F.a., G.

faint, K. C. C.) A. C. C. Ext. communis, F.a., G. fair K. C. C.) A. C. C. The ulnar and median muscles were normal.

Diagnosis. The musculospiral nerve was involved in callus.

Treatment. On October 9, 1917 an operation was performed by Dr. A. R. MacAusland. Through a 5-inch incision, the musculospiral nerve was exposed just above the elbow, and followed up about an inch into very dense scar, where its course could not be traced farther. Without disturbing this region to any extent, the nerve was exposed on the axillary side as it entered the musculospiral groove, where it was found to be free for a short distance. It then entered dense scar tissue, but was carefully traced for about 1 inch more to the region of the very deep posterior scar. The dissection was completed through the incision on the outer side of the arm. The nerve ran into scar with only slight tendency to bulb. Exploration of scar farther revealed no nerve elements. The gap of about 3 inches was filled in with a section of the cutaneous nerve from the inner side of the musculospiral nerve in the axilla. It was not possible to bring the nerve ends together with graft, even by the expedient of crossing it in front of the humerus.

October 12, 1917. No pain, no temperature.

October 23, 1917. Clean; healed. Tendon transplantation seemed advisable.

November 13, 1917. Operation: Tendon transplantation. Flexor V. rad. into extensors of thumb, extensors longior and brevior and other extensors.

November 14, 1917. The patient had considerable pain. The circulation was good.

November 19, 1917. The patient was much more comfortable. He was advised to wear a long cock-up splint, with strap and thumb piece.

November 23, 1917. The thumb was to be extended. The wound showed slight sepsis.

November 26, 1917. The wound was clean. A short cock-up splint was to be applied.

Transplantation of the tendons for musculospiral nerve paralysis has been a most successful operation, as the tendons used are constant and strong. The early attempts to convert tendons into ligaments were made by Tilanus,[75] Codivilla,[14] Reiner,[67] and Gallie.[26] Jones,[39] Francke,[25] Müller-Aachen,[54] Vulpius,[80] Drobnik,[19] and Murphy[55] advocated this procedure in cases of extensive destruction of the nerve.

Jones[39] has outlined a tendon transplantation operation in which he converts the three extensors into ligaments so that the carpus can be fixed in the best functional attitude of dorsiflexion and still permit movement at the wrist-joint, but not in the direction of the deformity.

His operative technic consists of making a 3½-inch incision from just above the back of the wrist-joint extending up the middle of the forearm. By retracting the extensor ossis metacarpi pollicis and the extensor brevis pollicis, the two radial extensors may be followed along the forearm and divided high up and the ends pulled down. A tunnel is then drilled across the radius from the outer side, a little over an inch above the line of the wrist-joint. After the tendons have been scarified the extensor carpi radialis longior is pulled through the tunnel from the outer side and the brevior from the inner side. Their ends overlap and are sewed with a continuous catgut suture. In the same way the extensor carpi ulnaris is followed up to the forearm, divided, and the ends drawn through a tunnel in the ulna. Any tendency toward radial deviation of the hand by the pull of the radial extensor is thus corrected. The hand and forearm are encased in plaster. It is important to support the hand in the dorsiflexed position from the time the first catgut suture is inserted until the last plaster bandage is applied. In two or three months the patient may use his hand.

In a case of complete paralysis of the nerve Müller[54] tried tendon transplantation by cutting the tendon of the flexor carpi ulnaris and uniting it with the extensor tendons of the fingers. Seven months later the tendon of the flexor carpi radialis longus was cut and sutured to the tendon of the abductor of the thumb and the extensor carpi radialis longus. The patient was then capable of lifting the hand to a horizontal position and of abducting the thumb.

Murphy[55] released the flexor carpi radialis dorsally for 4 inches by tunneling through a button-hole incision. It was passed subcutaneously downward to the upper margin of the posterior annular ligament. The extensor tendons of the thumb and of each finger (two for the index and two for the little finger) were transfixed. The tendon of the thumb and of the index finger were attached obliquely from above downward and inward so that extension would not bring the inner three fingers into play ahead of the thumb and index finger.

Vulpius[80] reported 28 cases of tendon transplantation and Drobnik[19] reported 16 cases.

Sir Robert Jones[40] makes use of the pronator radii teres to produce extension of the wrist, by inserting it into the two radial extensors, and the flexor carpi radialis and the flexor carpi ulnaris to produce extension of the fingers and thumb by insertion into these tendons. During the whole procedure of tendon suture he keeps the wrist and fingers in complete dorsiflexion and the thumb in full abduction in order to procure the best action from the transplanted tendons. After operation the limb is placed in a splint which keeps the wrist in full dorsiflexion and the metacarpophalangeal and the interphalangeal joints flexed at an angle of about 10°.

Jones has used this technic in 20 cases. All the patients were

able to dorsiflex the wrist with the fingers closed and then to extend the fingers while the wrist remained in dorsiflexion.

Pathology. In operating for musculospiral nerve paralysis, the nerve is often found intact, but stretching over bony fragments or involvement in scar tissue or callus prevents it from having normal power.

If the nerve is crushed or torn the changes differ from those which occur as the result of severing by a sharp knife. In the latter case there is no contact between the two ends of the nerve and the changes differ in the proximal and distal parts. The proximal end becomes markedly bulbous. The distal end becomes shrunken, tapering, or slightly bulbous.

If the nerve is crushed it becomes inflamed and the inflammatory condition may lead to complete destruction. The nerve sheath may not be damaged, but the nerve fibers being inflamed, a constriction or a bulbous formation may develop within the sheath.

Reparative Processes. The regenerative process depends upon the trauma, the pathology and nourishment of the nerve.

Henriksen[36] made experimental investigations to determine the exact regenerative processes in a nerve that was completely divided and in one damaged in a crushing injury. He found that after complete division regeneration begins immediately, developing most rapidly in the central stump where fully organized myelin fibers may exist as early as ten days after injury. The first histological sign of regeneration is activity of the neurilemma nuclei which begin to proliferate. The protoplasm at the poles of the nuclei increases and grows into thin threads through the old Schwann sheaths and out into the severed nerve ends forming a bridge between the latter. Henriksen found that in the course of a few days these threads may bridge a gap of more than 0.5 cm., and that the old Schwann sheaths are pierced by long protoplasmic threads before the old threads have completely lost their structure. Fully characteristic nerve segments may be found in the central stump ten days after severance.

When a nerve is severed, its muscle loses weight and degenerative changes occur. At the same time the sarcolemma nuclei become active and new cellular matter forms in the muscle. When innervation begins, these cells form the basis for the formation of young muscular fibers. It is difficult to tell just when the muscle regains tone, but it may be late, five to six weeks after a primary suture.

Henriksen, in experimenting on rabbits, could find no essential difference in the process of regeneration when the nerve was sutured or when it healed unaided. In fact, the nerve fibers were at first found deflected as a result of the pull of the thread, although later they straightened out. Nerve suture, however, is necessary when obstacles prevent spontaneous healing.

One would naturally assume that a crushed nerve would regenerate

more easily and quickly than a severed nerve, but clinical examinations show that physiological restitution is often not so complete and is often slower in a case of a crushed nerve. The nourishment may be established more rapidly, but disturbances may appear in the process of regeneration, or the myelin differentiation may be disturbed, thus hindering the healing. After a complete severance of the nerve, the mass growing out from the ends to form the bridge between the ends thickens, and the nerve recovers its smooth appearance. If the nerve is crushed the thickness is uneven and it infiltrates the surrounding tissues. The peripheric part of the nerve is swollen and edematous.

Literature. After von Busch[10] and Ollier[59] in 1865 reported good success in operating in cases of paralysis following fractures of the humerus, many similar cases were recorded in literature. In 1886, von Bruns[9] reported 189 cases of nerve injuries. Seventy-three of the 138 cases of the upper extremities were musculospiral nerve paralysis following fractures of the humerus.

In 1889 Bowlby[7] issued statistics of the operated cases that had been published. All the cases, 2 by Trélat,[77] 2 by Bidder, 1 each by Erickson, Ollier, Whitson, Delans, Israel,[38] Tillaux,[76] and Hueke had resulted from fractures of the humerus and were due to stretching, contusion or pressure. The results in 7 of these cases were satisfactory.

Goldstein[29] in 1892, Wölfler[83] in 1895, Neugebauer,[56] Zoege-Manteuffel,[84] and Drewitz[18] in 1895, reported several cases in which the nerve was found compressed in scar masses or bony callus. Successful results were obtained by operative interference.

In 1899 Riethus[69] described fully 7 of his cases. In 5 cases the nerve was compressed by bony callus or fibrous tissue. Complete cures were effected by operative interference in 2 of the cases and essential improvement was obtained in 2 cases. The result in the fifth case was not reported. Excellent results were obtained in 2 other cases in 1 of which the nerve was stabbed on the edge of a fragment of bone, and in the other in which the nerve was stretched over a sharp bony edge.

The same year Willmers[82] reported a successful result.

In 1900, Keen[42] reported a series of 7 cases, in 6 of which operations were performed for paralysis of the musculospiral nerve following fracture of the humerus. Complete restoration of function was secured in 2 cases by suture of the nerve. A useful arm was obtained in 1 case in which the humerus was resected to approximate the ends of the nerve over a gap of 5 cm. As the other patients did not carry out the postoperative requirements, very little improvement took place in 2 cases and no improvement in 1 case.

In 1 case of complete division of the nerve by a knife blade, Keen sutured the nerve ends with silk thread. Fourteen months later the patient had a good, useful hand.

Launois and Lejars[44] reported a successful case in paralysis following a fracture.

Braüninger,[8] Kramer,[43] and Reisinger[68] also reported good results in freeing the nerve from compression.

In 1905, Piper[60] published his monograph on the subject of musculospiral nerve paralysis following fractures of the humerus. After reviewing the literature from early times and describing the various types of operative technic, he cited 4 cases from the Kieler Clinic. One case was not operated. The second in which the nerve was pleated and a layer of the triceps laid between it and the bone, resulted in a weak hand. In the third case the nerve was found intact, but twisted above the seat of fracture; paralysis was overcome by freeing the nerve. In the fourth case the nerve was intact but involved in callus. The definite outcome of the operation was not recorded, but the latest record was the beginning of a degenerative reaction.

Scudder and Paul[71] reported 11 cases of suture in the Massachusetts General Hospital. Eight cases were relieved by operation. The other 3 cases were failures.

Of 12 cases reported by Borchard[6] in 1907, 2 were unsuited for operative handling; in 2 cases the nerve was sutured; in 3 cases it was simply loosened from adhesions; in 3 cases bony masses and scar tissue were removed; in 1 case it was necessary to excise the radial head, and in the twelfth case nerve grafting was employed to bridge a large defect. Except in the last 2 cases on which it was too early to report, the condition was cured by operation.

In 1909, Harrison[33] reported 2 cases, 1 in which the nerve was compressed by callus and 1 in which the nerve crossed in front of the humerus. Operation on the first case in which a flap of the nerve was turned in to bridge a wide gap, resulted in a good serviceable hand. In the second case it was necessary to divide the humerus in order to place the nerve in position. In three and a half months the patient could extend his hand to an angle of 150° with the forearm, and further improvement was expected.

Els[21] reported 2 cases of secondary suture. Perfect function resulted in the first case from operation for partial tearing of the nerve over a bony fragment. The result in the second case of paralysis due to the involvement of the nerve in scar tissue, was good, but the hand was somewhat weak.

Charbonnel[12] reported a case of double fracture and splintering of the humerus followed by nerve paralysis. The nerve was freed from between the long supinatus and the anterior brachialis, and in six and a half months the patient had normal movements.

Barkley[3] reported a case in which the humerus was broken in two places, and there was a loss of 4 inches of substance of the nerve. The ends were anastomosed with the median nerve, and complete use of the hand resulted.

In 1911, Morestin[49] reported 3 cases on which he had operated. In 1 following fracture of the humerus, the nerve was freed from between the fragments and sutured, and in one month there were good prospects for success. In the second and third cases of paralysis, likewise following fractures, the nerves were found embedded in callus. Fifteen days after operation in the second case, the patient could extend the hand and fingers almost to normal. Operation on the third case also resulted in the return of all normal movements.

Schwartz[72] operated for a case of paralysis following fracture of the humerus. He freed the nerve from callus and interposed a layer of muscular and fibrous tissue between it and the bone. In ten months recovery was complete.

Gaudier and Deladrière[28] reported a case of paralysis following fracture of the humerus. Five months after the nerve was freed from adhesions the patient had recovered all movements.

In 1912, Nikoloff[58] cited a case in which the paralysis appeared three weeks after the healing of a fracture of the humerus. To bridge the gap, a tube of fibrous cord was made and the non-paralyzed end of the nerve sutured to the paralyzed end. A muscle layer was inserted to separate the nerve from the bone. A complete return of movement was obtained.

Judet[41] cited a case of secondary paralysis following fracture of the humerus in which the nerve was found compressed by a spicule of bone. Operation resulted in a complete cure.

Ferraton[23] sutured a nerve that had been destroyed in a comminuted fracture of the humerus caused by a bullet. All movements of the hand returned.

Murphy[55] reported establishing end-to-end union of the nerve by applying a flap. In another case he united the ends of the nerve at the central septum to the triceps muscle. He did not report his results.

Gallois and Tartanson[27] reported 2 successful cases in which paralysis had followed fractures. After isolation of the nerve from the callus, a layer of muscle was inserted between it and the bone to prevent further complications.

In 1914, Mosti[52] cited a case of secondary suture that resulted in complete success. Quénu[64] also reported a successful case of secondary suture. Hohmann[37] operated on 1 case of paralysis following fracture of the humerus.

In 1916, Dawbarn and Byrne[16] did a splitting neuroplastic operation in a case of destruction of the nerve from a fracture of the humerus. An irregular form of regeneration resulted.

Successful results from suturing of the nerves were reported by Souques,[74] Loewenstein[47] and Ranschborg.[65] Moszkowski[53] presented a case in which a pedicled flap of the triceps muscle was used to bridge the defect in the nerve. At the time of his report

it was too early for complete restoration but signs of regeneration were apparent. Two successful nerve suture operations for complete division of the nerve were presented by McCurdy[48] in 1917.

Beck[4] operated for a paralysis resulting from a fracture that had occurred seven months before. In operation a tubule of fascia lata and fat was transplanted into the extensor tendons. Twelve weeks after the operation, considerable power had returned to the muscles.

Morris[50] reported a successful case of secondary suture for paralysis following non-union of a fracture of the humerus. In discussion of his report, Green and Hitzrob reported similar cases in which they had been successful.

Hartwell[34] reported a case of a successful suture forty-six days after section of the nerve by a stab wound.

Due to the frequency of injury to the musculospiral nerve in war wounds, there were many operations performed between the years 1917 and 1921. Gosset,[30] in 1923, summed up very well the results of these operations.

In 1917, Gosset,[30] himself, reported 144 cases. In 44 cases of freeing of the nerve, there were 26 successful results, 10 cases of improvement, and 8 failures. In 27 cases of suture for complete sectioning, there were 16 good results, 1 case of improvement, and 10 failures. In 2 cases of suture for incomplete sectioning, there was 1 cure and 1 failure.

In 1918, Gosset and his pupil Charrier studied 76 cases. In 18 cases in which the nerve was freed from compression, 95 per cent recoveries were obtained. The condition of the other patients was improved. Thirteen cases of complete sectioning in which the nerve was sutured, resulted in 4 recoveries and 3 failures due to bad technic. The condition of the other 6 patients was slightly improved. In 21 cases of incomplete sectioning, there was a fibrous formation between the nerve ends which some operators believed might be used as a means of conductivity. In the 5 cases in which this tissue was utilized there were 4 failures. In the other cases the fibrous formations were excised and an end-to-end suture was done. There were 9 good results, 4 cases of improvement, and 3 failures. These results show clearly that the fibrous formations do not act as conductors of nerve influence.

Dumas[20] reported the results of 115 cases that were operated upon. In 18 cases of freeing the nerves from compression, 83 per cent good results, and 11 per cent fair results were obtained; in 41 cases of incomplete severance 70 per cent successful results and 11 per cent fair results; in 46 cases of sectioning with some fibrous continuity remaining, 43 per cent successful results, 10 per cent fair results and 46 per cent failures; in 10 cases of complete severance treated by suturing, 1 fair result. The other cases were failures.

In 1918, Delagénière and Tinel[17] reported 181 sutures with 88 per cent positive results. Villard[79] reported 8 suture operations with 4 good results.

Reder[66] reported a case of complete paralysis caused by a shot wound. At operation a strip of muscle taken from the head of the triceps was wound around the point of injury. In forty weeks all movements, except the ability to pick up a pin, were possible.

Auvray[2] in 1919, collected the results of 31 cases of wounds of the nerve operated in 1915. Of 15 cases of simple freeing of the nerve from compression, 7 patients obtained complete restoration of function; 4 an improved condition, and there was 1 failure; of 11 cases of end-to-end suture, 8 patients obtained complete restoration and there were 3 failures; 1 case of excision of a cicatricial nodule from the middle of the nerve was successful; and 1 case of nerve graft 10 to 12 cm. long from the internal brachialis cutaneous nerve resulted successfully. Three cases of anastomosis and redoubling of the upper end of the nerve were failures. On the average Auvray found amelioration had begun at the end of several months, usually four to eight.

In discussion of Auvray's report Wiart cited statistics less satisfying. Of 25 sutures, there were only 5 complete cures, and 5 cases of improvement; of 61 cases of freeing the nerve there were 20 complete cures, and 20 ameliorations.

In 11 cases of suture, Cestan[11] obtained 5 complete cures. The condition of 4 other patients was improved by operation. Two cases were failures.

Putzu[62] obtained 85 per cent cures in operations of freeing the nerve and 47 per cent cures in suture operations. Dane[15] secured 50 per cent good results. Platt[61] collected 35 cases of nerve suturing in which 26 very good results were obtained.

From the results of the above cases it is seen that operations of freeing the nerve give 95 per cent good results and suture operations give 45 to 55 per cent.

Henriksen,[36] in 1923, reported 5 successful cases in 2 of which the nerve was sutured, in 1 4 cm. of the humerus was resected to bridge a gap of 6 cm., and in 2 cases the nerve was freed from callus.

Conclusions. 1. The nerve may be injured in three ways: The nerve trunk may be crushed without damage to the sheath; the nerve may be completely divided; power may be lost through the involvement of the nerve in scar tissue or callus.

2. Early recognition and treatment of nerve injuries in connection with fractures and severe traumatisms is very important. We may expect a perfect result in cases of immediate suture of the nerve. While intervention in cases of old standing has given good results, it is the general opinion that the chances of success are lessened after the elapse of a long period of paralysis.

3. Simple freeing of the nerve is very often the only procedure necessary to relieve the condition. In cases of complete division of the nerve or in cases in which there is need to excise a portion of it because of a fibrous formation, nerve suture has been found the most satisfactory procedure for the approximation of the nerve ends. If the nerve suture does not relieve the condition, or if the case is not reparable by the various methods of manual stretching, neurotomy or nerve grafting, then tendon transplantation gives satisfactory results.

4. After severance of a nerve, healing begins spontaneously. In cases of nerve suture function develops in the same manner as in spontaneous healing. After secondary suture sensibility returns early. Muscle control usually appears in the course of two to four months and is complete in from six to nine months, depending upon the location of the nerve injury.

BIBLIOGRAPHY.

1. Ashhurst: Trs. Phila. Acad. Surg., 1911, **13**, 30.
2. Auvray: Bull. et. mém. Soc. de chir., 1919, **45**, 1291.
3. Barkley: Lancet-Clinic, 1910, **104**, 508.
4. Beck: Surg. Clin., Chicago, 1918, **2**, 406.
5. Blenk: Monatschr. f. Unfallheilk., 1903, **10**, 1.
6. Borchard: Deutsch. Ztschr. f. Chir., 1907, **87**, 1.
7. Bowlby: Injuries and Diseases of Nerves, 1889.
8. Braüninger: München med. Wchnschr., 1900, **47**, 290.
9. von Bruns: Neurol. Centralbl., 1902, **21**, 1042.
10. von Busch: Sitzungsb. d. nied.-rhein. Gesellsch. f. Nat.-u. Heilk. zu. Bonn, 1862–3, p. 155.
11. Cestan: Rév. neurolog., 1918, **25**, 148.
12. Charbonnel: Jour. de méd. de Bordeaux, 1910, **40**, 499.
13. Cheyne: Manual of Surg., 1900, **2**, 382.
14. Codivilla: Arch. di ortopl, 1899, **16**, 225.
15. Dane: Brit. Med. Jour., 1921, **2**, 885.
16. Dawbarn and Byrne: New York Med. Jour., 1915, **102**, 730.
17. Delagénière and Tinel: Bull et mém. Soc. de chir., 1918, **44**, 524.
18. Drewitz: Monatschr. f. Unfallheilk., 1896, **3**, 8.
19. Drobnik: Reported by Piper.
20. Dumas: Bull. et mém. Soc. de chir., 1917, **43**, 1184.
21. Els: Beitr. z. klin. Chir., 1910, **68**, 394.
22. Eve: South. Pract., 1907, **29**, 306.
23. Ferraton: Bull. et mém. Soc. de chir., 1912, **38**, 299.
24. Fessler: Deutsch. Ztschr. f. Chir., 1905, **78**, 60.
25. Franke: Arch. f. klin. Chir., 1898, **67**, 763; Berl. klin. Wchnschr., 1899, **36**, 244.
26. Gallie: Ann. Surg., 1915, **62**, 481.
27. Gallois and Tartanson: Lyon méd., 1912, **118**, 757.
28. Gaudier and Deladrière: Echo méd. du nord, 1911, **15**, 25.
29. Goldstein: Deutsch. Ztschr. f. Chir., 1895, **40**, 566.
30. Gosset: a. Résultats obtenus dans la chirurgie des blessures des nerfs périphériques par projectiles de guerre (presented before the International Congress of Surgery, London, July 18, 1923; Arch. méd. et phar. miliatir., 1917–1920, **68–72**.
31. Grisson: Deutsch. med. Wchnschr., 1904, **30**, 901.
32. Hamilton: Arch. Neurol. Psych., 1920, **3**, 277.
33. Harrison: Practitioner, 1909, **83**, 698.

34. Hartwell: Surg. Clin. North America, 1921, **1**, 399; Ann. Surg., 1921, **73**, 665.
35. Henle: Arch. f. klin. Chir., 1906, **79**, 1044.
36. Henriksen: The Results of Surgical Treatment of Injury of the Nerves (Presented before the International Congress of Surgery, London, July 18, 1923).
37. Hohmann: München med. Wchnschr., 1914, **61**, 2352.
38. Israel: Gaz. hebd. de med., 1884, **21**, 281.
39. Jones: Jour. Orthop. Surg., 1919, **1**, 135.
40. Jones: Orthorp. Surg., London, 1921.
41. Judet: Paris chirurg., 1912, **4**, 292.
42. Keen: Med. Chron., Manchester, 1900, **3**, 337.
43. Kramer: Beitr. z. klin. Chir., 1900, **28**, 423.
44. Launois and Lejars: Rév. de chir., 1903, **27**, 574.
45. Létiévant: Traité des sections nerveuses, Paris, 1873.
46. Lobker: Centralbl f. Chir., 1884, **2**, 841.
47. Lowenstein. München. med. Wchnschr., 1916, **63**, 1405.
48. McCurdy: Am. Jour. Orthop. Surg., 1917, **15**, 711.
49. Morestin: Bull. et mém. Soc. de chir., 1911, **37**, 1179.
50. Morris: Ann. Surg., 1919, **69**, 338.
51. Morton: Lancet, 1918, **1**, 373.
52. Mosti: Policlin. (sez chir.), 1914, **21**, 563.
53. Moszkowski: Wien. klin. Wchnschr., 1916, **29**, 725.
54. Müller: Ztschr. f. klin. Med., 1899, **38**, 433.
55. Murphy: Surg. Clin., Chicago, 1912, **1**, 91.
56. Neugebauer: Beitr. z. klin. Chir., 1896, **15**, 465.
57. Neuhof: The Transplantation of Tissues, New York, 1923, p. 171.
58. Nikoloff: Nord. méd., 1911, **18**, 203.
59. Ollier: Gaz. hebd. de méd. et de chir., 1865, **2**, 515.
60. Piper: Fraktura humeri mit Verletzung des Nervus radialis, Kiel, 1905.
61. Platt: Brit. Med. Jour., 1921, **1**, 596.
62. Putzu: Riforma med., 1919, **35**, 906.
63. Quain: Anatomy, Vol. **3**, Part II, 303.
64. Quénu: Bull. et mém. Soc de chir., 1915, **41**, 215.
65. Ranschburg: Deutsch. med. Wchnschr., 1916, **42**, 1546.
66. Reder: Trs. South. Surg. Assn., 1918–19, **21**, 355; Ann. Surg., 1919, **70**, 226.
67. Reiner: Ztschr. f. orthopäd. Chir., 1904, **13**, 451.
68. Reisinger: Beitr. z. klin. Chir., 1902, **36**, 618.
69. Riethus: Beitr. z. klin. Chir., 1899, **24**, 703
70. Roques de Fursac: Berlin klin. Wchnschr., 1900, **37**, 853.
71. Scudder and Paul: Ann. Surg., 1905, **1**, 1118.
72. Schwartz: Bull. et mém. Soc. de chir., 1911, **37**, 1131.
73. Sherren: Brit. Med. Jour., 1910, **1**, 130; Injuries of Nerves and Their Treatment, New York, 1908, p. 310; Modern Treatment of Nervous and Mental Diseases, Philadelphia and New York, 1013, **2**, 54.
74. Souques: Rev. Neurolog., 1916, **19**, 99.
75. Tilanus: Nerderl. Tijdschr. v. Geneesk., 1898, **2**, 925.
76. Tillaux: Bull. et mém. Soc. de chir., 1862, **8**, 836.
77. Trélat: Bull. et mém. Soc. de chir., 1882, **8**, 834.
78. U. S. A. Manual of Neuro-Surgery.
79. Villard: Lyon méd., 1916, **125**, 192.
80. Vulpius: Reported by Piper.
81. Williams: Brit. Jour. Surg., 1918–19, **6**, 315.
82. Willmers: Dissertation, Bonn, 1899.
83. Woelfler: Prag. med. Wchnschr., 1895, **20**, 530.
84. Zoege-Manteuffel: St. Petersburger med. Wchnschr., 1896, **13**, 9.

Reprint from
SURGERY, GYNECOLOGY AND OBSTETRICS
September, 1921, pages 223–245

MOBILIZATION OF THE ELBOW BY FREE FASCIA TRANSPLANTATION WITH REPORT OF THIRTY-ONE CASES[1]

By W. RUSSELL MacAUSLAND, M.D., Boston
Surgeon-in-Chief, Orthopedic Department, Carney Hospital

In a previous paper (38), read before the Orthopedic Section of the American Medical Association on June 23, 1914, I reported 4 cases in which I had gained mobility in ankylosed elbow-joints by means of arthroplasty. In 2 of these, I used the Murphy method interposing pedunculated flaps of fat and fascia; in 2, free flaps of fascia lata. At the same time, I gave a résumé of the literature on previous attempts at mobilization in this joint. I should now like to consider briefly the contributions which have been made to date to the literature on this subject and also to report my arthroplasties in full.

Ankylosis of the elbow results either from an infectious process or from traumatism. The latter is usually a fracture dislocation with wide separation. The large amount of callus which forms as a result of this injury at first interferes mechanically with motion; later, an ankylosis results, usually fibrous in character.

The infectious process may be either acute or chronic. In the former case, the causative agent is usually the streptococcus, the pneumococcus, or the gonococcus. The onset is sudden and the course severe, ending usually in a bony ankylosis.

We may, on the other hand, have a slow, insidious, polyarthritic process. The focus of infection is situated elsewhere, and the joint condition is caused by the hæmatogenous deposits in the joint, either of attenuated bacteria or of toxins. The primary focus is often difficult to locate. The ankylosis results from adhesions both within and without the joint and is, at least at first, fibrous.

In the problem of treatment of any ankylosis, the location of the joint has to be considered. In the elbow, conditions are different from those in any other of the large joints. In the lower extremity, stability is far more important than motion. Here, particularly at the knee, a firm, painless joint in good position is far more useful than a wabbly one continually subject to strains and wrenches. In a shoulder ankylosed in an abducted position, a useful degree of motion may be had by the resulting hypermobility of the scapula. A stiff wrist in a good position, i.e., hyperextension, is serviceable; moreover, as structures here are complicated, the joint does not lend itself readily to arthroplasty. In the elbow, on the other hand, no position of ankylosis is favorable to function and any position is ungainly.

Many methods have been tried to gain mobility in the elbow. Various nonabsorbable materials have been used. Gluck and others inserted ivory pegs; Pupovac, magnesium sheets, and other metals. Besides these, wood, celluloid, gutta percha, and temporary packings of gauze have been used. Taylor (67) advocated a mixture of yellow wax and lanolin.

[1]Read before the Southern Medical Association, November 15, 1920.

Widely varying organic substances have been tried. Rechet (57) covered the ends of the resected bones with periosteal flaps in various joints. Hofmann (32), in 1906, reported a case in which he transplanted periosteal flaps from the tibia to the resected end of the bones of the elbow. He obtained full extension and flexion to 80 degrees.

Weglowski (74) reported a case in which he used successfully cartilage transplanted from the rib in an ankylosed elbow.

Von Frisch (23) used periosteal grafts from the tibia in an elbow ankylosed from gonorrhœal arthritis. Only 25 degrees motion was obtained. The author attributed the result to lack of after-treatment.

Herzberg (30) reported 4 cases in which transplantation of joints was done after resection. Ankylosis was the result of trauma. Three of the cases were children.

Greiffenhagen (26) reported 3 cases in which periosteum was used in elbow-joints.

Mauclair (39) used cartilage from the astragalus to cover the rough ends. X-ray later showed these fused to the bone.

More recently, cartilage grafts were used by Delangenière (16) after a resection had been done. The operation showed no advantage over an excision, as some instability of the joint followed. These methods have now been abandoned.

Excision has a few advocates but, except for this, arthroplasty has succeeded all other methods. The first case reported is that of Verneriel (72) in 1860. He gained motion by the use of a flap of muscle and fascia, interposed after resection of an ankylosed jaw. Helfereich's (28) report, however, in 1893 brought the matter to more general attention. He also used a muscle flap for interposition.

Albarran (1) reported a case in which ankylosis had followed operative reposition. A partial resection was then done by which a good immediate result was obtained but later ankylosis again occurred. A third operation was undertaken which consisted of a resection of the olecranon and interposition of a muscle fascia flap of the triceps. After two years, there was a range of motion from 65 to 115 degrees. Extension was possible without the aid of gravity. Pronation and supination were normal. There was no lateral motion.

Nélaton (45), in a case of ankylosis following a neisserian infection, resected an elbow and interposed a flap of the brachialis anticus. Two years after the operation, flexion and extension were normal, but pronation and supination were much decreased. Active extension required the weight of gravity.

In 1903, Quénu (56, b) reported an arthroplasty of the elbow for an ankylosis following a severe trauma of the arm, consisting of a fracture of both bones of the forearm and destruction of the soft parts. After resection, he interposed a tendon fascia flap. There resulted flexion to a right angle and good but incomplete extension. There was good pronation but difficulty in maintaining an intermediate position. The patient died a few months after the operation of pulmonary tuberculosis.

Delbet (17) also reported mobilizing an elbow in a girl of six, which had become ankylosed in infancy, resulting in complete atrophy of the arm. At his first operation, he resected the joint without breaking up the ankylosis. Two months later after re-ankylosis, he intervened again, removing the bony spicules that had formed, 0.5 centimeter thick, from the humerus, the radius, and the ulna, and interposing some fibers of the flexor carpi ulnaris. Chloroform mobilization was necessary a month later but the final result was good, with flexion to a right angle and extension nearly complete.

Berger (7), in the same year, mobilized a fibrous ankylosis by remodeling the bony parts and inserting a flap of the anconeus which he sutured to the brachialis anticus. He had not at the time of his report obtained active motion.

Schanz (62), in 1904, reported a mobilization of a bony ankylosis following rheumatism. After chiseling through the joint, he enlarged the sigmoid fossa, removed a piece of the trochlea, and interposed a flap of fat from the under side of the forearm. Three months after the operation, the arm could be used for ordinary purposes.

Murphy (43,a) first used his fascia method October, 1901, on a knee-joint. A large layer of fascia lata with a thin layer of muscle tissue attached was dissected from the outer surface of the vastus externus, with its base below and anterior. A small flap of fascia covering the vastus internus was dissected free and placed between the patella and the femur. He first mobilized the elbow by this method in 1904 in a case of ankylosing arthritis. A pyriform flap of deep fascia was dissected from the posterior surface of the triceps. The flap was 4½ inches long by 2 inches wide at its upper end and received its blood supply from a broad pedicle which remained attached to the muscle and fascia just below the level of the olecranon. After the bony parts had been remodeled, the fascia was drawn down and turned into the joint around the inner margin of the olecranon. The proximal portion of the flap covered the trochlea, lined the olecranon depression and the lesser sigmoid cavity, while the distal portion covered the external condyle. Subsequent events showed that the flap was not carried sufficiently high on the anterior surface of the humerus to permit adequate flexion of the joint. Five months later, the patient could pass his hand through an arc of 5 inches. Pronation and supination were about one-half normal. His second case was reported 2 months after operation. The hand could be moved actively

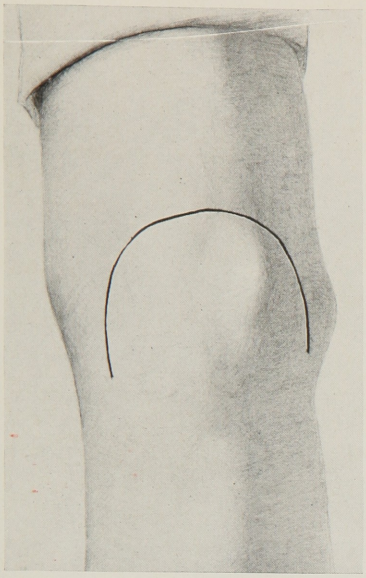

Fig. 1.

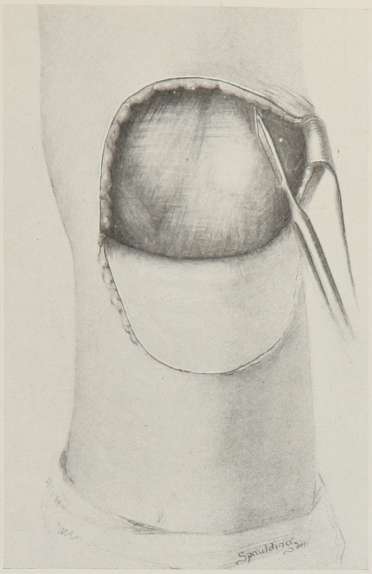

Fig. 2.

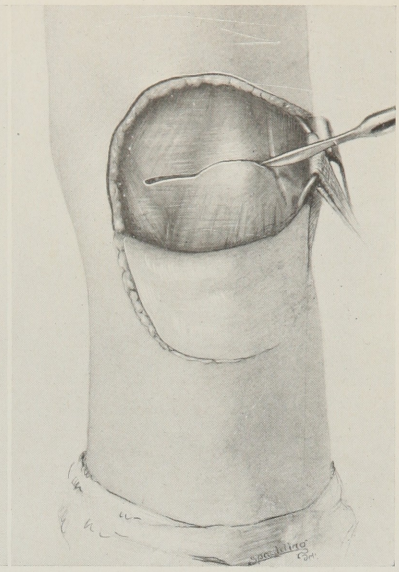

Fig. 3.

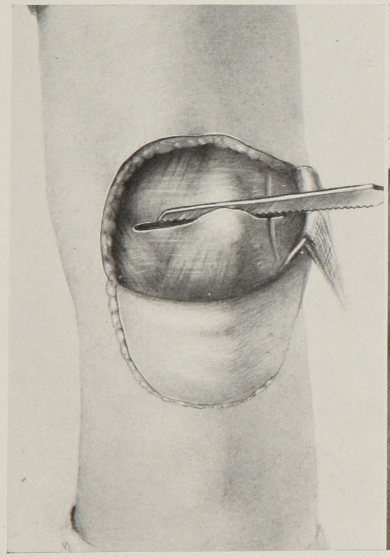

Fig. 4.

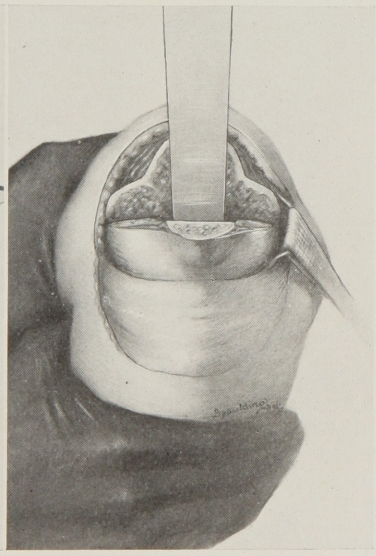

Fig. 5.

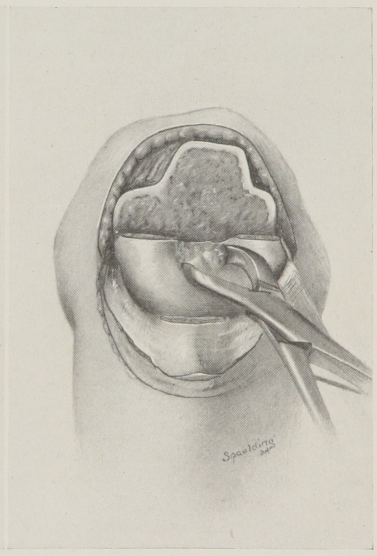

Fig. 6.

Fig. 1. Line of incision.
Fig. 2. Dissecting out ulnar nerve.
Fig. 3. Cutting through the muscle and fascia down to the joint.
Fig. 4. Sawing through olecranon and end of humerus
Fig. 5. Splitting off tip of olecranon with chisel.
Fig. 6. Cutting out with rongeur forceps bit of olecranon tip left in humerus.

through an arc of 3 inches and the elbow forcibly flexed to an acute angle and extended to 160 degrees. Pronation and supination were approaching normal.

Hoffa (31), in 1906, reported a series of arthroplasties, seven of which were on the elbow. In one, a magnesium plate was used. This operation was unsuccessful owing to the formation of gas in the joint causing a fistula which closed only after the rest of the plate had been removed from the joint. The other operations in which fat, fat and fascia, or fascial flaps were used, were all successful. In 2 of these

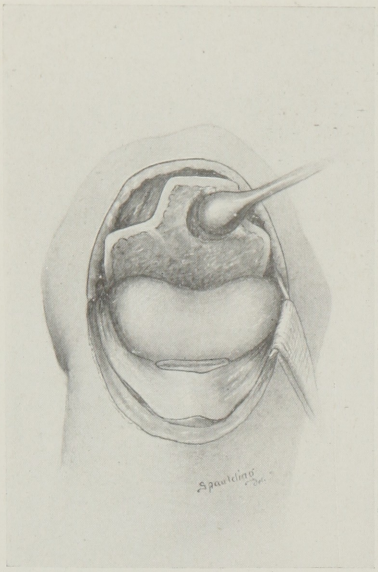

Fig. 7.

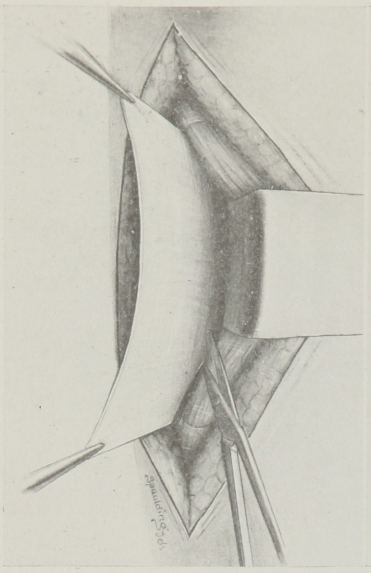

Fig. 8.

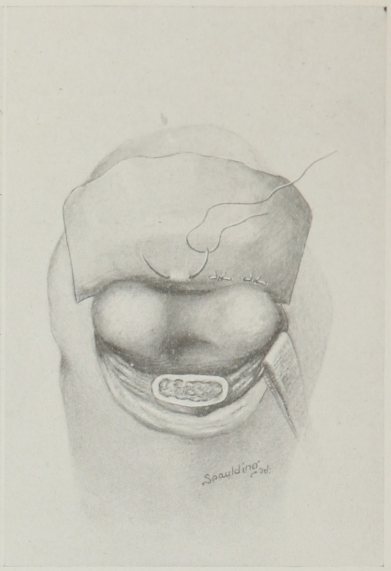

Fig. 9.

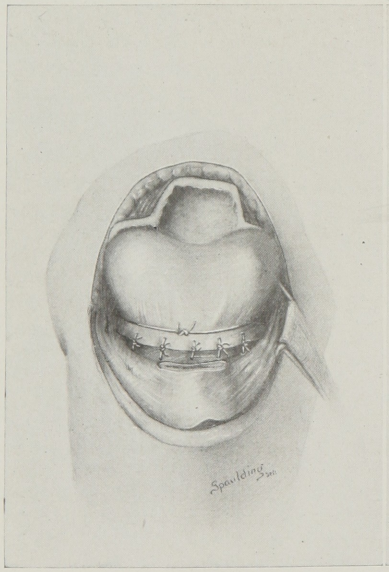

Fig. 10.

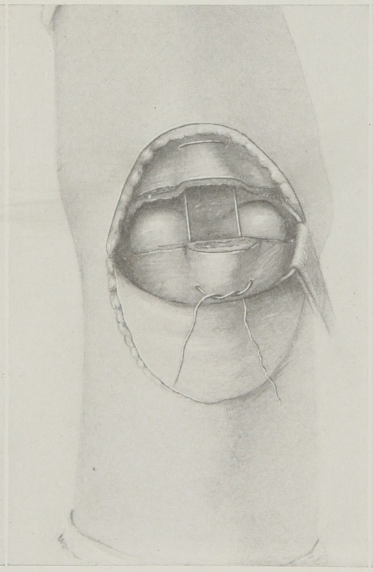

Fig. 11.

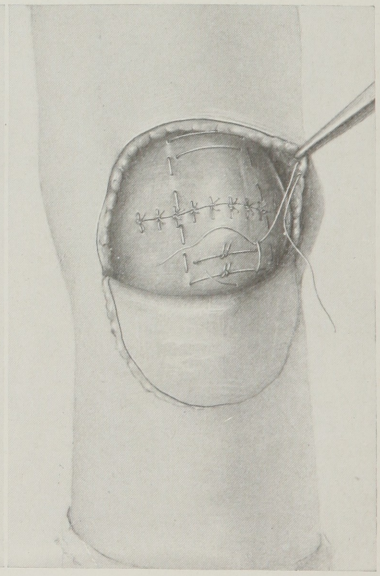

Fig. 12.

Fig. 7. Scooping out ulna and radius with curette.
Fig. 8. Cutting fascia lata from thigh.
Fig. 9. Sewing the flap of fascia lata to the elbow-joint anteriorly.

Fig. 10. Fascia sewed over humerus; tied with chromic catgut suture.
Fig. 11. Kangaroo suture throug hulna and olecranon tip.
Fig. 12. Stay sutures.

cases, the ankylosis followed scarlatina; in the others, gonorrhœal infection.

In 1905, Quénu (56,c) reported a third case in which there was great atrophy of the muscles. He used for a flap the inner part of the triceps sutured to the anterior ligament. Passive movements were begun in 10 days and later electrical treatment used but, as active motion was incomplete at the end of 2 months, he made a second intervention to recover a part of the tendon of the triceps, a large portion of

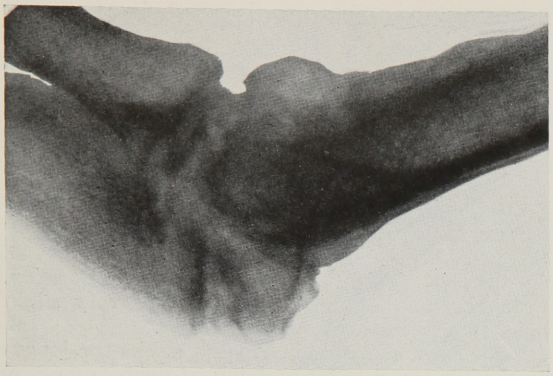

Fig. 13. Case 2. M. R. Roentgenogram showing ankylosis before arthroplasty.

which had been sacrificed. He cut the portion interposed close to the bone. He could then ascertain that there was no adherence between the superior surface of the interposed segment and the inferior cut surface of the humerus. The same condition obtained on the inferior surface. The tendinous segment had left a distinct cavity. The tendon of the triceps was sectioned and re-inserted on a little fibrous flap previously dissected on the forearm. The patient gained not quite complete extension and flexion to a right angle.

Dupuy (20), in 1905, reported 5 arthroplasties. Three of these were done by Jeannel, one by Kirmisson, and one by Launay. Jeannel used flaps of the brachialis anticus; Kirmisson, of the biceps; and Launay, a flap from the anterior ligament and the brachialis anticus. In all, good results were obtained. In two of Jeannel's cases, normal movements were obtained; in the other, the degree of motion was less but satisfactory function was gained. In Kirmisson's case, all the movements were present and the function good 5 months after the operation. Launay obtained passive motion from 80 to 155 degrees with free pronation and supination 5 months after the operation.

Huguier (35,a), in 1905, reported 2 cases operated on by Nélaton, with the interposition of a muscle flap. In one case, he gained good motion. In the second, re-ankylosis occurred. Huguier reported a third case by Ombredanne, by the same method.

Scudder (63) reported in 1906, 1907, and 1908, several cases in which he used Murphy's method successfully.

Pereira (50), in 1906, in an unreduced subluxation resected the ends of the bones and interposed a flap of triceps muscle with almost perfect functional result.

Bazy (6), in 1907, mobilized an elbow using a flap from the brachialis anticus. Nine months later, the function of the arm was almost perfect.

The same year, Stein (64) reported 3 cases from Bier's clinic in which triceps flaps were used. All were successful.

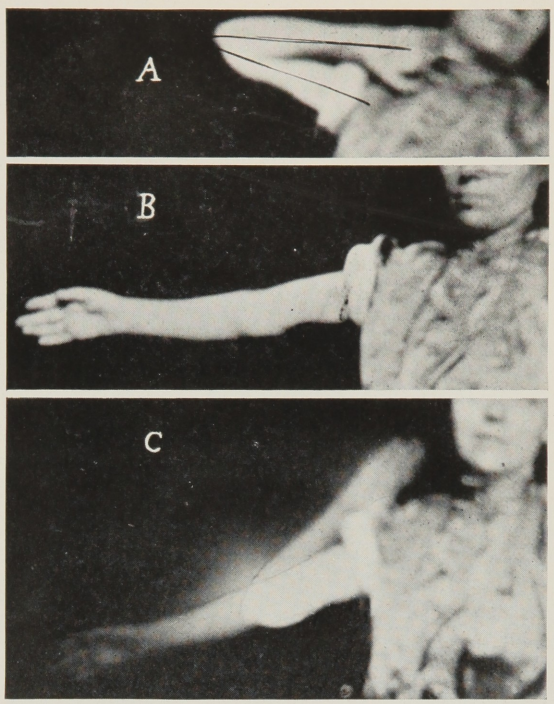

Fig. 14. Case 2. M. R. End-result. *a*. Voluntary flexion; *b*, voluntary extension; *c*, range of motion.

In 1909, Huguier (35,b) reported an ankylosis which he mobilized, using a flap of brachialis anticus. Sixteen months later, the patient could touch his shoulder with his hand and extend his forearm to 150 degrees.

Cifuentes (11) reported in the same year a similar arthroplasty in which he obtained a month after the operation a good functional result with normal movements.

In 1910, Reiner (58) reported a series of twenty-eight arthroplasties, twenty-five of which were given in full with the after-results. Two others, recent cases, were reported with good immediate results. In three others, the histories were unknown. Of the others, nineteen gave useful arms, although one was a flail joint which lacked power but could be controlled by the muscles. The poor results were due in one case, a fracture luxation, to extreme atrophy of the muscles, and in a tubercular case, to extensive resection of the diseased tissue necessary, resulting in a useless flail joint. Re-ankylosis occurred in two cases. In one, it was due to operation too soon after trauma, a fracture luxation, and lack of after-treatment. In the other case, the author attributes the result to the disease, myostitis ossificans.

Thom (68) reported in 1910 a case of ankylosed elbow operated on by Ritter. He used freely transplanted fascia lata as an insert after the parts had been made freely movable. On discharge, there was

Fig. 15. Case 3. R. T. Roentgenogram showing position of ankylosis before arthroplasty.

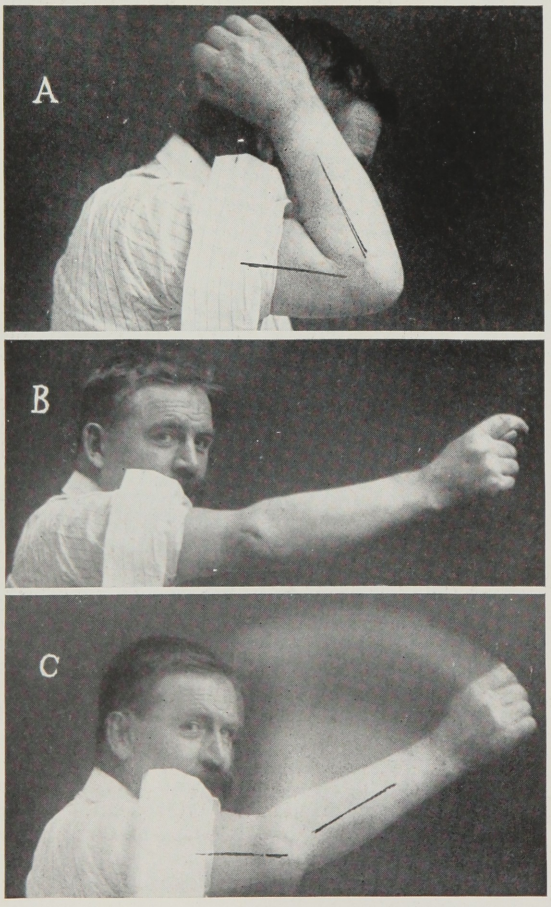

Fig. 17. Case 14. W. D. End-result. *a*, Voluntary flexion; *b*, voluntary extension; *c*, range of motion.

Fig. 16. Case 3. R. T. End-result. At left, voluntary flexion; at right, voluntary extension.

65 degrees flexion and 100 degrees extension. Pronation and supination which were very slight before the operation were unchanged.

Wille (76), in 1911, interposed supinator longus fascia with good result, gaining 95 degrees motion.

Whitman (75) reported two cases of arthroplasty of the elbow in which he used Murphy's method.

In 1912, Edmunds (21) reported an elbow ankylosis following fracture in which this method was likewise used. At the time of the report, active motion was not possible on account of the great atrophy of the muscles.

Denk (19) reported two of von Eisenberg's cases in which elbow-joints were mobilized with free fascia transplants with good functional results.

Neff (44) reported a case in which he interposed a pedunculated triceps aponeurosis flap between the humerus and ulna and the radius and ulna. Seven months after the operation, there was active painless motion of 180 degrees to 30 degrees and only slight lateral mobility. The joints of the wrist and hand, which were previously partially ankylosed, regained from a third to a half their normal range of mobility with the return of function to the elbow.

Delbert (18), in 1912, reported having done nine resections of the elbow with articular grafts. Most of these were too recent to determine the results, but he reported in detail two cases which were of a year's duration and appeared permanent. In one of these he used cartilage from an ankle-joint, in the other cartilage from an elbow. Both gave good functional results.

Charput (10,a) reported three cases in which he resected a flap of fat the size of the palm from the thigh and encapsulated the lower end of the humerus with it, suturing it to the neighboring muscles by anteroposterior and lateral sutures.

Conrad (12), in 1912, published a dissertation on the use of muscle flaps as interposing material. We have been unable to obtain a copy of this thesis.

Pomponi (53) advocates the use of a pedunculated fascial flap by the method of Durante. He cites one case in which he gained complete pronation and supination, nearly normal extension and flexion to 60 degrees.

Murphy (43,b) reported among a series of arthroplasties done by him twelve on the elbow by his pedunculated fat fascia flaps.

Mauclaire (39) mobilized an elbow, using cartilage from the astragalus to cover the defects. One fragment was put on the lower end of the humerus,

another between the radius and ulna. A roentgenogram later showed these grafts fused to the bone.

Osgood (47) reported sixteen attempts at mobilization by various methods in the different joints. He advises against arthroplasty in the hands of untrained operators.

Putti (55), in 1913, reported his arthroplasties to date. These included twelve elbow cases in which he used Kocher's incision and a free flap of fascia lata. He obtained stabile joints with a useful degree of motion. His histological research is referred to elsewhere.

Roepke (59) reported ten cases of ankylosis of the elbow in which he did arthroplasties using free fat flaps to interpose between the joints. He advised against beginning passive motion too soon. One of these cases was one of arthritis deformans shown in 1911 before the Medical Society of Jena. In others, the ankylosis had resulted from trauma, neisserian infection, and tuberculosis.

Exner (22) reported a case fourteen months after an arthroplasty in which a free flap of fascia lata was interposed. The arm was somewhat unstable but gave good function. The patient could lift heavy weights. At the same time Pupovac reported a second case by the same method.

Darling (13) reported an arthroplasty with the use of a pedunculated flap done in the presence of active infection. The immediate result was good.

Harris (27) discusses the contra-indications to arthroplasty. He reports two elbow cases by the Murphy method. In one he gained 75 degrees motion. In the other, there was 60 degrees motion.

Turner (71) reported an arthroplasty of the elbow for an ankylosis following a severe osteomyelitis. There had been a musculospiral paralysis from which the patient made a perfect recovery. The elbow had entirely healed but, at the time of operation, a small area of latent infection was found. Turner used a posterior skin incision and inserted a flap of fascia lata. The elbow was put up in extension. The next day, there was a recurrence of the paralysis with signs of local infection. Later, fearing re-ankylosis,

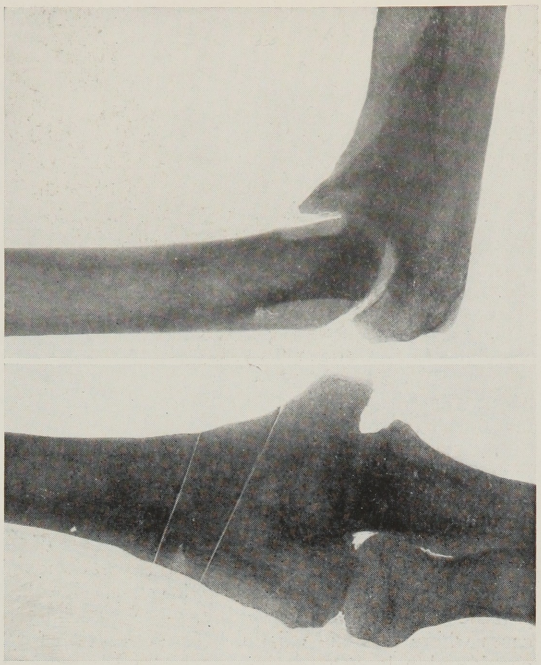

Fig. 18. Case 5. E. M. Above, Anteroposterior roentgenogram after arthroplasty; below, lateral roentgenogram after arthroplasty.

he manipulated the elbow under ether into extreme flexion. Six months later, the boy had motion from 50 to 120 degrees and a useful arm, though the muscles were still atrophied.

The same year Murphy (43,c) reported an arthroplasty by his usual method. The patient left the hospital in 5 weeks with free motion within an arc of about 45 degrees.

Vulpius (73) believes that the elbow and hip offer the best chances for arthroplasty. He prefers

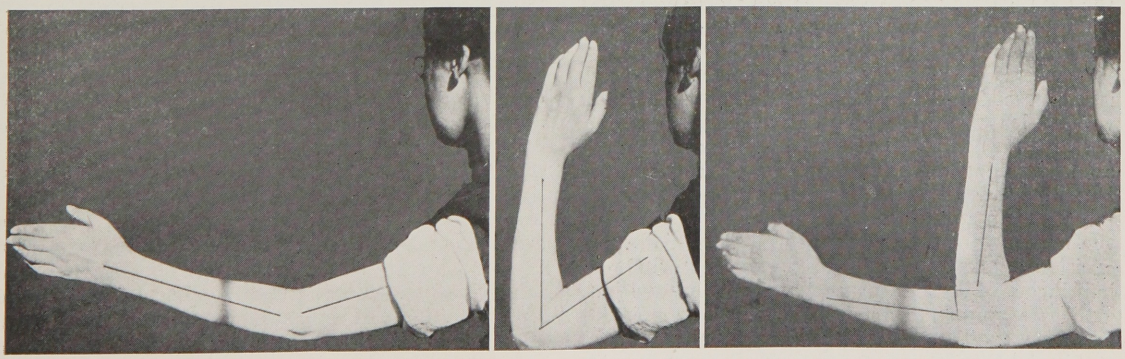

a *b* *c*

Fig. 19. Case 5. E. M. End-result. *a*, Voluntary flexion; *b*, voluntary extension; *c*, range of motion (not full range).

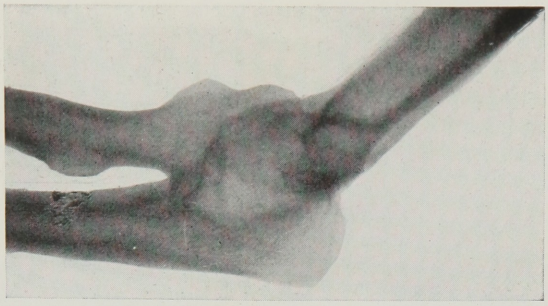

Fig. 20. Case 7. E. S. Roentgenogram showing position of ankylosis before arthroplasty.

pedunculated flaps but also uses free flaps of fat or fascia and fat or Baer's membrane.

In 1914, Payr's (49) oldest case was about 4 years. He emphasizes the importance of removing the capsule or at least the synovialis as well as the fibrous cartilage. Payr has never met with a secondary dislocation nor a loose joint except in some of his first knee cases. The initial gain in motion was preserved or even increased with use. He had trouble with persistent swelling, more especially in cases where this had existed before operation for a considerable length of time or had been marked. He believes convalescence is shortened by waiting until the swelling has subsided. If re-operation is needed, he advises waiting at least 6 months. He reports twenty-two arthroplasties, of which three were elbows, one with a good result and two with very good results. He believes that if the indications are correct and the technique and after-treatment good, a favorable result is to be expected in 70 to 80 per cent.

Pupovac (54) reported a case of a girl of 19 whose elbow had become ankylosed at 130 degrees as the result of a severe arthritis. He did an arthroplasty using a posterior incision and a free fascial flap, gaining motion from 105 to 140 degrees. Five months later, he re-opened the joint and removed some exuberant bone that united the humerus with the ulna, gaining 70 to 130 degrees motion.

Owen (48) believes that the hip and shoulder offer the best fields for arthroplasty. The poorest prognosis is in the elbow and knee but if the former is ankylosed in extension, operation is advisable, as it will at least get the elbow into better position.

Davis (14) thinks that we should be conservative about opening a joint ankylosed by tuberculosis. He finds the elbow one of the most satisfactory joints for an arthroplasty as well as an excision but the results with the former are more brilliant. An excision requires the removal of one to one and one-half inches of bone to insure movement but, with an arthroplasty, only sufficient bone need be removed to interpose the flap and it is almost certain to give a stabile joint. He uses two pedunculated flaps, one from either side. The joint, he believes, should have drainage.

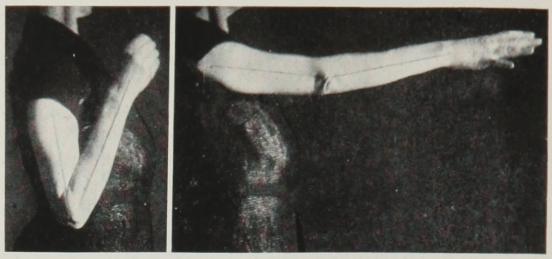

Fig. 21. Case 7. E. S. End-result. At left, voluntary flexion; at right, voluntary extension.

McCurdy (40) advocates the pedunculated flap in preference to the free flap, as he believes that the nutrition is better and that fascia will slough and require removal. He gives no experimental nor clinical evidence to bear out this statement. He prefers the Baer membrane, as it is more easily adjusted and there is, therefore, less blood clot; therefore less adhesions and better end-results.

Murphy (43,d) reported in 1915 a case of ankylosis following fracture. The elbow was ankylosed at about 150 degrees with a few degrees of motion. Seven weeks after operation, there was good pronation and supination and perfect freedom of motion.

Ashhurst (4) uses an incision along the external supracondylar line and the external condyle detached from the humerus with an osteotome. A pedunculated flap is inserted and the external condyle replaced by means of a Lambotte self-boring screw. He reports five cases. In these cases, there were three good end-results. One case had a flail joint with very slight power of extension. The fifth case had a limited motion but the patient refused forcible manipulation.

Gilbert (24) cites a case of dislocation of the elbow which existed 3 months. Good use of the joint was obtained after a Murphy arthroplasty.

Tubby (70) gives a careful consideration of the indications for arthroplasty. He believes that the best time for the operation is in early adult life, between 18 and 30 years. The mental state of the patient must be considered, as co-operation is essential; the occupation of the patient must be considered; the causative factor must be considered. The condition of the soft parts is important. A thin, scanty, and scarred skin will not be sufficiently nourished to stand the trauma. From the X-ray examination, an approximate opinion as to the condition of the joint is gained. He prefers a muscle flap for interposition but has also used fat and fascia and Baer's membrane. He does not begin passive motion for four weeks but thinks that active motion should be begun earlier. He reports one elbow case in which he used a muscle flap. At the time of the arthroplasty, insufficient bone was removed and re-ankylosis took place. Eight months later, he did a secondary operation to remove the mass of new bone. Following this, all movements were free but the elbow was slightly flail.

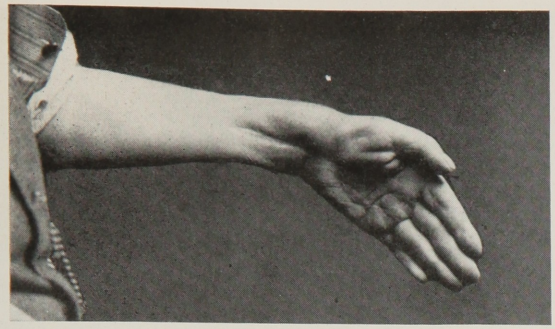

Fig. 22. Case 8. W. D. Position of ankylosis before arthroplasty.

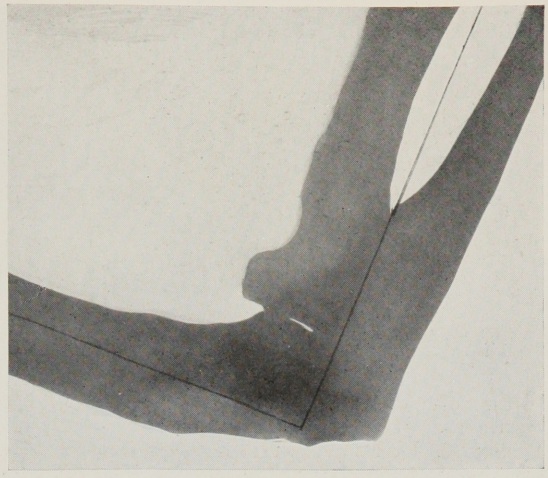

Fig. 23. Case 8. W. D. Roentgenogram showing ankylosis before arthroplasty.

Charput (10,b) reported a case of arthroplasty for ankylosis following luxation of the elbow. He used two lateral pedunculated flaps and sewed the skin up tight. The arm was put up in a sterile dressing in extension. The following day, the arm was flexed. Mobility returned in 2 days. In 42 days, extension and flexion were complete and vigorous. He attributes the good result to sewing up the wound without drainage and the immediate mobilization.

Graff (25) describes a case in which he interposed a flap of triceps muscle with almost complete return of normal motion.

A brief report of an arthroplasty with a pedunculated flap is given in Kennedy's case (36). The end-result is not reported.

Murphy (43,d) reported a case showing perfect motion seven months after arthroplasty for ankylosis from a fracture. A second ankylosis from tuberculosis showed a good end-result.

Whitman (75) exhibited before the New York Surgical Society a case in which an arthroplasty had been done for a fibrous ankylosis following tuberculosis. Four years before, an arthroplasty had been done using a pedunculated flap. At the second operation, the fibrous ankylosis was found to have become bony. Whitman used a flap of fascia lata at this operation. Whitman believes that in an ankylosis following tuberculosis, a free fascial transplant is essential to success, as the tissues about the joint are atrophied. His case showed a perfect end-result with normal flexion and 165 degrees extension.

Brown (8) gained 80 to 150 degrees motion in an arthroplasty by the Murphy method. The arm had been ankylosed in extension following acute metastatic arthritis.

Rovsing (60) reported before the Northern Surgical Society 2 successful cases in which the Murphy method was used. The ankylosis was the result of fracture. In the discussion Bergman and Haglund expressed the opinion that mobilization of the knee should not be attempted.

Moszkowicz (42) in his report in 1916 on his operations on war injuries to joints, gives among other cases 6 elbow arthroplasties. In all of these, a useful degree of motion was gained.

Plummer (52) reported two arthroplasties in which he used pedunculated fat and fascia flaps. One of his cases became infected and subsequently a portion of the end of the humerus had to be removed. The resulting joint was somewhat flail but gave good function. His second case also had good motion but his facility for moving the joint was not very good.

McKenna (41) advocates a modification of the Murphy method. He uses a very long flap extending well out over the external condyle and an external flap for the head of the radius. He believes that success is more certain when the arthroplasty is done early, as the atrophic changes about the joint are less. For this reason, it is important to make a correct diagnosis of the infecting agent. The gonococcus lives a comparatively short time in the joint tissues and an arthroplasty may be done earlier in an ankylosis from this agent than in one from staphylococcus or streptococcus or a chronic infection as tuberculosis. In the discussion which followed, Gibbons reported an arthroplasty of the knee that had come to his notice in which hypermobility existed necessitating the permanent use of a brace.

Ryerson (61) gives in detail his operative technique in arthroplasty on the elbow-joint. He uses a long posterior incision avoiding the olecranon. The triceps tendon is cut and a thin shell of bone removed from the external condyle, taking the origin of the extensor with it. Then a shell from the internal condyle is removed. The joint is dislocated. After it is remodeled, a flap of fascia lata is used to interpose.

Thomson (69) reports the end-results in an elbow arthroplasty by the Murphy method. Ankylosis was the result of sepsis following a fracture. Seven months later, elbow motion was good but somewhat



a *b* *c*

Fig. 24. Case 8. W. D. End-result. *a*, Voluntary flexion; *b*, voluntary extension; *c*, range of motion.

restricted. His successful cases have all been traumatic. He believes that neisserian infection is a contra-indication to arthroplasty, as it stimulates bone formation. Tuberculosis is also a contra-indication on account of the recrudescence of the disease.

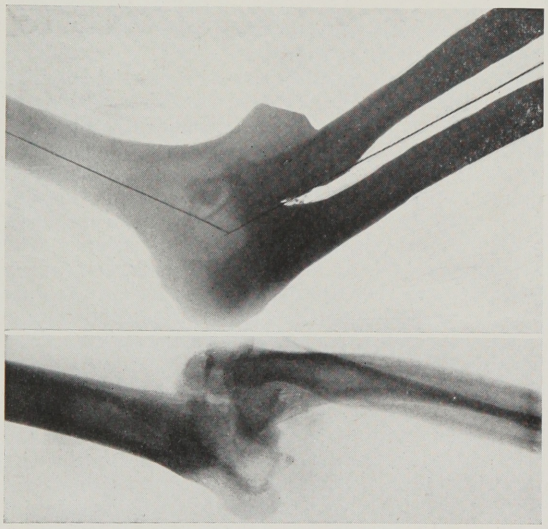

Fig. 25 (above). Case 11. E. S. Roentgenogram showing ankylosis before arthroplasty.

Fig. 26. Case 11. E. S. Roentgenogram showing dislocation after arthroplasty.

Ceccarelli (9) used strips of fascia lata in an arthroplasty on a post-traumatic ankylosed elbow. The end-result was perfect flexion, extension to 165 degrees, and almost normal pronation and supination.

Olivieri (46) reports two arthroplasties with interposition of strips of brachialis anticus. The end-results were perfect.

In 1918, Baer (5) reports in full his arthroplasties to date, by the use of chromatized membrane. In one hundred cases, there were three arthroplasties on the elbow-joint. In one of these, re-ankylosis took place, one died, and the third showed 25 degrees motion. He believes that the elbow is the least favorable joint for arthroplasty and that the success from the interposition of muscle or fascial flaps is due to the amount of bone removed rather than to the flap itself and that these operations are in fact excisions. In the discussion of this paper, Galloway and Freiberg express the opinion that an arthroplasty has no advantage over an excision. Davis states that with an arthroplasty a more stabile joint is obtained.

Albee (2) uses a vertical incision directly over the olecranon. After retracting the ulnar nerve and dissecting the soft tissues, he saws through the olecranon from within outward. After remodeling the joint, he interposes a flap of fascia lata containing as much fatty tissue as possible. The arm is put up in plaster at right angles. After 10 days, passive motion is begun.

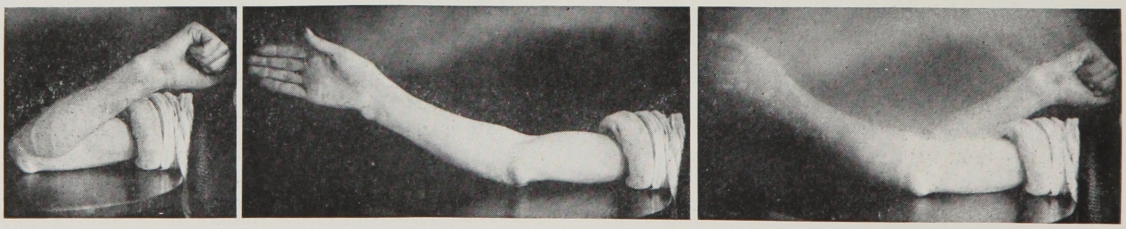

a *b* *c*

Fig. 27. Case 11. E. S. End-result. *a*, Voluntary flexion; *b*, voluntary extension; *c*, range of motion.



a *b* *c*

Fig. 28. Case 12. M. D. Motion 4 months after arthroplasty. *a*, Voluntary flexion; *b*, voluntary extension; *c*, range of motion.

Henderson (29), in 1918, tabulated the end-results of the 43 arthroplasties done at the Mayo clinic. Twenty-one of these were on the elbow. He found the prognosis most favorable in the jaw and next in the elbow. The knee was the most unfavorable position. In reports from other surgeons he found a general agreement as to prognosis.

Kerr (37) reported an arthroplasty of the elbow, giving in detail his method of operation. He interposed some peri-articular fascia. The result was a useful, movable joint with no atrophy of the muscles.

Hohmann (34) reported 5 elbow arthroplasties in 1918 in which he inserted part of the triceps with good immediate results. Lange at the same time showed 6 cases in which useful joints were obtained and the patients were enabled to resume their old occupations. He used fat or muscle flaps.

Murphy's (43,a) experiments on animals led him to conclude that fatty tissue was essential to the new joint foundation. This fatty tissue, he believed, under pressure formed connective tissue and the breaking down of fat globules together with this hyperplasia of connective tissue resulted in the formation of bursæ. Similar results were reported by his assistant, Neff.

Sumita (66), in 20 experiments on dogs, interposed muscle and tendon as well as fascia between the surfaces of resected joints and found no marked difference resulting from the tissue used.

Davis (15) found that the interposed fascia did not degenerate but preserved its normal histological characteristics. Putti (55) came to the same conclusions.

Hohmeier and Magnus (33) obtained the same end-results with and without the interposition of living tissue.

Allison and Brooks (3) studied the production of joints with free and pedunculated fascial transplants and also with chromacized membrane and fascia impregnated with silver nitrate. They found no difference in the end-result between pedunculated and free flaps. They found with Baer's membrane the reaction of the surrounding tissues was of such intensity that even at the time the membrane was disintegrating there were formed adhesions between the granulating surfaces. The silver impregnated fascia caused relatively little reaction in the surrounding tissues.

Steindler (65) found in experiments on a small series of dogs that no adhesions were formed after scraping the cartilage covering either with the insertion of fascia or in controls. Pedunculated muscle fascia flaps were transformed with a con-

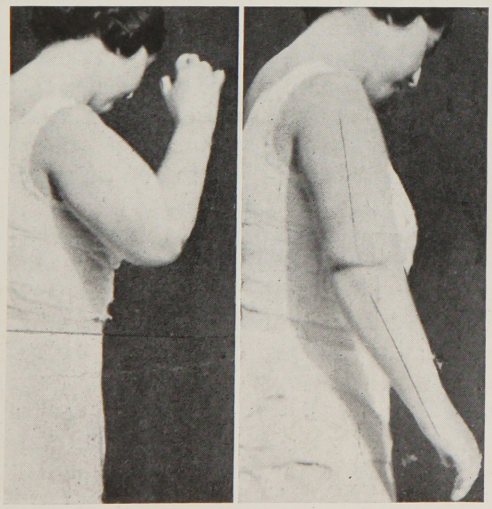

Fig. 29. Case 15. L. P. End-result after arthroplasty. At left, voluntary flexion; at right, voluntary extension.

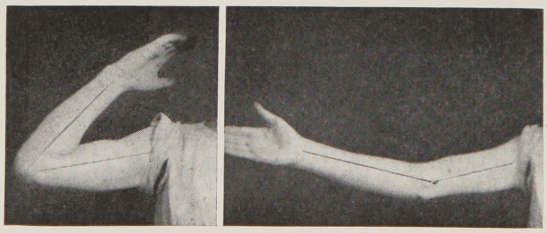

Fig. 30. Case 17. I. H. End-result. At left, voluntary flexion; at right, voluntary extension.

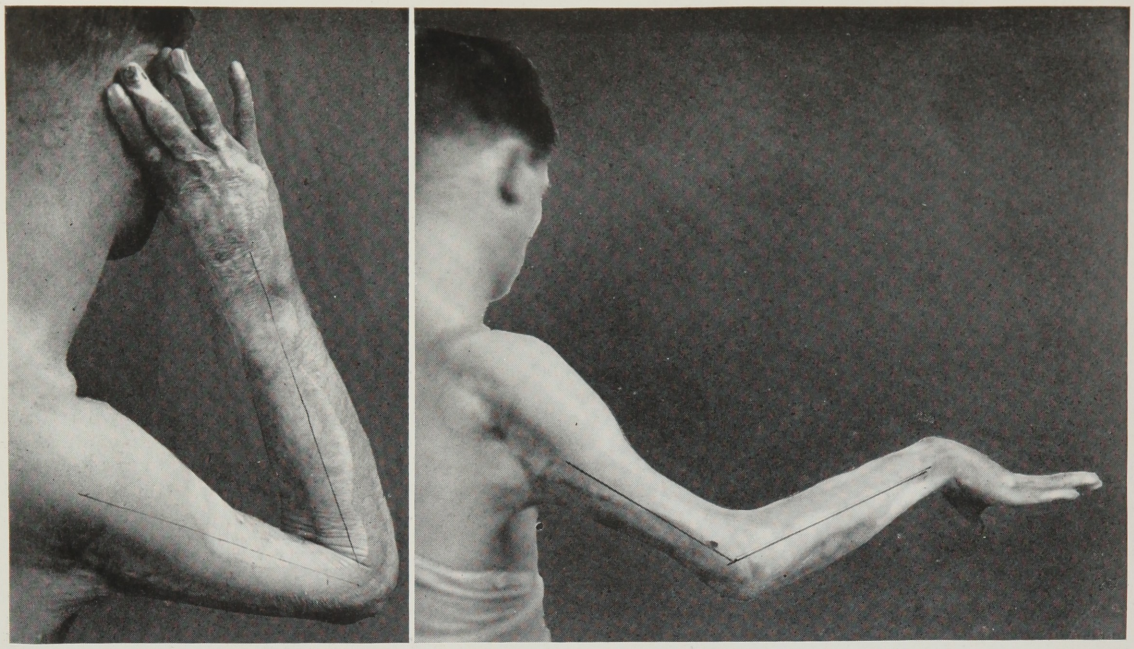

Fig. 31. Case 19. J. T. End-result. At left, voluntary flexion; at right, voluntary extension.

nective-tissue pannus adherent to the denuded areas of the bone. The denuded areas showed lacunar reformation of cartilage but no re-formation of bone.

Phemister and Miller (51) obtained similar results in the elbows and knees of dogs whether no interposing material was used or free or pedunculated flaps were used. The flaps largely break down and the resulting joints are alike in the three types of operation. They do not see how any appreciable amount of nutrition can be furnished by the circulation through the pedicle. They believe that the circulation in the surviving portions is through adhesions to the parts with which they come in contact.

INDICATIONS AND CONTRA-INDICATIONS

No attempt at mobilization should be made until epiphyseal growth has ceased. If it is made before this, it is impossible to remove sufficient bone to secure good motion without grave danger of injury to the epiphyseal line. Ankylosis is almost sure to result.

Where the joint has been the seat of an infectious process, arthroplasty should not be done until all signs of an active process have ceased. As a rule, however, we should not wait too long, as convalescence is lengthened where atrophy of the soft parts from disuse is marked. The exception to this rule is in the case of a tubercular joint. Here, it is a matter of considerable question as to whether an arthroplasty should be done. If at all, it should be done only very late, a number of years after all acute symptoms have subsided. Even then we run a risk of lighting up a quiescent process.

OPERATIVE TECHNIQUE

The arm from the wrist to the shoulder and the leg on the same side from the hip to the knee are given a two-day preparation. At the time of the operation, a tourniquet is applied to the upper third of the arm and an application of iodine made to the skin.

A semicircular incision is then made, beginning over the external condyle (Fig. 1) running down about 2 inches and up over the internal condyle. The wound is sponged with alcohol and carefully clamped off to avoid handling the skin during the operation. The flap containing skin and superficial fascia is then dissected back to the base line and retracted. The ulnar nerve is isolated and dissected out of its sheath (Fig. 2). It is sometimes difficult to find this nerve, but it is always to be sought at the inner side of the in-

ternal condyle. It should be dissected out carefully with a blunt dissector so as not to break nor injure it. After it has been freed for 1.5 inches, gauze is passed beneath the nerve and it is retracted to the ulnar side. It is then freed further with blunt dissection with gauze.

A transverse incision is then made extending down through the periosteum (Fig. 3). This incision follows in direction the superficial one and outlines a flap which is to be dissected back and preserved *in toto* for subsequent covering for the joint. The pulling back of this flap is a hard and tedious process until it is well started, after which it can be peeled back readily by blunt dissection. It is the inner side that is the hard part, as the layer is thin here and we must exercise great care not to buttonhole it. The olecranon is then sawed through. After this, it is frequently possible to break open the old joint. In some cases, however, ankylosis is bony and the joint cavity obliterated. Cases of this kind are the most difficult. It is in these cases necessary to saw through the joint. The tip of the olecranon has to be chiselled out and dissected back with its posterior flap. Usually the olecranon is too large and it is well to take off a little of it.

The capsule, fascia, and ligaments are then dissected back so as to allow the lower end of the humerus to protrude into the wound when its edges are snipped off with rongeur forceps and a new trochlear or intercondylar surface formed. A shoemaker's rasp is used in filing the extremity as near like the normal humeral end as possible. After this modelling, a piece is removed corresponding to the olecranon fossa in the normal humerus. One has to be careful about making this cup, as the success of the operation depends largely upon attention to such small details. This modelling is largely done with a saw and a file.

To insure good function, the joint surfaces should fit accurately before the fascia is applied, but the joint should not be too loose. Only sufficient bone must be removed to give free motion. If too much of the ends of the bones is removed, a flail joint will result, giving the operation no advantage over an excision. When this mortising is completed, the fascial flap is dissected from the leg (Fig. 8). An incision is made on the outer side of the thigh,

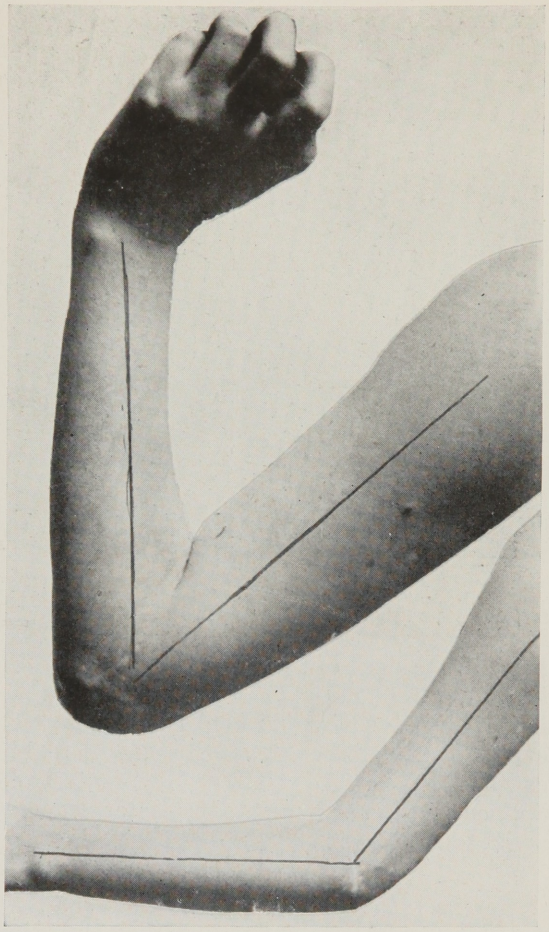

Fig. 32. Case 21. I. L. End-result. Above, voluntary flexion; below, voluntary extension.

a little below the middle, extending down to the fascia lata. After a flap of fascia 5 to 7 inches long by 4 to 5 inches wide is dissected out, the wound is closed.

This fascia, which is free from all fat, is placed about the newly fashioned humeral condyles and attached anteriorly to the capsule (Fig. 9) and posteriorly to the periosteum of the lower end of the shaft of the humerus with interrupted chromic catgut sutures No. 2. Chromic catgut No. 2 is then wound twice loosely around the shaft just below the interrupted suture line.

The forearm is placed in apposition to the condyles. Two drill holes are then made in the olecranon process and two others opposite

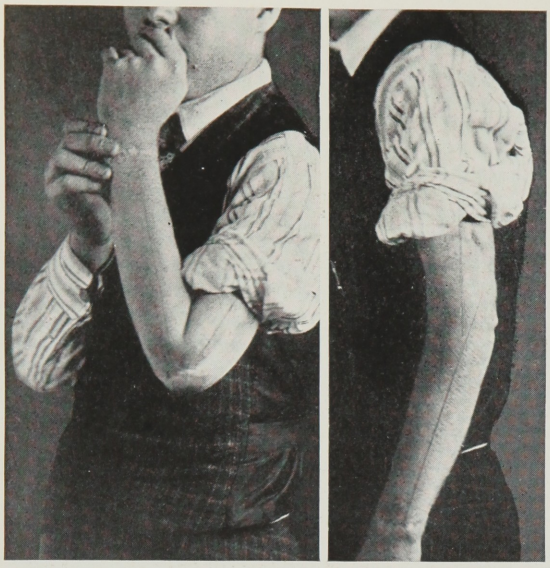

Fig. 33. Case 24. F. A. End-result. At left, voluntary flexion; at right, voluntary extension.

them in the shaft of the ulna. Through these, kangaroo tendon is passed and tied. The inner layer is now sutured with chromic catgut No. 2 and the skin and fascia with plain catgut No. 2. Dry sterile dressings are applied and the arm put up in plaster beyond a right angle.

AFTER-TREATMENT

If there is no evidence of infection, the cast should remain on for a week. It is then split and the dressing changed. If there is a persistent temperature, a window should be cut in the cast and the wound inspected.

Passive motions are begun in about 10 days, if normal healing has taken place. The arm is always kept above a right angle. After 3 weeks, gentle massage is applied. Baking is begun in 6 weeks, three or four times a week.

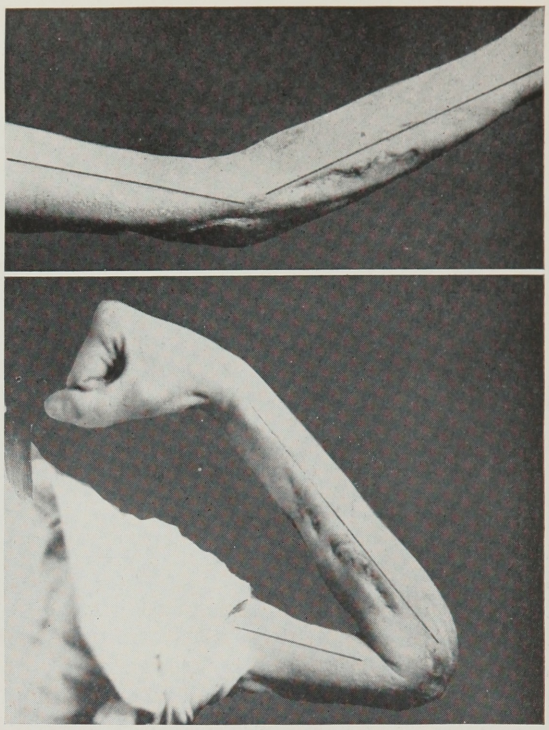

Fig. 34. Case 25. F. D. End-result. Below, voluntary flexion; above, voluntary extension.

The ultimate success in these cases depends very largely on the after-treatment. The patients should be under observation for a long period of time. Frequent X-rays should be taken so that we may follow the bony changes in the joint. If motion begins to shut down, the arm should be manipulated under an anæsthetic and the elbow put up in acute

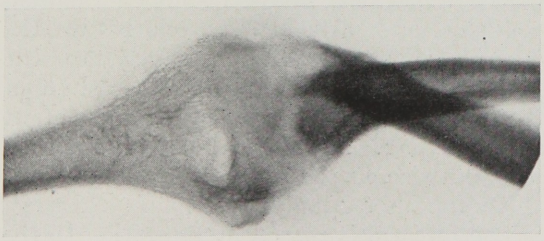

Fig. 35. Case 26. S. S. Roentgenogram showing ankylosis before arthroplasty.

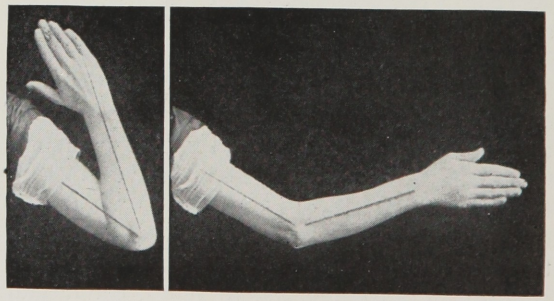

Fig. 36. Case 26. S. S. End-result. At left, voluntary flexion; at right, voluntary extension.

flexion. Occasionally, motion becomes limited, due to an exuberant growth of new bone. In this case, a secondary operation should be done to remove this, but it should not be undertaken for at least 3 months after the original operation.

Case 1. F. P., December, 1909, fell on her elbow in March, 1908. The injury was treated as a sprain and the elbow put up in a splint. She recovered except for a slight stiffness and pain, but as time went on the motion became less. Later, she was under observation for 6 weeks in the out-patient department.

On November 18, 1908, an attempt was made to gain motion by removing as much exuberant bone as possible. Following the operation, the patient suffered from a Volkmann's paralysis. She made a splendid recovery from this paralysis but, unfortunately, on account of the sensitiveness of the elbow, there was not so much motion as before the operation. An arthroplasty was therefore advised. This I did in December, 1909, using the Murphy method.

The circulation of the skin above the original site of the flaps became somewhat diminished and there was a small amount of sloughing. The wound was dressed each day and on the fifth day daily attempts at motion were begun. In the course of a month, massage and baking were again taken up and continued until May, 1910.

The patient was last seen April 11, 1919. She had at this time motion from 45 to 125 degrees and no tenderness. Except for extension, the result was perfect. Previous to her marriage, she had used her arm daily in her employment as a stenographer.

Case 2. M. R. for 13 years had had attacks of rheumatism affecting the ankles, elbows, and knees. The physical examination was negative except for the joints. Both knees were slightly flexed and the right one was ankylosed showing scars on either side. The right ankle showed some contraction of the tendo achillis. The left elbow showed good motion except for 10 degrees limitation in extension; the right was ankylosed at 125 degrees.

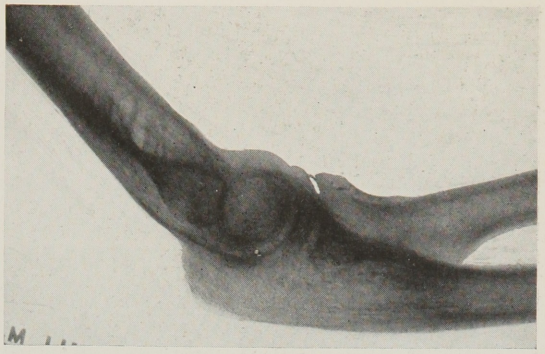

Fig. 37. Case 27. N. B. Roentgenogram showing position of ankylosis before arthroplasty.

The patient was admitted to the orthopedic service of the Carney Hospital, September 6, 1910, where very slight improvement took place in her knees and feet under conservative treatment. In October, on account of the swelling and bogginess of the left knee, an arthrotomy was advised. This was done October 19. Daily manipulations were begun on the fifth day, and an uneventful recovery took place as regards the knee.

As the elbow was stiff and in an ungainly position, operation on this joint was advised. On November 5, 1910, an arthroplasty by the Murphy method was done on this joint.

November 10, the right hand was considerably swollen and painful, for which pressure and hot fomentations were applied. The skin on the upper part of the arm became somewhat necrotic from poor circulation and later sloughed.

November 30, passive motion was begun and repeated daily. The first attempt was made at motion, when 30 degrees were attained. Following this, progress was continuous and a gradual gain in motion was made. Later, massage was ordered for the hand, forearm, and shoulder.

January 11, 1911, about 30 to 40 degrees of motion in flexion and extension were obtained. The wound showed heavy granulation tissue. A week later she

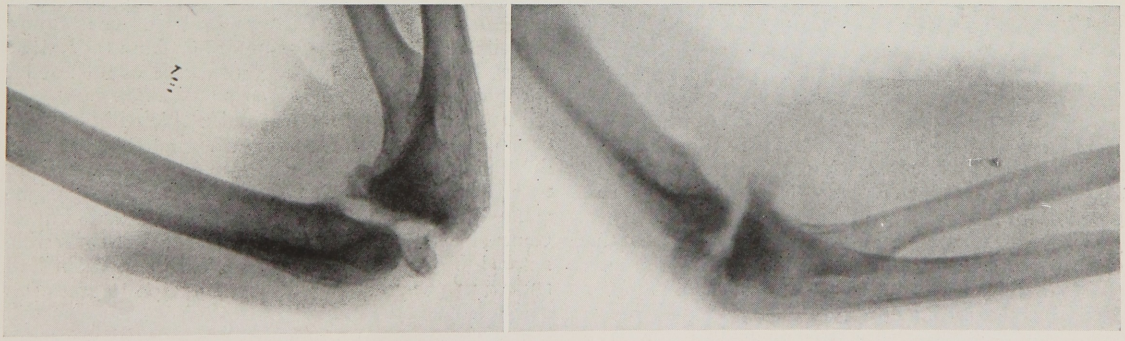

Fig. 38. Case 27. N. B. End-result. At left, voluntary flexion; at right, voluntary extension.

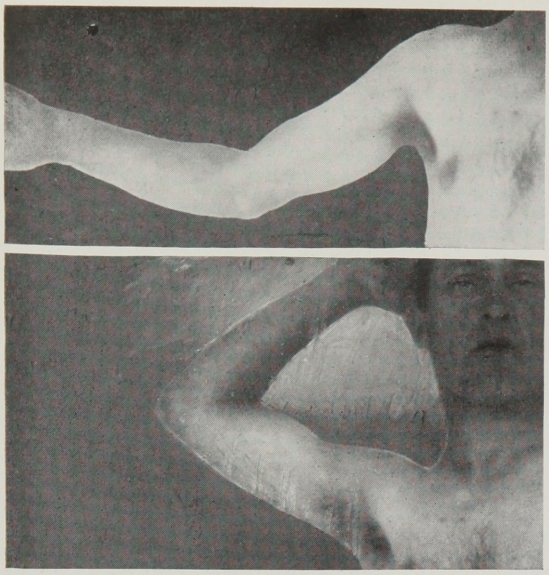

Fig. 39. Case 28. W. M. End-result. Below, voluntary flexion; above, voluntary extension.

was discharged from the hospital. Dressings were to be done at home.

February 28, she was readmitted to the hospital for manipulation when normal motion was obtained.

March 13, the patient was discharged to continue massage and manipulation at home. Since this time, she has been seen in the out-patient department. There is practically no lateral mobility and the end-result is perfect function.

Case 3. R. T. In this case, ankylosis had followed a fracture 5 years previously. A year and a half before, an attempt was made at the Massachusetts General Hospital to gain motion by open operation, followed by Zander treatment and baking. At the time when I first saw her, there was no pain in the arm but the stiffness was increasing. For this, an arthroplasty was advised.

On July 26, 1911, I did an arthroplasty by the Murphy method. The ether recovery was good but the patient showed a mild paralysis of the ulnar nerve which disappeared 2 days later.

The wound was dressed daily, when it showed considerable discharge of fat necrosis, but no infection was apparent. The arm was very sensitive and painful on movement. The motor power of the third and fourth fingers was restored but sensation was still slightly impaired. Following this, recovery was uneventful, and patient was discharged from the hospital on August 19 to report to my office.

October 24, the patient was readmitted to the Carney Hospital for manipulation, which was done the following day. She was discharged on October 26 with the arm in acute flexion.

February 18, 1914, the patient could extend the elbow to 165 degrees and flex to 25 degrees. The patient plays the piano and does all her housework.

Case 4. W.D. was referred to me by Dr. A. W. Shea of Nashua, New Hampshire, and was operated upon before the New Hampshire Surgical Club. On March 25, 1911, he received a contused wound of the left thumb, which became septic, requiring, 1 week later, his entrance to the hospital, as sepsis had become general. Five incisions were made in the left hand, two in the left wrist, one close to the left elbow-joint, and one in the left hip. All had drains put in. A student in the hospital opened a swelling near the right elbow and cut into the joint. At the end of 21 weeks the patient was discharged from the hospital with bony ankylosis of the right elbow with but a few degrees of motion in the left elbow. Both joints were slightly flexed. The left wrist had a sinus which still drained a little and he had little motion in the fingers, being unable to flex them to a right angle with the palm of the hand. He was unable to feed himself or to touch his head with either hand. He entered St. Joseph's Hospital a few weeks later and I did an arthroplasty on his right elbow, in March, 1912, using a flap of fascia lata to interpose. A hard bony ankylosis was found. The skin was closed with silkworm-gut and a voluminous dressing applied with the arm at a right angle. Arm and forearm were placed on pillows with heavy dressings but no splint. Passive motion was begun on the fifth day. Primary union took place in the wounds of the elbow and thigh. Passive motions were continued and increased, but at the end of 6 weeks it was found that the patient could not use either biceps or triceps muscles and he had lost all power from long disuse. However, after several weeks he educated the muscles by counting and attempting contraction at the same time and finally was able to flex the forearm himself, since which time improvement has continued.

He has now full motion in flexion, extension, and rotation and is able to feed himself and to do chores about the house and put on his own clothes. Previous to operation, he was entirely helpless, unable to care for himself in any way.

Case 5. E. M. Two years before, the patient became ill with infectious arthritis which at first affected the knees. The trouble started slowly with general poor health. There was no history of a neisserian infection but the patient was very much constipated and suffered more or less from tonsillitis. Later, the elbows became painful and could not be straightened out.

Physical examination showed a thickening of the capsule of the left elbow, with about 35 degrees limitation in motion. The left knee showed extension to within fifteen degrees of straight. The patient walked with a marked limp and flexed knees. General treatment was prescribed, with forcible extension of the knees. As motion in the arm had shut down leaving it ankylosed at 100 degrees, an arthroplasty on this joint was advised.

February 25, 1913, I did an arthroplasty, using my fascia lata method.

March 24, the arm showed no swelling. There was little pain and the patient's general condition was fair. There was about 15 degrees motion. Gentle manipulation was ordered.

December, 16, the wound had healed by first intention; supination was three-quarters normal, extension was to 170 degrees and flexion to 10 to 15 degrees beyond a right angle. The patient could reach the opposite shoulder with the thumb with ease but could not dress the lower part of the hair. The muscular power was as good as in the right arm. To gain more motion, a forcible manipulation was advised.

December 29, under ether, extension to within five degrees of straight was obtained and flexion to 45 degrees.

January 26, 1914, examination of the arm showed no lateral mobility and no crunching crepitation. Mobility was from 150 degrees to 70 degrees.

December 10, 1914, the patient showed voluntary motion from 55 degrees to 145 degrees.

Case 6. M. B. was admitted to the House of Mercy Hospital, Pittsfield, June 15, 1913, suffering from a bony ankylosis of the right elbow. Two days later, I did my usual arthroplasty putting up the arm in plaster in full extension. Recovery was uneventful. The arm was twice manipulated under ether, on July 29 and on August 13 to gain further flexion. She was discharged September 24, wearing her arm in a short sling. This was a clinic case and I have been unable to obtain any later data on the case.

Case 7. E. S. was admitted to the Carney Hospital, August 11, 1913, for immobility of the right elbow and right knee. Six years previously, the patient had had an acute illness accompanied by fever and pain and swelling in the joints, for which she was treated in her home, without relief. At the end of 8 months, the pain and swelling had disappeared from her left shoulder and elbow so that she was able to feed herself, but she remained in bed for 12 months and after this was in a wheel-chair for 2 years. The symptoms continued to subside on the left side until at the end of the third year, she was able to get about with a cane. As the fever continued to subside and the pain and swelling disappeared, fairly good motion returned to all the joints except the right elbow and the right knee, in which pain and stiffness continued at the end of the fourth year and no motion was possible. This condition continued up to the time of admission. August 14, roentgenoscopy revealed an ankylosis of the elbow-joint and of the patella to the femur.

August 20, I did an arthroplasty of the right elbow, using a flap of fascia lata. A light plaster cast was applied. Following the operation, the patient made a good ether recovery. There was slight pain in the elbow.

August 27, the cast was split for dressing.

September 1, the wound had healed by first intention except for a slight discharge on the upper border. September 4, daily manipulation of the elbow was ordered.

September 10, the arm could be extended completely and flexed to 15 degrees beyond a right angle.

September 15, traction was applied for flexing and extending the arm.

October 1, active motion was possible.

October 15, I manipulated the arm under ethyl chlorid.

She was discharged from the hospital. May 15, 1919, 5 years and 10 months after operation, she writes "the arm is doing excellent work." Photographs taken at this time show practically full extension and flexion.

Case 8. W. D. The previous history of this case is given under Case 4. After the arthroplasty on the right elbow, the patient requested that a similar operation be done on the other elbow. The roentgenogram showed a bony ankylosis at 90 degrees. On January 31, 1914, I did an arthroplasty on the left elbow-joint, using the same method applied in the case of the right elbow. The end-result was a stabile useful elbow, with motion from 60 to 160 degrees.

Case 9. R. B. was seen in consultation March, 1914, suffering from partial loss of function of the left elbow, as the result of an old fracture of the olecranon and external condyle and was unable to extend the elbow beyond a right angle, with supination limited one-fourth. An arthroplasty was advised.

This was done at the Carney Hospital on March 17, 1914. The usual technique was used and the arm put up in a sterile dressing in extension. The boy made a good ether recovery, slept well, and suffered no pain.

The wound remained clear until the 23d when it appeared reddened and showed some discharge. The following day, the axillary glands were tender to the touch and the hand showed some œdema. Hot poultices were applied.

By the 27th, the pain was relieved and the glands were not palpable. The wound was clean. Two silkworm-gut sutures were applied to prevent the spreading of the wound.

On March 31, a plaster cast was applied from axilla to finger tips in 15 degrees flexion and one-half supination.

On April 1, manipulations were begun and continued daily.

On April 11, the patient showed full pronation and supination but only about 45 degrees flexion.

On April 18, a splint was applied to increase flexion.

On April 23, I gained 45 degrees flexion, putting the elbow up in plaster in acute flexion. This cast was split on April 29. On May 1, the arm was put up in plaster at 10 degrees' flexion. A window was cut in the plaster and the wound dressed. The patient was then discharged to have the arm dressed by his family doctor. I have been unable to obtain later reports on this case.

Case 10. E. E. had fractured his elbow 8 years before. He entered the Massachusetts General Hospital 11 days later. The roentgenogram showed a supracondylar fracture, probably epiphyseal, with a

good deal of displacement of the lower fragment. A closed reduction was attempted under ether and the elbow put up in plaster with only a little flexion. Seven weeks later, he re-entered the hospital. At this time, the X-ray showed a very faulty position with some ankylosis of the joint. An osteotomy of the joint was done and the arm elevated. The arm was put up at an angle of about 150 degrees and the patient discharged to the convalescent home.

Three weeks later, he re-entered the hospital. At this time the elbow was swollen and very tender. The elbow was incised and the abscess drained and hot soaks ordered. He was discharged a month later.

Two months later, he re-entered the hospital for persistent sinuses in the arm, which were incised and drained. A week later, he was discharged relieved.

The patient entered the Carney Hospital November 28, 1913. At this time there was considerable atrophy of the arm and forearm. The elbow was ankylosed at 85 degrees and showed the scars of the previous operations. Ether manipulation was done on the wrist and later on the elbow.

Later, December 24, 1913, an excision of the semilunar, scaphoid, and pisiform was done.

On January 14, 1914, I did an arthroplasty on the elbow. At the time of the operation, the ulnar nerve was not found in its usual bed, probably having undergone degeneration. No bony landmark could be made out.

He made a good recovery from the operation. The wound remained clean but showed a slight serous exudate. Later, the wound showed a slight slough.

The elbow was manipulated on February 20, gaining motion to a right angle.

Five weeks later he was discharged to be treated by his family physician.

This case was not seen again until recently, when he showed a fibrous re-ankylosis with marked muscular atrophy.

Case 11. E. S. sustained a fracture of the right elbow on October 4, 1913, as the result of a fall of 42 feet. The roentgenogram showed a transverse fracture of both condyles with the radial head dislocated laterally and anteriorly.

Physical examination was negative except for the right arm. The shoulder appeared normal. The elbow was held at 150 degrees extension with less than 3 degrees motion. Supination was limited one-fourth. The wrist showed a Colles fracture unreduced. Flexion and extension were both one-half normal. Eversion was limited three-quarters and inversion four-fifths.

On March 25, 1914, I did an arthroplasty on the right elbow, using a flap of fascia from the thigh. When the joint cavity was opened, it was found that the synovial tissue was hypertrophied and there was much fibrous callus formation infiltrating the articular surfaces. A transverse fracture of both condyles was noted. The head of the radius was impacted and was surrounded by callus formation.

Five-eighths of an inch of the condyles was sawed off square at right angles to the shaft of the humerus. The joint surfaces were smoothed off and the operation completed according to my usual method. The arm was put up in plaster in an extended position. The patient made a good ether recovery but suffered considerably from pain, for which morphia was ordered, and the following day the arm was put up in suspension. He continued to suffer considerable pain for four days, after which the pain abated.

On March 29, the wound was dressed and was found clean with some serous discharge.

March 30, the cast was split and a voluminous dressing applied with splints to the forearm.

March 31, the patient was seen in consultation by Dr. Courtney, who reported a tourniquet paralysis and advised electricity and massage.

April 1, the wound was dressed and found clean and healing by second intention.

April 5, the patient was out of bed and walking about the ward. When dressed, the wound was found clean.

April 10, the wound was dressed. The motion in the elbow was good with good supination and about 45 degrees flexion. A nerve report was ordered.

April 15, the nerves were reported responding to the faradic current. The prognosis was considered good. Massage was advised.

April 18, the patient was discharged from the hospital to report daily at my office.

November 30, the patient re-entered the hospital for operative interference in an attempt to gain increased motion. Both bones of the forearm had dislocated backward and the head of the radius was very much enlarged. Motion was from 150 degrees to 50 degrees with the carrying angle markedly increased.

On December 2, after the usual preparation, a 4-inch incision was made over the external condyle. The removal of the enlarged head of the radius caused a marked increase in motion but the posterior dislocation was not improved. The internal condyle was chiseled loose and removed through a small incision over the fragment. After the end of the humerus was smoothed as much as possible with a rasp, the wound was closed and a cast applied with the arm at right angles. A good ether recovery followed.

After the operation, the patient suffered considerably and showed some swelling of the arm. On the fourth day, the cast was split, when the patient experienced relief.

On the 7th, the patient was comfortable and out of bed. The following day he was discharged to report to my office. The end-result shows nearly normal range of motion with a stabile, useful joint.

On October 29, 1920, he writes: "I can crank a Ford. I can do anything that I ever could. My work is driving and repairing automobiles and I have had to change a 38-7 tire on the road, which requires the use of two good arms."

Case 12. M. S. had suffered from a chronic arthritis, probably a neisserian infection, affecting both wrists, the left knee, and the right elbow. The

trouble had begun 4 years before and was gradually getting worse until she was unable to work. The left knee showed thickening and slight heat. It was held in 45 degrees permanent flexion and showed only 10 degrees motion. Her left wrist was ankylosed. The right elbow was ankylosed at right angles and was painful at one-half supination.

The patient entered the House of Mercy Hospital on June 18, 1914, where an arthrotomy followed by oil injections was done on the knee and an arthroplasty on the elbow. Four months after arthroplasty, the patient showed a range of motion from 60 to 140 degrees and a stabile, useful joint.

Case 13. M. F. had a severe polyarthritis when 6 years old. At this time, she was under treatment at the Holyoke City Hospital for 10 weeks, receiving general treatment from which she experienced temporary relief. Since then, she has suffered recurrent attacks of acute arthritis.

When she entered the Carney Hospital on April 23, 1914, physical examination showed an involvement of her elbows, wrists, fingers, knees, and ankles in the infectious process. Motion was limited and the joints were swollen and contained a small amount of fluid. The elbows were ankylosed at 125 degrees. Consultation was held with the medical, surgical, and laryngological staffs, whose reports were negative, except in regard to the tonsils. Following their removal on May 16, she showed marked improvement in the hands and feet under conservative orthopedic treatment.

On June 10, her wrists, ankles, and knees were manipulated under ether. From this operation, she made an uneventful recovery.

As her elbows were ankylosed, an arthroplasty was advised on the right elbow. This I did on July 1 by my usual method. She made an uneventful recovery and on July 26 showed motion from 50 degrees to almost normal extension. Flexion later increased to within 15 degrees of normal.

On August 12, I manipulated the arm and put it up well beyond a right angle. On August 19, the elbow could be manipulated without force to beyond a right angle, with force to within 5 degrees of full. Following this, however, motion gradually shut down and the end-result was re-ankylosis. I believe that this result is to be expected in children, on account of the impossibility of removing sufficient bone without injury to the epiphyses.

Case 14. A. M. had suffered from infectious arthritis for 10 years. Her fingers, knees, and elbows had become stiff.

Physical examination was negative, except for the joints. The right elbow was ankylosed at 90 degrees with about 30 degrees motion. The wrists were ankylosed in slight flexion. Previous to the arthroplasty, her feet and knees were manipulated.

On November 14, I did an arthroplasty, inserting a flap of fascia lata. Convalescence was uneventful.

On February 10, I manipulated the elbow under ether, holding the elbow in acute flexion with bands of adhesive. She was discharged from the hospital on April 2 with motion from 45 to 100 degrees.

Case 15. L. P. I saw the patient for the first time July 10, 1914. The trouble had begun November 23, 1912, when she was confined in bed with a temperature of 102° and swelling of the wrists and ankles. It had progressed ever since in spite of orthopedic and other treatment.

Physical examination showed marked involvement of all the joints of the arms and legs with ankylosis and more or less pain and swelling. The left wrist was ankylosed at 35 degrees radial adduction and the left shoulder showed a bursitis. The left elbow showed a few degrees motion and was held rigidly at about 135 degrees extension.

The patient was advised to have the shoulder manipulated and put up in plaster and to have the deformity of the wrist corrected. For the elbow, an arthroplasty was advised.

On July 10, I did an ether manipulation of the hips, knees, and feet.

January 13, 1915, an arthroplasty was performed on the left elbow. The olecranon was found ankylosed to the humerus. Both humerus and ulna showed a large amount of bone atrophy.

On October 13, I operated on the wrist for ankylosis. I excised the heads of the first phalangeal joints of the four fingers besides the distal metacarpal head of the thumb and fourth finger.

On February 6, 1916, I did an excision of the shoulder.

The latest report on this case is July 23, 1919, at which time flexion was perfect; when standing or sitting, complete extension is possible. The action of the elbow, however, below a right angle is weak, due to muscular atrophy.

Case 16. G. F. The trouble began 8 years before with an infectious arthritis affecting the fingers of the right hand. Later, she had other attacks involving the other hand, the feet, ankles, and knees. About a year before she entered the hospital, she was confined to her bed for 8 weeks with an attack involving the elbows, hands, and ankles. Subsequent to this, the mobility in her hands and elbows had diminished. She entered the Carney Hospital on December 27, 1913, for relief of this condition.

Physical examination at this time showed marked involvement in the arthritic process of the elbows, fingers, ankles, and toes. The right elbow was ankylosed at 155 degrees. The left elbow showed motion from 160 degrees extension to 45 degrees flexion.

The patient received general treatment and was referred to the surgical department for an ileosigmoidostomy. She left the hospital relieved following this operation.

In January, 1915, she re-entered the hospital for relief of the stiffness of her joints. Since the ileosigmoidostomy, her general health has improved. Her joint condition, however, has remained unchanged.

Physical examination showed the right elbow permanently ankylosed, the left ankylosed at 90 degrees with 5 degrees motion.

On January 20, 1915, I did my usual arthroplasty on the right elbow. She made a normal recovery and left the hospital with a good amount of motion.

After she left the hospital, she had another acute attack of arthritis which affected this joint. Gradually, motion became more painful and shut down. For this condition, she re-entered the Carney Hospital. The X-ray showed anteriorly the development of new bone. A secondary operation was done at which the head of the radius was removed as well as the exuberant bony tissue.

Case 17. I. H. had fallen on her elbow 4 months before she entered the hospital. She had suffered considerably from pain and was unable to use her arm. At this time, I manipulated her elbow under ether and later manipulated it every 2 weeks in the Carney out-patient. On account of the limitation in motion, an arthroplasty was advised.

She entered the Carney Hospital on June 22, 1915. At this time, the elbow was slightly tender and motion was limited to forty degrees. There was no pain but the joint was somewhat enlarged and the bones felt rough. The roentgenogram showed an old fracture of the lower end of the humerus.

On June 23, I did an arthroplasty of the elbow-joint, using a free flap of fascia lata, after which the patient made a good ether recovery. The following day, the plaster was trimmed about the fingers. The fever and swelling of the hand continued for several days until, on the 28th, the cast was bivalved, when the temperature dropped and the œdema disappeared.

On July 3, the patient was up in a chair. On the 6th, the dressing showed a slight superficial sepsis. The motion of the arm was very much increased. She was discharged from the hospital on July 15, to report to the out-patient department. Following this, there was a gradual return of motion.

In June, 1919, 3 years after the operation, she showed a range of motion from 37 to 125 degrees.

Case 18. D. S. While playing basket ball, the patient had been pushed against the wall, injuring the right elbow. He suffered a good deal of acute pain immediately following this and soreness had persisted for several weeks. The elbow had gradually become stiff. Twelve months before this, D. S. had had an acute condition in the elbow, when it was hot and painful, but quieted down quickly.

Physical examination showed the right arm held in about 105 degrees flexion. About one-fourth pronation was allowed and supination was limited one-half. The patient's grip was good and he had apparently full use of the fingers and hand. There was very slight capsular thickening and the fossæ on either side of the olecranon were not as sharp as normal. The musculature of the arm was good. Sudden jerks in flexion and extension were painful.

Arthroplasty was advised. This was done by my usual method at the House of Mercy Hospital, Pittsfield, September 23, 1915.

The patient was last seen 2 years after the operation. He has been working with the General Electric Company and has been admitted to the National Guard. He states that in damp weather he has a little aching pain and cannot do heavy lifting. He can dress himself. In October, 1917, while playing a game, his arm was strained and something snapped, but he was able to keep on playing. The fingers got a little stiff afterward with pain up the arm. The weakness and inability to use the arm lasted 4 weeks but was followed by perfect recovery.

The arm at this time showed extension to 125 degrees and flexion to 20 degrees, pronation one-half. Musculature was good. He shows a perfect functional result.

Case 19. J. T. One year before the arthroplasty, his right arm had been severely burned while he was at work in a paper mill. The burn had become septic, resulting in marked contraction of the scar tissue for which an extensive skin graft had been done with very good result. His elbow, however, had remained stiff.

Physical examination was negative except for the right arm. The scar tissue extended from the fingers to the axilla on both anterior and posterior surfaces. The thumb was abducted one-half and the fingers held in hyperextension. They could, however, be flexed.

On October 4, 1915, I operated upon the elbow doing an arthroplasty with a flap of free fascia. At operation, the ankylosis was found to be fibrous.

The patient made a good recovery from the ether. The wound was dressed on the second day when it was found clean, but the skin suggested a slough in the middle of the incision. He was discharged from the hospital on the 22d after an uneventful recovery.

Two months later, the elbow showed a range of motion from 45 to 140 degrees and was free from pain.

Case 20. J. C. The right elbow had become stiff following an acute infection of the entire arm. Later, there had been a discharging sinus near the elbow-joint.

Physical examination was negative except for the right arm which showed some atrophy. All motions of the shoulder were normal. The elbow was solidly ankylosed at 165 degrees. Motion of the hand was limited. The X-rays showed a bony ankylosis of the elbow-joint.

On February 27, 1917, I did an arthroplasty by my usual method. This case was unusual in that the remodeling was very difficult. Ordinarily, after the olecranon has been sawed through, you can break open the joint or, at least, there is soft bone that is readily sawed through. But in this case, the joint was solidly ankylosed and every vestige of the joint had disappeared.

Following the operation, the wound showed some bloody oozing. On March 5, a window was cut in the cast and the wound was found healed and clean. The patient was out of bed on the 10th and 7 days later was discharged from the hospital. Baking and

massage were continued. The end-result was a stable elbow with good function.

Case 21. I. L. Her left elbow had become ankylosed as the result of an arthritis of 10 months' duration. When I first saw her, October 3, 1916, her elbow was very sensitive and painful. About 10 degrees motion was allowed in the joint which was held in 130 degrees extension. Supination was about one-third normal.

In spite of conservative treatment, the elbow continued to stiffen. As a roentgenogram taken February 17, 1917, showed a bony ankylosis, an arthroplasty was advised. This was done March 6, 1917, and was followed by an uneventful recovery.

Miss L. was last seen May 26, 1919. She stated that only occasionally did she have slight pain. Motion in the elbow was from 45 to 145 degrees and she had a stable, useful arm with no lateral mobility. Rotation was limited to 15 degrees in the mid-position. This loss of motion is apparently due to the enlargement of the head of the radius and its excision was advised.

Case 22. C. M. had a complete bony ankylosis of the left elbow in 145 degrees extension. The condition had existed for 17 years, since the patient was 14 months old, when she had broken her arm. The X-ray showed a complete obliteration of the joint.

On August 23, 1917, I did an arthroplasty at St. Luke's Hospital, New Bedford. After an uneventful recovery, the patient was discharged a week later to report weekly to the out-patient department.

On September 6, the cast was split and the wound dressed. The patient had 15 degrees motion. Her arm was put up in a sling and she was asked to manipulate the arm and report again in 2 weeks.

September 27, she returned and was advised to continue treatment.

On October 11, the patient did not show much gain in motion. She admitted that she was not carrying out instructions regarding exercising the arm. She was advised to have an ether manipulation.

October 25, she reported at the hospital but again was found not to be carrying out instructions.

November 1, she showed a slight improvement. She was advised to increase her exercises.

November 8, she was referred to the hospital for an ether manipulation.

December 20, she was again advised to have the elbow forcibly manipulated.

January 3, 1918, an ether manipulation was done and the arm strapped up in 30 degrees flexion.

On January 10, the patient reported and was found to be doing well. She was asked to report each week.

When the patient reported again a week later, she was found to be again not following directions. A further manipulation was advised.

On January 31, she visited the clinic for the last time. Manipulation was again advised. Since this time, she has been seen several times by our social worker and urged to return for further treatment, but this she has steadily refused to do. She is working daily in a mill. When last seen, May 19, 1919, she stated that she felt the arm would have been all right if she had come again for operation, but was afraid of the pain and her mother did not want her to go again to the hospital. This case shows the necessity of the co-operation of the patient in the after-treatment.

Case 23. M. R. fell on January 12, 1918, fracturing her elbow. Splints were applied at this time and remained on for 3 weeks. On March 7, an operative attempt was made at the Brockton Hospital to gain motion. I first saw Miss R. on June 4, 1918. At this time, her elbow was swollen and painful and allowed motion only from 155 to 160 degrees. It was held in permanent pronation with no motion in the radio-ulnar joint. There was a slight discharge.

A few weeks later she entered the Carney Hospital and on June 27 I manipulated the arm and applied a cast which was kept on 4 days. She was then discharged with her arm in a sling.

As the arm again stiffened, she re-entered the hospital February 10, 1919. At this time, her elbow was ankylosed at 90 degrees. On February 12, I did my usual arthroplasty. The soft tissue surrounding the joint presented a mass of scar tissue from which the ulnar nerve could not be isolated. The tissue through which the nerve must have run was therefore dissected back and retracted *en bloc*. The line of the old joint was discovered with difficulty.

The patient made a good ether recovery and was fairly comfortable the following day after some pain on the previous night. The cast was stained through by the discharge from the wound.

On February 14, a window was cut in the cast over the area of operation and a sterile alcohol dressing applied. The bloody discharge from the wound still continued on February 17. This condition remained unchanged until the 26th, when the wound showed some healing upon the outer side of the elbow. On the 28th, the discharge had decreased in amount but the dressing showed a slight amount of pus on the inner side.

On March 4, motion was possible from 80 to 105 degrees without pain.

On March 10, the arm was put up in a sling in as acute flexion as possible and daily manipulation of the fingers begun. The wound was still discharging.

On March 24, the discharge had decreased slightly in amount. The finger motions had increased.

On March 31, the condition was unchanged. Light massage was begun on the upper and lower arm. Dressings were continued twice a day.

On April 7, the arm was put up in a sling at about 70 degrees flexion. There was still a discharge. On April 14, there was some swelling back of the elbow-joint but no fluctuation was felt. The arm was kept quiet and the swelling subsided in a few days. The discharge gradually decreased, and on April 20 the patient was discharged to have the dressings done by her local doctor.

Case 24. F. A. suffered on May 30, 1916, from a severe osteomyelitis of the left humerus. The arm

was incised at this time and a sequestrum removed. Since then, his general condition had improved but he had suffered from wrist-drop since the operation, and motion in the elbow had been lost.

When A. was referred to me, the arm showed a seven and one-half inch scar on the outer aspect. There were two sinuses which discharged creamy pus. The shoulder motions were one-half normal. The elbow was slightly thickened and showed local heat. It was ankylosed at 110 degrees with a few degrees motion. There was complete wrist-drop. X-ray showed a diffuse osteomyelitis involving the whole humerus with some evidence of sequestrum formation in the upper third. A subperiosteal resection of the shaft of the humerus was done. From this operation, he made a good convalescence.

On August 15, 1917, the arm showed the scar healed. There was apparently a total regeneration of the humerus. The shoulder showed 45 degrees motion in abduction with good anteroposterior movements. The elbow was ankylosed at 100 degrees with a few degrees motion. Supination was limited. His wrist was fitted with a hyperextension splint.

On June 4, 1918, as the elbow had not discharged for a year, an arthroplasty was advised. This was done July 24 at the Carney Hospital. The elbow was found ankylosed at 160 degrees. There was a musculospiral paralysis.

Convalescence was uneventful. On August 10, the cast was removed. On August 10, motion without discomfort was possible from 70 to 120 degrees. He had a slight rise of temperature on the 13th but this quickly dropped. He was discharged from the hospital on August 17 to have dressings done by his family physician and to report from time to time to my office.

September 7, he showed 15 degrees motion. On September 17, there was less motion. On October 24, motion had shut down to 8 degrees and a manipulation was advised. This was done on November 10, 1918, following which the elbow showed 10 degrees motion.

On November 5, 1919, I did a tendon transplantation for the relief of the musculospiral paralysis with excellent result.

However, as motion in the elbow was restricted, further operative interference was advised. For this, the patient entered the Brooks Hospital where, on July 7, I removed the head of the radius and three-quarters of an inch of the humerus.

He made a good recovery. On July 28, he had motion from 45 to 90 degrees. On August 25, he had motion from 75 to 135 degrees. On October 26, he showed motion from 40 degrees to 160 degrees.

Case 25. F. D. In 1910, the right elbow became swollen and tender. At this time an open operation was done on the joint. Six months later, another operation was done, after which the elbow drained for 4 years and he lost the entire use of the arm.

Physical examination showed marked atrophy of the muscles of the arm. There were numerus scars above and about the elbow. The elbow was ankylosed at 180 degrees. Finger and shoulder motions were normal.

On August 10, 1918, by my usual method, I did an arthroplasty on his elbow. He made a good recovery and had a normal convalescence. Two weeks later, he was discharged to have daily dressings done by his family doctor. Motion at this time was from 80 to 100 degrees without pain.

He reported at my office on August 30. At this time, the wound was not quite healed. The elbow showed 30 degrees motion. Following this, he was seen about every 6 weeks. On October 18, the wound was found healed. Motion gradually increased.

On December 9, 1919, he showed motion from 35 to 145 degrees with full supination. The elbow was stable with no lateral motion. He has no pain, works as a telegraph operator and "lifts anything."

Case 26. S. S. was first admitted to the Burbank Hospital, Fitchburg, December 5, 1917, with a subacute neisserian infection. Five years previously the right knee had become swollen, and remained so for 3 months. A month later, the right elbow became swollen and painful. At that time, she could bend the elbow but, as this caused pain, she did not do so. At the time of her admission, she could not bend the elbow nor lift the arm, and the elbow region was swollen and painful. The Wassermann test was positive. She remained in the hospital 38 days, receiving general treatment and was discharged relieved.

She returned to the out-patient department, July 1, 1918. The arm was then put up in plaster from wrist to shoulder to remain on 2 months. She was told that her elbow would probably become stiff and would require an arthroplasty later.

On January 9, 1919, the patient was advised to have an arthroplasty done as her elbow had become stiff. Following the operation on February 6 she had an uneventful recovery. The cast was removed in 2 weeks, after which passive motion was begun. She was discharged March 18, 1919.

When last seen, April 3, 1919, she had a range of motion from 45 to 135 degrees.

Case 27. N. B. was admitted to the House Mercy Hospital, Pittsfield, on March 4, 1919, for the relief of an ankylosis of 4 months' duration, the result of an infectious arthritis. There was marked atrophy of the left deltoid but no pain nor tenderness in the shoulder-joint and no limitation of motion. The left elbow was ankylosed at 150 degrees. She remained at this time in the hospital for a month under conservative treatment, then left the hospital unrelieved and was advised to return later for operative interference.

On June 24, she re-entered the hospital. At this time, the elbow was ankylosed at 150 degrees. I did my usual arthroplasty and obtained a very good immediate result. The convalescence was uneventful but the patient did not co-operate in the after-treatment, spoiling what would otherwise have been an excellent result.

On September 16, following manipulation, she gained voluntary extension to 150 degrees. She returned to the outpatient department for massage and manipulation until December, 1919. At this time, she had motion from 75 to 120 degrees and a useful, stable arm.

Case 28. W. M. had fractured his olecranon as the result of a fall. Following an open operation in which the olecranon was fastened in place with silver wire, the elbow gave him no further trouble until a year later following a second injury. When moving a heavy box, a second box had fallen and hit him on the elbow. Two weeks later, when he reported to the hospital, he was in great pain and showed a discharging sinus from which a piece of wire which was protruding was easily removed. Free drainage was established and later the arm was twice curetted. He was discharged March 21 after a tempestuous illness, to report to the out-patient department for dressings. In July, the wounds had healed and the patient was discharged to return in 6 months for an arthroplasty.

This I did on July 9, 1919, and on his discharge from the hospital on September 4, he was able to flex and rotate his arm voluntarily. He is still undergoing treatment and manipulation, baking, and massage. On October 18, 1919, he had voluntary motion from 158 to 105 degrees. On October 30, 1920, he had voluntary motion from 60 degrees to 135 degrees.

BIBLIOGRAPHY

1. Albarran. Cited by Hoffa, loc. cit.
2. Albee. Orthopedic and Reconstruction Surgery. 1918, p. 965.
3. Allison and Brooks. Surg., Gynec. & Obst., 1913, xvii, 645.
4. Ashhurst. Ann. Surg., 1915, lxii, 302.
5. Baer. Am. J. Surg., 1918, xvi, 170.
6. Bazy. Bull. et mém. soc. chir., Par., 1907, xxxii, 520.
7. Berger. Bull. et mém. soc. chir., Par., 1901, xxix, 998.
8. Brown. California St. J. M., 1916, xiv, 146.
9. Ceccarelli. Riforma med., Napoli, 1917, xxxiii, 1173.
10. Charput. (a) Bull. et mém. Soc. chir., Par., 1912, xxxviii, 452; (b) 1915, xli, 1540.
11. Cifuentes. Rev. de espec. méd., Madrid, 1909, xii, 73.
12. Conrad. Dissertation, Kiel, 1912.
13. Darling. Physician & Surg., 1913, xxxv, 71.
14. Davis. Ann. Surg., 1914, lxi, 438; 1915, lxii, 378.
15. Davis. Johns Hopkins Hosp. Bull., 1911, Oct.
16. Delangenière. Bull. et mém. soc. chir., Par., 1917, xliii, 2195.
17. Delbet. Bull. et mém. soc. chir., Par., 1903, xxix, 1172.
18. Delbert. Gaz. méd. d. Par., 1912, lxxxiii, 117.
19. Denk. Arch. f. klin. Chir., 1912, xcvii, 458.
20. Dupuy. Thèse de doct., Toulouse, 1903.
21. Edmunds. Med. Press & Circ., 1912, xciv, 574.
22. Exner. Wien. klin. Wchnschr., 1913, xxvi, 1821.
23. Frisch, von. Wien. klin. Wchnschr., 1911, xxiv, 9222.
24. Gilbert. Texas St. M. J., 1915, xxxi, 226.
25. Graff. Deutsche med. Wchnschr., 1915, xli, 1502.
26. Greiffenhagen. St. Petersb. med. Ztschr., 1913, xxxviii, 93.
27. Harris. Texas St. J. M., 1913, xxix, 213.
28. Helfereich. Verhandl. d. deutsch. Gesellsch. f. Chir., 1894, xxiii, 504.
29. Henderson. Am. J. Surg., 1918, svi, 30.
30. Herzberg. Dissertation, Berlin, 1913.
31. Hoffa. Ztschr. f. orthop. Chir., 1906, xvii, 1.
32. Hofmann. Zentralbl. f. Chir., 1906, p. 16.
33. Hohmeier and Magnus. Beitr. z. klin. Chir., 1914, xciv, 547.
34. Hohmann. Berl. klin. Wchnschr., 1918, lx, 122.
35. Huguier. (a) Thèse de doct., Par., 1905; (b) Tribune méd., Par., 1909, xli, 197.
36. Kennedy. Tr. Roy. Acad. M. Ireland, 1915, xxxiii, 223.
37. Kerr. Surg., Gynec. & Obst., 1920, xxx, 518.
38. MacAusland. J. Am. M. Ass., 1915, lxiv, 312.
39. Mauclaire. Bull. méd., Par., 1913, xxvii, 66.
40. McCurdy. Pennsylvania M. J., 1914, xviii, 606.
41. McKenna. J. Am. M. Ass., 1917, lxix, 891.
42. Moszkowicz. Berl. Ztschr. f. Chir., 1917, cv, 168.
43. Murphy. (a) Tr. Am. Surg. Ass., 1904, xxii, 313; (b) Ann. Surg., 1913, lvii, 595; (c) Murphy's Clinics, 1914, iii, 523; (d) J. Am. M. Ass., 1915, 851; (e) Murphy's Clinics, 1916, v, 641.
44. Neff. Surg., Gynec. & Obst., 1912, xv, 529.
45. Nélaton. Bull. et mém. soc. chir., Par., 1902, xxviii, 687.
46. Olivieri. Semana méd., Buenos Aires, 1917, xxiv, 127.
47. Osgood. Surg., Gynec. & Obst., 1913, xvii, 6.
48. Owen. Ann. Surg., 1914, lix, 426.
49. Payr. Deutsche Ztschr. f. Chir., 1914, cxxix, 341.
50. Pereira. Brazil-med., Rio de Jan., 1906, xx, 361.
51. Phemister and Miller. Surg., Gynec. & Obst., 1918, xxvi, 406.
52. Plummer. Surg., Gynec. & Obst., 1917, xxiv, 509.
53. Pomponi. Gior. di med. mil., 1912, lx, 418.
54. Pupovac. Wien. med. Wchnschr., 1914, xxvii, 151.
55. Putti. Arch. d. ortop., Milano, 1913, xxx, 1.
56. Quénu. (a) Bull. et. mém. Soc. chir., Par., 1902, xxviii, 724; (b) 1903, xxix, 112; (c) 1905, xxxi, 622.
57. Rechet. VIII Cong. chir., Lyon, 1894. Arch. prov. Chir., 1896.
58. Reiner. Deutsche Ztschr. f. Chir., 1910, xiv, 209.
59. Roepke. Deutsche Chir. Kong., 1913, 116.
60. Rovsing. Tr. XI North. Surg. Cong., Gotenb., 1916.
61. Ryerson. Surg. Clin. Chicago, 1917, 1, 197.
62. Schanz. Muenchen. med. Wchnschr., 1904, 2228.
63. Scudder. Boston M. & S. J., 1906, clv, 375; Ann. Surg., 1907, xlv, 297; 1908, xlvii, 711.
64. Stein. Dissertation, Bonn, 1907.
65. Steindler. J. Iowa St. M. Soc., 1916, vi, 284.
66. Sumita. Arch. f. klin. Chir., 1912, xcix, 755.
67. Taylor. Pennsylvania M. J., 1912, xvi, 294.
68. Thom. Deutsche Ztschr. f. Chir., 1910, cviii, 424.
69. Thomson. Edinburg M. J., 1917, xix, 176.
70. Tubby. Am. J. Orthop. Surg., 1915, xii, 381.
71. Turner. Edinburgh M. J., 1914. xii, 433.
72. Verneriel. Arch. de méd., 1860.
73. Vulpius. Muenchen. med. Wchnschr., 1914, Mar. 17.
74. Weglowski. Zentralbl. f. Chir., 1907, Apr. 27.
75. Whitman. Ann. Surg., 1911, liv, 860; 1916, lxiii, 503.
76. Wille. Norsk. Mag. f. Lägevidensk., 1911, ix, 40.

BACKACHE*

W. Russell MacAusland, M.D.

BOSTON, MASS.

BACKACHE, because of its prevalence and its many etiological factors, is a subject of great interest to the entire medical profession, and any discussion that aids in its diagnosis and treatment is warranted. Like many medical problems it has been approached too frequently from the standpoint of the specialist. The orthopedist, urologist, gynecologist, psychiatrist, each has interpreted the cause of backache from his respective point of view. The orthopedist who is called upon to treat a large number of cases of backache should appreciate the variety of factors giving rise to the pain, and should realize that a wide knowledge of clinical conditions often is required for the solution of the problem. Backache, like arthritis, if approached with a narrow vision, not only may be treated without relief, but actual damage may be done to the patient by the removal of the so-called foci of infection. Undoubtedly, many laparotomies have been performed without relief because the pelvis alone was considered. On the other hand, many types of retentive apparatus have been employed in cases where the lesion was entirely or largely surgical. Therefore, in order that the proper treatment may be advised, a very thorough investigation of all possible etiological factors should be made. The surgeon who does not use every means at his disposal, is bound to be unsuccessful in the treatment of a large proportion of his cases. On the other hand, it is my opinion that when great care is used, the treatment of backache is satisfactory.

GENERAL SURGICAL, MEDICAL AND NEUROLOGICAL LESIONS, WITH REFERRED BACK PAIN

Genito-urinary System. It has been demonstrated many times that the following conditions may frequently be associated with back pain.

1. Floating kidney.
2. Diseases of the kidney.
3. Perinephritic disease.
4. Uretal conditions.
5. Deformities and displacement of the pelvic organs.

*This lecture was delivered on Nov. 9, 1923.

Reprinted from Practical Lectures, *Delivered under the Auspices of* The Medical Society of the County of Kings, Brooklyn, New York, [1923–1924 series], pages 275–288. Published by Paul B. Hoeber, Inc., New York. Copyright, 1925.

In most cases it is possible either to prove or to rule out any of the above conditions. If present, they may be accepted as a definite factor, but it should be borne in mind that even when found, they may be of only little importance in the causation of back pain.

Prostatitis and spermatocystitis have been considered definite causes by Baker,[2] Young, Geraghty and Stevens,[84] and Smith.[45] Therefore, an examination of a man is not complete without determining the condition of the prostate gland and its adnexa.

In women, malposition of the uterus has long been regarded as a potent cause of backache. Gradually, however, the old theory of pressure of the retroposed uterus on the nerves has been discarded and the more advanced gynecologists are admitting that pelvic disorders are not the direct causes of backache, but that they are usually concomitants. Graves,[17] Cooley,[9] Brooke,[6] Reynolds and Lovett,[38] Sever[44] and many others emphasize the association between pelvic conditions and back pain. Phaneuf[35] seems to me to have expressed the most reasonable view on the subject, namely, that the ordinary deformities of the uterus, such as retroversion, anteflexion, etc., are not causes, but that the heavy, boggy, mildly infected uterus sinking low in the pelvis, may definitely cause back pain by pulling on the nerve structures. A heavy, subinvoluted uterus represents the type of lesion that may give rise to back pain.

Cancer in the pelvis might also bring about a similar condition, although in such cases there is the possibility of the involvement of the nerve sheaths, and even of the nerves themselves.

Backache associated with menstruation seems to me to represent a combination of the factors: nerves, fatigue, and the laxity or susceptibility of the pelvic joint to strain.

Abdominal Conditions. Abdominal conditions associated with back pain are very numerous, particularly those representing infections, such as the infected gall-bladder, appendix, etc. The dragging of a large scrotal or abdominal hernia may also be accompanied by back pain. New growths should, of course, be considered separately. Metastases of the spine take place with such frequency that actual local disease in the spine must be considered in every case, and such a condition will be treated under lesions of the spine.

Neurological Lesions. The neurologist finds many conditions giving rise to back pain. Cases that present definite diagnostic signs of irritation or degeneration in the central

or peripheral nervous system should come directly under his care. Those which represent neurasthenic, functional or hysterical conditions, should be examined with great care, as frequently such cases are malingering. In my opinion such a diagnosis is rarely justified.

Focal Infections. In regard to focal infections as a cause of backache, I believe they act always through intermediate conditions, the most common of which is arthritic infection. Focal infections, therefore, may be considered under the treatment of arthritis, the well-known cause of back pain. I do not wish to belittle the importance of focal infections, but I do wish to emphasize the need of giving attention to the intermediate condition that the infection produces, as well as to the eradication of the focus itself.

BONE AND JOINT CONDITIONS WITH REFERRED BACK PAIN

Static and Postural Lesions. The term "static" implies an alteration in the relation that the different parts of the body bear to each other. The human body works always in fixed lines and planes, with certain variations and limits of motion. Checks to the motion of the back are ligaments about the lower end of the spine which are particularly strong and relax only under extreme stress and strain. If abnormal positions are maintained for a sufficient length of time, these ligaments may be constantly strained, or the spine or other structures may be affected, and static backache result. Constant postural and static strain may affect the back to such an extent as to cause actual arthritic changes in addition to backache (Fig. 95). If a chronic condition persists, the postural defect may progress to actual displacement of the last lumbar vertebra. This may be demonstrated by lateral *x*-rays of the spine (Fig. 96). The displacement causes a pinch in the posterior vertebral body and is responsible for much of the pain, arthritic changes and referred leg pain occurring in this type of case.

Postural changes causing backache may be classified as flat back, lordosis, round shoulders, faulty position in the back itself, or they may be secondary from abdominal ptosis or overweight.

The static defects are chiefly due to flat feet, knock-knees, short leg, congenital hip and scoliosis.

Many of the postural defects develop from assuming a definite position in occupation or from performing constant rhythmic movements involving the spine.

A great deal has been written upon the recognition of this

static element. In 1910, Reynolds and Lovett[38] propounded the "static" theory that backache is due to the forward displacement of the center of gravity of the body and that the undue strain on the posterior muscles and ligaments causes the pain. Goldthwait and Osgood,[16] Brooke,[6] Dameshek,[11] Kuth,[24] Woodbury,[47] Ogilvy,[30] Graves,[17] Marshall,[28] Kosmak,[22] O'Ferrall,[29] have written upon the importance of this static disturbance.

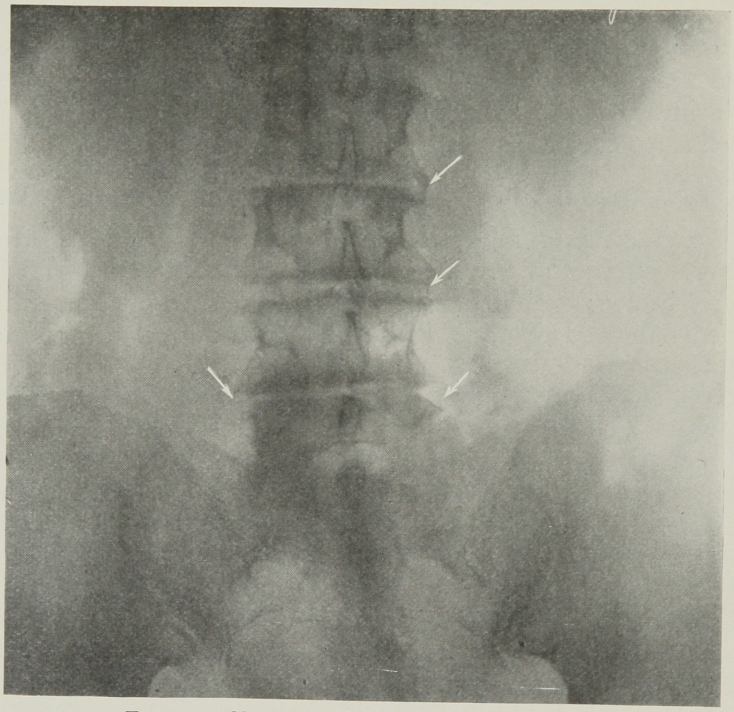

FIG. 95. Showing arthritic changes of the spine.

LOCAL LESIONS IN BONE, MUSCLES AND LIGAMENTS

Infections. In my experience, arthritis of the spine has proved to be the most frequent cause of back-pain conditions. Definite pathological symptoms are found, which, for the most part, are amenable to proper treatment. Arthritis of the spine is practically universal and may be demonstrated in the spine of almost every person over forty years of age. Arthritis of the spine, as of other joints, may be of various types—hypertrophic, osteoarthritic, etc. (Figs. 95 and 97). Infection from a distant foci passing through the blood may localize in a back strained from postural, static or traumatic conditions.

Limitation of motion, so characteristic of joint disease, is associated with this arthritic process. Muscle spasm, protective in nature, acting with the usual checks of motion, gives rise to an abnormal limitation.

Cancer, tuberculosis, syphilis and other diseases of the bone may also cause definite pain.

Traumatic. Injuries may result in strain or fractures.

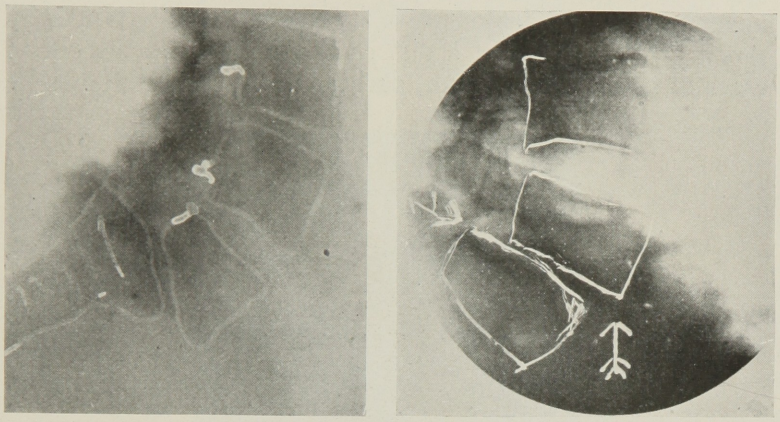

A *B*

FIGS. 96 *A* AND *B*. Showing forward displacement of the fifth lumbar vertebra.

The structures involved in the traumatic processes are the sacroiliac joints, the lumbar spine and the lumbosacral junction.

Strain. A change from the normal position produces a strain on the ligaments and muscles. A simple muscular or ligamentous strain is a common industrial complaint. The strain may be acute or chronic. Faulty posture may cause an acute strain. A dorsal position on a table maintained for a long period during operation, may produce an acute strain of the lumbar ligaments. Chronic strain occurs in cases of congenital dislocation of the hip, short leg and static defects in the lower back. The chronic types may develop into low-grade arthritic processes. Therefore, in making an examination, these static, traumatic and infectious processes should be kept in mind.

There has been much controversy in regard to the dislocation, relaxation and subluxation of the sacroiliac joints. As early as 1870, relaxation and subluxation were associated with pregnancy. Since 1905, when Goldthwait and Osgood[16] explained their theory in regard to the dislocation of the sacroiliac joints, there has been considerable dis-

cussion. Some have agreed that slight dislocations are possible, others have demanded pathologic and radiographic proofs.

More recently it is being recognized that these displacements have been overestimated. Actually the joints between the sacrum and the ilium are the most perfectly protected in the whole human body. Four major ligaments and several minor ones give protection. In my entire practice I have never been able to demonstrate, by clinical examination or by *x*-rays, the presence of a dislocation of the joint, except in cases of severe traumatism, such as occur in automobile or

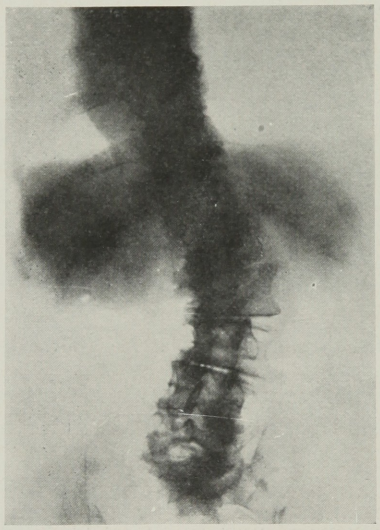

FIG. 97. Showing hypertrophic scoliosis.

railroad accidents. Relaxation and subluxation of the sacroiliac joints are infrequent, occurring only during the course of pregnancy, and they tighten up very early after delivery. It is of significance that during pregnancy, when these joints are relaxed, symptoms of back pain are only rarely present. In cases of overweight, postural conditions cause strain in these relaxed joints, and increase the symptoms and disability.

Many of the lesions supposedly of sacroiliac origin, are actually lumbosacral. This feature is often brought out in a routine examination of the back in cases of postural defects, in which there is an actual forward displacement of the fifth lumbar vertebra on the sacrum (Fig. 96).

The acute attacks that are frequently relieved by osteopathic treatment are simply muscle cramps following

ligamentous strain. Such a condition is seen in cramps in the calves of the legs following overexercise and overuse.

Frequently, heat, massage and manipulation will increase the circulation and give relief.

Fractures. Infrequently, fractures occur in the region of the sacroiliac joints. In the lumbar region a crush fracture occurs most commonly at the junction of the vertebrae. Crush fractures of the articular processes and fractures of transverse process are uncommon.

Fracture, or lateral displacements of the coccyx, usually cause localized pain. In chronic cases it is largely postural in

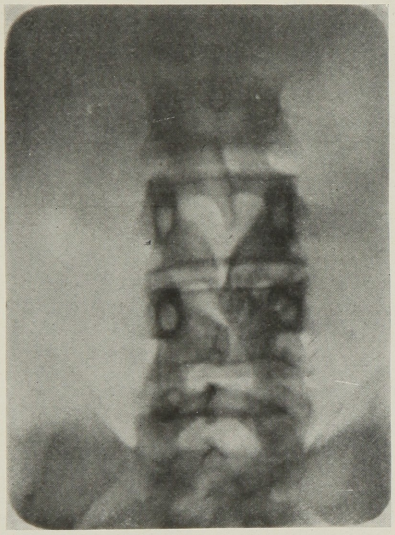

FIG. 98. Showing spina bifida.

origin, with neurasthenic conditions superimposed. In traumatic cases in which a definite fracture or displacement of the tip of the coccyx is demonstrated by digital examination and the *x*-ray, the condition is often relieved by the removal of the fractured or displaced tip. In some cases, however, pain persists after the removal. Surgery in this type of case is not to be advised.

Congenital Abnormalities. Congenital abnormalities in general should not be considered an actual cause of back pain, but merely a predisposing factor. These abnormalities in themselves rarely give rise to symptoms, without some extraneous cause, which is most frequently static, postural, traumatic or infectious.

Not infrequently, spina bifida or failure of the closure of the

posterior arches, from which the patient has no symptoms, is found in a routine examination of the spine (Fig. 98).

Varying degrees of sacrilization, from a mere broadening or lengthening of the transverse process of the fifth lumbar vertebra to an actual antler wing on one or both sides, may be found. This sacrilization is undoubtedly of congenital origin (Figs. 99 and 100). Ludloff[27] and Scheede[43] made the first careful study of the appearance of the structure in *x*-rays. It varies in size and in position with reference to the level of the iliacs. It may be increased in length and width and flattened out into broad, bilobed structures, tipping upward and backward. It may develop to conform with the shape of the adjacent iliacs. O'Reilly[31] studied the *x*-rays of 300 patients

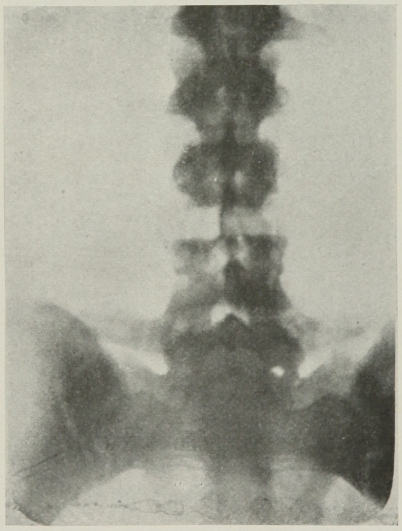

FIG. 99. Showing long transverse process of the fifth lumbar vertebra.

suffering from backache. He found three general types of transverse processes of the fifth lumbar vertebra, the straight type, the fan-shaped type and the bulbous, the last being most common. It was his opinion that occupation played an important part in the development of these variations. Abnormalities of the last lumbar vertebra will cause no symptoms unless aggravated by static, postural, traumatic or infectious lesions. In such cases it is more difficult to relieve the condition. In 3 cases I have found it necessary to resort to surgical interference.

If the transverse process is so long that it comes in close contact with the iliac crest without actually being con-

nected by a bony bridge, a bursa may develop. In some cases pressure may result in the fusion of the tip of the process with the ilium.

Only a few cases of excision have been reported in literature. Some surgeons have tended to discourage the operation, as they claim damage may be done to the nerve structures coming out above or below the transverse process. Others believe with Epstein[13] that the postoperative treatment, not the excision itself, relieves the condition.

Blanchard and Parker[5] reported the first successful case of excision in 1915. Rugh,[42] Adams,[1] Lavieri[25] and Knox[23]

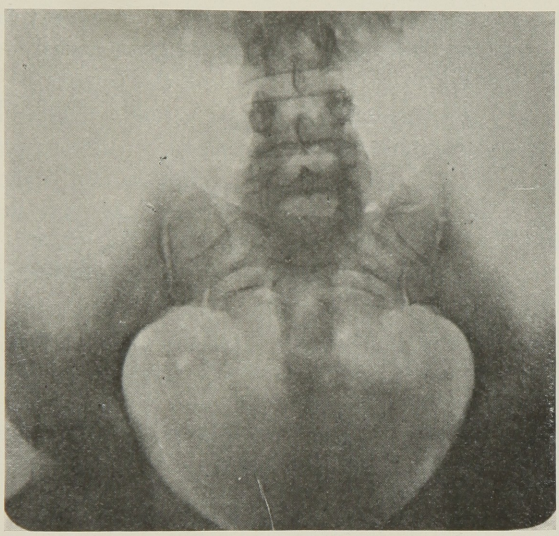

FIG. 100. Showing sacrilization of the transverse process of the fifth lumbar vertebra.

have each reported a successful case since that time. Knox reported operating on 3 other cases on which it was too early to report, but which presented good prospects.

PATHOLOGY

The pathology of these bone and joint conditions occurring in the spine does not differ from the pathology of bone and joint lesions elsewhere. The intervertebral discs may be regarded as joints. They become thinned and absorbed. The edges of the adjoining bone become hardened and form spurs.

Swelling about a badly strained, infected or diseased articular process causes impingement on the nerve which

emerges from the spinal canal through a small foramen. This foramen is practically bony in outline and confines the nerve in its bony canal. Pressure, therefore, has an effect out of all proportion to similar pressure elsewhere on nerves.

The *x*-ray pathology is easy to interpret in advanced cases, but in cases in the early stages, there is an extraordinary lack of appreciation of the slight changes.

The swelling of tissues along the spine tends to give a "washed-out" appearance to the bone and joint shadows.

There is also slight thinning of the intervertebral discs, and the edges of the vertebrae become slightly penciled, due to atrophy.

There may be a slight asymmetry of one vertebra upon another, showing that one joint has given away somewhat more than its fellow on the opposite side.

All the above signs seem to be frequently overlooked, and yet each is of importance.

Diagnosis

The diagnosis of the so-called orthopedic causes of back pain is based upon the same signs as appear in the examination of any joint.

1. Deformity.
2. Limitation of motion (asymmetrical or symmetrical).
3. Muscle spasm.
4. Definite pain or soreness on extremes of motion (when motion is forced with sudden jerk).
5. Local tenderness.
6. Local heat.
7. Local swelling.

The three latter factors may be observed only when great care is used in the examination of the lower lumbar and sacroiliac joints. Anteroposterior and lateral radiograms should be taken in erect and recumbent positions. In general, a probable orthopedic cause for back pain may be certain in any patient who presents limitation of motion of the spine, and may be considered very probable in all cases in which this limitation of motion is accompanied by muscle spasm and local tenderness and pain.

Treatment

Bed. The bed is one of the first factors to consider in the treatment of backache. Most beds sag, whether a person is stout or thin. This sag alone may cause back pain and if continued, produce chronic back strain. This condition

should be corrected so that the back is held in proper position during rest. The most convenient method is to place a fracture board between the spring and the mattress, placing a blanket crosswise on the board so that it will come under the upper lumbar spine.

All static defects, such as flat-foot, knock-knee, round shoulders and abdominal ptosis should be eliminated by mechanotherapy, correction of faulty habits, and exercises. If deformity is corrected and the proper habit of standing, sitting and lying is formed, no further treatment will be necessary.

In the infectious type of case, all existing foci of infection should be eliminated. The patient must improve his general condition by fresh air, sun exposures and good habits. Supportive treatment may be necessary, depending entirely upon the severity and chronicity of the process. In the acute stages, bed treatment is most important. As soon as the symptoms have subsided and the deformity has been corrected, some type of retentive or supportive apparatus is absolutely necessary in order to hold the correction and relieve the patient of further strain. This support may be removed when the surgeon judges that recurrence is impossible. The apparatus should be removed as soon as possible, and baking, massage and all other means employed to stimulte circulation and increase the musculature and the ligamentous tone.

If these infectious elements and all static and postural defects are eliminated, most of the back trouble, if of orthopedic origin, will be relieved.

In cases of back pain due to pelvic lesions alone, or associated with true back lesions, the pelvic, intra-abdominal or general medical problems must be treated hand in hand.

Conclusions

The most constant cause of backache from an orthopedic standpoint is low-grade arthritis. An infectious element, usually present, associated with a chronic strain, produces many of the cases of arthritis that appear in middle life.

I am certain that static and postural elements enter into almost all low back pain of orthopedic origin.

Congenital abnormalities, in themselves, are not a cause of back pain, but they may be a potential danger, making differential diagnosis and treatment more difficult.

BIBLIOGRAPHY

1. Adams. In discussion of Blanchard and Parker's paper. *Am. J. Orthop. Surg.*, Phila., 1915–16, xiii, 250.

2. Baker. *Am. J. Orthop. Surg.*, 1917, xv, 819.
3. Behrend. *N. York M. J.*, 1920, cxii, 409.
4. Bevan. *Tr. Am. Urol. Ass.*, iii, 397.
5. Blanchard and Parker. *Am. J. Orthop. Surg.*, 1915–16, xiii, 250.
6. Brooke. *Habneman. Montb.*, Phila., 1917, lii, 531.
7. Bullard. *N. York M. J.*, 1921, cxiii, 142.
8. Byran. *Surg., Gynec. & Obst.*, Feb., 1911.
9. Cooley. *Illinois M. J.*, Chicago, 1920, xxxvii, 195.
10. Crossen. Diseases of Women, St. Louis, 1922, p. 195.
11. Dameshek. *Boston M. & S. J.*, 1922, clxxxvii, 830.
12. Davis. *Am. J. Orthop. Surg.*, Bost., 1917, xv, 803.
13. Epstein. *Med. Rec.*, 1921, xcix, 734.
14. Fassett. *Am. J. Orthop. Surg.*, Bost., 1917, xv, 826.
15. Gellhorn. Gynecological and Obstetrical Monographs. New York-London, 1923.
16. Goldthwait and Osgood. *Boston M. & S. J.*, 1905, Nos. 21 and 22.
17. Graves. *Am. J. Orthop. Surg.*, Bost., 1917, xv, 807.
18. Henneberg. *Gynécologie et Obstétrique*, viii, No. 2, 1922.
19. Henniger. *Am. J. Orthop. Surg.*, 1917, xv, 814.
20. Hunner. *N. York M. J.*, 1916, civ, 5.
21. Hutchins. *J. A. M. A.*, Sept. 23, 1916, lxvii, No. 13.
22. Kosmak. *N. York M. J.*, 1915, cii, 589.
23. Knox. *Texas State J. M.*, Fort Worth, 1921–22, xvii, 355.
24. Kuth. *J. Bone & Joint Surg.*, Bost., 1922, iv, 357.
25. Lavieri. *Illinois M. J.*, Chicago, 1919, xxxvi, 197.
26. Lynch. *Am. J. Obst. & Gynec.*, iv, No. 4, Oct., 1922.
27. Ludloff. *Fortschr. a. d. Geb. d. Röntgenstrahlen.*, ix and xi.
28. Marshall. *Boston M. & S. J.*, 1916, clxxiv, 591.
29. O'Ferrall. *J. Bone & Joint Surg.*, Bost., 1922, iv, 384.
30. Ogilvy. *N. York M. J.*, 1914, c, 1107.
31. O'Reilly. *J. Orthop. Surg.*, 1921, iii, 171.
32. Osgood. *Tr. Am. Ass. Genito-Urin. Surg.*, ii, 283.
33. Paul, W. E. Boston. Views submitted personally.
34. Peacock. *Northwest Med.*, Seattle, 1922, xxi, 12.
35. Phaneuf, L. E. Boston. Views submitted personally.
36. Platt. *Med. Chron.*, Manchester, 1914–15, lx, 80.
37. Proust. *Gynécologie et Obstétrique*, viii, No. 2, 1922.
38. Reynolds and Lovett. *J. A. M. A.*, Mar. 26, 1910, liv, No. 13.
39. Roberts. *N. York State J. M.*, N. Y., 1919, xix, 18.
40. Rosenbeck. *N. York M. J.*, 1921, cxiii, 138.
41. Rubin. Gynecological and Obstetrical Monographs. New York-London, 1923.
42. Rugh. In discussion of Blanchard and Parker's paper. *Am. J. Orthop. Surg.*, Phila., 1915–16, xiii, 260.
43. Scheede. *Fortschr. a. d. Geb. d. Röntgenstrahlen*, xvii, 255.
44. Sever. *Boston M. & S. J.*, 1918, clxxviii, 323.
45. Smith, George Gilbert. Boston. Views submitted personally.
46. Van Zwaluwenburg. *J. Mich. M. Soc.*, Grand Rapids, 1916, xv, 428.
47. Woodbury. *N. York State J. M.*, N. Y., 1919, xix, 18.
48. Young, Geraghty and Stevens. *Johns Hopkins Hosp. Rep.*, Balt., 1906, xiii, 271.

Paul B. Hoeber, Inc., 67–69 East 59th Street, New York

WE 7 qM117c

35830140R

NLM 05174767 1

NATIONAL LIBRARY OF MEDICINE