
NATIONAL LIBRARY OF MEDICINE
NLM 00555187 3

SURGEON GENERAL'S OFFICE
LIBRARY.
ANNEX
Section,
No. 167138.
3—1639

A TEXT-BOOK ON SURGERY

GENERAL, OPERATIVE, AND MECHANICAL

BY

JOHN A. WYETH, M. D.

Professor of Surgery in and President of the Faculty of the New York Polyclinic Medical School and Hospital; late Surgeon to Mount Sinai Hospital and Consulting Surgeon to St. Elizabeth's Hospital; Member of the New York Pathological Society; of the New York Surgical Society; of the Academy of Medicine; of the New York State Medical Association; of the New York County Medical Association; Honorary Member of the Texas State Medical Association; of the College of Physicians and Surgeons of Little Rock, Arkansas

THIRD EDITION, REVISED AND ENLARGED

LIBRARY
SURGEON GENERAL'S OFFICE
SEP.-23.-1899
167138

NEW YORK
D. APPLETON AND COMPANY

WO
W979t
1897

Copyright, 1887, 1890, 1897,
By D. Appleton and Company.

To the Memory of his Friend,

J. MARION SIMS, M. D.,

WHOSE BRILLIANT ACHIEVEMENTS CARRIED

THE FAME OF AMERICAN SURGERY

THROUGHOUT THE CIVILIZED WORLD,

THIS BOOK IS AFFECTIONATELY DEDICATED

BY THE AUTHOR.

PREFACE TO THE THIRD EDITION.

The original edition of this work was published in 1886. It was revised and enlarged in a second edition in 1890. Within the period of seven years to this date (November, 1897) so many important advances have been made in surgical science and the operative technique that the author has found it necessary again to revise and practically rewrite this volume. To add all that was new and acceptable to that which experience had already demonstrated to be useful has of necessity increased the number of pages and size of the book. By careful elimination of matter which could with least disadvantage be left out, this volume, however, only exceeds the former by one hundred and twelve pages.

It has been the author's aim to retain those features of the original work which made it available to the busy practitioner for quick and ready reference, and to add to this edition some elementary pages which may commend it to teachers for their undergraduate pupils. With this end in view the matter has in great part been rearranged.

The introductory section is devoted to surgical pathology, subdivided into six chapters. These chapters treat of inflammation and the process of repair in the various tissues of the body, and the differences in repair in a tissue affected with simple or non-infective and infective (or suppurative) inflammation. Specific and non-specific urethritis, erysipelas, actinomycosis, glanders, tetanus, malignant œdema, hydrophobia, tuberculosis, syphilis, leprosy, diphtheria, and typhoid infection are also embraced in this portion of the work.

Chapters VII and VIII are devoted to surgical dressings, sterilization, asepsis and antisepsis, and anæsthesia.

In Chapters IX and X are given hæmorrhage, wounds, burns, skin grafting, frostbite, furuncle, carbuncle, ulcers, and gangrene. Bandaging is given in Chapter XI, and Chapter XII is devoted entirely to amputations.

Chapters XIII, XIV, and XV deal with the lymphatic vessels and glands, veins, arteries, aneurism, and ligation of the vessels.

In Chapters XVI and XVII are given the lesions of the bones and joints, and the various operative measures for their correction.

The Chapters from XVIII to XXIX inclusive are devoted to regional surgery, and in that portion of this section in which the abdomen is considered many important changes have been made and much new matter added. Chapter XXX takes up deformities and their correction, while the final chapter (XXXI) is devoted to the subject of tumors.

To his former associate, Dr. J. A. Bodine, late Adjunct Professor of Surgery in the New York Polyclinic Medical School and Hospital (now resident in San Antonio, Texas), and to his present assistant, Dr. J. Shelton Horsley, the author is greatly indebted for the index.

In the article on Refraction he gratefully acknowledges the work of his friend and colleague Prof. David Webster; and for many valuable suggestions in the chapter devoted to the surgical lesions of the female genital organs he is deeply indebted to the enthusiastic and able Professor of Gynæcology, Dr. W. R. Pryor.

With great liberality the publishers have placed no restrictions upon the work, as attested by the numerous and costly illustrations, there being in all nine hundred and thirty-eight, of which about two hundred new engravings have been added to this edition.

THE AUTHOR.

PREFACE TO THE SECOND EDITION.

In revising this work scarcely a chapter remains untouched. While some are not materially altered, others are practically re-written. In the chapter on Inflammation is embodied the latest accepted ideas of surgical septicæmia. The article on the Eye is new, and, in addition to the surgery of this organ, includes the study of Refraction, and the application of glasses in correcting errors in the visual apparatus. The most recent and approved methods of dealing with lesions of the abdominal viscera—viz., intestinal anastomosis, exsection of a portion of the alimentary canal, procedures for the radical cure of herniæ, cholecystotomy, etc.—have been added to the text. A new chapter on the Surgery of the Genito-Urinary Organs of Females is inserted. Supra-pubic cystotomy for stone or tumor of the bladder is given a prominence not hitherto accorded so valuable a procedure; and scarcely less useful are the plastic operations for the cure of urinary fistulæ. In the department of Diseases of the Rectum and Anus the latest methods of surgical interference are considered.

The author acknowledges gratefully the assistance received from his friends, Prof. David Webster, in the article on Refraction, and Dr. W. W. Van Arsdale, who is wholly responsible for the greatly improved index.

The drawings for many of the new cuts were done by Dr. Henry Macdonald, of New York city, whose thorough work is well attested.

The Author.

PREFACE TO THE FIRST EDITION.

The author has endeavored to give in the following pages the accepted facts in surgical pathology and diagnosis, together with the methods of treatment which modern surgery has introduced, or has elected as worthy of continued application from the practice and teaching of the past. In the effort to condense into a single volume, of about eight hundred pages, the essentials of the science and art of surgery, not only is a discussion of theories out of the question, but many measures of treatment—the comparative usefulness of which has been demonstrated—must of necessity be omitted.

In an age when books upon this subject are plentiful, this work was undertaken not without misgivings, yet with a determination to leave nothing undone which would add to its usefulness and make it an exponent of modern and progressive surgery. Such rapid advances are being made, that marvelous results are to-day achieved by measures unknown to the profession but a few months earlier. The introduction of *cocaine hydrochlorate* as a local anæsthetic marks an epoch in surgical practice; and yet this wonderful agent has scarcely been mentioned in works on surgery. Again, the *antiseptic method* of treating wounds, originated within the last few years, has brought with it such protection to life and usefulness, that it deserves a more thorough consideration than is often allotted it by surgical writers, and should be universally accepted and practiced.

The author believed that the general profession was not sufficiently impressed with the dangers in delaying surgical interference in lesions of the cavities and their viscera, notably the cranium, abdomen, and pelvis. These, and other considerations which will be found in the text, were among the reasons which led him to hope that this book

would prove acceptable to his fellow-workers, and especially to that numerous class of physicians who are compelled to do a general practice, and who can find neither time nor opportunity to select from the vast quantity of surgical literature the facts essential to the prompt and successful management of their cases. That this hope was not without foundation is attested by the reception accorded to the work by the medical press, and by the necessity of a second issue within three months after its publication.

To the many sources from which much needed help in its compilation and illustration was obtained—however accredited in the text—the author desires to acknowledge an especial indebtedness, and to the engravers, Messrs. H. Senior and Company, for the general excellence and prompt execution of their work. An examination of the volume will attest the liberality of the publishers, who have contributed greatly to its success.

THE AUTHOR.

April 20, 1887.

A TEXT-BOOK ON SURGERY.

SURGICAL PATHOLOGY.

CHAPTER I.

INFLAMMATION AND THE PROCESS OF REPAIR IN THE TISSUES.

Inflammation.—Inflammation, from *inflammo*, "to set on fire," is a disturbance of nutrition in the tissues of a part of the body, characterized by prolonged hyperæmia, the emigration of leucocytes through the vessel walls (diapedesis), the transudation of plasma and lymph, and general cell proliferation in the area involved. Inflammation may be *non-infective* or *infective*.

In *non-infective* inflammation the changes involved in the process of repair or regeneration so nearly resemble the phenomena of embryonic development that the term "physiological inflammation" is almost permissible; on the other hand, in *infective* inflammation, which is caused by bacterial invasion, the changes are so rapidly destructive as to suggest the name of "pathological inflammation."

The grosser symptoms—*heat*, *redness*, *swelling*, *pain*, and *loss of function**—while always present in the inflammatory process, do not strictly belong in this definition, since one or more of these symptoms are present in non-inflammatory conditions. Thus, vascular tumors, such as nævi (angeiomata), although characterized by permanent hyperæmia and *redness*, are not inflammatory. Blushing, associated with certain emotions, is accompanied by *redness*, which is a physiological condition. Persistent, *active* hyperæmia occurring after injury of the sympathetic nerves may be accompanied by *redness* and *swelling* without inflammation. *Passive* hyperæmia, which is due to interference with the return of blood through the veins or the flow of lymph through the lymphatics, causes œdema or swelling, which is also non-inflammatory. Again, the temperature of the blood in some portions of the body, as in the hepatic vein, in strictly physiological conditions, has been registered as high as 107° F. (41·6+° C.), and this extraordinary *heat* is not inflammatory. Finally, *pain* is not infrequent, as in neuralgia, where all other symptoms of inflammation are absent.

* *Calor, rubor, tumor, dolor et functio læsa.*

While the phenomena of inflammation are in general common to all the tissues, there are some variations by reason of structure, as in bone, which is only slightly expansile, and in cartilage and the cornea, in which no blood vessels exist.

Non-infective or Simple Inflammation.—In an animal body in which the processes of nutrition are normal the tendency in the tissues which

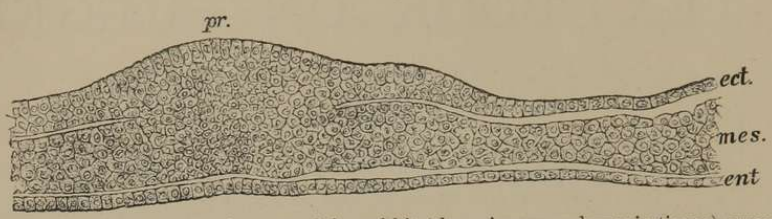

Fig. 1.—Karyokinesis of the fecundated ovum of the rabbit (the primary embryonic tissue) arranged in three layers—the ectoderm, mesoderm, and entoderm. At *pr.* the ectoderm and mesoderm have fused together. (Kölliker and Quain).

are the seat of inflammation or local disturbance of nutrition (there being, of course, no bacterial invasion) is rapidly to restore the original condition of these tissues, and since physiological repair is so closely analogous to physiological growth, the student must bear in mind the normal development of the tissues. The fecundated ovum of the parent is a typical cell, which, by the process of primary division of the nucleus (karyokinesis) * indefinitely repeated, develops myriads of protoplasmic cells which compose the primary embryonic tissue, the *blastoderm*. These cells arrange themselves in three groups or layers—the outer, or *ectoderm*, the *mesoderm*, and the *entoderm*. The ectoderm, by continuous proliferation, is developed into the epithelia of the skin, buccal cavity, the epithelia of the organs of sense, of the ventricles of the brain, the canal of the spinal cord, and forms the nervous tissues. The entoderm, excepting the buccal cavity, forms the epithelia of the alimentary canal and the glands in connection with it. The mesoderm forms the renal epithelia and the epithelia of the vessels and serous surfaces, and all connective tissue, cartilage, bone, muscle, tendon, ligament, etc. (Quain).

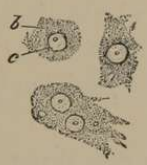

Fig. 2.—Three cells from the early embryo of the cat (highly magnified). *b*, protoplasm; *c*, nucleus with nucleolus; the lower one a double nucleated cell. (After Sharpey and Quain.)

In the normal processes of waste and repair, as epithelia or connective-tissue cells are worn out and disappear, new cells are proliferated by the parent stock to replace them. Epithelial cells by karyokinesis reproduce their kind, and in like manner the connective-tissue group reproduce connective tissue. In simple inflammation from the embryonic tissue which is the common product of the proliferation of all the fixed or resident cells in the area involved, the destroyed cells are replaced by new cells by proliferation of their parent stock, just as a grain of wheat produces wheat.

The ordinary phenomena of non-infective inflammation are as follows: As a result of injury without bacterial invasion there is a *spas-*

* From χαρυον, nucleus, and χινησις, movement.

modic contraction of the terminal arterioles, the capillaries, and venules in the injured area, followed almost instantly by dilatation of these vessels far beyond their normal caliber. The volume of blood is at once greatly increased to fill the enlarged channels, and the current is more rapid, since capillary resistance is less. After the lapse of about one hour the current begins to slacken and gradually becomes slower than before the injury. This slowing of the current is not due to recontraction of the vessels, but to a clogging of their channels with the corpuscular elements of the blood. The red blood-corpuscles and the plaques * floating in the plasma occupy the center of the vessels, while the white corpuscles (leucocytes), which normally exist in the blood in the proportion of from 1 to 1,000 to 1 to 250 of the red corpuscles, are largely increased and are seen to adhere to the vessel walls (Fig. 3). Since the force of the current is greatest in the arterioles and least in the venules (which have the capillaries between them and the heart to retard the circulation), the leucocytes can not adhere to the lining membrane of the arterioles; a considerable number are seen attached to the capillaries, while the venules are practically choked with them, and it is through the walls of the venules that they emigrate (diapedesis, *διαπηδᾶν*, to ooze through) and wander into the intervascular spaces (Fig. 3.) Some few pass through the capillaries, but none have been observed to escape through the walls of the arterioles. The leucocyte, which has the power of changing its form (Fig. 10), pushes through the line of union of the flat epithelium which composes the wall of the venule, displacing the cement substance, and finally emerging at the outer side of the vessel, which by its elasticity at once closes the aperture of escape. Coincident with the clogging of the venules and the emigration of the leucocytes, by reason of the force of the heart's action, the plasma oozes

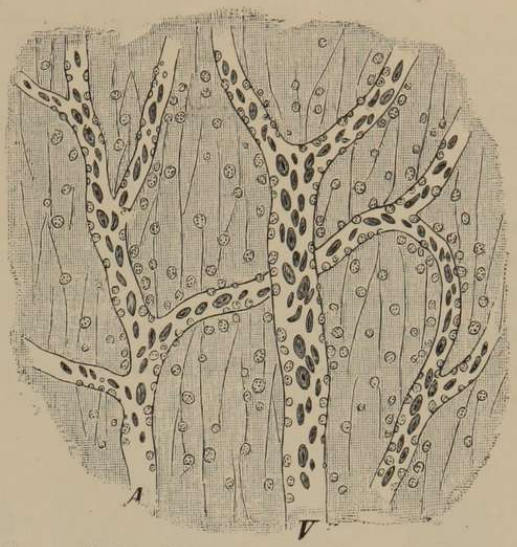

Fig. 3.—Inflamed mesentery of a frog. *V*, vein; *A*, small artery and capillaries. The red corpuscles are seen in the center of the current; the white blood-corpuscles creep along their inner walls, some being in the process of emigration; the surrounding tissues contain many of these which have already emigrated from the vessels. (Tillmann.)

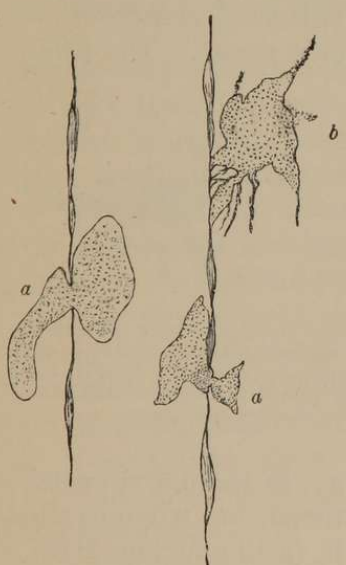

Fig. 4.—Diapedesis or emigration of leucocytes through the walls of a venule. *a*, incomplete, *b*, complete emigration (schematic). (Tillmann.)

* The plaques or "third corpuscles" of the blood measure from 1·3 to 3·5 micromillimetres in diameter, and are supposed to be embryonic red blood-corpuscles. They consist of a colorless pro-

through the walls of the blood vessels, producing *active* œdema, and a little later pressure on the lymphatic vessels by the mass of newly formed

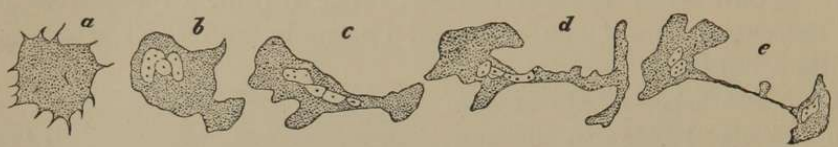

Fig. 5.—A white corpuscle or leucocyte of the newt's blood with three nuclei. *a*—*e*, successive forms assumed at intervals of a few minutes. (After Klein and Quain.)

cells causes a transudation of lymph—*passive* œdema—which, mingling with the escaped plasma, coagulates outside the vessels. In some instances red blood-corpuscles and plaques may also escape in the wake of the emigrating leucocytes without vascular rupture and produce slight discoloration due to the decomposition of *hæmatin*, the coloring matter of the red disk. *Ecchymosis*, however, is usually caused by rupture of the vessels, with free extravasation, and the formation of blood clot which is invaded by and probably serves as food for the proliferating cells. The appearance of the escaped leucocytes in the tissues is marked by a sudden activity in the various protoplasmic elements of the area involved. Every normal cell in the zone of irritation takes part in this activity of proliferation; but since the connective-tissue cells largely predominate, they have attracted the greatest attention of observers and furnish as well the greater portion of the embryonic tissue. The protoplasm of the fixed or resident cell increases in size, and the nucleus undergoes remarkable changes (Fig. 8). The connective-tissue cell (Fig. 7) consists of a minute particle of protoplasm in the center of which is a nucleus. The nucleus is made up of a network of nucleoli and thread-like bodies which are readily stained and has an investing membrane of its own. In the normal condition of the tissues the fixed cell is somewhat flattened, but when excited to proliferation it rapidly swells and the threads in the nucleus form a thicker network, soon followed by an hour-glass contraction of these thickened threads * (karyomitosis), near the center of the nucleus, where

Fig. 6.—White corpuscles or leucocytes treated with water and with acetic acid. 1, first effect of the action of water upon a white blood-corpuscle; 2, 3, white corpuscles treated with dilute acetic acid; *n*, nucleus.

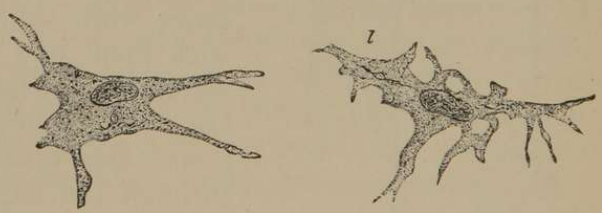

Fig. 7.—Two connective-tissue corpuscles from the subcutaneous connective tissue, highly magnified. The dark streak below *l*, in the right-hand corpuscle, is a lamella which happens to be projecting toward the observer, and is seen in optical section. (After Sharpey and Quain.)

toplasm, and are present in the proportion of about 1 to 20 of the red disks. A micron, or micromillimetre, is $\frac{1}{25000}$ of an inch. The Greek character μ will be used to denote a micromillimetre.

* Karyomitosis, from χαρυον, *nucleus*, and μιτος, *thread*. This term is applied to the increased size and changes in the *threadlike* contents of the nucleus.

it rapidly divides in two, the thin capsular membrane closing in and surrounding each new, as it did the parent nucleus (Fig. 8). The main body of the cell may now divide and form two new cells, each with a single nucleus, or the protoplasm may simply enlarge without division, the nuclei dividing indefinitely within the cell. In this way the polynucleated or "giant cells" are formed (Fig. 20).

It is now held that all cell proliferation takes place by this process of *karyokinesis*, or primary division in the nucleus. The dilatation of the blood vessels, with the increased supply in the part, the escape of leucocytes, plasma, and lymph, and the enormous cell proliferation, cause the *heat*, *redness*, *swelling*, and *pain* of inflammation, together with the *loss of function* in the part, as well as a partial or complete stoppage (*stasis*) of the circulation in the inflamed area. Stasis is always more pronounced at the center of the disturbed zone, and here the discoloration is deeper, gradually diminishing toward the periphery. The sudden contraction and immediate dilatation of the vessels is due to a

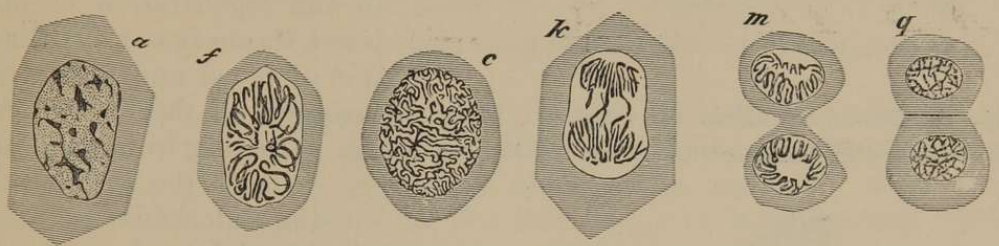

Fig. 8.—Karyokinesis in the cells of salamander larva. *a*, cell in rest, showing parts of the nuclear network colored black; the remaining portion of the nucleus is the nuclear matrix; *c*, nucleus transformed into closely contorted filaments; *f*, filaments converging toward the center with commencing separation into an upper and a lower portion; *k*, separation more advanced; *m*, a further step in the process in which the perinuclear protoplasm is taking part; *q*, two cells, the product of karyokinesis, the nuclear network again assuming the cell in repose. (After Flemming and Quain.)

momentary irritation of the vaso-motor nerves and the paralysis which follows their injury. It is difficult to explain just why the leucocytes appear in such large numbers at the seat of inflammation. It is claimed that they are attracted there by some chemical change in the parts involved, and this is termed *chemiotaxis*.* It was formerly taught that the leucocytes not only stimulated proliferation in the cells of a part, but that they themselves underwent proliferation and aided in the formation of the common embryonic tissue; but this is now disclaimed, and more recent observers assert that they have no function beyond the stimulation of the fixed cells, and that they are taken up as food by the proliferating embryonic tissue, while some of them re-enter the vessels and again take their place in the circulation. When infection occurs they are found in large numbers, forming *pus corpuscles* and floating in the *pus serum*.

In *non-infective* inflammation the process of repair begins within a few hours after the injury. The phenomena of regeneration are practically identical in all vascular soft tissues. In bone, by reason of the

* The property living cells exhibit, with reference to non-living organic material, by virtue of which they approach or recede from certain substances. In *positive* chemiotaxis the cell approaches, in *negative* it is repelled (Sternberg).

dense structure which surrounds the vessels and medulla, and in the two non-vascular structures, the cornea and cartilage, the process differs somewhat and will be specially studied. In infective inflammation the destruction of tissue is much greater, the process of repair is slower, and regeneration is always imperfect. Chemical and mechanical destruction of the tissues is always followed by the formation of a fibrillated connective tissue, producing a scar or *cicatrix.*

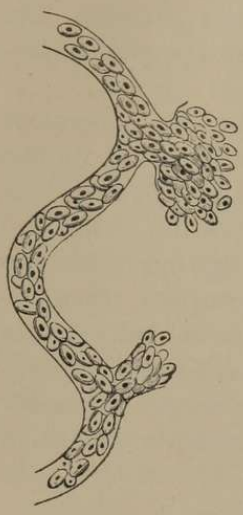

Fig. 9.—(After Paget.)

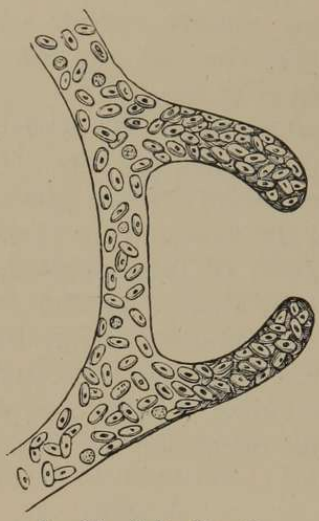

Fig. 10.—(After Paget.)

The most important step in the regeneration of injured tissue is the distribution of blood and nutrition by the new formation of vessels. From the stumps of the divided or occluded capillaries, buds (Fig. 9) of protoplasm, springing from the new cells of the proliferating endothelia, are projected into the mass of embryonic cells. Some of these meet and fuse with similar buds projecting from opposing surfaces of the inflamed area, or at times two

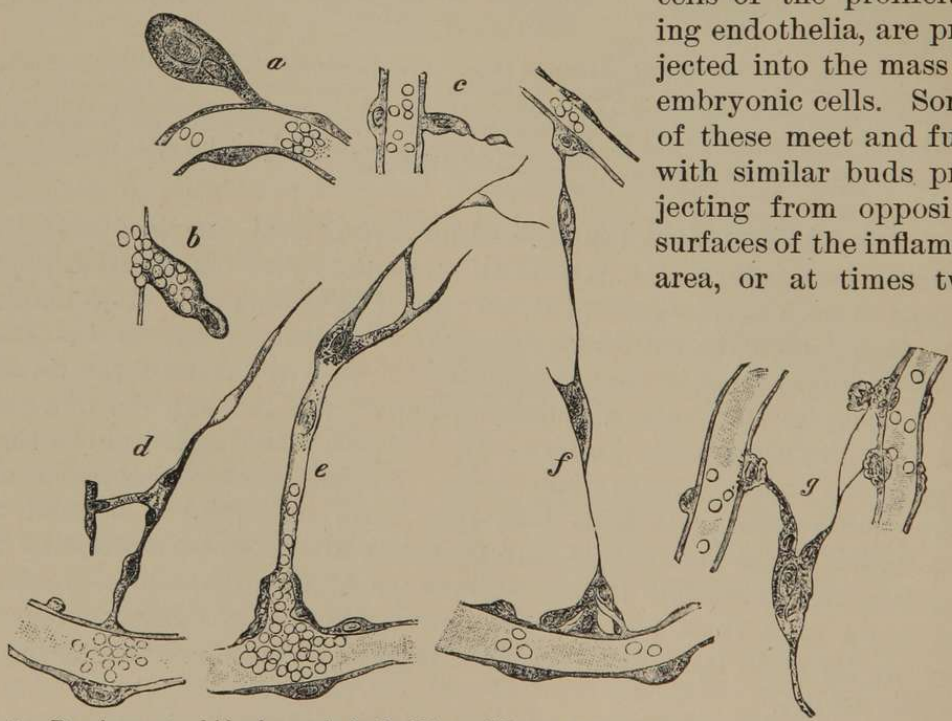

Fig. 11.—Development of blood vessels by budding; different forms of buds. *a*, *b*, *c*, first stages; *d*, *f*, *g*, simple and branching solid buds; *e*, vascular bud which is being made hollow and which already contains blood-corpuscles. (After Tillmann.)

buds from the same surface unite to form a capillary loop (Fig. 10). Some of these embryonic vascular buds begin as tubules, communicating with the vessels (*e* Fig. 11), while others are more solid prolongations of

protoplasm not yet canalized (*d* Fig. 11). According to Ranvier, the centers of these undergo liquefaction, and thus becoming cannulated, they ultimately communicate at their extremities and become continuous with the vessels from which they spring. The cells of the embryonic tissue immediately in contact with the new canals aid in forming the walls of the newly made vessels. When hæmorrhage has occurred, the *coagulum* is rapidly infiltrated with the new cells and disappears after a vari-



Fig. 12.—Steps in the fibrillation of connective-tissue cells. (After Paget.)

able time, either undergoing granular metamorphosis or is taken up as nourishment by the proliferating cells. Even in aseptic inflammation many of the capillaries and vessels disappear as the result of the contraction which takes place in the final stage of inflammation. This formation of connective tissue (Fig. 12) in septic inflammation is so much more extensive that occlusion of the newly formed capillaries is often complete, giving the peculiar bleached appearance to cicatrical tissue.

In the *skin* the repair in the deeper layers of the cuticle is carried on by the proliferating prickle cells and the elongated and granular cells of Langerhans, while in the corium the embryonic tissue springing from the fixed connective-tissue cells develops into a new connective tissue.

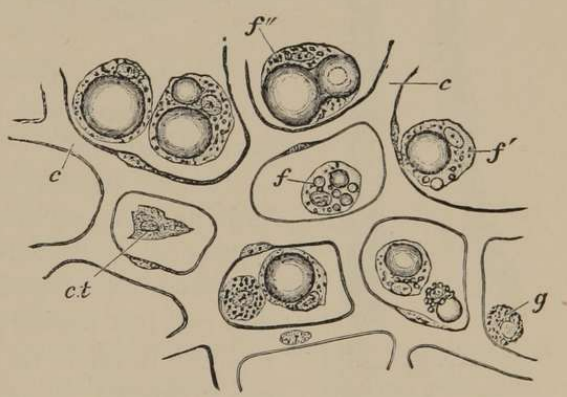

Fig. 13.—Deposition of fat in connective-tissue cells (adipose tissue). *f*, a cell with a few isolated fat droplets in its protoplasm; *f'*, a cell with a single large and several minute drops; *f''*, fusion of two large drops; *g*, granular cell, not yet exhibiting any fat deposition; *c t*, fat connective-tissue corpuscle; *c*, *c*, network of capillaries. (After Sharpey and Quain.)

In *adipose* tissue the fat vesicles, when ruptured, allow the escape of their contents, which disappears by granular metamorphosis. The nucleus of the capsule enters into the general cell proliferation, the capsule itself being originally a connective-tissue cell. As the inflammatory process subsides, fat droplets again appear in certain of the new embryonic cells which are gradually distended and form new fat vesicles (Fig. 13).

In the regeneration of *muscle* the process is somewhat analogous to

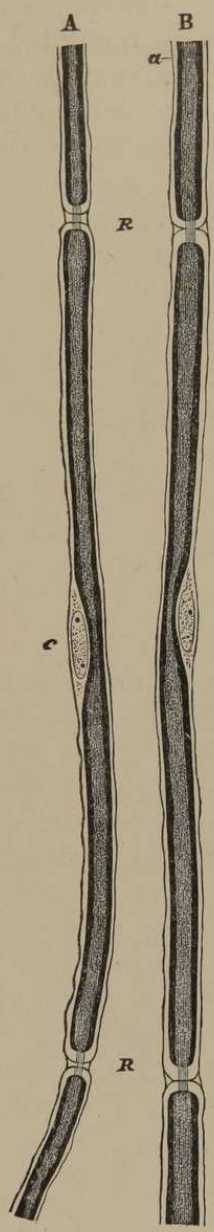

Fig. 15.—Portions of two nerve fibers stained with osmic acid (from a young rabbit). 425 diameters. R,R, nodes of Ranvier, with axis cylinder passing through; *a*, primitive sheath of the nerve; *c*, opposite the middle of the segment indicates the nucleus and protoplasm lying between the primitive sheath and the medullary sheath. In A the nodes are wider, and the intersegmental substance more apparent than in B. (From a drawing by Mr. J. E. Neale, after Sharpey and Quain.)

the budding in new forming capillaries. From the ends of the muscular fibers, which are infiltrated with embryonic cells (to the formation of which the muscle cells or *sarcoblasts* and the connective-tissue cells of the perimysium contribute), protoplasmic swellings or buds, which are rich in nuclei, are projected. By division of the nuclei (practically analogous to the formation of muscle plates from the mesoderm in the embryo) the new fiber is constructed, meeting and becoming continuous with the buds from the opposing surface. These formative cells arrange themselves in elongated or fusiform shape, in which, later on, fine longitudinal striæ are seen. The transverse striæ appear about the twenty-first day. Muscle has not the reproductive power of other tissue, and when the injury is extensive, or when infection or suppuration occurs, the lost substance is replaced by fibrillated, connective, or cica-

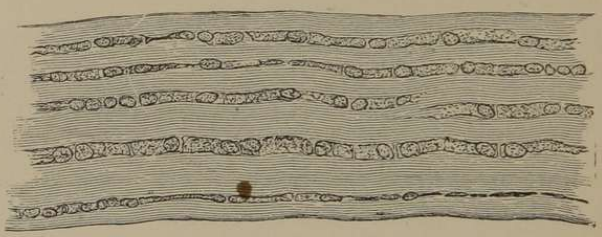

Fig. 14.—Tendon of mouse's tail, showing chains of cells between the tendon bundles; 175 diameters. (After Sharpey and Quain.)

tricial tissue. Even when new fibers are produced, their arrangement is not so symmetrical as in the normal muscle.

In the regeneration of *tendon*, the tendon cells and the connective-tissue cells of the sheaths are the agents of proliferation and repair in inflammation as well as after surgical or accidental division. A tendon cell is a fusiform body of protoplasm containing a single nucleus in which are several nucleoli. They are arranged in rows between the layers of fibers. From these rows tendon buds are projected, which, growing longer, become fibrillated and arrange themselves in parallel layers, interlocking with the growing fibers or buds from the opposite side.

The process of repair in inflammation or injury of the *ligaments* is practically identical with that of tendons and need not be separately considered.

In *nerves*, in exceptional cases, the repair or reunion takes place soon after extensive injury, with the resumption of function. As a rule, however, restoration of function takes place very slowly. The

essential element of conduction is the *axis cylinder* (Fig. 15). In some nerves and at points in many nerve strands the outer sheath (nucleated sheath of Schwann) and the medullary sheath (white substance of Schwann) are absent, the axis cylinder alone being present. This axis cylinder is the greatly elongated branch of a central nerve cell (Fig. 16). When destroyed by inflammation or by traumatism, that portion of the axis cylinder on the peripheral side of the lesion undergoes destructive metamorphosis, and the function of the nerve can not be restored until the central end of the axial band buds out and is prolonged throughout the nerve to replace the cylinders which have been destroyed. In two or three weeks after the lesion, pale, delicate processes are seen budding out from the axis cylinders of the central end into the inflammatory embryonic tissue. This process of budding is only from the central end of the divided nerve, and differs from that in the regeneration of capillaries, tendons, and muscle, in which the budding is from both the proximal and distal ends. (Bügner claims that the cells in the nucleated sheath, by their proliferation, aid in the restoration of the cylinder, and these he terms *neuroblasts*.)

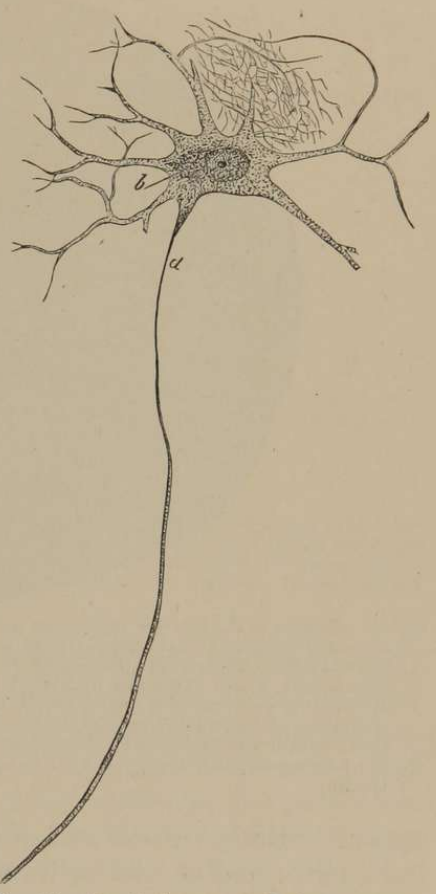

Fig. 16.—Ramified nerve cell from anterior cornu of spinal cord of man. *a*, axis-cylinder process; *b*, clump of pigment granules. Above the cell is seen part of the network of fibrils. (After Gerlach and Quain.)

The slowness with which nerve trunks — the seat of inflammation or injury — resume their function gives weight to the theory which holds that the projection of the axial band is alone from the central and parent nerve cell. As much as twelve months have elapsed after careful, aseptic reunion by suture before any restoration of function was observed in cases in which complete recovery resulted. In no other tissue is the process of repair so slow. It is evident that careful apposition, without unnecessary tension of the sutures, is essential to successful union.

Periosteum and Bone.—Non-infective inflammation of the periosteum causes a rapid proliferation of the connective-tissue cells of the superficial or fibrillated layers of this structure, and of the rich supply of cells, the *osteoblasts*, of the layer nearer the bone. The nerve, blood and lymph vessels, and the contiguous bone must of necessity take part in the process, and when at the seat of injury the fascia or tendon perforates the periosteum to insert their fibrillæ deep into the meshes of the bone, they also contribute something to the production of the embryonic

tissue. From the tenth to the fifteenth day after the injury in adults the cells which have remained soft begin to be infiltrated with calcareous matter (*callus*). From the twentieth to the thirtieth day, under ordinary conditions, this (provisional callus) begins to be absorbed and may dis-

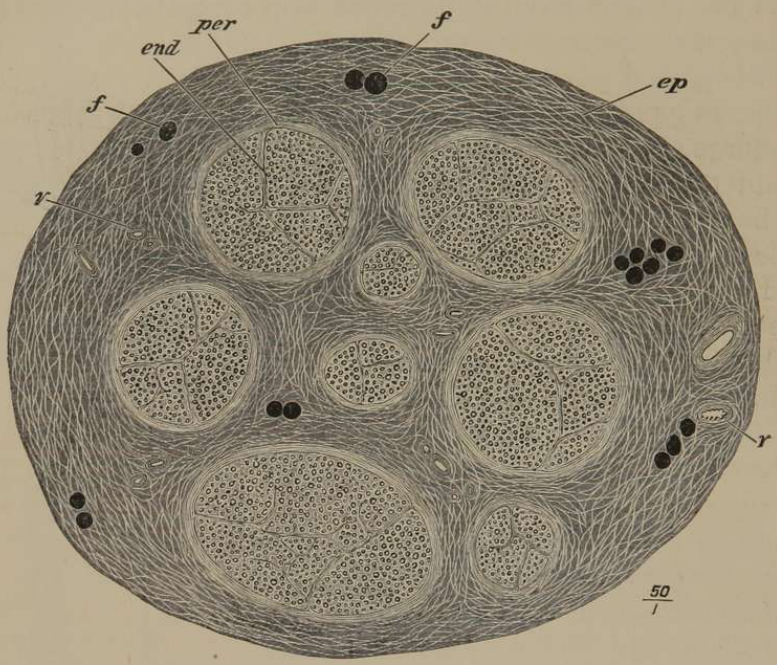

Fig. 17.—Section of the internal saphenous nerve (human), made after being stained in osmic acid and subsequently hardened in alcohol. Drawn as seen under a very low magnifying power. *ep*, epineurium, or general sheath of the nerve, consisting of connective-tissue bundles of variable size, separated by cleft-like areolæ, which appear as a network of clear lines, with here and there fat cells (*f f*) and blood vessels (*v*); *per*, funiculus inclosed in its lamellated connective-tissue sheath (perineurium); *end*, interior of funiculus, showing the cut ends of the medullated nerve fibers, which are imbedded in the connective-tissue within the funiculus (endoneurium). The fat cells and the nerve fibers are darkly stained by the osmic acid, but the connective tissue of the nerve is only slightly stained. (After Sharpey and Quain.)

appear entirely by the end of sixty days. In some instances, however, it in part remains and is transformed permanently into bone to form a *node* or *exostosis*.

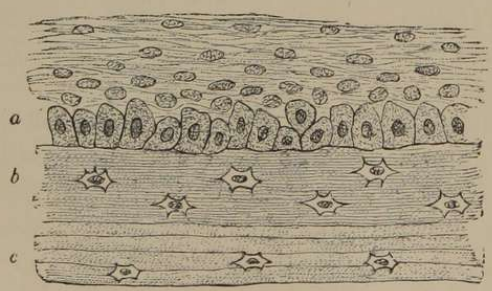

Fig. 18.—Periosteal formation of bone from osteoblasts *a*; *b*, newly formed bone; *c*, old bone. × 300. (After Tillmanns.)

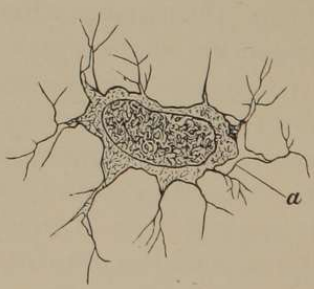

Fig. 19.—A bone cell isolated and highly magnified. *a*, proper wall of the lacuna, shown at a part where the corpuscle has shrunk away from it. (After Joseph and Quain.)

A typical non-infective inflammation of bone is seen in *simple* fracture, the immediate result of which is hæmorrhage from the vessels of the periosteum, the compact substance and medulla, as well as the accidental bleeding from the contiguous soft structures. The coagulum of

blood and lymph covers the broken ends, extends a short distance into the medullary cavity and Haversian canals, pressing back the medulla and infiltrating the space about the point of fracture. Into this clot and throughout the inflamed area the emigrating leucocytes crowd, and all the phenomena of cell proliferation which their presence excites takes place. The periosteal osteoblasts (Fig. 18), the bone corpuscles (Fig. 19) which fill the lacunæ, the "giant cells," or *myeloplaxes* of Robin (very large masses of protoplasm, containing usually many nuclei (Fig. 20, *c*)), or, if only one, this very large, and the common and very much smaller

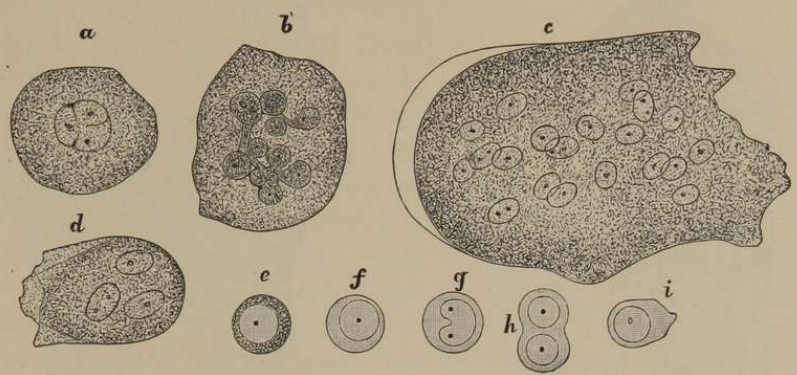

Fig. 20.—Multinuclear cells from bone marrow, highly magnified. *a*, a large cell the nucleus of which appears to be partly divided into three by constriction; *b*, a cell the enlarged nucleus of which shows an appearance of being constricted into a number of smaller nuclei; *c*, a so-called giant cell (myeloplaxes) with many nuclei; *d*, a smaller cell with three nuclei; *e–i*, other cells of the marrow. (After Sharpey and Quain.)

mononuclear cells of the medulla (marrow cells (Fig. 20)) (found not only in the central medulla, but also in the Haversian canals, and possessing the amœboid properties of the leucocytes), all undergo active proliferation. The deeper cells of the periosteum are at first most active and throw out a rich mass of embryonic tissue, which envelops and surrounds the broken ends and by the tenth day begins to be infiltrated with lime salts to form a callus. From the fifteenth to the twentieth day this (Fig. 22) ensheathing callus is complete and holds the fragments immovable while the process of ossification is going on. There forms also about the same time, in the young, a weaker callus from the central medulla cells (pin callus) and from the marrow cells of the Haversian canals—the interosseous callus. In older persons, after about fifty years, it is held that no central or pin callus forms. It is probable that in all cases the chief factor in the regeneration of bone is the *bone corpuscle* (Fig. 19). It is well known that the periosteal cells (osteoblasts (Fig. 18)) will reproduce bone in children and in early adult life, and in inflammation this doubtless assists in the process, but the bulk of their product usually disappears by absorption, as does the medullary callus. In that portion of the embryonic tissue which springs from proliferating bone-corpuscles and usually is interposed between the contiguous surfaces of fractured bone, the cells are transformed into *hyaline* substance, in which *cartilage* cells appear. As in the original development of bone, this cartilage is soon infiltrated by true osteoblastic tissue, forming the osseous lamellæ. In addition to the osteoblasts there appear multinucleated cells (myelo-

plaxes of Robin and osteoclasts of Kölliker) which arrange themselves in rows or circles and cause partial absorption of the osseous substance, giving, according to Sharpey, the festooned appearance to the Haversian

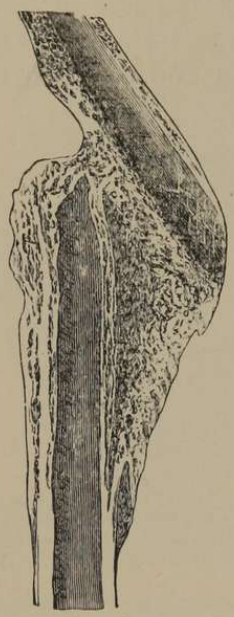

Fig. 21.

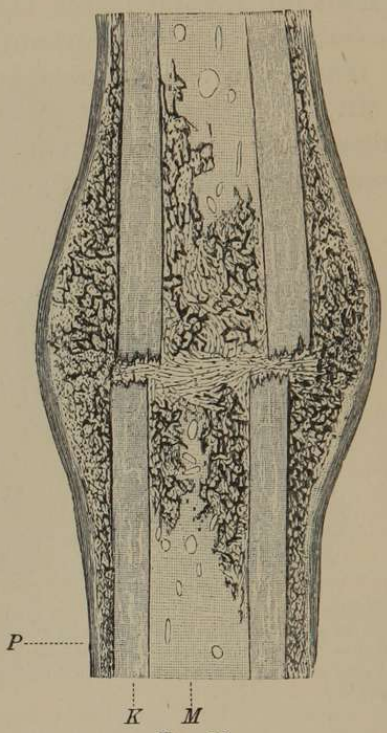

Fig. 22.

Fig. 21.—Fracture healed with deformity (callus luxurians). (After Tillmanns.)
Fig. 22.—Longitudinal section through a fracture of the femur three weeks old. *P*, periosteum; *K*, bone; *M*, medulla. Periosteal callus and medullary callus. The intermediary callus consisting of periosteal granulation tissue, which is ossified only in some places and is partly cartilaginous. (After Tillmanns.)

spaces (Fig. 23). Through these canals, thus produced by absorption, the new-formed vessels make their way.

While the process of repair in bone, as just given, is closely analogous to the formation of bone from the blastoderm—namely, primary formation of cartilage and the replacement of this by osteogenic tissue—this does not always occur. In certain bones of the skeleton (the flat bones of the skull) osteogenesis is not preceded by cartilage formation. In inflammation with loss of substance, when suppuration has occurred, as in an infected compound fracture, embryonic tissue is *directly* converted into bone.

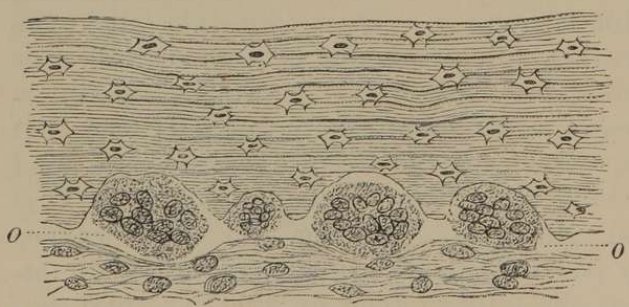

Fig. 23.—Lacunar absorption of bone by osteoclasts (*O*), which lie in Howship's lacunæ. × 250. (After Tillmanns.)

In inflammation of the *cornea* (keratitis) the changes are very much the same as in inflammation of the tissues which possess blood vessels. While the blood does not circulate in the cornea proper, there are certain

channels, called plasma canals, through which plasma and lymph convey nutrition from the blood vessels to the tissues of the cornea. These plasma canals undergo a dilatation in the earlier stage of inflammation analogous to that of the blood vessels in other tissues, and there is also a transudation of the increased fluid between the lamellæ of which the cornea is composed. General proliferation ensues in the corneal corpuscles, which is preceded by emigration of leucocytes from the blood vessels into the plasma canals. The presence of this new embryonic tissue causes opacity or clouding of the cornea. When the inflammatory process continues for a sufficiently long period blood vessels shoot out from the corneal margin into the cornea, projecting their capillary buds along the spaces formerly occupied by plasma canals, and the condition of *pannus* is established. If infection occurs, suppuration soon takes place with the widespread destruction which follows the presence of pus. The development of blood vessels into the inflamed area is a conservative process, in response to the demand for increased nutrition and for removing the inflammatory products which undergo granular metamorphosis. Ultimately these new blood vessels diminish in size and gradually disappear.

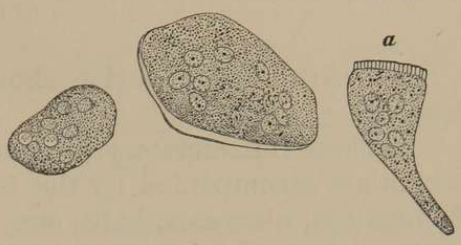

Fig. 24.—Three osteoclasts from absorption surfaces of growing bone. 400 diameters. *a*, with thickened striated border. (After Kölliker and Quain.)

In *cartilage*, inflammation is unlike that which occurs in the cornea, for in cartilage there are no vascular spaces whatever. Nutritive material is absorbed directly by the cartilage cells and hyaline substance from the blood vessels at the point of contact of the cartilage with the bone. In the early stages of chondritis, the cartilage cells are swollen, the nuclei enlarged, the intercellular substance (hyaline) becomes liquified, or, in the milder form, may undergo molecular degeneration. If the inflammation be sufficiently prolonged, blood vessels may be projected into the area involved. Cartilage is a tissue of such low vitality that the process of repair is always slow. While it has not been demonstrated, it is in all probability true that new cartilage cells are produced from the embryonic tissue, the product of the original cartilage cells. When infection by bacterial invasion occurs, the destruction of the tissue is more extensive and the cartilage cells and hyaline substance are generally not reproduced, but are replaced by cicatricial tissue.

CHAPTER II.

INFECTIVE INFLAMMATION, BACTERIOLOGY, SUPPURATION, AND SEPTICÆMIA.

INFECTIVE inflammation should be considered under the following headings:

1. Those inflammatory processes (not involving the mucous surfaces) which are accompanied by the formation of pus—i. e., *suppurative* inflammation, abscesses, boils, etc.

2. Suppurative inflammation of the mucous surfaces, of which gonorrhœa is a type.

3. Non-suppurative inflammatory lesions, as erysipelas, hospital gangrene, anthrax, glanders, tetanus, malignant œdema, foot and mouth disease, hydrophobia, tuberculosis, actinomycosis, syphilis, and leprosy, in none of which pus is formed without *mixed infection.*

4. Non-suppurative lesions of the mucous surfaces, of which diphtheria is a type.

5. Certain lesions of the skin and its appendages, due to the lodgment of micro-organisms or other parasites in the hair follicles or upon or in the substance of the skin.*

Suppuration.—Suppurative inflammation is due to the presence in the tissues of some form or forms of pyogenic (πυον, pus; γενεσις, begetting) micro-organisms. These enter the system usually through an abrasion or wound in the skin or mucous surfaces, but they may effect an entrance through the sebaceous or hair follicles, where no breach or fissure of the skin is discernible, as in furuncles (boils) and carbuncles, or through the broken or unbroken surface of the respiratory and digestive tracts. The presence of these organisms in deep abscesses where no wound exists—as in osteomyelitis, suppurating joints, etc.—proves that they are transported by the blood, and it is very probable that they are frequently present in the blood of every person. When the conditions of nutrition are perfect, or nearly so, these invading germs fail to find food suitable to their life and multiplication, and so perish. This condition is known as the *normal resistance* of the tissues. It implies the definition of the term *health.* If there exists a suitable *nidus* for growth, such as a blood clot, or if the vitality of the individual or any portion of the tissues is low (the normal resistance deficient), septic organisms readily proliferate and carry on destructive warfare.

Surgical pathology accepts the germ causation of disease, and also the presence in the body of living elements of protoplasm, acting not only

* Diseases of the skin do not belong in the category of surgical affections, and will be omitted.

with unmistakable intelligence in the repair of injured tissues, but equally so in resistance to invasion and destruction by organisms which assail from without. Septic inflammation is then a struggle for existence between the defending army of protoplasmic elements, of which our bodies are in great part composed, and the attacking hordes of bacteria, hungry for the food our tissues furnish.

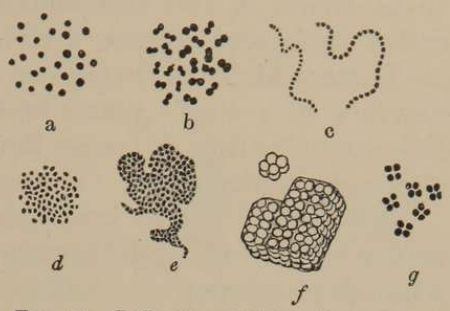

FIG. 25.—Different varieties of cocci. *a*, smaller and larger cocci; *b*, diplococci; *c*, chain coccus (streptococcus); *d*, *e*, clusters of cocci in the form of a bunch of grapes (staphylococci); *f*, sarcina (packet coccus); *g*, micrococcus tetragonus. (After Tillmanns.)

Although in this section we are chiefly concerned with those types of inflammation accompanied with suppuration, it will be convenient, in discussing *pyogenic bacteria*, to refer incidentally to organisms which do not produce pus, and to follow the suppurating lesions with the non-suppurative infectious diseases.

Bacteria.—Bacteria (*bacterium*, *βακτεπιον*, a rod or staff) is a general term applied to all these minute organisms, and the science which treats of them is *bacteriology*. To attempt a classification of pathogenic organisms in the present condition of science would be unsatisfactory. The rapid advances which are being made in bacteriological research will, in the next few years, result in a classification of these organisms which may prove acceptable; but the difference of opinions at this date among men who have made important discoveries and achieved brilliant results in the advancement of surgical and medical science do not justify at present the adoption of any of the proposed classifications.*

Bacteria have been named chiefly by reason of their shape. Those which under the microscope appear like bits of broken rods are called *bacilli*† (*bacillus*, a little stick). The very longest bacilli are sometimes called *leptothrix* or hair-like (λεπτος, slender, *θριξ*, hair). When curvilinear or spiral in outline, *spirilla*‡ (spirillum, a curve). When round

* Sternberg, agreeing practically with Baumgarten, suggests an arrangement in three groups: (1) micrococci; (2) bacilli; (3) spirilla. As *micrococci*, he groups the small cocci which reproduce themselves by *fission* and do not produce *spores*, usually without spontaneous movement; these bodies are nearly spherical, and when segmentation is complete may be found single or in bunches, called staphylococci (from *σταφυλη*, a bunch of grapes). *Ascococcus* (Bilrothii, *ασκος*, pouch, *κοκκυς*, berry). The cocci of this group are associated in globular or lobulated masses, held together by rather firm *intercellular* substances (zoöglœa). *Leuconostoc.*—This coccus is found, solitary or in chains, *surrounded* by a thick gelatinous envelope, forming zoöglœa quite firmly held together; *streptococcus*, associated in chains as a result of division in one direction only; *diplococcus*, when divided into two and remaining for a certain period associated in pairs. *Merismopedia.*—Division in two directions, forming groups of four in a single plane (tetrads). *Sarcina.*—Division in three directions, forming cubes or packets of eight or more elements agglutinated together.

† *Bacilli*, rod-shaped, filamentous (not spiral) organisms, in which there is no differentiation between the extremities of the rod, proliferate by division in a direction transverse to the long axis of the rod or by the formation of endogenous spores; may be rigid or flexible, motile or non-motile.

‡ *Spirilla*, curved rods or spiral filaments, rigid or flexible, motile, rotating in the direction of the long axis of the filaments, proliferate by division into two, or by the formation of endogenous spores. All of the pathogenic bacteria now known belong to one or other of the above-described genera.

or nearly so, they are termed cocci (*κοκκυς*, a berry or kernel). Some of these divide in two and remain attached in a single envelope, and are called *diplococci* (*διπλοος*, double).

Those which divide in two directions, forming fours which adhere together in a single plane in the same gelatinous envelope, are called *tetragonus* or *tetrads* (*τετρα*, four, and *γωνια*, angle), a four-angled or four-cornered arrangement.

When they divide into spherical bodies, which at times cluster together by *surface* agglutination, they are called *staphylococci* (*σταφυλη*, a bunch of grapes).

When they proliferate in one direction indefinitely, like the links of a chain and remain joined together, they are called *streptococci* (*στρεπτος*, a chain).

Adhering in groups or blocks, *zoöglœa* (*ζῶον*, animal, and *γλοιος*, a glutinous substance).

Arranged in cubes, they are *sarcina* (*sarcire*, to arrange in order, as a package or bale).

While bacteria are chiefly of vegetable origin, consisting, when fully developed, of an element of protoplasm, containing albuminous matter, fats, salts, and water, and enveloped in a shell of *cellulose*, recent investigators have described a form, the *mycetozoa* (*μυκης*, fungus), which seems to belong half way between the vegetable and animal kingdoms, and the *protozoa* (*πρῶτος*, first or beginning) (animal), which are considered the very lowest form of animal life.

Fig. 26.

Fig. 27.

Fig. 26—Staphylococcus pyogenes. (Pure culture.) (Modified from Landerer.)
Fig. 27.—Streptococcus pyogenes. (Pure culture.) (Modified from Landerer.)

Bacteria reproduce their kind in two ways: by division (fission) and by spore formation (sporulation).

In fission the parent germ usually becomes elongated, and near its center a pale line may be observed in a direction transverse to the long axis of the germ. This line becomes clearer and clearer until it disappears entirely, and the two products are separated into independent organisms.

In sporulation the protoplasm of the germ seems to condense and harden and inclose usually a single spore. On account of the thickening of the capsule, the spore is able to resist destruction to a greater degree than the parent organism.

Many bacteria are capable of motion while a large group are non-motile. Those that are non-motile (certain of the cocci) are at times seen to sway *en masse*. This molecular motion is also called the "Brownian" movement. Quite recently Ali-Cohen, in two different micrococci, has demonstrated flagella with motion. By a recent method of staining, Loeffler demonstrated flagella—long hairlike fins—on many important pathogenic bacteria. These may be seen at one or both ends, and in some types, as the typhoid bacillus, they grow out in all directions,

not unlike the fiber which adheres to the cotton seed. These flagella are often very long and have a wavy motion (Fig. 30).

Certain forms of bacteria can live without oxygen; they are called *anaërobic*. The greater number require oxygen and are termed *aërobic*, while others (comparable to the amphibious animals) can live with or without oxygen. Those which thrive best in a medium containing oxygen, yet can exist, however stunted, when this gas is absent, are termed *facultative aërobic* bacteria. All bacteria develop best in alkaline media. The rapidity of their proliferation is remarkable. Under favorable conditions a single organism will, within twenty-four hours, by dividing and redividing every hour, produce more than sixteen million of its kind, and they have been known to undergo fission in so short a time as twenty minutes. The presence of moisture is always required for their development, and, as a rule, they develop best where *light* is excluded.

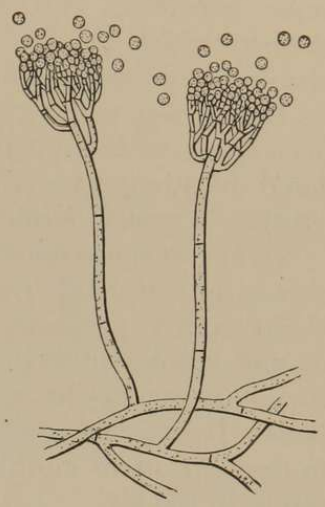

FIG. 28.—Penicillium glaucum. × 500. (Tillmanns.)

Certain of these micro-organisms form coloring matter and are classed as *chromogenic* bacteria. Others produce rapid fermentation, and are called *zymogenic*.

Bacteria which exist outside of the living body in putrefying animal or vegetable matter are called *saprophytes*, while those which dwell in the living tissues are called *parasites*. Some of these organisms, ordinarily saprophytes, but capable of existing within the living body, are called *facultative parasites*.

Bacteria which possess the faculty of liquefying the tissues with which they come in contact produce pus and are called *pyogenic bacteria*.

The principal pathogenic bacteria of surgical interest are: Staphylococcus pyogenes aureus, epidermidis albus, citreus, fluorescens, cereus, flavus; micrococcus pyogenes tenuis, gonococcus, micrococcus tetragonus, micrococcus lanceolatus; streptococcus erysipelatis (Fehleisen), streptococcus pyogenes; bacillus pyocyaneus and pyofluorescens, bacillus ruber and fœtidus, bacillus coli communis, bacillus tetani, anthracis, syphilis, tuberculosis, mallei, lepræ, typhi abdominalis, diphtheriæ.*

As yet little is known concerning the *mycetozoa* and *protozoa*. The former, sometimes called *myxomycetes*, are not distinctly animal or plant, but seem to be nearer to the *amœbæ*, the lowest form of animal life, than to *bacteria*, the most elementary plants. As *protozoa* are classed the following: Plasmodium malariæ, the germ of molluscum

* Sternberg gives the thermal death point in streaming steam of the more important organisms as far as known as follows: S. p. aureus, 58° C. = 136·4° F.; citreus and albus, 62° C. = 143·6° F.; m. tetragonus, 58° C. = 136·4° F.; streptococcus pyogenes, 54° C. = 129·2° F.; s. lanceolatus, 56° C. = 132·8° F.; b. typhi, 56° C. = 132·8° F.; anthrax, 54° C. = 129·2° F.; malleus, 55° C. = 131° F.; diphtheria, 60° C. = 140° F.; gonococcus and hydrophobia, each 60° C. = 140° F.; tuberculosis, 70° C. = 158° F.; all spores, 100° C. = 212° F.

contagiosum, and a peculiar amœbic organism found in the discharges of dysentery (Tillmanns). The fungi or molds—viz., penicillium, oidium, monilia, mucor, aspergillus, and especially actinomyces—are at times important. Certain skin diseases, such as favus, pityriasis versicolor, tinea tonsurans, etc., are caused by growing fungi. The fungus of thrush, which attacks mucous surfaces, has been found in multiple abscesses (metastases) in the brain. Aspergillus is occasionally met with in the cornea and external auditory meatus. Mucor mycelia has also been observed in multiple abscess of the brain, lungs, and bowels. Yeast fungi (blastomycetes (Fig. 29)) are rarely, if ever, of special interest, excepting in gastric fermentation, where they play an important rôle.

Of the various micro-organisms of pus, the staphylococcus pyogenes aureus is the most common, being the chief factor in suppuration in about eighty per cent of all cases. This organism measures 0·7 μ in diameter, is killed at the boiling point—100° C. (212° F.)*—and in laboratory experiments at 58° C. (136·4° F.), but will resist desiccation for ten days. It is aërobic and practically universal in distribution, being found in the soil, upon clothing and hands, especially beneath the nails, but rarely in the air.

The next in order of importance is the staphylococcus pyogenes (epidermidis) albus, which from the researches of Welch, of Johns Hopkins, is of considerable surgical importance. According to this careful investigator, it should be considered an almost constant inhabitant of the epidermis. It lives deep in the follicles of the skin, and is usually the cause of stitch abscess. This demonstrates the necessity of careful scrubbing of the integument in the operative field, and the dissolution of sebaceous matter by the use of ether poured upon the skin.

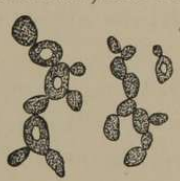

Fig. 29.—Yeast fungus. Saccharomyces cerevisiæ. Vacuoles are present in some of the larger cells.

The staphylococcus citreus, fluorescens, cereus, flavus, and the micrococcus pyogenes tenuis, are unimportant varieties. The gonococcus will be separately considered in the article on gonorrhœa.

The bacillus pyocyaneus gives the color to blue pus; the bacillus pyofluorescens is found in green pus, and consists of small rods with slightly rounded ends, two or more of which are linked together and possess active movement. It does not sporulate.

The bacillus ruber (Ferchmin) is found in red pus.

The bacillus fœtidus is a rare form, found in abscesses chiefly of the perirectal region.

The bacillus coli communis (3 μ in length and 0·6 μ in breadth) is of

* A simple rule for the conversion of Centigrade to Fahrenheit, and *vice versa*: 212 F.—32 × 5 ÷ 9 = 100 C.; 100 C. × 9 ÷ 5 + 32 = 212 F.

Example:

212 F.
32
180
5
9)900
100 C.

100 C.
9
5)900
180
32
212 F.

great surgical interest, since it is considered the chief agent in pus formation in all suppurative processes in the peritoneal cavity, hepatic abscess, suppurating gall bladder, and appendicitis. Welch has found it in pure cultures in fifteen different inflammatory conditions.

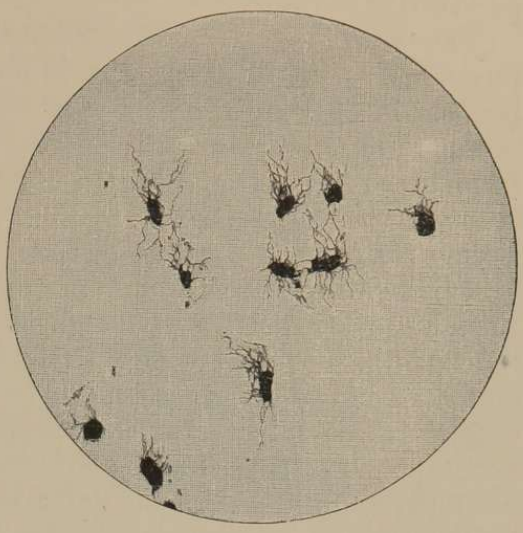

Fig. 30.—Typhoid bacilli with numerous fine flagella. (After Tillmanns.)

The streptococcus pyogenes and the streptococcus erysipelatis, so far as microscopical appearance is concerned, can not be differentiated. The former appears in chains of from four to six cocci, or at times a dozen or more, linked together in a single chain. It is facultative anaërobic, non-motile, and, in common with all cocci, reproduces itself by fission. It possesses great vitality in living tissues. There is one clinical point of difference which is of interest between the streptococcus pyogenes and the staphylococcus pyogenes aureus. This latter organism is associated with acute circumscribed inflammatory processes, with rapid pus formation (circumscribed abscess), while the streptococcus tends to produce a spreading suppurative process or a diffuse phlegmon or abscess. The different behavior of the streptococcus of erysipelas will be considered in the chapter on erysipelas.

The micrococcus tetragonus, discovered by Gaffky in 1881, in the pus of acute abscesses, is found in the sputum of tuberculous subjects as a rule, as well as in the saliva of a certain proportion of healthy individuals. It is 1 μ in its longest diameter, and while usually grouped in fours (as its name implies) and inclosed in a jellylike capsule, it is occasionally met with in groups of two and three. It is aërobic and under certain conditions will produce fatal septicæmia. Experiments on animals show at times wide dissemination of the organism throughout the body, while in others local points of inflammation have been found.

The micrococcus lanceolatus was discovered by Sternberg in 1880 in the buccal cavity and saliva of otherwise healthy individuals in about twenty per cent of all cases. It is constant in the brick-dust sputum of fibrinous pneumonia. It appears commonly in the form of a diplococcus, although it may be in chains of from four to six links. In shape it is not unlike the unstriped muscular cell, being fusiform, somewhat sharper at one end than the other. When they join together they adhere by their broader ends. Fresh preparations from the blood of animals and saliva, examined under the microscope, show, although not invariably, a capsule surrounding these linked organisms. When injected into the peritoneal cavity or veins of animals a rapidly fatal septicæmia is produced. It is considered the specific germ of lobar pneumonia, and has

also been found and is believed to be a factor in producing cerebro-spinal meningitis, pleuritis, arthritis, otitis media, endocarditis, and pericarditis.

The typhoid bacillus (Fig. 30) has been found in pure cultures in the pus of osteomyelitis of the ribs, in acute otitis media, empyema, localized peritonitis, either during or as a sequela of typhoid fever. It is oval or fusiform in shape, with stubby, rounded ends, and has projecting from its surface in all directions very fine hairlike flagella, with which it propels itself in active motion. Stained by Loeffler's method it looks not unlike a cotton seed with particles of the lint still adherent. In typhoid fever it is found in the blood, fæces, and urine, showing the wisdom of the thorough sterilization of these excreta. After death the bacillus is found widely disseminated and chiefly crowded in the spleen, liver, kidneys, and lymphatics connected with the intestinal canal. In animal experiments Saronelli observed that when the *normal resistance was impaired* by injecting certain other organisms—as the bacillus prodigiosus, proteus vulgaris, or bacterium coli commune—fatal typhoid lesions resulted in animals in which he could not obtain a reaction prior to the preliminary inoculations. Similar results were obtained by placing the animals where they were compelled to breathe foul air for from five to thirty days. This bacillus may be destroyed in the urine and fæces by adding five, or preferably ten, times the quantity of boiling water.

The micrococcus of tetanus, anthrax, malignant œdema, syphilis, tuberculosis, glanders, leprosy, and diphtheria will be considered separately with those diseases.

The fungus of thrush and the mucor mycelia have also been found in metastatic abscesses of the brain, lungs, and intestines, and are entitled to be considered as possibly pyogenic organisms.

Suppuration.—Pyogenic bacteria possess the property of dissolving or liquefying the tissues with which they come in contact, especially those in which nutrition is disturbed by injury. The embryonic cells of the inflammatory process yield rapidly to their destructive presence. The coagulated exudate of lymph and plasma or extravasated blood is liquefied into *pus serum*, and the leucocytes, some living but mostly dead, float in the serum thus made, and with other cells of the embryonic tissue not yet disintegrated form the *cellular* elements of pus. The connective tissues are also dissolved and appear in shreds mixed with the pus cells and serum. This collection of pus is called an *abscess*. When well defined and held in position by a limiting membrane or wall it is a *circumscribed* abscess, and when without a barrier it infiltrates the tissues, a *diffuse* abscess; a rapid and recent collection of pus is an *acute*, a collection of long standing and free from pyogenic organisms (tuberculous fluid) is called a *cold* abscess. The lining membrane or wall of a circumscribed abscess is a new formation of inflammatory origin, the inner surface of which is a



Fig. 31.—(After Agnew.)

granulation tissue studded with capillary loops, as in the embryonic tissue of a wound undergoing repair. It is in part a *pyogenic* membrane (Fig. 31), since it furnishes the dead and cast-off embryonic cells which float in the pus serum, while the leucocytes, the pus cells proper, wander in from the capillaries as well as from the extravascular spaces. The deeper layers of this wall of defence against further invasion by micro-organisms is composed of rank after rank of connective tissue and other fixed cells, active in the proliferation of a common embryonic tissue.

A chronic, *subacute*, or *cold* abscess differs from the preceding in the slowness of its development and the absence of those symptoms of local and constitutional disturbance which characterize the acute formation of pus. It occurs, as a rule, in diseases of the bone and joints, and in individuals of low vitality (diminished resistance), and is most frequently seen in connection with *caries* of the spine (Pott's disease), in other forms of tuberculous ostitis, and in tuberculous lymphomata. Such abscesses are, as a rule, of tuberculous origin, and do not contain true pus. While in gross appearance the contents may resemble pus, the microscope shows that the normal elements of pus are not present. Under such conditions the danger of general infection from the bacillus of tuberculosis is small. The bacillus tuberculosis produces a subacute inflammatory process, which results in a rich granulation tissue, the base of which is composed of newly formed cells, the embryonic tissue of the inflammatory process, which hedges in the tuberculous focus and tends to prevent systemic invasion. The tendency of these products of the tuberculous process is to undergo rapid degeneration, due in part to the toxic product of the bacillus (chemical action) as well as by anæmia, both local and systemic. As a result of this retrograde metamorphosis, caseation and liquefaction of caseous material occurs, the product being a white liquid of varying consistence, resembling but not being pus.

Under favorable conditions these collections of tuberculous fluid tend to absorption. In the majority of instances the wall of embryonic cells offer sufficient resistance to invasion of the tuberculous germs into the general system. The liquid is absorbed ultimately and carried away as a harmless product, and the remaining caseous matter undergoes granular metamorphosis and of itself ultimately disappears. Such pathological processes do not have symptoms in any way in common with abscesses proper, which are the seat of acute inflammation caused by pyogenic germs. Pain is not a marked symptom, since they can exist for months and are not suspected until the collection of this milky fluid is sufficient to attract attention by pressure upon the abdominal viscera, or protrusion due to its size.

It is a recognized fact that these tubercular foci can become infected with pyogenic micro-organisms without direct communication with the air. Certainly, if the medulla of bone can become infected without a direct or external communication, it is just as easy to infect a deep-seated tuberculous fluid when conditions for infection are favorable, the germs traveling through the blood and being deposited in a suitable pabulum.

The treatment of the two classes is clearly indicated. The simple

tuberculous focus, under ordinary conditions, when located in the epiphyses of the long bones or in the vertebræ or in deep situations, may be left alone to undergo absorption, taking pains by careful nourishment and hygienic precautions to increase the normal resistance of the tissues and prevent general infection. On the other hand, when in the lymphatic glands or in superficial locations readily accessible, or when a tuberculous accumulation is the seat of a mixed infection, as determined by the ordinary symptoms of septic infection, local and general, then a careful aseptic invasion and removal or evacuation is indicated.

Pus.—Pus is a liquid or semiliquid of varying color, for, while usually yellowish white, it may possess a well-marked hue of red, blue, orange, or green. It consists of a fluid portion, *pus serum;* cellular elements, to be described as *pus cells;* various micro-organisms; at times red disks, crenated, and in various stages of disintegration; fat globules, fibrin, and shreds of necrotic tissue not yet liquefied, and crystals of cholesterin. There are also found in pus, paraglobulin, serum albumin, myosin, leucin, tyrosin, and potassium albuminate (Fig. 32).

Recent pus is usually alkaline in reaction but when exposed to the air it becomes acid. Moreover, it may be without odor, but when accompanied by decomposition of necrotic tissue, from which gases are evolved, or when proceeding from an inflamed area contiguous to the alimentary canal, it is often extremely offensive.

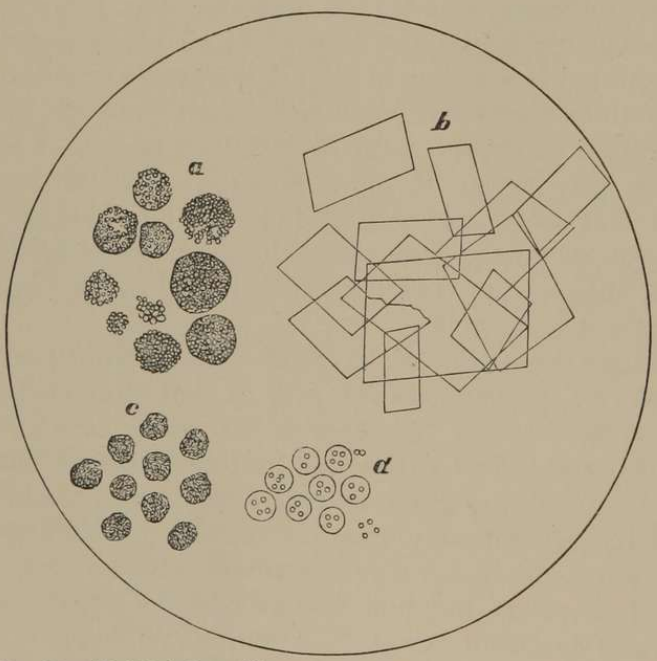

Fig. 32.—(Modified from Thomas.) *a*, compound granular corpuscles; *b*, crystals of cholesterin; *c*, pus cells; *d*, same after addition of acetic acid.

Surgical (septic or bacterial) pus does not coagulate. Pus serum, although furnished from the vessels of the inflamed area, is prevented from coagulation by the liquefying action of *bacterial peptone*, a product of bacterial ferment and decomposition.

Pus cells are chiefly white blood-corpuscles, which by chemical attraction (chemiotaxis) have crowded into the inflamed area. Treated with dilute acetic acid, they seem to possess two or three nuclei, rarely a single nucleus.

The single nucleated cells, found in large numbers in pus and classed as pus-corpuscles, are cast-off products of the new embryonic tissue, due to cell proliferation. In recent pus, and in a warm medium, some of the corpuscles are capable of amœboid movement. Their number varies

from four hundred thousand to one million six hundred thousand in one cubic millimetre.

The poisonous products of bacteria, if separated from the micro-organism from which they are derived, produce suppuration or toxic symptoms similar to those produced by the bacteria, but the poisonous effect is only transient, since the parent bacteria is essential to maintain prolonged septic infection.

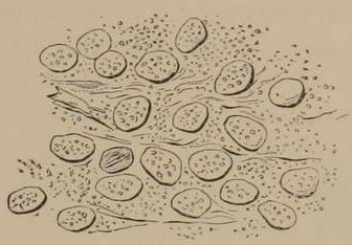

Fig. 33.

Fig. 34.

Fig. 33.—Pus from an acute abscess, showing pus cells, shreds of broken-down connective tissue and micrococci. (After Landerer.)

Fig. 34.—Bacilli of blue pus. (After Landerer.)

Certain sterilized chemical substances, as well as sterilized bacteria, will, when injected into the tissues, cause inflammation and a liquefaction of the exuded plasma and connective and embryonic tissues with which they come in contact, and produce a creamy liquid which very closely resembles *true surgical pus*. The inflammatory process, however, is mild, and systemic infection does not occur. Surgical writers have termed this "laboratory pus."

Treatment.—In the treatment of inflammation the first great essential is rest, and this should be as complete as possible. If necessary to assure this, some form of fixation apparatus should be applied. In non-infective inflammation, as a rule, nothing further than this will be required to bring about absorption of the excess of embryonic tissue and coagulated exudates, and the repair or regeneration of the tissues which have been injured. As far as local applications are concerned, as a rule, patients prefer cold to heat. The neatest way to apply cold is by the rubber ice bag, which can be laid directly upon the inflamed part, with a piece of lint or thin layer of cotton batting between the skin and the ice bag. The cold-water coil (Fig. 35) is also very useful. In the absence of these preferable methods, benefit may be derived by applying towels dipped in cold water, partially squeezed out, and laid directly upon the inflamed surface. When one of the extremities is the seat of lesion, the painful throbbing, which is often a part of inflammation, may in good part be relieved by elevation of the limb. For the upper extremity the Fluhrer swing (Fig. 36) is useful for this purpose, and adds to the patient's comfort. A very important feature in the treatment of all surgical lesions is a careful attention to the condition of the alimentary canal. It is of great importance that before an operation the alimentary canal be carefully emptied by the administration of from one to two grains of calomel triturates—preferably one grain repeated in four hours. If after twelve hours no movement of the bowels has taken place, this should be followed by one or two teaspoonfuls of Epsom salts, or half a tumblerful of Hunyadi water, or some other effective saline laxative. Whenever any inflammatory process is under treatment, it is just as important to keep the bowels open every day or every other day after, as it is before the operation. There is

no more important precept in surgery than this, and the surgeon fails in his duty who does not fully appreciate the dangers of *intestinal toxæmia*.

In *suppurative inflammation* more urgent measures are demanded. It is difficult to deal with any form of infective inflammation without the use of the knife, even in its early stages, and the sooner the knife is used in these cases, as a rule, the better. It is a surgical axiom that wherever infection has occurred and pus is forming, the sooner an incision is made the quicker will recovery follow and less danger ensue to the life and comfort of the patient and the usefulness of the part involved. The treatment of all abrasions or deep-

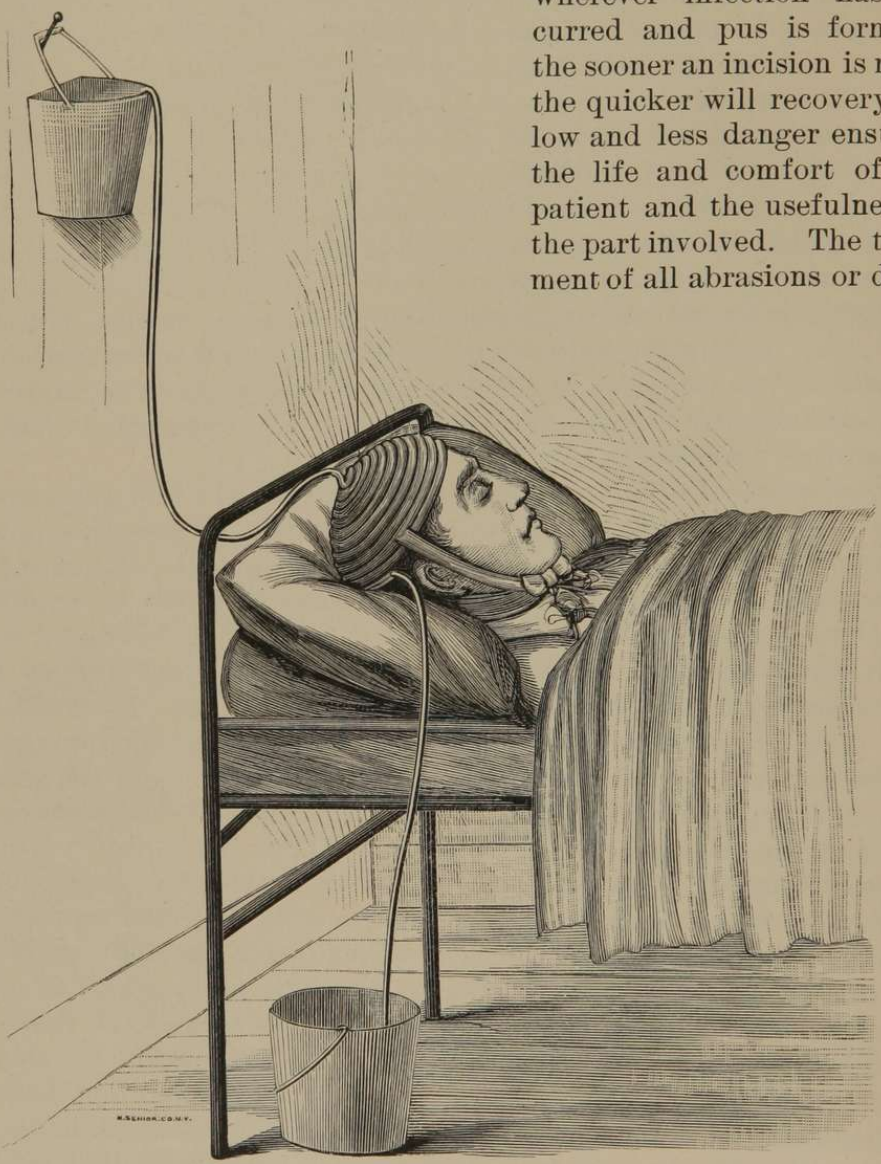

Fig. 35.—(Modified from Fischer.)

er wounds should be strictly antiseptic from the moment a wound comes under consideration. If the laity were thoroughly trained in the simplicity and safety of the sterilization of wounds, not one in a hundred of the serious accidents of infection would occur. Patients should be instructed to keep on hand tablets of bichloride of mercury with directions for making a simple and safe solution in which any part of the body may be immersed or bathed; and, this being done, to dry the

wound off with a clean towel that has been boiled, press the edges of the abrasion together, and cover the exposed surface with a layer or two of ordinary collodion, applied with a brush or poured on. When, however, a wound has been neglected and sepsis is established in the earlier stages, the next best thing is to cocainize the part by the injection of from one to ten minims of a two-per-cent solution into the integument about the wound, taking pains to follow the directions given in the use of cocaine in the chapter on local anæsthesia; then incise in the safest direction the focus of infection, and inject from thirty to sixty minims of a 1-to-3,000 bichloride solution into the tissues, making a complete circle of the area of infection. When lymphangitis is established and septic inflammation has taken place along the lymphatic channels toward

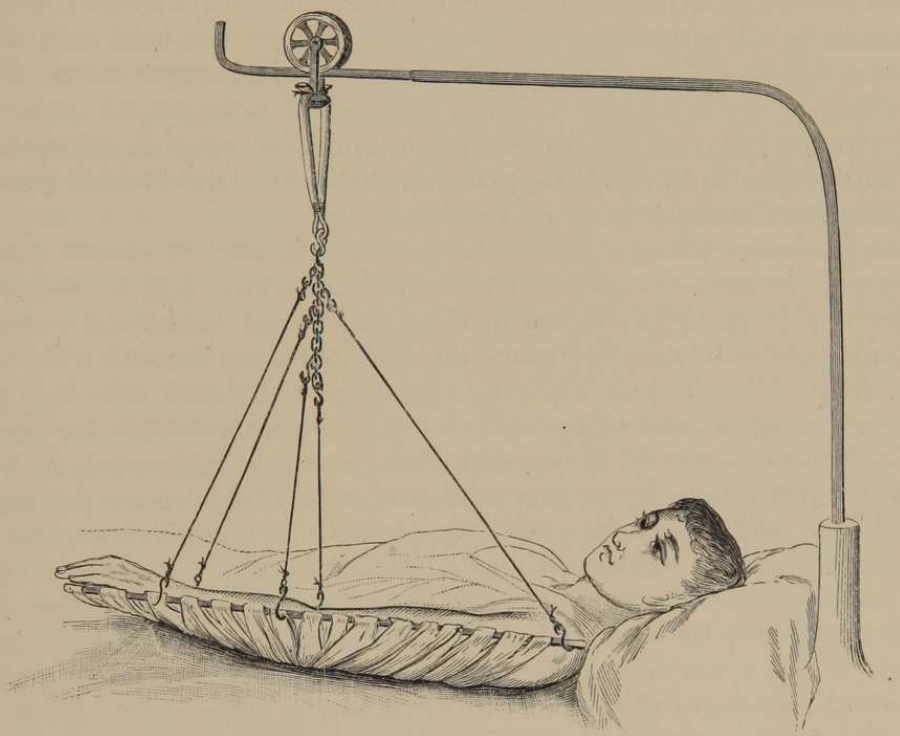

Fig. 36.—Fluhrer's swinging cradle (Mt. Sinai Hospital).

the center of the body, at the first indication of suppuration in the glands they should in like manner be incised so that the current of septic matter coming into them from below may be poured out into a wound where sterilization is secured by antiseptic moist dressing and infection beyond the lymphatic glands prevented.

In a condition of general cellulitis resulting from infection it is imperative to make multiple incisions, not only to relieve tension and prevent gangrene, but to give free escape to septic matter and to permit sterilization of the deeper portion of the infected tissues and secure as thorough drainage as may be possible. On general surgical principles, all incisions should be made parallel with the axis of the body. Any variation from this practice should be made for the purpose of keeping away from any nerves or vessels which might run in another direction.

The recognition of an acute abscess will depend upon certain symptoms of a local as well as a constitutional character. The sudden rise of temperature, preceded by a chill or series of rigors, are symptoms of purulent infection. The local signs are those of inflammation—heat, pain, redness, and swelling. Fluctuation is also present in well-advanced cases. The integument and subcutaneous tissues about an abscess are often œdematous and doughy. The positive test is, however, by *aspiration.* A hypodermic syringe (used only for this purpose) with a large-sized

Fig. 37.—Exploring-needle and syringe.

needle (Fig. 37) is invaluable. The needle should be held over a flame or boiled just before using. It is best to employ strict antiseptic precautions in aspiration as in other surgical procedures. A preliminary injection of one or two minims of two-per-cent cocaine solution with the finest needle will prevent pain. If incision is determined upon, the same anæsthetic may be employed.

In the neck or in any vascular region it is best to dissect carefully down to or near the abscess wall. In some cases it is safer to push a dressing forceps tightly closed through the tissues into the abscess, then separating the blades and stretching the opening, through which, after irrigating with 1-to-3,000 bichloride solution, a drainage tube is inserted.

The constitutional symptoms of septic infection should be combated by careful attention to the condition of the alimentary canal, as heretofore described, and the prompt and persistent effort by careful nourishment (and stimulation, if necessary), and by a bountiful supply of as pure air as can be obtained, to hold the tissues of the patient as nearly as possible in a condition of normal resistance. The survival of the patient depends upon the power of the tissues to resist destruction from the invading micro-organisms until, failing to find a suitable pabulum for their rapid proliferation, they perish. In suppurative cases, after incision a warm, moist dressing of weak bichloride or of plain sterilized gauze covered in with protective or oil silk to prevent evaporation, is often advisable. In exceptional instances an aseptic poultice, made by wetting flaxseed meal or any other substance in warm bichloride solution (1 to 5,000), may be employed with benefit.

Septicæmia.—*Septicæmia* (σηπτικός, putrid, αἷμα, blood), or blood poisoning (with or without metastases), results from the entrance into the blood channels of either an infectious organism or the ptomaine or toxic product of such organism, or of gaseous emanations from the decomposition of diseased tissues of the body or of ingested material. The term *pyæmia* was formerly used to imply the entrance into the blood of the semi-solid products of suppuration, while *septico-pyæmia* is now proposed by some writers to express a mixed condition of septicæmia and pyæmia. It seems to me, however, that an effort should be made to simplify the terms used in pathology, and that *septicæmia* would express

a condition of blood poisoning in which metastases do not occur, while *septicæmia with metastases* would express all that is contained in the term "pyæmia." The term septico-pyæmia is entirely unnecessary.

Septicæmia, or blood poisoning, may be caused not only by the presence of bacteria in the tissues, but can also be produced by *ptomaines*,* or toxic products derived from these organisms entirely separated from the bacteria which produced them. When septic *bacteria* are present, the septicæmia is sudden, and may continue indefinitely, while the septicæmia resulting from the *toxic products* alone is temporary. Septic infection takes place in the vast majority of cases from an abrasion or wound of the skin or mucous membrane; bacteria, entering here, travel into the tissues, lymph spaces, and blood vessels, and in severe cases are rapidly disseminated by the blood. They attack by preference the white blood-corpuscles until these seem to be mere aggregations of bacteria. The red blood-corpuscles later become disintegrated, and after death the blood is dark in color and decomposes rapidly. Hæmorrhages occur in the gastro-intestinal tract and various organs; the spleen and liver are enlarged and softer than normal; the kidneys are seriously affected and seem, from the shoals of micro-organisms found in them, to be chiefly depended upon for the elimination of the bacteria. Septicæmia in severe cases is introduced by high and continuous fever, with, however, varying temperature, rapid pulse, great discomfort, and a feeling of prostration. In milder cases fever may be wanting. In some instances there are repeated chills, followed invariably by a rapid rise of temperature. From the point of infection the progress of invasion is marked by *lymphangitis* and at times by *phlebitis*, a condition favorable for the development of pyæmia and inflammation of the skin and subcutaneous connective tissue. The lymph glands between the wound of infection and the central organs become enlarged and break down in suppuration. When the cellulitis or phlegmon is extensive, gangrene may ensue on account of the tension of the parts involved and the interference with the circulation. The parts are swollen, and often extremely painful.

In the treatment of septicæmia it is of vital importance to regard all wounds as capable of conveying infection to the tissues; and if the principles of prophylaxis just given in the treatment of infective inflammation were carefully carried out, there would be no such thing as septic infection. When infection has taken place, and free incision been made, it is advisable, after making the incisions, to keep the hand or part in-

* Various basic substances containing nitrogen and in chemical constitution resembling the vegetable alkaloids have been isolated by chemists from putrefying material and from cultures of bacteria concerned in putrefaction, as well as from certain pathogenic organisms. These products are called *ptomaines* (πτωμα, a corpse). In contradistinction to the ptomaines are the *leucomaines* (λευκωμα, white of egg), which differ from the foregoing in that they are derived from tissue changes in the body independent of the presence of bacteria. Among the ptomaines are neuridin, cadaverin, putrescin, saprin, methylamine, dimethylamine, and trimethylamine. Also neurin, derived from decomposition of brain matter and putrefying muscular tissue; cholin, found in hogs' bile, in the yolk of eggs, etc.; muscarin, found in poisonous mushrooms and putrefying fish; peptotoxin, tyrotoxicon, typhotoxin, from cultures of typhoid bacillus; tetanin, from tetanus-bacillus cultures.

volved submerged in a warm solution of bichloride of mercury (1 to 2,000 to 3,000) for at least half an hour after the incisions are made. Beyond this local treatment not much can be done except to support the patient in every way by careful nourishment and proper stimulation. When the lymphatic glands become engorged and are about to suppurate, they should be incised and treated as the original point of infection.

Septicæmia with Metastases.—In *septicæmia with metastases* (pyæmia) the symptoms just given as characteristic of simple septicæmia are exaggerated; the resistance of the tissues in the inflamed area seems lessened; the blood vessels are invaded by the bacteria (Fig. 38), and, as a result, clots or *thrombi* form upon the vessel walls, which, under the

Fig. 38.—Bacilli of septicæmia in a vein of the diaphragm, taken from a septicæmic mouse. White blood-corpuscles, some containing bacilli and some changed into masses of bacilli. × 700. (After Koch.)

disintegrating action of the micrococcus of inflammation, break down, and thus purulent fragments are swept along the blood channels to the heart, from whence they are distributed through the lungs to the various organs of the body. They form *emboli*, or arrested clots, chiefly in the capillaries of the lungs, and each embolus may form a metastatic abscess. From here other thrombi are developed, and these are swept into the circulation and distributed by the left ventricle to the entire system. If the point of infection is in the area of the portal system the liver is apt to be the seat of metastatic abscesses. In Mr. Thomas Bryant's analysis of two hundred and three cases at Guy's Hospital the lungs were involved in one hundred and eighty-seven, and in seventy-eight of these, infarctions occurred in no other organ. The fever in pyæmia is usually preceded by a chill, and this is apt to recur with more or less frequency during the disease. The febrile movement does not follow a regular course, but is generally intermittent. After a high temperature there is a sudden fall, often coincident with profuse and exhausting sweats. The thermometer not infrequently within a period of twelve hours will vary from 96° to 104° F. The condition of these patients is deplorable and the prognosis very grave. Recovery is extremely rare. I have, however, seen one or two cases in which recovery ensued after metastatic abscesses had formed.

The treatment of pyæmia does not differ from that given for septicæmia, except that it is essential to open any metastatic abscesses that can be reached within the limit of safety to the patient.*

* In 1890 a young lad of sixteen years came to me suffering from pyæmia as a result of urethral infection due to the use of a sound for old organic stricture. There was no specific urethritis. Metastatic abscesses had developed in the sterno-clavicular articulation of the right side, in the right elbow, right hip joint, left knee joint, and there were four or five metastatic abscesses of the soft parts in various portions of the body. The septic temperatures were high and continuous. Every symptom of most pronounced pyæmia was present. The joints were opened and drained, discharging considerable pus, and drainage was kept up for from three weeks to four months. By great care and careful feeding the patient recovered, and is to-day, five years after, in perfect health in every particular.

CHAPTER III.

SPECIFIC AND NON-SPECIFIC URETHRITIS.

Urethritis.—The general inflammatory lesions of the urethra should be considered under two headings, *specific* and *non-specific.*

Specific urethritis (misnamed *gonorrhœa*, from γονος, semen, ῥειν, to flow) is a violently contagious disease affecting by preference the urethra in the male and the urethra and vagina in the female, occasionally invading the rectum. In many instances, chiefly in neglected cases, the virus of specific urethritis, either alone or by *mixed* infection with one or more other forms of *pyogenic* bacteria, invades the glandular apparatus of the vulva, the uterus, and Fallopian tubes in the female, while in the male it may involve the glandular apparatus connected with the urethra and the entire seminiferous tract, leading from the floor of the prostatic urethra to the substance of the testicles. It may also involve the follicular apparatus of the prostate, the membranous and prostatic urethra, and the bladder, and, in exceptional cases, the march of the inflammation is along the ureters to the pelvis and calyces of the kidney.

Upon the conjunctiva it readily establishes a violent and destructive inflammation, and in rare instances spreads along the lachrymal canal into the nose and mouth. The germs of specific urethritis have also been found in peri-urethral abscesses, in the pus of suppurating buboes, and by metastasis in certain lesions of the joints which are at times met with in the progress of this disease, the so-called "gonorrhœal rheumatism."

The specific germ of urethritis was discovered by Neisser in 1879, and was termed by him *gonococcus.* In size it varies from 0·8 to 1·6 μ in length and 0·6 to 0·8 μ in width.*

A single germ is kidney- or bean-shaped, but it appears almost always as a diplococcus, two of the bean-shaped bodies adhering with their concave surfaces toward each other. Gonococci are found not only free in gonorrhœal pus, and in large numbers within the substance of the *pus corpuscles*, but never within the nucleus of the cell. In like manner they penetrate the epithelial cells which come away with the urethral discharge. C. W. Allen, in 1887, demonstrated the gonococcus in gonorrhœal pus which had dried for several weeks upon the clothing by scraping the stains, macerating, and staining (Lustgarten).

* A micromillimetre equals $\frac{1}{25000}$ of an inch.

The specific action of the gonococcus of Neisser was demonstrated by Bumm, who from even the twentieth generation of a pure culture produced typical gonorrhœa in a healthy urethra.

In order to appreciate the importance of the gonococcus in the urethral discharge, it is well to study the micro-organisms of the normal

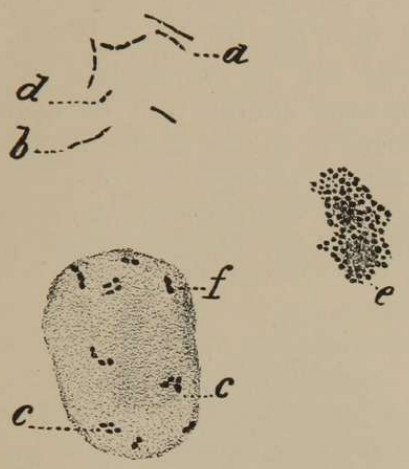

Fig. 39.—*a*, *b*, *d*, Smegma bacilli, which may be mistaken for tubercle bacilli; *c*, *f*, diplococci in small hyaline cell—pseudo-gonococcus; *e*, staphylococcus pyogenes aureus.

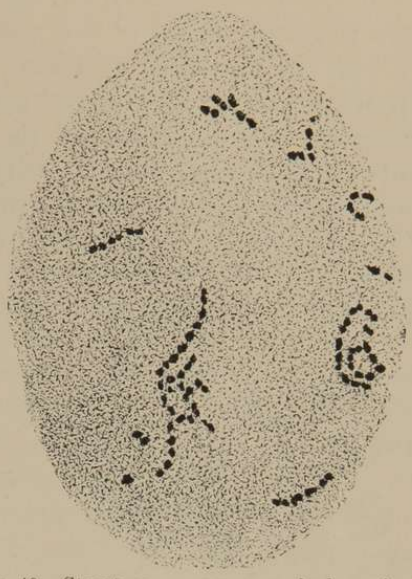

Fig. 40.—Streptococcus pyogenes in large hyaline epithelium of urethra.

urethra. According to Lustgarten, the principal organisms of the normal urethra are: 1, The *smegma bacillus*, closely resembling the tubercle bacillus, which requires careful study in diagnosis to exclude tuberculosis of the urinary tract; 2, the *pseudo-gonoccoccus*, found at times in the cast-off epithelia within the pus corpuscles, and therefore practically not to be differentiated from the gonococcus; 3, the *staphylococcus pyogenes aureus;* and 4, the *streptococcus pyogenes.*

While it has been claimed that the diagnosis of specific urethritis (gonorrhœa) can be made positive by the presence of the gonococci in the pus corpuscles, it is considered by competent investigators to be extremely difficult unless the presence of this organism is taken into consideration, along with the grosser symptoms of gonorrhœal infection. According to Lustgarten, who has made careful investigations in this department, "several species of diplococci resemble completely Neisser's gonococcus in shape and staining qualities, especially in being decolorized by Gram's method." It is essential, therefore, in diagnosis, to recognize the shoals of diplococci crowding the pus corpuscles, epithelial cells, and floating free in the discharge, and associate these with the general and grosser symptoms of specific urethritis.

A simple and rapid method of demonstrating the gonococcus of Neisser is as follows: Place a small drop of the discharge upon a cover glass and smear by rubbing two cover glasses together; dry it by passing one of the cover glasses with pus side upward through a spirit flame two or three times; immerse this at once in a solution of

methyl blue; wash off the excess of coloring matter by holding it under clear running water or by dipping the glass several times into clear water; dry the stained pus well by pressing with blotting paper; then cover it with a small drop of cedar oil; put on a thin cover glass and examine with a lens magnifying from 700 to 1,000 diameters. The peculiar double bean-shaped arrangement of the diplococci will be seen within the protoplasm of the pus corpuscle and epithelium.*

When the discharge is scanty it may be obtained on a film of cotton wrapped about a probe and introduced into the urethra. When the microscope is not employed the diagnosis will be emphasized by the history of exposure, the time elapsing between contact and the appearance of the discharge, the peculiar, irritating character of the discharge, and the progressive increase of the same during the first five or six days.

Symptoms.—When the virus is brought in contact with the mucous surface of the urethra, the period of time which elapses before local

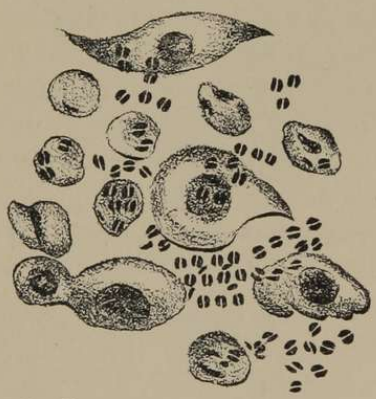

FIG. 41.—Pure gonococci, free and within lymphoid and epithelial cells.

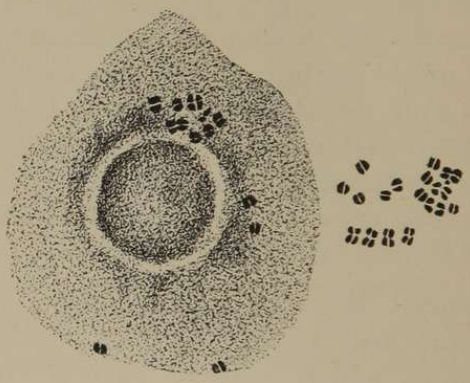

FIG. 42.—Pseudo-gonococcus in an epithelial cell and free.

symptoms of inflammation appear varies greatly in different individuals, and even in the same individual in different inoculations. It is very probable that the condition of the mucous membrane at the time of contact, as well as the variations in the normal resistance of the patient's tissues, have a great deal to do with the rapid progress of the inflam-

* Gram's method, which may be used in doubtful cases, is more complicated. To fresh aniline water (aniline oil shaken well with water and filtered through moistened filter paper) a concentrated alcoholic solution of gentian violet is added, drop by drop, up to the point of saturation —i. e., until the liquid loses its transparency. The cover glass prepared as above is allowed to float on this solution for ten minutes. It is then washed with water, and placed for five minutes in a solution of iodine (one part), iodide of potassium (two parts), distilled water (three hundred parts), and from there put in absolute alcohol, where it remains until no more color is extracted. After a renewed washing, the preparation is subjected for half a minute to a second process of staining in a weak (light-brown) watery solution of Bismarck brown or vesuvin, washed again with water, and examined as before in water or Canada balsam. If a preparation treated in this manner shows blue diplococci, it is sure that they are not gonococci; but in case of brown diplococci, no absolute certainty is reached. For the bacterioscopic examination of gonorrhœal or urethral discharges a good microscope with Abbe's condenser and highly magnifying lens is needed. Dry objective lenses are not to be recommended except Zeiss's new apochromatic system, while a one-twelfth-inch homogeneous immersion lens and an ocular No. 2 and No. 3 will answer the purpose very well. (Lustgarten.)

mation, and it may be that the virus in some instances is more intensely infective than in others. Thus the period of incubation varies from a few hours to several days, and in very rare instances as much as two weeks have elapsed between the contact and the recognition of the inflammatory process. The limit, however, between twenty-four hours and three days will include the large majority of cases of specific urethritis. Usually the earliest symptom is a burning sensation at the meatus, which is more severe as the urine is escaping. The lips of the meatus soon become swollen, usually everted, prominent, and red. When carefully separated, a thin film of muco-pus will be seen coating the mucous membrane. The *first stage* of the disease may be considered as beginning at the moment of contact, and ending with the first appearance of suppuration. The average duration is from two to ten days. From this period, *in neglected cases*, the inflammatory symptoms increase for from four days to as much as two weeks. The quantity of pus discharged varies from a few drops to several drachms in the twenty-four hours. It is increased by exercise, by unnecessary exposure to cold and wet, the use of alcoholic stimulants, any form of dissipation, and improper diet. The color of the discharge varies from the bluish-white hue of the first few drops to the yellow and yellowish-green tinge of that discharged during the height of the inflammatory process. In some instances it becomes stained with blood as a result of rupture of the capillaries in the engorged mucous membrane.

The *second stage*, that of increasing inflammation and suppuration (in cases not treated), lasts about twelve days. It is followed by the *third stage*, that of decreasing inflammation, the duration of which is from three to six weeks. In addition to the purulent discharge and the pain which characterizes the second stage of the disease, there is a diminution in the size of the stream of urine, due to the swollen and puffy condition of the mucous membrane of the urethra. In the milder forms of gonorrhœa there are no other symptoms present in the second stage. In many neglected cases, however, the inflammatory process extends into the membranous and prostatic urethra, thence along the seminal ducts, oftentimes into the bladder, epididymis, and testicle, producing serious consequences. In the female it may produce endometritis and salpingitis, resulting either from infection of the specific germ or from a mixed infection with other pyogenic organisms, which find their way into the Fallopian tubes, causing abscesses, producing sterility in the vast majority of cases, and ultimately leading to the necessity of surgical interference. In males, infiltration of the vascular erectile tissue of the corpus spongiosum occurs in a varied degree, and occasionally the exudation extends into the corpora cavernosa. A more frequent complication of gonorrhœa is inflammation of the glans penis (balanitis) and of the prepuce (posthitis), due not only to mechanical irritation of the part, but to direct infection. As a result of such extensive inflammation, the penis is liable to various deformities, painful in an extreme degree, and not without danger to its integrity. *Chordee*, or bowing of the organ, is a common symptom. It becomes in part or wholly erect, and, on account of the

infiltration of the vascular spaces of the spongiosum with the embryonic inflammatory tissue, it fails to expand with the corpora cavernosa.

Pathology.—Strictly speaking, the morbid process is an inflammation of the mucous membrane of the urethra and the submucous connective tissue with or without extension to other organs. It commences at the meatus and travels backward. The epithelium is swollen, there is marked hyperæmia of the submucous tissue, with the escape of leucocytes, the production of pus, and the formation of the common embryonic tissue of inflammation. In milder cases the products of inflammation undergo retrogressive changes and are absorbed, while in other instances connective-tissue development is precipitated, ending in cicatrization and the formation of *stricture.* The organic elements of gonorrhœal pus are leucocytes, embryonic cells, epithelia, and blood-corpuscles.

In a certain proportion of cases the virus of gonorrhœa becomes absorbed and metastasis occurs in the *joints*, producing also *endocarditis* at times, the gonococcus being found in these secondary lesions as in other metastatic abscesses.

Treatment.—From the foregoing, the importance of beginning the treatment of gonorrhœa at the earliest possible moment is evident. At the first recognition of the disease the urethra in both sexes and the vagina in the female should be irrigated at once, preferably twice, in the twenty-four hours, with a solution of 1 to 3,000 permanganate of potash, two quarts of this solution being used at a sitting. A convenient formula to have on hand for a ready solution is: Permanganate of potash, ʒj; water, ℥vj. A tablespoonful of this solution to one quart of hot water gives a 1-to-3,000 solution. A fountain syringe should be employed (preferably one with a thermometer attached, so that the exact degree of heat may be ascertained), holding two quarts of the solution, at an elevation sufficient to give the proper degree of pressure, generally three feet above the level of the urethra. In male patients the standing posture is preferable, while female patients should lie down, as in using the ordinary douche. Since the gonococcus is killed by a temperature of 140° F. (Sternberg), the nearer this can be approximated in the application of the permanganate-of-potash solution the better. Usually, however, a temperature of 100° F. to 115° F. is as high as can be borne. Above 120° F. there is some danger of coagulating the albumin of the tissues. When patients are exceedingly sensitive, an injection of from one drachm to as much as three drachms of a two-per-cent solution of cocaine may be thrown into the urethra. For males, a glass catheter of the smallest diameter, five or six inches long, with lateral perforations (two or three in number) near the point, is preferable, for the reason that it can be easily introduced and thoroughly disinfected after each introduction by boiling. The ordinary glass female catheter is perfectly satisfactory for this work. It should be lubricated with glycerin, and not with oil or vaseline, since the presence of these last two agents prevents the contact of the solution. Care should be taken not to push the instrument to or beyond the cut-off muscle, for fear of inoculating the deep urethra. A similar precaution should be taken in the shallow female

urethra, and in douching the vagina the opening of the vulva should be closed at times so that this cavity may be thoroughly distended in order to bring the solution in contact with the entire surface. If a glass catheter can not be obtained, an ordinary rubber instrument may be employed, but a second lateral perforation should be made opposite the one which is found in the ordinary male catheter. The opening should not be directly in the end of the instrument, for fear the solution may be thrown back through the cut-off muscle, nor, for the same reason, should the meatus or urethra be compressed. It is important that the instrument be of small size, to permit the free return and escape of the injected liquid.

In addition to the local treatment, the following formula should be prescribed *per os:*

℞ Salol..... ʒj;
Ol. gaultheria..... ʒij.

The dose of this solution is twenty drops four times a day. It may be given in water, on sugar, or, preferably, in capsules. The effect of this is to sterilize the urine, which, as it is passed, aids in the antisepsis of the urethra.

In the notes of one hundred and eight acute *primary* cases of gonorrhœa treated in my genito-urinary clinic at the New York Polyclinic Medical School and Hospital by Prof. J. A. Bodine and the author, in which the diagnosis was made by the microscope, the average date at which the coccus disappeared from the discharge was the thirteenth day; in some cases as early as the sixth, and in others as late as the twenty-fifth day of the disease. In some of these cases there was a slight glairy discharge which continued for a few days, but in none of these was the gonococcus present. *In no single case did epididymitis or any remote complications ensue.*

In addition to local treatment, it is always important to carry out the strictest asepsis, in order to prevent the inoculation of the conjunctiva of the patient or physician with this virus. Thorough disinfection of the hands in a 1-to-500 solution of bichloride is of great importance, and of this the patient should be cautioned at the first visit. An important adjuvant in treatment is rest, regulation of diet, and manner of living. The diet should be simple and nutritious; stimulating beverages, such as alcohol, coffee, and tea, should be avoided. The bowels should be kept open daily, and, if necessary, by the use of calomel triturates or saline laxatives. In the first week of the disease citrate of potash (twenty grains, four or five times a day) decreases the irritating effect of the urine upon the urethra. The hip bath in warm water every night and morning not only insures a degree of cleanliness which is desirable, but is also of value as an antiphlogistic. The free discharge of pus from the urethra, vagina, and prepuce is essential. The discharge should drop into a dressing or bag of oil silk, or rubber tissue, or thick cloth, made to fit without pressure, and held in place by strings fastened to a belt worn around the waist. Absorbent cotton is useful in taking up the discharge.

Several pieces of ordinary water-closet paper loosely wrapped about the penis and twisted in front of the glans affords a ready and satisfactory receptacle with drainage.

Balanitis and *posthitis* (inflammations of the glans and prepuce) are conditions existing in a varying degree in almost all cases of specific urethritis, the acrid discharge readily affecting the epithelial covering of these organs. When the foreskin becomes swollen, tense, and painful, the annoying condition of *phimosis* results, and in some cases *paraphimosis* ensues, and may require operative interference to prevent sloughing. In phimosis it is often necessary to irrigate the glans beneath a tight foreskin with the permanganate solution, either with a specially constructed syringe with a delicate nozzle or with a common fountain syringe. If these milder measures do not suffice, an incision through the prepuce along the middle line of the dorsum should be made to expose the excoriated surfaces or to relieve tension.

The introduction of escharotics, as nitrate of silver, solid or in solution, into the urethra, is rarely justifiable in view of the successful results obtained with permanganate of potash. In a few instances I have employed the method of Dr. F. A. Lyons,* of New York, successfully, and it may be used with propriety under conditions where it is urgent to arrest the discharge in four or five days, even at the risk of producing a deeper inflammation of the peri-urethral tissues than is ordinarily justifiable. The method is as follows:

After the patient has urinated for the purpose of cleansing the canal, and is in the recumbent posture, the operator injects into the meatus with an ordinary funnel-pointed rubber syringe one drachm of a four-per-cent solution of nitrate of silver. This is held in the urethra for from two to three minutes by the watch. There is little pain at the time and not a severe smarting on urination during the next twenty-four hours, at which time the treatment is repeated, provided that on careful examination of the discharge gonococci are found; if not, no further treatment is necessary. A two-per-cent solution should be used for the second injection, and for a third if gonococci are still present.

Non-Specific Urethritis.—This form of urethritis is due to infection of the mucous membrane of this canal by pyogenic organisms independent of the gonococci. Traumatism due to external violence, or excessive sexual indulgence, the introduction of unclean instruments, foreign substances, calculi, etc., produce conditions favorable for the lodgment and proliferation of pus-making organisms and the development of a purulent discharge. It is usually of short duration, mild in character, and involves only a limited portion of the canal. The *diagnosis* may be made from the absence of the *gonococci* in large numbers and within the pus cells and epithelia, as given in specific urethritis, and from the absence of the symptoms of a violent infection. The *treatment* is rest, the removal of any course of irritation, the dilution and sterilization of the urine, and irrigation, as in gonorrhœa.

* "New York Medical Record," vol. xlvii, p. 549.

CHAPTER IV.

ERYSIPELAS, HOSPITAL GANGRENE, ACTINOMYCOSIS, GLANDERS, TETANUS, MALIGNANT ŒDEMA, FOOT AND MOUTH DISEASE, HYDROPHOBIA, AND TUBERCULOSIS.

Erysipelas.—Erysipelas (ἐρυσός, red, πέλας, skin) is an infectious inflammation of the skin and connective tissue immediately subjacent, or of the mucous membrane and the submucous tissues, and particularly of the lymphatic channels which permeate these structures (Fig. 43). The inflammation and disease may confine itself to the cutaneous surface alone, or it may be limited to a mucous surface, or, commencing in one of these structures, it may pass the muco-cutaneous border and invade the other. It is caused by a specific micro-organism, the *streptococcus erysipelatis* (of Fehleisen).* An abrasion of the skin or mucous membrane is essential to the lodgment and development of this germ and the consequent disease. Though usually existing as a chain coccus composed of two or many links, it is frequently met with in the tissues as a single germ. Effecting a lodgment, this streptococcus (although classed as a non-motile germ) rapidly proliferates, finds its way into the lymphatic canals, and spreads with rapidity, not only following the current of the lymph toward the center of the body, but with almost equal rapidity spreading toward the extremities. As the lymphatic channels become engorged with the rapidly proliferating elements, they break through the walls of these vessels, invade the intervascular spaces, and are found attached to and infiltrating the embryonic tissue and exudate of the inflammatory process, which they excite. They have been found also within the protoplasm of the leucocytes, and this is cited as an evidence of *phagocytosis* (φαγειν, to eat, κυτος, a cell)—that is, the property which the leucocytes possess of destroying and appropriating as food invading micro-organisms (Fig. 44). Most of these cocci, however, are only attached to the leucocytes and lymph corpuscles and are not within the protoplasm. As the inflammation subsides, the shoals of

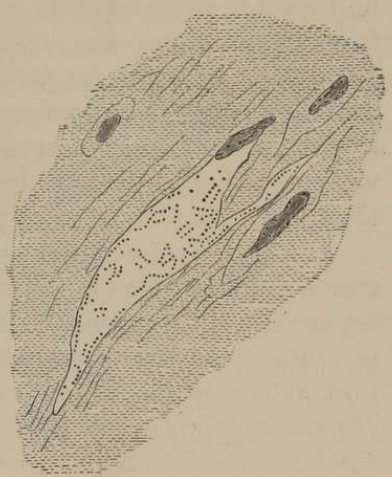

Fig. 43.—Streptococci of erysipelas. × 700. Section through a lymph vessel of the skin (Flügge).

* This organism as determined by Sternberg is destroyed in streaming steam at 54° C.

germs disappear from the center or oldest areas of inflammation and are found more numerously near the periphery, which, in all probability, is due to the fact that they rapidly exhaust the material upon which they depend for existence, the older or first developing organisms perishing near the center of infection. In exceptional instances, due probably to a subnormal resistance of the tissues attacked, the streptococcus makes its way through the walls of the venules and thus produces rapid general and usually fatal septicæmia, with or without metastases.

a *b* *c*

FIG. 44.—Phagocytes (Metschnikoff). *a*, an anthrax bacillus about to enter a white blood-corpuscle; *b*, the anthrax bacillus within the white blood-corpuscle; *c*, white blood-corpuscle with anthrax bacilli which have become broken into pieces.

Doyen seems to have established a close relationship between erysipelas and puerperal fever. In both mild and severe cases of this fever, he found a streptococcus which, under the microscope, could not be differentiated from the micro-organism of Fehleisen. By inoculations (according to Senn) he found that the streptococcus obtained from the inflamed tissue of puerperal fever caused erysipelas, and, *vice versa*, the streptococcus found in erysipelas developed puerperal fever. Clinically, we must then conclude that the micro-organism of puerperal sepsis is identical with that of erysipelas.

The coccus of erysipelas very closely resembles the streptococcus pyogenes, as heretofore mentioned, but there seems little doubt that they are separate specific germs, for aseptic injections of erysipelas cultures do not produce pus; therefore when pus is found complicating the inflammation of erysipelas it is due to a mixed infection with pyogenic bacteria. *Hajeck* demonstrated in fifty-one inoculations of animals that the erysipelas microbe causes a migrating dermatitis which perfectly resembles erysipelas in man, while similar injections of the streptococcus pyogenes produces a deep-seated inflammation which in almost every instance was accompanied by suppuration. Studying these tissues with the microscope, confirmation was emphasized in the fact that the erysipelatous cocci were found in shoals *in the lumen of the lymph vessels*, while the pus streptococci, in common with all pyogenic bacteria, infiltrated *all* the tissues, even passing through the vessels into the circulation, as given by Senn.

Erysipelas occurs more frequently upon the face than any other part of the body, and particularly about the nose, for the reason that the face is most exposed to contagion and the germs rapidly find lodgment in the abrasions, however small, which are common about the junction of the mucous membrane of the nose with the skin. It begins as an acute dermatitis; the skin becomes red, swollen, and painful, due to the tension which the rapid infiltration causes in the canals and between the lymphatic spaces. The epidermis has a glazed, shiny, bright appearance; the color is deeper in the center of infection, tending to a dark,

mottled hue, while the bright red spreads to the periphery of the inflamed area, gradually fading into the normal color of the integument. The redness at first may not always diffuse itself, but may occur in several foci or centers of inflammation, radiating along the lymphatic channels. By fusion these rapidly form a solid surface bright red in color. The inflammation and discoloration spread in all directions, travelling toward the center of the body, however, with little more rapidity than against the lymphatic current. Cases are recorded in which two or more surfaces of the body have been attacked simultaneously or successively. In one of my cases, in which I inoculated pure sterile cultures of erysipelas for the cure of sarcoma, the dermatitis and discoloration traveled from the point of inoculation, on the anterior aspect of the left thigh, and within five days spread over the abdominal wall as high as the nipple of the same side. In this case there was no suppuration.

In portions of the body where the integument is loosely attached the exudate is usually extensive and the swelling considerable. Large vesicles or blebs develop in the part involved, which contain clear or straw-colored serum. Suppuration does not take place unless mixed infection has occurred. As the disease develops, rigors occur and cold and hot sensations alternate, while a general feeling of discomfort and uneasiness pervades the patient ; the temperature rises to a high degree, with rapid pulse and the ordinary symptoms of high febrile movement. In severer cases, when the organism invades the venules, the internal organs become affected. Albumin is present in the urine, which is dark in color, and occasionally there is hæmaturia, with the presence of the pathogenic streptococci in the urine. These cases almost invariably end fatally. In ordinary cases (*simple cutaneous erysipelas*) the tendency of the disease is to recovery in from four to six days with limited tissue destruction. In others it may last for one, two, or three weeks, and in some cases there seems to be a chronic form of the disease, which entirely disappears for months, and then recurs without marked constitutional disturbance. When suppuration or sloughing occurs (the *cellulo-cutaneous* or *phlegmonous* variety) of course the prognosis is more grave. Under such conditions the symptoms of septic infection are exaggerated and general septicæmia, with or without metastases, ensues.

Attacking the mucous membrane, the course and prognosis of the disease do not differ materially from that just described.

Diagnosis.—Erysipelas, within the first twenty-four or forty-eight hours of its appearance, may be taken for dermatitis, or simple erythema, phlebitis, lymphangitis, or cellulo-dermatitis.

Dermatitis occurs, as a rule, from local irritation, and is not accompanied by any of the constitutional disturbances which accompany erysipelas. In simple inflammation of the skin the color is red, but it never has the glazed appearance which is always present in a typical erysipelas. *Erythema*, a mild form of dermatitis, may also be mistaken for erysipelas. In *erythema papulatum* the exposed and extensor surfaces, as the dorsum of the hand and the posterior aspect of the forearm, are apt to be involved. There is no wound of inoculation ; very slight, if

any, infiltration of the skin proper. Children and younger adults suffer most frequently. It lasts for only a few days, then fades away, leaving a dry scale to indicate the location of the papule. Owing to the various shapes and the different shades of color assumed by the papules, and efflorescence of the erythema, it has been divided into *erythema annulare*, *erythema gyratum*, and *erythema iris.**

In *erythema intertrigo* there is a general redness of the skin in parts subjected to friction or irritation from perspiration. *Erythema nodosum* is almost peculiar to chlorotic females. The color, at first bright red, soon changes to a dark hue. The patches are oval, elevated, and nodular.

Phlebitis and *lymphangitis* are more severe forms of inflammation than those just given, and are accompanied with constitutional symptoms not unlike those present in a typical erysipelas. The chief point of diagnostic value relates to the anatomical arrangement of the vessels, for in phlebitis and lymphangitis the lines of inflammation and discoloration travel along the course of the vessels without the general and widespread efflorescence of erysipelas.

Diffuse cellulitis occurring from a poisoned wound, as with a dissecting knife, or after the bite of a serpent, will offer no difficulty in diagnosis. It may, however, occur without a recognized cause. The subcutaneous tissues are first attacked, and the skin may or may not be involved in the process of inflammation. There is swelling and painful tension of the part affected, and, if the process be uninterrupted, transudation of serum occurs, causing œdema, and giving a doughy feeling on pressure. Pus may be found in quantity, and infiltration become extensive. This result is more apt to occur in diffuse non-specific cellulitis than in phlegmonous erysipelas. This condition, especially when the skin becomes involved, offers considerable difficulty to a positive diagnosis. If, however, the peculiar symptoms heretofore given be carefully considered, and a comparison instituted between them and the phenomena of the various diseases which may simulate or complicate erysipelas, it will be found that, in the great majority of cases, a correct diagnosis may be made.

Treatment.—The streptococcus of erysipelas is destroyed in a 1-to-1,000 bichloride solution within fifteen seconds, and the inference is natural that the injection with a hypodermic syringe immediately around the periphery of the beginning focus of erysipelatous inflammation would arrest the spread of the disease. Of course this treatment could only be justified where the circle of injection would not require enough of the mercuric chloride to endanger systemic poisoning from this substance. I have used a 1-to-500 solution under such conditions in an area one inch in diameter without any symptoms of poisoning and with arrest of infection. It should be employed when the first limited blush of the disease is observed. As the injection is painful, a weak cocaine solution, either Schleich's normal or a one- or two-per-cent solution, should be employed to produce local anæsthesia.

* Neumann, "Handbook of Skin Diseases." Bulkley. D. Appleton & Co., 1872.

St. Klein reports three cases of erysipelas treated with excellent results with a preparation of equal parts of ichthyol and vaseline applied over the affected parts two or three times. The skin should be thoroughly cleansed with warm water and soap before the application. The ointment should be gently rubbed into the surface and the parts covered with a compress wet with a solution of salicylic acid, and over this a thick layer of cotton wadding (Senn).

Kraske and *Kuhnast* recommend scarification or limited incisions entirely around the area just outside the border of inflammation, followed by irrigation with a five-per-cent solution of carbolic acid and the application to the erysipelatous area of compresses wet with a 2·5-per-cent solution of carbolic acid, the compresses to be changed once or twice a day (Tillmanns). A 1-to-1,000 bichloride solution, however, should be preferred to the carbolic-acid compresses. In making these incisions general anæsthesia is to be employed; they should be made in latticework fashion, as advised by Dr. W. Meyer.* The incisions should not extend through the skin, but well through the epithelial layers down to the corium. The point of these incisions should not be nearer than half an inch to the margin of redness (Fig. 45). The lines should be about one inch long and about half an inch apart and parallel with each other, forming a zigzag fence or latticework entirely encircling the inflamed area. In these cases the disease has frequently been arrested, the discoloration extending into the angles of the latticework incision, but not crossing the incised lines. When the arm or leg is involved in its entire circumference, two complete circles of the latticework incision should be made, one above and one below the erysipelatous area. When a mixed infection occurs, and when the swelling is great and gangrene threatened as a result of the extensive exudate, parallel and sufficiently deep incisions directly through the swollen parts should be made to lessen tension, and these wounds treated by a moist bichloride dressing (1-to-3,000), covered over with cotton batting.



Fig. 45.—Zigzag incisions, actual length. (After Meyer.)

Certain constitutional measures aid in the success of the local treatment. The bowels should be kept open and the most careful nourishment should be ordered. The patient should be isolated at the earliest suspicion of the disease and placed by preference in a large, warm, well-ventilated room. All dressings should be strictly antiseptic, the attend ants should bathe their hands in 1-to-500 bichloride solution, all instruments should be boiled as soon as used, and every precaution exercised to prevent spreading of the disease. The surgeon, while visiting a

* "New York Medical Record," March 15, 1890.

patient with erysipelas, should wear a gown moistened in 1-to-2,000 bichloride solution, and should bathe the hands, face, beard, and hair in the same before visiting other surgical cases. All furniture in the room should be well washed in 1-to-500 bichloride solution, the bedclothes boiled, and mattress and pillows burned to prevent further infection.

The prognosis in erysipelas is favorable in the vast majority of cases, and this should encourage us in advising *artificial inoculation* of this disease in certain cases of *malignant neoplasm*, as in sarcoma, in which, without any doubt, cures have been effected by the institution of acute septic infection.

A disease milder in type and somewhat similar to erysipelas, which in all probability is an infectious, non-suppurative dermatitis, is met with at times in the persons of those who are brought in contact with the skins and meat of animals. Pain is slight, and usually confined to the point of infection. It has been called *erysipeloid*, but is so rare that it does not call for special mention.

Hospital Gangrene.—Hospital gangrene, formerly one of the most terrible of all the infectious diseases connected with the treatment of wounds, has practically disappeared since the introduction of aseptic and antiseptic surgery. During the civil war it caused the destruction of several thousand wounded soldiers. The epidemics that occurred then seem to have been fatal by reason of improper nourishment and lack of cleanliness. It occurred more frequently in the fall and winter than in the summer months. Cases are so rarely met with now that no experimental investigations have been made to determine the peculiar micro-organism of this disease. In some experiments upon animals Koch discovered an organism, a streptococcus, which had a diameter of about 0·5 μ, which produced gangrene and was always present in his experiments upon mice. It is likely that this organism is closely related to the streptococcus of erysipelas, but it is more destructive. The tissues become swollen and discharge an enormous quantity of yellowish serum. During the civil war almost fifty per cent of the cases proved fatal; the cause of death was a severe form of septicæmia, due to the absorption of the products of decomposition in the tissues involved. The treatment then was to destroy the infected area with the actual cautery, or, as Hamilton recommended, with pure bromine.

Actinomycosis.—The germ of actinomycosis (actinomyces), a disease quite common in animals, is rarely met with in man. It is classed with the fungi. It was described by Bollinger in 1877, and seen by James Israel in man a year later (Warren). To the naked eye the organism appears to be about the size and shape of a millet seed, yellowish brown or green in color, soft in consistence; under the microscope it consists of clusters of wavy, bushy shreds, or club-shaped projections (Fig. 46). The most common seat of infection in man is the mouth, or it may be ingrafted upon any abrasion of the skin. It is characterized by inflammation and swelling, of a slow chronic type, with indurated margins to the sinuses formed by the discharge of serum and pus, which is usual in this disease. The fungus is not a pyogenic organism, hence the pus is

due to a mixed infection. When the gum is infected the bone also becomes involved and breaks down. The disease progresses slowly as a rule. The diagnosis rests upon the recognition of the peculiar millet-seed particles discharged from the swelling which can be seen under the microscope if not by the naked eye.

The disease may attack the lungs through the respiratory tract, or make its way through the mediastinum and attack the deeper organs; or pass into the alimentary canal and produce fatal results. Iodide of potassium in large doses has destroyed the organism in a number of cases and should be faithfully tried before resorting to operation. Every effort should be made to remove all the tissues involved in the early stages of the disease, and careful disinfection should be made with a strong solution of bichloride of mercury. Local use of nitrate of silver has succeeded in destroying the fungus and producing a cure when applied early in the history of infection.

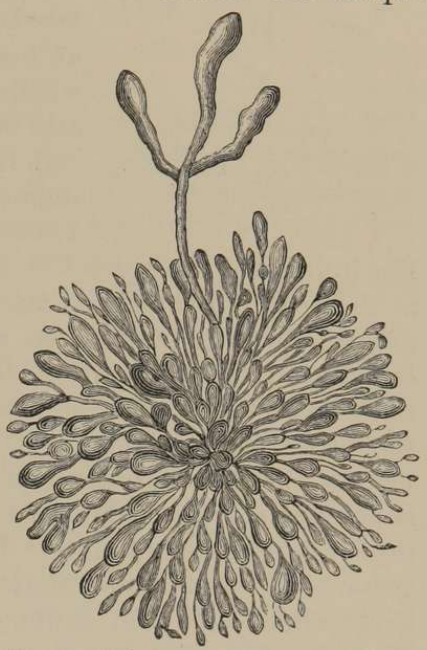

Fig. 46.—Actinomyces (ray fungus) with one branching filament separated from the others. (Ponfick.)

Anthrax. — *Anthrax* ("milzbrand," "splenic fever," "charbon," "malignant pustule"), a disease frequent in animals in certain portions of Europe, less frequent in the United States, attacking by preference cows, sheep, and horses, is rarely met with in man.

The specific germ, the *bacillus of anthrax* (Figs. 47 and 48), was discovered in 1850 by Davaine and Rayer. Under the microscope they appear as bright, transparent rods, with slightly rounded or swollen ends, giving a dumb-bell appearance, are from 3 to 6 μ in length and 1 to 1·5 μ in width, do not possess spontaneous movement, are *aërobic*, and perish in moist heat at 54° C. In chains of three or more links, they are compared to the articulation of the phalangeal bones or joints of bamboo rods (Warren). In *sporulation*, according to this author, the first indication is a thickening in the middle of the rod, which soon becomes a bright spot of irregular outline. In fresh bouillon at a temperature of 37° C., where a generous supply of oxygen can be obtained, the spore soon loses its glistening appearance and increases in length. The enveloping membrane gives way and the young bacillus projects from the opening; the shell finally disappears and the completely developed bacillus is hatched out. Spores do not develop in the living body or in the cadavers of animals dead from this disease. Before sporulation the bacillus is readily destroyed by a temperature of 54° C., but it is exceedingly difficult to destroy the spores. While the action of the gastric juice is usually fatal to this organism, the *spores* are unaffected and pass into the small intestine, where they develop. Infection in man is most frequently

through a slight wound in the skin, and occasionally through the respiratory tract. Those engaged in handling hides and caring for animals are most frequently affected; the bite of flies has also been known to convey this organism into the body. The period of incubation is from one or two hours up to as many days. In the few cases that I have seen infection has been rapid. In one instance the patient was inoculated on the side of the nose by a fly. Within an hour the infected point became painful and within six hours this area was deeply injected and swollen. The tension was relieved by a crucial incision under cocaine anæsthesia, and the immediate injection of bichloride solution (1 to 1,000) into the wound and the tissues surrounding it arrested the spread of the bacilli. In neglected cases the tissues at the seat of inoculation may become gangrenous, and as infection progresses there is high fever, nausea, vomiting, headache, disturbance of circulation and respiration, in severer cases, ending in convulsions. In these cases the bacillus enters the circulation and is distributed through the blood to all the organs. The treatment of malignant pustule demands the thorough saturation of the tissues about the wound by the subcutaneous injection of a 1-to-1,000 solution of corrosive sublimate. Immediate excision of the point of inoculation or thorough destruction with the cautery will suffice when the injection is not possible. After free incision in neglected cases, hot aseptic poultices should be applied. According to Warren, the bacillus pyocyaneus has been found to exert an inhibitory action upon the development of the anthrax poison, and it is yet possible that this organism may be employed as a therapeutic agent.

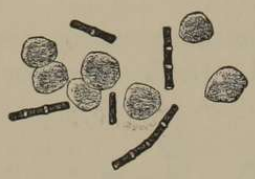

Fig. 47.—Blood from a mouse with anthrax, dried on the cover glass and stained with methyl violet. Red blood-corpuscles and anthrax bacilli. × 700. (Koch.)

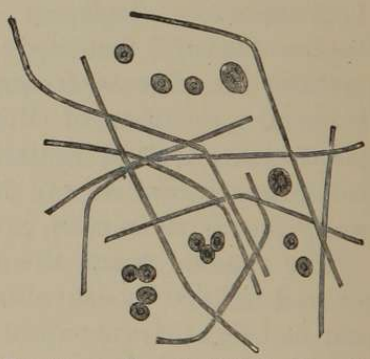

Fig. 48.—Anthrax bacilli joined together in the form of threads from a three hours' old culture of the blood of a guinea-pig in humor aqueus. × 650. (Koch.)

Glanders.—Glanders (farcy) is a disease met with chiefly in horses, but it can be transmitted, with the exception of cattle, to other domestic animals, and also to man. It is caused by the introduction of a specific bacillus which was first positively demonstrated by Loeffler and Schultz. They are delicate rodlike bodies, growing in the presence of oxygen at a temperature ranging from 25° C. to 40° C., and are without motion. They enter the body usually through an abrasion of the skin or mucous membrane, or may be carried into the system by the respiratory apparatus. It has been shown that in all probability they can pass through the unbroken skin and through the hair follicles. This organism is killed at a temperature of 55° C. It occurs most frequently in persons who work among horses, from which animal the disease is usually contracted. It has been known to attack the conjunctiva and the mucous membrane of the nose, but is more frequently

met with in the integument. In the mucous membrane of the respiratory tract and in the skin it is characterized by the presence of peculiar nodules, varying in size, and metastatic nodules are found in the deeper vessels (Tillmanns). In the acute form, destruction of the tissue involved is exceedingly rapid, with all the symptoms of severe general sepsis: pain in the back, joints, and limbs, high fever, and marked destruction of tissue at the seat of infection; lymphangitis, with widespread inflammation of the skin overlying the lymphatics, with suppuration, are also symptoms of this disease. In the subacute or chronic form, the local symptoms are less manifest, but metastases in the spleen, liver, kidneys, and other viscera occur. When found in the tissues, the glanders bacilli are in parallel groups or collections. The diagnosis of the disease must depend upon the peculiar appearance of the nodes and the association of the person attacked with animals known to have the disease. Tillmanns suggests a ready method of diagnosis: Inject the discharge from the suspected case into the peritoneal cavity of a male guinea-pig, and if the disease be glanders, in two or three days there will occur invariably swelling of the testicles, which increases during the next few days. In the treatment of this disease, as in all local affections, it is essential to destroy as early as possible the germs at the seat of infection. As advised in tetanus and anthrax, free incision, the use of the Paquelin cautery, or a free introduction of a 1-to-1,000 bichloride solution may be employed. When it occurs in the conjunctiva, of course this can not be done, but the eye can be thoroughly bathed with a strong bichloride solution, care being taken to wash out the excess of the solution.

Fig. 49.—Bacillus of glanders. Pure cultures upon glycerine-agar, teased specimen stained with carbolic-fuchsin. × 100. (Fränkel and Pfeiffer.)

Tetanus.—*Tetanus*, or "lockjaw," is an infectious disease caused by the lodgment in a wound of the skin or mucous surface of a specific microorganism known as the *tetanus bacillus* of Nicolier. It is one of the smallest bacilli and develops by sporulation. The spore or seed developing in one end causes this to swell, giving the rod a shape like a tack or drum-stick (Fig. 50). Its habitat is the soil, decomposed fluids, manure, and in the purulent discharge of a person affected with this disease. It is slightly motile, and is classed among the obligate anaërobic organisms —that is, it can not live where it comes in contact with the oxygen of the atmosphere. It is difficult to destroy the spores, and pus containing them has been dried for sixteen months, yet produced lockjaw when introduced under the skin of animals. They are readily killed when exposed to a tempera-

Fig. 50.—Tetanus bacilli with spores from an agar culture. × 1,000. (Kitasato.)

ture of 100° C. (212° F.). The toxic product or ptomaine of the tetanus bacillus, separated from these organisms by germ-free filtration, will, when introduced into the blood of animals, produce typical tetanus, but, as with other toxic products, it is not apt to prove fatal, since the symptoms are only temporary, the bacillus itself being necessary to prolonged sepsis. The bacillus of Nicolier, so far, has not been found in the blood or in any of the central organs. It is evident, therefore, that it remains near the wound of infection, where it generates a violent poison, which is absorbed and produces rapid infection and the convulsions peculiar to this disease.

The time which may elapse between the receipt of the injury and the appearance of the muscular spasms varies from a few hours to several weeks; usually within the first three weeks after the injury. The earlier symptoms refer to an unusual degree of irritation and pain in the wound, which is apt to be out of proportion to the degree of inflammation present. The sense of pain is often referred along the sensory tracts toward the centers. Irritability, a sense of unusual muscular excitability, a

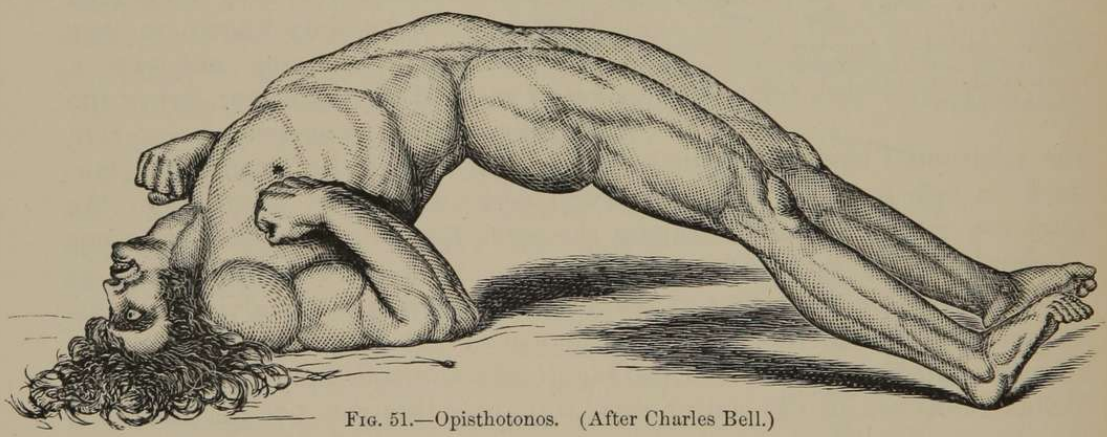

Fig. 51.—Opisthotonos. (After Charles Bell.)

feeling of malaise and apprehension, are among the symptoms which precede the convulsive attacks. The muscles supplied by the motor filaments of the fifth nerve are among the earliest to respond to this abnormal stimulus, hence the commonly accepted term of *lockjaw*. In the milder cases the tonic spasms may be altogether confined to these muscles. In severer cases the sense of distress is referred to the epigastric region, and this is followed by tonic muscular contraction, commencing with the diaphragm, and involving in quick succession the muscles of the jaws, larynx, and back of the neck and dorso-lumbar region. Respiration is interrupted, the expression of distress is extreme, the face becomes cyanotic, and death may occur from fixation of the respiratory muscles. The chief distortion is that of more or less complete extension of the spine (*opisthotonos*). An exaggerated illustration of this condition is given in Fig. 51, from the well-known picture of Sir Charles Bell. When the tonic spasms are confined to the anterior muscles, and the body is bent forward, the condition is known as *emprosthotonos*, and if curved laterally, *pleurothotonos*. The spasm continues until the muscles

are unable longer to contract, when a gradual and partial relaxation occurs. Successive attacks follow rapidly, being precipitated by the slightest cause, as the jar communicated by walking upon the floor, or the contact of the hair or clothing upon the hyperæsthetic integument. Occasionally the muscles near the infection are first seized with convulsions, as in the muscles of the calf when the foot is the seat of lesion.

Notwithstanding the violent nature of this affection, the mind, in the great majority of cases, remains clear until carbonic-acid poisoning occurs from prolonged fixation of the respiratory muscles. The pulse and temperature vary between great extremes, records of the former running from the normal up to 160 beats per minute, and of the latter from 98·5° to 112° F. The intense heat which is premonitory of a fatal termination, and which continues for a considerable while after death, is supposed to be due to coagulation of the albuminoid principle of muscle, the myosin (Fricke). Death may take place in a single paroxysm, or the patient may survive a number of attacks.

Prognosis.—The danger of death diminishes if the patient survives the seventh day (Prof. D. W. Yandell), although the vast majority of cases end fatally before this. The gravity of the prognosis usually depends upon the violence of the paroxysms, the rise in pulse and temperature being also proportional to the severity of the convulsions. The period which elapses between the receipt of the accident and the appearance of the tetanic spasms is not without importance in prognosis, the chances of recovery being increased with the longer interval. The death rate in those cases in which tonic spasms occurred within two weeks after the injury is 62 per cent; from 14 to 21 days, 17 per cent; 21 to 44 days, 17 per cent; 50 per cent of all fatal cases terminate within seven days after the first paroxysm; 33 per cent from the seventh to the tenth day.

Diagnosis.—Hysteria is more apt to be mistaken for tetanus than any other disease. In hysteria there is usually no elevation of temperature, and the symptoms of great and acute distress are wanting. Hysteria occurs chiefly in females; tetanus, in a large majority of cases, in the opposite sex. It may be necessary at times to differentiate between the tetanoid spasms of strychnia poisoning and true tetanus.

Strychnia tetanus ensues within a few minutes after the poison has been taken; the muscles of the jaw are not first affected as in tetanus, and are not always rigid during the attack. The convulsive movements in strychnia poison are of short duration, and complete relaxation occurs, while in tetanus the muscular rigidity is continuous.

Hydrophobia may be distinguished from tetanus in the character of the lesion which causes it, the peculiar clonic or interrupted spasm of the muscles, especially those of the larynx, and in the generally longer period of incubation in rabies.

The post-mortem changes are chiefly noticeable in the spinal cord where there occur extravasations of blood in the interstitial connective tissue of the cord and peripheral nerves and a granular infiltration of the nerve cells (Tillmanns). In the wound there is hyperæmia and swelling

and usually great pain. Suppuration does not occur unless some pyogenic organism has produced in the wound a mixed infection.

Treatment.—If a wound has been in contact with earth or other germ-carrying media, it should be immediately disinfected by immersion for fifteen to thirty minutes in bichloride solution (1 to 1,000), protected afterward by a moist sterilized dressing. When there is a deep punctured wound, as from a nail thrust in the sole of the foot, a syringe should be used to force the antiseptic solution in thoroughly, and all foreign matter should be carefully removed. This precaution should be taken in all cases. If infection has been established before the wound is seen by the surgeon, it would be well to attempt destruction of the nests of bacilli in the immediate vicinity of the abrasion in the hope that by destroying these the supply of ptomaines may be cut off and a fatal termination prevented. For this reason I would be in favor of injecting bichloride solution into the wound in all directions. Free excision may be performed in suitable cases, as this has occasionally proved successful. To relieve pain and spasm, the subcutaneous use of morphia is advised. Chloral hydrate, forty to seventy grains at a dose, *per rectum*, has been recommended. The percentage of deaths among cases treated with chloral hydrate, as given by Kane, was ninety-four out of one hundred and thirty-four. Tillmanns states that in ninety-three cases treated with chloral hydrate in combination with other remedies there were thirty-three deaths. This writer also recommends chloroform inhalation. De Renzi reports the cure of three out of five cases. His treatment is to place the patient in a dark room, plug his ears with cotton in order to shut out all sound, and allow no one to approach the patient except his attendant, and that in the gentlest manner possible; isolation should be absolute. There should be no light in the room, and a strictly fluid diet is given. For the relief of pain he recommends belladonna and ergot internally. Lately the treatment of this disease by the use of tetanus antitoxine is advised. According to R. T. Hewlett, tetanus antitoxine is obtainable in three forms, viz., (1) blood serum; (2) dry form, one gramme of which corresponds to ten cubic centimetres of the serum; (3) the serum may be precipitated with alcohol, and the precipitate dried (Tizzoni's antitoxine), which is the most concentrated form (Senn). The dose varies from five or six cubic centimetres to as high as one hundred and sixty-seven cubic centimetres. This quantity was given by Roux, and caused no general disturbance beyond producing urticaria. Such a large dose will rarely be required. Henle recommends from twenty to forty centimetres of the fluid serum for the first day, followed by ten to twenty cubic centimetres every six to twelve hours afterward. (One gramme of dry serum is equal to ten cubic centimetres of the fluid serum.) With Tizzoni's antitoxine the dose is two grammes to begin with, and 0·6 of a gramme in subsequent doses. It is administered by hypodermic injection with a syringe sufficiently large to necessitate only a single puncture. Antiseptic precautions should be taken in its administration. It should be given as soon as the disease is recognized. The quantity necessary will increase rapidly with the duration of the disease.

Hewlett suggests, on account of the prophylactic action of antitoxine in rendering the body proof against tetanus, that it should be administered early in cases where this infection is strongly probable. Injections of five cubic centimetres will suffice (Senn).

Malignant Œdema (*Gangrene foudroyante*).—The *bacillus of malignant œdema* resembles somewhat the bacillus of anthrax, but is not quite so large; it is capable of movement, and is found in parallel groups or in chains of three or more, forming long curvilinear bands. By Loeffler's method of staining delicate lateral cilia may be demonstrated. It is anaërobic, and in the presence of even a small quantity of oxygen its power of motion ceases. It reproduces its kind by sporulation, and the spores may be seen either in the center or end of the rod. It was called by Pasteur the *Vibrion septique*. It is found in fertile soil, foul water, and in decomposed matter. It measures 3·0 to 3·5 μ in length and about

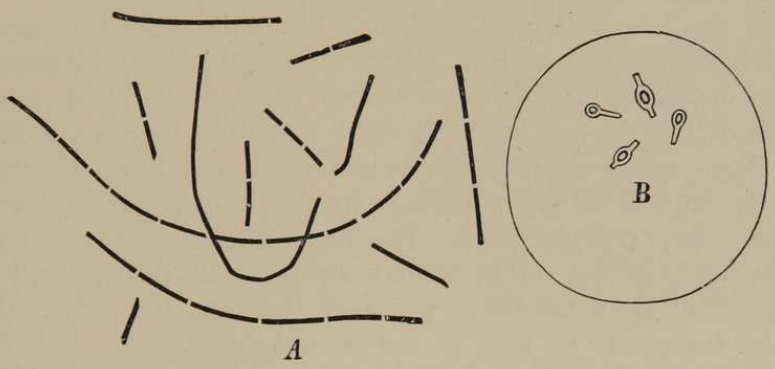

Fig. 52.—*A*, bacillus of malignant œdema. *B*, spore formation. (After Tillmanns.)

1·0 μ in breadth, and has pointed or rounded ends. In laboratory cultures with a temperature of 98 to 99° F. by the end of twenty-four hours the spores make their appearance.

Fortunately, malignant œdema is rarely met with in man, since it is a very fatal disease. The bacillus seems to possess the property of producing rapid decomposition of the tissues with which it comes in contact. When it does attack man it usually finds a lodgment in necrotic or gangrenous tissue. As a result of the decomposition caused by this *saprogenic* organism (σαπρός, putrid, γεννᾶν, to beget) gases are generated which produce extensive *emphysema* of the part involved. The rapidly gangrenous processes, of which many epidemics were reported in military hospitals in former days, were probably due to the presence of this then unrecognized micro-organism. The virulence of the toxic products (ptomaines) of malignant œdema is demonstrated in the fact that death occurs from their absorption before suppuration is established in cases where pyogenic bacteria are numerous. When the disease is established the thorough removal of the infected area and the prompt and vigorous use of antiseptics is indicated.

Foot and Mouth Disease.—Foot and mouth disease (aphthæ epizooticæ, so named from the vesicular eruption found in the mouths and clefts between the hoofs in animals) is a rare acute infectious disease,

transmitted to man from domestic animals, especially cows, sheep, and hogs, less frequently from horses and dogs ; it is communicable to man by infection through a wound or abrasion of the skin or mucous membrane, or by drinking milk from cows upon whose udders the vesicular eruption characteristic of this disease is present. The specific micro-organism has not yet been demonstrated. The symptoms as given by Tillmanns in stomach infection are stomatitis, gastro-enteritis, with fever, and a vesicular eruption scattered over the body. When infection through a wound takes place there is swelling (local and extending along the lymph channels) and later eruption. As a rule, it is not fatal in adults, but it has destroyed children of low vitality. The treatment is chiefly local and does not differ from that recommended in glanders. The general treatment should look to sustaining the vitality of the patient by proper nourishment until the violence of the disease passes by.

Hydrophobia.—Hydrophobia, or rabies, is an infectious disease acquired from the bite of a dog, wolf, or other animals of that group. A specific micro-organism has not yet been satisfactorily demonstrated. Pasteur has obtained by his experiments upon animals by continuous transference of the disease an antitoxine of rabies which is constant in its effect. It is obtained from the spinal cord and brain of inoculated animals. By the use of this substance he was able to immunize healthy dogs from the bite of mad dogs. His experiments have with seeming success also been carried on in human subjects, in Europe and in New York city, by Dr. Paul Gibier, a pupil of Pasteur, but as yet the demonstration of immunity in man is not entirely accepted. It is believed that, as in tetanus, the micro-organism of hydrophobia remains in the wound of infection, generating the toxic products, which, being carried by the circulation to the spinal cord and brain, cause hyperæmia, irritation, and the convulsions which follow as one of the symptoms of this disease. According to Tillmanns, ninety per cent of cases of hydrophobia in man result from the bite of the dog ; cats and wolves, four per cent ; foxes, two per cent.

The period of incubation varies from two weeks to as much as one year, in which time the wound of infection may be entirely healed. When systemic infection begins it is usually characterized by a feeling of uneasiness and depression ; in rare instances pain is felt in the wound, and in from one to several days convulsive movements of the pharyngeal and respiratory muscles occur. The reflexes are all exaggerated, and the effect is similar to that in tetanus. The convulsive seizures gradually increase in severity, and death follows, due to exhaustion from inability to swallow, as well as from the depressing influence of the virus. According to Charcot, the principal lesions met with in the deadhouse are inflammatory changes in the nuclei of the motor nerves. The diagnosis of rabies must depend chiefly on the knowledge of the inoculation from an animal either known or properly suspected of being rabid. The first indication in treatment is to neutralize the virus immediately. In the case of a child which was bitten by a dog that had been isolated for suspected rabies, within ten minutes after the infection I injected a 1-to-

1,000 bichloride solution in the wound and into the tissues for an inch around. Not the slightest evidence of any form of infection occurred in this wound. The dog, however, was not rabid, as it is living and healthy now, five years after the accident. A free excision of the wound or the application of the Paquelin cautery is also advised. Labial suction of the part should be made as soon as the bite has been received. In the method of immunization or protective inoculation as practiced by Pasteur the immunizing fluid of the proper strength is injected subcutaneously, and by preference in the abdominal wall. It should be fresh and absolutely sterile, and it is advised to make the injections mild in character for the first treatment, and in three or four days to increase the quantity gradually. There is nothing in the Pharmacopœia which has any special effect on this disease. The treatment is to keep the patient in a dark room, as free from noise and disturbance as possible. Reasoning from the beneficial effects obtained by the antitoxine of diphtheria, I would not hesitate to advise the trial of the method of Pasteur in hydrophobia.

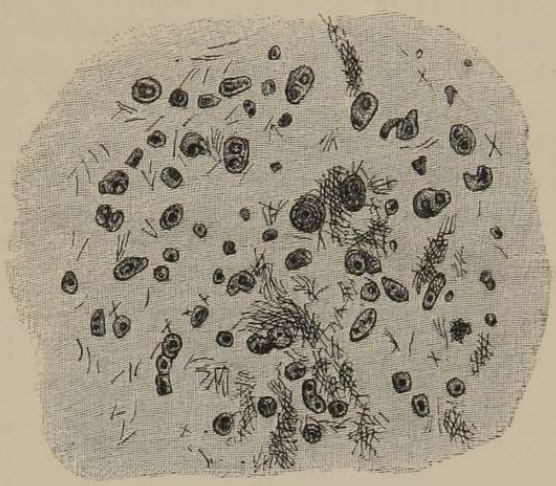

Fig. 53.—Tubercle bacilli (lung). × 700. (Koch.)

Tuberculosis.—Tuberculosis is an infectious inflammation of low grade caused by the *Bacillus tuberculosis* and characterized by the formation of nodules or *tubercles*, and never suppurating unless by mixed infection with pyogenic bacteria. No tissue or organ is exempt. In surgical practice tuberculosis of the lymphatic glands, bones, joints, skin, mucous surfaces, and periosteum are the principal lesions. The study of tuberculosis is not second in importance to any other disease, since one tenth of all who die perish from this affection.

The specific organism was discovered by Robert Koch in 1882. It varies in length from 1·5 to 3·5 μ and 0·2 μ in breadth, and is slightly curvilinear in shape, with rounded ends. It is non-motile, does not form chains, but is frequently observed in pairs or bundles. It multiplies by sporulation, and a single rod may contain as many as six spores, recognized as clear bright spots which do not take the ordinary stain. While thriving best in a medium containing oxygen (aërobic), it can exist without it, and is therefore classed with the *facultative* organisms. In the giant cells of the tuberculous process it is found in large numbers, usually collected in the periphery of these bodies. In tubercular nodules or foci which have undergone cheesy degeneration the bacillus is rarely met with, but the caseous material found in the nodules is rich in spores, from which infection may readily take place.

The bacillus of tuberculosis may be carried into the tissues through

abrasions of the skin or find its way into the system through the respiratory or alimentary tract. It is believed the chief source of infection is in the expectorated matter from individuals who are afflicted with pulmonary tuberculosis; it retains its vitality in sputa which has been dried for three years, and the dust about hotels and localities where consumptives congregate, where strict hygienic rules for the destruction of expectorated matter are not carried out, is rich in germs which readily produce tuberculosis. Probably the next in importance as a source of infection is cow's milk, and this is particularly true in regard to children. Tuberculosis is exceedingly prevalent in cattle, especially in herds that are kept in or near large centers of population.* The bacillus tuberculosis is found not only in the milk of cows with tuberculosis of the udder, but in those affected with general tuberculosis with seemingly healthy milk bags.† In unsterilized milk, germs of tuberculosis (and other diseases) may be lodged in the mouth, where frequent abrasions constantly occur. Infected meats not sufficiently cooked may also carry these germs into the system. From the buccal walls they find their way into the lymphatic channels and soon produce tuberculous changes in the lymphatic glands beneath the jaw and in the neck (the so-called "scrofula" of ancient writers). Even when swallowed, the vitality of the bacillus is not impaired by the action of the gastric juices, nor even by the toxic products of decomposition. When the bacillus of tuberculosis is lodged in the tissues it establishes a circumscribed inflammation of mild type. The cells of the part immediately in contact with these organisms undergo proliferation, and a tubercular nodule is formed. At the center of the nodule the bacilli perish first, while at the periphery their proliferation continues, and they advance with the process of inflammation toward the surrounding tissues. Examination under the microscope shows the nodule to be composed of leucocytes, epithelioid and large "giant" cells, all held together in a nodular mass by a delicate reticulum. Even the mild degree of inflammation which this organism produces attracts leucocytes which wander through the vascular walls to the intervascular spaces and form so-called "lymphoid" cells, which appear near the periphery of the nodule. Between the "giant" cell and these the epithelial cells are found (Senn).

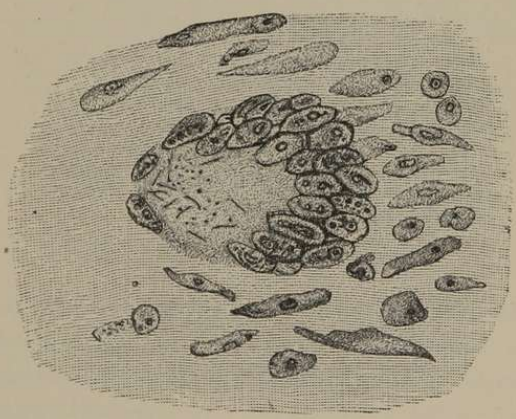

FIG. 54.—Giant cell with tubercle bacilli. × 700. (Koch.)

In the fibrous tuberculous nodule connective-tissue proliferation predominates. The nodule is grayer or more pearl-like in appearance and there is no well-marked reticulum.

* Dr. R. G. Freeman, "N. Y. Med. Record," March 28, 1896.

† Ibid. Bang. Schmidt's "Jahrb.," 235, p. 22.

The third variety, the hyaline nodule, is occasionally met with, caused, as is supposed, by hyaline degeneration of the reticulum. According to Senn, Chiari regards this as a benign change opposed to caseation, which latter process favors infection. The tendency of both the reticular and fibrous tubercular nodules is toward caseation, which begins, as already given, in the center of the nodule and advances with the extension of the inflammatory process. This caseous material is composed of the *débris* or wreck of all the cells that have undergone destructive metamorphosis, evidently resulting from lack of nutrition in the center of the nodule as well as from the chemical action of the ptomaines produced by the bacilli (Vissman). Occasionally the investing connective-tissue capsule is found to have undergone a calcareous change in the effort to confine the infectious spores. Certain individuals are more prone to infection by the bacilli of tuberculosis than others, due, in all probability, to diminished normal resistance of the tissues.

The forms of tuberculosis which come within the domain of surgery will be considered in the chapters which treat of the different regions of the body involved.

CHAPTER V.

SYPHILIS.

Syphilis.—Syphilis is an infectious disease confined to the *human* family, and affecting in a varying degree the nutrition of all the tissues of the body. The specific micro-organism of this disease has not yet been satisfactorily demonstrated. In 1884, Lustgarten, dermatologist to Mount Sinai Hospital, in the examination of discharges from specific lesions and in the exudate of syphilitic ulcers, found a bacillus which he believed to be the specific infective agent. He described it as a straight or curved bacillus, resembling the tubercle bacillus, but differing somewhat in reaction from staining. It is usually curved, or at times "S"-shaped, with knoblike swellings on the ends, 3·5 to 4·5 μ in length and 0·25 to 0·3 μ in diameter. Lustgarten also described the presence of spores in this organism. They are not found free in the tissues, but inclosed in cells about twice as large as blood-corpuscles, one or two in a single cell, occasionally more.

Fig. 55. — Wandering cells with syphilis bacilli. ×1,050. (Lustgarten.)

Eve and Lingard, in 1886, obtained in cultures from the blood of syphilitic patients who had not undergone mercurial treatment bacilli which in form and dimensions resembled the tubercle bacillus and which stained readily by Gram's method, but not by Lustgarten's (Sternberg).

Other investigators claim to have found Lustgarten's bacillus in preputial smegma.

In practice, two distinct forms are met with—namely, the *acquired* and the *inherited.*

Fig. 56. — Dry preparation of pus taken from a syphilitic sclerosis with syphilis bacilli. × 1,050. (Lustgarten.)

Acquired syphilis ensues when the specific virus is carried into the lymph or blood channels of a human being not syphilitic at the time of inoculation.

While it is generally believed that an abrasion of the skin or mucous surface is essential to the absorption of the virus, it is extremely probable that, if it is brought and kept in contact with the thin unbroken skin or mucous membranes, absorption may occur. A disease, the germs of which are transported within the spermatic elements, and with such po-

tency that the impregnated ovum is affected, can, under favorable conditions, in all probability be transmitted by unbroken cutaneous or mucous surfaces through which it is demonstrable that the absorption of other elements occurs.

The chief source of the contagion is in the fluid which transudes from the surface of the initial lesion or ulcer (chancre), and, next in order, that from mucous patches. The blood of a syphilitic patient also carries the poison and produces the disease if injected into or inoculated upon the tissues of another. The same is true of the matter or fluid from the cutaneous lesion of the secondary stage of syphilis. It is doubtful if the lesions of tertiary syphilis are capable of reproducing the disease.

Saliva from a syphilitic subject, unmixed with the discharge from mucous patches, fails to produce syphilis. Seminal fluid from a syphilitic man, in any stage of the disease, is held to be not directly contagious. However, the mother may acquire the disease from a child *in utero*, the child being syphilitic from the spermatozoa. Milk from a woman in any stage of syphilis will not produce the disease if injected into the tissues or ingested as food.

The transudation from a fissure in the nipple of a syphilitic nurse will, if lodged in an abrasion upon the lips, tongue, or buccal wall of the child, produce the specific disease in a non-syphilitic subject. On the other hand, a syphilitic child may inoculate a healthy nurse. The urine, tears, and sweat of syphilitic patients do not convey the specific virus. Pus from a vaccine pustule on a syphilitic subject does not convey the virus of this disease even when the vaccination is successful. If, however, blood or the fluid from any early syphilitic lesion is mingled with the pus, syphilis results.

While the most frequent seat of inoculation is upon the genital organs, or in their immediate vicinity, it may occur at any part of the body. Physicians are frequently inoculated on the finger in examining patients and in like manner they may transfer the virus to others. Dentists and barbers may also transfer the virus from a syphilitic to a non-syphilitic subject. The contagion may be direct or indirect. In the former, the virus of a specific ulcer is brought directly in contact with an abrasion upon a non-syphilitic subject. In the latter, the poison adheres to some intermediate agent, and thence is conveyed to the abrasion.*

The clinical history of a typical case of acquired syphilis left without treatment, and in a certain proportion of cases in which treatment is instituted, is divided by usage into three stages—primary, secondary, and tertiary. In a majority of cases, when properly managed, the later manifestations may be eliminated, and the secondary stage made shorter and less severe.

* In one of my cases the inoculation occurred in a fissure of the lip in the person of a merchant who was using a glass in common with a customer in sampling wines. In 1883 a patient presented himself at the clinic who had had a specific ulcer and syphilis resulting from being tattooed upon the arm. The operator moistened the point of the needle with saliva in which the virus from mucous patches was mingled, and thus conveyed it into the integument.

The *primary stage* includes: 1, absorption of the virus; 2, the ulcer; 3, local lymphangitis and adenitis.

The symptoms which belong to the *second stage* are the cutaneous eruptions, mucous patches, fever, arteritis, condylomata, alopecia, iritis, and general adenitis. In the *tertiary stage* the pathological changes are chiefly confined to the arteries, viscera, bones, the integument, and the subcutaneous and submucous connective tissues. This is the period of gummy tumors, connective-tissue formations, arterial occlusion, and deep ulcers of the skin and mucous membranes.

The usual duration of the first stage is from six to nine weeks. Secondary symptoms may, however, appear at the fifth or sixth week from the date of inoculation. On the other hand, in rare instances, they may be delayed to between the third and sixth month. The limitation of the stages of this disease is in great part arbitrary.

The duration of the second stage varies from the fifth or sixth week (or in delayed cases the sixth month after contact) to about the end of the first year after the inoculation.

The tertiary stage begins at the end of the preceding stage, and may last indefinitely.

First Stage.—When the specific virus is brought in contact with a broken cutaneous or mucous surface, absorption may begin at once or be delayed for a considerable period. The abrasion may be so insignificant that the patient's attention is not attracted to it, and, although the virus is lodged in it, it may heal over within a few days. If subjected to irritation by friction, or the simultaneous inoculation with the virus of phagedenic ulcer or other virus, inflammation supervenes, and an ulcer more or less phagedenic in character appears.

Absorption takes place chiefly through the lymphatics. It may occur through the blood vessels, and it is possible that in those cases in which constitutional symptoms appear with great rapidity and severity, the dissemination of the virus takes place in this latter way.

The rapidity of lymphatic absorption varies. There is usually a period of about three weeks from the time of lodgment of the virus until the local inflammatory process is recognized. That the specific virus has passed into the neighboring lymph channels before the appearance of the ulcer (chancre) seems satisfactorily proved in the repeated experiment of freely excising the initial lesion at its earliest appearance, in which cases constitutional infection was not retarded or prevented.

The *ulcer* of syphilis always appears at the point where absorption of the virus took place. From the inoculation to its appearance, the lapse of time is usually about three weeks—not less than ten days; occasionally delayed as many weeks. Its duration varies from two to ten weeks, occasionally longer. It often begins as a small papule, from the covering of which a clear serum escapes, or from the beginning it may exist as an erosion. There may be one or many, owing to the number of points simultaneously inoculated.

An uncomplicated initial lesion, not subjected to irritation, does not tend to ulcerate. It is usually circular or oval in outline, is shallow, in-

creasing gradually in depth from the periphery toward the center, and its surface is covered with a yellow serous transudation.

Grasped between the thumb and finger, it is found to be indurated, but not painful. The induration is closely limited to the sore, and terminates rather abruptly, not fading off gradually in a wide infiltration of the skin or neighboring tissues.

When the specific ulcer of syphilis is inoculated with pyogenic bacteria or a virus which induces phagedena, its peculiar character is lost, and it becomes in appearance and behavior a non-specific sore. If from friction, or the application of corrosive substances, or the cautery, an acute inflammation is precipitated, the specific character of the lesion also disappears.

Local lymphangitis and adenitis always occur in syphilis during the formation and existence of the initial ulcer. Commencing in the lymph channels immediately around the lesion, the process travels in the direction of the nearest glands. If the sore is well on one side, the glands of that side are usually first affected. When situated in the median line, or if ulcers exist on both sides, the adenitis is apt to be bilateral. In very exceptional cases, ulcer of one side is followed by unilateral adenitis on the opposite side of the body. Dating from the appearance of the sore, from eight to fourteen days usually elapse before enlargement of the inguinal glands is noticed. Less frequently, three or four weeks intervene.

From one to seven distinct glandular nodules may be felt. They are hard, yet slightly elastic to the touch, not painful under ordinary pressure, and freely movable beneath the skin. The size varies from those which are so small as scarcely to be recognized up to a half inch or more in diameter. There is no periadenitis, and, unless an acute or phagedenic inflammatory process is superadded, the glands do not become matted together in one hard, painful lump, nor does the integument become red and painful, as in the adenitis of phagedenic ulcer or gonorrhœa.

The primary adenitis continues into the second stage, in which induration of the glands is general.

When the ulcer is situated upon the lips, tongue, or mouth, the submaxillary plexus becomes enlarged. Adenitis of the epitrochlear and axillary glands follows inoculation upon the fingers, hand, or forearm.

Second Stage.—Cutaneous and mucous lesions, alopecia, fever, headache, arteritis, lymphangitis, adenitis, iritis, and osteitis.

The cutaneous lesions of syphilis (*syphilides*) may be macular, papular, vesicular, pustular, and tubercular. Of these forms of eruption, some are peculiar to the secondary period, others to the tertiary, while, as will be seen, some are met with in both the second and third stages.

The *macular* syphilide is usually first seen occurring as indistinct spots or stains, not elevated, and varying from a light red to a slate or copper color. They appear very frequently at the limit of the first stage of syphilis, about the sixth or seventh week after the ulcer occurs, but

often later than this period. The portion of the body where the maculæ are usually first seen is upon the abdomen, whence they may extend over the entire cutaneous surface. In size they vary from a pin-head to round or oval spots a half inch or more in diameter.

The *papular* syphilide occurs in several forms which may be present in the secondary or tertiary period. The mucous surfaces, as well as the integument proper, are affected. Not infrequently the papulæ are preceded or accompanied by maculæ. The papulæ assume various shapes, some being small and pointed, others broader at the base and flat on top, in shape like a truncated cone. Upon mucous surfaces the papular character of the eruption may be observed if seen early in its appearance; but, on account of the moisture present, the papules soon disappear, leaving patches which may be elevated or depressed. *Mucous patches*, when recent, are red in color, but later become covered with a grayish film.

The papular syphilide, which occurs near the junction of the skin and mucous surfaces, or in the deep folds, as those below the mammary glands in women, and between the thighs and gluteal regions in fleshy individuals of either sex, not infrequently, as a result of uncleanliness and irritation, becomes developed into papillary or warty growths known as *condylomata* (Fig. 57).

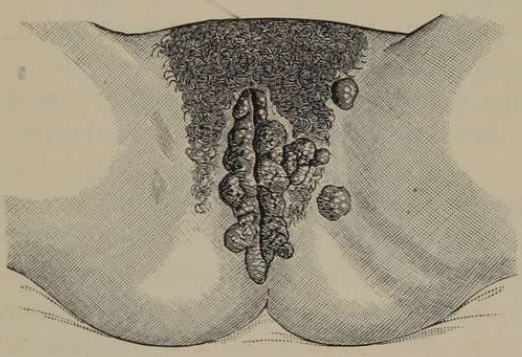

Fig. 57.—Vegetating condylomata of the vulva. (After Bumstead and Jullien.)

The eruption comes out in some cases over the entire body; in others the face is exempt. The palms of the hands and the soles of the feet are not infrequently invaded. At times the trunk is chiefly occupied, the face, hands, and feet escaping. The margins of the papulæ are well defined, varying in size as did the maculæ, and also in color. In the main they are darker, and the pigmentation is more marked. The eruption disappears by absorption of the cells which have infiltrated the papillæ and corium, and this may occur with or without desiccation or scaling. The *scaling syphilide*, or so-called *psoriasis syphilitica*, is at times with difficulty differentiated from true psoriasis, especially when the venereal inoculation is denied.

The *vesicular* syphilide is peculiar to the second stage, and is seldom observed. The vesicles, like the papules, may be small, pointed, and gathered in clusters, as in herpes; or larger, like the vesicles of chicken-pox, and scattered at varying intervals over the entire body. Commencing as vesicles, they may become pustules, which, as evaporation occurs, are covered with small crusts or scabs.

The *pustular* syphilide may be met with on all parts of the body, and may originate as a pustule, or, as stated above, become pustular from a vesicular or papular origin. This variety of cutaneous lesion,

while most common in secondary, is not infrequently seen in tertiary syphilis. The smaller-sized, more superficial pustules, belong naturally to the earlier period; those with wide bases and more extensive tissue destruction, to the later manifestations.

The pustular syphilide originates around and in the hair follicles. In mild cases, and when of small size, the limit of infiltration and pustulation is immediately around the follicle. In other cases the infiltration is wider, and the destructive process more extensive.

Scabbing, with underlying ulceration varying in extent, is the common history of all pustular syphilides, although extensive molecular death of tissue is less apt to occur in the secondary than in the tertiary stage. The color of the crusts varies from black to a brownish-copper color. If the scab is removed, the walls of the ulcer will be seen to be precipitate and curvilinear in outline, while the floor is covered with a varying amount of fluid and detritus.

The *tubercular* syphilide is so rarely a lesion of secondary syphilis that it will be described with the symptoms of the third stage of this disease.

It is exceedingly rare to observe all of the foregoing syphilides in any single individual. The macular and papular eruptions are frequently met with together, while the pustular syphilide usually exists alone.

Alopecia occurs in a varying degree in most cases of syphilis. Though noticed chiefly in the scalp and beard, all the hairy portions of the body are involved. Except in the case of the pustular syphilide, the follicles are rarely destroyed, so that, as the violence of the attack is diminished, the hairs are reproduced. Alopecia, from general seborrhœa, is one of the later manifestations of syphilis.

Fever.—Elevations of temperature occur in the second stage of syphilis in a large proportion of cases. In mild attacks it may not be observed, but in many instances the thermometer will register from one to two or three degrees above the normal. The febrile movement usually begins when the virus has passed through the first network of lymphatics and is being disseminated throughout the tissues. It may precede the eruption or occur with it, and, as a rule, continues after the eruption fades away.

Headache, usually referred to the frontal region, at times to the vertex or base, occurs during the period of fever, and is generally proportionate to the intensity of the febrile movement.

Arteritis, *lymphangitis*, and general *adenitis* occur in the second stage, and, in neglected cases, continue until the third stage. *Iritis* is not uncommon in secondary syphilis. It is usually unilateral, and may be recognized by immobility of the iris, photophobia, and by the red injection of the membrane.

Pathological changes in the bones do not occur, as a rule, in the earlier stages of syphilis. Pain, usually mild in character, is present in some cases in the second stage, but lesions of the osseous structures belong especially to the last stage of this disease.

Third Stage.—The lesions of *tertiary* syphilis rarely manifest themselves earlier than the second year of the disease. Once present they may continue for a while, and disappear, to return at varying intervals during the life of the individual. No tissue or organ is exempt from the grave pathological changes induced by the syphilitic virus in this stage.

Skin.—Externally, the changes in the skin are chiefly those of ulceration. Nodules, resulting from cell-proliferation and accumulation in the deeper layers of the skin, and at times in the subcutaneous tissues (*gummata*), appear, and after existing for a variable period of time may, by interference with the nutrition of the part, lead to molecular death of the adjacent tissues, or, failing in this, undergo fatty metamorphosis and absorption. If an ulcer exists, it has the usual shape of the syphilitic sore—round, oval, or curvilinear, with regular edges, not ragged or indented. When granular degeneration of the new tissue occurs, the skin immediately over the tubercle has a stretched or glazed appearance, and is slightly discolored.

A not infrequent pustular cutaneous lesion of the third stage of syphilis is known as *rupia syphilitica.* In very rare instances a pustular syphilide, similar in appearance and with difficulty differentiated from rupia, occurs as a secondary lesion. I presented one such case, with an unmistakable history of acute syphilis, to the New York Pathological Society in 1884. The pustules in rupia syphilitica are usually circular or oval in shape, appear as slight elevations or blebs, which soon break open. The sero-purulent contents ooze out; evaporation and scabbing occur; the crusts, by reason of the new deposit underneath, are gradually lifted, and give to the scab a laminated, rough appearance, not unlike that of an oyster-shell. The crusts have a dark-brown or slightly greenish hue.

When the late cutaneous lesions of syphilis attack the fingers, the nail or matrix is affected (paronychia), causing a roughened condition of the nail and a swollen matrix, leading frequently to temporary, and occasionally to permanent, loss of the organ. In like manner, permanent alopecia may occur from destruction of the hair follicles.

Nervous System—Brain.—Paralysis is one of the most frequent lesions of tertiary syphilis, and may result from one of several causes, namely—pressure of a gumma developed within the brain-substance, proper or upon the investments; pressure from syphilitic exostosis of the skull; destruction of brain-cells by connective-tissue hyperplasia in the neuroglia, with consequent cicatrization and contraction; more or less complete occlusion of the arteries (*endarteritis obliterans*).

Hemiplegia, partial or complete, is the rule. Occasionally the center of language is alone affected. Dementia may ensue as a result of softening or pressure, and epilepsy may be classed among the late manifestations of this disease.

Chronic *meningitis* is an occasional symptom of late syphilis. It is accompanied by headache, dull and persisting in character, impairment of intellect, interference with the functions of one or more of the cranial

nerves by extension of the morbid process, resulting at times in ptosis, strabismus, or impairment of vision, hearing, taste, smell, etc. The more serious cases progress gradually to coma and death. There is in all an elevation of temperature, loss or impairment of appetite, and derangement of the entire digestive apparatus.

The *spinal cord* and its *membranes*, though less frequently attacked than the brain, may be involved as a result of similar pathological conditions. Paraplegia, more or less complete, ensues, involving at times the bladder and rectum. In milder cases co-ordination is disturbed, with little or no loss of muscular power. Pain may be present, referred to the back at or near the seat of the lesion, or along the distribution of the sensory nerves, or anæsthesia may occur.

One or more of the *nerves*, sensory or motor, may in like manner be affected as a result of the development of gummata, or connective-tissue changes in the neurilemma, or the pressure of exostoses or other neoplasms.

Bones.—Periostitis and *ostitis*, especially in those portions of the skeleton most exposed to sudden changes in temperature and to direct violence, are among the more frequent lesions of tertiary syphilis. The bones of the skull, the spine of the tibia, and the clavicle, are more often involved. The swelling caused by the inflammatory exudation may be readily appreciated by palpation, and pain or tenderness is present on direct pressure. The tumefaction results from the formation of new bone (exostosis), which in some instances persists indefinitely.

Gummata are developed upon or beneath the periosteum, forming soft, semi-fluctuating swellings, usually circular in shape, and from a half inch to an inch or two in diameter. These tumors, or *nodes*, while not very painful under ordinary pressure, are the seat of exacerbations of pain which are usually experienced at night. They frequently break down in a process of ulceration which involves the underlying bone.

When the inflammatory process is violent, extensive necrosis may occur. A peculiar type of ostitis in the later manifestations of syphilis is that known as osteitis rarefaciens, in which there is no suppuration or exfoliation, a portion of the bone-substance undergoing absorption, giving to the part involved a porous or worm-eaten appearance.

Hypertrophy of the bones, even to a remarkable degree, is not uncommon, and may be due to the development of compact substance beneath the periosteum, or the entire cancellous portion may be replaced by this eburnated tissue. On the other hand, the hypertrophy is in some cases entirely cancellous in character, the bone taking on two or three times its natural thickness.

Joints.—The pathological changes in bone may also be accompanied by like changes in the articulations.

Synovitis, with thickening of the membrane and surrounding capsule, is present, accompanied by impairment of motion and pain of a dull character. In severer cases, the cartilages and bones become involved, leading to osteo-arthritis and destruction of the joint.

Heart and Vessels.—Fatty degeneration of the heart-muscle, following syphilitic myocarditis, and the formation of gummata upon the pericardium or within the muscular walls, are the chief lesions of this organ in the tertiary period. The pericardium may also be affected, and in like manner the endocardium, which may undergo atheromatous degeneration or give rise to vegetations. Of the vessels, the capillaries always affected in the first and second stages, are not so seriously involved in the last stages as the arteries. The veins are rarely affected. Arteritis, especially the variety known as *endarteritis obliterans*, is one of the most common and grave lesions of chronic syphilis. While the larger trunks are involved, the more characteristic changes occur in the terminal arteries and arterioles. The cerebral vessels are especially susceptible.

Lymphatics.—Gummatous deposits occasionally take place in the lymphatic glands in tertiary syphilis. The superficial set may break down and discharge their contents. The deep glands undergo granular degeneration with absorption, or the gummatous material undergoes caseous or calcareous degeneration.

Respiratory System—Nose.—The mucous membrane may be thickened, or may be more or less destroyed by ulceration. The cartilage and bony framework of this organ are very often destroyed.

Larynx.—The mucous membrane of the larynx may also be thickened, or the seat of ulcers or vegetations. Chondritis and perichondritis are not infrequent; and, as a result of the chronic inflammation, stricture and stenosis, more or less complete, may occur from cicatricial contraction. It may also be the seat of gummata. The trachea and bronchi are subject to similar lesions, inducing stricture.

In the lungs the principal lesions are—(1) chronic interstitial or fibrous pneumonia; (2) more or less widely disseminated gummatous deposits, usually in the lower portions of these organs.

Digestive System—Mouth.—Superficial ulcers of the walls of the buccal cavity are not infrequent; deep, destructive ulcers are rare. This can not, however, be said with truth, concerning the palate, where, as a result of gummatous deposits or general infiltration, the most rapid and irreparable destruction of tissue may occur. The curtain of the soft palate is frequently destroyed, the bony septum between the mouth and nose is perforated, while in extreme cases the pillars of the fauces and the pharynx are involved. Other lesions of the *pharynx* do not differ from those of the buccal cavity.

Tongue.—Gummatous deposits may occur in any portion of this organ, causing local or general tumefaction. Whether superficial or deep, they tend to break down, giving rise to ulcers varying in size and depth. The other principal lesion of the tongue in the tertiary period is more or less widely diffused connective-tissue hyperplasia, giving rise to a varying degree of enlargement. As the new-formed tissue contracts it gives to the organ a lobulated appearance, the boundaries of the lobules being well-marked fissures in the line of the contracting bands.

Œsophagus.—Partial or complete occlusion of the œsophagus may occur from—(1) connective-tissue hyperplasia in its walls, or the contrac-

tion following ulcer (organic stricture); (2) the mechanical obstruction from gummatous deposits in the walls or in the immediate neighborhood of the œsophagus; (3) pressure from exostoses, aneurisms, enlarged glands, etc. Syphilitic ulcers of the stomach and alimentary canal have been observed, though rarely. Gummata form here, however, with a certain degree of frequency, and stricture of the pylorus, and of the intestinal canal above the rectum, is known to occur in a certain proportion of cases. The *rectum* is especially liable to become seriously involved in the late manifestations of syphilis. Here, as elsewhere, stricture may result from fibrillation and contraction of the inflammatory tissue with which the walls of this organ and the peri-rectal tissues may become infiltrated. Again, ulcers originating within the gut, or extending from a like inflammatory process about the anus and the external tissues, or the presence of gummatous material, may all induce more or less serious contraction of the lumen of the rectum. Of the solid abdominal viscera, the *liver* is most seriously affected. The pathological changes are—(1) connective-tissue hyperplasia, or chronic interstitial hepatitis, or syphilitic cirrhosis, which may be general or local; (2) gummata in any portion of the organ; (3) waxy degeneration from long-continued general sepsis.

The *spleen* may undergo similar changes. Slight enlargement may occur from the excess of white corpuscles (leucocythæmia), which is the rule in this disease.

The *pancreas* is rarely affected.

Genito-urinary System.—Amyloid degeneration of the kidneys occurs as a result of the long-continued sepsis of syphilis, as with other chronic forms of blood poisoning. In like manner, under conditions favorable to connective-tissue hyperplasia, the fibrous stroma of this organ becomes thickened, with consequent atrophy of the excretory or glandular elements (chronic interstitial nephritis).

Gummata of the kidney is not as common as in other viscera.

Orchitis, although occurring while some of the secondary symptoms may be present, is essentially a late manifestation of this disease. It is important to recognize it, since several varieties of sarcocele require immediate surgical interference. Syphilitic orchitis should be suspected in all cases of tumor of this organ in which there is a history of specific infection. In syphilis, the enlargement is apt to occur in both organs about the same time. The growth is smooth and spherical, and when lifted conveys the sense of unusual weight. It is not painful, excepting always the sense of dragging, which is at times annoying. Slight hydrocele not infrequently accompanies this form of orchitis.

The testicles are not exempted from gummatous deposits. In rare instances these break down, causing more or less destruction of the substance of these organs. The penis is occasionally the seat of syphilitic infiltration in the later stages of this affection.

The Eye.—Syphilitic iritis has been given as occurring in the second stage of this disease. It may also occur as a later manifestation. Inflammation of the sclera, choroid and ciliary bodies, lens and capsule,

retina, and (though rarely) of the optic nerve, are of varying frequency in the tertiary period. Lesions of the muscles may be due to connective-tissue new formations between the fasciculi, resulting in granular degeneration of the muscle substance and contraction of the new tissue. It may occur in the second as well as the third stage of this disease. These contractions, if not relieved, may result in anchylosis of the joint in immediate anatomical relation to the muscles involved. Gummata are not of frequent occurrence. They terminate by suppuration or by absorption. Inflammation in the tendons and their sheaths may also occur.

Fingers and Toes.—The fingers and toes, during the tertiary period of syphilis, in a certain proportion of cases become the seat of gummatous deposits, the skin and subcutaneous tissues may be infiltrated, or the bones and cartilages may be involved. When the infiltration is confined to the soft parts, the entire organ will appear swollen and purple or reddish in color. When the bone is the seat of the deposit, it may be limited to a single phalanx (Fig. 58) or invade all the bones of the finger. The process terminates in ulcer, necrosis, or granular degeneration of the cells of the new tissue, and absorption.

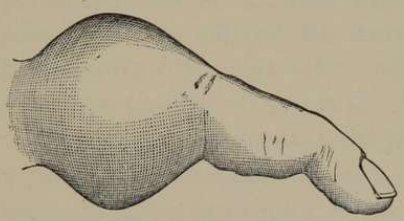

FIG. 58.—Syphilitic dactylitis. (After Bergh and Bumstead.)

Pathology of Syphilis.—The chief feature in the pathology of syphilis in all of its stages is the proliferation of an embryonic tissue, usually of a type so low that it is not capable of organization into a definite tissue. From the initial lesion and the primary lymphangitis and adenitis to the final lesions of the viscera, this cell-proliferation continues, and the different effects witnessed in different individuals, or in the same individual, in the various stages of the disease, depend chiefly upon the degree of impairment in the nutrition of the tissues. The cell-accumulation in and around the capillary loops of the cutaneous papillæ, which produce a macular or papular syphilide in one individual whose tissues are in a condition of perfect nutrition, will produce a squamous or vesicular eruption in another, or a pustular syphilide in a third who has the unfortunate inheritance of a gouty, scrofulous, or tubercular dyscrasia. Or a papular lesion of the first stage, in which the process of nutrition in the tissues is normal, may be replaced by a rupia in the tertiary period when assimilation is less perfect.

If the initial lesion of syphilis is excised and examined with the microscope, the following conditions will be observed: The epidermis in the immediate vicinity of the ulcer is more or less completely destroyed. The membrane which covers the floor of the ulcer is composed of pus cells, fragments of epidermal cells, cells of the Malpighian layer, and fragments of connective-tissue and other detritus. These elements vary in proportion as the process of necrobiosis is limited or extensive. In the deeper portions of the Malpighian layer, and in and around the papillæ where these layers are not wholly destroyed, and in the connective-

tissue layer of the skin, there is a general infiltration with the embryonic cells of the syphilitic process.

The arterioles, veins, and capillaries are more or less completely occluded. The cell-proliferation is especially marked in the arterioles, the adventitia and intima are thickened, the thickening being more marked in the latter, while the lumen of the vessel is more or less encroached upon by the new-formed tissue. The venules undergo analogous changes. The walls of the lymph-channels are thickened, and many of these vessels are crowded with cells. The infiltration is, however, limited to the immediate borders of the ulcer, and the line between this and the uninvaded tissue is sharply defined. As the mass of cells gradually obstruct the vessels, the nutrition of the new tissue is interfered with, and it either undergoes granular metamorphosis or breaks down more rapidly as a slough. The absence of pain in the chancre is also explained by the gradual pressure upon the terminal nerves and the comparative dryness of the typical sore by the arterial occlusion.

The *lymphatics* immediately around the ulcer, and those leading from it to the nearest glands, are more or less filled with the new cells, and their walls appear thicker than normal.

The changes which occur in the glands in the earlier stages of syphilis consist in a hyperplasia of the connective-tissue cells of the stroma and thickening of the fibrous framework, together with an increase in the cell elements of the gland substance proper.

The *cutaneous* lesions of secondary syphilis result from the more or less complete obstruction of the capillary loops of the papillæ by the cells of this indifferent tissue. The walls of the capillaries undergo degeneration ; the coloring matter of the blood escapes, causing the peculiar staining of the syphilides. In the macular syphilide the abnormal cell accumulation is less than in the papular eruption. The changes which occur in mucous patches differ very slightly from those described in the cutaneous lesions. The epidermis soon breaks down ; the Malpighian layer and papillæ are infiltrated with the cell elements ; while the capillaries, arterioles, and lymphatic vessels undergo changes almost identical with those described in the initial lesion.

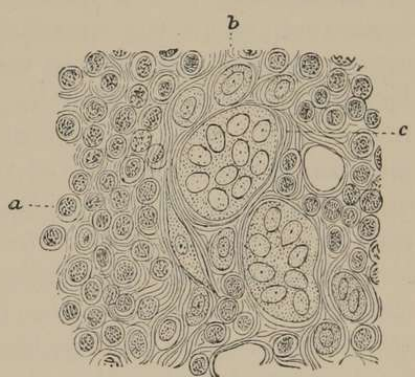

FIG. 58.—Section through a hard chancre; *a*, round-celled infiltration; *b*, large mononuclear cells; and *c*, polynuclear giant cells. Hæmatoxylin staining. × 300.

In the later or tertiary lesions of the skin in syphilis the infiltration is deeper. Cutaneous gummata consist of aggregations of the cell elements heretofore described, which are crowded into the subcutaneous areolar tissue, into the connective tissue of the true skin, in the walls of and just outside the vessels, while the endothelia of these vessels undergo proliferation and aid in their occlusion. Ulceration ensues from the rapid arrest of nutrition, and the process of necrobiosis is aided by the

depressed condition of the tissues which usually exists in the tertiary stage of syphilis. The tertiary lesions of the mucous surfaces are analogous to those of the integument.

The pathology of visceral syphilis presents two distinct morbid processes: (1) the hyperplasia of the connective-tissue stroma of the organs (cirrhosis); and (2) the aggregation of the syphilitic embryonic cells (gumma). The character of these changes in the different organs has been given.

Diagnosis.—In a typical case of acquired syphilis a diagnosis may be made upon the following symptoms: 1, an ulcer in appearance and behavior like that described as belonging to the initial lesion of this disease, the sore occurring not less than ten days, and usually about the twentieth day, after an exposure; 2, induration and enlargement of the nearest lymphatic glands occurring in from eight to fourteen days after the appearance of the ulcer; 3, after from two to four weeks of seeming arrest of the infection, the development of headache, pain in the back, slight febrile movement, with an eruption (sixth to seventh week after the appearance of the sore) over all or a portion of the body, accompanied with an unusual sense of dryness or soreness of the mouth, pharynx, or fauces; 4, following or occurring with these symptoms, general adenitis.

In the majority of cases, excluding even those in which the sore is concealed, as in the urethra, etc., little value can be placed upon the appearance of the ulcer at the point of infection. The classical "initial lesion" of syphilis, with its well-defined margin of induration, feeling like a "split pea" or piece of cartilage when grasped between the thumb and finger; the absence of pain and peripheral inflammation; the peculiar "scooped-out" concavity of the sore, the surface of which is covered with a scanty, serous transudation, is so frequently absent in cases in which the later and unmistakable signs of this disease are developed, that it alone can scarcely be relied upon in arriving at a diagnosis. As stated heretofore, the syphilitic virus may be lodged in and absorbed from a phagedenic ulcer in which not a single feature of the specific sore is present. The same is true of the herpetic ulcer, or that resulting from traumatism or the inoculation of any form of virus. All of these ulcers are grouped under the heading of "mixed sores" or mixed infection.

Induration of the glands is more reliable in a diagnostic sense. When the typical initial lesion is present, the ensuing adenitis is also typical. In the inguinal region one gland of the group after another is enlarged and becomes indurated. The process is slow and deliberate. There is no periadenitis, the glands do not adhere to each other and the intervening tissues, nor to the integument. Each body may be distinctly made out by palpation and moved beneath the skin independently. There is no tenderness, and the gland is leathery to the touch. Even when the sore is *mixed*, if the phagedenic or inflammatory process is not severe, the adenitis is more apt to be specific than inflammatory, and will possess the features of syphilitic bubo in a sufficient degree to admit of

recognition. When the specific infection is complicated with a typical phagedenic ulcer or gonorrhœa, the resulting bubo does not possess a single appreciable feature of syphilitic adenitis.

The eruption of syphilis is, of all the symptoms of this disease, the most reliable. When the sore is mixed, and the character of the adenitis doubtful, the early cutaneous and mucous lesions are, in the vast majority of cases, appreciable and unmistakable. Headache, rise in temperature, pains in the back, etc., are confirmatory symptoms, but independently of no value. The same may be said of dryness or soreness of the mouth, pharynx, and fauces. Lastly, general adenitis, which occurs in a varying degree in all cases of syphilis in which mercurialization has not been affected at a very early date, is a strong confirmatory symptom, and of great value in diagnosis if all the other lesions have escaped observation. The greatest importance is attached to induration of the epitrochlear, and to the occipital and post-mastoid glands. The former can scarcely be recognized in their normal state. In general adenitis a single body, feeling like a small bean in shape, may be recognized at the inner aspect of the arm just above the elbow, where it lies superficial, and internal to the basilic vein. When any inflammatory process exists in the member beyond the elbow, the enlarged gland possesses no specific diagnostic value. In like manner lesions of the scalp, face, or mouth may cause enlargement of the occipital or mastoid lymphatic glands.

A diagnosis of syphilis in the tertiary period must depend upon a careful study of the history of the case and the presence of one or more of the lesions which belong to this stage, and which have been fully described.

Prognosis.—A favorable prognosis in syphilis will depend upon—1, the physical condition of the individual affected at the time of inoculation; 2, the recognition of the disease within the first four or eight weeks of the disease; 3, the faithful and energetic co-operation of the physician and patient in carrying out the measures to be given.

That syphilis is a curable disease there can be no doubt. Under favorable conditions the symptoms disappear, leaving little or no trace of the infection. In common with all diseases, its severe or fatal results are seen in patients with an inherited or acquired dyscrasia, and in those whose nutrition is seriously impaired, or in neglected cases. Even in the worst class of cases the prognosis is not wholly unfavorable if proper treatment is instituted and maintained.

The recognition of this disease and institution of treatment at the earliest possible moment is very important. The prognosis is more favorable in the exceptional cases when a diagnosis can be based on the typical initial lesion or the earliest adenitis, for, if this is done, the violence of the infection may be modified and the deeper lesions rendered less severe. Even when, by reason of the uncertain character of these earlier lesions, a positive diagnosis can not be arrived at until the eruption is seen, a favorable prognosis may be made.

Treatment.—The treatment of syphilis is divided into—1, measures which tend to destroy the potency of the virus and aid in absorption of

the inflammatory products of this disease; and 2, those which tend to improve the nutrition of the tissues. Both are essential to the successful management of this formidable affection.

To the former belong the preparations of mercury, and iodine in combination with potassium; to the latter tonics, the careful regulation of the habits of living, nutritious diet, and healthful and moderate exercise.

Nothing is more satisfactorily demonstrated in scientific medicine than the power of mercury to neutralize and destroy the virus of syphilis. Its administration should usually begin with the positive recognition of the disease, and it is always advisable to wait until the diagnosis is assured, rather than to begin treatment with the uncertain recognition of the sore or bubo.

The management of a case of syphilis should be carried on for a period of two years.

It is of the utmost importance that the person affected should be impressed with the gravity of the situation and the certainty of disaster if the rules laid down by the medical adviser are not strictly obeyed. With the proviso of obedience, the prognosis should be as encouraging as possible. Responsibility for the result of treatment in this disease should not be assumed unless the patient consents to keep himself under observation for the period above given. All excesses should be prohibited. The use of tobacco and alcohol in any shape is scarcely allowable. In certain cases, where digestion and assimilation are impaired, a small quantity of whisky, claret, or sherry may be taken with meals. Sexual indulgence, if from no other than humanitarian motives, should cease for at least a year from the appearance of the initial lesion. The child of parents, either of whom is within the first year of syphilitic inoculation, becomes the victim of a dyscrasia which, if not fatal to life, is fatal to the perfect usefulness of its possessor.

In addition to the danger of direct inoculation during the prevalence of the chancre, is that of infection to the mother from the fœtus *in utero* or the child in the act of parturition. A patient under treatment for syphilis should retire early and at a regular hour, avoid excessive use of the eyes, especially at night, sudden changes in temperature, and all articles of diet which are not readily digestible.

Of the preparations of mercury, preference should be given to the protoiodide. It is conveniently administered in pills of one quarter grain each. To begin with, one of these pills should be given three times a day one hour after eating. The indications for a diminution in the quantity are pain of a cramp-like nature in the stomach or bowels, with or without diarrhœa, and the occurrence of salivation. Clinical experience teaches that salivation does not occur with the protoiodide until after a colicky diarrhœa which should be a timely warning for diminishing the dose. If diarrhœa results, it will be advisable to administer about one quarter grain of opium with each pill of protoiodide, or to reduce the daily number of the pills. Under such conditions, inunctions with mercurial ointment are of great value. Salivation may be guarded against

by careful observation of the gums. At the earliest indications of tenderness felt when the teeth are firmly pressed together, or when direct pressure is made upon the alveolus, the dose should be diminished, or, if necessary, discontinued for a few days.

It will usually suffice to administer one quarter grain three times a day for the first month, and at the expiration of this time to increase the daily quantity to gr. j. It will rarely be necessary to give more than this quantity, although in some cases the full beneficial effects of the remedy may not be realized until a larger daily dose is given. The mercury should be continued without interruption—excepting for the reasons just given—for the first six months after commencing the treatment. At the expiration of this period it is a good plan to discontinue the proto-iodide for two weeks, and then administer the iodide of potassium in doses of grs. x–xx or xxx three times a day for one month. This should in time be stopped, and the pills resorted to for a period of two months, and so on, alternating these two remedies to the end of the first year of treatment. For the first six months of the second year the alternation should be equal—i. e., one month of the potassium salt, and the next the protoiodide. For the last six months of treatment the iodide of potassium should alone be given.

In addition to the foregoing it is of great importance that tonics should be administered from the commencement of the disease, and especially in delicate patients. In carrying out this part of the treatment much better results will be obtained in the alternate exhibition of several tonics rather than in the continued use of a single remedy. A preparation of iron, quinine, and strychnine on one day, given in the proper dose immediately after each meal; an emulsion of cod-liver oil with the hypophosphites of lime and soda, each gr. j to the tablespoonful on the next day; and tincture of the chloride of iron on the third day, will be found a convenient and useful method of rotation.

When protoiodide of mercury can not be obtained, the biniodide, in doses of gr. $\frac{1}{16}$ to $\frac{1}{12}$, or bichloride of mercury (corrosive sublimate), gr. $\frac{1}{20}$ to $\frac{1}{16}$ to $\frac{1}{12}$, may be substituted.

If, for any reasons, mercurial inunctions become necessary, proceed as follows: Take about a teaspoonful of mercurial ointment and rub it well into the skin of the groin and under the arms. Or spread the ointment on lint and apply it to these parts, holding it in place by lightly fitting clothes or bandages. It should be used only at night, and removed upon rising by washing with warm water and soap.

The hypodermic injection of corrosive sublimate in the treatment of syphilis, while objectionable on account of the annoyance produced by the insertion of the solution beneath the integument, may become necessary in certain patients who can not be brought under its influence in any other manner.

The injections should be made under the skin of the back and with most careful asepsis. From gr. $\frac{1}{16}$ to $\frac{1}{8}$ of corrosive sublimate may be used once or twice a day, watching the effect closely. A few minims of two-per-cent cocaine preceding the mercury will lessen the pain.

In the treatment of the tertiary lesions of syphilis practically the same rule of practice should be adopted as just given for the second year following the appearance of the initial lesion. The employment of iodide of potassium in full doses hastens the absorption of the inflammatory products of this stage, while the protoiodide destroys the potency of the virus. Both remedies should be administered in doses as large as can be borne without interfering with the functions of the digestive organs or producing any serious constitutional disturbances.

In the treatment of gumma and the destructive cutaneous tertiary lesions met with in neglected cases large doses of iodide of potassium are imperative. The dose should be gradually increased until either the symptoms of iodism are present or the lesions disappear. As much as 960 grains a day I have employed with curative effect.

Inherited Syphilis.—The fœtus may become syphilitic from a syphilitic father or mother. If pregnancy occurs within the first year, and especially in the first six months of the disease in the mother, the child becomes inoculated, either dying *in utero*, or, if carried to term, usually perishes within a few weeks after its birth. If, however, the disease is recognized and proper treatment instituted, a more favorable prognosis may be made.

In the second year after infection, if properly treated, a mother may bear a non-syphilitic child, although the chances are against complete immunity. During the third and each succeeding year, under judicious management, the prognosis is still more favorable.

A female patient should be advised of the great danger of pregnancy within the two years immediately following inoculation. When she has been under constant and proper treatment for this length of time, and has been perfectly free from symptoms for one year, the gravity of the danger is diminished. If she has not been treated, she should under no circumstances be made liable to pregnancy. In case such a woman becomes pregnant, she should be treated carefully for syphilis, and in this way the infection of the child may be modified, if not prevented.

The virus of syphilis may be conveyed by the spermatic elements, and the embryo thus become inoculated.* The prognosis is more favorable in proportion to the length of time which has elapsed after the initial lesion, and to the thoroughness of the treatment instituted. A syphilitic man should not beget a child within two years after the initial sore, nor at any later period unless thorough treatment has been instituted and one year has elapsed since the disappearance of all symptoms of the disease.

Symptoms.—The symptoms of specific infection in the child manifest themselves usually within the first eight or twelve weeks after birth. Occasionally the disease is latent, and the symptoms do not appear until

* As heretofore stated, a non-syphilitic mother may be inoculated from a syphilitic child in the act of parturition. That the mother is also subjected to the influence of this virus from carrying the offspring of a syphilitic father is proved by *Colles's law*, which is, that a previously healthy mother of such a child can nurse it without danger of chancre of the nipple and syphilitic infection, while a non-syphilitic nurse will become inoculated.

a variable period has elapsed. Even puberty may be reached before it is evident. Excepting the chancre, the local lymphangitis and adenitis, the evolution of the symptoms of inherited syphilis is not unlike those of the acquired form. The lesions are cutaneous, mucous, and visceral.

The macular or papular syphilide occurs in most cases, and may be distributed over the general surface or confined to certain limits. It is usually first seen upon the abdomen, and from this starting point it becomes more or less widely distributed. At the muco-cutaneous margins, and in the folds of the skin where irritation is greater and moisture exists, condylomata are not infrequent, and are often persistent. Vascular, pustular, and tubercular syphilides occur in a certain proportion of cases. The tubercular form is rare. The pustular form (syphilitic pemphigus) indicates a low order of tissue vitality, and justifies an unfavorable prognosis.

Lesions of the mucous surfaces occur either before or with the cutaneous lesions. Papules and excoriations (mucous patches) are found in the buccal cavity, on the tongue, fauces, and pharynx. Fissures of the lips are not uncommon, and especially in the angles of the mouth. The infection of the mucous membrane of the nose and air passages leads to the distressing coryza and cough so often noticed in syphilitic infants. Gummata of the skin and of all organs occur in the same manner and with the same pathological significance as in the acquired form.

Treatment.—The preparations of mercury antagonize the virus in this as in the acquired form of syphilis. The careful mercurialization of the mother during pregnancy is important in preventing the development of the disease in its severer forms. Inunction with the ointment of mercury should be first faithfully tried in the treatment of syphilis in the newly born. One drachm of mercury to one ounce of lard is the proportion recommended by Brodie. This is spread upon a soft flannel belt and worn continuously around the patient's waist. The ointment should be renewed as needed. If the beneficial effects of the mercury are not secured by this method, the internal administration may be resorted to, but in no case until after a thorough trial of the inunctions. The biniodide of mercury in doses of $\frac{1}{200}$ grain, in combination with one quarter grain of the iodide of potassium, is advisable to begin with. The dose may be carefully increased if necessary. The nourishment of the child should be most carefully attended to, and it should have the benefit of pure air and comfortable surroundings.

CHAPTER VI.

LEPROSY, DIPHTHERIA, TYPHOID, DISINFECTION OF EXCRETA.

Leprosy.—Leprosy is a disease exceedingly rare in the United States, and in a practical work on surgery demands scarcely more than mention. It is caused by the *Bacillus leprœ*, discovered by Hansen in 1879. It is incapable of motion, appears as a slender rod with rounded ends, and closely resembles the bacillus of tuberculosis. It is invariably present in leprosy, but is not as yet universally accepted as the specific germ of this disease. It is rarely found in the blood, exists in the skin, spleen, and liver, but is more apt to be met with in the skin, especially around the end organs of the sensory nerves. According to Warren, it is found within the epithelioid cells and occasionally within the leucocytes. The disease occurs in two forms, the *tuberculated* and the *non-tuberculated* or anæsthetic. It is difficult to differentiate one from the other except by the loss of sensation in the skin, which is a feature of the anæsthetic form. The invasion of the disease is slow and insidious and may last for many years. It begins with a general feeling of depression, loss of appetite, pain in the bones, and progressive prostration. Lesions of the skin are most marked. Tuberculated leprosy is characterized by the appearance of nodules which are usually round in form and vary in size from a small shot to an inch or more in diameter. They are usually met with about the face, but may occur on any part of the body. In the anæsthetic form the disease begins with the appearance of blebs of irregular arrangement, with marked hyperæsthesia that lasts for a short time and is followed by loss of sensation. Up to this date no method of treatment has been found efficacious and the disease is considered incurable. It is universally the custom to isolate those affected. It is more than probable that the advances made in the treatment of infectious diseases by the use of antitoxine will result in placing leprosy in the list of diseases that can be cured or prevented.

Fig. 59.—Lepra cells with bacilli. × 700. (Flügge.)

Diphtheria.—Diphtheria is a specific, infectious disease, attacking usually the mucous membrane of the respiratory tract and by preference the surface of the tonsils, pharynx, fauces, and larynx, and occasionally first observed in the nose or naso-pharynx. It is capable, however, of infecting any mucous surface or any point of abrasion either upon the skin or mucous membrane. The germ of this disease was recognized by

Klebs in 1883 and more fully demonstrated by Loeffler in 1884, and is known as the Klebs-Loeffler bacillus.

The *Bacillus diphtheriæ* exists as a small rod, generally curved, with rounded ends, two or three μ in length, with a diameter of 0·8 μ According to Sternberg, bacilli from the same culture vary greatly in diameter and shape. One or both ends may appear swollen or the central portion may be thicker than the ends. It is reproduced by fission, never by spore formation. It is classed with aërobic, non-motile, and non-liquefying organisms. Milk is given by Sternberg as a favorable medium for the growth of the *Bacillus diphtheriæ*, and he considers this fluid a dangerous medium for conveying the disease to the throat of children. It resists desiccation for several weeks, and, after being thoroughly dried, may reproduce itself if a suitable pabulum be found. Another organism almost identical with the bacillus of diphtheria, and practically impossible of differentiation by the microscope, has been found in the mouth and throat and described by Loeffler, Roux, and Yersin. This *pseudo-bacillus* of diphtheria possesses no pathogenic property, but when found, even if the constitutional and local symptoms of diphtheria are not present, it is advisable to treat such a throat or suspected region without delay with the strict antisepsis employed in the management of this affection. The toxic products or *ptomaines* of the bacillus of diphtheria are absorbed by the blood, and in severe cases rapidly produce an intense anæmia caused by the destruction of the red blood-corpuscles. It seems to exercise also a specific action upon the cells of the tissues, affecting powerfully the nutrition of the nerve cells, hence the frequent paralysis which is associated with diphtheritic sepsis. As given by Prof. Welch, a violent mixed infection often occurs in diphtheria due to the passage into the blood of pyogenic cocci.

Symptoms.—The symptoms of diphtheria are local and constitutional. The local symptoms consist of a characteristic membrane which in many cases is difficult to differentiate from other non-diphtheritic exudates. It is usually located upon the tonsils, spreading from this starting point down along the fauces and into the larynx or upward into the posterior nares and nose. With the diphtheritic exudate there is usually a peculiar odor and irritating discharge, swelling of the nearest lymphatic glands (submaxillary, as a rule), and a tendency to bleeding where the membrane is becoming detached. The membrane of diphtheria is closely adherent to and incorporated with the superficial epithelia of the mucous membrane upon which it organizes, while non-diphtheritic exudates, rest upon the epithelia and are easily removed without the bleeding which follows removal of the true diphtheritic membrane.

The *diagnosis* can be determined by the presence of the Klebs-Loeffler bacillus, together with the constitutional symptoms, the most positive feature of which is the profound prostration in these cases and which is out of all proportion to the fever and the local manifestations (Dillon Brown). The pulse is usually very rapid, but in certain rare and fatal cases it may be slow. The temperature usually rises high, but may be normal, and often subnormal, in rapidly fatal cases. The kidneys are

apt to be involved early in the disease, albumin and casts appearing in the urine within the first five days. There is occasionally an eruption of the skin, varying from a transient rash to dark-red spots or patches (maculæ), due to extensive extravasation.

In summing up the diagnosis, Prof. L. Emmet Holt concludes that—

(1) Pseudo-membranous inflammation, if in the larynx, is almost invariably true diphtheria—i. e., due to the Loeffler bacillus.

(2) Pseudo-membranous laryngitis following a primary pseudo-membranous inflammation of the tonsils, nose, or pharynx, is in the great majority of cases due to the Loeffler bacillus.

(3) Pseudo-membranous laryngitis following pseudo-membranous inflammation of the tonsils, nose, or pharynx, occurring as a complication of measles, scarlet fever, or influenza, is more frequently due to another kind of infection, usually the streptococcus, than to the Loeffler bacillus.

Treatment.—Serum therapy must be accorded the first place in the treatment of diphtheria. According to Holt, it is essential that a reliable preparation be employed. He prefers that prepared by the New York Board of Health or by Behring. It will keep for three to six

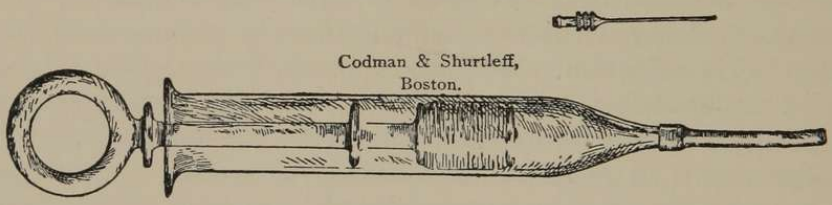

Fig. 60.—Syringe for serum injection.

months without deterioration. A slight turbidity and some floccular deposit are always present in the serum, but when it shows a milky turbidity or emits an odor suggestive of decomposition it should not be used. Serum usually comes in phials containing five cubic centimetres and is said not to be injured by freezing or extreme heat, but it should not be subjected to extremes of temperature if this can be avoided, and should be kept in a dark, moderately cool place. The most thorough asepsis should be practiced in the injection of this serum into the fat and connective tissue beneath the skin. The apparatus to be used should be thoroughly boiled before each injection. A glass syringe (Fig. 60) with a piece of rubber tubing attached and a good-sized needle, capable of carrying the serum into the tissues, make a simple apparatus which can be thoroughly cleansed by boiling. Dr. Holt prefers to inject a small quantity of a concentrated serum, as it is much less apt to produce rash, joint swellings, etc., which larger injections sometimes cause. The dose is to be measured not by the amount of serum, but by the number of antitoxine units it contains. A child under two years of age should receive 1,000 units in a severe case and 600 in a mild case, repeating the dose in from eighteen to twenty-four hours if no improvement is seen, and again after a similar interval if necessary. A child over two years of age should receive 1,000 units in a mild case as an initial dose, a second one being rarely necessary, and from 1,500 to 2,000 units in a severe case, repeat-

ing the dose as above given. With a concentrated serum, 2·5 cubic centimetres (38 minims), give 1,000 antitoxine units. Formerly it required a third of an ounce of Behring's serum to obtain this number of units.

Prof. H. M. Biggs, of New York, has collected over 13,000 cases treated by serum with a general mortality of eighteen per cent. Under older methods of treatment, the mortality rate was from thirty to sixty per cent. The most convincing argument in favor of the antitoxine method of treatment is to be drawn from a study of the cases of laryngeal diphtheria, of which there were 1,256. In 652 of these no operation (intubation or tracheotomy) was done. There were 128 deaths, in 48 of which laryngeal obstruction was responsible for the fatal result. In 564 there was clinical evidence that the larynx was involved, yet recovery took place without operation. Of the 372 physicians who reported cases, 350 recognized the efficacy of the antitoxine in preventing the extension of membrane into the lower respiratory tract.

The following is a summary of Dr. Holt's conclusions:

"1. The antitoxine serum is essentially harmless.

"2. To be of value it must be injected early, at least during the first three days. Sooner in laryngeal cases.

"3. There is no trustworthy evidence that it injures the heart, the lungs, the kidneys, or the nervous system, but, on the contrary, much that it diminishes the danger to all these by the diphtheritic poison, when it is used early and in sufficient doses.

"4. Properly given, it neutralizes diphtheria toxæmia, and controls pseudo-membranous inflammation due to the Loeffler bacillus; but it has no effect upon general septicæmia, nor upon pseudo-membranous inflammations due to streptococci like most of those occurring with measles and scarlet fever.

"5. With the antitoxine, *cardiac stimulants are to be used* as formerly whenever required by the condition of the pulse. Young and intractable patients may be more injured than benefited by any form of local treatment. For others, nasal injections of a warm salt solution (for cleanliness only) are to be recommended in nasal and nasopharyngeal cases.

"6. Every child exposed to diphtheria should receive an immunizing dose of the serum, from 100 to 300 units being given according to the age of the child. This will usually afford protection for at least a month."

Intubation.—In surgical interference for tracheal or laryngeal stenosis resulting from diphtheria intubation has practically superseded the operation of tracheotomy. We are indebted to Dr. Joseph O'Dwyer, of New York, for this brilliant innovation. According to Drs. O'Dwyer and W. P. Northrup, of New York, in addresses made before the British Medical Association in 1894, "the indications for intubation are a progressive and unremitting dyspnœa which allows any considerable part of the posterior portion of the lungs to become uninflated, and when the labored breathing begins to produce sensible exhaustion. When intubation is to be performed wind the child from chin down in a light blanket, shoulders, arms, and hands included. Pin the blanket

closely about the neck without making a bulky roll to interfere with depressing the introducer handle. In this way the elbows are pinioned to the side and the hands are held across the abdomen. The attendant holding the child should sit in a straight chair bolt upright, the child in her lap, and both facing the operator. The attendant grasps the child's elbows firmly, clasps its legs between the knees, securing thechild in a firm grasp, immobilizing it without interfering with the expansion of the chest. The position of the child should be as though it were suspended from the top of its head. Another assistant stands behind the nurse and grasps the child's head

Fig. 61.—Gag.

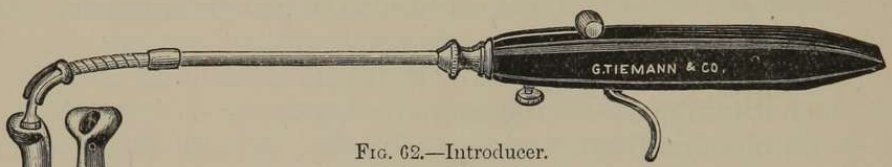

Fig. 62.—Introducer.



Tubes.

between his hands in order to hold it firmly, and when the gag (Fig. 61) has been inserted includes it within his grasp to insure its steadiness. The operator, sitting squarely facing the child, inserts the gag, opens the mouth widely, and gives the handle to the assistant. With the introducer (Fig. 62), armed with the tube of proper size,* already threaded, the operator inserts the index finger, hooks up the epiglottis, crowds his finger to one side, passes the tube beyond it until it engages in the chink of the glottis, elevates the handle, and gently presses the tube down till the head is within the box of the larynx and the introducer lies crowded upon the tongue. He then, with the trigger, loosens the obturator, holds the tube with the left index finger while withdrawing the obturator, and with a gentle thrust presses the tube's head well into the larynx and removes the finger and gag. Always keep the introducer in the middle line, otherwise the obturator will pinch in the caliber of the tube and draw the tube with it as it is withdrawn. The handle of the introducer should be held most lightly between the end of the thumb and finger. In this way it is impossible to use enough force



Fig. 63.—Scale.

* Dr. O'Dwyer's directions are as follows: The tubes are of various sizes, and are constructed on a scale (Fig. 63) somewhat like the urethral sounds. No. 1 is intended for a child eighteen months old, or less; No. 2, between eighteen months and three years; No. 3, for the fourth year; No. 4, for the fifth year, and so on.

When the proper tube is selected for the case to be operated on, a fine silk thread is passed through the small hole near its anterior angle, and left long enough to hang out of the mouth, its object being to remove the tube should it be found to have passed into the œsophagus instead of the larynx. The obturator is then screwed tightly to the introducing instrument, to prevent the possibility of its rotating while being inserted, and passed into the tube.

to make a false passage. It is easy for a right-handed operator inadvertently to carry his handle to the left of the child's middle line. Everything depends upon the coolness and skill of the operator and the absolute quiet of the child, who must be firmly and immovably held.

"Should the first attempt fail, it is better to make repeated short attempts than one prolonged effort. When the tube is properly lodged in the larynx, there will be some rattling on the first respiration and subsequent cough and expectoration. The cough argues well for the sensitiveness of the parts, and the gag may be removed as soon as the tube is in place, but the thread should remain until all obstruction to breathing has been overcome and the physician is assured that there is no partially detached false membrane in the trachea below the tube. An expert operator can remove the thread in the course of ten or twenty minutes, but since the removal of the tube requires a good deal of skill, it would be better ordinarily to leave the thread in for the purpose of removing the tube when the time comes. Children with teeth, however, are apt to chew the thread in two unless it is sunk down and buried between two teeth.

"To remove the tube when the thread is not left in, the child should be held in the same position as before; carry the left index finger past the epiglottis, hook it up, rest the tip of the finger on the arytenoid cartilages, and carry the extractor point to the end of the left index finger; elevate the handle so that the point will be directed forward from the left index finger on the arytenoid into the aperture of the tube. The guard screw of the extractor lever should be carefully set to avoid injury to the tissues in case the extractor jaws should be opened by mistake in the soft parts instead of in the tubes. As to the time of removing the tube, it depends upon the age of the child and the condition of respiration as affected by the disease; the average is about five days. Should a piece of false membrane be loosened, which is characterized by a croupy cough, rattling due to obstruction of outgoing air, and other symptoms of threatened asphyxia, the tube should be removed at once."

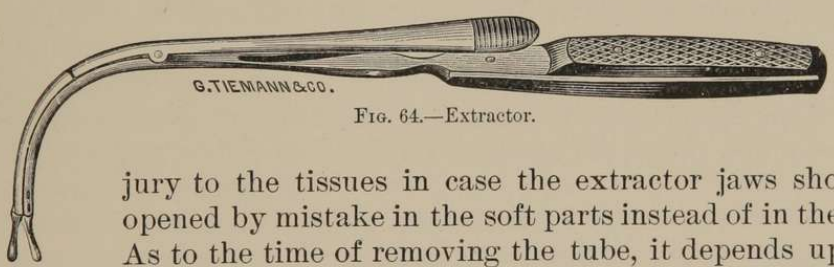

FIG. 64.—Extractor.

"Feeding a child after intubation is the great difficulty. When the effort of swallowing is accompanied by strangling, the child should be laid with the head lowered so that it swallows uphill, as any fluid which gets into the tube during the act of swallowing quickly runs out. The child should be fed either with a spoon or a nursing bottle."

NOTE.—A consideration of the bacillus of typhoid fever does not come within the domain of surgical pathology, but deserves mention from the fact that it has been met with in abscesses, which, however, were probably due to mixed infection during the process of typhoid fever. The thermal death point of this organism is 56° C. (138·8° F.) in streaming steam.

Disinfection of Excreta.—Under certain conditions, the surgeon may be called upon to advise in the disposition of infectious excreta: the discharges of dysentery, tuberculosis, diphtheria, yellow fever, scarlet fever, typhus and typhoid patients; the vomited matter in cholera, diphtheria, yellow fever, scarlet fever; the sputum in tuberculosis, diphtheria, scarlet fever, and pneumonia; and the urine of all patients with infectious diseases. The most efficacious method is by burning, and if this can not be done, the next best thing to be done is to pour boiling water, in quantity five or ten times greater, upon the material to be disinfected. Chloride of lime of the best quality (which should yield twenty-five per cent of available chlorine and which costs about one cent a gallon), is an excellent disinfectant. Distilled or pure water (six ounces to one gallon of water makes a proper solution). One quart is necessary to disinfect each rectal discharge. Expectorated matter should be discharged into a vessel filled with this solution.

CHAPTER VII.

SURGICAL DRESSINGS, ASEPSIS AND ANTISEPSIS, STERILIZATION OF MATERIAL, OPERATING ROOM, INSTRUMENTS.

Asepsis and Antisepsis.—The materials used in the performance of a surgical operation and the after-treatment form an important part of the surgeon's outfit, and the methods of preparing and preserving the apparatus needed for dressing wounds in the aseptic and antiseptic practice of to-day deserves most careful consideration.

This practice, which embodies the great principles of *cleanliness* and *carefulness*, is so well established among the best surgeons in America and Europe that any argument in its favor, as compared with the methods of one or two decades ago, is unnecessary.

Ligatures and Sutures.—Catgut, silk, silkworm gut, kangaroo or deer tendon, and silver wire will meet every requirement in tying vessels and closing wounds. Catgut has practically superseded all other substances as a ligature. The conditions which would justify the application of a silk, metal, or any non-absorbable ligature to an artery are rarely present. Strings or cords made from animal tissues, as buckskin, ox aorta, nerve, tendon, and whalebone, known under the general name of "broad ligatures," have been successfully employed in the occlusion of the larger vessels, but their use is limited in comparison with that of the violin strings, which are easily obtained, prepared, and preserved, and are, moreover, cheap.

Preparation.—Commercial or unprepared catgut can now be secured in almost any surgical supply or drug store, and should be selected from the sizes marked 00, the very finest, to as high as No. 12. The sizes for ordinary use are Nos. 0, 1, 2, 3, 4, and 6. No. 0 is fine enough for the ligation of the smallest vessels and for sutures. Some surgeons, however, prefer No. 00 for these purposes. No. 6, on the other hand, is too large for sutures, but may be used with advantage in tying large vessels, as the iliacs and subclavian and the cord in operations for castration. For ordinary purposes the sizes above this are not required.

It is always best, when possible, to secure suture material from manufacturers who have all the facilities for its thorough sterilization. Of late years I have been using with great satisfaction that prepared by Messrs. Van Horn & Ellison, of Park Avenue and Forty-first Street, New York city. Their method is as follows :

Remove the small threads which are tied around each bunch of cat

gut ; place it in a bottle or jar containing benzine, in which it is to soak ten days and for the very largest sizes two weeks, in order to remove the fat and oily matter ; then wash it well in purified ether (Squibb's) until all traces of benzine have disappeared ; wind loosely on sterilized glass reels and transfer to a strong glass jar having a cover which can be tightly closed by a clamp. This jar should contain ninety-five-per-cent alcohol, and is then placed in a steam-pressure sterilizer and boiled for one hour at a temperature of 215° F. Repeat this boiling in ten hours in



Fig. 65.—Case of suture bottles.

absolute alcohol, then transfer the gut to the final receptacle, containing absolute alcohol. The small bottles (Fig. 65), which have been previously sterilized, hold from fifteen to twenty feet of catgut. When placed in this final receptacle they are sterilized in a dry-heat sterilizer at a temperature of 250° F. for twenty minutes, and immediately sealed upon cooling. Frequent strict bacterial tests have been made upon this material, and it has been found pure. In the room in which aseptic material is prepared there should be no dust. By running a strong steam atomizer through the room an hour or two before exposing the clean material all dust will be precipitated. It is well to handle the material with sterilized instruments rather than with the fingers.

My own method of preparing suture material is as follows, and it is always preferable to prepare small quantities at a time : Whenever it is exposed to the air or touched, as when a portion of the contents of a bottle has been used at an operation, it should be again sterilized before it is used by boiling in absolute alcohol for forty minutes. As the infection, if present, is only on the surface, it does not require longer treatment. Select the proper sizes of raw catgut (ordinary violin strings) and soak in benzine for six days. If benzine can not be had, soak in Squibb's ether for four days. When benzine is used, wash the catgut in pure ether until all traces of benzine have been removed. While the catgut is soaking it should be agitated occasionally to aid in freeing it from fat and impurities. Transfer the gut to a clean wide-mouthed bottle filled with absolute alcohol and boil in a water bath for four hours as



Fig. 66.—Sealed tube of catgut.

follows: Place a folded towel in the bottom of an ordinary asparagus boiler (Fig. 67) or any utensil used for boiling, and stand the bottles on this; a toothpick or bit of wood should be put alongside the stopper to give vent to the alcohol vapor and prevent explosion. The water in the boiler need not be more than three or four inches in depth. As alcohol boils at about 170° F., it is not necessary to bring the water to the boiling point. The bottles should be sealed when cool. Catgut should always be kept in absolute alcohol, and it should be reboiled after a bottle has been opened, for reasons above given. It must be remembered that ordinary alcohol as purchased contains about fifteen per cent of water which ruins the tensile strength of the gut. Such alcohol can be made approximately absolute by breaking up in it pieces of gelatin, which rapidly absorb the water. After the gelatin swells with the absorbed water, the alcohol can be poured off. A better method, however, is to filter the alcohol through powdered anhydrous sulphate of copper. This is prepared by baking ordinary bluestone in an oven until it loses its water of crystallization and crumbles into a fine powder. Deer and kangaroo tendon sutures and ligatures require the same method of sterilization as catgut. On account of the larger size of this material, it requires longer submersion in benzine and ether.

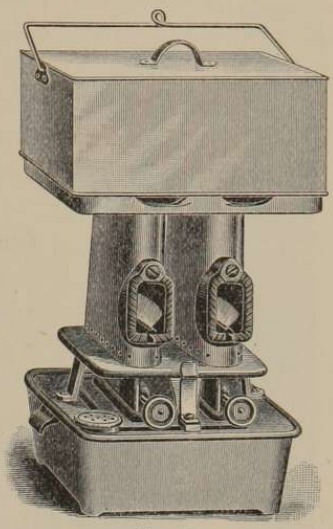

Fig. 67.

Chromicized Catgut.—The introduction of deer and kangaroo tendon sutures has lessened the need of chromicized catgut, but in certain emergencies it may be required. The following formula of Messrs. Van Horn & Ellison is recommended. The gut is prepared with benzine and ether, as given above, washed in absolute alcohol, and thoroughly dried, it being very important to remove all moisture. It is then cut in lengths of two yards each and wound on small glass reels, and allowed to soak for thirty or forty hours, according to the size of the threads, in the following solution:

℞	Bichromate of potash	gr. jss;
	Carbolic acid	gr. x;
	Glycerin	gr. x;
	Alcohol	ʒ ij;
	Distilled water	ʒ vj.

Mix.

It is taken from this solution and dried very slowly at a temperature *never higher than 120° F.* for at least three days, and then boiled in absolute alcohol for one hour, as given before in the preparation of plain catgut. The reels are next placed in bottles containing absolute alcohol with fifteen grains of glycerin to each ounce. The glycerin prevents the gut from getting too brittle. Catgut chromicized in this way will remain in the tissues from twenty to thirty days.

Silkworm gut should be boiled in water for an hour and transferred to long glass tubes, longer than the length of the gut to prevent bending (Fig. 68). These tubes are open at one end and contain two per cent of carbolic acid in alcohol. They should be sterilized in the dry sterilizer in the same manner as advised for catgut and silk, and then sealed. A *ready method* for sterilizing silkworm gut is to wrap as much as will be needed for the operation in a towel, and boil it well until needed.

Fig. 68.

Fig. 70.

The most thorough method of sterilizing all forms of silk suture material is by steam at fifteen pounds pressure for thirty minutes. It is done by winding silk loosely on glass reels. Place these in a glass tube open at both ends, the opening being filled with plugs of cotton, which will allow the steam to circulate freely through the tube. They are put in the sterilizer and subjected to pressure as above. Since all surgical silk contains impurities, it should be boiled in alcohol twenty minutes in order to remove them. It is then transferred to the final bottles, which contain alcohol, and which are then put in the dry sterilizer and sealed. Iron-dyed silk can not be treated in alcohol, as it dissolves the color. It should be boiled in water. This material is best kept in a solution containing twenty-five per cent boiled absolute alcohol, three per cent acetic acid, and two per cent carbolic acid.

In ordinary practice silk can be sterilized by boiling in an ordinary asparagus boiler for one or two hours. It should be kept in closed bottles in absolute alcohol (Fig. 69). In doing intraperitoneal work, as an additional precaution, the needles to be used are threaded with the silk and are run two or three times in a towel, the towel carefully folded and placed in the boiler and boiled with the instruments, to be taken out when needed. In like manner silkworm gut and silver wire may be rendered sterile at the time of operation.

Fig. 69.—Silk-bottle.

Gauze, cotton, and dressings are best sterilized by steam at fifteen pounds pressure for thirty minutes.

Silver wire may be readily sterilized by passing to a red heat through an alcohol flame or by boiling.

Sponges.—Most surgeons have discarded marine sponges in favor of gauze mops, which can be boiled and are inexpensive. When used a good quality of soft, close-mesh sponge should be selected.

Sand and calcareous matter are removed by pounding the sponge on a hard surface with sticks. This should be done carefully. The sponges are then placed for twenty-four hours in a weak solution of hydrochloric acid—one half ounce of acid to a pint of water—then removed, squeezed, and washed in warm water until all free acid is removed; then steeped for half an hour in a solution of permanganate of potash, thirty grains to a pint of water, washed thoroughly in plain water, and placed in the following solution: Hyposulphite of sodium, five ounces; hydrochloric acid, one ounce; water, two pints. Allow to remain for two hours; remove and place in running water or rinse thoroughly in warm water until all traces of the last solution are removed. They should then be kept dry in sterile glass jars.

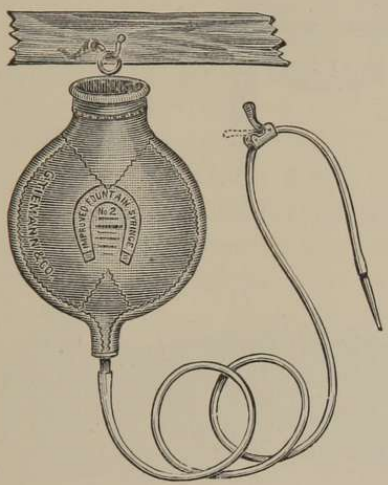

Fig. 71.

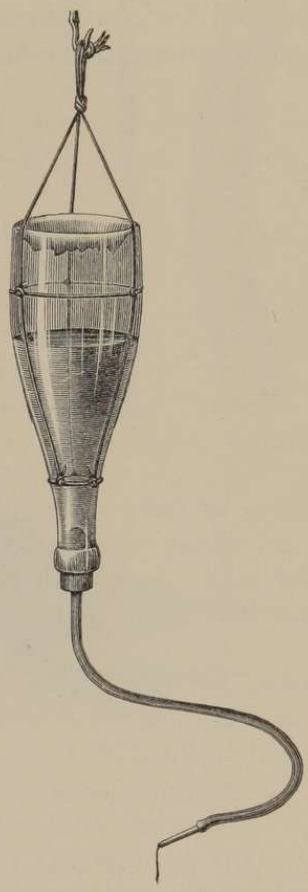

Fig. 72.

Sponges should not be kept in bichloride. Carry them wrapped in rubber tissue and inside the sponge bag. They may be sterilized by the above process after use in a clean case, but should always be thrown away after use in pus. The cheapest and probably safest sponge is a mop made of sterilized gauze—a dozen thicknesses of the gauze cut in convenient sizes and hemstitched around the edge. These are to be boiled in the sterilizer before the operation. Pads made twelve inches square are useful in abdominal work.

The *sponge bag* is made of cloth, lined with rubber, and closes with a draw string. These bags can be thoroughly cleansed and washed with bichloride. Gauze, cotton, safety pins, rubber adhesive, rubber tissue, hand brushes, etc., can be carried in this way.

Irrigators.—A rubber bag, capable of holding at least two quarts, with an extra long tube attached, makes a good irrigator. The ordinary fountain syringe (Fig. 71) may be employed, or the more modern apparatus with thermometer attached, which is preferable. The nozzle should

be of smooth glass, sufficiently heavy to resist breakage, about five or six inches long and not more than a quarter of an inch in gross diameter, slightly pointed, with a lumen of an eighth of an inch. An emergency irrigator is shown in Fig. 72; it is made by placing a perforated cork in an ordinary wine bottle, fitting a piece of glass tube, quill, or cane, to which rubber tubing is attached; the bottom is broken in and a string netting thrown around it for suspension. When no irrigator can be had, solutions may be poured on to a wound from a pitcher or cup. A ready method for continuous irrigation is shown in Fig. 73. It consists of a bucket suspended over the part to be irrigated in which the solution is

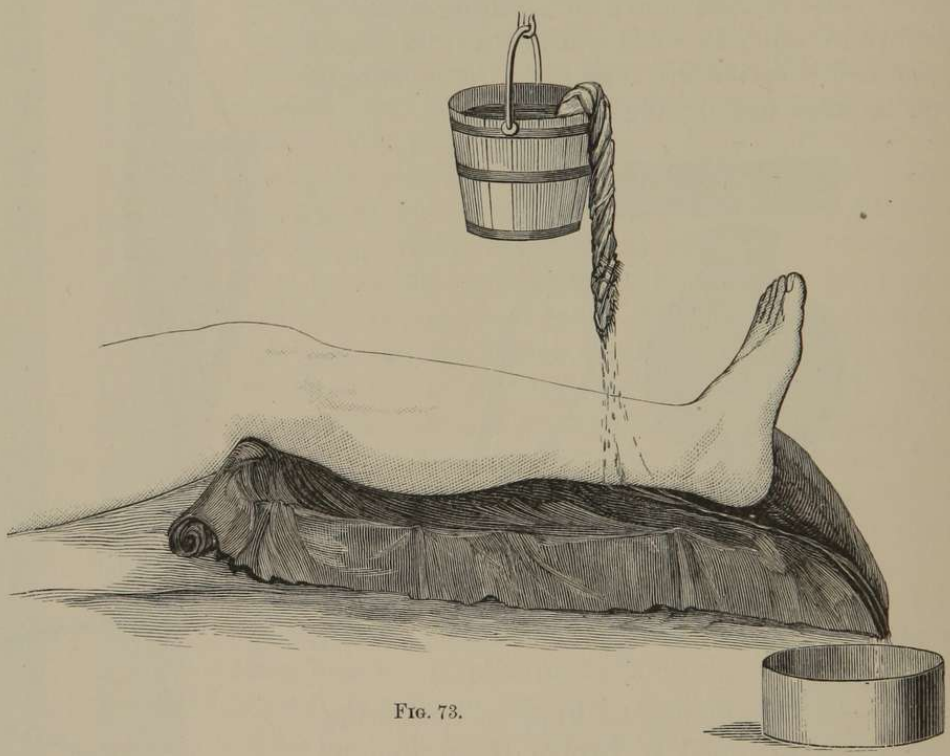

Fig. 73.

placed, out of which is allowed to descend a piece of cloth loosely twisted, one end being in the bucket of solution, which, by capillary attraction, drips continually.

Drains.—As a rule, aseptic wounds in which hæmorrhage has been properly arrested before the application of the dressing will not require drainage, and since the presence of a drain invites infection it should be avoided if possible. When necessary, a twist of sterilized catgut, as is shown in Fig. 74, will answer every purpose, the serum or even slight oozing finding its way into the dressing along the threads. The twist should fit loosely in the wound of exit, since it may by swelling completely occlude it and prevent drainage. Occasionally, however, it is essential to use rubber tubing. Two qualities are required—soft and hard. When possible, the soft-rubber tubing should be employed, as it gives less discomfort to the patient; but where any pressure may be exercised upon the tube, the white, stiffer rubber should be used. It may be perforated, as shown in Fig. 75, or not, as may be demanded.

Rubber tubing can be absolutely sterilized by boiling for half an hour or an hour before using, and the piece to be used should be placed in the sterilizer and boiled when the silk ligatures and instruments are put in before the operation is begun, and only taken out when they are to be used.

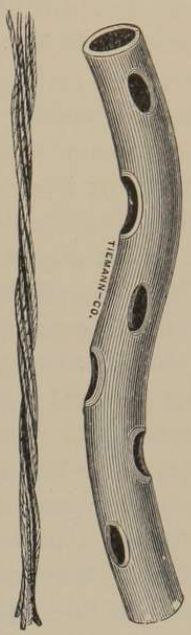

Fig. 74. Fig. 75.

Protective.—Thin rubber tissue or oil silk is often advantageously employed to protect the wound from the atmosphere and to prevent evaporation from a wet dressing. Rubber tissue is to be preferred and should be kept in a cool, dry place. It should be dipped in a 1-to-1,000 bichloride solution before it is used. It is not applied next to the skin, for a solution of this strength would produce dermatitis, but should be laid over the dressing.

Gauze.—Carbolized gauze is now no longer used, and the simple sterilized dressing has practically superseded the sublimate gauze. To prepare cotton cloth to be used for dressings, take a bolt of cheese cloth and cut it into pieces one or two yards long; place in boiling water for two or three hours; rinse in cold water and soak in liquor sodii chlorinatæ (one part to five of water) for twenty-four hours. Rinse again in clear water and fold the gauze away in towels in a clean drawer. When about to use the gauze for a dressing it is placed in the sterilizer and boiled. If a dry-heat sterilizer is at hand, it should be placed in that and subjected to a high degree of heat.

Fig. 76.—Ribbon of gauze in sealed tube for wick-drainage or deep packing.

If bichloride gauze is required, plain sterilized gauze should be dipped into a 1-to-3,000 solution of bichloride and squeezed as dry as possible before using. When bichloride gauze is brought into contact with the skin, however, it is so irritating that its use has been practically discarded.

Absorbent cotton is so difficult of preparation that the practitioner is obliged to buy it as prepared for the market. It can be sterilized as heretofore given. The ordinary absorbent cotton of the surgical market is not to be commended and should always be resterilized. This material forms such an important part of a surgical dressing that it should be prepared with great care. None should be used that has not been submitted to heat sterilization after manufacture.*

Syringes, Aspirators, and Hypodermic Needles.—Hypodermic needles should be sterilized after each insertion. They can be boiled in a teaspoon in the flame of a candle or gas jet before and after use, and this precaution will save any possible infection from this source. An aspirating needle should be passed through the flame

* I prefer the article obtained from Van Horn & Ellison.

of a spirit lamp or thoroughly boiled before and after being used. When used in a pus case, the whole syringe should be boiled for at least five minutes. This process is not very destructive even to hard rubber. If the washers become too brittle, they can be replaced. A reliable syringe, wholly of metal, which could be perfectly sterilized is greatly needed.

In every operating bag two or three hypodermic syringes, an extra aspirator, two or three hard-rubber syringes with delicate nozzles (vaginal syringes), a six-ounce glass barrel syringe with hard-rubber finishings for injections into the bladder or flushing wounds when necessary, and a soft-rubber fountain syringe for general irrigation, should be carried. In an emergency a fountain syringe can be used for saline transfusion. It should always be boiled for five minutes before being put to this last purpose. If a glass medicine dropper or the canula of the pocket-case trochar and canula is attached to the end of the tubing, a very simple apparatus for intra-venous saline injection is at hand. The solution should be used at a temperature of 110° to 115° F., registered by a thermometer attached to the irrigator. "As hot as the hand can bear" is an ordinary test for the safe temperature of the solution for "transfusion," which holds approximately a level teaspoonful of chemically pure salt to a pint of boiled and filtered water. Absorbent cotton is a ready and excellent filter material.

All solutions for hypodermic injection, such as morphine, cocaine, strychnine, etc., in distilled water develop a fungus in a short time, which invites sepsis. If they are made, however, in a saturated solution of boric acid, this fungus does not develop and the solution remains aseptic. Saturated boric acid should be kept on hand, and is easily made by placing half a pound of ordinary boric acid in a half-gallon bottle filled with boiled water and shaken until saturated. Cocaine should be kept in a cool spot, for at a temperature higher than 60° F. it begins to lose its anæsthetic property.

Catheters should be carried dry in a screw-cap bottle. They can be boiled without much damage if of pure rubber, and there is no other way of thoroughly disinfecting them. They should be lubricated always with glycerin, which is sterilized in the process of manufacture.

Vaseline for surgical purposes should be carried in closed tubes, the quantity to be used to be compressed out of the tube as required. Open jars in which the finger or instruments are thrust are quickly infected and remain so.

Needles after being polished should be carried in absolute alcohol to prevent oxidation.

Antiseptics.—In antisepsis preparations of mercury stand at the head of the list. Sternberg's experiments show that the biniodide of mercury is actively antiseptic in a proportion of 1 to 20,000 in distilled water (or clear water free from lime salts); mercuric chloride (bichloride), 1 to 15,000; protoiodide, 1 to 10,000. The mercuric chloride (corrosive sublimate) is most commonly used, and should answer every purpose. It can be obtained in tablets containing fixed proportions, to be mixed

with water as needed, one tablet to one pint of water giving a 1-to-1,000 solution. The stronger solutions (1 to 500 and 1 to 1,000) are rarely used, except for disinfection of the hands before an operation or to prevent infection of the operator when exposed to a poisonous wound. Sublimate irrigations are much less used now than formerly, but I do not think they should be altogether discarded. When flushing a wound a stronger solution than 1 to 5,000 is rarely employed, and even then precaution should be taken to thoroughly remove all moisture by sterile sponges or gauze mops. For irrigating broad surfaces and in large cavities, such as the pleural cavity in empyema, sterilized *normal* salt solution is preferable to a bichloride solution ; this is made by dissolving a drachm and a half of salt in thirty-three and a half ounces of boiling water (a heaping teaspoonful to one quart). A 1-to-1,000 solution of bichloride of mercury will destroy the spores of anthrax after several hours' exposure. Stronger solutions are therefore indicated in operations where spores exist, as in the removal of tuberculous glands which have undergone cheesy degeneration. In the presence of ordinary pyogenic cocci a 1-to-5,000 solution will suffice.

Permanganate of potash is antiseptic in a solution of 1 to 285 parts.

Alcohol is not to be relied upon under any conditions as an antiseptic.

Pyoktanin destroys the streptococcus pyogenes and anthrax bacillus in a 1-to-1,000 solution. The deep-blue staining which it causes renders it very objectionable.

Iodoform is very slightly antiseptic but when made sterile it aids in wound antisepsis by absorption of the moisture necessary to the proliferation of the septic organisms. The following method of sterilizing iodoform will render it a safe agent: Take the crystals known in trade as "non-conglutinating," place in a glass bottle and cover with a 1-to-500 bichloride solution ; allow this to stand forty-eight hours, occasionally shaking it. After the crystals have settled to the bottom all adulterated matter will float on the surface and may be removed by pouring off the supernatant liquid. Wash off the bichloride by shaking in distilled water that has been boiled and allowed to cool ; pour off the water and dry the iodoform slowly in an oven with mild heat.

In making iodoform gauze the crystals are rubbed into the sterilized gauze by the hand, using by preference a clean sterile board or glass table. In abdominal surgery I would recommend the use only of fresh gauze made by a reliable firm.

Acetanilide, a coal-tar product, is now extensively used in surgery and seems to be likely to replace iodoform. The disagreeable and penetrating odor of the latter renders it always objectionable. Dr. L. Lofton has employed this agent extensively in the treatment of chancroid, herpes, and ulcers. Burns of large area were thickly sprinkled with powdered acetanilide every three days, over this sterile gauze and cotton batting, without toxic effect and with great satisfaction.*

* "Southern Med. Record," April, 1896.

Operating Room.—A clean room free from dust, good light, and a generous supply of fresh air are of the first importance. The light, by preference, should fall upon the operating table from a point above the level of the patient. A skylight, or a tall, wide window are best. At night, electricity, gas, lamps, candles, or torches, mentioned in the order of preference, may be used. The temperature of the room should be rather above that which is conducive to the comfort of the operator and his assistants, to prevent the loss of body heat from the patient, often necessarily exposed, and at times deprived of normal heat by hæmorrhage and shock. Moreover, in the event of asphyxia, it may be imperative to introduce suddenly fresh air from open windows, which would lower the temperature to a dangerous degree if the room were not properly heated. In all operations the patient's legs and arms should be wrapped in warm clothing or cotton wool, and all parts not necessarily exposed kept warm. The room should be large enough to hold the apparatus and permit free, prompt movements of the assistants. The floor should be of wood or some hard material, not porous, and never carpeted; the walls and ceiling clean and free from unnecessary drapery. When dust prevails, a steam spray should be run for an hour before the operation is begun, to precipitate the dust and clear the atmosphere. Beside the operating table there should be two or three

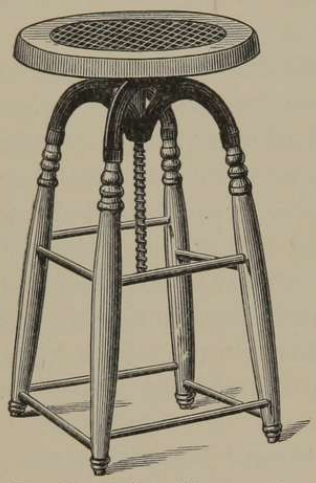

Fig. 77.—Adjustable operating stool.

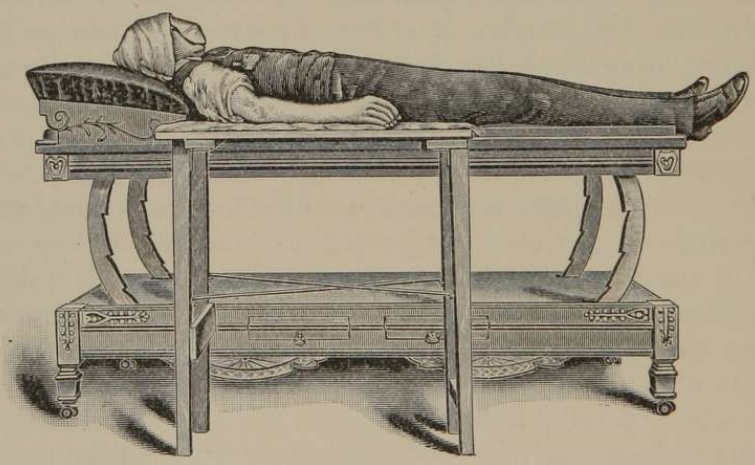

Fig. 78.—The Nedofik adjustable operating table.

small side tables covered with clean sheets to hold instruments, trays, dressings, etc., and an adjustable stool (Fig. 77) is a comfortable accessory.

In the selection of an operating table, it will add greatly to the comfort and convenience of the operator if it is adjustable, so that its surface may be raised or lowered. It is often essential to have one end of the table elevated considerably more than the other in certain operations. The Nedofik operating table (Figs. 78 and 79) I have found of great serv-

ice. It can be raised and lowered at will, and can also be elevated at either end when required, as in operations for hernia, hysterectomy, or when collapse occurs from cerebral anæmia. When not in use as an

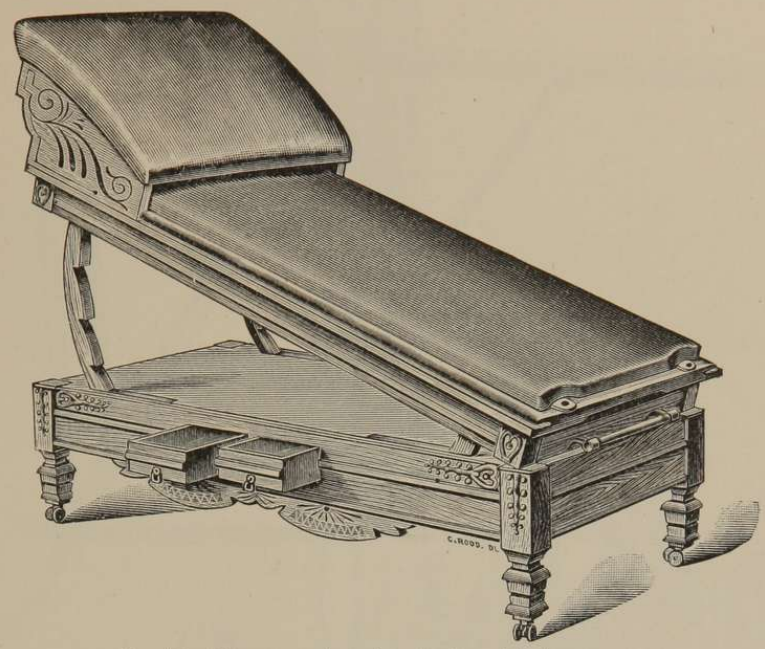

Fig. 79.—The same adapted to the Trendelenburg posture.

operating table it can be lowered so that it takes up the minimum of space. When a portable table is required, the apparatus devised by Dr. W. R. Pryor will prove very satisfactory. It can be folded up as shown in Fig. 80, and can readily be adjusted to the horizontal position (Fig. 81), which can be changed with the patient upon it to the Trendelenburg posture or any desired elevation. An ordinary kitchen or dining table, five or six feet long, or two smaller tables placed end to end, covered over

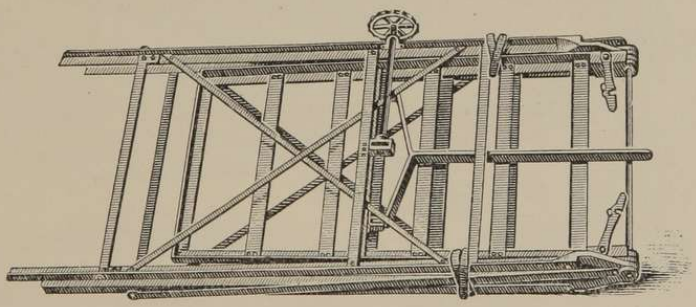

Fig. 80.—Prof. W. R. Pryor's operating frame folded for transportation.

with several layers of blankets or comforters, and over this an oilcloth, makes a useful operating table. A plain inch plank, six feet long and twenty or twenty-two inches wide, and two wooden benches or horses such as carpenters use, of proper height, will suffice.

Trays for holding instruments should be made of porcelain or agate ware, about two inches in depth and of a length to suit the various in-

struments (Figs. 82, 83). These trays should have a turned corner for readily emptying the solutions, and should be made in gradually reduced sizes, to fit one within the other, for compactness in carrying. Several

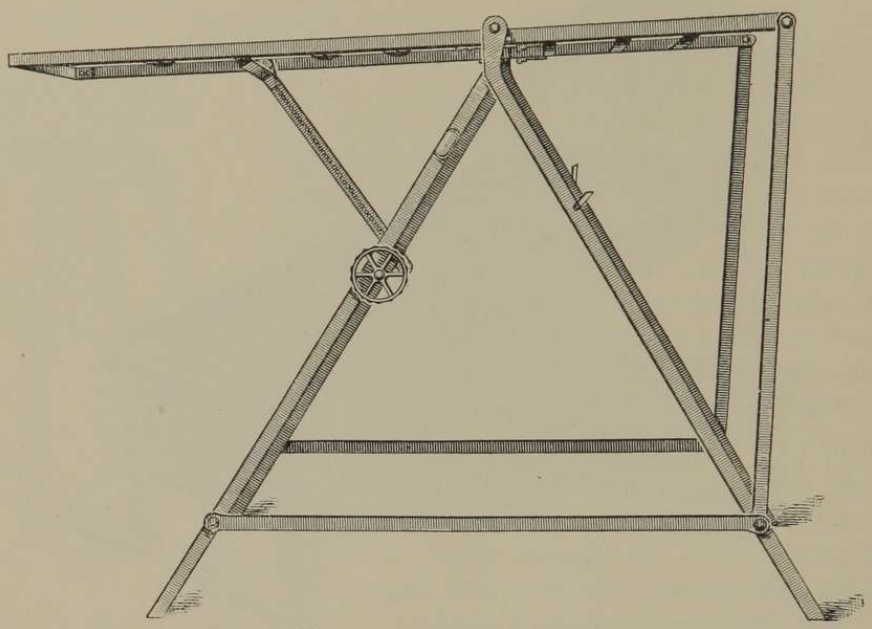

Fig. 81.—The same in position for ordinary uses.

pus basins (Fig. 84) are essential in case of vomiting or for catching fluids from wounds or after irrigation. Fig. 85 represents a suitable side stand and small outfit for an operating room. A number of bowls and pitchers of porcelain or glass for holding solutions should be on hand. The

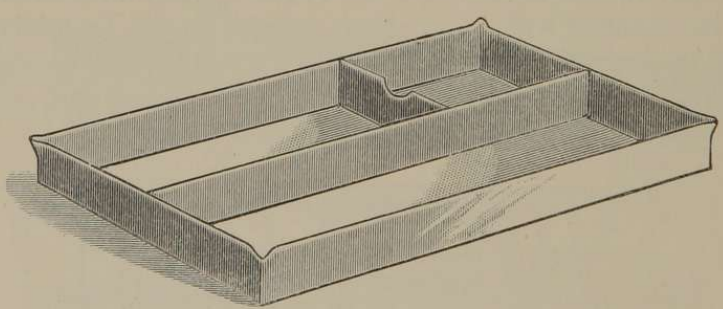

Fig. 82.



Fig. 83.

Fig. 84.

dressings and gauze to be employed should be put into the sterilizer and boiled until required. Iodoform or acetanilide gauze and cotton batting can not be made wet, therefore they should all be carefully sterilized by the manufacturer and protected from infection by the surgeon.

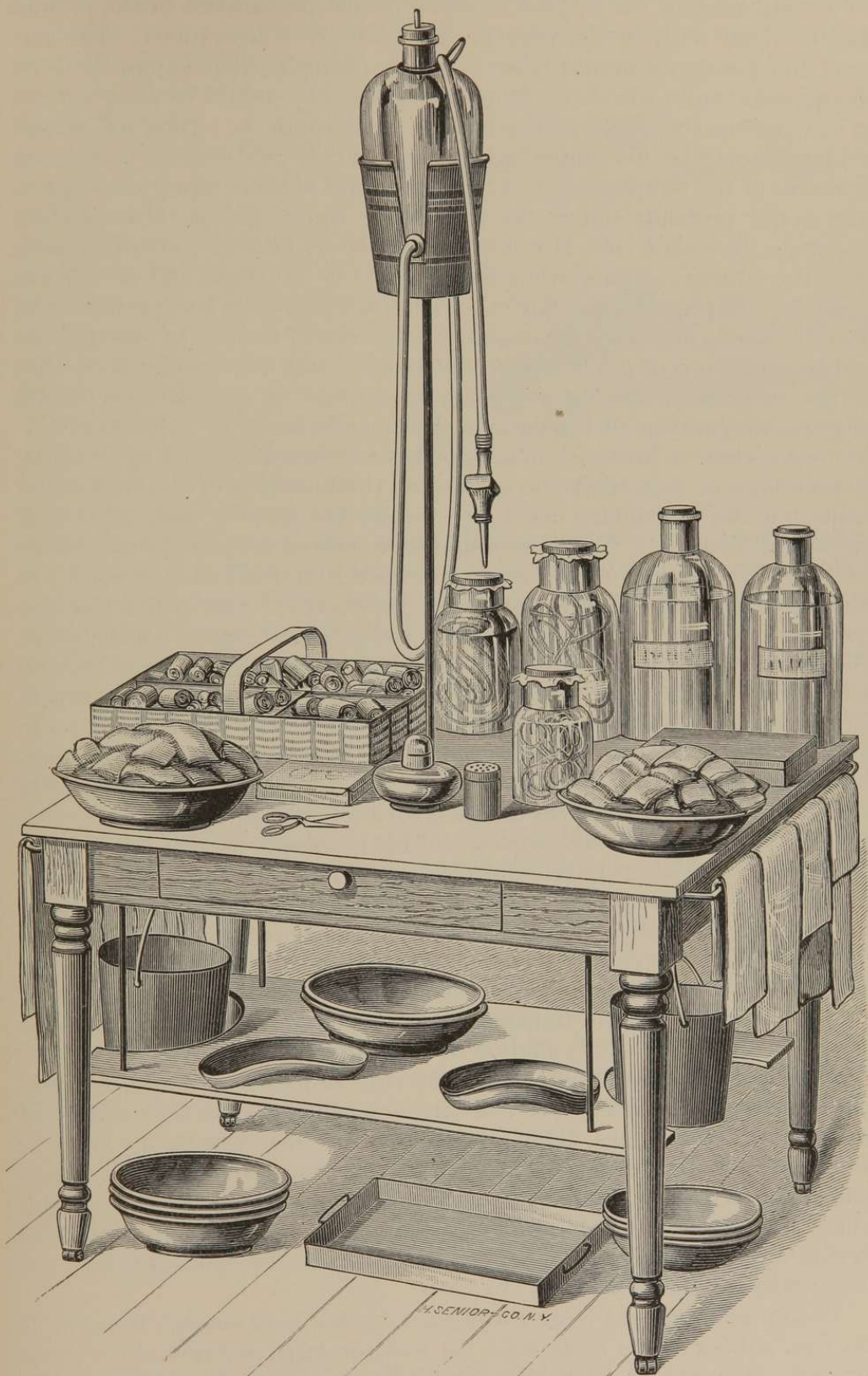

Fig. 85.

Preparation of the Patient.—The physical preparation of the patient will be dealt with in the various operative procedures given. The surgeon and assistants should labor by every means to dispel anxiety; even the question as to whether a favorable prognosis should be made known to the patient should be determined by circumstances. The professional obligation may be discharged when the nearest relatives or friends are informed if the temperament of the individual is such that great depression would probably follow the knowledge by the patient of impending disaster. In such a case it would be wise to withhold a grave prognosis from the patient. The surroundings should be as bright and cheerful as possible. Expressions and acts of sympathy and kind attentions from friendly hands aid much in attaining a successful issue. In emergencies and in conditions of grave sepsis which have just come under the notice of the surgeon it may be necessary to operate at once without careful physical preparation of the patient, which adds much to ultimate safety. In most instances, however, much good can be accomplished by devoting several days, or even weeks, to increasing the nutrition of the tissues and preparing the alimentary canal to exclude the serious complication of *intestinal toxæmia.* The bowels should be moved always the day before and daily for several days before the operation, and after as well. In abdominal work it is best to withhold solid food for four or five days before the operation, giving the patient concentrated liquid nourishment. The field of operation, if it does not annoy or alarm the patient, should before the anæsthetic be thoroughly shaved, scrubbed with a clean brush, green soap, or etherized Castile soap, then well wet with ether in order to dissolve the fat within the sebaceous follicles, washed with strong mercuric solution (1 to 500 or 1 to 1,000), then covered with gauze dipped in a 1-to-1000 solution, and held in place with a bandage.

The preparation of the surgeon and his assistants is comprehended in the greatest possible personal cleanliness. No one should be admitted to an operation who has been in a room with a contagious disease without having made an entire change of clothing and taken an antiseptic bath. The nails should be closely trimmed always; the hands and arms up to the elbows should be scrubbed with sterile soap and water and brush until perfectly clean, and immersed in a 1-to-1,000 sublimate solution for several minutes. Welch's method of sterilizing the hands is as follows: The hands and nails should be cleansed with brush, soap, and hot water, and then soaked in a 1-to-500 mercuric solution; rewash in a change of water two or three times, using a brush that has been sterilized; immerse the hands for one or two minutes in a warm saturated solution of permanganate of potash, then in a warm saturated solution of oxalic acid, where they remain until complete decoloration is effected; wash with sterilized salt solution or water that has been boiled, then immerse two minutes in sublimate solution (1 to 500).

The operator should wear a waterproof gown long enough to reach to his feet, rubber boots to protect his feet, or large wooden shoes made for this purpose. It is usually preferable to have the sleeves of the operating gown terminate at the elbow, and over the rubber gown the

operator and each assistant should wear a long coat made of duck linen or heavy cotton goods of any kind that will stand boiling, extending at least to the knees, and with sleeves reaching a little below the elbow. A goodly number of these should be kept on hand, and should be washed, boiled, and stored where they will remain sterile. Attendants should be carefully warned after their hands have been sterilized not to touch the face, hair, beard, clothing, basins, or handkerchief, using sterilized towels for all purposes, and when, by accident or necessity, any substance is touched with the hands, they should be immediately immersed in a 1-to-1,000 bichloride solution. This should be done at frequent intervals in any event, in order to guarantee cleanliness and prevent infection, especially where poisonous wounds are being dealt with.

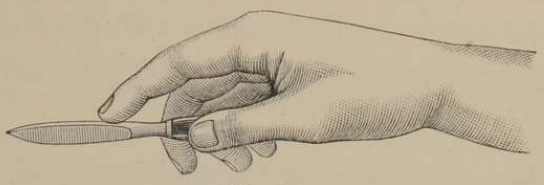

Fig. 86.

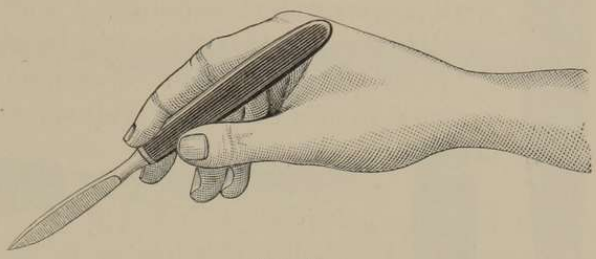

Fig. 87.

The staff of attendants should be as follows: A trained anæsthetizer, next to the operator the most important position, and one, unfortunately, too often left to a tyro; a nurse to attend upon the wants of the etherizer; a first assistant, who stands convenient to the operator, to sponge; a second assistant to hand instruments as needed; an orderly to attend to the dressings, to prepare the Paquelin cautery, or to do general useful duties; at least two other assistants for holding retractors or for other duties, and where irrigation is needed, to attend to that feature; and one or two nurses to rinse sponges or to prepare mops as required. It must be remembered that in the conduct of an operation the operator, himself being the responsible party, must keep his eyes and ears upon his assistants and condition of the patient as the anæsthesia progresses. When the operation commences and the knife or other instrument is lifted from the sterile solution in which it has been submerged, the assistant should shake from it the few drops of liquid which adhere. The different methods of holding the scalpel when making the incision are

Fig. 88.

represented in Figs. 86, 87, and 88. Holding the handle with the index finger on the back, as shown in Fig. 86, is easier for the operator and

brings into play more of the knife's edge for rapid work than the position shown in Fig. 87, in which the point of the knife only is brought into play. In making the incision it is generally necessary to stretch and thus steady the integument with the fingers of the other hand (Fig. 88).

Irrigation is only practiced now in operations in or near an infected spot, such as an ulcer, sinus, abscess, or about the rectum, as in hæmorrhoids. In clean operations where no infection exists it will suffice to flush the wound at the end of the operation with a 1-to-3,000 bichloride solution, and dry it out very thoroughly immediately with mops or sterile sponges. For operations within the various cavities special directions will be given.

Instruments.—Much of success in practice depends upon the possession of a variety of well-selected instruments. They should



Fig. 89.

Fig. 90.

Fig. 91.

be of the very best material, made after well-approved patterns, and as simple in construction as possible. The handles should be sufficiently large to be grasped firmly in the hand and made of steel. The surfaces should be highly polished and smooth, not even permitting the stamp of the instrument maker.* As no instrument can be made absolutely aseptic without boiling, they should be so constructed as not to be injured by this process.



Fig. 92.

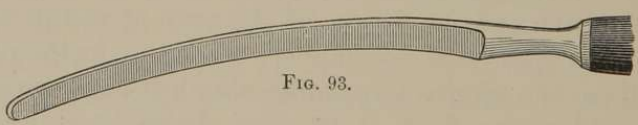

Fig. 93.

Fig. 94.—Little's lithotomy-knife.

Every surgeon must be guided in the selection of his armamentarium by the character and extent of his work. For general practice the following list will in the main be found satisfactory :

For making flaps by transfixion, two amputating knives (Fig. 89) may be conveniently employed. The largest of these measures seven-

* These cuts are made from instruments in my general operating case, and the name of the maker appears only in the engravings.

teen inches over all; with twelve inches for the blade, which is five eighths of an inch in width ; the smaller knife is of similar pattern, the blade being eight inches long by half an inch wide. For compactness and economy the single large blade will answer the purposes of both. I have made several amputations at the hip joint with the ordinary scalpel.

Fig. 95.

Fig. 96.

Fig. 97.

About eight *scalpels* are required, the blades ranging from one inch to three inches in length, with the end of each handle shaped for dry dissection (Figs. 90 and 91).

Two curved *bistouries* (Figs. 92 and 93) are essential, one sharp, the other probe-pointed, with at least three and a half inches of cutting edge. For the performance of perineal lithotomy (an operation now practically obsolete), a long scalpel would in an emergency suffice, but the sharp-pointed knife with four inches of cutting edge (Fig. 94) is preferable.

In operating for cleft palate, the instruments shown in Figs. 95, 96, and 97 are essential. The blades of the first two should have a cutting surface of an inch and a half, in order to give sufficient sweep in freshening the edges of the palate. The gum lancet (Fig. 97), for dividing the mucous and periosteal tissues on the hard palate preparatory to sliding, should be shaped as represented in the cut. For the subcutaneous section of tendons and fascia, a probe-pointed tenotome (Fig. 98), shaft and blade measuring two inches, with one inch of cutting surface, and a fascia knife (Fig. 99), sharp-pointed and the same length, will suffice.

Fig. 98.

Fig. 99.

Retractors, or instruments for separating the edges of operating wounds, should have long shafts and handles, so that the hands of assistants may be well away from the wound and operator. Some should have sharp hooks with two, three, or more prongs (Fig. 100) ; others should have dull prongs or plain and flat, usually curved, but sometimes bent at right angles, as shown in Fig. 101. When metal retractors are not convenient, the insertion of strong silk threads at various points in the edges of the wound serve as most satisfactory retractors. The strings can be left long and retraction made with the hands of the assistant two or three feet from the operative field.

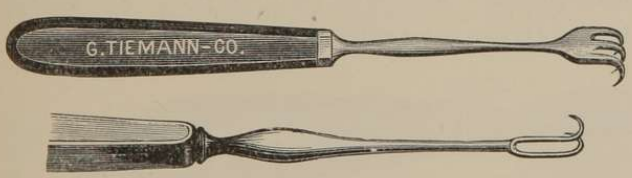

Fig. 100.

The *tenaculum* (Fig. 102) is a most useful instrument, and two are usually needed.

An *aneurism needle* (Fig. 103) should have a capacious eye, a small

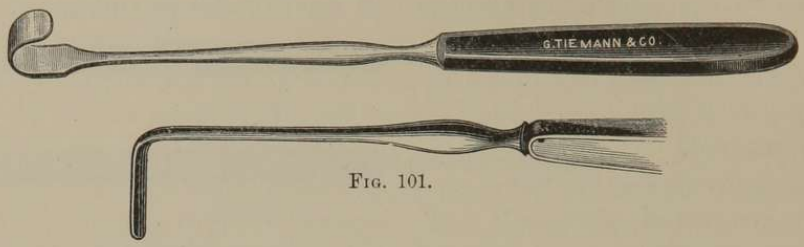

Fig. 101.

curve in one direction, and a beaded point which can not be forced through the wall of a vessel. It may also serve for retraction.

Fig. 104 represents a most convenient *saw* for amputations and exsections. It has two blades, either of which may be adjusted. The combined *keyhole* and *metacarpal saw* (Fig. 105) has three blades of different lengths, and is very useful in exsections of the superior maxilla and in all osteoplastic operations about the face, as well as for minor operations where the saw is required.

Fig. 102.



Fig. 103.

Chisels of several shapes and different construction are required.

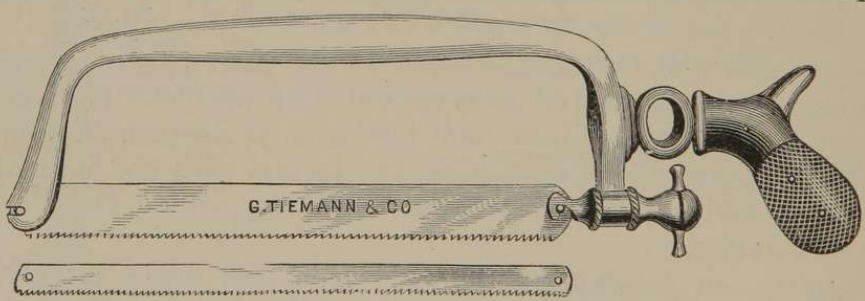

Fig. 104.—Bow-saw, with two blades.

Fig. 106 represents Vance's *osteotome.* At least two of these are necessary, and should measure respectively one half and three eighths of an

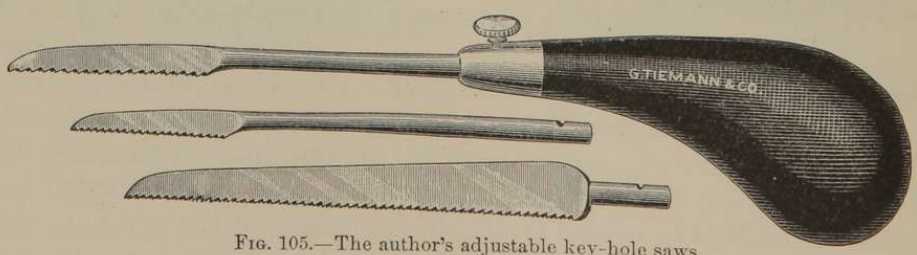

Fig. 105.—The author's adjustable key-hole saws.

inch in width at the cutting edge, and the narrower one should be considerably sharper at the point. The ordinary grooved straight chisels

of the wood joiner, which can be secured at any hardware store, are used for the operations of chiseling or troughing the long bones in osteomyelitis, and answer the purpose admirably. The very smallest of these can be employed in the more delicate operations, as opening into the mastoid cells in empyema, although special instruments for this operation are preferable. A convenient hammer with malleable surface, for driving the chisel, is seen in Fig. 107. An ordinary mallet of hard wood is cheaper and better; it can be boiled, and therefore kept aseptic.



Fig. 106.

Fig. 108 represents *Volkmann's sharp spoon*, an invaluable instrument in bone surgery. There should be at least three sizes of this instrument, all made very strong. The diameter of the largest scoop should be about half an inch, and the smallest three sixteenths of an inch. In clearing out the medulla after amputations for osteomyelitis in which the periphery of the bone is not involved and in which the amputation is made well below the level of the disease in the medulla, the canal may be curetted with the ordinary uterine curette.

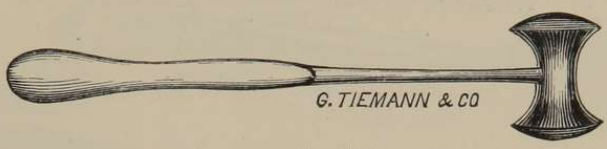

Fig. 107.

Fig. 108.

Fig. 109.

Sayre's *periosteal elevator* (Fig. 109) and the adjustable three-bladed instrument of Goodwillie (Fig. 110) will meet every indication. The latter may be used with special benefit in operations upon the palate.

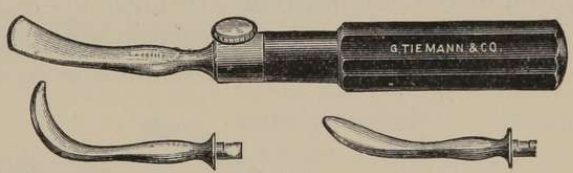

Fig. 110.

Bone drills (Fig. 111) are not so frequently required as formerly. The burred drill is practically obsolete. The open-edge smaller-sized drills are useful in wiring fractures, etc. A shoemaker's awl will usually suffice.

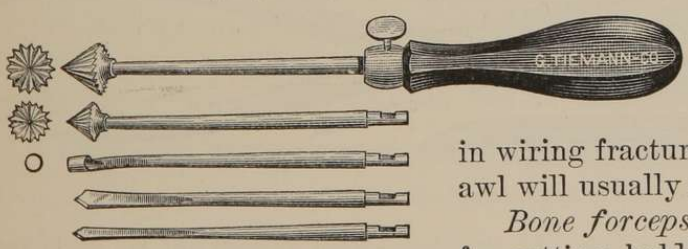

Fig. 111.

Bone forceps should be constructed for cutting, holding, and extracting purposes. Fig. 112 represents a useful instrument which cuts as a pair of scissors on the flat.

In operations upon the cranial bones cup-shaped *rongeurs* (Fig. 113) and the *fenestrated forceps* (Fig. 114) are invaluable. The instrument of Dr. De Vilbis (Fig. 115), of Ohio, I have used with great satisfaction, as

Fig. 112.

it makes a narrow section and will cut through the bones of the cranium with less force than any other instrument.

Figs. 116 and 118 represent very useful instruments which may be used as sequestrum forceps and for various purposes.

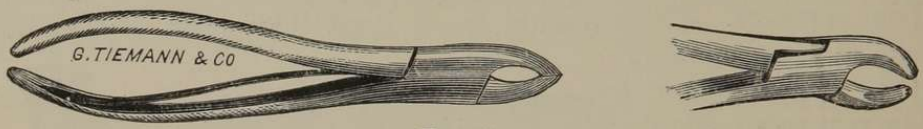

Fig. 113.

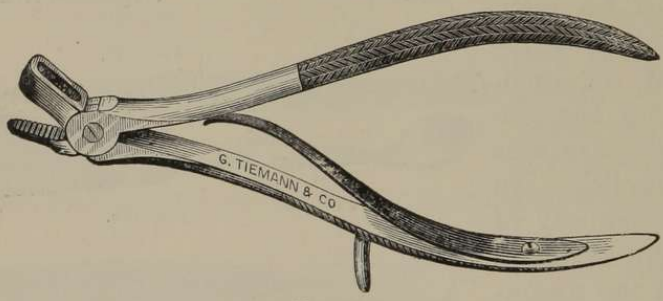

Fig. 114.

The *lion-tooth forceps* (Fig. 117) is of great service as a holder in excision of the smaller bones or large necrotic fragments.

The best *trephine* for general work is that of Galt (Fig. 119), the burr of which is conical. A convenient size measures five eighths of an inch

Fig. 116.—Improved sequestrium- and trepanning-forceps.

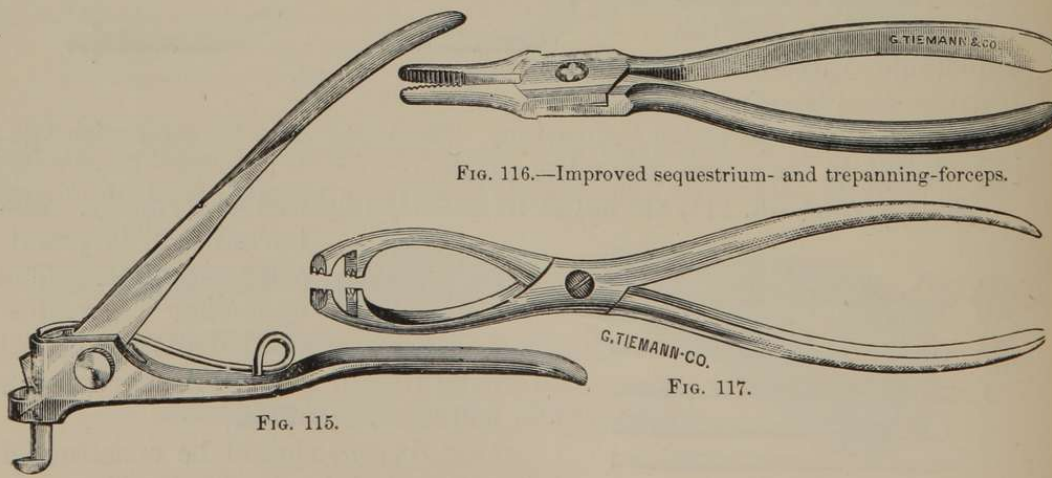

Fig. 117.

Fig. 115.

in diameter at the cutting teeth, gradually enlarging to seven eighths of an inch at the base, where the spiral teeth terminate. In its employment, as soon as the resistance in front ceases the side teeth take hold so

greedily that further rotation is difficult and the operator is thus warned that the button is divided and the instrument has reached the dura; the teeth, however, may be driven on to the dura, and considerable care is required. The central bit should be advanced about one eighth of an inch beyond the level of the teeth, in order to fix the instrument until the side teeth have cut a well-marked circle in the bone. The bit is then made to recede entirely out of the way, as the trephine will be held in place by the circular trench already made.



Fig. 118.

For the arrest or prevention of hæmorrhage the Esmarch bandage may be used. There should be two bandages of strong white rubber,



Fig. 119.

each two inches wide and four yards long. With these the blood can be entirely driven from the tip of an extremity to the trunk, and at the same time complete constriction can be made by one of the bands.

An excellent elastic tourniquet can be made of strong rubber tubing, about half an inch in diameter. When the tourniquet is applied with or without rendering the extremity bloodless it should not be too tightly drawn, as injury may be done to the nerves and paralysis follow. In amputations where the constriction is made close to the incision this precaution is not essential.



Fig. 120.

Two convenient styles of *hæmostatic forceps* are shown in Fig 120: Esmarch's long-nosed, and the mouse-tooth forceps. All artery forceps should be about five inches long, perfectly smooth, and, when clamped, dull on the edges, so that the ligature which is being tied will not be cut by the instrument. There should be at least twelve—four mouse-tooth and eight long-nosed.

Sponge holders (Fig. 121) can not be dispensed with. They should

Fig. 121.—Dr. Southgate Leigh's sponge holder.

be ten or twelve inches long, made in two separate halves of solid metal. Any form of clamp forceps may be used as sponge holders.

A half dozen pairs of scissors form an essential part of a general operating case: Dressing scissors (Fig. 122), straight or angular (Fig.

123), two pairs of scissors curved on the flat, five to eight inches long respectively (Fig. 124), one sharp-pointed, five inches long, curved on the flat, and straight sharp-pointed scissors.

Needle holders are indispensable. A Sims vesico-vaginal needle holder is an instrument generally useful. Fig. 125 represents a con-

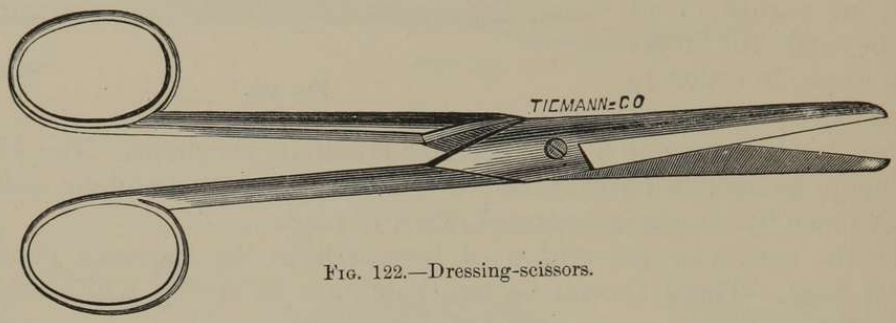

Fig. 122.—Dressing-scissors.

venient and satisfactory holder. All instruments with joints or sliding catches should be so constructed that they can be taken to pieces for purposes of cleansing.

A general assortment of needles, curved, half-curved, and straight—

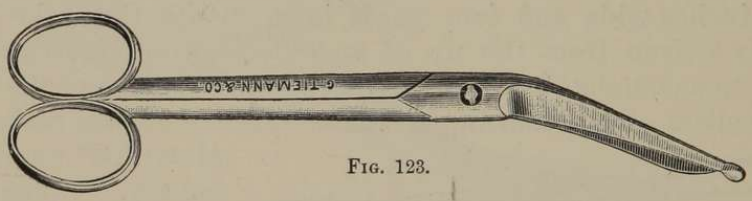

Fig. 123.

the finest, for plastic work about the face; Hagedorn's needles with Fowler's modification (half twist, permitting it to be used in the ordinary needle holder); short, strong needles, partly curved and straight for lacerated cervix; and needles for laceration of the perinæum are required.

Several anatomical forceps fully seven inches long (Fig. 126), so that the hand may be held a sufficient distance from the wound; one plain,



Fig. 124.—Sims's curved scissors.

Fig. 125.—Wyeth's needle-holder.

one mouse-tooth with or without catches, and one long, perfectly smooth forceps for holding the first knot of a ligature firmly until the second knot is fastened.

Probes of malleable material, preferably silver or nickeled copper, of various sizes, are needed. The large, soft, flexible probe of Fluhrer (Fig. 127) is an excellent instrument for following up old sinuses.

A *grooved director* (Fig. 128), of good size, malleable, and with a dull point, is essential.

Other instruments will be given with the operations for which they are especially designed.

For transportation, instruments may be best carried in long canvas rolls, along the center of which a piece of tape is basted, leaving a loop under which to slide each instrument. These rolls should be wide enough to fold over the instruments on either side, then rolled and tied. The sharp instruments should have their edges protected by wrapping absorbent cotton over the blades. Knives, however, can be carried with less danger of dulling their edges in plain metal or unlined wooden cases containing nothing but a metallic framework in which the knives fit in their receptacles, all of which can be easily cleansed.

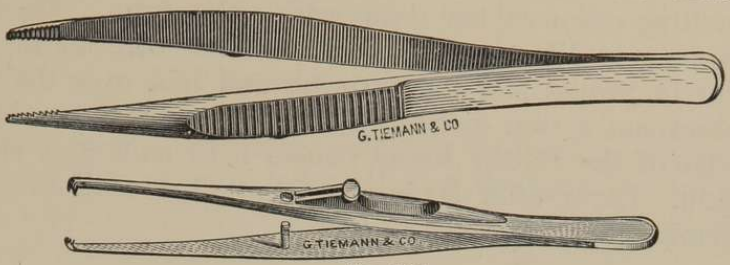

FIG. 126.

The Bag.—One or more bags of strong Russia leather, 17 × 10 × 8 inches, with snugly fitting lids and no cloth lining to catch and hold dust. The bag should be frequently wiped out with a towel moistened in 1-to-1,000 bichloride solution, and a plain dry towel should be folded and kept in the bottom of the bag to absorb any liquids that may be spilled in transportation.

Razor and Soap.—Shaving the operating field should always precede the scrubbing brush and soap. An excellent surgical soap made from the formula of Dr. J. A. Bodine is as follows:

Castile-soap shavings, one pound. Boil in one gallon of water until liquefied. When cooled to about the temperature of the body, dissolve seven grains of mercuric chloride (one tablet), and when entirely cooled,

FIG. 127.—Fluhrer's light flexible bulb-tipped probe.

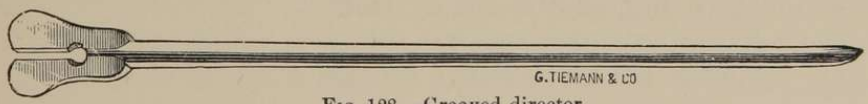

FIG. 128.—Grooved director.

add four ounces of ether. Powdered marble dust may be added on account of its advantage in scrubbing dirt out of the folds of the skin and follicles.

Collodion.—Collodion, plain and sometimes saturated with iodoform, is essential to seal up wounds that need no drainage. Upon the face and exposed surfaces plain collodion is preferable; on the body in general the iodoformized collodion is used—

Iodoform crystals, sterile..... gr. xlviij;
Flexible collodion..... ℥j;

Apply with camel's-hair brush, which should never be dipped in the bottle, and always thrown away after using. All solutions should be poured out into a suitable vessel in about the quantity needed, the excess being thrown away to prevent infection of the whole. This method of sealing wounds is invaluable in preventing infection in the region of the groin or rectum and in wounds near the mucous surfaces.

When collodion is not at hand, a wound may be thoroughly sealed by melting clean rubber tissue with chloroform. The rubber tissue should be immersed in 1-to-1,000 *cold* bichloride solution for a few minutes, then cut in proper size for covering and laid over the wound. A pellet of absorbent cotton moistened with chloroform, brushed lightly along the edge of the rubber tissue, causes it to melt and closely adhere to the skin. Layer after layer can be applied until the proper protection is guaranteed.

CHAPTER VIII.

ANÆSTHESIA.

ANÆSTHESIA means loss of sensibility. It may be *local* or *general.* In the former, the sensibility of a limited portion of the body is more or less completely lost, while the patient remains conscious; in the latter, both consciousness and sensibility are lost.

Local anæsthesia may be obtained in a remarkable degree by the judicious employment of the hydrochlorate of cocaine, for the application of which agent to surgical use the world will ever be indebted to Dr. Karl Koller, of New York city.

While the two- and four-per-cent solutions are chiefly employed, satisfactory anæsthesia may be obtained with one-per-cent or even weaker solutions than these. In extremely rare instances a ten-per-cent solution may be employed, but great care should be taken in its administration. Alarming and even fatal results have followed the careless employment of the stronger cocaine solutions. I have employed this agent in a great many operations for a period extending over several years, and have never seen an alarming symptom. Practically all the ordinary operations and some major procedures may be safely and satisfactorily performed under the influence of this anæsthetic. In operations upon the extremities, where the circulation may be partially or completely arrested by the compression of an elastic bandage around a finger, the forearm, arm, leg, or thigh, more cocaine can be used than upon the trunk, where the circulation can not be controlled. Eighteen grains of cocaine hydrochlorate to one ounce of distilled water is approximately a four-per-cent solution. One grain of boric acid added will prevent the development of fungi in the solution. Applied to the cornea and conjunctiva by dropping one or two drops of a two-per-cent solution into the eye, or upon any mucous surface, it is rapidly absorbed by the epithelia; the capillaries of the part become at first contracted and the end organs of the sensory nerves are paralyzed. Upon the unbroken integument it produces practically no effect. Injected into the tissues through a hypodermic needle (for which method we are indebted to Dr. J. Leonard Corning, of New York city), it produces anæsthesia wherever it reaches—in bone, muscle, subcutaneous tissues, or the skin. Injected into the substance of a nerve, it is rapidly absorbed and produces anæsthesia in all parts in the range of distribution of the nerve trunk beyond the point of injection. The quantity to be used in any case will vary with the susceptibility of the individual, and this should be cautiously studied in each case. Even

a few drops in the eye may, in rare instances, produce noticeable systemic effects. Upon the mucous membrane of the buccal cavity and pharynx a drachm of a four-per-cent solution in an operation lasting half an hour may be employed, brushed on with a camel's-hair pencil or applied with a sponge. The excess of cocaine is washed off and diluted with the saliva, which, of course, should not be swallowed. For the subcutaneous and intracutaneous injection of cocaine, a perfectly clean syringe and the finest possible hypodermic needle, thoroughly sterilized, should be employed. Operating upon any surface of the body where control of the circulation is impossible, the following method should be employed: Given a necessary incision of two inches in length to expose a tumor requiring dissection for one inch on either side of this line; should the quantity of cocaine necessary to secure anæsthesia for this extent be thrown in at once, absorption by the vessels would take place and constitutional poisoning supervene in from one to five minutes. The pupils would become widely dilated, the action of the heart greatly increased, and mental exhilaration, as evidenced by singing or incoherent speech, would ensue.

Having thoroughly cleansed the surface to be operated upon, insert the very tip of the delicate needle barely beneath the epidermis; it should not be thrust through the skin, but an effort should be made to carry the needle halfway through the skin to the papillary layer, just where the end organs or loops of the sensory nerves terminate. This is more readily accomplished by carrying the needle almost parallel with the cutaneous surface. When the needle has reached this part of the integument, carefully regulated pressure on the piston should force out one fourth of a minim, which usually causes a slight stinging sensation and produces a little white wheal at the point where the cocaine distends the cuticle. One fourth of a minim of a four-per-cent solution will immediately and entirely deaden the sensibility and will permit the skin to be incised for about half an inch, and this should be done with a sharp knife either directly on the needle, or this quickly withdrawn and the incision made. The patient should be asked to notify the operator the moment that a painful sensation is felt. It will be seen that section through the injected and tense skin, with the bleeding which ensues, allows the immediate escape of part of the cocaine, while the necessary manipulation aids in squeezing it out. The needle should now be reintroduced in the commissure of the wound and forced through the middle of the skin for a quarter of an inch and another portion of a minim expressed, the needle withdrawn, and the knife carried through the wheal thus produced. Five minims of a four-per-cent solution properly employed will permit an incision of two or three inches in length with perfect anæsthesia. After the skin is divided, the subcutaneous tissues are practically without sensation, and if the retractors are so placed that the hooks impinge upon the under surface of the skin and close to the edge where the anæsthesia has been obtained, the patient will feel nothing beyond the dragging and pulling which is common to all these operations. Moreover, the skin for a distance of from one half to three quarters of an inch on either side of the incision may be dis-

sected up without further injection of cocaine. It is always essential to work rapidly. As the dissection proceeds in the deeper tissues, a nerve filament or vessel in the line of incision may be encountered, and these usually require an extra minim of the solution. A painful sensation is felt almost invariably when a vessel is grasped or cut, even when no nerve can be made out, and I am led to believe that arteries are sensitive to touch through their vasomotor or sympathetic connections. Should such an operation have to be prolonged for an hour or more, as I have done in a number of instances, the danger of cocaine absorption is very slight, and, if it occurs, it is taken into the system so gradually that a tolerance is acquired and no bad effect produced. The larger proportion of that which remains is appropriated by the sensory nerves, which seem to hold on to the cocaine for from twenty to forty minutes before the sensation begins to return. I have used twenty, forty, and sixty minims of a four-per-cent solution in a single operation without any symptoms of absorption. In one instance I exposed the upper end of the sternum, removed almost the entire manubrium, cleaned out one sterno-clavicular articulation, and scraped the posterior wall of an abscess which had formed behind the sternum at this point, the bone itself being the seat of tubercular disease, and this without pain or shock. In operations upon the hands or fingers, as in opening phlegmons, a rubber tourniquet may be thrown around the base of the finger or the wrist, compression being sufficient to either entirely arrest or very much retard the return of blood to the heart until the operation is over; then in the line of the proposed incision the cocaine can be used a little more recklessly than advised in operating upon the body. So painful, however, is a phlegmon of the finger that I have made it a rule never to carry the needle through the inflamed integument, but to introduce it preferably upon the back of the finger, where the tactile sense is less, and carry it beneath the skin to some point near the proposed line of incision, and inject the cocaine from the under surface. In this way complete anæsthesia can be obtained, these painful swellings incised, evacuated, and dressed before the tourniquet is removed and sensation restored. It is important in loosening the tourniquet not to remove it entirely, but to allow the circulation to be restored only for a few seconds, then again tighten the tubing for four or five seconds and repeat this until several minutes have elapsed before the constriction is finally removed. This precaution is taken to prevent the sudden passage of any excess of cocaine into the circulation.

In operations upon the leg, the thigh, the forearm, or the arm, the same control of the circulation may be exercised by constriction of the limb between the wound of operation and the heart. So safe and satisfactory, however, is the employment of cocaine by the method described in operating upon the trunk, that I now rarely use the tourniquet, or, when employed, the constriction is just sufficient to retard the venous flow. In operations upon the bones, cocaine anæsthesia is not always satisfactory, and general narcosis is preferable; but for the removal of many superficial tumors, covering an area from one to three inches in

diameter, incising infected wounds (phlegmons), removal of ingrowing toe nails, amputations of the fingers, incising or clipping off external hæmorrhoids, excision of limited portions of the lips, and similar minor procedures, this agent is safe and satisfactory. In the urethra its employment gives the greatest satisfaction. As far down as the cut-off muscle, a complete anæsthesia can be obtained by using a two- to four-per-cent solution. The quantity should be graduated to the case under consideration, and, when using cocaine for the first time in any subject and for any purpose, it should be borne in mind that it is important to learn the dose the patient will require or tolerate, since in very exceptional instances an individual may be met with in whom cocaine can not be used. Again, in urethral surgery, it has been frequently noticed that patients who exhibited no constitutional symptoms in the injection of cocaine prior to and during an internal urethrotomy will absorb a dangerous quantity when an injection of the same amount of the same strength solution is made for the introduction of the sound on the third or fourth day after the first operation. This increased susceptibility is accounted for by the fact that the solution is not so readily absorbed from an unbroken surface as when brought into contact under pressure with the rich network of vessels and embryonic tissue which result from the incision in the walls of the urethra. For a second operation, a weaker solution or a smaller quantity should be employed, gradually increasing the amount as the case will permit.

Recently Schleich, of Germany, has introduced the method of "*infiltration anæsthesia*," in which a very weak solution of cocaine hydrochlorate is employed in connection with a solution of common salt and a small quantity of morphine. He recommends three formulæ, the first for operations on highly sensitive areas, where there is inflammation or neuralgia; the second for operating on moderately sensitive areas; and the third, the weakest possible solution for extensive operations, to be used alone or with the stronger solutions. These solutions should be kept in a cool room, the temperature in which should not be higher than 66° F. A convenient tablet containing the proper proportions for ready use is as follows: *

No. 1, Strong.

Cocaine muriate	0·2 (gr. 3);
Morphia muriate	0·025 (gr. $\frac{2}{5}$);
Soda chloride	0·2 (gr. 3);
Distilled water sterilized	q. s. to 100 c. c. (fl. oz. $3\frac{2}{5}$).

No. 2, Normal.

Cocaine muriate	0·1 (gr. $1\frac{1}{2}$);
Morphia muriate	0·025 (gr. $\frac{2}{5}$);
Soda chloride	0·2 (gr. 3);
Distilled water sterilized	q. s. to 100 c. c. (fl. oz. $3\frac{2}{5}$).

* Prepared by John Wyeth & Brother, of Philadelphia.

No. 3, Weak.

Cocaine muriate ..... 0·01 (gr. $\frac{1}{6}$);
Morphia muriate ..... 0·025 (gr. $\frac{2}{5}$);
Soda chloride ..... 0·2 (gr. 3);
Distilled water sterilized ..... q. s. to 100 c. c. (fl. oz. $3\frac{2}{5}$).

When these solutions are not to be used immediately, boracic acid (gr. v) should be added to each ounce of water in order to prevent the development of septic fungi.

Of the No. 1 solution, as much as six and a half fluid drachms (25 cubic centimetres) may be used; of the No. 2, three and a half fluid ounces (100 cubic centimetres); of the No. 3, as much as a pint (500 cubic centimetres) may be employed at a single operation.

No. 2 should be preferred in most cases; No. 1 is only to be employed in tissues that are excessively painful, where the No. 2 solution will not secure satisfactory anæsthesia. The No. 3 solution is employed when necessary in the deeper tissues, as in the fat and muscles.

A large-sized syringe holding two or three drachms should be preferred, and the very finest needle. The barrel of the syringe should be carefully graduated and a check placed upon the threads of the piston to prevent the accidental discharge of a greater quantity than is required.

The initial point of puncture may be anæsthetized by using a minim of a four-per-cent solution; through this the needle which is to convey the weaker solution may be carried. When the needle has been conveyed just beneath the skin, a certain quantity of the solution (five to ten minims) is forced out until a pale wheal is noticed about half an inch in diameter. The needle is withdrawn and inserted in the anæsthetized zone of the first wheal, and this is continued indefinitely until the entire surface is ready for incision. The tissues may be at once divided and the dissection continued until sensation is felt, when additional solution may be employed. In prolonged operations the anæsthesia may disappear in from ten to twenty minutes, requiring a repetition of the injections. The distention of the tissues in cocaine anæsthesia interferes to some extent with the rapid repair and union of wounds, but not sufficiently to contraindicate its general use.

General Anæsthesia.

For capital operations and for most procedures in children who are too young to submit quietly to cocaine anæsthesia general narcosis is preferable. For this purpose ether and chloroform are employed, and, in rare instances, where neither of these agents can be used with safety, the hypodermic use of morphine, or the administration of a considerable quantity of whisky, or a combination of both, will produce a satisfactory condition of anæsthesia.

In selecting one of these agents for the production of narcosis, the surgeon should not only thoroughly understand the physiological action of ether and chloroform, but should, when possible, acquaint himself by

every available means with the physical condition of the patient, with special reference to certain organs—as the heart, kidneys, and respiratory apparatus—which experience teaches are apt to suffer in the presence of these anæsthetics. It is known that chloroform tends to depression of the heart under certain conditions, and that the majority of instances in which death has occurred in chloroform narcosis have been due to heart failure, the fatal result ensuing in the first stage of anæsthesia, the stage of excitement. It would be dangerous to use this anæsthetic in a patient with weak heart action due to atheroma of the coronary arteries or to fatty degeneration of the heart muscle. In chronic valvular lesion of the heart chloroform is not as safe as ether. When nephritis exists, either acute or chronic, chloroform is to be preferred to ether, provided the condition of the heart does not contraindicate the use of the chloroform. In laryngitis, bronchitis, pulmonary emphysema, extensive pleuritic effusions, and in patients who have chronic pneumonia or consolidation due to tuberculosis or syphilitic gummata, the narcosis of chloroform is preferable and, in the ultimate, equally as free from danger as ether. So far as the conduct of the operation is concerned, chloroform is also preferable in operations within the peritoneal cavity, for the reason that it is less apt to produce vomiting during and after the operations, which is always to be avoided when possible.

The administration of ether produces an engorgement of the veins, especially in the neck, face, and head, which does not occur with the administration of chloroform; and in certain procedures, as the removal of goitre and other large vascular tumors of this region, chloroform is generally preferable.

In very young children chloroform is better taken than ether by reason of the tendency of the latter to produce an irritation of the respiratory tract and the formation of frothy mucus, which at times seriously interferes with oxygenation of the blood. In children of five or six years of age up to adult life, with a perfectly sound organization, ether is in general to be preferred as an anæsthetic agent, subject to the exceptions above given. In obstetric practice, by common consent, chloroform is employed.

Alcoholic subjects and persons suffering from abnormal accumulation of adipose tissue take ether badly, and it is my custom to use chloroform in this class. When a patient behaves badly under the careful administration of one of these agents, the other should be given a trial. In an emergency, where it becomes necessary to perform an operation within three or four hours after the ingestion of a considerable quantity of solid food, chloroform is preferable.

The statistics collected by the German Surgical Congress and by investigators in England and in the United States show that the general death rate after chloroform is greater than after ether, in the proportion of about three or four to one. But in determining the value of statistics it is well to bear in mind the fact that it requires a very considerable experience and the thorough knowledge which this implies to give

either safely, and that, unfortunately, in too large a proportion of cases, the most important part of a surgical procedure is usually intrusted to young men who have not the requisite knowledge and skill to give an anæsthetic.

Whenever possible, before administering an anæsthetic, the patient should be prepared both physically and mentally for the ordeal. The bowels should be thoroughly moved one or two days before the operation, and on the day of the operation no solid food whatever should be permitted. The patient should be impressed with the fact that there is no danger in well-conducted narcosis, which always gives encouragement and removes an important element of danger—the apprehension of impending disaster. The presence of solid food or coagulated milk in the stomach is dangerous, for, should the patient vomit, solid particles may be carried into the larynx or trachea and produce fatal asphyxia.

It may also be well to mention the inflammability of ether and chloroform, ether being somewhat more inflammable than chloroform ; for this reason, care should be taken to prevent the approach of a light or cautery point nearer than two or three feet of the inhaler.

Method.—As a precaution against accidents, the anæsthetizer should always have near at hand : (1) a wedge or screw-shaped piece of wood for forcing and holding the jaws apart (Fig. 129) ; a Sayre periosteal elevator is a good substitute, or a sequestrum or large bone forceps ; (2) some form of mouth gag, such as Goodwillie's (Fig. 130) or Gross's (Fig. 131), with which to keep the jaws permanently open if necessary ; (3) a tenaculum or forceps for drawing out the tongue (Fig. 132) ; (4) a large-sized curved needle, armed with a stout silk thread, for transfixing this organ should the emergency arise ; (5) two or three sponge holders with sponges *tied* on, for mopping out the pharynx, throat, and mouth (Fig. 133) ; (6) a bottle, graduated, so that the anæsthetizer may know the exact quantity of ether or chloroform taken (Fig. 134) ; (7) several ounces of undiluted whisky, with a large hypodermic syringe, loaded for use, and an ordinary syringe for a whisky-and-warm-water enema ; (8) a pus basin or pan in case of vomiting ; (9) plenty of towels to guard against infection of the operating wound from the contents of the buccal cavity.

Fig. 129.—Hard-rubber oral screw.

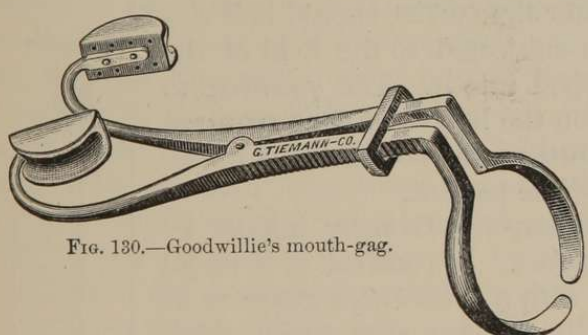

Fig. 130.—Goodwillie's mouth-gag.

Fig. 131.—Gross's speculum oris.

Twenty minutes before the narcosis is begun, *in all cases* (except in children under four or five years of age) *a hypodermic injection of morphine with a small quantity of atropine* is extremely valuable (sul-

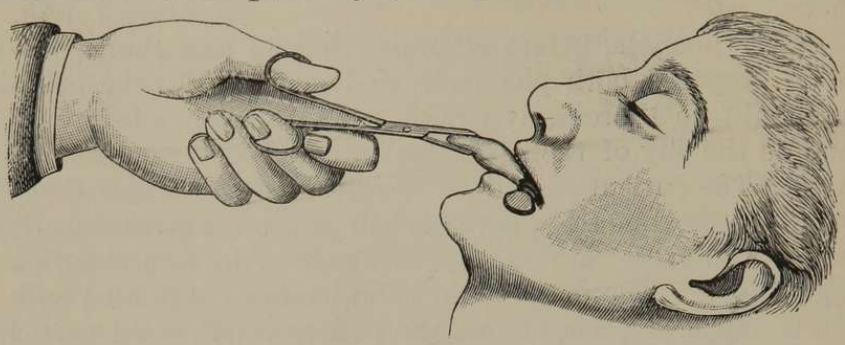

Fig. 132.

phate of morphine, gr. $\frac{1}{4}$, and sulphate of atropine, gr. $\frac{1}{200}$). There are several good reasons for this preliminary injection: It is a heart stimulant and counteracts the depressing influence of the anæsthetic upon this organ; it also stimulates the patient to a marked degree and relieves the mind of apprehension and anxiety; it diminishes the susceptibility of the larynx and respiratory tract to irritation, and does away with the coughing and sense of strangulation; it induces more rapid narcosis, prevents struggling, and decreases the tendency to vomit. Before the anæsthetic is begun, it is important to request the removal of any artificial teeth and to be sure that no foreign body whatever is in the mouth.

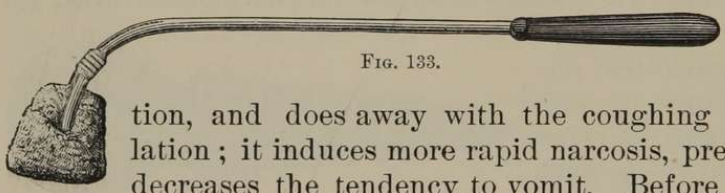

Fig. 133.

The following points are essential in the successful administration of ether: Only the best *quality* of *ether fortior* should be employed. That manufactured by Dr. Squibb is generally preferred in America. It should have a specific gravity not greater than 0·728, should boil violently when in a test tube it is subjected to the heat of the hand, and a bit of glass is dropped into it. The *quantity* to be used will depend in part upon the length of time required for the performance of the operation, the construction of the inhaler, and the idiosyncrasy of the patient.

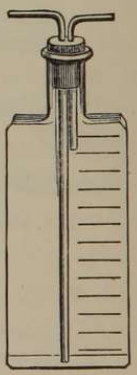

Fig. 134.

For the administration of ether, the Ormsby inhaler is, in my opinion, the best apparatus. It consists of a metal mouth and nosepiece, shielded with a soft-rubber guard to fit over the mouth and nose; within this is a wire screen which holds a sponge, and over all is a good-sized flexible rubber bag, in which it is advisable to drop a second good-sized sponge. About two ounces of ether are poured into the sponge within the mouthpiece, and, when this becomes saturated, the excess drops into the rubber bag and is taken up by the sponge which is in it. In order to prevent apprehension on the part of the patient, and to lessen the danger of irritating the respiratory tract, the cone should not be immediately placed over the nose and mouth, but gradually approached, so

that the olfactory apparatus may become accustomed to the presence of the ether. It is gradually carried nearer and nearer until it rests upon the face and chin, entirely shutting out the outside air. As the patient breathes, the expired air is forced into the inhaler, through the sponge, and into the rubber bag, where it becomes saturated with the vapor of ether; in the act of inspiration, this air and the ether vapor, somewhat warmed by the expired air, are carried into the lungs.

It is evident that this method furnishes to the respiratory apparatus ether vapor rarefied by and mixed with warm, expired air. By warming this vapor some of the dangers of bringing cold ether in contact with the larynx and trachea, bronchi and pulmonary vesicles, are diminished. When it is remembered that the expired air has a temperature varying from 93° F. to 94·5° F., it will be readily understood how such heat will effect the ether used with the Ormsby apparatus. The expired air is again inspired and breathed over and over again until there is added to the narcosis of ether an element of controllable asphyxia. In ordinary respiration, one fifth of the oxygen carried in by a single respiratory effort is absorbed by the blood. If there was no leakage to the apparatus, it is evident that it would take but a few respirations to consume all the oxygen contained in the mask, and that true asphyxia must supervene. Such, however, is not the case in the practical use of the inhaler. The partial asphyxia aids rapid anæsthesia, dulling the sensibility and lessening the resistance to the absorption of the vapor. The degree of asphyxia can be controlled and perfectly regulated by the trained anæsthetizer.

In forty-one carefully noted cases in which this apparatus was used at my service in the Mount Sinai Hospital in 1892, the average duration of the time which elapsed from the moment the mask was applied to the time when the patient became unconscious was five minutes and three quarters; from the moment the patient became unconscious until the ether was discontinued, the average time was twenty-nine minutes; from the discontinuance of the ether until consciousness returned (reaction), the average time was five minutes; from the commencement of the operation to its completion, the average time was twenty-one minutes and a half; the average quantity of ether used was two ounces and a half. This quantity represents the amount of ether poured out of the bottle, a certain proportion of which was left in the inhaler, while a certain smaller proportion was wasted by evaporation. It is probably safe to say that the average quantity absorbed by the blood did not amount to over two or two ounces and a quarter. In thirty-one out of the forty-one cases the patients did not vomit during or after the inhalation. In one case sugar was present, but was not affected by the anæsthetic.

Directions for Use. Cleansing.—Remove the sponge and cleanse in tepid water; disinfect in 1-to-500 bichloride solution; again wash it in tepid water and squeeze thoroughly. The balloon and mouthpiece should be dipped in a bichloride solution and immediately washed in tepid (not hot) water.

Pour into the sponge in position two ounces of ether. If the patient

is nervous and unusually apprehensive of danger, for a minute or two gradually accustom him to the smell of the ether. Ask him to take a full inspiration, and, as the expiration begins, apply the mask tight over the mouth and nose. The sense of irritation and suffocation can in the main be thus avoided. For the first minute or two allow no admixture of fresh air. At the first indication of asphyxia—the commencing purple in the ears and cheeks—tilt the mask a little to one side and allow fresh air to pass in. As it does not pass through the sponge, the ether vapor is not materially chilled. I usually tilt the mask at the commencement of one inspiration and shut it down at the close of the inspiratory effort, and then hold it down for the next two or three respirations. From half an ounce to two ounces of ether may be added as the condition of the patient or the requirements of the operation may demand.

During the administration of an anæsthetic perfect quiet should be maintained; moving about the room, conversation, and any noise tends to alarm the patient, especially as he approaches the borderland of unconsciousness. A word of encouragement now and then does much to allay apprehension. Precaution should be taken to have one or two assistants stand near the operating table to hold the patient in case he begins to struggle or resist. It is best to refrain as long as possible from touching the patient, for oftentimes this will precipitate a struggle which otherwise might be avoided. When help is scarce, a rope or leather strap may be thrown over the chest and knees and around the table, and tightened if necessary. In this the *first stage* the face usually becomes flushed from capillary distention, the pulse is increased in force, and frequency, and there is apt to develop slight delirium from ether intoxication. The character of the breathing will almost always indicate that the stage of excitement is passing into the *second stage*—that of relaxation and unconsciousness. The respiration becomes regular and soft, and by separating the patient's eyelids and gently touching the cornea with the tip of the finger the absence of any reflex action demonstrates that the patient is completely insensible. The arms fall limp and helpless, and in many cases, about this time, the breathing may be interfered with on account of the relaxation of the muscles which pass from the hyoid bone to the chin, permitting the tongue to fall back upon the larynx. The finger inserted just above the angle of the jaw on the ramus, making slight pressure, will overcome this by pushing the jaw forward, and in this way lifting the hyoid bone and tongue in the same direction (Fig. 135). Stertorous respiration in general indicates a too profound narcosis,

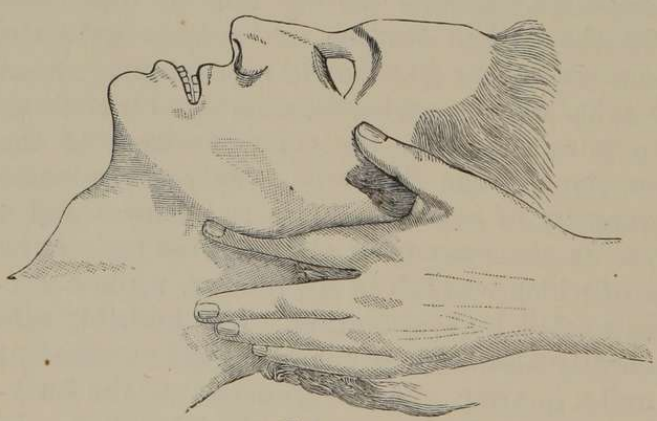

Fig. 135.

especially if at the same time the corneal reflex is absent, and then the cone should be tilted a little to one side in order to admit more oxygen to the lungs. Careful attention to details, keeping the patient just unconscious and no more, will minimize the quantity of ether and prevent asphyxia and vomiting. Should vomiting occur, it is usually desirable to turn the patient a little on one side, so that any ejected matter may flow out of the mouth and away from the larynx. When mucus collects in the naso-pharynx or about the larynx, this should be removed with the sponges on holders. When the patient turns blue quite suddenly, showing threatened severe asphyxia, the jaws should be prized open with the screw or wedge and held open by the anæsthetizer while an assistant seizes the tongue with a tenaculum or forceps and pulls it forward. At the same time the windows should be opened for the admission of fresh air. If the act of respiration should be suspended, artificial respiration by Sylvester's method should be at once employed.

Sylvester's Method.—Slide the patient over the end of the table until the head hangs down, tilt the foot of the table up by placing the lower

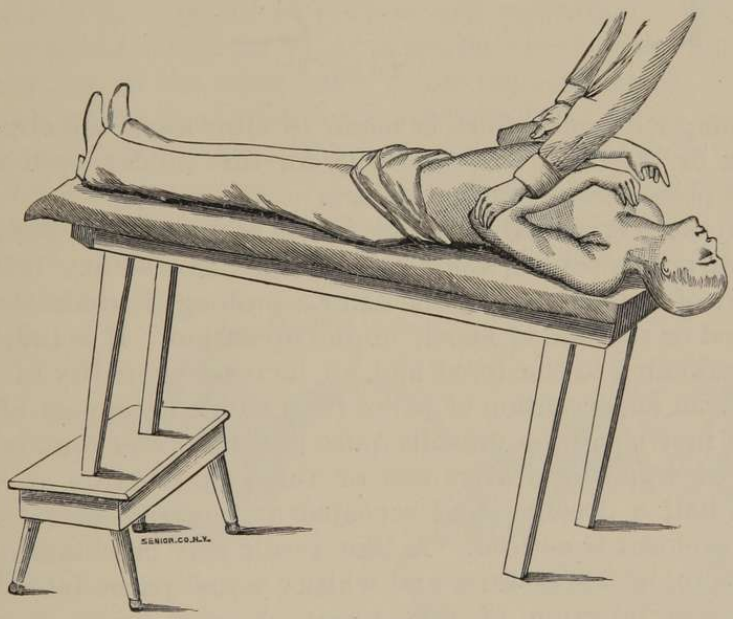

Fig. 136.

legs on a stool or chair. Stand at the patient's head as he rests upon the inclined plane, and seize the arms at or near the elbow, pressing them down upon the thoracic walls, thus forcibly emptying the lungs (Fig. 136), and immediately thereafter extending them upward parallel with the long axis of the body, aiding in the expansion of the chest (Fig. 137); this is repeated eight or ten times a minute, and kept up by relays of assistants, if necessary, until voluntary respiration is established or the heart has ceased to beat. It is important that these manipulations should in no way interfere with the assistant who is holding the tongue out of the mouth and the gag in place. If, in the judgment of the surgeon, the respiratory failure has been caused by occlusion of the larynx or trachea, a rapid tracheotomy should be done. The insertion of a

tracheotomy tube is not, under such circumstances, advisable, it being safer to grasp the edges of the incised trachea with tenacula, or insert a silk suture through the skin and trachea on either side and hold the

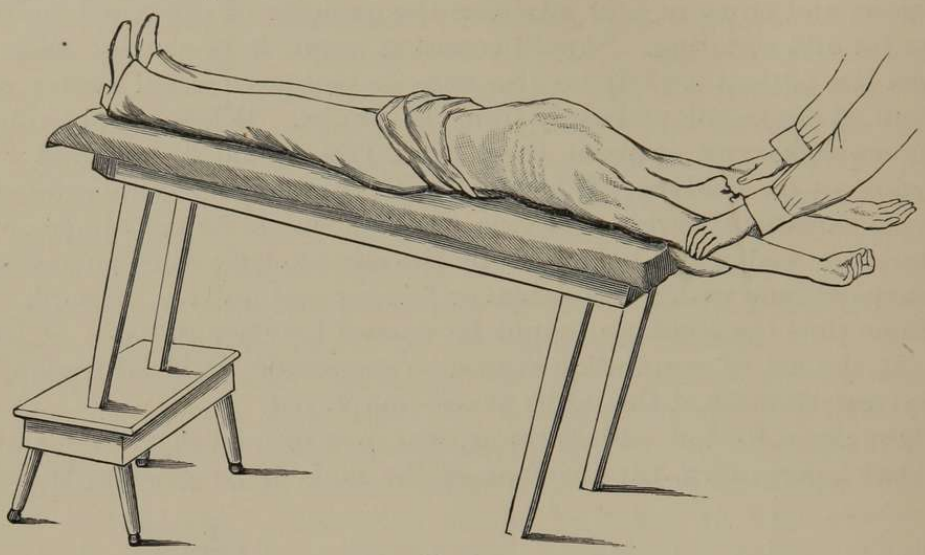

Fig. 137.

wound gaping while an effort is made to clear away the obstruction of the larynx or trachea. The necessity for this (under such conditions) formidable procedure is extremely rare.

Heart failure is exceedingly rare in the early stage of ether narcosis. A weak heart, as a rule, is stimulated by the anæsthetic. It is more apt to be a part of the later stage, and after a prolonged administration with loss of blood or the added shock of the operation. It is indicated by a gradual weakening in the force and an increased rapidity of the pulse, or by the rapid supervention of pallor from sudden stoppage of the heart. When the first condition prevails, pure rye whisky or brandy should be administered hypodermically, two or three syringefuls at once (each syringeful half a drachm), and repeated at intervals of a few minutes until improvement is noticed. A like result may be obtained by injecting a teacupful of warm water and whisky (equal parts) into the rectum. A hypodermic injection of one twentieth of a grain of sulphate of strychnine may be combined with the whisky. Elastic bandages should be thrown around the extremities in order to drive all the blood to the centers. When sudden syncope occurs, place the patient's head lower than the body by allowing it to hang over the upper end of the table, while the lower end is well elevated (see Fig. 136). At the same time strike sharply upon the pericardial region with the palm of the hand, and shower the chest and epigastrium with cold water.

When the Ormsby inhaler can not be had, an emergency apparatus can be made by folding cardboard or several layers of newspaper into a cone eight or ten inches long and five or six inches across the large end. This can be covered with a towel or napkin and a sponge or piece of soft cloth placed inside, and the ether poured directly into this.

The Allis inhaler (Fig. 138) is objectionable on account of the free ad-

mixture of air with the ether vapor, which carries this at too low a temperature in contact with the respiratory tract. Moreover, in my opinion, with the use of this apparatus too large a quantity of ether is carried into the blood and an additional strain thrown upon the kidneys in its elimination. By folding and tying loosely a piece of oil silk over the free end of this inhaler, this objection can be partially remedied.

Fig. 138.—The Allis inhaler.

Ether narcosis may also be secured and maintained by administering this agent by the rectum—a method introduced by Pirogoff about the year 1847. However, it has proved so dangerous in practice that its use is scarcely justifiable.

Chloroform.—Pure chloroform is a colorless, volatile liquid, with a specific gravity of 1·480, not highly inflammable ; it has a peculiar odor, at first sweetish to the taste and afterward burning and pungent. Applied to the skin and prevented from rapid evaporation, it produces redness and vesication. When shaken with pure sulphuric acid in equal parts, no discoloration ensues. *Impure* chloroform, on the other hand, colors the acid brown.

The preparations for chloroform narcosis differ in no essential features from those just given. Since this anæsthetic is more powerful, a much smaller quantity is used. A simple napkin folded into a square of five or six inches will suffice as an inhaler. The apparatus of Esmarch (Fig. 139) is, however, preferable. It is composed of a wire frame shaped

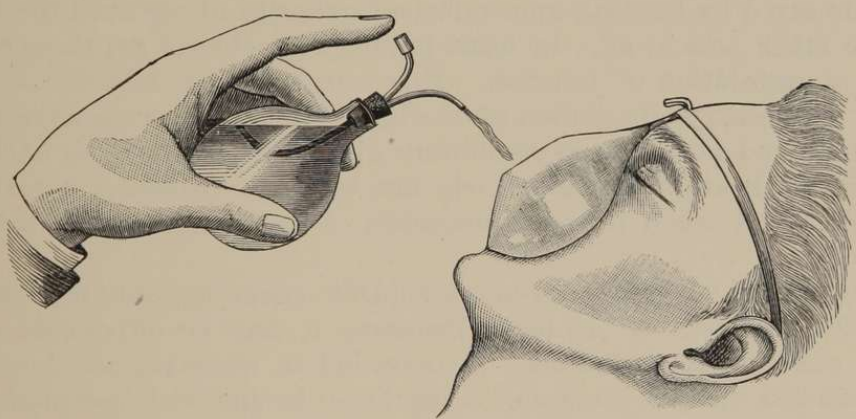
Fig. 139.

to fit over the nose and mouth, the center wire extending up an inch or more, and bent into a hook. Over this a piece of canton flannel or soft cloth is stretched so tightly that the threads are parted sufficiently to allow the free passage of air through the covering. To the upper end or hook a tape is attached and tied around the head in such a position that the inhaler falls over the mouth and nose. The administration is begun by pouring twelve or fifteen drops of the anæsthetic upon the inhaler or napkin. A free admixture of air is necessary. The napkin should not be held in contact with the lips or nose, for fear of shutting off the proper

quantity of air. It is a wise precaution to cover the skin about the mouth and nose with vaseline to prevent the irritating effect of the chloroform. In two or three minutes the same quantity is renewed, and so on until sensibility and consciousness are lost. Chloroform narcosis may also be divided into three stages.

The *first* is the stage of excitation. In this the pulse is usually increased in force and frequency, the face is flushed, the pupil normal or contracted; delirium may be present, with muscular rigidity, varying in degree in different subjects. It is almost always well marked in patients of the alcohol habit. The *second stage* is that in which sensibility and consciousness are lost, yet in which the functions of the heart and respiratory organs are performed in an almost natural manner. The pupil is now dilated and arterial tension diminished. In the *third stage*, that of profound paralysis, the breathing becomes shallow and stertorous, the heart beats rapid and weak, and the arterial tension is markedly diminished.

The *second* is the *operative stage*. The *third* should be avoided. Death during the inhalation of chloroform occurs from both heart and respiratory failure, and may take place in any stage of the narcosis. It is the heart, however, which fails in the vast majority of fatal cases, and this organ not infrequently suddenly and without warning ceases to beat. On the other hand, ether, when given in lethal doses, paralyzes the respiratory muscles, of which there are almost always premonitory symptoms that will not escape the acute observer and cautious surgeon. When natural respiration fails, artificial means may be readily employed and life saved by keeping up a sufficient quantity of air until the effects of the ether pass away. In heart failure from chloroform there is little hope of restoration of function. However, a careful selection of cases and a preliminary stimulation of the heart by a hypodermic injection of morphine and atropine, as heretofore given, will render the danger of death from heart failure extremely rare when the necessary precautions are taken and when the administration of the anæsthetic is in expert hands.

The use of *morphine* as an *anæsthetic* agent has not received the attention it deserves. In some instances it may be impossible to use ether, chloroform, or cocaine. I succeeded in removing the larynx on one occasion without the use of a trachea tube and with complete anæsthesia by producing a profound narcosis by the hypodermic use of morphine. I gave the patient two ounces of whisky half an hour before, and repeated this five minutes before the operation; twenty minutes before the operation one quarter of a grain of morphine hypodermically and an additional quarter of a grain was administered five minutes before the operation was begun. In the case referred to, as there was slight sensation, I gave the patient an additional eighth of a grain; and in the course of the operation, which lasted an hour and forty minutes, in which the larynx was exposed, the entire right half of it was removed, together with one half of the left ala of the thyroid cartilage with the vocal cords; the patient was entirely free from pain and did not remember after the

operation any painful experience. In using morphine in this way, precaution must be taken to have ready everything for antagonizing a too profound narcosis, and the amount of morphine employed must be carefully regulated to produce the required anæsthesia. The antidotes to morphine poisoning (atropine sulphate, gr. $\frac{1}{100}$; strychnine sulphate, gr. $\frac{1}{20}$) should be in hypodermic syringes ready for use, and strong coffee for rectal injection. Prof. J. M. Matthews, of Louisville, Ky., has produced satisfactory narcosis, and has succeeded in doing major operations with the use of whisky alone, giving one ounce at a dose and repeating it every ten or fifteen minutes until the patient is thoroughly unconscious. A combination of whisky and morphine I have used with great satisfaction in one or two instances where the condition of the heart would not permit the use of other anæsthetics.

CHAPTER IX.

HÆMORRHAGE—WOUNDS AND WOUND SUTURE.

Hæmorrhage and Hæmostatics.—The control of hæmorrhage is one of the most important features of surgical practice. Anatomically, hæmorrhage may be considered as *arterial*, *capillary*, and *venous*. Clinically, it may be *primary*, occurring at the time of injury, or *secondary*, occurring after the establishment of inflammation and the commencement of repair, this period beginning in from twenty-four to thirty-six hours after the injury. Secondary hæmorrhage may be due to what is termed *reaction* in the patient's condition, a gradual increase of volume of blood after sudden hæmorrhage due to abstraction of fluids from the tissues and consequent increased force in the action of the heart. It may also occur from separation of sloughs, or from any death of tissue in the part involved.

Natural hæmostasis occurs (1) from the contraction and retraction of a divided vessel; (2) from spontaneous coagulation of blood in presence of the atmosphere. When a vessel is completely severed it contracts longitudinally within its sheath, and at the same time its circular muscular fibers decrease its normal diameter. Contact of the blood with the roughened sheath tends to induce coagulation, and if to this is added atmospheric contact the process is more rapid. Diminished volume of blood and weakened heart also favor the formation of clot. The finishing process in natural hæmostasis is the permanent closure of the vessel by the exudation of plastic lymph and cicatrization which results from inflammatory cell proliferation.

Secondary hæmorrhage rarely occurs in wounds that have been made aseptic. However, it may occur in aseptic as well as septic wounds when there is a diseased condition or atheroma of the vessel walls. It is commendable surgery to consider all wounds as possibly subject to hæmorrhage, for the careful attention which this conclusion carries with it may prevent loss of life in the exceptional cases.

In certain conditions, such as inflammatory œdema, and in some tissues, as in the tongue, the scalp, and bone, a sufficient retraction of the divided vessels can not take place, and hæmorrhage is apt to be severe and continuous until arrested by direct compression or by ligature.

The surgical means for the arrest of hæmorrhage are :

1. Direct pressure upon the bleeding surfaces, which may be effected by pressing into the wound any substance convenient in the emergency —a clean towel or handkerchief, or any clean cloth; pressure of the

finger or closed fist upon the vessel, first above the wound, and, if this does not arrest the hæmorrhage, below it, in order to control both the arterial and the venous flow.

2. Constriction, which is one of the safest ready means for the control of bleeding in any of the extremities. This may be made with a folded towel, the sleeve of a coat, a belt, or a bridle-rein, but preferably with an elastic tourniquet. If any of the first-mentioned articles are used, it may be necessary to introduce between the member and the constrictor the rung of a chair or a walking-cane with which to twist the tourniquet in order to arrest the hæmorrhage (Fig. 145).

When the hæmorrhage is from the trunk, pressure on the wound or upon the vessels going to the wound must be relied upon. Capillary oozing or considerable hæmorrhage from small arterioles and veins may be readily controlled by the application of an ordinary roller bandage over a pad or dressing placed on the bleeding surface; the amount of pressure to be applied will be determined by that necessary for the arrest of hæmorrhage, but it should never be so powerful that the circulation in the limb beyond the compression is completely shut off for more than thirty minutes at a time. Equally adjusted pressure from the tip of the extremity, applied up to and beyond the point of bleeding, will overcome this difficulty. Under such conditions, the toes and fingers should be left exposed, so that the circulation can be closely observed. Esmarch's elastic bandage furnishes the ideal method of temporary control of hæmorrhage during surgical operations. When it is properly applied, hæmostasis is complete and entire, scarcely a drop of blood being lost even in operations upon bone. It should always be employed in operations upon the extremities. In anæmic subjects compression should be applied forcibly from the tip of the extremity up to near the point of disease, but under no condition should the elastic bandage ever be carried over a diseased surface, since the powerful compression it exerts may drive septic matter into the veins or lymphatics and thus produce irreparable damage. When the elastic bandage has been applied, a constrictor should be placed well above the point of operation, and when this is done the Esmarch placed below can be removed (Fig. 140).

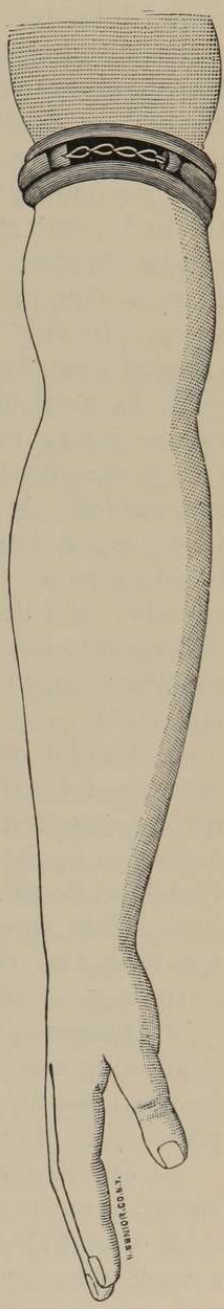

Fig. 140.

3. Elevation of a limb at right angles to the body, gravitation returning the bulk of the blood to the center. The value of posture in the arrest of hæmorrhage can not be overestimated. Even traumatic hæmorrhage

that is violent with the body prone upon the ground will often cease spontaneously if the part is elevated as high as possible ; and in wounds of the thigh close to the body it has been my habit to place the patient upon a table or bed and to elevate the feet so that the body reclines at an angle of 45.° After all operations upon the hands, forearms, feet, and legs, the elevated posture should be maintained in order to prevent oozing into the dressing. It may be well to say, however, that in certain cases of amputation, as at the hip joint, it is not always wise to drive all the blood which may be in the sound portions of the diseased limb into the body, especially in plethoric individuals, since the great proportional increase in the blood will throw upon the heart more work than it has been accustomed to perform. In applying constriction to a member of the body, care should be taken to use a wide rubber bandage when such can be obtained, since, if a narrow loop or piece of rubber tubing is used, there is danger of too much pressure being exercised upon a narrow space. In this way nerves have been injured, and I have seen several cases of temporary paralysis result from this practice.

4. In surgical work the artery forceps is the most satisfactory means of preventing or arresting hæmorrhage. When vessels are seen in the course of a dissection they should be clamped on either side before they are divided. Much time can be saved in an ordinary surgical operation by having a large number of artery forceps. Many of these applied to bleeding points produce coagulation in the vessels before the operation is ended, and the application of a ligature is unnecessary. Other vessels will have to be secured, and modern experience teaches us that carefully sterilized catgut is perfectly safe, and the most satisfactory of all ligature materials.

5. Torsion or twisting. By this method the divided ends of an artery are seized by the forceps and twisted round and round three or four revolutions, and the forceps unclasped and removed. The mechanism of occlusion is the destruction of the elastic and endothelial layers of the vessel, while the connective-tissue sheath and the adventitia are twisted into a fine thread which does not unwind after the forceps have been removed, and the vessel is thoroughly occluded. Torsion answers well in the case of small arteries.

6. Acupressure is practically obsolete in modern surgery. It consists in running a needle or a long silver or metal pin underneath the vessel to be compressed, and throwing a figure-of-eight thread over the two exposed ends of the needle.

7. The ligature is the chief reliance of the surgeon. In ligation of the larger arteries —the subclavians, carotids, iliacs, and femorals—large-sized catgut (No. 5 or No. 6) is preferable. In tying the exposed ends of a divided artery it is advisable to seize the end with a dissecting forceps and, with a dull instrument, preferably a grooved director, dissect back the sheath and connective or other tissues which overlap the end of it, so that the ligature may be properly applied to the clean vessel wall. In tightening the ligature it is not necessary to use such pressure that even the endothelial and elastic coats are divided ; but the walls should be

snugly brought into contact, and it is well enough, when the first knot is run down and tied, to leave both ends of the ligature perfectly slack, until the second and even the third knots are run down and secured. If after the first knot is tied the operator pulls or makes tension on either end of the ligature, he will be apt to loosen it at the point of constriction, and he may thus tie the finishing knot without having occluded the vessel. The theory was advanced by Scarpa many years ago, and was demonstrated by myself in 1880, and in the later classical work of Ballance and Edmunds, that the process of occlusion after deligation of arteries was by proliferation of the endothelia and connective-tissue cells of the vessel and the well-known process of cicatrization, following inflammation in all the soft structures of the body, and that the formation of a clot was not at all essential to permanent occlusion.

Many surgeons still use silk as a ligature, and others have substituted materials other than catgut, such as ox aorta (Barwell), deer sinew (Wragg), and sterilized nerve tissue (used in a number of deligations by the author). I have tied the larger arteries many times with catgut, and have never yet seen a secondary hæmorrhage, and see no reason why any other substance should be substituted for this excellent material. The few accidents which have been recorded were in all probability due either to an inferior article, which introduced septic matter into the wound and set up inflammation and suppuration, or to the vessel being tied over-tight, weakening the walls, which gave way under the action of the heart.

In applying a ligature to an artery at a point remote from the lesion —that is, to an undivided artery—the vessel should be exposed and, when it is necessary to avoid including in the ligature a nerve or vein in close relation, its sheath carefully picked up by the forceps and nicked, so that the aneurism needle (or the silver probe, which can be used for this purpose when no aneurism needle is at hand) may be inserted between the sheath and the walls of the vessel, and made to pass around it; the artery, being thus exposed, can be tied as heretofore advised. When, however, the artery has a separate sheath the ligature may safely include this with the vessel. I have done this in many instances, and am of the opinion that the blood supply to the vessel wall (vaso vasorum) is less interfered with than when the sheath is opened and partially detached. It is the practice of many good surgeons to apply two ligatures when a vessel is tied in continuity, half or three quarters of an inch apart, opening the sheath continuously for this purpose, and then dividing the artery midway between the two ligatures. I have never employed this method and do not see the necessity for it. It is held by some, however, that there is less likelihood of secondary hæmorrhage if the natural longitudinal tension of the vessel is relieved by its division, both ends retracting into their sheaths, as they do in division in ordinary wounds. All ligature material should be absolutely sterile when employed, and should correspond to the size of the vessel to be secured, as heretofore given. In making the knot, one of two methods may be selected—namely, the *single* knot, or the *double* or *friction* knot. The former is so well repre-

sented in Fig. 141 that it will not require description. A little practice will show the superiority of this over the *false* knot shown in Fig. 142, which is more apt to slip. In the *friction* or *double* knot (Fig. 143), the end of one side is passed twice under and over the other for the first

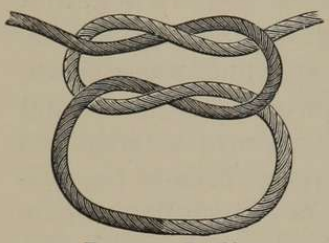

Fig. 141.—Reef knot.

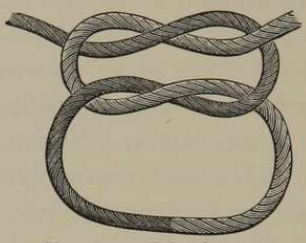

Fig. 142.—False knot.



Fig. 143.—Friction knot.

loop, instead of once, as just given. When the ends of the ligature are drawn upon, and the vessel constricted, the first knot holds without danger of slipping until a second single knot is added to it. As to the application of one or the other of these loops, the single knot will suffice for all vessels which are freely exposed and superficial, where the surgeon can be assured that the first turn holds fast until the second has secured it or where the bite of the first knot may be grasped and held with the long smooth forceps made for this purpose, and which prevents all danger of slipping. In deep wounds, where the knot must be run down with the finger tips and the forceps can not be employed, the double knot should be preferred. After being tied, the ends are cut with the scissors about one quarter of an inch from the knot. As to how much force it is necessary or proper to exert in the application of a ligature to an artery it is impossible to say. This point will be fully discussed in the chapter on Surgery of the Arteries.

8. Heat, either in the form of the actual cautery or in that of water heated to from 120° to 140° F., is a very excellent hæmostatic under certain conditions. Demonstrations of the value of the actual cautery are seen in the ordinary operation for hæmorrhoids with the clamp and cautery. In large oozing surfaces, compression with towels dipped in hot water is an excellent means of stopping capillary hæmorrhage.

9. Cold, in the shape of ice or very cold water, is not so valuable a hæmostatic as heat, but acts in the same way, by exciting contraction of the non-striated muscle fibers.

10. Styptics, such as persulphate of iron, are sometimes employed, but it is difficult to understand under what conditions their use would be justified.

Dr. Roswell Park, of Buffalo, has pointed out the advantage of a solution of antipyrine in controlling hæmorrhage, especially over the small vessels in the pia mater. It is sterile and does not interfere with prompt healing, and causes contraction of the vessels, but not coagulation of escaped blood. It is applied as a spray.

Gallic and tannic acids may also be mentioned, but, like the iron salts, they are not to be employed when compression or heat or cold can be used.

It may be well to mention the action of certain well-known internal remedies, which cause arterial contraction or lessen the heart's force, and may occasionally be of service in arresting bleeding.

11. In amputations where extensive muscular masses are cut across, as in the thigh or hip, and where oozing is always troublesome, it is advisable to pass deep sutures of strong catgut through the muscles in various directions, tying them, and thus exercising firm compression upon bleeding capillaries and even larger vessels, which otherwise would require separate ligatures and much valuable time.

12. Hæmorrhage from bone, as in operations upon the skull, where the sinuses in the diploë are divided, may be arrested by plugging with Cunningham's sterile wax (castor oil ʒ j, white beeswax ℥ j, melt together at a high heat for purposes of sterilization, and keep in sealed test tube). This may be softened for use by holding the tube in hot water. Sterile wooden pegs may be inserted in the bleeding canals in an emergency.

13. Ligation of the extremities. One of the most difficult forms of hæmorrhage to control is that occurring within one of the cavities of the body, especially in the cranial and thoracic cavities. Intraperitoneal wounds are almost always amenable to direct interference by abdominal section and the application of the ligature to the bleeding point. But this is not always true, especially in certain conditions of shock, where the surgeon may doubt the propriety of operative interference. In wounds of the lungs and in pulmonary hæmorrhage from any cause direct hæmostasis is practically impossible.

Under any condition of hæmorrhage in any of the cavities of the body where direct interference can not be employed it should be the aim of the surgeon to diminish the blood pressure at the bleeding point. To this end the application of ligatures upon the extremities of the body at the shoulders and at the hip joint may be efficacious. They should be just tight enough to interfere with the return of blood in the veins, yet not sufficiently tight to occlude the artery, for the blood must flow out through the arteries and be prevented from returning by the pressure of the ligatures on the more yielding veins, in order to fill the tissues of the extremities with blood and thus hold that much of the circulating fluid in reserve until the hæmorrhage can be arrested by coagulation at the point of bleeding. It may be safely assumed that one third of the entire volume of blood may thus be held in abeyance. The danger of shutting off too much blood in this way and producing cerebral anæmia or heart failure, from the lack of volume of blood upon which the heart may act, must not be forgotten, and this must be determined by the case under treatment. The ligatures may be left on fifteen or twenty or as many as thirty minutes, and when they are removed it should be done gradually, since the return of the blood which has been imprisoned in the extremities might so suddenly increase the volume in the vessels, the heart's action being likewise increased, that the coagula might be forced out of the vessels at the point of hæmorrhage.

Wounds.

A wound is a sudden solution of continuity in one or more of the tissues of the body. By common consent, such lesions in bone and cartilage are called *fractures*.

Wounds are *operative* and *accidental*, and may be classified under four leading heads—namely, *incised*, *punctured*, *lacerated*, and *contused*. Any breach of continuity may become inoculated with a virus, or venom ; it is then a *poisoned* wound.

Perforating injuries, caused by missiles projected from guns, demand especial consideration as *gunshot* wounds. An *incised* wound is made by a clean cut with a sharp instrument. A *punctured* wound is caused by a narrow instrument which penetrates but does not cut laterally. A *lacerated* wound is made by a dull instrument which tears the tissues. A *contused* wound is one in which the tissues are more bruised than separated.

The changes which occur in the tissues during the infliction of a wound, and in the process of repair, are as follows : Take, as an example, an incised wound across the anterior aspect of the middle of the thigh.

As the section is made, the capillaries, arterioles, and venules within the field of irritation instantly contract, and immediately thereafter become dilated. With the impingement of the knife the tissues retract, and hæmorrhage occurs. The wound fills with blood, and, if no large vessels are divided, the bleeding may cease spontaneously by coagulation. The chief factor in rapid coagulation after a wound is the presence, in increased quantity, of the white corpuscles, which increase, as before stated, always takes place within the irritated zone. Under the abnormal conditions present, coagulation results from a combination of the paraglobulin of the leucocytes with the fibrinogen of the plasma. This process not only occurs in the blood extravasated, but extends along the capillaries back from the edge of the wound to the nearest anastomosis.

Immediately following these changes, hyperæmia, redness, swelling, heat, and pain occur in the edges of the wound, and general cell proliferation ensues, as described in the chapter on inflammation. No repair of tissue is possible without this inflammatory process. It may be mild in degree, yet it must of necessity exist. A reunion of atom to atom, capillary to capillary, and a resumption of function without cell proliferation, can not occur.

If the hæmorrhage is, as it should be, entirely arrested, the wound thoroughly dried under every aseptic precaution, the parts brought together by properly adjusted pressure from deep as well as superficial aseptic (preferably absorbable) sutures, the surface of the skin carefully dried and immediately coated with a thick layer of sterile collodion, the changes which the tissues undergo in the effort to restore the integrity of the part are about the same as those described in the section on re-

generation or repair of tissue in non-infective inflammation. Hyperæmia is present, increased number of leucocytes, diapedesis, and general cell proliferation. Any coagulated plasma or serum which may have escaped after the wound is closed will be immediately infiltrated with the new cells of the embryonic tissue and the wandering leucocytes, and serves as food for these bodies of protoplasm. From this mass of embryonic tissue, by selection, the process of repair is carried on. Vascular buds are projected from the proliferating endothelial cells of the blood vessels at their divided and occluded ends; these meet with buds from opposing surfaces and unite to form new vessels as described. In the same way and from the original cells which composed the tissues new connective tissue, muscle, nerve, and epithelia are thrown out. In from four to ten days the process of contraction begins, and some of the new blood vessels may be obliterated by this normal fibrillation of the connective-tissue cells; but the majority remain to carry on the permanent circulation of the part. Any excess of tissue under normal conditions undergoes granular metamorphosis, while that which is needed in the function of the part remains and takes the place of that destroyed. When, however, infection occurs, as when the wound is treated by the open method or has not been asepticized, the changes differ inasmuch as suppuration is precipitated and the liquefaction of the new embryonic tissue takes place in varying degree. Under such conditions, the process of repair is greatly crippled, cicatrization or fibrillation of the new tissue is much more exaggerated, and naturally the function of the part is only partially restored. Such wounds always heal by cicatrization, and it is this contraction of the connective tissue which forms the scar, obliterates the vascular supply, and gives the bleached appearance almost always observed in cicatricial tissue. An open granulating wound becomes covered with integument by the formation of new epithelium from the edges of the wound. This gradually extends from the periphery toward the center, causing a shrinking of the granulation tissue, until the whole surface is skinned over.

Treatment.—The arrest of hæmorrhage is the first indication. Incised wounds bleed most freely, and are more dangerous in this particular than lacerated and contused wounds. In one the vessels are smoothly severed, in the other the ends are torn in shreds. In the larger vessels retraction of the media and intima occurs, and coagulation is more readily effected. Punctured wounds do not bleed seriously unless the larger vessels are opened. On account of the extensive lacerations caused by missiles projected from guns, the same may be said of wounds of this class.

Hæmorrhage from an artery should be controlled by pressure over the main trunk, between the wound and the heart, until the ends of the vessel can be secured with the catgut ligature. Venous hæmorrhage requires the elevation of a part (when an extremity is involved), and pressure upon the distal side of the wound until the ligature can be applied to the bleeding point. While not so essential, it is best to tie both ends of a divided vein. Direct pressure in the seat of a wound will

arrest ordinary hæmorrhage. When the bleeding is from an extremity, an emergency tourniquet may be made by tying a bridle rein, rope, piece of cloth (as the leg of a pair of trousers, or coat sleeve), or any other substance, around the part above the wound, and twisting this by means of

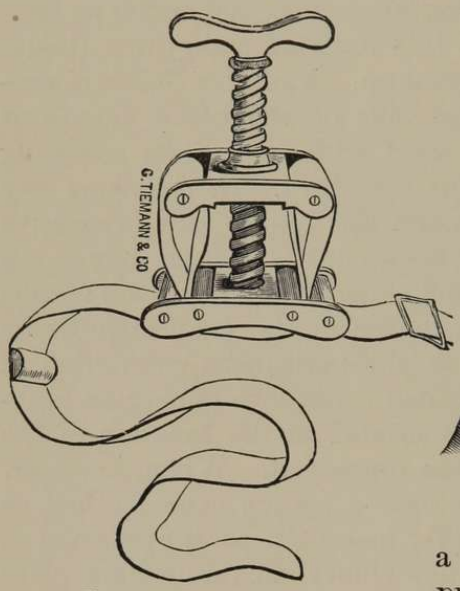

Fig. 144.—Petit's tourniquet.

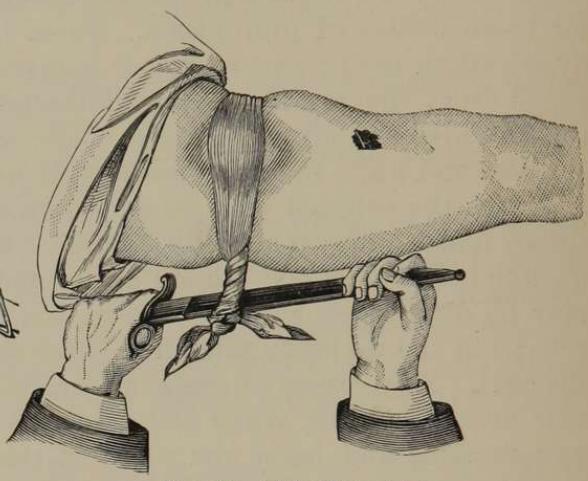

Fig. 145.—(After Esmarch.)

a stick, bayonet, sword, or gun barrel, properly inserted (Fig. 145). The efficiency of this method of compression is increased by placing a pad over the main artery. Compression of an artery with the thumb or finger, or a padded key or stick, will be of service in any emergency where a tourniquet can not be had.

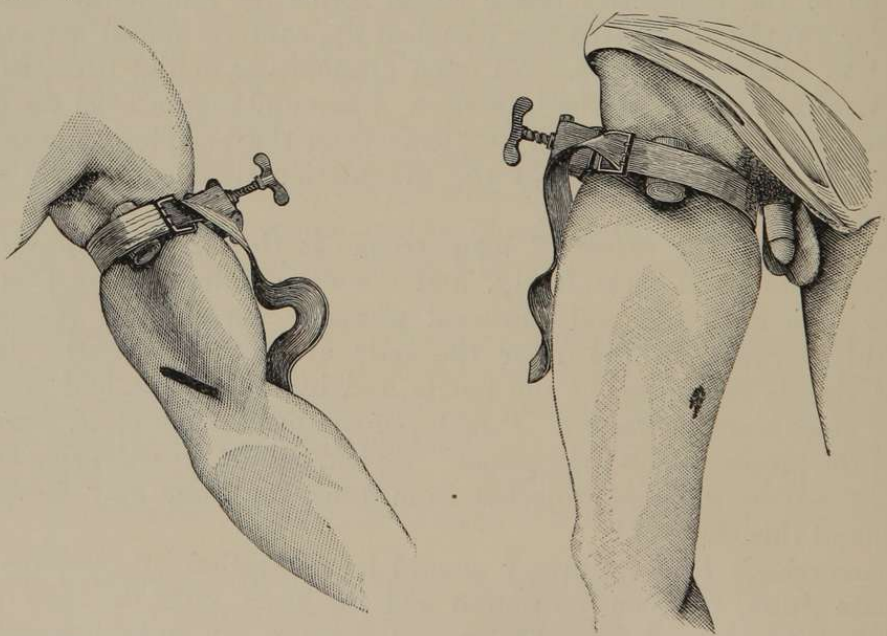

Fig. 146.—Petit's tourniquet applied for the brachial and femoral arteries. (After Esmarch.)

The tourniquet of Petit (Fig. 144) is one of the older and more useful instruments. Its application is illustrated in Fig. 146.

Esmarch's elastic bandage (or a piece of strong rubber tubing) is

the most generally useful of all the constricting hæmostatic apparatus. It may be thrown around a part, between the bleeding point and the heart, or it may be applied from the tip of the extremity, and over and on the cardiac side of the wound, and here secured (Fig. 147), while the portion beyond is removed. In this way the limb is rendered bloodless. This excellent apparatus may be employed in compression of the iliacs (Fig. 148) and the abdominal aorta (Fig. 149). The rubber tubing effectually controls all hæmorrhage of the extremities, the use of which is demonstrated in the chapter on amputation at the shoulder and hip joints.

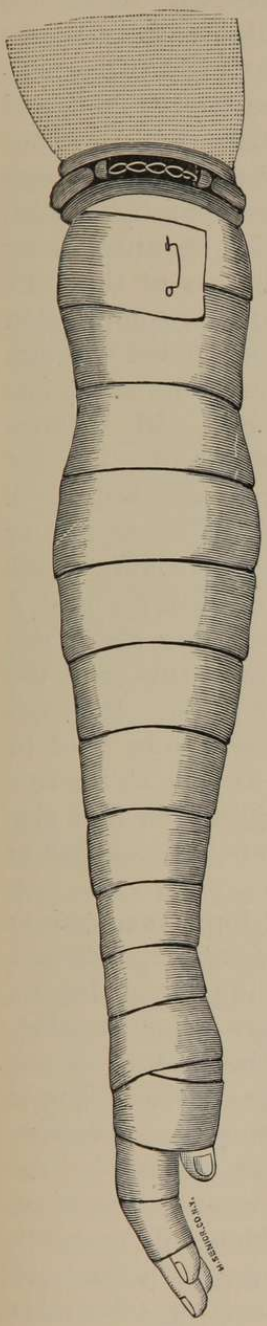

Fig. 147.—(After Esmarch.)

When the immediate flow of blood is arrested by any of the foregoing methods, the permanent arrest of hæmorrhage must be secured by the ligature at the divided point. For this purpose the artery forceps and the catgut ligature, already described, will be found by far the most preferable. *Torsion* is not

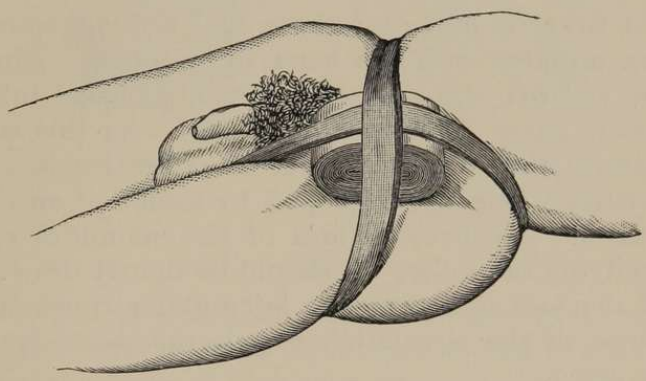

Fig. 148.—(After Esmarch.)

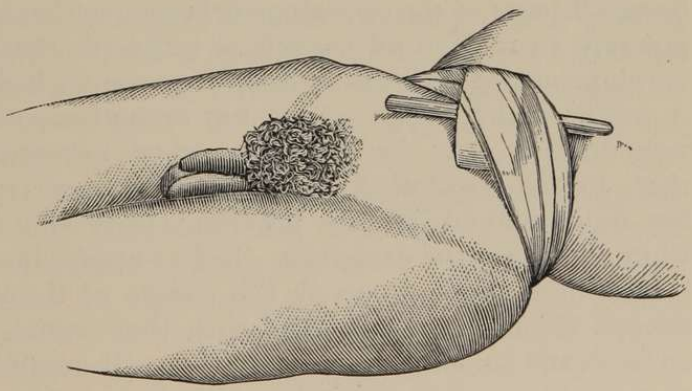

Fig. 149.—(After Esmarch.)

as safe as the ligature, and should not be employed when catgut can be had. The *actual cautery*, packing with *styptic cotton*, and *acupressure* are methods never to be employed when anything else can be done. If a wound must be packed, and if sterilized gauze can not be had for

this purpose, use clean linen or cotton cloth. *Cold* water, or preferably water *heated* to about 120° to 130° F., will prove of value as a hæmostatic. *Elevation* of a part, and well-adjusted compression by dressing and bandage, will always be made available by the surgeon of experience. While the ligatures are being applied, and, in fact, before this time, the entire surface of the wound should be irrigated with 1-to-3,000 sublimate solution, and thoroughly cleansed of all clots or foreign matter. Next to sublimate, the purest water should be freely used, and this, if possible, should first be boiled and allowed to cool to about 110° F. It rarely occurs in an extensive wound that all hæmorrhage can be stopped, for a general oozing takes place from capillaries too numerous to tie. Hæmorrhage of this character may be arrested by elevation of the part, or pressure either by approximation of the walls of the wound, by packing with sterile gauze, or by general compression of the part with a bandage. Buried sutures of catgut carried through the muscles and fascia not only secure approximation of retracted tissues, but arrest bleeding. If the edges are to be closed with sutures, the packing must be temporary. It is most successfully practiced by crowding the wound full of sterile gauze wrung out of hot water. A hot towel is laid over these, and firm pressure made for about five or ten minutes with the hand or a roller. After the important vessels are secured, the wound is closed, drainage tubes, if needed, inserted, a sterile gauze dressing applied, and over this cotton wadding about one inch in thickness. A layer of protective is placed over this, and the necessary pressure employed by means of an ordinary roller. It is impossible to convey an idea of the amount of compression to be used in applying the roller. It should be tightly drawn, and as long as the tips of the toes or fingers are left out for constant inspection, so that any arrest of the circulation may be immediately discovered, no danger is incurred.

In closing a wound by sutures, the points of chief importance are to bring all parts of the opposing surfaces together with equally distributed pressure to remove all coagula or serum so that no nidus is left for the development of bacteria and to dispense with drainage when possible. A wound which gapes at the top or bottom, or in the middle, is not well dressed. As for drainage, when necessary, the cardinal law is that, in the position in which the part must rest after the operation, the fluids should readily gravitate from the deepest portion of the wound out into the dressings. Before approximating wounded surfaces, if lacerations have occurred, the shreds of tissue, which will probably slough, should be trimmed off with the scissors, and the walls rendered as fresh and smooth as circumstances will admit. It is always desirable that the edges of the wound in the skin should be perfectly smooth, so that a close adaptation may be secured and an ugly scar avoided. This is especially essential upon the face, neck, and hands. In all such wounds the skin along the line of sutures should be carefully dried and coated over with several layers of clean collodion, which seals it hermetically.

In closing shallow wounds, it will usually suffice to pass the needle one eighth of an inch from the edge, so that it will emerge well down toward the bottom of the wound. It should now be entered in the opposite wall of the wound at the same depth, and brought up through the integument at a point corresponding to that where the needle originally entered. When a suture inserted in this manner is tied (Fig. 150), it is readily seen that in approximating the wounded surfaces the pressure is equally distributed at the surface and in the deeper portions. When important vessels and nerves are in relation to the walls of the divided tissues, care should be taken to avoid transfixing these. Of the various forms of suture, that known as the *interrupted* is the most useful and satisfactory. As shown in Fig. 150, the stitches may all be on the same plane, or there



Fig. 150.

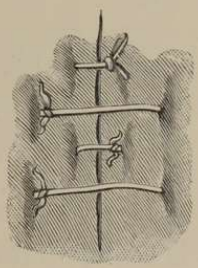

Fig. 151.



Fig. 152.

may be a wide and deep, and an intermediate and more superficial row, as shown in Fig. 151. Whatever form is employed, care should be taken that as the knot is tightened the edges of both sides should be exactly on the same level. In order to effect this, it is often necessary to lift one side with a director or hook, or depress the other to the proper level with a dull instrument. No fat or shred of tissue should be allowed to bulge up between the edges, but should be pushed out of sight with a probe or forceps while the suture is tied. In order to prevent slipping, the first knot should be the double friction loop, which is the only one that will hold its grip while the second single loop is being tied to secure the knot, or the first single knot should be held with smooth forceps until the second knot is tied. It is best to keep the knots away from the line of the approximated edges. In tightening the sutures the effort should be made to bring the lips of the wound together nicely without sufficient tension to pucker or wrinkle the skin, or to cause it to be infolded or to be turned white from too much pressure. When expedition rather than nice adjustment is desired, the *continuous* suture (Fig. 152) may be practiced. The needle is always passed at a right angle to the axis of the wound, although that part of the suture which is visible crosses it obliquely. The *mattress* suture, shown in Fig. 153, and the *quill* suture, at Fig. 154, are practically obsolete. They possess

no advantages which do not belong to the *interrupted* or *continuous* methods.

The *silver-wire* suture is usually interrupted. The application is well shown in Fig. 155. After the proper apposition is secured by the first twist, made with the fingers down at the level of the skin, the ends should be clasped in an artery forceps and turned eight or ten times.

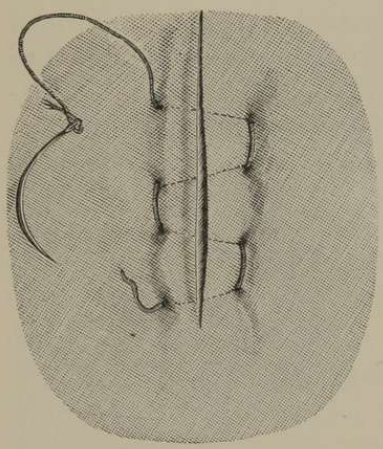

Fig. 153.

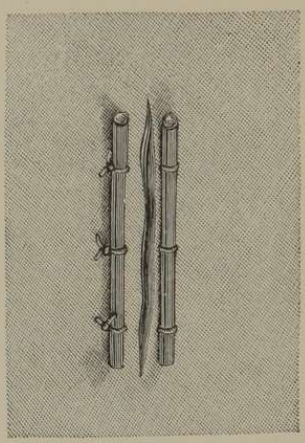

Fig. 154.

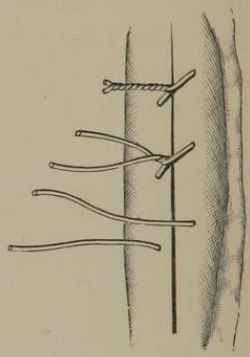

Fig. 155.

The *pin suture* (Fig. 156) is still popular with a number of surgeons, especially in operations for hare-lip. Silver pins, or the ordinary iron pin of commerce, may be employed, and the adjustment of the opposing

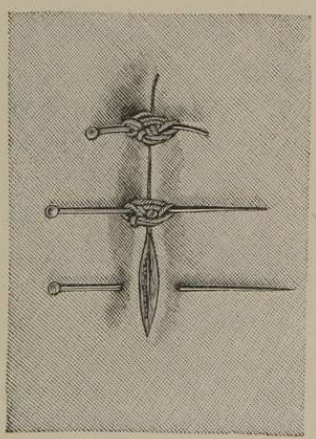

Fig. 156.

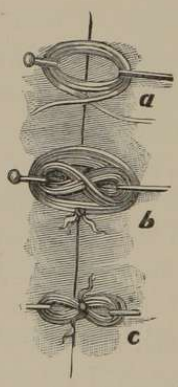

Fig. 157.

Fig. 158.

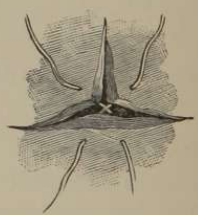

Fig. 159.

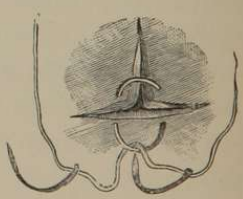

Fig. 160.

surfaces made more complete by throwing a silk or catgut interrupted loop, or figure-of-8, around the ends of the pin (Fig. 157), or a continuous figure-of-8 applied, as shown in Fig. 158.

When it becomes necessary to close a three-cornered wound, a *cross-suture* (Fig. 159) may be utilized, or the *double-needled* suture (Fig. 160) may be substituted.

Superficial lesions may be closed and held together by collodion or by adhesive strips, although this method is less exact than the sutures.

The strips should be cut narrow, and it is always necessary to have the parts to which they are applied dry and warm, else the plaster will not stick. The adhesive strips hold readily when warmed, as they are applied, or when moistened with turpentine. The strips may be dovetailed, or, while the edges of the wound are held in apposition, laid directly across the line of approximation.

Another method, less frequently employed, yet useful at times, is to take a piece of plaster and fasten it to the skin parallel with the edge of the wound. A half inch of this margin is folded back, and to this hooks are attached and elastic threads drawn directly across or in figure-of-8 fashion, graduating the pressure necessary to a proper apposition.

The *needles* for carrying sutures should be of various patterns, and of all sizes, for different purposes. Some are straight and round, others are lance-shaped ; some should be crescentic, others straight for the half or two thirds of the shaft nearest the eye, and curved toward the point. In general a needle should not cut laterally while it is being introduced, since the lance-pointed variety not infrequently causes annoying hæmorrhage by division of vessels, which the round, or smooth needles would push to one side.

A good *needle holder* is one of the most useful instruments of the operator's outfit. It should have a handle large enough to be well grasped without cramping the fingers, and strong enough to stand any required force. For general use the instrument of Sims is the best.

After the wound is closed, and the final irrigation made, the antiseptic dressings heretofore described should be applied.

When *hæmorrhage* has been so profuse that death from syncope is imminent, the head should be lowered so that gravity will aid the flow of blood to the brain in the hope of maintaining its functions. The administration of whisky by the mouth or hypodermically is indicated. If the bleeding is occurring internally, an effort must be made to confine as much blood as possible in the extremities, and to hold it there until, the pressure at the bleeding point being relieved, stasis, coagulation, and arrest occur. This method I have practiced in several serious cases, and have seen its efficacy demonstrated. Both arms near the shoulder, and both thighs six inches below Poupart's ligament, are constricted by towels, cloths, or bandages of muslin or rubber, which are tightened just enough to retard or arrest the return venous circulation, and not to interfere with the outgoing current in the arteries. In this way several pounds of blood may be held away from the bleeding-point and turned into the circulation when the hæmorrhage ceases. Care must be taken not to produce fatal syncope by keeping too much from the brain, and also not to return too much of the pent-up volume into the circulation at once. When fatal syncope is threatened, the injection of a solution of one heaping teaspoonful of *sterile* table salt to one quart of water which has been boiled and allowed to cool down to 110° to 120° F. should be done.

Six pints of this mixture at the temperature given have been successfully introduced. Two to four pints will usually suffice. This simple and efficient method of transfusion may be effected through a vein or an

artery, by preference the median basilic or cephalic vein at the elbow, or in any vein opened in an operation. The apparatus I employed is shown in Fig. 161. It consists of a funnel, to the tip of which a rubber tube is attached. To the end of the tube is a cannula for introduction into the vein. Open the vein, or utilize one already opened, in the wound if this is possible. Warm the solution to about 115° F., fill the apparatus, and allow a small quantity to escape through the pipette in order to be sure that no air is introduced. If then the stopcock is turned, or the rubber tube compressed, the cannula will be held full of fluid. After it is carried into the vein it should be held in place by a ligature tied around the vessel just behind the expansion at the nozzle. If the stopcock is now turned on, the fluid gravitates into the vein. The quantity and rapidity of the injection may be regulated by pressure upon the tube, or by elevation of the funnel. The introduction should be slowly and gradually accomplished. Any ordinary syringe, if thoroughly cleansed, may be employed. Care should always be taken to prevent the introduction of air. Prof. R. H. M. Dawbarn employs a large graduated glass irrigator which is kept at proper temperature by immersion in a basin of hot water. From half a pint to as much as five or more may be used, the quantity to be determined by the character of the pulse, which is reduced from 140 to 90 beats after one or two pints have flowed in. A fountain syringe which has been boiled and the cannula of the ordinary trochar will suffice. In some instances a glass medicine dropper has been substituted.

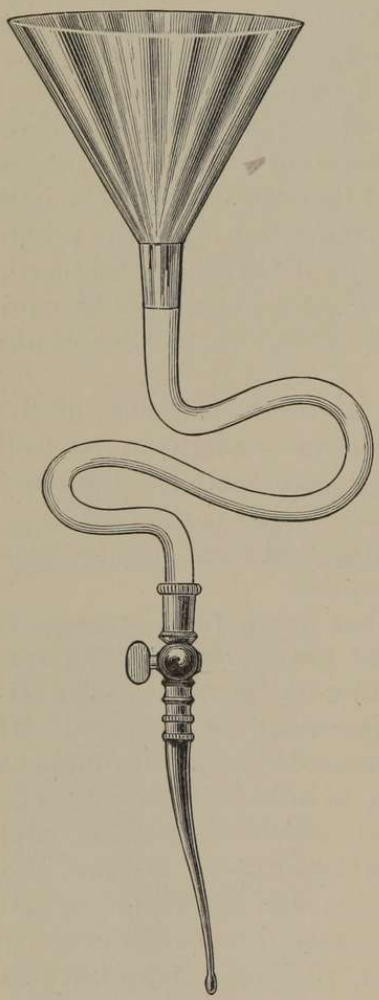

Fig. 161.

The older methods of transfusion with defibrinated blood, or direct transmission from the arm of the giver to that of the patient, are now completely superseded by the saline solution. Successful transfusion of simple water at the temperature of the blood has also been accomplished.

Poisoned Wounds.—When a *venom* or *virus* is introduced into the tissues through a solution of continuity, it is called a poisoned wound.

Snake Bite.—The venom of certain reptiles carried into the circulation through a wound produces alarming and, at times, fatal results. The intensity of its action is in proportion to the quality and quantity of the poison absorbed, as well as to the rapidity of its introduction. Thus, the venom of the cobra and rattlesnake is more fatal than that of many

other forms. Again, the venom lodged in the skin and subcutaneous areolar tissues, and absorbed by the lymph vessels and capillaries, is far less potent for evil than that which is injected into a vein, overwhelming the heart and sensorium by its rapid introduction.

The order of toxicity in serpent venom, so far as known at this date, is as follows: 1. Cobra (*Naia tripudians*), a native of India; rattlesnake (*Crotalus durissus* and *C. adamanteus*), of southern North America; *Bothrop jararacassa* and *B. jararaca*, closely allied, according to Dr. Robert Fletcher,* in the intensity of its venom to its congener, the North American rattlesnake; American copperhead (*Trigonocephalus contortrix*); the American moccasin (*Toxicophis atrapiscus* and *T. piscivorus*); the spreading adder, of the order *Vipera berus*.

The venom of snakes is excreted by a gland situated near the eye. In the act of striking or biting it is forced by a compressor muscle along a channel, or groove, in the fangs. In the quiescent state the fangs (one on either side) are folded backward, and are buried in grooves in the mucous membrane of the roof of the mouth. When ready for use, they are drawn forward by erector muscles. Rattlesnake venom, according to Dr. S. Weir Mitchell,† has a specific gravity of 1·044, and an invariably acid reaction. Its color is from a greenish to a straw tint. Conjointly with Dr. Edward T. Reichert,‡ he has isolated three proteids—namely, venom peptone, venom globulin, and venom albumen. Venom globulin is intensely toxic, producing rapid extravasations of blood; venom peptone is less poisonous, but produces, when injected into the breasts of pigeons, intense sloughing. The albumen venom is not yet fully understood. Bromine, iodine, sodium, and potassium hydrate and potassium permanganate destroy chemically the toxic property of the venom of the rattlesnake, copperhead, and moccasin. Serpent venom produces no poisonous effect in the tissues of the reptile which produces it, or in the tissues of any venom-producing reptile. It is poisonous to non-venomous snakes.

As just stated, the symptoms resulting from snake bite in man vary with the toxicity of the venom, the amount introduced, and with the rapidity with which it is carried into the circulation. A keeper in the London Zoölogical Gardens was bitten on the nose by a cobra, and died in a little more than one hour.# Dr. Wainwright, of New York city, died within six hours after being bitten by a rattlesnake.‖ Dr. G. A. Kunkler△ reports the case of a boy six years old who died during a convulsion on the fourth day, after being bitten on the foot by a copperhead. The venom is seemingly as potent in cold as in warm weather. Dr. E. P. King◊ treated a patient in whom well-marked toxic symptoms

* "American Journal of the Medical Sciences," July, 1883.

† Smithsonian Contributions, 1860. "New York Medical Journal," 1868.

‡ "Philadelphia Medical News," 1883.

Bryant's "Surgery."

‖ Hamilton's "Surgery."

△ "Cincinnati Lancet and Observer," 1859. "American Journal of the Medical Sciences," April, 1883.

◊ "American Journal of the Medical Sciences," April, 1884, p. 428.

were developed after being bitten by a copperhead which, although torpid, had recovered its activity under the influence of heat. When the clothing intervenes, the venom is likely to be in part arrested, and the effect less severe.

Pain of a sharp or stinging character is usually felt in the wound. Fright or shock may mask this symptom. Swelling rapidly ensues, and in rattlesnake bite ecchymosis is not uncommon. The swelling extends in all directions, but is most marked in the line of the lymphatics toward the center. Headache, fever, rigors, irregular breathing, and a low, feeble pulse, with nausea, may be present. Adenitis, abscess, or sloughing usually occur. If death does not ensue, the case may terminate favorably in two or three days, or last for weeks and months.

Treatment.—The immediate indication is the removal of the venom. Labial suction is an efficient method, and may be safely practiced, provided that there is no abrasion on the lips or contiguous mucous surfaces. Inoculation is more dangerous about the mouth and neck than elsewhere, since the great swelling may close the trachea or larynx. Next in order of readiness is free and immediate excision of the tissues within a radius of half or three fourths of an inch from the puncture, or free incisions may be made so that the flow of blood may wash the venom out.

Permanganate of potassium is probably the best chemical, and whisky (or alcohol in some other form) the best physiological antidote. Dr. de Lacerda,* of Brazil, recommends the immediate injection in and around the wound of a 1-per-cent (gr. v to ʒ j) solution of the permanganate in water, and also an intravenous injection if the venom has had time to enter the circulation. Dr. Robert Fletcher † states that Richards, of Calcutta, after repeating Lacerda's experiments, recommends a 5-per-cent solution in cobra poison ; ʒ j to ʒ iv of a solution, varying from gr. v to gr. x to water ʒ j, would be about the safest treatment for rattlesnake venom ; and the weaker solutions for copperhead and moccasin bites. It must not be forgotten that this salt is toxic in overdoses. Vulpian produced death in a small dog with an injection of gr. vij. Whisky, or any form of alcohol, is a favorite cardiac stimulant, and may be taken in adults in large quantities without intoxication. Care must be taken in adminstering alcohol to children, since it has occasionally proved fatal.

When great swelling occurs, and gangrene is threatened on account of tension, free incisions or puncture should be made.

The venom of some of the lizard family, as the Gila monster ‡ (*Heloderma suspectum*) and the toad # (*Bufo vulgaris*), also possesses toxic properties). The treatment should be about the same as given above for serpent venom, though not quite so energetic.

* "Gazette des hôpitaux," 1881, pp. 597 and 891. Also, a valuable paper by Dr. H. C. Yarrow, "American Journal of the Medical Sciences," April, 1884.

† "American Journal of the Medical Sciences," July, 1883.

‡ Mitchell and Reichert, "Medical News," Philadelphia, 1883.

"Gazette des hôpitaux," 1881, p. 598.

Venom introduced with the sting of the *scorpion* not infrequently causes death in the Orient, although the sting of the North American scorpion is not dangerous. I have failed to hear of a death from this accident, although I have made personal inquiry from numerous practitioners in the South and West, who have had much experience with these cases. In a personal experience, in which I was stung by a scorpion in the palm of the hand, no unpleasant symptom followed. As soon as the insect was brushed off, the venom was removed by sucking the wound, and by expression.

The venom of the *tarantula*, and other spiders, is occasionally fatal. In a private communication, Dr. Thomas A. Pope, of Texas, who has seen many cases of tarantula bite, reports one fatal case. Death did not ensue, however, from the changes induced in the blood by the venom, but from asphyxia due to closure of the larynx and trachea from great swelling, the man having been bitten in the neck.

The swelling is usually severe, and an erythematous rash occurs about the second day. This may occupy one half or all of the body. Sloughing at the wound almost always occurs.

The stings of *bees*, *wasps*, *hornets*, etc., possess a venom which, while rarely fatal, is painful and annoying. The application of an alkaline solution will, if immediately used, neutralize the pain and the tendency to swelling. Clay moistened into a paste with the saliva is an effective remedy used by the negroes in the Southern States. The sting should be removed if it has remained in the wound. In the case of a negro child, three years old, who had just a minute or two before been stung by about forty bees, no serious symptom ensued. The treatment followed was brushing the insects off with a sheet, and thoroughly sponging the entire body with a solution of a teacupful of ordinary saleratus in two quarts of water.

The venom of the *centipede* scarcely deserves mention. I am told by physicians practicing in the sections infested by these *Myriapoda* that their toxic power is much exaggerated. The slight effects which follow their foot-marks and the bite of the tarantula should be treated by permanganate of potassium locally and stimulants internally.

Gunshot Wounds.—Wounds of this variety may properly be divided into those in *civil* and those in *military* practice. In civil life the wounds inflicted by the shotgun, small-bore hunting rifle, pocket pistol, and toy guns are much less dangerous than those made by the more formidable weapons employed in warfare.

With the exception of the charge projected by the shotgun and the small hunting rifle, all missiles now used are conoidal or oblong in shape (Fig. 162).

Projectiles fired from ordnance are both round and conoidal, solid and hollow, the latter being usually explosive. Grape, canister, bombs, and some solid shot are spherical, while most of the shells are cylindro-conoidal.

A gunshot wound is always *contused* or *lacerated*. It may be *simple* or *complicated:* simple when the missile alone passes through the tis-

sues; complicated when fragments of cartridge, wadding, powder, clothing, or other foreign matters are carried in with it.

The degree of laceration made by a gun projectile is, as a rule, in an inverse ratio to the rapidity of its projection. It may also depend upon the shape of the missile, and the additional destruction caused by displaced fragments of bone, etc. A conoidal projectile is more destructive than one which is spherical, for when in its transit the point meets with

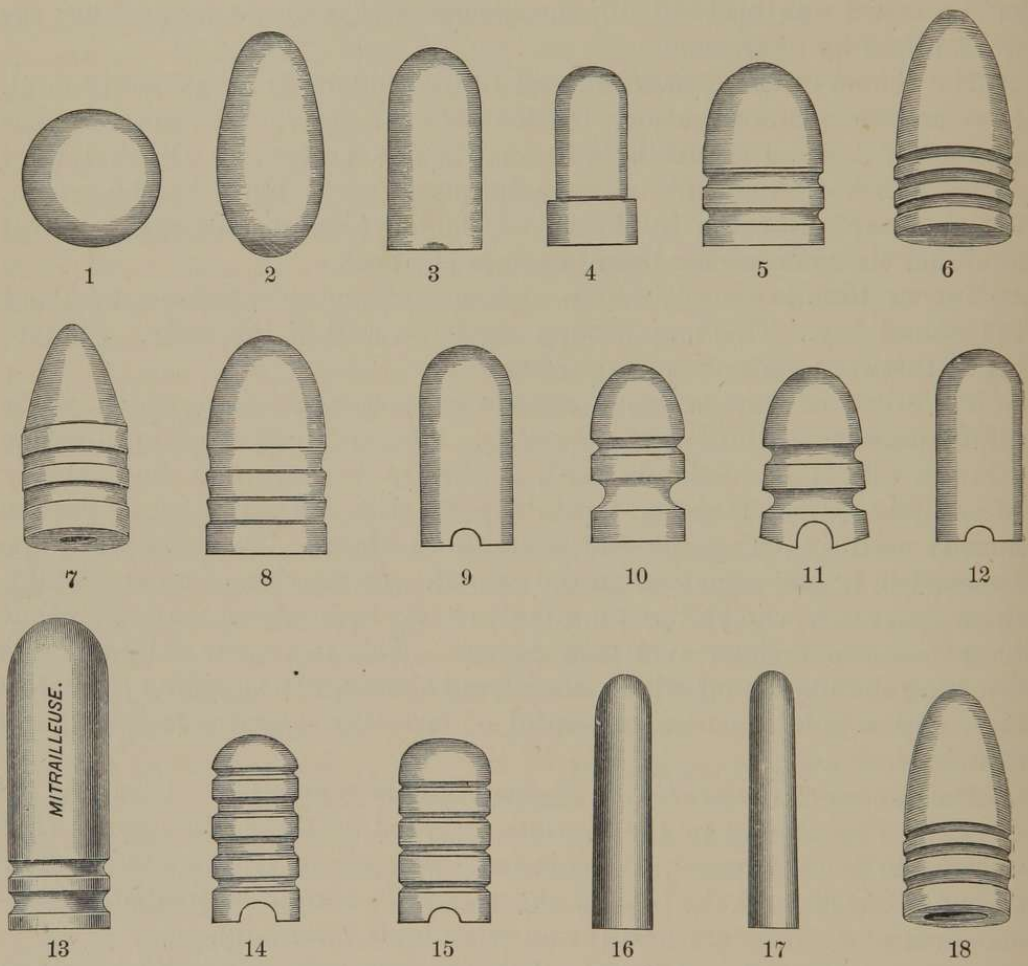

FIG. 162.—1, Old round musket ball, weight, 480 grains; 2, Needle gun, 530 grains; 3, Chassepot, 387½ grains; 4, Belgian rifle, 385 grains; 5, Bavarian rifle, 386 grains; 6, Enfield rifle, 530 grains; 7, old Austrian rifle ball, 400 grains; 8, Snider rifle, about 400 grains; 9, Martini-Henry, 485 grains; 10, Mauser, 337 grains (improved, 216 grains); 11, Mannlicher, 372 grains (improved, 235 and 165 grains); 12, Prussian rifle, 372 grains (improved, 203 grains); 13, Mitrailleuse, 840 grains; 14, Carcano rifle, 170 grains; 15, Schmidt rifle, 215 grains; 16, U. S. Army Krag-Jorgensen, 235 grains; 17, U. S. Navy bullet (caliber, 0·236); 18, Springfield conical, 500 grains. (After Agnew, Bryant, Wyeth, and Fischer.) *

resistance, it tends to turn over and over on its long axis, loses in great part its axial rotation, and thus plunges through the tissues. When a ball passes in and out of the body, it will be found that the wound of entrance is smaller than that of exit, and is seemingly much smaller than the projectile. The infolding of the skin and its elasticity will account for the small size of the entrance. The diminution of the momentum

* Wounds of the Mannlicher Magazine Rifle, etc. Dr. A. M. Fernandez de Ybarra. "Army and Navy Journal," May 12, 1894.

and the tumbling of the projectile as it plunges through the tissues, together with the non-resistances of the skin at the exit, will account for the larger size of this opening. When a projectile passes completely through the tissues there is usually a single opening of exit. Occasionally the object is divided after entrance, and makes two or more holes of exit, or one part of the bullet may lodge and the other pass out. Fragments of bone or teeth displaced by a missile may be driven out through the integument.

If the velocity of a missile is great, and the tissues traversed offer no special resistance, the wound of exit will be in the direct line of that of entrance. Bodies traveling with diminished velocity or meeting with formidable resistance will be deflected, and may pursue a most unexpected course. Instances are recorded of bullets which have made a half or the entire circuit of the body, passing just beneath the skin. Still more remarkable are the instances of extensive fracture of bones which have been produced without any evidence of injury to the integument. Longmore * relates the case of a soldier who had the whole shaft of the humerus shattered by a cannon ball, yet the skin remained as white and as sound as if it had not been touched. Numerous instances of similar lesions are recorded.

Treatment.—As with all other wounds, the arrest of hæmorrhage is the first indication in gunshot injuries. The various means to accomplish this end have already been given. It should be the recognized duty of the profession to instruct the general public in the use of the simpler means for arresting hæmorrhage. In military service each soldier should be taught by actual demonstration where and how to make compression in order to control the blood supply to a part. In actual warfare the vessels should be outlined by nitrate-of-silver tracings, and with especial indications at those points where pressure will prove most efficient. The ready construction of a tourniquet by means of a belt, coat sleeve, bridle rein, etc., tied around the limb at the proper place, and then twisted by a bayonet, sword, gun barrel, or stick, is an important lesson for an emergency. Next in order, and no less essential in the successful management of a gunshot wound, is *cleanliness* and *drainage*. In the best-regulated armies of to-day each soldier carries in his cartridge box a well-protected ball of iodoformized gauze, with the instructions to lay this over the wound as soon as possible, and to hold it there by a belt or bandage until the surgeon arrives. In the antiseptic treatment of these injuries irrigation with 1-to-3,000 sublimate solution is thoroughly done. All foreign matter or fragments of bone or destroyed tissues are removed, bone, catgut, or rubber drains inserted, and the regulation antiseptic dressing applied.

When sublimate solution can not be had, the freshest and purest water should be employed, and, when time allows, this should be boiled and used at 110° F.

Following a serious gunshot or other injury (or at times a violent

* Holmes's "Surgery," vol. ii, p. 134. William Wood & Co. 1875.

emotion without any appreciable lesion), a condition of prostration or partial collapse occurs, which is known as *shock*. Shock may be defined as a condition of collapse resulting from physical injury (usually with severe hæmorrhage), or mental emotion whereby the functions of the nerve centers are more or less completely suspended. The degree of shock is often determined by individual susceptibility, and is not always in proportion to the severity of the injury. The symptoms are pallor, coldness of the skin, thready, irregular, or rapid pulse, nausea, vomiting, clammy perspiration, and an anxious and fixed expression.

Judicious stimulation is the great indication, for, while reaction must be brought about, the quantity of stimulants should be kept at the minimum. Rye whisky by the mouth, rectum, or hypodermically should be preferred.

Hot bottles, warmed blankets, friction, etc., are useful adjuvants in the treatment of shock. Injection of salt solution when hæmorrhage has been excessive is the first and immediate indication.

The advisability of searching for a gunshot missile which has lodged in the body, or which has traversed any of the cavities, as well as the treatment of wounds of special organs, will be discussed hereafter.

Gunshot wounds of the extremities should be treated with strict regard to the principles of modern aseptic and conservative surgery. The former sacrifice of important parts of the body before the days of antiseptic surgery may have been in great part justified, for by the methods then in vogue deep infected areas could in no other way be disposed of. The primary amputation of an extremity for gunshot wound uncomplicated by extensive comminution of one of the long single bones or wholesale destruction of the joint surfaces at the elbow or knee should be exceedingly rare. It should be the practice to anæsthetize all such cases and enlarge the point of entrance (and of egress, if such there be) of the missile, and by the aid of the Esmarch bandage and bloodless method of exploration remove all foreign matter, making a careful search for the missile if it be lodged in the tissues, remove all pieces of bone which are splintered and entirely separated, thoroughly disinfect the wound, and establish careful drainage either by catgut twist or rubber tube. It should be borne in mind that all forms of drainage invite infection, and it is of great importance, especially in the class of cases under consideration, to keep a moist antiseptic dressing over the ends of the drainage apparatus. Extensive loss of substance in the tibia, with the fibula uninjured, may be remedied by osteoplastic transposition of the small bone into the gap left by the injury in the larger bone. Extensive injury to the shaft of the femur or humerus rarely calls for immediate amputation until every justifiable means has been tried for the preservation of the limb, even if shortening ultimately results. Wounds of the hip joint should rather be drained by the ordinary incision for hip-joint excision than primary amputation, which adds the shock of such a major operation to that already induced by a serious injury. When the extremity has been practically torn away by larger missiles, there may be justification for immediate amputation.

CHAPTER X.

BURNS, SCALDS, SKIN-GRAFTING, FROSTBITE, FURUNCLE, CARBUNCLE, ULCERS, GANGRENE.

Burns and *scalds* are classified in degrees varying from the mildest form, which produces a simple inflammation of the epidermis, to the most severe form, which destroys all the tissues or organs of a part. The gravity of the prognosis is usually in proportion to the extent of surface of the integument destroyed rather than to the depth of the destructive process. Burns of the head and face are most dangerous; those of the extremities least grave. Recovery is exceptional after destruction of one third of the cutaneous surface. Death may result from shock, ulcer of the duodenum, or exhaustion from prolonged suppuration and septic absorption.

The history of a slight burn or scald involving only a limited area of the integument, and not extending beyond the skin, is simply one of local disturbance. Cold-water immersion is the indication in treatment. When, however, a considerable extent of tissue is involved, symptoms of profound constitutional disturbance rapidly supervene. The patient is seized with chills or rigors, suffers excruciating pain, betrays in his expression the extreme anxiety felt as to his condition, and sinks into a condition of collapse, which is often the prelude to a fatal issue. When not rapidly fatal, the duration of this stage is from six to thirty-six hours. It is followed by the stage of reaction and inflammation. The character of the febrile movement depends upon the extent of the destruction of the tissues, and upon the concurrence of certain lesions of the thoracic and abdominal viscera. Inflammation of the duodenal glands, and the formation of ulcer with perforation, is not of infrequent occurrence during the second week after the accident. Peritonitis, pleuritis, or pneumonitis may add to the gravity of the prognosis. Laryngitis and bronchitis are apt to follow the efforts at inspiration in the presence of scalding steam.

Treatment.—The immediate indication is to relieve pain by the administration of morphine hypodermically, or some form of opium by the rectum or stomach. Stimulation with whisky or brandy by enema, or by the mouth, is also indicated to prevent collapse, or to modify the intensity of shock which is apt to follow a scald or burn. The use of both opium and alcohol should be made with a certain degree of caution, for there is danger from a too profound narcosis with the former, while alco-

hol in excess will unnecessarily add to the fever of reaction, which always follows if the patient should rally from the shock.

The clothing should be carefully removed, and the burned surface shielded from the atmosphere by an immediate application of a mixture containing equal parts of linseed oil and lime water. If this preparation can not be obtained, a coating of ordinary white lead, as mixed for use in painting dwellings, is an efficient protective when poured over the burn. Flour sprinkled over until all the excoriated surface is well hidden is a method of treatment which may be carried out in almost any emergency. Rubber-tissue protective laid over the raw surface, and cotton batting applied on top of this, never directly upon the burned surface, is equally efficient. Lint dipped in 2-per-cent carbolized oil may be used directly on the wound. Any great degree of pressure should not be permitted upon the excoriated surfaces. In the not infrequent form of burn in which the back and posterior aspects of the extremities are chiefly involved, the prone position should be maintained.

When suppuration and sloughing commence, great cleanliness should be observed, to prevent the absorption of septic matter. The dressings should be changed as often as the thermometer indicates septicæmia, but not oftener. Absorbent-cotton pellets moistened in 1-to-5,000 sublimate should be used in cleansing the burned surface. A mixture of vaseline (the white variety is preferable) and iodoform, in the proportion of ʒ j of the former to ʒ j of the latter, is a useful dressing in the stage of granulation. This should be applied on surgeon's lint, and covered over with rubber protective. It often becomes necessary to arrest exuberant granulations by the free use of lunar caustic, or the projecting buds may be clipped off with the scissors—a method objectionable, however, in the bleeding which always follows this practice. Compression by strips of adhesive (diachylon) plaster is a better method of repressing the overgrown granulation tissue. When the destruction of integument has been so extensive that in the process of cicatrization the granulating surface is not re-covered by skin, transplantation should be practiced. The various methods are *grafting*, *sliding*, or *transplantation in mass*.

Grafting may be done by clippings about one twentieth of an inch in diameter, and cut out so that only the epidermis and Malpighian layers are included. The epidermis is pinched up with a pair of mouse-toothed forceps, and clipped off close to the forceps with sharp curved scissors (Reverdin). A spot of granulating surface is selected, rendered aseptic, and the graft laid on bottom side down and pressed snugly into the granulating bed. A similar graft for every quarter inch of surface will suffice. These should be left uncovered from one half to one hour. A layer of protective is then placed over the entire surface, and a light sterile-gauze dressing applied, held on with a roller or adhesive strips. This dressing should remain unmolested for at least forty-eight hours, in order to give the grafts time to take hold, and, when the dressing is changed, great care should be taken to prevent their dislodgment. Water should not be used in the dressing. At the end of about the third day, if the graft has "taken," a bluish-white spot will be seen, the

color fading away gradually at the edges until it is merged in the general granulating mass. Grafts situated near the skin will unite and proliferate more rapidly and surely than those farther out in the wound.

When an extensive area is to be grafted over, the method of Thiersch should be employed. It is as follows : The surface from which the skin grafts are to be taken should be thoroughly shaved, scrubbed with soap and water, the skin follicles cleansed with ether, then thoroughly mopped with a 1-to-500 mercuric-chloride solution, and again with normal salt solution * to remove the mercury, and the place covered with a dressing wet with the salt solution. In some instances, such as superficial burns or ulcers, especially where careful treatment has kept the granulating surfaces aseptic, and even in cases which have become foul and then thoroughly cleansed, the grafts may take hold and live, but it is advisable to remove with the curette, or preferably with the knife, the edges of the ulcer down to the healthy skin, together with the granulations which are shaved off with the knife, or scraped if the sharp spoon is employed. The bleeding surface should be carefully sterilized by normal salt solution, which should be boiled just before using, and hæmorrhage stopped by pressure with sterilized gauze for the double reason that the escaping blood would lift the grafts up from the prepared bed, while a coagulum would invite infection. Grafts or flakes of skin, including chiefly the epithelial layers, are shaved off with a very sharp, broad-bladed razor, long enough to permit a free sawing movement, which facilitates the cutting of thin sections. Moisten the blade in salt solution, make the skin tense, and remove large, thin flakes. From half an inch to an inch in width and from two to three inches or more in length is a convenient size for lifting and transplanting. These grafts include the epithelia down to the papillary layer ; even including some of the connective-tissue stroma of the corium will not interfere with growth, provided the areolar tissue does not come with it. Keep the graft moist all the time with salt solution and carry it directly to the surface to be covered, sliding it from the razor to its proper place on the wound, bottom side down. As the tendency of these grafts is always to roll toward their raw surface, each should be gently unfolded with dull forceps or a probe and laid flat down. Piece after piece should be applied and carefully adjusted along the edges of the wound and to each other like paving stones until the entire surface is floored. The whole is then covered over with thin strips of rubber tissue about half an inch in width. The rubber tissue should be sterilized in mercuric-chloride solution, washed off in salt solution, and shaken before being applied. It is well enough in applying these strips to leave here and there a little crevice or crack, through which any accidental transudation may escape. Directly over the strips a layer of sterile gauze, absorbent cotton, a large piece of rubber tissue, and over all a bandage with light compression.

In from thirty-six to forty-eight hours the dressing may be removed,

* Normal salt solution, six tenths of one per cent., approximately gr. ijss to water ℥ j.

not disturbing the protective, however, for from one to two weeks. Upon removing the protective, it should be carefully taken off so as not to lift the grafts; if suppuration has occurred, the fluid should be absorbed with gauze mops or cotton wet with salt solution, the parts being touched very lightly.

When the condition demands, several thicknesses of grafts may be laid, one over the other, at the original or a subsequent operation. Some operators employ Esmarch's bloodless method when an extremity is involved, as it prevents bleeding and saves time in operating. The constriction is not removed until the operation is completed and the dressing applied, the compression of the final roller preventing oozing.

The more remote changes in Thiersch skin grafts have been studied by Goldmann ("Annals of Surgery," vol. xix, 1894), who says that cell proliferation in the middle layer of the epidermis is vigorous, and this continues two or three months; the outer layer is cast off more rapidly than in normal skin, due to the novel and insufficient nutrition, the exfoliation ceasing when the new vessels are sufficiently formed beneath the skin. Mobility of the new skin in case of small defects was noticed in about eight weeks, longer in larger wounds. He also demonstrated in skin thus developed elastic fibers and connective tissue; sensation is restored slowly, traveling from the periphery to the center, showing that the new skin from Thiersch grafts requires from two to eight months to become fully formed. It is a matter of importance that all dense cicatricial tissue, as after deep burns, should be dissected away, since grafts do not yield satisfactory results when planted upon scar tissue.

Dr. Z. J. Lusk, of Warsaw, N. Y. (Medical Record, December 7, 1895), reports a new and original method which, from the published cases, deserves recommendation: A patient, twenty-two years of age, of robust constitution, was scalded by falling into a pan of boiling brine, and was seen very soon after the accident. Great bags filled with serum hung from his sides and other parts of the body. Both arms were completely stripped of epithelium, which hung in shreds about the wrists, having been scraped down in his efforts to get out of the pan. The buttocks were also covered with large blisters; the skin on the lower extremities hung in shreds, bleeding in many places. There were numerous small vesicles on the face and neck, and large erythematous patches over the chest and abdomen, but no vesication except in the right infra-clavicular region. The gravity of the case may be understood when it is considered that the burned area covered more than two thirds of the body. One month after the accident grafting was commenced. The only cutaneous covering on the left leg was seven inches wide at the trochanter major, narrowing to two inches at the knee, covering one third of the leg to within two inches above the ankle. The right, eleven inches wide below the trochanter, narrowing to a point two inches above the right knee, commencing two inches and a half below, covered one third of the leg, narrowing to one inch over the ankle. The right knee from two inches and a half below to two inches above had no dermal covering; left, the same, except two inches on the outer surface. The upper

extremities were covered only by narrow strips on the outer aspect, except at the elbows, both of which were denuded of skin. An elliptical space over the lumbar region, five by nine inches, and one of about the same diameter over the left shoulder, were without dermal protection. There were in many places deep gangrenous sloughs, the underlying tissues resuming a more healthy appearance.

Thiersch's method could not be employed, as there was no surface from which to shave epithelial layers, and no one could be found to give strips of skin. On February 16th grafts were made as follows: Attached to the dorsum of the right foot by one edge, the other being free and raised a quarter of an inch, was a patch of dry exfoliated epithelium, extending nearly across over the surface, at the distal end of the metatarsal bones; the floating part was from an inch to an inch and a half wide; from this I clipped off a piece an inch square, softened and sterilized it in warm boric-acid water and divided it into twelve grafts, which were applied to the anterior granulating surface of the left thigh. The result was eminently satisfactory. Seven out of the twelve grafts took, and rapidly developed into vigorous islands of skin. The subsequent treatment consisted in using this dried epithelial tissue with which these large raw surfaces were covered with substantial skin by April 1st. The man began sitting up a few days prior to this date, and with the attendant's aid could walk about the room. He improved rapidly during the month of April, and on May 1st began doing light work.

The following experiments were made in the presence of my assistants and others: A little to the right and two inches below the trochanter major of the left leg there was a raw surface three inches and a half in diameter. At the proximal end of the great toe there was a dry, bleached patch of epithelium which had been thoroughly isolated from the body seven weeks, being held only by ends of hair. With this material this raw surface was completely healed in twenty-one days.

In the second case there was varicose ulcer, two inches and a half in diameter, three inches above the ankle on the outer surface of the left leg, covered with unhealthy granulations and bathed with foul-smelling discharge. The ulcer was thoroughly curetted, and followed by stimulating applications, so that in ten days the granulations appeared healthy. A surface on the left thigh near the anterior superior spinous process was made aseptic, and on it was applied a piece of emplastrum cantharidis two inches long by one inch wide. Vesication was produced in six hours, when the plaster was carefully removed. The epithelium was detached at the edges of the blister, washed in boric-acid solution, after which all moisture was aborbed with sterilized cotton, and it was then suspended in a small wide-mouthed bottle, which was plugged with aseptic cotton for a stopper and kept at a temperature between 55° and 70° F. It was thoroughly dry in three days, and a piece one inch square was divided, making twelve grafts, which were applied as before given. Nine of the twelve grafts took and grew rapidly, so that within twenty days the ulcerating surface had a substantial epithelial covering.

In a letter dated March 26, 1896, Dr. Lusk reports another case of

burned surface, five by three inches, in which he applied twenty-five grafts the same size as the foregoing. The material used was a patch of dry, exfoliated skin adhering by the edge to the dorsum of the right foot. The patient recovered.

After the epidermis is separated by vesication (a special plaster called *canthis* he considers preferable) it is lifted and washed for a few moments in warm boric-acid water; the moisture is then absorbed with aseptic cotton. The granulations to be covered are thoroughly bathed with normal salt solution, taking care to cause no bleeding. Grafts about one twelfth of an inch square are cut and pressed or sunken into the granulations. The dressing consists first of a thin layer of aseptic borated cotton saturated with a mixture composed of balsam of Peru ʒ j, to castor oil ℥ j. Over this three or four layers of dry cotton, all held firmly in place with strips of rubber adhesive plaster, and over all a light roller bandage. *No oil silk or rubber protective should be used.* On the third day the bandage is carefully removed and the cotton gently separated down to the first dressing. In this case the dressings were not changed until the thirteenth day, when the surface was found to be studded with minute islands of skin, and the patient was entirely cured within thirty days.

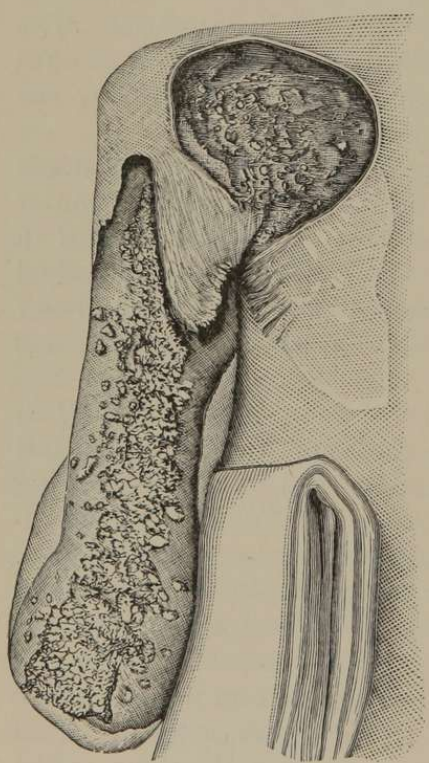

Fig. 163.

Dr. J. H. Girdner * has demonstrated that pieces of skin taken from a healthy man six hours after death by accident, "cut into a great many small pieces," and laid upon a healthy granulating surface, will become revitalized. The results of this demonstration are very valuable (Fig. 163).

Transplantations of skin in large pieces by entire removal, or with a pedicle left until the vascular supply is established between the granulating surface and the transplanted integument, may also be successfully accomplished. It is essential that the skin which is completely detached should be clipped or scraped on its under surface until only the Malpighian layer and epidermis are left. The presence of fat on the reticulated corium will almost always prevent success. When sliding is attempted, it is essential that the pedicle should be of good width, and that the tension on it should not be great, so that the integrity of the blood supply may not be interfered with, and sloughing ensue. Upon the face and neck, where the vascularity is so great, a smaller pedicle may

* "Medical Record," vol. xx, p. 119.

be used, and greater tension employed than on other portions of the body.

When there is not sufficient integument immediately about the uncovered surface to supply the want, the flap may be secured from some other portion of the body. Thus in extensive destruction of the integument on the front of the leg, I have succeeded in covering in the surface by turning a flap from the posterior aspect of the opposite leg, leaving a wide pedicle, and fastening the two members in an immovable position with plaster of Paris, so that the flap remained in its proper place and free from strain. After about ten days the pedicle may be divided. In the case of a boy who had been seriously burned in the hand and forearm and where the cicatricial contraction displaced the fingers, deformed the hand, and threatened amputation of the member by obstruction of the radial and ulnar, I did the following operation with success: All the cicatricial tissue of the wrist and arm was dissected off down to the tendons and bones, which were in good condition. Two parallel incisions, six or seven inches long and four inches apart, were then made from the ensiform cartilage down to the umbilicus, and the strip of skin dissected up in the middle and left attached at both ends. When the small amount of bleeding had been arrested, the hand was slid beneath this flap, the under surface of which was brought in contact with the raw surface, where the cicatricial tissue was removed from the arm and held in place by stitching the edges together with silk. Iodoform dressing was applied, and the hand and arm held immovable by adhesive plaster. Fig. 164 shows the condition of the hand, and Fig. 165 the method of transplantation. On the tenth day the strip of skin was divided above and below, and the cuff of skin folded around the wrist and stitched in position. The operation succeeded, and amputation was avoided. A second similar operation was done to restore the integrity of the palm. In all cases of transplanting skin no more of the subcutaneous tissue should be lifted with the integument than is necessary for

Fig. 164.

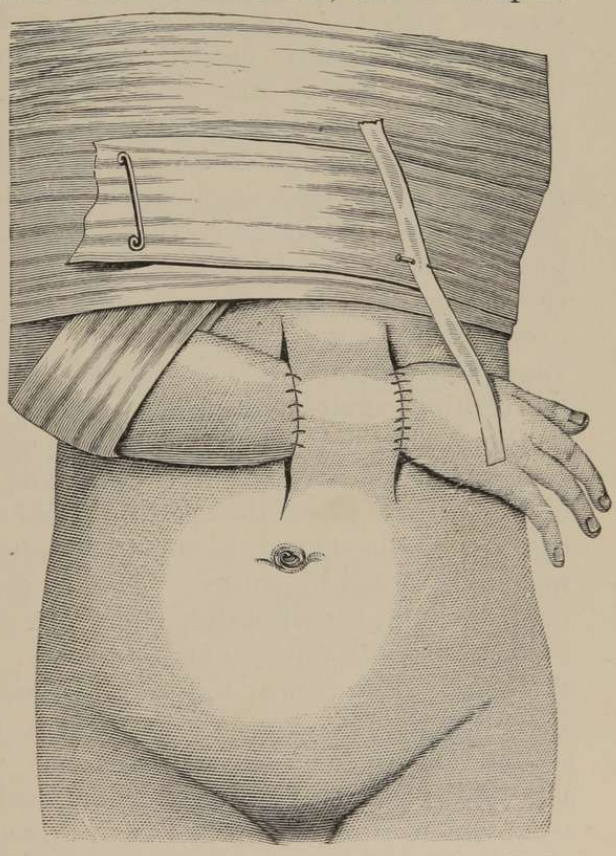

Fig. 165.—The author's case of transplantation from the abdomen to the arm.

the vitality of the flap. In short flaps a very thin dissection should be effected; in longer pedicles a good deal of tissue should be left to insure the safety of the blood vessels.

Transplanting in mass, in which the piece of integument, at least one inch in surface measurement, is entirely severed from its original attachment, and laid upon the granulating surface, is not so successful as the preceding methods. The smaller grafts are much preferable. When this operation is done, the piece to be transferred should be trimmed or scraped so thin that nothing but the epidermis and Malpighian layer remains.

Krause * reports twenty-one cases of large skin grafts transplanted in mass without a pedicle; in these more than a hundred flaps were used, of which only four suffered complete necrosis. Spindle-shaped flaps of all sizes from twenty-five centimetres in length to eight centimetres in width, down to very small pieces, were employed. The following procedure is essential to success: The surface upon which the transplantation is to be made must be either a fresh wound, or, if a granulating surface, it must be converted into a fresh wound. For the extremities, he advises that the limb be rendered anæmic by the Esmarch method. Careful asepsis must be carried out and the granulations vigorously scraped with the sharp spoon, or, preferably, cut away with a sharp knife down to fairly normal tissue, the whole field irrigated with sublimate solution, and this washed off with salt solution, then thoroughly dried with sterilized gauze; instruments and hands must be dry. Krause uses sterile gauze as a dressing, firmly bandaged over the wound. After the dressing has been applied, the tourniquet is removed from the limb. There should be added to this description, which is taken from an editorial by Dr. James P. Warbasse, that if the graft is made upon any of the extremities, the elevated position should be maintained after the operation for six or eight hours to prevent oozing. Krause further advises careful disinfection of the skin from which the grafts are removed, but cautions against vigorous scrubbing with brushes. The skin should be thoroughly bathed with bichloride solution, washed off with salt solution, and dried with sterile gauze. The grafts should be removed with careful aseptic precautions, and planted without moisture. They are cut oval or spindle-shaped, because the defects left of this shape can be immediately closed by suture. Quickly separating the skin from the subcutaneous fat, the whole flap should be outlined by incision, lifted at one angle with tooth-forceps, and cut away. It will be seen from this that the skin is split as near to the subcutaneous fat as can be done without including the fat. As soon as the flap is removed, it should be folded, wound surface together, and the patch, which contracts to two thirds or less of its original size, should be placed at once on the wound surface, from which all bleeding has been arrested by compression or the occasional twist of a vessel. No ligatures are permissible, and no sutures are applied to the flap; it is allowed to rest in the wound and contract,

* "Verhandlungen der deutschen Gesellschaft für Chirurgie," 1893; "Annals of Surgery," vol. xviii, 1893, p. 450.

and should not be put upon the stretch; it will settle snugly down in the wound, where it soon adheres. By applying pressure to the flap for a short time, it becomes cemented to the wound surface by a thin layer of coagulum, which holds it when the pressure is removed.

When possible, the whole defect should be covered with a single graft, and in estimating the proper size it must be remembered that when lifted the piece will shrink to about two thirds of its original size. In order to hold the flap firmly in position a five-per-cent sterile iodoformized gauze bandage is carried around the extremity. Over this a moderately firm dressing, and the limb immobilized by a splint. The first dressing should be made on the third or fourth day, since vesicles often form which should be opened. In order to prevent disturbing the graft, only the outer dressing should be first removed, and the parts then soaked in boiled and warm boric solution for an hour or more, until the iodoform bandage does not adhere. On reapplying the dressing, a piece of iodoformized gauze thickly covered with boro-vaseline should be placed over the graft. This same dressing should be repeated when necessary. After four days the flaps are pale, or may be purple, or livid and swollen. At the end of eight days they take on a reddish tint, the epidermis usually exfoliates, and little spots of necrosis may appear. These grafts do equally well when planted on muscle, fascia, connective tissue, periosteum, dura mater, or directly on a denuded cortical or cancellous bone surface.

Defects in hairy surfaces can be covered with grafts of hair-producing skin. Sensation returns ultimately.

Dr. P. A. Morrow, of New York, has successfully planted grafts which included the entire thickness of the skin and scalp, using a punch or trephine, cutting out buttons of material and accurately fitting them to depressions or beds in the scar tissue. In some instances the hairs reappeared, though not as luxurious in growth as before.

Destruction of tissue by *acids* or *alkalies* requires no special consideration beyond the adoption of measures to neutralize the excess of the agent in the part involved. The after-treatment does not differ from that of the granulating surfaces of burns and scalds from fire, boiling water, or steam.

Frostbite.—The effect of prolonged and extreme cold upon the animal tissues is to cause occlusion of the capillaries, loss of sensation, and death by gangrene. The *treatment* is to attempt a gradual restoration of the circulation by friction in a low temperature. A part of the body benumbed by cold should never be submitted suddenly to a high temperature, but should be bathed and rubbed in snow or cold water, the temperature of which is slowly elevated. When gangrene results, amputation is demanded after the line of demarkation is established.

Furuncle.—A boil is a circumscribed infectious inflammation, commencing usually in the hair follicles and sebaceous glands, and extending to the subcutaneous tissues. It is caused by the lodgment in a suitable nidus of some pyogenic bacteria. The proliferation of this organism produces inflammation, and by liquefaction of the tissues sup-

puration and localized gangrene. The occurrence of boils in certain derangements of nutrition, as diabetes mellitus, tuberculosis, etc., would go to prove that the pyogenic organisms are frequently present in the hair follicles of all persons, and under certain conditions find soil suitable for development. A boil may be differentiated from a carbuncle by the more acute inflammatory process of the furuncle, with almost always a single point of suppuration, well-defined, limited redness, and the acute character of the pain. In carbuncle the inflammation extends more widely and deeper, the induration is greater, there are several points of suppuration, and the febrile symptoms more appreciable. The *treatment* looks to an early relief from tension in the integument, and the separation and discharge of the slough and pus. Incision should be performed at once. The judicious use of cocaine hypodermically will prevent pain, and much suffering will be avoided by prompt action. The application of cold or heat is at times useful. Poultices are almost universally employed to soften the skin and hasten the discharge of the dead tissue. It is a waste of time to wait for so slow a process. After incision a warm, moist sublimate flaxseed poultice or dressing should be applied, and continued until a cure is effected.

The constitutional treatment should be directed to the correction of any existing dyscrasia. The preparations of iron and mercury are, in my opinion, the best general remedies. Tonics, good food, regulation of the alimentary apparatus, and good hygiene are essential. Sulphide of calcium (gr. $\frac{1}{10}$ to $\frac{1}{4}$ three or four times a day), arsenic, the iodides, cod-liver oil, with the hypophosphites of lime and soda, are among the remedies most recommended.

Carbuncle.—This disease—which, as Prof. A. R. Robinson* remarks, has been misnamed "*anthrax*"—is an infectious inflammatory process of a low order, involving chiefly the skin and the connective tissues immediately beneath it, and in some instances extending into the deeper organs. Anthrax or *malignant pustule* is not in its incipiency a suppurative disease; carbuncle is always so. The process is akin to that of furuncle, though indicative of a more depraved condition of the tissues. While the infection in furuncle is single, as a rule, in carbuncle there are two or many centers of infection with pyogenic bacteria, which may or may not gradually coalesce in one wide area of inflammation and necrosis. When this occurs the inflamed area breaks down in several places, giving discharge to pus (usually in small quantity), as well as to dead tissue. It is apt to occur as a complication of the same diseases with which furuncles are seen—diabetes mellitus, tuberculosis, etc.—and in parts of the economy subjected to more than ordinary irritation, as the back of the neck, where the collar presses, and in the gluteal region.

The *symptoms* of this affection are a sense of malaise, loss of appetite, headache, fever, varying in intensity, which is followed by or accompanied with a deep-seated and severe pain in and about the local expression of the disease. The skin at this point becomes tense, injected,

* "Manual of Dermatology," 1884.

doughy to the touch, throbbing, and painful; the epidermis becomes lifted at various spots in the inflamed area, vesicles form, localized gangrene occurs, and the dead matter sloughs away. Not infrequently the necrotic process rapidly extends through the areolar tissue beneath the skin some time before the integument breaks down. The extent of necrosis varies under different conditions, and may be general or limited. The constitutional symptoms are determined by the amount of septic absorption and the degree of pain experienced.

The process of repair is by granulation, the development of an embryonic tissue which advances from the sides and bottom of the cavity as the slough is carried away. As to the length of time carbuncle may last, nothing positive can be stated. Usually from three to seven weeks; at times, when the process is subacute, several months.

The *prognosis* depends upon the condition of the patient, the age, the location and extent of the lesion, and the ability of the capillaries and lymphatics to resist septic absorption. Occurring in diabetes or any dangerous malady, it hastens a fatal issue. Situated upon the face, the gravity of the prognosis is increased. This is in great part due to the intense pain which follows an invasion of that part of the body in which the trifacial nerve is distributed. When located on the thorax, the pleura may become involved, thereby causing a grave complication.

The *treatment* should look to the immediate improvement of the patient's vitality by all available means. The local treatment should be directed to the removal of the entire area of infection at an early date. In this way alone can the great danger of septicæmia be averted, or the relief of tension by incisions, and the discharge of septic matter.

Poultices, if employed, should be made with 1-to-5,000 sublimate solution, as heretofore directed.

Ulcers.—An ulcer is the result of molecular death in the integument or mucous membrane, and the underlying areolar or submucous tissue, and is due to the presence of one or several varieties of pathogenic bacteria. The arrest of nutrition which these organisms produce may be local, as in the ulcer of chancroid, or general, as in the late manifestations of syphilis, scorbutus, etc. Occurring with a dyscrasia, ulcers are even then more apt to occur in parts of the body subjected to abnormal interference with the circulation.

Specific ulcers will be considered with the diseases of which they form a part. *Ulcers* may be divided into two clinical groups—the *active* and *indolent*. In one, the material for repair is in excess; in the other it is deficient. One of the most frequent seats of ulcer is upon the anterior aspect of the tibia at its middle and lower portions. They occur usually in the aged, and chiefly among the poorly fed and laboring classes, where the erect posture is of necessity maintained for many successive hours. Varicosities of the veins of the lower extremities must be put down as a common cause of non-specific ulcers.

The *treatment* of ulcers must be directed to the cause of the tissue destruction. In varicosities the integrity of the circulation should be restored by supporting the vessels by mechanical means, or relieving the

overpressure by position. For the former the elastic stocking, properly adjusted, is invaluable. Martin's elastic bandage is an excellent apparatus, but requires considerable care in its even and skillful application. When neither of these methods is available, pressure may be successfully employed by means of flannel or muslin bandages. An elevated position of the foot and leg should be maintained in all ulcers of the lower extremities.

An *indolent* ulcer demands stimulation. This may be effected by the oakum dressing. Soft, clean oakum should be well soaked in 1-to-3,000 sublimate, squeezed out, laid over the ulcer, and held well in place by a roller. It should be changed every three or four days. Supporting the edges of the sore with well-adjusted strips of diachylon plaster is also a commendable practice. The strips should be cut about three fourths of an inch wide, and crossed in a spiral manner (Fig. 166).

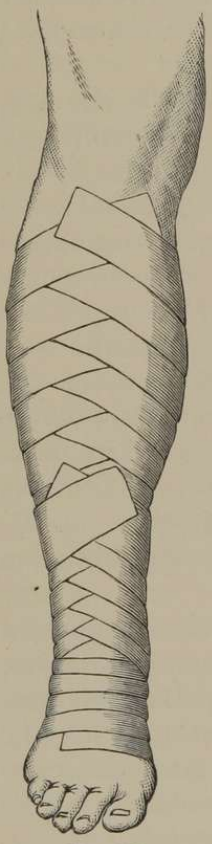

Fig. 166.

Irritable ulcers require rest and soothing applications. One of the most satisfactory preparations for the treatment of all forms of ulcers, granulating surfaces, incised accumulations of pus, septic wounds of all kinds, burns, etc., where absorption of moisture is desired, is the *balsam-oil* mixture first employed by Prof. W. W. Van Arsdale in 1884. It forms an excellent, slightly astringent, and unirritating dressing. For ordinary use it suffices to cover the surface with a mat of absorbent gauze, painting it over thickly with a brush. Enough gauze should be used to absorb the quantity of exudate for the time it is to be left on. Over the absorbent gauze, cotton batting is laid, over this rubber tissue or oil-silk protective, and a light bandage over all. When it can be obtained, the sterile preparation should be used. It is made by submitting castor oil for at least two hours to a temperature of 160° C. (320° F.). A special chemical thermometer is necessary for this purpose. The sterilized oil should then be poured into bottles taken out of boiling water, immediately corked with rubber stoppers similarly sterilized. The sterile oil will suffice without the addition of the Peruvian balsam, but I usually prefer to add this, and this must be done as the oil is poured out at the time of using. Balsam can not be heated without destroying its value. Twenty minims of balsam to the ounce of castor oil is the proportion. For infected wounds, while the aseptic preparation is always to be preferred, yet, when it can not be obtained, the ordinary cold-pressed castor oil of the drug stores can be used, and the balsam added in the same proportion as given. I know of nothing equal to this valuable preparation. The oil acts in a twofold way—the surface of the wound is moistened by it, while the liquid excretion from the wounded surface is carried off in the dressing by capillary attraction. The removal of moisture cripples the proliferation of bacteria, and in this way

aids in antisepsis. Its use does not contraindicate the employment of certain useful dusting powders, such as subiodide of bismuth, which will be found most excellent in combination with this dressing, or acetanilide, which is recommended on page 87. The constitutional treatment of all patients suffering from ulcers is of first importance.

Gangrene is death of a part of the body from the gradual or sudden arrest of its nutrition. The term is usually applied to the process of mortification in the softer structures. The analogous condition of bone is called *necrosis*. Animal tissues have two modes of dying—the one is *molecular*, or death by granular metamorphosis, in which no trace of the anatomical or histological properties of the tissues remains ; the other is death *in bulk*, in which, although the tissues deprived of life undergo rapid decomposition and ultimate disintegration, they retain for a time something of their original form. It is to denote this last variety of tissue death that the term *gangrene* is employed.

There are three varieties—namely, the *acute*, or *moist ;* the *chronic*, *senile*, or *dry ;* and the *contagious*, *phagedenic*, or *hospital* gangrene.

Acute Gangrene.—The chief cause of moist gangrene is the sudden obstruction of the afferent or efferent vessels of a part. Whether the artery is alone occluded, as by an embolus, the ligature, or an accidental solution of its continuity ; or whether the venous current is arrested while the artery is permeable ; or whether the arrest in both systems is simultaneous, as by the constriction of a finger with a ring, or in the case of a strangulated hernia—the part beyond the lesion is charged with blood which, arrested in its flow, loses its vitality and takes an early part in the work of decomposition which ensues.

When an *artery* is obliterated, the vitality of the tissues on the peripheral side of the occlusion depends upon the integrity of the collateral circulation. If the occlusion is gradual, the enlargement of the collateral branches is usually sufficient to carry the necessary supply of blood. There is scarcely a point in the arterial system where a collateral route may not be established, provided the process of obliteration is not too sudden, and the blood has not, by reason of constitutional disturbance, been deprived of its nutritive properties. When these conditions do not prevail, mortification ensues with a rapidity proportionate to the partial or total arrest of nutrition. Pallor is the immediate and earliest symptom of arterial obstruction, followed by coldness of the skin and pain, which is usually not acute. Beginning in the parts farthest removed from the heart, the phenomena of death extend toward the center until the border line is reached between the living and dying tissues. Congestion and swelling are not marked features of arterial gangrene. The normal contractility of the tissues, an elevated position, and the influence of the return current in veins with which those of the part involved communicate, tend to empty the vessels beyond the seat of obstruction. Of necessity, however, a considerable quantity of blood remains, and when its flow is arrested its function is lost, and its elements join in the general decomposition which ensues. In the putrefactive process, gases, notably sulphuretted hydrogen and those resulting from

decomposition of the fatty tissue, are evolved, and the coloring matter of the blood is liberated. Myosin, the albuminous principle of muscle, coagulates, giving a temporary sense of rigidity, and the serum which remained in the vessels undergoes transudation, and is generally distributed among the tissues. Cutaneous sensibility is soon lost, and the momentary pallor gives way to a grayish hue, which deepens into a greenish-black color. Though not so marked as in the condition resulting from venous occlusion, the skin and subcutaneous tissues become infiltrated with fluid and gases, giving a doughy feel upon pressure, and at times the peculiar crackling of emphysema. Serum and hydrogen, in the effort to escape, may at various points be caught under the impervious epidermis, which is lifted up into blisters. In resisting gangrene, certain tissues retain their anatomical features longer than others. Bone and tendon are slow to disappear, and at times the arteries will resist destructive change, when the tissues through which they pass have been entirely destroyed.

In a case which recently came under my observation, through the courtesy of Prof. Fluhrer, at Mount Sinai Hospital, in which gangrene was induced by a plaster-of-Paris dressing (applied in another institution for supposed fracture of the humerus), mortification was present first in the thumb and tip of the index finger, gradually involving the other fingers and back of the hand to the carpus, where the process seemed arrested in an apparent line of demarcation in the integument. The gangrene continued, however, beneath the skin, involving the extensor muscles, which, after amputation above the elbow, were found to have entirely disappeared, while much of the integument over them retained its vitality. When once inaugurated, mortification extends to a point where nutritive changes in the tissues are sufficiently active to resist death. The line between this embryonic zone and the blackened slough is called the *line of demarcation.*

The line of demarcation is, as a rule, irregular in extent. When a part has been constricted until death ensues, the line of separation may be a well-defined circumference; but in arterial occlusion this is a rare exception.

Accompanying the phenomena above detailed, shoals of organisms proliferate in the tissues involved, and rapid putrefactive changes occur; the soft parts drop away in offensive sloughs, leaving the bone projecting from the stump of this *natural amputation.*

The symptoms of gangrene from *venous* obstruction differ in some essential features from mortification after *arterial* occlusion.

Engorgement is more marked, since the cardiac and arterial forces are at work over-distending the tissues beyond the obstruction with blood. The skin is of purplish hue from the start, pain is intense, the swelling great, and, until coagulation is accomplished, there is a sense of throbbing in the affected part. There is at first an elevation of temperature, which, however, is of short duration. Blisters are more numerous, and putrefaction occurs more rapidly.

Gangrene from combined arterial and venous occlusion has its type

in a strangulated hernia, or in mortification of a finger which has been constricted by a ring. In this variety, arrest of the circulation and coagulation of the blood are more abrupt. The remaining features of this form of mortification do not differ materially from those heretofore described.

Treatment of Moist Gangrene.—When an artery is obstructed, the first indication is to remove the obstruction. Failing in this, to promote the establishment of a collateral circulation, and to maintain the temperature of the part affected. The position of the limb should be such that pressure upon the structures through which the anastomotic branches run should be avoided. Cotton batting should be carefully wrapped about the part to the thickness of several inches, and oil silk or rubber-tissue protective wrapped around this. No pressure by bandages should be employed. The application of hot water, directly or by bottles, is to be deprecated, for heat is now known to produce capillary contraction. The extremity may be slightly lowered, in order to invite the flow of blood, although care should be taken to prevent obstruction of the veins.

While these *local* measures are being adopted, certain *constitutional* remedies may be indicated. These relate primarily to cardiac stimulation, opium to relieve pain and palliate shock, and to an early improvement in the nutritive quality of the blood; the administration of alcohol and beef juice, and the careful combination of those articles of food which are acceptable to the patient, and are known to be rich in nitrogen. Any intercurrent disease or complication will indicate a modification of the treatment to suit the emergency. As death progresses and the sloughing begins, all structures which can be removed easily and without pain should be cut away with dressing forceps and scissors. Iodoform, freely sprinkled over the sloughs, will prove a good deodorizer, or the dead part may be kept wrapped in sublimate gauze, soaked in 1-to-2000 solution, and kept moist by protective.

Hæmorrhage is rare in this variety of gangrene, yet when it does occur it demands the ligature or compression.

The treatment of gangrene where the vein alone is obstructed, in which, as has been stated, the condition of engorgement is extreme, demands the elevation of the part in order to facilitate the escape of blood through the venous channels. The tension of the part may at times demand incisions through the deep fascia. The same precautions as to temperature must be taken here. The constitutional treatment will be less stimulating, yet supporting, and the local management of the dead part will be the same as given.

When all the vessels are subjected to pressure, it is essential to relieve the constriction as early as possible. However, the vitality of an organ seemingly dead should not be despaired of, since restoration of function after prolonged strangulation is occasionally witnessed. When, as in phlegmonous or other inflammation, the tension is so extreme that gangrene is threatened by pressure of the exudation upon the capillaries or larger vessels, free incisions should be made, parallel with the general direction of the vessels, and of sufficient depth and number to relieve the

tension. When, as in threatened gangrene of a finger, the swelling is severe, increasing, as it does, the tension of the organ and its own destruction, incisions are also demanded, and may prevent mortification before the constricting body is removed.

Chronic, Senile, or Dry Gangrene.—Dry gangrene may occur in any period of life. Although children and adults are occasionally attacked, it is in the vast majority of cases a disease of the aged; hence it is called *senile* gangrene.

Calcareous degeneration of the arteries, which is given as a cause of senile gangrene, is of itself a result of general impairment of nutrition; and it is to this failure of the heart to force the proper quantity and quality of blood to the tissues that we must look for the cause of this disease. *Diabetes mellitus* in patients of fifty years of age or older is often accompanied with gangrene of the lower extremities.

With a circulating fluid so deficient in nutrition, and a heart so crippled in its action that its function is illy performed, it is not difficult to understand that the pressure of a shoe, a contusion of the foot, or the lodgment of atheromatous or calcareous particles in the terminal arterioles or capillaries, would precipitate a morbid process, scarcely awaiting even an accident for its inauguration.

Symptoms.—In many cases of dry gangrene there is no history of an injury. Symptoms of constitutional debility from general impairment of nutrition usually precede the local expression of the disease. The lower extremities are most frequently affected. The patient suffers at times from coldness of the hands and feet. Shooting pains are not infrequently felt, and cramps occur in the muscles of the feet and calf of the leg. In exceptional cases there are none of the above premonitory symptoms, the first indication being the appearance of a brown or black discoloration on the foot or toe, or an insignificant excoriation may be the starting point of the morbid process.

From this the disease travels in the direction of the heart with varying rapidity. If the condition of anæmia is extreme, there will be no inflammatory discoloration in front of the advancing line of mortification, the skin changing from its normal pale color into the black, dead hue of the mummified part. The putrescent odor of wet gangrene is absent, and, instead of the swollen, doughy appearance of acute mortification, the part involved becomes hard and shriveled. The march of the disease is comparatively slow, and not infrequently death from exhaustion ensues before the line of demarcation is formed. In exceptional instances the disease confines itself to the toes, or anterior part of the foot.

Treatment.—The part affected should at once be enveloped in cotton batting and oil silk or protective, and placed in a position consistent with the comfort of the patient. No operative procedure is justifiable until a well-defined line of demarcation is established, unless septic absorption occurs to threaten the safety of the patient. The most important treatment is directed to the nutrition of the individual and the increased vigor of the heart. Opium, to relieve pain, is as much of a necessity as stimulants and food.

CHAPTER XI.

BANDAGING.

BANDAGES are employed in surgical practice to retain dressings in position, to secure compression and support to any portion of the body, to maintain any required degree of immobility, and to render an extremity partially or completely bloodless.

They are made of cotton muslin of various degrees of fineness, crinoline, woolen goods, and India rubber. Cotton bandages are most generally employed, but, on account of the greater elasticity of flannel, these are preferable for certain special dressings. Crinoline is only used for plaster-of-Paris bandages. Martin's rubber bandage and Esmarch's bloodless tourniquet are very useful in maintaining the firm compression of a part, either as a means of support or of emptying the vessels.

The muslin should be soft, not starched, and of two kinds—a fairly heavy quality, and the light cheese-cloth. Both should be cut in pieces from eight to ten yards in length. The former can be torn; the latter must be cut. The selvage edge is removed, and the cloth divided into strips varying in width from four, three, two and a half, and two inches, with some one inch or less in width. For the chest and abdomen the wide bandages are needed, the two- and three-inch strips for the arms, legs, head, and neck, and the narrow strips for the hands and fingers. All the loose ravelings along the edges should be pulled off, and the bandages made into compact, smooth rollers.

Bandages may be rolled by hand, but the work can be better and more rapidly done by machinery. In Fig. 167 is pictured a bandage roller, simple in construction and cheap. It should be fastened to the edge of a solid table by screws or movable clamps. The end of the strip to be wound is passed in and out over the four bars at the base and apex of the machine, and then around the shaft, so that one edge of the bandage touches the end of the upright. As the crank is turned, the strip is held tightly, and, as it runs over the rods, wrinkling or folding is prevented. A home-made apparatus may be constructed as follows: Take a cigar box, remove the top and one end, bore a hole in each sidepiece near the open end, and through these pass

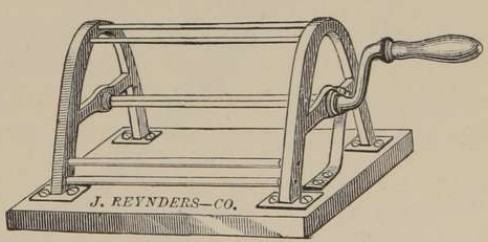

FIG. 167.

a piece of telegraph wire bent in the shape of a windlass and crank. Wires may be run through at other points to serve the same purpose as the four rods in the other machine, or a chink cut in the end through which the bandage travels toward the spindle.

In making plaster-of-Paris bandages, these same machines may be employed, but the crinoline must be loosely rolled, and the powdered plaster worked in with the hands so well and thoroughly that the meshes of the cloth can not be seen. Considerable experience is required to prepare a good plaster bandage, and a poor one will spoil a dressing. Plaster bandages should be made from fresh gypsum on the day they are to be applied. Cotton and flannel bandages should be kept in a chest or closet away from dust and moisture. Plaster or plaster bandages which have deteriorated from absorption of moisture should be subjected to dry heat in an oven to drive out the excess of moisture.

Methods of applying Bandages.—The various portions of the body may be bandaged by the *simple spiral*, *reverse spiral*, *simple figure-of-8*, and the *figure-of-8 reverse*.

The *simple spiral* turn is most useful in bandaging those parts of the body where there is no sudden increase in the diameter and volume of the part. It is impracticable under other circumstances.

Hold the bandage in the hand most convenient, with the back of the roller toward the limb (see Fig. 168); with the unoccupied hand take the

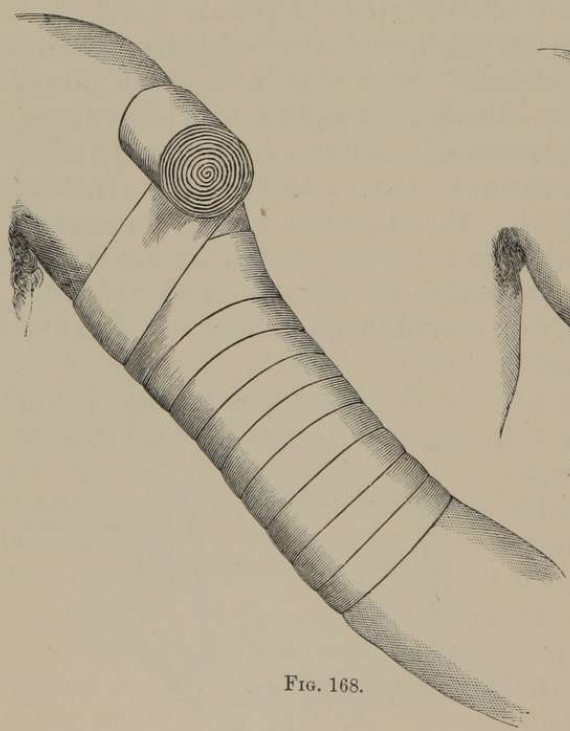

Fig. 168.

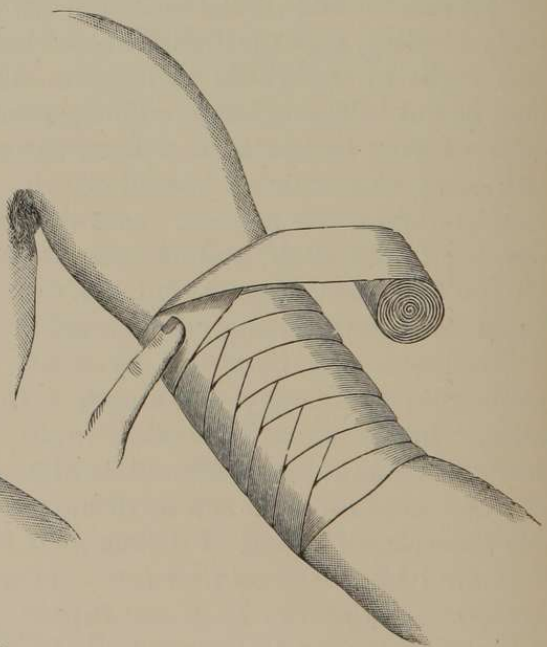

Fig. 169.

free end of the bandage, lay and hold it upon the inner border of the limb, and carry the turn by the front to the outer side of the part to be bandaged.

Having carried the roller twice around the part to secure it, ascend the limb spirally, leaving about one third of each turn uncovered by the last.

The *reverse-spiral* turn (Fig. 169) is applied as follows:

Taking the left arm to be bandaged, hold the roller in the right hand, with its convexity toward the limb, and carry it from the inner or ulnar border, by the front, to the outer or radial border, and thus around the arm by two circular turns to secure the roller. Then, having carried the bandage to the outer side, ascending the limb gradually, lay the thumb of the left hand upon the lower edge of the bandage, press it firmly against the limb to prevent slipping, loosen the roller considerably in the right hand, at the same time turning it one-half turn toward the operator. This process is to be repeated as often as necessary, keeping the reverses well upon the outer border and anterior aspect of the extremity.

The Simple Figure-of-8 Turn.—After the bandage is secured, as heretofore described, ascend the limb sharply, from the inner to the outer border, so that at this outer border the lower edge of the roller shall be several inches above the starting-point. Carry the roller directly across and *behind* the limb to the same point on the opposite side; then obliquely downward in front, crossing the ascending turn at a right angle. When the outer border is again reached, carry the roller behind and directly across the limb to the starting-point (see Fig. 170).

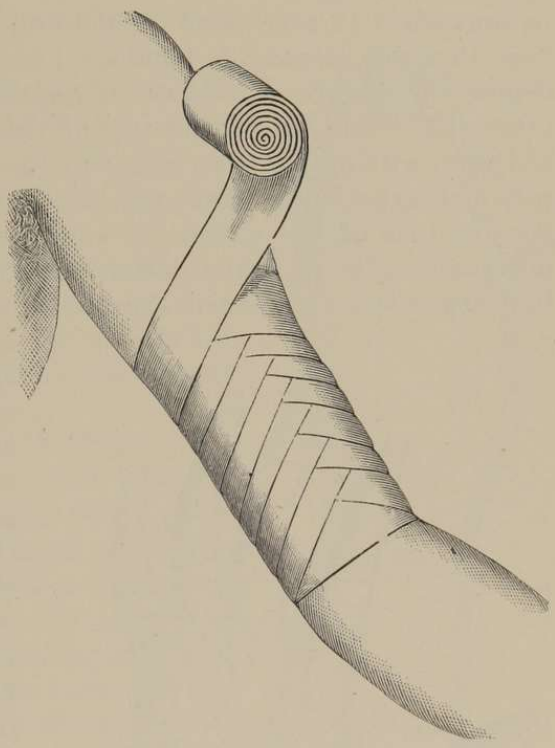

Fig. 170.—The figure-of-8 method.

The Figure-of-8 Reverse.—Commence exactly as for the simple figure-of-8 until the bandage has passed across the posterior aspect of the limb, and is about to descend obliquely along the inner aspect to the front. With the index-finger of the unoccupied hand hold the lower edge of the bandage tightly against the part, while the roller is slackened and turned half over in a direction away from the limb. This reverse in the figure-of-8 may also be made anteriorly, and, when the conformation of the part demands it, may be made both anteriorly and posteriorly.

Of these four methods, the *simple spiral* is more readily applied. When the diameter of the extremity increases rapidly it will not suffice, since it grasps the part at the upper edge of the roller while the lower stands out free and loose.

For all purposes the *spiral reverse* is more generally useful. In competent hands it can be applied to all portions of the body except where the members join the trunk, when it must give place to the *simple*

figure-of-8 turn. Thus, the *spica* at the groin and shoulder, the occiput and chin dressings, and the neck and shoulder bandages, must describe this shape. The *figure-of-8 reverse* is of great use in getting over the calf of the leg in very muscular subjects, where not infrequently all the other methods will fail to hold.

The important rule in bandaging is to *equalize the pressure from periphery to center.* The circumstances of the case will determine the degree of compression. It requires a great deal of study and practice to become expert in applying dressings. One should thoroughly familiarize one's self with each of the methods, for not infrequently a part to be dressed will require a combination of several methods. The question of how tight to apply the bandage may in part be left to the sense of the patient when an anæsthetic is not employed. After an extensive operation, in which Esmarch's bandage has been applied, a very considerable degree of compression is often required to prevent the oozing which otherwise would follow the use of this tourniquet. No amount of description will impart this sense to the inquirer; it can only come from personal experience. One precaution is imperative: the tips of the fingers or toes of the extremity bandaged must always be left open for observation, for if strangulation is threatened it will always be earliest indicated here. A watch should be set on every case where there is ground for anxiety, with directions to slit the dressing with the appearance of any symptom of strangulation.

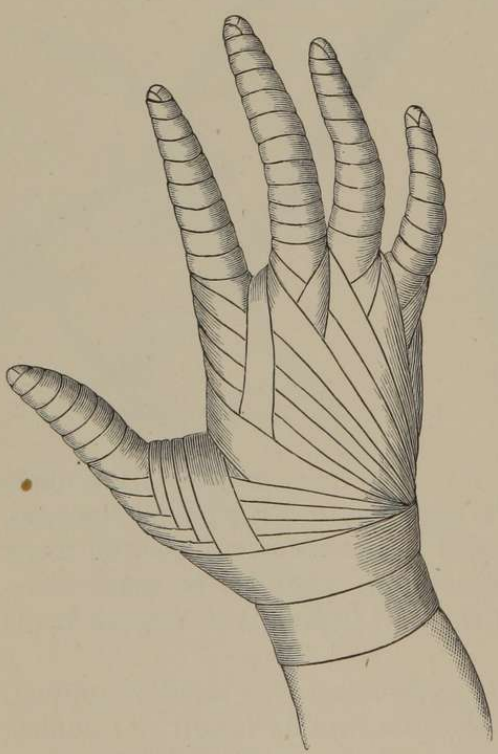

Fig. 171.—Hand-, thumb-, and finger-bandage. (The author's modification of the old method.)

Special Bandages—The Hand and Fingers by the First Method (Fig. 171).—Take a roller between three fourths and one inch in width, and ten yards in length. Let the hand to be bandaged be pronated, and commence by taking two or three turns of the roller around the carpus, going from the radial over the back of the wrist to the ulnar side. Having in this manner secured the roller, carry it from the radial side of the wrist obliquely across the dorsum of the hand to the ulnar border of the root of the little finger, then spirally around the little finger two turns to its extremity. Next, return by careful spiral turns, or a spiral reverse, if necessary, to the root of the finger, covering it equally and nicely. From the radial border of the base of the finger the bandage is carried over the back of the hand to the ulnar side of the carpus,

then under the wrist, by the front, to the radial side, and again over the dorsum of the hand around to the ulnar side of the same finger, repeating the figure-of-8, as before. Two turns are then thrown around the wrist to secure the former bandage, and the roller is carried in the same manner to the remaining fingers.

When the index-finger is reached, on account of the great space between its root and the thumb, it is advisable to make four or five extra figure-of-8 turns around its base, carrying the bandage a little lower with each successive layer toward the thumb.

Having reached the thumb, the roller is carried spirally to its extremity, as in the other fingers, but in returning, when the last, the interphalangeal, joint is reached, the figure-of-8 turn is commenced at this point, and continued until the ball of the thumb is completely covered.

This method may be applied to the thumb alone, or to any one or more of the fingers, when the remainder of the hand does not need to be bandaged, and is equally efficient in securing splints to these organs.

One objection to it, and a very formidable one to the practitioner, is the length of time necessary to apply it. A more rapid and almost equally effective way is the hand-bandage by the *second method* (Fig. 172).

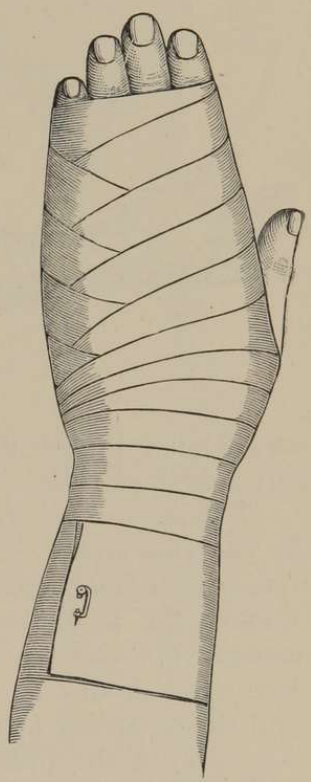

Fig. 172.

Place pellets of cotton between the fingers, and a fair-sized tuft in the palm of the hand. Take a bandage from one to two inches in width, carry it one or two turns around the hand where the phalanges join the metacarpus, until it is secured, and then by nicely adjusted figure-of-8 turns (the crossings on the dorsal aspect of the fingers) cover the hand from the tips of the fingers back. When the bandage reaches the thumb in the crotch between it and the index, and begins to roll up, it should be clipped with the scissors deeper and deeper along the edge nearest the thumb with each successive turn until the cut extends to the middle of the roller. Then a split should be made in the middle parallel with its long axis, and the thumb stuck through this; the next split is nearer the distal edge, while with the succeeding turn it may be brought clear of the thumb on its carpal aspect. A spiral, with or without the reverse, will hold on the incline from the thumb to the carpus.

The Forearm, Arm, and Shoulder.—From the carpus to the elbow the spiral reverse or figure-of-8 will usually be required, on account of the pyramidal shape of the part. When the elbow is reached, if the right-angle position (Fig. 173) is determined upon, the figure-of-8 around the humerus and forearm will suffice to climb along the elbow; or the simple spiral, carried over the same ground in the flexure of the joint, and

gradually ascending over the convexity, will accomplish the same purpose. For the arm the spiral, simple or reverse, will carry the bandage to the axilla. When the projection caused by the tendon of the pectoralis major is reached, the roller is carried from the inner side by the front, over the point of the shoulder, around the back, and underneath the opposite arm, across the chest to the anterior and outer surface of the humerus, then underneath the arm, making a figure-of-8 turn, one loop of which surrounds the arm, and the other the thorax. These turns are continued, gradually ascending until the root of the neck is reached. It is best to fill the axilla of both arms with absorbent cotton to prevent chafing, when this dressing is to be worn for any length of time.

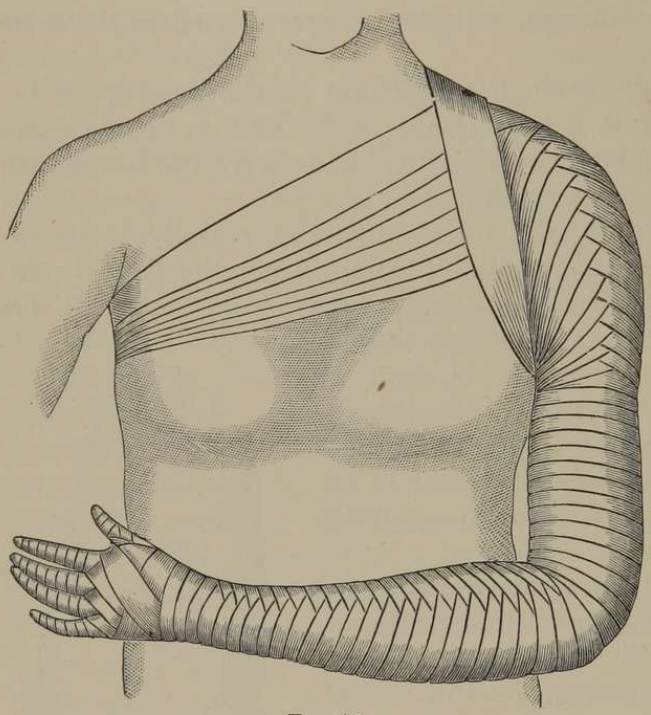

Fig. 173.

The Toes, Foot, Leg, and Thigh.—The great toe may be bandaged by carrying a narrow roller spirally around it, from the tip to the metatarso-phalangeal joint, and thence by a figure-of-8 around the ankle. This last turn should be several times repeated, in order to hold the dressing firmly. It is customary to include all of the toes in the general foot-bandage.

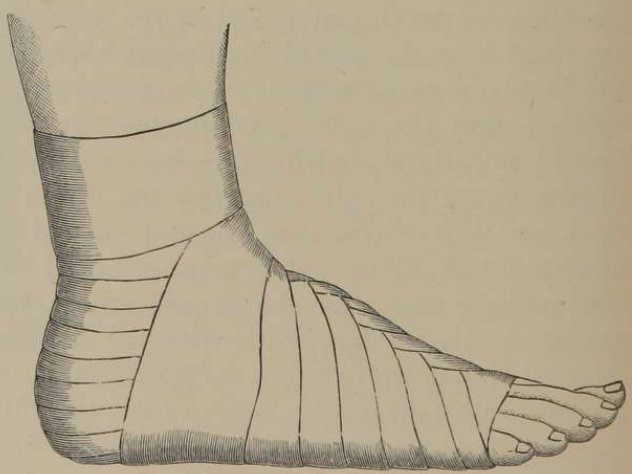

Fig. 174.—The author's foot-bandage with a single roller.

To bandage the foot, begin by placing bits of absorbent cotton between the toes. Take a roller from two to two and a half inches wide, and about ten yards long. Lay the end of the bandage parallel with the axis of the leg, half-way between the two malleoli in front, and carry the roller by the inner side to the heel, so that the middle of the bandage will be over the center of the

heel's convexity, and on to the starting-point. Next, make another turn around the ankle, carrying the posterior edge of the bandage over the center of the turn that has just preceded it, and make one or two other turns in front of this until the heel is completely covered (Fig. 174).

The bandage is then carried around the heel in the same direction, so that its anterior border rests on the middle of the *first* turn, and the roller is carried from the fibular side of the heel across the dorsum of the foot to the tibial side of the great toe. It then travels under the bases of the toes to the little toe, making a couple of complete turns around the foot at this point, and, when the roller has again reached the fibular side of the little toe, it is made to cross the dorsum of the foot obliquely to the tibial side of the heel, keeping the lower edge of the bandage about a quarter of an inch above the bottom of the heel. Repeat this figure-of-8 turn until the entire foot is thoroughly concealed. It is best to cut with the scissors each turn of the roller about half through just when it crosses the front of the ankle, so that the accumulation of the bandage at this point may not interfere with the movements of the ankle-joint.

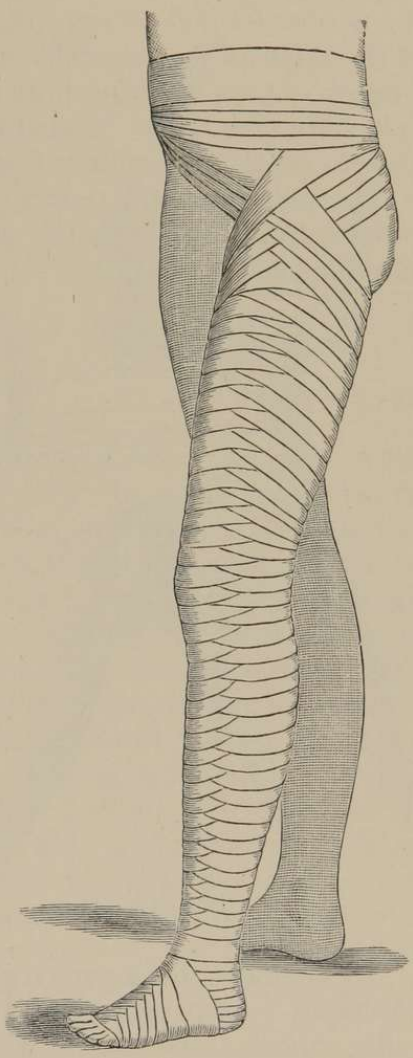

Fig. 175.

The crossings of the figure-of-8 bandage on the dorsum of the foot should be kept a little to the fibular side of the median line.

When the ankle is reached, the bandage should be carried up the leg by the spiral reverse until the sudden prominence of the muscles of the calf is reached, when, if necessary, the figure-of-8 reverse should be practiced to just below the knee. From this point up to the trochanter the simple figure-of-8, spiral, or spiral reverse, may be employed, according to the shape of the limb. When the level of the gluteal fold is reached, carry the roller obliquely upward and outward about half-way between the trochanter major and anterior iliac spine, on across the sacro-lumbar region to just above the upper margin of the iliac crest of the side opposite the limb being bandaged, thence downward across the abdomen and the groin to the front and outer side of the thigh, and back behind to the inner side at the point of starting. This manœuvre is repeated until the entire hip and groin are covered, when the roller is carried spirally around the pelvis

and abdomen as high as the umbilicus. The completed bandage is shown in Fig. 175. The portion of this bandage which goes around the thigh, groin, and pelvis is called the *single spica* for the groin, and is admirably adapted to the retention of a dressing upon a bubo or wound of this region, and also makes an efficient temporary compress for the support of an inguinal hernia. A *double spica* with a single roller may be made by carrying the roller, which has already partially covered in the groin and hip of one side, directly across the back to a point half-way between the trochanter and anterior iliac spine of the opposite side, over the front of the thigh to the inner side, and thence behind and outward, describing a figure-of-8 around the thigh and pelvis in a direction the reverse of the preceding (Fig. 176). A modification of this for controlling hæmorrhage after internal urethrotomy is shown in the chapter on urethrotomy.

The abdomen and thorax should be bandaged by the simple or reverse spiral until the axilla is reached in the male, and the mammary gland in the female.

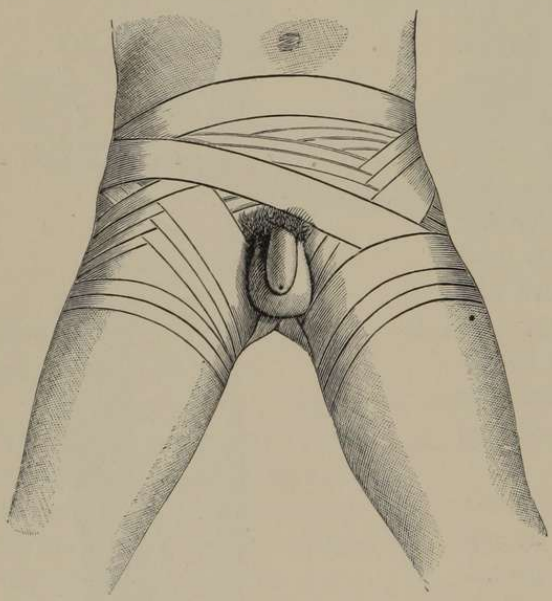

Fig. 176.—(After Fischer.)

Fig. 177.—(After Fischer.)

To bandage the mammary gland it is best to place a thin layer of absorbent cotton over this organ, and under the axilla as well. The roller, about three inches wide, should be carried two or three times around the thorax just below the breast, which, if pendulous, should be lifted well up toward the clavicle. If the right breast is to be bandaged, the operator, standing in front, should carry the roller from the patient's right to the left side, around the body, and then obliquely upward across the front of the chest, catching the under surface of the gland, passing over the left clavicle, making a figure-of-8 around the shoulder and axilla, and then across the back to the starting-point (see Fig. 177). It is now carried directly around the chest, and, when the circuit is completed, again travels obliquely upward on a plane about one inch higher than the preceding turn. This is repeated until the organ is entirely covered. When both

breasts require support, the second may be bandaged in the same way by an additional roller, or, as shown in Fig. 178, a single bandage may be thrown around the thorax and neck in figure-of-8 fashion, so as to support both organs.

Fig. 178.—(After Fischer.)

Bandages for the Head and Face.—For retaining ice-caps, or other dressings to the head, the hood-bandage will be found convenient, while its modifications will suffice to keep a dressing upon any limited portion of the scalp (Fig. 179).

To apply this, take a roller twelve yards long and two and a half inches in width, rolled from both ends to the center. Holding one head of the roller in each hand, the surgeon, standing behind the patient and laying the middle of the bandage across the forehead just over the eyebrows, carries one roller in the right and the other in the left hand around the head, above the ears, and crosses them under the occiput, so that the roller which went to the rear in the left hand will travel again to the front over the same path. The roller in the right hand is then carried over the head, in the median line, from the occiput to the nose, and at this point it is caught and held down by the encircling turn carried in the left hand. Then carry the roller which came over the median line of the head back again to the rear, so that its right edge will rest on the middle of the first turn. It is again caught under the encircling turn at the occiput, is carried to the front on the opposite side, and continues to travel from before backward in an ellipse that is constantly increasing, until it blends with the encircling turn upon the sides of the head, near the ears. Each successive turn of the elliptic should leave about one third of the turn that preceded it uncovered in the center. Of course, the ends will meet at the same point, before and behind, where the reverses are made.

Fig. 179.

If it is only required to maintain a dressing in the median line of the scalp, it will suffice to carry a circular turn or two around the head, just above the eyebrows and ears, and below the occiput, while an antero-posterior strip is pinned to this in front and behind.

The Head and Chin Bandage (Fig. 180) may be made to serve several purposes—namely, to retain a dressing on the chin and lower face, the same upon the scalp at any portion, and also for temporary fixation of the lower jaw after fracture of this bone. It is applied as follows:

The end of a bandage from one inch and a half to two inches in width is held about half-way between the left ear and the occipital protuberance, while the roller is carried to the front and obliquely across the head, just in front of the right ear, under the chin, up in front of the left ear, then across the scalp, passing backward between the right ear and occiput to beneath this protuberance, when it is carried beneath the left ear straight across the front or labial aspect of the chin, and around by the right side to the point of commencing. This manœuvre should be repeated several times, and the dressing then completed by carrying the roller twice around the head above the ears and eyebrows, and beneath the occiput, and pinning a strip along the median line of the scalp at the various points where the turns cross each other.

Fig. 180.

Knotted Bandage.—This dressing (Fig. 181) is sometimes em-

Fig. 181.—(After Berkeley Hill.)

ployed in the arrest of hæmorrhage from wounds of the temporal and other vessels of the scalp.

Take a piece of cork or wood, about an inch in diameter and one quarter of an inch in thickness, and wrap it with sublimate gauze or lint to make a compress. Apply this to the bleeding point, and lay over it the center of a double-headed roller, carrying the turns around the head, above the ears. They are then crossed over the compress, one end is carried under the chin, the other over the top of the head, and are again crossed on the opposite temple. Having carried the rollers again around the head, and crossed them firmly over the compress, the ends are pinned securely and cut off. A horizontal slip may then be pinned to the anterior, middle, and posterior slips of the knotted bandage, beginning in the median line on the forehead, then back to the center of the middle slip, and then to the slip underneath the occiput, to hold the dressing securely in position.

To bandage the eye (the left, for example), hold the end of the strip half-way between the right ear and occiput, and bring the roller forward over the left eye and malar eminence, and around backward beneath the ear and occiput to the point of starting, and repeat once. When the second turn arrives at the right ear it should pass above this and com-

pletely around the skull, just above the eyebrows and below the occiput, in order to secure the oblique turn. Complete the dressing by alternating between the horizontal and the oblique direction of the roller (Fig. 182).

For the upper lip a dressing is readily secured by a narrow bandage passing horizontally around

Fig. 182.—(After Esmarch.)



Fig. 183.

beneath the nose and ears, and held in place by the head-stall attachment, as in Fig. 180.

Handkerchief Bandages.—In addition to the foregoing, emergency dressings for different parts of the body may be extemporized from pieces of cloth cut in various shapes—the so-called *handkerchief bandages.*

Head and Face.—A simple hood (Fig. 183) may be made as follows: A piece of soft muslin is cut, 27 by 23 inches, folded over for 6 or 7 inches along its greatest measurement, and laid upon a table, with the short piece underneath. Place the index-finger at the middle of the folded edge, and turn the nearest corners toward the center, forming a pyramid. Now roll the remaining straight edge up until it is on a level with the edge which was turned under, and place upon the head, so that this edge will be put above the eyebrows, while the rolled portion comes across the occiput, and the ends are pinned beneath the chin. The conical tip may be pinned down, if desired.

The *four-tailed cap* is made from a piece of muslin, 45 inches long by 10 wide, split from each end to within 4 inches of the center. Each of the four tails is 5 inches in width. Lay the center of the piece across the vertex, carry the posterior tails forward over the ears, and tie them under the chin and the anterior backward beneath the occiput (Fig. 184).

Fig. 184.

The *head and face hood* is made as follows: A piece of soft, light cloth, 40 inches square, is

folded and laid across the head in such a manner that the shortest fold which is on top comes to the level of the eyebrows, while the longer reaches to the tip of the nose (Fig. 185). The corners belonging to the

Fig. 185.—(After Esmarch.)

Fig. 186.—(After Esmarch.)

fold which is parallel with the line of the eyebrows are tied snugly beneath the chin. The longer fold is now turned up to the level of the eyebrows, while the corners belonging to it are drawn forward until freed, and are then carried back and tied beneath the occiput (Fig. 186).

For holding an ice-bag or dressing upon the head, the *skull-net* (Fig. 187) will be found of use. It is made of cotton threads, is tightened around the head by a tape, which draws it together like the strings of a reticule, and is further secured by a strap tied under the chin.

Fig. 187.—(After Esmarch.)

The *four-tailed dressing for the chin and lower jaw* is made by splitting a strip of muslin, 6 inches wide and 45 inches long, from each end to within 1½ inch of the center, placing its middle over the chin, and turning the posterior tails upward in front of the ears to be tied over the vertex. The anterior tails are now carried back below the ears, crossed once, and pinned beneath the occiput, while the ends are carried upward and forward and tied upon the forehead (Fig. 188).

Fig. 188.

Other special dressings will be described in the chapters on Regional Surgery.

The T bandage, made by sewing the end of one piece of muslin seven inches wide and about four feet long to the middle of a second piece of the same width and about five feet in length, is essential in holding a dressing over the anal or perineal region. One belt is fastened around the waist and the tail brought between the legs and pinned in front to the belt. For abdominal dressings a wide piece of muslin may be snugly drawn and pinned around the body.

CHAPTER XII.

AMPUTATIONS.

An amputation is the complete separation of any projecting organ or member from the body. While the term may be applied to operations in which the breast, penis, scrotum, cervix uteri, etc., are cut away, by long usage and common consent it is now restricted to removal of the extremities or their subdivisions.

An amputation may be *accidental*, as when a limb is torn, cut, or crushed off by machinery; *natural*, when, as in senile gangrene from gradual failure of the heart, or pathological changes in the arteries, the dead portion is separated at the line of demarcation; or *surgical*, when scientifically performed.

When in an amputation the line of section is through the substance of the bone, the operation is said to be in *continuity*, and when through an articulation, in *contiguity*. The removal of a part which is useless or deformed, the presence of which, however, does not threaten the life of the individual, is called an amputation of *expediency;* under more urgent conditions, the operation is one of *necessity*. Amputations of necessity are further subdivided into those after *accident* and those after *disease*.

In amputations after accident, the period in which the operation may be performed is divided into the *immediate*, *primary*, and *secondary*. An *immediate* amputation is done during the prevalence of shock, and usually within from two to six hours after the receipt of the injury necessitating the operation; *primary*, after reaction from shock, and before inflammation is established—usually within twenty-four hours after the injury; *secondary*, when performed after this limit, and during the prevalence of inflammation.

The danger of death after amputation depends chiefly upon the *character* of the injury, and the *location* of the line of section. The prognosis becomes grave in proportion to the exhaustion of the patient as a result of hæmorrhage, shock, sepsis, or of any dyscrasia or intercurrent disease.

As to the *line of section*, there are practically no exceptions to the law that the rate of mortality is proportionate to the diameter of the part divided and the proximity of the section to the trunk. Thus, amputations of the lower extremity are more fatal than those of the upper, those of the hip more fatal than through the middle and lower third or through the leg, while the same comparison holds good from the shoulder out.

As to the *age* of the patient, it may be said that the death rate gradually increases with each decade of life.

The prognosis in operations of *expediency*, when properly performed, is almost always favorable, for the reasons that the general condition of the patient is usually good, and the section through healthy tissues. Amputations after *non-malignant disease*, such as destructive arthritis and osteitis, are comparatively free from danger, provided that general sepsis and consequent exhaustion have not occurred prior to the operation. Amputations necessitated by malignant neoplasms are especially dangerous only in proportion to the degree of malignancy in the tumor, together with the general deterioration of the tissues as a result of the prevailing cachexia.

Amputations after accident are most fatal, and the statistics show that immediate or primary operations are, in general, more dangerous than those done in the secondary period.

Lastly, the value of the *bloodless* operation, together with the safety from inflammation and sepsis, which a thorough knowledge and practice of the *antiseptic method* guarantees, can not be overestimated in diminishing the death rate after amputation. The employment of Esmarch's bandage, the deligation of the vessels, careful irrigation, and aseptic dressings have been heretofore described.

Amputations are much less frequent now than formerly, and in the present rapid advance in the science and art of surgery the time is not far removed when amputations for other cause than gangrene will be comparatively rare. To the consummation of this hope the education of the laity becomes the first duty of the practitioner. Very few deformities would lead to the necessity of amputation if in their incipiency the services of a skillful surgeon were obtained. And this is equally true of those lesions of the joints and bones for which the necessity of amputation would be exceptional if, at the earliest symptoms of disease, the proper treatment were instituted. Even when, from neglect, extensive necrosis or destructive arthritis shall have occurred, exsections of the diseased tissues should always be preferred to amputation, notwithstanding the shortening which may result, for a stiff joint and a short limb, capable of even limited motion and body support or function, is far better than the most perfect prothetic apparatus.

Malignant or non-malignant neoplasms often unnecessarily lead to amputation when an early and wide excision of the growth would in great probability have arrested the disease and saved the limb. In cases even of doubtful diagnosis, in the earlier days of the appearance of the tumor, the benefit of the doubt should be given to the ultimate safety of the part, and the knife freely used.

As to the propriety of performing an *immediate* amputation after injury, it is exceedingly questionable. The conditions which would justify this practice will rarely prevail. Even *primary* operations should be exceptional in this age when the value of cleanliness is so fully appreciated.

Antiseptic Methods.—In compound comminuted fractures, primary amputation should rarely be undertaken although two inches or more of

the bone is crushed. The separated fragments should be removed, the part immobilized, cleanliness obtained, and tension relieved. When the fracture connects with the hip or shoulder joint and the *blood vessels have been crushed or torn*, primary amputation may be required; and where pulpification is so extensive that the member is hanging by shreds of crushed tissue, the immediate or primary operation is permissible.

I am confirmed in these views by the published report of Dr. W. L. Estes,* of Bethlehem, Pa., formerly house surgeon at Mount Sinai Hospital, in an experience based upon three hundred and forty major amputations. Dr. Estes says: "In estimating the gravity of the prognosis based upon laceration of the soft tissues, muscular laceration should receive less consideration than injury to the skin. Limbs with extensive laceration of the muscle and comminution of bone with slight injury to the skin may be saved; but where there is extensive injury to the skin, however slight the laceration of the muscles, I have rarely succeeded in saving a compound comminuted fractured extremity. If, however, the muscles are pulpified, amputation is indicated. Violent injury to a principal set of vessels does not always call for amputation, especially when the injury is fairly well removed from the shoulder or hip joint."

In the management of these cases, two steps are of great importance: Arrest of hæmorrhage by direct compression over the lacerated or injured tissues, if this is possible, and, if not, above the injury, and the immediate introduction of a sufficient quantity of salt solution to overcome the great tendency to fatal collapse (shock), due chiefly to loss of blood. Thoroughly cleansing of the wounded tissues by irrigation is essential with a 1-to-10,000 mercuric-chloride solution, or by very warm water which has been boiled and allowed to cool down to 120° F. When extravasations or transudations have occurred underneath the skin, which is not broken and is tense, multiple punctures should be made which permit the escape of liquid, and under such circumstances Estes insists that no drainage tube be employed or gauze inserted into these punctures for capillary drainage. When it is possible, the part should be submerged in a hot 1-to-10,000 bichloride solution. By immobilizing the part and aiding the patient to rally from the shock, with careful asepsis we can afford to wait for amputation at a later date, if necessary.

How to Amputate.—In every amputation the preservation of the life of the patient is the first great principle to bear in mind; the second is to preserve the greatest amount of usefulness for that part of the member which is left with the body. Since hæmorrhage is the chief factor of shock, to prevent loss of blood is essential. Practically every amputation should be governed by these laws.

When hæmorrhage has not occurred before the case is in the hands of the surgeon, this element of danger may, thanks to modern surgery, be eliminated. There is not an amputation, from the fingers to the shoulder joint or from the toes to the hip joint, in which hæmorrhage

* "A Contribution to the Study of Modern Amputation," by W. L. Estes, M. D. "New York Medical Record," November 3, 1894.

can not be eliminated as a prominent factor of danger to the patient's life. And even when extensive bleeding has occurred before amputation is undertaken, the introduction of hot salt solution into an exposed vein, or in a vein at the bend of the elbow, does much to eliminate the great danger of shock from hæmorrhage. Therefore, beyond the saving of blood and of as much of the limb as is possible, I have never practiced any fixed rules as to *how* to amputate, even in the formation of flaps. We should make the flap always with a view of saving as much as possible of the limb, excepting amputations for malignant disease, when it is always wise to get far away from the neoplasm. I have considered the tarsus and the metatarsus as a single bone, paying no attention to joints, taking only the precaution to remove any thin film of bone or cartilage which might still remain when the saw passes close to one of the articulations. Some surgeons make an exception to this rule in the matter of an amputation at or near the ankle joint, claiming that a better degree of usefulness can be obtained by a properly adjusted artificial foot to the stump of a Symes's amputation than to one which saves either a portion of the os calcis (Pirogoff, Le Fort), or when part or all of the astragalus is left in (Hancock). From the ankle to the hip the same conservative idea should prevail, unless the line of the saw passes within an inch of the knee joint or above the trochanters. In these conditions it is conservatism to remove the upper end of the tibia and amputate at the knee joint, and to enucleate the head of the femur. In amputations of the hand the preservation of as much tactile sense, together with as much of the member, as possible should be the rule. This should hold especially in the case of those who use the hand in any vocation. In certain cases of those who do not labor, amputations which sacrifice even more of the member are justifiable. For example, a more shapely hand is often left by the removal of a portion of the metacarpal bone with the finger.

In the effort to prevent loss of blood in an amputation, it may not be always essential to success to force out all the blood that is in the member to be sacrificed. When the quantity of blood is normal, or nearly so, and there has been no hæmorrhage and the patient is in good condition, the sudden crowding of the blood that may be in the limb, such as the lower extremity, into the remaining vessels may put a strain upon the heart that will produce a serious result.

Of the seven hip-joint operations that I have performed by my own method, the only case I lost was that of a young man, about nineteen years of age, with a sarcoma of the knee. Estimating all the blood that ran out of the wound from the leg, he did not lose in all more than five ounces. The pulse was full and bounding after he was put to bed, and it seemed to me that it was one of the most favorable cases I had had. I left the patient in the hands of an assistant and went to the country; the man went into shock about three hours after the operation, and died without ever having reacted. His kidneys were normal; the anæsthetic given was ether, with an Ormsby inhaler, and the quantity was very small. He died, in my opinion, from overstrain on the heart muscle.

In emptying the member of blood, elevation of the extremity will cause the greater part to gravitate into the vessels of the trunk. In anæmic cases, application of the Esmarch bandage from the periphery almost to the location of the disease, skipping over this and again applying it above the seat of lesion, will entirely exsanguinate the member, with the exception of a small quantity of blood which may be contained in the diseased portion.

When, as in an amputation at or near the ankle joint, a rubber tourniquet is applied to the thigh, care should be taken to use a wide rubber band and not a rubber tube, since the accumulative pressure of the rubber tubing is sometimes great enough to injure the nerve. I have seen paralysis follow in several instances as a result of traumatic neuritis caused by the tourniquet.

In high amputations, near the shoulder or hip, this objection does not prevail, since pressure on a nerve is immaterial at that point.

I have discarded, in general amputations of the leg or arm, any method looking to obtain a long posterior and short anterior flap (Teale), with the idea of bringing the cicatrix away from the end of the stump. Estes thinks lateral flaps for the leg give the best stumps for workingmen. I have always held that a circular skin flap, with or without a lateral incision, as the emergency may demand, is the ideal flap, the muscles being divided an inch or more above the level of the circular incision through the skin, and the bone sawed on a level with the muscle. Dissection of the periosteum from the end of the bone in order to secure a periosteal flap is entirely unnecessary and should not be done.

In certain cases of amputation, when osteomyelitis has prevailed, it was thought that the surgeon might be called upon to carry his amputation high up, close to the shoulder or hip joint, in order to get above the disease in the bone. This is not good surgery, for the longer the limb, the more useful to the patient, and bones that are the seat of osteomyelitis can be readily cured, provided the canal is opened even near the knee or elbow joint and the bone carefully curetted up to the end of the canal. The insertion of a drainage tube through which aseptic irrigation is made every day or two, and the gradual withdrawal of the tube, will cure the disease in the bone and leave the stump long and useful (Fig. 275). I have in several instances carried out this plan with invariable success.

One other point has been of great service to me in effecting rapid amputation. When making a hip-joint amputation or an amputation through large masses of muscular tissue, after tying large arteries, such as the two femorals and the circumflex branches, in order not to lose time that is usually spent in applying forceps to oozing surfaces, I pass deep catgut sutures through great masses of muscle all the way across the whole cut surface and tie these firmly. In this way the muscles are brought together and compression exercised, which prevents bleeding. Ten or fifteen minutes can be saved by this practice in an ordinary amputation.

Method.—In making an amputation, no matter what shape the inci-

sions may take, it is essential that the soft parts which are to form the covering or hood for the bone shall be long enough to be free from tension after the sutures are adjusted and the dressing completed. It is always wiser to err on the safe side, and make the flaps a little too long than too short, for it is a simple matter to trim them down to the proper length. In doing this, some allowance must always be made for the additional retraction which occurs after the tourniquet is removed and consciousness is restored.

The direction of the line of incision, and the shape of the cuff or flaps, will depend in part upon the shape of the limb at the point of section, as well as the condition of the soft tissues from which the covering is to be made.

While the rule just given—namely, to have plenty of flap—is essential, it is scarcely of less importance to guard against all interference with the nutrition of the integument which covers in the stump. To this end rough handling and the employment of strong and irritating solutions should be avoided. In general, that flap will unite most readily, and prove most satisfactory, in the formation of which the normal relation of the skin to the subcutaneous soft tissues is least disturbed.

It is always preferable to divide the skin, muscles, vessels, and other soft tissues squarely across, and not obliquely, as must of necessity be done in forming flaps by transfixion. The *solid-flap* method is applicable to most amputations in patients of slight muscular development, and with little or no subcutaneous areolar tissue, for a closely dissected skin flap in this class of cases is objectionable, on account of the danger of sloughing. When the soft tissues at the line of section are very thick, and when the integument is well guarded by a fair quantity of underlying fat, the solid flap will be found objectionable, and flaps composed of skin and the subcutaneous tissues, down to the deep fascia, preferable. The circular *skin flap*, or some modification of this method, will be found, in general, most useful and satisfactory.

The methods of amputating an extremity may therefore be: First, *solid flap*, composed of all the soft tissues lifted from the periosteum; second, *skin flap*, composed of the integument and the subcutaneous tissue, down to the deep fascia; third, *mixed flap*, composed of skin on one side, and of all the soft tissues on the other.

Flaps composed of the integument, together with all the underlying soft tissues, may be made by the circular method, forming a single cuff, or by the double-beveled flap, made by transfixion and cutting from within out, or by cutting directly down from the surface.

Circular Solid Flap, with Perpendicular Slit—First Method.—Supposing that the section is through the right humerus, at the junction of the middle and lower thirds, proceed as follows: Place the patient so that the member to be removed projects well over the edge of the table. Envelop the rest of the body with necessary wraps, and cover all in with rubber cloth, so arranged that if irrigation is used the fluid will not reach any portion but the arm. If folded into a trough-shape, the solution will be conducted into a vessel. The entire hand and arm

should be washed with soap and water, cleanly shaved for six inches above and below the line of section, and in succession washed with sulphuric ether and a solution of corrosive sublimate (1 to 3,000). If any inflamed or suppurating surfaces are exposed close to the line of amputation, these should be irrigated with sublimate, and thoroughly scraped out and again irrigated, after the Esmarch bandage has been applied. Sterilized towels are now wrapped about the hand, forearm, and arm, the extremity elevated, in order to facilitate gravitation of blood toward the center, and the Esmarch bandage tightly applied, from the finger tips to the axilla. As soon as the constricting band is secured at or close to the axilla, the bandage beyond is removed, leaving all exposed parts not in the field of operation covered with sterilized towels. The positions about the table are shown in Fig. 189. The *operator* stands so that the non-preferred hand (usually the left) grasps the member between the line of section and the trunk, and thus steadying the tissues, the instruments are used by the right hand. The *first*

Fig. 189.

assistant stands where he can most easily reach the wound, for purposes of sponging, retracting flaps, etc. ; the *second* is placed directly between the operator and the instrument trays ; the *third* attends to the anæsthetic ; the *fourth* holds the member to be removed, grasping the elbow with his left hand, and the wrist and forearm with the right ; the *fifth* attends to the irrigator ; the *sixth* and *seventh* are intrusted with the sponges, one of whom holds in one hand a basin of freshly squeezed out sponges, and in the other a second basin for those which have become

soiled or bloody. Both should be within easy reach of the first assistant. The duty of the seventh assistant is chiefly to rinse the sponges, procure fresh towels, etc. When possible, it is always convenient to have two extra orderlies or nurses—one for waiting upon the anæsthetizer, and the other for purposes of general utility.

Operation—First Method.—With the left hand slide the skin toward the shoulder, and at a point sufficiently below the line of section through

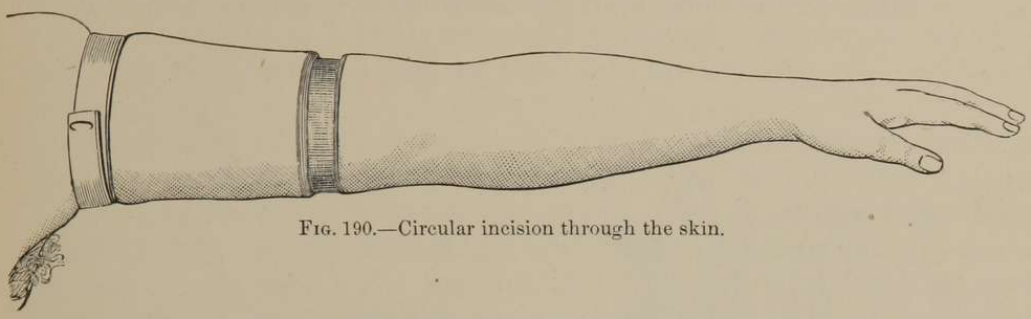

Fig. 190.—Circular incision through the skin.

the bone to afford ample covering (something more than one half the diameter of the limb, measured where the saw is to be applied), make a circular cut around the member, dividing the skin and subcutaneous fat down to the deep fascia (Fig. 190). The upper margin of this wound is

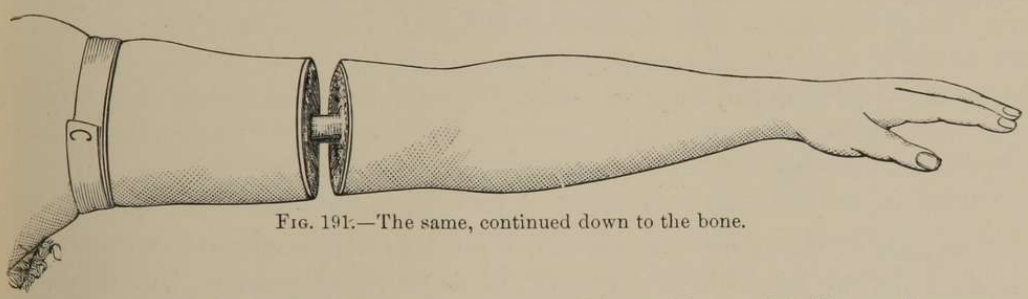

Fig. 191.—The same, continued down to the bone.

retracted toward the body as far as possible, and, at this line of retraction, with the same knife (a good scalpel is preferable) cut all the remaining soft tissues squarely down to the periosteum (Fig. 191). An incision is next made, parallel with the axis of the humerus, on the outer (or

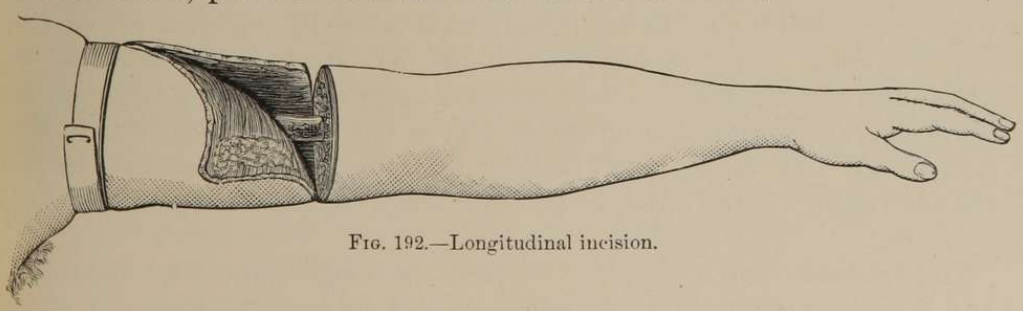

Fig. 192.—Longitudinal incision.

non-vascular) side of the arm, dividing everything to the periosteum, and extending up to the point where the bone is to be sawn through (Fig. 192). With a dry dissector (the handle of the scalpel will usually suffice) —only using a sharp instrument where necessary—lift the tissues closely from the periosteum until the solid cuff can be folded back (without overtraction or bruising) sufficiently to expose the bone at the point of

section. A towel which has been boiled or one moistened in 1-to-3,000 sublimate (or a split retractor) is now wrapped about the cuff or flap and the bone, so that the tissues which compose the flap may not be bruised or torn by the saw, and at the same time be protected from having the bone dust scattered over the cut surface (Fig. 193).

In applying the saw, it is best to place the center of this instrument against the bone close up to the retractor, always holding its blade in such relation to the bone that the sawn surface will be perpendicular

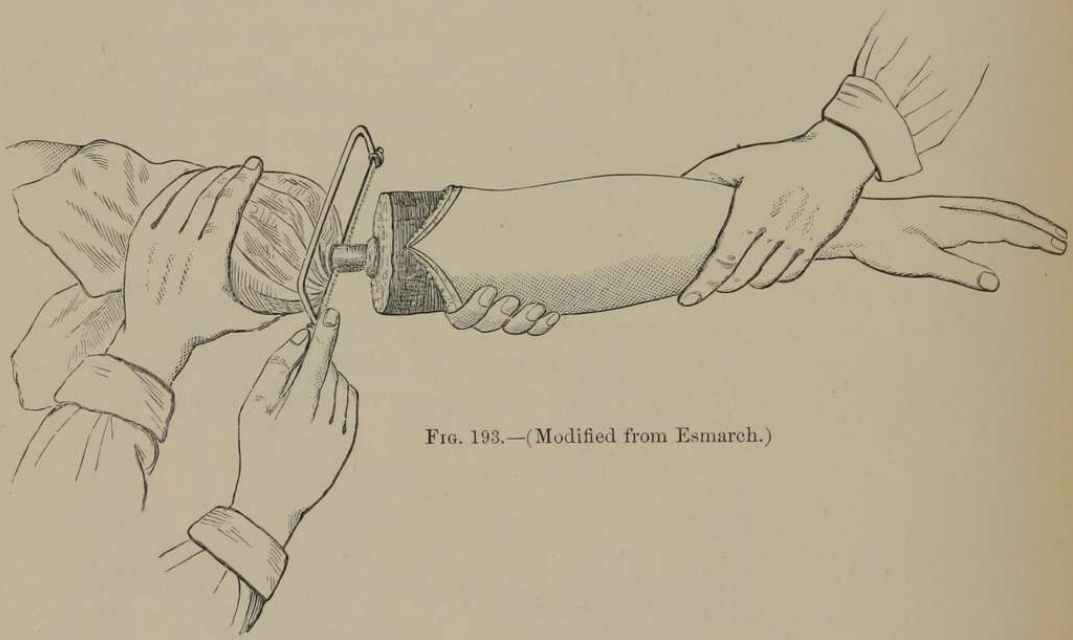

Fig. 193.—(Modified from Esmarch.)

to the axis of the bone. A few short strokes will suffice to cut a trench or hold for the saw, which may then be more rapidly used. The operator steadies the member with his left hand on the central side of the wound, while the assistant holds the extremity. As the section is about being completed, he is directed to cease all traction, simply supporting the weight of the limb, and thus splintering may be avoided. The last few strokes of the saw should be lightly and carefully made, to avoid the same accident. The retractor is allowed to remain after the bone is divided and the amputated part removed, and until, with a bone cutter or cartilage knife, the circumference of the cut surface is smoothed and rounded off. In doing this, the force applied should always be toward the center of the bone, to prevent stripping up the periosteum or splintering.

No periosteal cuff or flap for covering the end of the bone should be made. The retractor is now removed, the stump irrigated and thoroughly dried. The larger arteries and veins may be readily found, and the ends seized with the forceps. All the tissues should be carefully stripped from these by a blunt instrument (grooved director), and the catgut applied. The single knot will suffice for all vessels. Other "bleeding points" may be discovered by grasping the limb a few inches above the line of section and forcing out the small quantity of blood

which remains. Having proceeded thus far, the stump being elevated, the wound should be filled with clean warm sponges or dry gauze, covered with towels, and firmly compressed while the assistant removes the tourniquet. After waiting two or three minutes for the vessels to fill, one by one the sponges are carefully removed, and any bleeding points caught with the forceps. When these shall have been tied, the wound should again be flooded with warm 1-to-5,000 sublimate or plain sterile solution, packed with sponges well squeezed out, the whole covered in with towels, and bimanual compression employed for five minutes, when it will be seen that all bleeding has practically ceased.

In sewing up the cuff, alternate deep and superficial sutures should be employed; the former, about half an inch apart, should enter the skin half an inch from the edge of the wound, pass about the same depth through all the tissues, and emerge at the same distance from the wound on the opposite side. The intervening row should be halfway between the deeper sutures, and should be introduced to a depth of one fourth of an inch. In tying the sutures the double or friction knot should be employed for the first loop. The knots should be kept to one side of the line of apposition. A considerable degree of care is essential in bringing the edges nicely and accurately in apposition, for if the skin is infolded and the epidermal surfaces brought in contact, bad union will result, and the same is true if any of the subcutaneous tissues project between the edges. As the threads are being tightened, infolding may be obviated by lifting the edges with a grooved director, while the same instrument may be employed to push any projecting fat or other tissues back under the skin. In tying the knots, the degree of traction should just be sufficient to bring the plane surfaces of the wound together without wrinkling. As drainage invites infection, it should be avoided when possible. In clean wounds, a small wisp of catgut in one or two suitable points will be all that is required. When stumps are closed and dressings with proper compression applied, no oozing will occur and no drainage be needed. When a tube is used, as the stump is kept elevated after the operation, it should always lead from the deepest portion of the wound, and have exit at such declination that the free outflow of all fluids will take place into the dressings. A safety pin should be passed through one side of the tube to prevent its being pressed into the wound by the bandaging, or a suture may serve to hold it in position. A strip of iodoformized gauze is wound around the tube and carried along the line of approximation, extending about three fourths of an inch on either side. Or a narrow piece of disinfected protective may be substituted as a covering for the line of sutures. The stump, carefully dried, is now enveloped with sterile gauze to the thickness of about one inch. This should be applied in layers, starting from well above the end of the stump, by carrying a layer around the limb, and following this with a second, which overlaps the first about two inches, and so on until the last layer projects well beyond the end of the stump. Over the end a large, thick sheet of gauze is laid. A layer of absorbent cotton, about one inch thick, is now

wrapped around and over the end, and this enveloped by a large sheet of rubber-tissue protective. A roller is carried over all to hold the dressing in place, and to make compression sufficient to arrest oozing. It is impossible to say how much pressure should be employed, since this knowledge can only come from practice, but the bandage should be fairly tight. Pressing the flap against the end of the bone should be avoided. As the last bandage is being applied, a short splint, the end of which projects a couple of inches beyond the stump, may be inserted. This steadies the limb, and is useful in keeping the stump elevated, especially when an amputation is made near the trunk. If the last roller is a moistened starch bandage, it will be less liable to slip.

Such a dressing, under the strict antiseptic method, is not usually removed before the tenth or twentieth day, and in the majority of cases where an amputation is made through comparatively healthy tissues a single dressing is sufficient. The indications for its removal are hæmorrhage of an alarming nature, great pain, high febrile movement (not counting the reactionary fever which follows within twenty-four hours after the operation), and excessive discharge beyond the zone of antisepsis, with decomposition.

Ordinary bleeding may be controlled and permanently arrested by an extra tight roller, or Esmarch bandage, loosely applied for an hour or two. A rise in the temperature of 102° to 103° on the second day, or later, suggests inflammation and sepsis. Lastly, when the serum or fluids from the stump seep under the dressing and decompose, the change is necessitated on account of the odor. When a new dressing is made, the same antiseptic precautions should be employed.

Second Method—Oblique Solid Flaps by Transfixion.—Seize the arm with the left hand so that, as all the soft tissues are pinched up on its anterior aspect, the thumb and index-finger on opposite sides will be just above the point at which it has been decided to divide the bone. The point of a long knife is pushed from the outer side (right arm) horizontally down until it impinges upon the center of the bone; the handle is depressed, the point grazes over the bone, the handle is now elevated, and

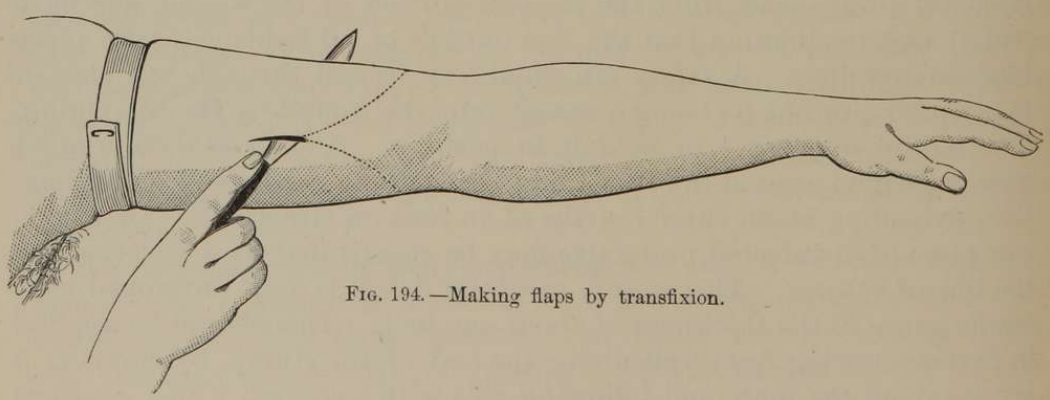

Fig. 194.—Making flaps by transfixion.

the point made to project exactly opposite and on the same plane with the point of entrance (Fig. 194). By a long sawing movement the knife is made to cut directly along the bone until within from one half to one inch of the

limit of the flap, when it is turned rather abruptly out, shaping a blunt, rounded flap. This is held back by the operator's left hand, the point of the knife is insinuated between the muscles and the bone, is made to glide along the posterior surface of the bone, and to come out at or very near the periosteum on the opposite side. A second symmetrical flap is made in the same way as the first. The retractor is applied, and the operation and dressing completed as before.

In making an amputation by transfixion, it is usually advised to cut the non-vascular flap first; but, with a safe tourniquet applied, this precaution is unnecessary.

Third Method—Oblique Solid Flaps, by cutting from the Surface.—Cutting from the surface toward the bone, the first crescentic incision outlines one flap and goes down to the deep fascia (Fig. 195). After the skin

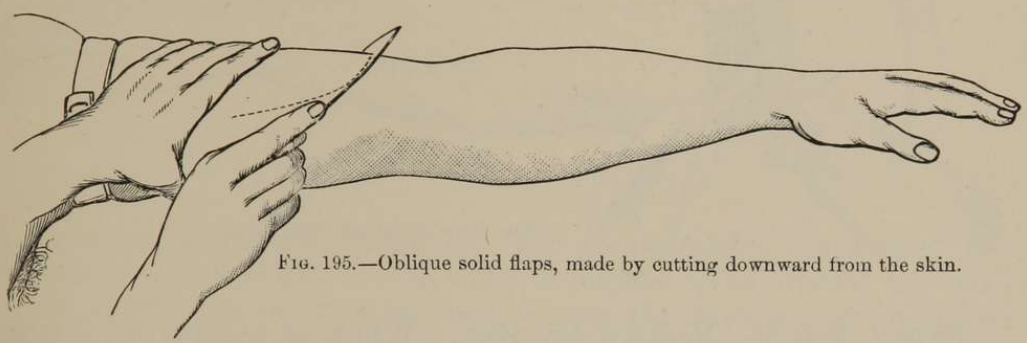

Fig. 195.—Oblique solid flaps, made by cutting downward from the skin.

retracts, the muscles and remaining soft tissues are divided from its edge obliquely down to the point of section through the bone. The opposite flap is made in the same manner, and the operation completed as before.

Skin-Flaps — Circular, Modified Circular, Oval, Double Crescentic, and Double Rectangular.

First Method—Circular.—Before commencing the incision, grasp the arm firmly near the line of incision, and slide the integument upward as far as it will go. In doing this operation, a scalpel will suffice, although the long knife is usually preferred. The incision should go straight down to the fascia which covers the muscles, and directly around the limb, so that the radius of the circle described will be at an angle of 90° with the axis of the humerus (Fig. 196 *a*). When this is completed, catch the edge of the flap with a mouse-tooth dissecting-forceps, put the connective tissues which attach it to the fascia about the muscles on the stretch by pulling the skin upward, and with well-directed strokes or touches with the point of the knife, which should be kept from wounding the skin, raise the flap throughout the entire circumference of the wound. As this dissection proceeds, the loosened sleeve of integument may be rolled up until the point where the muscles and bone are to be divided is reached (Fig. 196 *b*). Just at the margin of the reflected flap the soft tissues are now divided straight down to the bone, the line of section being

perpendicular to the axis of the limb. The periosteum should next be cut through in the circumference of the bone where the saw is to enter.

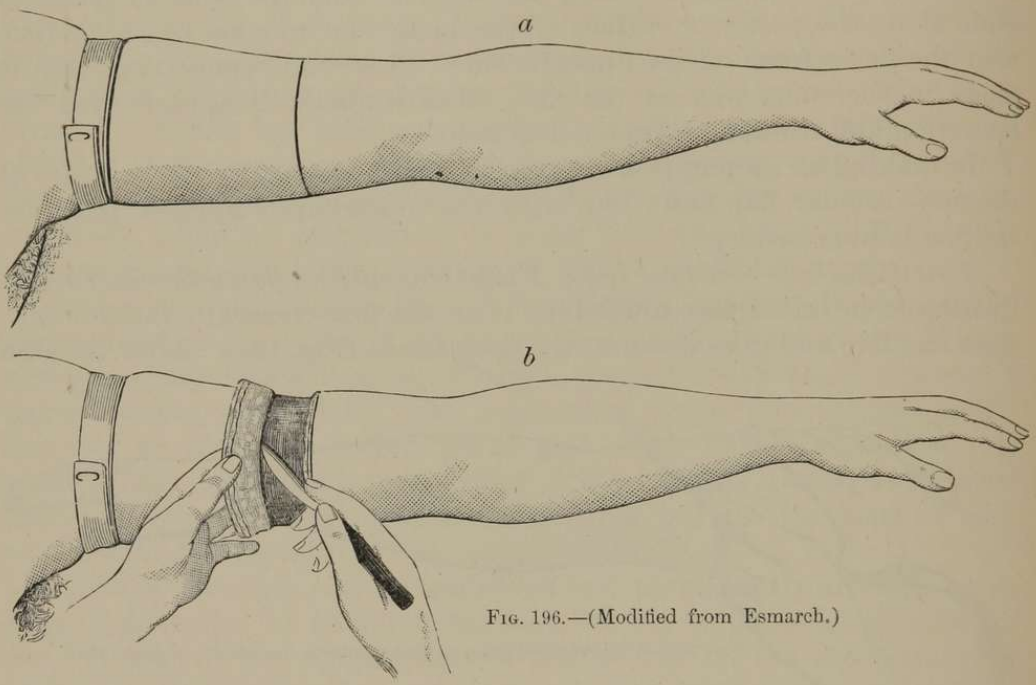

FIG. 196.—(Modified from Esmarch.)

Second Method—Modified Circular.—When, on account of the large diameter of the member, the flap requires to be dissected up for more than two inches, the foregoing method may be modified by a perpendicular incision through to the muscles. This renders the dissection more rapid.

Third Method—Oval.—It not infrequently occurs that the condition of the soft parts near the line of amputation will not permit of an incision directly around the limb without a too great sacrifice of the member. Under such circumstances, an oval or elliptical incision may be made, and in this way integument enough secured to cover in the stump. The longitudinal slit may be added to this operation.

Fourth Method—Double Crescentic.—The circular operation may be further modified by making two crescentic skin-flaps of equal size, the

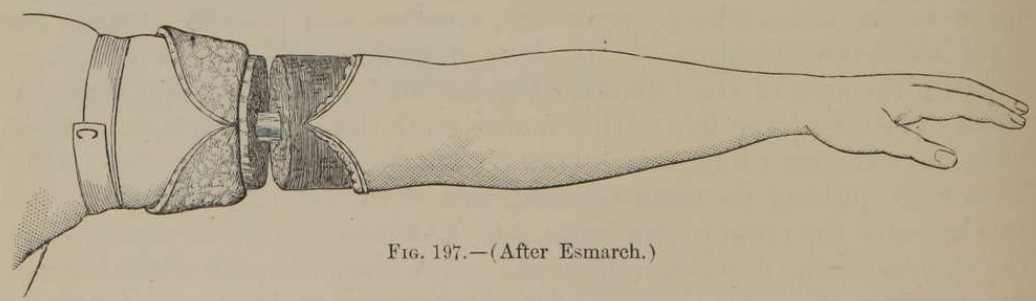

FIG. 197.—(After Esmarch.)

bases of these being at the line of section of muscle and bone. The same precautions as given above are necessary to secure enough integument to form a hood for the stump (Fig. 197).

Fifth Method—Double Rectangular.—The first step is to go around the limb just as if a circular operation were intended. This being done, two incisions, one on either side and exactly opposite to each other, are made perpendicular to the circular cut, and extending up the limb to a point on a level with the line of section through the muscles and bone (Fig. 198). The two flaps are now dissected up to this line, and the

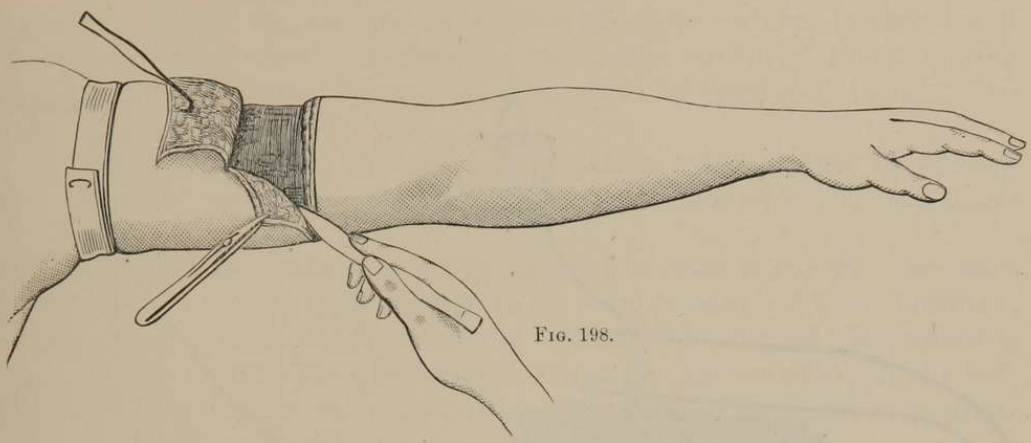

Fig. 198.

amputation completed as before. The commendable features of this procedure are the rapidity with which it may be accomplished, the small degree of violence inflicted in manipulating the flaps, and the readiness with which a stump is drained when the proximal angles of the lateral incisions are used as outlets for the tubes.

Mixed Flaps, composed of integument alone on one side and of all the soft tissues on the other, are the least commendable of all methods. The proper apposition of surfaces so uneven is difficult. When from any cause this operation is adopted, care must be taken to give proper support to the heavy solid flap to prevent dragging upon the sutures.

Résumé.—In thin and emaciated subjects the *solid* flaps should be preferred to the *skin* flaps, for the reasons that the nutrition of the skin is least disturbed by this method. In limbs of large diameter and a goodly quantity of subcutaneous tissue, the skin-flaps are preferable, since a covering under such conditions can be obtained with less sacrifice in the length of the bone. Of the solid flaps, the circular method is better than the oblique, since it divides all the tissues squarely. In making oblique flaps, transfixion is better than cutting from without inward. Of the skin-flaps, the circular incision should be preferred to the other methods where the limb is not very large; the double rectangular flaps where the stump is to be elevated and there is a large surface to drain.

Open Method.—When an amputation is made through tissues infiltrated with pus or other inflammatory products, where, in the judgment of the surgeon, the dangers of sepsis would be increased if the wound were closed, the open method should be employed, with constant or interrupted irrigation.

Before the days of antisepsis the success of this method was thoroughly demonstrated by Prof. James R. Wood and Prof. Dennis, in Bellevue Hospital, where the rate of mortality after amputations, in wards which had been recently vacated on account of puerperal fever, was reduced to the minimum in the history of that hospital. I have employed this method in a number of septic cases with great satisfaction.

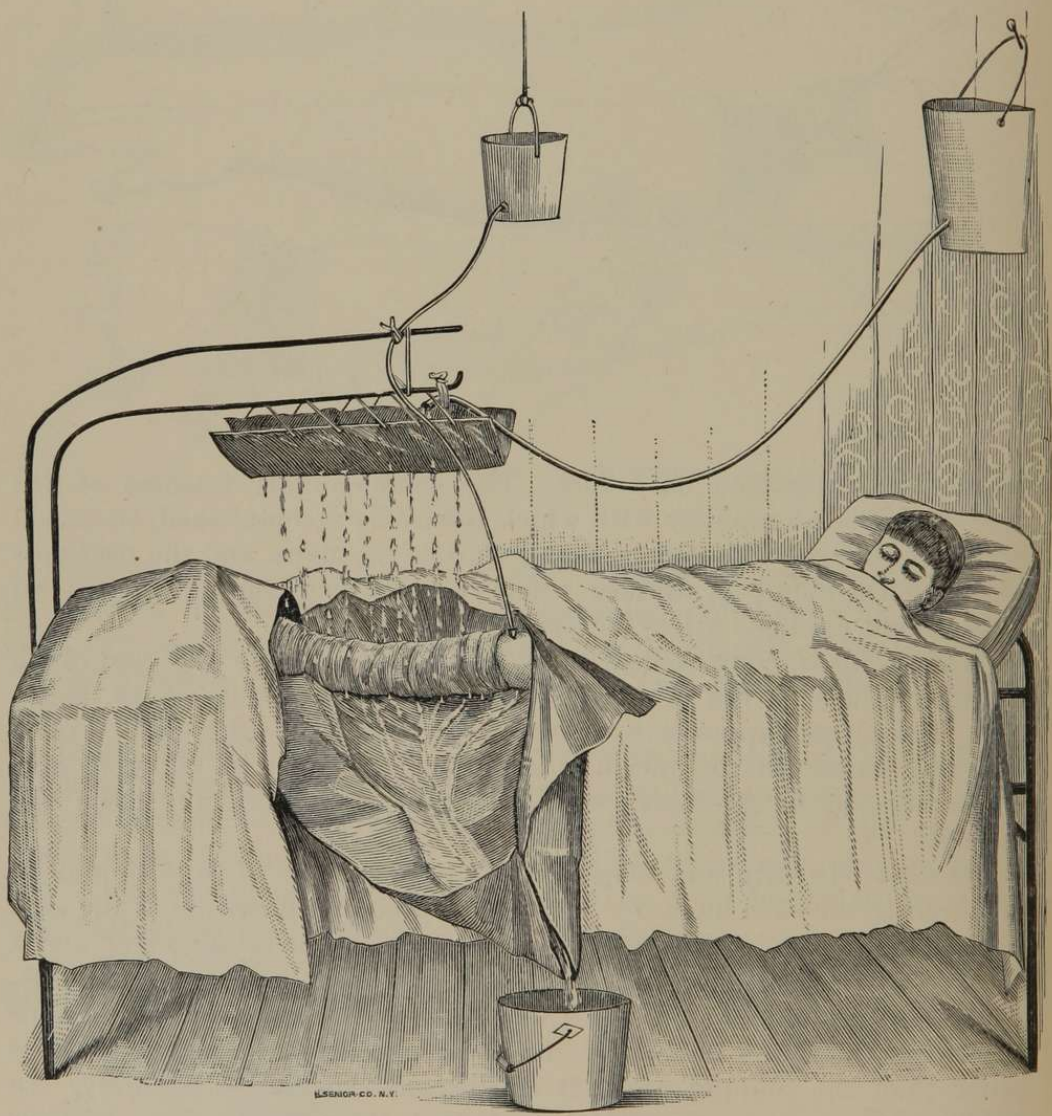

Fig. 199.

In performing the amputation, the flaps must be so shaped that irrigation can be easily accomplished without moving the stump. A circular cut, with a longitudinal incision on the upper surface, or bilateral flaps, are preferable. When the patient is put to bed the stump is placed in a position suitable for drainage, and rests upon an oil-cloth so arranged that the irrigating fluid runs away from the patient and into a basin at the bedside. The flaps should at first be held well open by a wad of sublimate gauze, and the stump loosely enveloped in a thin layer of this

material, so arranged that, as the water drips on it, it will pass through the gauze and over the raw surface.

Fig. 199 shows a ready-made irrigator in use in my service at Mount Sinai Hospital. A piece of sheet-tin, about a foot wide and of any required length, is shaped into a trough, the bottom of which is punched full of holes with an awl. A rubber tube leads the water from a tank into this trough, from which it trickles on to the wound in any required quantity. Or, as represented in the cut, the tube—which, in the case of the patient from whom the drawing was made, conveyed the irrigating fluid into a suppurating knee-joint—may also be employed to carry the water into the wound.

Sterile water should be used for irrigation. The danger of absorption from an extensive granulating surface precludes the sublimate solutions.

The only objection to which this method is open is the slowness with which the process of repair goes on in its employment. This is, however, an objection of little weight when the ultimate recovery of the patient is secured. As soon as the temperature shows an absence of sepsis the irrigation may cease, and the granulating flaps may be approximated gradually by bandages or adhesive strips.

Special Amputations.

Hand and Fingers.—A primary amputation of any portion of the hand is rarely justifiable. If there is only a small strip of tissue, the integrity of which is evident, an effort at the restoration of the nutrition and function of the part beyond should be attempted. If any doubt exists as to the result, the benefit of this should be given to the side of conservatism. It is essential to arrest hæmorrhage, cleanse the wounds under strict antisepsis, and especially by thorough immersion in a basin of warm sublimate solution (1 to 3,000), secure drainage, and place the parts in the best position for usefulness in case of recovery. Amputation may be done when necessitated by gangrene or necrosis.

Fingers — Interphalangeal Operations.—Between the second and third phalanges of the fingers, proceed as follows: Flex the terminal phalanx at about an angle of 90° to the axis of the second bone, and, one eighth of an inch anterior to the angle on the dorsal aspect, with a small, sharp-pointed scalpel make a transverse incision, extending half-way down the sides of the finger. From this point carry the incision forward, parallel with the axis of the digit, to within a quarter of an inch of the end, then across the palmar aspect of the tip to the opposite side, finishing the incision at the angle of the transverse cut (Fig. 200). Dissect the palmar flap up, keeping close to the bone, lifting the flexor tendon, with the skin, back to the articulation; divide the tendon opposite the joint,

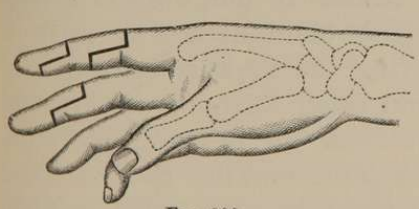

Fig. 200.

and disarticulate. The flap is now turned back, trimmed with the scissors to fit nicely, and stitched with silk or catgut sutures. By this method the acute tactile sense of the palmar aspect of the finger is preserved, and adds to the usefulness of the stump. This, and other amputations of the fingers, may be made without general anæsthesia, and with perfect insensibility, by the local use of cocaine. Just anterior to the metacarpo-phalangeal joint insert on each lateral aspect of the finger the needle of a hypodermic syringe, and inject in the entire circumference of the finger twenty minims of a 2-per-cent solution of cocaine hydrochlorate. One minute later constrict the root of the digit with an elastic ligature. In this way a painless and bloodless operation may be performed. If the insensibility is not complete at all points of the incision, inject additional cocaine, and by massage distribute it through the tissues.

In dressing these amputations the pressure on the end of the stump should be light, for fear of slough in the long flap. Usually no vessels need to be tied. The covering of cartilage does not require to be scraped or sawn off. When only a slight portion of the anterior tip of the second phalanx is involved in a destructive osteitis or injury, the remaining portion should not be sacrificed by a disarticulation at the posterior interphalangeal joint. The line of section through the bone should be about at the junction of the middle and anterior third of the phalanx. The incisions and flap are made as in the preceding operation.

In amputation with disarticulation at the posterior interphalangeal joint, flex at an angle of 90°, make a transverse incision over the dorsum of the finger, from one eighth to one fourth of an inch in front of the angle, which includes half the circumference of the member. From the ends of this line carry the incision directly forward on each lateral aspect of the finger to the crease on the palmar surface opposite the anterior interphalangeal joint. A second transverse incision in this fold completes the rectangular flap, which is now dissected back, and the disarticulation effected by placing the ligaments on the stretch and dividing these with a narrow, sharp scalpel. If any difficulty is found in entering the joint from the sides or front, it may be easily done by division of the extensor tendons over the dorsum, for these take the place of posterior ligaments. The method of amputation, as given for the operation at or near the articulation of the first and second phalanges of the finger, applies also to the thumb in amputation at the last joint, or through the first phalanx, within one fourth of an inch of its anterior extremity. This plan of making the flaps is far superior to that advised by Erichsen, Esmarch, and other authors who recommend cutting down and through the joint from the dorsum, and then forward along the palmar aspect of the phalanx, making the disarticulation and flap with a single stroke. In the first place, this is done with no little difficulty, for, however thin the blade, the character of the joint will scarcely allow an easy passage to the knife. Secondly, by the method of transfixion the flap is apt to be cut too pointed and beveled at the end.

At the Metacarpo-Phalangeal Joint—Thumb.—When the condition of the soft parts will permit, proceed as follows:

First Method.—Just over the joint, and in the middle of the dorsal aspect of the thumb, commence an incision and carry it along the surface next to the index-finger until half the circumference of the member is included. Along the dorsal and palmar aspects carry parallel incisions forward until near the interphalangeal joint, and connect these by a straight transverse cut across the palmar surface. Dissect the flap back, divide all tendons opposite the joint, disarticulate, tie the *dorsales pollicis* (one on either side of the back of the thumb), and the *arteria princeps pollicis*, which lies along the side of the metacarpal bone nearest the index-finger and divides into its terminal branches opposite the metacarpo-phalangeal joint. When the flap is stitched, the scar will be in good part concealed on the ulnar aspect of the stump.

Second Method.—A transverse dorsal incision is made over the articulation, extending half around and ending at opposite points on the external and internal lateral aspects of the thumb. Parallel lateral incisions are

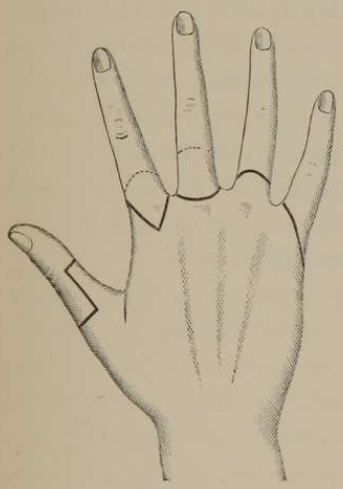

Fig. 201.

Fig. 202.

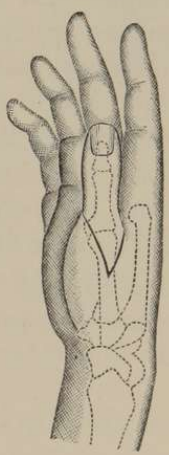

Fig. 203.

made as far forward as the interphalangeal joint, and the anterior extremities of these are joined by a transverse palmar cut (Fig. 201). The end of the metacarpal bone of the thumb should be left undisturbed, when not necrosed, when there is sound skin enough to cover it in. Under other conditions it may be divided with a fine saw or the exsector. The question of the appearance of the stump should be secondary to the usefulness of the member. It is especially important to a laborer that the end of the metacarpal bone of the thumb be preserved (Fig. 202). When the operation is performed upon one not compelled to do manual work, a more symmetrical appearance may be obtained by an oblique section of the metacarpal bone about half an inch behind the articular surface. When this is intended, the incision through the skin should be such that the long part of the flap is obtained from the radial and palmar aspect of the thumb, while the line of sutures is situated well on the dorsal surface of the stump (Fig. 203).

Index-Finger—At the Metacarpo-Phalangeal Joint—First Method.—When possible, the following method should be adopted, the object being to preserve the tactile sense and to leave the scar less prominent:

From the ulnar side of the knuckle, and just over the joint, make an incision which extends from this point forward as far as the web between the index and middle finger, and, in case of a large knuckle, a little beyond this point at the side of the digit. From the anterior end of this incision make a second cut directly across the palmar aspect of the phalanx until the middle of the radial side of the finger is reached, and complete the flap by cutting in a straight line from this point to the commencement of the first incision. When the disarticulation is completed, the *dorsalis* and *radialis indicis* arteries, and the *external digital* branches, tied with fine catgut, the corner of the flap is carried into the receding angle on the dorsal surface of the metacarpal bone and secured by sutures. When the head of the metacarpus is to be removed, the section of this bone should be slightly oblique, and the line of incision a partial oval, beginning at the web between the two fingers, and traveling along the crease formed by flexion of the finger on the metacarpus well up on the dorsum of this bone, about three fourths of an inch back of the joint. An incision, almost in a straight line, should now be made between the ends of this curved line (Fig. 201). Dissect the flaps clear and without making a disarticulation, expose the bone, and with a fine saw divide it obliquely from before backward, and from the ulnar toward the radial aspect. In amputation of the middle or the ring finger, the following method should be preferred:

Fig. 204.—(After Esmarch.)

Middle Finger.—Locate the articulation exactly, and over this point make a transverse incision extending on either side to the middle of the depression between this digit and the index- and ring-fingers (Fig. 201). From either end of this cut carry a lateral incision directly forward about

half way up the first phalanx, and connect these by a transverse incision across the palmar aspect of the digit (Fig. 202). Disarticulate and fold the palmar end of the flap back upon the dorsal transverse incision where it is stitched.

Another method is the oval incision, shown in Figs. 204 and 205. By the first method the tactile surface is better preserved. The head of the metacarpal bone should be left intact for the laboring classes. When the round expansion of this bone is removed, the gap between the index- and ring-fingers is not so wide. The bone should be sawed squarely across a half inch behind the articular surface. All that has been said of this digit applies with equal force to the ring-finger.

Fig. 205.—(After Esmarch.)

Little Finger.—The method recommended in amputation of the index at the metacarpal joint should be preferred in removing the little finger at the same level. The flap should be so shaped that the cicatrix will fall on the dorsum and toward the ring-finger. When the metacarpal bone is to be divided it should be cut with a slight obliquity. In this operation the oval incision shown in Fig. 206 should be made.

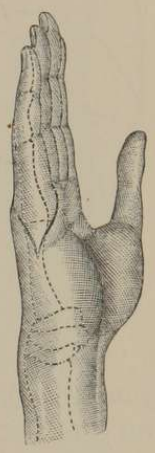

Fig. 206.

When two or more fingers require to be removed at the metacarpo-phalangeal joint, each one may be amputated by the methods described as especially suited to it, or a common antero-posterior flap may be made. As to the propriety of removing the ends of the metacarpal bones, the same rules apply as already given for the single amputations.

Through the Metacarpus.—When the end of the metacarpus can not be saved, these bones should be divided at any point three fourths of an inch or more anterior to the carpo-metacarpal articulation. If the injury extends behind this line, it is better to disarticulate at the carpo-metacarpal junction. In amputation through the metacarpus, the flap should be made chiefly from the palmar tissues, so that the line of sutures and the scar will be well on the dorsum of the hand, and as much of the tactile sense preserved as is possible.

Carpo-Metacarpal Disarticulation.—When all the bones of the metacarpus require to be removed, on account of a lesion not involving the anterior row of the carpus, the amputation should be made through the metacarpo-carpal line. If the anterior row is involved, the entire carpus should be removed. When the thumb is intact, and the metacarpal bones of the four fingers require removal, the incision as given by Esmarch should be followed. A curved incision is made across the palm, beginning at the middle of the web between the thumb and index-finger, and carried outward to the ulnar side of the base of the fifth metacarpal bone (Fig. 207). The dorsal incision commences at the web between the thumb and finger, and is carried obliquely upward toward the carpus

until the junction of the middle and upper third of the metacarpal bone of the index-finger is reached, whence it travels across the back of the hand to join the end of the palmar incision (Figs. 208, 209).

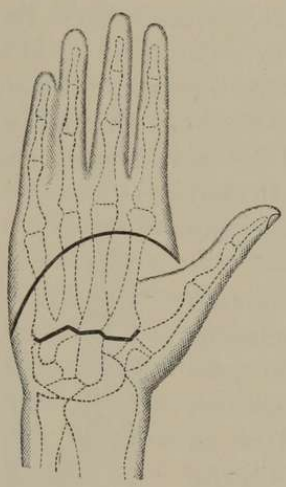

Fig. 207.

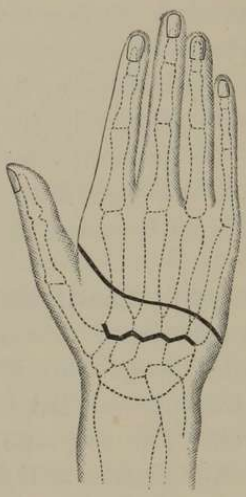

Fig. 208.

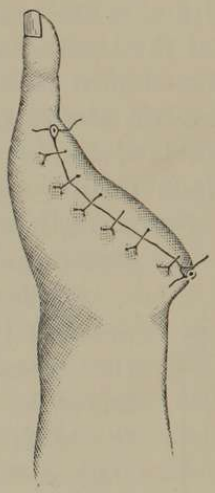

Fig. 209.

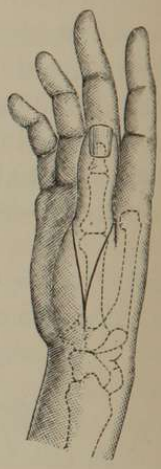

Fig. 210.

Amputation of the thumb with disarticulation at the carpo-metacarpal junction should be done as follows: Just over the carpo-metacarpal joint on the dorsal aspect of the hand commence an incision, and carry it directly along the metacarpal bone until half way to the metacarpo-phalangeal articulation, from which point it is made to travel along the groove between the thumb and index-finger to the middle of the web between these two members, thence on around the base of the thumb until the dorsal incision is reached (Fig. 210). In the case shown in

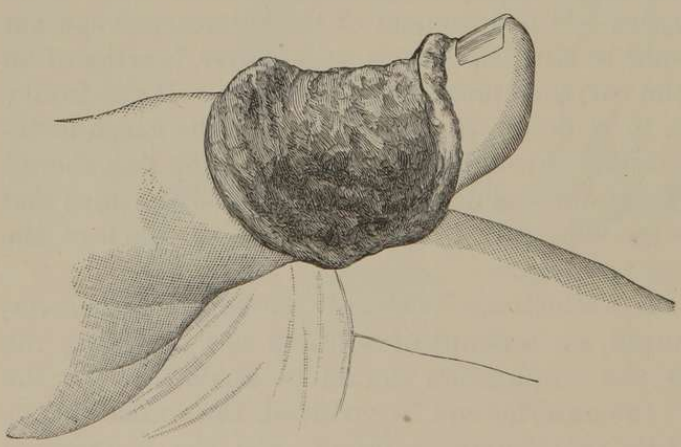

Fig. 211.—Epithelioma of thumb. (From a patient at Mt. Sinai Hospital.)

Fig. 212.—The same, after amputation at the carpo-metacarpal joint.

Figs. 211 and 212 this operation was performed. In amputation of the little finger, at the carpo-metacarpal joint, a similar incision is made (Fig. 213).

The character of the injury, the general condition of the individual,

the vitality of the parts involved, may necessitate various modifications of the foregoing methods. In the surgery of the hand, the rule in practice should be never to amputate when possible to avoid it, and never to remove any more than is absolutely necessary. Fig. 214 is that of an amputation after an injury from the explosion of a shot-gun, in which the thumb, index, and middle fingers, and their respective metacarpal bones, were blown off. The line of incision was a lateral one, and the disarticulation was at the carpo-metacarpal joint.

Fig. 213.



Fig. 214.

Radio-Carpal Joint.—In amputation at the wrist the carpus should be removed, even when all the bones of this group are not involved. The line of incision will depend upon the extent of the healthy tissues available for forming the covering to the stump. The long palmar and short dorsal flaps are preferable on account of the finer tactile sense of the covering thus secured. Moreover, the vitality of the palm is so great that, if ordinary precautions are observed in its dissection, sloughing will not occur.

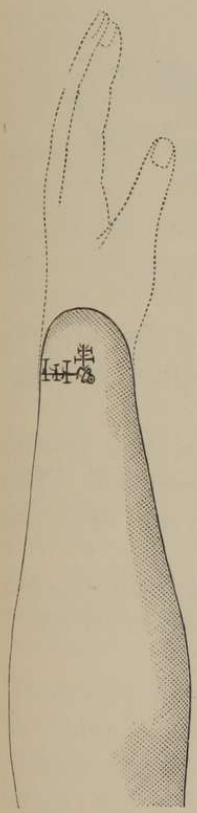

Fig. 215.

First Method.—Place the thumb and finger of the left hand respectively upon the styloid of the radius and ulna, and make an incision across the dorsal surface of the wrist which shall divide everything straight down to the bones and into the cavity of the joint. This incision reaches half-way down the lateral aspects of the wrist. At the radial end of this cut enter the scalpel, and, in shaping the long flap, follow the center of the dorsum of the metacarpal bone of the thumb as far as the metacarpo-phalangeal articulation. From this point cut directly across the palm to the ulnar side of the fifth metacarpal bone, and back along this to join the dorsal incision. Dissect the flap closely from the flexor tendons, and divide all tendons opposite the wrist-joint. Apply a cloth retractor, and saw through the styloid of the radius and ulna just at the level of the articular surface of the radius, but not necessarily taking a section from this surface. The *radial*, *ulnar*, *anterior*, and *posterior carpal* vessels are tied, the palmar flap is trimmed down to fit snugly, and stitched in proper position. The drainage-tubes come out on either side (Fig. 215).

Second Method.—If the condition of the soft tissues is such that the long palmar flap can not be obtained, the circular incision shown in Figs. 216 and 217 may be practiced. It is always advisable to make a longitudinal split in the cuff along its ulnar aspect. Under other conditions, a

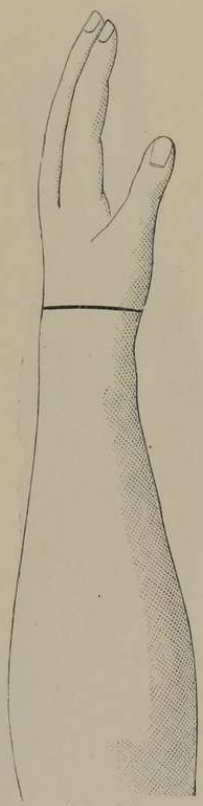

Fig. 216.

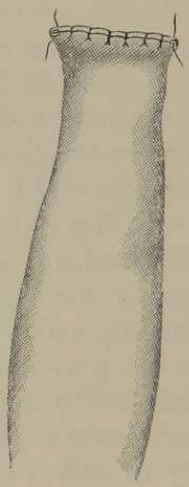

Fig. 217.—Showing cuff stitched and exit of drains after the circular method. (After Esmarch.)

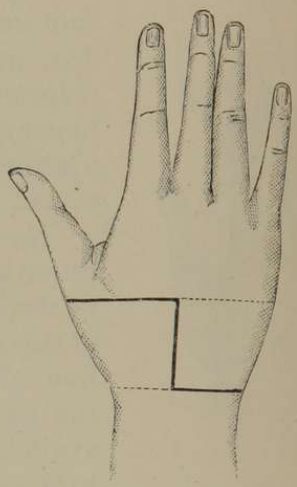

Fig. 218.

Fig. 219.

lateral flap may be utilized, after the third method (Figs. 218, 219), in the flap from the thumb side; or the fourth method in which the flap is taken from the ulnar aspect of the hand.

Forearm above the Wrist.—In amputations through the forearm, the circular or modified circular skin-flaps are, in general, preferable. The exceptions are in cases of marked emaciation when the solid flaps are indicated.

The anatomical relations of the parts concerned are admirably shown in Figs. 220, 221, 222, and 223, which, with only slight modifications, I have copied from Prof. Braune's magnificent work.

When the line of amputation is so close to the elbow-joint that division of the bones is necessitated within an inch of the articular surface of the head of the radius, the operation to be preferred is a disarticulation at the elbow, with removal of the olecranon. When the bones can be preserved at the level of the lower border of the bicipital tuberosity of the radius, the joint should not be invaded.

Amputation at this level (Fig. 223) should be made subject to the rules just given for other portions of the forearm between the wrist and the insertion of the *biceps humeri.*

At the Elbow-Joint — First Method. — Make a circular incision through the skin from one inch to one inch and a half below the level of the internal condyle. Along the posterior aspect of the ulna make a second incision, splitting the sleeve of skin as far back as the end of the olecranon. Dissect up the flap from the muscles and deep fascial attachment until the joint is exposed in front, and the olecranon posteriorly. Extend the forearm fully, enter the articulation between the head of the radius and the humerus, disarticulate, and saw off the articular surface at the level of the lower portion of the internal condyle. The drainage is from the highest point in the perpendicular incision.

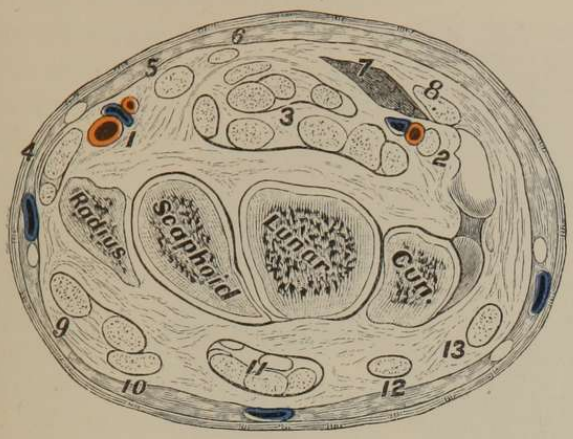

Fig. 220.*—Transverse section through the right upper extremity, one fourth of an inch anterior to the plane of the radio-carpal articulation. Looking at the surface of the stump. 1, Radial artery and veins. 2, Ulnar artery, veins, and nerve. 3, Tendons of deep and superficial flexors. 4, Tendon of extensor ossis metacarpi and primi internodii pollicis. 5, Flexor carpi radialis. 6, Palmaris longus. 7, Fibers of the flexor brevis minimi digiti, from the annular ligament. 8, Flexor carpi ulnaris. 9, 10, Extensor carpi radialis longior et brevior, and tendon of secundi internodii pollicis. 11, Extensor communis digitorum. 12, Extensor minimi digiti. 13, Extensor carpi radialis. Superficial veins and nerves are seen in the subcutaneous tissues.

Second Method.—Make a circular incision down to the deep fascia from one to two inches anterior to the tip of the internal condyle of the humerus, and, when the skin has retracted, at the level of the line of retraction divide all the tissues to the bones. Along the posterior surface of the ulna make an incision extending as high as the olecranon process. Dissect the soft tissues neatly from the periosteum and capsule back to the condyles on the lateral and anterior aspects of the humerus, and along the olecranon somewhat higher, in order to facilitate disarticulation and the complete removal of the synovial bursa, beneath the insertion of the triceps. When the disarticulation is completed, apply a cloth retractor and saw a portion of the articular surface off at the same level as

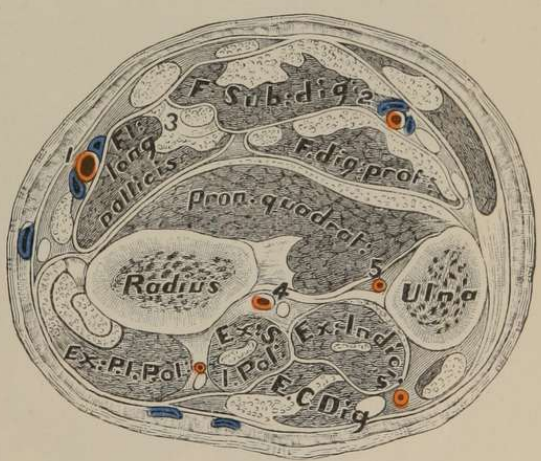

Fig. 221.—Transverse section showing the relations of the tissues divided in amputation through the lower third of the right forearm. Looking from below upward. 1, Radial artery and veins. Just below this, tendon of supinator longus, radial nerve, and close to the radius the tendons of the extensor ossis metacarpi pollicis and extensor carpi radialis longior and brevior. 2, Ulnar artery, veins, and nerve. 3, Median nerve. 4, 5, The posterior and anterior interosseous arteries.

* All of these cuts represent the surface nearest the patient's body, i. e., the surface over which the vessels are searched for after an amputation.

given in the preceding operation. The flaps are now sutured, leaving the drainage-tube out at the upper limit of the incision, over the olecranon.

Fig. 222.—Transverse section through the middle of the right forearm. Looking from the periphery toward the center. Showing the relations of the tissues divided in amputation at this point. 1, Radial artery, veins, and nerve. 2, Ulnar ditto. 3, Median nerve. 4, Anterior interosseous vessels.

Fig. 223.—Transverse section through the upper third of the right forearm. Looking from the periphery toward the center. 1, Radial artery, muscular branches, veins, and radial nerve. 2, Ulnar and interosseous arteries, veins, and median nerve. 3, Ulnar nerve. The tendon of insertion of the biceps is seen with the radius.

Fig. 224 shows the anatomical relations near the line of section of the soft parts involved in this amputation.

In no amputation is the superiority of the circular or modified circular *skin-flap* over the mixed flap of older operators more evident than the one under consideration. In the mixed operation, where the anterior flap was made by transfixion, cutting obliquely forward and outward, the large vessels were not evenly divided, nor was it without considerable care that the opposing flaps could be properly adjusted. The older method, in which the olecranon process was left in position, the saw passing through the neck of this process at the level of the lower portion of the articular surface of the humerus as soon as the joint was opened, has also been discarded. It has been demonstrated that nothing was gained by leaving the insertion of the triceps intact, while a second operation was occasionally necessary on account of necrosis of the olecranon.

Removal of a portion of the articular surface is not always advised by surgical writers. While it is true that the stump will heal as readily when the cartilage is scraped from the bone as when the saw is used, the latter is preferable, not only from the standpoint of appearance, but also that of usefulness.

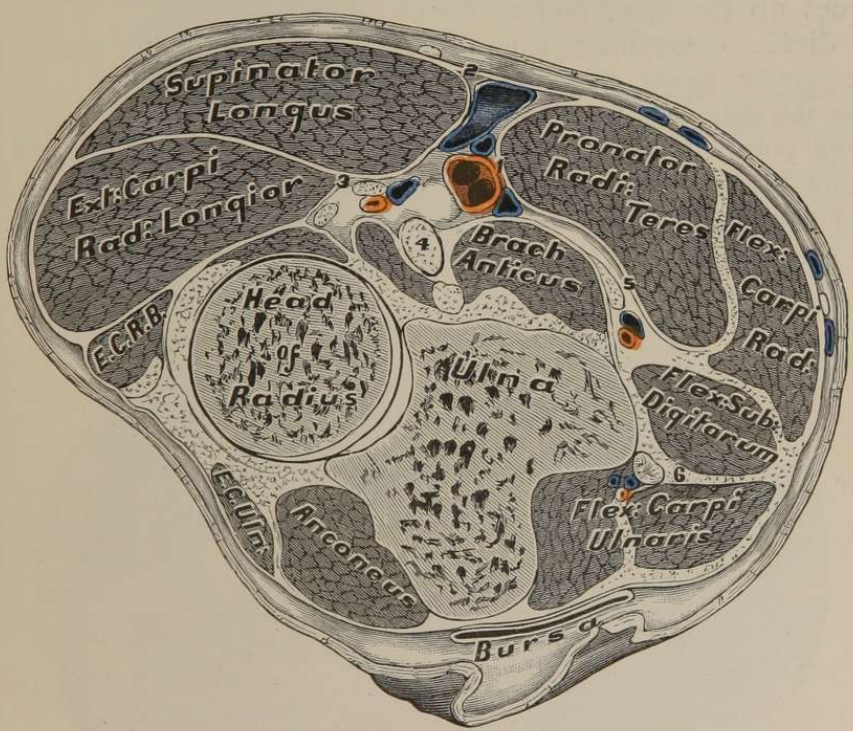

Fig. 224.—Transverse section of right arm just below the elbow-joint. Looking at the surface nearest the body. 1, Brachial artery at the point of division into ulnar and radial. 2, Median basilic vein communicating with brachial. 3, The radial and interosseous divisions of the musculo-spiral nerve and radial recurrent artery. 4, Tendon of biceps. 5, Median nerve and anterior ulnar recurrent artery. 6, Ulnar nerve and posterior ulnar recurrent artery.

Arm below the Shoulder-Joint.—The circular skin-flap is always preferable, except in cases of extreme emaciation, when, as heretofore given, the solid flaps are recommended.

First Method.—Make a circular cut down to the muscles, and a

longitudinal incision to the same depth along the outer side of the arm. Dissect the sleeve of skin carefully up to the line of section of the humerus, and at this point divide the muscles and bone. Drainage is effected in the manner shown in Fig. 225.

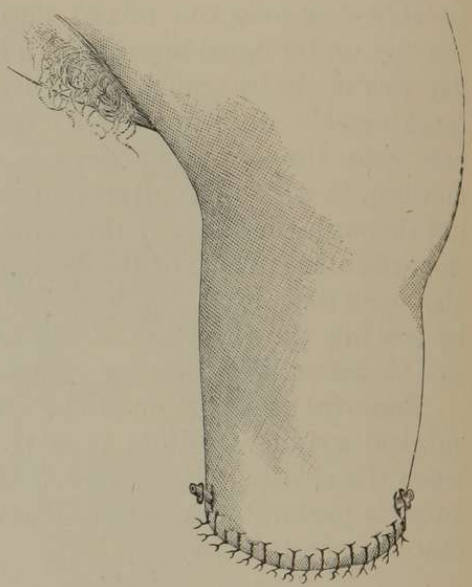

Fig. 225.—Showing sutures applied and exit of drains in amputation at the lower and middle thirds of the humerus.

The anatomical relations in the several regions of the arm are shown in Figs. 226, 227, and 228.

When the line of amputation is so near the shoulder-joint that section of the bone is required at the anatomical neck, the head of the humerus should be disarticulated.

Second Method.—Make a circular cut through the skin at a point sufficiently below the line of section through the humerus to permit a suitable covering. Allow the skin to retract up the arm, and at this point divide everything smoothly and squarely down to the bone. Render the skin and muscles tense, push the point of the scalpel down to the bone on the outer side of the arm, and lay the flap open by an incision which is parallel with the axis of the humerus. Dissect the tissues closely from the periosteum up to the point where the saw is to be applied, and, after protecting

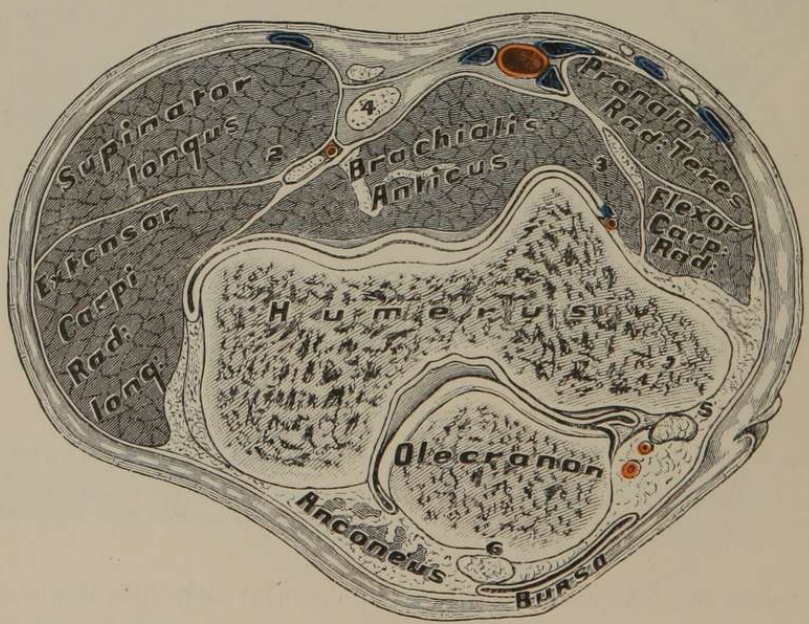

Fig. 226.—Section through the condyloid expansion of the right arm. Looking at the surface nearest the body. 1, Brachial artery and veins, and the median basilic vein. 2, Musculo-spiral nerve and superior profunda artery about the point of anastomosis with the radial recurrent. 3, Median nerve. 4, Biceps tendon. 5, Ulnar nerve. 6, Triceps tendon.

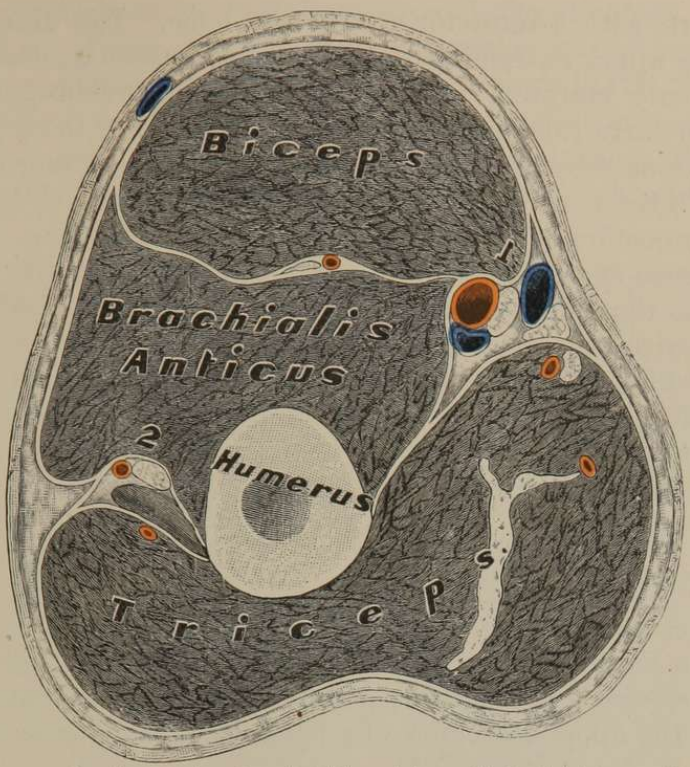

FIG. 227.—Transverse section through junction of middle and lower thirds of right arm. Looking from below upward. 1, Brachial artery, vein, median nerve, and basilic vein. Near by the ulnar nerve and inferior profunda artery. 2, Musculo-spiral nerve, superior profunda artery, and supinator longus muscle. Cephalic vein to outer side of the biceps muscle.

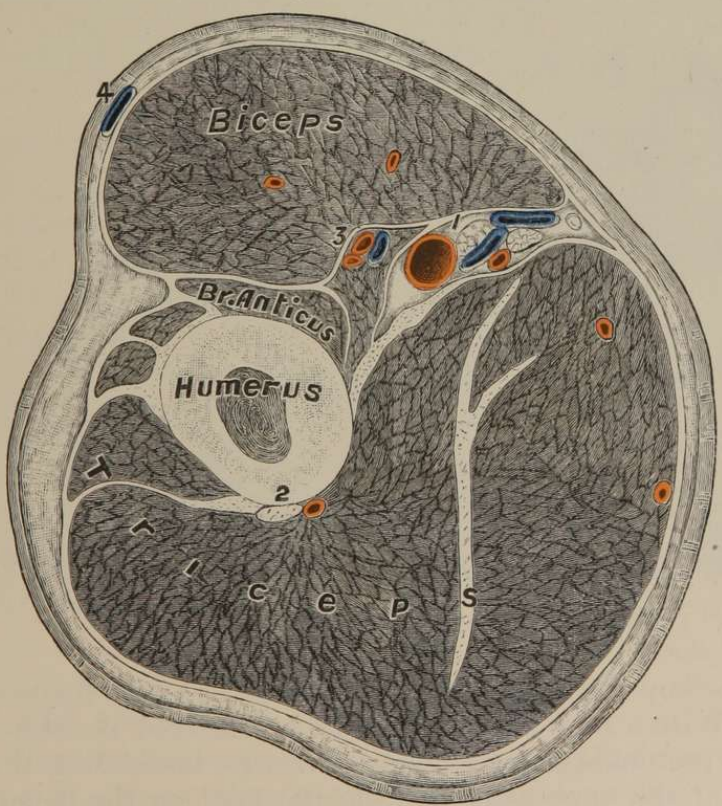

FIG. 228.—Transverse section showing the relations of parts divided in amputation just above the middle of the humerus. Right side. Looking toward the center. 1, Brachial artery. Near this the median nerve and brachial veins. Internal to it the ulnar nerve and inferior profunda artery. More superficial, the basilic vein. 2, Musculo-spiral nerve and superior profunda artery. 3, Nutrient artery in the substance of the coraco-brachialis muscle. 4, Cephalic vein.

the soft parts with a retractor, divide the bone. The drainage should be from the upper extremity of the perpendicular cut, which, with the stump properly elevated, will be the most dependent portion of the wound. An extra tube may be inserted at the end of the stump.

Amputations through the humerus, especially in young and growing bones, not infrequently fail of success by reason of so-called conical stump—a projection of bone through the tissues of the flap. This condition supervenes in a proportion of cases sufficient to justify the surgeon in stating at the time of such an operation that a conical stump may result even with very long flaps. I have met with one case in my own practice in which conical stump recurred after three reamputations. It is not definitely determined whether the projection is due to inflammatory changes in the end of the bone or to the growth of the stump of the humerus from the upper epiphysis.

Amputation at the Shoulder Joint—The Author's Method.

In 1888, at the New York Polyclinic Medical School and Hospital, I removed the outer portion of the clavicle, the glenoid, acromion and coracoid processes, and a small portion of the body of the scapula, together with the upper extremity of a patient suffering from a large sar-

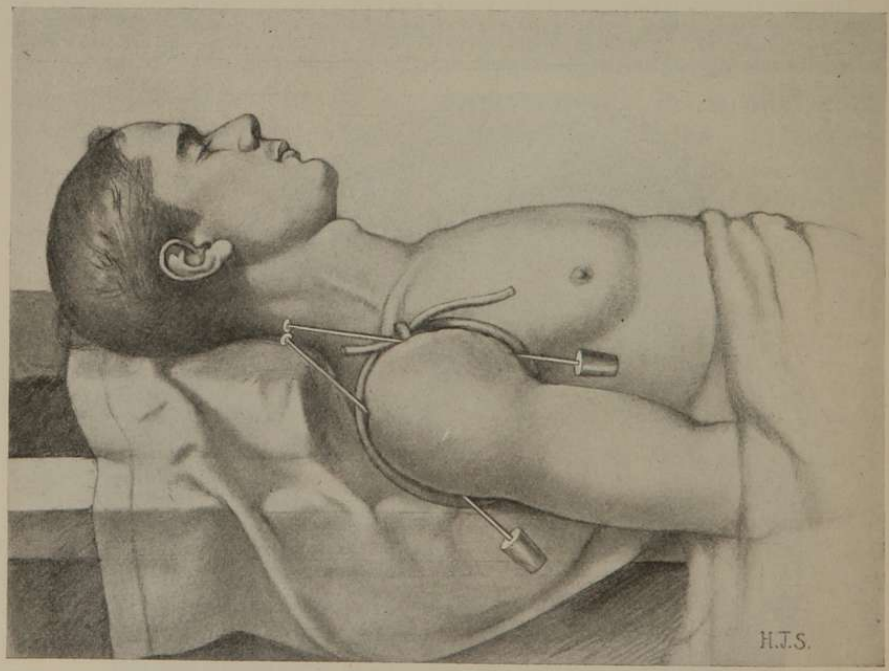

Fig. 229.—Shoulder-joint amputation. Pins and rubber-tube tourniquet in position. The Esmarch bandage has been removed. (From drawings by H. J. Shannon.)

coma of the upper articular end of the humerus by the following original method: With a stout mattress needle I transfixed the skin and a portion of the pectoralis major muscle about three inches from the shoulder, and at about the same distance from the joint on the dorsum scapulæ I introduced a second needle in such a way that when I carried a strong

white-rubber tube four or five times around the shoulder above these needles, making strong traction, the compression was so great that the blood vessels going to the arm were entirely occluded (Fig. 229).

I have twice repeated this operation with perfect success in hæmostasis. It has since been done by Prof. J. H. Brinton, Prof. W. W. Keen, Prof. Roswell Park, and other surgeons, and has proved entirely

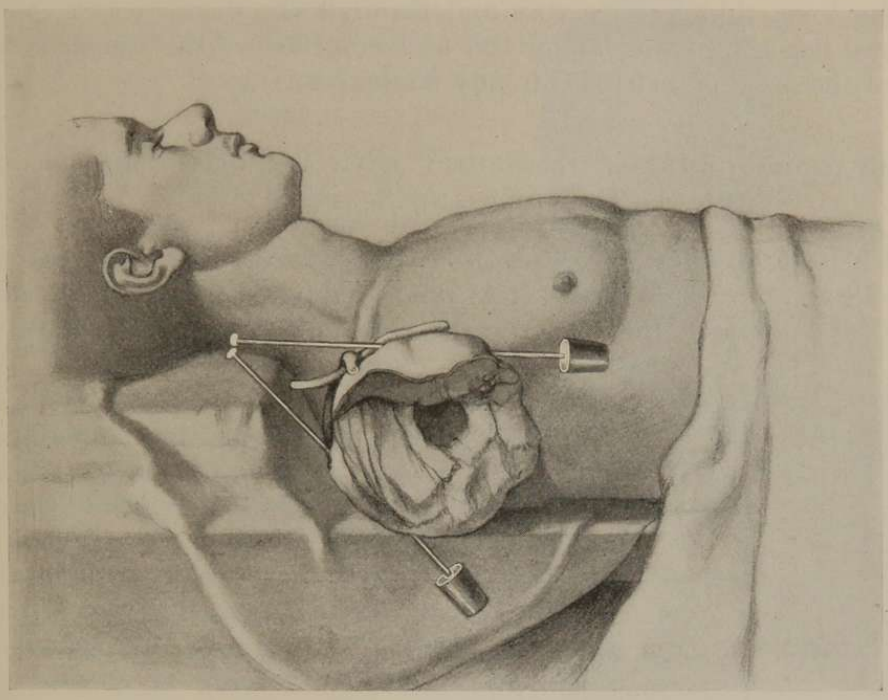

Fig 230.—The same after disarticulation and ligature of the vessels.

satisfactory in their hands. With this experience, I can recommend it to the profession as a safe method of controlling hæmorrhage in disarticulation of the shoulder joint or in operations about the shoulder. After the extremity has been exsanguinated by Esmarch's bandage, the pins should be introduced and the rubber constrictor applied, and the Esmarch bandage removed. The incisions for the flap should be made to conform to the conditions which demand the operation. When possible, the ideal amputation at the shoulder is a circular incision through the skin and down to the deep fascia, about four inches beyond the joint. A longitudinal incision is then made from the acromion process directly down to the circular incision, and the flap dissected back to the level of the joint and the latter disarticulated. When permissible, after disarticulation I leave the tissues upon the inner aspect of the humerus a little longer in order to get as much of the blood vessels beyond the constrictor as possible. The operation is completed with the tourniquet in position (Fig. 230). Silkworm-gut sutures with a twist of sterile catgut for capillary drainage will suffice for closing and draining the wound, which, as a rule, should be redressed about the fourth day.

The old method of Larrey may still be preferred by some operators.

It consists of a straight incision dividing all the tissues down through the capsule to the bone, from the tip of the acromion process to an inch below the articular surface of the head of the humerus. From the center of this cut make an incision on either side running obliquely down and forward, dividing all the tissues down to the periosteum, extending about two thirds of the distance from the apex of the shoulder to the axilla. Lift all the tissues from the bone, expose the joint, disarticulate, carry a long, thin knife across and through the capsule, and complete the oval flap by cutting along the under surface of the humerus in the line of the oblique incisions already made.

Removal of the Upper Extremity with All or a Portion of the Clavicle and Scapula.

When it becomes necessary to remove portions of the scapula or clavicle, or all of these bones, it is advisable to tie the subclavian artery (third division) and the transversalis colli and subscapular branches of the thyroid axis. When the disease extends so far upon the shoulder that it is impossible to secure flaps sufficient to cover the exposed surface, cut well away from the disease and allow the wound to heal by granulation, relying upon subsequent plastic procedures to cover in the stump. In a patient operated on in October, 1895, at the New York Polyclinic, I did a preliminary ligation of the subclavian and the two other arteries mentioned with *cocaine anæsthesia*, and at a subsequent operation amputated at the shoulder joint, leaving no material for flaps, as the operation was done for sarcoma which involved the soft tissues high up. Three weeks after amputation, and at two subsequent dates, I infected this wound with the streptococci of erysipelas, producing well-marked specific infection, which ran the usual course. The

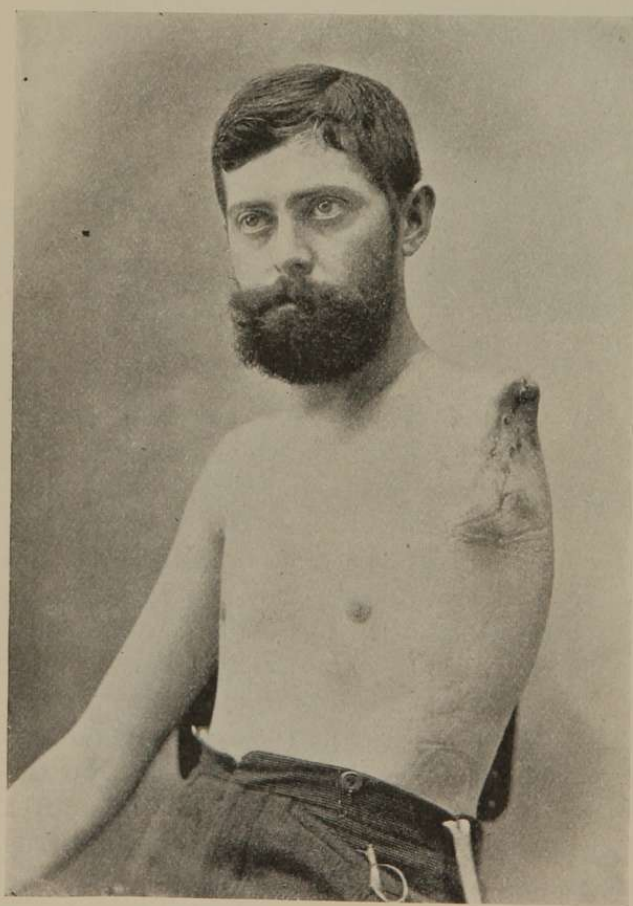

Fig. 231.—Author's case of amputation of the left upper extremity for sarcoma.

stump at this date (May, 1897) is well healed, and the patient is seemingly in perfect health, having a good color with marked increase in weight. I am acquainted with several cases in which this treatment has been successful.

On October 14, 1890, I removed the entire clavicle, the scapula and its muscles, the upper extremity, the outer half of the pectoralis major, and the pectoralis minor, ligating the subclavian artery in its third surgical division, and the suprascapular and transversalis colli branches of the thyroid axis in a man fifty-four years of age at the Mount Sinai Hospital. Nine months previous, a sarcoma had been removed from the long head of the triceps, but soon recurred. Three months later he was seen and amputation advised, but refused. As the tissues over the outer end of the clavicle and scapula were involved, it was deemed necessary to remove the scapula, the clavicle, and the muscles immediately connected with the shoulder. Very little blood was lost, and the patient recovered.*

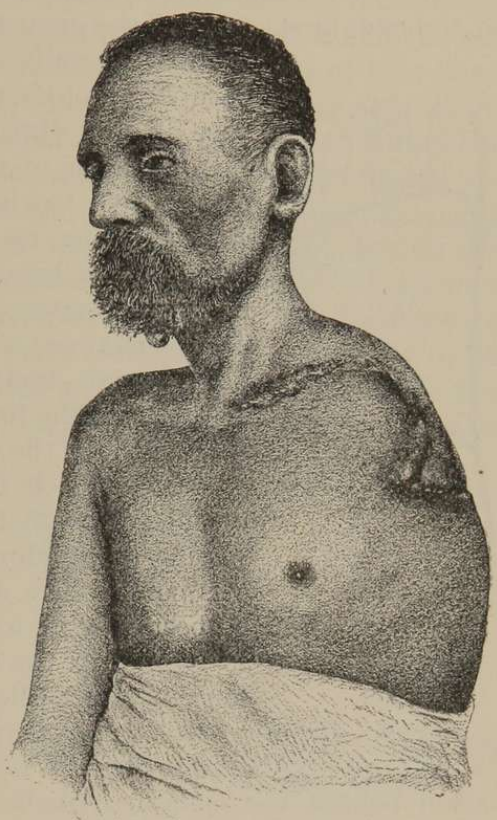

FIG. 232.—Author's case of amputation of the left upper extremity with the clavicle and scapula, 1890.

LOWER EXTREMITY.

Amputation of the Toes.—The same methods given for the fingers should be employed in amputation of the toes. The long plantar flap is preferable in these operations, not so much for the preservation of the more perfect tactile sense of this surface in covering the stump, but chiefly to bring the cicatrix on top and away from pressure. When an amputation is necessitated for a lesion near the articulation between the first and second phalanges in which only the anterior extremity of the first

* In an article in the "New York Medical Journal," January 17, 1891: I published six other cases of amputation at the shoulder joint—one by Niepce, in 1860, in a man thirty-two years of age, for machine injury; the arm, clavicle, and scapula were removed and the patient recovered.

Ferguson, 1860; female, twenty-six years, sarcoma; recovery.

Bell, 1885; boy, ten years, sarcoma; recovery.

Roswell Park, 1889; boy, ten years, railroad injury, shoulder almost torn off; recovery.

Roswell Park, 1892; male, middle-aged, enormous epithelioma over shoulder; recovery.

Ernst Schmidt, 1886; boy, railroad injury; recovery.

A remarkable showing of recovery in every case.

In thirty-nine cases in which the arm, scapula, and a portion of the clavicle were removed, twenty-eight recovered.

phalanx is involved, section through the bone should be preferred to disarticulation at the metatarso-phalangeal joint, provided that the line of section is through the anterior third of the phalanx. Disarticulation of two or more consecutive toes at the metatarso-phalangeal joint may be effected by a continuous incision. Amputation of all the toes at this articulation is performed as follows: Grasp and forcibly flex the toes, and make an incision, commencing just posterior to the inner aspect of the metatarsal joint of the great toe, curving forward along the side of the first phalanx to a point as far advanced as the web between the toes, and then across the base of each digit on this plane until the outer side of the metatarsal bone of the fifth toe is reached at a point corresponding to that at which the incision was begun. With the toes now fully extended, a symmetrical flap is next cut along the plantar aspect by an incision which almost merges into the first line at the anterior margin of the web (Figs. 233, 234). Dissect up each flap as far back as the metatarso-phalangeal articulation, leaving the tendons to be divided at this point. The disarticulation may be best effected with a strong narrow scalpel, while the ligaments are made tense by forced flexion.

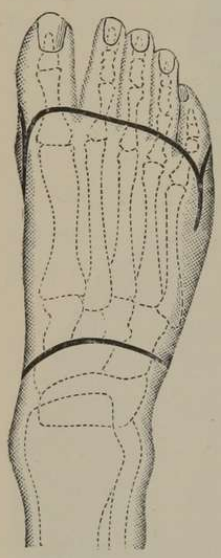

Fig. 233.

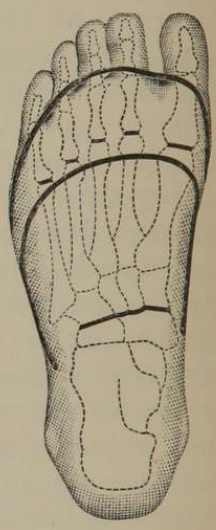

Fig. 234.

Second Method.—A separate amputation may be made for each toe.

Through the Metatarsus.—When the loss of tissue requires an amputation behind the metatarso-phalangeal articulation, section of one, or even all, of the metatarsal bones should be effected rather than unnecessarily sacrifice any portion of the foot by disarticulation at the tarso-metatarsal joint. The line of section should always be as near the anterior extremity as possible, and when it falls within three fourths of an inch from the tarso-metatarsal joint, a disarticulation should be made at this point.

Amputation through the entire metatarsus should be made with a long plantar and short dorsal flap, so that the scar will fall on the dorsum of the foot and away from pressure. The dorsal incision should be made almost directly across the foot, and on a line with the plane of section through the bones. The plantar flap should begin on the inner side of the first metatarsal bone, and follow this forward as far as is necessary to secure a flap of sufficient length. It is always wise to make this a little too long, so that it may be trimmed down and made to fit nicely as the sutures are being adjusted. The incision is next carried across the sole of the foot to the outer surface of the metatarsal bone of the little toe, and back along this to the point of junction with the end of the dorsal cut. All of the tissues should be divided directly down to the bones in this incision, and the flap dissected up, keeping the knife-

point always in contact with the periosteum, so that the vessels may be avoided. After the bones are sawn through, the lower flap is turned into position and suitably trimmed. The vessels are next secured, the sutures applied, and the drainage-tubes brought out at each side.

At the Tarso-Metatarsal Articulation—First Metatarsal.—Amputation of the great toe, with disarticulation of its metatarsal bone at the tarsal joint, is effected as follows: At a point about half an inch behind the articulation of the metatarsal bone with the internal cuneiform, and immediately between the dorsal and internal lateral aspects of this bone, commence an incision which is carried forward to the phalangeal junction. Thence it is continued around the base of the toe, across its plantar surface, and back through the web between the first and second digits, and back to the end of the straight incision over the metatarso-phalangeal joint (Fig. 235). Dissect the soft parts closely from the bone, taking care not to wound the plantar vessels, and disarticulate. The preservation of the posterior portion of the first metatarsal bone is always desirable, on account of its giving insertion to the peroneus-longus and partially to the tibialis-anticus muscle, the former being a strong supporter of the transverse arch of the foot, and the latter offering the chief resistance to the sural muscles.

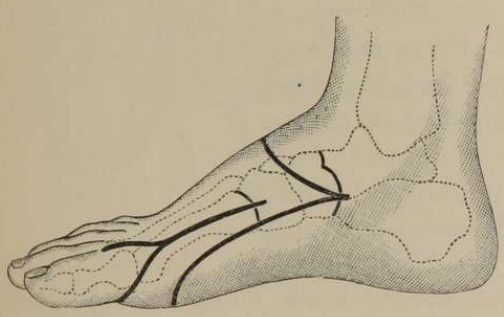

Fig. 235.

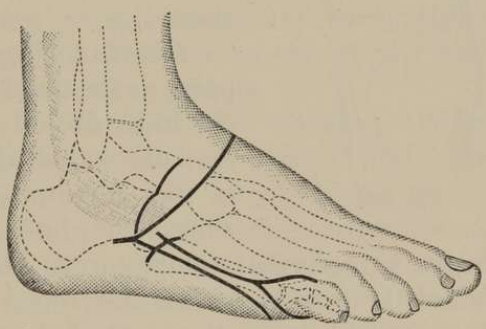

Fig. 236.

Fifth Metatarsal.—One fourth of an inch behind the tubercle of the fifth metatarsal, and over the center of the dorsal aspect of this bone, commence an incision, which is carried directly forward until near the first phalanx, when an oval is described around the base of the little toe (Fig. 236). Keep close to the bone in the dissection. The disarticulation is more easily effected by division of the peroneus brevis and peroneus tertius, and by entering the articulation from the outer side. The importance of the posterior portion of this bone is less than that of the metatarsal bone of the great toe, but it should never be needlessly sacrificed.

One or more of the intervening metatarsal bones may be removed in an amputation of their respective toes in practically the same manner as the preceding. The incision should be begun far enough behind the tarso-metatarsal joint to thoroughly expose the ligaments and facilitate disarticulation—not an easy process when only a single bone is to be removed. The incision should be made exactly along the middle line of the dorsal aspect.

Amputation of the entire metatarsus should always be made through the articular plane (Lisfranc). The modification of this procedure by Hey, which consisted in disarticulating the four outer metatarsal bones and sawing the end of the internal cuneiform off at the line of the second metatarsal bone, is altogether unnecessary.

Method—Dorsal Incision.—Place the thumb and index of one hand respectively half an inch behind the articulations of the first and fifth metatarsal bones with the cuneiform and cuboid, and at the most convenient one of these points commence the dorsal incision, carrying it directly forward to the base of the metatarsus, and then across the foot one fourth of an inch in front of the tarso-metatarsal articulation, finishing at the opposite side (Fig. 237). This incision should have a slight forward convexity, and should divide all tissues down to the bones. Dissect the flap closely from the periosteum to about one fourth of an inch behind the line of articulation.

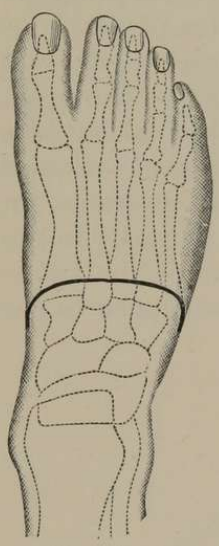

Fig. 237.

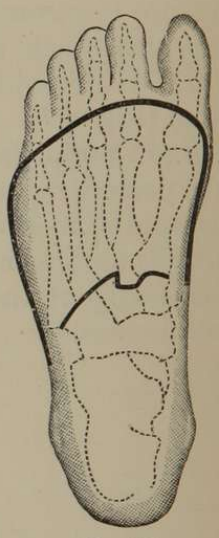

Fig. 238.

Plantar Flap.—From the same point as for the dorsal incision, carry the knife directly forward on the lateral aspect of the metatarsal bone to the metatarso-phalangeal joint, where the line of incision should begin to describe a curve until the interdigital web is reached, along which it travels across the foot, and thence back along the opposite metatarsal bone to the level of the tarsus (Fig. 238).

This flap should be lifted by deep dissection, keeping close to the under surface of the bones, in order to interfere as little as possible with the vascular supply. An assistant should now hold both flaps well back, while with a narrow, short scalpel the disarticulation is effected as follows:

Grasp the metatarsus with one hand and forcibly depress it until the ligaments are put upon the stretch. Enter the knife just behind the tip of the fifth metatarsal bone and carry it inward with a slight forward inclination, disarticulating on this plane, and in succession the fifth, fourth, and third bones, until the knife is arrested by the outer surface of the second metatarsal. The line of this articulation is almost parallel with that just followed, but it is placed from one eighth to one fourth of an inch posterior to it, and may be readily found by moving the metatarsal bone upon the cuneiform. The joint between the metatarsal bone of the great toe and the internal cuneiform is about one fourth of an inch anterior to that of its fellow, being continuous with the line of the three outer bones. The flaps should now be trimmed and nicely fitted, and any ragged ends of tendons clipped off by the scissors, after which the

vessels are tied and the sutures adjusted, leaving the drainage-tubes out at each angle.

One point of precaution is essential, namely, to avoid division of that part of the tendon of the tibialis anticus which is inserted into the internal cuneiform near its metatarsal articulation. One of the objections to this operation is the elevation of the heel, and the consequent depression of the stump by the action of the sural muscles, which action is practically unopposed if the insertion of the tibialis anticus is divided. Should this occur, or should the heel be too greatly elevated, the tendo Achillis should be divided as in talipes equinas. The line of section through the internal cuneiform bone is shown in Fig. 239. This—the operation of Hey—is objectionable, for two reasons. In the first place, it cuts away a part of the bony framework of the foot, which need not be sacrificed; and, secondly, it severs the attachment of the tibialis-anticus muscle.

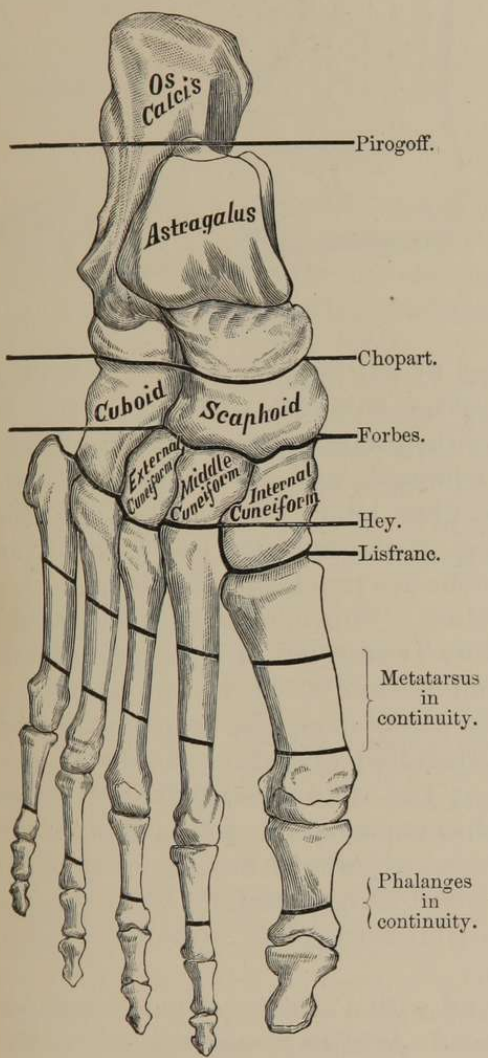

Fig. 239.

Through the Tarsus.—When removal of any part of the anterior row of tarsal bones is required, the following rules should be adopted: If the internal cuneiform is involved only on its anterior articular surface, it may be sawn through on the line of Hey (Fig. 239). If the middle or external cuneiform is involved only to a limited extent upon its anterior portion, as much as one fourth of an inch of this surface may be sawn or scraped off. Behind this limit a disarticulation from the scaphoid should be made. Through the cuboid the section should pass, as first advised by Dr. S. F. Forbes, of Toledo, Ohio (who performed this operation in 1863), through the middle of this bone on the line of the anterior surface of the scaphoid (Fig. 239).

Forbes's Method.—Disarticulation of the three cuneiform bones from the scaphoid, and section of the cuboid parallel with the plane of the anterior surface of the scaphoid (Fig. 239). The dorsal and plantar incisions are slightly anterior to and practically the same as in Chopart's amputation. The dissection should be made closely from the bones, and

the flaps trimmed and adjusted as in the preceding operation. Section of tendo Achillis may be done later, if necessary.

Medio-Tarsal—Operation of Chopart.—The dorsal incision is begun on a level with and an inch posterior to the tip of the base of the fifth metatarsal bone (for the adult foot). This point is about one fourth of an inch behind the articulation between the cuboid and calcaneum (Figs. 236–240). With a slight forward convexity the incision is carried across the top of the foot to the posterior margin of the tuberosity of the scaphoid, and then directly back from one fourth to half an inch (Fig. 235). The skin, tendons, vessels, and nerves are divided on this line, and the flap lifted until the joints between the astragalus and scaphoid and the calcaneum and cuboid are well exposed. From the ends of this first incision a long plantar flap is fashioned by cutting forward, as in shaping the flap for the operation of Lisfranc (Figs. 235, 236). Disarticulation is effected with a short, strong scalpel, while forcible extension is employed. The flaps are now to be properly trimmed, and the vessels secured. Division of the tendo Achillis may be done later. When required, this operation may be modified by sawing off the anterior half-inch of the astragalus and calcaneum. The incisions are practically the same.

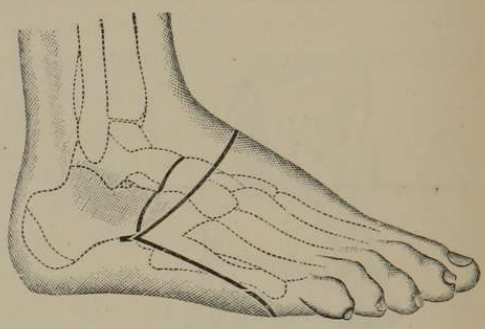

Fig. 240.

Calcaneo-Astragaloid Disarticulation.—This operation was first suggested by Lignerolles, first performed by Textor, but brought into prominence by Malgaigne. When in an amputation of the foot at the medio-tarsal joint it is discovered that the *os calcis* must also be removed, and if the astragalus is sound, the subastragaloid operation should be preferred to the amputation of Syme at the tibio-tarsal joint. By this method a shortening of about two inches is prevented, and, although the under surface of the astragalus is uneven, experience has shown that the pressure is safely distributed, and a useful stump results. Moreover, the degree of mobility maintained at the tibio-astragaloid articulation adds to the ease and comfort of locomotion.

Seize the foot with the left hand, and with a strong scalpel commence the incision by dividing the skin and tendo Achillis just at the level of the upper surface of the *os calcis*. From this point the incision is continued along the fibular side of the foot forward, dividing everything down to the bone, and curving slightly downward until, as it passes below the tip of the external malleolus, it is four tenths of an inch below this point (Fig. 241). The line of incision is now carried directly forward until near the tuberosity at the base of the fifth metatarsal bone, where it curves to the dorsum of the foot, crossing to the inner side over the anterior edge of the scaphoid, and then straight down and under the foot a half-inch beyond the middle of the sole (Figs. 242, 243). From this point a straight incision is made directly back to the point of beginning at the inner edge of

the tendo Achillis (Fig. 243). Lift the plantar flap by deep and careful dissection from the bone, leaving nothing but the periosteum, until the

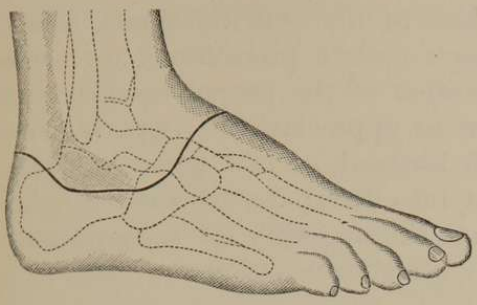

Fig 241.—(After Malgaigne.)

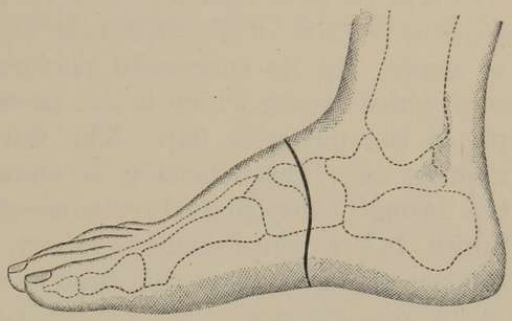

Fig. 242.—(After Malgaigne.)

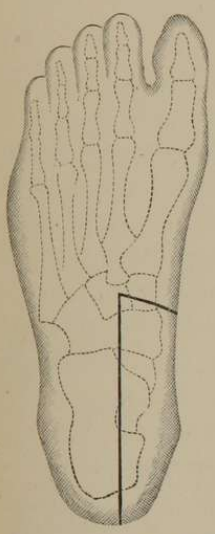

Fig. 243.—(After Malgaigne.)

calcaneo-astragaloid articulation is well exposed. The flaps being held by an assistant, the disarticulation is begun by opening the astragalo-scaphoid joint and removing the anterior part of the foot at the mediotarsal joint. The *os calcis* should now be seized with a lion-tooth forceps, and the disarticulation of this bone effected. The exposed tendons should be smoothly divided with the scissors at the higher portions of the incision. After deligation of the vessels the flap is properly trimmed and sutured, the cicatrix falling upon the dorsal and external lateral aspects of the stump.*

* Hancock's modification of this procedure, or the subastragaloid-osteoplastic amputation, is as follows: One incision begins beneath and at the posterior angle of the outer malleolus, and is carried along the outer surface of the foot to a point a half-inch anterior to the projecting base of the fifth metatarsal bone. A second incision is made along the inner border of the foot, commencing posteriorly about the center of the internal malleolus and terminating anteriorly at a spot opposite the end of the external incision. The anterior ends of both cuts are joined by a curved incision made with its convexity forward across the plantar aspect of the foot, and dividing all the tissues well down to the bone. Reflect this flap back as far as the projections at the under surface and in front of the tuberosity of the *os calcis*, and make a fourth incision across the dorsum of the foot immediately behind the head of the astragalus. Apply the saw upon the under surface of the calcaneum a little anterior to its center, and cut through the bone obliquely from below upward and backward (Fig. 244). With the knife enter the mediotarsal joint, pass the instrument under the head of the astragalus, and, cutting from before backward, sever the interosseous ligament and detach the anterior part of the foot, together with the segment of the *os calcis*. Saw off the head of the astragalus, and with a sharp bone-cutter (or saw) remove the two articular cartilages (and a thin slice of bone) from the under surface of the astragalus. As the flaps are adjusted, the sawn surface of the calcaneum is brought into apposition with the under surface of the astragalus. See "Lancet," September, 1866, p. 257.

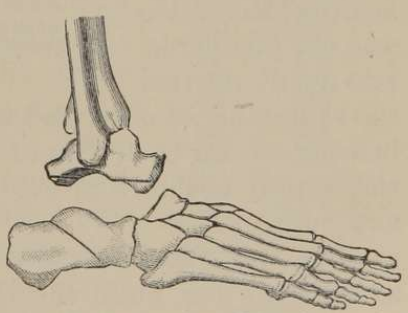

Fig. 244.—Section of *os calcis* and astragalus in Hancock's operation.

Amputation of the Foot—Tibio-Tarsal (Syme's).—When the astragalus must be removed, together with the foot, the amputation of Syme, which involves a disarticulation of the tibio-astragaloid joint, and a subsequent section of the articular surfaces of the tibia and fibula, should be made. In its successful performance certain precautions are necessary, chief among which is the preservation of the proper vascular supply to the posterior flap. The failure to appreciate the importance of making the plantar incision far enough forward, as laid down by Syme, has brought this procedure somewhat into disrepute, for Prof. Stephen Smith, in his comprehensive report, says the necessity for re-amputation is 3 per cent greater in this than in any other amputation.

In my "Prize Essay," published in 1876,* I demonstrated that the arterial distribution to the calcaneo-plantar flap was chiefly derived from the external plantar artery, and from the posterior tibial so near the bifurcation of this vessel into its terminal branches, that any line of incision in the formation of this flap which necessitated the application of a ligature at or very near its bifurcation was not justifiable. I do not doubt that the sloughing so often met with at this point is caused by carrying this incision too far back toward the tuberosity of the calcaneum. The arterial supply is shown in Fig. 245, from my "Essays in Surgical Anatomy and Surgery." †

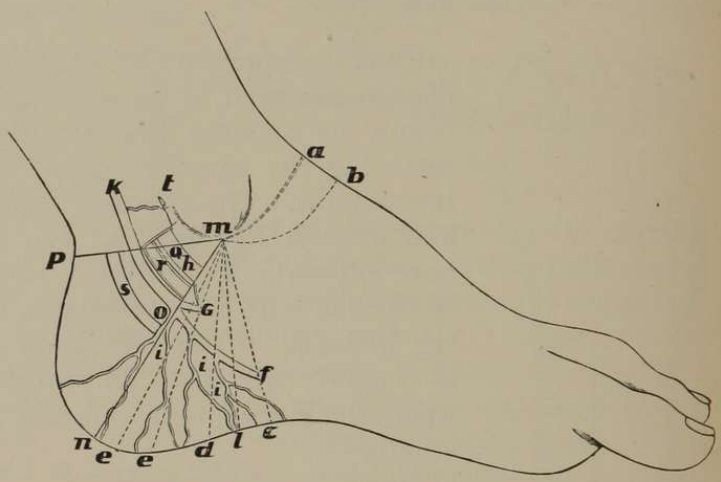

Fig. 245.—Diagram showing the arterial supply to the calcanean region, on the tibial side of the foot. (Drawn by the author, from the average of eighty-seven dissections.) *m*, Internal malleolus. *p m c n*, Tibio-tarsal quadrilateral, the surgical region of this articulation. *k*, Posterior tibial artery. *o*, Its point of bifurcation into *g*, Internal plantar, and *f*, External plantar artery. *i i i*, Calcanean branches of external plantar. *t*, Articular branches from posterior tibial. *h*, Articular branch from internal plantar. *q*, Tendon of tibialis posticus muscle. *r*, Tendon of flexor longus digitorum. *s*, Tendon of flexor longus pollicis. *m c*, The line of incision of Gross. *m l*, *m d*, *m e*, *m e*, Lines of incision showing that the nearer the incision approaches the heel, the more danger is incurred of cutting off the principal blood-supply to the calcanean flap, in amputation. *m n*, Line crossing the usual point of bifurcation of the posterior tibial. *m a*, *m b*, Anterior incision.

Modified Procedure.—With the foot held at an angle of 90° to the axis of the leg, place the thumb at the tip of one malleolus, and the index at the other, and from the center of the malleolus internus carry an incision directly across the sole of the foot to a point one fourth of an inch anterior to the tip of the malleolus externus. This incision should divide all the tissues to the bones, and, as will be seen in Figs. 246 and 247, its perpendicular portion descends in a direction slightly anterior to

* "American Journal of the Medical Sciences," April, 1876. † William Wood & Co., 1879.

the axis of the tibia. The ends of this cut are united by a second, which arches sharply upward about on the line of section of the bones, and should also divide tendons and all intervening structures, opening into the joint. The foot should now be firmly grasped and extended, so as

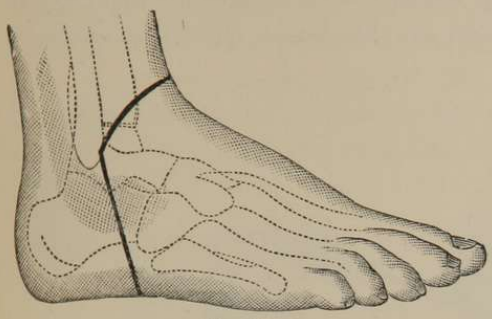

Fig. 246.

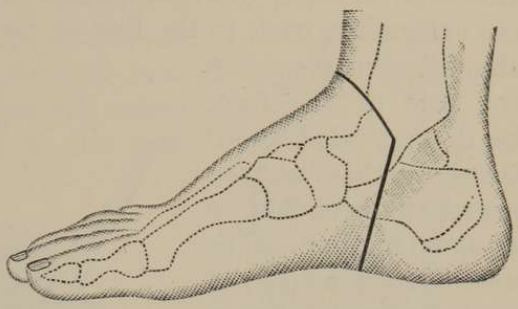

Fig. 247.

to make tense the anterior ligament of the ankle, which is easily divided. Carrying the knife to either side of the articular surfaces of the astragalus, the lateral ligaments are cut, and the joint thus widely exposed. An assistant now holds and depresses the foot, while the operator carefully dissects the tissues closely from the astragalus and calcaneum. Care should be taken not to bruise the flap by too great traction. In dissecting along the inner surface of the ankle, the knife should be kept close to the bones, so that when the lesser process of the calcaneum is reached it will slide behind and under this process, passing between it and the flexor tendon and the vessels. If this precaution is not taken, the arteries may be wounded and the nutrition of the flap seriously impaired. As the dissection proceeds, the foot is further depressed, and the tendo Achillis separated from its insertion into the tuberosity of the calcaneum, in doing which care must be taken not to button-hole the flap. The posterior portion of the *os calcis* may now be brought through the joint, and the dissection continued in this direction or finished by working back along the under surface of this bone. After the foot is removed, the flaps are lifted from the tibia and fibula until a section of these bones can be made just on the level of the anterior articular margin of the tibia (Fig. 248). It is not necessary to remove the articular surface. The flaps should now be trimmed and fitted, and the vessels tied. As the sutures are applied, it will be noticed that there is a redundancy of tissue in the long flap, leaving a cup-shaped cavity; but this can be thoroughly drained from the angles of the wound, and disappears when the stump is healed (Fig. 249).

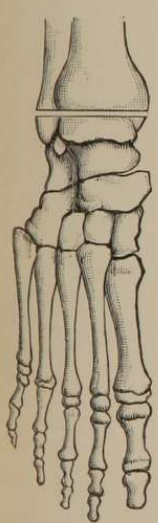

Fig. 248.

Fig. 249. — Stump after Syme's amputation. (After Malgaigne.)

Syme's amputation at the ankle has been modified by the osteoplastic operations of Pirogoff, Le Fort, Gunther, and others.

Pirogoff's Method.—The dorsal and plantar incisions are made from the same points, and are practically the same as in Syme's amputation. However, in order to avoid redundancy of the soft tissues and to expose the calcaneum back to the line of section of this bone, the lower incision should, when it reaches the sole of the foot, be carried back about three fourths of an inch nearer the heel than in Syme's method. The dorsal incision does not ascend so high upon the ankle by the same distance. The joint is opened through the anterior incision, and the lateral ligaments divided until the anterior upper surface of the *os calcis* can be displaced forward through the articulation, when it is sawn through on the line indicated in Fig. 251, the instrument running parallel with the edges of the incision. The soft parts are now carefully lifted from the articular ends of the tibia and fibula, and these bones divided horizontally so that all the articular cartilage is removed by the section. The angle described by these two lines of section is about 90° (Fig. 251). The flaps are adjusted so that the plane of the calcaneum is brought snugly in apposition with that of the tibia and fibula. The drainage should be from the dependent angles of the wound (Fig. 252).

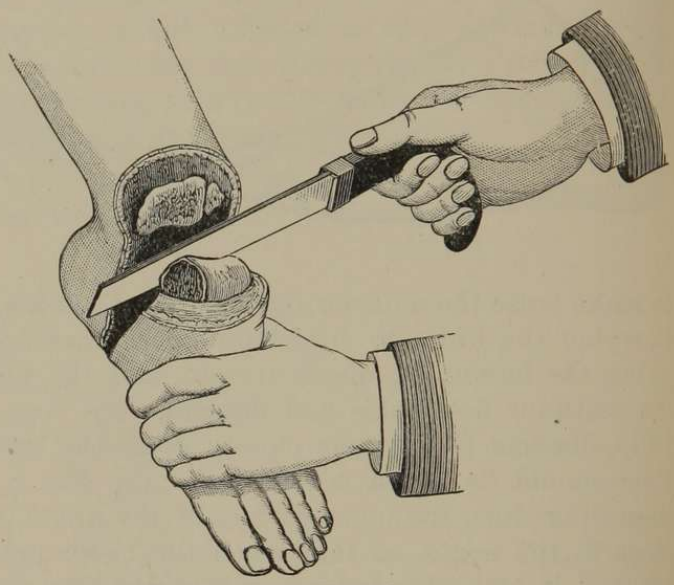

Fig. 250.—(After Esmarch.)

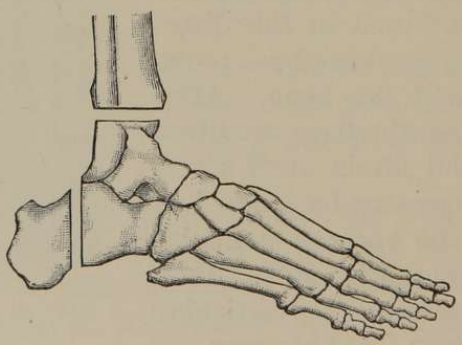

Fig. 251.—(After Esmarch.)

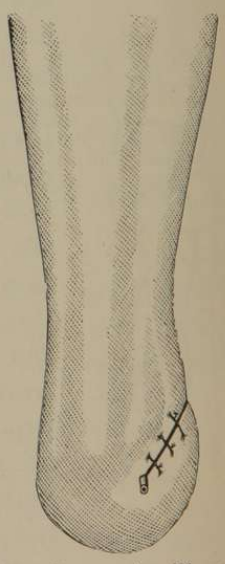

Fig. 252.—Stump after Pirogoff's amputation. (After Malgaigne.)

Le Fort's Method.—Three fourths of an inch below the external

malleolus commence an incision which is carried directly forward to within half an inch of the calcaneo-cuboid articulation. From this point it describes a curve with an anterior convexity over the dorsum of the foot, following the line of the astragalo-scaphoid joint until the inner border of the foot is reached (Fig. 253), when it is carried back and ended at a point about one inch in front of the tip of the internal malleolus, which point is directly between the tuberosity of the scaphoid and the tip of the malleolus. From the anterior limit of the straight incision below the external malleolus describe a plantar flap also with a forward convexity across the sole of the foot, as shown in Fig. 254. Dissect up the dorsal flap, in order to expose the tibio-tarsal joint, taking great care in lifting the inner angle not to wound the tibial and plantar arteries. The disarticulation of the astragalus from the calcaneum is next effected by introducing a thin knife from the fibular side between these bones, and dividing the interosseous ligament. Then remove the front of the foot at the medio-tarsal joint, and complete the disarticulation of the astragalus, and with the saw remove the upper segment of the calcaneum on the level of its articular surface (Figs. 255, 256). The tibia and fibula

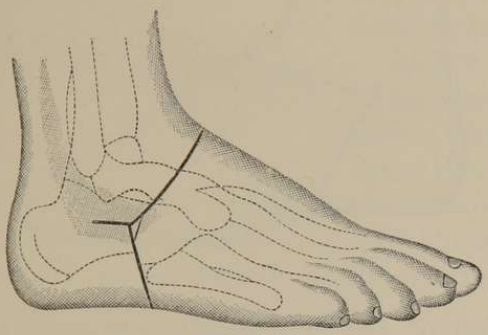

Fig. 253.—(After Le Fort.)

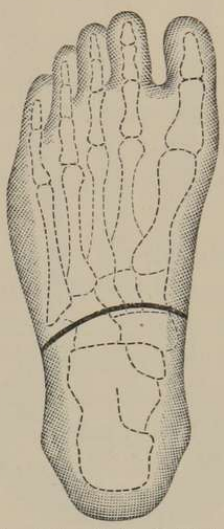

Fig. 254.—(After Le Fort.)

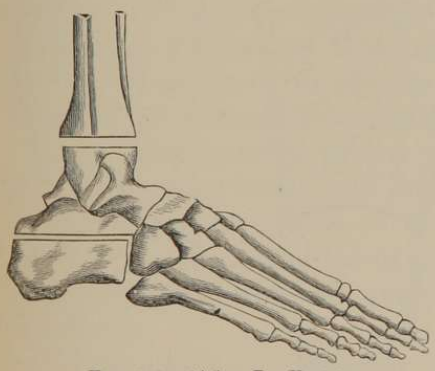

Fig. 255.—(After Le Fort.)

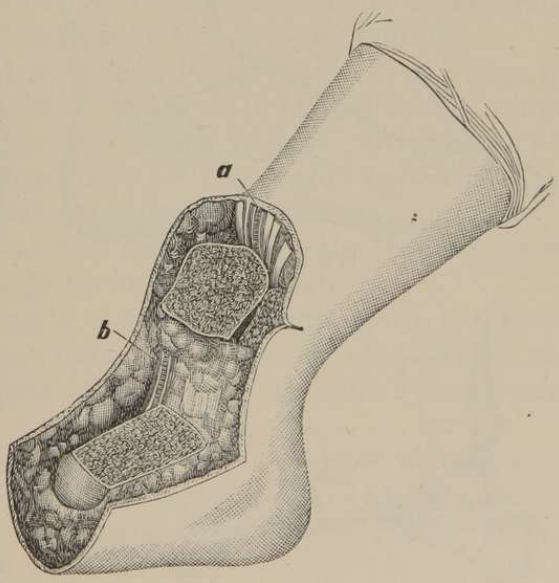

Fig. 256.—(After Le Fort.)

are now horizontally divided just at the level of the articular plane of the tibia, as in Syme's operation (Fig. 248). In adjusting the flaps, the sawn surface of the calcaneum is brought into apposition with that of the tibia (Fig. 257). Or, having exposed the tibio-tarsal joint, divide the ligaments, disarticulate, as in Syme's operation, and, having drawn the astragalus and calcaneum forward until the upper

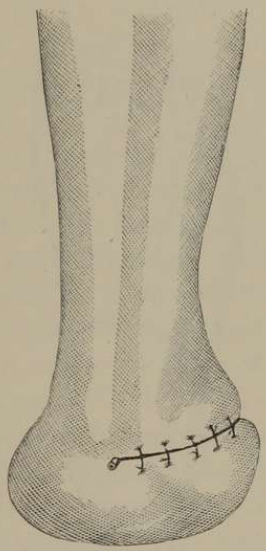

Fig. 257.—Stump after Le Fort's amputation. (Le Fort.)

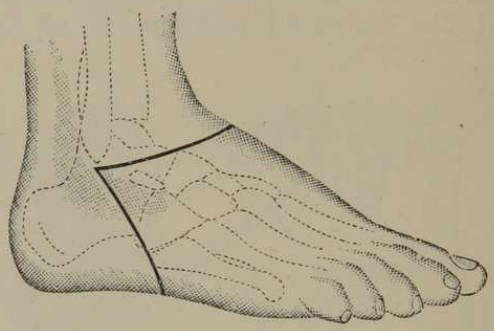

Fig. 258.

portion of the *os calcis* is exposed, insert a key-hole saw behind the tuberosity, and saw through this bone on the line already indicated.

Gunther's modification of this procedure is shown in Figs. 258, 259, 260, 261, 262, taken from Esmarch's hand-book, and the crescentic section

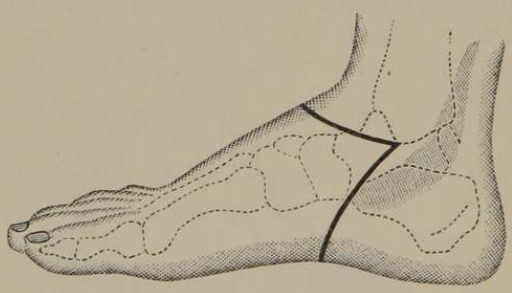

Fig. 259.

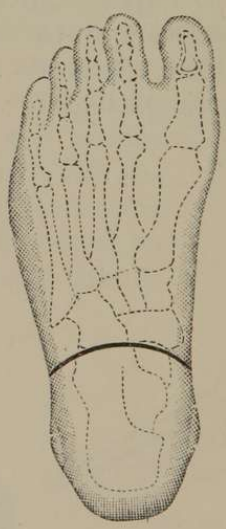

Fig. 260.

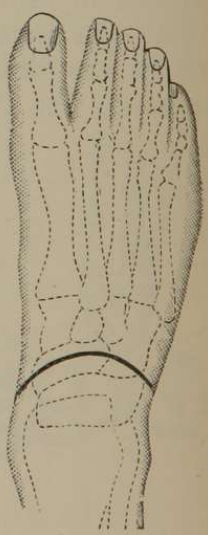

Fig. 261.

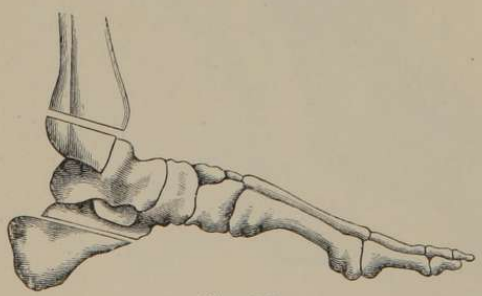

Fig. 262.

of the bones, as practiced by P. Bruns, is seen in Fig. 263, from the same source.

Summary.—In amputations of the foot the following rules should be observed: The terminal phalanges of all the toes should be removed by disarticulation when it becomes necessary to remove a portion of the entire thickness of these bones. The same rule applies to all the second

phalanges, except that of the great toe, which should be sawn through at any point anterior to its middle. If a section posterior to this is required, disarticulate from the metatarsal bone. What has been said of the second phalanx of the great toe applies with equal force to the proximal phalanges of all the other toes.

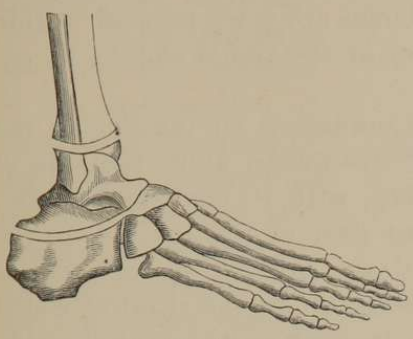

Fig. 263.

None of the metatarsal bones should be disarticulated from the tarsus when a section is possible not less than three fourths of an inch anterior to each tarso-metatarsal joint.

When a section posterior to this line is required, a tarso-metatarsal disarticulation should be effected. *Hey's* operation is only justifiable when the anterior face of the internal cuneiform is diseased. As much as the anterior fourth of each cuneiform bone, and the anterior half of the cuboid, may be sawn off, in preference to the sacrifice of the bony framework, by Forbes's or Chopart's operation.

When the cuneiform bones must be removed, and the posterior half of the cuboid is sound, Forbes's operation should be preferred to Chopart's. Chopart's procedure is next in order. For laborers, the operations of Le Fort and Pirogoff, carefully and skillfully done, should be preferred to the tibio-tarsal disarticulation. I formerly preferred the Syme stump, but when a good union at the proper angle is obtained between the calcaneum and tibia after Pirogoff's or Le Fort's method, I am of the opinion that pressure on the heel and remaining sole is better endured.

Even at the risk of a second operation being required, an effort to preserve the greatest possible portion of the foot is justifiable, except when it may seriously threaten the life of the patient. The value of a surface accustomed to pressure can only be thoroughly appreciated in the after-adjustment of an artificial apparatus.

Leg.—Amputation at any portion of the leg above the line of section in Syme's operation should be made by one of two methods.

When amputation is to be made below the middle third, the bone may be sacrificed in order to obtain flaps. If above the middle third, no bone should be sacrificed, every inch of bone being desirable for purposes of leverage.

In amputations just below (within one and one half inch of the knee), bone may be sacrificed to secure flaps. In general, the nearer the amputation is to be made to the body, the greater should be the care to secure bone.

1. *Modified Circular Skin Flap.*—At a sufficient distance beyond the point at which the bones are to be divided make a circular cut through to the deep fascia, split the flap directly over the fibula, up to the point of section through the bones, and carefully dissect up the cuff. When the flap is reflected, at the level of its base divide all the soft tissues squarely down to the bones, which are next sawn through. The spine of

the tibia should be trimmed down, to prevent too acute pressure and sloughing of the skin at this point, a not infrequent occurrence when this precaution is omitted. The drainage is at the fibular side, and, as the leg should be elevated, the tube should come out at the highest point of the perpendicular incision. When the bones are sawn through within six inches of the knee joint, the remainder of the fibula should be exsected.

2. *Method of Prof. Stephen Smith.*—Commence an incision in the center of the anterior surface, and carry it downward along the side of the leg, so as to make a slightly curved flap, with its convexity below; when the incision passes over the prominent part of the leg toward the posterior surface, incline it upward until the middle of the limb is reached, where it should be continued directly up to the point at which the bone is to be divided; make a similar incision on the opposite side (Fig. 264); the flaps, consisting of the skin and fascia, are dissected upward about an inch, at which point the muscles are divided squarely

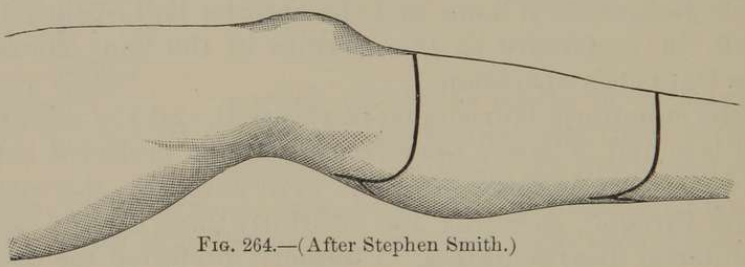

FIG. 264.—(After Stephen Smith.)

down to the bones. After the bones are divided, the hood is brought over the stump and sutured, leaving the drainage at the upper part of the posterior incision.

In very emaciated subjects, to forestall the liability of sloughing in the flaps, the first circular cut should go directly through all the tissues down to the bones, and the perpendicular incision along the fibula also down to this bone. All the tissues should then be lifted closely from the periosteum and interosseous membrane, forming a solid flap, reflected up to the point at which the bones are to be divided. Estes advises as best adapted for artificial support double lateral skin and muscle flaps for the leg.

The time to apply an artificial limb is just as soon after an amputation as it can be borne. Waiting means only a loss of time, and causes the stump to become enervated from want of use.

If amputation is done for malignant disease, it is better to wait longer in order to see if there will be a recurrence of the neoplasm.

When the line of amputation approaches nearer than three inches from the upper articular surface of the tibia, a complete disarticulation at the knee should be performed. At or below this point the upper portion of the bone should be preserved, and the fibula exsected. After recovery from the operation it will be found that the tibia is flexed upon the femur, so that, in the adjustment of an artificial limb, the chief pressure may be comfortably borne upon the normal tissues in front of the patella and the tuberosity of the tibia. The greater pressure in any

prothetic apparatus used after amputation, at or above the knee, falls upon the ischio-perineal region.*

Knee Joint.—First Method—Modified Circular Skin Flap.—About three inches below the patella make a circular sweep around the leg, dividing the skin and fascia. Join this by a perpendicular incision in the middle line of the posterior aspect of the limb, extending through the skin and fascia, and at least as high as to the level of the top of the patella. Dissect the skin back carefully, keeping close to the anterior surface of the patella, as the skin over this bone is usually very thin. It is not necessary to dissect the cuff as high on the lateral and posterior aspects as in front, since the anterior incision is made to allow

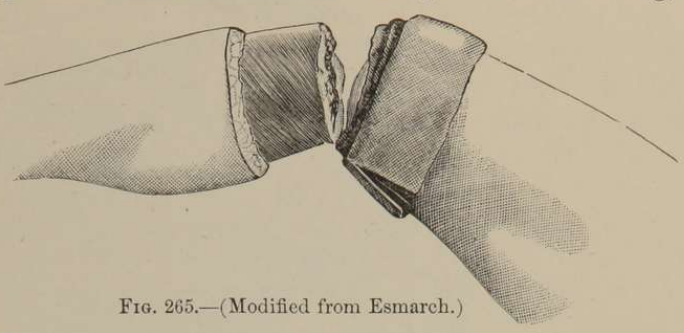

Fig. 265.—(Modified from Esmarch.)



Fig. 266.—(After Esmarch.)

* The older operations, which consisted in making a long and a short flap on opposite sides of the leg, are now fallen into general disuse. They are the methods of Teale, Lee, Sedillot, and others.

Method of Teale—Long and Short Rectangular Flaps.—The long flap, folding over the end of the bone, is formed of parts generally devoid of large blood vessels and nerves, which structures are left in the short flap. The size of the long flap is determined by the circumference of the limb at the place of amputation, its length and breadth being each equal to half the circumference of the limb at this point. The short flap is one fourth as long as the other. The incisions and stump, after Teale's method, are shown in Fig. 267.

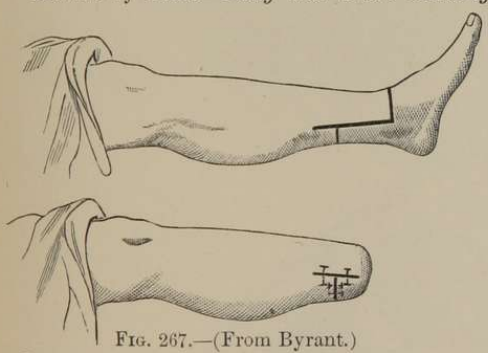

Fig. 267.—(From Byrant.)

Sedillot's Method—Long Fibular, Short Tibial, Flap.—Opposite the point at which the bones are to be divided insert a long, thin amputating knife, the point of which shall graze the spine of the tibia and the outer surface of the fibula, and come out through the outer aspect of the calf. Cut downward close to the bones, and make a long, rounded flap. The short flap is made by an incision with a slight downward convexity (Fig. 268).

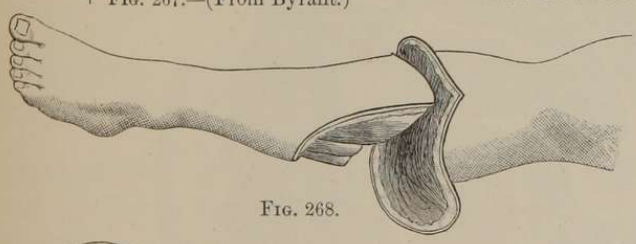

Fig. 268.

Lee's Method.—The length of the flaps is determined as in Teale's amputation. The long flap is posterior, and includes the skin and sural muscles. The deep muscles and the vessels are divided squarely at the base of the flap (Fig. 269).

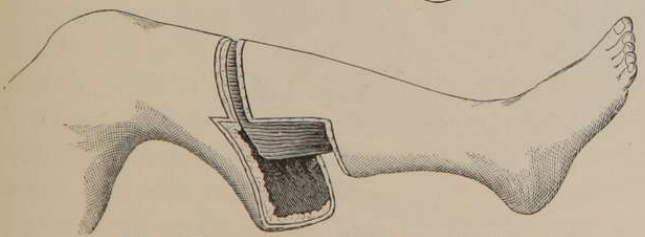

Fig. 269.—(Ashhurst's "Encyclopædia.")

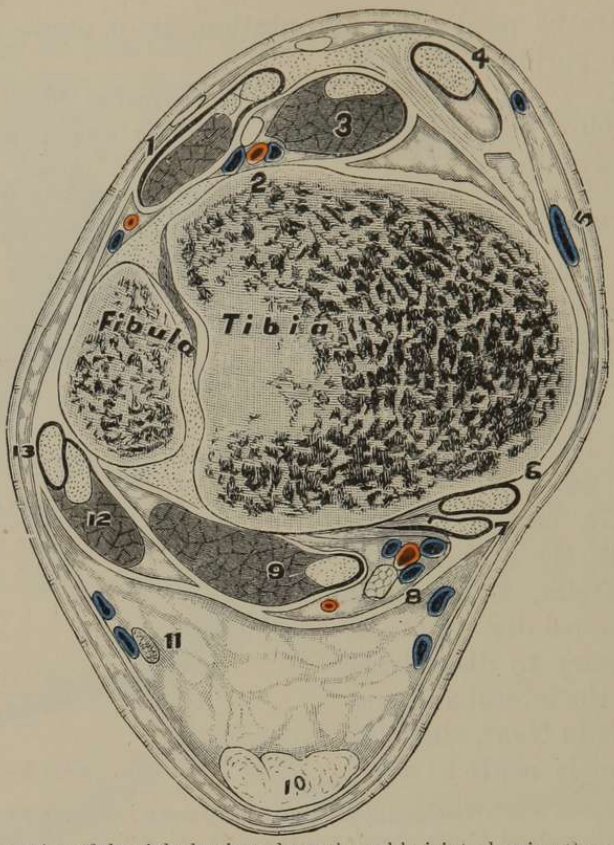

FIG. 270.—Transverse section of the right leg just above the ankle joint, showing the relation of the parts on the plane of section through the malleoli in Syme's, Pirogoff's, Le Fort's, Gunther's, and Bruns's amputations. Looking at the surface nearest the body. 1, Extensor longus digitorum. 2, Anterior tibial vessels and nerve. 3, Extensor proprius pollicis. 4, Tibialis anticus. 5, Internal saphena vein. 6, Tibialis posticus. 7, Flexor longus digitorum. 8, Posterior tibial artery, veins, and nerve. 9, Flexor longus pollicis. 10, Tendo Achillis. 11, External cutaneous nerves. 12, Peroneus brevis. 13, Peroneus longus.

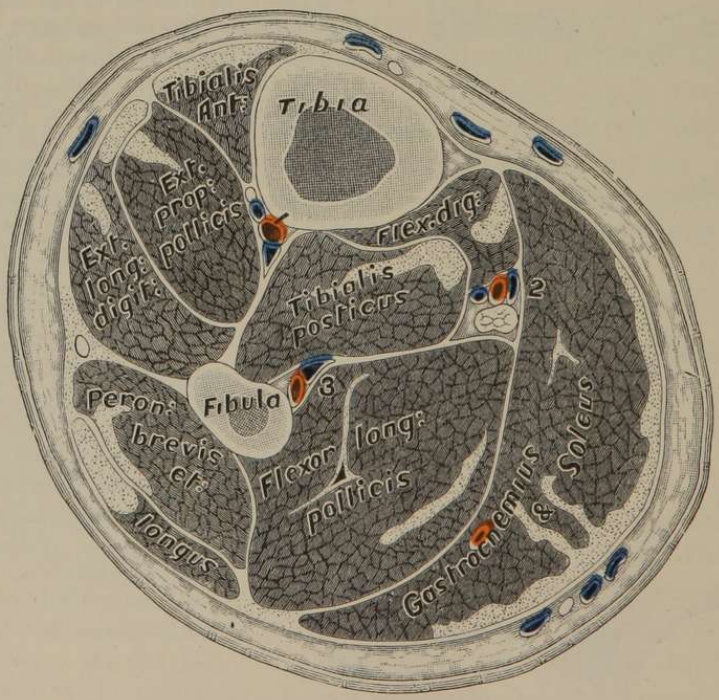

FIG. 271.—Section through lower third of right leg. Looking toward the center. 1, Anterior tibial nerve, artery, and veins. 2, Posterior tibial artery, veins, and nerve. 3, Peroneal artery and veins.

of the removal of the patella and dissection of the synovial sac just above it. Divide the tendon of the quadriceps at the upper limit of the patella, turn this down, cut the lateral ligaments and capsule along the edges of the condyles of the femur, flex the leg strongly on the thigh, divide the crucial ligaments, and, as soon as the posterior ligament of Winslow is exposed, introduce a long knife and remove the leg by cutting squarely through the soft tissues at the back of the articulation. A cloth retractor is now applied and a slice of bone

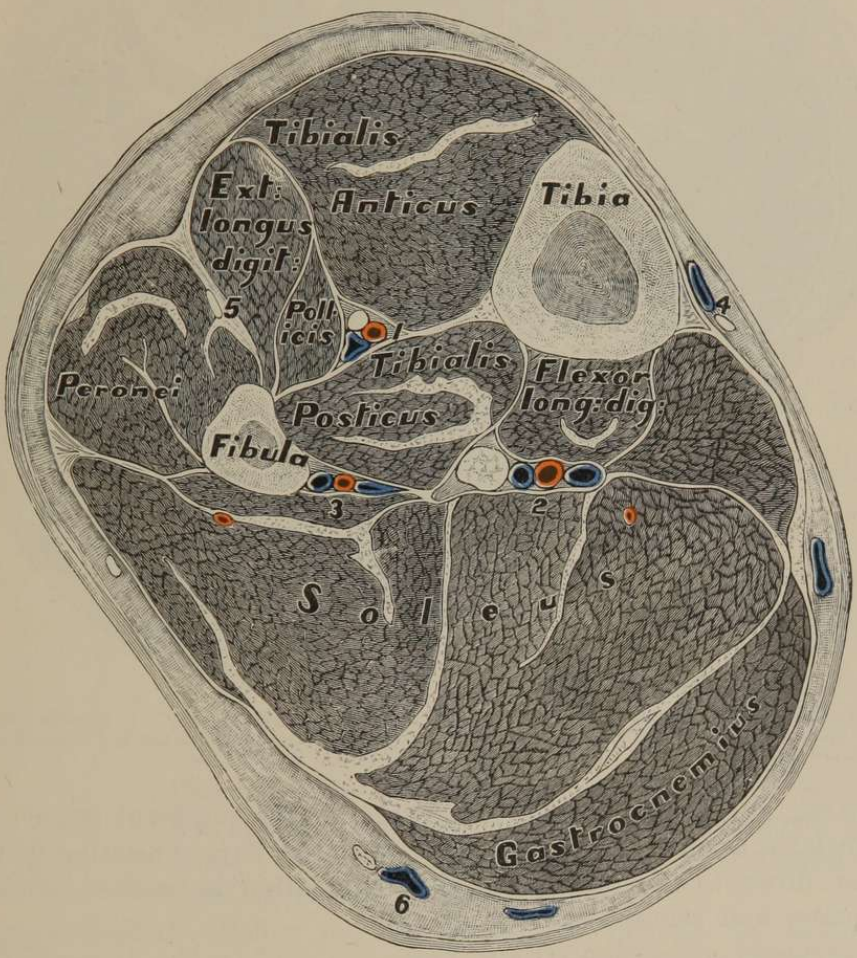

Fig. 272.—Section through the middle of the right leg. Looking from below upward. 1, Anterior tibial artery, veins, and nerve. 2, Posterior tibial artery, veins, and nerve. 3, Peroneal artery and veins. 4, Long saphena vein and nerve. 5, Musculo-cutaneous nerve. 6, Short saphena vein and nerve.

removed with the saw, leaving a smooth surface. Should the articular end of the femur be diseased, the section may be made high enough to remove this, provided the saw does not enter the medullary canal. With the cutting-forceps round off the sharp edges of bone, tie the vessels, and close the flap as in Fig. 266.

Second Method (*Operation of Prof. Stephen Smith*).—With a large scalpel commence an incision about an inch below the tubercle of the tibia, and cut to the bone; carry it downward and forward beyond the curve of the side of the leg, thence inward and backward to the middle

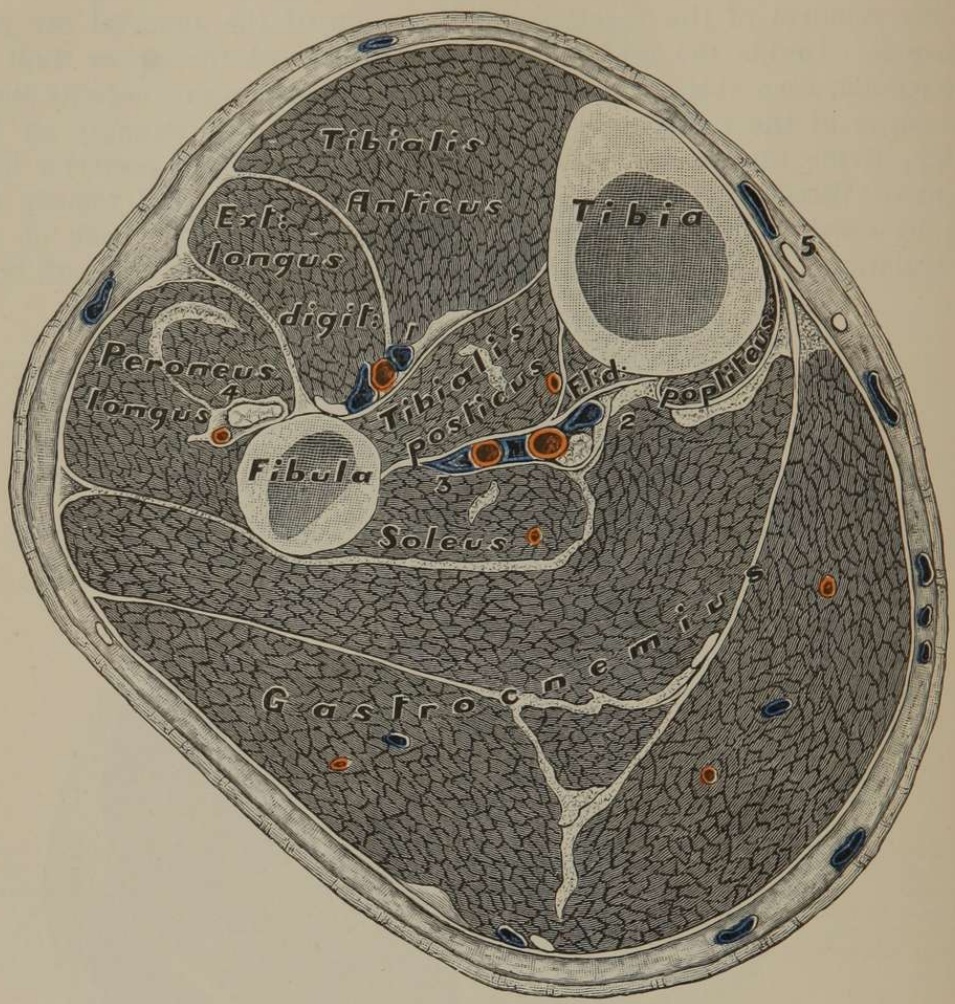

Fig. 273.—Section through upper third of right leg. Surface nearest the body. 1, Anterior tibial vessels and nerve. 2, Posterior ditto. 3, Peroneal vessels. 4, Musculo-cutaneous nerve. 5, Internal saphena vein and nerve.

of the leg, thence upward to the middle of the popliteal space; repeat this incision upon the opposite side; raise the flap, consisting of all the tissues, down to the bone until the articulation is reached, divide the ligaments, and remove the leg as in the previous operation (Fig. 274). The flap should be lifted from the patella, and this bone removed.

"Care should be taken that the incision is inclined moderately forward down to the curve of the side of the leg, to secure ample covering for the condyles, and that upon the internal aspect it should have additional fullness for the purpose of insuring sufficient flap for the internal or larger condyle" (Smith).*

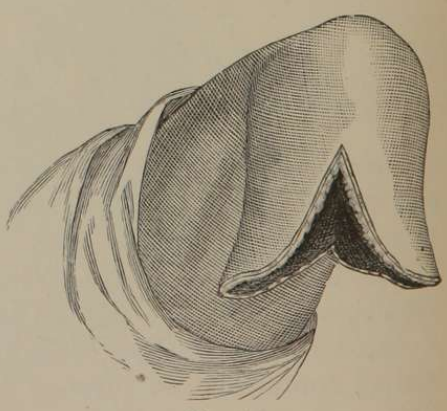

Fig. 274.

* The method of Carden—namely, long anterior skin-flap, and the short posterior skin and muscular flap, made by the long knife carried through the joint—is inferior in every respect to

After the flaps are stitched the drainage-tube makes its exit through the upper posterior angle of the wound.

When in amputation near the knee the femur is the seat of osteomyelitis, the indications are to thoroughly cleanse the canal by means of a long Volkmann's spoon and irrigate with sublimate solution; introduce a long drainage-tube the full length of the canal and bring this out through the flap exactly in line with the axis of the canal (Fig. 275).

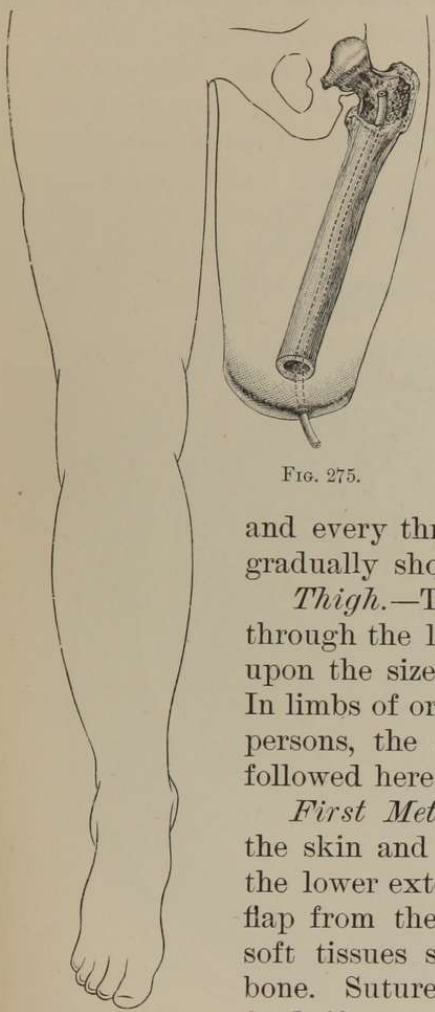

Fig. 275.

In this way the danger of a higher amputation is avoided and a longer stump secured. In two instances of amputation just above the knee, after exsection of this joint in which osteomyelitis occurred in the femur, I carried out this practice successfully.

Irrigation through the tube should be practiced about the seventh day and every three or four days after this, and the tube gradually shortened.

Thigh.—The method to be selected in amputations through the lower two thirds of the thigh will depend upon the size of the member at the point of election. In limbs of ordinary size, and particularly in emaciated persons, the operation advised in the arm should be followed here.

First Method.—Make a circular incision through the skin and fascia, joined by a perpendicular cut on the lower external aspect of the limb. Dissect up the flap from the muscles, and divide all the remaining soft tissues squarely at the point of section of the bone. Suture the flap, and drain from the outer upper (and, if necessary, lower) angle.

Second Method.—Below the line of section through the femur, at a distance sufficient to furnish an ample flap, by a circular incision divide the integument down to the muscles, allow the skin to retract, and at the line of retraction divide the remaining soft tissues down to the bone.

either of the foregoing operations. Carden recommended section through the condyles. Gritti introduced an osteoplastic modification by making a long rectangular skin-flap from the front of the knee and leg, which is dissected up deeply, lifting the patella in the flap. Behind, a short flap is made similar to that in *Carden's* method. Section is made through the bone about an inch above the tip of the internal condyle, and the articular surface of the patella is then sawn off. This procedure may be best accomplished by grasping the flap with the left hand and stretching it over the knuckles, so that the articular surface of the patella looks directly upward, where it is fixed quite immovably. As the flaps are adjusted, the sawn surface of this bone is brought into contact with that of the femur. Some operators secure it here by transfixing with an ivory pin. The whole procedure is not only difficult and tedious, but wholly unnecessary.

On the anterior and external aspect of the thigh, by a perpendicular incision extending as high as the point of section of the bone, divide everything to the bone, and from the periosteum, with a dry dissector, lift the solid flap. Apply the cloth retractor and saw through the bone. As the stump is placed in an elevated position, with the thigh also

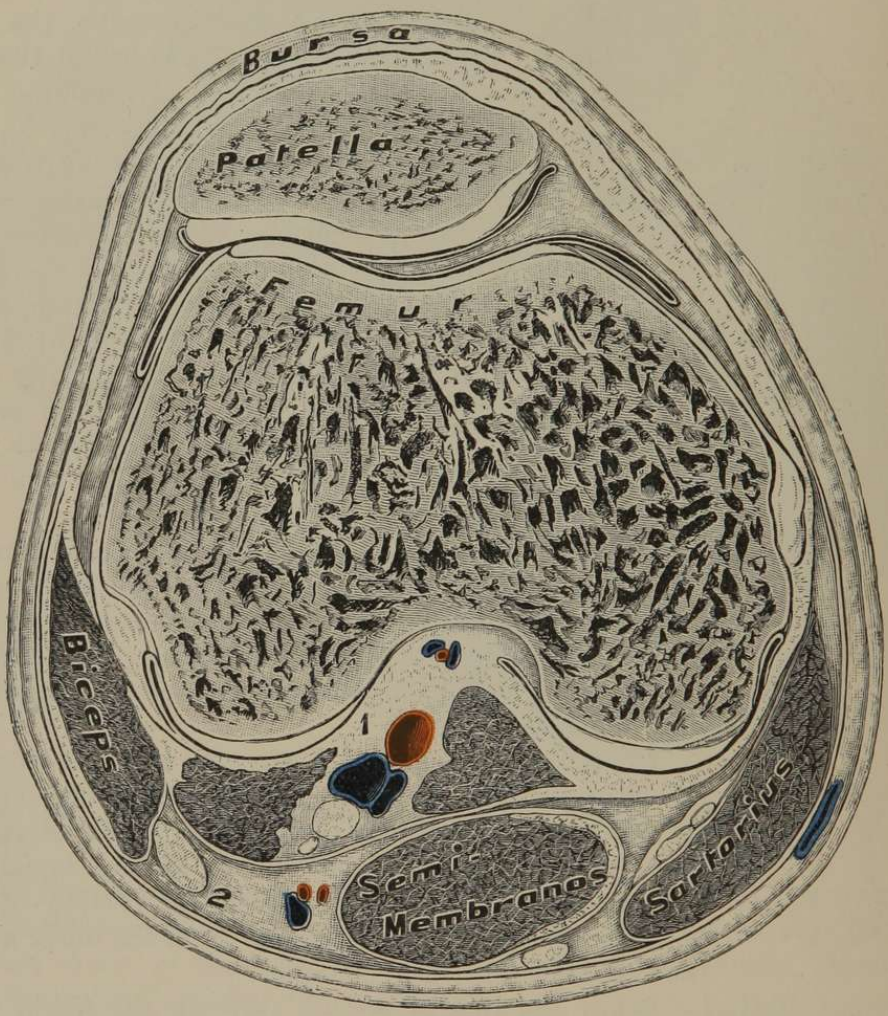

FIG. 276.—Section through the right femur at the condyles and at the middle of the patella. Looking at the central surface as exposed after amputation at this point. 1, Popliteal artery, vein, and internal popliteal nerve. 2, External popliteal or peroneal nerve. The capsule and the synovial cavities are admirably shown, as well as the *bursa mucosa patellæ*.

abducted and rotated outward, the drainage is naturally at the upper angle of the perpendicular incision.

*At the Hip Joint.**—Disarticulation at the hip joint is by far the most formidable in the list of amputations. In 1881 Prof. John Ash-

* At Bardstown, Ky., in August, 1806, Dr. Walter Brashear amputated at the hip in a negro lad, seventeen years of age, on account of a severe fracture of the femur and laceration of the soft parts. A circular incision was made, the muscles divided well below the hip joint, and the vessels secured as the operation progressed. Then a longitudinal incision along the outer side of the limb exposed the remainder of the bone, which, being freed from its muscular attachments, was disarticulated at the socket (Prof. D. W. Yandell, "American Practitioner and News," 1890). Dieffenbach's name has been prominently associated with this operation among surgeons, but

hurst, Jr., wrote: "The removal of the lower limb at the coxo-femoral articulation may be properly regarded as the gravest operation that the surgeon is ever called upon to perform, and it is only within a comparatively recent period that it has been accepted as a justifiable procedure. The most pressing risk is that of hæmorrhage."

In 1890 I applied for the first time, and with success, in an amputation at the hip joint, the method which I had used more than a year previous in amputation at the shoulder joint. Since that date I have performed the operation seven times, and it has been done in a number of instances by other operators. The method is as follows:

The patient should be placed with the sacrum resting upon the corner of the operating table, the sound limb and arms being wrapped with cotton batting and thoroughly protected from unnecessary loss of heat.

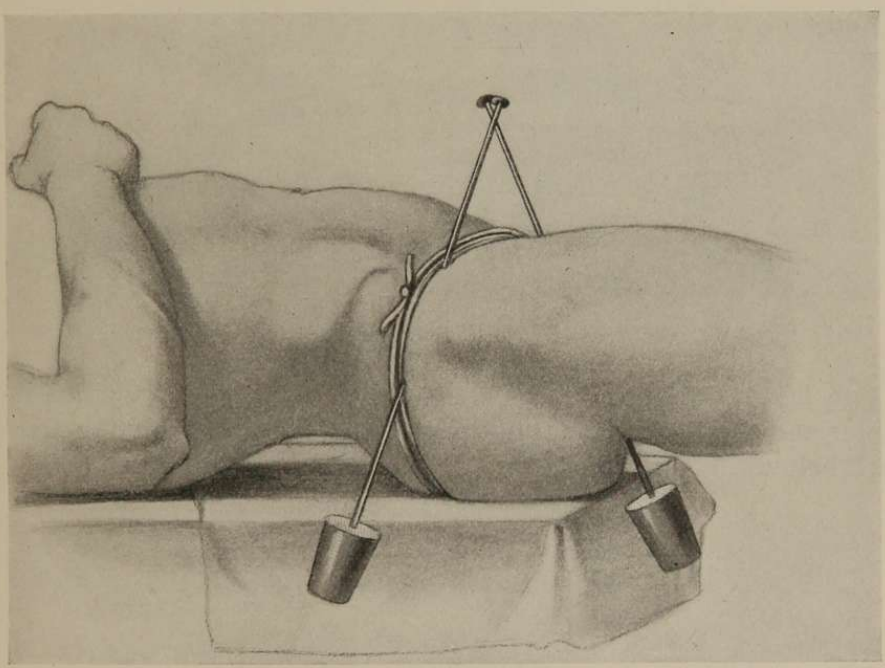

Fig. 277.—Hip-joint amputation. Pins and rubber-tube tourniquet in position. The Esmarch bandage has been removed.

The limb to be amputated should be emptied of blood by elevation of the foot and by the application of the Esmarch bandage, commencing at the toes. Under certain circumstances, the bandage can only be partially applied. When a tumor exists, or when septic infiltration is present, pressure should be exercised only to within five inches of the diseased portion for fear of driving the septic material into the vessels. After injuries with great destruction—crushing or pulpefaction—one must generally trust to elevation, as the Esmarch bandage can not always be applied. While the member is elevated, and before the Esmarch is removed, the rubber-tubing constrictor is applied. The object of this constriction is the absolute occlusion of every vessel above the

Dieffenbach did not take his degree in medicine until 1822, sixteen years after the pioneer Kentuckian had performed his operation, which was the first hip-joint amputation in the United States.

level of the hip joint, permitting the disarticulation to be completed and the vessels secured without hæmorrhage and before the tourniquet is removed. To prevent any possibility of the tourniquet slipping, I em-

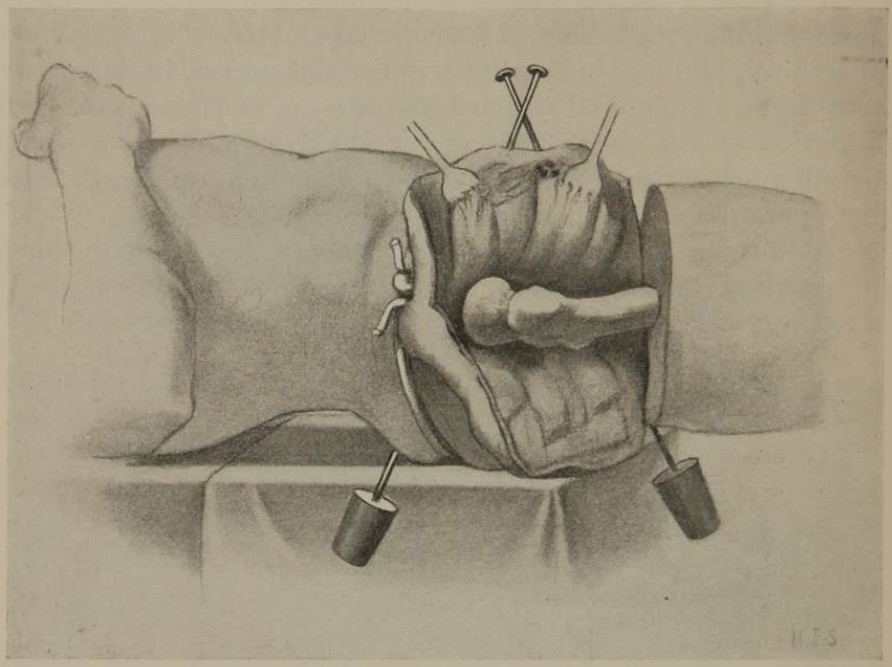

Fig. 278.—The same, showing the soft parts dissected from the bone and the capsule exposed.

ploy two large steel needles or skewers, three sixteenths of an inch in diameter and ten inches long, one of which is introduced one fourth of an inch below the anterior superior spine of the ilium and slightly to the

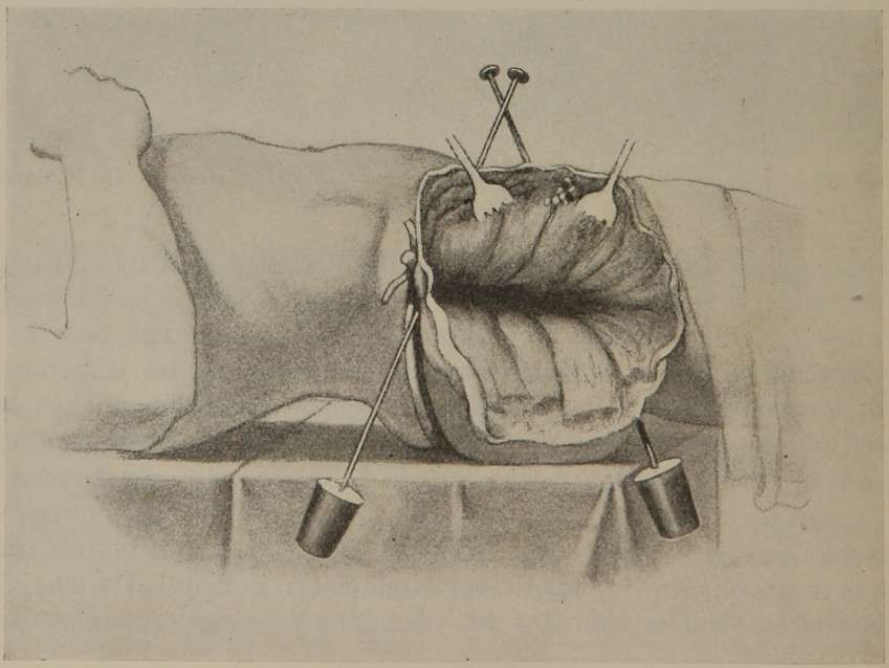

Fig. 279.—The same, with the disarticulation complete. Constrictor still in position.

inner side of this prominence, and is made to traverse superficially for about three inches the muscles and fascia on the outer side of the hip, emerging on a level with the point of entrance (Fig. 277). The point of the second needle is thrust through the skin and tendon of origin of the adductor longus muscle half an inch below the crotch, the point emerging an inch below the tuber ischii. The points should be shielded at once with a cork to prevent injury to the hands of the operator. No vessels are endangered by these skewers. A mat or compress of sterile gauze, about two inches thick and four inches square, is laid over the femoral artery and vein as they cross the brim of the pelvis ; over this a piece of strong white-rubber tubing, half an inch in diameter when unstretched and long enough when in position to go five or six times around the thigh, is now wound very tightly around and above the fixation

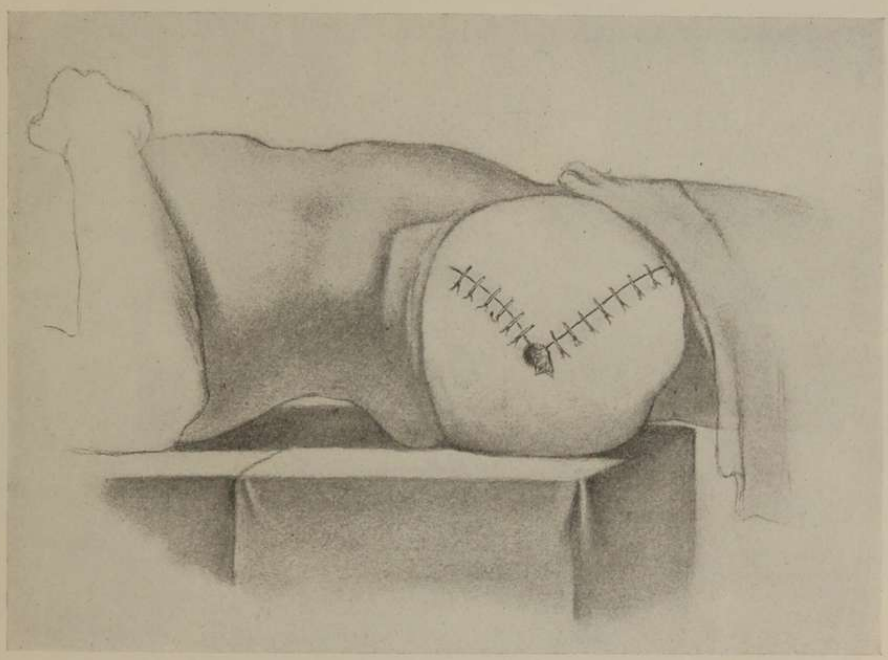

Fig. 280.—The operation completed

needles and tied. If the Esmarch bandage has been employed, it is now removed. Excepting the small quantity of blood between the limit of the Esmarch bandage and the constricting tube, the extremity is bloodless and will remain so.

In the formation of the flaps, the surgeon must be guided by the condition of the parts within the field of operation. When permissible, the following method seems ideal :

About six inches below the tourniquet a circular incision is made down to the muscles, and this is joined by a longitudinal incision commencing at the tourniquet and passing over the trochanter major. A cuff that includes everything down to the muscles is dissected off to near the level of the trochanter minor. At about this level, the remaining soft parts, together with the vessels, are divided squarely down to the bone by a circular cut (Fig. 278). At this stage of the operation the cen-

tral ends of the divided superficial and deep femoral veins as well as arteries are in plain view and should now be tied with good-sized catgut. This done, the disarticulation is rapidly completed by lifting the muscular insertions from the trochanters and digital fossa, keeping very close

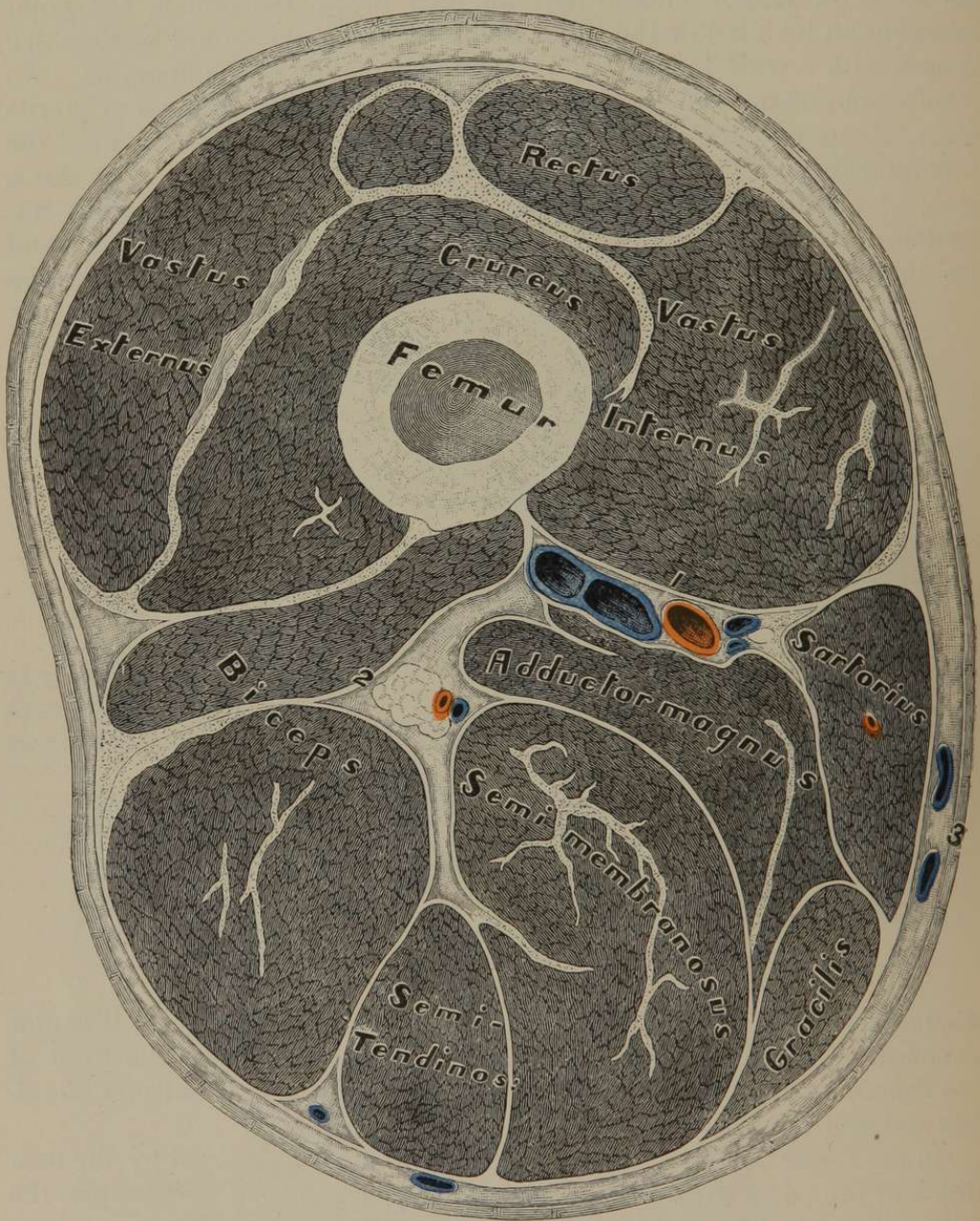

FIG. 281.—Section through right thigh at Hunter's canal. Looking at the surface attached to the body. 1, Femoral vessels and long saphenous nerve. 2, Great sciatic nerve and arteria comes. 3, Long saphena vein.

to the bone with knife or scissors and holding the soft parts away with retractors. The capsular ligament is now exposed and divided, and, by forcible elevation, adduction, and rotation of the femur, it is widely opened, the *ligamentum teres* ruptured, and the caput femoris dislocated (Fig. 278). If properly conducted up to this point, not a drop of blood

has escaped except that which was in the limb below the constrictor when this was applied. The remaining vessels which require the ligature should now be sought for and secured. They are, first, the *saphena vein*, which, on account of its proximity to the main trunk, should be tied; the *sciatic artery*, which will be found near the stump of the sciatic nerve; the *obturator*, which is situated between the stump of the

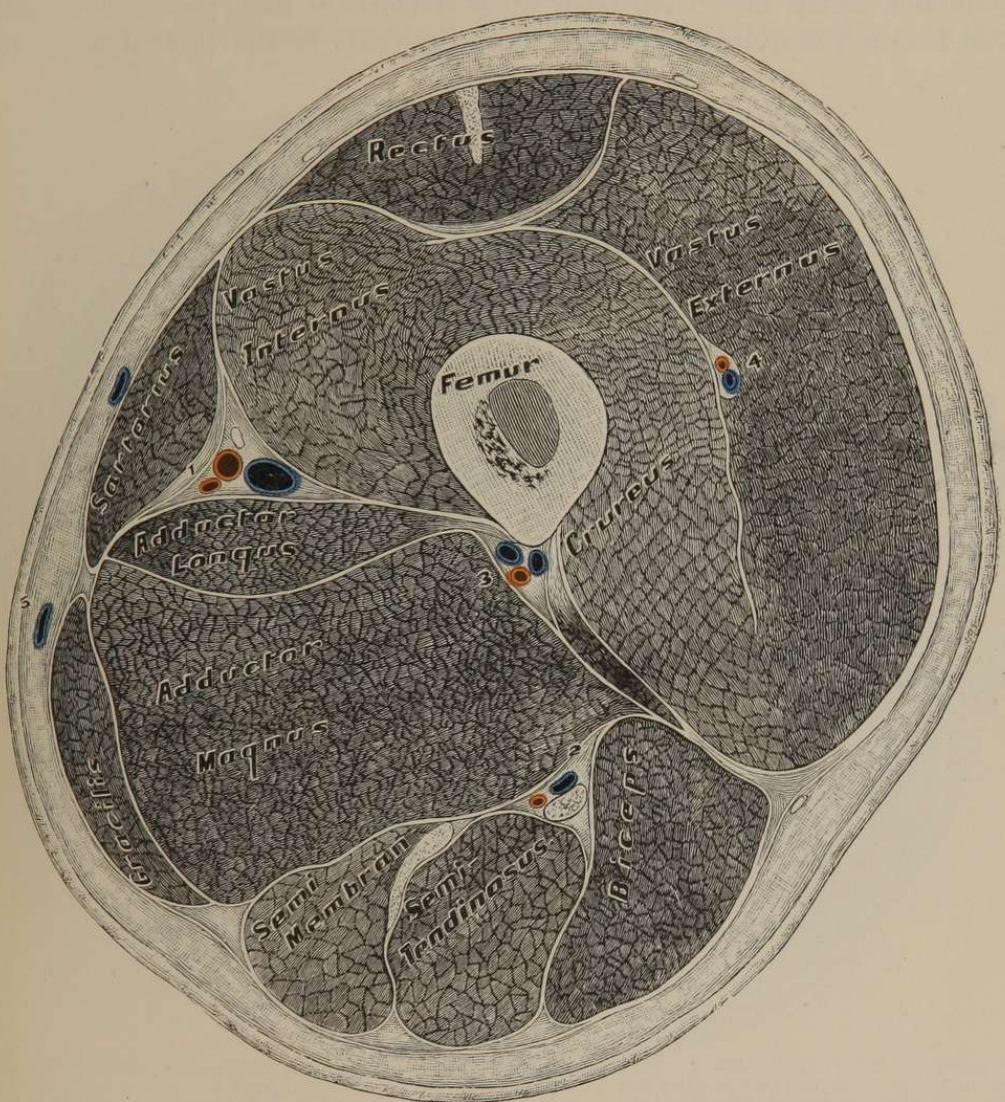

FIG. 282.—Section through left thigh at its middle. Looking at the surface attached to the body. 1, Superficial femoral artery, vein, and saphenous nerve. 2, Great sciatic nerve, and the arteria comes nervi ischiadici. 3, Terminal branch of profunda femoris. 4, Descending branch of external circumflex. 5, Long saphenous vein.

adductor brevis and magnus, usually about halfway from the center of the shaft of the femur to the inner side of the thigh, the vessel being on a level with the anterior surface of the femur; the *descending branches* of the *external circumflex*, two or three in number, usually found about an inch and a half outward and downward from the main femoral vessels beneath the rectus and in the substance of the cruræus and vastus externus. The *descending branches* of the *internal circumflex* are insignifi-

cant and are usually found on the level of the femoral vessels in the substance of the adductor longus and between it and the adductor brevis and pectineus (see Fig. 284).

In tying the larger femoral vessels, I make it a rule to dissect both the superficial and deep femoral stumps back from a half to three fourths of an inch so that I can apply the ligature behind any of their branches which may have been divided close to their points of origin, and I do not hesitate to include the large veins in the same ligature in

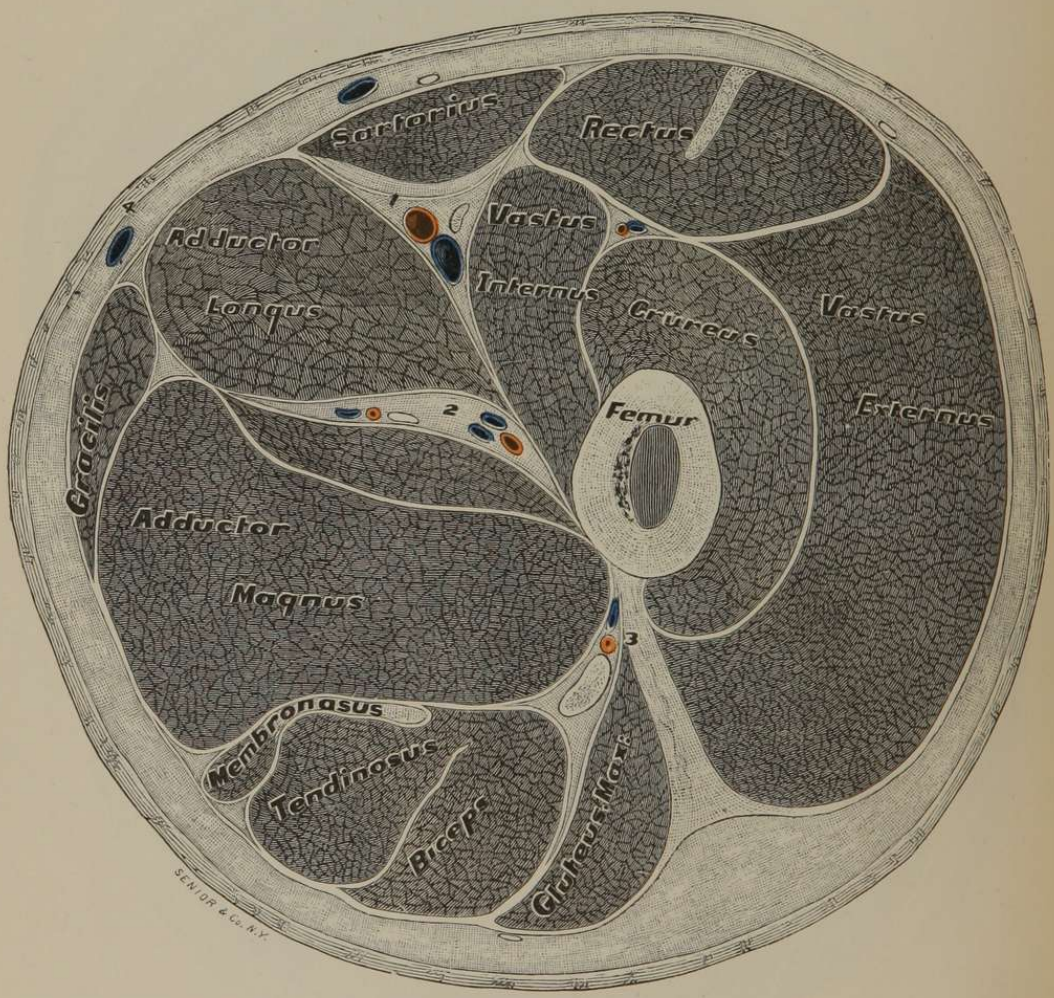

FIG. 283.—Section through left thigh in the upper third. 1, Superficial femoral artery, vein, and saphena nerve. 2, Deep femoral vessels; near by the obturator nerve and vessels. 3, Sciatic nerve and vessels.

order to save time. With the vessels I have mentioned quickly secured, there is really no necessity for even temporarily loosening the tourniquet. If the operator is not sure that he has found and securely placed the ligatures upon these larger vessels, it is a simple matter to loosen slowly the grasp of the tourniquet until the pulsation of the larger trunks is perceptible. No attention should be paid to the general oozing from the large muscular surfaces which have been divided. If every oozing point were ligatured, from half an hour to an hour would be consumed in securing a dry wound in the majority of instances. In order to hasten

the operation and stop the oozing, I introduce a snug packing of sterile iodoform gauze ribbon into the cavity of the acetabulum and the space between the muscles from which the bone has been removed, leaving one end of the ribbon to pass out between the flaps for the purpose of its removal. With a long, half-curved Hagedorn needle, armed with good-sized catgut, deep sutures are passed through the stumps of the divided muscles in such a way that large masses of muscle are brought tightly together when these sutures are tied, taking two or three inches into the

Fig. 284.—Transverse section of left thigh through lesser trochanter. Looking from below upward. 1, Saphenous vein. 2, Superficial femoral vein and artery. 3, Profunda femoral vein and artery, anterior crural nerve between the two arteries. 4, Obturator nerve and artery. 5, Sciatic nerve and artery.

grasp of each suture. The needle is not passed in the proximity of the large vessels or the sciatic nerve. This effectively and rapidly controls all oozing. Nothing remains but to close the flap with silkworm-gut sutures, dry and cleanse it off thoroughly, seal it with collodion in its entire extent to prevent any infection from the genital or anal region, apply a large, loose dressing of iodoform and then sterile gauze, and a tight bandage over the first light dressing. The pins are then removed and the remainder of the dressing completed. Preliminary pressure of the light dressing prevents oozing and the wound remains dry.

When, from destruction of the parts, by accident or disease, or by the proximity of a neoplasm, this ideal method is not practicable, any modification may be employed, preference being given to the incision which keeps farthest from the tumor and gives the healthiest flaps. When there is not sufficient material to cover the stump, it is even safer to err on the side of an unclosed wound and trust to granulation or grafting for ultimate closure.

In the first two operations I did, I divided the femur on a line with the incision through the muscles, tying the vessels, removing the tourniquet, and then dissecting out the upper fragment of the femur. I found it exceedingly difficult to disarticulate the head of the bone, and, at the suggestion of the late Dr. J. B. Murdock, of Pittsburgh, Pa., who witnessed the operation, I have since left the femur intact in order to facilitate the disarticulation.

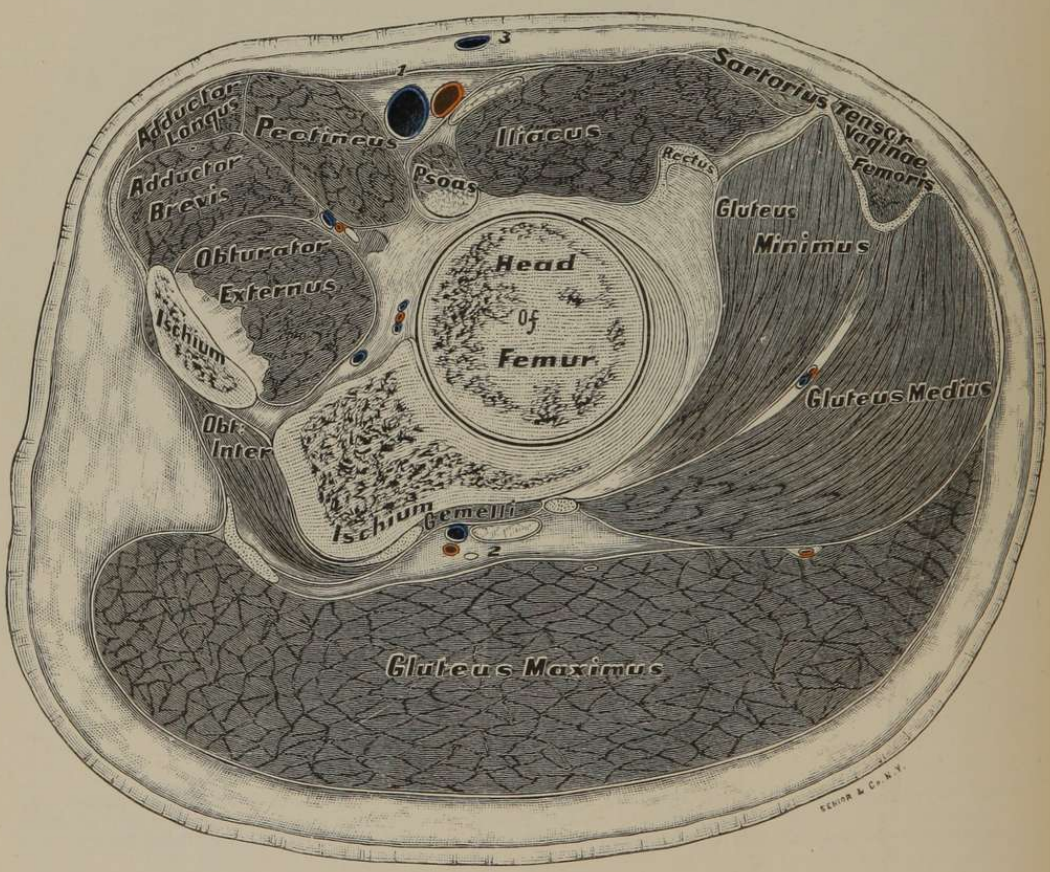

Fig. 285.—Section through the left hip. Looking from below upward. Reduced from life size. 1, Femoral vein, artery, and crural nerve in order from within outward. 2, Great sciatic nerve, artery, and vein. 3, Epigastric vein. 4, Vessels to acetabulum.

In regard to the steel pins, Prof. Deaver, of Philadelphia, Pa., has held the rubber tourniquet in place without the pins, substituting a tight strip of roller bandage underneath the tube in front and behind, an assistant making strong traction upward.

Prof. Emory Lanphear, of St. Louis, Mo., succeeded in doing the operation with only one, the outer pin, in position.

The fixation pins are not expensive, can easily be obtained in any part of the country, and they obviate every risk of hæmorrhage. I see no reason for failing to employ them as directed.

I have the histories of sixty-nine cases of amputation at the hip joint in which this method of controlling hæmorrhage was employed. There were fifty-six males and thirteen females, of which eleven died, a death rate of 15·9 per cent.

Dr. John F. Erdmann, in the "Annals of Surgery," September, 1895, says that from January, 1884, to January, 1895, there were eighteen hip-joint amputations done in Bellevue, Roosevelt, St. Luke's, Mount Sinai, Chambers Street, German, and Presbyterian Hospitals, with eight deaths, a mortality of 44·4 per cent. If from this list are eliminated seven cases done by my method—all of which recovered—it leaves the mortality ratio by other methods in the hospitals of New York 72·7 per cent.

I would not imply that such a death rate as this would follow any other method of operation, for I know that in the hands of careful and thorough operators much better results would follow. I need cite no more than the brilliant results of Estes, of Bethlehem, Pa., in his series of successful cases, chiefly after accident and done by tying all bleeding points as the dissection was carried on, of McBurney, with abdominal section and direct digital compression of the aorta, and Tilden Brown, with his ingenious clamp, etc. But I insist that this method of hæmostasis is so simple, so safe, so universally applicable, that it removes from the operation every possible element of danger as far as hæmorrhage is concerned.

	Operator.	Date.	Age.	Sex.	Diagnosis.	Result.	Remarks.
1	John A. Wyeth, New York.	Feb., 1890	39	Male.	Osteosarcoma.	Recovered.	At first operation femur was divided at level of lesser trochanter; sixteen days later head of the bone was enucleated.
2	John A. Wyeth, New York.	Feb., 1890	34	Male.	Neurosarcoma of internal popliteal nerve.	Recovered.	The tumor of the nerve was extirpated in February, 1888; recurred, and limb was amputated at lower third of thigh in October, 1888; recurred again, and amputation at hip joint was performed.
3	John A. Wyeth, New York.	1892	17	Female.	Osteosarcoma of lower end of femur; amputation and recurrence in stump.	Recovered.	Amputation through lower third of femur was performed by Dr. Allen, of Cleveland, in February, 1892.
4	John A. Wyeth, New York.	Nov., 1893	28	Male.	Chronic hip-joint disease.	Recovered.	The femur was so firmly anchylosed to the ilium that force could not break them apart, requiring a chisel and hammer to effect separation.
5	John A. Wyeth, New York.	Aug., 1894	19	Male.	Sarcoma of lower third of femur.	Died.	Rallied well from operation, but twenty-six hours after, his pulse became rapid and weak, suggesting shock. The surgeon in whose charge I had left the case injected two pints of hot saline solution, but the patient died forty hours after operation.

	Operator.	Date.	Age.	Sex.	Diagnosis.	Result.	Remarks.
6	John A. Wyeth, New York.	Oct., 1895	20	Male.	Osteosarcoma of femur.	Recovered.	No hæmorrhage. Discharged cured.
7	John A. Wyeth, New York. Operation by J. A. Bodine.	July, 1895	18	Male.	Osteosarcoma of femur.	Recovered.	No hæmorrhage. Nothing of special interest.
8	Sam. H. Pinkerton.	1892	17	Male.	Tuberculous ostitis of femur.	Recovered.	
9	Sam. H. Pinkerton, Salt Lake City.	1892	10	Male.	Tuberculous ostitis of femur.	Recovered.	
10	Sam. H. Pinkerton, Salt Lake City.	1892	42	Male.	Extensive necrosis of femur.	Recovered.	
11	Sam. H. Pinkerton, Salt Lake City.	1892	43	Male.	Extensive necrosis of femur.	Died.	Death twelve hours after operation from shock; no hæmorrhage.
12	Sam. H. Pinkerton.	1892	17	Male.	Ostitis of femur.	Recovered.	
13	Sam. H. Pinkerton.	1892	6	Male.	Compound comminuted gunshot fracture of femur.	Died.	Two hours after operation, death from shock.
14	A. M. Phelps, New York city.	Dec., 1891	..	Male.	Long-standing destructive osteoarthritis.	Recovered.	
15	A. M. Phelps.	1892	..	Male.	Osteomyelitis of entire femur.	Died.	Death from exhaustion twelve hours after operation; condition of patient so bad that operation contra-advised, but performed at urgent request of parents.
16	A. M. Phelps.	1891	55	Male.	Osteosarcoma.	Recovered.	
17	A. M. Phelps.	1895	16	Male.	Osteosarcoma of knee.	Recovered.	
18	A. M. Phelps.	....	11	Male.	Osteomyelitis.	Recovered.	
19	Emory Lanphear.	1890	9	Male.	Osteomyelitis of femur.	Recovered.	"Wyeth's bloodless method, by which failure to control hæmorrhage seems to me to be impossible."
20	Emory Lanphear.	1892	15	Male.	Osteomyelitis of femur.	Recovered.	
21	Emory Lanphear.	1893	28	Male.	Osteomyelitis of femur.	Recovered.	
22	Emory Lanphear.	1892	28	Female.	Osteoma of femur penetrating sciatic nerve.	Recovered.	
23	H. O. Walker.	1892	14	Male.	Osteosarcoma.	Recovered.	"We have in this a safe and reliable method for controlling hæmorrhage which, in my judgment, is superior to any yet offered."
24	H. O. Walker.	1893	21	Male.	Chronic hip-joint disease.	Recovered.	
25	H. O. Walker.	1893	young man.		Chronic hip-joint disease.	Died.	Death from exhaustion in four hours; no hæmorrhage.
26	C. B. Nancrede.	Nov., 1892	32	Male.	Osteosarcoma.	Recovered.	
27	C. B. Nancrede.	1893	31	Male.	Osteomyelitis of femur.	Recovered.	
28	John B. Deaver.	1890	20	Female.	Chronic osteoarthritis.	Recovered.	
29	John B. Deaver.	1893	20	Male.	Osteomyelitis of femur.	Recovered.	
30	J. Ewing Mears.	1892	10	Male.	Chronic osteoarthritis of hip.	Recovered.	
31	A. E. Mallock.	1892	30	Male.	Chronic osteoarthritis of hip.	Recovered.	Operation lasted thirty-five minutes.

	Operator.	Date.	Age.	Sex.	Diagnosis.	Result.	Remarks.
32	R. L. Swan.	1892	19	Female.	Chronic osteoarthritis of hip.	Recovered.	
33	G. A. Baxter.	1891	17	Male.	Railroad pulpefaction of right foot, leg, and left lower extremity as high as middle of thigh.	Died.	Patient rallied well; four hours later raised himself in bed to reach a glass of water, and instantly expired. No bleeding after operation.
34	W. B. Johnston.	1892	39	Male.	Railroad pulpefaction of lower extremity as high as middle of thigh.	Died.	Death ninety hours after operation from shock and exhaustion. "There was not one drop of arterial blood, and only a slight venous oozing from the muscular tissue."
35	J. D. Thomas.	1891	18	Male.	Femoral vessels divided in Scarpa's triangle by red-hot bar of iron; impending gangrene.	Died.	Great hæmorrhage from the accident. On seventh day after injury, amputation; death thirty-six hours later. No bleeding after operation.
36	Wm. F. Fluhrer.	May, 1890	18	Female.	Osteosarcoma of femur.	Recovered.	"As little blood was lost as in an ordinary amputation at the middle of the thigh."
37	Charles McBurney.	May, 1890	34	Male.	Osteosarcoma.	Recovered.	"No other appliance that had been suggested for the purpose could in any way compare in utility with that of Dr. Wyeth's."
38	Frank Hartley.	Mar., 1892	26	Female.	Osteosarcoma.	Recovered.	
39	Merrill Ricketts.	Feb., 1893	23	Female.	Osteosarcoma.	Recovered.	"The operation was entirely bloodless."
40	C. A. White.	May, 1891	23	Male.	Osteosarcoma.	Recovered.	Patient was up and about after operation, but on the twenty-seventh day was seized with pneumonia, and died five days later.
41	W. W. Keen.	Jan., 1892	30	Female.	Osteosarcoma.	Recovered.	Patient five months pregnant at time of operation. "It was reserved for an American surgeon to devise what is undoubtedly the best method, and in fact which I think we can now call the only method, of hæmostasis in amputation at the hip joint."
42	M. J. Ahern.	1892	22	Male.	Osteosarcoma.	Recovered.	
43	J. B. Murdoch.	Feb., 1892	17	Male.	Osteosarcoma.	Died.	Death from shock twenty-two hours after operation. "I believe this method to be the best, and the one destined to supersede all other methods for the temporary arrest of hæmorrhage."
44	J. McFadden Gaston.	Nov., 1890	..	Male.	Osteosarcoma.	Died.	Death on twenty-sixth day from septicæmia. "There was absolutely no trouble from hæmorrhage, and I feel satisfied that with this process all bleeding may be prevented in amputation at the hip joint."
45	A. J. McCosh.	1892	27	Male.	Osteosarcoma.	Recovered.	
46	F. W. Parham.	Oct., 1893	3	Male.	Osteosarcoma.	Recovered.	

	Operator.	Date.	Age.	Sex.	Diagnosis.	Result.	Remarks.
47	J. M. Holloway.	Nov., 1892	27	Male.	Osteosarcoma.	Recovered.	Patient was discharged from hospital on tenth day and went to his home, a distance of seventy miles, on the twelfth day.
48	R. T. Morris, Texas.	April, 1894	19	Male.	"Tumor" of thigh.	Died.	Died eleven days after operation from tubercular peritonitis; cause of death proved by autopsy. "While making the skin incisions it was noticed that the limb was not completely exsanguinated, and the tourniquet was retightened, after which no bleeding resulted."
49	H. H. Vinke.	Aug., 1894	16	Female.	Sarcoma of thigh.	Recovered.	Used crutches in seven weeks. "Absolutely no loss of blood. There is probably no method which commends itself for simplicity and effectiveness so much as Wyeth's."
50	J. S. Horsley.	Oct., 1894	36	Male, negro.	Recurring sarcoma of femur.	Recovered.	"No more blood was lost than in an amputation through the thigh. It remained for Dr. Wyeth to so perfect these methods as to make this amputation practically a bloodless operation."
51	George W. Miel.	Nov., 1894	41	Male.	Osteosarcoma of thigh.	Recovered.	"A very satisfactory means of controlling hæmorrhage."
52	F. Tilden Brown.	Dec., 1894	22	Male.	Osteosarcoma of triceps femoris.	Recovered.	"Hæmostatic effect all that could be desired."
53	S. B. Fowler.	1890	54	Male.	Traumatic osteitis of femur; bedridden for fifteen years.	Recovered.	Recovery without suppuration; no hæmorrhage. Patient now living (1896).
54	Robert Weir.	Jan., 1895	..	Male.	Sarcoma of femur.	Recovered.	No recurrence up to February, 1896.
55	F. W. Murray.	June, 1894	18	Male.	Sarcoma of femur.	Recovered.	Pins were by mistake too small; they bent and caused slight hæmorrhage.
56	C. K. Briddon.	June, 1894	23	Male.	Sarcoma of femur.	Recovered.	"So little blood was lost that the patient suffered scarcely at all from shock."
57	W. T. Bull.	May, 1895	5	Female.	Osteosarcoma of femur.	Recovered.	Primary union; time of operation, forty minutes.
58	Thomas R. Wright.	1895	..	Male.	Sarcoma of knee.	Recovered.	
59	Thomas R. Wright.	July, 1896	50	Male, negro.	Sarcoma of knee.	Recovered.	Lost comparatively no blood. Temperature 103° F. and pulse 120 before operation.
60	A. Schachner.	1895	55	Male.	Fracture of femur; gangrene.	Recovered.	First dressing six days after operation.
61	H. H. Grant.	1895	33	Female.	Chondroma with sarcomatous degeneration.	Recovered.	Enormous chondroma with sarcomatous degeneration; tumor weighed sixty-five pounds when removed. Operation lasted thirty-five minutes; bloodless except for some oozing. "Method leaves nothing to be desired."
62	Daniel Strock.	1894	35	Male.	Limb pulpefied.	Died.	Railway crush; limb pulpefied, including upper third of thigh; hæmorrhage entirely controlled; patient died of shock; patient bled profusely before admission to hospital.
63	W. R. Stewart.	1895	35	Male.	Sarcoma.	Recovered.	Was well November 19, 1896.

	Operator.	Date.	Age.	Sex.	Diagnosis.	Result.	Remarks.
64	Eugene Boise.	1895	21	Female.	Sarcoma.	Recovered.	No loss of blood; vessels nearly all tied before tubing was removed. "Method of amputation is all that could be desired."
65	D. C. Hawley.	1896	21	Male.	Sarcoma left femur, extending to within four inches of trochanter.	Recovered.	No blood was lost. Patient in bad condition at time of operation; fracture at femur had occurred before amputation. "Control of hæmorrhage perfect."
66	L. L. Shropshire.	1895	20	Male, negro.	Sarcoma lower middle third of left thigh.	Recovered.	Operation done in thirty minutes; not over one ounce of blood was lost. Patient left hospital in two weeks. Living and well October, 1896.
67	Howard Lilienthal.	1896	16	Male.	Chondro-sarcoma from trochanter down.	Recovered.	"Your method was employed to my great satisfaction."
68	W. W. Van Arsdale.	1896	13	Male.	Osteomyelitis.	Recovered.	Destruction of soft parts of thigh, with suppurative infection; patient was extremely septic.
69	T. D. Rushmore.	1896	14	Female.	Sarcoma of femur.	Recovered.	

An analysis of these sixty-nine cases as to the efficiency of this method of controlling hæmorrhage shows that it was perfectly satisfactory in every instance but two:

In Dr. Morris's case the first incision in the skin demonstrated that the constriction was not tight enough. This was corrected and the operation completed without bleeding.

In Dr. Murray's case the pins were not of sufficient strength and yielded to the pressure, causing slight hæmorrhage.

Of the eleven fatal cases, five had suffered extensive injury with hæmorrhage, and were profoundly in shock owing to pulpefaction of the limb and loss of blood.

In Dr. Baxter's case there was pulpefaction of the right foot and leg and of the entire left lower extremity as high as the middle of the thigh.

In Dr. Johnston's case the lower extremity was pulpefied as high as the middle of the thigh.

In Dr. Thomas's case the femoral artery had been divided in Scarpa's space and the hæmorrhage had been very profuse and prostrating.

In Dr. Strock's case the limb was pulpefied in a railway crush as high as the upper third of the thigh.

Dr. Pinkerton's case was one of compound comminuted gunshot fracture, the patient dying of shock.

The factor in these fatal cases was hæmorrhage before operation, but none occurred during or after the procedure. In none was employed the precautionary injection into the veins of normal salt solution at 110° F., which should be done prior to operation in every case in which shock has been wholly or in good part caused by hæmorrhage.

Of the other fatal cases, Dr. Murdock's died from shock twenty-two hours after the operation, as there was no other possible cause of death. Dr. Pinkerton's case of necrosis of the femur died in shock twelve hours after the operation. There was no hæmorrhage. Dr. Gaston's case died on the twenty-sixth day after the operation from *septicæmia*. Dr. Phelps's case of osteomyelitis was very much exhausted from prolonged sepsis, and died twelve hours after the operation. Dr. Walker's case was a similar one of chronic hip disease, and the patient died four hours after the operation. Dr. Morris's case died eleven days after the operation from tubercular peritonitis, as demonstrated at the autopsy.

My own fatal case died partly from shock, yet after the operation he was in better condition than any of my other patients. Twenty-six hours later, while I was absent from the city, my assistant, for what he took to be symptoms of shock coming on, injected two pints of hot saline solution. This patient has lost no blood. The quantity of blood forced out of the limb into the trunk in a patient otherwise plethoric threw more work upon the heart than it could accomplish.

In the forty cases of sarcoma for which amputation was done there were four deaths—10 per cent; in the twenty-two cases of inflammatory bone disease, three deaths—13·6 per cent.

The method of amputation at the hip joint just given has been tried for a sufficient number of times and by operators of varying experience to determine the success of the method. If for any reason it can not be applied, I would recommend the method of Estes, of gradual dissection, tying the vessels as the operation proceeds, making digital compression over the pubic rim when the femoral vessels are divided until they are secured. The method of opening the abdominal cavity to permit the introduction of two or more fingers to make digital compression of the aorta is not, under ordinary conditions, a justifiable operation.

As an indication of the low mortality rate after amputations done by an experienced operator by modern surgical methods, the statistics of Dr. Estes are of great value: Of 307 single major amputations, 27 died, or 8·79 per cent, and these include 13 fatal cases which were in exceedingly grave condition at the time of operation. In the last period of six years, in which precautionary measures were carried out to prevent hæmorrhage and the operation deferred until the condition of acute anæmia was somewhat relieved, there were 180 single major amputations and only five deaths, or 2·77 per cent mortality, including six hip-joint amputations.

Dr. John F. Erdmann, of New York, in the "Annals of Surgery," September, 1895, gives 703 amputations done in Bellevue, New York, Roosevelt, St. Luke's, Mount Sinai, Chambers Street, German, and Presbyterian Hospitals between 1884 and 1894, with 109 deaths—15·5 per cent—including among these 18 hip-joint amputations with 8 deaths—44·4 per cent; shoulder amputations, 24 cases with 6 deaths—25 per cent.

	Amputations.	Deaths.	Per cent.
Wrist	7	..	....
Forearm	71	1	1·4
Elbow	6	..	....
Arm	88	16	18·0
Shoulder	24	6	25·0
Foot	64	5	7·8
Leg	156	19	12·0
Knee	46	6	13·0
Thigh	223	48	21·5
Hip	18	8	44·4
Total	703	109	15·5

	Freshly traumatic cases.	Average age.	Deaths.	Average age at death.	Per cent.
1884 to 1889	47	34	12	43	25·5
1889 to 1894	20	35	4	58	20·0

	Cases.	Deaths.	Per cent.
1884 to 1889	114	19	16
1889 to 1894	61	9	14

The following tables, from Ashhurst's Surgery, are given to show the diminished ratio of mortality between the method of to-day and that of thirty years ago:

I. *Summary of Seventy-one Cases of Hip-joint Amputation for Injury in Civil Practice by Old Methods.*

Nature of Operation.	Recovered.	Died.	Total.	Mortality per cent.
Primary	6	25	31	80·6
Intermediate	5	7	12	58·3
Secondary	5	6	11	54·5
Reamputation of thigh stump	4	1	5	20·0
Not stated	4	8	12	66·6
Total number of cases	24	47	71	66·1

II. *Summary of Two Hundred and Seventy-six Cases of Hip-joint Amputation for Disease by Old Methods.*

Nature of Operation.	Recovered.	Died.	Undetermined.	Total.	Mortality per cent.
Amputation of entire limb	136	95	14	245	41·1
Reamputation of thigh stump	20	10	1	31	33·3
Total number of cases	156	105	15	276	40·2

CHAPTER XIII.

SURGERY OF THE LYMPHATIC VESSELS AND GLANDS, VEINS AND ARTERIES.

THE pathology of the lymphatic vessels closely resembles that of the veins, with which they are intimately associated. The history of the two systems is practically identical. One essential point of difference having a pathological significance is that the lymphatic vessels are closed tubes, since at varying intervals in their route to the center each trunk breaks up into smaller branches until they end in capillaries in the substance of a lymphatic gland. It is believed that there is no direct communication between the afferent and efferent vessels in these glands. It follows that infectious material passing into these vessels can not rapidly enter the systemic circulation. Each gland is a sieve which retards and often arrests its progress and modifies its effect. With the veins, however, there is no resistance to rapid, direct systemic infection, often with widespread metastases.

Lymphangitis means an infection of all the structures which make up the wall of a lymph-carrying vessel. The endothelial lining, the muscular and connective tissues are alike involved. Hyperæmia and cell proliferation occur, and there may be coagulation of the lymph and occlusion of the ducts. Should the organism be pyogenic in character, suppuration is present. *Phlegmon* of the fingers resulting from pyogenic infection, so frequently met with (especially in careless surgery), is a type of suppurative lymphangitis, while that variety which results from infection with the *Streptococcus erysipelatis* is a typical non-suppurative lymphangitis. Inflammation of the lymph ducts is rarely of traumatic origin, and while inflammatory changes evidently result from an injury, as a blow upon the skin which bruises the part, yet this form of non-infective inflammation rarely comes to the notice or care of the surgeon. It is the infective lymphangitis which is of great surgical impor. tance.

The *symptoms* of *acute infective lymphangitis*, while varying in intensity proportionate to the virulence of the infection and the condition of the tissues infected (normal or diminished resistance), are the same in essential features in every case. Following an inoculation with any septic matter, within a few hours there is a sense of uneasiness and burning in the immediate vicinity of the wound. Pain is not usually severe until the swelling is well marked. At the end of from twenty-four to thirty-six hours the injection of the superficial vessels

which lead from the local inflammation toward the center may be recognized. These red lines give a peculiar sensation to the touch. While the outline of the vessel can rarely be made out by palpation, there is often an appreciable thickening and tension in the tissues immediately over and around it. Pain is present in some instances, while in others even direct and strong pressure causes little or no disturbance. When the nearest gland or plexus is reached by the inflammatory process, by pressure upon these a sharp sense of pain is experienced. The febrile movement, which may ensue within twenty-four hours, though usually not well marked at this early period, is generally introduced by a chill or a series of chilly sensations, characterized by pallor and the "picked-goose" roughness of the skin. The temperature rises rapidly above the normal, and may reach a high degree. Nausea, vomiting, delirium, and the train of symptoms which accompany septicæmia may follow; but this is, fortunately, the exception. If the conditions are unfavorable to the progress of the disease, the temperature declines gradually, resolution occurs, and the symptoms of inflammation disappear in from one to two weeks.

In the *diagnosis* of *lymphangitis* it is well to bear in mind that in *phlebitis* the lines of red discoloration are wider than in the disease under consideration, that there is a more general condition of œdema, that the lines of inflammation follow well-known and appreciable veins, that these veins are very painful to pressure, and that they are easily recognized as hard, semi-elastic, knotty cords.

The treatment of acute infective lymphangitis is local and general. Cold applications in the early stages are preferable, and, in general, more agreeable to the patient. An ice bag, cold rubber coil, or cold cloths will suffice. The part affected should be kept in perfect repose. The point of infection should be freely incised, and hot aseptic poultices applied, in order to induce suppuration and to favor the discharge of pus. If the infection is evidently traveling along the lymphatics, any points of induration should be incised or punctured, in order to give vent to septic matter. If complicated with general cellulitis and great tension, parallel incisions should be made to prevent gangrene. It is important to regulate the alimentary apparatus and to support the patient's tissues with the best nourishment, pure air, and cheerful surroundings.

Subacute or *chronic infective lymphangitis* is associated with general systemic infection, as in syphilis and tuberculosis.

Adenitis (inflammation of the lymphatic glands) always exists with infective lymphangitis. In acute infective adenitis the inflammatory changes go on with extreme rapidity. The cells of the reticulum and endothelia proliferate rapidly, and the presence of pyogenic organisms, with their well-known property of liquefying the tissues, produces suppuration. The necrosis of tissue is facilitated by the great pressure which rapid cell proliferation causes within the non-elastic, resisting capsule of the gland.

The *symptoms* are a sense of soreness and tension, sharp throbbing

pain, increased on slight pressure, swelling, and redness of the superjacent skin. The suppuration commences in the center of the gland, and gradually extends until the tissues around are involved. The constitutional symptoms are similar to those given in lymphangitis. If the inflammatory process be of the subacute form, the enlargement is more gradual, and pain and the other symptoms of acute adenitis are absent. Later in the history of this process fatty and caseous degenerations may occur, ending in resolution. In chronic adenitis the tumors are more solid and firmer to the touch, since the enlargement is due in greater part to the proliferation and hyperplasia of the connective-tissue stroma.

In the *treatment* of *acute adenitis* perfect quiet must be enforced. Local applications are indicated as in lymphangitis. If suppuration is evident, early incision is indicated. Frequently one after another of the glands in a group breaks down in the process of suppuration, forming sinuses which undermine the neighboring tissues, when it is necessary to lay each abscess open freely and scrape out every particle of diseased tissue with a Volkmann's spoon. Thus treated, the wound should be packed with sterile gauze, and treated as an open wound throughout. If recovery does not follow, a thorough dissection should remove the diseased glands.

Tuberculous adenitis is not only one of the most important forms of lymphangitis, but a lesion scarcely second to any in the domain of surgery, since it is an exceedingly frequent form of tuberculosis, ultimately ending fatally in all cases, and requiring for its relief a timely and thorough surgical extirpation. While it may be met with in any part of the body, it is vastly more frequent in the glands of the neck beneath the jaw and in the chain of lymphatics following the deep jugular vein. The bacillus tuberculosis, as already given, finds an entrance to the lymphatic channels through an abrasion of the buccal cavity or face, and travels along these channels, producing a mild form of lymphangitis, which rarely attracts the attention of the patient until the germs, reaching the substance of the gland, find their progress arrested and conditions suitable for development. They immediately precipitate an inflammatory process of mild type, in which all the cells of the gland take part, producing, as given in the chapter on tuberculosis, "giant cells," epithelioid and the so-called lymphoid cells. In a short while the organisms in the center of the various nodules perish for lack of food, the younger generations growing in the periphery of the inflamed area until the capsule of the gland itself is attacked, leaving in the nodules, which undergo caseous degeneration, the spores of tuberculosis. These may lie dormant for a long period and reproduce the disease when the capsule ruptures and favorable conditions are found for their proliferation. Occasionally the process may arrest itself before the capsule is involved, or until the investing membrane becomes so thickened and indurated that no exit can be found for their further march. At times these undergo calcareous degeneration in the effort to include the infecting organisms. When mixed infection occurs, an acute inflammation and suppuration is established with all the symptoms of acute adenitis.

The symptoms of tubercular adenitis are a gradual and persistent enlargement of the lymphatic glands, directly in line of that part of the body exposed to infection, usually, as stated, in the neck. I have met with tubercular infection of the mammary glands through the nipples in which the pectoral lymphatic glands were first involved. They may be slightly tender on pressure; more frequently do not give pain on touch unless pyogenic infection has occurred, when they are exquisitely sensitive. The treatment demands early and thorough extirpation; and, in the present light of science, the obligation of the surgeon can be conscientiously discharged only by advising this.

The *adenitis* of *syphilis* is due in like manner to a subacute inflammatory process in which the so-called lymphoid cells predominate. It does not require surgical interference, but disappears with the proper treatment of the constitutional disease.

In addition to the simple enlargement of the *lymphatic glands* due to *pyogenic infection* (simple infectious lymphoma), tubercular and syphilitic lymphomata, and lymphosarcoma, there are two interesting and rather obscure varieties which may be classified as *leucæmic* lymphoma ("Hodgkin's disease") and *malignant* lymphoma (Billroth's disease). By some writers these two diseases are considered identical, and it is difficult to differentiate them by a microscopical study of the glands involved, but there are certain clinical features which separate them widely enough to justify the classification above given.

In Hodgkin's disease, as in Billroth's, young adults from twelve to twenty-five years of age are most frequently affected. The glands in any part of the body may be the seat of lesion in Hodgkin's disease, and from the beginning point of invasion, as a rule, the lymphatic glands of the entire body are progressively involved. The skin becomes pale and waxy, the spleen enlarged, various lymphatic nodules become closely merged together without inflammation, and lymphatic tissue metastases occur in the spleen, lungs, liver, and other organs. The red blood disks are greatly diminished, and there is not only a comparative but an actual increase in the number of leucocytes. There is no pain except that due to pressure.

In Billroth's disease the lymphatic glands of the neck are, as a rule, alone involved. Occasionally those of the axilla have been seen to be affected coincident with those of the neck; but even in these cases the disease is limited to this region and differs from Hodgkin's disease in this clinical feature. The anatomical changes in the glands are seemingly identical with those of Hodgkin's disease, but metastases in the various organs have not been observed, and, as will be seen in considering the treatment, the one will yield quite readily to remedies, while the other is hopeless from its incipiency.

In the treatment of Hodgkin's disease little can be done by reason of the fact that constitutional treatment is of no avail, and the widespread dissemination of the enlarged glands renders local injections impracticable.

The following interesting and typical case was recently treated in my

clinic at the New York Polyclinic Medical School and Hospital by Prof. J. A. Bodine. The patient, a girl, nineteen years of age, had noticed commencing enlargement of the cervical glands. This was at first confined to the left side, but gradually invaded the glands of the right side. These were firm, slightly elastic, and movable upon the underlying structures as well as the skin. The submaxillary space on the left side was soon entirely filled with the nodes, and there was great deformity. She had been operated upon in another clinic, under the mistaken diagnosis of tubercular lymphoma, and a number of glands were removed. Recurrence took place within a few months, and no further operative measures were undertaken. Two years later she came to my clinic on account of the dyspnœa caused by pressure. The case seemed hopeless, but the following treatment was instituted, consisting of injections of a one-per-cent. solution of arseniate of soda (gr. ivss to ℥j of distilled water). In addition to this she was given every day twenty to thirty drops of Fowler's solution by the mouth. Two or three times a week, at stated intervals, from three to ten minims of the solution were injected into the substance of the various enlarged glands. She received never more than ten minims of this solution at one sitting, in which not more than three injections were made. The greatest possible care was taken to prevent infection. The syringe used was made perfectly sterile by boiling, as was also the needle, the skin thoroughly prepared, and a fresh solution made of distilled water was employed. The nodes gradually disappeared, and in the course of six months the patient was seemingly cured.

Owing to accidental infection, two glands suppurated, and small abscesses were opened and the broken-down tissues removed by clean dissection.

Filaria (*sanguinis hominis*).—The presence of this parasite in the lymph channels often leads to obstruction and serious pathological changes in these vessels and the contiguous tissues. From the parent nest in the lymph canals the crop of organisms escape into the blood vessels. In the blood they are rarely detected during daylight, but in the night, especially several hours after dark, they leave their hiding places in the deeper viscera and invade the general circulation. The filaria, about $\frac{1}{80}$ of an inch long and constantly in motion, is the embryo of the *filaria Bancrofti*, which is found only in the lymph channels. The parent female is about three and a half inches long and very slender. The male has not yet been accurately studied. The disease is usually contracted from water, where the ova have been deposited by mosquitoes and other blood-sucking insects. The filariæ in the blood do not produce any particular symptoms, but the longer organisms which lodge in the lymph ducts produce obstruction, inflammation, connective-tissue hyperplasia, extravasation of lymph, and general thickening and swelling of the parts, known as elephantiasis. There is no known method of relieving the body of these parasites. It is probable that, as with other parasites of the blood, they may be destroyed by a prolonged high temperature, as in typhoid or remittent fever.

Wounds of the lymphatic vessels may occur in common with solu-

tions of continuity in other tissues. The escape of lymph, and occlusion of the vessels involved, back to the first collateral branch, is the rule, as with the blood vessels. If the vessel be large, as when the thoracic duct or the deeper channels of the leg are divided, the ligature or compression of the distal end is necessary to prevent a lymph fistula. It has been demonstrated that the lymph and chyle can be carried into the circulation by collateral routes, after occlusion even of the thoracic duct.

Varicosities occur at times in the lymphatic vessels, as in the veins. The causes and treatment are essentially the same. As a result of obstruction, in some instances, *cystic dilatations* occur, which, according to Bellamy, are usually found in the tongue, lips, and about the neck. Hydromata of the neck are at times congenital. In their structure they are trabeculated, the caverns filled with lymph. The location is beneath the occiput, and the tumor is symmetrical, the cyst of each side of the median line being lined with lymphatic endothelia.

New formations of lymphatic vessels occur occasionally, and blood vessels developing in these give rise to a mixed new growth, known as lympho-angeioma.

Phlebitis.

Phlebitis means an inflammation of the tissues which form the walls of a vein. Endophlebitis, mesophlebitis, and periphlebitis are terms used to designate the inflammatory process involving respectively the inner, middle, and outer layers of the vessel wall. This process involves a tubular structure, made up in general of an inner layer of flat, polygonal cells (*tunica intima*), the middle layer (*media*), composed chiefly of elastic tissue, and the outer layer (*externa*), containing elastic loops, connective tissue, and unstriped muscle. Blood vessels and nerves traverse the outer and middle tunics, following the connective-tissue bundles.

The cells of the lining membrane are smaller than the arterial endothelia, and are imbedded in a fibrillated, intercellular substance (Cornil and Ranvier). The elastic and muscular tissues are less developed than in the arteries (Heitzmann). These are so irregularly arranged that any division into middle and external coats is, in great part, artificial and imaginary. Moreover, many of the veins contain no muscular tissue, while their connective tissue varies in quantity in different parts of the body. The sinuses of the dura mater, the veins in bones, and those of the retina have no muscular fibers, while the jugulars, subclavians, and venæ cavæ have a relatively small quantity, or are entirely devoid of this tissue. Again, the arrangement of the muscular tissue differs in different veins. The inferior vena cava, the portal and renal veins have an inner, circular, and an external, longitudinal layer, while the femoral and popliteal veins have the longitudinal fibers more internal. This tissue is still more complicated in the saphenous veins, where the internal layers are arranged longitudinally, with a number of alternating, or transverse and longitudinal, layers placed externally to these.

The elastic layer begins immediately external to the basement sub-

stance which supports the endothelial layer, and is here somewhat isolated and well defined; but from the external surface of this central, elastic lamina springs a network of elastic fibers, through the loops and in the meshes of which are woven the muscular and connective-tissue fibers.

The vasa vasorum follow the connective-tissue bundles in their distribution to the tissues of the wall down to the elastic layer. Nerves from the sympathetic system have been demonstrated in the larger veins.

The valves are delicate reduplications of the internal coat, having a well-defined, elastic reticulum, especially on their distal or convex surface (Heitzmann), and muscular fibers at the point of attachment to the venous wall.

The vascular area—the outer and middle layers—is first concerned in the inflammatory process. The endothelial tunic, as a result of these structural changes, is subsequently involved. It then appears cloudy, thickened, and rough, and may become separated in shreds (Frey). In the vascular area, during the earlier stages, the capillaries of the vasa vasorum become swollen, the white corpuscles migrate into the extravascular spaces, and the normal connective-tissue cells are stimulated into proliferation, resulting in a thickening of the wall, due to the presence of these embryonic cells and the excessive hyperæmia. As in arteritis, the vitality of the endothelial tunic becomes impaired, and it is more or less projected into the cavity of the vein, the cells of this tunic undergoing proliferation. After a few days granulation buds push out from this embryonic tissue of the endothelia, and new capillaries are developed in the granulation masses, anastomosing and becoming a part of the circulation of the vasa vasorum, as well as leading into the coagulum which occupies the caliber of the vein.

At the point of contact of the outer surface of the thickened endothelial layer with the internal surface of the middle (elastic) layer, large sinuses are developed, which receive the blood from the capillaries of the middle tunic. These sinuses are lined with an endothelial layer, which rests upon the contiguous connective tissue. From these larger vessels fine capillaries are given off, which permeate the thickened internal layer, and some of these also pass into the organizing coagulum.

When a *thrombus*, caused by the sudden coagulation of the blood in a vein, is examined in its recent state, it is found to be composed of successive laminæ of fibrin and corpuscles, and the more recent of these laminæ are external. When the vein is first occluded by this sudden coagulation of the blood, the pressure from behind is so great that the coagulum is compressed toward its center, while the current, more and more impeded in its progress, flows between the periphery of the clot and the inner surface of the vessel, adding, layer by layer, fresh deposits of coagulation upon the thrombus. A microscopical examination of such thrombi reveals a vast number of white corpuscles in various stages of fatty degeneration, with layers of fibrin intervening.

Experiments have shown that not only does the inflammatory process, by reason of its invasion of the intima, produce changes in the blood

which lead to stasis, but that there may be also a dangerous endosmosis of septic matter, which is swept along toward the heart and lodged in the capillaries of the various organs (*emboli*), producing infarctions, abscesses, and, almost invariably, irreparable damage (septicæmia with metestasis). The adhesion of the intima, and the formation of a fibrinous clot—which may completely occlude the vessel (*occlusion thrombus*), or may merely plaster over the endothelial tunic (*peripheral thrombus*)—are efforts toward prevention of this endosmosis.

The process of repair in tissues capable of successful resistance, in venous inflammation, is one of organization of the embryonic cells, fibrillation, and contraction, resulting in partial or complete occlusion. In tissues of low and impaired vitality, infection not infrequently occurs, with pus formation, usually terminating in death. Microscopical sections from such specimens of phlebitis show that the leucocytes and embryonic cells have undergone retrogressive changes, and that the tissues are infiltrated with pus corpuscles. Necrotic spots are not infrequent, often opening into the caliber of the vessel.

Since phlebitis is a frequent cause of thrombosis, and since venous thrombosis is the most frequent form of intravascular coagulation, a consideration of this process must naturally find a place here. Virchow has endeavored to show that primitive phlebitis is extremely rare, and that, when a clot is produced in a vein which is inflamed, the coagulation has more often preceded than followed the inflammation. Cornil and Ranvier do not accept this theory.

Fibrin, the immediate factor in coagulation of the blood, does not exist as such in the normal condition of this fluid. Under healthful conditions, the blood would circulate always without any deposit of fibrillated fibrin in the economy.

So delicate, however, is the sensibility of the blood to mechanical irritation or hindrance in its flow, that the slightest injury or roughening of the endothelial lining membrane may produce a deposit of fibrillated fibrin. A delicate needle, or wire, or thread, thrust into the lumen of a healthy vessel, precipitates coagulation upon the foreign body. The white corpuscles are found clustered in great numbers on the foreign body, and, when the mass is examined with the microscope, the corpuscles seem to serve as starting points for the development of fibrin (Reichert).

A number of theories have been advanced to account for the coagulation of the blood. The views indorsed by Ballance and Edmunds in their classical work on "Ligation in Continuity" (page 145) is that of Hammersten: "that coagulation is due to the action on the fibrinogen of the blood plasma of a ferment derived from the lethal disintegration of blood-platelets, a special variety of white blood-corpuscles of small size."

Syphilitic Phlebitis.—Mr. Hutchinson has called attention to the very few cases of syphilitic phlebitis which have been recorded, and yet he says that most surgeons are familiar with the fact that inflammations around varices, and even about otherwise healthy veins, are

not infrequent in syphilitic subjects.* Mr. Hutchinson further says: "I think also that I have seen several cases in which the thrombosis and phlebitis were attended by other conditions sufficiently peculiar to justify a belief that they were of specific origin. In some there has been great excesses of inflammation, a large hard mass forming in the cellular tissue, and threatening to slough, much as subcutaneous gummata often do. These cases are much benefited by the iodide of potassium, so far as prevention of sloughing is concerned, but the thrombotic plugging remains." †

Gouty Phlebitis.—Subjects (says Mr. Bryant) who are gouty from hereditary or acquired causes are liable to phlebitis. Paget has described the affection in his "Clinical Lectures," and Mr. Gay has written upon it. In such cases the phlebitis may have no intrinsic characters by which to distinguish it, yet not rarely it has peculiar marks, especially in its symmetry, apparent metastases, and frequent recurrences. Like other forms, it is more common in the lower than in the upper extremities, yet it may be found anywhere. It affects the superficial rather than the deep veins, and often occurs in patches, affecting on one day, for example, a short piece of the saphenous vein, and the next another portion of the same vein, some other distant vein, or a corresponding piece of the opposite vein.

The inflamed portions of the vein usually feel hard and are painful to the touch. The soft parts covering the vein become slightly thickened, and often have a dusky, reddish tint. When the deep veins are involved, œdema appears, with the well-recognized results of obstruction : the limb becomes big, clumsy, featureless, heavy, and stiff ; its skin is cool, and may be pale, but more often has a slightly livid tint, which may be recognized by comparison with the other limb ; and it has mottlings from small cutaneous veins, visibly distended. The limb, thus enlarged, feels œdematous throughout, but firm and tight-skinned, not yielding easily to pressure, and not pitting very deeply.

The constitutional symptoms associated with this affection vary from some slight febrile condition to those met with in acute gout. Complete recovery may take place in this as in other forms of phlebitis, the veins becoming pervious in some cases and obstructed in others. The risks of embolism are also the same (Bryant).

Causes and Clinical History of Phlebitis.—The classification of phlebitis as *traumatic* and *idiopathic* is not strictly scientific. It would be better to consider it as *non-infective* and *infective.* A traumatic phlebitis may belong to one or the other variety. As infective phlebitis would be classed all forms which are due to the presence of pathogenic organisms, such as suppurative and tuberculous phlebitis ; while that form which occurs, although rarely, in syphilis, known as *syphilitic phlebitis*, and the lesion classed by Mr. Thomas Bryant as *gouty phlebitis*, might, in the present state of our knowledge, be considered as phlebitis due to irritation and disturbed nutrition of the venous walls from the

* J. H. C. Simes and J. William White, in Cornil on Syphilis. † Ibid.

blood charged with toxic (chemical) products. Traumatic phlebitis may be caused by partial or complete solution of continuity of the venous walls from a blow or penetrating wound, or by violent muscular action and pressure, as in lesions of the popliteal vein, from forced flexion of the knee, or varicosities of the lower extremities where great strain or tension is caused by gravitation of blood and the inability of the heart to force it toward the center. The inflammation of the uterine sinuses during and after parturition, which Cornil and Ranvier named "spontaneous phlebitis," is now known to be a form of infective inflammation of the sinuses due to the entrance of septic organisms. *Non-infective* phlebitis scarcely demands special consideration, for, unless infection occur, the inflammatory process is so simple that the normal condition is quickly restored without appreciable disturbance.

Infective or septic phlebitis is, however, one of the most serious of the surgical diseases. It may involve one or more veins, and the process travels with the vessels in the direction of the heart. The vessels become swollen, tense, and resemble the normal veins when the return circulation is arrested, although more cordlike in feel and less elastic. They may be traced by the dull-red color of the skin immediately over the diseased veins. Pain is constant and is rendered intense by pressure. The œdema of the parts on the distal side of the lesion is in proportion to the obstruction to the return circulation caused by the inflammatory process, and the infiltration of the perivascular tissues. The febrile movement varies with the violence of the attack, the rapidity of its progress, the intensity of the septic process, and the capacity of the tissues to resist invasion.

Treatment.—Positive and complete rest is the first great essential. Manipulation or movement is always dangerous, since interference will not only exaggerate the inflammatory process, but may possibly cause the separation of thrombi, which lodge in the lungs, or are disseminated generally through the tissues, producing septicæmia with metastases. If the disease should assume the suppurative form, the inflammation being diffuse and the œdema extensive, free incisions should be made parallel to the veins in order to relieve tension and secure drainage. To such wounds the balsam-oil mixture of Van Arsdale should be applied, or a moist 1-to-5,000 bichloride dressing, with warm irrigations at intervals, until the more urgent symptoms have disappeared. Careful attention to the alimentary canal, good feeding, and a free supply of fresh air will complete the constitutional treatment. When an extremity is involved, it should be slightly elevated to favor the return circulation.

Arteritis.

Arteritis is a term applied to an inflammatory process which involves the entire thickness of the arterial wall. When the inflammatory change is confined to the inner coat, or intima, it is designated as *endarteritis;* when to the outer coat, or adventitia, as *periarteritis;* and when to the middle coat, or media, as *mesarteritis.*

Endarteritis, which does not rapidly disappear soon after its inception, is apt to result in lesions of the media and adventitia, and in like manner a lesion of the external tunic will in all probability involve, by the extension of the morbid process, the other coats.

There are, however, certain well-defined exceptions. Endarteritis is, as an isolated lesion, capable of demonstration. We shall see that a superficial inflammation of the endothelia, with its resultant fatty degeneration, is not infrequent. And since atheroma and other arterial lesions are due to interference with the blood supply through the vasa vasorum, or to defect in the quality of the blood distributed to the adventitia through which the vessels ramify, we must recognize a periarteritis as the initial stage of this lesion.

Inflammation may be established in any or all parts of the arterial system. One form of arteritis will involve the larger trunks, while another will pass these without molestation, and establish itself in the distant arterioles. Simple endarteritis is most apt to occur in the aorta and arteries of the second magnitude, while syphilitic arteritis, the most marked feature of which is an endarteritis, may attack the larger trunks, but chiefly confines itself in its later manifestations to the small and smallest arteries.

The internal coat of the larger arteries is composed of two parts: 1. An endothelial lining membrane, consisting of a single layer of flat, polygonal, nucleated cells, slightly elongated in the axis of the vessel; in edge view, these cells appear spindle-shaped, on account of the elevation of the nucleus at its center (Heitzmann); 2. A subendothelial layer of flattened, nucleated, anastomosing cells resting in a fibrillated basement substance, the direction of the fibrillæ being generally parallel with the long axis of the artery (Cornil and Ranvier). There are no vessels in the middle and internal coats. In the external coat are found arteries, capillaries, veins, lymphatics, and nerves.

Pathogeny of Arteritis.—The causes of arteritis are numerous. A frequent form is that resulting from injury, and known as *traumatic arteritis*. The pathogeny of *non-traumatic* (*idiopathic*) *arteritis* embraces every form of dyscrasia. It follows in the train of syphilis, tuberculosis, rheumatism, gout, alcoholism, and nephritis, or any chronic morbid process which poisons the blood or impairs its nutritive qualities. These varieties will be considered under special headings.

The sequelæ of arteritis, as far as the arteries are concerned, may be fatty infiltration or degeneration, atheroma, secondary calcification, occlusion, dilatation, aneurism, ulceration, and rupture. Remotely, there may occur partial or complete loss of function of the organs beyond the lesion, and partial or general necrosis or necrobiosis. I shall consider arteritis under two great heads, *traumatic* and *non-traumatic*, subdividing these as their pathogeny or pathology may justify in the consideration of each separate type.

I. Traumatic Arteritis.—Arteritis may result from violence, either from without or within. External violence will produce an inflammation of all the tunics of an artery, in the majority of cases, while vio-

lence from within is more apt to cause an endarteritis. *Arteritis from external causes* is never an uncomplicated injury. The perivascular tissue is of necessity involved in the inflammatory process. In the arteritis resulting from deligation of an artery, from the forcible compression of a vessel, as in bending the knee, from the pressure of a tumor, or from a blow in the track of the artery, there is always an accompanying inflammation of the surrounding, injured tissues.

The pathology of traumatic arteritis does not differ greatly from the inflammatory process which occurs in other vascular tissues. Immediately following the injury there is a marked increase in the vascularity of the adventitia. The vasa vasorum become swollen, the white blood-corpuscles crowd into the capillaries, and pass into the extra vascular spaces, while a rapid proliferation of the normal cell elements of the arterial tunics takes place. The connective-tissue cells of the adventitia and the flat and polar cells of the intima all take part in this process. The walls of the vessel become abnormally thickened, while, owing to the projection inward of the intima, the caliber of the vessel is diminished. If the intima has been broken or bruised by the injury, the encroachment upon the caliber of the vessel will be more rapid, for, inaddition to the mass of embryonic tissue pushing into the lumen of the artery, there will be a deposit of fibrin upon the roughened and projecting internal tunic. The white corpuscles in the passing blood current adhere to the inflamed surface, while the disintegration of the blood platelets precipitates the fibrin to form a coagulum. This coagulum is found to consist of alternate layers of leucocytes and fibrin. In the meantime, if the inflammation be not so severe that rapid necrosis occurs from the sudden arrest of the blood supply through the vasa vasorum, new-formed capillaries push through the mass of embryonic cells, into the "granulation buds" which project into the lumen of the vessel (Fig. 286).

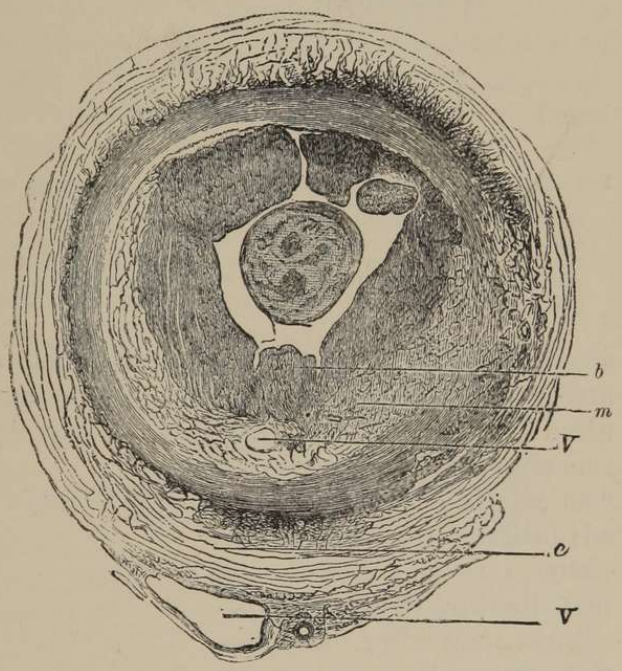

FIG. 286.—Traumatic arteritis. Transverse section of the carotid artery of a dog, fifteen days after ligature; *b*, granulation buds formed from projection of the intima. In the center of the figure one of these buds has been completely cut across; *m*, portion of the media modified by the inflammatory process; *e*, adventitia; *V V*, vessels cut across, one of which is newly formed in the intima. Magnified 15 diameters. (After Cornil and Ranvier.)

This form of arteritis may result in permanent occlusion of the vessel (*endarteritis obliterans*), or the function of the artery may be restored. If occlusion occurs, it results from the organization of the embryonic

cells into a new tissue which undergoes fibrillation and contraction (a process of cicatrization) to such an extent that the new-formed capillaries are more or less occluded, and the artery shrinks to become a fibrous cord (Fig. 287). Or the coagulum may undergo fatty degeneration, and be swept away with the current of blood, the vessel remaining pervious and bearing but little trace of the inflammatory process through which it has passed. The microscopical appearances of a localized traumatic arteritis are typically represented in Fig. 288, which is copied from a section made from the carotid of a horse. The animal was in a healthy condition at the time of the operation. I tied the artery with a broad carbolized ligature, the sciatic nerve of a calf. In the fifth week the animal was killed. The artery was pervious. The location of the ligature was easily recognized by the peculiar, whitish, pearly appearance of the intima at the point of tying, where it was slightly elevated. The adventitia did not show any changes to the naked eye. The ligature had evidently slipped soon after the operation, probably within a few hours. The intima was not broken, but simply bruised within the grasp of the ligature. Active proliferation of the cells of the intima had resulted from this irritation. Not only is the intima seen to bulge into the lumen of the vessel, but the mass of embryonic tissue encroaches outward upon the media, which is thinner at this point than

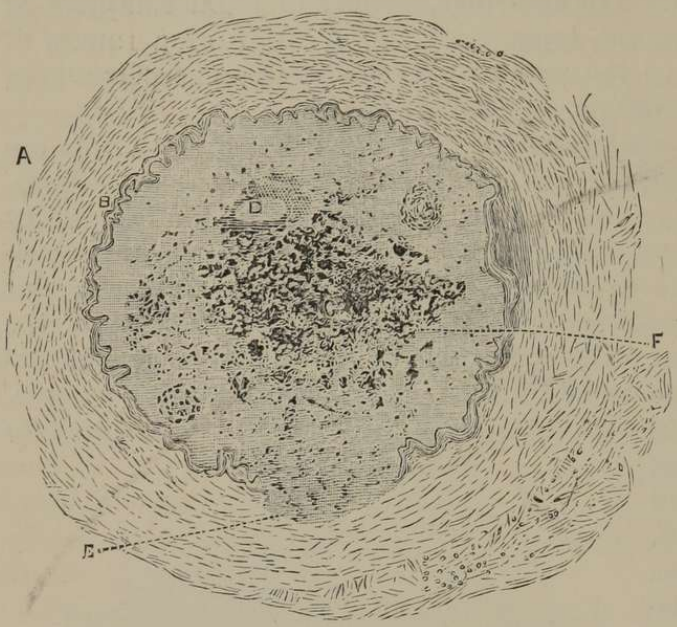

Fig. 287.—Endarteritis obliterans, not syphilitic. Transverse section of the basilar; A, muscular layer; B, elastic layer. The lumen of the artery is entirely filled with a new formation, which has become canalized by new vessels at D D F; C, blood pigment; E, hyaline material, part of the new formation encroaching on the media at E, and seen elsewhere. (Drawn by Dr. W. L. Wardwell, from a specimen borrowed from Prof. W. H. Welch. Magnified 60 diameters.)

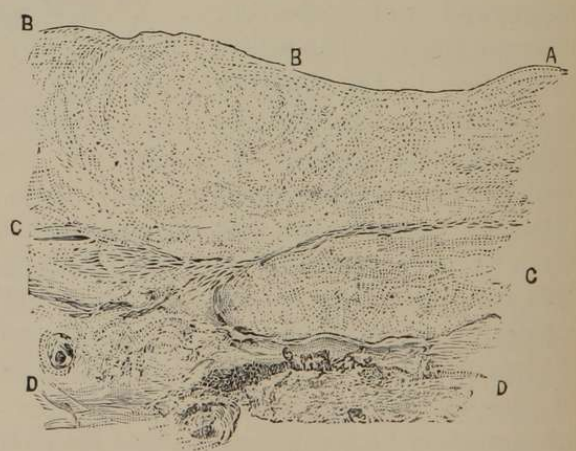

Fig. 288.—Traumatic endarteritis. Section from the common carotid of a horse, tied with a broad nerve ligature, showing at B B the proliferation of the intima. The inflammatory new formation is projected into the lumen of the vessel, and has caused partial atrophy of the media, C; A B, the intima; B B, portion of the intima in the grasp of the ligature; D, the adventitia, slightly changed, with small-cell infiltration. (Drawn by Dr. W. L. Wardwell, from the author's specimen. Magnified about 40 diameters.)

elsewhere. At one point the media has entirely disappeared, leaving the intima and externa in actual contact. The adventitia has not undergone much change. A few inflammatory corpuscles are found among the connective-tissue bundles. If, after an injury which induces arteritis, the vessel be not occluded throughout the extent of the lesion, and the injury or resulting septic infection be so severe that rapid occlusion of the capillaries in the arterial wall takes place, suppuration or necrosis occurs, with hæmorrhage. Or particles of septic matter may pass into the vessel and lead to infarctions, or septicæmia with metastasis.

Treatment.—No definite plan of treatment can be outlined for traumatic arteritis. The circumstances of each case must be separately considered. To prevent gangrene, and to guard against hæmorrhage, are the indications most to be regarded. Rest, position, quiet, and careful nutrition are the most important points of treatment.

Traumatic arteritis resulting from *causes within the vessels* usually begins as an endarteritis. Many cases of acute traumatic endarteritis are described as idiopathic inflammations. They are none the less due to violence—to the impinging force of the blood current; for this lesion occurs at those points in the arterial system where blood impact is greatest. Endarteritis and the fatty degeneration resulting from it (Figs. 289, 290) are most frequently seen in the sinus magnus of the aorta, in the

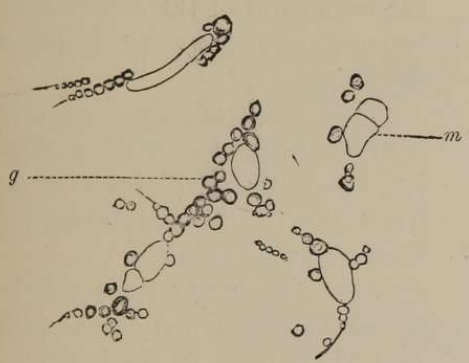

FIG. 289.—Arteritis with fatty degeneration of the intima of the aorta. The nuclei of the normal cells are represented by the larger bodies, one of which is seen at *m*; the smaller bodies, as at *g*, are fatty granules. Magnified 400 diameters. (From Cornil and Ranvier.)

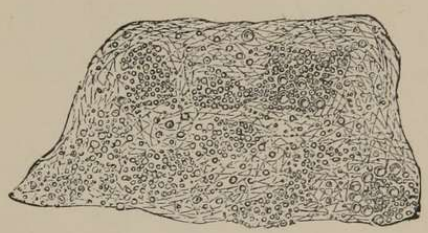

FIG. 290.—A form of fatty degeneration after arteritis. Fatty degeneration of the internal coat of the aorta. Minute yellowish-white patches scattered over the lining membrane of the vessel. A very thin layer peeled off and magnified 200 diameters, showing fat molecules and the distribution of fat in the intima. (From Green.)

transverse segment of the arch of the aorta, at the aortic bifurcation into the two common iliacs, and in the arch of the innominate. The arteries of athletes, which are subjected to prolonged distention, resulting from violent muscular exercise, are prone to suffer from this disease.

Vegetations from the heart may produce traumatic endarteritis when they are extensive enough to pass through the aortic valves, thrashing the intima with each heart systole. Fragments from whatever source, carried along the vessels, produce arteritis at the point of lodgment.

If we examine the intima of an artery which has been the seat of recent endarteritis, it will be seen to be swollen, and thicker and softer than normal. The swelling is not usually general and continuous, but

occurs in patches or hillocks of quite regular contour, which project into the lumen of the vessel. The intima is usually injected, and reddish in color, though, according to Cornil and Ranvier, when the inflammation has been of a very severe type, the swollen intima is paler than normal. If the inflammation be of recent origin, these patches will present an unbroken surface; but if softening has occurred, the centers of the elevations break down, resulting in erosions or ulcers, as they have been styled by some pathologists. Green says that they are due to softening of the intercellular substance, and that the cells and granular matter, becoming loose from this softening, are washed out by the blood current. These erosions resemble considerably the superficial erosions found often in the mucous membrane of the stomach. At times they are covered over with a layer of fibrin, which, upon close inspection, is found to be composed of one or more laminæ of fibrillated fibrin, with corpuscular elements entangled in or resting between them.

Beneath the projecting intima is found a mass of tissue, consisting of embryonic and large anastomosing cells resembling the normal connective-tissue cells of the most external structure of the intima. Hyperplasia of the normal cell elements is more marked as we approach the inner layers of cells of which the intima is composed, the proliferation growing gradually less extensive as the elastic lamina is neared. This condition is a feature of acute endarteritis, and differs both from the inflammation of the atheromatous process and from syphilitic endarteritis.

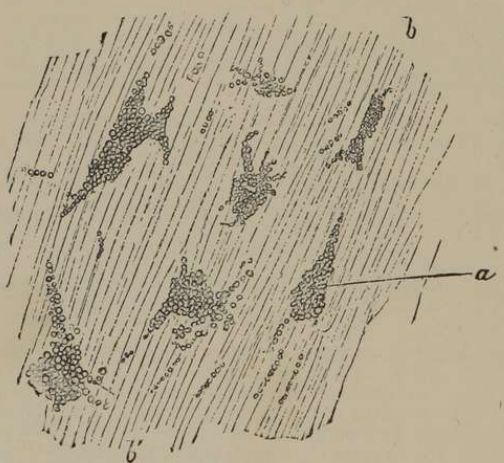

Fig. 291.—Arteritis with fatty degeneration. Fatty degeneration of the internal coat of the arteries from a thin layer stripped from this membrane. *a*, Fat granules in irregular patches over the surface. The granules have resulted from fatty degeneration of the cells of the intima. *b*, Fibrillated tissue. Magnified 200 diameters. (Cornil and Ranvier.)

This mass of new-formed embryonic tissue is, in all probability, the immediate result of proliferation of the normal cell elements of the intima.

The adventitia does not long remain undisturbed by the pathological changes in the intima. It takes on an inflammatory process in a varying degree, and this tunic is found thickened from the proliferation of its (connective-tissue) cells. If the process be obstinate and persistent, a true arteritis is developed, and all the pathological conditions which have been described on a previous page may be present.

The media is not greatly altered in the early stages of endarteritis or periarteritis, though in calcification it is apt to be first attacked, as it is likewise in fatty infiltration and degeneration.

Acute endarteritis may terminate in recovery, leaving no permanent trace of its having existed, or it may pass into a chronic inflammation, which usually ends in fatty degeneration.

This degeneration begins in the endarteritis proper, and travels toward the media. The appearances of an artery which has undergone this change are well shown in Fig. 291.

Fatty degeneration, in its microscopic appearances, resembles very much the atheroma which is, at times, found in the intima. It can, however, by gentle and careful scraping, be removed, revealing the more or less normal tissues underneath, while in advanced *atheroma*, which involves the deeper structures first, no trace of the normal tissues can be discovered.

Chronic arteritis may follow an acute endarteritis, as has been indicated above, although the chronic arterial lesions, as a rule, begin with periarteritis or mesarteritis.

II. Non-Traumatic or Idiopathic Arteritis.—The inflammatory process in idiopathic arteritis differs only in degree from that heretofore described as occurring in traumatic arteritis. When not due to syphilis, gout, rheumatism, nephritis, or some dyscrasia, it is usually a part of an inflammation of the tissues immediately surrounding an artery. The process commences in the adventitia, and is analogous to that of traumatic arteritis in the character of the changes which occur.

Atheroma and Calcification.—One of the frequent and most serious terminations of chronic arteritis, no matter what may have produced the

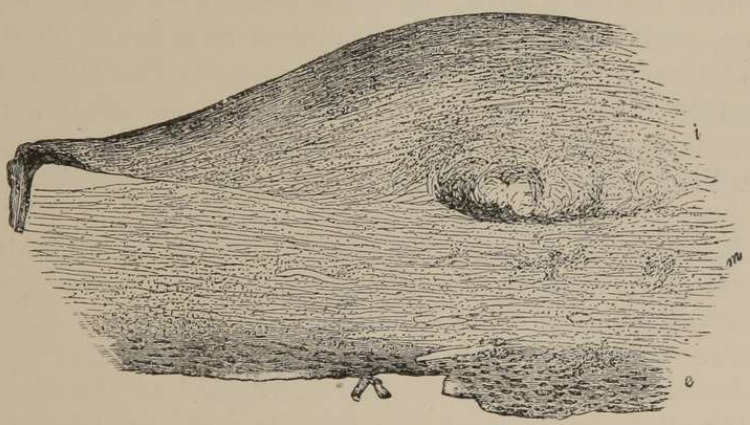

Fig. 292.—Atheroma following arteritis. Section of aorta undergoing the atheromatous change, showing the cellular infiltration of the deeper layers of the inner coat, and consequent bulging inward of the intima. The new tissue has undergone more or less fatty degeneration. There is some cellular infiltration of the middle coat. *i*, the internal; *m*, the middle; *e*, the external tunic. Magnified 50 diameters and reduced one half. (Green.)

lesion, is the condition known as atheromatous degeneration (Fig. 292). It is essentially a disease of malnutrition. It may be a senile change, not of necessity co-existent with another disease. It is, as will be proved hereafter, prone to attack the arteries, especially those of the brain, in syphilis, and the larger arteries in other affections. The fatty degeneration of endarteritis is a primary lesion, that of chronic arteritis is secondary. The one is local, the other general. Recovery from the one is possible, and the danger of death is slight. Shreds of fatty material may be carried by the blood and lodged in the cerebral or other remote vessels, doing great injury; but this accident is rare. The possibilities of chronic arteritis with atheroma are always grave. Above the dangers

of thrombosis and embolism, and of calcification, are those of aneurism and hæmorrhage. The early recognition of this condition, though exceedingly difficult, is no less important. Atheroma commences in the deeper tissues of the arterial wall, and, advancing in the line of blood supply, taps the sources of nutrition of the deeper tunics, causing their loss of function and disappearance. It is a true necrobiosis.

The fatty degeneration of atheroma not only involves the innermost layer of the intima (as does that form of degeneration which follows endarteritis), but the muscular-fiber cells undergo complete metamorphosis, while the elastic lamina is the seat of extensive infiltration. In severe cases the work of destruction is complete, the normal tissues disappearing, and leaving nothing but a granular *débris*.

Atheroma does not usually destroy an extensive area of the intima. The patches may be numerous, but not large. The molecular disintegration is confined to certain well-defined spots, in the center of which is found the softened, broken-down "pulp" which has given rise to the term "atheroma." Examined under the microscope, the contents of these pulp cavities will be found to consist of fat granules, granular corpuscles, and cholesterin crystals, exactly analogous to those sometimes found in cold abscesses. Shreds of fibrous tissue may be present. It can be readily conceived how the rupture of one or more of these pulp cavities, together with the weakened state of the middle and outer coats, would lead to the formation of aneurism. This danger is not so imminent when the inflammatory process has advanced slowly, for the reason that secondary calcification (a conservative process) is more apt to take place. The same may be said of primary calcification where the lime salts are deposited in the "coagulation necrosis" of the media.

The atheromatous and calcareous degenerations may exist in the same location and at the same time. While the cell structure of the intima is being transformed into granular matter, the fibrillated basement substance nearest the media is the seat of calcareous deposit, at first granular, the granules adhering to form clusters or flakes. At the same time, the nuclei of the muscular-fiber cells are filled in and around with calcareous matter. The entire muscular coat may be converted into a calcified cylinder, or, as is most usual, the process may be confined to isolated patches. In either case, the entire thickness of the wall may eventually undergo the same morbid changes.

When the layer of cells between the calcareous deposits and the blood current has been broken down by the atheromatous process, it may disappear in the blood and leave the flakes of calcareous matter exposed to view from within. These in turn may be carried away, or they may be undermined by the blood current and lead to aneurismal pouches by dissection. With atheroma, calcareous degeneration may invade the entire arterial system, the arteries of the extremities becoming brittle and unyielding. The smaller arteries are most apt to be involved, especially those of the brain.

In many cases of atheromatous and calcareous degeneration in the

aged, enormous dilatations occur. The dilatation is not uniform, as a rule, but the walls of the dilated artery (usually the aorta and the arteries of the second class) are pouched in many places. The calcareous matter will be found to be thickest in those portions of the wall which are less dilated, while the dilated pouches have undergone a more complete fatty degeneration. This condition is commonly known as *arteritis deformans*.

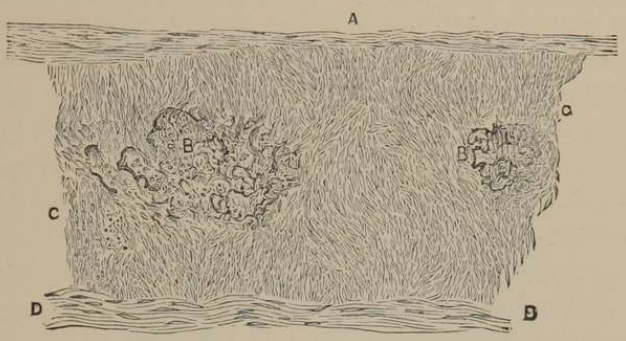

Fig. 293.—Showing calcareous degeneration of the media. A, intima; C C, media; D, adventitia; B B, calcareous patches. Ulnar artery. Magnified about 60 diameters. (From a specimen prepared by Dr. W. L. Wardwell.)

The middle coat may be in places entirely destroyed, when the changed intima will be joined with the adventitia by a connective-tissue new formation, which contains vessels passing directly to the intima. Loss of the elastic tunic is one of the immediate causes of spontaneous aneurism (Cornil and Ranvier).

This condition of atrophy of the elastic lamina is well shown in Fig. 293, which was drawn from one of my specimens.

Calcification of arteries has been especially studied by my former pupil, the late Dr. W. L. Wardwell, of New York city, in Conheim's Laboratory. His experience includes examinations made from twenty-five cases at the request of Conheim, who approved his conclusions. Dr. Wardwell says all authorities recognize a morbid change in the arteries known as calcification, and the majority look upon it as a change secondary to atheroma or endarteritis. Few of these recognize a primary calcification not dependent upon a preceding inflammation. This condition is, however, the chief change in the senile calcification of arteries. The microscopic appearances of primary calcification are well shown in Fig. 294.

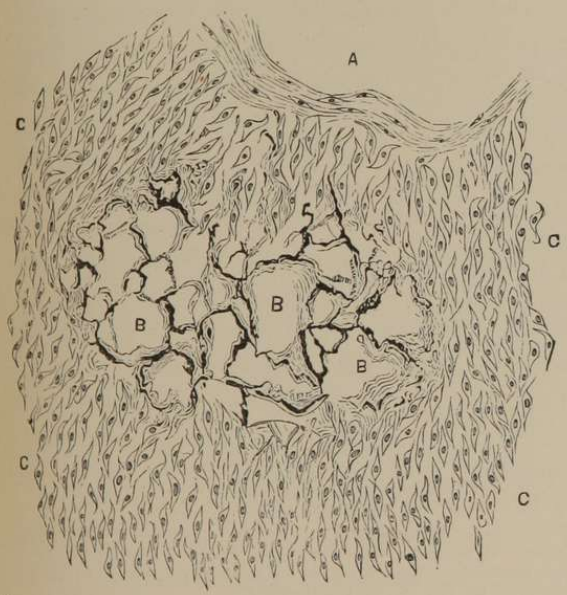

Fig. 294.—Arteritis with primary calcification. Section from human radial artery, showing at B primary calcification of the media, C. A, the intima comparatively unchanged. (Drawn from specimens prepared by Dr. W. L. Wardwell, at Conheim's Laboratory. Magnified about 350 diameters.)

Conheim states that in senile arterial calcification sometimes the media, sometimes the interna (its outermost layer), is affected, and that in them the lime salts are deposited. Moreover, that this deposit of lime

takes place here because these tunics have been subjected to the greatest strain.

Weigert* describes a "hitherto undescribed" process known as *coagulation necrosis*. He argues that all tissues have the power of spontaneously coagulating, it being necessary for such an occurrence that the cells should die, give up their ferment and fibrino-plastic material, and then become saturated with a fibrinogen-holding lymph. This morbid process he holds may occur in tissues the most diverse in character, as in cheesy glands, infarcts of the spleen or kidneys, tumors, the inflammatory material around parasites, tubercle, etc. Macroscopically, these coagulated spots have a peculiar, stiff appearance, and, microscopically, they are recognized by the fact that the cell nuclei have disappeared, and can not be made to appear by reagents or by the material used for staining in microscopical examination.

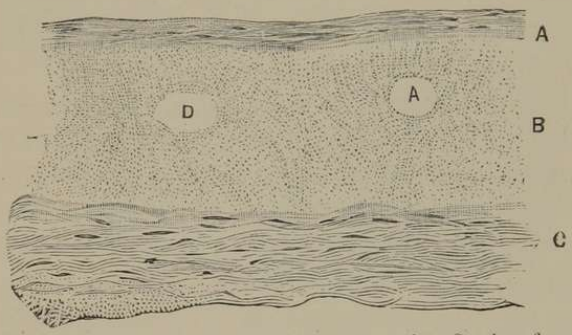

Fig. 295.—Arteritis with coagulation necrosis. Section from human artery treated with acetic acid, showing at D spots of coagulation necrosis which contained calcareous salts before being treated with the acid; A, intima; B, media; C, adventitia. (Drawn from specimen prepared by Dr. W. L. Wardwell. Magnified about 40 diameters.)

These conditions are shown in Figs. 295 and 296.

Syphilitic Arteritis.—Arteritis is a part of the pathology of syphilis. The first danger to life in this disease comes from the changes in the capacity of the arteries. No part of the arterial system is exempt, though the most serious lesions are found in the vessels of the brain, and next in the aorta. They become grave in the larger trunks on account of the atheroma resulting from the syphilitic poison (inducing aneurism), and in the smaller arteries (especially those of the brain) from occlusion or atheroma.

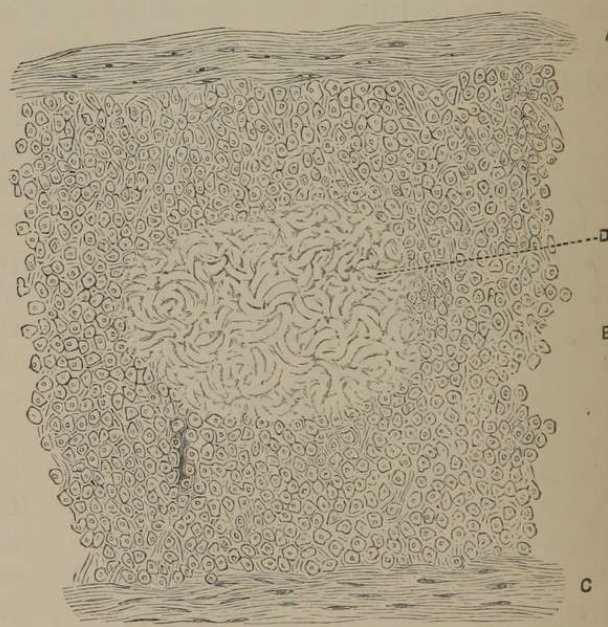

Fig. 296.—Posterior tibial artery. Section showing coagulation necrosis. A, intima; B, media; C, adventitia; D, spot of coagulation necrosis. Magnified 360 diameters. (From a specimen prepared by Dr. W. L. Wardwell.)

Even in the initial lesion of syphilis (the chancre), according to Biesiadecki, the capillaries of the papillæ have in their thickened walls

* Virchow's "Archiv," Bd. lxxix, S. 87.

many nuclei, some of which are seen to project into the lumen of the vessel.

The arteries of the base of the brain, especially the basilar and those at the commencement of the fissure of Sylvius, are often seriously involved. I have seen two cases in which death resulted from anæmia of the medulla, due to a more or less complete thrombosis of the basilar artery. One of these died in my presence. A few days previous to his death he had complained of dizziness, and of a sensation as of insects crawling over the integument of the extremities. Death was quite sudden, and was due to respiratory failure. He became quickly unconscious, the respiratory movements were irregular, and co-ordination of movement between the expiratory and inspiratory muscles was seemingly lost. The mode of death was different from anything I had ever witnessed. At the autopsy, the basilar, just where it divided into the two posterior cerebrals, was found almost completely occluded by a thrombus. There was no other lesion which could have accounted for death. Syphilis had existed for several years.

In the second case syphilis had existed for nineteen years, with right hemiplegia for the last sixteen years of life. This patient was under my care for nearly five years. She would never consent to take the iodides or any medicine. Her mind was clear up to the time I last saw her before death, which occurred suddenly one night. I did not see her until life was extinct, but, from the description of the mode of death given me by Dr. F. J. Ives, who was present, I was led to express the belief that a similar condition existed as in the case first referred to. On examination, I found a thrombosis of the basilar artery in exactly the same location. Fig. 297 represents a section of the artery near the thrombus. The lumen of the vessel is seen to be about two thirds occluded. The adventitia is slightly thickened, and the cell elements in it are distinctly fusiform, and regularly parallel with each other and with the contour of the adventitia. The wavy elastic layer is easily recognized, and in that portion of the artery in which the syphilitic inflammatory material is deposited the waves of the media are more numerous and shorter than in other portions of the vessel. In the center of the mass, occupying a portion of the caliber of the artery, is found a hyaline-look-

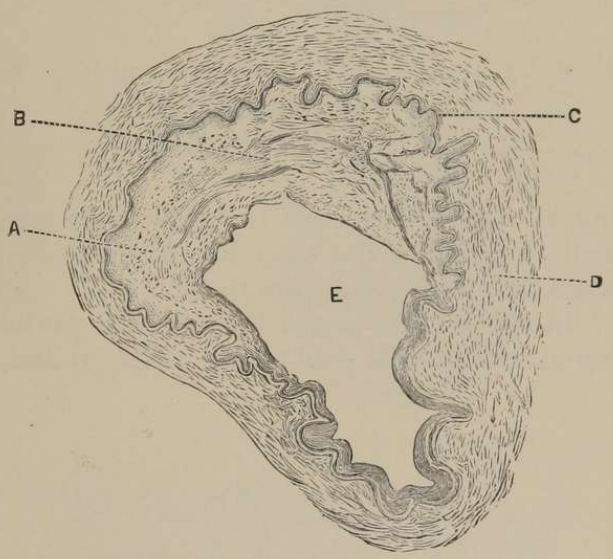

Fig. 297.—Syphilitic arteritis. Section of basilar; E, lumen of vessel about two thirds filled with new formation at A B; C, media; D, muscular layer and adventitia. From a patient dead from syphilis. (Specimen of the author's, drawn by Dr. Wardwell. Magnified about 40 diameters.)

ing spot which took the carmine stain more readily than the general mass of the thrombus. It contains embryonic cells in about the same quantity as the surrounding tissue. The adventitia is not regularly thickened, being three or four times as deep in some portions as in others, and presenting in the section a nodulated appearance. Viewed with a magnify-

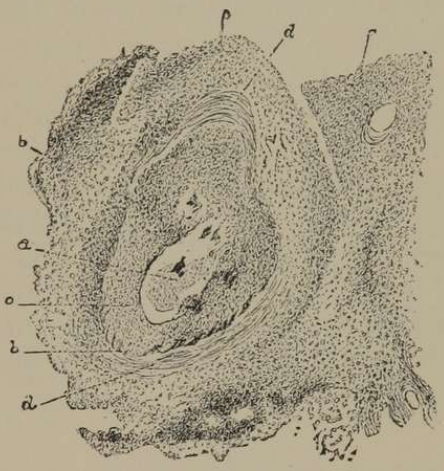

Fig. 298.—Syphilitic arteritis. Shows section of small cerebral artery near a gumma, magnified 30 diameters. *a*, lumen of vessel; *b*, boundary of inner middle coats; *c*, thickened inner coat; *d*, middle coat; *e*, external coat; *f*, infiltrated pia mater. (After Greenfield.)

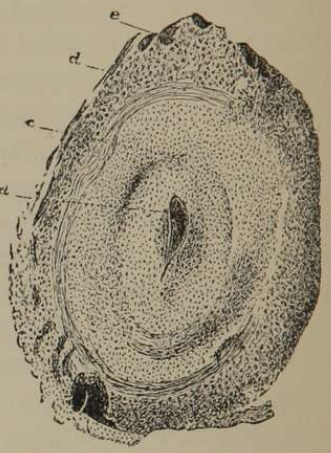

Fig. 299.—Syphilitic arteritis. Section of small artery of cerebellum, magnified 30 diameters. *a*, lumen of vessel; *c*, thickened inner coat; *d*, muscular coat; *e*, outer coat. (After Greenfield.)

ing power of about five hundred diameters, that portion of the arterial wall external to the wavy line (the elastic layer), seen in Fig. 297, presents the following appearance:

In the most external limit of the section of the adventitia there are found clusters of embryonic cells, round, and larger than the cells

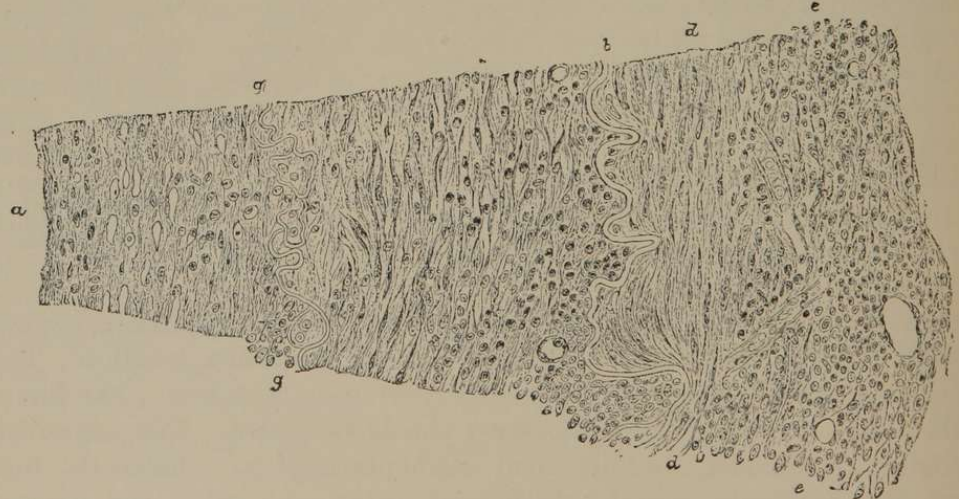

Fig. 300.—Syphilitic arteritis. Segment of the preceding specimen, magnified 170 diameters. *a*, lumen of vessel; *b*, fenestrated membrane; *a*. *c*, thickened intima; *d*, muscular coat; *v*, adventitia; *g*, new-formed imperfect elastic lamina. (After Greenfield.)

found in any other portion of the specimen external to the elastic lamina. These cells are somewhat smaller in size than those found in the new-formed tissue of the intima, though they differ in shape, since

those in the intima appear both round and fusiform, while the cells in the outer edge of the externa appear almost invariably round. It may be possible that they are fusiform cells cut transversely in the section; though after careful examination I am led to conclude that they are round. At various points these cells do not exist, the external layer being that of fusiform cells arranged with great regularity parallel to the contour of the wall of the artery. Where the wall of the vessel external to the elastic lamina is thickest, these spindle cells are more numerous, and have a greater transverse diameter than at the narrower portions, where they seem to have elongated and become thinner—seemingly a true process of fibrillation and contraction of embryonic (inflammatory) cells.

Continuing the examination farther inward, as the white, wavy, elastic zone is crossed, just within and almost in exact apposition with this is a somewhat irregular and thin layer of cells, fusiform in section, vary-

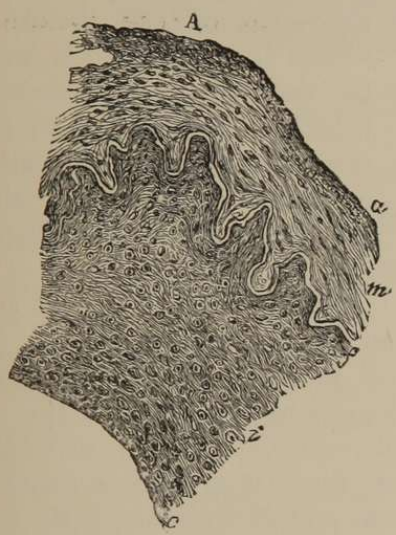

Fig. 301.—Syphilitic arteritis. Transverse section of a segment of the middle cerebral artery of a syphilitic patient. *i*, the thickened intima; *e*, the endothelium; *f*, the fenestrated membrane; *m*, the muscular coat; *a*, the adventitia. (From Barlow's Specimens, Green's "Pathology.")

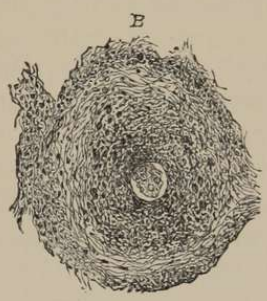

Fig. 302.—Syphilitic arteritis. Section from a small artery of the pia mater cut transversely, showing the inner coat much thickened, a diminution of the lumen of the vessel, and a considerable infiltration of the adventitia. A clot is seen to occupy a great part of the lumen of the vessel. (From Barlow's Specimens, Green's "Pathology.")

ing in depth from a single row to two or three rows, and in some points entirely absent. These are doubtless a remnant of the original endothelia of the intima; just internal to these, and in fact continuous with them, is the great mass of new-formed, inflammatory tissue which juts into the lumen of the vessel. This mass is composed of large, mostly fusiform, cells, distinctly nucleated and occupying about as much space as the intercellular substance in which they are imbedded.

According to Greenfield, the inflammatory process in and around the perivascular canals in syphilis is entirely different from that in tubercular infiltration of these canals.

In vessels examined by Barlow, the same changes are reported as those given above (Figs. 301, 302). The adventitia and muscular coats

were more or less affected, "but obviously the principal changes have taken place in the intima."

Rheumatic Arteritis.—Arteritis may occur in connection with acute rheumatism. Bryant states that this is a rare form of disease. Rheumatic endocarditis is not so rare, and it is possible that endarteritis may exist in the aorta in many cases of endocarditis. This and the arteritis of gout and nephritis (Fig. 303) belong to the domain of medicine rather than to that of surgery, and will not therefore be considered in this work.

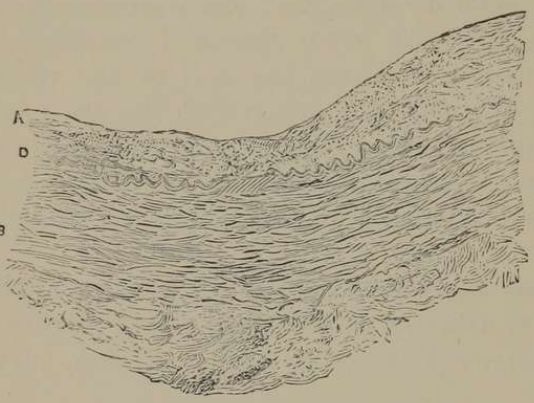

FIG. 303.—Arteritis with chronic nephritis. Section from posterior tibial artery of patient dead from Bright's disease, showing at A great thickening of the intima, the result of chronic endarteritis. The elastic lamina, D, unchanged. The muscular layer, B, slightly thickened. C, adventitia greatly thickened at places by small-cell infiltration. Drawn from specimens prepared by Dr. W. L. Wardwell, at Conheim's Laboratory. (Magnified about 40 diameters.)

The *treatment of arteritis* resolves itself simply into the treatment of the disease of which it is a part. It would be useless to increase the length of this article by a recapitulation of the various methods and remedies which have been employed. If the pathogeny and pathology of the affection are understood, its therapy is not difficult.

Arterial Thrombosis and Embolism.—Though not as frequent as in phlebitis, thrombosis and embolism often result from arteritis. The pathology of thrombosis has been given in the section on phlebitis. The process in the arteries is closely analogous to that in the veins.

The perfect type of thrombosis from acute, traumatic arteritis is found after the application of an occluding ligature around an artery.

By reason of arrest of the blood current and disturbance of the equilibrium normally existing between the blood and the containing vessels, coagulation takes place on the cardiac side of the ligature, extending back as a rule to the first collateral branch. Immediately following the injury to the vessel, under aseptic conditions, the process of inflammation—arteritis—commences. The tension of the ligature to such degree as to divide the inner or middle coat, or both, is unnecessary.*

The coagulation thrombus disappears by fatty degeneration. The permanent occlusion is due to new-formed tissue springing from the normal cells of the intima and the fixed cells of the adventitia. O. Weber held that the clot became organized into a true tissue, into which

* The author's researches are confirmed by the classical work of Ballance and Edmunds on "Ligation in Continuity," page 468: "Wyeth says the tension of the ligature to such a degree as to divide the inner or middle coat, or both, is unnecessary. I have tied arteries (carotid and subclavian) in human beings and in horses and dogs, and have specimens which demonstrate successful occlusion of the vessel without division of either of the three tunics. Scarpa advanced this idea years ago, but surgeons generally have decried it. None the less it is true, and I am fully convinced by experience that it is safer than the division of one or two coats of a vessel by tightly drawing a narrow cutting ligature around the artery."

blood vessels were projected from the vasa vasorum (Fig. 304). But Cornil and Ranvier long since disproved this. Bubnoff held that the white blood-corpuscles emigrated through the walls of the ligatured ves-

Fig. 304.—Longitudinal section of the artery of a dog fifty days after the ligature. Clot injected. Magnified 40 diameters. (After O. Weber.)

sels, permeated the clot, and caused its organization ; but Durante (Cornil and Ranvier) demonstrated that the leucocytes only traverse the walls of the vessel when this has been tied with a double ligature, causing a death of the included vessel, and that the leucocytes travel through this dead tissue. They do not permeate the walls of an otherwise healthy artery which has been tied with a single ligature.

Cell proliferation takes place rapidly in the intima ; granulation buds project into the territory occupied by the clot (Fig. 305) ; blood vessels derived from the vasa vasorum permeate the projecting granulation tissue, invade the clot, meet with vessels from the opposite side, and join with these in a continuous circulation ; the embryonic tissue organizes, gradually contracts (process of cicatrization), and the walls of the vessel are permanently occluded by this fibrillation. Afterward the new-formed vessels disappear to a great degree, being obliterated by the process of contraction.

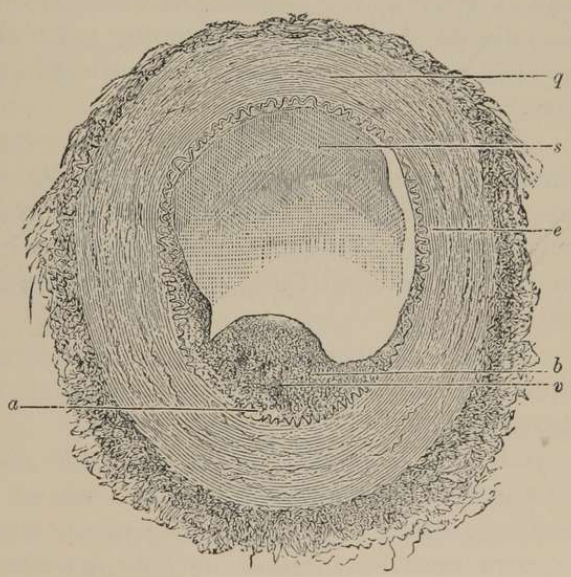

Fig. 305.—Traumatic endarteritis. Transverse section of the femoral artery of a dog eight days after the application of a ligature. *e*, the elastic lamina ; *p*, the media ; *b*, granulation bud projecting from the intima into the lumen ; *v*, new-formed vessel running through the inflammatory tissue. At *a* the elastic layer has partly disappeared. Magnified 30 diameters. (From Cornil and Ranvier.)

Thrombosis from acute arteritis is rare. Chronic arteritis is not infrequently the cause of occlusion. Syphilitic arteritis is apt to develop thrombosis of the cerebral arteries. Arterial thrombosis (excluding the vessels to the brain and walls of the heart) is not as dangerous to life as venous thrombosis.

The process is usually so gradual that the collateral circulation is established before occlusion of the main trunk occurs. This may, indeed, escape observation until the enlarging superficial arteries attract attention.

Vascular Tumors.

We may recognize six varieties of vascular tumor, apart from true aneurism. These are: 1. Arterial varix; 2. Cirsoid arterial tumor (cirsoid aneurism); 3. Arterial cutaneous tumor; 4. Capillary cutaneous tumor; 5. Venous cutaneous tumor (these three varieties are usually classed together under the name of angeiomata); and 6. Venous varix, or simple varix (varicose vein).

Arterial Varix may be defined as a dilatation and elongation of an artery of the second magnitude (as the external iliac or common carotid), of the third (as the external carotid or posterior tibial), or of the fourth (as the temporal, facial, superior thyroid, or palmar branches of the radial and ulnar). Cruveilhier has reported a case of *arterial varix* of the external iliac artery. I have made one dissection of *arterial varix* of the superior thyroid artery, in which this vessel was greatly elongated, and as large as the external or internal carotid. It was tortuous, but not sacculated, the dilatation being general. Tillaux* reports a case of *cirsoid aneurism* of the hand, with dilatation of the arteries of the forearm and humeral region.

Treatment.—Arterial varix may be treated by compression, or by the ligature, when such a procedure becomes necessary. In a case which I saw after the patient's death, and in which the superior thyroid artery was involved, the ligature would have been advisable. The artery was in a healthy condition, with the exception of its increased length and caliber.

When connected with *cirsoid arterial tumors*, the solidification of these by ligature, cautery, or injection, will usually cure or palliate the arterial varix.

Cirsoid Arterial Tumor (*Cirsoid Aneurism*).—The *cirsoid arterial tumor* is an elongation and dilatation of the terminal subcutaneous arterioles (normally of a diameter of about one fiftieth of an inch). These tumors may be general or circumscribed. A single arteriole may be affected, or many arterioles may be involved.

The causes of *cirsoid arterial tumors* are not positively known. They occur most frequently upon exposed surfaces of the body, as on the neck, head, and hands. The face and head are most frequently the seat of all forms of vascular subcutaneous and cutaneous tumors.

* "Gaz. des hôpitaux," 1882, p. 1083.

Excluding those of the orbit, I have collected more than ninety cases in which the carotid arteries were tied for these lesions.

Either peripheral or central disturbances of the functions of the vasomotor nerves may lead to loss of tone in the muscular walls of the arteries. Frostbite and blows have been mentioned as causes of cirsoid aneurism. Berger reports a case of cirsoid tumor of the hand caused by irritation, from constant pressure of an instrument which the patient used in his trade. The disease may be congenital, or may result from the increased growth of a cutaneous nævus. It is met with most frequently between the ages of fifteen and thirty.

Symptoms.—Abnormal pulsation is the first symptom of cirsoid aneurism. Petit describes the sensation imparted to the palm of the hand as similar to the vermicular motion of a mass of earthworms.

With the stethoscope, a *bruit de souffle* is distinctly audible. Pain is not constant, and is only due to the pressure of the growth upon the cutaneous nerves. As the tumor progresses in size, more marked inflammatory changes occur; adhesions to the skin take place; and ulcerations, with alarming hæmorrhage, are not infrequent. In some instances, especially in cirsoid tumor of the scalp, pressure of the growth upon the calvaria may interfere with the nutrition of the skull.

Treatment.—It may be said of the treatment of cirsoid arterial tumors, in common with arterial, capillary, and venous cutaneous tumors, that no method is as safe or sure as direct local treatment. For a long time deligation of the main trunk or trunks was the favorite practice. Sometimes this was done to arrest hæmorrhage due to ulceration or accident, in some few cases to arrest hæmorrhage after or during an attempt at removal, but most frequently the intention was to cut off the blood supply. Since the vast majority of vascular tumors occupy the neck, face, and scalp, the carotids have been often tied in the treatment of these growths. In my "Essays in Surgical Anatomy and Surgery"* I have collected 98 cases of ligature of the carotid for vascular growth above the clavicle, and chiefly of the head. This number does not include 60 cases of pulsating vascular tumor within the orbit. The results are not such as to encourage the careful operator in a repetition of the procedure.

Even in the nine cases in which both common trunks were tied,† only one was cured (not, however, until after compression was made over the tumor), and two were improved. Mussey's patient was only improved after the second ligation, but was cured after a bloody excision. The tumor was exceedingly large, and the dilated arteries were tied one by one. More than twenty ligatures were applied, and the hæmorrhage is said to have been dangerously profuse.

Other surgeons besides Mussey‡ who have practiced excision of cirsoid arterial and other "vascular tumors" are Busch,‡ Heine,‡ Graefe,#

* New York, 1879.

† The operators were Blackman, Gunderloch and Müller, Kuhl, Mussey, Pirogoff, Robert, Rodgers and Van Buren, Ullman, and Warren.

‡ See the author's "Essays in Surgical Anatomy and Surgery," New York, 1879.

Holmes's "System of Surgery," second edition, vol. iii, p. 540.

Gibson,* Buchanan,† Sydney Jones,‡ Warren,# Weitzer,* Guéniot,* and Hart.* The latter froze the tumor, and cut well into the sound tissue; little blood was lost. The late Prof. Spence, of Edinburgh, cured a deep-seated erectile tumor of the hand by galvano-puncture. ‖ Nélaton operated in a cirsoid tumor of the forehead in a similar way, and with like success.

Direct local compression has been tried by patient and expert surgeons, but has not met with success. In carefully performed excision through the sound tissues and near the limit of disease will be found the safest procedure.

Angeiomata.—The three next varieties of "vascular tumor," which may be grouped together under the name of *Angeiomata*, are: (1) The *Arterial Cutaneous Tumor*, or *Aneurism by Anastomosis*, composed of dilatations or elongations of the arterioles, either normal or new-formed, in the skin; (2) the *Capillary Cutaneous Tumor*, consisting of dilatations and elongations of the normal or new-formed capillaries of the skin; and (3) the *Venous Cutaneous Tumor* (*Cavernous Nævus*), composed of dilatations of the normal or new-formed venous radicles of the skin.

The angeiomata are considered by some writers as strictly new formations of blood vessels. There is little doubt, however, that many vascular tumors are chiefly made up of normal vessels which have undergone dilatation or hypertrophy. Other names that have been given to angeiomata are congenital nævus, erectile tumor, telangiectasis or plexiform angeioma, aneurism by anastomosis, cavernous nævus, and fungus hæmatodes. According to Depaul, one third of the children born in one of the eleemosynary institutions at Paris had congenital nævi, the greater number of which disappeared spontaneously during the first few months of life. They occur chiefly in the skin, and are especially apt to appear on the forehead, face, ears, and neck.

Structure and Symptoms.—Angeiomata commonly form flattened, slightly projecting tumors, varying in size from a mere speck to as much as an inch in diameter, and are composed of new-formed, dilated, freely anastomosing capillaries, arterioles, and veins, in irregular, labyrinthine masses. They vary in color, being at times grayish blue or red. Often the only indication of their presence is the appearance of a diffuse redness over a considerable surface. Examined microscopically, the walls of the vessels are crowded with cells, and the vessels are imbedded in a network of fibrous and adipose tissue. The superficial and deep cutaneous vessels—including the vessels of the hair follicles, sweat glands, and adipose tissue—join in the formation of these tumors. The disease may extend into the muscles and deeper tissues.

The majority of angeiomata are soft and yielding, and can be emptied

* Holmes's "System of Surgery," second edition, vol. iii, p. 540.

† "British Medical Journal," June, 1875, p. 835.

‡ "Lancet," 1882.

See the author's "Essays in Surgical Anatomy and Surgery," New York, 1879.

‖ "Medical Times and Gazette," August 21, 1875, p. 209.

by pressure; but when of great vascularity and long standing, when there has been an extensive proliferation of the perivascular connective tissue, pressure will not cause their disappearance. Some are very painful, and others entirely free from sensibility.

Venous cutaneous tumors are composed, in great part, of new-formed, erectile tissue, analogous to that found in the corpora cavernosa. Their structure is white and dense, the caverns communicating freely with each other. In rare instances they are known to contain chalky concretions (*phlebolites*). The circulation is active in these tumors, and their volume variable.

The walls of the sinuses contain a dense, fibrous stroma, involuntary muscular tissue, and striated muscular fibers when the tumor is encroaching on the muscles. They are lined by the same endothelium as the normal veins.

These tumors are not all erectile, and some which have been erectile for a time lose this property. Gross describes a form of nævoid tumor as *nævoid elephantiasis*, consisting of a hypertrophied condition of the skin and subcutaneous connective tissue. The affection, which is either congenital or comes on soon after birth, is found usually in the lower extremities, though it may occur elsewhere.

Angeiomata may develop in lipomata and other neoplasms. They have been known to originate as a result of injury or frostbite. In addition to the tissues already mentioned in which anegiomata are developed may be mentioned the spleen, kidney, liver, and lung. The liver is frequently, the lung very rarely, involved. In bones, this disease exhibits the same erectile characters as in other structures (Fig. 306). It occurs in the flat bones by preference, especially those of the cranium, jaws, and scapula, being often very painful, and grave as to prognosis. Angeiomata are not infrequently situated on the labia of women.

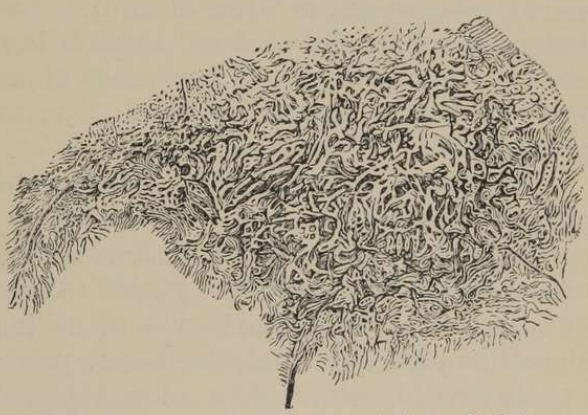

Fig. 306.—Aneurism by anastomosis in parietal bone. (Erichsen.)

The question of the relation of these tumors to carcinomata and sarcomata is worthy of consideration. J. Müller has reported a *malignant* (recurrent) angeioma. A case of melanotic degeneration of a congenital nævus in a woman aged forty has been reported. The vascular dilatations in osteo-sarcomata, and in other forms of carcinoma and sarcoma, are analogous to those found in cavernous angeiomata. Some of the malignant tumors pulsate like the angeiomata. An angeioma may be diffuse or encapsulated.

The *prognosis* depends upon the size and location of the neoplasm.

The *diagnosis* is not difficult in the superficial tumors, but in those

deeply situated, and in the track of large vessels, the differentiation from aneurism is not easy.

The arterial and capillary cutaneous tumors are almost always congenital; the venous tumors are rarely so. Angeiomata may be distinguished from osteo-sarcomata, which have perceptible pulsation, by the crackling impression conveyed to the sense of touch from the malignant tumors of bone.

Several consecutive telangiectases may occur in the same individual. Hutchinson, reports the case of a child which had over one hundred nævi, all distinct and superficial. Vascular tumors on the scalp have an element of danger not present in angeiomata elsewhere, in that they at times grow to such an extent as to cause necrosis of the calvaria.

Treatment.—Angeiomata have been known to heal without surgical interference, as a result of an infectious inflammation.

Angeioma of the face, or of any exposed surface where a scar is to be avoided, is best relieved by the clean cut of the knife, since the cicatrix is less deforming than that produced by other modes of treatment. I have removed a number of these growths from the scalp and face. The incision should be made along the edge of the tumor, *cutting only through healthy tissue.* When this precaution is taken, hæmorrhage is not dangerous. Of course the operation is not justifiable if telangiectasis involves more surface than can be covered by stretching or sliding the sound integument, or when it requires removal of the eyelid, ala nasi, or too much of the lip or ear. In such instances galvano-cautery needles should be employed. In cavernous tumors of large size the following method, recommended by Prof. Esmarch, of Kiel, should be recommended:

Immerse a middle-sized silk thread for half an hour in tinct. ferri. chlor.; remove and dry and sterilize by heat. The tumor surface is carefully cleansed and a round, straight, or slightly curved needle is armed with this thread and passed through the tumor in all directions at intervals of about one fourth of an inch. The first series of threads should be passed through the deeper portions and parallel. If the nævus is considerably elevated, a second layer should be inserted at a right angle to the first. The threads are cut off a half inch from the surface of the tumor and left in position. A light sterile gauze dressing should be laid on, and over this a layer of borated cotton, held in place without too much compression by a bandage.

In from two to four days complete coagulation occurs and the threads are to be removed. If absorption is not rapid, the coagulated mass may be removed by dissection. By this procedure I succeeded in consolidating and removing an enormous cavernous nævus of the face. The disfigurement was very slight.

Venous Varix, Varix, or Varicose Vein.—This variety of "vascular tumor" consists of a dilatation and elongation of the deep or subcutaneous veins. This condition may exist in any portion of the body, even in the bones (Cornil and Ranvier). It may involve a small portion of one vein, superficial or deep, or, as is most usual, a chain of veins. It is most

frequently observed in the superficial veins, though Verneuil says that varix is really as common in the deep-seated as in the superficial vessels (Bryant). It is especially prone to occur in the saphena veins. Hæmorrhoids and varicoceles are common forms of varix. Unusual types are the dilatation of the jugulars from stenosis of the vena cava descendens, and that of the superficial abdominal veins from stenosis of the ascending cava. Such conditions are described by some authors as simple hypertrophies or dilatations of veins. Any long-continued dilatation constitutes a varix. Hyperplasia of the normal tissues of the venous wall is the natural sequence of prolonged pressure and increased function. The hypertrophy of the wall is not always equal to the resistance of the increased pressure; hence sacculated pouches occur when the vessel wall becomes much thinner than normal, not infrequently resulting in rupture. Varix is of frequent occurrence in women who have had repeated pregnancies (Billroth).

Poorly fed and hard-worked persons, especially those who work in the upright posture, are more prone to varix than others. There can be no doubt that gravitation is the chief and immediate cause of this disease. The veins most subject to the greatest, prolonged blood weight, and least protected by pressure, are involved in the great majority of cases. Paralysis of the muscular walls, either by atrophy of the muscles or interference with the function of the *nervi vasorum*, may cause varix. This is proved by the fact that a small segment of a single vein in the upper portion of the body, where the anastomosis is free and gravitation can not be considered as a factor in the dilatation, may be the seat of this affection.

In well-marked *varix* the veins are greatly increased in caliber and in length, so that they seem coiled and twisted upon themselves in knotted masses. They are narrowed in caliber at frequent intervals, these contractions opening into expanded pouches, in general appearance not unlike the sacculated large intestine. The valves are wholly inefficient, often flattened against the wall, or at times partially destroyed. At the level of the valves the walls are exceptionally thickened. The thickening is due to a multiplication of the muscular elements and hyperplasia of the connective tissue. The connective-tissue new formation is abundantly distributed in the meshes of the elastic network, and the bundles of fibers are usually arranged parallel with the long axis of the vessel. This accounts for the longitudinal ridges seen on the inner surface of the affected veins (Cornil and Ranvier). Even the nutrient vessels of the walls of these varicose veins—the *vasa vasorum*—have undergone hypertrophy, and are themselves the seat of varix, forming at times venous caverns in the wall of the vessel, which communicate with the vein. The internal tunic is not, properly speaking, thickened, except at the points of attachment of the valves, or where a thrombus has formed.

Immediately external to the middle elastic tunic, the muscular tissue appears increased in quantity, arranged in transversed and perpendicular laminæ, separated by bundles of hypertrophied connective tissue, which are not infrequently stained with granular pigment. Calcareous deposits

occur primarily within or between these connective-tissue bundles (Cornil and Ranvier).

Hyperplasia of the connective and other tissues in the immediate vicinity of the varix of long standing presents the usual appearances of elephantiasis. Small spots of ulceration occur as a result of malnutrition, and, coalescing, form the large and obstinate ulcers seen so frequently in varix of the legs. The veins become greatly elongated and assume different shapes, irregularly sinuous or corkscrew-like, twisted upon their axes, and frequently, on account of perivascular inflammation, matted together by new-formed connective tissue into venous tumors. Occlusion of varicose veins may result from thrombosis, and a cure may thus ensue. Frequently concretions are found in varicose veins, at times adherent to the walls. These concretions are called *phlebolithes* or *phlebolites* (Dunglison).

Treatment.—Varicose veins may be treated radically or conservatively. Occurring in young or middle-aged subjects, the operation of deligation or excision should be performed. In the case of a student at the United States Military Academy at West Point, who, at the end of his second year, developed large varicosities of the right saphenous vein, for which he was about to be discharged, I operated by excising this vein in its entire length, applying ligatures to the collateral branches. It was first tied about two inches below the saphenous opening in the thigh, and an incision through the skin made the entire length of the vein. The collateral branches were tied off, the main trunk and the varicosities excised, and the wound closed with catgut and covered with a dressing of sterilized gauze. The patient recovered cured.

When the varicosities are confined to the leg, if large and tending to inflammation, they should be excised. Small varicosities may be operated upon with cocaine anæsthesia and catgut ligatures applied at two or more points along the course of the vein. In the conservative treatment an elastic stocking properly fitted gives great comfort and prevents the formation of ulcers. When this can not be obtained, an Esmarch elastic bandage may be employed or a tight-fitting flannel bandage may be applied.

Moles.

Closely connected with the more superficial forms of vascular tumor are the abnormal, circumscribed hypertrophies of the skin, which are known as *moles*. They may be, and usually are, congenital, or they may be developed at any period of extra-uterine life. All portions of the cutaneous surface may be the seat of this form of hypertrophy, but the exposed surfaces, such as the face, neck, and hands, are most frequently affected. The hypertrophy which constitutes the mole may involve all or any one of the tissues which enter into the anatomy of the integument. The most frequent variety is that which occupies the face, as a simple elevation from which a few stiff hairs grow. It is not stained with pigment, and differs very slightly, if at all, in color from the normal skin. The lesion here is a true hypertrophy of all the tissues

of the skin, chiefly in the derma and papillary layer. The vascularity is slightly increased, and the sebaceous glands connected with the hair follicles take part in the hypertrophy. On other portions of the body this form of mole (*nævus vulgaris*) will have no hairs growing from its surface.

Nævus pigmentosus is not usually a thickening of the entire cutis, as is the simple mole just described, but its pathological condition is an excessive deposit of pigment in the Malpighian layer and in the epidermis. It varies in color from a slate-gray to a blue, mahogany, reddish-brown, or wine-color. At times the pigment mole will extend over a large area, occupying as much as one third or one half of the face. The lobule of the ear, and the integument between the eyes and over the temple, is the most common location of this deformity. Another name for these spots is "*port-wine mark.*"

When the hypertrophied area of skin is studded with hairs, it is known as *nævus pilosus*, or hairy mole. It follows from the name that this kind of hypertrophy can only occur on those portions of the cutis in which the hairs grow. The plantar surfaces of the feet and the palms of the hands are never affected. They may or may not be stained with pigment. The majority of hairy moles are not colored.

Moles, whether simple, hairy, or pigmented, are benign. As a result of irritation and infection, they may become ulcerated, or may develop into malignant growths. Carcinomata, especially of the melanotic variety, are frequently described as having resulted from inflamed pigment moles. Alarming hæmorrhage has been known to occur from a mole more than usually vascular, in which ulceration had been established by friction of the clothing.

Treatment.—As long as no deformity or inconvenience results from these formations, it is better to let them alone. When situated upon the face, of such size or position that they become offensive to the eye, they may be removed by simple excision. The incision should be elliptical, and well away from the growth, going entirely through the thickness of the skin. The wound should be closed with fine sutures, or drawn nicely together with adhesive strips. The simplest method of procedure is to produce local anæsthesia by cocaine, and operate quickly. *Port-wine marks* may also be excised.

If a mole should at any time take on inflammatory action, or give any indication of malignancy, immediate excision would be imperative, and the incision should be wide of the supposed area of the disease.

CHAPTER XIV.

ANEURISM.

An aneurism is a sacculated tumor, the cavity of which communicates with an artery, and in rare instances also with a vein.

They may be classified as *spherical*, *fusiform*, and *dissecting*.

A *spherical* aneurism is one in which the tumor is well defined, its diameter being larger than that of the opening of communication with the vessel. It may spring from any portion of the arterial wall (Fig. 307, *e*), or, in rare instances, the vessel walls may yield in all directions to form the tumor (Fig. 307, *c*).

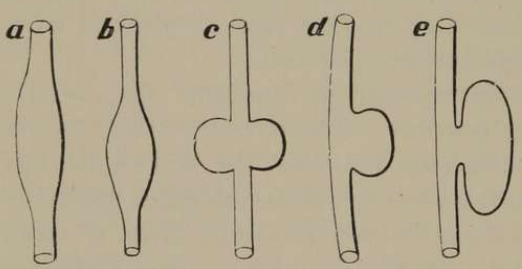

Fig. 307.

A *fusiform* aneurism is one in which there is a gradual and general dilatation of an artery in its entire circumference (Fig. 307, *a*, *b*). A spherical aneurism may occasionally develop from the wall of a fusiform dilatation.

A *dissecting* aneurism is one in which, owing to pathological changes in the intima, the blood insinuates itself between the inner coat and the adventitia, dissects the intima from the media and adventitia, and reenters the vessel at a distant opening.

Aneurisms are further divided into the *true* and *false*. To the former belong all tumors the walls of which are composed of the walls of the vessels from which they spring; to the latter belong those tumors the walls of which are composed of inflammatory new-formed tissue.

Cause.—A true aneurism is always preceded by *arteritis*, which results in atheromatous degeneration of the normal elements which compose the arterial wall.

The *pathology* of arteritis and the relation of this condition to various dyscrasiæ—as syphilis, nephritis, gout, rheumatism, etc.—have been fully dwelt on in a preceding chapter. Syphilis improperly treated induces aneurism in a large proportion of cases. The relation of violence to these tumors must not be lost sight of. No matter how severe the dyscrasia and the general condition of arteritis, which is a part of it, it is well known that in the large majority of cases aneurisms develop at those points in the arterial system which are subjected to the greatest violence from heart action, or muscular or mechanical pressure. Thus the arch of the aorta, and that portion of the arch in the direct axis of

the left ventricle, is very prone to aneurism, as are the great vessels near their origin from the aortic curve. The popliteal arteries, subjected as they are to violence in forced flexion of the legs, are frequently the seat of aneurismal dilatations.

From a study of the various conditions which produce aneurisms, it is evident that the normal wall of an artery can not form the sac of the aneurism. Some of the normal anatomical elements may be present in the sac, but the integrity of the whole is impaired.

An aneurism may in rare instances communicate with a vein (*varicose aneurism*) (Fig. 308). The direct communication of a vein and artery without a sac is known as *aneurismal varix* (Fig. 309).

If an aneurismal tumor be examined, it will be found to contain coagulated blood in all stages of fibrillation. The peripheral portion of the clot is composed of irregular laminæ, and, if examined with the microscope, the laminated appearance is found to be due to alternate layers of white corpuscles, and upon these a deposit of fibrin. As the center of the tumor is approached, the coagulation is evidently more recent, while in the cavity of the aneurism a soft post-mortem clot is usually found.

Fig. 308. Varicose aneurism.

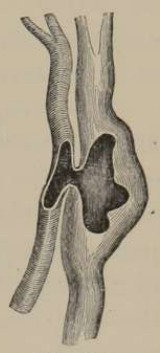

Fig. 309. Aneurismal varix.

Fusiform aneurism occurs most frequently in the thoracic aorta, with especial preference for the arch. It may affect the entire aorta, and the great vessels derived from it. Not only is the diameter of the arteries increased, but the hypertrophy results in a considerable increase in their length. Not infrequently a group of fusiform expansions may be seen with strips of sound and non-dilated artery intervening. Calcareous deposits occur in patches, and seem to give strength to the walls, since those portions give way more readily which are not the seat of calcification.

Coagulation is not apt to occur, as in sacculated aneurisms; in fact, it is a rare condition. Fusiform aneurisms develop slowly, and, as a rule, are painful and dangerous only when, by reason of their large growth, they exercise undue pressure upon important organs. Thus, in dilatation of the transverse arch, or of the right subclavian, spasm of the glottis occurs from irritation of the recurrent laryngeal nerves, or respiration and deglutition may be seriously embarrassed by direct compression of the trachea or œsophagus. Fusiform dilatation of the abdominal aorta may produce serious results from disturbance of the vaso-motor system, by compression of the sympathetic ganglia near the diaphragm, by partial or complete occlusion of the thoracic duct, etc.

Dissecting aneurisms are rare as compared with the other two varieties. The dissection or lifting of the thin lining membrane of the artery from the media usually occurs in the long axis of the vessel. If the middle and outer coats do not become involved in the degeneration which

has affected the inner coat, this form of aneurism may continue indefinitely, without leading to a fatal termination, although the danger of embolism can not be overlooked.

If the other layers give way, a sacculated aneurism is formed, with the adventitia for the sac, or rupture may occur, leading to fatal extravasation.

A *false*, or so-called "*diffuse*," aneurism results from the solution of continuity in all the coats of the vessel wall, and the sudden diffusion of blood into the peri-arterial tissues. The extravasation continues until the resistance of the surrounding tissues is equal to the pressure of the column of blood within the vessel. As a result of the extravasation, an inflammatory process, of variable intensity and usually non-infective, is established, which results in the formation of a limiting membrane, or aneurismal sac.

The *prognosis* in aneurism varies under widely differing conditions. In general it is a grave affection, the gravity depending, in a great degree, upon the location and character of the tumor and the physical condition of the individual affected. An aneurism of the cranial cavity will produce rapidly serious effects by compression of the brain. The gravity of a prognosis diminishes as the location of the tumor is removed from the cavities. Aneurism (especially the sacculated variety) of the aorta, innominate, subclavian, or iliac arteries, is an exceedingly dangerous affection, while the same condition in the distal arteries yields readily and safely to surgical interference in the great majority of cases. The prognosis may also, in part, depend upon the degree of discomfort experienced by the patient, from the effects of pressure upon contiguous organs. Neuralgia of the most painful and obstinate kind, resulting from pressure of the tumor upon a neighboring nerve, may hasten a fatal termination by loss of sleep and rest, and the general impairment of nutrition. Occlusion of the accompanying vein may occur, producing œdema and gangrene. Again, the gravity of the prognosis is increased when, by reason of its location, the sac of an aneurism is in contact with a bony surface, since rupture is not infrequently precipitated by attrition against the roughened bone.

The *symptoms* of aneurism are, in great part, *local*. They refer to the direct development and effect of the tumor. A sense of unusual throbbing pain, more or less severe, and swelling in the line of an artery (when the aneurism is outside of a cavity) which pulsates with the cardiac systole, which, when not resting upon a hard surface, is expansile in all directions, and which gives to the sense of touch a *tremor* not easily described but readily appreciated, are symptoms which point in general to the diagnosis of aneurism. The stethoscope, applied to the tumor, conveys to the ear the peculiar sound ("*bruit*") caused by the passage of the blood current from the narrow vessel into the expanded aneurismal sac and out again. If the tumor be situated upon one of the arteries of the extremities, compression upon the cardiac side will cause a cessation of the pulse tremor and bruit, and diminution of the swelling, while pressure upon the distal side will temporarily exaggerate these symptoms.

When an aneurism is developed as a result of a wound of an artery, the immediate symptoms of hæmorrhage and swelling, with the pulsating character of the tumor, will clearly indicate its presence. The differentiation is chiefly between solid or cystic tumors, which develop along the line of the artery, and are lifted by the arterial pulsation. Abscesses, or serous cysts, are the most difficult to recognize. In the formation of an abscess there is a previous history of inflammation. An aneurismal tumor expands equally in all directions, while any other tumor travels with the arterial pulse in one direction only—that of least resistance. In cases of great difficulty of diagnosis it will be justifiable to aspirate the tumor with the finest hypodermic needle.

Left to nature, the progress of an aneurism is, with rare exceptions, to a fatal termination. The deposit of fibrillated fibrin within, and the inflammatory new-formed tissue without, may retard, but rarely arrests, the progress of the disease. Added to the danger of death from rupture of the sac, or compression of neighboring organs, is that of inflammation and sloughing as the result of infection or overtension of the skin as the tumor approaches the surface. The hope of recovery is in the gradual deposition of fibrin within the sac, causing its ultimate occlusion, or that of the vessel or vessels immediately connected with it. The danger of gangrene in the parts beyond the tumor is lessened with the gradual establishment of the collateral circulation, while the sac and its contents are less apt to inflame than when the occlusion is sudden and the clot recent.

The *treatment* of aneurism is *constitutional* and *local*. The constitutional treatment is directed toward the judicious support of the physical powers of the patient, the relief from pain, and the production of a condition of the blood favorable to a deposit of fibrillated fibrin in the tumor.

The local measures are directed to the mechanical control and arrest, either gradual or immediate, of the circulation in the aneurism, with the same end in view, namely, the formation of fibrin within the sac.

Constitutional measures alone offer little hope of a cure, and are applicable only to cases where the dangers of operative interference are sufficient to contra-indicate any surgical procedure. In this plan of treatment rest in bed is the first and essential requirement. In conjunction with this there may be administered certain remedies which diminish the rapidity of the circulation, or affect the blood vessels or blood in such a manner that the gradual deposit of fibrin in the sac is produced. *Valsalva's* method of rest in bed, venesection, and gradual starvation, in order to slacken the blood current and thus cause coagulation in the aneurism, is now almost entirely abandoned. Though heroic, this plan of treatment is not without good results, as will be shown in the report of cases of special aneurism.*

Tufnell modified Valsalva's method by omitting bloodletting and substituting a restricted diet, with the minimum of fluids. Rest in the

* See "Subclavian Aneurism," fourteen cases by Valsalva's method.

recumbent position must be rigidly enforced. Among the remedies which have been recommended for internal administration, iodide of potassium is most important. It is especially efficacious in syphilitic aneurism, and it is often essential to combine mercury with it.

Among the many surgical procedures instituted for the relief of aneurism, those two which deserve the first consideration are *compression* and the *ligature.*

Compression may be employed on the cardiac side of an aneurism, close to the tumor, without an intervening collateral branch, or at a distance from the sac, with one or more intervening branches. It may be employed on the distal side, with or without intervening anastomosis, or directly to the surface and back of the tumor, or, again, on both peripheral and central sides, with or without direct compression of the aneurism.

The *ligature* may be applied on the *cardiac side* of the tumor, there being one or more branches given off between the ligature and the sac

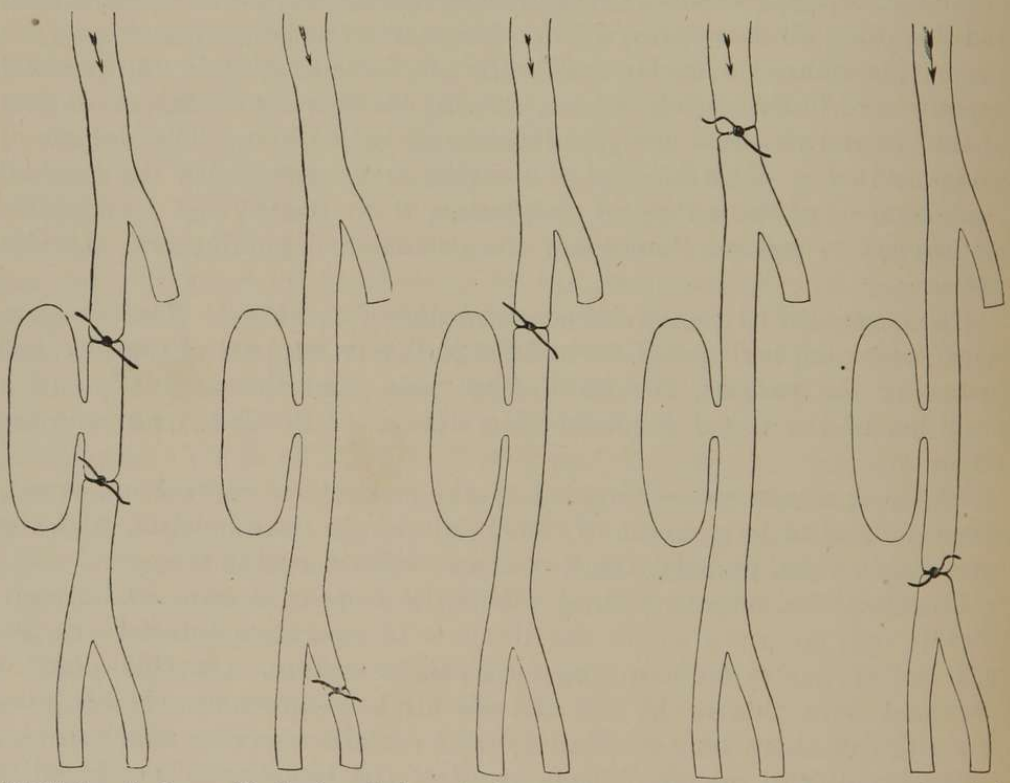

Antyllus's method. Wardrop's method. Anel's method. Hunter's method. Brasdor's method.

FIG. 310.

(Hunter's method), or without an intervening branch (Anel), or on the *distal side* without (Brasdor), or with an intervening branch (Wardrop), or close to the tumor on both the distal and cardiac side, with or without extirpation of the tumor (Antyllus) (Fig. 310).

When interrupted pressure upon the main trunk, on the cardiac side of an aneurism, is possible, it is the first method of treatment to be adopted. It can only be contra-indicated when the tumor is so near to the great cavities from which the arteries emerge that there is not suffi-

cient room for its accomplishment. or when, on account of the anatomical arrangement of contiguous nerves and veins, compression is painful or inexpedient, or when, as will occur only in exceptional instances, rupture is imminent; then the ligature is demanded.

Compression may be *manual* or *instrumental*, and *continuous* or *interrupted*.

Given a popliteal aneurism, as an illustration, compression on the cardiac side, with an intervening branch, may be employed as follows:

Digital or Manual.—The patient being placed in a position comfortable to himself and convenient to the operator, is, if the necessity demands, put under the influence of an opiate or anæsthetic. Compression is then made with the pulp of the thumb laid upon the femoral artery, just where it crosses the rim of the pelvis, until pulsation in the tumor is diminished or arrested. Additional force is gained by pressing the thumb or fingers of the opposite hand on the dorsum of the thumb first employed. When from fatigue further compression is impossible, the operator is relieved by the next of the detail, and so on. After a lapse of from two or three hours to at times as much as three days, the tumor ceases to pulsate, becomes firm and inelastic, and remains permanently occluded.

Mechanical.—A method less tiresome to the operator, no more annoying to the patient, and almost, if not equally, as effective, is as follows: One or two sticks of hard wood about an inch in diameter, and from four to six feet in length (small-sized hoop poles or a crutch will suffice), are covered at one end with an India-rubber tip, or compress of some soft substance. The other end is tied to the ceiling with a string or to a bar

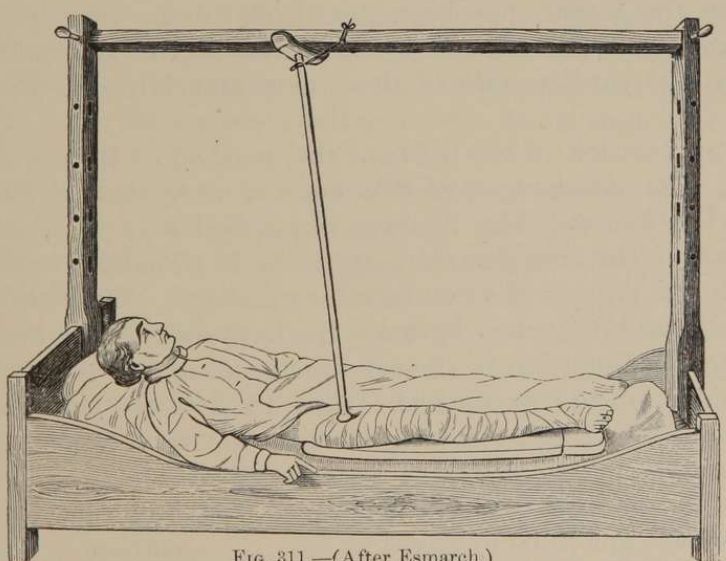

Fig. 311.—(After Esmarch.)

over the bed, and allowed to descend until the tipped extremity rests with the required weight upon the vessel to be compressed (Fig. 311). It may be convenient to employ two poles, so that one may press a few inches lower down than the other. If one is employed, the assistant or

patient can be directed to change the point of pressure at intervals, in order to prevent pain or excoriation. For this same purpose the late Prof. Alpheus B. Crosby successfully employed an elastic tube partially filled with shot to give it the requisite weight. The tube was suspended above the bed and the pressure regulated by the quantity of shot.

Various tourniquets, with one, two, or three compression pads, have been used with the same object in view, and with varying success. Among the better of these instruments is Charles K. Briddon's compressor (Fig. 312).

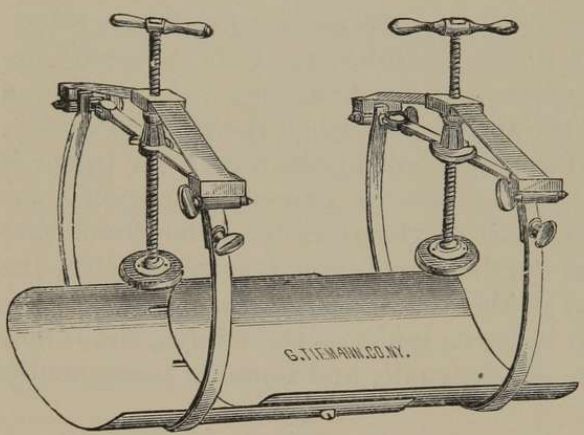

Fig. 312.—Briddon's compressor.

Compression with the mechanism just described may also be employed on the *distal* side of the aneurism, although with less hope of success than in pressure on the cardiac side, which is among the most successful of the conservative methods at the surgeon's command.

Direct pressure upon the aneurismal tumor has been employed in a few instances with a fair degree of success. Six cases of subclavian aneurism treated in this manner will be given hereafter, with description of the mechanism.

Pressure on both the distal and cardiac sides, with or without direct pressure on the tumor, has been practiced by the employment of Esmarch's bandage. The method is inferior to digital or mechanical compression on the cardiac side of the tumor, and is decidedly more dangerous.

In the application of the ligature the method of Hunter is generally preferable. The advantages of this method over that of Anel may be enumerated as follows: The ligature is applied at a distance from the aneurism where the artery is more apt to be in a healthy condition, thus diminishing the danger of secondary hæmorrhage. The existence of one or more collateral branches between the ligature and the tumor renders the process of coagulation in the sac less rapid, and consequently firmer. The only objection to this method of operating is the possibility of failure due to too free anastomosis, whereby the necessary diminution of the circulation is prevented.

The method of Anel is rarely performed, for the reason that the walls of the vessel are apt to be diseased so near the aneurism.

Deligation upon both sides of, and close to, the tumor (method of Antyllus) is not practiced, except in particular cases, where the aneurismal tumor has numerous anastomoses connecting directly with the cavity of the sac, as is not infrequent in popliteal aneurism, in which the sac is usually dissected out. That part of the operation of Antyllus

which consisted in incision of the tumor and packing the sac is not advised.

The operations of deligation upon the distal side of an aneurism, so close to the tumor that no collateral branch intervenes (Brasdor), or at a point more remote with one or more collateral branches intervening (Wardrop), are procedures which have been frequently employed, especially within the last few years. Preference is given to Wardrop's operation.*

Aseptic catgut prepared strictly after the method of Van Horn and Ellison, as given on another page, is the safest and most reliable of all materials in the deligation of arteries. The larger sizes should be used for the larger vessels: Nos. 4 to 6 for the *iliacs*, *femorals*, *subclavians*, and *carotids*, and proportionately smaller ligatures for the smaller vessels. Should it ever become permissible to tie the aorta, I would prefer twists of a number of filaments of No. 3 or 4 catgut, rather than one large solid cord.

Among the methods of treatment of aneurism which have been practiced with varying degrees of success are *teasing* the inner surface of the sac wall with a long aseptic needle, as practiced by Macewen, of Glasgow; the *introduction of a large number of silver pins* plunged into the sac as in a pincushion, and left in from twelve to twenty-four hours, as practiced by myself; *massage* or *kneading; flexion;* and the *introduction of wire or horsehair* into the sac.

Teasing the Sac.—Macewen successfully practiced this method, which consists of the introduction of a long, delicate sterile needle into the cavity of the sac, bringing the point of the needle along the wall in various directions, by this means exciting more rapid formation of coagulum in the roughened wall. In aneurisms at the root of the neck, as of the ascending or transverse aorta, of the innominate or carotid arteries, or of the subclavians close to the carotid, the danger of clot being washed into the vessels leading to the brain should not be overlooked.

Acupuncture consists in the introduction of needles or, preferably, silver pins. In one case of large thoracic aneurism of the ascending aorta, in which I was afraid to employ Macewen's method for fear of clot being carried to the brain, under careful aseptic precautions, I introduced about two dozen silver pins, two inches long, to their full depth into the aneurismal sac, the pins being about one fourth of an inch apart. They were left in from twelve to twenty-four hours, and produced well-marked coagulation. The operation was repeated twice in this case; the aneurism diminished rapidly in size, and the patient

* There is no evidence that Brasdor ever did more than suggest the distal operation. Deschamp was the first to perform it (October 6, 1798), but without success. Wardrop modified the operation and established it by successful practice in 1825. (See article by the author, "American Journal of the Medical Sciences," January, 1881, p. 155; and "Prize Essay of the American Medical Association," 1878, p. 94.) The general results of this procedure have been such as to encourage its repetition, although the manner in which a *partial* arrest of the circulation through the aneurism by deligation on the distal side of the tumor induces coagulation in the sac is difficult of explanation.

was discharged much improved. He returned to his work, and a year later died from dislodgment of a clot which was swept into the carotid artery, causing fatal cerebral anæmia.

Massage or *kneading* has been successfully performed in a few instances. The aneurism is manipulated with the intention of detaching from the sac enough of the fibrillated clot to plug up the efferent vessel and thereby practically tie the artery on the distal side (Brasdor). It is of doubtful propriety except in small aneurisms situated in the arms or legs. The danger of embolism in the cerebral circulation is too great to justify this or any similar procedure upon an aneurism connected with a vessel leading toward the brain.

Flexion or *posture* is practically a method of *direct compression*, using the normal tissues for a pad. It is employed in popliteal aneurism, where the knee is flexed and fastened so as to compress and partially occlude the tumor between the tibia and fibula, and the femur. It is a justifiable method in rare instances. The same practice may be instituted at the elbow, but is impracticable at the axilla on account of the arrangement of the nerves.

The introduction of *watch-spring*, *silver-wire*, *horsehair*, *catgut coil*, or any other foreign solid substance into the cavity of an aneurism will rarely be justifiable except as a last resort in cases where the ligature or compression is impossible. For its execution a pointed canula is usually employed, which, having been introduced into the sac, the wire or gut is pushed through. The quantity used varies from two or three feet up to several yards. More of the catgut may be introduced than of the metal, and the animal ligature should always be preferred if this procedure is adopted.

Special Aneurisms.

Aneurism of the Thoracic Aorta.—The ascending and transverse portions of the arch are most frequently affected. If the dilatation is *fusiform*, both of these segments are apt to be involved; if it is a *sacculated* aneurism, it is usually confined to one or the other segment. Sacculated aneurism of the ascending arch high up, or of the transverse arch, usually involves the orifice of one or more of the great vessels which originate here, although, as in the specimen figured below (see Fig. 313), not infrequently the mouth of the sac opens close to these vessels, but does not involve them.

The diagnosis of aneurism of the arch is generally obscure until the dilatation has advanced to such an extent that pressure symptoms are evident. Pain of varying intensity may be present in the earlier stages of development of both fusiform and sacculated aneurism. A symptom of great diagnostic value is disturbance of the laryngeal muscles, due to pressure upon the recurrent laryngeal nerve of the left side. This occurs in dilatation of the transverse or descending segment of the arch. The aneurismal bruit may be recognized as soon as the sacculation is well advanced. Interference with respiration, or deglutition, or the return circulation in the veins, is among other and important pressure symptoms.

The appearance of a tumor with an expansile pulsation synchronous with the cardiac systole, in the upper thoracic region, determines the diagnosis of aneurism. The differentiation of dilatation of the arch, from a similar condition of the innominate, left carotid, or left subclavian in the thorax, is difficult, and at times impossible. A number of errors in diagnosis by competent and honest observers are on record.

The following points will aid in arriving at a diagnosis: The tumor in aneurism of the ascending arch is usually first appreciated to the right of the sternum, between the clavicle and the third rib. The pressure symptoms do not affect the voice until the tumor is recognizable in the right side of the root of the neck, where it involves the right recurrent laryngeal nerve. Respiration may be interfered with, or cough produced by compression of the right bronchus. This condition will be recognized by the hissing râles distributed over the area of the right lung. Aneurism of the transverse arch is usually first recognized to the left of the sternum on about the same plane as for the ascending segment. Laryngoscopical examination will demonstrate that whatever of muscular paresis exists is confined to the left vocal bands. If the tumor rises into the neck, its appearance will have been preceded by pressure symptoms of longer duration and greater severity than in either innominate, carotid, or subclavian aneurism.

Innominate aneurism usually appears at the upper margin of the sternum in the space between the two tendons of origin of the right sterno-mastoid muscle, or in the interclavicular notch. The disturbance of the circulation through this vessel so affected may be recognized by the difference in the force and character of the pulse wave in the radial arteries of the two arms. In *aortic* aneurism, when the innominate is not compressed by the tumor, the pulse wave will be the same in both arms. It must, however, be borne in mind that in sacculated aneurisms, springing, as they not infrequently do, from the arch in immediate proximity to the orifice of the innominate, and rising to the root of the neck, in front of or behind this artery, a positive diagnosis is scarcely possible. The pressure on the innominate may retard or weaken the right radial pulse, when this vessel is not involved, while the aneurismal bruit is present in the exact location of this vessel.

Aneurism of the left carotid artery will first appear at the left sterno-clavicular articulation in the line of this vessel. The murmur will be transmitted toward the distribution of this vessel, and will not be heard in its fellow opposite.

When the left subclavian is involved, the swelling will usually appear to the left of the sterno-mastoid muscle, and the pulse in the left radial will differ from that of the right. When the descending aorta is the seat of aneurism, the diagnosis is still more obscure. The peculiar murmur is most easily recognized by placing the stethoscope to the left of the vertebral column in the interscapular space. The chief pressure symptoms are those which affect deglutition and lift the heart forward.

The *clinical history* of aneurism of the thoracic aorta usually ends in the death of the individual. In addition to the symptoms given in the

method of diagnosis, the gradual expansion of the tumor leads to more painful and graver conditions. Anxiety, loss of sleep, pain, and cough usually prostrate the patient; erosions of the ribs, sternum, clavicles, and vertebræ occur, and sloughing, septic absorption, or hæmorrhage may produce a fatal termination.

The *medical treatment* is rest in bed, and the safe and judicious combination of Valsalva's and Tufnell's methods as given. The *surgical* treatment is of the most heroic order, and should not be instituted until

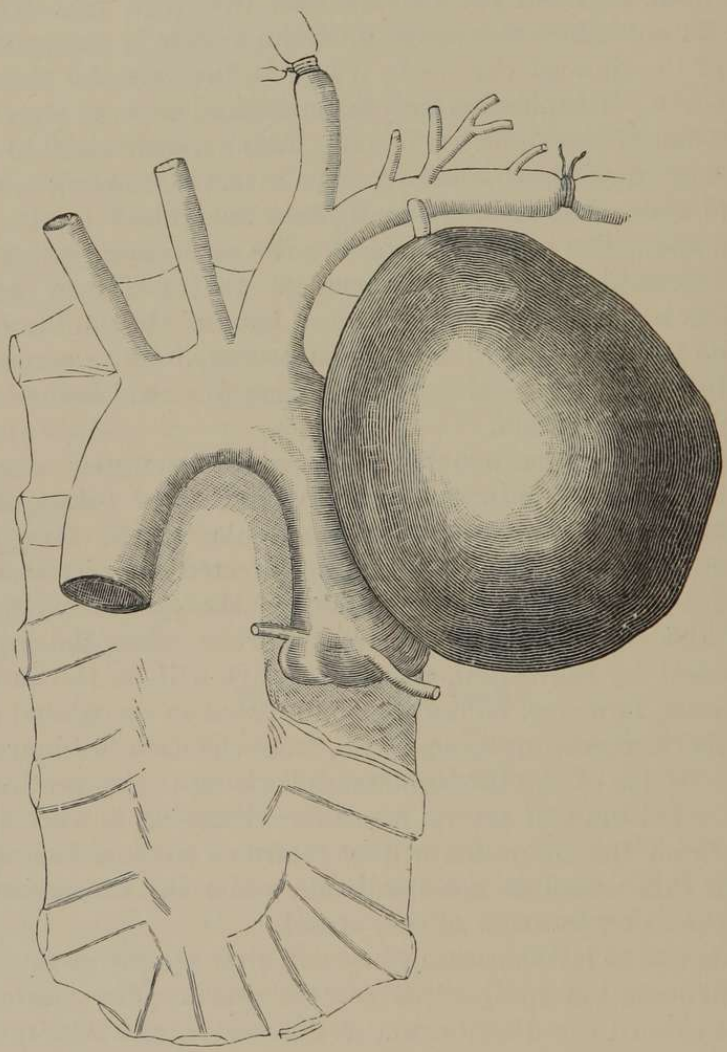

Fig. 313.—The author's case of aneurism of the ascending aorta.

a reasonable trial of the other methods has proved them as inefficient, as death is inevitable. This treatment is the deligation of one or more of the great vessels which are derived directly or indirectly from the arch—i. e., *the distal operation.*

That this operation is justifiable, under certain conditions, has been demonstrated. Among a number of cases in the statistics of this procedure, the following are from personal experience:

On the 21st of September, 1880, I tied the right carotid and subclavian arteries

simultaneously for the relief of an aneurism of the ascending portion of the aorta.* The history of the aneurism dated back sixteen months. Having developed rapidly, it projected through the right second intercostal space, causing such pain that the operation was undertaken. This was the second operation which had knowingly been undertaken for the relief of aneurism of the ascending aorta. Despite the prostrated condition of the patient, she recovered, the tumor diminished perceptibly in size, became more solid, and her general condition was much improved. One

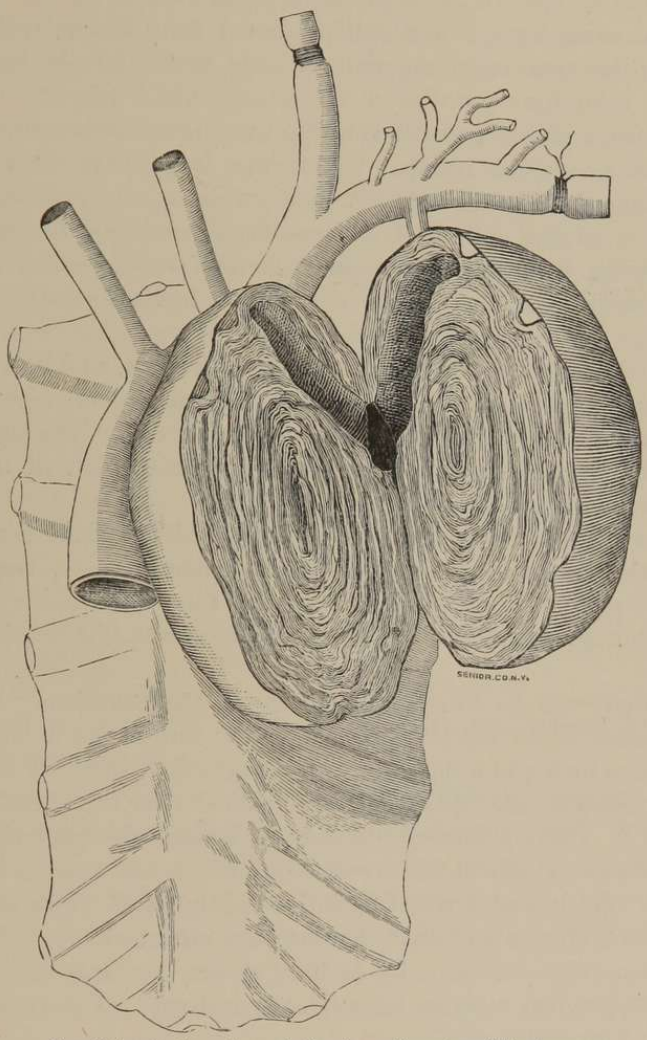

FIG. 314.—Section through the long diameter of the tumor.

month after the operation she was discharged from the hospital, and traveled to a neighboring State, where she died, one year later, from acute diarrhœa. I secured an autopsy, which revealed an aneurism (Figs. 313, 314) as large as an orange springing from the ascending aorta, at its junction with the transverse segment. The orifice of the tumor was an oval, about half an inch by one inch in extent. The tumor was solidified with permanent clot on its lateral and posterior aspects. On the upper anterior surface, which had worn away the sternum and second rib, the sac was thin, with a recent clot which filled a cavity not quite an inch in diam-

* For a full report of this, and all the other cases up to that date, see paper by the author in "American Journal of the Medical Sciences," January, 1881.

eter. The tumor was practically solidified, and had this patient not returned to her dissipated practices (alcoholism), I do not doubt that her recovery would have been complete.

Prof. H. B. Sands performed the same operation, in 1866, for a supposed innominate aneurism.* The tumor diminished after the operation, and visible pulsation ceased. The patient died, thirteen months later, from the pressure of the tumor which sprang from the junction of the ascending and transverse segments, just in front of the innominate. C. F. Maunder's patient died, on the fifth day, from occlusion of the aorta by a clot which projected from the aneurismal sac. The tumor sprang from transverse segment, a little to the left of the innominate.† Heath's patient lived four years after the double distal ligature. The aneurism diminished in size, and the general condition was much improved. The sac ultimately burst, with a fatal result. The tumor originated from the ascending aorta.‡ Mr. Richard Barwell and Mr. Lediard have also performed this operation for aneurism of the arch. Mr. Barwell's patient died fifteen months after the operation, dying from dissipation and "general wearing out." The aneurism was completely filled with laminated clot. Mr. Lediard's patient survived ten months.#

Hobart tied the right subclavian in its first division, and the right common carotid, for a supposed innominate aneurism. Fatal hæmorrhage occurred from the seat of ligature on the carotid on the sixteenth day. The autopsy showed a pyriform aneurism originating from the aorta, just to the left of the innominate. The sac was filled with a firm coagulum.‖

Thus, of seven cases of simultaneous deligation of the right carotid and right subclavian arteries, two died on the fifth and sixteenth days, respectively, from the effect of the operation. The remaining five recovered, with evident improvement. A point of great interest is to notice the *effects of the operation upon the tumor.*

In my case there was no immediate change in the aneurism. Within twenty-two hours the diminution was evident, and by the fourth day it had shrunk from an elevation of one inch and a half above, down almost to the level of the skin upon the thorax. In Sands's case "the tumor diminished after the operation, and visible pulsation ceased." There was no diminution in Maunder's case, but after death the sac was almost completely filled with recent clot, which had even occluded the aorta. In Heath's case "the tumor gradually diminished in size." The symptoms so far disappeared in Barwell's patient that that surgeon informed me, "The aneurism is, judging from symptoms, cured." In Lediard's case the "laryngeal symptoms disappeared; the tumor had a more consolidated feeling." The sac in Hobart's case "was filled with firm coagulum."

The evidence in these cases, in which the right subclavian and right carotid arteries were simultaneously tied for aneurism of the arch of the aorta, involving the last portion of the ascending segment, or the first portion of the transverse segment, or both, points to the conclusion that, in *sacculated aneurism affecting the arterial limit just given, the double distal ligature tends to produce consolidation of the tumor, and to relieve the symptoms of distress caused by its presence.*△

In the study of cases in which one or the other primitive carotid has been tied for uncomplicated aortic aneurism I am enabled to collect but nine instances. In the

* See "American Journal of the Medical Sciences," January, 1881.

† Ibid. ‡ Ibid. # Ibid. ‖ Ibid.

△ See autnor's case of deligation of the left subclavian and left common carotid arteries for aneurism of the transverse portion of the arch, page 303.

limits of a text-book it will be impossible to give a detail of such cases, however interesting to the student. I refer him to my article on this subject in the "American Journal of the Medical Sciences," January, 1881. The operators were Montgomery, T. Holmes, Barwell, Tillanus, Rigen, O'Shaugnessy, Annandale, Heath, and Bryant. The *left carotid* was tied in six cases, and all recovered. Montgomery's patient died, four months after operation, from purulent pericarditis. The tumor had solidified and sloughed. Holmes's case was much improved, and, in answer to my inquiry concerning this case, in 1880, five years after the operation, he writes that the patient is still living, that there is pulsation and bruit in the thoracic portion of the aneurism, but there is no longer any tumor perceptible in the neck.

Barwell's case was greatly relieved, dying four months later of another affection. Tillanus's operation was followed by recovery and diminution of the tumor, dying suddenly five months later (probably from cerebral embolism). The sac was completely filled with coagulum. Rigen tied the carotid, February 21, 1829. The patient was relieved, and the tumor diminished considerably in volume. On May 9th was operated on for strangulated hernia, and died June 13th, as was supposed, from asthma. The tumor was solidified. In Heath's case the relief for a long period was marked and undoubted. The patient lived nearly four years, dying ultimately of rupture of the sac.

O'Shaugnessy tied the right carotid, with fatal rupture of the aneurism into the mediastinum on the tenth day. Annandale performed the same operation with immediate relief and success. Mr. Bryant's patient died on the tenth day. The right carotid was tied, with no effect on the aneurism. The results in these instances also lead me to conclude that, in sacculated aneurisms of the aorta, near the origin of the innominate and left carotid, deligation of one carotid, especially the left, is a justifiable procedure when the conservative method of rest and restricted diet has failed.

Aneurism of the thoracic aorta beyond the transverse segment is not amenable to surgical treatment.

Aneurism of the Innominate Artery.—The symptoms of this formidable lesion have been given on a preceding page. It is frequently complicated with aneurismal dilatation of the aorta, or of the two vessels into which it usually bifurcates. It will be interesting to study the results of operative procedures under the following subdivisions:

1. *Innominate Aneurism.* 2. *Aortic innominate Aneurism.*—For innominate aneurism, (*a*) the double simultaneous distal ligature (carotid and third division of the subclavian); (*b*) the double non-simultaneous distal operation; (*c*) distal deligation of the carotid artery alone; (*d*) distal deligation of the subclavian artery alone.

*Simultaneous Deligation of the Right Common Carotid and the Right Subclavian Artery (Third Division) for the Relief of Innominate Aneurism.**—Prof. J. L. Little performed this operation in 1877. The patient recovered, was much improved, and died from pleuritis, not associated with the aneurism, three years later. The carotid and subclavian were slightly involved. Durham's patient died on the sixth day, as was reported, from "shock." The possibility of cerebral embolism is worthy of consideration in explaining the sudden death of this patient.

* For more complete details, see preceding reference.

M'Carthy's case died, on the fifteenth day, from hæmorrhage on the proximal side of the subclavian ligature. Prof. Eliot's patient died, on the twenty-sixth day, from hæmorrhage from the sac. Prof. L. A. Stimson's patient recovered, with marked improvement and consolidation of the aneurism. The tumor became very much smaller, and the symptoms were relieved. Death occurred, twenty-one months after the operation, from phthisis. The sac was filled with firm clot. In the case operated upon by Prof. R. F. Weir, death resulted, from rupture of the sac, on the fifteenth day. Rossi's patient died on the sixth day, most probably from cerebral anæmia, since, at the necropsy, the left vertebral was the only pervious artery leading to the brain. Ensor's case ended in death, from rupture of the sac, on the sixty-fifth day. Barwell operated, with recovery and marked improvement. King's patient died, from hæmorrhage from the aneurism near the carotid ligature, on the one hundred and eleventh day. Gerster's case recovered, with gradual improvement.* McBurney, 1887 : Male, thirty-five years, probably syphilitic ; noticed tumor in the neck at inner end of clavicle and voice became affected ; diagnosis of aneurism involving the innominate and origins of carotid and right subclavian. Rest in bed and potassium iodide did not affect the development. Operation ; catgut ligature to right carotid and third portion of subclavian ; pulsation in tumor almost entirely ceased. Method of Tufnell carried out. Nine months after operation the tumor was at least one fourth its original size and the voice only slightly hoarse. The patient made a complete recovery, and died of Bright's disease three years and eight months later, and suffered from no pressure symptoms until a few weeks before death. The aneurismal sac was filled by a large laminated clot.

Of these twelve cases, recovery, with a cure more or less perfect, took place in five, while death occurred in seven. It is very probable that, if in some of these fatal cases the operation had been performed earlier, the rate of mortality would have been lower.

The double distal operation, with varying intervals between the deligation of the carotid and the subclavian arteries, has been performed in the following instances: Prof. A. B. Mott tied the subclavian artery in a patient who had had the right carotid deligated one year previously. The patient died, three years after the last operation, from phthisis. The aneurism was cured. In Heath's case the carotid was first tied, with temporary amelioration of symptoms. Two years later the subclavian was operated upon. The aneurismal bruit disappeared, and the urgent symptoms disappeared. Four months later the patient died from traumatic pleuritis, caused by a fall while drunk. The tumor was consolidated. In Wickham's case the interval was two months and nine days. Immediate and temporary relief followed both operations. Death ensued from rupture of the sac on the forty-fourth day. Malgaigne's patient was not materially benefited by the first operation. Three months later the subclavian was tied, followed by death, from rupture of the sac, on the twenty-first day.

A glance at these cases, and a careful study of their more complete histories, can not but impress one with the gravity of the surgical procedure under consideration. The postural, dietetic, and medicinal method should be thoroughly tried in all cases where the disease has not progressed so far that death is imminent from pressure, or the suffering so intense that life becomes intolerable. Under these last conditions the operation is justifiable. If the conservative method, after a courageous

* "German Hospital Records," 1883–'84, New York city.

and faithful trial, does not arrest the disease, then again the operation is demanded. There is little choice between the simultaneous deligation and the operation with an interval. The carotid should always be first tied, to prevent the danger of cerebral embolism.

Innominate Aneurism treated by Deligation of the Carotid, or the Subclavian. (The Single Distal Operation.)—The records of surgical literature contain fourteen instances in which, for the relief of aneurism involving the innominate artery alone, the distal ligature was applied to the right carotid.

In one single instance (Evans's) a cure was effected, and this after suppuration occurred in the sac, which discharged twenty-four ounces of pus.

Of the *fourteen* cases, *eight ended fatally.* Seven of these died between the second and twenty-first day, and in one of these it is evident that death was caused by the consolidation of the aneurism.

Another surgical procedure for the relief of innominate aneurism, which has received the sanction of eminent practitioners, is that of single deligation of the subclavian artery in its third division. The operators are Wardrop, Broca, and Thomas Bryant. Each case recovered, with marked improvement. Wardrop's patient lived two years, and died partly from the effect of pressure of the aneurism and partly from general systemic failure. The tumor was firmly soldified, with the exception of a small central channel which led into the carotid. Broca's case died, from pulmonary gangrene, five months later. Consolidation was also almost complete in this case. Bryant's patient was living one year after the operation, and there was evidence of solidification in the tumor.

While it is scarcely possible to base a definite opinion upon a study of such a limited number of cases, the evidence seems to be in favor of the operation of tying the subclavian in preference to the carotid for innominate aneurism. It would be natural to infer that the danger from cerebral embolism would be great after such a procedure, yet it evidently did not occur in any of these instances.

In aneurism involving both the innominate and the aortic arch, the double distal operation is recorded in eight instances.

In the following cases the two vessels were tied at the same operation, excepting one in which there was an interval of only twenty-four hours. Mr. Barwell, in one instance, with a recovery and very great improvement. The patient died, nineteen months later, from bronchitis. The tumor was firmly consolidated. The same surgeon, in a second case (with an interval of twenty-four hours), with recovery and great improvement. Death from broncho-pneumonia three months later. The tumor, as large as a tennis ball, was solid, excepting a central globular cavity one inch in diameter. The same surgeon, in a third case, which ended fatally, from asphyxia, in thirty hours. Mr. Holmes's patient died from exhaustion two months after operation. The sac was full of recent clot. Mr. Lane's case terminated fatally within three months, from rupture of the sac. The patient operated upon by Mr. Hodges died, with symptoms of broncho-pneumonia, on the twelfth day. There was no sacculated aneurism, but an extensive fusiform dilatation of the innominate and aorta. Ransohoff's case ended fatally, from asphyxia, in seven days.

In one instance Mr. Bickersteth operated, with an interval of forty-nine days, but without benefit, as the patient died from the progress of the disease in three months.

The results in these cases do not encourage a repetition of this operation in well-marked instances of aorto-innominate aneurism. The conservative methods offer the best hope of palliation.

The deligation of one of the primitive carotids has been performed in six instances for the relief of aneurism involving the innominate, complicated with dilatation of the aorta or the first portion of the right subclavian or carotid.

Pirogoff tied the left carotid in two cases. One died within a week, from hemiplegia and coma; the sac was completely filled with clot. The other recovered, and was improved up to two months, when the history ceases. In the remaining four cases the right carotid was tied. The operation by Hewson terminated fatally on the tenth day, from asphyxia, due to pressure from the consolidated tumor. The two terminal branches of the innominate were also involved. Campbell's patient suffered a like fate, from the same cause, while Key's was also fatal in four hours, from coma. Hutchison's died on the forty-first day from asphyxia due to pressure of the enlarged and consolidated aneurism.

In six cases, five died within a few days after the operation, and three of these seem to have ended fatally from consolidation of the aneurism, the very object for which it was performed.

Aneurism of the Common Carotid Artery.—Aneurism of the carotid may occur in any part of the course of this vessel, being in rare instances intra-thoracic (when the left trunk is involved).

The diagnosis of aneurism of the left carotid, low down, depends upon the presence of the aneurismal bruit at the site of the tumor, this murmur being carried along in the distribution of the artery. Pressure symptoms are referable to laryngeal interference from compression upon the pneumogastric; or distention of the left internal jugular, and in rare instances the left subclavian vein. The presence of the swelling is usually first recognized in the space between the two tendons of origin of the left sterno-mastoid muscle. Aneurism of the right carotid, within the first inch of its course, gives rise to the ordinary symptoms of this lesion, just beneath the sterno-mastoid muscle, at and immediately above its clavicular origin.

Aneurism of the vertebral artery, in its lower portion, may be differentiated from that of the carotid by compression of this latter vessel high up. If the thumb be placed over the carotid, at its bifurcation, and pressed firmly and directly backward against the vertebral column, such compression will not affect the circulation in the sac of a vertebral aneurism, while if involving the carotid it would be visibly affected. Then, again, vertebral aneurism is, in nearly every instance, of traumatic origin, and the traumatism is usually a stab wound, while aneurism of the carotid is almost always idiopathic.

In the differential diagnosis of these two lesions higher in the neck, the same method is applicable. It should not be forgotten, in the effort

to form a diagnosis, that careless manipulation of a cervical aneurism is not allowable, on account of the danger of detaching a clot, which may pass up into the brain. If the tumor involve the carotid or its branches, compression of the primitive trunk, low down, will arrest the pulsation in the sac. This is best accomplished by relaxing the sterno-mastoid muscle of that side, and grasping the vessel between the thumb and finger carried behind the muscle. On account of the deep seat of the vertebral artery its compression by this manœuvre is impossible. This last vessel may be compressed by placing the thumb one inch directly below the transverse process of the sixth cervical vertebra, and pressing backward. Above this point it is impossible, since the vessel runs into the vertebral foramina.

The treatment of carotid aneurism is surgical and palliative. The latter method refers to the postural, dietetic, and medicinal treatment of aneurisms in general. The only surgical procedure which should be recommended is the ligature. While it is true that some cases are recorded as cured by digital compression, I can not but consider this method as dangerous, for the reason that, in the process of consolidation where the circulation is only temporarily interrupted, cerebral embolism may occur. The animal ligature, with antiseptic cleanliness, offers the safest means at our disposal. The operation varies with the seat of the tumor. It may be divided into deligation upon the *distal* and *cardiac* side of the aneurism.

The distal ligature has been applied in seven recorded instances—five on the right and two on the left carotid. Two deaths occurred from hæmorrhage: one from the distal side of the (silk) ligature on the sixty-first day, the second case from rupture of the aneurism on the sixty-seventh day. A third case recovered, but the progress of the disease was not arrested, and death followed the rupture of the sac on the ninety-first day. The remaining four cases were either much improved or cured. The use of the catgut ligature would probably have saved the patient operated upon by Lambert, in which silk was used, causing death from hæmorrhage on the sixty-first day.

Deligation upon the cardiac side is always preferable when a sufficient extent of sound artery can be secured around which to apply the ligature.

In my "Essays on the Surgery and Anatomy of the Great Vessels of the Neck" I have recorded 106 cases in which the artery was tied on the cardiac side of the aneurism; 69 recovered; rate of mortality, 35 per cent. For aneurism of the external carotid or its branches, 17 recoveries and 5 deaths. Of the 17 recoveries, 16 were cured. For aneurism involving the common carotid alone, the death rate was 44 per cent. When the aneurism involves the common, external, and internal carotids, the ligature should be applied to the common trunk, on the cardiac side, while the distal ligature may be applied to the external trunk, at the same time securing the larger branches derived from this vessel between the ligature and the bifurcation. By this operation the circulation through the tumor, and in the direction of the brain, is practically arrested.

Aneurism of the external carotid demands the deligation of this vessel and no other, when by a careful dissection it is discovered that

there is a half or three quarters of an inch of this trunk between the bifurcation and the sac. In three instances I have placed the ligature around the external carotid exactly at the crotch of the bifurcation, tying also the superior thyroid branch. All recovered without accident. In the event that this method is impracticable, the common trunk must be tied.

Aneurism of the internal carotid, in the neck, should be treated by the deligation of this vessel, between the sac and the common trunk, if possible. When a sufficient surface of healthy artery can not be obtained, the common and external carotid should be tied, together with all branches derived from the external, on the cardiac side of the ligature. I performed this operation in one instance, resulting in the rapid and permanent cure of a large extra-cranial aneurism of the internal carotid. The common trunk was first tied, then the superior thyroid, and external carotid, just above its origin.

Aneurism of the internal carotid may occur in the cavernous or cerebral portions of this vessel. In the petrous canal dilatation is practically impossible. Not infrequently an arterio-cavernous aneurism occurs from the giving way of the septum between these two vessels. The cause may be traumatic, as in fracture at the base of the skull, or the communication may be established without appreciable cause.

The symptoms of aneurismal dilatation here are of two kinds: those referable to pressure upon the brain and nerves, and those due to interference with the return venous current through the ophthalmic vein. If the arterio-venous communication has occurred, exophthalmus is marked, and the eyeball is projected forward with each arterial pulse. Singing in the ears, dizziness, with varying loss of function due to pressure, are other symptoms of this condition.

The ophthalmic artery may be the seat of aneurism, within the cranial cavity or in the orbit. True sacculated intra-orbital aneurism of this artery is extremely rare, only two cases being recorded,* although pulsating tumors, as arterio-venous aneurisms, angeiomata, cirsoid arterial tumors, etc., are not infrequent in this locality. The chief point in the diagnosis, and the one which has an important bearing in treatment, is compression of the carotid. If pulsation ceases, and the other symptoms disappear, the indication is clear that the ligature should be applied to this vessel. The common trunk should be tied, in order to cut off the free communication between the branches of the external carotid and the ophthalmic in the orbit. In my Essays are given fifty-two instances in which this operation was done for pulsating non-malignant tumors of the orbit, with a death rate of 11·5 per cent.† About 75 per cent of recoveries after this operation result in cures. In severe cases extirpation may be necessitated.

Aneurism of any branch or branches of the external carotid should be treated by the ligature of the branch involved, or the external trunk.

* Prof. Sattler's classical paper in Graefe and Saemisch's "Handbuch der gesammter Augenheilkunde," Leipsic, 1880.

† "Prize Essays of the American Medical Association, 1878," William Wood & Co., New York.

Aneurism of the Subclavian Arteries.—The subclavian arteries may be affected in any portion of their extent, although, on account of the pressure exercised by the two scaleni muscles, between which their second portion lies, this division is less frequently involved in aneurismal dilatation. The seat of this disease is by preference in the third portion, the first division being next in order. Exposure to violence or muscular effort undoubtedly has much to do with the development of subclavian aneurism, since males are very much more frequently affected than females, while the tumor is found on the *right* side in the great majority of cases.

The first portion of the right subclavian is not infrequently involved in the progress of an innominate aneurism. Upon the left side aneurism of the thoracic portion of this vessel is rare.

Subclavian aneurism, as it usually develops, is first recognized as a pulsating tumor, felt rather than seen behind the clavicle, and to the outer side, or behind the sterno-mastoid muscle. It may be mistaken for a glandular or other tumor of the soft tissues. The symptoms which have been already detailed will serve as a guide for proper differentiation. Difficulty may arise, even after the aneurismal character of the swelling has been recognized, in determining from what vessel the tumor springs. As has been said, the progress of aortic aneurism gives rise to pulsation and pressure symptoms, located in the thorax for a considerable period prior to the approach or appearance of the tumor at the root of the neck. In fact, aneurism of the aorta, in many instances, produces death before it attains such magnitude. On the right side, this knowledge will aid materially in recognizing the seat of the lesion, and, fortunately, aneurism of the arch and subclavian occurs most often on this side of the body. The differentiation of aneurism of the thoracic portion of the left artery, from the same lesion of the arch, near the origin of the subclavian, is somewhat more difficult. When the tumor involves the subclavian its appearance in the neck is more rapid than in the aortic aneurism, while interference with the return circulation in the arm, which may appear early in the history of subclavian aneurism, is rare when the aorta is the seat of this lesion. Again, in aneurism of the second or third portion of the arch, which does not involve the subclavian, the pulse wave in the left radial will be of equal force and synchronous with that of the right side.

The *treatment* of *subclavian aneurism* is a subject of great importance, and one which, from a study of a number of cases, has led to great diversity of opinion and practice.*

The methods may be divided into the surgical; the postural, medical, and dietetic; and the palliative or expectant. The employment of any of these means will, again, be in great part determined by the portion of the artery involved in the disease. The surgical treatment comprises the ligature or compression on the cardiac or distal side; or pressure applied directly to the sac, and massage.

* See classical paper by Prof. Edmond Souchon, of New Orleans, "Annals of Surgery," November and December, 1895.

The application of the proximal ligature for the relief of subclavian aneurism presents an array of disasters which should attract the attention of the surgeon.

In a former edition and in my essays on the arteries I tabulated 17 cases in which the innominate, either singly or with the carotid and vertebral, had been tied, with 16 deaths; and in the "Boston Medical and Surgical Journal" of August 8, 1895, Dr. H. L. Burrell supplements these with 12 cases additional, or 29 in all, as follows:

INNOMINATE NEAR BIFURCATION INVOLVED WITH THE CAROTID AND SUBCLAVIAN.

No. 1 (Valentine Mott, New York, 1818).—Death, twenty-sixth day, by hæmorrhage. Silk ligature.

No. 2 (Graefe, Berlin, 1822).—Death, sixty-eighth day, from hæmorrhage. Operation for subclavian aneurism.

No. 3 (Norman, Bath, 1824).—Death, third day, from hæmorrhage. Operation for subclavian aneurism.

No. 4 (Arendt, St. Petersburg, 1827).—Death, eighth day, from sepsis. Operation for subclavian aneurism.

No. 5 (Hall, Baltimore, 1830).—Death, sixth day, from hæmorrhage. Operation for subclavian aneurism.

No. 6 (Bland, Sidney, 1832).—Death, eighteenth day, from hæmorrhage. Operation for subclavian aneurism. Ligature, thread.

No. 7 (Dupuytren, Paris, 1834, reported but not performed by him).—Death, third day, from hæmorrhage. Operation for subclavian aneurism.

No. 8 (Lizars, Edinburgh, 1837).—Death, twenty-first day, from hæmorrhage. Operation for subclavian aneurism.

No. 9 (Hutin, Paris, 1842).—Death, twelve hours after operation, from hæmorrhage. Operation for secondary hæmorrhage after a penetrating wound.

No. 10 (Gore, Bath, 1856).—Death, seventeenth day, from hæmorrhage. Operation for subclavian aneurism. Hemp ligature.

No. 11 (Pirogoff, St. Petersburg, 1856).—Death, forty-eight hours, from probable septicæmia. Operation for subclavian aneurism.

No. 12 (Cooper, San Francisco, 1859).—Death, ninth day, probably from sepsis. Operation for subclavian aneurism.

No. 13 (Cooper, San Francisco, 1860).—Death, thirty-fourth day, from hæmorrhage. Operation for subclavian aneurism.

No. 14 (Smyth, New Orleans, 1864).—Recovery. Operation for subclavian aneurism. *Carotid and innominate ligated, and fifty-four days later the vertebral also.*

No. 15 (Lynch, 1867).—Death, twelfth day, from hæmorrhage. Operation for secondary hæmorrhage after gunshot wound.

No. 16 (Porter, Dublin, 1867).—Died of hæmorrhage six weeks after. Operation for subclavian aneurism. Clamp applied to innominate for three days and then removed.

No. 17 (Bickersteth, Liverpool, 1868).—Death, ninth day, from hæmorrhage. Operation for subclavian aneurism.

No. 18 (A. B. Mott, New York, 1868).—Death, twenty-third day, from hæmorrhage. Aneurism burst into pleural cavity. Operation for subclavian aneurism (Mott's operation). *Innominate* and *carotid* tied.

No. 19 (Partridge, Calcutta, 1870).—Death, one and one half hours after, from hæmorrhage. Previous operation, ligature for aneurism of *carotid thirteen days before.*

No. 20 (Buchanan).—Death in a few minutes from shock. Operation for subclavian aneurism.

No. 21 (O'Grady, Dublin, 1873).—Death, twenty hours after operation, from shock. Operation for subclavian aneurism. *Removed inner two inches of clavicle.*

No. 22 (Thompson, Dublin, 1882).—Death, forty-second day, from hæmorrhage. Operation for subclavian aneurism. Tape ligature of ox aorta.

No. 23 (Banks, Liverpool, 1883).—Death, thirty-seventh day, from hæmorrhage. Kangaroo tendon. Operation for subclavian aneurism. *Innominate* and *carotid* ligated.

No. 24 (Bull, New York, 1884).—Death, thirty-third day, from hæmorrhage. Operation for subclavian aneurism. *Innominate, right common carotid*, and *vertebral* arteries were all ligated simultaneously with a double catgut ligature.

No. 25 (May, Birmingham, 1886).—Death, nineteenth day, from hæmorrhage. Catgut ligature. Operation for subclavian aneurism.

No. 26 (Durante, Rome, 1887).—Death, sixteenth day, from hæmorrhage and hemiplegia. Operation for subclavian aneurism. *Innominate, carotid*, and *vertebral* ligated.

No. 27 (Lewtas, India, 1889, Mendon Hospital, Punjab).—Recovery. Catgut ligature. Operation for hæmorrhage following traumatic aneurism of subclavian by fragment of gun barrel which exploded. Ligated *carotid* and *innominate.* Mr. Lewtas writes me in 1896 that his patient was entirely well six months after the operation.

No. 28 (Coppinger, Dublin, 1893).—Recovery. Operation for subclavian aneurism. *Innominate* and *carotid* both ligated. Living and perfectly well July 15, 1896 (letter from Dr. Coppinger and Dr. Fitz Gibbon to author).

No. 29 (Burrell, Boston, 1895).—Recovery, all symptoms relieved, and patient out and about. Two silk ligatures on innominate. Operation for fusiform aneurism of carotid, subclavian, and innominate arteries. Death, from arterial sclerosis and an enlarged and dilated heart, on the one hundred and fourth day.*

Of the twenty-nine cases, twenty-five died from the immediate effect of the operation (eighty-six per cent); four cases are reported as recovered. In Smith's case the innominate and the carotid were tied, and fifty-four days later the vertebral. The patient lived ten years, and died from hæmorrhage from the aneurism for which the operation had been performed. In Lewtas' case the history closes after six months; the innominate and carotid were tied, and the patient may be considered cured. In Coppinger's case the patient was living and perfectly well January 15, 1896; innominate and carotid tied; also given as cured. In Burrell's case the innominate alone was tied, and the patient recovered from the immediate effects of the operation, but died suddenly on the one hundred and fourth day.†

* To this list might be added Twyman's case (Souchon), in which, for traumatic diffuse aneurism of the first portion of the right subclavian, he tied the innominate and right carotid. Coma and death eighteen hours after operation.

† R. F., male, fifty-four years; family history negative. Patient in good health always until two years before operation, January 15, 1895, when he noticed a little shortness of breath. Denies venereal disease or rheumatism. Eighteen months ago he felt a lump in the left side of the throat

Dr. Edmond Souchon ("Annals of Surgery," November and December, 1895), in a classical paper, properly considers aneurism of the subclavian arteries under the head of *traumatic* and *idiopathic*. He gives fifteen cases of traumatic aneurism of the right side which were due, as he states, to a direct blow and not to obscure traumatism, such as so-called strains:

Colles, 1811; subclavian aneurism; ligature silk (?); first portion right subclavian half an inch from innominate; death, fourth day, from hæmorrhage at seat of ligature.

Bullen, 1823; subclavo-axillary aneurism; ligature third portion; recovery; second day, venesection, twelve ounces; hæmorrhage from wound on the sixteenth and seventeenth days; seventy-fifth day, hæmorrhage from the sac; patient ultimately recovered.

Arendt, 1827; innominate tied half an inch below bifurcation; death, eighth day, exhaustion, no hæmorrhage; artery closed.

Wattman, 1833; subclavian aneurism due to gunshot; ligature third portion; death from hæmorrhage.

Overt, 1848; ligature first portion; death, hæmorrhage.

Roux, 1855; ligature second portion; death, hæmorrhages.

Pitha, 1856; ligature second portion; death, pyæmia.

Cruveilhier, 1859; ligature first portion and common carotid; death, exhaustion.

which, on exercise, throbbed and seemed to choke him; no pain. Two weeks ago, after a long walk, the choking sensation increased. Physical examination shows an enlarged area one finger's breadth to the right of sternum; sharp, blowing, systolic and diastolic murmur, especially well marked on the right; marked pulsation of vessels on right side of neck; expansion thrill and systolic *bruit*; nothing of interest as regards lungs or other organs; urine, 1016; slight trace of albumin; no microscopical examination; temperature normal.

Operation.—Incision at anterior edge of right sterno-mastoid muscle from the level of the coracoid cartilage to two inches below the upper border of the sternum; from this point another incision, extending outward four inches in length to the junction of the outer and inner thirds of the clavicle. This skin flap, with the fascia and platisma muscle, was turned back, the sterno-mastoid severed close to its insertion in the clavicle and sternum. The hyoid muscle was divided, exposing a fusiform aneurism in the right subclavian and right carotid arteries, extending down and on to the innominate. The right sterno-clavicular articulation and right half of the cartilage of the sternum was gnawed off with bone forceps to expose the innominate. The right innominate vein and the left innominate vein going down to form the superior vena cava with the pneumogastric and recurrent laryngeal nerve, resting on the innominate artery, were all clearly in sight. The sheath was opened and the innominate artery isolated. The artery was one and one quarter inch in circumference. A flat-braided silk ligature was then passed around the vessel and tied in a square knot, which was gradually tightened, fully three minutes being spent in securing it, care being exercised not to cut the artery too strongly. Half an inch higher up a second ligature was passed in the same manner, tied in a square knot, and cut short; muscles sutured into their position; aseptic dressing applied; operation lasted an hour and a half. No pulsation in right carotid and radial. Right arm wrapped in cotton wool and bandaged. The right pupil reacted more slowly to light. Very little shock or pain. Uneventful recovery.

On the sixty-ninth day he walked to the operating theater to a clinic, and left the hospital about this time. On the morning of the one hundred and fourth day, having been very comfortable previously, the patient sat up in bed, complained of shortness of breath, became pale, and died in twenty minutes.

Autopsy.—Heart greatly hypertrophied, cavities dilated. The innominate artery was completely closed just at the origin of the subclavian and carotid. General arterio-sclerosis, with dilatation and thickening of the aorta and large arteries. Occlusion of innominate by the upper ligature; severance of artery by the lower ligature, with healing, the ligature remaining within the artery and the continuity of the lumen being restored. Syphilis.

Langenbeck, 1862; second portion; death, pyæmia.

Thiersch, 1882; ligature third portion; sac opened and clots turned out; compression; death, pyæmia.

Langenbeck, 1884; bullet wound; repeated hæmorrhages; incision of sac; clots turned out; ligation of both ends; cured.

Langenbeck, 1884; knife wound; diffuse aneurism; incision of sac after sawing clavicle; clots turned out; both ends ligated.

Lewtas, 1885; given with ligature of innominate artery; incision of sac; clots turned out; ends not tied.

A. B. Miles, 1893; gunshot wound middle of third portion; diffuse aneurism; precautionary ligature placed on first portion of subclavian, occluding vessel by pulling on loop and compressing with finger at the same time; digital compression of axillary; incision, and clots turned out; proximal end first tied, then distal end; precautionary ligature then removed; wound granulated and patient recovered.

Twyman, 1890; girl, eighteen years; traumatic diffuse aneurism caused by fracture of right clavicle at junction of outer and middle thirds; ligatures of innominate thirty-one days after accident; carotid also tied; coma; death eighteen hours after operation. Autopsy showed wound in first portion of subclavian one sixth of an inch beyond the origin of the thyroid axis and the vertebral.

Of the fifteen cases, four recovered and were cured. Of these four cases it will be seen that the sac was incised and clot turned out in three (Miles, Lewtas, and Langenbeck), and in the fourth (Bullens) the sac ultimately suppurated or broke down and the contents were discharged through the trachea. In only one of the fatal cases was the sac opened and the vessel secured at both ends.

So far as I am able to learn, in no instance has a ligature been successfully placed on the first or second portion of the subclavian on the right side, the failures being due, in my opinion, to the nearness to the heart and the directness of the force of the blood current as it is ejected from the left ventricle. From a study of these cases, the inference is clear that, when driven to the extreme of operative interference, the surgeon should resort to the temporary loop thrown around the vessel on the cardiac side, after the method of Miles, with compression on the distal side, turning out clots, and treating the aneurism as an aseptic open wound with ligature on healthy arterial tissue on both sides of the sac. It seems to me that as a preliminary measure the excision of the clavicle in order to expose freely the operative field would be a wise precaution.

According to Souchon, the ligature has been applied in all instances upon the third portion of the right subclavian for aneurism of this portion of the artery alone or involving the axillary beyond the seat of ligature. All died but one, the case of Green—male, thirty-five years; small tumor of outer part of artery; ligature close to the scalenus; patient well several years after operation.*

It has been applied to the second portion in two cases (Souchon), those of Liston and Gay; both perished.

* The other operators were Colles, Travers, Brodie, Gore, Blaker, Stanley, Gregg, Drayton Paget Auvert.

Ligation of the first portion alone of the right subclavian has been done eight times, all fatal.* The first portion of the right carotid has been tied simultaneously for aneurism of the third portion of the subclavian in one case (Liston)—death from hæmorrhage from the subclavian ligature.

One case of simultaneous ligation of the first portion of the subclavian, common carotid, and vertebral, by Willard Parker, of New York; fatal.

The first portion of the right subclavian artery has been tied ten times, alone or simultaneously with other arteries, for idiopathic subclavian aneurism of the third portion; all fatal; and all died from distal hæmorrhage from the subclavian except one case (Partridge's), which died of pyæmia, and one case of Arendt's, which died of exhaustion.

The innominate has been tied alone fifteen times for right subclavian aneurism, as already given; all fatal.†

Burrell's case, which died on the one hundred and fourth day, is not included, as it was for aneurism of the subclavian, carotid, and innominate at its bifurcation. In A. B. Mott's and Coppinger's cases the innominate and common carotid were tied for aneurism of the subclavian. Mott's case died, and Coppinger's case recovered and was living two years after the operation. The aneurism was in the second and third portions of the artery, and as large as a hen's egg; the carotid was ligated in two places, and divided between; silk ligatures. Two years after operation this patient was in St. Bartholomew's Hospital; his nervous system seemed broken down, but he was free from any sign of the old aneurism.

Two cases of ligation of the innominate, common carotid, and vertebral simultaneously—Bull and Durante; both perished from hæmorrhage.

Simultaneous ligation of the common carotid and innominate, and, fifty-two days later, of the vertebral—the famous case of Smyth, of New Orleans; recovered from the operation, and died ten years later from hæmorrhage from the aneurism.

In another case in which the innominate and carotid were tied simultaneously with ligation of the subclavian, sixty-seven days later the patient died of hæmorrhage.

One case of ligation of the third portion of the subclavian as a distal operation for aneurism of the same portion of this vessel was done by Monod: Male, fifty-one years; tumor, size of small hen's egg; ligation of outer part of third portion of subclavian between tumor and clavicle; common carotid also tied. Four months after operation all vestige of tumor disappeared. June 8, 1895, patient well (Souchon).

Ligation of axillary alone as a distal operation on the right side; three cases; all fatal.

Franz Schopf extirpated successfully a solidified aneurismal sac of the right side on account of pressure which it exercised. Patient recovered, with improved use of upper limb.

Amputation at the shoulder joint has been performed five times, with two recoveries. In one of these cases Rose also tied the carotid.

* The operators were Arendt, Bayer, Liston, Mott, Hayden, O'Reilly, Partridge, Auvert, Liston and Parker.

† The operators were Mott, Graefe, Norman, Dupuytren, Hall, Bland, Lizars, Gore, Pirogoff, Porter, Bickersteth, O'Grady, Thompson, May, and Bennet.

Souchon has collected seventeen cases of traumatic aneurism of the left subclavian :

Dupuytren, 1819; puncture wound; seven years later, aneurism, size of child's head; ligature second portion; tumor solidified; three years later it suppurated, was opened, and recovery took place.

Sawinkoff, 1823; ligation in third portion; cured.

Gibbs, 1823; result of blow; ligature third portion; cured.

Auchincloss, 1833; died; cerebral anæmia (coma).

Majeste-Lallemande, 1834; second portion; cured.

Periera, 1835; just outside scalenus; cured.

Earle, 1835; third portion; cured.

J. C. Warren, 1844; third portion; hæmorrhage from operating wound controlled by plugging; cured.

Manec, 1848; shot wound; ligature third portion; cured.

V. Mott, 1850; ligature third portion; cured.

T. G. Morton, 1866; ligature second portion; forty-three days later, suppuration of sac, frightful hæmorrhage; subclavian tied; amputation at upper third; hæmorrhage, sixty-seventh day; shoulder-joint amputation; cured.

Madden, 1868; gunshot wound; ligature just outside scalenus; scapular artery also tied; cured.

Marchesano, 1875; bullet wound; ligature first portion; twenty days after operation, death from slipping of the ligature and hæmorrhage.

McKinnon, 1880; pistol-shot wound; ligature just outside of scalenus; six days later, terrific hæmorrhage; bag of shot, weighing two pounds and a half, placed as compress on wound; hæmorrhage arrested; cured.

Michel, 1883; gunshot wound; ligature second portion; cured.

O'Reilly; axillary (or subclavio-axillary) aneurism from reduction of dislocated shoulder; ligature third portion; cured.

Parke, 1891; gunshot wound; third portion; cured.

An analysis of these cases shows the remarkable fact that only two deaths occurred in the entire group, confirming the statement made in my essays on the arteries that the fatal results in ligature of the right subclavian or innominate were caused not only by the nearness to the heart, but by the unfortunate position of the innominate artery, which is in a direct line with the impact of the blood current forced out by the left ventricle. With these favorable results in mind, the surgeon can, by the ligature on the cardiac side, approach the left subclavian artery for relief of aneurism with a fair prospect of success.

In addition to the foregoing, Dr. W. S. Halsted ("Johns Hopkins' Bulletin," 1892) gives the history of a colored man, fifty-two years of age, in which with a silk ligature he tied the first portion of the left subclavian, excised the sternal portion of the clavicle, applied a ligature to the axillary artery as well, and excised a subclavio-axillary aneurism. The extirpation of this aneurism lasted three hours and a half. This may be considered the first successful deligation of the left subclavian artery in the first surgical division, as the patient recovered. In one other fatal case it was attempted by Dr. J. Kearney Rodgers, of New York.

In the second edition of this work I reported one hundred and thirteen cases in which the *subclavian* was tied in the *third surgical* division for *subclavio-axillary* aneurism, with forty-seven deaths. For simple *axillary* aneurism seventy-nine

cases were tied in the *third* portion of the subclavian, with thirty deaths; forty-nine recovered, and forty-six of these were reported cured.

The value of the expectant plan may be estimated in the following cases:

SYNOPSIS OF 22 CASES OF SUBCLAVIAN ANEURISM IN WHICH "NO TREATMENT" WAS UNDERTAKEN.

18 deaths, 4 spontaneous cures.

Eighteen fatal cases. Dates of death after tumor was noticed (and when surgical interference might have been undertaken).

1 case. Aneurism had existed for "some time." Died twelve weeks after admission to hospital.
1 case. Not known how long aneurism had existed.
1 case. Lived "some months." Died of exhaustion and suppuration caused by pressure of sac.
1 case. Died of rupture of sac twenty-four years after recognition of aneurism.
1 case. Died from asphyxia caused by pressure of sac, eight years.
1 case. Died from external rupture of sac two years and eight months after recognition of aneurism.
1 case. Died from exhaustion from pressure of sac two years after recognition.
1 case. Died from dyspnœa from pressure of sac, two years after recognition.
1 case. Died from dyspnœa and exhaustion from pressure of sac one year and a half after recognition.
1 case. Died from rupture of sac into lungs one year and a half after recognition.
1 case. Died from rupture of sac into lungs eight months and half after recognition.
1 case. Died from rupture of sac into tissues, becoming diffused, and causing death by pressure, five months and a half after recognition.
1 case. Died from rupture of sac, death by pressure, five months after recognition.
1 case. Died suddenly (probably from cerebral clot) one year and a half after recognition.
1 case. Died suddenly, cause not stated, not rupture of sac.
2 cases. Died from rupture of popliteal aneurisms.
1 case. Died from typhoid pneumonia three years after recognition.

Of the four cures, three remained well; one died about four years later from rupture of an aortic aneurism. Of these eighteen fatal cases in which no treatment was undertaken, three died of other diseases than aneurism.

Of the thirteen cases in which the duration of life is noted after the recognition of the aneurism, the sum total is forty-seven years and nine months.

The sum of life in the thirteen cases after deligation of the innominate is about eight months, a difference in favor of non-interference (in an equal number of cases) of about forty-seven years of life.

SYNOPSIS OF 14 CASES TREATED BY VALSALVA'S METHOD.

(*More or less modified.*)

1 case. M.; R. Subclavian aneurism. Size, hen's egg. Venesection; cold and lead lotion locally. Recovered. Two and a half years later was working as a carter in the city.

1 case. M.; R. Subclavian. Immense size. Venesection. Cold and astringents locally. Tumor reduced in size and firmer; lost sight of while in process of cure.

1 case. M.; R. Subclavian (syphilitic). Valsalva's method and antisyphilitics. Cure complete.

1 case. M.; R; age forty-five. Subclavian (syphilitic). Valsalva's method and antisyphilitics. Cured and seen well six years later.

1 case. M.; age forty-two. Subclavian. Venesection. Digitalis. Rest. Marked improvement, so that patient left hospital and was lost sight of.

1 case. M.; age fifty. Subclavian. Was treated for an intercurrent attack of rheumatism by rest, strict diet, and antiphlogistics. Cured.

1 case. M.; age thirty-nine. Subclavio-axillary (Pancoast's case). Valsalva's method had been tried and considered a failure. Operation determined on. Carried into operating room. Patient fell into collapse and operation was postponed. Recovered cured. (It is stated that a large dose of aconite had been given by mistake just before the operation was to have taken place.)

1 case. M.; age thirty-seven. Subclavian. Venesection. Valsalva's method and careful and persistent direct compression for one year and a half. Cured.

1 case. M.; age fifty-one. Subclavio-axillary (by Pelletan). Valsalva's method. Cured.

5 cases treated by this method (in part) were fatal. Venesection was not practiced except in one case. Only local and constitutional treatment. All died within twelve months of the recorded recognition of the disease; one from ulceration into trachea, hæmoptysis, and exhaustion; two from external bursting of sac; two from exhaustion and coma (with pressure on the trachea in one case).

Summary.—Fourteen cases. Cured, seven; improved, and in process of cure when lost sight of, two; died, five. No venesection in four of five fatal cases. One successful case modified by direct pressure.

Synopsis of 6 Cases treated by Direct Pressure upon the sac (Modifications given).

(*All subclavian aneurism.*)

1 case. M.; forty-six years; R. Leather "cup" molded over tumor and held in place by figure-of-8 straps around shoulders and axilla. Cured in fourteen months. Did light work during treatment, and had no other medication.

1 case. M.; thirty-nine years; L. Enormous size. Treated by cold and pressure "in turns." Small cannon ball suspended so as to press comfortably. Discharged relieved. Some months later violent inflammation (from fall), suppuration, rupture of sac; discharged two quarts of pus and blood. Cured. Debility of arm probably permanent.

1 case. M.; forty-one years. (Thirteen months' duration.) Kept in bed, on back; ice locally; restricted diet. Third day air cushion for twelve hours, with intermissions amounting to three hours. Every half-hour interval of ice. Treatment for seven days. Tumor began to subside, and was cured in twelve months.

1 case. (T. Holmes.) ("Lancet," February 12, 1876, p. 237.) Subclavian. Treated by direct pressure from rubber ball. Cured.

1 case. (Dupuytren.) Direct pressure. Resulted fatally.

1 case. (Porter.) Exposed axillary and passed needle under it. Thirty-five days later exposed innominate and passed the "acupressure needle" under it. Died from hæmorrhage from innominate on tenth day.

(In one case given in preceding table, direct pressure was practiced with Valsalva's method.)

Summary.—Five cases of "direct pressure" (without operative procedures). Cured, four; died, one.

Synopsis of Cases of Massage or Kneading in the Treatment of Subclavian Aneurism.

Of this method there are six cases.

Three cured; viz., by Fergusson, Little, and Porter.

Three died; viz., by Fergusson, Hilton, and Morgan.

(See "Guy's Hospital Reports," vol. xvi, p. 42 *et seq.*)

In addition, Mr. Bryant, in his "Practice of Surgery," p. 190, gives a case by Dutoit, of Berne, in which a subclavian aneurism was cured by injection of ergotin around the sac under the skin, and digital compression.

Poland cured one case by digital pressure on the cardiac side. A third case was tried for forty-six hours and abandoned on account of pain from pressure. The patient died from exhaustion. Paget tried mechanical pressure in a fourth case, but abandoned it as a hopeless undertaking. A fifth case by Verneuil was improved, but lost sight of before a cure was effected.

From the study of the foregoing history of subclavian, subclavio-axillary, and axillary aneurisms, I have reached the following conclusions:

Deligation of the innominate artery, or the subclavian in its first surgical division, are operations so dangerous that they should be undertaken only in extreme conditions.

The first indication in the treatment of these lesions is pressure, judiciously applied. If possible, the compression should be exercised between the tumor and the heart. Next in preference, direct pressure upon the body of the aneurism. Perfect and persistent rest should be enforced, and with this the method of Tuffnel offers the surest and safest means of palliation and cure.

In making direct compression, the elastic ball introduced by Mr. Holmes seems best adapted. This should be applied gradually, in order to accustom the patient to its presence. Massage is so inferior to the plan just detailed that it may be omitted from practice.

Should all these means fail after a persistent trial, and should the surgeon, from the appearances, judge that rupture was on the eve of occurring, ligature of the innominate should be performed, provided that the ligature could not be applied to the subclavian proper.

When the aneurism involves the last portion of the subclavian or the axillary, the ligature should be applied to the third division of the subclavian. Compression should always be tried in these, as in all other

cases, before resorting to the ligature. The histories show a far more favorable prognosis in operations on the left side.

Aneurism of the *brachial*, *radial*, and *ulnar* arteries, or their branches, is comparatively rare, and when seen is almost always the result of a wound. The diagnosis is not difficult. The treatment required is digital or mechanical compression on the cardiac side of the tumor. If this fail, direct compression of the sac may be added, and, if a thorough trial of these two methods is not successful, a catgut ligature should be applied, as near the aneurism as the condition of the artery will permit. Extirpation of a solidified or large aneurism may be essential to remove a deformity or the pain resulting from pressure.

Aneurism of the Vertebral Artery.—Aneurism of the vertebral is almost always the result of a punctured wound. A rare exception to this rule is the case of idiopathic aneurism of both vertebrals reported by Dr. Anderton, of New York city.* It occurs most frequently in that portion of the vessel between the atlas and the transverse process of the sixth cervical. The chief point in diagnosis is the differentiation between the lesions in question and carotid aneurism.

The difficulty of distinguishing vertebral from carotid aneurism in the neck arises from the fact that direct pressure from before backward, in the lower portion of the neck, will interfere with or arrest pulsation in aneurisms of *both* vessels.

If, however, the head be flexed upon the chest, and the sterno-mastoid muscle thus relaxed, the *carotid* can be compressed by grasping the muscle and artery between the thumb and finger, which are pressed deeply behind the outer and inner borders. This will not involve the vertebral.

Again, if the *carotid* be forcibly compressed by the thumb, backward and inward, against the vertebral column, at any point above the transverse process of the sixth cervical, the *vertebral* will not be included, since it is protected by the processes.

In my Essays are recorded five cases in which the common carotid was tied for supposed carotid, but in reality vertebral, aneurism. All ended fatally.

In the treatment of this lesion direct pressure may be employed, since prolonged compression of the artery before it enters the foramen in the sixth transverse process is impossible. One successful result of this method is recorded. If the disease continues to increase, deligation of the vessel in its first portion may be effected. This is a very difficult operation, and has rarely been attempted. The only operators so far are Smyth, Parker, Alexander, and myself.

Aneurism of the *internal mammary*, and other smaller branches of the subclavian, does not demand separate consideration. Aneurism of the *intercostal* arteries occurs in rare instances, usually as a result of fracture of a rib or a stab wound.

Aneurism of the Thoracic Aorta.—Aneurism of the thoracic aorta (exclusive of the arch) rarely demands surgical interference. Bourget,†

* "Medical Record," vol. xx, p. 354.

† "Annales de la Suisse Romanne," 1892; "Annals of Surgery," 1892.

of Lausanne, Switzerland, reports a case of large thoracic aneurism which presented in the space between the scapula and the spinal column. In order to produce coagulation, the method of Bacelli was successfully instituted. A watch spring two millimetres broad and thirty-seven centimetres long, with a spiral five centimetres in diameter, was used. The point was sharpened and boiled in a solution of hydrochloric acid, not only to make it aseptic but to cover it with a film of ferric chloride as a coagulating agent. A small slit was made in the sac, and, while an assistant held the spiral unwound, the end was introduced, and the spring, recoiling upon itself within the sac, rapidly drew the entire metal tape into the cavity of the aneurism. The wound was sealed; the patient complained of no pain during or after the operation. Tumor decreased in size; intercostal pains were lessened in intensity. One month later, exploratory puncture showed the aneurism solidified; pulsation ceased, and the patient gained three kilogrammes and a half in weight. The postural and dietetic treatment, with venesection when strictly indicated, should precede operative interference.

Aneurism of the Abdominal Aorta.—Aneurismal dilatation of this section of the aorta occurs most frequently near the diaphragm. The entire vessel may be the seat of fusiform aneurism. Females are less frequently attacked than the opposite sex. In corpulent persons the diagnosis is difficult. Tumors of the central organs, as the stomach, pancreas, transverse colon, and the superjacent mesentery, may be mistaken for aneurism. On the other hand, in emaciated persons, unnatural expansion of the aorta during the cardiac cystole has led to a mistake in diagnosis. The history of the development of the tumor, the presence of the aneurismal tremor and bruit, and the recognized general expansion of the sac, with the arterial pulse, will enable the careful observer to arrive at a correct diagnosis.

The treatment is chiefly expectant, and the most persistent trial of the postural and dietetic method can do but little more than prevent the rapid development of the aneurism. Operative interference may, when all else fails, be considered justifiable.*

* The introduction of steel wire may be undertaken. Dr. F. Lange ("Annals of Surgery," 1887), of New York, reports a case of aneurism of the abdominal aorta treated by the introduction of a wire into the sac. The patient was a man, forty-five years of age. Three metres of thin wire were introduced through a puncture made with trocar and cannula. The needle was again inserted a few days later, and twelve metres (about thirty feet) of wire introduced. Salt solution was thrown into the cephalic veins at the same time. The aneurism gradually increased, and the patient died of pneumonia twelve days after the operation.

Dr. A. G. Gerster ("N. Y. Med. Jour.," February, 1891), of New York, presented a specimen of aneurism of the aorta in which he had introduced thirty-five feet of wire. The patient died four weeks after. The specimen showed how little coagulation around the wire had taken place in that length of time.

In performing this operation it may be done without an anæsthetic through a small-sized trocar and cannula, care being taken to exclude any of the viscera between the abdominal wall and the trocar. The trocar-cannula is introduced into the sac, the trocar withdrawn, and the wire (which must of necessity be very fine) introduced through the cannula; or an anæsthetic may be given and laparotomy performed in order to carry the wire directly into the sac. The results of this operation do not offer much encouragement to a repetition of the practice.

Aneurism of the Branches of the Abdominal Aorta.—Aneurism of any of the visceral or parietal branches of the abdominal aorta may occur. The location of the tumor and the characteristic symptoms of aneurism will point to the vessel affected. When treatment is necessary, the same method should be employed as for aneurism of the main trunk. Exploration under strict antisepsis may be made, and deligation with the animal ligature practiced, if the tumor is sufficiently removed from the aorta to allow the application of the ligature to non-diseased tissue.

Aneurism of the Iliac Arteries.—Aneurism of the common iliac arteries and of the two primary divisions of this vessel close to their points of origin is, fortunately, of rare occurrence. The diagnosis may be made by a study of the history of the case, by palpation, coupled with exploration by the rectum or vagina. In the treatment of this lesion compression of the abdominal aorta should be faithfully tried, and with this restricted diet and rest in bed. When possible, careful, graduated, direct compression may be employed. Compression of the aorta may be digital, or by means of a horseshoe tourniquet, with or without an anæsthestic, as may be found applicable in the case under treatment. Compression of the abdominal aorta has been practiced by incision through the median line, holding this vessel partly or completely occluded by light pressure with the thumb and index finger. This practice might be found advisable for the cure of such a dangerous lesion.

Ligation of the abdominal aorta has been recommended, and has been performed eight times, with a fatal result in each case. The longest survival after the operation was ten days. It is doubtful if success can be obtained by the immediate occlusion of the abdominal aorta in any case in which a capacious collateral circulation has not been established as a result of the lesion. In a very extreme case in which this operation would be justifiable, graduated deligation has been recommended. The method suggested is the application of three ligatures in the course of the vessel, the superior constricting only slightly the lumen of the vessel; the next, removed an inch away, if possible, occluding about half of its lumen; while the third entirely occludes the vessel. These ligatures, of kangaroo or deer tendon, should be broad enough to compress a considerable surface of the vessel. It is in such an operation as this that Valsalva's method of venesection would be applicable; or it might be more conservative to apply a single ligature, occluding about one half of the lumen of the vessel, which would aid in the development of the collateral circulation, following this operation by a further partial occlusion in three or four days.

In iliac aneurism lower down, with compression of the abdominal aorta or common iliacs from the front of the abdomen, may be combined Prof. Sands's method of digital pressure by means of the hand introduced into the rectum; or Davy's lever may be employed in the same way. As a last resort, the common iliac may be tied.

A patient operated upon by Dr. F. Lange, within recent years, recovered and was cured.

In the "Annals of Surgery," 1895, Dr. T. S. K. Morton reported a case

of ilio-femoral aneurism cured by transperitoneal ligation of the external iliac artery.

In the "Lancet," 1891 ("Annals of Surgery," 1891), Dr. H. P. Symonds, of England, under anæsthesia applied Lister's abdominal tourniquet to the left common iliac. The aneurism ceased to pulsate. Pressure was kept up for seven hours, and again applied for two hours. The tumor became solidified, and a cure resulted. Peritonitis and enteritis resulted, but were not fatal.

Aneurism of the internal trunk is amenable to treatment by compression of the aorta or common iliac, or by ligation of the primitive trunk.

The abdominal aorta has been tied in the following cases of iliac aneurism: *

No.	Operator.	Date.	Sex.	Age.	Result.
1	Astley Cooper.	1817	M.	38	Died in forty hours. Ligature applied three fourths of an inch above bifurcation of aorta. Tumor measured eight inches in long axis.
2	James.....	1829	M.	44	Died in three and one half hours. Femoral tied thirty-three days before aorta. Tumor increased in size and aorta tied. Ligature applied seven eighths of an inch above bifurcation.
3	Murray.....	1834	M.	33	Died in twenty-three hours. Tumor extended as high as the umbilicus. External iliac involved. Gangrene was threatened. Ligature half an inch above bifurcation.
4	Monteiro.....	1842	M.	31	Died in ten days. Large diffuse aneurism of femoral. Aorta ulcerated at seat of ligature, and death took place from hæmorrhage.
5	South.....	1856	M.	28	Died in forty-three hours. External and common iliac involved.
6	McGuire.....	1868	M.	30	Died in eleven hours. Sac, which involved *both* common iliacs, burst during operation, when a hasty ligature was thrown around the aorta.
7	Watson.....	1869	M.	?	Died in sixty-five hours. Nine weeks after ligature of common iliac hæmorrhage occurred, when aorta, external and internal iliacs were tied. No hæmorrhage after operation.
8	Stokes.....	1869	M.	50	Died in twelve hours. Right common and external iliac and femoral involved.

When the aneurism is located upon the external iliac, compression with the tourniquet may be employed over the aorta or common iliac artery. Prof. Sands has advised and practiced digital pressure of the common iliac by means of the hand introduced into the rectum. Pressure from within the rectum may also be accomplished by means of a bougie or piece of wood properly padded (Davy's method). As a last resort the common iliac may be tied. This operation, though dangerous, has been successfully accomplished in several instances in late years. A patient recently operated upon by Dr. Lange, of New York, recovered and was cured. Aneurism of the internal trunk † is amenable to treatment by

* Gross's "System of Surgery."

† The internal iliac has been tied in antiseptic practice:

1. F. S. Dennis. 1886. Male, aged eighteen years. Gluteal aneurism. Cured. "N. Y. Med. Jour.," 1887.

2. F. S. Dennis. 1886. Female, aged sixty years. Double gluteal aneurism; both iliacs tied. Died. On fourth day, suppression of urine. Ibid.

3. W. L. Chew. 1886. Male, aged forty-six years. Gluteal aneurism. Recovered. Ibid.

4. Treves. 1892. Male, aged eighteen years. Sarcoma of buttock. Improved. "Brit. Med. Jour.," 1892.

compression of the aorta or common iliac, or by deligation of the primitive trunk.

Prof. J. D. Bryant* reports the cure of a large aneurism of the right iliac after Macewen's method. Delicate needles were introduced and the sac teased by drawing the point of the needles along the wall of the aneurism opposite to the point of introduction. The teasing lasted about half an hour, and two of the needles were left in twenty-four hours. Six days later there was no appreciable change, and the operation was repeated, followed by marked improvement. The tumor diminished in size and pain ceased. The tumor now extends across the brim of the pelvis, encroaching upon the region of the umbilicus, and seems solid and hard.

Aneurism of the branches of this vessel usually occurs in the gluteal and sciatic. The earliest symptoms are referable to the presence of the tumor. It must be distinguished from abscess or hernia. Aspiration would determine the presence of the former, and the symptoms of hernia, with absence of pulsation, would indicate the escape of the viscera through the great sciatic foramen. The treatment is difficult and often ineffectual. Direct compression should be first tried. Incision into the sac, turning out the clot, and tying both ends, has been successful in four of six cases reported by Fischer. The ligature may also be applied between the sac and the point of exit of the artery, or, as a last effort, the common iliac may be tied.

Poncet, of Lyons (1887,) ligated the right internal iliac artery for aneurism of the right buttock. The patient was a man, twenty years of age, tumor the size of fist; ligature, carbolized silk; patient died two months later of hæmorrhage after abundant suppuration.

Aneurism of the Femoral Arteries.—Aneurism of the *superficial femoral* artery is comparatively frequent. It occurs by preference in the upper half of the artery, and in males in the great majority of instances. In rare instances the disease is symmetrical.

The diagnosis is not difficult, since the expansile pulsation of the tumor can, in most cases, be readily appreciated by palpation. The presence of a tumor in the line of the artery, with the characteristic pulsation, tremor, and murmur, all of which signs disappear when the iliac artery or aorta is firmly compressed, points almost unerringly to a diagnosis. The greatest danger of error lies in the presence of an abscess. Abscess is, however, of rare occurrence in this region, except as a sequence of spinal caries or hip-joint disease, and these conditions, existing with the other common symptoms of the development of abscess, would lead to its recognition. If doubt should still exist, after even the most careful survey of the case, the hypodermic needle would settle the diagnosis.

5. Wherry. 1892. Male, aged twenty-one years. Aneurism of buttock. Recovered. "Lancet," 1893.

6. Annandale. 1894. Aged twenty-two years. Trauma of buttock; intraperitoneal ligature. Recovered. "Edinburgh Hosp. Reports," 1894.

* "Annals of Surgery," vol. xvii, 1893.

Treatment.—Aneurism of the *femoral* artery will, in the vast majority of cases yield to judicious and patient compression. When the tumor extends as high as Poupart's ligament, or above this point, the chances of success are diminished, since pressure will have to be applied to the *common* or *external* iliac or the *aorta*. Under such conditions direct compression, by means of Holmes's elastic ball, applied so gradually that inflammation of the sac will not be precipitated, should be first faithfully tried. Ligature of the *common* or *external iliac* should be deferred until all other remedies have failed, and, when there is a choice between these two procedures, the deligation of the *external iliac* should be preferred, on account of the anastomoses of the branches of the *internal iliac* with the vessels of the thigh. Direct compression of the sac was once successfully practiced by Dr. Brown, of Boston, in a case of femoral aneurism at Poupart's ligament. The weight employed may be as much as twelve pounds. Iron balls were used in this case. The patient was confined to bed for ten months. When the tumor is so far away from Poupart's ligament that digital or mechanical compression of the femoral upon the rim of the pelvis can be made, this treatment should be adopted. Extreme flexion of the thigh upon the abdomen has succeeded in producing a cure in a few instances. Direct pressure upon the tumor, with the limb extended, is less painful and equally efficacious. When the necessity for the application of the ligature occurs, the effort should be made to reach the artery below the origin of the *profunda femoris*, since the danger of gangrene is much less if this great collateral route is open. The distal ligature (Wardrop) should be tried before resorting to ligation of the common or external iliac.

The treatment of aneurism of the lower portion of the *femoral* does not materially differ from the above.

Aneurism of the *profunda femoris* is rare, occurring usually as a complication of this condition in the *common* trunk, or as a result of a punctured wound.

The treatment will include pressure on the cardiac side, or direct compression, and, as a last resort, ligature of the common femoral, or iliac.

Aneurism of the Popliteal Artery.—This is a very frequent seat of aneurism. Subjected, by reason of its unfortunate location, to the accidents of compression in extreme flexion of the leg, it frequently suffers those pathological changes which end in aneurismal dilatation, and is only second in order of frequency to the aortic arch, which yields to the violence of the cardiac systole. As with aneurism in other locations, it occurs most frequently in males, and in the active period of life, being rare in childhood and youth, and most common in the years from twenty-five to fifty.

Diagnosis.—On account of the infrequency of tumors in this region, other than aneurism, the diagnosis is not difficult. The characteristic symptoms of this malady will determine its differentiation from glandular enlargements, exostoses, overdistended bursæ, or abscess.

Treatment.—In the treatment of popliteal aneurism the patient should be placed in the recumbent posture, with the leg of the affected side

slightly flexed. A soft mattress should be used, and the thigh and leg held in a comfortable and fixed position by means of a pillow under the popliteal space, and sand bags laterally. Under the influence of an opiate, or in extreme cases complete etherization, digital or mechanical pressure should be employed upon that portion of the artery lying in Scarpa's triangle (Fig. 311). Within this limit the point of compression may be shifted, in order to prevent too great local irritation.

In obstinate cases compression on the cardiac side may be re-enforced by forced flexion of the leg on the thigh, or by direct pressure upon the tumor. The instances will be exceedingly rare where a patient and skillful employment of these methods of compression will not succeed in effecting a cure. Consolidation may result in one or two hours, or it may require several hours or days. Acupressure and massage are not to be employed. The elastic bandage of Esmarch has not given results which would justify its further use. When compression, either on the cardiac side or directly upon the aneurism, fails, the deligation of the femoral, in the extreme lower angle of Scarpa's space, is demanded.

The operation of tying the vessel above and below the aneurism and the removal of the tumor by dissection should not be practiced unless the solidified mass is so large or so situated that it causes compression of the nerves or popliteal vein, producing unbearable pain, or seriously threatening gangrene from interference with the return circulation.

Aneurism beyond the Popliteal.—Aneurism of the peroneal or tibial arteries, or their branches, is rare. In diagnosis and treatment this lesion, when situated in this portion of the arterial system, requires little or no special consideration. When the tumor is so situated that the vessel immediately involved can not be occluded by compression, this may be directed to the femoral, or, in aneurisms of small size, direct pressure may be sufficient to effect a cure. The ligature will be demanded if other methods fail.

Arterio-venous Aneurism.—*Arterio-venous* aneurisms are of two kinds. In one variety the communication is direct, the contiguous walls of the artery and vein being closely adherent immediately around the opening leading from one vessel to the other. This is called *direct arterio-venous* aneurism, or *aneurismal varix.*

When a sac intervenes it is called an *indirect arterio-venous* or *varicose aneurism* (Fig. 308).

The cause is usually traumatic, resulting most frequently from punctured wounds, although any inflammatory process which induces necrosis of the arterial and venous walls may lead to this form of aneurism. In exceptional instances the communication has either not been established, or at least has escaped observation for several years after the injury. This lesion may occur in any portion of the economy. In former years it was observed most frequently in front of the elbow joint, where it was produced by the accidental puncture of the brachial in the operation of venesection. It occurs not infrequently in the neck, as a result of wound of the *carotid* artery and *internal jugular* vein.

The chief points in the differential diagnosis between varicose aneu-

rism and aneurismal varix are the presence of a tumor and the peculiar aneurismal *bruit* and tremor, which conditions exist in the former.

In both varieties of this disease the veins become greatly distended and tortuous, and pulsate forcibly with each contraction of the heart, while the pulsation in the artery beyond the lesion is perceptibly diminished.

In the treatment of varicose aneurism, compression of the artery should be employed on both sides of the tumor, while direct pressure should be made upon the sac, between the two vessels. When, from the location of the lesion, this method is not feasible, or when, after a faithful trial, it has failed to produce a consolidation of the aneurism, the ligature will be required. Catgut should be used, one thread being passed around the artery just above, and another just below the tumor. When so situated that the vein involved in the lesion is not necessary to the integrity of the part, as in the forearm, this may also be secured on the distal side of the foramen of communication.

Operative interference in cases of *aneurismal varix* is not so frequently indicated as in *varicose aneurism*, owing to the comparatively slow progress of the disease. Experience has shown that deligation of the affected artery is far more dangerous in this condition than in the indirect variety. Fatal secondary hæmorrhage is recorded in a number of instances, while in others gangrene has resulted from closure of the artery. Compression should be employed as in the treatment of the form just considered. When the lesion is situated in the vessels of an extremity much comfort may be secured by the employment of an elastic bandage or stocking, as in the treatment of venous varix. As a last resort, amputation may be practiced.

Nissen ("N. Y. Med. Jour.," November 28, 1891) reports the case of an arteriovenous aneurism of the carotid and cavernous sinus caused by a wound made over the right eyelid by the prong of a fork which was followed by exophthalmos, which became bilateral, though more pronounced in the right eye. There was no pulsation or thrill in the eye. A diagnosis of rupture of the carotid artery into the cavernous sinus was made. The right carotid was tied and strong compression made on the left common carotid, lasting each time for one minute and continuing for two weeks. At the end of that time the *bruit* was much lessened in intensity, and the exophthalmos of the left eye had disappeared, while of the right but little remained.

In the discussion, Wölfler reported a case of pulsating exophthalmos in a woman, forty years of age, which was cured in eight days by methodical compression of the carotid.

Aneurisms in General.

The importance of syphilis in the pathogenesis of aneurism can not be too fully appreciated. Although traumatism determines the location of the aneurism to a certain extent even in syphilitic subjects, if this infection were recognized early and properly treated, the degeneration of the arteries, which is the one great lesion of syphilis, could not occur, and this dismal story of failure in the treatment of aneurism of the larger

vessels would not be told. The subject will be reverted to in the chapter on syphilis.

Again, the early institution of treatment most rigid in character—rest, restricted diet, and compression, either local, distal, or cardiac—is imperative in order to test the value of this method in the arrest of the disease before the vitality of the patient is so sapped that operative interference may be undertaken when there is a fair prospect of success. So far as direct surgical interference is concerned, it seems that, after compression, the needling method of Macewen offers the best hope of inducing coagulation with the smallest risk. The possibility of cerebral embolism should not be overlooked in aneurism of the ascending and transverse arch of the aorta or of the vessels leading to the brain.

*The Author's Case of Deligation of the Left Subclavian and Left Common Carotid Arteries.**—In February, 1889, under chloroform narcosis, I tied with catgut ligatures the left common carotid and left subclavian artery (third division) for the cure of aneurism of the transverse arch. The patient, male, forty-eight years old, had syphilis seventeen years before, had neglected treatment, and syphilitic arteritis ensued. Symptoms of aneurism appeared about two years before date of operation. The iodides had been faithfully tried, but the symptoms of pressure by the tumor increased, and the operation was done as a last resort. He died seventy-two hours later from suppression of urine and asphyxia, due to syphilitic gummata, involving chiefly the right lung, which was almost entirely solidified. Commencing with the origin of the left carotid and extending beyond that of the left subclavian was situated a spherical aneurism about three inches in diameter filled with firm clot almost wholly organized. It pressed heavily on the trachea and œsophagus and the left recurrent laryngeal nerve. It extended from the seventh cervical to the second dorsal vertebra (Fig. 315). This aneurism was practically cured, and the organized clot had without doubt resulted from the medical and expectant treatment. The smaller proportion of softer and recent clot was produced by the ligature.

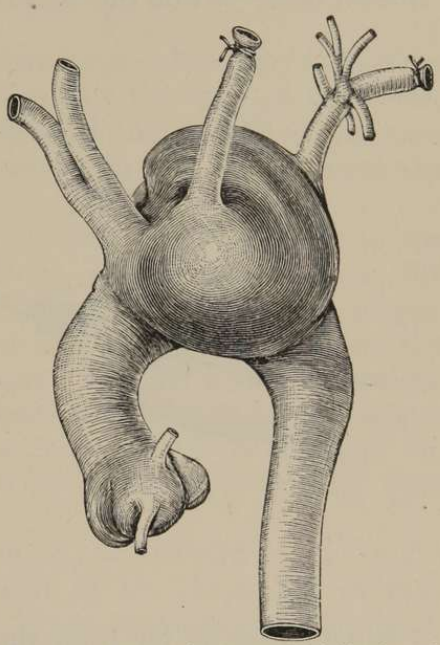

Fig. 315.—The author's case of deligation of the left carotid and left subclavian arteries for aneurism of the transverse portion of the arch.

* A recent and successful case of deligation of the right common carotid and subclavian arteries for aneurism of the arch is reported by Dr. F. T. Meriwether, of Asheville, N. C., in "Annals of Surgery," May, 1889.

CHAPTER XV.

LIGATION OF ARTERIES.

Operative Surgery of the Arteries.—In tying an artery, all of the details of the antiseptic method given heretofore should be scrupulously carried out. While the incision should be along the line of the artery,

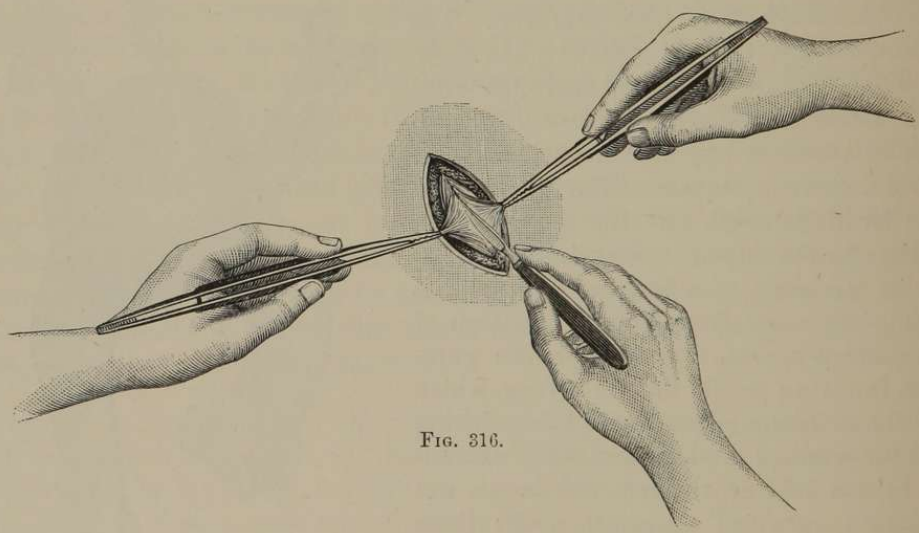

Fig. 316.

it should lean as far from the accompanying vein as possible. In approaching the vessel after the skin is divided, the fascia and all inter-

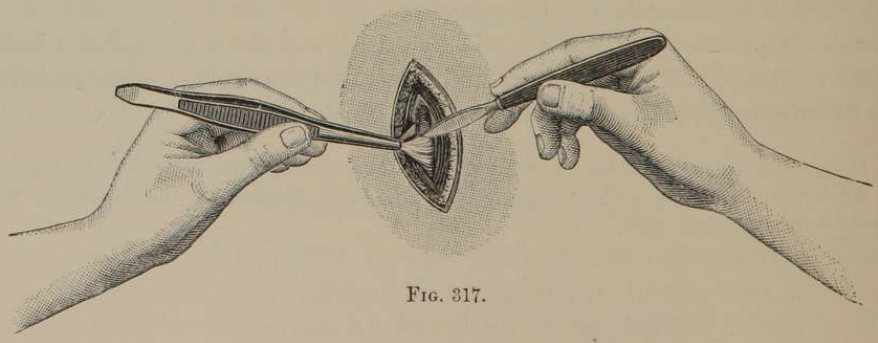

Fig. 317.

vening tissues should be grasped between two long, delicate dissecting forceps (Figs. 316, 317), until the sheath is reached, and this is opened

in the same manner. As soon as the wall of the artery is exposed the sharp-pointed instruments should be laid aside. A dull-pointed aneurism-needle, or a flexible silver probe, should now be passed between the sheath and the vessel, and carried carefully around the artery, keeping the point close to the wall of the vessel. When a nerve or vein is in close relation, the instrument should be introduced on the side nearest these, thus insuring their exclusion. The dull-pointed probe, bent to the proper curve, may be used to great advantage in almost all operations upon the arteries. After the point is carried around the vessel and brought up out of the sheath, the ligature may be tied over the slight bulbous expansion of this instrument, which, when withdrawn, leaves the ligature around the vessel. The force employed should be sufficient to occlude the vessel, yet not enough to inflict unnecessary violence upon its walls. The ends of the string should be cut off for one fourth to one half of an inch from the knot, and the wound closed for a permanent dressing.

Ligation of the Innominate Artery—Anatomy.—The *arteria-innominata* is derived from the transverse segment of the arch of the aorta, immediately in front of the trachea, just behind the middle of the sternum, at a level varying from one half to one and a half inches below the upper margin of the manubrium.

From this origin it travels obliquely upward, backward, and to the right (crossing the trachea from its center), and bifurcates, near the upper margin of the clavicle, between the *sternal* and *clavicular* origins of the *sterno-mastoideus* into the *carotid* and *subclavian arteries*, the first of these coming from its anterior aspect, the last a direct continuation of the *arch of the innominate*. The *innominata* in rare instances originates to the left of the trachea; more frequently it is given off before it reaches the windpipe. As a rule, it is longer in females than in males.

In twenty-eight cases in which I measured the distance of the origin of the innominate from the commencement of the aorta, the average was three inches and a half. In thirty-seven measurements made to determine the length of the innominate artery, the average was one inch and a half, the shortest specimens being three fourths and the longest two inches.

Operation.—Place a firm cushion crosswise beneath the shoulder-blades, so that the head will fall well back, and thus draw the artery upward. Have an assistant draw the arm and shoulder of the right side forcibly downward, while the chin is elevated and the face turned slightly to the left.

With the patient completely anæsthetized, and every arrangement made for expedition, make, from the center of the interclavicular notch, an incision about three inches in extent along the clavicle. A second incision, commencing at the inner border of the sterno-mastoideus, about two inches and a half above the clavicle, is made to unite with the first incision at the middle of the interclavicular notch. Dissect the flap upward until the sterno-mastoid muscle is exposed, the sternal and two

thirds of the clavicular origins of which should be divided upon a grooved director carefully introduced. Superficial to the muscle some small veins will be found, and underneath its clavicular portion is the junction of

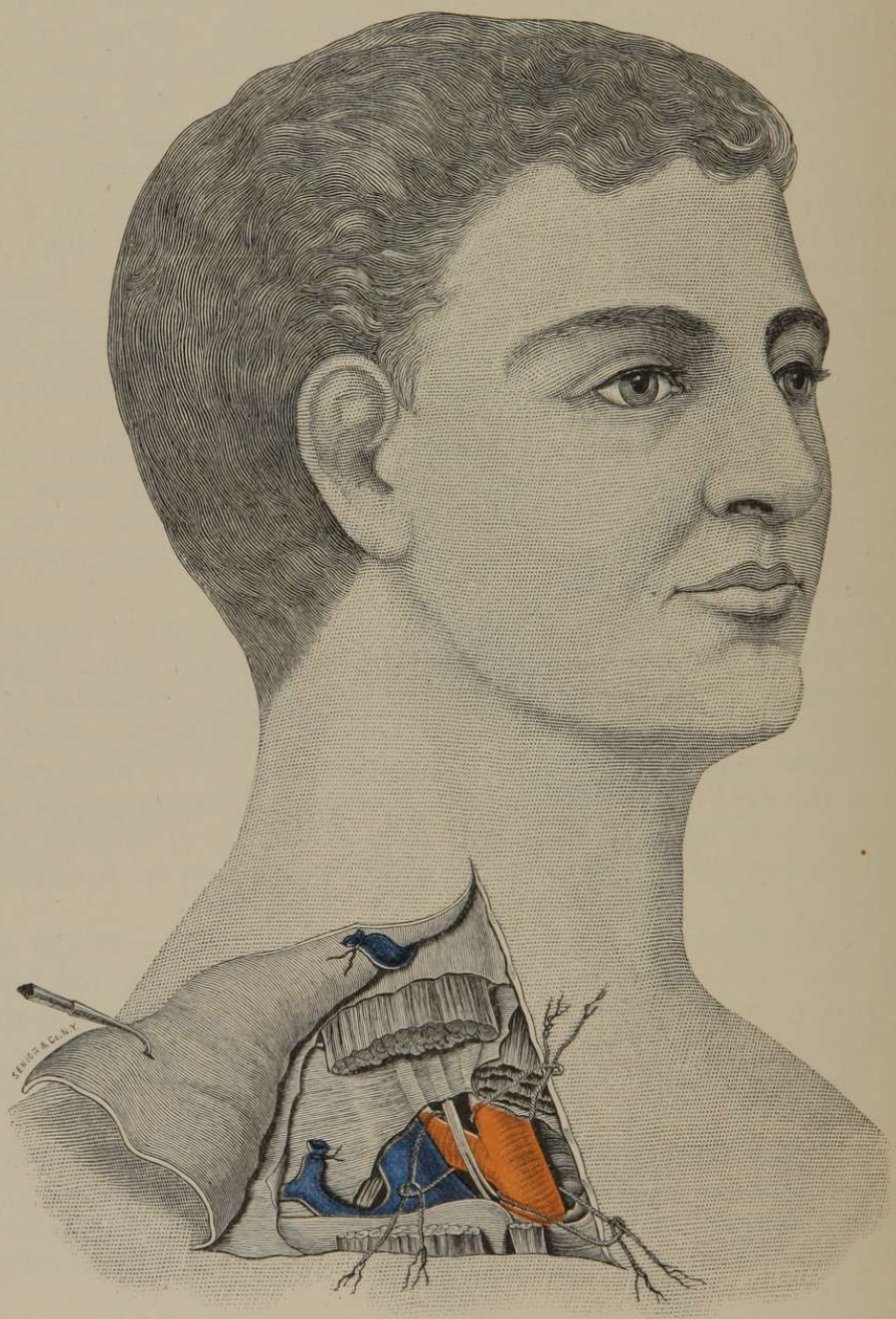

Fig. 318.—Showing the relations of the parts involved in deligation of the innominate artery; the right subclavian and carotid in their first divisions.

the subclavian and jugular veins, in dangerous proximity. The anterior jugular veins will be seen immediately beneath the muscle, and should be tied and divided. Dissecting carefully, with the handle of the scalpel, the connective and areolar tissue in which these veins are imbedded, the

origins of the *sterno-hyoid* and *sterno-thyroid* muscles will be reached, and, when these are divided carefully upon the director, the right carotid will be seen near the center of the wound. Following this down, the *arteria innominata* will be found just behind the *sterno-clavicular* articulation (Fig. 318). Being exposed with the scalpel-handle, or any dry dissector not likely to wound the vessel, the aneurism-needle should be passed from right to left behind the artery, care being taken to avoid wounding the right *vena innominata* and the *pneumogastric nerve*, or puncturing the *pleura*, in which the artery is *partly imbedded*. It is well to bear in mind that the left innominate vein crosses this artery, although usually very low down. When the aorta is situated low in the *thorax*, it may be necessary to remove the sternal end of the clavicle and a segment of the sternum, as was done by Cooper, of San Francisco, in two instances, and later by Burrell.

An element of danger in this operation is the origin of an abnormal branch from the innominate. In the cases of Lizars and V. Mott this anomaly existed, and death was caused by *hæmorrhage at the seat of the ligature*. In thirty-four consecutive subjects which I examined as to this feature, I found an abnormal branch to be derived from the innominate in five. When the necessity for occlusion of the arteria innominata arises, and the conditions are such as to permit it, the following method should be followed: The right common carotid should first be tied, one inch above its origin. By a careful dissection the first division of the subclavian and its branches should then be exposed, drawing the internal jugular to the outer side until the vertebral is secured. Avoiding the phrenic nerve, as it descends to the inner side of the scalenus anticus, the internal mammary and branches of the thyroid axis should be secured, and finally a ligature of large, smooth catgut, or prepared nerve placed around the subclavian artery, about the middle of its first portion. A careful study of the anatomy and surgery of this region leads me to conclude that this procedure, though difficult of execution, offers a better prospect of success than deligation of the larger and primitive trunk, nearer the heart.

In the operation and after-treatment of the wound the most careful antisepsis should be practiced.

Ligation of the Common Carotid Arteries and the Internal Jugular Vein—Anatomy.—In one hundred and twenty dissections I found the *common carotid* artery to bifurcate on a level with the notch between the two alæ of the thyroid cartilage in one hundred and sixteen. The anomalies of this vessel are so rare that they do not deserve mention in this work.

Operation.—A firm cushion should be placed under the shoulders and lower part of the neck, with the chin elevated, and the face turned in the direction away from the side upon which the operation is to be performed. A line extending from the tragus of the ear to the sterno-clavicular articulation will cover, and be parallel with, the *internal* and *common carotid* arteries in their surgical length. This line will strike the center of bifurcation of the primitive carotid almost invariably on a level with the upper border of the thyroid cartilage, and the anterior edge

of the *sterno-mastoideus* from one inch and a quarter to one and a half below this level. The point of election is about one inch below this bifurcation, and at the upper border of the anterior belly of the omo-hyoid muscle.

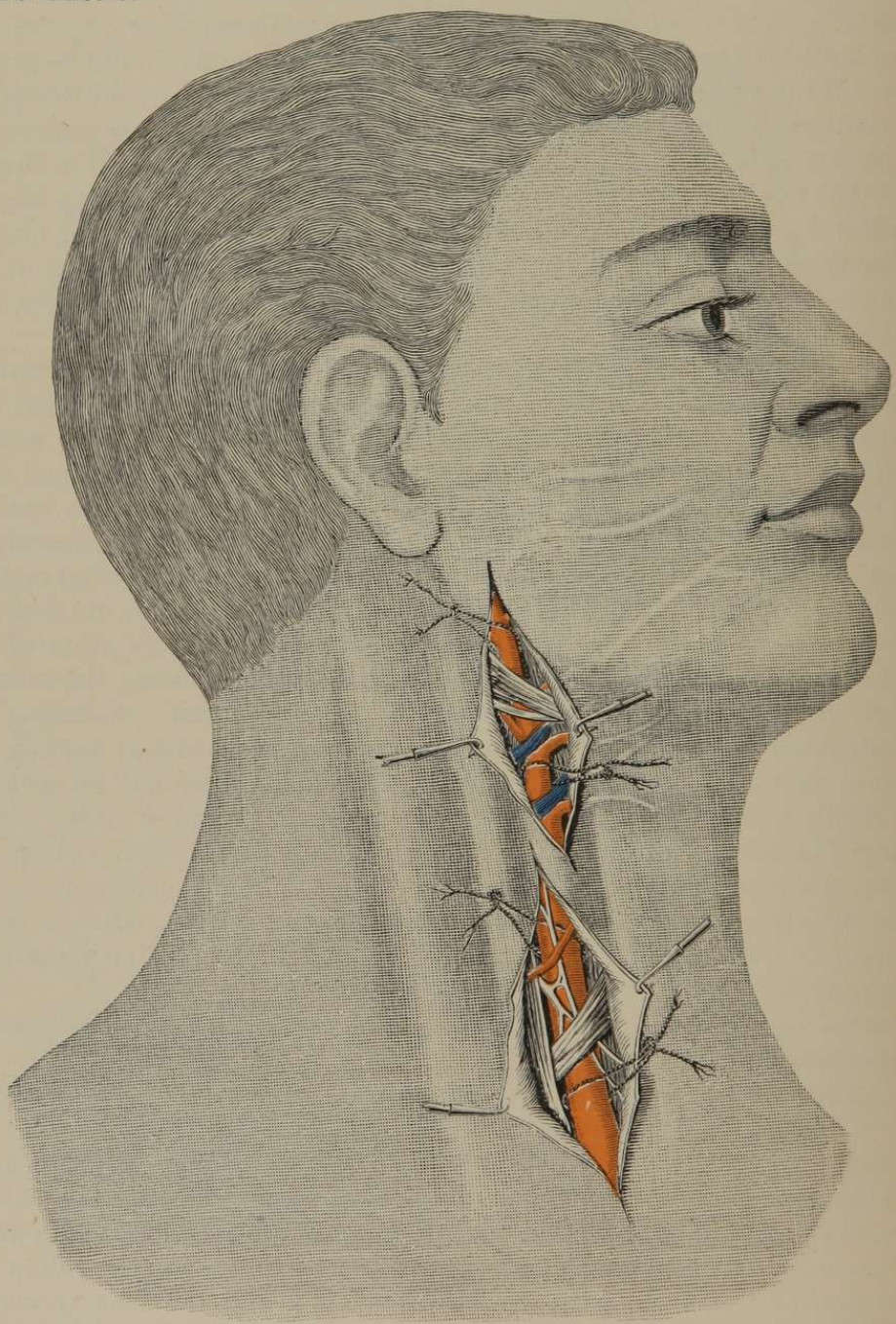

FIG. 319.—Showing lines of incision and relation of parts involved in deligation of the common carotid, above and below the anterior belly of the omo-hyoid, and the external carotid below the lingual and above the facial.

The incision, being made with its direction as above given, its center about one inch below the bifurcation, extending from one-and-a-half to two inches above and below this point, will divide first the integument,

and with this the thin *platysma myoides*, some filaments of the *superficialis colli* nerve, of no importance, and some small veins passing from the *anterior*, either to the *internal* or *external jugular veins*. About the center of the wound the edge of the *mastoideus* will be seen, and below this (usually) the anterior belly of the *omo-hyoideus* (Fig. 319, lower half). The sheath of the *carotid* and *jugular* vein is now exposed, often crossed by the *thyroid* veins, and the *cervicalis descendens* artery, the *descendens noni* nerve almost invariably lying upon the center of the sheath, being parallel with the axis of the *common* and *internal carotids*. In two instances I have seen the *superior thyroid* artery turn directly down, in front of the *common* trunk, for an inch or more, and then turn abruptly inward to be distributed to the thyroid body. Under such abnormal conditions this vessel would probably be divided. The *communicans noni* is occasionally found crossing the sheath from without inward, to anastomose with the *descendens*. These nerves will be drawn to the outer or inner side of the wound, as is most convenient. The sheath should be opened on its *tracheal* side, as far as possible from the *jugular vein*, and the needle passed from without inward, being kept close to the artery in order to avoid wounding the *vein* or including the *pneumogastric* or *sympathetic nerves*. The sheath should be well opened, and the artery clearly exposed, so that the needle may be manipulated with more of certainty and less danger from these too common and unfortunate accidents. In several instances the artery has been transfixed; the *jugular* has been wounded; the *pneumogastric* or *sympathetic* nerves included in the ligature, for want of precision in separating the artery from the vein. Certainly the danger of slough in the artery is not so great as the dangers above enumerated. Just as the needle is being introduced, pressure above upon the vein would empty it of blood, and of course diminish the danger of wounding it.

The operation of tying the carotid, just below or behind the omo-hyoid, is practically the same as that just described (Fig. 319).

In order to secure this vessel at the root of the neck, an incision should be made in the carotid line, extending from the sterno-clavicular articulation upward a distance of three or four inches, and between the two heads of origin of the sterno-mastoid muscle. This will divide the integument, superficial fascia, platysma, and deep fascia, and some descending superficial nerves. The fibers of the sterno-mastoid may be separated and held to either side by retractors. Immediately beneath it will be found the anterior jugular vein, and some small branches emptying into it. If not easily displaced, they should be secured with a double ligature, and divided between the threads. The fibers of the sterno-hyoid or sterno-thyroid muscles should next be divided on a grooved director, and turned aside or separated in the line of the artery. The vessel will be seen deeply situated in the line already given. The ligature should be passed from the outer side. Or an L-shaped incision, similar to that made for deligation of the innominate (Fig. 318), may be made, and the carotid found by separating the sternal tendon of the mastoideus muscle and turning this outward. For the left carotid see Fig. 320.

The approach to the vessel in this region should be very cautious, especially upon the left side of the neck, since the internal jugular vein crosses from the outer to the inner side by the front. On the right side

Fig. 320.—Showing the relations of parts involved in deligation of the left carotid, at the root of the neck, and the left subclavian in its first surgical division.

the vein is a little more external. The pneumogastric nerve lies behind and to the outer side of the artery, while the inferior thyroid artery and sympathetic nerve are more deeply situated. The aneurism-needle

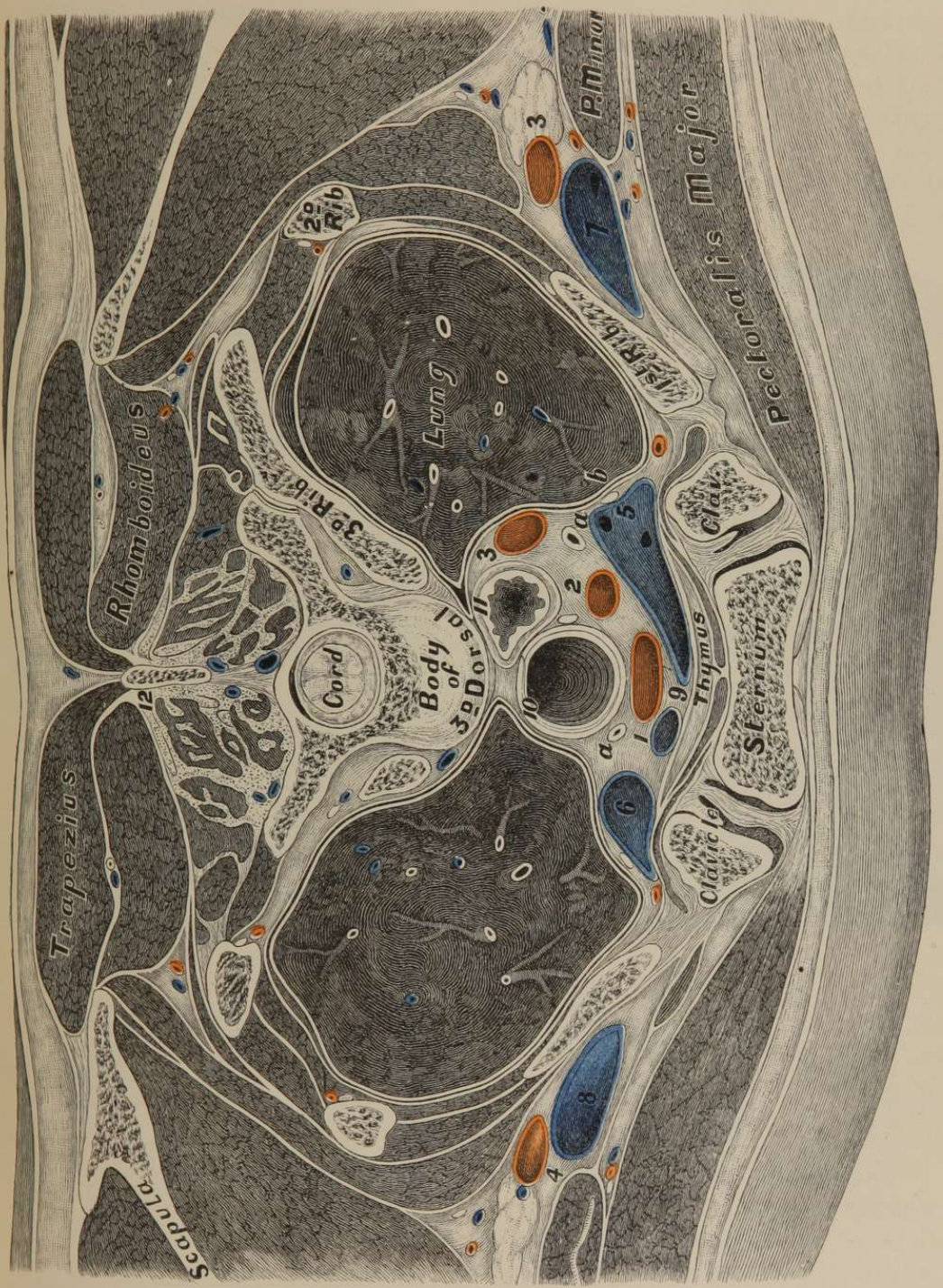

FIG. 321.—Showing the relations of the important organs at the root of the neck and apex of the thorax. Frozen horizontal section at the level of the third dorsal vertebra. (After Braune.) 1, Innominate. 2, Left carotid. 3, Left subclavian. 4, Right subclavian arteries. 5, 6, Left and right innominate veins. 7 and 8, Subclavian veins. 9, Inferior thyroid vein. 10, Trachea. 11, Œsophagus. 12, Spinous process of second dorsal vertebra. *a a*, Pneumogastric nerves. *b*, Phrenic nerves.

should be passed around the artery, from the outer toward the inner side.

In the "Prize Essay" of the American Medical Association for 1878 I collected histories of 789 cases in which the common carotid artery had been tied for all causes, of which 323, or 41 per cent, died. The death-rate will never again reach this alarming figure. The introduction of animal ligatures and asepsis have already greatly diminished the ratio of mortality in operations upon the arteries.

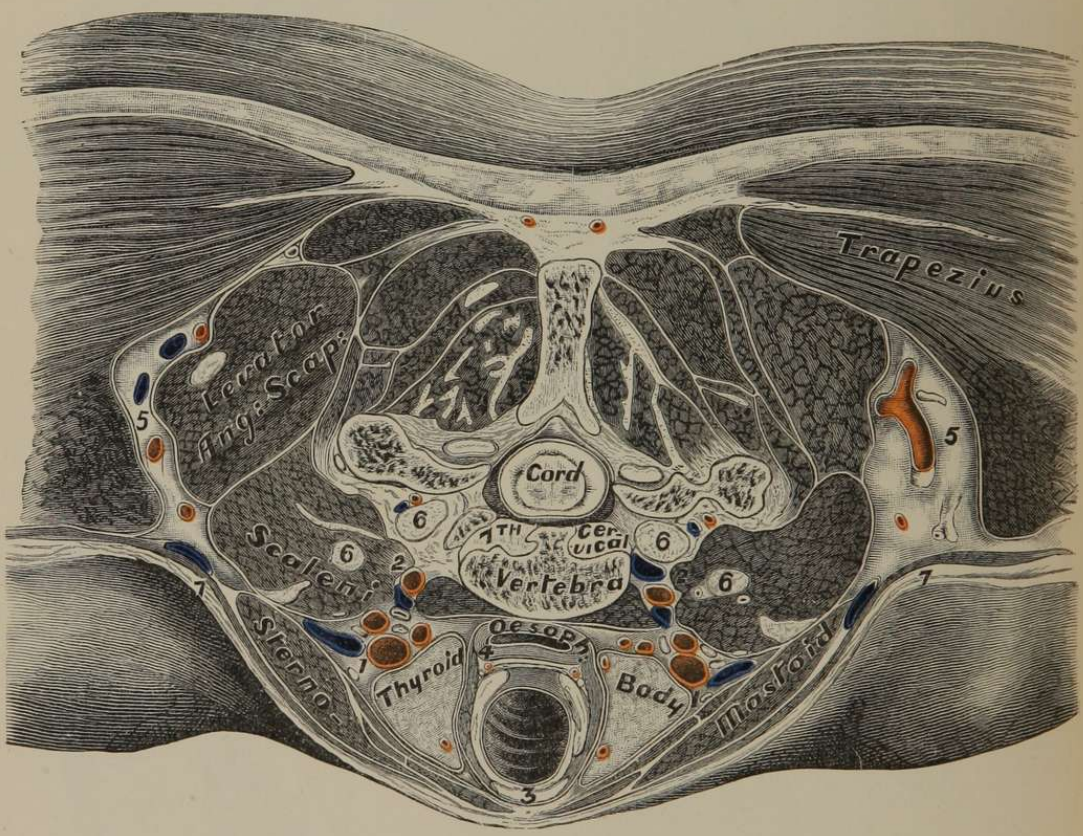

FIG. 322.—Horizontal section at the level of the seventh cervical vertebra. 1, 1, The right and left common carotid arteries and the internal jugular veins. 2, The right and left vertebral arteries and veins. Directly between the vertebral and carotid arteries is seen the sympathetic nerve and the inferior thyroid artery and some of its branches. The pneumogastric nerves are seen between and slightly posterior to the internal jugular veins and the common carotids. 3, Trachea. 4, Œsophagus. 5, Transversalis colli artery and veins and descending branches of the subclavian artery. 6, Cords of brachial plexus. 7, 7, External jugular vein. (After Braune.)

Thirty-four cases are on record in which both trunks were tied, of which twenty-five recovered.*

Ligation of the Internal Carotid Artery—Anatomy.—This vessel is a direct continuation of the common trunk, and, while straight in its lower portion, it becomes slightly tortuous as it approaches the carotid canal. An abnormal branch was found to be derived from its first portion in seven of one hundred and twenty dissections.

Operation.—The position is the same as for tying the common trunk.

* *Op. cit.* See also Riegner's case, "Centralblatt für Chirurgie," No. 26, 1884.

The incision should be made in the carotid line, with its center from one half to three quarters of an inch above the upper border of the *thyroid cartilage.* The same structures will be divided superficially, and the veins will be seen superficial to the artery. As shown in *C*, Fig. 324, they

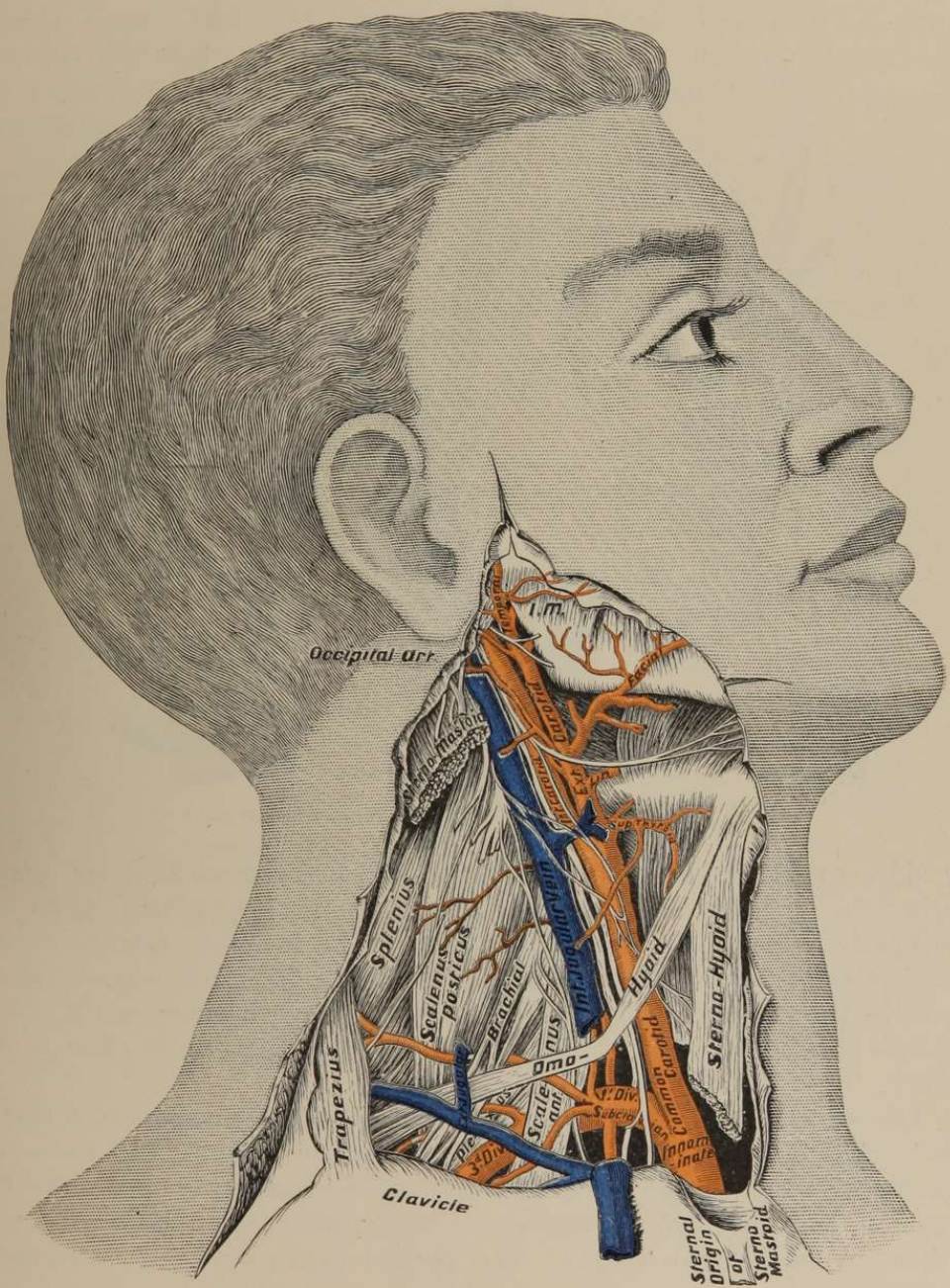

Fig. 323.—The usual relation of the contents of the surgical triangles of the neck. From the author's dissections.

may cross the internal carotid almost at a right angle, or (as in *A* or *B*) they may empty into a single trunk, and run parallel with the *external carotid.* This last is the most usual way, but it will be scarcely possible to ligate the *internal carotid* without ligature and division of some of

these veins. The *descendens-noni* nerve will be seen running along the artery, the *hypoglossal* crossing it about one inch from the bifurcation. The vessel being exposed, the needle is introduced on the out-

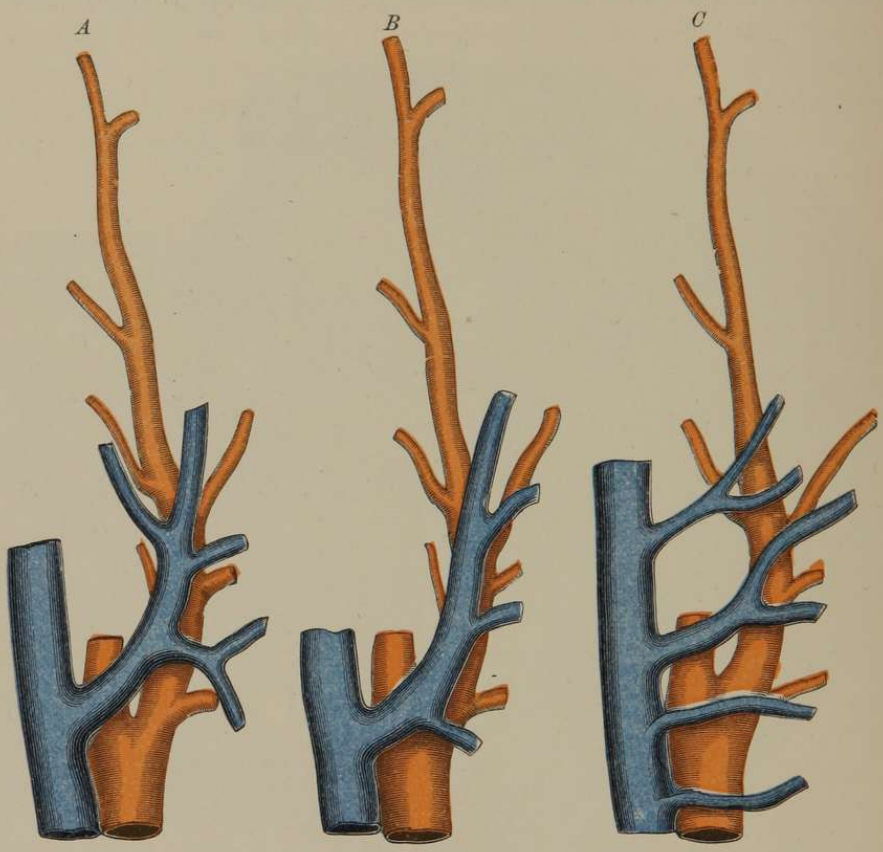

Fig. 324.—Relation of the veins to the carotids. (Life size.)

er side, avoiding the *jugular* vein and *pneumogastric* nerve externally, the *external carotid* internally, and the *hypoglossal* nerve superficially. The *pharyngea ascendens* is in intimate relation to the *internal* carotid, running parallel with it on its inner aspect. Occasionally the first cervical ganglion of the sympathetic extends as low as this point. It will be avoided by keeping the needle close to the artery.

The internal carotid artery has been tied nineteen times, with twelve recoveries.* In six of the fatal cases the common trunk had been previously and ineffectually secured, and in the remaining case I tied the common, external, and internal carotids, in removing an immense tumor which involved these vessels. The patient died from shock in eighteen hours.

Ligation of the External Carotid Artery.—From the extensive distribution of its branches to the exposed portions of the neck and face, the *external carotid* artery demands a more careful consideration than any single vessel of the human body.

* *Op. cit.*

Anatomy.—Leaving the *common* trunk at the upper border of the *thyroid cartilage*, well forward of the anterior border of the *sterno-mastoid* muscle, this vessel arches forward and upward (its concavity looking toward the lobule of the ear) until, on an average of ·92 inch above the bifurcation, after giving off the *facial* branch, it turns obliquely upward and backward to a point opposite the insertion of the *external pterygoid* muscle into the neck of the condyle of the lower jaw, where it terminates by dividing into the *temporal* and *internal maxillary* arteries.

Eight regular branches belong to this vessel (though some anatomists, among whom are Hyrtl, Wilson, and Richardson, describe nine). On its anterior aspect arise from below, upward, the *thyroidea superior*, *lingualis*, *maxillaris externa*, and *maxillaris interna*. On its posterior and internal aspect the *pharyngea ascendens*, and posteriorly the *occipitalis*, *auricularis*, and *temporalis*.

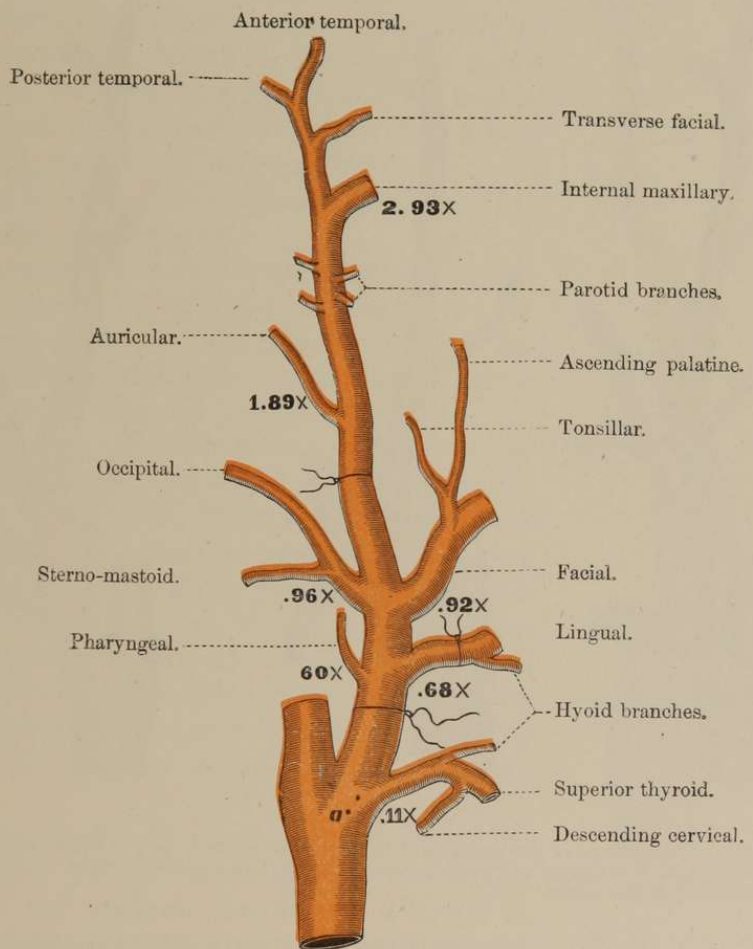

Fig. 325.—The external carotid and its branches. The average arrangement of one hundred and twenty-one dissections by the author. (Life size.)

The usual arrangement of these branches is seen in Fig. 325, which is the average of one hundred and twenty-one dissections. Abnormal deviations from this relation of the branches to the parent trunk

occur occasionally, and types of these may be seen in Figs. 326 and 327. The relations of the veins to these arteries are shown in Fig. 324.

Operation.—The external carotid may be tied in the majority of cases at two points, viz., between the origins of the *thyroidea superior* and *lingualis*, about one quarter of an inch above the septum of bifurcation (see Fig. 325), or between the origins of the *maxillaris externa* and *auricularis*, about one inch and a half above the *thyroid cartilage*. At the lower point of election the operation is the same as for ligature of the *internal carotid* on the same plane, except that the *external carotid* is usually from one quarter to one half inch nearer the median line than the *internal*.

Notwithstanding that the analysis of one hundred and twenty-one consecutive dissections has convinced me of the propriety of ligaturing



Fig. 326.—Unusual arrangement of the branches of the external carotid. 1, The lingual and facial from a common origin. 2, The lingual and facial superior thyroid from a common origin. 3, Close relation of first five branches to each other.

this vessel, and that the history of the cases in which it has been tied shows a rate of mortality far below that of ligature of the *common carotid*, yet the proximity of large and important branches to each other, or to the bifurcation of the *common carotid* in many instances, makes it of the utmost importance that the surgeon should proceed with great care and discretion. The wound should be thoroughly cleansed, and the vessel

examined with scrupulous care above and below the ligature, and any collateral branch or branches within less than one quarter of an inch should be also secured.

Should the artery be found to be normal (as in Fig. 325), I would place the ligature nearer the *lingualis* than the bifurcation, and tie this vessel separately. If (as in Fig. 326, 3) a rare form should exist, I would ligature close to these branches, and tie each of them in its turn. This same conservative rule must apply to every case.

The operation at or above the posterior belly of the digastric is comparatively safer, and is applicable to all lesions above this point. The incision should extend from the lobule of the ear along the ramus of the jaw, down to the level of the thyroid cartilage. Cutting through the superficial structures, the artery will be found just behind the posterior belly of the digastric muscle.

Above this level—that is, after the artery enters the parotid gland—it is so situated that it should not be cut down upon. The incision would involve the *facial nerve*, causing paralysis of the muscles of expression. In malignant disease of the parotid, where this gland is removed, the vessel may as well be secured here as not, since the operation itself usually destroys the *facial nerve*.

Fig. 327.—An enlarged superior thyroid artery.

It is a remarkable fact that, notwithstanding the close proximity of the branches of the *carotid*, in a number of instances in which it has been ligatured without the precaution of securing immediate collateral branches, there has not followed secondary hæmorrhage. No explanation of this fact has appeared so definite as the one given by Prof. H. B. Sands, "which takes into account the remarkable reparative power of the tissues surrounding this vessel. Suppuration is extremely rare, the wounded tissues soon become consolidated by plastic material, and secondary hæmorrhage is prevented by changes occurring *outside of*, as much as by changes taking place *within*, the vessel ligatured."

On account of the importance of maintaining the integrity of the circulation to the brain, ligation of the common carotid, for a lesion in the distribution of the external carotid, should never be performed when a sufficient distance remains between the lesion and the bifurcation of the common trunk to allow of the application of the ligature. I have the histories of ninety-three cases of ligature of the external carotid, in sixty-nine of which this vessel alone was tied. Of these sixty-nine cases only three died, while

the death-rate after ligature of the common trunk, for the same period, was 41 per cent.

Ligation of the Superior Thyroid Artery—Anatomy.—This branch was present in every instance in one hundred and twenty-one dissections. It originated almost invariably on a level with the thyroid notch. In one of twenty-five cases it will be found to have a common origin with the lingual, or the lingual and facial. See Fig. 326, 1, 2.

Operation.—With the neck in the surgical position, i. e., with the head thrown back and the face turned to the opposite side, make an incision two inches long, parallel with, and one fourth of an inch in front of, the *carotid line.* The center of this incision must be on a level with the thyroid notch. Immediately beneath the skin and *platysma myoides* will be seen the *thyroid*, *lingual*, *hyoid*, and other veins, which may assume either of the forms or relations shown in Fig. 324, A, B, being most common. These being tied and divided, the artery will be found opposite the point above indicated.

The thyro-hyoid nerve will occasionally be seen passing across this artery, although usually nearer the median line. The external laryngeal passes beneath it.

Ligation of the Lingual Artery—Anatomy.—From its origin, usually opposite the cornu of the hyoid bone, it ascends obliquely upward and inward, and is superficial until it passes underneath the *stylo-hyoideus* and *digastricus* (posterior belly), and then more deeply behind the *hyo-glossus.*

In two of one hundred and twenty-one cases it originated in common with the superior thyroid, and in two other instances with this vessel and the facial. In thirty-one of one hundred and twenty-one cases it arose from a trunk common to it and the facial, being abnormally associated in one in every three and a half dissections.

Operation.—The *lingual* artery may be secured either below the digastric or above this point, where it passes beneath the hyo-glossus.

For the low operation make an incision as in the case of the *superior thyroid*, except that its *center* should be *opposite the os hyoides.* The artery will be found in the *lingual triangle*, bounded posteriorly by the *external carotid*, above by the *digastric* muscle, below by the *os hyoides.* The *middle constrictor* muscle is behind it; the *platysma myoides* in front, and under this the veins above noted. The hypoglossal nerve is usually *just above* it as it crosses the *carotid*, while the *thyro-hyoid* branch of this nerve crosses the artery on its way to the muscle it supplies.

The high operation is one of considerable difficulty. The face should be well turned to the opposite side, the chin elevated, and held perfectly immovable. Beginning immediately over the os hyoides, near the median line of the neck, an incision is made outward, and parallel with this bone as far as the great cornu, where it is curved upward to the angle of the jaw (Fig. 328). This crescentic flap is turned up, and with it the sub-maxillary gland, in a groove on the under surface of which

the facial artery runs. As soon as the hyoid bone is exposed it should be fixed with a tenaculum and drawn steadily down. The posterior

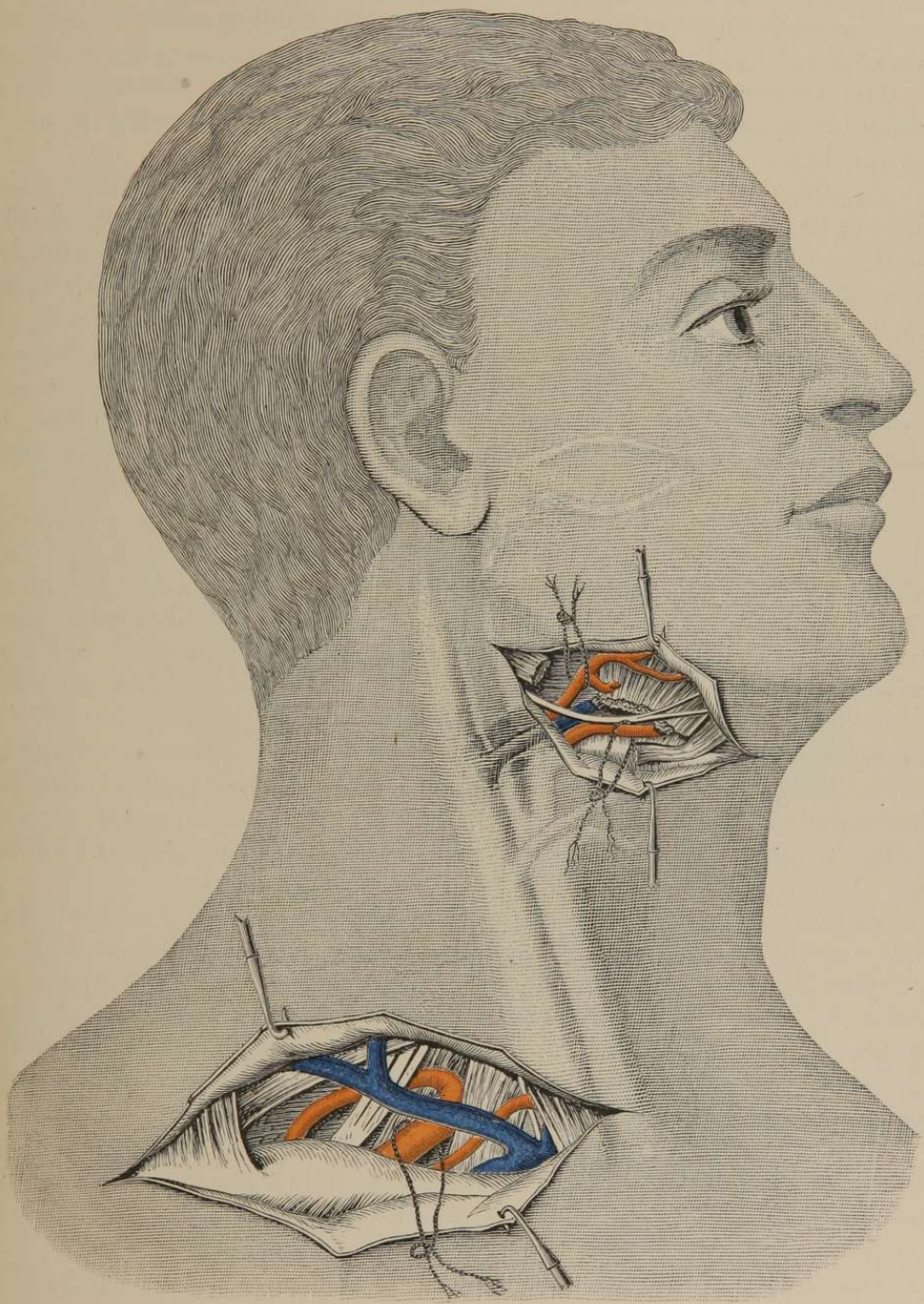

Fig. 328.—Ligation of the right subclavian in its third surgical division; the facial in the neck and the lingual beneath the hyo-glossus muscle.

belly of the digastric will now be seen passing obliquely downward and forward to the central tendon in the hyoid bone. Passing beneath this muscle, and superficial to the hyo-glossus, is seen the hypoglos-

sal nerve, which runs parallel with and above the artery. Depress the posterior belly of the digastric, insert a director beneath the posterior fibers of the hyo-glossus, and divide these. The artery will be found just beneath this muscle, resting upon the middle constrictor of the pharynx.

The ligation of this artery is frequently practiced preliminary to excision of the tongue for malignant disease, and occasionally to arrest hæmorrhage.

Ligation of the Facial Artery—Anatomy.—The facial artery was present in one hundred and twenty of one hundred and twenty-one dissections. In the instance in which it was missing its facial distribution was taken by the *transverse facial* from the *temporal*, and its cervical by branches from the *lingual* and the *external carotid*. Its origin is usually about one fourth of an inch above the *lingual*. It is the longest branch of the *external carotid*. In thirty-one of one hundred and twenty cases it arose in common with the lingual, and in two instances it was from a trunk in common with this artery and the *superior thyroid*.

Operation.—In its cervical distribution this vessel will require to be tied at or near its origin from the *carotid*. The incision along the axis of the *carotid*, as given before, with its center a quarter of an inch above the hyoid bone, will lead to the facial. The posterior belly of the *digastricus* will be found with its center usually above the origin, but soon crossing the artery. The ninth nerve is just below. For lesion of this vessel in the face it can be readily secured as it crosses the *inferior maxilla* in the depression at the anterior border of the *masseter* (Fig. 329). Before making the incision, which should be parallel with the horizontal portion of the inferior maxilla, the skin should be well pulled up from the neck, so that, after healing, the cicatrix will fall below the jaw.

Ligation of the Ascending Pharyngeal—Anatomy.—This artery was derived from the *external carotid* in one hundred and eleven of one hundred and twenty-one cases, and from the *internal carotid* in four others. It usually comes off at a point opposite the origin of the *lingual*, and occasionally from the bifurcation of the *primitive carotid*. A pharyngeal branch is not uncommon from the occipital.

Operation.—The *external carotid* must be exposed by an incision the center of which is opposite the level of the hyoid bone. The vessel will be seen ascending between, and parallel with, the *external* and *internal carotids*.

One fatal case is recorded from hæmorrhage after a wound of the *ascending pharyngeal*.

Ligation of the Occipital Artery—Anatomy.—The *occipital* was present in one hundred and twenty of one hundred and twenty-one dissections, and it was found to be opposite the facial in the majority of cases. In the subject in which it was missing, a large branch from the *inferior thyroid* (not the *ascending cervical*) took its distribution. Not

infrequently the *posterior auricular* or a *pharyngeal* branch arose from this vessel.

Operation.—It may be secured near its origin, or behind the mastoid process. For the low operation, make an incision in the *carotid line*, the center of which is about one inch above the thyroid notch. After divid-

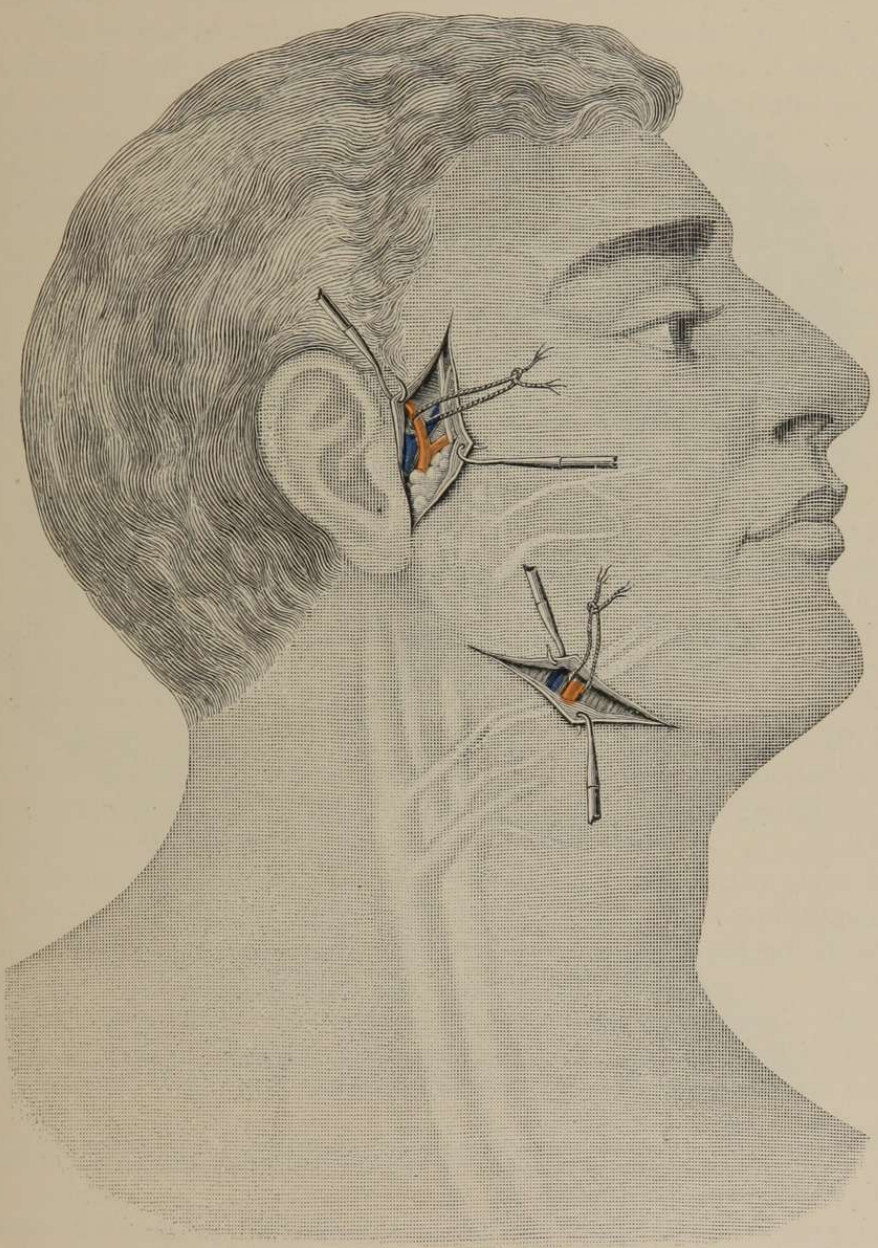

Fig. 329.—Ligation of the posterior temporal at the zygoma, and of the facial upon the inferior maxilla.

ing the deep fascia the hypoglossal nerve will be seen, which, if followed backward, will lead unerringly to the artery, underneath which it winds. The posterior belly of the digastric muscle will usually require to be lifted upward.

Behind the mastoid the occipital may be tied where it passes beneath

the cranial attachment of the sterno-mastoid muscle (Fig. 330). From one half to three fourths of an inch behind the mastoid process an incision about two inches long should be made, extending upward and backward. The aponeurosis of the sterno-mastoid muscle is divided on a director, and the artery exposed. The constant relation of this vessel

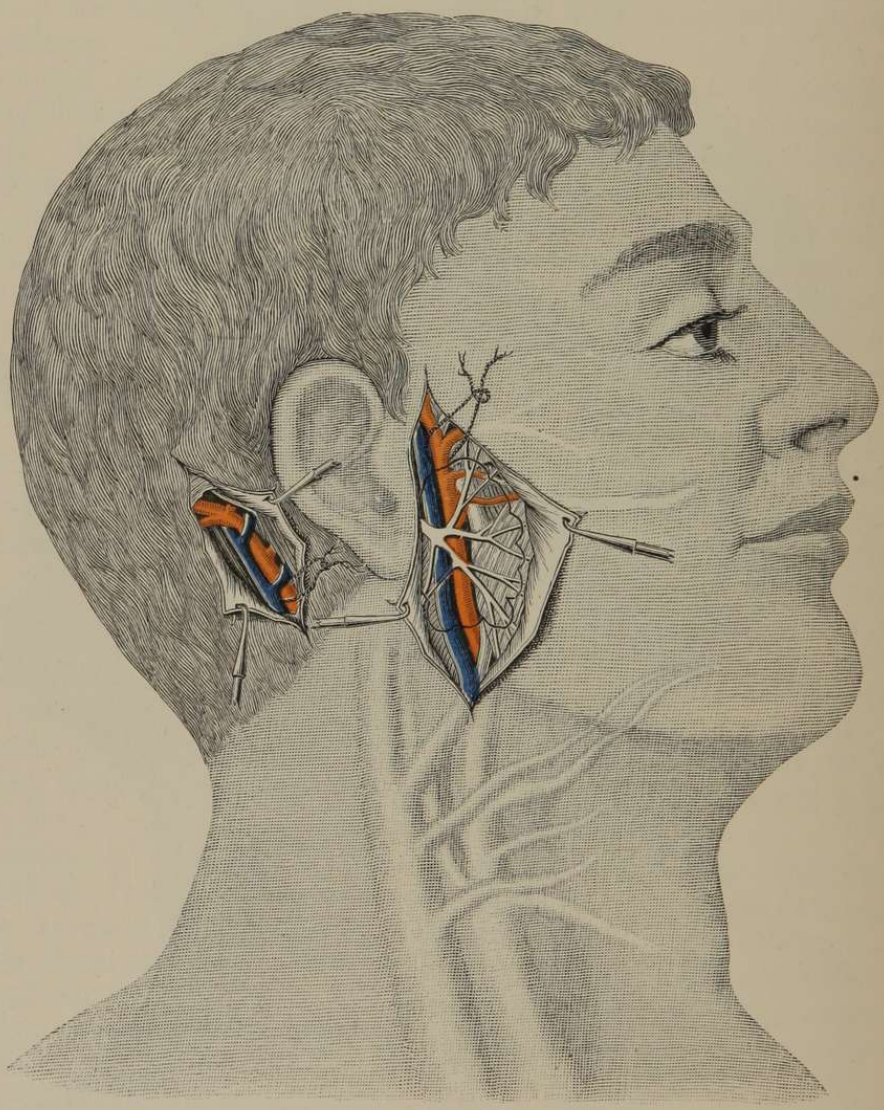

Fig. 330.—Ligation of the occipital behind the mastoid process and the common temporal near the zygoma, also showing the relations of the facial nerve to the terminal portion of the external carotid.

to the groove on the under surface of the mastoid process will serve as a valuable guide.

The *common carotid* has been tied in several instances for lesions of the *occipital*. This should never be done.

Ligation of the Posterior Auricular—Anatomy.—In eleven of one hundred and twenty-one dissections this vessel arose from the *occipital*, and in four it was absent. Its origin is usually one inch and four fifths above the thyroid notch.

For anatomical reasons, in lesions of this artery the *external carotid* should be tied, just above the posterior belly of the digastric, between its origin and that of the *occipital*. It runs under the parotid gland, is crossed by the facial nerve, and has beneath it the spinal accessory.

Ligation of the Temporal and Internal Maxillary Arteries—Anatomy.—The *temporal* and *internal maxillary* arteries begin at the terminal bifurcation of the *external* carotid, in the substance of the parotid gland, at an average distance of two inches and nine tenths from the thyroid notch.

Operation.—The *temporal* artery may be secured by a perpendicular incision immediately in front of the tragus of the ear, where it crosses the zygoma superficially (Fig. 330). For lesions of this vessel above the temporal fossa, and often in wounds in this region, the ligature will be unnecessary, since direct compression, by means of the knotted bandage, will suffice. When either this artery or the *internal maxillary* are wounded in the substance of the parotid gland, the *external carotid* should be tied at the posterior belly of the digastric. The same procedure is indicated in lesions of the *internal maxillary*, in its deeper portions.

Ligation of the Internal Jugular Vein.—The intimate relation of this vein to the *internal* and *common carotid* arteries renders it accessible by the same incisions laid down for the ligation of the arteries. The vein is contiguous to the artery, and is external and slightly superficial to it. On the left side, at the root of the neck, the jugular comes more to the front, while on the right side it tends to the outer side.

The rules which apply to the ligation of arteries apply with equal force to the ligation of veins. The jugulars should be encircled with an animal ligature, not tied with a lateral loop, as has been practiced. The aneurism-needle should be passed from the inner side.*

The anterior, external, and posterior jugular, and other veins of the neck, do not demand especial consideration. When, in operations in the neck, it becomes necessary to divide them, a double catgut should be applied, and the vessel divided between the two ligatures.

The Subclavian Arteries and their Branches—Anatomy.—The *right subclavian*, larger, shorter, and more superficial at its origin than the left, is derived from the *innominate behind* the origin of the carotid, about the level of the upper margin of the clavicle (more frequently above than below this line), behind the interval between the two tendons of the *sterno-mastoideus*. It is the direct continuation backward, upward, and outward of the *arch of the innominate*, and is continuous with the *axillary artery*, at the lower edge of the first rib. Its average length is 2·83 inches.

The *left subclavian*, derived 1·23 inch beyond, to the left of, and more deeply situated in the thorax than, the innominate, travels almost verti-

* See Prof. S. W. Gross's admirable article in "American Journal of the Medical Sciences," 1867.

cally upward, until it mounts above the upper surface of the first rib, when it curves very abruptly outward and downward, passing behind the scalenus anticus and thence to the lower edge of the first rib. Its length, in the average, is 3·74 inches.

Each subclavian has three *surgical divisions*. The *first division* of the right artery is from its origin from the *innominate* to the inner bor-

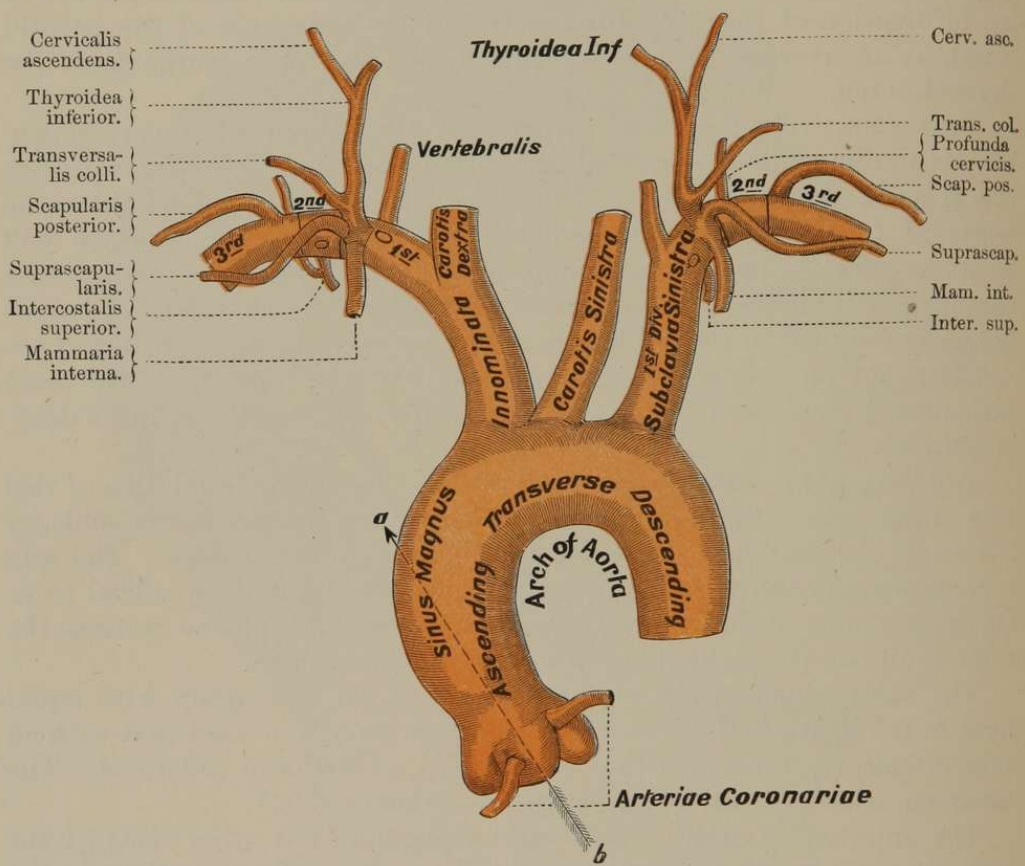

Fig. 331.—Relation of the great vessels to each other at their origins from the arch of the aorta, and the relation of the branches of the subclavian arteries to each other. From the author's dissections.

der of the *scalenus anticus*. That of the left artery, from its origin at the arch of the aorta to the inner border of the *left scalenus anticus* (Fig. 331).

The second and third portions of both vessels are identical as regards direction and relation, being different in the origins of their respective branches. The *second surgical division* of each is entirely to the *inner* side of the *inner border* of the first rib. The *third portion* rests chiefly on the upper surface of the first rib, and extends from the outer border of the scalenus anticus to the lower border of this rib.

The *first portion* of the *right subclavian* varies from three fourths to one inch and a half in length, the average length being 1·15 inch.

The *first portion* of the *left* artery varies from one inch and a half to three inches, the average length being 2·06 inches.

The *second portion* of the *right subclavian* averaged ·58 inch, the same division of the *left subclavian* being ·56 inch in length.

The *third portion* of the *right* artery is a little less; the same division of the *left subclavian* a little more than 1·11 inch in length.

Nine important branches arise directly or indirectly from the *subclavian* arteries: the *vertebral*, *internal mammary*, *transversalis colli*, *suprascapular*, *inferior thyroid*, *cervicalis ascendens*, *superior intercostal*, *profunda cervicis*, and *posterior scapular*.

The *right vertebral*, the branch most constant in origin, arises from the superior and posterior aspect of the main trunk (Fig. 332) and passes upward to the vertebral foramen, in the sixth cervical vertebra; at times to the fifth; less frequently to the fourth. The relation of this branch is important. In the vast majority of subjects it will be found between one fourth and three fourths of an inch to the inner side of the inner margin of the scalenus anticus.

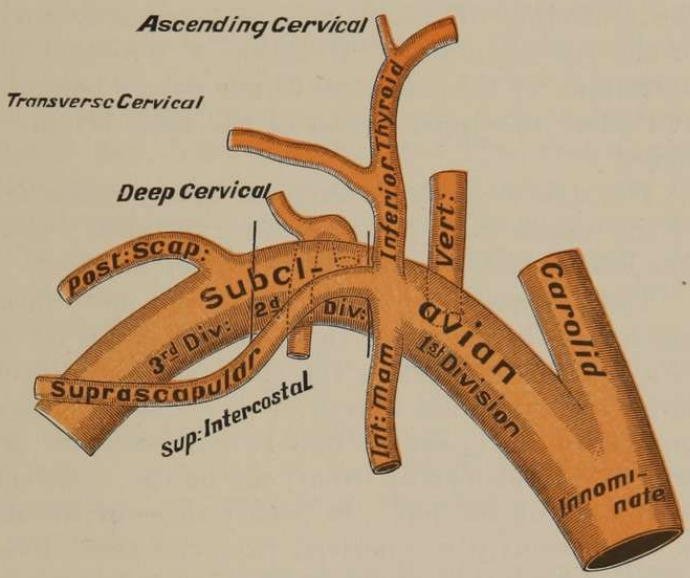

Fig. 332.—Plan of the right subclavian artery and its branches. From the author's dissections. (After Quain.)

The *left vertebral* (Fig. 331) arises, in 4 per cent of cases, from the aorta. In most subjects it will be found within three fourths of an inch of the left scalenus muscle.

The *internal mammary* artery arises at the inner border of the scalenus anticus. It is occasionally from the thyroid axis. The phrenic nerve passes usually in front, occasionally behind it. Behind the costal cartilages it runs parallel with the edge of the sternum, about half an inch external to it.

The *thyroid axis* arises also just within the scalenus. The *inferior thyroid* branch arises from the axis, in almost every case on the left side. On the right, in twenty-six cases examined, it originated from the *innominate* in three, and directly from the subclavian in three instances. It passes upward (inclining at first a little inward) until it arrives at a point between the third and seventh (incomplete) rings of the trachea, where it turns abruptly inward, going behind the *common carotid* and *jugular*, in front of the *vertebral*, and is distributed chiefly to the lower portion of the thyroid body.

The *transversalis colli* passes outward in front of the *scalenus muscle* and the *phrenic nerve*, underneath the *omo-hyoid*, and in front of or

between the cords of the brachial plexus, and is distributed to the *trapezius* muscle, sending a branch in the direction of the posterior border of the scapula, which anastomoses with the *posterior scapular* artery; and, when this last vessel is not present, this descending branch is continued along the border of the scapula to anastomose with the subscapular branch of the axillary.

The *suprascapular artery*, intimately associated with the preceding, travels suddenly downward and outward from its origin near the inner edge of the *scalenus anticus*, passes between the *subclavian artery* and *vein*, in front of the *phrenic nerve*, crosses in front of the third division of the main trunk, and goes to the suprascapular fossa under the protection of the clavicle, anastomosing with the *dorsalis scapulæ* of the *subscapularis*. It gives off a branch (frequently wounded in operations in this vicinity) which passes behind the *sterno-mastoideus* and along the upper border of the manubrium. (It is not usually mentioned.)

The right *superior intercostal* artery comes from the second division of the subclavian in almost every instance; occasionally from the first. The left is usually from the first division.

The *posterior scapular*, one of the most important branches of the subclavian, in a surgical view, since it must be in dangerous proximity to a ligature applied in the third surgical division (not given in many standard text-books, except as an occasional branch of this artery), was present in thirty-six of fifty-two dissections, or 69 per cent. It was present in nineteen of twenty-six on the *right* side, and in seventeen of twenty-six on the left. In twenty-three of the thirty-six cases in which it was present it was derived from the third division; in the remaining thirteen, from the second division, close to its outer limit. On the *right* side 74 per cent came from the subclavian, within one fourth of an inch to the outer and inner side of the external border of the scalenus muscle; 26 per cent external to this.

On the *left* side 82 per cent were within one fourth of an inch to the outer and inner side of the line dividing the middle and external thirds of the main trunk; 18 per cent were to the outer side of this. The tendency of this important branch is to originate near the scalenus, i. e., within one fourth of an inch of its outer edge. When this vessel is present the *transversalis colli* is small, and when absent the descending branch of the transversalis takes its distribution. Passing outward behind the most superficial cords of the brachial plexus, it turns sharply downward, along the posterior border of the scapula, to anastomose with the *subscapular* branch of the *axillary*.

Operation—The Right Subclavian in its First Surgical Division.—The incisions are the same as for the *arteria-innominata* (Fig. 318). When the sterno-hyoid and sterno-thyroid muscles have been divided on the director, the *internal* jugular vein will be seen directly in front of the artery. It may be drawn to the inner side (or outer, if more convenient), carefully using for this purpose a dull retractor. Care must be exercised not to injure the pleura which rises against the

artery in deep inspiration. A dull-pointed aneurism-needle may now be passed around the vessel, taking care not to wound the subclavian or innominate vein, or the recurrent laryngeal nerve. The *vertebral*, *internal mammary*, and branches of the *thyroid axis*, should also be secured.

The conditions which will justify this operation will rarely occur, yet, when the operation is demanded, every source of danger from hæmorrhage should be avoided. The necessity of securing the carotid at the same operation must be determined by the operator. I am of the opinion that it is safer to occlude this vessel also.

The *subclavian* artery has been tied in its first surgical division eighteen times, and all fatal. In five of these cases the common carotid was also tied. In only one case was the left subclavian tied. Of the thirteen single operations, two (Ayres and Bullen) were for the arrest of hæmorrhage from shot wounds in military practice, with one death in half an hour and one on the eighth day, from hæmorrhage. The other eleven cases are given on another page. In only five of these thirteen cases is the source of hæmorrhage stated, and in each of these the bleeding was from the *distal* side of the ligature, the proximal side being closed. A knowledge of this fact leads me to insist upon the ligation of the vertebral and other branches of the first division.

In five instances the right carotid was also tied simultaneously by Liston, Parker, Hobart, Cruveilhier, and Kühl. In three of these, fatal hæmorrhage ensued from the distal side of the ligature.

The left *subclavian* artery was tied in its first division once by Rodgers, and fatal hæmorrhage occurred from the *distal* end of the artery, and by Halsted successfully.

Ligation of the Left Subclavian Artery in its First Surgical Division—Operation.—From a point on the clavicle one fourth the distance from the center of the interclavicular notch to the acromion process commence an incision, and carry it to the inner border of the sternal tendon of the mastoid muscle. From the inner extremity of this line carry a second incision for three inches along the anterior border of the sterno-mastoideus. In dissecting this flap lift with it the mastoid muscle divided upon the director, then divide the sterno-hyoid and thyroid muscles, and feel for the pulsation of the artery, which ascends deeply behind and a little outside the sterno-clavicular articulation. The *internal jugular* vein will be drawn outward, and, passing the finger along the inner border of the *scalenus* muscle, the artery will be felt to pulsate. The *thoracic duct* usually is to the right of and a little behind the artery opposite the upper border of the *sternum*. On a level with the insertion of the *scalenus* it arches to the left, crosses in front of the *subclavian*, in front of the *scalenus*, behind the *internal jugular*, and curves downward to empty into the *subclavian* at its junction with the *jugular* to form the left *innominate* vein. On account of the intimate relations of the *thoracic duct* to the *left subclavian* artery as this vessel goes behind the *scalenus*, the ligature should not be attempted close to this muscle, nor should the dissec-

tion be carried fully to the *scalenus*. The artery should be tied as low down as possible, the *duct* being less likely to be injured here, since in passing behind the aorta it is deeper than the artery. It will be found behind and to the right, the pneumogastric in front and to the right, the left *vena innominata* crossing in front, while the pleura is directly behind. The case of Halsted, of Baltimore, is the first successful case on record.

The *vertebral* and other branches of the left subclavian are in such proximity to the thoracic duct that it will be dangerous to attempt to tie them at this point.

Ligation of the Subclavian Arteries in their Second and Third Surgical Divisions—Operation.—The procedure is essentially the same on the two sides. Place the shoulders upon a cushion, pull downward on the arm of the side to be operated upon, and turn the patient's face to the opposite side. Find the location of the scalenus anticus, as in the preceding operation. Slide the skin well down upon the clavicle, and along this bone make an incision three or four inches in length, commencing one inch to the inner side of the scalenus muscle and terminating near the anterior edge of the trapezius. Allowing the skin to resume its normal relations, the incision will be carried above the clavicle. Upon a director divide the outermost of the clavicular fibers of the mastoid muscle. The internal *jugular vein*, seen in the anterior portion of the wound, will be carefully drawn to the inner side, the operator keeping well above the junction of this with the subclavian, and thus avoiding the *lymphatic duct.*

A prominent plexus or group of veins, viz., the *external jugular*, *transversalis colli*, and *suprascapular*, will be seen traversing the wound, coming from their respective origins, toward the *subclavian*, near the *jugular*. These should be secured with a double ligature, and divided, or held aside. Dissecting carefully, the *suprascapular* and *transversalis colli* arteries will be observed running, in general, in the direction of the first incision. The posterior belly of the *omo-hyoid* may be found in the upper margin of the wound, crossing the scalenus at about a right angle. The *transversalis colli* and the *suprascapular* may be secured or held to one side, the finger passed along the scalenus until the tubercle on the first rib is felt, immediately behind which the artery will be found. If it shall have been determined to tie the artery in its second portion, the *scalenus anticus* muscle will be cut upon a director, the operator being careful to avoid the *phrenic nerve*, which crosses the muscle in front, coming from above downward and inward. (It is between the layers of the sheath of this muscle.) The ligature is next passed around the artery from before backward, care being taken not to wound the pleura.

If the third division of the artery is to be secured, the part of the above operation relating to the division of the *scalenus* will be omitted. The nearest cord of the brachial plexus must be carefully excluded, posteriorly to the artery; the subclavian vein in front and below (Fig. 328).

The *subclavian arteries* have been tied behind the scalenus anticus thirteen times, with four recoveries. All of the fatal cases were on the right side.

In one of the "Prize Essays" of the American Medical Association I published the histories of two hundred and fifty-one ligations of the subclavian artery in its third surgical division, of which one hundred and thirty-four ended fatally. As far as these histories relate to aneurism they have been given. A study of the remaining cases led me to conclude that in all lesions causing dangerous hæmorrhage in the upper brachial or axillary regions an effort should be made to control the bleeding at the seat of injury. Failing in this, deligation of the subclavian, in its third division, is demanded.

Ligation of the Vertebral Artery—Operation.—Locate by pressure the carotid tubercle (the transverse process of the sixth cervical vertebra). The point at which the artery is to be secured is one inch directly below this bony prominence, which must be the center of a perpendicular incision, four inches in length. Commence the incision at the outer border of the sterno-mastoid muscle, where the external jugular vein crosses. The internal jugular is seen and drawn inward. The transverse cervical artery, and one or two smaller veins, are met with next, and drawn to the outer side of the wound. The scalenus anticus muscle is now brought into view, and to the inner side of this a depression between this muscle and the longus colli. In this sulcus the artery lies, the vein being in front of it. In my case I had to tie the vein with a double ligature, divide, and turn the ends aside in order to secure the artery.

Ligation of the Internal Mammary—Operation.—This vessel may be secured, as has been described, close to the parent trunk, or it may be tied in one of the intercostal spaces. In the third or fourth space make an incision, about two inches in length, obliquely from without inward and downward, the center of which should be about half an inch external to the edge of the sternum. Divide the fibers of the pectoralis major and the intercostal muscle, and clear away the tissues with a blunt-pointed instrument. The artery, with its venæ comites, will be seen in front of the fibers of the triangularis sterni, which separates it from the pleura on the right and the mediastinum on the left side. In separating the veins from the artery, care should be taken not to break through the thin structure between the vessel and the cavity.

The other branches of the *subclavian* artery do not require especial consideration. The *inferior thyroid* is often tied in the removal of goitre. I have, in six operations, found and deligated it prior to ablation of a bronchocele. It will usually be seen on the tracheal side of the *common carotid*, just below the anterior belly of the omo-hyoid.

Ligation of the Axillary Artery—Anatomy.—This artery may be tied at any part of its course. On account, however, of the difficulty of approach of that portion beneath the pectoralis minor, it is usually

secured in the axilla, below this point, or between the upper margin of this muscle and the lower border of the first rib.

Operation.—With the head thrown back and the shoulders elevated, allow the arm to remain by the side of the body. About two inches from the sternal end of the clavicle, and half an inch below its inferior border, carry an incision outward, parallel with this bone, a distance of from three to four inches. This incision may divide a superficial vein which passes from the cephalic over the clavicle. The clavicular fibers of the pectoralis major and the costo-coracoid membrane are divided upon the director. The axillary vein will then be seen in the anterior portion of the wound, lying in front of the artery, which may be felt to pulsate, or seen just external to it. More external still may be seen the anterior cord of the brachial plexus, while in the lower portion of the wound the cephalic vein crosses over to empty into the axillary, below the clavicle. Beneath the clavicle the subclavius muscle may be seen. The needle should be passed from before backward. If necessary, a second incision may be made, beginning in the center of the first and carried in the direction of the axilla, as recommended by Chamberlain.

This operation is somewhat more difficult than ligation of the *subclavian* in its third division, but it is preferable, on account of being farther removed from the heart. Delpech advised an incision beginning at the junction of the middle and outer third of the clavicle, and separating the deltoid and pectoralis muscles.

Operation below the Pectoralis Minor.—Shave and cleanse the axilla, and extend the arm at a right angle to the body. Divide the dis-

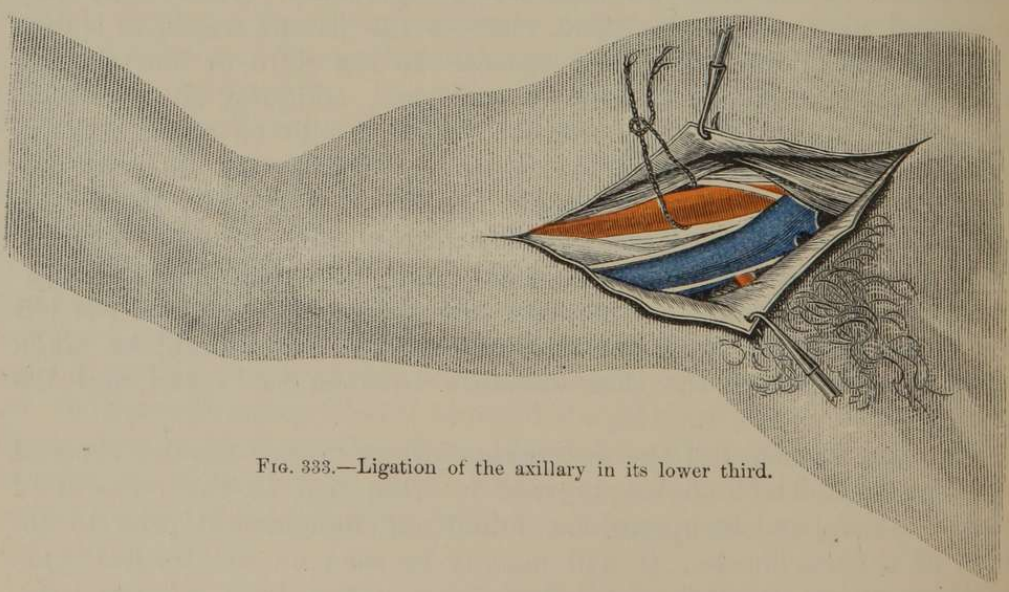

Fig. 333.—Ligation of the axillary in its lower third.

tance between the two folds of the axilla into thirds, and the junction of the anterior and middle thirds will indicate the position of the artery. On this line make an incision in the axis of the arm, well up into the axilla. Cutting through the skin and fasciæ, the contents of this space will

be seen. The vein lies internal to the artery, often overlapping it, and should be drawn carefully backward. The median nerve overlies the artery, or is on its anterior aspect, and should be drawn forward when the needle is passed from behind forward (Fig. 333).

Ligation of the Brachial Artery —Anatomy.—This artery lies in the furrow along the inner border of the coraco-brachialis and biceps muscles, tending more and more to the front as it nears the elbow-joint. In the lower half or three fourths of its course it has its venæ comites on either side, with occasional communications across the track of the artery. The median nerve crosses it by the front, from the outer side, on its way to the forearm, while the basilic vein is well to the inner side. As this vein passes up toward the axilla it pierces the deep fascia, and lies on the inner side and close to the artery, joining with the venæ comites to form a single large trunk.

Operation.—A line drawn from the junction of the middle and anterior thirds of the axillary space (as above given) to the middle of the elbow-joint, in front, will pass over the brachial artery in its entire length. The place of election is the middle of the arm. At this point make an incision, three inches in length, over the artery and in its axis. Dividing the skin and deep fascia, the white cord of the median nerve will be first seen, on the outer side of the brachial, overlapping the companion vein on this side. Just internal to this is the artery, with the other accompanying vein and the basilic in close relation (Fig. 334). The ligature should be passed from the inner toward the outer side. The op-

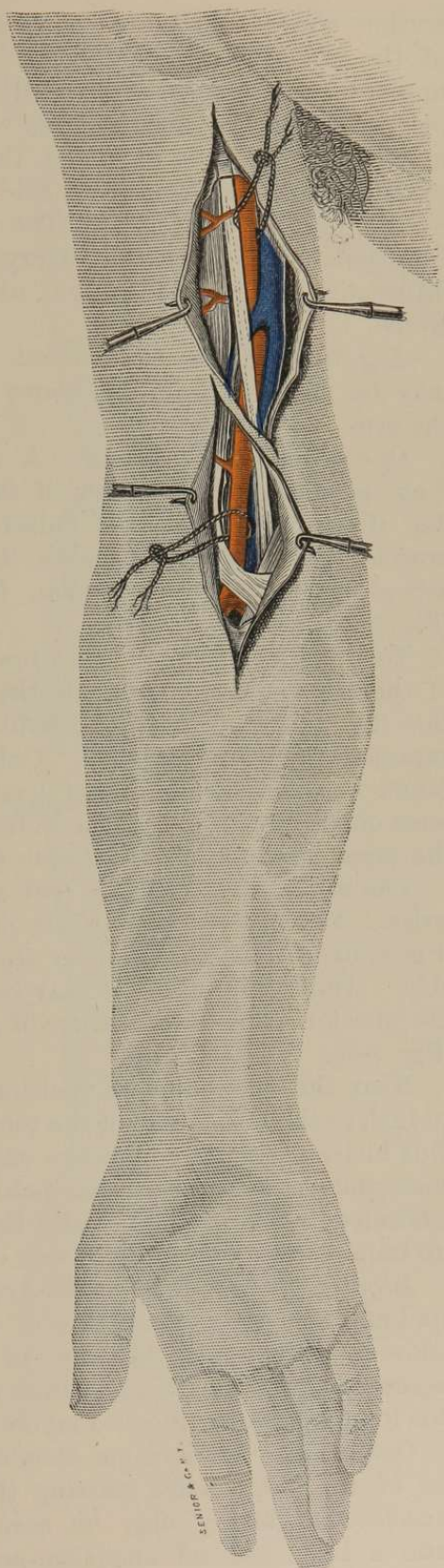

Fig. 334.—Ligation of the brachial near the middle and the lower third.

eration above this point is essentially the same. In the lower third of the arm proceed as follows: On a level with the condyles of the humerus, and between the median basilic vein and the tendon of the biceps, commence an incision, which is carried upward three inches in the brachial line. Cutting through the deep fascia, the artery is readily found to the radial side of the median nerve, and surrounded by its veins (Fig. 336). The needle is passed from the inner side. Occasionally the brachial artery is double, while more frequently it bifurcates into the radial and ulnar, at a varying distance above the elbow.

Ligation of the Ulnar and Radial Arteries.—The *radial* artery may be tied immediately above the wrist, or in the upper third of the arm.

Operation at the Wrist.—A vertical incision, one inch and a half long, is made in the center of the depression, between the outer border of the radius and the radial border of the extensor carpi radialis muscle. Immediately beneath the deep fascia the artery will be observed, with its *venæ comites*, from which it is separated and tied (Fig. 335).

To find the artery in the upper third, draw a line from the middle of the elbow-joint, in front, to the styloid process of the radius. Along this line make an incision, about three inches in length, avoiding the superficial veins, if possible. Cutting directly down, the artery will be found between the supinator longus externally and the pronator radii teres on the ulnar side. The radial nerve is well to the radial side, and the venæ comites on either side (Fig. 336).

The *ulnar* artery may be tied at the bend of the elbow, and near the wrist. As it passes beneath the pronator radii teres and flexor muscles, it is so deeply situated that an attempt to deligate it here is not justifiable. Above this point it may be secured by a downward extension of the incision given for ligature of the brachial at the bend of the elbow (Fig. 336).

Near the wrist-joint an incision should be made about a quarter of an inch to the radial side of the tendon of the flexor carpi ulnaris muscle. This incision should commence one inch above the level of the pisiform bone, and extend upward one inch. The ulnar nerve will be seen partly concealed by the tendon, while the artery and its accompanying veins are immediately on its radial side (Fig. 335).

Ligation of the Intercostal Arteries—Anatomy.—The artery lies behind and near the lower border of the rib, the vein above, and the nerve below it. From near the angle of the rib to the vertebral column it is separated from the thoracic cavity by the pleura alone, but in front of this it runs between the two layers of intercostal muscles.

Operation.—An incision should be made just along the lower border of the rib. After passing through the outer plane of intercostal muscles the artery may be seen and secured. Or, failing in this, take a long, curved aneurism-needle, and through a puncture near the lower border of the rib pass it behind the artery and around the

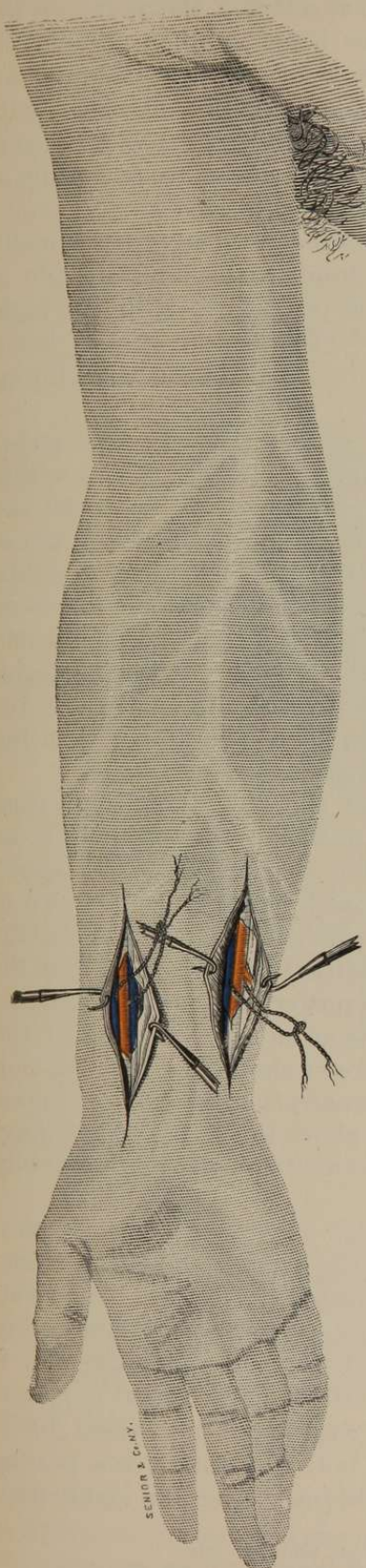

FIG. 335.—Ligation of the ulnar and radial arteries of the wrist.

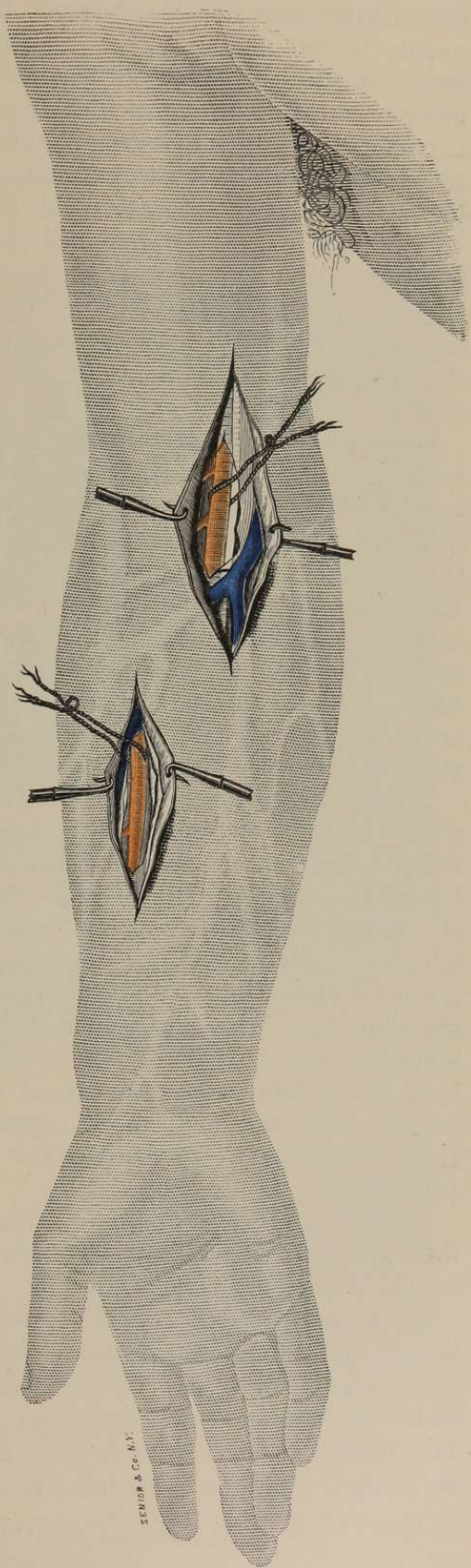

FIG. 336.—Ligation of the radial in the middle of the forearm and of the brachial at the bend of the elbow.

rib, taking care not to puncture the pleura. When the point of the needle is felt at the upper margin of the bone, another puncture is made to allow its escape. The needle is now armed with a strong catgut and withdrawn. A pellet of sublimate gauze is laid over the skin, between the points of exit and entrance, around which the ligature is tied. In exceptional cases it may be necessary to remove a portion of the rib.

Ligation of the Abdominal Aorta—Anatomy.—The aorta usually bifurcates upon the body of the fourth lumbar vertebra, a little to the left of the median line. This point is on a level with the highest point of the iliac crests, and is a little to the left of and below the umbilicus. The point of election is one inch above the bifurcation.

Operation, Median.—In the *linea alba* make an incision, six inches long, the center of which corresponds to the umbilicus. When within an inch of the navel, curve to the left three fourths of an inch, and one inch farther on regain the middle line. Divide all the tissues down to the parietal peritonæum, and then arrest all bleeding before opening this. After opening into the cavity, the transverse colon should be displaced upward, and the small intestines brought out through the wound and secured in a soft cloth, kept warm with sterile towels. With the fingernail or a blunt director scratch through the peritonæum and expose the aorta, around which a large animal ligature should be passed from the right side.

Lateral Incision.—From the free end of the left eleventh rib commence an incision, which carry downward to within three fourths of an inch of the anterior superior iliac spine, thence parallel with Poupart's ligament to its middle. Divide the three abdominal muscles down to the parietal peritonæum. When this is reached, use the fingers, the nails of which have been closely pared, and lift the peritonæum from the posterior abdominal wall. Passing over the posterior iliac crests and into the iliac fossa, the ridge formed by the psoæ muscles is reached and must be crossed. The lumbar nerves and ureter should be avoided, and, by a free dilatation of the wound and concentration of light, the aorta may be seen and tied, about three inches above the lumbo-sacral junction. Of these two procedures the former is anatomically and surgically preferable.*

Ligation of the Common Iliac Artery—Anatomy.—The common iliac arteries extend from the left side of the body of the fourth lumbar to the sacro-lumbar junction. It is crossed by the ureter in front, near its bifurcation, and by some filaments of the sympathetic nerve higher up. The left common iliac vein lies wholly internal, and is on a plane somewhat deeper than the artery. The inferior mesenteric vein crosses the left artery, but is within the peritoneal folds. The right iliac artery crosses in front of both the iliac veins, passing at a right angle to the left vein and obliquely over the right, until

* The abdominal aorta has been tied ten times, all fatal.

near its termination the artery is in front of and external to the vein (Fig. 337).

Operation—Anterior Incision.—Make an incision in the linea alba extending from about one inch above to about five inches below the umbilicus. Avoid the umbilicus as directed in the ligation of the aorta. Arrest all bleeding before the parietal peritonæum is opened. When this is done, draw the small intestines out through the wound and protect them in a

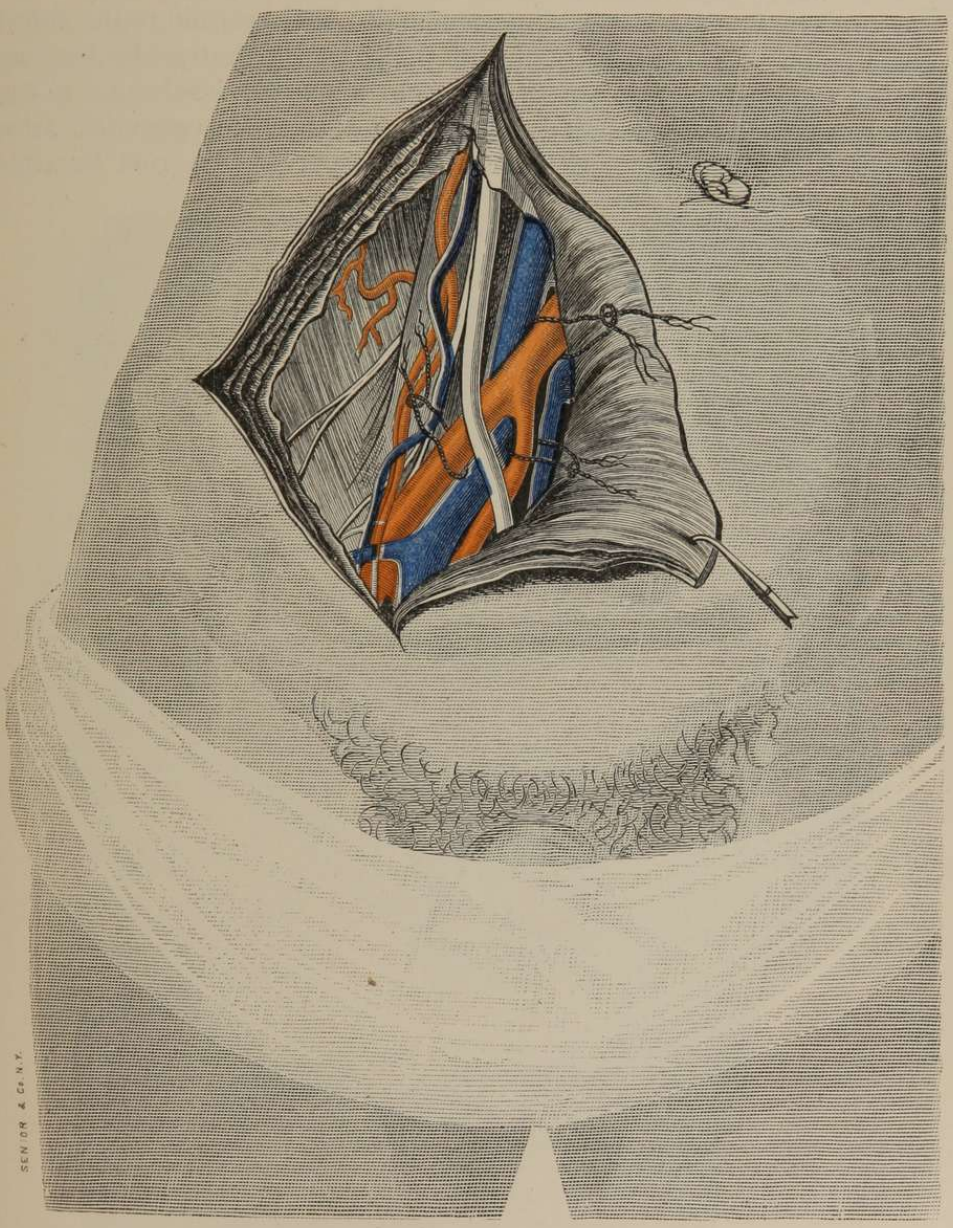

Fig. 337.—Dissection showing the relation of the right common external and internal iliac arteries and veins. The ureter is seen crossing the iliac near the bifurcation.

soft, clean cloth, kept warm by sterile towels. The posterior wall of the peritonæum is scratched through by means of two dissecting-forceps and the aneurism-needle passed from within out.

Lateral Incision.—Same as for the aorta.* The anterior incision is preferable.

Ligation of the Internal and External Iliac Arteries—Anatomy.—The *internal iliac* artery, less than two inches in length, has the ureter in front, its accompanying vein and the lumbo-sacral nerve behind.

Operation.—Through the Peritonæum.—Proceed as in the same operation for the primitive iliac. If necessary, a transverse incision may be added to that in the linea alba.

Behind the Peritonæum.—One inch and a half internal to the anterior superior spine of the ilium begin an incision, which travels downward and inward across the track of the external iliac. Be careful not to carry the deep incision far enough internally to divide the epigastric artery. Cut down to the parietal peritonæum, and separate this from its attach-

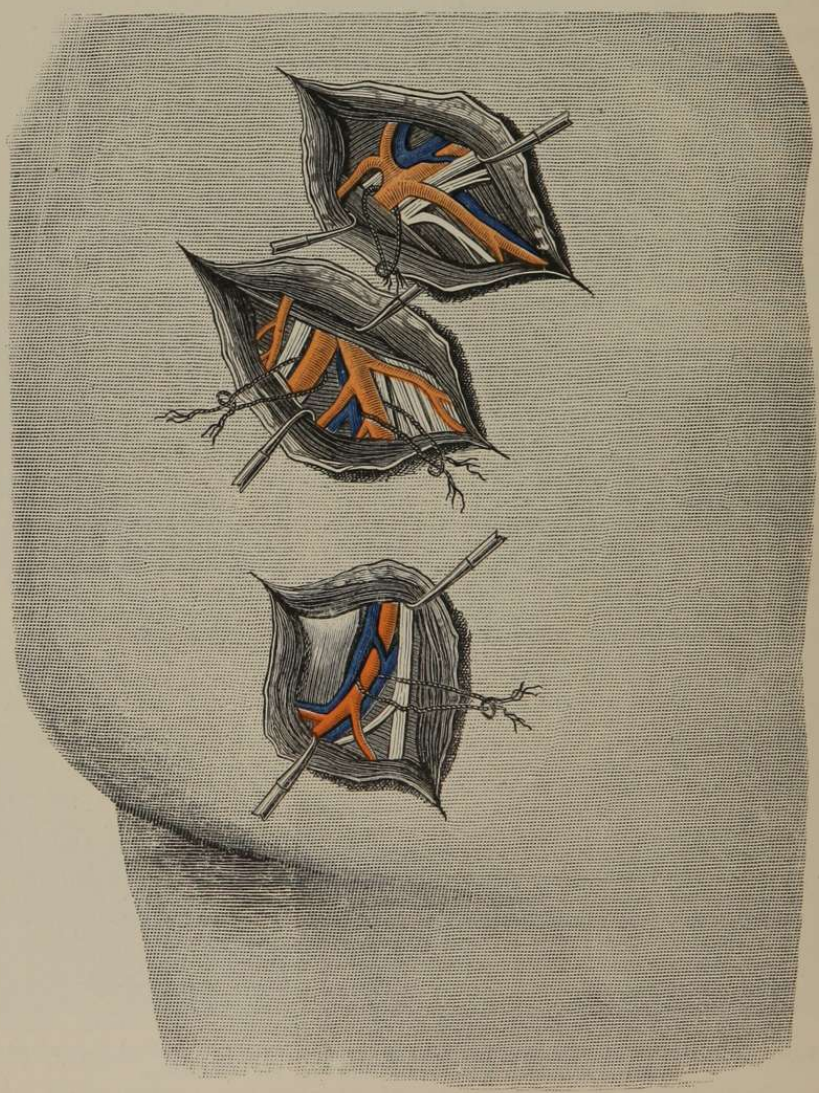

Fig. 338.—Ligation of the gluteal, internal pudic, and sciatic arteries.

* This artery has been tied about seventy times. For aneurism about 33 per cent recovered, while for hæmorrhage almost every case ended fatally.

ment to the abdominal wall and iliac fossa, along the iliac artery. When the bifurcation is reached, draw firmly with a retractor upon the upper lip of the wound and pass the needle from the inner side.* This operation may be demanded in sciatic or gluteal aneurism, or hæmorrhage from these vessels. The former method is preferable.

The Gluteal Artery.—Make a five-inch incision, on a line extending from the spine of the last lumbar vertebra to the trochanter major. The center of this line will indicate the point at which the artery emerges. Separate with a dull instrument the fibers of the gluteus maximus, displace anteriorly the gluteus medius, and find the groove between the minimus and the pyriformis. Follow this groove upward to the bony edge of the notch, and the artery and veins will be found (Fig. 338, upper incision).

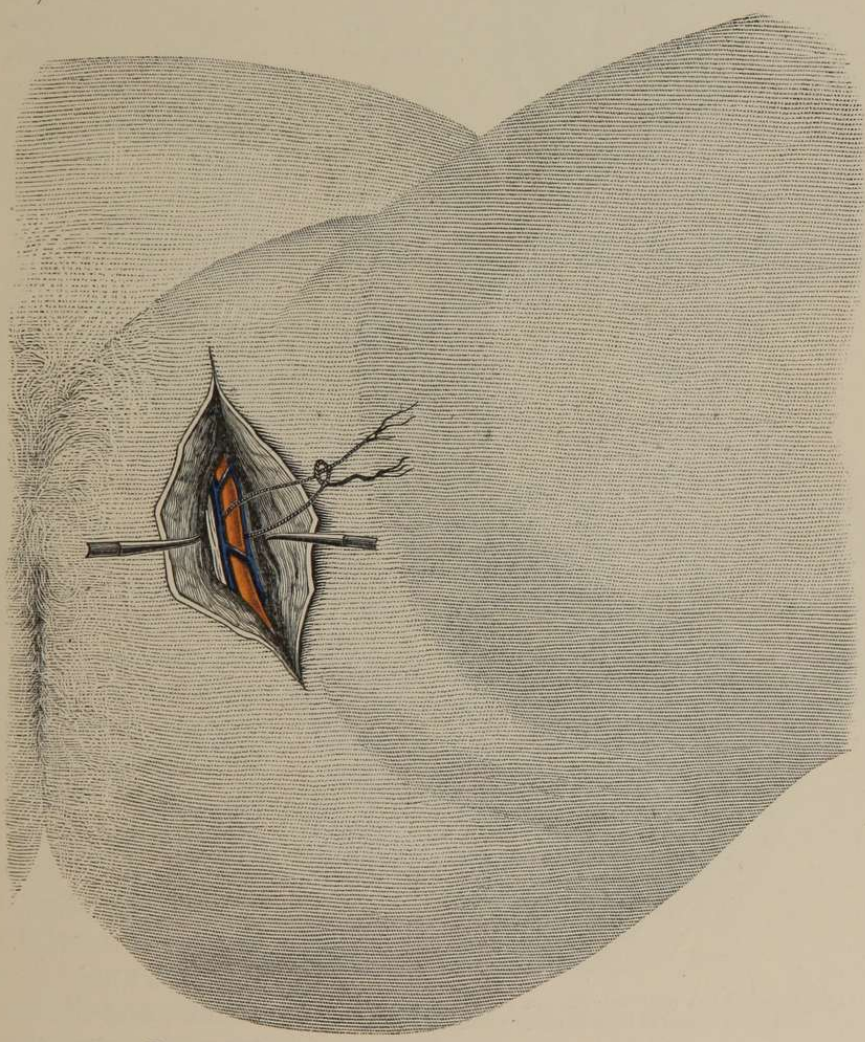

Fig. 339.—Ligation of the internal pudic in the perinæum.

The Sciatic.—Make an incision, five inches long, on a line from the middle of the sacral spines to the trochanter major. Separate the fibers of the gluteus maximus and find the lower border of the pyriformis. The

* The internal iliac has been tied about thirty times, with a death-rate of 66 per cent.

great cord of the sciatic nerve will now be seen emerging from beneath the muscle, and immediately in front of this the small sciatic nerve and the sciatic artery. The *internal pudic* artery is just anterior to this, upon the spine of the ischium (Fig. 338, middle incision). The sciatic artery may also be secured opposite the *tuber ischii*, along the outer border of which it runs (Fig. 338, lower incision).

The Internal Pudic in the Perinæum.—With the patient supine and the thigh abducted, make an incision in a line with the symphysis pubis and tuber ischii. The artery will be found as it runs along the inner margin of the ramus of the pubis (Fig. 339).

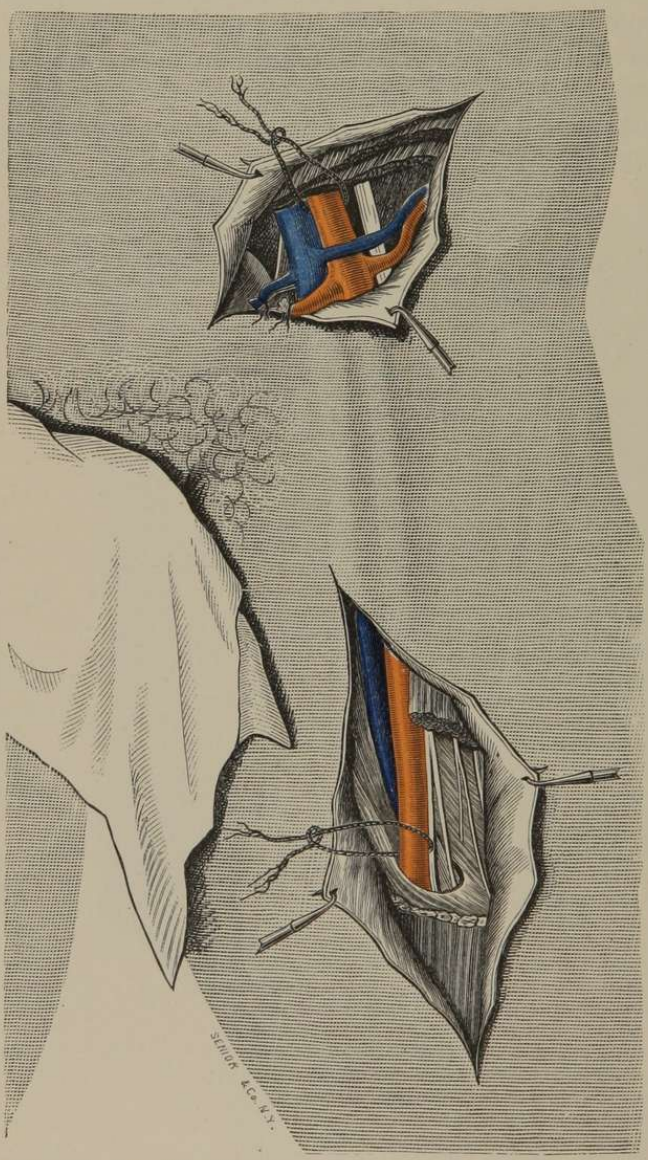

Fig. 340.—Ligation of the external iliac in its lower portion, and of the femoral in Hunter's canal.

Ligation of the External Iliac in its Lower Portion.—The *external iliac* has in relation to it the accompanying vein internally. The spermatic vessels cross it, and in the male the vas deferens is internal to it at the inguinal ring.

Operation.—One inch to the inner side of the anterior superior spine of the ilium commence an incision, which is carried in the direction of the middle of Poupart's ligament, and terminates one inch above this point, without entering the internal ring. Divide the three muscles down to the transversalis fascia, arrest all bleeding, divide the fascia carefully, retract the upper lip of the wound, and lift the peritonæum from the iliac fossa and artery (Fig. 340). Displace any overlying lymphatics and introduce the needle from the inner side.*

* Ligation of the external iliac has proved fatal in almost every instance in which it was tied for hæmorrhage. For aneurism about 67 per cent recover.

The deep *circumflex* and the *epigastric* branches, which arise about half an inch above the ligament, may also be tied by this incision. In its upper portion this vessel may be secured by the same operation as for the common iliac.

Ligation of the Femoral Artery—Anatomy.—At Poupart's ligament the vein is on the same plane as the artery, and immediately internal to it. One quarter of an inch to the outer side, and deeper than the artery, lies the anterior crural nerve. One inch and a half from the ligament the *profunda femoris* arises from the outer aspect of the common trunk, and from one to two inches lower passes behind the superficial femoral. Four inches from Poupart's ligament the relations have changed to such

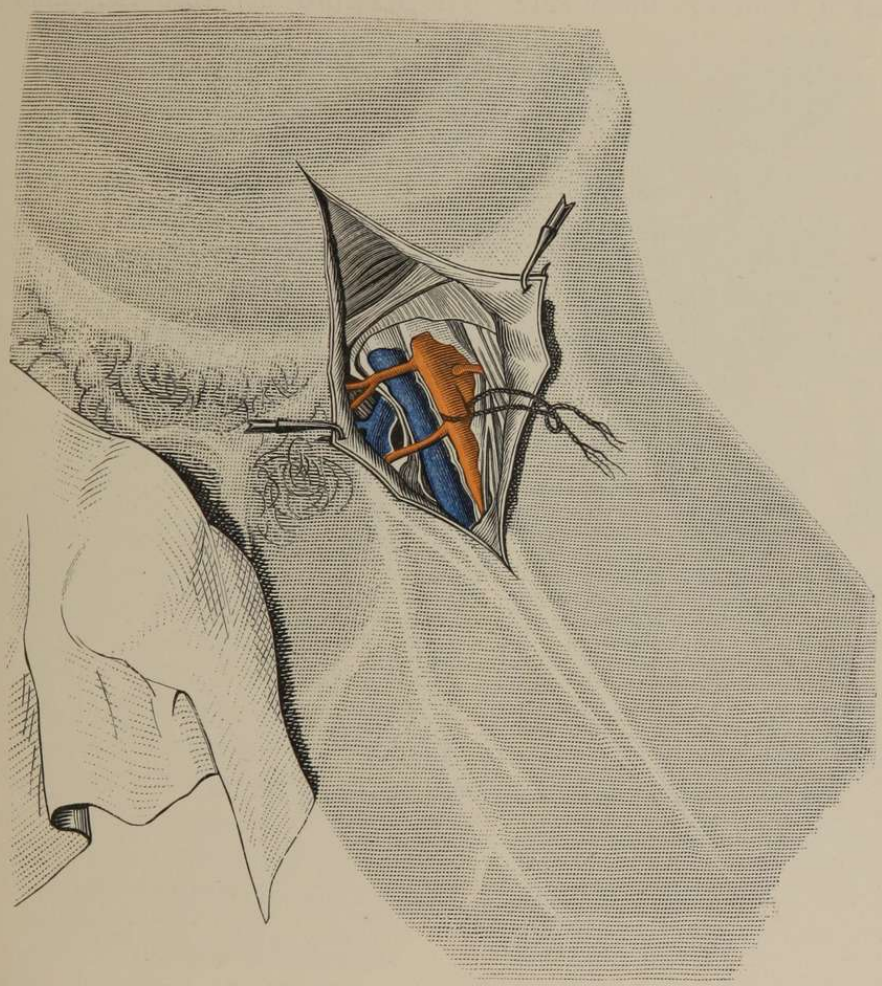

Fig. 341.—Ligation of the superficial femoral in Scarpa's space.

an extent that the femoral vein is deeper and slightly behind the artery. The long saphenous nerve lies upon the sheath of the artery, in its middle third, and occasionally sends a branch through *Hunter's* canal. The *sartorius* muscle covers the femoral artery in all of its course except the first four inches, where it is superficial.

Operation.—A line from a point half way between the symphysis pubis and the anterior superior spine of the ilium to the internal condyle

of the femur will run over and parallel with the femoral. It may be secured in any part of its course.

In Scarpa's Space.—The point of election for tying the superficial femoral is from four to five inches below Poupart's ligament. With this as the center, make an incision three inches long on the line already indicated. Beneath the skin and fascia some superficial and unimportant vessels may be divided; the fibers of the sartorius will be seen in the lower portion of the wound, and should be drawn downward with a retractor. The saphenous nerve will next be seen on the outer side of the common sheath of the vessels. The sheath should next be incised, and the artery carefully isolated by inserting a dull director beneath and around it from the inner side. The ligature is passed the same way.

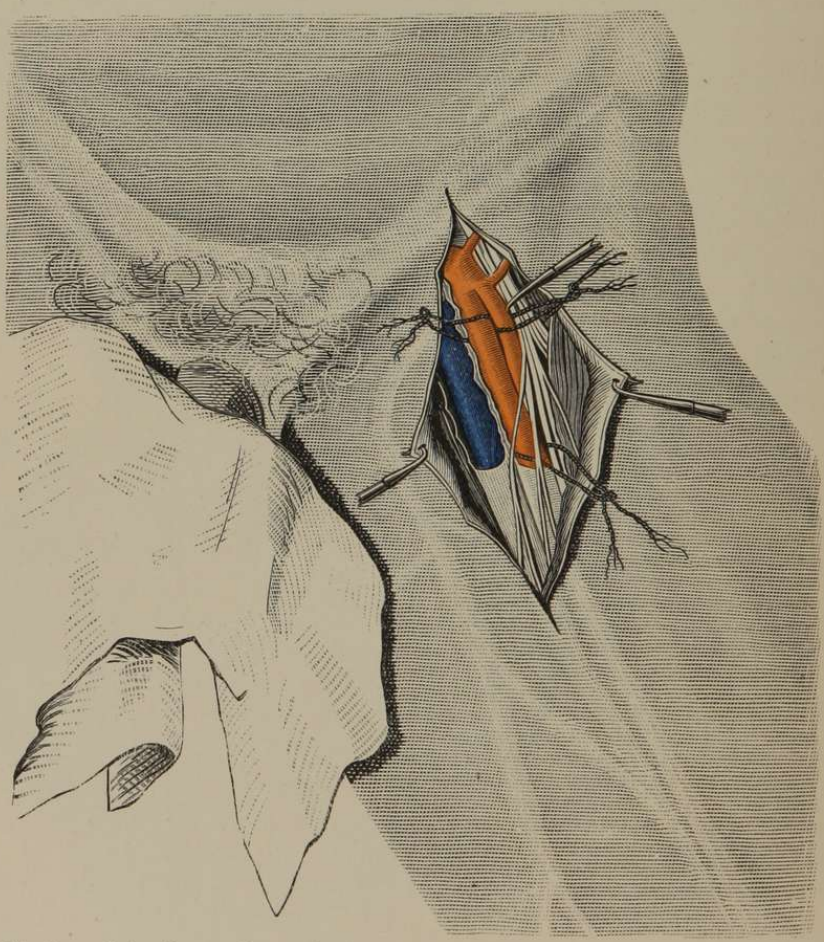

Fig. 342.—Ligation of the deep and superficial femoral near the bifurcation of the common femoral, and in the apex of Scarpa's triangle.

In this same plane an incision may be made to expose the artery lower down, where it is completely hidden by the sartorius. This muscle may be drawn to the side most convenient to the operator (Figs. 341, 342).

In Hunter's Canal.—Find the junction of the middle and lower thirds of the thigh. In the femoral line, with this point as the center, make an incision, about four inches in length, directly down to the sheath of the

sartorius, which is incised and the muscle displaced outward. Immediately upon opening the posterior layer of the sheath of the muscle, the oblique aponeurotic fibers which pass from the adductor magnus to the vastus internus—forming the anterior wall of Hunter's canal—are seen. These may be divided on a director, or the sheath opened half an inch above this point. The saphenous nerve is on the sheath, and the vein is behind and to the outer side (Fig. 343).

The Common Femoral above the Profunda.—Make an incision in the femoral line, from three fourths of an inch above Poupart's ligament downward for three inches and a half. Do not divide the ligament, but approach the artery one half inch below. The superficial epigastric vein and artery may be wounded. Divide the fascia lata, and pass the ligature from within out. (Dissection shown in Figs. 341, 342.)

The Profunda Femoris.—Make an incision in the femoral line, three inches and a half long, the center opposite a point one inch and a half to two inches below Poupart's ligament. As above, approach the common trunk and search along its outer border for the origin of the profunda* (Fig. 342). Pass the ligature from within out, one inch from its origin. Avoid the branches of the anterior crural nerve.

In wounds of the posterior femoral region it may be necessary to tie this vessel as well as for aneurism. Ligation of the *common femoral* is rarely called for, and should only be done in extreme cases. In modern surgical practice, deligation of the superficial femoral is comparatively free from danger.

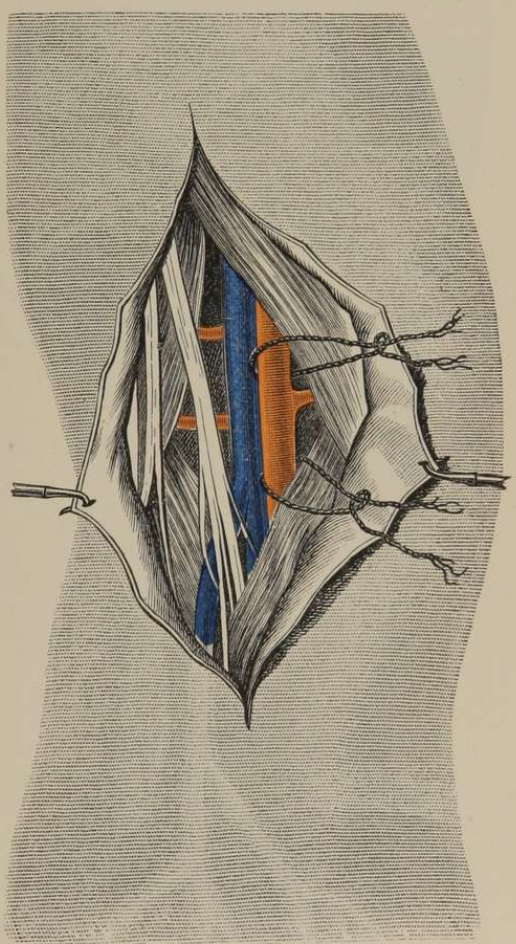

Fig. 343.—Ligation of the popliteal artery. Relations of contents in the left lower extremity.

Ligation of the Popliteal—Operation.—Place the patient on his belly, with the popliteal space looking upward. Make an incision, four inches long, beginning two inches and a half above the level of the joint, at the outer edge of the semi-membranosus tendon, and extending down through the middle of the space. Dividing the dense, deep fascia, the areolar tissue which sur-

* In a large majority of subjects I have found this branch given off one inch and a half below the ligament.

rounds the vessels and nerves of the space will be seen, and at the same time, and superficially, the popliteal nerve. Draw this and the vein which is immediately below outward, and the artery will be seen deeply situated, and in the upper part of the space internal to the vein. Lower down the relations change, the nerve crossing superficial to the vein, and this overlying the artery (Fig. 343).

Ligation of the Posterior Tibial Artery at the Middle of the Leg.— Make an incision, half an inch from and parallel with the inner margin of the tibia, three inches and a half long. Avoid the internal saphenous vein. After passing the deep fascia, look for the lower tibial fibers of the soleus, which pass obliquely from this border of the tibia backward and slightly downward. Divide these on a director, and with the finger separate the sural from the flexor muscles. Retracting the edges of the wound, the artery will be seen, with a vein on either side and the posterior tibial nerve lying just behind. The vessels are held down by the common sheath of the deep muscles (Fig. 344).

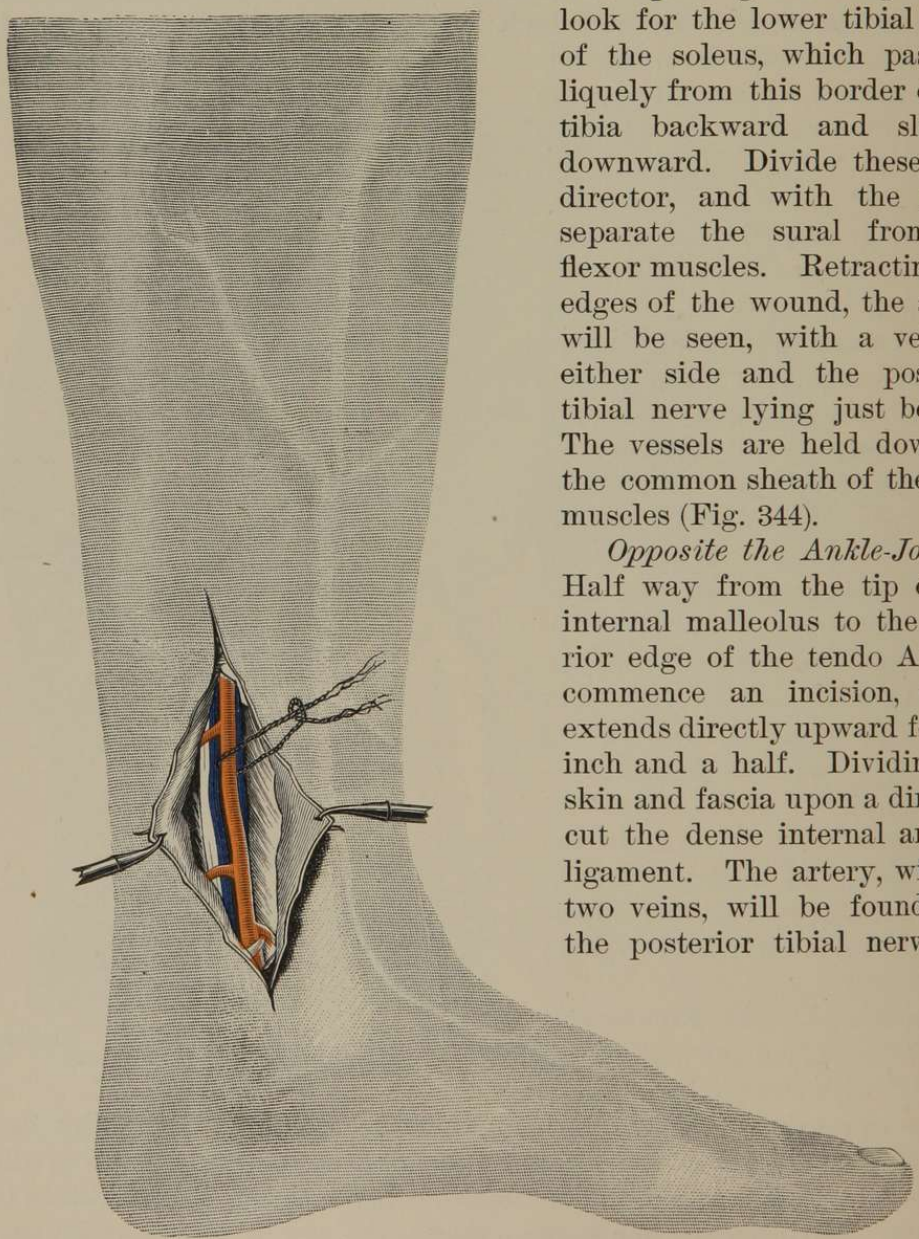

Fig. 344.—Ligation of the posterior tibial above the malleolus.

Opposite the Ankle-Joint.— Half way from the tip of the internal malleolus to the anterior edge of the tendo Achillis commence an incision, which extends directly upward for one inch and a half. Dividing the skin and fascia upon a director, cut the dense internal annular ligament. The artery, with its two veins, will be found with the posterior tibial nerve and tendon of the flexor longus pollicis behind, and the flexor longus digitorum and tibialis posticus in front. As the artery curves around the mal-

leolus it will be found one third the distance from the tip of the malleolus to the convexity of the heel.

The Anterior Tibial at the Middle of the Leg.—A line from a point half way between the anterior tuberosity of the tibia and the head of the fibula to a like point between the two malleoli, in front of the ankle, will indicate the position of this artery. At the middle of the leg make a four-inch incision in this line, dividing everything down to the dense fascia immediately over the muscles. Split this on a director and dissect it up carefully, searching for the interspace between the tibialis anticus internally and the extensor proprius pollicis externally. Finding this, discard the knife, and with the finger separate the muscles, and the artery, veins, and nerve will be found deep down upon the interosseous membrane, the nerve being external and slightly in front, and the veins wound about the artery. In order to relax the muscles and admit the light, flex the tarsus on the leg (Fig. 345).

At the Lower Portion.—One inch above the tip of the internal

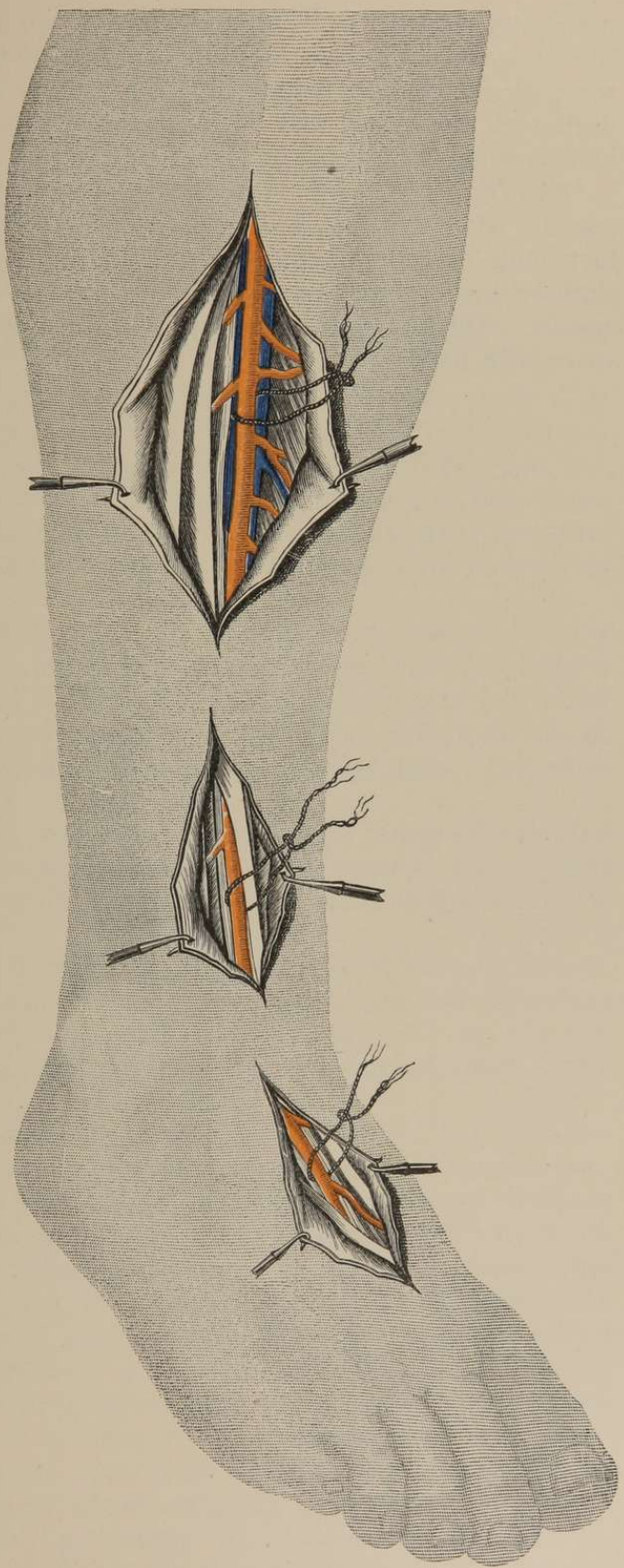

Fig. 345.—Ligation of the anterior tibial in the middle and lower third of the leg, and of the dorsalis pedis artery.

malleolus begin an incision, and carry it two inches upward, in the tibial line above given. This incision is along the fibular border of the extensor pollicis, between which and the tendon of the extensor communis digitorum the artery will be found, with the nerve on the fibular side, and its companion veins on either side.

The Dorsalis Pedis.—One fourth of an inch to the fibular side of and parallel with the tendon of the extensor pollicis make an incision, one inch long, over the tarsus. The artery and veins will be seen on a plane slightly deeper than the tendon, with the nerve on the tibial side of the vessels. This line is a continuation upward of the first metacarpal interspace (Fig. 345).

CHAPTER XVI.

THE SURGICAL DISEASES AND SURGERY OF THE BONES.

Ostitis.—Inflammation in bone may be *acute* or *chronic*, *general* or *circumscribed*, *traumatic* or *idiopathic*. It may involve the periosteum (*periostitis*), the compact and cancellous substance (*ostitis*), and medulla (*endostitis* or *osteo-myelitis*). Endostitis and periostitis may occur independently, yet ostitis, more or less severe, must of necessity be a part of a pronounced inflammation of either the periosteum or the endosteum and medulla.

The termination of inflammation in bone is in *resolution* or local *death*. In resolution the inflammatory embryonic tissue undergoes granular metamorphosis and is absorbed, or it may be in part converted into new bone. If the bone dies it may be cast off as a *sequestrum*, or remain imprisoned in a shell of new-made osseous tissue, the *involucrum*.

When the inflammatory process is severe, or the arrest of nutrition sudden and complete, *necrosis*, or death in mass, occurs; under other and milder conditions of death in bone, the process of dissolution is known as *caries*.

In *necrosis*, which is aptly compared to *gangrene* of the soft tissues, the cast-off portion retains something of its original form and character; in *caries*, which is the molecular death, or *ulceration* of bone, the cell elements disappear by granular degeneration, leaving no trace of the original structure.

Pathology.—Simple, traumatic, non-infectious ostitis has been described in the chapter on Surgical Pathology and Repair of the Tissues.

Periostitis and *ostititis* (when not traumatic) are infectious diseases, due to the presence in the periosteum or bone of certain micro-organisms or their ptomaines. There have been recognized in these acute lesions the staphylococcus and the streptococcus pyogenes aureus, the pneumococcus, the bacillus of typhoid, of tuberculosis, and the bacillus coli communis. These organisms are all pyogenic except the bacillus tuberculosis, which, in all probability, will not produce a septic pyogenic ostitis unless by mixed infection with one of the pyogenic cocci.

In *periostitis* not only the periosteal covering but the superficial layer of bone is always involved, resulting in practically a superficial ostitis or osteo-myelitis with periostitis. It is usually a local disease, involving a limited surface of the periosteum, although at times the entire covering of any bone may be affected. It is of more frequent oc-

currence upon exposed surfaces, as the spine of the tibia, the phalanges (bone felon), and the skull. It is always accompanied with great pain and febrile movement, requiring at times immediate relief by incision and evacuation of pus. In incising the soft parts and superficial covering of the bone, it is well at the same time to use the chisel, penetrating a considerable distance into the substance of the bone in order to determine how much of the bone or the Haversian canals are involved. In a rarer form of the disease, called *periostitis albuminosa* by Ollier (Roswell Park), pus formation does not occur, there being a gelatinoid or mucoid liquid instead of pus. Park suggests that it is the bacillus tuberculosis which is the cause of this lesion. Evidently it is not a pyogenic organism.

Acute osteo-myelitis is an infectious disease, due generally to the staphylococcus and streptococcus pyogenes aureus, although the bacillus coli communis, bacillus tuberculosis, or bacillus typhoidii have been found in the pus discharged from the infected foci. It consists of a rapid infectious inflammation of the medulla of the central canal or the cancellous tissue of the bone, and involves the Haversian canals and the medullary threads which are found in these channels. It is usually painful in the extreme, and the destruction of bone is rapid from the fact that this tissue is non-expansile, and does not yield, as do the softer tissues, in the presence of pus, resisting liquefaction and delaying the discharge of pus and broken-down septic material. It is characterized by high febrile movement and by intense pain, which is exaggerated by motion of the extremity or striking the bone which is involved. It demands immediate interference and evacuation of the purulent contents. Simple incision and trephining of the canal of the bone affected is not sufficient; an extended incision should be made, or several incisions, and the bone completely troughed, so that it may be thoroughly drained. The after-treatment consists in packing the cavity thus made with iodoformized or sterile gauze and treating the wound by the open method. The most frequent form of ostitis or osteo-myelitis and periostitis is due to the presence of the bacillus tuberculosis. The vertebræ, ribs, and sternum are more frequently involved, and next in order are the tibia, the bones of the tarsus and metatarsus and femur. In the long bones the initial focus is usually at the epiphysis, the joint becoming infected by direct invasion through the articular surfaces. In the soft bones (vertebræ, ribs, sternum, etc.) the soft cancellous tissue is the seat of tuberculous deposit.

Tuberculous inflammation of bone is a subacute process, not as rapidly destructive as acute osteo-myelitis, oftentimes going on without exacerbations of temperature and without pain sufficient to attract the attention of the patient or surgeon. The presence of a rich granulation tissue, which is part of the tubercular process, produces molecular disintegration of the substance of the bone (*caries*), at times causing death *en masse* of more or less of the bony tissue (*necrosis*). When the granulation tissue is exuberant, the name of *ostitis interna fungosa* has been applied. When caseous, it is called *ostitis interna caseosa*, and

in rarer instances, where the granulation tissue is scant, the bone may break down in practically a dry molecular disintegration, known as *caries sicca.*

Tuberculous ostitis, or osteo-myelitis, is not infrequently converted into an acute infectious process by mixed infection, the pyogenic organisms finding in the tuberculous granulation tissue a suitable medium for their proliferation and development. Whether it be an acute or chronic myelitis, operative interference is demanded. In tubercular disease of the vertebral column direct interference is not possible, and this form of tubercular disease of bone will be considered in the treatment of Pott's disease. In all accessible locations the indications are exposure of the part affected by incision as free as possible, and a thorough removal by the chisel or spoon of all diseased bone. It is better in all cases to treat such wounds by the open method, changing the dressing every two to four days as indicated.

Osteomalacia—Rachitis.—Osteomalacia (*mollities ossium*) is a disease of adult life, and is especially apt to occur in child-bearing women. The chief pathological change is the disappearance of the earthy constituents from the bones, and their presence in the blood and excretions in abnormal proportion. Softening is often present to such an extent that marked distortions occur from muscular contraction and superincumbent weight. The medulla of the bones is the seat of congestion, often resulting in extravasation of blood. In the later stages the bony lamellæ disappear by absorption, the process commencing from within.

The *treatment* consists in the prevention of fracture and deformity by proper precaution, and the restoration of the osseous system to its normal condition by generous diet, studied hygiene, tonics, and the administration of the hypophosphites of lime and soda, with cod-liver oil and iron.

Rachitis, or "*rickets*," is strictly a disease of childhood and youth. Although it attacks the entire osseous system, its disastrous effects are chiefly observed in the bones of the skull and the long bones of the lower extremities. The bones of the skull become thickened and prominent, the sternum is advanced and angular ("pigeon-breast"), and the bones of the lower extremities are curved antero-posteriorly or laterally. While the diameter of a rachitic bone is usually increased at all points, the enlargement is more marked near the extremities. Rickets is a disease of malnutrition. Its chief pathological feature is the formation of an embryonic tissue, which in normal condition is converted into bone, but in the rachitic diathesis only partially (if at all) undergoes ossification. The cells of the periosteum are unusually active in this proliferation, as are the cartilage bone-making cells; yet this new tissue remains in great part embryonic, without the formation of the osseous lamellæ.

The *treatment* of rickets is, first, to prevent deformity, and, secondly, to relieve the dyscrasia. Rachitic children should be kept in the recumbent posture, or, if allowed to stand or walk, artificial support should be given to the lower extremities and spine. The medical indications are

nutritious diet, out-of-door life, and the administration of the hypophosphites of lime and soda, with cod-liver oil and tonics. The correction of the deformities which may result from rickets will be considered in the chapter on Orthopædic Surgery.

Acromegaly.—This term is applied to a condition of hypertrophy of certain bones of the body, as well as an increase of the soft structures. The hands and feet in many instances become enormously enlarged and out of proportion to the rest of the body, while in others the bones of the head and face, especially of the lower jaw, are affected. The central viscera are, as a rule, not involved. It is usually a symmetrical disease, the corresponding bones of the two sides of the body being alike affected. It gives to the individual a peculiar and unnatural appearance.

Actinomycosis of bone is a rare affection, but should be borne in mind, as it is occasionally met with, especially in the lower jaw, infection taking place through the alveolar process from a decayed tooth.

Hydatid cysts have also occasionally been met with in the bones.

Syphilitic ostitis and *periostitis* are given in the chapter on Syphilis. Periosteal gumma is met with most frequently upon the bones of the skull and upon the tibia, this painful affection being more marked when the patient retires at night. The deeper gumma of bone, also due to the presence of the lymphoid tissue of the syphilitic process, in common with periosteal gumma, does not suppurate unless mixed infection occurs.

Ostitis deformans (Paget's disease) may occur in any of the bones. In some cases this affection resembles osteomalacia, in which, from pressure or superincumbent weight, the bones give way, producing all kinds of deformities. It is a general disease and symmetrical, the bones of the two sides being alike involved. After the deformities have occurred, a supernatural hardening (sclerosis) takes place, leaving the bones harder than normal.

Fractures.

A fracture is a sudden solution of continuity in bone or cartilage. The term is commonly applied to lesions of bone. A fracture may be partial or complete; transverse, oblique, or longitudinal; single, double, or multiple; simple, comminuted, compound, and complicated. A partial fracture occurs when a bone *breaks* or splinters on one side (its convex surface) and *bends* on the opposite (green-stick fracture). In a complete fracture there is a total solution of continuity. A transverse fracture, or one in which the line of cleavage is, in general, at a right angle with the axis of the bone, is rare as compared with the oblique. A longitudinal fracture is a split in the long axis of a bone. It is frequently caused by penetrating wounds (gunshot), or may result from a fall with great violence upon the hands or feet, when the cleavage commences in the articular surface. In this way the astragalus may be driven between the fragments of a longitudinal fracture of the tibia, or a like accident occur at the knee or wrist.

A single fracture is *one* break in *one* bone; a double fracture is a

solution of normal continuity in two bones of one member, as the ulna and radius, the tibia and fibula; multiple fracture is a term applied to two or more separate breaks in one or several bones. When a bone is broken in one direction, and at one point, without injury of any surrounding organ or perforation of the skin, it is termed a *simple* fracture; if there are more than two fragments it is a *comminuted* fracture; if any part of the fractured surface communicates with the atmosphere it is a *compound;* and if it communicates with a joint, or involves in the fracture the wound of any important organ, as a large artery or vein, or, as in fracture of a rib, occasionally the pleura or lung is wounded, it is a *complicated* fracture. An *impacted* fracture is one in which the fragments are splintered and interlocked with more or less complete immobility.

A fracture may be caused by external violence, directly or indirectly applied, or by muscular action, or both forces may unite in the production of the lesion. As an example of direct violence, in the effort to ward off a blow from the head the ulna may be broken directly beneath the contusion of the soft parts. A blow on the vertex which fractures the base of the skull, or a fall on the foot which breaks the femur, are common examples of fracture from indirect violence. Contraction of the quadriceps extensor may fracture the patella, or the same lesion may result from a fall on the knee, in which the direct violence and the action of this powerful muscle *unite* to cause the fracture. In addition to these direct agencies, certain conditions of the tissues predispose to fracture. The bones of the aged break more readily and are slower in repair than the young and middle-aged. There is a not infrequent condition of fragility in the bones of the insane which, either alone or together with excessive and uncontrollable muscular action, renders them liable to break. I have seen one specimen of this nature in which every rib was broken, and some of these in two or more places. As heretofore stated, fracture is common in the disease known as osteomalacia, and may occur, though less likely, in rachitis. Sex, vocation, and manual preference also predispose to fracture. Men suffer much more frequently than women, and any vocation which exposes to violence increases the proportion of fractures. The bones of the right, the preferred side, are more frequently broken than the left.

Symptoms and Diagnosis.—The symptoms of fracture are: *Loss of function; absence of normal contour; preternatural mobility; crepitus; pain.* A broken bone which is not impacted no longer acts as a support, or sustains muscular contraction. The natural shape or outline is more or less distorted by displacement of the fragments. Careful manipulation will determine the overriding, measurement will show shortening, while comparison with the uninjured side will determine the degree of asymmetry.

Crepitus, which is not always necessary to correct diagnosis, is the sensation imparted to the touch, and occasionally recognized by the ear, when the rough fragments are moved so as to grate upon each other. The diagnosis of an *impacted* fracture is more difficult, since crepitus and

mobility are absent. Shortening must of necessity exist, which, with partial loss of function and more or less pain and thickening at the point of fracture, will lead to the recognition of the lesion. A longitudinal

Fig. 346.—Fracture of radius and ulna near the wrist.

fracture or fissure is often with difficulty recognized, and may escape detection.

The Roentgen ray photograph and the fluoroscope are most valuable adjuncts in the exact diagnosis of fractures (Figs. 346, 347).



Fig. 347.—Overlapping fracture of radius and ulna and interosseous union. (Case of Mrs. J. K. B.)

Process of Repair.—The first and immediate result of a fracture is hæmorrhage, which occurs from the arteries, arterioles, capillaries, ven-

ules, and veins of the medulla, compact substance, periosteum, and any surrounding soft parts which may be involved in the injury. As a result of the irritation determined by the accident and hæmorrhage, inflammation is precipitated. Hyperæmia of the bone and contiguous soft tissues ensues. As in *ostitis*, absorption of the bony walls of the Haversian canals occurs with the dilatation of the vessels, and general cell proliferation follows. In the medullary cavity proper, in the medullary spaces of the Haversian systems, in the periosteum, and the inflamed surrounding tissues, this process is common. As in all inflammatory processes, the leucocytes are present in great numbers. The medullocells, myeloplaxes, osteoblasts, periosteal cells, and connective-tissue corpuscles, undergo rapid proliferation, resulting in the formation of a mass of embryonic cells, which infiltrate the clot between and around the fragment. New-formed capillaries are projected into and through this granulation tissue in the same manner as in the process of repair in wounds of the soft parts.

If the broken ends do not come in contact with the air—that is, if the fracture is not *compound*—the process of repair in bone after an injury is similar to the physiological process of development of this tissue—namely, the embryonic tissue is developed into cartilage cells, and these, undergoing proliferation, develop into a secondary embryonic tissue, which is formed into bone. If, however, air is admitted to a wound in bone, the process of ossification in the embryonic tissue is more rapid and direct, since the intermediate stage of cartilage-cell formation does not occur.

A portion of this new-formed tissue, which results from the irritation following a fracture, undergoes a process of calcification by the absorption of inorganic material from the blood, and is known as *callus*. That portion which lies around and on the outer side is the *ensheathing* callus; between the fragments, the *intermediate;* and within the medullary canal, the *central* or "*pin*" callus.

In an adult or middle-aged person, commencing within the first few hours succeeding a fracture, the embryonic tissue, which is formed in varying quantity, remains soft and yielding until about the tenth day, when the cells begin to be infiltrated with calcareous matter. The process of solidification in the callus is complete at a period varying usually from fifteen to thirty days. It is more rapid in children, and slower in the old.

When complete displacement with overlapping occurs, or when an aponeurosis or tendon, or other dense tissue, separates the broken ends, the process of callus-building is interfered with, and failure of ossification may result—*ununited fracture*. Usually a greater portion of the callus becomes absorbed within from thirty to sixty days after the fracture. This is especially true of the ensheathing layer and the central callus. That portion which intervened between the opposing surfaces becomes organized into permanent bone. The pin callus remains for a while, and may completely occlude the medullary canal, but usually at a later period undergoes absorption. In some cases the medullary canal

is not re-established. Fig. 348 shows a section of a broken femur in which, after a considerable lapse of time, the canal was still occluded. The peculiar *stalactite* (exostosis) occurred at the seat of fracture. The permanency of the external callus and its development into exostoses depends chiefly upon the disturbed nutrition of the part. It has been

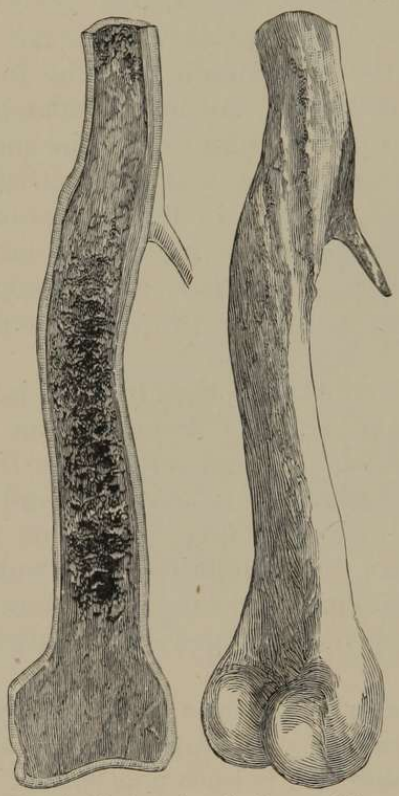

FIG. 348.—Longitudinal section of a fractured femur, showing permanent occlusion of the medullary canal. The stalactite exostosis is well shown in the right-hand figure. (From a specimen of the author's.)

FIG. 349.—Permanent thickening from new-formed bone in a fractured humerus. (From a specimen of the author's in the Wood Museum.)

noticed that when a fracture occurs near the insertion of a group of muscles (as at or near the trochanter), exostosis is the rule, and may be very extensive.

Prognosis and Treatment in General.—The prognosis of a simple fracture in a healthy child or adult is always favorable. The danger is increased with the multiplicity and complications of the accident. A compound fracture is sufficiently grave to demand the greatest attention. Death may result from sepsis or very infrequently from fatty embolism. A longitudinal fracture is a more serious injury, especially grave, as far as the integrity of the member is concerned, when a joint is implicated.

In all forms of fracture the prognosis increases in gravity with each decade beyond the third. When the fracture is complete, and displacement has occurred, exact reposition is impossible, and shortening almost inevitable. The exceptions are extremely rare, especially in the single bones, as the femur, humerus, and clavicle.

The great end to be achieved in the *treatment* of fractures is a reduc-

tion of the displacement to as near the normal as possible, and the absolute retention of the parts as replaced. Reduction may usually be accomplished without an anæsthetic, but where the overlapping is considerable, and muscular contraction and rigidity marked, narcosis should be secured. A compound fracture demands, with fixation, perfect asepsis, and when this is doubtful, free drainage. The fragments should be reduced, even when it is necessary to remove projecting ends with the forceps or saw to effect this. Once placed in position, they should be kept at rest, with openings and counter-openings. The various methods of treatment will be described with each fracture.

Fig. 350.—Case of I. J. Lichtenberg. Showing condition of femur twenty-five years after gunshot fracture (at "the Wilderness," 1864). At *a*, sequestrium projecting from center of shaft. Two small particles of lead may be seen imbedded at the edge of the opening. Numerous exostoses. Amputation done January 8, 1889.

Special Fractures—Cranium.—The bones of the skull may be fractured by *direct* or *indirect* violence. Direct, when the bones give way immediately beneath the point which is struck; indirect, as when, by falling from a height and striking on the feet or buttocks, the base of the skull is fractured by the force transmitted through the vertebral column. A rarer form of indirect fracture of the skull is that known as fracture by *contre-coup*, in which the bones give way at a point opposite to that at which the injury is received.

Fractures of the skull may occur with or without compression of the brain or meninges. The outer table may be depressed by crushing into the diploë without fracture of the inner or vitreous table, and, strange as it may appear, in rare instances the inner table is broken, while the outer plate is not depressed. More frequently both tables are involved. Fractures of the skull may be simple, compound, comminuted, complicated, single, or multiple. They are chiefly divisible into those of the *vertex* and those of the *base*.

Fractures of the base are usually due to *indirect*, those of the vault to *direct* violence. A blow on the top of the head may produce a fracture only at the base, or at both the apex and base. Usually the break occurs at a point directly in the line of the force which causes the lesion. Aran demonstrated, by dropping cadavers from a height, that when the frontal region received the blow the fracture usually took place in the anterior fossa, the middle parietal and the occipital region giving

the key to a fracture respectively in the middle and posterior fossæ. A blow on the chin has been known to produce a fracture by driving the inferior maxilla against the temporal bone. A fall on the buttocks may produce a comminuted fracture, the force being transmitted through the vertebral column. Fig. 351 is a copy from a specimen I placed in the Wood Museum of Bellevue Hospital. The patient, a heavy man, a sailor, fell through the hatchway to the hold of a ship, a distance of about twenty feet, striking on the buttocks. Death occurred instantly. The head was not bruised. The cause of death was a comminuted fracture, extending through the temporal, occipital, and sphenoid bones.

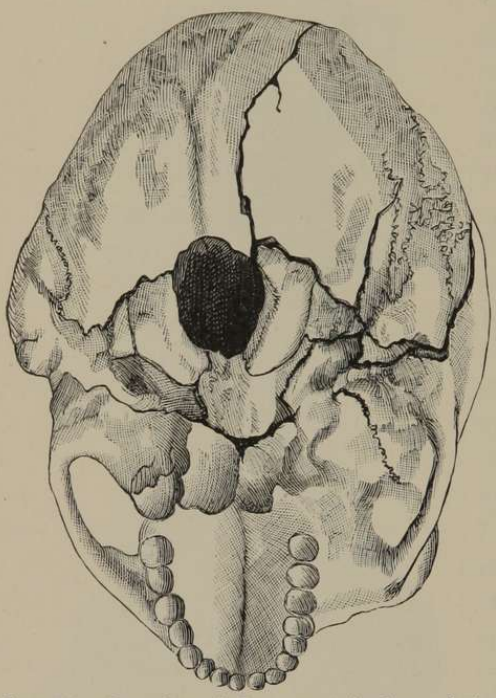

Fig. 351.—Comminuted fracture at the base of the skull, from a fall on the buttocks. (From a specimen of the author's in the Wood Museum.)

Diagnosis.—The diagnosis of fracture of the vertex may be readily determined when an open wound exists. In many instances a depression may be determined by palpation, even when the scalp is unbroken. Symptoms of compression of the brain are not reliable aids in the diagnosis of fracture in the first few days after an injury, for the reason that any violence sufficient to produce a fracture is also likely to produce symptoms of concussion which might easily be mistaken for compression. The escape of brain substance or ventricular fluid is of course an unmistakable sign. At the base, one of the most reliable symptoms of fracture, yet not always a positive indication of this lesion, is hæmorrhage, or the escape of a serous fluid from the ears. This only occurs, however, when the line of fracture passes through the petrous portion of the temporal bone. Swelling of the vault of the pharynx is not without significance when any violence has been suffered which leads to the suspicion of fracture of the skull. If the basilar process of the occipital bone is involved, extravasation will not unlikely be present in this region. Loss of vision or the sense of smell indicates a lesion of the anterior fossa. In many instances the diagnosis must rest wholly upon subjective symptoms.

Based upon no objective symptoms, the differentiation between *concussion* and *compression* of the brain is difficult, and often impossible.

In general, it may be said that the symptoms of *compression* are those of paralysis, usually unilateral and more profound than the symptoms of concussion.

In simple *concussion* the patient may be aroused to partial consciousness, the respiratory movements of the muscles of the face will be sym-

metrical, equality of the pupils is maintained, and vomiting is of frequent occurrence. In *compression*, stupor is apt to be prolonged and profound, the facial muscles are drawn to one side, and the buccinator of the affected side is apt to puff out with the expiratory effort. There may be inequality of the pupils, and vomiting is absent.

In the *treatment* of concussion of the brain the first indication is rest. The recumbent posture, with the head elevated, should be maintained. If there is marked coldness of the skin, and evidence of great prostration or impending collapse, warmth should be applied locally, and stimulants hypodermically. Stimulants must, however, be given with discretion, since the fever of reaction may be increased by their excessive use. After the shock passes off, cold applications to the head are essential.

The *treatment* of fractures at the base is generally expectant. Surgical interference may however be called for. In fractures of the vault, with depression, in adults, the trephine should be applied as soon after the injury as is consistent with the patient's safety. If shock is present without serious compression, it will be wise to wait until reaction is established. When, however, dangerous depression exists, immediate operation, even without an anæsthetic, is demanded. When the symptoms of depression are not prominent, an exploratory incision is justifiable in order to determine with certainty whether there is compression of the brain or meninges. With antiseptic precautions this operation adds little to the gravity of the patient's position.

A *comminuted* fracture always demands the elevation and removal of the fragments. A linear fracture, with depression, even if this is thought to be confined to the outer plate, also demands the trephine as far as the diploë, and, if the depression involves the inner table, this should also be raised and the fragments removed. A fracture made by a narrow instrument, or other penetrating substance, as a gunshot missile, etc., demands the trephine at the point of entrance.

Localized paralysis, coming on immediately after an injury to the skull, calls for trephining at once. It is always better to operate early than to defer interference until inflammatory symptoms are present. The danger is enhanced by such delay.

Operation.—Besides the ordinary cutting and hæmostatic apparatus, a trephine and elevator will be found necessary, while a rongeur and sequestrum forceps will be of great service. Of the various trephines, the conical instrument of Galt is preferable.

The scalp, within two or three inches of the wound, should be shaved perfectly clean, and it, together with the hair, soaped and scrubbed with a clean brush, then moistened with ether, and washed with a 1-to-3,000 sublimate solution. A rubber band or piece of drainage tube carried around the head, dipping beneath the occiput, and passing above the ears and eyebrows, may be used to control bleeding from the scalp. In cutting down to the bone, any wound which may exist should be utilized, and may be enlarged by a crucial incision, if found necessary. The periosteum should not be lifted.

When the fracture is well exposed, if there is great comminution, and if the fragments are not tightly impacted, they may be lifted by the elevator without trephining. If this instrument is required, advance the central bit about an eighth of an inch beyond the level of the circular teeth, and fasten it firmly here by turning the screw near the center of the shaft. The point of the bit should be applied upon the solid unfractured bone, about a fourth of an inch from the fissure, and the greater part of the button lifted from the uninjured bone. The instrument is now caused repeatedly to rotate for a half circle and back, and sufficient pressure is made to carry the point and teeth into the calvarium. When the teeth have cut a circle about one sixteenth of an inch in depth, the instrument should be removed, and the bit slipped up the shaft to its original position. As the operation proceeds, the trephine should be removed every few turns and the ring cleaned out with a toothpick. A slight bleeding is apt to occur when the diploë is entered. As soon as the inner table is divided the instrument becomes locked and practically immovable. Wounding the dura mater is scarcely probable if the trephine is held perpendicular to the plane of the bone which is being cut. If the button does not come up with the instrument, it should be lifted out with the elevator or forceps. The elevator may now be carried carefully under the edge of the depressed bone, and, using the solid surface for a fulcrum, lifted into position, or, if comminuted, removed. It is always important to look for any fragments, however small, which are apt to be broken off from the vitreous table and driven between the *dura mater* and the skull. If the dura be torn, the bleeding should be arrested by catgut ligatures, and the wound in this membrane closed by sutures of the same material. In passing a needle through the dura it is a wise precaution to employ a grooved director to shield the thin vessels of the pia mater from the needle.

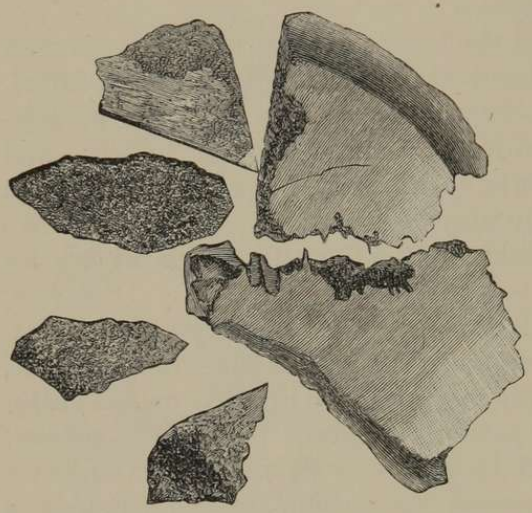

Fig. 352.—Fragments removed by the trephine and elevator in a depressed fracture caused by a blow with a hammer. The beveling at the expense of the vitreous table is well shown.

The wound should be treated under strict antisepsis, and a twist of sterile catgut inserted for drainage.

The trephine should not be applied over the track of the longitudinal or lateral sinuses and the middle meningeal artery. Depressed bone may be lifted from these vessels. Hæmorrhage, if it occur, may be controlled by the ligature or by compression.

Nasal Bones.—One or both nasal bones may be fractured and depressed, and in severe injuries the nasal processes of the superior maxilla and the perpendicular plate of the ethmoid are involved.

Hæmorrhage from within the nose is usually severe, and may require the tampon of the anterior and posterior nares. The reposition of the fragments should be effected with great care. A strong, blunt, and narrow instrument passed along the septum nasi until it is in contact with the inner surface of the fragments, together with lateral pressure from without and at the base of the nose, will best reduce the displaced pieces. In order to hold the fragments in position, the method of treatment introduced by Dr. Lewis D. Mason will be found preferable.* After reposition, as above described, a steel drill is passed directly across the nose, being entered through the line of fracture or beneath it. The accompanying cut (Fig. 353) illustrates the employment of this procedure. This patient received a kick which drove the nasal process of the superior maxilla of the right side and the right nasal bone into the cavity of the nose. The deformity was marked and the voice greatly changed and unusually nasal in tone. The bones could be readily replaced, but would return to their abnormal position as soon as the instrument was withdrawn. Under ether I replaced the fragments, and, while held in proper position, I drove one of my steel fixation drills from side to side, passing it beneath the loosened pieces. A light loop of iodoform gauze was twisted across the nose and over the ends of the drill. The instrument remained in place ten days, was removed, and a perfect cure obtained.

Fig. 353.—Case of O'Toole.

When the blow is received on the side of the nose, the fracture and depression may be unilateral. In such cases, replacement effected after the manner just described will usually suffice, since the fragments are not likely to be displaced when once in position. When the fracture is bilateral, the drill should be entered at the level of solid and unbroken bone, on one side, if possible. When the bones are widely comminuted a second drill may be utilized. In those instances where the perpendicular plates of the ethmoid or vomer are broken, after reposition and fixation with the drills, any lateral deviation of the septum should be corrected. Plugs of gauze may be carried into the nares, if necessary.

At times, and especially in children, when the nasal arch is struck from the front, the fracture occurs at the naso-maxillary suture, and the nasal bones are driven in without comminution. In this variety of depression considerable force is needed to effect reduction. Such is the rapidity with which repair and union occur here, as in all the bones of the face, that, if the effort at reduction is delayed for more than

* "Annals of Anatomy and Surgery," vol. ii, pp. 110 and 199.

twenty-four or forty-eight hours it will be exceedingly difficult to accomplish.

Fracture of the *malar* bone occurs rarely, and is the result of violence so great that usually the upper jaw and other bones are broken. Every effort should be made to restore the normal contour to the face by reposition of the fragments, none of which should be removed, since the vitality of the bones of the face is so great that necrosis after injury is exceptional.

When the fracture is compound, and this is usually the case, the fragments may be lifted into place through the wound, by means of the bullet-screw elevator, or other instruments; or, as advised by Hamilton, the finger or thumb may be passed underneath the lip to the zygomatic arch, which can be utilized as a point for pressure. At times, however, it may be necessary to enter the *antrum maxillare* by trephining or drilling through the anterior wall of the antrum. The point of entrance should be immediately above the first (or anterior molar) tooth, at a distance of from one half to three quarters of an inch below the inferior margin of the orbit.

Fracture of the *zygomatic process*, either of the malar or temporal bones, may occur singly or as a complication of the fracture just treated. If the force which produces the lesion does not wound the temporal or maxillary arteries, the treatment is simple. If the depression is sufficient to cause deformity, cut down to the arch, insert a hook elevator, and lift the bone into place, or preferably, as advised by Prof. Rudolph Matas, insert a full-curve (semicircular) Hagedorn needle threaded with silk (followed by silver wire) through the soft tissues near the depressed bone, passing behind and beneath it. Strong traction on the suture will pull the displaced fragment in position. To hold it until union occurs Matas ties the wire over a narrow splint resting on a pad of iodoformized gauze. It is necessary to limit mastication by the application of a bandage, as in fracture of the lower jaw.

The *superior maxilla* may alone be broken, although it is usually complicated with fracture of other bones. A blow received at the roots of the teeth may drive the alveolar and palatal arch downward, or, if the direction of the impinging body is from before backward and upward, the antrum may be opened.

The treatment is to cleanse the wound antiseptically and replace all pieces of bone as well as possible.

The following case illustrates in a remarkable degree the vitality and reparative power in the bones in the face: In September, 1884, a robust Irishman, about forty years of age, came into my service at Mount Sinai Hospital. He had just been kicked by an unshod horse. The crescentic wound extended from the center of the forehead down by the nasal process, along the facial groove, and out beyond and below the malar bone. The soft tissues were lacerated, and the bones extensively comminuted. The wound was cleansed of particles of manure, straw, etc. Strict antisepsis was employed, thoroughly cleansing the wound and replacing every piece of bone. The torn edges were pared and closed

by silk sutures. Rapid union ensued, without the exfoliation of any portion of the bone.

The great desideratum is the prevention of a scar. Upon the face the greatest care must be taken to avoid deformity. If the soft tissues are torn and contused, the edges of the wound should be smoothly pared and nicely approximated by fine silk sutures.

When the destruction of the bone is so extensive that, even after reposition of the pieces, the fragments will not remain in place, it may be necessary to use the lower jaw as a splint, by fixation of the two rows of teeth, with the head and chin figure-of-8 dressing, as for fracture of the lower jaw. The interposition between the teeth of short strips of gutta-percha, thoroughly softened in warm water, will firmly fix the broken to the unbroken bones, and admit of the introduction of liquid food between the upper and lower incisors.

Fracture of the *inferior maxilla* may occur in rare instances through the *symphysis menti*, but much more frequently external to this and near the opening of the mental foramen. The majority of all fractures are of the body, and within the first inch and a half leading backward from the symphysis.

Fracture of the *angle* or *ramus* is infrequent, and is usually the result of a blow upon the side of the jaw. The *coronoid process* is rarely if ever broken, except by penetrating bodies. The condyle may be broken through its neck by a fall or blow on the chin, or by force applied laterally at or near the angle.

Diagnosis.—Among the symptoms of this lesion are pain at the point of fracture and loss of function. If the break is complete the diagnosis is made evident in the displacement which usually occurs, and by the presence of crepitus. The bone may, however, be broken without displacement, and where crepitus is not present. Under such conditions, while a diagnosis may not be positive until the swelling which indicates the formation of callus ensues, the jaw should be kept at rest by one of the methods to be described. When the fracture occurs at or posterior to the mental foramen, the temporary loss of function of the inferior dental nerve, which is not infrequent, points almost unerringly to a recognition of the character of the lesion. When the neck of the condyle is broken, the chief symptom is pain in this region, with partial or complete loss of function. Crepitus is with difficulty elicited by the surgeon, although it may be evident to the patient.

Treatment and Prognosis.—Immediate reposition of the broken and displaced surfaces, and as perfect a degree of rest as possible, are the first and chief indications for treatment. When the presence of a partially displaced tooth offers an obstacle to close adaptation it should be removed. When reduction is effected, one among the following methods may be employed:

A simple and ready method, which may be used until a more secure apparatus is constructed, is found in the four-tailed bandage (Fig. 188). The fragments being carefully adjusted, the bandage is applied as already given on page 166. The figure-of-8 chin and head bandage (Fig. 180) is

also an excellent emergency dressing for fracture of the lower jaw. If this is intended to be used permanently, a leather or gutta-percha cup should be constructed, to fit over the chin and well along the body of the jaw. The material should be cut from three to three and a half inches wide and about six to seven inches in length, and split from each end in its long axis to within three fourths of an inch of the center. One strip should be about half an inch narrower than the other. If gutta-percha is used, this should be dipped in warm water for a minute or two, until it becomes softened. It is then laid across the chin, the upper and narrow ends are turned back over and parallel with the body of the jaw, while the lower ends are turned upward and made to cross outside the horizontal ends. The bandage is applied over this cup, which soon hardens into an unyielding dressing. Leather may be prepared in the same way, but requires to be soaked longer than the rubber. Inter-dental splints, made of gutta-percha strips, cut about one inch and a half in length, from one fourth to one half an inch in width, and about one fourth of an inch in thickness, are sometimes employed to fix the molar teeth immovably, and at the same time to separate the anterior teeth enough to permit the introduction of liquid food. These strips should also be softened, and, when placed between the teeth, the crowns of the molars are pressed into the rubber by the bandage. When the fracture is through the molar region, the strip on the broken side is placed on either side of the fracture.

The most suitable apparatus is that of Prof. Hamilton, seen in Fig. 354. It consists of a chin-and-head strap, made of strong, soft leather. This piece, where it passes under the chin, is shaped so that while it may not cause uncomfortable pressure at the base of the tongue, it is wide enough, as it passes up on to the side of the face, to include the angle of the jaw in its support. From this point it is gradually narrowed, until at the temple it is an inch in width, and the same where it is buckled at the fronto-parietal suture. A piece of cloth, fashioned so as to fit like a cup over the chin, is sewed on to this. A second strip is buckled around the head, across the forehead and beneath the occiput, and from this point an antero-posterior strap passes forward to the maxillary piece, to which it is attached at the fronto-parietal junction. By shortening or elongating this strap the direction of the pressure on the jaw can be changed, while it prevents the maxillary strip from pulling forward. Apiece of soft lint or cotton should be placed under each buckle. If, after the apparatus is applied, the teeth fit so closely together that it is impossible to introduce liquid nourishment, inter-dental splints of gutta-percha should be employed. In some instances it will be necessary to unite the fragments by silver-

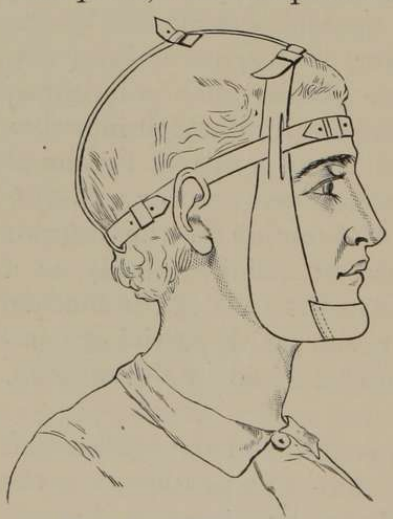

Fig. 354.—(After Hamilton.)

wire sutures. The sutures usually require to be removed after union is secured.

A patient with a fractured jaw should not be allowed to talk, and, when in bed, should be required to rest in the dorsal decubitus, so as not to press laterally upon the injured bone.

The *prognosis* is usually favorable. Fixation by ossification occurs in from two to five weeks. In some cases later, while in a small number, in which proper treatment has been delayed, or the character of the injury severe, or the condition of repair in the patient unfavorable, union is delayed or fails utterly. In instances of delayed union fixation should be faithfully tried. If this fails, and the function of the jaw is seriously impaired, the point of fracture should be exposed by incision, the broken edges scraped, one or two holes drilled through each fragment, one fourth of an inch from the edges, and fixation secured by means of silver wires.

Fracture of the *cartilages* of the *larynx* is of rare occurrence. Simple fracture heals without retentive apparatus, quiet being the chief indication. The prognosis is grave in proportion to the danger of asphyxia from inflammatory swelling or emphysema. When the force has been great, and the comminution extensive, death may occur from shock or other complication before asphyxia from occlusion of the trachea supervenes. When this last danger is threatened, tracheotomy should be performed early.

When the *os hyoides* is broken, the fragment, if displaced or driven through the soft tissues, may be brought into position by introducing one finger into the mouth and pressing with the other hand from without. It is scarcely possible to retain the ends in apposition, and fibrous union is apt to occur. The accident is rare, is not dangerous, and the prognosis consequently favorable.

Clavicle.—The clavicle is, next to the radius, more frequently the seat of fracture than any other bone. In children the fracture is rarely complete, and consequently overlapping is not met with, as is the rule in adults. The break occurs, in a large majority of instances, in the middle third, i. e., in that portion of the bone between the attachments of the trapezius and sterno-mastoid muscles. This fracture may be caused by direct violence, or by indirect force, as a fall upon the shoulder or the extended arm.

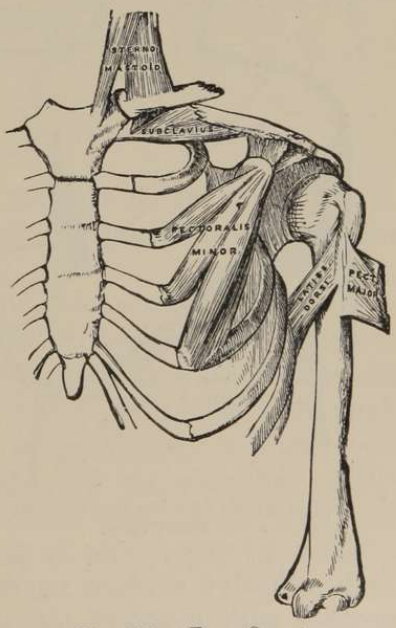

FIG. 355.—(From Gray.)

The character of the displacement is shown in Fig. 355. The inner fragment is held in position by the mastoideus muscle, and is prevented from being carried upward by the costo-clavicular ligament. The weight of the arm and shoulder drags the

outer fragment downward, while the contractions of the pectoralis major, latissimus dorsi, and subclavius muscles carry it toward the middle line of the body, beneath the inner fragment. In rare instances the displacement is the reverse.

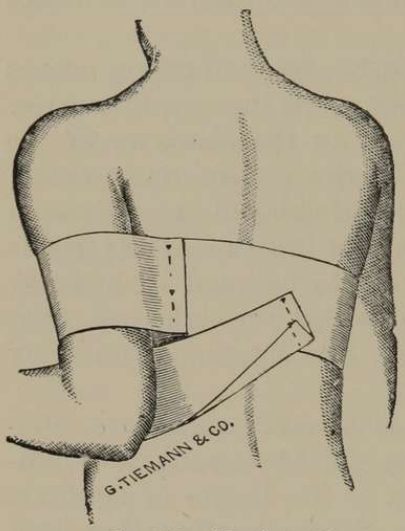

Fig. 356.—The first strip.

The diagnosis rests upon loss of function, pain at the seat of lesion, possibly crepitus, loss of symmetry, shortening, and recognition of displacement by palpation.

The *prognosis* is good as to restoration of function, although in complete fracture, overlapping and a certain amount of permanent deformity and shortening are almost inevitable.

Treatment.—In complete fracture overlapping of the fragments may be corrected, and the ends brought into apposition, by first carrying the arm and shoulder backward, and then elevating the shoulder. This is the principle involved in Prof. Sayre's excellent method of treating this lesion, which is as follows: Cut two strips of strong adhesive plaster (moleskin is preferable) about three inches wide and several feet in length. Just above the elbow of the arm on the injured side, one strip,

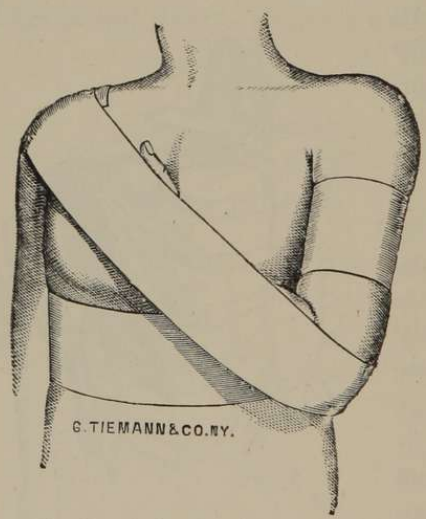

Fig. 357.—Sayre's dressing for fractured clavicle. Front view.

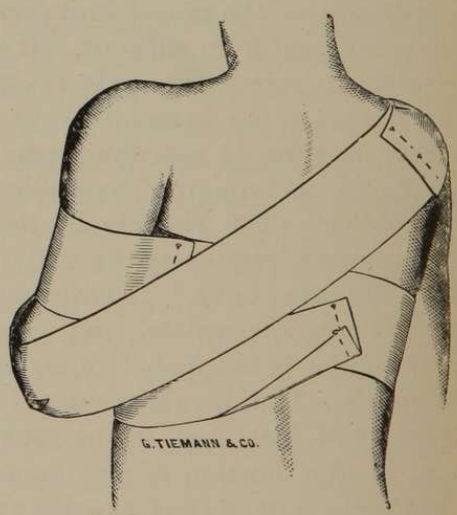

Fig. 358.—Back view.

with adhesive surface nearest the body, is passed around the arm and secured with a safety pin, so that it will not constrict the member (Fig. 356). The hand is now laid over the middle of the sternum, the shoulder elevated, and the elbow carried well backward by an assistant, while the operator carries the plaster directly around the body by the back, fastening it snugly to the integument. The second strip is split near its mid-

dle for about three inches, for the accommodation of the elbow, and is applied along the forearm and over the shoulder of the sound side, and obliquely around the back to the same point (Figs. 357, 358). A wad of absorbent cotton should be placed in the axilla of the affected side, and between the hand and the sternum. The plasters should be stitched or fastened securely with safety pins.

A convenient and effective ready method is that of Prof. Moore, of Rochester. A strip of sheeting, eight inches in width and three yards long, is held near its center across the palm of the operator, who, for the left clavicle, grasps the elbow of this side from behind. That end of the strip which is next the patient's body is passed between the arm

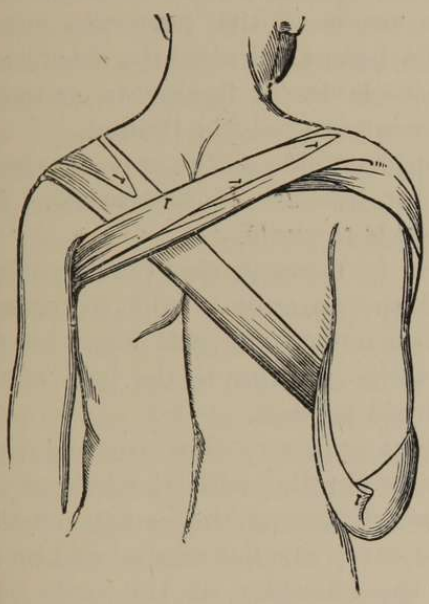

Fig. 359.—Moore's method.

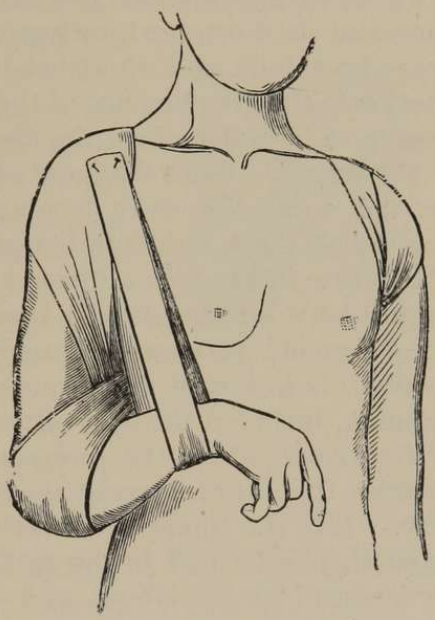

Fig. 360.—Moore's method.

and chest, then up in front of and over the clavicle of the injured side, obliquely across the back, under the opposite axilla, thence across the right clavicle, and over this to the back.

The opposite end is passed to the front of the arm at the elbow, between the first strip and the arm, and is then carried around the back. An assistant now carries the elbow backward and upward, and, while held in this position, the bandage is tied, sewed, or pinned. A sling to support the forearm is added. This is practically a figure-of-8 bandage around the elbow of the broken side and the shoulder of the sound side. The hand is carried across the chest, slightly elevated, and is held in a sling. Safety pins are inserted at the points of crossing (Figs. 359, 360).

In incomplete fracture, and in children, especially during the summer months, when the plaster tends to produce irritation of the skin, Velpeau's method is preferable. (See Dislocations.)

Any form of apparatus should be worn at least four weeks.

The *scapula* is almost always broken by direct violence. It is

thought to have been fractured in a few instances by muscular action alone.

Acromion Process.—The *acromion process* is usually broken by a fall on the shoulder or a blow received from above. The fracture may occur anterior to, through, or behind the acromio-clavicular articulation. The *diagnosis* is evident from crepitus, preternatural mobility, and depression of the outer end of the clavicle. The treatment is to bend the forearm at a right angle to the arm, and throw a roller under the forearm, at the elbow, and over the clavicle and shoulder of the affected side, fixing the head of the humerus in the upper part of the shoulder joint and lifting the acromion into its place.

Coracoid Process.—When this process is broken the tendency to displacement is downward, owing to the action of the pectoralis minor, coraco-brachialis, and short head of the biceps. Unless the fracture is anterior to the attachments of the coraco-clavicular ligaments, or unless these have been detached, the displacement can only be limited.

Treatment.—Place the hand of the injured side on the opposite shoulder, and apply Velpeau's bandage as for fracture of the clavicle. The prognosis is good, although fibrous union is the rule.

Fracture of the *glenoid process*—that is, through that portion of the scapula between the glenoid fossa and the anterior portion of the base of the coracoid process—has not yet been noted. Several instances are recorded, however, of fracture which, while anterior to the base of the acromion, included the base of the coracoid process.

Treatment.—Flex the forearm at right angles to the arm, and carry it across the chest, leaving the humerus parallel with the axis of the body. Lift the humerus directly upward against the coraco-acromial ligament, place a pad in the axilla, and carry a roller around and under the forearm, at the elbow, and over the shoulder of the same side. Every other turn should be carried horizontally around the body. By this means the head of the humerus keeps the fragment in position.

Fracture of the spine of the scapula is rare, but below this it is of more frequent occurrence. Velpeau's bandage, or any method which will give the minimum of discomfort and the greatest degree of rest, will be most successful.

Humerus.—Fracture of the *humerus* occurs most frequently in its lower third, while the proportion of fractures in the middle and upper thirds is about equal.

In the upper third this bone may be broken through the anatomical neck; just below this line, through the tuberosities; immediately below the tuberosities (the surgical neck); or through the shaft. It may also be fractured longitudinally, with separation of the tuberosities.

Fracture of the *anatomical neck*, or intra-capsular fracture, is rare. It is caused by a blow or fall directly on the shoulder.

Diagnosis.—There may be crepitus. If the shoulder is fixed and the humerus grasped below and up to the tuberosities, and crepitus is felt by moving the head against the glenoid cavity, the character of the injury is evident. If impaction into the shaft has occurred, crepitus

will be absent, but shortening will be ascertained by careful measurement.

Bony union after intra-capsular fracture is rare, unless impaction has occurred. Osteo-arthritis may result, rendering exsection of the joint necessary.

Fracture through the tuberosities occurs also from direct violence. The symptoms closely resemble those of the variety just described. The prognosis is more favorable, since bony union is the rule. Prognosis as to freedom of motion should be guarded, since exostosis may result to such an extent as to interfere with the usefulness of the arm.

Fracture through the surgical neck is of far more frequent occurrence than the intra- or extra-capsular fractures at the anatomical neck. It may result from direct violence, although not infrequently a fall upon the hand or elbow may produce it. The bases of the tuberosities are rarely involved in fracture of the neck in adults —except in the young, when separation at the epiphysis may occur. In the middle-aged and old the point of fracture is usually about one inch below the tuberosities.

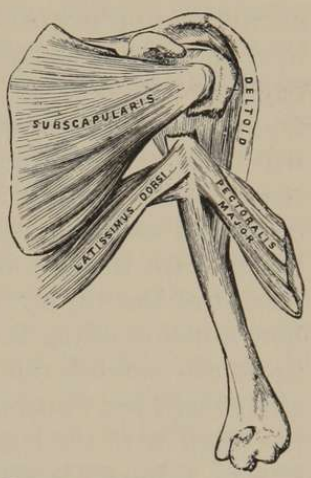

Fig. 361.—Showing the mechanism of displacement in fracture of the surgical neck of the humerus. (After Gray.)

Displacement may occur in any direction, although as a rule it is not extreme. The tendency of the lower fragment is to be drawn upward by the deltoid and triceps, inward by the pectoralis major and latissimus dorsi, and upward and inward by the short head of the biceps and the coraco-brachialis (Fig. 361).

Longitudinal Fracture.—This form of fracture, though rare, occurs from direct injury. The split usually runs through the head of the humerus and along the bicipital groove, resulting in a separation of the greater tuberosity from the shaft. The bone will be found to be flattened and wider than normal, while a deep groove marks the line of cleavage. The prognosis is unfavorable as to restoration of function.

Differential Diagnosis.—In *dislocation* of the shoulder joint there is always abnormal immobility; the muscles of the shoulder and arm are rigid; a measurement over the acromion and around through the axilla will be at least one inch greater than on the non-dislocated side; the head of the bone will be felt out of its normal position; if the hand of the affected side is laid upon the opposite shoulder, the elbow can not be made to touch the chest wall.

In *fracture* without impaction, crepitus and shortening; more or less pain on motion; mobility free; the circumference not increased; the head of the bone in position; with the hand of the affected side upon the opposite shoulder the elbow drops to the chest. With impaction, all of these symptoms except crepitus.

Treatment.—Reduction of displacement is usually affected by extension from the flexed forearm, the shoulder being fixed by traction in the

opposite arm, or by a sheet carried around the body, just under the axilla. In the first manœuvre it is usually best to hold the arm at right angles to the body, and, continuing the extension, to bring it down parallel with the chest, in which position it is to be fixed. To this is added direct manipulation of the fragments. The choice of dressings may be made between plaster of Paris and a cup-shaped splint of gutta-percha, sole leather, or bookbinder's board. Properly adjusted, either of these materials will suffice.

In the treatment of fractures in general, with the exception of certain fractures which will be separately considered, plaster-of-Paris immobilization gives the greatest satisfaction. After the bones have been placed in apposition, and while extension and counter-extension are being made, a canton-flannel roller, or an ordinary muslin bandage, should be applied over a single layer of cotton batting, which is placed next the skin. Compression of this bandage, and of the plaster-of-Paris bandage which is to follow, should be snug, yet not very tight. The tendency of the tissues under the bandage is to become smaller, and it will be found, within a few days after application of the plaster of Paris, that this will appear loose, even when it has been tightly applied. The danger of swelling as a complication of ordinary fractures does not contra-indicate the use of gypsum. It may be applied immediately upon receipt of the injury, and it is not necessary or advisable to wait to see how much swelling is going to occur in the limb. If the proper precautions are carried out, no harm will ensue. It has been my practice, almost without exception, in fractures of the humerus or lower portion of the thigh or of the leg and back, to apply the plaster at once. As soon as it sets, I immediately spilt it from one end to the other down to the flannel bandage which envelops the cotton batting and the limb. As the plaster is accurately applied, and is stiff, no displacement of the fragments can occur; and should swelling take place in the absence of the surgeon, it is a simple matter for any one to insert a pair of scissors and divide the flannel bandage which alone constricts the limb. In this way no amount of swelling can produce gangrene. The plaster-of-Paris dressing should be one eighth of an inch thick, or more. The limb should be held in perfect apposition by extension and counter-extension until the plaster hardens. This dressing is usually left on from four to six weeks, and longer in old persons. When the limb atrophies to such an extent that the dressing becomes loosened, a strip, half an inch wide or more, and for the entire length of the dressing, may be removed from the plaster dressing, and the whole more tightly adjusted by an ordinary roller outside.

If a shoulder cap is to be applied, a pattern is first made by cutting a piece of paper to fit over the shoulder and down the arm. It should be large enough to spread over a part of the scapular and pectoral region and to embrace two thirds of the circumference of the arm. The pasteboard, gutta-percha, or leather is cut to correspond to this, and is immersed in hot water until it is soft and pliable, when it is lined with a thin layer of absorbent cotton and molded over the arm and shoulder,

where it is secured by a roller, applied as above. The inner side of the arm is protected by cotton or cloth. The forearm and hand should be bandaged and held in front of the ensiform cartilage by means of a sling. If the dressing becomes loose, an additional roller should be applied. Any dressing for this fracture should be worn continuously for at least four weeks. In order to prevent contraction of the biceps, it will be advisable to fully extend the forearm every two or three days.

Fracture of the shaft of the humerus near the head of this bone is, in a certain proportion of cases, complicated with dislocation. It is believed to occur as a result of falling upon the hand or forearm while the arm is in abduction. I have met with two instances in which this occurred, and in both cases the patients had fallen with great violence upon the injured side. The fracture usually occurs at the surgical neck. The first case was in the practice of Dr. Charles McBurney, during his temporary absence. The patient, a heavily built man, was thrown from his carriage. Under an anæsthetic it was discovered that fracture existed at the surgical neck, with dislocation of the head of the humerus beneath the coracoid process. Fourteen days after the accident Dr. McBurney operated upon the patient by an original method, which was eminently successful. An incision was made on the outer aspect of the upper fragment, a good-sized hole drilled in this, and a stout, blunt hook inserted, strong traction being made upon the upper fragment in the proper direction; the arm and forearm were carried up nearly at a right angle to the body, and with the hook inserted in the bone and the fingers on the humerus vigorous traction was made. The effort required was very considerable, but no change of direction was needed, reduction being accomplished at the first attempt. The fractured surfaces were then brought into apposition, but not wired, an aseptic dressing applied, sterile gauze and plaster of Paris over all.

The second case came under my care at the Polyclinic Hospital. The patient was a woman, forty-seven years of age, who stated that she had had a fall two weeks previously, and had been unable to use her arm since the accident. A diagnosis was made of dislocation of the right shoulder, with fracture of the humerus at the surgical neck. I proceeded to carry out the operation suggested by Dr. McBurney, following exactly the same method and using his instrument, but no amount of force I could apply in any direction would carry the displaced head into the glenoid fossa or the capsule. The head of the bone was immovably fixed, and I was compelled to exsect the upper fragment. I learned later that this patient had had an accident of a like character one year before, and that the dislocation I was dealing with was an ancient one; the last accident evidently had fractured the bone which had been dislocated in the first.

Fractures of the shaft of the humerus, although chiefly caused by direct violence, are not infrequently the result of a fall on the hand or elbow, and may, in rare instances, be caused by muscular action alone. The displacement, which is usually not marked, will in great part be determined by the direction of the line of fracture. If the break is above

the insertion of the deltoid, while the lower fragment is drawn upward by the deltoid and the long muscles extending from the scapula to the elbow, the upper fragment is apt to be drawn toward the thorax by the pectoralis major and minor and latissimus dorsi muscles (Fig. 361). If the break is below the deltoid tubercle, the displacement and overlapping will, in general, follow the obliquity of the fracture. The lower fragment is apt to be drawn behind the upper longer piece.

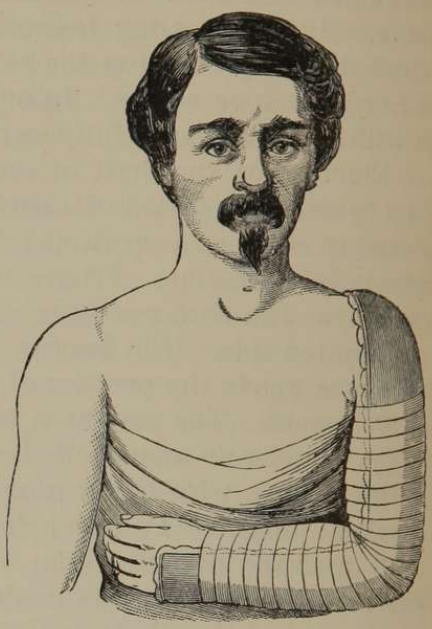

Fig. 362.—Apparatus for fracture of the humerus at any point above the condyles. (After Hamilton.)

A not infrequent complication of fractures of the shaft of the humerus is the injury to one or more of the nerves which are in intimate relation to the bone. The musculo-spiral nerve is most frequently involved. A number of instances have come under my observation in which paralysis of the extensor muscles (wrist drop) has followed injury to this nerve by fragments of bone at the time of fracture, or by pressure of the callus which is thrown out. If a nerve has been injured at the time of fracture—that is, if paralysis be present—it would be advisable to cut down upon the seat of fracture and determine whether the nerve has been sufficiently injured to demand suture. In two instances I have had to cut down and chisel away the callus around the nerve, in one case making a section of the nerve with resuture.

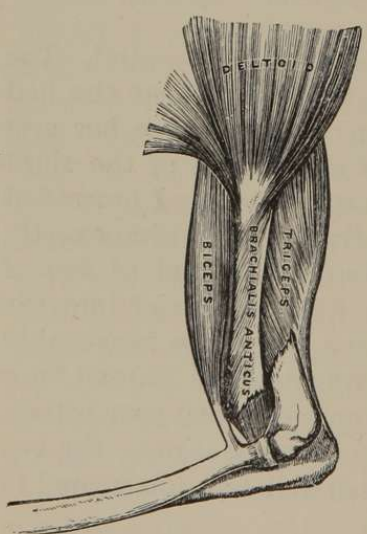

Fig. 363.—Showing mechanism of displacement in fracture above the condyles. (After Gray.)

The *treatment* is practically the same as that just given. If the cup-shaped splint is used it should be made longer, and an extra short, narrow, internal splint may be added (Fig. 362). The plaster-of-Paris dressing is to be preferred.

Fracture at the condyloid extremity of the humerus may be divided into: 1, transverse fracture above the condyles, caused by violence applied to the elbow; 2, epiphyseal separation (on a plane lower than the above); 3, transverse fracture, with a longitudinal split into the joint (inter-condyloid); 4, fracture of the external condyle; 5, of the internal condyle; 6, of the external epicondyle; 7, the internal epicondyle.

In transverse fracture above the condyles the obliquity is usually from behind forward and downward (Fig. 363), the inferior short frag-

ment being carried up behind the longer. When the lower fragment is split into the joint, the displacement is the same.

In epiphyseal separation the displacement is not great, unless the capsule is badly torn, as a result of extreme violence.

The treatment of these varieties of fractures is the same—reduction by extension and counter-extension, holding the fragments as well in position as possible, placing the forearm in supination at an angle of 90° with the humerus (right angle), and enveloping the member with plaster of Paris from the axilla to the end of the metacarpus. Experience has taught that passive motion should not be attempted during the process of repair, it being better to wait four or six weeks, until union has occurred, before allowing motion.

The *internal condyle* is broken much more frequently than the external. It is more prominent, and, in the act of falling backward, the arms are thrown out from the body in such a manner that the inner condyle first receives the force of the fall. The fracture may be confined to the tip (extra capsular), or it may include a portion of the internal epicondyle, and lead into the joint through the trochlear surface.

In treating fracture of the internal condyle, the same angle is advisable, with the forearm so placed that the thumb is upward (semipronation).

Fracture of the *external condyle* is of rare occurrence. The line of cleavage usually commences about the middle of the external condyloid ridge, and runs obliquely to the articular surface, in the groove between the radial eminence and the trochlear surface, or through the center of this surface. The diagnosis is determined by the crepitus, degree of mobility of the fragment, and by the partial loss of function of the extensor or flexor muscles (as the outer or internal condyle is affected).

Fig. 364.—Double condyloid or T-fracture of the humerus. (Helferich.)

For the external condyle, plaster of Paris should be applied, as for fracture of the internal condyle, from the axilla to the metacarpus, with the forearm in supination.

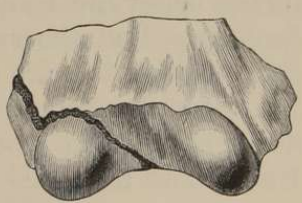

Fig. 365.—Fracture of eminentia capitata and external condyle by force transmitted along the radius from a fall on the hand. (Helferich.)

Separation of the epicondyles is of rare occurrence, and demands no especial mention. The indications for treatment are similar, and the prognosis more favorable than for fracture of the condyles.

In all of these fractures at or near the elbow the surgeon should protect himself always by the most guarded prognosis. On account of the formation of callus, or even the slightest displacement of the fragments, the articular surfaces and the relations which the various bones at the elbow bear to each other are so changed that motion in this complex joint is more or less permanently impaired, and a perfect result is practically impossible. I have seen a considerable number of cases in which

the *eminentia capitata* of the humerus, upon which the head of the radius articulates, has been broken loose, taking with it, as a rule, a part of the external condyle, as the result of a fall upon the outstretched hand, the force applied to the hand being imparted through the radius to the *eminentia capitata*. The callosities in these fractures are, as a rule, extensive and the deformity well marked. The term "gunstock fracture" has been applied to this injury.

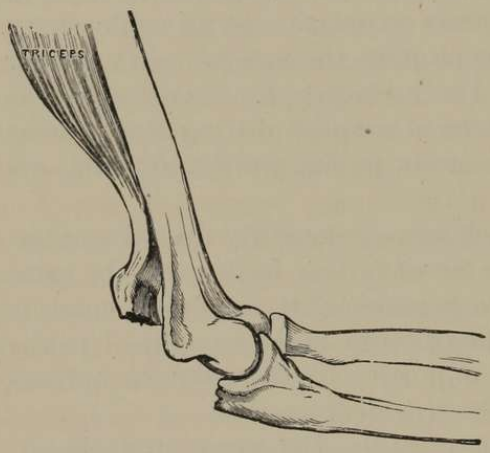

Fig. 366.—Displacement of the upper fragment in fracture of the olecranon. (After Gray.)

Forearm — Ulna. — Fracture of the *olecranon process* usually occurs as a result of a fall on the elbow, when the forearm is in strong flexion. It is occasionally caused by contraction of the triceps. The line of fracture is most frequently at the epiphyseal junction. The displacement is upward, in the line of the triceps (Fig. 366).

The diagnosis may be determined by loss of function, crepitus, which may be obtained when the forearm is fully extended, or by appreciation of the separation of the two fragments.

Treatment.—Extend the forearm to the fullest degree consistent with comfort. Make a soft-board splint, two or three inches wide, and long enough to extend from within two inches of the carpus to the same distance from the axilla. Cut a deep notch on either side, three inches below the level of the line of fracture. Pad the splint with batting, making it twice as thick in the bend of the elbow as elsewhere, and wrap it with a roller. Lay the splint on the anterior surface of the arm and forearm, and secure it near the ends by several turns of the roller. Next, take a flannel bandage (on account of its elasticity), and, commencing below, cover the forearm and splint by circular turns until the notch is reached, at which moment the roller is carried well above the upper fragment, around the posterior aspect of the arm, and down again, to be secured in the notch on the opposite side of the splint. This oblique turn is repeated until the fragments are in apposition, when the whole is secured by as many circular turns as are needed (Fig. 368). Within a week the fracture should be inspected, by

Fig. 367.—Hamilton's olecranon splint. (After Hamilton.)

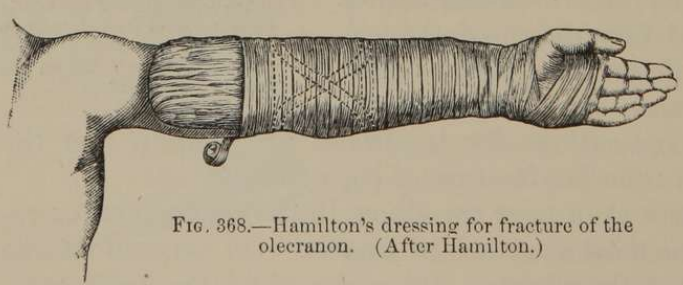

Fig. 368.—Hamilton's dressing for fracture of the olecranon. (After Hamilton.)

removing a portion of the dressing, and additional turns applied if any separation has occurred. After five or six weeks the splint should be removed, and careful passive motion made, while the fragments are supported by the operator. The union is apt to be ligamentous.

Fracture of the *coronoid process* is exceedingly rare. The diagnosis is difficult—often impossible. If the lesion is strongly suspected, secure quiet by applying a splint in extreme flexion.

Fracture of the ulna, in its shaft, occurs in the effort to ward off a blow, or as a result of a fall directly upon the bone.

The diagnosis is usually not difficult, even when displacement is slight. In suspected fracture of one of the bones of the forearm, if compression be made by grasping both bones at a point remote from the suspected break, and pain or abnormal mobility be caused at that point, the diagnosis of fracture is fairly clear. If crepitus is obtained, all doubt is dissipated.

Displacement of the upper fragment is always slight. The lower may be drawn toward the radius by the pronator quadratus. The obliquity of the cleavage, and the direction of the force which produced the lesion, will almost always determine the displacement.

Radius.—Fracture of the radius above the bicipital tuberosity is one of the rarest forms of injury, and, when present, is with great difficulty recognized. The cause is direct violence. Displacement of the upper fragment will be slight, unless the fracture is complicated with a dislocation at the radio-humeral joint. The action of the biceps will tend to draw the lower fragment forward. The best position for treatment is to flex the forearm on the arm, with the palm turned upward, and to apply an anterior splint, wider than the arm, and provided with an interosseous pad. If the displacement forward is extreme, a compress may be employed.

Fracture of the radius between the bicipital tuberosity and the insertion of the pronator radii teres is also usually from a direct blow, although it may result from a fall on the hand, or from muscular action.* While the obliquity of the line of fracture will in great part determine the displacement, the tendency is for the lower fragment to be carried toward the ulna by the conjoined action of the pronator quadratus and pronator radii teres muscles, while the upper fragment is rotated outward by the biceps. When the bone is broken below this point the lower fragment tends toward the ulna. The upper may be held out by the biceps, or carried toward the ulna if the pronator radii teres is contracted (Fig. 369).

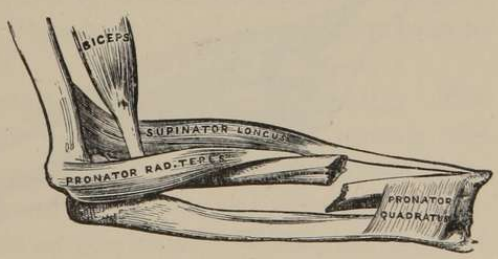

FIG. 369.—Displacement of the fragments in fracture of the radius in its lower third. (After Gray.)

Treatment.—The position which renders the approximation of the fragments most easy is that of supination; but in this position the two

* Packard, in Ashhurst's "Encyclopædia," vol. iv. William Wood & Co., New York.

bones are almost in apposition, and the danger of osseous union between them, with loss of lateral motion, is increased. For this reason it is safer to fix the limb halfway between supination and pronation (with the thumb pointing upward). (The application of the splint is the same as for fracture of both bones.)

Fracture at the Carpal End of the Radius.—Fracture through the cancellous expansion of the lower end of the radius is the most frequent of all fractures; that of the clavicle next in order. The line of fracture is in general transverse, and within one inch of the articular surface, being usually nearer the anterior margin of the articular surface, and running obliquely upward, on to the dorsal aspect of the bone, at a distance varying from one fourth to one inch above the posterior lip. In very exceptional instances the posterior lip or rim is split off, the line of fracture leading from the articular surface upward, on to the dorsal aspect of the bone (Barton's fracture). The styloid process is also occasionally broken off, or, when the violence of the fall is great, the bone may be split in its long axis by the first impact of the carpus, and afterward transversely fractured by the forced extension and strain on the anterior ligaments.

Though a fall on the back of the hand has been known to produce a transverse fracture of the cancellous expansion of the carpal end of the radius in a few instances, in the vast majority of cases the force is first received upon the palmar aspects of the fingers and the palm, with the hand in forced extension.

The mechanism of this lesion is this: In the act of falling, the hand is thrown out, and the force of the fall is received first upon the palm, and chiefly upon the anterior extremity of the metacarpus, whence it is transmitted backward to the carpus, and to the anterior radio-carpal ligaments. As the extension is continued, the strain on this ligament is increased, until the bone begins to yield on its anterior aspect, close to

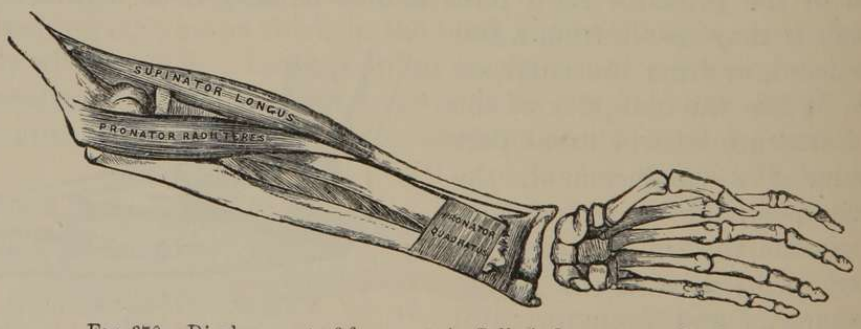

Fig. 370.—Displacement of fragments in Colles's fracture. (After Gray.)

and parallel with the radial attachment of the ligament, and, as the force is continued, the line of fracture travels upward and backward. The same force which produced the fracture by forced extension and impact of the body will, if continued, produce the usual displacement, causing the lower fragment to ride backward upon the upper, and frequently causing impaction of the compact posterior rim of the upper, into the spongy substance of the lower fragment (Fig. 370). With the upward

displacement of the lower fragment, the strong fibrous band spread over the dorsum of the radius at its carpal extremity, the function of which is to hold the extensor tendons in position, is torn loose, and frequently raised half an inch or more as it is continuous upward with the periosteum of the radius (Fig. 371). It is this band of fibrous tissue, together with the partial impaction of the fragments, which makes reduction difficult, and in some instances impossible, by direct extension and counter-extension.

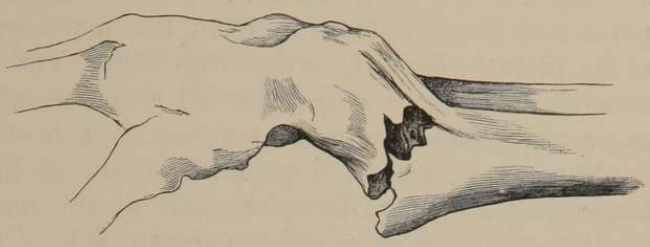

FIG. 371.—Colles's fracture, showing the fibrous band which prevents reposition.

Treatment.—When, after careful examination, there is found any degree of displacement of the lower fragment, upward and backward upon the upper, proceed as follows:

With the back of the patient's hand turned upward, the operator with one hand grasps the forearm in such a way that, while the radius is firmly held, the thumb is immediately above the line of fracture. With the other, the hand of the patient is grasped so that his (the surgeon's) thumb (or index finger, if preferred) presses firmly upon the back of the lower fragment. The hand is now carried strongly back toward the dorsal aspect of the radius (forced and extreme extension), and while in this position the lower fragment becomes unlocked, and may be pushed into place by the thumb, while at the same time the hand, under strong extension, is carried into the straight position. If this manœuvre fails it should be repeated, *and under ether if there is great pain or muscular resistance.* Too much stress can not be laid upon this. The cause of so much deformity after this accident is in many cases due to imperfect reposition. If no displacement exists, extension or the employment of any force is contra-indicated. Surgery is indebted to Prof. L. E. Pilcher, of Brooklyn, for his contributions to this important subject.

In many instances, however, deformity will inevitably remain. The shortening which may result from the accident, or, in the young, the injury to the epiphysis, which may retard the growth of the bone in its long axis, causes a deflection of the hand to the radial side, and an abnormal projection of the styloid process of the ulna. When, as in some exceptional instances, the radio-ulnar ligaments are torn, and, as described by Prof. Moore, of Rochester, the tendon of the extensor carpi ulnaris is displaced, the tendency to deformity is even greater. When proper reduction is obtained, any dressing which keeps the parts at rest will secure a good result.

The diagnosis of Colles's fracture is not difficult. The silver-fork deformity which results from the backward and upward displacement of the lower fragment, the history of the accident, and pain at the seat of injury point to the character of the fracture. Crepitus may not always

be elicited; the hand is directed toward the radial side, and the styloid process of the ulna is unusually prominent. After reduction has been accomplished, a most satisfactory dressing is a snugly fitting gauntlet of plaster of Paris, extending from the metacarpo-phalangeal articulation to six inches above the wrist (Fig. 372). The patient should be advised to move the fingers of the affected side a number of times daily, in order to prevent adhesions of the tendons to their sheaths. If plaster of Paris is not at hand, a padded posterior splint of light board or heavy pasteboard may be placed from the end of the metacarpal bones back near to the elbow, with a short anterior splint, extending halfway in the palm of the hand, snugly adjusted with a roller bandage or adhesive plaster. An extra wad of cotton placed between the splint and the dorsum of the metacarpus fixes the hand in semi-flexion, in which position the extensor tendons are kept tense and aid in preventing redisplacement of the lower fragment.

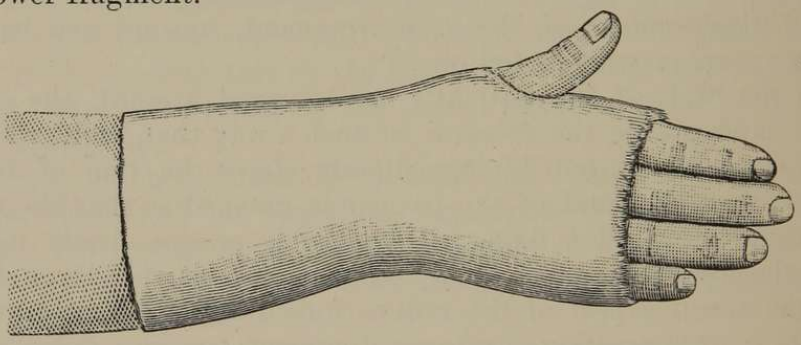

Fig. 372.—Plaster-of-Paris dressing for Colles's fracture.

Fracture of the styloid process, and longitudinal fracture, should be treated by the gypsum dressing.

In fractures of both bones of the forearm proceed as follows: Prepare two splints of thin board, one, the posterior, to extend from within one inch of the olecranon to the ends of the fingers; the anterior to extend from the elbow to the carpus; both wider than the forearm at every point. Pad these with some soft material, considerably thicker in the center than elsewhere, to serve as an interosseous pad. Wrap each splint with a bandage to hold the padding in place. An assistant grasps the patient's hand and arm above the elbow, and, with the forearm at a right angle to the humerus, held in a position halfway between supination and pronation, makes steady extension, while the operator makes a careful reposition of the fragments. Apply the splints so that the interosseous pads will push the muscles down and between the radius and ulna. Then fasten them by a bandage made tight enough to prevent slipping. If, in the course of a few days, the dressing becomes loosened, it can be tightened by applying an additional roller. The forearm is carried in a sling. The treatment should be continued for about four weeks, when passive motion at the elbow, and supination and pronation, should be made, and the dressing readjusted for another week. This simple dressing is sufficient for all fractures of one or both bones of the forearm (excepting Colles's or Barton's).

Compound fractures of the bones of the forearm require fixation by this method, and the security of open wounds, free drainage, and strict antisepsis.

Carpus—Metacarpus—Phalanges.—Fractures of the carpus occur from great and direct violence, being almost invariably compound. The treatment should be fixation, rest, and drainage under antiseptic precautions.

The metacarpal bones may be broken by direct violence or by blows or falls on their distal ends. This fracture is not uncommon with boxers. I had under observation three brothers, professional pugilists, each of whom had a metacarpal fracture, and one of whom had also a fracture of the radius, all received while sparring. In the young, in rare instances, separation may occur at the epiphyses, which are at the phalangeal extremities of the metacarpal bones of the fingers, and at the carpal extremity for that of the thumb. The fracture of a metacarpal bone, broken by indirect violence, is usually situated in its middle. The accident is recognized by pain, displacement, or crepitus. The treatment is reduction by extension and counter-extension, with direct manipulation and the application of an anterior splint, padded and arched so as to fill the concavity of the palmar aspect of the bone, and to extend to the end of the finger. A posterior splint is also applied, both fastened by a roller. The danger is from fixation of the extensor tendon as a result of inflammation. Passive motion of the finger every day will prevent this result. In epiphyseal separation the treatment is the same but the prognosis is not so favorable.

Fractures of the Phalanges.—In the treatment of fractures of these bones the same principles are involved as for the metacarpus. The chief precaution is to prevent stiffening of the finger from adhesion of the tendons to their sheaths. Passive motion should be made as early as the sixth day.

The Sternum—Ribs—Vertebræ.—The *sternum* may be broken by direct or indirect violence. In recent cases reposition may be effected by pressure, or by lifting with an elevator. In the treatment of these cases the most perfect quiet should be enforced.

Fracture of the *ribs* or of their *cartilages* may result from (1) indirect violence, as a blow upon the sternum; (2) from a direct injury; or (3) from muscular contraction.

The longer ribs are most liable to fracture. When the force is applied to the sternum, the break most frequently occurs at or just anterior to the middle of the bone.

The displacement is usually slight. Hæmorrhage from division of the intercostal vessels is one of the immediate dangers, while localized inflammation of the parietal pleura is inevitable. The diagnosis will depend upon pain, elicited by pressure on the bone at a point remote from the fracture, and occasionally by a peculiar click or crepitus felt by the hand applied over the lesion during a full respiratory act. The respiratory movement is less free upon the affected side.

Treatment.—Fixation of the chest wall, as far as is possible, is the

indication in treatment. To this end, the affected side should be shaved, and adhesive strips, cut one inch and a half in width and long enough to reach from the sternum to the vertebral spines, are tightly applied, extending far enough above and below the broken rib to cover the three or four adjacent bones. The strips should overlap about one half of their width.

The body of a *vertebra* may be broken by indirect violence, as a fall from a height, the patient striking on the head, feet, or buttocks, or the bone may be crushed by extreme flexion or extension (occasionally due to muscular action), or by direct injury, with or without penetration. The character of the injury, the displacement of the spines, pain, and symptoms of pressure upon the cord or nerves will lead to a correct diagnosis.

The treatment of fractures of the vertebral column has attracted much attention within recent years. In 1896, before the Surgical Section of the American Medical Association, I gave my personal experience in surgery of the spinal cord, embracing a number of cases of fracture of the vertebra with compression, which had come under my observation. Among them was the case of G. W. V., male, thirty-one years of age (Fig. 373), who, April 19, 1888, while working at the bottom of an elevator shaft, was struck by the descending car on the head and shoulders and violently doubled over forward, resulting in fracture of the eleventh and twelfth dorsal and first lumbar vertebræ. There was immediate paraplegia, the bladder and rectum being involved in the paralysis. For six months he remained helpless in bed without treatment. At the end of this time I saw him. He was still suffering from paraplegia from the navel down, and could not control his bladder, which overflowed unless he was catheterized, nor his bowels, which moved involuntarily. I treated him with forced extension, using a plaster-of-Paris apparatus which I devised, and which he wore for more than a year. It consists of a zone or girth of plaster of Paris which, snugly applied, extends from the point of fracture up to the axilla, and of a second zone, the upper margin of which is at the point of fracture and catches on the expansion of the hips below. Into these zones, at three different and equidistant points, are placed iron staples, worked into the plaster dressing. When the plaster hardens, extension bars are placed in the staples, and these by key and ratchet lengthened, thus

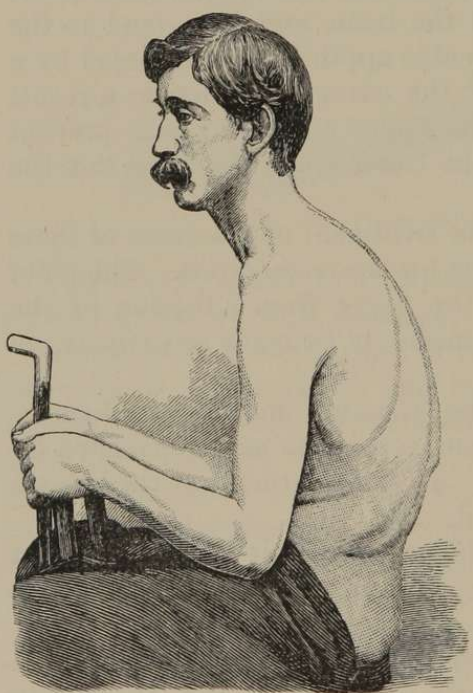

Fig. 373.—Fracture of the vertebræ. Case of G. W. V.

forcibly lifting the superincumbent weight from the point of fracture. He improved gradually under this treatment, and now, nearly ten years after the accident, is able to walk with the aid of a cane, but has a shambling gait, has not recovered the function of the bladder, and is at times troubled with trophic sores over the sacrum.

There were two cases of fracture of the *cervical vertebræ*, in one of which, as a result of a fall upon the back of the head, the fifth cervical vertebra was crushed and the spinal cord divided at this level. Paralysis from the level of the nipples down immediately followed, and symptoms of interference with the phrenic nerves. Four days after the injury I removed the laminæ and spines of the fourth, fifth, and sixth cervical vertebræ. The fifth was fractured near the junction of the two laminæ with the bifurcated spine. One side of the fractured lamina had been driven forcibly into the substance of the cord, crushing it completely, but without penetrating the dura. On opening the latter, the cord was found to be pulpified, but there was no hæmorrhage. The patient was not improved by the operation, and died eight days later from respiratory failure, due to ascending degeneration of the cord, which involved the phrenic nerve. Hypostatic pneumonia developed.

In the second case the seventh cervical was the seat of fracture. The patient was admitted to Mount Sinai Hospital on October 9, 1895. The arms were slightly involved in the paralysis, which was complete from the lower portion of the scapula down. He was placed in bed on the back, and extension applied to the chin and counter-extension to the legs. He was profoundly disturbed as to temperature, respiration, and pulse—to such an extent that operation was not deemed safe. The chart for October 12th, the third day after admission, is as follows. The temperature was taken in the rectum:

October 12th.	Temperature.	Respiration.	Pulse.
1 A. M.	96·0°	12	42
3 "	95·8°	12	44
5 "	93·0°	14	46
7 "	92·6°	16	98
8 "	90·8°	14	45
10 "	92·0°	9	42
12 noon	91·8°	10	36
2 P. M.	91·8°	9	30
4 "	91·8°	9	30
6 "	92·4°	20	35
8 "	93·6°	9	38
12 midnight	95·2°	10	43

In this case the fracture was caused by a fall downstairs, striking on the sacral region. On October 20th, the temperature rose to 103°, respiration 20, and pulse 55. The patient was living, seven months after the accident, with complete paraplegia and partial paralysis of both arms; there were at this date large bedsores over the sacrum, due to trophic disturbance.

In one case fracture was due to a blow from a heavy stone, striking directly upon the spines of the tenth, eleventh, and twelfth dorsal vertebræ. Eight days after the injury I removed the laminæ of these ver-

tebræ, the fragments of which had been driven upon the dura, crushing the cord without penetrating the dura mater. No hæmorrhage outside or inside the dura. The third day after the injury the patient expressed his belief that there was an improvement of motion. This was only temporary, however, and now, nearly a year after the operation, he has complete paraplegia and large trophic bedsores.

In a second case, due to direct violence, a pistol ball with fragments of bone were driven into and completely divided the cord at the level of the junction of the third and fourth dorsal vertebræ. Complete paraplegia followed, and six months after the injury I removed the laminæ of the third and fourth dorsal, together with a rim of lead adherent to these at the point of entrance. There was no improvement, and the patient died of general exhaustion eight months later.

Included in this list are two cases in which complete paraplegia resulted from a fall, with no evidence of fracture, as determined by careful examination, and later by operative interference and removal of the laminæ of the vertebræ at the seat of arrest of function in the cord. In both instances the spinal cord was atrophied, having evidently undergone degeneration. There was a thickening of the dura in each case (pachymeningitis hæmorrhagica externa). Both cases perished ultimately from general exhaustion, and were cases in which, in all probability, hæmorrhage occurred outside the dura from slight injury to the bodies of the vertebræ, compression of the cord and its destruction being due to the hæmorrhage, the clot having ultimately been absorbed.

In one case a young man, twenty-one years of age, was thrown from the cowcatcher of a locomotive; he was picked up unconscious. When consciousness was restored, it was found that he was paralyzed from the iliac spines down, including the bladder and rectum. For seven months he was treated by rest in bed and a plaster-of-Paris jacket. Motion returned to a very slight degree. Seven months after the injury I removed the laminæ of the last two dorsal and first lumbar vertebræ. As soon as he recovered from the anæsthetic it was noticed that there was immediate slight improvement in motion in the feet. This continued, and now, six years after the operation, he has fairly good use of the lower extremities, can flex and extend the legs and thighs, and walks about with a crutch and cane.

There were several other cases of fracture with complete destruction of the cord, some of which were operated upon, others in which operation was not deemed advisable.

Of all the eight cases operated upon, only one died soon enough after the operation to suggest that this was a factor in the fatal result. If properly performed, it may be considered not a dangerous procedure, and, in my opinion, should be done in all cases in which paraplegia, whether partial or complete, has followed the accident immediately or within a few hours, unless the injury has occurred so high up that the profound disturbance of respiration and pulse contra-indicates interference.

One of the most encouraging cases is reported by Prof. R. H.

M. Dawbarn, of New York, in which a girl fell from a height and was immediately paralyzed. Removal of the laminæ was done within five hours of the accident. The cord was compressed by displaced bone, which was removed, the patient completely recovering within a few months, with no evidence of paralysis. Had this patient not been operated upon, the cord would in all probability have undergone degenerative changes within a short period of time, and its function been permanently impaired, even after compression was removed.

When complete paraplegia has existed for several months, owing to the hopeless condition of these cases, an exploratory operation is justifiable, in the hope of relieving, if only to a slight extent, the paralysis from compression.

The prognosis is, however, unfavorable in the vast majority of cases, since the cord is evidently easily destroyed by compression from a fragment of bone which does not penetrate the dura.

The method of operating I employed in each case is as follows:

With the patient in the prone position, reclining somewhat upon one side, in order to interfere as little as possible with the movements of respiration, an incision, the center of which is the seat of lesion, seven or eight inches in length, is made directly over the spines. Retraction should be made by strong hooks, which controls hæmorrhage in good measure; the attachments of the muscles should be scraped from the bones in order to avoid wounding any vessels. In this way the laminæ are finally exposed, divided with a small *rongeur*, and removed one after another until the dura is sufficiently exposed. After the wound is entirely dry, the dura is opened by a sharp-pointed knife, cutting down carefully in the middle line until there is an escape of a drop or more of clear cerebro-spinal fluid. Through this primary puncture a dull-pointed, grooved director should be inserted, and the dura divided exactly in the middle line as far as necessary. When the fluid escapes, the edges of the dura can be held apart by mouse-tooth forceps and the cord inspected. If the latter is touched with the finger, it should be very lightly and carefully done. A light, dull-pointed probe should be passed up and down from the point of opening, to determine whether or not compression of the cord exists above or below. In one instance, following this precaution, I found, as the probe was arrested by the projecting bone, I was an inch below the real point of compression. The dura should be closed by fine interrupted catgut sutures, about three sixteenths of an inch apart, and the muscles of the two sides stitched together with strong catgut sutures. Silkworm-gut sutures are used for the skin wound. It is always wise to leave a twist of catgut projecting from the level of the dura, and out at the inferior angle of the wound, as some oozing is apt to occur which, if not allowed to escape, would exercise compression upon the cord. Most careful asepsis should be practiced. The patient should remain upon the back for the first week or ten days after the operation. I usually dress the wound about the fourth or fifth day. Patients seem to suffer no material inconvenience from removal of the laminæ of two or three vertebræ.

When for any reasons operation is not performed, the patient should be put to bed and extension and counter-extension made from the head and legs. Every care should be taken to prevent pressure sores on the back, buttocks, and heels, and strict aseptic care of the urethra and bladder in drawing off the urine is essential. Later the extension bars, as just described, may be applied, or the Sayre jacket or Shaffer brace.

Fracture of the *articular processes* is of less frequent occurrence. This accident results from extreme extension (dorsal), or may occur from direct or indirect violence.

When the *spinous processes* are broken, the lesion may occur near the extremity, but more frequently the laminated expansion is the seat of fracture.

The indications in all forms of injury to the vertebral column are to relieve pressure upon the cord and nerves, and insure all possible fixation. While, from the anatomical construction of the spinal column, extension is limited and difficult of accomplishment, yet it may be obtained in a sufficent degree to relieve the injured structures from the greater part of the superincumbent weight. When the bodies are injured, dorsal extension throws, in part, the weight from the spongy bodies on to the compact processes.

Fractures of the *sacrum* are rare, and, when occurring, are due to direct violence by penetrating bodies, or to falls from such heights that other and serious complications render the prognosis grave.

No treatment except enforced quiet is called for primarily. When ostitis and necrosis occur as a result of comminution, operative interference may be required.

Fracture of the *coccyx*, with displacement forward, is not uncommon. The accident occurs from a fall or blow directly upon the tip of the spine. The symptoms are those of pressure upon the rectum, causing difficult defecation, proctitis, and at times fissure or ulcer. Pain is always present, and is due to inflammation as well as pressure upon the fifth sacral and coccygeal nerves (coccygodynia). The only treatment is removal of this bone, which is almost always followed by relief.

The incision is made over the bone, in the posterior median line, the muscular attachment being divided close to the bone. Care must be taken to avoid wounding the posterior plexus of veins, or the rectum.

The wound should be thoroughly dried, closed with catgut sutures, and sealed with collodion to prevent infection.

Os Innominatum.—Though rarely fractured as compared with other portions of the skeleton, the ilium, ischium, or pubes may be broken singly, or all may be involved in a common lesion at the acetabulum. The force causing the fracture may be directly applied, or, less frequently, by an indirect blow, as a fall on the foot or great trochanter, in which the head of the femur may be driven into the acetabulum with such violence as to cause fracture.

When the fracture is confined to the iliac crest the diagnosis will be determined by preternatural mobility, crepitus, and pain, in conjunction

with the history of the case. When the bones of the deeper basin are broken, digital exploration by the rectum or vagina will be necessary.

The treatment demands reposition and rest. When the acetabulum is involved, extension to the foot and leg (Buck's method), with the foot of the bed elevated, should be practiced. When possible, the bed should be so arranged that defecation may be accomplished without lifting the pelvis. A modification of Crosby's fracture bed would answer this purpose well. Fixation of one or both thighs, including the pelvis and lower portion of the abdomen and spine, could be well effected by surrounding these parts with a plaster-of-Paris dressing. The prognosis will depend, in great part, upon the extent of the injury sustained by the pelvic viscera. Rupture of the bladder or deep urethra may complicate fracture of the pubic bones. Incision and drainage is essential. Intra-peritoneal rupture will require suture.

Fractures of the *femur* may be best studied in three groups, viz. : (1) of the upper extremity (including the neck and trochanter) ; (2) of the shaft ; (3) of the lower or condyloid extremity.

Fracture of the *neck* of the *femur* may take place wholly within, partly within and partly without, or wholly outside of the capsule. This accident rarely occurs in the young and middle-aged. It is a lesion of old age, and women suffer more than men. The anatomical cause is chiefly a condition of senile rarefaction, which begins usually about the fiftieth year.* It has been demonstrated that the change in the relation of the axis of the neck to that of the shaft in the aged is not enough to account for the greater prevalence of this accident in the old, nor is there a marked diminution of the animal constituents of bone at this time of life. The change is one of senile atrophy.

Fracture of the neck of the femur is usually caused by force transmitted from below upward, and along the shaft of the femur. In many instances the accident is trivial. The specimen shown in Figs. 374 and 375 was taken from a patient who broke her femur while in the act of kneeling in church.† It has been known to occur even while turning over in bed. The line of fracture may be at any part of the neck, and in exceptional cases is through the epiphysis. When the fracture is near the trochanteric line, or when these tuberosities are involved, it is usually the result of direct violence—that is, a fall or a blow upon the hip.

The *diagnosis* of fracture of the neck of the femur may be determined by the study of the history of the symptoms. If, after a fall upon the foot or knee, or directly upon the trochanter, there results *pain* in the hip, *eversion* of the foot, *loss of function* in the member, *shortening*, and *crepitus*, fracture at the neck is probable. These symptoms are, however, not always present. Pain is the most constant, eversion is the

* Prof. L. A. Stimson, "Treatise on Fractures," Henry C. Lea's Son & Co.

† This patient was treated by Dr. Selden, of Norfolk, Va., and, from the history of the case, together with the appearance of the specimen, I consider it an intracapsular fracture, with osseous union. Prof. F. H. Hamilton, to whom I showed the specimen, considered it rather a condition of senile atrophy.

rule, inversion the exception, in about the proportion of eight to one. The turning outward of the leg and foot is probably due to gravity, and when inversion occurs it is due to a peculiarity in the locking or

Fig. 374.

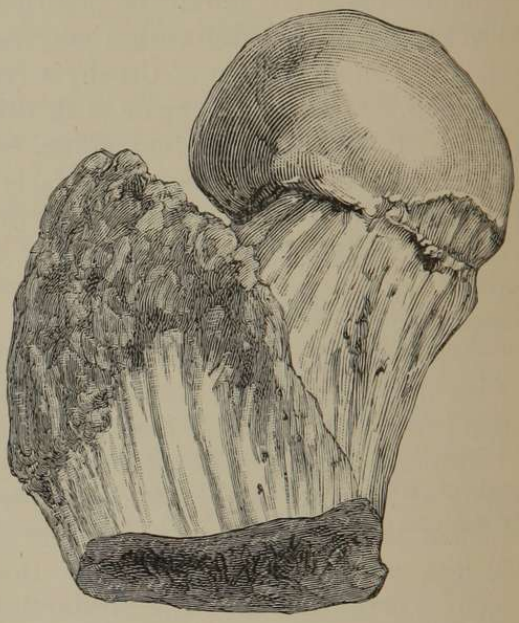

Fig. 375.

overlapping of the fragments. Loss of function is not always entire, for in some instances—and very probably in impacted fractures—the patient has been known to walk a considerable distance upon the limb after the fracture. This is, however, a rare occurrence.

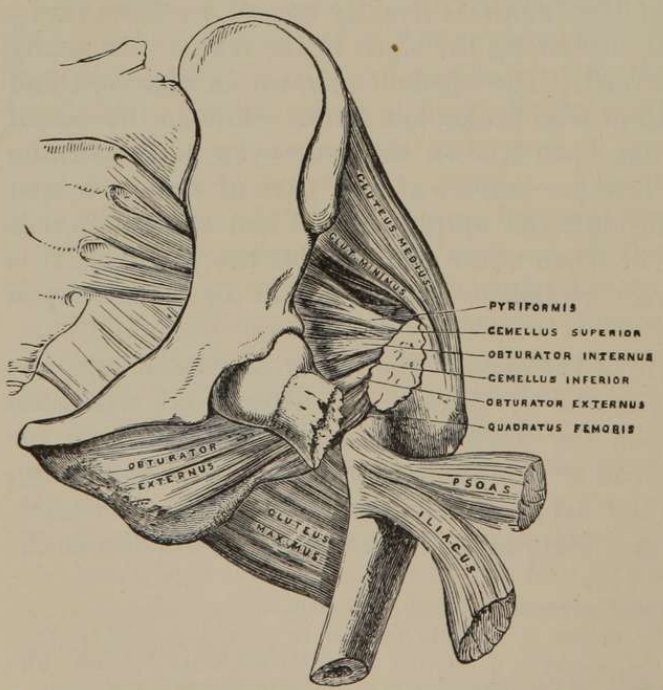

Fig. 376.—Showing the displacement of the fragments in fracture of the neck of the femur. (After Gray.)

Shortening is determined by comparative measurement of the two sides, from the anterior superior spine of the ilium to the inner malleolus. The internal malleoli should be made to touch, and should be directly in a line with the symphysis pubis, umbilicus, and interclavicular notch. The end of the tape should be held on the thumb nail, and pressed well into the notch, just under the anterior superior spine. It is then carried along

the inner side of the thigh, knee, and leg, to the under edge of the inner malleolus. The degree of shortening will vary from one fourth of an inch up to two or more inches. The occasional normal inequality in the length of the two lower extremities should not be lost sight of. This varies from one eighth to, in some instances, as much as one inch and over. To determine that the shortening is between the trochanter and the acetabulum, apply *Nélaton's* test; a line drawn from the tuberosity of the ischium to the anterior superior spine of the ilium passes over the upper surface of the great trochanter. The distance the tip of the trochanter may be above this line will give the degree of shortening. Bryant's test is, with the patient resting upon the back, the legs parallel and extended, to drop a line from the anterior superior spine and to measure the distance between this line, at its nearest point to the trochanter and this tuberosity. If the fracture is above the trochanter the tuberosity will be found nearer the line than on the sound side.

Crepitus can not always be obtained. In the case of impaction it is not possible without the employment of force sufficient to unlock the fragments, and in many cases of fracture above the trochanteric line, without impaction, crepitus is not felt. Any unnecessary manipulation of the hip is contrary to the best rules of practice, and an effort to elicit crepitus should, therefore, not be made.

It is difficult, and at times impossible, to determine at what particular portion of the neck the fracture has occurred. Practically it makes little difference, as the treatment is the same.

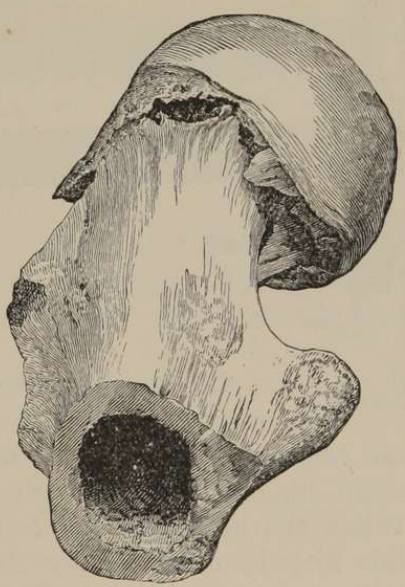

Fig. 377.—Fracture of the neck of the femur, with impaction. (Bigelow.)

Treatment.—Rest in the dorsal decubitus, with fixation of the pelvis and the affected limb, are the immediate indications. In the majority of cases pain is not present, and, since union is scarcely to be expected, the extremity may be held in proper position, and with the least discomfort, by sand bags placed on each side and pressed well up to the injured member. To secure more perfect fixation, extension in a limited degree may be desirable. To obtain this, place the patient upon a hard mattress. If the bed is too soft and yielding, place wide boards underneath the top mattress in order to hold it smooth and firm. Elevate the foot of the bedstead from six to ten inches, by placing the legs at this end upon blocks of wood or bricks. Cut two strips of strong adhesive plaster (Maw's moleskin is preferable) about two inches wide and long enough to extend from the hip to beyond the sole. Lay one of these upon the inner and outer surface of the thigh and leg, exactly opposite each other, and hold them in place by a well-adjusted roller. The strips can be more nicely applied if they are partially divided with the

scissors, in a direction upward and inward, at intervals of about two inches. Six inches below the knee the bandage is interposed between the strips and the integument. In order to prevent pressure upon the malleoli, a stick about six inches in length is placed between the ends of the adhesive strips, and the extension weight is attached to this. It is intended by this method to make the traction from the femur and not from the leg.

A piece of board provided with a pulley is next fastened to the foot of the bed, so that the tip of the pulley will be on a level with the malleoli. The weight will vary from two or three up to eighteen pounds. A pound for every year of life up to eighteen is the rule ; but this is too much for fracture above the trochanter. About ten pounds is sufficient for all ordinary cases. Shot in a bag, or smoothing-irons, are usually employed for the extension weight, which is tied to the string (Fig. 378). The patient's body serves as the counter-extending force, the gravitation toward the head of the bed being about counteracted by the weight attached to

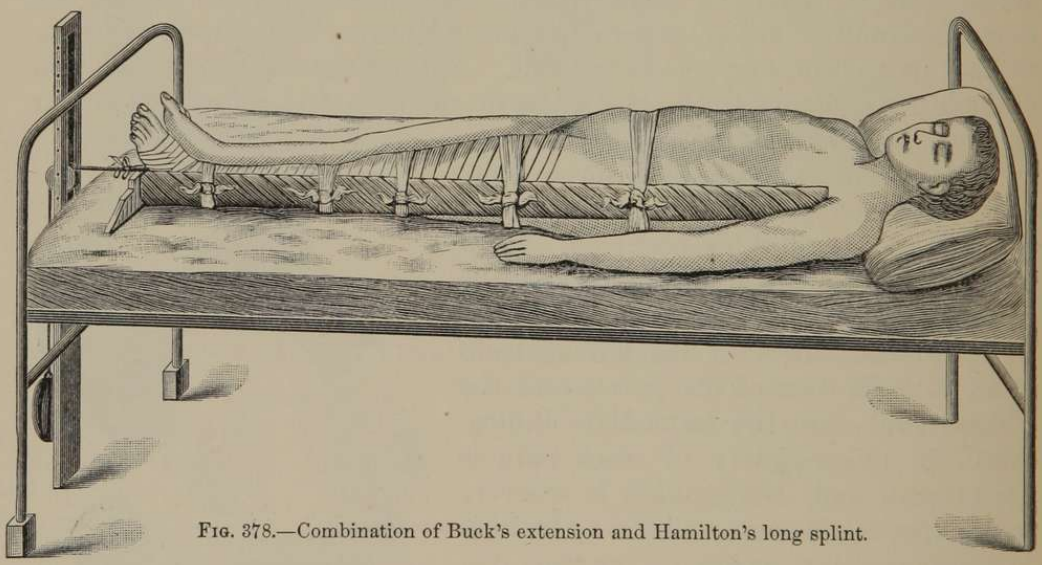

Fig. 378.—Combination of Buck's extension and Hamilton's long splint.

the foot. Additional benefit and comfort may be obtained by laying small, long bags, filled with sand, on either side of the thigh and leg. When the limb tends too strongly to outward rotation (or inversion) this may be corrected by the sand bags, or by Prof. Hamilton's long splint, which is shown in Fig. 378, and which is tied by strips of bandage from the axilla to the ankle. The foregoing is practically Buck's extension, to which may be added Hamilton's long splint.

In some instances it may be found advantageous to use Volkmann's sliding foot piece, seen in Fig. 379. This consists of a posterior splint for the leg, to which is attached a foot piece having the angle shown in the cut. This splint should be perforated for the heel, and rest upon two cross-bars of wood, which in turn slide up and down on a rectangular frame. Upon the upper edge of these parallel bars a tongue is cut, and a corresponding notch or groove in the cross-bars. This apparatus is complicated and will rarely be needed. Buck's extension, with Hamil-

ton's long splint, or preferably the sand bags, will meet almost every requirement, and give the greatest satisfaction.

In order to prevent the bedclothing from coming in contact with the fractured limb, wire screens (Figs. 380, 381) may be employed.

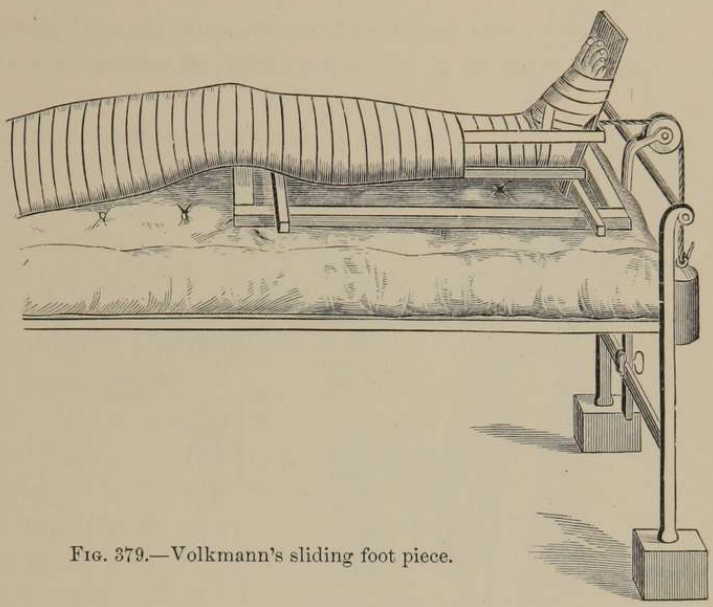

Fig. 379.—Volkmann's sliding foot piece.

The most easily managed and simply constructed apparatus for making the necessary extension and counter-extension, in applying the fixed dressing for fractures of the lower extremity, is made as follows:

Into each end of a table, about five feet long, two holes are bored, and into these two perpendicular pieces are fitted, two feet long and about two inches in diameter, while a strong horizontal bar connects the two upper ends. One of these uprights is smoothed, rounded, and padded, to prevent injury to the perinæum.

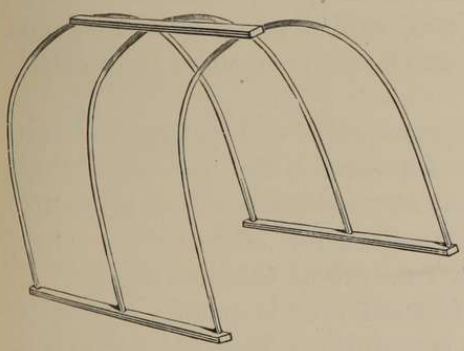

Fig. 380.—(After Esmarch.)

The foot of the injured side being nicely bandaged, the patient is placed upon the table, astride the padded upright (Fig. 382), with the perinæum against it, and is suspended by a strap passed over the horizontal bar and underneath the sacrum, being elevated from the table sufficiently to allow free manipulation of the bandages under the back. The head and shoulders are supported upon pillows, the foot of the uninjured limb rests upon a stool, a clove-hitch or double loop is thrown around the ankle, and to this a block and pulley is attached, the opposite end of which is fastened to the wall. Extension is then applied until, by measurement from the anterior superior spinous process of the ilium to the lowest point of the inner malleolus, the two legs are found to be of the same length. The pelvis, thigh, and leg are then

Fig. 381.—(After Esmarch.)

covered with a dry roller, or a trousers' leg, or piece of soft blanket, and the plaster rollers applied. Accessory splints of zinc, copper, tin, or hoop iron may be worked in with the plaster bandages if desired.

The *prognosis* in this class of cases should always be guarded. Useful limbs result in a large majority of cases, but the function of the hip is not often fully restored.

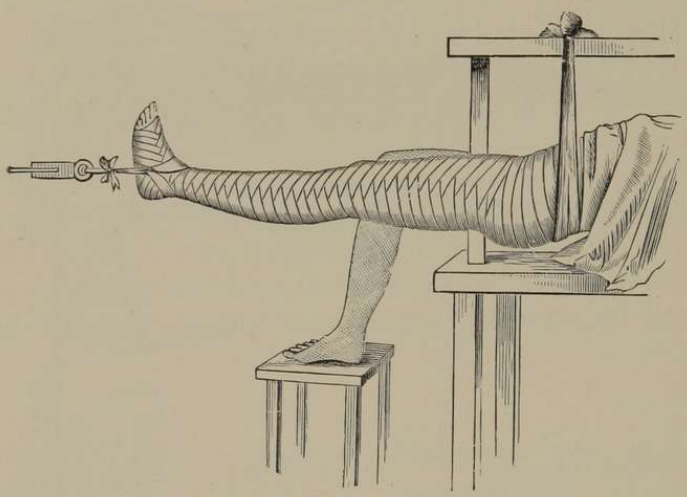

Fig. 382.

Fracture of the Trochanter.—Separation of the great trochanter is a rare accident. The cause is direct violence. A diagnosis must rest upon independent mobility of the tuberosity, with crepitus. The treatment should be fixation, firm compression by bandages, and rest.

Fracture through the Trochanters.—Fracture through the trochanters is also comparatively of rare occurrence. The diagnosis may be determined by shortening, crepitus, pain, and loss of symmetry and function. A strong diagnostic feature is, that a portion of the trochanter may remain attached to the neck.*

Buck's extension with Hamilton's long splints will suffice for treatment in the majority of cases of this fracture. The plaster-of-Paris dressing may be used, but for its application anæsthesia is necessary. The prognosis is more favorable as to restoration of function. Occasionally enormous exostosis occurs after fracture at this locality.

Fractures of the Shaft.—The shaft of the femur is usually broken by direct violence, or indirectly by a force transmitted from below upward. In exceptional instances the fracture is caused by muscular contraction alone. The line of fracture is generally oblique, and the displacement is determined chiefly by the direction of this line. In complete fracture overlapping is the rule. When the break is in the upper portion the lower fragment is drawn up by the long muscles extending from the pelvis to the neighborhood of the knee joint, and, as shown in Fig. 383, the upper fragment is usually rotated outward by the external rotators, and tilted up and to the front by the psoas and iliacus. When the fracture is near the knee joint the lower fragment is tilted backward by the action of the gastrocnemius, popliteus, and plantaris muscles. The upper fragment is acted upon in a milder degree by the same muscles that caused its displacement in the higher fracture (Fig. 384).

Fractures at the condyles may include transverse fracture near the

* Prof. L. A. Stimson, *op cit.*

epiphyseal line, or through the epiphysis proper; transverse fracture, with a split into the intercondyloid notch; or one or the other condyles may alone be broken off.

The *diagnosis* of fracture of the shaft of the femur is not difficult, as a rule. Preternatural mobility, crepitus, pain, and shortening will usually determine the character of the injury. When the joint is involved, in addition to the usual symptoms of fracture the knee becomes much swollen.

Treatment.—In the treatment of all fractures between the trochanters and the knee joint the choice rests between the method by Buck's extension and the plaster-of-Paris dressing. When the fracture is below the middle of the thigh, the plaster-of-Paris dressing is to be preferred and may be applied without anæsthesia, provided that by extension the muscles yield and the fragments come in apposition. The bandages need not extend higher than the level of the perinæum, but should take in the foot. When the knee joint is involved, passive motion should be commenced on the sixth or eighth week, and continued at intervals thereafter. Whatever method is employed, immobilization at the seat of fracture should be maintained for five or six weeks. In all fractures of the thigh, between the middle of this bone and the neck, Buck's extension will be found most generally applicable and satisfactory.

Fig. 383.—Displacement of fragments in fracture of the thigh in the upper third. (After Gray.)

Fig. 384.—Displacement of fragments in fracture of the thigh in the lower third. (After Gray.)

In fracture of the femur in children, the plaster-of-Paris dressing is to be preferred. The reposition of the fragments should be made under anæsthesia, and the parts immediately immobilized. This class of patients are not easily controlled and kept quiet by the use of the ordinary apparatus.* In one instance of fracture at the trochanters in a child just delivered, I placed the extremity in the position assumed *in utero*, the thigh flexed on the abdomen, the leg flexed on the thigh, enveloped the parts with flannel bandages, and applied plaster-of-Paris rollers from the ankle to the axillæ. The dressing was removed on the twenty-first day, and the cure was perfect. There is no shortening or impairment of function, and the child, now ten years old, walks and runs with perfect motion.

* In one instance, in the case of a child three and a half years old, with a fracture at the middle of the thigh, chloroform narcosis was obtained during natural sleep, the child not becoming conscious while passing under the influence of the anæsthetic.

Patella.—Fracture of the patella is usually caused by violent contraction of the quadriceps extensor muscle, or by a blow or fall upon this bone, or both of these factors may combine to cause this lesion. The line of cleavage is usually transverse, and in the majority of instances just below the middle of the patella. It may be broken in an oblique or longitudinal direction, or in several directions at once—"*stellate* fracture."

When muscular contraction is the chief or sole factor in this break, the line of cleavage is usually transverse. Longitudinal and stellate fractures are the result of direct violence. Fracture of the patella is usually complete, the separation of the fragments varying from a small fraction of an inch up to two or more inches. The separation is generally more marked on the internal than the external border. In rare instances incomplete fracture may occur, the cartilage not giving way. Such cases are scarcely recognizable without exploration, the few recorded being seen post-mortem. Fracture of the patella is more frequent in men than in women, and occurs mostly in the decades from the twentieth to the fortieth years.

FIG. 385. — Displacement of fragments in fracture of the patella. (After Gray.)

The *diagnosis* may be made from loss of function, pain at the seat of injury, and separation of the fragments. Inability to extend the leg, or marked impairment of function, is always present. The limb may, however, be used to support the body if it is allowed to fall into the straight position. One of my patients, with a separation of three fourths of an inch, walked, unaided, a quarter of a mile immediately after the accident. Hæmorrhage between the fragments occurs in all cases, and therefore communicates with the synovial membranes, which are interposed between the posterior surface of the patella and the general cavity of the joint, and, in cases where the separation is well marked (from half to one inch and over), it is more than probable that the reflection of the synovial lining, from the lower anterior portion of the joint below the patella upward and forward to the front of the intercondyloid notch, is torn, and that whatever of extravasation occurs is into the general cavity of the joint. This occurred in the only knee I have opened, immediately after this fracture. More or less effusion into the joint follows in the majority of cases. In longitudinal and stellate fractures the separation is usually slight.

Treatment.—A patient with a broken knee-pan should be immediately put to bed, in the dorsal decubitus, the affected limb kept straight, and the foot and leg elevated on pillows. In case of swelling and inflammation at the knee, cold cloths or the ice bag should be applied. The mechanical treatment should commence at once.

Cut a piece of strong adhesive plaster (moleskin is preferable, or, if this can not be obtained, double the ordinary adhesive plaster) about ten inches in length and broad enough to cover the whole front of the

thigh above, fitting snugly above the upper limit of the patella. To the center of this stitch a strong piece of webbing about an inch in width and several inches in length ; a second piece of plaster, somewhat smaller than the first, is applied from the lower limit of the patella and extending down the leg eight or ten inches. To the center of this, at the middle of the *ligamentum patellæ*, a buckle corresponding to the size of the tongue of webbing is stitched with silk thread. With the leg in extension, these strips of adhesive plaster are bandaged snugly to the thigh ; by passing the tongue into the buckle and pulling upon it, the fragments are not only closely applied to each other but the webbing prevents the fragments from tilting. The whole extremity from the perinæum, including the foot, is now invested with plaster of Paris, and a window is made over the knee joint in front so that the fracture may be kept under observation during treatment. From day to day the straps may be tightened as the condition of the patient may demand (Fig. 386). Should the cast become loosened by shrinkage of the limb, a strip of sufficient width should be cut out in front for the whole length of the cast, and an ordinary roller bandage applied to make it fit more snugly. In this way the action of the quadriceps extensor is temporarily paralyzed. In five or six days the patient may move about carefully on crutches, and after he becomes accustomed to the use of these he can walk about and attend to business without danger to the limb. This dressing should remain undisturbed for from eight to ten weeks, at the end of which time it should be removed, and while the fragments are held closely in apposition by the hand of the surgeon, passive motion is made flexing the leg, not farther than twenty-five degrees from the anterior plane of the thigh. A lighter plaster dressing is then applied, and the patient can go another month without its removal, when the same passive motion is repeated, and this should be continued for as much as six months from the date of injury. After this time a posterior splint of light and strong shellac board may be applied in the morning and removed upon going to bed, the patient going about with the aid of a cane. The atrophy of the muscles of the thigh and leg should excite no concern. In fact, the security of firm ligamentous union depends in good part upon this muscular atrophy.

Fig. 386.—Fracture of the patella.

The functions of the muscles and of the joint are fully re-established as soon as the apparatus is left aside and the patient begins to use the limb. The essential point in the treatment of fracture of the patella is to prevent stretching of the filaments of the ligament or fibrous tissue which is to hold the pieces together, and if this is properly attended to, a union will be obtained of such character that the functions of the leg will be practically restored. The failures which have occurred in the treatment of these injuries have been due chiefly to lack of appreciation of this fact. I have treated a good number of cases of fracture of the patella, and by this rigorous method have never failed to restore the usefulness of the limb.

Instead of the shellac splint I have in a number of instances had prepared a legging made of light steel bars, worked in with strips of bandage soaked in glue. These are fitted to a plaster cast of the limb, then cut down on one side and corset hooks attached, so that it may be laced on by the patient.

In an emergency, when this apparatus can not be obtained, the method employed by the late Frank H. Hamilton should be employed. It is as follows:

A posterior splint is made to extend from near the heel to the gluteal fold. Shellac board is best suited for this purpose, but sole leather, gutta-percha, or a piece of plank will suffice, if these lighter articles can not be obtained. If either of the first three articles is employed, the piece should be cut wide enough to envelop from one half to two thirds of the circumference of the limb. Three inches above and below the center of the knee joint a tongue, one inch wide and two inches long, should be cut, and turned out so that the attached end is nearest the joint. This splint is dipped in warm water until soft enough to be molded to the part, when it is lined with a sheet of absorbent cotton and applied on the posterior aspect of the limb. The cotton or padding material should be considerably thicker opposite the popliteal space, in order to prevent complete extension of the leg. Secure the upper and lower ends by turns of the roller thrown around the thigh and leg, and next begin the oblique or approximating turns by carrying a flannel bandage around the leg, so that it catches behind the lower tongue, whence it is carried obliquely upward above the upper fragment, across the quadriceps, and back to the starting point. This is continued until the upper fragment is brought into apposition with the lower. For the lower fragment the bandage is made to catch behind the upper tongue upon the splint. When the fragments are approximated the entire limb is invested by the roller.

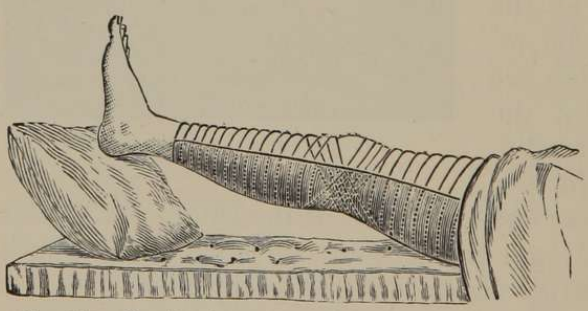

FIG. 387.—Hamilton's apparatus for fracture of the patella. (Hamilton.)

After the dressing is applied the same position is maintained for two

weeks. The portion of the bandage immediately over the fracture should be opened on the fifth or sixth day, and a careful inspection made, in order to determine whether the roller has slipped and re-separation occurred. If the bandage is at all loose it should be tightened, but never drawn so tightly that it produces any discomfort.

This inspection should be repeated every five or six days, but the splint is never taken off until the eighth week, when passive motion at the knee joint should be made.

The after-treatment is the same as just given.

When such satisfactory results can be obtained by the conservative methods just detailed, it does not seem to me advisable to perform the operation of wiring the fragments together, an operation, no matter how skillfully done, not free from danger to the integrity of the joint or limb, and, in rare instances, to the life of the patient. Cases are on record in which amputation was necessary and death followed this operation.

I have had under observation at one time three cases in which the ligamentous union was so firm that a refracture of the upper fragment took place before the fibrous union would give way.

In certain cases of wide separation and loss of function, and in all cases of open wound in which infection has occurred, the operation of wiring is justifiable. It is performed as follows:

Under strict asepsis, an incision is made across the joint opening between the fragments, and all clots removed, with any soft tissues which may have intervened. The fragments are then drilled for a single or double set of wires, as may be determined upon. The drill holes enter obliquely through the fragments half an inch from the margin and come out upon the broken surface about one eighth of an inch in front of the synovial surface. All fluid is now removed by gauze sponges, the wire is twisted, and the fragments brought together. The drills invented by Prof. William F. Fluhrer, of New York, will be found very useful in this operation. The wound should be closed with catgut sutures and sealed without drainage. It is sometimes necessary, when this operation is done for the relief of old cases with wide separation, to divide the insertion of the quadriceps extensor muscle from above, in order to bring the fragment down. A straight splint or plaster-of-Paris cast is applied to hold the extremity immovable. After eight weeks the patient is allowed to move about, and passive motion should be made.

Many cases of wide separation, however, retain the function of the limb in a remarkable degree. In a case occurring in my practice, from which the two accompanying cuts were taken, there is a separation of more than three inches with the leg flexed (Fig. 388), and nearly one inch and a half in extension (Fig. 389); yet this patient has perfect use of the limb. No approximation of the fragments was ever attempted in this patient. He was kept in bed, with the leg elevated, for six weeks, and an ordinary roller applied after this, without any effort of bringing the fragments together.

Longitudinal fractures of the patella should be treated by fixation of the muscles of the thigh and leg, and lateral approximation of the frag-

ments by flannel bandages, well applied over a thin layer of absorbent cotton.

Stellate fractures, in which the air is not admitted to the joint, should be treated by Hamilton's method.

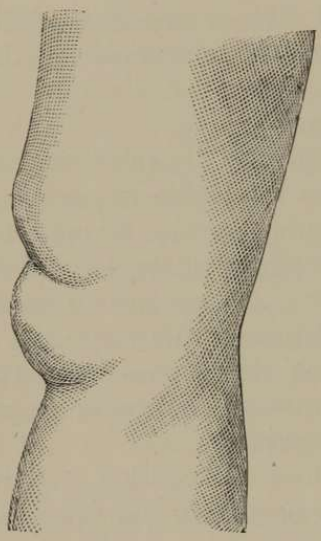

Fig. 388.

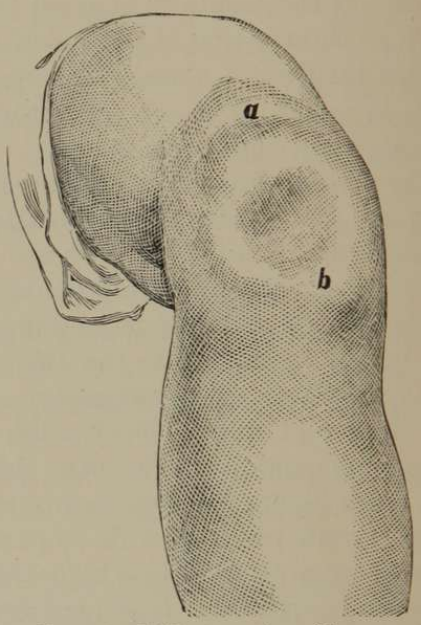

Fig. 389.—Wide separation of fragments (from *a* to *b*) with perfect function of limb.

In *compound* fractures of the patella in which the joint is laid open, the cavity of the joint should be carefully drained and strict antisepsis employed. If the fragments are widely separated, and can not be kept in approximation, strong catgut or fine wire sutures may be employed to hold them in position. Such instances will rarely occur.

Leg.—Fracture of one or both bones of the leg occurs next in frequency to that of the radius, the clavicle, and ulna. The upper end of the tibia is usually broken by direct violence, although a fall from a height upon the foot may produce a longitudinal or oblique fracture communicating with the joint. The separation sometimes takes place through the epiphysis. The most common point of fracture is the junction of the middle and lower third. The fibula may be broken at the same level, or at a point removed from the line of fracture in the tibia, or this last bone alone may be broken.

Near the ankle joint, fracture of the tibia (malleolus) and a complete break of the fibula is comparatively frequent. In this (Pott's) fracture (called also railroad or street-car fracture, since it is often caused by jumping from a car in motion) the foot is powerfully everted, and the principal strain falls upon the internal lateral ligament of the ankle joint. As the force is continued, either the internal lateral ligament or the inner malleolus must yield, and, as usual in this test between ligament and bone, the latter yields. As a rule, a crescent of bone is torn off with the ligament, or the entire malleolus is wrenched off at a higher point. The pressure upon the inner aspect of the external malleolus forces this outward, and the fibula above is bent inward and usually breaks about two

or three inches above the tip of the malleolus. If great force is exercised in the production of this fracture, the inferior tibio-fibular ligament may be torn away, or, more likely, the outer lip of the articular surface of the tibia broken off. In exceptional instances, inversion of the foot will produce fracture of the inner malleolus by direct pressure of the astragalus, and of the external malleolus or fibula by traction on the external lateral ligament.

In fracture of the tibia alone the displacement will be determined by the direction of the line of fracture. Marked overlapping or displacement is prevented by the unbroken fibula. In the upper portion, with a transverse fracture, the deformity is slight. At the lower and middle third the obliquity is usually considerable, and from below upward and backward (Fig. 390). The upper fragment is tilted forward by the action of the quadriceps extensor, and partly by the pressure of the upper end of the lower fragment, which is thrown

Fig. 390.—Displacement of fragments in fracture of the tibia, near the junction of the lower and middle third. (After Gray.)

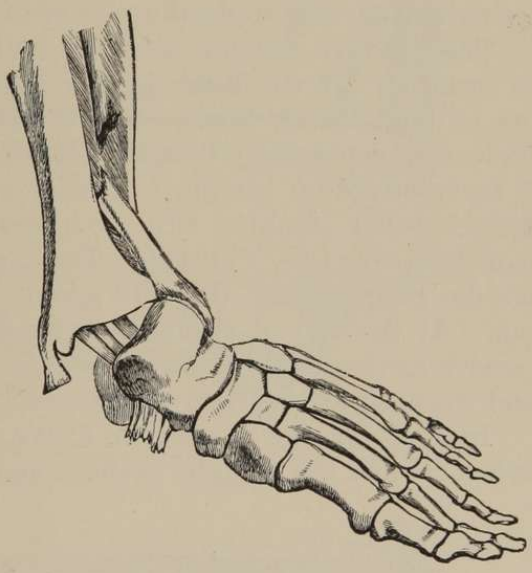

Fig. 391.—Displacement of the fragments in Pott's fracture. (After Gray.)

in the same direction by the contraction of the sural muscles and the consequent lifting of the heel. The deformity in Pott's fracture is shown in Fig. 391. In complete fracture of both bones of the leg, overlapping and displacement are the rule.

Diagnosis.—Fracture of the fibula alone may exist without detection, although a careful examination, with direct pressure, will usually elicit crepitus or reveal the point of fracture by abnormal mobility and pain. Fracture of the tibia is easily made out by palpation along the spine, crepitus, loss of symmetry, and pain. These symptoms, together with the history of the accident, will leave little room for doubt in any case.

Pott's fracture is recognized by the peculiar eversion of the foot, the abnormal prominence of the internal malleolus, pain, and loss of function. Crepitation of the fragments of the malleoli may be elicited, and preternatural mobility of the fibula, at a point two or three inches above the

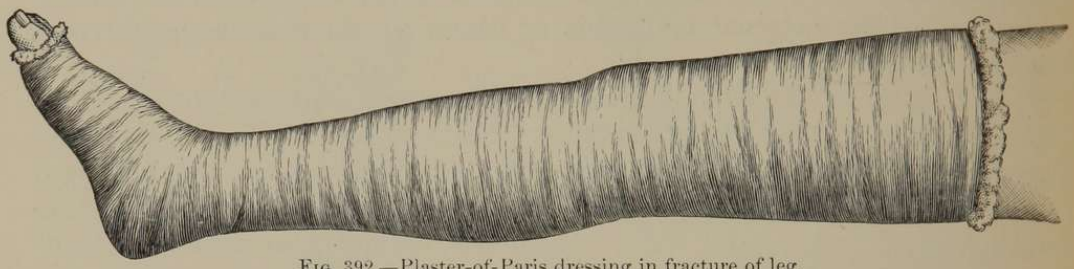

Fig. 392.—Plaster-of-Paris dressing in fracture of leg.

tip of the outer malleolus. In inversion with fracture the outer malleolus is prominent. Fracture of both bones is easily made out by the deformity, abnormal mobility, and crepitation.

Treatment.—In most cases of fracture of one or both bones of the leg it is the best practice to reduce the displacement by extension and counter-extension, and apply the plaster-of-Paris dressing at once.

This should extend at least halfway up the thigh, in all cases, in order to fix the knee joint. It is applicable to all fractures of one or both bones, from the knee down to and including the malleoli. Extension can usually be made from the heel and ankle by an assistant. A layer of cotton batting is placed next to the skin, a dry muslin or flannel roller, making firm compression, is applied, and the plaster bandages over this (Fig. 392). The plaster cast should be split down the middle line, in front, to guard against even the remote danger of swelling. At the end of six or eight weeks all splints should be removed, passive motion made at the knee and ankle, and the apparatus reapplied and worn for at least two weeks more.

In applying the plaster in *Pott's* fracture the eversion needs to be overcome and the straight position maintained while the gypsum is hard-

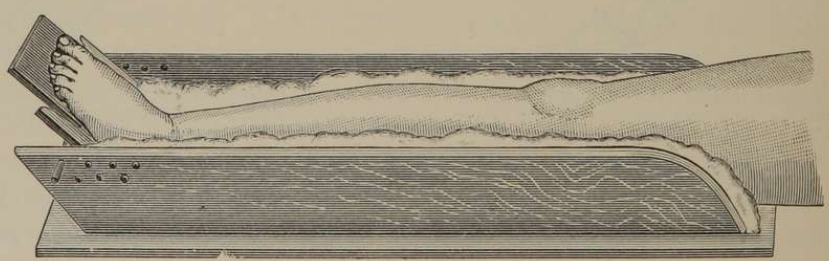

Fig. 393.—Fracture box.

ening. Where the deformity is extreme the foot should be held in a position of slight overcorrection until the cast hardens.

When plaster-of-Paris can not be had, starch is next in order, or splints of felt, leather, bookbinder's board, metal, or wood may be employed. When swelling has occurred the fracture box (Fig. 393) is a most useful apparatus. It consists of a bottom, a foot piece, and two movable

side-pieces. This may be placed upon a pillow or box to give it a slight elevation, or the apparatus may be modified after Petit's box (Fig. 394), since the position of partial flexion is usually more comfortable than full extension.

If any extension is needed it may be secured by a bandage around the ankle and foot, which is also passed through the holes in the foot piece. In fixing the leg in this fracture box the sides are turned down, a thick layer of cotton or some soft material arranged for the leg to rest upon, and shaped to fit the natural contour of the calf. The sides are also packed, turned into position, and fastened. As soon as the first swelling subsides, or as soon as it is evident that no marked swelling would occur, the plaster of Paris should be applied.

Compound fractures of the leg are treated by immediate reduction of the deformity, by free drainage where infection is evident, and strict antiseptic precautions. For perfect fixation, and at the same time leaving the wound open for irrigation and inspection, the interrupted or the fenestrated plaster-of-Paris dressing is the most generally useful. If the injury is slight and limited, the fenestrated dressing is preferable. Extension is made from the foot, and, after reposition and drainage are secured, the plaster bandages are applied. As soon as the dressing sets, windows large enough to permit of free inspection are cut immediately over the wound and at the points of exit of the drainage tubes below. A good-sized twist of sterile catgut should always be preferred to a rubber drain, unless suppuration is present. A wire loop, worked into the plaster or tied around the leg after hardening has taken place, will serve as a medium for suspending the limb at any required height (Fig. 395).

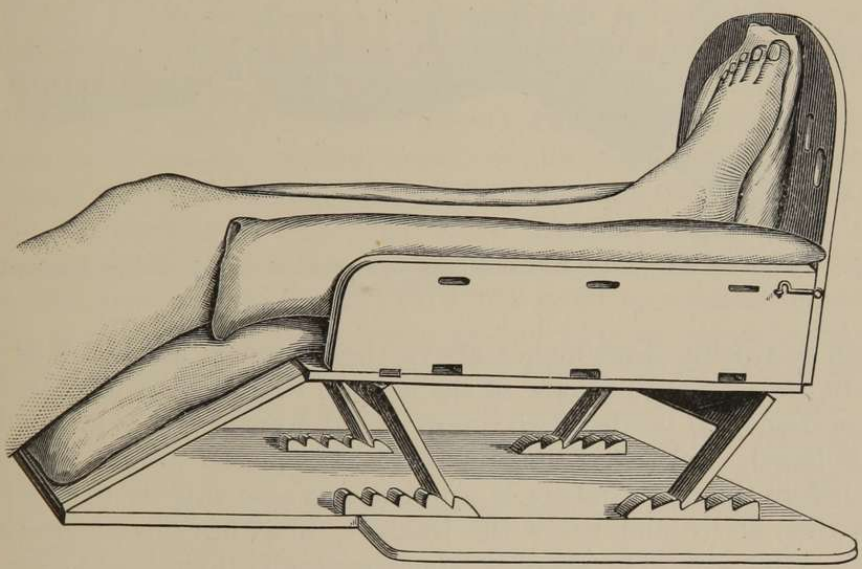

Fig. 394.—Petit's fracture box. (After Stimson.)

The interrupted plaster dressing is less satisfactory and more difficult of application. The entire leg and foot, and halfway up the thigh, are covered with a dry flannel or muslin roller, which passes over the

wound, retaining the sublimate and iodoform gauze in place. A strong piece of bar iron, or two or three thicknesses of hoop iron, or a twist of from four to six ordinary telegraph wires, is now shaped to follow the outline of the foot and leg up to within three inches of the wound and exit of the drainage, at which point it is bent up for several inches, and passes over the wound much like the handle of a valise (see Fig. 396).

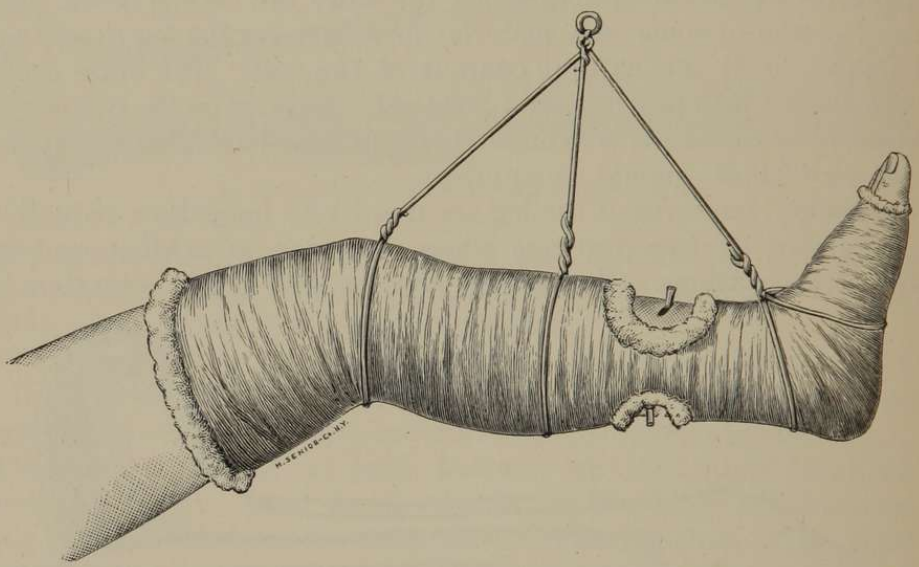

Fig. 395.—Fenestrated plaster-of-Paris dressing for fixation and through-drainage in infected compound fractures.

As soon as a point three inches above the wound is reached it is again made to conform to the shape of the leg and thigh. A separate straight piece of iron, or, if needed, two pieces, about sixteen inches in length, are also prepared. A layer of absorbent cotton is placed around the leg and thigh before the first bandage is applied, and over this the plaster rollers are carried, above and below the fracture, to within three inches of the wound. After several layers of bandage (generally three thicknesses) have been applied, this much is allowed to harden, and upon this the long iron splint is laid, in front, and the short pieces posteriorly and laterally (out of the way of the drainage tubes), and are fixed by additional turns



Fig. 396.

of the plaster bandages and by plaster mortar worked in with the hands. That portion of the bar which is shaped like the handle of a valise should be stiffened by winding around it several thicknesses of the plaster rollers, and adding a sufficient quantity of plaster mortar. Suspension is made from the ends and center of the wire.

The fracture box may be employed when plaster can not be obtained.

Foot.—The bones of the tarsus may be broken by direct or indirect violence.

The diagnosis is not always easily made. The best method of treatment is fixation with a plaster-of-Paris dressing. When the os calcis is broken, and the tuberosity drawn up by the sural muscles, the leg should be flexed well upon the thigh, and the tarsus extended in order to relax this group of muscles, or the tendo Achillis divided.

Fracture of the astragalus is rare. In one instance I removed this bone after a fracture about half an inch from the anterior or scaphoid articulation. The accident resulted from a horse falling upon the foot. The body of the bone was twisted so that the malleolar surface was uppermost.

Fracture of the metatarsal bones and phalanges should be treated in the same manner as the corresponding bones of the upper extremity.

Ununited Fractures—Fibrous Union.—In a certain proportion of cases union between the ends of broken bones is delayed beyond the time usually required for ossification, and may remain permanently ununited.

The *causes* of ununited fracture are: (1) Failure to secure immobility; (2) presence of muscle, tendon, nerve, or other substance between the fragments; (3) violent and prolonged inflammation of the broken bones and the surrounding soft parts in which granular degeneration occurs with considerable loss of bone substance; (4) any intercurrent disease which interferes with nutrition; (5) a too great separation of the fragments. If the ends of broken bones are not kept in contact, and at the same time immovable, fibrous union may result, for by motion the provisional callus is injured, and may disappear by absorption as a result of continued irritation. If the fragments overlap, so that no portion of the broken surface of one side is in contact with that of the opposite end, no matter how well adapted the dressing may be, muscular contraction may retard or prevent union.

The intervention of any of the soft tissues, or any foreign substance, may prevent the formation of callus, and lead to fibrous union.

Ostitis after fracture may lead to destruction of the fragments, and of the shafts of bone, to such an extent that union can not occur. Instances are on record where, resulting from fracture, rarefying ostitis has destroyed the entire bone.

Any general condition of impaired nutrition increases the liability to fibrous union. Rickets, osteomalacia, syphilis, tuberculosis, or any acute febrile disease supervening upon fracture, tends to interfere with or to delay bony union.

When by any reason the broken surfaces are separated, osseous union will probably not occur. This accident and result are exemplified in fracture of the patella, where fibrous or ligamentous union is the great rule.

The *diagnosis* of fibrous union is determined from continued preternatural mobility at the seat of fracture after two months have elapsed. Crepitus is not to be depended upon, as the ends of the fragments may

be rounded off by absorption, and covered over with inflammatory new-formed material, or at times with cartilage.

Treatment.—Any constitutional disease, especially syphilis, or any impairment of nutrition, must be specially treated. In the administration of tonics, cod-liver oil, with the hypophosphites of lime and soda, should play an important part.

It is of importance to fix the broken part immovably by the plaster-of-Paris or other solid dressing. This should not be removed for eight or ten weeks, when passive motion of any articulation near the seat of fracture, and necessarily included in the dressing, should be made. After the first movement of the joint the dressing should be reapplied and the passive motion repeated every second week. Great care should be preserved to prevent motion at the seat of fracture. If, after the lapse of from ten to fourteen weeks, there are no indications of union, a mild inflammation should be induced in the tissues immediately about the fracture. This may be accomplished by forcibly rubbing the ends of the bones together (after an anæsthetic has been administered), and then investing the member with gypsum dressing. In obstinate cases more radical measures may need to be adopted.

With the part rendered bloodless and under careful asepsis, the line of non-union is exposed by incision (usually longitudinal), the soft parts lifted from the ends of the bone, and all new tissue scraped or chiseled from the fractured surfaces. If the broken surfaces are sufficiently extensive, as in oblique fracture of the tibia, a steel drill or nail serves an excellent purpose. While the wound is still open, so that the nail may be properly guided, this is inserted obliquely through the skin and soft tissues in such a way that it is made to pass through one fragment and well into the other, pinning them closely together. The wound should then be thoroughly dried with sterile gauze, closed with catgut and sealed with collodion, also sealing around the nail at the point of entrance through the integument; iodoform gauze next to the collodion covering, and a roller to make firm compression to prevent oozing. The Esmarch should not be removed until the gypsum is applied and the extremity elevated. A plaster-of-Paris dressing should be applied over all, which should remain undisturbed for from eight to ten weeks. When it is removed and the nail withdrawn, passive motion should be made in any joint which has been locked up by the plaster, and the gypsum again applied.

In other cases wiring may be necessary. The ends of the bones are well exposed, the surfaces freshened as above, and a hole drilled about half an inch above and below the line of fracture. Large, soft silver wire is carried through and the ends twisted, bringing the fragments snugly together. When the fractured surfaces are practically at right angles to the shaft of the bone, a single wire may suffice to keep them in apposition; but when the break is oblique, or when, in reuniting bones, a single wire passed through the drill-holes will not suffice to hold the ends in apposition, a circular loop or belt of wire should be used, including in its grasp both fragments.

In certain cases where absorption has occurred, and the fragments are pointed and narrow, the ends may require to be divided with the chisel in order to secure a greater surface for apposition. In a case of ununited fracture of the tibia, three months after the injury, I succeeded in obtaining osseous union by applying a plaster-of-Paris dressing and permitting the patient to bear a certain amount of weight upon the foot, until the fracture gave him a sense of throbbing and pain. The foot was then lifted from the ground by crutches for two or three days, and again used to a slight extent. It was then kept entirely still, and this irritation resulted in bringing about bony union. In wiring the humerus after fracture, the great danger of failure lies in the difficulty of immobilization. In all of these cases plasterof-Paris should be applied from the hand to the shoulder and around the thorax, thoroughly enveloping the upper extremity.

CHAPTER XVII.

SURGERY OF THE ARTICULATIONS.

Dislocations.—A dislocation is the displacement of the articular surface of one bone from its normal relation with another. Dislocations are *traumatic*, *pathological*, and *congenital*. They are also *partial* or *complete*, *simple*, *complicated*, and *compound*.

Traumatic dislocations are sudden, and result from violence; *pathological* when, from disease of the joint, the bones and ligaments are more or less destroyed; *congenital* when, from failure of development, the normal contiguity of the articular surfaces can not be maintained. A dislocation is said to be *partial* when any portion of the articular surfaces are still in contact; *complete* when one articular surface overlaps the other; *simple* when there is no other lesion than displacement and injury of the capsule; *complicated* when there exists with the dislocation a fracture into the joint; *compound* when, by reason of a wound, the air is in contact with the dislocated surfaces. Again, a dislocation may be *recent* or *ancient*, the limit of the former variety being from a few hours to two or three weeks. A *primitive* luxation is one in which the dislocated surfaces retain the same position as at the time of the accident, *secondary* when another position is assumed.

In a dislocation the capsule is almost invariably ruptured. It may occasionally, as at the shoulder joint, be simply stretched without a solution of its continuity. When great violence is employed in producing it, the muscles, tendons, nerves, vessels, fascia, and skin about the joint may be more or less involved. The changes which follow are practically those of acute synovitis, arthritis, or peri-arthritis.

Dislocations occur chiefly in adult life, and are most frequent in those joints which enjoy the greatest freedom of motion, and, at the same time, are subjected to the heaviest strains. The condition of the individual, the tonicity of the muscles, and the strength of the ligaments, have a great deal to do with the frequency of dislocations. All things being equal, patients with poorly developed muscles and relaxed ligaments are more prone to these lesions than the well developed and vigorous.

The diagnosis of a dislocation rests chiefly upon *abnormal immobility* and *asymmetry*. Pain is usually present.

Special Dislocations—Inferior Maxilla.—Displacement of the condyles of the lower jaw, from its articulation with the temporal bone, may occur on one or both sides; usually it is bilateral. The condyles slip

forward and are engaged partly beneath the zygoma, in front of the *eminentia articularis*, and partly between the zygoma and the temporal fossa. Muscular action alone may produce this luxation, or it may be caused by external violence.

The *symptoms* are great pain, difficult deglutition, and indistinct articulation (especially of the labial sounds). The lower teeth are unusually advanced, the mouth is opened, and the saliva trickles over the lips.

In unilateral luxation the chin points toward the sound side, and the teeth are less widely separated.

In the diagnosis the chief point of differentiation is fracture at or near the condyle. In fracture the condyle may possibly be recognized in its normal position by palpation; immobility is not marked; the mouth is not opened; crepitus may be obtained.

Reduction.—In bilateral displacement, wrap the thumbs with several layers of bandage or cloth, to protect them from being bitten when reduction is accomplished. Place one thumb along the inferior molars of each side, and the fingers beneath the body of the jaw; press downward and backward with the thumbs, while the fingers lift the chin upward.

Or place a thick roll of leather, piece of wood, or firm cork, between the upper and lower posterior molars of each side, and upon these, as a fulcrum, lift the chin upward, and at the same time push backward in the direction of the socket.

If both of these methods fail, they should be repeated under anæsthesia. It may sometimes be advisable to attempt the reduction of one side by either of the above methods, and retain it in position while reducing the other.

After reduction is completed put on a head and chin figure-of-8 bandage, and allow it to remain for a week (Fig. 180), or apply Hamilton's head-stall for fracture of the lower jaw (Fig. 354). In several instances, where the dislocation has become permanent, the symptoms have gradually subsided, and a fair degree of motion and usefulness acquired through the false joint.

Clavicle.—The sternal end may be displaced *forward* on the manubrium, *upward* above the sternum, *backward* behind the manubrium. The last two varieties are rare. The cause of the first form is usually force applied to the shoulder with the arm thrown backward. In the case of a boy fifteen years old, treated by myself, the displacement was caused by a comrade catching him by both shoulders, placing his knee in the middle of the back, between the shoulder-blades, and violently pulling the shoulders back.

The diagnosis is not difficult, the reduction easy, but the maintenance of the bone in position difficult. A compress, covered with adhesive plaster to prevent slipping, placed upon the bone after reduction, and firmly held in place by a roller, is a proper method of treatment. The arm should be fixed with Sayre's apparatus for fractured clavicle, in order to prevent a repetition of the luxation.

The outer end of the clavicle may be displaced above or below the acromion process, and above or in front of the coracoid process. Displacements under the acromion and in front of the coracoid are very rare.

The *symptoms* are very distinct, and the reduction not surrounded with great difficulty. When replaced, however, the bone is with difficulty maintained in position. By drawing firmly outward upon the shoulder of the affected side, and pressing the clavicle downward into position, reduction will be successfully accomplished. Place a firm compress over the end of the bone, bend the forearm at right angles to the arm, and carry one or two strong strips of adhesive plaster over the compress, behind the shoulder, along the arm to the olecranon, and again by the front over the compress. Re-enforce this by a bandage, and place the arm in a sling. If luxation recurs, tighten the adhesive strips, and place the arm in a Velpeau's bandage. To apply this bandage, place the hand of the affected side almost upon the opposite shoulder, fixing a wad of cotton beneath each axilla. Lay the end of a roller on the shoulder-blade of the sound side, and carry the bandage over the acromial end of the clavicle of the injured side, and the front of the arm for a short distance, passing obliquely to the under surface at the elbow, and around beneath the well axilla to the point of starting. Repeat this to secure the roller, and then carry the bandage horizontally around the chest and over the tip of the elbow. The oblique and horizontal turns are alternated until the shoulder and arm are completely enveloped (Fig. 397).

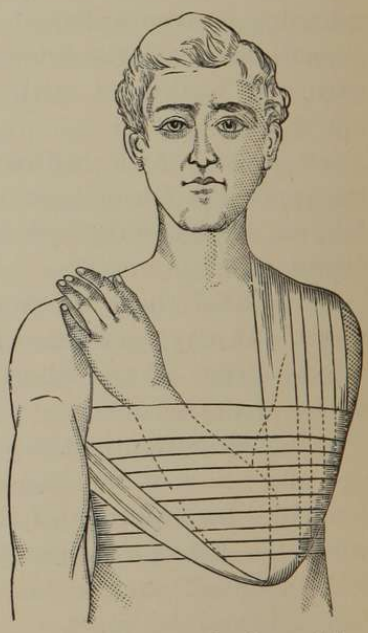

Fig. 397.—Velpeau's bandage. (After Stimson.)

Humerus, at the Shoulder.—Dislocation at the shoulder-joint is by far the most frequent. It may take place in three directions—*backward*, under the spine of the scapula (*subacromial* and *subspinous*); *downward*, below the glenoid cavity (*subglenoid*); and *forward*, beneath the coracoid or clavicle (*subcoracoid* or *subclavicular*).

The first variety is of rare occurrence. The subacromial dislocation is only a partial displacement, and becomes complete when the head of the bone passes well beneath the spine of the scapula (Fig. 402). The subglenoid is more frequent, but not so common as the subcoracoid. Displacement forward under the clavicle is rare. On account of the coracoacromial ligament, and the additional protection afforded to the joint above by the acromion process, dislocation directly upward can scarcely occur.

Subcoracoid and Subclavicular Dislocation.—In the more frequent variety of luxation—the subcoracoid—the capsule is ruptured along the

lower and inner portion, extending to the insertion of the subscapularis muscle. It is caused by violence applied directly to the shoulder from without inward and forward, or to the elbow or hand when the extremity is extended. The head of the humerus rests upon and in front of the inner rim of the glenoid cavity and just underneath and in contact with the coracoid process (Fig. 404). The acromion process is unusually prominent, a depression is felt beneath it, while the head of the bone is seen and felt in an abnormal position beneath the coracoid. The humerus stands stiffly away from the chest at an angle varying from twenty to thirty degrees. The circumference of this shoulder, measured over the acromion and through the axilla, is greater by at least one inch than on the opposite side (Callaway). If the hand of the affected side is placed upon the sound shoulder, the elbow can not be carried down to the chest-wall (Dugas).

According to Kocher—whose researches are based on anatomical as well as clinical demonstrations, the obstacle to reduction is tension of the capsule, especially of the coraco-humeral ligament, with consequent closure of the rent through which the head of the humerus has escaped. If this displacement exists, by carrying the humerus directly down until the arm touches the side of the chest-wall, rotating it outward and then carrying the elbow in front of the chest to the middle line, the capsule is relaxed and the rent is opened. It only remains to rotate the humerus slightly toward the body, when the head slips through the opening back into its normal position.

Dr. Charles A. Powers, of New York, has shown that the recumbent posture is preferable to the sitting position which was original with Kocher. The steps of this method are well shown in the accompanying cuts taken from his article.*

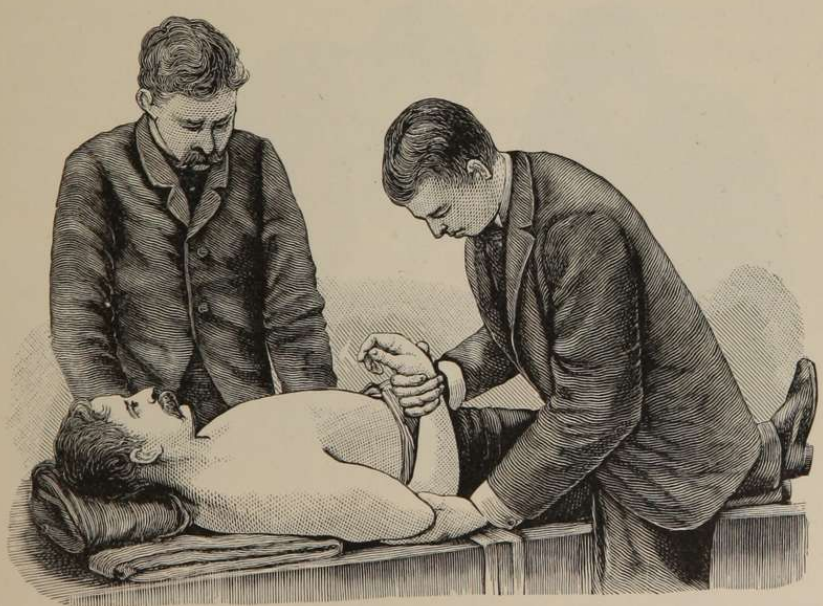

Fig. 398.—First Movement. The elbow is adducted to the body and drawn downward. (The arm and wrist should be firmly grasped, as shown in the figure.) (After Dr. C. A. Powers.)

* "Medical Record," March 30, 1889.

Method.—Place the patient on the back, upon a hard table or the floor, with an assistant holding the shoulder of the sound side firmly down. The operator grasps the member of the injured side at the wrist

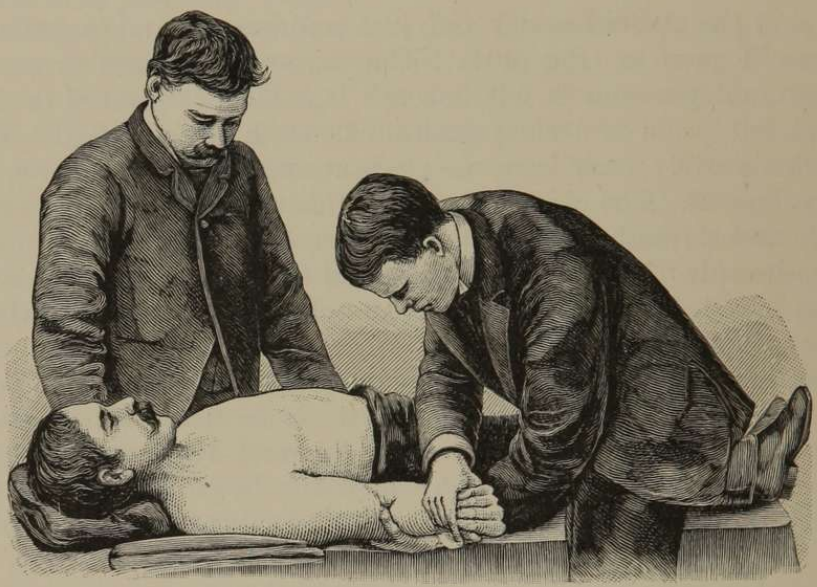

Fig. 399.—Second Movement. The arm is rotated out until firm resistance is met. (Practically until the long axis of the forearm points directly outward.) (After Dr. C. A. Powers.)

and elbow and brings the humerus well against the wall of the chest (Fig. 398). Outward rotation is made until the long axis of the forearm points directly outward (Fig. 399), when the elbow is brought along the front of the chest to the median line (Fig. 400) and the hand of

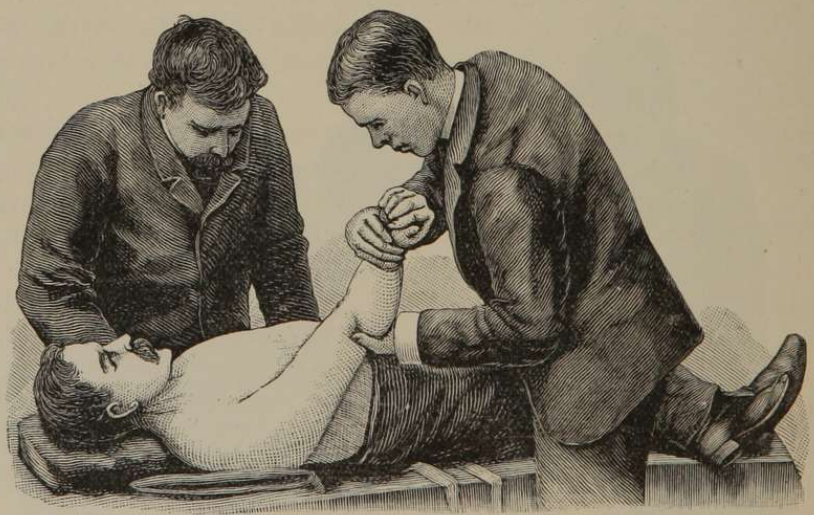

Fig. 400.—Third Movement. With the external rotation of the arm still maintained, the elbow is carried forward and upward on the chest. (After Dr. C. A. Powers.)

the affected side placed on the sound shoulder (Fig. 401). If this fail, repeat the procedure. An anæsthetic is not usually required, but should be given if, after two or three efforts, reduction is not accom-

plished. The method of using the foot in the axilla, as given for subglenoid luxation, may also be tried.

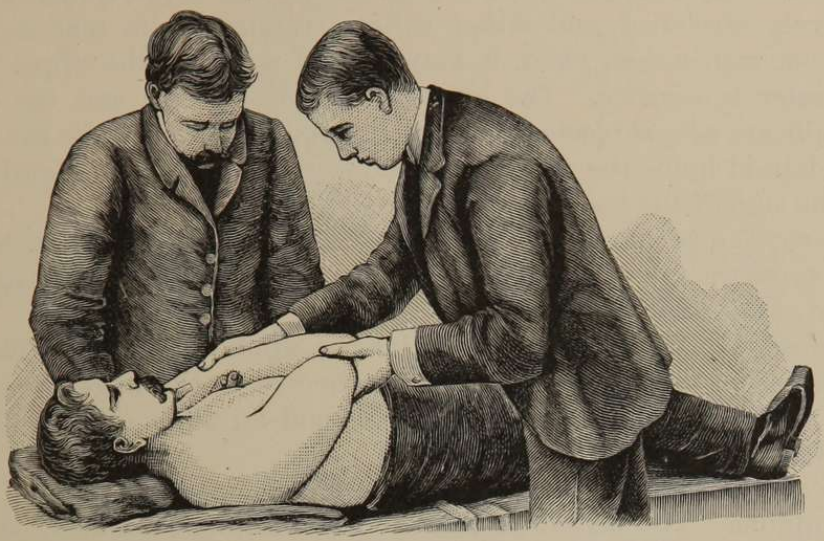

Fig. 401.—Fourth Movement. The hand is placed on the sound shoulder. (After Dr. C. A. Powers.)

The *subclavicular* variety of this forward dislocation is only an exaggeration of the subcoracoid, in which the head of the bone slips underneath and internal to the coracoid, and rests against the serratus magnus and behind the pectoralis minor, below the clavicle (Fig. 401). The causes are the same, and the symptoms differ in little else than the presence of the head of the humerus nearer to the clavicle. The arm stands slightly out from the body, and the elbow is tilted backward. The tension on the posterior scapular muscles is greater, and rupture of their attachments often occurs, while the anterior insertion of the subscapularis may be dissected up. Pressure on the axillary vessels and nerves is more marked in this luxation. Reduction may be effected by the means just described.

Subglenoid Dislocation.—In the subglenoid luxation the capsule is stretched or torn along its lower surface, and the head of the humerus rests upon the margin of the glenoid cavity in a partial dislocation, or, if

Fig. 402. Subacromial and subspinous. (Bryant.)

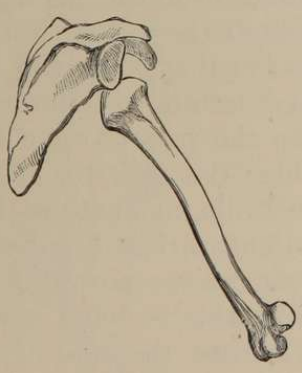

Fig. 403. Subglenoid. (Bryant.)

Fig. 404. Subcoracoid. (Bryant.)

Fig. 405. Subclavicular. (Bryant.)

the capsule is torn, it (usually) slips in front of the long tendon of the triceps, and is lodged upon the axillary border of the scapula, immediately below the articular surface (Fig. 403). The supra-spinatus muscle is severely stretched, and either suffers rupture of its tendon or substance, or, rather than yield, it may tear off a rim of the upper facet of the greater tuberosity. The long head of the biceps and the coracobrachialis are also subjected to great strain or rupture, while the tension of the deltoid holds the arm in a position with the elbow slightly tilted from the side of the body.

Among the less frequent complications of this lesion may be mentioned pressure upon the circumflex and axillary nerves, and injury or rupture of the great vessels.

The cause of this dislocation is violence applied to the shoulder in a direction from above downward, or indirectly to the hand, forearm, or elbow, with the humerus raised at or beyond an angle of 90° to the axis of the trunk.

The *diagnosis* of a subglenoid luxation will depend upon the following symptoms: The acromion process is unusually prominent, the head of the bone is not in its normal relation to this process, and may be felt low down in the axillary space. There is a depression in the anterior axillary fold in these subjects. The arm is fixed in such a manner that the elbow is directed outward from the side of the body (Fig. 406). As in all the shoulder dislocations, the arm is so held that, if the hand of the injured side be placed on the opposite shoulder, the elbow can not be made to drop down upon the wall of the thorax. This, the test of Dugas, is important in differentiation from fracture in which there is such a considerable degree of motion possible that the arm can be brought well down upon the chest. There is always preternatural immobility in a dislocation. Another excellent method of differentiation is that of Callaway, based upon the fact that the circumference, measured over the acromial end of the clavicle and the acromion, and through the axilla, is in a dislocation much increased over the normal, or over that present in fracture at the neck. Crepitus, when obtained, will determine a fracture.

Fig. 406.—Subglenoid. (Bryant.)

Reduction—First Method.—Place the patient upon a table, bed, or upon the floor. For the left shoulder the operator removes the shoe from the left foot and places it in the axilla, against the thorax. He now seizes the arm and forearm of the patient, carries it out at a right angle to the axis of the patient's spine, and makes powerful traction in the direction of the glenoid cavity. While this is being effected the arm is brought inward, parallel with and against the side of the body (Fig. 407). The foot not only serves to effect counter-extension, but is also used as a fulcrum for lifting the head of the bone over the edge of the

glenoid facet into the articular cavity of this process. If this can not be accomplished without ether, after one or two trials the anæsthetic

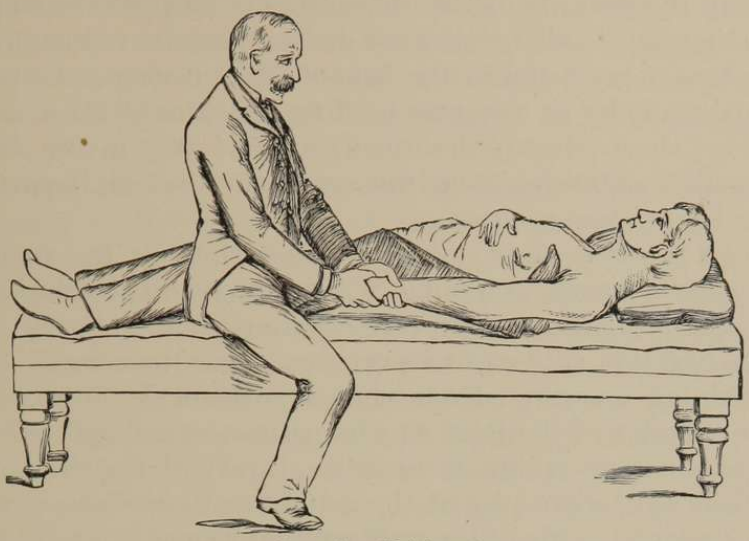

Fig. 407.—(Erichsen.)

should be given. After reduction a shoulder-cap of book-binder's board, leather, or gutta-percha should be applied, and worn for at least one week.

Second Method.—Fix the scapula by placing a folded sheet or long cloth around the body, so that the upper margin of the cloth will touch the axillary folds. The ends are intrusted to an assistant, who, standing on the sound side, makes counter-extension. The surgeon now takes hold of the arm about its middle with one hand, and near the elbow with the other, and carries it slowly and steadily away from the body, and in the direction of least resistance. When it is at a right angle to the axis of the body, strong traction is made, with slight axial rotation. If the manœuvre is still unsuccessful, carry the arm higher, until extension is made in the line of the axillary border of the scapula (Fig. 408).

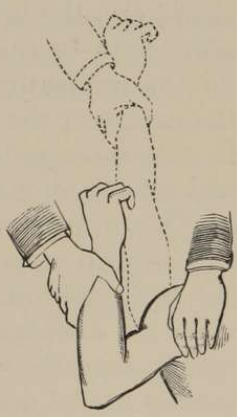

Fig. 408.—(Bryant.)

Fig. 409.—(After Hamilton.))

Third Method.—Place the patient in a chair, so that, with the foot of the operator on the edge of the seat, his knee will come snugly into the axilla. Place one hand upon the shoulder to steady it, while the other seizes the arm near the elbow. With the knee as a fulcrum, use the hu-

merus as a lever, which, being depressed, carries the head of the bone into position (Fig. 409). Extension from the forearm, and counter-extension through the medium of the opposite arm, may also be employed.

The *subacromial* and *subspinous* dislocations are reducible by extension and counter-extension in the line of displacement. Counter-extension may be made by an assistant holding the arm of the sound side, or by the folded sheet (already described) applied just in the axilla. The operator makes extension from the arm and forearm, imparting to the humerus a slight axial rotation.

General Considerations.—Recent dislocations at the shoulder may not always be reduced, and some which are readily replaced are with difficulty held in position. Rupture of any muscle, or group of muscles, renders the luxation subject to recurrence, since there is no antagonism to the remaining muscles. Even when reposition is effected and maintained, the function of the joint may be permanently impaired on account of injury to the surrounding structures. Injury of the circumflex nerve has been followed by atrophy of the deltoid and teres minor, while traumatism of the great cords of the axillary plexus and injury of the vessels have led to impairment or loss of function in the extremity. Ligature of the subclavian artery and amputation have been necessitated after dislocation of the shoulder-joint.

These injuries may occur at the time of the displacement, or they may be produced by a lack of skill or the employment of too great force in the efforts at reduction.

After one or two days from the date of a luxation at the shoulder (as elsewhere) the difficulties of reduction increase, and are in general proportionate to the length of time which has elapsed since the accident. At the expiration of the first week inflammatory adhesions occur, and the cavity of the joint is in part filled with the products of inflammation. In rare cases reduction has been accomplished at the end of three, six, and twelve months.

The propriety of attempting reduction in ancient shoulder luxations will depend upon the individual case. It will frequently occur that, in the new position, attachments are formed, with ligaments, cartilage, and synovial membrane, with fair, yet limited, motion in the false joint, which, together with the free mobility of the scapula upon the thorax, gives a useful degree of motion to the arm. Under such conditions any attempt at reposition is unnecessary.

In well-selected cases, where an ancient dislocation can not be reduced by any other means consistent with safety to the tissues about the joint, and where motion is so limited that the usefulness of the arm is seriously impaired, direct incision, under strict antiseptic precautions, may be employed, and reduction thus effected, with or without excision of the head of the humerus. When complicated with fracture of the surgical neck, McBurney's operation of direct incision, drilling the upper fragment just outside the capsular attachment, inserting a hook, and by traction reducing the dislocation, is advisable. The fracture should be treated in the same manner as if no dislocation had existed.

Dislocations at the Elbow-Joint.—The upper end of the radius may be displaced forward on to the anterior surface of the humerus, near the coronoid fossa, or backward upon the olecranon process. The anterior displacement is met with somewhat more frequently than the posterior.

In the displacement forward the orbicular and a portion of the external lateral and anterior ligaments are ruptured; in the opposite luxation only the first two are lacerated.

The *forward* displacement is caused by direct violence applied to the posterior aspect of the upper end of the radius, or by falling upon the palm of the hand, the full force of the contraction of the biceps being thus added to the force transmitted along the shaft of the bone.

Symptoms.—Careful palpation will reveal the abnormal presence of the head of the radius near the center of the humerus, while pressure along the outer condyle will demonstrate its absence from its natural position. The forearm is semiflexed and slightly pronated.

Treatment.—Flex the arm and push the head of the bone forcibly downward in the direction of the articulation. When reduction is accomplished, place a compress over the upper end of the bone and the external condyle, and bind it firmly in position. The arm should be snugly bandaged, and carried in a sling for several weeks.

The *backward* dislocation is recognized by the presence of the head of the bone in an abnormal position near the olecranon, behind the external condyle.

Treatment.—While an assistant makes strong extension and counter-extension from the hand and arm, the operator makes direct pressure upon the head of the bone, forcing it in the direction of the articulation. As the displacement is being corrected the assistant should carry the forearm in a position of supination. The after-treatment consists of a compress and bandage, worn for several weeks.

The *prognosis* of this injury is generally not favorable, since it is very apt to recur after reduction, and may become permanent. A fair degree of usefulness is maintained, however, in many cases of chronic luxation of this end of the radius. The production of a rich callus, more or less permanent, resulting from raising the periosteum as the ligaments are torn is a frequent cause of impaired motion after this injury.

Complete forward dislocation of the ulna alone, at the elbow, can not occur without fracture of the radius or extensive laceration of the radio-ulnar ligaments.

Subluxation of the Head of the Radius.—This lesion is met with usually in children from nine years old and under, and is much more common than complete dislocation at this joint. It is caused by sudden traction on the hand or forearm in lifting a child by a single arm or in saving it in the act of falling.

The symptoms are loss of function, the arm often hanging as if it could not be moved. Motion at the wrist may be, however, free. Pressure over the head of the radius causes sharp pain. Passive flexion at the elbow is permitted to about 60°, when resistance may be met with. Complete extension is also painful. With the forearm flexed at right

angles to the arm, pronation is possible, but is slightly resisted, while supination causes great pain. If, however, this movement is carried to the extreme, a distinct click may be heard and felt at the head of the radius, with which the pain suddenly ceases and free motion is re-established (W. W. Van Arsdale).* Reposition is thus effected. With the patient sitting or standing in front of the operator, he grasps the arm just above the elbow with one hand, while with the other the forearm is seized near the wrist. The forearm is now flexed to an angle of ninety degrees with the arm, and steadily rotated into a position of extreme supination. As above stated, the reduction is accompanied by a perceptible slip or click. A splint should be applied to hold the arm quiet in the right-angle position for four or five days.

The pathological conditions of this lesion are not thoroughly understood. Since it is caused by pulling upon the radius, the cup-shaped articular facet of the head of this bone is evidently abnormally separated from the humerus. One theory is that the soft parts are interposed either by muscular action or by atmospheric pressure, while another holds that the edge of the head of the radius is slightly locked on the humerus, a complete dislocation being prevented by the integrity of the capsule.

Dislocation of *both radius and ulna* at the elbow may take place in all directions.

The dislocation backward may be produced by falling upon the hand with the forearm almost extended ; by a blow upon the anterior aspect of the forearm, near the elbow, a blow upon the posterior surface of the humerus, in its lower portion, or force applied at the same time, in opposite directions, upon these surfaces. The coronoid process will be found lodged in the olecranon fossa, the upper end of the radius resting on the posterior aspect of the external condyle.

The anterior ligament and the anterior fasciculi of the external and internal lateral ligaments are torn loose, and in extreme cases the orbicular ligament may give way, although the yielding of the external ligament usually saves the circular ligament from being torn. The tendon of the brachialis anticus is stretched or is broken loose from the coronoid process. Pressure upon the brachial artery may be so great that pulsation at the wrist is diminished or absent, while in extreme cases the median, ulnar, or musculo-spiral nerves may be injured.

The usual position of the forearm is one of almost complete extension, with pronation. Measurement from the inner condyle to the styloid process of the ulna will demonstrate shortening. Muscular rigidity is marked, and motion of the displaced bones difficult and painful. From these symptoms the diagnosis can be readily made. If swelling has ensued, and the tumefaction is great, it is not always easy or possible to recognize the character of the injury. It is best under such conditions to anæsthetize the patient, determine the exact nature of the injury, and treat it at once rather than wait until the swelling is reduced.

* "Annals of Surgery," June, 1889.

Treatment—Reduction—Method of Astley Cooper.—With the patient seated in a chair, the operator places his foot on the seat so that the anterior aspect of the patient's forearm will be brought in contact with the anterior surface of the surgeon's knee. The forearm should now be grasped near the wrist and forced flexion made, using the knee as a fulcrum, and at the same time as a point of resistance to the extension made by pulling upon the forearm (Fig. 410).

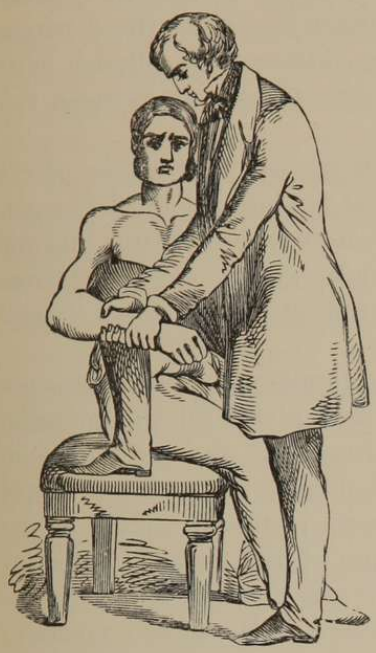

Fig. 410.—(Erichsen.)

Flexion unlocks the coronoid process from the olecranon fossa, and extension carries both bones forward into position. Unless the operator is positive that perfect reduction has been accomplished, the joint should be freely flexed and extended to test its working capacity. Care must be taken to hold the muscles in check while this manipulation is going on, for fear the bones may again slip out of place. Bandage the arm and forearm, and apply a splint, which should be worn for a week or two. When an anæsthetic is used the recumbent posture should be maintained. The bare foot may be utilized instead of the knee. A cloth or sheet folded around the arm, just above the elbow, may be used for counter-extension. Liston advised strong extension from the forearm, and counter-extension from the shoulder, with the arm and forearm held straight. If any considerable difficulty is met with, anæsthesia in the recumbent position should be used.

Dislocation of the radius and ulna *forward*, without fracture of the olecranon, is of rare occurrence, and is always the result of great violence. Rupture of the posterior and lateral ligaments occurs, and the triceps tendon is torn or greatly stretched, while the brachialis anticus and biceps are relaxed. The posterior portion of the olecranon rests upon the anterior articular aspect of the humerus, or may slip into the coronoid fossa. The forearm is bent at an angle varying from 90° to 120° to the anterior surface of the humerus, and is well supinated. Motion is painful and limited. The character of the injury may be determined by the absence of the olecranon projection, the smooth, broad, posterior surface of the lower end of the humerus being readily appreciated.

Treatment.—An anæsthetic is usually required. With the forearm held at about a right angle to the arm, make extension from the wrist, and counter-extension from the lower anterior surface of the humerus, in order to disengage the olecranon process from the coronoid fossa, and, when this is effected, make direct pressure downward upon the anterior aspect of the forearm, near the elbow. After the bones slip seemingly into position, careful examination should be made to see that the radius is in its proper relation to the external condyle, for the ridge between the

two sigmoid cavities of the ulna may lodge in the groove between the trochlear surface and the articular surface for the head of the radius.

In the *outward lateral* dislocation the luxation is usually partial. The cause is direct violence applied to the inner aspect of the forearm, near the joint, or to the outer aspect of the humerus, low down, or to force applied simultaneously, in opposite directions, upon these two surfaces.

The *diagnosis* will rest chiefly upon the increased prominence of the inner condyle, and the difficulty of recognizing the outer condyle by palpation. The angle at the elbow is about 120°, motion is wanting, and the hand is pronated. Reduction is best effected by strong extension from the forearm, counter-extension from the humerus, and direct lateral pressure in the direction of the displacement.

Inward dislocation is always incomplete (Hamilton). The causes are direct violence in the opposite direction to that given for the luxation outward. The internal condyle will be less prominent, the external more prominent, the olecranon will be seen crowded over to the inner aspect of the joint, while the head of the radius rests near the middle of the articular surface of the humerus. The position of the forearm is that of flexion. Reduction is difficult, and should be effected in ether narcosis. Extension and counter-extension should be made in the flexed position, and the arm gradually brought out straight, while at the same time direct pressure is made, in proper and opposite directions, upon the humerus and forearm, near the joint.

Dislocation of both bones backward is the most frequent form of displacement at the elbow. Incomplete external and incomplete internal luxation are next in order of frequency, while the forward dislocation is most infrequent.

In the posterior variety the direction of the force may be such that a deviation to one or the other side may occur. The treatment is practically the same. Direct lateral pressure in the line of the normal position of the bone may be required in addition to the mechanism of reduction above given. Partial anchylosis is not infrequent after these lesions. Passive motion should be begun within two weeks after the injury, and repeated daily if no acute inflammation is produced.

Wrist-Joint.—Dislocations at the carpo-radial joint are very rare. Only a few instances of complete *backward* or *forward* luxation of the carpus are on record. Lateral dislocations are considered impossible without fracture of the styloid process of the radius or ulna. The two principal displacements occur with about equal frequency. In the *backward* variety the anterior aspect of the carpus rests upon the dorsal rim of the cancellous expansion of the radius, the reverse being true in the dislocation *forward*. The anterior and posterior ligaments are partially or completely ruptured, and the annular ligament, which binds the tendons down, may be torn and the tendons displaced.

The *cause* of the *backward* displacement is a fall on the back of the hand, or a blow upon the dorsum of the radius, just above the wrist, while the hand is in extreme flexion. Violence of a similar

character, applied in the opposite direction, will produce the *forward* luxation.

The *diagnosis* must be made between Colles's fracture and dislocation. In *dislocation* the deformity from the over-riding carpus is much greater than after fracture. In Colles's fracture the swelling on the dorsum of the wrist is smooth and rounded. When impaction has not occurred crepitus may be obtained.

Reduction is effected by extension and counter-extension from the forearm and hand, to which direct pressure in the line of displacement should be added.

Dislocation of the *metacarpal* bones, at their carpal extremities, is rare. Luxation of the metacarpal bone of the thumb is most frequently met with. The carpal end of this bone may be displaced partially or completely, in a *forward* or *backward* direction. When the end of the bone rests upon the dorsum of the trapezius it can be easily recognized.

Extension and counter-extension, with direct pressure, is usually sufficient to accomplish reposition. A clove-hitch or snare may be thrown around the thumb to insure extension. Reduction is at times difficult, and the history of this accident is not without a record of failure both as to replacement and retention when replaced.

In the displacement forward, on account of the thickness of the soft parts, the end of the bone can not be easily recognized. An unusual depression may be observed on the radial and dorsal aspects of the wrist, just in front of the os trapezium.

Strong extension with counter-extension is necessary, and to this should be added direct pressure, applied near the end of the displaced bone.

Luxation of the remaining metacarpal bones occurs rarely, and, when met with, the displacement is usually partial, and toward the dorsum of the carpus.

The *phalanges* may be dislocated either *backward* or *forward* at the metacarpal articulations, or at the interphalangeal joints. The character

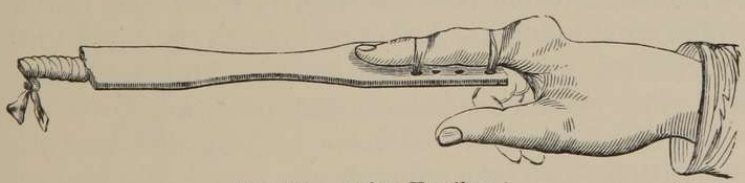

Fig. 411.—(After Hamilton.)

of the lesion is easily recognized, and the reduction, as a rule, is not difficult. Extension with a clove-hitch, or with the apparatus shown in Fig. 411, will effect reduction. In some instances operative interference is demanded when reposition by extension and pressure can not be effected. Careful asepsis should be observed. On opening into the joint, the resisting ligaments should be snipped with a sharp bistoury, when the displacement may be easily corrected.

Hip-Joint.—While the head of the femur may be displaced from the cotyloid cavity in any direction, it is customary to consider *four* distinct

luxations: (1) *Upon the dorsum ilii;* (2) *into the ischiatic notch;* (3) *into the obturator foramen;* (4) *upon the os pubis.* Practically these lesions occur in each of the quadrants of a circle, the center of which is the center of the acetabulum.

As shown in Fig. 412, about 50 per cent of all luxations at the hip occur in the iliac quadrant, 30 per cent in the ischiatic, 11 per cent in the obturator, and 7 per cent in the pubic. Two per cent occur beyond these regions. Cases are on record where the head of the bone was lodged on the tuber ischii, in the perinæum, and just beneath the anterior-superior spine of the ilium.

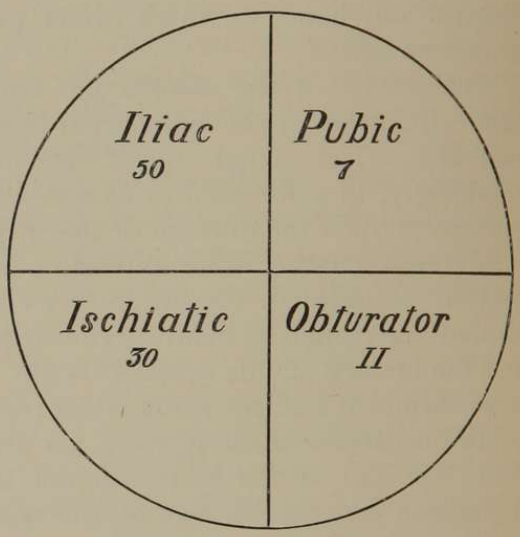

Fig. 412.—Showing the proportion of displacement in the four quadrants of a circle about the acetabulum.

The capsule is usually torn at its inferior and posterior surface. It may be a slit or tear in the long axis of the ligament, or frequently a broad rupture occurs along the edge of the cotyloid cavity. The ligamentum teres (when present) is always torn. The ilio-femoral (or Y) ligament is very rarely completely ruptured. The injury to the muscles and surrounding structures is always severe, and varies in proportion to the degree of violence which caused the luxation, together with the particular direction of the displacement.

In the displacement upon the *dorsum ilii* the glutei muscles may be lacerated, bruised, or lifted from the ilium by the head of the bone, but not by tension on their tendons, for, with the exception of the lower fibers of the maximus, their axes are slightly shortened in the new position. The obturator internus, externus, gemelli, and quadratus femoris are greatly stretched, or torn entirely loose. The pyriformis is not so apt to suffer. The pectineus, iliacus, and psoas are carried upward and outward. When the head of the bone is projected into the *ischiatic notch*, the conditions as to the muscles are practically unchanged. The sciatic nerve and vessels are pressed upon and may be contused or lacerated. In the displacement upon the pubes the psoas and iliacus may be injured, while the femoral vessels and anterior crural nerve are more or less pressed upon. When the head of the bone is lodged in the *obturator foramen*, the obturator externus muscle and the obturator vessels and nerves are more or less contused, while the glutei and the remaining external rotators are put upon the stretch.

Causes.—Dislocations at the hip may be congenital, pathological, or traumatic in cause.

Congenital luxations, rare in occurrence, are the result of interference

with normal development. Failure to complete the process of ossification in the three bones which compose the acetabulum leaves a soft and fibro-cartilaginous cup or sac, through which, when the weight of the body is sufficient, the head of the femur is more or less completely displaced into the pelvic cavity. Absence of the ligamentum teres is not alone sufficient to account for displacement when the bones, capsule, and muscles are normal, for it is not infrequently absent in cases which have never suffered a luxation. Moreover, the majority of cases in which this ligament has been ruptured by one luxation do not suffer a second displacement. An abnormally long, loose, or relaxed capsule will lead to sub-luxation or displacement without rupture of the capsule. Failure of development from the cervical epiphysis is another cause of congenital dislocation at the hip.

Pathological dislocations are caused by chronic arthritis. The bones are more or less destroyed, and the capsule breaks down, permitting dislocation of the head of the bone as a result of muscular action or slight violence.



Fig. 413.—Position of extremity in dislocation of the head of the femur upon the dorsum ilii. (After Hamilton.)

Traumatic luxations are direct or indirect. The most frequent cause is a fall from a height or from a carriage in motion, the person striking upon the foot or knee, with the thigh carried in such a direction that its axis is at a considerable angle to that of the spinal column.

Anatomically considered, the most favorable position for the two posterior, and by far the most frequent displacements, is when the thigh is flexed at about an angle of 90° to the axis of the body. If the thigh be adducted, the tendency is to rupture the capsule on its posterior-inferior surface, with escape of the head on to the *dorsum ilii*, or into the *ischiatic notch*. When in a position of abduction, the rupture is likely to occur on the lower anterior aspect of the capsule.

A fall directly upon the trochanter, with the thigh in adduction or abduction, with extreme outward or inward rotation, is apt to produce rupture of the capsule and luxation.

Symptoms.—In dislocation upon the *dorsum ilii*, with the patient standing erect upon the uninjured extremity, the trochanter of the displaced femur will be nearer the anterior-superior spine of the ilium than that of the opposite side; the thigh is slightly flexed upon the abdomen, adducted, and rotated inward. The head of the bone may be appreciated

in the new position. The shortening is from one to two inches, and in the vast majority of cases the great toe of the injured side is directed to or rests upon the instep of the opposite foot, while the knee of the luxated side is in front of, and slightly above, its fellow (Fig. 413). Muscular rigidity and fixation are extreme. In very exceptional cases there is eversion of the foot, with slight abduction, which Prof. Bigelow holds to be due to extensive and unusual laceration of the ilio-femoral ligament.

When the head of the bone is lodged in the *ischiatic notch*, the general characters of the deformity are the same, yet not so well marked. The degrees of flexion and adduction are less extreme, the trochanter is less prominent, and there is not so much shortening.

In the *thyroid* displacement the

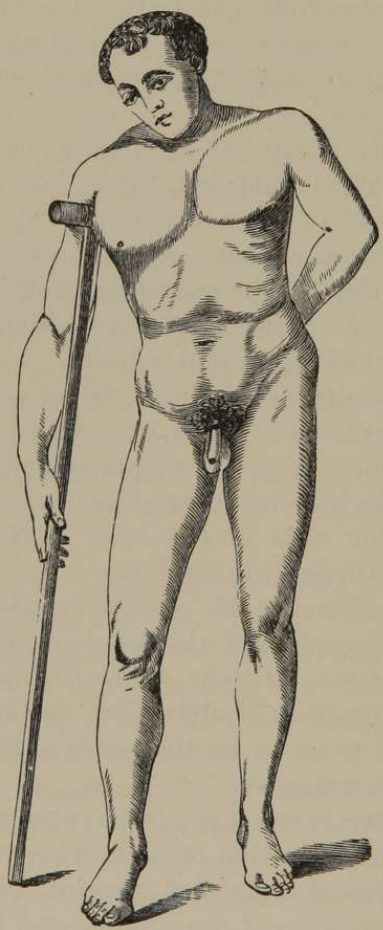

Fig. 414.—Position of extremity in dislocation of the head of the femur into the thyroid foramen. (After Hamilton.)

Fig. 415.—Position of extremity in dislocation of the head of the femur upon the pubes. (After Hamilton.)

extremity is increased in length, and the thigh is abducted and slightly flexed upon the abdomen. The toes may be turned slightly in or out, although they usually point to the front. The hip is less prominent than normal. The head of the femur may at times be recognized in the new position, although, on account of the tense condition of the adductor muscles, this is in some instances impossible (Fig. 414).

When the dislocation occurs *on the pubes* there is abduction, slight flexion, and slight outward rotation. The foot is carried away from that of the sound side, and the toes are pointed outward. The chief diagnostic feature of this displacement is the presence of the head of the bone at Poupart's ligament (Fig. 415).

The differential diagnosis is between muscular spasm or rigidity and fracture.

Spasm or rigidity of the muscles about the hip may occur as a result of an acute or subacute inflammatory process in the joint, or in the periarticular tissues, or in certain cases of ostitis of the lumbar vertebræ, sacrum, or ilium, in the neighborhood of the psoas and iliacus muscles. This condition of partial immobility may be differentiated from that of dislocation by the absence of the *shortening*, which is present in the displacement on the dorsum ilii and into the ischiatic notch, the *lengthening* in the thyroid luxation, while the head of the bone on the pubes will determine the character of this lesion. The absence of the characteristic deformity of each of these forms of dislocation will determine the diagnosis of muscular spasm or rigidity. The symptoms of fracture near the hip have been given. *Shortening*, *preternatural mobility*, and *crepitus* are to be chiefly relied upon in differentiation.

Reduction—Dislocation on the Dorsum Ilii—Bigelow's Method.—In complete ether narcosis, place the patient upon a strong, low table, or upon the floor, in the dorsal decubitus. Grasp the leg of the dislocated side, just above the ankle, with one hand, and near the knee with the other, flex the leg on the thigh, and the thigh on the abdomen, to nearly an angle of 90° with the surface of the floor, adduct the thigh until the knee of this side is carried to about the middle of the sound thigh, and then cause the knee to describe a circle *outward* and *downward* until the leg is brought to the floor in its normal position (Fig. 416). If the luxation is not reduced the manœuvre should be carefully repeated. This method of reduction by manipulation is based upon the resistance to reduction which is made by the ilio-femoral ligament (when this is not torn).

Fig. 416.—Reduction of dislocation on the dorsum ilii by manipulation. (After Bigelow.)

The normal position of this ligament is shown in Fig. 417, and its relaxation by flexing the dislocated thigh upon the abdomen is shown in Fig. 418; and it is readily seen that if, with the thigh in this position, abduction, with outward rotation, is practiced, the head of the bone will be lifted over the margin of the acetabulum and carried in the direction of the socket.

Fig. 417.—The ilio-femoral or Y ligament. (Bigelow.)

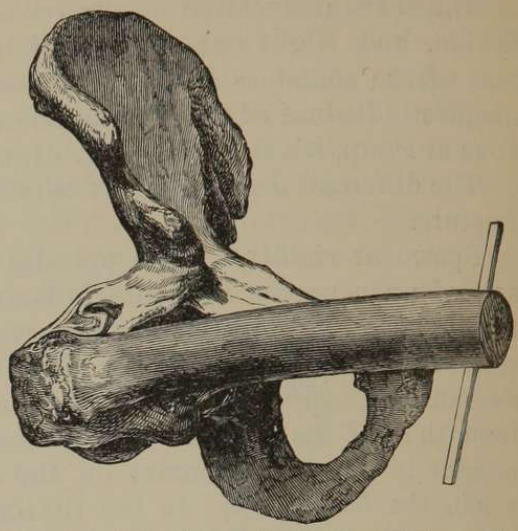

Fig. 418.—Relaxation of the ilio-femoral ligament by flexion and adduction of thigh. (Bigelow.)

*Crosby's Method.**—Place the patient on the floor, in the dorsal decubitus. Flex both legs on the thigh, and the thighs on the abdomen, and, with the arms locked underneath the knees, raise the patient from the floor so that the body will rest only on the neck and shoulders. If, after suspension lasting two or three minutes, reduction is not accomplished, the patient should be swayed from side to side, thus adding alternately slight abduction and adduction to the extension. While the displacement may be overcome without anæsthesia, it is much more easily and surely effected with it.

The same result may be accomplished by employing vertical extension in the manner recommended by Bigelow and shown in Fig. 419.

Hamilton's Method.—The patient is in the dorsal decubitus, and the limb is grasped as in Bigelow's method. "Flexing the leg on the thigh, the knee is to be carefully lifted toward the face of the patient, until it meets with some resistance; it must then be

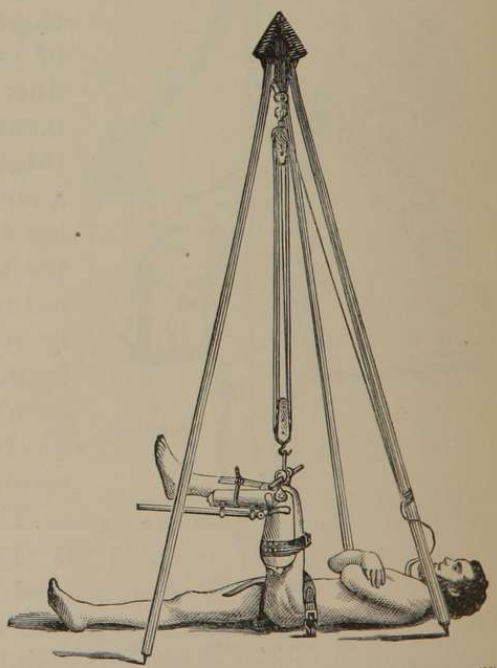

Fig. 419.—Reduction of dislocation on the dorsum ilii by vertical extension. (Bigelow.)

* This method was introduced by the late Prof. A. B. Crosby.

Fig. 420.—Cooper's method of extension and counter-extension in reduction of dislocation into the ischiatic notch. (Hamilton.)

moved outward and slightly rotated in the same direction, until resistance is again encountered, when it must be brought downward again to the bed."

The older method of violent extension, by means of blocks and pulleys, should not be employed, unless all other means have failed.

Reduction of Dislocations into the Ischiatic Notch.—In this luxation the mechanism of reduction is practically the same as for the preceding displacement. One point must be guarded against—the danger that, when the head of the femur reaches the margin of the acetabulum, it may be deflected below the rent in the capsule, and lodge in the thyroid foramen.

If extension and counter-extension after the older method (Astley Cooper's) be necessitated, the pelvis should be fixed by a sheet folded and passed through the perinæum and over the groin, and extension made from above the knee, with the thigh flexed almost to an angle of 90° with the abdomen, and adducted until the knee is carried in front of the opposite thigh (Fig. 420).

Reduction of Dislocations in the Thyroid Foramen—Method of Bigelow.—Place the patient upon the floor, in the dorsal decubitus, flex the leg on the thigh, and the thigh on the abdomen, making, at the same time, slight abduction. Then rotate the femur inward, adduct, and carry the knee to the floor.

The older method involved extension in a lateral direction, by means of a sheet folded and

Fig. 421.—Reduction of dislocation into the thyroid foramen. (Bigelow.)

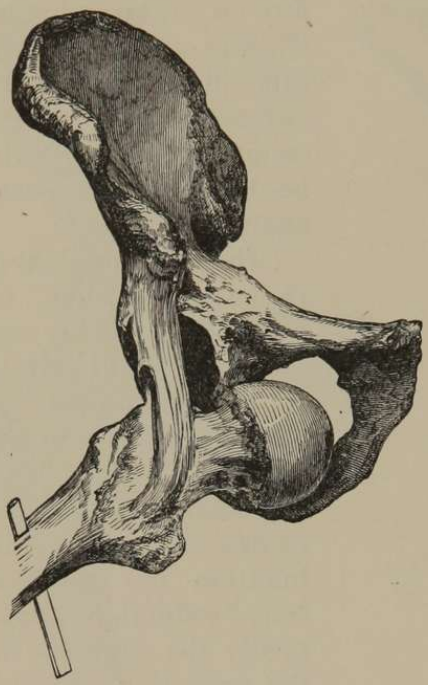

FIG. 422.—Showing the relation of the ilio-femoral ligament in dislocation of the head of the femur into the thyroid foramen. (Bigelow.)

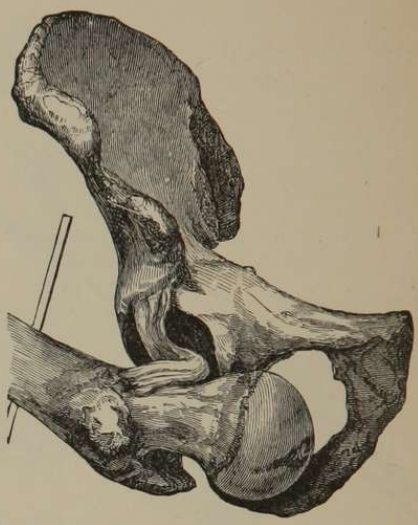

FIG. 423.—Showing how flexion of the thigh on the abdomen relaxes the ilio-femoral ligament in dislocation into the thyroid foramen. (Bigelow.)

passed around the inner surface of the thigh, while the pelvis was fixed by a sheet passed around this part of the body, and upon which traction was employed in an opposite direction (Fig. 424). If pulleys can not be had, the sheet which is carried around the thigh should be tied into a loop and laid over the shoulder of the operator.

Reduction of Dislocations upon the Pubes —Hamilton's Method.— When the head of the bone is lodged well over the pelvic rim the thigh should be abducted and rotated outward, in order that the head may be thus lifted over the pubes, and then flexed upon the body, adducted, and brought down. Rotation outward should cease as soon as the head of the bone has risen above the pubes. When the head has not passed above the rim of the pubes, outward rotation is not called for.

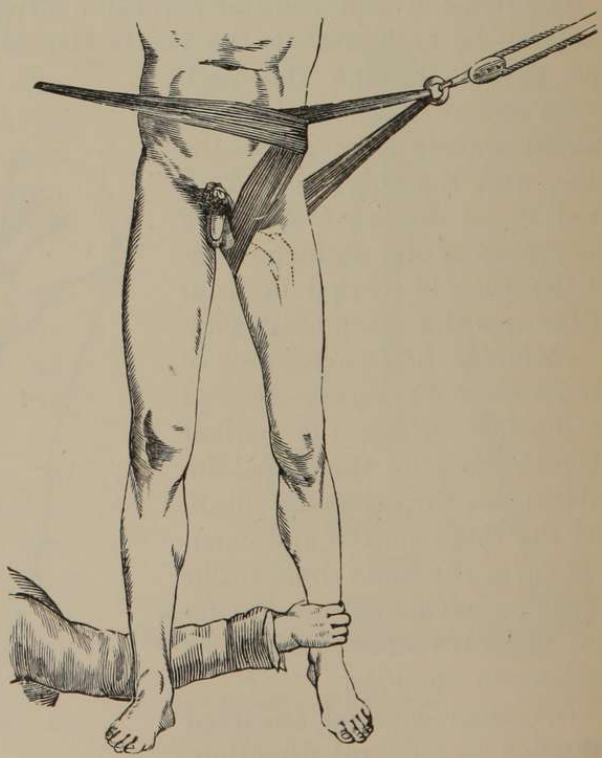

FIG. 424.—Cooper's method of reducing dislocation into the thyroid foramen. (Hamilton.)

If in this manœuvre the bone slips into the thyroid foramen, the manipulation given for this luxation should be practiced.

By Extension and Counter-Extension—Hamilton's Method.—Place the patient upon the edge of a bed or table, so that the injured limb may

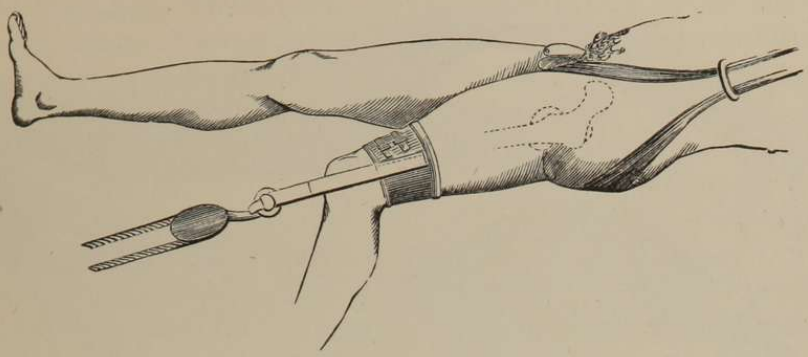

Fig. 425.—Reduction of dislocation upon the pubes by extension and counter-extension. (Hamilton.)

fall slightly over the edge. Extension is made from the thigh, and counter-extension from the perinæum and groin, in the direction indicated in Fig. 425. The tendency of modern surgery is to rely upon manipulation under anæsthesia rather than resort to the forcible methods of extension and counter-extension.

The *after-treatment* of hip-luxation involves fixation of the muscles about the joint for from two to six weeks. A gutta-percha, heavy pasteboard, or leather splint, molded to the side of the pelvis, thigh, and down to the ankle, applied upon a thin layer of absorbent cotton, and held in place by a leg-, thigh-, and spica-bandage, should be employed.

The *prognosis* as to rapid restoration of function is not always favorable. The injury to the capsule, and more especially to the muscles around the joint, may lead to an impairment of the hip, more or less permanent. In permanent luxations, in some instances, a fair degree of mobility may be developed. Reduction has been successfully performed as late as four and six months after the injury.

The treatment of *congenital* dislocations of the hip, and of *pathological* luxations, will be given later.

Dislocations at the Knee—The Tibia from the Femur.—Displacement of the femoral end of the tibia may occur as a result of *congenital malformation*, *disease*, or *accident*.

Congenital luxation is rare, and is usually partial. As a rule, the tibia is displaced forward, although the opposite condition may prevail. Absence of the patella has been observed in several of these cases.

Pathological dislocations will be given under the head of diseases of this joint.

Traumatic luxation at the knee is comparatively rare. The tibia may be completely or partially displaced, and in any direction. Partial dislocation is the rule. Complete luxation is apt to be complicated with a wound. A compound dislocation usually occurs forward or backward. The *cause* is direct violence. A blow upon the anterior aspect of the tibia, near the joint, or the posterior-inferior portion of the femur, may

cause a *backward* displacement of the tibia, while violence from opposite directions may produce a *forward* dislocation. The same force applied laterally may also produce the *lateral* displacements. A favorable condi-

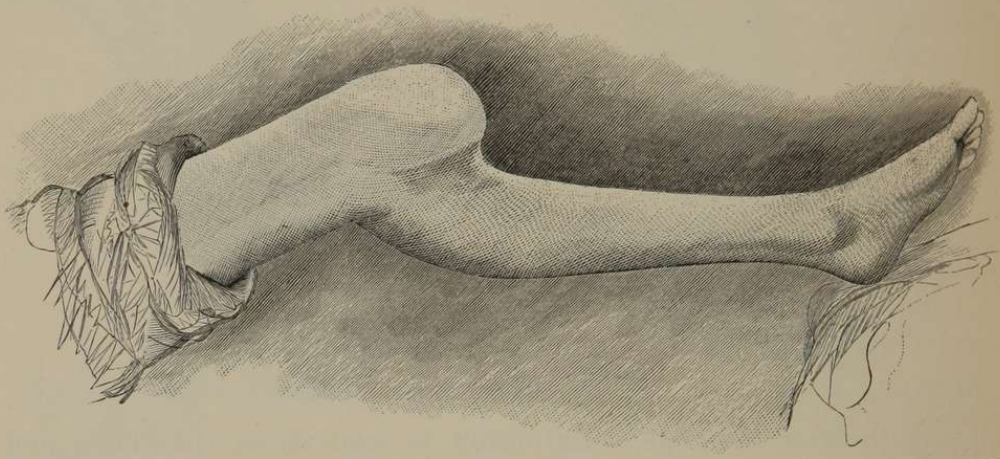

FIG. 426.—The author's case of backward dislocation of the tibia at the knee, caused by stepping into a hole while in the act of running. (From a drawing by Dr. Mewborn, fifteen years after the accident.)

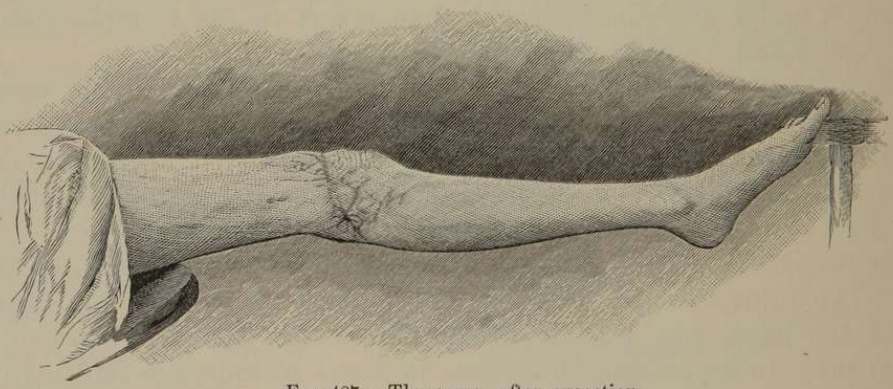

FIG. 427.—The same, after exsection.

tion for luxation is the application of violence when the leg is in extreme flexion. A sudden twisting or wrenching of the femur upon the tibia when the foot is so caught that rotation on the heel is impossible, is favorable to rupture of the ligaments, and lateral or oblique incomplete luxation.

The *symptoms* of dislocation at the knee are usually clear. In the *backward* variety the antero-posterior diameter of the knee is increased, the tibia projects into the popliteal space, and the condyles of the femur are unusually prominent. In the *forward* variety the antero-posterior measurements are also increased, the anterior edges of the tibia are easily detected in the advanced position of this bone, while the condyles of the femur are unusually prominent posteriorly. The tibia may be rotated upon its axis. In the *lateral* displacements the condyle of the femur is recognized as projecting on one side, while the flat end of the tibia is felt on the opposite side. The transverse diameter of the joint is increased in proportion to the degree of displacement, which is, however, rarely complete.

Treatment.—Reduction is readily effected by extension and counter-extension, with direct pressure and counter-pressure in the proper direc-

tions. Once reduced, fixation should be secured by Buck's extension, with sand-bags applied to the limb, or an investing splint should be employed.

The *prognosis* after this injury is unfavorable. The function of the joint is rarely fully restored. The question of *amputation* after dislocations of the knee, where there is extensive injury of the surrounding structures, is one of great importance. Shock is more profound in this luxation than in dislocation at any other joint. A primary amputation will rarely be justified except after laceration of the popliteal vessels. All antiseptic measures should be employed, and amputation only advised after every effort consistent with the safety of the patient's life has been made. Exsection is preferable, and offers not only a greater degree of safety but a more useful result.

Dislocation of the Patella.—This bone may be displaced by muscular action, without the aid of external violence, or by an injury alone. When the ligamentum patellæ is ruptured, it is carried *upward* for a varying distance by the contraction of the quadriceps. It can only be displaced *downward* by a blow received upon its upper margin sufficient to tear it loose from its muscular attachments. Dislocation *outward* is the more frequent variety, and occurs as a result of muscular contraction and from violence. Displacement *inward* is the result of a blow received upon the outer margin of the bone. In the *lateral* dislocations, in rare instances, the patella is turned obliquely on its edge, or it may possibly be completely inverted.

The *symptoms* of these various luxations are unmistakable, and the reduction, by relaxing the quadriceps and pressure, not difficult.

The after-treatment is directed to the prevention of recurrence.

Dislocations at the Ankle-Joint.—Dislocations at the tibio-tarsal articulation may occur in four directions, viz., *forward*, *backward*, *inward*, and *outward*. In the last two forms fracture of one or the other malleolus is apt to occur.

Dislocation of the tibia *inward* is caused by a fall upon the foot at a time when it is turned outward, the body-weight being brought to bear upon the inner aspect of the heel and great toe. This form of sprain is frequently caused by leaping from a wagon or car in motion. It may also result from a heavy blow upon the fibular side of the leg, near the ankle, when the foot is solidly fixed against the ground. The displacement is usually partial. A complete luxation is apt to be compound.

The *symptoms* of *inward* dislocation are the great prominence of the inner malleolus and the peculiar twist of the foot, so that the inner side of the heel and the great toe rest on the floor while the sole looks obliquely outward and upward. The only displacement it may be mistaken for is that of the astragalus from the os calcis.

The *treatment* is to bring the foot into the normal position by pressure and counter-pressure, and fix it with a splint and bandage. On account of the great swelling which is likely to occur, an immovable dressing should not be applied until the acute symptoms of inflammation have subsided.

The *symptoms* of *outward* displacement are the reverse of the inward, and can without difficulty be recognized. Displacement of the tendons

of the long and short peronei muscles, from their sheaths behind the external malleolus, is likely to occur in this accident. After reduction at the joint these should be pushed into place, and an effort (rarely successful) made to hold them in position by a compress and bandage, applied before the splint for the luxation is adjusted.

Forward dislocation may occur as the result of a blow upon the back of the leg, near the ankle, while the foot is firmly placed upon the ground; by falling forward with great violence, when the momentum of the body is suddenly arrested by the foot striking against the ground; or by falling backward, with the foot so fixed that great and unusual extension of the tarsus takes place.

The *symptoms* are unnatural prominence of the heel, shortening of the distance between the toes and the front of the tibia, on the displaced side.

Reduction.—Place a clove-hitch around the heel and instep for extension, and make counter-extension from the thigh. Flex the leg so as to relax the sural muscles, and make forcible extension from the foot. As soon as the extension is well begun the operator places his foot against the front of the patient's tibia, just above the ankle, and pulls forward on the foot, at the same time flexing it on the tibia.

Backward displacement is caused by violence applied in a direction opposite to that which produces the *forward* luxation, and the *symptoms* are exactly the reverse.

The *treatment* demands reduction by extension and counter-extension, and direct pressure.

Dislocations at the ankle are often complicated with fracture, or may be compound. In any form of injury an effort should be made to save the foot and joint. The ankle is exceedingly tolerant of surgical interference, and, with strict cleanliness and antisepsis, amputation on account of complicated or compound dislocation will be rarely necessary.

The fibula may be displaced from its articulation with the tibia at its upper or lower end. At the upper end it is usually luxated forward, as a result of direct violence from behind, although it is possible to have the reverse occur. The bone will be felt in the abnormal and anterior position, and may be pushed directly back into place. In the backward displacement the biceps muscle may produce the luxation, or it may be from violence applied from the front. Strong and continued pressure must be employed to retain the bone in position until adhesions occur. During the treatment the leg should be flexed on the thigh in order to relax the biceps.

At the lower end dislocation of the fibula alone, without the tibia, is exceedingly rare. Anatomically, it may occur in both directions. Reduction may be effected by direct pressure. The fibula may be displaced outward from the tibia by the astragalus being driven upward between these bones.

Dislocations of the Bones of the Tarsus.—The *astragalus* may be partially or completely dislocated forward, backward, outward, or inward. The luxation is usually incomplete. On account of the great violence necessary to its production it not infrequently is compound, or

complicated with a fracture. Violence of the same character as that which produces displacement of the tibia will cause dislocation of the astragalus.

Treatment.—Luxation of the astragalus is a serious accident. The efforts at reduction do not always succeed, and, even when reduction is effected, the injury to the joint may be such that loss of function results. Direct pressure and counter-pressure, while the patient is profoundly anæsthetized, offer the best means of successful reduction. Displacements of the metatarsal bones and phalanges of the toes are treated in the same general way as described for similar lesions of the hand.

The Vertebræ.—Dislocation may occur at any articular surface of the vertebral column. The accident is always serious, the gravity being proportionate to the degree of displacement and the injury to the cord and nerves.

Luxations are more common in the *cervical* region. One or both articular processes may be displaced forward or backward upon the vertebra below. In the *unilateral* displacement the fibro-cartilage between the bodies is only slightly involved, and, while there is pressure upon the nerves passing out of the intervertebral foramen, there is no pressure upon the cord. In the *bilateral* form the cartilage is torn, the body more or less involved in the luxation, and the cord compressed.

The *causes* are muscular contraction, or violent twisting of the neck by accident.

The *symptoms* of unilateral displacement are pain—which may be referred to the distribution of the nerves passing through the intervertebral foramen involved—at the seat of luxation and rotation of the head, in a forward dislocation, so that the chin points to the side opposite to that upon which the injury exists. When the luxation is backward, the face is turned toward the seat of injury.

In the case of a young lady which came under my observation, the right articular process of the fourth cervical vertebra was displaced forward by sudden and violent muscular contraction. Pain was acute at the seat of luxation, and numbness down the right arm indicated compression of some of the filaments forming the brachial plexus. Reduction was effected as follows: The patient being seated in a chair, the shoulders were held immovable and the head further rotated to the left; then strong extension was made by lifting the patient from under the chin and occiput, at the same time carrying the head back to the right. Relief was immediate and permanent.

In bilateral luxation careful extension and direct pressure and counter-pressure should be practiced.

Dislocation of the condyles of the occipital bone from the atlas is probably always fatal. Luxation at the atlo-axoid joint, with fracture of the odontoid, is also fatal.

Ribs.—The ribs may be displaced from their vertebral articulations. The cause is direct violence, and the displacement usually forward. The true ribs may be dislocated at the junction of these organs with their cartilages, near the sternum. The treatment for these luxations is the same as for fracture.

Diseases of the Joints in General.

Inflammation of a joint may be *simple* or *infective*. It may involve the entire anatomical structure of the articulation, or may be limited to a portion of the capsule or its lining membrane. When the lining membrane is alone involved it is called *synovitis* (a similar condition of the tendon sheaths is known as *thecitis* or *teno-synovitis*). When the ligaments of a joint are involved it is called *syndesmitis*. When all of the structures are involved—bone, cartilage, ligaments—it is known as *arthritis* or *osteo-arthritis*.

A typical simple (non-infective) inflammation of the joint structure occurs after an ordinary *sprain*. The first symptom is pain and swelling proportionate in general to the extent of the traumatism. Hyperæmia and dilatation of the capillaries in the basement membrane of the synovial membranes and ligaments occur, followed by emigration of leucocytes into the intercapillary spaces as well as into the cavity of the joint, in which there is almost always a transudation of serum. The synovial fluid is increased in quantity, richer in cell elements than normal, and frequently discolored by red blood-corpuscles or free hæmatin. Not only is the capsule distended, but frequently the communicating bursæ are also abnormally filled with fluid. The embryonic cells, which are the product of the inflammatory process, are found not only lining the synovial surface, but there is also a connective-tissue hyperplasia in the substance of the capsule. Simple arthritis or synovo-arthritis as described (pyogenic infection not having occurred) tends to recovery. The inflammatory symptoms subside, repair goes on rapidly, absorption of the exudate takes place, and, when uncomplicated by rupture of the capsule or fracture of bone or cartilage, its function is restored. Should infection occur, the clinical history is entirely different. The symptoms of pain and swelling are exaggerated ; pus forms in the joint; the liquefying action of the toxic products generated by pyogenic organisms destroy the synovial surfaces and produce erosions of the cartilaginous facings of the bone and the interosseous fibrocartilages, if such exist ; softening or thickening of the capsule, increased abnormal hyperæmia, invasion of the periarticular tissues, and, in the natural course of this form of arthritis, rupture of the capsule and escape of purulent contents follow. Neglected cases of pyogenic infection of a joint lead generally to the involvement of the bones connected with the articulation. Osteomyelitis may in this way occur.

Treatment.—The first essential in the treatment of simple traumatic synovitis, or synovo-arthritis (sprain), is rest. This is best secured by the recumbent posture and elevation of the part involved. The ice bag or cold applications are usually grateful. Immobilization of the part by plaster of Paris or by some fixed dressing, between which and the injured member a considerable layer of absorbent cotton is interposed, produces a compression which aids in the absorption of inflammatory products. In sprain at the ankle, as advised by Prof. V. P. Gibney and others, tight strapping with adhesive plaster from the dorsum of the

foot around the ankle and lower leg in figure-of-eight fashion has been used in late years, especially in subjects who are unable to give up work. As soon as the injury is received, the strapping is applied; the shoe is worn as if nothing had happened, and the patient is advised to go about regardless of the sense of discomfort which may be present. A considerable number of successful cases treated in this way have been reported by various surgeons.

The treatment of *infective arthritis*, or synovo-arthritis, demands absolute rest from the moment of its inception and the energetic efforts of the surgeon to arrest the invasion of the joint and to build up the normal resistance of the patient. Between the danger of opening into an infected joint and instituting drainage and the threatened destruction of the structures from the presence of a further accumulation of pus in the capsule, the surgeon is frequently at a loss what course to pursue. Since the judicious employment of cocaine renders the procedure practically without pain, especially in children over twelve years of age and in all adults, it would be proper to attempt an evacuation of the purulent accumulation in the capsule by careful aspiration and irrigation through a large-sized aspirating needle with a boiled saturated solution of boric acid cooled down to 110° F. Care should be taken to exhaust all of the fluid possible from the joint through the largest aspirating needle, and, of course the needle should be thoroughly aseptic before it is used even in a septic joint. The opening should be at once sealed with gauze or collodion and an absorbent compress applied to the joint. It is proper to say that in the author's experience such measures have usually failed, incision and drainage being ultimately necessary. When incision is determined upon, it should be free, and in a large joint, such as the knee; a single opening upon the outer or inner side of the capsule will usually suffice. Thorough irrigation should follow the incision, and it is well to insert a medium-sized rubber drainage tube which has been taken out of the sterilizer immediately before using. The period for which drainage should be employed will be determined by the symptoms. When the pus has practically ceased to flow from the tube, it may be removed, and the same careful aseptic dressing applied until recovery is complete.

Penetrating Wounds. — Ordinary incision, puncture, or lacerated wounds of a joint are serious only as they cause infection. An aseptic incision or punctured wound, as in exploration of the joint, is practically without risk. An accidental, punctured wound requires no further treatment than aseptic management and complete rest, unless symptoms of infection occur. It should then be treated according to the directions just given. In *laceration* of a joint, where the air or any infectious agent has been carried into the latter, it should at once be made sterile by irrigation with boric acid solution and the wound closed with or without drainage, as may be demanded. In *gunshot* wounds of the joint the same treatment should be instituted. These are somewhat more formidable on account of the destruction of bone which is likely to follow the passage of a ball through a joint. It is advisable to cleanse

the wound of entrance and exit, taking the usual antiseptic precautions, keeping the member in complete rest while repair is going on. This method was followed in a recent case of penetration of the knee joint with a ball from a Colt navy pistol, and no sepsis occurred, the joint resuming perfect function within six months after the accident. When infection does occur, the ordinary surgical rules for infected joints should be followed.

Dry Synovitis, or Synovo-arthritis, is occasionally met with in surgical practice, especially in rheumatic subjects. It is an inflammation of the synovial membrane of the capsule in which there is not only no transudation of fluid into the capsule, but the normal synovial secretion is diminished, and in many cases, even when properly cared for, ending in loss of function or anchylosis. These cases require rest so far as the joint is concerned, and an effort to correct the diathesis which causes the inflammation.

Tuberculous Arthritis.—By far the more frequent form of subacute and chronic arthritis which comes under the surgeon's observation is tubercular in character. Tuberculous arthritis may originate in the deposit of the *bacilli of tuberculosis* directly in the synovial membrane or articular structures proper, and this condition is found as a rule in adults, or indirectly by invasion from foci of this disease in or near the epiphyses contiguous to the joint. This last method of invasion is more frequent in children. The symptoms of tuberculous joint disease vary in some respects owing to the direct or indirect involvement of the cavity. There is also a marked difference between traumatic arthritis and this specific form of infection.

Acute arthritis is always a painful affection, and is almost always traumatic in origin. In tuberculous arthritis pain is rarely acute, and is intermittent and mild in character. If pyogenic (mixed) infection occurs, pain and high temperature ensue.

When tubercular ostitis precedes the arthritis, pain of a mild character is more apt to be constant.

When the synovial membrane becomes the seat of tuberculous deposit it becomes softened and thickened, covered with a rich layer of granulation tissue, and relaxed, permitting pathological dislocations, flexions, rotations, etc., to take place.

The treatment of these cases, both constitutional and local, will be taken up with the special management of the various joints.

Diseases of Special Joints.

Of the Hip.—Arthritis of the hip, hip-joint disease (*morbus coxæ*, or *morbus coxarius*), is a frequent and formidable affection, and one which, in many instances, will baffle the best medical and surgical care through months and years of suffering, ending in destruction of the joint, and frequently in death. It is a disease of childhood, occurring chiefly in the period of rapid growth. It rarely occurs after the twelfth year. It may occur at any time prior to this age, the majority of cases being between the ages of three and six years.

The pathology of *morbus coxæ* will vary with the peculiar character of the lesion. The morbid changes which occur in that variety which is most frequently met with are those of tubercular *ostitis*, followed by destructive *arthritis*. The initial lesion occurs as an interference with, or arrest of, nutrition, near the diaphyso-epiphyseal cartilage (Fig. 428, *a*), due to the deposit of tuberculous material at this location. It may begin on the diaphyseal or epiphyseal side. According to Prof. Gibney,* the initial lesion appears in the several centers of ossification about the same time. It is an *ostitis rarefaciens*. The cancellous cavities become filled with embryonic cells, absorption of the lamellæ occurs, the inflammatory new products may undergo a slow process of fatty metamorphosis, may become caseous, or with mixed infection the process may terminate in pus formation. The development of the bone is arrested, the ostitis, commencing in the deeper portions, travels in all directions, destruction of the diaphyso-epiphyseal cartilage occurs, with separation of the epiphyses (*diastasis*). While these changes are going on, the lining membrane of the capsule becomes involved, the process being one of *chronic synovitis*, which, as has been stated, terminates inevitably in inflammatory changes in the tissue proper of the capsule. The joint becomes filled with the products of inflammation, the capsule, overdistended and weakened, ruptures either spontaneously or as a result of motion, and dislocation may occur. With separation of the epiphysis and destruction of the neck of the femur shortening ensues.

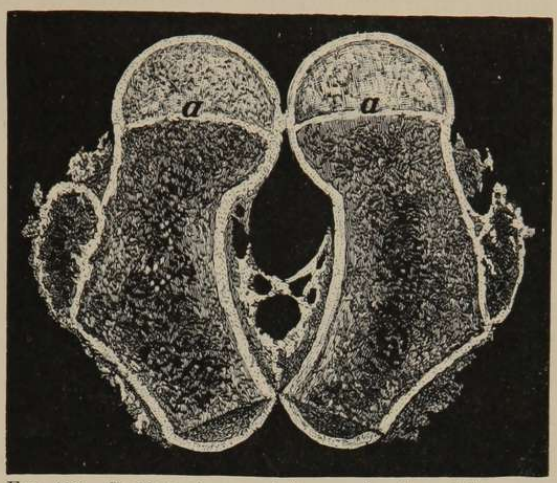

FIG. 428.—Section of normal femur of a boy eight years old. (After Gibney.)

Occasionally the initial ostitis may be situated in the bones which form the cotyloid cavity. It is held that hip-joint disease may, in rare instances, result from a peri-articular inflammation, first a *syndesmitis*, secondly a *synovitis*, lastly *arthritis*.

Causes.—The causes of hip disease are chiefly predisposing. Any dyscrasia which impairs nutrition in general favors the lodgment and proliferation of the bacillus tuberculosis and tends to destructive ostitis and arthritis. Traumatism may, and undoubtedly does, precipitate the inflammatory process in many cases, yet the ordinary violence to which this joint is subjected will rarely induce *coxitis*, except in children affected with some constitutional disease. Excessive use or a blow may produce synovitis, but, in a healthy patient, rapid recovery is almost certain. If diastasis occurs as a result of accident, *ostitis* ensues, and

* "The Hip and its Diseases," Bermingham & Co., New York, 1884.

impairment of the joint follows, yet this is an exceedingly rare injury. Rupture of the ligamentum teres, which must occur in a traumatic luxation, could not induce destructive arthritis in an otherwise healthy individual.

The *symptoms* of hip disease are divisible into *two stages*. The *first stage* embraces all the phenomena of inflammation, up to a positive and appreciable destruction of the structures which enter into the formation of this joint. The *second stage* embraces the phenomena of destruction, namely, shortening of the neck, diastasis, rupture of the ligamentum teres and capsular ligament, and luxation.

Among the earlier signs of this disease is pain, referred directly to the hip joint, or it may be to the hip and knee joints, of the affected side, and in some instances the pain is felt wholly in the knee of the same side. This symptom is most exaggerated at night and in the early morning hours, and after the child begins to move about may disappear. The distribution of the obturator nerve to both articulations will account for the reflex sensibility in the knee. In a certain number of cases the patients will deny all sense of pain, and even under pressure may not exhibit signs of suffering. In children this effort at concealment (not uncommon) is incited by the fear of being subjected to surgical treatment. If, however, a careful examination is made, rigidity of the muscles about the hip will be evident. In standing erect, the weight of the body will be brought upon the sound extremity, the gluteal fold on the affected side is partially obliterated (Fig. 429), and in walking there is almost always a perceptible limp. The iliacus, psoas, and adductor muscles are usually in an abnormal state of tension; hence the initial flexion of the thigh, and outward rotation or eversion of the foot.

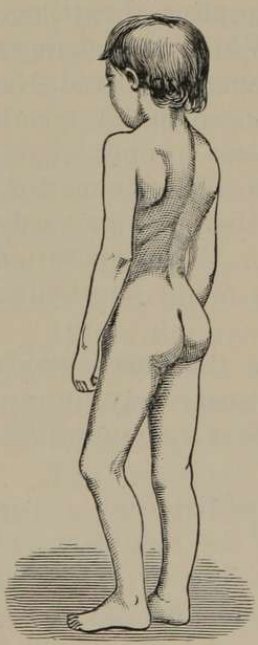

Fig. 429.—(After Sayre.)

Rigidity of the psoas and iliacus muscles—one of the more positive early symptoms of hip disease—may be demonstrated in the following manner: If the patient be stripped and laid flat on the back, on a hard, level surface, and both legs drawn

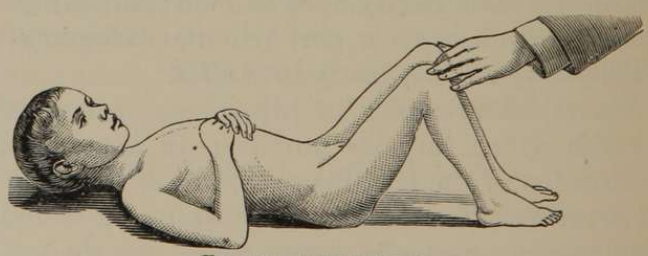

Fig. 430.—(After Sayre.)

up (Fig. 430), it will be seen that the sacrum, spines of the vertebræ, the scapulæ, and occiput rest in contact with the table. If the sound leg be now extended and the popliteal space brought well down against the surface of the table, the lumbar spine is only very slightly, if at all, lifted from the table (Fig. 431). If there be rigidity of the muscles

named, as a result of hip disease, on the suspected side, when the effort is made to bring this leg into a position parallel with the sound one, it will be seen that extension of the thigh is limited, and that the motion of the hip joint is transferred to the lumbar vertebræ, so that when the popliteal space touches the table the lumbar spines are lifted from one to three inches from the surface (Fig. 432).

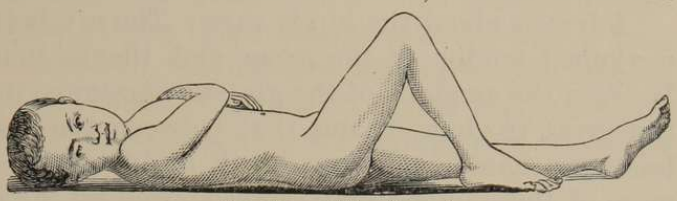

Fig. 431.—(After Sayre.)

The duration of the first stage varies from two or three months to as much as one year, and in exceptional cases longer.

In the *second stage* the thigh is further flexed on the abdomen, adduction is more pronounced, and shortening is present in a degree varying with the extent of destructive ostitis in the acetabulum, or head and neck of the femur, and to the character of the luxation. In the usual position of the foot of the affected side, in this stage, the great toe or inner surface of the tarsus rests upon the dorsum of the well foot, or on the spine of the tibia. The shortening —which may be determined by measuring from the anterior-superior spine of the ilium to the inner malleolus —will vary from half an inch to several inches. Nélaton's or Callaway's test—already given in the articles on fractures of the femur—will demonstrate that the shortening has occurred above the trochanter.

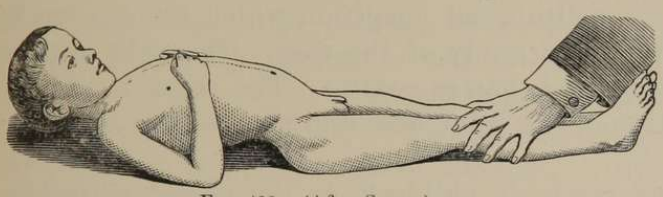

Fig. 432.—(After Sayre.)

When suppuration occurs, the capsule gives way, and sooner or later, if surgical interference is delayed, sinuses open through the skin, about the trochanter, or in the groin. Perforation of the acetabulum takes place in a certain proportion of cases.

Diagnosis.—Disease of the hip joint may be differentiated from bursitis, peri-articular inflammation, rheumatism, neuralgia, sacro-iliac disease, or ostitis of the trochanter or ilium. It is also important to determine whether the initial lesion is a *synovitis* or an *ostitis*.

Synovitis may be caused by excessive use of the joint, by strain or concussion, by sudden exposure to cold, or it may result as a symptom of gout or rheumatism. It is a painful affection from its incipiency, and the pain increases with the march of the effusion into the joint and the distention of the capsule. Motion increases the pain, which is usually so severe that all movement of the joint is firmly resisted. The cause may usually be traced to an injury. Synovitis due to gout or rheumatism occurs usually in adults; coxitis is practically a disease of childhood.

When *ostitis* is the initial lesion, the approach of the disease is insidious and much less painful. When present, the pain in ostitis of the head

and neck of the femur is deep-seated and dull, and motion is comparatively free. Rotation and pressure of the head upon the capsule and in the acetabulum do not produce the sharp sense of pain felt in synovitis. Ostitis is the rule in children, synovitis in adults.

Bursitis about the hip is rare. The sac between the capsule and the conjoined tendon of the psoas and iliacus muscles, and those situated between the tendons of the gluteus maximus, medius, and minimus and the great trochanter, and that between the quadratus femoris and the lesser trochanter, may one or all be involved. Inflammation in one or more of these bursæ may be recognized by the limited extent, as well as the acuteness of the pain elicited by direct digital pressure immediately over the known position of the sac. Pain in the knee is not present in bursitis at the hip. Rigidity is not general in the muscles about the joint.

Peri-articular inflammation is a painful affection, causing marked lameness from the start; it is accompanied by local swelling and tenderness if superficial, and usually by exacerbations of temperature, all of which will render it easy of recognition.

Muscular rheumatism is rarely confined to the muscles of the hip. It is an expression of a constitutional condition which can not but be elicited by a careful history and study of the case. The pain is more severe and more early recognized than in coxitis. The painful territory may be outlined by fixation of the joint and digital pressure upon the muscles involved.

Neuralgia occurs very rarely in children, in the period when hip-disease is most likely to appear. The exacerbations of pain are more sudden in development and acute in character, and occur with greater frequency and regularity than in hip disease. Motion is tolerated better in neuralgia than in coxitis. The symptoms of ostitis which lead to arthritis, if carefully studied, will show a wide difference from neuralgia about the hip.

In *arthritis* or *ostitis* at the sacro-iliac junction pain is caused by forcibly pressing the ilium against the sacrum. The same symptoms may be elicited by direct pressure posteriorly over the sacro-iliac articulation. Motion at the hip is only slightly if at all embarrassed.

Prognosis.—In hip-joint disease commencing—as is the rule—in *ostitis* or *epiphysitis*, the prognosis is bad as regards restoration of function. Partial or complete anchylosis, with a variable degree of shortening, will result, in the vast majority of cases, no matter how skillfully treated. The proportion of fatal cases can scarcely be determined. It is safe to say that at least five per cent of all cases in which the lesion begins as an ostitis end in death in from one to six years.

In traumatic synovitis of the hip the prognosis is favorable. A restoration of function is the rule.

Treatment.—The treatment of hip disease may be divided into *mechanical*, *operative*, and *constitutional*.

In the early stage of coxitis *rest* to the inflamed articulation, in the

position of least discomfort, is essential. A diseased joint demands protection not only from traumatism in the effort at locomotion, but from reflex and involuntary muscular spasm. Fixation of the muscles which act upon and about this joint can be best secured by extension from the lower part of the thigh and counter-extension from the perinæum. It has been shown by Bradford and Lovett, of Boston, that in order to gain the full benefit of extension at the hip, the femur should not be brought out entirely straight, but should rest about five degrees short of full extension (175°).

If a child with hip disease be seen very early in the history of this affection, flexion of the thigh upon the abdomen will not have occurred to any extent, but, in cases where the inflammatory process has gone on for some time, the iliacus and psoas and adductor muscles will have become rigid and shortened to such an extent that the thigh can not be immediately brought out straight.

In the former class of cases the apparatus about to be described can be at once adjusted ; in the latter, extension in the recumbent posture is necessary until the shortening in the ilio-psoas muscles is overcome.

In fact, since in all cases some time must elapse between the discovery of the lesion and the preparation of the mechanical apparatus, it is a wise practice to put the patient to bed at once, and apply the extension as follows: Cut two strips of moleskin plaster, from one inch and a half to two inches wide, and long enough to extend from six inches above the trochanter to below the sole of the foot. Adjust one to the outer and one to the inner aspect of the thigh, allowing the upper end, which is to be doubled back upon itself and woven in with the roller, to extend four or five inches above the level of the trochanter. Mold them carefully to the contour of the limb, bringing the strips exactly over the inner and outer condyles of the femur, and hold them by a well-adjusted bandage, beginning from above. In order to prevent the plaster from wrinkling, it is necessary to clip it with the scissors, obliquely upward from each edge, at intervals of an inch or two. As the extension is exerted only from the femur, the adhesive strips should not be applied to the skin below this point. The bandage is commenced just at the level of the great trochanter, and that portion of the strips which extends above this is to be turned down and worked in with the roller.

That part of the plaster which is exposed from the knee down should be doubled by laying a second strip of equal width on this, the adhesive surfaces coming together. In this way it is not only strengthened, but is prevented from sticking to the dressing.

The extension weight—varying from seven to twenty-five pounds—is applied as in Buck's apparatus. The dorsal decubitus should be maintained, for, if the sitting posture is assumed, the iliacus and psoas muscles are not materially affected by the extension. To secure this result the long splint of Hamilton should be applied from the axilla along the thigh and leg, and firmly secured by a bandage carried around the chest, pelvis, and thigh. Or a pillow slip may be pinned to either side of the bed, passing over the chest.

As soon as the thigh is fully extended the following mechanism should be adjusted. It is one which is now employed by Dr. Newton M. Shaffer, after many years of trial and a large experience in the management of these cases, in the New York Orthopædic Hospital and Dispensary. It embodies the principle of extension from the pelvis and counter-extension applied to the *femur* from the trochanter down to the condyles. It can be so arranged as to take advantage of any degree of deformity, correcting flexion, abduction or adduction, and is a modification of an apparatus which was original with Dr. Henry G. Davis, devised by him over forty years ago. It consists, first, of a pelvic band (Fig. 433) so curved behind and in front as to make the shortest possible perineal pads. This band should be made of annealed steel strong enough to bear the weight of the body of the patient. Attached to this is the cylinder which extends down the leg along the outer side to a point opposite the ankle joint. Accurately fitted into the cylinder is a traction rod with a foot piece, and the connection between the cylinder and the traction rod is regulated by an adjustable rack and pinion. The pelvic band, accurately adjusted, is fixed by two short perineal pads attached to it in front and behind, and the entire leg is connected with the traction rod by adhesive plasters which envelop it entirely and extend high up on the thigh, making practically all the traction from above the knee. The connection between the adhesive plasters and the foot piece is made by leather straps (Fig. 433).



Fig. 433.—Shaffer's modification of Taylor's hip splint.



Fig. 434.—Four-tailed adhesive strip, with buckle ready for application.

This apparatus may be used in various modifications, not only in the treatment of the deformity, but after the deformity has been modified, in which latter case it is so adjusted that the weight of the body falls entirely upon the perineal straps—in other words, forming a double ischiatic crutch. When the deformity is removed or essentially modified, the patient may walk with or without crutches, as the conditions may demand. After a certain length of time has elapsed, the joint

reaches a stage of convalescence where simple protection is necessary rather than traction. The modified apparatus then becomes very useful. The modification consists in adjusting the foot piece and cylinder into a well-fitting shoe, which takes the place of the adhesive-plaster traction. The end of the cylinder is inclosed in the shoe worn by the patient

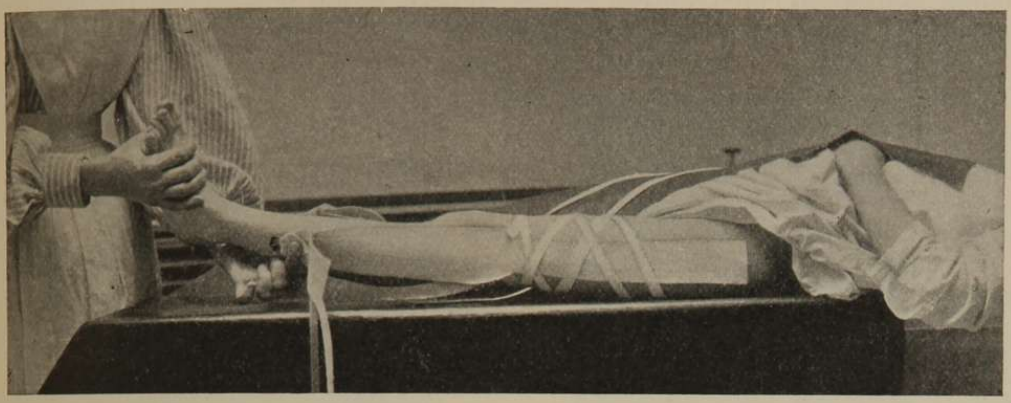

Fig. 435.—Showing the manner in which the tails are interwoven. First step.

instead of passing on the outer side, and, in addition to the outer bar, an inside bar is added with thigh and calf bands and an automatic knee spring, which enables the patent to bend the knee as occasion may require. It has the same hip-joint and perineal pads, and affords a modi-

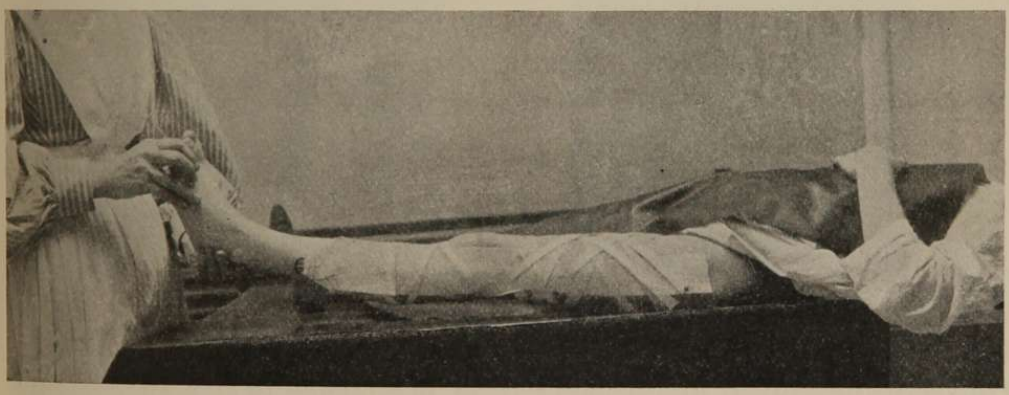

Fig. 436.—The same, before the bandage-roller is applied. Second step.

fied traction support to the hip joint. When strong abduction is necessary the instrument shown in Fig. 437 will be found useful.

Among many orthopædic specialists the question of preference between this form of apparatus and some modification of H. O. Thomas's method of treating hip-joint disease is not easily decided. Of all the applications of Thomas's idea which have been carried into effect, the following is the most commendable: It consists of a long malleable iron bar, which extends from near the axilla down the back parallel with the spinal column, over the buttocks, and down the posterior aspect of the thigh and leg, curving beneath the heel, and terminating opposite the center of the plantar arch (Fig. 439). At this termination a crossbar from three

to four inches long is welded, from the tips of which the extension straps are adjusted. At the upper end of this perpendicular bar there is a metal bar or belt which encircles the thorax for two thirds of its circumference, terminating in straps of strong webbing fastened together with a buckle. At a point opposite the anterior-superior iliac spine a pelvic band, similar in construction to the thoracic band, is adjusted for fastening the instrument around the pelvis at the iliac prominences. To this

Fig. 437.—Shaffer's abduction hip apparatus.



Fig. 438.—Thomas's hip splint.

band buckles are attached behind and in front for double perineal pads. Opposite the gluteal fold a metal band is attached, which encircles the thigh at this point. Farther down, at the junction of the inferior with the middle third of the tibia, another metal band is attached. When adjusted accurately to the contour of the back, buttock, thigh, and leg, it should extend three inches below the extremity, so that when the patient stands, the instrument will rest upon the floor while the foot swings free and clear.

The apparatus is applied as follows: The four-tailed adhesive plasters are applied to the leg as above directed; the splint is then adjusted by fastening, first, the perineal straps snugly, so that the pelvic band will come just below or on a level with the anterior-superior spines; the thoracic and pelvic bands are connected by means of the webbing straps; the leather spraps attached to the foot piece of the brace are then fastened into the buckles attached to the plaster on the leg, and firm, steady

traction made. The entire limb and brace are then incased in a lightly applied muslin bandage so as to prevent any wabbling of the limb. A high shoe is adjusted to the opposite limb, and the patient allowed to walk with this and a pair of crutches.



Fig. 439.—Thomas's hip splint (with American extension).

The length of time for which this treatment should be continued will be determined by the result achieved. It is often a necessity for one, two, or three years, and sometimes even longer, and should be worn for several months after all active symptoms of coxitis have disappeared.

Conditions may arise in which the apparatus just described can not be applied. A fairly good substitute, and one which secures fixation, is the plaster-of-Paris dressing, which is applied from the line of the nipple around the abdomen and over the hip, thigh, and leg, including the foot of the affected side. In order to apply it while the leg is in a condition of fairly good extension, the patient may be made to stand on the sound foot upon an elevated stool, allowing the lame foot to be pendant. An assistant on either side holds the patient upright, and another makes traction downward as the plaster is applied. The bony prominences should be carefully padded. The child should be allowed to go about after the plaster has hardened, and should wear an elevated shoe, four or five inches high, on the sound foot. This will permit locomotion without danger to the integrity of the affected hip.

Vance, of Louisville, Ky., has invented a molded-leather splint, which is applied in the same way, and covers the abdomen, hip, and thigh down to and below the knee, and answers the same purpose as the plaster-of-Paris; but as this latter is so much more readily obtained and more generally applicable, it may be relied upon in the early stages of hip-joint disease and in the later stages after extension and counter-extension in dorsal decubitus has brought the leg down to the proper plane.

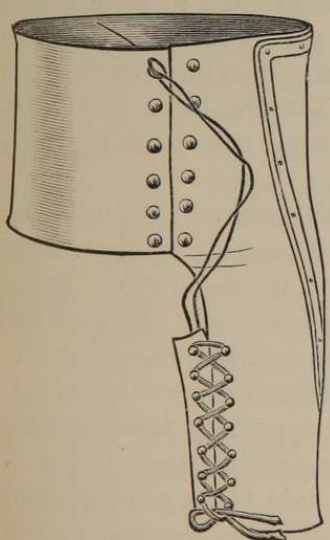

Fig. 440.—Leather splint.

When sinuses exist as a result of disease of the hip joint, some slight change in the application of the apparatus selected will be necessary. It is always essential that the openings of the sinus or sinuses be properly protected by absorbent dressings in such a way that free discharge may be secured without soiling the apparatus.

The constitutional treatment of this disease is of great importance.

Carefully selected diet, out-of-door life, cod-liver oil, the hypophosphites of lime and soda, and tonics are indicated.

In the *second* stage of hip disease operative interference may in rare cases be demanded: (1) To relieve pain on account of suppuration and the retention of pus, or to prevent sepsis from insufficient drainage; (2) to arrest ostitis in the head and neck of the femur, and in the acetabulum.

Fig. 441.—Plaster-of-Paris splint for hip disease.

When pain is so severe that fixation with extension will not afford relief, it is safe to conclude that distention of the capsule exists, or that in the structures which form the joint, or are immediately around it, suppuration has occurred to such a degree that free incision is necessary.

The question of performing a radical excision of the hip joint is one upon which a divergence of opinion still prevails. I am convinced, however, that this operation should not be done except as a last resort and when the symptoms of septic absorption are so well marked and severe that radical interference is demanded. Careful conservative treatment by well-adjusted apparatus, incision and drainage of all pus accumulations, and careful general treatment of these patients will result not only in securing the recovery of the patient, but will give a more useful joint in the vast majority of cases. In the rare cases in which excision of the hip joint is deemed necessary the wound should be packed with iodoform gauze and treated by the open method, not even partially closed by sutures.

The gauze may be changed every few days, the wound irrigated with 1-to-3,000 sublimate solution, and again filled. Extension by the weight and pulley, in the dorsal decubitus, is necessary for from three to six weeks after the operation, unless the child is strapped in the wire breeches recommended by Prof. Sayre (Fig. 442) immediately after the exsection. The chief recommendation of this apparatus is that it allows the patient to be carried out of doors or about the house with perfect freedom from motion or pain. The objection is its costliness, which puts it out of the reach of many patients. The extension in bed is very satisfactory in its results, and, with attention to ventilation and the amusement and entertainment of the little patient, the confinement need not be a formidable objection.

When the wire apparatus is used the following directions should be

carried out: Pad the instrument well, so that too great pressure at any one point may not occur. Place the patient in it so that the anus will project well over the crotch. It is well to insert a piece of protective under the sacrum and buttocks to prevent soiling. Fasten the well leg and the body to the instrument by rollers. Lay the extremity of the affected side in its splint, and screw the foot piece up until it touches the sole. Apply two strips of adhesive plaster in the same manner as heretofore given, attach these to the foot piece, and make the necessary extension by turning the screw in the proper direction (Fig. 443). After from four to six weeks, no matter whether the wire apparatus is used or extension in bed employed, the long splint of Shaffer or Thomas or the high shoe and crutches should be adjusted, and the case treated as given for the first stage.

FIG. 442.—(After Sayre.)

Within the last few years the operation of drilling into the neck and head of the femur, in certain cases where the initial lesion is an ostitis, has been advocated and performed in a number of instances by Mr. Macnamara.* The object of the operation is to give escape to, and secure drainage of, the products of the inflammatory process, at or near the epiphysis, and thus prevent disintegration of the bone and invasion of the joint. To be beneficial it must be done early in the disease.

FIG. 443.—(After Sayre.)

The operation is neither dangerous nor difficult. A longitudinal incision, from two to three inches in extent, is made along the middle of the trochanter, down to the bone. The wound should be deep enough to permit the fingers to locate the neck of the femur, on its upper and latteral surfaces, so that the drill may be directed along its center. The chief danger to be avoided is entering the cavity of the joint by carrying the drill too far. The small Volkmann spoon is well adapted to this operation.

Knee Joint.—Acute synovitis of the knee is frequently of traumatic origin, resulting from the excessive strain to which this joint is subjected, and also on account of its exposed position. It may occur in the history of gout, rheumatism, gonorrhœa, and other diseases.

The chief *symptoms* are pain and swelling. Pain may be elicited by motion, or by direct pressure at any part of the joint, but it is, as a rule,

* "Gibney on the Hip," Bermingham & Co., New York, 1884.

emphasized over the coronoid ligaments, along the articular margin of the tibia, on either side of the *ligamentum patellæ*.

The *treatment* consists of *rest* by *fixation*. As a rule, the most agreeable position is that of slight flexion, with the limb elevated and the leg resting over a pillow. Fixation may be best secured by extension from adhesive strips, reaching from just below the knee to beyond the sole. The weight will vary from three to fifteen pounds, according to the age of the patient. It must not be forgotten that the ligaments of the knee joint are susceptible of overstretching from too great and prolonged extension. Permanent relaxation or flail joint may result from overweight employed for too long a time. Cold, applied by means of the ice bag, is a most useful remedy during the acute stage of inflammation. When pain is very severe, and when the capsule is greatly distended, aspiration may be indicated. This should be done with all antiseptic precautions, and with great care in preventing the entrance of air. The needle may be introduced on either side of the patella, at the point of greatest distention, or where fluctuation is most marked. The diagnosis may be made positive by a small exploring hypodermic needle and aspirator. Or, when the tumefaction is evident above the patella, the needle may be carried from above downward, behind this bone. After the excess of fluid is withdrawn a fair degree of compression should be exercised by enveloping the joint with borated cotton, held firmly down by a roller. Passive motion of the joint may be omitted for as long as six weeks, with or without a fixed dressing as may be required.

When an acute synovitis of the knee becomes infected and pus is present, incision and evacuation of the pus, with irrigation, and drainage of the joint are indicated. As a rule, a single lateral incision made near the posterior level of the joint, as the patient rests in the recumbent posture, will suffice. A sterile rubber drainage tube, about two inches long with a diameter of a quarter of an inch and stiff enough to resist being occluded by contraction of the incision, should be inserted. The joint may be irrigated as often as indicated, probably once a day, with a warm saturated solution of boric acid or a 1-to-5,000 mercuric-chloride solution. When pus ceases to flow, the tube may be removed and a small wick of iodoformized gauze inserted for from two to six days.

The danger of anchylosis after acute synovitis of the knee joint, lasting not longer than from one to six weeks, is slight. It is always greater after *suppurative* synovo-arthritis, or *osteo-arthritis*.

Destructive *osteo-arthritis* of the knee joint may commence as a synovitis, either traumatic or idiopathic, or it may begin as an ostitis (tuberculous) in or near the epiphysis of the tibia or femur, the joint being secondarily involved. The latter is by far the more frequent source of chronic knee-joint disease.

Symptoms.—Pain is not, as a rule, a prominent symptom of ostitis near the knee, and, when the joint has become involved and the cartilages eroded, in many instances the degree of pain felt is far from being proportionate to the gravity and extent of the destructive process. In exceptional cases pain may be excessive, and may be felt in the

hip as well as the knee, or may be referred entirely to the acetabulum. As the disease progresses the swelling increases, and is due not only to effusion into the capsule, but also to thickening of the ligaments, and, to a certain extent, to changes in the ends of one or both bones which enter into the formation of this articulation. Later the ligaments give way, and dislocation of the tibia backward, with slight outward rotation, occurs (subluxation). In the earlier stages of the ostitis certain constitutional symptoms appear, and remain throughout the course of the disease.

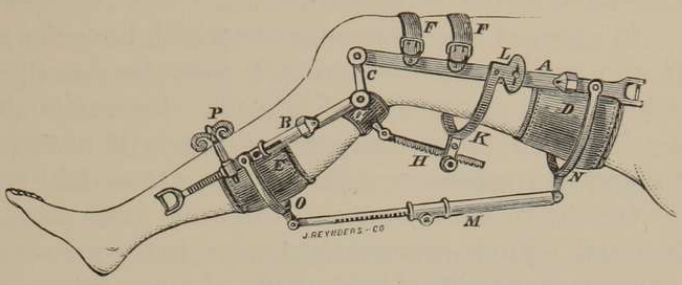

Fig. 444.—Shaffer's extension knee splint.

Treatment.—When tubercular arthritis of the knee joint is recognized in the early stages, the indications are as complete rest as possible for the joint surfaces. This can be obtained in a moderate degree by simple fixation with plaster of Paris, but this does not give the degree of extension which is essential to success. If, however, no extension apparatus can be obtained, the leg should be incased in plaster of Paris, closely applied while extension is being made, from the level of the perinæum down to and including the foot. It is better to leave the knee a little short of full extension—about five degrees of flexion. Shaffer's knee splint or brace (Fig. 444) is capable of meeting the various indications of extension, fixation, and rotation.

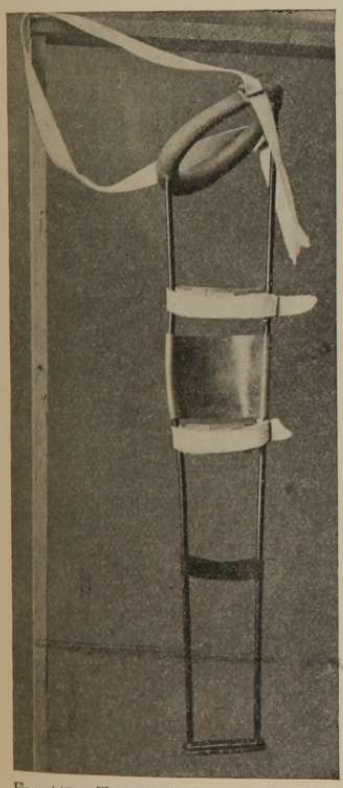

Fig. 445.—Thomas's knee and ankle brace.

A simple, less costly, and very efficient apparatus is Thomas's knee splint. It consists of a metal ring at the upper or perineal end, joining two parallel bars of iron, the ring having an angle of about forty-five degrees to the inner bar. These bars project below the foot, and the instrument terminates in a ring of iron (Fig. 445). The upper or thigh ring is well padded and fits closely upon its inner aspect against the perinæum and tuberosity of the ischium. It is fastened to the leg by leather straps and corset lacing or by an ordinary roller bandage. A shoulder strap or suspender, intended to hold the instrument against the perinæum, passes over the shoulder of the side opposite to that of the disease. A high shoe is placed upon the sound foot, and the patient walks at once with and later without the aid of crutches, the

weight of the body falling upon the perinæum and end of the brace, allowing no concussion in the knee joint. This apparatus, chiefly commendable for simplicity and cheapness, does not give as satisfactory extension as the Shaffer splint.

In cases of knee joint disease which have not received proper attention in the earlier stages there will very frequently be found a condition of subluxation of the tibia (Fig. 446). Extension in bed in two directions, as shown in the accompanying cut, will have to be made until the extremity is straight enough to wear either the Shaffer or Thomas splint.

Operative interference at the knee joint may, in rare instances, be demanded. Such extreme measures, however, should not be adopted until a thorough trial has been made of a carefully applied and well-attended

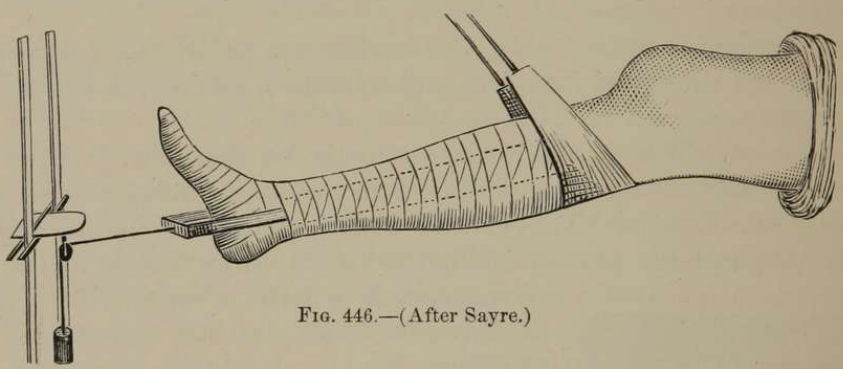

Fig. 446.—(After Sayre.)

orthopædic apparatus. Sometimes it requires three or four years to arrest the disease and effect a cure by these means, but it is often accomplished with a very fair degree of motion left in the joint. Operative interference, when it becomes necessary, may consist of incision of the capsule and drainage when, as determined by high temperature and great pain and constitutional disturbance, pyogenic infection has taken place, or excision of the joint and removal of the diseased portion of the bone with Volkmann's spoon or gouge may be required. Gouging will suffice in some instances where the destruction of bone is limited, but generally, when forced to a radical step, it will be found better to make a clean excision at the parts, according to the rule laid down for excision at the knee joint.

Diseases of the Ankle Joint.—The pathology, causes, and symptoms of disease at the ankle do not differ from those at the articulation just considered.

Synovitis is oftener *traumatic* than *idiopathic*. The exposed position of this articulation, which is called upon not only to sustain the entire body weight, but is also frequently subjected to great lateral strain, renders it exceedingly liable to injury.

The symptoms of acute traumatic synovitis at the ankle are usually not obscure. Swelling, pain, and heat, following prolonged or violent exertion, a twist, sprain, or other injury, bear strong evidence of inflammation within the joint.

The injury most difficult to differentiate from intra-articular synovitis, and one which frequently complicates synovitis here, is inflammation of

the sheaths of the tendons which play around the joint. The evidence of *thecitis* is pain in the track of the tendon, either elicited by direct pressure or by placing the foot slowly in a position which will cause the greatest tension of the tendons, and then requiring the patient to move the foot in various directions which are resisted by the operator. To test the peronei muscles, carry the foot well inward, hold it firmly, and ask the patient to turn the foot out. Thecitis in the track of these tendons will arrest the effort at abduction and outward rotation. The reverse of this manœuvre will serve to demonstrate a similar condition in the flexors and internal rotators.

Tuberculous synovitis of the ankle joint is less painful and comes on slowly. Synovitis from exposure to cold, gout, or rheumatism is frequently symmetrical, attacking either both ankles at the same time, or first one and then the other. Traumatic and tuberculous synovitis, on the other hand, are almost always unilateral.

The *prognosis* of simple synovitis of the ankle, when proper, vigorous, and prompt treatment is instituted, is in general favorable.

Treatment.—Acute synovitis, whether of traumatic or idiopathic origin, demands rest, with an elevated position of the foot. Simple cases will require no more than this, with hot or cold applications, or lead-and-opium wash, applied by soft cloths laid loosely around the ankle, or blotting paper kept wet with vinegar. The employment of compression will depend upon the sense of relief it may give the patient. Absorbent cotton or soft sponges may be used, applied carefully with a flannel or muslin roller. The method of immediate strapping with adhesive plaster and permitting the patient to walk about, has been employed of late with success, and is recommended by so high an authority as Gibney. It consists in enveloping the foot from near the torso-metatarsal junction, the ankle, and lower fourth of the leg in tight-fitting strips of adhesive plaster, applied in figure-of-8 fashion and partially overlapping each other.

Aspiration of the joint to relieve extreme tension from effusion applies here as in other articulations. The needle should be entered in front, between the anterior margin of the external malleolus and the contiguous surface of the tibia, away from the vessels and nerves which are opposite the middle of the joint.

In subacute or chronic synovitis, or in gonorrhœal arthritis, compression is indicated, and will often cause absorption of the excessive effusion in the joint. It is especially demanded after aspiration, to give support to the parts, and to prevent a further effusion.

Extension is indicated when its employment gives relief from pain, which rest and fixation without extension do not afford. Fixation with liquid glass or plaster of Paris secures rest to the joint in most cases, and permits of locomotion on crutches.

Arthritis of the ankle is more often due to tuberculous *ostitis* of the tibia or the astragalus.

The *symptoms* are those of ostitis, elsewhere given, and the *diagnosis* and *prognosis* do not differ materially from similar lesions in other articulations.

When osteo-arthritis with pyogenic infection is evident, operative interference is indicated, for the reasons that (1) early incision, by giving discharge to the contents of the capsule, retards or arrests the destructive process; (2) the common experience of surgeons is that the invasion of this joint is practically without danger to the patient's life.

Complete exsection of the articular ends of the tibia and fibula, and of the upper half of the astragalus, is rarely called for. An incision upon the side which, from the symptoms present, will give the best access to the diseased bone, and the free use of Volkmann's spoon in removing the dead tissues, will usually suffice. The foot should be kept at rest, and the patient directed to go on crutches until several months after the discharge has ceased and the sinus closed. The operation of gouging is more successful in osteo-arthritis at the ankle than in any other articulation. Complete exsection is only admissible when the destruction is very extensive.

Synovitis and osteo-arthritis of the articulations of the tarsus and metatarsus are treated upon the same general principles as just given for the ankle.

The Shoulder Joint.—Synovitis of the shoulder is usually general; in rare instances it may be local. It may affect the general synovial surface of the capsule, be reflected into the synovial sheath of the long head of the biceps, the bursa under the tendon of the subscapularis, or that beneath the infra-spinatus, or in rare instances, especially in the earlier stages, one or more of these bursæ may be inflamed, while the joint is not invaded. The bursa between the deltoid and the capsule may also be the seat of bursitis, although this sac does not communicate with the joint. The diagnosis of inflammation in one or more of the bursæ about the shoulder may be determined as follows: 1. Direct digital pressure upon any single bursa will indicate the sensibility of the part. 2. Extend the forearm fully, grasp the hand and elbow of the patient, and, while the head of the humerus is pulled away from the glenoid cavity, direct the patient to make strong flexion, which the operator firmly resists. If inflammation of the sheath of the long head of the biceps exists, pain will be experienced in the anterior and outer portion of the joint as this tendon is made tense. 3. When the bursa under the infra-spinatus is inflamed, if the arm is rotated inward, and held in this position, pain will be felt when the tendon of this muscle is made to press strongly on the bursa, in any effort at outward rotation.

An opposite manœuvre will serve as a test for the bursa beneath the tendon of the subscapularis. In *general synovitis* each of these movements will be productive of pain, and the differentiation is chiefly between neuralgia and muscular rheumatism. In *neuralgia* pain is rarely constant, the exacerbations appearing at intervals of comparative regularity, and extending in the recognized course of the nerves. Motion is not painful in the degree which characterizes either synovitis or rheumatism, and, if persisted in, the sense of pain may entirely disappear. Swelling is not a feature of a neurosis. In rheumatism of the muscles about the

joint the pain is superficial, and may be elicited by digital pressure upon the substance of the muscles.

The treatment of synovitis is the same at all joints. Artificial extension is indicated when the weight of the extremity is not sufficient.

Aspiration is a safe and efficient means of relief from pain, and is indicated when there is marked capsular tension. The needle should be entered through the center of the joint in front. Fixation of the joint by a shoulder cap of felt, cardboard, or leather, should be secured immediately after aspiration. When ready for application, lay upon the surface of the board which is to be nearest the skin a layer of absorbent cotton, which shall be wide enough to extend entirely around the arm and over the shoulder, place it in position, and secure snugly by a figure-of-8 bandage around the arm and shoulder.

Acute *suppurative* synovitis demands an immediate evacuation of the purulent contents of the capsule by incision and drainage. The line of incision is from the anterior internal tip of the acromion, parallel with the fibers of the deltoid along the anterior margin of the great tuberosity. The capsule is opened external to the long head of the biceps, and, while traction is firmly made upon the edges, the cavity may be thoroughly explored and cleansed. It is of vital importance that in this, as in every cavity which is the seat of purulent inflammation, drainage should, when possible, be established from that portion of the wound which is most dependent. As the patient rests in bed the posterior and outer part of the capsule is lowest. A dull-pointed dressing forceps should be carried into the capsule through the anterior incision and bored through the inferior posterior wall and all the tissues to the skin, and when this is pushed ahead of the instrument an incision should be made to allow the escape of the instrument. The wound is stretched by opening the jaws of the instrument, and a rubber tube pulled into place as the instrument is withdrawn. In *tuberculous osteo-arthritis* of the shoulder-joint exsection may be called for, after all conservative measures have failed.

The Elbow Joint.—Synovitis of this articulation need not be separately considered. The same general principles of diagnosis and treatment apply here as in other joints. Tuberculous osteo-arthritis demands gouging or exsection when careful corrective mechanical treatment has failed. The operation will be given hereafter.

The Wrist Joint.—Inflammation of the synovial membranes of the wrist or in the immediate neighborhood of this joint is of frequent occurrence. It is often traumatic in origin, and not infrequently tuberculous It may attack the synovial sac between the ulna and radius; that between the radius and the fibro-cartilage and the first carpal row; the general synovial sac between the first and second rows and the metacarpus; or that between the base of the first metacarpal bone and the trapezius (Fig. 447). Inflammation of the sheaths of the tendons on the dorsum of the carpus or on the palmar surface may also complicate a carpal synovitis, or exist alone. The contiguity of these various structures renders a positive diagnosis of great difficulty. If, when the

bones of the forearm are grasped near their center and pressed together, sharp pain is elicited at the wrist, synovitis of the radio-carpal sac is indicated. When the swelling is well defined at the edge of the articular end of the radius, extends across the wrist, and is limited to the situation of the first row of the carpus, the radio-carpal sac is probably alone involved. When the several capsules are involved the swelling is general. In *thecitis* the pain is superficial, and usually extends for some distance along the tendons above and below the joint. Contraction of the muscles, the tendons of which are involved, will point to the location of the inflammation. Differentiation of synovitis from Colles's fracture will depend upon a study of the symptoms of this lesion already given. *Tuberculous osteo-arthritis* in its earlier stages is comparatively a painless process, and even after the capsule is invaded is rarely as painful as an acute synovitis.

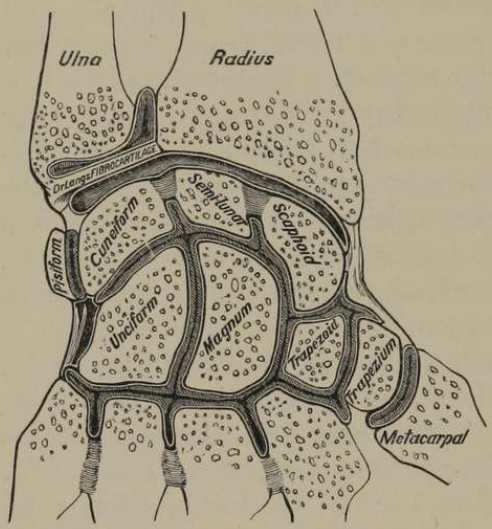

Fig. 447.—(After Gray.)

Treatment.—Synovitis of the wrist does not demand separate consideration. Destructive osteo-arthritis requires gouging rather than exsection. Synovitis of the metacarpal or interphalangeal joints should be treated on general principles of rest and fixation.

Exsections of the Joints

The Hip—Sayre's Operation.—Place the patient on the sound side; carry the point of a strong scalpel perpendicularly down to the bone exactly halfway between the anterior-superior spine of the ilium and the tip of the trochanter major;* cut along the neck of the femur, keeping the knife firmly in contact with the bone, carrying the incision midway between the center and posterior aspect of the trochanter, and then curving it slightly forward as it passes about an inch below the tuberosity (Fig. 448). Through this incision, which divides the capsule and thickened periosteum, insert the elevator and lift the periosteal investment from the diseased bone. When the trochanters are involved, the tendons, inserted into these eminences and into the digital fossa just above the great tuberosity, usually require to be detached with the knife, the point of which, in order to avoid wounding any vessels, should be kept in close contact with the bone. As soon as the periosteum is freely raised, the bone should be divided, with the chain saw or a dull-pointed keyhole or metacarpal saw, and the upper fragment lifted out with the elevator. The sawed surface should be carefully inspected in order to see if the disease extends farther down the bone, ne-

* The extremity should be held parallel with the axis of the spine, with the foot normally rotated outward.

cessitating a second division. The acetabulum should next be examined, thoroughly scraped with a Volkmann's spoon, and all dead tissue removed. Hæmorrhage is usually insignificant, and, if occurring, should be arrested as the operation progresses. The wound should be thoroughly irrigated with 1-to-3,000 sublimate, all shreds of tissue and particles of bone removed, and the entire cavity, after being thoroughly dried, filled with sterile gauze, well packed in, and held in place by a thigh and pelvic spica. The patient should now be put to bed with an extension apparatus applied as given for the early treatment of hip disease. Sand bags may be laid along the leg to hold the foot in the proper degree of outward rotation, or a splint may be used. The long splint from the axilla to the heel is often required to prevent a child from sitting upright in bed. The first dressing is changed usually about one week after the operation, and once or twice a week thereafter. After four or five weeks the case should be treated as in the first stage. Prof. Sayre prefers, and frequently employs, the wire breeches for the

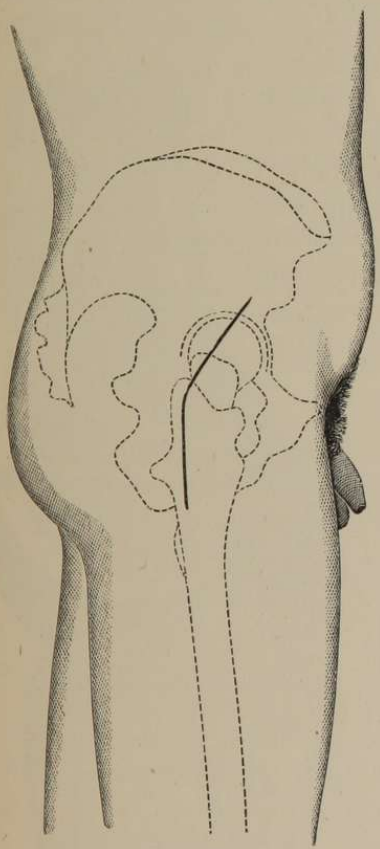

Fig. 448.

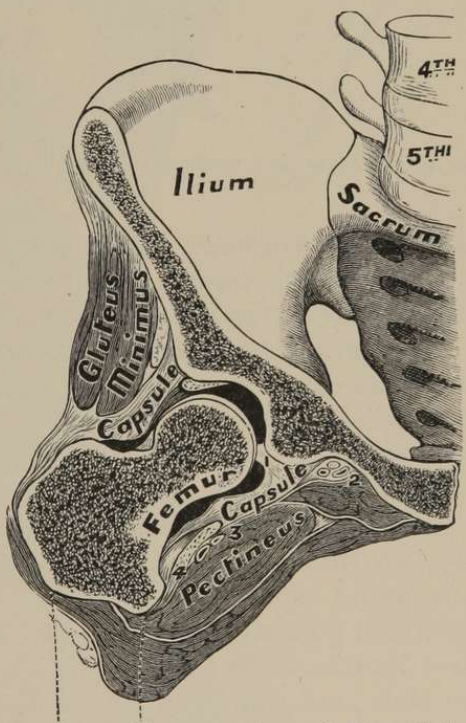

Fig. 449.—1, Ligamentum teres. 2, External obturator muscles and obturator vessels. 3, Circumflex vessels. 4, Conjoined tendon of psoas and iliacus. (After Braune.)

first few weeks after the operation. This apparatus can not always be obtained, and the extension in bed has proved perfectly satisfactory.

In a certain proportion of cases the disease is not arrested by the first operation, and a second is required.

The outline of the parts involved in this operation is well shown in Fig. 449.

Excision of the Knee Joint—Operation.—Under rigid asepsis elevate the foot in order to empty the extremity of blood, and after a minute or two apply the rubber tourniquet above the middle of the thigh.

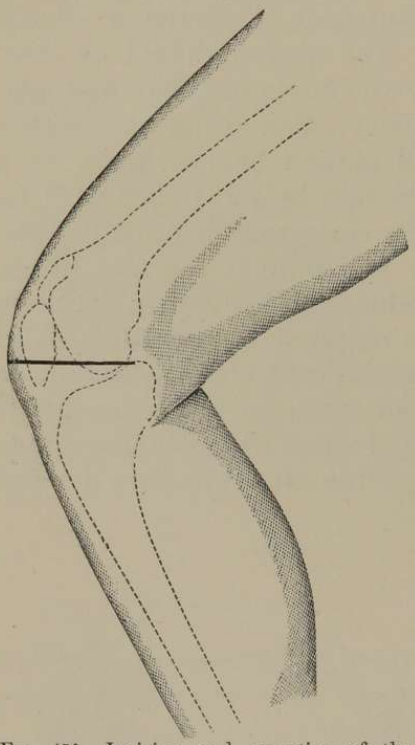

Fig. 450.—Incision and exsection of the knee.

With the leg straightened out, or slightly flexed (Fig. 450), an incision is made across the center of the patella and down on each side until the level of the posterior surface of the tibia is reached. These points must be low in order to secure drainage. The skin flaps or cuffs are now dissected and rolled up until the upper one is turned back about three inches, the lower two inches. As the flaps are held well away by assistants, the operator cuts down to the femur through the tissues, parallel with the attached edge of the reflected upper flap, lifting everything from the anterior aspect of the femur and its condyles together with the patella, the attached fringes, ligamentum patellæ, and coronary ligaments—thus clearing in one mass all the tissues which envelop the anterior three fourths of the joint.

By sharply bending the knee the crucial ligaments are exposed and divided, the lateral ligaments cut away, and the disarticulation effected. In stripping the attachments of the ligamentum posticum Winslowii from the tibia and femur, the operator should closely hug the bone and thus avoid wounding the vessels. This dissection posteriorly should extend about three fourths of an inch below the level of the tibia and one and a half inch above the lowest surface of the condyles. Determining now the amount of bone necessary to be removed, a cloth retractor is applied so as to protect the soft parts from bone detritus or injury, and a slice thick enough to freshen the head of the tibia is sawed away, as nearly as possible parallel with the normal plane of the articular surfaces, or at a right angle to the perpen-

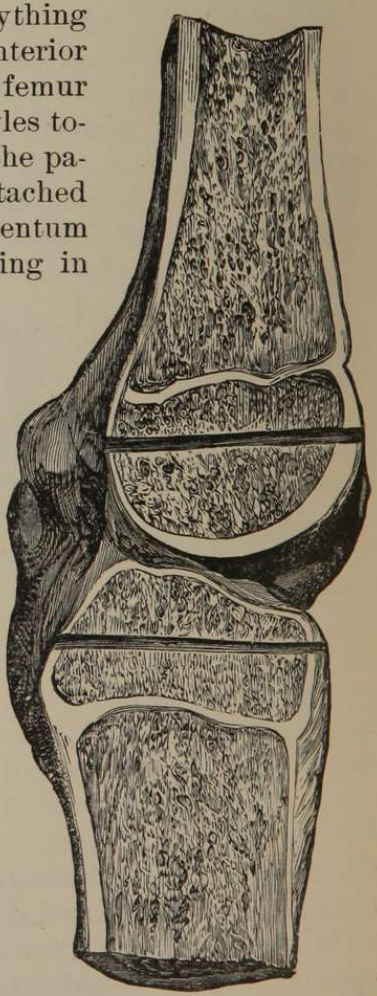

Fig. 451.—Showing the proper line for sawing between the epiphyses of the tibia and femur and the joint cavity.

dicular axis of this bone. Should the section expose a focus of disease which dips down into the bone, this should be cleared out with a scoop

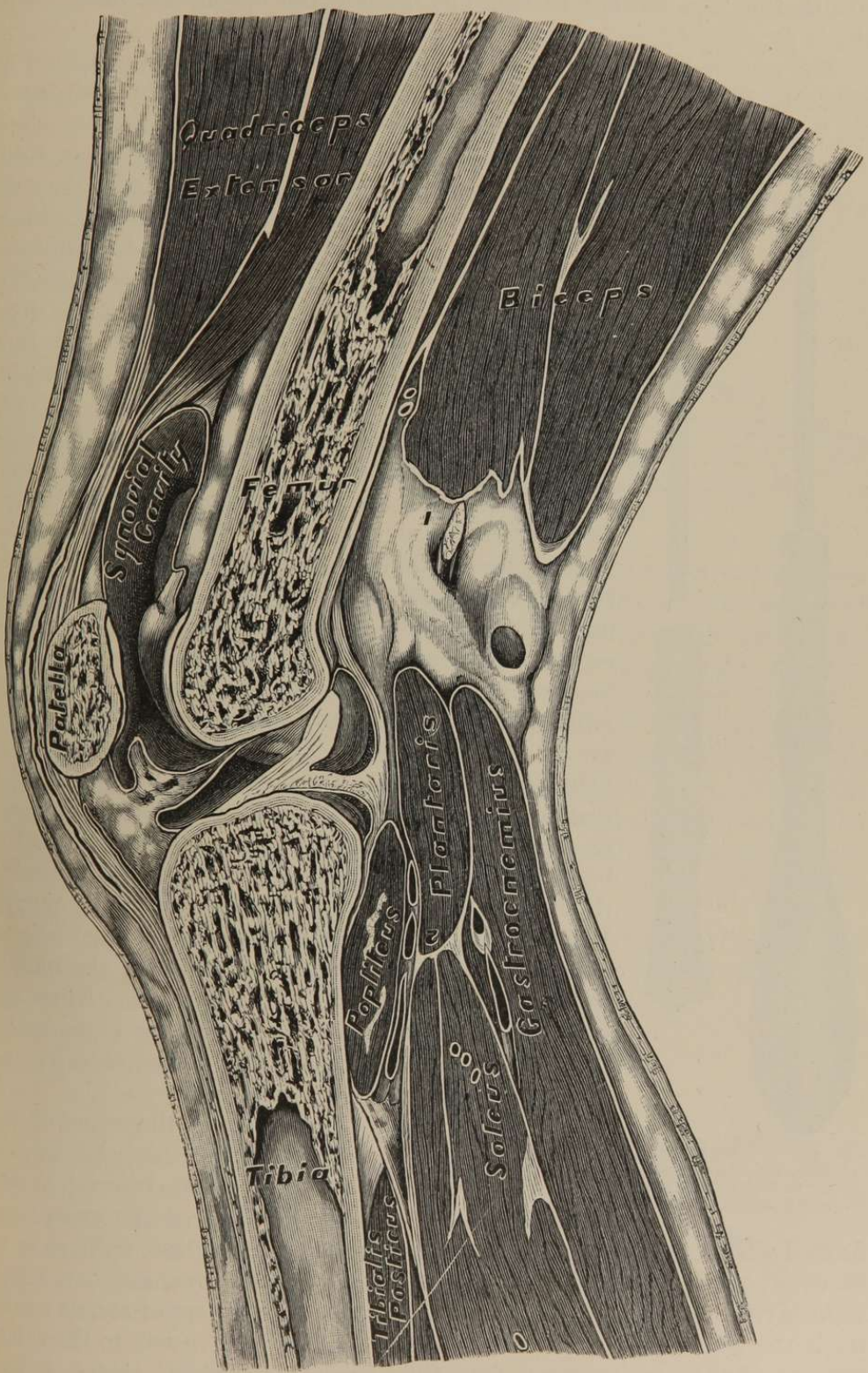

FIG. 452.—Longitudinal section through the knee joint. 1, Peroneal nerve. 2, Popliteal vessels. (After Braune.)

or Volkmann's spoon, and finally mopped with a strong bichloride solution (1 to 500). It is important, and especially in children and young adults, that the section should not involve the epiphyseal lines. (Fig. 451.)

The section through the end of the femur should now be made (Fig. 452). It follows that if the limb is to be straight in the position of anchylosis, the sawed surfaces of the two bones must be parallel. I have found it of great value to employ this method. By pulling on the foot the limb is fully straightened, and the articular surface of the femur separated from the sawed surface of the tibia. If the operator will now start the saw into the femur, sighting by the flat face of the tibia, the instrument will cut directly parallel with this. If by error the section of the tibia has been slightly oblique, that of the femur will have a like obliquity, and therefore the bones will fit snugly with the extremity straight.

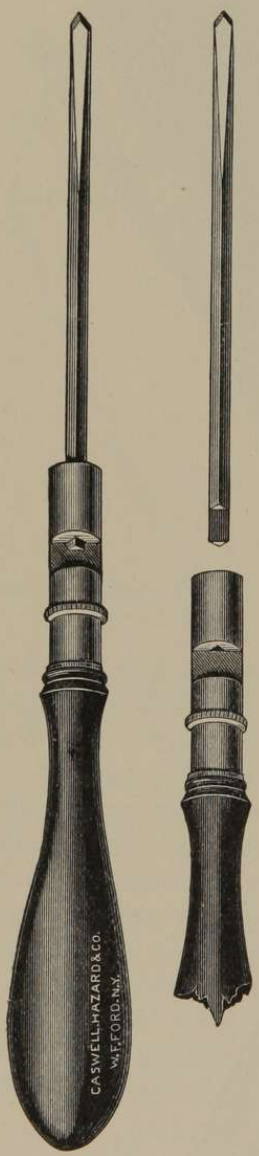

Fig. 453. — Wyeth's drills, with adjustable handle, for fixation of the bones in knee-joint exsection.

The next step is to dissect away with forceps and curved blunt scissors all the diseased capsule. This should be done thoroughly, and even the bursæ that communicate with the joint should be cleaned out. If care is not taken, a portion of the sac which extends up beneath the quadriceps tendon will not be removed. All bleeding points should be tied with catgut and hæmorrhage stopped. The bones are now brought in exact apposition, and while so held the steel drills (Fig. 453) are introduced. I usually carry two of these in from below upward, passing them through the skin about two inches below the sawn surface of the tibia and directing them obliquely through the tibia into the femur. When the end of the drill has reached the compact substance of the femur, it is stopped, the handle unshipped, and the drill left in position. Three are used, one on either side from below, and one directly down the median line from above, entering the femur and passing into the tibia.

As the leg is now held steady the edges of the wound in the skin are sewed together with catgut, and two short twisted catgut drains inserted at the inferior angles. The united lips of the wound are dusted with iodoform, a narrow strip of aseptic protective, split so as to fit over and not obstruct drainage, lies over the sutures, and over this a light layer of iodoform gauze and then successive layers of sterile gauze, until the whole limb from the ankle to the hip is invested to the thickness of about two inches. One thickness of absorbent cotton is now applied, and on the top of this successive layers of veneering or thin

wooden splints under firm compression of a roller. Over all, a layer of starched crinoline bandage is placed. This dressing is allowed to remain on for six weeks, and when changed the drills are pulled out. Should it for any reason become necessary to remove the dressing about the fourth week, the pins may then be extracted.

The roller should be firmly drawn, so that a considerable pressure may be exercised upon the part, to prevent oozing. The elasticity of the cotton distributes the pressure equally, and controls hæmorrhage without causing discomfort. It is the practice of some surgeons not to apply

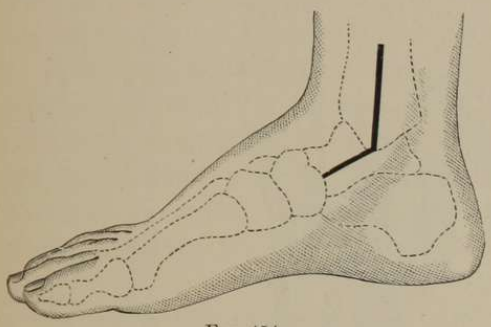

Fig. 454.

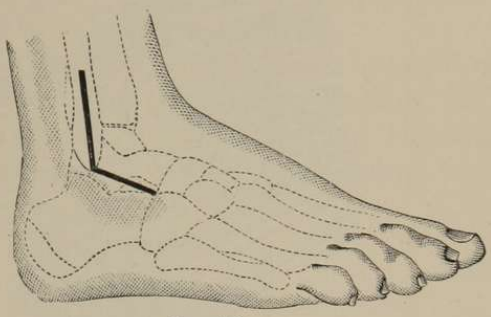

Fig. 455.

a single ligature in this operation, but to rely wholly upon compression for the control of bleeding. It is better to search for and tie the larger vessels which may have been divided. As in all the antiseptic operations, the indications for a change of dressing are hæmorrhage, high temperatures, and decomposition of the discharge beyond the zone of asepsis. When the wound is dressed, careful antisepsis should be practiced. Recovery, with anchylosis in the straight position, is the result desired. This operation has met with remarkable success within late years. The drills are preferable to nails in fixation. They are carried into position by steady pressure on the handle, with a slight half-rotary movement. When they can not be obtained, the parts may be held in apposition by wiring the bones together.

The Ankle Joint.—For the complete exsection of the articular ends of the tibia and fibula and the astragalus, proceed as follows : Commence an incision on the internal surface of the tibia, about two inches above the tip of the inner malleolus, and carry it directly down to this point, and thence forward, from one inch to one inch and a half along the tarsus, in the direction of the metatarsal bone of the great toe (Fig. 454). A similar L-shaped incision is made upon the

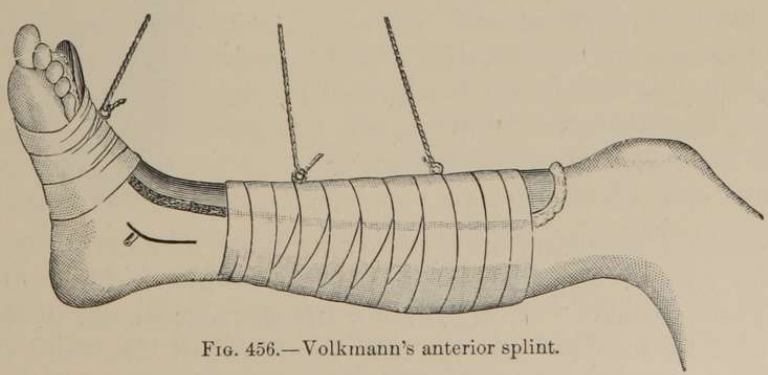

Fig. 456.—Volkmann's anterior splint.

fibular side of the joint (Fig. 455). These incisions divide all the tissues down to the bone. With the Sayre elevator lift the periosteum, with its attachments to the superjacent soft tissues undisturbed, from the diseased portions of bone. Expose the outer malleolus and fibula as high as it is

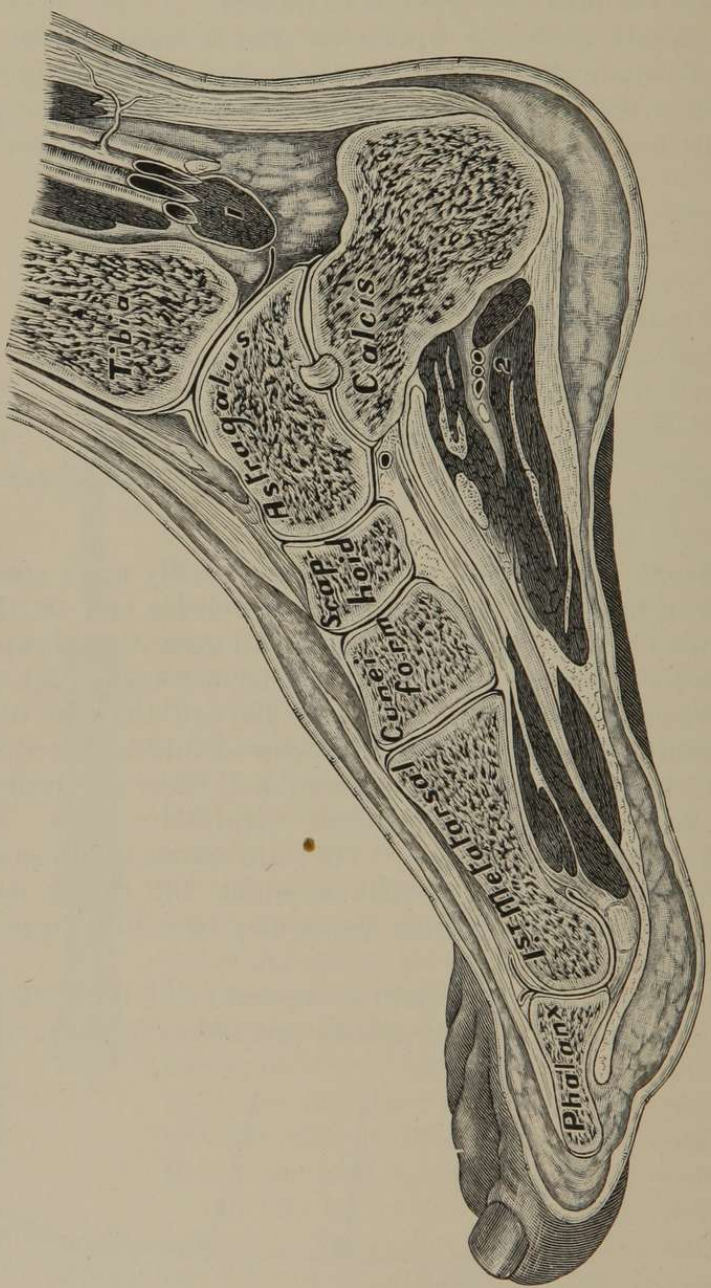

Fig. 457.—Section through the lower portion of the leg and foot, showing the relations of the parts in exsection of the ankle joint. 1, Posterior tibial artery, veins, and nerve. 2, External plantar vessels. (After Braune.)

deemed necessary to remove this bone, and divide it with the exsector (or chisel). As soon as the piece is removed the joint is thoroughly exposed to view. Now, further lift the periosteum of the tibia and tarsus, and, by forcibly bending the foot inward, dislocate the tibia and inner malleolus outward, through the wound on the fibular side. The diseased surface may be sawn off with an ordinary saw, or with the exsector. The section through the astragalus may be made with a gouge, chisel, or a

keyhole saw. Usually no vessels of importance are wounded in this dissection, since, by keeping beneath the periosteum, they are lifted with the tissues. The periosteum should not be elevated over the healthy bone. The sawed surfaces are now brought in apposition, so that the foot will be at an angle of 90° with the axis of the leg. Fixation may be secured by transfixion with small steel drills, carried obliquely from above downward, entering on the internal aspect of the tibia and the external surface of the fibula, and passing into the astragalus (in the same manner as at the knee). The wound should be closed with catgut, leaving a small catgut drain to pass out on each side. An aseptic dressing should be applied, and over this plaster of Paris.

If the drills are not employed, the parts should be held in apposition while a plaster-of-Paris dressing is applied. Or a Volkmann's splint (Fig. 456) may be applied to the anterior extremity of the foot and leg, and the parts fixed with plaster of Paris, or simple roller. This splint may be made of wood, or sheet or hoop iron, properly padded with sterile gauze.

If the bones are not extensively involved, a single L-shaped incision will suffice to expose the joint, and the dead bone can be removed with the gouge or Volkmann's spoon and a counter-opening made for drainage. This operation is always to be preferred at the ankle.

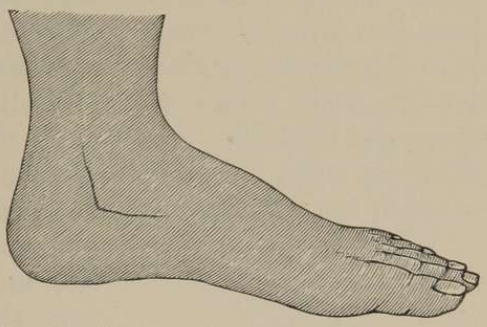

Fig. 458.—The foot after exsection of the astralagus and articular ends of tibia and fibula.

When, in an exsection of the ankle, the astragalus is so much involved that its removal is necessary, the upper surface of the *os calcis* should be smoothed off with the chisel or keyhole saw, and brought up in apposition with the plane surface of the bones of the leg. Fig. 458 represents a foot after recovery upon which I did this operation in 1885.

The Shoulder Joint.—Exsection of the head of the humerus is readily effected by a single straight incision, about five inches in length, made from the acromion process directly down the arm, parallel with and splitting the fibers of the deltoid (Fig. 459). The periosteum should be carefully lifted as far as the ostitis extends, and the soft tissues about the capsule raised with the elevator. The edges of the wound should be held wide apart by blunt retractors, and the tendons of insertion of the supra- and infra-spinatus, teres minor, and subscapularis divided close to the tuberosities with the curved blunt scissors. The sheath for the long head of the biceps should be laid open, and this tendon held aside. The bone should now be divided at the limit of the disease. When the section is completed a strong hook should be fastened into the end of the upper fragment, in order to lift it and facilitate the separation of the soft tissues on the inner and under surface from the bone and capsule. The capsular ligament should be trimmed from the margins of the glenoid cavity and removed with the head of the humerus. All diseased tissues

should be dissected out with the curved scissors, and, if the head of the scapula is involved, all disorganized bone should be scraped away with the spoon or rongeur. The capsule should now be divided and the head of the bone dislocated upward through the wound. The division is then made with a narrow saw, taking the precaution to protect the soft parts from injury. Upon examining the wound left after this operation, it will be seen that the deepest portion is behind and to the outer side of the end of the shaft. Into this depression carry a closed dressing forceps, and bore through to the skin, pointing the instrument to the inferior and outer aspect of the arm. Divide the skin over the point of the forceps, dilate the opening by separation of the handles, and draw a catgut twist drainage from below upward through the hole. A second shorter twist should make its exit through the anterior and lower angle of the incision, and the wound closed throughout with catgut. The forearm should be held in a sling or fastened across the abdomen. The application of Esmarch's bandage, and the rubber tubing in the axilla and over the clavicle and scapula, renders this operation practically bloodless. The rate of mortality is exceedingly low. With careful antisepsis it is practically without danger to life. A second operation for the removal of dead bone is occasionally required.

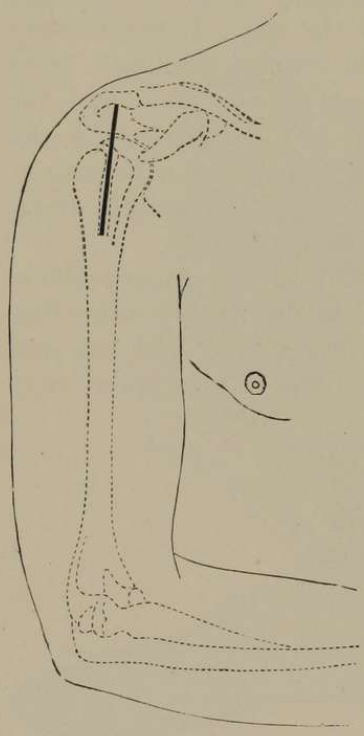

Fig. 459.

The Elbow Joint. — Flex the forearm on the arm and make a straight incision, commencing in the middle of the posterior aspect of the humerus, about one inch above the condyles, and extending over the center of the olecranon process, along the ulnar, for from two to three inches (Fig. 461). The tissues should be carefully lifted from the bone and capsule, and held to eitherside by blunt retractors. When the trough between the olecranon and internal condyle is approached, extra care should be taken not to wound the ulnar nerve, which passes in this groove. It may be avoided by keeping close to the bones with the knife or elevator. The articular end of the humerus should be exposed, as high as the

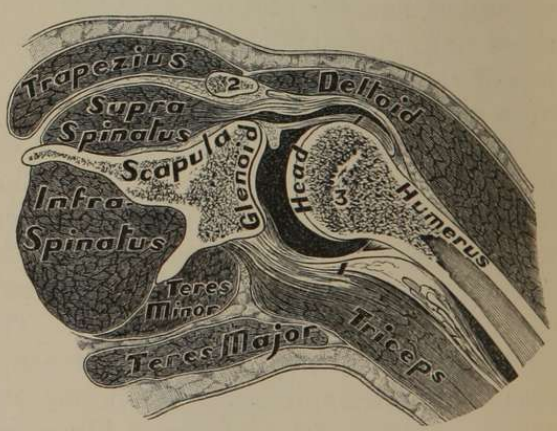

Fig. 460.—Longitudinal section through the shoulder joint, showing the relations of the bones, ligaments, and muscles immediately about the articulation. 1, The capsular ligament. 2, The acromion. 3, Epiphysis. (After Braune.)

point of section, by peeling off the soft tissues with the periosteum, after which a retractor is applied and the bone divided at an angle of 90° to the shaft of the humerus. The ends of the ulna and radius may now be readily displaced backward, exposed to the point of section, and divided on a line parallel with that through the humerus. As in all the joint exsections, a careful dissection of all the diseased capsule and soft parts must be made. The wound is drained from the most dependent portion by means of catgut, and closed with sutures of the same material. An anterior splint, previously fitted to the arm and forearm, and fashioned so as to hold the forearm halfway between flexion at a right angle and complete extension, is wrapped with gauze and laid on the anterior aspect of the extremity, and fixed by a roller to the arm and forearm, to within a few inches of the incision. A sublimate dressing is next applied to the wound, with cotton and protective, and a bandage over this to effect compression and to hold it in position. When a change of dressing is required, this last bandage only is removed. After the sixth week passive motion should be commenced, and should this not produce

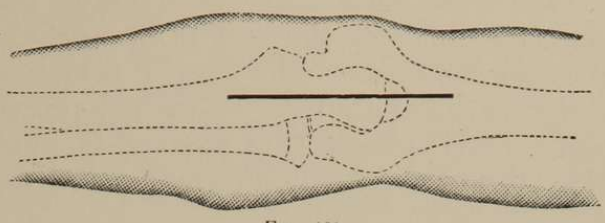

Fig. 461.

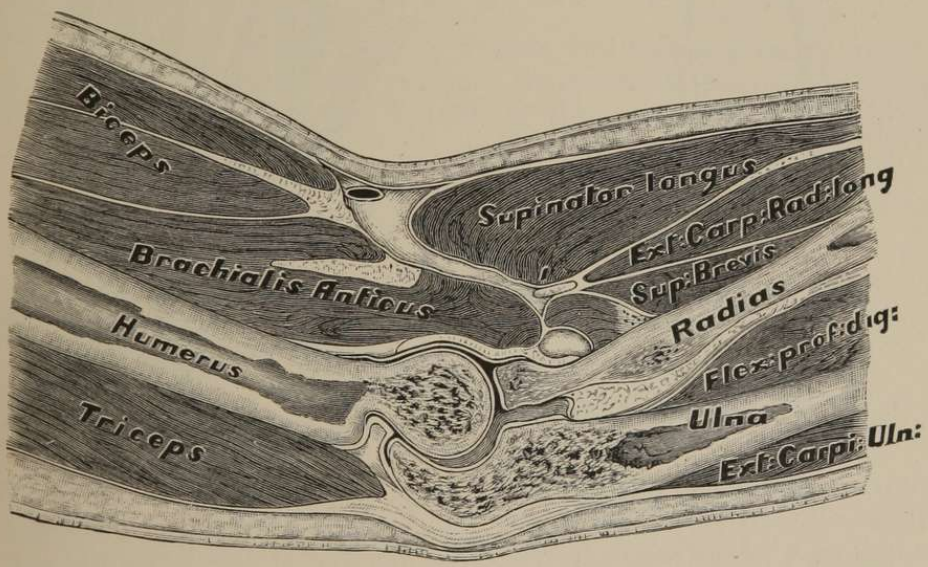

Fig. 462.—Longitudinal section through the elbow joint. 1, Radial nerve. Superficially on the flexor surface the median basilic vein is seen cut across. (After Braune.)

a too painful inflammatory reaction it should be repeated once or twice a week for two or three months. Anæsthesia is essential. A very considerable degree of mobility may be gained by this practice, although the rule in this exsection is fibrous anchylosis, with limited motion of the joint and function of the extremity.

Exsection of the elbow is not a dangerous procedure, and, although not usually attended with the success which follows some other opera-

tions (as those upon the shoulder and ankle), it should be preferred to amputation. The anatomical relations at this joint are shown in Fig. 462.

The Wrist Joint.—The exsection of this joint is attended with considerable difficulty, not only in the performance of the operation, but in the after-treatment. Moreover, it is more apt to be followed by failure, resulting in amputation. Of the two procedures—viz., the double lateral and parallel incisions (Fig. 463) and the single longitudinal dorsal incision (Fig. 464)—the latter is preferable when the destructive process is not so

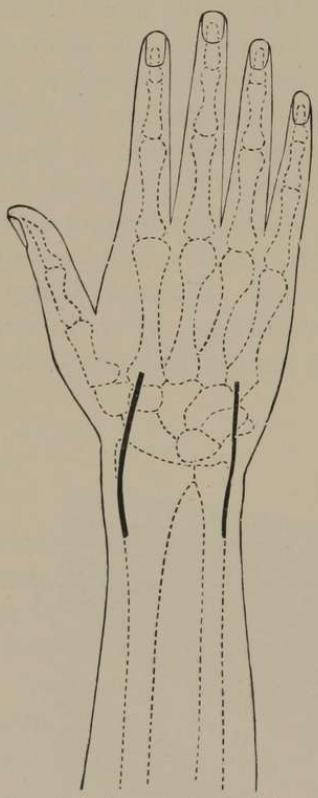

Fig. 463.—Bourgery's operation (modified).

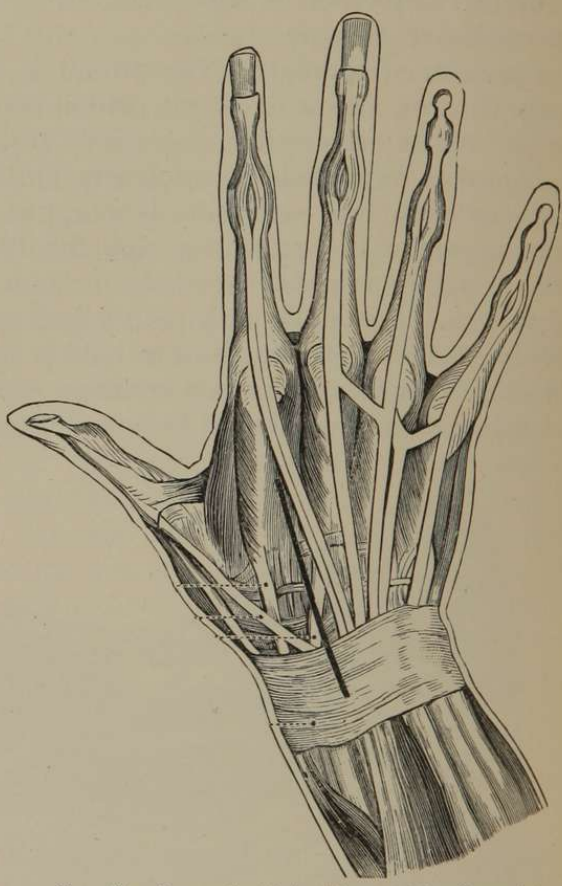

Fig. 464.—Langenbeck's incision. (After Esmarch.)

extensive, and when the spoon or gouge may be used, while the former will give the freest access to the bones when the saw or exsector is to be employed in the removal of a large portion of the bones which enter into the composition of this joint.

In the operation with a single dorsal incision the wrist should be made prominent, by flexing the hand on the forearm, and the integument divided along the tendon of the extensor communis digitorum, which goes to the index finger, the incision extending from the middle of the metacarpus to one inch and a half above the tip of the styloid processes. The tendon may be retracted to the side most convenient. The posterior segment of the annular ligament is divided, and the tissues lifted from the bones with the elevator. The end of the radius should

be removed with the exsector or gouge, when the carpus may be displaced backward through the incision, and removed wholly or in pieces. When the section is completed, the surfaces should be brought in apposition and fixed upon a well-adjusted anterior splint. Or an interrupted dressing may be applied by incasing the forearm in plaster of Paris to within an inch of the incision, and the fingers and hand in the same material, back as far as the anterior limit of the wound. A piece of hoop iron (or several pieces of telegraph wire twisted into a single piece) is shaped as shown in Fig. 465, incorporated into the plaster upon the arm, and made to loop over the wrist to the tips of the fingers, where it is turned back underneath the hand, and is fastened to the plaster here by an additional gypsum bandage (Fig. 466).

In the other operation one incision is made along the outer and dorsal aspect of the metacarpal bone of the little finger, over the styloid of the ulna, and one inch along this bone. The radial incision should commence on the dorsum of the metacarpal bone of the index finger, pass backward and slightly toward the radial surface of the forearm to a point half an inch above the tip of the styloid process, and thence directly upward along the dorsal aspect of the radius. In extensive operations it may become necessary to divide the tendon of the extensor ossis metacarpi

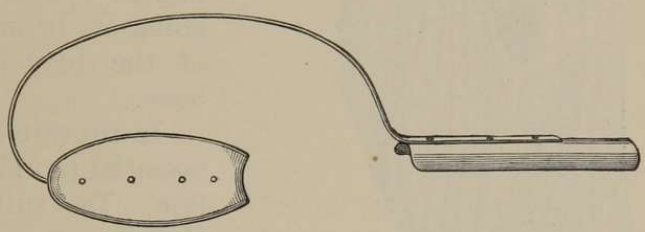

Fig. 465.—Esmarch's interrupted splint for exsection of the wrist.

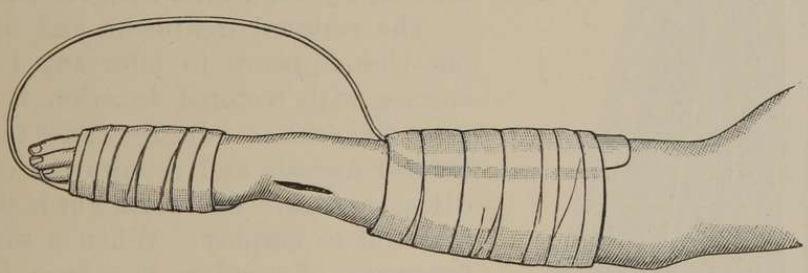

Fig. 466.—The same applied.

pollicis, which is crossed by the incision. When done, the ends should be reunited by silk sutures when the operation is finished. The tissues are lifted from the bones and capsule as before, and the sections made with the exsector or keyhole saw.

Metacarpo-Phalangeal and Inter-Phalangeal Joints.—Excision of the metacarpo-phalangeal, on the inter-phalangeal articulations, may be done when the destruction of bone is limited. The same general rule, viz., that an excision is preferable to amputation, is applicable both to the hand and foot. At the terminal joints, however, the small size of the last phalanges will rarely permit of any operation except amputation.

Tendons.—Of the diseases which affect the tendons or their sheaths and which require surgical interference, tuberculosis is by far the most

important. It may affect any tendon of the body, but is chiefly met with in the sheaths on the dorsum of the wrist. The symptoms are usually those of swelling, which gives a puffy appearance to the entire back of the hand. Pain, at times severe, is not, however, a constant symptom. The only operative procedure which promises success, is that which exposes the tendons involved by an incision, usually longitudinal, and a thorough dissection of the sheath from the tendon. The use of an Esmarch bandage facilitates the operation. Most careful asepsis should be practiced, the wound closed, and the patient should be directed to move the fingers while the process of repair is going on, in order to prevent adhesions of the tendon to the integument or bone.

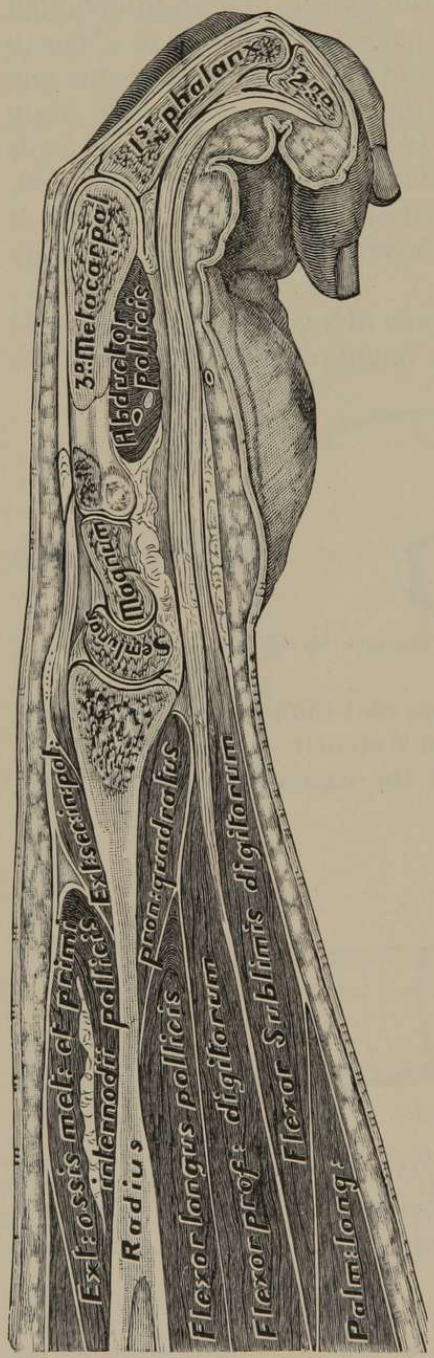

Fig. 467.—Longitudinal section through the forearm, wrist, and hand. (After Braune.)

In rupture or division of tendons it is essential to unite these at once by operation. Two sutures of fine silk are passed entirely through the substance of the tendon, about one eighth of an inch from the end, then tied and left in position.

Rupture of the tendon of the *quadriceps extensor femoris* is the most important injury connected with tendons.

The rational treatment, and the only one that appears to offer any hope of success with restored function, is to expose the seat of rupture under the most careful asepsis and reunite the ends by direct suture. Silkworm gut is the best material to employ. When a sufficient fragment of tendon has been left attached to the patella, the sutures should be passed through this. When rupture has taken place close to the bone, two holes should be drilled in the upper segment of the bone, as practiced by Buchanan, of Pittsburg, and the tendon of the muscle firmly united to this by a double set of silkworm-gut sutures. The sooner the operation is done after the injury, the better. The limb should be immobilized in full extension after the operation.

When the *ligamentum patellæ* is torn, suture should be attempted, as for the quadriceps tendon. The prognosis is even more unfavorable.

In certain forms of paralysis, especially of the muscles which move the fingers, hands, and feet, it may at times be required to *transpose* a portion of the tendon of a non-paralyzed muscle and unite it to the tendon of one which has lost its function, the method of Dr. B. F. Parrish ("New York Medical Journal," October 8, 1892, (of Kentucky. The tendon, or one half of the tendon, of a live muscle is in this operation sutured to the divided tendon of a dead or paralyzed muscle. Whether the union shall be end to end or lateral (overlapping) must be determined by the conditions to be corrected.

Elongation of the tendons of contracted or shortened muscles may also be effected by partial division on opposing surfaces at a given distance, splitting the intervening portion and uniting the half ends by suture.

CHAPTER XVIII.

REGIONAL SURGERY.—THE HEAD.

Tumors of the Scalp.—Tumors of the scalp are *congenital* and *acquired.*

Congenital cysts are deeply situated, being beneath the skin, and not infrequently below the fascia and muscles. Their contents are chiefly white or yellow fluid, and at times hairs (*dermoids*). Each tumor may consist of a single cyst, or there may be several grouped together (multilocular), the mass rarely attaining a size greater than an inch in diameter.

If left alone they may ulcerate from pressure or injury, or, in rare instances, may cause atrophy and perforation of the calvaria and dura mater. They should be removed in early childhood. The operation consists in dissecting out the sac, with its contents. As a rule, small wounds of the scalp, situated where a scar will not be apparent, do not need to be stitched. The edges should be approximated and held thus by a dressing of sublimate gauze and a bandage.

Acquired cysts, commonly called "wens," are of two varieties, one due to retention of sebum in a sebaceous follicle, the duct of which has been obstructed; the other caused by extravasation of blood, where the clot has been absorbed, leaving the serum more or less stained by the decomposition of hæmatin. They are round, smooth tumors, are superficial, and found most frequently upon the upper and posterior portion of the scalp. They are mostly multiple, are unilocular, and contain a granular, cheesy substance. The treatment is removal with the knife. The hair should be shaved from the tumor, and for a slight distance beyond its base. Complete anæsthesia can be obtained by injecting ℥ iv to vj of a 4-per-cent solution of cocaine in the line of incision, and around the base of the tumor. With a sharp bistoury transfix the mass through its base, and lay it open. The integument over the center of the tumor will be found exceedingly thin (not thicker than ordinary writing paper), and may be easily separated from the thickened sac, which should now be seized with a strong pair of forceps and torn out of its bed. If any strong adhesions are found they should be divided with the blunt scissors.

Sebaceous cysts occasionally become inflamed and infected, the capsule breaks down, the contents escape, and a mass of *granulation tissue* replaces the original tumor. The new-formed capillaries in this tissue frequently give way, causing repeated hæmorrhage. They should be scraped out with a sharp spoon, and the sac removed by dissection.

Horns, or dense epithelial outgrowths, are occasionally seen upon the scalp and face. Some of these excrescences attain large size. They should be removed by an elliptical incision around the point of attachment. The incision should remove the entire thickness of the integument.

Lipomata, or *fatty tumors*, are of infrequent occurrence beneath the scalp, and, on account of the dense integument, they grow very slowly and rarely attain large size. The diagnosis between sebaceous and fatty tumors of this region is not always easy. The treatment is removal by dissection, which is easily effected by lifting the tumor from its capsule with the finger or the blunt scissors. The capsule need not be removed.

Nævi, *port-wine marks*, and other *vascular tumors*, are quite common upon the scalp. They have been treated of in a previous chapter.

Papillomata, or *warts*, occasionally covering a large territory, are found in this region. In one case which came under my care a flat papilloma, two inches in width, extended from the right temple to the middle line of the scalp. They should be clipped closely with the curved scissors, their bases burned with the actual cautery or nitric acid, and the operation repeated until a cure is effected.

Ulcers from *syphilitic gumma* of the skull are quite frequently met with in the scalp.

Tuberculosis (lupus) of the skin is rare in this region.

Elephantiasis, or general thickening of the scalp from connective-tissue new formation, is, fortunately, rarely met with. Ligation of the vessels feeding the diseased area will afford temporary relief, and is a justifiable procedure.

Hæmatoma has been considered in the chapter on Wounds of the Scalp.

Abscess of the scalp requires free incision, irrigation, and drainage. Any doubts as to the character of the swelling may be dissipated by exploration with the hypodermic syringe and a good sized needle.

Pneumatocele, or "*air tumor*," is occasionally met with beneath the scalp. It results from disease or fracture of some of the bones, permitting communication with the cavities, as the frontal sinus, or the Eustachian tube, etc., and the escape of air beneath the skin. Evacuation of the contents by pressure, with or without puncture, and a compress to prevent recurrence, will produce inflammatory adhesions and effect a cure.

Ostitis, or *periostitis*, is not uncommon in the calvaria. The causes are the same as for ostitis elsewhere. Great care should be observed in the treatment, on account of the proximity of the meninges and brain. Ostitis with exfoliation demands early recognition and immediate operative interference. The rubber tourniquet around the skull may be employed to control bleeding. A free horseshoe or crucial incision should be made, and all the diseased bone removed with the sharp spoon. When the exfoliation is confined to the outer table of the skull the prognosis is favorable. The wound should be kept open, well drained,

and allowed to heal by granulation. If pus is found beneath the inner table, enough of the bone should be cut away with the rongeur to permit the free escape of all the products of inflammation. The patient should be required to rest in the position which secures most perfect drainage. A loose aseptic dressing should be applied.

Abscess of the Frontal Sinuses.—Chronic inflammation of these sinuses demands, as a rule, energetic and thorough operative measures. The accumulation of pus may interfere with the integrity of the eye, often breaking out through the orbit. Headache, great discomfort, and frequent and dangerously high temperatures indicate the sepsis which is occurring.

The operation I prefer is the following: Shave the eyebrow of the affected side and make an incision through the middle line of the brow so that when the hairs grow out the scar will be concealed. The incision should be free, extending across the root of the nose, if necessary. When the bone is exposed, the sinus is entered by chiseling with a small curved-edged instrument through the anterior lamella of the frontal bone at the inner angle of the supra-orbital arch. A light mallet should be employed and the chisel should be held with the point directed to the nose, so that a slip would not enter either the eye or brain. Continuing into the sinus, an opening one fourth of an inch in diameter should be made and the walls of the cavity thoroughly scraped with the sharp spoon.

A strong dressing forceps should now be carried into this opening, against the upper turbinated bones, and made, by boring, to crush through into the nasal cavity. A probe is next carried through this hole and brought out at the nostril of the affected side, and by this a strong silk thread is carried through. A good-sized piece of gauze—so twisted that while the end is as small as a cord the middle portion is as large as the finger—is tied to the string and drawn through the sinus into the nasal cavity and out at the nostril. The entire twist of gauze is now pulled through. This breaks away the turbinated bones, does not cause annoying hæmorrhage, and leaves perfectly free drainage into the nose and mouth. In several cases which have come under my care this method has been attended with gratifying success.

The edges of the wound should be united with fine silk sutures. In cases where the disease is unusually extensive and the discharge profuse, it will be advisable to carry a small soft-rubber drainage tube in through the wound down into the nose, leaving one end projecting through the nostril and the other at the inner angle of the incision above. For one or two weeks after the operation irrigation through the tube with warm boric-acid solution (gr. v–℥ j) should be practiced once a day. When the tube is removed it should be drawn out through the nose. If both sinuses are involved, an incision on one side may succeed in effecting a cure by breaking down the shell of bone which intervenes, and curetting the opposite sinus with the sharp spoon.

The effort to cure abscess of the frontal sinus by incision and drainage at the angle of the orbit is not only apt to fail, but it endangers the

integrity of the eye from the presence of the drainage tube and the accumulation of inflammatory products.

Osteoma, or *exostosis*, occurs quite frequently upon the bones of the skull. When not due to syphilis it should be removed early, by the gouge or chisel, as there is always danger of pressure upon important organs if allowed to remain. Syphilitic hyperostosis requires the specific treatment given for this dyscrasia.

Encephalocele, or *hernia cerebri*, is a protrusion of the brain substance through an opening in the calvaria. This condition usually occurs in children suffering from *hydrocephalus*, the protrusion taking place through the abnormally enlarged *fontanelles*. The dura mater surrounds and is carried in front of the mass, lying in contact with the pericranium. When the meninges alone protrude, the tumor is known as a *meningocele*. While this variety of tumor may occur at any point in the line of sutures, a favorite seat is in the median line of the skull, below the occipital protuberance. It may be covered with integument, or, as with certain forms of *spina bifida*, the meninges form the outer covering.

Meningocele is often incurable. Careful compression may limit the further development of the tumor, and in rare instances the opening in the skull closes spontaneously and a cure results. When the mass is covered with integument and the pedicle small, a rubber ligature gradually tightened is advisable.

Hernia cerebri may occur after perforation of the skull from any cause, as fracture or necrosis. More frequently the mass which protrudes is made up of a granulation tissue containing no elements from the brain substance, while at times these masses are composed of both brain and granulation tissue (Fig. 468). The character of the tumor will be recognized from its rapid development after perforation of the calvaria.

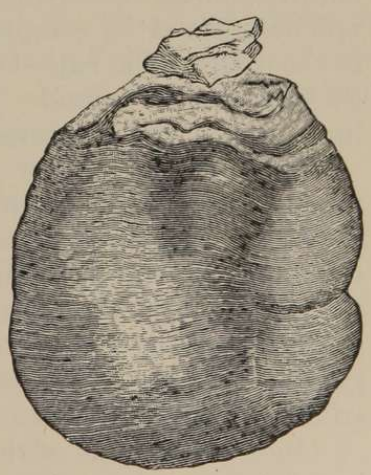

Fig. 468.—Mass composed of brain substance and granulation tissue, removed by Dr. E. J. Beall from a boy whose skull had been fractured. Exact size.

Treatment.—When the mass is small, and is just beginning to project, compression should be employed to prevent a further protrusion. It is not safe to attempt a reduction of the tumor. The hair should be shaved from the scalp near the opening and disinfection accomplished by sublimate irrigation, and a compress of sterile gauze and absorbent cotton applied. If the tumor does not rapidly slough away, it should be removed at the level of the scalp with the elastic ligature or the actual cautery.

Sarcoma of the dura mater is a grave condition, fortunately of infrequent occurrence. In the process of development the tumor is apt to cause absorption of the calvaria, and finally perforation. This usually occurs long after symptoms of pressure from within have been developed. If the

patient survive the compression of the brain, the tumor ultimately undergoes necrosis and breaks down into a dirty mass, in which the process of ulceration is accompanied by frequent hæmorrhage.

Carcinoma of the meninges may occur as a result of metastasis, although rarely if ever occurring primarily in this situation.

In sarcoma and carcinoma of the dura mater little more can be done than to relieve pain by the employment of narcotics.

Hydrocephalus is primarily a tubercular disease of the arachnoid and pia mater in childhood. The gross lesion is a transudation of the serous fluid from the pia and arachnoid into the cavities of the ventricles, the arachnoid, and subarachnoid spaces, Distention of the ventricles, compression of the brain substance, separation of the sutures, enlargement and deformity of the head, projection of the eyeballs, downward squint, and loss of cerebral function, are the symptoms, invariably ending in death.

Treatment.—Tapping will at times relieve the more urgent symptoms of distention and compression. Careful antisepsis should be practiced, and the aspiration made through one of the lateral angles of the anterior fontanella. A small needle should be introduced, and three or four ounces slowly withdrawn, the operation occupying from fifteen to thirty minutes. This treatment is palliative, and is only justifiable in the effort to relieve the suffering of the patient. A cure is impossible.

Wounds of the scalp should be treated as wounds of other parts of the integument. *Incised* wounds should be rendered aseptic, and may be closed by sutures, or the edges brought into apposition by a sterile-gauze compress and bandage. Sutures are as well tolerated here as elsewhere. When there is no especial desire to avoid a scar, sutures may be omitted, unless the wound is so extensive and gaping that apposition can not be effected by compression. Silk is preferable in stitching wounds of the scalp. The hair should be trimmed for a fourth or half inch from the edges of the wound. When no large vessels have been divided, the introduction of the sutures will suffice to arrest the bleeding.

Lacerated wounds of the scalp are at times very extensive and formidable. Several instances are reported of complete avulsion of the female scalp from the entanglement of the hair in machinery. In such cases transplantation of integument becomes necessary, in order to prevent ostitis from denudation of the calvaria. Ordinary lacerated wounds should be rendered aseptic, and may be treated by a compress of sterile gauze, or sutures employed, after the torn and bruised edges have been trimmed off with the scissors.

Contused wounds of the scalp are usually followed by marked swelling, due to extravasation of blood (hæmatoma) beneath the pericranium. The treatment consists in cold applications, by means of the ice bag or cloths taken from ice water. If suppuration occurs, incision should be promptly made. A form of serous cyst sometimes results from hæmatoma of the scalp. It should be treated by aspiration, and, if one or two evacuations do not effect a cure, it should be incised and the cyst wall dissected out.

Gunshot wounds of the scalp which penetrate to the meninges or brain require careful aseptic management and the removal of all pressure upon the brain. It has been advised by Horsley and Kramer that artificial respiration should be persisted in after unconsciousness from gunshot wounds of the brain. It is held that the primary effect of the concussion is to paralyze the respiratory center.

Punctured wounds of the scalp are not serious, as a rule, when no sepsis is introduced through the wound, and when the bones are not penetrated.

Penetrating Wounds of the Skull.—When a foreign body has penetrated the cranial cavity and passed out, and the patient survives the immediate effect of the accident, the wounds of entrance and exit should be cleansed of loose fragments of bone, or any foreign body. To accomplish this it will be not only justifiable, but often imperative, to enlarge both openings, by use of the trephine, and, while employing strict antiseptic precautions, to secure free drainage for the discharge of blood or other fluids from the track of the missile. When severe intra-cranial hæmorrhage occurs, no attempt should be made to arrest it by plugging the wounds through the skull, for fatal compression of the brain might thus result. If the vessels involved can not be reached from the enlarged openings, and secured by hæmostatic forceps or the ligature, the head of the patient should be elevated, in order to diminish the pressure at the bleeding point. This may in part be aided by ligation of the extremities, as heretofore described.

If there is only a single opening, and the body is lodged within the cranium, a careful inspection should be made about the wound of entrance, and, if the presence of the missile can be recognized, it should be at once extracted, even if the application of the trephine is required. If the bullet shall have entered the substance of the brain—which can be determined in part by the careful employment of a light Nélaton's probe, provided with a good-sized porcelain tip, introduced through the wound in the skull, sufficiently enlarged by the trephine—the probabilities are that it has passed through the brain in the line of projection of the missile, and is lodged beneath the skull, at or near a point directly in the line of its projection. This condition was found to exist in the remarkable case operated on by Prof. W. F. Fluhrer, in Bellevue Hospital, in 1884. The patient, aged nineteen years, received a pistol-shot wound, entering at the forehead and passing through the brain, in the line shown in Fig. 469. The hole of entrance was enlarged by biting off the edges of the bone with a rongeur. An alarming hæmorrhage from a vessel of the pia mater was controlled by a small artery clamp, or forceps. The patient's head was placed so that the supposed track to be explored was perpendicular to the surface of the table. A good-sized porcelain-pointed Nélaton's probe

Fig. 469.—Fluhrer's case of penetrating pistol-shot wound of the cranium. (After Fluhrer.)

was carefully introduced, and allowed to find almost its own way in the track left by the bullet. This instrument passed to a depth of six inches, where, a slight resistance being met with, it was allowed to remain. The direction of the probe indicated the point on the opposite side of the skull, at which the missile had most probably struck. Three fourths of an inch below this line the trephine was applied. Upon removing the disk of bone the dura mater appeared dark from blood effused beneath it. An incision was made through this, and the track of the bullet through the pia mater was discovered. It had struck the inner surface of the calvaria, had rebounded with a downward deflection, and was found about half an inch from the hole made by the trephine. A small rubber drainage tube was passed entirely through the track made by the bullet, and left projecting at each opening. Irrigation through the tube was not attempted. The wounds were dressed with iodoformized gauze, loosely laid on, and an antiseptic dressing over this. The patient recovered and returned to his occupation, suffering only with a slight impairment of memory and occasional muscular spasm.

The important lesson to be learned from the case above given is the necessity for great care in attempting to follow the track of a bullet through a substance so soft as the brain. If at any time any force is necessary to carry the probe along, all such interference should be discontinued, as it is very easy to push even a blunt, light, porcelain-tipped probe through this soft tissue. The tolerance of the brain to small foreign bodies should not be lost sight of. In many cases it is wiser to trust to encapsulation of the bullet than to search for it when it has passed beyond the dura. In the case of a young lad nine years of age, who came under my care, a twenty-six caliber conical bullet had entered just over the middle line of the right eye, passing directly backward through the brain. There was no paralysis, pain, or inconvenience from this injury. Under an anæsthetic, twenty-four hours after the accident, I made an incision which exposed the wound of entrance into the skull, enlarged the opening with the rongeur, and removed some pieces of bone that had been driven into the dura and brain. As the bullet had passed out of sight into this organ, the wound was sterilized and an iodoformized-gauze dressing applied. The patient recovered without accident, and is now, five years after, perfectly well, and at no time has suffered any suggestion of inconvenience from the presence of this foreign body in his brain.

Not infrequently compression of the brain occurs from hæmorrhage between the skull and the dura mater, or from a collection of pus, exostosis, depression of bone, or tumor within the cranium. Within recent years researches in cerebral anatomy and physiology have enabled scientists to determine, with accuracy sufficient to justify the application of their conclusions to surgical practice, from the disturbance of function in certain portions of the economy, the region of the brain involved in the zone of compression. That portion of this subject which is most capable of demonstration, and therefore most practical, relates to the interference with motion in certain muscles, or groups of muscles, which

have their "centers of motion" situated contiguous to the fissure of Rolando, and to certain disturbances of the mind and the senses chiefly located in the cortex of the brain. According to Lucas-Championnière,* who adopts the conclusions of Charcot and Pitres, our knowledge of this subject may be summarized as follows: "In a lesion followed by paralysis of the *lower extremity* the trephine should expose the summit of the *ascending parietal convolution*, on both sides of the upper end of the fissure of Rolando (Fig. 470). Of the *upper extremity*, the middle third

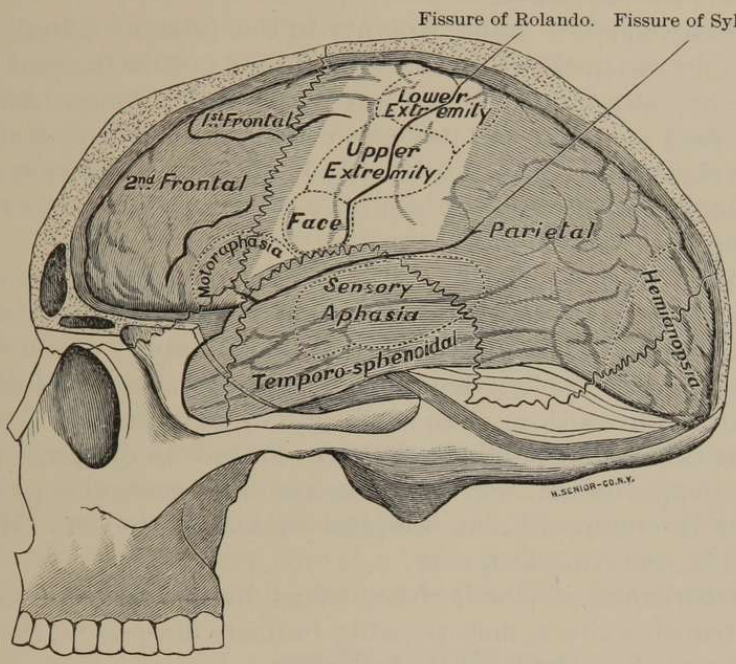

Fig. 470.—(Modified after Championnière.)

of the *ascending frontal* convolution, also on both sides of the center of the fissure; *upper* and *lower* extremities, *both* regions just given; *upper extremity* alone, with *motor aphasia*, *foot of third frontal* and lower third of *ascending frontal* convolutions, in zone marked *motor aphasia* in Fig. 470. *Facial paralysis*, lower third of the *ascending frontal* and foot of *second frontal convolutions*. *Aphasia* alone, foot of *third frontal*."

After a careful analysis of all the cases of cortical lesions of the brain published in America, and a thorough review of the results of foreign investigators, Prof. Starr arrives at the following conclusions:†

"1. Various powers of the mind are to be connected with activity in various regions of the brain, the surface of the organ being the seat of conscious mental action.

"2. The highest qualities of the mind—intellect, judgment, reason, self-control—require for their normal display integrity of the entire brain,

* "La trepanation guidée par les localisations cerebrales." V. A. Delahaye et Cie, Paris, 1878.

† "Cortical Lesions of the Brain." M. Allen Starr, from "American Journal of the Medical Sciences," July, 1884.

but especially of the frontal lobes. A change of disposition and character may be considered as symptomatic of disease of the brain, and, in the absence of other symptoms, of disease of the frontal lobes.

"3. The power of sensory perception is distributed over the various regions of the brain with which the various sensory organs are anatomically connected. In these regions objects are not only first consciously perceived, but are also subsequently recognized; and hence it is in these regions that the memory pictures are stored, by whose aid the act of recognition is accomplished.

"(*a*) Disturbance of sight, whether in the form of actual blindness, or of failure to recognize or to remember familiar objects, or of hallucinations of vision, may indicate disease in the occipital lobes. An examination of the field of vision will indicate which lobe is affected, since blindness in the right half of both eyes may be due to destruction of the left lobe, and blindness of the left half of both eyes may be due to destruction of the right lobe.

"(*b*) Disturbance of hearing, either actual deafness in one ear or hallucinations of sound on one side (voices, music, etc.), may indicate disease in the first temporal convolution of the opposite side. Failure to recognize or to remember spoken language is characteristic of disease in the first temporal convolution of the left side in right-handed persons, and of the right side in left-handed persons. Failure to recognize printed or written language has accompanied disease of the angular gyrus at the junction of the temporal and occipital regions of the left side in three foreign and in one American case.

"(*c*) Disturbance of smell, either as an hallucination or as a loss of power to perceive odors, may possibly indicate disease in the temporosphenoidal region on the base of the brain.

"(*d*) Disturbance of taste can not, as yet, be connected with disease in any region. This is due to lack of care in testing this sense in cases of brain disease.

"(*e*) Disturbance of general sensation—including the senses of touch, pressure, pain, and temperature, together with the sense of the location of a limb—may occur either in the form of subjective perceptions of such sensations without objective cause, or in the form of impairment of these sensations. In either case it indicates a disease in the central convolutions, and possibly in the adjacent portion of the parietal lobules.

"4. The power of voluntary motion of the muscles of the opposite side of the body is located in the two central convolutions which border the fissure of Rolando. Motions of the face and tongue originate in the lower third of this region; motions of the arm, in the middle third; motions of the leg, in the upper third.

"Spasms in a single group of muscles, or paralysis of a single group of muscles, may indicate disease of its motor area. Extensive spasms or paralysis may indicate a large area of disease in this region; but if more marked in a single group of muscles than in others it may indicate a small focus of disease in the motor area of that group affecting other motor

areas indirectly and coincidently. Paralysis following spasm in one group of muscles is a characteristic symptom of disease in the central region.

"5. Disturbance of the power of speech indicates disease in the convolutions about the fissure of Sylvius, on the left side in right-handed persons, and on the right side in left-handed persons. If the patient can understand a question and can recall the words needed for a reply, but is unable to initiate the necessary motions involved in speaking, the disease is probably in the third frontal convolution, and in the adjacent portion of the anterior central convolution. If the patient can not recognize spoken language, but can repeat words after another, or can use exclamations on being irritated, the disease is probably in the first temporal convolution. If the patient can understand and can talk, but replaces a word desired by one that is unexpected, the disease is probably situated deep within the Sylvian fissure, or in the white substance of the brain, and involves the association fibers which join the convolutions just named.

"In making a diagnosis of cortical disease care must be taken to distinguish between direct and indirect local symptoms; and also to separate clearly lesions of the cortex from those of the various white tracts within the substance of the brain."

As far as the disturbances of motion are concerned, these points of interest bear such close relation to the fissure of Rolando that it is necessary to determine approximately its location. Championnière's line is as follows: From the posterior border of the malar process of the frontal bone, at the upper outer angle of the orbit *A* (Fig. 471) draw a line *A B*,

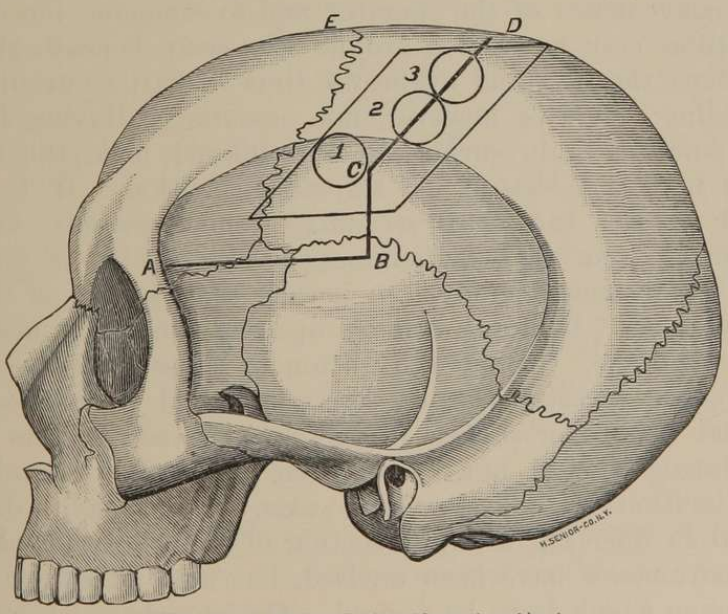

Fig. 471.—(Modified after Championnière.)

directly backward, a distance of two and four fifths inches. From *B* draw a perpendicular line, one inch and one fifth long, to *C*, then from *C*, upward and backward, to *D*, which shall terminate in the sagittal suture,

two and one fifth inches directly behind the junction of the coronal and sagittal sutures *E*. The point of junction of the sagittal and coronal sutures is not always easily recognized in the adult. If, however, the distance from the root of the nose (the naso-frontal suture) to the posterior-inferior border of the occipital protuberance be measured, the point *D* (Fig. 471) will be found to vary from three quarters of an inch to an inch posterior to the center of this line. The junction of the sagittal and coronal sutures is directly above the external opening of the auditory canal. The researches of Championnière may be particularly applied as follows: In complete and persistent hemiplegia, where the history of the case may exclude extravasation in the deeper ganglia, the center or bit of a large-sized trephine should be placed in the middle of this line, at 2 (Fig. 471), on the side opposite to the paralysis. If there is loss of motion or convulsive movements of the lower extremity alone, the trephine should be applied in the upper third of the line, at 3. When the upper extremity alone is involved (the lesion being probably in the middle third of the ascending frontal convolution), the operation should be performed opposite to the middle and in front of this line. When simple aphasia is present, the trephine is to be applied at the lower end, and well in front of this line, 1. If, when the button of bone is removed, the cause of the compression is not revealed, the opening should be enlarged by the rongeur, or by reapplying the trephine.

In elevating a portion of the cranial vault for exploration, or the relief of compression of the brain, the following rules should be applied: The entire scalp should be closely shaved, thoroughly cleansed, and rendered aseptic. A proper elevation should be given the head, to suit the convenience of the operator and to command the best light. A rubber tube may be carried around the scalp beneath the occiput and just above the ears and eyebrows, thus in part controlling all external bleeding. This is, however, not essential. Having determined upon the point of brain surface to be explored, make this the center of a large horseshoe-shaped or trap-door incision. If it has been determined to lift the skull *en masse*, the horseshoe flap is not raised separately, but the bone being exposed in the line of incision, the soft parts are retracted enough to permit the devision of the cranial vault in this line. In doing this an opening should be made with a small Galt trephine. When the button of bone is removed, a dull-pointed grooved director, slightly curved, should be inserted between the dura and the under surface of the skull, to see that no adhesions exist. A furrow should now be cut from the skull conforming to the horseshoe incision through the soft parts. Considerable difficulty is experienced in effecting a rapid section of the skull in many cases. Various instruments have been devised, but none of them have given the satisfaction which is to be desired. The cup-shaped rongeur or the fenestrated bone forceps (Figs. 113, 114) are most commonly preferred. Dr. A. De Vilbiss, of Toledo, Ohio, has invented a very useful instrument (Fig. 115). With it great force can be exercised over a limited area of bone to be divided, and the section made with greater rapidity than by

the older fenestrated forceps. So far the burr drills or saw revolving by a dental or electric motor have not proved satisfactory. The instrument becomes overheated from friction, and the operation is delayed. There is also some risk of wounding the vessels of the dura or brain unless it is well shielded or used with very great caution.

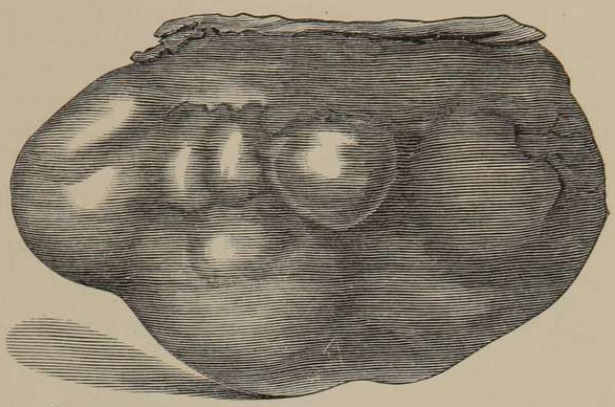

Fig. 472.—Appearance of the tumor with dura attached. Natural size. (Keen.)

The pericranium not having been raised, the bone may be replaced after the operation, without material impairment of its vitality.

The dura mater is next opened by a crescentic or crucial incision and reflected. Any offending mass should be removed. If nothing abnormal appears upon exposure of the cerebral surface, the question of invasion of this organ, or of further surface exposure, must be determined by the gravity and prominence of the symptoms and the condition of the patient. Exploration with a fine probe which will not cut or penetrate the vessels may be carefully done to the depth of one or two inches, and the increased resistance of a neoplasm will at times in

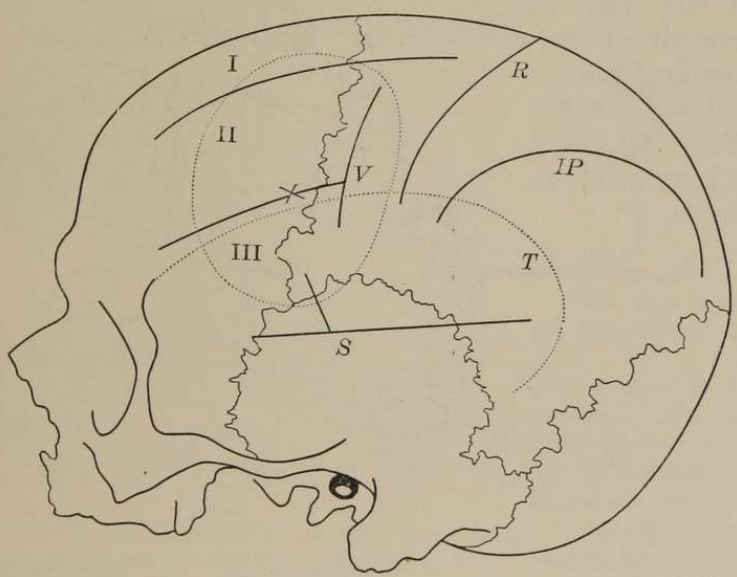

Fig. 473.—Diagram of the skull showing the site of the tumor. *S*, Fissure of Sylvius. *R*, Fissure of Rolando. *IP*, Intraparietal sulcus. *V*, Vertical or precentral sulcus. *T*, Temporal ridge. I, II, III, the first, second, and third frontal convolutions. The oval dotted line represents the tumor, the cross (×) the site of the scar. (Keen.)

this way lead to its recognition and location. In removing a deep-seated tumor considerable brain substance may be divided. In many instances the neoplasm can not be found, or is so deeply situated that the operation has to be abandoned. Hæmorrhage should be controlled by fine-

catgut ligatures, and by aseptic water at about 110° to 120°. On account of the delicate structure of these vessels, the ligatures should not be drawn too tight or any lateral traction made, for fear of tearing or cutting through.

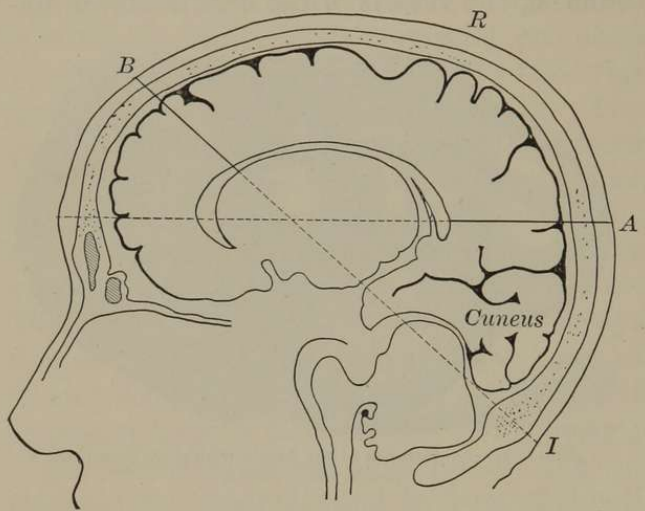

Fig. 474.—Antero-posterior section of the head half an inch from the median line. *R*, Fissure of Rolando. *I*, Inion. *A* and *B*, (solid) lines of puncture, the dotted lines showing their imaginary continuation to the fixed points. (After Keen.)

The wound in the dura should be closed with catgut sutures. A fine catgut drain may at times be indicated. The bone is next turned back into place and the soft parts sutured. If only a moderate surface is to be exposed, the soft covering should be lifted separately and the large trephine employed. The button of bone removed has been replaced in a number of instances successfully by immersing it as soon as cut out in warm sublimate (105° F.) and placing it again in the hole from which it was taken. It would be dangerous to attempt restoration of the bone when the underlying dura is destroyed or removed. The success achieved in late years in this department of surgery by Horsley,* Keen,† Allis, and others justifies the hope that still greater progress is probable in the near future. ‡

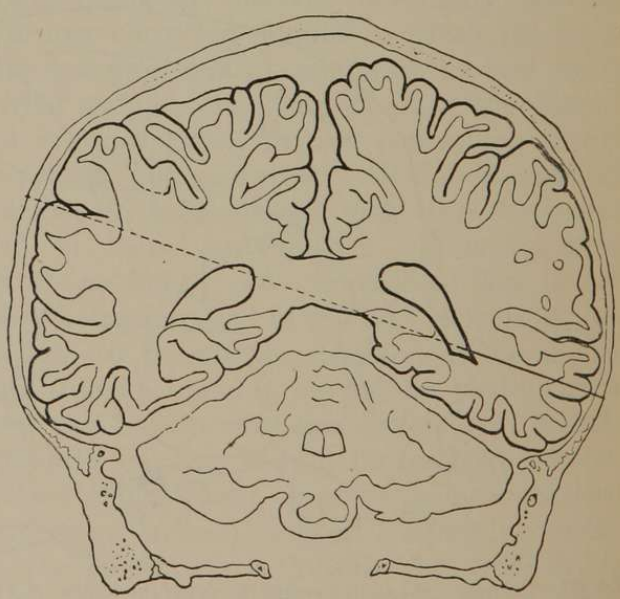

Fig. 475.

* "American Journal of the Medical Sciences," April, 1887.

† See same, October and November, 1888.

‡ This case of brain surgery (Prof. W. W. Keen, "American Journal of the Medical Sciences," October, 1888) illustrates so well the value of operative interference that an abstract is appended:

Tumor of Brain Epilepsy.—A man, aged twenty-six, at the age of three fell and struck his head upon a brick. He remained comatose one hour. At twenty-three years of age he had an attack of severe neuralgic pains. These symptoms increasing, culminated, in February, 1885 (twenty-four years old), in epileptic convulsions, and, in April, paralysis of right face, arm, and leg. Epileptic attacks ceased from November, 1886, to June, 1887. A small scar a quarter of an inch long persisted, located two inches and a quarter to the left of median line and three inches behind the left external angular process. December 8, 1887, it was tender to pressure. Temperature over the scar, 95·5° F.; cor-

When laceration of brain has been produced by fragments of bone or other foreign substance, drainage is an essential feature of successful

responding point on opposite side, 94·4°. December 15, 1887, operation under ether and incision through the scar down to the bone; no indication of injury to the bone. A nick was made in the skull just at the seat of the scar. Large semi-elliptical flap three inches and a half broad; convexity of incision posterior for drainage was cut and turned forward. Trephine an inch and a half in diameter applied so as to include point under the old scar. Dura adherent to the button in the lower half. Hard mass recognized, and a second button removed. Rongeur used, to fully expose the remainder of the tumor. Dura opened. It was adherent to the tumor, and a portion of it was removed with the neoplasm, which was enucleated with the finger. Bleeding controlled by fine catgut and hot water, 115° to 120° F. The cavity occupied by tumor was one half filled by the resilient brain tissue before operation was completed. A bundle of horsehairs for drains was carried across the wound and left projecting at each side. Small rubber tube inserted. Patient recovered, improved in mind and body, although mild convulsive movements occurred at rare intervals. In 1896 Dr. Keen writes me this patient "is still doing well after nine years."

Keen also proposes the following procedure for the relief of abscess of the lateral ventricles or in hyperdistention by any fluid:

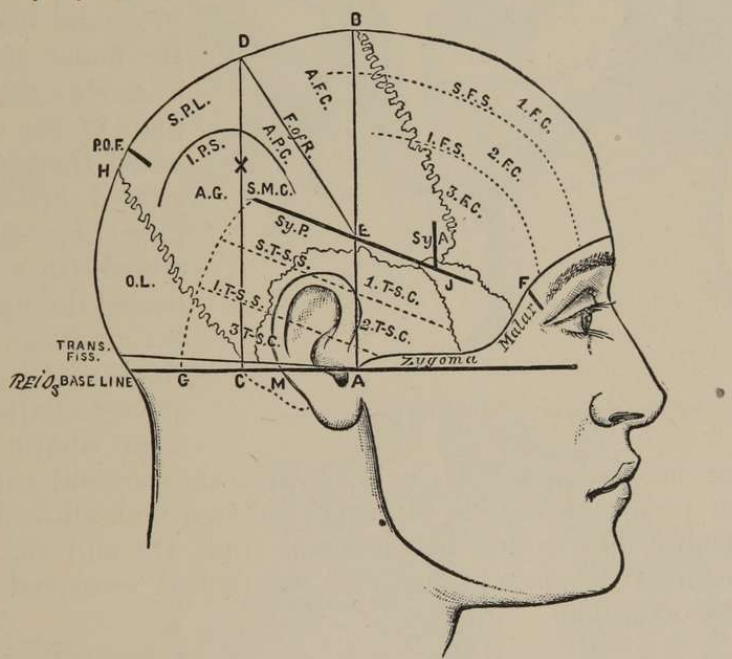

Fig. 476.—Diagram to show the relations of the brain to the skull (modified from Reid). J B, coronal suture; B, bregma; F, external angular process; H, lambda; H C, lamboid suture; J, pterion; M, mastoid process; X, parietal eminence; Sy. A., Sy. P., anterior and posterior limbs of Sylvian fissures; F. *of* R., fissure of Rolando; A. F. C., A. P. C., ascending frontal and ascending parietal convolutions; S. F. S., I. F. S., superior and inferior frontal sulci; 1 F. C., 2 F. C., 3 F. C., frontal convolutions; S. T.-S. S., superior and inferior temporo-sphenoidal sulci; 1 T.-S. C., 2 T.-S. C., 3 T.-S. C., temporo-sphenoidal convolutions; I. P. S., intraparietal suture; S. P. L., superior parietal lobule; S. M. C., supra-marginal convolutions; A. G., angular gyrus; P. O. F., parieto-occipital fissure; O. L., occipital lobe; G, C, M, A, Reid's base line.

I. Trephine halfway from the external occipital protuberance to the upper end of the fissure of Rolando, half to three quarters of an inch to either side of the middle line. Puncture toward the inner end of the supraorbital ridge of the same side (Fig. 474 A). The puncture will pass through the precuneus, and the normal ventricle will be struck at some point in the posterior horn at from two inches and a quarter to two inches and three quarters from the surface of scalp.

II. Trephine at one third of the distance from the glabella to the upper end of the fissure of Rolando and half to three quarters of an inch to either side of the middle line. Puncture in the direction of the external occipital protuberance (Fig. 474 B). The puncture will traverse the first frontal convolution well in front of the motor zone, and the normal ventricle will be struck in the anterior horn at about two inches to two inches and a quarter from the scalp.

III. Trephine one and one fourth inch behind the meatus and one and one fourth inch above

treatment; indeed it is imperative, for drainage is as necessary in the cranial cavity as elsewhere. This point is well illustrated in a brilliant case recently reported by Dr. Oscar H. Allis.* A man received a comminuted fracture of the frontal bone, with extensive lacerations of brain tissue. The fragments were removed and the wound cleansed. The lesion extended along the frontal bone to its horizontal plate, which was also fissured. In order to secure drainage, with the finger of one hand as a guide, the cribriform plate of the ethmoid was bored through by a drill carried up through the nose (Fig. 477). A probe armed with a ligature was passed through and a rubber drainage tube three eighths of an inch in diameter pulled through from above downward, the upper end being left on a level with the cerebral surface of the cribriform plate. A second tube was inserted and allowed to project from the nose and wound in the skull (Fig. 478 and Fig. 479). An antiseptic dressing was applied, and the patient recovered without an unfavorable symptom.

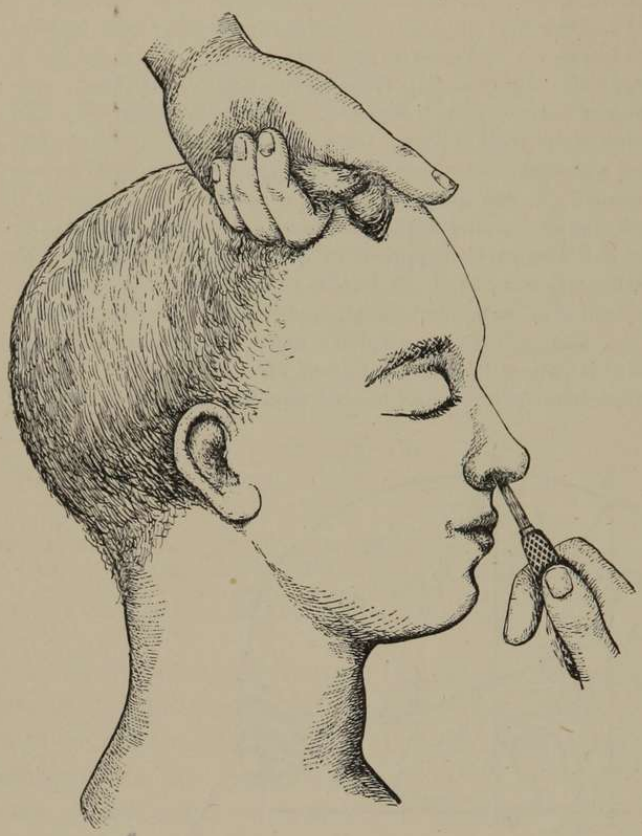

Fig. 477.—Drilling through the cribriform plate. (Allis.)

Reid's base line. (This line extends from the lowest part of the infraorbital margin through the middle of the external meatus to the ear.)

Puncture toward a point two and one half inches directly behind the opposite meatus (Fig. 475). The puncture will traverse the second temporo-sphenoidal convolution and enter the normal lateral ventricle at the beginning or in the course of the descending cornu at a depth of about two to two and one fourth inches from the surface. In this route the measurements are for an adult skull. They should be somewhat reduced for children. The depth necessary for puncture will depend somewhat upon the thickness of the skull and variations in the diameter of the skull from youth to old age, as well as upon the distention of the ventricle with effusion. This, the lateral route, has the great disadvantage that it will develop an abscess of the temporo-sphenoidal lobe, as well as dropsy of the ventricle. It is well to state that the center for hearing of the opposite side may be penetrated through this opening, but, as it has been done a number of times without impairment to the hearing, this objection should not prevent the operation. At the ventricular end of the puncture the optic thalamus may be injured, but this risk must be taken.

Dr. Keen writes me in June, 1896, that further experience recommends this route. As will be seen in the treatment of otitic brain abscess, it is through this part of the skull that the operation is done.

* "Annals of Surgery," July, 1889.

In fracture through the middle fossa, where blood or cerebro-spinal fluid escapes through the ears, natural drainage may be secured through the auditory meatus. In all such cases this canal should be cleansed with sublimate solution, and aseptic-cotton pads applied to absorb the discharge and prevent septic infection.

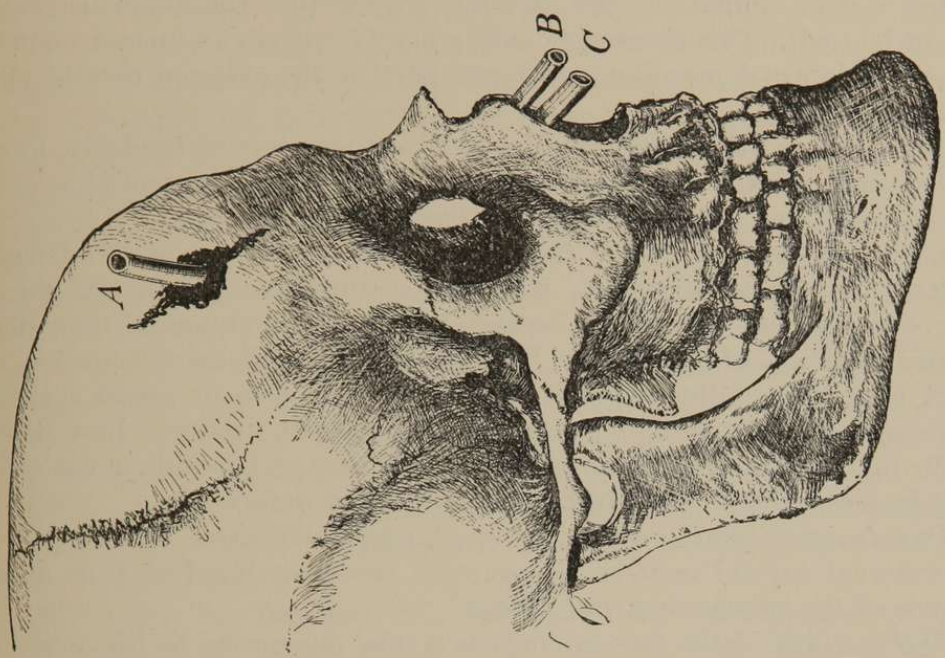

FIG. 479.—*A*, *B*, Through drain. *C*, Short tube. (Allis.)

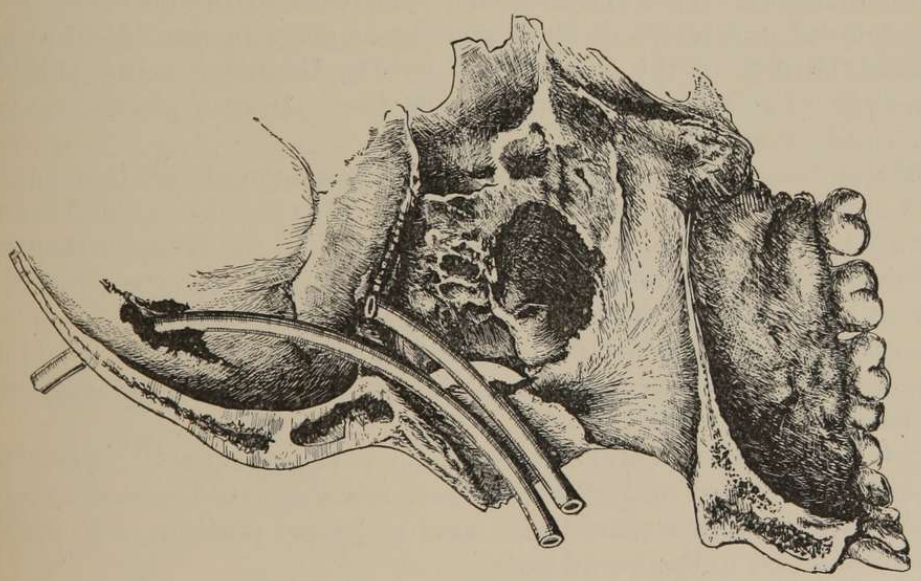

FIG. 478.—Drainage tubes in position. (Allis.)

SURGERY OF THE FACE.

Wounds.—Incised wounds of the face usually bleed profusely. The two essential features in treatment are to arrest hæmorrhage and secure repair with the least possible deformity. When the bleeding is only slight, bringing the edges together with fine silk sutures will arrest

it. When ligatures are applied, catgut should invariably be employed. Every wound of the face should be treated with the strictest antisepsis. The approximation of the edges should be accomplished with exactness. The finest black iron-dyed silk is the best material, and the interrupted suture should be preferred. If the character of the hæmorrhage necessitates central deligation, the *external carotid* (not the common trunk) should be tied. This necessity could scarcely arise in an incised wound, unless the internal maxillary or upper part of the external carotid was involved.

Contusions of this region require, as in other parts of the body, local applications, usually of cold water or the ice bag. Ecchymosis is, as a rule, present, and is persistent in the tissues about the eyes.

Lacerated wounds of the face are serious, on account of the danger of disfigurement after repair. If the procedure does not involve much loss of tissue, the edges may be pared smoothly and united with silk sutures, under careful asepsis. If there has been extensive contusion, a small catgut-twist drain should be left at each end, to guard against the danger of infiltration of pus in the subcutaneous tissue. In wounds which involve the circular muscles of the eyes and mouth, great care must be taken to guard against contractions and deformities.

Punctured wounds require no special consideration. Deligation of the external carotid may be necessitated to arrest bleeding from deep wounds of the spheno-maxillary fossa.

Shot wounds of the face are not, as a rule, dangerous to life, even in military practice. Of 3,312 cases, in which fracture of the bones of the face occurred as a result of shot wounds, as given in the "Medical and Surgical History of the Civil War," by Dr. George A. Otis, only 340 died, while of 4,914 flesh wounds only 58 died. In civil practice the rate of mortality is still lower.

When the missile has penetrated the spheno-maxillary fossa, or divided any deep-seated vessels, the necessity of tying the external carotid may arise. A ball or any foreign body lodged in the bones or tissues of the face should be immediately removed, when this can be accomplished without an operation which may incur the danger of deformity. When, however, the missile is deeply lodged, and is of small size, it should not be molested until there is evidence that it will not remain encapsuled and harmless.

Bones or fragments of bone which have been displaced in part, but not entirely stripped of periosteum and vascular attachments, must not be removed, since, if replaced and held in proper position, they usually become reunited to the sound bone.

The Eye.

Wounds of the eyelids and of the circular muscle of the eye scarcely require special consideration. In *incised* or *lacerated* wounds a careful approximation of the edges of such wounds with the finest silk sutures, and the maintenance of the parts in a condition of perfect quiet, are

essential. A saturated solution (about grs. xv to ℥j of water) of boric acid is to be preferred for purposes of cleanliness. *Contusions* about the eye should be treated by cold applications, using a very small and light ice bag, or frequent changes of bits of linen cloth, taken from a block of ice.

New Formations.— Vascular growths (nævi or angeiomata), usually of the capillary variety, are not infrequent in the vicinity of the eye. When of small size, not exceeding a half or three fourths of an inch, they may be successfully destroyed by the hypodermic injection of from two to five minims of a 50-per-cent solution of carbolic acid or pure alcohol. The quantity, though small, should be well disseminated in the growth. Great care should be taken not to allow any of the solution to enter the eye.

Removal by free excision is not practicable when the tumor is of large size, and when the palpebral margins are involved, or when their shape and situation are such that deformity is apt to follow the excision. A careful application of the rules of plastic surgery to the region of the eye will often obviate deformity, even after extensive dissections with loss of tissue in the vicinity of this organ. What has been said of the excision of vascular growths applies equally to all forms of neoplasms in this region which—themselves a deformity, or malignant in character—require removal.

When this can be done with safety, it is of the utmost importance that the palpebral margin be left intact for at least one eighth of an inch in width. The palpebral branch of the ophthalmic artery, which runs parallel with and about this distance from the free margin of the lid, should not be wounded when it is possible to avoid it. When the dissection is completed, a tongue of skin may be slid from the malar region across the wound, provided the space to be filled does not measure more than one half inch in its transverse diameter. It is at times advisable to

Fig. 480.

Fig. 481.

divide the tension by sliding a shorter flap from the direction of the nose. For larger spaces a flap may be turned from the cheek, hand, or arm, as given hereafter. Fig. 480 represents the space left after the removal of a myxo-sarcoma of the face, and Fig. 481 the method of covering in the

deficiency. From the outer angles parallel incisions were continued through the skin toward the ear, as far as was necessary to secure integument enough to slide across the gap. The *transverse facial* artery, which runs about one fourth of an inch below and parallel with the zygoma, should be kept in the flap, which is dissected up until the end nearest the nose can be carried across to the edge of the wound upon the nose and stitched at this point. The lower border is next fastened, and after this the palpebral border is stitched to the upper margin of the tongue of skin with the finest suture material. The sutures may be removed in from four to six days. It is necessary to arrest all bleeding from the bottom of the cavity left after a dissection; that from the edges will be arrested by the sutures.

Fig. 482.

The tension on the flap should not be so great that the blood supply is seriously interfered with. After the first sutures are inserted, it will be well to wait for a few minutes in order to see that the circulation is established. Fig. 482 and Fig. 483 are taken from a patient from whom a large nævus was excised, and the wound filled by free dissection and sliding of the integument of the cheek. Little or no eversion or dragging down of the lid will follow in these operations when carefully performed.

Epitheliomata may be cured by the application of Marsden's paste even when they involve the free border of the lid. Careful attention will prevent the irritation of the conjunctiva by arsenious acid.



Fig. 483.

Sebaceous tumors (retention

cysts) are occasionally met with on the outer surface of the lids, and in the skin about the orbit. They should be removed by thorough dissection of the sac. When situated upon the lids they rest between the integument and the tarsal cartilage. The line of incision should be parallel with the free border of the lid, to avoid dividing the horizontal fibers of the orbicularis muscle.

Hordeolum, or "stye," is a pyogenic infectious inflammation of the sebaceous gland and hair follicle at the palpebral margin. It is a *furuncle* of the lid. Warm or emollient applications hasten the suppurative process and soften the epidermal covering. The treatment consists in early evacuation of the contents by pressure after pricking the stye with a delicate sharp lance or needle. Professor David Webster recommends sulphide of calcium, gr. ss., twice each day as a corrective and preventive of hordeolum.

Chalazion.—Obstruction of one or more of the ducts of the Meibomian glands causes a swelling and inflammation of the gland, or tube behind the point of obstruction. These protrusions appear on the conjunctival surface of the tarsal cartilage, and should be treated by puncture through the edge of the lid, with evacuation of their contents by pressure on both surfaces of the lid, directed from the base toward the free border, in the effort to squeeze out the plug and thus restore the normal condition of the excretory duct. A thorough curetting of the walls of the sac by means of a Daviel's cataract spoon introduced through the incision renders a recurrence of the tumor less liable (Webster). Any incision on the under surface of the lids should be made parallel with the ducts of these glands. A rare form of cystic tumor occasionally develops in the substance of the tarsal cartilage. It may be cured by incision and destruction of the sac, or by evacuating the contents and injecting one minim of 50-per-cent carbolic acid into the cyst.

Blepharitis or inflammation of the lids may affect all or a limited portion of these organs. It most frequently involves the ciliary margins, and is known as *blepharitis ciliaris*. In rare instances the cartilages are involved. *Acute blepharitis* demands rest and local antiphlogistic applications. Cloths dipped in warm water are in general more agreeable. In *chronic blepharitis ciliaris* the scaly covering of the inflamed borders of the lids should be removed by the prolonged use of warm boric-acid water and a mop of soft lint, having first trimmed the lashes closely. When this is done the inflamed surface should be lightly touched with a pencil of lunar caustic. At night the lids should be lubricated with a small quantity of cosmoline.

Blepharospasm, or spasm of the *orbicularis palpebrarum* muscle, results usually from irritation of the conjunctiva or cornea. It may, in rare instances, occur without any inflammatory exciting cause (idiopathic blepharospasm). The treatment is rest and the removal of the cause of the spasm. In rare cases division of the muscle through the outer canthus is demanded to relieve pressure on the conjunctiva, cornea, and globe.

Blepharophimosis, or narrowing of the palpebral opening, is due to contraction of the lids at the outer canthus or angle. It may be relieved

by an incision commencing in the outer angle and carried directly out through the entire thickness of the commissure for the required distance, extending the cut in the skin a short distance farther than that in the conjunctiva. The edges of the skin and mucous membrane are then united by silk sutures, as shown in Fig. 484.

Lagophthalmos.—Inability to close the eyelids may be due to protrusion of the globe from tumors of the orbital cavity, or of the globe; it occurs in the disease of which enlargement of the thyroid body and "exophthalmos" are symptoms; in staphyloma and in paralysis of the facial nerve. It is a serious condition, on account of the liability of ulceration of the cornea from prolonged exposure of the anterior surface of the globe. The indications in *treatment* are first *palliative* in keeping the lids closed by bandaging, or uniting the edges by sutures. When the condition is permanent, the operation of *tarsoraphy* is to be performed as follows: Introduce a horn spatula between the globe and the lids at the outer canthus; make the tissue tense, and with a sharp knife remove the free borders of the upper and lower lid for a distance sufficient to close the eye to the desired extent. The incision should remove the roots of the ciliæ. The opposing edges are now united with silk sutures.

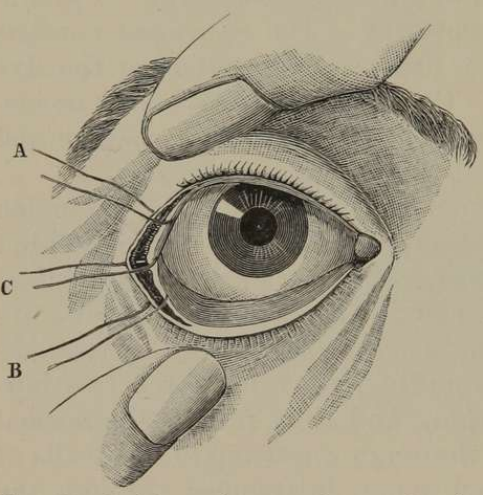

Fig. 484.—Incision and sutures in operation for blepharophimosis. (De Wecker.)

Blepharoptosis.—Ptosis, or inability to lift the upper lid, may be due to partial or complete paralysis of the third nerve, or the filament which supplies the levator palpebræ; to adhesions from inflammatory affections of the lid; to the presence of neoplasms or to acquired or congenital weakness of the levator muscle. Ptosis due to paralysis may be corrected by excising an elliptic-shaped piece of the skin of the upper lid, including the areolar tissue and the fibers of the orbicular muscle. The lower incision should run parallel with the margin of the lid and about one quarter inch above it. The edges of the two incisions should be united with silk sutures.

Symblepharon is a term applied to adhesions of the lids to the ocular conjunctiva. Limited adhesions may be broken up repeatedly until a cure is effected by the extension of an epithelial covering over the granulating surfaces. When the adhesions are extensive, Teale's operation may be performed. Supposing the condition shown in Fig. 485 to exist, the symblepharon is cut through at *A*, in the line of the corneosclerotic function, and the lid is dissected up to the normal fold of palpebral and ocular conjunctiva (*D*, Fig. 486). Two flaps (*B* and *C*, Fig. 486) are now dissected up from the conjunctiva, and turned down and stitched in position to cover the raw surface left by the dissection of the adhered

lid. The spaces left by lifting the flaps are closed at once by fine silk sutures (Fig. 487). The island of tissue left on the cornea is allowed to disappear by atrophy.

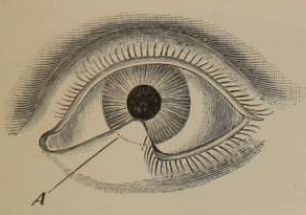

Fig. 485.
Symblepharon. *A*, Incision through the attached conjunctiva at the corneo-sclerotic junction. Teale's operation. (Swanzy.)

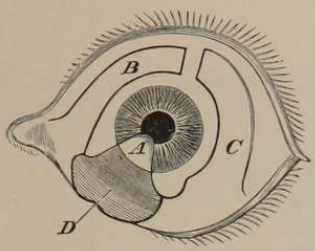

Fig. 486.
The same. *D*, Adherent conjunctiva dissected down. *B*, *C*, Incision for flaps to cover this wound. (Swanzy.)

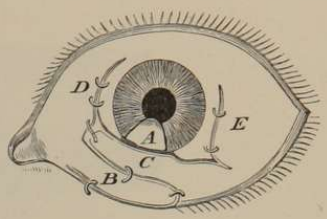

Fig. 487.
The same. *A*, Tip of symblepharon left to disappear by absorption. *C*, *B*, Flaps turned and sewed into new position. *D*, *E*, Wounds closed by sutures. (Swanzy.)

Ectropion, or eversion of the lid, may be *partial* or *complete*, and is due first to weakness of the orbicularis palpebræ muscle, especially to the palpebral fibers; second to cicatricial contractions due to injury or disease of the soft parts above the eye, or of the bones surrounding the orbital cavity. The lower lid is usually involved.

The *treatment* is operative. In mild cases, those in which no cicatricial adhesions have occurred, the following operation, as given by Swanzy, is advised:

Method of A. Robertson.—Thread a long quarter-curved needle with each end of a small Chinese twisted-silk ligature, about fifteen inches long; with one of these perforate the entire thickness of the lid one line from the ciliary margin and one quarter of an inch to the outer side of the center (*b*, *a*, Fig. 488). The needle is now passed over the conjunctival surface of the lid, till it meets the fold of conjunctiva reflected from the lid on to the globe through which the needle is thrust—the point being directed slightly forward—and pushed slightly downward under the skin of the cheek until a point is reached from one to one and a quarter inches below the edge of the lid, where it is brought out. The other needle is introduced in a corresponding manner at the same distance from the middle line on the inner side (*a'*, *b'*, *d'*, Fig. 488).

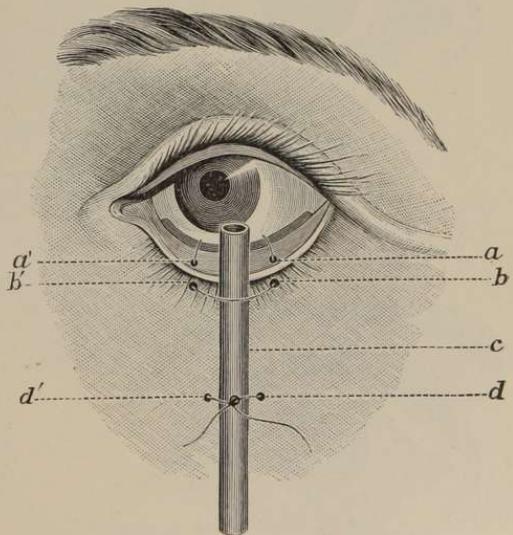

Fig. 488.—Robertson's operation for ectropion of the lower lid. (A. Robertson.)

A piece of thin sheet-lead, about one inch long and one quarter inch broad, rounded at its extremities and smooth on all surfaces and edges, bent to fit the curvature of the eyeball, is now slipped under the loops of the ligature that

pass over the conjunctival surface of the lid; at the same time a short piece of small rubber drainage-tube is passed beneath the loop on the cutaneous surface just below the ciliary margin. Now, as the ends are

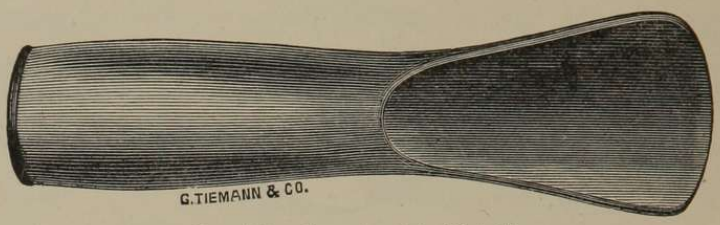

Fig. 489.—Jaeger's plate lid-holder.

drawn gradually tight, the edge of the lid is made to revolve inward over the upper edge of the piece of lead, while the tarsal cartilage is molded to the curve of the lead, and the lid assumes its normal position. The threads are tied below over the rubber tube, *d*, *d*. The sutures and lead are removed from the fourth to the sixth day.

In mild ectropion, due to limited cicatricial adhesions, Wharton Jones's V Y operation may be adopted.

As shown in Fig. 490, a V-shaped incision is made so as to include the scar, the flap dissected up, and the underlying cicatricial adhesions cut out. The lid is lifted into its normal position, stitched to its upper fellow, if necessary, to hold it in place, and the edges of the wound sutured from below upward, leaving a Y-shaped scar (Fig. 491).

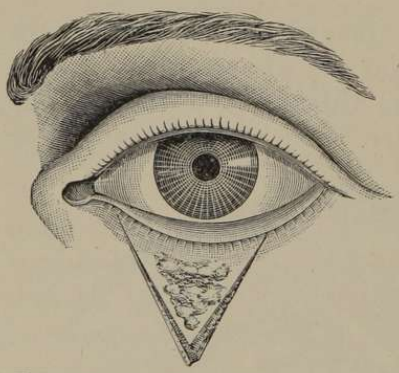

Fig. 490.—Wharton Jones's operation for ectropion of the lower lid. (De Wecker.)

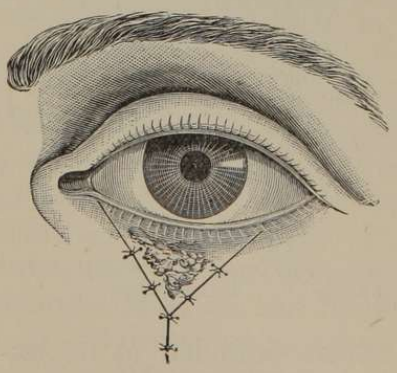

Fig. 491.—The same, after the flap is dissected up and the sutures tied. (De Wecker.)

Fig. 492.—Complete ectropion of lower lid, due to cicatricial contractions after ostitis of the orbital margin.

In more extensive adhesions (Fig. 492), in which neither of the foregoing methods will meet the indications, a plastic operation is inevitable. Make one incision, parallel with the free border of the lid,

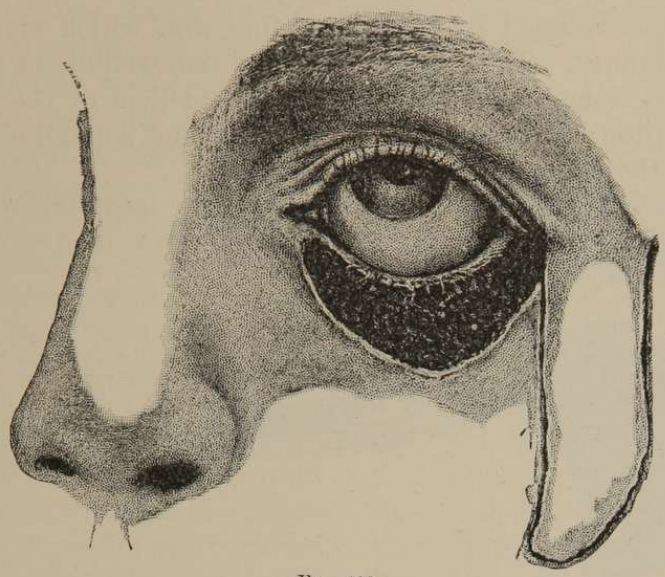

FIG. 493.
Showing the cicatricial tissue dissected out, and the flap to be turned from the cheek outlined.

which shall extend beyond the cicatricial tissue to be removed. Dissect out freely all adhesions and cicatricial material, until, when left to itself, the remaining edge of the lower lid rises into its natural posi-

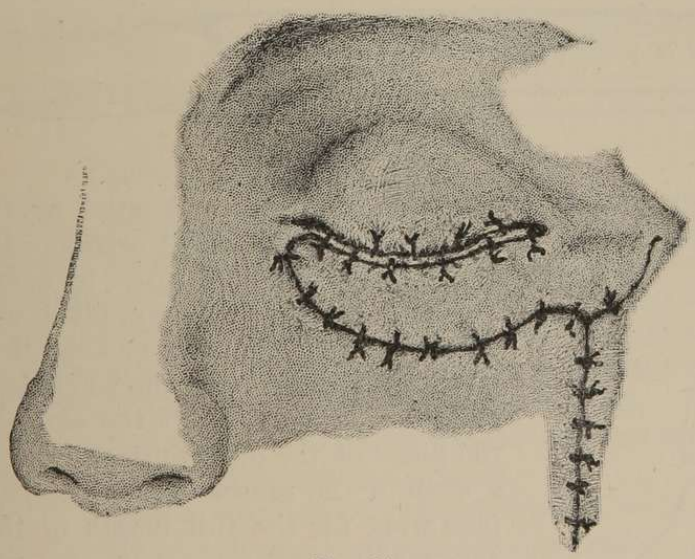

FIG. 494.
The flap stitched into position, and the wound formed by its removal closed. The lids temporarily sutured.

tion. In order to fill the deep oval cavity (Fig. 493) left by such dissection, a flap may be turned from the cheek, forehead, or arm. The plan of the flap from the cheek is shown in Fig. 494. It should be cut by measurement, so as to fit without tension. As soon as it is

turned across to its new position, the eyelids should be stitched together, and the flap accurately and carefully sutured to the margins of the elliptical wound. Before the lower row of sutures is inserted, the edges of the perpendicular wound from which the flap was removed should be approximated by sutures of fine silk, which material should be used throughout. The stitches are to be removed about the fifth day. If any puffing remains at the seat of the pedicle of the flap, it may be relieved, after a few months, by dissecting out a small elliptical piece and bringing the edges together.

When the cavity from which the flap has been taken can not be entirely closed by suture, small Thiersch grafts should be employed to prevent a broad cicatrix.

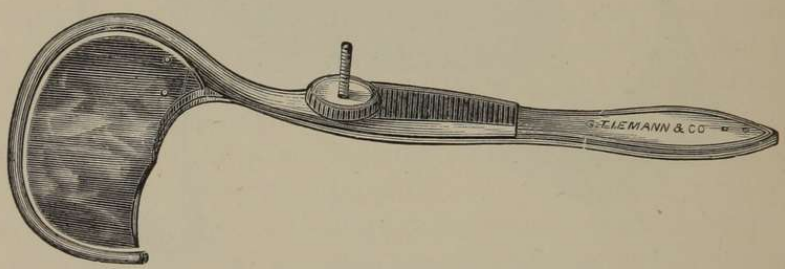

Fig. 495.—Knapp's entropion forceps, or clamp.

Entropion, inversion of the lid, usually results from chronic inflammation of the conjunctiva and tarsal cartilage. It is more frequent in the upper lid. In mild cases relief may be obtained by excising an



Fig. 495 A.—Lid scalpels.

elliptical strip of the integument of the lid and stitching the edge of the wound together. When, however, the tarsal cartilage is involved, Snellen's method will prove more satisfactory.

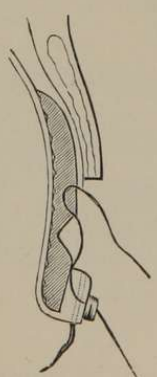

Fig. 496. — Perpendicular section showing character of dissection. The muscular strip and a triangular strip of the tarsal cartilage are removed. (De Wecker.)

With Knapp's clamp applied, make an incision through the skin one eighth of an inch from and parallel with the whole length of the margin of the lid. Lift the *skin-flap*, expose the fibers of the orbicularis muscle, and excise a strip of the muscle about one twelfth of an inch wide for the full length of the incision. The tarsal cartilage is now seen, and from it as far as it is exposed a wedge-shaped piece is excised with a sharp knife (Fig. 496). The apex of the wedge points toward the conjunctiva, but the section should not extend entirely through the cartilage. Three sutures are now inserted, each entering from without

inward, traversing the skin and muscle (Fig. 497) of the strip left at the palpebral margin; then in the same direction it is carried across the wound into the upper bevel of the incision in the cartilage, from which it emerges (without transfixing the integument of the flap), to be again brought out through the tissues it first entered, about one eighth of an inch distant from the point of entrance. Each end of the suture is fastened with a shot, to prevent it cutting through.

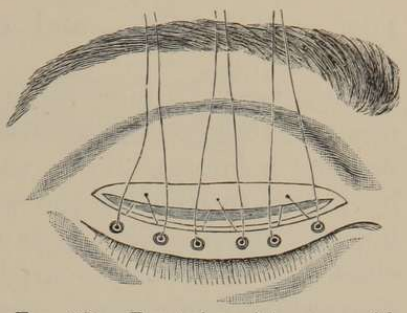

Fig. 497.— Front view of the same, with sutures inserted ready to be tied. (De Wecker.)

Eczema of the eyelids is not of very frequent occurrence. Swanzy recommends the daily removal of the crusts by bathing the parts in a warm solution of bicarbonate of potash, drying, and then painting with solution of nitrate of silver (gr. xx to water ℥j); after this an ointment of boracic acid (gr. xxx to ℥j) is applied.

Epicanthus.—This term is applied to a congenital defect which consists of a fold of skin stretched across the inner canthus and the caruncula. It may be relieved by excising an elliptical piece of integument in the long axis of the nose just between the eyes. The width of the excised portion must be sufficient to remove the deformity when the edges of the wound are drawn together by sutures.

Restoration of the Eyelids.—In destruction of the lids by accident or disease it becomes necessary to restore the covering to the globe. Flaps may be turned from the neighboring healthy integument or borrowed by a plastic operation from the arm. In many cases much damage may be prevented by applying good-sized and numerous grafts to the exposed surfaces while granulation is going on.

The Lachrymal Gland and Ducts.

Disease of the *lachrymal gland* is rare. In inflammation of this organ (*dacryoadenitis*) tenderness and swelling may be observed in the upper outer portion of the orbital cavity. In well-marked enlargement from any cause, the eyelid is pushed forward and the globe displaced downward and inward. An abscess here should be opened by puncture through the base of the lid at the most convenient point. When a neoplasm develops in the gland, extirpation should be done by incision in the fold of the upper lid, just beneath the brow.

Epiphora, or continual overflow of tears, is caused by obstruction in the system of canals which normally should conduct the secretion of the lachrymal gland from the margins of the lids into the nasal cavity, or by displacement of the *punctum lachrymale*, so that the tears can not enter the orifice. On account of its position, the lower canaliculus is of much more importance to the drainage of the eye than the upper.

Epiphora due to disturbance of the canaliculus may be present as a symptom of any displacement of the lower lid, from swelling, paraly-

sis, or cicatricial contraction, the direction of the puncture being so changed that neither gravity nor the normal suction-force will carry the secretion into the opening. Occlusion, partial or complete, may occur either from lodgment of foreign substances, products of inflammation, pus, epithelia, etc., and occasionally to calcareous formations (*dacryoliths*).

The most common form of obstruction is, however, met with in the nasal portion of the excretory apparatus. Catarrhal inflammation of the mucous membrane lining the canal or cyst may occlude the duct either by approximation of the walls or by excessive secretion of tenacious mucus. Such condition is met with in patients of all ages, occurring chiefly in the poorly nourished and scrofulous or tuberculous subjects, who suffer from chronic nasal catarrh and ophthalmia, or ostitis of the neighboring bones. As a result of obstruction in the nasal duct, *dacryocystitis*, or inflammation of the lachrymal sac, may ensue with distention, the swelling showing beneath the skin at the inner angle of the eye (*muco-cele*).

The *treatment* of displaced *punctum lachrymale* should be directed to the restoration of the lid to its normal position. In partial obstruction, due to catarrhal conditions, relief may be obtained by slitting the canal with the canaliculus knife or scissors, and frequently repeated irrigations

Fig. 498.—Agnew's canalicula knife.

with the lachrymal syringe. When obstruction occurs, dilatation by means of probes is indicated. Should the stricture be close and resisting, the knife should be carefully introduced and a division effected, the dilatation being continued by inserting the probes at intervals of two to six days. The prognosis in many cases, no matter how faithfully and skillfully treated, is not favorable.

In slitting up the canaliculus the delicate probe-pointed knife or scissors should be introduced at the inferior punctum, and carried toward the canthus for a distance of about one sixth of an inch, the slit extending for this distance. The wound should be kept open by forcibly separating the edges once or twice a day, until the cut surfaces are covered with epithelium and the trough becomes permanent. Some operators in *chronic dacryo-cystitis* prefer to slit the upper canaliculus and pass the probes by this route. The bulb-pointed dilating-probes should now be carefully introduced, beginning with the smaller sizes (Fig. 499). As soon as the bulb enters the sac, it should be gently and slowly directed along the nasal duct until it is arrested by the floor of the nose. The larger sizes may be introduced as in the treatment of stricture of the



Fig. 499.—Théobold's lachrymal probes.

urethra. After full dilatation is secured the channel should be washed out daily, for about ten days, with a 1-per-cent boracic-acid solution. For this purpose Anel's syringe (Fig. 500) will be found useful. The probe-pointed nozzle is introduced into the sac and the water forced through until it flows freely into the nose. If the obstruction recurs, the probes should be reintroduced at regular intervals, gradually increasing until a permanent opening is effected.

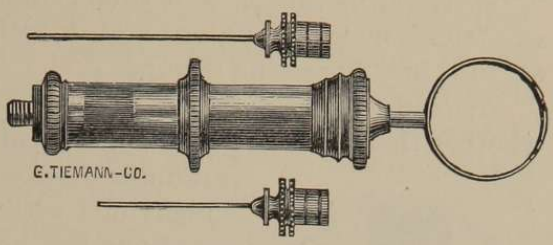

Fig. 500.—Anel's syringe.

Trichiasis, or turning in of the eyelashes, occurs with entropion, but may exist independently. Occurring with inversion of the lid, it does not require any other interference than that given for the cure of entropion. When the ciliæ turn in without inversion of the lid, the proper method of treatment is total excision of the hair-follicles. This should be accomplished by two parallel incisions made along the margin of the lid, one on either side of the row of hairs, and extending deep enough to insure the complete removal of the roots of the ciliæ. When only a few hairs are at fault, the follicles may be destroyed by the galvanic needle. When depilation is demanded, the instrument shown in Fig. 501 will be found of great service. In *distichiasis* there is an extra row of ciliæ; these require removal by the method just given.

Fig. 501.—Gruening's depilating forceps.

The Conjunctiva and Cornea.

Conjunctivitis may be acute or chronic, and circumscribed or diffuse. *Simple conjunctivitis* may result from prolonged strain or over-use of the eyes, from the lodgment of foreign particles, or exposure to strong winds. The hyperæmia may be confined to a limited portion of the mucous membrane, or spread over the entire palpebral and ocular conjunctiva.

The treatment consists in the instillation of two or three drops of cocaine, two to four per cent solution, at intervals of from one to several hours, the removal of any foreign matter, rest by closure of the lids, or the dark room and the application of soft cloths taken from cold boracic-acid solution (grs. x to ℥ j) or from a block of ice.

Follicular conjunctivitis may follow an acute simple inflammation, and is characterized by the development of small red points or elevations scattered over the deeper portions of the palpebral surfaces of the mucous membrane and the contiguous reflection of the ocular conjunctiva. The elevations are swollen and distended lymphatic channels and follicles. The disease is characterized by considerable pain, inability to use the

eyes, and a sensation as if a gritty or sandy substance were present. In *treatment* the condition of the general system should be improved by tonics and nutritious diet; rest to the diseased organs, and the daily application, by means of a camel's-hair brush, into the conjunctival sac of a small mass, about one-eighth-inch diameter, sulphate of copper gr. ss. to ij in ʒ j vaseline (Swanzy).

Granular Conjunctivitis (*Trachoma*).—It is not yet positively known whether there is any real pathological difference between follicular and granular disease of the conjunctiva. Trachoma is chiefly met with among the poorly fed, who live in unwholesome surroundings. It is held to be contagious at all times, and, when a muco-purulent discharge is plentiful, the contagious nature of the affection is evident.

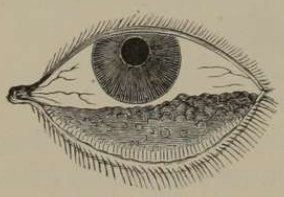

Fig. 502.
Granular lower lid. (Eble.)

In the earlier stages there appear upon the lower lid round, granular elevations, scattered here and there, or the whole mucous membrane may be thickly studded. As a result of the chronic inflammation the lid is at first thickened. As the process is continued, the usual cicatrization and contraction results, causing, in obstinate cases, deformities of the lids and great and persistent discomfort.

The treatment includes the measures just given for follicular conjunctivitis. In addition, either the sulphate of copper stick or nitrate of silver in strong solution—grs. x–xx to ʒ j—or the *mitigated lunar caustic*. Nettleship advises the following strength: "Nitrate of silver, one part; nitrate of potash, two parts, fused together and run into molds to form short pointed sticks; used for granular lids and purulent ophthalmia." Applied daily, or less frequently, as may be demanded. When these measures fail, canthoplasty may be done and the diseased tissue dissected from the lids.

In both varieties of trachoma the cure is greatly accelerated by the operation of *expression*, or squeezing out the contents of the granular elevations by means of Prince's forceps. More can be accomplished by this operation when done thoroughly than by any other method of treatment (Webster).

Gonorrhœal Ophthalmia.—Conjunctivitis caused by the introduction of the virus of gonorrhœa into the eye should be treated with great care and persistency from the first symptom of this painful affection. Usually a single organ is attacked. It is important that, while the effort to cure one eye is being made, the other should be protected from the contagion. To effect this, a watch glass, to the edge of which adhesive plaster is attached, is placed over the sound eye and closely fastened to the skin about the orbit by the plaster, so that it is hermetically sealed. This should not be removed until the other eye is well.

In the local treatment of the affected eye it is required to remove the purulent discharge by frequent irrigation with warm boracic-acid water or by the pellets of lint or absorbent cotton, and to brush over the everted lids once or twice a day, as the attack is light or severe, a solution of

nitrate of silver (grs. xx to ʒ j). The excess should be immediately washed off with tepid water. Cold applications are of great importance, and a very efficient method is to apply frequent changes (every one or two minutes) of pieces of lint about two inches square, which are taken directly from a block of ice and laid over the inflamed organ. In this form of conjunctival inflammation, as in others where the injection is marked and the thickening great, and where painful *blepharospasm* occurs, or where a free discharge of purulent matter can not be effected by ordinary means, *canthoplasty* is required. This operation consists in slitting the outer canthus in the direction of the ear, and in this way dividing the fibers of the orbicular muscle.

In gonorrhœal conjunctivitis the impairment of function in the muscle is not intended to be of long duration, and the wound is left open. In some cases of spasm of this muscle, and where a chronic inflammation exists, the mucous membrane is stitched to the skin along the edges of the wound, thus preventing a reunion. Reunion may be effected later by paring the edges and bringing the parts together after the lesion for which the canthoplasty was performed is healed. Cocaine should be used to relieve pain, and all adhesion between the ocular and palpebral mucous surfaces should be broken up as soon as discovered.

Conjunctivitis in the new-born (*ophthalmia neonatorum*) is a form of purulent ophthalmia which usually results from the inoculation of the conjunctiva with septic matter present in the genital passages of the mother. It may come from carelessness on the part of the nurse, herself affected with a leucorrhœa, etc., or from the lodgment of any virus in the eye of the child. The *treatment* is *prophylactic* as well as *curative*.

The eyes of a child born of a mother known to be suffering from a vaginal discharge of a purulent character should, as soon as possible after birth, be washed or mopped out with clean warm water, or boracic-acid solution, to be followed with one or two drops of a 2-per-cent nitrate-of-silver solution (grs. x—ʒ j) once or twice a day, for three or four days.



Fig. 503.—Drop-glass for the eye.

The pus should be gently removed by pellets of absorbent cotton, dipped in warm boracic-acid solution, the lids everted, and nitrate-of-silver solution (grs. v-x to ʒ j) applied to the inflamed surfaces by means of a camel's-hair brush. The excess should be immediately washed away by the free use of warm water. This should be repeated every day until the purulent discharge is notably diminished.

The eyes should be carefully cleansed with warm solution of boracic acid every half hour day and night, or as often as any secretion appears between the edges of the eyelids.

Croupous conjunctivitis is a contagious disease met with in children, and characterized by injection of the mucous membrane and the deposit of a film or membrane upon the conjunctiva.

The *treatment* consists chiefly in frequent washing of the eye with warm boracic-acid water in the earlier stages. When suppuration supervenes, the indications are the same as for purulent ophthalmia.

Diphtheritic Conjunctivitis.—In this disease, which is exceedingly contagious, the inflammatory process is rapid and often hopelessly destructive. The lids soon become greatly swollen, and the mucous membranes are glazed over with a tough, closely adherent diphtheritic membrane. The period of infiltration varies from six to ten days, and is followed by the stage of suppuration.

Treatment.—The immediate danger is destruction of the cornea, the circulation being more or less interfered with by the false membrane. Since all pressure should be eliminated, in extreme cases it will be advisable to perform *canthoplasty*. Cold-water dressings should be employed in the early stages. Leeches to the temples are advised. When suppuration ensues, astringents are indicated.

Pterygium is the name given to a vascular network which extends from the ocular conjunctiva on to the cornea. It is usually situated on the inner side, less frequently on the outer portion of the globe. It is commonly triangular in shape, the apex encroaching more or less upon the corneal surface. It is caused by constant irritation from dust or sand, or fine particles of matter floating in the air, and is therefore chiefly met with in sandy, arid regions.

When small and not progressive, it is advisable not to interfere with pterygium. When it is growing steadily, it should be tied off or removed by dissection. For the first method the pterygium is lifted at the margin of the cornea, and a fine silk thread carried beneath it here. A second is carried beneath the base of the mass at the conjunctival fold. The ligatures are tied and cut short. In a few days they come away, and the vascular tuft disappears; or a dull instrument, as a strabismus-hook, may be inserted beneath the pterygium, which is gradually detached and divided with the scissors. One or two sutures are inserted to close the wound, where the base of the growth is cut away from the conjunctiva.

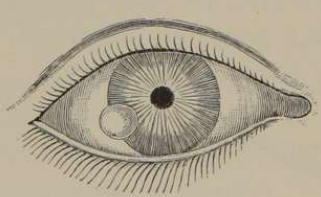

Fig. 504.
Pinguecula. (Swanzy.)

Pinguecula.—This is a small, yellow elevation occasionally met with at the inner or outer margin of the cornea (Fig. 504). It occurs usually in the aged, and should not be molested unless it seriously interferes with vision or comfort. It is a simple hypertrophy of the tissues of the conjunctiva.

Lupus of the conjunctiva is exceedingly rare, and does not require special consideration.

Epithelioma here does not differ from this affection on other mucous surfaces.

Cystic tumors occur in the conjunctiva in a certain proportion of cases, and demand extirpation.

Polypus develops occasionally on the semilunar fold, or caruncula, and should be clipped off.

Lithiasis, or calcification of the secretion of the Meibomian glands, appears in the shape of little white spots or elevations on the inner surfaces of the lids. As they produce considerable irritation of the conjunctiva and cornea, they should be picked out with a needle-point after anæsthesia with cocaine is secured.

Xerosis is a term applied to a dry condition of the conjunctiva resulting from changes in the structure of this membrane and deficient supply of the secretions which moisten this surface. The indications are to remove, if possible, any chronic inflammatory condition, and keep the eye moist by artificial means.

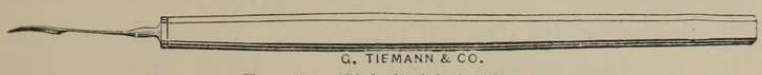

Fig. 505.—Sichel's iris knife.



Fig. 506.—Daviels's curette.

Cornea.

Foreign Bodies and Wounds.—Non-penetrating wounds of the cornea should be thoroughly cleansed with warm boracic-acid solution, and the lids closed with a bandage until repair is effected. A penetrating wound should be treated on the same principle as the incision for cataract.

A foreign body lodged upon or buried in the cornea should be at once removed. Anæsthesia with cocaine is essential. Oblique illumination by means of the convex lens is of value in locating the body. A clean needle or knife-point may be used in lifting the foreign substance out.

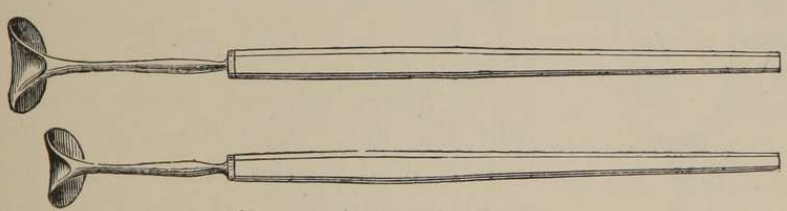

Fig. 507.—Desmarres's retractors.

Keratitis, or *corneitis*, may originate from injury or disease of the cornea proper or by extension of the inflammatory process from the conjunctiva or sclerotic, iris or choroid. The symptoms are pain variable in character, interference with vision, especially if the infiltration occurs toward the center of the cornea, and the appearance of a cloudy film upon the normally clear and transparent membrane.

Diffuse idiopathic keratitis usually commences at the periphery and travels toward the center. Occurring as a feature of a constitutional dyscrasia (syphilis, tuberculosis, etc.), both eyes are usually, though not simultaneously, involved.

Abscess of the cornea may be recognized by the grayish-yellow color of the pus collection and the greater density of the membrane at this point. In many cases the transudation or escape of the purulent liquid

takes place into the anterior chamber, and may be seen to occupy the lower portion of this space (*hypopyon*).

Treatment.—In *traumatic keratitis* the removal of all irritation, disinfection with warm boracic-acid solution, relief from pain by cocaine locally or morphia internally, and the exclusion of light by the dark room, bandage, or shade, are the indications.

When the disease is *secondary* to inflammation in other parts of the globe or conjunctiva, the treatment should be directed to the original malady as well as to the protection of the cornea.

Diffuse keratitis demands active constitutional treatment to increase nutrition and neutralize the virus of general infection. In *abscess*, tension should be relieved by careful puncture. Penetration of the anterior chamber with the instrument should be avoided, unless the pus here is rapidly increasing; it should then be evacuated.

Pannus is a term applied to a condition of opacity of the cornea due to the formation of a vascular network beneath the epithelial covering of this membrane. It is associated with a conjunctivitis, the vessels really extending from the conjunctiva into the cornea.

If the disease is due to chronic granular lids, entropion, distichiasis, etc., the cause should be at once eliminated. In milder cases of persistent pannus a cure may be effected by excision of a zone of conjunctiva and subconjunctival tissue from around the cornea (Nettleship). In severer cases the local use of jequirity-bean is advised. Prof. David Webster recommends the following:

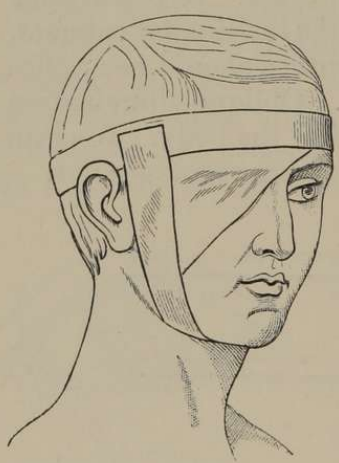

Fig. 508.

One jequirity-bean coarsely powdered is placed in an ounce of water for four hours. The patient is then required to bathe the affected eye very freely with this solution for ten or fifteen minutes, letting some of it get into the eye. One thorough washing will usually produce the characteristic membrane of the conjunctiva. If this does not succeed, the operation should be repeated. Or the bean, very finely pulverized, may be applied to the whole palpebral conjunctiva.

A convenient shade or screen for the eye is shown in Fig. 508.

Ulcus Corneæ.—Ulcers of the cornea may follow injury, or the eruption of herpes or small-pox; they are met with in conditions of general malnutrition (syphilis, tuberculosis, etc.), and may also occur with inflammation of the other structures of the eyeball, or of the lids or conjunctiva.

Herpetic vesicles occur at times upon the cornea, either as *herpes zoster ophthalmicus* or *herpes corneæ febrilis* (Swanzy). They appear as groups of clear vesicles, the superficial covering of the vesicle giving way within a few hours and leaving a shallow ulcer. In *treatment*, herpes, or the resulting ulcer, demands little beyond protection from

light, the removal of all irritation by the bandage, and the prevention of infection by careful aseptic irrigation.

Phlyctenulæ of the Conjunctiva and Cornea.—Phlyctenular ulcers occur almost invariably in strumous subjects, either with or without any direct exciting cause. When first noticed they are usually papules or pustules on the conjunctiva or cornea or both. There is, however, a localized hyperæmia in and near the spots where the elevation occurs which precedes the papule or pustule. Breaking down and discharging their contents, ulcers of variable extent are formed. They frequently develop on the conjunctiva and sclerotic without invading the cornea. Not infrequently, however, the process of ulceration travels on and toward the center of the cornea, leaving behind a trail of enlarged vessels, giving to the whole a comet-like appearance (Fig. 509). Perforation may follow in a certain proportion of cases. These ulcers may occur in all ages, but are chiefly met with after the third year and before the twenty-fifth year of life.

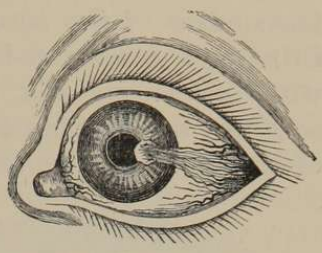

Fig. 509.
Phlyctenula of the conjunctiva and cornea. (Travers.)

Ulcus Serpens.—The acute serpiginous ulcer is probably due to infection. It commences as a grayish film or spot, breaking down from the center, leaving sharp, precipitous edges (as in phagedenic chancre), "one part of which is more densely opaque than the rest; this infiltrated advancing edge is the distinguishing mark of the ulcer" (Nettleship).

Treatment.—In phlyctenular keratitis and conjunctivitis warm applications of boracic-acid water are useful. Pain should be relieved as heretofore directed. If blepharospasm is present, *canthotomy* may be necessary. The ulcers should be stimulated locally by use of nitrate of silver to those on the conjunctiva, the mitigated stick; while weaker solutions (gr. v–x, ℥ j) may be used for the corneal ulcers. In given cases the ulcers may be scraped out or burned with the fine galvano-cautery platinum wire. The prevailing dyscrasia should be corrected by appropriate remedies. The nutrition should be increased, and an out-of-door life advised.

In acute serpiginous ulcer active measures are often imperative, the phagedenic process marching rapidly to perforation and collapse of the globe. Hot boracic-acid water applications at intervals of an hour or two are advised for relief of pain. Cocaine may also be instilled. If the ulcer does not remain stationary, it should be carefully and thoroughly burned with the cautery needle upon the same principle as for chancroidal ulcer of the skin. When the serpiginous ulcer dips down into the deeper corneal tissue and undermines it, it should be laid open by incision in its entire extent.

Staphyloma Corneæ.—Bulging of a portion of the corneal surface may result from intra-ocular tension upon a point weakened by ulceration or cicatrization. *Conical cornea* differs from this in being due to atrophic (not inflammatory) changes in the central portion of the cornea,

this part projecting by reason of intra-ocular tension. When perforation takes place, the aqueous humor escapes and usually carries the iris with it, this latter structure being caught in the opening, where it adheres. This condition is known as *anterior synechia.*

When the staphyloma involves a limited portion of the cornea, iridectomy should be done, making the artificial pupil behind the best remaining surface of the cornea. In complete staphyloma, vision being lost, Critchett's operation is advisable. Five half-curved needles, threaded with fine strong silk, are passed from above downward through the sclerotic, being made to enter and exit half-way between the insertions of the recti muscles and the posterior edge of the staphyloma. When

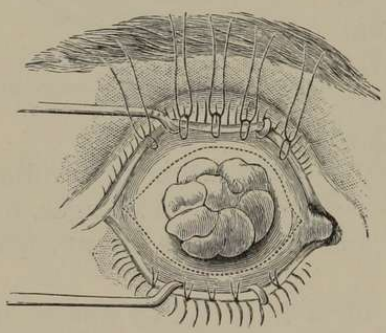

Fig. 510.—Needles introduced in Critchett's operation for staphyloma. (Abadie.)

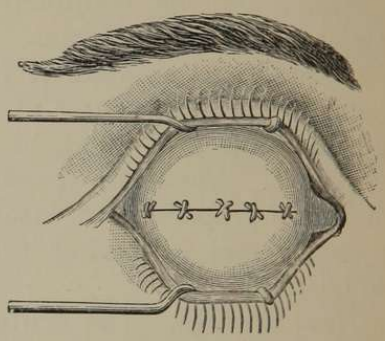

Fig. 511.—The same, after the sutures are tied. (Swanzy.)

the point of each needle has emerged about one quarter inch, it is allowed to remain, and the staphyloma is divided by a horizontal incision. The flaps are now snipped off with the scissors about one twelfth inch in front of the needles, this line (see the dotted line, Fig. 510) being through the sound sclerotic. The needles are next drawn through and the sutures tied, as in Fig. 511.

In *conical cornea*, if any operative interference is deemed advisable, the conicity should be reduced by inducing cicatrization at and about the apex of the projection.

Von Graefe's Method.—Just to one side of the apex of the cone remove with the knife a small bit of the surface of the cornea without penetrating the anterior chamber. Every third day for about two weeks this wound should be touched with the mitigated pencil of nitrate of silver. Then puncture through this scar every second or third day for one week, evacuating at each puncture the aqueous humor. The wound is now allowed to heal.

Nebula, *macula*, and *leucoma*, are terms used to designate degrees of corneal opacity—the first being so slight as to be scarcely discernible, the second a more serious lesion, while in leucoma the opacity is complete. The grayish ring seen at the corneal margin in many old persons —*arcus senilis*—is due to fatty degeneration of the cells of the cornea, near the sclerotic junction. This condition occasionally exists in the middle-aged and in young children. While not a contra-indication to operative interference, that it suggests faulty nutrition should not be forgotten in prognosis.

Sclerotic.

Simple incised wounds of the sclerotic heal readily. Lacerations are more serious by reason of the greater violence accompanying such injuries. No special treatment is demanded beyond rest and cleanliness.

Scleritis.—Inflammation of the sclera is usually circumscribed, and may or not be accompanied by an appreciable thickening of this tunic. As a rule, the affection is not painful, unless it extends so widely that the choroid, cornea, or iris is involved.

Treatment should be directed to the prevailing dyscrasia. It is met with as a late manifestation of syphilis, and is also a symptom of rheumatism. No local medication is advisable, beyond the limited instillation of atropine to prevent iritis. Rest, and light cloths wet in warm boracic-acid solution locally, are advised. A single thorough application of the actual cautery will frequently abort this disease, which under other methods of treatment usually lasts many months.

Iris.

Iritis is most frequently seen as a late manifestation of syphilis or in chronic rheumatism. It also may occur with inflammation of the cornea or sclera. The symptoms are abnormal immobility, thickening and cloudiness of the organ, irregularity of the pupillary margin, and adhesions to the anterior surface of the capsule of the lens (posterior synechiæ). The injected zone is usually of a pinkish color. Vision is more or less affected; and pain, though not always a symptom, is usually present. In rare cases the pupil is *occluded* by the formation of a membrane from the products of inflammation.

The *treatment* of iritis is local and general. To prevent permanent adhesions and to relieve pain, the instillation of atropine solution—gr. iv to water ℥j—is imperative. From one to two minims should be dropped in the conjunctival sac every hour, in the first few days of the attack. The degree of synechia is evident as soon as the iris is affected by the atropine, and even when the adhesions between the capsule of the lens and the iris are not completely relieved, firmer and more injurious adhesions will be prevented. Bloodletting at the temples, either by scarification and cups, or dry cupping, hot fomentations, etc., are local remedies of value. Rest to the eyes should be complete, and exposure to draughts or extreme changes in temperature are to be avoided. Any constitutional disease should be treated or any diathesis corrected by internal medication. Saline laxatives are indicated, as in other inflammatory affections.

In extreme cases, when all other remedial agents fail, *iridectomy* may be necessitated. This operation will be described hereafter. The permanent changes to which the iris is subject, after iritis, are adhesions (*synechiæ*), atrophy of the curtain at one or many points as the effusion disappears, and changes in color due to absorption of the normal pigment.

Choroid and Ciliary Body.

Choroiditis is occasionally of traumatic origin. The lines of rupture are seen most frequently near the optic disk, and in recent injuries may be concealed by extravasation. *Idiopathic choroiditis* occurs often in the tertiary step of syphilis. A less frequent variety is of tuberculous origin.

The diagnosis rests chiefly upon examinations with the ophthalmoscope. Disease is evident from the abnormal paleness due to atrophy and diminution of the blood-supply. It may be general and symmetrical in the two eyes (*syphilis*), or confined to one or more isolated patches (*tuberculosis*). In the syphilitic variety, changes in the retina are more evident. In very old persons an extensive area of atrophy may occasionally be observed, situated, as a rule, at the fundus.

The indications in treatment are to correct the prevailing dyscrasia, by specific remedies and tonics, and to give the eye as complete rest as possible.

Cyclitis occurs rarely except as in conjunction with inflammation of the sclerotic choroid or iris.

Sympathetic ophthalmitis is a term applied to inflammation in one eye, followed by a like disturbance in and threatened destruction of the other. It is very apt to occur, after *traumatic cyclitis*, from a penetrating body. Dislocation of the lens, iritis, or any inflammatory process, without penetration, and the entrance of air or a foreign substance, may also cause this form of ophthalmitis.

The invasion from one eye to the other is now believed to be by means of septic bacteria traveling along the optic nerve and chiasm. When once declared, the remedy of most avail is enucleation of the diseased eye. It is important that this operation be not too long postponed. The chief difficulty to be surmounted is to determine when it is necessary to operate. The following rules may serve as a guide :

When a penetrating septic body has entered the eye and destroyed vision, it would be wise to enucleate even before iritis and cyclitis are established, and if these symptoms of ophthalmitis are present, operation is imperative. Enucleation is indicated in an eye in which a foreign body is lodged with vision not materially impaired when the earliest symptoms of irido-cyclitis supervene.

Idiopathic inflammation of the interior of the globe, which destroys vision, also indicates enucleation.

Operation.—Seize the conjunctiva with a mouse-tooth forceps near the margin of the cornea, and with delicate scissors divide the conjunctiva evenly all the way around close to the cornea. Introduce the strabismus-hook and divide the internal muscle at its insertion into the globe. The other recti muscles are then successively divided. The ball is then carried toward the nose and a dull-pointed scissors curved on the flat is carried (concavity to the globe) backward and the nerve divided close to the ball. The attachments of the oblique muscles are next cut through.

An artificial eye should not be worn until the stump is healed, which requires about five weeks.

Glaucoma.—This disease is almost always met with after the fortieth year, and is more common in the hypermetropic than in the myopic eye.

The prevailing symptom is an increased tension of the eyeball.

Glaucoma may be acute, subacute, or chronic. In rare instances, it occurs with great rapidity (*g. fulminans*). More frequently it is slower in its progress. The earliest symptom is dimness of vision. Patients usually complain of indistinctness of sight, as if they were looking through frosted glass. These attacks are at first commonly periodic, but the interference with vision soon becomes permanent. Halos or rainbows are seen when an artificial light is looked at. The cornea has a dead and glazed appearance, the pupil is dilated, the anterior chamber shallow, and the iris is not so movable as normal. If the pulp of the finger is pressed upon the eyeball, it is felt to be hard and abnormally inelastic. Pain is not always present. Inflammation may or may not occur. Blindness sooner or later supervenes, unless prevented by treatment. The causes of glaucoma are, as yet, not satisfactorily explained. It is more generally held that obstruction of the efferent lymph-channels, or of the vessels which carry off the intravascular fluids, is the chief cause of this disease.

Fig. 512.—Jaeger's angular keratome.



Fig. 513.—Beers's keratome.

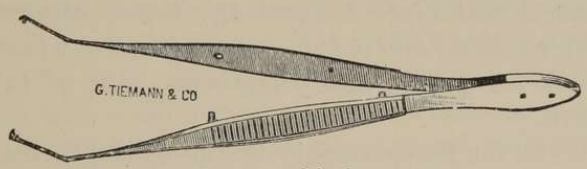

Fig. 514.—Iris forceps.

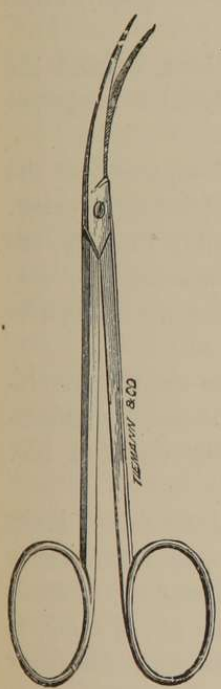

Fig. 515.
Curved iris scissors.

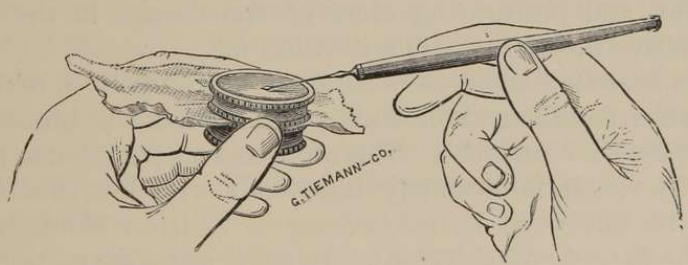

Fig. 516.
Drum for trying the edge of eye instruments.

Treatment.—The chief reliance is in *iridectomy*. With the iridectomy knife, enter the anterior chamber by cutting through the sclerotic near the corneal border, exposing the upper margin of the iris for at least one fifth of its circumference. Divide the iris at one end of the incision in a line radiating from its pupillary margin to its ciliary attachment, by traction tear it from the ciliary attachment and divide

with the scissors at the other limit, severing one fifth of the membrane (Fig. 517). No particle of iris should be allowed to be caught and remain in the wound. The after-treatment consists in bandaging the eye, and complete rest.

Fig. 517. — Iridectomy for glaucoma. (De Wecker.)

In mild cases, a smaller section of the iris should be made. The edge may be drawn out with the forceps and a loop of iris clipped off with the scissors.

Crystalline Lens.

Cataract, or opacity of the lens, although chiefly encountered after the fortieth year of age, may occur at any period of life. It may be divided into—1, *congenital* or *infantile cataract;* 2, *cataract of adult and middle life* (before forty); 3, *senile cataract.*

Cataracts are also classified according to their location in the lens—*nuclear*, or central; *cortical*, or peripheral; and *capsular.*

Nuclear cataract occupies the center of the lens, either permanently, or spreads gradually until the organ is entirely involved. It is at first observed as an opacity or cloudiness immediately behind the pupil, white or amber-brown in color.

Cortical cataract commences near the margin of the lens, behind the iris, and is characterized by grayish-white lines or streaks projected toward the center of the pupil.

In the *capsular* variety the cloudiness or opacity is confined to the anterior shell of the capsule, the substance of the lens not being affected.

Cataracts which are congenital, or only observed in early infancy, are classified as *anterior polar*, or *pyramidal; lamellar*, or *zonular; central*, *posterior polar*, and *fusiform.* All of these types are comparatively rare.

The *anterior polar* variety is due to the formation of a chalky concretion in the center of the anterior lamellæ of the lens, caused by inflammation and perforating ulcer of the cornea in the early days of life. Operative interference is not called for.

In *lamellar* or *zonular* cataract the opacity is limited to a thin layer of lens-substance, about half way between the nucleus and the anterior and posterior surfaces. The nucleus and peripheral portions are normal. When vision is seriously interfered with by this form of opacity, it may be improved by *iridectomy* or incision through the anterior layer of the capsule (*discission*). In some cases extraction is advisable.

In *central* cataract the deeper fibers of the lens only become opaque. It may be treated in the same way as the zonular opacity. *Posterior polar* cataract is seen deeply behind the center of the lens. Operative treatment is rarely demanded, and when indicated discission is advised.

Fusiform opacity extends from the posterior to the anterior pole. It is very rare.

Cataracts are *primary* when the opacity is developed independent of any other lesion of the eye, and *secondary* when some other lesion exists.

A *traumatic* cataract occurs as a result of rupture of the capsule, with or without perforation, allowing the aqueous humor to invade the crystalline substance. A *Morgagnian* cataract is one in which partial liquefaction of the cortex has taken place, and the nucleus drops to the lowest portion of the capsule. The opacity occurring in *diabetes mellitus* is called *diabetic* cataract.

Cataracts are also termed *senile*, *hard*, and *soft*. Senile cataract occurs, as its name implies, in old persons, usually very late in life, but not unfrequently as young as the fortieth year. This variety, though usually firm or *hard*, is at times soft. Under forty years cataracts are usually *soft*. A cataract is said to be "ripe" when the entire lens has become opaque.

Symptoms and Diagnosis.—With senile cataract the earlier symptoms are disturbance of vision. Indistinctness of vision for distant objects is usually first noticed, and, in certain cases, multiple images of one object are observed. If the cataract is *nuclear* or central, vision is improved by shading the eye, thus allowing the pupil to dilate. In *cortical* cataract this is not the case, but by dilatation of the pupil with atropine the presence of the peripheral opacity may be detected. When a cataract is general and ripe, blindness for objects is complete, although light and darkness are appreciable.

Examined in ordinary light a well-marked nuclear cataract may be recognized; but it is by focal illumination and by the ophthalmoscope that a diagnosis is positively made. The pupil should be dilated.

A large nucleus with very fine radiating striæ indicates a hard cataract, while a small nucleus and large striæ suggest a soft opacity. If the cataract be *ripe*, no clear space will be discovered between the nucleus and the iris, and no shadow will be thrown upon the nucleus by the iris. Focal (oblique) illumination—i. e. concentrating by means of a prism the rays of a strong light let fall obliquely upon the cornea—is essential in this examination. By the ophthalmoscope the normal red reflex from the fundus is absent (Swanzy).

As it is important to have a cataract ripe when an operation is undertaken, *Foster* submits the following general guide: Cataracts which are ripe, according to the tests just given, and in which there are *no sectors shining like mother-of-pearl*, are considered ripe for operation. In color they are white, yellow, or gray; also when the lens is wholly occupied with a brownish-yellow nucleus. This may be semi-transparent, and the iris throw a distinct shadow.

Treatment.—When a cataract is not ready for operation, the vision may be improved by glasses, which shade the eyes, allowing the pupil to dilate, and by the instillation of weak atropine solution. These measures apply to opacities at or near the antero-posterior axis of the lens.

Opacities of the lens may be removed by three methods: *Solid extraction*, *absorption after discission*, and *suction*. The first method is applicable to all forms of ripe cataract; the lamellar, central, posterior polar, and fusiform varieties are treated by discission when any operative interference is indicated; soft opacities are removable by suction.

Extraction is not imperative when only one lens is affected, vision being about perfect in the other, unless the cataract is becoming over-ripe. It is advisable to remove only one lens at a single operation, even in double ripe cataract.

Operation is not advisable when any serious intra-ocular complication exists, or when insurmountable opacity of the cornea is present. It is always advisable to allay any existing inflammation of the ball or appendages before an operation for cataract. When a cataract is not ripe, its solidification may be hastened by *massage* of the globe—that is, by pressure applied over the ball with the tips of the fingers. The massage should last a few minutes, and be repeated every few days as indicated.

Operation of Extraction.—Two principal methods of extraction are at present employed, viz., (1) *simple extraction* and (2) *extraction after iridectomy.* The former is the ideal operation, and, although at this date not so generally employed, is fast gaining in popularity.

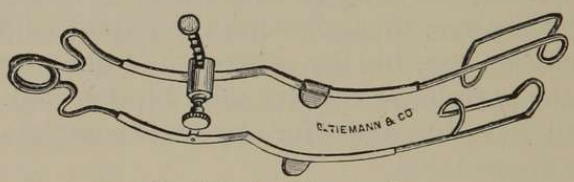

Fig. 518.—Graefe's speculum.

Simple Extraction.—The most careful asepsis is demanded. The eye should be irrigated with warm boracic-acid solution (gr. x–xv to ℥j). The instruments should be thoroughly cleansed by boiling and immersion in alcohol. Anæsthesia is obtained by dropping several minims of 2-per-cent cocaine hydrochlorate into the eye, five minutes, and again three minutes, before the operation. The head should be so held that

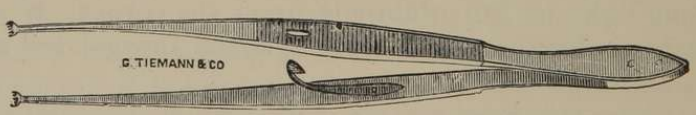

Fig. 519.—Graefe's fixation forceps.

the cocaine rests in contact with the upper surface of the cornea through which the incision is made. When ready to operate, the eye and conjunctival sac should be dried with absorbent boracic-acid cotton pellets. The speculum is introduced and secured, and the conjunctiva seized with fixation-forceps just below the center of the lower margin of the cornea. The ball is drawn slightly downward and steadied, while the



Fig. 520.—Graefe's linear knife.

knife, cutting edge upward, is entered *through the cornea* just at the corneo-sclerotic junction, carried carefully across in front of the iris, which must not be touched, and out at a point corresponding to that of entrance (Fig. 521). By careful to-and-fro movements, the flap

is made by cutting upward through the cornea just anterior to the sclerotic junction. The line between the angles of this flap should cross the cornea a little more than one third the distance from the upper to the lower margin. As this section is being made, and before the aqueous humor escapes, an assistant should slightly lift the speculum, so that no pressure may be made by it upon the ball.

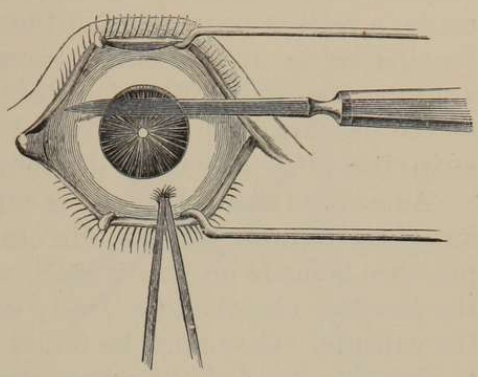

Fig. 521.—Introduction of Graefe's knife, showing size of corneal flap in extraction of cataract. (Swanzy.)

The cystotome is now carried through the wound, kept clear of the iris by the operator, who very cautiously scratches through the anterior capsule, through the whole width of the pupil. Care must be taken not to press so hard against the lens as to dislocate it. As soon as the capsule is opened, gentle pressure in an upward direction should be exercised by means of the spoon against the lower margin of the cornea, or pressure with the finger on the lower lid may suffice to deliver the

Fig. 522.—Cystotome and Daviels's spoon.

lens through the pupil and out through the wound of incision. The pressure should be carefully gauged to effect only the exit of the cataract, and not to rupture the zonula. The wound should now be examined, and no particle of iris, lens, or capsule should be left in the incision. A drop of eserine solution (gr. ij–℥j) is now instilled into the conjunctival sac in order to contract the pupil. The eye is finally irrigated with the boracic-acid solution and the dressing applied, and both eyes closed by bandaging. The patient is required to remain quiet in a light room for a week. The first change of dressing should be made on the second day, and daily thereafter. Strict asepsis is essential at each change of dressing. The light should be excluded only from the eyes by bandages and shades, and *not* from the room. At the end of a week or ten days a black silk shade may be substituted for the bandages, and in from two to three weeks the patient will need only medium smoke coquilles to protect his eyes from the strong light. He should not be fitted with cataract glasses until all signs of redness and sensitiveness have disappeared.

Extraction with Iridectomy.—The speculum is introduced and secured, and the ball steadied by grasping a fold of the conjunctiva, just below the center of the lower margin of the cornea (Fig. 521), with a mouse-tooth fixation-forceps. The ball is drawn slightly downward, and the Von Graefe knife, edge upward, is made to enter the cornea, just at the sclerotic junction, at a point three milimetres (about one eighth of an inch) below the highest margin of the cornea (or about one third of the distance between the upper and lower margins of the cornea). The

point is then made to emerge accurately opposite the entrance, when, by a gentle movement of the knife, the flap is completed by cutting through the cornea, just anterior to its junction with the sclerotic. As this flap is made, a certain proportion of the aqueous humor escapes. The fixation-forceps being, at this stage, transferred to an assistant, the iris-forceps are introduced, and the iris seized at a point corresponding to the center of the incision, and carefully drawn out through the wound. A narrow strip, including the entire depth of the iris, is then excised.

As soon as the iridectomy is completed the operator relieves the assistant of the fixation-forceps, directs that the speculum be lifted, so that no pressure is made on the eyeball, while, with the cystotome carried into the anterior chamber, he freely scratches through the anterior layer of the capsule. Care must be taken not to press so hard against the lens as to dislocate it. It is also important to see that no shred of the capsule is dragged out into the wound in withdrawing this instrument. The globe should now be depressed, either with the forceps or by the patient's volition, and the cataract extracted by gentle pressure with the spoon from the lower margin of the cornea upward. The pressure should be carefully gauged, and the wound examined as above described. Should bleeding occur, this may be checked by a light compress of cold boracic solution. The after-treatment is the same as just given.

If the primary incision should not be large enough to allow the easy escape of the lens, it should be enlarged, preferably with the iris-scissors; it should be free, to begin with. If any fragments of the lens adhere to the capsule or are caught in the wound, they must be worked out by careful manipulation. Should the zonula be ruptured, allowing the vitreous to escape, the lens should be extracted with the scoop. The vitreous should be divided with the scissors at the level of the wound.

Should septic infection occur, suppuration of the wound follows, with usually destruction of the eye. The treatment should be frequent irrigation with boracic-acid solution, and the galvano-cautery wire applied to the margins of the wound. When iritis is precipitated, atropine should be instilled and warm boracic-acid water dressings applied.

Strong convex glasses are necessary after the operation, but the eyes should not be used for reading, etc., for three or four months. Two pairs of glasses should be prescribed—one for reading and another for vision.

Discission.—After dilatation with atropine, ether or chloroform should be administered to prevent any movement which might displace the lens, the speculum introduced, and the field of operation rendered aseptic.



Fig. 523.—Beers's straight needle.

The point of the cataract-needle is made to pass through the cornea near the outer margin, and the point carried to the center of the pupil, where it enters the capsule of the lens (Fig. 524). The capsule and the

anterior superficial layers of the lens are torn open by gentle movements of the point of the instrument, which is then withdrawn, being careful not to injure the iris. The pupil should be kept fully dilated, renewing the instillation every few hours, if necessary, for several days. Cold applications and a dark room are the chief indications in the after-treatment. If successful, the lens becomes opaque after a week or more, and gradually disappears by absorption. A second operation may be necessary.

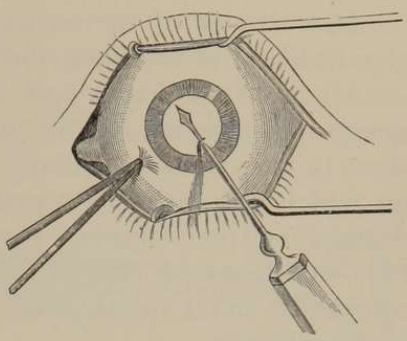

FIG. 524.—Introduction of the needle in discission. (Swanzy.)

Suction.—Dilate with atropine, administer ether, incise the cornea half-way between its center and margin, perform discission, and introduce the nozzle of the syringe into the lens, when it and the capsule are broken up. The softened lens is sucked into the cylinder by steady and gradual traction on the piston. Strict asepsis is essential. A single introduction of the instrument is advisable. The after-treatment is the same as for discission.

THE VITREOUS.

Hyalitis, or inflammation of the vitreous, may result from traumatism, with or without the presence of a foreign body, or by the extension of some idiopathic inflammatory process from the choroid, iris, on any portion of the globe. Syphilitic choroiditis is especially apt to produce hyalitis. The immediate symptom is opacity due to extravasation of blood, or the exudation of the products of inflammation. The vitreous breaks down, becoming more fluid than normal (*synchisis*). Flakes or small collections of more solid matter may be seen to change position as the position of the globe is changed. "Spots before the eyes" (*muscæ volitantes*) occur chiefly in myopic subjects, and are due to changes in the vitreous.

The exact condition of the vitreous can usually be made out by careful examination with the ophthalmoscope.

Foreign bodies, when composed of small bits of metal, may be removed by the electro-magnet. Should the wound in the sclerotic be not sufficient, it should be enlarged and the middle of the magnet carried into the vitreous. The metal, if not impacted, adheres to the magnet and is withdrawn. When the foreign body is non-metallic, operative interference is of doubtful propriety unless general inflammation is taking place. Idiopathic hyalitis should be treated by rest to the eye and by special medication.

THE RETINA.

Inflammation of the retina (*retinitis*) may occur independently of lesion of any other portion of the eye, or it may be part of an inflam-

mation of the choroid, ciliary body, iris, vitreous, or by extension from the optic nerve. It is not uncommon in syphilis, and follows thrombosis and embolism of the vessels. It is met with in nephritis, in diabetes, and in severe cerebral hyperæmia.

Detachment of the retina from the choroid may be due to extravasation of blood or transudation of serum.

All these conditions may be determined by a careful analysis of the symptoms present and by ophthalmoscopic examination. The indications in treatment are chiefly to correct the general condition of disease on which the retinitis depends. When of traumatic origin, the chief reliance is upon complete rest and warm fomentations. In certain morbid conditions of the external portions of the retina, objects appear unusually small (*micropsia*). The opposite of this condition is known as *megalopsia*.

Night-blindness (*hemeralopia*) is usually only a symptom of *retinitis pigmentosa*, but sometimes occurs in other diseases of the retina and optic nerve.

Day-blindness (*nyctalopia*) is generally due to exposure to strong light, as the glare of the ocean in the tropics, and may occur in persons of faulty nutrition.

Optic Neuritis.—The optic nerve is at times the seat of neuritis which may originate here, or descend from the brain along the nerve; it may be secondary to retinitis, or become involved by contact with morbid changes occurring in the lymph spaces and other tissues contiguous to it. The subjective symptoms are varying degrees of interference with vision. *Amblyopia* (dimness of sight), or *amaurosis* (complete blindness), may be present. These symptoms may be present without perceptible change in the appearance of the retina or optic papilla. When the lesion is beyond the disk, atrophic or other changes of the papilla may be recognized by the ophthalmoscope.

In some instances the obliteration of the retinal image is confined to a portion of the field of vision, usually one half (*hemianopsia*). If one eye only is involved, the lesion is peripheral and limited to the nerve or retina of the affected eye. If binocular, the lesion is in or posterior to the optic chiasm. The inner half of one and the outer half of the other eye are usually obscured.

Color-Blindness.—There is a congenital defect of the retina in which the individual is incapable of recognizing certain colors, as *red*, *green*, and *blue*; a little more than three per cent of males are so affected. Of thirteen hundred and eighty-three men in the employment of the Pennsylvania Railroad Company examined by Dr. William Thomson, fifty-five were absolutely color-blind. It is less common in women. The usual method of testing is that with Professor Holmgren's colored woolen threads. If the patient is wholly color-blind, he will be unable to differentiate between the principal colors. Partial color-blindness may be detected by a careful test with the woolen threads, requiring the suspected person to match to the leading colors those which to him appear of the same or nearly the same shades.

Strabismus.

Strabismus, or "squint," may be *convergent* or *divergent*. The former is by far the more frequent variety, and is usually observed in young children. It results from a loss of the normal equilibrium in the muscles of the eye, and when first noticed is often intermittent, appearing in one eye and then the other (*alternating*). As a result of prolonged and repeated efforts at *accommodation* (contraction of the ciliary muscle causing relaxation of the zonula, with consequent increase in the antero-posterior diameter of the lens), the internal rectus becomes permanently shortened.

Fig. 525.—Lawrence's strabismometer.

The degree of convergence may be determined by the strabismometer (Fig. 525). Let the patient fix his vision on a distant point directly in front of him; place the center of the instrument directly beneath the center of the pupil, and measure the distance from this point to the inner angle of the eye. The same measurement on the affected side will determine the degree of convergence on that side.

Treatment.—Tenotomy is indicated in convergent strabismus for the relief of deformity, as well as for the correction of vision. The prospect of a perfect result is better in recent cases than in those of long standing, in which the external rectus has been overstretched and permanently weakened. In children, about the seventh year is the best period for



Fig. 526.—Graefe's strabismus hook.

operation. Tenotomy of the internal rectus is thus done: The conjunctiva is first anæsthetized with cocaine solution, and two to four minims may be injected into and beneath the conjunctiva, immediately about the insertion of the muscle. The speculum is introduced, and the conjunctiva, just on the inner side of the eye, picked up with the forceps and divided with the scissors. The strabismus-hook (Fig. 526) is next carried into this opening and guided beneath and behind the tendon of the rectus internus, which is pulled forward and divided at its insertion into the sclerotic. The hook should be again introduced, to make sure that a thorough division is effected. A pad of cotton dipped in boracic-acid solution, held in



Fig. 527.—Strabismus scissors.

place by a dry cotton compress and bandage, should be worn for one or two days. When strabismus makes its appearance in adult life, it is usually due to paralysis, partial or complete, of one or more of the orbital muscles. The lesion producing paralysis may be situated in the brain or in the orbit. Disease of the bones about the foramina of exit of the nerves which supply these muscles, the presence of syphilitic gummata, or any neoplasm, will produce, by pressure on the nerves or muscles, a more or less complete paralysis. Rheumatism is occasionally a cause of strabismus.

In the *treatment* of strabismus due to paralysis, operative interference is not indicated until all other remedial agents have been exhausted in vain. When operation is demanded, not only should division of the contracted muscle be effected as just described, but the weaker muscle may be shortened by *advancing its insertion.*

Take, for example, the external rectus. Perform tenotomy as heretofore described. A small curved needle is threaded with fine silk and carried from the ocular side out through the divided muscle and the conjunctiva. Each end of this double suture is now threaded to a curved needle and passed beneath and through the conjunctiva, coming out near the margin of the cornea and about one eighth of an inch from the vertical meridian of the eye above and below (Fig. 528). The needles are cut away, and the two ends of the lower threads tied together, at the same time that an assistant ties the upper ends. These sutures are allowed to remain about forty-eight hours. The amount of shortening in the muscle advanced can be increased by carrying the first needle farther back through the muscle. In order to get the best possible result, the shortening should be slightly more than appears necessary at the time of operation.

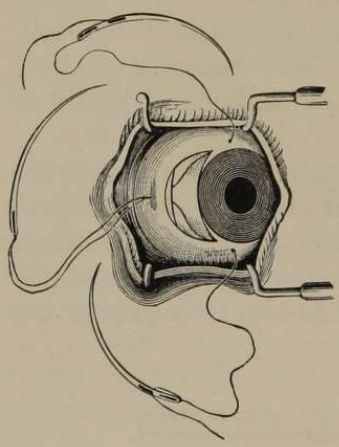

Fig. 528.—Advancement of the rectus. (De Wecker.)

Refraction.—The Ophthalmoscope.*

By the *refraction* of the eye we mean its power, when in a state of rest, of bringing parallel rays of light to a focus. In normal refraction, or *emmetropia*, the focus for parallel rays is upon the retina (Fig. 529). When the focus for parallel rays is not on the retina, there is said to be an error of refraction. The term *ametropia* includes all the errors of refraction. The principal forms of ametropia are: 1, *myopia;* 2, *hypermetropia.* All the other forms of ametropia are included under the head of *astigmatism*, in which the refraction differs, in degree or kind, in opposite meridians of the same eye.

* The author desires to acknowledge his indebtedness to his friend, Prof. David Webster, M. D., by whom this article on Refraction was written.

The difference in refraction of eyes is due to their difference in shape. While the emmetropic eye is nearly spherical, the myopic eye



Fig. 529.—Showing concentration of rays of light (*a*, *b*, *c*) on the retina (*d*) in normal refraction. (Swanzy.)

is egg-shaped—too long in its antero-posterior diameter; and the hypermetropic eye turnip-shaped—too short in its antero-posterior diameter. Thus, while the principal focus of the emmetropic eye is upon the retina,



Fig. 530.—Showing rays converging to focus (at *a*) behind the retina (*b*, *c*). The hypermetropic eye. (Swanzy.)

that of the hypermetropic eye is behind the retina (Fig. 530), and that of the myopic eye in front of it (Fig. 531).

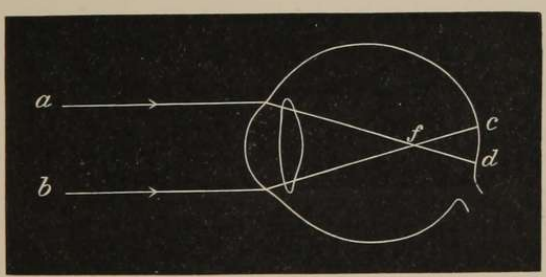

Fig. 531.—Showing concentration at (*f*) of rays of light (*a*, *b*) in front of retina (*c*, *d*) in myopia. (Swanzy.)

Astigmatism is usually due to asymmetry, or irregularity of surface, of the cornea, probably sometimes to a like condition of the lens. The varieties of astigmatism are six in number: 1, *simple myopic;* 2, *compound myopic;* 3, *simple hypermetropic;* 4, *compound hypermetropic;* 5, *mixed;* and, 6, *irregular astigmatism.*

In simple myopic and simple hypermetropic astigmatism, the principal focus of one meridian of the cornea is upon the retina, while the principal focus of the opposite meridian is anterior to the retina or behind it, accordingly as the astigmatism is myopic or hypermetropic.

In compound myopic astigmatism all the meridians of the eye are

myopic, but one of them more so than any of the others, and the meridian at right angles to it less so than any of the others.

In compound hypermetropic astigmatism all the meridians of the eye are hypermetropic; but one of them more so than any of the others, and the meridian at right angles to it less so than any of the others. In mixed astigmatism one meridian of the eye is myopic, while the opposite meridian is hypermetropic. In irregular astigmatism different parts of the same meridian possess different degrees of refraction. Hence this form of astigmatism is the only error of refraction, which can not be corrected by glasses. It is, in every sense of the word, irremediable.

It is obvious that persons with emmetropic eyes, and with unimpaired accommodation and well-balanced ocular muscles, do not need spectacles. Persons with any of the different forms of ametropia are liable to become the subjects of asthenopia from eye-strain. Such persons complain of inability to use their eyes, pain in their eyes and temples, headache, nausea, and various nervous disorders.

Hypermetropia is congenital, as a rule, and is said to be due to an arrest of development of the globe in its antero-posterior axis. It is sometimes the result of changes in the refractive media, as in the hardening of the crystalline lens that occurs in old age, or the removal of the lens by operations for cataract.

Parallel rays of light passing through the hypermetropic pupil do not meet on the retina, but converge toward a point behind it. Objects are, therefore, seen under circles of diffusion; and such eyes, in order to see distinctly, contract their ciliary muscles sufficiently to so increase the convexity of the crystalline lens that the focus will be brought forward upon the retina. This act is involuntary, and produces more or less strain upon the eyes. For such persons the *strongest convex* spherical glasses should be selected with which they can distinctly see objects distant twenty feet or more. If the asthenopic symptoms only accompany or follow the use of the eyes for reading and other near work, it may be sufficient to wear the glasses only for the near. But when the asthenopic symptoms are constant, and are only aggravated by near work, the glasses should be worn constantly.

In selecting glasses for the relief of asthenopia, no matter what the error of refraction, it is always well to examine the eyes with the pupil dilated. While sulphate of atropia is the most reliable mydriatic, if used in solution sufficiently strong to paralyze the accommodation, it incapacitates the eyes for near vision for at least ten days.

When the object is to ascertain the true refraction with as little inconvenience to the patient as possible, it is sufficient for all practical purposes to drop into the eyes a few minims of a 3-per-cent solution of homatropine hydrobromate at intervals of fifteen minutes, until seven or eight instillations have been made, and to test the refraction ten or fifteen minutes after the last instillation. If the homatropine produces redness of the eyes, as is often the case, this may be relieved by a single instillation of a 4-per-cent solution of cocaine hydrochlorate, which, at the same time, increases the effect of the homatropine in paralyzing the

ciliary muscle. The effect of these mydriatics passes off inside of twenty-four hours. In cases where it is desirable that the patient should have the benefit of a prolonged rest of his accommodation, regardless of inconvenience, it is better to use the sulphate of atropia (a 1-per-cent solution).

In some cases of asthenopia from hypermetropia, glasses correcting the total error of refraction are worn with comfort from the start. In the majority of cases, however, when the accommodation reasserts itself, such glasses make the eyes practically myopic, and the indistinctness of vision thus produced so annoys the patient that he rejects them. It is safer, therefore, to wait until the hypermetrope has recovered from the effects of the mydriatic, and then to order the strongest convex glasses that he can wear with comfort. When his eyes have become accustomed to these, they should be exchanged for stronger ones, and these changes should be repeated at intervals of two or three months until the total hypermetropia is corrected. After that it is probable that the patient will need no further change of glasses, and that the relief of his asthenopia will be permanent.

Myopia may be apparent or real. Apparent myopia is due to spasm of the ciliary muscle, and may be diagnosticated from true myopia by ascertaining the true refraction under the effects of atropine. Spasm of the ciliary muscle is usually the result of over-use of the eyes. Such patients should be kept under atropine for several weeks, wearing medium smoked coquille glasses to protect the retina from excessive light. When the spasm of the ciliary muscle fails to reassert itself after the use of the mydriatic is stopped, convex glasses, correcting the hypermetropia, which almost always exists in such cases, should be substituted for the coquilles, and the patient should be cautioned not to resume the excessive near use of his eyes. True myopia is the result of the lengthening of the antero-posterior diameter of the eyeball, and is rarely congenital. There often exists a hereditary tendency to myopia; and it is a matter of common observation, that where the father or mother is myopic the children are apt to develop the same condition during school-life. Myopia is frequently developed in children, however, where there is no traceable hereditary tendency. It almost invariably first shows itself during early school-life, and the first intimation of it is that the child fails to see the letters and figures on the blackboard across the school-room. It is encouraged by the use of the eyes by insufficient light in a vitiated atmosphere, and in a stooping position, during the period when the eyes are undergoing rapid development along with the other organs of the body. It is of the greatest importance that it should be arrested as soon as possible; for highly myopic eyes are nearly always diseased eyes, and are in great danger of developing staphyloma posticum, retinal and choroidal changes, floating bodies in the vitreous, and detachment of the retina. Myopic patients should be fitted with glasses at as early a period as possible, the weakest concave glasses being selected for them, with which they can see distant objects distinctly. They should wear such glasses constantly; by so doing, arrest of de-

velopment of the ciliary muscle will be avoided, as will also excessive strain upon the interni. Attention to their general health should not be neglected, and the amount of use of their eyes for near work should be limited. Their eyes should be tested at least once in six months, and a careful record kept of the results of such testings, for it is only in this way that we can tell whether the myopia is stationary or progressive, and, if the latter, whether rapidly so or not. If the myopia is increasing rapidly, near work should be entirely stopped, and the patient should be put upon atropine and colored glasses, and turned out into the open air. Myopia usually ceases to be progressive somewhere between the ages of twenty and thirty. Aside from all consideration of the health of the eyes, myopes should wear the correcting glasses for educational reasons.

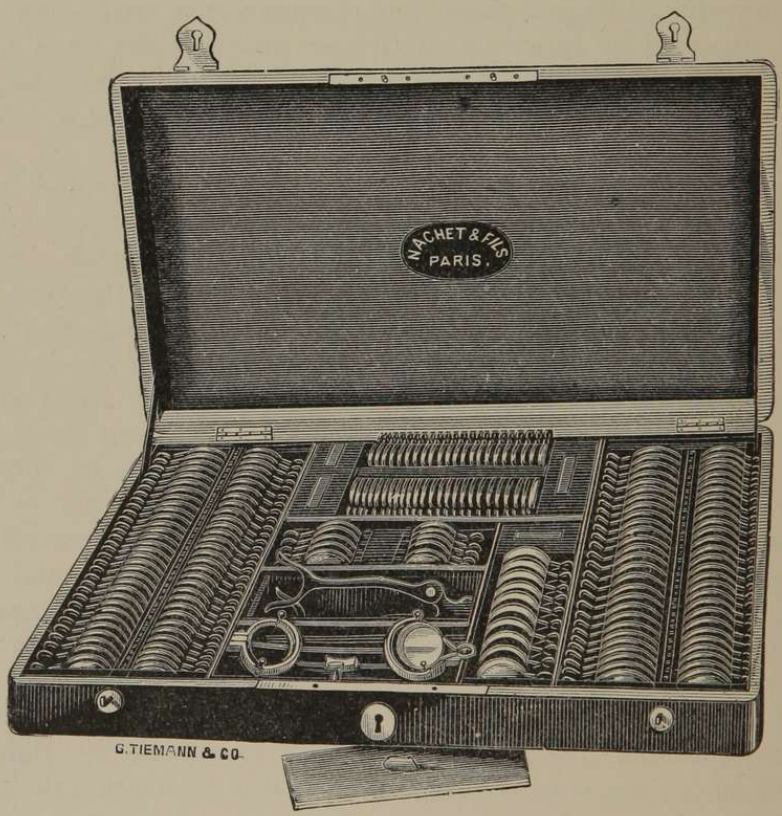

Fig. 532.—Nachet's trial-set.

Astigmatism, especially when only slight and correctable by an unequal contraction of the ciliary muscle, is a prolific source of asthenopia. When it exists in the higher degrees, the patient makes no attempt to correct it; sees indistinctly at all distances, and is comparatively free from asthenopic symptoms. The slighter degrees, then, should be corrected with glasses for the relief of asthenopia; the higher degrees for the purpose of procuring distinct vision. Of course, in fitting patients with glasses for the correction of astigmatism, convex and concave cylindrical lenses are necessary. For simple hypermetropic astigmatism that convex cylindrical glass should be selected which brings the focus of

the hypermetropic meridian forward upon the retina, and thus makes distinct vision possible without an effort of accommodation. For simple myopic astigmatism the concave cylindrical glass should be selected which throws the focus of the myopic meridian back upon the retina, and thus renders the eye practically emmetropic. For compound hypermetropic astigmatism a convex spherical with a convex cylindrical glass is necessary; while in compound myopic astigmatism the error of refraction is corrected by the combination of a concave spherical and a concave cylindrical glass. Mixed astigmatism is corrected by a convex cylindric and a concave cylindric combined, and with their axes at right angles to one another.

In prescribing glasses for astigmatism the greatest care should be taken to adjust the axes properly. The cylindric trial-glasses should always be placed before the eyes in trial-frames made for the purpose, and the direction of the axes read in degrees from the frames. Ophthalmologists use Snellen's test-types in examining for errors of refraction, and the cases of trial-glasses made by Nachet (Fig. 532) are as good as any.

Testing for Glasses.

For determining errors of refraction and fitting patients with spectacles, the surgeon should provide himself with Snellen's and Jaeger's test-types and with a case of trial-glasses, including spherical and cylindrical glasses, convex and concave, trial-frames with the degrees of a semicircle marked upon them, etc. The patient should be placed at a distance of twenty feet from Snellen's test-type, with the light shining upon the test-type and not upon the face of the patient. Each eye should be tested separately, the other being kept open and covered with a screen.

Snellen's test-type is so constructed that the letters in each line subtend an angle of five minutes at the distance marked in feet above the line. The line marked 100 should therefore be read at one hundred feet; that marked 20, at twenty feet, etc. Vision is recorded *fractionally*, the distance from the test-type being set down as the *numerator*, while the number of the line read is set down as the *denominator*. Thus, if a person with his right eye reads Snellen No. 70 at twenty feet, the vision would be recorded thus: R. V. $= \frac{20}{70}$. If with his left eye he reads Snellen No. 20 at twenty feet, it is recorded L. V. $= \frac{20}{20}$. The vision of the right eye would be two sevenths of the normal, while that of the left eye would be one, or normal. If a patient reads $\frac{20}{20}$ with each eye, we know that his vision is perfect in both eyes, but still he may be *hypermetropic*, and straining his accommodation in order to see distinctly. We should always test such a patient with convex spherical glasses. If the weakest glass blurs his vision, he has no manifest hypermetropia. The vision and refraction of such a patient should be recorded thus:

R. V. $= \frac{20}{20}$; E. L. V. $= \frac{20}{20}$; E. (emmetropic).

If the patient can read Snellen No. 20 at twenty feet through a convex spherical glass, the *strongest* one through which he can read it represents his manifest hypermetropia. Thus—

R. V. = $\frac{20}{20}$; Hm. 1·75 D. L. V. = $\frac{20}{20}$; Hm. 1·50 D.

would mean that the patient had perfect vision without a glass, or with any convex spherical glass from the weakest up to + 1·75 D., right eye, and + 1·50 D., left eye; but that stronger glasses than those indicated would blur his vision. Those glasses should, therefore, be prescribed. If the patient sees less than $\frac{20}{20}$, we may suspect myopia or astigmatism. For instance, the formula—

R. V. = $\frac{20}{200}$; $\frac{20}{20}$ with − 4 D. L. V. = $\frac{20}{100}$; $\frac{20}{20}$ with − 3 D.

means that, without glasses, the patient sees $\frac{20}{200}$ with his right eye, and $\frac{20}{100}$ with his left eye, and that − 4 dioptries is the *weakest* concave glass with which he can read $\frac{20}{20}$ with his right eye, and − 3 dioptries the weakest with which he can read $\frac{20}{20}$ with his left eye.*

Again, the patient may be astigmatic. Suppose we find—

† R. V. = $\frac{20}{40}$; $\frac{20}{20}$ with + 1·25 D. c. ax. 90°.

L. V. = $\frac{20}{50}$; $\frac{20}{20}$ with + 1 D. s. ⌒ + 1·50 D. c. ax. 90°.

We have here simple hypermetropic astigmatism in the right eye, and compound hypermetropic astigmatism in the left. In the right eye, the vision is brought up to $\frac{20}{20}$ by a convex cylindric, one and a quarter dioptries, axis 90°; while in the left the combination of a convex spherical and a convex cylindrical is required.

In another case—

R. V. = $\frac{17}{200}$; $\frac{20}{20}$ with − 3·25 D. c. ax. 180°.

L. V. = $\frac{3}{200}$; $\frac{20}{20}$ with − 3·75 D. s. ⌒ − 2 D. c. ax. 180°.

Here we have simple myopic astigmatism in the right, and compound myopic astigmatism in the left. In mixed astigmatism the refraction may be corrected and the vision brought up to the normal by either of three different combinations of lenses. Thus—

R. V. = $\frac{20}{50}$; $\frac{20}{20}$ with + 1 D. c. ax. 90° ⌒ − 1 D. c. ax. 180°.

L. V. = $\frac{20}{70}$; $\frac{20}{20}$ with + 2 D. c. ax. 90° ⌒ − 2 D. c. ax. 180°.

The equivalent glasses would be—

R. + 1 D. s. ⌒ − 2 D. c. ax. 180°.

L. + 2 D. s. ⌒ − 4 D. c. ax. 180°. Or,

R. − 1 D. s. ⌒ + 2 D. c. ax. 90°.

L. − 2 D. s. ⌒ + 4 D. c. ax. 90°.

In fitting patients with cylindric glasses the direction of the axes is read from the degrees marked on the trial-frames toward which the axes point in giving the best vision.

Presbyopia, or old sight, is an impairment of the accommodation due to the gradual hardening of the crystalline lens, the result of age. Persons who are emmetropic, or slightly hypermetropic, usually need glasses for near purposes when from forty to forty-five years of age. The higher degrees of hypermetropia necessitate the use of glasses for reading much earlier. In the lower degrees of myopia the use of glasses

* In the dioptric scale of numbering spectacle-lenses the unit is a weak lens of 100 centimetres focal length, or D. (one dioptre). A lens with focal length of 50 cm. = (2 D.), etc.

† This reads: Right vision equal $\frac{20}{40}$; $\frac{20}{20}$ with convex 1·25 Dioptries, cylindric, axis 90°. Left vision equal $\frac{20}{50}$; $\frac{20}{20}$ with (+) convex 1 D. spherical, (⌒) combined with convex 1·50 D. cylindric, axis 90°.

for reading may be deferred considerably longer, while in the higher degrees they may never be needed at all. Presbyopes, no matter what their refraction, should be suited with the glasses, generally convex, with which we find experimentally they can read most comfortably. Generally the weaker convex glasses are selected in the early stages of presbyopia, and these are exchanged for stronger ones as the patient advances in life.

Heterophoria.—Insufficiency of the extrinsic ocular muscles—latent or dynamic squint.

When the extrinsic ocular muscles are not well balanced, as when the interni are relatively stronger than the externi, or one of the inferior recti weaker than its fellow of the opposite side, there is a tendency of one eye to deviate in the direction of the relatively stronger muscle. If the eye should actually deviate, *diplopia* (double vision) would result, and would be productive of great annoyance. Therefore, single, binocular vision is always maintained as long as possible, and in order to its maintenance, an extra innervation has to be supplied to the weaker muscle. This constant strain causes asthenopia, headache, nervousness, etc. In some cases the strain can be removed by the use of prisms worn with their bases toward the weaker muscles, alone, or combined with the lenses which correct any existing error of refraction. But in many cases it becomes necessary to restore equilibrium of the muscles by a tenotomy of the stronger or a tendon resection of the weaker muscle.

The different kinds of correctable heterophoria (tendency to deviation of the visual lines) are: 1. Hyperphoria (a tendency upward of one eye). 2. Exophoria (a tendency outward). 3. Esophoria (a tendency inward).

In order to ascertain with accuracy the kind and amount of heterophoria, the surgeon should provide himself with a phorometer (an instrument of precision invented by Dr. George T. Stevens, of New York), and a set of square prisms, of one degree and upward.

The patient is seated facing a lighted candle, which is situated on a level with his eyes, and twenty feet, or more, distant. The horizontal bar of the phorometer is placed in front of his eyes and a few inches away from them. In a slot in this horizontal bar is placed a frame containing two prisms of 4° to 8° each, bases toward the nose, and on looking at the candle through these prisms, the images are thrown to the nasal side of the macula, and the patient has homonymous diplopia. If both inferior recti are of equal strength, and likewise both superior recti, neither eye will deviate upward, and the two candles will appear in a horizontal line, or on a level. But if one eye deviates upward, the image will be thrown upon the supero-nasal quadrant of the retina of that eye, and will be seen on a lower level than that seen with the other eye. The prism placed before the eye that sees the lower candle, base down, which brings the candles on a level, measures the amount of hyperphoria.

Having tested for hyperphoria, the horizontal prisms should be removed and replaced by a prism base down in front of one eye. This will produce vertical diplopia by throwing the image of the candle-flame

on the retina below the macula, so that it will be projected above. If the two flames are seen in a vertical line, there is no insufficiency of the interni or externi. But if the images are homonymous, there is insufficiency of the externi; and the prism, base out, that makes them vertical, measures the esophoria.

If the images are crossed, there is insufficiency of the interni; and the prism, base in, that makes them vertical, measures the exophoria. In making these tests, the horizontal bar of the phorometer must be carefully adjusted by means of the attached screw or ratchet and spirit-level.

In order to arrive at a more positive idea as to the relative strength of the ocular muscles, it is necessary to measure (1) the abduction, (2) the adduction, and (3) the sursumduction.

The abduction is measured by the strongest prism that can be overcome by the externi—that is, the strongest prism, base in, through which the patient can see singly at twenty feet or more. In like manner, the strongest prisms, base out, through which the patient has binocular single vision, measure the adduction; and the strongest prism, base down, over one eye, through which the patient sees singly, measures the sursumduction.

In hyperphoria of 1° or more, the superior rectus of the hyperphoric eye may be divided; in esophoria of 2° or more, the internus may be cut; and in exophoria of 2° or more, the externus may be snipped. But if the surgeon would avoid an over-correction, thus leaving the eyes in a worse condition than before, he must follow the method advocated by Stevens:

1. Make a small opening in the conjunctiva over the tendon to be cut.
2. Seize the center of the tendon with delicate but strong forceps, made for the purpose, and button-hole it with delicate probe-pointed scissors.
3. Introduce one blade of the same scissors between the tendon and the sclera and the other blade between the tendon and the conjunctiva, and cut transversely to one border of the tendon, and then, reversing the scissors, cut transversely to the other border of the tendon.
4. The eyes should now be tested with prisms, and if the heterophoria is not nearly corrected, the scissors may be again introduced and the loosening up of the insertion be carried a little further. Thus by cutting cautiously, a little at a time, and then testing with candle and prisms to ascertain how much effect has been obtained, it is not difficult for the dexterous operator to correct the deviation with considerable accuracy. No surgeon should undertake these operations with the ordinary clumsy instruments in vogue. The necessary instruments particularly adapted to the purpose, and to tendon-resection, are made by Messrs. Tiemann & Co., of New York. Tendon-resection is practiced in cases where the heterophoria is too great to be corrected by a graduated tenotomy of the stronger muscle without limiting the excursion of the eye in that direction. In such cases it is better to partly correct the deviation by tenotomy and to correct what remains by tendon-resection of the weaker mus-

cle. In performing this operation, by Stevens's method, the tendon is divided as in graduated tenotomy. A delicate hook is then slipped beneath and caught into the under surface of the divided tendon which is now drawn out of the conjunctival aperture and caught some lines from its extremity with delicate fixation forceps. A small, very sharp, curved needle, armed with a fine silk thread, is now passed through the muscle from without inward, as far back as the operator thinks necessary, and then the portion of the muscle anterior to the needle is excised with scissors. The needle is then carried through the stump of the insertion of the muscle, including the capsule of Tenon and overlying conjunctiva, and the thread drawn through and loosely tied.

The patient should now be placed in the position for testing with prisms, and the knot drawn just tight enough to correct, or slightly over-correct, the deviation. In both these operations the lids may be held open by a speculum, an elevator, or the fingers of an assistant. The stitch may be removed at the end of three or four days. No after-treatment is required, as there is rarely any inflammatory reaction.

Tenotomy and tendon resection for the correction of heterophoria should be resorted to only after all other means for the relief of asthenopia have been exhausted.

Ophthalmoscopy.

The general practitioner should familiarize himself with the use of the ophthalmoscope sufficiently to be able to diagnosticate gross lesions of the globe situated posterior to the crystalline lens. He should provide himself with an ophthalmoscope with tilting mirror and convex and concave lenses ranging from one to twenty dioptries. The pupils should be dilated with homatropine or cocaine, 2-per-cent solution in either case. The patient should be seated in a darkened room, with a lamp placed on a level with the eye to be examined, a little behind and to one side. The observer then rests the ophthalmoscope against the inner angle of his orbit and throws the light into the eye with the mirror, at the same time looking into the pupil through the aperture in the mirror. He thus gazes at the papillary area while the patient looks up, down, right, and left. If the reflex from the pupil is, in all positions of the eye, of a uniform clear pinkish or reddish color, it is to be inferred that there are no gross lesions of the refractive media. If the red reflex from the fundus is interrupted by dark spots, there are opaci-

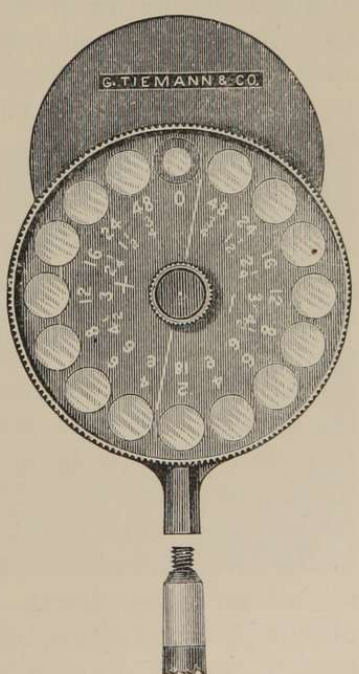

Fig. 533.
Loring's Student's Ophthalmoscope.

ties of the media, and the surgeon must proceed to locate them. If they move while the eye is fixed, they are floating bodies in the vitreous. If they move with the eye and stop when the eye stops, they are opacities either of the cornea or of the crystalline lens. If of the cornea, they will be seen by oblique illumination. This is also true of opacities situated on the anterior capsule and in the front portions of the crystalline lens. If in the posterior portions of the lens, they will appear to move in an opposite direction to the eye. Opacities in the periphery of the lens are seen only when the eye is so turned that the observer looks through the pupil very obliquely. For more minute examination of any opacity already discovered, the observer should turn on over the aperture of his ophthalmoscope a + 10. D., and approach the eye to within its focal distance, about four inches. In this way he will obtain a greatly magnified view. In high degrees of myopia and hypermetropia pigment patches in the fundus may be mistaken by the novice for opacities of the media. These are excluded by seeing them in their true position while examining the fundus.

There are two methods of examining the fundus: 1, The indirect; 2, the direct.

In examining the eye by the indirect method, the observer interposes a two-inch or two-and-a-half-inch lens, between his ophthalmoscope and the patient's eye, at about its focal distance from the eye, his own eye being twelve to fifteen inches away. In this manner he gets an inverted image of the fundus, magnified some three or four diameters. By directing the patient to look successively in different directions, he thus easily scans the whole fundus.

In using the direct method, the observer approaches his eye with the ophthalmoscope as close as possible to the eye he is examining, often touching the brow or nose of the patient with his instrument. In this way he sees only a small portion of the fundus at a time, but that is in its true position and is magnified some seventeen diameters, more or less. The examined eye being myopic, he must turn on the *weakest* concave lens with which he can see the fundus distinctly; and this, while it enables him to see the fundus clearly, at the same time measures the amount of myopia. If the patient is hypermetropic in a moderate degree, the fundus will be well seen without any lens; but if the observer would estimate the amount of hypermetropia, he must turn on the strongest convex lens through which he can see the fundus distinctly. In astigmatism only one meridian of the fundus is seen distinctly at a time, the opposite meridian being seen through a stronger or weaker lens. If the observer has an error of refraction, he must take it into account in estimating refraction with the ophthalmoscope. Some of the grosser lesions to be looked for by the surgeon are:

1. *Optic Neuritis.*—Here the ophthalmoscopic appearances vary. In the milder cases only the nasal, or upper, or lower, border of the disk is obscured by swelling, while in the severer cases the whole papilla is greatly swollen and its outline entirely obliterated. The retinal vessels are tortuous, while the veins are enlarged and the arteries are either of

normal size or diminished. There may or not be ecchymoses upon the disk or in the retina. Rarely the central vision and visual field are perfect. In most cases, however, both are impaired, and often vision is reduced to perception of light. In optic neuritis or "choked disk" of both eyes intracranial tumors should always be suspected. Optic neuritis may, however, depend on a variety of causes, such as kidney disease, lead-poisoning, meningitis, syphilis, etc.

2. *Atrophy of the Optic Nerve* is recognized by the paleness of the optic disk and the smallness of the retinal blood-vessels. It may be consecutive to optic neuritis, or it may be ushered in as "primary" atrophy. Therefore the conditions which produce optic neuritis should be sought in cases of atrophy. It frequently occurs in poisoning by tobacco and alcohol, and is often a symptom of progressive locomotor ataxia. It is found in advanced stages of retinitis pigmentosa.

3. *Retinitis* is distinguished by bright or whitish patches in the retina. When these arrange themselves about the macula lutea in a stellate form, the cause is generally found to be kidney disease. They are often accompanied by retinal hæmorrhages. Diabetes and syphilis are among the other causes of retinitis.

4. *Choroiditis* is known by white patches in the fundus, generally bordered irregularly with black pigment, and with the retinal vessels passing over them. The cause is often obscured. It is sometimes due to syphilis.

5. *Glaucoma simplex* is always characterized by excavation, or cupping of the optic disk. The retinal vessels appear to end abruptly at the discal border. The bottom of the excavation can be seen through a sufficiently strong concave lens. Around the disk is a ring of choroidal atrophy exposing the white sclera. There is often pulsation of the retinal arteries. Central vision is usually impaired, and the visual field limited, especially on the nasal side.

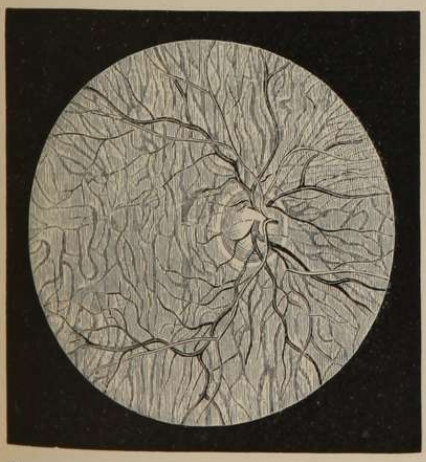

FIG. 534. — Ophthalmoscopic appearance of healthy fundus in a person of very fair complexion. Scleral ring well marked. Left eye, inverted image. (Wecker and Jaeger.)

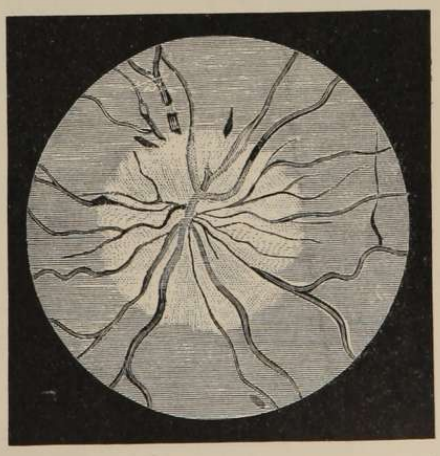

FIG. 535. — Ophthalmoscopic appearance of severe recent papillitis. Several elongated patches of blood near border of the central inflammatory area. (After Hughlings Jackson and Nettleship.)

Surgery of the Ear.

Neoplasms of the auricle require extirpation as in other portions of the body. Epitheliomata of this organ treated with Marsden's paste are cured with less loss of substance and subsequent disfigurement than by excision. Angeiomata of small size may be cured, without excision, by injecting the tumor with a few minims of 50-per-cent carbolic-acid solution. *Cartilaginous* growths are occasionally met with about the ear. Their usual location is just in front of the tragus. I removed two in front of one ear and one from the opposite side in a patient twenty-two years of age. Similar tumors were present in the person of his father and another member of the family.

Wounds of the auricle should be treated with the view of preventing any deformity.

Lacerations of the lobule from the violent removal of an earring may be corrected by paring the edges and uniting them by fine silk sutures. The hypodermic use of cocaine will secure perfect anæsthesia in all ordinary operations upon the auricle.

Drooping of the ears to a degree amounting to deformity should be treated in children by strapping the auricles close to the skull, by means of an elastic band around the forehead and occiput.

In extreme cases it is advisable to cut out an oval-shaped piece from the posterior surface of the concha. This section should include the entire thickness of the cartilage. The sutures of silk should be inserted through the skin of the dorsum and the cartilage. When they are tightened, if the deformity is not relieved the cartilage should be further excised.

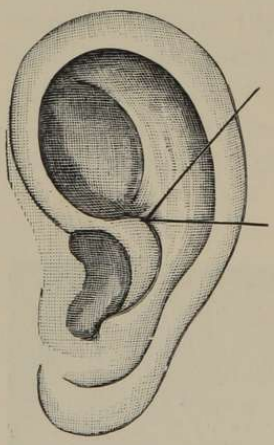

Fig. 536.—(After Reeves.)

Fig. 537.—(After Reeves.)

Adhesions of the auricles to the scalp should be dissected loose, the organs crowded forward, and, if necessary, skin should be transplanted to fill in the gap and prevent a recurrence of the deformity. Hypertrophy of the auricle should be corrected by excision of a triangular piece, after the method of Martino, shown in Figs. 536 and 537.

Auditory Canal.—Foreign bodies in the auditory canal may be recognized by inspection or with a light gutta-percha probe (Fig. 538), and

Fig. 538.—Sexton's hard-rubber double probe.

should be removed by the careful employment of the angular forceps (Fig. 539), or, if firmly impacted, the ring curette (Fig. 540) may be re-

quired. For locating and seizing the body the head mirror should be employed to concentrate the light in the canal. The solid-silver speculum of Wilde, always required in examinations of the deeper portions of the canal and of the membrana tympani, may also be of assistance in



Fig. 539.—Sexton's ear forceps.

Fig. 540.—Sexton's double ear hook, to extract foreign bodies.

locating the foreign body, although this can usually be done, if the light is properly directed, by pulling upon the auricle so as to strengthen the canal.

Impactions of cerumen should be removed by irrigation with warm water. The stream should be delicate, and should be directed to one side of the obstruction in order to melt away a portion sufficient to allow the force of the injection to operate upon the mass from behind. The curette or scoop may also be advantageously employed in removing these impactions.

Furuncles of the auditory canal are quite frequently met with. Their presence is marked by acute pain, located in a circumscribed area, and by redness and swelling.

The treatment consists in alleviating pain by the use of anodynes if necessary, and by softening the skin over the inflammatory process by the use of emollients. Cotton lubricated with vaseline should be introduced. As soon as the formation of pus is evident, it should be evacuated by puncture or incision.

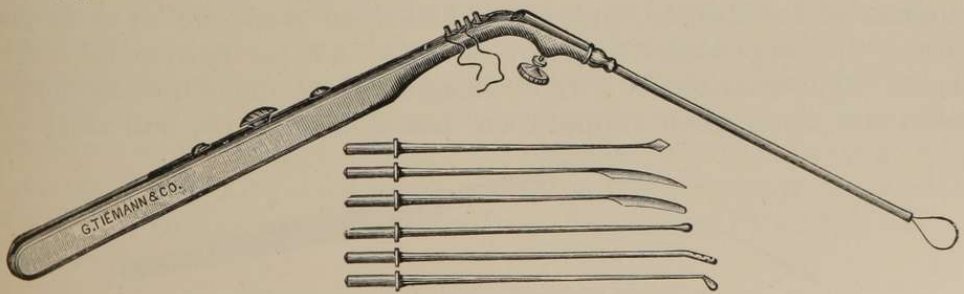

Fig. 541.—Sexton's snare.

Neoplasms of the auditory canal demand removal by the snare (Fig. 541), forceps, or by excision. Polypus of this tube may be single or multiple, and, when of sufficient size to fill the canal and become constricted, may break down and cause a fœtid discharge.

Occasionally the auditory canal is occupied by a parasite known as *aspergillus*, the spores of which are developed with great rapidity, filling up the canal and causing inflammation, obstruction, and more or less interference with hearing. Finely powdered boric acid should be blown deeply into the canal at repeated intervals until the fungus is destroyed.

Middle Ear—Membrana Tympani.—The drum of the ear may become involved by extension of an inflammation from the auditory canal, or it may be secondary to an *otitis media*, or it may in rare instances be inflamed without either of the foregoing complications.

Inflammation of the middle ear is in most cases preceded by pharyngitis, and is thus affected by invasion through the Eustachian tube. It may be produced by traumatism, or the initial lesion may be situated within the cavity of the tympanum, or in the mastoid cells, which communicate with the cavity. Otitis media is not uncommon in children as a sequel of *scarlatina* or *rubeola*.

The earliest symptoms of this affection is pain of a severe character, accompanied by partial arrest of hearing. Fever is present, and may be preceded by a chill or rigors. When suppuration occurs, and the mastoid cells are involved, the pain is intensified and the febrile movement at times very high. In a case of this character which I saw, and in which the operation of puncture and trephining the mastoid process had been delayed, fatal pyæmia occurred. Specimens of blood taken from this patient just before death were rich in bacteria. Percussion with the finger tip over the mastoid region exaggerates the sense of pain. Upon examination with the otoscope and head light, the drum of the ear will be seen to be more opaque than normal, its vascularity increased and bulging toward the meatus if there is pus in the middle ear.

The *treatment* of *otitis media* should be directed to the arrest of the inflammatory process by warm fomentations, by the application of leeches to the temples and mastoid region. Quinia, iron, stimulants, and well-selected diet are indicated in the effort to improve the general condition of the patient. It is of great moment that the tension of the tympanum and of the mastoid cells should be relieved early in the progress of the disease, and, even when there is a doubt as to the presence of pus, explorative puncture of the *membrana tympani* should be made. The operation is without danger, is not difficult of accomplishment, and, even when suppuration has not occurred, will often give

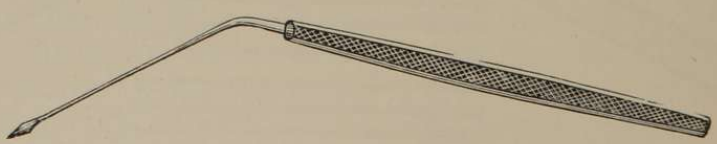

Fig. 452.—Politzer's tympanum perforator, angular.

great and immediate relief. A proper instrument for this procedure is shown in Fig. 542. The silver speculum and reflected light should be employed so as to bring the membrane into plain view, and, while the head of the patient is held motionless, the point of the perforator is

carried against the drum on its posterior inferior quadrant, and barely pushed through. The puncture should not be more than one eighth of an inch in length. If there shall have been an effusion of serum, or if pus is present upon the withdrawal of the instrument, a small quantity of fluid will escape through the puncture. If necessary to the establishment of free drainage, the opening may be enlarged.

When *otitis media* is complicated with inflammation and suppuration of the mastoid cells, these should be opened and drainage secured at once by removing the outer shell of the mastoid process. In children this procedure is not always necessary on account of the very thin shell of bone which incloses the cavity of the mastoid antrum, and which readily gives way and allows egress to the pus formed within. In drilling or trephining the mastoid cells, proceed as follows :

The skin over and near the mastoid process should be shaved and cleansed, and a free incision made in a vertical direction, the center of the cut being opposite the center of the auditory meatus and one fourth of an inch from the posterior wall of the bony canal. If any difficulty is experienced in lifting and reflecting the integument, a short transverse cut should be made backward from the middle of the perpendicular incision. The periosteum should be scratched off at the point where the bone is to be perforated, unless necrosis has already occurred and only a thin shell of bone remains. In this condition the shell should be lifted off and the cells cleaned out. When the bone has a healthy appearance on the exterior it should be cut through with a trephine, gouge, or chisel. The trephine employed should not be more than a quarter of an inch in diameter, and the center of the hole made (no matter what instrument is employed) should not be farther than a quarter of an inch posterior to the wall of the auditory canal on account of the proximity of the lateral sinus and the veins of the diploë which empty into it. After the instrument has traveled about an eighth of an inch into the bone it should be removed and the circular track inspected. The entrance to the cells will be indicated by a slight hæmorrhage, and, if abscess is present, by a few drops of pus. As soon as the bleeding is seen the button of bone should be lifted by the elevator and the remaining cancellous tissue scooped out with the iron spoon or the scalloped gouge. The abscess should be irrigated with a 1-to-3,000 sublimate solution, and the wound dressed with a loose gauze dressing. If (as has occurred in several instances) marked bleeding occurs—probably from wounding some large vein near its entrance into the sinus—it may be arrested by packing with sterile gauze and the drainage established a few hours later, when the hæmorrhage has ceased, by substituting a loose dressing.

The Nose.

Acquired Lesions.—Fracture of the bones of the nose has been already considered.

Epistaxis, or hæmorrhage from the nose, is often severe enough to demand surgical interference. The bleeding may at times be arrested

by diminishing the blood pressure in the vessels of the nose by *ligation of the extremities*. This consists in applying an elastic bandage (or an ordinary roller, if the rubber can not be obtained) around the thighs and arms close to the trunk, and making the pressure strong enough to arrest, in great part, the return of blood through the veins without arresting the circulation in the arteries. When the hæmorrhage ceases the ligatures should be gradually loosened, so that the volume of blood which has been confined in the extremities may not be too suddenly returned to the heart. *Plugging* or *tamponing the nares*, if properly done, will succeed if all other methods fail. First, determine accurately the nostril in which the bleeding is occurring. Take a piece of fine sponge at least an inch in diameter when dry (and it should be introduced without being moistened, so that when in position in the posterior nares it will expand as the blood moistens it), and tie around its center three strong silk threads. A soft catheter or bougie is now introduced into the nostril from the front, keeping the point of the instrument well on the floor of the nose. As soon as the end is seen or felt behind the soft palate, it is drawn out of the mouth by the forceps or fingers. Two of the three threads are attached to the point of the instrument, which is then pulled back through the nostril. When the threads come out of the nose in front they are seized by the fingers of one hand while the sponge is carefully guided into position *behind* the soft palate with the other. Once well in the posterior naris it is held in position and made to exert the necessary compression by tying the two anterior strings over a softened sponge packed into the nostril in front. The third thread is brought out of the mouth, and is to be used in dislodging the tampon when the hæmorrhage has ceased. Lint, soft rags, or cotton may be used for plugs when a sponge can not be obtained. A long probe or a loop of soft wire may be used instead of the bougie.

Foreign Bodies.—Buttons, seeds, and other substances are often lodged in the cavity of the nose. The usual seat of lodgment is in the anterior part of the inferior meatus, or between the lower turbinated bone and the septum, and occasionally they are pushed beyond this into the middle meatus. When allowed to remain, inflammation of the lining membrane always ensues, and ostitis is not infrequent.

The diagnosis depends upon physical exploration by means of the head mirror, a strong light, and the metal probe. The presence of a body lodged in the nasal cavity may be at times indicated by the change of the voice from its natural to a nasal tone. Removal is urgent, and may be effected by inspiration through the mouth and forced expiration through the nose, with the mouth and nostril of the unaffected side closed. In adults the act of sneezing will sometimes succeed in dislodging the substance. A strong, slender forceps, bent at an angle so that the hand of the operator will not shut out the light, is the most suitable instrument to be employed in its removal. When the body is lodged well back it may be pushed through into the pharynx and ejected from there.

Rhinolites, or *nasal calculi*, are occasionally found in these cavities.

It is probable that they come from the lachrymal apparatus, since they are found in the immediate neighborhood of the entrance of the nasal duct. Moreover, *dachryolites*, or lachrymal concretions, are not very infrequent in the lachrymo-nasal apparatus. These bodies should be removed with the forceps as soon as discovered.

Neoplasms.—The most frequent variety of tumor within the nasal cavity is the *myxoma*, or so-called *gelatinous polypus*. Next in order of frequency is the *fibroma* or *fibrous polypus*. Both of these belong microscopically to the connective-tissue tumors, the myxomata being allied to the embryonic, the fibromata to the more developed connective-tissue tumors. *Papillomata*, or *warts*, are not infrequently seen at the edges of the mucous membrane of the nostrils. Lastly, there may be a general *hypertrophy* of the mucous membrane of the nose, causing a tumefaction of the turbinated tufts, and partial, or may be complete, occlusion of the nares.

Gelatinous nasal polypi are usually pear-shaped, the bulk of the tumor tending toward the floor of the nose. The pedicle is attached to one of the thick velvety tufts, most frequently in the upper or middle meatus. There may be a single tumor, although the rule is for them to be multiple. They are of light grayish color, and are covered by mucous exudation.

The *symptoms* are chiefly those due to pressure and obstruction of the nares. Changes in the voice are not marked until the presence of the tumor has been suspected from pressure and irritation. This irritation gives rise to an excessive secretion and discharge from the nose, and occasionally to prolonged and violent fits of sneezing.

The *diagnosis* may be rendered positive by physical exploration. The shrinkage of the turbinated tufts, following the local use of cocaine hydrochlorate, renders inspection more easy.

Treatment.—The only rational method of treatment is removal and destruction of the pedicle and contiguous mucous membrane. Avulsion may be effected by seizing the growth with a long, delicate polypus forceps, and twisting the tumor around until the pedicle is wrung off, then applying pure nitric acid or the galvano-cautery to the stump. The *wire écraseur* or *snare* of Jarvis is greatly to be preferred (Fig. 543). After the wire loop has been passed around the tumor, and slipped up to the pedicle, it should be slowly tightened, since by this method the danger of hæmorrhage which always follows the use of the forceps is avoided. From one to two hours may be consumed in the division of the growth, the screw being turned from time to time. Nitric acid or the cautery should be applied to the stump in all cases, since without this recurrence is almost certain.

FIG. 543.—Jarvis's snare.

Fibromata, or *fibrous polypi*, are much less frequent than the *myxomata*. As a rule they are deeper situated. They require the same treatment as above given. Occasionally large tumors of the nasal cavities

require for their complete removal section of the nasal and superior maxillary bones. In this procedure the skin and periosteum should be left intact, and osteoplasty performed in order to prevent necrosis.

Papillomata, or *warts*, which occur at the junction of the mucous membrane of the nares with the integument, should be clipped off with curved scissors and their bases burned with pure nitric acid.

Hypertrophy of the turbinated tufts may exist to such an extent as to demand interference. Such enlargement should be treated exactly as one would treat true polypus.

With the careful employment of cocaine these hypertrophies can be painlessly removed with the nasal saw.

Fissures of the nares may be relieved by the repeated local use of the lunar-caustic pencil.

Ozæna.—Ozæna is the name given to a chronic inflammation of one or more of the nasal cavities, or the sinuses communicating with them. It may be confined to a process of ulceration of the soft tissues alone, but the bone is usually involved. Syphilitic ozæna is probably the most common form. It frequently occurs with other dyscrasiæ. It is accompanied by a fœtid odor and a muco-purulent discharge, partially liquid and partially solid. Atrophy, or destruction of the turbinated tufts, is not infrequent, so that there is abnormal space within the nares.

The *treatment* is local and general. The removal of diseased or dead bone is imperative, and irrigation with the weaker sublimate or boric-acid solutions should be regularly made.

Dobell's solution will be found of use: Carbolic acid, gr. x; biborate and bicarbonate of soda, each, ℈j; glycerin, ʒx; to this add water to make ℥x. This should be used five or six times a day as a douche. The general condition of the patient should be improved by the administration of well-selected tonics and food, and by out-of-door life.

Superficial epithelioma, situated upon the nose or face, should be destroyed by the application of Marsden's paste. If the first application is not sufficient, it should be repeated in three weeks.

The *frontal sinus* may be involved in some of the diseases which affect the nose. New growths, abscess, or ostitis may demand the application of the trephine in the removal of a neoplasm or dead bone, or the evacuation of pus.

Deviation of the nose from the median line may be congenital or acquired. The septum alone may project to one side, or the entire organ be displaced laterally or upward. When the distortion is due to malformation of the bones, these must be forced into position, with or without fracture.

Deviation of the septum to such an extent that deformity is produced or one nostril closed often requires correction.

The method of Prof. John B. Roberts has yielded good results.

Make a long incision at the most prominent portion of the deviation, and supplement this by chopping the septum full of incisions with the stellate punch. If there is an angular deviation close to the palatal

process of the superior maxillary bone, make an incision from front to back at the most prominent part, and do not chop the upper portion with the stellate punch. If the deviation is a curved one, split the cartilage along the most prominent portion and then chop the rest of the septum until it has lost its resiliency. Afterward cut away with the chisel or saw any horizontal bony edge that may remain at the bottom. If some small triangular pieces are removed by the interlacing of the incisions made with the forceps, it makes no difference, since the openings left are very small and will soon become closed. To hold the septum in place, use steel pins (Fig. 544), either those with spherical heads of glass, or the flat-headed pins which were devised some years ago. When the head of the pin is to be within the nostril, those with the glass heads are better; when the head is to lie against the exterior of the nose, the flat heads are preferable.

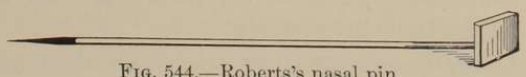

Fig. 544.—Roberts's nasal pin.

After having divided the septum (*a*, Fig. 545), as above described, introduce a pin (*b*) into the more open nostril and thrust its point through the anterior part of that portion of the divided septum. Displace this part into the desired position, thrust the point of the pin onward and bury its point deep in the tissues at the back part of the nasal chamber which was formerly occluded. This holds the septum firmly in its new location. The head of this pin will be just inside of the anterior naris which was not obstructed, and will lie against the columella. It should be allowed to remain about one week, for if left a longer time its head will probably cause ulceration from pressure, and may become deeply buried in the tissues of the columella. Its work is usually accomplished within a week. It is often well to introduce a second pin (*c*, Fig. 545), from the external surface of the front of the nose just below the nasal bones, which aids in keeping the septal cartilage pinned into proper place. If this pin has a flat head, it may be covered with a small square of court-plaster. The patient can then go about the streets without attracting attention.

Fig. 545.—Roberts's method of holding the septum in correct position by means of pins. The upper part of the septum, immediately above the oblique incision, projected too far this way (i. e., toward the reader). It is now pressed the other way (i. e., from the reader), and is held there by the pins. *a*, Incision through the septum. *b*, *c*, Pins in position.

In many instances hypertrophy of the turbinated bones, or permanent thickening of the vascular membrane covering them, obstructs the nose to such an extent that the passage of air by these channels is difficult or impossible, or deviation of the septum may result. Under such conditions, removal of the turbinated bones and tufts is indicated. The inferior tuft is commonly implicated. A sufficient degree of anæsthesia may usually be obtained by the careful application of cocaine hydrochlorate—4-per-cent solution—brought directly in contact with the mucous surfaces to be incised by means of pellets of cotton, attached to

delicate probangs. A small quantity may be employed through the nostril by means of the atomizer. When the anæsthesia is effected, the turbinated bone may be sawed through at its attachment to the superior maxilla. Should hæmorrhage be troublesome, it may be arrested by plugging the nostril.

Hypertrophy of the nose, due to increased vascularity, may be corrected by repeated incisions across the track of the enlarged vessels, by galvano-puncture, or by causing their obliteration by injections of 50-per-cent carbolic-acid solution, as for *nævus*.

Plastic Surgery of the Nose.

Loss of substance may occur from the accidental or surgical ablation of all or a portion of this organ, or from its destruction by disease. The diseases which most frequently produce loss of substance are *syphilis*, *lupus*, and *epithelioma*. *Sarcoma*, *elephantiasis*, or any neoplasm, may involve the nose and cause loss of tissue in its removal. One of the most distressing lesions in neglected cases of (tertiary) syphilis is necrosis of the cartilages and bones of the nose, resulting in great disfigurement. Occasionally sloughing occurs, from the presence of a phagedenic syphilide during the second stage of this disease. This accident occurred in the patient from which Fig. 549 was taken.

Rhinoplasty may be partial or complete. Complete rhinoplasty is performed when the skin, cartilages, and bones of the nose have been carried away. In such cases nothing remains but an irregular sunken pit, leading almost directly into the pharynx.

The successful and satisfactory restoration of this organ is rarely accomplished. It would be well, in all cases of complete loss of the nose, to consider some form of prothetic apparatus before resorting to a plastic operation.

The operation consists (1) in paring the margins of the opening and the integument immediately around the opening, in apposition to which the transplanted flap is to be brought; (2) in the transportation of a properly shaped piece of skin, with its underlying tissues, from its normal to the new position.

The flap may be taken entirely from the forehead, or one half from each cheek, or from the arm. One of the most frequent causes of failure in this operation is the caving-in of the ridge of the new nose, and, in order to better prevent this, the platinum support to be described may be employed.

First Method—Complete Rhinoplasty from the Forehead.—Cut a piece of chamois-skin, or soft, thin leather, of the shape represented in Fig. 546. Adjust this to the line of the nasal cavity, to see if it is large enough and of proper shape. Bear in mind the following points: 1. The flap once dissected up tends to contract. It should therefore be considerably larger than a pattern which fits exactly. 2. The isthmus (*d*, Fig. 546) must not be too narrow, for fear that the vitality of the flap may be insufficient. It should always be cut so as to include the angular

artery, and should be broader than represented in the accompanying cut. It should take in a portion of the hair-covered eyebrow, since this insures a width of pedicle sufficient to nourish the flap, and the hairy stump, when turned back after the circulation is established, restores the normal brow. 3 The distance from the isthmus (*d*) to *e é*, where the lower edge of the new nose is to be, should be considerably less than the distance from *d* to *a c*, in order to prevent tension of the flap and interference with the circulation through the pedicle, *d*. Lay the pattern on the forehead and outline the flap by making punctures at intervals of every fourth of an inch along its edges. The incision, made through the tissues and periosteum, should begin at *d* and be carried to *a c c a*, and then down to a point in the eyebrow further outward than represented by the dark line at *d*. The smaller incisions in the flap *a b* or *c b* are made to provide for the septum and alæ of the new nose, when the platinum support is not to be used. The flap is now dissected up with the

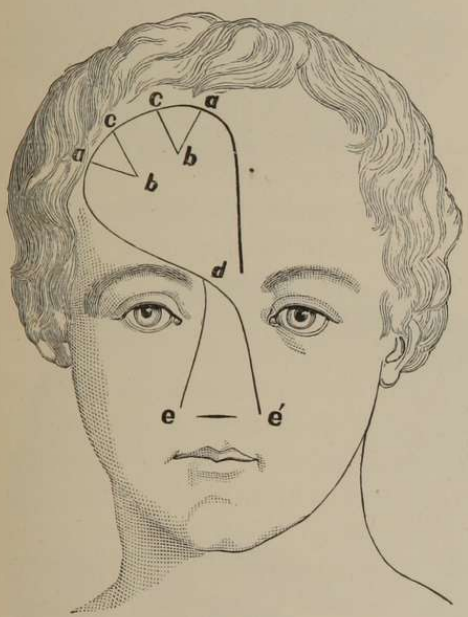

Fig. 546.—(After Linhart.)

Fig. 547.—(After Malgaigne.)

periosteum as far as the pedicle, when it is turned down and sewed into position with fine silk sutures. The operation is completed when the entire flap has been accurately stitched to the freshened edges of the cavity, as shown in Fig. 547. Pieces of rubber tubing may be inserted in the nostrils to hold the alæ in position, or a plug of sterile gauze not too tightly packed in may be substituted. It should be changed as often as it becomes moistened. The upper part of the wound on the forehead is drawn as near together as can be done, with silkworm-gut sutures, and an iodoform-gauze dressing is applied. No pressure must be exercised upon the pedicle, or flap, which should be loosely enveloped in the dressing. In about two weeks the circulation will have been sufficiently established between the flap and the edges of the cavity to permit the section of the pedicle, the stump of which is used in filling up the gap upon

the forehead. In returning the pedicle to its original position, it is advisable to dissect out the granulation tissue in the wound, so that the returned portion will sink to the proper level. The exposed surface which remains upon the fore-

Fig. 548.—(After Szymanowsky.)

Fig. 549.—Erosion of the ala nasi.

head should be covered in by grafting after the methods already given. Fig. 548 represents a rhinoplasty done by a Hindoo surgeon in 1793.

Partial Rhinoplasty.—When there is only a partial loss of substance the operation is less difficult, and the prospect of success greater. When one ala is involved, as shown in one of my cases (Fig. 549), the flap may be made from the cheek (Fig. 550). In this patient I trimmed the cicatricial edges of the scar and turned a flap, as indicated by the dotted lines, and stitched it to the nose. The wound in the face was partially closed by sutures. The pedicle was divided on the fourteenth day and turned back into the wound, the granulations hav-

Fig. 550.—Flap transplanted.

Fig. 551.—Transplanted portion in the new position after division and return of the pedicle.

ing been previously scraped out. Angular depressions or "nicks" caused by fracture of the cartilage or bones of the nose, and when of long duration, may be relieved by making a longitudinal incision the center of which is over the deepest portion of the depression. Under *most careful* asepsis the skin is lifted by subcutaneous dissection until a pocket of suitable size is formed on either side. All bleeding should be absolutely arrested by warm dry compresses. A piece of thin sheet platinum cut in diamond-shape and bent to conform to the normal cutaneous surface of the nose is taken from the sterilizer, inserted beneath the skin, and the wound closed with fine silk sutures. Sterile collodion dressing over all. Fig. 552 shows the result of this method after a very distressing deformity of this nature.



Fig. 552.—Subcutaneous platinum support restoring the normal outline of the nose.

When the integument of the nares is intact and the tip of the nose is shriveled and sunken, the employment of the three-legged platinum support or ridgepole advocated by Dr. Robert Weir will relieve to a considerable extent the deformity. The upper lip and nasal attachments are lifted freely from the bones of the face by subcutaneous dissection with curved scissors, commencing along the attachment of the upper lip to the alveolus of the superior maxilla, and by this route detaching the alæ nasi and contiguous integument from the maxilla and nasal bones. The ridgepole of platinum is now inserted from underneath the lip, the lateral prongs or legs resting upon the superior maxilla of either side, while the upper prong rests between the skin and the nasal bones. The

greatest care is essential to prevent the accidental displacement of the apparatus.

Congenital Lesions of the Nose.—Occasionally the lateral halves of the nose fail to unite, resulting in the deformity known as bifid nose. There may be *partial* or *complete absence* of this organ, or when present the nares may be occluded, or it may be complicated with the extreme cases of harelip. The operative procedure for the relief of this last deformity will be given in connection with congenital cleft of the lip. Occlusion of the nares may be relieved by cutting through the membrane in the direction of the normal opening. For the correction of forked nose, or the absence of this organ, no fixed rule of practice can be laid down.

The Lips and Cheeks.

Wounds.—Accidental *wounds* of the lips are usually incised or lacerated. If badly torn, the ragged edges should be smoothly trimmed, washed with sublimate solution, and secured with interrupted silk sutures. When the wound is through the entire thickness of the lip, the sutures should include the mucous membrane. A very fine suture should be used in the vermilion border to insure absolute approximation here. Adhesive strips are not reliable. In children the silkworm-gut support as given with the operation for harelip should be employed, as it best resists the constant strain to which sutures of the parts are subjected in the act of crying.

Diseases of the Lips.—Among the diseases which involve the lips and the contiguous structures are *epithelioma*, *lupus*, *papilloma*, *nævus*, *cysts*, *lipoma*, *adenoma*, *phlegmon*, *ulcers*, and *general hypertrophy* and *fissures*.

Epithelioma.—One of the most frequent causes of removal of portions of the lips is the presence of *epithelioma*. It is a disease of middle and old age, involves usually the lower lip, and occurs in the great majority of instances in males. Epithelioma may attack the lip without any appreciable cause, but in most cases the appearance of the neoplasm is preceded by prolonged irritation at the place involved. A jagged or projecting tooth, the habitual use of a pipe stem or cigar, are frequent causes of this disease. It will also result from the irritation caused by chronic fissure or ulcer of the lip.

Symptoms.—It begins as a small ulcer with rather abrupt margins, in the bottom of which is a dirty granulation tissue partially hidden by thin pus. In its earlier stages it is not readily distinguished from the benign ulcer which may be found upon the lip. The preceding history of a prolonged irritation should always suggest epithelioma, especially if it occurs after the age of thirty, and upon the lower lip. Labial chancre may be differentiated by the indurated base, which is characteristic of this lesion. Adenitis in the line of lymphatics along the lower jaw comes on in the earlier stages of syphilis, while in epithelioma the sore may exist for months without perceptible enlargement of the lymphatic

glands. In syphilis the appearance of the eruption, together with the history of the case, will lead to correct differentiation.

Epithelioma of the lip is a dangerous affection. Left alone, it destroys life within a period varying from one to four years. It spreads at times with rapidity, eating away the tissues in all directions. It may confine itself to the soft parts, or attack the maxillary and nasal bones. Engorgement of the submental, sublingual, submaxillary, and cervical glands is almost inevitable if the disease is not destroyed in the first few months of its existence. The glandular enlargement is at first not always due to metastasis, but may result from simple adenitis following the inflammatory process in the margins of the ulcer.

Treatment.—Epithelioma involving mucous or muco-cutaneous surfaces, especially of the lips, buccal cavity, and tongue, is more dangerous by reason of the tendency to rapid glandular infiltration in this situation. The greatest safety lies in the early and free excision of the diseased tissues. Marsden's paste, while preferable in epithelioma of the skin, is second to the knife in the treatment of this disease in the locality under consideration. The incision should be well away (about half an inch) from the infiltrated margin, and if any lymphatic glands are enlarged, they should be thoroughly extirpated. In closing the gap left by removal of a good portion of lip, the principles of plastic surgery already given should be employed in restoring the part to as near the normal condition as possible.

The prognosis as to permanent cure will depend in great part upon the time which has elapsed between the appearance of the *initial epithelial ulcer* and the date of operation. If infiltration of the lymphatic channels or glands has occurred, recurrence is inevitable. However, in many cases the progress of the disease is so slow that several years may elapse between the recurrence and a fatal termination. In 1884 I removed a large number of infiltrated glands from the neck of a man about fifty years of age who had had an epithelioma of the lip excised twelve years prior to that date. Five years after the operation, a gland at the lower end of the jaw became enlarged and was removed. The patient lived eight years after my operation, and two years after a fourth operation. He died of another affection in no way related to the epithelioma. There was no sign of a recurrence at the time of his death.

Lupus.—Lupus erythematosus and vulgaris usually attack the tissues of the nose, cheeks, and lips, at times producing extensive loss of substance. The erythematous variety is first seen as small red papules, projecting slightly above the epidermis, and covered with scales. It is a disease of the sebaceous glands and ducts, causing chronic inflammation of the skin and atrophy of all the elements of the cutis. Its progress is slow, and the prognosis is usually favorable when the disease is confined to a limited area. It does not affect the general health of the patient, and often heals spontaneously, leaving a flat, smooth scar. When disseminated it is more dangerous, not infrequently ending in fatal complications. The *treatment* requires generous diet, tonics, and out-of-door life. Among the local agents recommended in lupus ery-

thematosus is green soap, which should be spread on lint and pressed closely upon the affected part, or rubbed in with the finger every day. Prof. A. R. Robinson, in addition to the above, also recommends a 10-per-cent solution of oleate of mercury brushed over the diseased surface.

If the disease does not yield to these milder measures, the sharp spoon should be employed and the broken-down tissue thoroughly scooped out. Emollients, cold applications, or poultices may be used afterward, according to the requirements of the case.

Lupus vulgaris is a more formidable affection. In its earlier stages it consists of a number of soft red dots in the deeper layers of the integument, which gradually appear as papules upon the surface. The characteristic lesion is the infiltration of the skin with an abundant small cell new-growth. It is believed to be a tuberculosis of the skin. The integument breaks down and is cast off as a slough. The new-formed cells also undergo granular metamorphosis, and disappear with the other destroyed tissues. The only disease likely to be mistaken for common lupus in the adult is epithelioma. Lupus begins usually in childhood, while epithelioma is exceedingly rare before the age of thirty. The ulcer of lupus is not so painful as that of epithelioma, nor its edges so hard and elevated. The *treatment* of this affection is often unavailing. The constitutional treatment is the same as for lupus erythematosus. Locally, a 10-per-cent ointment of pyrogallic acid, spread upon linen and closely laid upon the diseased surface, is a useful remedy. It should be applied twice daily for several days, and then poultices or ointments used until the slough is removed. In certain cases it is advisable to scrape the ulcer well with a sharp spoon, and then apply the pyrogallic acid for one or two days.

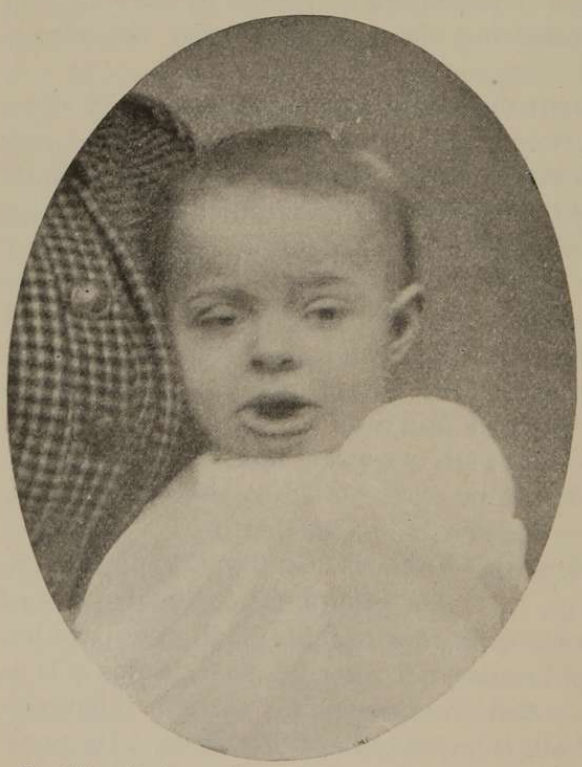

Fig. 553.—Angioma of lower lip. Removed by dissection.

Nævus.—As has been stated in the article on diseases of the vascular system, arterial, capillary, and cutaneous vascular tumors are occasionally located upon the lips and cheeks, and require removal by the knife, ligature, or injection. Their excision often causes extensive loss of tissue. It may at times be cured by galvano-puncture, inserting the needle just through the skin and perpendicular to its surface. The punctures should usually be about one eighth of an inch apart. Anæsthesia is necessary.

When the deformity results from the *cavernous* nævus, the hypertrophied vessels should be removed by dissection, using care to preserve the vermilion border.

Moles are less formidable, and rarely require an extensive reparative operation after excision.

Papilloma, *lipoma*, *adenoma*, and *fibroma* do not, as a rule, require extensive incisions and loss of tissue in their removal.

Cystic tumors of the lip are not infrequent, occurring as spherical swellings beneath the mucous membrane. They are caused by obstruction of the duct of a labial follicle, and contain a thick, ropy fluid. The treatment involves a careful and thorough excision of the sac.

FIG. 554.—The same two years after operation.

Fissures, or "*chaps*" of the lip may occur independently of any constitutional disease. They may be cured by a local astringent, as alum, or caustic nitrate of silver, applied once a day for two or three days. When these more simple remedies are without avail, excision should be practiced. When fissure of the lip is allowed to remain, and the general condition of the patient is bad, necrosis of the mucous membrane immediately contiguous ensues, causing a grayish-red ulcer. The treatment consists in the local use of astringents and the improvement of the patient's nutrition.

Phlegmon of the lip is rare. It is a painful affection, and not devoid of danger. The pathology of carbuncle has been given. The proper treatment is early and free incision through the skin, deep fascia, and muscles, and the employment of aseptic poultices.

Hypertrophy of the lip is occasionally met with. It may be confined to the mucous and submucous tissues, or the entire thickness of the lip may be involved. It occurs usually in the upper lip, but may be seen occasionally in the lower lip. When extensive enough to require operative interference, the proper method is to dissect out in the long axis of the lip a portion of the tissue between the skin and mucous membrane, and approximate the edges of the wound with silk sutures.

Hair on the Lips of Women.—Permanent epilation may be effected by introducing into the follicle of each hair the point of a fine platinum needle, which is then heated by the galvanic current. The employment of cocaine renders this operation painless.

Reparative Surgery of the Lips.—A plastic operation may be demanded in acquired or congenital lack of tissue in the upper lip. In the lower lip congenital deformity is exceedingly rare.

Harelip.—Harelip is a congenital defect caused by an arrest of development in the tissues which form the upper lip. Instead of uniting in the median line, a fissure exists which may include either

the soft structures of the face or palate, or the bones of the palate as well. In rare instances the cleavage passes up into the eye and cranium (Figs. 555 and 556). Harelip is usually unilateral, and may be so small that it is scarcely noticed, as in Fig. 557, or it may extend halfway to or completely into the nasal cavity (Figs. 558, 559, and 560). One side of the lip is much

Fig. 555.

Fig. 556.

thicker than the other. In *double* harelip (Fig. 576) the fissures are about the same distance from the median line. Both may extend into the nose, or one (and rarely both) may be partial. The portion intervening may be composed of a portion of the lip and gum, with one or more rudimentary teeth, at a varying angle of projection. The central piece is occasionally attached to the nose. In incomplete single harelip the nostril is not as flattened and deformed as when the fissure extends through the pre-maxillary bone and the palate and alveolar processes of the superior maxilla (Fig. 561). The location of this fissure is most frequently between the first and second incisor teeth, and through the inter-maxillary bone, and not, as frequently given by some writers, between the second incisor and canine teeth, extending backward through the pre-maxillary suture.

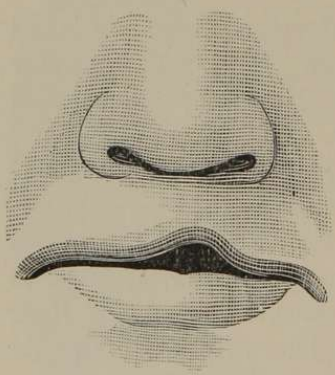

Fig. 557.

In *double harelip* the cleft in the palate is usually double, while the centerpiece may be attached to the vomer (Fig. 562), or the pre-maxillary portion may be united to one side of the superior maxilla (Fig. 561). In rare instances the fissure passes obliquely upward and outward, involving the eyelid, orbit, and cranium, producing frightful deformity, as shown in Fig. 556.

Treatment.—The only relief from this deformity is in a plastic operation. It should be done early, and, when possible, within the first few weeks of life. Hearty and well-nourished infants, with simple unilateral

harelip, should be operated upon at birth. If they are feeble, an effort at forced nutrition should be made, and the operation postponed until

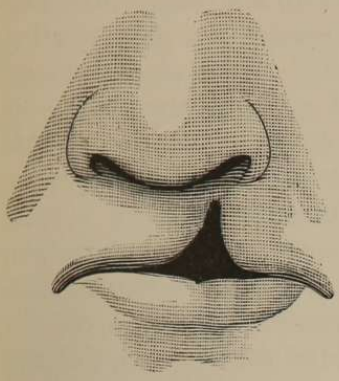

Fig. 558.

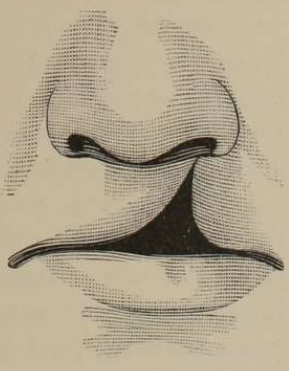

Fig. 559.

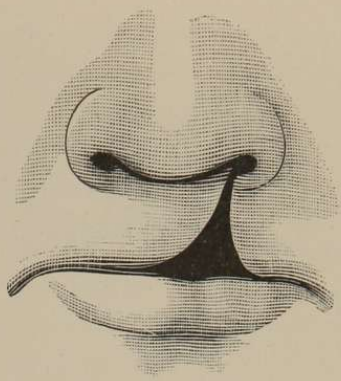

Fig. 560.

the patient is brought into proper condition. Double or single harelip, with cleft palate, should be operated upon early, since by drawing the lip together the tension on the superior maxillary bones facilitates closure of the interosseous cleft.

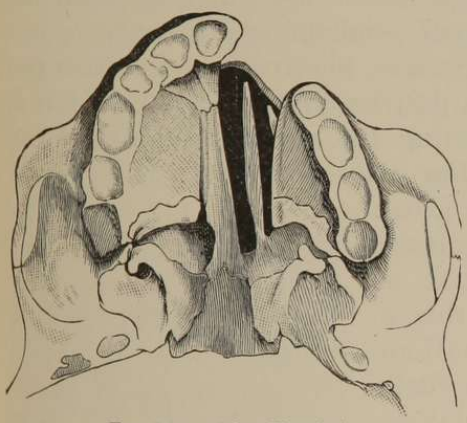

Fig. 561.—(After Koenig.)

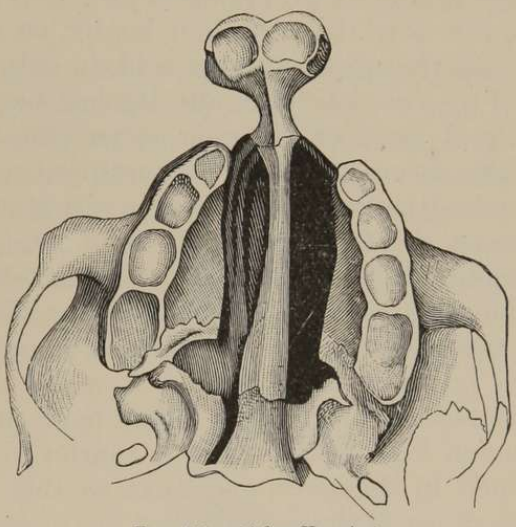

Fig. 562.—(After Koenig.)

The methods of operating are numerous. The essential features of every operation are, to trim the edges of the fissure in such shape that, when they are approximated, the gap will be closed and no depression left in the vermilion border of the lip.

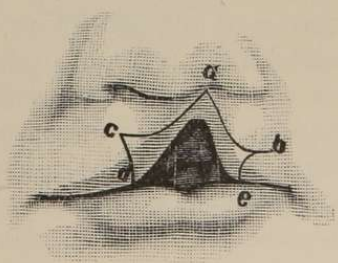

Fig. 563.—(After Linhart.)

Single Incomplete Harelip—First Method.—Having estimated the extent of surface required to fill up the deficiency, with a long, sharp knife prick the integument of the lip at *a*, *b*, *c*, *d*, and *e* (Fig. 563), as guides to the deep incision. Then the operator, standing in the position which best suits his convenience, seizes the lip between his thumb and finger, so as to control hæmorrhage, and, while the opposite side is held by an assistant, transfixes it at *a*, cuts

from *a* to *c*, by smooth, short strokes of the knife, removes and reinserts the blade at *d*, and cuts into the angle at *c*. This manœuvre is repeated in the line *a*, *b*, *e*. With a strong, blunt pair of scissors the soft tissues are freely lifted from the bone, until the edges of the wound can be approximated without any degree of tension. When the ala nasi is flattened this should be loosened and brought into proper position as the sutures are inserted. If, as frequently occurs, one side is so much thicker than the other that difficulty is experienced in keeping the approximated edges on the same plane, a part of the under surface of the thicker side should be clipped off with the scissors. Silk sutures of moderate size should now be inserted, the needle passing entirely through the skin, muscular tissue, and mucous membrane of the parts to be approximated. They should be close enough together to hold the edges of the wound in proper apposition. It is advisable to insert a trial suture quite near the vermilion border on either side, and with this approximate the edges of the wound, in order to be sure that the proper fullness of the free border of the lip has been secured. By dragging down the tip of the incised lip on either side with tenacula, and inserting a fine silk suture through the vermilion substance, the little notch, which frequently occurs after a single operation, may be prevented. After this is done, the following method of supporting the cheeks, and preventing either motion in the upper lip or tension upon the sutures, I have employed in a large number of cases with great satisfaction. A strong silkworm-gut suture is prepared as follows: A small shot is clamped on one extremity; next to this a small lead button from a quarter to half an inch in diameter, and next to this a little cushion or pad consisting of five or six layers of iodoformized gauze. The suture is now threaded on to a half-curved needle, which is carried from without inward through the tissues of the cheek about halfway from the corner of the mouth to the ala of the nose, and a little external to the nose. Coming out of the mouth, the needle is reinserted from the inside of the opposite cheek and comes out at a point corresponding to that at which it entered. Care must now be taken to see that the suture is passed directly under the mucous membrane of the lip which has just been united. The needle is passed through a pad of iodoformized gauze, which is run down upon the suture until it strikes the skin of the face; over this a second lead button is carried, and upon this a shot is placed. An assistant, standing behind the patient, places his first two fingers on either side of the child's face and forcibly pushes the lips and cheeks toward the middle line,

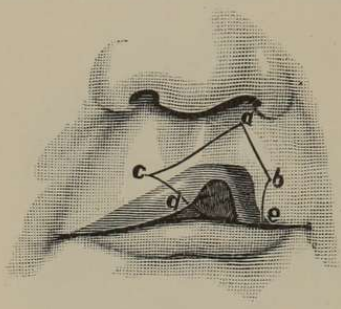

Fig. 564.

Fig. 565.—Single U-shaped harelip.

fully relaxing and puckering the upper lip. The shot is now run down upon the loose end of the suture, and when the requisite tension has been obtained, is clamped by forceps. In this way everything is made entirely immovable. No dressing is applied. It is better to feed the patient for eight or ten days with a spoon or through a tube, which prevents anything coming in contact with the upper lip. The sutures may be removed, as a rule, between the eighth and tenth day after the operation, and with these the supporting silkworm-gut suture. It is very difficult to prevent a slight notch from occurring in the vermilion border after any operation for harelip, and it is often necessary to repeat the operation several times to get a good result. It is my rule to permit three or four months to elapse between these operations in order to determine the amount of correction which may be necessary.

Fig. 566.—The same eight days after operation, showing the author's silkworm-gut support to prevent strain upon the sutures.

When the fissure is wider, the angles *b* and *c* should be made deeper, as shown in Fig. 564. When approximation is completed, *c* and *b* unite, while the points *d* and *e* project below the level of the normal lip. Any redundancy of tissue or overlapping should be allowed to remain until all shrinkage has occurred, when the excess may be trimmed off at the level of the lip.

Second Method—Operation of Malgaigne.—With a sharp bistoury pare the edges of the fissure, by cutting a strip on each side, from the apex down to about one eighth of an inch from the free border of the

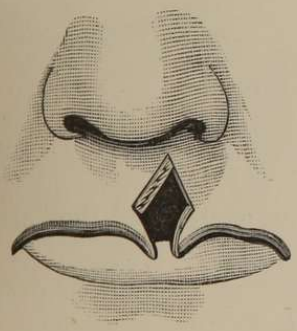

Fig. 567.—(After Malgaigne.)

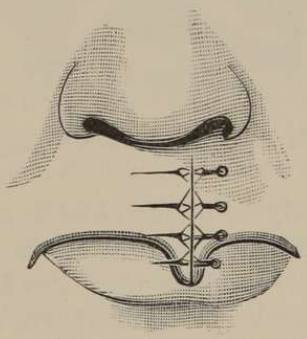

Fig. 568.—(After Malgaigne.)

lip. The strips are turned down as shown in Fig. 567, and, after the lip on each side is dissected up from the bone, the edges are approximated and united (Fig. 568). It is best to dispense with the pins. The projecting portion is treated as in the preceding operation.

Third Method—Operation of Langenbeck.—Upon one side of the fissure, as at *b* (Fig. 569), remove a narrow strip from the apex out through the vermilion border. On the opposite side, *a*, the incision extends only to within one eighth to one fourth of an inch of the free border. After

the lip is freed from all attachments, the edges are approximated and fastened, as shown in Fig. 570.

Fourth Method—Operation of Nélaton.—Make an incision parallel with the upper half of the fissure, on either side, the incision arching

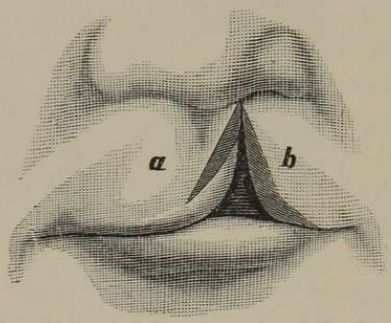

Fig. 569.—(After Linhart, Langenbeck.)

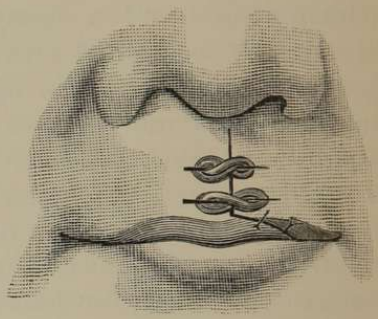

Fig. 570.—(After Linhart.)

over the apex, as shown in Fig. 571. When completed and turned down, a diamond-shaped or elliptical opening is formed (Fig. 572). The pins should be introduced from near the lateral angles.

Complete Single Harelip — With Cleft of the Superior Maxilla.—In certain cases where the fissure is of great width, and extends through the floor of the nose, important modifications of the foregoing procedure are at times necessary. The operation is one of considerable difficulty,

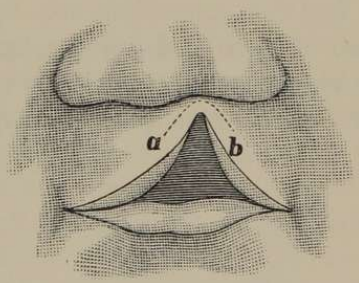

Fig. 571.—(After Nélaton, Koenig.)

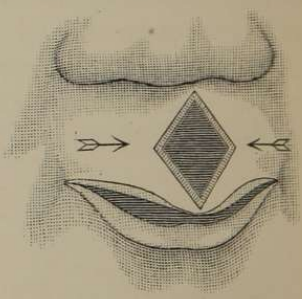

Fig. 572.—(After Koenig.)

not only as to the closure of the fissure, but on account of the flattening of the wing of the nose on the affected side.

It is evident that the flattening of the *ala nasi* can not be overcome unless the bony arch upon which the nose is to rest is perfected, and this should be done before any operation upon the lip is undertaken. When the inter-maxillary bone is attached to and projects from one side of the alveolar arch, this may be turned back into position and fastened to the opposite superior maxilla. In doing this in very young children, the method advised is to freshen the edges by removing with the knife the mucous covering over the surfaces which are to be brought in contact. When this is accomplished, a hole should be drilled about half an inch from the margin of the fissure in the bones of the two sides, and through these a good-sized silver wire is passed, in such a way that when it is ultimately twisted and the ends cut off, the twist shall be on the ex-

external surface of the alveolus and beneath the lip. If this precaution is not taken the tongue will be injured on the stubs of wire. In very young infants the maxillary process may be forced into position by pressure with one or both thumbs, an assistant holding the child's head firmly between his hands. When the bone will not yield it should be perforated in a number of places with an awl. In this way it is made to bend or break without materially interfering with its source of nutrition. The line of perforation should be about one inch away from the edge of the fissure. If it will not yield to pressure with the thumbs it should be seized with a strong bone sequestrum forceps and violently forced into proper position and the wire twisted. The operation on the soft parts should not be undertaken until the bones are firmly united. About two months should elapse before the operation is done upon the lip. With the alveolar arch thus perfected, the deformity of the lip and nose is more perfectly corrected.

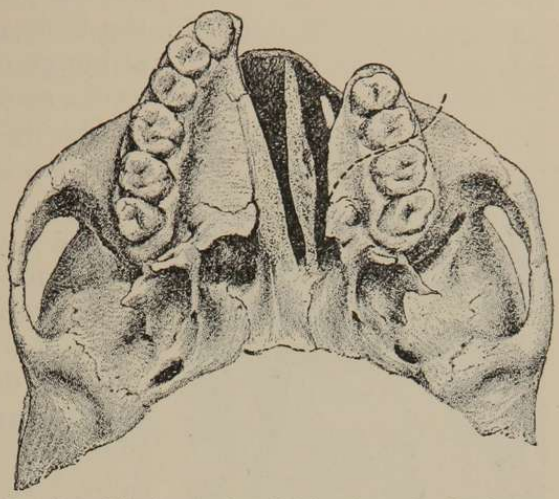

FIG. 573.—Showing at dotted line where the alveolar process is divided prior to advancement.

When the inter-maxillary bone is entirely deficient on one side, leaving a wide gap in front, as shown in Fig. 573, I have successfully carried out the following procedure:

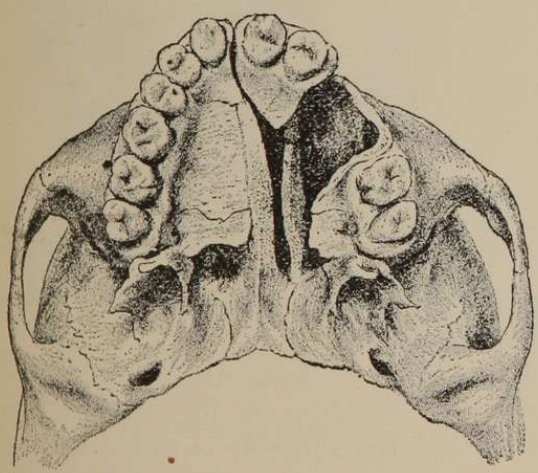

FIG. 574.—The same after advancement and suturing in position, completing the alveolar arch on which the alæ nasi rest.

Operation.—After anæsthesia is effected, a hole is drilled through the bone about one fourth of an inch from the edge of the fissure and large enough to permit the introduction of a large, soft silver wire. The edges to be approximated are freshened with cutting forceps or knife, and about halfway back along the alveolar process of the *short* side, between two teeth (Fig. 573), a strong cutting forceps, chisel, or scissors divides the upper jaw deeply and freely at a right angle to the plane of the alveolus. Instead of inserting a lever to pry the piece forward, it is best to carry a very strong cord in the fissure made by the cutting instrument, and pull on this until the fracture is complete and the anterior fragment is advanced.

When this is done, a few twists of the silver wire bind the freshened surfaces together and hold the piece in its advanced position (Fig. 574). As the soft parts have not been disturbed, the bone gets its nutrition from this source, although cut off posteriorly. At least eight weeks should elapse before the plastic work on the lip is undertaken. By this time the nutrition of the bone in its new position is assured.

Fig. 575.—Complete harelip with cleft of the superior maxilla two years after operation.

The results I have obtained by this operation are far more satisfactory than by any other method with which I am acquainted.

Double Harelip.—The method of operation for double harelip will depend upon the size and position of the middle piece, and the width and depth of the lateral fissures. The edges of the central tip must be trimmed and freshened. The length of the incision, *a b* (Fig. 576), and the extent of the dissection of the lip from the jaw, will depend upon the space to be covered in. The margin from *a* to the root of the nose is not freshened, since it forms the floor of the nostril when the operation is completed. The condition of the parts when ready for the sutures is shown in Fig. 577. The points *b b* meet in the median line of the lip, while *a a* are sewed to the central piece.

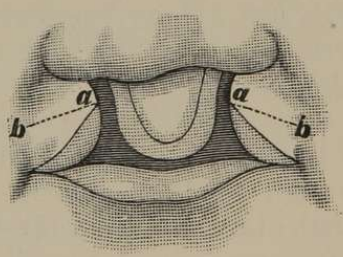

Fig. 576.—(After Koenig.)

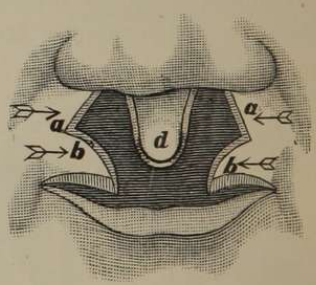

Fig. 577.—(After Koenig.)

When the inter-maxillary process is centrally attached (Fig. 562) it can usually be forced back into good position.

Cheiloplasty—Upper Lip.—In addition to congenital deficiency of the lips, not infrequently as a result of accident or disease, or the removal of abnormal growths or cicatrices, the surgeon is called upon to relieve the deformity and inconvenience resulting from this loss of tissue.

In the upper lip, when the loss of substance is not extensive, as in Fig. 578, the unsightly appearance may be remedied by making two incisions, curved as represented by the lines *a d*, *a d*, from the side of each ala nasi downward and inward to the apex of the fissure. The soft tissues should be dissected up and brought into position by sutures applied

as in Fig. 579. If after the dissection the tension is still so great that the parts do not come well into position, a horizontal incision should be made on either side, beginning near the root of the nose, and carried directly outward, or slightly outward, and downward, as the shape of the flap may require. Where there is greater loss of substance, Burrows's

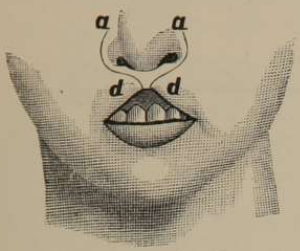

Fig. 578.—(After Roser.)

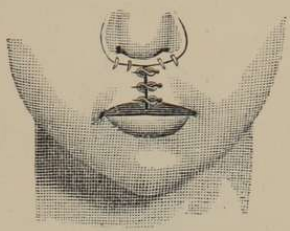

Fig. 579.—(After Roser.)

method is advisable (Fig. 580). Make a horizontal incision on each side, commencing in the angle of the mouth, and going entirely through the lip, *a b*, *c d*, and unite these at *k* and *j*. Dissect out the triangular piece *j a b*, *k c d*. Make now two other horizontal incisions, which run into the nasal cavity *g h* and *f e*, and dissect out two smaller triangles, *f e m* and *g h l*. The proximal edges of the quadrilateral flaps *g h c d* and *e f a b* should now be fastened and freely lifted by dissection, and the sutures introduced. It will be observed that as the edges are approximated, the lines *d k*, *b j*, *m f*, and *l h*, will be united with *c k*, *a j*, *m e*, and *l g*.

A third method, which is useful in certain cases, is as follows: After the disease is removed, an incision, *c a* (Fig. 581), is carried from the alæ of the nose upward and outward. The length of this cut and its

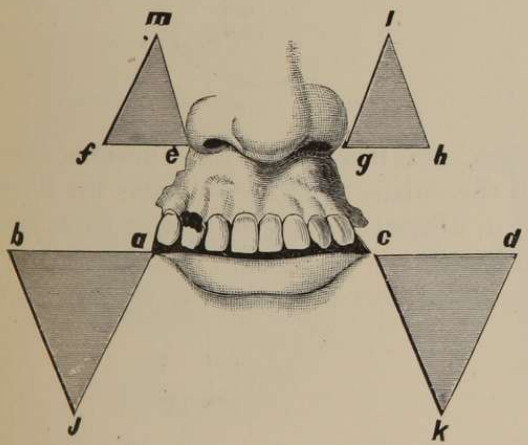

Fig. 580.—(After Linhart.)

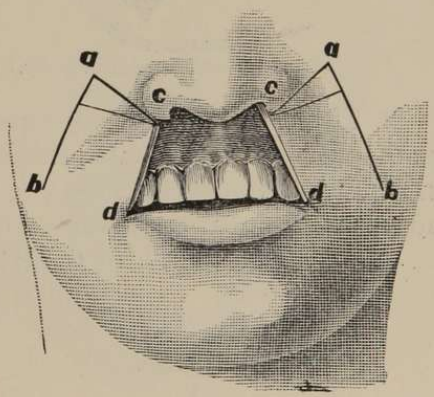

Fig. 581.—(After Linhart.)

obliquity depend upon the distance to be filled between the normal line of the lip and the nose. A second incision, *a b*, is now carried deeply forward and outward, making a quadrilateral flap which hinges at *b d*, and is dissected up, and the edges, *c a*, are brought in apposition and secured to the median line.

Lower Lip.—When the loss of tissue has left a cavity triangular in shape, as in Fig. 582, that one of the following methods may be

selected which in the judgment of the operator is best adapted to the case:

1. A horizontal cut, *a b* (Fig. 583), is made outward from the angle of the lip, and a second one, *b c*, parallel with the freshened edge of the fissure. Both

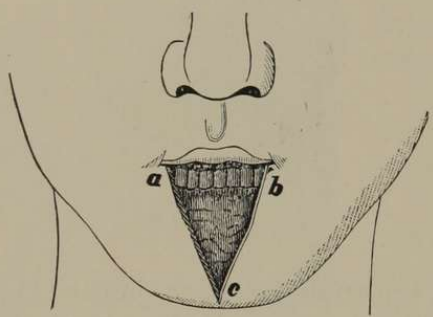

Fig. 582.—(After Szymanowsky.)

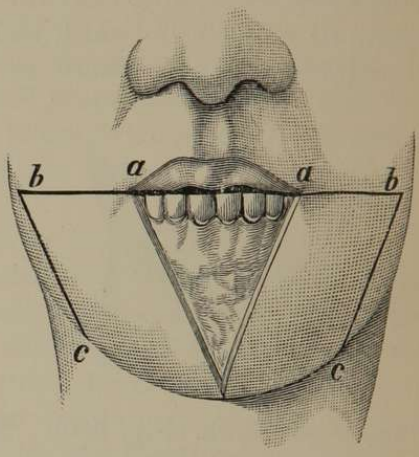

Fig. 583.—(After Linhart.)

flaps are now loosened and slid toward the median line, and united by sutures. Along the free border of the new lip stitch the mucous membrane to the skin with fine silk sutures. The gap left on either side is also wholly or partially closed by sutures or grafts.

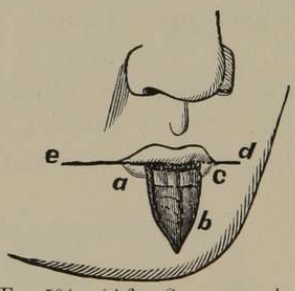

Fig. 584.—(After Szymanowsky.)

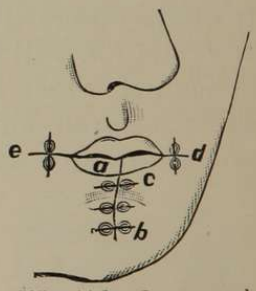

Fig. 585.—(After Szymanowsky.)

2. If the fissure is less extensive, make a horizontal incision from each angle of the mouth through the entire thickness of the lip for a sufficient distance (Fig. 584), *a e*, *c d*, dissect up the triangular flaps, and adjust with sutures, as shown in Fig. 585.

3. When the apex of the triangular defect does not dip down too far

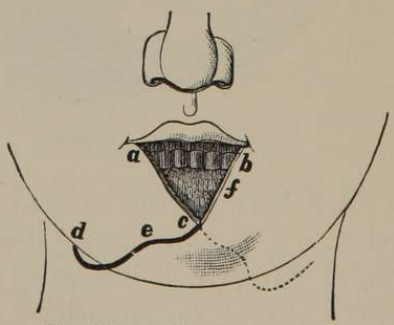

Fig. 586.—(After Szymanowsky.)

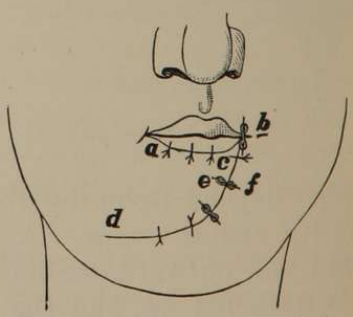

Fig. 587.—(After Szymanowsky.)

from the teeth, the unilateral sliding operation of Blasius may be practiced. From the apex of the angle, *c* (Fig. 586), make a deep cut, *c e d*,

downward and outward over the side of the chin, in the main a continuation of the line of the defect, *b f c*. The flap, *a c e d*, is dissected up and slid so that *c* is attached to *b* (Fig. 587).

4. When the defect extends in the shape of an isosceles triangle with the apex low down upon the chin, the method of Burrows (Fig. 588) is applicable. Two triangular pieces, *a f h*, *b g k*, are removed from the tissues just above the angles of the mouth. The edges of the fissure

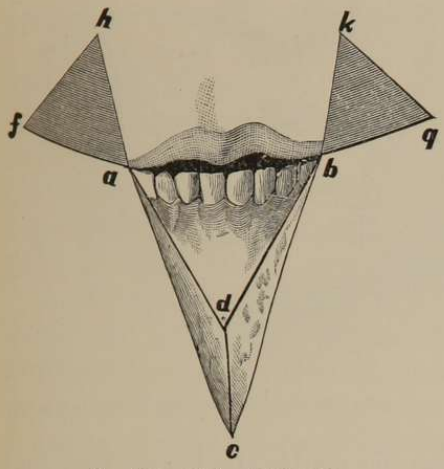

Fig. 588.—(After Linhart.)

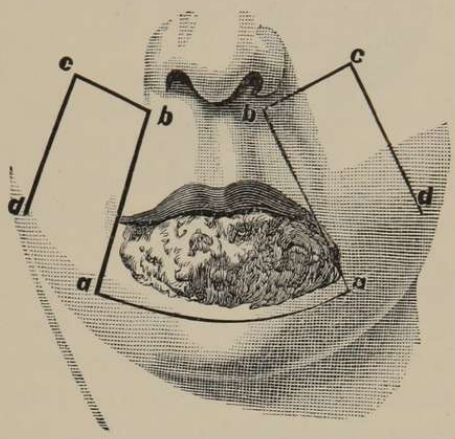

Fig. 589.—(After Linhart.)

are freshened, the flaps, *f a d g b d*, dissected loose, and the lines, *a c*, *b c*, approximated by sutures.

5. When the defect is long and rectangular, as shown in Fig. 589, the procedure of Von Bruns may be successfully employed. The diseased tissue being removed, the quadrilateral flaps, *a b c d* (Fig. 589), are dis-

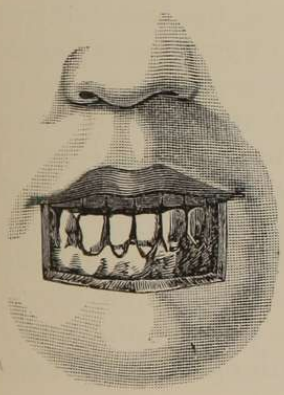

Fig. 590.—(After Linhart.)

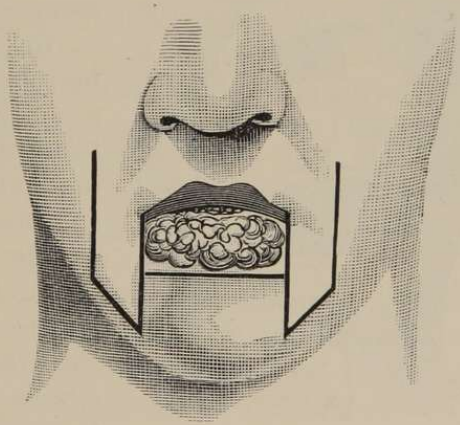

Fig. 591.—(After Malgaigne.)

sected out and brought down, uniting *c b* in the median line and *a b* on either side of the line *a a*. The defect left on both sides of the outer aspect of the upper lip may be wholly or in great part closed by sutures. The outer incision should not be carried far enough back to wound the duct of Steno.

6. Or the flaps may be turned from below, as advised by Sedillot (Fig. 591).

Cheeks.—When the loss of substance is not extensive, the edges may be dissected up to a limited extent, pared, and brought directly together by sutures. If this can not be accomplished, incisions shaped as shown

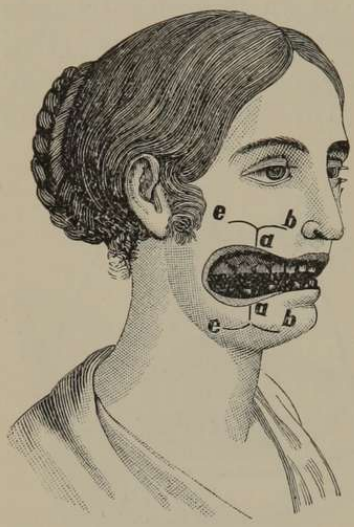

Fig. 592.—(After Roser.)

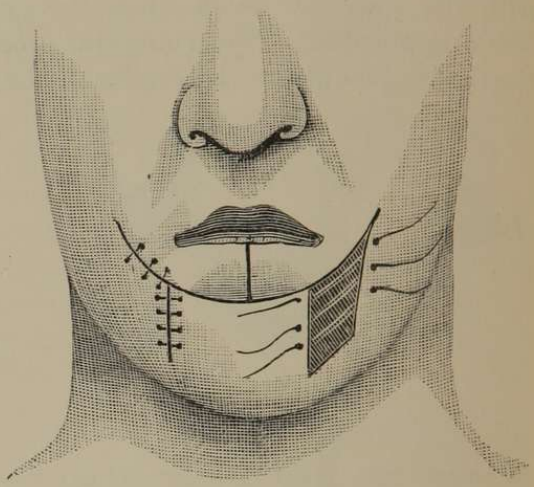

Fig. 593.—(After Malgaigne.)

in Fig. 592 (Mütter's method), *a b*, *a e*, may be made, the flaps lifted, and brought together by sutures. The gaps left above and below may be also closed at once.

Sliding a flap from the neck is shown in Fig. 594, where the flap, *b a d*, is brought up to fill the oval space left by removal of the diseased tissue, *b c a*. The pedicle is divided as soon as union has occurred, and the stump returned, as in *rhinoplasty*.

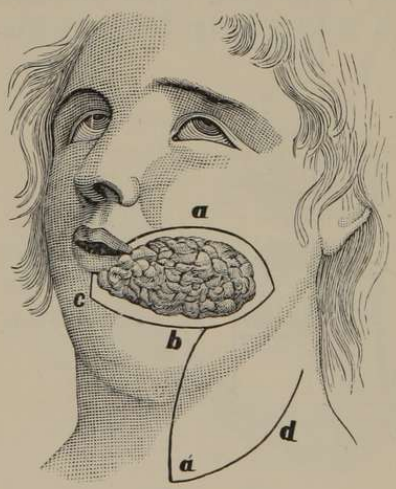

Fig. 594.

In *contraction* of the mouth the orifice may be enlarged by incising the angles in a horizontal direction, finishing the operation by stitching the skin and mucous membrane together. Or an elastic ligature may be introduced through the cheek at the required distance from the angle, brought out at the corner of the mouth, and tied. During the slow process of cutting through, the track of the wound becomes covered with epithelia, and reunion is prevented.

In the selection of any of the plastic methods heretofore given, the surgeon must be guided by the requirements of each case. It is a wise precaution to make a guarded prognosis, for, no matter how successful from the surgical standpoint, the operations do not, in the majority of instances, secure the expected improvement in the personal appearance of the patient.

Parotid Gland and Duct.

Salivary fistula may be confined to the main parotid duct in any part of its course, or to the primary ducts within the substance of the gland.

It may result from a wound or any inflammatory and necrotic process due to obstruction from salivary calculi or other disease of the parotid and buccal regions. Exploration of the duct with a delicate blunt probe is accomplished thus: Find the outlet at the papilla on the mucous membrane of the buccal cavity near the junction of the second bicuspid and first molar teeth of the upper jaw. Introduce the probe, carrying it at first slightly outward. When it is arrested by the natural curve of the duct, pull the corner of the mouth and the cheek directly outward, thus straightening the tube. The general direction is backward, toward the auditorymeatus.

The diagnosis of salivary fistula or of obstructed duct may be determined as follows: By means of absorbent cotton or lint remove all moisture from the mucous surface where the papilla is situated, and place some sapid or acid substance on the tongue. If there is no obstruction, the flow of saliva is immediately perceived. In case of fistula the secretion will flow out through it. Calculi of Steno's duct, or of any of the salivary ducts, should be removed by dilatation, if this is possible, and if not, by incision. The prominent feature of stone is swelling of the cheek from retention of saliva. I removed three small concretions from the duct of Steno in a child of eight years. The face was immensely swollen, and an operation for lymphangiectasis had been undertaken. The cure was complete after the removal of the calculi.

In the treatment of salivary fistula the object aimed at is to stop the flow of saliva on the outside and turn it into the mouth. Arm a probe with a silk seton and carry it through the fistula into the buccal cavity, bring the thread out through the mouth, and tie the two ends together. In about ten days the flow into the mouth will be fully established, when the seton should be removed and the outer opening closed by a compress until cicatrization occurs. It may, at times, be necessary to freshen the edges and bring them together with a suture.

Riberi operated successfully by cutting through the integument down upon the duct behind the opening, passing a ligature around it, and carrying this and the end of the duct into the buccal cavity, where it was left open. The wound in the integument was immediately sutured.

In a case recently treated by the author, the following method was successful in restoring the flow of saliva into the mouth: A boy twelve years old had scarlatina at seven, which was followed by obstruction of the left duct of Steno. A fistulous opening occurred spontaneously behind the ear. Cutting down through the cheek in the anatomical line of the duct, this was discovered to be obliterated for the last half inch of its course. It was divided just posterior to the limit of occlusion, and an incision opposite this point made directly through into the buccal cavity.

Two fine silk threads were inserted in the wall of the duct at the end, and these sutures were stitched to the mucous membrane of the cheek at the edges of the incision just made. The wound in the integument of the face was closed, excepting the anterior angle, where a small rubber tube was inserted. This tube projected into the cavity of the mouth by the side of the new opening for the duct. This was done to form a fistula in case the wound in the mucous membrane should close and obstruct the duct. A compress was placed and worn on the fistulous opening behind the ear. The tube was removed in five weeks, and the external outlet closed by silk sutures. At this time, also, the old fistulous opening was closed. The saliva up to this time flowed about equally out of the hole behind the ear and the opening in front. After this it came only through the end of the duct in the mouth.

Fistula of the primary ducts within the substance of the gland may require the forced atrophy or ablation of this organ. An effort at occlusion should be made by direct pressure upon the abnormal opening, or by careful dissection in the line of the fistula, when this can be safely done. When, however, the fistulous tract is deeply situated, it will be found almost impossible to effect a cure without serious risk of interfering with the integrity of the seventh nerve, the motor filaments of which are in intimate relation with this gland. Removal of the parotid gland, for any cause, becomes a serious operation, since it necessarily implies paralysis, more or less complete, of the muscles of the face ; when it is entertained, the patient should be thoroughly acquainted with the prospect of paralysis which will follow. In non-malignant cases the greatest care should be exercised in avoiding division of the filaments of the facial nerve. Even in the arrest of hæmorrhage, as the operation proceeds, the application of the forceps should be carefully made, so that the branches of the nerve may not be injured or included in the ligature. When the seat of malignant disease, a thorough ablation is essential, and the nerve is necessarily sacrificed.

Tumors of the Parotid.—About 30 per cent of all neoplasms of this organ are enchondromata, 25 carcinomata, while the remaining 45 per cent are about equally divided between sarcomata, fibromata, myxomata, and cystomata. Enchondroma, carcinoma, and fibroma occasionally are found developing at the same time in this organ. Simple hypertrophy is rare, although hyperplasia of the gland tissue occurs in a varying degree in the progress of most of the neoplasms which attack this organ.

Tumor of the parotid is rare prior to the thirtieth year of life, being met with chiefly between the thirtieth and fiftieth years. As to the period when the various forms appear, it may be said that carcinoma occurs generally after the fiftieth year, while enchondroma, sarcoma, myxoma, and fibroma develop in the earlier decades. Sarcoma is apt to develop in childhood or early adult life.

Diagnosis.—All forms of tumor of the parotid, as a rule, develop slowly. In the earlier stages of their development they are movable within the limited area of mobility of the gland. This is true of both the benign and malignant growths. Later, even the benign neoplasms

may become fastened between the temporal bone and fascia and the ramus of the jaw, but not to the overlying integument. The malignant growths are more rapid in development, and earlier in their history are bound down to the surrounding tissues, may become adherent to the integument, and produce great pain and disturbance by reason of pressure upon the nerves and vessels with which the gland is in close relation.

The cartilage tumors are nodular, hard, and slightly elastic to direct pressure. Cancer is also nodular at times, but not so hard as enchondroma. Cancer comes, as a rule, after the forty-fifth to fiftieth year, and the other neoplasms before this period. The lymphatic glands are involved in cancer, and rarely enlarged in any other form of neoplasm. Sarcoma occurs earliest of all. Cysts are elastic, may present fluctuation, while the exact character of this variety may be determined by exploration with the aspirator. If of great importance in determining the plan of treatment to be pursued, a section of the diseased organ sufficiently large for microscopic examination should be removed ; in this way a positive diagnosis is assured.

Removal of the parotid gland is a difficult operation. In many cases of tumor of this organ in which the neoplasm is developed at the expense of the under portion of the gland, the internal jugular vein, internal carotid artery, and the important nerves and ganglia situated here become so involved that complete extirpation is impossible during life. This condition was found to exist in a case in which I removed all of the organ anterior to the deep vessels. Having at first tied the external carotid artery, the dissection was comparatively bloodless. When the tumor is of small size, it may be entirely removed. Section of the various divisions of the facial nerve or of the main trunk is almost inevitable. In a patient in whom both parotids were removed by the author for large carcinomata, with an interval of about six weeks, both external carotids were tied. The facial paralysis was at first complete, but after two years there was marked improvement in motion of the face muscles.

Operation.—Make a crucial incision over the mass, the perpendicular cut being in the line of the external carotid artery. Turn the flaps back from the anterior aspect of the tumor, and approach its deeper portions from below in the line of the vessels. As soon as the external carotid can be exposed, it should be secured with a catgut ligature. All bleeding should be arrested as the operation proceeds. In lifting the under surface of the tumor from its bed, the operator should keep close to the mass, using a dull instrument for fear of wounding the internal jugular vein and other important vessels or nerves. The blunt scissors curved on the flat, the handle of the scalpel, or the thumb and finger nail may be utilized for this purpose. The facial nerve and its branches which run through the neoplasm should be saved, if possible. As before stated, if the tumor is extensive, this is scarcely possible on account of the great length of time it would require. If, in the course of the operation, it is discovered that the neoplasm dips down beneath the jaw and styloid process, and surrounds the vessels and nerves, its complete ex-

tirpation is impossible. As much of the mass as can be lifted should now be transfixed near the middle with a double elastic ligature, tied, and the part external to the ligature cut away.

The *prognosis* in cancer and sarcoma of the parotid is always grave, even after removal. The probabilities of recurrence, and the certainty of facial paralysis should be fully explained before operation. In benign tumors which show a tendency to increase, operation should be advised. It is always important to attempt the removal of the neoplasm early in its history.

Parotitis—"Mumps."

Inflammation of the parotid gland occurs chiefly in children, but is occasionally met with in adults. In males it is, at times, accompanied by orchitis, and in females the mammary glands and ovaries are affected. The symptoms are pain and swelling of the gland, difficult deglutition, and slight febrile movement. The prognosis is favorable, the disease yielding to warm applications, quiet, and the judicious employment of laxatives. In rare instances atrophy of the testicle has been known to follow the inflammation of this organ, occurring as a complication of "*mumps*."

Abscess of this organ may occur as a complication of the eruptive or continued fevers. Under these last conditions the prognosis is always grave. The presence of pus is recognized by the intense character of the pain experienced, the febrile movement, the doughy condition of the skin and areolar tissue in front of the organ, and by aspiration. The abscess should be evacuated by aspiration, puncture, or incision.

Submaxillary Gland.

This organ may become inflamed and suppurate, or be the seat of neoplasms. Its removal is a simple procedure, and may be accomplished by a crescentic incision commencing at the angle of the jaw, dipping three quarters of an inch toward the hyoid bone, and ending one and a half inch in front of the angle at the lower border of the jaw. The flap of skin should be raised with the platysma muscle as far as the jaw, and the deep cervical fascia divided. The gland rests beneath and internal to the bone and upon the mylo-hyoid and hyo-glossus muscles. The submaxillary branch of the facial artery may be divided.

The Jaws.

Superior Maxilla.—Periostitis, ostitis, and abscess of the upper jaw may be caused by infection through a carious tooth, or in the upper jaw from the antrum, or pathological changes within the bone proper. Ostitis of the maxilla is more apt to occur in children, and especially in those of a strumous diathesis. Phosphorus poisoning and the syphilitic dyscrasia lead also to inflammation and caries of this bone.

The *symptoms* of ostitis and abscess here do not differ from those already given in the general chapter on bone diseases. Pain is, perhaps, more acute in ostitis within the distribution of the trifacial nerve. It is

elicited by direct pressure, and, when the process is associated with a carious tooth or its roots, the exact location may be determined by striking the tooth sharply with a metallic substance.

The *treatment* is to relieve the tension by puncture or incision, or by extraction of one or more teeth in case they are connected with the diseased surface. The removal of dead bone is demanded. When exfoliation has occurred, the operation is much simplified. If free drainage is secured by early incision, the arrest of the spread of the disease is practically insured. *Chronic alveolar abscess* is often cured by extraction of an offending tooth. When this fails, the diseased surface should be exposed by incision, and a thorough removal accomplished. When possible, all sequestra should be removed from within the oral cavity in order to avoid a scar upon the face.

Syphilitic ostitis, and that variety which occurs from absorption of the fumes of phosphorus, require specific constitutional treatment as well as operative interference.

Abscess of the antrum of Highmore may occur as the result of an inflammatory process in the mucous membrane lining this cavity, by extension of an infective inflammation from the nose, or in connection with ostitis of the upper jaw, or from the presence of foreign bodies or neoplasms within its cavity. The chief symptom is pain, referred to the region of the antrum. The febrile movement of acute abscess is usually present. The pus may force its way through the opening into the meatus, or cause necrosis in the bone and discharge in any direction.

Treatment.—Free drainage must be established in all cases. This can be accomplished in two ways: First, and preferably, by making an opening directly into the antrum from beneath the cheek and just above the roots of the first molar tooth. For temporary drainage in the suppurating antrum, this opening will suffice. It may be enlarged by biting away a portion of the wall of the antrum around the hole made by the drill. It is important to explore the cavity with the probe or finger in order to determine the presence of dead bone or any tumor or other offending substance. Drainage must be maintained until the discharge of pus has ceased. In a case which came under my observation I found a supernumerary tooth which was lying loose in the antrum. The old method of drainage was to extract the anterior molar tooth and break through directly into the antrum; but, on account of the annoyance from the easy entrance of food through this opening, it will be better to employ the higher drainage.

Among the many other diseases to which the antrum is subject are myxoma, fibroma, papilloma, sarcoma, and carcinoma. The differentiation of these growths is extremely difficult. The small electric arc light introduced in the pharynx, nose, or mouth will illuminate the antrum and aid in diagnosis. When doubt exists as to the character of the neoplasm, an exploratory operation for the purpose of positive diagnosis should be made.

Operation for Removal of a Tumor from the Antrum of Highmore.—For the removal of small neoplasms of the antrum, the method already

given of incision underneath the lip and cheek and above the roots of the molar tooth will be found sufficient as advised and practiced by Prof. Robert C. Myles. For larger growths, the following simple method I have found extremely satisfactory, and have removed through this incision tumors entirely filling the cavity of the antrum of Highmore, and projecting into the nose and pharynx. A horizontal incision is made about one fourth of an inch below and parallel with the inferior orbital margin, and extending from the outer angle of the orbit to near the canthus of the eye. A second incision joins the inner extremity of this cut at a right angle, and divides all the tissues down to the bone, extending to the level of the wing of the nose. The filaments of distribution of the fifth nerve are divided and all the tissues are lifted with the periosteum. The anterior wall of the antrum is broken through by a small chisel, and the opening enlarged with the rongeur until the entire anterior wall is removed piece by piece. The antrum is now exposed, the tumor removed, and the hæmorrhage arrested by a packing with iodoform gauze, which is then removed and the wound closed, leaving a little catgut twist for drainage at the anterior inferior angle, when this is deemed necessary. The loss of the anterior wall of the antrum produces very little deformity.

When a naso-pharyngeal tumor of large size has developed into the antrum and is pressing into the spheno-maxillary fissure, producing bulging of the eye, and into the zygomatic and pterygo-maxillary fossa, the following operation, which was first performed by the writer in 1894, may be employed: In the patient upon whom it was first done the tumor was a large vascular fibroma which sprung from the base of the pterygoid process of the sphenoid bone, filled the naso-pharynx, and had broken through the posterior wall of the antrum. It projected upward into the sphenoid fissure and zygomatic and pterygo-maxillary fossæ. The eye was pushed well out of the socket and toward the nose, and the cheek and temporal region were greatly swollen. The patient was a young man, nineteen years of age, and in bad condition from frequent hæmorrhages from the tumor, loss of appetite, and sleeplessness.

An incision was made beginning along the temporal arch two inches back of the outer angle of the orbit, following the temporal arch to the edge of the orbital cavity, along the frontal process of the malar bone, curving parallel with and one eighth of an inch from the orbital margin, until the point of the knife reached half an inch to the inner side of the infra-orbital foramen; then downward to the level of the ala nasi and outward through the cheek until the point of the knife neared the opening of Steno's duct (Fig. 595). This incision was down to the bone from the point of beginning to the lower part of the superior maxilla, where the antrum of Highmore rests upon the alveolar process of the upper maxilla opposite the first molar tooth. Hæmorrhage was carefully stopped throughout the entire incision by pressure and by ligating with catgut the larger vessels which were divided, but the soft tissues were in no way dissected up from the bone, except when it became necessary to enter the orbital cavity in its outer half, where the tissues were

carefully lifted from the bone and the eye displaced toward the median line (taking care not to press upon or injure this organ), until the anterior commissure of the spheno-maxillary fissure came into view. I then passed in this a keyhole saw with the teeth turned upward, and sawed through the junction of the malar with the frontal bone. The saw was then turned over with the teeth directed downward, and beginning at the same point I rapidly cut through the floor of the orbital cavity, traversing the infra-orbital foramen until I had sawed through the antrum of Highmore at the level of the alveolar process of the lower maxilla. A hook was then placed in the outer angle of the orbit, and a quick, sharp jerk fractured the zygomatic process of the temporal bone, displacing the side of the face, completely exposing the antrum of Highmore, the zygomatic fossa, and the pterygoid and spheno-maxillary fissures. The hæmorrhage was severe, but was controlled by packing sponges into the wound and making firm compression. So sudden was the hæmorrhage that the pulse jumped from 85 to 140, and the patient, who was before the operation in a condition of extreme exhaustion, seemed about to expire in collapse. As a precautionary measure I had inserted into the median cephalic vein a pipette for injecting hot salt solution, and had everything in position for immediate use. At this juncture the faucet was turned on, and one pint of the saline solution, already prepared and kept so hot that the hand could scarcely be borne in it with comfort (temperature 110° to 120° F.), allowed to run into the vein. Under the pressure of this solution the heart rallied and came down to eighty-five beats to the minute. The tumor was again exposed, and with a periosteal elevator lifted out of the antrum of Highmore, and from its attachments to the pterygoid process of the sphenoid bone. By opening the patient's mouth, which depressed the coronoid process of the inferior maxilla, the pterygo-maxillary fissure and the zygomatic fossa were well exposed. The whole antrum was packed with a long wick of iodoform gauze, which was allowed to project at the anterior inferior angle of the wound, from which it was drawn on the

Fig. 595.—Dotted line indicates the incision for the author's osteoplastic resection of the malar bone and wall of the antrum maxillare. Case of Charles Bull. One year after operation.

third day after the operation. The bone, which had been temporarily displaced with the soft parts adherent, was then brought back into position and held there by stitching the soft parts along the line of incision. A bandage and compress were applied in order to maintain approximation. No sutures were inserted in the bones. The patient made an uninterrupted recovery. He is now, three years after the operation, entirely well. The bones have all united in their normal position; he has perfect use of the eye, and, although the filaments of the facial nerve were divided, he still has motion of the orbicularis palpebrarum muscle. Disfigurement from the scar is insignificant.

Besides the novelty of this procedure, there are three points which are important. First of all, the character of the anæsthesia, morphine being almost entirely relied upon. The amount of chloroform taken was only two drachms in one hour and forty minutes of narcosis. I have done a number of major operations with this combination of morphine and chloroform, or morphine and ether, in operations about the respiratory tract; and in one instance, in removal of the larynx, I used nothing but morphine and obtained complete narcosis and anæsthesia, the operation lasting an hour and thirty-two minutes, the patient remaining perfectly quiescent during the operation, suffering no shock and with no memory of pain.

The second important point is the value of transfusion with a salt solution, to prevent collapse and shock under great and sudden loss of blood. During this operation, five pints in all were allowed to run into the veins, and the blood became so thin that practically salt water ran out of the vessels in the line of the incision, showing the red corpuscles were almost exhausted, and yet we were able to make the patient's pulse drop from 130 and 140 (the rapid pulse of collapse) to 80 or 90 beats per minute, full and strong.

Finally, the persistence of motion in the orbicular muscle of the lids after division of the branches of the seventh nerve.

The orbicular portion of the muscle is supplied solely by the facial nerve. This portion, however, is not necessary to the act of closing the eye. In fact, the palpebral portion is quite distinct from the orbicular, and its action is habitually involuntary. It receives nerve impulse from the sympathetic plexus around the cavernous sinus. In addition to the nerve fibers from the seventh, the upper lid may and does get motor impulse thus: The ophthalmic or first division of the fifth receives fibers from the fourth and third, and frequently from the sixth, prior to its division into nasal, frontal, and lachrymal. Some or all of these motor fibers may go with the lachrymal branch of the ophthalmic. After the lachrymal supplies the tear gland, it sends fibers to the upper lid (Gray).

The lachrymal not infrequently arises by two filaments, one from the ophthalmic and one from the sixth nerve. Thus the upper lid would get motor impulse from the abducens (sixth).

If the ophthalmic has received motor fibers from the fourth, third, and sixth, as already stated, the supra-orbital branch of the frontal nerve

which goes partly to the upper lid would carry motor influence, and from this same (frontal) nerve the lower lid could be supplied through the infra-trochlear.

Operation for Removal of the Upper Jaw.

A quarter of an inch below the inner canthus of the eye commence an incision and carry it downward along the naso-maxillary groove, curving in the contour of the ala nasi, then horizontally beneath the ala to the median line of the lip, where it turns directly downward, dividing the lip in the median fissure. From the point of beginning carry a second incision one fourth of an inch below and parallel with the inferior margin of the orbit out to the prominence of the malar bone (Fig. 596). Dissect up the soft tissues of the cheek, and turn the flap downward and outward. If the disease is so extensive that the incision does not expose the parts sufficiently, a horizontal cut may be made outward from the angle of the mouth. This is rarely necessary.

The bone may be divided by the saw inserted in the spheno-maxillary fissure, cutting through the nasal process with a chisel. Extract an incisor tooth, and with a chisel or bone-cutting forceps divide the alveolus and the palate process by inserting one blade in the nose and the other in the mouth. These sections being accomplished, avulsion is made by means of elevator and forceps. The operation is completed by the closure of the wounds with fine silk sutures. If, in section of the palate, the Paquelin cautery is used, hæmorrhage will be less annoying.

Fig. 596.—(After Roser.)

Preliminary tracheotomy and plugging the pharynx and larynx with sponges in order to prevent hæmorrhage into the trachea is never required.

If the patient be placed well upon the side and the neck twisted over so that the mouth is dependent, the blood will gravitate easily out of the mouth, and thus dispense with the necessity for a trachea tube. This position should be employed in all cases of operation upon the mouth where hæmorrhage is serious.

For simple osteoma, or for necrosis of the upper jaw, this bone may be removed without incision in the cheek. I removed the left superior maxilla, except the orbital plate entirely from within the mouth. In necrosis, when the subperiosteal operation is permissible, the procedure is devoid of great difficulty.

Neurectomy.—Exsection of a portion of the second division of the fifth nerve may be made at three points—at its exit from the infra-orbital canal, within the canal, or at the foramen rotundum. As the lesion which causes neuralgia of the fifth nerve is usually central, the operation now generally recommended is removal of the ganglion of Gasser. An incision about one inch long, parallel with and half an inch

below the lower margin of the orbital cavity, will expose the point of exit of the second division. When this alone is involved it is proper to resect this branch, in the hope of avoiding the more formidable procedure. The center of this cut should be over the infra-orbital foramen, which is just halfway between the outer and inner angle of the orbit. The nerve may be exsected here or destroyed by twisting the central end. It may be reached at a point considerably behind this by removing with the small chisel a circle of bone immediately around the foramen of exit, and following the nerve along the floor of the orbit. The nerve runs directly backward, and may be followed by breaking off the lower shell of the canal as far back as the posterior wall of the antrum, where it should be twisted and thus destroyed to or beyond the foramen rotundum.

Intracranial Neurectomy and Removal of the Gasserian Ganglion.

In a large proportion of cases of trifacial neuralgia the procedures which attack the peripheral distribution of that nerve do not effect a radical cure. Nothing short of intracranial section and extirpation of the ganglion of Gasser will insure permanent relief. According to Prof. Tiffany, of Baltimore, the credit of first doing this operation rests with Rose, of London, after whom may be mentioned Novaro, Horsley, Andrews, Krauser, and others. In 1892, Dr. Frank Hartley,* of New York, made public a method which he was able to demonstrate successfully in practice. It is as follows:

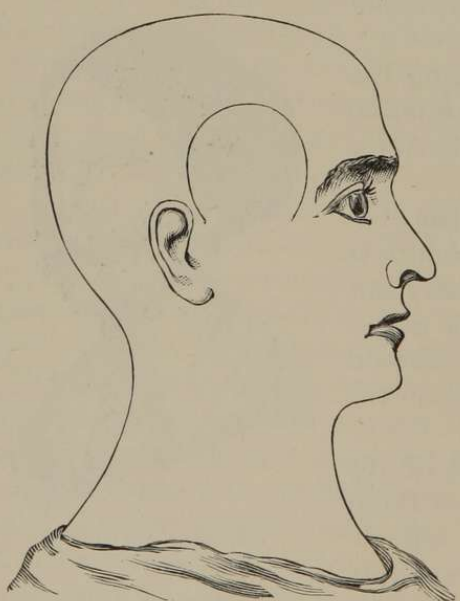

Fig. 597.—(After Hartley.)

The side of the head being thoroughly shaved and cleansed, a horse-shoe-shaped incision is made (Fig. 597). The extremities of the incision rest on a line drawn from the external angular process of the frontal bone and the tragus of the ear, the highest point of this incision reaching the supra-temporal ridge, the diameter of the circle being about three inches. The incision is carried down to the periosteum of the skull in all portions except one inch above the zygoma. The divided soft tissues are retracted, and with a small curved chisel a groove is cut in the bone corresponding to the divided periosteum and extending only to the vitreous plate, except at the highest point of the rounded portion, where the entire thickness of the skull is removed sufficiently to admit the point of an elevator. A periosteal elevator is here inserted and used as a lever to break the bone on a line between the

* "New York Medical Journal," March 19, 1892.

"corks" of the horseshoe incision. In this way a "trap-door" flap, consisting of skin, muscle, periosteum, and bone, is turned down, exposing the dura mater over a circular area three inches in extent. A catgut ligature is now thrown around the middle meningeal artery, the dura carefully lifted from the bone, and the floor of the middle fossa of the skull exposed. Broad retractors are used to lift the dura with the brain, in order to expose the round and oval foramina. Any hæmorrhage which occurs can be stopped by pressure with sponges. The second and third divisions of the fifth nerve should now be isolated at their respective foramina, and by slight pressure the dura mater can be stripped from the nerve to beyond the ganglion of Gasser. With a tenotomy knife the nerve should be cut at the foramina, and that portion between these points and a point on the central side of the Gasserian ganglion excised. Care should be taken not to injure the third, fourth, and sixth nerves, which are in close proximity. A good-sized catgut twist drainage is put in and allowed to come out at the lower angle of the wound. The trap-door flap of bone, muscle, and periosteum is now placed in position and stitched with catgut sutures. Hartley has used the same method in exploring the posterior fossa, in a case of suppurating meningitis following otitis media.

It is not now considered necessary to restore the bone, but to cut it away in bits to an extent sufficient to give all room required for the operation. An observation of Tiffany is of great practical value. He noticed that, when first opening the cranium, the brain entirely filled the cavity, and the dura appeared tense, due to the presence of cerebro-spinal fluid. He punctured the dura and evacuated the fluid, "after which the brain fell quite away from the field of operation and the dura mater rested, wrinkled, on the surface of the brain, as a sheet loosely thrown over a bed." In removing the nerve, he begins with the second division. Separating the dura from it, he passes a ligature around it with a long aneurism needle with a short curve, then strips back the dura to reach the third division and the ganglion. A similar ligature is passed around the third division. With gentle traction upon the ligature, with a long, sharp curette he separates the nerves and takes away the adjacent portion of the ganglion, dividing the nerves at the round and oval foramina last. In none of his cases has there been injury to the *third* cranial nerve, and all recovered. In one case, fourteen months after the operation, the anæsthesia was disappearing. The sense of taste was preserved after division of the second and third nerves. Sensations of heat and cold were appreciable after division of these nerves of ordinary sensation. He suggests the use of the electrode to recognize and avoid section of the motor branch of the third division of the fifth nerve.

The Lower Jaw.

Infectious ostitis of the inferior maxilla is of frequent occurrence.

Various forms of fibroma, fibro-myxoma, encysted fibroma, enchondroma, and, in rare instances, angioma, have been observed in this bone, but of new formations sarcoma is most frequent. Cystic formations

resulting from failure of normal development of the teeth are not uncommon.

Ostitis occurs most frequently in children. It is usually secondary to disease of the teeth, and in very rare instances is caused by inhalation of the fumes of phosphorus. While this process may be located at any portion of the jaw, the neighborhood of the angle seems to be most frequently affected.

The *symptoms* are pain, followed by swelling of the jaw and contiguous soft tissue, ending in abscess, which, if left alone, eventually opens and discharges.

Treatment.—As soon as the character of the disease is evident, an incision or puncture should be made through the overlying tissues and periosteum, in order to give free exit to pus and loose particles of bone. The operation for removal of the dead bone may be delayed for several weeks until exfoliation has taken place. Diligent effort should be made to reach the diseased bone from within the mouth, and this can be done in a large proportion of cases. With the patient well over on the side the blood will flow out and not interfere with the larynx. Incision, when necessary, should always be made below the line of the jaw if this is feasible, so that the resulting scar will be less apparent. Usually by following the track of the abscess it will lead directly to the dead bone surrounded by an *involucrum.* This often requires to be chiseled or forced open to allow the extraction of the *sequestrum*, which may be readily removed with ordinary bone- or dressing-forceps. The cavity should be well scraped with a Volkmann's spoon, a drainage tube left in, and the edges of the wound adjusted with silk sutures. The deformity due to the rich deposit of callus disappears with the absorption of this material. When all or any portion of the entire thickness of the jaw requires removal for ostitis, the subperiosteal operation is imperative, since by this means alone is it possible to have a reproduction of the bone. The method of procedure, when the bone is the seat of a neoplasm, depends upon the character of the new formation. If there is any doubt as to the benign character of the tumor, a piece should be removed and examined microscopically before operation.

FIG. 598.—Complete removal by disarticulation of the right half of the lower jaw from within the mouth. Six months after operation.

In sarcoma, cancer, and enchondroma of the jaw, the subperiosteal operation can not be performed, since the sound tissues must be included in the ablation, in order to secure immunity from recurrence. Enchondroma, though not intrinsically malignant, tends to recur if not freely excised.

Operation.—When it is safe and possible, the diseased portion of the lower jaw should be removed without breaking the continuity of the bone. If a portion of the entire thickness of the organ is removed, the

tendency to displacement is inward, thereby interfering with mastication. The entire thickness of the jaw should be included in exsection for malignant neoplasm.

Resection of the lower jaw may be accomplished from within the buccal cavity, as done by J. Marion Sims in 1845 ("American Journal of the Medical Sciences," October, 1847).

Dr. Sims writes: "There are several considerations to recommend this operation in preference to the usual one with its extensive incisions: (1) There is no external mutilation; (2) as the third branch of the fifth pair of nerves was divided at the outset of the operation, its subsequent stages were comparatively free from pain; (3) as no important blood vessels are cut, no ligatures are required; (4) there is no trouble with the after-treatment; (5) it is just as easy of performance as the old operation."

Fig. 599.—Osteo-sarcoma of inferior maxilla. Disarticulation from within the mouth.

I have in women twice performed the operation of dividing the inferior maxilla in the middle line at the chin with the wire saw, and disarticulating at the temporo-maxillary joint without external incision. These are the only two operations of this character on record within my knowledge. In one case the disease was osteo-myelitis, and the operation was practically subperiosteal. Hæmorrhage was insignificant. The patient recovered with very slight deformity, as shown in Fig. 598. In these cases, as soon as the diseased jawbone is removed, in order to prevent displacement of the remaining portion toward the median line, it should be wired to the teeth of the upper jaw and held in proper position until the wound of operation has healed enough to permit the insertion of an artificial apparatus.



Fig. 600.—One year after operation.

In the second case the same operation was successfully performed for osteo-sarcoma, in which the disease was as yet entirely confined to the central portion of the left half of the inferior maxilla (Fig. 599). No effort was made at subperiosteal removal, as it was essential to freely dissect away with the mass the soft tissues on either side. The girl recovered, and one year after the operation there was no sign of a recurrence, and very slight deformity (Fig. 600). The danger from hæmor-

rhage is slight, and the flow of blood into the larynx can be easily prevented by placing the patient upon the side corresponding to that on which the operation is to be performed, keeping the mouth well open with retractors, and the head tilted in such a position that the blood runs freely out of the mouth. Silk-suture retractors inserted through the lip at various points in the entire circumference of the mouth will stretch this orifice and materially aid in rapidity of the operation. As soon as the disarticulation is completed the wound should be tightly packed with sterile gauze, in order to arrest hæmorrhage. When the danger of bleeding is past, usually in forty-eight hours, the packing should be removed, and not replaced.



Fig. 601.—(After Roser.)

If there is extensive malignant disease and the attachments to the soft parts are firm, the intra-oral operation is not indicated, and external incision is necessary. The simplest method is an incision from the angle of the mouth directly outward and slightly downward, avoiding Steno's duct. The soft tissues can be dissected off and division made in the median line with the saw or forceps, and the disarticulation at the temporo-maxillary joint effected. In certain cases the incision of Roser (Fig. 601) through the median line in front of the chin and underneath the jaw may be employed, since the scar is somewhat less prominent in this position than when made directly across the face.

In all formidable operations about the mouth where rapid work is imperative, chloroform is to be preferred as the anæsthetic.

Resection of the inferior dental nerve may be performed at the mental foramen, or at the commencement of the dental canal at the angle of the jaw.

The *mental foramen* is situated about halfway between the inferior border of the bone and the alveolus. A line let fall perpendicularly from the interspace between the two bicuspid teeth of the lower jaw will pass over the opening. A curved or crucial incision will expose the nerve at this point.

The foramen of entrance of the inferior dental nerve is very near the center of the quadrilateral formed by the anterior and posterior margins of the ramus, the lower horizontal border of the angle, and an imaginary horizontal line on a level with the lowest portion of the sigmoid notch.

An incision about two inches long and slightly curved is made so that its middle will be about the center of the parallelogram above de-

scribed. The trephine should be applied over the center of the quadrilateral. The best indication of having reached the nerve is the bleeding through the track of the trephine when it passes into the cancellous tissue of the jaw. This comes from the wounded inferior dental vessels. An elevator placed in the cut will now lift the button of bone, and expose the nerve. The entire portion in the limit of the trephine should be excised. Temporary relief is almost invariably secured, although a recurrence of pain is not uncommon after several months. As before stated, the exsection of the Gasserian ganglion is the final resort.

Anchylosis.—Motion of the jaw may be limited or entirely prevented by muscular rigidity, cicatricial contractions, or true anchylosis at the temporo-maxillary articulation.

The area of motion in partial anchylosis may be increased by forcible separation of the lower from the upper jaw by the mouth gag or screw. This should be repeated at frequent intervals, gradually increasing the pressure. In severe cases a false joint may be successfully established by section of the bone anterior to the point of fixation, usually at or above the angle. Care must be taken to make frequent passive motion in order to prevent bony union at the point of section.

The Teeth.

Extraction.—Dental forceps should be of different patterns, the jaws bent at various angles to the shaft, and the handles large enough to be grasped firmly and securely by the operator.

The gum immediately around the neck of the tooth should be freely incised with a lancet, since if this precaution is not taken it may be unnecessarily torn away with the tooth. The injection of cocaine around the tooth will render the cutting painless. The jaws of the forceps are applied on either side of the neck, and forced down toward the root until they grasp the tooth firmly, and yet not forcibly enough to cause crushing, at the margin of its alveolar insertion. The direction of traction is determined by the normal direction of the axis of the tooth. In extracting the incisors and canine teeth, the forceps represented in Figs. 602 and 603 are applied as described above, and, when firmly fixed, a slight forward and backward movement, with limited rotation, will loosen the root, while traction should at the same time be made in a direction upward and slightly forward for the lower jaw, and downward for the teeth of the upper row. For the bicuspids and molars, the instruments shown in Figs. 604, 605, and 606 are preferable.

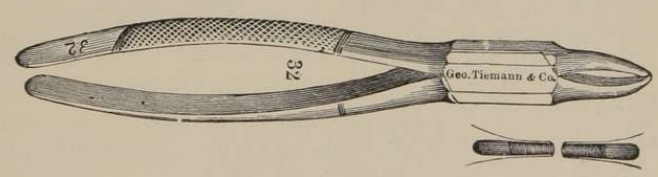

Fig. 602.—Incisor, straight root.

Fig. 603.—Incisor, half-curved root.

The bicuspids and molars may be loosened by lateral motion or rocking. The direction of traction is slightly inward for the lower teeth, and slightly outward for those of the upper jaw.

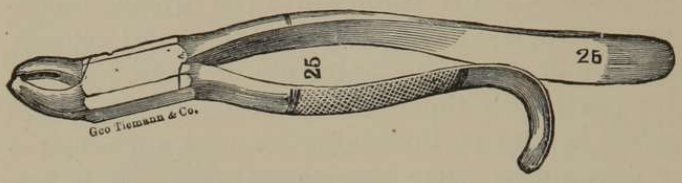

Fig. 604.—Wolverton's upper bicuspids.

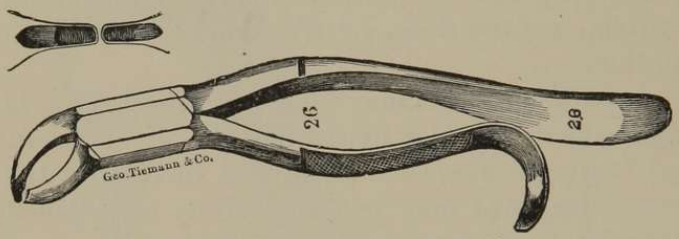

Fig. 605.—Wolverton's lower bicuspids.

Fracture of a root or shelving of the alveolus will occur at times in the most skillful hands, and abscess and necrosis may ensue. Fragments of the teeth should be gouged out by using an elevator. Hæmorrhage, usually insignificant, may at times be dangerous, death having occurred from this cause in one or more instances. Cold or heat, or packing the cavity with a compress of cotton or lint, will effect its arrest. In extreme cases the compress may be saturated with Monsel's solution, or alum, or any astringent, and left in for forty-eight hours. Anæsthetics may be employed with great safety in dental surgery. Nitrous oxide is of every-day use, and ether is safe and effective. A considerable number of fatal cases are recorded in which chloroform had been administered in extracting teeth. The same rules should offer in selecting the anæsthetics as for other surgical procedures. The patient should be placed in the recumbent posture for either anæsthetic. Careful attention to the teeth and gums is an essential feature of preventive medicine. Malignant neoplasms are frequently caused by the irritation from projecting teeth. Tuberculous and pyogenic infection is a common occurrence from exposed abrasions in the mouth.

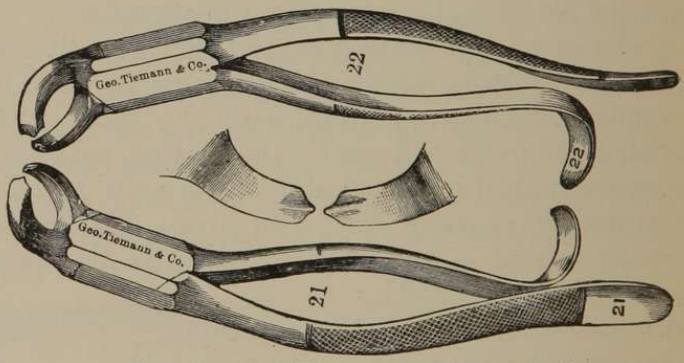

Fig. 606.—Harris's lower molars, for the two sides.

The Palate.

Uvula.—On account of elongation or hypertrophy of this portion of the soft palate, its excision is at times required. It may be accomplished by taking hold of the tip with a mouse-tooth forceps, and with a long curved scissors removing as much as required. Local anæsthesia may be obtained by mopping the uvula with a small quantity of a 4-per-cent

solution of cocaine hydrochlorate at intervals of three minutes for fifteen minutes before the operation.

Tumors of the palate, abscess, necrosis, and ulceration are not infrequent, and demand the same treatment as in other portions of the body.

Malignant neoplasms of the palate should be thoroughly destroyed by the Paquelin cautery. In two cases which came under my care this was done with no recurrence in five years and one year respectively.

Cleft palate may be confined to the soft palate ; it may include with this a portion or all of the hard palate and alveolus, or it may be confined to the hard palate alone. In exceptional cases there is no cleft in the soft structures while the bones in front are separated. It is usually congenital, although it may be acquired, as in the perforations which ensue as a result of syphilitic ulceration and necrosis.

The cleft in the hard palate is most often single, the vomer being attached to one side of the palate process of the superior maxilla (Fig. 561). Occasionally it is double, there being a central piece—the vomer—which runs forward and is attached to the pre-maxillary bone (Fig. 562).

Treatment.—The treatment of cleft palate is operative and mechanical. The earlier children are operated upon the better. As described in the operation for harelip, the anterior bony cleft should first be closed after the method given. If the child is well nourished and in fair general condition, this should be done in the first six or eight weeks after birth. The cleft in the soft palate is more difficult to deal with in young infants, and operative measures upon this portion may with propriety be deferred until the child is one year old. By this time the anterior cleft and the harelip have been relieved by operation. The union of the posterior cleft (soft palate) should always, when possible, be effected before the child learns to use articulate language. If done later than this period, the subject will have to unlearn the acquired false articulation. Moreover, if operation is too long delayed, the palate muscle, naturally deficient, will undergo further atrophy, as the result of disuse. It is well to state that there is in many cases such a normal failure of development in these muscles that they can not be made to stretch across the gap and restore the *velum pendulum palati* without shortening the soft palate to such an extent that the subject is unable to completely close the upper vault of the pharynx. In these cases articulation will always be defective.

In children, chloroform should be used ; in adults, a sufficient degree of local anæsthesia may be obtained by the employment of hydrochlorate of cocaine to enable the operation to be done with the very valuable aid of the patient.

In a case operated upon by myself, the parts to be incised were brushed over with a 4-per-cent solution of cocaine at intervals of two or three minutes for half an hour preceding, and about every five minutes during, the operation. The anæsthesia was perfectly satisfactory, and complete union resulted after the first operation. The normal Schleich solution may be injected as required.

Operation of Staphylorrhaphy.—The first object in this operation is to keep the mouth of the patient widely opened. For this purpose I prefer Goodwillie's gag. The tongue may be depressed with a spatula if necessary. When an anæsthetic is employed, the narcosis should not be profound, for, if laryngeal sensibility is completely lost, blood or mucus may pass into the larynx and trachea instead of being swallowed. The patient's head being firmly held by an assistant, the soft palate is seized by a mouse-tooth fixation forceps, and with a blunt-pointed, long, narrow knife a strip about one eighth to one sixteenth of an inch wide is removed from the edges of the fissure, in its entire length (Fig. 607). The entire margin of the cleft must be carefully freshened, for if any point is left uncut union will fail. The bleeding is next arrested by small sponges, on staffs, dipped in hot water and squeezed dry.

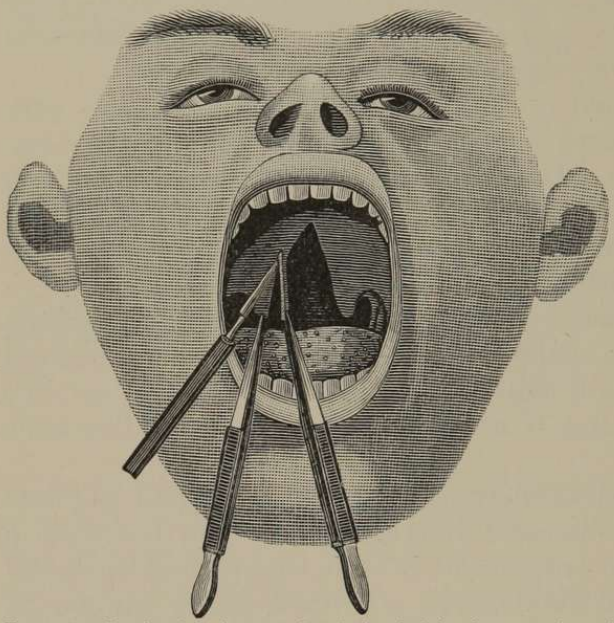

Fig. 607.—Freshening the margin of the cleft in the operation of staphylorrhaphy. (After Malgaigne.)

In uniting the freshened edges, Dr. Goodwillie's hollow needle (Fig. 608) is a useful instrument, while the silkworm-gut suture leaves nothing to be desired in this operation.

To the shaft adjust one of the needles which, from its shape, is best adapted to the peculiar form of the fissure to be closed, and push one of the silkworm bristles through from the butt to the point until it projects, and then draw it back one eighth of an inch within the eye of the needle. Seize the edge of the flap with the forceps, and at a point between one

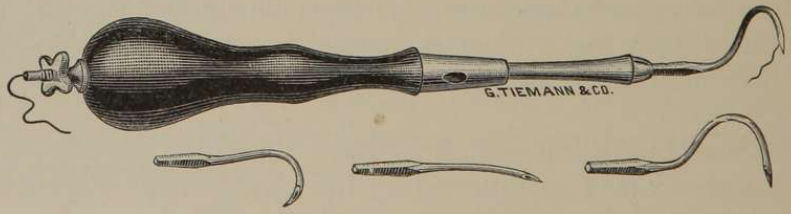

Fig. 608.—Goodwillie's hollow needle for silkworm-gut suture in the closure of cleft palate.

eighth and one fourth of an inch from the freshened margin of the fissure insert the needle from before backward, through the side corresponding to the operator's right hand (left side of the patient), and then through the opposite side, at a like point from behind forward. In order to facilitate the passage of the needle, the flap must be held steadily with the forceps. As soon as the needle has transfixed the second flap and

the eye is visible, the operator pushes on the bristle at the butt of the needleholder, causing the other end to come out of the eye of the needle, when it is seized with the forceps and drawn forward. Holding this end firmly, the needle is withdrawn, leaving the suture in position. The ends of this are now fastened together with a perforated shot, and held aside until all are inserted. The sutures should be about one fourth of an inch apart. When the last one is inserted, the operator ties one after another from above downward. The first knot is single, and this is run down tight and repeated with two additional knots to secure it. The ends are then cut off, one fourth of an inch from the knot. This material ties easily, does not slip or break, is not absorbable, and holds its place until removed.

A smaller spiral needle (not canulated) with the eye at the point is at times preferable when the strip of tissue is narrow. It is threaded and carried through one or both sides, the end of the suture grasped with forceps, and the needle withdrawn.

After the sutures are tied it will be observed that (as a result of the fissure, the levator palati and palato-pharyngeus muscles being shortened) there is now marked tension of the soft palate, which, if not relieved, will pull upon the sutures and cause separation of the edges of the wound. To obviate this, a sharp knife is thrust through the palate, about the center of the posterior margin of the horizontal plate of the palate bone of that side, and an incision made, in a direction downward and outward, to within from one fourth to one half of an inch from the free border of the palate, near the hamular process, as in Fig. 609. This incision divides the levator palati of either side. The anterior and posterior pillars of the fauces should also be snipped with dull-pointed scissors. All of these wounds close later by granulation. It is important to keep the muscles of this region at rest for ten days after the operation.

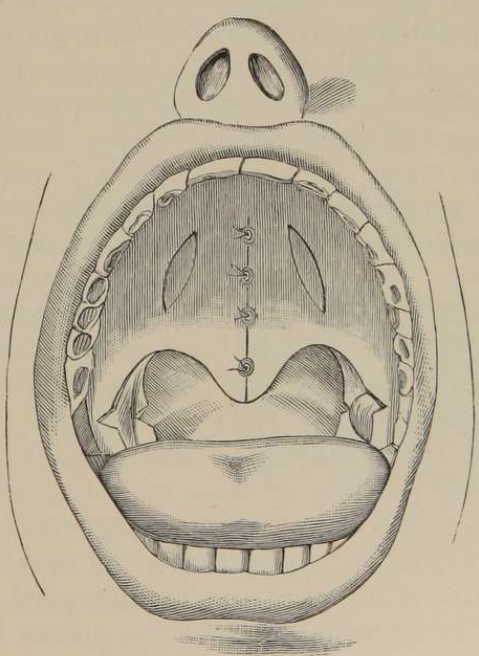

Fig. 609.—(After Agnew.)

When the cleft extends into the hard palate, as shown in Fig. 610, the fissure may be closed by sliding the membrane lining the vault of the palate.

The edges of the fissured soft palate are freshened, as in the preceding operation. Along the edges of the bony fissure an incision (*a b*, Fig. 610) is made with a knife shaped like a gum lancet, and, by the aid of curved elevators, the membrane lining the bony palate is carefully lifted with the periosteum. Another incision is now made on either side of the fissure, close to and parallel with the junction of the alveolus

with the palate processes, *A B*, through which the elevator is again introduced, and the periosteum lifted until the whole flap included between *B A* and the edges of the fissure *a b* is detached. When the roof of the mouth recedes sharply from the gum to the edge of the fissure it will be easier to insert the elevator along the lateral incision and lift the lining membrane until the instrument projects in the fissure. If severe hæmorrhage follows the incision, the wound should be temporarily packed with gauze, or pressure with the finger may arrest the bleeding.

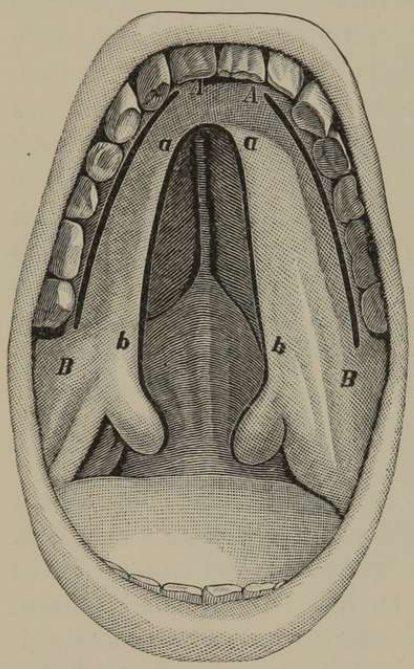

Fig. 610.—Incisions in sliding the periosteum for closure of the bony cleft. (Modified from Koenig.)

The flaps are now ready for sliding, and the sutures are introduced along the freshened edges, as in the preceding operation.

When the cleft extends still farther forward through the alveolus, and the fissure is wide, it will become necessary to carry the palate processes toward the median line by an osteoplastic operation. One method has already been given in treating of harelip. The following may be found applicable in some instances, and was recommended by the late Prof. D. Hayes Agnew. In this procedure no effort is made at lifting the periosteum, and it is better to attempt the approximation of only one portion of the cleft at a sitting. In order to secure all the nutrition possible the soft palate should be first united. The anterior or posterior portion of the bony fissure may be closed at the next operation, as follows: Freshen the edges of the soft parts along the fissure. Drill two holes through the bony palate of either side, one fourth of an inch distant from the edges to be approximated, and insert two strong silver wires, as shown in Fig. 611. On either side, close to and parallel with the alveolus, make two incisions through to the bone, as at *A B* (Fig. 610), and drill with an awl a series of holes in the track of these incisions. A few strokes of a small chisel will now break the palate processes in a line with the holes, when, by twisting the wires, the loosened plates will be approximated in the median line. After union has occurred in this portion of the cleft, the operation may be completed in the anterior portion, by drilling the palate and alveolus, and breaking this last through from the front with a chisel, approximating the sides as above, or by forming a complete alveolar arch as given in the section on harelip.

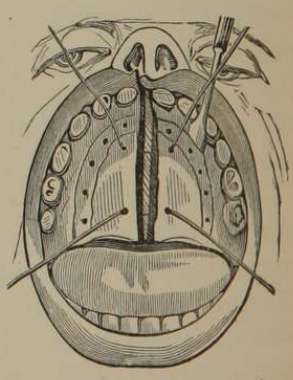

Fig. 611.—(After Agnew.)

Perforations of the palate are treated practically in the same way as congenital cleft, by freshening the edges, and, if necessary, sliding the periosteum, as above given.

The Tongue and Buccal Cavity.

Wounds of the tongue bleed profusely, especially if the larger vessels along its under surface are divided. The arrest of hæmorrhage is easily and safely accomplished by introducing the index finger back over the dorsum to the root of the tongue, and bringing the organ forward and forcibly compressing it against the symphysis menti. The tip of the organ should be turned upward, and the forceps applied at the bleeding points. In the substance of the tongue the vessels are also readily secured in the same manner. Should any difficulty arise, a silk thread may be carried around the bleeding vessel by means of a curved needle, or it may be transfixed with a tenaculum and the thread tied around the hook.

Glossitis—Hemiglossitis.—Inflammation of the tongue may result from the same causes and assume all the phases of inflammation common to the soft tissues in other portions of the body. It may be acute or chronic, ending in ulceration or hypertrophy. The process may begin superficially, as after the ingestion of some irritating substance, or it may commence in the deeper portions of the organ as a diffuse phlegmonous process. In some instances only one lateral half of the organ is involved.

Treatment.—Inflammation of the tongue from any cause should be closely watched, on account of the danger of asphyxia from rapid enlargement of this organ. In this emergency tracheotomy should be performed. If abscess forms, incision or puncture is demanded. Scarification may be required in rapid enlargement of this organ from engorgement of the vessels.

Hypertrophy of the tongue is both congenital and acquired. It may exist in adult life, although it is in general a condition of childhood. The enlargement is due to hypertrophy of the lymphatic plexuses of this organ and to a general hyperplasia of the connective-tissue elements. The muscular substance undergoes granular metamorphosis. The cause of this disease is not understood. The organ may become so large that it protrudes from the mouth, pushes the teeth out of their normal position, and interferes with deglutition and respiration to such an extent that its partial or complete removal becomes necessary. In a child of twelve years with congenital macroglossia tremendous hæmorrhage occurred in an effort at removal. Not only was the operation discontinued, but intravenous injection of salt solution was necessary to prevent a fatal issue. Cystic tumors of the tongue may be mistaken for hypertrophy. A diagnosis may be made by exploration with a good-sized aspirator needle.

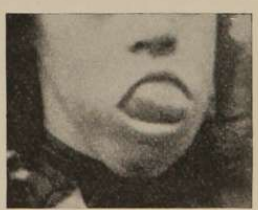

Fig. 612.—Author's case of macroglossia.

In mild cases deligation of the lingual artery of one or both sides may be done, and this may be followed by excision of a portion of the organ. The tip may be amputated, or a triangular section may be removed from the central portion, the sides being brought together by sutures.

Atrophy is a rare disease, and is due to diminution of the blood supply, or to lesions of the trophic nerves of this organ.

Cystic tumors of the tongue may be caused by closure of the outlet to any portion of the follicular apparatus (retention cysts), or less frequently by the lodgment in this organ of a parasite, the *cysticercus.*

The *diagnosis* is made positive by exploration. The *treatment* required is excision of the sac with the scissors, or the less bloody operation of opening it with the Paquelin cautery, burning the lining membrane thoroughly, and packing the cavity with iodoformized gauze. The precaution should be taken to make the packing from one piece of gauze, and of securing it by a thread attached outside, in order to prevent its accidental escape backward.

Angioma of the tongue is rare. When present, the treatment is removal by the ligature.

Abscess of the tongue should be treated by aspiration, and hyperdistention of the sac with 1-to-3,000 sublimate solution immediately withdrawn. If this does not succeed, an incision should be made and drainage secured.

Ulcers of the tongue appear as a symptom of various conditions. They occur in syphilis with frequency. They may occur as a result of general catarrh of the pharynx and mouth, or as a result of any violence. If an ulcer exists as an expression of a dyscrasia, the treatment must be chiefly constitutional. The local treatment consists in cleanliness and the application of nitrate of silver, or other stimulating remedies.

The tongue is at times the seat of *papilloma*, *lipoma*, *fibroma*, *sarcoma*, and one or two instances of *enchondroma* in this organ are reported. *Epithelioma* is not infrequent, and is the most important of the neoplasms of this organ, not only on account of its greater frequency, but also on account of its grave character and the necessity of arriving at an early diagnosis. The late manifestations of syphilis (ulcers, gumma, fissures), ulcers of tuberculosis, and some specific ulcers, and papilloma, may be mistaken for this neoplasm.

If a patient has a syphilitic history, gumma or specific ulcer will naturally be suspected. If large doses of potassium iodide be administered for two or three weeks, the specific ulcer will respond to this remedy. If no impression is made upon it, it should be treated as malignant. As regards all other suspicious sores of this organ, it will be the wiser practice to treat them also as malignant growths, for it is a well-recognized fact that papillomatous, tuberculous, and simple ulcers of the tongue (as elsewhere), chronic in character, are capable of transformation into epithelioma. If these sores are removed early in their history, no mutilation is required, the operation is without danger, only

a small portion of the organ need be sacrificed, and the focus of disease is removed before its malignant nature is declared or metastasis occurs. If an epitheliomatous ulcer exists, its character may be determined by microscopical examination, as given by Butlin.* If the scraping from a tuberculous, syphilitic, or simple ulcer is placed in a drop of water on a slide, pus- and blood-corpuscles, particles of food, bacteria, and a few normal or almost normal epithelial cells are observed. If the scraping from an epitheliomatous ulcer be examined, in addition to the above will be seen a great number of abnormal epithelia, varying in size and shape, some flattened scales, others round or oval, others elongated, with caudate prolongations. The cells are generally granular, and possess from two to three or more nuclei, much larger than the normal nuclei of these cells. In some instances the "swallow's-nest" arrangement may be observed.

If no ulcer is present, a section for microscopical examination may be removed from the indurated mass.

Operation.—The method of procedure must be determined by the extent of the organ to be removed. If the induration is confined to the tip, and does not extend more than one inch behind this point, the line of section should be at or near the center of the tongue. It should always be well away from the disease. An inch from the nearest induration will be safer than to allow the line of section to approach the neoplasm in order to save more of the tongue. When the lateral aspect of the anterior half is involved, the line of section need not pass at right angles to the axis of the organ, but may curve around parallel with the limit of induration at a sufficient distance from it. In this way the anterior portion of the opposite half may be, in part, preserved. If the floor of the mouth is infiltrated, it should be dissected from its attachments to the jaw, and the diseased part removed with the tongue. If the disease extends to the middle of the tongue, and involves its entire width, the organ should be removed at its base, and the floor of the mouth thoroughly cleared of all suspicious tissue. The lymphatics in the middle line below the symphysis menti, in the submaxillary region, and down the neck, should be examined and removed if metastasis has occurred.

When the floor of the mouth, together with the anterior two thirds of the organ, are involved, and metastasis is evident in the deeper lymphatics, the propriety of surgical interference is questionable. A cure is not probable, and the operation formidable and dangerous. The removal of the ulcerating portion may be done as a palliative measure.

In general, chloroform is preferable. It is essential for the teeth to be held widely separated by the gag, and the lips held out of the way by flat, blunt retractors.

When the tip of the tongue is to be removed the écraseur may be employed. It should be applied well posterior to the ulcer. Bleeding from the stump is controlled by forceps and silk ligatures.

* "Diseases of the Tongue," Lea Brothers & Co., Philadelphia, 1885.

When a more extensive operation is required, the following method will be advisable:

A strong silk thread should be passed through the sound tissues of the tongue near the end and intrusted to an assistant. It is to be used in lifting the organ as the dissection proceeds. The attachment along the lower jaw should first be divided with the scissors or knife and the tissues dissected up until the tongue can be lifted freely to a point at least one inch behind the induration. The écraseur loop should now be placed around the organ and the division made. Any bleeding points on the stump can be readily seized with the long-nosed narrow forceps and tied with silk ligatures. In the after-treatment no dressing is applied to the wound in the mouth.

If, for any reason, more space is required in the ablation of this organ than can be obtained through the natural orifice, one of the following procedures may be adopted :

1. *Gant's* incision through the cheek, from the angle of the mouth in the direction of the lobe of the ear as far as required (Fig. 613, *a*). This incision gives a full view of the lateral aspect of the tongue, and may be made upon both sides when the disease is bilateral and extends beyond the middle of the organ. The edges of the wound are afterward brought together by silk sutures.

2. *Billroth* employs a curved incision made parallel with the arch of the inferior maxilla below the symphysis (Fig. 614), dividing all the tissues on this line until the floor of the mouth is opened.

3. *Kocher* has lately devised an operation the incision in which is shown by the line *b d e c* (Fig. 613). A preliminary tracheotomy is done and the pharynx stuffed with a carbolized sponge to which a string is attached. The excision extends along the anterior border of the sterno-mastoid muscle, from the level of the lobule of the ear to the level of the hyoid bone, along this bone to near the median line, and thence to the symphysis menti. The skin and platysma are turned up on the jaw, the lingual and facial arteries and veins are tied as they are encountered, all enlarged glands are extirpated, and the muscles and floor of the mouth separated along the attachments to the lower jaw to any required extent. If the entire tongue is to be removed, the opposite lingual is also tied. Through this opening the tongue is drawn out, dissected from its anterior and lateral attachments, surrounded with the cautery loop and divided, or cut off with the écraseur or scissors.

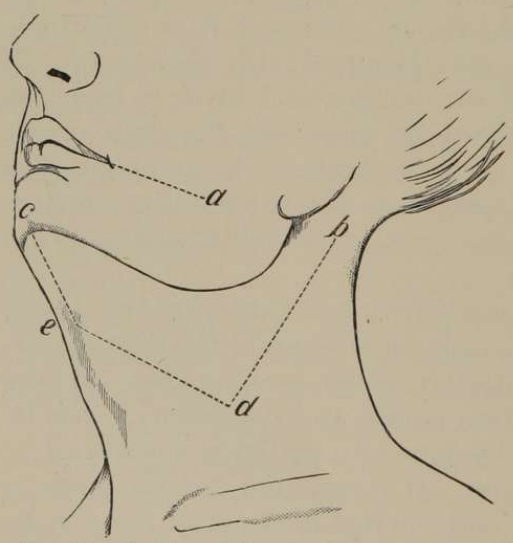

Fig. 613.—Incision of Gant and Kocher. (After Butlin.)

In the after-treatment the trachea tube is left in place, and the pharynx, mouth, and wound filled with sponges dipped in a 5-per-cent carbolic-acid solution, the excess of the acid being washed off with water before the sponges are applied. The wound is dressed twice a day, and liquid nourishment given at each change of the dressing.

The operation of Kocher is objectionable on account of the extent of the dissection, the danger of submitting such a large wound to the probability of septic infection from the mouth, and the complication of tracheotomy, which lastoperation is not necessary. The free inspection of the tissues of the neck which it permits, and the command of the base of the tongue which it allows, are in its favor.

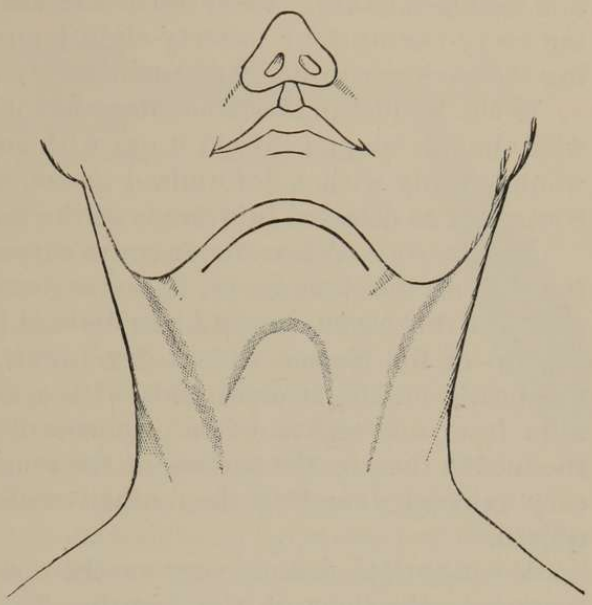

Fig. 614.—Billroth's incision. (After Butlin.)

The preliminary ligation of the lingual arteries prolongs the operation. The bleeding points can be readily secured, as the dissection is being made.

The operations in which the organ is removed through the mouth are simpler, and require much less time in execution. Extreme cases only call for the operations of Gant, Billroth, or Kocher.

The after-treatment consists in rinsing the mouth at frequent intervals with a warm solution of permanganate of potassa (gr. ss. to ℥j), anodynes to relieve pain, and generous liquid diet.

Ranula.—This name is applied to certain tumors, cystic in character, which are situated immediately beneath the anterior and lateral portions of the tongue. Ranula is usually acquired, although it may be congenital. The tumor is almost always single; occasionally there is one on either side of the organ. Commencing as a result of obstruction to the outlet of one of the subdivisions of the sublingual gland (rarely as a result of occlusion to one of the terminal ducts), it may grow, when left undisturbed, to great size, crowding the tongue out of its position, rising above the level of the teeth, and protruding through the muscles of the chin until it appears beneath the skin above the hyoid bone.

The treatment is to evacuate the contents and dissect out the sac or cause its obliteration by inflammatory adhesion. The Paquelin cautery is the best instrument to employ in removal. Etherize the patient, introduce the gag, lift the tongue upward with the forceps, protect the lips and teeth by means of flat retractors, seize the wall of the cyst with a mouse-tooth forceps, and with the platinum knife at a red heat dissect away the anterior wall. After the fluid escapes, dilate the cavity, and

make a thorough digital exploration of the sac. The cautery knife should now be carried slowly back to the deepest portions, searing all sides of the cyst wall. The wound should be well packed with a single piece of iodoformized gauze. The after-treatment consists in changing the packing every twenty-four to forty-eight hours, and at each dressing irrigating the cavity with 1-to-2,000 sublimate solution.

If the Paquelin thermo-cautery is not convenient, seize the cyst wall with the forceps and dissect it out with curved, blunt scissors. Pack the wound firmly with iodoformized gauze, as above. Hæmorrhage may be controlled as directed in wounds of the tongue.

Tongue-tie.—When the frænum extends an unusual distance toward the tip of the tongue, or is so narrow that it checks the free movements of this organ, it should be divided in the following manner: Seize the tip of the tongue with a dry towel, carry it upward so as to put the bridle on the stretch, and, with a curved scissors, divide the frænum from one eighth to one quarter of an inch nearer to the floor of the mouth than to the surface of the tongue. This precaution is necessary to avoid wounding the ranine vessels. The gag may be used if required.

A *congenital* defect, very rarely observed, is the adhesion of the tongue to the floor of the mouth. The adhesions should be broken up at birth, and the operation repeated daily until free mobility is secured.

Equally rare is the bifid or snake tongue, which results from arrest of development or failure of union of the two halves from which this organ is formed. The edges should be pared, and the two halves united in the median line by sutures.

Tonsils.—Acute tonsillitis is of very frequent occurrence, causing, in a varying degree, pain, difficulty of deglutition, and interference with phonation, deglutition, and respiration.

The *pathology* of this affection consists in dilatation of the blood and lymph vessels, emigration of leucocytes, and proliferation of the connective tissue and other cell elements of the tonsil. The gland rapidly enlarges, producing great tension of the pillars of the fauces, and projects toward the median line, at times filling the pharynx and crowding the velum upward and backward.

Acute tonsillitis may end in resolution, the gland rapidly diminishing to its normal size, or in ulceration or suppuration (abscess), or the acute process may subside into a chronic form of inflammation, which induces permanent hypertrophy of the organ.

The local *treatment* of acute tonsillitis consists in the application of hot water as a gargle, and scarification of these organs when the tension is sufficient to produce great pain. The internal administration of aconite tincture and quinine is highly recommended.

Abscess of the tonsil should be opened as soon as its presence is detected. The discharge of pus always brings great relief. If the symptoms lead to the suspicion of pus, exploration with the hypodermic aspirator needle should be made to determine the diagnosis. The internal

carotid artery and jugular vein are well back from the tonsil, on a level with the posterior wall of the pharynx.

The object in operating early is to prevent œdema of the glottis, which may occur when the abscess is large or situated behind the body of the tonsil. A more remote danger is rupture of the abscess during sleep, and escape of the contents into the larynx.

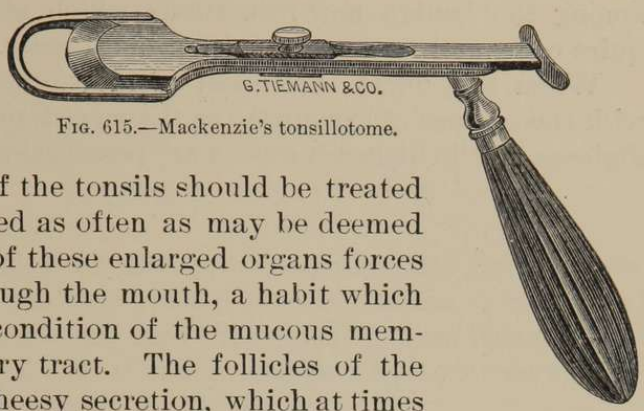

Fig. 615.—Mackenzie's tonsillotome.

Chronic hypertrophy of the tonsils should be treated by partial excision, repeated as often as may be deemed necessary. The presence of these enlarged organs forces the patient to breathe through the mouth, a habit which often induces a catarrhal condition of the mucous membrane lining the respiratory tract. The follicles of the tonsils discharge a dirty, cheesy secretion, which at times becomes retained in the gland and undergoes calcification. Calculi one fourth of an inch in diameter have been removed from this organ.

Tonsillotomy.—Excision of the tonsils is an operation practically free from danger. In children who can not control themselves, anæsthesia should be used, the gag introduced, and the tongue depressed by an assistant. The operator seizes the exposed portion of the organ with a long mouse-tooth forceps or a tenaculum, pulls it slightly toward the median line, and with a long-handled pair of scissors, curved on the flat,

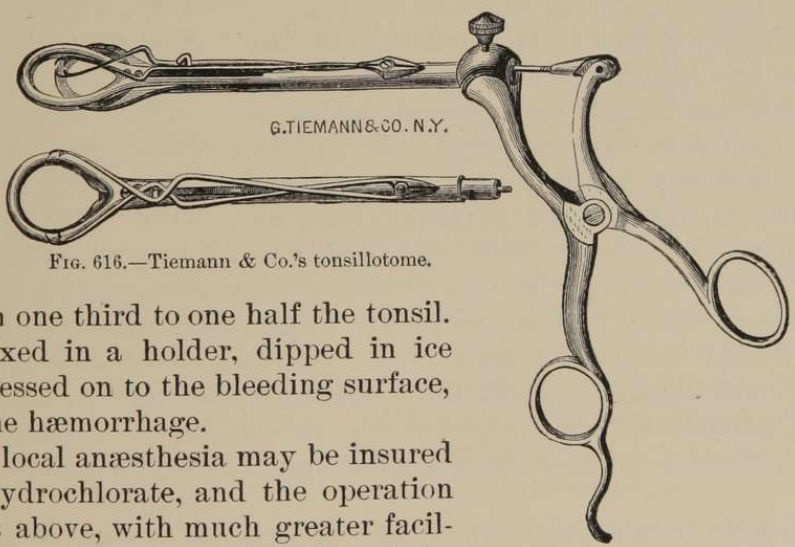

Fig. 616.—Tiemann & Co.'s tonsillotome.

clips off from one third to one half the tonsil. A sponge, fixed in a holder, dipped in ice water and pressed on to the bleeding surface, will arrest the hæmorrhage.

In adults local anæsthesia may be insured by cocaine hydrochlorate, and the operation performed as above, with much greater facility, since the intelligent co-operation of the patient is of great value. If the long scissors can not be had, a long, curved, probe-pointed bistoury may be used instead. The tonsil is lifted from its bed by a tenaculum, and the knife carried through as above.

Various tonsillotomes have been introduced, and for some cases are very useful, but for simplicity and general application the instruments above selected will answer all purposes. Among the best of the tonsil-

lotomes is that of Mackenzie (Fig. 615), and Tiemann's instrument (Fig. 616).

The tonsil is also occasionally the seat of malignant neoplasms, as sarcoma and carcinoma, while cystic tumors, fibroma, and lymphoma are among the benign new formations which attack this gland. They require early and thorough excision in all cases.

When this organ is the seat of inoperable sarcoma the inoculations with the toxines of erysipelas or the mixed products of the bacillus prodigiosus and Fehleisen's coccus are permissible.

CHAPTER XIX.

THE NECK.

Wounds.—Wounds of the neck may prove rapidly fatal from hæmorrhage inducing syncope; from hæmorrhage into the trachea, causing fatal asphyxia; from the entrance of air into the veins; or from injury to the cord, at or near the medulla. Death from sepsis may occur as a more or less remote sequence of a wound in this region.

Treatment.—The immediate indications are to arrest hæmorrhage at once, and prevent asphyxia, or the admission of air into the veins. Hæmorrhage should be controlled by pressure directly in the wound, until the injured vessels can be secured by the ligature. The entrance of air into the veins must be carefully prevented, by constant pressure on the cardiac side of the lesion, until the forceps have been successfully applied on the bleeding point.

When the wound is *incised* or *lacerated*, and is above the hyoid bone and has severed the hyoid muscles, in addition to the prevention of hæmorrhage into the larynx the tongue must be drawn forward, for when these muscles are divided it falls back upon the glottis, and may occlude the larynx. If the trachea is opened, the edges of the wound should be held apart with tenacula, the head dropped over the end of a table, any clots removed, and artificial respiration practiced by Sylvester's method. When the pneumogastric, hypoglossal, or other important nerves have been divided, the ends should be brought together by a delicate silk suture. It is also advisable to unite the ends of divided muscles by sutures. An incised wound of the œsophagus should be closed immediately. Lacerated wounds of this tube should be allowed to close by granulation. Difficulty in deglutition follows severe wounds of the throat, not infrequently necessitating the introduction of liquid food through the œsophageal tube, or feeding by the rectum.

Punctured wounds of the neck should be dressed antiseptically, and compression employed to arrest hæmorrhage. If this does not succeed, the ligature should be applied.

Gunshot wounds should be treated in practically the same manner. Missiles of small caliber deeply lodged should be left alone, since they usually become encapsuled and remain harmless. When superficial and readily detected, they should be extracted by the forceps. In the effort to locate a bullet it is always important to place the parts in about the same position as at the time when the missile penetrated. If this is not

done, the muscles and fascia become displaced, and the track of the wound obstructed. Gunshot wounds traversing the outer lateral and superficial posterior regions of the neck are not, as a rule, dangerous. If the vertebral column is involved, the prognosis becomes grave. A missile traversing the tissues of the neck laterally, and in front of the vertebral column, is apt to inflict fatal injury.

Abscess.—Abscess of the neck occurs most frequently in children. It is met with in infective adenitis, or periadenitis, tonsillitis, and in caries of the upper cervical vertebræ, or base of the skull (retro-pharyngeal abscess). Collections of pus in the upper cervical regions, and in the superficial portions of the root of the neck, tend to become encapsuled, or may open ultimately through the integument. Retro-pharyngeal abscess, if left alone, not infrequently travels downward along the deep fascia of the neck, and may open into the mediastinum.

The *diagnosis* of abscess in the neck, from the various tumors which are found in this region, depends upon the febrile movement present in abscess, the acute and persistent character of the pain, and fluctuation. The value of exploration, with an aspirator needle large enough to carry pus, should not be lost sight of in the effort to arrive at a positive diagnosis.

The *treatment* is evacuation, either by the method of aspiration and hyperdistention already given, or by puncture or incision, and free drainage. When the abscess is situated in a portion of the neck rich in vessels, it should be opened by cutting carefully down upon it, so that any hæmorrhage encountered may be immediately and readily controlled. If a puncture is determined upon, the knife should be introduced in the part farthest from the vessels, and along the aspirator or exploring needle as a guide. As soon as the sac is entered by the instrument it is withdrawn and a dull-pointed dressing forceps, tightly closed, is carried into the abscess, when, by forcible separation of the jaws, the puncture is enlarged.

The finger may now be introduced, or, if this can not be done, the forceps will indicate the size and most dependent portion of the sac. If the first opening has not been made at the lowest part of the abscess, or is not so situated that thorough drainage is secured, it should be enlarged so as to extend this far, or a counter-opening made by boring through with the forceps until the skin is distended over the point of the instrument, when it can be safely incised. Drainage should be maintained, and the cavity irrigated with 1-to-3,000 sublimate solution.

The *diagnosis* of retro-pharyngeal abscess depends upon the following symptoms: Pain, a feeling of soreness and stiffness in the neck, swelling, with protrusion of the posterior wall of the pharynx if the disease is high up, interference with deglutition and respiration. In the earlier stages all of these symptoms will not be present, but as soon as this dangerous condition is suspected an effort should be made to locate the abscess by palpation and aspiration.

In evacuating the pus an incision should be made in the pharynx, as near the median line as possible. When a large quantity of fluid is

present the head should be inclined downward as the incision is made, so that the contents of the abscess may not gravitate into the larynx. This danger may be obviated by partially emptying the sac by the aspirator before the incision is made. When the sac extends low down the neck it should be entered and drained from below. Deep retro-pharyngeal abscess may be reached, as a rule, by the incision and dissection laid down in the operation of *œsophagotomy*.

Phlegmon of the neck demands free incision in all cases, when such incision does not encroach upon the important organs of this region.

Tumors of the Neck—Solid and Cystic—Lymphoma.—Pathological changes in the lymphatics of the neck account for the large majority of swellings in this region. Lymphoma of the neck may be solid or cystic, benign or malignant.

Tumors of the cervical glands may comprise simple lymphoma, the result of hypertrophy and hyperplasia; tubercular lymphoma, lymphosarcoma, and lymphangiectasis.

Tubercular lymphoma occurs most frequently in the submaxillary and upper carotid triangle, and next in order of frequency along the line of the great vessels beneath the mastoideus, and lastly in the subclavian region. In some instances these tumors attain enormous proportions, filling in the neck to the level of the lower jaw and clavicle, and, if not removed, produce annoying pressure upon the respiratory apparatus or the œsophagus. They should be removed by operation at the earliest possible moment if a cure is to be effected. When left until they are of considerable size and numerous the prognosis even after thorough operation is unfavorable, since the infection in these cases will have passed already into the mediastinal and bronchial glands.

Excision is not indicated in the rare cases of lymphoma of the neck known as Billroth's disease. The local injection and internal administration of Fowler's solution is the proper treatment, the details of which are given elsewhere.

Fatty tumors are apt to occur upon the posterior aspect of the neck, and occasionally in the clavicular region. They are comparatively rare in the anterior and upper triangles.

Cystic Tumors.—Cysts of the neck are congenital and acquired.

Congenital cysts are rare. The form most frequently observed is that already mentioned as a dilatation and hypertrophy of the lymphatic vessels (lymphangiectasis). They are usually multilocular, and may extend deeply and, at times, assume enormous proportions.

Branchial cysts are occasionally met with as a congenital variety. They usually open somewhere near the middle line below the chin and about the thyroid cartilage, and discharge a small quantity of clear or slightly purulent fluid. The orifice occasionally becomes occluded, but again opens when a sufficient amount of fluid has accumulated. They can not be cured unless deep dissection follows them carefully to their connection with the tissues near the hyoid bone and base of the tongue. This may be done without difficulty, as the duct-wall is thickened and

cartilaginous to the touch. It may readily be seen by keeping the wound dry.

Acquired cysts are seen chiefly along the line of the mastoid muscles, having a tendency to occur in the neighborhood of the parotid gland, less frequently in the subclavian triangle.

Cysts resulting from extravasations of blood may also occur here, and occasionally distention of the bursæ in the thyro-hyoid region produces cystic tumors. They require thorough and careful dissection to secure the removal of the entire cyst-wall.

Thyroid Body.—Hypertrophy or hyperplasia of this organ may be partial or complete. All, or a part, of one lateral lobe is usually affected; less frequently the isthmus is alone involved. The offshoots of this body which are met with at times near the hyoid bone, near the inner edge of the sterno-mastoid muscle, and occasionally dipping down behind the œsophagus, may also become enlarged. *Goitre*, or *bronchocele*, attacks females more often than males. No climate or condition of living affords a positive immunity from this disease, although in certain localities, as in the valleys of Switzerland, it is frequently met with. The cause of goitre is unknown. It is prone to occur in those whose surroundings are damp and unwholesome and among the poorly fed. The influence of heredity is recognized in the occurrence of this disease in the children of patients affected with bronchocele.

A goitre may be *solid* or *cystic*. In solid goitre the enlargement may be caused by a general hypertrophy of the normal elements which compose this body, or some of these elements may undergo proliferation and increase at the expense of the others. When the tumor is hard and tense, it is called *fibrous* goitre, and in this form the chief pathological change is an increase in the connective-tissue elements of the stroma.

In *cystic* goitre the tumor is caused by the accumulation of a dark-brown fluid within the substance of the organ. There may be one or more separate collections of fluid, although a multilocular arrangement is most common.

The *diagnosis* of goitre is not difficult. The presence of a tumor in the region of the thyroid body, usually unilateral, occasionally bilateral, moving with the trachea in the act of deglutition, capable of very perceptible enlargement during coughing or any prolonged and violent expiratory effort, are symptoms which point quite clearly to bronchocele. As to determining the character of the tumor, one must depend upon palpation in great part, and also upon exploration with the aspirator. Fibrous goitre is dense, hard, very slightly elastic, often presenting irregularities in surface. Cystic bronchocele is round, smooth, elastic, movable, and, even when the capsule is greatly distended, fluctuation is perceptible. The use of the exploring needle, and the withdrawal of a portion of the fluid contents for microscopical examination, is important in diagnosis.

The fluid from a cystic goitre varies in color from amber to dark brown and almost black. Under the microscope crystals of cholesterin, crenated red blood-corpuscles, large compound granular cells, leuco-

cytes, etc., are seen. The characteristic contents of *hydatid cysts* are easily recognized and excluded. Fibro-cystic, or mixed goitres, possess some of the characteristics of both the foregoing varieties. The feeling of solidity is not so great as in the fibrous, and is less elastic and with a less appreciable sense of fluctuation than in cystic bronchocele.

Sarcoma and *carcinoma* of this organ are hard, solid tumors of rapid development, steadily increasing in size, and in their growth binding the invaded organ to the integument, muscles, and fascia of the neck. *Abscess* would have a previous history of inflammation, pain, and febrile movement. *Aneurism* of the carotid appears usually to the outer side of the thyroid region, and presents the symptoms of expansion with the heart's systole, the aneurismal thrill and murmur, all of which symptoms disappear after pressure upon the artery on the cardiac side of the tumor.

The diagnosis of other cervical tumors may be considered here. Tubercular lymphomata are recognized by their anatomical locations, and by their slow process of development.

In many instances these tumors of the glands remain quiet for a variable period, when pyogenic infection occurs, with the formation of acute abscess. They are found most frequently along the lower border of the inferior maxilla in the lower carotid region, along the under surface and posterior border of the sterno-mastoid muscle, and in the subclavian triangle.

Metastatic lymphoma, secondary to epithelioma or other malignant disease of the face, will be recognized by the history of the case. Lympho-sarcoma of the neck is, in its earlier stages of development, with difficulty differentiated from simple adenoma. It grows, however, with much greater rapidity, and, by its tendency to become fixed to the surrounding tissue, suggests its malignant nature. It is most usually located about the center of the neck and beneath the sterno-mastoid muscle.

Treatment.—Cystic goitre does not yield to constitutional measures. Solid tumors should be treated by the administration of full doses of potassium iodide. If marked diminution in the size of the tumor does not follow within the first few weeks of this treatment it should be discontinued.

Bronchocele, either solid or cystic, which is small in size and not perceptibly increasing, does not demand surgical interference. Such tumors should be kept under observation, and if at any time there is a marked increase in size operative interference is called for, before the mass has assumed such proportions that its removal involves considerable danger to life. According to Kocher, another contra-indication to surgical interference is the presence of a goitre involving the entire organ, since—although the operation may be recovered from—death results in from one to two years, from the development of a strumous condition not unlike that known as myxœdema. Physiological experiments have shown that a like condition results from the total extirpation of the thyroid body in animals. When complete extirpation is made the patient should be given thyroid extract in proper doses.

Another contra-indication is calcareous degeneration of a considerable portion of the mass, causing a condition of friability in the vessels which renders their deligation unsafe.

Operation—Cystic Goitre.—Make a perpendicular incision, about three inches in length, over the center of the tumor. Divide the integument, fascia, and intervening muscles down to the sac. Upon approaching this, the dissection should be carried on between two anatomical forceps, lifting only a thin bit of tissue at each grasp of the instruments, and looking closely for any vessels which may run upon or through the anterior wall of the tumor. When the wall is reached it should be divided in the same manner, and, upon the escape of the contents through the opening, this should be enlarged by introducing the dressing forceps and dilating. The opening in the wall should be about one inch long. A continuous catgut suture should be carried through the integument, stitching this to the edges of the sac. The cyst should now be well irrigated with boric-acid solution, and rubber drainage tubes introduced, one into the deepest and another in the upper portion of the sac. A loose aseptic dressing should be applied. The indications for changing the dressing are hæmorrhage, rise in temperature above 103°, and for purposes of cleanliness. In two of my cases in which large cysts were evacuated there was considerable febrile movement for the first week after the operation. As the cyst becomes filled with granulation tissue, the tubes should be gradually shortened.

In the removal of a solid unilateral goitre, a crucial incision is preferable. This should be very free, in order to give a full view of the wound. The dissection should expose the entire anterior surface of the mass before attempting to get beneath it at any point. Care must be taken not to tear or incise the substance of the tumor, since it bleeds profusely, and is often so friable that it will not hold a ligature. The object of the operator should be to get into the capsule of the tumor. Working with the dry dissector between this and the surface of the neoplasm much bleeding may be avoided. Whenever a vessel is seen in the track of the dissection, it should be seized in two places with the forceps (the narrow-jawed instrument is preferable), divided between them, and each end tied with stout catgut.

In lifting the tumor the operator should work along the outer side, and pass under the mass from this aspect. In this way the superior and inferior thyroid vessels may be ligatured in the earlier stages of the operation, and the chief source of bleeding controlled. The presence of the recurrent laryngeal nerves, as they pass upward on either side, in the space between the trachea and œsophagus, should not be forgotten. By keeping close to the capsule of the tumor the least risk will be incurred. The veins passing into the mass are at times of great size, and the walls of those in the tumor are in some cases very friable, causing much annoyance and delay, in repeatedly breaking down under the ligature and recurring hæmorrhage. In one of my cases the internal jugular vein was involved in the mass to such an extent that it was necessary to tie this vessel above and below, and divide it. When all of

the tumor is free, except the isthmus, this should be surrounded with a small elastic ligature, and divided. The edges of the wound are now closed with catgut, the drainage tube and rubber ligature brought out at the most dependent portion of the incision, and a sterile dressing applied. The ligature comes away by drawing upon it about the eighth day.

The *prognosis* from this operation is favorable in a large majority of cases. It only becomes grave in the larger tumors, and the chief element of gravity here is the exhausted condition of the patient, resulting from pressure of the mass. It must, however, be classed among the more formidable operations, although modern surgery has greatly reduced the death rate.

In the removal of double goitres, if the two tumors are of large size, the two operations may be done with an interval of two or three weeks, should the first operation be unavoidably prolonged. In the double simultaneous operation, the better incision is that of Kocher, whose magnificent achievements in thyroidectomy leave him unquestionably the first of surgeons in this field. It is Y-shaped, the oblique prongs running from below the ear on either side and uniting at the most convenient point near the pomum Adami in the middle line. Thence a single median incision extends down to and somewhat beyond the sternal notch. Reflecting the flaps, the masses are well exposed. The intra-capsular dissection should now be continued as just described.

Hydatid cysts are in very rare instances met with in this organ. They should be treated by incision and drainage, as laid down in the management of cystic goitre. When the tumor is of small size (two inches or less in diameter), aspiration and hyperdistention with boric-acid solution may be tried. The fluid should be at once withdrawn and compression maintained for several days.

In *carcinoma* and *sarcoma* of this body, complete thyroidectomy is demanded.

Exophthalmic Goitre—Basedow's or *Graves's Disease.*—In this disease the thyroid body is increased in size, chiefly due to the dilatation of the arteries and veins in its substance. There is a varying degree of hyperplasia of the glandular substance and the connective-tissue stroma. This condition is accompanied by violent chronic palpitation of the heart and protrusion of the eyeballs. The cause of this disease is not known. It is generally considered to be a nervous disorder. It is met with in women about twice as often as in men. After death the heart is found to be hypertrophied and dilated. The size of the thyroid tumor is greatly diminished after death, and the exophthalmos disappears. This form of goitre is rarely amenable to surgical treatment.

In the medical treatment of exophthalmic goitre the galvanic current directed to the sympathetic ganglia of the neck is highly recommended. The direct current is employed, one electrode being placed over the spines of the cervical vertebræ, while the other is passed over the enlarged thyroid from the sternum to the lower jaw.* This treatment

* Dr. Doughty, of Augusta, Ga., has met with gratifying results in this method of treatment.

should be supplemented by tonics, thyroid extract, out-of-door life, attention to increased nutrition of the tissues, and abstention from all violent exercise or excitement.

The Larynx and Trachea.

The operations upon these organs in the neck are *thyrotomy*, *laryngotomy*, *laryngo-tracheotomy*, *tracheotomy*, and *exsection* of the larynx or *laryngectomy*.

Thyrotomy is indicated in the removal of neoplasms or foreign bodies from the larynx, which can not be reached through the mouth by the aid of the laryngoscope and forceps or snare. The patient should be placed upon the table, with the head well depressed. Make a perpendicular incision from near the center of the hyoid bone, in the median line of the pomum Adami, as far down as the cricoid cartilage. The bleeding is thoroughly arrested, and the two wings of the thyroid cartilage divided exactly in the angle of union. This should be done with great care, in order to avoid wounding the vocal bands, which are attached on either side of the median line, in front. If at this stage of the operation a tenaculum is inserted, on either side, the alæ may be drawn apart, freely exposing the interior of the larynx. In closing the wound the cartilages are not included in the sutures, it being sufficient to bring the edges of the skin together.

In *laryngotomy* the opening is made through the crico-thyroid membrane. It is indicated in œdema of the glottis, obstruction of the larynx by new growths, foreign bodies, and exceptionally in rapid inflammatory swelling of the tonsils or pharynx, with occlusion of the larynx.

When the emergency demands it, rapid laryngotomy may be performed as follows: Make a single incision from the notch in the upper margin of the thyroid cartilage, in the median line, to the lower edge of the cricoid ring, then turn the knife edge upward and thrust the point through the crico-thyroid membrane. A hook should now be quickly inserted on either side, and the edges of the wound separated. Traction not only opens the wound in the membrane to admit the air more freely, but it also arrests the bleeding. When tenacula can not be had, a fair substitute may be extemporized from wire, or the ordinary metal hairpin. The opening in the membrane may be enlarged by a transverse incision when necessary.

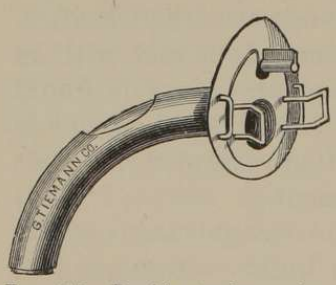

Fig. 617.—Double trachea tube, silver, plain.

When expedition is not urgent, the bleeding from the wound in the integument should be arrested before the opening into the larynx is made.

If it is necessary to keep the wound open, a silver trachæa canula (Fig. 617) should be inserted. This instrument is secured by a tape tied around the neck. When it becomes obstructed, the inner canula should be withdrawn, cleansed, and reinserted, and, if necessary, the larger tube remaining in

the larynx should be brushed out with a small brush or mop. When this instrument is worn it should be carefully watched, as long as any danger of its becoming obstructed exists. It may be worn indefinitely in cases of permanent laryngeal stenosis.

Laryngotomy without a Tube.—When a canula is not at hand, a needle, armed with fine, strong silk, should be passed, on either side, through the integument and cricoid membrane, brought out through the opening in the larynx, and the suture tied. It is best to employ two sutures in each side of the wound. These may be tied behind the neck, or attached to bits of adhesive plaster and fastened to the integument, so as to keep the wound open. A strip of plaster should be laid on each side of the wound, to prevent the thread from cutting into the integument.

Laryngo-tracheotomy (an operation rarely performed) consists in extending the incision of laryngotomy through the cricoid cartilage, and the upper one or two rings of the trachea.

Tracheotomy is more frequently done than either of the operations just given. The trachea may be opened (1) above the isthmus of the thyroid body, the upper three or four rings being divided; (2) the isthmus may be tied with a double ligature, divided, and the trachea opened beneath it; (3) the opening into the tube may be altogether below the isthmus.

It will rarely be found necessary to divide the isthmus. The operation above the isthmus is simpler, and should be preferred in all cases where the obstruction is in the larynx. For the removal of a foreign body lodged in the bifurcation of the trachea, or in either bronchus, the lower procedure should be adopted. This operation should also be preferred in diphtheritic croup when all other measures have failed. The results achieved with the laryngeal tube of Dr. O'Dwyer, of New York, justifies a faithful trial with this instrument before resorting to the formidable operation of tracheotomy in diphtheritic croup.

. . . . . .

High Operation.—Place the patient on the back, in such a position that the head falls well over the end of the table. If an anæsthetic is not given, one assistant should hold the extremities immovable, while a second steadies the head. The operator should stand to the patient's right, facing the light. It is important that the head be held so that the nose and symphysis menti will be directly in line with the interclavicular notch and umbilicus, for if this precaution is not taken the trachea may be displaced, an accident which might lead to great annoyance, especially in children, in whom this tube is always very small. The incision should be exactly in the median line, commencing at the center of the thyroid cartilage and extending downward one inch and a half, or more if necessary. The edges of the wound should be separated by retractors, and the incision continued down to the tube. All bleeding should be arrested by the forceps and ligature before the trachea is opened, for fear of suffocation from the entrance of blood.

In some subjects it will be found that the isthmus of the thyroid body

is situated so high that an opening sufficiently long can not be made without displacing it downward. This may be done by dividing with the curved scissors the muscular and ligamentous bands which are attached to the isthmus below, and the hyoid bone and thyroid cartilage above. This section should be made on either side of the incision, opposite the first ring of the trachea. After all bleeding has ceased, the knife should be carried into the trachea with the edge directed upward, and the two or three upper rings divided.

Low Operation.—The incision through the integument extends from the cricoid cartilage to the level of the inter-clavicular notch. Separate the sterno-thyroid muscles in the median line, and carry the dissection carefully down to the trachea, avoiding the isthmus of the thyroid body and the inferior thyroid vein, a branch of which is in front of this tube. The anterior jugular vein occasionally is in the median line. Any of these vessels coming within the line of incision should be secured with a double ligature before being divided. The trachea will be found deeply situated, and should be incised through four or five rings, in the same manner as advised in the preceding operation. If a trachea tube is not at hand, the operation may be completed, as advised in laryngotomy, without a tube.

Foreign Bodies in the Larynx, Trachea, and Bronchi.

Foreign bodies in the respiratory tract are, in almost all instances, introduced by way of the larynx, into which they may fall by gravity or be drawn in by the suction force of the inspiratory effort. Occasionally they enter directly from without, as in stab or gunshot wounds, or may make their way in from the œsophagus by perforation or from the rupture of an aneurism or abscess. Pieces of coin, buttons, teeth, seeds, threads, pins, blow-gun darts, shot, particles of food, etc., are among the most frequent substances lodged in the air passages. A foreign body may lodge just behind the epiglottis, across the rima glottidis, in the ventricle between the true and false bands, between the vocal cords, or, passing these, it may descend into the trachea or bronchus. If it be a solid and smooth body, it will pass into the bronchus and continue to descend until the smaller diameter of the tube arrests its progress. Any substance with projecting, sharp edges, or long and pointed, as a pin or fish bone, may become lodged across the windpipe at any point.

The symptoms of a foreign body in the air passages are immediate and remote. Strangulation, cough, and cyanosis immediately after the escape of any substance backward from the mouth or nose, or matter which has been regurgitated from the stomach, always suggest the entrance of foreign matter into the larynx or trachea. In some cases death ensues almost instantly from asphyxia. In others the symptoms of strangulation last for a few moments and then disappear, leading the patient or attendant to believe that the foreign body has been coughed out or swallowed. The momentary cyanosis and strangulation are caused by spasm of the laryngeal muscles, induced by direct irrita-

tion from the foreign body. As soon as these relax a forcible inspiratory effort may carry the substance downward to the trachea or bronchus, or the expiratory cough may have discharged it into the mouth. In any event, the symptoms of asphyxia disappear unless the offending substance is so large that, even when sucked into the trachea, it completely occludes this tube. The remote symptoms of foreign bodies in the air passages are chiefly inflammatory. Traumatic trachitis, bronchitis, pneumonia, gangrene, and abscess may ensue. Abscess and gangrene are rare. Bronchitis is inevitable, and localized or lobar pneumonia is not infrequent.

The *diagnosis* may be determined by inspection, palpation (either direct or intermediate), and by auscultation, together with a due regard for the sensations experienced by the patient. Inspection is only possible with the laryngoscope. Direct palpation is only possible when the substance is lodged in the larynx, since the tip of the finger can not be carried beyond this point.

Auscultation is of great aid to diagnosis, especially when the body has passed deep into the respiratory tract. Diminution or absence of the normal vesicular murmur over one entire lung indicates the partial or complete occlusion of one primary bronchus by the foreign body. If this interference is limited to only a portion of the lung, the indication is that the body has passed into one of the subdivisions of the bronchus.

The compensatory increase of the normal vesicular respiration in the opposite lung will be proportioned to the interference with the function of the affected side. When a narrow body becomes lodged in the trachea or bronchus, its presence is indicated by a sibilant or hissing sound, heard with greatest intensity over the point of lodgment, and carried upward and downward with the expiratory or inspiratory movement.

The presence of pain persisting in a given locality points to the seat of lodgment of the foreign substance. Persistent spasm of the larynx until tolerance is acquired suggests lodgment in the ventricle of this organ.

Treatment.—The immediate indication is the prevention of fatal asphyxia, and this may require rapid laryngotomy or tracheotomy, and, in exceptional instances, the resuscitation of the patient by the method of Sylvester. As soon as this danger is obviated, the removal of the foreign body may be undertaken. It is well to remember that in a few instances symptoms of asphyxia have been produced from the epiglottis having been drawn into the rima glottidis by a powerful inspiratory effort.

When fatal asphyxia is not threatened, no immediate operation is indicated. The patient should be turned head downward and violently shaken, and at the same time made to cough or sneeze. If the substance is smooth or heavy, it may be dislodged and expelled in this manner.

If this procedure is unsuccessful, the question of operative interfer-

ence should be considered. If the body can be located in the larynx, it can readily be removed by the operation of thyrotomy if the patient is a child, or by laryngotomy and the introduction of the little finger into the organ through the wound in the adult, pushing the offending substance upward into the pharynx. Either of these procedures is practically free from danger. When the foreign body has passed into the trachea or bronchi, the necessity for operative interference will depend upon its size, shape, and location. If it is small, and produces no marked disturbance of respiration, and is deeply lodged, no effort should be made to remove it, for the following reasons: When small it is not apt to inflict serious damage; tracheotomy and the introduction of instruments into the respiratory tract are not without risk; lastly, the uncertainty of finding or dislodging a small body should be taken into consideration.

When, however, the character of the foreign body is such that its presence is a source of great danger to the patient, and it can not be removed without operation, surgical interference is demanded. The position for the patient is the same as for tracheotomy, and this operation should be done as low down as possible. When the trachea is opened, the little finger should be carried downward to the bifurcation in the hope of locating the body, and, if discovered, it should be grasped with a pair of forceps and removed. If it is not encountered below, the upper portion of the tube should be examined in the same way. If it can not be reached by the finger, the angular alligator forceps (Fig. 618) should be carried into the bronchial tubes, carefully regarding any arrest in the progress of the instrument.

A solid or large body may be felt and seized without great difficulty. A small, light substance may be touched without any sense of resistance to the hand of the operator. If it can not be recognized, the point of the instrument should be carried into the bronchus in which the body is located, the jaws separated, and, while open, carried about half an inch farther in, and then closed and withdrawn in order to see if the object has been grasped. This manœuvre is repeated several times until the whole length of the bronchus has been searched. If the foreign body is not found, it will be judicious to search in the opposite bronchus, for it is possible for it to have been dislodged in the course of the exploration, and carried by the respiratory effort into the trachea and down into the other tube. If proper forceps can not be obtained, a loop of silver wire may be used.

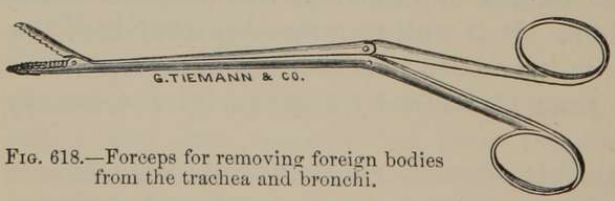

Fig. 618.—Forceps for removing foreign bodies from the trachea and bronchi.

The exploration of the trachea should be done with great care not to inflict unnecessary violence upon the mucous membrane.

If the body is removed, the wound may be left to heal by granulation, simply closing it with adhesive strips, or, if the patient has borne the anæsthetic well, it will, be better to stitch the trachea with catgut, and

the edges of the wound separately with the same substance. If the object is not found, the tracheal wound should be kept open by inserting a large trachea tube, or by sewing the tracheal rings to the edges of the divided integument and keeping the wound open by tying the strings behind the neck.

Figs. 619 and 620 exactly represent an air-gun dart which was lodged in the right bronchus of a boy twelve years old, who came under my care in 1884.* In the act of filling his lungs to project the dart from the gun it was carried into the trachea. Spasm of the laryngeal muscles followed for a few moments, with marked cyanosis. After this there were no symptoms of disturbance beyond a slight cough. I performed tracheotomy at the lowest point possible, dislodged the body by forceps carried into the bronchus, when it was ejected during a violent paroxysm of coughing. The wound was left to close by granulation.

Fig. 619.—Dart, as it came from the bronchus.

Fig. 620.—The same, before it entered.

When a foreign body is lodged deep in the lung and is producing dangerous septic inflammation of this organ, or the pleura, and is so situated that it can be reached by resection of one or more ribs, surgical interference may be entertained.

Laryngectomy, or exsection of the larynx, although a formidable operation, is, under certain conditions, justifiable. It may be partial or complete. The gravity of the procedure may be estimated from the fact that over one third of all the cases have died within eight days of the operation.

The conditions which justify this procedure are the invasion of this organ by malignant neoplasm, and, in rare instances, destructive chondritis, with infiltration and threatened occlusion of the respiratory tract. If, after a careful study of the case, the surgeon is convinced that there is a fair probability of relief from pain and prolongation of life by the removal of the diseased structures, greater than he would be likely to obtain by the palliative operation of tracheotomy, he is justified in advising the operation. When the tissues about the larynx are widely infiltrated with the malignant neoplasm, the operation is not justifiable.

Complete laryngectomy is performed as follows: Under chloroform narcosis an incision is made from above the hyoid bone in the median line over the *pomum Adami* and downward in the direction of the middle line of the manubrium. A transverse incision crosses this at the level of the coracoid cartilage, taking care not to wound the great vessels and important structures lying on the side of the neck. A careful dissection is

* "New York Medical Journal," November, 1884, p. 487.

made and all hæmorrhage controlled as the operation proceeds. The wound should be perfectly dry when the division of the trachea is effected. After this is exposed and dissected free from the œsophagus by the finger, a probe-pointed, curved bistoury should be carefully inserted between the œsophagus and the trachea at the point at which the windpipe is to be divided, and when everything is ready, a quick division of the trachea is made and the dissection completed from *below* upward. In this way no bleeding can escape into the respiratory tract. By placing the patient with the head considerably lower than the feet, I have done this operation without the use of the Trendelenburg or any similar tube. In fact, this complicated apparatus is a hindrance rather than an aid to rapidity in this procedure. It is usually necessary to treat these wounds by the open method, closing only the angles of the incisions. Great after-care is essential in preventing the descent of saliva or ingested liquids into the trachea. When the operation does not of necessity demand the removal of a portion of the anterior wall of the œsophagus or that portion of the pharynx immediately below the tongue, and this is opened into the upper portion of the operative field, this part of the wound should be closed at once so that the patient may be able to swallow without the use of the stomach tube. The tube should be held in reserve in all cases for the purpose of feeding. It is always advisable to sew the integument either to the edges of the tracheal wound or to leave this projecting from the partially closed wound to prevent septic infiltration as well as to obviate the danger of emphysema.

Partial laryngectomy is performed in the same general way as the complete operation. The value of morphine as an adjuvant in securing profound narcosis with the minimum of chloroform or ether can not be overestimated, especially in connection with this particular operation. In fact, it is possible to obtain complete anæsthesia with this agent alone without chloroform or ether. In the case of a patient, sixty-two years of age, with epithelioma of the right half and the anterior portion of the left half of the larynx, involving the vocal cords, I did an extirpation after the following method: A preliminary tracheotomy was done two weeks before the operation; I endeavored to administer chloroform through the trachea tube, but such was the irritability of the respiratory tract this had to be stopped. One fourth of a grain of morphine was injected under the skin, and twenty minutes later one sixteenth of a grain additional. Fifteen minutes after the second injection the patient was in a semiconscious condition and the anæsthesia was quite apparent. The operation was begun by making a longitudinal incision running from above the hyoid bone down well over the larynx as far as the wound in the trachea. A crucial incision was made just over the *pomum Adami*, exposing the larynx. All bleeding points were secured as the dissection was made. The patient was unconscious and gave no evidence of feeling pain. About twenty minutes after the operation was begun another sixteenth of a grain of morphine was injected. In all seven eighths of a grain were used during the operation, which lasted an hour and thirty minutes. The entire right half of the thyroid and cricoid cartilages were

removed and the upper half of the left side back to the pharynx, including the vocal bands and muscles. The patient remained perfectly quiet during the operation, at no time felt any pain, and made a satisfactory recovery. I have employed this agent in a number of instances in other operations with very great satisfaction, always taking the precaution to have at hand, in hypodermic syringes, ready for use, the antidotes to opium narcosis—viz., atropine, caffeine, with strychine for heart stimulation when indicated.

Neoplasms of the Larynx and Trachea.—Almost every form of new growth has been removed from the larynx. No portion of the organ is exempt. The symptoms are referable to the location of the neoplasm and to its size, and in a certain sense to its shape. Those situated upon the vocal bands are first noticed, on account of interference with the voice. A neoplasm may develop in the ventricle, and not be noticed until it encroaches upon the cords. Dyspnœa occurs earlier, when the tumor is situated upon the rima glottidis.

Cough is not a prominent symptom, for the reason that the slow and progressive development of the neoplasm gradually accustoms the larynx to its presence. Spasmodic cough does, however, occur in pedunculated growths, which are moved to and fro as the air rushes in and out of the larynx.

The *diagnosis* may be made from the symptoms detailed, but chiefly by palpation and the laryngoscope. The location is simple, but the differentiation as to the character of the growth is at times difficult. *Papillomata* are most frequently met with, and papilloma in the larynx possesses the same general properties observed in these growths in more exposed quarters. They are most commonly found upon the vocal bands. The tumor may appear in the mirror as a single wart-like fungus, or pinkish-gray tuft upon the cords or laryngeal wall, or there may be several which fill a great part of the opening. The fibroid laryngeal polypi (*fibromata*) are chiefly pyriform, pedunculated, and smooth, in location and color resembling the papillomata.

Enchondromata of the larynx, less frequently observed than the two preceding neoplasms, are developed from the cartilage proper of the larynx. They are usually seen in the vicinity of the crico-arytenoid articulation. *Cystic* tumors are rare. Occlusion of the duct of the *sacculus laryngis* will lead to the appearance of a tumor in the ventricle, between the true and false bands. Other cysts may result from simple follicular occlusion. *Telangiectasis*, or *angioma*, is a still rarer form of laryngeal tumor. *Carcinoma* (*epithelioma*) is, unfortunately, not a rare disease of this organ. *Sarcoma* is very rarely met with. *Epithelioma* of the larynx, in common with all malignant (as well as benign) neoplasms, occurs chiefly at the upper portions of the organ.

The treatment of all forms of benign tumors of the larynx is their removal with the knife, scissors, the snare, or caustics. Removal of malignant growths, to an extent sufficient to prevent recurrence, without a total or partial laryngectomy, is rarely possible. Benign growths, especially the smaller new formations, may be removed best by chromic-

acid crystals directly applied at frequent sittings. A small pellet of cotton is attached to the end of the applicator, and a particle of chromic acid, of convenient size, is picked up on this and carried down to the tumor. The crystals adhere to the lint until they come in contact with a moist surface. In carrying the instrument through the mouth, care must be taken to avoid touching the mucous surfaces. Epithelioma in its early development may be successfully destroyed by this escharotic. The operator should take advantage of the anæsthetic properties of cocaine to render the pharynx and larynx tolerant of manipulation. Nitrate of silver may also be used, but is inferior to chromic acid.

Avulsion, or tearing away the neoplasm, is a useful and frequently employed method. For this purpose various forms of forceps have been used. Pedunculated tumors may be snared and cut away with the wire loop of Jarvis. Fibromata often adhere so tenaciously that they can not be torn away without damage to the larynx. Care should be taken to regulate the force so that injury to the vocal bands or the smaller cartilages may be avoided.

The operation of *thyrotomy*—heretofore described—gives the best command of the cavity of this organ, and allows the more thorough and safe removal of the neoplasm.

Neoplasms similar in character to those found in the larynx may occur in the trachea and bronchi. The location of the new growth may be determined from the physical signs.

The treatment is strictly surgical, and involves physical exploration of the respiratory tract, with avulsion or excision of the growth, or the introduction of the trachea tube to prevent asphyxia.

Pharynx and Œsophagus.

Pharynx.--Neoplasm of the walls of this cavity are comparatively rare. They occur usually in the vault, and are attached to the mucous membrane, or periosteum, beneath the basilar process. The treatment consists in removal by the snare or galvano-cautery, or, if the tumor is of considerable size, by the knife. In some instances deligation of both external carotid arteries is advisable. In one instance I was compelled to do this to avoid almost fatal hæmorrhage from a very vascular tumor of this region. Inoperable cases may be benefited by ligation of both external carotids. The method described in operations upon the upper jaw is, however, to be preferred.

Foreign bodies are not infrequently lodged in this organ. They may be discovered by inspection with the pharyngoscope, or felt with the index finger.

The *treatment* is removal by the aid of the mirror and curved forceps.

Œsophagus.

Rupture of the œsophagus, though several instances are recorded, is exceedingly rare. The accident occurs in forced efforts at deglutition after overdistention of the stomach. The *symptoms* are intense pain in

the region of the rupture—which is usually in the long axis of the tube and near the diaphragm—followed by rapid and fatal collapse. Vomiting does not occur, although the contents of the stomach may be emptied, in part, into the mediastinum.

Foreign Bodies.—The lodgment of bodies in the œsophagus, resulting in partial or complete occlusion, is of frequent occurrence. The *symptoms* depend in great part upon the character of the foreign substance. A sharp and narrow body—as a bone, pin, needle, or splinter of wood—will produce pain at the seat of lodgment, but will allow the passage of liquid and semi-solid ingesta. Soft, compressible particles of large size may completely occlude the tube, and cause pressure upon the trachea sufficient to induce marked asphyxia. The diagnosis must, in part, be based upon these symptoms and the history of the accident. Pressure over the seat of lodgment of a sharp substance will ex-

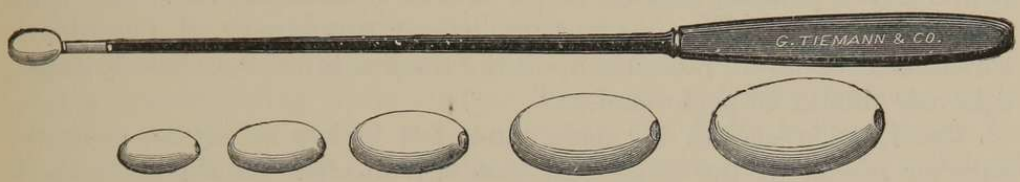

Fig. 621.—Œsophageal sound and bulbs.

aggerate the sense of pain, while the inability to swallow liquids will indicate the complete occlusion of the tube. The introduction of the elastic œsophageal sound (Fig. 621) will demonstrate the presence of any occluding body.

In order to introduce this instrument, lubricate it with the white of an egg, or glycerin, and cause the patient to throw the head back so as to bring the axis of the mouth and pharynx in line with that of the œsophagus. Insert the bougie so that the point will glide over the root of the tongue and strike the posterior wall of the pharynx behind the larynx. The tongue should not be drawn out of the mouth. Spasm of the glottis will prevent the instrument passing into the larynx, while, if kept in the median line and pushed carefully down, it will pass into the œsophagus.

The location of the foreign body will be indicated by stoppage of the sound. The *prognosis* is usually favorable when the occlusion is not complete. If the distention is great enough to interfere with respiration, the gravity of the accident is increased. Inflammation, abscess, and perforation of the œsophagus may occur if the obstruction is not removed within the first few days. In a case seen in consultation in 1896, perforation took place from the lodgment of a chicken bone about two inches above the cardiac orifice. Abscess and emphysema of the mediastinum ensued. Four days after the accident I made an incision at the upper margin of the sternum on the right side, entered the upper mediastinum, and gave vent to a quantity of exceedingly offensive gas. The pus was too deeply seated to escape through this incision.

Treatment.—When a foreign body is lodged in the œsophagus, and does not completely occlude its caliber, it may usually be dislodged by

producing emesis. If there is complete obstruction, the act of vomiting should not be excited, nor is the employment of a sound or bougie to push the object into the stomach permissible.

When the substance lodged does not occlude the œsophagus, and emesis has failed to dislodge it, the umbrella probang (Fig. 622) should be introduced. This instrument is lubricated, closed, and passed into



Fig. 622.—Bristle probang, for removing foreign bodies.

the œsophagus until the bristles are well beyond the point of lodgment, when they, by pressure upon the whalebone handle, are projected, completely filling the tube, and the probang withdrawn. If the introduction of this instrument is difficult or painful, an anæsthetic should be administered.

In case of complete obstruction, where the danger of inanition is threatened, or where pressure upon the trachea must be relieved, *œsophagotomy* should be performed.

The incision should be made about five inches in extent, along the anterior border of the left sterno-mastoid muscle. If the occlusion is high up, the center of this cut should be opposite the point of obstruction. If it is below the sternal level, the tube should be opened as low down as possible. If necessary, the sternal origin of the mastoideus may be divided. The carotid artery and jugular vein are left to the outer side. The thyroid body should be drawn outward or lifted upward. The omo-hyoid, thyro-hyoid, and sterno-hyoid muscles should be held to the inner side. A sound should now be introduced into the œsophagus, in order to serve as a guide to the operator. The opening should be made on the lateral and posterior aspect in order to avoid the recurrent laryngeal nerve. With the finger introduced into the wound, the foreign body may be felt and removed by the alligator forceps. It is usual to leave the wound open. For the first three or four days after the operation the patient must be fed by a tube introduced through the mouth and beyond the wound.

Stricture.—Stricture of the œsophagus may be spasmodic or organic. The irritation caused by an organic stricture may not only exaggerate the degree of constriction by exciting spasm of the muscular fibers of this tube in the immediate vicinity of the stricture, but also at points remote from the seat of the organic lesion.

Organic stricture is comparatively rare. It may result from inflammation of the œsophagus caused by the ingestion of scalding water, strong acids or alkalies, the lodgment of foreign bodies, by wounds of the neck, the presence of a neoplasm, an aneurism, or by the local expression of some general dyscrasia, as in syphilis.

The *diagnosis* is determined by interference with deglutition and by physical exploration with the bulbous bougies.

The *prognosis* is unfavorable, although a fatal termination may not be reached for a considerable period.

The *treatment* consists in dilating the stricture by means of elastic bougies, introduced at intervals of two or three days. These instruments should be softened by being placed in warm water for a few minutes before they are used. The mechanism of introduction is the same as for the bulbous bougies just described. An extra long whalebone bougie, after the pattern of Bank's dilating urethral filiform bougie, will prove of service in strictures of such small caliber that the ordinary œsophageal bougie can not be introduced.

Internal œsophagotomy is a justifiable procedure in cases of organic stricture which will not yield to careful and persistent efforts at dilatation. In its performance, the œsophagotome of Prof. Sands (Fig. 623) has been successfully employed. As described by this surgeon,* the shank of the instrument, which is fifteen inches and a half in length and four millimetres in diameter, is a flexible tube, made of narrow, spiral steel plate, secured within by two pieces of fine wire, in order to prevent stretching or separation of the spiral coil. The instrument is provided with a variable number of steel bulbs, each bulb being furnished with a corresponding knife blade. The bulb is firmly fastened by a screw to the distal end of the shank, and the knife is attached to an inner flexible steel rod, manipulated by a thumb screw at the proximal end of the instrument. By turning this screw, the knife is drawn out from its concealed position within the bulb, the back of the blade sliding over a firm inclined plane. An index on a dial plate indicates the amount of projection of the blade, the maximum being two millimetres and a half. A small sliding ring on the spiral tube is used to indicate the distance of the stricture from the incisor teeth. The bulb being conical, the operator can readily perceive when it comes in contact with the stricture, before he projects the blade. In operating, a bulb must be employed which exactly fits the stricture; the depth of the incision will then just equal the distance to which the blade is projected by the action of the screw in the handle. The bulb is introduced beyond the stricture, and the instrument withdrawn until the shoulder of the bulb indicates that it is in contact with the inferior or gastric border of the



Fig. 623.—Prof. Sands's œsophagotome.

stricture. It is then turned so that the knife is posterior, the screw in the handle which projects the blade is turned to the required extent, and the constricting band divided by pulling the instrument outward until resistance ceases. The blade is then concealed and the œsophagotome withdrawn. The dilating bougies may be introduced at once, or this may be postponed for twenty-four hours. The danger to be guarded against is an incision through the wall of the œsophagus. With the instrument of Prof. Sands this is scarcely possible, especially when the

* "New York Medical Journal," February, 1884.

smaller bulbs are used, since the greatest projection of the blade is only a little more than one twelfth of an inch.

When the occlusion is so complete that the œsophagotome can not be employed, or if for any reason this method of procedure is contra-indicated and inanition is threatened, the operation of *gastrostomy* is imperative. It is not only to be commended in permanent occlusion of the œsophagus from stricture, a diverticulum, or neoplasm, but in those cases in which extensive inflammation has resulted from the ingestion of corrosive substances. In this last condition the operation is intended to keep the organ at rest during the process of repair, in which nothing but water is passed through the œsophagus. It is always advisable to operate early in all conditions.

Operation.—Two operative methods may be entertained. The most modern, the operation of Sebanijew and Frank, which has met with considerable favor in late years and which has for its chief aim the establishment of a valvular fistulous opening for the prevention of regurgitation of food from the stomach, consists of an incision, four or five inches in length, beginning near the xyphoid appendix, parallel with and a little less than two inches distant from the costal cartilages of the left side. All bleeding should be stopped as the operation proceeds. When the anterior sheath of the rectus muscle is opened in the line of this incision, retractors are inserted and the edges of the wound held apart. The fibers of the rectus are separated in their normal perpendicular arrangement by a blunt instrument, and the posterior sheath of this muscle and peritonæum are then incised in the same (perpendicular) direction. The stomach is now drawn out through this opening and the silk suture passed through the peritoneal and muscular coats (not entering the cavity) at a point near the fundus, which is used in drawing out a conical pouch of the stomach about an inch and a half in extent (Fig. 624). At this stage of the operation the edges of the parietal peritonæum, including the posterior sheath of the rectus, are stitched carefully with fine silk to the peritoneal surface of the stomach entirely around this cone, the sutures going deep to take good hold in the muscular coat. A second incision an inch in length, parallel to the first and slightly above the ribs, is now made through the skin. By a careful dissection which lifts only the integument, this wound is made to communicate with the first incision, and the silk suture passed into the stomach is brought up underneath the loosened integument and

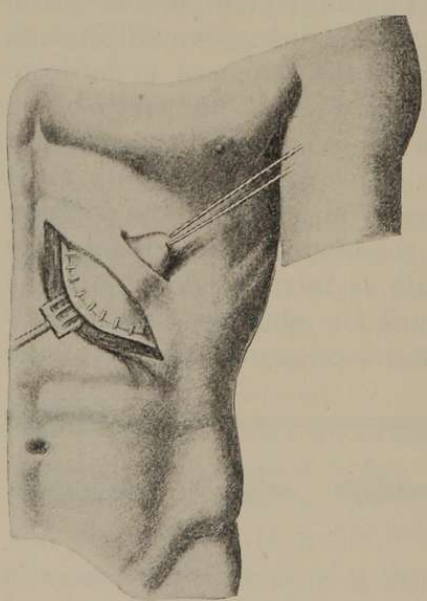

FIG. 624.—Incision made and cone of fundus of the stomach drawn out. A row of sutures have stitched the peritonæum of the abdominal wall and the posterior sheath of the rectus to the stomach. Sebanijew-Frank method.

out of the last and smaller incision, pulling the apex of the conical pouch of the stomach out of this opening (Fig. 625). The first incision is now closed with silkworm gut, and the apex of the cone of the stomach incised for about half an inch and sutured with fine silk to the wound in the integument, the stitches passing entirely through the coats of the stomach and the skin (Fig. 626).

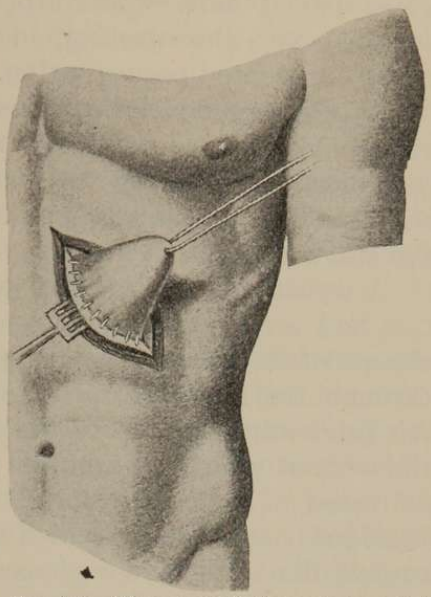

Fig. 625.—The same with the second parallel incision made, skin raised, and stomach drawn through.

The patient may be fed at once if the condition demands it, but it is usually safer to wait for at least twenty-four hours in order to secure peritoneal adhesions. This method proved very satisfactory in a patient operated upon by the author in 1896.

When operations for the establishment of gastric fistula are undertaken in cases in which there has been œsophageal stenosis of long standing, it must be borne in mind that the stomach is always greatly contracted, and that the fundus is lifted higher up toward the diaphragm than normal. In some instances it is difficult to lift even the fundus of the stomach up to the edges of the wound, and the operation just detailed is not practicable.

The older method, which is simpler, requires exposure of the stomach by an incision similar to that described in the foregoing operation. The stomach is immediately drawn into the wound and sutured with fine silk to the parietal peritonæum and skin, including the posterior sheath of the rectus muscle, in the entire circumference of the wound. A continuous suture may be employed, although the interrupted suture is generally used. This suture should also include the muscular coat of the stomach with the serous, but should not perforate the mucous coat. Silkworm-gut sutures may now be inserted in the upper and lower angles of the incision in the integument, partially closing this wound. It is best not to open into the stomach until twenty-four or forty-eight hours have elapsed, by which time union will have occurred between contiguous peritoneal surfaces, thus avoiding infiltration into the peritoneal cavity. Should the necessity for nutrition be extreme and rectal alimentation not to be relied upon to sustain the pa-

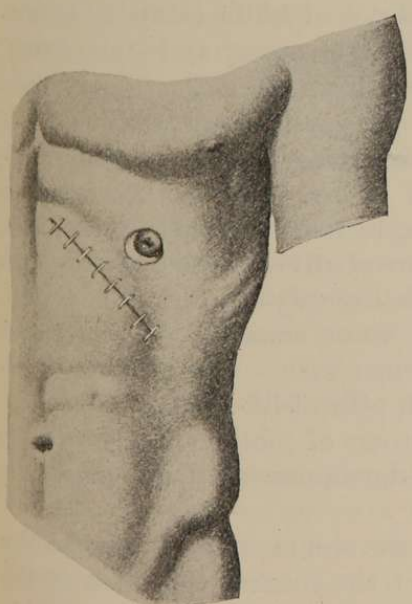

Fig. 626.—The operation completed.

tient, a quantity of milk may be injected by means of a large aspirating needle into the stomach at the point of attachment. In several instances after a fistula has been established by firm adhesions I have used an hour-glass-shaped hard-rubber nipple with a lumen of one third of an inch inserted into the opening, in order to keep it patulous. A cork fitted to this prevented regurgitation.

Liquid or semisolid articles of food may be introduced directly into the stomach, or, as practiced in the remarkable case of Dr. L. L. Staton, of North Carolina, the food may be masticated and thus submitted to the action of the saliva, and may then be forced from the mouth into the stomach through a tube.

A woman about forty-five years of age who came under my observation had accidentally swallowed a corrosive substance, producing acute closure of the œsophagus. I performed the operation of gastrostomy, and through the artificial opening she was nourished for about ten months. An interesting feature of the case was that at the time of the accident the woman was three months pregnant, and went to full term and was delivered of a healthy child. After the acute inflammatory symptoms subsided, the strictures which resulted were successfully treated by interrupted dilatation by œsophageal bougies.

In certain cases of stricture of the œsophagus in which only the finest filiform bougies can be introduced it may be found necessary to operate from the gastric instead of the pharyngeal end of the œsophagus. A small-sized bougie to which a strong silk thread is attached is carried into the stricture, through the cardiac orifice of the stomach and brought out at the mouth, or an opening in the œsophagus, drawing the silk thread with it. Strictures have been divided by a sawing motion of the string (Abbe) or by pulling through a series of bulbs (Maydl), gradually increasing in size, which are attached to the string at regular intervals. Dr. Lange has successfully employed this method, having a blade (œsophagotome) attached to each bulb. The subsequent treatment in these cases consists of the introduction of œsophageal bougies, gradually increasing in size. Of these methods, that of Dr. Robert Abbe is to be preferred. For its performance, an opening in the œsophagus in the neck is required. The sawing motion of the thread divides the stricture and permits the interrupted introduction of dilating soft bougies.

New Formations.—Epithelioma is the most common neoplasm met with in the œsophagus. *Sarcoma* is rarely met with. Cancer occurs usually between the thirty-fifth and sixty-fifth year of life. The favorite location is near the diaphragm. The symptoms of malignant growth are chiefly those due to obstruction and the development of the cancerous cachexia.

Non-malignant neoplasms are slower in development, and, beyond the dysphagia they may produce, do not affect the general condition of the patient.

Treatment.—Malignant new growths of the œsophagus always justify a grave prognosis, especially so when situated in the lower portions of this organ. Beyond palliative treatment by dilatation with bougies, or

gastrostomy after deglutition is seriously impaired or impossible, nothing can be done. Non-malignant neoplasms are also not amenable to surgical interference when situated below the level of the upper border of the sternum. When the upper portion of the œsophagus is involved, operation is indicated, not only to relieve dysphagia, but in the effort to remove the disease.

Œsophagectomy, or exsection of a portion of this organ, may occasionally be justified in the removal of a malignant growth of limited extent and situated in the upper portion of the tube. The probability that, before the character of the neoplasm is discovered, infiltration of the neighboring tissues will have occurred, almost precludes a favorable result, and is therefore a strong argument against the propriety of the operation.

Diverticula, or pouches communicating with the cavity of the œsophagus are occasionally met with. They may be congenital, but are more frequently acquired. They communicate with the œsophagus usually on its posterior wall. Cervical œsophageal diverticula open into the main tube at the junction of the œsophagus with the pharynx, whence the pouch may extend between the vertebral column and the œsophagus as far down as the bifurcation of the trachea. Thoracic œsophageal diverticula occur most frequently opposite the origin of the bronchi.

The *causes* of these abnormal pouches are various. As stated, they may be the result of a failure in normal development. A stricture of the œsophagus may lead to a dilatation and pouching of this organ in that portion immediately above the seat of constriction. Degeneration of the muscular fibers of the tube in a limited area may lead to a hernia of the mucous membrane, in which, by the impaction of ingested matter, a diverticulum is formed. Ulceration of the lining membrane at any point, and from any cause, may lead to the development of a sac or pouch by the infiltration of ingesta behind the mucous membrane.*

The diagnosis of these diverticula is made with great difficulty, and little hope of relief is offered, even when the character of the lesion is recognized.

The presence of the tumor is indicated by dysphagia, and this symptom may vary in severity with the act of deglutition which carries food into the pouch. Dyspnœa may be present as the result of pressure upon the trachea and bronchi, and phonation may be interfered with if the pneumogastric or recurrent laryngeal nerves are involved.

The *treatment* is chiefly palliative, and consists in the use of liquid diet.

Fistula of the œsophagus may occur as a result of a penetrating wound, or from an abscess or ulceration which destroys a portion of the œsophageal wall. A few instances of supposed congenital fistula have been reported.

The *diagnosis* will depend upon the passage of ingested matter

* Rokitansky has advanced the theory that thoracic diverticula result from atrophy of the bronchial lymphatic glands, which are situated on the anterior and lateral aspects of the œsophagus.

through the outer opening, or the successful introduction of a probe from without.

The *treatment* is surgical, and on the same principle as applied to all fistulous tracts; they should be laid open by incision, packed to arrest bleeding, and afterward allowed to close by granulation. Or, as in the recent procedure for the relief of fistula in ano, the lining membrane of the fistula may be dissected away and the wound closed throughout with catgut sutures.

CHAPTER XX.

THORAX.

Mammary Gland—Congenital Defects.—One or both of these organs may be absent; one may develop fully while the other remains in its primitive condition; there may be three, four, or five, the supernumerary glands being placed upon the back, abdomen, axilla, or thigh. The nipple may be absent or retracted, and may be bifid or multiple, as many as half a dozen occurring within the limit of the areola.

The author presented to the New York Surgical Society a case in which a supernumerary gland was situated in the axilla. The development of this organ simultaneously with the normal breasts produced great pain by pressure upon the branches of the axillary plexus. Relief followed extirpation of the abnormal gland.

Inflammation of the nipple occurs, as a rule, in the early period of lactation, abrasions produced by the gums of the infant affording lodgment to septic organisms. Tuberculosis and syphilis may also be acquired through these abrasions.

The first indication in treatment is to give the organ rest. Pain may be relieved by emptying the milk ducts by artificial means. A child should not nurse at an infected nipple or breast. Thorough cleansing with warm sterile water or boric-acid solution should be done at frequent intervals. When suppuration is present, incision and drainage are essential.

All incisions should be made in the direction of the efferent ducts in lines radiating from the nipple.

Eczema, or *fissure* of the nipple, is of frequent occurrence during lactation. It is always annoying, and at times causes severe pain. Every source of irritation should be removed. Boric-acid solution is indicated in the early stages, and later glycerite of tannin or other astringent. Chronic inflammatory processes of the nipple which are intractable, resisting all constitutional and local remedies, demand free incision and ablation of the diseased area.

Epithelioma is the most frequent form of malignant neoplasm of the nipple. When of recent growth and superficial in extent, Marsden's paste will give the most satisfactory result. If the deeper ducts or substance of the gland are infiltrated, the entire breast should be removed, and the axillary glands explored and, if involved, thoroughly dissected out.

Papilloma, *fibroma*, *angioma*, *cysts*, etc., may occur in this organ, and should be removed by the knife as soon as discovered.

Mastitis.—Septic inflammation of the breast frequently follows infection of the nipple, the pathogenic organisms traveling along the galactiferous and lymphatic ducts. A single lobule or subdivision of the gland or the entire organ may be involved. In the more severe forms of inflammation the process may extend backward into the submammary tissues and axilla.

Traumatic mastitis is usually circumscribed, the integument and subcutaneous areolar tissue being also involved. The deeper tissues escape unless great and unusual violence has been inflicted. If pyogenic infection takes place, suppuration with the various symptoms which belong to septic inflammation will be present.

Non-traumatic infective mastitis is almost always connected with lactation, occurring usually during the first few weeks after parturition. Functional, or sympathetic mastitis (non-infective) occurs at intervals in non-pregnant females, the symptoms being associated periodically with the menstrual function. Mastitis is also a symptom of *parotitis* or "*mumps.*"

Symptoms.—The first indications of inflammation of the mammary gland are pain and localized induration. The pain is constant, and usually severe in character, and may extend along the ribs to the axilla. It is due, in great part, to obstruction of the milk ducts and hyperdistention from retained excretion. The induration is usually well defined, and may consist of one or more nodules. Injection of the skin is marked over the area of induration. The temperature is elevated one or two degrees, the pulse increased in frequency, and a well-pronounced chill or a series of rigors is apt to be a feature of the earlier stages of this disease.

Treatment.—As soon as inflammation is threatened the breast should be supported by a bandage, or long, soft towel, or handkerchief thrown around the neck and shoulder and beneath the gland, holding it in the position of least discomfort. In the stage of hyperæmia the application of a light ice bag, with limited compression of the organ, is advisable. Artificial means should be employed to empty the breast. It is important to recognize the earliest collection of pus, and to relieve it by aspiration or incision. When the induration is localized and well marked, it is good practice to explore under cocaine with the large hypodermic needle to determine the presence of suppuration; or the bistoury may be used.

When *abscess* exists the pus should be freely evacuated by incision. The incision should, as before advised, be parallel with the direction of the galactiferous ducts. When the cavity is opened, the nozzle of the irrigator should be introduced and the abscess thoroughly washed out with 1-to-3,000 permanganate-of-potash or 1-to-5,000 sublimate solution. Drainage should be secured, and a loose dressing applied. The point of incision should be made in the lower portion of the sac, so that drainage may be free. At times it may be necessary to make a counter-opening.

Less frequently abscess may form in front of the glandular tissue beneath the integument or between the capsule of the gland and the thorax. Ostitis or periostitis of the ribs may be the cause of deep-seated submammary abscess.

Hypertrophy of the mammary gland is a physiological process, usually occurring at puberty and during pregnancy and lactation. In rare instances there is an extensive pathological hyperplasia of the connective-tissue elements of this organ, resulting in great enlargement. The *diagnosis* may be based upon the hard character of the mass, there being none of the softness and elasticity which belong to the normal breast. The hyperplasia is general, involving the entire framework of the organ, which will render it easy of differentiation from any form of neoplasm, for these grow from recognized centers of induration. The diagnosis meets with confirmation if the enlargement takes place after puberty, and in a non-pregnant woman.

In the *treatment* of this condition in the earlier stages well-adjusted and prolonged compression should be tried. This may be effected by a thick layer of absorbent cotton laid over the breast and held firmly down upon it by a roller. In advanced cases a free excision of the organ is demanded.

Tumors of the Breast.—New formations in the mammary gland are among the more frequent surgical diseases. The microscopical characters of tumors are elsewhere described. Unfortunately, they are more frequently *malignant* than *benign*. Although tumors of the breast occur chiefly in females, they are not uncommon in males. Among the non-malignant tumors are *adenoma*, *myxoma*, *fibroma*, and *enchondroma*. Various forms of cysts are also met with, while syphilitic gumma and tubercular deposits may occur in this organ. Carcinoma (scirrhus, encephaloid, colloid, and epithelioma) and sarcoma are the malignant neoplasms which are found in the breast.

Adenoma of the mammary gland is comparatively rare. The pathological change, a hyperplasia of the glandular tissue proper, is usually circumscribed. The tumor is of small size, freely movable with the breast, and does not form adhesions with the capsule, integument, or submammary fascia. There is no inflammatory process connected with its development, no enlargement of the axillary glands, no dilatation of the veins of this region, and little or no pain. It is found in nursing women, but is also not uncommon in early puberty and in women who have not borne children. It is not the rule for cystic degeneration to take place in this neoplasm, although such cysts may be met with in rare instances as a result of degeneration of the new-formed cells of the deeper portions of the growth.

Adenoma, of itself a benign neoplasm, is believed to be capable either of developing into carcinoma or of exciting the carcinomatous change in the organ. Not only in the simple circumscribed form of this neoplasm, but in that variety sometimes called tubular adenoma, in which the hyperplasia of the glandular cells is not confined to the acini and terminal ducts, but extends into and involves the galactiferous ducts as

far as the nipple, and which is more generally diffused than in the simpler form above described, it is admitted that the transformation into carcinoma is possible and at times rapid.

Treatment.—The tumor should be excised. If it is small it may be removed by sacrificing only that part of the gland tissue immediately around it. Upon the recurrence of the growth, the entire breast should be excised.

In removing adenoma or other small tumor of the breast, it may be exposed by linear incision through the skin and subcutaneous areolar tissue. As a rule, this incision should radiate from the nipple toward the circumference of the breast, parallel with the galactiferous ducts. When the tumor is well exposed by retraction of the edges of the wound and subcutaneous dissection, it should be removed, taking care to go beyond the limit of the disease about half an inch, cutting through sound breast tissue. When the hæmorrhage is arrested, strong subcutaneous catgut sutures should be introduced into the breast tissue on either side of the space left by removal of the tumor. When these sutures are tied, the edges of the wound in the breast are approximated, and the depression which otherwise would exist and cause a deformity is prevented. The edges of the incision in the integument should be closed by a separate row of sutures.

When a benign tumor involves more than half of the breast it is safer to remove the entire organ. It is usually advisable not to sacrifice the nipple in these cases. If the incision through the skin be carried along the fold or crease between the under surface of the breast and the chest wall, the integument of the breast, including the nipple, may be raised and the tumor and glands thoroughly exposed and removed. When the wound is closed, it will be seen that the scar is concealed in this fold.

Myxoma is very rarely met with in the mammary gland. It may occur as a single nodule and develop slowly from a single center, or it may develop from several centers and rapidly invade the entire organ. It is not adherent to the skin until inflammatory adhesions occur preliminary to ulceration of the mass. Infiltration of the axillary glands occurs only as a result of inflammation. The nipple is not retracted.

The prognosis is favorable if the tumor is discovered early in its development, and if in the excision a sufficient portion of healthy tissue is removed with the neoplasm. The *treatment* is free excision. The entire gland should be sacrificed, and, if the organ is wholly involved, the line of incision should be well out from the limits of the tumor in the healthy tissues.

Fibroma of the mammary gland may occur at any period of life. It is rarer in the aged than in the young, occurring mostly in persons under forty, and occasionally under puberty. This form of connective-tissue hyperplasia may affect the entire organ (as in general hypertrophy, already described) or a circumscribed area. A nodular or circumscribed fibroma is a hard, dense tumor, freely movable with the gland, and may or may not be painful. Shrinkage of the breast occurs at times as a

result of the cicatricial contraction of the new-formed tissue, and, when near the nipple, its retraction may resemble that of scirrhus. As a rule, this variety of tumor is of slow development. Not infrequently it undergoes cystic degeneration. The axillary glands are not involved, nor do adhesions occur until after atrophy of the gland with retraction of the new-formed connective tissue. It should be removed by the same wide and free excision as recommended for myxoma.

Enchondroma of the breast is very rare. It is apt to be circumscribed. Calcification has been observed in some of the few recorded cases of this neoplasm. Occasionally it is found with carcinoma. Enchondroma of the breast should be freely excised.

Cysts.—Among the forms of cystic tumors found in this gland are galactocele, sanguineous, dermoid, and hydatid cysts, and the forms which occur in the degeneration of adenoma, fibroma, myxoma, and carcinoma.

Galactocele is a cyst caused by obstruction of the ducts which convey the milk toward the nipple. The obstruction is followed by distention of the tubes and *acini*. Examined with the microscope, the contents of these cysts consist of epithelial cells in various stages of granular metamorphosis, and milk globules.

The diagnosis may be determined by aspiration. The treatment consists in incision and evacuation of the contents with drainage until the cysts may be obliterated by the process of granulation.

Dermoid and *hydatid* cysts are exceedingly rare in this situation. The diagnosis may be determined by aspiration, and the proper treatment is excision. Cysts may occur in the breast from the extravasation of blood after contusions, or from the non-traumatic rupture of blood or lymph vessels. They heal readily after incision and drainage.

Tuberculosis of the breast is rare. It is usually due to direct infection through the nipple. The nodules may be disseminated generally through the gland or beneath the capsule, or there may be one or more large collections. They are hard to the touch. The history of the case will aid in determining the character of the lesion. If there is no general dissemination of tubercular matter—that is, if the disease is limited to the mammary gland—this organ should be freely excised.

Sarcoma of the breast attacks usually the young and middle-aged. It is rarely general in its development, but commences as a single nodule, more apt to occupy the upper portion of the organ than the lower, whence it invades the gland and circumjacent structures in every direction. The rapidity with which it grows depends in part upon the microscopical character of the neoplasm, and in part upon the age of the patient. Sarcoma develops more rapidly in the young, and the round-cell sarcoma, which variety is most frequently met with in the breast, is more rapid in its development than the spindle-cell sarcoma. In the earlier stage this tumor, though firm and nodular, is freely movable with the gland. Its growth, however, is often so rapid that the skin and subcutaneous tissues, the submammary fascia, and the muscles of the chest become involved, the breast stands out full and tense, and be-

comes immovable. The superficial veins are greatly enlarged. As a rule, the lymphatic glands of the axilla are not involved until suppuration of the mass induces axillary adenitis.

Differentiation between round and spindle-cell sarcoma is difficult unless the tumor is examined with the microscope. Practically, the differentiation is not important. The first variety is softer to the touch, more rapid in growth, and is more vascular. It is apt to occur in the younger class of patients.

Both forms of sarcoma tend to the formation of cysts within their structure. As stated, they may be due to fatty degeneration of the embryonic elements of the tumor, or may result from caverns of blood which have become cut off from the general circulation through the tumor.

The diagnosis of sarcoma of the breast depends upon the age of the patient, the rapidity of its growth, and the absence of axillary engorgement. The treatment consists in free excision. The action of pyogenic and erysipelatous organisms upon sarcoma will be given in the chapter on tumors.

Carcinoma is by far the most common form of neoplasm met with in the breast. The order of prevalence of the four varieties is *scirrhus*, *encephaloid*, *colloid*, and *epithelioma*. Cancer of the mammary gland occurs in rare instances in males. In women it is met with most frequently in the period from the fortieth to the sixtieth years of life. It may occur later than this, and is rarely seen earlier than the age of thirty. Women who have never been pregnant are affected, though probably not so liable as those who have borne children.

Scirrhus of the breast appears usually as a single hard nodule or lump, situated in the substance of the gland, movable within this organ, but firmly imbedded in it; or two or more nodules may appear simultaneously in different parts of the gland, which eventually approach each other so as to form a nodulated mass. The growth of scirrhus is, as a rule, not rapid in the earlier stages of its development, but, after reaching a certain size, it spreads with increasing rapidity. The length of time which may elapse between the commencement of the neoplasm and metastasis in the subpectoral and axillary lymphatics varies in different individuals. It is, however, in general proportionate to the rapidity of the growth of the neoplasm. Pain, which is a symptom of this disease, is lancinating in character rather than dull and continuous. It is usually more severe in tumors which develop rapidly.

Cancer of the breast may assume the form of a single large, rounded, and nodular mass, or nodules of various sizes may develop in the organ or be scattered in knots or groups beneath the integument, in the pectoral muscles, or along the line of lymphatics leading into the axilla. If left unmolested, scirrhus soon invades the tissues around the breast, the muscles of the chest becoming infiltrated, the skin attached to the mass, and the nipple retracted. On account of pressure the circulation in the most remote portions of the invaded gland is interfered with, and ulceration ensues, giving rise to a more or less extensive granulating sur-

face, from which there is a discharge of a serous-like fluid containing blood-corpuscles, embryonic, pus, and cancer cells. In the later stages lymphatic engorgement is more extensive, and the effects of compression upon the thoracic and axillary nerves more evident. Not infrequently the subclavicular, supraclavicular, and cervical lymphatics become engorged. Pressure symptoms are not alone confined to the nerves, but the interference with the return circulation in the axillary vein may produce general œdema of the extremity.

Encephaloid cancer of the breast differs only in degree from the scirrhous variety. It is softer under pressure, grows with much greater rapidity, ulcerates earlier and more extensively, is more prone to hæmorrhages, and tends to a more rapidly fatal termination. It is more apt to recur after removal.

Epithelioma of the breast is rare. It commences in or near the nipple, and may extend along the epithelial lining of the lactiferous ducts, or spread along the integument of the areola. Although ulceration begins earlier, its progress is slower and less painful than in either of the forms of cancer just given, which attack the deeper structures of the gland. If not extirpated, the entire gland may be infiltrated, metastasis occurs, and death follows from general exhaustion.

Prognosis and Treatment.—The prognosis of cancer of the breast is always grave, the gravity varying with the character of the neoplasm, the general condition of the patient, and the length of time the tumor has existed before excision. Left without surgical interference, a fatal termination is reached usually within from one to two years after the appearance of the disease. Encephaloid is most rapidly fatal, scirrhus next in order, and epithelioma last. Death ensues from exhaustion caused by suppuration, pain, anorexia, and infiltration of the various organs by metastasis. In isolated cases scirrhus of the breast reaches a certain point and remains stationary for a number of years before again enlarging and producing a fatal issue. In one instance in a woman seventy-five years of age, seen by the author in the practice of Dr. S. N. Leo, a well-marked scirrhous cancer had been nine years present, and without glandular infiltration or a fatal issue.

With the operation as performed in modern practice the prognosis is much more favorable. This practice implies early recognition of the presence and character of the neoplasm, immediate and wide extirpation of the invaded organ, and a careful dissection of all metastatic foci in the glands of the axillary plexus. As to the selection of cases in which operation is justifiable, it may be admitted that interference is called for in all cases in which the lymphatic engorgement has not extended beyond the axillary region, and in which the invasion of the pectoral and thoracic muscles is not so deep or extensive that a clean excision is possible without opening into the thorax. Even when metastasis of the cervical lymphatics has occurred, relief may be gained. It is well to bear in mind that a simple non-malignant enlargement of the glands may occur before true metastasis has taken place.

It should be the practice in all cases of cancer of the mammary gland

to open into the axilla in order to be sure of the condition of the glands, for these organs may be the seat of cancerous infiltration which can not be recognized without incision.

As to treatment, the following line of practice should be adopted:

A tumor of the breast occurring in either sex after the thirtieth year of life should be excised as soon as discovered. The contraindications to this procedure are: (1) a condition of prostration so extreme that a surgical operation would involve great and unusual risk to life; (2) metastasis to such an extent that complete removal of the neoplasm is impossible.

The incision and dissection should be far away from the limit of the tumor in the healthy tissues. When only a small portion of the organ is involved, it is advisable to extirpate the entire gland. When the patient is under thirty years of age, and when the tumor is thought to be benign in character, the less radical operation of enucleation of the neoplasm may be undertaken. Any new formation so removed should be carefully examined, and, if found to be malignant, a wider incision should be made, either at the first indication of recurrence, or preferably at once.

Operation.—The patient is placed upon the table with the chest slightly elevated, the breast and axilla of the affected side near the edge. The arm, intrusted to an assistant, should be held at a right angle to the body, and the head directed to the opposite side. The integument of the axilla and within the field of operation should be shaved, washed with soap and warm water, afterward with ether, and finally with 1-to-2,000 sublimate solution. The diseased organ should be handled as gently as possible. Sterile towels should be laid over the exposed surface, leaving only the part to be removed in sight.

In removal of the mammary gland for cancer, two important points present themselves to the surgeon. First and most important is that the operation be done at the earliest possible moment. If this were properly done within the first two to four months in every case of neoplasm of the breast, few would perish, where a great many are sacrificed by delay.

Secondly, and scarcely less important, the operation when done should be thoroughly done. It is as important to remove the entire lymphatic apparatus from the clavicle through the axillary space down to and with the breast as it is to remove the breast itself. It is very exceptional when metastases have not occurred in the lymphatics of the pectoralis minor and axilla, if a tumor has existed in the breast for two or three months.

The incision should be far away from the tumor. When the skin is divided, the knife should be at least two inches from the indurated border of the cancerous mass. No manipulation of the breast should be permitted, for fear of driving cancer cells into the lymphatics. If there be any doubt as to the diagnosis, it will be proper to incise the tumor as the first step in the operation, in order to determine its exact nature. The dissection should commence in practically all cases at the clavicle. As a rule there is no superficial or cutaneous infiltration in this

region, and the incision may be made in such a way that after the dissection is completed the skin readily comes together. No special incision need be recommended if the essential point be borne in mind that the contents of the axilla and the pectoral muscles must be exposed. The incision most commonly adopted is one which begins at the point of insertion of the tendon of the pectoralis major muscle into the humerus, curved slightly inward in a direction which will go wide of the edge of the tumor and around the breast, describing a circle which meets with the first portion of the incision. A second incision is made from about the center of the clavicle and extends parallel with and one inch to the

Fig. 627.—Incision for wide extirpation of the breast and axillary contents in carcinoma mammæ. (Modified from Halsted.)

inner side of the axillary vessels. By this precaution the cephalic vein is not endangered. When the upper triangular flap is lifted the axillary space may be thoroughly exposed (Fig. 627). Hæmorrhage is arrested in the line of incision as the operation proceeds. The triangular flap in the upper portion of the dissection is stripped of fat, leaving nothing but the skin, and this is reflected over the point of the shoulder out of the way. The triangular flap in the axilla is lifted in the same way, being free from fat, keeping the scissors or knife close to the under surface of the integument, and is reflected downward. The flap nearest the chin of the patient is next lifted and reflected, until the pectoralis muscles are exposed and the upper and most important portion of the field of operation is in view. The pectoralis major muscle should be separated from the humerus through its tendon and close to the point of insertion. This can safely be done, since the finger can be inserted between this and the vessels of the axilla to serve as a guide to its division. This muscle is then reflected toward the chest. The operator now carefully removes that portion of the pectoralis major muscle which is attached to the clavicle immediately over the point where the axillary artery and vein rest under this bone. This accomplished, and all hæmorrhage arrested by the application of forceps and ligatures when required, with the greatest

care the operator strips all the fat, lymphatics, and loose tissue from the fascia of the axillary vein and artery, tying with fine silk the venous branches, which must be divided usually within one eighth to one fourth of an inch of the point of entrance into the parent trunk. When the pectoralis minor muscle is reached in the dissection, its insertion into the coracoid process should be divided, and it in turn reflected inward toward its point of origin from the chest. The dissection is then continued down the vein and artery until the lower boundary of the axilla is reached. At this stage of the operation it is well to pack the wound with sterile gauze. Then, beginning from above downward, the connective tissue and lymphatics which rest upon the chest wall and the under surface of the pectoralis minor muscle are carefully removed, dividing the small pectoral muscle well out toward its origin. The upper fibers of the pectoralis major are removed in the same way, and, lastly, the lower portion of the pectoralis major is dissected from the ribs, and with it the breast, which still remains attached. In a single instance where the axillary vein was studded with infected lymphatics this vessel was tied at the clavicle and entirely removed with all of its branches, leaving nothing but the artery and nerves in place. The patient recovered and survived the operation two years without any recurrence in the seat of operation, the cancer recurring in the opposite lung. The danger of seriously wounding the axillary vein is not great. When in the course of the dissection a branch coming into this vein is wounded close to the parent trunk, the stump of the branch may be grasped with an Esmarch forceps and a fine silk ligature tied around it on a level with the wall of the vein. I have done this in several instances without any hæmorrhage. By taking care not to injure the cephalic vein in the primary incision, this vessel will carry on the circulation in the arm even after the axillary is obliterated. Sterilized silk should be used in preference to catgut for this particular ligature. In cleaning out the axilla, the dull-pointed scissors, or dulled grooved director and the finger nail, will be found the most suitable instruments, and preferable to the knife, with which, even in the hands of an expert, annoying accidents may occur. In closing this wound, the upper portions of the flap fall easily together, and by bringing the arm down to or slightly upon the chest the large space left by removal of the breast may be in great measure closed. The raw surface left should heal by aseptic granulation, but may ultimately have to be closed by grafting. For this latter requirement I should recommend the method of Lusk.

After the pectoral muscles have been removed, the clavicular fibers of the deltoid enable the arm to be carried across the chest.

In very recent cases it may not always be necessary to remove all of the pectoral fibers of the pectoralis major muscle. The pectoralis minor should be removed in all cases, as it is more often infected with cancer than the larger muscle. As this latter muscle is important to the use of the arm, only the lower half of the pectoral portion—that portion in immediate relation to the breast—should, if consistent with the ultimate safety of the patient, be removed. All of the tissue on the under surface

of the fibers immediately over the axilla should be carefully removed in all cases.

In uniting the flaps, silkworm gut is the best suture. It is advisable to carry a good-sized catgut twist out of the lowest portion of the axilla through the skin, to give escape to any oozing. The dressings often require to be changed on the second or third day.

For the improved technique and results in this operation, surgery is indebted to Prof. Halsted, of Baltimore.

Abscess of the thoracic walls usually results from ostitis of the clavicle, sternum, ribs, scapula, or vertebræ, or enchondritis of the costal cartilages of tuberculous origin. If not incised, they open spontaneously through the integument and discharge pus and at times particles of bone and other detritus. Spontaneous cure may occur, although this is the exception. Sinuses usually result, and continue until the diseased tissues are excised. The most common seat of ostitis is in the sternum and the sternal ends of the ribs. The indications in treatment are to lay the sinuses open, carefully following each to its terminus, scrape the indurated lining membrane away with the scoop, and remove all dead bone by scraping with the Volkmann spoon or exsection in mass. Opening into the pleura or mediastinum should be avoided. When the abscess leads behind the sternum, as in a case which came under my care, a segment of this bone should be removed in order to expose and drain the cavity. In one instance the manubrium and a portion of two ribs were removed with cocaine anæsthesia. In exsection of a portion of one or more ribs, the incision should be made along the center of the bone, the periosteum lifted with the elevator (first from the anterior surface and then from behind), and the bone divided with the cutting forceps. All of these wounds should be packed with sublimate gauze.

Exsection of the clavicle may be demanded in ostitis of this bone. In a case operated upon by myself for necrosis, the incision extended the entire length of the bone, and the excision was subperiosteal throughout. A new and strong clavicle formed, with perfect motion at the sternal and acromial articulations. The shortening was half an inch. Six years after the operation the function of the injured side is perfect.

Empyema.—Pus may collect in the pleural sac as a circumscribed abscess, or exist in the general cavity of the pleura.

The diagnosis may be determined from the elevation of temperature usually present, by dullness on percussion over the fluid, and by aspiration, using the smaller needles. The treatment consists in evacuation of the purulent contents by incision. The contents of the pleural cavity should not be too rapidly evacuated. Fatal syncope has occurred in several instances during this operation. The object is to drain the cavity of the abscess at its most dependent portion, which should be determined by the introduction of the needle in several of the intercostal spaces. The opening should be made about opposite the center of the rib, preferably a little posterior to the middle. A longitudinal cut is made over the middle of the rib down to the bone, and the tissues lifted from the

periosteum by the elevator. On the inner surface the costal pleura is lifted from the rib. About two inches of the rib should be removed with bone forceps. When the costal pleura is divided, it will be indicated by the escape of pus and the entrance of air. Partial collapse of the lung of the affected side follows. A drainage tube, or preferably two tubes, are carried and secured by transfixion with safety pins. The cavity should now be washed out with sterile warm water and a loose absorbent dressing applied.

Portions of several ribs should be excised when necessary to thorough drainage, or to close a circumscribed abscess, as advised by Estlander.

Ostitis or other diseases of the scapula do not require especial consideration. Removal of any portion or all of this organ may be effected.

Wounds of the Chest.

Wounds of the chest are divided into penetrating and non-penetrating. A penetrating wound is one which opens into the pleural cavity or mediastinum. Pneumothorax, with hæmorrhage into the pleural sac, may occur, however, without an external opening, as when, after a contusion of the chest, a fractured rib penetrates the lung, the inspired air filling the pleural cavity and causing collapse of the lung.

Contused wounds of the chest may be accompanied by fracture of the ribs, lacerations of the muscles, or followed by pleuritis with or without either of the above complications.

Non-penetrating wounds of the chest, whether incised, lacerated, or punctured, are treated as directed for such lesions in other parts of the body. The same may be said of gunshot wounds which do not involve the bony framework of the thorax or pass into the cavities.

Penetrating wounds of the thorax are dangerous in proportion to the size of the entering substance, the direction and depth of the track of the wound.

Punctured wounds, not involving the heart and great vessels, are not usually fatal, while death is apt to follow even small lesions of these organs. *Incised* wounds are more dangerous, while *gunshot* wounds are still graver lesions.

Passing in any direction into or through the mediastinum, a gunshot wound is apt to inflict fatal violence. In the lungs and pleuræ the prognosis is not so grave, being proportionate to the size or shape of the missile and to the nearness of its approach to the great vessels at the root of the lung.

The extensive lacerations of the small missile fired from the Krag-Jorgensen rifle have been mentioned.

Again, if a rib is fractured at the point of entrance, the gravity of the prognosis is increased from the destruction by and the lodgment of particles of bone driven into the lung. Wounds produced by round missiles of small caliber, not fatal within a few hours, are apt to end in recovery. Conical missiles which strike the chest wall and turn or "plunge" on their long axes produce extensive and usually fatal injury.

Diagnosis.—Penetrating wounds of the chest, involving the lung, are accompanied almost always by bleeding from the mouth, dyspnœa, and by the passage of air in and out through the wound with each respiratory act. The dyspnœa is due to blood in the bronchial tubes and trachea, and often to partial collapse of the lung, which is caused by the entrance of air through the wall of the thorax.

The admission of air to the pleural sac does not, however, always follow a penetrating wound, on account of its small size or the valvular arrangement of the tissues through which it passes.

Shock is usually profound if the lung is wounded. A wound of entrance and exit, with the pleura and lung directly between, indicates lesion of these organs. Occasionally, however, a ball strikes against a rib, is deflected, and sweeps around the chest beneath the skin and makes its exit at a remote point without entering the pleural cavity.

Treatment.—The arrest of hæmorrhage is the immediate indication. This may be hastened by deligation of the extremities, as already given.

Any bleeding from the vessels of the thoracic wall should be arrested by the ligature. Foreign bodies, fragments of bone, etc., near the wound or entrance or exit, should be removed. When hernia of the lung occurs, if seen before strangulation has taken place, it should be irrigated with sterile warm water or 1-to-5,000 sublimate solution and reduced. If gangrenous, the protruding mass should be tied with the elastic ligature and the dead portion removed. Gangrenous foci of the lung or circumscribed pulmonary abscess may also be opened for drainage in extreme cases by section through the thoricac wall. Adhesions of the pulmonary to the thoracic pleura will facilitate this operation.

Uncomplicated wounds of small size should be closed at once by an iodoform and sterile gauze dressing, well applied. If symptoms of pleural empyema follow, an opening may be made for drainage, provided that the presence of pus is demonstrated by the aspirator.

In complicated wounds, where the opening is large, or where fragments of bone, clothing, or any foreign substance have been driven into the pleura and lung, the wound should be kept open for drainage and treated by irrigation, as directed for empyema.

In *wounds of the heart* the right auricle and ventricle are most frequently injured. Punctured wounds are less apt to prove fatal than those produced by gun missiles. Fischer has collected four hundred and fifty-two cases of wounds of the heart, with seventy-two recoveries.*

The *symptoms* of injury to the heart are those of profound shock. The pulse is irregular, and, if there is hæmorrhage into the pericardium and mediastinum, symptoms of pressure on the heart muscle are soon evident.

The means employed to arrest internal hæmorrhage elsewhere may be used here. Quiet should be enforced. Under proper conditions the pericardium and heart may be exposed by operation and sutures of sterile catgut applied to a wound of one or both of these structures.

* "Archiv für klinische Chirurgie," 1868.

CHAPTER XXI.

THE ABDOMEN.

The Stomach.—Gastrostomy, which operation has been described in the article on œsophageal stricture, is required occasionally in the removal of *foreign bodies* which have been carried into the stomach and can not find an exit through the pylorus or be ejected in the act of vomiting. *Gastroliths* of considerable size, formed by the accretion of ingested matter, have in this way been removed. Although a considerable degree of tolerance may be present, if the size and shape of the foreign body are such that the probability of its removal by natural means are remote, the stomach should be opened. Two methods may be followed: First, gastrostomy, the details of which do not differ materially from those already given. It may, however, be necessary to make a larger opening in the stomach for the removal of the foreign body than when the operation is performed simply for the purpose of feeding. When feasible, the better operation is *gastrotomy*. In this operation the stomach is exposed by the same incision as for gastrostomy, usually enlarged in whatever direction may be required after the situation, size, and shape of the body to be removed has been ascertained. When the stomach is fully exposed, an effort should be made to draw it up into and through the wound as far as possible, where it is held by silk threads inserted into the walls, the needle which introduces these not passing into the lumen of the stomach. The organ may then be incised, and the foreign body extracted either by the finger or a suitable instrument. Great care should be taken to so protect the margins of the abdominal incision with mops of gauze, to prevent the entrance of any septic matter into the peritoneal cavity. The wound in the stomach should be closed at once by the Lembert suture, with not more than one eighth of an inch between the stitches. If the stomach can not be drawn up into the wound, the abdominal incision may, if necessary, be further enlarged and sterilized pads inserted in such a way that the contents of the stomach can not come in contact with the peritonæum after it has been incised. The same method of suture for the stomach wall should be employed. As to the choice between these two operations, when the foreign body is small, and in the hands of an expert operator, *gastrotomy* would be preferable. For a larger foreign body, or in less expert hands, the operation of *gastrostomy* would be the safer procedure, the wound in the abdominal wall and stomach being permitted to close by granulation.

It is an essential feature of either procedure that the stomach be thor-

oughly washed out before the operation and that no food be taken for twelve hours preceding the anæsthetic. For washing out the stomach, the ordinary œsophageal tube and pump or the stomach siphon may be used.

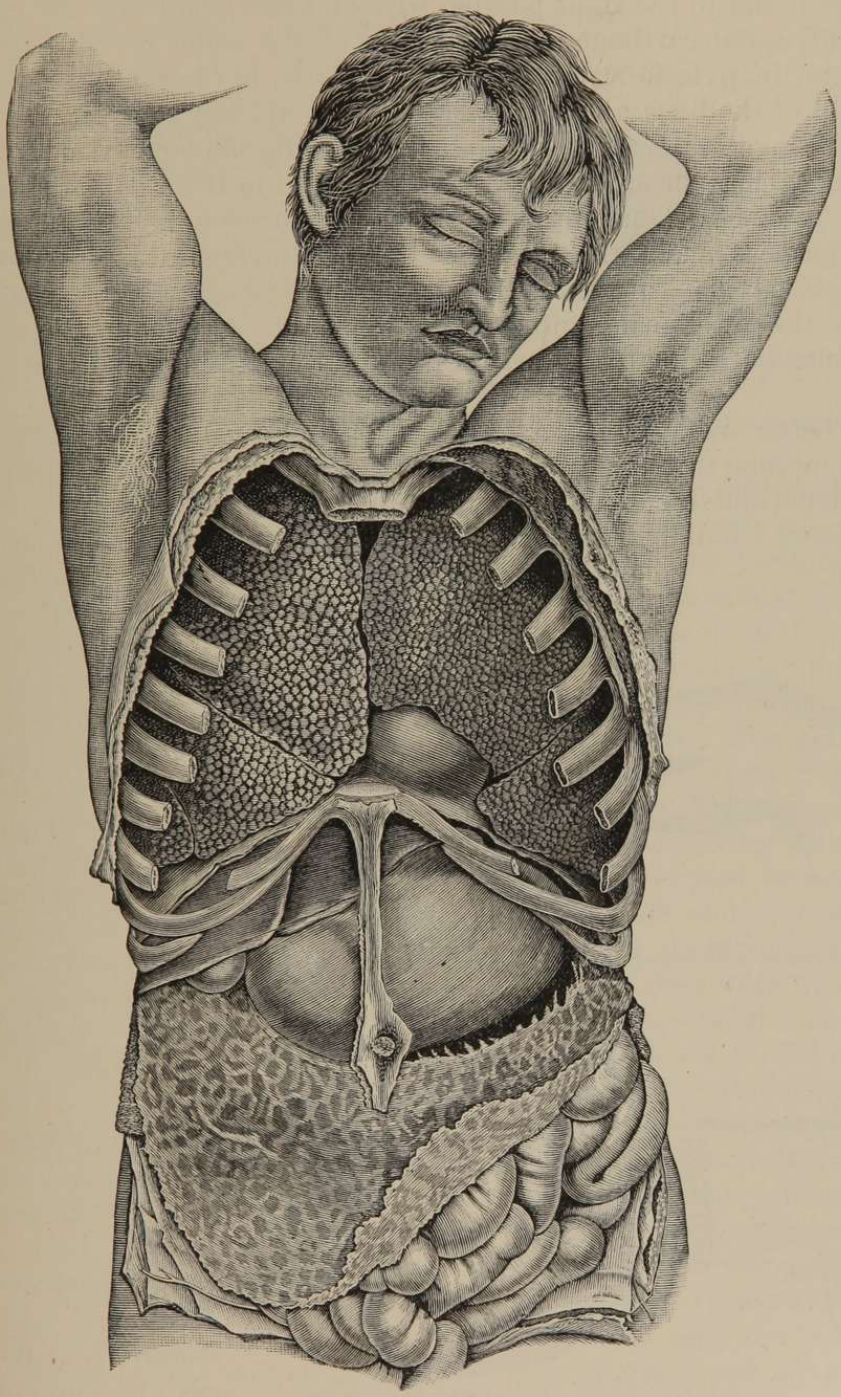

Fig. 628.—(After Maclise.)

Gastrotomy may also be required in certain cases of stricture of the pylorus. At least temporary benefit may be obtained by the introduction of the finger through a limited incision in the stomach wall near the

pyloric end, carrying the finger into the pylorus and making careful dilatation of the stricture. The incision for exposing the pyloric end of the stomach should be about five inches in length, commencing at a point one inch to the left of the apex of the ensiform cartilage, and extending downward and to the right parallel with and one inch below the curve of the right costal cartilages. On account of the usual overdistention of the organ in pyloric stricture, the pylorus is, in these cases, further to the right of the linea alba than normal. Should the stenosis be so great that the finger can not be introduced, dressing forceps, or any dilating instrument, may be substituted. The incision in the stomach should be closed by Lembert sutures. If, after the incision in the stomach at the pylorus is made, the passage into the duodenum is found to be so nearly closed that dilatation can not be successfully accomplished, one of the three following procedures must be adopted, and may be done immediately, should the condition of the patient be such as to permit it.

The better operation is *duodeno-gastrostomy*, which consists of a longitudinal incision through the strictured pylorus along the anterior aspect of the stomach and duodenum. The incision usually extends from an inch to an inch and a half in the stomach tissue and the same distance over the pylorus into the duodenum. The stricture is divided in this incision, and the posterior internal surface of the wall of the stomach, the pylorus, and duodenum are brought well into view by inserting a tenaculum above and below in the center of the incision, and widely separating the edges of the wound. Holding the wound thus open in diamond shape, the duodenum is brought over upon the stomach and sutures are inserted, beginning at the upper and lower angles made by retraction with the tenacula. Sutures should be of silk, and inserted after the method of Lembert. It will be seen that in this operation the duodenum is folded over and sewed on to the opening in the stomach in such a way

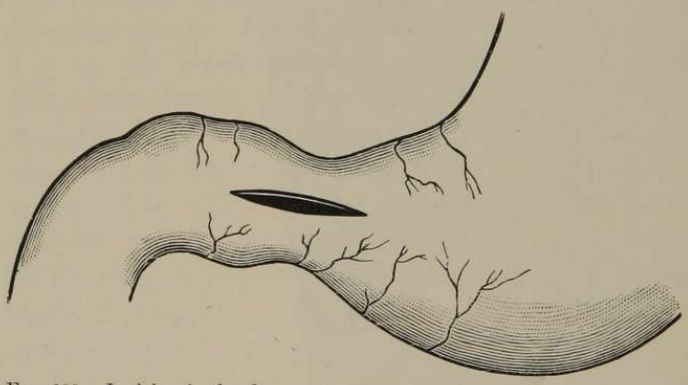

Fig. 629.—Incision in duodeno-gastrostomy. (From Park's "Surgery.")

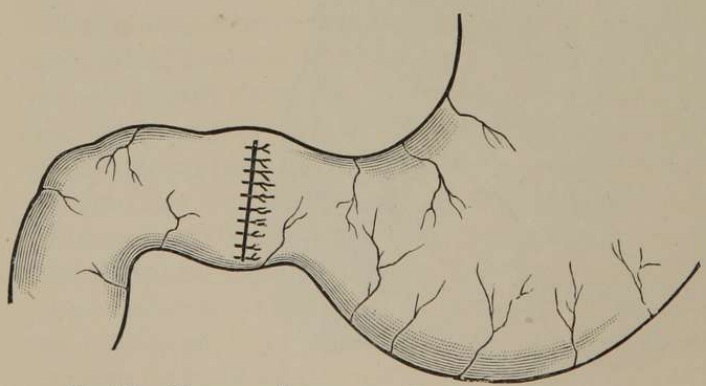

Fig. 630.—The same after suture. (From Park's "Surgery.")

that a stricture no longer exists, the contents of the stomach falling directly into the duodenum beyond the pylorus. Should any difficulty be experienced in uniting the edges of this longitudinal incision, the opening may be enlarged in diamond shape by excising a triangular section from either margin.

Gastro-enterostomy is the operation next in order of preference.

This operation was first done by Wölfler, of Vienna, in 1881, and is performed as follows: A perpendicular incision is made along the median line, beginning at the xyphoid appendix, and down in the direction of the umbilicus, as far as may be necessary to thoroughly expose the stomach and duodenum. This may be re-enforced by a transverse incision on either side. The most careful asepsis is essential in all these operations within the peritoneal cavity, and the sterile mats are necessary in order to prevent the contents of the viscera coming in contact with the peritoneal surfaces. A preliminary irrigation of the stomach immediately before the anæsthetic is given, and for several days previous to the operation, should not be forgotten. The duodenum may be made out and carefully followed, and a loop of the jejunum, as close to the duodenum as practicable, should be selected for the anastomosis. The point having been selected, the contents are carefully removed from five or six inches of the intestine by pressure with the fingers, and the gut kept empty by the fingers of an assistant, or, preferably, by tying with sterile tape. An incision at least three inches in length should be made into the anterior wall of the stomach about the middle of this organ and near the greater curvature. The incision should divide all the coats down to the mucous membrane, but should not at first enter the cavity. A similar incision is then made into the intestine, the operator endeavoring to divide the peritoneal and muscular coats down to the mucous membrane. The lower edges of these two incisions are united by a running (continuous) suture of fine silk, the needle passing through the muscular and peritoneal coats of the stomach and into the peritoneal and muscular coats of the intestine until the two edges are thoroughly united. The incision is then continued through the mucous membrane into both organs, and the remaining edges are united throughout the extent of the wound. This being done, it is advisable to re-enforce with a second row of interrupted sutures which include only the peritoneal and muscular coats. When this procedure is adopted, and the operator is convinced by inspection that there is reasonable doubt that metastasis has occurred, he should excise the diseased area, going well beyond the margins of induration, and close the stomach and duodenum, as shown in Fig. 632.

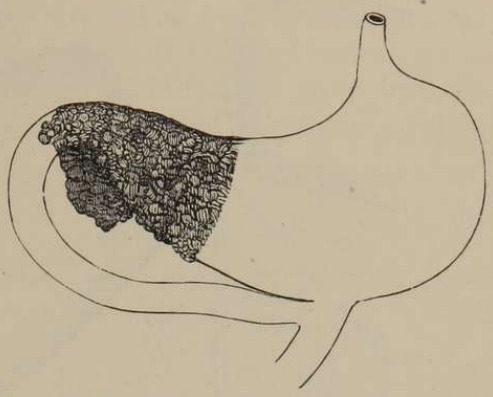

Fig. 631.—Wölfler's operation for gastro-enterostomy.

Of all the operations for lateral anastomosis between the hollow organs of the abdominal cavity, it seems that the rapid method with some form of segmented plate could better be employed in this particular operation

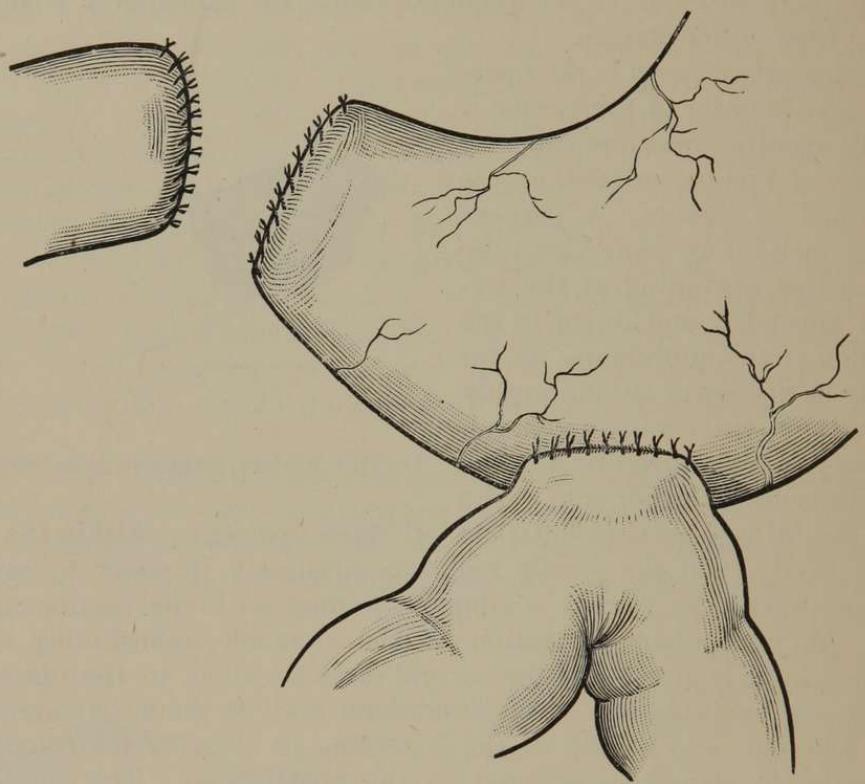

Fig. 632.—Wölfler's operation modified by excision of the diseased area and closure of the duodenum and pyloric end of the stomach. (From Park's "Surgery.")

than all others. The insertion of the number of sutures required in Wölfler's procedure consumes a great deal of time, and where time is a factor of such great importance it would be proper to employ the segmented rubber plates of Dr. Byron Robinson.

Dr. Robinson gives the following directions for making the segmented rubber plates:

Take two pieces of a rubber band, similar to those used in closing a purse or a bundle of papers, about two and a half inches long and three quarters of an inch wide. For larger openings the bands should be longer. Cut the corners off as shown in Fig. 633, and in the center of each band to be approximated cut out a triangular piece, leaving, when the two halves come together, a square aperture in the middle of the plate. Cut out two round holes on each side, half an inch apart. The holes are left large, so that the part of the chamois-skin ring to be described with the linen thread will easily pass through. From a piece of chamois skin cut off several long strips, or wide shoe strings, and twist two or three of these strings together into a ring. This ring is fastened to the plate, as shown in Fig. 634, with catgut sutures. Finally loop the six linen sutures (Barber's linen thread, No. 40) on the ring armed with six milliner's needles, and the plate is ready for use. The incision through the walls

of the stomach and small intestine should be three and a half or four inches in length. One plate should be carried through the opening into either organ to be approximated and the needles made to traverse the wall from within, emerging at a proper distance from the edge of the incision. Each thread of one plate should bear an accurate relation to the corresponding thread of the opposite plate, so that when all the sutures are tied the compression will be equally distributed and no puckering permitted. When tied, the sutures should be cut short and the line of union be re-enforced by a carefully applied continuous suture

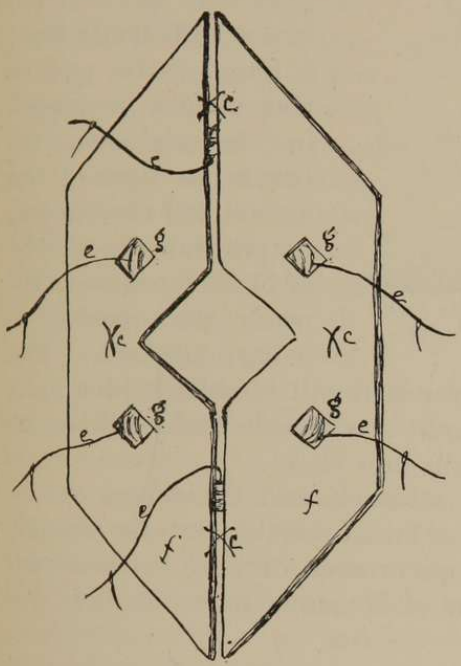

Fig. 633.

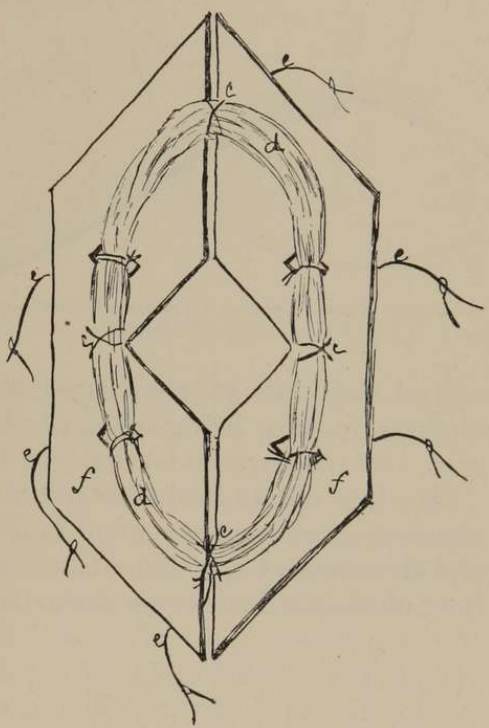

Fig. 634.

Fig. 633.—Robinson's segmented rubber plates. Fig. 633 represents the face of the segmented rubber plate for anastomosis; *c c c* and *c* mark the points where the catgut sutures stitch the sheepskin ring to the rubber bands, *f* and *f*, composing the plate; *e* indicates the six sutures armed with six needles; *g* notes the two lateral holes in the plate. The two end sutures appear between the edges of the rubber bands. The plates, of course, can be made of any size to suit the aperture.

Fig. 634.—The same, showing the chamois-skin ring. Fig. 634 shows the back of the segmented rubber plate for the anastomosis; *f* and *f* indicate the two pieces of rubber band composing the plate; *d d* marks the sheepskin ring stitched on to the rubber bands at *c c c* and *c* with catgut; *e* marks the six sutures armed with six needles. The aperture to allow fecal circulation can be made of any size, as well as the plates. This plate is about the proper size to use in the small intestines of any adult human.

(Lembert) of fine silk. This same technique will also apply to lateral intestinal anastomosis.

Gastro-pylorectomy.—Excision of the pylorus and the pyloric extremity of the stomach and reunion of the divided surfaces by suture is an operation exceedingly formidable, and very rarely justifiable. It should only be entertained in cases of stenosis or complete occlusion of the pylorus from non-malignant ulcer, in which *pyloroplasty* (duodeno-gastrostomy) could not be done, or in cancer of this portion of the stomach and duodenum, recognized in the early stages before metastasis had occurred. The incision through the abdominal wall is the same as

for Wölfler's operation, extended somewhat farther to the patient's right side, in order to give a better exposure.

All hæmorrhage should be arrested before the parietal layer of the peritonæum is incised. When this is done, the finger should be introduced and the pylorus located by following along the anterior smooth surface of the stomach, beneath the overlapping free border of the liver. If it be discovered that the incision is not sufficiently free, a large sterile pad or mat should be placed in the abdomen between the edges of the wound and the viscera, to prevent the escape of blood into the cavity while the opening is being enlarged. The wound should be widely dilated, the liver and gall bladder held up out of the way (care being taken not to wound this friable and vascular organ), and the parts to be removed brought into view.

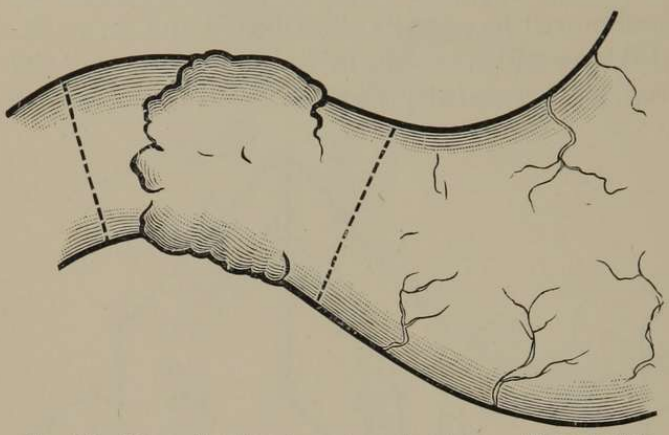

Fig. 635.—Lines of section in gastro-pylorectomy. (From Park's "Surgery.")

Having determined the extent of stomach and duodenum to be removed, these organs should be lifted as far as possible into the wound, and the omental attachments, on both curvatures, divided between two rows of catgut ligatures as far as the line of excision, and no farther. As

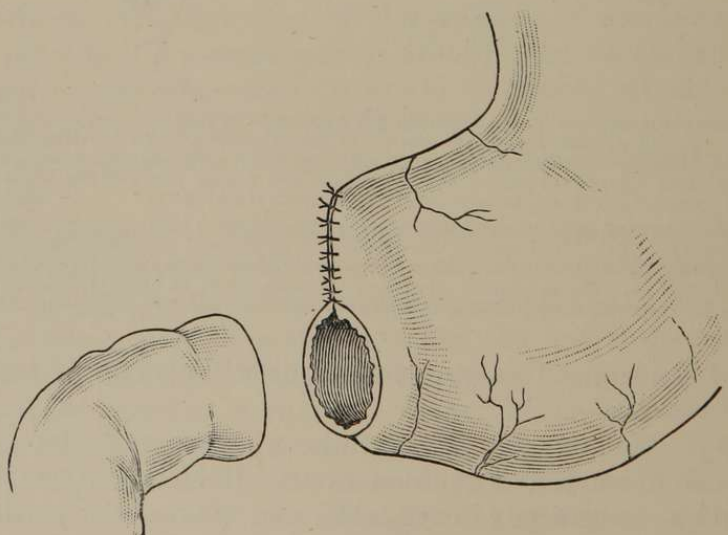

Fig. 636.—Partial suture of the stomach. (From Park's "Surgery.")

soon as the peritoneal attachments are divided, a mat, which has just been taken from the boiler and squeezed as dry as possible, should be placed under the parts to be excised in order to prevent blood or other

matter from getting into the peritoneal cavity. The wall of the stomach is next cut through in a transverse direction, and, when a sufficient opening has been made, all fluids or other matter should be removed by small soft sponges attached to holders. Some operators apply a clamp across the stomach just above and to the duodenum just below the line of excision. All hæmorrhage should be arrested as the operation proceeds. If a clamp is not employed, a silk loop should be thrown around the duodenum to prevent its slipping downward. When the diseased portion is removed, the wound in the stomach should be closed from the lesser curvature downward, until the opening left is of the same size as that in the divided duodenum. The materials to be used are fine iron-dyed silk and small half-curved needles.

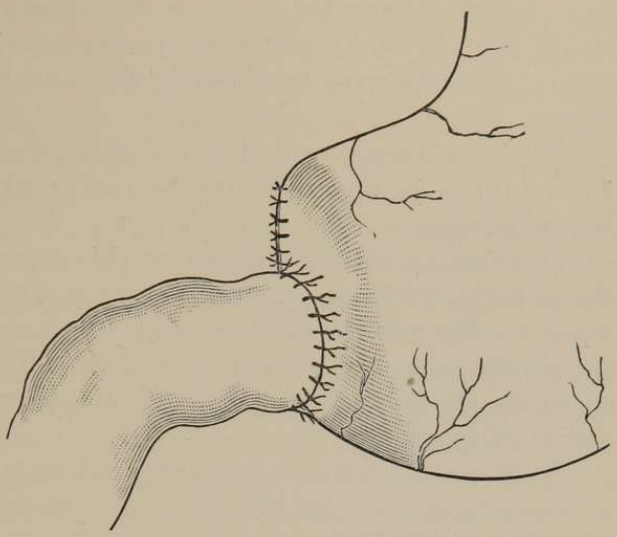

Fig. 637.—The reunion completed. (From Park's "Surgery.")

The method of closure is by the *Czerny-Lembert* suture (Fig. 638). The first row is inserted from the inner side, the needle passing through the mucous membrane, submucous, and slightly into the muscular tissue, but not the peritonæum. The posterior half of the wound should be closed first. The outer suture, which is that of Lembert, passes beneath the peritoneal covering, practically running through the muscular layer, but does not pierce the mucous membrane. The needle is introduced on one side three sixteenths of an inch from the cut edge of the viscus, and is made to emerge one sixteenth of an inch from the margin (passing about one eighth of an inch beneath the peritoneal coat). It is then carried to the opposite side and introduced in the same manner one sixteenth of an inch from the cut edge and brought out one eighth of an inch farther on. This suture should be repeated every eighth of an inch. As fast as introduced the ends should be tied together and intrusted to an assistant. The sutures are not finally tied until all are inserted, and are then secured from above downward.

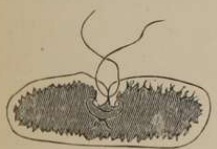

Fig. 638.—The Czerny-Lembert suture. The upper suture is Lembert's, the lower is Czerny's.

When the upper portion of the aperture in the stomach is closed, the sutures should be carried from the edges of the remaining aperture across to corresponding points upon the duodenum, and, when the entire circumference is completed, should be tied and cut off close to the knot. After a careful cleaning of the peritoneal cavity, strong silkworm-gut sutures are carried through the integument, muscles, fascia, and peritonæum, and the wound closed. The stomach should be kept at rest for the

first day or two. An enema of beef tea and whisky should be given every four or five hours. From two to four ounces of the former to ʒ j–ij of the latter may be administered at each injection. Crushed ice in moderate quantities may be given in the mouth. After two days, milk and liquid food in small quantities (a teaspoonful at a time with intervals of several minutes) may be given by the mouth, and solid food by the tenth day.

Perforating ulcers and *penetrating wounds* of the stomach are subject to the same operative procedures as advised in similar conditions in the intestines.

Duodenum.—Operations upon this organ must be chiefly confined to the upper portion on account of the relations of the bile and pancreatic ducts to the middle portion, and the body of the pancreas and great mesenteric vessels to the lower third. In rare instances impaction of gallstones in the common duct at or near the duodenal opening requires operative measures.

Duodenostomy has been performed in several instances for the relief of stenosis of the pylorus, but without encouraging success. The incision through the abdominal wall is the same as in pylorectomy. The opening is made in the upper portion of the organ. Digital or instrumental dilatation of the stricture is done through the opening.

The intestinal wound should be closed at once with Lembert sutures. Dilatation when indicated should preferably be made through the stomach.

Obstruction of the Alimentary Canal below the Pylorus.

Partial or complete occlusion of the alimentary canal may occur from a variety of causes, namely: 1, impaction of fecal matter; 2, foreign bodies; 3, intussusception; 4, volvulus; 5, constriction by bands; 6, by adhesions; 7, omental and mesenteric slits; 8, diverticula; 9, neoplasms; 10, stricture; 11, true hernia.

The impaction of ingested matter may occur at any part of the alimentary canal, although this accident occurs in the great majority of cases in the large intestine. The cæcum and ascending colon are the most common seats of fecal impaction, the sigmoid flexure next in order.

The symptoms upon which a diagnosis is made are the presence of a tumor in the line of the colon, which is not painful on pressure, may be molded by firm and prolonged compression, is movable, and has formed gradually. In the sigmoid colon and rectum digital exploration will demonstrate the nature of the mass. Vomiting, tenderness, and shock, so common in acute obstruction, are absent, or, if present, only occur in the latter stages and in extreme cases.

The *treatment* consists in the repeated injection of warm water until the bulk of the tumor is softened, when laxatives may be given by the mouth. The method of injection is as follows: Place the patient in the knee-elbow position, or upon the right side with the pelvis elevated. In this position the pressure is in great part taken off the rectum, and a

greater degree of tolerance is obtained. The fountain irrigator is the best instrument, and from two to four pints or more may be thrown slowly in at one operation. The water should be allowed to remain in the colon as long as possible. When the impaction is near the anus, it may be removed with the finger or by a spoon.

Foreign Bodies.—Indigestible substances of various kinds, introduced by accident or intentionally, at times pass through the stomach into the intestinal canal and become lodged. In rarer instances they are introduced through the anus.

Biliary calculi which have passed through the common duct into the duodenum, or, causing ulceration of the gall bladder and duodenal wall, enter the canal in this manner, may also cause intestinal occlusion. Again, obstruction has been caused in a number of instances by *concretions* (enteroliths) composed of ingested material insoluble in the gastro-intestinal juices and from which the moisture has been absorbed. They are met with chiefly in the colon and vermiform appendix.

The symptoms vary with the suddenness or completeness of the obstruction, as well as with its location. Sudden occlusion is accompanied by pain of a colicky and violent character, usually referred to the seat of the obstruction. Shock is also present in acute stoppage of the canal. Vomiting is an early and prominent symptom of occlusion of the small intestine, coming on at a later period, when the colon is involved. On the other hand, constipation is a feature of stoppage in the large intestine, while fecal matter in varying quantity may continue to pass *per anum* for several days after occlusion above the ileo-cæcal valve. In arriving at a diagnosis, palpation and percussion will be of value. The knowledge of the accident when a body has been swallowed will, of course, establish the character of the occlusion. Insane or hysterical individuals often indulge in such practices. Biliary colic and jaundice not infrequently precede occlusion from calculi which escape by the common duct, while tenderness in the region of the liver and duodenum must be present in a varying degree in cases of perforation of the duodenal wall by large calculi from the gall bladder.

Tenderness is also present in cases where delicate sharp objects (pins, needles, etc.) have passed through the walls of the intestine and are wandering in the cavity of the peritonæum or in the pelvis.

The *treatment* which should be instituted in obstruction by foreign bodies will depend in great part upon the symptoms which ensue. If the occlusion is complete and the symptoms are alarming, operative interference should not be delayed. The only doubt which may be thrown upon the propriety of operating is the presence of shock or collapse in an extreme degree. If this condition is present, morphine and whisky hypodermically should be administered in the effort to bring about reaction. If no urgent symptoms follow the presence of a foreign body in the alimentary canal, expectant measures may be employed in the hope that it may pass out by the rectum. When a foreign body has been swallowed and has gone beyond the stomach, and its shape is known to

be such that it may cause perforation of the intestinal wall, or that the possibility of its being passed through is remote, it is the wiser policy not to lose valuable time by procrastination, but to operate at once. When introduced through the anus or lodged in the rectum or lower portion of the sigmoid flexure of the colon, it may be removed through the natural opening.

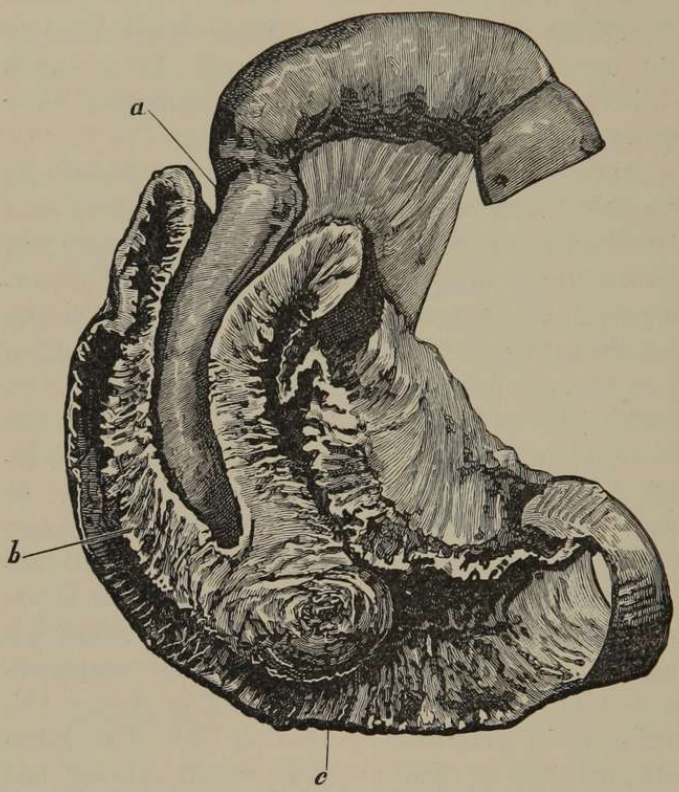

Fig. 639.—Intussusception of the jejunum. *a*, Internal cylinder. *b*, Middle cylinder. *c*, External cylinder. (After Treves.)

Intussusception, or the telescoping of one part of the intestinal canal into another (Fig. 639), may occur at any portion of the bowel.

It is most frequent in infancy, being at that time of life the most common cause of intestinal obstruction. In the small intestine, it is called *enteric;* in the colon, *colic;* and when occurring at the ileo-cæcal valve, *ileo-cæcal* intussusception. Multiple invagination in the small intestine is not infrequently found on autopsy in children in whom no symptoms existed before death, and which evidently occurred in the last few minutes of life.

Dr. L. Emmet Holt collected 385 cases of intussusception under three years of age. Of these, 28 were under four months old; 113 were between four and six months old; 71 between seven and nine months; 18 between ten and twelve months; 32 between one and two years; 96 between two and ten years. Three fourths of all the cases occurred in children in the first two years of life, and one half between the fourth and ninth months. It is more frequently met with in males than in females, in a proportion of 174 to 94. Its association with any general disease is too infrequent to be of any importance. It is caused by irregular action of the muscular walls of the intestines. One part of the tube, by reason of irritation, becomes stiff and small by contraction of the circular muscular fibers, while the part immediately below is relaxed, and into this the smaller and stiffened part telescopes. The mesentery is drawn in with the bowel. Intussusception need not necessarily cause obstruction and strangulation, but in most cases both are present, and produce the usual symptoms of occlusion. Gangrene may occur, due to strangulation of the mesentery as it becomes

crowded in with the invaginating gut. In some instances parts of the gangrenous intestine are passed by the rectum. The symptoms are those of sudden and severe pain and vomiting, symptoms of (abdominal) shock, tenesmus, especially when the tumor is low down toward the rectum, and bloody and mucous evacuations. The tumor may usually be felt on the left side along the sigmoid flexure, or by rectal examination. The abdomen is not distended in the early stages of the disease, but later, when obstruction becomes established, tympanites is well marked. The pain is usually intermittent, as in colic, and is excruciating during the attacks. The most marked symptom is the passing of blood or bloody mucus. The temperature during the first twenty-four or forty-eight hours usually rises, but may be normal or subnormal in the early stages of the attack, due to shock. The prognosis depends on the age of the patient and the character of the invagination. If it is recognized within the first few hours and energetically treated, the death rate will be very much lower.

Treatment.—When the disease is recognized within the first twelve or twenty-four hours, an anæsthetic should be administered and the patient completely relaxed, placed upon the back with the thighs flexed, and the table inclined, so that the head may be considerably lowered. Inflation through the rectum and colon or the injection of liquid may be employed. Inflation is preferable for the reason that it is somewhat more easy to determine when reduction has been accomplished by air than by water. Danger of intestinal rupture is not very great, as it occurred only once in two hundred and twenty-five cases in children. An ordinary hand bellows can be used with a long catheter attached, introduced well up in the colon. The introduction of air should be effected gradually, and its escape prevented by pressing the buttocks closely together. Manipulation of the tumor is advised while the air is being introduced. The best guide as to the quantity of air to be introduced is the distention it produces. Fifteen or thirty minutes may be allowed for the effort. When bellows can not be obtained, warm water, at a temperature of about 105° F., may be substituted. A fountain syringe may be used, and the pressure increased by elevation. The quantity of water should be determined by the degree of fullness felt along the line of the colon. The water should be allowed to escape, and if the tumor has not disappeared, it may be again tried, and, failing in a second attempt, laparotomy should be resorted to. In intussusception, as in all other intestinal lesions, delay is always dangerous; for many reasons early operation should be performed; invagination is usually slight in the beginning, swelling and adhesions have not occurred, and mechanical reduction is easier. In one of my cases, seen on the fifth day, the ileo-cæcal valve protruded through the rectum, and no amount of force would disinvaginate the adherent and strangulated mass. Out of sixteen operations done on the first or second day, forty-four per cent recovered; in forty-four operations after the third day, there were seven recoveries. Cathartics should not be used at any time.

Volvulus, or twisting of a loop of intestine, occurs usually in the sigmoid flexure of the colon, although the remaining portions of the colon, or cæcum and small intestine, may be occluded by this accident. The loop may become twisted upon itself at its mesenteric attachment, or one loop may be twisted over a second. The last variety is more apt to occur in the ileum and lower jejunum. The principal cause of volvulus is an abnormally long mesentery, allowing unusual freedom of motion to the loop of intestine which is attached to it. This defect may be congenital or acquired. Constipation and the habitual distention of the sigmoid flexure by fecal matter is probably the most frequent cause of elongation of the meso-colon and increased length of this part of the large intestine. Volvulus occurs more frequently in men than in women, and is met with in adults more than in children. When the conditions are favorable, a suitable position or an accident in movement is sufficient to rotate the loop on its axis, causing occlusion by the weight of the loop and mesentery brought to bear upon a limited surface. The symptoms of volvulus are those of acute intestinal obstruction. Pain similar to that of colic is present from the start. Constipation is the rule, and indicates the sigmoid colon as the seat of the lesion. Tenesmus is present in a certain number of cases, and is additional evidence that the colon is involved. Distention of the abdomen to an extreme degree occurs in a large proportion of cases, developing more rapidly in volvulus of the colon. Vomiting is rarely present until late in the history of the case, and, when it appears early, it suggests obstruction in the small intestine. A condition of shock more or less profound supervenes if relief is not obtained. Diminution in the quantity of urine is present in a certain proportion of cases.

Without interference the prognosis is fatal probably without exception in every case of complete volvulus. Strangulation of the loop and enormous distention of the part involved occur.

Treatment.—If the symptoms point to the sigmoid flexure or colon as the seat of the twist, the introduction of warm water into the rectum is indicated. The patient should be placed in the knee-elbow position. The introduction should be made gradually, and may prove successful in recent cases where adhesions have not occurred, or where the distention of the gut is not too great. If this measure is not successful within a few hours, abdominal section should be performed, the hand introduced, and the loop untwisted.

Constriction by Bands.—Bands of cicatricial tissue resulting from old as well as acute peritonitis cause intestinal obstruction in a certain proportion of cases. This accident occurs chiefly in adults, about equally in both sexes, being due to pelvic inflammations in women and to appendicitis and traumatic peritonitis in men (Treves). The bands vary in length, breadth, and points of attachment. The lower jejunum and ileum are involved in almost all cases. The symptoms are in general those of acute obstruction of the small intestine. Pain is violent in the beginning, and in the majority of cases is referred to the part involved. Vomiting is an early and persistent symptom, and, as is common in obstruction above

the ileo-cæcal valve, is apt to be stercoraceous. Shock is usually more prominent in this form of occlusion than in those heretofore given. The urine is diminished in quantity. The abdomen is not tympanitic as a rule, although the constricted loop may be greatly distended, and may be recognized as a distinct tumor by palpation or percussion, or by vaginal or rectal exploration.

The diagnosis must be made from the history of a former peritonitis and the presence of the symptoms above given. The prognosis is grave, and the indication for treatment is early operative interference.

In addition to inflammatory bands, intestinal occlusion is occasionally caused by the pedicle of an ovarian or uterine tumor, or the Fallopian tube may act in the same manner.

Adhesions between contiguous loops of intestine, resulting from peritonitis, may occur in such a manner as to lead to occlusion. The symptoms do not differ materially from those just given, and the treatment is the same.

Strangulation through Slits in the Omentum and Mesentery.—Occasionally a loop of intestine slips through an opening in the omentum or mesentery, becomes imprisoned and strangulated. The rent may be congenital or result from an injury, penetrating or non-penetrating. The small intestine (ileum) is most frequently involved, and the aperture occurs as a rule in the mesentery of the last part of this organ. Strangulation of the colon in this manner is exceedingly uncommon. With the exception of the presence of a tumor, the symptoms are the same as those in hernia of the small intestine with strangulation. Early operative interference offers the only hope of relief.

Constriction by Diverticula.—Pouches or cavities communicating with or attached to the intestines may be true or false—i. e., congenital or acquired. Meckel's diverticulum, which is attached to the last two or three feet of the ileum, may remain patulous and open at the umbilicus, or more frequently it ends in a blind extremity which may be continued as a cord to the umbilicus. When it exists it represents the vitelline duct of the embryo, in which the normal process of closure and obliteration has not taken place. The vermiform appendix may also be classed with the true diverticula. False diverticula occur in both the small and large intestine, being slightly more common in the colon. Their mode of origin is not as yet satisfactorily explained. They are found to project between the two layers of peritonæum along the mesenteric border of the small intestine, and into the appendices epiploicæ of the colon (Treves). They are herniæ of the mucous membrane projecting through an aperture in the muscular layer.

Constriction and strangulation of a loop of intestine by Meckel's diverticulum are much more apt to occur than by the false pouches. The vermiform appendix in rare instances may become twisted upon its axis and strangulated, or it may cause the constriction of a neighboring loop of the ileum.

There are no symptoms peculiar to obstruction from true or false diverticula, and the nature of the lesion can only be discovered by ab-

dominal section, which is indicated in this form of intestinal occlusion.

Neoplasms.—Various new formations, both benign and malignant in character, may occur in the intestinal canal and lead to obstruction by projecting into the lumen of the gut, or by pressure from without or by development within the wall proper, producing narrowing. *Fibroma*, *fibro-myoma*, and *lipoma* are of rare occurrence. *Angioma* is also exceptional in this location. *Adenoma* is a more common form, developing from the glandular apparatus, and more particularly from the follicles of Lieberkühn in the large intestine.

Sarcoma and *carcinoma* are also met with, both as primary and secondary growths. The symptoms of obstruction are, as a rule, gradual in development, and the presence of a tumor may be recognized by palpation with the abdominal muscles in complete relaxation. Cancer is the most common of these new formations, and is apt to be located in the colon or rectum. According to Haussmann and Treves, the variety of cancer met with in the large majority of instances is a *cylindrical epithelioma*, encephaloid and scirrhus being very exceptional. The growth may cause constriction by extending completely around the lumen of the tube, or, by developing on one side, cause stenosis by its bulk and by the contractions which result. The diagnosis of cancer may be made in those cases in which the disease is situated in the rectum or lower portion of the sigmoid flexure by digital examination or by the aid of the speculum. Situated higher up, the presence of a tumor, the age of the patient (over forty as a rule), and the peculiar cachexia will aid in arriving at a correct diagnosis.

Stricture.—The partial or complete occlusion of an intestine, by cicatricial contractions following inflammation or ulceration of its mucous and submucous or muscular layers, constitutes a true intestinal stricture. Constriction by peritoneal bands, or the infiltration accompanying cancer, is not considered as stricture proper.

Any disease which produces loss of substance in the inner layers of the wall of the gut may produce stricture. The ulcers of typhoid fever, tuberculosis, dysentery, syphilis, and chronic intestinal catarrh, or those resulting from injury by ingested matter, by traumatism, or the necrosis following strangulated hernia, are the chief lesions which precede true stricture of the intestine. Cicatrization in an ulcer which has its longest axis at a right angle to that of the intestine is more apt to lead to obstruction than one which has its long axis in an opposite direction. Stricture occurs in adults, of forty years or more, oftener than in the young, being rarely met with in children under ten years of age. No portion of the alimentary canal, from the pylorus to the anus, is exempt, yet stricture of the duodenum and upper jejunum is comparatively rare; the ileum, near the cæcum, is more frequently attacked, while the large intestine, and especially the sigmoid flexure and rectum, is the most common seat of this grave and painful affection.

The symptoms of stricture are those of progressive narrowing of the intestine. The intensity of the symptoms will be proportionate to the

rapidity with which stenosis results and to the portion of the canal involved. Pain is not marked until the narrowing has arrived at a point where ingested matter passes through with difficulty. It is spasmodic in character, and occurs at varying intervals. Distention of the intestine above the seat of stricture, with consequent hypertrophy of the wall, follows sooner or later in all cases. The continued irritation of the bowel from the pressure of fecal matter induces ulceration of the mucous and submucous tissues at and above the seat of stenosis, and perforation may occur.

Vomiting is an earlier symptom in stricture of the ileum and jejunum than when the colon is involved. There may be diarrhœa or constipation, or these conditions may alternate, and are therefore of no diagnostic value. Tenesmus is rare, and the abdomen is not distended except in case of peritonitis. As far as the previous history may be of value in locating the seat of the lesion, it is known that dysenteric ulcers are usually found in the rectum, sigmoid flexure, and cæcum, and in the order of frequency in which these organs are given: typhoid ulcers (which rarely cause stricture) in the lower ileum and cæcum; those of chronic catarrh in the colon; syphilis (gumma) in the rectum and ileum; and tubercular ulcers in the lower ileum (Treves).

The diagnosis of stricture must be based upon a study of the symptoms above given, except the cases in which the lesion is in the rectum or lower part of the sigmoid flexure, where digital or instrumental exploration may be made.

Treatment.—Stricture of the rectum and lower part of the sigmoid flexure of the colon should be treated by dilatation or division. Above this point the only hope of relief is by *exsection* of the part involved with *end-to-end anastomosis*, or by *lateral intestinal anastomosis*. Enterostomy and colostomy (*fecal fistula*) are palliative surgical measures, to be instituted when other means are not indicated.

Abdominal Section for Intestinal Occlusion.

In all lesions of the intestines in which it becomes necessary to invade the abdominal cavity the incision should be made directly over the seat of lesion. When the seat of the obstruction can not be determined without exploration, the linea alba should be selected. The cæcum, ascending and descending colon, can be more directly approached from an opening in the lateral aspects of the abdomen immediately over these viscera. The sigmoid flexure and upper portion of the rectum may be best exposed by an incision parallel with Poupart's ligament, and about two inches internal to the left anterior spine of the ilium. In general, it may be said that the smaller the incision the better, yet the opening should always be sufficient to admit of thorough exploration, and, if necessary, large enough for inspection. The patient should rest upon the back, with the head and shoulders slightly elevated, in order to relax the abdominal muscles. Under certain conditions the modified Trendelenburg posture is advisable. Strict attention should be paid to the anti-

septic details already given. All bleeding should be arrested before the parietal peritonæum is incised. This should be punctured, and a very dull-pointed, grooved director inserted, and the peritonæum divided on this instrument. The opening should be not larger than will suffice to admit the finger, and if then found necessary to enlarge it this can be done. When possible, McBurney's method of separating and retracting, without division of the fasciculi of the abdominal muscles or their aponeuroses should always be preferred. As soon as this is accomplished, the seat of obstruction should be sought. The escape of intestines or omentum through the wound should be prevented by holding sterile mats over these viscera and pressing them back into the peritoneal cavity. If, upon exposing the small intestines, some of the coils are found to be greatly distended while others are collapsed, it is pretty safe to conclude that the obstruction is near at hand, and the collapsed loops should be carefully passed between the fingers up to the obstruction. It is scarcely possible, in the condition in which the viscera will be found, to determine exactly which is the upward or downward direction of the coils, and it may be necessary to begin at the cæcum and work upward.

Senn determined by experimentation that by touching the peritoneal surface of the bowel with a little powdered chloride of sodium, a reversed peristalsis will ensue. In this way the upward direction of the bowel may be recognized.

If the coils which present are so enormously distended that they seriously interfere with the exploration, the gas should be evacuated by puncture with the knife and immediate closure with Lembert sutures. Multiple punctures may be required, since it often occurs that not more than one or two feet of intestine will be emptied from a single opening.

When, as not infrequently happens, by reason of procrastination in asking for surgical relief, the condition of the patient is so critical that a prolonged operation is not indicated, it is the better practice to seize the first presenting loop of *distended* intestine, stitch it to the abdominal wound, and establish immediately an artificial anus. The alarming symptoms of obstruction thus allayed, the occlusion can be dealt with at a subsequent operation. I have in a number of instances successfully employed this method, removing the obstruction, and afterward restoring the continuity of the canals.

If the cæcum is found to be distended, the lesion is evidently in the colon, and this organ should be followed to the obstruction. If biliary calculi, a foreign body, or enteroliths are found, the part involved in the obstruction should, if possible, be brought out at the wound, protected by warm towels, the escape of matter into the cavity of the peritonæum prevented by napkins, and the body removed by an incision in the long axis of the gut, and, when possible, opposite the mesenteric attachment. The length of the opening should be sufficient to allow of the removal of the body without bruising or tearing. If the part can not be brought out, it should be laid upon mats and the peritonæum in this way protected from the escape of fecal contents. This accident may be in great part

prevented by compression of the gut above and below the obstruction. The wound in the intestinal wall is next closed by Lembert's suture.

When intussusception exists, the invaginated portion should be brought into full view, and careful traction employed in the effort at reduction. If this can not be accomplished, or if strangulation and necrosis exist, exsection of the necrosed portion should be made at once, if the condition of the patient is such as to justify a prolonged operation. If not, the dead loop or portion should be brought out at the incision in the abdomen, cut away, and a fecal fistula established. In this emergency Bodine's operation may be found of great value. The restoration of the intestinal canal may be accomplished at a subsequent operation. If, however, operative interference has not been too long postponed, it will be advisable to proceed with the exsection at once.

Exsection—or, as it is sometimes called, *resection*—of the intestine is a very proper operation, and one which, if performed early enough, with the careful attention to details it requires, will succeed in the majority of cases. This operation is one of such importance that, in describing the technique, the following case is given in detail:

Leah R——, Russian, fifty-six years of age, housewife, was admitted to Mount Sinai Hospital on October 9, 1886, with the following history: For ten years she had had a swelling in the left groin, which would disappear when she was lying down and return when she was standing erect. She had not worn a truss. Two weeks before admission she discovered that the tumor no longer disappeared upon going to bed, but became painful, tender, and more swollen. She had not vomited up to the time of arriving at the hospital, but there had been no evacuation of the bowels for six days prior to her admission.

On admission, a swelling as large as an ordinary fist was found occupying the inner aspect of the left groin and thigh. The skin over the tumor was red in color, tender and doughy to the touch, and fluctuation was evident. The tissues around were slightly emphysematous. The patient's appetite was gone; she was emaciated, having lain in her present condition ten days in a tenement house, without proper care. The temperature was normal.

A diagnosis of strangulated femoral hernia was made, ether administered, and the tumor incised. Several ounces of foul pus mixed with intestinal matter were discharged. No trace of a hernial sac or of intestine could be discovered, such was the gangrenous condition of the mass. Upon introducing the little finger into the femoral canal, a slight opening into the intestine could be felt. Into this a closed dressing forceps was introduced, and the opening dilated by separating the jaws of this instrument. This was intended to secure the freer exit of ingested matter from the upper portion of the occluded gut.

A loose dressing of iodoform gauze was laid over the wound. The patient improved in condition after this operation, under mild stimulation and liquid diet (milk, beef tea, beef juice, whisky, sherry, etc.).

Only a small quantity of ingested matter escaped when the gauze dressing was changed on every second or third day.

On October 22d, thirteen days after the first operation, with ether narcosis, laparotomy was performed. The patient was placed upon the back, with the pelvis elevated upon a firm cushion. With Volkmann's spoon the granulation tissue was first scraped from the walls of the abscess, the hole into the intestine plugged with a pellet of iodoform gauze, the cavity of the abscess irrigated with 1-to-1,000 sublimate, and then tightly packed with iodoform gauze.

The integument about the femoral canal was washed thoroughly with soap and warm water, cleanly shaved, washed with ether, and finally with 1-to-1,000 sublimate solution. Hot sterile towels were laid over that portion of the body near the groin, leaving only a spot exposed measuring six by four inches.

An incision four inches in length was made parallel with the outer border of the rectus muscle, the lower end being over the *femoral ring*. All bleeding was arrested, so that before the peritonæum was opened the wound was absolutely dry. Catgut ligatures were employed. Great care was observed to keep to the inner side of, and away from, the epigastric vessels which were exposed in the dissection. The parietal layer of the peritonæum was picked up with a fine forceps, opened, and further divided upon the finger as a director.

Upon looking into the abdominal cavity, one or two loops of normal small intestine were seen, and upon displacing these upward, a third loop was seen to be imprisoned in the femoral opening. That part of this loop above the constriction was slightly distended, while the part on the side nearest the rectum was contracted until it was about two thirds of the diameter of the upper segment. The obstruction of the intestinal canal at the ring was complete. A hot sterile mat was placed beneath the imprisoned loop in such a manner that it held the loose loops of small intestine back, and was ready to receive any foreign matter which might escape from the gut when it was divided.

Two long-jawed scissors forceps (used as clamps) were then placed so as to close the loop of gut which was caught in the ring. One of these rested against the inner surface of the ring, and the other only sufficiently removed from this to permit of a division of the intestine between the forceps.

As soon as this was effected, the loose end, with one pair of forceps attached, was brought out through the abdominal wound and placed in a warm towel. As the forceps which constricted the ring of gut attached to the femoral canal was removed, a tuft of sponge was tightly packed into this ring to prevent any infection from the abscess with which it communicated.

Of the loop which had been liberated, about ten inches (five above and below the point of occlusion) were drawn out of the abdomen, sterile mats carefully placed so as to close the wound and prevent any escape of matter into the peritoneal cavity, and the exposed gut protected by covering with warm towels. A piece of cotton tape, previously boiled,

one fourth of an inch wide was then tied four inches above and below the limits of the gangrenous opening, so as to completely occlude the lumen of the gut (*d*, *d*, Fig. 640). When the forceps clamp was removed, the opening into the intestine was seen to occupy two thirds of the circumference of the canal. The gut was then cut across at a right angle to its axis by a single stroke with the straight scissors (*a*, *b*, Fig. 640). These lines of section were well out in sound tissue. The piece of intestine removed measured two inches and a half. A triangular piece of the mesentery was also removed (*b*, *c*, *b*, Fig. 640) in such a man-

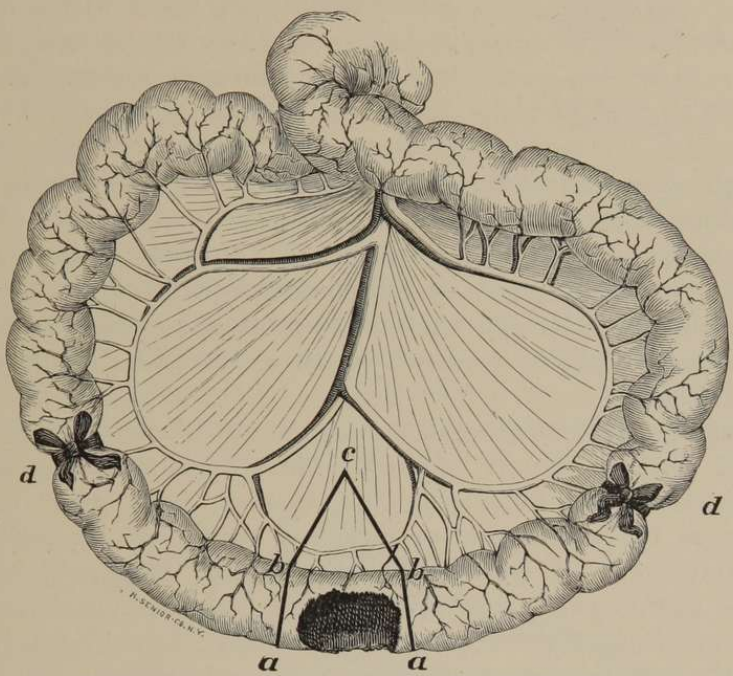

Fig. 640.—Loop of small intestine. *a*, *b*, Lines of section through the gut, removing the gangrenous portion. *b*, *c*, Same through the mesentery. *a*, *a*, Gangrenous portion of ileum. *d*, *d*, Occlusion of the afferent and efferent tubes by tape ligatures.

ner that the mesentery was left projecting nearly one fourth of an inch beyond the end of the intestine. This should be done to insure the vascular supply to the gut at the line of section.

The bleeding from the mesentery was profuse, requiring a dozen catgut ligatures. From the ends of the intestine only a slight oozing occurred. The cavity of the gut from the tapes to the openings was carefully emptied of all matter and washed out with Thiersch's solution. Nothing escaped from the lower end.

The edges of the divided mesentery were first united by eight interrupted catgut sutures about one fourth of an inch distant from each other. When the intestine was reached, the mesenteric attachment of each end was carefully brought into apposition and the work of stitching the ends of the cylinders to each other begun.

In doing this, two forms of suture should be employed: 1. A suture through the mucous membrane alone—*Czerny's suture.* 2. That through the peritoneal coat alone—*Lembert's suture.*

In Fig. 641, which represents a longitudinal section through the

ends to be approximated, is shown at *b* the Czerny suture as it is passed through the mucous layer of the gut from the inner surface of the canal; while at *a* the method of introducing the Lembert suture through the peritoneal layer is shown.

When a gut is cut across, the longitudinal muscular layer retracts, carrying the peritoneal layer with it, and leaving the thick mucous membrane projecting about one eighth of an inch. The object of the Czerny suture is to bring the mucous membrane and the connective tissue, upon which it rests, together, and thus strengthen the line of union after adhesion occurs. If this is not done, the slight adhesions between the peritoneal surfaces obtained by the Lembert suture might give way under the distention of the intestine by gas or ingested matter. The objection to passing a suture entirely through the wall of the gut, and thus approximating all the coats at once, is the danger that the perforation may be followed by escape of gas or other contents. The inversion of the mucous membrane by Czerny's suture, and of the peritoneal layer by Lembert's suture after the threads are tied, is shown in Fig. 642.

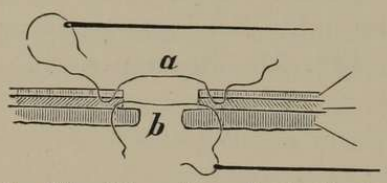

FIG. 641.—Schematic. *a*, Lembert's suture. *b*, Czerny's suture.

In suturing the intestine, the very finest black silk, and delicate half-curved needles, should be used. The thread should be made thoroughly sterile. In commencing the sutures, first insert one Czerny suture just at the mesenteric or attached border of the intestine, and tie this, the knot, of course, coming within the lumen of the gut. The needle should pass from within through the mucous layer at a distance of about three sixteenths of an inch from the free border (Fig. 641), out along the free border of the same end, and, being carried across to the opposite end, should be made to enter below the muscular and mucous layer, and to emerge through the mucous layer three sixteenths of an inch from its cut edge. A Lembert suture should be next inserted just at the edge of the mesenteric attachment, as follows: * The needle is made to enter the peritoneal coat one eighth of an inch from the edge, and, passing between the serous and mucous coats, is again brought through the peritoneal layer about one twenty-fifth of an inch from the edge (Fig. 641, *a*). At a point exactly opposite, the same stitch is passed through the peritoneal layer of that side for the same distance, and

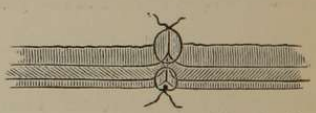

FIG. 642.—Schematic. Showing the inversion of the peritoneal layer by tying Lembert's suture, and of the mucous membrane by Czerny's suture.

* When the peritoneal surfaces of the intestine are held in apposition by this suture, adhesion occurs in a remarkably short time. In January, 1887, I was called in consultation in a case of suspected volvulus. Upon opening the abdomen, it was found impossible to untwist the loop without puncture and evacuation of the contents of the greatly distended gut. The opening, one fourth of an inch long, was closed by four Lembert sutures at 11.30 A. M. Three and one half hours later the patient died. On autopsy, not only had well-marked adhesion taken place, but the silk threads were with difficulty recognized, being hidden beneath the inflammatory exudation.

this thread is tied. In knotting all of these sutures, it is a wise precaution to use the *double* or *friction* knot for the first tying, for by so doing there is no danger of the suture slipping and the parts separating as the second turn is being made. A second Lembert suture should now be inserted on the other side of the mesenteric attachment, and an *intermediate* suture passed between these, through the substance of the mesentery and down into the strip of intestine which here is uncovered by peritonæum. *Extra care must be taken to see that this part of each end of the cylinder is in perfect coaptation.* The sutures are now inserted for the remainder of the apposing surfaces. The Lembert sutures should be one eighth of an inch apart. The mucous or Czerny sutures should be from one fourth to three eighths of an inch apart. It is evident that while the Czerny suture is tied, leaving the knot within the cavity of the intestine for the first part of the operation, the last few threads must be tied, leaving the knot imbedded between the mucous and muscular layers of the wall. All of the threads should be cut off close to the knot.

In this operation I had to leave the space between the sutures on the upper end of the gut a little wider than on the lower, for the diameter of the efferent tube was considerably smaller than that of the afferent portion. The intervening space was a flush one eighth of an inch on one side, and a scant one eighth of an inch on the other. When the sutures were all in, the constricting tapes were removed. The gut immediately

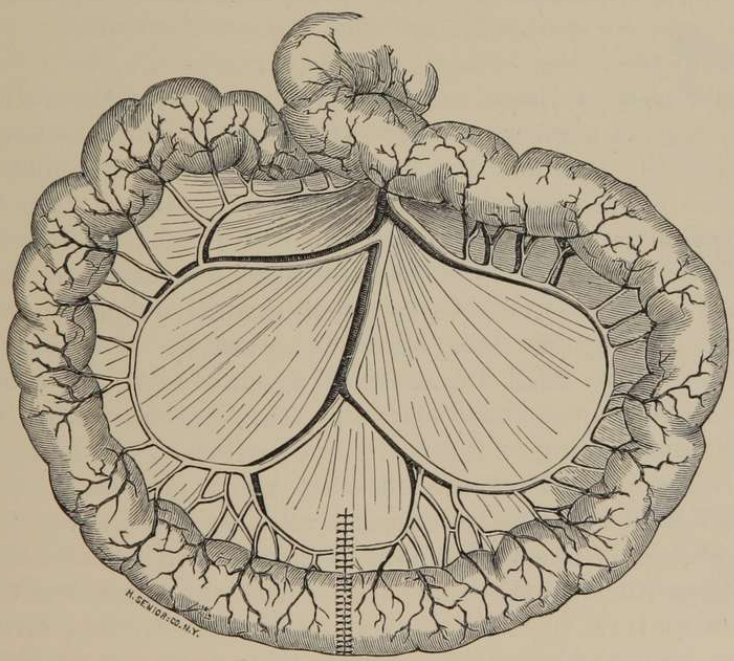

Fig. 643.—Showing the line of sutures in the mesentery and around the intestine.

filled with gas, and the intestine below the line of suture expanded to a size equal to that of the portion above the line of union. That the wound was tightly closed, was demonstrated by forcing the contents of the intestine from opposite directions toward the sutures. No gas escaped.

The appearance after the tapes were removed is shown in Fig. 643.

At intervals of about five minutes during the operation, a small quantity of warm, sterile water was poured over the exposed intestine. The warm towels upon which it rested were changed every ten or fifteen minutes. No fluid was allowed to get into the abdominal cavity. Finally, the intestine was carefully washed with this solution, and returned into the cavity of the peritonæum.

It was now necessary to deal with the ring of intestine which occupied the femoral opening, and which led from the abscess into the abdominal cavity. Two strong silk threads were passed entirely though the opposing walls of this rim of intestine, and tied so as to bring the edges well together. I then passed a silver probe from the hernial abscess cavity up through the femoral canal, and through the ring of adhering intestine between the two silk threads, until the end of the probe projected a half inch into the cavity of the abdomen. The ends of both threads were tied to the probe, and this withdrawn, bringing the sutures out through the saphenous opening. By making strong and continuous traction on these, the mucous membrane was everted, the peritoneal surfaces brought in contact, and the femoral opening closed. This procedure effected a radical cure of the hernia.

The wound in the parietal layer of peritonæum was closed by catgut sutures. The abdominal incision was closed with silk sutures, which included all the tissues down to the peritonæum. *For the prevention of ventral hernia after laparotomy, it is very important to include the fascia and aponeuroses of the muscles in the sutures.*

The patient recovered without accident.

In certain cases of intestinal resection, even after the sutures are all applied, it may not always be a safe procedure to drop the loop of intestine back into the peritoneal cavity and close the abdominal wound at once. In one case upon which I operated for the closure of a fecal fistula in the ileum, in which about two inches of the intestine had to be resected, there was an impaction of fecal matter in the large intestine which I could not remove by most careful irrigation through the fistula above and by the long rectal tube below. Knowing that after the continuity of the canal was restored by end-to-end anastomosis great strain would come upon these sutures, with possible rupture at the line of union and destruction of my patient, I performed the following operation: On December 2, 1892, the intestine above and below the opening was plugged with tight-fitting sponges and the intervening portion and the wound and integument about the wound thoroughly cleansed. I carried an incision through the skin parallel with the margins of the opening and one half an inch from its edge, making this elliptical incision about three inches long and one and one half inch wide at the widest portion. The dissection was carried through the fascia, fat, and muscles toward the line of adhesion made by the row of sutures in the original enterostomy, so that when this was reached and the peritonæum opened the wound presented a beveled edge, widest at the cutaneous surface.

The coil of intestine from which the fistula opened and one coil adherent to this were now brought through the wound, and iodoformized

gauze was packed around the edges to prevent septic or foreign matter from getting into the peritoneal cavity. A tape was tied around the intestine eight inches above and below the opening, the sponges removed from the gut, and the cavity washed out with Thiersch solution. By careful trial sutures, it was seen that if the fistula was closed by a row of longitudinal sutures the lumen of the gut would be only one third of its original size. I then, with sharp, straight scissors, through healthy intestine on either side of the opening, removed three inches of the gut, dividing it at right angles to its axis, together with a triangular strip of mesentery which was excised, taking care to leave the mesentery overlapping the end of the gut by at least one fourth of an inch to secure vascular supply to this important point in the operation. The method of suture was identical to that just described, taking care to put in the extra sutures at the mesenteric attachment. In returning the united bowel to the abdomen a mat of iodoformized gauze five inches wide and about eight inches long was passed under the coil of intestine until it rested upon the mesentery. One end of this mat was brought out through the wound. A similar piece was inserted on the opposite side until it touched the mesentery exactly opposite the first piece. Tufts of iodoform gauze were placed upon the bowel for two inches on either side of the line of sutures until the level of the abdominal incision was reached. On the fourth day the gauze was all removed, and the isolation of the sutured intestine was perfect. It rested, held by adhesions and walled off from the general peritoneal cavity and was about three inches below the level of the incision in the abdomen. On the eighth day, after considerable tenesmus and straining, one or two sutures at the line of union gave way and fluid ingested matter escaped. This small opening closed spontaneously in about one week and the patient recovered. Ventral hernia occurred at the seat of the abdominal incision, and will probably ensue in a large proportion of cases treated in this manner. This hernia is, however, readily retained by an abdominal belt with slight compression.

Fig. 644.—Murphy's button. The segments pressed nearly to complete closure.

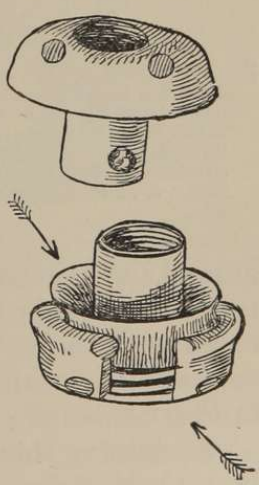

Fig. 645. — The same—showing construction of the separated segments.

When the condition of the patient is such as to demand a more rapid procedure than union by suture, as just described (which in skilled hands will take at least one hour to perform), I would advise the employment of the Murphy button.

These buttons are made of various sizes to suit different portions of the alimentary canal.

They consist of two small circular bowls (Fig. 645) so arranged that when properly adjusted in that portion of the bowel where the anastomosis is to be made they close together by a double ratchet (Fig. 644) compressing the inverted peritoneal surfaces of the ends of the intestine and securely holding these

surfaces in apposition until adhesion occurs. The thread, which has tied the end of the gut around the central portion of each segment of the button *and inverted the peritonæum*, becomes loosened by necrosis from pressure, and, with the button, in from seven to fifteen days drops loose in the alimentary canal and is carried along until it is passed with the fecal matter through the rectum. At Fig. 646 the method of passing the suture in and out around the margin of the bowel is shown. With a straight needle, armed with a medium-sized silk suture, carry the needle through the bowel, a little more than one eighth of an inch from the cut edge passing through the peritoneal coat and into the lumen of the gut. One fourth of an inch farther on, the suture is carried on the same level through the mucous membrane and out through the peritonæum to the outside. It is then carried over the free (cut) edge of the bowel again to the inner side and through, and this in and-over suture is continued (as shown in the drawing) until the bowel has been perforated by the needle from the mucous-membrane side out to the peritoneal surface just at the beginning of the attachment of the mesentery to the intestine. It is then carried over the cut edge of the mesentery around and back through this membrane at the same depth from the edge as for the intestine, then back again over the cut edge of the mesentery, and on in like manner as for the opposite side of the gut to a point of emergence about one eighth of an inch from the point where it entered. The two ends of the threads are now ready for the insertion of one segment of the button. This is grasped by the forceps and carried into the end of the bowel deep enough to allow the gut to be snugly folded around the central shaft or stem, when the two ends of the thread are tied into a single knot and are drawn upon. Like the mouth of a reticule that is being closed, the wall of the intestine is folded and puckered until it fits tightly around the central shaft of the button, as shown in Fig. 647, where the threads are cut off close to the knot.

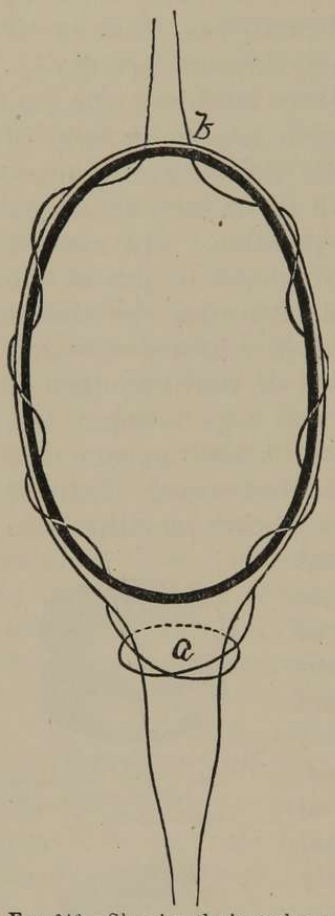

Fig. 646.—Showing the in-and-out method of inserting the silk suture around the end of the divided intestine and over and through the mesentery near its attachment. *b*, Point of beginning. *a*, Including the mesentery.

Examining this end of the bowel, it is readily seen that when the opposite half of the button has been in like manner applied, and has been pushed into this, there would be nothing but peritoneal surface of the gut in contact. If the mucous membrane should become everted, or if the thread is not so thrown over the mesentery as to invert this thoroughly, and bring peritoneal surfaces in apposition, there will be failure of union, sloughing, and perforation at these points. The whole success

of this operation rests upon the careful application of the button. The other half of the button is applied in the same manner, and then the two are brought together with the smaller invaginated into the larger. By pressing them steadily together they close until the peritoneal surfaces are snugly in contact, and the operation is completed. In this operation, as in end-to-end suture, the greatest care must be taken to prevent any foreign substance from entering the peritoneal cavity. It is well to add that while a fair degree of success has already attended the use of this apparatus, it is at this date still on trial, and it is to be hoped that it may prove so efficient as to become permanently established in the surgery of the intestinal tract. In a patient seen with Dr. X. O. Werder, of Pittsburg, this surgeon removed several feet of the small intestine, securing a successful end-to-end anastomosis with the Murphy button. A considerable number of successful results are on record.

While almost any cool and careful surgeon could make an approximation by this apparatus, there are very few, comparatively, who have the experience or the skill necessary to do an end-to-end anastomosis by suture within a reasonable limit of time. It must not be forgotten that a number of fatal cases have already been reported, caused by the button not coming away, or its lumen becoming closed or the intestines occluded by the weight. In the case of a man twenty years of age, in whom I did a lateral anastomosis between a loop of small intestine and the descending colon, for relief of a fecal fistula in the cæcum, the button dropped into the small intestine, from which it was removed by operation on the one hundred and twenty-seventh day after the insertion.

Maunsell's method of end-to-end anastomosis is not to be recommended as compared to the less complicated operations just given.

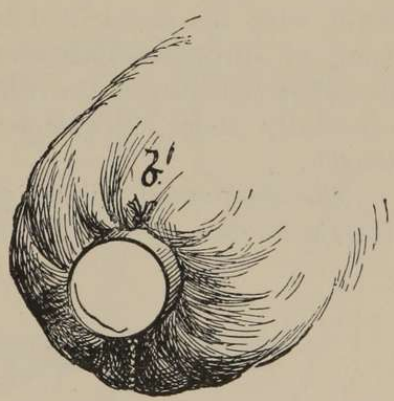

Fig. 647.—One segment of the button fastened in one end of the intestine (to be united) by the purse-string suture tied at *b*. The complete inversion of the peritoneal surface is properly accomplished.

Exsection of the colon is somewhat more difficult than the operation upon the small intestine, on account of its irregularity in size and the deeper location of all of this organ except the transverse portion. It should be brought into or out of the incision if possible, or, if this can not be done, the opening in the linea alba may be enlarged in the direction best suited to the case. If, after exploration through an incision in the linea alba, the obstruction is found to be in the cæcum, ascending or descending colon, and the part involved is so firmly fixed that it can neither be brought into view through the wound in the median line nor by an additional transverse incision of two or three inches, it will be advisable to close this opening and expose the part by an incision immediately over it.

Lateral Intestinal Anastomosis.

Lateral anastomosis of one portion of the intestinal tube to another must always be considered as an operation not of choice, but of emergency, never to take the place of end-to-end anastomosis when this latter operation can reasonably be performed with comparatively small risk to the patient. The ultimate results in lateral anastomosis have been much worse than in the end-to-end operation, which, when successfully performed, re-establishes the alimentary canal, usually without any diminution of its caliber, while the opening made in lateral anastomosis continues to contract and, in a large proportion of cases, becomes insufficient to permit the passage of ingested matter. The great fault in the technique as heretofore performed is that the opening of communication has not been made sufficiently long. For this reason the Murphy button is not applicable except as a temporary expedient lasting for three or four weeks, as the original opening of the button is of necessity so small that it rapidly becomes insufficient by contraction. As shown in the operation of gastro-enterostomy, lateral anastomosis by direct suture is not only an operation difficult in technique, but requires a great deal of time even in expert hands. For this reason many efforts have been made to devise some mechanical apparatus which will hold a sufficient extent of the approximated intestinal walls in contact until adhesive inflammation can be effected and a permanent agglutination of the surfaces secured. Senn, with his decalcified bone plates, was the pioneer in this department of surgery. This method, however, has practically been abandoned on account of the difficulty of obtaining decalcified bone plates, especially those of sufficient size to secure an opening of sufficient length.

The segmented rubber plates (Fig. 634), as devised by Dr. Byron Robinson, can be readily made of any desired length, and would take



Fig. 648.—Grant's enterotome.

less time in coaptation of intestinal surfaces in lateral anastomosis than would be required in direct suture. It is advised to run a rapid continuous re-enforcement suture after the plates are tied in position. Dr. H. H. Grant, of Louisville, has devised an instrument and an operation which, when slightly modified, is, in my opinion, one of the best yet devised. When the part to be incised is drawn through the wound in the abdominal wall and cut away after the well-known aseptic methods, the instrument, which is shaped like a large clamp, is introduced into the intestine,

a blade entering each of the two ends to be approximated; the blades are then shut together, and in the act of closing they divide the approximated walls and at the same time bring the peritoneal surfaces of the

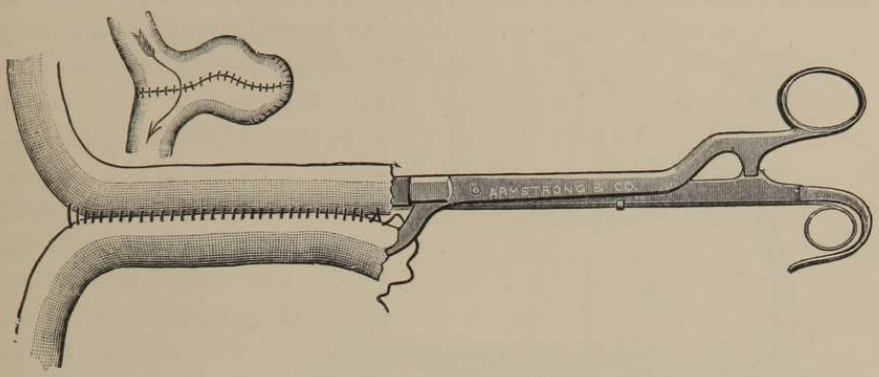

Fig. 649.—Prof. H. H. Grant's instrument and operation for lateral intestinal anastomosis.

two pieces of intestine in apposition. Everything is firmly held in this way while a rapid continuous silk suture is carried around. The instrument is then removed and the open ends of the intestine closed by inversion and rapid peritoneal sutures. This operation has been successfully done by Dr. Grant, and is exceedingly ingenious. The modification which I should practice would be to increase the length of the blades of this instrument in order to enable a surface of at least four inches to be divided, so that a larger opening of communication, and one that will persist for a longer time, would be secured.

The operation of Prof. J. A. Bodine for the establishment of a permanent or temporary fecal fistula is well adapted for securing a lateral anastomosis when the fecal fistula is no longer required. The technique when it is intended or thought likely to be necessary to restore the continuity of the alimentary canal, differs from that used when a permanent fistula is to be established in only one particular. When the fistula is intended to be permanent, the mesentery is included between the two rows of stitches in order to stiffen the spur. This will be required in those cases where there has

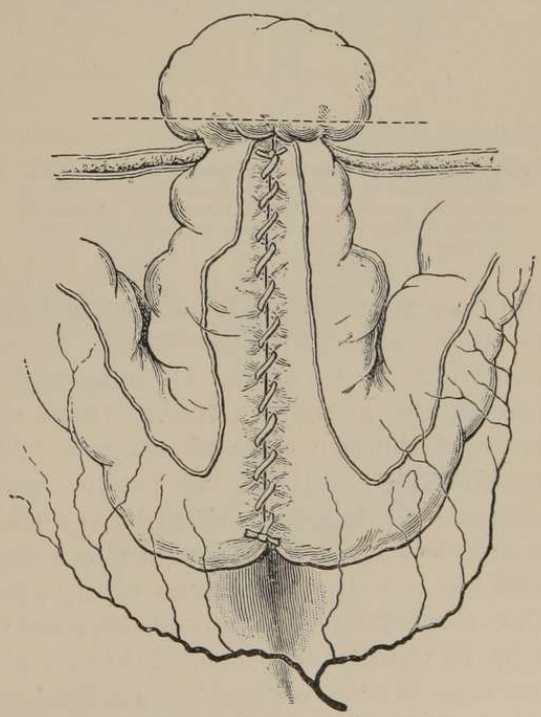

Fig. 650.—Prof. J. A. Bodine's operation for lateral anastomosis, with ultimate restoration of the continuity of the canal, showing one side of the loop after it has been sutured, passed back into the cavity, and stitched into the abdominal wound. The lesion is left protruding, and the dotted line indicates where the protrusion is to be clipped off.

been complete exsection of the rectum or where it is permanently or hopelessly occluded. When the continuity of the intestine is to be restored, of course the mesentery is excluded from between the two approximating rows of sutures. Later, when these walls have become agglutinated by inflammatory adhesions, the gut is divided without interfering with the blood supply. The method is as follows: As soon as the proper incision through the peritonæum is made, a sterile pad is introduced while the operator stitches the parietal peritonæum to the integument with a continuous catgut suture. If there be a tumor, stricture, or necrotic focus upon the intestine, it is brought out through the wound until six inches of healthy intestine on each side of the part to be excised are exposed. The two limbs of the loop, with the lesion at the apex of the knuckle, are laid side by side and a running stitch of fine silk, beginning at the point where the exsection is desired, is carefully inserted, uniting the two pieces of intestine close to and parallel with the mesenteric border for six inches (Fig. 650). If the fistula is to be permanent, the mesenteric attachment is halfway between the two rows of sutures. If temporary, the loops are approximated, leaving the mesentery free. There should be about an inch of space between the two rows of sutures. At the deepest portion of the approximation—that is, the portion most remote from the part to be excised—the sutures should be inserted across the bowel so as to insure a complete approximation at this point and prevent any possibility of leakage into the peritoneal cavity after the septum has been divided. The row of sutures should represent an elongated U. The sutured loop is then passed back into the abdomen until the point where the intestine is to be excised is on a level with the skin surface, and it is here stitched into the margin of the abdominal wound with a continuous suture of strong catgut. If the excision is to take place at once, as in cases where a fistulous opening is urgent for the patient's safety, this last suture should be of silk, but as peritoneal surfaces are brought together, if the opening can be left for twenty-four or thirty-six hours, adhesions will have formed in that time and catgut may be employed. Silk is, however, in my opinion, the safest suture. If waiting is permissible

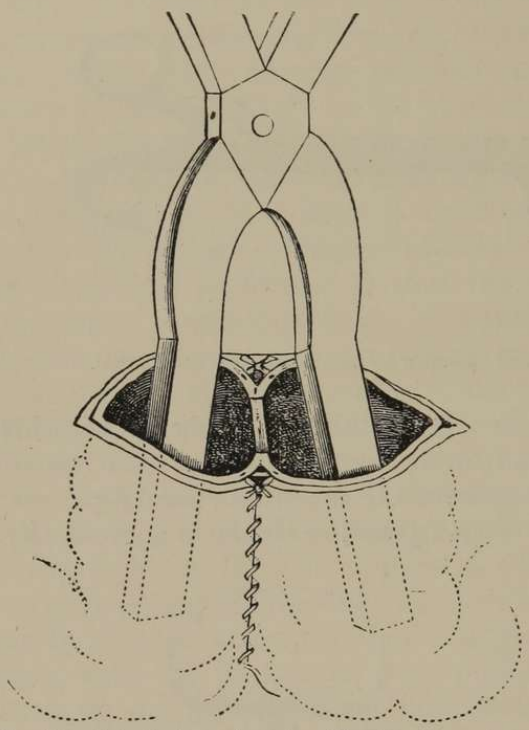

Fig. 651.—Intestinal anastomosis. Showing the septum to be divided in restoring the fecal current. Grant's clamp in position for the division. (In permanent colostomy this septum remains as a rigid and effective spur.

after twelve, twenty-four, or thirty-six hours, cocaine anæsthesia (2-per-cent solution) may, if necessary, be employed, and the protruding intestine snipped off with scissors on a level with the skin. After one or

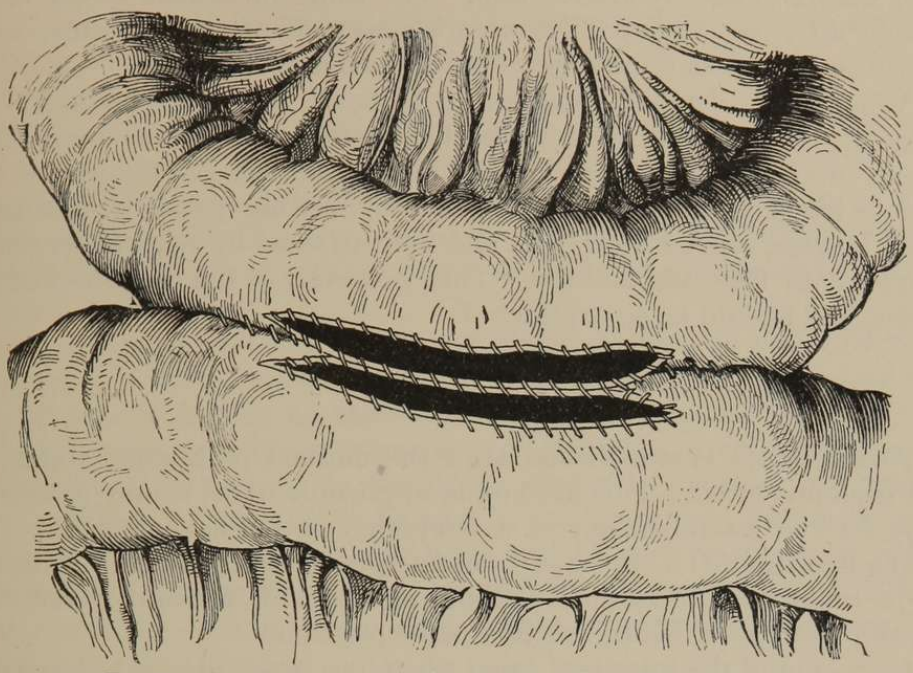

Fig. 652.—Lateral anastomosis by direct suture. (From Park's "Surgery.")

two weeks, or a longer period, if this be required, the septum between the two rows of sutures may be divided by Grant's enterotome (Fig.

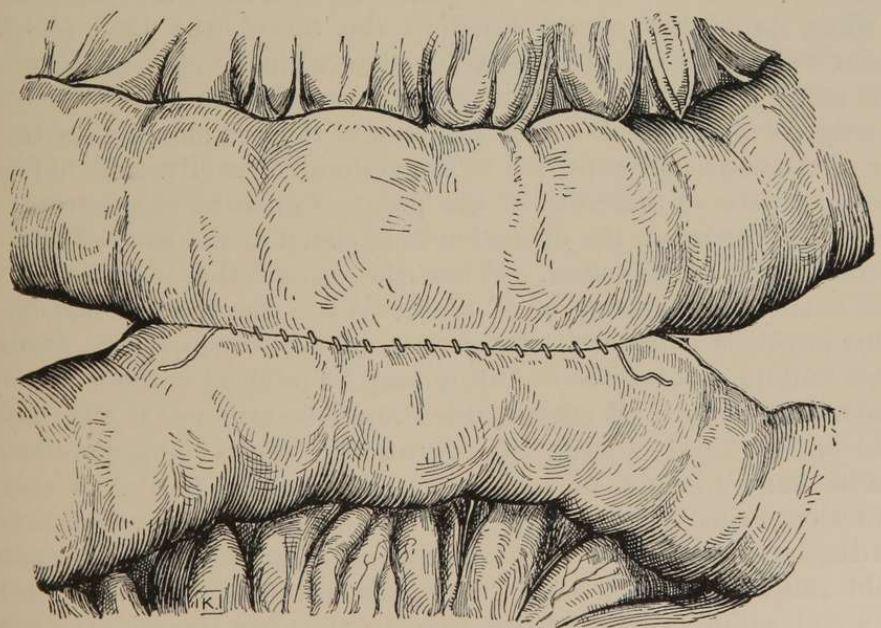

Fig. 653.—The same completed. (From Park's "Surgery.")

651) or a pair of straight scissors, introducing one blade into the upper and the other into the lower bowel channel, guiding the blades back by

means of the finger, to the middle line between the two rows of sutures and cutting to the required depth. The passage of the fecal current prevents reunion of the divided septum, and in the course of time the fecal fistula closes by granulation. The same procedure would be advisable after strangulated hernia with necrosis of the intestine, where end-to-end anastomosis by direct suture is not permissible.

When no mechanical apparatus is at hand, and the situation of the lesion to be corrected is such that the operation of Bodine or any other of the procedures mentioned is not feasible, direct anastomosis of contiguous loops of intestine may be made by making parallel openings of equal lengths, one on each loop, and uniting them by continuous suture, as shown in Figs. 652 and 653. This, however, is the operation of last choice, and should be so considered.

Fecal Fistula.

Fecal fistula is established after the method of Bodine, which has just been described. This method is applicable to colostomy or enterostomy for the establishment of a temporary or permanent fistula. The great advantage to be expected from this procedure is that the continuity of the canal may be restored without subsequent laparotomy and without employing the clumsy method of Dupuytren.

Occlusion of the intestinal canal when due to *volvulus* is accompanied by unusual distention of the twisted loop, which, in cases where the sigmoid flexure is involved, is at times enormous. It is impossible in certain cases to untwist the gut without evacuating its contents. If these are gaseous, this can be done by puncture by a large aspirating needle, but when liquid has accumulated in the bowel, the loop should be brought well out of the abdominal incision (which should be guarded by sterile gauze pads) until an opening can be made with a scalpel to permit the escape of the contents. The gut should then be closed with Lembert sutures, cleansed and returned to the abdominal cavity, and untwisted. When gangrene or stricture at the point of crossing of the two twisted portions has occurred, the operation of excision or the method of Bodine for fecal fistula is indicated. When the constriction is caused by *peritoneal bands*, these should be divided. When the loop of intestine has become imprisoned beneath the *pedicle* of a tumor, ovarian, fibroid, or dilated Fallopian tube, the occlusion may be relieved without removal of the offending body. Of course, this should be removed if the condition of the patient would justify the operation. When contiguous loops of intestine have adhered in such a way as to cause partial or complete obstruction, excision or the formation of a fistula is indicated, provided the adhesions are not so small in extent that they may be separated. Should this last method be practiced, the administration of calomel triturates and saline laxatives is essential in the after-treatment to keep up intestinal peristalsis, and in this way prevent readhesions. When a loop of intestine has become imprisoned in a slit in the mesentery or omentum, the slit should be enlarged, the loop released, and the opening

closed by catgut sutures. If necrosis has occurred, the gut should be excised or a fistula established.

Intestinal obstruction due to *diverticula* should be treated by division of the contracting tissues. A false diverticulum can scarcely be removed with safety, but, if necessary, Meckel's diverticulum may be excised. In closing the stump, the peritoneal coat should be turned in by Lembert's suture.

The foregoing methods would apply in cases of *neoplasm* with excision of a portion of the intestinal canal if this be required. Upon exploration, should a malignant tumor be found with infiltration to such an extent that complete removal seems impossible, the palliative measure of forming a fistula without removal of the neoplasm may be entertained.

Stricture of the rectum, or of the sigmoid flexure, or of the descending colon low down, usually requires either a division or dilatation of the stricture by employing the long rectal specula of Kelly; or, if this operation is not possible, a permanent fecal fistula after the method of Bodine should be formed in the upper sigmoid flexure or descending colon. When the stricture is located in the lower part of the ileum or first part of the cæcum, ileo-colostomy may be performed, using Robinson's rubber anastomosis plates. An opening of communication at least three and a half or four inches long should be secured to counteract the contraction which ensues.

CHAPTER XXII.

THE ABDOMEN (*continued*).

HERNIA.

A HERNIA, literally defined, is a tumor formed by the escape of the whole or a portion of any viscus from its normal cavity. By common consent, the term is now almost wholly restricted to protrusions of *intestine* or *omentum* (or both) from the cavity of the *abdomen* or *pelvis*, and these protrusions may occur through an opening which is *congenital* or *acquired*. *Complete inguinal hernia* following the descent of a testicle, or *ventral hernia* due to failure or perfect union in the aponeuroses of the abdominal muscles, are instances of the former; while a protrusion of the intestine after a *wound* of the abdominal wall or the descent of the bowel into or through the inguinal canal after birth are examples of acquired hernia. The hernia may take place into an adjoining cavity, as the thorax (diaphragmatic), or may protrude beneath the skin (femoral, umbilical, ventral, etc.).

CLASSIFICATION OF HERNIÆ.

Herniæ are classified according to their place of escape: *inguinal*, *femoral*, *umbilical*, *ventral*, *diaphragmatic*, *gluteal*, *obturator*, *lumbar*, *vaginal*, *pudendal*, and *perineal*. The term ventral is applied to all herniæ occurring at points on the abdominal wall other than those indicated in the classification just given. Of herniæ in general, the inguinal variety forms about 80 per cent of all cases; femoral, 10; umbilical, 5; the remaining varieties, 5. Of every five patients affected with hernia four are males. Inguinal hernia in males occurs more often in the first ten years of life than in any subsequent decade, the period from the twentieth to the fortieth year being next in order of frequency. According to Kingdon, femoral hernia in *males* of all ages is met with in four of every hundred cases; in the first decade in one of every three hundred, in the second two per cent; in the third and fourth together, 4½ per cent; the fifth and sixth, six per cent; and after this, eight per-cent. In *females* inguinal and femoral herniæ are met with in about equal proportions. The latter variety is rarely met with before puberty, but occurs chiefly during the child-bearing period (Thomas Bryant).

Structure of Herniæ.

The contents of the hernia are inclosed in a *sac*, almost always formed by the peritonæum lining the abdominal cavity. The sac may be carried immediately in front of the escaping intestine or omentum (femoral, umbilical, etc.), or these viscera may descend into a sac already formed by the escape of some other organ, as the testicle (inguinal, scrotal). In the rare cases of hernia of those portions of the large intestine not covered by peritonæum there is no true sac. That part of the sac which looks directly into the abdominal cavity is called the mouth, the constricted portion between this and the main cavity or *body* is the *neck*, while the deepest or most protruding portion is the *fundus*. When the intestine alone enters into the formation of a hernia it is called *enterocele*; if omentum alone, *epiplocele;* if both are inclosed in the sac, *entero-epiplocele*. The coverings of a hernia outside of the sac will vary with its location, and will be given in the consideration of the different varieties.

As far as the sac itself is concerned, it varies in thickness generally in proportion to the age of the hernia. In a recent hernia it is exceedingly thin, while in some forms of scrotal hernia, of long duration, it may be as much as $\frac{1}{16}$ or $\frac{1}{8}$ of an inch in thickness. A hernia is said to be *reducible* when the contents of the sac can by any means be returned into the cavity of the abdomen; *irreducible* when adhesions exist to such an extent that this can not be effected; *strangulated* when the circulation in the tumor is wholly or in part arrested by constriction at any portion (usually at the neck).

Special Herniæ.

Inguinal Hernia.—An inguinal hernia may be *direct* or *indirect*, *complete* or *incomplete*, *congenital* or *acquired*. The *indirect* or "*oblique*" variety is much more frequently met with. In the *male*, the contents pass into the *internal abdominal ring*, and follow the *spermatic cord* along the inguinal canal, at times descending into the *tunica vaginalis testis*. In the *female*, the descent is in the canal of Nuck, following the round ligament in the inguinal canal, and at times as far as the labium. *The epigastric vessels are internal to the neck and behind the body of an oblique inguinal hernia* (1, Fig. 654.)

A *direct* hernia does not enter the *internal* abdominal ring, but pushes the fascia which is to the inner side of the epigastric vessels and immediately behind the external ring directly in front of the *tumor and out at the external ring.*

Therefore the epigastric vessels are external to the neck, and may be displaced slightly in front and to the outer side of a direct inguinal hernia (2, Fig. 654.)

An inguinal hernia is said to be *complete* when the contents protrude beyond the external ring; *incomplete* when the tumor is within this limit. A *complete* inguinal hernia in the male may descend into the cavity of the tunica vaginalis testis, the contents resting in contact with

the testicle (*congenital*) (Fig. 655), or it may be arrested in the tubular sheath which surrounds the spermatic cord (*infantile*), the contents not in contact with, but pressing upon, the testicle (Fig. 656).

There is a third and rarer form of inguinal hernia, known as the *encysted* hernia of Astley Cooper. This variety of hernia is produced as follows: The vaginal process on that part of the peritoneal pouch which surrounds the spermatic cord from the *internal* to the *external*

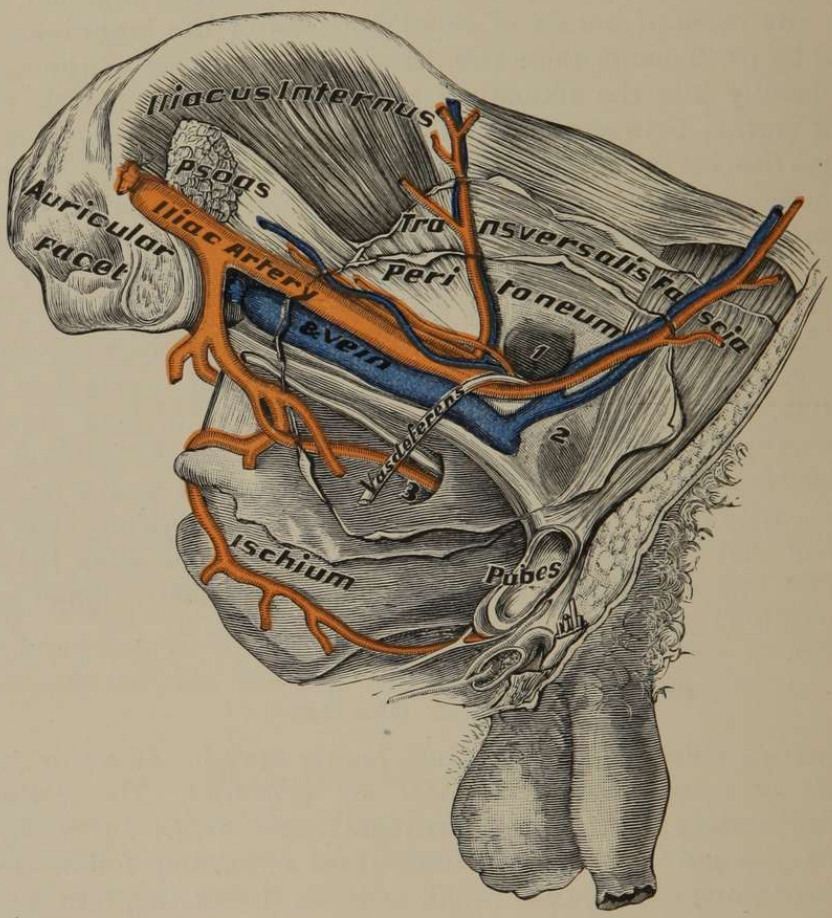

Fig. 654.—The relations of the points of escape of oblique and direct inguinal and obturator herniæ to the important vessels of the pelvis. 1, Internal abdominal ring. 2, Point at which a direct inguinal hernia commences. 3, Obturator canal, artery, and nerve. The epigastric vessels are seen passing upward between 1 and 2. (Modified from Maclise.)

ring, and which normally is closely adherent to the cord, not permitting the entrance of any of the abdominal contents, is closed at the *internal*, but remains unclosed at the *external* ring. The hernia descending, pushes before it the parietal peritonæum as in ordinary hernia, and carries it gradually downward until it is protruded into the unclosed vaginal process below, forming in this way two sacs.

It will be seen that an oblique inguinal hernia is *congenital* when it follows exactly in the route traveled by the *testicle* in its descent and lies in contact with this organ. This form of hernia exists generally at birth, but it has been known to occur after birth and even in adult life in rare instances where the vaginal process and tunica funiculi have not firmly united and are easily broken through.

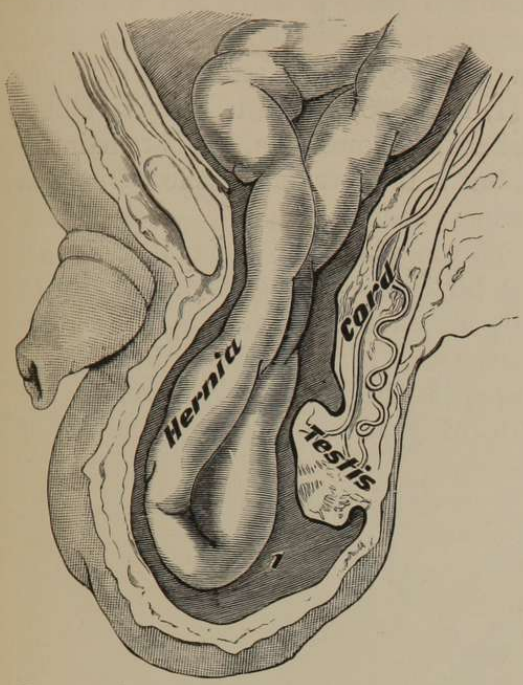

FIG. 655.—Congenital oblique inguinal hernia. Sac formed by the *tunica vaginalis et funiculi*. 1, Cavity of the tunica. (After Maclise.)

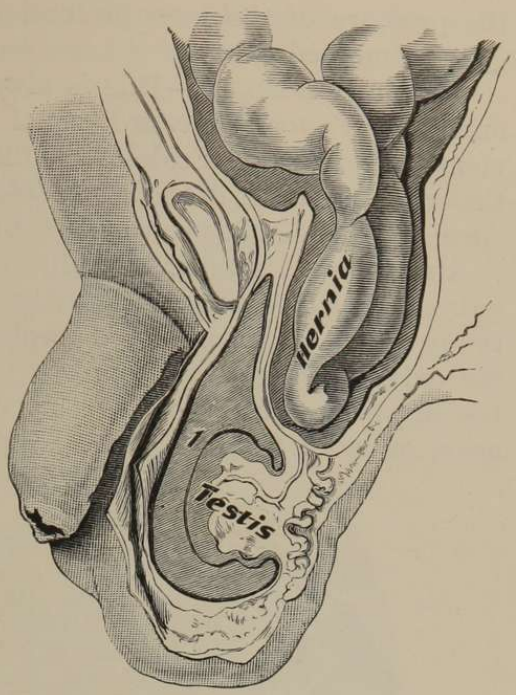

FIG. 656.—Infantile hernia (acquired), the intestine carrying with it a process of peritonæum by the side of the occluded spermatic tube. (After Maclise.)

In an *infantile* hernia, which occurs, as its name implies, usually soon after birth, but which may also, in exceptional instances, occur later in life, the intestine descends along the tubular sheath which surrounds the spermatic cord, but finds this sheath closely attached to the cord at the upper margin of the testicle, where it is arrested; and while by its weight it may descend into the scrotum and pass beyond the level of the testicle, it never lies in contact with it, as in the case of congenital oblique inguinal hernia. In general, therefore, we may say that an inguinal hernia is *congenital* or *acquired*, the *congenital* form existing at birth, while the *acquired* hernia (Fig. 657) is one which comes on after birth, and is caused chiefly by

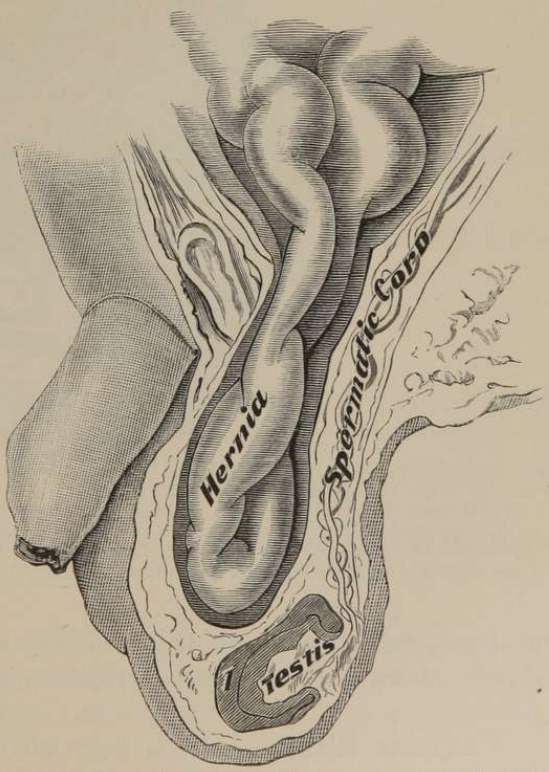

FIG. 657.—Complete (acquired) inguinal hernia as it occurs in the adult. Not communicating with the cavity of the *tunica vaginalis testis*. (After Maclise.)

the pressure of the intestine or omentum from *gravity* and *muscular effort* combined.

Femoral Hernia.—This is always an *acquired* hernia. The tumor enters the *femoral* or *crural* canal (1, Fig. 658) beneath Poupart's ligament just to the inner side of the iliac and femoral vein. If it remains in the crural sheath it is an *incomplete*, but if it protrudes at the *saphenous opening* (Fig. 659) it is a *complete* femoral hernia.

Umbilical Hernia.—Umbilical hernia is either congenital or acquired. It exists not infrequently at birth in both sexes on account of the patulous condition of the omphalo-mesenteric duct. In this variety the only covering of the tumor is the *sheath* of the umbilical cord. In the acquired form the intestine escapes either directly through the navel or more frequently to one side of this contraction. The sac of

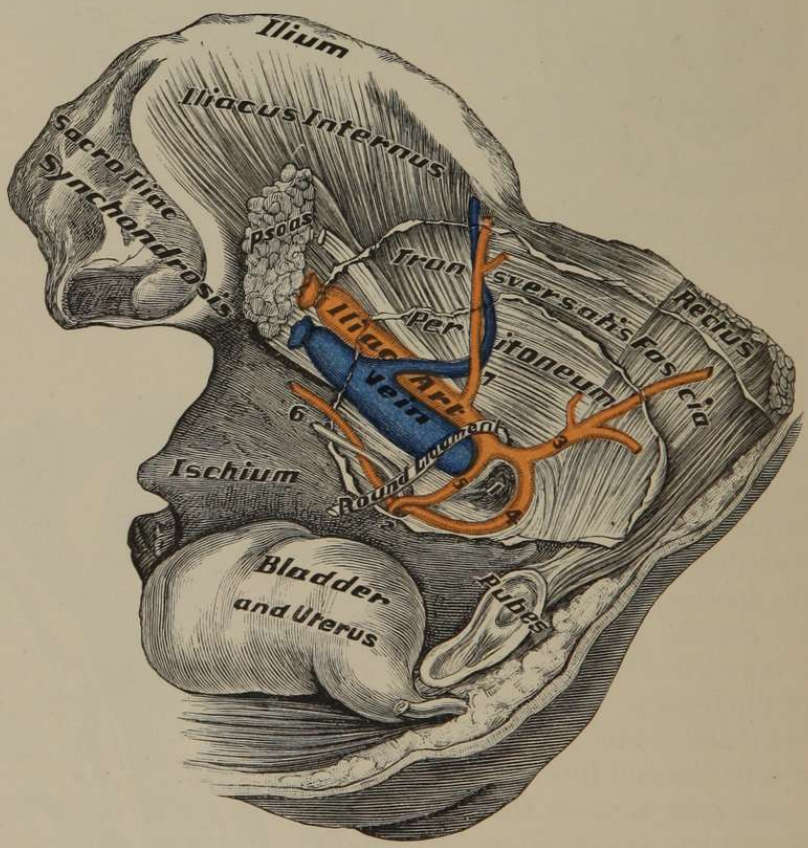

Fig. 658.—Showing the femoral ring and its relations to the iliac vein and the obturator artery when derived from the deep epigastric. 1, Femoral ring. 2, Obturator foramen. 3, Deep epigastric artery. 4, Abnormal origin of the obturator running internal to the neck of a femoral hernia. 5, The same, descending external to the neck of a femoral hernia. 6, Normal obturator artery. 7, Circumflex branch of external iliac. (Modified from Maclise.)

an *acquired umbilical* hernia is composed of the *parietal layer, of the peritonæum*, and the outer covering of *integument* and *subcutaneous fat.*

Ventral Hernia.—This may also be congenital or acquired. The protrusion may occur at birth as a result of failure of development in the muscles of the abdomen. It is usually met with along the linea

alba above the umbilicus. The acquired form may occur at any point, and results from accidental or surgical wounds of the muscles and fascia

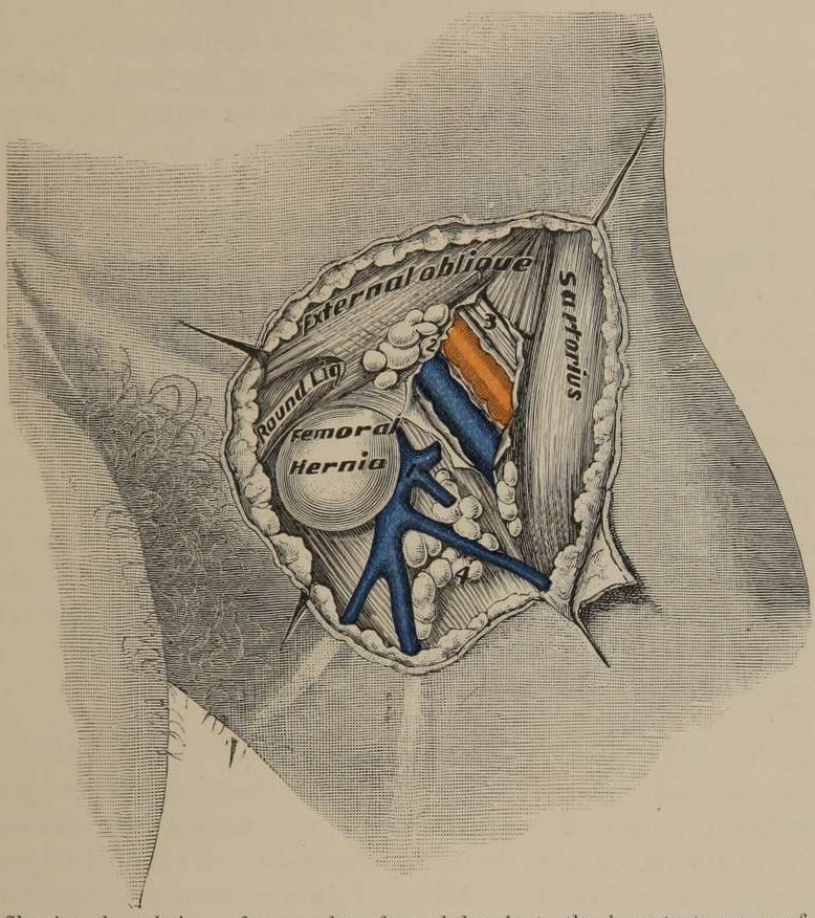

Fig. 659.—Showing the relations of a complete femoral hernia to the important organs of the groin. 1, Saphenous vein passing beneath the falciform process. 2, Femoral vein and artery. 3, Crural nerve. 4, Plexus of femoral lymphatic glands. (Modified from Maclise.)

and occasionally from pregnancy. It is quite frequently met with in the wounds of incision in laparotomy.

Rarer Forms of Hernia.

Diaphragmatic hernia is usually due to a wound or rupture of the diaphragm. It may result from a congenital defect in this muscle. It generally occurs on the left side on account of the protection afforded by the liver on the right side.

Gluteal hernia is extremely rare. The escape of the viscus is through the *sciatic* notch, and it may occur above or below the pyriformis muscle.

Obturator hernia takes place in the *thyroid* (obturator) foramen, usually in the upper portion of the canal which gives exit to the obturator vessels and nerves (3, Fig. 654) It is more common in women than in men.

Lumbar hernia occurs in the region situated between the twelfth rib and the crest of the ilium.

Hernia into the *vagina* occurs as a rule with partial or complete *prolapse* of the *uterus*, or after loss of substance allowing escape of the intestine.

Perineal hernia descends to one side of the median rhaphe of the perinæum between the *bladder* and the rectum in the male; between the *rectum* and the *vagina* in the female, traveling along the inner slope of the levator ani muscle. It is extremely rare, but has been known to follow the operation of lithotomy.

Pudendal hernia, in which the bowel passes down between the *ramus of the ischium* and the *vagina*, forming a tumor in the labium, and *sacro-rectal* hernia, which is described as having occurred in failure of the junction by ossification of the separate bones composing the sacrum, are rarely met with.

There is also at times a hernia of the *ovary* into the canal of Nuck, and there are two instances on record in which a hernia of the Fallopian tube alone existed in this canal. One of these cases was in the practice of the author, and, having become strangulated, caused the death of the woman by infectious peritonitis, the infection spreading through the disintegrating sac into the peritoneal cavity. The *bladder* has also been known to protrude into the inguinal canal and through the external ring, the author having observed two cases.

Symptoms, Diagnosis, and Treatment of Hernia.

Symptoms and Diagnosis of Inguinal Hernia.—When gradually acquired, the presence of a small swelling or tumor near the center of Poupart's ligament, or a little to the inner side of this point, is usually the first symptom of *inguinal hernia*. In a certain proportion of cases the appearance of the swelling has been preceded by a feeling of weakness or uneasiness referred to this region, which only disappeared when the recumbent posture was assumed, or when strong upward pressure was made by the hand.

If suddenly acquired, the presence of the tumor is noticed soon after a violent strain of the abdominal muscles. Pain is almost always present, and the patient is generally aware that rupture has occurred.

The diagnosis of inguinal hernia involves (1) the differentiation between the *direct* and *indirect* variety, and (2) between inguinal and femoral herniæ and the various swellings which may occur in this region: varicocele, hydrocele, bubo, incarcerated testicle, ovary, cyst, Fallopian tube, new formations, abscess, and aneurism.

A *direct* inguinal hernia is exceptional. The tumor formed by it is apt to be spherical (Fig. 660), is situated nearer the median line, and the neck will be found to enter the abdominal cavity immediately behind the external ring.

The tumor formed by an *oblique inguinal* hernia is oval or elliptical in the incomplete (Fig. 661) and oval or pyriform in the complete variety. The history of the swelling, if gradually developed, will indicate that the tumor commenced at the middle of Poupart's ligament and traveled

toward the pubes. In cases of long standing, and when the tumor is of large size, the diagnosis between the direct and indirect form is scarcely possible, from the fact that the inner edge of the internal ring

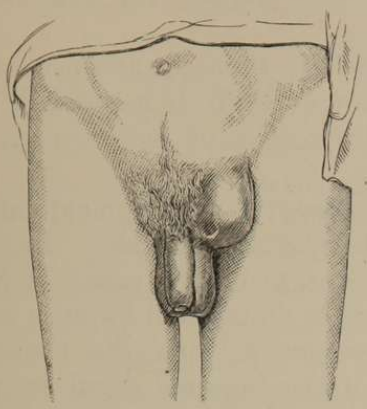

Fig. 660.—Direct inguinal hernia. (After Thomas Bryant.)

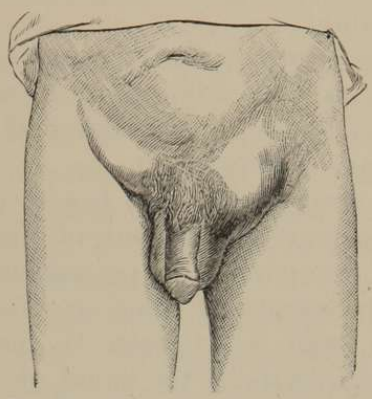

Fig. 661.—Incomplete oblique inguinal hernia. (After Thomas Bryant.)

has been dragged down until it occupies a position just behind the external opening.

A *femoral* hernia is situated below Poupart's ligament, and near its attachment to the spine of the pubes, to the inner side of the femoral vessels (Fig. 662). In lean subjects the neck of the tumor can be readily traced to the canal at this point. In corpulent persons the diagnosis is more difficult. The swelling of *varicocele* commences in the lower posterior portion of the cord and increases gradually upward. To the touch the distended veins feel like worms. The tumor has none of the elasticity of hernia.

In the recumbent posture a *varicocele* and a *non-incarcerated* inguinal hernia will both disappear. If after the disappearance firm pressure is made with the fingers, and the patient is directed to resume the upright posture, the varicocele, despite the pressure, will return, while the hernia can not descend. *Coughing* does not give an impulse to *varicocele*. The accumulation of fluid in *hydrocele* of the *tunica vaginalis* is first noticed in the most inferior portion of the scrotum; the swelling is spherical at first, and becomes pyriform after the cord is involved. Hydrocele is translucent, and fluctuation may be detected. *Encysted hydrocele* of the cord near the external ring or within the inguinal canal may make differentiation more difficult. The impulse from coughing is not marked in hydrocele, the sense of weakness is absent, the cyst is small, and usually remains so. If, after full consideration, doubt still exists, aseptic aspiration with the finest hypodermic needle will clear up the diagnosis without danger.

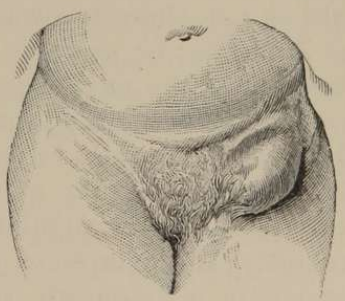

Fig. 662.—Femoral hernia. (After Thomas Bryant.)

Bubo.—In *chronic adenitis* the glandular character of the swelling can be made out distinctly. In *acute adenitis*, although the peri-

lymphatic infiltration is so extensive that the glands can not be recognized, the redness of the skin, the great tenderness on pressure, and the superficial character of the pain, with the coexistence of a urethritis or sore upon the penis or scrotum, will serve to establish the character of the lesion.

Incarcerated testicle may be suspected if there is absence of the organ on that side. If the testicle is not extensively atrophied, pressure will give the peculiar and characteristic sense of pain experienced in injury of this organ.

In *neoplasms* there is a history of progressive development entirely disassociated from that of hernia, as heretofore detailed. Incarceration, temporary or permanent, of an *ovary* in the canal of Nuck may be suspected when on coughing there is no marked impulse to the tumor, and when pain is increased coexistent with the menstrual period. *Cysts* of the canal of Nuck or of the inguinal canal are rare, but have been met with in a number of cases—four or five within the experience of the author. They differ from herniæ in general since they are irreducible, and do not impart well-marked impulse on coughing.

Abscess, which not infrequently appears above Poupart's ligament, is accompanied with inflammatory and septic symptoms which do not accompany hernia. Abscess of this region occurs with adenitis, as just stated, and with osteitis of the vertebræ or ilium. The recognition of either of these lesions will lead to the diagnosis of abscess.

In the manipulation of a hernial tumor, the sensation imparted to the fingers will vary with the contents of the sac and the condition of the mass. If it contain only *omentum*, it is doughy to the feel, and will yield dullness on percussion. If the mass is composed of *intestine*, it is elastic and more or less tympanitic on percussion. The "colicky" pain felt when the intestine is firmly compressed is of diagnostic value in determining the contents of a hernia. Whether a hernia is reducible or not, there is always a perceptible impulse imparted to the tumor in coughing or sneezing. In *strangulated* hernia the diagnosis rests first upon the existence of a swelling, which is present in almost all cases. In very exceptional instances there is no protrusion noticeable. The next symptom is pain at the seat of the hernia. In character it is compared to that of *intestinal colic*, and when not intensified at the point of strangulation it is usually referred to the umbilical region. The symptoms of occlusion are more remote, and while very strong in a diagnostic point of view, are practically not of much importance, because a diagnosis should be made and treatment instituted before the effects of obstruction are made evident. The cessation of fecal discharges may not occur in intestinal obstruction for several days after the occlusion, when the small intestine alone is involved, since the contents of the bowel below the constricted point may be evacuated. The *vomiting* of recently ingested food or drinks followed by stercoraceous matter is the last and strongest evidence of occlusion. *Distention* of the abdominal walls, with *tympanitic resonance*, is, when

taken in connection with other symptoms, a strong link in the chain which makes the diagnosis conclusive. *Hiccough* is present in many cases, but is apt to be one of the later evidences of obstruction. *Shock, that condition in which, as a result of an emotion or injury, the functions of the nerve centers are more or less completely suspended,* is present in a varying degree in almost all cases of strangulated hernia. It is evident in a rapid and weak pulse, occasionally missing a beat, or varying in exacerbations of rapidity and slowness; coldness of the skin with unnatural perspiration, lack of facial mobility, the eyes wide open and staring, the only expression being that of pain or great anxiety. In omental hernia the pain is not so intense as in intestinal hernia, and the symptoms of occlusion are always absent.

Treatment of Inguinal Hernia.—The treatment of *inguinal hernia* may be considered under the following heads: (1) the reducible; (2) the irreducible (not strangulated); (3) strangulated. For a hernia not strangulated, the operative measures are *palliative* or *curative;* in strangulated hernia early operation is always indicated.

A *reducible inguinal hernia* should be returned to the abdominal cavity and retained there by the constant and careful employment of a truss or bandage and compress. In accomplishing the reduction the patient should rest upon the back with the thighs flexed upon the abdomen and the pelvis elevated. In this position gravity carries the intestine and omentum toward the diaphragm, and this traction from within readily reduces the mass. If this should not succeed, gentle pressure with the hand will suffice. *Taxis* improperly performed or carelessly prolonged is not without great danger. Once reduced, an effort should be made to prevent recurrence.

For *incomplete* or slight hernia, in patients who are not compelled to do heavy work, the House elastic truss is most comfortable and safe. In all other cases the steel spring truss must be worn. The pad will vary in size as the character of the rupture may require. The hard-rubber or wooden pads are preferable in the great majority of cases. A truss should be applied before leaving the recumbent posture, and should not be removed again until this posture is resumed. When ordering a truss the following rule should be observed: Describe fully the character of the hernia. If the case is one of complete inguinal hernia of the left side, take a lead tape, lay one end directly over the internal ring of this side, and carry the tape across the abdomen to the right, just below the anterior superior spine of the right ilium, and across the gluteal region to the same point below the left superior spinous process. Press the malleable lead closely to the integument in order to get an exact outline of the surface to which the truss is to be applied, and trace this directly upon a sheet of paper. The instrument maker in using this tracing can model the spring to fit more comfortably, and after this temper the metal to make the required pressure. When there exists a bilateral hernia a double truss should be worn. A fair temporary truss may be made as follows: A piece of cloth or a tuft of wool, cotton, or oakum is rolled into a compress

about half the size of the fist, covered with adhesive plaster (the adhesive surface being external), and is laid immediately over the inguinal canal after the hernia has been reduced; while the patient is in the recumbent posture, a spica bandage is carried around the pelvis and thigh so that the compress is held firmly in position. The adhesive plaster which surrounds the compress adheres to the skin and to the spica bandage.

When an inguinal hernia can not be retained by a truss, operative interference is indicated. In cases where the hernia can be retained, and yet interferes with the comfort or usefulness of the individual, operation for radical cure is also advisable. In irreducible hernia which interferes with comfort or usefulness or which is increasing in volume, or in persons going beyond the reach of proper surgical aid, operation for the radical cure should be undertaken. In aged persons operation should be avoided unless strangulation has occurred. By reason of the great advances due to careful asepsis and improved operative technique, together with the increased safety in anæsthesia as practiced at this time, even the more conservative surgeons are leaning to the side of operative interference. That death is exceedingly rare following this operation done on properly selected cases and by experienced operators will be seen from a study of the statement of Prof. Eduard Bassini, of Padua, who had one death in 251 cases, this death from pneumonia, the wound having healed without suppuration. Svennsen and Erdman record 200 operations, no death; Lucas Championnèire, 266 cases, one death; Kocher, 119 operations, one death (due to pulmonary embolism on the fifteenth day after the operation, when the wound was completely healed); Macewen, 98 cases, one death from scarlet fever; Roswell Park, 85 cases, no deaths (Dawbarn). In the author's experience no death has resulted.

Radical Cure of Inguinal Hernia.

The following procedure, which, in my opinion, combines the better features of three methods for the radical cure of inguinal hernia, I have tried in a number of cases with great satisfaction. It meets so fully every requirement that no other operation is given:

Make an incision through the skin and fat down to the aponeurosis of the external oblique muscle, commencing about two inches internal to and one inch above the level of the anterior superior spine of the ilium, and extending obliquely downward and inward to the spine of the *os pubis*. Divide by *splitting* upon a grooved director, or with dull-pointed scissors, the aponeurosis of the external oblique muscle at the external ring to a point about one inch beyond the location of the internal ring. Dissect the inner flap of this aponeurosis toward the median line until the conjoined tendon (of the internal oblique and transversalis muscles) is brought well into view. The outer flap is also reflected until the shelving or scroll-like edge of Poupart's ligament is well exposed (Fig. 663). The structures of the spermatic cord and the hernial sac are carefully

separated from each other, and the sac should be freed from all attachments well down to the inner surface of the internal ring. The method of loosening the sac with the finger is shown in Fig. 664. The operator is now ready to open the sac and reduce the contents of the hernia, if this has not been done by posture or careful manipulation aided by the relaxation due to the anæsthesia. This is done preferably by picking up the sac with two pairs of forceps and carefully cutting through between them with the point of the scalpel until a few drops of serum exude. This liquid is present in practically all cases of hernia. When non-

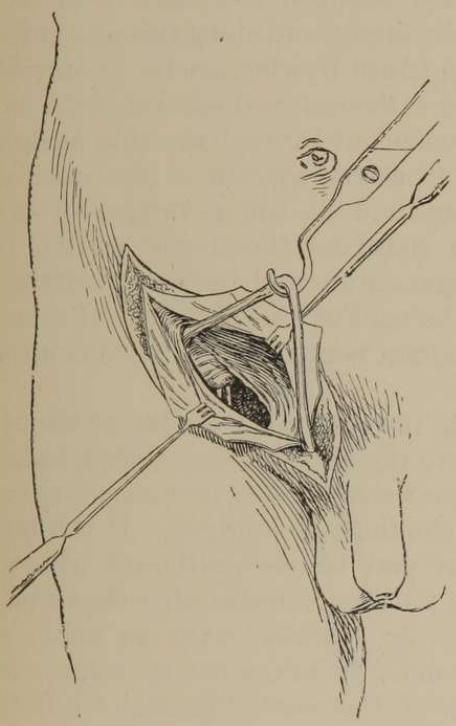

Fig. 663.

Fig. 664.

Fig. 663.—Showing incision through the skin and the aponeurosis of the external oblique divided and held out of the way with retractors so as to expose the internal abdominal ring. The spermatic cord is lifted on a dull hook. The hernial sac has been carried above the cord and concealed beneath the internal oblique after the method of Macewen. (After S. E. Milliken.)

Fig. 664.—Showing the method of separating with the finger the sac from the margins of the internal ring and conjoined tendon. (After Macewen.)

strangulated, it is a clear or straw-colored fluid, but in strangulated hernia it has a dark and sometimes bloody tint. A grooved director is now to be inserted through this small puncture and the sac further divided until an opening large enough to admit the finger is made, when the contents should be examined by touch. Should the sac contain only intestine which is non-adherent, it can be readily reduced. If there be a mass of omentum, it can also be returned to the abdominal cavity, unless it has been so long compressed that its structure is indurated and changed, in which case it should be tied off with strong aseptic catgut. The operator should assure himself that there are no adhesions in the deeper portions of the neck and mouth of the sac and that the reduction of the contents is complete. Being freed from all attachment to the cord as well

as to the immediate edges of the internal ring, the sac is now transfixed at its tip with a strong catgut ligature, which is secured by tying. The needle is then carried through both walls of the sac back and forth along its entire length (Fig. 665), coming out for the last time at the level of the peritonæum lining the abdominal wall at the inner surface and upper margin of the internal ring. Having loosened, as above directed, the sac and peritonæum from the margin of the ring and the transversalis fascia for about one inch, the index finger (Fig. 664) is inserted between the neck of the sac and the transversalis fascia, and along this as a guide the same long Hagedorn-Fowler needle is carried and made to traverse the entire thickness of the abdominal wall and come out through the skin an inch above and away from the margin of the original incision. Being assured of the reduction of the contents by again reducing the finger, traction is made upon the catgut suture and the sac is wrinkled upon itself and drawn tightly against the wall of the abdomen after the method of Macewen (Fig. 666). An assistant continues the traction upon this suture until the wound is closed.

Fig. 665.—Showing the action of the catgut suture upon the hernial sac as it is being drawn and anchored beneath the conjoined tendon. (After Macewen.)

The second step consists in stitching the conjoined tendon of the internal oblique and transversalis muscle to the shelving or scroll-like edge of Poupart's ligament. For this purpose strong deer or kangaroo tendon (Van Horn and Ellison's) sutures should be employed. If this can not be obtained, sterilized silkworm gut may be used, although non-absorbable ligature material may cause suppuration months after the wound has closed. These sutures should also be inserted with an ordinary curved Hagedorn-Fowler needle. Care must be taken not to wound the iliac vein which lies close to the margin of Poupart's ligament which is included in the suture. It is my practice to insert a very dull grooved director over the vein and carry the point of the needle along the groove until its point can be turned upward in transfixing the edge of Poupart's ligament. In passing the needle through the inner margin of the canal, the transversalis fascia should be included with the conjoined tendon. About six sutures are required for this step in the operation. The lower two sutures near the pubis should include a portion of the outer border of the rectus muscle. Care should be taken in tying the uppermost stitch that it does not too tightly squeeze the cord. These sutures should take a good bite of all the structures on either side of the canal to be closed, but should not go more than a quarter of an inch into the shelving edge of Poupart's ligament. In Fig. 667 this part of the operation is illustrated with four of the sutures inserted. It is seen that the cord makes its exit through the abdominal wall at the upper instead of at the lower end of the inguinal canal. When the vessels

Fig. 666.—Showing the sac folded up and covering the abdominal aspect of the internal ring. (After Macewen.)

of the cord are hypertrophied, as in varicocele, the suggestion of Halsted, to exsect all veins not necessary to the function of the testicle, should be carried out. In Fig. 667, the reflected flaps of the aponeurosis of the external oblique muscle are still seen held back by retractors. The next step in the operation is to permit the cord to drop into the wound and rest upon the first row of sutures, while the final row of the same material or strong catgut closes the aponeurosis of the external oblique muscle over the line of the cord, as seen in Fig. 668. A row of catgut sutures closes the wound in the skin. A roll or pencil of iodoformized gauze, one inch long and one

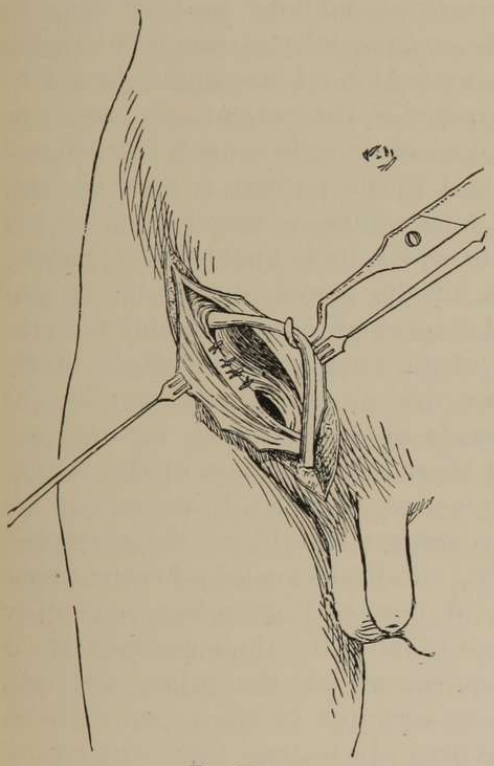

Fig. 667.

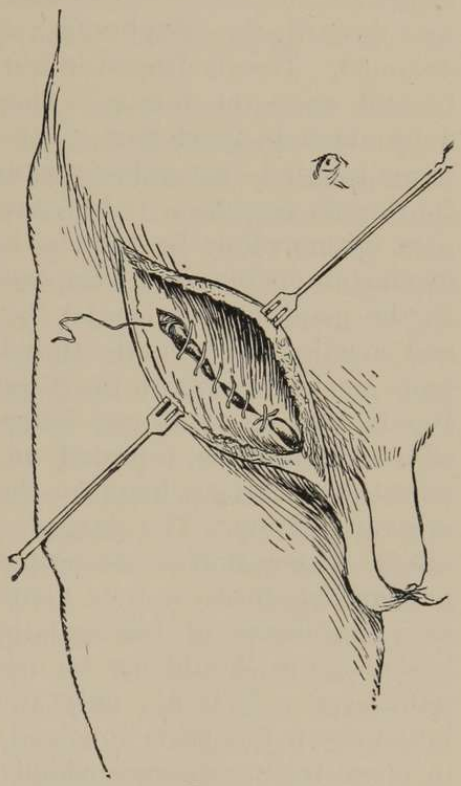

Fig. 668.

Fig. 667.—Method of suturing the conjoined tendon to the shelving edge of Poupart's ligament. The aponeurosis of the external oblique retracted on either side as before. Two more sutures are to be inserted to close the ring near the pubic spine. (After S. E. Milliken.)

Fig. 668.—The recently divided aponeurosis of the external oblique sutured over the cord by means of a continuous suture of kangaroo tendon. (After S. E. Milliken.)

quarter of an inch in diameter, is now laid on the skin by the catgut suture which holds the sac against the abdominal wall. By winding the suture in figure-of-eight fashion about the pencil of gauze the sac is permanently anchored in its new position. Compression over the field of operation should be made to prevent oozing while the line of incision is hermetically sealed with sterilized collodion, over which the ordinary gauze and cotton dressing is applied. It is important to continue compression of the wound while the dressing is being applied, for the reason that as no drainage is attempted in this operation, all moisture should be kept out of the wound and all oozing prevented. Hermetically sealing prevents danger of infection from the urine or any other source. The

patient should be kept in bed preferably for six weeks, when this is possible, and should not be allowed to quit the recumbent posture even to sit up in bed for three weeks after the operation. A spica bandage that will give moderate support should be worn for six or eight weeks after the patient has left his bed, when all support should be discarded.

Treatment of Strangulated Inguinal Hernia. — With the first symptom of strangulation the patient should be placed in the dorsal decubitus, with the foot of the bed elevated at least twelve inches, the pelvis raised upon a pillow, the legs flexed on the thighs, and the thighs on the abdomen, so that the intestines and omentum will gravitate toward the diaphragm; or the knee-shoulder position may be assumed. Towels dipped in hot water and partially squeezed out should be laid upon the tumor. The administration of morphine should be determined in good part by the character of the patient. It should be borne in mind that unless posture and careful taxis cause a reduction of the hernia operation is imperative, and if the patient is relieved from pain by morphine he may be lulled into a false sense of security and decline an operation, the importance of which he is unable to appreciate. In the manipulation (taxis) the neck of the tumor should be grasped and steadied between the thumb and fingers of one hand and the contents pushed gently in the direction of the canal with the other. Taxis should not be continued longer than five or ten minutes at any one effort. It may be repeated at intervals of ten minutes, or from ten minutes to half an hour for the first three or four hours of the history of strangulation. The dangers of delay are so great, however, and the safety of operation so assured, that operation should not be postponed longer than three or four hours. The manipulation of a hernial tumor after six hours of strangulation is of doubtful propriety, and after twelve hours should not be attempted at all after the anæsthetic is administered. It is not only to be condemned for the injury one may inflict upon the parts involved, but on account of the procrastination in operative interference which it invites. It is true that occasionally reduction is effected after symptoms of strangulation lasting for a longer period than this; but these cases are so extremely rare, and the danger of a fatal termination so much increased by the delay, that it will be wiser to proceed at once to the operation. In justification of early operation, it may be said that the large majority of cases which end fatally are those in which strangulation has existed for from twelve to twenty-four hours and upward before surgical interference; and that abdominal section in a patient not exhausted by suffering or disease is almost free from danger. The high rate of mortality after kelotomy will only be materially reduced when it is performed not later than twelve hours, and, better still, within the first six hours of strangulation.

Operation.—The pubes, scrotum, and integument near the tumor should be shaved, scrubbed with a clean, stiff brush, with green soap and warm water, washed with ether in order to dissolve the fat and clear out the sebaceous follicles, and finally with a 1-to-1,000 subli-

mate solution. The patient, fully anæsthetized, should be placed upon a table nearest the edge most convenient to the operator with the pelvis slightly elevated. The parts about the field of operation should be covered with warm sterile towels, leaving a space about six by eight inches uncovered. In males the prepuce should be sealed over with rubber protective melted on with chloroform.

The incision should be in the long axis of the tumor, and may be made by cutting directly down upon the mass, or by pinching up the skin and fat immediately over the swelling, transfixing it and cutting outward. It should be of good length, extending from one inch above the internal ring to the spine of the pubes. All bleeding should be arrested at once with catgut ligatures.

The first difficult point in the operation is the recognition of the sac. This comes into view after the skin and fat and deep fascia have been divided and held apart by the tractors. When one is uncertain as to when the sac is reached, it is a safe procedure to grasp the coverings of the hernia with two "rat-tooth" forceps, lifting only a very thin portion at each time, and carefully cutting with the scalpel or the dull scissors between the grasp of the two pairs of forceps, until finally a few drops of serum, clear or straw-colored in the case of a recently strangulated hernia, black or bloody-looking fluid in the case of a long strangulated or necrotic mass, exude from the puncture. This will occur in the proportion of forty-nine out of fifty operations. In very rare cases the sac may be adherent to the intestine, and puncture of the gut has occurred under such circumstances. Even should this occur, it is not a dangerous thing, as it can be closed before reduction is effected by Lembert's suture. As the fluid begins to escape through the puncture in the sac, a grooved director with a very dull point is inserted through the aperture and the sac divided until the finger can be admitted, when it is introduced and the sac further incised as desired. The contents are now clearly in view. A thorough irrigation should be made, using warm boric-acid solution or water that has been boiled and allowed to cool to 110° or 120° F. The strangulation of the neck prevents the irrigating fluid or any septic matter from entering the peritoneal cavity. The hands of the operator should now be carefully recleansed. By carrying the index finger of the left hand toward the constriction, with the palmar surface upward, the nail can be slipped under the constricting band, usually at the neck of the sac. Very frequently I have been able to stretch or tear this band of constriction with the finger nail unaided by the knife by making the pressure directly upward. The intestine is not injured in the least, nor can any harm be done. Within a minute or two the nail and the soft end of the finger will so stretch the band of constriction around the hernial contents that the intestine drops back into the peritoneal cavity. If this can not be done with the finger nail and finger, it should be introduced in the same way, and a long, probe-pointed bistoury carried flatwise along the palmar aspect of the finger until the dull point passes between the sharp edge of the ring and the nail. The edge is now turned upward

against the ring and pressed against this by the finger upon which it rests. The direction of this cut is upward and very slightly inward in inguinal hernia. It should not extend beyond an eighth of an inch. The finger nail is usually sufficient to enlarge the opening after the first few fibers are divided.

Before allowing the contents of the hernia to return to the peritoneal cavity, these should be carefully examined as to their condition. As soon as the strangulation is relieved, the wound and exposed intestine or omentum should be covered in with towels dipped in hot sterile water or Thiersch's solution and left for from five to ten minutes in order to determine whether the circulation can be re-established or not. The

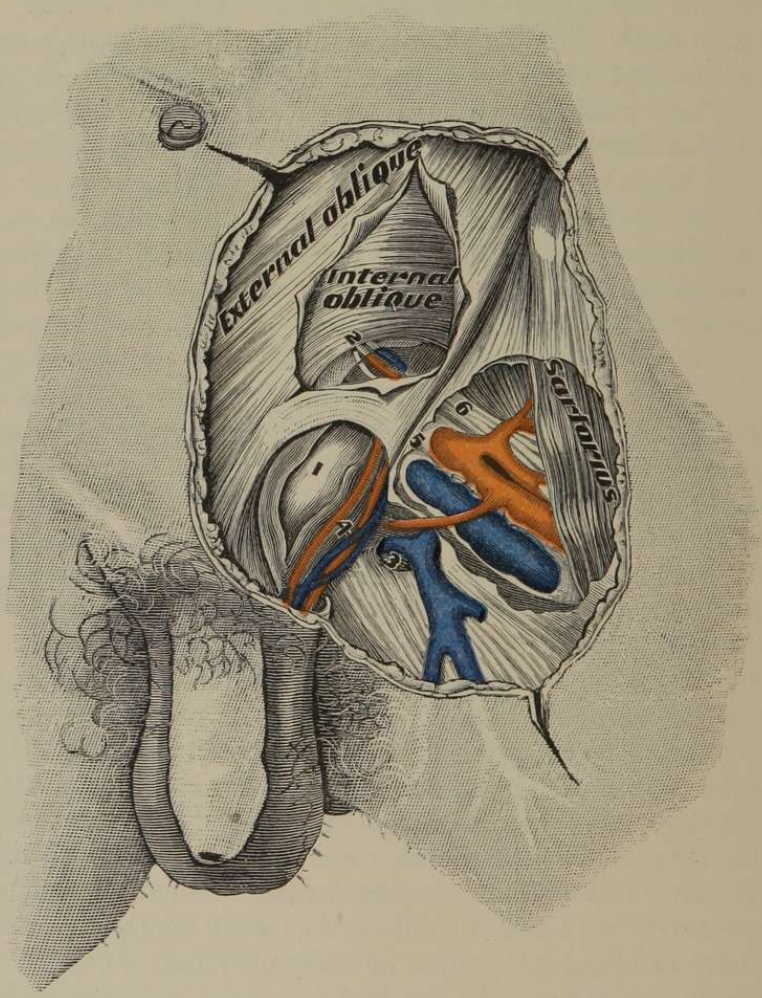

Fig. 669.—Showing the relations of a direct inguinal hernia to the epigastric vessels and the spermatic cord. 1, Hernial tumor. 2, Epigastric vessels in front of and external to the neck of the tumor. 3, Saphenous opening and vein. 4, Spermatic vessels. 5, Femoral vessels. 6, Crural nerve.

color of strangulated intestine varies from pinkish-gray to a black, motley color. The contents of a hernial sac should not be returned into the abdomen unless the color changes to a healthy red after the strangulation is freely relieved. If, after from five to twenty minutes, the circulation is established, reduction should be effected. In accomplishing this, posture is important, and the intestine should be carefully

pushed in between the thumb and finger. Once returned, the inner opening should be stopped with the finger or a plug of sterilized gauze fastened to a string or holder so that blood or the contents of the sac may not run into the peritoneal cavity. If a small surface of omentum, say an inch in breadth and about an inch long, is contained in the

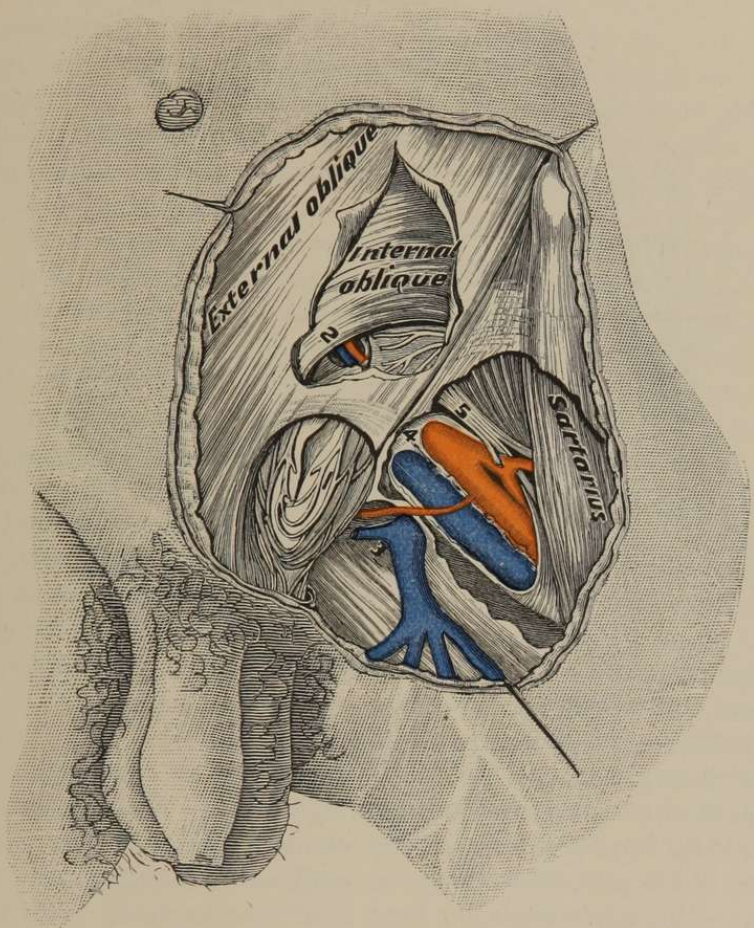

Fig. 670.—Showing the relations of an oblique inguinal hernia. 1, Tumor covered by cremasteric fascia. 2, Epigastric vessels behind and to the inner side of the neck of the tumor. 3, Saphenous vein and opening. 4, Femoral vessels. 5, Crural nerve.

sac, and is materially unchanged, it may be reduced with the intestine; but if the strangulation has existed for some time, or the omental tissues are indurated and abnormal, or in any way suggest the possibility of infection, it should be withdrawn through the opening until healthy omentum is reached, and through this healthy surface catgut ligatures should be passed and tied and the portion beyond the ligature cut away. In large herniæ where a great deal of omentum has been imprisoned, it is usually the best practice to treat the protruding omentum as just described. The stump of the omentum is dropped back into the peritoneal cavity. If the condition of the patient is such as to warrant a further operation at this time, the operation for radical cure as just described should be performed. In case the intestinal wall is broken

down, or is so nearly necrotic that its return into the cavity of the abdomen is attended with danger of rupture of the gut and escape of its contents, two alternatives present themselves: to leave the intestine protruding and establish an artificial anus, or to exsect the dead portion and sew the ends together. If the patient is in good condition, and especially if in the prime of life and usefulness, exsection should be done. If, on the other hand, collapse is imminent, or if there is anything in the condition of the patient to contraindicate a prolonged operation, the fecal fistula should be established, and a restoration of the alimentary canal postponed for a few days, or maybe weeks.

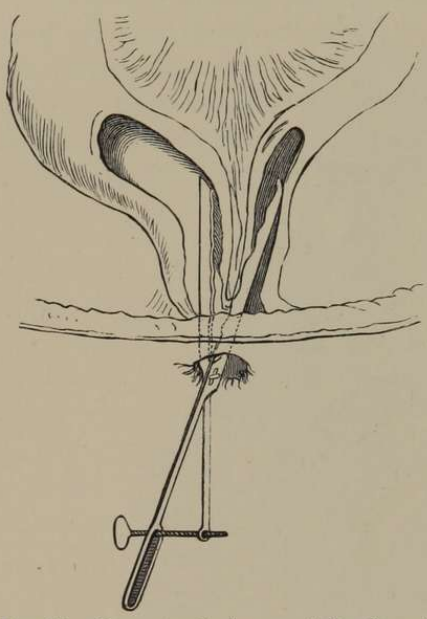

Fig. 671.—Dupuytren's clamp. (After Gross.)

Immediate exsection of the bowel is performed as follows: Having released the strangulation as above described, both ends of the loop are drawn out until five or six inches of sound gut are exposed. These may be grasped by the thumb and finger of an assistant close to the level of the abdominal wall, or, if the hand of an assistant would be in the way, a broad disinfected tape may be tied loosely around each end of the intestine near the ring to prevent the possibility of retraction or escape of the bowel or its contents inward.

The operation is then completed, inserting the sutures after the method already given. When it is necessary to establish a fecal fistula the method of Dr. J. A. Bodine is advisable. This method, as above described, is an improvement on the clamp method of Dupuytren (Fig. 671). The older procedure may be utilized in restoring the canal in fistulous openings in which no long spur was formed. The blades are introduced one into each end of the intestine, closed, and allowed to remain in this position. Pressure causes adhesion between the wall of the contiguous limbs and sloughing of that part immediately beneath the blades, thus restoring the canal.

Inguinal hernia in the *female* has the same relation to the epigastric vessels as in the male subject. In the complete form the contents may descend into the labium. The treatment does not differ materially from that just given. It is simpler, for the reason that the spermatic cord is not involved, and is therefore more readily cured by operation. Cysts of the canal of Nuck not infrequently simulate a hernial tumor; or, as before said, the ovary, and, rarely, the Fallopian tube may be in the canal.

Treatment of Femoral Hernia—This form of hernia is more difficult to retain in place with a truss, which apparatus produces more discomfort than when worn for inguinal hernia. It is more likely to

become incarcerated and strangulated than any other variety. The prognosis is therefore more unfavorable. The diagnosis depends upon the presence of a tumor in the location already given, the neck of which can be traced to an opening at the inner side of the thigh just external to the spine of the pubes and below Poupart's ligament. The impulse in coughing is present, though usually less perceptible than in inguinal hernia. Cysts are less apt to complicate a femoral than an inguinal hernia. Enlargement of the lymphatic glands will not be apt to mislead, since there will have been a history of adenitis, a gradual increase in the size of the glands, which may be recognized as a group. The absence of impulse in the act of coughing will further aid in the exclusion of hernia.

The symptoms of strangulation differ in no essential features from those in inguinal hernia.

A *reducible* femoral hernia should be retained within the abdomen by a truss, the pad of which presses firmly over the femoral ring, just external to the spine of the pubes. The pad should be hard and small, so that it may not compress the femoral vein, and the spring should be strong, for this form of hernia is not only difficult to retain, but is doubly dangerous when it escapes by the side of the pad. In reducing femoral hernia, position is invaluable, and taxis may be of aid. The best position without taxis is the knee-shoulder posture, in which the abdominal muscles and fascia lata are relaxed and the contents of the abdomen gravitate toward the diaphragm. Or the dorsal decubitus may suffice, with the pelvis elevated, as well as the foot of the bed, and the thighs flexed upon the abdomen. In performing taxis, it must be remembered that the bulk of the hernia must pass directly backward to clear the falciform process of the fascia lata, and then upward in the direction of the femoral canal. *Operation* for the radical cure of femoral hernia may be determined by the general rules given for the inguinal variety. If the sac is large a portion of it may be cut away, and the remainder carried to the inner aspect of the abdominal wall near Gimbernat's ligament and anchored there in the same general way as described in treatment of the sac by the Macewen method. In the effort to close the femoral ring, tendon and next in order silkworm-gut sutures are preferable, and care must be taken to avoid the femoral vein, which is almost in contact on the outer edge of the crural canal. The falciform process of the fascia lata and pectineal fascia should be stitched together and to the edge of Gimbernat's ligament. In irreducible (not strangulated) femoral hernia operative interference is more positively indicated from the fact that strangulation is very apt to occur, and that the employment of a compress to prevent a further descent of the mass is harmful.

So rapid are the changes which occur in the contents of the sac in *strangulated* femoral hernia that early operation is imperative.

The preparation for the operation is identical with that for inguinal hernia. The most thorough shaving of all the integument near the operative field is essential. When narcosis is complete, the patient should be lifted by the legs in such a way that the thighs will be flexed

upon the abdomen and the pelvis raised considerably higher than the thorax. While in this position taxis, in a direction at first slightly backward and then upward, should be practiced. If reduction is not effected in from five to ten minutes it should be discontinued.

The incision should be longitudinal in direction, along the middle of the tumor, with its center over the femoral ring. The length will vary with the size of the protrusion, but three or four inches will usually suffice. It should be made by cutting directly down upon the sac, and when this is reached the dissection should be continued between two dissecting forceps. As the sac is punctured, a few drops of fluid will escape, and a grooved director may then be inserted, the opening carefully enlarged until the index finger can be introduced and carried upward until the edge of the falciform process is felt and the nail is under the sharp constricting edge of Gimbernat's ligament. At this stage of the operation the hernial sac should be carefully irrigated with 1-to-5,000 bichloride or boric acid solution. The contents of the sac must be kept between the finger and the femoral vein and the edge of the nail against Gimbernat's ligament, just at its insertion at the os pubis. I have frequently been able, by scratching with the nail and firm pressure with the end of the index finger, to tear or stretch Gimbernat's ligament at this point enough to relieve the strangulation and effect reduction without the use of the bistoury ; however, if this can not be done, a long, probe-pointed knife should be carried flatwise along the palmar side of the finger, with the cutting edge directed toward the median line. The constriction is relieved by lifting or scraping the attachment of Gimbernat's ligament from the os pubis, and in doing this the cutting edge of the knife should not be carried beyond this ligament, nor should it have any other direction than inward toward the symphysis. If these precautions are not observed, a dangerous complication may arise in the division of the obturator artery (or vein) in cases in which it is derived from the epigastric branch of the external iliac. In eight fatal cases of this character recorded, the patients were all females. This abnormal derivation occurs in women, as determined by the author in a study of this artery, in nearly fifty per cent of cases, and in men in twenty-five per cent, while the vein arches over the femoral ring in a larger proportion of subjects.*

The manner in which the artery arches over the crural ring is shown at 1, Fig. 658. When the strangulation is released, the contents of the sac are returned into the abdomen.

Umbilical Hernia.

The diagnosis between this form of hernia and other tumors of the umbilical region will depend chiefly upon the impulse conveyed to the hernia in the act of coughing, or in crying. If the hernia is made up of omentum—and this is not uncommon in adults—it will be doughy to the feel and flat or dull on percussion, while the intestine will be more or

* Author's "Essays in Surgical Anatomy and Surgery," New York, 1878.

less resonant. Cyst of the omphalo-mesenteric duct would be translucent and fluctuation would be present. In congenital hernia, the extreme thinness of the covering renders the recognition of the character of the tumor easy. The transverse colon often descends into the sac of an umbilical hernia.

Treatment.—In *congenital* hernia at the navel, which is covered only by the thin membrane of the cord, the tumor should be returned at once, the margins of the aperture through which it has escaped pared, and the opening closed by carefully adjusted silk sutures, supported by adhesive strips drawn in dovetail fashion across the abdomen at the weak point or by a firmly rolled bandage. If covered over with integument it should be reduced, a small, firm compress laid over the opening, and secured in place by adhesive plaster applied as just described. The *acquired* form is treated in the same general way. In reducing umbilical hernia the recumbent posture, with the legs slightly flexed, is advisable, and careful taxis is often necessary. The truss should be worn when in the upright posture and at night when patients are suffering from cough. In mild cases a light rubber belt will suffice after retiring, but the heavy apparatus should be adjusted before leaving the recumbent posture.

Irreducible hernia, not strangulated, may be held in position by a properly adjusted cup-shaped compress.

The danger of strangulation is always present, and the advisability of operation must be determined by the circumstances of each case. On account of the great thickness of fat in some of these subjects, and the enormous size of the hernial mass, the operation for the radical cure when not strangulated becomes formidable, and when strangulated, is accompanied with more than ordinary danger. In operating for the radical cure the sac should be divided along the edges of the opening. The edges should be drawn up, pared with the scissors, and the aperture closed by strong sutures of silk which include skin, fascia, muscles, and the peritonæum of the abdominal wall, the needle piercing this last tissue about one fourth of an inch from the pared edge. As the sutures are tightened, the opposing surfaces of the parietal peritonæum of the two edges will be united.

With the first symptoms of strangulation the patient should be anæsthetized, and a final effort at reduction made by a careful taxis. If this does not succeed, the operation should be made at once. The incision in a small hernia should be vertical, with its center corresponding to the neck of the hernia. When the mass is large a double elliptical incision may be made, as there is a redundancy of skin and fat which can well be dispensed with. On account of the exceeding thinness of the integument over the hernia at times, great care should be exercised in cutting down upon the tumor. As soon as the sac is punctured a dull director is introduced and the sac divided sufficiently to allow the introduction of the finger, upon which the further division of the sac is effected. If the finger nail can now be insinuated between the neck of the hernia and the constricting ring, it should be done, holding

the palmar aspect of the finger toward the pubes. A probe-pointed bistoury is introduced flatwise along the finger as a guide, and the constriction divided for not more than one fourth of an inch at first, the direction of the cut being toward the median line.

The management of the strangulated bowel or omentum should be the same as advised in inguinal hernia. I prefer to cut the sac away as above advised, freshen the edges of the opening, and bring all the layers which compose the abdominal wall together with one set of sutures. When large masses of changed omentum are found in these herniæ they should be tied in sections with clean catgut ligatures, not including more in the grasp of the ligature than would represent the ordinary little finger of the hand. It sometimes takes as many as six or eight sets of ligatures to completely remove the mass. The omentum should be divided about one fourth of an inch external to the ligature, and, when all is cut away, the stumps dropped back in the abdominal cavity. It is my practice, as soon as reduction is effected and before the sac has been cut away around the margin of the ring, to introduce a pad of sterilized gauze (secured by a string so that it may be withdrawn), taken out of hot Thiersch solution or hot sterilized water, and laid over the intestines immediately beneath the opening.

When the sutures have all been inserted and are ready for tying, the pad should be withdrawn.

Other Forms of Hernia.

Ventral hernia is amenable to the same general treatment as hernia of the acquired umbilical form. In operation for the cure of hernia following the incision of laparotomy the same operation would suffice. In one of the author's cases the recti muscles during violent straining at parturition were split apart from a point three inches below the xiphoid appendix to within an equal distance of the pubes. At least two thirds of the intestinal contents were prolapsed into this enormous hernia. An elliptical incision throughout the extent of the tumor was made, and closure effected by silk sutures, following the method described for umbilical hernia. A perfect cure was effected.

In *diaphragmatic hernia* the diagnosis must be based upon the symptoms of obstruction. Pleuritis will be present in a varying degree. When this accident is suspected, and symptoms of obstruction are present, it is imperative to make the median incision below the xiphoid appendix, and by exploration with the hand the hernia may be reduced by traction with or without dilatation of the opening in the diaphragm. The prognosis in these cases is unfavorable if operative interference is delayed.

The recognition of *gluteal hernia* is also difficult. If with the symptoms of obstruction there is pain in the region of the sciatic notch or in the distribution of the gluteal or sciatic nerves, which is increased by direct pressure, the presence of gluteal hernia may be suspected. If a tumor can be made out, it is still more positive. To locate the notch, place the patient on the belly and hold the leg perfectly straight, with the toes

pointing directly downward. A line drawn from the posterior-superior spine of the ilium to the upper surface of the great trochanter will cross over the foramen.

The incision should be free, and the fibers of the gluteal muscles separated with the finger. The vessels should be carefully avoided if the constriction is divided.

Obturator hernia may be present without any appreciable tumor. It may be recognized by digital exploration through the rectum or vagina. Pressure upon the obturator nerve may produce pain in the hip or knee. If the symptoms of obstruction are present, the hand should be introduced through an incision in the linea alba, when, by careful exploration of the pelvis, the character of the lesion can be determined. In an effort at reduction by traction from within, the thigh should be rotated outward to relax the obturator muscle. If necessary, an incision may be made immediately over the foramen and the constriction divided from below. When the fibers of the pectineus muscle are divided the tumor will be encountered.

Lumbar, *vaginal*, and *pudendal* herniæ do not demand especial consideration. The diagnosis will depend upon the appearance of the tumor, with the symptoms of strangulation when the constriction is sufficient. The return of the mass which follows prolapsus of the uterus into the vagina may be effected by direct reposition of the uterus, or by conjoined manipulation with one hand introduced through an opening in the linea alba.

Hernia in Children should be treated in the main as advised for adults. On account of the inability of children to control themselves, a diagnosis is attended with some difficulty and is, as a rule, determined by the impulse imparted to the hernial mass as the child struggles and cries. They are usually reducible when the children are held with the head downward, with gentle taxis upon the tumor. It is very essential that an effort should be made to cure the herniæ of children by a proper application of and careful attention to the truss. The hard pad (celluloid) of the Hood pattern, as recommended by Dr. S. E. Milliken, is light, easily adaptable, and can be kept clean.

The truss should never be removed from its point of pressure except by the physician or a nurse who has been carefully instructed in its application and use. In healthy children a cure is often effected within two or three months. In others it is often impossible to effect a cure. If strangulation should occur, it should be relieved by operation at once, and in cases where a cure can not be effected by the truss and where the tumor is not readily retained by this apparatus, operation for the radical cure should be done. When not forced to interfere earlier, it is better to operate about the fourth or fifth year. The same operation advised for adults is admirably adapted to these cases. On account of the great thinness of the sac and the importance of expedition in very young subjects, the sac should be rapidly tied off and excised as advised by Bassini. It is my rule after operation to put all children in the plaster-of-Paris spica at once, in order to insure the recumbent posture. In operations about

the genital apparatus of children the iodoformized collodion dressing is recommended, because it hermetically seals the wounded surface and prevents infection from urine or other sources.

Fecal Fistula.—A fecal fistula may exist between any portion of the intestinal canal and the exterior through the integument; from the intestine into a normal cavity, as the bladder or uterus, and thence to the exterior; into an abnormal cavity, as an abscess, and thence out through one of the hollow organs or directly to the skin; or it may lead into a *cul-de-sac* or blind pocket.

Fecal fistulæ are *congenital* and *acquired.*

Imperforate anus is the most frequent cause of congenital fistula. The pressure of accumulated matter at the extremity of the canal induces inflammation, ulceration, and perforation, with extravasation of the bowel contents. If the congenital obstruction is low down, the opening may occur through the perinæum, bladder, or vagina. If higher up, the fistula may open through the abdominal wall at the umbilicus, or below this point in the linea alba, or posteriorly near the spine. A rare cause of congenital fistula is the presence of the omphalo-mesenteric duct, or Meckel's diverticulum, which, as heretofore stated, opens at the umbilicus.

Acquired fecal fistulæ may be *surgical* or *accidental.* Colostomy and enterostomy are examples of the former, while the latter result from perforating wounds of the intestinal canal, either from the exterior, as by *gunshot* or *punctured wounds*, or by the passage of some ingested sharp or hard body through the intestinal wall; or by perforation of the intestine by an ulcer or abscess, or from gangrene due to strangulation, contusion, etc.

The *diagnosis* of a fecal fistula which communicates directly with the exterior is made evident by the escape of gas and ingested matter. Indirect fistulæ can also be determined by the careful examination of the discharges from the organs through which they pass. In a case reported by Dr. Krackowitzer, in the "Transactions of the New York Pathological Society," an ulcer of the appendix vermiformis had opened into the bladder. The diagnosis of entero-vesical fistula was established by the escape of a lumbricoid worm from the urethra. Blind fistulæ can not often be made out until demonstrated by exploration.

In determining into what portion of the intestinal canal the fistula opens one must consider, first, the character of the discharge; second, the distance from the rectum, as determined by injections.

In *congenital fistulæ* opening into the perinæum the inference is natural and generally correct that the lower portion of the large intestine is involved. If bile is freely discharged through a *congenital* or *acquired* fistula, it is safe to conclude that the opening is not very far removed from the duodenum or upper portion of the jejunum. The odor of gas or ingesta escaping from the large intestine is usually more offensive than that from the small bowel.

When caused by a wound, the known direction and character of the penetrating body will aid in arriving at a correct idea of the gut penetrated.

A fistula resulting from appendicular or perityphlitic abscess occurs almost always in the cæcum, more rarely in the lower portion of the ascending colon or lower ileum. When the colon is involved the location may be determined by slowly injecting milk *per rectum*, having measured the quantity injected until it begins to flow out at the external opening.

The *prognosis* of fecal fistula depends upon its character. Congenital fistulæ are obstinate under treatment. Acquired fistulæ may be cured in the majority of instances.

Treatment.—Congenital fistulæ, resulting from imperforate anus, can be healed by the establishment of an opening in the perinæum which shall communicate with the most dependent portion of the blind gut. When this is done, a pad worn over the fistulous opening will lead to its gradual occlusion. When the fistula is the result of a patulous omphalomesenteric canal, it may be closed by sutures or by a compress.

Acquired fistulæ not infrequently heal spontaneously. The operation consists in cutting down upon the opening in the gut and laying freely open all sinuses which communicate with the fistulous outlet. As the track of the fistula is often tortuous, it is at times exceedingly difficult to follow it. A repetition of the method employed in the following case will be of service in the more complicated operations:

In 1880 a young man came under my observation on account of a pistol-shot wound. The ball had entered the abdomen on a level with and about one and a half inch to the inner side of the left anterior superior spine of the ilium. From the direction in which the weapon was aimed, the missile was thought to have passed directly back and lodged in the iliac fossa. There were no immediate symptoms of perforation of the intestine. An abscess formed which discharged from the wound of entrance, and, about six weeks after the receipt of the injury, a fecal fistula was established. The fistulous track was so long and tortuous that it could not be followed. After the anæsthesia was complete, warm milk was thrown into the bowel until it ran out at the opening. The stream of milk was then followed without difficulty, and the opening discovered. All communicating sinuses were laid open and packed with gauze. The wound closed within a month, and the patient was cured.

It will be advisable, in attempting to close the fistula, for the patient to maintain a position which will prevent the gravitation of ingested matter into the opening.

Closure of the external orifice by means of sutures is not advisable, since it may induce fecal infiltration. A recovery is usually hastened when the margins of the wound in the integument can be stitched to the edges of the opening into the bowel, as directed in enterostomy.

In persistent fistula of the cæcum as met with after appendicitis a lateral anastomosis between the small intestine and descending colon may relieve the pressure at the fistula and aid in a cure.

Colostomy.—The establishment of a fecal fistula between the colon and the abdominal wall is usually performed in the lower part of the descending colon, or in the sigmoid flexure.

Colostomy is indicated as a palliative measure in occlusion of the alimentary canal on the anal side of the operation by stricture, neoplasms, volvulus, intussusception, or any lesion for the relief of which *exsection* or lateral anastomosis is not permissible. In chronic *colitis* or *proctitis* it is a curative operation, in giving complete rest to the diseased bowel until recovery ensues.

The operation of Amussat—*right lumbar* colostomy—has practically been abandoned. It might be demanded in occlusion of the colon at the hepatic flexure, a condition very rarely met with. Colostomy in the transverse colon is also rarely called for, and, when necessary, can be readily accomplished in the same general way as the operation in the left inguinal region presently to be described, since both are trans-peritoneal operations. In operating between the splenic flexure of the colon and the rectum, the descending colon is now rarely selected. If conditions prevail which demand colostomy in this portion of the large intestine, the operation of Callisen—*left lumbar* colostomy—may be performed, but it should be stated here that the trans-peritoneal procedure in the *left inguinal* region (Littré) is always to be preferred. Left lumbar colostomy is performed as follows: Place the patient on the right side, inclined well over upon the abdomen. The objective point is the posterior surface of the descending colon, at a point situated halfway between the crest of the ilium and the last rib, and halfway between the spinous process of the third lumbar vertebra and the anterior-superior spine of the ilium. Make an incision about five inches in length, the center of which shall strike this point, commencing about an inch from the vertebral spines. The direction of this incision should be obliquely from above downward and forward—that is, parallel with the lumbar vessels and nerves. Dividing the skin and fascia, the posterior border of the abdominal muscles and the anterior border of the quadratus lumborum muscle will be seen. The posterior wall of the colon—that portion which is not included in the peritonæum—will be found a little behind the border of this muscle. A safe guide is to insert the finger along the edge of the quadratus muscle and feel for the kidney. The gut is immediately in front of this organ. It is important to keep well toward the spine in order to avoid opening into the peritonæum. Usually at this juncture, with the wound perfectly dry, the wall of the intestine can be picked up with the finger and lifted toward and into the wound. If it has receded, deep pressure upon the anterior wall of the abdomen will bring it into view. If the cavity of the peritonæum is not opened, it is scarcely possible to get hold of the small intestine. The colon may be recognized by its large size, sacculated wall, and longitudinal bands. If there is any doubt as to the large intestine being the one which presents, the expedient of pumping air into the rectum may be resorted to, the immediate distention of the colon proving its close relation to the rectum. As soon as the bowel is brought into the wound it should be transfixed by two strong silk sutures, introduced about an inch apart, through the integument of one side into the intestine for about half an inch and out again and up through the mar-

gin of the incision in the integument on the opposite side. The colon is now held well up into the wound by traction on the sutures in the hands of an assistant, while the operator makes a longitudinal incision in the wall of the gut superficial to the threads which have transfixed it. When this is done, the center of each ligature is drawn out by a tenaculum, divided, and the four threads tied securely. From two to four additional sutures may be introduced on each side, to guard against the infiltration of fecal matter. The wound in the integument should now be closed from each end down to or very near the level of the opening in the colon.

If there is much escape of fecal matter immediately following the operation, a dressing need not be applied. The patient should be made to lie upon the back, in which position gravity favors the escape of the bowel contents. At times it is convenient to apply a loose dressing, with a bandage around the abdomen. In from three to seven days the stitches can be removed, and after the wound is healed a compress and belt should be worn to prevent the escape of fæces until the convenience of the patient is suited.

If, in the search for the colon, the cavity of the peritonæum is opened, it should be immediately sewed up with continuous catgut sutures.

If, after colostomy, prolapse of the intestine occurs, it may be returned and held in place by a properly adjusted compress of gauze. If the opening contracts to such an extent that the escape of fecal matter is hindered, it should be dilated with the finger or by incision.

Left inguinal colostomy (Littré) is performed as follows: An incision is made through the linea semilunaris just internal to the left anterior superior spine of the ilium over the sigmoid flexure of the colon. It should be no more extensive than is absolutely necessary for exposure of the intestine. The sigmoid flexure may be recognized by its thick, muscular structure, longitudinal bands, its sacculated arrangement, appendices epiploicæ, and pale color. Any loops of small intestine which present at the wound will be seen to be smooth, shining, pinkish in color as compared to the larger intestine in this location, with no recognizable arrangement of the muscular layers. They may be displaced to the right, and the finger, carried into the wound along the left peritoneal wall and down into the upper margin of the iliac fossa of this side, will without failure come in contact with the upper portion of the sigmoid or the lower portion of the descending colon, which is readily drawn out and through the wound. The aim of this operation, whether it is intended to establish a *temporary* or a *permanent fistula*, is to construct an opening so formed that there can be no descent of fecal matter into that portion of the intestine below the field of operation. The formation of a *prominent* spur is essential to success. Bodine's method, given on page 637, should be carried out. The after-treatment is the application of a loose dressing to catch the discharge. No direct pressure should be applied, for the reason that escaping fecal matter might infiltrate the margin of the wound or tear loose some of the stitches. If a fistula is not immediately needed, it is advisable to defer this for thirty-six or

forty-eight hours, so that peritoneal adhesions may form. An important point in the technique, as shown by Prof. J. M. Mathews, of Louisville, Ky., is the placing of a small piece of rubber protective over the intestine and wound in order to prevent annoying adhesion of the intestine to the *gauze* dressing. In a number of instances fatal prolapse or hernia of the intestine has occurred through the wound as a result of coughing or vomiting. In order to prevent this, great care should be exercised either by manual compression of the wound when the patient coughs or vomits, or by a bandage of strong adhesive straps applied in such a way that this accident can not occur.

CHAPTER XXIII.

THE ABDOMEN (*continued*).

PERITONITIS—RETROPERITONEAL ABSCESS—APPENDICITIS.

Wounds of the *peritonæum* will be considered in the section on penetrating wounds of the abdomen.

While *non-infective* peritonitis may occur, as after a blow upon the abdominal wall which inflicts violence to this membrane yet does not expose it to direct pyogenic infection, practically every case which requires surgical consideration is *infective* peritonitis. That no tissue of the body is so well adapted to the rapid proliferation of septic organisms and absorption of their ptomaines as the peritonæum is evident in the alarming symptoms of sepsis which ensue within a very short period after the contact of pathogenic germs.

Acute infectious peritonitis may result from the escape of pyogenic germs from the alimentary canal, either through a perforation communicating directly with the peritoneal cavity (as an ulcer), or the germs may travel through a non-perforated area which, as the result of gangrene has lost its normal resistance. Thus peritonitis occurs in intussusception, volvulus, constriction by bands, internal herniæ, or any sudden interference with the circulation in the intestinal tract. In peri-renal abscess or in urinary infiltration of the prevesical (extraperitoneal) space, peritonitis ensues by invasion of pyogenic organisms through this membrane into the general cavity. Gonorrhœal cystitis in both sexes, colitis and proctitis, and, in the female, septic metritis and salpingitis, are frequent causes of peritonitis. Foreign bodies penetrating to this cavity almost invariably convey contagious germs and cause widespread infection. Again, infective organisms may be carried into the peritonæum through the circulation without any perceptible local inflammatory process to communicate the disease. It has been known to occur as a concomitant of syphilis, rheumatism, and, in a few instances, with gonorrhœa, without direct infection, and, as is well known, tuberculous peritonitis may occur through the blood. This form (tuberculous peritonitis) will be dealt with separately from infective (pyogenic) peritonitis.

The organisms which more frequently produce acute infectious peritonitis are the *Bacillus coli communis*, the *Streptococcus* and *Staphylococcus pyogenes*, the *Pneumococcus*, and, probably, the typhoid bacillus.

The *symptoms* of acute septic peritonitis are, in general, *pain* of an intense character, which, in the very earliest stages, is in a good proportion of cases referred to the region of the umbilicus even when the seat of in-

fection is remote from this point. As a result of pain, marked muscular rigidity of the abdominal wall is present, and in many instances this rigidity is limited to the muscles more immediately over that portion of the peritoneal cavity in which infection has commenced. So great is the tenderness even in the early stages that the legs will be involuntarily drawn up, and the thighs flexed upon the abdomen to relieve tension of the abdominal wall. *Vomiting* occurs in a certain proportion of cases, and is usually entitled to be considered a symptom of rapidly developing and severe infection. It is a feature of shock and is present in cases of acute perforation or gangrene before paralysis of the intestines from septic absorption has occurred. *Shock* with profound depression is a symptom of the severer cases. The expression of the face is one of alarm. The eyes seem wider open than normal and have a glassy appearance. The face is relaxed and the normal expression lost. Within from two to twelve hours after the beginning of the infection the abdomen becomes *distended*, the distention being not only due to a transudation of fluids (pus, serum, etc.), but also to the accumulation of gases within the intestinal canal as a result of paralysis and arrest of the normal functions of this tube. The *pulse* and *temperature* follow the usual history of profound sepsis and are more marked in this disease, since absorption is extremely rapid. The *temperature* varies from 100° to 105° or higher, often reaching this degree within twelve hours of the first symptoms of invasion. The *pulse* may run as high as 140 or 150, and is thready and weak.

Treatment.—When the pain is insignificant and the temperature does not mount up rapidly to 103°, 104°, or 105°, and when there is no abdominal rigidity, or distention, and vomiting is absent—in other words, when there are no well-defined symptoms of perforation or of gangrene—surgical interference is not demanded, although it is always well in every case of peritonitis, mild or severe, to be prepared for operation when the occasion may demand. It is in these milder cases of peritonitis that the administration of purgatives, such as calomel triturates, followed by a saline, if required, is capable of giving relief by osmosis from the septic area into the intestinal canal (*drainage through the bowel*). When, however, there is serious doubt as to the extent of infection, it is the part of wisdom to err on the side of exploration, feeling sure that should any serious condition be demonstrated by the exploration it can be rectified with a better hope of recovery at this period than if deferred until a later hour.

When the origin of peritonitis is obscure and the indications for operation are clear, it is better to choose the incision through the middle line about halfway between the umbilicus and the symphysis pubis. Peritonitis arising from septic lesions of the bladder, uterus, Fallopian tubes, rectum, or sigmoid flexure of the colon is always best approached through this incision and demands different treatment from a general widespread peritonitis. When the peritoneal cavity is entered by this incision, if there is a gush of fluid, purulent or sero-purulent, without marked odor of decomposition, it is a question whether it would be

better to irrigate in such a case with hot (normal) salt solution or to endeavor to make a careful toilet of the lower portion of the abdominal contents by using sterilized mops. Many good surgeons hold that a septic peritonitis which involves only the lower portion of the peritoneal cavity (pelvis) may be spread to the general cavity by irrigation, whereas it may safely be controlled by direct toilet with the addition, in women, of drainage through Douglas's *cul-de-sac;* and this is my practice. If, however, there is widespread infection with foul-smelling fluid, as is often met with in neglected cases of appendicular peritonitis, nothing is left but thorough irrigation with hot salt solution, which should be done as follows: With the irrigator at an elevation sufficient to give the required pressure, a good-sized and rather stiff rubber tube should be carried into the various portions of the peritoneal cavity, and a large quantity of fluid used until it runs out clear and clean. It is often necessary to irrigate with the tube low down in the pelvis much longer than in the upper portions of the cavity. These cases are almost always fatal, no matter what care is exercised in the irrigation and subsequent toilet. All infectious cases require some form of drainage. In women it is almost always advisable to cleanse the vagina and open through Douglas's *cul-de-sac*, carrying a loose ribbon packing of iodoformized gauze through this route, and at the same time to leave the abdominal incision open, packing from above with the same material in the hope of arresting absorption by capillary drainage. It is better before packing to dry out the excess of salt solution remaining after irrigation. It is of vital importance in the successful management of these cases that the bowels be kept moving as actively as possible, and the combination of calomel triturates and Epsom salts will generally suffice. Extra large doses are demanded, since there is more or less paresis of the intestinal tube.

Tuberculous peritonitis (subacute) results from the lodgment of the *Bacillus tuberculosis* in this membrane or in the viscera immediately beneath it. The bacilli may be carried through the blood and be generally disseminated, but are more apt to infect the peritonæum by direct invasion through the alimentary canal or through the genital apparatus in both sexes. Tuberculous peritonitis exists in two forms: the *moist* or *dropsical* (ascitic), and the *dry, fibrino-plastic* or adhesive variety. In the moist variety the peritonæum is studded with tubercles usually of small size, which may be localized or generally disseminated. Transudation of serum is a feature of this form, and the quantity is in proportion to the area of peritonæum involved. In some cases it becomes encysted in one or more locations. In the fibrino-plastic or dry form there is no serous transudation, but a fibrinous exudate, by which the mesentery and the intestines become agglutinated to each other. Some authors consider a third variety, the *ulcerative* form, but, as this is simply a degeneration of the tuberculous nodules (cheesy degeneration), analogous to that which occurs in other parts of the body, I see no reason for considering it as a separate variety.

The symptoms of tuberculous peritonitis are not well marked in the

early stages. It is usually not a painful disease. There is the disturbance of nutrition characteristic of tuberculosis of other organs. The first symptom which calls attention to the nature of this affection is the collection of fluid in the pelvic cavity, and later in the general cavity in the moist form, or the agglutination of the intestines in the dry form.

The *treatment* consists in opening into the cavity through the median line, as above given, and thorough irrigation with the hot sterile salt solution, continuing the irrigation for fifteen minutes, closing the wound and allowing the abdomen to retain a good quantity of the fluid. In a number of cases very marked improvement has followed this method of treatment, and cases have been reported as greatly improved in which nothing was done in the way of irrigation, simply opening the abdominal cavity for purposes of exploration, exposing the surfaces to the contact of air and the insignificant traumatism connected with the operation of digital exploration.

Abscess in the Abdominal Region (not Intraperitoneal).—Abscess may occur between the parietal layer of the peritonæum and the muscular walls of the abdomen, as in the prevesical space in urinary infiltration; between the abdominal muscles and beneath the skin; in the loose tissues behind the peritonæum (retroperitoneal), and between the liver or spleen and diaphragm (subphrenic), or within the substance or within the capsule of any of the viscera (as in hepatic abscess). In the newborn, in which the urachus does not close promptly, an abscess is occasionally met with.

The diagnosis of extraperitoneal abscess will in part depend upon the localized pain or tenderness on pressure, induration, and œdema which occur with pus formation, together with the usual exacerbations of temperature, with or without rigors or a chill. In patients with thin abdominal walls, fluctuation may be appreciable in extraperitoneal abscess. In the more obscure cases the employment of direct exploration, with cocaine anæsthesia or the careful use of the aspirating needle, will aid in making the diagnosis.

In treatment, the immediate indication is to evacuate the contents of the abscess by direct incision. When it has been located by the aspirating needle, this can be followed down while in position, as it demonstrates the depth of the abscess. The combined aspirating needle and grooved director of Prof. J. A. Dibbrell is a useful instrument in such operations. The principles of free drainage and irrigation apply to these as to other collections of pus.

Retroperitoneal Abscess.—Abscess behind the peritonæum is usually circumscribed, but occasionally it may be diffuse. Commencing at any portion of the posterior abdominal wall, the pus tends to dissect up the loose tissues behind the peritonæum and to travel downard. In patients suffering from tuberculous disease of the spine in which mixed infection occurs and in many cases in which there is no mixed infection, these collections of fluid will descend by gravitation, if the patient is up and about, and will point either above Poupart's ligament, external to its center, following the anterior sheath of the psoas and iliacus muscles, or

along the posterior sheath underneath Poupart's ligament, opening into Scarpa's space, or over the iliac crest, in the gluteal or lumbar region, at the obturator foramen, or less frequently it may empty into the colon, rectum, bladder, uterus, vagina, or pass out through the perinæum. Occasionally the dissection is upward into the pleura in persons confined to bed or in the recumbent position. In cases of rupture of the bladder (prevesical) or urethra, pus is at times found behind the peritonæum as high as the liver and spleen, and in appendicular abscess, involving by infection the extraperitoneal space, it may travel upward and break through the diaphragm into the pleura and be evacuated through the lungs and trachea.

The etiology of these various abscesses has been already given.

Diagnosis.—The physical signs of the earlier stages of pus formation behind the peritonæum are not well marked. With the muscles fully relaxed, deep pressure upon the abdomen from before backward may demonstrate the presence of the swelling. Rigidity of the muscles of the affected side is apt to be present, and in walking there is usually a perceptible limp. When the inflammatory process is situated in the region of the iliacus and psoas muscles, flexion of the thigh on the abdomen, however slight, is apt to occur. The constitutional symptoms of acute abscess will be the chief reliance in arriving at a correct diagnosis. The history of an injury or the presence of a lesion of any of the organs situated in this region will suggest the probability of abscess.

Extravasation of blood (*hæmatoma*), as far as the swelling is concerned, may simulate abscess, and in one particular may mislead, since the blood dissects up the loose tissues, and the tumor may present at any of the locations named for the pointing of the abscess. The suddenness of the tumefaction in hæmorrhage, the history of an injury (or, it may be, aneurism), and the absence of septic fever, are sufficient to exclude abscess. Lesions of the kidneys may be recognized by a careful study of the urine. In hydronephrosis the swelling will occur without marked pain or fever, comes on gradually, while the history of the case will point to obstruction. Tenderness along the spines of the vertebræ suggests abscess. Lastly, the aspirator needle introduced from behind will determine the character of the swelling.

Treatment.—Incision and free drainage should be the rule of practice in acute retroperitoneal abscess. When the pus is deep-seated, operation should be delayed, provided the symptoms of septic absorption are not too urgent. The patient should be kept quiet and in bed, and in the dorsal decubitus. The operation and after-treatment are practically the same as in extraperitoneal abscess.

Appendicitis.

Appendicitis is an infectious inflammation of the vermiform appendix, through the diseased or perforated wall of which septic organisms emigrate, producing local or general peritonitis. It is more frequent in men than in women in the proportion of three to one, and is met with in the majority of cases before the twenty-first year of life.

The appendix comes off from the inner back part of the cæcum at its lower end, immediately where the three longitudinal muscular bands of the colon come together. It is retained in position, usually, by a small fold of peritonæum, which forms its mesentery (meso-appendix). Unless it is closed by a stricture or an enterolith, it communicates with the cæcum by a small opening, which is sometimes guarded by a fold of mucous membrane, forming a valve. This, however, does not prevent ingested matter from passing into it from the cæcum in a large proportion of subjects. The average length of this organ is about three inches, but it may vary from one to nine inches. The diameter of the lumen varies from one eighth of an inch to one inch. It is exceptional for the lumen to exceed one fourth of an inch in diameter. According to Prof. Joseph D. Bryant's investigations, based upon 144 dissections, in 34 its direction was inward; inward and behind the cæcum in 32; inward and slightly downward in 28; downward into the pelvis in 21; directly downward and inward in 9; upward and backward in 3; upward and outward in 2.

The meso-appendix does not always entirely cover this organ with peritonæum, at times leaving a slight surface upon the posterior aspect, which, in common with the cæcum, is uncovered and is in contact with the iliac fascia. In addition to the peritoneal covering there is a thin layer of longitudinal muscular fibers; underneath this, a layer of circular muscular fibers, a rather thick mucous layer, and a very thick mucous membrane which is studded with closed follicles and lined with cylindrical epithelium.

The chief source of blood supply to the appendix is a branch which arises from a loop of the colica media. This branch runs along the border of the meso-appendix, giving off branches which pass into the organ. When the meso-appendix is wanting, the artery runs directly along the peritoneal covering of the appendix. In exceptional cases, according to Prof. George R. Fowler, the vessel passes directly to the tip of the organ, giving off no branches until it is reflected in the submucosa. Probably it is in these cases of limited arterial supply that rapid gangrene occurs.

Anatomically, the appendix occupies an unfortunate position. It is subjected to distention from semi-liquid *ingesta*, which enter it from the cæcum by gravitation. By reason of muscular insufficiency it is unable to empty its contents. Moreover, in addition to being distended from within, the weight of the loaded bowel tends to interfere with the proper supply of blood to its walls. That pressure has a good deal to do with the development of appendicitis seems evident from the fact that it is so much more common in persons leading a sedentary life, where, by reason of the sitting posture, pressure is greater than in those who move about in the upright position. Thus, impaired circulation and partial or complete occlusion, due to the accretion of ingested material (enteroliths), or follicular inflammation resulting in closure by swelling, or the formation of stricture, are conditions which prevent the escape into the cæcum of irritating and septic material and produce appendicitis.

The instances in which fruit seeds cause this disease are comparatively rare.

Appendicitis should be considered under the following heads:

1. The first and most common form, *imflammation* of the *mucous membrane*, may be general, but is more apt to localize itself in a given point. As long as the disease is superficial and there is practically free drainage of the inflammatory and infectious material through the canal of the appendix into the cæcum, these cases are not serious. There may be a certain sense of discomfort, and probably slight pain due to muscular contraction of the organ, but no general symptoms of peritonitis are present until the submucous and muscular coats are involved. When this occurs, *even without perforation*, the invading organisms, chiefly the *bacillus coli communis*, may pass through the diseased membrane and involve the peritoneal layer, causing a more or less severe form of local peritonitis. When peritonitis is established, pain, varying in intensity, is present, and, with this, rigidity of the abdominal muscles immediately over the location of the appendix. If the obstruction disappears, the peritonitis may subside and perforation is not probable. If, however, the occlusion persists, the peritonæum becomes more and more inflamed, plastic exudation takes place rapidly, and adhesions are formed between the inflamed peritoneal surfaces of any contiguous intestine or mesentery and the peritonæum lining the abdominal wall. In this way the diseased organ may be partially or completely hemmed in. It is this form of appendicular inflammation in which well-marked symptoms prevail for a few days and then disappear, the exudate undergoing granular metamorphosis (resolution) and absorption. Even when suppuration is established, the abscess in a certain proportion of cases may be circumscribed by the adhesions and general peritoneal infection prevented. Very exceptionally a rich inflammatory exudate is thrown out and organizes (without suppuration) until the appendix is entirely buried. In several instances I have seen a solid investment of organized exudate from half an inch to an inch in thickness, in the center of which was found the atrophied remnant of the appendix.

In other cases the process of invasion is so rapid that the peritoneal adhesions are insufficient to circumscribe the forming pus, and a widespread or general peritoneal infection ensues.

2. *Perforative* appendicitis is, naturally, a much more severe form than that which has just been described. In all probability the chief cause is an overdistention of the appendix beyond the seat of obstruction, the inflamed wall giving way through a necrotic or ulcerated spot. Sudden and violent muscular exertion is also known to have caused rupture of this organ. Localized gangrene or ulceration of the wall not infrequently results from pressure of a fecal concretion (enterolith). Perforation is followed by the sudden escape of the contents of the appendix. Local peritonitis of a severe character is at once instituted, and general peritoneal infection is the rule. If the patient be kept absolutely quiet, even under such unfavorable conditions, and when operative interference is not undertaken at once, *as it should be*, ad-

hesions may in a small proportion of lucky cases hem in the focus of infection.

3. *Gangrene* of the appendix is an exceedingly severe form. It is due to arrest of blood supply either from pressure or hyperdistention, or by constriction from an inflammatory band. In some instances the process is so rapid that in twelve hours the entire organ is gangrenous. Through the disorganized membrane, even when rupture has not occurred, septic organisms freely pass and establish a peritonitis which is rarely circumscribed by adhesions. Gangrene of the appendix demands early recognition and immediate operation.

Symptoms.—The symptoms of appendicitis differ considerably in the non-perforative and the perforative forms of the disease. Pain is the first symptom, and is usually felt as sharp in character, at times not unlike a severe cramp of the bowels, but more persistent. In the commencement of the attack it is not always referred to the exact location of this organ. In about one half of all cases the pain is referred to the region of the umbilicus. If direct pressure with the end of one finger is made upon the appendix the sharp sense of pain elicited will determine this to be the seat of inflammation. A line drawn from the anterior-superior spine of the ilium to the umbilicus passes above the usual location of this organ, the most frequent position of which is one inch below the center of this line.

Another early symptom of appendicitis, and one which rather suggests a more serious form, is nausea with or without vomiting.

With the patient resting upon the back, the legs drawn up to relax the abdominal muscles, if the hand be gently drawn across the abdomen from the left iliac spine over to the right, in practically all cases the comparative rigidity of the muscles immediately over the appendix will be appreciated. Even the experienced observer may mistake this muscular resistance for an inflammatory mass.

In arriving at a conclusion as to whether perforation or gangrene of the appendix has begun, the expression of the patient's face is of value. In the more serious abdominal lesions, even in the very earliest stages, the symptoms of shock are evident. The expression of anxiety or fright, the disturbed breathing, which is thoracic rather than abdominal in type, the rapid pulse and beginning rapid elevation of temperature, are indications of profound disturbance, and are met with not only in rapidly developing appendicitis, but in strangulated hernia, intussusception, volvulus, gunshot wounds, etc. The temperature is of vast importance in the diagnosis. In perforation or gangrene the thermometer will register 103° or higher within the first eight or twelve hours.

The following is an illustrative case of gangrene of the appendix:

A male patient, twenty years of age, an athlete in perfect physical condition, was awakened about two o'clock in the morning by a sharp sense of pain felt in the region of the umbilicus. By 9 A. M. the temperature was 102·5°; at 1 P. M., 104°. He had vomited two or three times between 2 A. M. and 9 A. M. There was marked rigidity of the muscles over the seat of the appendix, and tympanitic resonance over the lower abdomen; the pulse was 120, with *facies abdominalis.*

Operation at 2 P. M., exactly twelve hours after the first symptom of the attack. The appendix was three inches long, one fourth of an inch in diameter, curved upon itself like a snail shell, and entirely gangrenous from its extremity to within one half of an inch of its origin from the cæcum. There was no perforation. There was well-marked and rapidly spreading peritonitis. Careful dry sponging with sterilized gauze removed all source of infection, and the operation was completed in the manner which will be described later on. Within twelve hours the temperature went down to 100° and gradually to the normal point, and the patient made an excellent recovery.

TYPICAL PERFORATIVE APPENDICITIS.—A lad of seventeen, while playing base-ball, was suddenly seized with intense pain in the right iliac fossa, which was so severe that he sank upon the ground and had to be carried home. There was no direct injury. He was seized with nausea and vomiting, and the pain was so severe that the attending physician administered morphine by hypodermic injection. Localized muscular rigidity, rapid rise of temperature, and increased pulse rate followed, with *facies abdominalis*. At the expiration of three hours reaction was established, the temperature remaining as high as 102·5° F. In operating upon this case the appendix was found to be ruptured to the extent of about one fourth of an inch, through which perforation a fecal enterolith had escaped. The patient recovered.

In all cases of this class immediate operation should be advised or responsibility disclaimed.

In a large majority of cases of appendicitis the symptoms of pain are mild in character, and in some instances so mild as scarcely to attract the attention of the patient, unless called to this particular part of his body by direct pressure. Vomiting is not the rule, and rigidity of the abdominal muscles may or may not be present in the first twelve or fifteen hours of the disease. The temperature either does not rise or is only slightly elevated above the normal. If the patient remains in bed for two or three days, by careful examination a small mass may be made out, which gradually increases for a few days and then as gradually fades away. The tumor in these cases is usually made up of a limited plastic exudate, which agglutinates one or more contiguous intestinal and peritoneal surfaces together to form a mass. In other and severer cases, in which also no perforation has occurred, pyogenic organisms may pass through the diseased membrane, infect the peritonæum, and an abscess, varying in size, may result. The process of pus formation, however, in these cases is so slow that the local peritonitis excited by its presence may secure firm adhesions and prevent general peritoneal infection. Ultimately, adhesions are formed between the abscess wall and the peritoneal lining of the abdomen, in front or laterally, in the direction of the right iliac spine, or in the lumbar region, through which adhesions the abscess may be opened without entering the peritoneal cavity. In rarer forms of appendicitis with pus formation, especially in those cases in which the cæcum is situated low down in the pelvis, or where the appendix has a direction downward, the abscess extends into the pelvic cavity and encroaches upon the rectum, bladder, or uterus and ovaries. In these cases examination *per rectum* or *per vaginam* will reveal the presence of the tumor, and it is usually advisable to

open such abscesses through the rectum by an operation to be described.

Before dismissing the subject of diagnosis it would be well to bear in mind that *colic* of the appendix may at times suggest appendicitis. In a certain proportion of subjects this organ has well-developed muscular walls, capable of strong peristaltic action, and in the effort to eject from its cavity ingested matter, colicky sensations are experienced, which, with the muscular rigidity accompanying the seizure, may readily deceive the inexperienced diagnostician.

Colic or inflammation of the cæcum may also be mistaken for appendicular inflammation.

Operative Technique.—When an abscess has formed and is clearly recognizable, not only from the history of the disease lasting from four to ten days, but by careful palpation, the surgeon has no alternative but to evacuate the pus by direct incision. The introduction of an aspirator needle is not safe. It may traverse the free peritoneal cavity before entering the abscess, and upon withdrawal may infect the general peritonæum. As a rule, careful palpation after the anæsthetic has been administered will indicate the point at which the adhesions of the abscess to the peritonæum of the abdominal wall exist. An incision should be made with its center opposite this point. As a precaution against ventral hernia, the method advised by McBurney should be practiced. The incision down to the muscles should be made in the direction of the fibers of the external oblique muscle, and should be sufficiently long to thoroughly expose the field of operation. The fibers of the external oblique muscle should then be split, *not* cut, and held apart by strong retraction. The fibers of the internal oblique and transversalis muscles are carefully separated at the point immediately over the tumor by the dull scissors, and blunt retractors inserted under these and firm traction in an upward and downward direction made, *taking care not to press down upon the tumor, nor to make upward traction for fear of rupturing the abscess wall.* When the peritonæum is exposed it can usually be determined whether or not adhesions are formed directly under this point. If there are no adhesions the viscera may be seen during the act of respiration to slide freely over its inner surface. Should adhesions exist, the aspirator may now be used with safety to determine the exact depth into the pus cavity from the peritonæum. If the pus is superficial, the abscess may usually be opened safely and easily by carrying the dull dressing forceps into the puncture made by the needle until it is felt to enter the abscess cavity, when, by separating the jaws of the instrument, the opening is enlarged sufficiently to evacuate its contents. The finger may be introduced with great care for fear of breaking through adhesions, and search made for an escaped enterolith or extravasated material. A drainage tube should be inserted and the muscles stitched in their normal relations with catgut sutures. An abscess cavity of this kind should be irrigated with the greatest care. Adhesions may be broken down by the pressure of the irrigating fluid and fatal peritonitis established. If any irrigation is performed, only a small

quantity of boiled water or boric acid solution should be employed. It should be allowed to run in without pressure and with free escape through the opening or tube. A loose iodoform and sterile gauze dressing, with absorbent cotton over all, is then applied, which should be changed as indicated. Recovery takes place in a very large proportion of cases of this class. The danger of ventral hernia is remote, since neither the nerves nor muscles have been divided. Search for the diseased appendix or an attempt to dissect out the entire plastic exudate should not be made. While this may be successfully performed, a risk of general infection is incurred far beyond the benefit to be derived. Should the peritonæum have been incised, and the operator find himself in the free peritoneal cavity, this opening can be utilized in finding that part of the abscess wall where adhesions are firmly established. This being done, the exploratory incision should be closed at once by stitching the peritonæum with catgut and suturing the muscles in position as just advised, and a second incision made directly over the point of adhesion and the abscess evacuated as above described.

In a certain proportion of cases, fortunately rare, it will be found that the abscess is adherent only to the posterior central wall of the abdominal cavity over the psoas muscle or near the sacro-iliac junction, or to the end of the cæcum, so far from the iliac spine and from the anterior abdominal wall that no adhesions have formed between these surfaces through which it could be safely opened. When these conditions prevail, it is safer not to open the abscess at that operation, but to wall it off with iodoform-gauze packing in order to secure adhesions, applying a careful aseptic dressing over all. After twenty-four or forty-eight hours adhesions will have formed, and, on removing the packing, the abscess can be opened without the danger of general peritoneal infection. In rare instances these abcesses break through the lumbar or iliac fascia posteriorly, and descend behind the cæcum, where they may be evacuated through a lumbar incision, or, as occurred in one of my cases, pass behind the liver and discharge into the lung and through the trachea and mouth.*

When the abscess forms in or burrows into the pelvic cavity in contact with the rectum, it should be evacuated through the wall of this gut. With the patient in the position for perineal section, by inserting a Sims's vaginal speculum, with digital exploration or the use of the aspirator, the cavity of the abscess can be reached and opened by puncture and the insertion of the dressing forceps as above described. A rubber tube should be inserted and careful drainage secured. Irrigation should be carefully employed.

In gangrene or acute perforation, if the case is operated upon in the first twelve hours (as should be done) any septic matter which has escaped should be carefully removed by dry sponging with sterilized gauze just taken from the boiler. This method is, in such cases, safer than flooding the abdominal cavity with water or salt solution, either of which

* This patient, a physician, recovered and is now, five years after his illness, in perfect health.

may spread the infection to remote portions of the general cavity as yet not invaded. The perforated or gangrenous appendix, when lifted into the wound, should be surrounded by iodoform gauze pads, to guard against the escape of infective material into the peritoneal cavity; a medium-sized silk ligature should be thrown around the organ and tied about one fourth of an inch from the cæcum, where the wall of the appendix is healthy. The appendix should now be clamped a little beyond the ligature and divided between the clamp and the ligature with scissors and removed. The funnel-shaped end of the stump should be curetted, and disinfected by rubbing a fragment of a corrosive-sublimate tablet thoroughly over the exposed internal surface. The excess of mercury should be removed by a film of gauze, which renders the stump perfectly dry, or the portion beyond the ligature may be rendered aseptic by direct application of the Paquelin cautery. The ends of the silk ligature are then cut short.

Many experienced operators pay no further attention to the stump, and it is considered safe to let it drop back into the cavity of the peritonæum. It is, however, a more scientific procedure when the peritoneal surfaces of the cæcum have not been destroyed by exudation, to invaginate the stump by seizing it with a pair of long-tipped artery forceps and pushing it into the cæcum. While thus invaginated, the contiguous peritoneal surfaces of the cæcum are united by Lembert sutures and the forceps removed. The reticule string suture of Dr. Dawbarn is also a rapid and successful method of invaginating the stump. A short distance from the appendix, a needle armed with a silk thread is carried in and out of the wall (without penetrating the lumen) of the cæcum, describing a circle about the stump and coming out near the point of entrance. By drawing on the ends and tying, and at the same time removing the forceps, the invagination is effected.

The question of complete closure of the abdominal incision is extremely important. In cases that are operated on early, where a clean dissection and removal can be made, and where the operator is sure that no focus of sepsis remains, it is advisable to thoroughly dry with sterile gauze or perfectly aseptic sponges the region of the cæcum, the mesentery and the intestinal loops contiguous, and to extend this process of drying deep down into the pelvis, behind the rectum and on either side of the bladder, until no moisture remains.

When the McBurney incision has been employed, the peritoneal wound, usually an inch or an inch and a half in length and running transversely, is closed by continuous catgut suture, and after this the separated muscular fibers are stitched to each other with catgut, as before directed. When there is danger of septic infection, it is better to pack the wound rather than to close it. When packing is resorted to, the opening into the abdominal cavity is usually enlarged, and it may be necessary to divide some few of the muscular fibers, leaving the wound about two inches in length. If six or seven layers of clean, iodoformized gauze, four or five inches wide and six or seven inches long, be laid one upon another, a sterile mat of proper thickness is secured. In walling

off the infected appendix, one of these mats is carried well below and to the inner side of the cæcum and the stump of the diseased organ, and pushed down with the fingers until it is snugly applied; the other end is brought out through the abdominal wound and is turned over on the skin of the abdomen. Another mat of the same size is inserted upon the opposite side of the cæcum, while a third is placed under the end of the cæcum and comes out at the inferior extremity of the wound. A fourth fills the upper end and simply rests on the anterior surface of the gut. By this method the septic focus, the stump of the appendix, is entirely walled off from the general peritoneal cavity, and loose iodoformized gauze is laid in until the wound is filled up to a level with the abdomen. In from twenty-four to forty-eight hours perfect adhesions will have formed between the organs which come in contact with the wall of iodoformized gauze. The packing can then be removed, and there will be no danger of general infection should rupture of the cæcum or appendix take place. The great objection to this method is the danger of ventral hernia, which may ensue. It is important at the time of operation, when the packing is begun, to insert silkworm-gut sutures at proper distance in the edges of the wound, including the skin, muscles, and peritonæum, and leave them untied until the packing is removed; then a drainage tube or a wick of gauze should be carried down to the region of the appendix, brought out at one angle of the wound, and the sutures tightened. The patient should be required to rest in the recumbent position and not to submit the wound to unnecessary strain for six weeks, and after that time a belt or bandage should be worn for two or three months.

In a certain proportion of cases when the abdominal peritonæum is incised, it will be seen that the general peritoneal cavity contains pus or septic material. Under such conditions, it is imperative to make a thorough toilet of the peritoneal cavity. When there is pus only in the pelvic portion it is not wise to flush the abdomen with hot salt solution, as is sometimes advised. It is better practice to enlarge the incision, expose the intestines that occupy this portion of the abdomen, and dry them thoroughly with hot sterile gauze, taking special pains to see that the pelvis is thoroughly mopped out.

It would be advisable, under certain conditions, to drain through the vagina in women, opening into Douglas's *cul-de-sac* and packing with a loose wick of iodoformized gauze, which can be drawn through the vagina.

This method of dry cleansing is especially advisable when that form of pus exists which is milky in color and free from feculent odor. Such pus is not violently septic. When the abdomen is generally distended and flooded with bad-smelling and septic pus, then general irrigation with hot saline solution is advisable. These cases are almost always hopeless, but this practice should be carefully carried out, removing the excess of fluid and drying out as thoroughly as possible. Wicks of iodoformized gauze should be inserted into the deeper cavities to secure as much capillary drainage as possible.

General Considerations.—The operative treatment of appendicitis marks an epoch in surgery, and while many have done much to popularize the operation, to Dr. Simon Baruch, formerly of South Carolina, but now of New York city, to the late Prof. Henry B. Sands, and to Dr. Charles McBurney, of New York city, the chief credit is due for enforing recognition of this procedure.

Experience has demonstrated that a certain proportion of cases of appendicitis, variously estimated at from fifteen to forty per cent, in which there is more or less well-marked peritonitis and exudation, undergo spontaneous resolution, the patient being fully restored to health and living indefinitely without a recurrence of the disease. The vast majority of this group are those cases in which pain is slight, pulse and temperature without marked exacerbation, with local muscular rigidity absent or only slightly noticeable. Operative interference in this mild form is not indicated. Absolute rest in bed in the dorsal decubitus and light or fluid diet are features of successful management. In addition, cleansing out the rectum and descending colon by careful irrigation, the administration of calomel triturates, half a grain to a grain once or twice a day, in order to empty the small intestine and the cæcum and colon without producing violent peristalsis, add to the patient's safety.

The surgeon should be in touch, however, with every suspected case of appendicitis, and when, at any time, symptoms of a sudden increase of septic invasion appear, operation should be advised. It is safer to err on the side of exploration than to procrastinate until the vitality of the patient is seriously weakened by septic absorption. In no department of surgery is thorough and careful technique more essential to the safety of the patient than in this operation.

CHAPTER XXIV.

THE LIVER.—GALL BLADDER.—SPLEEN.—PANCREAS.—WOUNDS OF THE ABDOMEN AND VISCERA.

Neoplasms.—New growths of the liver are not of very common occurrence, and when they do exist they scarcely come within the domain of surgery. Primary cancer is exceedingly rare. Metastatic carcinoma is, however, not infrequent when this disease is present in the alimentary canal or mesentery. Cancer of the liver, as a rule, develops slowly, and has a history of progressive emaciation with the peculiar cachexia which belongs to this disease. It occurs usually after the fortieth year of life, and when the tumor develops sufficiently to project below the free border of the ribs is nodular to the touch. It may or may not be accompanied by ascites. The occurrence of dropsy in the abdomen will indicate that the carcinoma is situated near the transverse fissure of the liver and is causing pressure upon the portal vein at or near its point of entrance into this organ. Disseminated metastases rarely produce ascites, since they consist of small nodules, widely scattered over the organ. Operative interference is not called for in carcinoma of the liver unless it be the removal of fluid from the peritoneal cavity.

Tapping the Abdominal Cavity in Ascites.—The patient should sit upright, usually on the edge of the bed or in an armchair. The bladder should be entirely emptied before the operation. The integument should be thoroughly cleansed in the middle line about halfway between the umbilicus and the symphysis pubis. Two or three minims of a four-per-cent solution of cocaine should be injected in order to anæsthetize the skin, which should then be punctured with a sharp scalpel; a good-sized trocar and canula should then be introduced by slow semi-rotation and gradual pressure, which will be relieved as soon as the abdominal peritonæum is punctured, and will indicate to the operator that the cavity is entered. The trocar is then withdrawn, leaving the canula in position through which the fluid will escape. Should the patient at any time show signs of syncope, the chair should be tilted back or the patient laid upon the bed, care being taken to keep the finger over the end of the canula in order to prevent the entrance of air when the patient lies down. As soon as the stream begins to break up into drops, showing that the fluid above the level of the perforation has escaped, the canula should be removed. At times a loop of intestine or piece of omentum will float against the internal opening of the canula and arrest the current; but this sudden arrest will not be mistaken for the gradual cessa-

tion of the flow. At times it may be advantageous to apply a broad binder over the abdomen, making an incision in this to expose the point of puncture, and have it held behind by an assistant who makes strong traction in order to more thoroughly empty the abdominal cavity. In one case of tumor of the liver, for the relief of which five gallons of fluid were withdrawn each week for seven weeks, an exploratory incision was made over the mass which projected from and was continuous with the left lobe of the liver and extended down as far as the umbilicus. It was dense, hard, and very vascular. No attempt at removal was made; the wound was packed with iodoformized gauze, which succeeded in causing the formation of strong adhesions between the tumor and the abdominal wall. The wound was treated by the open method, and local infection with suppuration ensued. The tumor diminished in size and, as a result of the adhesions of the mass to the abdominal wall, the pressure upon the portal veins was relieved and the ascites did not return. Four years have elapsed since the operation, and the patient is in a fair condition of health, weighing one hundred and sixty pounds and attending regularly to active business. The tumor is about one half the former size.

Hydatid Cysts.—Cystic tumors caused by the presence of the echinococcus hominis, the larva of the tænia echinococcus or tapeworm, occur in the liver more frequently than in all other portions of the body. They vary in size, may be multiple or single, and may be lodged in any portion of the organ. The capsule or periphery of the cyst is firm and dense, and may undergo calcification. Developing in the liver, hydatid cysts may perforate the diaphragm, rupture, and pour their contents into the pleura or lung; or they may extend into the abdominal cavity as far down as the pelvis. In rare instances they open into the stomach, vena cava, duodenum, or colon.

The diagnosis of hydatids of the liver may be made from abscess by recognizing an elastic fluctuating tumor, which is free from tenderness or any of the symptoms of inflammation or septicæmia which are always present in abscess; from cancer of the liver by its fluctuation, cancer being solid, hard, and nodulated. The cachexia of cancer does not occur in hydatids.

In distention of the gall bladder jaundice is apt to exist, while it is an exceptional complication of hydatid cysts. Aspiration with a delicate needle will be necessary to positive diagnosis. Hydatid cysts contain a watery liquid, nearly clear or of a light straw-color. In some instances fragments of the hooklets and other contents of the cysts may be discovered.

Treatment.—The contents should be drawn off with the aspirator and the operation repeated if necessary. A single evacuation not infrequently effects a cure.

The needle should be introduced into the most superficial portion of the tumor. As the cyst is being emptied, the abdominal wall immediately around the needle should be pressed toward the tumor, and, when the operation is finished, this should be continued by a compress of sublimate gauze, held snugly in place by a bandage. The object of this is to pre-

vent infiltration of the fluid into the peritoneal cavity. In performing this operation an anæsthetic should not be administered, on account of the danger of rupture of the cyst from vomiting. Cocaine may be employed locally. Complete rest in the recumbent posture should be enforced for at least a week after the aspiration. If at any time suppuration is precipitated, direct incision and free drainage are imperative. If repeated aspirations fail to effect a cure, adhesions being formed as a result of the frequent introduction of the needle, an incision may be made, or the operation of Verneuil performed. This consists in the introduction of a large trocar and canula, evacuating the contents, and inserting for prolonged drainage a large rubber tube through the canula, which is then withdrawn, leaving the tube in position.

Hepatic Abscess.—A circumscribed collection of pus within the substance of the liver is comparatively rare. It occurs more frequently in the tropic or semi-tropic climates than in colder regions. The frequency of colitis and enteritis in the southern zones will account for the greater number of cases of abscess of the liver, the infected particles being absorbed by the vessels of the portal system and carried into this organ. There may be one large abscess or a number of smaller ones scattered throughout the organ. They may be deep or superficial, and no part of the liver substance is exempt. The most frequent situation is in the deeper portions of the right lobe.

Contusions or lacerations do not lead to the formation of abscess unless pyogenic infection occurs.

Penetrating wounds and the lodgment of foreign bodies are among the traumatic causes of suppurative inflammation of the liver.

Ingested substances, such as bones, needles, etc., have been known to pass from the alimentary canal and make their way into the liver substance, producing suppuration and abscess. Abscess of the liver may also occur during the course of acute hepatitis, where neither injury nor metastasis has occurred.

Symptoms and Diagnosis.—The early recognition of hepatic abscess is exceedingly difficult, especially when the pus is located in the deeper portions. Pain is not a prominent symptom, unless there exists a perihepatitis, in which case it is exaggerated. There is a sense of heaviness or fullness about the liver, exacerbations of temperature occur, with general impairment of health. Jaundice is not present unless the bile duct is compressed by the tumor. Cancer of the liver develops slowly, has a history of progressive emaciation, occurs usually after forty years of age, and is nodular to the feel.

Pleural empyema, or subphrenic abscess, may be mistaken for abscess of the liver, especially when the accumulation is considerable and the liver is displaced downward. It may be recognized by the interference with the expansion of the lung of the affected side, and by the change in the percussion sounds with the change in position of the thorax, in which the fluid of empyema is displaced. Subphrenic abscess of the right side may also be mistaken for true hepatic abscess, and is sometimes difficult to differentiate from localized empyema of the lower

portion of the pleura. In free empyema, change of posture will, of course, change the percussion notes. The diagnosis of subdiaphragmatic abscess is given on another page.

Overdistended gall bladder may be mistaken for abscess; but this error may be eliminated by bearing in mind its location in front and low down, where abscess is exceedingly rare, and also by observing that a distended gall bladder is appreciably movable independently of the liver.

Hydatid cyst of the liver is not painful, and is not accompanied with exacerbations of temperature, with the exception of the very rare occurrence of inflammation of the cyst, when a differentiation is practically impossible without aspiration and the examination of the fluid.

When the accumulation of pus is considerable, the tumefaction may be recognized by palpation and the diagnosis made positive by the exploring needle.

The *prognosis* is unfavorable. Left alone, a fatal termination occurs in almost all cases—by rupture into the peritonæum in about thirty per cent, into the lung in twenty-five per cent, while in a smaller proportion of cases the abscess opens through the integument.

Treatment.—Evacuation is the only rational treatment. In the choice of methods the character of the abscess will determine the employment of the aspirator or drainage by incision.

Aspiration is advisable when the abscess is deeply located, and especially when firm inflammatory adhesions have not been formed between the wall of the abscess and the abdominal or thoracic parietes. In performing this operation the following plan should be adopted:

The most superficial point of the abscess should be located by careful exploration with the smallest aspirator needle, and the thickness of the intervening tissue measured. In using the evacuator it is necessary to have a good-sized needle to prevent solid particles or shreds of tissue from the abscess wall from occluding it; but it is always safer, if firm adhesions have not occurred, to employ the smaller points, since, after the needle is withdrawn, pus is not so apt to escape and find its way into the pleural or peritoneal cavities.

The aspirator needle should be introduced in the same opening and to the same depth as the exploring needle, and the pus slowly withdrawn. It is considered a safer plan not to completely empty the cavity at the first operation. The procedure should be repeated on the second or third day. A piece of iodoformized gauze should be laid over the puncture and held in position by a roller. When, after repeated use of the aspirator, a cure is not effected, and when the tissues between the most superficial portion of the abscess and the integument have become so solidified by adhesions that infiltration of pus can not occur, the abscess should be opened by direct incision, its contents allowed to escape, the sac thoroughly irrigated with sterile warm water, and a drainage tube inserted. If, after cutting down to the wall of the abscess, it is discovered that adhesions have not occurred, the sac should not be opened. The wound should be packed with gauze, and, in four or five days, after adhesions have been established, it may be incised.

Subphrenic Abscess.—As a result more frequently of gastric ulcer situated in the posterior and pyloric ends of the stomach, pyogenic infection and pus accumulation take place between the diaphragm and the liver (or spleen).

In rare instances, traumatisms, in which the liver or spleen has been torn loose from its attachment to the diaphragm, have caused this form of abscess. True hepatic or splenic abscess, located in the upper or diaphragmatic surfaces of these organs, may also produce subphrenic abscess.

The *diagnosis* of subphrenic abscess is at times exceedingly difficult. I have met with only three cases, which presented the usual gross symptoms of septic infection, with pain, which in two cases was referred to the region of the liver, in the third case to both liver and spleen. In this last case the abscess had burrowed from the spleen to the upper surface of the liver. In the other two cases the pus accumulation was located over the liver. In addition to the symptoms of blood poisoning and the local symptoms of pain there was increased dullness on percussion, and in one case a marked displacement of the liver downward, and even after the reparative process this organ remained two and a half inches lower than its normal position. In one of my cases it was difficult to determine whether the abscess was caused by a traumatism or by a gastric ulcer, since the abscess developed after quite a severe injury, although this patient had suffered from the symptoms of gastric ulcer for a year or two previous to the formation of the abscess. In the second case, that of a lad of sixteen years, the abscess followed a violent fall in which there were evidences of injury of the kidney (bloody urine). The kidney was explored by a colleague, but no lesion was found. Several weeks elapsed before I saw the patient. Dullness over the liver attracted attention to that part, and a diagnosis of subphrenic abscess of the right side was made. The diagnosis was confirmed by the introduction of a delicate aspirating needle after the patient had been anæsthetized. The following operation was performed, and is the only operation which should be entertained when adhesions have not occurred between the upper surface of the liver and the abdominal wall:

Having located the pus by aspiration with a delicate needle, which should be left in position, it is advisable to draw off a certain amount of the fluid for the reason that the instrument of necessity passes through the costal and diaphragmatic pleura before entering the abscess, and withdrawal of the needle would infect the pleural cavity. An incision is made over a rib, about the eighth or ninth, and about three inches of the bone excised. The needle being still in position, the pleura is incised for about one inch and a half. The diaphragm is now caught with mouse-tooth forceps, brought up into the thoracic incision, and, by the repeated insertion of a continuous silk suture, the diaphragm is stitched in buttonhole fashion to the costal pleura. This procedure entirely shuts off the pleural cavity from the danger of infection. An incision is next made through the diaphragm along the needle, and dressing forceps are carried into the abscess and the opening enlarged. Irrigation through

the rubber drainage tube with sterile warm water, repeated every day or two as indicated, is the proper after-treatment.

In operation for subphrenic abscess over the spleen the same method of procedure should be followed as just described. When adhesions have formed, the pus may safely be discharged by direct incision near the margins of the ribs.

Displacements of the Liver.

The liver is at times partly or completely displaced from its normal location as a result of accident, by a direct blow, or fall upon the feet from a height, but more often from tight lacing in women. In the single instance which I have met with in a woman thirty-eight years of age, who had an exceedingly small waist, there was a large movable tumor reaching down to the spine of the ilium on the right side. Upon opening the peritoneal cavity, it was discovered to be the whole right lobe of the liver with the gall bladder attached. It was considerably changed in shape and was only connected with the left lobe which was in the normal position, by an isthmus two inches in width and one quarter of an inch in thickness. It was lifted into place and anchored there in the following manner:

Silkworm-gut sutures were armed with a long needle at each end. One needle was passed entirely through the substance of the liver and then out through the abdominal wall at a point about the end of the twelfth rib. The second needle was carried through the liver about one inch from the route which the first one had traveled and on through the abdominal wall, coming out about half an inch from the point of exit of the first needle. This staple stitch was repeated about two inches below in the substance of the organ, and is practically identical with the method of anchoring the kidney employed by Dr. R. Harvey Reed, of Columbus, Ohio.

The ends of the silkworm-gut sutures were tied over little pencils of iodoform gauze. I then closed the peritoneal wound immediately over the upper convex surface of the liver, and with catgut sutures quilted an area representing about four square inches of the liver substance by passing sutures directly through the superjacent tissues, carrying the needle well into the substance of the liver. These were tied, and in this way the peritonæum was quilted to the liver in order to secure adhesions. With a view to producing further adhesions, the wound was packed with sterile gauze and left to close by granulation. The patient was placed in bed in the recumbent position, and a large wad of cotton placed over the abdominal wall so as to retain the liver in position until adhesions occurred. The long staple sutures were removed on the tenth day, and the woman recovered with the organ in position and greatly improved in health and general comfort. Six months after convalescence she is able to attend to her duties as housemaid and seems to be entirely well.

Gall Bladder.

Cholecystotomy may be indicated in obstruction of the cystic or common duct from any cause, or the accumulation of gallstones in this organ, and at times to secure drainage in infectious inflammation (empyema) of the gall bladder. The nature of the lesion to be dealt with may be determined by a careful study of the symptoms. When jaundice is marked and occurs with or immediately after a sharp exacerbation of pain referred to the region of the gall duct, there is reason to believe that this duct has been obstructed by a concretion which has passed into the common duct where it has lodged. While pain is a frequent symptom of stone in the gall bladder and is well marked when the small concretions get into the cystic duct, yet bile absorption (jaundice) is not present unless either the common duct is involved, or the hepatic obstructed above the junction with the cystic duct. A stone passing into the cystic duct and working its way to the neighborhood of the junction of the cystic with the hepatic duct may produce compression and closure of the hepatic duct and cause *icterus*. It must not be forgotten that jaundice frequently occurs without the lodgment of gallstones, as in duodenitis and occasionally from the presence of neoplasms, etc., and that acute colic may result from the decomposition of ingested matter and generation of gases which occur in the absence of the bile, and may thus simulate the acute pain due to the lodgment of gallstones. When the concretions are numerous and lodged within the gall bladder, they may remain for years without attracting the attention of the patient. They are, however, apt to induce by their presence inflammatory changes in the lining membrane of the gall bladder, subjecting it to infection when conditions are favorable to the development of pyogenic organisms in this location. In this manner the gall bladder may be practically converted into an abscess wall, this condition giving rise to the well-known symptoms of pus accumulation and general sepsis.

The presence of hydatids of the liver may produce tumefaction and certain obstructive symptoms simulating enlargement of the gall bladder but the absence of pain and jaundice or septic infection would scarcely permit the careful observer to be deceived.

Operative interference is very frequently demanded in the various conditions which have just been described, and the great advance in the surgery of the gall bladder may be justly claimed for our own country. Cholecystotomy was first done by two pioneer surgeons, Dr. Bobbs, of Indiana, and Dr. J. Marion Sims, the priority belonging to the first-named surgeon, although Dr. Sims operated shortly afterward and without knowledge of the operation of his colleague. It was undoubtedly due to the publication of his case and the indorsement of the operation by this eminent man that cholecystotomy was brought to the attention of the profession at large.

An incision into the gall bladder for the purpose of drainage or for the removal of concretions is not, in general, a dangerous procedure. The method I have followed in the majority of instances has been to

make an incision through the abdominal wall over the well-known location of the gall bladder, preferring the transverse to the perpendicular incision, unless an exploratory incision only is required, in which case the latter is preferable. The gall bladder is brought up to the edge of the wound and sutured to the peritoneal surface around the margin of the incision. The gall bladder can be at once opened if necessary, or this can be delayed for twenty-four or forty-eight hours in order to permit the formation of adhesions, thus rendering it more safe. When the incision is not made immediately, two silk sutures should be inserted in the wall of the bladder at either end of the proposed incision. These sutures should be left long and serve as guides, when the operator is ready to make the incision, after which they should be removed. Through the wound a soft-rubber tube is inserted and irrigation practiced with sterile warm water, the tube being allowed to remain until the symptoms justify closure of the wound.

For the removal of gallstones lodged deep in the gall bladder and in the cystic duct I have operated successfully as follows: As soon as the

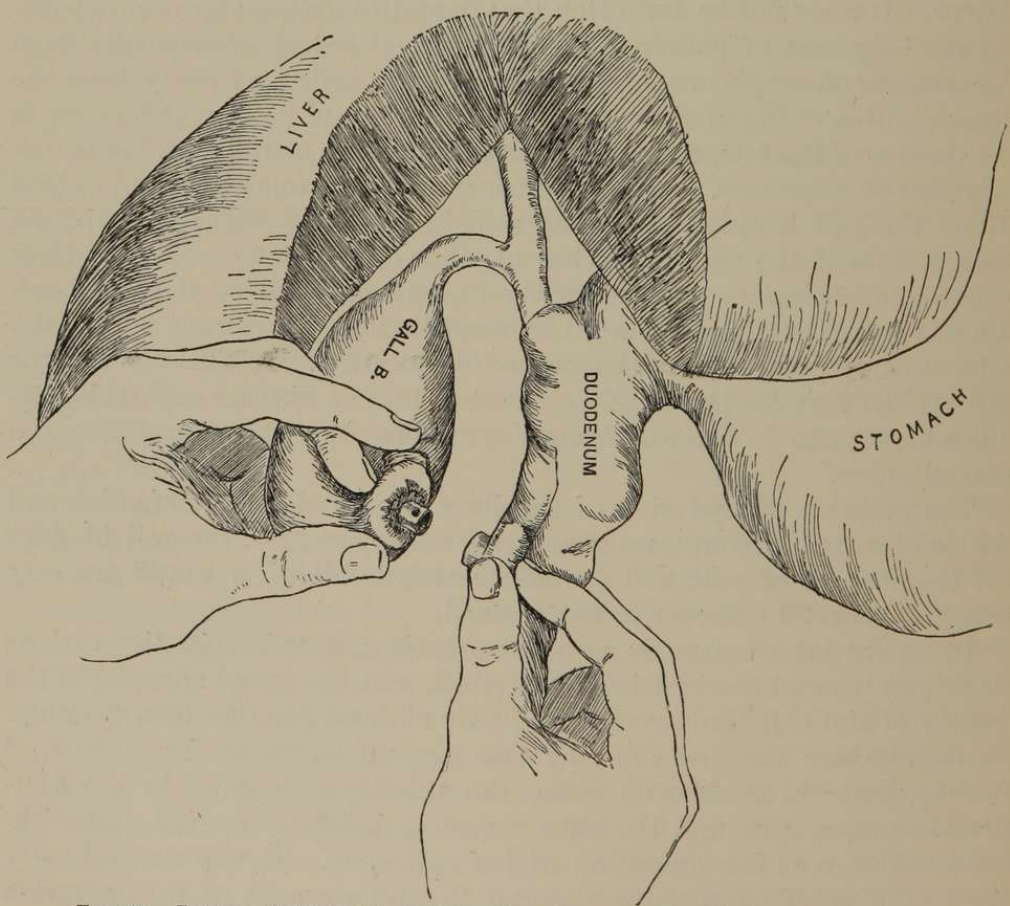

FIG. 672.—Button as held when pressed together when performing cholecysto-enterostomy.

opening in the gall bladder was made, a soft-rubber tube was attached to the nozzle of a glass syringe holding four or five ounces. The point of the tube was then carried as far down into the gall bladder and duct as it would pass. By forcing in the contents of the syringe and distend-

ing this organ and then reversing the action of the piston, the concretions were removed. Through a larger abdominal incision, with sterilized gauze mats inserted in such a way as to protect the abdominal cavity from the contents of the organ, the gall bladder may be incised, calculi removed, and the organ immediately closed by Lembert's sutures. In one instance by this method I removed successfully fifty-nine concretions, one of these fully an inch in diameter, closing the abdominal wound at once. As a rule, however, I consider the former procedure as the safer. When the symptoms point to occlusion of the hepatic or common duct these should be exposed for careful inspection. An assistant should hold the liver out of the way, using only the fingers for retraction. The concretions may be recognized by the touch. If soft in composition, they may at times be dislodged by compression between the thumb and finger and carried into the duodenum.

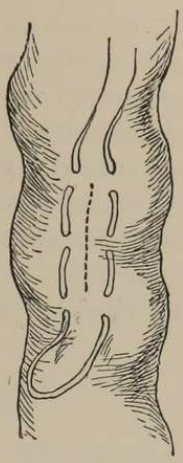

Fig. 673.

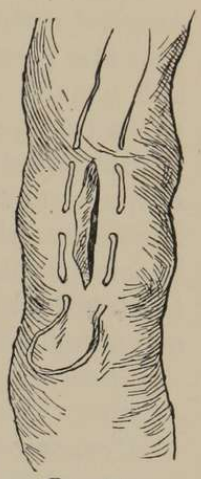

Fig. 674.

When the concretion is firm and immovable the duct should be incised immediately over the stone, which is then removed and the opening closed by fine silk sutures. In one of my cases, which ended fatally after an exploratory operation, the hepatic duct from the transverse fissure down to the location of the cystic duct was closed with concretions which could not pass beyond this point.

Within recent years the operation of opening into the common gall duct for obstruction due to calculus has been considered extra-hazardous and difficult, and surgeons have suggested (Nussbaum, 1880) making a fistulous opening between the gall bladder and the small intestine near the junction of the duodenum and the jejunum. The first operation was done by Monastyrski in 1887, but was unsuccessful. Dr. Jacob Michaux, of Richmond, Va., one of the first to perform this operation in the United States, suggested the operation of cholecysto-enterostomy. The operation has been greatly perfected by Dr. J. B. Murphy, of Chicago, by the use of the button which bears his name. It is probable that in this procedure the Murphy button will be found more satisfactory than in any other, and, in my opinion, it should be given the preference in this operation. The operation is thus described by Dr. Murphy: A perpendicular incision is made three inches long and three inches from the right of the median line over the gall bladder. The duodenum and gall bladder are drawn into the wound, and an incision made in the duodenum large enough to admit one half of the button (Fig. 672). The method of inserting the suture to tie around the button is shown in the accompanying cuts, Figs. 673 and 674. The thread should be inserted before the bowel is opened, and every precaution should be taken to pre-

vent the escape of any bowel contents into the peritoneal cavity. The same form of suture is then inserted into the gall bladder at a point which, after trial, will permit the two surfaces to come snugly together. Any gallstones that are present may be removed before the button is inserted. The other half of the button is then placed in the gall bladder, the suture tied, as in the intestine, and the approximation made. The bile passes through the opening in the button into the duodenum, and usually the symptoms of jaundice disappear. After adhesion between the approximated bowel takes place, the button drops either into the intestinal tube or into the gall bladder. When it drops into the alimentary canal it is discharged with the fæces, but if it drops into the gall bladder it will cause discomfort, and may ultimately require removal. If this operation is not done, the only other method is to make the anastomosis between the bladder and a loop of small intestine by incision and silk sutures.

The Spleen.

Pyogenic infection (abscess) of the spleen is one of the more important surgical lesions of this organ. It is fortunately rare. It may result by metastasis, infectious particles being lodged in this as in other organs, producing usually infarctions and multiple abscesses.

The symptoms of abscess of the spleen are those of general septic infection by pyogenic organisms. Pain is not a prominent feature unless the abscess is superficial and involves the capsule. Abscess may form between the diaphragm and the spleen (subphrenic) and involve the spleen, or, *vice versa*, infection may begin in this organ and break through the capsule and form subphrenic abscess. The symptoms are in the main obscure, and it may be necessary to explore by incision in order to determine accurately the diagnosis. The treatment does not differ from that given for hepatic abscess.

Displacement of this organ may occur owing to the enlargement which sometimes occurs in chronic malaria or in leucæmia.

Cysts.—The diagnosis and treatment of cysts of the spleen do not differ in any essential features from similar lesions in the liver.

Hernia of this organ may occur through a wound in the abdomen or through an opening resulting from extensive sloughing. If the hernia is recent, and the prolapsed portion is not strangulated, it should be thoroughly cleansed in 1-to-5,000 sublimate solution and returned into its normal position. The structure of the spleen is so delicate that it breaks down readily if undue force is employed. If the organ is lacerated, it will be advisable to throw an elastic ligature around it at the level of the skin, apply an antiseptic dressing, and allow the mass to be removed by sloughing or by the scissors as soon as adhesions have occurred at the opening. When strangulation has taken place, the ligature will not be required.

Complete *splenectomy* may be demanded in displacement of this organ, followed by interference with the functions of other viscera, or for the relief of pain caused by the spleen in an abnormal position. It has

been performed in several instances on account of the enlargement of this organ in leucocythæmia, but without the success which would encourage a repetition of the operation.

In the extirpation of a wandering spleen, the incision should be by preference in the linea alba, when the tumor is near enough to be reached through an opening here. All adhesions should be divided between double catgut ligatures. The splenic vessels should be tied with a double ligature of strong silk, and divided between the knots.

Pancreas.—Cystic tumors of large size are occasionally met with in this organ, and have been successfully removed by incision in the median line, the operation being practically the same as in ovariotomy.

For the cure of *ventral hernia* the following method has given, in my experience, the best results: The incision and dissection should thoroughly expose the line of separation in the muscular tissues and the fascia or aponeuroses of these muscles and their peritoneal lining. The torn edges of the fascia and muscles should be freshened before the sutures are applied. It is sometimes necessary to dissect an oval piece of integument from the region to be approximated on account of the excess of skin which may be present and which will fold or wrinkle up when the sutures are tied. An essential feature is that the sutures, which are preferably of silkworm gut or strong, perfectly aseptic silk, should be passed through the integument, and each layer of muscle and fascia and emerge on the peritoneal lining of the abdominal wall about one fourth of an inch from the freshened edge. These sutures should be not farther than one fourth of an inch apart. It will be seen when they are tied that the peritoneal margins will fold together for immediate adhesion and the muscles and fasciæ are closely approximated. An exceedingly important point in the treatment is that the parts united should be subjected to no strain; nor should the patient resume the erect posture until six weeks have elapsed from the time of operation. I usually remove the sutures about the tenth day. A supporting bandage or strong, closely applied adhesive strips around the body should be used as a precautionary measure. The dorsal decubitus for six weeks after the operation is fully as important as the approximation of the tissues by suture.

Wounds of the Abdomen.

Injuries of the abdomen are divided into *penetrating* and *non-penetrating*, and both of these varieties are again divisible into those which involve the viscera and those in which the organs escape.

Non-penetrating Wounds of the Abdominal Walls.—Contusions may involve the integument, produce extravasation in the subcutaneous tissues, rupture of the muscles, or displacement or rupture of a viscus and death without any external evidence of injury.

Simple contused wounds of this region demand no especial consideration. If abscess occurs, the same rule of treatment which applies to abscess elsewhere is applicable here. *Rupture* of one or more of the muscles may occur as the result of a blow on a muscle in tension, or by

muscular action alone. The rectus abdominalis is most frequently torn. Hernia is apt to follow this injury unless immediate union is secured by freshening the ruptured surfaces and uniting them by suture. Perfect rest and well-adjusted pressure are of great importance to insure success. A truss or supporter should be worn should hernia ensue.

Displacement or rupture of an organ (as the kidney, spleen, etc.) may be caused by direct violence or by a severe fall. The diagnosis will, in the first lesion, depend upon the absence of the organ from its normal place and the recognition of the tumor in the new position. Laceration is followed by hæmorrhage, at times profuse, which is evident from great pallor and a rapid and weak pulse. If the intestine is involved, the escape of gas or fæces is followed usually by profound shock, tympanites, and peritonitis. Emphysematous crackling may be recognized on palpation.

The first indication in treatment of a displaced viscus is to place the patient in such a posture that gravity will aid in the restoration of the organ to its normal position. A compress and bandage may be useful in some instances. In rupture of a solid organ profound quiet should be maintained. When hæmorrhage is alarming, deligation of the extremities is advisable. If the symptoms of rupture of the alimentary canal are present, the abdomen should be opened in the median line, the rupture closed, or an artificial anus established, and the peritoneal cavity carefully cleansed.

Non-penetrating *incised*, *punctured*, or *shot* wounds of this region do not demand especial consideration. The former should be closed, while it is usually safer to treat the punctured and shot wounds by placing a sublimate compress over the opening.

Penetrating Wounds.—Wounds of the abdomen which penetrate without wounding any internal organ should be closed in the same manner as directed for the closure of surgical wounds through the belly. If an internal organ is involved the abdomen should be opened, the character of the lesion ascertained, and proper surgical treatment instituted. Among the symptoms which aid in arriving at a diagnosis are the following: If the injury is followed by the vomiting of blood it is fair to conclude that the stomach or duodenum is involved; if blood is passed by the rectum, that the wound is farther along the bowel; or, if hæmaturia exists, that the kidney, ureter, or bladder is injured. If the odor of intestinal gas or fæces is present, the inference is clear that the alimentary canal is opened. Bile, gastric juice, or recently ingested matter seen in the wound or recognized by the sense of smell indicates the character of the injury and the location of the perforation. The crackling sound peculiar to emphysema, elicited by palpation, indicates the presence of intestinal gas in the loose tissues, beneath the peritonæum (Dennis). Tympanitic resonance over the liver, which has appeared suddenly and which is persistent, is a diagnostic sign of perforation of considerable value. Shock is usually severe, although in some cases it may be slight and of short duration.

In shot wounds the location of the wound of entrance (and exit, if it

exists), together with the known direction of the missile and the force with which it was propelled, will be of aid in determining the character of the lesion within. A bullet passing directly or obliquely into the abdomen, at or below the level of the umbilicus, can scarcely miss the intestinal tube, and will be more apt to make a number of holes than a single wound. Above this point the chances of escape are more favorable, yet so fortunate a result is exceptional. The direction and depth of a stab wound may also be determined by the appearance of the wound and an examination of the instrument with which it was inflicted. The persistence of pain in a given point within the abdomen is a recognized symptom of a penetrating wound.

Many of the foregoing symptoms may not be present within the first few hours after the receipt of a wound which has penetrated the alimentary canal, and beyond the external wound and a varying degree of shock there may be no symptom of perforation. Temporary contraction of the muscular fibers of the stomach or intestine, or prolapse of the mucous membrane into the wound, may prevent, for a time, the escape of gas or ingested matter, and the appearance of the more pronounced symptoms of perforating wounds of the alimentary canal.

The distention of the alimentary canal by hydrogen gas forced into the rectum, as advised by Senn, in order to determine, by the escape of the gas into the peritoneal cavity and out by the superficial wound, the presence of a penetrating wound of the intestine, is, in my opinion, not advisable. In wounds of small aperture, as is well known, escape of intestinal gas or other contents may not occur. These would be opened by the induction of gas, and extravasation ensue. When doubt exists, abdominal section and direct exploration are preferable.

Treatment.—When there is a wound in the wall of the abdomen, the immediate indication is to determine whether it opens into the cavity. In order to do this, the disinfected finger, or the light and porcelain-tipped Nélaton probe, should be introduced, and, if necessary, the opening should be enlarged. Cocaine anæsthesia may be sufficient for this procedure. If the wound is confined to the abdominal wall it should be treated in the aseptic method advised for ordinary wounds of the soft tissues. If it extends through the wall, the abdomen should be opened and the condition of the viscera examined. As to whether the incision should be an enlargement of the accidental wound or made in the median line, the location and direction of the wound must determine. The section should be, preferably, through the linea alba. If the lesion is not more than six inches from this line, and if the direction of the wound is backward or tending toward the center, the median incision should be chosen. Under other conditions the section may be through the wound of entrance.

In this procedure the details of the antiseptic method should be carried out, as directed in operation for the relief of intestinal obstruction. When the peritoneal cavity is opened, if it contain clotted blood which is known not to have entered from the wound of operation, or ingested matter, or if gas escape through the opening, the penetrating character

of the wound is evident. If none of these signs are present the disinfected hand should be introduced and the internal surface of the wall examined at the supposed point of entrance. In examining the intestinal canal it is advisable to begin with the loops of small intestine which present at the incision. These should be carefully drawn out through the opening, and, as fast as inspected, surrounded with towels moistened in warm, sterile water, and supported in the hands of an assistant, who should not allow them to drag heavily upon the exposed mesentery. If an opening be found in the gut it may be at once closed, or noted and passed over until the entire canal and cavity have been examined. If a cutting or puncturing sharp instrument has inflicted the wound, its edges will be found sufficiently smooth to be sutured at once, and should be brought together by Lembert's suture (Fig. 675). If the hole has been made by a bullet, and has rough and torn borders, as in Fig. 676, its edges should be trimmed smooth, with curved scissors, and then closed. When only a narrow strip of tissue separates two openings, they should be converted into a single elliptical wound, and sutured. The proper distance of the sutures from each other is shown in Fig. 675. While these are being inserted the intestine should be laid upon towels spread over the abdomen near the incision. The escape of fecal matter into the cavity of the peritonæum should be prevented by flat sponges or sterile mats placed around the margins of the wound. If the wound in the wall of the gut is so extensive that, in closing it, the lumen of the tube will be seriously constricted, the injured portion should be exsected and reunited preferably by end to end anastomosis. If the condition of the patient will not justify a prolonged operation, Bodine's method may be substituted. After all wounds are stitched and hæmorrhage is arrested, the cavity of the peritonæum should be carefully cleansed. This is effected by sponges, attached to holders, carried into all parts of the cavity. When fecal extravasation has occurred it is better to cleanse the infected areas carefully with sponges or mops moistened in sterile hot salt solution, or in 1-to-10,000 mercuric chloride, drying the parts thoroughly with sponges or mops wrung out of the salt solution, in order to wash away any excess of mercury which may have remained. It is never advisable to flood the entire cavity with hot sterile water or salt solution when this can be avoided, unless there

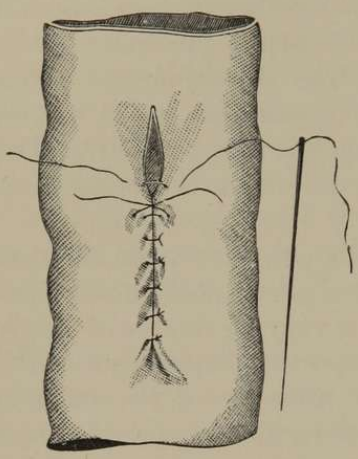

Fig. 675.—Lembert's suture for closing wounds of the intestines. (After Esmarch.)

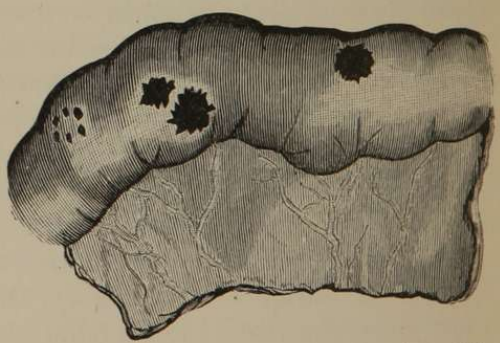

Fig. 676.—Pistol-shot wound of small intestine. (After Bull.)

has been a general, widespread contact of an infectious material, such as pus in an old perforative appendicitis, since in this way infection can be carried to parts that have not yet been infected. It is better to depend on local antisepsis and, ultimately, a Mikulicz drain from the deepest part of the basin, or a glass drainage-tube or a loose packing of iodoformized gauze. When any general flooding is demanded, the same method should be employed as given in the treatment of perforative appendicitis.

The intestines should now be returned and the wound closed.

No especial treatment can be laid down for wounds of the solid viscera or of the great vessels. The arrest of hæmorrhage, the removal of extravasated blood, and the establishment of drainage when needed are the indications.

The argument in favor of operative interference in penetrating or supposed penetrating wounds of the abdomen may be briefly stated as follows:

1. The enlargement of a wound sufficiently to demonstrate whether or not it opens into the cavity of the peritonæum is a simple procedure, practically without danger.

2. Abdominal section is not a difficult, nor, under ordinary conditions, when skillfully and properly performed, a dangerous operation.

3. A penetrating wound of the abdomen, left without surgical interference, is always attended with great danger.

4. If any vessels of size are divided, hæmorrhage is an immediate danger, and peritonitis a serious and probably fatal complication.

5. If the alimentary canal is opened, death is almost inevitable. The few recorded cases of recovery form such an infinitesimal proportion of the whole that they should carry no weight against interference.

It may be justly claimed that to American surgery is due the great advances which have been made in the treatment of penetrating wounds of the abdominal cavity. In 1847 Dr. Newell, of New Brunswick, N. J., "made an abdominal incision and sutured the intestine in a case of gunshot wound, cleansed the cavity, closed the wound, and the patient recovered."

A similar operation was done by Kinloch, of South Carolina, in 1882, and by Kollock, of the same State, in 1884, who sutured two pistol-shot wounds of the colon and one of the small intestine, with a successful result.

The operation was not brought prominently before the profession until the celebrated paper of Dr. J. Marion Sims was read before the New York Academy of Medicine, on October 6, 1881. This paper attracted widespread attention, and may truly be said to be the starting point in the surgical invasion of the abdominal cavity for penetrating wounds.

In 1884 Dr. Bacon Saunders, then of Bonham, Texas, opened the peritoneal cavity after a stab wound with symptoms of hæmorrhage, tied the mesenteric artery, which had been divided, and cleansed the cavity, with a successful result. A brilliant case of (intra-peritoneal) gun-

shot wound of the bladder, the first on record, was reported by Dr. Amos B. Walker, of Texas, and is given in the chapter on injuries of the bladder. In 1885 Dr. W. T. Bull successfully performed his operation for multiple perforation by a pistol ball. In 1886 Dr. W. O. Roberts, of the University of Louisville, operated for a stab wound of the intestine, with success. Following this pioneer work, successful cases have been reported of late years in many instances.

CHAPTER XXV.

RECTUM AND ANUS.

Diseases of the Rectum and Anus—Congenital Defects.—Arrest of development in the rectal and anal portions of the alimentary canal, though not so frequent as at the upper or buccal extremity, is unfortunately common enough to justify a consideration of the different kinds of deformity which may here be met with, and the mode of treating them.

Absence of the anus is one of the most frequent congenital lesions of the alimentary outlet. The rectum may be partially developed, and terminate within the pelvis in a blind pouch at a point more or less removed from the normal opening (Fig. 677); there may be a partial development of the anus (Fig. 678); the rectum may be entirely absent (Fig. 679); or it may be present in the pelvis, opening abnormally into

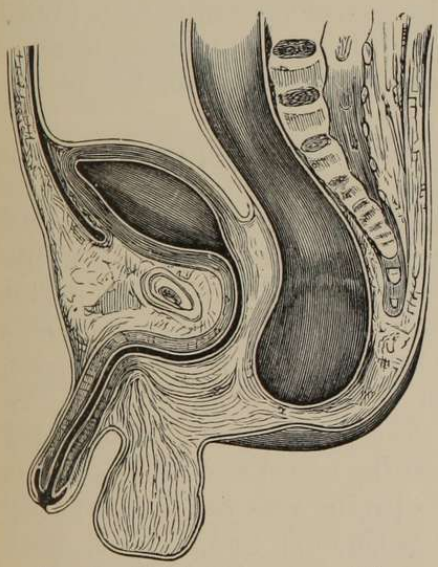

Fig. 677.—Atresia of the anus. (After Esmarch.)

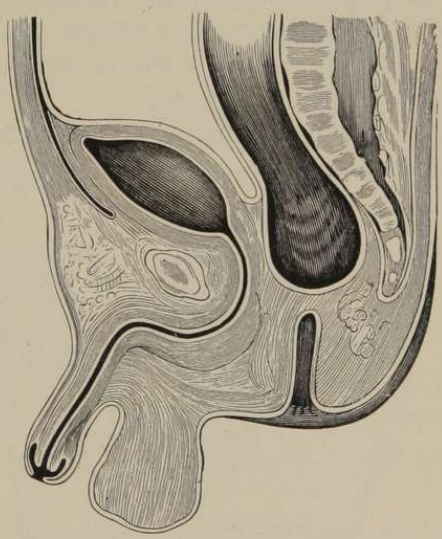

Fig. 678.—Atresia of the rectum, with a rudimentary anus. (After Esmarch.)

the bladder, vagina, uterus, or urethra (Figs. 680 and 681). In the simpler forms of atresia ani only a thin membrane is stretched across the otherwise normal opening. The more complicated varieties are those in which a greater distance intervenes between the end of the defective intestine and the perinæum.

Diagnosis.—Absence of the anus is easily established by inspection. The more important and difficult point is to determine the distance from

the perinæum to the end of the pouch. When the intervening tissue is thin, the accumulation of matter within the tube may cause a protrusion in the perinæum which is exaggerated when the infant cries. If the finger

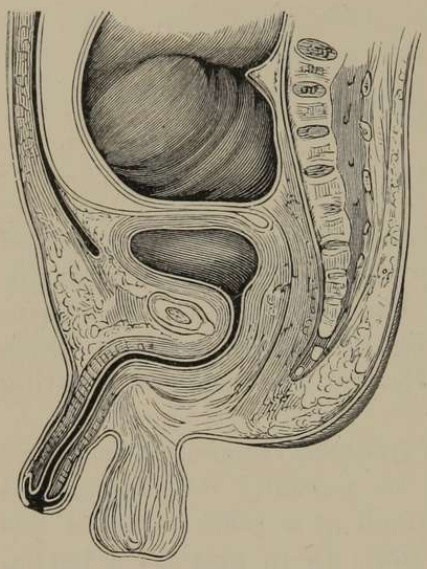

Fig. 679.—Atresia of the anus and rectum. (After Esmarch.)

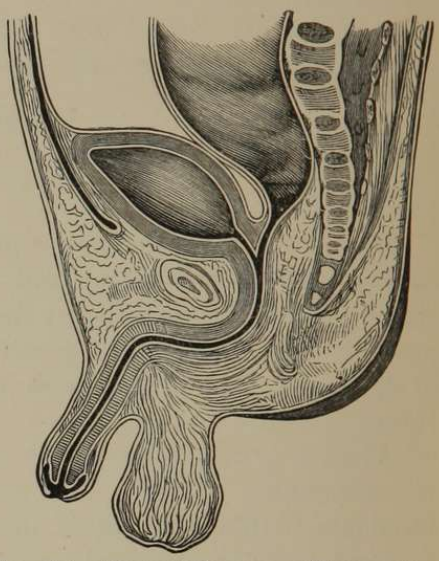

Fig. 680.—Atresia of the anus and lower portion of the rectum; the upper part opening into the urethra. (After Esmarch.)

be pressed into the perinæum, an impulse somewhat comparable to that felt in the expulsive efforts of a patient with hernia may be appreciated.

Exploration by the vagina, when the capacity of this tube will permit, will aid in diagnosis.

When the intestine opens into another hollow organ, or through the integument in an abnormal position, the only diagnostic sign is the presence of fecal matter in the natural discharge from the organ or at the abnormal opening. In atresia recti in female children, the bowel opens most frequently into the uterus or vagina, and in males into the bladder. At times the communication is established between the bowel and the urethra, or a false opening may occur at any point in the perinæum, and, in rarer cases, in some remote portion of the body.

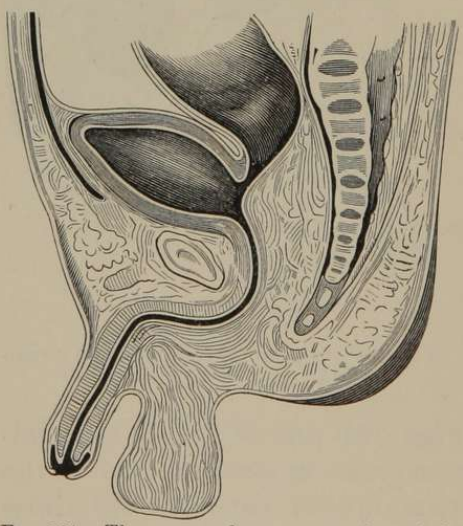

Fig. 681.—The same; the upper portion of the rectum opening into the bladder. (After Esmarch.)

Treatment.—The indications are to establish an opening as near the natural position of the anus as possible. If the blind pouch can be reached by the exploring aspirator, the needle should be left in place as a guide. The operative procedure is to dissect gradually toward the supposed location of the end of the gut, keeping an open and clear wound by using retractors and arresting all hæmorrhage.

The incision through the integument should be in the median line, with its center just in front of the tip of the sacrum and coccyx, for, if the *sphincter ani* is present, even in an imperfect condition, it is important to preserve it to aid in the voluntary control of the bowel when the operation is completed. When there exists only a thin septum, this muscle is usually well developed, and the operation is a simple incision and divulsion of the membrane. In more formidable operations, the location of the urethra and bladder, and in females the vagina and uterus, must be kept well in mind, for in infants the pelvic diameters are very small, varying from one to one and a half inch. It is a safe rule to proceed cautiously along the sacral curve. Moreover, it is wiser to dispense with an anæsthetic, since the expulsive efforts in crying may aid in finding the end of the gut.

When it is reached, if it is possible, the end should be loosened, drawn down, and sutured to the integument of the edges of the incision. If this is not done, the opening usually contracts, necessitating repeated dilatation by the use of the finger, tents, or a divulsor. In some instances it has been found necessary to remove the coccyx in order to effect the union of the bowel with the skin.

When, after proceeding as far as the immediate safety of the infant will justify, the bowel can not be discovered, the propriety of colostomy or enterostomy may be entertained. When the intestine ends directly in the uterus or vagina, and there is no pouching behind these organs toward the perinæum, it is best not to interfere. If, however, the bladder or urethra is involved, an opening should be made or colostomy performed.

In exceptional cases the anus is present in a condition of more or less perfect development, while at the same time the rectum does not communicate with it, but terminates in a blind pouch at a varying distance from the perinæum.

The effort should be made to establish a communication between the two pockets by dissection through the tissues which intervene.

When the opening from the rectum is abnormally small (a congenital stricture), dilatation, incision, or divulsion should be performed.

The unfavorable prognosis in all these cases should not be concealed. Inflammation, visceral complications, dilatation of the bowel above with retained ingesta, insufficient assimilation, pain, etc., render a favorable issue exceedingly improbable.

Pruritus Ani.—Persistent itching about the anus may be caused by a variety of skin diseases, as eczema, herpes, pityriasis, and erythema, or by irritation of the end organs of the sensory nerves from over distention in the act of defecation. It is also a symptom of hæmorrhoids, fissure of the anus, or may be due to the presence of the thread-worm (*ascaris vermicularis*). The character of the itching is burning, painful, and aggravating, and the desire to scratch is almost irresistible. The successful management of pruritus ani will depend upon the recognition of the disease of which it is a symptom.

Eczema of the perinæum and anus is more apt to occur in a warm

temperature, where perspiration is excessive, and in corpulent individuals where considerable friction occurs between the folds of integument of this region. The skin becomes infiltrated and thickened, fissures are formed, and the mucous membrane at the anal opening may become involved.

Treatment.—The part affected should be kept clean and friction prevented as much as possible. In the acute eczema of the anal region a warm bath, without soap, should be taken two or three times a day, the parts thoroughly dried, and sprinkled with powdered starch or lycopodium. If excoriations exist, lead-and-opium wash should be tried. In chronic eczema of the anus, in order to effect a cure, it is often necessary to remove the accumulation of scales by the local use of green soap for a day or two, and then smearing the surface with diachylon salve.

Herpes may be recognized by the character of the eruption, which is vesicular, the vesicles being grouped in bunches around the anus. Those which rupture and are subjected to irritation present flat and slightly ulcerating excoriations. The treatment consists in thoroughly washing the surface involved with a warm solution of boracic acid, grs. xv–℥j of water, by means of pellets of absorbent cotton moistened in the solution. This should be followed by applying an astringent ointment, composed as follows: plumbi acetatis, grs. iij; acid. tannic, gr. j; morphiæ sulph., grs. iij; adipis, ℥j.

Erythema is a mild form of inflammation of the integument, occurring here as a result of friction between the folds of skin of the two sides and the irritation from perspiration or other fluids. The warm bath, followed by sprinkling the part affected with starch or lycopodium, will usually effect a cure.

Pityriasis versicolor occasionally exists in the ischio-rectal region. This disease can be recognized by the brownish slate-color of the parts involved. The cause is a vegetable parasite, the spores and mycelia of which may be easily recognized by the microscope. It yields readily to pure sulphurous acid, which may be applied by means of a camel's-hair pencil. Corrosive sublimate (gr. j to water ℥j) may be applied by mopping with absorbent cotton dipped in this solution.

When pruritus occurs with hæmorrhoids or fissures, the treatment must be directed to these affections. If it is caused by overdistention or irritation of the rectum and anus, the use of enemata and laxatives will arrest the disease. The local application of a 4-per-cent solution of cocaine hydrochlorate will dull the sensibility of the part and temporarily stop the pain and itching.

Ascarides, or "thread-worms," are not an uncommon cause of pruritus ani. They vary in length from a quarter to half an inch, are somewhat lighter in color than the mucous membrane, and are not readily seen unless this membrane is everted and carefully examined. Santonin in full doses should be administered for two or three days, followed by a free purgation. When this is accomplished the bowel should be distended with an enema of lime-water, retained for fifteen minutes, if

possible, and repeated. As soon as the last injection is evacuated, a pint of water, in which grs. xx of carbolic acid are thoroughly dissolved, should be thrown into the rectum and retained for about five minutes. The injection of lime-water and carbolic acid in solution should be repeated for several days to insure a thorough destruction of these annoying parasites.

Enemata of the infusion of quassia are also highly recommended in the extermination of the ascaris vermicularis.

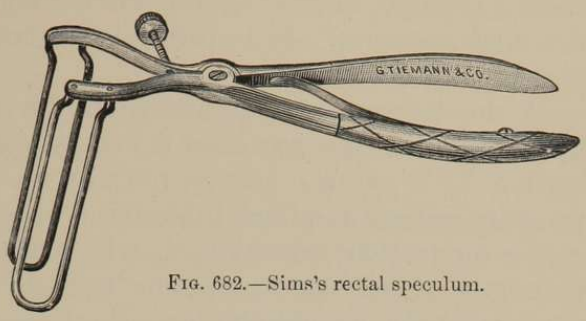

Fig. 682.—Sims's rectal speculum.

Foreign Bodies.—Foreign bodies in the rectum are usually introduced through the anus, and not infrequently lodge here, having passed through the alimentary canal. Their presence may be recognized by digital exploration, or, when of small size, the speculum may be employed.

Digital exploration of the rectum may be performed with the minimum of discomfort by curving the thoroughly lubricated finger to conform to the shape of the lower portion of the bowel. The direction from the anus is upward and forward for the first inch and a half, and then upward and slightly backward.

If a speculum is employed, that of Sims (Fig. 682) should be preferred.

A small body may be readily removed by seizing it with a long forceps after dilatation with this instrument. A large substance may require anæsthesia, with forcible divulsion of the sphincter, or a posterior linear rectotomy before it can be removed. When the object is made of glass or any fragile substance, great care should be taken to prevent its breaking.

Fistula in Ano.—A fistula of the anus or rectum may be *complete* or *incomplete*. The last variety is further divided into the *incomplete external* and the *incomplete internal* fistula.

In the complete form the track of the fistula, more or less sinuous, leads from the wall of the rectum or the anal margin out through the

Fig. 683.—Complete fistula in recto.

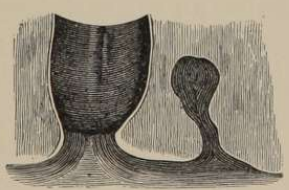

Fig. 684.—Incomplete external fistula.

Fig. 685. — Incomplete internal fistula.

integument of the perineal, ischio-rectal, or gluteal regions (Fig. 683). In the incomplete external variety, the track opens through the skin, but does not communicate with the rectum (Fig. 684); while in the incomplete internal fistula the track opens into the bowel only (Fig. 685).

Causes.—The loose areolar tissue which surrounds the lower portion of the rectum possesses a low vitality. Its nutrition is more or less im-

paired by overdistention of the bowel, which renders it a suitable nidus for the lodgment and proliferation of infectious organisms. If these do not find their way here through the blood channels, they may readily effect entrance by the lymphatic channels which communicate with abrasions (fissures, ulcerating hæmorrhoids), etc., which are common near the anal aperture. It is rarely by direct perforation of the bowel wall that infection occurs.

A not infrequent source of infection is the bacillus tuberculosis. As is well known, this organism is not pyogenic, nor does it produce inflammation of a painful nature, nor any recognizable exacerbations of temperature unless a mixed infection occurs and pus is produced. Whenever suppuration takes place, whether tuberculosis be present or not, pain is a prominent symptom, and there is a marked febrile movement. As the pus accumulates the tissues break down, and the abscess opens into the bowel or through the integument. A complete fistula may be developed from either of the incomplete varieties by partial occlusion of the original opening, thus causing the pus to seek an outlet elsewhere.

Abscess of this region may be superficial or deep. When superficial, it is apt to open through the mucous membrane, just above the junction of the skin and mucous membrane. When the deep variety opens into the rectum, it is usually at a point from three fourths of an inch to two inches from the margin of the anus. A single abscess may have one or more openings into the rectum or through the skin.

The *diagnosis* of fistula in ano is not difficult. It depends upon the history of an abscess followed by a constant or frequently recurring discharge of pus, the pain being severe until the abscess is evacuated, and recurring in a varying degree with the temporary closure of the outlet. An area of induration usually exists, and the opening may be discovered either through the skin or within the anus. If an external opening exists through which gas or fecal matter escapes, a complete fistula is demonstrated. When an external opening is formed, unless the abscess is very recent, there is almost always an internal opening, although it may not be found. The diagnosis may be further made clear by exploration with the probe, an operation which is rendered practically painless by the injection of a 2-per-cent solution of cocaine hydrochlorate into the abscess cavity. If a single injection does not sufficiently dull the sensibility, it should be repeated.

No matter where the external opening is situated, the track will, in the great majority of instances, run just beneath the skin toward the anus. The probe should be allowed to find its own way, and when well in, the point at which it impinges upon or opens into the bowel can be determined by the finger in the rectum.

Treatment.—When seen early, a peri-rectal infection or beginning abscess should be incised (not punctured) and drained by loosely packing it with a ribbon of iodoformized gauze. The incision can be made with cocaine anæsthesia, using the 2- or 4-per-cent. solution as required. In the early stages there is very rarely any communication with the

bowel, and the majority of such cases can be cured in this stage. If, however, the formation of pus is extensive, and the loose areolar tissue has been dissolved or dissected up until a large pocket is formed, it is extremely difficult to effect a cure without performing a radical operation. Should circumstances necessitate postponement of the thorough procedure, the incision and drainage should be done immediately. Tuberculous fistulæ may exist without pyogenic infection, and often with very insignificant pain. The operative treatment of this variety is practically the same as that to be given for the radical cure of *fistula in ano.*

Operation.—A laxative should be administered and the bowels thoroughly emptied the day before the operation. The perinæum and region of the anus should be cleanly shaved. The patient should be placed upon the back, with the sacrum resting on the edge of the table, the legs flexed on the thighs, and the thighs on the abdomen, and separated; or upon the side in the Sims position. The probe should be carried into the fistula, the lubricated index finger of the left hand into the rectum, and the point noted at which the instrument strikes the rectum. The probe is now withdrawn and the grooved director introduced in the same track. If the opening into the bowel can not be found, the operator should determine by the touch the thinnest point on the intervening wall, and at this location bore through into the rectum, supporting the mucous membrane near the point of the instrument with the finger in the bowel. As soon as the director is felt in the cavity of the gut, the point should be brought out at the anus, the sharp-pointed curved bistoury carried along the groove, and the fistula laid open by dividing the intervening bridge of tissue. If a second sinus exists, it should be incised in the same way, but it is always advisable to make only a single incision through the sphincters. The bleeding is usually insignificant, and may be arrested by pressure, or the ligature. The finger should now be carried into the wound, and, if it is discovered that the abscess extends higher along the wall of the rectum than the point at which the director was carried through, the intervening wall should be divided with the blunt scissors. It is important that the incision in the gut should extend to the depth of the abscess when this point is less than three inches from the anus. A careful search for any pockets or sinuses should be made, and these, if found, should be laid freely open. The fistulous tract and abscess wall should be thoroughly scraped out with the Volkmann sharp spoon, or the indurated and infected lining membrane dissected out with curved scissors or scalpel. In tuberculous infiltration, in order to effect a cure, it is essential that all the tissues invaded by the tubercular bacilli be thoroughly removed. The entire wound should be packed with plain sterile or iodoformized gauze, held in place by a compress of absorbent cotton and a T-bandage. This dressing should be allowed to remain in place for two or three days, when, with the first evacuation of the bowels, it is carried away. After this the wound is not repacked, but, for purposes of cleanliness, it may be washed out by allowing the patient to sit in a basin of warm

water once or twice a day, or by irrigation, and an outside dressing applied.

The wound rapidly heals by granulation, and, in the vast majority of cases, a cure is effected by a single operation. Temporary incontinence of fæces results in all cases where both sphincters are divided, but a permanent loss of function is exceptional. It is more apt to occur in females, and for this reason a more guarded prognosis should be made in this class of patients. In the rare instances in which an internal incomplete fistula is present, the cavity of the abscess should be opened by incision through the skin, and the operation completed as just given.

A division of the external sphincter is not necessary in the mildest class of cases, in which the abscess is recent and small, and in which the sinus runs just beneath the skin and opens at the margin of the anus. Under all other conditions it should be partially or completely divided.

Prophylaxis.—Upon the first appearance of inflammation in the ischio-rectal or perineal region, the integument immediately over the most superficial point of the induration should be incised, and a free puncture made into the inflamed tissues. This should be followed by the insertion of a small packing of gauze which should be changed daily. Too great distention of the rectum should be prevented by the adminstration of laxatives, and an enema of warm water should be given just before the bowel is emptied. By this method the tension is relieved and an outlet given to the products of inflammation before the process extends into the deeper tissues. A cure without further operation will be effected in a fair proportion of cases.

After an abscess is once formed, whether the fistula opens into the rectum or through the integument, or has both outlets, the case demands operative interference. The proportion of cures by the use of injections into the fistula, or the application of stimulating remedies, is very small. Of the radical operations, preference should always be given to that of free incision. The *elastic ligature* should only be tried on patients who are unwilling to remain in bed, or to be operated upon with the knife, to whom the merits of the two operations have been explained, and who relieve the surgeon of the probabilities of failure. It is also applicable to those cases in which the fistula enters the rectum so high up that incision is impracticable. A guarded prognosis should be made in this class of patients.

Operative interference is contraindicated in multiple fistulæ in the aged, or in patients in a weak and debilitated condition. When the tubercular diathesis is well marked, an operation should not be done unless great discomfort is caused by the fistula, and, when performed, the prognosis should be guarded.

Fissure.—Fissure of the anus is most frequently met with on the posterior portion of the outlet. It may, however, exist at any part of the anal circumference, or in the rectum above the sphincter. The tear is usually through the mucous membrane, although the muscular fibers

may be more or less involved. The chief cause is overdistention of the anus in the evacuation of hardened fæces, together with the presence of sharp substances in the matter discharged. In like manner, foreign bodies introduced into the rectum may produce it. Fissure may result from the inflammation and ulceration of a hæmorrhoid, or from any chronic inflammatory process in the rectum.

The chief symptom is pain of an acute character, exaggerated by an evacuation of the bowel, and continuing some time after the act in a violent spasm of the sphincter muscle. By careful and gentle dilatation of the anus, it may be seen or recognized by the touch as a line of induration running parallel with the axis of the bowel. The employment of cocaine will render the exploration more thorough, and will permit the introduction of the speculum.

Treatment.—The administration of laxatives, and the employment of enemata of warm water and olive-oil, will remove the chief source of irritation, while the stimulating effect of the lunar-caustic pencil applied in the fissure, and repeated every two or three days, will usually effect a cure. Cocaine should be employed to deaden the sensibility before the silver is applied. If a more radical procedure is necessary, it will consist in—1, a partial division of the sphincter in the line of the fissure; or, 2, temporary paralysis of this muscle by divulsion.

As the second operation usually requires ether narcosis, the partial division should be first employed. In its performance local anæsthesia should be obtained by the application of 4-per-cent cocaine to the inflamed surface, together with the injection of 2-per-cent solution by introducing the needle just beneath the fissure in its entire extent. The sphincter should now be made tense by separating the sides of the speculum, and an incision made through the depth of the fissure, dividing about half of the thickness of the muscle. In the after-treatment, the bowels should be kept open. Divulsion of the sphincter is performed as follows: The patient, fully anæsthetized, is placed upon the back, with the thighs separated and flexed on the abdomen. The operator, having lubricated both thumbs, introduces one and then the other to their full length, and gradually and without rupture of the muscular fibers stretches the opening directly to the right and left until the palmar aspect of each thumb is in contact with the inner surface of the tuber ischii. A towel, held in place by a roller or T-bandage, should be applied to prevent soiling. The rest obtained by the paralysis of the sphincter allows the fissure to heal. The function of the muscle is restored in from eight to twelve days. I have several times performed this operation with very slight pain with cocaine anæsthesia by Schleich's method.

Ulcers.—The traumatic causes of ulcer of the rectum are the same as those given for fissure of the anus. Ulcer may also result from any acute or chronic inflammatory process of the lower bowel. It is a not infrequent sequence of dysentery, and may be met with in that form of proctitis which results from prolonged diarrhœa. Inflammation of a hæmorrhoidal tumor will produce ulcer of the lower portion of the rec-

tum, and the same is true of the gummatous deposits of the late stages of syphilis. A primary chancre or a chancroid may be located at the anal margin, and less frequently in the bowel. These two varieties of ulcer are usually seen in women suffering with pudendal chancre or chancroid. Tubercular deposits in the rectum may also break down, and thus cause ulceration in the wall of this organ.

The symptoms of ulcer of the rectum vary with the character of the sore and with its location. If the lesion is situated within the grasp of the sphincter muscles, tenesmus is apt to be a marked feature. The ulcer from a traumatism, or following an acute inflammatory process, is more apt to be painful than that which is a part of a subacute or chronic catarrh, or which occurs with tuberculosis or syphilis. A common symptom of all ulcers of this organ is the presence of more or less blood and mucus or pus in the discharges. The diagnosis may be confirmed by inspection with the speculum, and by digital exploration. Rectal illumination by reflected light, as given by Dr. J. Marion Sims and applied in the diagnosis of lesions in the sigmoid colon by Dr. J. G. Carpenter, of Kentucky, and more prominently brought into notice by Dr. Howard Kelly, is a valuable aid to correct diagnosis of ulcer, stricture, neoplasm, or other lesions of the sigmoid flexure or rectum. Tubercular ulcer of the rectum very rarely exists before the symptoms of deposits in the lungs are present. Upon inspection they are recognized by their yellowish color, usually small size, and their dissemination over a considerable area of the mucous membrane. In the more fully developed ulcers the caseous degeneration of the inflammatory products may be observed.

Mr. Allingham describes a rare form of ulcer which he has occasionally observed in the rectum, and which he has named *lupoid*, or *rodent* ulcer, of this organ. Its usual location is near the anus. It tends to spread widely, the floor of the ulcer is red and dry, the margins irregular and precipitous. It is very probably tubercular in character.

Chancroidal ulcer of the rectum may be recognized by the precipitous margins of these sores, and by the rapidity with which they spread. In patients affected with phagedenic ulcers of the genital organs, the inoculation may occur by direct contact of the secretion of the venereal sore, or the virus may be conveyed through the medium of the nails in the act of scratching. Under such conditions the sore usually first appears upon the mucous membrane of the margins of the anus, and extends later into the rectum. The diagnosis must be based upon the peculiar appearance of the ulcer, together with the probabilities of infection from a contiguous venereal ulcer.

The hard syphilitic or true chancre is rarely observed in this region, and, when met with, is usually confined to the anal margin. It possesses here the same well-recognized features of the specific ulcer of the genital organs, from which source the virus is conveyed usually by the nails, and occasionally by immediate contagion.

Ulcers of the rectum resulting from the breaking down of the gummatous deposits of tertiary syphilis are chiefly seen just along the upper margin of the sphincter muscle. From this point they extend upward,

and may involve the entire rectum and invade the colon. These ulcers are usually multiple, varying in size from a small point to a half inch or more in diameter, and in depth may involve only the mucous membrane, or the muscular and connective-tissue stroma may be destroyed, and in some instances perforation may occur. The process of destruction is greater in the older ulcers, and the various stages may be observed by examining the bowel from below upward. The appearance of the ulcers as above described, together with the history of syphilis, will enable the observer to arrive at a correct diagnosis. Traumatic ulcers, and those resulting from the breaking down of hæmorrhoidal tumors, will be recognized by the appearance of the sore and the history of an accident or hæmorrhoids.

As far as a cure of the ulcer is concerned, a favorable *prognosis* may be made in all ulcers of the rectum except the tubercular. These may be relieved by treatment, but, being expressions of an incurable dyscrasia, permanent relief can not be expected. A more remote, as well as greater evil which often results from ulcer, is stricture of the rectum, and the danger of stricture is usually proportionate to the extent of the destructive process. Phagedenic chancroidal ulcer, and the ulcers of gumma and dysentery, are especially prone to induce stricture.

Treatment.—The common indication in the treatment of all forms of ulcer of the rectum is to keep the bowel in as complete repose as possible. Every effort should be made to keep it clear of fecal matter. This may be accomplished by the repeated employment of enemata, and by the administration of proper articles of diet, all of which should be capable of absorption in the stomach and small intestines. Milk, meat juice, soft-boiled eggs, rice, wheatena, corn-meal mush, etc., will afford variety and sustain the patient's nutrition.

In irrigation of the diseased surface, warm or cold water may be used at the temperature which is most agreeable to the patient. The best apparatus for this purpose is the fountain syringe. The smallest glass nozzle, thoroughly warmed and oiled, should be employed, and from one to two pints of fluid may be introduced at one injection. A larger quantity may be employed when the colon is involved. If the patient is placed upon the left side, with the buttocks elevated, a greater degree of tolerance will be obtained in the rectum. The fluid should be retained for a few minutes, if possible.

When the ulcer encroaches upon the sphincter muscle, causing painful tenesmus, the hypodermic use of morphia or opium suppositories may be required to relieve the spasm. In obstinate cases divulsion or division of the sphincter may be done as a last resort.

In the treatment of the ulcers which result from dysentery, catarrh of the rectum, an injury, or breaking down of hæmorrhoids, the plan just given should be adopted. It is often advisable to add from grs. v–x of nitrate of silver to the pint of water thrown in, and, if the ulcer can be reached, recovery will be hastened by the local use of the lunar caustic. An excellent remedy for the alleviation of pain and the relief of tenesmus is a suppository composed of gr. ij each of iodoform and co-

caine hydrochlorate, introduced from three to five times in twenty-four hours. As already stated, in obstinate and extreme cases, lumbar colostomy may be necessitated.

Chancroidal ulcer of the rectum requires the most energetic treatment. Ether should be administered, the sphincter divulsed, the ulcer exposed by the speculum, its surface scraped with the curette, and a thorough cauterization effected with nitric acid. The cocaine and iodoform suppositories should be employed in the after-treatment.

True syphilitic chancre of the rectum rarely demands local treatment. It yields readily to the constitutional remedies employed in syphilis.

The specific ulcer of the later stages of syphilis requires the constitutional treatment recommended for the late manifestations of this disease, and locally, irrigation and the cocaine and iodoform suppositories.

Tubercular ulcers should be treated chiefly by the administration of cod-liver-oil emulsions, the iron tonics, the hypophosphites of lime and soda, and carefully selected diet. Irrigation with warm water will be found useful. When pain and tenesmus exist, relief may be obtained by the means already given.

Fig. 686.—Stricture of the rectum from connective-tissue new formation in the submucous layer. (After Bushe.)

In rodent, or lupoid ulcer, the Paquelin cautery knife should be employed, and a thorough excision of the diseased surface effected.

Stricture of the Rectum.—Stricture of the rectum may be congenital or acquired. Partial and complete congenital occlusion of this organ has already been considered. Acquired stricture is usually the result of an inflammatory process in the walls of the rectum, and at times in the tissues which surround this organ (Fig. 686). New formations (cancer, etc.) may also cause a partial or complete occlusion of the rectum, not only by reason of the bulk of the cells proper of the neoplasm, but on account of the inflammatory process which it causes in the connective-tissue elements of the bowel.

The lumen of this portion of the intestine may be partially or completely occluded by pressure of a tumor not connected with the bowel, or by the presence of some displaced organ, as the uterus, bladder, etc. Lastly, spasmodic stricture may occur from contraction of the circular muscular fibers of the rectum.

As stated on a previous page, organic stricture frequently follows ulcer of the rectum, and is especially apt to occur in the process of cicatrization after dysenteric ulcers and those of the tertiary stage of syphi-

lis. The accidents of parturition not infrequently tend to stricture, and this may account for the greater prevalence of this lesion in females than in males.

Stricture of the rectum may be *narrow* or *linear*, or *long* and *tortuous*. The usual location is about two inches above the margin of the anus, although any part of the organ may be involved. The earlier symptoms of this lesion are interference with the act of defecation, pain with the passage of fæces, and the presence of blood or mucus in the discharges. In some instances the fæces are tapelike, or are abnormally shaped, although this symptom may not be present when the stricture is high up, since the fecal matter, after it passes through the constriction, may assume the shape of the bowel below. If the constriction is situated within the first four inches of the bowel, its presence and caliber may be determined by digital exploration. When with difficulty reached by the finger, the patient should be directed to strain as if at stool, in order to force the obstruction nearer the anus. Beyond this limit the bulbous bougies or direct illumination and the sigmoid speculum must be relied upon. The bougies are of all sizes, each consisting of an oval bulb of hard rubber, attached to the end of a flexible whalebone staff. In introducing them the patient should rest upon the back while the bougie, warmed and oiled, is guided up the bowel, upon the index finger of the left hand, which is carried its full length into the rectum (Fig. 687). If resistance is met with, only careful and gentle pressure should be exercised, for undue violence may drive the bulb through the wall of the gut. The inferior limit of the stricture is indicated by the first obstruction encountered. If the bulb can be carried through the constriction, the resistance ceases, but is again experienced when, upon withdrawing it, the shoulder of the instrument catches at the upper limit of the obstruction. The lower border of the stricture is again indicated when all resistance ceases in withdrawing the bulb.

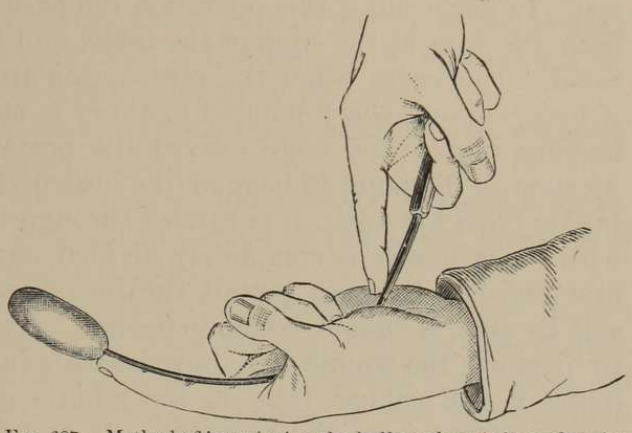

Fig. 687.—Method of introducing the bulbous bougie in exploration of the rectum. (After Bushe.)

Treatment.—The surgical treatment of stricture of the rectum may comprise *dilatation* or *division* of the cicatricial tissue or *colostomy*.

The character of the obstruction and its location will determine the means to be employed. When the stricture is linear, and is located near the anus, relief may be obtained by dilatation. For this purpose the finger should be employed, and the operation repeated at necessary intervals until a sufficient opening is secured. If the cicatricial tissue is dense, and does not yield in the effort at dilatation, it should be incised to a slight depth at four or five points of its circumference, and

the finger again introduced. The incisions may be made with a probe-pointed bistoury, carried along the finger as a guide, or the anus and bowel may be stretched with the Sims rectal speculum up to the point of obstruction, and the knife introduced without a guide. If this procedure is not successful, the only alternative is *posterior linear rectotomy*. In performing this operation the patient is placed upon the back, with the anus at the edge of the table, and the legs drawn up and separated. The parts below the obstruction are dilated with the speculum. A long, curved, sharp-pointed bistoury is carried through the stricture, keeping the cutting edge toward the posterior median line of the gut. As soon as the point is beyond the obstruction, *but not more than four inches from the anus*, it is carried through the wall of the bowel, which, with the stricture, is completely divided out through the anus. If the first incision does not permit the introduction of the first two fingers side by side, it should be made deeper. Hæmorrhage is readily stopped by packing the wound and bowel with gauze, taking the precaution to insert a stiff rubber tube in the middle of the dressing to allow the escape of gas from the intestine. If any important vessel is divided, it may be secured with the forceps or by transfixation with a tenaculum. The dressing is allowed to remain in place for four or five days, and is not replaced after the bowels are moved unless bleeding should occur. Continence of fæces is restored after from three to six weeks. No matter how thoroughly divided, the tendency is to recurrence, which necessitates interrupted dilatation at intervals of from three to six weeks during the life of the patient. It is usually not necessary to practice dilatation within the first six or eight weeks after the operation.

When the stricture is situated more than four inches above the anus, rectotomy is not permissible on account of the proximity of the large hæmorrhoidal vessels, the peritonæum, and pelvic fascia. Dilatation with the soft-rubber bougies (Fig. 688) may be tried, and, if this fails, a rectotomy may be done as high as the limit already given, which will allow the introduction of the hand to this point and the finger into the

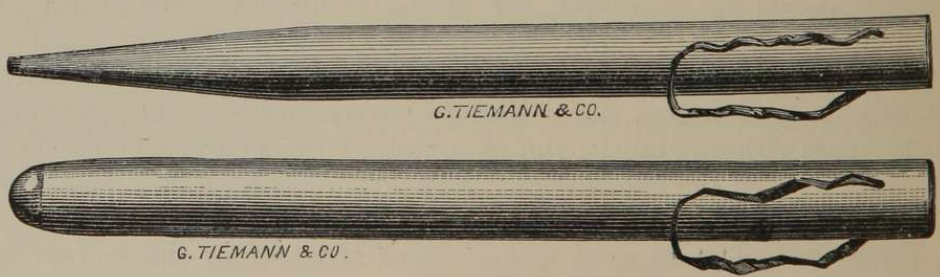

FIG. 688.—Soft-rubber rectal bougies (twelve sizes).

stricture. This may now be nicked with the bistoury, as above described, and digital or instrumental dilatation effected. Rectal bougies before being used should be made thoroughly flexible by immersion in warm water. In their employment only a mild degree of force should be exercised, for fear of perforating the wall of the intestine.

When all other measures fail, *colostomy* is the last resort.

Neoplasms of the Rectum and Anus.

Carcinoma.—Of the malignant new formations which are found in this organ, *epithelioma* is the most common, *scirrhus* and *encephaloid* cancer being next in order of frequency. The latter is comparatively rare. Cancer of the rectum occurs about equally in the sexes, and almost always in the middle-aged and old, although in exceptional instances it has been observed before the age of twenty-five.

Epithelioma begins in the mucous membrane, scirrhus and encephaloid carcinoma in the submucous tissues.

The former is slower in development and less apt to recur after removal. The most common location of cancer of the lower bowel is at the upper margin of the sphincter muscle.

The *prognosis* is grave, the duration of life varying from one to two or three years, and in exceptional cases longer. Usually the earliest symptom of cancer of the rectum is pain with the act of defecation. If the disease is located at the margin of the anus, it can be recognized before there is any interference with the discharge of fecal matter. Later, hæmorrhage is of frequent occurrence, although, as a rule, it is not profuse in character. After an evacuation of the contents of the bowel, the pain, though less intense, remains for some time. A sense of fullness or "bearing down" is a marked feature of this disease in the majority of cases.

Diagnosis.—If operative interference is to be undertaken, it is important that an early diagnosis be made. Epithelioma, as has been said, begins in the mucous membrane, the cells of the new formation break down early, the ulcer being present in some instances before there is marked induration. On the other hand, induration and thickening are observed early in the history of scirrhus and encephaloid.

Non-malignant stricture of the rectum is always preceded by a history of chronic inflammation. To the touch, the cicatricial character of the tissue may be recognized by its firmness and sharp borders. It is not nodular, like cancer, nor is there a deep and wide infiltration of the surrounding tissues in simple stricture, which condition is common to scirrhus and encephaloid, and the later stages of epithelioma. In doubtful cases it will be advisable to remove a portion of the mass for microscopical examination.

The *treatment* of cancer of the rectum may be *palliative* or *radical*. The former looks to the prolongation of life and the alleviation of pain by the employment of careful dietetic and medicinal measures. The regular daily introduction of warm water will prevent the lodgment of fecal matter and secure the greatest possible immunity from irritation. The iodoform and cocaine suppositories will be found useful in alleviating pain, and morphine may be employed if all other measures fail. As the disease progresses it will be found necessary to practice dilatation of the stricture at intervals which should be as far removed as possible, or partial or complete division may be required.

Colostomy by Bodine's method is essential in the palliative treatment

of carcinoma of the rectum. In forming the spur for a permanent artificial anus by this method, in order to stiffen it the mesenteric attachment should be left between the two rows of sutures. The *radical* cure consists in the free excision of the bowel at a point well above the tissues involved in the neoplasm. Formerly the death rate after this operation was exceedingly heavy, but under improved methods the danger is materially lessened. The important question to be decided is whether the operation promises well for the complete cure of the patient. If the disease is limited to a small portion of the intestine, which condition prevails in cases seen early, the diagnosis may be confirmed by excision of a small portion under cocaine anæsthesia, for microscopic study; or if the clinical signs point—as these do in most cases (Mathews)—to the development of a malignant growth, then excision should be undertaken at once, when it can be done with more safety to the patient and without the loss of enough bowel to interfere too seriously with the function of the alimentary canal. When the disease is within three inches of the anus, and there is no infiltration toward the bladder or the vaginal wall and uterus, the excision may be undertaken. Under other conditions the dissection between the walls of the vagina and the rectum is difficult, bloody, and not justified, from the fact that recurrence is practically certain within a short period. When so much of the bowel must be removed, together with the peri-rectal fat, that the upper end of the divided intestine can not be brought in contact with the lower segment or within a short distance of it, it may be necessary to close permanently the anal aperture and rely upon the artificial anus in the groin for the discharge of ingested contents. When this is done, or when the disease is so far advanced that an extensive dissection is probable, the artificial anus should be made before the operation, giving the patient two or three weeks to recover. Diverting the fecal current at the sigmoid flexure gives the rectum a rest and puts the parts in better condition for operation. The following method is advised:

Resection of the Rectum.—Operation of Prof. James P. Tuttle.

The patient is prepared by the daily administration of calomel triturates and saline laxatives for three or four days before the operation. Intestinal asepsis is essayed by the administration of naphthalin and salol, each grains ten to twenty three times a day, and, when stricture does not prevent it, high enemata of boric-acid solution are given twice daily. The parts are thoroughly shaved, all external antiseptic precautions taken, and, after the patient is anæsthetized, the rectum is thoroughly irrigated with 1-to-5,000 bichloride solution. When an artificial anus has been established by colostotomy prior to the operation, it will only be necessary to give a purgative the day before the operation, and salol and naphthalin need not be given. Irrigation with boric-acid solution and the mercuric chloride is, however, indicated. The patient is placed on the left side in the Sims position, with a firm pillow under the hips, the legs being well flexed. An incision is made about half an inch

from the margin of the sacrum, beginning at a point opposite the third sacral foramen and extending down to the tip of the coccyx. This incision is on the right side of the sacrum and farther away from this bone, and in this way differs from the Kraske operation. The incision is carried through the sacro-coccygeal ligament into the cellular tissue behind the rectum. Bleeding is checked by pressure with gauze in the hands of an assistant. The rectum is now readily detached from the anterior wall of the sacrum with the fingers, and gauze is packed into the space thus made in order to arrest bleeding and to prevent wounding the gut when the bone is cut across. A transverse incision is now made over the upper limits of the first incision across the sacrum and thoroughly down to the bone. The sacrum is rapidly cut with the chisel, and the flap thus formed is turned downward toward the left side, giving full view of the pelvic cavity and affording ample room for all manipulations. At this period it will become necessary to clamp the middle and sometimes the lateral sacral artery, but all bleeding of the skin has generally ceased by pressure. The detachment of the coccyx from the insertion of the levator ani will allow the bony flap to fall back easily and out of the way. Gauze should now be laid over the cut end of the sacrum to prevent scratching of the surgeon's hands or of the intestine as it is dragged downward. Careful examination is now made and the extent of the disease determined. If this clear exposition demonstrates that the infiltration is so widespread and extensive that the prognosis is exceedingly unfavorable, the operation may be abandoned and the parts restored to their original position with the minimum of harm. If the procedure is carried farther, the next step is to dissect up the areolar tissue surrounding the rectum and, freeing all the attachments above the limits of the growth, drag it down to the point of proposed section. If the peritonæum is to be opened, it is better to cut the lateral folds with scissors. Where the meso-rectum interferes with bringing the bowel down, a long-bladed clamp should be applied to it close to the sacrum, and it should then be cut as far away from the sacrum as possible in order to avoid wounding the superior hæmorrhoidal artery. It is essential to avoid wounding this artery, since gangrene is exceedingly apt to follow if this supply is cut off. Having freed the rectum from its higher attachments until it can be brought down to the point desired, the peritoneal cavity should be well filled with iodoformized gauze or the opening stitched with catgut. The gut should be clamped across or tied just below the point at which it is proposed to suture it. A second clamp or ligature is placed below this and the intestines cut through between these two. Both ends of the gut should be cauterized with pure carbolic acid in order to prevent infection from any septic matter which may exude, and then wrapped with iodoformized gauze in order to further protect the parts from infection. The lower segment should now be dissected out, and this can be done with almost no hæmorrhage, as the blood supply has been cut off by the clamp above. The middle and inferior hæmorrhoidal arteries may bleed some, but this is usually insignificant. If there is healthy tissue between the disease and the anus, it

is best to resect the diseased portion and make an end-to-end union. If this is not possible, the mucous membrane should be dissected from the margin of one side of the anus, and the end of the rectum which has been brought down invaginated into this opening and sutured to the surrounding skin. The external sphincter when it is left *in situ* should be well dilated and even incised, in order to prevent any obstruction to the free passage of fecal matter. Where it is impossible to preserve the sphincter we may be able to leave the levator ani, which may be of great value in the re-establishment of the fecal current. When the lower segment has been sutured to the level of the skin, the sutures are inserted at the margin of the posterior wound, in order to remove as far as possible any tension which may be exercised on the lower stitches. The clamp upon the meso-rectum is removed at the end of the operation and iodoformized gauze packed into the space in the hollow of the sacrum. The bone flap is restored to its position and maintained there by silk-worm-gut sutures passed through the skin and periostæum along the transverse incision. The rest of the wound is left unsutured, and the ends of the gauze, which walls off the peritonæum and fills up the sacral space, are brought out at its lower angle. When it is impossible to bring the gut out and attach it to the lower segment, it may be sutured in the sacral wound, or, as advised by other operators, an incision may be made in the gluteus maximus muscles, directing the end of the gut through this and suturing it to the skin. In this way these muscular fibers are used in the effort at continence.

Polypus.—Three distinct forms of polypi are found in the rectum, namely—the *villous*, *mucous*, and *fibrous*.

The first of these is the most important, for, while essentially benign in the earlier stages of its development, it may, as a result of the irritation to which it is subjected, become malignant. It is composed of newly-formed villi, which resemble the normal villi of the rectum. They are very vascular, and differ from the mucous or fibrous polypus not only in their minute structure, but in gross appearances and the character of their attachment to the mucous membrane. While these latter are pedunculated, often hanging by a narrow stem, the villous growth has a broad attachment frequently as thick as the tumor is long.

The mucous or soft, and the fibrous or hard, polypus of the rectum does not differ in any essential particular from that already described in affections of the nasal cavities. In some instances the deeper portions of the tumor undergo cystic degeneration, forming the so-called *cystic polypus*.

Polypi of the rectum may occur at any period of life, being comparatively frequent in childhood. The most common location of these tumors is on the posterior wall of the bowel, just above the internal sphincter. The pedunculated variety in some instances protrude through the anus, causing violent tenesmus. When not removed these neoplasms may break down, causing ulcer or fissure of the bowels, severe hæmorrhage, or by their weight cause prolapse of the mucous membrane.

The *diagnosis* is readily made by inspection or digital exploration, after the rectum is thoroughly cleansed by an enema. The *treatment* consists in removal of the tumor by the forceps, scissors, or ligature.

Villous papilloma, or "villous tumor," according to Mathews, is the rarest form of rectal neoplasm. "It is likely to be mistaken for polypus because it is pedunculated. In polypus the stem is round, in villous tumor broad." The clinical feature of most importance is the frequent hæmorrhage which occurs from rectal papilloma, caused by the passage of ingested matter. The treatment consists in the removal of the mass after a ligature has been thrown around it close to the pedicle. It is a wise precaution after removal to thoroughly touch the base of the tumor with the Paquelin cautery. There is very little danger of hæmorrhage in such treatment.

Neuralgia.—Pain, neuralgic in character, is occasionally felt in the rectum or about the anus. In some instances it is caused by displacement of the *coccyx*, the bone in the abnormal position pressing upon the fifth sacral or coccygeal nerve, or directly against the wall of the bowel. The diagnosis is readily made out by direct examination. The only means of cure is by removal of the displaced bone.

The operation is performed as follows: The patient is placed upon the side and an incision is made in the median line, from the tip of the coccyx to about one inch above the sacro-coccygeal articulation. The tissues are first lifted directly from the dorsal aspect of the bone, and then the anterior surface is exposed by beginning at the tip and keeping close to the smooth face of the coccyx. There is no danger of wounding the bowel if this precaution is taken. When the dissection is completed, the bone should be divided at the sacro-coccygeal junction with the cutting forceps or chisel.

Idiopathic neuralgia of the rectum and anus may occur as in other portions of the body. Spasm of the sphincter is occasionally due to this cause.

Prolapsus Recti.—Protrusion of the rectum may be *complete* or *incomplete*. In the incomplete variety the lining membrane of the bowel is alone protruded. The everted portion may include a narrow ring of the mucous membrane near the anus, or it may measure an inch or more in width. In the complete prolapsus more or less of the entire thickness of the wall of the rectum is dragged downward and everted. The process commences usually near the anus, and in the complete form the fascia which attaches the rectum to the promontory of the sacrum is elongated, and the peritonæum dragged down toward the anal aperture. In the pocket thus formed a loop of intestine may descend and become strangulated.

Prolapsus recti may occur at any period of life, although usually met with in children. In a varying degree it exists as a complication in all cases of chronic hæmorrhoids. It is frequently caused by frequent and prolonged straining at stool. A predisposing cause in adults is habitual constipation, with the overdistention of the bowel which is the result of this condition. In children, it is thought that the peculiar

shape of the sacrum, the curve of which is much less pronounced than in adults, renders this class of patients more liable to prolapsus. It is probable that indiscretions in diet, the lack of restraint, and the low, squatting posture too often permitted in children in the act of defecation, are more responsible for this accident than the straight position of the bowel.

Diseases of the bladder and prostate, uterus and ovaries, pregnancy, or the presence of a tumor, are also to be considered as exciting causes of this lesion. Finally, the weak and infirm are more liable to be affected than the robust.

When prolapsus occurs it is accompanied with a sense of distention, heaviness, and dragging down, which causes great pain and anxiety to the patient. In recent cases in which there is only an eversion of the mucous membrane, this will be seen projecting beyond the limit of the anus on one or both sides, or in severer cases including its entire circumference. The prolapsed fold or ring is of a reddish-purple color, varying with the degree of strangulation, and is broken at intervals by furrows or depressions which, in the main, seem to radiate from the center of the protrusion. When complicated with hæmorrhoids, these will be easily recognized by their shape and color, giving a swollen and nodulated appearance, which could not exist in simple eversion. In differentiating partial from complete prolapsus, the chief points are the thinness of the prolapsed ring in the partial form, and the radiating direction of the furrows. In complete prolapse the mass is markedly thicker, more strangulated, and the folds of mucous membrane are more nearly circular in arrangement.

Treatment.—In *acute* prolapsus the immediate indication is to relieve the strangulation and restore the prolapsed portion to its normal position. The removal of the cause or causes of the accident is next in importance. The first indication is met by placing the patient upon the left side, with the pelvis well elevated, the shoulders and head depressed, or in the knee-shoulder position, in either of which the return of the bowel is aided by gravity. The fingers of the operator and the protruded mass should now be well lubricated, and steady and gentle pressure exercised upon the tumor in the direction of the normal position of the bowel. In almost all cases this practice will succeed. When, on account of spasm of the sphincter, the strangulation is so great that gangrene is threatened and reduction impossible, an anæsthetic should be administered and forcible dilatation effected by the thumbs of the operator, after which the mass will readily return within the anus. Once reduced, the greatest pains must be observed to prevent the repetition of the accident. Fecal accumulation and straining should be prevented by the injection of cold water when there is a need or desire for an evacuation, and by the use of the bedpan. In children it is essential that they should not be allowed to squat upon a low vessel, or place themselves in a constrained position at stool. The position assumed should be one where gravitation will not carry the intestines toward the anus. Lying upon the side, with the buttocks slightly projecting over

the edge of the bed or table, or defecating in the knee-elbow position, should be insisted upon. Any condition which contributes to the cause of prolapse must be removed or palliated. When, despite all conservative methods, the prolapse becomes chronic, growing progressively worse, operative interference becomes imperative. The preparation of the patient is the same as for other operations about the rectum. After the narcosis is complete, the patient is placed in the lithotomy position, with the pelvis elevated to such an extent that the intestines will gravitate toward the diaphragm, the mass returned, and a large sponge introduced well up into the bowel. The sphincter ani and rectum should now be widely dilated with the speculum until the walls of the bowel are brought clearly into view. The Paquelin cautery knife, heated to a light-red color, is carried into the bowel as high as the limit of the prolapsed portion, and drawn straight down the wall of the gut to the margins of the anus, burning its way through the mucous membrane. The depth of the furrow must be determined by the extent of the prolapse. If the entire thickness of the rectal wall is involved, as in complete prolapsus, the wound should extend well into the muscular layer. In partial prolapse it will suffice to go down to the muscle. From four to six incisions should be made at equal distances from each other. Partial divulsion of the sphincter should be made before or after the operation, in order to prevent spasm and to secure rest. A complete recovery will follow in the large majority of cases. If the Paquelin cautery can not be obtained, strong iron wire, or rod iron, may be used by heating in the ordinary furnace. The after-treatment is to keep the patient quiet with mild opium narcosis, and after five or six days to move the bowels with a cold-water enema, keeping the patient in the recumbent posture. The cure is effected by the formation of inflammatory adhesions between the mucous membrane and muscle, and between the outer wall of the rectum and the peri-rectal connective tissues and fasciæ. The older operation of excising a V-shaped piece of the mucous membrane and afterward uniting the edges by sutures, is bloody and troublesome, and not to be compared to the procedure above given.

In chronic prolapse, the most satisfactory procedure is the operation of Whitehead, carried out as if it were being done for hæmorrhoids instead of prolapse. It is well to bear in mind, as emphasized in the description of this operation for hæmorrhoids, the danger of cutting away too much of the mucous membrane. Whitehead's operation is better adapted to chronic prolapse than any other procedure.

Hæmorrhoids.

Hæmorrhoids, or "piles," are vascular tumors or varicosities formed beneath the mucous membrane of the rectum and anus. They are divided anatomically into *external* and *internal* hæmorrhoids. Internal hæmorrhoids are again divided into *venous*, *arterio-venous*, and *capillary* hæmorrhoids.

The veins which are involved in hæmorrhoids belong to two plexuses,

between which, ordinarily, there is not a free anastomosis. The inferior or external hæmorrhoidal plexus is situated in the last portion of the rectum, within about one inch of the anus, and the blood from this part returns by way of the middle and inferior hæmorrhoidal veins to the iliacs, and thence by the inferior cava to the heart. The superior or internal plexus occupies the rectum above this point, and from this portion the blood returns by the portal system, passing through the liver.

In their incipiency, *external hæmorrhoids* are simple varicosities of the inferior plexus. Later, as a result of engorgement and repeated inflammation, the walls become thickened from the presence of newly formed connective tissue, which, in the process of contraction peculiar to this product of inflammation, often causes obliteration of the vein within the tumor. The remains of these tumors are seen in almost all cases of chronic external hæmorrhoids, where they appear as tags of thickened skin of variable size and shape, collected around the margin of the anus.

Internal hæmorrhoids of recent development are also varicosities of the internal or portal plexus, but when of long duration the tumors very frequently contain arterioles of considerable size. The mucous membrane of the deeper portions of the rectum is at times studded with small, raspberry-like elevations, which bleed profusely, are found to contain a rich network of capillaries, and for this reason are termed *capillary hæmorrhoids.*

External Hæmorrhoids—Acute and Chronic.—This form of tumor, commonly known as "dry piles," is of frequent occurrence. Few individuals live beyond the age of forty without being affected with this lesion. The chief cause is habitual constipation and the overdistention of the lower portion of the rectum in the act of defecation. Prolonged straining at stool, even without the discharge of fecal matter, will also aid in the development of piles. Gravitation by reason of the erect posture is also entitled to a consideration in the ætiology of hæmorrhoids, since man is the only animal thus affected. Pressure upon the iliac veins or the inferior cava by the gravid uterus, or any form of tumor, will also aid in producing varicosities of the hæmorrhoidal veins as well as in those of the lower extremities.

A patient who is suffering from an acute external hæmorrhoidal tumor will usually give a history of constipation and straining at stool, with an unnatural sense of fullness and heaviness about the anus, and of considerable pain while the evacuation is taking place, for several days before the protrusion is noticed. Immediately after an evacuation a swelling is noticed just outside of the anus which is painful to the touch, and which can not be pushed into the bowel. Upon inspection, a recent external hæmorrhoidal tumor usually appears tense and glistening on the surface, and red or reddish blue in color. It is partly within and partly outside of the anus. There may be a single swelling, which is spherical in shape, or it may be crescentic, occupying half of the anal margin. If not observed until after several days have elapsed, and when the tension or partial strangulation has not been re-

lieved, ulceration may have occurred, with inflammation and induration of the tissues near the base of the tumor. In other instances which do not come under the observation of a physician, the patient goes to bed, pushes the tumor within the anus, the symptoms disappear within a day or two, to recur again and again under the same conditions.

Chronic external hæmorrhoids differ from the acute form just described in the following particulars: They are brown or bluish in color, are not tense or painful, are loose and flabby, and have a thickened, leathery feel when pinched between the fingers.

Treatment.—This may be palliative or curative. Tension in the tumors may be lessened by placing the patient in the knee-shoulder position and making gentle pressure upon the mass until it slips within the anus. The cure of acute external hæmorrhoids, however, is so simple that it is rarely advisable to delay operation. There are rarely more than two or three of these masses, and by injecting directly into each one two to five minims of a 2-per-cent cocaine solution, all sensation is lost as the tumor is incised with a sharp-pointed curved bistoury, carried through its base, splitting it and turning out the clot, and inserting a little film of boric cotton or sterile gauze to arrest bleeding. The wound heals in the course of a week and the hæmorrhoids do not recur. In the case of chronic external hæmorrhoids with prolapsus ani, the operation of Whitehead is indicated. Old withered-up external hæmorrhoids may be easily removed by grasping the tumor with a pair of mouse-tooth forceps, and cutting it off with scissors. Cocaine anæsthesia may be employed if deemed necessary.

Internal Hæmorrhoids.—Constipation, overdistention of the rectum, and prolonged straining at stool must also be considered as among the principal causes of internal piles. In addition to these, any disease of the liver which causes a retardation of the return of blood through the portal circulation will aid in producing internal hæmorrhoids.

Pressure upon the portal vein, or upon the inferior mesenteric vein, whether due to an overloaded condition of the alimentary canal or a tumor, will produce the same effect.

Symptoms.—Internal piles, as a rule, cause little or no pain or annoyance until they are sufficiently developed to be caught in the grip of the sphincter, or are protruded through the anus. Previous to their descent, however, a variable amount of bleeding has usually occurred, often enough to attract the attention and excite the alarm of the patient. This is especially true of the arterio-venous and capillary tumor, although the venous tumor not infrequently gives rise to considerable hæmorrhage.

Upon digital examination the presence of the hæmorrhoids may be easily recognized, and ocular demonstration may be made by the careful dilatation of the sphincter with the Sims rectal speculum. If a free enema of warm water be administered, the tumors will usually protrude with the discharge of the water if the patient is placed in the squatting posture, and is directed to make a strong expulsive effort.

Treatment.—Internal hæmorrhoids may be cured by the ligature or the clamp and cautery. Whitehead's operation is rarely applicable to

this form of venous tumor. Capillary hæmorrhoids should be treated by the direct application of the Paquelin cautery. Patients suffer less pain and may be cured more quickly by means of the clamp and cautery than by the ligature, and this method should be selected when possible. It is, however, not so safe an operation when the tumors are large and vascular and protrude from the anus. It is more applicable to the small tumors than the ligature. Post-operative hæmorrhage after the cautery is rather more frequent than after the ligature. The insertion of the rectal tube to be described with the operative procedure tends to prevent any dangerous hæmorrhage.

Operation by the Ligature.—The preparation of the patient is the same as in other operations about the rectum. When fully anæsthetized, the lithotomy position should be preferred, or, if help is scarce, or the convenience of the operator is better suited, the patient may be placed upon the left side, with the left arm behind the body and the thighs and legs flexed.

The first step is the dilatation of the sphincter, which is accomplished by introducing the thumbs or first and second fingers of each hand and stretching the muscle in all directions, until relaxation is complete. This should not be too rapidly effected, for fear of tearing the fibers. A soft sponge secured by a strong silk thread is carried into the rectum above the piles, in order to prevent the descent of fecal matter; or a Barnes's dilator, as recommended by Dr. Willis P. King, may be introduced and then filled with water. The bowel should then be irrigated with 1-to-5,000 sublimate solution.

Seated in front of the patient, the operator—presuming that the tumors are present in the entire anal circumference—introduces one or two fingers of his left hand and by pressure with the palmar surface of the fingers from above downward, brings the mucous membrane, which lines the hæmorrhoidal tumors and these tumors well down to the margin of the anus.

With the sphincter well dilated and the hæmorrhoids plainly in view, the tumor may be grasped with mouse-tooth forceps and the mucous membrane covering the hæmorrhoid snipped with scissors near the level of the bowel wall. This should be stripped off, taking care not to cut the vessels which form the vascular mass; and when the mucous membrane is dissected from the pedicle, a strong silk ligature may be thrown around and the tumor cut away. Should the pedicle be broader than half an inch it should be transfixed and tied with the double (crossed) ligature. It is not necessary to close the opening in the mucous membrane. Should the vessels be prematurely cut with the scissors, they can be grasped with mouse-tooth artery forceps, or a suture may be inserted by means of a curved needle and tied. At times a large-sized Sims vaginal speculum, two or three inches in diameter, will be found an excellent instrument to expose the tumors after complete dilatation of the sphincter ani. The method just given is applied to each tumor in succession until all are divided. Another method is to transfix without dividing the mucous membrane and tie off the tumor at the level of the lining membrane of

the rectum with a double silk thread. It is always advisable to see that they are interlocked before they are tied. The threads may be disassociated by traction on the ends and then interlocked by carrying on one side of the tumor one thread two turns over the other. After tying, the tumor is cut off near the ligature, a thorough irrigation made, and the rectal sponge withdrawn. A stiff-rubber tube, about a quarter of an inch in diameter and four inches long, should now be well wrapped with iodoformized gauze until it has a gross diameter of about three quarters of an inch; this is lubricated with vaseline and introduced into the anus for three inches and held in place by a pad of gauze and a T-bandage. The function of this padded tube is to prevent oozing from the bowel should one of the ligatures slip, or should the wounds of the Paquelin cautery be stretched open by the removal of the sponge. It also prevents the accumulation of gas, which would cause spasmodic action of the sphincter muscle. It is advisable to give a hypodermic of morphine as the operation is being completed, as pain is present in practically all cases. Calomel triturates should be given within six hours after the operation, usually one or two grains. In this way the bowels are moved on the second day after the operation, and every day thereafter by calomel triturates or saline laxatives. It is not good practice to bind up the patient's bowels for five or six days or a week after the operation, for great pain and annoyance are caused when fully formed or hard fecal matter is forced through the bowel. The tube comes away with the first action of the bowels and is not replaced.

Excision of the Hæmorrhoidal Varicosities, together with a Circle of the Terminal Mucous Membrane of the Rectum—Whitehead's Operation.—The preparation of the patient and position on the table are the same as just given.

The sphincters are thoroughly paralyzed by digital stretching, so that they have no grip, and permit the hæmorrhoids and any prolapse there may be to descend without the slightest impediment.

By the use of scissors and dissecting forceps the mucous membrane is divided at its junction with the skin round the entire circumference of the bowel, every irregularity of the skin being carefully followed.

The external and the commencement of the internal sphincters are

Fig. 689.—Smith's hæmorrhoidal clamp (ivory-plated).

then exposed by rapid dissection, and the mucous membrane and attached hæmorrhoids thus separated from the submucous bed on which they rested, are pulled bodily down, any undivided points of resistance being snipped across, and the hæmorrhoids brought below the margin of the anus.

The mucous membrane above the hæmorrhoids is now divided transversely in successive stages, cutting about one fourth of an inch at a time, inserting a suture of strong catgut before the division is made. The sutures should be tied at once, and this repeated in the entire circumference of the anus. It is important that the sutures should be so closely applied that the mucous membrane and skin are absolutely in apposition throughout the entire circumference. It is more important that too much of the lining membrane be not sacrificed. Whitehead advises torsion to all bleeding points, but catgut ligatures are more reliable. If the operator keeps close to the external sphincter and works with the blunt-pointed scissors there will be very little bleeding. The dressing is the same as just given for the application of the ligature.

The operation with the *clamp* and *cautery* is performed as follows: After stretching the sphincter, the tumor is drawn out and grasped at its base between the jaws of the clamp (Fig. 689), and the blades closed by tightening the screw in the handles until the hæmorrhoid is strangulated. It is advised to grasp the hæmorrhoids in such a manner that the instrument points directly up the bowel. With the scissors the mass is cut away about one fourth of an inch external to the clamp, and the cut surface thoroughly cauterized with the Paquelin or the actual cautery. The ivory plates upon the jaws of the clamp protect the mucous membrane of the bowel from being burned. When this is done, the blades should be slowly separated, and, if any oozing is seen, the bleeding point should be again touched with the cautery. The after-treatment is the same as for the preceding operation.

In *capillary hæmorrhoids* the chief symptom is hæmorrhage. The bleeding occurs with and after each stool, or may follow violent exercise or straining. If the finger is carried into the bowel, no tumors are felt, and there is usually no tenesmus. If the speculum is employed, the mucous membrane will be seen to be studded with bleeding points or tufts projecting a slight distance from the normal level of the lining membrane of the rectum. They are red, not unlike small raspberries in appearance, and bleed profusely at the slightest provocation. They are really new formations or chronic granulation tissue, rich in capillary loops.

The *treatment* consists in dilatation of the anus and rectum with the speculum, and in touching the bleeding points with the Paquelin cautery until all bleeding ceases. If the cautery is not at hand, pure nitric acid should be applied.

CHAPTER XXVI.

GENITO-URINARY ORGANS.—KIDNEYS.

Wounds.—Rupture of the kidney may occur not only *directly* from a *penetrating* wound, but from a blow without penetration inflicted over this organ, and *indirectly* as from a fall from a height, striking on a remote part of the body as the buttocks or feet. The immediate symptom is hæmorrhage, which is proportionate to the extent of the injury and especially to the location of the wound in the kidney. If only a limited area of the cortex is torn, the bleeding may not be dangerous, but where the larger vessels near the hilum are involved, alarming hæmorrhage may occur, while shock, vomiting, pallor, cold perspiration, rapid and weak pulse, are present in the majority of such cases. Pain is severe at times and is felt not only in the region of the organ, but is transmitted in the direction of the ureters into the bladder, producing tenesmus, extending down the leg, and in males to the testicle, of that side which is generally retracted toward the external ring. Extravasation of urine takes place, and when the capsule is torn it may find its way either through a posterior rupture into the loose areolar tissue of the retroperitoneal space, or, in cases of anterior rupture of the capsule, it may escape into the peritoneal cavity. Hæmorrhage occurs also into the uriniferous tubules and pelvis of the kidney, gravitating along the ureters into the bladder, where it may be in evidence in the discharged urine. At times blood clots form either in the ureters or in the pelvis of the kidney, preventing the urine from flowing into the bladder and producing what may be mistaken for partial suppression of urine, the urine from this kidney being discharged either into the retroperitoneal space or through an external wound, if such exists. There may be, however, as a result of injury and the consequent shock, a partial suppression of urine without regard to the occlusion of the ureter on one side. The more remote symptoms of rupture of the kidney, which are met with usually from twelve to twenty-four hours after the injury, are increased localized tenderness, distention or swelling in the lumbar region, and exacerbations of temperature, with or without rigors or chills, due to septic infection either from urine which is not sterile or through the external opening.

Treatment.—The immediate indication is the arrest of hæmorrhage, and when the conditions are alarming this should be done by immediate incision over the known location of the organ, and the hæmorrhage controlled either by packing with sterile gauze when the cortical substance alone is involved, or by direct suture with sterile catgut through

the cortical substance when the location of the rupture and the character of the hæmorrhage will require. When the larger vessels near the hilum are involved, direct ligature at the bleeding point is advisable, or, in cases of great depletion, where valuable time would be sacrificed in the effort to find the bleeding points, a temporary ligature *en masse* to the pedicle of this organ will be justifiable. In counteracting the dangerous effects of such hæmorrhage, the immediate injection of a hot saline solution is of inestimable value. When septic infection has occurred, as will be determined by the symptoms just given, careful exploration with an aspirating needle, under cocaine anæsthesia, should be made at the point of selection (usually that of greatest tenderness), and if pus is discovered, an incision should be made, the pus evacuated, and the wound irrigated with mercuric-chloride solution (1-to-10,000) and drained with a rubber tube or iodoformized gauze wick. Even when pus can not be discovered by the aspirating needle, incision is indicated if there are pronounced symptoms of sepsis. The kidney may be easily reached by a perpendicular incision extending from an inch above the level of the last rib three or four inches downward parallel with the spines of the lumbar vertebræ and from three to three and a half inches from these spines. It is located just in front of the outer border of the quadratus lumborum muscle, its lower extremity reaching nearly to the umbilicus. Should the organ be practically destroyed as the result of injury, free drainage will secure safety, and some time should elapse—usually six weeks to three months—before removal of the disintegrated organ should be undertaken, in order to enable the remaining kidney to become accustomed to its increased function.

The kidney is often the seat of morbid changes, which occur partly from internal violence (calculus), or structural changes, which may at times demand surgical interference. *Pyelitis*, *pyonephrosis*, *hydronephrosis*, *nephrolithiasis*, *tuberculosis*, *gumma*, and certain new formations, as *cysts*, *carcinoma*, *sarcoma*, *rhabdomyoma*, *adenoma*, and *angioma* are among the chief diseases of a surgical nature.

Pyelitis, Pyelonephritis, and Hydronephrosis.

Pyelitis, an inflammation of the pelvis and calices of the kidney, is of frequent occurrence. When the substance of the kidney becomes involved it is known as pyelonephritis. In extreme cases the whole kidney may be converted into an immense abscess, divided and subdivided by trabeculæ, but limited by the original distended capsule. Inflammation of the renal pelvis, uncomplicated with any other lesion of the urinary apparatus, rarely develops symptoms appreciable to the patient or surgeon. When it assumes surgical proportions it is usually secondary to a pathological condition somewhere in the genito-urinary tract. A frequent cause is nephrolithiasis. A stone or calculus lodged in the pelvis induces inflammation by its presence or by obstruction of the ureter, and causes a distention of the pelvis with urine (hydronephrosis), or when pus is present with the retained urine (hydro-pyonephro-

sis). Or the disease may be due to an ascending inflammation, ureteritis, cystitis, or urethritis, or to an obstruction to the outflow of urine, caused by an enlarged prostate or tumor or urethral stricture, with overdistention of the bladder and ureters and renal pelvis, ultimately destroying the substance of the kidney.

The disease is usually bilateral unless caused by renal calculus or stricture of the ureter on one side. Another frequent cause of pyelitis and pyelonephritis is tuberculosis, which is often secondary to a tubercular focus in the lungs or elsewhere. The prolonged use of blennorrhetics—cantharides, turpentine, cubebs, etc.—improperly employed in the treatment of gonorrhœa, may cause an active congestion of the kidney, from which pyelitis or pyelonephritis results. The pregnant uterus, or uterus enlarged from other causes, may, by pressure upon the ureters, cause pyelitis. In rare instances violence from without may be a cause, and the disease may also result from a suppurative inflammation surrounding the kidney (perinephritis). Certain systemic infectious diseases, such as scarlet fever, diphtheria, osteomyelitis, etc., are associated with pyelitis and pyelonephritis. In these cases, however, the inflammation rarely proceeds to recognizable pus formation, and its presence is overshadowed by the gravity of the primary disease.

Direct extension of an acute gonorrhœal inflammation of the kidney, as given by Keyes, is not, as a rule, associated with appreciable renal symptoms.

Diagnosis.—Pyelitis and pyelonephritis are nearly always associated with symptoms of cystitis. A chill occurring during the course of a cystitis suggests pyelitis. The history of an antecedent attack of renal colic, a dull pain in the loin radiating down the course of the ureter and inner side of the thigh, with retraction of the testicle on that side, are strong evidence of the presence of this disease. In long-standing pyelonephritis a tumor may be made out by deep palpation. Tubercular pyelitis may be suggested by the presence of tubercular disease elsewhere. Careful examination of the urine is the most important step in diagnosis. The sudden disappearance of the pain, decline in temperature, and symptoms of sepsis, with an exaggerated quantity of pus in the urine, should confirm the diagnosis. These cases of explosive pyelonephritis are not uncommon. The reaction of the urine to litmus paper is of importance. In pyelitis the urine is excessively acid, remaining so for several days upon standing, with a greenish, oily deposit of pus and *débris*, while in severe cystitis, without involvement of the kidney, the urine is neutral or even alkaline from ammoniacal decomposition. Under the microscope, pus, mucus, occasionally hyaline and granular casts, blood corpuscles, and epithelial cells, peculiar to the renal pelvis, are found. In the diagnosis of this disease the cystoscope may be used with advantage to determine if it be unilateral or bilateral. The bladder should be thoroughly washed out with warm boric-acid solution to free it from all pus and mucus, then, with about half a pint of this solution in the bladder, the cystoscope should be carefully introduced through the urethra and inverted, holding the mirror well

above the floor of the trigonum, the electric light turned on, and search made for the urethral outlet. The boiling up of pus, mucus, and shreds from the ureter which leads down from the diseased kidney can readily be seen. A ready means of diagnosis is to wash the bladder out thoroughly, and after fifteen or twenty minutes to collect the urine by the introduction of a clean Nélaton catheter. If the pus is abundant and evenly mixed with the urine, it undoubtedly comes from the kidney.

Treatment.—When pyelonephritis exists exploration and drainage are indicated with removal of the kidney, if the condition demands it. As a rule, however, it is safer to delay the nephrectomy until several months of drainage in order not only to build up the condition of the patient by the arrest of septic absorption, but to accustom the opposite organ gradually to the additional labor placed upon it. In milder cases the treatment of the disease is usually the treatment of the cause. The cystitis should be treated by rest in bed, warm fomentations over the bladder and kidney to relieve pain, diluent drinks, and the administration of salol, oil of wintergreen, or other sterilizing diuretics internally; occasionally irrigation of the bladder with warm boric-acid solution is of advantage.

Urethral strictures should be divided, obstructing tumors removed, or the bladder drained above the pubes; stone in the ureter or kidney pelvis, if made out, should be removed by direct incision. Tuberculosis of the kidney, if unilateral, can not be cured other than by nephrectomy. In the female benefit may be derived from direct irrigation of the pelvis of the kidney through the ureter. The method first practiced by Pawlik, of Prague, and perfected and popularized in America by Kelly, of Baltimore, deserves careful consideration, and is given in the article on the ureters.

Hydronephrosis.—Hydronephrosis, the gradual distention of the pelvis of the kidney caused by an accumulation of the urine from an obstruction to its outflow, is usually attended by more or less atrophy of renal substance. It sometimes reaches enormous dimensions, and again may be so small as to escape observation. The condition is always a primary stage of pyelonephritis. Chronic hydronephrosis nearly always results in a suppurative inflammation. It is either a congenital or an acquired lesion. When congenital, it is the result of partial or complete occlusion of the ureter or urethra. When acquired, it is the result of an impacted calculus in the ureter, or stricture of this tube, pressure of pelvic tumors, growths in the bladder encroaching upon the urethral or ureteral outlet, flexion of the ureter due to movable kidney, enlarged prostate in old men, and urethral strictures.

The diagnosis is quite difficult unless the swelling is sufficiently large to attract the attention by its size or to cause symptoms of compression of the abdominal organs. In most cases where the obstruction is not permanent but recurs at intervals, the disappearance of the swelling with the discharge of an extraordinary quantity of urine is a positive symptom of hydronephrosis. Pain may be absent or excruciating in character.

Pressure of the tumor upon the overlying colon may give rise to disturbance in this tube. Uræmia is at times present and of serious character when the disease is bilateral. A positive diagnosis can be made with safety by exploratory puncture with an aspirating needle. The disease may coexist with a hydatid or an ovarian cyst, or cyst of other organs in the region of the kidney, such as the pancreas or spleen, or with abdominal ascites. In the latter, however, the level of the fluid changes with the different positions assumed, and the history of an antecedent liver trouble almost always precedes ascites. Hydatid vesicles are found in the urine or obtained by exploratory puncture, and enable us to diagnose this cyst, which is rarely bilateral, while hydronephrosis is frequently so. Cysts of the spleen and pancreas are rare, and the early history of their origin will point away from the kidney.

In the treatment of hydronephrosis, attention should be directed to prophylaxis. The diagnosis of nephrolithiasis, enlarged prostate, or urethral stricture should demand the surgeon's attention before hydronephrosis results. In the majority of cases, with moderate tumefaction, operative measures are not indicated. Symptoms of uræmia call for warm baths, diaphoretics, and purgatives, in the effort to eliminate by the skin and bowels the necessary quantity of urea. When large enough to interfere with the comfort of the patient, or when well-marked sepsis supervenes, the fluid should be evacuated. If suppuration has resulted in the sac, preference should be given to free incision. The wall of the cyst may be stitched to the abdominal wound, or if urgent symptoms be not present, the dissection may be carried down to the cyst capsule and the wound packed with sterilized gauze for a day or two, until adhesions have taken place, after which the contents should be evacuated. In milder cases a sterile aspirator needle should be introduced at the most prominent part of the obstruction near the last rib, and the contents removed. Injections of iodine, carbolic acid, and other irritating substances should not be practiced. Impacted calculus demands removal.

Nephrolithiasis.

The most frequent condition of nephrolithiasis is where the urinary salts are precipitated in crystalline form within the kidney tubules, pelvis, or other portion of the urinary tract. A gouty or rheumatic diathesis predisposes to *gravel*. A renal stone is formed by these small urinary crystals aggregating around a nucleus of epithelium, mucus, blood-clot, or other organic substance. Although chiefly composed of uric acid in various combinations, or oxalic acid in combination with lime, these calculi may be as variable in composition as those to be considered in connection with diseases of the bladder. According to analyses made by Taylor of the calculi in the Hunterian Museum, those occurring in children are chiefly muriate of ammonia; in adult life, uric acid; and after forty years of age, oxalate of lime. They may be found in the substance of the kidney, in the pelvis, or projecting from one into the other; more frequently, however, they are met with in the pelvis of the kidney. A

kidney stone may be single, in size varying from small particles of sand to several ounces in weight; or there may be several hundred small ones of irregular size, round and smooth by mutual friction.

The symptoms are variable. Unless severe pyelitis supervenes, or mechanical obstruction to the outflow of urine from the pelvis by impaction in the ureter is evident, the patient's attention may not be attracted to the kidney. If, however, sudden occlusion of the ureter ensues, it produces symptoms of great distress. If the stone is small and smooth, it may find its way into the bladder without much pain; but when large enough to distend the ureter, or rough, pain is extreme. It may be constant or spasmodic, and is usually referred to the neighborhood of the impaction. In males the testicle of the affected side is drawn up toward the external ring, and the pain may radiate down the thigh and leg. Vomiting may be present. The duration of the attack varies from a few hours to days. When the stone escapes into the bladder the relief is as sudden as the attack. In some instances, however, it becomes hopelessly impacted. The presence of blood in the urine is important in connection with the pain, especially so when it is increased by exercise and diminished after rest in bed. The microscope may also show epithelial cells characteristic of the renal pelvis. The discovery of small calculi that have passed with the urine confirms the diagnosis.

Treatment.—In patients known to have the uric-acid diathesis, or when the characteristic brick-dust deposit is in the urine, the kidneys should be flooded by administering large quantities of alkaline water, and by sterilization of the urine with salol and gaultheria, as heretofore given; such patients should be advised to live on a low diet, largely vegetable, to abstain from alcoholic liquors, and to take plenty of outdoor exercise. The urine should be examined occasionally, and if found very acid, thirty grains of citrate of potassium in a large tumbler of water should be given three times a day. When the paroxysms of pain, due to the passage of the stone through the ureter, occur, morphine or chloroform should be used to allay the extreme suffering. A hot bath and fomentations may be used with benefit. In extreme cases and when the stone is known to have become impacted, exploratory operation should be done and the stone carefully removed. Should the kidney be entirely destroyed by the presence of a large number of stones or by pyelonephritis and the disease be confined to one kidney, the question of nephrectomy may be entertained. If a portion of the kidney is still capable of excreting urine, it is advisable to pack the wound and allow it to heal by granulation. If the stone be not found in the renal substance or pelvis, the whole length of the ureter must be palpated. The operations of nephrotomy and ureterotomy are described on another page.

Cysts of the Kidney.—Cystic tumors are occasionally encountered in the kidney. They are caused by an obstruction along the course of the uriniferous tubules, causing a dilatation or cyst formation from retention of the urine, are usually small, and may be single or multiple. The conglomerate variety is a true cystic degeneration of the kidney, and is rare.

Both kidneys are usually involved, and for this reason the prognosis is grave. The degeneration continues with the formation of cysts, until in course of time all trace of kidney substance disappears. When bilateral, surgical treatment is not called for. Hydatid cysts, due to the lodgment of the ova of the *Tænia echinococcus*, are met with occasionally in the kidney. The tumor may become so large as to be mistaken for an ovarian cyst. Pressure symptoms on the contiguous viscera or distinct bulging in the region of the affected organs will probably be the only indication of its presence. A differential diagnosis between these renal cysts may be made by aspiration. The fluid from a hydronephrosis would be urine; that from a simple or conglomerate cyst, albuminous; while fluid from a hydatid would contain the characteristic hooklets. It is a safe rule in practice, when a tumor of the kidney becomes large enough to be appreciated by palpation and inspection, and should prove to be cystic in character, to evacuate the contents. This may be done by aspiration or, better, by an incision into the cyst, stitching the cyst wall to the edges of the wound.

Solid Tumors of the Kidney.—Of the solid tumors which affect the kidney, *sarcoma* is the most frequent; it occurs chiefly in the young, and is occasionally congenital. Carcinoma of the kidney usually assumes the (so-called) *encephaloid* form, less frequently the *melanotic*. A rare form of tumor known as *rhabdomyoma* or *myosarcoma* sometimes occurs in this organ. In the differentiation between sarcoma and carcinoma of the kidney the only guide is the age of the patient, for, as just said, sarcoma occurs almost always in the young, and carcinoma rarely before the thirtieth year of life. The presence of a tumor solid in character in the region of the kidney, with symptoms of pressure upon the ureter, renal vein, or ascending vena cava, and displacement of the mass downward in the direction of the navel, would indicate the presence of a solid neoplasm. Pressure upon the spermatic vein in the male may produce varicocele. Exploration with a view to extirpation is the only way to confirm the diagnosis as soon as a solid neoplasm is recognized. In the removal of large sarcomata in children, and, in fact, in all operations upon large vascular tumors of the body, the Trendelenburg posture is preferable, since the gravitation of the blood to the chest and to the upper extremity lessens the danger of hæmorrhage. In some of these cases a long transverse incision from the middle line to the quadratus lumborum, combined with the perpendicular lumbar incision, is essential to the safe removal of renal neoplasms.

Fibroma of the kidney has been met with in few instances, and, while not a malignant growth, it should be removed, since it produces great discomfort by displacing the organ.

Movable and Floating Kidney.—The kidney may be displaced *directly* by a blow over the seat of this organ, or *indirectly* by a fall from a height, the individual striking upon the feet, stretching or rupturing the fascial attachments. It may also be displaced by tight lacing in women, especially on the right side, where expansion of the chest is interfered with and the liver forced downward upon the kidney in the

inspiration act. It may also be displaced, as just said, by increased weight due to hydronephrosis and the development of tumors in connection with it. Rapid absorption of the perirenal fat—as in pregnancy or in disease—adds to the tendency of this organ to gravitate from its normal position. Displacement of the kidney may also be congenital. In a case which came under my observation the kidney was found in the pelvis.

A kidney is said to be "floating" when it has descended so far that it has pushed the peritonæum ahead of it and is encapsulated in the peritonæum, in the same manner as the testicle in its descent. It is "movable" when it is displaced but not encapsulated by peritonæum.

Diagnosis.—A thickened and enlarged gall bladder, a tumor of the colon, or mesentery, or omentum, should be carefully excluded. In one instance a lobular prolongation of the right lobe of the liver, in shape not unlike the kidney, was mistaken by me for a floating kidney—which organ was found in its proper place. Opening into the peritoneal cavity, the tumor was found to be a projection from the liver with the gall bladder attached. It was connected with the liver by a well-defined isthmus about two inches wide and one fourth of an inch in thickness. The presence of a tumor in the lower portion of the hypochondriac or in the lumbar region, in shape conforming to that of the kidney, reducible in the direction of the normal position of this organ, and disappearing by gravitation in the same direction when the pelvis is well elevated, are physical signs which point decidedly to a misplaced kidney.

Bimanual palpation will aid in the diagnosis. It can be best recognized with the patient in a semi-reclining position, with the abdominal muscles entirely relaxed. Certain symptoms, such as renal colic, due to overlapping or doubling of the ureter and its temporary occlusion, or a dragging, peculiar, and sickening sensation which accompanies this lesion, should be of value in arriving at a correct diagnosis

The treatment of this condition is surgical in all cases in which the condition of the patient will justify operative interference. The method practiced by Prof. George Ben Johnston, of Richmond, Va., has yielded in his hands very satisfactory results, and is to be preferred. He employs the lumbar incision to expose the organ, the fatty capsule of which is peeled off; the capsule proper is then incised for two or three inches of its length, reflected on either side of the incision for one fourth of an inch, and these reflected edges are stitched to the muscles and deep fascia by two rows of sutures, preferably kangaroo tendon or strong catgut. In making the incision, the patient should be on the side—the right side in operation upon the left kidney, and *vice versa*. It should begin a little above the last rib and extend well down to the crest of the ilium, along the outer edge of the quadratus lumborum muscle just where this is in contact with the aponeuroses of the abdominal muscles, about three to three and a half inches from the vertebral spines. Some of the lumbar vessels are usually divided and should be secured at once. By strong retraction the retroperitoneal space is readily found. Should the peritonæum by accident be opened, it should be stitched up at once with

catgut. In some instances where the space between the ribs and the iliac crest is unusually limited, a transverse incision may be added, and this should be freely made, keeping just below the level of the twelfth rib. It is usually advisable not to close these wounds, but to pack with iodoform gauze after partial closure by sutures. The same incision is sufficient for all cases of exploratory nephrotomy, or for exposure and drainage of the pelvis of the kidney, or for the removal of stone.

When *nephrectomy* is undertaken, two methods may be entertained: the posterior or retroperitoneal, and the anterior or intraperitoneal method. If the mass to be removed is very large it is advisable to dissect the peritonæum well up to the vertebral column in order to expose the pedicle of the kidney, and in order to accomplish this a transverse incision joining the perpendicular or lumbar wound is necessary. It is much safer for the patient to be subjected to a free incision which commands the large vessels not only of the pedicle but the newly formed vessels which may have developed with the tumor.

When the anterior operation is undertaken, the incision is made along the *linea semilunaris* until the peritoneal cavity over the kidney is freely opened and the intestines are displaced under hot sterilized pads toward the median line, the posterior peritonæum carefully divided and dissected away until the pedicle of the kidney is exposed and the vessels secured. It is always advisable that the posterior incision in the peritonæum should be made external to the colon, displacing this organ to the median line. A single ligature each for the artery, vein, and ureter will suffice. The wound through the peritonæum should be closed by catgut sutures, the abdominal wound with silkworm gut, with no attempt at draining.

In the posterior operation packing and drainage after partial suture is advisable.

Ureters.

Congenital lesions of the ureter rarely call for surgical interference. Occasionally this tube comes off from the kidney in a normal position and ends in a *cul-de-sac*, or a valve may be present which prevents the escape of urine into the bladder. Instead of entering the bladder, the ureter may open into the canal of the urethra in either sex; or occasionally it may terminate in the vagina. Cases have been reported where two or more ureters or prolonged calices proceeded from one kidney and united below in a single tube. If any of these conditions can be determined, the operative treatment would require either a removal of the kidney or the transfer of the end of the ureter, first, into the bladder, if this be possible, or out through the integument at the most convenient point to establish the urinary fistula. In all such operations it is essential before extirpation of the kidney to determine the presence and condition of the opposite organ. If there are two kidneys, one of these being normal, it is advisable to remove the offending organ rather than to lead the ureter into the vagina or intestinal canal, on

account of the discomfort produced by this procedure and the danger of ascending infection.

There are three narrowings in the normal ureter, the first about one and a half inch from the pelvis of the kidney; the second, at the point of crossing of the iliac artery; the third, at the entrance into the muscular wall of the bladder. It is at these points that calculi or inflammatory matter, pus, etc., drifting downward from the pelvis are apt to lodge.

The ureter is a muscular cylinder, varying in length from ten to fifteen inches. It descends in a slightly curved line from the kidney to the urinary bladder, and its relation to the peritonæum should be carefully studied. Normally it is so firmly adherent to this membrane that when the peritonæum is lifted the ureter goes with it. In retroperitoneal operations it may be easily found attached to the peritonæum and running about half an inch external to the line of adhesion of this membrane to the spinal column.

Traumatic lesions of the ureter may occur from penetrating wounds and (in certain cases of fracture) from projecting particles of bone, or perforation may occur from the pressure of an impacted calculus. The treatment demands exposure of the seat of injury, suture of the divided ends of the canal, as will be described hereafter, or, if this is not possible, the establishment of an external urinary fistula, after which at some proper time the removal of the kidney of that side may be considered. Impaction of a calculus in the ureter may be determined by the symptoms already given in the section on nephrolithiasis, and in addition the X ray may be called into requisition.

If the lodgment has occured at the two lower contractions, palpation by the rectum or vagina for the lower, and direct palpation through the abdominal wall for the upper narrowing, may succeed in locating the stone. An incision may be necessary to a correct diagnosis, especially when the stone is located in the upper contraction, and, when found, if the stone can not be crushed between the thumb and finger, the ureter should be opened and the calculus removed.

Longitudinal wounds of the ureter which communicate with the peritoneal cavity should be closed by direct suture, and in all such operations thorough drainage should be secured. When longitudinal wounds of the ureter, accidental or incised, do not open into the peritonæum, it is not necessary to employ sutures, since such wounds usually close by granulation.

In dealing with the ureter, the extraperitoneal route should be used whenever possible. Cicatricial stenosis, if not too extensive, should be treated by Fenger's method. Make a longitudinal incision through the contracted portion; bring the upper and lower ends of the incision together by folding the ureter upon itself, and unite the contiguous surfaces to each other with silk sutures (Fig. 690).

To expose the ureter in the retroperitoneal space, make an incision from the last rib to near the iliac crest, parallel to and three and a half inches from the vertebral spine. From the anterior spine, when neces-

sary, the incision should be extended inward and downward to near the center of Poupart's ligament. Upon reaching the peritonæum, this is carefully detached and raised by the finger until its line of adhesion to the spinal column is reached. The ureter will be found adhering to the peritonæum from half an inch to one inch from the line of adhesion of the membrane to the spinal column. On account of the position of the vena cava ascendens on the right side, the line of adhesion is somewhat more external.

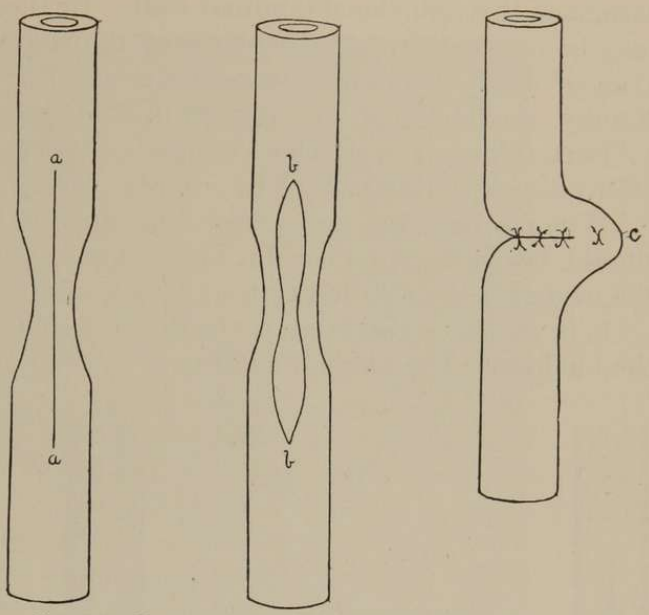

Fig. 690.—Fenger's method for relief of stricture of the ureter.

In *transverse* wounds with complete division, efforts at direct suture and reunion have all failed on account of the great difficulty of manipulation in so deep a situation and the retraction and separation of the ends. The more rational procedure is to form a fistula by transferring the end of the upper portion of the divided tube to the integument at a convenient point, usually near the kidney posteriorly. For security, a ligature may be applied to the lower end. The question of nephrectomy will be a later consideration.

Implantation into the bowel is such a great inconvenience to the patient, as a rule, and accompanied by such risk of ascending infection, that it is scarcely advisable.

In Van Hook's operation invagination of the upper into the lower segment has been successfully performed. "Ligate the lower portion of the tube one eighth or one fourth of an inch from the end with silk; with fine, sharp-pointed scissors, make a longitudinal incision beginning one fourth of an inch below the ligature, the opening to be twice as long as the diameter of the ureter. In the upper portion of the ureter, with scissors, make an incision beginning at the open end of the duct and carrying it up one fourth of an inch. Pass two very small cambric sewing needles, armed with a single catgut thread, through the wall of the upper end of the urethra, one eighth of an inch from the extremity and from within outward, the needles to be one sixteenth to one eighth of an inch apart (Fig. 691). These needles are now carried through the slit in the side of the lower end of the ureter into and down the tube for half an inch, where they are pushed through the wall of the duct side by side. By traction upon this catgut loop pulling upon the two cambric needles, the upper segment of the duct is drawn into the lower seg-

ment. This being done, the ends of the catgut thread are tied together securely. The ureter is now carefully enveloped with peritonæum and fine silk sutures inserted, passing only through the muscular layer (Figs. No. 2 and 3).

Operations involving the lower third of the ureter are difficult of performance through the abdominal wall. In the female the operative field may be reached through the vault of the vagina, as done by Prof. H. C. Coe, of New York, or it may be reached through a suprapubic cystotomy, the danger of urinary infiltration being carefully borne in mind.

Partial resection of the sacrum by the method of Kraske may also afford access to this part of the ureter.

When a calculus is extracted by any of these methods, the wound should be packed and careful iodoform-gauze-wick drainage established, the wound being allowed to heal by granulation.

It is at times essential to transfer the end of a divided ureter into the bladder. The method suggested by Van Hook and successfully per-

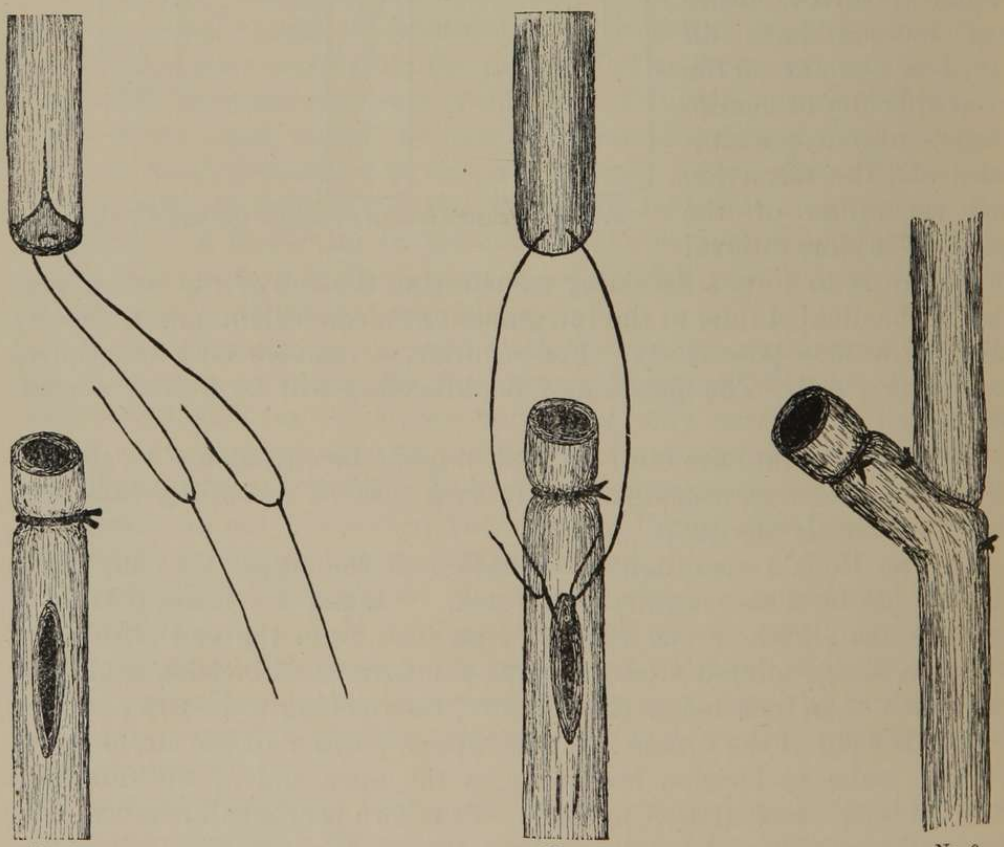

Fig. 691.—Van Hook's method of anastomosis of the divided ureter.

formed by Prof. Florian Krug is as follows: The left ureter having been divided, a small opening was made into the bladder and the end of the upper section of the ureter carried through this wound. Several rows of carefully inserted silk sutures attached the tube to the wound in the bladder, care being taken not to permit the needle to penetrate through

the muscular layer into the lumen of the tube. Careful catheterization was practiced in order to keep the bladder empty and to prevent leakage by hyperdistention.

Catheterization of the Ureters—Method of Kelly.—Direct exploration of the ureter and irrigation of the pelvis of the kidney through this tube

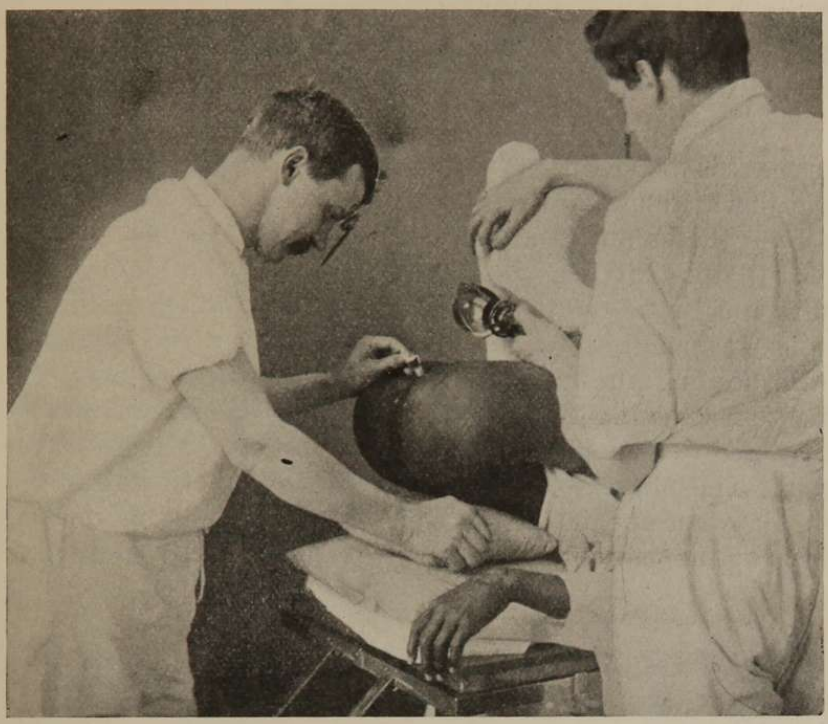

Fig. 692.—Direct ocular inspection and catheterization of the ureters in the female. (Howard Kelly.)

is done as follows: The apparatus required consists of a female catheter, a conical urethral dilator and several specula with obturators, a common head mirror, a lamp with an Argand burner or electric droplight,

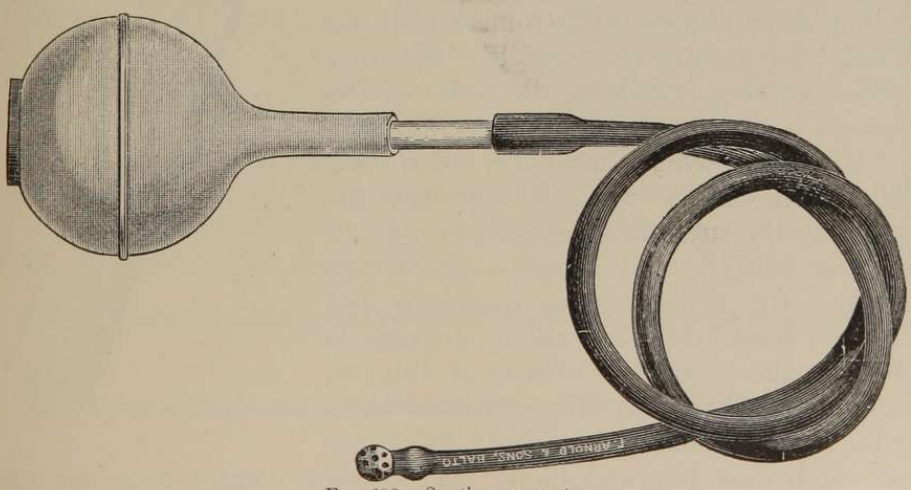

Fig. 693.—Suction apparatus.

a pair of long, delicate mouse-tooth forceps, a suction apparatus for completely emptying the bladder, a ureteral searcher, a ureteral ca-

theter without any handle, cushions for elevating the pelvis, or an inclined plane.

Careful cocainization of the urethra will in many instances enable the operator to examine the bladder and catheterize the ureters practically without pain. Should necessity demand, general narcosis may be employed.

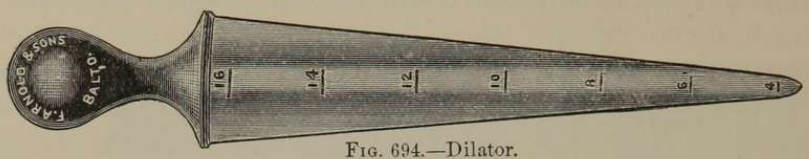

Fig. 694.—Dilator.

The patient is placed upon the back near the edge of the table with the pelvis elevated as shown in Fig. 692. The bladder is completely emptied by catheter and the suction apparatus (Fig. 693). The conical graduated dilator (Fig. 694) is gently bored into the external orifice of the urethra until it is dilated as much as eight or ten millimetres. A speculum corresponding to the size indicated by the dilator is next introduced, holding the handle at first well above the level of the external meatus, carrying the end on through the urethra and into the bladder by gently sweeping the hand downward and inward over the symphysis. The obturator is now withdrawn, and the bladder at once fills with air, with an audible suction sound. If the air does not rush in, the hips of the patient are still further elevated (from twelve to sixteen inches above the level of the table, Fig. 692). With the head mirror attached, an electric droplight or bright lamp is held close to the patient's symphysis pubis to make the angle of reflection as small as possible. Now, by properly directing the light, all parts of the bladder are easily accessible to direct inspection. Any urine which has collected during the dilatation can be removed through the speculum by the suction apparatus, or by cotton pellets held by the mouse-tooth forceps (Fig. 696). By exposing the trigonum and turning the speculum about thirty degrees to one side or the other, the orifices of the ureters are seen. The urine will appear at short intervals in jets from the orifice; in pathological conditions, pus and blood may be seen coming from one ureter while the other discharges normal urine. The mucous membrane of the bladder is usually of a deeper rose-color near the orifice of the ureter; at times it is deeply injected. The searcher (Fig. 697) may be intro-

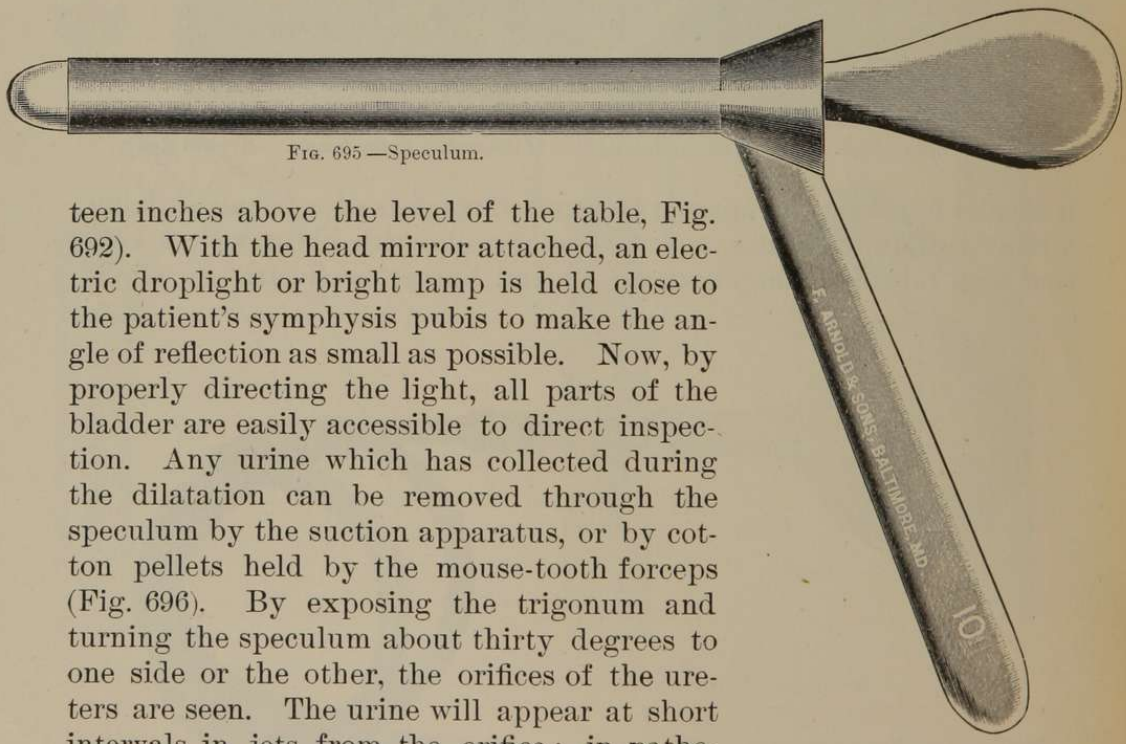

Fig. 695.—Speculum.

duced through the speculum into a suspected ureteral orifice, which, if found, will allow the searcher to pass in for several centimetres. The latter is then withdrawn and the ureteral catheter (Fig. 698) introduced. By leaving this catheter in the ureter for a few minutes, the urine which descends from the kidney of that side will be discharged through it, while the urine from the opposite side collects in the emptied bladder, thus affording an opportunity to make a separate analysis of the urine of each kidney. The diagnostic value of this practice is evident. If the patient is stout, or if the bladder for any reason does not readily distend with air, the inspection will be best conducted in the knee-breast posture.

Pawlik's method.—Free-hand ureteral catheterization is practiced in the following way: The patient is brought with the buttocks to the edge of the table, with the legs and thighs sharply flexed. The vulva and vagina are cleansed with soap and water and the urine drawn from the bladder and preserved for inspection. The bladder is then injected with a solution of methyl blue, about six ounces. The posterior vaginal wall is now retracted with a Sims speculum, which exposes the anterior wall. On close inspection two prominent folds will be seen sweeping over the anterior wall about halfway up and out to the sides on to the lateral walls toward the cervix. These are the "ureteral folds" of Pawlik, the pioneer in this method. Parallel to and just above these folds the ureters are to be sought. Kelly's ureteral sound is now introduced through the urethra into the bladder and held with the concavity of its tip toward the floor of the bladder. A little pressure on the floor reveals its position to the eye, which is kept on the vaginal wall. It is now guided in the direction of the ureteral folds, and, should it catch in the ureteral orifice, it will at once be felt to have a determinate direction as it slips backward and outward toward the posterior pelvic wall. The ureter may now be palpated on the sound. If the catheter is in the ureter, after waiting a few minutes, the urine begins to flow, drop by drop, clear and unmixed with the methyl solution, demonstrating that it is being collected at a point above the bladder. For the recognition of stricture or stone in the lower portion of the ureter, this method is invaluable.

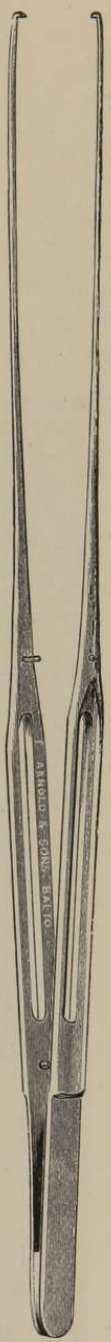

Fig. 696.
Forceps.



Fig. 697.—Searcher.

Fig. 698.—Catheter.

CHAPTER XXVII.

THE BLADDER AND PROSTATE.

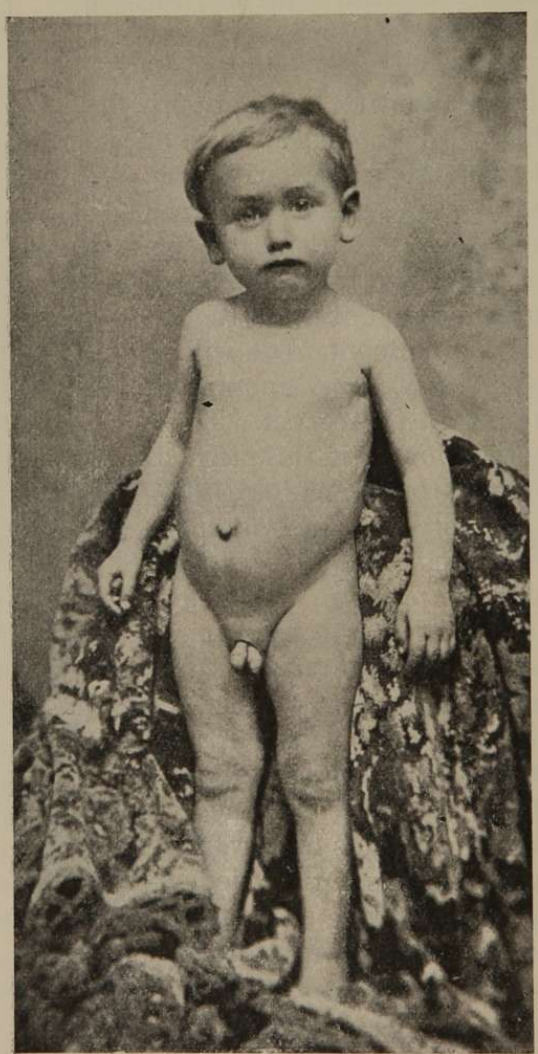

Fig. 699.—Double penis. Case in practice of Dr. J. D. Cole, of Tennessee.

Congenital malformations of the bladder are fortunately rare. There may be complete absence of this organ, the ureters opening directly on the surface or into the vagina or rectum; there may be more than one bladder or a normal bladder divided into two parts by a septum. In these cases in the male there may be a double penis with a separate urethra to each bladder. In the case of the child (Fig. 699) born in 1894 there are two organs, "each penis perfectly formed, one a little to the left of the median line and a little lower than the other, which is nearly in the middle line. They are one fourth of an inch apart at the level of the skin. He passes a good stream of urine through both urethræ at the same time. A single urethra in the perinæum bifurcates into a channel for each penis. The scrotum is divided into three compartments. The right and left compartments contain each one testicle, and in the middle pouch is something which feels like a testicle. The anus was imperforate. I operated by an incision three inches in depth, when the blind end (*cul-de-sac*) of the rectum was found and freely opened."* The child recovered, and is now living at two years of age.

Exstrophy, or eversion of the bladder (Fig. 700), is almost always

* Personal communication from Dr. J. D. Cole, of Newbern, Tennessee, to author.

met with in males. It is caused by a failure of development in the anterior pelvic and abdominal regions. The integument, muscles, pubic bones, and anterior part of the bladder wall are missing. Through this gap the part of the bladder which may be present is protruded, as a mass of variable size (depending upon the extent of the deformity and upon the position of the patient), from one inch up to three or four inches in diameter. In the erect posture it is always largest, being pushed out by the descent of the abdominal viscera, and may be complicated by hernia of the intestine. The mucous membrane, which covers the mass, is in appearance not unlike a recent non-strangulated *prolapsus ani*. The orifices of the ureters may be found opening at some point on the lower portion of the protrusion, and are often considerably dilated. In all cases of exstrophy the genital apparatus is rudimentary. The penis is wholly or in great part wanting. The urethra may be seen as a simple groove, into which the seminal ducts enter. The scrotum, at times entirely absent, may in other cases be present, lodging the testicles, or it may be bifid, with one organ in each sac, or entirely missing, the testes remaining in the abdomen, or lodged in the groin or thigh.

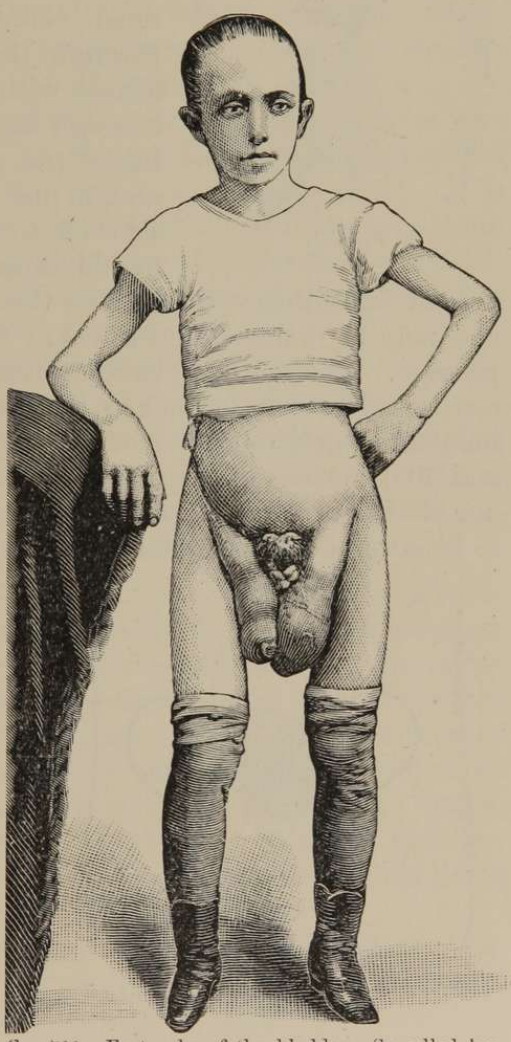

Fig. 700.—Exstrophy of the bladder. So-called hermaphrodite.

The degree of *exstrophy* varies in proportion to the extent of the malformation. In the more favorable cases the pubic bones are almost united at the symphysis, and the protrusion consequently small.

In females the genital organs are also rudimentary. The clitoris, nymphæ, vagina, and uterus may be absent or displaced, and only partially developed. The general appearances of the tumor are the same in both sexes.

In males the condition of bifid scrotum and absence of the penis resembles somewhat the normal genitals of the female, the so-called hermaphrodite.

Exstrophy of the bladder, even in a mild form, is a source of great annoyance.

The *treatment* is chiefly palliative, and consists in the application of

an apparatus, with or without operative interference, to drain the urine and prevent excoriations. A suitable instrument is shown in Fig. 701. The operative treatment consists in an effort to cover in the protruding mass by integument borrowed from the immediate vicinity of the tumor.

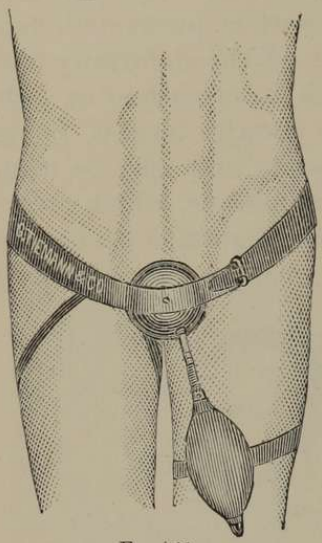

Fig. 701.

The chief difficulty lies in protecting the flaps from suppuration excited by contact with septic urine. Silkworm-gut or silver-wire sutures are always to be used. To protect the flaps from the urine, Levis's procedure more nearly meets the indications. It consists of establishing a false urethra from that portion of the undeveloped bladder near the orifice of the ureters through the perinæum. A large, long needle armed with good-sized thread or wire is passed through the wall of the bladder just at the opening of the ureters and brought out in the perinæum just in front of the anus. The wire is allowed to remain as a seton, and through the fistula thus established, and enlarged by interrupted dilatation with bougies, the urine flows. If necessary, the testicles may be removed and the skin of the scrotum used to line this false passage. When this is accomplished, the second stage of the operation consists of covering the exstrophy with integument turned over from the immediate neighborhood of the deformity. Wood's method (Figs. 702 and 703) consists of three flaps, two lateral and one central. The central one should be square, its width at least one third greater than the defect to be covered ; its length sufficient to cover the bladder space completely

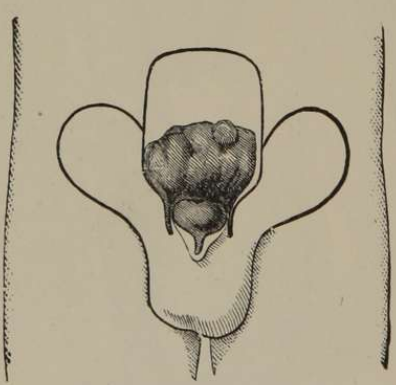

Fig. 702.—Wood's method. Outline of flaps.

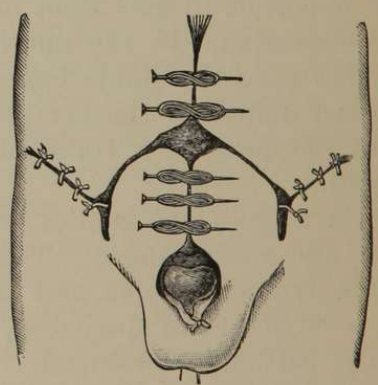

Fig. 703.—The same after the sutures have been applied.

when turned down, also allowing one third for contraction. The flaps should consist of skin and superficial fascia. The two lateral pear-shaped flaps are now dissected up from the groin with breadth equal to the length of the first flap and length equal to the width of the defect to be covered. These flaps when dissected up are reflected across the reversed abdominal flap, meeting in the median line and united with

silver-wire or silkworm-gut sutures. These sutures should without complete perforation include a portion of the thickness of the abdominal flap, so as to keep the surfaces in contact. The deficiencies left after the removal of the flaps should be drawn as nearly together by sutures as possible. Any space which can not be covered is allowed to granulate or is repaired later by grafting. A perfect functional result is not to be hoped for in view of the absent sphincter. Some form of apparatus to control the urine will always have to be worn.

Hernia Vesicæ, or Cystocele.

Hernia of the bladder is of very rare occurrence. In the male it usually occurs through the inguinal canal, and is almost always associated with some form of intestinal or omental hernia. It rarely descends into the scrotum. In the female it usually takes the form of a cystocele into the vagina. It occurs most often in the aged and in those who have atonic and dilated bladders. The bladder becomes top-heavy and flabby, and readily prolapses into the patulous inguinal canal. It is important that a correct diagnosis be made, as the condition may simulate hydrocele of the cord, and thus, under error of diagnosis, be incised. The practical point in diagnosis is the diminished size of the tumor after micturition or withdrawal of the urine by catheter.

The treatment consists in restoring the organ to the normal position, as the hernia which it complicates is cured by radical operation.

The prolapse of this organ in females (cystocele) will be considered in the chapter on gynæcology.

Wounds of the Bladder.—Rupture.

Wounds of the bladder may be caused by penetration from without, as from a stab or gunshot wound, by rupture from overdistention, by violent concussion over the lower abdominal region when the organ is even only partially distended, by instrumentation, and by direct injury from displaced fragments of the pelvic bones. Penetrating wounds of the bladder are rare, not only on account of the protection afforded by the pelvis, but because its usual condition is that of only partial distention. This is especially true of wounds received in military practice, since the majority of soldiers, under the excitement which attends going into action, voluntarily empty this organ.

A distinction should be made between bladder wounds which communicate with the peritoneal cavity and those which penetrate the organ in that part of its surface not covered with peritonæum.

Diagnosis.—The diagnosis of a penetrating wound of the bladder will depend upon the escape of urine through the external opening, should the situation of the external wound be favorable for the discharge of urine, the presence of blood or foreign matter of any kind in the urine drawn by catheter, severe pain over the region of the bladder, constant desire with inability to pass water, and usually profound shock. If these points are considered, together with the receipt of an

injury, a penetrating wound, or the coexistence of a disease of the bladder wall, or an obstruction to the outflow of urine from any cause, the diagnosis should be readily made. It must be remembered that the symptoms differ considerably according to the location of the wound. If the posterior or peritoneal surface is perforated, the urine will escape into the peritoneal cavity, producing in most cases rapidly supervening symptoms of peritonitis, accompanied with extreme prostration ("abdominal shock"). This, however, does not occur in all cases, and in rare instances, when the urine is aseptic, it may remain in the peritoneal cavity for many hours without producing infection or any marked symptoms of peritoneal inflammation. When the perforation is through that part of the bladder wall not covered by peritonæum, there occurs usually rapid and widespread infiltration of the loose connective tissue of this region, followed by symptoms of œdema and, in the presence of septic urine, rapid rise of temperature, pain, and rigors, and the usual phenomena of septic infection and pus formation. Wounds of the bladder are rare in children, and naturally much more frequent in men than in women, the proportion being ten to one.

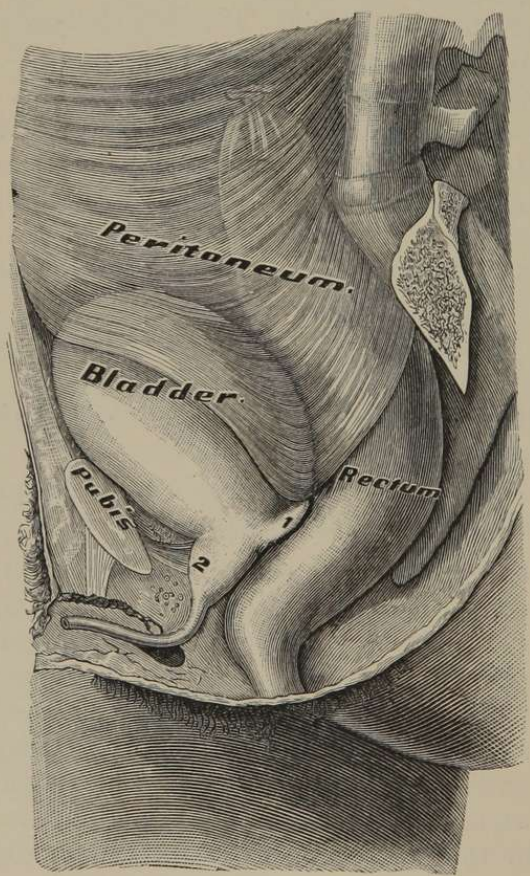

Fig. 704.—The relations of the peritonæum to the bladder when distended. (After Tarnier.) 1, The situation of the trigonum vesicæ. 2, Prostatic urethra.

The diagnosis may be confirmed by introducing a catheter through the urethra, which usually gives escape to a small quantity of bloody urine. If an aseptic solution, such as boiled water of proper temperature (120° F.), or boric-acid solution, be carefully measured and injected, it will be found, if there is a perforation, that the quantity returned through the catheter will be considerably less than that injected, as a certain portion will escape through the rupture, and will not re-enter the bladder. If there be no rupture, the distention of the bladder by the injected liquid will be evident by percussion above the symphysis pubis.

In *rupture* of the bladder from overdistention where no injury has been received, the history of the case is one of long retention and overdistention, great suffering, constant desire to urinate, and finally a feeling as if something had given way, followed by partial or complete temporary relief from the pressure within the bladder.

The *prognosis* in rupture of the bladder is always grave, the gravity depending in good part upon the location and extent of the opening. If the urine escapes into the peritoneal cavity, death is inevitable, unless operation is performed in the first few hours of the extravasation, and even then, if the urine be markedly septic, the ratio of mortality is high. In extraperitoneal rupture the prognosis is more favorable.

Treatment.—The indications are to establish the diagnosis at the earliest possible moment after the receipt of the injury by the use of the methods just advised, and when these fail and the character of the injury is not clear, an exploratory operation is advisable. If the diagnosis be clear, operation is imperative. In intraperitoneal rupture, nothing is left but to perform laparotomy in the median line between the umbilicus and the symphysis pubis, taking care not to use the Trendelenburg posture or to elevate the pelvis, for fear that extravasated urine may be brought in contact with peritoneal surfaces not yet involved in the infection. The escaped urine should be removed by careful sponging, and the pelvic basin thoroughly flushed with hot saline solution, boiled water or boric-acid solution at 120°, and this carefully dried out with gauze mops. Any loops of intestine in contact with the urine should be brought out through the wound, protected with hot towels, and carefully cleansed with mops of sterile gauze. The abdominal incision should be free, in order to expose the rent in the bladder, which should then be sutured with fine sterilized silk, applied after the manner of the Lembert suture in intestinal surgery. If the edges of the wound are ragged, they should be clipped with scissors and the sutures inserted not more than one eighth of an inch apart, and should begin and end one fourth of an inch beyond each end of the rent, in order to insure perfect closure. It is safer in practically all cases after a bladder wound is closed to insert a Mikulicz gauze packing or drain, which consists in introducing a piece of sterile gauze, the size of an ordinary handkerchief, the center of which is pushed down into the deepest part of the pelvis behind the bladder in the form of a sac or stocking. Into this pocket a good-sized wick of iodoformized gauze is carried and brought out at the lower angle of the abdominal incision. At this stage of the operation it is advisable to perform a perineal cystotomy, through which a drainage tube should be inserted and secured in place to establish through drainage of the bladder. If the urine is in this way discharged, the bladder wall will unite readily. The abdominal wound should be closed from above downward, leaving a small portion of the lower angle open for the extraction of the Mikulicz drain. Perineal drainage should be continued for about ten days, and requires constant attention. Should the bladder even partially fill, leakage would probably occur with fatal peritonitis.

In those rare cases where the perforation is near the trigonum and intraperitoneal it is advised by some operators to distend the rectum with a Barnes dilator, in order to lift the bladder and bring the wound into view.

In extraperitoneal perforations the indications are to secure imme-

diate free drainage, which may be done through the perinæum at the most convenient point, and this, when necessary, should be re-enforced by suprapubic incision and counter-drainage from the prevesical space. Wounds of this variety close spontaneously. It is better to rely upon the Mikulicz drain than to stitch the edges of an intraperitoneal rent of the bladder to the abdominal wound.

The first successful operation for gunshot wound of the bladder was performed by Prof. Amos C. Walker, of Fort Worth, Texas, March 3, 1890. Ten hours after the injury from a 38-caliber pistol ball the abdomen was opened. The pelvis was filled with blood clot and urine. The bladder was perforated near the summit, it having been distended with urine at the time of the shooting and thus lifted above the symphysis pubis. The ragged aperture in the bladder was held open by tenacula and the edges pared smooth. Silk sutures (Lembert) closed the wound. After careful peritoneal toilet, the abdominal incision was closed without drainage. Six hours after operation the catheter was introduced and some bloody urine removed. This was repeated in six hours, and after that period the patient passed his water voluntarily. The recovery was perfect. The only criticism of this brilliant pioneer work is that for the assurance of safety the catheter should have been used every three or four hours for as many days.

Cystitis.

Cystitis, an infectious inflammation of the urinary bladder, is of frequent occurrence. It may be due to direct infection from septic inflammation of the urethra, as frequently occurs in gonorrhœa and after traumatism of this canal by the use of sounds, or by the downward extension of a pyelonephritis. It is present in practically all cases of tumor or persistent urethral obstruction, paralysis of the bladder, stone, etc. It may be superficial, involving only a portion of the mucous membrane, or at times the entire epithelial lining. Most frequently, however, the lesion is limited to the most dependent portion of the organ, the *trigonum*, the internal ureteral orifices and prostate, which is properly considered a part of the urinary bladder. It may be interstitial, involving the muscular coat, and, in very aggravated forms, it may invade the serous coat, producing pericystitis and peritonitis. According to the intensity and duration of the inflammation, cystitis should be considered as *acute* and *chronic*. Acute cystitis is most frequently caused by the extension of an infectious urethritis into this organ or by using an unclean catheter. Vaginitis and severe metritis may produce cystitis by direct extension of the infectious process. It may be caused in rare instances by sudden and unguarded exposure to cold and wet. Certain drugs, as cantharides, may produce it, and again it appears in connection with certain exanthematous fevers. In rare instances, a blow upon the abdomen immediately above the pubes or an injury in the perineal or rectal region will cause cystitis. Chronic inflammation is present as a rule in all cases of neoplasm of the blad-

der, vesical calculus, enlarged prostate, stricture or other obstruction, and is sometimes due to the irritation of concentrated urine. In tropical countries chronic cystitis is caused quite frequently by the presence of a parasite (*Bilharzia hæmatobia*), one instance of which disease is elsewhere given.

Acute cystitis is usually temporary and disappears under proper treatment, leaving no persistent lesion of the bladder. The most common pathological change is an injection of the blood vessels of the trigonum. This congestion may at times be so severe that rupture of the capillaries takes place, with hæmorrhage into the bladder. The mucous membrane is swollen and œdematous, and the superficial epithelial cells become loosened and detached. In very severe cases extensive ulceration, and even sloughing of the mucous membrane, may be present.

In the *chronic* form of cystitis the extreme pain which accompanies acute cystitis is usually absent. The urine becomes thick and alkaline in reaction, and flakes of mucus containing bacteria, epithelial cells, pus, and other *débris* are present. The bacteria convert the urea into carbonate of ammonia, producing the well-known ammoniacal decomposition of the urine, which intensifies the inflammation. The bladder wall itself becomes thickened. The normal folds or *rugæ* are hypertrophied. The thickening may be caused by an increase of the muscular elements. There is usually, however, atrophy of these elements with a hypertrophy of the connective tissues, in which the cavity of the bladder is lessened, *concentric hypertrophy*. When the cavity is increased and the walls thickened, it is called *eccentric hypertrophy*.

Causes.—Directly or indirectly, gonorrhœa may stand as the chief cause. Stricture of the urethra, especially in the membranous portion, enlarged prostate (*in which case it is more often the result of catheterization than of the actual obstruction*), calculus, vesical tumors, paralysis with decomposition of urine, gout, and rheumatism are other causes. An attack is precipitated by exposure to cold and wet, and pyelitis and pyelonephritis are nearly always accompanied by inflammation of the bladder.

Symptoms.—The most prominent symptom of acute cystitis is a constant desire to micturate with the passage of only a few drops of urine, accompanied by pain, burning, and straining (tenesmus). The pain may extend to the perinæum or above the pubes, radiate down the inner side of the thighs, or to the sacral region. Again, there may be pain at the head of the penis. The pain is increased at the close of the attempt to urinate, and reaches its intensity as the last few drops are forced out. The diagnosis is clear when frequent micturition, pain, and pus in the urine are present. If there be rupture in the capillaries due to intense congestion, blood will be present in the urine, although it is only in severe cases that this is found, and its presence is usually discovered only by the microscope. The urine, as a rule, is neutral or alkaline in reaction, with a distinctly foul odor, and always contains albumin due to pus.

Microscopical examination of the urine is of great value in making the diagnosis and should always be employed. There may be fever or not. In mild cases there are no symptoms other than those referable to the bladder. In severe cases constitutional symptoms, such as chills and high temperature, may be present.

In chronic cystitis all of the symptoms described in the acute form are lessened; pain may be slight or entirely absent, but the urine is always thick and fœtid.

Treatment.—In acute cystitis it is of first importance to secure perfect rest in bed in that position which gives the least sense of discomfort. As the inflammation is usually confined to the most dependent portion of the organ, the trigonum and the prostatic urethra, it is advisable to elevate the foot of the bed and place a pillow under the patient's hips. By these means pressure upon the irritated viscus by the intestines, which usually rest upon it, is relieved. Morphine for the alleviation of pain and the enforcement of rest are necessary. Hot or cold applications, as found most agreeable to the patient, should be employed. The use of morphine *per os* or hypodermically, in my opinion, is preferable to suppositories, which must, of necessity, produce a certain amount of irritation when they are inserted so near a diseased organ. The rectum should be carefully emptied by a warm enema or by the administration of calomel triturates. The free administration of water—preferably alkaline waters, such as Vichy—and citrate of potassium in twenty-grain doses are advised. In both the acute and chronic forms of the disease it is essential to eliminate all alcoholic drinks.

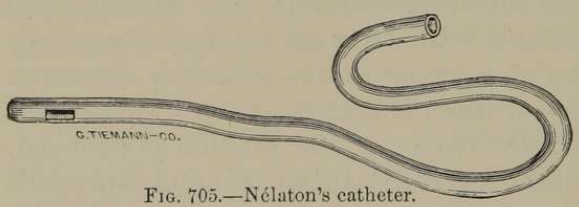

Fig. 705.—Nélaton's catheter.

In chronic cystitis, treatment should be directed first to the cause of the inflammation. When resulting from the presence of a stone or tumor of the bladder or prostate, from retention by stricture or any other obstruction, causing ammoniacal decomposition and a general cystitis, removal of the stone or tumor and of the obstruction is imperative. Cystitis resulting from pyelitis can not be cured unless the pyelitis is first relieved. In certain forms of retention resulting from paralysis or atony of the muscular walls of the bladder, the retention may be relieved by



Fig. 706.—Velvet-eyed gum catheters, curved and straight.

the employment of the soft catheter, and the condition of the organ temporarily relieved by irrigation. The soft-rubber catheter of Nélaton (Fig. 705) produces less irritation than the harder instruments, and should be preferred. An instrument of good size, Nos. 12 to 14, United

States scale, with a perfectly smooth point should be selected. It should be perfectly sterile, warm, lubricated with sterile sweet oil or glycerin, and introduced with the patient resting on the back. An effort should be made to carry the eye of the instrument just deep enough to

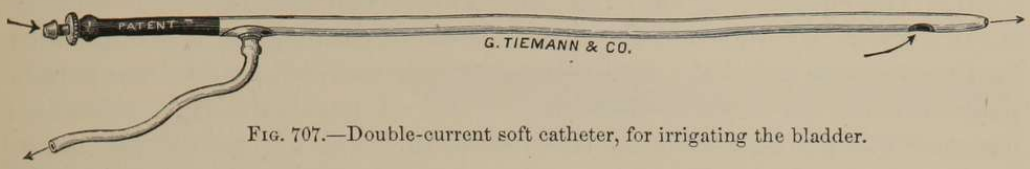

Fig. 707.—Double-current soft catheter, for irrigating the bladder.

project well into the bladder without touching the posterior wall. The double-current soft catheter (Fig. 707) is a useful instrument for bladder irrigation, but is not necessary for successful treatment. Its objections are that it is costly and more difficult to keep thoroughly sterile than the simpler instrument. The advantage it possesses is that the inflow and outflow is constant. The ordinary simple catheter will, however, answer every purpose. It is important to prevent the admission of air into the bladder by filling the catheter with the fluid to be injected when the eye of the instrument is passed to the cut-off muscle. If the bladder should be partially filled with urine at the time of introduction, the air which is in the instrument will be forced out immediately by the outflow of urine. For the purposes of irrigation, a warm solution of permanganate of potassium, 1 to 5,000 (three grains to the quart) is employed, and next in order a solution of boric acid, one drachm to the pint, and, when these are not convenient, clean water which has been boiled and allowed to cool down to a temperature of 100° to 105° F. may be used. Several pints of the irrigating fluid are placed in a fountain syringe, a small quantity is allowed to run through the nozzle to displace the air, the point of the nozzle is then introduced on the end of the catheter and the irrigating fluid allowed to run in slowly, and the bladder distended to the point of tolerance. It is then allowed to empty itself through the catheter, and this is repeated until the fluid which escapes is clear. These irrigations may be repeated once or twice weekly if necessary.

A simpler method of irrigation of the bladder which obviates the use of the catheter is as follows: The nozzle of the irrigator should be carried into the meatus and the anterior urethra flushed out in order to render it aseptic. Then by firmer pressure of the nozzle at the meatus, the urethra is gradually distended by hydrostatic pressure, and in the course of a minute or more the cut-off muscle gives way and the fluid runs readily into the bladder. If there is marked resistance due to spasm of the compressor urethræ, if the patient is advised to attempt to empty his bladder, this muscle immediately gives way and the water flows back into the bladder. As soon as it is sufficiently distended, the patient is allowed to evacuate the injected fluid and the operation is repeated until the fluid returns clear.

In cases that resist all conservative measures, incision with drainage, preferably by the suprapubic method (or through the perinæum, as in the median operation for stone) is imperative.

My clinical notes contain twenty cases of suprapubic cystotomy for chronic cystitis uncomplicated by tumor or stone. This condition existed in all the cases of stone and tumor, making twenty-nine additional, or a total of forty-nine cases operated upon in which chronic cystitis existed. The shortest period of drainage was seventeen days; the longest, eight weeks. In twelve of the twenty cases of drainage in uncomplicated cystitis a cure resulted; two others were improved, and in one permanent drainage was established on account of paralysis of the bladder; one case was not benefited by the operation.

Paralysis of the bladder may be partial or complete. It may be caused by violence inflicted directly to the organ or in its immediate neighborhood, by pathological changes in its muscular tissue, or by traumatic or idiopathic lesions of the cerebro-spinal axis; or it may occur under the influence of certain emotions in which no lesion is recognizable.

The prolonged overdistention of the organ which is common in prostatic hypertrophy will induce the same condition.

In the *treatment* of this affection the first indication is to prevent prolonged distention of the organ by catheterization, which should be repeated at least twice in twenty-four hours. If a catheter can not be introduced, suprapubic aspiration should be practiced. Cystitis may be avoided if the urine is carefully and regularly drawn off with careful antiseptic precautions. Attention should next be directed to the removal of the cause of the paralysis. If the paresis is permanent, suprapubic drainage is advisable.

Retention.—As just stated, paralysis of the muscular walls of the bladder is a cause of retention of urine. Lesions of the sensory nerves of this organ also induce retention, which is proportionate to the loss

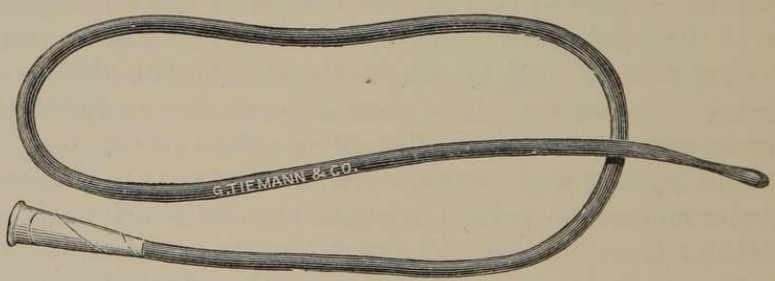

Fig. 708.—Filiform catheter.

of sensibility. The chief cause, however, is some form of obstruction at the neck of the bladder or in the urethra. As will be seen in treating of hypertrophy of the prostate, this is a frequent cause of retention. Organic stricture, spasm of the compressor urethræ (or "cut-off") muscle, and mechanical occlusion of the urethra, are also common causes of this affection.

Diagnosis.—Distention of the bladder may be determined by palpation, percussion, and exploration. In this condition it rises well above the level of the symphysis pubis, at times as high as the umbilicus, and causes tension of the recti muscles or protrusion of the abdomen. In one instance I drew off six quarts of urine. By direct pressure, the de-

sire on the part of the patient to urinate may usually be increased, and, if the abdominal walls are thin, the spherical character of the organ may be recognized.

In *treatment*, the evacuation of the contents is the immediate indication. The patient should be put to bed and given the benefit of a full dose of opium. This agent is useful in alleviating pain, in securing relaxation of the muscular elements of the urethra and prostate, and —by producing diaphoresis—in diverting fluids from the kidneys to the excretory apparatus of the skin. A soft-rubber (Nélaton) catheter should be preferred; but, if this can not be introduced, a firmer, olive-pointed instrument (Fig. 710) should be employed. The silk-woven and gummed catheter (Figs. 711 and 712) is also a useful instrument, and if, on account of its elasticity, it can not be introduced, the stylet of Prof. Keyes (Fig. 713) should be inserted into the catheter to give it the required stiffness. The metal catheter (Fig. 714), if properly constructed and carefully introduced, can be made

Fig. 709.—Black French catheter, blunt-pointed.

Fig. 710.—Black French catheter, olive-pointed.

Fig. 711.—Gummed silk-woven catheter.

Fig. 712.—Gummed silk-woven bougie.



Fig. 713.—Dr. Keyes's wire stylet.

to safely overcome any ordinary resistance. It should be of heavy silver, strong, perfectly smooth, and should have a curve corresponding to that of the normal urethra. In size it should correspond to No. 10, 12, or 14, U. S., and the larger sizes should be preferred.

The introduction of a metal catheter or sound through the normal urethra into the bladder is accomplished as follows: The patient is placed upon the back with the lower extremities parallel with the body. If about ʒj to ij of a 2-per-cent solution of cocaine hydrochlorate is introduced, the normal sensibility will be lost as far back as the compressor muscle. The urethra is then flushed with warm boric-acid or permanganate-of-potash solution. The catheter is placed in water at a temperature of about 105° to 110° F., and, when warmed through, is lubricated with sterilized sweet oil or glycerin. If the operator is right-handed, it is best to stand on the left side of and facing the patient. The penis is seized with the left hand and held steady while the end of the catheter is carried into

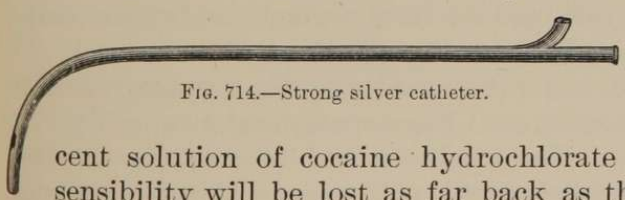

Fig. 714.—Strong silver catheter.

the meatus. At this stage of the procedure the shaft of the sound is parallel with Poupart's ligament, and, as soon as the first four inches have passed into the urethra, while it still descends, the handle is gradually brought toward the median line. The point is now engaged in the bulb, or at the anterior layer of the triangular ligament, and the shaft is about perpendicular to the plane of the abdomen. Without exercising any force to push the instrument in the direction of the bladder, the handle is slowly and steadily carried downward until the shaft is parallel with the anterior surface of the thighs. While this manœuvre is being effected, the point is tilted from the floor of the bulb into the membranous portion which offers the greatest resistance, not only because it is the narrowest part of the canal, but because the compressor-urethræ muscle must be overcome. All the time that the instrument is being pushed toward the bladder the penis should be pulled over the catheter, for in this way the lining membrane is put upon the stretch and the introduction greatly facilitated. When the neck of the bladder is reached, the instrument will usually have penetrated a distance of eight or nine inches. It should be borne in mind that even a silver catheter is capable of doing damage to the urethra if improper force is employed in its introduction. There is usually no resistance except by the compressor muscle, and this is only spasmodic. If the point of the instrument is kept well against this obstruction by depressing the handle between the thighs, it will slip by with the first relaxation of this muscle. The methods of introducing an instrument into the bladder in abnormal conditions of the urethra and prostate will be given later.

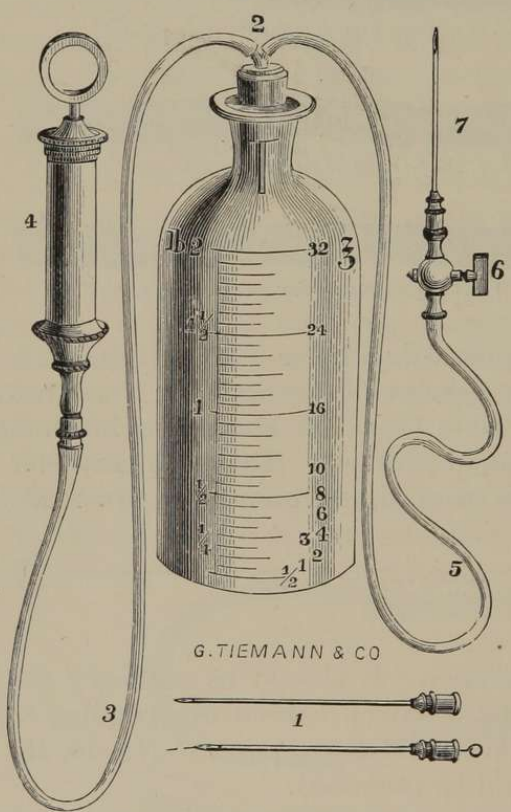

Fig. 715.—Tiemann & Co.'s aspirator.

If it is found impossible to reach the bladder by the urethra, the urine should be evacuated by the aspirator. The apparatus shown in Fig. 715 will give general satisfaction. The needle should be carefully cleansed by boiling. The medium or smallest needle will suffice. If its introduction is preceded by a small hypodermic syringe needle, and ♏ x of 4-per-cent cocaine are injected, the operation will be painless. The pubes being shaved and disinfected, and everything in readiness, the cock (*6*, Fig. 715) is closed ; the air is exhausted from the receiver (*2*) by working the pump (*4*). The patient should be placed in the sitting posture, and the needle introduced a half inch above the symphysis and pushed directly

backward a distance of two inches. The cock is now opened, and the urine flows into the bottle. If it becomes necessary to empty the receiver, the stopcock should be turned, to prevent the entrance of air into the bladder. When the aspirator is not convenient the small trocar and canula may be introduced. The danger of leakage at the point of puncture is insignificant.

When the character of the obstruction or disease is such that a permanent urinary fistula is necessary, suprapubic cystotomy is advised.

Incontinence of Urine.—Incontinence of urine occurs when the compressor urethræ is partially or completely paralyzed. It is also present in a proportion of cases of prolonged overdistention of the bladder (overflow), the pressure from behind overcoming the normal resistance of these muscles. Irritation of the bladder from any cause may produce tenesmus of this organ, and consequent inability to retain the urine. This is especially apt to occur in children during sleep, in the earlier hours of morning, when the bladder is full.

Women are more frequently affected with incontinence than men, which fact is explained not only in the better tone of the muscular system in males, but in the absence of the prostatic muscle in females, which, according to Henle, is of great aid in holding the urethra closed. The general relaxation of the pelvic muscles as a result of parturition may also account for the more frequent occurrence of incontinence of urine in women.

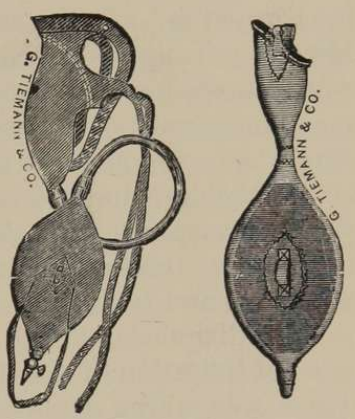

Fig. 716.—Female and male urinals, for incontinence.

The palliative treatment consists in applying a urinal for the reception of the water as it dribbles away (Fig. 716).

Curative measures should be directed to a removal of the cause of incontinence. These will be given with the various lesions of which it is a symptom. In the nocturnal incontinence of children the habit may be corrected by causing the patient to be awakened and the bladder emptied once or twice during the night.

Dr. H. Marion-Sims reported to the New York Obstetrical Society a number of distressing cases of incontinence of urine in adult females. These cases were cured by gradual and frequently repeated distention of the bladder. His method was to introduce, by means of a Davidson syringe through a catheter, cold or tepid water beginning with ʒ j, holding this in for some minutes and then allowing it to be evacuated. The next day an ounce and a half was injected, and this was continued until one pint or more was easily contained. In this manner tolerance was established and a cure effected.

Suppression of Urine.—Not infrequently after prolonged operations under ether or chloroform narcosis, and especially on patients the subject of nephritis, the function of the kidneys is partially or completely suspended. Suppression may also follow an injury of any part of the body and as a result of any strong emotion. It may occur in subjects

with no recognizable lesion of the kidneys, but, as said before, is especially liable to occur where these organs are diseased. The skin is usually hot and dry, the pulse rapid and full, there is great restlessness and anxiety, and the temperature is elevated several degrees above normal. The diagnosis may be confirmed by the introduction of the catheter, when the bladder will be found to be contracted and empty, or containing only a small quantity of urine. Suppression of urine is an extremely dangerous condition, and, if not relieved, rapidly induces uræmic coma and death. The best method of treatment is believed to be the intravenous injection of hot salt solution in the same manner as described in the article on transfusion. From one to two pints may be injected. In milder cases the urinary function may be restored by the hypodermic injection of morphine and of digitalis in the form of digitaline, re-enforced by warm drinks and external applications to promote diaphoresis.

Neoplasms of the Bladder.—The bladder may be the seat of *papilloma*, *myxoma*, *carcinoma*, *sarcoma*, and *myoma*. *Papillomata* or "villous growths" are the most frequent of the neoplasms of this organ. Microscopically, they are composed of a series of loops of a vascular network covered with epithelium of the same type as that of the mucous membrane, only of a more luxuriant growth. They may be multiple or single, as many as forty having been removed from a single bladder. As a rule they are located on the floor and lower portion of the posterior wall. I have met with them springing from a single stem like that of a mushroom, terminating in a vascular tuft from two to four inches in diameter, and in one instance filling the summit of the bladder.

The diagnosis of this new formation depends chiefly upon (1) symptoms of irritation of the bladder (frequent micturition); (2) hæmorrhage due to a breaking down of particles of the growth; (3) the recognition of fragments under the microscope. The urine of such patients undergoing ammoniacal decomposition is usually alkaline in reaction, and produces, as a rule, severe cystitis.

Myxoma is a very rare form of neoplasm of this organ. Microscopically it has a thicker framework than papilloma, and the cells are rounded instead of elongated. This growth appears in young people, while papilloma is very rarely seen in persons under thirty years of age.

Myoma is also exceedingly rare. It is composed of newly formed muscular fibers mixed with fibrillated connective tissue which form slight elevations in the walls of this organ or project slightly into the lumen (sessile tumor).

Cystic tumors of the bladder are also rarely met with, and are generally of the nature of hydatids and dermoids.

Sarcoma of the bladder may occur at any time of life. It has been seen in an infant, and has been met with in several cases under twenty, between twenty and fifty, and up to as late as seventy years of age.

Carcinoma usually occurs as a general infiltration of the walls of the bladder, there being a general thickening, with here and there slight elevations. It generally develops slowly, and metastasis does not occur so rapidly here on account of the sparse distribution of lymphatic channels

in the walls of this organ. It is, with rare exceptions, a disease of advanced life.

In arriving at a positive diagnosis of tumor of the bladder and of the character of the neoplasm, in addition to the symptoms just detailed and to the microscopical examination of the abnormal matter in the urine, the employment of the cystoscope will be found of great value. In using this instrument, the bladder should be washed out thoroughly with a quantity of warm, clear, saline solution, after which the instrument is introduced and the examination made. If for any reason a diagnosis can not be determined by the cystoscope or by palpation or by the introduction of a sound through the urethra, exploration of this organ may be safely made by suprapubic incision. When a tumor is present the incision should be free and the edges of the abdominal and bladder wounds widely retracted. A strong light and reflector will be found of great value in this procedure. The pedicle of a papilloma may be readily caught at its base with suitable forceps and twisted off. The blades should grasp the pedicle very close to the bladder wall, and it is better to bring away a tuft of mucous membrane with the forceps. A middle-sized Spencer Wells fenestrated ovarian-sac forceps is a convenient instrument for this purpose, and may be guided by the finger to the point of attachment of the neoplasm. For more resisting tumors, such as the tough masses which project backward and upward from the prostate, I have devised a double cup-shaped instrument which has proved very satisfactory in a number of cases. After the tumor is removed hæmorrhage should be arrested and the bleeding point thoroughly touched with the Paquelin cautery.

In cases of carcinoma which involve a large part of the bladder wall a cure can not be expected by any other operation than a complete removal of this organ, or of a considerable portion of it. This has been done several times and the patients have recovered, but the condition which exists after such an operation is so deplorable that it should always be made clear to the patient before it is undertaken.

The Urine—Quantity.—The average quantity of urine excreted by the kidneys of the normal adult is about fifty-six ounces in twenty-four hours. This quantity varies with the amount of fluids ingested, the activity of the sweat glands, and the elimination of liquids by the alimentary canal.

It is of an amber- or straw-color, which is due to the presence of indican, urobiline, etc. The greater the quantity, as a rule, the lighter the color. It is dark in proportion to the intensity of the destructive changes in the tissues, as in prolonged exertion, or during the progress of fevers. Carbolic acid and bile turn the urine brown or greenish-black, and blood (hæmaturia) gives it its characteristic tinge. The normal odor of urine is peculiar to itself. An artificial aroma is easily substituted by the ingestion of certain foods and drinks, as gaultheria, turpentine, asparagus, etc.

Reaction.—Healthy, fresh urine is acid in reaction, changing litmus from blue to the faintest red or rose color. Acid urine will at times be-

come alkaline within a few minutes after its discharge. The ingestion of alkaline substances in vegetable foods gives a neutral or alkaline character to the urine passed within a short time after eating. The same is true of the alkaline salts, potash, soda, etc. Urine, alkaline in reaction as it leaves the urethra—the alkalinity not due to food or medication—is an indication of disease of the bladder.

Specific Gravity.—The specific gravity varies in the normal condition from 1·005 to 1·030. Usually the increase in quantity is accompanied by a smaller proportion of solids and a consequent lower specific gravity. This is not the case in diabetes, where the quantity is abnormally large, while the urinometer may register as high as 1030-1040.

It becomes a matter of great importance to determine through the chemical and microscopical analysis of the urine the condition of the organs which excrete this fluid and those through which it passes in its way to the exterior. Certain conditions of the kidneys, as in Bright's disease, render the prognosis of a surgical procedure more grave, and may justify a modification of the treatment.

Urea.—Urea is the result of destructive tissue metamorphosis. It is increased by the ingestion of nitrogenized food and by excessive muscular exercise. The average daily quantity excreted by the urine is about four hundred and fifty grains, which, with the estimate of the daily urine at fifty-six ounces, is about gr. j of urea to ʒ j of the urine.

Any marked diminution of this proportion indicates failure in the elimination of the products of waste in the tissues and the danger of *uræmia.* The simplest quantitative test, and one sufficiently exact for practical purposes, is the following : To make it, it is required to have a Doremus ureaometer, which resembles a medium-sized test tube, whose open end is dilated and also bent at an acute angle with the rest of the tube, about an inch and a half from the dilated and open end. The tube is filled with a twenty-per-cent solution of caustic soda and then one cubic centimetre of bromine is introduced through a pipette. A thorough admixture is secured by agitation. One cubic centimetre of urine is now carried through a pipette to the bottom of the dilated end of the ureaometer, well beyond the angle, and slowly liberated, so that the gas which is generated will rise in the long and closed end of the cylinder. The percentage of urea (which is represented by the volume of nitrogen evolved) is read off from the graduated scale fixed on the tube.

Albumin.—Albumin in the urine of one in health is exceedingly rare. It is said not to indicate disease if present in small quantity soon after the excessive ingestion of albuminous foods.

In isolated cases its presence is ephemeral. In a case presented before the New York Pathological Society, by Prof. Janeway, albuminuria could be produced at will by increased mental activity. In a condition of repose no trace was discoverable.

Albumin is always present in urine which contains pus, independent of any affection of the kidneys.

It may be recognized by the tests with heat and nitric acid. To employ the heat test, fill a tube half full of urine, to which, if alkaline or

faintly acid in reaction, one or two drops of acetic acid should be added. Hold the tube so that the flame of the spirit lamp will heat the upper inch of urine. If, just before the boiling point is reached, a cloudy white film pervades the heated mass, the presence of albumin is demonstrated.

The nitric-acid test is not so reliable as the preceding. When albumin is thought to be demonstrated by its use, the heat test should be applied to confirm it. Into a small test tube drop from ♏ x–xx of pure nitric acid. Hold the tube slanting and allow the urine from a glass pipette to run gently down the side until it floats upon the acid. Albumin is indicated by a white or cloudy ring formed in the layer of urine immediately in contact with the acid.

Sugar.—The urine of *diabetes mellitus* has a high specific gravity, is passed in great quantity, and has a characteristic sweet odor. This form of sugar may be recognized by *Trommer's test*, in which an oxide of copper is produced by boiling diabetic urine (grape sugar) with a solution of potash and copper. Fill a test tube for one inch with the suspected urine, and add one or two drops of a solution of sulphate of copper—just enough to give the whole a pale-blue tint. Add the potash solution in quantity equal to one half the urine. When sugar is present, a pale-blue hydrated oxide of copper will be thrown down and immediately redissolved. If the mixture is now slowly heated to near the boiling point, a reddish-brown suboxide of copper will be precipitated. Objections to the copper tests are lack of stability of the solutions and the fact that excessive uric acid and creatinin occasionally produce the sugar reaction. The most satisfactory sugar test is Nylander's. The formula for the solution is: Rochelle salts, 4 parts; caustic soda, 10 parts; water, 100 parts. Heat to the boiling point, add bismuth subnitrate to saturation (about two parts), and filter. To eight parts of urine in a test tube add one part of the solution, and heat until a white cloudy precipitate is produced, which, if sugar be present, turns an intense black on standing a few minutes.

When a quantitative analysis is desired, the fermentation test will be found simple and sufficiently accurate for practical use. Fill a wide-mouthed bottle with the urine, and register the specific gravity at the time. Place a small piece of yeast in the urine, and set it aside in a warm place for from twelve to eighteen hours, until fermentation has occurred, and again take the specific gravity. The difference in degrees of the urinometer, as registered before and after fermentation, will represent the number of grains of sugar in the ounce of urine.

Pus- and Blood-Corpuscles—Epithelia.—Pus cells in the urine may come from an inflammation in any portion of the urinary tract, from the kidney to the meatus, or from the communication of a sinus or abscess with the urinary apparatus. Urine containing pus may be acid, alkaline, or neutral in reaction. In acid urine the corpuscles are prominent and easily recognized; when the reaction is alkaline, they are usually destroyed, and appear as ropy or gelatinous strings, more resembling mucus than pus. If the urine is examined immediately after being

passed, a few corpuscles may be recognized. When allowed to stand for some minutes the pus cells collect in the bottom of the vessel. Examined with the microscope, they are seen to be spherical and faintly granular. On account of the absorption of water they are swollen and less distinct than pus cells from a recent abscess. The addition of acetic acid renders the nuclei more distinct. The source of pus found in the urine may frequently be determined from the symptoms present, together with the microscopical appearances of the urine. If with the pus-corpuscles flat, large epithelia are abundant, the inflammatory process is in all probability situated in the bladder, where these epithelia belong. In females a larger, flat epithelium from the vagina often finds its way into the urine. The cells from the vagina are more often disposed in drifts or groups than the bladder epithelia. Large spherical or polygonal cells may come from the kidney tubules or the male urethra. They are about twice the size of a pus-corpuscle. Whether they are derived from the kidney or the urethra may in great part be determined by the presence or absence of urethritis. Conical or ham-shaped cells may come from the pelvis of the kidney, prostate, and glandular apparatus of the urethra. They are usually not so abundant as the other varieties.

Hæmaturia.—Blood in the urine may come from traumatic or idiopathic hæmorrhage into the Malpighian tufts or kidney tubules; from the pelvis or ureters as a result of calculi or ulceration; from the bladder as a result of instrumentation, calculi, wounds, foreign bodies, neoplasms, ulceration, parasites, or the hæmorrhagic diathesis; from the prostate or accessory organs and from the urethra.

The administration of certain remedies may account for the appearance of blood in the urine. Hæmaturia occurs at times as a symptom of malarial fever, and, in women, as a form of vicarious menstruation.

Blood in the urine may be recognized by its characteristic coagula, by the red or reddish-brown color it imparts to this fluid, the presence of the corpuscles under the microscope, or the fibrinous casts of the tubules of the kidney or ureters. In rare instances the blood disks are entirely destroyed, and the coloring matter set free. This condition is apt to occur in ammoniacal urine.

When urine containing blood is boiled, a white or cloudy coagulum is formed, its density depending upon the quantity of blood present.

If bloody urine is allowed to stand without being agitated, the corpuscles settle to the bottom of the vessel, and may be recognized by their red or amber color. Under the microscope they may assume different shapes. In *acid* urine the disks retain their biconcave conformation for a long time. When the hæmorrhage is slight, they float isolated; if profuse, they may be caught in coagula or collect in rouleaux. If the reaction is feebly acid, or where the corpuscles are submitted for a considerable time to the action of the urine, they lose their biconcave shape, and become distended, swollen, and spherical. They may be recognized from pus-corpuscles by their smaller size, transparency, and in not con-

taining granular bodies. At times they retain their flat shape and appear with serrated edges.

Blood casts usually come from the kidney tubules, and are composed of fibrin in which the red disks are entangled in varying proportion. In some, large clusters or groups of blood-corpuscles are seen, with an occasional epithelial cell from the kidney or urinary passages. When the disks have been completely destroyed, as in the decomposition of the coloring matter in ammoniacal urine, and the organic elements of the blood are not recognizable with the microscope, the spectroscope may be relied upon to demonstrate the presence of the coloring matter.

In determining the source of blood in hæmaturia the following points should be considered: When the bleeding is urethral, the first discharge of urine is most deeply colored. A clot of blood preceding or accompanying the discharge of urine indicates urethral hæmorrhage. In males, if spermatozoa are entangled in the coagula, the suspicion of hæmorrhage from the *vasa deferentia*, *vesiculæ seminales*, or prostatic apparatus is entitled to consideration, although the fact must not be overlooked that these elements may mingle in the urethra with blood from any part of the urinary passages.

When the bleeding is from the pelvis of the kidney pain and other symptoms of stone or pyelitis will often precede the hæmaturia. Not infrequently, however, the hæmorrhage is, next to the presence of pus in the urine, the first indication of pyelitis.

In hæmorrhage from the bladder there are often symptoms of cystitis which will point directly to this organ as the source of the bleeding. In differentiating the source of blood from the kidneys, ureters, and the bladder, the method of Thompson and Van Buren may be resorted to with success. Introduce a soft catheter just within the neck of the bladder, draw off the contained urine, and wash out the organ with clean water. If, during the irrigation, the water which flows away contains blood, the hæmorrhage is from the bladder walls. If it flows away clear, then empty the bladder, place the finger over the end of the catheter, allow it to remain introduced, and wait until a small quantity of urine has accumulated. This is drawn off, and, if it is bloody, and if the clear water now thrown in comes out unstained, the inference is fair that the bleeding is from the ureters or beyond. The cystoscope should be employed in cases in which doubt may exist after the foregoing methods have been tried.

Hæmorrhage from the urethra is rare except from violence, the lodgment of calculi, or from ulceration.

Hæmaturia due to parasitic lodgment in the walls of the bladder is exceedingly rare in this country. In 1883 a young man of white parents —a native of Natal, Africa—came under my care on account of chronic hæmaturia. He was at this time twenty-six years of age, and had had bloody urine at intervals for thirteen years. His health was not seriously impaired. The urine was faintly acid; specific gravity 1·020, with only a trace of albumin, which was readily accounted for by the slight amount of blood. About the middle and toward the last stage of the act

of micturition a few strings of clotted blood were discharged. Placing these under the microscope, I discovered a number of bodies (Fig. 717) shaped much like a watermelon seed, except that the small end was more pointed. These were evidently the eggs of the parasite known as *Bilharzia hæmatobia*, the hæmaturia resulting from the rupture of capillaries caused by the presence of nests of these ova in the mucous membrane of the bladder. This disease is frequent in Africa and Asia, but almost unknown in North America. The body of the male parasite is about four lines in length, threadlike, and flattened anteriorly (Aitken); the female a little shorter and more delicate. They inhabit by preference the portal vein and the walls of the bladder. In treating my patient I saturated him with large doses of santonin for a week, and injected the bladder daily with alcohol, beginning with a 1-to-20 solution, and increasing it to the extreme degree of tolerance by the bladder. The patient improved in every respect, but the hæmaturia was not entirely arrested when he returned to Africa, in November, 1883, since which time I have not heard from him.

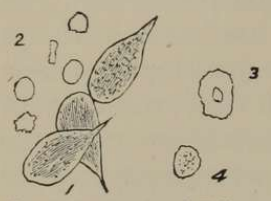

FIG. 717.—1, Ova of Bilharzia hæmatobia. 2, Crenated blood disks. 3, Epithelium. 4, Pus cell. (From the author's case.)

The parent distoma is killed by high febrile movement, and with its death the hæmaturia ceases.

The *treatment* of hæmaturia must be directed to the disease of which it is a symptom. The patient should be required to remain in the recumbent posture. Large doses of citrate of potash will prove beneficial in rendering the urine less irritating. Opium is advisable, not only on account of the relief from pain it affords, but because it secures complete quiet, which is essential, and prevents the too frequent evacuation of the bladder.

When the hæmorrhage is from this organ, and does not yield to the measures above given, the injection of cold or hot water, or of astringent solutions, may be employed. If villous growths are present, they should be removed by cystotomy.

Sterilization of Urine.—Sterilization of the urine is of great importance in the treatment of all surgical lesions of the urinary tract. It was brought prominently to the notice of the profession by the late Prof. Edward R. Palmer, of Louisville, Ky. It may be effected by the administration of the following formula:

℞ Oil of gaultheria ..... ʒ ij;
Salol ..... ʒ j.

Sig.: Take *per os* in capsules containing twenty drops, or the same quantity on sugar, three or four times a day.

Next in order is the administration of boric acid, five grains four or five times a day, which will produce a similar beneficial effect.

Eucalyptol has been recommended by Prof. J. Nevins Hyde, of Chicago, for this purpose. I have used in a large number of cases the gaultheria and salol preparation, and prefer it to other remedies. Foul-smelling and infectious urine becomes odorless and sterile

within twenty-four hours of the administration of eighty drops of this mixture.

Stone in the Bladder.

Urinary calculi may form in any portion of the kidney, in the pelvis or ureters, in the bladder or urethra. They are concretions of the various inorganic substances which are common to the urine. Organic particles, such as epithelia, mucus, and various inflammatory products, often enter into the formation of calculi. When an aggregation of the urinary salts occurs within the kidney tubules, the probabilities are that the stone so formed will remain imprisoned in this organ (renal calculus) until removed by ulceration or operation. Forming in the larger straight tubes of the pyramids, a urinary concretion may, while yet minute, escape into the calix and pelvis, and pass down the ureter into the bladder, or remain lodged in the pelvis or excretory duct.

It is, moreover, probable that the majority of calculi found in the bladder, or passed by the urethra, originate as concretions in the straight tubes, calices, or pelves of the kidneys, whence they drift outward to the bladder, and there by continued accretion become large enough to attract attention, even if the transit along the ureter was unnoticed. Undoubtedly a fair proportion of vesical calculi are formed in this organ proper, and the greater number of these may be grouped in the class of calculi which form around nuclei composed of foreign substances, or animal matter, such as epithelia, inflammatory products, etc. Conversely, it is admitted that animal matter may form the nucleus of a kidney or pelvic concretion, while a bladder calculus may also be formed by accretion of the purely inorganic elements of the urine.

A calculus is rarely of uniform composition, more frequently combining two or more inorganic as well as organic elements in its formation. In the nomenclature it is the practice to give to the stone the name of the preponderating element.

That most commonly observed is composed principally of *uric acid* and the urates. These stones are of fair consistency, yellowish or light-brown in color, not very smooth when single, yet not so rough as oxalate-of-lime concretions. They may attain a diameter of two or three inches. As a rule, they form in urine which is distinctly acid in reaction.

The *mulberry* or oxalate-of-lime calculus is next in order of frequency, and relatively more so in children than in adults. It may exist in all sizes, and varies greatly in color. The smaller concretions are light in color and fairly smooth; the larger are exceedingly rough, with jagged edges, and are dark brown in color, in rare instances white. Oxalate-of-lime calculi usually commence in the kidney, and pass as small particles to the bladder. The most severe forms of "renal colic" are due to the slow and painful passage of these rougher concretions along the ureters.

Phosphatic calculi come next in order of frequency, and are divisible into three classes: the *ammonio-magnesian* and *phosphate-of-lime* (*fusible*), *neutral phosphate of lime*, and *ammonio-magnesian* calculi.

Fusible calculi are more often met with than the other two forms of phosphatic concretions. They are gray or white in color, readily friable, and light. The hardness is proportionate to the lime phosphate present. They attain large size, and conform themselves to the shape of the bladder.

The *neutral phosphate-of-lime* calculus is rare. It may form in the kidney, though it originates chiefly in the bladder. All the phosphatic calculi are chiefly vesical in origin, being found with ammoniacal urine, which is present with chronic vesical catarrh. The *ammonio-magnesian* phosphatic concretion is equally rare, and differs very slightly in its chemical and physical characters from that just described.

Other and still rarer forms of urinary concretions are the following:

Cystin.—This variety is usually smooth, occasionally corrugated, yellow in color when fresh, inclining to a greenish hue when long removed. They break readily, do not show a marked concentric arrangement, and are somewhat greasy to the feel.

Xanthic or uric-oxide calculi have only been reported in two or three instances. They are of concentric formation, smooth and greasy to the feel, and vary in color from gray to brown.

Carbonate-of-lime calculi are usually multiple, and are light gray in color and chalky in consistence.

Organic calculi, consisting of epithelia, blood, etc., are not infrequent as nuclei for other varieties, but exceedingly rare as independent forms.

Stone in the bladder is a misfortune that may befall every age and condition of human life, from the fœtus *in utero* to the old and decrepit. The period of greatest exemption is from twenty to fifty years of age. It is comparatively frequent in children, and here must be chiefly of renal origin and due to the excess of inorganic elements in the urine, since obstruction and inflammatory diseases of the urinary tract rarely exist at this age. After fifty, when prostatic, cystic, and urethral obstruction are more frequently met with, the formation of calculi, vesical in origin, is more common. As to sex, stone is more frequent in males. It was formerly argued that there was no difference in the frequency of stone in the sexes, but that the short and dilatable urethra of the female allowed a ready escape to the concretion before it became sufficiently large to produce any organic disturbance. When, regardless of the statistical evidence which shows that the number of deaths in males from urinary calculus is ten times greater than in females, we consider that one of the most frequent causes of stone is the gouty diathesis, and that gout is more frequent in men; and, again, that prostatic and urethral obstruction is peculiar to this sex—it must be conceded that the conditions for the formation of calculi are more frequently present in males.

In the *ætiology* of stone in the bladder two great factors are recognized: The one includes all conditions of the economy which favor precipitation of the inorganic elements of the urine; the second all obstructive and inflammatory lesions which produce decomposition of the urine in the bladder, the detachment of epithelia, and the accumulation of

other organic elements which serve as nuclei around which the salts of the urine are congregated.

In the first category are hereditary tendencies, such as gout and rheumatism. Certain conditions of malnutrition undoubtedly lead to a precipitation of the urinary salts, for children poorly fed and cared for are much more apt to suffer from calculus than those who are well fed and comfortably clothed and sheltered.

It can scarcely be doubted that residence exercises a causative influence upon the formation of calculus. In the United States, northern Alabama, Tennessee, and Kentucky afford a large number of this class of cases, while in New York and the New England States stone in the bladder is exceedingly rare.

In the group of local causes may be classed all cystic diseases in which the products of inflammation collect in the bladder and form nuclei, around which concretions occur; prostatic enlargement inducing retention, cystitis, and decomposition of urine; stricture, and all obstructive and inflammatory lesions of the urethra which may involve or affect the integrity of the bladder; the presence of any foreign matter in the bladder, or paralysis of the bladder from any cause.

The Symptoms and Diagnosis.—It may be stated at once that, however much has been and may be said of the value of the various symptoms of stone, the diagnosis rests upon one simple expedient, the introduction of a metallic instrument into the bladder, and in contact with the stone. For this purpose the ordinary steel sound is usually sufficient. The bladder should be allowed to contain about half a pint of fluid, and when the instrument is introduced it should be manipulated so that the convexity of the curve will glide over the floor of the bladder back and forth from the neck to the posterior wall of the organ, at the same time depressing the bladder toward the rectum. By this manœuvre the stone will be induced to gravitate to the deeper portions in contact with the instrument, or so close to it that a sharp, quick turn to right or left will bring the calculus and metal into appreciable contact. In certain cases of prostatic hypertrophy the calculus may remain concealed immediately behind the enlarged organ, and in such a position that the sound can not be brought in contact with it. Under such conditions Thompson's searcher (Fig. 718)



Fig. 718.—Thompson's searcher.

will be found useful. The objection to this instrument is the difficulty of its introduction from the abrupt nature of the curve near the tip. When once introduced its value is readily appreciated. Turning its point downward and moving as if to withdraw it, there is no portion of the floor that it will not thoroughly search.

When a stone can not be appreciated with a full or half-filled bladder it may be felt if this organ is completely emptied. Not only is the calculus driven toward the neck of the bladder when it is emptied of urine,

but the hardness and weight are more readily appreciated, since it is held in the grasp of the organ, and can not slip away when the sound touches it. In some forms of vesical calculus the stone becomes partially or completely *encysted* in some portion of the bladder wall. The calculus may drop into an abnormal pouch in the bladder; it may sink by a process of ulceration into the walls, and be partially or completely surrounded by a newly formed inflammatory tissue, or it may have been lodged in the ureter near its termination.

Again, a stone may be caught in the upper portion of the bladder without being sacculated. In sounding for stone in adults narcosis is rarely required, especially where there are no symptoms of severe cystitis and tenesmus. In children an anæsthetic should always be employed. When the calculus can not be felt after careful search it is at times a successful expedient to introduce the finger into the rectum and make upward pressure upon the base of the bladder, and firm pressure downward upon the abdomen just above the symphysis pubis.

Vesical calculus may be suspected in a patient who has had renal colic, or has passed by the urethra particles of gravel, and afterward develops a cystitis. Not infrequently, however, a concretion goes from the kidney into the bladder without attracting the attention of the patient. If it lodges here and increases slowly in size, it may remain for months or years without giving any symptoms of cystitis, or marked annoyance. Usually, however, when a stone is present, and is so light and smooth that it does not affect the mucous membrane of the bladder, it attracts attention by mechanical interference with the escape of urine, dropping at times into the orifice of the urethra, and suddenly shutting off the flow during micturition.

When a stone, by reason of its size, weight, and roughness, begins to cause cystitis, frequent micturition is a prominent symptom. A burning or smarting pain, referred to the end of the penis, is a frequent symptom in this, as in idiopathic inflammation of this organ. At times the pain is referred to the scrotum, penis, uterus, and other organs, or along the nerve tracts in the lower extremities. In any jolting movement, as in riding on horseback or in vehicles without springs, or in walking about, the pain is increased. Tenesmus is often violent toward the end of urination, when the stone is grasped by the contracting bladder. The urine almost always contains pus, and blood is frequently present. Hæmaturia, with calculus, occurs chiefly during the waking hours, when the patient is moving about. It is more apt to be met with in oxalate-of-lime calculi than in the other varieties. In the rare instances in which stone exists with villous growths of the bladder, hæmorrhage is often excessive. When a calculus is of large size it may by pressure produce pain and symptoms of disturbance in other organs, as the vagina, uterus, or rectum. The size and character of a stone in the bladder may, in a measure, be determined by exploration with the sound, as well as by palpation.

A large stone is usually felt as soon as the sound enters the neck of the bladder. The sense of resistance is greater, and a fair idea of its

proportions may be made out by passing the metallic sound along its surfaces. A small stone is often with difficulty recognized. Pressure above the symphysis pubis, and intravaginal or rectal exploration, are not without value in estimating the size of a calculus. If the click of the sound is sharp and clear, and if the surface is rough and grating to the sense of touch conveyed along the instrument, an oxalate-of-lime stone may be suspected, and, if the patient is a child, the suspicion is strengthened. Hæmaturia, and all the symptoms of cystitis, are, as a rule, increased with this form of calculus. In patients with the gouty or rheumatic diathesis, *uric-acid* stone is the rule. The acidity of the urine in a measure excludes phosphatic calculus. In the exceptional instances in which a portion of the surface of the bladder has become incrusted with the inorganic elements of the urine, this condition may be determined by the immobility of the concretion when the sound is brought in contact with it. The absence of a spherical calculus can be determined by digital exploration through the rectum or vagina, combined with pressure from above the symphysis pubis.

Treatment and Prognosis.—The attempts to dissolve vesical calculi by the administration of remedies by the mouth, or by solutions thrown into the bladder, have not met with encouraging success. While there is little doubt that the correction of a dyscrasia which is favorable to the formation of stone may prevent or retard the further growth of an existing concretion, there is no evidence to prove that a stone in the bladder was ever diminished in size or removed by this plan of treatment.

The proper treatment of stone in the bladder may be divided into the *curative* and *palliative*. To the former belong the operations of *lithotomy* and *lithotrity;* to the latter are systematic medication and hygiene, together with the employment of all local means calculated to relieve pain and prolong life. The conditions under which lithotrity should be preferred to suprapubic lithotomy are rare, and are given with the description of the operation.

Lithotrity.—If the symptoms are not so distressing as to demand immediate interference, from ten days to two weeks should be devoted to the careful preparation of the patient. It is not only important to improve the general condition, but also to accustom the urethra to the introduction of the sound. Strict adherence to the practice of antisepsis as given for the bladder and urethra is required.

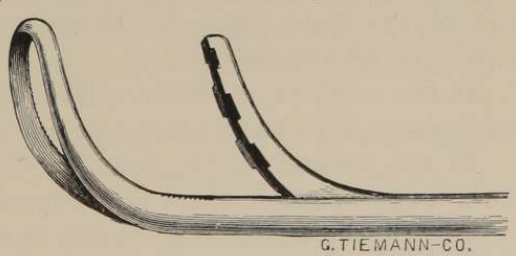

Fig. 719.—Fenestrated jaws of Thompson's lithotrite.

The instruments required are the lithotrite and an apparatus for washing out the detritus.

Of the various crushing instruments which have been introduced, that of Sir Henry Thompson is to be preferred (Fig. 722). It is commendable for its lightness, strength, and smooth action. With the heavier instruments the sense of touch is not so delicate and acute. The lighter lithotrite is strong enough to crush any calculus which may be

safely removed by this operation. Moreover, it is especially to be commended for the fenestrated jaw in the female blade, which allows the male blade to pass entirely through, and thus avoids the danger of choking and fouling. It consists of a male blade (Fig. 720), or sliding rod, which fits into a fixed or female blade (Fig. 721), which is deeply hollowed out for its reception.

The seizing and crushing action of the lithotrite is double. When the male blade is carried through the hollow handle into the slot in the



Fig. 720.—Male blade of Thompson's lithotrite.



Fig. 721.—Female blade of Thompson's lithotrite.

female blade, a simple and rapid to-and-fro movement can be executed by pushing or pulling on the male blade with the right hand, while the left steadies the female blade, to which the handle is attached. This movement can be made very effective in seizing the stone and in crushing the smaller fragments without taking the extra time in sliding the catch which throws on the screw motion of the instrument.

When, however, a stone is caught in its grasp by the sliding movement just described, and is so solid and resisting that a sufficient and safe crushing force can not be employed, the catch on the top of the handle

Fig. 722.—Thompson's lithotrite adjusted.

is slipped upward. The sliding movement is now impossible, and the more powerful screw motion substituted. By turning the wheel at the end of the male blade to the right, the stone can be felt to give way under the crushing force.

In the removal of vesical calculi by this operation two procedures are recognized, viz., *complete* and *incomplete* lithotrity.

In the former, or Bigelow's method, narcosis is required; the stone is entirely crushed, and the fragments washed out at a single operation. In the latter, anæsthesia is not employed; the calculus is only partially comminuted, and the fragments are left to pass off with the urine.

Complete lithotrity has almost entirely superseded the older operation. It is preferable in all cases where the condition of the patient justifies the risk of shock from a capital operation under narcosis.

Operation.—The patient, being narcotized, is placed upon the operating table, in the dorsal decubitus, with the pelvis raised about half a

foot by pillows placed under the sacrum. If the bladder has not been emptied just before the operation, the urine is now drawn off and about one pint of tepid water injected, thus distending this organ and rendering the mucous membrane less liable to injury from being picked up by the instrument. The lithotrite, having been properly warmed, oiled, and tested as to its working capacity and strength, is now prepared for introduction by sliding the male blade completely down until its tip passes into the fenestra of the female blade. As the convexity of the male blade is serrated, great care must be taken not to push the rough surface beyond the level of the female blade, since the introduction of the instrument, improperly adjusted, would do unnecessary violence to the floor of the urethra.

A right-handed operator should stand at the patient's right side. The instrument is locked and carried into the bladder by the same manœuvres as given for the introduction of the sound or metal catheter. When the beak is well into the bladder, it is carried along the floor, with the tip pointing upward, until it meets with the resistance of the posterior wall of the bladder, when it should be slightly withdrawn. The handle should now be elevated, in order to depress the floor of the bladder with the convexity of the curve. Held firmly in this position, the lithotrite is opened by withdrawing the male blade about two inches. The operator should now strike the handle of the instrument with the knuckles or hand hard enough to carry the concussion to the bladder, in order to dislodge the calculus and allow it to fall into the lowest portion of the organ, and within the grasp of the lithotrite, which is now closed by pushing the male blade down. If the stone is seized, it will be made evident by the failure to close the blades, and, when caught, it should be firmly held, the screw movement adjusted, and the wheel rotated slowly. Having thus secured the stone, the instrument should be moved to and fro, in order to assure the operator that the wall of the bladder is not caught. In crushing a calculus, the rapidity with which it is done should be determined by the sense of resistance experienced. It is not safe to employ force sufficient to spring the blades. A stone which can be safely crushed will yield perceptibly under a few turns of the screw. Phosphatic stone can often be rapidly comminuted without adjusting the screw. Uric-acid calculi require more power, while the oxalate-of-lime at times can not be crushed at all.

If the manœuvre above described fails after being several times carefully repeated, search must be made in other quarters. Holding the instrument beak upward, the convexity still upon the floor of the bladder, separate the blades, turn the shaft half over to the right, and then close the blades. If the stone is seized, hold it steady, adjust the screw motion, tighten the grip by a slight turn of the wheel, and carry the instrument back to the middle line with the beak pointing upward. If it does not move freely, the indication is that the bladder has been picked up, and of course the blades must be separated and another effort made. With the instrument shown there is little danger of this accident. The same manœuvre may be tried on the opposite side. If there is pros-

tatic enlargement, it may be necessary to turn the beak downward into the pocket on the floor of the bladder. If, after a half hour's search, the seizure has not been effected, the operation should be discontinued.

When the stone has been seized and broken once, the same manœuvres should be carefully yet rapidly repeated until no large pieces remain. It will usually be found easy to crush the smaller pieces by the sliding movement alone. The instrument should now be closed until the blades have the same relation as when introduced, and then withdrawn. The *evacuator* consists of a rubber bulb capable of holding about one pint. At the upper end is a funnel and stopcock for filling and closing the apparatus. Below is attached a glass globe, in which the particles of stone gravitate as fast as they are drawn into the evacuator. Between this and the rubber bulb is a second stopcock, and a place for attaching the catheter. It is advisable to insert a piece of rubber tubing, about five inches in length, between the catheter and the evacuator, in order to prevent the jarring motion imparted to the bulb from being conveyed to the instrument in the bladder. The catheters (Fig. 723) are of different sizes and shapes, ranging from No. 14 to No. 25, U. S. The evacuation is much more rapid with the larger instruments. However, the urethra should not be overdistended. In general, the catheters which are only slightly curved near the tip, with the eye at the extremity, are preferable. In filling the bulb, in order to exclude the air, the glass ball is first detached, filled with clean warm water, and readjusted. Both stop-cocks are now open, the end of the tube closed with the finger, and water poured into the funnel until the bulb and tube are filled to overflowing. The cocks are then closed, and the instrument intrusted to an assistant. The catheter, well oiled, is carried into the bladder, and as the water is escaping the lower end of the rubber tube attached to the evacuator is slipped over the end of the instrument. The bulb is grasped between the thumbs and fingers of both hands and squeezed, thus forcing the greater part of its contents into the bladder. It is now allowed to expand; the water rushes back out of the bladder and brings with it the smaller particles of stone which fall down into the glass sphere. This part of the operation may be expedited by rapidly half emptying the bulb into the bladder, and as rapidly allowing it to expand. When it is seen that particles of the calculus cease to fall into the receiver, the catheter should be withdrawn, the lithotrite reintroduced, and a second crushing done. The bladder is again washed out, and these operations should be alternated until all detritus is removed, unless alarming symptoms should

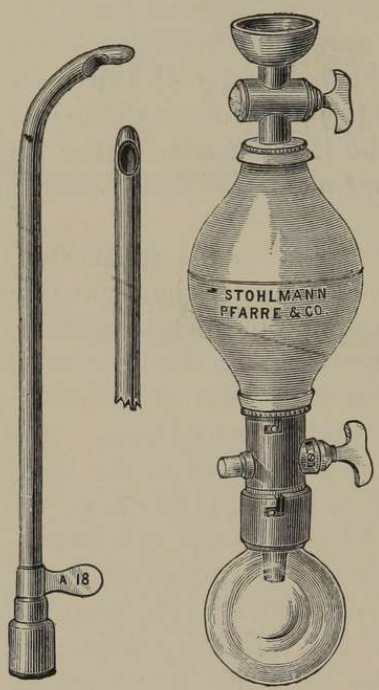

Fig. 723.—Thompson's improved evacuator and catheters.

supervene, when of course all operative measures should be discontinued. If the glass receiver becomes filled, it should be detached and emptied. At times particles of calculus become lodged in the catheter or tube, and require to be dislodged with a stylet. From one to one and a half hour may be allowed for this operation from the commencement of the anæsthesia. The prognosis will be more favorable with the shorter period, but it is wiser to proceed carefully and remove the stone thoroughly, even if a longer time is required. The absence of all fragments can be recognized by placing the ear over the bladder at the symphysis while the evacuator is being worked. The click of any fragments against the catheter can be distinctly heard. The introduction of a sound will also determine the presence of any pieces.

In the after-treatment opium is essential to relieve pain and tenesmus. Citrate of potash, grs. xx, three or four times a day, with flaxseed tea, will render the urine less irritating. The soft catheter may need to be employed to evacuate the bladder.

In incomplete lithotrity the crushing is done in the same manner as just described. A fair degree of urethral anæsthesia may be secured by the employment of cocaine. The lithotrite is only introduced once, and not more than five or ten minutes are consumed in the operation. The evacuator is not employed, the detritus being expelled in the act of urination.

Cystotomy or Lithotomy.—Cutting into the bladder for the removal of stone is performed through the perinæum or through the abdominal wall, just above the symphysis pubis. Incision through the rectum in males is no longer a recognized procedure, while the vesico-vaginal operation is rarely, if ever, indicated, since it necessitates a second operation to close the fistula.

Suprapubic Cystotomy.

At various times in the history of surgery the operation of suprapubic cystotomy has been brought to the attention of the profession, to achieve a short-lived popularity and then be relegated to obscurity. Under the impulse of modern surgery, the operation has taken a position from which it is safe to say it will not again recede.

To perineal cystotomy it should be preferred in practically all cases in which entrance to the bladder by an operative wound is desired. For the removal of all forms of neoplasm no other method is to be compared to it. For the extraction of foreign bodies so shaped or so large that they can not be withdrawn by means of the small Thompson lithotrite without undue violence to the urethral canal it is to be preferred. It is the better operation in all cases of vesical calculus, with the exception of very small and soft calculi in adults in whom the urethra is capable of freely admitting the lithotrite and the bladder is not affected with marked cystitis. Under such conditions, in expert hands, *litholapaxy* is permissible, the fragments being removed either by the act of urination or with the evacuator. In all forms of cystitis due to prostatic hypertrophy the perineal operation can not be compared to the suprapubic incision. In females it

should absolutely supersede the establishment of a vesico-vaginal fistula, for, with proper care, a perfectly satisfactory drainage and rest to the bladder can be obtained by suprapubic siphonage, a method which will not only cure the cystitis, but saves the patient from a secondary and formidable operation in the closure of a vesico-vaginal fistula.

The foregoing conclusions are based upon an experience in fifty-one cystotomies done upon forty-nine subjects for various conditions, the operation being of necessity repeated in two cases for recurring infectious cystitis, in a child four years of age and in a male of fifty-four, in which latter case, after removal of a tumor of the middle lobe of the prostate, cystitis recurred. Both of these cases recovered, cured.

Of the entire number of patients, four died. Of these fatal cases, one, a man sixty-eight years of age, with chronic general concentric hypertrophy of the prostate and severe chronic cystitis, expired on the fifteenth day after the operation from general exhaustion and well-marked symptoms of cerebral softening. In this case no effort was made to remove any portion of the prostate, and nothing was done, in fact, but a suprapubic cystotomy for the purpose of drainage. A second case, also a male, and of the same age (sixty-eight), with chronic cystitis, caused by hypertrophy of the middle lobe of the prostate, which was easily and quickly removed, proved fatal on the third day after operation from a well-marked apoplectic stroke, the patient having had, some months previously, a slight attack of this same nature. A third case, seventy-five years of age, died on the eighth day after the removal of a small calculus in uræmic coma following suppression of urine. A fourth case, that of a woman sixty-five years of age, who had suffered from chronic cystitis for six years, died nine weeks after operation from general exhaustion and failing mental power, which suggested strongly, to my mind, a condition of cerebral anæmia, or the softening of senility.

It will be seen from the above that the danger of death after this operation is not great, and it is not without interest to note that in all of the four fatal cases cerebral symptoms were prominent. As in all other surgical procedures, the old and worn out perish.

I have arranged my cases in the following order: First, *tumors*, of which there were eighteen cases; thirteen of these were connected with the prostate; three were papillomata of the wall of the bladder; two unclassified tumors, one a small sessile elevation in the trigonum and the other a simple pedunculated mass growing out from the internal orifice of the urethra in a woman, removed with the finger, and, while easily recognized, was crushed in the act of removal and lost in the effort to extract it (probably myxoma).

Of the thirteen tumors of the prostate, one was cancer of the left lobe and body in a male twenty-four years of age, a palliative curettage being done to relieve pain from pressure. The patient perished several months later from metastasis.

The twelve cases of prostatic hypertrophy furnish to my mind the most interesting group. Prostatic hypertrophy from a clinical standpoint is general (concentric) or local in character. When local, there is almost always the so-called tumor of the middle lobe with hypertrophy of one or other of the lateral lobes, but not of the entire organ. In six of my twelve cases there was concentric hypertrophy, and by this I mean such

an abnormal development of the tissues of this organ that not only does it expand in all directions (excepting anteriorly, in which direction its development is arrested by the triangular ligament) until the canal of the urethra is practically occluded, but the organ projects backward into the cavity of the bladder, forming a mass which may properly be likened to a prolapse of the rectum of long standing. As these cases occur in general in persons well along in life and, as a rule, so broken down in health as a result of this condition that a formidable operation is scarcely permissible, I have in all of these cases declined to attempt any removal of the enlarged organ, but advised permanent suprapubic drainage. The objections to extirpation are forcible, since removal of that portion of the organ projecting back into the bladder would not relieve the obstruction, while the removal of the entire organ under such conditions would be exceedingly dangerous to life and, in my opinion, entirely unjustifiable. Moreover, in all of these cases there is such a chronic condition of overdistention of the bladder and partial paralysis as a result of hyperdistention, that the bladder is unable to empty itself even after the obstruction is removed. The proper operation, therefore, in these cases, is drainage.

In six cases there was a tumor in the middle lobe, and this obstruction was removed. In three of these cases calculi were present, which, however, did not complicate the operation. The only fatal case among the prostatic operations was one who died from apoplexy on the third day after the operation, and who at the time of death was in excellent condition as far as the bladder, prostate, and operative wound were concerned. Of the five cases which recovered after the tumor of the middle lobe was removed, two were lost sight of and I have not been able to find them. The other two survivors could partially empty the bladder for years after the operation, but, having acquired the habit of using a catheter before operative interference, continued to use it until the death of one from old age, eight years after the operation.

As far as my experience may be of value, the conclusion is reached that cases are exceptional when after either hypertrophy of the middle lobe or concentric hypertrophy of this organ, which has existed for a period of one or two years, and caused repeated hyperdistention of the bladder, it is able to empty itself to the satisfaction of the patient even when the obstruction no longer exists. The importance of early interference is clear.

Of the three cases of papilloma, the patients were aged forty, thirty, and fifty years respectively. The tumor sprang from the posterior wall in each case, in two from the upper posterior wall or toward the summit of the bladder, and in one from the posterior inferior wall about halfway between the two ureteral openings. This last case had a very narrow stem or pedicle, seemingly about half an inch in diameter and about an inch in length, expanding into a cauliflower-like mass two or three inches in diameter. The other two sprang from broader bases, and, while cauliflower-like in development, were not so easily dealt with as to their points of origin. All recovered from the operation, and one is living with no recurrence during the four years which have elapsed since the

operation. The other two died from recurrence and general exhaustion caused by the hæmorrhage and cystitis which ensued, one nine and the other thirteen months after the operation.

Second, *cystitis*. The most frequent disease of the bladder which requires drainage is *chronic cystitis*, for this is not only present in practically all cases of tumor and stone, but occurs in a large majority of cases in which there are no calculi present and no neoplasm or enlargement of the prostate. My clinical notes contain twenty operations for chronic cystitis uncomplicated by tumor or stone. These operations were done in nineteen patients, two of whom were males four years of age. One of these had cystitis with tuberculosis of the bladder, which, of course, was incurable, although the child recovered from the operation and was discharged from the hospital. The second case had compression myelitis with paralysis and an infectious cystitis due to the use of the catheter, which required bladder drainage; he recovered, and was seemingly cured, but several months later a recurrence took place through a second catheter infection, and the operation had to be repeated. This patient recovered, and was ultimately cured of the compression myelitis by laminectomy and the removal of a tumor of the spinal cord, and became fully restored to usefulness.

Only one death occurred in these nineteen cases, and that was in a case almost hopeless from the start, the woman being sixty-five years of age, who was very much exhausted from a cystitis of six years' duration, and who died nine weeks after the operation from general exhaustion and cerebral softening.

Exclusive of the two children of four years just mentioned, the ages varied from twenty-one to sixty-five, the average being about forty-five years. The shortest period of drainage was seventeen days, and the longest eight weeks (except the case of permanent drainage). In twelve of these cases of drainage a cure resulted; two were improved; in one permanent drainage was established on account of paralysis of the bladder due to prolonged overdistention, and a single case was not improved by the operation.

Third, *calculus*. For calculus there were eleven operations, with one fatal case from suppression of urine and uræmic coma; three of these cases were complicated by prostatic tumor. The calculi varied in size from the very smallest up to two inches in diameter, and from a single calculus to more than a hundred small soft stones in one case.

Fourth, *foreign bodies*. For removal of foreign bodies there were two cases, a piece of metal catheter that had been broken off in one case, and in the other (that of a female), a large stiff hairpin was removed. Both cases recovered.

Fifth, *exploratory cystotomy*. There were two cases of exploratory cystotomy, in which both patients recovered.

Operation.—It is important not only to shave those parts in the immediate field of operation, but the perinæum, the inner surface of the thighs, and the region of the anus and buttocks. It is almost impossible to prevent an occasional overflow of urine in the after-treatment, and if

the hairs are all removed the parts can be much more readily cleansed and unpleasant odors prevented. The patient should rest upon the back, with the legs in full extension and upon a table so constructed that, at the proper moment, a modified Trendelenburg posture may be secured. The full Trendelenburg is not desirable, but, if the pelvis can be lifted a foot above the level of the shoulders, the weight of the intestines will be taken off the bladder, which is an advantage. There is no necessity under any circumstances to use rectal distention. For dilating the bladder, I prefer water. Bristow's air inflation I have never tried, but I fail to see any material gain in its employment. I employ a soft catheter and a glass barreled syringe containing four ounces of warm boric-acid solution, or water which has been boiled and cooled to about 110° F. From twelve to sixteen ounces are forced into the bladder, and in males this can be held in by tying rubber tubing around the urethra and catheter, in females by digital pressure upon the urethra from below upward against the arch of the pubis. The incision I prefer is the longitudinal, the lowest angle of which is one inch below the upper margin of the symphysis pubis and the upper angle about three inches above this bone. Separating the muscles in the median line, all hæmorrhage should be arrested as the operation proceeds. With dull-pointed, curved scissors, the insertion of the recti muscles are snipped away for from one fourth to three fourths of an inch on either side of the median line close to their attachment to the pubic bone. If the operation is for the removal of a stone of small size or a foreign body, or for exploration or drainage in uncomplicated cystitis, it is not essential to have a wide external wound or a large incision into the bladder. I therefore modify the incision and exposure of this organ as the operation may require. When there is a tumor, as the greatest possible room is required, I usually add to the longitudinal a short transverse incision parallel with the pubic crest and divide the muscles at their insertions laterally somewhat farther, always taking care, however, not to approach too near the fibers of the external abdominal ring. When these muscles are divided and held back with retractors, the loose areolar tissue situated between the bladder and the surface of the pubic bone and the abdominal muscles is readily seen and separated from its slight attachment to the bone. If, then, the finger is carried down with the back of the nail in contrct with the surface of the pubic symphysis, this prevesical fat can be easily detached from the bladder with the nail as a dissector and carried upward for a distance of from one and a half to two inches, and, in certain cases of tumor of the upper posterior wall of the bladder, the peritonæum may be still further dissected off by lifting the prevesical fat and carrying the peritonæum up with it. However, the peritonæum is rarely seen ; only once or twice has it come into view in the cases I have operated upon. It would be no serious matter if it were torn through or incised if it were immediately sutured with catgut. If at this stage of the operation it is evident that the bladder is not sufficiently distended to bring it well under the touch of the surgeon or to lift the peritonæum high enough, four or eight ounces more of the fluid may be injected through the

catheter, which has been left in. When a tumor is to be removed, or a stone of large size, requiring a good deal of operative interference within this organ, before opening the bladder I usually insert two loops of silk thread, which are carried by means of a short curved Hagedorn needle entirely through the bladder wall, one on either side of the proposed line of incision. A little fluid will escape through these punctures, but will not interfere with the operation. These loops are left long and tied at least a foot from the margin of the incision, and are intended to steady the anterior wall of the bladder by proper traction as the operator is at work within the bladder. In this way undue dissection of the anterior bladder wall from its normal attachments can be prevented. In rare instances, where one or more large veins appear on the anterior wall, if a line of incision can not be secured to one side and safely removed from these veins, catgut ligatures should be passed, by means of a short-curved needle, and the vessels secured and divided between the ligatures. In removing tumors it is very important to have a large incision through the bladder wall, and to dilate this widely in all directions by retractors so inserted that the cavity of the bladder is well exposed and the point of attachment of the tumor brought in sight. In removing papillomata they can usually be scraped off with the finger nail or an ordinary uterine curette. The point of attachment should then be thoroughly burned with the Paquelin cautery. For hypertrophies of the prostate it is not so essential to have the tumor so exposed, since the cutting forceps can be applied directly by the sense of touch, placing the tip of the index finger upon the mass to be removed, and carrying the forceps down with one blade on each side of the finger until the blades are guided on to the mass. The forceps I have had made for this purpose

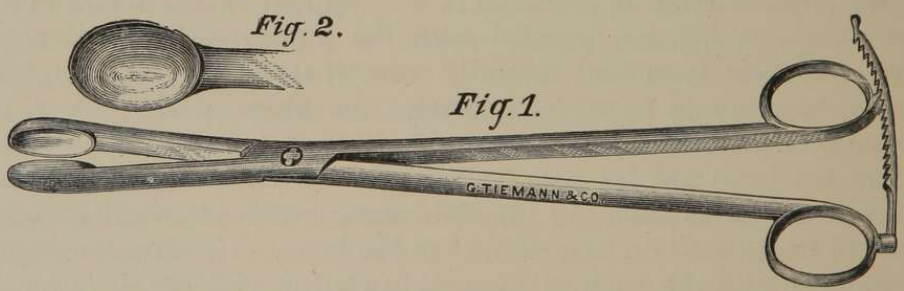

Fig. 724.—The author's forceps for removing tumors of the prostate and bladder.

have double cup-shaped blades, which, when the tumor is seized, are closed but do not entirely cut off the section grasped. The removal is made by twisting, in order to prevent the hæmorrhage which would result from a clean cut of these hard tumors. I do not apply the Paquelin cautery to prostatic hypertrophies. When any well-marked hæmorrhage is present, hot-water irrigation will aid in controlling it. I have on no occasion had to pack the bladder for hæmorrhage, but would not hesitate to do this if necessary. In operating for the removal of foreign bodies, a much smaller incision is required, and for small calculi an incision an inch long in the bladder will suffice. I have found it much easier to remove these stones by slipping them along with the index

finger until they present at the wound in the bladder. My objection to using an instrument for removing calculi is the fear of breaking off small particles which may escape detection and remain in the bladder. I have never had any trouble in extracting stones in this manner. In one instance, where more than one hundred were removed, I used a good-sized bladder scoop, as it expedited the operation.

The after-treatment of these cases must, of course, vary. When there is no well-marked inflammation of the bladder, as after removal of a small stone or tumor or foreign body, or after exploration of the bladder in which no lesion was found, the operator may close the bladder by *immediate suture*. This is a very desirable method, for the reason that it does away with the necessity for suprapubic drainage and the slow process of closure of the wound, which, if left alone, takes from two to three weeks. In closing the bladder, I prefer firm small catgut, and the suture used is not unlike the Lembert suture employed in intestinal surgery. The needle is inserted about one eighth of an inch from the cut edge and comes out near the edge, yet not upon the cut surface, nor does the needle go into the cavity of the bladder. The sutures should be about one sixteenth of an inch apart. I do not think it is conservative surgery to close the superficial wound over this line of sutures, but prefer to put in a light packing of iodoform gauze, for fear that the catgut sutures might possibly give way. I have performed this operation in only two of my cases, and in both of these the wound closed primarily without leakage.

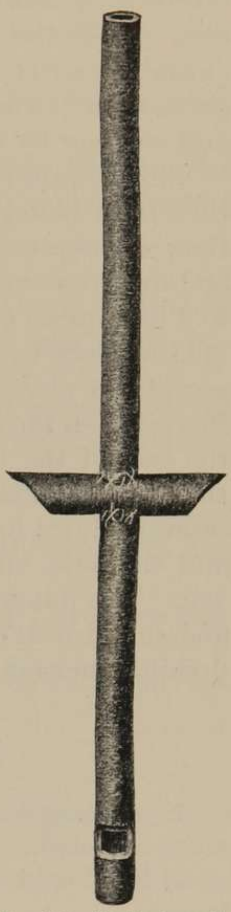

FIG. 725.—Bodine's modification of Trendelenburg's T-tube.

A catheter should be inserted and allowed to remain in for three days after the operation, or the water should be drawn by catheter every three or four hours in order to prevent any distention of the organ or strain upon the sutures. If for any reason the surgeon should deem it best not to undertake immediate suture of the bladder, he may rest assured that in from three to four weeks the wound will close by the ordinary process of repair in practically all cases.

In drainage, the use of the rubber tube is essential for the comfort of the patient. The ordinary T-shaped Trendelenburg tube is very unsatisfactory. Dr. J. A. Bodine has modified this by extending that part of the tube which projects into the bladder at least four and a half inches beyond the crosspiece, which is intended to catch within the bladder on either side of the incision in this organ. As the end of the tube is thus kept in the deepest portion of the bladder, the siphonage is more satisfactory. After the tube is introduced and before the wound is closed, it is better to throw in a good quantity of warm boric-acid solution in

order to flush the bladder and wash out any clots which may have been overlooked. The wound may be partially closed by one or two superficial sutures in the upper and lower angles, or left entirely open and filled with a light packing of iodoformized gauze around the tube. The duration of drainage should be determined by the condition of the bladder. After the removal of a tumor or stone uncomplicated with severe chronic cystitis, the tube may be removed in five or six days. In five or six more a portion of the urine will be discharged through the urethra, and entirely by this route in ten days or two weeks more.

Since there is usually danger of overflow due to obstruction of the tube from blood clot during the first twenty-four hours after the operation, a generous quantity of absorbent cotton should be placed around and over the wound. When the tube is placed in position, it is attached to a long piece of tubing which is carried down the side of the bed and held in place by safety pins, and through this the urine is carried into a receptacle placed to receive it. Siphonage may be started by injecting the solution into the long tube until the bladder is well filled, holding the end of the tube higher than the summit of the bladder, removing the syringe, and closing the tube by pressure of the finger; the end is brought down lower than the level of the bladder, the pressure released, and the fluid allowed to run out of the tube, thus establishing siphonage. The danger of infiltration of urine between the bladder and the abdominal wall or the pelvic bones is not to be considered when the abdominal incision is open and loosely packed.

Cystotomy for Tumors of the Prostate.

1. Male, aged 59. Concentric hypertrophy; permanent drainage; recovered; much improved.

2. Male, aged 77. Concentric hypertrophy; permanent drainage; recovered; improved.

3. Male, aged 80. Concentric hypertrophy; permanent drainage; recovered; improved.

4. Male, aged 74. Concentric hypertrophy; permanent drainage; recovered; cured. Over one hundred small calculi.

5. Male, aged 55. Concentric hypertrophy; drainage three weeks; recovered; permanent drainage advised, but declined.

6. Male, aged 68. Concentric hypertrophy; permanent drainage; died fifteenth day from exhaustion and cerebral softening.

7. Male, aged 67. Tumor middle lobe, one calculus removed; tube removed sixth day; wound closed sixteenth day; recovered; cured.

8. Male, aged 67. Tumor middle lobe removed; recovered; cured.

9. Male, aged 48. Tumor middle lobe removed; one calculus; recovered; cured.

10. Male, aged 54. Tumor middle lobe removed; drainage eight days; recovered; cured.

11. Male, aged 49. Tumor of middle lobe removed; ten calculi; recovered; cured.

12. Male, aged 68. Tumor middle lobe removed; died third day, of apoplexy; had had one previous attack.

13. Male, aged 24. Cancer of left lobe and body of prostate and contiguous bladder; curettage; recovered; died in four months of metastasis.

Papilloma.

14. Male, aged 40. Upper posterior wall; two years' duration; drainage; wound closed sixteenth day; recovered; improved. Died six months later from exhaustion from recurrence and cystitis.

15. Male, aged 30. Posterior inferior wall near ureter, mushroom stem, top of tumor three inches in diameter; recovered; cured.

16. Male, aged 50. Upper posterior wall, broad pedicle; tumor filled bladder; recovered; improved. Died thirteen months later from exhaustion from recurrence and cystitis.

Tumors unclassified.

17. Male, aged 36. Sessile elevation in trigone; curettage; supposed myoma; left pyelonephritis; recovered; not improved. Died over a year later from pyelonephritis.

18. Female, aged 20. Small pedunculated tumor, supposed myxoma, projecting from internal orifice of the urethra into bladder; immediate suture; recovered; cured.

Calculus.

19. Male, aged 46. Large; drainage six days; sinus closed forty-fourth day; recovered; cured.

20. Male, aged 60. Calculus formed on fragment of catheter four inches long; drainage five days; recovered; cured.

21. Male, aged 16. Oxalate of lime, one inch in diameter; drainage ten days; recovered; cured.

22. Male, aged 50. Three calculi; recovered; cured.

23. Male, aged 30. Single calculus; recovered; cured.

24. Male, aged 45. Single calculus, two inches in diameter; drainage twelve days; recovered; cured.

25. Male, aged 3. Single calculus, half inch in diameter; no tube; wound closed eighth day; recovered; cured.

26. Male, aged 75. Single calculus, three fourths inch in diameter; suppression of urine on eighth day; death.

Note.—Four additional cases of stone complicating tumor are already given with tumors of the prostate.

Chronic Cystitis uncomplicated with Tumor or Stone.

27. Male, aged 40. Drainage three weeks; recovered; cured.

28. Male, aged 54. Recovered; cured.

29. Male, aged 22. Drainage three weeks; recovered; cured.

30. Male, aged 39. Drainage three weeks; recovered; cured.

31. Male, aged 65. Recovered; cured.

32. Male, aged 58. Drainage four weeks; recovered; cured.

33. Male, aged 63. Drainage three weeks; recovered; cured.

34. Male, aged 30. Recovered; cured.

35. Female, aged 65. Drainage seven weeks; died nine weeks after operation from exhaustion and cerebral softening.

36. Male, aged 40. Recovered; improved.

37. Male, aged 39. Recovered; cured.
38. Male, aged 26. Recovered; cured.
39. Male, aged 28. Drainage seventeen days; recovered; cured.
40. Male, aged 21. Drainage two months; recovered; cured.
41. Male, aged 51. Drainage eight weeks; paralysis from overdistention; pyelonephritis; recovered; improved.
42. Male, aged 60. Paralysis from overdistention; permanent drainage; recovered; improved.
43. Female, aged 24. Pyelonephritis; recovered; improved.
44. Male, aged 4. Tuberculosis; curetted; recovered; not improved.
45. Male, aged 4. Paralysis from compression myelitis; catheter infection; drainage fourteen days; recovered; cured.
46. Male, aged 4. Re-infection; drainage four weeks; recovered; cured.

Exploratory Cystotomy.

47. Female, aged 43. Immediate suture; recovered; cured.
48. Male, aged 48. Pyelonephritis; recovered; not improved.

Closure of Fistula.

49. Male, aged 68. Incision, curettage, and drainage; recovered; cured.

Foreign Body.

50. Male, aged 41. Metal catheter, four inches long; drainage five days; wound closed fourteenth day; recovered; cured.
51. Female, aged 16. Heavy wire hairpin, four and a half inches long; drainage through wound eighteen days; recovered; cured.

Perineal lithotomy, or the *low operation*, may be done by three methods—the *lateral*, *bilateral*, and *median* operations. A combination of the median and lateral incisions is sometimes performed, and is known as the *medio-lateral* procedure.

Lateral lithotomy is thus performed: Two hours before the operation the rectum should be emptied by a free enema of tepid water, and the perinæum cleanly shaved. The patient should be placed upon the back, the sacrum resting near the edge of the table, the thighs flexed toward the abdomen, slightly abducted, the feet brought down and secured to the hands and wrists by several turns of a roller. Each leg is intrusted to an assistant, while a third, selected for his special fitness, and upon whom the duty of holding the guide devolves, stands beside the patient's abdomen, facing the operator.

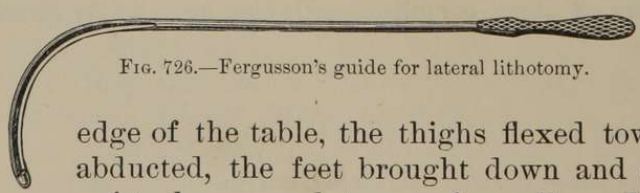

Fig. 726.—Fergusson's guide for lateral lithotomy.

If the bladder is not fairly distended with urine, a Nélaton's catheter should be introduced, and about a pint of fluid injected. A Fergusson's guide, grooved laterally (Fig. 726), is next carried into the bladder. The probabilities are that the stone will be felt by the sound. If the calculus has been recognized within a day or two, and if in the meantime the urine has been carefully watched and no solid substance has escaped by the

urethra, no prolonged effort should be made at this juncture to demonstrate its presence.

The proper position for the guide is shown in Fig. 727. The shaft is held about perpendicular to the surface of the table, the point well into the bladder, while the convexity of the curve rests against the perinæum. The scrotum is now lifted directly upward, and the primary incision is made with the sharp scalpel. It commences in the median line about one inch and a half directly in front of the anus, and is carried downward and outward as far as the posterior margin of the anus, passing halfway between the inner surface of the patient's left *tuber ischii* and the anal margin (Fig. 728). The integument and fasciæ having been divided, the operator proceeds through the upper half of the wound by cutting down upon the guide, which

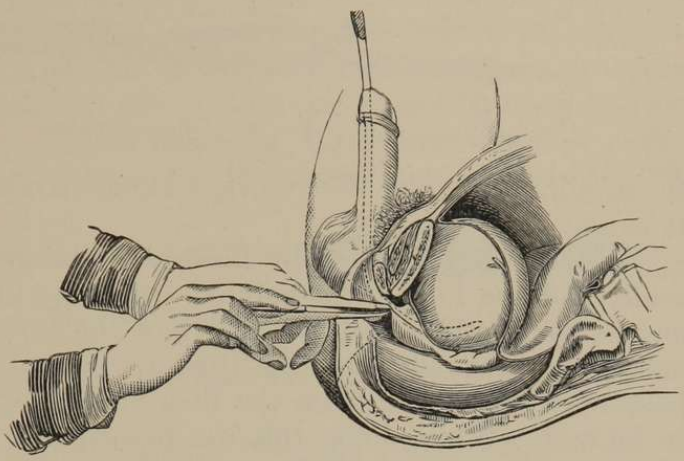

Fig. 727.—Guide in position in lateral lithotomy. (After Bryant.)

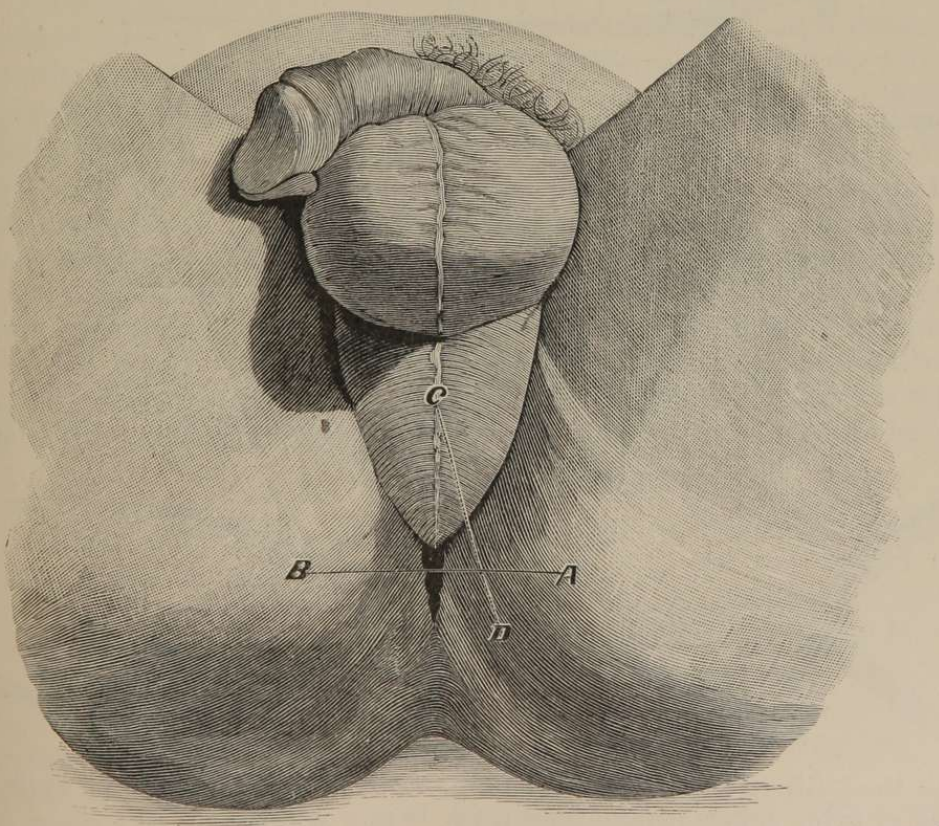

Fig. 728.—*C D*, Line of incision in lateral lithotomy. *B A*, Imaginary line between the tuberosities of the ischia. (After Maclise.)

may be readily felt with the finger. When this is nearly reached, the groove in this instrument will be made out, and, by pressing the nail of the left index finger into it, the point of the knife can be guided through

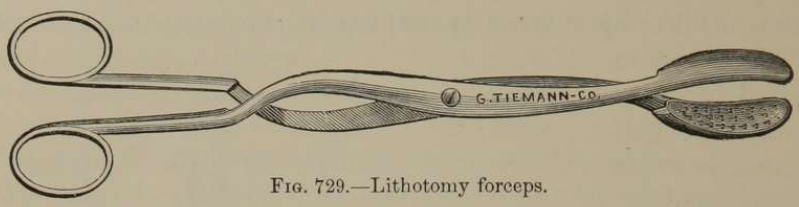

Fig. 729.—Lithotomy forceps.

the urethral wall into the groove, making an opening about half an inch in extent.

With the finger nail kept steadily in the groove, the scalpel is laid aside, and the long probe-pointed lithotomy knife (Fig. 94) taken up and its point guided into the groove of the guide. At this stage of the operation the sound is slightly lifted up, so that the pressure which has heretofore been made upon the floor of the urethra will be transferred to its roof. While doing this the probe point of the knife should be firmly and steadily pressed upward against the instrument, for, unless this precaution is observed, it may slip out of its proper place. The operator now seizes the shaft of the sound with the left hand to assure

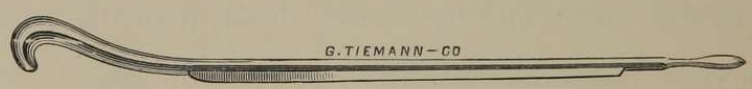

Fig. 730.—Scoop and conductor.

himself, by moving this instrument slightly, and also by sliding the knife along the groove, that the two instruments are in actual contact, and then, turning the cutting edge of the knife obliquely toward the patient's left side, and more nearly parallel with the transverse than with the antero-posterior diameter of the patient's body, pushes it along the grooved guide into the bladder. In executing this manœuvre it is necessary to tilt the point of the knife upward and press it very firmly into the groove lest it slip out and cause confusion. When the probe point arrives at the end of the groove and catches, the incision through the left lobe of the prostate may be lengthened by pushing the sound

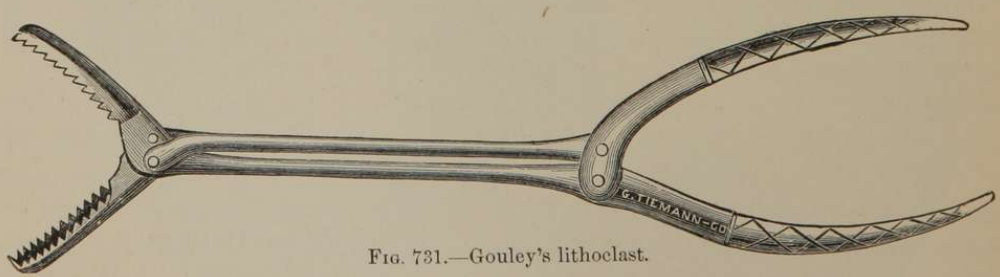

Fig. 731.—Gouley's lithoclast.

with the knife in the proper direction. As the incision is being made, a gush of urine takes place. The knife is now withdrawn, the finger carried into the bladder, and the stone located before the sound is removed.

The size of the calculus should be determined, and, if necessary, the lower portion of the primary incision may be enlarged. While this is being accomplished, it is advisable to carry the index finger into the rectum to avoid wounding this gut.

The forceps (Fig. 729) should now be introduced and the stone removed. This instrument can not always be carried in through the wound if the finger is allowed to remain, and is at times difficult of introduction without a guide. To prevent delay, the conductor (Fig. 730) should be passed along the finger into the bladder and allowed to remain after the finger is withdrawn. If the blades of the forceps are now closed upon the flange of the conductor, the instrument can be made to slide

Fig. 732.—Lithotomy scoop.

accurately along the guide into the bladder, after which the conductor should be removed.

In removing a stone with the forceps two precautions are essential: 1, not to pick up the wall of the bladder with the calculus; and, 2, not to employ force enough in grasping the stone to crush it.

When the stone is grasped, if the instrument can be moved freely within the bladder, it is evident that this organ is not caught.

With small calculi the extraction is easily accomplished. When the stone is large, a certain amount of force is justifiable and necessary to stretch the wound to its utmost; but this force should never be used unless the operator is satisfied that the stone and jaws of the forceps can be brought through the wound without serious injury to the blad-

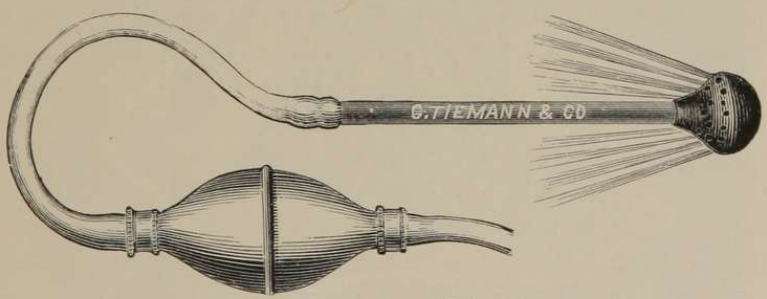

Fig. 733.—Van Buren's débris syringe.

der and prostate. If the stone can not be extracted whole, it should be crushed with the forceps or lithoclast (Fig. 731), and removed in fragments. The larger pieces may be caught with the forceps, the smaller with the scoop (Fig. 732). A stream of water should also be forcibly thrown in through the wound, in order to bring away any small particles which may have escaped notice (Fig. 733). Finally, a sound should be introduced and search made for a second stone or any fragments lodged in the more remote portions of the bladder.

Among the accidents which may complicate perineal lithotomy, in addition to that of wounding the rectum, which has been mentioned, is

hæmorrhage from the artery of the bulb and other vessels of the perinæum. The ligature will control all superficial bleeding, and, should a deep vessel be divided, it may be transfixed with a tenaculum and tied, or the hook allowed to remain in the wound for a day or two. If the oozing is free and general, an umbrella compress (Fig. 734) should be made by tying a piece of oiled silk or rubber tissue to a canula or bougie. This is carried into the wound and compression made by packing sponges beneath the cloth which is brought in contact with the bleeding surface.

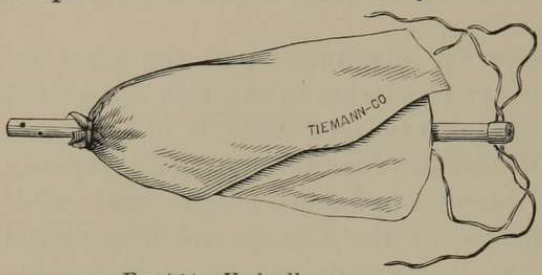

Fig. 734.—Umbrella compress.

The after-treatment of lateral lithotomy is simple. The wound is left open and unmolested. The urine passes through this for a few days or weeks, and gradually resumes the urethral channel as the incision closes

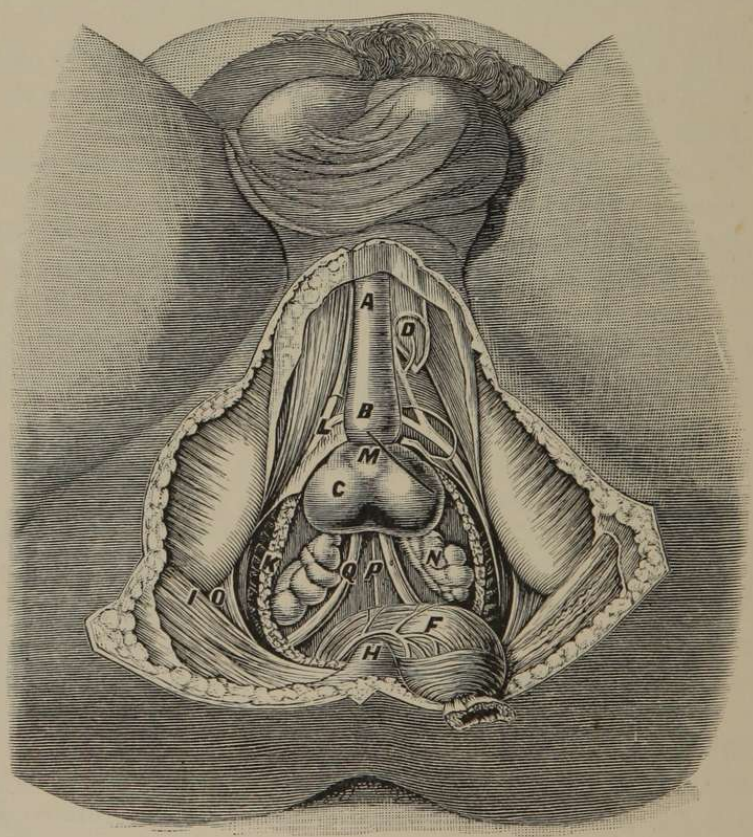

Fig. 735.—*A B*, Bulbous portion of the urethra. *C*, Right lateral lobe of the prostate. *M*, The line of incision in lateral lithotomy. *D*, Corpus cavernosum. *F*, Rectum. *N*, Vesicula seminalis. *Q*, Vas Deferens. *L*, Artery of the bulb. (After Maclise.)

by granulation. In some cases the urine passes through the urethra uninterruptedly. The patient should remain in bed for two or three weeks.

The anatomical relations of the parts involved in this operation are shown in Fig. 735.

Bilateral Lithotomy.—In performing this operation a curved incision is made, beginning halfway between the tuberosity of the ischium and the anus on one side, and terminating at a corresponding point on the other. The incision crosses the median raphé of the perinæum from one half to three quarters of an inch in front of the anus. The guide used in this operation should be grooved deeply in the middle of its convex surface. As soon as this instrument is reached, the urethra is opened in the membranous portion, and the finger nail carried into the groove on the sound. The bisector—a probe-pointed two-edged lithotome—is introduced by sliding the tip of the instrument along the nail into the groove. The operator now takes hold of the staff, depresses the handle of the bisector, and, keeping the probe-point in the groove, pushes the knife into the bladder directly in the median line. In this operation the prostate is divided equally on both sides of the urethra.

Median Lithotomy.—The position of the patient is the same as in the two preceding operations. The best staff or guide is that of Prof. Little (Fig. 736), which has a deep, wide groove.

It is introduced and held in such a position that the staff is perpen-



Fig. 736.—Little's lithotomy staff.

dicular to the plane of the body, the tip well in the bladder, with the convexity of the instrument pressing firmly and steadily toward the perinæum. The finger is now carried into the rectum in order to guard against puncture of the anterior wall of this organ. Little's lithotomy knife is entered just about a half-inch anterior to the anus in the median line, the edge of the blade directed upward, and is pushed straight inward until the point strikes into the concavity of the groove in the staff at the anterior limit of the prostate. It is then made to cut forward and upward until the membranous portion is divided, and, as it is withdrawn, the incision in the perinæum is lengthened in all about one and a half inches. The finger is now introduced, the sound withdrawn, and the wound, prostatic portion of the urethra, and neck of the bladder dilated until the stone can be felt and extracted with a slender forceps.

Of the four methods of cutting for stone just described, the suprapubic has practically superseded all others, and fortunately it does not require the extensive list of instruments which the low operations demand. The lateral and medio-lateral are next in order of preference. The bilateral procedure is rarely if ever indicated.

Stone in the Bladder of Females.—Vesical calculi are not met with in females as frequently as in males. Many conditions which conduce to

the lodgment or formation of stone in the male bladder, and are common in this sex, are either impossible to, or rarely occur in, females.

Another explanation of the comparative infrequency of stone in females is the short and dilatable urethra, allowing the escape of many small concretions which in men would lodge in the *cul-de-sac* behind the prostate. The symptoms do not differ from those given in stone in the bladders of males. The *diagnosis* rests upon exploration with a searcher, combined with digital exploration *per vaginam*, and direct pressure over the pubes.

Treatment.—Small calculi found in the bladders of females may be readily removed by lithotrity. The short and distensible urethra permits of the introduction of the largest evacuating catheter, and greatly facilitates the operation. The older method of dilatation or divulsion of the urethra and extraction in mass by forceps is not justifiable. Large calculi and small oxalate-of-lime concretions, which may not be easily and completely crushed, should be removed by the suprapubic operation. Incision through the vesico-vaginal septum requires a second operation for its closure, and of itself is more complicated than the suprapubic method.*

Foreign Bodies.—Foreign substances in the bladder are usually introduced through the urethra. Less frequently they pass through the walls of this organ, as in gunshot wounds, etc. In exceptional instances foreign matter finds its way into the bladder through a fecal or vaginal fistula. Pus in a number of cases of appendicitis has found its way into this organ. In several cases of this character worms have escaped from the intestines and found an exit through the urethra.

The symptoms are usually those of stone in the bladder, with cystitis in a varying degree. The diagnosis may be evident from the history of an accidental or intentional introduction of the foreign substance. The matter can usually be recognized by the searcher. If a few weeks have elapsed, the foreign body will probably be coated with a deposit of urinary salts, and will impart to the sound the grating or click peculiar to stone.

The *treatment* consists in removal of the offending substance as soon as possible. If it is small, round, and smooth, it may be extracted through the urethra with the lithotrite. For this purpose the smallest instrument should be employed. If it is too large to be brought out in mass, it may be chopped up or crushed, and then extracted piecemeal, in the jaws of the lithotrite, or washed out through the evacuator. Fig. 737 represents an English gum catheter which was removed in this manner. The two larger pieces were grasped by the end and drawn out; the remainder was caught in the lithotrite, and brought out one piece at a time.

When the substance is so large or of such a shape that it can not with safety be brought through the urethra, cystotomy is imperative.

The Prostate Body.—Disease of the prostate is almost always a condition of adult life. This organ is rudimentary in childhood, and while,

* Prof. George Ben Johnston, of Richmond, Va., from a careful study of this subject, concludes that stone is 4·72 per centum more prevalent in whites than negroes in the United States.

from direct injury, as in catheterization, lithotomy, or any form of violence, or by the extension of any of the rarer forms of disease which affect the bladder or urethra of children, this body may be involved, it only assumes its true importance after it has taken on its functional activity.

Prostatitis.—Inflammation of the prostate may be partial or complete, as well as acute or chronic. It may affect the epithelial and glandular or muscular and connective-tissue structure of this complex organ. Pros-



Fig. 737.—Gum catheter removed from the bladder by the lithotrite. (The author's case.)

tatitis rarely originates in the substance of this body, which is usually involved by the extension of an inflammation from the bladder, urethra, or other organs and tissues in its immediate neighborhood. Urethritis, cystitis, epididymitis, and proctitis are among the more common causes. To these may be added excessive venereal excitement, all forms of traumatism, whether by violence applied to the rectal or perineal regions, or by instruments in the urethra, and the presence of calcareous or amylaceous concretions.

The *symptoms* are usually well marked. Pain in the acute form of inflammation is usually intense and burning in character. There is a sense of fullness and throbbing in the organ. With the finger in the rectum the enlargement may be appreciated, together with abnormal heat and throbbing of the arteries. Pain is increased by direct pressure in the perinæum or rectum, and also in the act of urination. Fever is present in proportion to the severity of the local process. Suppuration and the formation of an abscess are usually indicated by exacerbations of temperature and by interference with micturition.

The first indication in the *treatment* of this painful affection is rest in the recumbent posture. The bowels should be kept open. The ice-bag to the perinæum will be found of value. If retention of urine occurs, it should be relieved by the use of the smaller soft catheter. Suprapubic aspiration may be demanded in severe cases. Scarification of the perinæum and the application of cups are highly recommended as local measures. If abscess exists, it should be evacuated by the aspirator or incision through the perinæum. Rupture may occur into the urethra, or the abscess may find an opening through the perinæum or rectum.

Hypertrophy.—Chronic progressive enlargement of the prostate occurs in about one third of all males who live through the period from fifty to seventy-five years of age. The increase in volume is not a true hyperplasia, for the glandular functions, as well as the muscular power of the organ,

decrease with the hypertrophy. In some portions of the mass the muscular tissue is increased, but the bulk of the enlargement is due to the presence of newly formed connective tissue. The induration is in proportion to the excess of the new tissue over the normal muscular and glandular elements. In some instances, though rarely, the glandular elements are increased; but this is, in all probability, only observed in the earlier stages of hypertrophy, before the connective-tissue elements are in sufficient quantity to cause atrophy of the glandular apparatus. The enlargement may be local or general. In general hypertrophy, while the increase in size is in all directions, it is more marked in the posterior portions, where it encroaches upon the neck of the bladder. Not infrequently one lateral lobe is greatly enlarged, or the hypertrophy may be central, resulting in the development of a middle or third lobe, which, by progressive enlargement, not only changes the axis of the normal urethra, but occludes, in a variable degree, the outlet of the bladder. This last condition is well shown in Fig. 738, and that of general hypertrophy of the muscular, fibrous, and glandular tissues, with narrowing of the urethra, in Fig. 739.

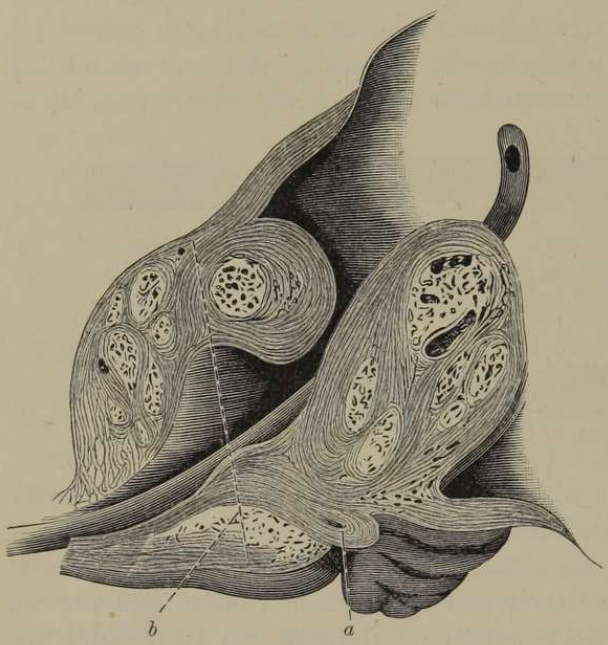

Fig. 738.—Longitudinal section of hypertrophied prostate, in a patient seventy-four years of age, showing a false passage tunneled by a catheter. *b*, Line of transverse section shown in Fig. 739. *a*, Duct of vesicula seminalis. (After Socin.)

Symptoms.—The increase in size is usually so gradual that the condition of hypertrophy does not attract the attention of the patient until interference with the flow of urine occurs. As a result of retention the bladder is distended, the contractility of its muscular walls is diminished, and chronic cystitis inevitably ensues. The changes which take place in this organ—thickening of the walls, occasional sacculation, the formation of calculi, dilatation of the ureters, etc.—have been given. In severe cases the functions of the rectum may be interfered with.

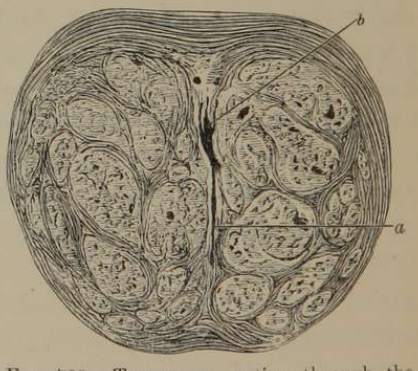

Fig. 739.—Transverse section through the center of the prostate of a patient seventy-four years old. Hypertrophy of fourteen years' duration. *a*, Urethra. *b*, Caput gallinaginis. (After Socin.)

The *diagnosis* may be determined by the presence of the symptoms

just given, by digital exploration by the rectum, and the introduction of a sound or bougie by the urethra.

The *treatment* is chiefly palliative. When recognized early in its history, every source of irritation should be removed from this organ. The bowels should be kept open, the irritability of the urine diminished by the administration of alkaline diluents, and all venereal excitement prohibited. In those affected with gout or rheumatism, judicious diet and medication may arrest, or at least retard, the progress of the disease in the prostate. When symptoms of obstruction to the escape of urine supervene, operative interference is frequently called for. If the hypertrophy is general and the caliber of the urethra is encroached upon, dilatation by means of the olive-pointed French bougies or the conical steel sounds may be required. The introduction of instruments should cease with the first symptoms of septic urethritis. Careful asepsis should be practiced. When the enlargement is chiefly in the posterior portions of the organ, dilatation is not indicated. In order to prevent cystitis, it is important that every effort should be made to thoroughly empty the bladder at each act of urination.

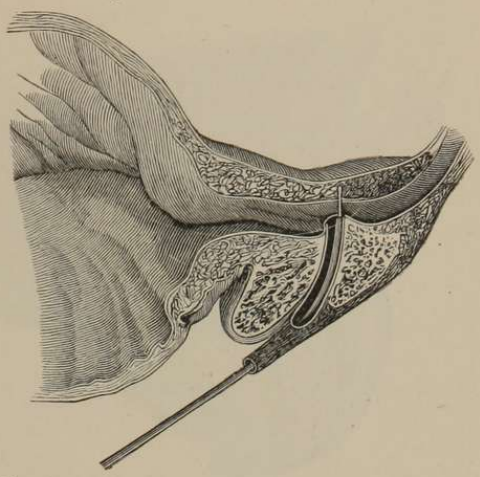

Fig. 740.—Showing the relations of the floor of the bladder to the prostatic urethra in the normal condition of this body. The bristle is passed from the ejaculatory duct into the urethra. (After Socin.)

The relation of the urethra to the base of the bladder, in the normal condition of the prostate, is well shown in Fig. 740. The impediment to

Fig. 741.—Hypertrophy of the prostate, showing the asymmetrical development of the middle or third lobe. *a a*, Openings of ureters. (After Socin.)

the complete evacuation of the bladder in enlargement of the posterior and middle portions of this body may be more readily understood by referring to Fig. 741.

If the sitting or standing posture is maintained, it is evident that a certain quantity of urine will remain in the *cul-de-sac*, behind the prostate, even if the ball-valve formed by the hypertrophied middle lobe is held back by the catheter. In many cases this difficulty may be overcome and benefit gained by evacuating the bladder, with or without the catheter, in the knee-shoulder position. The introduction of the catheter in prostatic hypertrophy is such an important feature in the treatment of this disease, and at times is surrounded with such difficulties, that it becomes important in each case to study the condition of the neck of the bladder and urethra, to determine, with as much accuracy as possible, the deviation of this channel from the normal.

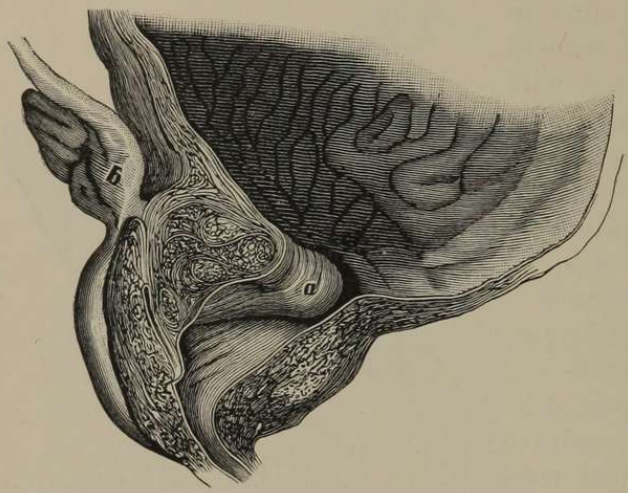

FIG. 742.—Antero-posterior section of the same specimen.

The normal curve of the urethra is shown in Figs. 743, 744. When hypertrophy of the prostate occurs, the distortion is practically an elon-

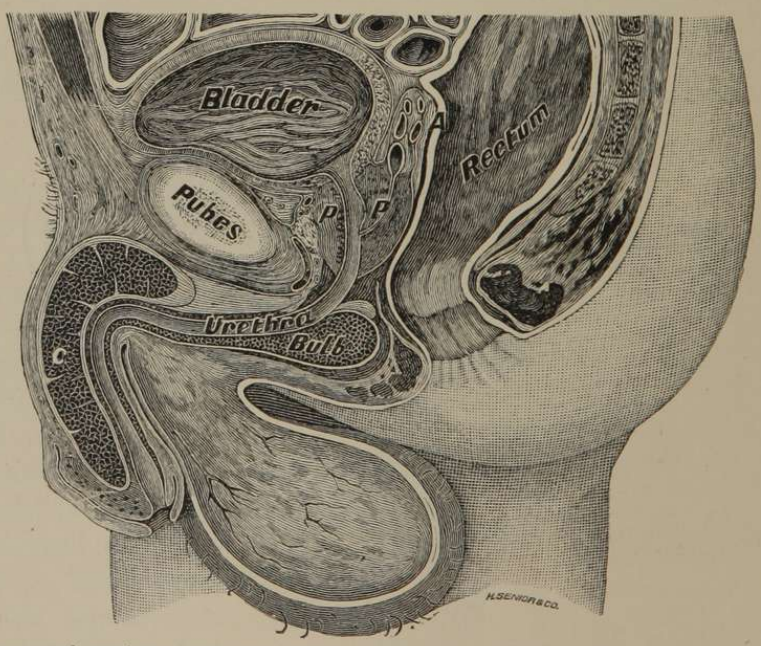

FIG. 743.—The normal urethra of the male adult. From a frozen section. Reduced from life size. (After Braune.)

gation and exaggeration of the natural curve from the triangular ligament back to the opening into the bladder (Fig. 745).

In the exploration an olive-pointed black French catheter, in size

about No. 14 (U. S. scale), will be found to be a safe and satisfactory instrument. If warmed and oiled, it will usually pass to the neck of the bladder without resistance, and, in a majority of instances, the obstruction may be overcome by pushing steadily upon the catheter. No harm can arise from this procedure. If, however, the bladder is not entered, the instrument should be withdrawn, armed with the wire stylet, bent to suit the curve of the deep urethra, and again introduced. A careful degree of force may now be employed to overcome the obstruction, but undue violence must be avoided. The distal end of the catheter and stylet should be well depressed in the effort to pass by the obstruction. If the manœuvre is successful, the stylet is withdrawn, leaving the catheter in position until the bladder is emptied. If the introduction can not be effected, suprapubic aspiration may be done, and

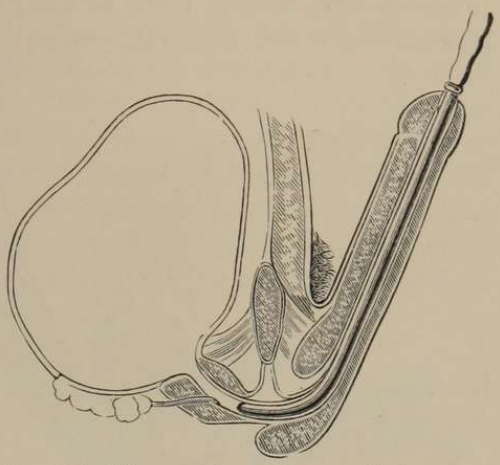

Fig. 744.—The sound passing around the normal curve of the urethra. (After Van Buren and Keyes.)

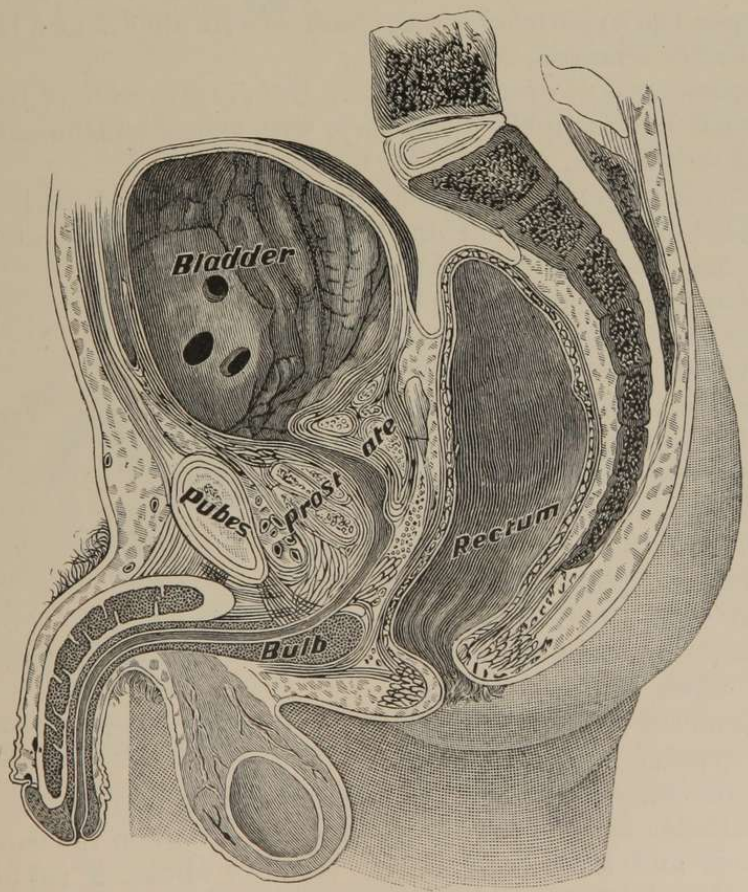

Fig. 745.—The change in the direction of the urethra caused by hypertrophy of the prostate. (After Socin.)

the patient should be put to bed and narcotized with morphia. Under the quieting influence of this remedy spasm of the muscular fibers of the prostate and vesical neck is allayed, frequently resulting in temporary relief from retention. Its value can scarcely be overestimated in the management of obstinate cases of retention and cystitis caused by prostatic hypertrophy.

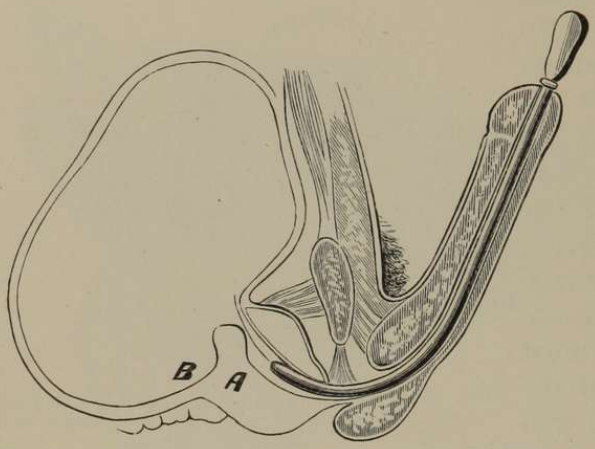

Fig. 746.—Showing the increase in the curve of the urethra in prostatic hypertrophy, and the necessity of a longer curve in the catheter. (After Van Buren and Keyes.)

The propriety of operative interference, beyond catheterization or puncture of the bladder, may be entertained in a certain proportion of cases. It is especially indicated when intense urethritis is caused by the necessary and repeated catheterization. Under such conditions, *cystotomy* may be done.

Suprapubic cystotomy offers the most accessible route to this cause of obstruction, and is not attended with great danger. In several of the author's cases the hypertrophy was identical with that shown in Fig. 747, and was readily removed.

In hopeless cases of cystitis resulting from obstruction of the urethra, from prostatic hypertrophy, cystotomy, with the establishment of a permanent urinary fistula, may become necessary.

After the suprapubic operation has been performed, and the wound has by granulation contracted down upon the ordinary drainage tube, this tube may be removed and a permanent apparatus inserted. This consists of a large-sized soft Nélaton catheter, which is carried through the fistulous opening until it rests comfortably within the bladder, usually about three inches from the level of the integument. This catheter is made to pass through a perforated hard rubber-plate about three inches long and two inches wide. To the corners of this plate are fastened four tapes, two of which are carried around the body and tied, the other two passing under the perinæum, in the same way as the perineal straps of a truss, to hold the drainage catheter firmly in its proper position. When the wound is entirely healed, and the patient begins to move about, a rubber urinal, which receives the outer end of the catheter, is fastened to the inner

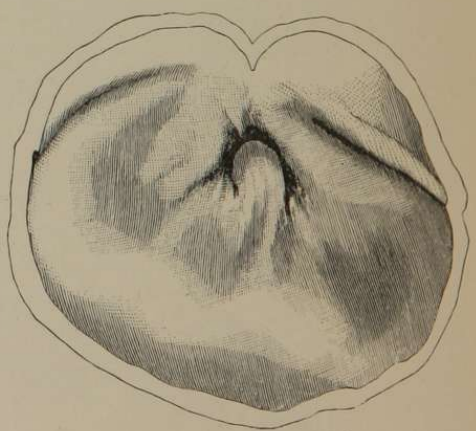

Fig. 747.—A ridge of hypertrophied prostate seen from within the bladder. (After Socin.)

side of the thigh and leg. This urinal extends down the leg, and is so arranged that by turning a little stopcock situated near the ankle it may be emptied when necessary.

Prostatorrhœa.—Chronic prostatitis, or catarrh of the prostate, in a majority of cases follows an acute inflammation of this organ. Its chief cause is, therefore, an extension of a cystitis or urethritis to the epithelial lining of the glandular portions of this body. In a certain proportion of cases it originates as a subacute inflammatory process located in the glandular substance. It is in this form most frequently seen in weak, scrofulous, or tubercular adults about the period of puberty. Prostatorrhœa is a symptom of general hypertrophy of this organ in the earlier stages of enlargement, gradually diminishing as the connective-tissue hyperplasia encroaches upon and destroys by compression the glandular apparatus.

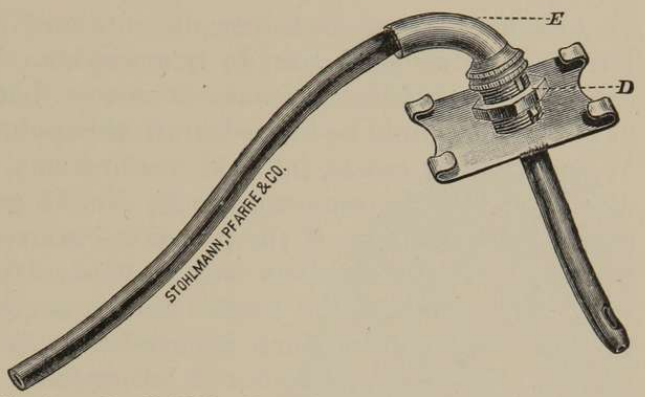

Fig. 748.—Dr. F. Tilden Brown's permanent suprapubic apparatus for bladder drainage.

The leading symptom of this disease is the discharge of a small quantity of bluish-white fluid from the meatus. It is noticed particularly by the patient before the first micturition in the morning, having accumulated during the night. A drop or two may be squeezed from the urethra by pressure along the under surface of the penis from the perinæum forward. It is carried out with the first flow of urine, and, if not observed previously, usually escapes notice. In the severer type of cases the prostatic fluid may be seen immediately after urinating or during the intervals of micturition, as a bluish mucus, moistening the meatus and prepuce, and slightly tenacious and stringy when wiped off. This fluid is also frequently observed when the contents of the rectum are discharged, especially if the fæces are hard and fully formed. Prostatorrhœa occurs in excessive or prolonged venereal excitement.

The *diagnosis* depends upon the exclusion of spermatorrhœa and urethritis. The symptoms of spermatorrhœa are in general so similar to those of prostatorrhœa that a positive differentiation can only be made by microscopical examination. The fluid which escapes may be examined alone, or the first ounce or two of urine passed after a comparatively long interval in urinating may be caught in a separate vessel, allowed to settle, and a drop of the sediment placed upon the slide. The presence of spermatozoa will confirm the diagnosis of spermatorrhœa. The urine first passed after a discharge of semen should not be examined, since under such conditions these elements are found in perfectly normal subjects. In differentiating between prostatorrhœa and gleet, the exploration of the urethra will be necessary. The absence of a stricture

or of marked tenderness in the canal in front of the prostatic portion will exclude urethritis, with the exception of a rare form of chronic follicular urethritis, which, as will be seen further on, may or may not be preceded by a gonorrhœa or stricture. In follicular urethritis, tenderness is not marked. If a large-sized bulbous wire bougie is carried back to the membranous portion of the urethra, and is then withdrawn while the urethra is held in close contact with it, the yellowish-white flakes or plugs of cheesy material will be squeezed out of the follicles and be seen adhering to the bulbs.

Treatment.—The correction of any diathesis which predisposes to a catarrhal condition of the mucous membranes is an important step in the general treatment of prostatorrhœa.

Among the local measures, distention of the prostatic urethra by the introduction of steel sounds is advisable. The larger sizes should be employed, and if the meatus is so narrow that it will not admit No. 20 or 21 (U. S.), it should be incised up to this point as a preparatory measure. When stricture exists, internal urethrotomy should be performed. The dilatation may be commenced with No. 17 and increased to No. 21 at a single operation ; or, if the procedure is attended with pain of a severe nature, the larger numbers may be used at the third or fourth introduction. The point of the sound should not be carried farther than the neck of the bladder, which is between seven and eight inches from the meatus. The operation should be repeated from two to three times a week—not often enough to cause a general urethritis.

Local medication is at times of great value. The method which yields the best results is the deep injection of nitrate of silver, varying in strength from ten to forty grains to the ounce. As a rule, a ten-grain solution is the proper strength to commence with, and is increased as the exigencies of the case demand. The instrument employed is the Keyes-Ultzman syringe (Fig. 749). Under the ordinary aseptic rules the syringe is filled with the proper solution, lubricated with glycerin, and carried back until the point can be felt to pass behind the cut-off muscle and rests in the deep or prostatic urethra. The quantity of the solution injected is usually from five to ten minims, repeated every two or three days. It is usually followed by a slight and temporary sense of irritation or burning.

Fig. 749.—Keyes-Ultzman syringe.

Spermatorrhœa.—This term is used to designate the escape of semen from the ejaculatory ducts without an orgasm. This fluid may find its way into the bladder, but usually escapes by the meatus. The symptoms of this disease do not differ materially from those given in prostatorrhœa. The diagnosis can only be made certain by the recognition of the spermatozoa with the aid of the microscope. It occurs at times in conditions of great physical prostration, as a result of excessive and un-

natural venereal indulgence, and from interference with the function of the muscular elements of the prostate.

The *treatment* is general and local. Measures looking to the improvement of the moral and physical condition of the patient should be adopted. The local treatment is the same as that given for prostatorrhœa.

Aspermatism.—The spermatozoa are wanting in adults whose testicles have been removed or destroyed by disease, in patients in whom both organs have failed to descend and have undergone atrophy; in all cases of complete obstruction of the *vasa deferentia* or ejaculatory ducts, and in certain cases of senile atrophy of these organs. These conditions are rarely amenable to surgical treatment.

Tuberculosis of the Prostate.—Tubercular disease of this organ, though rarely observed, may be primary, or more frequently is secondary, to tubercular deposit in other viscera, as the testis, epididymis, lungs, etc. It is more apt to occur in the young and middle-aged than in the old. The diagnosis can not, as a rule, be easily made. In some cases there are no symptoms of tuberculosis. If with a subacute or chronic lesion of this organ there is a history of phthisis, the deposit of tubercular matter may be suspected. When the febrile movement, hectic flush, profuse sweats and emaciation of this disease are present, a correct diagnosis is readily made. The enlargement and nodular character of the prostate may be made out by digital exploration by the rectum. The treatment is altogether palliative.

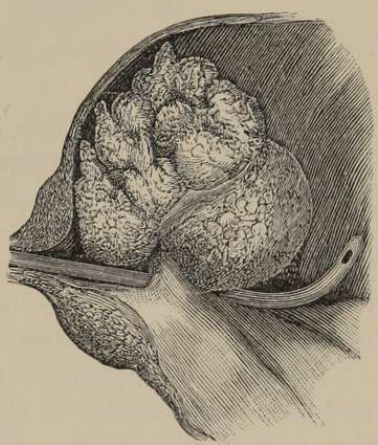

Fig. 750.—Sarcoma of the prostate and neck of the bladder, with obstruction. The catheter has tunneled the neoplasm. (After Socin.)

Carcinoma.—Cancer of the prostate is also rare. It is more apt to occur primarily than by metastasis. Primary cancer of this organ is more frequently seen in young adults than in the old. In the middle-aged and old it is more likely to occur by invasion from a neighboring organ, as the rectum.

In the earlier stages the symptoms of this disease do not differ materially from those of simple hypertrophy. As simple hypertrophy is rare in the young and middle-aged, the presence of a tumor of this organ at this time of life should be regarded with a suspicion of malignancy. The absence of the symptoms of abscess is in some degree a confirmation of this suspicion. If the tumor develops rapidly, carcinoma or sarcoma may be diagnosticated, for, although the disease may continue for one or two years, or even longer, the invaded organ soon assumes a size not met with in non-malignant hypertrophy. Hæmorrhage of a profuse character is apt to follow the introduction of a sound or catheter when carcinoma or sarcoma is present.

Sarcoma is also rare in this organ (Fig. 750). It is more apt to occur

in the young than in the middle-aged and old. The symptoms differ in no essential feature from those present in cancer. The *prognosis* of both diseases is grave, and the treatment palliative.

Prostatic Concretions.—Concretions in this organ are of two kinds—the *corpora amylacea* and *calculi*. The former are small bodies which frequently exist in the follicles of the prostate. Their mode of origin is unknown. They give the well-known amyloid reaction with iodine. Stone in the prostate may originate in the deposit of inorganic elements from the blood and fluids of this organ, either in the follicles originally (Fig. 751) or as accretions upon the amyloid bodies just described.

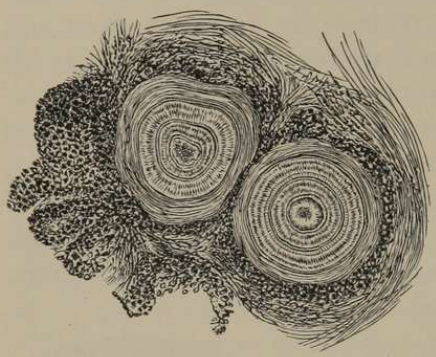

Fig. 751.—Calculi in the prostatic follicles. (After Socin.)

The *symptoms* of prostatic concretions are chiefly those due to the inflammation or enlargement which they produce. Corpora amylacea not infrequently exist in the prostate, causing little or no discomfort. When of large size, especially when they grow by reason of a deposit of inorganic substances, they cause inflammation of the follicles and destruction of the glandular epithelia. A positive *diagnosis* can only be made by bringing a sound or catheter in contact with the concretion. When the stone is situated in the deeper portions of the organ it will escape detection by this method, but the tumefaction it causes may be recognized by digital exploration *per rectum*.

The interference with the escape of urine caused by calculi of the prostate is analogous to that which occurs with general hypertrophy of the body of this organ. The stream of urine is diminished, but remains about the same size, and escapes steadily throughout the act of urination. There is no sudden and complete interruption of the current, as in stone in the bladder, or in enlargement of the middle lobe of the prostate. Calculi of this organ may escape into the urethra and lodge there, or work their way back into the bladder, or pass out at the meatus.

The *treatment* is palliative until operative interference is necessitated on account of dysuria. An exploration should be made by the suprapubic incision and an effort made to remove the concretion from this side. Failing in this, a perineal incision is necessitated, but the prostate should not be incised if it can be avoided. The stone may be removed with the scoop or narrow forceps.

Neuralgia of the prostate and neck of the bladder is occasionally met with. Pain is present in this organ when no symptoms of inflammation are discoverable. It is usually exaggerated during and immediately after micturition, and after a seminal emission. The introduction of a sound shows great tenderness of the deep urethra. The instrument carried into the bladder does not produce the tenesmus and pain common to cystitis. An examination of the urine will demonstrate the absence of pus, which will also serve to exclude inflammation of the bladder or

prostate. The causes of this infection are as a rule obscure. Irregular or excessive venereal indulgence is considered to be one of the most frequent causes of neuralgia in this organ. The treatment involves the removal of every possible source of irritation. The constitutional measures recommended in neuralgia in other parts of the body should be employed. Locally the galvanic current is especially indicated. If the urine is extremely acid and burning, benefit will be derived from the administration of large quantities of alkaline and diluent drinks.

CHAPTER XXVIII.

THE URETHRA—PENIS—TESTICLES—SCROTUM.

Gonorrhœa has been considered in the chapter on infectious diseases.

Among the *complications* of gonorrhœa are balanitis, posthitis, paraphimosis, prostatitis, cystitis, epididymitis, orchitis, bubo, ophthalmia, and retention of urine.

Balanitis and *posthitis*, inflammation of the glans and prepuce, are conditions existing in a varying degree in almost all cases of gonorrhœa. Among the circumcised, or those with short and retracted foreskins, posthitis need not occur, but the acrid discharge will always affect the epithelial covering of the glans in the immediate neighborhood of the meatus. When the foreskin is long and adherent, or not readily drawn behind the glans, it usually becomes swollen and tense, retains the irritating discharge, and inaugurates an exceedingly painful and annoying condition of phimosis. Even when thus swollen, if the prepuce can be retracted, it is apt to be caught behind the corona and become irreducible, with ensuing strangulation, if not relieved by operative interference. Preputial sloughing will occur in a certain proportion of neglected cases.

In the treatment of gonorrhœa certain measures were detailed looking to the prevention of these complications. When, however, they are present in a mild degree, balanitis and posthitis disappear with proper attention to cleanliness. The glans and prepuce should be irrigated by being submerged in a vessel of warm water. Soap should not be employed. The hip-bath, already given as useful in the general management of the disease, is especially so in this complication.

The inflammatory phimosis of gonorrhœa, as of non-specific *balano-posthitis*, demands active measures of treatment. In milder cases it may suffice to maintain cleanliness by the frequent sub-preputial injection of tepid water. For this purpose a syringe with a delicate dull point or nozzle, about an inch in length, is needed. It should be oiled, carefully introduced between the glans and prepuce, and the contents slowly discharged. An irrigating apparatus may also be attached to the nozzle, and a continuous current applied, which does away with the irritation of repeated introductions of the nozzle. If these milder measures do not relieve the pain, tension, and threatened strangulation, an incision should be made. The prepuce may be nicked in several places, or a director introduced in the median line above, along the groove of which a bistoury is carried, and the division effected.

When inflammatory paraphimosis exists, adhesions rapidly occur at a point just behind the corona, on the dorsum penis, rendering a reduction impossible unless these transverse bands are divided. The reduction of a paraphimosis is undertaken in this manner: The organ is held in a vessel of cold water for a few minutes, or cold cloths are wrapped loosely over and around the swollen parts. When removed, the glans and prepuce are thoroughly lubricated, and the organ grasped so that while the soft parts of the thumbs press the glans backward, the fingers are drawing the prepuce to the front. Or the penis may be grasped by the thumb and finger of the left hand, and the foreskin drawn forward while the glans is pushed backward by the thumb and fingers of the opposite member. When the reduction is accomplished, the patient should be directed to make every effort to prevent a recurrence of the accident.

If the efforts at reduction fail, the contractions on the dorsum, behind the glans, should be divided by one or more incisions in the long axis of the penis. Œdema of the prepuce, especially of the lower portion, is apt to occur, even in cases of recent paraphimosis, and, when the condition has existed for a day or two, infiltrations occur, which may persist for a long time after the constriction is relieved.

Prostatitis and cystitis, occurring with gonorrhœa, require treatment not differing from that already given. *Retention* must be relieved by the small soft catheter or by suprapubic aspiration. *Epididymitis*, or inflammation of the vas deferens and the globus major and minor, is one of the most painful complications of gonorrhœa. Perfect physical quiet, with support of the scrotum and testicle, are essential. At the earliest indication of an extension of the infection along the vas deferens, every effort should be made to arrest the disease before it reaches the epididymis or to confine it at least to the globus major. The anatomical arrangement of the globus minor, which is composed of a single tube in numerous convolutions, makes it more easy of occlusion by inflammation than the multiple tubules which compose the globus major. Sterility not infrequently follows an epididymitis which seriously involves the globus minor. The last of these measures may be secured by using the handkerchief sling, which is made as follows:

Attach a belt or piece of roller around the waist, above the pelvis; fold a good-sized silk handkerchief in a triangular shape, carry the center of the long side of this triangle beneath the scrotum, at the perineoscrotal junction, attach one of the long ends to the belt, near the anterior superior spine of the ilium, on either side, and bring the short piece directly upward, in front of the scrotum and penis, and pin it to the belt in the median line; or the ends may be tied just above the root of the penis (Fig. 752).

Another method is to place a three-cornered cushion beneath the scrotum, close up to the perinæum, and allow the testicles to rest upon this support; or two thickly folded towels may be pinned together and carried tightly around the thighs at the level of the perinæum.

At times the tension of the parts is so great that, not only to relieve

pain, but to prevent gangrene, puncture or incision is imperative. The most immediate relief will follow this operation. A sharp narrow blade is preferable, and, if the instrument is not made for this especial purpose, it may be extemporized by projecting the point of an ordinary sharp-pointed bistoury half an inch beyond the surface of a cork through which the knife is thrust. With this guard attached, the punctures may be made rapidly and without danger of penetrating too deeply.

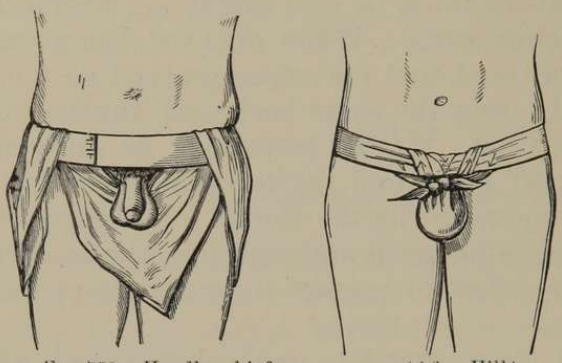

Fig. 752.—Handkerchief suspensory. (After Hill.)

Although the procedure is very painful, it is usually so rapidly accomplished that an anæsthetic is not necessary. The injection of a two-per-cent cocaine solution will afford a fair degree of anæsthesia. The operator holds the scrotum and testicle so as to make tense the skin over the epididymis and to expose it properly to view, and then by well-directed and rapid thrusts punctures the organ in from two to four or six points, scattered over the induration. A free discharge of dark or black blood usually follows, and in from twenty to thirty minutes the pain is greatly if not entirely relieved. The antiseptic precautions should be carried out in this procedure.

Orchitis is an infrequent affection in gonorrhœa. The treatment is in general similar to that of the last-named disease. The diagnosis is readily made out by the touch, for, when hydrocele does not coexist, the induration of the organ can not well be mistaken. Poultices of tobacco have long enjoyed a reputation in the treatment of orchitis and epididymitis, but when warm applications are indicated, well-saturated and frequently changed warm cloths will be found equally satisfactory in the effect produced, and much more cleanly than the poultices. In the majority of instances cold will be more agreeable than heat. The ice bag may be utilized in the following manner with great satisfaction: A bladder or rubber bag is filled with crushed ice, placed upon the three-cornered perineal cushion, and the inflamed organ allowed to rest upon it. If the cold is too great for comfort (and the patient may usually be relied upon to determine this), a layer or two of lint or cotton may be interposed. It occasionally becomes necessary to puncture or incise the tunica albuginea in orchitis somewhat after the fashion given in puncture for epididymitis. Two methods are employed, namely: to carry a sharp-pointed, long knife through a single puncture of the scrotum down to the testicle, and incise the fibrous capsule in one or more places parallel with its long axis and along its anterior surface; or to use an instrument similar to that employed in epididymitis, and make several punctures through the scrotum and the anterior portion of the capsule.

Inguinal adenitis, or *bubo*, occurs in a considerable proportion of cases of specific urethritis, and is apt to be bilateral. The disease is

readily recognized by the swelling in the groin. The inflammatory process is usually so rapid in its invasion that the different glands in this group of lymphatics can not be made out, the entire group being matted together in one mass of embryonic cells infiltrating the tissues around the glands as well as involving their substance. The gonorrhœal bubo tends naturally to suppuration. In mild cases, and where the proper measures are taken at the early appearance of the adenitis, this disaster may be averted; but in others, partly owing to the unfavorable condition of the tissues and to the continued irritation from motion, pus formation can not be prevented.

In the treatment of acute inflammatory bubo, perfect rest is imperative, and the dorsal decubitus should be maintained. Local medication is of little value. The employment of cold will be found agreeable in the earlier stages, and may serve to prevent suppuration. The ice-bag may be employed by laying it upon a circular pad placed around the bubo. In this way the pressure is entirely taken off the inflamed surface. After the formation of pus is inevitable, warm cloths or poultices should be substituted. When pus is formed, a free incision under cocaine anæsthesia should be made.

Chronic suppurative adenitis of the inguinal glands occasionally persists long after the gonorrhœa which caused it has disappeared. The only remedy is to dissect out the diseased glands with the curved scissors, or scrape them out with Volkmann's spoon.

Gonorrhœal *proctitis* is a rare affection, and does not call for especial consideration.

Ophthalmia, resulting from the inoculation of the conjunctiva with the virus of specific urethritis, has been considered with lesions of the eye.

Gonorrhœal Rheumatism.—In a certain proportion of individuals suffering from gonorrhœal inoculation at a period varying from five or six days to several weeks from the date of the attack, symptoms not unlike those occurring in gout or rheumatism make their appearance in the joints, tendons, and bursæ, and less frequently in the nerves and eye. The parts involved become more or less swollen and painful. The pain, however, is less than in ordinary rheumatism. The febrile movement is not high, and the character of the urine is unchanged, in both of which features it differs from ordinary rheumatism (Fournier). Neuralgia occasionally supervenes in the course of this disease. In a certain proportion of cases the eye is affected, but the ophthalmia here in no way resembles that of gonorrhœal conjunctivitis. The pathology of this disease is not understood. It is claimed by some observers that the diplococcus occasionally met with in the fluid removed from the joints in this affection is not the gonococcus of Neisser. The treatment is entirely expectant.

Gonorrhœa in females is usually less severe than in males, and yields more readily to treatment. The chief seat of the inflammation is in the vagina. The urethra and bladder may also become involved. From the vagina the infection often spreads to the uterus and tubes, re-

sulting in sterility by occlusion of these ducts. In the treatment, quiet is of first importance. The warm hip-bath should be employed several times a day, and the vagina irrigated at regular intervals with warm permanganate-of-potash solution (1 to 3,000), thrown in from a fountain syringe.

Non-specific urethritis may be caused by injury, as from the introduction of a catheter or any foreign body, the lodgment of a calculus, the injection of an irritating substance, or from without, as in striking the perinæum upon the saddle in riding, or excessive coitus. It may also result from infection from an unclean vagina or urethra in which pyogenic yet non-specific bacteria are present. It is usually of short duration, mild in character, and does not involve the entire length of the canal. In a medico-legal sense it may be necessary to determine whether specific infection is or is not present, and, as stated on a previous page, this can only be decided by the microscope, together with a careful study of the grosser symptoms of this disease already given, and in no other way. Non-specific urethritis should be treated by the removal of the offending substance, by rest and irrigation, as in the specific form of the disease, and sterilization of the urine is advisable.

Gleet, or Chronic Urethritis.—Gleet is a name given to the prolonged discharge from the urethra of a variable quantity of muco-purulent, bluish-white fluid. This discharge is a transudation from the mucous and glandular epithelia of the urethra. In gleet, all or any limited portion of this tube may be affected. The pathological change is a puffiness of the lining membrane, due to hyperæmia of the subepithelial vascular area, with a tendency to embryonic and connective-tissue formation. In some points patches of erosions or tissue necrosis occur. The epithelia lining the glandular apparatus—as those of the prostate, Cowper's glands, and the urethral follicles—become more or less involved. Not infrequently the outlets to these follicles become obstructed by the superficial inflammatory process, resulting in the formation of one or more retention cysts, which project into the lumen of the tube.

Any form of acute urethritis may pass into this chronic condition of gleet; or a urethritis, subacute in its character from the beginning, may continue as a gleet.

Although chronic urethritis may exist without the presence of stricture of the urethra—as in follicular urethritis—the exceptions to this rule

Fig. 753.—Klotz's endoscope.

are extremely rare. Any chronic interference with the normal caliber of the urethra serves to induce a catarrhal condition of the mucous membrane of this canal, which, commencing near the seat of stricture, may involve any portion of the tube.

The *treatment* of gleet involves, primarily, the removal of the cause. Taking stricture as the chief cause, urethrotomy with dilatation, or dilatation without cutting, is demanded. In mild cases without close organic stricture, the introduction of the steel sound will often effect a cure. The methods of procedure will be given in full in the treatment of stricture of the urethra.

In *chronic follicular urethritis* it is best to examine carefully with the endoscope (Fig. 753) the urethral canal, and apply nitrate of silver directly to the diseased surfaces.

Stricture of the Male Urethra.—Strictures of the urethra may be divided into two classes: *true* or *organic*, and *false* or *spasmodic*.

A permanent diminution of the caliber of this canal, as a result of an inflammatory process, constitutes a true or organic stricture. A spasmodic stricture exists when the normal caliber is diminished as a result of contraction of the voluntary or involuntary muscular elements connected with the urethra.

Congenital non-inflammatory narrowing of the meatus does not constitute a stricture. The normal contraction of the compressor-urethræ or "cut-off" muscle is also excluded in the definition of spasmodic stricture.

An organic stricture may be *annular*, *tortuous*, *single*, or *multiple*.

In annular, or ring stricture, the cicatricial contraction involves the entire circumference. It may vary in width from a line to one inch.

In tortuous, or irregular stricture, an inch or more of the urethral canal is involved.

Two or more annular or lateral strictures may unite to form a tortuous or irregular stricture.

The *pathology* of stricture of the urethra is that of an inflammation of variable intensity involving the epithelial and submucous basement membrane of this canal, together with the deeper tissues of the corpus spongiosum, and occasionally of the corpora cavernosa. This process usually begins from within, but may originate in the deeper tissues of the penis and involve the urethra secondarily.

In a typical case there is first an increased vascularity of the submucous area, followed by emigration of leucocytes and cell proliferation. The lining membrane becomes puffy and swollen, and the diameter of the canal is diminished. As the acute inflammation subsides, the puffiness disappears, but the caliber of the tube is again diminished by the contraction which takes place in the newly formed connective-tissue elements (cicatrization).

Causes.—Among the causes of stricture, specific urethritis ranks first, a fact which emphasizes the importance of the early recognition and prompt treatment of this disease.

Any violence inflicted upon the urethra, either from without, as by a blow upon the perinæum or penis, or from within, as by the reckless use of instruments, the lodgment of calculi or other foreign bodies, may also cause a stricture.

Chancroidal ulcer within the meatus is a rare cause of this lesion.

Location.—The most frequent seat of organic stricture is in that portion of the urethra limited behind by the compressor-urethræ muscle, and in front by the suspensory ligament at the junction of the penile with the perineal urethra. Next in order is the first inch within the meatus. Stricture in the prostatic portion is rare. As stated in the consideration of diseases of the prostate, it may occur in general hypertrophy of this organ.



Fig. 754. Dick's gum bougie, with oval tip.

Diagnosis.—The symptoms of stricture are a gleety discharge, interference with the escape of urine or semen, and pain. A muco-purulent discharge continuing for several months is almost pathognomonic of this lesion, and justifies exploration in order to determine the presence of stricture. Interference with the escape of urine from the bladder when atony of this organ and hypertrophy of the prostate are eliminated is also a symptom of importance. A twisted or forked stream, when not of diminished volume, has no significance, for this may exist with a perfectly normal canal. Pain is not often a symptom of organic stricture, but, when present, is not without value as an indication of localized inflammation.

No matter what symptoms may exist, a diagnosis can only be arrived at by instrumental exploration, which can be done without pain, and the exact location and character of the stricture made positive.

For this purpose the bulbous bougie is invaluable. These instruments are of two kinds—the elastic or gum bougie of Dick (Fig. 754), and the oval-tipped wire bougie of Otis (Fig. 755). The gum bougie is rarely used. They should be made of all sizes, commencing with No. 6 and ending with Nos. 21 or 23 (U. S. scale). For practical purposes every alternate size, from Nos. 6 to 23 inclusive, will suffice. The wire bougies are thoroughly satisfactory instruments, and incapable of injury to the urethra if ordinary care is taken. The bulbs are oval, the wire is flexible, and is screwed into the bulb for security.

In the effort to locate a stricture, the different diameters of the normal urethra at various points in this canal must be borne in mind. The meatus is least dilatable, and the membranous portion next in order. Immediately behind the meatus there is an expansion into the fossa navicularis, and from this point to the suspensory ligament (the junction of the penile and perineal urethra) the diameter is about the same. From the suspensory ligament to the anterior layer of the triangular ligament the diameter gradually increases. This, the bulbous portion, is the largest part of the canal. Behind the membranous portion there is a second expansion in the prostate (Fig. 756).

The patient should be placed upon the table or bed in the dorsal decubitus. In order to secure insensibility, from ʒj to ʒij of a two-per-cent solution of cocaine should be thrown into the urethra with the ordinary urethral syringe introduced no farther than well within the meatus. While

a stronger (four-per-cent) solution may be required and with safety employed, the idiosyncrasy of each patient must be studied by commencing with ʒj of a two-per-cent solution and gradually increasing the quantity and strength as required. In five to fifteen minutes local anæsthesia is obtained. A bulb of medium size is selected and properly warmed



Fig. 755.—Otis's oval-tipped wire bougie for locating strictures of the urethra.

and oiled. The wire is not curved in exploration of the urethra anterior to the membranous portion. The penis should be held at about a right angle to the plane of the body, and, as the instrument is being introduced, the organ should be elongated in order to obliterate any folds in the mucous membrane. This membrane is not so closely attached to the connective tissue of the corpus spongiosum but that it can be perceptibly displaced up and down and doubled upon itself if sufficient force is applied. If no stricture of caliber smaller than the bulb is encountered, it will glide smoothly and uninterruptedly down to a point about five inches from the meatus, where it will be arrested, having reached the end of the bulbous portion and lodged in a pocket just in front of the anterior layer of the triangular ligament. Withdrawing the instrument, it will in all probability return as smoothly as it entered. If, however, a stricture exists, and the bulb used is about the size of the lumen of the stricture, as it is carried into the urethra a slight resistance will be felt. As the instrument is withdrawn, the broad shoulder of the oval will come in contact with the posterior surface of the obstruction, where it will be arrested. The penis should now be allowed to retract, and the thumb and finger of the left hand slipped down to the level of the meatus, where the wire is grasped and slightly bent. The instrument is steadily drawn through the stricture, and, as soon as the resistance ceases, the wire is again bent at the level of the meatus. The distance between the two points at which the wire is bent represents the extent of the stricture.

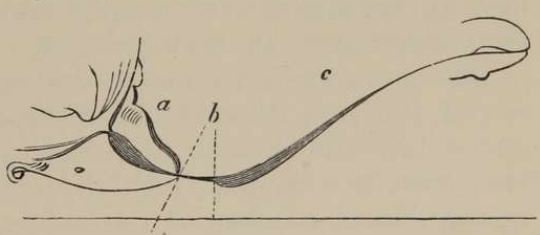

Fig. 756.—Longitudinal section of the urethra, showing the diameter of the canal at various points. *a*, Prostatic; *b*, membranous; *c*, penile portion. (After Thompson.)

When it becomes necessary to search the urethra beyond the bulbous portion, the wire should be bent to correspond to the normal curve of the deep urethra. The handle of the instrument should be bent in an opposite direction in order to prevent the possibility of getting the point of the bougie turned toward the perinæum. It is introduced in the same

way as the catheter or steel sound. When the triangular ligament and compressor urethræ muscle are encountered, by depressing the handle toward the thighs of the patient, the bulb is made to rise out of the pocket in front of the anterior layer of the ligament and to pass into the membranous portion. If a stricture is present the resistance, if not felt as the bulb goes through, will certainly be appreciated as it is withdrawn, if the instrument is large enough. If the patient is not narcotized, spasmodic contraction of the compressor muscle may arrest the bulb, and, in a certain sense, simulate stricture.

In the resistance of the muscle there is a roundness, smoothness, and elasticity which differ from the rough surface of cicatricial tissue and the inelastic grip of a stricture. When the obstruction is felt, the same method of measurement and location is to be observed. A stricture may be roughly estimated by the introduction of a catheter, ordinary bougie, or steel sound, but it can not be intelligently or satisfactorily defined without the oval bulbs.

Not infrequently it will be found that the meatus is too narrow to admit a bulb of sufficient size to define the stricture, necessitating division of the meatus (*meatotomy*). This operation may be done with an ordinary scalpel or bistoury, but with nothing like the exactness and freedom from pain which is secured when the urethrotome is employed. The incision should be made in the median line, and should correspond to the floor of the urethra. It should not extend deep enough to wound the artery of the frænum, nor should it be any deeper than is sufficient to admit the larger bougies.

If the bistoury is employed, the operator grasps the glans between the thumb and finger of the left hand, introduces the knife, cutting-edge downward, a distance of a half-inch, and cuts carefully outward. The injection of cocaine solution into the tissues of the part incised or the local application of a few cocaine crystals within the meatus will render the incision along the floor painless.

The operation can be more accurately and satisfactorily done by the use of the Otis dilating urethrotome (Fig. 756). It should be introduced into the meatus until the knife is about three fourths of an inch from the opening, with the cutting edge of the concealed blade turned toward the floor of the urethra. The dilating screw at the end of the instrument is now turned until the meatus is put fairly on the stretch, when the knife is drawn quickly through and the division effected. If the blades are too widely separated, the opening may be too deeply slit. If the first incision is not sufficient, this manœuvre should be repeated. The small amount of bleeding which at times follows can be readily controlled by plugging the wound and the anterior half-inch of the urethra with a small strip of iodoform gauze. To prevent a recontraction, it is necessary to introduce the straight sounds, at intervals of from two to four days, for two or three weeks after the operation.

Treatment.—The treatment of *organic* stricture of the urethra should be considered under two headings: first, those situated in any part of the

urethra anterior to the membranous portion; and, second, those of the membranous urethra.

Internal urethrotomy is applicable practically to all strictures anterior to the membranous urethra, while those of the membranous portion, with rare exceptions, may be relieved by a modification of the same procedure.

External urethrotomy, or "perineal section," is indicated in the exceptional cases in which the stricture is so tight and tortuous that a dilating filiform can not be introduced to make way for the urethrotome; when a fistula or abscess complicates the stricture, and when the cicatricial tissue is so extensive that recontraction takes place after one or more trials of the less radical operation. When properly performed it yields gratifying results. The method of *gradual dilatation* by the repeated introduction of sounds was formerly much in vogue, and even now is practiced by some surgeons, but it is much more painful and requires a greater length of time to effect a satisfactory result than with direct urethrotomy followed by dilatation with sounds.

Complete divulsion or rapid dilatation of a stricture is rarely indicated, and is practically an obsolete operation.

Partial divulsion by the dilating filiform bougie of Banks is often necessary as a preliminary to internal division.

Internal urethrotomy in ordinary cases of stricture is performed as follows: The urethra should be thoroughly irrigated with a 1-to-3,000 permanganate-of-potash solution or a saturated solution of boric acid. This may be done in the manner directed in the treatment of gonorrhœa. Or the tip of an ordinary urethral syringe may be pressed firmly into the meatus and its contents expelled until the urethra is fully distended, the fluid being thus forced into the follicles and deeper portions of the canal. This should be repeated four or five times, and the excess of fluid forced out by pressure before the cocaine solution is introduced. A very satisfactory anæsthesia can be effected by injecting into the urethra with the same syringe from one to three or more drachms of a two- to four-per-cent solution of cocaine, which is forced in, and the meatus held tightly as the instrument is withdrawn to prevent the escape of the solution. In about five minutes the anæsthesia is complete, when by releasing the pressure on the meatus the cocaine runs out. As already stated, the employment of this agent in any manner, and especially in the urethra, should be made with care. When using it for the first time in a patient, the smaller quantity should be tried and the constitutional effect closely observed. A bulbous bougie is next introduced and the stricture definitely located. If the bougie produces pain and no constitutional effects have been observed from the cocaine, either the quantity of the solution may be increased or a three- or four-per-cent solution employed in order to effect a satisfactory anæsthesia. The distance from the meatus to the posterior boundary of the stricture is now measured on the urethrotome, beginning at the point where the knife is projected and extending toward the handle. Half an inch should be added to this in order to be sure that the knife is carried well beyond the stricture, and it is generally ad-

visable to indicate this point on the instrument by a small ring clipped from a rubber tube and slid over the shaft. It is now ready for introduction.

The urethrotome (for which excellent instrument we are indebted to our fellow-countryman, Prof. F. N. Otis) consists of a shaft, handle, and blades. The shaft is composed of two bars, which can be separated or closed by turning a screw at the handle, where there is also arranged a dial which registers the exact degree of dilatation by the separation of the bars. In the upper bar of the shaft is a slide or groove along which the knife is carried, and when this arrives near the point of the instru-



Fig. 757.—Otis's dilating urethrotome, with the author's cog-wheel attachment.

ment the blade sinks into a depression and disappears. I have added to this instrument a cog-wheel apparatus attached near the handle, by the use of which the knife is carried steadily forward or backward as desired, and is made to cut with mathematical precision. In expert hands this addition is not necessary, the original instrument of Otis being eminently satisfactory. The patient should rest upon the back, with the legs fully extended, while the surgeon stands at the patient's right side. With the bars of the instrument closed, the knife inserted, and the blade concealed, the shaft is lubricated with glycerin as far as it is to be introduced. The glans penis is grasped between the thumb and finger of the left hand, the organ held in the same position as when the stricture was located, and the instrument with the cutting edge of the knife exactly in the middle line of the roof of the canal carried into the urethra until the rubber ring touches the meatus. If the measurements have been correctly taken, the blade of the instrument is now a quarter of an inch beyond the posterior wall of the stricture. The left hand, releasing the penis, is made to grasp the urethrotome and steady it, while with the right hand the dilating screw is turned until the arrow on the dial indicates a separation of the bars nearly equal to the diameter of the bulb which located the stricture. The degree of resistance felt by the hand of the practiced surgeon will indicate whether or not the necessary dilatation is effected without consulting the dial. Taking hold of the end of the knife at the handle, this latter instrument is made to travel through the stricture from behind forward and accurately along the median line of the *roof* of the urethra. As the knife advances, the resistance of the stricture can be readily felt as it is steadily and firmly drawn through the cicatrix until all resistance ceases and the knife moves smoothly. Without changing the position of the instrument, the knife is rapidly pushed back to its original position and the dilatation increased by one or more turns of the screw, and the knife again carried forward and back as for the first incision. The bars should now be still further sepa-

rated in order to part any cicatricial bands that may have escaped the knife (modified divulsion). When this is done, by reversing the screw the bars should be partially closed and withdrawn. If the bars are closely approximated, the mucous membrane may be caught and torn. A bulb equal in size to the caliber of the urethra is now introduced, and this should pass freely up and down the canal. If it catches at any point, further incision is required. Finally, a full-size, straight sound is carried through the stricture. The urethra should now be again irrigated. The most careful asepsis should be practiced in urethral surgery, and no instrument should be introduced which has not been cleansed and boiled prior to its use.

Hæmorrhage after internal urethrotomy is usually slight. When the incision has been made in the pendulous part of the urethra, it may be readily arrested by turning the penis up on the belly, laying a handful of cotton or gauze on the organ and strapping it down by a bandage carried around the pelvis. In the posterior portion of the urethra a compress of cotton applied along the perinæum will control the bleeding (Fig. 759). The patient should be put to bed at once and remain quiet for several days. Not infrequently in from two to twelve hours after urethrotomy, or after the introduction of a sound or catheter, the patient is seized with rigors or pronounced chills followed by a considerable rise of temperature. This, the so-called "urethral fever," is due to septic infection in the wounds inflicted upon the canal. When the temperature rises to 103° or more it is a wise precaution to administer from two to eight grains of acetanilide and to give the patient an alcohol or cold-water sponge bath until the temperature is below 100° F. The repeated introduction of steel sounds or of gum bougies is essential in the after-treatment of internal urethrotomy. The dilatation should be commenced usually on the second or third day after the operation. If fever exists, the use of the sound should be postponed until there are no symptoms of infection. Cocaine anæsthesia should be employed, for, as a rule, the reintroduction of the sound is more painful than the primary operation. The quantity of cocaine used at this stage of the treatment should be less than for the original cutting operation. The urethra in the operative field is now covered with a granulation tissue capable, under too great pressure, of rapid absorption of the solution of cocaine and of carrying it into the system, producing constitutional and at times alarming symptoms. When it has required two or three drachms of a two-, three-, or four-per-cent solution for the primary operation, before introducing the sound for the first time, I begin with the injection of one drachm of a two-per-cent solution, carefully watching for the symptoms of systemic absorption, gradually increasing the quantity until a safe and satisfactory degree of anæsthesia is obtained. For the penile urethra the *straight* sounds are preferable to the curved instruments. Beginning with the proper size, usually about No. 17, the numbers are gradually increased until the urethra at all points is dilated to its normal caliber. This procedure should be repeated every third or fourth day for three or four weeks, and every fifth or sixth day for about two

months following. It is essential to keep the walls of the incision through the strictured portion open by the interrupted dilatations until the wounded surface is covered with newly-formed epithelium. Should cystitis, epididymitis, or orchitis ensue after urethrotomy, all operative measures should be discontinued until these symptoms disappear.

The *prognosis* after urethrotomy should be guarded. Many cases do not recur, but a stricture of long standing with extensive induration, no matter how thoroughly divided and carefully treated, tends to recon-



Fig. 758.—Banks's dilating filiform bougies.

tract. In some instances it thus becomes necessary to employ dilatation either with the sound in the hands of the surgeon, or with the soft bougie if this duty is intrusted to the patient, at intervals of from two to three weeks or months, as the case may require, during the life of the patient. In a certain proportion of cases the stricture will be found so tight that the urethrotome can not be passed through it, necessitating partial divulsion by the *dilating* filiform bougie. This excellent instrument, devised by Dr. E. A. Banks, of New York, meets every indication. With the urethra cocainized as heretofore directed, it may be injected with a small quantity of glycerin or sterilized oil and the filiform carried into the meatus and down the urethra until it meets the obstruction. By careful manipulation it is made to find its way through the most tortuous stricture. As soon as the filiform portion is engaged in the stricture, continued pressure carries this portion into the bladder, while the larger dilating portion of the shaft stretches or tears the cicatricial bands sufficiently to admit the urethrotome. This small instrument, in the vast majority of cases of stricture, accomplishes in skilled hands, in five to thirty minutes, a greater degree of dilatation than the method of continuous dilatation employed by Sir Henry Thompson accomplished in a week. As it is elastic and readily bends back upon itself when an obstruction is encountered, it is a perfectly safe instrument in competent hands. When fully introduced, the filiform portion curls upon itself, producing no injury to the bladder. In rare instances, where the dilating filiform bougie can not be made to pass beyond the obstruction, external urethrotomy is demanded.

Modified Internal Urethrotomy.—When a stricture of the membranous portion of the urethra exists and a filiform bougie can be passed through it and there is no urethro-perineal fistula or abscess, relief from the obstruction may be obtained by this operation. The stricture is partially divulsed by the forced introduction of the Banks dilating filiform bougie, as just advised in very tight strictures of the pendulous portion of the urethra. If an ordinary-sized dilating filiform bougie is not large enough to make room for the urethrotome, it should be followed by a

larger instrument of the same kind. As soon as the way is clear for the urethrotome, the ordinary straight instrument of Otis (Fig. 757) is carried into the urethra until the membranous portion is reached. Placing the left hand upon the penis over the pubic arch and pressing down upon the body of this organ, putting the suspensory ligament upon the stretch, and at the same time depressing the handle of the instrument until the shaft is parallel with the surface of the thighs, the curved urethra is made into a straight channel and the point of the urethrotome with the slightest possible pressure is forced through the stricture until its tip rests in the neck of the bladder. As a rule, the stricture grasps the instrument in this position tightly. Without separating the bars, the knife is now drawn forward and backward along the middle line of the roof of this portion of the urethra, partially dividing the stricture. If the bars are then separated, in the majority of cases the stricture readily gives way by divulsion in the line of the partial incision. If the stricture is still unyielding, requiring greater force in the separation of the bars of the urethrotome than seems proper to the operator, a very slight dilatation may be made and the knife again drawn through in order to make a deeper incision, and thus enable the divulsion to be completed. Two objections may be made to this operation: first, the danger of hæmorrhage from the artery of the bulb or the artery of the corpus cavernosum; second, its lack of thoroughness in completely removing the cicatricial tissue. If the method is closely followed, there is no possible danger of hæmorrhage. The knife is used only in dividing the most prominent bands of the stricture—those farthest from the vessels—the remaining bands being torn through by the divulsing power of the instrument. The arteries which surround or arch over the urethra are elastic tubes which stretch under the divulsion; and while the unyielding bands of cicatricial tissue are torn across, the vessels are not injured.

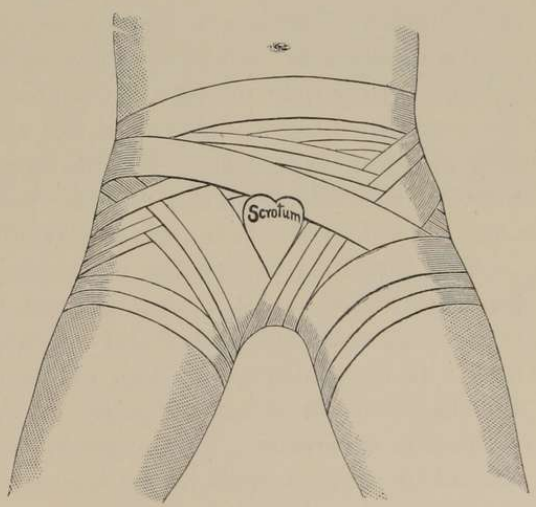

Fig. 759.—The author's method of compressing the penile and perineal urethra to control hæmorrhage after internal urethrotomy.

I have employed this method in a large number of cases, and have never had any hæmorrhage. As to its inefficiency, necessitating the continued, interrupted use of bougies or sounds, the same may be said of many strictures of the anterior urethra which are treated practically by all surgeons in the same manner. Moreover, if a very long and dense stricture be encountered, which does not yield readily to the method of dilatation, perineal section may then be resorted to for the radical cure. I am convinced that this last-named operation is performed in a great many cases where modified internal urethrotomy

would give relief and satisfaction. Hæmorrhage from the deep urethra, as well as from the perineal portion anterior to the triangular ligament, may readily be controlled by compression. A large wad of absorbent cotton is placed on the perinæum, extending from the anus forward to the scrotum; in front of the scrotum, along the penile urethra, a second cotton compress is applied, and a bandage passed around the pelvis in a figure-of-eight fashion over the iliac crests and around the hips. In case there were any bleeding backward into the bladder, the introduction of a large-size sound would act as a direct hæmostatic. The necessity for such a procedure will never be indicated when proper care is taken.

The after-treatment consists in interrupted dilatation by the introduction of straight or curved sounds.

External urethrotomy, or *perineal section*, is an operation for the relief of close organic stricture of the bulbous or membranous portions of the urethra which can not be reached through this canal. With the exception of those cases where urinary fistula or chronic abscess exists as a result of stricture, the conditions which justify this operation are rare.

It is performed with or without a guide. When a sound or bougie can be carried through the obstruction into the bladder the procedure is much simplified. Without this guide the operation is surrounded with considerable difficulty. In external urethrotomy the patient is placed in the lithotomy position, being prepared as for this operation. After the anæsthesia is complete, a careful and final effort should be made to carry a filiform or soft bougie through the stricture and into the bladder. If this can not be done, a good-sized sound should be carried down to the obstruction, and this will serve to guide the operator to the commencement of the stricture.

An incision is then made exactly in the median line, the anterior limit being slightly in front of the ascertained commencement of the stricture, the posterior extending toward the anus a sufficient distance. In making this incision the scrotum should be held up by an assistant, who is directed not to displace the median raphe to either side. The legs must also be held in the same relative position.

The bleeding is usually considerable, as the vascular tissue of the bulb is divided. All vessels should be secured; but the oozing, which is general, need not retard the operation. As soon as the sound or filiform, at the anterior margin of the constriction, is seen, the division should continue along the guide until the healthy urethra is reached beyond the stricture. If no guide has been introduced, the dissection should be carried back in the known direction of the base of the bladder, guided by the location of the prostate with the finger introduced into the rectum. The first indication that the canal is reached behind the stricture will be a gush of urine. On account of the obstruction, the urethra between it and the bladder is widely dilated, and for this reason is more readily found. It is essential to the success of this operation that all cicatricial tissue be dissected out. A large-sized steel sound should now be introduced through the meatus and into the bladder. If

any difficulty is met with in introducing this instrument, a flexible bougie may be substituted. It is not advisable to leave the instrument in the urethra. In order to prevent bleeding, the wound should be packed temporarily with gauze, held in position by a T-bandage. A fatal hæmorrhage occurred in one of the author's cases, the packing having become loose while the patient slept.

The urine usually escapes through the wound for the first few days, and afterward partly through the wound and partly through the urethra. In rare instances it escapes uninterruptedly through the urethra. The after-treatment consists in the introduction of the sounds or bougies (as above directed) through the urethra as far as the neck of the bladder. This operation should be repeated every three or four days until the urine ceases to escape through the wound, and once a week thereafter for several months. In urinary fistula and peri-urethral abscess the operation is practically the same. The urethra is opened in the area involved and the stricture incised and dissected out.

Interrupted Dilatation.—In the treatment of stricture of the urethra by this method there are required *steel sounds* and *flexible bougies.* Steel sounds are of two patterns, the straight and curved. The former are preferable for dilating strictures anterior to the membranous portion, and when properly constructed and in experienced hands they will suffice for dilatation of the deep urethra. The curved instruments may also be employed. The most satisfactory instruments are those constructed

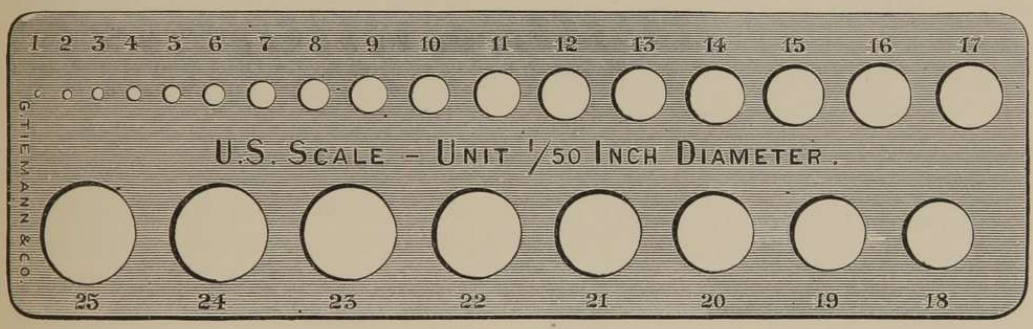

FIG. 760.

upon the United States scale,* which commences with the smallest steel instrument, $\frac{9}{50}$ of an inch in diameter, and increases $\frac{1}{50}$ of an inch in diameter for each successive sound to No. 25 inclusive, equal to $\frac{25}{50}$ of an inch. Nos. 1 to 8, inclusive, are filiform and elastic bougies.

A *straight sound* should be eight inches in length clear of the handle, slightly conical from the tip, back for a distance of one and a half inches. This conicity should increase one size for every half inch for this distance. Thus, a sound which measures No. 17 at the tip increases to

* The unit of the French scale is one third of a millimetre (about $\frac{1}{75}$ of an inch), and each size up to No. 30, inclusive, increases one third of a millimetre in diameter. Divide any given number of this scale by three, subtract the quotient, and the remainder approximates the corresponding size on the above scale. Thus No. 30, French, divided by $3 = 10$; $30 - 10 = 20$; or, No. 30, French = No. 20, U. S. The instruments on this scale are manufactured after the author's directions by Tiemann & Co., of New York city.

No. 18 one half inch back, to No. 19 at one inch, and is No. 20 at one and a half inch from the point, and continues this size for the entire shaft.

A *curved sound* should be nine inches long clear of the handle. The curve should involve only the last two inches. The conicity extends also one and a half inch from the tip, increasing one size for every half

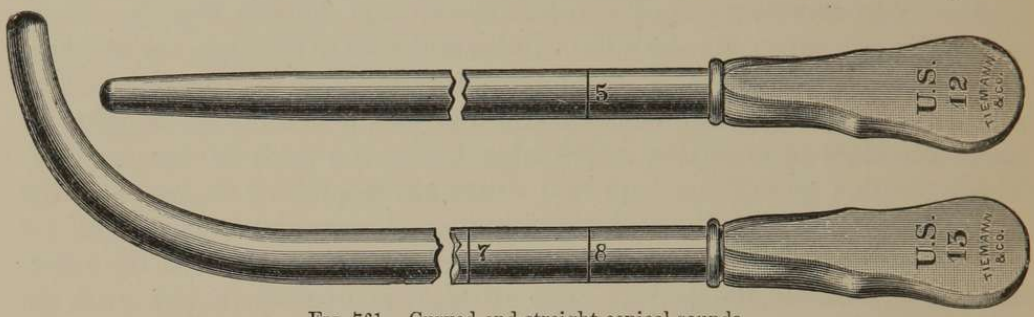

Fig. 761.—Curved and straight conical sounds.

inch until the full size is reached at one and a half inches from the point. Thus, an instrument the shaft of which measures No. 20, is 17 at the tip, 18 at one half inch, and 19 at one inch farther back.

The curve should be made to correspond to that of the normal deep urethra, which is that of a circle with a diameter of three and a quarter inches; "and the proper length of arc of such a circle to represent the subpubic curve is that subtended by a chord two and three quarters inches long" * (Fig. 762).

Flexible bougies are of various sizes, being conical for two or three inches, and olive-pointed. They are exceedingly useful instruments, and, when warmed before introduction, are incapable of injury to the urethra, even when an unusual degree of force is employed. The black French bougie is preferable. The filiform instrument has already been described.

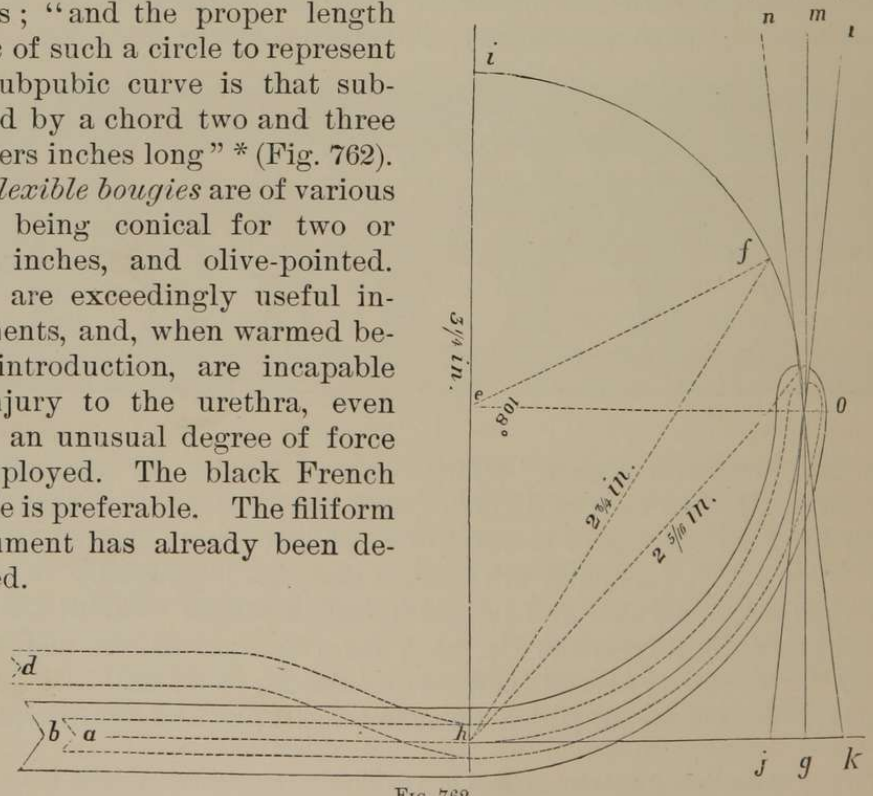

Fig. 762.

In dilating a stricture with the conical steel sound, the method of introduction is identical with that given in using the metal catheter. In

* Van Buren.

the interrupted dilatation a mild degree of force is exercised, and the *séance* is repeated on every second, third, or fourth day. The length of the interval between the introductions must be determined by the symptoms in each case, the object being to accomplish moderate divulsion at each sitting without producing marked inflammation. The sound should never be carried beyond the point where its full dilating power is applied to the stricture. In this way irritation of the prostatic urethra and neck of the bladder may be avoided in all save the deepest variety of strictures.

Fig. 763.

Fig. 764.

Fig. 765.

Fig. 766.

The dilatation of strictures by the use of conical steel sounds should be limited to those cases in which the stricture is of sufficient caliber to admit at least No. 15, U. S., and is narrow or linear in character, so that it may be made to give way without the employment of too great force. The smaller sounds are capable of penetrating the walls of the urethra unless they are used with great skill and carefulness, while the larger instruments will not, within the limit of safety, succeed in the dilatation or rupture of a broad or tortuous stricture. Incision with the urethrotome is a safer and less painful operation, and the sounds serve an admirable purpose in the after-treatment.

In using the soft bougies in the anterior portion of the urethra, they may be passed in straight; but, when the deeper portion is invaded, they should be curved as much as possible, to correspond to the subpubic curve of this canal.

Foreign Bodies in the Urethra.—Calculi occasionally lodge in the urethra, and substances introduced through the meatus—as fragments of a catheter, etc.—may require removal by the surgeon. The diagnosis will be evident from the symptoms of obstruction to the escape of urine, by recognition of the body by digital pressure along the canal, and by exploration through the meatus. Stone may be made out by the grating sound which is emitted, or by the sense of friction upon a rough and hard surface which is conveyed to the fingers along the sound. A metallic substance may also be recognized by the peculiar click which is elicited when it is brought in contact with the exploring instrument.

Removal with cocaine anæsthesia may be effected through the meatus, or by incision directly through the floor of the urethra at the point of lodgment. It is always desirable to avoid incision through the urethral wall when, by the use of forceps or any mechanism, the extraction can be effected through the meatus without doing too great violence to this canal. If the substance is narrow and smooth, it may be seized

with the forceps (Fig. 767) and extracted. The straight alligator-forceps, or the instrument of Hale, is preferable for the anterior portion of the urethra, while for the deeper part the curved instrument is more

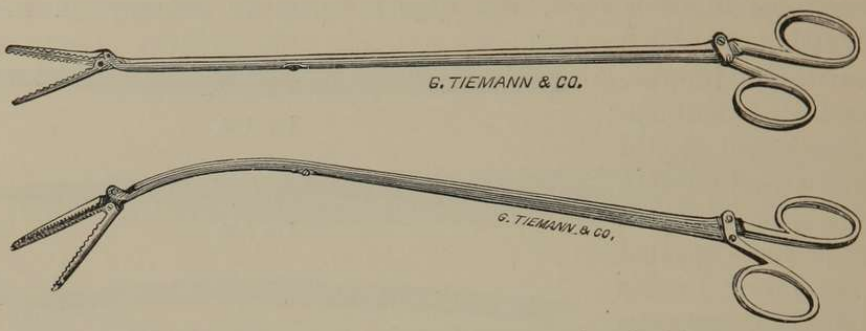

Fig. 767.—Straight and curved alligator-jawed urethral forceps.

suitable. For a round body, the scoop or curette will prove more satisfactory (Fig. 769).

In using the forceps, the instrument closed should be carried down until its beak strikes the foreign substance, when the jaws should be slowly separated and pushed farther in, so that they may pass between

Fig. 768.—Hale's instrument for removing foreign bodies from the urethra. (After Linhart.)

the lining membrane of the urethra and the body. They should then be firmly closed and cautiously moved a slight distance to and fro in order to determine whether the mucous membrane has been caught in the instrument. This danger will in great part be obviated if, just at the moment when the jaws are applied to the foreign substance, the urethra is put upon the stretch by pulling upon and elongating the penis. The canal should be lubricated by an injection of sweet oil. If stricture exists, urethrotomy may be necessary before the substance can be extracted. In a case which came under my care, two strictures were divided with the urethrotome. From behind the first constriction two calculi were removed, and several after the second stricture was divided (Fig. 770). In this operation a scoop proved more serviceable than the forceps.

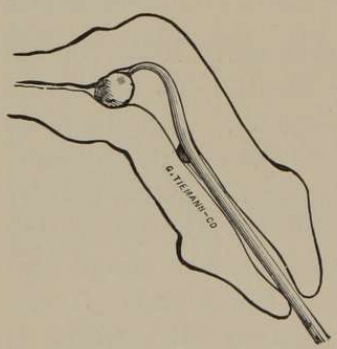

Fig. 769.—Curette, or scoop, for the removal of calculus in the urethra. (After Van Buren and Keyes.)

In a second operation I found it necessary to perform external urethrotomy, cutting directly down upon the calculi (two in number), which were easily removed through the incision. The direct injection of cocaine into the tissues secured complete anæsthesia. The wound should be left to close as in the ordinary operation of perineal urethrotomy.

Urinary Fistula communicating with the Urethra.—In congenital or acquired urinary fistula communicating with the urethra the following

operative measures are indicated: When the fistula opens in the perinæum or lower surface of the penile urethra, the method of Szymanowski offers the surest prospect of success. It is essential that all inflammation in and about the field of operation be allayed, sinuses slit up and healed, and all strictures divided, or stretched and cured. The bowels should be well emptied for two or three days before the operation. For perineal fistula the lithotomy position is preferable; the parts should be shaved and disinfected. Proceed as follows: Let the dark spot at *F* (Fig. 771) represent the opening of the fistula. A straight incision *A B* is made, passing along one edge of the fistula, extending three quarters of an inch each way from the opening. This incision passes through the skin and superficial fascia. The edge of this incision is raised, and, dissecting away from the fistula, the skin is lifted to form a pocket, the bottom of which is the dotted curved line *A C B*, and the lifted edge or entrance to this pocket the straight incision *A F B*. On the opposite side, corresponding accurately with the attached bottom of the pocket *A C B*, a curved incision *A D B* is made, the greatest depth of the flap being from three quarters to one inch. From this flap, with a pair of small scissors curved on the flat, remove the epidermis, except over an area amply sufficient to cover the fistulous opening. (This area is represented in white between *F* and *D* in Fig. 771).

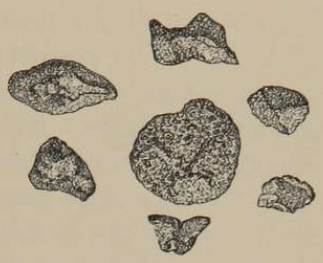

Fig. 770.—Calculi removed from the urethra. (The author's case.)

The flap *A D B* is now dissected up, taking with it a generous allowance of subcutaneous fat and fascia, down to about an eighth or three sixteenths of an inch of the original straight incision *A F B*,

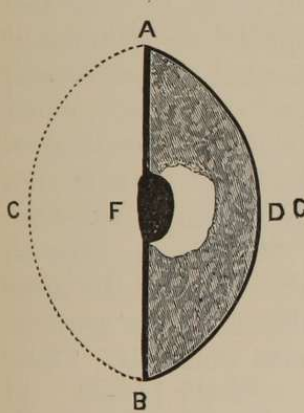

Fig. 771.

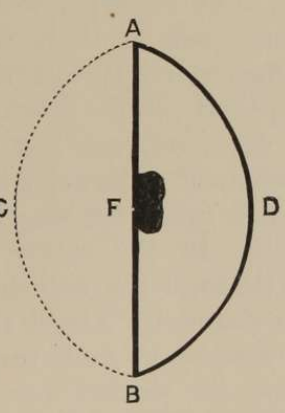

Fig. 772.

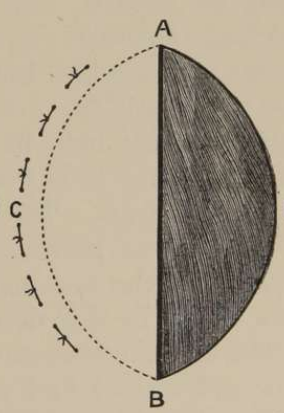

Fig. 773.

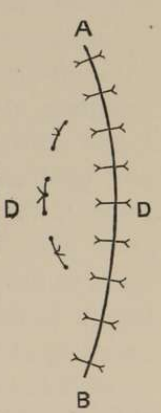

Fig. 774.

this attachment being left to give it a sufficient blood supply. As this *A D B* is turned over toward *C*, it hinges on the attached edge *A F B*, and, as it is slipped beneath the pocket *A C B F*, it will be seen that the undenuded (white) portion suffices to form the new floor of the urethra. It being ascertained that the flap fits accurately, it is brought out again and a series of five or six loops of fine catgut sutures are inserted by carrying the needle through the skin one eighth inch from the

curved dotted line *A C B* into the bottom of the pocket, and beneath the integument, directly opposite and through the free edge of the flap *A D B*, and back again, being brought out finally one quarter inch from the point of entrance *A C B* (Fig. 773). As these sutures are tied, the flap is inverted and secured. It now remains to close the open wound by sutures of fine silk, which snugly approximate the lines *A B* and *A D B*. The result is shown in *A D B* (Fig. 774). It is important to keep the bowels from moving and the patient quiet with morphia for several days. Every three or six hours the soft Nélaton catheter should be inserted, the urine drawn off, and the bladder washed out with four or five ounces of warm boric-acid solution, gr. x–℥j. On withdrawing the catheter the end should be closed in order to prevent the escape of even a few drops of its contents in the urethra. The silk sutures should be removed about the seventh day, and the use of the catheter discontinued only when the wound is thoroughly united. Strict asepsis in the field of operation and sterilization of the urine are necessary. In rare instances the floor of the prostatic and posterior part of the membranous portion of the urethra may be destroyed, and the fistula open directly into the rectum.

The following case which came under my care will serve to illustrate this form of fistula : *

The patient, twenty-seven years of age, merchant, came under my care in August, 1887. He came of healthy stock, and had had no sickness of a serious character until 1883, when symptoms of vesical calculus supervened, for which a left lateral lithotomy was done in August, 1886. The stone removed was reported to be the size of a hen's egg.

A urethro-perineal fistula remained after this operation, and from August, 1886, to August, 1887, four attempts were made to close this opening, without success. In the last of these operations a drainage tube about one and one half inches in length was inserted in the perineal opening and left with the deep end in the urethra. This tube, about three sixteenths of an inch in diameter, was lost sight of, the surgeon and patient supposing it had escaped externally and had been thrown away with the dressings. The last operation was followed by considerable pain, which was persistent. In the course of three months an abscess opened into the rectum through the anterior wall, and the urine began to flow freely in this new channel. About this time the perineal opening closed and an abscess formed in each tunica vaginalis. These were incised, and when I first saw the patient were entirely healed. At this date (August, 1887) nearly all the urine passed through the rectum. The patient suffered greatly, and had to be kept constantly under the influence of opium.

An examination *per rectum* revealed the presence of a stone, the end of which was on a level with the anterior surface of the rectum, about one inch beyond the anal aperture. The opening was slightly dilated, and the stone was removed through the rectum by means of strong for-

* Read before the Ontario Medical Association at Toronto, June, 1888.

ceps. It had formed in and upon the drainage tube, and is seen in natural size in Fig. 775. After consultation with Dr. Edward L. Keyes, it was determined to prepare the patient for operation, which was done, and on September 13, 1887, I operated as follows:

The patient, in ether narcosis, was placed in the Sims position and a large Sims vaginal speculum was introduced. The opening through the anterior wall of the rectum measured three fourths of an inch in length, with an irregular width of from one eighth to one fourth of an inch. It led directly into the urethra near the junction of the membranous and prostatic portions. The floor of the urethra was entirely destroyed. The right edge (patient's right) of the opening was seen to be undermined, as shown by the dotted surface *B* (Fig. 776).

Fig. 775.—Calculus formed on a piece of drainage tube as a nucleus. (Actual size.)

I determined to attempt the formation of a new floor to the urethra by turning the mucous membrane of the rectum into this position. The operation performed was a modification of the method of Szymanowski. Two crescentic incisions were made, as shown at *A A* (Fig. 776), being about parallel with the edges of the opening, but approaching more closely at its upper and lower angles. These incisions went deep into the wall of the rectum and included the mucous and muscular layers. The two lateral flaps were dissected up, the left to within an eighth of an inch of the edge of the opening; the right could not be carried so far on account of the pocket which undermined this side.

The flaps were now turned toward each other and their raw edges made to meet in the middle line, while the raw surfaces looked into the

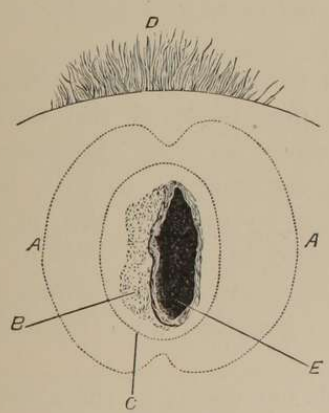

Fig. 776.

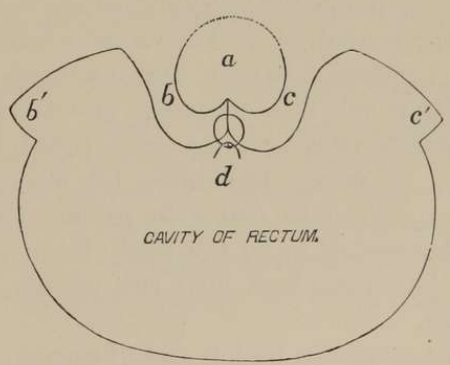

Fig. 777.

Fig. 776.—Showing the anterior wall of the rectum, and opening into it at *E*, a sinus from the membranous and prostatic urethra. *B*, Cul-de-sac, which undermined the right margin of the opening. *A A*, Line of incision, along which the flaps were dissected as far inward as *C*. For their nutrition the two lateral flaps depended upon the limit between the dotted line *C* and the margins of the opening *E*. *D*, The perinæum.

Fig. 777.—Schematic. Transverse section through the urethra and rectum, showing the method by which the flaps were turned from the mucous membrane of the rectum to make the floor of the urethra. *a*, Urethra. *b*, The right flap dissected from *b′*. *c*, The left flap from *c′*. *d*, The silkworm-gut suture in position (not entering the cavity of the urethra).

rectum and the mucous surfaces into the urethra (Fig. 777). Sutures of silkworm gut were inserted, as shown at *d* (Fig. 777). These sutures were about three sixteenths of an inch apart, and were so inserted that

they did not penetrate to the cavity of the urethra. On account of the thinness of the flap at one point I was compelled to pass one suture into the urethra.

A Nélaton catheter was carried through the meatus and urethra into the bladder, and through this the urine ran out at intervals. Whenever the urine accumulated enough to create a desire to expel it, about six ounces of Thiersch's solution were thrown in to dilute it; and when this, with the normal contents of the bladder, were evacuated, the same quantity was thrown in again and immediately expelled. In this way the wound was kept practically free from irritation by the urine. Divulsion of the sphincter ani removed all danger or annoyance from spasm of this organ. The bowels were kept quiet for nine days, and liquid diet was enforced. The patient had been placed on liquid diet for ten days prior to the operation.

The sutures were left *in situ*. The wound healed promptly, and the patient left for his home in three weeks after the operation. In April, 1888, seven months later, he returned, complaining of slight irritation in the rectum, and said he thought, at rare intervals, a few drops of water escaped into the bowel. On examination, three of the sutures were still in position, but no opening could, by most careful search, be discovered. The sutures were removed, and in a few days the patient was discharged. A second case, practically identical with this, was operated upon in the same way and cured.

Congenital Malformations of the Urethra.—In exstrophy of the bladder the urethra is absent, and, in certain rare anomalies, it may open into the groin, upon the side of the glans penis, in the median line of the dorsum penis (epispadias), in the median line below at any point on the corpus spongiosum (hypospadias).

Hypospadias is the most common of the congenital deformities of the urethra. When the opening is within one inch of the normal position of the meatus, operative interference for the purpose of establishing a new urethral canal is scarcely indicated. It will, however, in many instances be found necessary to enlarge the abnormal opening in order to permit the free escape of urine. When the false meatus is so far back that in sexual intercourse the semen can not be ejaculated into the vagina, a plastic operation may be undertaken.

In a case in which the abnormal opening was situated at the anterior peno-scrotal junction I succeeded in forming a satisfactory and useful urethra by the following method: On either side of the median line of the under surface of the penis from the abnormal opening to the glans the epidermis was removed with scissors for the space of about three sixteenths of an inch in breadth, leaving about three eighths of an inch of undenuded skin between the two parallel furrows of denudation. Passing the needle in and out through the undenuded skin just at the edges of denudation, fine silk sutures (interrupted) were inserted in such a manner as to bring the vivified surfaces together to fold into a cylinder the strip of integument between these. As the urine was allowed to

escape through the abnormal opening, infection did not occur, and prompt union was obtained.

In a second operation, made three weeks later, the same method was applied to close the abnormal opening. The urine was drawn by careful aseptic catheterization, and this wound also closed promptly. Had it failed, I would have employed the method of Szymanowski.

I should not hesitate to apply this method to the deformity of epispadias.

Neoplasms.—Papillomata and fibromata are occasionally met with growing from the mucous membrane of the urethra. They produce symptoms of obstruction varying with their shape, size, and point of

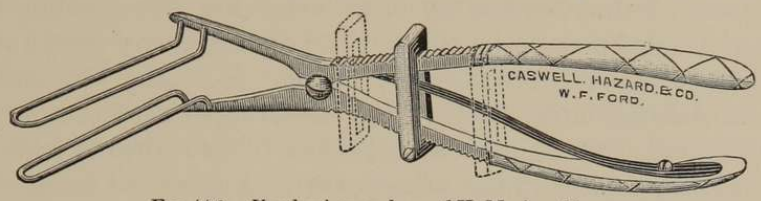

Fig. 778.—Urethral speculum of H. Marion-Sims.

attachment. They may be observed by means of the urethral speculum (Fig. 778), or when deeply situated the urethroscope (Fig. 752) will establish the diagnosis. The only treatment is removal, which may be done by the wire snare or by torsion with forceps. In extreme cases a longitudinal incision may be required in the median line of the floor of the penis in order to effect removal.

Cancer may originate in this canal, or more frequently may extend here from malignant disease of the prepuce and glans. Dr. Melville Wasserman has reported a number of cases of primary epithelioma of the urethra.* Tuberculosis also occasionally attacks the urethra.

The Penis.—The congenital malformations of the urethra just given may be included with deformities of the penis. The corpus spongiosum is at times arrested in development, while the corpora cavernosa are fully formed, causing the organ to bow when an erection occurs. One cavernous body is, in rare instances, not fully formed, and, when an erection takes place, the curve is lateral, with the concavity toward the affected side. The penis is occasionally double, with separate urethræ. In hermaphrodites it is rudimentary.

Inflammation of this organ is rare, except as a result of traumatism. It occasionally becomes involved by the extension of a phlegmonous or erysipelatous process from the scrotum or abdomen, or from urethritis and posthitis. The organ becomes greatly swollen, and a painful condition of chordee is almost constant. Retention of urine may occur, as well as suppuration or gangrene.

In the treatment of mild inflammation of the penis, local applications will usually prove sufficient. The tendency to erection should be controlled by the use of opium or chloral and potassium bromide in full

* Epithélioma primitif de l'Urèthre, Paris, 1895.

doses. When gangrene is threatened, free incisions in the long axis of the organ should be practiced.

Wounds of the penis, involving more than the integument, always bleed profusely. Hæmorrhage may be controlled by direct compression with a roller, or by throwing a few turns of an elastic ligature around this organ near the pubic junction. When the urethra is divided in whole or in part, it is best to stitch the separated walls together by close sutures of delicate silk. Catgut, though more desirable in one sense, is too readily absorbed to hold the edges of the wound in contact for a length of time sufficient to secure union. It is not usually necessary to insert a catheter, and it is best to dispense with this on account of the irritation it causes. Before and after each urination the urethra should be irrigated without distention. Should the operation by direct suture fail, Szymanowski's procedure will close the fistula. Any tendency to stricture may be treated later. When the dense capsule of the corpus cavernosum is divided, this should be included in the sutures which are carried through the wound in the integument. A guarded prognosis should be made in all deep injuries of the penis. Distortion during erection, and stricture, are frequent results of such lesions.

Fracture of the *corpora cavernosa*, an accident which occurs in rare instances as a result of great violence to the erected organ, is a difficult injury to treat. Deformity, with more or less loss of function, is apt to ensue. The organ should be laid up on the abdomen, and kept in a condition of as perfect quiet as possible. Cold applications are indicated, and, in case of *strangulation* from effusion of blood or from any other cause, free longitudinal incisions may be necessitated.

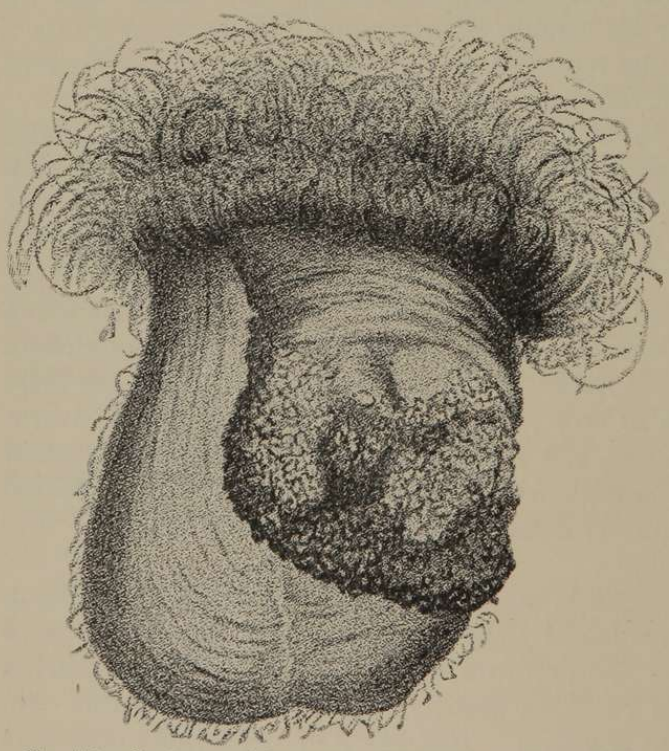

Fig. 779.—Carcinoma of the penis. (From a case in Mount Sinai Hospital.)

Carcinoma. — Epithelioma of the penis is not an uncommon affection. It commences as a small pimple or erosion on the mucous surface of the prepuce or on the glans, gradually spreading until, if left alone, the entire organ is involved and destroyed. The margins of the ulcer are indurated, elevated, sinuous, and slightly everted. The induration, as a rule, is confined to the immediate borders of the sore, not extending into the

deeper tissues unless inflammation supervenes. As the disease progresses, the center of the surface becomes studded with buds of newly formed cells and capillaries, giving it an appearance not unlike a cauliflower (Fig. 779). Ulceration occurs at various portions of the mass, and a dirty quality of pus is exuded. The odor from the decomposing tissues is peculiarly penetrating and offensive.

Within a period of time, varying from two to six or eight months, enlargement of the inguinal glands is observed. This enlargement may be inflammatory or metastatic. As a rule, metastasis is not rapid in epithelioma of the penis, and induration of the glands does not, on this account, preclude the hope of cure after amputation.

The principal cause of epithelioma of the penis is prolonged irritation of the glans and prepuce from retained secretions. All the cases which have come under my observation have occurred in patients with unusually long and tight prepuces.* It is usually met with in the middle-aged and old, although it sometimes occurs in early adult life.

The *diagnosis* of epithelioma is not very difficult after ulceration takes place. The indurated sinuous and everted borders of the ulcer, the red, cauliflower-like appearance of the mass, and the steady progress of the disease in the destruction of all the tissues in its path, are symptoms not met with in any other lesion of this organ. Warty growths (papillomata), when not seen early in their development, may at times simulate epithelioma, especially when these vegetations are luxuriant, are undergoing ulceration, are covered with purulent matter, and are the seat of repeated hæmorrhages. No matter how widespread the papillomatous neoplasm may be, at the outskirts of the mass will be found tufts or minute warts sufficiently isolated to be recognized. In the very earliest stages of development of the ulcer of epithelioma, it is scarcely possible to make a positive diagnosis between it and chancroid, or even a simple ulcer of the prepuce and glans penis.

Treatment and Prognosis.—In well-marked epithelioma of the penis the safest method of treatment is an immediate excision of the neoplasm by amputation. The line of amputation should always be wide of the limit of the disease. If the induration of the ulcer is well defined, and is limited closely to the margins of the erosion, the amputation may be made with one inch of sound tissue intervening. If the inguinal glands are enlarged, and if the surgeon has reason to be satisfied that the enlargement is due rather to inflammatory engorgement than to metastasis, the operation is still advisable, and the prognosis not altogether unfavorable. The inguinal glands should be dissected out at the same time as a precautionary measure. When metastasis of the glands is unmistakable, amputation may be done to rid the patient of the foul and ulcerating mass, although a favorable prognosis can not be entertained. In the earlier development of the growth, where a sufficient extent of healthy tissue intervenes between the induration and the line of excision,

* In an experience of fifteen years in attendance at Mount Sinai Hospital, I have not met with a case of epithelioma of the penis in an individual upon whom in early life circumcision had been performed.

amputation offers a strong hope of permanent relief. In the earlier period of development of the ulcer, if doubt exists as to its character, it is advisable to administer the iodide of potassium, together with proto-iodide of mercury, for a number of weeks. The application of Marsden's paste to the ulcer should, however, be made when it is first observed. If it be epithelial in character, the paste offers a strong hope of cure, and beyond the temporary inconvenience it produces no harm.

Operation.—Amputation of the penis may be performed by two methods: 1, simple amputation; 2, amputation with transplantation of the urethra to the perinæum. In the selection of the method, the operator must be guided by the nearness of the disease to the pubes and scrotum. Ordinarily, when the induration is limited to the glans, a simple amputation may be made at a point about one inch posterior to this. If the line of amputation must be chosen at or very near the level of the pubes, the second method will be preferable, for the reason that retraction of the stump will always occur, and the urine escaping over the scrotum will keep up a constant and annoying excoriation and condition of uncleanliness. In the operation with transplantation of the urethra, the urine is voided in the squatting posture, and escapes freely behind the scrotum.*

Simple Amputation.—Having shaved and thoroughly cleansed the pubes, scrotum, and penis, throw an elastic ligature around the organ at the level of the pubes. If the line of amputation is very near the ligature, this may be prevented from slipping by transfixing the penis with a large needle just in front of the tourniquet. Seize the mass with a double hook, and, holding it steady, with a long, thin-bladed knife cut the organ smoothly off at a point at least one inch behind the disease. A tenaculum should be in readiness to prevent the erectile tissue from retracting. The tube of the urethra should now be dissected up for half an inch, and the tissues of both cavernous bodies again divided on a level with the point to which the dissection of the spongiosum has been carried. The urethra is now split by passing the knife through its roof and floor, and a silk suture carried through the end of each lateral half. A thread is also passed through the dense capsule of the corpora cavernosa to prevent their retraction when the elastic ligature is removed. All vessels which may be recognized before loosening the rubber band should now be secured with catgut ligatures, and the remaining bleeding points caught up as the tourniquet is gradually loosened. The sutures passed through each half of the urethra are now carried through the edge of the incision in the skin to which it is sewed. A simple dressing completes the operation.

Humphrey's Operation.—The elastic ligature is carried around the penis close up to the level of the pubes, as in the preceding operation, and the organ severed as near the ligature as possible. The vessels in the corpora cavernosa should be tied at once. An incision should now

* I have performed this, the operation of Humphrey, three times, and in none of these patients has any unpleasant symptom followed. Two of the cases were under observation three years after the operation.

be made through the skin along the under surface of the corpus spongiosum, back to and splitting through the base of the scrotum, so as to expose the tube of the urethra for about two and a half inches. This tube is carefully dissected out from its attachment beneath and between the two corpora cavernosa for this distance, and is turned down on to the perinæum through the slit in the posterior wall of the scrotum. The urethra should next be split along the median line of its roof for a distance of half an inch back from the end, and the edges stitched to the margins of the wound in the integument of the perinæum. The operation is completed by closing the posterior slit through the scrotum, and stitching the margin of the wound in the skin of the anterior wall of the scrotum to that of the belly at the root of the penis, so as to cover in and include the stump of the amputated corpora cavernosa. The appearance of the parts after this operation is shown in Fig. 780.

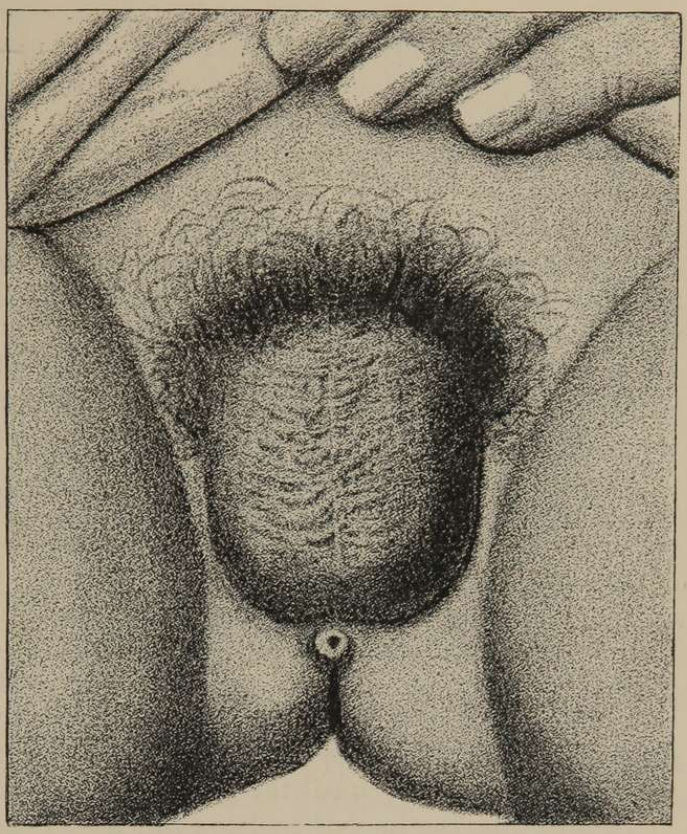

Fig. 780.—Humphrey's operation. (From a case of the author's at Mount Sinai Hospital.)

Sarcoma of the penis is exceedingly rare. It may be recognized by its rapid development, the absence of glandular enlargement, the general invasion of the cavernous bodies—in certain cases producing a continuous and painful erection of the organ—and by its resemblance to the well-known appearance and behavior of sarcomatous tumors in other portions of the body. The treatment should consist in immediate amputation.

Phimosis, or inability to retract the prepuce behind the corona glandis, is a frequent condition of childhood, and occasionally met with in adult life. It is both a congenital and an acquired affection, and may be partial or complete. The prepuce may be adherent to the glans, or phimosis may exist without adhesions, the opening in the foreskin being so narrow that retraction is impossible. A prepuce ordinarily retractile may become irretractile as a result of any inflammatory process of the glans and foreskin. This condition is not infrequently met with in gonorrhœa and with chancroid.

Congenital phimosis is an unfortunate affection, preventing perfect cleanliness by retention and decomposition of the retained secretions and urine, and inducing a condition of irritation which it were better to avoid by timely operative interference. Inflammatory or acquired phimosis always requires careful attention, and very frequently a surgical operation, to prevent gangrene or to expose a subpreputial chancroid.

The operative measures may include: 1, amputation of the prepuce (circumcision); 2, dilatation of the preputial orifice with forced retraction; 3, incision of the anterior portion of the prepuce and retraction.

The first of these procedures should be preferred in all cases in which there is no inflammatory process present, while the latter is advisable in phimosis with acute balano-posthitis.

Operation.—In adults, circumcision may be done with almost perfect freedom from pain by the proper employment of cocaine. In children under six years of age, narcosis is advisable.

In adults, proceed as follows: Cleanse the parts to be operated upon with 1-to-5,000 sublimate solution, and throw an elastic ligature around the penis at the level of the pubis. From ℥ xx–xxx of a four-per-cent cocaine solution are now injected by inserting the needle at the margins of the preputial orifice, and carrying it back between the mucous membrane and integument of the prepuce a little behind the proposed line of section. In the middle of the dorsum three or four minims are forced out of the syringe, the needle *partially* withdrawn and carried a half-inch to right and left of this point, and a like quantity is injected, and so on until the entire line of amputation is anæsthetized. As a rule, it will suffice to insert the needle once in the median line above and once at the frænum, and from these two locations it may be thrust beneath the skin to either side until the prepuce is completely encircled.

In selecting the line of incision the best rule is to allow the parts to assume their normal relations, and mark the foreskin, by repeated punctures with the scalpel, parallel with and one fourth of an inch an-

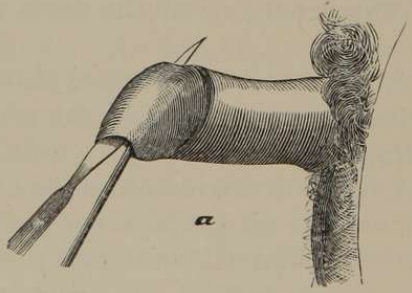

Fig. 781.

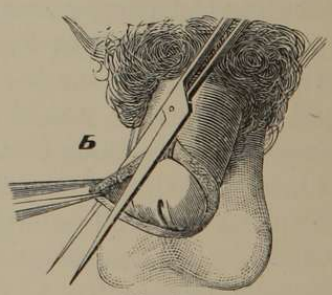

Fig. 782.

terior to the outline of the corona of the glans. A dull-pointed, grooved director should now be passed between the upper surface of the glans and the prepuce, in the median line, until the point is at the line of amputation. A sharp-pointed bistoury is next slipped along the groove in the director, thrust through, and the foreskin split by cutting from behind forward (Fig. 781). Or this incision may be made from before backward with a pair of straight scissors. The edges of the flaps

are now seized with a pair of mouse-tooth fixation forceps, and trimmed off with scissors, being careful to follow the line already indicated (Fig. 782).

When these incisions are completed, it will be observed that the edge of the divided mucous membrane remains at the level of the incision—namely, a quarter of an inch in front of the outline of the corona glandis—while the skin retracts beyond the corona. The mucous membrane should now be turned back, and its edge stitched to that of the incision in the skin. Fine catgut should be used, and an interrupted or a continuous suture employed. The former is somewhat more accurate, although it requires much more time in its insertion than the latter. It is important, in the effort to secure immediate union, that at all points the approximation is carefully made between the margins of the integument and mucous membrane. After the sutures are inserted, the mucous membrane rolls back, leaving the stitches behind the corona (Fig. 783). The elastic ligature is now removed, and a light dressing applied over the line of sutures. This operation is entirely bloodless. The patient should be directed to prevent the urine from getting into the wound. The sutures disappear by absorption, and the union is complete in from four to ten days.

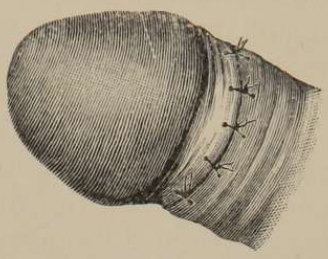

Fig. 783.—(After Malgaigne.)

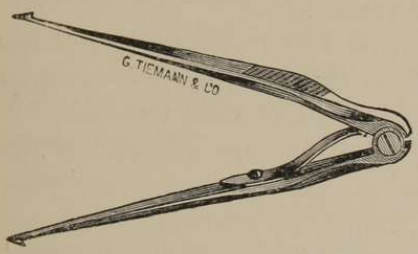

Fig. 784.—Girdner's phimosis forceps.

When the prepuce is adherent to the glans, it will be found impossible to introduce the grooved director as above unless the adhesions are first broken up. Under these conditions, the following operation should be performed: Carry the phimosis forceps (Fig. 784) into the opening of the prepuce, and allow the blades to expand so that the hooklets at the tip will catch in the mucous membrane. The foreskin is now drawn well to the front by an assistant, while the operator slips the thumb and finger of the left hand along the penis and grasps the foreskin just in front of the meatus. The foreskin is next amputated with the scissors just in front of the finger and thumb (Fig. 785). As retraction takes place, it will be seen that the line of section in the skin is near

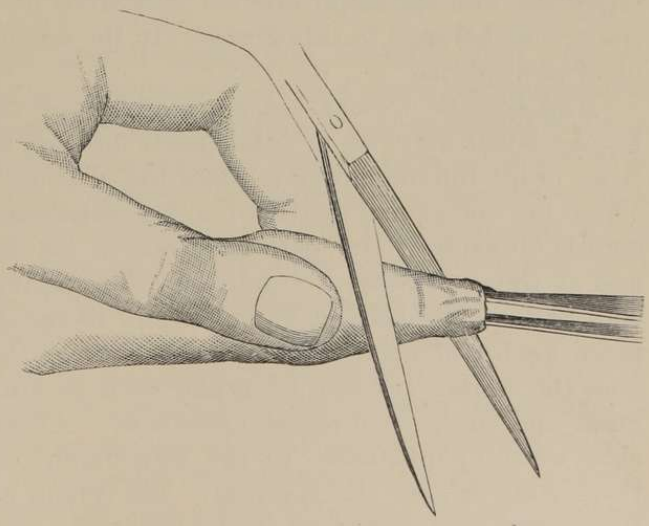

Fig. 785.

the corona, while that in the mucous membrane is only a little back of the meatus. This should be seized with the mouse-tooth forceps, and the adhesions broken loose or divided with the scissors. The mucous lining should now be pared back to a sufficient distance, and, if necessary, a second division of the prepuce made. The sutures are applied as in the preceding operation.

Dilatation or *divulsion* of the prepuce yields a satisfactory result in young boys. Circumcision is not indicated, as a rule, since, if the prepuce is enlarged, the foreskin shortens by a normal process of atrophy. It is performed by introducing the point of a small, closed dressing forceps into the opening of the foreskin, and stretching or tearing this by forced separation of the blades. The operation is completed by retracting the prepuce and breaking up all adhesions. In the after-treatment it is essential to move the foreskin back and forth over the glans once or twice daily to prevent the re-formation of adhesions.

Incision limited to the anterior half-inch of the foreskin, and in the median line of the dorsum, is advisable where the opening is very small and dilatation difficult. Retraction should be immediately effected.

Ulcers of the Penis.—Sores may occur upon the integument of the penis, usually near the prepuce; upon the mucous lining of the foreskin; the glans; within the meatus; and along the urethra. Venereal sores are occasionally met with upon the integument of the scrotum, abdomen, perinæum, and thighs. Ulcers of the penis only will be considered here. They are divisible into two classes—namely, the non-specific and the specific ulcer. To the former belong the sores which follow abrasions and the eruption of herpes. They are more or less phagedenic in character, the extent and rapidity of the process of necrobiosis being due to the degree of virulence of the inoculating micro-organism, and the impoverished condition of the tissues attacked. The *chancroid* belongs to this group. In the second class belongs the specific ulcer of syphilis.

Non-specific Ulcers.—A *simple* ulcer of the penis is extremely rare. It may occur here, as in other parts of the body, as a result of traumatism, or an inflammatory process not due to the inoculation of a virus. Thus, the molecular death of a variable extent of tissue may follow a simple abrasion if the part involved is not kept free from all irritation, and if there prevails a condition of impaired nutrition, in which, as is well known, the tissues yield readily to the destructive process. Under more healthful conditions, an abrasion of the glans or prepuce undergoes the simple process of repair seen in similar lesions of the integument and mucous surfaces elsewhere. Abrasions usually occur on the sides of the penis, close to the attachment of the prepuce, just behind the corona or near the frænum. The glans is rarely involved, although the meatus, especially at its lower angle, may be torn. Bleeding sufficient to attract the attention of the patient is rare, unless extensive laceration has occurred.

The *ulcer of herpes* is usually situated upon the surface of the mucous lining of the prepuce, less frequently upon its cutaneous surface,

and the glans. It begins as a vesicular eruption. There may be one or many. Multiple herpetic vesicles may be scattered or in clusters, linear, semilunar, or circular in arrangement. In the recent state the herpetic vesicle is round at its base, measuring from one twelfth to one twenty-fifth of an inch in width. It consists of a thin investing membrane resting upon a slightly red and irritated base, and containing a clear, serous fluid, which often escapes by rupture of the membrane before the vesicle is observed. Upon the skin they rapidly dry on account of evaporation of the fluid contents, and the floor of the patch becomes covered over with a light incrustation. Upon the mucous and moist surfaces incrustation does not occur. The circumference of the base exposed after rupture of the vesicle is usually round, with well-defined walls leading perpendicularly down to the bottom of a shallow excavation.

In typical cases of genital herpes the morbid process ends here, the sore healing without suppuration. Not infrequently, however, the floor becomes covered with a layer of pus, the walls are undermined and break down, forming an ulcer which is phagedenic in character. The character of the pain varies. In some instances there is a stinging, burning sensation felt in the part affected; in others there exists total insensibility.

Herpes is a neurosis due to a local irritation of the nerve terminations in the part attacked. In some instances a severe neuralgia of the branches of the sacral or lumbar plexuses exists at the time of the eruption on the glans and prepuce. Uncleanliness is a frequent cause of this disease. Any irritation of the glans or prepuce may induce it, and one attack is apt to be followed by a second.

In mild and ordinary cases it runs its course in from ten days to two or three weeks. In other forms, especially when infection occurs, it may last for a number of weeks, and is usually complicated by lymphangitis and adenitis.

Phagedenic ulcer of the genital organs was formerly held to be the result of the inoculation of a specific poison—the virus or micro-organism of "chancroid"; but, since ulcers which in appearance and behavior do not differ from the so-called chancroidal ulcer have been produced by inoculation with the infectious material taken from the pustules of acne, from gonorrhœal pus, etc., the specific nature of this virus can not be maintained. Even the specific ulcer of syphilis will, as a result of repeated and prolonged irritation, take on a phagedenic character.

This ulcer results most frequently from direct contagion, the virus being lodged in an abrasion of the integument, prepuce, or glans. The period of incubation—that is, the length of time between the date of the contact and the recognition of the sore—will vary in different individuals. It has been seen within twenty-four hours, and, in rare instances, as much as twenty days have elapsed. In a very large majority of cases the inflammation is observed within the first nine days after the inoculation. The rapidity of its appearance depends chiefly upon the thoroughness with which it is brought into contact with the tissues in an abrasion, and the condition of the tissues at the time of the invasion. The ulcer is

usually located on the side of the penis, just behind the corona glandis at the preputial attachment, at the points where abrasions are most frequent. It may be on the cutaneous surface of the prepuce, upon the body of the penis, the scrotum, or within the meatus. There may be one or more, owing to the number of abrasions and the distribution of the virus. A single ulcer may result from the confluence of several contiguous points of inoculation. It is first noticed as a light redness or flush, usually circular or elliptical in shape, or, if the abrasion is irregular in outline, it will conform to this. Within a few hours after the appearance of the redness its center becomes elevated and a pustule is formed, which soon breaks down, discharging a small quantity of matter.

If the sore is not seen early, the pustule may escape observation. When the inoculation occurs upon a surface denuded of its mucous membrane or epidermis, a pustule is not formed. The walls of a phagedenic ulcer are usually precipitous. At times the superficial layers of the skin resist disintegration longer than the deeper layers and subcutaneous tissues, giving the edges an undermined appearance. It tends to spread in width rather than in depth, although in a certain proportion of cases extensive destruction of tissue may occur in all directions. The floor of the ulcer is covered with a creamy pus and the broken-down tissues in various stages of decomposition. A small quantity of matter of creamy consistence may be removed with a pellet of cotton. A membrane or film of a yellowish-brown color usually adheres to the floor with considerable tenacity.

A zone of redness extends along the edges of the ulcer in advance of the tissue destruction. In many ulcers this is not more than a line in width. If the sore is subjected to irritation, the inflammatory redness and induration may spread widely into the surrounding tissues.

Pain, which is always present, varies, as a rule, with the extent of the inflammatory process.

In a typical phagedenic ulcer of the penis, lymphangitis and adenitis of the inguinal glands are always present in a varying degree. In the simpler forms adenitis does not occur, although the lymphatic channels in the neighborhood of the sore may be involved. Inguinal adenitis or *bubo* is always a painful complication. It may be lateral or bilateral. If the sore is in the median line, or if there are ulcers on both sides, both groups of glands will be affected. Suppuration of the inguinal bubo of phagedenic ulcer is not uncommon. The violence of the inflammatory process here is subject to the same conditions as given for the primary ulcer. One or more glands may be involved and suppurate. In severe adenitis the inflammation extends to the tissues immediately surrounding the glands. The mass appears as one large swelling, over which the integument is red and œdematous, and to which it is adherent. Phagedenic bubo is apt to follow a virulent phagedenic ulcer of the penis.

Treatment.—Simple ulcer of the penis, if left without interference, usually heals within a few weeks; the ulcer of herpes is usually more obstinate. The process of repair may be greatly facilitated by a careful removal of all sources of irritation. Strict cleanliness is essential, no

matter what form the ulcer may assume. Finally, powdered aristol, applied two or three times daily, affords protection and aids in the absorption of moisture.

In addition to the foregoing, it is essential to keep the sore uncovered by the prepuce, which should be worn back behind the corona. Circumcision may at times become necessary to obtain a permanent cure. If the simpler remedies just given do not succeed, the local use of the nitrate-of-silver pencil is indicated.

In phagedenic ulcer, as a rule, more vigorous measures are necessary. The severity in local treatment will depend, however, upon the rapidity of molecular death in the tissues. If its progress is slow, and the inflammation mild in character, recovery may be brought about by the treatment laid down for simple and herpetic ulcer. If within the first few days of its appearance the spread of the sore is rapid, or if, when first brought to the notice of the physician, it is more than a quarter of an inch in diameter, and the zone of redness spreads well out into the tissues, it should be treated as follows: By the introduction of a delicate hypodermic needle through the sound tissues, after which its point should be carried under the base of the ulcer, from ten to twenty minims of a four-per-cent solution of cocaine should be injected, by which means complete anæsthesia may be secured. The pus should now be removed from the bottom of the sore with a pellet of absorbent cotton on the end of a small piece of wood. The parts immediately about the ulcer should be coated over with vaseline or oil, to protect them from excoriation. A small quantity of carbonate of soda should be on hand to neutralize any excess of acid. In applying pure nitric acid, the ulcer should, if possible, be held so that it will contain the acid without letting it run over the edges. It is best applied by means of a wooden match or toothpick dipped in the acid, and the point immediately carried into the floor of the ulcer. It should be conveyed into every portion of the sore, and allowed to remain in contact with the virus for one or two minutes. The excess may now be soaked out with the cotton pellets, and the ulcer filled with soda. A piece of lint moistened in vaseline will serve as a dressing. When nitric acid can not be had, the actual cautery should be employed.

Iodoform may be dispensed with, on account of the disagreeable odor of this substance.

When phagedenic ulcer occurs beneath an irretractile prepuce, this should be incised and the sore treated as above. Ulcer of the meatus should also be burned with nitric acid. Complete rest is essential, and constitutional measures looking to the improved nutrition of the tissues are strongly indicated. If suppuration occurs in the glands of the inguinal region, free incision should be made and free drainage established. Phagedenic bubo should be treated in the same manner as the phagedenic ulcer. Chronic adenitis, in which the glands are discharging at varying intervals, is rarely cured without a thorough extirpation.

Scrotum.— Wounds of the scrotum should be treated as similar lesions elsewhere. On account of the great vascularity of the tissues, re-

pair is usually rapid. The contractility of the dartos and cremaster muscles will prevent early union unless the stitches are closely applied. If the testicle is protruded, it should be disinfected with 1-to-10,000 sublimate, returned to its normal position, and the cavity of the tunica vaginalis also washed out with the sublimate solution. In closing the wound with catgut sutures, the edges of the opening in the tunica should be included. A small catgut drain may be inserted into the cavity and emerge at the lower angle of the incision.

Contusions should be treated by rest in the horizontal posture, cold applications and mechanical support beneath the posterior aspect of the scrotum.

Œdema of the scrotum occurs with general anasarca and with ascites. The integument is tense, pale, and doughy; pits upon pressure, and, after puncture with the hypodermic needle, a clear, watery serum escapes. Besides the indications for constitutional treatment directed to the disease proper, puncture with the lancet in several points will temporarily relieve the tension and danger of gangrene.

Eczema and other cutaneous lesions of the scrotum do not demand especial consideration. The same general principles of treatment apply with equal force to all the cutaneous surface. The prognosis is unfavorable on account of the irritation to which this organ is subjected from friction with the clothing and thighs, and especially owing to the peristaltic movements of the dartos and cremaster muscle.

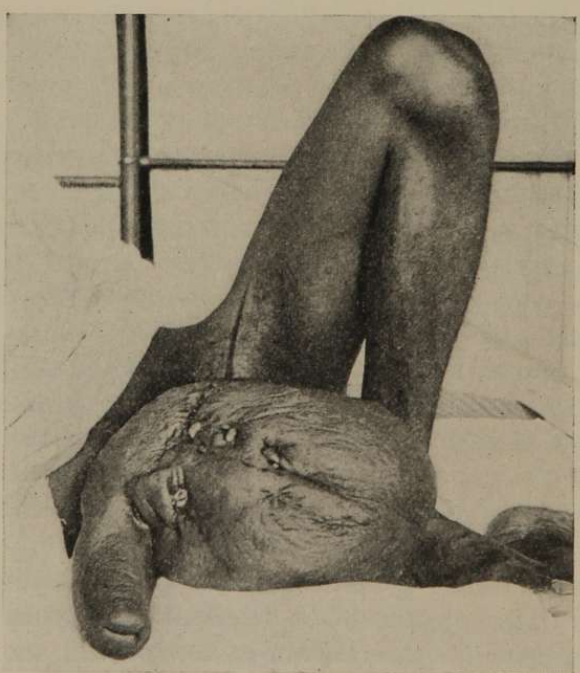

Fig. 786.—Elephantiasis of scrotum and penis. Native of Bermuda. Cured by complete ablation. (The author's case.)

Cysts, due chiefly to the retention of sebum, are occasionally seen in the scrotum. They are usually situated near the raphé, or laterally and posteriorly upon the base of the scrotum. When large enough to cause inconvenience, incision and extirpation of the sac are demanded.

Erysipelas, although rare in this portion of the body, is met with, and is often obstinate under treatment. *Gangrene* is one of the chief dangers, and must be guarded against by free incision as soon as the tension is great. *Phlegmon* of the scrotum should be treated by warm applications, poultices, etc., and by early incisions to relieve tension and give escape to septic matter. Free drainage and sublimate irrigation are indicated.

Elephantiasis scroti, comparatively of rare occurrence in the tem-

perate and colder zones, is frequently met with near the equator; and in some of the West Indies and the islands of the South Pacific Ocean it occurs with great frequency.

The pathology of this form of connective-tissue hyperplasia has been given. The cause is undoubtedly one of prolonged irritation. The only treatment is extirpation with the knife. No fixed rule of operating can be laid down. The penis is at times buried in the neoplasm, and should be carefully dissected out. The incisions should be made so as to give a cutaneous flap in front and behind sufficiently large to contain the testes and cord without pressure after the connective-tissue new formation has been dissected out. When the penis is included in the new growth, the integument should be saved, to cover this organ. If this can not be done, flaps may be turned from the thighs and abdomen.

The hæmorrhage in this procedure may be controlled by working between fixation forceps, or by the adjustment of an elastic tourniquet around the scrotum near its attachment to the perinæum.

Fig. 786 represents a typical case of this affection which I successfully removed in two operations, with ten days' interval, in 1893. The patient, a negro fisherman from Bermuda, is entirely well. The entire scrotum, testicles, and penis were removed.

Angioma of the scrotum is rare, and demands treatment similar to that advised in the chapter on these vascular formations.

Epithelioma is more frequently seen than either of the foregoing neoplasms, and calls for immediate excision. The so-called chimney-sweep's cancer was often located on the scrotum.

Fistulæ, or *sinuses* of the scrotum, may be caused by abscess of the tunica vaginalis testis, or by any lesion of the testicle. Abscess of the perinæum or urinary fistula may also cause fistula of the scrotum. Stony concretions are occasionally met with in fistulæ of the scrotum through which the urine makes its escape.

The treatment should be directed to a relief of the cause of the fistulous tracts. If this is accomplished, the sinuses should be laid open and allowed to close by granulation.

Hæmatoma.—Extravasation of blood may occur either in the tunica funiculi, in the tunica vaginalis testis, or in both. In the former it may be *diffuse* or *circumscribed*. It is usually diffuse, the extravasation extending from the abdominal opening to the epididymis. When only a portion of the sheath is involved, the hæmatoma is generally confined to the upper segment.

The chief causes of extravasation are rupture of one or more vessels by direct traumatism, or by overdistention from prolonged strain, which retards the return circulation, causing rupture of a vein.

Hæmatoma of the tunica vaginalis testis is rare, except as a complication of chronic *periorchitis serosa* (hydrocele) or direct violence.

The diagnosis of hæmatoma in either of these positions depends upon its sudden development, the tendency to enlarge progressively, and pain from the sudden distention. The tumor is not translucent. The exact nature may be determined by aspiration.

Serous effusion (hydrocele) into the sheath of the cord or testis progresses slowly and painlessly. The tumor is translucent. Exploration with the hypodermic needle and syringe is a safe, painless, and positive means of diagnosis.

Hernia may be eliminated by a consideration of the history of the case and the absence of impulse in the tumor upon coughing.

Treatment.—Hæmatocele may be treated by the expectant method, or by surgical interference.

Simple and limited extravasation requires rest in the dorsal decubitus, and the ice-bag locally. After the hæmorrhage is arrested, absorption may be expedited by judicious and well-applied pressure by strapping. When the extravasation is extensive, an incision should be made under strict antisepsis, the clot turned out, the bleeding point ligated, drainage secured, and the wound closed. Death has followed in some instances where operative procedure has been too long delayed.

Hydrocele and Spermatocele.

Hydrocele (periorchitis) is a term employed to denote an accumulation in the sac of the testicle of a serous fluid (Fig. 787). It may be an *acute* or a *chronic* affection. The fluid contents may be contained in a single sac, or, as occurs in rare instances, there may be adhesions of contiguous surfaces to each other in one or more places, holding the fluid in two or more separate cavities.

Acute hydrocele of the tunica vaginalis testis may occur from any acute inflammatory process of the epididymis or testis The serous membrane appears red and injected, the capillaries enormously distended and filled with blood. The surface is less smooth than normal, the epithelium gradually disappears, and emigration of leucocytes occurs. A soft, pinkish, elastic substance is deposited upon the surface of the membrane. Similar flaky masses are also to be found in the fluid contents. Acute hydrocele is usually accompanied by pain, rarely goes on to suppuration, and disappears with the inflammatory process which precipitated it. The diagnosis, if necessary, can be confirmed by careful aspiration with a very fine aseptic aspirating needle. The treatment is complete rest of the part involved.

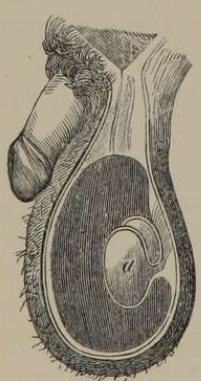

Fig. 787.—Hydrocele of the tunica vaginalis testis. (After Linhart.)

Chronic hydrocele is by far the most frequent form which comes under the observation of the surgeon. It occurs at all times of life, and seems to have no preference for one side or the other, but frequently involves both serous cavities. It develops slowly, shows no tendency to disappear spontaneously, and may attain tremendous proportions.

The ætiology of this disease is not satisfactorily explained. It is frequently found occurring with chronic, subacute inflammation of the epididymis or testicle, but as often exists when no inflammatory lesions can be determined. The walls of the sac in most cases, and in all cases

of long duration, appear thicker than normal, showing a proliferation of new connective tissue, and frequently there is much induration. In rare instances calcareous and even osseous deposits have been noticed. The epithelial covering is but little impaired. It is whiter than normal, but retains its peritoneal gloss. The quantity of fluid contained in the sac varies considerably, at times reaching a gallon or more. It is pale straw or amber colored, and may be greenish brown or chocolate color and opaque. Pus is not present unless some septic infection has occurred. It is neutral or slightly alkaline in reaction, and the specific gravity varies, being usually from 1020 to 1026. When the fluid is dark brown or red, it contains blood, due to rupture of small vessels upon the vascular granulation tissue which has developed upon the surface of the membrane.

The symptoms of the disease are little more than a gradual accumulation of fluid, the enlargement showing first in the lower part of the scrotal sac and extending upward. Pain is rarely present in chronic hydrocele. As the fluid accumulates, the testicle is generally pressed upward and backward.

In the diagnosis of this affection it is important to exclude the presence of hernia, which may complicate it. When the hydrocele is small and occupies the lower portion of the scrotal sac, differentiation is easy; but when it is of large size, extending as high as the external ring and lying in front of the spermatic cord, differentiation is not so easy. It is important to bear in mind that the history of a hernia is that of a swelling appearing first along the inguinal canal and then out through the external ring, gradually extending downward in the direction of the testicle, and that a hydrocele begins below and extends up. The introduction of the finger into the external ring and the absence of any impulse on coughing will exclude hernia. Holding a bright light upon the opposite side of the scrotal sac, the serous fluid of a hydrocele becomes translucent, while a hernia would obscure all light. A hydrocele could scarcely be mistaken for a varicocele, the peculiar wormlike feel of this latter condition clearly pointing to its recognition. A varicocele disappears with the recumbent posture. Lastly, a positive diagnosis can be made by aspirating with an aseptic and very fine needle. Even if an error were made and an intestine punctured by this needle, no harm would result.

The treatment of chronic hydrocele has been greatly simplified in modern practice. In the vast majority of cases of ordinary size, containing less than twenty-five ounces of fluid, the tumor can be cured by the method of Levis. The anterior aspect of the tumor should be thoroughly cleansed with soap and water and a little mercuric-chloride solution. In an area one inch in diameter, with a delicate hypodermic needle inject three to five minims of a four-per-cent solution of cocaine. Through this anæsthetized area, after grasping the scrotum to make it as tense as possible, is thrust a trocar and canula which have just been taken out of the boiler. This canula should be threaded in order to fit the screw tip of an ordinary large-size hypodermic syringe. As soon as

the point of the trocar and canula pass freely into the cavity of the sac, the trocar is withdrawn and the fluid allowed to escape. Gentle pressure applied to the sac, taking pains not to allow the canula to be extruded, will empty all but a few drops of fluid. The next step in the operation is the injection of liquid carbolic acid, ninety-five per cent pure. The quantity to be thrown in varies with the size of the tumor, twenty minims for a sac containing two to six ounces, gradually increasing to as much as sixty minims for a sac containing a pint or two. Care should be taken not to carry any air through the syringe into the cavity. The fluid having been evacuated and the proper quantity of carbolic acid placed in the syringe, the thread is now screwed into the corresponding threads of the canula, a little clean vaseline is spread upon the scrotum around the needle puncture to prevent any possible leakage of acid on the integument, and the contents of the syringe forced in. When the canula is withdrawn, gentle massage of the scrotum is practiced until the injected carbolic acid has been brought into contact with every part of the tunica vaginalis testis. Strange to say, this operation is almost entirely free from pain, and in many instances I have performed it as above described, the patient not knowing when the instrument was introduced or when the carbolic acid was injected. No dressing is required, and, while it is best for the patient to remain quiet for at least twenty-four hours after the operation, I have in a number of instances operated upon laboring men who would come into the clinic from their work and return to it afterward with the loss of only one hour. If properly done, this operation should cure about seventy-five per cent of all cases of hydrocele at a first injection. When it fails, it should be carefully repeated, increasing or diminishing the quantity of acid thrown in as is necessary to insure a perfect result. It is important that the strictest asepsis be carried out, since the introduction of any septic organism would produce a painful process of suppuration not without danger to the patient. Twenty-four or forty-eight hours after this operation the scrotum appears as large as ever, is heavy, and seems solid or doughy to the feel. After a week or ten days it begins to decrease in size, and, since the epithelial lining which furnished the serum has been destroyed by the injection, it does not again refill with fluid, but gradually contracts down, and adhesions form, thus effecting a cure. The walls of the scrotum, however, are usually much thickened by a chronic hydrocele, and never regain their former thinness.

Another method is known as *Volkmann's* operation. Shave the scrotum and pubes, and wash the parts thoroughly with brush, soap, and water, and afterward with mercuric chloride. The sac of the hydrocele is then opened by an incision varying in length from three to six inches or more, as the case may require, upon the anterior surface of the tumor. All bleeding should be arrested as the operation progresses. When the sac is reached it should be incised to correspond to the length of the incision in the contracted scrotum. Allow the fluid to escape, and with a good-sized continuous catgut suture stitch the parietal layer of the tunica vaginalis to the edge of the wound in the integument, making a

wound not unlike a buttonhole. After irrigation with a 1-to-5,000 mercuric-chloride solution insert a wick of iodoform gauze in the upper and lower portions of the cavity. A sterilized dressing is placed over all, which need not be changed before the fourth or fifth day, and often two or three changes will suffice to effect a cure.

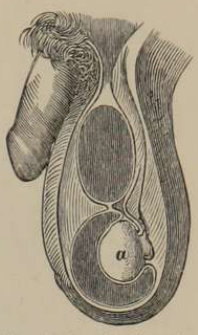

Fig. 788.—Hydrocele of the cord encysted.

In my practice of late years the conditions are very rare which call for ether or chloroform narcosis in the performance of this operation. Even in cases in which a cure can not be effected by the simple method of Levis I do not find it necessary to secure any better anæsthesia than that obtained with cocaine. A four-per-cent solution injected into the integument of the scrotum in the line of incision in front, and the use of Schleich's normal solution for the deeper section, will give perfectly satisfactory anæsthesia in the vast majority of instances, enabling the operator to open the sac, discharge its contents, and irrigate and insert the wick drain without pain.

Hydrocele of the cord is much less frequently met with, and consists in the accumulation of a fluid in character similar to that of hydrocele of the tunica vaginalis.

Hydrocele of the tunica funiculi (Fig. 788) appears as a round, slightly elongated cyst or tumor, movable in all directions with the tissues of the cord, not communicating below with the tunica vaginalis or above with the peritoneal cavity. It rarely attains a large size, although as much as three ounces of fluid may be met with in rare cases.

The diagnosis between hydrocele of the tunica funiculi and spermatocele in this same region is exceedingly difficult, and can not be positively made without aspiration. Fluid drawn off from a hydrocele of the cord is straw-colored, while that of a spermatocele is milky-white, and not unlike the fluid which is found in a cocoanut. Should the diagnosis be still doubtful, the microscope will demonstrate the presence of spermatozoa if the case is one of spermatocele. For all practical purposes the differentiation is of no moment, since the treatment is the same in both —incision under the same antiseptic precautions as given for Volkmann's operation, opening into the sac, irrigating with mercuric-chloride solution, packing with iodoform gauze. Careful asepsis should be carried out in order to prevent suppuration, for the inflammation which can be secured by cleanliness will obliterate the sac in much less time than that which occurs with pus formation.

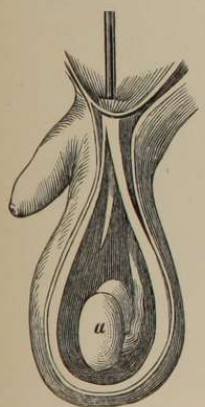

Fig. 789. — Congenital hydrocele. The tunica funiculi communicating with the tunica vaginalis testis and the peritoneal cavity. *a*, Testis. (After Linhart.)

Hydrocele may sometimes be *congenital*, fluid descending from the peritoneal cavity and along the cord and extending into the tunica vaginalis (Fig. 789). Hydrocele of this variety, however, is rarely met with, and does not require treatment unless it persists. It is occasionally met with in very

young infants, and becomes separated from the peritoneal cavity by closure of the tunica funiculi in the inguinal canal. Hydrocele in children, when not congenital, is not infrequent, and may often be cured by simple, clean evacuation of the fluid with a hypodermic apparatus without injection. It should be thus treated for one or two or three times, after which, should the fluid re-form, from one to three minims of pure carbolic acid should be thrown in after another aspiration.

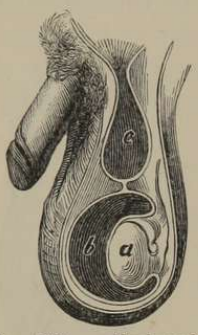

FIG. 790.—*c*, Hydrocele of the cord communicating with the peritoneal cavity. *a*, Testis. *b*, Small effusion into the tunica vaginalis. (After Linhart.)

Varicocele.—Varicosities of the veins of the spermatic plexus are not uncommon. Varicocele is chiefly caused by gravity and the mechanical interference with the return of blood through the spermatic veins. It occurs with greater frequency on the left side, where the vessels are pressed upon by the sigmoid flexure of the colon with its almost constant weight of fecal matter. In addition to this, the greater length of the left spermatic vein, which enters the renal vein at a right angle to its axis, and is poorly protected by valves, are causes which serve to produce varicosities upon this side more frequently than in the right plexus. Any occupation which necessitates the erect posture is apt to add to the susceptibility of this disease. Hereditary tendencies must be considered in its ætiology, for frequently members of a family through several generations will be affected.

The earlier *symptoms* are a feeling of heaviness or dragging down on the side affected, with the appearance of a small swelling in the line of

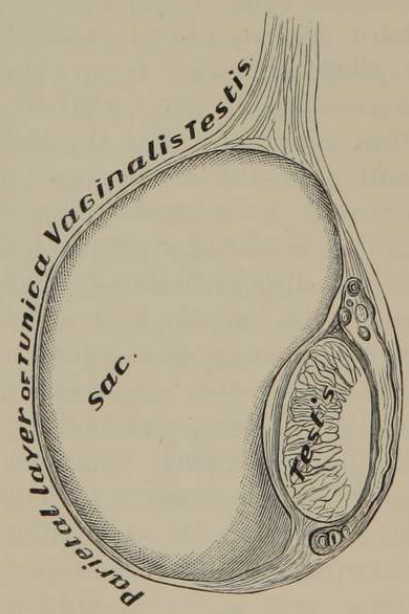

FIG. 791.—Usual form of hydrocele. (After Kocher.)

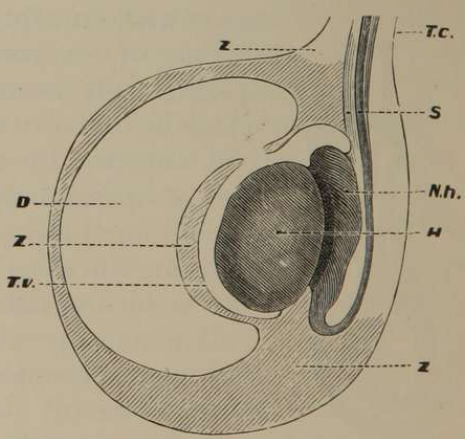

FIG. 792.—Bilocular hydrocele. *T c*, Parietal layer of tunica. *S*, Spermatic cord. *N h*, Epididymis. *H*, Testis. *D*, Cavity of diverticulum. *T v*, Cavity of the tunica vaginalis proprius. *Z z*, Inflammatory new formation between the visceral and parietal layers. (After Kocher.)

the cord. Pain is variable, and is sometimes referred to the cord or to the inguinal region or down the leg. The testicle hangs lower than

natural, and along the cord can be felt a network of turgid veins extending from the epididymis toward the external ring. To the touch they seem not unlike a knot of earthworms. The swelling is apt to be largest at the lower extremity (Fig. 794).

The *diagnosis* is not difficult. The swelling of inguinal *hernia* is spherical, and, when composed of intestine, it is resonant on percussion. If the hernia is reducible, and is returned into the cavity of the abdomen

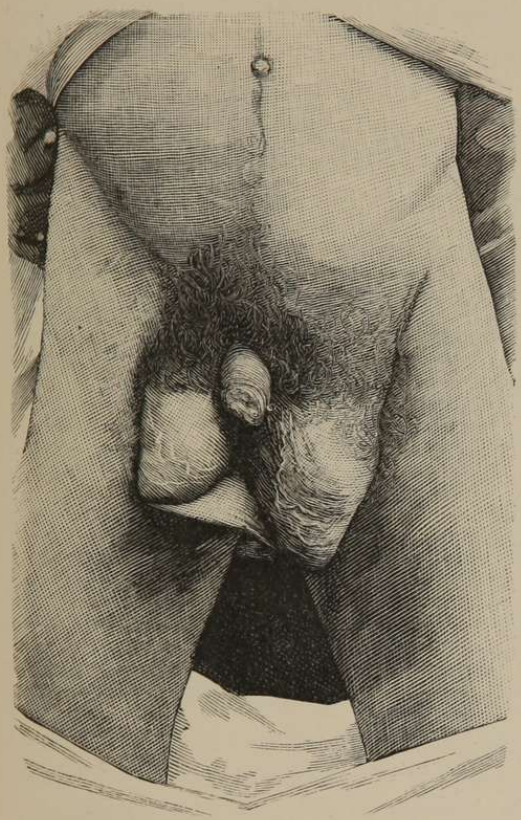

Fig. 793.—Double hydrocele of the tunica vaginalis testis. (From a patient operated upon at Mount Sinai Hospital.)

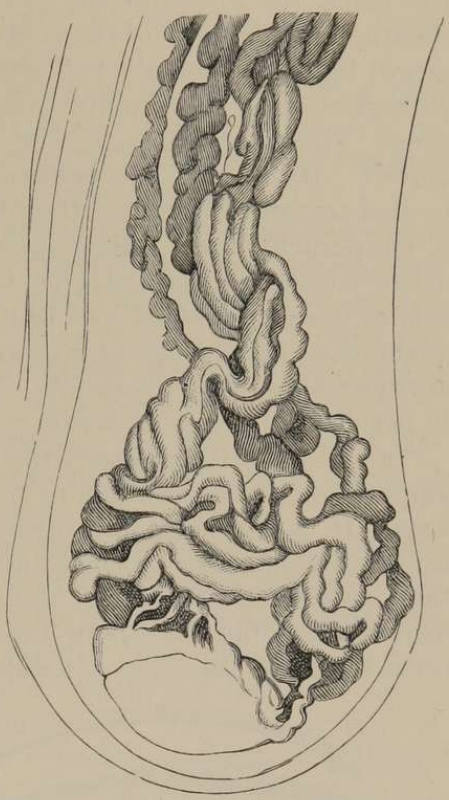

Fig. 794.—Varicosities of the spermatic plexus of veins, with atrophy of the testicle. (After Kocher.)

with the patient in the recumbent posture, and if the index finger is carried into the internal ring and held there while the patient is made to stand erect, the veins will again refill and demonstrate the varicocele, while the hernia will be prevented from descending. Hæmatoma, or hydrocele of the cord, can be recognized by aspiration with the hypodermic syringe.

Treatment.—In general, a well-adjusted suspensory apparatus constantly worn when in the erect position will obviate the necessity for an operation. A double elastic apparatus is advisable. When the annoyance of the suspensory bag is great, or if it is ineffectual, operative interference is demanded. There is but one method for the radical cure of varicocele that is advisable. It is as follows:

Shave and thoroughly cleanse with brush, soap, and water the entire field of operation and contiguous surfaces. An incision is made that

should extend from one inch above the external abdominal ring, down along the spermatic cord, through the tissues of the scrotum to the upper margin of the epididymis. Careful dissection will expose the entire cord without wounding any veins which enter into its composition. The vas deferens can be easily recognized, not only by the sense of touch, since it feels like a round leather shoestring when pressed between the fingers, but can be recognized by the eye. This should be carefully separated from all the remaining tissues of the cord, together with one or two veins, the artery of the vas deferens and the nerve, which are in one sheath, from the level of the epididymis to the external ring. A good-sized catgut ligature—usually the largest size—is now tied around the part to be excised near the epididymis, and a second ligature at the external ring. The intervening portion is cut through with scissors and removed. By leaving the ends of the two ligatures fairly long, these can be tied together, bringing the testicle up in proper position and holding it temporarily until adhesions occur. The wound should be carefully dried, closed, and sealed with iodoform collodion. It is a wise precaution to insert a twist of two or three strands of catgut in the lower angle of the wound, in order to give exit to the serous transudate which nearly always follows this operation. The collodion can be lifted at this point to permit the escape of serum or blood.

In the majority of cases the scrotum will be found so elongated that amputation of the redundant portion is essential to comfort and cleanliness. In performing this operation the testicles should be pushed well up toward the external ring, and a little more of the scrotum amputated than may seem necessary; the tissues are retracted to a much greater degree under the anæsthetic than normal. The operation is much facilitated by using the scrotal clamp (Fig. 795), which, if properly adjusted,

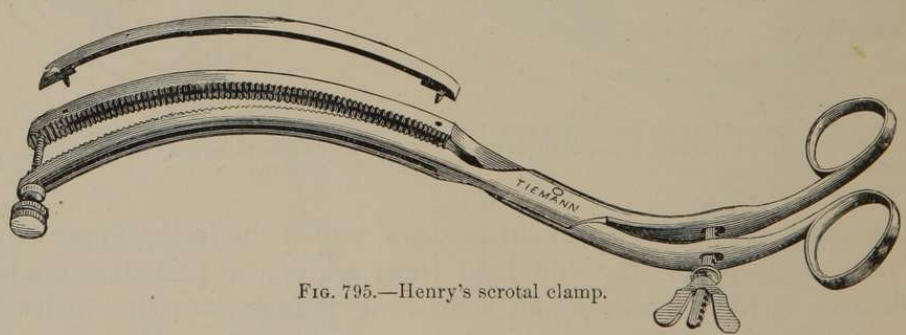

Fig. 795.—Henry's scrotal clamp.

will hold the tissues firmly while the amputation is being made, and the wound closed with strong catgut sutures, thus preventing all hæmorrhage and the necessity of applying any ligatures in the line of incision. If this instrument can not be obtained, Smith's hæmorrhoidal cautery clamp may be used, applying the clamp over a portion of the line of amputation, making the section about one fourth of an inch in front of it, and inserting and tying the sutures before further section is made. If no apparatus can be obtained, the fingers of an assistant will prevent hæmorrhage while the operation proceeds. This wound should be sealed at once with collodion.

The Vesiculæ Seminales and Vas Deferens.—The *seminal vesicles* are occasionally wanting, from failure of development, or from atrophy as a result of inflammation. *Wounds* of these organs are rare. If incised or punctured, temporary fistula may result, with subsequent atrophy. *Inflammation* of the vesiculæ seminales occurs by extension from the urethra or from the epididymis and vas deferens, or with prostatitis or proctitis. Occlusion of the ejaculatory duct induces overdistention of these organs. Several cases of calculus of the duct have been recorded.

The *diagnosis* in dilatation, hypertrophy, or inflammation of these cysts depends upon careful rectal exploration.

The *vas deferens* is more or less involved in all inflammatory processes which occur in the epididymis. It is also subject to invasion by inflammation from the urethra and prostate. Tuberculosis of this vessel may follow tuberculosis of the testes and epididymis.

In chronic vesiculitis benefit may be derived by the stimulation which results from digital pressure or massage. This is done by carrying the index finger into the rectum until these organs are felt, and exercising gentle, steady pressure with the tip of the finger applied from behind forward. I have had no personal experience with the method, but favorable reports have been made. The knee-chest posture is advised.

Epididymis.—Neoplasms of the sheath of the spermatic cord are rare. In his excellent monograph, Kocher mentions isolated cases of lipoma, fibroma, or myxofibroma and sarcoma.

Epididymitis results occasionally from direct violence, but is chiefly due to urethritis and the extension of the inflammatory process along the vas deferens. Metastatic or "sympathetic" inflammation of this organ is very rare. It may be acute or chronic. The inflammatory process may be confined to the epididymis or invade the testicle. Acute epididymitis always involves the tunica vaginalis (with which it is in contact), and very frequently the testicle. Specific urethritis stands first in order in the causation of epididymitis. The introduction of a sound or catheter, the lodgment of a calculus in the urethra or prostate, stricture, cystitis, and prostatitis may also cause this disease.

The *symptoms* of acute epididymitis are a sense of uneasiness or pain, varying in intensity in the organ affected, or in the cord or groin. It is increased by pressure, when the erect posture is assumed, or in walking.

In severe cases a chill or rigors occur, followed by a marked rise in temperature. Upon inspection there will be more or less induration along the posterior border of the testicle, with heat, redness, and tension. The testicle is more or less enlarged, and very frequently there is a serous transudation into the cavity of the tunica vaginalis testis.

The pathological changes consist chiefly of hyperæmia and infiltration of the connective-tissue framework with embryonic cells. The epithelial lining membrane is also thickened and injected.

The *diagnosis* depends upon the symptoms above given. The *prognosis* is usually favorable. One attack, however, predisposes to another. In some instances occlusion of the efferent apparatus results from contraction of the products of inflammation, and sterility follows. Sper-

matic fistula may result. As before stated, the prognosis is more serious when the globus minor is involved.

The *treatment* consists in the administration of saline laxatives in order to empty the alimentary canal. The patient should be placed upon his back, and the inflamed organ supported by either a three-cornered pillow between the thighs, or a towel pinned around both thighs just below the base of the scrotum. Upon this a small bladder filled with crushed ice may be placed, and the inflamed organ allowed to rest upon it. If cold is not grateful, warm cloths or a poultice may be substituted. The application of from three to six leeches will at times relieve the local congestion.

Usually rest in bed will alone suffice to effect a cure. In some instances operative interference is indicated.

The Testicle.

The Testicle.—Wounds of this organ do not demand especial consideration. Hernia of the tubules not infrequently occurs from incision or puncture of the tunica albuginea. Reduction is practically impossible. The protruded portion should be tied off with a catgut ligature, the excess of substance beyond the thread cut off, and the organ returned to the normal position.

Inflammation of the testis (orchitis) may result from direct violence, from the extension of an epididymitis, or from metastasis. Orchitis is met with as a symptom of "mumps," but the relation between these two processes is not understood.

The *symptoms* are enlargement of the organ, with pain usually intense in the acute variety. The swelling is slow on account of the great resistance offered by the tunica albuginea. The skin over the organ is tense and reddened, and at times œdematous, especially when an epididymitis precedes the inflammatory process in the testicle.

In severe cases gangrene may ensue, and the tunica vaginalis and scrotal walls may become involved. In mild cases the *pathological* changes are chiefly hyperæmia and the formation of a limited amount of embryonic tissue along the blood-vessels and in the connective-tissue septa of this organ. In the severer forms this process is greatly exaggerated, and as a result of the extensive hyperplasia the circulation is arrested, and death of the tubular structure ensues. Or, if gangrene does not occur, atrophy of the excretory apparatus follows as a result of contraction of the products of inflammation. In some instances the swelling subsides, leaving no marked changes in the organ.

Prognosis.—Mild cases, especially in the forms occurring with urethral epididymitis, generally terminate in one or two weeks in recovery and restoration of the organ to its normal condition. In cases where the symptoms are severe from the start, the prognosis is grave unless early relief is afforded, and even then it is not always favorable.

Treatment.—Rest in the dorsal decubitus should be insisted upon in

even the mildest cases, for not infrequently dangerous orchitis is provoked by neglect of this precaution.

The position of the testicle should be elevated, as in epididymitis. The local application of cold is grateful and advantageous in most cases. The organ is, however, so sensitive that no pressure is tolerated. This can be obviated by making a ring of cloths wrapped around a small hoop, leaving a lumen large enough to include the scrotum and penis. The ice bag is laid upon this ring, which prevents any pressure upon the testicle.

When the effusion is rapid, causing dangerous tension of the fibrous capsule, surgical interference is imperative.

The operation consists in seizing the organ with the left hand, so as to render it steady and the skin tense, puncturing the scrotum and parietal layer of the tunica vaginalis testis, and thus subcutaneously making a series of incisions through the tunica albuginea on its anterior and antero-lateral aspects. The incisions should be about half an inch in length, and are much preferable to simple puncture.

The danger of hernia testis does not contraindicate this procedure.

Chronic orchitis, not due to syphilis, is comparatively rare. When it occurs, it usually follows an acute inflammation. The pathological change consists in a thickening of the tunica albuginea and of the connective-tissue septa. Embryonic cells, collected in groups or nests, in various stages of development, are crowded along and around the blood-vessels and seminiferous tubules, as well as scattered about in the intertubular spaces. As the process continues, the tubules disappear under the pressure of the new products of inflammation. In a certain proportion of cases cysts form in the following manner: The peripheral cells of one or more foci of the embryonic tissue organize into connective tissue and aid in forming the investing capsule. The cells within this new capsule undergo granular metamorphosis, and later liquefaction, by absorption of fluid from the surrounding vessels. In other cases foci of suppuration (multiple abscess of the testicle) may remain from an acute inflammation and be present in chronic orchitis long after the acute symptoms have subsided. The contents of these foci may also undergo caseous degeneration.

The *symptoms* of chronic orchitis are those of progressive enlargement of this organ. In some instances pain is wanting, in others it is present, though less intense than in the acute form, while in a third category may be classed cases of chronic orchitis with intercurrent attacks of acute inflammation and the accompanying exacerbations of pain. The organ varies in size from two to four or five inches in its greatest diameter. Much annoyance may be occasioned by the dragging upon the cord.

The *diagnosis* is between hydrocele of the tunica vaginalis, inflammation of the walls of this cavity, with exudation and thickening and adhesion to the testicle, syphilitic orchitis, and tuberculosis testis. Hydrocele is easily excluded by fluctuation, translucency, and aspiration. In periorchitis with exudation and adhesions, differentiation will at times

be difficult. The obliteration of the cavity of the tunica vaginalis renders the superficial tissues less freely movable upon the body of the testis. In orchitis the surface of the enlargement is smooth, spherical, and of like consistence at all points; often in periorchitis ridges of new tissue can be made out; there are soft spots or depressions which can be recognized by careful palpation.

If syphilitic orchitis is suspected (even if the history of this disease is denied), it will be advisable to administer the protoiodide of mercury and the iodide of potassium for several weeks. The marked diminution of the tumor will be confirmatory of the suspicion of the syphilitic dyscrasia. The extraordinary weight of a syphilitic testicle should be borne in mind.

Tuberculosis testis is usually preceded by the deposit of tuberculous matter in the epididymis. Pain in this affection, when uncomplicated by pyogenic infection, is insignificant and entirely disproportionate to the rapidity of the infiltration and enlargement. Moreover, orchitis and epididymitis may usually be traced to some direct and exciting cause which is absent in tubercular disease.

The indications in *treatment* are, first of all, to remove every cause of irritation, to keep up the tone of the system by judicious feeding and medication, and to support the heavy organ by suspension. When these measures fail to arrest the disease, or when the pain becomes so great that the patient's comfort is interfered with, or when the disintegration of the organ is threatened, castration may be entertained. Before carrying out such an extreme measure, the precaution should be taken to explore the organ through an incision in the scrotum, in order to determine its exact condition before removing it.

Tuberculosis of the Testicle and Epididymis.—True miliary tuberculosis of the testicle and epididymis is comparatively rare. Many cases which have been recorded as tuberculosis must, upon analysis, be classed with a non-tubercular inflammation, the embryonic tissue of which has undergone caseous degeneration.

Primary tubercular disease of the testicle is the exception. The epididymis is usually first invaded, and from this point the new tissue spreads into the testicle, and not infrequently along the vas deferens to the seminal vesicles, as well as to the tunica funiculi and tunica vaginalis testis.

While it may be slow in some instances, as a rule the invasion is rapid, occupying from two to eight weeks in a general infiltration of both organs. The *symptoms* are, upon the whole, obscure. One point of great diagnostic value is that the pain is entirely disproportionate to the rapidity and extent of the tumefaction. In simple orchitis and epididymitis, pain is extreme and pressure unbearable. In *tubercular* orchitis pain is, as a rule, slight, and may not be present at all. In a certain proportion of cases there will be sudden and recurring exacerbations of pain, indicating a circumscribed acute orchitis, the result of irritation from the presence of the cell elements of the tubercular process or a mixed (pyogenic) infection. Ulceration and the formation of fistulæ occur in a certain proportion of cases.

In simple orchitis and epididymitis the cord is not involved, while not infrequently in tuberculosis the deposit rapidly travels along the vas deferens. Grasped between the fingers, the tubercular organ is felt to be hard, and its surface uneven and nodular.

The initial morbid change is the deposit around the seminiferous tubes of clusters or nests of lymphoid cells. Within the tubes the endothelia are thickened and are undergoing granular or caseous metamorphosis. Later, the connective-tissue septa become infiltrated with the new cells. The process ends in compression and destruction more or less complete of the tubules. The centers of these clusters of cells farthest removed from the vascular network undergo granular or caseous metamorphosis, forming at times cystlike caverns, or at other times abscesses and fistulæ.

Treatment.—The prognosis of tubercular disease of these organs is so grave that when an early diagnosis can be made out, extirpation of the diseased tissues should be considered. If only one side is involved, and the other organ is fully developed, there should be no hesitation in advising the operation of castration.

When the diagnosis is doubtful, it will be wise to keep the patient under constant observation, with especial regard to the advance of the disease along the cord, and when this is evident, and when there is no positive evidence of tubercular deposits elsewhere, extirpation is indicated in order to prevent invasion of the prostate and general dissemination. When both organs are involved, the question of complete castration may be submitted to the patient.

Enchondroma of the testicle is not altogether infrequent. It occurs most often after injury. While it is prone to originate in this organ, it may spread from the epididymis to the testicle. The volume of the organ varies, at times reaching a large size. Enchondroma testis, as with almost all forms of neoplasm seated in this structure, is apt to undergo cystic degeneration.

The *diagnosis* must be based upon the hard, elastic feel peculiar to this form of tumor.

The treatment is either expectant or operative, as circumstances may demand. Castration is indicated when the disease is unilateral, and when the size of the tumor is such that the function of the opposite organ is threatened. The mixed treatment should be thoroughly tested in all instances where the diagnosis is obscure.

Adenoma testis occurs chiefly from the twentieth to the fortieth year of life. It has so far not been observed during childhood.

The development of the tumor is usually rapid, attaining a diameter of three or four inches or more. Only one organ is usually affected. Pain is not a prominent symptom in the earlier history of this neoplasm, but, after the growth attains a sufficient bulk, it causes more or less pain by pressure and weight. To the touch it is soft and compressible. The formation of cysts in various portions of the neoplasm is frequent (cystoadenoma).

Under the microscope the epithelia of the seminiferous tubules are

seen to be swollen, while their caliber is more or less completely occluded with the round cells of the new (adenoid) tissue.

The *prognosis* is not favorable, and the *diagnosis* difficult. Since the function of the organ is wholly impaired, and since the rapid development of the tumor is of itself an indication of the gravity of the lesion, the matter of exact recognition of adenoma is not important. In all of these rapid and threatening neoplasms, especially when a single testicle or epididymis is involved, the safest course is in early and prompt excision.

Carcinoma.—Both scirrhus and medullary cancer may develop primarily in the testicle or epididymis. The encephaloid variety is most frequently encountered. The microscopical characters of these different varieties of cancer will be given in the chapter on tumors.

Carcinoma of the testis is apt to occur about the age of puberty, although it may be met with later in life. One organ is affected as a rule. It is more apt to begin in the testicle than in the epididymis. In the early stages of the development cancer of the testes is not painful, but as the disease advances the suffering may be intense. Early removal offers the only hope of cure, and this, unfortunately, is not great.

Sarcoma testis occurs at all ages, but is chiefly confined to childhood and early manhood. Following the general law of sarcomata, that of the testicle is rapid in growth, attaining at times an enormous size. This is one of the chief diagnostic points of this tumor, which is hard, usually pyriform in shape, and of comparatively smooth contour. Castration offers the only hope of relief.

It will be seen from the foregoing that accurate diagnosis of the various neoplasms which develop in the testicle is difficult and often impossible. Almost all of these morbid processes lead to destruction of the organ and loss of function, and immediately or remotely threaten the life of the individual.

Thus tuberculosis, adenoma, carcinoma, and sarcoma may be classed as malignant. Enchondroma, although not intrinsically malignant, leads to loss of function, and in this particular justifies operative interference. The same applies with greater force to cystic degeneration of this organ, since cysts often develop in malignant neoplasms of the testicle. In view of these facts, when only a single organ is involved, it will be advisable in the early history of any neoplasm of this organ to consider the propriety of castration.

The operation is thus performed: Shave the scrotum and pubes, and make an incision extending from the external abdominal ring along the anterior surface of the cord and testicle to the base of the scrotum. When the morbid process involves the scrotal tissues, and even when there is a suspicion of involvement, the primary incision should be carried well away from the suspected tissue into the healthy structures.

Two points of importance are suggested in the removal of this organ. The first is to make an incision into the mass in order to clear up the diagnosis; the second is to secure the vessels by the ligature applied near the external ring, and thus prevent the danger of forcing septic or

metastatic matter in the lymph channels or vessels leading toward the center. The cord should be exposed at the ring, the vas deferens isolated, and a large, double catgut ligature thrown around so as to include the entire cord except the vas deferens. This is twisted around the cord while the exploratory incision is being made, and, if the diagnosis is confirmed, the catgut is tied and the cord divided between the two ligatures. The diseased organ is then dissected out, the hæmorrhage arrested, drainage secured, and the wound closed with catgut sutures. A single dressing will usually suffice. When the vas deferens is divided, the accompanying artery should be separately tied.

Malposition.—One or both of these organs may be absent from the normal position in the scrotal sac. The descent from the abdominal cavity may be prevented by narrowing or closure of the inguinal rings, or the inner ring may be passed, the testicle being arrested at the outer opening, and thus imprisoned in the canal; or, passing both rings, it may lodge beneath the skin near the pubic crest, or in the perinæum or groin. Occasionally the testicle remains entirely within the abdominal cavity. Another rare form of malposition is when the organ is turned obliquely or crosswise in the scrotum.

Misplaced testicle does not usually give rise to great inconvenience until the approach of puberty, when its normal development is interfered with by compression. If it is lodged in the inguinal canal, where it is acted upon by muscular contraction, it may cause pain at an earlier period. The descent of a hernia upon a testicle thus imprisoned gives rise to considerable annoyance. An imprisoned testicle is occasionally the seat of a neoplasm. The symptoms are those of pain, neuralgic in character, and the diagnosis must depend upon the absence of the organ from its normal place and its recognition in the position of the abnormal swelling.

Misplaced testicle requires no special treatment until it becomes a source of inconvenience or annoyance, or is the seat of some new formation. Extirpation may become necessary. It is better, when both organs are abnormally situated, to endeavor to bring one or both into even a limited scrotal sac, when, as frequently occurs, it may be relieved from compression by transferring it either just beneath the skin or between the abdominal muscles and the abdominal layer of peritonæum.

Supernumerary testicle does not occur. In several instances a cyst or other neoplasm has been mistaken for an extra organ.

Traumatic dislocation of the testicle may also occur. Dr. Ramon Guitéras* reported a dislocation of this organ into the loose tissues between the integument of the penis and the body of this organ. A successful reduction was made by a long incision which exposed the testicle, and was continued until the contracted tunica vaginalis testis was opened.

* "Medical Record," January 4, 1896.

CHAPTER XXIX.

THE GENITO-URINARY ORGANS IN FEMALES.

Lesions of the Vulva and Perinæum—Wounds.—Incised or *lacerated* wounds of the vulva are frequently accompanied by profuse hæmorrhage, especially when the venous plexuses which compose the *bulbs of the vestibule*, on either side of the vaginal orifice, or the large *connecting veins* which extend upward to the clitoris, are divided. Incision or rupture at or near the median line, the *posterior commissure* of the vulva, is not followed by hæmorrhage, as a rule, since the vascular network does not extend so low.

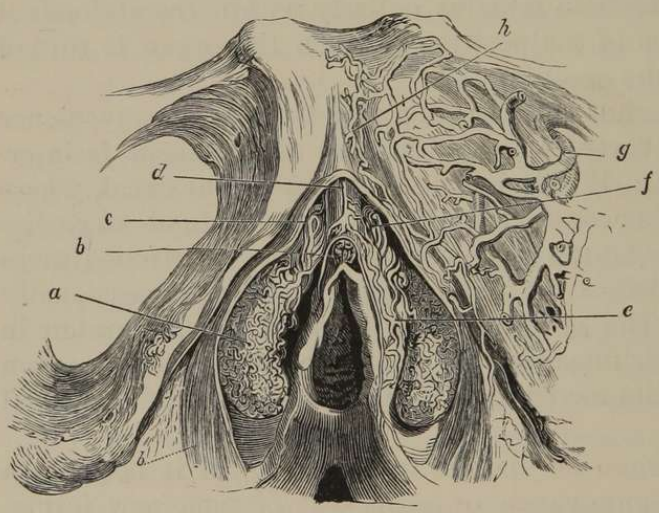

FIG. 796.—Showing arrangement of the erectile tissue and venous plexuses about the vulva. *a*, Bulb of vestibule. *b*, Clitoris. *c*, Connecting veins. *d*, Dorsal vein of clitoris. *e*, *f*, Deeper veins. *g*, *h*, Communication between obturator and vulvar vessels. (After Quain.)

Bleeding may be arrested by direct compression with a pledget of gauze or lint, or, in case of extensive injury, by the ligature.

Contusions of this part of the genital apparatus may be followed by *hæmatoma* or *abscess*. Hæmatoma also occurs in rare instances in pregnant women from overdistention and rupture of the veins without direct violence.

In this variety of swelling operative interference is not advisable, unless the tumor is so large that it seriously interferes with the comfort of the patient, or unless sloughing is imminent or suppuration supervenes. When *abscess* occurs, it should be incised and drainage secured by stuffing loosely with iodoform gauze. Abscess here is most frequently situated in the region of Bartholin's gland, between the vaginal orifice and the *erector clitoridis* muscle. *Boils* are not infrequent in this same location, and require to be opened, kept clean by constant care, and when sluggish in healing should be touched thoroughly with lunar caustic.

As a result of injury, and occasionally as a congenital affection, *adhesions* of the labia exist. This condition should not be mistaken for the

hymen, which membrane is situated farther inward. The treatment required is a careful separation of the adhering surfaces in the median line and the insertion of a plug of gauze or a glass cylinder, which is allowed to remain until the raw surfaces become covered with epithelia.

Rupture of the Posterior Commissure of the Vulva and Perinæum.—Rupture of the perinæum may be *partial* or *complete*. In *partial* rupture the laceration may involve the tissues down to or partly through the *sphincter-ani* muscle. *Complete* laceration extends through to the

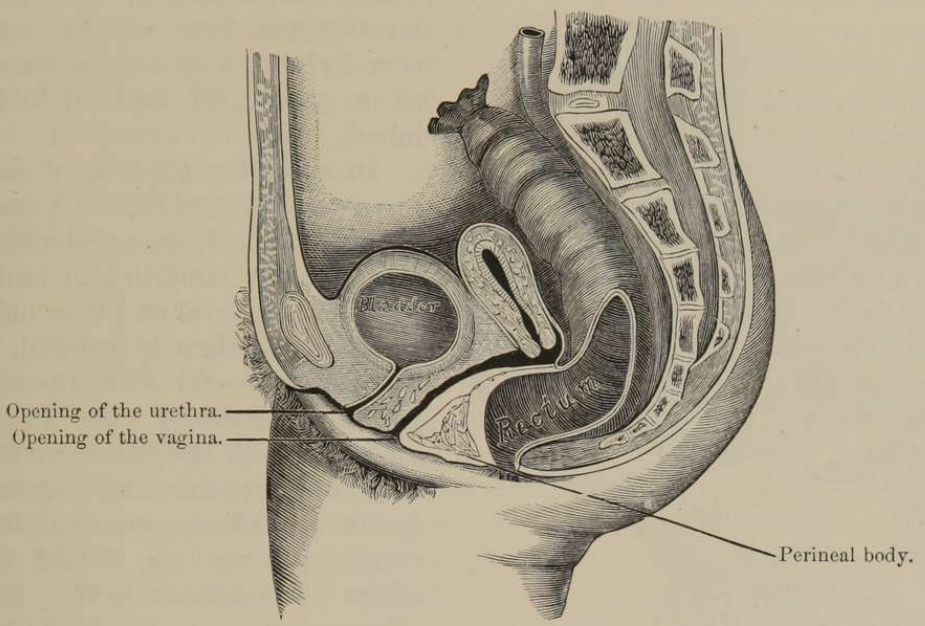

Fig. 797.—Showing in perpendicular section the perineal body and its support to the bladder, vagina, and rectum. (After Thomas.)

anus and involves more or less of the recto-vaginal septum and wall of the rectum. In very rare instances the laceration is *central*, in which case a sinus is developed, extending from the inferior vaginal wall or floor to some point on the perinæum, the *fourchette* and *sphincter ani* remaining intact.

Rupture of the perinæum may occur at any stage of the child-bearing period. The frequency of this accident is in general proportionate to the size of the child, the rapidity of delivery, and the age of the mother at the period of first confinement.

A breech presentation, in which the head and arms are crowded together through the vagina and vulva, is apt to produce severe laceration, especially when, in order to prevent too prolonged pressure on the cord, rapid delivery is necessary. Rapid expulsion of the child by the first few and violent uterine contractions, or by the use of forceps before natural dilatation has been effected, will add greatly to the danger of rupture of the perinæum. Parturition occurring for the first time after the thirtieth year of life is also more apt to be attended with laceration of the perinæum than at an earlier period, when the tissues are more yielding.

There may result from perineal lacerations: *hæmorrhage*, and *loss of function in the sphincter-ani muscle*, *rectocele*, *cystocele*, *proctitis*, *cystitis*, *prolapsus*, and *other displacements* of the uterus and its appendages (Fig. 798).

Treatment.—The indications are to restore as near as possible the normal relations of the separated tissues. In *incomplete* rupture, or even when the laceration extends barely into the anal margin, the *best time* to operate is immediately after the delivery of the placenta. The contra-indications to operative interference here are exhaustion by reason of hæmorrhage, or a prolonged and difficult labor.

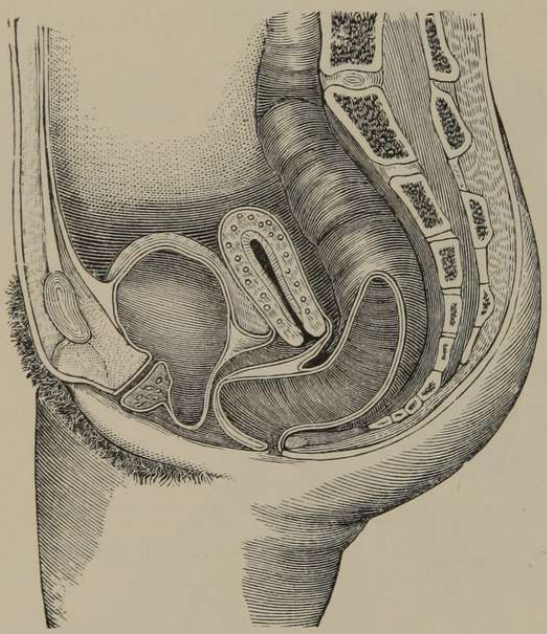

Fig. 798.—Rectocele and cystocele following destruction of the perineal body. (After Thomas.)

In complete rupture of the *recto-vaginal septum* the operation is of necessity so prolonged that it is advisable to wait until involution has taken place, and the patient's vigor is restored.

Operation for Old Incomplete Rupture of the Perinæum.—In all operations about the vulva, perinæum, vagina, cervix, and uterus, most careful aseptic precautions should be taken. In addition to this, the alimentary canal should be so thoroughly emptied that, if necessary, the bowels may be kept quiet for several days after the operation. The following method may be carried out, with such slight variations as may be indicated in any special case: Calomel triturates, one fourth of a grain, should be administered at seven, eight, and nine o'clock at night for four days before the operation. A strong, nutritious diet of simple food—beef, mutton, wheatena, milk, etc.—should be given up to the day preceding that of the operation. Twenty-four hours before the operation the vagina should be thoroughly mopped and cleansed with a solution of mercuric chloride (1 to 5,000), and, after drying out the excess of the solution, snugly packed with sterilized gauze slightly moistened with 1-to-5,000 bichloride solution. This should be removed when the patient is under the anæsthetic, and after the parts have been shaved and the external genitals scrubbed with soap, water, and brush, the cleansing of the vagina is repeated. A purgative should not be given the night before, nor an enema on the day of an operation on the vulva, vagina, or anus.

The instruments and material required are a pair of sharp-pointed scissors curved on the flat, a tenaculum or good tissue forceps, a strong needle-holder, some strong round needles, without cutting edges, with a

half-curve near the point, varying from about one and a half to two inches in length, each armed with a loop of fine strong Chinese twisted silk, for carrying the wire through, some silver-wire sutures, one foot long each (No. 27 for deep, No. 33 for superficial sutures), a piece of small-sized rubber tubing. By holding the end of the silver wire over a spirit lamp, it melts and is easily shaped into a shot, which prevents it from being accidentally jerked through when introduced.

Place the patient upon the table on the back, the sacrum near the edge, the legs flexed on the thighs, and the separated thighs flexed on the abdomen, and held by two assistants, who also separate the labia.

A close inspection of the torn surfaces should now be made, so that the full extent of the laceration may be realized. This will not be difficult to determine, since the peculiar, glistening, smooth surface of the cicatrix is readily made out. By carefully approximating these surfaces before using the scissors, the extent of denudation may be appreciated. The clover-leaf shape of the denuded area is well shown in Fig. 799, extending upward along the labium of either side and well up into the depression or angle, where the floor of the vagina and labium come together. Upon the floor of the vagina the denudation should extend backward to the crest of the rectocele or elevation formed by the bulging forward of the floor. The tissue to be removed in freshening the torn surfaces should be picked up by the tenaculum or forceps, and shaved off with the scissors. It is advisable to commence at the lowest portion of the scar by taking up a strip from the patient's left directly across the perinæum to the right. In this way the parts yet to be lifted are not obscured by the bleeding.

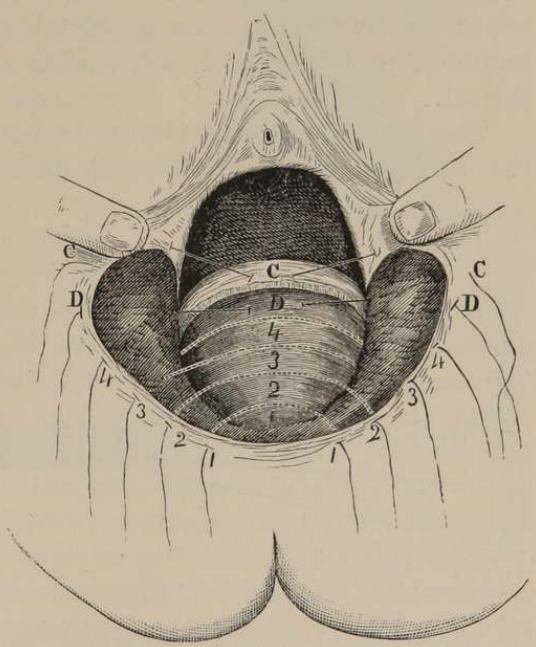

Fig. 799.—Operation for diminishing the vaginal outlet by external sutures after rupture of the perinæum. (After Emmet.)

Denudation of the vaginal floor can be most rapidly accomplished by inserting one or two fingers into the rectum and making tense and elevating the surface to be freshened over the ends of the fingers.

The sutures are now introduced, commencing with No. 1, near the *sphincter ani*. They should be inserted about one fourth of an inch apart and the needle should enter the same distance from the edge of the wound. It is well to include a liberal quantity of tissue. As the needle is carried through from the (patient's) left to right side, it should be carefully guided, so that it does not emerge at any point on the denuded surface (nor by any mishap penetrate into the rectum), and finally

be brought out through the integument of the right side at a point exactly opposite its entrance. As each suture is passed, the finger in the rectum will enable the operator to guide the needle safely through the recto-vaginal septum. After two or three sutures are passed, on account of the distance across the denuded area, it may be necessary to bring the needle out in the middle line. It should be reintroduced at the same point, so that the suture will not be exposed.

The suture next to the last (*D*, Fig. 799), after passing through the labium, is not made to pass into the recto-vaginal septum until the needle approaches the middle line of the septum, where it is passed through this for about the extent of one inch.

The uppermost suture of all, *C*, enters at the upper limit of the freshened surfaces, passes through the labium, comes out in the cavity of the vagina, and then, just above the limit of the denudation on the recto-vaginal septum, it is made to traverse this for about one half of one inch (an auxiliary or supporting suture). As each wire is drawn through, the ends should be loosely twisted to prevent being pulled out by accident. When all are inserted, the wound should be thoroughly cleansed and disinfected with sublimate solution and dried and the wires twisted, commencing with the lowest, No. 1. The twisted ends are left about two inches long, are gathered together in a bundle (Fig. 800), and included in a piece of soft-rubber tubing held in place by a bit of thread.

The patient's thighs should be bandaged together. She may rest on the back or side as preferred, and the catheter should be employed every five or seven hours, in cases where the urine can not be naturally voided. It should be the operator's aim to permit no movement of the bowels for two or three days, and when this occurs an enema of warm water should be employed to secure a soft or liquid discharge. The passage of solid matter will seriously endanger the success of the operation.

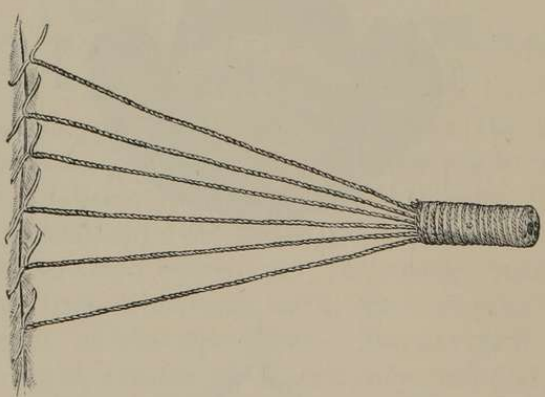

Fig. 800.—Sutures twisted, and the ends covered with a piece of rubber tube.

The sutures should be removed in eight or ten days. The most suitable position is with the patient on the back, the thighs held together and flexed well upon the abdomen. The lowest wire is first disengaged and gently pulled upon until the right side (patient's left) of the buried loop is seen, when the scissors' point is passed beneath and made to divide it. Care should be taken not to separate the barely united surfaces, and this is best avoided by drawing the twisted stub of the divided suture toward the side on which it was cut. Abduction of the thighs should not be allowed until about the fourteenth day.

Immediate Perinæorrhaphy.—After the placenta has been expelled, the uterus should be firmly compressed in order to cause rapid and thorough contraction, and also to force out any remaining clots of blood. The vagina should then be disinfected as above directed, and a plug of iodoform-gauze strips inserted to prevent the descent of any fluids from the uterus while the sutures are being passed. These are inserted in the same way as just described for secondary perinæorrhaphy, and the freshly lacerated surfaces untouched by the scissors are at once approximated. The vaginal tampon is now removed. The after-treatment does not differ from that above given.

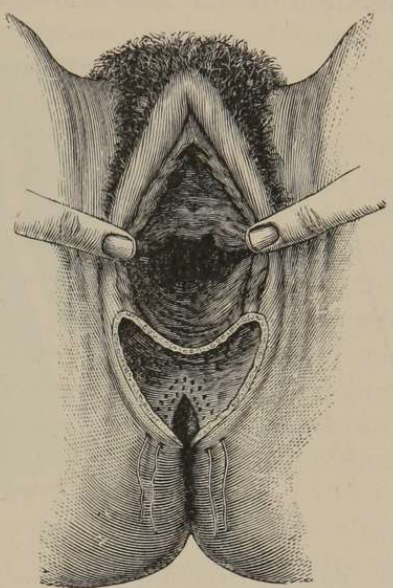

Fig. 801.—Surface denuded in complete perineal rupture, and the first two sutures in position. (After Thomas.)

Secondary Operation for Complete Laceration of the Perinæum.—The most rigid preparatory treatment should be carried out, the object being to empty the entire alimentary canal of all solid matter, and to prevent, as far as possible, the accumulation of gas. To this end a liquid diet should be ordered for one week before the operation, a copious enema of warm water and inspissated ox gall should be given daily, and on alternate days a free laxative, discontinuing the latter twenty-four hours before the operation.

The chief objects of this operation, given in order of importance, are: (1) restoration of the functions of the *sphincter-ani* muscle, and (2) restoration of the perineal body. The denudation should extend along the triangular cicatricial surface of each half of the divided perinæum and entirely along the edges of the rent in the recto-vaginal septum. For the first suture, the needle is introduced just at the margin of the anus and one quarter of an inch from the denuded surface. It is now directed through the recto-vaginal septum to the angle of the rent, then back along the opposite side, and made to emerge at a point corresponding to its insertion (Fig. 801). Great care should be taken to prevent the needle entering the rectum. A second suture is passed parallel with this. The remaining sutures are inserted as in the operation for incomplete rupture. The bowels should not be allowed to move for four or five days after the operation, and then an enema should be *administered by the physician.* Should gas accumulate in the rectum, it may be removed by the careful insertion of a small soft catheter.

When the rent in the recto-vaginal septum is bifid (a rare occurrence) the edges should be correspondingly freshened, and the sutures inserted as shown in Fig. 802. The sutures should be removed on the eighth or tenth day (Emmet).

When the laceration is *central* (not communicating with the rectum) it is advisable to incise the strip of tissue between the sinus and the

fourchette, pare the edges of the laceration, and insert sutures as in the operation for incomplete rupture.

Diseases of the Vulva.—The vulva and adjacent cutaneous surfaces may be the seat of syphilitic, chancroidal, tubercular, and epithelial ulcers, of ulcers resulting from abrasions or fissures which have been in contact with gonorrhœal virus, a leucorrhœal discharge, or the urine; and of warty excrescences (condylomata) and sarcoma.

The primary lesion of *syphilis* and the *chancroidal ulcer* in this location do not differ materially from those already given. *Tubercular* ulcers follow a chronic course; they are irregular in outline, and are characterized by a deeper infiltration of the subcutaneous tissues than in the acute forms of ulcers. *Epithelioma* of the vulva possesses the same characteristics as given for this condition on other muco-cutaneous surfaces. Condylomata have already been considered. Epithelioma and sarcoma of the vulva are occasionally met with and demand early and wide removal with the knife. In a case of sarcoma seen with Dr. X. O. Werder, of Pittsburg, the right half of the vulva and a portion of the urethra were dissected away with the neoplasm. The hæmorrhage was insignificant.

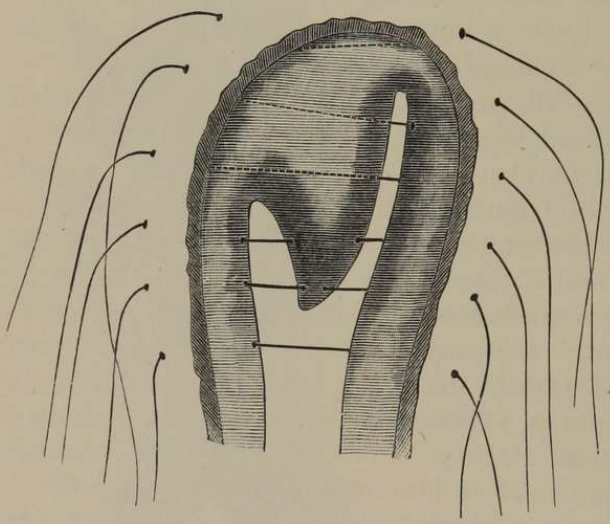

Fig. 802.—The direction of the sutures in a cleft laceration through the recto-vaginal septum. (After Emmet.)

Treatment.—A typical syphilitic ulcer requires no local treatment. When an ulcer of this region takes on a phagedenic character it should be at once thoroughly cauterized. I prefer the red-hot wire or Paquelin's cautery. If these agents can not be employed, pure nitric acid will suffice. The injection into the tissues beneath and around the ulcer, of from gtt. v–x of a four-per-cent solution of cocaine hydrochlorate, renders the free use of the cautery painless. After destroying the ulcer, an ointment of cocaine hydrochlorate, gr. ij; iodoform, gr. j; morph. sulph., gr. ss.; olei theobrom., q. s., may be applied as an emollient local anæsthetic.

Lupoid or *tubercular* ulcers should be dissected out, or deeply injected with pure liquid carbolic acid, until sloughing is produced. Mild forms of this ulcer may be cured by scraping with a sharp spoon or ring-scoop, and repeating this procedure at intervals of two weeks, until cicatrization ensues. *Epithelioma* and *sarcoma* should be freely excised. Arsenious acid may be successfully applied to epithelial cancer which has not extended too deeply within the vagina. *Papillomata* may be radically destroyed by clipping them off with curved scissors and burn-

ing the stump with nitric acid. In all forms of ulcer of the vulva complicated with vaginal discharge, repeated irrigation of this canal with warm sublimate solution (1 to 5,000) should be practiced.

Vulvitis from direct injury should be treated by complete rest, aided by the sitz-bath of warm water and by emollient applications.

Gonorrhœa in the female is not infrequently confined to the vulva and meatus urinarius, but may extend to the vagina, uterus, and tubes, and to the bladder. The symptoms of inflammation supervene, as a rule, rapidly after the contact, there being first noticed a sense of burning over the meatus and along the urethra, especially severe during and immediately after micturition. There soon follows a purulent and occasionally a bloody discharge from the urethra and vagina. The diagnosis of gonorrhœa in the female is not so easily made as in the male, since a vaginal discharge not specific in character may conceal the true nature of the disease. The discharge directly from the meatus is the most direct symptom of gonorrhœa. In the *treatment*, complete rest is indicated. The warm sitz-bath is of great importance. Irrigation of the vagina (and urethra when involved) with warm 1-to-3,000 permanganate-of-potash solution should be performed two or three times a day. If commenced early in the disease, the invasion of the uterus may be prevented; this is of vast importance, since serious lesions (*pyosalpinx*, *sterility*, etc.) may result from infection of the uterus and Fallopian tubes. Sterilization of the urine is indicated.

Vulvo-vaginal abscess may be caused by gonorrhœal infection. Incision and drainage is indicated, and when by this method a cure is delayed, curettage or a clean dissection of the glandular tissues involved should be done.

Pruritus vulvæ is a distressing and often an obstinate disease. The sense of itching, burning, or formication may be felt at the vulva, in the vagina, or over the entire pudendal region. It is paroxysmal in character; the attacks may occur at all times, but more frequently are severest immediately after the patient goes to bed. This condition is met with in females of all ages, but is more apt to occur about the cessation of the menses. In addition to superficial lesions of the genital organs, displacement of the uterus, chronic inflammation of the vagina, or any disorder of the deeper organs, may cause pruritus of the vulva. The indications in treatment are to correct any existing pathological condition. Grailly Hewitt advises a mixture of one part of chloroform to six of almond oil.

Hernia of the labium may be recognized from the history of the case, the tumor having first been noticed above at the canal of Nuck, descending more or less gradually into the labium.

Cystic tumors here originate in the substance of the labium.

Hernia of the *ovary* is occasionally met with. The *diagnosis* may be made as follows: In hernia of the bowel or omentum an impulse will be transmitted on coughing; it may be reducible; it is first observed in the canal of Nuck, extending subsequently into the labium. A prolapsed ovary is painful on pressure, giving a peculiar sensation not met

with in compression of a cyst or loop of intestine. The character of a cyst may be positively determined by exploration with a very fine and thoroughly aseptic hypodermic needle and syringe. An exacerbation of pain in a tumor in this locality, about the menstrual period, would suggest the presence of a misplaced ovary.

The treatment of hernia in the female is given elsewhere. A prolapsed ovary should be extirpated, and a cyst of the labium or canal of Nuck should be removed.

Symphyseotomy.—This operation, which consists in the division of the cartilage between the two pubic bones in the median line at the symphysis, is indicated in a certain proportion of cases which, by abnormal narrowing of the pelvic outlet, would otherwise be subjected to the more formidable operation of abdominal hysterectomy or to cephalotripsy. It was first done in the United States by Dr. J. O. Williams, of Houston, Texas. It has been done a number of times since, and has been brought prominently before the profession by Prof. Edward A. Ayers, of New York, who has reported a number of cases.*

The operation may be performed subcutaneously as advised by Dr. Ayers, or by the open incision after the older method of Morisani or Pinard. Ayers's method is as follows: After shaving the parts, under thorough asepsis, secure full dilatation of the cervix if possible without risk to the child. The patient is brought to the edge of the table and placed in the lithotomy position. A small male urethral sound is introduced into the bladder, and with it the urethra and lower portion of the bladder are held firmly to the patient's left side. The labia minora and clitoris are then drawn well up and also to the patient's left. The operator introduces the left index finger into the vagina, and carries this along the posterior curve of the symphysis to the top of the joint in the median line. A small incision is now made about one half inch below the clitoris. A curved, probe-pointed bistoury is passed into this wound close against the joint to the top of the symphysis, until the probe point is felt against the end of the left index finger, which is behind the bone. The cutting edge of the blade is turned downward, the back of the knife being toward the vessels of the clitoris. The bistoury is now worked carefully down through the cartilage of the symphysis. The success of the division is determined by the separation which ensues, the left finger being able to appreciate the space between the bones as they are separated. In dividing the subpubic ligament it is advisable to change the direction of the bistoury and cut up instead of down. In Dr. Ayers's cases the separation varied from two to two and a half inches, enabling the easy delivery of the child by the application of forceps. If for any reason the operator may not feel justified in attempting the subcutaneous operation, separation can readily and with perfect propriety be secured through an open wound made above the genital apparatus, exposing the symphysis pubis, by a modification of the incision given for suprapubic cystotomy. Under careful antiseptic precau-

* "New York Polyclinic Journal," May 15, 1896.

tions there can be no danger in such a procedure, and the section is made entirely under the inspection of the operator. Such a wound should be thoroughly dried and closed at once. If any infection has occurred it is safer to pack with iodoform gauze and treat by the open method. In the after-treatment of these cases it is important to see that the bladder does not become pinched between the pubic bones as they are brought together after delivery has been accomplished. A simple means of coaptation of the bones is the use of broad strips of adhesive plaster, brought from just behind each trochanter and across in front. In addition to these two suggestions of Prof. Dawbarn, Dr. Ayers advises that the patient be placed upon an ordinary cot bed in which the trochanters are so pressed upon as the patient lies upon the back that union is aided. Dr. Ayers has devised a cot (Fig. 803) which has given satisfaction in his practice.

The Vagina—Vaginitis.—Inflammation of the vagina should be treated by rest, irrigation, as in gonorrhœa, and the sitz-bath. The pa-

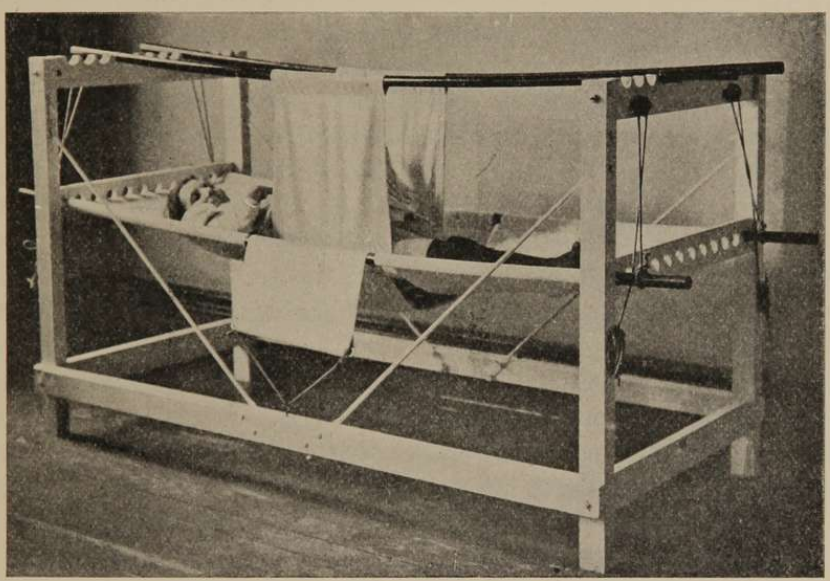

Fig. 803.—Prof. Edward A. Ayers's Symphyseotomy Cot.

tient should lie on the back, the sacrum resting upon a bedpan, and the solution applied by means of a fountain irrigator from a height sufficient to give the stream considerable force. Pressing the labia together will retain the solution until the canal is thoroughly distended. As soon as the more acute symptoms have subsided—and in all forms of chronic vaginitis—the thorough application of nitrate of silver, ʒ j–ij to water ℥j is indicated. This may be repeated in from five to eight days, as needed. Before introducing the stronger solution, it is advisable to cover the external genitals with vaseline to prevent the burning which would otherwise occur on the exposed surfaces.

Vaginismus, or "spasm of the vagina," is chiefly due to an abnormally sensitive condition of the vaginal orifice. Vaginitis is not usually present. Upon introducing the finger, the *hymen* will often be found

tense and resisting. An effort to carry the finger into the vagina will be extremely painful, and will cause spasm of the sphincter-vaginæ muscle.

Treatment.—Place the anæsthetized patient on the back, with the sacrum resting on the edge of the table, the thighs separated and held by assistants, and make the antiseptic toilet. With the hymen exposed by holding the labia apart, seize this membrane with mouse-tooth forceps and dissect it out close to its vaginal attachments. Introduce two fingers, dilate the vagina, and with the knife make two parallel incisions on the lateral aspects of the vaginal wall throughout its length. These incisions should extend about through the vaginal wall. Then introduce the Sims's glass vaginal plug (Fig. 804), adjusting the instrument so that the urethra will fit into the concavity on its upper surface. It should be removed in six or eight hours, the vagina irrigated and the cylinder reintroduced. After the first twenty-four hours it may be worn three or four hours daily. This should be kept up for two or three weeks, or until all trace of the vaginismus has disappeared.

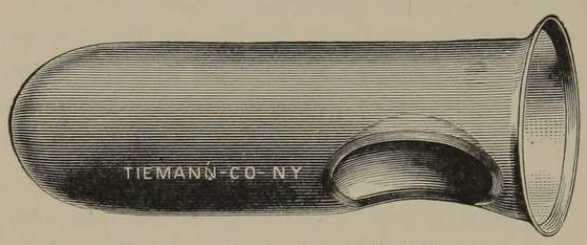

FIG. 804.—Sims's glass vaginal plug.

If the glass plug can not be obtained, a moderate packing of strips of iodoformized gauze will suffice. In mild cases simple digital divulsion of the sphincter-vaginæ muscle may effect a cure. It is occasionally associated with endometritis, ovaritis, and salpingitis, and can not be relieved until the deeper lesions are cured.

Stricture of the Vagina.—Occlusion of the vagina may be *partial* or *complete*, and may be *congenital* or *acquired*. The diagnosis is readily made by digital examination or by inspection. Imperforate or partially obliterated hymen need not be mistaken for true stricture, when it is borne in mind that this membrane is situated just at the entrance to the vagina, while stricture proper occurs beyond this point in a large majority of cases. The exact situation of the obstruction may be readily appreciated by making a digital exploration of the rectum, thus locating the cervix uteri, while the other index finger is introduced *per vaginam* as far as the stricture. In complete obstruction (*atresia*), the absence of the menstrual discharge should be considered in arriving at a diagnosis.

Treatment.—In partial occlusion, due to bands or a membrane, these should be divided or ruptured, a thorough dilatation accomplished, and the glass cylinder of Dr. J. Marion Sims introduced, as in the treatment of vaginismus. When there is a narrowness of this canal, without well-marked contracting bands, it will suffice to dilate with bougies, gradually increasing in size until a cure is effected. The operation may be repeated two or three times a week, or less frequently should any severe inflammation supervene.

When the opening is so small that the finger can not be introduced, a probe-pointed bistoury may be carried through and the obstruction

divided in several directions, after which forcible dilatation should be practiced.

When complete occlusion exists, the canal should be opened up by cutting through the adherent walls in the ascertained direction of the *cervix uteri*. By dilating the canal as wide as possible to the point of obstruction, then locating the cervix with the index finger of the left hand in the rectum, while the sound is kept constantly in the urethra and bladder as an additional guide, the dissection may be safely accomplished. The Sims glass cylinder should be employed in the after-treatment.

Rectocele and Cystocele.—As a result of overstretching during labor, and especially when the perineal body has been ruptured, the posterior wall of the vagina, with or without the contiguous wall of the rectum and the anterior wall of the vagina, with the bladder, may protrude into the vagina. The former condition is known as *rectocele*, the latter as *cystocele*.

The uterus and its appendages are also more or less dragged downward, the cervix approaching the *ostium vaginæ* and in extreme cases protruding between the labia—*prolapsus uteri*.

It is important to correct each or all of these conditions at the earliest possible moment. The operation for the cure of *rectocele* consists in removing the mucous membrane from the posterior wall of the vagina over an area sufficiently large, and then introducing sutures of silver wire, or, next in order of preference, silkworm gut, to hold the freshened surfaces together until union has occurred. Since rectocele exists so frequently with laceration of the perinæum, the two conditions should be corrected by a single operation. The method of procedure for partial rectocele has been given with perinæorrhaphy.

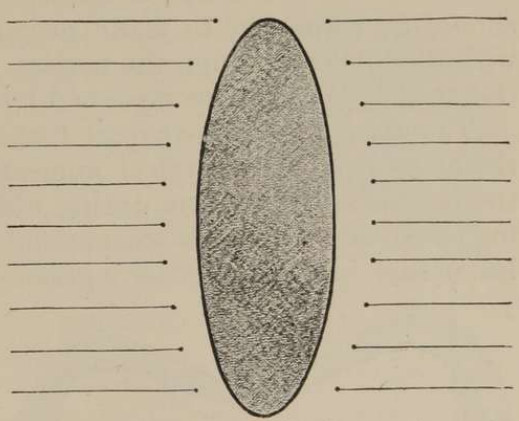

Fig. 805.—Oval denudation for the cure of rectocele, with sutures passed. (After Thomas.)

The extent of denudation may be determined by approximating the sides of the floor of the vagina with tenacula. The mucous membrane should now be trimmed off with sharp-pointed scissors curved on the flat. The freshened area may be oval in shape, as in Fig. 805, or may vary to suit any particular operation, bearing in mind the object to be attained, namely, a uniform narrowing of the tube so as to render descent of the uterus or rectal wall impossible. It is advisable to begin the denudation at the vulva and work upward, for in this way the blood does not obscure the field of operation. The mucous membrane may be rapidly pared off by lifting the posterior wall of the vagina forward by means of one or two fingers introduced into the rectum. Sutures of silver wire are next introduced, as shown in Fig. 805. While this is being done, the finger

should be kept in the rectum, so that the needle may not enter this cavity. On account of the pain caused in removal, silver wire or silkworm gut are objected to by some operators and chromicized catgut sutures have been in late years substituted. Properly prepared, these sutures will hold the raw surfaces in apposition for eight or ten days and secure good union. Greater quiet should be demanded, however, than is necessary when wire is employed. When the perinæum is torn and perinæorrhaphy is necessitated, silver sutures should be employed for this part of the operation.

For *cystocele* a similar operation is performed on the upper or anterior wall of the vagina. In order to prevent the possibility of wounding the urethra or bladder, or allowing the needle to enter while the sutures are being inserted, a large sound should be kept in the bladder during the operation. When rectocele exists with cystocele, associated with partial prolapse of the uterus, the operation on the posterior wall, by restoring and holding the uterus in its proper place, may also relieve the cystocele. Unless this latter condition exists in a severe form, it is advisable to await the result of the operation for rectocele before operating on the anterior wall.

Vesico-Vaginal Fistula.—A fistulous opening from the bladder into the vagina may be *surgical* or *accidental.*

In order to secure drainage of the bladder for the relief of chronic cystitis, or for other purposes, *kolpo-cystotomy* is at times performed. Suprapubic cystotomy has, however, in late years practically superseded this older operation. Section of the bladder wall should be in the median line, and should as nearly as possible bisect the triangle formed by the orifices of the ureters and urethra. A sound introduced into the bladder should be employed to make prominent the floor of this organ, while with the Sims speculum, the patient being in the Sims position, the section may be readily accomplished by a long-curved bistoury.

The form of vesico-vaginal fistula most difficult to deal with, and therefore of greatest surgical interest, is that which follows sloughing of the vesico-vaginal septum during difficult parturition. Fortunately, the increased skill of the accoucheur and the wider dissemination of practical knowledge in midwifery have greatly diminished the number of cases.

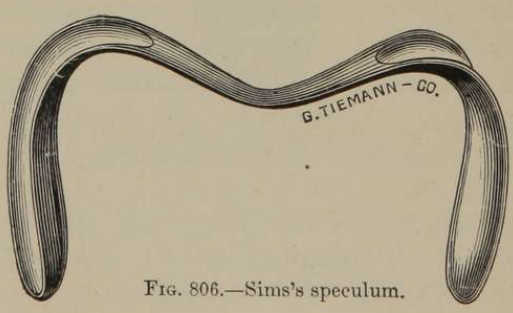

Fig. 806.—Sims's speculum.

In closing a fistula here, the following general points are important: The vagina and bladder should be got into the best possible condition by rest and irrigation of these organs for some days before the operation. When well-marked bands of cicatricial tissue exist in the neighborhood of the margins of the fistula, these should be divided, and a bulb or glass tube of large size introduced to keep the vagina distended. This cylinder should be worn for the few days preceding the operation. With the patient in the Sims position and a large

Sims speculum (Fig. 806) introduced, the operation is commenced by paring the edges of the fistulous opening. This is done by curved scissors or the bistoury, the former being preferable. If any portion of the sinus is left unfreshened, the wound will fail of union. All cicatricial tissue should be dissected away, for only fairly healthy tissue will unite. The section extends through the mucous membrane of the vagina and directly through the vesico-vaginal septum, beveling this down to *but not through* the mucous membrane of the bladder. The sutures should next be introduced, the needle entering one fourth of an inch from the edge of the wound, and coming out so as not to include the mucous membrane of the bladder. Dr. J. Marion Sims, who originated this operation, insisted that the sutures should be close together—from one eighth to three sixteenths of an

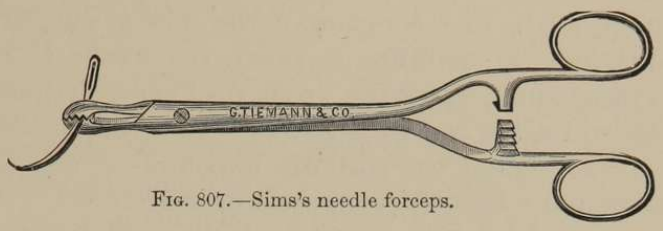

Fig. 807.—Sims's needle forceps.

Fig. 808.—Sims's fork for approximating the silver sutures at the level of the wound.

inch apart. The sutures are of the best silver wire, No. 28 or 29, and are carried into place by a silk loop with which the needle is threaded. When the wire is being introduced, in order to prevent the suture tearing through, it is advisable to use the fork (Fig. 808), to take the strain off the soft parts. When all the wires are introduced, the margins of the wound are approximated by gentle traction on the two ends of the wire, the fork is carried down to the level of the wound, and the wire twisted upon this, as shown in Fig. 809. The ends are clipped about three quarters of an inch from the wound. A Sims sigmoid catheter or a soft Nélaton catheter should be secured in the urethra and bladder. The sutures are removed about the eighth day, the patient being in the same position as for the operation.

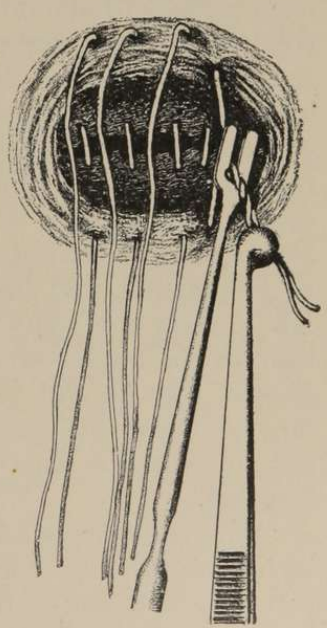

Fig. 809.

After the operation the patient should be kept quiet in bed, resting by preference upon the side. The urine should be drawn at regular intervals, when the stationary catheter is not employed.

In the closure of recto-vaginal fistulæ the same operative measures are indicated.

Cervix Uteri.—Lacerations of the cervix may be classified as unilateral, bilateral, anterior, posterior, and stellate. They are also complete or incomplete. The bilateral variety is most

frequent, the unilateral next, the remaining forms being comparatively rare. In a complete laceration, the tear extends through all the tissues of the cervical wall into the vaginal vault; the incomplete variety extends into but not through the wall of the cervix.

The principal indications for operative interference are, pain, constant in character, either local or reflex, hypertrophy or thickening of the tissues of the cervix, as a result of granulations along the line of the laceration, cystic degeneration of the cervix, sterility from occlusion of the internal os, inability to carry the fœtus to term, etc. The danger of epithelioma, resulting from prolonged irritation of a fissured surface, should never be lost sight of. The preparation of the patient has been given. When the narcosis is complete, she is placed in the Sims position and a large Sims speculum introduced. A strong tenaculum should now be hooked securely into the sound portion of the cervix and the uterus drawn toward the vulva. A second tenaculum is firmly inserted at the edge of the rent, the margin of which is now trimmed off with the Sims adjustable knife, or, if this is not at hand, Emmet's cervix scissors. In freshening the edges of the laceration, the section should extend thoroughly into the angle of the tear, and all cicatricial or granulating surfaces should be most carefully removed. When the tissue along the line of the tear is densely cicatricial, it must be deeply excised, since restoration of the cervical canal can not be accomplished when the cicatrix remains.

When a bilateral laceration exists, the denuded area should extend well out to the vaginal surface of the cervix and inward to the level of the internal *os*, or remaining cervical canal. It is usual to leave unfreshened a space of about one fourth of an inch wide, as shown at *a a*, Fig. 808, which space corresponds to the canal to be restored by the operation. The opposite fissure is prepared in the same manner, and the wire sutures are then inserted. The most suitable needle is short and strong, with a slight cutting edge on one side, this cutting edge limited to the first one fourth of an inch from the point. This should be armed with the silk which serves to carry the wire, and passed through the vaginal portion of the cervix, one fourth of an inch from the edge of the wound, and brought out barely within the undenuded area *a a* left to form the walls of the canal (*1*, *1*, Fig. 810). The deep suture—that in the angle—should be first inserted. When all the sutures are passed, they should be twisted in the order of insertion. It is important to bring the freshened surfaces accurately together, taking care not to twist the wire too tight, for fear of strangulating the tissue in its grasp.

After the sutures are all twisted, they should be cut at one fourth of an inch from the line of union and a sound introduced, to see that the canal is not by accident occluded.

The patient should be put to bed and kept perfectly quiet and the sutures be removed on the eighth or tenth day. This is accomplished by placing her in the same position as for the operation, cleansing the parts thoroughly, lifting the deepest suture with the forceps until one side of

the diverging wire is seen, and then dividing this with the sharp-pointed wire scissors. Great care and considerable skill are necessary to prevent the tearing apart of the freshly united surfaces. The patient should remain in bed for a week or ten days longer. When cystic degeneration exists with a single or double laceration it is advisable to substitute one of the following methods of amputation of the torn and diseased cervix.

Amputation of the Cervix.—This procedure is also recommended in hypertrophy of the cervix and general cystic degeneration. Cystic degeneration is caused by connective-tissue hyperplasia resulting from chronic infectious inflammation, the new tissue occluding the glandular outlets, and causing a retention of their normal secretion, which may remain a clear fluid, but in the majority of cases undergoes pyogenic infection. Not only the glands of the superficial, but of the deeper part of the cervix, are involved. As a result of the retained secretion and the hyperplasia the cervix is greatly increased in size. When the hypertrophy or degeneration is extensive, and it becomes necessary to sacrifice practically all the tissues, the wedge-shaped operation should be performed as follows: A double volsella is fastened into the anterior and posterior lips of the cervix and the uterus dragged down until the cervix is near the orifice of the vulva. A short, broad speculum and retractors may be used when needed. With a knife or sharp-pointed scissors the cervix is completely incised on either side almost to the cervico-vaginal junction. Depressing the anterior lip with the volsella, a transverse incision is made across this lip from right to left, the knife being inserted from one quarter to one half an inch from the margin of the cervico-vaginal junction. The direction of the cut should be upward, passing a little more than halfway through the thickness of the cervix. The knife is then withdrawn, the anterior lip raised, and an incision made parallel with this on the inner or mucous surface of the cervix. In this way a wedge-shaped section is removed, leaving a trough on the stump which remains. The same incision is made on the lower or posterior lip of the cervix at the same plane, and sutures are inserted in order (Fig. 811) to bring the edges of the wound together, leaving a partial cervical canal lined with normal mucous membrane. The destruction of the cervical mucous membrane is always to be avoided, for the reason that it never reproduces itself, as does the endometrium. After the sutures are inserted, the condition of the parts is as shown in Fig. 812. When septic

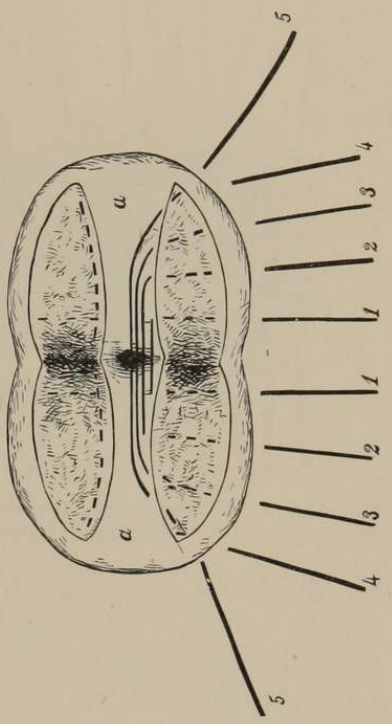

Fig. 810.—Showing the area of denudation and the method of passing sutures in bilateral laceration of the cervix. (Mundé.)

endometritis is present, this should be cured by curettage at least one week before the operation on the cervix.

When a less extensive removal of the tissues is permissible, the following operation, developed by Dr. Florian Krug, should be substituted. As described and recommended by Dr. W. R. Pryor* it is as follows: After careful shaving and scrubbing, and after thorough vaginal antisepsis, the operator, using a short Sims speculum, with bullet forceps, grasps the anterior lip of the cervix and drags the uterus down. Having de-

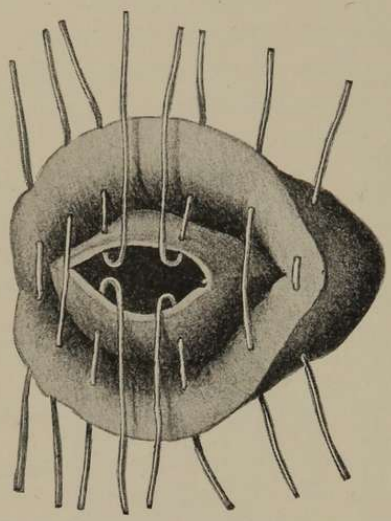

FIG. 811.—Wedge-shaped amputation of the cervix uteri. ("American Text-book of Gynæcology.")

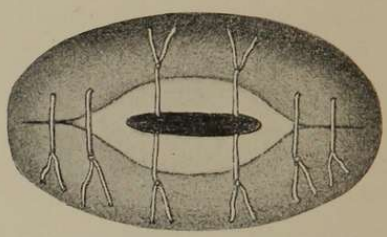

FIG. 812.—The same after the sutures are tied.

termined the direction of the cervical canal and located the internal os, the cervix, with scalpel or scissors, is split literally as high as the vaginal junction (Fig. 813), leaving a long anterior and posterior lip. Upon the anterior lip at the point where the new os is to be, an incision about one fourth of an inch deep is made across the base of the upturned flap, forming a "bench" (Fig. 813). Carrying the knife above the forceps a second incision is made from above downward, running obliquely into the bottom of the first cut (Fig. 814). The plug thus removed should include no more than the diseased tissues. A similar plug is in the same manner removed from the posterior lip. In Fig. 815, *e f a* represents the line of the incisions on the anterior lip, and *a c b* the posterior. The diseased surfaces are represented by the shaded lines, and the incisions may vary with the extent of the degeneration. A short curved needle, threaded to carry No. 26 silver wire, is entered in the center of the upper edge of the anterior cut and made to emerge on the cut surface. It is re-entered and brought out upon the cervical canal (Fig. 816). The points of entry and emergence must be such that the angles *a e* (Fig. 816) are nicely adjusted. A suture on

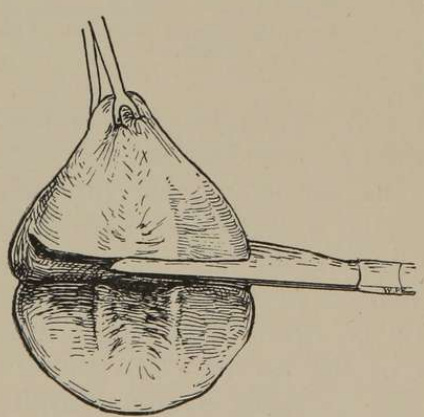

FIG. 813.—The cervix has been split bilaterally. The anterior lip is held by bullet forceps and the scalpel is shown making the anterior "bench." (*e f* of Figs. 815 and 816.) (After Pryor.)

* The New York Polyclinic Journal, July, 1897.

either side of this is inserted in the same manner. This operation is repeated on the posterior lip, and the sutures twisted (Fig. 817). When these six sutures are twisted there will be at each angle a redundance of

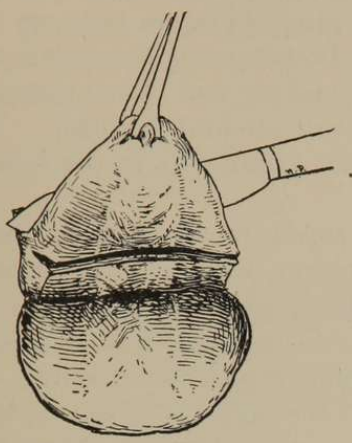

Fig. 814.—The "bench" has been made on the anterior lip, and the scalpel is shown cutting away a portion of the anterior lip. (*d f* of Figs. 815 and 816.) (After Pryor.)

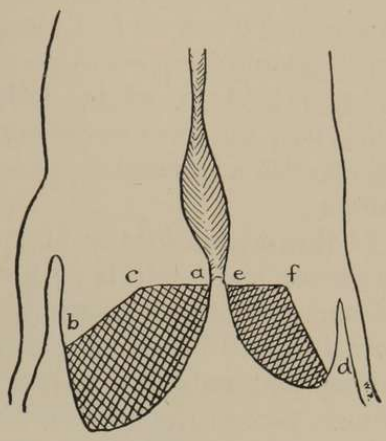

Fig. 815.—The shaded portions of the cervix are to be amputated. *e f* on the anterior lip and *a c* on the posterior lip represent the "benches." (After Pryor.)

tissue, which should be cut away with scissors (Fig. 817). The raw surfaces are then approximated by wire sutures, two or three on each side, as required. These last sutures are passed through both lips of the wound, as in trachelorrhaphy. The wire is cut short, and the vagina loosely plugged with iodoformized gauze, which is changed on the third and sixth days. On the tenth or fourteenth day the sutures are removed. Prof. Pryor does not use mops or sponges in this operation, but relies upon interrupted irrigation with one-per-cent sterile salt solution. The appearance of the stump after the sutures are twisted is shown in Fig. 818.

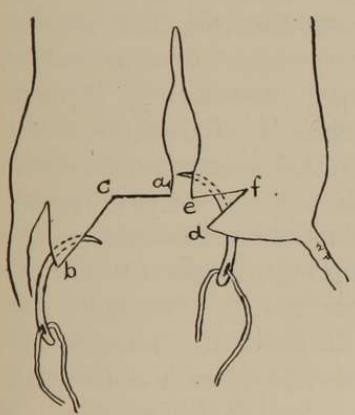

Fig. 816.

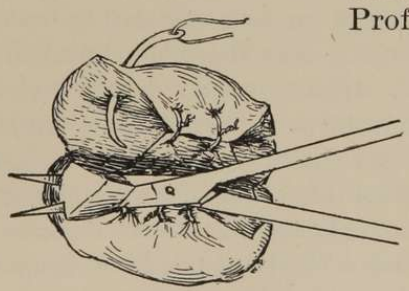

Fig. 817.

Fig. 818.

Fig. 816.—The diseased portions have been amputated. Anteriorly the needle has been made to penetrate both lips of this flap, and folds the vaginal portion, *d f*, over to the "bench," *e f*. Posteriorly the needle is introduced into the vaginal portion only at *b*. The "bench" on the posterior lip is at *a c*. (After Pryor.)

Fig. 817.—Upon the anterior lip the central sutures (*d e* of Fig. 816) have been passed and tied, thus forming the anterior portion of the new cervical canal. Upon this lip the redundant portion of the "bench" has been cut away, and the first introduction of the through-and-through suture is shown. Upon the posterior lip the central sutures are shown twisted and the scissors are in the act of cutting away the redundant "bench." (After Pryor.)

Fig. 818.—The new cervical canal is shown formed by approximation of the centers of each lip, after twisting the center sutures on each lip. The lateral through-and-through sutures are shown twisted. The completed operation. (After Pryor.)

Hysterotomy and Abdominal Hysterectomy.—Hysterotomy, or cutting into the uterus for the extraction of the fœtus from the living mother, is an operation which has been greatly perfected within the last few years, chiefly owing to the labors of Saenger, Leopold, and Tait. It is indicated when at full term it is found impossible, on account of insurmountable disproportion between the diameters of the pelvic outlet and the child, to effect delivery by the vagina, and when symphyseotomy will not give sufficient outlet for instrumental delivery. When this condition is evident, proceed as rapidly as possible in the following manner:

If the membranes are not already ruptured, break them. Disinfect the vagina and genitals with sublimate solution, 1-to-3,000. Prepare the abdomen as for an ovariotomy, and make a long abdominal incision, controlling all bleeding with catgut ligatures as the operation proceeds. Having entered the abdominal cavity and made the opening large enough, place three or four silk sutures at the upper end of the wound in order to narrow the opening as soon as the uterus is drawn out of the incision, thus avoiding extrusion of the intestines. Drag the uterus outside the abdominal cavity, and close the upper portion of the wound by tightening the sutures already in position. If the intestines should be protruded, protect them with warm towels wrung out of sterile salt solution, and beneath the uterus pass sterile-gauze mats or towels to protect the abdominal cavity from the entrance of blood. Around the cervix uteri pass a stout piece of elastic tubing, and draw it tight, thus arresting the circulation in the uterus. Immediately incise the uterus in the median line and in its long axes, limiting the incision below to the peritoneal reflection, thus avoiding the large circular sinuses about the os internum, and extending it upward if necessary. Remove the child, and hand it to an assistant to resuscitate. The uterus will now usually contract. Introduce the hand into the uterus and remove the placenta. The uterine cavity is next to be dried out with gauze. Unless the cervical canal is widely dilated (and this should be ascertained before the operation), the use of a utero-vaginal drainage tube is indicated, and this latter must be of stiff rubber or glass. The next step in the operation is the insertion of the sutures in the wall of the uterus. First ascertain whether the peritoneal covering of this organ is sufficiently movable to allow it to be folded in between the sides of the incision. If need be, dissect it up from its attachment to the muscular fibers a slight distance and fold it in between the lips of the wound. The deep sutures are passed as shown in Fig. 819. These should be of silver wire, because they are cleaner and held more unyieldingly than silk. They should be close enough to control hæmorrhage and secure accurate adjustment of the sides of the wound. They should enter the peritoneal covering about half an inch from the edge of the wound, and pass through it and the muscular wall to the decidua, which must not be included in the suture; then across to the other side through the muscular and serous coats. After twisting the silver sutures, the superficial sutures of fine silk are introduced. These are to be from twenty to thirty in number, and are em-

ployed to secure perfect coaptation of the serous edges of the incision. They are introduced in the same way as Lembert's suture of the intestine. Lastly, the twisted silver wires are cut off about half an inch from the level of the incision in the uterus, and the ends turned down parallel with the surface of this organ.

The incision in the abdominal wall is closed, as after ovariotomy. There are certain conditions which can only be determined by inspection

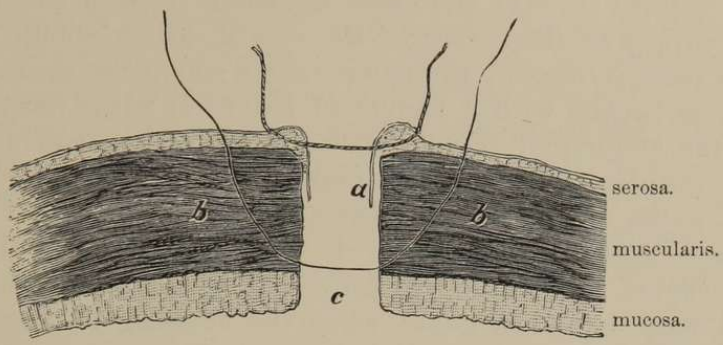

FIG. 819.—Sutures in Cæsarean section. Method of passing the sutures in closing the wall of the uterus after hysterotomy. *a*, The peritoneal covering dissected up along the edge of the incision and inverted by the catgut suture, after the method of Lembert. *b*, The muscular substance, with the silver-wire suture passed through. *c*, Decidua. (Drawn by Dr. W. R. Pryor.)

through the incision in the abdominal wall which may contraindicate the operation just given, and necessitate a modified procedure.

If the patient has been long in labor, and considerable time has elapsed after the membranes have ruptured; if there is a putrid discharge from the vagina; if the symptoms of septic fever are present, with the perimetrium dulled and adherent to the muscular wall of the uterus, the operation of amputation of the uterus at the os internum may be indicated. If malignant disease of the cervix is present, the entire organ should be removed. If the pregnant uterus be the seat of a fibro-myoma, and so situated as to render delivery impossible, or if a rupture of the walls of the uterus has occurred, which is so ragged in outline that it can not be sutured, hysterectomy is indicated. The objects aimed at in all operations for the artificial delivery of children at term are preservation of the mother's life and future health, with, if possible, the non-mutilation of her generative organs and the delivery of a living child.*

Hysterectomy during Pregnancy.—Porro's operation, which is more often fatal than hysterotomy, is sometimes called for in the removal of an infected uterus at the same time that the delivery is effected by hysterotomy. In performing this operation, an abdominal incision is made similar to the one just described. As the bladder is usually high up in these cases, and in good part uncovered by peritonæum, care must be taken that the incision does not wound this organ. As soon as the uterus is exposed it should be drawn out of the abdominal cavity. A strong rubber ligature is now thrown around the uterus at the cervix.

* As regards statistics, Saenger gives thirty Cæsarean sections performed as above described, with a mortality of 26·7 per cent.

The intestines should be protected by sterile mats or warm towels, which have been boiled. These should also be placed underneath the uterus, in order to protect the peritoneal cavity from the entrance of blood or infectious material. As soon as the rubber ligature is securely tightened around the cervix the uterus should be rapidly incised and the child extracted at once. A linear incision is preferable. The uterus should now be divided as close to the rubber ligature as possible, and ligatures applied through the broad ligaments on each side to cut off all vascular supply to the stump of the cervix, which should then be excised. A careful toilet of the pelvic cavity should be made, after which it should be packed with a ribbon of iodoform gauze introduced either through the abdominal incision from above or through an incision in Douglas's *cul-de-sac*, and the abdominal wound should be closed. The iodoform gauze should be withdrawn through the vaginal opening five or six days after the operation. It is very essential in this operation that the vagina be rendered as aseptic as possible. It should also be repacked with iodoform gauze when the dressing is changed. When the gauze is removed from Douglas's *cul-de-sac* a second and much smaller packing should be reinserted.

Vaginal Hysterectomy.—For the removal of the uterus on account of small myoma, incipient carcinoma of the cervix or the endometrium, and for the relief of persistent septic metritis, the incision through the vagina may often with propriety be selected. In any event it is advisable to curette the endometrium thoroughly in order to eliminate that source of possible infection while the operation is being performed, and to thoroughly disinfect the vagina after the curettage has been done and the cervical canal stuffed with iodoformized gauze.

The patient rests upon the back, a short, wide duck-bill speculum is inserted, and lateral retraction made when necessary to expose the uterus. A strong double volsella is fastened into both lips of the cervix, and strong traction is made to drag the uterus well into the vulvo-vaginal outlet. When the uterus to be removed is the seat of malignant disease that is fairly well advanced, the technique differs somewhat from that employed in cases where there is no malignant disease or infectious inflammation. In these conditions the dissection can be made closer to the body of the uterus than when malignant disease is present. The most important point in the procedure is to avoid the ureters, which lie in rather close relation to the anterior incision which should be kept as close to the body of the uterus as possible. In malignant disease the incisions should be well away from the limit of induration. The instrument which will be found most generally useful is the short, curved scissors, and they may be sharp-pointed or dull. In the hands of some surgeons the cautery knife has been found an excellent instrument, since the heat it engenders prevents bleeding and leaves practically an aseptic wound (Prof. W. M. Polk). The incision proceeds on the anterior surface of the body of the uterus until the tissues begin to yield readily, when the finger may be inserted and the nail used to strip off the peritonæum from the organ. When the dissection has proceeded

until the peritonæum is exposed on the anterior face of the uterus, the incision should be carried laterally on each side around the cervix, and the posterior incision in this way repeated. It will be seen that this dissection reaches entirely around the circumference of the cervico-vaginal junction. Care must be taken, however, that the incisions on the lateral aspects of the uterus be not too deep, not more than one fourth to one half an inch, because the broad ligaments come down upon the side and the uterine artery is in close proximity and might be wounded. The posterior incision is made in the same manner, until the fingers can be carried into Douglas's *cul-de-sac*. At this stage of the operation, just before entering the peritoneal cavity, the patient should be placed in the modified Trendelenburg posture, so that the intestines will gravitate away from the field of operation. The fingers may now sweep easily over the entire uterus, behind as well as in front, and the condition of the tubes and ovaries readily made out. The next step in the operation is the application of Pryor's lock forceps. The first pair are

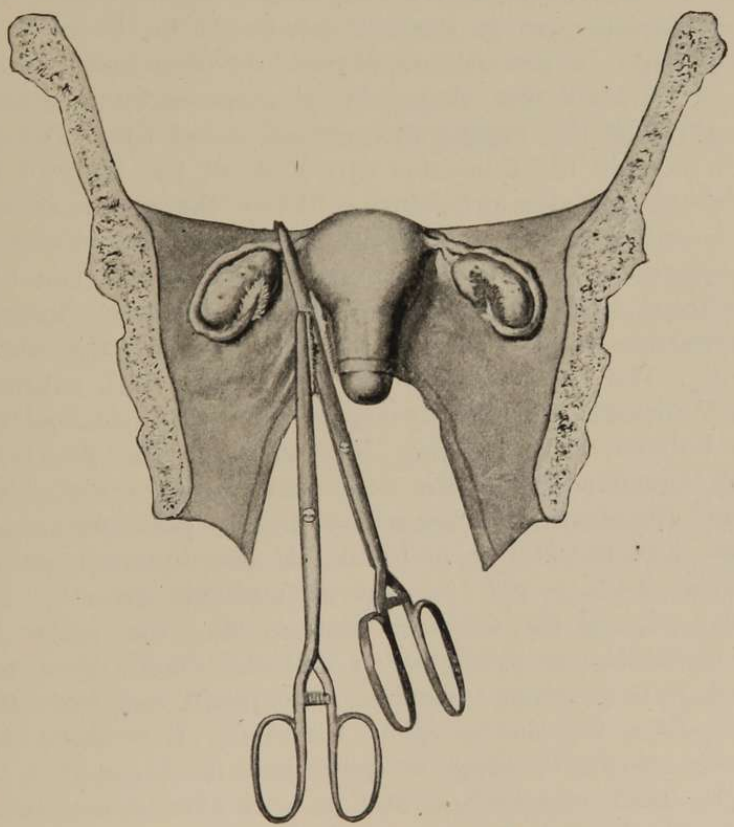

Fig. 820.—Application of Pryor's lock forceps.

applied on one side of the cervix, keeping as close to the body of the uterus as possible, in order to prevent including the ureter in the clamp (Fig. 820). Another clamp is placed in the same position on the other side and locked. With the scissors the broad ligament is divided between the clamp and the body of the uterus as high as within one eighth of an inch of the tip of the clamp. A second clamp

is applied in the same line with the first, but the point is directed a little farther out. This second clamp is intended to include the remainder of the broad ligament, and to control the ovarian artery as the first clamp did the uterine. When the instruments are applied on the opposite side the division can be completed and the uterus removed. There should be no hæmorrhage, but if there has been any oozing it should now be dried out and the cavity packed with a single strip of iodoform gauze. The packing should extend until the vagina is well filled down to the vulvar orifice and should be changed on the fourth or fifth day, or earlier should any symptoms of septic infection be present.

Hysterectomy, Partial or Complete, for Fibro-myoma, Carcinoma, etc.—Fibroid tumors of the uterus not only cause great discomfort, and at times destroy life by direct pressure upon contiguous organs, but they frequently undergo certain cystic and malignant changes which, if neglected until fully advanced, render successful removal extremely difficult. In addition to the foregoing septic infection of these tumors and hæmorrhage are not infrequently dangerous complications. It is essential that they be subjected to surgical treatment in the earlier stages of their development. When uterine fibroids develop just beneath the endometrium, if of small size, they may be removed by means of the dull saw-curette through the vagina and cervical canal by proper dilatation. Those which involve the muscular substance of the body of this organ require a more formidable procedure. When the uterus is so involved that it is necessary to remove the entire organ, one of the following methods may be employed: After opening the abdomen the uterus and fibroids are freed from adhesions. A temporary elastic ligature is tied around the cervix, and the uterus cut away, leaving the stump in the shape of a V. The blood vessels are now ligated with catgut, and the sides of the V brought together by layers of close sutures of silk which begin at the bottom of the cavity. This mode of suturing is continued until the top is reached, when the peritonæum is carefully adjusted over the stump and the elastic ligature removed. The peritonæum is cleansed of blood, etc., and the abdomen closed. If the myoma is pedunculated and the uterus itself is not the seat of multiple growths, the tumor should be cut off, and the suturing done at the point where the tumor grew. Or, if the tumor is sessile, so that the elastic ligature can not be employed, it is possible to incise the capsule, enucleate the tumor, and bring the flaps together as above directed. It is more satisfactory not to treat the pedicle by the extra-peritoneal method.

Prof. J. R. Goffe has devised and in a number of instances successfully performed the following operation: After opening the abdominal cavity, and while the tumor is still *in situ*, the ovary and tube upon one side are drawn up and a ligature is passed through the upper border of the broad ligament outside the adnexa and tied, thus controlling the ovarian artery; one end of this same ligature is rethreaded into the pedicle needle, and the broad ligament is transfixed a second time nearer to the tumor and just above the uterine artery and this is also tied. A temporary ligature is now placed near the horn of the uterus to control any

reflex hæmorrhage from the neoplasm. The broad ligament is cut down to the lower point of transfixion, the tumor is then rotated and the same method performed on the other side. The mass is now delivered through the wound, and the lower angles of the incisions through the broad ligaments on either side are connected by an oval incision through the peritonæum, first across the anterior and then across the posterior surface of the tumor. The flaps are then dissected down, the one in front carrying the bladder and ureters into safety. One end of the ligature is again threaded into the pedicle needle and is passed inside these peritoneal flaps close to the cervix and below the uterine artery. This is repeated on the opposite side and the ligatures cut short. The tumor is then cut away on a level with the internal os. The cervical canal is disinfected with applications of carbolic acid. The flaps are then stitched together with a running catgut suture over the top of the stump, care being taken to make them cover all the ligatures on either side. Silk ligatures are used on the broad ligaments and catgut for stitching the flaps. The advantage of using a single ligature for each broad ligament is that it puckers up the end of the ligament and carries it down alongside of the cervix, so that the raw surface is very easily covered by the peritoneal flaps. In a general way the advantages claimed for this operation and the superiority over the method of total extirpation consist in the following points:

1. It involves the least possible loss of blood; indeed, it is rare for any hæmorrhage to occur.

2. It is easy of execution, for the reason that the stump of the cervix can be brought up near to the abdominal wound and the details of disposing of the traumatic tissue carried on with ease and comfort to the surgeon.

3. It is applicable to a very large proportion of fibroid tumors.

4. It requires less time than total extirpation.

5. Convalescence, as a rule, is rapid and free from complication. Moreover, the patients require no special after-treatment whatever. It is not necessary to put gauze in the cervix or in the vagina, consequently there are no dressings to be attended to. The open-bowel treatment is employed, and as a rule the patient urinates without assistance.

Hysterectomy for Fibro-myoma; the Stump being brought out at the Wound and attached there.—In rare cases it may be necessary to bring the pedicle or stump of the cervix or uterus into the abdominal incision and attach it there. After the organ is exposed and all adhesions tied with double ligatures and divided between these, or broken loose where the double ligature can not be utilized, the elastic ligature should be thrown around the uterus at the cervix, the rubber passing under the ovaries and compressing the broad ligament against the cervix. This ligature is drawn tight and tied, the second part of the knot being over a coarse silk thread. When the last knot of the elastic ligature is made, the silk thread is tied around this to prevent slipping.

The fibroid is then held up and cut off above the elastic ligature. The stump is next grasped by strong forceps and trimmed. Sutures are

then passed, first through the edge of the peritonæum lining the abdominal wall near the incision and then through the stump below the ligature, in such a way that when they are tied the cavity of the peritonæum is completely closed, leaving the stump of the uterus and the constricting tube exposed to view. Steel pins or skewers should be passed through the stump above the ligature. The wound is now closed as after ovariotomy, the stump dusted freely with iodoform, and a loose packing of amyloform gauze applied. When the sutures are all inserted, the hard-rubber plates or shields of Dr. H. Marion Sims (Fig. 821) should be placed between the ends of the skewers and the skin. The indications for pelvic drainage are the same as after an ovariotomy. The cervical canal in the stump should be curetted before passing the steel pins; otherwise, a fistulous opening may persist through the vagina, uterine stump, and the line of incision. Frequently the fibroid is attached to the unenlarged uterus, and has a narrow pedicle. In such a case, the uterus and appendages may be left and the new growth removed, treating the stump in the same way as if the uterus had been removed. This method should never be adopted when it is possible to enucleate and drop the unattached pedicle into the abdomen.

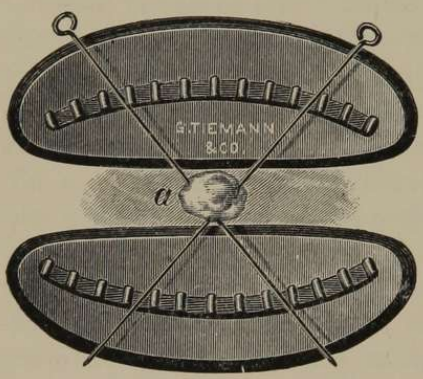

Fig. 821.—Sims's skewer shields.

Surgical Diseases of the Fallopian Tubes—Salpingitis.—Pyogenic infection of the Fallopian tubes may demand surgical interference when peritonitis is precipitated, or when from occlusion the products of inflammation are retained and the tube is distended, forming a cystlike tumor.

The most prominent symptom of salpingitis is pain. When general pelvic peritonitis does not exist, it is confined to the affected side. It is usually continuous, with exacerbations of severity, which are especially marked just before, during, and after the menstrual flow. In some instances, when the flow is established, the suffering is less intense. The menstrual discharge is, as a rule, increased in quantity. Exacerbations of temperature occur in all cases of acute septic infection. Salpingitis, in the vast majority of cases, results from the direct extension of infection from the uterus. Endometritis or metritis following gonorrhœa, abortion, normal parturition, or that resulting from a chronic inflammation due to malposition of this organ are the chief conditions which precede this affection.

By direct palpation over the abdomen of the affected side, it will be seen that the muscles of this side are abnormally tense, and that acute pain if present is confined to a limited and well-marked area, which corresponds to the normal position of the tube. In the vagina, a leucorrhœal discharge is usually observed, and diligent examination will reveal great tenderness near the cervix, upon the side involved. The uterus may be normally situated, but is laterally displaced when the

tumor is at all large. With bimanual examination, often necessary under ether, there will be found an elastic, if not fluctuating, tumor, springing from one or the other uterine cornu, and directly attached to the uterus ; perhaps bulging into the vagina ; sausage-shaped when moderately large, but round when as large as an orange ; at times movable, but usually more or less fastened to the uterus, bladder, rectum, or pelvic fascia by adhesions. This tumor may be but a part of a general inflammatory mass filling up the pelvic cavity and rendering fluctuation difficult to recognize. In such a case, the uterus is fixed to this mass. As a rule, the tube is prolapsed, and drags with it the ovary, the latter being external to and above the cyst. Vaginal incision will, if necessary, always clear up the diagnosis.

Treatment.—Pus tubes may be removed by the vaginal route or by abdominal section. In either case the preparation of the patient is the same as heretofore given. Pus tubes of ordinary size can be removed by incision into Douglas's *cul-de-sac* and enucleation through this wound. In this operation a *modified* Trendelenburg posture is advisable, for the reason that in this position the intestines will gravitate above the level of the pelvis and away from immediate contact with the infectious material should rupture of the abscess occur. It is very important after removal of pus tubes by the vaginal or any other method to thoroughly cleanse the pelvis with sterile-gauze mops. If, during the operation, pus has escaped from the tube or abscess and the operator is not positive that septic matter has not been brought in contact with the intestines or omentum, he should add the abdominal incision in order to be sure of a thoroughly aseptic toilet. When this is done, an iodoform-gauze strip should be packed into the wound and the vagina filled. The patient should be kept quiet for two weeks. The gauze packing may be removed in from three to five days and replaced by a smaller quantity.

When the pus tube is of large size and bilateral, it is better to approach it through an incision in the linea alba. The Trendelenburg posture should be used in this operation, and the intestines carefully lifted from the pelvic cavity and kept from coming in contact with the area of inflammation. Even when the high operation is done it is best to open into Douglas's *cul-de-sac*, in order to secure drainage. The iodoform-gauze packing is removed *per vaginam.*

The Ovaries.—Removal of the ovaries may be necessitated on account of—1, cystic degeneration ; 2, cirrhosis ; 3, abscess ; 4, cystic, and 5, solid tumors.

In cystic degeneration the ovary is enlarged, and the interior of the organ is filled with small cysts with dense, fibrous capsules. They can in some cases be seen through the investing membrane, and, if punctured, will give exit to a fluid usually clear, but at times brown, or even decidedly stained with blood. The tumor is elastic to the touch, usually spherical, and rarely attains a diameter of as much as two inches. The fimbriated extremity of the Fallopian tube is often adherent to the diseased ovary. In rare instances the broad ligament and tube may surround the cystic tumor. The left organ is affected more frequently than

the right, for the same reasons as given for the more frequent occurrence of varicocele in the left scrotum (see VARICOCELE). The pathology of this affection is not yet definitely settled.

In *cirrhosis* the ovaries are usually small, and have a furrowed or withered appearance ; occasionally they are found normal in size, or even slightly enlarged. The normal Graafian follicles are entirely destroyed in well-marked cases.

In more recent cirrhotic disease of these organs the cavities of the follicles are distended with a bloody fluid. This condition is almost always due to a connective-tissue hyperplasia, resulting from a subacute inflammatory process in the ovary.

In *abscess* of this organ it is enlarged, and may contain one cavity or several separate collections of pus. When the abscesses are small and multiple, the gross appearances of the organ are not unlike those of an ovary with cystic degeneration. Suppurating salpingitis (or pyo-salpinx) may be present with abscess of the ovary, and, in rare instances, by reason of fusion and rupture of the contiguous walls, there results a large single abscess. Multiple extravasation of blood may occur in abscess of this organ. If not relieved by operation, the pus may eventually find an exit through the vagina, bladder, or intestine. Adhesions, as a rule, occur between the ovary and one or more of the contiguous organs, or to the pelvic fascia.

Symptoms.—In *cystic degeneration* and *cirrhosis*, dysmenorrhœa is the most prominent symptom. It is more severe with the former, but is severe in the cirrhotic ovary. The pain usually precedes the menstrual flow from a few hours to several days, and in extreme cases may continue from one period to the next. It is usually referred to the groin of the affected side, and thence the painful sensations may radiate over the abdomen and down the extremity. Hysterical convulsions are very apt to be present in the more severe cases. The menstrual flow is scanty or normal in amount when the ovaries are cirrhotic ; but with cystic degeneration the flow is generally increased, and hæmorrhage may be the most prominent and dangerous symptom. The uterus is apt to be slightly above the normal size, with the ovaries in cystic degeneration, and somewhat smaller when these organs are cirrhotic. Not infrequently retroversion is observed as a symptom of cystic ovary, in which case this last-named organ is prolapsed. The uterus is commonly free and movable, unless hæmatocele or peritonitis has occurred. If cystic, the ovary is easily felt, often low down in Douglas's pouch. If cirrhotic, it is hard to find. From clinical manifestations it appears that cystic degeneration is due to a degree of inflammatory action more severe than that which leads to cirrhosis, because peritonitis and pelvic hæmatocele more often accompany the former. Cystic and cirrhotic ovaries are always sensitive to pressure.

In *ovarian abscess* there is usually a history of gonorrhœa, puerperal septicæmia, an acute exanthema, or a severe attack of metritis or peritonitis. When the abscesses are small, the symptoms do not greatly differ from those of cystic ovaries ; but when at all large, the patient has

hectic fever and rigors. The pain in the pelvis is constant, but is liable to exacerbations. Repeated attacks of pelvic peritonitis follow each other. When the ovary is converted into one large abscess, and the tube is not affected, dysmenorrhœa is not a constant symptom, and there is an absence of the nervous phenomena observed in the other forms of ovarian inflammation.

The uterus is usually drawn to the affected side as a result of the pelvic peritonitis which usually accompanies these cases. The lateral fornix of the vagina is encroached upon when the abscess is large, and then fluctuation can be obtained. The abscess, whether large or small, is usually but part of the mass of inflamed tissue which occupies the pelvis on the affected side. The ovary is enlarged and low down. As abscess of the ovary does not often occur alone, and as the sole lesion of the pelvic organs and tissues, the symptoms which appear are partly due to the intercurrent diseases—salpingitis, hæmatocele, peritonitis, etc. When an ovarian abscess ruptures into the peritoneal cavity, a fatal general peritonitis is the result. If it opens into the vagina, it usually does so just below the cervix in the posterior wall, at the bottom of Douglas's pouch, where the vaginal wall is thinnest. The technique which has been given for the removal of infectious salpingitis or abscess of the broad ligament will apply to the rare cases of ovarian abscess.

Large Cystic Tumors of the Ovary and Broad Ligaments.—Cystic tumors of the ovary are occasionally unilocular. In the vast majority of instances they are multilocular. The pathology and pathogenesis of these neoplasms are not yet definitely settled, and, since a discussion of the various theories advanced is scarcely permissible in a text-book, the student is referred to the various standard works upon pathology.

The most common form of ovarian tumor—the *cyst-adenoma*—is always multilocular. The surface of such a tumor is glossy, often silver-white. The sac is usually firm, its contents being a thick fluid, with a grayish-brown or reddish tint. The outline of the cyst may be perfectly symmetrical and round; or it may have one main cyst, and numbers of smaller ones springing from it; or two or three cysts of about equal size may constitute the entire mass. But, be the shape what it may, secondary cysts will always be found in some part of the tumor. At one or more points the cyst wall may be exceedingly thin or softened as a result of the rupture of inter-cystic walls, those of the secondary cysts being thinner than that of the larger. Softening of the wall may also occur when the neoplasm is malignant; or as a result of interference with its nutrition from twisting of the pedicle; or from suppuration in the cyst wall. In exceptional instances in old cysts there sometimes exists a communication between the cyst cavity and the bowel or bladder as a result of necrotic changes where the two have become adherent.

In size cyst-adenomata of the ovary may vary from a few inches in diameter up to those of enormous size, weighing many pounds, and filling the entire abdomen. The veins lie both superficially as distinct vessels and deeply in the cyst wall as sinuses; the arteries are more deeply situated and are large. This tumor may be generally adherent

to the peritonæum and other organs with which it comes in contact, or connected at various points by isolated bands. In rarer instances no adhesions may be met with. The pedicle of an adeno-cystoma may be attached to both sides of the uterus, two distinct tumors having met and coalesced. At times the tumor derives its nourishment from bands uniting it to the abdominal parietes or viscera, its own pedicle having been twisted off.

A form of multilocular cyst, connected with the ovary, known as "*Rokitansky's tumor*," has been observed in a few instances. It consists of a series of cysts containing a clear fluid. The cysts hang in bunches and are connected with each other by delicate fibrous bands. The entire mass does not usually reach a size larger than the fist.

Dermoid cysts are not altogether infrequent in the ovary. These tumors have thick walls, are dark-colored, are filled with a dark fluid in which are found particles of hair, teeth, bone, etc. They may be multilocular, or they may contain but one cyst.

Hanging from the fimbriated extremity of the Fallopian tube, or just beneath it, is also found a small, thin-walled cyst, with clear contents, called by some the "hydatid of Morgagni." If examined carefully while it is floated in clear water, it will be seen to be a continuation of the horizontal tubes of the *parovarium*.

Cyst of the Broad Ligament.—There is also met with a cyst of considerable size, with perfectly clear contents and very thin walls, which is sometimes pedunculated, but generally with a broad attachment located either upon the broad ligament or the uterus. A small cyst of a similar nature may spring from the covering of the Fallopian tube and be pedunculated, or arise just beneath the Fallopian fimbriæ, and be either sessile or pedunculated.

Solid Tumors.—Fibro-myomata appear as smooth, firm bodies. They do not, as a rule, contract adhesions with neighboring structures.

Sarcomata have about the same clinical appearance, except when very vascular, in which state they are softer and more elastic than are fibro-myomata. Carcinomata of the ovary are very nodular, and when large they may contain one or more cavities in their interiors. Secondary deposits in other viscera are found with these tumors. The symptoms of all solid tumors are so obscure that the exact character of any of these neoplasms can scarcely be determined, excepting by microscopic examination.

Symptoms.—Tumors of the ovary are usually first noticed upon one side of the pelvis. The ordinary cyst-adenoma is not painful until it is so large that it presses upon the pelvic and abdominal viscera. If inflammation supervenes from any cause, pain is a prominent symptom. Amenorrhœa is the rule, although in a certain proportion of cases menstruation is normal. Menorrhagia is rare. If left without interference, pressure upon and displacement of the neighboring viscera is the rule, and, if peritonitis does not ensue, death ultimately results from asthenia. Not infrequently adhesions are formed between the bladder and the neoplasm to such an extent that, as the tumor grows, the bladder is dragged

upward to the neighborhood of the umbilicus. In large tumors, dyspnœa, œdema of the lower extremities, enlargement of the superficial abdominal veins, and nephritis occur as a result of pressure.

Upon examination, it is usually easy to detect the presence of the tumor. The uterus lies in front of the cyst, or is displaced laterally if the tumor be large enough to crowd it out of its normal position. The uterus is not increased in size, and is movable independently of the neoplasm. The latter is an important feature in differentiation, and may be best determined with the aid of the elevator carried into the uterus. When the cyst is large, the uterus is dragged high up and fixed against the symphysis pubis. The bladder may lie over the front of the tumor as high as the umbilicus. But when the tumor is so large as to have completely risen out of the pelvis, the bladder reaches, even when not adherent to the cyst, a point somewhat above the suprapubic notch. The enlargement of the cyst gives to the abdomen a rotundity not seen with distention from ascites alone. Ascites commonly coexists with large cysts. If not large and non-adherent, the tumor can be raised out of the pelvis without the uterus. It may also be depressed in the pelvis. When the secondary cysts are large and project from the surface of the main cyst, they may be quite readily distinguished. If one hand is laid flat upon one side of the mass and the other side is given a sharp tap with the fingers, the fluid character of the contents of the neoplasm may be easily appreciated. When the walls of the tumor are very thick and the distention marked, fluctuation may not be felt.

In *solid ovarian neoplasms* pain is apt to be present early in the history of the growth, and the general health of the patient may show signs of deterioration before there is any marked increase in the size of the tumor. This is especially true of malignant new formations.

Fibro-myoma of the ovary is so often associated with similar changes in the uterus that the slight menorrhagia which occasionally accompanies these cases may reasonably be ascribed to uterine hyperplasia. Upon abdominal palpation, with vaginal exploration, a hard and usually movable tumor may be appreciated. At times it is attached to the surrounding structures to such an extent that mobility is absent. The uterus is not enlarged, is often displaced backward, and is generally freely movable with small tumors. When malignant, the tumors are of rapid growth. Ovarian fibro-myoma grows slowly, gives little pain, never immediately influences the general health ; is generally smooth, or with but a few nodules ; not very sensitive, and is usually freely movable independently of the uterus. Dermoid tumors may appear clinically as cystic or solid, according as their fluid or solid contents predominate. Adenocystomata and dermoid cysts are occasionally met with in young children.

The Removal of Tumors of the Ovary and Fallopian Tube.

The removal of a tumor of the ovary, broad ligament, or Fallopian tube, cystic or solid, is performed as follows:

Preparation of the Patient and Operation.—The rule already given for the preparation of the patient should be carried out. It is important in all these major operations that the legs, arms, and chest of the patient be carefully wrapped in warm flannels, and protected from loss of heat consequent upon prolonged exposure. The patient should lie on a table with the legs extended, or, as many operators prefer, with the sacrum down near the edge of the table and the feet resting on a chair, with the thighs abducted and held by an assistant. The modified Trendelenburg posture will be found most convenient to the operator. The incision should be in the median line, about three inches in length, and should commence about five inches above the os pubis.

The recti muscles should be separated and all bleeding arrested by catgut ligatures before the peritonæum is opened. When the parietal layer of the peritonæum is reached, catch a small point of this membrane with a tenaculum or forceps, grasp this point between the thumb and finger, to make sure that no omentum or intestine is picked up, and make a small incision with the scissors. Through this opening introduce the broad-grooved director, and further divide the peritonæum. Two fingers should now be carried into the abdomen, and a careful exploration made. A blunt, round instrument (a No. 20 United States urethral sound will suffice) carried in and swept over the tumor will demonstrate the presence of any adhesions between it and the anterior wall of the abdomen. If the tumor is free, drag it up to the incision; and, if it is cystic, hold it so that with the aid of sponges placed around the margins of the incision none of the fluid can escape into the peritoneal cavity. Introduce the large trocar and evacuate the fluid contents. As the sac is being emptied, drag it farther out of the incision, and, when all the fluid escapes, free the tumor of all adhesions to the intestines or other structures. All large adhesions may be tied with the double catgut ligature, and cut between, while small adhesions, or those so situated that the ligature is impossible, should be torn through. Great care is required in separating the sac from the wall of the intestine. As soon as the pedicle is freed, the sac should be grasped with a long-jawed pedicle forceps (Spencer Wells's sac forceps) and cut away. The pedicle should be transfixed near its middle with an aneurism needle armed with a large double silk ligature and the two threads drawn through. In tying the threads on either side of the pedicle cross them, as shown in Fig. 822, and tie firmly. If the pedicle does not bleed, the ligatures should be cut short. The ovary of the opposite side should be examined. The cavity of the peritonæum should be carefully mopped out with gauze, and the wound closed as directed in

Fig. 822.—Showing the manner in which the two threads of a double ligature should be crossed in the center of the pedicle.

laparotomy for intestinal obstruction. If a solid tumor is encountered, and when a cystic tumor has such thickened walls that it can not be readily brought out at the wound, the incision may be enlarged. It is, however, advisable to keep the abdominal wound as small as possible when the small size of the opening does not interfere with the safe manipulation within the abdomen. *Dermoid cysts* are usually so solid that they are removed without an effort at tapping.

A *cyst* of the *broad ligament* requires to be stripped out of the capsule, and hæmorrhage arrested by packing, and the abdominal wound closed.

Deformities and Malpositions of the Uterus.—Anteflexion.—Pathological anteflexion of the uterus occurs in a large proportion of nullipara after the twenty-fifth year of life. The uterus is usually high in the pelvis, the body bent sharply forward upon the cervix, the latter occupying a nearly normal relation to the axis of the vagina. Upon introducing the sound, it will usually meet with resistance at the internal os, requiring manipulation or a sharp curve of the instrument in order to pass. The menstrual flow is apt to be interfered with in varying degree in these cases, especially in the early part of the period. Intermittent cramps occur, but when the flow is well established the pain diminishes. A mild form of leucorrhœa and endometritis is apt to be present. Cure of the endometritis and of the stenosis can be effected by curettage after incision or forcible dilatation. In a certain proportion of cases dilatation without incision will effect a cure. This may be accomplished by introducing under careful asepsis the ordinary curved male urethral sound, at intervals of two or three days for two weeks before the expected flow, or the cervical dilator may be employed. This can usually be done without an anæsthetic.

Retroflexion and Retroversion.—These positions of the uterus may be congenital or acquired. Retroflexion is usually congenital, and congenital retroversion has also been met with. Congenital retroflexion is practically incurable by any operative procedure, and it is advisable to attempt to relieve by curettage the condition of endometritis which usually prevails. In these cases distention due to fecundation may often accomplish much for the relief of the deformity. The acquired backward displacements of the uterus may be considered in two classes, *movable* and *fixed*. When movable, the uterus is usually low down, either bent or turned backward. The body and cervix are usually enlarged. As a rule, there is a profuse leucorrhœal discharge. The chief causes of this condition are subinvolution and sepsis. The diagnosis may be made by the introduction of one or two fingers into the vagina and abdominal palpation. It is best not to introduce a sound if this can be avoided. Digital exploration through the rectum will often locate the body of the uterus turned back upon this part of the intestine. When seen in the first few weeks after parturition, palliative measures, such as reposition of the organ and sustaining it in its normal position by vaginal tampons soaked in glycerin, or by wearing a suitable pessary, may effect a cure, and a radical operation be thus avoided. When

a pessary is employed, it should be steadily worn except for two days each week, when the vaginal tampon is substituted.

When backward displacement has occurred as a result of subinvolution, and six months have elapsed since parturition, more radical measures must be instituted. The condition of endometritis must be relieved by curettage, and any degeneration of the cervix or laceration treated as the indications demand. Laceration of the perinæum should be attended to, and any rectocele or cystocele corrected. In replacing the uterus, general narcosis is usually required. The patient should be placed upon the back in the lithotomy position, two fingers are introduced into the vagina and passed behind the cervix, and then forward toward the symphysis pubis with firm pressure. In thin patients, the hand on the abdomen can aid in the reposition by crowding the fingers down hard, following the curve of the sacrum. At the same time the fingers in the vagina are pushed behind the top of the uterus, which is lifted up toward the symphysis. It is kept in this position by the hand on the abdomen, while the fingers in the vagina are now brought anterior to the cervix and the neck and body of the uterus pushed up toward the promontory of the sacrum. The tampons should be introduced while the cervix is held in position by the pressure of the two fingers in the vagina. A pessary may be substituted if this be deemed expedient.

Replacement of the uterus by means of the repositor may at times be done, and when employed careful antiseptic precautions should be taken. Certain cases of extreme backward displacement of the uterus may be relieved by the operation of Alexander. This consists of an incision which exposes the external abdominal ring, between the pillars of which and through the inguinal canal the round ligament makes its escape. By careful dissection this ligament is found and traction made upon the free end until the uterus is drawn well up toward the anterior abdominal wall. The round ligament is then stitched into the pillars of the ring in this new position, and the same procedure repeated on the other side.

A still more radical operation which will secure fixation of the uterus in this position, should Alexander's operation fail, is by laparotomy through the linea alba halfway between the symphysis pubis and the umbilicus. In the Trendelenburg position, and through a small incision, two fingers are introduced and the fundus of the uterus brought up to the incision, where it is stitched by sterile silk sutures. The wound in the peritonæum is then closed with catgut, and the muscles brought together by separate sutures of the same material. When adhesions exist and the uterus is partly or wholly immovable, it is necessary to break these up by the finger through the incision in the linea alba.

Freund's operation for prolapse of the uterus is done as follows: For one or two weeks before the operation the prolapsed portion should be kept well up within the vagina by the use of the vaginal tamponade, rest in bed, and wearing a T-bandage. Just in front of the cervix, and at the side of the vagina, a small piece of vaginal mucous membrane is removed. A slightly curved needle, armed with Chinese twisted silk

with which to pull the silver wire through, is made to sweep entirely around the circumference of the vagina at the level of the incision through the mucous membrane. Of course, this requires the needle to come out and be reintroduced at two or three separate points, care being taken to introduce it through the same hole through which it made its exit. Having encircled the vagina, the needle is brought out at the first point of entrance, and, half an inch lower down, near the vulva, the same procedure is repeated, and so on until the vulvar orifice is reached. The threads are now armed with No. 24 silver wire, and, beginning with the deepest one, are drawn underneath the vaginal mucous membrane. The cervix is pushed high up with a blunt instrument, and the upper sutures tightened by twisting, so that the tip of the finger can just be inserted within its loop. It is now cut short, the twisted portion bent down and tucked under the edge of the little cut in the wall of the vagina. The entire suture is now buried. The same procedure is gone through with the other sutures, usually about four. The second suture is not drawn as tight as the first, nor the third as tight as the second, and so on, since the tension increases as the vulva is reached. A strip of iodoform gauze is now inserted into the vagina as high up as the cervix. The patient should remain in bed for from six to eight days. Careful asepsis is essential. The ends of the wire become covered with granulation tissue, and the sutures remain permanently in place. The operation is not intended for women who have not reached the menopause.

Curettage.—In partial or complete amputation of the cervix, especially when cystic degeneration has taken place, the success of the operation will depend upon careful asepsis of the uterus, which, in the majority of cases, is also the seat of an infectious inflammation—endometritis. This can be obtained only by curettage. This operation, as performed for sterility, purulent endometritis, as a palliative measure in carcinoma, or for the arrest of hæmorrhage, is done as follows: The uterus is pulled down with the double volsella and the direction of the cervical canal determined by the sound. In the case of a narrow cervix, it should be incised on both sides by introducing a curved, probe-pointed bistoury. The dilator is next introduced and the cervix gradually and intermittently stretched. In the nulliparous uterus, a dilatation of half an inch will be sufficient. In multipara, a larger opening, being readily secured, is desirable. The uterus is now irrigated with sterilized one-per-cent salt solution or a 1-to-3,000 permanganate-of-potash solution. A curette is introduced and carried back to the fundus and withdrawn in the axis of the uterus, making moderate pressure, but not sufficient if a sharp curette is employed to penetrate into the muscular substance. Repeating this manœuvre so as to cover the entire cavity, the whole endometrium is scraped off. Particular attention should be paid to the deep angles where the Fallopian tubes enter, and, in order to reach these, a smaller curette is sometimes required. The furrow across the fundus uteri is scraped by carrying the curette transversely from one tubal orifice to the other. The curettage should not be so forcibly applied to the cervical canal as to destroy the mucous membrane, which, unlike that

of the uterus, is not reproduced. The cavity of the uterus should be thoroughly dried or mopped with small tampons of iodoform gauze on forceps, after which it is packed full of gauze, using by preference a single long ribbon. A small uterus will hold about one yard of gauze one inch wide. In the after-treatment, if the patient can empty the bladder every six hours she should be permitted to do so ; otherwise the catheter should be used. In non-septic cases, the gauze should be allowed to remain five days. In pus cases, it should be removed in three days. If the uterus does not measure more than four inches in depth, it need not be packed a second time, but in organs of greater depth than this a second, and often a third packing may be necessary. When the packing is removed, if the uterus is practically dry, irrigation is not necessary. The patient may be allowed out of bed on the six or seventh day. The vagina should be carefully packed with iodoform gauze, changing the packing about every two days for three or four weeks after this operation in order to prevent infection.

Exploratory Operation through the Vagina, Utero-vaginal Asepsis.—For purposes of exploration in cases of doubtful diagnosis of lesions of the pelvic viscera, especially of the genito-urinary apparatus, the method advised by Prof. W. R. Pryor, of New York, will be found of inestimable value. It is not only commendable for its safety and simplicity, but is especially useful from the fact that it enables the surgeon to operate upon a fair proportion of cases for whatever lesion may be developed by the exploration.

It demands, first, careful asepsis of the uterus, vagina, and external genitals.

Utero-vaginal Asepsis.—At least two days before the operation the vagina should be thoroughly washed out with a 1-to-3,000 solution of mercuric chloride, using sponges on holders or gauze mops. The excess of solution should be removed, and the vagina packed with sterile gauze moistened in a 1-to-5,000 mercuric solution, sufficient pressure being used to obliterate all the folds of the vaginal mucous membrane. After the patient is anæsthetized the external genitals should be thoroughly shaved, scrubbed with a stiff brush and soap and water, and dashed over with ether. The gauze packing is now removed from the vagina and the uterus curetted, irrigated with boiled one-per-cent salt solution cooled down to 110° F., and the cavity of the uterus carefully mopped out with sterile or iodoform gauze, in order to remove any shreds of the lining membrane which may have remained. A little plug of iodoform gauze is inserted into the cervix. The vagina should now be finally cleansed with 1-to-5,000 bichloride solution, using a long, soft, jeweler's brush to reach all the recesses of the vagina, the cavity of which should finally be thoroughly dried with sterile gauze. The double volsella is now fastened into both lips of the cervix, and by a slight upward and downward movement the posterior cervico-vaginal junction is clearly seen as a crescentic fold, which appears just behind the cervix. This fold is caught up with long, mouse-tooth forceps, and the mucous membrane cut through with the scissors at *y* in Fig. 823. This incision is

extended laterally half an inch on either side of the median line x, x, cutting through the mucous membrane only, and not entering the peritoneal cavity with the scissors. Making firm downward traction upon the volsella, the operator pushes his finger into the *cul-de-sac* as high as the internal os. If the finger has not already perforated the peritonæum, the cavity is wiped dry and this membrane picked up with forceps and cut through. Through this opening the index finger or two fingers may be inserted, and a careful digital exploration and examination of the pelvic contents made. Should more than this be required, inspection may be made by tearing the vaginal mucous membrane and peritonæum out to the points A A. Should the tissues resist the tearing, the scissors or scalpel may be used to increase the opening laterally. The medium blade of the long Péan retractor is introduced into the pelvic cavity, the forceps on the posterior flap are removed, and the cervix freed from the traction forceps. The Péan-Pryor trowel is now inserted into the pelvis and the uterus forced up behind the symphysis (Fig. 824). Into this opening a gauze pad, to which a string is attached, is introduced to hold the intestines up and to absorb any blood that may escape. The patient, still on the back, with legs bent on the trunk, is now thrown into Trendelenburg's posture. By gentle manipulation with small, gauze pads held on Hunter's forceps, the intestines and omentum are made to enter the abdominal cavity. If these are held down by adhesions they should be carefully freed. If a pus cavity is found while these adhesions are being broken up, the patient should not be placed in the extreme Trendelenburg posture, for fear that infectious material will gravitate into and infect the general peritonæum. If pus is found, it should be carefully evacuated and all moisture absorbed, and everything made as aseptic as possible. The

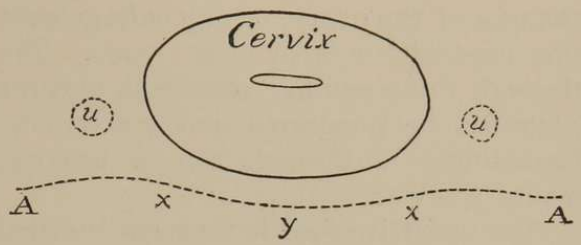

Fig. 823.

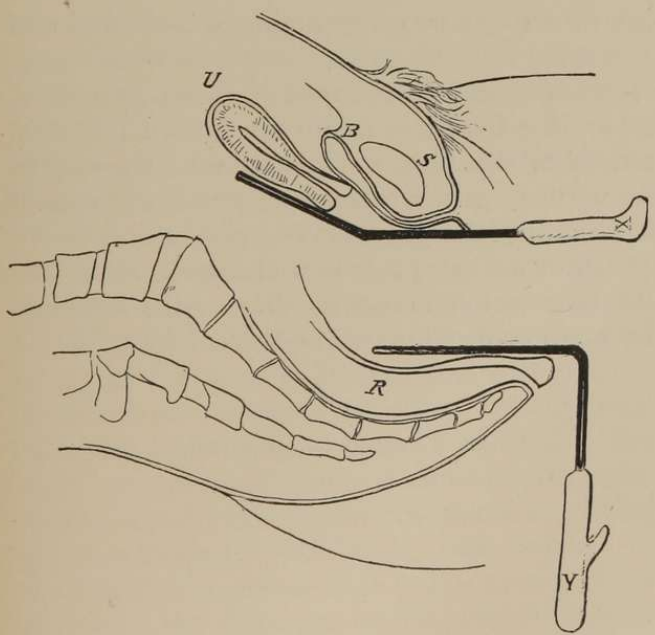

Fig. 824.

contents of the abdominal cavity should be thoroughly walled off from the pelvis by a series of gauze pads or mats, to which strings are attached, and it is well to keep a careful count of the number used, so that all may be accounted for when the operation is completed.

In cases of hydrosalpinx, cysts of the broad ligament, fibroid changes of the ovary, or any enlargement with inflammation of the tube, this exploration is of great value. The ovaries may be easily drawn through this opening, examined, and removed when diseased. Ovarian cysts can be punctured and evacuated, and the same may be said of hæmatoma. Adhesions can be broken up and an accurate diagnosis made.

The operative field is thoroughly dried with mops, the pads removed, and a loose plug of iodoform gauze inserted just within the edges of the wound in the vagina. The cavity of the pelvis is in no sense packed with gauze, but the plug should be sufficient to fill the opening and prevent any possible protrusion of the intestines. The uterus should be again thoroughly swabbed out and snugly filled with a single ribbon of iodoform gauze. It is now pushed back into position and the vagina filled with the same material. A self-retaining catheter is inserted into the bladder and the sphincter ani dilated in order to give complete rest to the parts involved. It is best not to give any morphine, and the bowels should be moved in twenty-four hours by calomel triturates or salines, and the patient kept on a light diet for four or five days. In forty-eight hours the bladder should be irrigated with a boric-acid solution (five grains to the ounce), or a 1-to-3,000 permanganate solution, and the catheter removed. On the third day the patient is put in Sims's position and the vaginal and uterine packing removed without irrigation. The uterus is not repacked, but the vagina is again filled with iodoform gauze. In from seven to ten days the plug in the vaginal rent may be removed. This may be done without general narcosis, but if the patient is very nervous an anæsthetic should be given. The cervix and uterus should be held in proper position as the plug is withdrawn, so as not to break up adhesions, and the vagina is again filled with iodoform gauze. The patient should remain in bed for two or three weeks, preferably the longer term.

CHAPTER XXX.

DEFORMITIES.

DEFORMITIES OF THE SPINAL COLUMN.

Any noticeable deviation from the normal curvatures of the vertebral column constitutes a deformity. They are *congenital* and *acquired*, *temporary* or *permanent*. They are divisible into two great classes, namely, those due to lesions of the column (bones or cartilages), and those due to lesions of the soft tissues (muscles and ligaments). To the former belong dislocations, fractures, destructive ostitis, and spina bifida; to the latter, muscular torticollis, lateral or rotary-lateral curvature (*scoliosis*), stoop-shoulder (*cyphosis*), curvature from pleuritic adhesions, collapse of the lung, contractions of cicatrices following burns, scalds, phlegmon, etc.

Lateral and Rotary-lateral Curvature.—Simple lateral curvature of the spine—that is, a bowing to one side without rotation of the vertebræ—is extremely rare. It may occur in any portion of the column to a slight extent, although rotation is very apt to take place with the curvature. It is more often observed in the cervical region than elsewhere, and is known as *torticollis*, or "*wry-neck*."

Fig. 825.—Muscular torticollis. (After Sayre.)

The causes of wry-neck are—1, loss of parallelism, or balance of power between opposing muscles, and 2, cicatricial conditions.

Muscular torticollis is by far the most frequent form, and, in common with all deformities resulting from lesions of the muscles, the right side is usually affected. The right sterno-mastoideus muscle is the principal seat of tonic spasm, or there is partial or complete paralysis of the same muscle of the left side, causing this organ to stand out in relief; the right ear is drawn down toward the clavicle of that side, while the chin points well to the left (Fig. 825). The trapezius not unfrequently is contracted with the mastoid muscle. The splenius, scaleni, platysma myoides, or levator-anguli scapulæ, are less frequently involved. Loss of equilibrium between the muscles of the two sides occurs chiefly in chlorotic patients in whom the normal muscular tone is greatly diminished, rendering the organ of the left (or

non-preferred) side unable to resist the more developed muscles of the right half of the body. In other cases the lesion may be situated in the central nervous ganglia, or in the track of the nerve.

Inflammation of the muscular substance (myositis), or of the tendons or sheaths of the muscles, is an occasional cause of wry-neck. Any inflammatory process may lead to shortening of the muscles, and to contractions in the fasciæ and connective tissues of the neck. Muscular torticollis is met with most frequently in the young, may exist at birth, is seen in females oftener than males, and in this class of cases is apt to occur about the age of puberty. In some instances, in addition to the tonic spasm of the muscles involved, a clonic or irregular convulsive movement occurs.

Diagnosis.—The recognition of torticollis is usually free from difficulty. The elimination of caries, dislocation, fracture, and wry-neck caused by cicatricial contractions, is determined from the history of the case and by inspection and manipulation.

When one sterno-mastoid muscle is contracted, the chin is pointed to the opposite side, and the occiput made to approximate the clavicle of the side corresponding to the contracted muscle. The splenius capitis draws the mastoid process downward and backward toward the spine of the seventh cervical vertebra.

The *prognosis* in muscular torticollis is usually favorable—less so in clonic than in tonic muscular spasm. In wry-neck due to contractions of the fasciæ, tendons, etc., the deformity is with difficulty relieved.

Treatment.—Chlorosis, or any dyscrasia, should be treated by tonics and internal medication, by properly selected diet and out-of-door life. The development of the muscles of the left (or weaker) side is essential. Kneading, massage, and electricity will be found useful adjuvants. Mechanical appliances should be used in overcoming the contractions in the offending muscles. Artificial muscles, composed of elastic bands or rubber tubing, more nearly fulfill the indications. The origin and insertion should correspond to that of the normal muscle. A thoracic belt or jacket of plaster of Paris, leather, or silicate of soda, properly adjusted, will serve for the points of fixation of the lower end of the elastic material. The upper insertion near the occiput is best secured by a stall carried around the head above the ears and across the forehead. In order to prevent it from slipping, the portion which rests upon the skin of the forehead should be made of strong adhesive plaster (as advised by Prof. Sayre). The tension on the rubber muscle may be increased from day to day, if necessary. If this method does not succeed, the apparatus (Fig. 826) should be tried. The mechanism is well shown in the accompanying cut, the correction of the deformity being effected by means of a series of joints situated at the back of the neck, which are worked by a key, and can be fixed at any angle of flexion and rotation.

The operative procedures include stretching or division of the muscle or muscles affected, tenotomy, neurectomy, division of the fascia, and the free dissection of cicatricial tissue. Of these operations, tenotomy of the sterno-mastoideus is most frequently demanded. A puncture is

made a little to the outer side of the clavicular tendon of this muscle, and a long, probe-pointed tenotome slid flatwise (the cutting edge downward) upon the outer anterior surface of the clavicle. As soon as the point of the instrument has passed between the clavicular and sternal origins, the edge is turned outward, making the muscle tense, and the tendon is divided subcutaneously. The sternal origin is divided by an additional puncture. After tenotomy the prothetic apparatus should be employed until recovery is complete. In dividing the body of this muscle, or the trapezius, splenius, or levator-anguli scapulæ, the open method should be followed.

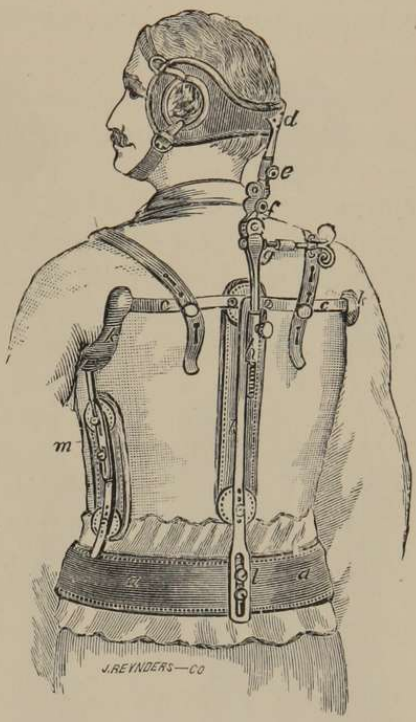

Fig. 826.—Apparatus for the correction of muscular torticollis.

Violent and sudden stretching of the muscles, with or without anæsthesia, is not advisable. Exsection of that portion of the spinal accessory nerve which is supplied to the sterno-mastoid and trapezius muscles is occasionally performed in order to paralyze the permanently contracted muscles. It is preferable to a simple division or to stretching of the nerve, for the reason that a divided nerve may reunite, and, after stretching, the function of the nerve is only temporarily impaired.

In order to expose this nerve, make an incision about four inches in length, following the posterior border of the sterno-mastoideus muscle, and commencing on a level with a point halfway between the lobule of the ear and the angle of the jaw. The fibers of the muscle should be sought, and, recognizing these, the posterior edge is exposed. By keeping the wound dry, and working close to the under surface of the muscle, the vessels will be avoided and the nerve will be seen running obliquely downward and outward, and passing into the muscle. One or two superficial nerves are sometimes seen radiating from the cervical plexus. From one half to one inch of the nerve should be excised. After this operation, mechanical treatment should be instituted for a short time.

In torticollis due to cicatrices, simple division of the contracting tissue affords only temporary benefit. The only legitimate method is to dissect out the offending tissue, slide sound skin over the wound thus made, and use mechanical treatment until the deformity is overcome.

Deformities due to *dislocations* and *fractures* of the cervical vertebræ have been considered, and those resulting from *caries* of this portion of the spine will be given hereafter.

Lateral and Rotary-lateral Curvature of the Dorso-lumbar Spine.—Simple lateral curvature of the dorso-lumbar spine is exceedingly rare.

It is complicated in almost all cases by rotation of the vertebræ upon each other, and in deformity here from muscular causes, the rotation precedes the lateral curvature.

Lateral curvature is usually caused by an inequality in the length of the lower extremities. Fig. 827 was taken from a boy in whom the right extremity was one and a half inch shorter than the left. With both soles on the same plane, marked lateral curvature (convexity to the right)



Fig. 827.

Fig. 828.

Fig. 829.—Lateral curvature after recovery from lumbo-sacral spondylitis.

was observed. By placing the foot of the short side upon a book of the required thickness, the deformity disappeared (Fig. 828).

Inequality in the length of the lower extremities is not uncommon, even in individuals who have not suffered from injury or disease. A difference of as much as one inch has been noted, while from one half to one fourth inch is quite common.

Cicatricial contractions on one side of the chest or abdomen, as after extensive burns or in chronic pleuritic adhesions with collapse of the lung, also produce this deformity. The treatment will be considered with that of rotary-lateral curvature.

Rotary-lateral Curvature.—Rotation of the bodies of the vertebræ upon each other, and upon the sacrum and subsequent or simultaneous lateral curvature, is one of the most difficult deformities to correct. The chief cause is loss of the normal equilibrium of the muscles of the two sides of the trunk. The tendency to deformity is increased by the habit of sitting sidewise at the table or desk, with one shoulder drooping while the other is elevated, or in the twisted and unnatural position which

females on horseback assume. A large majority of those affected are chlorotic girls, between thirteen and eighteen years of age, although this deformity is occasionally met with in muscular and healthy porters or laborers who habitually carry heavy weights upon one shoulder. The rotation most frequently commences in the lumbar region. The spines are pointed to the right, while the anterior aspect of the bodies of the vertebræ are made to look toward the left. The convexity of the curve is to the left, the right shoulder is prominent, the apex tilted outward, the angles of the ribs on this side project abnormally, and there is a folding in or wrinkling of the skin between the iliac crest and the thorax (Fig. 830).

The chief agent in this distortion is believed to be the latissimus-dorsi muscle. Acting upon the tips of the long spines of the lumbar vertebræ from its insertion in the humerus (and indirectly through the pectoralis major, from the clavicle and sternum), the spines are twisted to the right, causing the rotation of the bodies to the left; the shoulder blade is tilted outward, and the ribs are bent under the contraction of this long and comparatively powerful muscle.

Fig. 830.—Rotary-lateral curvature in a girl fifteen years of age.

In some instances the abdominal muscles take part in the unilateral contraction, while in others the deformity commences with the rotation of the dorsal vertebræ by the action of the serratus-magnus, rhomboidei, and deep short muscles of the back. No matter where the primary curve takes place, a second or compensatory curve follows in all chronic cases.

The *diagnosis* of rotary-lateral curvature will depend upon the prominence of the shoulder blade, bulging of the ribs, and the approximation of the crest of the ilium and thorax of the right (or affected) side. Caries of the spine may be eliminated by the absence of abnormal temperature, freedom from pain when direct pressure is made from the head along the vertebral column, and absence of symptoms of compression of the cord or nerves in the intervertebral notches. Psoas abscess is present in a certain proportion of cases of ostitis of the vertebræ.

In *simple lateral* curvature the ribs are not projected, as when rotation occurs, nor is the tip of the shoulder blade so prominent.

The *prognosis* varies with the character of the lesion. In recent lateral curvature, due to inequality of length in the extremities, it is favorable. In rotary-lateral curvature, within the first few months of the lesion, a cure may be effected. In old cases, while the deformity may be arrested, it is difficult and often impossible to restore the normal contour of the spine and ribs.

Treatment.—When the lesion is due to loss of equilibrium in the

muscles of the two sides, especial attention should be directed to the development of the organs of the weaker side, and at times it is necessary to impair the nutrition of the muscles of the stronger half of the trunk. When the deformity is on the right side, the muscles of the left arm and side should be exercised by the use of the dumb-bells, elastic strap, swing, or horizontal bar. It is often advisable to place the right arm and hand in a sling, to prevent the further development of these muscles. Massage or kneading, confined to the left half of the body, and the galvanic current to the same region two or three times a week will be advisable. Tonics, judicious feeding, and out-of-door life are essential features of treatment. The patient should be directed to sit squarely upon the buttocks, and not to droop or loll to one side. In reclining, the body should be placed in such a position that the offending muscles are put upon the stretch (Fig. 831). The deformity is temporarily overcome by the employment of Wolff's cradle (Fig. 832). The belt passes over the projecting ribs and shoulder blade, thus bringing the weight of the trunk upon these parts, while gravity aids in overcoming the curvature in the lumbar region.

FIG. 831.—Patient lying in a position to overcome contraction of the muscles of the *left side* of the abdomen and thorax. (After Reeves.)

In a certain proportion of cases, mechanical support of the thorax is indicated, especially in those cases where from muscular weakness it is almost impossible to hold the spine erect. For this purpose the plaster-of-Paris jacket or the perforated corset may be used. The latter (Figs. 833, 834) I have found very satisfactory. It is to be commended, for the reason that it can be readily removed at night, and is more cleanly than a permanent plaster jacket. When the gypsum is applied it should be split down the front, taken off and fixed for lacing so that it may be removed when necessary.

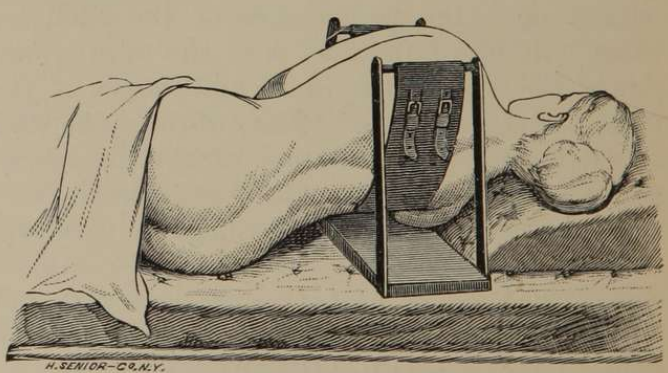

FIG. 832.—Wolff's suspensory cradle. Patient in position when the contraction is on the right side (with the right shoulder blade and ribs projecting). (After Reeves.)

This perforated corset is made as follows: A plaster-of-Paris jacket is applied as hereafter directed, and as soon as this hardens (in from ten to thirty minutes) it is split down the median line in front, removed from the body, and the cut edges placed and held in apposition by a bandage carried around and over the entire jacket. This shell is to be used as a mold in which a cast of the deformed thorax is to be made. It is thoroughly greased on its inner surface, placed upon the floor, and filled with stiff plaster mortar. When this hardens, the shell is removed, leaving an exact cast of the thorax, upon which the corset is to be built.

The materials needed are white glue, ordinary muslin rollers, flat spring steel about one eighth of an inch wide and very thin, and one yard of Canton flannel. Place the flannel with the soft plush next to the plaster, and stitch this tightly to the model, so that it is not wrinkled. It should be sewed only along the middle line in front. The glue should now be dissolved in warm water. Strips of bandage about two feet long and two inches in width are dipped in the glue and laid on the flannel which is around the model. As soon as a single thickness has been applied, strips of the steel wire, cut not quite as long as the corset, are placed one inch apart over its entire surface, and held in place by a string wound around as they are laid on. A long, dry roller is next carried around the model from above downward, and drawn so tight that the steel springs are made to conform exactly to the surface of the corset. Upon this two additional layers of the short strips of roller dipped in glue are laid. The corset should be left for several hours in the hot sun, or by a fire, until it is thoroughly dried. It is then split down the front, removed, and the edges bound with chamois skin. Hooks for lacing should be fastened along the edges in front. Perforations may be made between the springs with a wadding punch. This apparatus, when properly made, fits accurately about the body in the most favorable position for the correction of the deformity. It can be removed at night upon retiring and for bathing, changes of clothing, massage, and electricity. It is lighter and cleaner than the plaster-of-Paris

Fig. 833.—Corset made after Vance's method.

Fig. 834.—The same, applied.

jacket. When the necessary materials can not be had, the plaster jacket should be employed.

Dr. Newton Shaffer, of New York, recommends the apparatus used by him in a large experience, and shown in the accompanying cuts. The pelvic band and straps support a perpendicular bar, which terminates in the axilla of the unaffected side, and from this bar the traction force is exerted. The perforated metal shield presses upon the angles of the distorted ribs (Fig. 836).

Operative interference in muscular scoliosis is rarely called for. In extreme cases, when the latissimus dorsi of one side is greatly shortened

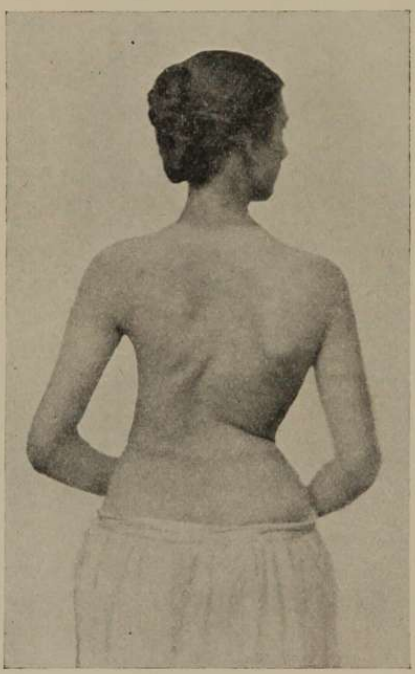

FIG. 835.—Scoliosis or rotary-lateral curvature.

FIG. 836.—The same, with Shaffer's rotary-lateral-curvature apparatus applied.

and increased in development, correction of the curvature may be expedited by the subcutaneous division of this muscle.

When lateral or rotary-lateral curvature of the spine results from inequality in the length of the lower extremities, the first indication in treatment is to elevate the shoe of the short side, and thus bring the plane of the iliac crests at a right angle to the axis of the vertebral column. If the deformity is not entirely corrected by this plan, the measures just detailed should be also employed.

When the deformity is caused by superficial cicatricial contractions, their division is essential. In pleuritic adhesions, with collapse of the lung, the treatment given for rotary-lateral curvature due to muscular asymmetry should be adopted.

Anterior and Posterior Curvature of the Spine.—Anterior curvature, or "stoop shoulder," usually occurs in the dorso-cervical regions; occasionally the entire column is involved. It may be caused by—1, partial or complete paralysis of the erector muscles of the back; 2, tonic spasm

of the abdominal muscles; 3, from inadvertence, as in the habit of allowing the shoulders to droop forward, with or without the carrying of burdens; 4, cicatricial contractions in the anterior thoracic and abdominal regions; 5, heredity.

Complete paralysis of the muscles of the back is exceedingly rare. Unilateral paresis is not altogether uncommon. The most frequent condition is one of general impairment of muscular tone, the head and upper spine gravitating forward as the muscles yield, until the posterior ligaments are elongated and the anterior margins of the intervertebral disks narrowed by compression. The habit of carrying a heavy burden upon one shoulder is more likely to induce rotary-lateral curvature than *cyphosis*. The indications are to correct the deformity by the use of braces, and to increase the tone of the muscles the nutrition of which is impaired.

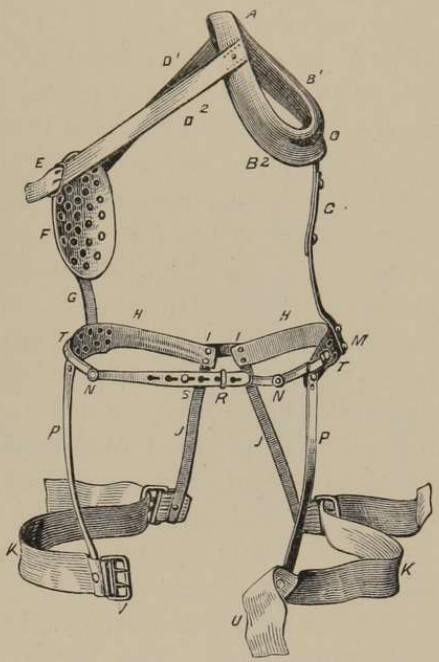

Fig. 837.—Shaffer's apparatus for correcting scoliosis.

To meet the former, in mild cases a double elastic brace, such as is shown in Fig. 838, will be sufficient. Massage, electricity, tonics, and out-of-door life are also essential features of treatment.

Posterior curvature of the spine, *lordosis* or "sway-back," is far less frequent than the condition just described. It occurs almost always in the lumbar region. In the later months of pregnancy it is a common condition, and is met with in individuals with unusual development of the stomach and abdominal viscera, or in cases of chronic abdominal tumor (fibroid, etc.).



Fig. 838.—Nyrop's spring brace. (After Reeves.)

Spondylitis.—Destructive ostitis of the vertebræ, commonly known as Pott's disease, occurs usually between the third and fifteenth year of life. In exceptional instances it is observed prior to three years of age, while not more than one fifth of all cases occur after the fifteenth year. It is therefore eminently a disease of the growing period, when rapid nutritive changes are taking place in the bones.

While no portion of the spine is exempt, the disease is much more frequent in the dorsal vertebræ, which are involved in about two thirds of all cases. The lumbar and cervical portions of the column are about equally liable to destructive ostitis. Occipito-cervical disease is rare.

Ostitis in the lower cervical region is apt to involve the upper dorsal by extension, and the same is true of ostitis of the lower dorsal in their relation to the lumbar vertebræ. Lumbo-sacral disease is not altogether uncommon. Destructive ostitis of the spine is divided into *occipito-cervical*, *cervical*, *cervico-dorsal*, *dorsal*, *dorso-lumbar*, *lumbar*, and *lumbo-sacral*, according to the recognized location of the disease.

Causes.—Tuberculous infection is the cause of Pott's disease in a large majority of cases. The bacillus tuberculosis is especially liable to attack the cancellous tissues of the vertebræ, which bones, together with the sternum and ribs, are the last to take on the changes of adult life. In the pathology of ostitis it was shown that the medulla of these bones remains in the red or embryonic condition long after the marrow of other bones has undergone the adult or yellow change, and that consequently they are for a prolonged period liable to accidents consequent upon rapid nutritive changes, and especially to capillary rupture and extravasation. How much more liable to accident and infection are these structures when they are weakened in any way by general impairment of nutrition. Although a fall upon the feet or hands, or violent flexion of the spine, or a blow upon the sternum or ribs, or a penetrating wound, may lead to destructive ostitis, yet destructive inflammation of these structures as a result of traumatism is comparatively rare. Carcinoma and sarcoma of the vertebral column is very infrequent. Destructive ostitis of one or more vertebræ is occasionally caused by pressure from aortic aneurism.

Clinically, destructive ostitis is met with in two forms—the dry and the suppurative. The latter variety is more common. In dry ostitis pyogenic infection does not occur, the bone cells undergo granular metamorphosis, and, together with the inorganic salts of this tissue, are absorbed. In these cases the breaking down of the bodies of the vertebræ, to the extent of marked deformity, may occur without recognized febrile movement. In the suppurative form, when mixed infection occurs, the destructive process is more rapid, and is accompanied by the formation of a variable quantity of embryonic tissue, the bone breaks down in bulk, and particles varying in size appear in the pus which results from the inflammatory process. The earliest pathological change in such cases is in the cancellous tissue of the body. In rarer instances the lesion commences as a synovitis in the costo-vertebral or interarticular joints, whence the disease may invade the intervertebral disks and bodies. Primary inflammation of the intervertebral fibro-cartilage is believed to be very rare. As the destructive process continues, the cancellous tissue of the body, and chiefly of the anterior portions of the column, breaks down (Fig. 839), causing abnormal curvature, with sharp projection of the spinous processes. The angular deformity is less apt to be present when the disease attacks the posterior portion of the body, where the superincumbent weight in great part falls upon the articular processes (Fig. 840).

Symptoms.—The clinical history of Pott's disease may be divided into two stages: The *first stage* includes all the phenomena which occur

up to the time when deformity is recognized; the *second stage* embraces all the changes met with after deformity. The usual symptoms of the first stage are pain and muscular rigidity, with varying exacerbations of temperature. *Pain* may be elicited when the patient assumes the erect posture, by direct pressure upon the spines of the vertebræ involved, and by concussion of the column transmitted from the head downward. When the bodies alone are involved (the usual condition) it may be lessened or made to disappear entirely by suspension of the patient from a portion of the column above the lesion; by bending the spine backward,

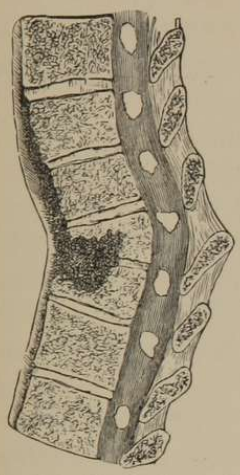

Fig. 839.—Destructive ostitis of the anterior portion of the bodies of the vertebræ. (After Noble Smith.)

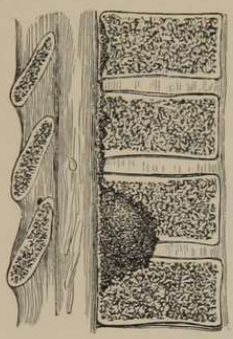

Fig. 840.—The same process in the posterior portion of the bodies of the vertebræ. (After Noble Smith.)

Fig. 841.—Deformity resulting from fracture of a vertebra. (After Noble Smith.)

thus throwing the weight upon the healthy articular processes; or by laying the patient face downward across the surgeon's lap, and making extension by separating the knees.

Muscular rigidity is recognizable in a majority of instances, and in children may be observed as a symptom of pain, when the presence of pain is denied. Fixation of the dorsal muscles is evident in the stiff and unusual manner in which the back is held as the patient moves about, and in the awkward posture assumed while sitting down. If directed to bend the vertebral column, as in stooping to pick up something from the floor, the movements are cautious and constrained, altogether lacking in the celerity and suppleness which are seen in flexion and extension of the vertebral column in health. In the earlier stages pain is dull and steady in character, and is usually local, being confined to the neighborhood of the part affected.

Elevation of temperature may be present at any stage of Pott's disease. It is, as a rule, the index of pyogenic infection with inflammatory and destructive processes. The thermometer may register from the normal as high as 101°–102° F., and only in exceptional instances as high as 104°. In a fair proportion of cases in the early stages, and especially in the dry form of ostitis, no elevation of temperature can be detected.

The *second stage* of the disease, that of deformity, may be present in

the course of a few weeks after the appearance of the first stage, or several months may elapse. All of the symptoms of the preceding stage are present in the second stage of Pott's disease. If proper treatment has not been instituted, interference with the functions of the cord at and below the seat of lesion, or of the nerves which pass out between the diseased vertebræ, is apt to occur, from displacement of the bones or as a result of inflammatory products pressing upon the spinal cord and nerves. Paralysis of motion and sensation, in a varying degree, occurs in a certain proportion of cases.

When deformity occurs the convexity of the curve is posterior in about ninety-five per cent of all cases. The "knuckle" may consist of a single spinous process (Fig. 839), or several spines may project, as in Fig. 841.

The degree of deformity depends upon the location of the disease, its extent, and in part to general relaxation of the erector muscles. It is greater when the lower cervical and upper dorsal vertebræ are involved (Fig. 842). The formation of pus and the resulting abscess and sinuses belong chiefly to the last stage of ostitis of the spine. The abscess may travel along the psoas muscle, opening near the middle of the groin above or beneath Poupart's ligament, the pus may escape through the inguinal canal, over the iliac crest, or through the sacro-sciatic notch ; or it may be arrested at a higher point and escape recognition, unless careful examination is made under ether narcosis.

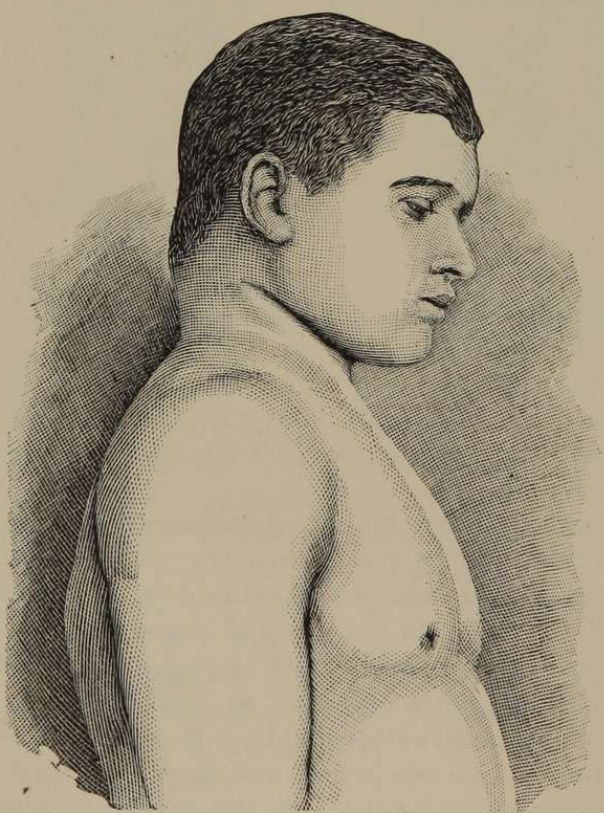

Fig. 842.—Caries of the bodies of the third, fourth, and fifth cervical vertebræ.

Spinal abscess is usually single, occasionally double. When occurring in the upper dorsal region it may be arrested by the diaphragm, or pass behind this into the sheath or fascia of the psoas muscle. Abscess in ostitis of the bodies almost always travels downward on one or the other side of the antero-lateral aspect of the spine. When the articular processes or laminæ are involved, the pus may penetrate the dorsal muscles and point posteriorly.

In occipito-cervical or upper cervical spondylitis, the pus collection often appears at the posterior wall of the pharynx (*retropharyngeal*

abscess). Interference with deglutition and phonation is not infrequent. The contents of an abscess resulting from destructive ostitis of the cervical vertebræ may also descend along the deep fascia of the neck and pass into the thorax or the mediastinum. In this manner it occasionally finds its way into the pericardium.

Amyloid changes of the viscera are among the late symptoms of chronic spondylitis.

Diagnosis.—In general the recognition of the disease will depend upon a history in accordance with most of the symptoms just detailed. As to the portion of the column involved, the appreciation of localized pain by direct or indirect pressure is an indication of value. When the efferent nerves are involved by pressure from the products of inflammation, certain disturbances in their course or distribution are of diagnostic importance. Spasm of the larynx, pharynx, diaphragm, pain down the arm, etc., naturally attract attention to the points of exit of the nerves supplying these parts. When tenderness in the region of the psoas muscles is evidenced by habitual indisposition to extend the thighs, lumbar ostitis may be suspected. When the gibbosity is recognized, a diagnosis is no longer doubtful. The early recognition of abscess in the abdominal region is possible only by palpation under profound narcosis.

If the articular processes are diseased, bending of the spinal column backward will increase the pain. Placing the patient on the abdomen, with the head and lower extremities depressed, will diminish it. When the bodies and intervertebral disks are involved, bending the spine backward will relieve the pressure symptoms.

Treatment.—In the mechanical treatment the indications are to secure fixation of the spinal column in the position of least discomfort to the patient. Judicious medication, good food, and pure air are the indications in the constitutional treatment. The character of the mechanism to be used will depend in good part upon the portion of the vertebral column involved. It is essential, in order that any apparatus may fully meet the indications, that not only shall the diseased bones and the healthy tissues be held practically immovable, but the superincumbent weight be lifted. Fixation may be accomplished by any form of well-adjusted apparatus, but lifting the weight of the body, which is above the seat of disease, is a more difficult undertaking.

The downward pressure upon the bodies when, as is usual, these structures are involved and breaking down, can be in great part obviated by extension or backward bending of the spine, in which manœuvre the pressure is transferred from the bodies and intervertebral disks to the articular processes and pedicles.

Much of the apparatus devised for the arrest and cure of Pott's disease is based upon this principle. Another method is based upon the principle of lifting the parts above the seat of the lesion, and removing in part the pressure, not only from the bodies but also from the articular processes (extension and counter-extension, or suspension).

To accomplish the former the spinal braces of Drs. Davis, Taylor, and Shaffer have been constructed. For complete extension or lifting,

the plaster-of-Paris jacket or the jury-mast of Prof. Sayre, and the suspension carriage of Dr. Meigs Case, more nearly meet all the indications.

In appropriate cases each of these forms of apparatus, if properly adjusted and intelligently worn, will accomplish all that is possible in the mechanical treatment of Pott's disease. Much of the discredit which is brought upon any particular apparatus can justly be charged to the lack of judgment in the selection of cases, want of skill in the adjustment of the instrument, and failure on the part of the attendant or patient in persisting in its use a sufficient length of time.

The selection of the apparatus best adapted to succeed will depend upon the location of the disease and the age and conformation of the patient. Clinically the spinal column is divisible into three regions: 1, embracing the occipito-cervical articulation, the cervical vertebræ, and down to the third dorsal; 2, from the third to the tenth dorsal; 3, from the tenth dorsal to the sacro-lumbar articulation.

The lower region is more amenable to treatment, the upper next, while the middle region, which is most frequently involved in ostitis, is the most difficult to manage.

Third Region.—In the mechanical treatment of Pott's disease in the third region, Sayre's plaster-of-Paris jacket, of light make and properly adjusted, will give great satisfaction. In its application the following articles are essential:

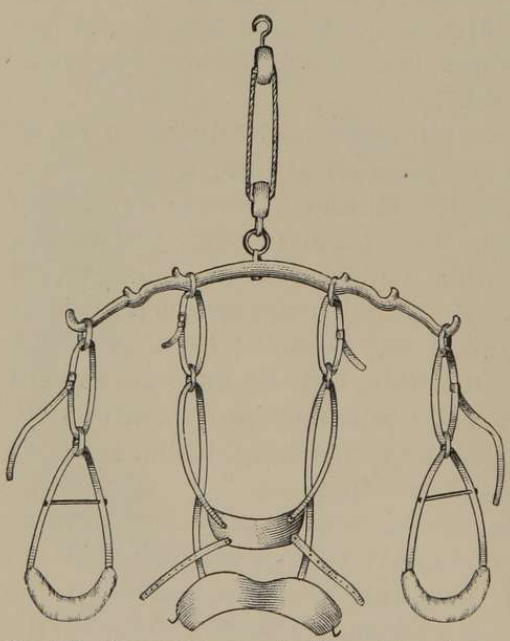

Fig. 843.—Suspension apparatus for applying plaster-of-Paris jacket. (After Sayre.)

1, A suspension apparatus; 2, a tight-fitting, seamless, knit shirt; 3, plaster-of-Paris bandages. The suspension apparatus of Reynders & Co. (Fig. 843) consists of an iron crossbar from which are suspended padded loops for each axilla, and a chin and occiput swing for lifting from these points. The crossbar is attached at its center to a block and pulley. After the knit shirt is applied, the arms of the patient are slipped through the padded loops while the collar is buckled around beneath the chin and occiput. The center and lateral suspension straps should be adjusted so that when the lift is made the tension will be equally distributed. The block of the pulley apparatus may be fastened to a hook in the ceiling or to the tripod (Fig. 844). The plaster bandages—the method of preparing which is given on page 156—should be perfectly fresh and well made, for a good deal of success depends upon the quality of the gypsum and the thoroughness with which it is worked into the meshes of the crinoline. As the direction for applying this

jacket, as given by Prof. Sayre—to whom the profession is indebted for bringing it so prominently into use—can not be improved upon, I give it in his language:

"Before applying the plaster bandage, I place over the abdomen, between the shirt and the skin, a pad composed of a towel folded up so as to form a wedge-shaped mass, the thin edge being directed downward. This is intended to leave room, when removed, for the expansion of the abdomen after meals, and so I call it the 'dinner pad.' It is important to make it thin where it comes under the lower edge of the jacket, or else the jacket would fit too loosely about the lower part of the abdomen. It should be taken out just before the plaster sets. It is always a good plan to get the patient to eat a hearty meal before the jacket is applied, but this precaution of allowing room for meals should never be neglected.

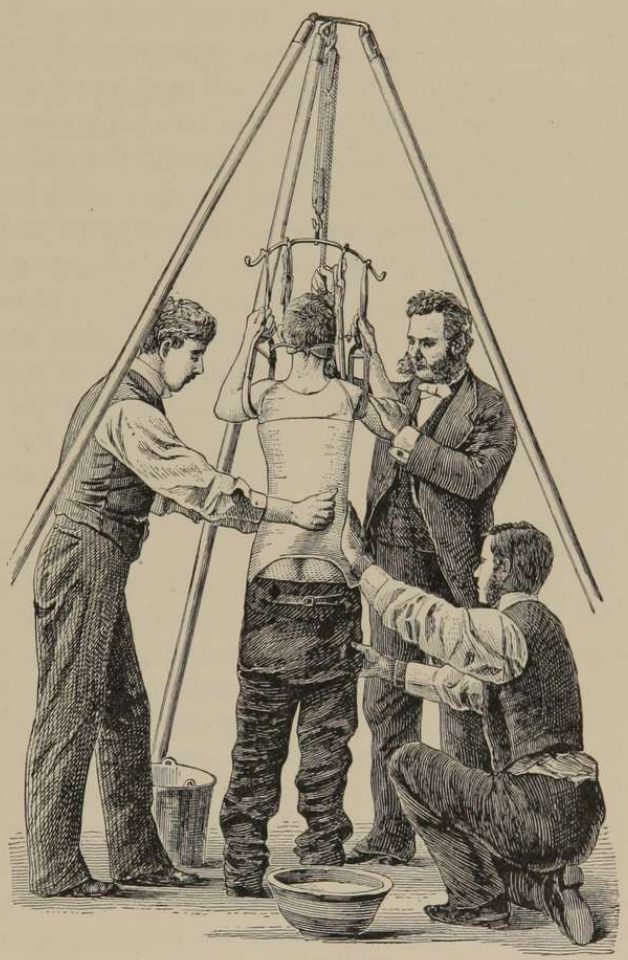

Fig. 844.—Suspension apparatus and tripod in position for lifting. (After Sayre.)

"If there are any very prominent spinous processes which, at the same time, may have become inflamed in consequence of pressure produced by instruments previously worn, or from lying in bed, such places should be guarded by little pads of cotton or cloth, or little glove fingers filled with wool placed on either side of them. Another detail, which I have found to be of practical value in some cases, is the application under the shirt, over each anterior iliac spine, of two or three thicknesses of folded cloth three or four inches in length. If these little pads be removed just before the plaster has completely set, such bony processes will be left free from pressure.

"If the patient be a female, and especially if she be developing at the time, it will be necessary to apply a pad under the shirt over each breast before the plaster bandage is put on. These pads should be removed just before the plaster sets, and at the same time slight pressure should be made over the sternum for the purpose of indenting the central portion

of the plaster jacket, and of thus giving form to the body, and of removing pressure from the breasts.

"The skin-fitting shirt having been tied over the shoulders, and then pulled down, and kept stretched by means of tapes applied, one in front, the other behind, near its lower edge, and tied tightly over a handkerchief placed on the perinæum, the patient is to be gently and slowly drawn up by means of the apparatus until he feels perfectly comfortable, and *never beyond that point*, and while he is retained in this position the plaster bandage is to be applied. A prepared and saturated roller, which has been gently squeezed to remove all surplus water, is now applied around the smallest part of the body, and is carried around and around the trunk downward to the crest of the ilium, and a little beyond it, and afterward from below upward in a spiral direction, until the entire trunk from the pelvis to the axillæ has been incased. The bandage should be placed smoothly around the body, not drawn too tight, and especial care taken not to have any single turn of the bandage tighter than the rest. Each layer of bandage should be rubbed most thoroughly with the hand by an assistant, that the plaster may be closely incorporated in the meshes of the crinoline, and bind together the various bandages which make up the jacket, thus making it much stronger than if attention is not paid to this particular. If you notice any spot which seems weak or likely to give way, pass the bandage over it, and then fold it back on itself, and do this until you have placed several thicknesses of bandage over this point, being careful to wet all well together, and then pass a turn completely around the trunk to retain any ends which might have a tendency to become detached.

"In a very short time the plaster sets with sufficient firmness, so that the patient can be removed from the suspending apparatus, and laid upon his face or back on a hair mattress, or—what is preferable, especially when there is much projection of the spinous processes or sternum —an air bed. Before the plaster has completely set, the dinner pad is to be removed, and the plaster gently pressed in with the hand in front of each iliac spinous process, for the purpose of widening the jacket over the bony projections. In the case of a young child with a small pelvis it may happen that the circumference of the body at the umbilicus is as great as around the pelvis, but, as the soft parts in the lumbar region allow us to mold the plaster as we choose, you can still obtain a point of support at the pelvis; if, as the jacket hardens, you will press it in at the sides above the ilium, and in front and rear above the pubes, the antero-posterior diameter above will be the longer, while below it will be the transverse one."

When the angular projection is extreme, or when an ulcer exists, it will be advisable to cut a hole in the jacket at this point large enough to prevent any undue pressure. In case of abscess, a window of sufficient size to allow free drainage, and a frequent change of dressing, should be made.

The commendable features of this plan of treatment are the extension obtained by suspension, fixation by the plaster while in the most favor-

able position, and the cheapness and readiness with which it may be employed.

The objections are, uncleanliness by reason of the immovable nature of the apparatus, and the excoriations which are a cause of considerable complaint. The first objection may be met by splitting the corset down in front and reapplying it each time while the patient is suspended, and making it tight by a roller carried around the body several times; or a row of hooks may be fastened on either side of the line of section and corset-lacing used to hold the jacket closely adjusted. As for excoriations, it may be said that no apparatus which grasps the body tight enough to secure fixation is free from this danger. When they occur with the plaster jacket, the fault generally lies either in the improper manner of its application or carelessness on the part of the attendant.

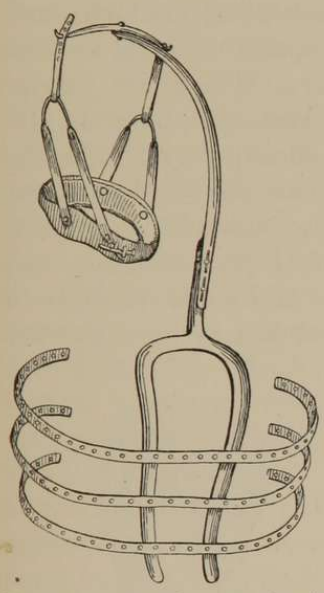

Fig. 845.—Sayre's jury-mast head-swing. (After Sayre.)

Second Region. — When the middle or dorsal region is involved, the plaster jacket is not so serviceable as in ostitis of the vertebræ in the lower region of the spine, although much good will be accomplished by the partial fixation of the thorax as high as to the level of the axillæ. The efficacy of this method diminishes the higher the diseased process is located, and, when the lesion invades the sixth dorsal, or above this point, the jacket without head suspension is almost useless. In all cases of Pott's disease above the tenth dorsal suspension of the head, or elevation of the chin is an essential feature of treatment. A favorable result would be achieved in a greater proportion of cases if this point were insisted upon, and the prejudice against the suspension apparatus or chin-lift overcome.

Fig. 846.—Jury-mast apparatus applied. (After Sayre.)

In the application of the jury-mast the patient should be suspended as just described, and a plaster jacket applied from just above the trochanters up as high as the axillæ. After two layers of the plaster bandages have been applied, the jury-mast is adjusted, and its framework covered in with the succeeding layers of bandage. The jury-mast (Fig. 845) consists of a back piece, in shape not unlike the inverted letter U, made of soft iron, which enables it to be accurately molded to fit the surface to which it is applied. To this are fastened two or three strips of tin, made rough by a series of perforations with an awl. To the upper end of the back piece a curved bar of light steel is attached, in such a

manner that it can be raised or depressed at will. At the end of this crane is a light crossbar, hooked at each extremity, from which the collar is suspended. After the first two layers of plaster bandages have hardened, the apparatus is bent to fit the surface of the back, and is adjusted to the jacket, with the middle piece or crane exactly in the median line of the back of the neck and occiput, and its extremity over the center of the top of the head, so that traction by the strips will be directly upward. It is fastened by carrying plaster rollers over the tin strips and back piece, and working in plaster mortar. When the plaster hardens, the apparatus is immovably incorporated into the jacket. The suspension collar should now be buckled beneath the occipital protuberance, and the strips tightened enough to lift the weight of the head from the neck. The jacket may be converted into a movable corset, by splitting it along the middle line in front and attaching hooks for lacing (Fig. 846). If the jury-mast can not be applied, in ostitis involving the vertebræ between the third and ninth dorsal, Shaffer's modification of Taylor's brace should be preferred.

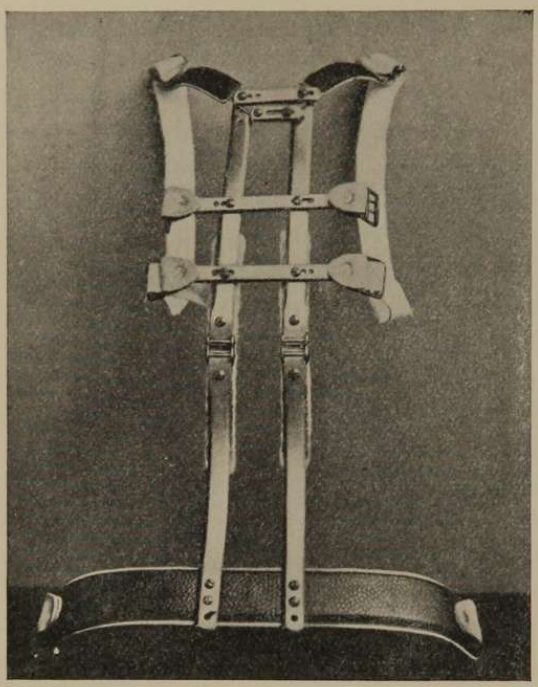

Fig. 847.—Shaffer's modification of Taylor's spinal brace.

"The patient is placed prone upon two tables of equal height, and the tables are then separated so that the diseased area may be freely accessible from all sides. One assistant grasps the patient under the axillæ, the other makes steady but easy traction at the thighs. While the patient is in this prone position the operator fits the uprights to the line of the transverse processes; in other words, adjusts the apparatus to the deformity. A pair of 'monkey-wrenches' may be easily used as a pair of levers with which to bend the annealed steel uprights into *any* shape. It takes but a few moments to adapt the uprights to the deformity. The traction is affording relief, and is not producing any injury. Then the ap-

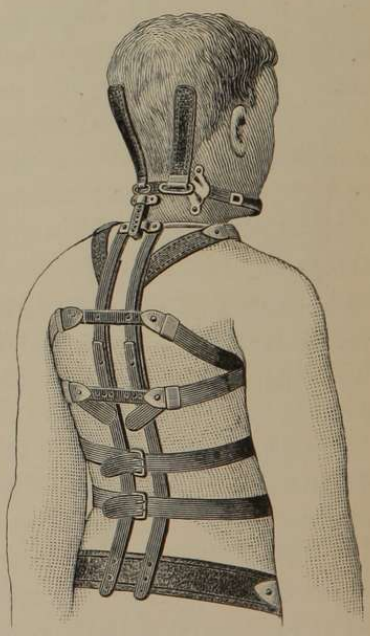

Fig. 848.—Shaffer's head and chin support added to Taylor's brace.

paratus is laid on the back accurately, traction is steadily maintained, and the thoracic and pelvic straps are fastened. When the operation is complete, the patient is firmly secured in an apparatus which affords a support that can be maintained by the thoracic, axillary, and pelvic straps, and the uprights are held, without undue pressure, in their position by the circular straps and bands." *

The value of this apparatus consists in the fair degree of fixation which it secures, but chiefly in the fact that, when properly applied, the dorsal spine is extended, that is, bent backward to such a degree that the weight from above is removed from the diseased bodies and transferred to the sound articular processes and pedicles. If this position is properly maintained, relief will usually follow in those cases where the bodies alone are involved. The chin-rest or elevator (Fig. 848), may be attached to this same apparatus.

First Region.—In ostitis of the vertebral column, from the third dorsal to the occipito-atloid articulation, the treatment should be by suspension from the chin and occiput, or by tilting or lifting the chin upward. In accomplishing this end the jury-mast, or chin-rest, applied and worn as just described, will meet the indications. Much good may be obtained from the judicious use of extension in the recumbent posture (Fig. 849). This apparatus may be worn at night, when the head stall of the jury-mast, or chin-lift, is removed. In the worst class of cases it is advisable to employ the extension in bed until the symptoms of paralysis are relieved. Instead of the block and pulley, with weight, the extension may be made by elastic bands attached to the chin-and-occiput collar, chin-piece, and the head of the bed, while, if necessary, fixation may be secured by elevating the head of the bed six or eight inches.

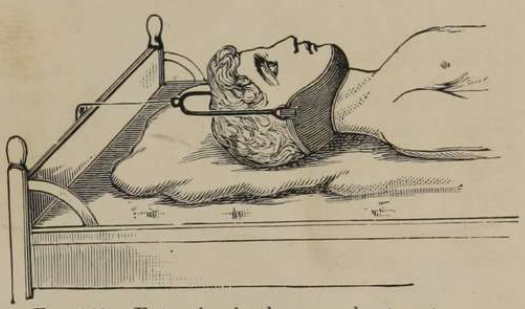

Fig. 849.—Extension in the recumbent posture. (After Reeves.)

The suspension carriage of Dr. Meigs Case, which lifts from the axillæ, chin, and occiput (Fig. 850), is a valuable apparatus in the treatment of Pott's disease in the cervical and upper dorsal region. If the degree of elastic suspension from the chin and occiput which it affords during the waking hours is continued during sleep, by the method of extension in the recumbent posture above given, success will be achieved in the majority of cases. It is chiefly objectionable by reason of its high price, which places it beyond the reach of many who can obtain the jury-mast.

As to the value of the various mechanical devices, Prof. Gibney concludes "that in very young children, from two to five years, the wire cuirass with a good rest for the head and means for making moderate trac-

* "Pott's Disease," etc., N. M. Shaffer, M. D. G. P. Putnam's Sons, New York, 1879.

tion, such as the swing in the jury-mast, is an excellent apparatus. In older children some modification of the Taylor chin-piece or the Whitman chin-rest attached to a plaster-of-Paris jacket or corset should be employed. For the practitioner remote from a large city, and with no good instrument maker at hand, nothing is quite so good as the plaster-of-Paris jacket with the jury-mast."

Fig. 850.—Dr. Meigs Case's suspension carriage, for both the standing and sitting postures.

The successful management of Pott's disease depends not only upon a thorough practical knowledge of the construction and application of the mechanical apparatus required, but upon the careful and constant attention of a competent surgeon during the entire time, from the incipiency of the spondylitis until several months have elapsed after consolidation is effected. The prevention of chafing and sores, the renewal or tightening of the apparatus, require almost as much skill as in the diagnosis and first adjustment of the mechanism. As regards abscess in ostitis of the vertebral column, it may be said that incision and drainage, as shown by Dr. Shaffer, are not indicated unless pyogenic infection of the tuberculous abscess has occurred. Pain, high temperature, and other symptoms of septic absorption will indicate infection. Fresh air, well-selected articles of food, and tonics are essential. In the severer cases, in which a myelitis is developed from compression by the products of inflammation, potassium iodide, in full and continued doses, is recommended by Prof. Gibney. In all cases where the recumbent posture is assumed, an effort should be made to keep the patient on the back, with a pillow so arranged that the spinal column is bent well backward, and the pressure on the bodies in this way partially relieved.

The suspensory cradle of Reeves will accomplish this end more successfully. A splint or shell is made of gutta-percha or sole-leather, and molded accurately to the back, from the sacrum to the neck. With this held in position by a roller, the patient, while lying down, is supported by the swing, as shown in Fig. 851.

Spina Bifida.—This condition results from a failure of development in the laminæ and spines of one or more of the vertebræ. Through the opening left by this incomplete closure of the bony canal the membranes of the cord are protruded, forming a sac of variable size, which is distended by the cerebro-spinal fluid. The cord itself may be wholly or in part spread out, and compressed against the sac, or the filaments of the cauda equina may terminate in bulb-like ends in the investing membrane.

Spina bifida is met with most frequently in the lumbo-sacral region, next in frequency in the neck, rarely elsewhere. One fissure may exist below and one above in the same child, though it is very rarely multiple.

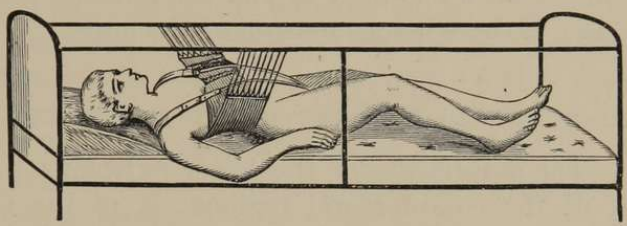

Fig. 851.—Reeves's suspensory cradle. (After Reeves.)

The tumor may vary in size from one inch to six or eight inches in the longest diameter, and may be sessile or pedunculated. It is elastic to the touch, and is usually covered by the integument, which is thinner than normal. In some instances the skin is wanting over the mass, the protruding *dura mater* forming the outside covering of the mass.

The character of the swelling may be recognized by its congenital origin, its location in the median line of the back, almost always in the lumbo-sacral region, its smooth contour, elasticity, and chiefly by its variable size. It becomes larger and more tense during the act of crying, and by pressure its contents may in part be forced back into the spinal canal and ventricles of the brain. Convulsive movements may follow too great and prolonged compression of the tumor. The prognosis is, as a rule, very unfavorable. Ulceration of the integument over the mass, followed by rupture of the sac, is apt to occur, usually ending in death. A recovery after this accident is rare, although such cases are reported. Or the tumor may remain indefinitely in about the same condition as at birth. Paralysis, more or less complete, in the lower extremities, is the rule.

The palliative treatment of spina bifida consists in the application of moderate compression over the tumor, at the same time protecting the integument from all irritation and injury. This plan of treatment should be followed out for one or two years, unless more radical measures are indicated by the failure of this method to arrest or greatly retard the growth of the swelling. When the tumor is suddenly increased in size and tension, temporary benefit may be obtained by drawing off a small quantity of the fluid. From ʒj to ʒj may be withdrawn by the aspira-

tor. The smallest needle should be employed, and the contents slowly evacuated. The quantity of fluid to be removed will vary with the size and tension of the tumor, and the effect produced by the aspiration. Two or three drachms will usually suffice. The operation may be repeated as often as the symptoms demand. It is advisable to introduce the needle through the side of the tumor rather than in the middle line. In spina bifida when the tumor is well pedunculated and the communication between the sac and membranes of the cord is not large, a cure may be effected by the method of Morton, which consists in the injection of the following solution: Iodine, grs. x; iodide of potassium, grs. xxx; glycerin, ℥j. From ℥ss. to ℥j or more of the fluid is withdrawn from the sac, and from ʒss. to ʒiij of the iodine solution injected, and the puncture covered with collodion. This operation may be repeated if necessary. A more radical procedure is the extirpation of the sac by dissection, covering in the cord by a plastic operation with skin flaps. The impaired vitality of the integument renders success difficult, especially if there is any tension of the flaps.

Deformities of the Lower Extremity.

The deformities of the lower extremity may be divided into those—1, of the coxo-femoral regions; 2, of the shaft of the femur in its entirety; 3, of the condyles; 4, of the tibia and fibula; 5, of the tarsus and metatarsus; and, 6, of the phalanges.

In this classification, distortions of the pelvis, such as in malacosteon and rachitis, are excluded, since they concern the obstetrician rather than the surgeon.

At the *hip* there may exist preternatural mobility, or partial or complete immobility with malposition. Preternatural mobility may be due to the following causes: Arrest of development in the bones which form the acetabulum; congenital failure of development of the head of the femur, or atrophy of this portion; to both of these conditions combined; abnormal length of the capsular ligament, and absence of the ligamentum teres. In a majority of these cases of congenital dislocation the abnormally small and misshapen head of the humerus is found in a shallow false growth near the rim of the normal site of the acetabulum, which latter is rudimentary and often filled with fibrous tissue.

Immobility with malposition results from inflammation of the joint and anchylosis, with or without destructive ostitis and loss of substance. Contraction of the psoas and iliacus or other muscles about the hip which are not overcome before anchylosis ensues is the chief cause of deformity. Dislocation with failure at reduction always induces deformity, and the same is true of fracture.

In preternatural mobility at the hip joint (congenital dislocation) the symptoms are chiefly a peculiar rolling gait, or oscillation to right and left in the act of walking, especially when the deformity is bilateral. While standing erect, the trochanters will be closer to the iliac crest than normal, which condition can be accurately determined by Néla-

ton's or Bryant's test. In these cases the anterior convexity of the curve in the lumbar region is exaggerated, giving the patient a sway-back appearance. If extension is made from the feet, while the trunk is fixed in the recumbent posture, the length of the patient will be considerably increased over that measured in the erect position. Absence of the head of the femur may be determined by palpation with outward rotation. Perforation of the acetabulum may also be made out by digital exploration *per rectum*.

Treatment.—Locomotion in some cases may be much improved by persistent effort on the part of the patient to train the muscles to hold the femur well up in the acetabulum in the act of walking. In this manner the rolling character of gait may be in great part corrected.

The palliative treatment of congenital dislocation of the hip consists in the application of some apparatus which will keep up an extension from the pelvis, such as would be accomplished by the double hip splint of Prof. Sayre, or the partial support of the body to aid in locomotion, as by the use of crutches or the wheel carriage of Dr. Meigs Case. Within recent years considerable attention has been given to the subject of operative interference for the partial or complete relief of this distressing deformity. It is advised by Dr. Bradford, of Boston, and Prof. V. P. Gibney, of New York. The latter recommends the following procedure:

"Any treatment, whether mechanical or operative, should be preceded by traction in bed with enough weight to diminish and, if possible, overcome the shortening. In children under three years of age this preliminary traction requires from one to three weeks; in older children, from four to eight weeks. The object is to overcome tension of the abductors and the muscles, which, together with the ligaments, are holding the bone in its abnormal position. Firm traction in the long axis of the limb, followed by extreme abduction, flexion of the thigh on the abdomen, and, finally, full extension with the hand over the trochanter major, forcing the head into the position where the acetabulum should be (i. e., the normal location of the socket). While the bone is held firmly in this position a plaster-of-Paris bandage is applied from the mammary line to the sole of the foot, care being taken to hold the limb in inward rotation and extreme abduction with forced extension. This apparatus should remain on four or five months, and should it become soiled, a new one should be applied under the same careful manipulation. After this time a short leather spica or a plaster-of-Paris short hip spica should be worn, and the child exercised on crutches with an elevation on the shoe of the sound limb, in order to keep the foot of the lame side from being used in walking.

"The operation of Lorenz may follow the preliminary traction of four or five weeks, as above given. An incision is made directly through the soft parts over the trochanter and head and neck of the displaced bone, until the Y- ligament and capsule are exposed. The capsule is opened in the line of the Y- ligament, and by strong outward rotation the head of the femur is rolled away from and exposes the site of the acetabulum. The finger will now recognize the rudimentary acetabulum, and with this

as a guide the bayonet spoon will make an acetabulum large enough to admit the head of the bone, which is usually small and misshapen. A very important step in the operation is to make the acetabulum large enough and leave enough room in the upper and outer portion to prevent the head of the bone from slipping out. It frequently happens that the posterior part of the capsule is folded into the posterior part of the acetabulum thus made, and it will be necessary to cut these folds away before the operation is completed. Deep and superficial sutures are to be

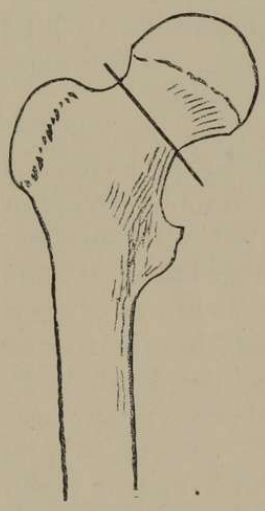

FIG. 852.—Adams's line of section. (After Poore.)

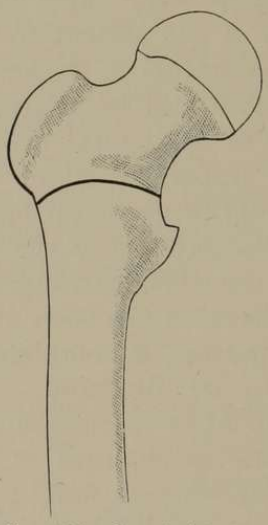

FIG. 853.—Sayre's intertrochanteric line of section.

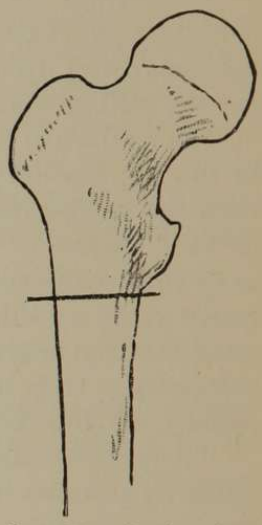

FIG. 854.—Gant's subtrochanteric line of section. (After Poore.)

employed, and, after the dressing, the limb should be put up in abduction and inward rotation in a plaster-of-Paris bandage from the mammary line to the sole of the foot. After healing of the wound, usually within two or three weeks, the dressing should be removed, and active and passive motion encouraged under the immediate supervision of the operator. A short leather spica may be employed as a convalescing support."

The success of this procedure will in a great measure depend upon the aseptic technique and absence of suppuration.

In *anchylosis* at the hip with malposition the thigh is generally flexed upon the abdomen and adducted with outward rotation. When destructive osteo-arthritis has occurred the trochanter will be seen nearer to the iliac crest than on the sound side, a condition which does not exist when the anchylosis has occurred from non-destructive arthritis.

On account of muscular rigidity the exact condition of anchylosis can not usually be determined without ether narcosis. A certain degree of mobility is present as a rule.

Treatment.—When the malposition is such that usefulness is impaired, or comfort interfered with, an effort to relieve the deformity by operation is justifiable, provided that all local inflammatory symptoms are absent and that the general condition of the patient is such that no

risk is incurred by the procedure. Under ordinary conditions the operation is not attended with danger.

In osteotomy at the hip for the relief of deformity three procedures may be entertained: Section of the neck of the femur, just above the great trochanter (Adams, Fig. 852); the intertrochanteric section of Sayre (Fig. 853); or the subtrochanteric operation of Gant (Fig. 854). The objections to Adams's line of section is that often, on account of disappearance of the head and neck of the bone, it is impossible; and, secondly and chiefly, if disease has existed at the joint, this line of section is so near the old seat of osteo-arthritis that the process of inflammation may be re-established. In anchylosis, without osteo-arthritis at the hip, it is to be preferred. In the vast majority of cases, Gant's section—just at the lower portion of the lesser trochanter—is preferable. The objects to be accomplished are, a section of the bone at this point at a right angle to the axis of the shaft, rotation of the femur into its normal position, and abduction.

Subtrochanteric Osteotomy at the Hip.—The patient is placed on the sound side, so that the femur to be divided is well exposed. The strict details of antisepsis should be carried out.

The upper surface of the great trochanter is felt, and the femur grasped between the thumb and finger. Upon the outer portion of the femur an incision is made, commencing about one inch below the most superior surface of the trochanter major, and extending downward about one inch. When the bone is exposed, the wound is held open by retractors, and Vance's narrow chisel introduced flatwise with the incision until the bone is reached, when it is turned so that the cutting edge is across the axis of the femur. In a child twelve years old the lower portion of the lesser trochanter (the line of section) is about one and a half inch below the tip of the great trochanter.

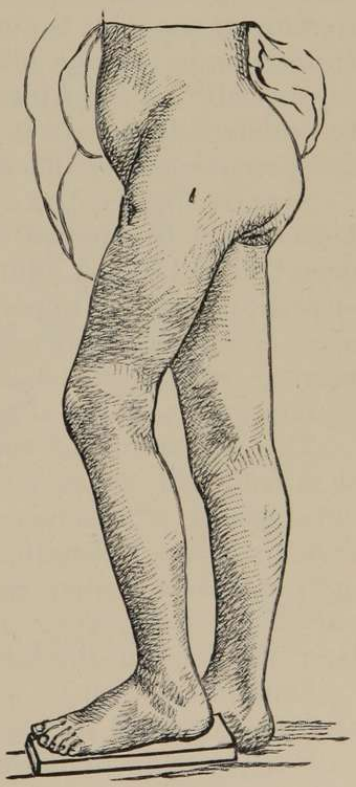

Fig. 855.—The proper position of the extremity after subtrochanteric osteotomy. (After Poore.)

While the limb is steadied by an assistant, a few blows with the mallet drives the chisel into the bone, which is cut from one half to three fourths through. Grasping the thigh near the knee with one hand, while the other steadies the part above the section, the remaining portion is readily fractured by carrying the thigh toward the median line. The wound is now thoroughly dried, closed with catgut sutures, and sealed with collodion. A sterile gauze dressing is applied. The thigh is rotated slightly inward, abducted to about five degrees from the axis of the spine, and flexed on the abdomen so that the axis of the femur joins that of the body at an angle of

fifteen degrees (Fig. 855). If in the position of deformity the thigh is abducted—a condition which rarely exists—the corrected position should be that of adduction about five degrees beyond the normal. The after-treatment is the same as for fracture at this point, namely, Buck's extension and Hamilton's long splint, or the plaster-of-Paris spica may be used.

In order to secure the necessary five degrees of abduction, the padding to the splint should be made several inches thicker opposite the acetabulum than at the knee, and the thigh and leg should be elevated upon pillows enough to secure the fifteen degrees of flexion required. When consolidation occurs with the extremity in this position, locomotion is good and more comfort experienced in the sitting posture than when the leg is perfectly straight. At the end of four or five weeks the patient may be allowed to go about on crutches, and in eight or ten weeks to walk without them.

The result to be achieved is osseous reunion at the point of fracture with the limb in the improved position. A false or new joint is not to be attempted. The hæmorrhage is usually slight, and a few catgut ligatures readily control all bleeding points. Forcible breaking up of adhesions or fracture at the joint is not permissible. Adams's section is made through an incision in the line advised for hip-joint exsection. Its center should correspond to a point just above the great trochanter. The chisel should be preferred to the saw in making the section, on account of the bone dust and detritus left by this latter instrument.

Sayre's line is halfway between Adams's and Gant's lines. The bone should be divided squarely across. The attempt to form an artificial ball-and-socket joint by making a concavity in the upper fragment, or rounding off the upper extremity of the lower fragment, is not advisable, because it prolongs the operation, and is apt to be followed by necrosis, with ultimate anchylosis. It is better to accomplish reunion in an improved position at once.

The deformities of the *shaft* of the femur are also congenital and acquired. An occasional congenital malformation is due to failure of development of this bone in its long axis. The femur may not be more than six inches in length, while the tibia and fibula are normal in development. As a consequence of rickets, the femur is occasionally curved outward, causing *genu varum*, or bowlegs, although, as will be seen later, the bones of the leg are chiefly involved in this deformity.

Shortening, with or without angular malposition, is sometimes seen after badly united fractures.

For the relief of these deformities osteotomy and osteoclasis may be done when the deformity is sufficient to justify the operation. In osteotomy the incision should be along the anterior and external aspect of the thigh farthest removed from the vessels. The only artery of importance here is the descending branch of the external circumflex. Osteoclasis is not permissible unless the fracture can be effected by manual force. In recent and badly united fractures, and in rachitic subjects, this may be done. The osteotome is preferable to the osteoclast. In over-

lapping fractures, with marked shortening (two to five inches), if the union is not angular, the deformity may be corrected and lateral spinal curvature obviated by a compensating high shoe. If for æsthetic reasons the patient insists upon it, a section may be taken from the sound femur and the ends brought together, as was done by Weir in one instance. The conditions which will justify this procedure are, however, rare.

Occasionally overlapping and badly united fractures of the thigh will be met with in which the callus, which persists, is so extensive that operation at the seat of fracture is impossible.

The deformities of the lower extremity of the femur are those of hypertrophy or elongation of one or the other condyle. The outer condyle is only exceptionally enlarged. The consideration of these pathological changes belongs properly to *genu valgum* and *varum*.

Genu Valgum.—When a normal subject stands erect, the inclination of the femur of each side is inward and toward its fellow, until the internal condyles are almost in contact. In other words, by actual measurement in a descent of eighteen inches from the head to the condyloid extremity, a separation of seven inches between the acetabula is reduced to three and a half inches from center to center at the knee. This obliquity is slightly increased in females, owing to the broader development of the pelvis.

If the articular facets of both tibiæ are brought firmly and evenly in contact with the condyles of the femur, it will be seen that the axis of the tibia is parallel with that of the spine.

Any outward deviation of this parallelism of the tibia with the axis of the body constitutes the deformity known as *genu valgum*, knock-knee, or in-knee (Fig. 856).

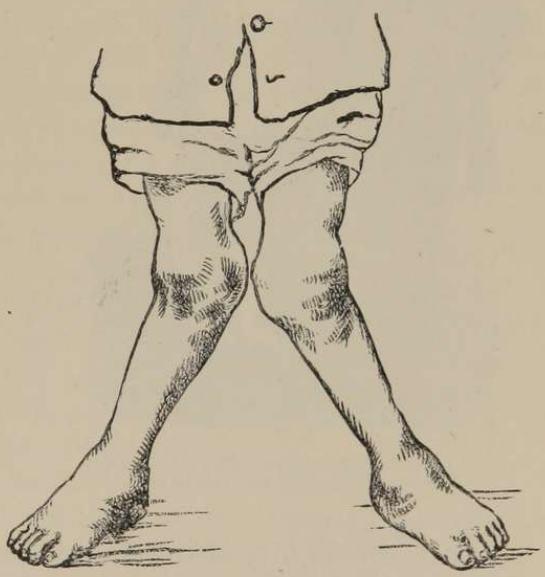

Fig. 856.—Genu valgum—Knock-knee or in-knee. (After Poore.)

Knock-knee may occur on one or both sides, in both sexes and at all ages. In exceptional instances genu valgum may exist on one side and varum on the other, as shown in Figs. 857 and 858. *Knock-knee* is usually *acquired;* occasionally *congenital*. It is most frequently seen in children and young adults suffering from an acquired or hereditary dyscrasia. As to the *causes*, we must look chiefly to changes in the bones at or near the knee joint. Any interference with the normal processes of nutrition and development in the bones will account for most cases of knock-knee, and the chief pathological condition is either that of rachitis, or one so closely allied to it that a distinction is difficult.

The most classical osseous lesion in genu valgum is the enlargement

of the internal condyle as compared to the external, and the resulting increase of the normal obliquity of the tibio-femoral articulation. This increased obliquity may be due to hypertrophy of the inner condyle; or to hypertrophy of the inner half of the upper tibial epiphysis; to atrophy of the outer condyle, or atrophy of the outer half of the upper tibial epiphysis; to a combination of two or more of these conditions; to a curve of the femur (convexity inward) from rickets, and to a like curve of the tibia and fibula.

There is no anatomical reason why the internal condyle should enjoy a better nutrition and greater development than the outer. There is, however, a very good mechanical explanation in this, that by reason of

FIG. 857.—Genu valgum and varum in the same patient, in Mount Sinai Hospital.

FIG. 858.—The same, after osteotomy of both femora. (The author's case.)

the marked obliquity of the femoral axis and the perpendicular direction of the tibial shaft when the subject is standing erect, the line of gravity brings the greater weight upon the outer facet of the tibia and the corresponding condyle of the femur. The distribution of this pressure equally over the entire articular surface belongs to the muscles controlling this joint; but owing to the excessive number and greater power in the adductor as compared to the abductor group, the internal obliquity is maintained and the pressure upon the outer articular surfaces increased. In the rachitic condition the bones are softened, and become distorted under pressure, and as a result of muscular action, while such deformities are resisted by the normal bones.

Knock-knee from incurvation of the shaft of the *femur* alone is exceedingly rare. When not due to abnormal changes in the condyles,

the cause of this deformity will usually be found in rachitic disease of the tibia and fibula, in which these bones are bent inward at the middle or lower third. The principal changes in the soft parts are elongation of the internal lateral ligaments, and a contractured condition of the biceps and popliteus muscles.

Symptoms.—The symptoms of knock-knee vary in different stages of the deformity. The approximation of the knees is a feature less noticeable than the divergence of the tibiæ. With the lower extremities fully extended, and the knees in contact, it will be noticed that the inner malleoli are separated from a few inches to a foot or more. When the lesion is due to changes in the inner condyle of the femur, it will be observed that, if the leg is flexed upon the thigh at an angle of 90°, the deformity is less apparent; and if complete flexion is made in mild cases of in-knee, it will disappear altogether; i. e., the tibia in extreme flexion will be parallel with the femur. The patella is displaced outward, and locomotion is more or less impaired. Pain is often present, from the unnatural strain upon the tissues, and fatigue with the slightest exertion is often noticed.

The *diagnosis* rests upon the recognition of the symptoms just detailed, and the *prognosis* is generally favorable when judicious and persistent *treatment* is instituted. Constitutional remedies and mechanical appliances are indicated early in the disease, and operative interference is justifiable when mechanical treatment can not effect a cure.

The first indication is met in out-of-door life, good food, diversion, tonics, cod-liver oil, and the hypophosphites of lime and soda.

The mechanical treatment should be insisted upon in all cases of children in which the deformity is not exaggerated, and should be persisted in for several years, if necessary. Any mechanism which is applicable in this deformity must afford a fixed point, opposite to and on the external aspect of the region of the knee joint, from which constant traction may be made. The apparatus of Prof. Sayre (Fig. 859) will be found of great use in meeting the chief indications. It consists of a pelvic belt of steel, padded so as not to excoriate, and a bar of steel hinged at the knee and passing down from the belt to the sole of the shoe, where it is fastened, as in the long hip splint already described.

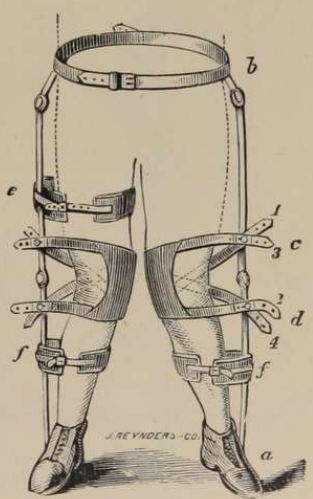

Fig. 859.—Sayre's apparatus for the correction of knock-knee. (After Sayre.)

Opposite each knee, and just above and below the joints—in order to distribute the pressure over a wider area, and thus prevent chafing or excoriations—are padded belts or bands which surround the limb; these are attached to the side-bars, and may be tightened at will in exercising the required traction to overcome the deformity. Elastic tension by means of rubber bands or webbing may also be utilized in this manner. The hinges at the knees allow the patient to bend these joints in walking,

and to assume the sitting posture. The instrument should be worn during the waking hours, and at night it will be advisable to make extension from both legs by Buck's method. The cost of this apparatus places it beyond the reach of many patients, and in this class of cases renders early operative interference more justifiable.

Osteotomy of the femur for the correction of chronic cases of genu valgum is an operation practically free from danger, and yields excellent results. The section should be made above the joint, and away from it a sufficient distance to avoid all danger of entering the articulation or injuring the epiphysis. Linear section should be preferred, since it is simpler than cuneiform osteotomy, and is equal to the correction of all cases excepting those in which there is extreme angularity at the seat of deformity. Such conditions rarely, if ever, occur in the femur. The older operations of Ogston, Reeves, Chiene, and Macewen, which involved the joint, are practically discarded. They are objectionable in this, that they invade the joint and endanger the functions of this important articulation. Transverse section above the epiphyseal line from the outside (MacCormac) or inner side (Macewen), should be preferred (Fig. 860).

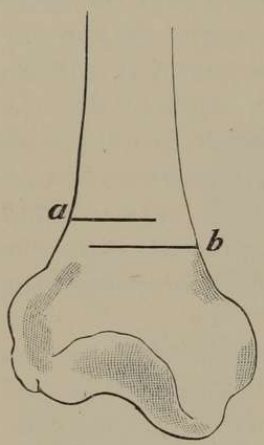

Fig. 860.—*a*, MacCormac's line. *b*, Macewen's line. (After Poore.)

Macewen's Operation.—In this procedure it is intended to divide the femur at a right angle to its axis through two thirds to three fourths of its thickness, at a point well above the level of the lower epiphysis. In a child ten years old the line of section should be one and three quarter inches above the most dependent portion of the articular surface of the internal condyle, and in an adult two and a half inches.

Fig. 861.—Ogston.

Fig. 862.—Reeves.

Fig. 863.—Chiene.

Fig. 864.—Macewen.

Strict aseptic precautions should be taken. If Esmarch's bandage is applied as high as the middle of the thigh, the wound will be kept dry and the operation greatly facilitated. Flex the leg on the thigh and ro-

tate the thigh outward so as to bring the inner aspect of the joint upward. Make an incision one inch long, following the direction of the internal condyloid ridge. The center of this incision should be opposite the point of section above given. The internal saphenous vein and the anastomotica magna artery should be avoided, and the tubercle for the insertion of the tendon of the abductor magnus felt. As soon as the bone is reached the chisel is carried down to it, parallel with the incision, and immediately turned with its cutting edge at a right angle to the axis of the femur. The inner and anterior shell of compact tissue should be first divided, and when the posterior portion is cut through the osteotome should be directed to the front so that when struck with the mallet it will be carried away from the vessels. As soon as the bone is cut through two thirds of its thickness, the remaining piece may be fractured by grasping the limb above and below the section, and using the other hand for a fulcrum and the leg as a lever, which is carried outward. As soon as the bone snaps, the leg is handed to an assistant, who is directed to steady it by making strong extension. The wound should now be thoroughly dried, a dressing of iodoform and sterile gauze applied, and the tourinquet removed. Firm compression with the roller is essential to prevent bleeding. The limb should be brought into the straight position by extension, and steadily held until a plaster-of-Paris bandage is put on and hardened. This dressing is allowed to remain for four or five weeks, as in simple fracture, when it is removed, and passive motion made at the joint. It is reapplied for a week longer, and then, as a rule, may be discontinued. MacCormac's procedure is practically the same as the above, with the exception that the section is made from the outer side of the femur. Of these two operations the incision from the outer side (MacCormac's) is preferable, for the reason that there are no vessels in the way. On the inner side the long saphenous vein and the anastomotica magna artery are endangered. Moreover, it does not matter from which side the bone proper is divided, as far as the correction of the deformity is concerned. When the tibia and fibula are involved in the deformity, section of these bones may be required at the same or a subsequent operation.

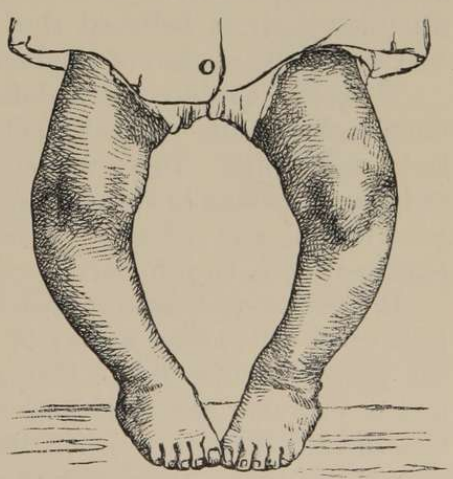

Fig. 865.—Genu varum, or bowlegs. (After Poore.)

Genu Varum.—In bowleg, or outward curvature of the lower extremity, one or both members may be involved. The bones of the leg are usually alone involved, although in some instances the femur may take part in the deformity (Fig. 865).

The principal cause of bowlegs is rickets, the softened bones yielding to the weight of the body or to muscular contractions. Genu varum is usually met with in childhood, but may occur in adults who are rachitic.

In *treatment*, the indications are the same as for knock-knee. The adjustment of any mechanical apparatus is, however, more difficult. Splints should be adjusted to prevent further deformity, or the patient should be prevented from bringing the weight of the body upon the diseased bones. In the meanwhile every effort should be made to correct the dyscrasia. As long as the bones remain in the softened condition of rickets, operative interference is not indicated. Osteotomy of the tibia and fibula at the point where the outward curve is most pronounced will, in the majority of instances, correct the deformity. In extreme cases it may be necessary to make sections at two or more points. If the femur is involved it should also be divided, although this complication will rarely be met with. The details of the operation and the after-treatment are practically the same as for genu valgum.

Osteoclasis should be substituted for osteotomy in those cases in which the fracture may be accomplished with little force and with the hands of the operator. It is objectionable when performed with the osteoclast, for the reason that the soft tissues are bruised to an extent which does not occur in osteotomy. Moreover, the line of fracture can not be directed with the same accuracy as in cutting with the chisel.

Anchylosis at the Knee, with Malposition.—For the correction of this deformity osteotomy is at times performed. When the degree of malposition is extreme, it may become necessary to divide the femur at a point from three to four inches above the most dependent portion of the articular surface of this bone. If after this section the limb can not be brought out straight, division of the tibia just below the tuberosity may be done. Exsection of the knee is, however, a preferable operation; and, since in modern practice the danger of this procedure is so greatly diminished, it is believed that the operation through the articulation will supersede section of the bone in continuity.

Talipes.—Clubfoot is a deformity in which there exists either an abnormal relation between the bones of the foot to each other, or to the tibia and fibula. There are six simple and several compound forms of talipes. The simple varieties are *talipes equinus*, *calcaneus*, *varus*, *valgus*, *cavus*, and *planus*. Among the compound forms are those of equino-valgus, equino-varus, calcaneo-valgus, calcaneo-varus, etc.

In *talipes equinus* the heel is drawn up, and the weight of the body falls upon the plantar aspect of the metatarsus, the toes and phalanges; the gastrocnemius and soleus are shortened, the tendo Achillis tense, and in extreme cases the heel can not be brought down to the ground. Callosities are formed upon the sole of the foot along the metatarso-phalangeal line. When paralysis of the anterior muscles of the leg has taken place, the toes are turned under, as in Fig. 869. In this condition there are atrophy and complete loss of power in the tibialis anticus, peroneus tertius, extensor longus digitorum, and extensor pollicis muscles.

Simple talipes equinus is not of very frequent occurrence, since it is almost always complicated with inward rotation of the tarsus, or talipes equino-varus.

Treatment.—When complete paralysis has not occurred, and if taken early, talipes equinus, whether congenital or acquired, may be cured, or marked deformity prevented, by the institution of proper treatment. Section of the tendo Achillis is rarely necessary when the case has not been neglected. The propriety of tenotomy can be determined by the degree of resistance met with in the effort to bring the sole of the foot to a right angle with the axis of the leg. If this can not be accomplished, or if, when the tarsus is firmly flexed on the leg, pressure upon the sural muscles produces a painful and marked spasm (Sayre), tenotomy is indicated, especially in those patients who can not afford the long-continued expense of mechanical treatment, and who of necessity can not remain long in the hands of an experienced surgeon. In simple equinus the indications are to overcome the muscular contraction by artificial appliances, and to restore the normal tonicity and power to the anterior tibial group of muscles.

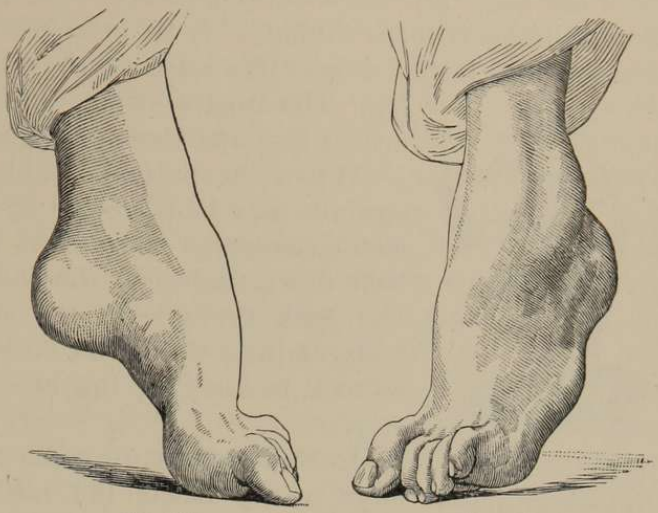

Fig. 866. Fig. 867.

Congenital talipes equinus. (After Churchill.)

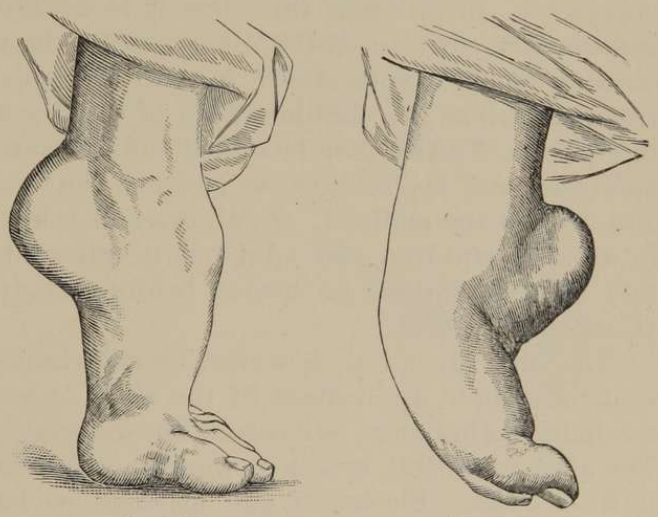

Fig. 868. Fig. 869.

Acquired talipes equinus. In Fig. 869 there has occurred complete paralysis of the extensor muscles. (After Churchill.)

When a child is born with talipes equinus (and all forms of congenital clubfoot should be treated from birth), deformity of the bones of the foot, and the too great stretching or elongation of the anterior muscles, may be prevented by the following simple means: Cut a piece of light board as wide as the sole and a little longer than the foot, and cover it with adhesive plaster in such a way that the sticking surface is next to the skin. This is laid along the sole of the foot, to which it is fastened by adhesive strips, and a light bandage, leaving the end of the board to project a little beyond the toes. From the end of the board traction

may be made by a strip of plaster carried upward and fastened along the front of the leg near the knee, sufficient tension being exercised to draw the foot into its natural position. Or, if deemed necessary, artificial muscles (rubber tubing) may be attached from the tip of the board to insertions fastened near the knee on the antero-lateral aspects of the leg. The apparatus must be carefully readjusted whenever it becomes loose or causes pain.

Fig. 870.—Bones of the foot of an adult with talipes equinus. (After Chance and Noble Smith.)

When the patient is able to walk, simple cases of equinus may be corrected by wearing a stiff, solid, and well-constructed laced shoe, which will hold the instep well down and keep the sole of the foot in close contact with the sole of the shoe. The weight of the body, falling upon the anterior portion of the foot, will aid in carrying the heel to the ground with each step.

In more obstinate cases the Sayre shoe (Fig. 871) more nearly meets the mechanical indications than any other apparatus. When there is no inversion of the foot (varus), the lateral rubber muscle *J G* is unnecessary. In ordering this shoe it is advisable to send to the instrument-maker the shoe at the time worn by the patient, and with this the distance from the sole of the heel to the upper articular margin of the tibia, as well as the circumference of the leg at this point. To this may be added the measurements around the foot, at the bases of the toes, and around the malleoli. In all cases of talipes in walking children and adults it is important that all excoriations be healed before any appliance is adjusted.

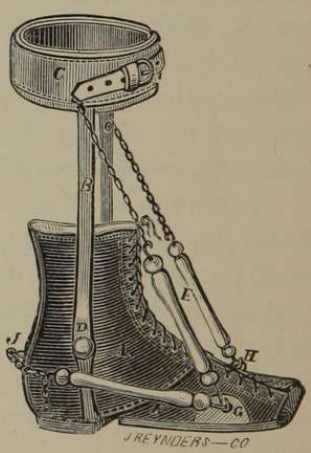

Fig. 871.—Sayre's clubfoot shoe. (After Sayre.)

The idea must not, however, be entertained that the simple application of the shoe, or any mechanical appliance, will correct the deformity. The after-treatment is a most important feature in these cases. Electricity and massage are important adjuvants. The weaker galvanic current should be preferred, the positive pole being placed along the track of the nerve which supplies the affected muscles, while the negative sponge is carried over the bellies of these muscles. The application should be made about twice each week, while massage should be employed twice daily.

In those cases where tenotomy is deemed advisable, the operation is performed as follows: The patient being placed under the influence of an anæsthetic, the tarsus is flexed forcibly upon the leg, in order to place the tendo Achillis and plantar fascia upon the stretch; a slight puncture of the skin is then made, a little anterior to the tendon, and on the inner side of the leg, slightly above the malleolus; this opening is now carried to the edge of the tendon by traction upon the integument, and the

tenotome introduced, with its flat surface toward the tendon. The tension upon the tissues is now relaxed, and the edge of the knife turned toward the parts to be divided; the tarsus is flexed strongly upon the leg, and the tendon again made tense, when the knife is pressed forward and outward through the tendon, which separates with a very audible snap. The thumb of the operator being placed over the tendon externally, acts as a guide and support, preventing the blade from passing through the integument and causing an open wound, an accident which should be carefully avoided. As soon as the division of the tissues is effected, the blade of the knife should be withdrawn, flatwise, and the thumb of the operator slipped over the slight puncture, which is at once covered with one or two strips of adhesive plaster; the plantar fascia can be divided in a similar manner, if desirable, the whole foot being then enveloped in cotton, and a snug roller bandage applied. The foot is now secured, by mechanical appliances, at a right angle to the leg, as heretofore described. Division of the extensor tendons of the toes is not often required. The best point of section is just over the metatarso-phalangeal articulation.

Talipes Calcaneus.—In this rare form of clubfoot the toes are drawn upward and the tarsus flexed upon the tibia; impairment of function exists in one or more of the sural muscles; the tibialis anticus, peroneus tertius, extensor longus digitorum, and pollicis are shortened. This deformity may be either congenital or acquired (Figs. 872, 873).

Fig. 872.—Congenital talipes calcaneus. (After Churchill.)

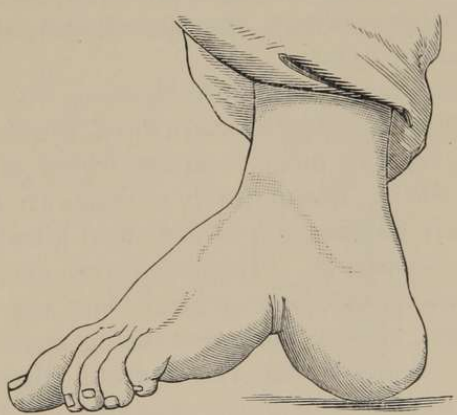

Fig. 873.—Acquired talipes calcaneus. (After Churchill.)

It is usually met with in children, or may occur at any period of life, from rupture of the tendo Achillis, or paralysis of the muscles of the calf of the leg, ununited fracture of the os calcis, etc. In this condition the mechanical and surgical appliances and treatment are exactly opposite to those of the preceding variety. An ununited section of the tendo Achillis should be corrected by cutting down upon this tendon at the seat of the division, freshening the divided ends, and sewing them together with silk sutures. Mild cases of calcaneus may be relieved by

the wearing of a well-fitting laced shoe, the weight of the body aiding in correcting the deformity. When the toes can not be brought down without the aid of additional pressure, the apparatus in construction similar to the one recommended for flat-foot can be applied. The object to be obtained is to elevate the heel and depress the toes by mechanical means. For this purpose, the shoe as devised by Dr. Sayre (Fig. 874) is admirably adapted. This is a strong laced shoe, with steel rods running up on either side of the leg to a collar below the knee, the rods being hinged at the ankle to allow of free motion at this joint; from the heel of the shoe a small steel spur is seen, to which is secured a strong piece of elastic, passing up to the collar around the leg. This rubber artificial muscle, taking the place of the gastrocnemius and soleus muscles, if made of sufficient tension, will elevate the heel and restore the foot to its normal position. There are, however, various instruments for the correction of this deformity, the surgeon modifying the shoe as may be required to suit each case. In addition to the mechanical appliances, the after-treatment, by electricity, massage, etc., should be carried out as in other forms of clubfoot where atrophy of the muscles and loss of power exist.

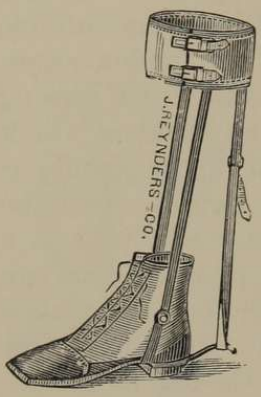

Fig. 874.—Sayre's shoe for talipes calcaneus. (After Sayre.)

Talipes Varus and Equino-Varus.—These deformities consist of an inward rotation of the foot, and are the most common forms of talipes (Figs. 875, 878). The majority of cases are those in which spastic contraction of the sural muscles also occurs (equino-varus). Talipes varus and equino-varus are more often congenital, but are frequently acquired, one or both feet being involved. The degree of deformity varies from slight inversion of the foot to the most exaggerated form in which the sole looks upward, while in the act of walking the dorsum rests upon the ground.

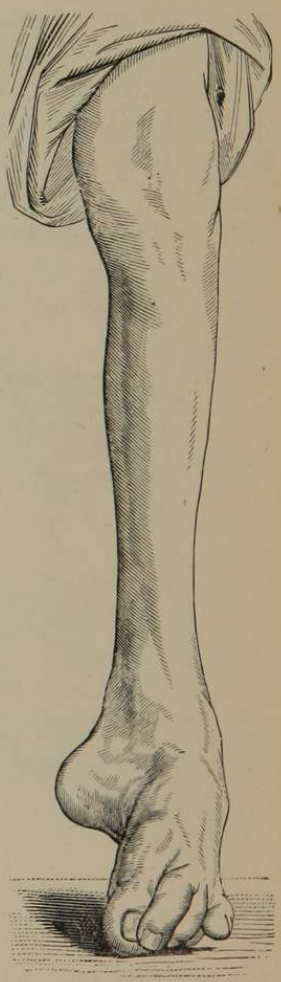

Fig. 875. — Talipes equino-varus in an adult. (After Churchill.)

The changes which the structures of the foot undergo are shortening of the plantar fascia and the internal lateral ligaments, together with a contractured condition of the tibialis anticus and posticus muscles and permanent deformity of the bones. The displacement of the bones of the tarsus will correspond to the extent of the deformity; the astragalus being tilted downward, the scaphoid is displaced inward and downward by the action of the tibialis posticus, the tubercle

on this bone becoming very prominent; there is in addition marked rotation at the astragalo-scaphoid and calcaneo-cuboid junctions, the displacement being especially marked in this last-named articulation.

When the deformity exists at birth, if not corrected early, the bones will become misshapen, and the deformity permanent.

The treatment of talipes equino-varus in the infant consists in the application of small rubber bands or pieces of tubing, which will make

Fig. 876. Fig. 877. Fig. 878.

Three grades of talipes varus. (After Churchill.)

constant and gradual traction in the line of the weakened or paralyzed muscles. This (*Barwell's*) method is as follows:

Cut a piece of strong adhesive plaster into the shape of a fan, which is split into four or five strips converging toward the apex of the fan (Fig. 879). "The apex of the triangle is passed through a wire loop with a ring in the top (Fig. 880), brought back upon itself, and secured by sewing. The plaster is firmly secured to the foot in such a manner that the wire eye shall be at a point where we wish to imitate the *insertion* of the muscle, and that it shall draw evenly on all parts of the foot when the traction is applied. Secure this by other adhesive straps and a smoothly adjusted roller.

Fig. 879.—(After Sayre.)

Fig. 880. (After Sayre.)

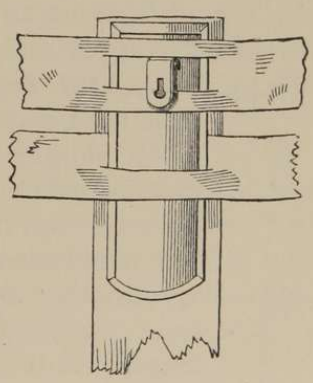

Fig. 881.—(After Sayre.)

"The artificial *origin* of the muscle is made as follows: Cut a strip of tin or zinc plate, in length about two thirds that of the tibia, and in width one quarter the circumference of the limb (Fig. 881). This is shaped to fit the limb as well as can be done conveniently. About an

inch from the upper end fasten an eye of wire. Care should be taken not to have this too large, as it would not confine the rubber to a fixed point. The tin is secured upon the limb in the following manner: From stout (moleskin) plaster cut two strips long enough to encircle the limb, and in the middle of each make two slits just large enough to admit the tin, which will prevent any lateral motion; then cut a strip of plaster, rather more than twice as long as the tin, and a little wider; apply this

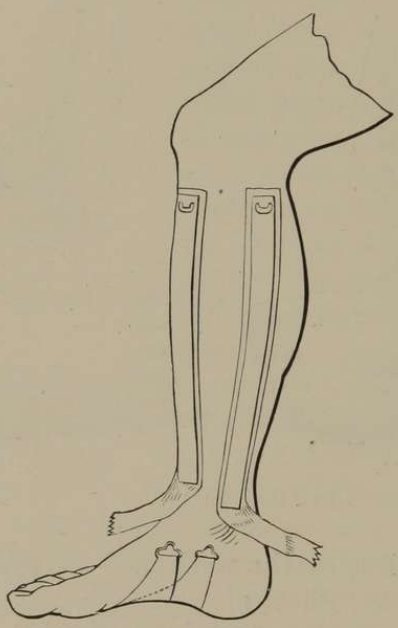

Fig. 882.—(From Barwell.)

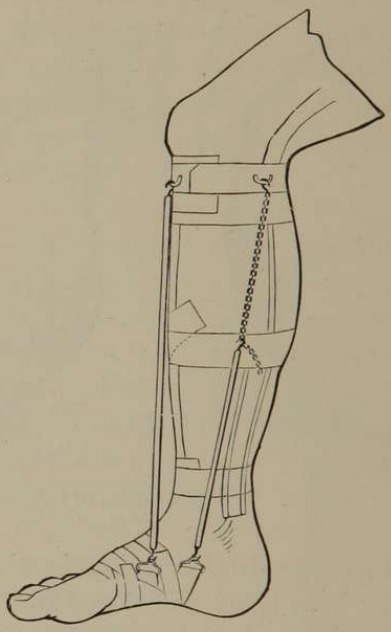

Fig. 883.—(From Barwell.)

smoothly to the side of the leg on which the traction is to be made, beginning as high up as the tuberosity of the tibia. Lay upon it the tin, placing the upper end level with that of the plaster (Fig. 882). Secure this by passing the two strips above mentioned around the limb (Fig. 883), then turn the vertical strip of plaster upward upon the tin. A slit should be made in the plaster where it passes over the eye, in order that the latter may protrude. The roller should then be continued smoothly up the limb to the top of the tin. The plaster is again reversed and brought down over the bandage, another slit being made for the eye, and the whole secured by a few turns of the roller. A small chain, a few inches in length, containing a dozen or twenty links for graduating the adjustment, is then secured to the eye in the tin.

Fig. 884.

Fig. 885.

"Into either end of a piece of ordinary rubber tubing, about one quarter of an inch in diameter and two to six inches in length, hooks of the pattern shown in Fig. 884 are fastened by a wire or other strong ligature (Fig. 885). One hook is fastened to the wire loop on the plaster on the foot, and the other to the chain above mentioned, the various links making the necessary changes in the adjustment.

"The dressing, when complete, is shown in Fig. 883." (Sayre.)

A roller should now be carefully and smoothly applied over the plaster and between the leg and the artificial muscles.

When the muscles can not be obtained, and in mild cases, in which the foot may be brought readily into position, a correction may be effected by means of one or more strips of adhesive plaster as follows: One end of the strip is laid upon the dorsum of the foot, near the bases of the third and fourth toes, whence it is carried in a slightly spiral direction to the inner border of the sole, and across the sole to the outer margin of the foot. As the foot is now brought into a normal position by the hand of the operator, the strip of plaster is laid along the outer and anterior aspect of the leg and thigh, and firmly secured by encircling strips of the same material. A bandage over all will hold the dressing in position.

When the patient is able to walk, the clubfoot shoe (Fig. 871) will give the greatest satisfaction. The rubber muscles should be applied and regulated in such a way that they will imitate as nearly as possible the normal action of the muscles they are intended to assist. A less expensive instrument, one which yields good results in the milder forms of talipes equino-varus, and which may be readily made by any ordinary worker in iron, is shown in Fig. 886. It consists of a sole-piece of sheet iron, which is riveted to a heel-piece of the same material, and is roomy enough to hold the heel of the patient without chafing. It should be nicely padded, to prevent the danger of excoriations. To this heel-piece is attached, by a hinge joint with limited forward and backward motion, an iron bar which extends to the padded iron collar around the leg, near the knee. The foot of the patient is secured to the sole-piece by adhesive plaster, with the aid of the instep strap shown in Fig. 887, and a flannel roller carried over all. As the perpendicular bar is now carried parallel with the leg, and held in this position by buckling the collar around the leg at the knee, the foot is turned outward and held in its normal position. An ordinary lacing shoe should be worn over the brace.

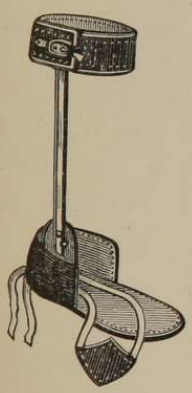

Fig. 886.—Iron shoe for talipes varus and equino-varus.

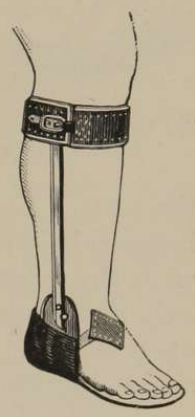

Fig. 887.—Iron shoe for talipes varus and equino-varus in position. The adhesive strips and bandage have been omitted in the cut.

An apparatus, the mechanism of which is somewhat similar to this, is highly recommended by Mr. Reeves, and is shown in Fig. 888.

The modification of Scarpa's shoe (Fig. 889) possesses some advantages over the iron shoe above described, and should be preferred to it when it can be obtained.

Tenotomy and *fasciotomy* will be found necessary in a large proportion of cases of talipes equino-varus, and, when not essential to ultimate success, it will greatly expedite the permanent restoration of the member to its normal position. The application of Esmarch's bandage from

the toes to above the knee, though not essential, renders the operative procedure more rapid and easy of execution. The tendo Achillis is divided as heretofore directed. In addition, the tibialis anticus and the tibialis posticus will, as a rule, require to be divided. The tendon of the tibialis anticus should be cut subcutaneously about one inch above its insertion into the internal cuneiform bone by introducing the tenotome beneath it from the middle line of the foot. It can be made prominent by forcible eversion of the foot. Division of the tendon of the tibialis posticus is best effected by an incision parallel with the inner border of the tibia just above the internal malleolus, where it lies in close relation to this surface of the bone. As soon as it is exposed, an aneurism needle should be passed beneath it, when it can be drawn out through the wound and divided with the scissors. Subcutaneous section of this tendon is a very difficult and uncertain procedure, while no mistake is possible through an open wound. If careful antisepsis is practiced, and if the wound is at once closed with catgut sutures, no suppuration can occur. The plantar fascia should be divided by introducing the tenotome flatwise under the fascia from the inner border of the foot, turning the edge outward, and cutting the fascia as it is made tense. Several lines of section through this fascia may be made when necessary. Each puncture should be closed with aseptic collodion.

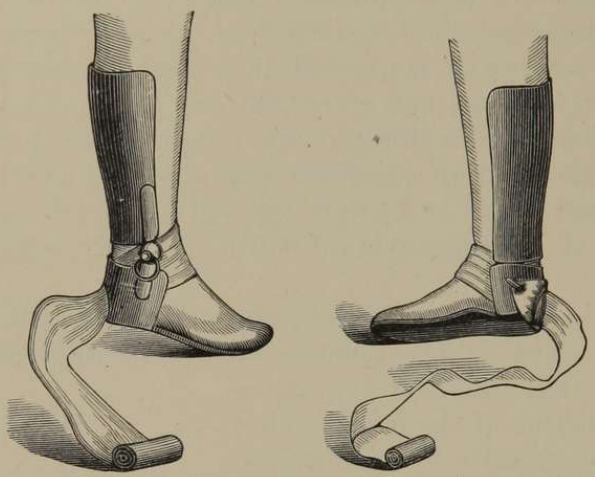

Outer view. Inner view.

Fig. 888.—Reeves's universal shoe, as it is being applied in the treatment of talipes equino-varus. (After Reeves.)

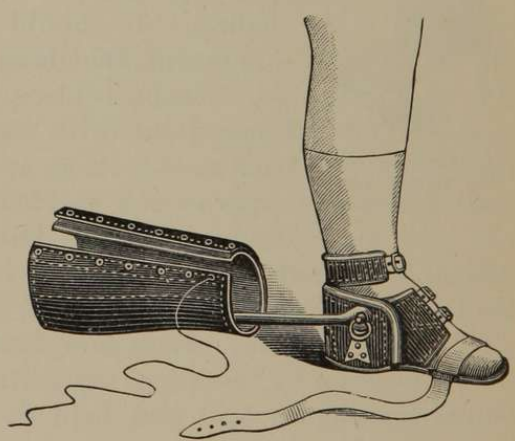

Fig. 889.—Modified Scarpa's shoe for talipes varus and equino-varus. (After Reeves.)

Tarsotomy. — In exaggerated and chronic cases of congenital talipes equino-varus a wedge-shaped exsection of a portion of the tarsus will at times permit a restoration of the foot to its normal position, and serve to restore in great part the usefulness of the member. In two recent cases in which I performed this operation the most gratifying results were obtained. In each case before operation the patient walked with the dorsum of the foot on the floor, and, in one instance, the toes pointed directly backward.

After Esmarch's bandage has been applied, a free incision is made along the fibular side of the foot, extending from below the external malleolus to the tarso-metatarsal junction. All the tissues should be lifted from the bones by the periosteal elevator, and the wedge-shaped section of the tarsus removed by the gouge or chisel. The anterior portion of the astragalus will require to be removed, and as much of the tarsus should be exsected as is needed to permit the restoration of the foot to the natural position; for it is not only necessary to evert the foot, but to make at the same time a marked rotation of that part of the member anterior to the line of section. The tendo Achillis should now be divided, and, as soon as the proper position is obtained, the incision closed and covered with iodoformized gauze, and a light dressing and compression bandage applied tight enough to arrest all oozing. A plaster-of-Paris dressing is now put on, and the foot held in position until this hardens. This last procedure can be facilitated by adjusting two strips of adhesive plaster, one of which will serve to hold the foot at a right angle to the axis of the leg, and the other to keep it rotated outward while the plaster is being applied and is hardening. The dressing may be removed not earlier than the fifteenth day, and should not be disturbed for a month unless from soiling or smelling it is necessitated.

In a certain proportion of cases which, from neglect to institute treatment immediately after birth, will not yield to the measures heretofore advised, great benefit may be derived from forcible manual twisting of the foot into a proper position. The patient is usually anæsthetized and the foot is so held that no strain will be brought upon the ankle joint while the process of twisting the bones of the tarsus is being carried out. While the patient is still under the anæsthetic a plaster-of-Paris dressing should be applied and the foot held in the improved position until the plaster is firmly set. This may be repeated from time to time, and should be considered one of the best methods in the treatment of all forms of talipes in which there is marked distortion of the foot and tarsus. If these means were carried out in all cases, the need for tarsotomy would be exceptional.

Talipes Valgus.—In this deformity the normal arch of the foot is lost, and the foot is everted (Figs. 890, 891). The contracted muscles are the peroneus longus and brevis, while the paralysis, as a rule, affects the tibialis posticus, anticus, and flexor muscles. When the tarsal arch gives way, the plantar fascia, calcaneo-cuboid ligaments, and short flexors become stretched, and the tibialis anticus is elongated. The yielding of these muscles may be due to paralysis, or to strain from the habit of carrying heavy weights.

Treatment.—In talipes valgus in an infant the eversion may be corrected by means of the adhesive strips applied as in the treatment of varus. The direction of traction is of course opposite. The artificial muscles, after the method of Barwell, are also as applicable here as in varus. The iron shoe, made with the bar to come upon the inner side of the leg, is as serviceable in mild cases of valgus as in varus or equino-varus. This apparatus is always worn inside of an ordinary

shoe. Nyrop's boot (Fig. 894) is highly recommended by Mr. Reeves. It consists of a stiff-soled lacing shoe, with a leg collar and iron or steel bar attached to the outer side of the shoe, with a lateral hinge opposite

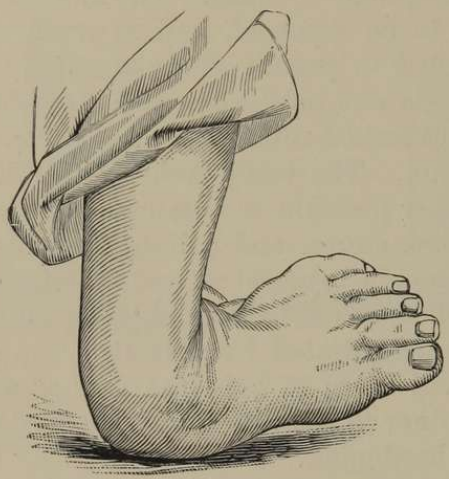

Fig. 890.—Congenital talipes valgus. (After Churchill.)

Fig. 891.—Acquired talipes valgus. (After Churchill.)

the outer malleolus. To the inner side of the sole, near the heel, is attached a strong piece of elastic webbing, by which inversion of the foot is effected by buckling the strap to the collar near the knee.

When tenotomy of the peronei muscles is indicated, they should be divided subcutaneously from three quarters to one and a half inch (owing to the age of the patient) above the external malleolus. Cuneiform tarsotomy may be applied to the correction of this deformity in exaggerated cases in adults. When the bones are thoroughly ossified it will be impossible to change the shape of these organs and restore the normal shape of the part by any mechanical apparatus, no matter how persistent in its use. The incision is made along the inner side of the foot, and the apex of the conical section must be at the outer border of the tarsus. The details of the operation and the after-treatment are practically the same as given for equino-varus.

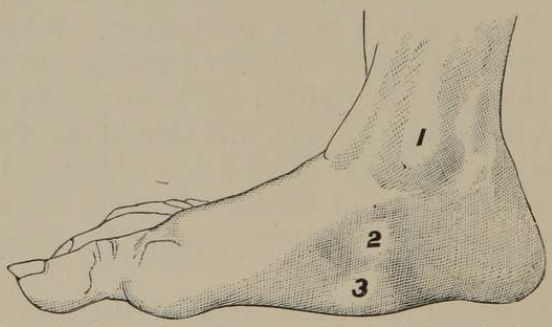

Fig. 892.—Inner view of a severe valgus of the right foot. (After Reeves.) 1, Inner malleolus. 2, Inner surface of head of astragalus. 3, Tubercle of scaphoid.

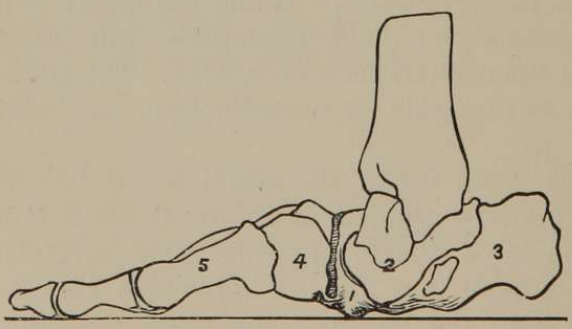

Fig. 893.—Inner view of the bones of a severe valgus. (After Reeves.) 1, Tubercle of scaphoid. 2, Astragalus. 3, Os calcis. 4, Internal cuneiform bone. 5, First metatarsal.

A very satisfactory and suc-

cessful method of treating flat-foot is that of Dr. Royal Whitman's, and is as follows: *

"The foot is first immersed in hot water, afterward vigorously massaged, especially about the dorsum, and is then slowly forced into a position of adduction. . . . This inward twisting is at first resisted by a mixed voluntary and involuntary muscular spasm, which gradually gives way under steady pressure. When the limit of adduction has been reached the foot is firmly held until all pain has subsided, when the patient is instructed to make voluntary movements of flexion and extension. The foot is then released and twenty minutes of voluntary exercises follow, and at intervals during the day the patient, by active muscular efforts and passive motion, constantly works to one end—namely, to regain the lost power of adduction—while once daily the twisting is performed by the surgeon.

Fig. 894.—Nyrop's shoe for talipes valgus. (After Reeves.)

"During the ten days, more or less, while this active massage is being performed, the patient is allowed to walk a little, wearing whatever support has been selected. The most satisfactory in practice and the most scientific in theory of any support with which I am acquainted is the brace advocated by Dr. Whitman. In each case it is made on an iron mold, with the cast of the foot in the corrected position as a model. The cast is taken a few days after the twisting by removing the plaster splint for the purpose. Another plaster splint is usually applied until the brace is ready. This steel brace extends from just behind the ball of the great toe to a point in front of the inner tuberosity of the os calcis; thus the foot rests on its normal supports, the inner flange reaches to a point in front of and a little below the internal malleolus, while the small outer one fits in behind the base of the fifth metatarsal. The weight on the outer border forces the inner part of the brace snugly up against the weak arch. The time required from the date of the anæsthesia until a patient can walk about with some comfort on these well-fitting supports is about three weeks. In a foot without stiffness, of course, they can be applied without the preliminary twisting and massage.

"These braces should be worn some six or more months ,depending upon the severity of the case, during which time the patient should himself continue the twisting and massage. They can then gradually be laid aside. The ultimate result is a flexible foot in a correct position without pain, and can justly be considered a radical cure. Although the proper application of this brace requires some skill in the use of plaster of Paris and a wise attention to the details of massage, the results warrant its use in an important case."

Talipes Cavus.—Hollow-foot is almost always an acquired deformity, although it may be congenital. It occurs with talipes calcaneus, equinus,

* Dr. Walter C. Wood, "Annals of Surgery," vol. xvi, p. 407.

and, in a mild degree, may complicate varus and equino-varus. In this deformity the antero-posterior arch of the foot is exaggerated, the plantar fascia and the muscles of the plantar region which have their origin behind the medio-tarsal joint, and are inserted anterior to this articulation, are shortened. The plantar fascia and the calcaneo-cuboid ligaments are also shortened. The sole of the foot no longer rests upon the floor, as in the normal condition (Fig. 895), but touches only at the heel and along the metatarso-phalangeal line.

Any inflammatory process of the plantar region may induce contraction of the fascia or ligaments; or spastic contraction of the muscles of this region from local or remote causes may produce this deformity. Commencing before the bones are softened, the distortion of the foot is apt to become permanent unless exsection or crushing is performed. Of these two procedures, tarsoclasis is the most readily accomplished; but, when the tarsoclast can not be had, section through the tarsus, with a thorough division of the plantar fascia, will be justifiable. Fortunately, few instances will occur where such harsh procedures will be called for.



Fig. 895.—Showing the surface of the sole which rests upon the floor in a normal foot. (After Sayre.)

In recent cases the deformity may be relieved by wearing a plain shoe with a low, broad heel and straight, thick sole. The plantar fascia should be divided in all cases which do not readily yield to mechanical treatment.

Talipes Planus.—Flat-foot has been partially considered with talipes valgus, with which condition it is almost always associated. The antero-posterior arch of the foot is more or less obliterated, and in severe cases the anterior portion of the sole spreads out or widens in its transverse diameter (Fig. 896).

Fig. 896.—Cast of the right foot in a case of talipes planus, at the Polyclinic.

The plantar fascia and calcaneo-cuboid ligaments are stretched, the internal lateral ligaments of the ankle joint are generally involved, while the tibialis anticus and the muscles of the plantar aspect of the foot are elongated. The principal cause of this deformity is the habitual carrying of heavy burdens, or pressure of the superincumbent weight of the body upon the arch of the foot, together with lack of tonicity in the muscles, and of strength in the ligaments and fascia.

Treatment.—It is exceedingly difficult and in the majority of cases impossible to correct this deformity. The best method is to support the arch of the foot by a comfortable adjustment of pressure by inserting a piece of felt in the sole of the shoe, just beneath the arch.

The *deformities of the toes* are congenital and acquired. The congenital deviations from the normal are the presence of one or more supernumerary toes (*polydactylus*), or the absence of one or more of these members (*syndactylus*).

In *polydactylus* the most frequent supernumerary toe is one connected with the great toe, attached usually on its inner or tibial aspect, near the junction of the metatarsal bone and phalanx. In a rare case of this deformity, reported by Prof. Sayre, there were eight toes on the right and ten on the left foot.

Treatment.—All minor deformities the removal of which does not endanger the life of the individual, or diminish the usefulness of the member affected, demand amputation within the first year or two of life, before the patient is old enough to become conscious of possessing a deformity.

Syndactylus is a term applied not only to the partial or entire absence of one or more fingers, but also to the condition known as congenital *web-toe.*

Web-toes may be treated in the same way as web-fingers. If neglected until the child is old enough to become accustomed to the deformity, operation is of doubtful propriety.

When one or more toes are missing, even when the deformity is offensive to the sight, the question of operative interference (except for relief from pain) should depend upon the degree of usefulness enjoyed by the deformed member. An important principle in the surgery of the foot is to save every particle of surface for the support of the body. This conclusion gains additional force in the ability to conceal the deformity by a properly constructed shoe.

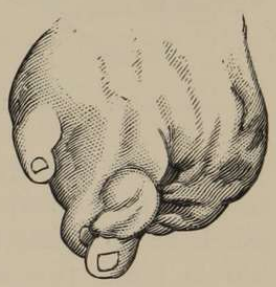

Fig. 897. — Syndactylus in the right foot of a boy. (After Reeves.)

The acquired deformities of the toes result in almost all cases from improperly adjusted shoes. The displacement may be in all directions, although those of the great and little toes are usually toward the median line of the foot. The middle toes may be flexed in one joint, extended in another, or crossed over each other.

Hallux valgus, or displacement of the great toe toward the fibular or outer side of the foot, is a common deformity (Fig. 899). In exaggerated instances mechanical or surgical interference is demanded. Hallux valgus is caused chiefly by shoes which are pointed at the tip and are too short for the foot. It may also occur with clubfoot, and generally with talipes varus and planus. The action of the muscles inserted into the base of the great toe must not be altogether overlooked in the ætiology of this deformity. Of the five muscles which arise from the tarsus and metatarsus and are inserted into this toe, all but one tend to carry it toward the fibular side of the foot.

In being displaced, the great toe is usually carried above the second or third toe, occasionally beneath it. The phalanx is more or less completely dislocated from the original articular surface of the metatarsal bone, being twisted around to its outer lateral aspect. The cartilage of the old portion disappears, and a new joint surface is developed on the external aspect of the metatarsal bone. From pressure, a callosity of

varying thickness develops over the tip of the metacarpus, adding greatly to the appearance of deformity.

Treatment.—Mild cases of hallux valgus may be cured by elastic tension steadily applied, as follows: A soft kid or chamois-skin cover is made for the affected toe, and to the end of this a piece of thin elastic webbing is attached. To the webbing a strip of adhesive plaster is stitched, and this is carried around the heel and is made to adhere along the outer side of the foot in such a way that the webbing is made to draw the toe outward (Fig. 898).

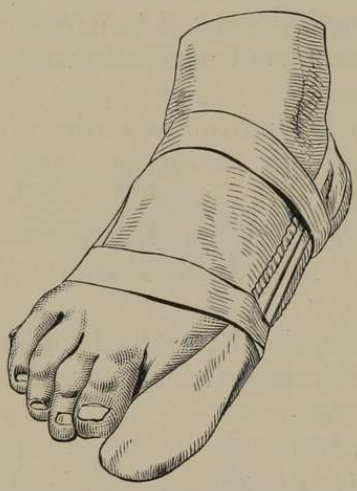

Fig. 898.—Sayre's method of treating hallux valgus. (After Sayre.)

In severe cases, operative interference can alone restore the toe to its normal position. The operation consists in an incision made along the inner side of the foot, the center of which is over the angular projection at the end of the metatarsal bone. The callosity should be removed, the joint opened, a wedge-shaped segment removed from the end of the metatarsal bone and the phalanx. Enough should be removed with the exsector or metacarpal saw to permit the bones to be brought into proper position, where they should be held by a silver-wire suture passed well into the bone a half-inch from the cut surface; or the bones may be held in apposition by transfixion with small steel drills. Fig. 899 is from a cast taken from a patient at Mount Sinai Hospital upon whom I did this operation in both feet. The degree of correction is shown in Fig. 900.

This operation is preferable to that of osteotomy of the first metatarsal bone just behind the articulation, for the reason that the callosity and projection opposite the joint can only be removed by excision.

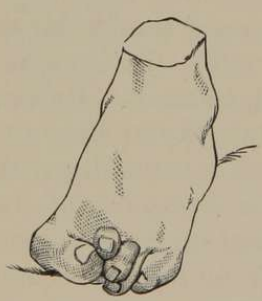

Fig. 899.—Hallux valgus. (From a patient at Mount Sinai Hospital.)

Hallux varus, or pigeon-toe, is a much rarer deformity, and occurs usually as a result of cicatricial contractions or from spastic action of the abductor-pollicis muscle. The treatment consists in adjusting a well-made shoe that will push the toe into its proper position. Division of any cicatricial tissue or the tendon of the abductor muscle may be necessary.

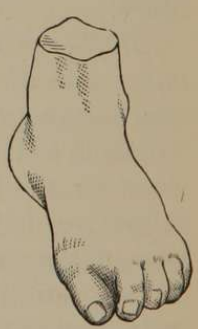

Fig. 900.—The same, after operation.

Displacement of the little toe is usually inward and beneath the fourth. The same treatment may be applied in this deformity as given for hallux valgus.

Flexion of the toes may be complete when there is paralysis of the extensor muscles. The most usual form is that in which the first phalanx is tilted upward, that is, seemingly extended, while the distal phalanx

is drawn downward, so that the nail is to the front, and the tip of the toes rests upon the ground. This condition is also known as *hammer-toes.*

The cause is chiefly one of improper shoeing, by which the toes are not allowed to be fully extended, and, being held in this cramped position by the shoe, the muscles and fasciæ become permanently shortened. The plantar fascia is usually involved in chronic cases. The extensor muscles become shortened as well as the flexors, which are, however, the principal agents in producing the deformity.

Extension of the toes beyond the normal line is a rare condition. It could only be caused by paralysis of the flexors.

Treatment.—In mild cases of incipient hammer-toes a cure may be effected by wearing a shoe long enough to allow these members to be extended. In more chronic and obstinate cases a metal sole should be adjusted so that an ordinary shoe can be worn over it. Just beneath the middle of the toes is a series of perforations in the sole, through which loops are passed. The toes are straightened by traction on the loops, which are tied below (Fig. 901). In some instances tenotomy of the long flexor and extensor muscles and of the plantar fascia is essential. The tendons of the extensor digitorum should be subcutaneously divided just over the bases of the toes; the flexor tendons near the middle of the plantar surface of these members.

Fig. 901.—Apparatus for hammer-toes. (After Reeves.)

Bunions are callosities resulting from intermittent pressure upon certain portions of the foot.

Corns are both *hard* and *soft.* A hard corn differs from a bunion only in size. Soft corns are small ulcers situated between the toes or in the fissures on the under surface. They are caused by friction of opposing surfaces and moisture.

Bunions and hard corns are to be treated by relieving the unnatural pressure which caused them. Comfortably fitting, yet not necessarily loose shoes, of soft leather, should be worn. Pieces of Canton flannel, cut into rings and laid upon each other so that the pressure will be distributed to the surfaces near the corn, will be advisable, in simple cases, even when loose shoes are adopted. A small tuft of cotton dipped in vaseline will aid in softening the hard covering. Soft corns may be readily cured by inserting pellets of absorbent cotton moistened with borax dissolved in glycerin, and applied so as to protect the raw surfaces and prevent friction.

Ingrowing nail is one of the commonest affections of the feet, and is almost always met with in the great toe. The palliative treatment is to cut away portions of the nail near the inflamed surface and protect this by a small pellet of lint moistened in the borax and glycerin mixture. The employment of cocaine, however, enables the surgeon to remove the offending nail without pain, and in this way a permanent and radical cure is effected. I have performed this operation repeatedly after the

following method: The foot and toes should be cleansed and thoroughly disinfected. An elastic ligature should be thrown around the toe, as close to the metatarsal junction as possible. The anæsthesia is effected by introducing the hypodermic needle of the cocaine syringe beneath the skin on the dorsum of the toe, half an inch behind the nearest surface of the nail—i. e., just about the posterior border of the matrix. Three or four drops of a four-per-cent solution are forced out here and the needle pushed under the skin, to right and left, until about fifteen minims have been injected across the toe and on either side of the nail toward the tip. The line of this injection is in the shape of a horseshoe. The needle should now be removed, and reinserted through the anæsthetized skin, and carried thence subcutaneously, until the anæsthesia is complete at all points around the nail. In from three to five minutes insensibility is perfect. An incision is first made from the middle of the posterior margin of the nail directly backward for half an inch. A second incision across the top of the toe, extending as low down as the most inferior portion of the nail, on either side, uniting with the central end of the perpendicular cut, gives the entire wound a T-shape. The two quadrilateral flaps of skin are now dissected up, turned one to the right and one to the left side, and held away by the weight of an artery forceps or by retractors. The nail should next be split from before backward in the middle line, the incision extending through the matrix as far back as the transverse incision through the skin. Both halves and the matrix should be thoroughly extirpated, all granulation tissue scraped out, and the foot dipped into a basin of warm sublimate solution, 1-to-2,000. At this juncture the elastic tourniquet should be removed, and the wound allowed to bleed for a minute. By this means the excess of cocaine solution is washed out of the tissues. The ligature should then be reapplied. The flaps are now brought into position, the space formerly occupied by the horny part of the nail packed with sterile gauze, and the entire toe enveloped in the same material. A narrow bandage should be applied firmly enough to hold the gauze in place, and to exercise sufficient compression to prevent bleeding. Over this a generous piece of protective should be thrown and a second bandage applied. When, in applying this bandage, the elastic ligature is reached, it should be taken off and the roller carried on to the foot. A single dressing usually suffices, and it need not be removed for ten days or two weeks. When the nail has cut into the soft parts only on one side, a less radical procedure is advisable. The cocaine is injected along the line of the ingrown nail, and a long wedge-shaped strip of skin and subcutaneous tissue removed with the scalpel. As the wound heals by granulation, the soft parts are retracted below the level of the nail. When it is not absolutely necessary to remove the entire nail, the soft tissues on the diseased margin may be excised, or a portion of the nail on that surface excised, including as much of the matrix as belongs to the section removed.

Deformities of the Upper Extremity—Clavicle.—Congenital absence of portions of one or both of these bones may exist. No case of complete absence of the collar bone is as yet on record. The partial deficiency

may occur on one or both sides, and is usually at the inner extremity. The indications in *treatment* are to use a figure-of-8 brace around the shoulders to prevent them from being approximated in part by the actions of the pectoral muscles.

Paralysis of the *deltoid* and *serratus magnus* muscles imparts to the shoulder a deformed appearance. In deltoid paresis the shoulder is flattened, and the acromion process more prominent and easily recognized. The arm is incapable of being lifted to a right angle with the spine. It may be due to injury of the circumflex nerve, or to a central nervous lesion. When the serratus magnus is paralyzed, the vertebral border of the scapula is tilted outward in a position of unusual prominence. Neither of these injuries is amenable to surgical treatment.

Anchylosis of the *shoulder* is more amenable to the operation of exsection than to forcible breaking up of the adhesions. This last procedure may be employed in cases of partial anchylosis in which no inflammatory process is going on. In *anchylosis* of the *elbow-joint* the same treatment is advisable.



Fig. 902.—Congenital fusion of the radius and ulner. (From a case at the Polyclinic.)

Deformities of the forearm are comparatively rare. Of the congenital variety, occasionally there exists a fusion of the two bones. The length of the forearm is normal, as is the motion at the elbow-joint, but supination and pronation are impossible. In the only case I have ever seen, from which Fig. 902 is taken, the hands were in the prone position. Operative interference was not indicated in this instance.

Distortions due to rickets are at times met with, and may result from the action of the muscles upon the softened bones, or to pressure from the habitual carrying of burdens in the hands. In destruction of one of the bones of the forearm by ostitis, or after its removal, deformity usually results, the deviation of the hand being toward the side of the missing bone (Fig. 903).

Treatment.—In deformity after rickets, correction by osteotomy is justifiable after the disease is arrested. In the distortions due to loss of substance there is little hope of relief. If the loss on one side is limited, exsection of a portion of the sound bone and reunion of the divided surfaces by wire sutures might be entertained.

Club-Hand.—Distortions of the hand, not unlike those already detailed as occurring in the foot, yet far less common, may be met with. The deformity may be at the wrist-joint, in the intercarpal or carpo-metacarpal articulations, and may be due to failure of development in the bones of the forearm or hand, to muscular paralysis, to fracture, dislocations, or cicatricial contractions.

Fig. 903.—Deformity resulting from subperiosteal exsection of the entire radius for ostitis. (From a case operated on at the Polyclinic.)

In the congenital deficiencies, the radius is more often wanting, or only partially developed, allowing the hand to be carried toward the radial side. The carpus is occasionally deficient. Not infrequently the congenital cases are symmetrical, and the lower extremities are also involved.

The muscles are deficient in some of these cases of osseous malformation. The usual condition in paralysis is that of flexion of the carpus and metacarpus upon the forearm.

This variety is termed *palmar;* the opposite, *dorsal* club-hand. When the displacement is lateral it is called *radial* or *ulnar*, as the hand is carried outward or inward. As in club-foot, there are compound forms of club-hand.

As to frequency in the congenital types, the radius being chiefly at fault, the *radial* distortion is most frequent. When from any cause the equilibrium between the muscles is impaired, the hand is usually flexed upon the forearm, and the condition is known as palmar club-hand. With this there may be radio-palmar or ulno-palmar deformity.

Fracture of the radius (Colles's), or epiphyseal separation, may induce a mild form of radial club-hand. Unreduced dislocations will, of course, cause deformity. Deformities due to cicatricial contraction, as after burns, extensive phlegmons, etc., are occasionally met with.

The treatment of all these different varieties of club-hand will depend

upon the particular cause. In the worst form of congenital deformity, amputation at or shortly after birth should be performed. Other and milder cases may be improved by mechanical apparatus constructed to meet the indications.

In muscular paralysis the same general rules of practice as laid down in club-foot due to this cause should be followed. *Tenotomy* may be necessary. The extensors may be subcutaneously divided about the middle of the metacarpal bones. The flexors slightly above the wrist-joint. The lateral deformities also will justify in some cases division of the contracting muscles. The rule to be followed is to do subcutaneous tenotomy when the tendon to be divided is far enough away from any important nerve or vessel to allow a perfectly safe and sure division of the tendon; if not, the tendons should be exposed by incision under strict antisepsis, and each one picked up on an aneurism-needle and divided in plain view.

The propriety of breaking up adhesion in anchylosis with malposition, or of resection, should be determined by the condition of the parts and of the patient, and the necessities of the case.

The Fingers and Hand.—Among the *congenital* deformities of the fingers are polydactylus, syndactylus, and web-finger, or fusion of two or more digits. The *acquired* deformities are due to contraction of the palmar fascia, of the muscles and tendons, to paralysis of certain muscles, and to osseous and articular lesions, both traumatic and idiopathic.

Supernumerary Finger (*Polydactylus*).—The usual location of one extra finger is on the radial side of the thumb or ulnar aspect of the little finger, near the metacarpo-phalangeal junction (Fig. 904). It may or may not possess phalanges or cartilages. If the phalanges exist, a synovial cavity will be found at the junction with the metacarpal bone, or with the phalanx of the normal member.

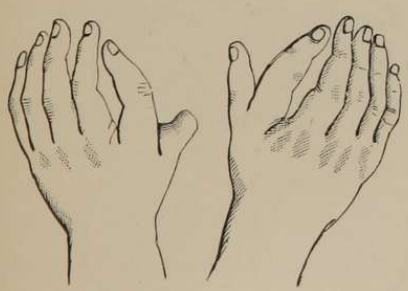

Fig. 904.—Supernumerary digits. (After Reeves.)

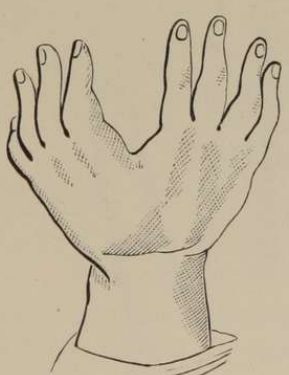

Fig. 905.—Double hand. (After Reeves.)

Fig. 906.—Stunted and webbed hand. (After Reeves.)

A rare form of supernumerary fingers is shown in Fig. 905, in which there is practically a double hand. Amputation of the supernumerary members should be made soon after birth.

In syndactylus, all or a portion of one or more fingers may be wanting (Fig. 906). Amputation of the deformed portion is usually advisable.

Web-finger is usually congenital, although it may be acquired. In mild cases, where the union between the contiguous surfaces is slight, and the web is thin, the following method will succeed: A round elastic ligature or cord is carried through the web just in front of the metacarpo-phalangeal articulation, and the ends are turned back and attached to a band around the wrist (Fig. 907). This is allowed to remain for three or four weeks, until the hole made by the ligature is lined with epidermis. A second puncture should now be made about one inch in front of the first, the ligature passed through this, and the ends tied. The constant traction of the elastic gradually cuts through the web, yet so slowly that the track of the wound becomes covered with epidermis. This procedure should be repeated until all the web is divided.

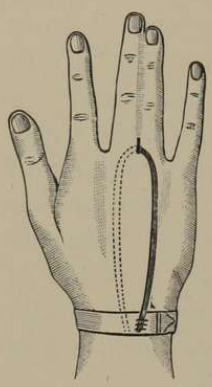

Fig. 907.—Elastic ligature passed through the web. (After Fort and Noble Smith.)

When the fingers are solidly united, the method of Didot should be preferred. An incision is made down the palmar surface of one finger (the index, Fig. 908) and along the dorsal surface of the adjoining member (the middle finger). The flaps are dissected up so that the one removed from the palmar surface of the index-finger remains attached to the middle finger, while the posterior flap is attached along the dorsum of the index-finger. They are then sutured in position (Fig. 909).

In those cases in which the bones are only slightly united, the line of union may be sawed through. When the bones are fused into one solid mass, an operation is not indicated.

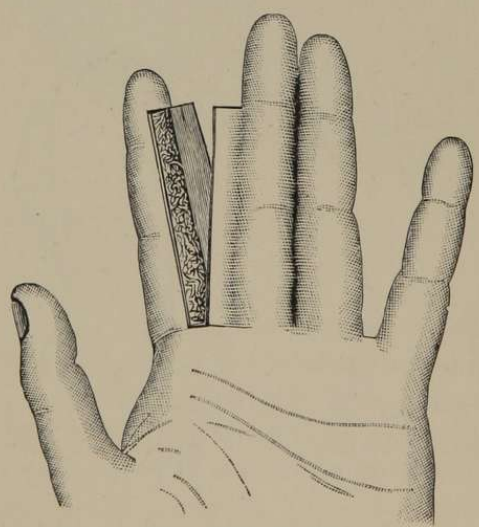

Fig. 908.—Didot's method of operating for web-fingers. (After Fort and Noble Smith.)

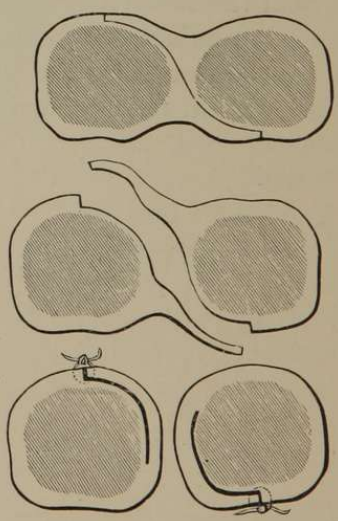

Fig. 909.—Transverse sections of the webbed fingers, showing in the upper figure the line of separation between the two flaps; in the middle, the outline of the separated flaps; below, the sutures are applied. (After Fort and Noble Smith.)

Chronic flexion of one or more fingers may result from paralysis of the extensor muscles, spastic contraction of the flexors, or from contractions of the palmar and digital fascia. Paralysis of the extensors may

be temporary or permanent. Lead-poisoning not infrequently leads to temporary impairment of the function of this group of muscles.

In neglected cases of chronic extensor paralysis, permanent shortening of the opposing muscles, with contraction of the palmar fascia, occurs.

The indications in treatment are to restore, if possible, the functions of the paralyzed muscles, and to prevent deformity by the adjustment of an apparatus which will keep the fingers extended.

Contraction of the palmar fascia, as a result of any inflammatory process, gives rise to the most common deformity of the fingers. Penetrating wounds of the palm, or idiopathic phlegmon, are exceedingly apt to result in fascial contraction and chronic malposition of the fingers.

This process takes place at times in persons of the gouty or rheumatic diathesis without any marked symptom of local inflammation. The tendons are not affected, as a rule, in the earlier stages of *Dupuytren's* contraction. In old cases the muscles are shortened. The fascial contractions are well shown in Figs. 910 and 911.

Treatment.—In mild cases, taken early in the commencement of the affection, a cure may be effected by repeated stretching of the fascia by fully extending the fingers involved. The instrument shown in Fig. 912 devised by Dr. Battey, of New York, will be found very useful in such cases. In obstinate cases fasciotomy is demanded. Division of the palmar fascia should be done as follows: The hand should be rendered

Fig. 910.—Dupuytren's contraction in the fascia of the palm and of the little finger. (After Noble Smith.)

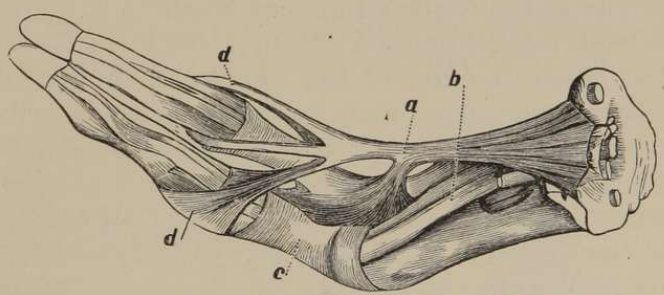

Fig. 911.—The same, in the middle and ring fingers. *a*, Contracted band of palmar fascia. *b*, Flexor tendons (not involved). *c*, Sheath of tendons. *d*, Digital prolongations of palmar fascia. (After W. Adams and Noble Smith.)

thoroughly aseptic by washing in sublimate solution, and made bloodless by Esmarch's bandage. The hypodermic injection of four-per-cent cocaine solution renders the operation painless. The delicate fascia knife should be introduced beneath the bands of fascia, which can be made prominent by extreme extension of the fingers, the edge turned upward, and a thorough division effected, taking care not to allow the knife to cut through the skin. Every resisting band should be divided until the fingers can be readily brought into a position of overcorrection. Two or three lines of section may be made in the palm and one or two through the digital prolongations of the fingers involved. By carefully inserting the knife closely beneath the fascia, the vessels of

the palm and fingers may be avoided. The palm should be covered with a thick layer of sublimate gauze, and a splint applied in order to keep the fingers perfectly straight. This should be worn for two or three weeks, at which time passive motion should be made and the splint reapplied for another week. After it is removed, thorough extension should be practiced at least once a day for several months.

Snap- or Jerk-Finger.—This name has been used to designate a condition in which free extension and flexion of one or more fingers is more or less interrupted. As the affected digit is being flexed or extended,

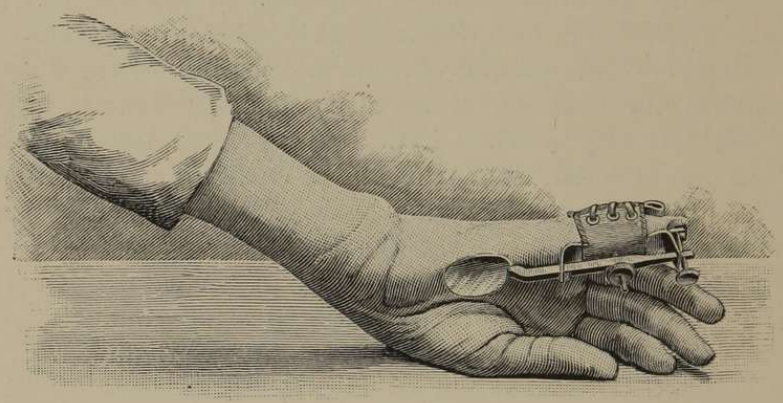

Fig. 912.

motion is arrested in a certain position, and, if a violent effort is made, or if flexion is continued by aid from the other hand, a perceptible jerk occurs as the obstruction is overcome. A nodular swelling, to the touch resembling the ganglia often met with on the back of the wrist, may be felt along the line of the tendon at or near the metacarpo-phalangeal joint. Snap-finger may be due to a circumscribed thickening of the tendon, or a disproportion between the size of the tendon and sheath for a limited area. This condition is believed to exist, especially in the thumb, where the jerk occurs in one third of all cases. Mr. Reeves thinks that in the fingers it is chiefly due to the synovial fringes catching upon the transverse process of the palmar fascia. This may occur not only "from thickening of this process of fascia, but also from rolling up or displacement of the synovial sheaths."

Snap-finger may be traumatic or idiopathic in origin. Strains on the tendons and fascia in the act of lifting, direct violence, as well as the gouty and rheumatic inflammations, are noted in the ætiology. The treatment consists in passive motion, and internal medication to correct any dyscrasia. If relief does not follow ordinary measures, an incision should be made and the enlargement dissected out.

In certain cases in which adhesion of the tendons to their sheaths and to the palmar and digital fascia occur chiefly as a result of penetrating wounds, it will—in order to relieve the deformity—be required to make an open dissection and divide the adhesions in plain view. Such operations can be done with impunity, and with an extraordinary degree of success, if the strict antiseptic precautions are observed. Esmarch's

bandage is essential to the operation, and cocaine anæsthesia I have frequently demonstrated to be perfectly satisfactory in these procedures. The wound should be closed at once with fine silk sutures. Catgut is not sufficiently reliable in this region. The danger of inflammation and contractions of the fascia from opening into the hand under sublimate irrigation and careful antisepsis are exceedingly remote. Even the most extensive injuries of the hand may be made to heal with as little deformity as often follows a simple wound in which inflammation and suppuration are established. Figs. 913 and 914 are taken from a hand one

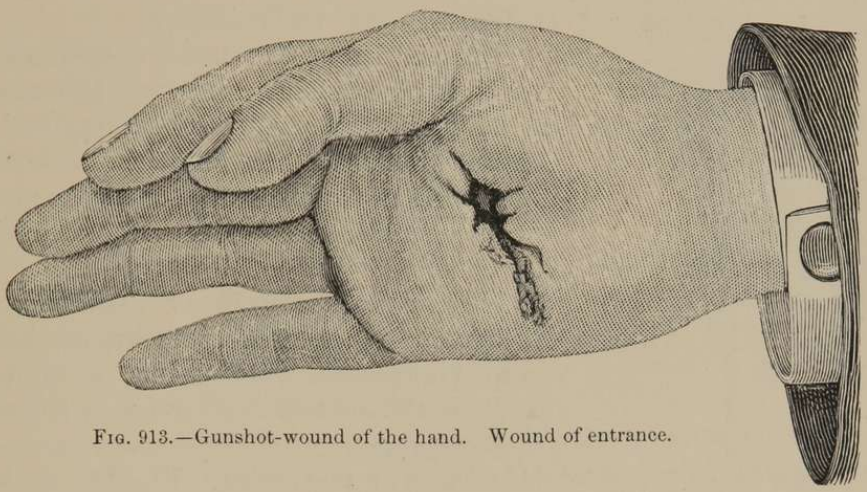

Fig. 913.—Gunshot-wound of the hand. Wound of entrance.

year after the receipt of a gunshot-wound. The muzzle of the piece was in contact with the skin at the time of the explosion, and the charge of small shot and wadding entered at the palmar aspect of the little finger,

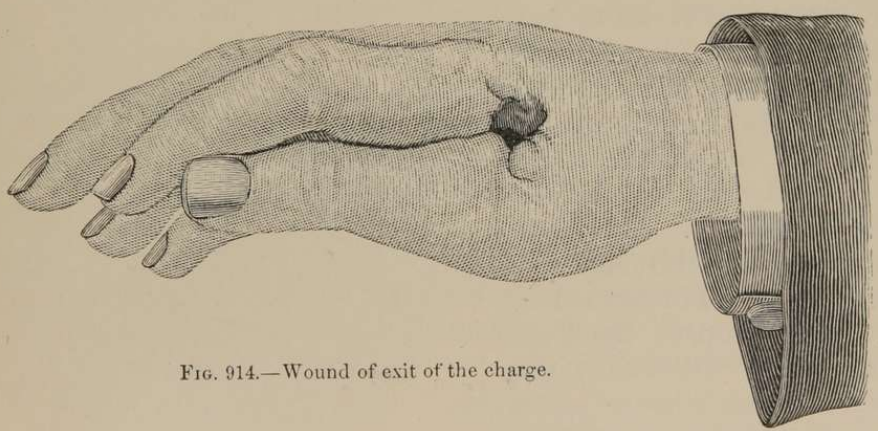

Fig. 914.—Wound of exit of the charge.

and passed out through the metacarpal bone of the index-finger and to the ulnar side of the thumb. The third and fourth metacarpal bones were broken, while the second was comminuted and almost all of it blown away. The flexor tendons and fascia of the palm were torn and divided. The treatment consisted in immersion of the member in 1-to-2,000 sublimate solution, thorough removal of powder and all foreign matter, reposition of attached fragments of bone and shreds of tendons,

fascia, and muscle in as near their normal relation as possible, and applying a sublimate-gauze dressing, placing the hand in the natural position and holding it there with a splint and roller. In this case motion was secured in every finger, and no contractions of the fascia have taken place.

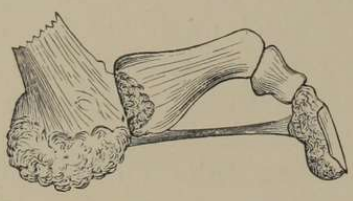

Fig. 915.—Deformity resulting from exostosis. (After Annandale and Noble Smith.)

When the tendons are divided, either in the forearm near the wrist or in the palm or along the fingers, it is essential that the divided ends be stitched together with silk sutures. Cocaine anæsthesia and Esmarch's bandage should be employed.

Deformities of the hand and fingers also result from exostosis and new formations of cartilage in the digits (Figs. 915 and 916). Amputation is indicated in the latter condition, while in exostosis relief may be obtained by direct incision and removal of the offending bone.

Fig. 916.—Deformity resulting from chondroma of the phalanges.

Phlegmon of the Hand and Fingers.—Phlegmon of the fingers is an exceedingly painful affection. Occurring, as it usually does, in the terminal phalanx, a knowledge of the arrangement of the fascia here is essential to proper treatment. Fig. 917 shows the intimate attachment of the connective-tissue fibers to the integument of the palmar aspect of the digit and to the matrix of the nail, the separation of the various layers to form spaces in which are contained quantities of fat. The general convergence of these bundles of connective tissue toward the center is well illustrated in the cut. They are intimately attached to the sheath of the tendon in front and to the periosteum posteriorly. The lymph-channels follow the layers of fascia from the skin toward the bone. Phlegmon of the finger ("*felon*," or "*whitlow*") may originate in the bone or periosteum, but most frequently begins in the soft tissues. On account of the arrangement of the fascia and lymphatics, the inflammation rapidly extends to the tendon or periosteum. The dense structure of the tissues here, which prevents their yielding to the pressure of the inflammatory infiltration, will account for the unusual degree of pain present in this affection.

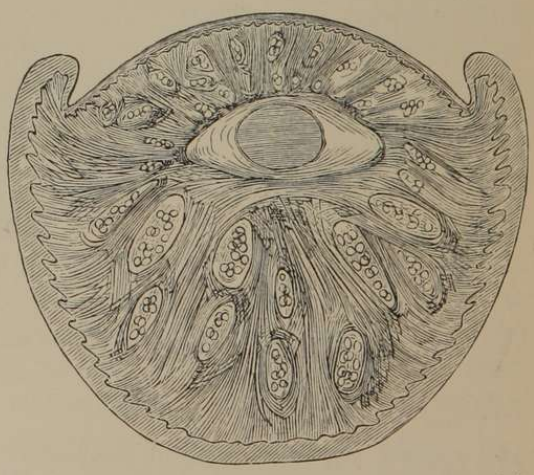

Fig. 917.—Showing the converging arrangement of the dense connective-tissue bundles in the finger around the last phalanx. (After Vogt.)

Phlegmon of the palmar aspects of the thumb or little finger, not relieved by early incision and disinfection, may extend along the sheaths of their tendons and invade the entire palmar fascia. Conversely, central phlegmon of the palm of the hand may radiate to these digits (Fig. 918).

Fig. 918.—Showing by injection the continuity of the synovial sheaths of the little finger and thumb with the large sac beneath the palmar fascia. (After Vogt.)

By reason of the anatomical arrangement of the sheaths of the ring, index, and middle fingers, closing as they do in blind extremities at the metacarpo-phalangeal articulations, the inflammatory process does not extend, as a rule, into the large synovial sac beneath the palmar fascia (Figs. 918 and 919). Upon the back of the hand and fingers phlegmon behaves as it does beneath the skin in other parts of the body.

In the *treatment* of *whitlow* the first indication is to relieve tension at the earliest moment by puncture or incision. The exact point of inflammation in the earliest stage of phlegmon may be recognized by direct pressure with a small pointed instrument, as a probe or director. Cocaine may be utilized to prevent pain when the incision is made. A rubber ligature tied around the finger to arrest the circulation, and a few minims injected into the line of incision, will deaden all sensibility. The incision should be free, and down to the tendon or bone, to insure relief of all tension. The part should then be submerged in warm sublimate solution, the ligature removed, and, after a minute or two of bleeding under water, an iodoform strip should be packed into the wound, and a moist aseptic dressing applied.

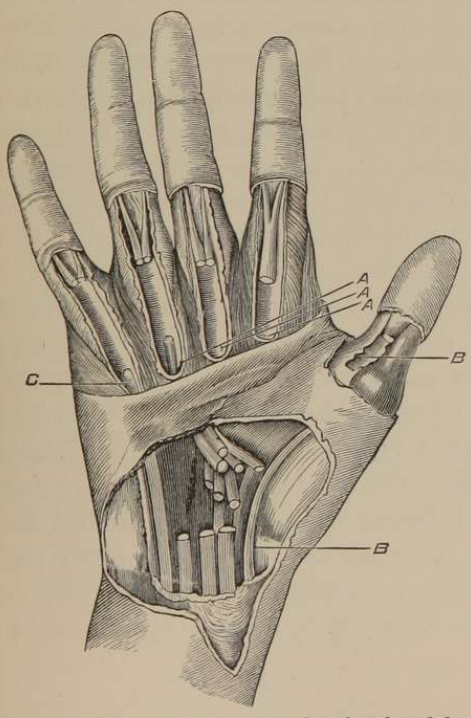

Fig. 919.—Showing at *A A A* the sheaths of the ring, middle, and index fingers ending in blind extremities toward the palmar sac. (After Vogt.)

When pus has formed and can be evacuated in this manner, the opening should be made upon the lateral aspects of the finger, in order to avoid the sheath of the tendon.

In phlegmon beneath the palmar fascia the same principles of incision and drainage should be applied, avoiding the larger vessels when possible.

Ganglion.—Ganglion is due to the localized collection of a variable quantity of synovial fluid in the sheaths of the tendons, or bursæ on the dorsum of the hand or wrist. Excision and dissection under cocaine anæsthesia, and strict asepsis, I have found to be the most satisfactory means of effecting a cure. They may be made to disappear by absorption, after subcutaneous rupture from a sharp blow with the back of a book or padded hammer.

Division of the tendons of any part of the hand or of the wrist near the hand demands careful asepsis and immediate suture of the tendons and nerves, if these be divided. When the wound is across the wrist, the skin should be freely dissected back in order to thoroughly expose the tendons, which usually are considerably retracted in the direction of the origin of the muscle; it also requires a thorough knowledge of anatomy in order to separate the various tendons and to unite the upper section to the proper tendon of insertion. I employ fine sterile silk sutures, using two threads to each tendon, and an additional thread when the tendon is unusually broad or strong, such as the flexor carpi ulnaris. The needle is passed entirely through the tendon between one eighth and one fourth of an inch from the divided edge. All sutures are inserted and approximation made gradually with the hand and arm in a position which will most thoroughly relax the tissues to be approximated. Nerve suture has been described. It is important in uniting such a nerve as the median or ulna at the wrist, to use fine needles, a round one preferably, which will not cut the nerve fibers, and to pass one needle and suture through the center of the nerve about one eighth of an inch from the cut surface; then on either side of this to insert a very delicate suture into the sheath of the nerve. Approximation should be very carefully made, not jamming the ends of the nerve together, but securing them snugly in apposition. The dressing should consist of iodoformized gauze with plaster of Paris over all, the hand being held properly flexed for six or eight weeks after the operation. The nerves reunite in from two to six weeks. Function may not always be early established, and in some instances months, and as much as two years, have elapsed before conductivity was restored.

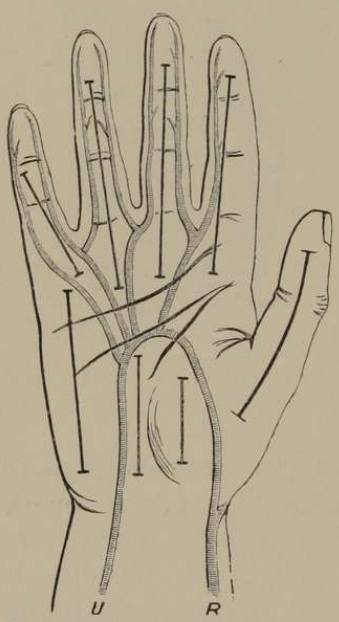

FIG. 920.—Showing outline relation of arteries, and line of incision which may avoid the more important vessels. (After Vogt.)

CHAPTER XXXI.

TUMORS.

THE word *tumor* (from *tumere*, to swell) was formerly applied to any abnormal formation or collection of matter within the body. The over-accumulation of fecal matter in the colon, the swelling due to extravasation of blood, or to the retraction of a muscle after rupture of its tendon; an abscess, a retention cyst, a hernia, a floating or displaced kidney, as well as all the recognized non-inflammatory neoplasms, as sarcoma, fibroma, lipoma, carcinoma, etc., were ranged under the comprehensive heading of *tumors*.

Of late years the application of the term has been more restricted. A tumor is now defined to be a *circumscribed, non-inflammatory mass, composed of new-formed elements which, having their type in the normal embryonic or adult tissues, are dependent upon these for nutrition, and yet are not amenable to the laws regulating and limiting the development of the normal structures.*

Circumscribed, because a general or widespread hypertrophy or hyperplasia does not convey to the eye or touch the idea of a swelling or tumor. The accumulation of fat in obesity can not be called a tumor, yet the fat so deposited over a wide area differs in no essential particular from that which forms a lipoma.

Non-inflammatory, for the reason that this most clearly separates true neoplasms from the cell proliferation of the ordinary inflammatory process, with its characteristic *heat*, *pain*, *redness*, and *swelling*.

New formations in this, that although the law established by Johannes Müller—that the elements of all tumors, no matter how changed from the normal, spring from and have their types in the normal tissues of embryonic or adult life—stands unquestioned, yet these elements, in their changed conditions, tend to persist or to grow indefinitely, in utter disregard of the laws of limitation in the development of normal tissues.

The efforts at classification of tumors upon a histological basis have not been generally satisfactory. Virchow, Foerster, Cornil and Ranvier, and other pathologists, with the same end in view, have arrived at conclusions scarcely reconcilable. A discussion of these various classifications belongs more properly to special works on pathology. Clinically, they admit of division into two heads—the *malignant* and *non-malignant*.

Malignancy in a tumor means its tendency to become multiple by metastasis; the tendency of the elements of which it is composed to

travel along the lymph or blood channels, and, thus disseminated, to reproduce the parent tumor; or its tendency to invade and destroy the tissues in its vicinity, and to recur *in loco* after extirpation.

Strictly speaking, the tendency of a neoplasm to induce death has nothing to do with the question of its malignant character, for certain tumors, as fibro-myomata of the uterus and simple ovarian cysts, tend to produce death by pressure and exhaustion as well as carcinomata and sarcomata by general dissemination.

The malignant neoplasms are grouped under two headings—*carcinoma* and *sarcoma*.

The non-malignant are as follows: *lipoma*, *fibroma*, *myxoma*, *osteoma*, *enchondroma*, *angioma*, *neuroma*, *myoma*, *adenoma*, *papilloma*, and *lymphoma*.

Carcinoma.—A cancer may be defined to be a tumor, composed of *embryonic cell elements* of varying shape and proportions, collected in groups, which groups or clusters are *partially separated by a well-defined stroma*.

While the elements of the carcinomata do not always differ so widely from those of the sarcomata (especially the more embryonic cells of this

Fig. 921.—Development of carcinoma. *s*, Bundles of fibrous tissue containing occasional connective-tissue corpuscles. *a*, Cancer cells in groups or rows between the stroma. (After Cornil and Ranvier.)

latter neoplasm), the alveolar structure of the stroma of cancer will always render it easy of recognition.

Cancer cells vary greatly in shape and dimensions, being round, flat, ovoid, fusiform, polygonal, and measuring from $\frac{1}{2500}$ to $\frac{1}{1200}$ and $\frac{1}{500}$ inch in diameter. Each cell may contain one or many nuclei. The nucleus is often of large size, at times occupying the greater portion of the cell

space. The nucleoli are especially prominent. The cell elements of carcinoma are contained within the alveoli, and float in or are in contact with a juice of varying quantity and consistence.

The walls of the alveoli are composed of a fibrillated structure of modified connective tissue. In old tumors the fibers of the stroma are closely packed together, while in more recent neoplasms connective-tissue corpuscles are frequently observed between the clusters of cells (Fig. 921). The alveolar arrangement of the stroma is well shown in Fig. 922, in which the cancer cells have been removed.

The alveoli are not isolated cavities, but communicate more or less freely. In the connective-tissue walls of the alveoli the blood vessels and lymph channels are lodged. In the development of a carcinoma the proliferation among the cells proper of the neoplasm excites a similar condition in the connective-tissue cells of the neighboring and involved tissues, and, coincident with the multiplication of the cancer elements, the connective-tissue elements are developed. In this way the stroma is formed around and among the cancer cells, and in rare instances this proliferation is so rapid that clusters of adipose cells are caught within the neoplasm and remain as such in the process of growth in the tumor.

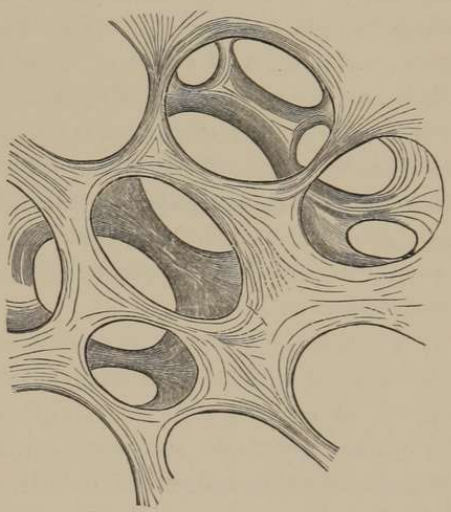

Fig. 922.—Stroma of cancer from which the cell elements have been removed. (After Cornil and Ranvier.)

Carcinomata spread by direct invasion of contiguous tissues, and along the route of the lymph channels.

It is not uncommon (as established by Cornil and Ranvier) for induration and hypertrophy of the ganglia of the nearest lymph plexus to occur before metastasis has taken place, a fact of great interest to the surgeon. This early glandular hyperplasia is due to the irritation caused by the neoplasm, and though less acute is not unlike the adenitis of an ordinary inflammatory process.

Three chief varieties of cancer are recognized—the *scirrhus*, *encephaloid*, and *mucoid* or *colloid*. *Epithelioma* will also be included under this heading.

Scirrhus, or hard cancer, is distinguished by the greater proportion and thickness of the *stroma*, in comparison with the cell elements. Many of the cells in this variety of neoplasm, especially those more deeply situated, undergo extensive granular metamorphosis, and appear as granular corpuscles, having lost all the characteristics of the cancer elements.

Encephaloid, soft, or medullary cancer is rich in cells and cancer-juice, while the stroma is very thin. It is more vascular, and in gross appearance is like broken-up brain-matter; hence the name encephaloid. Owing to the embryonic character of the new-formed blood vessels and

the lack of resistance from the scantily developed stroma, aneurismal dilatations of the vessels are common, and rupture frequently occurs.

Colloid cancer is characterized by the presence within the alveoli of a fluid rich in mucin, which substance also appears in all the foci that may be developed by metastasis. Many of the cells disappear, and those which remain are unusually large and swollen. The alveoli are also distended and the walls more translucent than in scirrhus.

The changes which cancers undergo are chiefly granular metamorphosis and ulceration. The cells of the deeper portions of the neoplasm, deprived of sufficient nourishment by reason of their central position, break down in a granular detritus, which is absorbed and carried away in part by the blood vessels, but chiefly by the lymph channels. In older tumors this gradual loss of cellular elements is followed by contraction of the stroma and sinking in or retraction of the integument. Inflammation and ulceration of a cancer may result from direct irritation from without, or may occur as a result of the growth of the neoplasm, which thus often cuts off its own nutrition. The process is not unlike ulceration in the normal tissues, only the granulations are often very exuberant and the death of tissue rapid. All forms of carcinoma are subject to the deposit of pigment, and under such conditions have been termed *melanotic* cancer.

Causes.—Cancer is a disease of adult and of late adult life. Scirrhus, encephaloid, or colloid cancer, under twenty years of age, is exceedingly rare. It occurs chiefly in the period of life between thirty and sixty. Women are more frequently attacked than men. Prolonged irritation is undoubtedly the chief exciting cause of the development of this neoplasm. In evidence of this conclusion is the fact that those portions of the body which are subjected to the greatest amount of irritation are most often affected. The mammary gland, pylorus, rectum, and uterus, are the more common locations of cancer.

Diagnosis.—The recognition of cancer is positive only by microscopical examination, and depends in part upon the peculiar characters of the cells already noted, but chiefly upon the appearance of the stroma. Clinically, the diagnosis will depend upon the age of the patient, the location of the tumor, its consistence, immobility, and the condition of the lymphatic glands in the line of the vessels toward the center. A tumor occurring after the age of thirty-five, of a mildly painful character, and increased when firm pressure is exercised; steadily, although at times slowly, enlarging, movable, it may be, beneath the skin or within the substance of the organ or part in which it is located, yet not freely so, should be looked upon with suspicion. If it has existed for several months, and there is retraction of the integument over a portion of the mass, together with induration of the nearest lymphatic glands, the diagnosis of cancer is almost positive. As between the three different forms of cancer, it may be said that scirrhus is much the more common, is slower in growth, and harder to the touch. Colloid cancer or the colloid degeneration of scirrhus is also hard, and grows slowly, and from palpation and inspection can not be differentiated from scirrhus

with any certainty. It is comparatively rare. Encephaloid is a soft, elastic tumor, not always of uniform consistence, but generally of smooth surface, and always of rapid growth. Its vascularity is therefore much more noticeable than that of either of the other varieties, and metastasis is more rapid. As between sarcoma, the chief diagnostic points are the age of the patient, sarcoma being more common in the young, cancer in the old and middle-aged; the lymphatics are not involved in sarcoma, except when extensive ulceration and septic absorption occurs; in general, the superficial veins of sarcoma are more dilated and perceptible, and the tumor more elastic.

The excision of a portion of a tumor for microscopical examination for purposes of diagnosis may in exceptional instances be justifiable. Any unnecessary irritation of the mass is reprehensible, since metastasis is more apt to occur under such conditions.

Epithelioma.—An *epithelioma* may be defined as a neoplasm, the embryonic elements of which assume, in a varying degree, the shape and arrangement of the normal epithelium. Developing usually in the skin or mucous membranes, they at times originate in tissues remote from them, as in the bones.

Malignant epitheliomata may be divided into two classes: 1, the flat or superficial; 2, the tubular or deep.

The first variety is by far the more common. It occurs by preference upon the muco-cutaneous surfaces, as the lips, prepuce, anus, vulva, etc., but may appear either upon the skin or mucous surfaces, remote from any line of union of these coverings, as the tongue, cheek, face, etc.

Flat epithelioma usually begins as a nodule or induration of small size, slightly reddened at its margin, the center of which very early in its history breaks down into a dirty ulcer which, when kept fairly clean, is reddish in color, and, when not cleansed, is covered with a grayish mass of pus and broken-down tissue, either solidified into a crust or scab, or in a softened state. The margins of the ulcer are sinuous, hard, and everted. It may limit itself to a small area, or develop steadily, and sometimes with great rapidity until, after extensive destruction of the tissues in its neighborhood, death ensues from hæmorrhage, sepsis, or metastasis. Pain, usually mild in character, is always a symptom of this disease. Lymphatic engorgement may occur in the first few weeks, but usually from four to eight months, and even a longer time, may elapse.

Examined microscopically, this form of epithelioma is seen to be composed of flattened cells, containing one or several nuclei, with a tendency on the part of the elements to form themselves in concentric layers (Fig. 923). In the center of these spheres of flattened epithelia are frequently seen a few cells which have undergone the colloid change. Farther out the surrounding cell elements are more embryonic in character, cylindrical, spherical, or polygonal from lateral compression, the mass being limited externally by a stroma of connective tissue, varying in quantity, which separates one epithelial nest from the others composing the entire neoplasm. In the process of ulceration an epithelioma is surrounded by

a zone of embryonic tissues due to the cell proliferation of the inflammatory process.

Tubular epitheliomata are considered somewhat less malignant than the lobular or bird's-nest variety just described. After reaching a certain stage in their development, they may remain stationary; but, in the majority of instances, the tendency is to grow, as well as to recur after removal. They are usually situated upon the skin, where they originate in the sweat or sebaceous glands or upon the mucous membranes, where they spring from the follicles of these surfaces. The antrum maxillare is occasionally the seat of this variety of neoplasm.

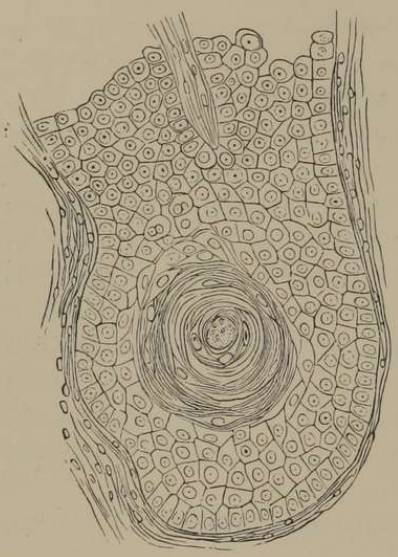

Fig. 923.—Lobular or spherical epithelioma, 250 diameters. (After Cornil and Ranvier.)

Microscopically, the flat-celled epitheliomata are composed of pavement or tesselated cells, crowded in tubules or cylinders, which are long, more or less irregular in shape, at times anastomosing with each other, and are held together by a stroma of connective tissue (Fig. 924).

The general shape of these neoplasms is oval or round.

Treatment.—The proper treatment of epithelioma will vary with the special character of the neoplasm and its location. The simpler forms of flat epithelioma developing away from a mucous surface—i. e., not communicating with a mucocutaneous surface—yield readily to the application of *arsenous-acid paste*, and of late years I have treated almost all of these cases by this method and with gratifying success. Even when situated near the eye and practically communicating with the mucous membrane of the eyelid, it may still yield to this remedy without danger to the integrity of the eye. On the other hand, when an epithelioma is situated upon the lip, it should be removed by free excision at the very earliest possible moment. Epithelioma of the tongue is one of the most malignant of all forms of neoplasm and is amenable to no other treatment than to early and wide extirpation of the part involved. After lymphatic engorgement and metastases, the application of Marsden's paste to the epitheliomatous ulcer is of doubtful propriety unless a thorough dissection of all the involved glands has been made prior to the application or at the same time. When, after metastatic invasion one or more of the lymphatic glands

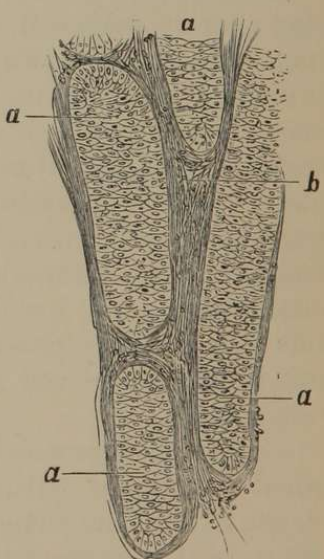

Fig. 924.—Tubular epithelioma. *a*, Tubules or cylinders cut obliquely. *b*, Connective-tissue stroma. (After Cornil and Ranvier.)

have been removed, it is my rule to apply arsenious-acid paste in the wound so made. The action of arsenious acid is to destroy the weak tissue of the epitheliomatous growth. In applying it, it is always essential that it rest in contact with a raw surface. If an epithelioma is covered with a thick crust, this should be removed either by the knife or by the application of caustic potash. The stick of caustic potash, when rubbed over these crusts, rapidly destroys them, and enables the surgeon to expose the underlying diseased surface in five or ten minutes. The formula which I most frequently employ is the following: Arsenious acid, two drachms; powdered gum acacia, one drachm; cocaine, eighteen grains. Mix and rub well together in a mortar. When ready for use, a sufficient quantity should be moistened into a paste about as thick as half-melted butter by adding water drop by drop. The paste should be laid about an eighth of an inch thick upon a piece of lint or gauze, and should extend about one eighth of an inch beyond the margin of the ulcer upon which it is applied. It is well not to cover more than a square inch of surface at a time, for fear of absorption of too much arsenious acid. The length of time the paste is to remain on will depend upon the result in a given case. I usually apply it about nine o'clock in the morning and leave it on until nine at night, when it is removed, and a simple dressing of vaseline applied. The next morning the paste is applied again and left on for about six hours. An application of eighteen hours with an interval of about twelve hours will suffice for ordinary cases. Upon the alæ nasi or eyelids four or five hours will be safer. The after-treatment is a simple vaseline dressing. In the very mildest form of epithelioma, such as is caused by friction of the spectacles upon the nose or that appearing in the form of little pimples upon the face, which have been converted into epithelioma by irritation, Marsden's old formula, equal parts of arsenious acid and gum acacia, will suffice.

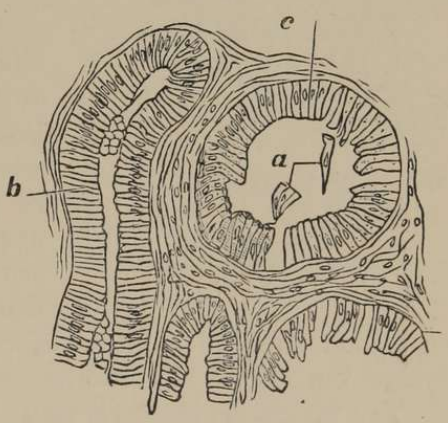

FIG. 925.—Tubular epithelioma with cylindrical elements. *a*, Tubule cut across. *b*, Tubule cut in its long axis. *c*, Cylindrical epithelia. (After Cornil and Ranvier.)

In the deep or tubular form the skin is usually not broken, the epitheliomatous elements having developed in the follicles and practically beneath the skin. The paste will not act directly upon the unbroken skin and therefore in these cases it is often necessary to remove the overlying skin by dissection, usually under cocaine anæsthesia, applying iodoformized gauze to arrest hæmorrhage, and then applying the paste after all bleeding has stopped. It is sometimes necessary after applying the paste to use the curette to scrape away the destroyed tissue. If the ulcer does not heal readily within two or three weeks after such application—i. e., if in one or two spots upon the margin there is any induration,

the application may be repeated on these places. The practitioner may rest assured that by following the above method in properly selected cases the vast majority will be cured by one application.

It has been observed in a number of instances that these milder forms of flat epithelioma have undergone certain modifications during an attack of erysipelas which was either located at the ulcer or in another portion of the body. One such experience occurred in my own practice; an epitheliomatous ulcer on the temple became infected with erysipelas, which ran its usual course, during which time the ulcer disappeared and remained absent for several months. It recurred, however, and was cured by the arsenious-acid paste.

Lymphadenoma.—This variety of neoplasm is entitled to be classed with the malignant tumors. It consists of new-formed lymphatic gland tissue, and may occur in pre-existing glands or in any of the tissues of the body. The liver, spleen, and kidneys, the testicle, the alimentary canal, the bones and integument, may all be the seat of these new formations. Coincident with the development of these neoplasms, the proportion of white blood-corpuscles in the volume of blood is enormously increased, until death ensues from leucocythæmia. These tumors may be of any size, from a millet seed up to several inches in diameter, are soft to the touch, and usually not well defined. They can not be diagnosticated from other gland tissues unless examined microscopically, when they are seen to consist of a connective-tissue framework or reticulum, along the fibrillæ of which run the capillaries, and in the meshes of the reticulum the lymph corpuscles are situated (Fig. 926).

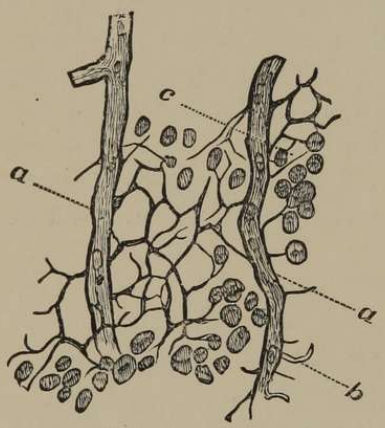

Fig. 926.—Reticular structure of a lymphatic intestinal follicle. *a b*, Capillary vessels with nuclei in their walls. *c*, Meshes of the reticular structure containing lymphatic corpuscles. (After Frey.)

The prognosis is grave, and the condition does not justify surgical interference.

Sarcomata.—A sarcoma is a tumor the elements of which have their type in the normal connective tissues. The cells of a sarcoma may be purely embryonic, or may, in a certain sense, resemble the more developed elements. They are, however, not capable of organization into a permanent tissue.

Classified according to the shape and size of the cell elements which preponderate in their composition, they are called—1, *round*; 2 *spindle*; 3, *giant-cell* sarcoma.

The cell elements of the sarcomata not only vary in size and shape, but in the number of their nuclei, of which there may be from one to thirty or more. In the more fully developed or spindle-celled neoplasm the elements are arranged in bundles which run in all directions. These tumors possess little or no intercellular substance, the elements resting in contact or separated by the blood vessels which freely permeate them.

The richness of the blood supply and the proportion of the tumor occupied by these channels are well shown in Fig. 927.

The size and number of the blood channels depend upon the structure of the tumor, the round-cell sarcoma being most vascular, while the vessels are less numerous and of smaller caliber in the spindle-cell variety.

The intercellular substance also varies in quantity, being scarcely perceptible in the round-cell tumor, and more distinct in the spindle or fusiform variety. In some of the sarcomata normal connective-tissue fibers may exist, and these are believed to have been caught in the development of the neoplasm.

The sarcomata in general develop with great rapidity, and tend to invade or infiltrate the structures in their immediate neighborhood. In this the different forms of tumor also differ. The round-celled neoplasm grows more rapidly than the others, and is more apt to invade the surrounding tissues than the fusiform-cell variety. It is not the rule for these neoplasms to become encapsuled, although this may occur in the spindle- or giant-cell variety.

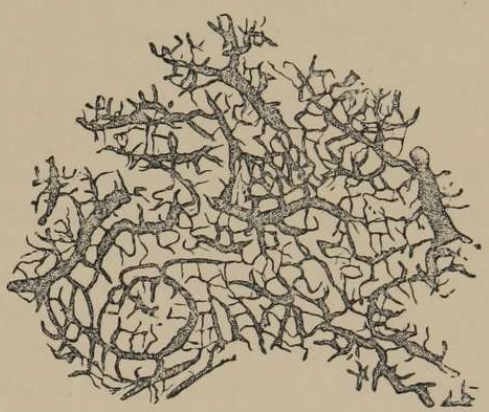

Fig. 927.—Injection of the vascular network of an osteo-sarcoma. (After Billroth.)

The three varieties of cells may exist in the same tumor. According to Cornil and Ranvier, a careful search will reveal the presence of giant cells in varying numbers in almost all sarcomata.

The retrogressive changes which these tumors undergo are fatty and calcareous degeneration. The deeper cells of tumors of considerable size —in other words, those farthest removed from the supply of nutrition— very commonly undergo the fatty or granular metamorphosis. Not infrequently this granular metamorphosis proceeds so rapidly that the blood vessels of the tumor become occluded with the fatty detritus (granular infarction). In this way the nutrition in certain portions of the growth is interfered with, increasing the area of fatty metamorphosis, or inducing gangrene from a sudden arrest of the blood current.

Calcareous degeneration occurs in certain of the sarcomata irrespective of their being situated in the neighborhood of bone. Pigmentation occasionally occurs, and this form is at times separately classified as melanotic sarcoma. It is apt to take place in the small, round-cell tumors. Acute inflammation in a sarcoma is almost always followed by the proliferation of an exuberant granulation tissue, with more or less extensive gangrene and death of the mass. Excessive and at times fatal hæmorrhage may occur in the process of sloughing.

A common accident in the evolution of a sarcoma is the extravasation of blood from rupture of the walls of the new-formed vessels. Such is the crude condition of these tumors that even the cells which compose the vessels are embryonic, and readily give way, allowing the escape

of blood among the cell elements and intercellular spaces. The more nearly the development of the cells approaches a normal tissue, the less probability there is of extravasation. The blood thus escaped may be absorbed or become encapsuled by pressure upon the cells near the point of rupture and become converted into a blood cyst.

Mucoid degeneration is also occasionally met with in these neoplasms. The cells of certain portions of the tumor disappear, leaving cysts or alveoli varying in size from the smallest up to as large as two or three inches in diameter in large tumors. The cysts are occupied by an amber-colored or reddish-brown fluid, which, examined with the microscope, demonstrates the presence of blood-corpuscles in various conditions of degeneration. Chemically, the fluid yields *mucin*. The name *alveolar* sarcoma (Fig. 928) has been given to this form of tumor.

Fig. 928.—Alveolar sarcoma. (After Green.)

Clinical Features.—Sarcomata may be met with in all conditions and at any period of life. Comparatively speaking, they are rare in old age, occurring chiefly in children and adults under thirty. Occasionally they are congenital. Both sexes are equally liable to be attacked. They are, as a rule, idiopathic in origin, in rare cases being due to, or at least following, an injury to the part involved in the neoplasm. Sarcomata are among the most malignant new formations, not only recurring *in loco* after removal, but tending to be disseminated by the blood vessels. Unlike the carcinomata, they have no lymph channels, and metastasis must occur by the blood vessels which enjoy free anastomoses with the caverns and sinuses of the neoplasm.

The degree of malignancy of a sarcoma is, in general, in proportion to the embryonic character of the elements of which it is composed. Thus, the round-celled tumors of rapid development are most malignant, the spindle-celled next, the giant-celled last in this order.

Fig. 929.—Sarcoma of the scalp and neck.

As to location, no tissue is exempt. They are frequently met with in the skin and subcutaneous tissues (Fig. 929); also the osseous tissues, especially the long bones, furnish a favorite seat for them. Those developing from within are chiefly the myeloid or giant-celled variety; those of periosteal origin are round- or spindle-celled.

Sarcoma of the bones, according to Prof. S. W. Gross, who has written a most exhaustive paper upon this subject, is exceedingly malignant, being only second to cancer of the soft tissues.

From the foregoing it is evident that the prognosis in any of the vari-

eties of sarcoma is unfavorable. The gravity increases with the duration of the tumor, its location near the trunk, and with the rapidity of its growth.

The round-celled, especially those which have undergone the *melanotic*, *mucoid*, or *alveolar* change, are most dangerous ; next, the spindle-celled, and, lastly, the myeloid or giant-celled variety.

Treatment.—Situated superficially, or in the soft parts, they should be excised as soon as observed. The incision should always be wide of the suspected limit, and the skin and all the tissues should be removed well beyond the tumor. When a bone is the seat of the new formation, no effort should be made to preserve the periosteum. The bone should be divided as far beyond the lesion as may be deemed consistent with the safety of the patient and the preservation of the function of the part involved.

When a sarcoma is developed upon an extremity, if it be small or of very recent date, a wide extirpation should be undertaken ; but, if there is at any time thereafter an indication of recurrence, amputation should be considered.

Sarcoma of the bones of the extremity calls for immediate amputation. If the tibia is involved, disarticulation at the knee is indicated. If the neoplasm is located in the femur below the middle, the bone should be removed at the hip. If the soft parts are not involved, a long flap should be made, and the femoral vessels divided as low down as possible.

Early and wide removal of all forms of sarcoma is the indication in treatment. In those cases which from the beginning, by reason of their location or as a result of neglect, have become so extensive as to be inoperable, the question of injecting into the substance of the neoplasm or under the skin the toxic products of certain bacteria may be entertained. Dr. W. B. Coley, of New York, has published the report of several cases of sarcoma of the tonsil and large tumors of the chest wall, axilla, etc., in which, under the influence of the persistent and frequently repeated injections of a sterile mixture of the bacillus prodigiosus and Fehleisen's coccus of erysipelas, the tumors have disappeared. A committee appointed by the New York Surgical Society to investigate this subject reported unfavorably on this method, having concluded that the few cases of recovery were due in all probability to an error in diagnosis, and that sarcoma had not existed. I have in a number of cases employed the injection of the mixed products as formulated and used by Dr. Coley, but in none of my cases has permanent benefit been derived. There is no doubt, however, that the virus of erysipelas is capable of effecting a cure in certain forms of sarcoma. I am of the opinion that an acute pyogenic infection may also cause a disappearance of some of these neoplasms. About ten years ago a gentleman consulted me in regard to a large, firm tumor occupying the abdominal wall about halfway between the umbilicus and the right anterior-superior spine of the ilium. He stated that he had been struck at this point by the end of a billiard cue several months previous to the appearance of the tumor, which grew steadily. When I

first saw him it was fully six inches by four in surface measurement, and three and a half inches in thickness. I believed it to be a sarcoma and proposed to remove it, but promised the patient that if the operation demanded the sacrifice of the abdominal wall to such an extent that he would practically have a hernia that would incapacitate him for work I would desist from the operation. Cutting down upon it, I found the case inoperable, but removed a large slice about half an inch thick throughout the entire extent of the mass. This was examined by Dr. William H. Welch, Dr. W. L. Wardwell, and myself separately, and each confirmed the diagnosis of spindle-cell sarcoma. A few days after the operation I injected five minims of Fowler's solution into the substance of the mass, and this was repeated daily for one week. The injections became so painful that they were then discontinued. As a result of these injections, the tumor and the skin immediately over it became infected and extensive suppuration ensued. The patient became much exhausted from the exacerbations of temperature due to septic absorption, but finally recovered, and is at this time entirely well, with no evidence of ever having had a neoplasm, excepting the scar of the incision.

Drs. A. G. Gerster, B. F. Curtis, and Andrew J. McCosh, of New York, have reported cases of cure of sarcoma after erysipelatous infection. Dr. Gerster's case occurred in Mount Sinai Hospital. A young girl was admitted suffering from a sarcoma of the leg, for which amputation was done. The disease recurred and amputation at the middle of the thigh was performed; again there was a recurrence, and, finally, amputation at the hip joint was made, but the disease recurred in the stump. The patient was abandoned, but fortunately contracted erysipelas in the wound. The recovery from the erysipelas was followed by complete and permanent disappearance of the tumor. She is now, several years later, entirely well. I am so convinced of the value of erysipelas in sarcoma that I should unhesitatingly advise it in properly selected cases. Upon osteosarcoma no cures have as yet been reported. It has probably more effect upon round- and spindle-cell sarcomata than upon other varieties. I have not yet tried it in melanotic sarcoma, but, on account of the extremely malignant character of this form of neoplasm, no positive benefit should be expected. Within the last two years I have made it a rule to inoculate with Fehleisen's coccus every case in which I have operated by free excision. The method is as follows: The tumor is removed by wide excision. After ten days or two weeks the edges of the wound are touched with the Paquelin cautery in order to raise a superficial dermatitis; as soon as this is established, usually within twenty-four hours, five minims of a pure culture of Fehleisen's coccus (intensified by passing through a rabbit) are injected just beneath the epidermis, where the lymphatic vessels are engorged as a result of the inflammation. This is usually followed within a few days by well-marked localized erysipelas with exacerbation of temperature. In about three weeks this treatment is repeated, and again in about two months. Under some conditions one

Fig. 930.—Round-cell sarcoma. (After Green.)

may have to repeat this as many as half a dozen times before the virus will take effect and typical erysipelas result. This method is still under trial, but deserves consideration, and is justifiable as an experiment in view of the hopeless condition which a sarcoma presents. The great secret of success in the preservation of life is, however, early operation, as well as the after-inoculation with erysipelas.

Special Forms of Sarcoma—Round-Cell Variety.—The cells are analogous to the embryonic elements of the ordinary inflammatory process, from which they can not be distinguished. They possess one or more nuclei and nucleoli, and are spherical, or with slightly irregular outlines from reciprocal pressure. The intercellular substance is homogeneous, and either very scanty or entirely absent (Fig. 930). The vessels and blood-channels have been described. This variety of sarcoma occurs everywhere. In the neuroglia of the brain and the neurilemma it is called *neuro-sarcoma* or *glioma.*

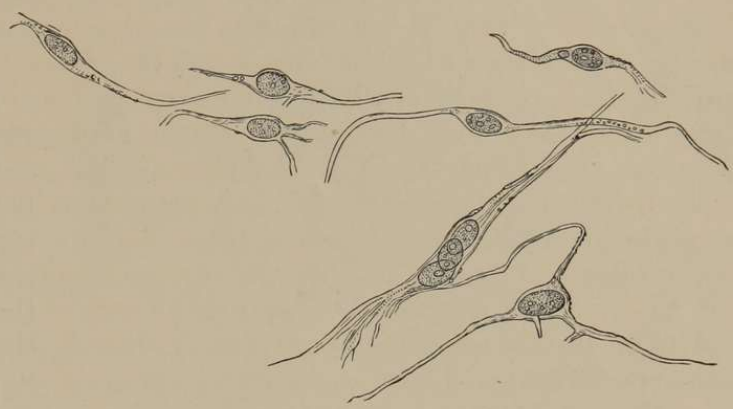

Fig. 931.—Multipolar cells of a sarcoma. (After Cornil and Ranvier.)

Spindle-Cell Sarcoma.—The cells of this variety are elongated or fusiform in shape, containing usually one, at times several, nuclei. The ends of the spindle may be single or bifurcated (Fig. 931). The cells vary in size from $\frac{1}{2500}$ to $\frac{1}{400}$ of an inch in diameter, and are arranged in bundles running in various directions (Fig. 932).

Fig. 932.—Spindle-cell sarcoma. (After Virchow.)

Clinically, this is the most common form of sarcoma. They are slower in development, firmer to the feel, and less vascular, and of smaller dimensions than the preceding variety. As stated, they are somewhat less malignant. They may, in rare instances, be encapsuled, although the rule is to invade the surrounding tissues. The favorite location for their development is the periosteum and in the substance of the bones.

They attack the glandular structures, not infrequently affecting the breast. While developing here, the increased vascularity of the neoplasms induces hyperæmia of the glandular apparatus of the breast with consequent proliferation of the epithelia, a condition which has been termed by Billroth adeno-sarcoma.

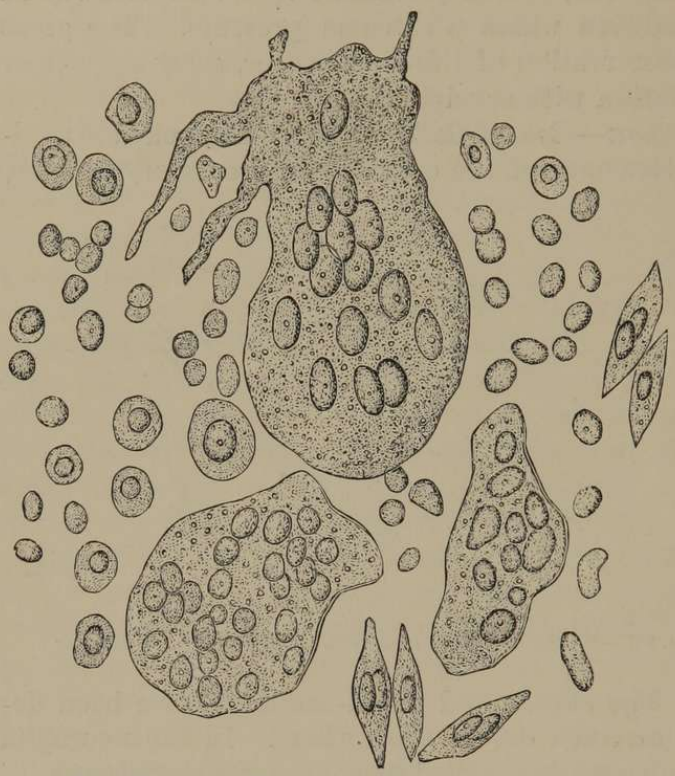

Fig. 933.—Giant-cell sarcoma. From a sarcoma of bone. (After Ordonez.)

Giant-Cell Sarcoma.—The cells of this neoplasm are of all sizes and shapes: spherical, fusiform, and irregularly oval, having at times one, at others thirty or more nuclei (Fig. 933). They closely resemble the cells of the normal marrow of fœtal bones. Clinically, this form of sarcoma is met with usually in the bones, especially in the lower jaw and the long bones. It may develop to an enormous size, remaining practically confined to a single bone; less frequently spreading to the surrounding soft parts. Bones so affected at times become friable, being readily fractured from the body-weight, or yield a crackling sound upon palpation.*

NON-MALIGNANT NEOPLASMS.

The *non-malignant epitheliomata* are the dry, pavement, or pearl-like epithelioma, papilloma, the adenoma, and the cystic tumors.

The *pearl epithelioma* is of rare occurrence. Microscopically, it is found to be closely akin to the bird's-nest tumours, which are classed with the malignant growths. The cells of the non-malignant and rare neoplasm are, however, flat, and collected in little dry, pearl-like bodies, gathered in clusters, and held together, or surrounded by a connective-tissue stroma. Occasionally, cholesterine crystals are seen in these bodies, and this fact induced Müller to name this form of neoplasm "*cholesteatoma.*"

The proper treatment is removal with the knife.

* For a consideration of the various mixed varieties of sarcoma, viz., osteoid, neuro- and lipo-sarcomata, angiolithic sarcoma, etc., the student is referred to the text-books on pathology, and especially to the excellent work of Cornil and Ranvier, which the author has drawn from extensively.

Papilloma.—A papilloma is a neoplasm, in structure not unlike the normal papillæ of the skin and mucous membranes. Each papilla possesses a connective-tissue framework which supports one or more new-formed vascular loops, and the whole is covered in with one or several layers of epithelia.

They may be met with upon the cutaneous, mucous, or serous surfaces.

The most frequent form of papilloma is the ordinary "wart." The hard or cutaneous wart is often seen upon the hands; the soft or mucous wart is frequently met with upon the prepuce, vulva, and anal margins. Corns are also classified as papillomata.

Mucous warts grow more exuberantly than those of the skin. Upon the prepuce, where they are kept moist and are subjected to irritating secretions and to friction, they form at times enormous masses. Hæmorrhage is a common accident, and sloughing, with the emission of a most offensive odor, is the rule in these larger neoplasms.

Essentially benign papillomata may, by long-continued irritation, be converted into, or replaced by, an embryonic neoplasm of a malignant type.

Treatment.—The indication is to destroy them at once. The best method to pursue is to grasp them with forceps, clip them off with scissors close to the attached margin, and apply nitric acid to the bleeding base of the neoplasm. Anæsthesia is obtained by moistening them for several minutes with a 4-per-cent solution of cocaine hydrochlorate. The nitric acid leaves a yellow stain, which is objectionable when the growth is situated upon an exposed surface.

Adenoma.—Adenomata are neoplasms the structure of which is analogous to gland-tissue. Following this analogy, they are of the racemose and tubular varieties. The racemose adenomata are extremely rare. They are composed of collections of acini held together by a varying quantity of connective tissue, and lined with epithelium. They may develop in all parts of the economy where the racemose glands are found. A favorate location is the mammary gland, occasionally the parotid, the lachrymal gland, and the roof of the mouth. They are slow in growth, are spherical in shape, and are freely movable in the structure in which they develop.

Tubular adenoma is more frequently observed than the racemose variety. The tubules are in some cases separated by a layer of new-formed connective tissue, while in others there is no perceptible intertubular stroma. The tubules may be single, but are more frequently bifurcated, and, as in the normal glands, commence in blind extremities and open upon the mucous surface. They are lined with one or more layers of glandular epithelium. These tumors are seen in the rectum and colon, in the uterus, especially the cervix, and occasionally in the nose (Fig. 934).

They are spherical or pyriform masses, covered with mucous epithelium as long as they are contained within the cavities; but when, by reason of excessive growth, they are exposed to the air, the covering becomes hard and smooth, like the epidermis.

Cysts.—A cyst is a tumor composed of a limiting membrane or capsule of connective tissue, lined by epithelium and filled with fluid or semi-fluid contents. The contained matter may be mucoid or colloid material, or sebaceous matter and epithelial cells in various conditions of degeneration.

Sebaceous cysts occur upon all portions of the external surface, and in rare instances develop in the deeper tissues.

The external sebaceous tumors are seen very frequently upon the face and scalp, and vary in size, measuring at times an inch or more in

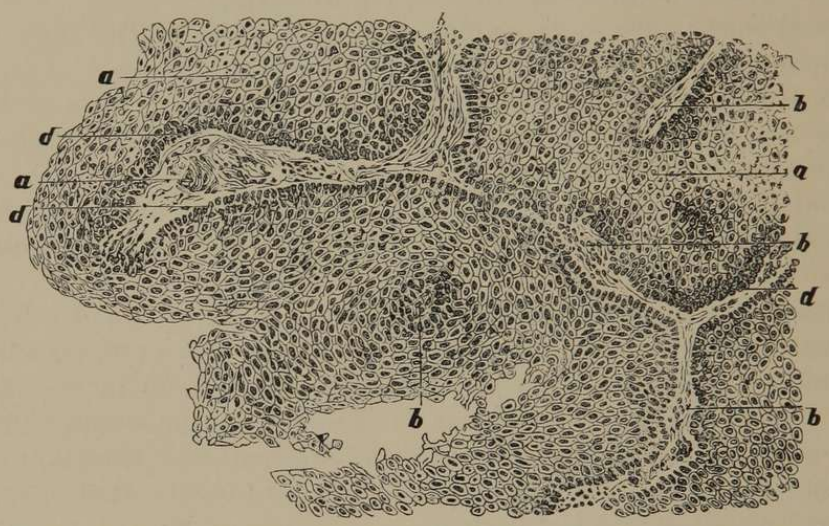

FIG. 934.—Nasal polypus. *a*, Pavement epithelia, of which the deeper layers, *d*, are cylindrical, and are arranged along the edges of the papillæ, *b*. A vessel is shown at *b*. (After Cornil and Ranvier.)

diameter. They are spherical or flattened tumors, soft and elastic to the touch, and freely movable upon the subcutaneous tissues.

The contents may be a white, cheesy matter or more fluid, and of an amber or brown color. Examined microscopically, it is seen to be composed of epithelial cells which have undergone a more or less complete granular metamorphosis, loose granules, compound granular corpuscles, cholesterine crystals, rudimentary hairs, etc. The wall of the cyst varies in thickness, being at times very thin and closely adherent to the surrounding structures, and at others thick and easily detached. Those upon the hairy scalp, commonly known as "*wens*," are usually filled with an amber-colored, jelly-like mass, which escapes upon section or puncture of the cyst. Upon the face, or other cutaneous surface, the contents are apt to be cheesy in character.

They are caused by cell-proliferation and the accumulation within the hair-follicle and communicating sebaceous gland of its normal secretion, which can not escape, owing to the partial or complete occlusion of the excretory duct. Cutaneous cysts, from direct violence, and often without any appreciable cause, may inflame and suppurate.

Dermoid cysts are closely analogous to the preceding, although situated in the deeper structures. They consist of a limiting membrane, and liquid and solid contents. In addition to the changed epithelial cells and

granular matter, these tumors often contain tufts of hair, rudimentary teeth, etc. They occupy by preference the ovary, but are met with in all parts of the body.

Mucous cysts are usually seen upon the lips, buccal cavity, vulva, and anus. They may occur in any portion of the alimentary or respiratory passages, or in any of the cavities lined by mucous membrane. The wall is thin, lined with epithelium, and adhering to the surrounding structures. The contents are a viscid mucus, resembling the white of an egg. The cause of the tumor is obstruction of the normal excretory duct. The character of the tumor may be suspected from the location and the spherical shape. A slight puncture, with compression, will reveal the mucous character of the contents.

Serous Cysts.—Cysts of the smaller serous cavities may result from hypersecretion of the normal fluid by the epithelia lining the serous membrane, in which the excess is not reabsorbed. The swellings often observed upon the back of the wrist and hand, and sometimes upon the dorsal aspect of the foot, are typical serous cysts, and result from hyperdistention of normal serous bursæ.

Lipoma.—A fatty tumor is a circumscribed collection of adipose tissue growing independently of the other tissues. Lipomata usually develop in the subcutaneous cellular tissue, and are frequently met with about the back of the neck and shoulders. From this location they occasionally are carried by gravity toward the sacrum, slipping downward between the integument and deep fascia. Situated superficially, they grow to be irregular and spherical or pyriform tumors of varying size; are usually single, but may be multiple. Less often they are met with in the glands, muscles, bones, and in the abdominal viscera.

Microscopically, they are composed of vesicles filled with oil or fat. The vesicles are connective-tissue corpuscles, the nuclei of which are displaced to the periphery and compressed against the investing membrane of the vesicle. These vesicles are held together in clusters of various size by a stroma of fibrous tissue, in the meshes of which the blood-vessels run. The whole tumor is in turn encapsuled.

Various names have been given to certain complex fatty tumors; when the inter-vesicular substance is myxomatous, *myxo-lipoma;* when the connective tissue is excessive, *fibro-lipoma;* in bone, *osteo-lipoma;* when very vascular, *angeio-lipoma*, etc.

Lipomata may undergo granular and calcareous metamorphosis, and may also become inflamed and break down as a very offensive and sloughing mass. They are altogether benign, and can only cause death by ulceration, sepsis, and hæmorrhage, or by pressure upon important organs.

The *diagnosis* depends upon the soft, uneven feel and the mobility of the mass. It is only to be differentiated from old abscesses or cystic tumors. If the history does not point to the diagnosis, the aspirator-needle will be of service.

The treatment is removal with the knife. The incision may be straight for a small tumor, but should be elliptical for large growths, in order to

do away with redundancy after the tumor is turned out. The capsule should be opened, and the tumor may be turned out almost wholly with the fingers.

Fibroma.—This variety of neoplasm is made up of fibrous tissue, the filaments of which are at times arranged in bundles which run in all directions; at others, there is little or no fascicular arrangement, the filaments being entangled in all directions. In the interstices of the bundles, or between the fasciculi, are found connective-tissue cells, the poles of which communicate with each other. The vascular supply is limited. Fibromata develop chiefly in the skin and subcutaneous tissues and periosteum, but may exist in any other portion of the body. They are usually single and small, occasionally multiple, and this form of tumor may attain an enormous size. In shape, those developing from the deeper tissues are spherical, and are hard to the touch. In the skin they are often pedunculated and pyriform. Fibromata may undergo a mucoid, granular, or calcareous degeneration, and are subject to inflammation and suppuration, as are other neoplasms. Possessing a low degree of vascularity, the danger of hæmorrhage is not great, unless a rich granulation-tissue has sprung up as a result of prolonged irritation.

Simple fibroma is benign, and the indications in treatment are removal by the knife.

Myxoma.—This neoplasm is made up of primitive connective-tissue cells, similar to those observed in the umbilical cord at birth. The cell-elements are spherical and fusiform in shape. The former are isolated and float freely in the gelatinous-like intercellular substance. The latter may possess two or more poles, and anastomose freely with each other, forming a continuous network or stroma throughout the mass. The vascular supply is rich. These neoplasms occur, as a rule, in the skin and subcutaneous tissues and upon the mucous surfaces, especially in the nose (mucous or soft polypi). They may develop, however, in any portion of the body, and have been observed in the muscles, bones, and nerves, the mammary gland, kidney, brain, etc. In shape, they are usually spherical, of small size, and are soft and doughy to the touch, and not painful unless by accident the sensory nerves are pressed upon by the tumor. As a result of rupture of the blood-vessels, cysts frequently occur in this variety of neoplasm.

The treatment is early and complete removal. Pure myxoma does not tend to recur after a thorough removal. In some instances, owing to the peculiar location of the neoplasm, a thorough extirpation is impossible, and in these cases the tumor may rapidly recur. The cases of general metastasis after supposed myxoma were probably instances in which the sarcomatous nature of the growth had been overlooked.

Myoma is a tumor composed of new-formed muscular elements. There are two varieties, namely, those composed of *striated* or voluntary, and those of *non-striated* or involuntary muscular fibers.

The first variety is extremely rare, and is of less clinical importance than the non-striated myoma.

In two instances the striated myoma has been seen in a congenital

tumor of the testicle, and in a few other instances of tumors developed wholly or in part in the embryo or fœtus. Dermoid cysts at times contain traces of striated muscle.

A *diagnosis* can only be made out by the recognition, under the microscope, of the characteristic striated muscular fiber. The *prognosis* is favorable, owing to the benign nature of the tumor, which, nevertheless, should be removed as soon as recognized.

In the non-striated myoma the fusiform elements are arranged in all directions, either in bundles or groups which interlace, or there may be a general interlacing of the separate elements without fascicular arrangement, as in many of the organs in which the smooth muscle is found. Between these bundles true connective-tissue cells exist, and in these spaces the vessels are found. The nuclei of these new-formed elements, as well as the muscle-elements proper, do not differ materially from the normal non-striated muscular fibers.

Non-striated myomata are often met with in the uterus. In many of these neoplasms there is a variable quantity of connective tissue, more or less organized, and for this reason the term fibro-myoma has been given to these tumors. They may grow from the wall of the uterus, toward the peritonæum (*extra-mural*), or develop in the substance of the uterine muscle, become encapsuled (*inter-mural*), or project from the internal surface into the cavity of this organ (*sub-mucous myoma*, *intra-mural*).

This variety of neoplasm has also been seen in various other localities, as the skin, alimentary canal at various points, the prostate, scrotum, etc. The diagnosis depends upon the recognition of the characteristic fusiform elements under the microscope. The method advocated by Cornil and Ranvier is to macerate the sections in azotic acid, twenty parts to one hundred of water, or caustic potassa, forty parts to one hundred of water. By this process the connective-tissue stroma is dissolved and the muscular elements liberated.

The prognosis in this form of myoma is favorable as far as recurrence is concerned when the removal has been thorough. They not infrequently produce death, either directly by pressure and interference with the normal functions of organs necessary to life, or indirectly by causing hæmorrhage, rendering the individual more likely to perish from some intercurrent affection.

Treatment.—They should be removed, when this can be done with a justifiable degree of safety.

Neuroma.—A tumor composed of new-formed nerve-tissue is rarely met with. Many so-called neuromata are connective-tissue neoplasms springing from the neurilemma. They may be made up of *nerve-cells* or *nerve-fibers* (Fig. 935).

The former are even rarer than the latter. Small particles of gray matter have been seen in dermoid cysts, and in a few instances neoplasms of this variety have been seen in the brain and spinal cord.

Fascicular neuromata may occur in the nerves. They exist as slight elliptical swellings or enlargements of the nerve involved, may be

single, or there may be a succession of nodosities in the course of the nerve.

The *symptoms*, in addition to the tumor, which may at times be made out by palpation, are those of pain or interference with the function of the part involved. A careful analysis with the microscope alone can determine an accurate *diagnosis*.

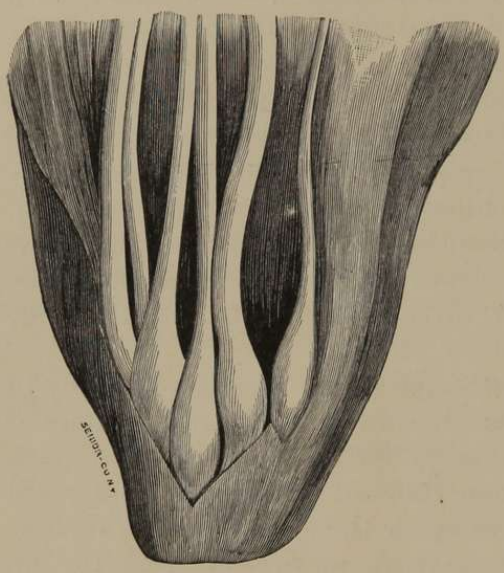

Fig. 935. — Neuromata developed in the divided nerve-tissues after amputation of the member. (After Cornil and Ranvier.)

The *prognosis* is not grave, in so far as the life of the patient is concerned, but the removal of the neoplasm may of necessity involve an injury of the trunk in or upon which it is located, and in this manner may add an element of gravity to the result. They should be extirpated, and, where (as will almost always be the case) the positively benign character of the neoplasm is not evident, a section of the nerve below and above the tumor, as well as a portion of the surrounding tissues, should be removed.

Angioma.—The angiomata are tumors of new-formed vessels, capillaries, arterioles, or veins. They are frequently congenital, and may also appear at any period after birth.

Microscopically, the simple forms are made up of capillaries, arterioles, and veinules in plexuses richer than the normal, and held together by a connective-tissue stroma of varying thickness. In the more formidable tumors—*cavernous nævi*—the vessels are larger, with thickened walls of dense connective tissue, and at times a quantity of nonstriated muscular fibers. The *vasa vasorum* are also met with in the walls of the sinuses.

The former variety appear as red or bluish spots or stains in the skin, of various sizes and shapes, at times rising above the level of the integument.

The method of *treatment* is fully described in the chapter upon diseases of the vascular system.

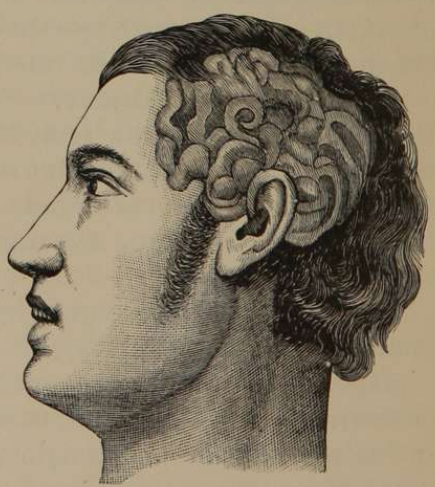

Fig. 936.—Angioma (cirsoid aneurism) of the temporal region.

Lymphangioma.—Tumors composed of new-formed lymphatic vessels are very rarely met with. In their construction they do not materially differ from the angiomata. The new tissue consists of a capillary

network of lymph-channels, in arrangement analogous to the capillary vessels in the smaller angiomata.

In the case shown in Fig. 937 I removed by dissection a plexus of lymphatic vessels about as large as a hen's egg. The walls were sacculated, and the vessels were distended with clear lymph. Situated in the cheek, this form of tumor may be mistaken for retention of parotid secretion due to stricture of Steno's duct or its occlusion by calculi. In other instances the lymph canals have a cavernous arrangement comparable to the structure of the cavernous nævus described in the article on vascular tumors.

Lymphadenoma.—Many forms of enlargement of the lymphatic glands are not true tumors, since they are not composed of new-made gland tissue, but are due to cancerous infiltration, to tubercle, to syphilitic adenitis, tubercular deposit, etc. Tubercular lymphomata should always be extirpated when tuberculosis of the deeper organs can be excluded, provided that the operation of removal does not involve a too great risk of life. The removal of enlarged glands from metastasis in cancer should also be done when there is a reasonable hope of cutting off the disease from the centers.

Fig. 937.—Lymphangioma of left buccal wall.

Chondroma.—New formations of cartilage develop in and from the connective-tissue cells of any portions of the body, excepting from cartilage proper. The bones and periosteum are favorite points of origin for these neoplasms. Developing from within the bone, a cartilaginous new formation is termed an *enchondroma;* if from the periosteum, a *perichondroma.* Quite a number of chondromata have been observed in the testicles and in the parotid glands. They may assume all sorts of shapes, growing into more or less spherical tumors, or the new tissue may be generally diffused in the normal tissue.

In the bones of the hand and fingers they give rise to marked deformities and to considerable pain, from displacement of the normal structures, and interference with nutrition (Fig. 938).

The new formation of cartilage is preceded by an inflammatory process varying in intensity, usually of a mild nature, yet resulting in the proliferation of the cells of the part involved, and the formation of an embryonic tissue from which the cartilage is formed, as in the normal development of this tissue. Some of these cells become the cartilage cells proper, and are collected in groups of different sizes, while others

form a connective-tissue stroma around the collections of cartilage cells. The vessels find their way along these bundles of connective tissue.

The proportion of connective-tissue stroma varies in different tumors. When the cartilage cells and groups are plentiful, with a limited quantity of intervening fibrous tissue, the mass is strictly a *chondroma.* When the stroma preponderates, it is termed a *fibro-chondroma.* In certain forms of these tumors there is a paucity of connective-tissue fibers

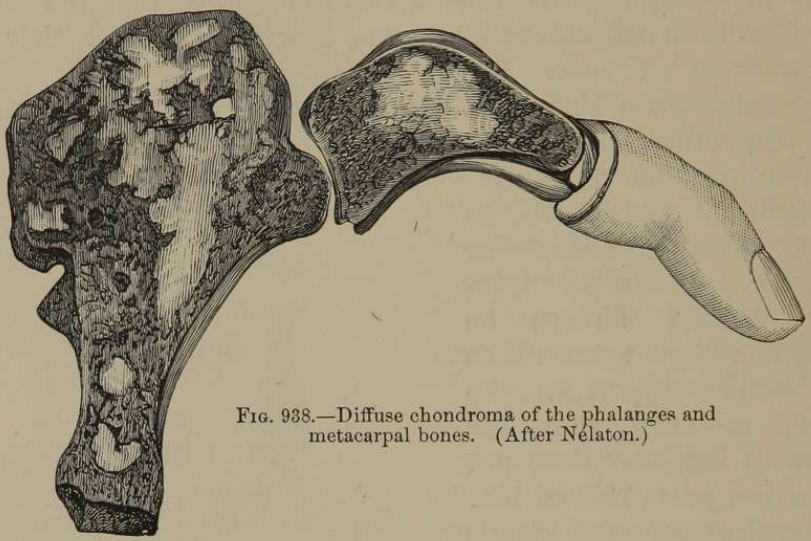

Fig. 938.—Diffuse chondroma of the phalanges and metacarpal bones. (After Nélaton.)

as well as cartilage cells, although both are present in quantity sufficient for recognition. The mass of tissue may be *embryonic*, and, under such conditions, the tumor may be sarcomatous in character. Simple chondroma is benign, but a mixed chondroma of an embryonic-tissue type must be classed with the malignant neoplasms.

Chondromata may undergo fatty or granular degeneration, may ossify in part, may become infiltrated with calcareous matter, or undergo the mucoid change.

Treatment.—Removal is indicated when pain is unbearable, or when the sarcomatous nature of the neoplasm is evident.

Osteoma.—Tumors of new-formed bone tissue may develop from the normal bone and periosteum, or in the tissues removed from the bones. There are three varieties—the *eburnated*, *compact*, and *spongy*.

In the first, or ivorylike neoplasms, the bone is exceedingly dense and hard, and contains bone corpuscles and canaliculi, which, though well marked, are more irregular in arrangement than in normal forms. This new-formed bone tissue, however, does not possess blood vessels. These tumors are especially apt to be observed upon the bones of the skull, notably those of the frontal and parietal regions.

The compact or spongy neoplasms are in structure analogous to the normal compact or spongy bone substance. In the latter the bony framework is light, and the medullary spaces larger than normal.

An osteoma formed upon the outside of an old bone is called an *exostosis;* developed within the medullary space, an *enostosis.*

Exostoses grow as more or less well-rounded tumors beneath the peri-

osteum, or as sharp spikes or thorns projecting from the bone. Such spines are in the great majority of instances directed upward (stalagmites) in the axis of the tendon in and about which they develop. In rare instances the direction is downward (stalactite).

Bony neoplasms may also develop in any of the cartilaginous tissues of the body, and this change is usually one of senility. Beyond this, bone may form in the muscles, choroid, the serous membranes in all locations, and in the integument.

Osteomata are always benign. If dangerous at all, it is from compression of important organs. Those developed from the internal surface of the cranial bones and along the vertebral canal are especially dangerous in this respect.

Treatment.—Interference is not called for, unless pressure upon important organs renders it necessary.

Keloid.—Keloid, a formation of scar tissue either resulting from a traumatism—i. e., in the scar of a wound which is healing—or without any apparent cause, is frequently met with in surgical practice. According to A. R. Robinson, it is a circumscribed connective-tissue new growth of the skin characterized by the appearance of one or more irregular, elevated, firm, smooth, reddish, somewhat elastic tumors. The cause of keloid is not as yet understood. It is a connective-tissue proliferation of peculiar type, which, as the process of fibrillation goes on, occludes the vascular supply of the part, and yet not to such a degree as to cause retrograde changes or absorption of the new tissue. Traumatic or *false* keloid is elevated from one eighth to one fourth or one half an inch above the level of the surrounding skin, and usually assumes the shape of the scar in which it has developed, while *true* keloid begins as a small nodule situated in the skin, becoming multiple in almost all cases. As a rule, these nodules develop to a certain size, growing for two or three years, then seem to reach their limitations and remain stationary for an indefinite period. Occasionally they undergo atrophy, but this is the exception; they usually last for life.

Treatment.—The treatment of keloid is one of the discouraging features of surgical practice. It is almost always an incurable disease, but rarely, if ever, destroys life. Sometimes the tumors disappear under the application of adhesive straps, which cause at least temporary atrophy, and the same result has been noticed in some tumors under the persistent application of flexible collodion. Dr. J. W. White reports a case of a young girl who received a lacerated wound of the face from broken glass. A disfiguring keloid developed in the cicatrix. All treatment was futile until she was given daily two to four doses each of five grains of thyroid extract. The scar was covered with a film of collodion to protect it from abrasions and to keep up gentle pressure. In six weeks the scar in its entire length had come down to the level of the skin, where it remained. The improvement seemed to be permanent.

I have removed these tumors in several instances, extirpating the skin and subcutaneous connective tissues freely away from the neoplasm, but recurrence took place in each case.

INDEX.

Abbe's treatment for œsophageal strictures, 594.
Abdomen, 610; abscess of, 674; affections of, 610; bandage for, 162; contusion of, 695; gunshot injuries of, 696; penetrating wounds of, 696; treatment of penetrating wounds of, 697; wounds of, 695.
Abdominal aorta, aneurism of, 296; ligation of, 334; ligation for iliac aneurism, 297; hysterectomy, 866; section, 625; viscera, wounds of, 699.
Abscess, 20; abdominal, 674; acute, 20; after caries, 20; alveolar, 549; ano-rectal, 761; aspiration of, 26; circumscribed, 21; chronic, 21; cold, 21; diagnosis of, 26; treatment of, 23; diffused, 20; in phlebitis, 241; membrane of, 21; metastatic, 28; of antrum of Highmore, 549; of cornea, 491; of frontal sinus, 462; of frontal sinus, treatment of, 462; of groin, 649; of jaw, 548; of joints, 28; of kidney, 729; of liver, 687; of mammary gland, 598; of neck, 574; of ovary, 874; of parotid gland, 548; of scalp, 461; of spine, 20; of spleen, 694; of testicle, 843; of thoracic wall, 607; of thyroid gland, 576; of tongue, 565; of tonsils, 570; of vulva, 848; perirectal, 706; perityphlitic, 681; retropharyngeal, 574; retroperitoneal, 674, 896; of spleen, 694; spinal, 896; subacute, 20; subphrenic, 689; wall, 21.
Absorbable animal drains, 84.
Absorbent dressings, 85.
Acceleration of blood current in inflammation, 3.
Accidental amputation, 168.
Accommodation, 505.
Acetabulum, fracture of, 380.
Acetanilide, 87.
Acid, boric, 86; for surgery of eye, 477; carbolic, for angeiomata, 477; near the eye, 477; chromic, for catgut, 81; nitric, in capillary hæmorrhoids, 726; in phagedenic ulcers, 831; oxalic, in sterilizing the hands, 92.
Acromegaly, 248.
Acromion process, fracture of, 364.
Actinomycosis, 37, 42; of bone, 348.
Active ulcer, 149.
Actual cautery as a hæmostatic, 122; in hæmorrhoids, 726;
Acupressure, 120.
Acupuncture in treatment of aneurism, 273.
Acute gangrene, 151.
Adams. Osteotomy of femur, 914.
Adenitis, 235; acute infective, 235; axillary, in diseases of the mammary gland, 602; cervical, 236, 575; inguinal, 800, 830; syphilitic, 57, 59, 237.
Adenoma, 957; of intestine, 624; of kidney, 733; of lip, 533; of mammary gland, 598; of testicle, 845.
Adeno-sarcoma, 950.
Adhesions of intestines, 622; of labia, 848; of prepuce, 825; tendons, 939.
Adhesive plaster in wounds, 130.
Adipose tissue, 7.
Administration of chloroform, 115; of ether, 109; of ether *per rectum*, 115.
Advancement of insertion of eye muscles, 506.
Aërobic bacteria, 17.
After-treatment of amputation, 178.
Agnew's canalicula knife, 486.
Air tumor of scalp, 461.
Albumin in urine, 758; tests for, 758.
Alcohol for catgut, 79.
Alcoholism, cause of arteritis, 244.
Alexander. Case of aneurism, 295; operation of, 880.
Alimentary canal, obstruction of, 618.
Alligator forceps, 584, 816.
Allingham. Ulcer of rectum, 710.
Allis, Oscar H. Brain surgery, 474; ether inhaler, 114.
Alopecia, 59.
Amaurosis, 504.
Amblyopia, 504.
Ametropia, 506.
Ammonio-magnesia calculi, 764.
Amœba, 17.
Amputation, 168; after-treatment in, 178; at ankle joint, 206; at calcaneo-astragaloid joint, 204; at carpo-metacarpal joint, 186; at carpo-radial joint, 189; at elbow joint, 191; at hip joint, 218; at knee joint, 215; at shoulder joint, 196; at tarso-metatarsal joint, 200; at tibio-tarsal joint, 206; by circular skin flaps,

173, 179; by circular solid flaps, 173; by double crescentic flaps, 178, 180; by double rectangular flaps, 181; by mixed flaps, 181; by modified circular flaps, 180; by oblique solid flaps, 178; by oval flaps, 180; continuous irrigation for, 182; Estes's views on, 170; for malignant tumors, 953; knives, 95; mediotarsal, 204; methods of, 173; of Bruns, 210; of Carden, 216; of Chopart, 204; of Esmarch, 186; of Forbes, 203; of Gritti, 217; of Gunther, 210; of Hancock, 205; of Hey, 202; of Lee, 213; of Le Fort, 208; of Lignerolles, 204; of Lisfranc, 202; of Malgaigne, 203; of Pirogoff, 208; of Sedillot, 213; of Stephen Smith, 212, 215; of Syme, 206; of Teale, 213; of Textor, 204; of Wyeth, 196, 218 ;of arm, 193; of breast, 604; of cervix uteri, 863, 865; of fingers, 183; of foot, 206, 210; of forearm, 190; of hand, 183; of index finger, 186; of leg, 211; of little finger, 186; of middle finger, 186; of mammary gland, 604; of penis, 824; of prepuce, 826; of ring finger, 186; of scapula, 198; of superior extremity, 196; of tarsus, 204; of thigh, 217; of thumb, 185; of toes, 199; open method of treating, 181; prognosis in, 168; primary, 168; secondary, 168, 169; special, 183; tibio-tarsal, 141; transfusion in, 171.

Amussat. Colostomy, 668.

Amylaceous bodies in prostate, 796.

Amyloid degeneration of the viscera, 897.

Anaërobic bacteria, 17.

Anæsthesia, 103; by rectum, 115; cocaine, 103; danger in, 113; general, 107; infiltration, 106; local, 103, 106; morphine, 116; of male urethra, 807; preparations for, 109; tracheotomy in, 113; whisky, 116.

Anæsthetics, 103, 107; chloroform, 107, 115; cocaine, 103; ether, 107, 110.

Anatomical relations of arteries of lower extremity, 339; arteries of neck, 307; arteries of upper extremity, 329; bones of carpus, 446; bones of foot, 203, 926; large vessels of aorta, 324; muscles of lower extremity (transverse sections), 214; muscles of upper extremity, 192; organs of female pelvis, 849, 883; organs of male pelvis, 644, 790, 791; organs of thoracic and abdominal cavities, 611; parts of elbow, 455; parts of foot, 452; parts of groin, 647; parts of hand, 456, 458; parts of head, 467, 472; parts of hip joint, 447; parts of knee joint, 449; parts of neck, 312, 313; parts of perinæum, 784; parts of peritonæum and bladder, 702, 781; parts of shoulder joint, 454; parts of urethra, 790, 791; parts of vulva, 848; rectum and anus, 790, 791; tunica vaginalis and peritonæum, 837, 838.

Anastomosis aneurism, 260; of intestine, 628, 634, 636, 638, 639.

Anchylosis of elbow, 933; of hip, 908; of jaw, 558; of knee, 916; of shoulder joint, 933.

Anderton. Case of aneurism of both vertebral arteries, 295.

Anel's syringe, 487; treatment of aneurisms, 270, 272.

Aneurism, 266; after wounds, 268; anastomotic, 260; arterio-venous, 301; aspiration of, 269; by anastomosis, 260; cirsoid, 258; diagnosis of, 267; diffuse, 268; dissecting, 267; false, 268; fibrillated, fibrin in, 267; fusiform, 267; needle, 96; of abdominal aorta, 296; of aorta, 274; of arch of aorta, 276; of axillary artery, 295; of brachial, 295; of carotid, 282; of common carotid, 282; of common iliac artery, 297; of descending aorta, 274; of external iliac artery, 297; of femoral artery, 299; of gluteal artery, 299; of iliac artery, 297; of innominate artery, 279; of internal mammary, 295; of ophthalmic artery, 284; of peroneal artery, 301; of popliteal artery, 300; of profunda femoris, 299; of radial artery, 295; of sciatic artery, 298; of subclavian artery, 281, 285; of thyroid gland, 576; of thoracic aorta, 274; of tibial artery, 301; of ulnar artery, 295; of vertebral artery, 295; prognosis of, 268; sacculated, 267; special, 281; spherical, 266; symptoms of, 268; treatment of, 269, 280; by acupuncture, 273; by Anel's method, 270, 272; by Antyllus's method, 270; by Briddon's method, 272; by Brasdor's method, 270, 272; by Crosby's method, 272; by compression, 270; by compression with fingers, 271; by compression with instruments, 271; by flexion, 274; by Hunter's method, 270, 272; by injection, 274; by iodide of potassium, 270; by massage, 274; by mercury, 270; by Tufnell's method, 269; by Valsalva's method, 269; by Wardrop's method, 270, 272; by wire, 274; by Wyeth's pins, 274; true, 266; varicose, 267.

Aneurismal varix, 301.

Angeioma, 260, 962; cutaneous, 260; diffuse, 260; encapsulated, 260; near the eye, 477; of intestine, 624; of kidney, 733; of larynx, 587; of lower jaw, 555; of mammary gland, 598; of scrotum, 833; plexiform, 260.

Angio-lymphoma, 962.

Animal ligatures in aneurisms, 273.

Ankle joint, amputation at, 206; dislocation of, 423; exsection of, 451; osteo-arthritis of, 443.

Annandale. Case of aneurism, 279.

Anterior synechia, 493.

Anterior tibial artery, 343.

Antero-posterior curvature of the spine, 892.

Anthrax, 43; bacillus of, 43; treatment of, 44.

Antitoxine of diphtheria, 74; of tetanus, 48; Tizzoni's, 48.

Antisepsis, 79.

Antiseptics, 86.

Antiseptic solutions, 86.

Antrum of Highmore, 548; abscess of, 548; diseases of, 549; drainage of, 549; tumor of, 549.
Antyllus's method of treating aneurism, 270.
Anus, absence of, 701; artificial, 667; atresia, 701; cancer, 715; eczema, 703; erythema, 704; fissure, 708; fistula, 705; neoplasms, 715; neuralgia, 704; pityriasis versicola, 704; pruritus, 703; ulceration, 709.
Aorta, abdominal, aneurism of, 295; ligation of, 334; for iliac aneurism, 297; aneurism of, 274; compression of, for hæmorrhage from wounds, 127.
Aphasia, operation for, 469.
Aphthæ epizooticæ, 49.
Aponeurosis, palmar, contraction of, 937.
Apparatus for cyphosis, 893; for exstrophy of bladder, 742; for fracture of lower jaw, 359; for knock-knee, 913; for talipes, 917, 919, 925, 928; for torticollis, 886.
Appendicitis, 675; gangrenous, 678; McBurney's incision in, 680; operation for, 680.
Arch of aorta, aneurism of, 276.
Arcus senilis, 494.
Arendt. Case of aneurism, ligation of innominate artery, 286.
Arm, amputation of, 193; bandage for, 159.
Arsenic in malignant lymphoma (Billroth's disease), 238.
Arsenious acid paste, 948.
Arterial cutaneous tumor, 258; cirsoid tumor, 258; embolism, 241; hæmorrhage, 118; occlusion in gangrene, 151; thrombosis, 241.
Arterial tumors, 258; varix, 258.
Arteries, 243; calcification of, 249; ligation of, 304; Wyeth's experiments upon, 246.
Arterio-venous aneurism, 301.
Arteritis, 243; acute, 244; coagulation necrosis in, 250, 252; deformans, 251; iodiopathic, 249; pathogeny of, 244; pathological anatomy of, 249; rheumatic, 256; sequelæ of, 244; syphilitic, 252; traumatic, 244; treatment, 256.
Artery forceps, 120.
Artery, ligation and statistics of anterior tibial, 343; of aorta, 334; of ascending pharyngeal, 320; of axillary, 329; of brachial, 331; of circumflex, 339; of common carotid, 307; of dorsalis pedis, 344; of epigastric, 339; of external carotid, 314; of facial, 318; of femoral, 339; of gluteal, 337; of iliac (common), 334; of innominate, 305; of intercostal, 333; of internal carotid, 312; of internal and external iliac, 336; of internal mammary, 325; of internal maxillary, 323; of internal pudic, 335; of lingual, 318; of occipital, 320; of popliteal, 341; of posterior auricular, 322; of posterior scapular, 326; of posterior tibial, 342; of profunda femoris, 341; of radial, 332; of sciatic, 337; of subclavian, 323; of superior intercostal, 326; of superior thyroid, 318; of suprascapular, 326; of temporal, 323; of thyroid axis, 325; of transversa colli, 325; of ulnar, 332; of vertebral, 325.
Arthritis, 426; infective, 426; non-infective, 426; tuberculous, 428.
Articulations, 426; diseases of, 426; inflammation of, 426, 427; sprains of, 426; tuberculosis of, 428; wounds of, 427.
Artificial arms, 667; legs, time to wear, 212; respiration, 113.
Ascarides, 704.
Ascites, tapping in, 685.
Asepsis, 79.
Aspergillus in the auditory canal, 520.
Aspermatism, 795.
Asphyxia, artificial respiration in, 113.
Aspiration of abscess, 26; of abscess of abdomen, 674; of abscess of liver, 687; of abscess of neck, 574; of abscess of spina bifida, 905; of abscess of tongue, 565; of aneurism, 269; of ankle joint, 443; of bladder, 754; of joints for synovitis, 426; of kidney, 729; of knee joint, 388, 440; of pleural cavity, 607; of shoulder joint, 444.
Aspirator, Tiemann's, 754.
Assistants, position of, during an operation, 174.
Asthenopia, 508.
Astigmatism, 506; varieties of, 507.
Astragalus, dislocations of, 424; exsection of, 453.
Atheroma, 249; a cause of gangrene, 151.
Athletes, prone to endarteritis, 247.
Atresia ani, 701; recti, 701; vagina, 858.
Atropine in iritis, 495.
Atrophy of optic nerve, 517; of tongue, 566.
Attrition due to aneurism, 274.
Auchincloss. Case of aneurism, 291.
Auditory canal, 518; accumulation of cerumen in, 519; aspergillus in, 520; furuncles of, 519; foreign bodies in, 519; fungous growths in, 520; neoplasms in, 519.
Auricle, 518; cartilaginous tumors, 518; drooping of, 518; hypertrophy of, 518; instruments, 519; specula, 519; wounds, 518.
Auricular artery, posterior, ligation of, 323.
Ayers's symphyseotomy cot, 857.
Ayers. Case of ligation of subclavian artery, 327.
Axillary artery, aneurism of, 295; ligation of, 429.
Axis cylinder of nerves, 9.

Bacilli, 15; methods of sterilizing, 20, 78.
Bacillus, anthrax, 47; coli communis, 18; fœtidus, 18; lepræ, 72; of blue pus, 18; of diphtheria, 73; of glanders, 45; of green pus, 18; of Lustgarten, 54; of malignant œdema, 49; of Nicolier, 45; of red pus, 18; of tuberculosis, 51; pyocyaneus, 18; pyofluorescens, 18; ruber, 18; saprogenic, 19; smegma, 31; typhoid, 20.

Bacteria, 15; aërobic, 17; anaërobic, 17; classification, 15; conditions for development, 17; origin of, 16; of normal urethra, 31; pyogenic, 17, 20; sterilization of, 20, 78.
Bacterial peptone, 22.
Bacteriology, 15.
Bag, operating, 86, 101.
Balanitis, 36, 798.
Balano-posthitis, 798.
Ballance and Edmunds. Deligation in continuity, 256; phlebitis, 241.
Balsam of Peru and castor-oil dressing, 150.
Bancrofti, filaria, 238.
Bandage, 155; elastic, 126; Esmarch, 99; figure-of-eight, 157; four-tailed, 165; handkerchief, 165; knotted, 164; Martin's, 155; methods of applying, 156, 158; method of preparing, 155; plaster-of-Paris, 156; reverse, 157; roller, 155; spica, 162; spiral, 156; T-, 167.
Bandages, for abdomen, 162; for arm, 159; for axilla, 159; for the breast, 162; for the chin, 165; for the eye, 167; for fingers, 158; for the forearm, 159; for the foot, 160; for the hand, 158; for the hip, 162; for the knee, 160; for the leg, 160; for the shoulder, 159; for the thigh, 160; for the thorax, 162; for the toes, 160; for ulcers, 150; for varix, 264.
Bands constricting the intestine, 622.
Banks, A. E. Dilating filiform bougies, 810.
Barlow. Case of aneurism, 278; syphilitic arteritis, 255.
Barton's fracture, 372.
Barwell. Case of aneurism, 278; operation for club-foot, 921.
Base of skull, fractures of, 355.
Basedow's disease, 579.
Basilar artery, occlusion of, 253.
Basins, 90.
Battey's treatment of Dupuytren's contraction, 937.
Baxter, G. A. A case of amputation at hip joint, 229.
Beall. Hernia cerebri, 463.
Bee stings, 135.
Bellamy. Cysts of lymphatic ducts, 239.
Berger. Cirsoid tumor, 258.
Bickersteth. Case of aneurism, 279.
Biesiadecki. Syphilitic arteritis, 252.
Bifid spine, 905.
Bigelow. Dislocation of hip, 417; lithotrity, 767.
Bilateral lithotomy, 785.
Bilharzia hæmatobia, 748, 762.
Biliary calculi, 619.
Billroth's malignant lymphoma, 237; operation for excision of tongue, 567; varix, 267.
Bistouries, 95.
Black wash, 830.
Bladder, 742; affections of, 742; aspiration of, 754; carcinoma, 756; drainage of, 777; exstrophy, 742; forceps, Wyeth's, 774; foreign bodies in, 786; gunshot wounds, 747; hernia, 745; hypertrophy, 787; inflammation, 748; irrigation of, 750; myoma of, 756; myxoma of, 756; papilloma, 756; paralysis, 752; parasites, 748; puncture of, 745; sarcoma of, 756; suprapubic operation on, 771; rupture, 745; stone in, 763; tumors, 756; wounds, 745.
Blasius, 542.
Blastoderm, 2.
Blepharitis, 479.
Blepharo-phimosis, 825.
Blepharoptosis, 479.
Blepharospasm, 479.
Blood, coagulation of, in wounds, 124; in phlebitis, 241; in the urine, 759, 760; transfusion, 139; platelets, 241.
Bloodless method in amputations, 169.
Blue pus, 18.
Blushing, 1.
Bodine. Colostomy, 637, 669, 715; method of intestinal anastomosis, 637; modification of Trendelenburg's tube, 777.
Boil, 147; in inflammation, 14; of perinæum, 848; of vulva, 848.
Boiled water for wounds, 128.
Boiling as a disinfectant, 80.
Boise, E. Case of hip-joint amputation, 231.
Bone, actinomycosis of, 348; caries of, 346; corpuscle, 11; drills, 97, 450; hydatid cyst of, 348; forceps, 97; hypertrophy of, 61; fracture of, 348; instruments, 97; hæmorrhage from, 101; metastatic abscess in, 26; necrosis of, 346; Paget's disease of, 348; process of repair of, 350; syphilitic lesions of, 59, 61; tumors, *vide* tumors, 943.
Bones, surgery of, 345; of the tarsus, dislocations of, 424.
Boric acid, 86; in surgery of the eye, 477.
Bothrup, 133.
Bowlegs, 915.
Bougie, Banks's, 810; bulbous, 805; Dick's, 804; dilating filiform, 810; flexible, 815; gum, 815; œsophageal, 589; Otis's, 805; oval tipped, 805; rectal, oval, 713; rectal, soft rubber, 714; silk, 815; urethral, 805, 810, 815; whalebone, 810.
Brachial artery, aneurism of, 295; ligation of, 331.
Bradford and Lovett. Hip splint, 433.
Brain, abscess, 467; compression, 354; concussion, 354; fissure of Rolando, 469; gunshot wounds, 355; hernia of, 463; localization of centers in, 467, 469; symptoms of injury to, 467; syphilis, 60; wounds, 473.
Brasdor's method of operating for aneurism, 270, 272.
Braune, frozen sections, 190; *vide* anatomical sections.
Breast, *vide* mammary gland, abscess of, 598; amputation of, 604; bandage, 162; tumors of, 599.

Briddon. Case of hip-joint amputation, 231; double tourniquet, 272.
Broad-jawed forceps, 97.
Broad ligament, cyst of, 875, 876.
Broca. Case of innominate aneurism, 281.
Bromine in hospital gangrene, 42.
Bronchi, foreign bodies in, 582.
Bronchocele, 576.
Brown. Case of aneurism, 300.
Brown, F. T. Case of amputation at hip joint, 230; suprapubic apparatus, 793.
Brownian movement, 16.
Bruit de souffle, 259.
Bruit in aneurism, 267.
Bruns, von. Amputation of foot, 210; cheiloplasty, 543.
Bryant. Arteritis rheumatica, 256; cases of aneurism, ligation of carotid and subclavian, 279; hernia in females, 642; phlebitis, 242, 243; pyæmia, 28; rheumatic arteritis, 256; test for dislocation of femur, 907; test for fracture of neck of femur, 383; varix, 263.
Bubnoff. Ligation of arteries, process of occlusion after, 257.
Bubo, diagnosis, 800; gonorrhœal, 800; inguinal, 800; phagedenic, 830; syphilitic, 57, 59, 237.
Buchanan. Excision of vascular tumors, 260.
Buck's method of extension, 381; for dislocations of knee joint, 423; for fracture of thigh, 381; for osteotomy of femur, 910.
Buds, vascular, forming capillaries in wounds, 125.
Bufo vulgaris, venom of, 134.
Bull. Case of aneurism, ligation of innominate artery, 287; case of hip-joint amputation, 230.
Bullen. Case of ligation of subclavian, 327.
Bullet probe, Nélaton's, 100.
Bunions, 931.
Burns, 139; dressings in, 140; ointment in, 140; skin-grafting after, 140; by chemicals, 147.
Burrows. Cheiloplasty, 543.
Bursitis of shoulder, 443.
Busch. Excision of vascular tumors, 259.
Butlin. Epithelioma of tongue, 567.
Button, Murphy's, 633.

Cabinet, operating, 91.
Cæsarean section, 866.
Calcaneo-astragaloid disarticulation, 204.
Calcaneum, amputation, 204.
Calcaneus, talipes, 919.
Calcareous degeneration of arteries, 249; degeneration of thyroid gland, 576; deposit in veins, 239.
Calcification of arteries, 249.
Calcium sulphide in furuncle, 149; in hordeolum, 479.
Calculous concretions of the gall bladder, 619; of the prostate, 796; of the tonsils, 571.
Calculus, biliary, 619; in the bladder, 763; in the prostate, 796; in the renal pelvis, 731; in Steno's duct, 545; in the ureter, 736; mulberry, 764; renal, 731.
Callaway. Diagnosis of dislocation of humerus, 403, 406.
Callisen. Colostomy, 668.
Callus, 10, 351; pin callus, 351.
Calomel after hysterectomy, 871; in inflammation, 23.
Campbell. Case of aneurism, 282.
Canal, auditory, *vide* auditory, 718.
Canaliculus lachrymalis, obstruction of, 486.
Canalization of cells to form capillaries in wounds, 6.
Cancer, 944; *vide* also epithelioma and carcinoma.
Canthoplasty, 489.
Canula for thyrotomy, 580.
Capillaries, formation of, in inflammation, 6; in wounds, 124.
Capillary cutaneous tumors, 260; hæmorrhoids, 726; hæmorrhage in wounds, how controlled, 118; thrombosis the cause of furuncle, 147.
Carbolic acid for angeioma, 477.
Carbuncle, 14, 148.
Carcinoma, 944; *vide* also epithelioma, 947; of antrum of Highmore, 549; of the anus, 715; of the bladder, 756; of the breast, 702; colloid, 945; encephaloid, 945; of the intestine, 624; of the kidney, 733; of the larynx, 587; of the liver, 685; of the mamma, 702; of the meninges, 464; mucoid, 945; of the œsophagus, 590; of the ovary, 876; of the parotid gland, 546; of the penis, 822; of the prostate, 795; scirrhus, 945; of the testicle, 846; of the thyroid gland, 576; of the tongue, 566; of the tonsil, 572; of the urethra, 821; varieties of, 949.
Carden. Amputation at the knee, 216.
Caries, 345; of bone, 346; of the jaws, 548, 555; of the spine, 897; of the teeth, 549; of the vertebræ, 893; sicca, 347.
Carotid, common, 307; aneurism of, 282; ligation of, 307; external, ligation of, 316; internal, ligation of, 312.
Carpal bones, dislocation of, 412; excision, 456; fractures, 375.
Carpo-radial joint, disarticulation of, 189.
Cartilages, inflammation of, 13; laryngeal, fractures of, 361; wounds of, 124.
Cartilaginous tumors of the ear, 518.
Case, Dr. Meigs. Suspension carriage, 904.
Casts in the urine, 759.
Castration, 846.
Cataract, 498; removal of, 499, 500, 501, 503; symptoms of, 499; varieties of, 498.
Catgut, 79; as ligatures and sutures, 121, 273; chromic, as ligature, 81; as drainage, 84; ligature in aneurism, 273; in wounds, 121.
Catheter, 86; double-current, 750; French, 753; gum, 750; Nélaton's, 750; silk, 753; silver, 753.

Catheterization, 750; of ureter, 739, 741.
Cautery, actual, in rabies, 48; for arterial varix, 258; in hospital gangrene, 42; in inflammation, 23; in phagedenic ulcer, 828.
Cavernous, bodies, fracture of, 822; nævus, 260, 962.
Cells, proliferation of, in fractures, 11; in inflammation, 2; in ostitis, 345; in syphilis, 64; in wounds, 124.
Cellulitis, diffuse, 40.
Centigrade, to convert into Fahrenheit, 18.
Centipede, venom of, 132.
Cerebral localization, 467, 469; hernia, 463,
Cerumen, impaction of, in auditory canal, 579.
Cervical adenitis, 236.
Cervix uteri, amputation of, 863–865; excision of, 863; lacerations, 861.
Chalazion, 479.
Chamberlain. Ligation of axillary artery, 330.
Championnière. Localization of cerebral symptoms, 467; of Rolando's fissure, 469.
Chancre, 56; of the anus, 709; of the rectum, 710; of the vulva, 854.
Chancroid of penis, 829; of rectum, 709; of vulva, 854,
Changes, tissue, in inflammation, 2; in wounds, 124.
Charbon, 43.
Charcot. Localization of brain symptoms, 467.
Cheek, moles of, 533; nævus, 533; plastic operations, 535; wounds of, 530.
Cheiloplasty, 540, 541.
Chemiotaxis, 5.
Chest, 608; gunshot wounds of, 608; injuries of, 608; wounds, 608.
Chiene. Operation for genu valgum, 914.
Chin bandage, 165.
Chisels, 96.
Chloral hydrate in rabies, 50; in tetanus, 48.
Chloroform as an anesthetic, 107; advantages of, over ether, 108; death from, 113; death rate of, 108; in rabies, 50; in tetanus, 48; test for purity of, 115.
Cholecystotomy, 691.
Cholesteatoma, 956.
Cholesterin crystals in pus, 22.
Chondritis, 585.
Chondroma, 963; of finger, 940; varieties of, 963.
Chopart's amputation through the tarsus, 206.
Chordee, 33; treatment of, 33.
Choroiditis, 496, 517.
Chromic acid, as an escharotic in the larynx, 588; catgut, 81.
Chromogenic bacteria, 17.
Cicatrization in wounds, 6, 125.
Circular skin flaps in amputations, 173, 179.
Circumcision, 826; cocaine anæsthesia for, 826.
Circumflex nerve, injury to, in dislocation of humerus, 408.
Cirrhosis of ovary, 874.
Cirsoid aneurism, 258; arterial tumor, 258; "bruit de souffle," 259; case of Tillaux, 258.
Citrate of potash after lithotrity, 771; for calculus, 767; for hæmaturia, 762; for renal calculus, 623; for urethritis, 35; in cystitis, 750.
Clamp for hæmorrhoids, 726; of Dupuytren, 660; scrotal, 840.
Clavicle, absence of, 932; amputation, 198; dislocations, 401; excision, 198, 607; fractures, 361; ostitis, 607.
Cleanliness, personal, 92.
Cleansing the hands before operations, 92; of gunshot wounds, 73; of parts in amputations, 170; of wounds, 73.
Cleft palate, 561; operation for, 562; instruments for, 562.
Clubfoot, 916.
Club-hand, 934.
Coagulation in inflammation, 4; in wounds, 124; necrosis in arteritis, 252; of blood in phlebitis, 241.
Cobra venom, 133.
Cocaine anæsthesia, 103; for catheterization, 753; for incision of bubo, 801; for incision of furuncles, 148; for opening of abscesses, 25; in abdominal section, 697; in anal fissure, 709; in anal fistula, 706; in conjunctivitis, 487; in exploration of urethra, 804; in extraction of cataract, 500; in extraction of teeth, 559; in fasciotomy of hand, 937; in hæmorrhoids, 723; in incomplete lithotrity, 771; in keratitis, 492; in laryngeal operations, 588; in ligation of varix, 264; in operation for cleft palate, 561; for hydrocele, 835; for ingrowing toe-nail, 931; in operations on tendons of fingers, 939; in pharyngeal amputations, 184; in phlegmon of finger, 941; in pruritus ani, 704; in removing moles, 265; in the surgery of external ear, 438; in tonsillotomy, 571; in urethrotomy, 807; solution, 86; suppositories in anal affections, 711; toxic symptoms of, 103.
Cocci, 16.
Coccyx, dislocations, 719; fracture, 38; neuralgia, 719.
Cod-liver oil in furuncle, 149; in morbus coxarius, 438.
Cohnheim. Calcification of arteries, 251.
Cold abscess, 21.
Cold, action of, on animal tissues, 147; as a hæmostatic, 128; in inflammation, 23; in lymphangitis, 235; in wounds, 128.
Cold water in burns, 139.
Cole, Dr. J. D. A case of double penis, 742.
Colic, renal, 731.
Collapse in burns, 139.
Colles. Case of aneurism, ligation of subclavian, 289; fracture of radius, 372; law, 70; transmissibility of syphilis, 70.
Collodion, 101.

Colloid carcinoma, 945; cysts, 959.
Colon, exsection of, 627.
Color blindness, 504.
Colostomy, 667; Amussat's method, 668; Bodine's method, 669, 712; Littré's method, 669.
Colpo-cystotomy, 860.
Columnar epithelioma, 947.
Common carotid, aneurism of, 282; ligation of, 307; statistics of, 312.
Common gall duct, operations on, 693.
Common iliac artery, aneurism of, 297; ligation of, 334.
Compound fractures, 349; of leg, 395; of patella, 392.
Compress, umbrella, 784.
Compression in inflammation, 67; instrumental, in aneurism, 271; in hæmorrhage, 128; in synovitis, 426; of ankle, 443; in vascular tumors, 260; of the brain, 354.
Concretions, calcareous, in arteries, 249; intestinal, 619; in the prostate, 796; of the gall bladder, 619.
Concussion of the brain, 354; diagnosis from compression, 354.
Condylomata, syphilitic, 58.
Congenital adhesions of prepuce, 827; hernia, 644; hydrocele, 837.
Conjunctiva, anæsthesia of, by cocaine, 487; tuberculosis of, 490; tumors of, 490.
Conjunctivitis, croupous, 489; diphtheritic, 490; follicular, 487; granular, 488; neonatorum, 489.
Conoidal projectiles, 136,
Constant irrigation, 182; in inflammation, 23.
Constriction of intestines, 622; of limbs for internal hæmorrhage, 131; of vessels in inflammation, 3; of vessels in wounds, 126, 127.
Contagion of anthrax, 43.
Contagiousness of hospital gangrene, 42.
Continuity and contiguity, terms used in amputations, 168.
Continuous compression for aneurism, 270; suture, 129.
Contraction of the hand due to paralysis, 937; of the mouth, 544; of the palmar fascia, 937.
Contrecoup, 353.
Control of hæmorrage from wounds, 119, 120, 122, 127; in operations on the tongue, 565.
Contused wounds, 124.
Contusions of the abdominal walls, 695; of the face, 476; of the kidney, 727; of the scrotum, 831.
Cooper. Ligation of innominate, 307; method of reducing shoulder-joint dislocation, 411; treatment of dislocation of elbow, 411.
Copperhead, venom of, 133.
Copper, sulphate of, for conjunctivitis, 488.
Coracoid process, fracture of, 364.
Cord, spermatic, affections of, 837; hydrocele of, 837.
Cornea, abscess of, 491; inflammation of, 2, 5, 12, 491; wounds of, 491; ulcers of, 492.
Corneitis, 491.
Cornil and Ranvier. Arterial ligation, 257; arteries, histology of, 244; arteritis, 244, 248, 251; classification of tumors, 943; giant cells in sarcoma, 956; induration and hypertrophy of glands, 945; metastasis, 945; permanent occlusion of arteries, 256; pathology of tumors, 943, 948; phlebitis, 239, 241, 243; spinal tuberculosis, 787; structure of arteries, 172; varix, 263; veins, histology, 239.
Corning. Cocaine anæsthesia, 103.
Corns, 931.
Coronoid process, fractures of, 371.
Corpora cavernosa, fractures of, 822.
Corpuscle, compound granular, 22.
Corrosive sublimate as an antiseptic, 79.
Cotton, absorbent, 85.
Cotton, styptic, 127.
Counter-irritants in inflammation, 26.
Cradle, Reeves's suspensory, 905; swinging, for elevation, 395.
Cramps, a symptom of gangrene, 154.
Cranium, fracture, 353.
Crepitus in fracture, 349.
Crinoline bandages, 155.
Crosby. Aneurism, treatment of, 272; dislocation of the hips, treatment of, 418; fracture bed, 381.
Cross-suture, 130.
Crotalus, 133.
Croup, laryngeal tubes in, 581; tracheotomy in, 581.
Croupous conjunctivitis, 489.
Crushing of stone in the bladder, 767.
Cruveilhier. Arterial varix, 258; case of ligation of subclavian and carotid, 327.
Crystalline lens, 498.
Cuboid bone, amputation of, 203.
Cuneiform bones, amputation of, 211.
Cunningham's wax, 123.
Curettage of uterus, 881.
Curette, urethral, 816.
Curvature, anterior, of the spine, 892; lateral, of the spine, cervical, 885; dorsal, 887; dorso-lumbar, 887; posterior, of the spine, 892; rotary-lateral, 888.
Cutaneous, angioma, 260; arterial tumor, 260; capillary tumor, 260; vascular tumors, 260; venous tumors, 260.
Cyclitis, 496.
Cylinder-celled epithelioma, 947.
Cyphosis, 885.
Cyst, 958; hydratic, *vide* hydatid, 579, 686; of antrum of Highmore, 549; of broad ligament, 876; of conjunctiva, 490; dermoid, 958; of kidney, 732; of larynx, 587; of lip, 533; of

liver, 686; of lower jaw, 555; of mammary gland, 600; mucous, 959; of neck, 575, 579; of nipple, 597; of ovary, 875; of pancreas, 695; diagnosis, 695; of scalp, 460; sebaceous, 460; serous, 460; of scrotum, 832; of spleen, 694; diagnosis, 694; of testicle, 846; of thyroid body, 576; of tongue, 566; of tonsil, 570; of vesiculo-seminalis, 841.
Cyst-adenoma of ovary, 875.
Cystic degeneration of ovary, 873; dilatation of lymphatic vessels, 239; polypus of rectum, 718; tumors of broad ligament, 875.
Cysticercus of the tongue, 566.
Cystine calculus, 764.
Cystitis, 748; cause of pyelitis, 728.
Cystocele, 745, 859; treatment of, 860.
Cystoma of parotid gland, 546.
Cystoscope, 756.
Cystotomy, 771; of gall bladder, 691; perineal, 812; suprapubic, 771.
Czerny-Lembert suture, 629.

Dacryo-adenitis, 485.
Dacryo-cystitis, 486.
Dacryoliths, 486.
Dactylitis, 64.
Daviels. Curette, 491; spoon, 501.
Davis. Spinal brace, 897.
Davy. Treatment of external iliac aneurism, 298.
Dawbarn. Case of spinal fracture, 378; reticule string-suture in appendectomy, 682.
Death-rate in amputations, 232; in tetanus, 47.
Deaver, J. B. Cases of hip-joint amputation, 228.
Dechamps. Aneurism, 273.
Deer tendon, 79, 121.
Deformans arteritis, 251.
Deformities, 885.
Deformity of the femur, 911; of the fingers, 935; of the hand, 934; of the hip, 428, 906; of the knee, 421, 440, 911; of the lower extremity, 906; of the spine, 885; of the toes, 928; of the upper extremity, 932.
Degeneration of arteries, 249; of thyroid gland, 576; of ovaries, cystic, 873; in arteritis, 249.
De Lacerda. Serpent wounds, treatment of, 134.
Deligation, *vide* ligation, 304; of arteries, *vide* artery, 206, 304; in continuity, 256; cause of arteritis, 245; for angeioma, 262; for cutaneous vascular tumors, 262; occlusion of arteries by, 256; with catgut, 272.
Delpech. Ligation of axillary artery, 330.
Deltoid muscle, paralysis of, 933.
Demarkation, line of, in gangrene, 152.
Dennis. Emphysema of abdominal cavity, 696; open method of treating amputations, 182.
Depaul. Congenital nævus, 260.
Deposits, urinary, 759.
Depression of cranial bones in fractures of the skull, 353.
Dermatitis, 39.
Dermoid cysts, 877, 958; of the mamma, 601; of the ovary, 958.
Dermoplasty, 140.
Desmarres. Retractors, 491.
Destruction of skin by acids, 147.
Detachment of retina, 504.
Deviation of nasal septum, 524.
Diabetes mellitus, 759.
Diapedesis, 1, 3.
Diachylon plaster for ulcers, 150; in burns, 140.
Diaphragmatic hernia, 664; treatment, 664.
Dibrell's grooved director and aspirating needle, 674.
Dick. Gum bougie, 804.
Didot. Operation for web-finger, 936.
Dieffenbach. Amputation of hip, 218.
Digital compression in aneurism, 271.
Diffuse aneurism, 268.
Dilatation of preputial orifice, 828; of vessels in arteritis, 244; in inflammation, 3; of urethral stricture, 807.
Diphtheria, 72; laryngeal tube for, 75; tracheotomy in, 581; antitoxine in, 74; intubation in, 75.
Diphtheritic conjunctivitis, 490.
Diplococci, 15.
Diplopia, 513.
Direct pressure for aneurism, 270.
Director, grooved, 101.
Disarticulation at astragalus, 204; at calcaneus, 204, 208; at carpo-metacarpal joint, 186; at carpo-radial joint, 189, 190; at hip, 218; at knee, 215; at metatarsal joint, 200; at shoulder, 196; at tarso-metatarsal joint, 200; at tibio-tarsal joint, 203; of finger phalanges, 183; of toes, 199.
Discission of cataract, 501.
Diseases of the joints, 426.
Disinfection in hospital gangrene, 42; of instruments, 79; of hands in operations, 92; of typhoid excreta, 78.
Dislocation of the ankle, 423; backward, 424; compound, 424; forward, 424; inward, 423; outward, 423; of the astragalus, 424; of the clavicle, 401; of the elbow, 409; of the fibula, at ankle, 424; of the fingers, 413; of the foot, 423; of the hand, 412; of the hip joint, 413; after-treatment of, 421; Bigelow's reduction of, 419; Crosby's reduction of, 418; Hamilton's reduction of, 419; congenital, 414, 906; diagnosis, 415, 416; iliac, 414, 419; pubic, 414, 419; reduction, 417; sciatic, 414, 419; statistics, 414; thyroid, 414, 419; of the humerus, 402; with fracture, 408; subacromial, 402; subcoracoid, 402; subclavicular, 405; subglenoid, 405; subspinous, 402; of the jaw, 400; of the knee, 421; of the lower jaw, 400;

of the metacarpo-phalangeal joints, 413; of the patella, 423; of the phalanges, 413; of the radial head (subluxation), 409; of the radius and ulnar at elbow, 410; of the ribs, 425; of the shoulder, 402; subacromial, 402; subcoracoid, 402; of the spine, atlo-axoid, 425; occipito-atloid, 425; of the tarsal joints, 424; of the tarsus, 424; of the testicle, 847; of the thigh, 413; of the tibia, 421; of the vertebra, 425; of the wrist, 412.
Dislocations, 400; complicated, 400; compound, 400; congenital, 400; diagnosis, 400; partial, 400; pathological anatomy of, 400; pathological, 400; primitive, 400; prognosis of, 400; secondary, 400; traumatic, 400; varieties of, 400.
Displacements of abdominal organs, 696; of liver, 690.
Dissecting aneurism, 266.
Dissection wounds, 132.
Distal ligature for aneurism of aorta, 276.
Distribution of assistants and nurses during operation, 93.
Diverticulum of intestines, 622; of œsophagus, 595.
Division of urethral stricture, 807.
Divulsion of anus, 709; of prepuce, 828; of urethral stricture, 807.
Dobell's solution, 524.
Dog bite, 50.
Dorsalis pedis artery, ligation of, 344.
Double crescentic flap, 180; rectangular flap, 181.
Double-current catheter, 751.
Double knot, 121.
Double-needle suture, 130.
Double penis, 742.
Drainage of bladder, 777; of skull, 355; in amputations, 177; in carbuncle, 14; in fracture of skull, 355; in gunshot wounds, 137; in osteomyelitis, 346; in suppuration of knee, 441; in wounds, 128; tubes, 84.
Drains, 84.
Dressings, 79, 128; apparatus used in, 91; application of, after operations, 131; after amputations, 178; balsam and oil, 150; for fractures, 395; in gunshot wounds, 137, 138; in skin grafting, 140.
Dressing scissors, 99.
Drilling for drainage of antrum of Highmore, 549; the trochanter in morbus coxarius, 439.
Drills, bone, 97, 450; Fluhrer's, 391.
Dropsy, abdominal, diagnosis, 731.
Drum for testing edge of instruments, 497.
Dry gangrene, 153, 154.
Duct of Steno, affections of, 545.
Dugas. Dislocation of humerus, 403, 406.
Dunglison. Phlebolites, 264.
Duodeno-gastrostomy, 612.
Duodenostomy, 618.
Duodenum, operations on, 618.
Dupuytren. Case of aneurism, 291; contraction of palmar fascia, 937; operation for strangulated intestine, 660.
Dura mater, carcinoma of, 464; sarcoma of, 463.
Durante. Permanent occlusion of arteries after deligation, 257.
Dutoit. Case of aneurism, 294.

Ear, adhesions, 518; cartilaginous tumors, 518; diseases and injuries, 518; drooping, 518; hypertrophy, 518; instruments for, 519; specula for examining, 519; wounds, 518.
Eburnated osteoma, 964.
Ecchymosis, 4.
Echinococci, *vide* hydatid.
Écraseur, in ablation of the tongue, 567.
Ectoderm, 2.
Ectropion, 481; operations for, 481.
Eczema of the anus, 703; of the eyelids, 485; of the nipple, 597; of the scrotum, 832.
Effusion, serous, into sheath of cord, 834; into tunica vaginalis, 833; of joint, *vide* synovitis.
Elastic, bandage, Esmarch's, 155; fiber in veins, 239; ligature, 99; for fistula ani, 708; silk for, varix, 272.
Elbow joint, amputation at, 191; anchylosis, 933; disarticulation, 191; diseases of, 445; dislocation at, 409; exsection, 454; synovitis, 445.
Elephantiasis, 832; nævoid, 261; of the head, 461; of the scrotum, 832.
Elevation as a hæmostatic in wounds, 128; in gangrene, 153; in inflammation, 23; periosteal, 97; in phlebitis, 243; of parts of skull, 470.
Elliot. Case of aneurism of innominate artery, 280.
Emboli, 241.
Embolism, arterial, 256.
Embryonic tissue in inflammation, 6; in wounds, 124.
Emergency tourniquet, 126.
Emigration of leucocytes in inflammation, 3.
Emmet. Cervix scissors, 862; perinæorrhaphy, 853; trachelorrhaphy, 853.
Emmetropia, 506.
Emphysema of abdominal cavity, 696; subcutaneous, in gangrene, 151.
Emprosthotonos in tetanus, 46.
Empyema, diagnosis, 607; irrigation of, 608.
Encephalocele, 463.
Encephaloid, 945; of mammary gland, 602; of rectum, 715.
Enchondroma, 963; of ear, 518; of larynx, 587; of lower jaw, 555; of mamma, 600; of parotid gland, 546; of tongue, 566; of testicle, 845.
Endarteritis, 243; obliterans, 60, 62, 245; syphilitic, 59.
Endocarditis rheumatica, 256.

Endophlebitis, 239.
Endoscope, 802.
Endosmosis in phlebitis, 241.
Endostitis, 61, 345.
Enostosis, 964.
Ensor. Case of aneurism of the innominate artery, 280.
Enterocele, 643.
Enteroliths, 619.
Enterostomy, 635.
Entoderm, 2.
Entropion, 484.
Enucleation of the eye, 496; of tumor of mamma, 604.
Epicanthus, 485.
Epicystotomy, 771, 785.
Epididymis, 841.
Epididymitis, 799, 841; chronic, 841; gonorrhœal, 841; tuberculous, 845.
Epilepsy, operation for, 472.
Epiphora, 485.
Epiplocele, 642.
Epispadias, 820.
Epistaxis, 522; treatment of, 522.
Epithelia in the urine, 759.
Epithelioma, 947; of the anus, 715; of the bladder, 756; of the breast, 602; of the intestine, 624; of the larynx, 587; of the lip, 530; of the mammary gland, 602; of the nipple, 597; of the nose, 524; of the œsophagus, 594; of the penis, 822; of the rectum, 715; of the scrotum, 833; of the vulva, 854; pearl, 956.
Equinia, 44.
Equinus talipes, 916.
Erectile tumors, 260.
Erichsen. Exarticulation of phalanges, 184.
Erysipelas, 37; dressings in, 40; germ of, 37; isolation in, 40; local treatment, 40; of scrotum, 832; phlegmonous, 39; precautions against, 41; prophylaxis, 41; in the treatment of sarcoma, 953.
Erysipeloid, 42.
Erythema, 39; anal, 704; annulare, 40; gyratum, 40; intertrigo, 40; iris, 40; nodosum, 40; of anus, 704.
Escape of leucocytes from blood-vessels in inflammation, 3.
Escharotic for angeioma, 262.
Eserine in extraction of cataract, 501.
Esmarch's bandage, 99, 127, 155; for aneurism, 272; for wounds, 127, 128; in amputations, 169; chloroform apparatus, 115; method of curing angeioma, 262; of exarticulation at shoulder joint, 197; at carpo-metacarpal joint, 187; of exarticulation of phalanges, 184; of treating aneurism, 272.
Esophoria, 513.
Ether, administration of, 107; by the rectum, 115; inhalation of, 107; inhaler, 110; in reducing fractures, 353.
Evacuation of abscess, 26; of abscess of liver, 688.
Evans. Aneurism of innominate artery, 281.
Eversion of the bladder, 742.
Examination of urine, 757.
Excision, of astragalus, 451; of branches of fifth nerve, 553; of cervix uteri, 863; of hæmorrhoids, 725; of joints, 446; of malignant neoplasms, 953; of Meckel's ganglion, 553; of moles, 265; of the ankle joint, 451; of the breast, 604; of the carpus, 454; of the clavicle, 607; of the elbow, 454; of the eye, 496; of the hip joint, 446; in coxitis, 438; of the inferior dental nerve, 558; of the interphalangeal articulations, 457; of the intestine, 627; indications for, 626; of the kidney, 735; of the knee joint, 448; in suppuration, 441; of the larynx, 585; of the lower jaw, 556; of the maxillary nerves, 553; of the metacarpal articulations, 457; of the œsophagus, 595; of the parotid gland, 547; of the prolapsed rectum, 720; of the pylorus, 615; of the rectum, 716; of the ribs, 607; of the scapula, 608; of the shoulder joint, 453; of the sphenomaxillary ganglion, 553; of the spleen, 379, 694; of the submaxillary gland, 549; of the tarsus, 451; of the testicle, 846; of the thyroid gland, 580; of the tongue, 567; of the tonsils, 571; of the upper jaw, 553; of the wrist joint, 457; of vascular tumors, 262; of wounds in rabies, 50.
Exophthalmic goître, 579.
Exophoria, 513.
Exostosis, 10; of the skull, 463; in fractures, 352.
Expediency, amputations of, 168.
Exploration of cranial vault, 465; of kidney, 735; of urethra, 804.
Exsection, *vide* excision.
Exstrophy of the bladder, 742; operation for, 742.
Extension, after exsection of hip, 447; for morbus coxarius, 433; for synovitis of hip, 433; of knee, 440.
External carotid, aneurism of, 283; ligation of, 316.
External iliac, aneurism of, 297; ligation of, 336.
Extirpation, *vide* excision; of angeiomata, 262; of lymphatic glands, 575; of Meckel's ganglion, 553; of the eye, 496; of the fifth nerve, 553; of the kidney, 735; of the parotid gland, 547; of the spleen, 379, 694; of the submaxillary gland, 575; of the thyroid gland, 580; of the upper jaw, 553.
Extraction of cataract, 499; of foreign bodies through the urethra, 815; of the teeth, 559.
Extremities, ligation of, 123.
Eye, 476; bandage for, 164; cysts, sebaceous, of, 477; enucleation of, 496; epithelioma of, 477;

nævi near, 477; new formations, 477; plastic operations near, 477; tumors near, 477; syphilis, 63; wounds, 476.
Eyelids, affections of, 485.

Face, 476; bandage for, 163; contusions, 476; gunshot wounds, 476; wounds, 476.
Facial artery, ligation of, 318.
Facial nerve, injury to, in extirpation of parotid, 547; in ligation of external carotid, 317.
Fahrenheit, rule for converting into Centigrade, 18.
Fallopian tubes, inflammation of, 872; removal of, 878.
False aneurism, 266.
False knot, 122.
Farcy, 44.
Fascia knife, 95.
Fasciotomy in Dupuytren's contraction, 937; in pes equino-varus, 923.
Fecal fistula, 640, 666; diagnosis and treatment, 667.
Fehleisen. Erysipelas coccus, 37.
Felon, 940.
Femoral artery, aneurism of, 299; ligation of, 339.
Femoral hernia, 646; diagnosis and treatment, 646.
Femur, dislocations of, 413; fractures of, 381; osteotomy of, 908.
Fenger. Operation on ureter, 737.
Ferguson. Case of aneurism, 294; lithotomy guide, 780.
Fever of reaction, 178; of septicæmia, 27, 28; splenic, 43; syphilitic, 59.
Fibro-chondroma, 963.
Fibro-lipoma, 959.
Fibroma, 960; of antrum of Highmore, 549; of bladder, 756; of intestine, 624; of larynx, 587; of lips, 533; of lower jaw, 555; of mamma, 600; of nipple, 597; of nose, 523; of parotid gland, 546; of tongue, 566; of tonsils, 570; of urethra, 821.
Fibromyoma of intestine, 624; of lower jaw, 556; of ovary, 877.
Fibrous union in fractures, 397.
Fibula, dislocations of, at ankle, 423; fractures of, 392.
Fifth nerve, excision of branches, 558.
Figure-of eight bandage, 157.
Filaria sanguinis hominis, 238; Bancrofti, 238.
Fingers, amputation of, 183; bandages for, 158, 159; contraction, 937; deformities, 935; disarticulation, 183; jerk-, 938; snap-, 938; supernumerary, 935; syphilis, 64; webbed, 936.
Fischer. Case of aneurism, 299; wounds of the heart, 609.
Fission, 16.
Fissure of the anus, 708; of the lips, 533; of the nares, 524; of the nipple, 597; of the palate, 560; of Rolando, 469.
Fistula, dissecting out, 707; fecal, 640, 666; diagnosis and treatment, 667; intestinal, 640, 666; of the anus, 705; operation for, 706; of the œsophagus, 595; of the scrotum, 833; of the parotid gland, 545; salivary, 545; urinary, 816; vesico-vaginal, 860.
Fixation of knee for suppuration, 440; of shoulder, 445.
Flap, double crescentic, 180; double rectangular, 181; modified circular skin, 180; mixed, 173, 181; oblique solid, by transfixion, 173; by cutting from the surface, 173; oval, 180; skin, 179; circular, 179; solid circular, 173.
Flaps, formation of, in amputation, 173.
Flat-celled epithelioma, 947.
Flat-foot, 928.
Fletcher. Serpent venom, 133; treatment of serpent-bite, 134.
Flexion of fingers, 936; of toes, 930.
Floating kidney, 733.
Fluhrer. Case of hip-joint amputation, 229; case of penetrating wound of the skull, 465; drills, 391; swinging cradle, 23.
Flour for burns, 140.
Foot, *vide* ankle; amputation, 203, 210; bandage for, 160; dislocation, 423.
Foot and mouth disease, 49.
Forbes's amputation through the tarsus, 203.
Forceps, anatomical, 101; artery, 99, 120; bone, 97; for extracting teeth, 559; hysterectomy, Pryor's, 869; for foreign bodies in trachea, 584; gouge, 98; hæmostatic, 99, 120; lion-jawed, 98; lithotomy, 782; mouse-toothed, 99; needle, 100; phimosis, 827; sac, 878; sequestrum, 98; Sims's needle, 861; urethral, 816; Wyeth's needle, 100.
Forearm, amputation of, 190; bandage for, 159; deformities of, 933; fractures of, 371.
Foreign bodies in the anus, 705; in the auditory canal, 519; in the bladder, 786; in the bronchial tubes, 582; in the cornea, 491; in the intestines, 619, 626; in the larynx, 582; in the nose, 522; in the œsophagus, 589; in the pharynx, 588; in the rectum, 705; in the skull, 465; in the stomach, 610; in the trachea, 582; in the urethra, 815; in the vitreous humor, 503.
Formation of capillaries in veins, 240; in wounds, 6, 125.
Forster. Pathology of tumors, 943.
Foster. Cataract, 499.
Four-tailed bandage, 165.
Fowl bones as drains, 84.
Fowler, G. R. Case of hip-joint amputation, 230.
Fox bite, 133.
Fracture box, 394.
Fracture, 348; by contre-coup, 353; comminuted, 349; complicated, 349; compound, 349; crepitus in, 349; direct, 353; fibrous union in, 397; green-stick, 349; impacted, 349; indirect,

353; of the acetabulum, 380; of the carpal bones, 375; of the clavicle, 361; of the coccyx, 380; of the corpora cavernosa, 822; of the femur, 381; condyles of, 387; great trochanter, 386; neck, 383; shaft, 387; of the fibula, 392; of the foot, 397; of the forearm, 371; of the head, 353; of the humerus, 364; condyles of, 369; neck, anatomical, 360; surgical, 365; shaft, 367; tuberosities, 365; of the hyoid bone, 361; of the ilium, 380; of the inferior maxilla, 359; of the innominate bone, 380; of the ischium, 380; of the larynx, 361; of the leg, 392; of the lower jaw, 359; of the malar bone, 358; of the metacarpal bones, 375; of the metatarsal bones, 398; of the nasal bones, 355; of the os innominatum, 380; of the patella, 388; of the patella, Hamilton's splint for, 390; of the penis, 822; of the phalanges, 375; of the pubes, 380; of the radius, 371; at inferior extremity of (Colles's), 372; diagnosis, 372; reduction by Pilcher's method, 373; at superior extremity, 371; of the ribs, 375; of the sacrum, 380; of the scapula, 363; at acromion process of, 364; at coracoid process of, 364; at glenoid process of, 364; at spine of, 364; of the skull, 353; at its base, 355; with depression, 354; of the sternum, 375; of the tarsus, 397; of the tibia, 392; of the ulna, 370; at coronoid process, 371; at olecranon process, 370; of the upper jaw, 358; of the vertebra, 375; at articular process, 380; at spinous process, 380; of the zygomatic process, 358; partial, 349; prognosis, 352; simple, 349; subcutaneous, 349; from projectiles, 349; symptoms of, 349; treatment of, 352; ununited, 351, 397.
Freund. Operation for prolapse of uterus, 880.
Frey. Pathology of the veins, 240.
Fricke. Heat in tetanus, 47.
Friction knot, 121.
Frontal sinus, 524; abscess of, 462.
Frostbite, 147.
Fungi, 17; in inflammation, 15.
Fungus hæmatodes, 260.
Furuncle, 147; treatment of, 149.
Fusiform aneurism, 266.

Galactocele, 601.
Gall bladder, 691; abscess of, 691; concretions, 691; distention of, diagnosis, 691.
Gall duct, operations on, 693.
Gallstones, operation for, 692.
Galt. Trephine, 98.
Galvano-cautery of tongue, 569.
Galvano-puncture for aneurism, 260; for angeioma, 260; for vascular tumors, 260.
Ganglion, 942; treatment of, 942.
Gangrene, 42, 49, 151; after frostbite, 147; foudroyante, 49; hospital, 42; natural amputation in, 152; of scrotum, 832; senile, 154; varieties of, 151, 153.
Gant. Excision of the tongue, 567; osteotomy of femur, 909.
Garreau. Prostatic syringe, 794.
Gases in gangrene, 49.
Gasserian ganglion, removal of, 554.
Gaston, J. McF. Case of hip-joint amputation, 229.
Gastrectomy, 615.
Gastro-enterostomy, 613.
Gastroliths, 610.
Gastro-pylorectomy, 615.
Gastrostomy, 610.
Gastrotomy, 610.
Gauge for urethral instruments, 813.
Gauze, disinfecting of, 85; iodoform, 87; preparation of, 85.
Gay. Case of aneurism, 289; phlebitis, 242.
General anæsthesia, 107.
Genito-urinary organs, affections of, 727; female, 848; in the male, 727.
Genu valgum, 911; osteotomy for, 914; treatment of, 913; varum, 915.
Germs in hospital gangrene, 42; *vide* also microorganisms.
Gerster. Case of aneurism of innominate artery, 280.
Giant-celled sarcoma, 950.
Gibney. Morbus coxæ, 428; Pott's disease, 903.
Gibson. Excision of vascular tumor, 260.
Gila monster, venom of, 133.
Girdner. Phimosis forceps, 827; skin grafts, 144.
Gland, lachrymal, etc., *vide* lachrymal, etc.; submaxillary, 548; mammary, 597.
Glanders, 44.
Glands, surgery of, 234; tuberculous, 236.
Glasses, testing for, 511.
Glaucoma, 497, 517; fulminans, 497.
Gleet, 802; diagnosis, 802.
Glenoid process, fracture of, 364.
Glioma, 955.
Glossitis, 565.
Gluteal hernia, 647, 664; diagnosis and treatment, 664.
Goffe. Operation for uterine myomata, 870.
Goître, 576; cystic, 576; exophthalmic, 579; fibrous, 576; operations for, 576, 580.
Gonococcus, 30, 31.
Gonorrhœa, 30; complications of, 798; injections in, 34, 798; in the female, 855; syringe for, 34, 798; treatment of, 34, 36.
Gonorrhœal bubo, 800; ophthalmia, 488; rheumatism, 801.
Goodwillie. Hollow needle, 562; mouth gag, 540; periosteal elevator, 97.
Gore. Case of aneurism, 286.
Gouging in arthritis of ankle, 443; of wrist, 446.
Goujon. Experiments on tissue formation, 56.
Gouley. Lithoclast, 782.
Gout, cause of arteritis, 255.

Gouty phlebitis, 242.
Gown, operating, 92.
Graefe, von. Case of aneurism, 259; excision of vascular tumor, 259; fixation forceps, 500; iridectomy, 494; linear knife, 500; operation for conical cornea, 494; speculum, 500; strabismus hook, 505.
Grafting of skin for burns, 140; Girdner's method, 144; Lusk's method, 142; Riverdin's method, 140; Thiersch's method of, 141.
Granular cells in wounds, 7, 125; corpuscles, compound, 22; metamorphosis in wounds, 7.
Grant. Method of intestinal anastomosis, 636; case of hip-joint amputation, 230.
Graves's disease, 579.
Green. Calcareous deposits in veins, 263; endarteritis, 248.
Greenfield. Syphilitic arteritis, 255.
Gritti's amputation at the knee, 217.
Grooved director, 101.
Gross. Cavernous tumors, 261; ligation of internal jugular vein, 307; nævoid elephantiasis, 261; phlebolites, 264; sarcoma of bone, 953.
Gruening. Depilating forceps, 487.
Guéniot. Excision of vascular tumor, 260.
Guitéras. Case of dislocation of testicle, 847.
Gum lancet, 95.
Gummata, 61; differential diagnosis from furuncle, 147; of tongue, 566.
Gunderloch and Müller. Ligation of carotid for vascular tumor, 259.
Gunshot missiles, 136; wounds, 135; hæmorrhage from, 137; of the abdomen, 696; of the alimentary canal, 699; of the bladder, 747; of the brain and membranes, 355; of the chest, 608; of the face, 476; of the hand, case of, 939; of the heart, 609; of the neck, 573; of the skull, 465.
Gunther's amputation, 210.
Gypsum bandages, 156; for fractures, 252.

Hæmatin, causing redness in inflammation, 4.
Hæmatocele, 834.
Hæmatoma of the cord, 839; of the female peritonæum, 848; of the scrotum, 833; of the tunica vaginalis, 833; of the vulva, 848.
Hæmaturia, 760; test for, 760.
Hæmorrhage, 118; after extraction of teeth, 560; after internal urethrotomy, 809, 811; from bone, 123; from moles, 265; intrafusion in, 131; in gunshot wounds, 135; in hospital gangrene, 42; in operations on the tongue, 567; excessive, 131; method of controlling, 118, 125; packing for controlling, 127; of the kidneys, 727, 760.
Hæmorrhoids, 721; capillary, 726; external, 722; internal, 722, 723; ulcers after, 709; clamp and cautery operation, 726; ligation of, 724; nitric acid in, 726; Whitehead's operation on, 725.
Hæmostasis, methods of, 118; in wounds, 119, 125; in vessels wounded, 125.
Hæmostatic forceps, 99, 120.
Hairs on the lip, 533.
Hale. Urethral forceps, 816.
Hall. Case of aneurism, 290.
Hallux valgus, 929; treatment, 930; varus, 930.
Hamilton. Dislocation at shoulder joint, 407; fracture of humerus, 367; of lower jaw, apparatus for, 359; of malar bone, 358; of olecranon, 390; of patella, 388; of radius, 371; of thigh, long splint in, 387; head stall, 401; long splint, for osteotomy of femur, 910; for morbus coxæ, 433; treatment of dislocation of hip joint, 418.
Hammer, 97.
Hammersten. Coagulation of blood, 241.
Hammer-toe, 931.
Hancock. Disarticulation at calcaneo-astragaloid joint, 205.
Hand, amputation of, 183, 186; bandages for the, 158, 159; contractions of, 937; deformities, 934; disinfection of, 87, 92; phlegmons of, 940.
Handkerchief bandages, 165, 799; suspensory, 799.
Harelip, 533; double, 540; operation for, 540; of Linhart, 541; of Szymanowsky, 542; of Koenig, 538, 540; of Langenbeck, 537; of Malgaigne, 537, 543; of Nélaton, 538.
Harris. Tooth forceps, 559.
Hart. Excision of vascular tumor, 260.
Hartley, Frank. Case of hip-joint amputation, 229.
Haussmann. Epithelioma of intestine, 624.
Hawley, D. C. Case of hip-joint amputation, 231.
Hayden. Case of aneurism, 290.
Head, bandages for, 163; gunshot wounds, 465; injuries and affections, 460; net bandage for, 166; wounds, 464.
Headache, syphilitic, 59.
Healing of wounds, 68, 125.
Health, definition of, 14.
Heart, 609; gunshot wounds of, 609; syphilis, 62; vegetations of, 247; wounds, 609.
Heart failure in ether or chloroform narcosis, 114, 116.
Heat as a hæmostatic in wounds, 122; bodily, in tetanus, 45; in inflammation, 1; treatment of gangrene by, 153; of inflammation by, 23.
Heath. Case of aneurism, 278, 279, 280.
Heine. Excision of vascular tumor, 259.
Heitzmann. Structure of arteries, 244; of veins, 239.
Heloderma suspectum, 134.
Hemeralopia, 504.
Hemianopsia, 506.
Hemiglossitis, 565.
Hemiplegia, operation for, 470.

Henle. Prostatic muscle, 755.
Henry. Scrotal clamp, 840.
Hepatic abscess, 687.
Hernia, 642; cerebral, 463; diagnosis, 463; diaphragmatic, 647, 664; treatment, 664; femoral, 646; diagnosis and treatment, 646, 660; operation for, 652, 660; gangrenous, 656; gluteal, 647, 664; inguinal, 643, 648; irreducible, 663; lumbar, 647, 664; obturator, 647, 664; of the bladder, 745; of the brain, 463; of the labium, 855; of the ovary, 855; of the spleen, 694; omental, 642; perineal, 648; radical cure for, 652; statistics of, 642; strangulated, 656, 661; treatment of, 656, 661; truss for, 651; umbilical, 646, 662, 663; diagnosis and treatment, 662, 663; vaginal, 648; ventral, 646, 664; treatment of, 664, 695; vesical, 745.
Herpes, corneal, 492; of anus, 704; of penis, 828.
Heterophoria, 513.
Heubner. Syphilitic arteritis, 252.
Hewitt. Pruritus vulvæ, 855.
Hewson. Case of aneurism, 282.
Hey. Modification of Lisfranc's amputation of the foot, 202.
Highmore, antrum of, affections of, 548; *vide* antrum.
Hilton. Case of aneurism, 294.
Hip, anchylosis of, 908; osteotomy for, 907, 908; Adams's osteotomy for, 908, 909; Gant's osteotomy for, 908, 909; Sayre's osteotomy for, 908, 909; congenital dislocation of, 906; Lorenz's operation for, 907; operations for, 907; subtrochanteric osteotomy at, 909.
Hip-joint, anchylosis of, 908; amputation at (Wyeth), 218; bursitis of, 432; deformities, 906; disease, 428; treatment of, 432, 908; dislocation of, 413; exsection of, 446; neuralgia of, 432; osteotomy near, 907-909; ostitis of, 431; rheumatism of muscles of, 432; synovitis of, 431; tuberculosis of, 428; splints for, 433, 435, 438.
Hobart. Case of aneurism, 278; case of ligation of subclavian and carotid, 327.
Hodges. Case of aneurism, 281.
Hodgkin's disease, 237; treatment of, 237.
Holder, lid, 482; needle, 100, 861; sponge, 99; *vide* apparatus.
Holding, method of, scalpel, 903.
Holloway, J. N. Case of hip-joint amputation, 230.
Holmes. Arterial cirsoid tumor, 279; case of aneurism, 279, 281, 294; elastic ball for compression in aneurism, 294; phlebolites, 264.
Holmgren. Color tests, 504.
Homatropine, 508.
Hood bandage, 165.
Hordeolum, 479; in aneurism, 274.
Hornet sting, 135.
Horns of the scalp, 461.
Horsley, J. Shelton. Case of amputation at hip joint, 230.
Horsley, V. Brain surgery, 472.
Hospital gangrene, 42.
Hot water for controlling hæmorrhage in the brain, 472.
Humerus, dislocations of, 402; fracture, 364.
Humphrey. Amputation of the penis, 824.
Hunter. Aneurism, ligation of arteries in, 270.
Hunter, J. B. Vaginal hysterectomy, 868.
Hutchinson. Nævi, 262; phlebitis, 241, 242.
Hutchison. Case of aneurism, 282.
Hyalitis, 503.
Hydatid cyst of the bladder, 756; of bone, 986; of the gall bladder, 691; of the kidney, 732; of the liver, 686; of the mammary gland, 600; of the thyroid gland, 576, 579.
Hydrocele, 834; diagnosis, 835; bilocular, 838; congenital, 837; encysted, 837; of the spermatic cord, 837; radical cure of, 836; symptoms, 835; treatment, 836; Volkmann's operation on, 836; method of Levis, 835.
Hydrocephalus, 464; tapping for, 464.
Hydrochlorate of cocaine, 103.
Hydrogen gas in intestinal wounds, 697.
Hydroma, 239.
Hydronephrosis, 730; diagnosis, 731.
Hydrophobia, 50.
Hydrops of antrum of Highmore, 549.
Hydro-pyonephrosis, 728.
Hydrorrhachis, 905.
Hyoid bone, fracture of, 361.
Hyperæmia in inflammation, 1; active, 1; passive, 1.
Hyperdistention of abscess, 24.
Hypermetropia, 506.
Hyperostosis of antrum, 549.
Hyperphoria, 513.
Hyperplasia of parotid gland, 546; of thyroid gland, 576.
Hypertrophy of the auricle, 518; of the lips, 530; of the mammary gland, 598; of the mucous membrane of the nose, 526; of the nose, 524; of the parotid gland, 546; of the prostate gland, 787; of the skin, 265; of the thyroid gland; 576; of the tongue, 565; of the tonsils, 570; of the turbinated tufts, 524.
Hypodermic injections of carbolic acid in erysipelas, 40; of cocaine, 105; of whisky, 131; in syncope, 131.
Hypodermic syringe, 85; in diagnosis of abscess, 26; of synovitis of the knee, 440; method of sterilizing, 85.
Hypopyon, 492.
Hypophosphites in furuncle, 149; in morbus coxæ, 438; in rachitis, 347.
Hypospadias, 820.
Hysterectomy, abdominal, 866; during pregnancy, 867; for carcinoma, 870, 872; for fibro-

myomata, 870, 872; partial, 870, 872; vaginal, 868; forceps, Pryor's, 869.
Hysteria, 47.
Hysterotomy, 866.

Ice bag, 23.
Icterus, 691.
Idiopathic arteritis, 244; phlebitis, 242.
Iliac artery, common, aneurism of, 297; compression of, 127, 219; ligation of, 334; external, aneurism of, 297; ligation of, 336; for femoral aneurism, 336; internal, aneurism of, 297; ligation, 338.
Ilium, fracture of, 380.
Immediate amputations, 168, 169; exsection of strangulated intestine, 651, 660.
Impactions of cerumen in the ear, 519; of fecal matter in the intestine, 618.
Imperforate anus, 666.
Incised wounds, 124.
Incision of abdomen for intestinal occlusion, 625; of cold abscess, 438; of prepuce, 826.
Incisions in anthrax, 44; in caruncle, 149; in dislocations, 408; in erysipelas, 40; in furuncles, 148; in gangrene, 153; in hospital gangrene, 42; in inflammation, 25; in lymphadenitis, 236; in lymphangitis, 40; in morbus coxæ, 438; in periostitis, 346; in phlebitis, 242; in suppurations of the knee joint, 440; in suppurations of the shoulder joint, 445; in swelling after serpent bites, 134; in tetanus, 48.
Incontinence of urine, 755.
Incubation of erysipelas, 37; of rabies, 50.
Index finger, amputation of, 186.
Indications for amputation, 168; for change of dressings, 178; for the substitution of chloroform for ether, 107.
Indolent ulcer, 150.
Infantile hernia, 645.
Infection, septic, 27.
Inferior maxilla, dislocation of, 400; *vide* jaw, 555.
Inferior thyroid artery, ligation of, 325.
Infiltration, anæsthesia, 106; of urine, 745.
Inflammation, 1; non-infective, 1; infective, 1, 2, 14; abscesses in, 14, 26; acute, 1; in bone, 2, 5, 348; calomel in, 23, 24; in cartilage, 2, 5, 13; causes of, 1; chemiotaxis in, 5; cicatrization in, 56; cold applications in, 23; in cornea, 2, 5. 12, 491; counter-irritants in, 23; formation of capillaries in, 6; heat in, 1; in treatment of, 23; intestinal toxæmia in, 24; in bone, 2, 5, 348; karyomitosis, 4; karyokinesis, 2; of ligaments, 8; local symptoms of, 1; of muscles, 7; of nerves, 8; pain in, 1; of penis, 821; of periosteum, 9, 345; phenomena of, 1; poultices in treatment of, 26; redness in, 1; resolution in, 5; septic, 15; of skin, 7; of submaxillary gland, 548; stasis in, 5; suppuration in, 14, 241; swelling in, 1; symptoms of, 1; of tendons, 8; treatment of, 23; vesicants in, 23; warm applications in, 23; without sepsis, 2.
Ingrowing nail, 931; treatment, 932.
Inguinal bubo, 800.
Inguinal hernia, 643, 648; congenital, 644; diagnosis of, 648; symptoms of, 648; in the female, 660.
Inhalers, chloroform, 115; ether, 110; Allis, 114; Ormsby, 110; ready-made, 114.
Inherited syphilis, 54, 70.
Injections, hypodermic, *vide* hypodermic; of carbolic acid in erysipelas, 40; of cocaine, 105; in arterial varix, 262; in gonorrhœa, 64, 66; in hydrocele, 835; in vascular tumors, 262.
In-knee, 911.
Innominate artery, aneurism of, 279; ligation of, 305; for subclavian aneurism, 323.
Innominate bone, fracture of, 380.
Inoculation for rabies, 50; in tetanus, 48.
Instruments, surgical, 79, 94; disinfection of, 79; trays for, 89.
Intercostal arteries, ligation of, 332.
Intercostal artery, superior, ligation of, 326.
Interdental splints, 360.
Internal carotid artery, ligation of, 312; and jugular vein, ligation of, 307; iliac artery, aneurism of, 297; iliac artery, ligation of, 336; mammary artery, ligation of, 325, 329; maxillary artery, ligation of, 323; pudic artery, ligation of, 335.
Interphalangeal amputations, 183; exsections, 457; joints, synovitis of, 445.
Interrupted suture, 129.
Intestinal toxæmia, 24, 92; anastomosis, 635; Bodine's method, 637; Grant's method, 636; lateral, 636; Maunsell's method, 635.
Intestine, anastomosis of, 627, 635; by Bodine's method, 637; by Grant's method, 636; by Murphy's button, 633; concretions in, 618; constriction of, 622; exsection of, 627; fistula of, 640; foreign bodies in, 619; gunshot wounds of, 698; internal strangulation, 623; intussusception, 620; obstruction, 625; occlusion of, abdominal section for, 625; puncture of, in obstruction, 626; suture of, 617; wounds of, 698.
Intima in endarteritis, 247; of arteries, 243; of veins, 239; rupture of, in a case of arteritis, 246.
Intraperitoneal abscess, 675.
Intratrochanteric section of femur, 908.
Intravenous saline transfusions, 86.
Intubation, 75; instruments for, 76.
Intussusception, 620.
Invagination of intestines, 620.
Involucrum, 345.
Iodides in aneurism, 270; in furuncle, 148; in goitre (cystic), 576; in Pott's disease, 904; in syphilis, 67.

Iodine in spina bifida, 905.
Iodoform as an antiseptic, 87; for amputations, 87, 169; gauze, 87; in war, 137; in hospital gangrene, 42, 153; suppositories, 711, 715; vaseline for burns, 140.
Iridectomy, 495; with extraction of cataract, 500.
Iris forceps, 497.
Iris scissors, 497.
Iris, syphilis of, 63.
Iritis, 495; syphilitic, 63.
Iron, chloride of, in furuncles, 148.
Iron-dyed silk for sutures, 79.
Irrigation, continuous, 83, 86; in amputations, 176, 182; during operation, 94, 128; of knee joint, 440; of wounds, 83, 128; of gunshot wounds, 137.
Irrigator, 83.
Irritable ulcers, 150.
Irritation a cause of malignant tumors, 946.
Ischium, fracture of, 380.
Isolation of patients for hospital gangrene, 42.

Jaeger's keratome, 497; lid holder, 482.
James. Case of aneurism, 298.
Janeway. Case of albuminuria, 758.
Jarvis's snare, 523.
Jaundice, 691.
Jaw, lower, 555; affections of, 555; anchylosis of, 558; bandage for, 165; dislocation of, 400; extirpation of, 556; fracture of, 559; necrosis of, 555; osteitis of, 555; phosphorus disease, 548; upper, 548; abscess of, 548; extirpation of, 553; fractures of, 358; phosphorus poisoning of, 548, syphilis of, 62.
Jequirity in pannus, 492.
Jerk-finger, 938.
Johnston, G. B. Operation for movable kidney, 734.
Johnston, W. B. Case of hip-joint amputation, 229.
Joints, diseases of, 426; infective inflammation of, 427; sprain of, 426; surgery of, 445; synovitis of, 428; syphilis of the, 61; wounds of, 427.
Jones, S. Cure of cirsoid aneurism, 260.
Jones, Wharton. Operation for cure of ectropion, 481.
Jugular vein, ligation of, 307; wounds of, in ligation of the carotid, 309.
Jury-mast, 901.

Kangaroo tendons, 79.
Karyomitosis, 4.
Karyokinesis, 2.
Kelly. Method of catheterizing the ureters, 739.
Keloid, 965; treatment of, 965; varieties, 935.
Kelotomy, 660.
Keratitis, 12, 491; diffuse, 491; herpetic, 492; phlyctænular, 493; secondary, 492; traumatic, 492; ulcerative, 492.
Kern. Brain surgery, 472; case of hip-joint amputation, 229.
Key. Case of aneurism, 282.
Keyes's wire stylet, 753; Keyes-Ultzman syringe, 794.
Keyhole saw, 96.
Kidney, 727; abscess of, 729; calculi, 731; carcinoma, 733; contusions, 727; cysts, 732; displacements, 733; dropsy, 730; encephaloid, 733; exploration of, 728; extirpation of, 735; floating, 733; hæmorrhage from, 760; hydatids, 732; hydronephrosis, 730; pyelitis, 729; pyelonephritis, 729; syphilis, 63; tumors, 733; wounds, 727.
King. Case of aneurism, 280; snake bite, 133.
Kingdon. Hernia statistics, 642.
Klebs-Loeffler bacillus, 73.
Klotz's endoscope, 802.
Knapp. Entropion clamp, 484.
Kneading treatment of aneurism, 274.
Knee joint, affections of, 439; amputation at, 213; anchylosis, 916; bandage for, 160; dislocations, 421; exsection, 448; knock-, 911; osteo-arthritis, 440; synovitis, 439; tuberculosis, 440.
Knife holder, 862.
Knife, method of holding, 93.
Knives, 95.
Knock-knee, 911.
Knot, 121; double, 121; false, 122; friction, 121; in intestinal sutures, 630; in sutures, 121; surgeon's, 121; reef, 121.
Knotted bandage, 164.
Kocher. Dislocation of humerus, treatment of, 403; excision of tongue, 567; myxœdema after goitrous tumors, 577; thyroidectomy, 580; tumors of epididymis, 841.
Koenig. Harelip, 538.
Koller. Cocaine, 103.
Kolpo-cystotomy, 860.
Krackowitzer. Entero-vesical fistula, 666.
Krug. Amputation of cervix uteri, 864.
Kühl. Case of ligation of subclavian and carotid, 327; ligation of carotid for vascular tumor, 259.
Kunkler. Snake bite, 133.

Labial hernia, 648.
Lacerated wounds, 124; of face, 476.
Laceration of cervix uteri, 861; of female perinæum, 849.
Lacerda. Treatment of snake bite, 134.
Lachrymal gland, affections of, 485; extirpation, 485.
Lachrymal sac, abscess of, 485.
Lagolithalmos, 480.
Lagophthalmos, 480.
Lambert. Case of aneurism, 283.

Laminectomy, 377, 379.
Lamphear, E. Cases of hip-joint amputation, 228.
Lane. Case of aneurism, 281.
Lange. Case of aneurism, ligation of common iliac, 298.
Langenbeck. Harelip, 537; incision in exsection of wrist, 454.
Laparotomy for occlusion of intestine, 625; for ovariotomy, 878.
Laryngeal symptoms in aneurism, 274; tubes, 76.
Laryngectomy, 585; partial, 586.
Laryngotomy, 580; for foreign body, 582.
Laryngo-tracheotomy, 581.
Larynx, 580; foreign bodies in, 582; fracture, 361; syphilis, 62; tubes for, 76.
Lateral curvature of the spine, 885; cervical, 896; dorsal, 898.
Lateral deviation of the septum of the nose, 524; lithotomy, 780.
Lawrence. Strabismometer, 505.
Laxatives in erysipelas, 40.
Lead and opium wash in synovitis, 443.
Lediard. Case of aneurism, 278.
Lee. Amputation of the leg, 213.
Leeches in epididymis, 842.
Le Fort. Amputation, 208.
Leg, amputation of, 213; artificial, time to wear, 212; bandages for, 160; fractures, 392.
Lembert. Suture of the intestine, 629; for the uterus, 867.
Leopold. Hysterectomy, 866.
Lens, affections of, 498.
Leptothrix, 15.
Leprosy, 72; bacillus of, 72; varieties of, 72.
Leucocytes, behavior of, in inflammation, 5; formation of capillaries by, in wounds, 6.
Leucocythæmia, 237.
Leucoma, 494.
Levis. Exstrophy of the bladder, operation for, 742; hydrocele, operation for, 835.
Ligaments, inflammation of, 8, 426.
Ligation, arterial, 121; in amputations, 176; knots in, 121, 122; of hæmorrhoids, 724; of the abdominal aorta, 334; for iliac aneurism, 297; statistics of, 334; of the anterior tibial artery, 343; of the ascending pharyngeal, 320; of the axillary, 329; of the brachial, 331; of the common carotid, 307; for occipital lesions, 322; statistics of, 317; of the common femoral, 339; of the common iliac, 334; statistics of, 336; of the dorsal, of the foot, 344; of the external carotid, 316; for extirpation of the parotid gland, 547; of extremities, 123; of wounds of the face, 476; statistics of, 317; of the external iliac, 336; of the facial, 318; of the femoral, 339; of the gluteal, 337; of the inferior thyroid, 325; of the innominate, 305; of the intercostal arteries, 332; of the internal carotid, 312; statistics of, 314; of the internal iliac, 336; statistics of, 336; of the internal maxillary, 323; of the internal pudic, 338; of the lingual, 318; of the occipital, 320; of the pharyngeal, ascending, 320; of the popliteal, 341; of the posterior auricular, 322; of the posterior tibial, 342; of the profunda femoris, 341; of the radial, 332; of the sciatic, 337; of the subclavian, 323; statistics of, 329; of the superior thyroid, 318; of the temporal, 323; of the ulnar, 332; of the vertebral, 329; of varicose veins, 264.
Ligature, 79, 121; as hæmostatic, 120; animal, 79, 121; application of, 121; arteritis after, 256; broad, 79; for aneurism, 270; for arterial varix, 262; in hæmorrhage, 120; method of applying, 121.
Lignerolles. Disarticulation at calcaneo-astragaloid joint, 204.
Lilienthal, H. Case of hip-joint amputation, 228.
Lime water and oil for burns, 140.
Line of demarcation in gangrene, 152.
Lingual artery, ligation of, 318.
Linhart. Rhinoplasty, 527.
Linseed oil and lime water for burns, 140.
Lion-jawed forceps, 97.
Lips, carbuncle of, 533; cysts, 533; epithelioma, 530; fatty tumors, 533; fibroid tumors, 533; fissure, 533; hair on, 533; hare-, 533; *vide* harelip; hypertrophy of, 533; moles, 532; nævus, 531; phlegmon, 532; plastic operations on, 533, 541; syphilitic ulcers, 530; ulcers, 530; wounds, 530.
Lipoma, 959; treatment of, 959; varieties of, 959; of intestine, 624; of lip, 533; of neck, 575; of scalp, 461; of tongue, 566.
Liquefaction of tissues by micro-organisms, 17.
Liquor puris, 5, 20, 22.
Liquor sodii chlorinati for gauze, 85; for sponges, 83.
Lisfranc. Amputation, 202.
Liston. Case of aneurism, 290; ligation of subclavian and carotid, 327; treatment of dislocations of the elbow, 411.
Lithiasis conjunctivæ, 491.
Lithoclast, 782.
Lithotomy, 780; bilateral, 785; forceps, 782; guide, 785; instruments, 785; knives, 94; lateral, 780; median, 785; perineal, 780; scoop, 783; suprapubic, 771; vesico-vaginal, 785.
Lithotrity, 767.
Little. Case of aneurism, 279, 294; lithotomy knife, 94; lithotomy staff, 785.
Little finger, amputation of, 186; disarticulation of, at carpo-metacarpal joint, 186.
Littré. Colostomy, 669.
Liver, 685; abscess of, 687; carcinoma, 685; diagnosis, 685; displacements of, 690; neoplasm of, 685; hydatid, 686; syphilis, 63.

Lizards, venom of, 135.
Lizars. Case of aneurism, 290; case of ligation of innominate, 307.
Lobular epithelioma, 947.
Local anæsthesia, 103; *vide* cocaine.
Localization of motor paralysis in brain centers, 467, 469.
Lockjaw, 46.
Loeffler. Glanders, 44.
Lordosis, 893.
Lorenz's operation for congenital dislocation of hip, 907.
Lower extremity, deformities of, 906; jaw, *vide* jaw.
Lucas-Championnière. Cerebral localization, 468.
Lumbar hernia, 647.
Lungs, 608, 609.
Lupoid ulcer of rectum, 709.
Lupus of cheek, 531; of conjunctiva, 490; of lip, 531; of nose, 531; of vulva, 854.
Lupus vulgaris, 531.
Lusk's method of skin grafting, 142; dressings for, 144.
Lustgarten. Syphilis bacilli, 54.
Luxations, *vide* dislocations, 400.
Lymph fistula, 239.
Lymphadenitis, 238; syphilitica, 62.
Lymphadenoma, 950, 963; of kidney, 733.
Lymphangiectasis, 575.
Lymphangeioma, 239, 962.
Lymphangitis, 234; acute, 234; chronic, 235; diagnosis, 234; in erysipelas, 40; of the penis, 821; subacute, 235; syphilitic, 62; treatment, 235; types of infection, 234.
Lymphatic glands, inflammation of, 237; vessels, diseases of, 234; inflammation of, 234; wounds of, 238.
Lymphatics, surgery of, 234.
Lympho-angeioma, 239.
Lymphoma, 237; arsenic in, 238; Billroth's, 237; leucæmic, 237; malignant, 237; of the neck, 575; of the tonsil, 570; simple, 237.
Lympho-sarcoma of neck, 575.
Lyons's treatment of gonorrhœa, 36.

MacCormac. Operation for genu valgum, 914.
Macewen. Operation for genu valgum, 914; operation for hernia, 653.
Mackenzie. Tonsillotome, 571.
Macnamara. Drilling in morbus coxæ, 439.
Maculæ, 494.
Macular syphilide, 57.
McBurney. Operation for appendicitis, 680; operation for dislocation of shoulder joint, 408; case of amputation at hip joint, 229.
McCarthy. Case of aneurism, 280; case of amputation at hip joint, 229.
McCosh. Case of hip-joint amputation, 229.
McGuire. Case of aneurism, 298.
Malarial fever, a case of hæmaturia, 760.
Malformations of the anus and rectum, 701; of the urethra, 820.
Malgaigne. Case of aneurism, 280; disarticulation at calcaneo-astragaloid joint, 204; operation for harelip, 537; rhinoplasty, 527.
Malignant œdema, 49; lymphoma, 237; pustule, 43; tumors, 943.
Malleolus, dislocations of, 423; fractures of, 397.
Mallet, 97.
Mallock, A. E. Case of hip-joint amputation, 228.
Malpositions of the testicle, 847.
Mammary artery, internal, 325; ligation of, 325.
Mammary gland, 597; abscess of, 598; adenoid tumors, 598; affections of, 597; amputations of, 604; angeioma, 600; bandage for, 162; colloid carcinoma of, 602; cystic tumors, 600; defect, 597; epithelioma, 602; fibroma, 600; hypertrophy, 598; inflammation of, 598; malignant tumors, 600; sarcoma, 600; scirrhus, 602; syphilis, 599; tuberculosis, 237, 600; tumors, 598.
Manual compression in the treatment of aneurism, 271.
Marion-Sims. Incontinence of urine, 821; urethral speculum, 821.
Marrow cells, 11.
Marsden's paste, 531, 948.
Martin. Bandage, 155.
Mask for chloroform inhalation, 115; of ether, 110.
Mason, L. D. Steel drills in fracture of nasal bones, 357.
Massage with treatment of aneurism, 274.
Mastitis, 598.
Mastoid cells, affections of, 520; drainage of, 520.
Mastoiditis, trephining for, 520.
Mattress suture, 129.
Maunders. Case of aneurism, 278.
Maunsell's method of intestinal anastomosis, 635.
Maxilla, *vide* jaw, 548; inferior, dislocation of, 400; fracture of, 559.
Maxillary artery, internal, ligation of, 323.
Mears, J. E. Case of hip-joint amputation, 228.
Meatotomy, 806.
Mechanical compression in the treatment of aneurism, 271.
Meckel, diverticulum of, 622.
Median lithotomy, 785; nerve, injury to, in dislocation of the elbow, 410.
Mediastinum, 608.
Medication before operation, 92; in inflammation, 23.
Medio-tarsal amputation, 204.
Medulla cells in tissue formation, 351.
Megalopsia, 504.
Melanotic carcinoma, 946; sarcoma, 953, 954.

Membrane, abscess, 26; mucous, of the tympanum, 520.
Meninges, carcinoma of, 464.
Meningitis, syphilitic, 60.
Meningocele, 463.
Mercury, bichloride of, as an antiseptic, 86; in syphilis, 67; in treatment of aneurism, 270.
Merismopedia, 15.
Meriwether. Case of aneurism, 303.
Mesarteritis, 243.
Mesoderm, 2.
Mesophlebitis, 239.
Metacarpal bones, amputation of, 186; dislocations, 413; fractures, 375.
Metacarpo-phalangeal exsection, 457.
Metastases in Hodgkin's disease, 237.
Metatarso-phalangeal joints, amputation at, 200; arthritis, 444; dislocations, 425.
Metatarsus, amputations of, 200, 202.
Methods of dressing wounds, 79; of performing amputations, 170; of sterilization, 79.
Micrococci, 15.
Micrococcus of erysipelas, 37; lanceolatus, 19; tetragonus, 19.
Micro-organisms, causing inflammation, 18; of blue pus, 18; of gonorrhœa, 30; of glanders, 45; of putrid infection, 18; of syphilis, 54; of tetanus, 46.
Micropsia, 504.
Middle ear, 520.
Middle finger, amputation of, 186.
Miel. Case of hip-joint amputation, 230.
Military gunshot wounds, 135.
Milzbrand, 43.
Misplaced testicle, 847.
Mitchell, S. Weir. Snake venom, 133.
Mixed flaps in amputations, 173, 181.
Mixed sores, 66.
Moccasin snake, 133.
Modified circular flaps, 179.
Modified internal urethrotomy, 810.
Moist gangrene, 151, 153,
Molds, classification of, 18.
Molecular death of tissue, 157.
Moles, 264; of cheek and lip, 532.
Mollities ossium, 347.
Monsel's solution for hæmorrhage after extraction of teeth, 560.
Monteira. Case of aneurism, 298.
Montgomery. Case of aneurism, 279.
Moore. Fracture of clavicle, 363; of radius near carpus, 373.
Morbus coxæ, 428; diagnosis, 430, 431.
Morgagni. Cataract, 499; hydatid, 876.
Morgan. Case of aneurism, 294.
Morisani. Operation of symphyseotomy, 856.
Morphine as an anæsthetic, 116; in burns, 139; in cystitis, 750; in renal calculus, 732; in suppression of urine, 753, 762.
Morris, R. T. Case of hip-joint amputation, 230.
Mortification, 151.
Morton. Spina bifida, 905.
Motor paralysis, operation for, 469.
Mott, A. B. Case of aneurism, 280, 286.
Mott, Valentine. Cases of aneurism, 286, 291; case of ligation of innominate, 307.
Mouth, contraction of, 544; syphilis, 62.
Mucocele, 486.
Mucoid carcinoma, 946.
Mucous cysts, 959; membrane of tympanum, 520; patches, 58.
Mulberry calculus, 764.
Müller. Cholesteatomata, 956; malignant angeioma, 261; pathology of tumors, 943.
Mumps, 548.
Murdoch, J. B. Case of hip-joint amputation, 229.
Murphy's button, 633; method of using, 644.
Murray. Case of aneurism, 298.
Murray, F. W. Case of hip-joint amputation, 230.
Muscæ volitantes, 503.
Muscles, artificial, 921; inflammation of, 7; reproduction of, 7.
Muscular rheumatism at shoulder joint, 444; spasm in diagnosis of hip-joint dislocation, 416.
Musculo-spiral nerve, injury to, in dislocations of the elbow, 410.
Musket ball, 136.
Muslin bandages, 155.
Mussey. Cirsoid arterial tumor, 259; operation for, 259.
Mütter. Plastic operation on the cheek, 544.
Mycetozoa, 16.
Mydriatics, 508.
Myelitis in tetanus, 46.
Myeloplaxes, in fractures, 351; in inflammation of bone, 11; in tissue formation, 1.
Myocarditis syphilitica, 62.
Myoma, 960; of the bladder, 756; uterine, operations for, 870, 872; varieties of, 960; treatment of, 961.
Myopia, 506, 509.
Myosin coagulation in gangrene, 152.
Myxœdema, 579.
Myxo-lipoma, 959.
Myxoma, 960; of the antrum of Highmore, 549; of the bladder, 756; of the lower jaw, 555; of the mamma, 600; of the nose, 523; of the parotid gland, 546.
Myxomycetes, 17.

Nachet. Trial glasses for testing vision, 511.
Nævoid elephantiasis, 261.
Nævus, cavernous, 260, 962; of the cheek and lips, 531; of the head, 461; near the eye, 477; pigmentosus, 265; pilosus, 265; vulgaris, 265.
Naia tripudians, 133.
Nail, ingrowing, 931.

Nancrede, C. B. Cases of hip-joint amputation, 228.
Narcosis, chloroform, 115; ether, 107, 112; morphine, 116; whisky, 116.
Nares, fissure of, 524; occlusion, 530; plugging, 522.
Narrowing of vagina, 859.
Nasal bones, fractures of, 355; pins, 357; septum, lateral deviation of, 524.
Natural amputations, 152, 168.
Nebula, 494.
Neck, abscess of, 574; acquired cysts of, 576; branchial cysts of, 575; cysts, 575; gunshot wounds, 573; hydroma, 238; lymphoma of, 575; simple inflammation of, 237; wounds of, 573; Billroth's disease of, 237.
Necrobiosis, 65; in arteries, 177; in ulcers, 150.
Necrosis, 151; of bone, 346; of calvaria after nævus, 261; treatment of, 262.
Necrotic process in carbuncle, 148.
Nedofik table, 88.
Needle, 131; aneurism, 96; cervix, 864; hypodermic, 85; holder, Sims's, 131, 861; holder, Wyeth's, 100; sterilization of, 85, 86; surgical, 131; suture, 131.
Neisser's gonococcus, 30.
Nélaton. Catheter, 760; cirsoid tumor, 260; harelip, 538; test line for deformities of hip, 906; for fracture of femur, 383; for morbus coxæ, 431.
Neoplasms, 943; malignant, 943; non-malignant, 956; of the frontal sinus, 524; of the intestine, 624; of the larynx, 587; of the nose, 523; of the pharynx, 588; of the urethra, 821.
Nephrectomy, 735.
Nephritis, a cause of arteritis, 244.
Nephrolithiasis, 731.
Nephrolithotomy, 732.
Nephrotomy, 735.
Nerves, branches of fifth, exsection of, 553; inferior dental, exsection of, 558; inflammation of, 8; optic, atrophy of, 517; regeneration of, 8; spinal accessory, exsection of, 887; syphilis of, 60.
Nettleship. Pannus, 492; trachoma, 488.
Neuralgia, facial, surgical treatment of, 553, 558; of the prostate, 796; of the rectum, 719; of the shoulder joint, diagnosis of, 444; of the sternomastoideus muscle, 885.
Neurectomy of fifth nerve, 553; of inferior dental, 558; of spinal accessory, 887.
Neuritis of optic nerve, 516.
Neuroblast, 9.
Neuroma, 961; symptoms of, 962; treatment of, 962.
Neuro-sarcoma, 956.
Nicolier. Tetanus bacilli, 45.
Nipple, abscess of, 597; eczema, 597; epithelioma, 597; fissure, 597; tumors, 597.
Nitrate of silver in prostatorrhœa, 794; in vaginitis, 857.
Nitric acid, in capillary hæmorrhoids, 726; in hospital gangrene, 42; in phagedenic ulcers, 831.
Nitrogenous food in gangrene, 153.
Nitrous-oxide gas in extraction of teeth, 560.
Normal resistance of tissues, 14.
Normal salt solution, 141.
Nose, affections of, 521; bifid, 529; calculi, 522; congenital lesions of, 529; deviation of septum, 524; epithelioma, 524; epistaxis, 522; fissure of, 524; foreign bodies in, 522; fracture of, 355, 521; hypertrophy of, 524; hypertrophy of the mucous membrane of, 524; hypertrophy of the turbinated bones, 524; nævus of, 524; ozæna, 524; plastic operations on, 527; plugging of, 522; polypus, 523; syphilis, 62.
Nutrition, before operations on the abdomen, 92; in hospital gangrene, 42; in phlebitis, 243.
Nyctalopia, 504.
Nyrop. Boot for talipes valgus, 826; spring brace, 893.

Oakum as a dressing for ulcer, 150.
Oblique flaps in amputations, 178.
Obstruction of the alimentary canal, 618.
Obturator hernia, 647; diagnosis and treatment, 647.
Occipital artery, ligation of, 320.
Occlusion, by thrombus, 241; intestinal, 620, 622; of the alimentary canal, 620, 622; of the basilar artery, 253; of the nares, 530.
O'Dwyer. Laryngeal tube, 76.
Œdema, active, 4; malignant, 37; passive, 4.
Œdema of the glottis, after tonsillar abscess, 570; of scrotum, 832; passive, 4.
Œsophagectomy, 595.
Œsophagotome, 591.
Œsophagotomy, 590.
Œsophagus, 588; bougies for, 589; carcinoma of, 594; diverticula, 595; epithelioma, 594; fistula, 595; foreign bodies in, 589; probang for, 590; pouches in, 595; rupture of, 588; sounds, 589; stricture, 590; stricture, treatment of, 590; stricture, treatment of, Abbe's method, 594; stricture, Sebanijew-Frank operation for, 594; syphilis, 62; tumors, 594; wounds, 588.
Ogston. Operation for genu valgum, 914.
Oiled silk, 85.
Olecranon, fractures of, 370.
Oozing, arrest of, in wounds, 128.
Opacities of the cornea, 516; of the lens, 516.
Open method of treating amputations, 181.
Operating bag, 86; gown, 93; room, 79, 87; stool, 88; tables, 88, 89.
Operation for artificial anus, 668; for cleft palate, 561; for non-union of fractures, 351, 39[illegible]; for strangulated hernia, 656.

Operations, plastic, on face, 541; for burns, 140; near the eye, 481, 484, 485; of the cheek, 541; of the lip, 541, 542; of the mouth, 533; of the nose, 527; preparation for, 92; surgical, method of conducting, 92.
Ophthalmia, gonorrhœal, 488; neonatorum, 489.
Ophthalmitis, sympathetic, 496.
Ophthalmoscope, Loring's, 515; mode of using, 515.
Ophthalmoscopy, 515.
Opium, after lithotrity, 771; in gangrene, 154; in hæmaturia, 762; in retention of urine, 752.
Opisthotonos in tetanus, 46.
Optic nerve, atrophy of, 517.
Optic neuritis, 504, 516.
Orchitis, 842; chronic, 843; gonorrhœal, 842; in mumps, 548; syphilitic, 63; tuberculous, 843.
O'Reilly. Case of aneurism, 219.
Ormsby's inhaler, 110; directions for use, 111.
O'Shaughnessy. Case of aneurism, 279.
Os innominatum, fracture of, 380; hyoides, fracture of, 361.
Osteo-arthritis of the ankle joint, 443; of elbow, 445; of the hip, 428; of the knee, 440; of the shoulder, 444; of the wrist, 446.
Osteoblasts, 9.
Osteoclasis of femur, 916.
Osteogenesis, 12.
Osteo-lipoma, 959.
Osteoma, 964; of skull, 463; treatment of, 965.
Osteomalacia, 347.
Osteo-myelitis, acute, 346; in femur, 217.
Osteoplastic operation for tumor of antrum of Highmore, 549.
Osteo-sarcoma, 950.
Osteotome, 97.
Osteotomy of femur, 908, 914, 916; of forearm, 934; subtrochanteric, 909.
Ostitis, 345; at the hip, 431; caseosa, 61; cause of non-union after fractures, 397; fungosa, 61; of the clavicle, 607; of the frontal sinus, 462; of the lower jaw, 555; of the ribs, 607; of the skull, 461; of the spine, 893; of the sternum, 607; of the thorax, 607; of the upper jaw, 548; osteoplastica, 61; rarefaciens, 61; sclerosa, 61; syphilitic, 57, 61; tuberculous, 51, 429.
Otis, F. N. Location of stricture, 805; urethrotome, 808; wire bougie, 805.
Otis, G. A. Statistics of shot wounds of the face, 476.
Otitis media, 520.
Oval flaps in amputations, 180.
Ovarian cysts, 875; multilocular, 875.
Ovariotomy, 878.
Ovary, abscess of, 874; carcinoma, 876; cirrhosis, 874; cyst-adenoma, 875; cystic degeneration of, 873; cystic tumors, 875; dermoid cysts, 876; fibro-myoma, 876; hernia of, 855; sarcoma, 876; solid tumors, 876; solid tumors, removal of, 878.
Ox aorta as ligature, 121.
Ozæna, 524; syphilitic, 62.

Packing, as a hæmostatic in wounds, 119; temporary, in wounds, 119.
Paget. Case of aneurism, 294; connective tissue in wounds, 124; disease of bone, 348; phlebitis, 242.
Pain, in aneurism, 268; in gangrene, 151; in inflammation, 1.
Palate, affections of, 560; cleft of, 561; operation for, under cocaine, 561; instruments for, 562; hard, cleft of, 562; perforations of, 565; tumors of, 561.
Pallor in gangrene, 151.
Pancoast. Case of aneurism, 293.
Pancreas, 695; cyst of, 695; syphilis of, 63.
Pannus, 13, 492.
Papilloma, 957; of antrum of Highmore, 549; of the bladder, 756; of the head, 461; of the kidney, 733; of the larynx, 587; of the lip, 532; of the nipple, 597; of the nose, 523; of the tongue, 566; of the urethra, 821; of the vulva, 854.
Papular syphilide, 58.
Paquelin cautery, in hæmorrhoids, 726; in hæmorrhage, 122, 127; in operations on the tongue, 567; in prolapse of the rectum, 720; in ranula, 570.
Paraglobin, relation of to stasis, 5.
Paralysis from constriction, 120; of muscles, causing contractions, 937; of the bladder, 752; of the deltoid muscle, 933; of the serratus magnus muscle, 933; syphilitic, 60.
Paralyzed muscle grafted to a healthy tendon, 459.
Paraphimosis, 36, 825.
Parasites, 17.
Parham, F. W. Case of hip-joint amputation, 229.
Parker. Case of aneurism, 290; case of ligation of subclavian and carotid, 327.
Paronychia, syphilitic, 60.
Parotid gland, 545; abscess of, 548; duct of, 545; extirpation of, 547; tumors of, 546.
Parotitis, 548.
Parrish. Muscle-tendon grafting, 459.
Partridge. Case of aneurism, 290.
Paste, Marsden's, 531, 948.
Pathology, surgical, 1.
Pawlik. Method of catheterizing the ureters, 741.
Péan-Pryor trowel, 883.
Pearl epithelioma, 956.
Pelvic organs, 731.
Penis, 821; amputation of, 824; carcinoma, 822; double, 742; fracture of, 822; herpes, 828; Humphrey's operation on, 824; inflammation

of, 821; malformations, 821; sarcoma, 825; ulcers, 828; wounds, 822.
Perforation of the antrum of Highmore, 549: of the palate, 565.
Periadenitis of neck, 574.
Periarteritis, 243.
Perichondroma, 963.
Perinæorrhaphy, 853.
Perinæum, laceration of, 848; operations for, 850; rupture of, 848.
Perineal cystotomy, 785; for wounds of bladder, 771; lithotomy, 780, 785; section for stricture of urethra, 812.
Perinephritis, 828.
Periorchitis serosa, 834; diagnosis, 834.
Periosteal elevator, 97.
Periosteum, inflammation of, 3, 4, 5, 9, 61, 345.
Periostitis, 3, 4, 5, 9, 61, 345; of lower jaw, 555; of upper jaw, 548; albuminosa, 346; syphilitic, 61.
Periphlebitis, 239.
Perirectal abscess, 702.
Perispermatitis, 834.
Perisplenic abscess, 694.
Peritoneal abscess, 671.
Peritonitis, 671; acute infectious, 671; symptoms of, 672; after burns, 139; laparotomy for, 672, 674; tuberculous, 673; treatment, 674.
Perityphlitic abscess, 679.
Permanganate of potassium as an antiseptic for serpent wounds, 134; in gonorrhœa, 34.
Peroneal artery, aneurism of, 300; artery, ligation of, 343; muscles, tenotomy of, 926.
Petit. Arterial cirsoid tumor, 259; fracture box, 395; tourniquet, 126.
Phagedenic bubo, 829; gangrene, 42; ulcer of penis, 829; ulcer of rectum, 709.
Phagocytosis, 37.
Phalangeal abscess, 574; joints, dislocation of, 413.
Phalanges, dislocations of, 413; fracture of, 375.
Pharynx, 588; abscess of, 574; affections of, 588; carcinoma, 588; foreign bodies in, 588; retropharyngeal abscess, 574; syphilis, 62; tumors of, 588.
Phelps, A. M. Cases of hip-joint amputation, 228.
Phenomena of inflammation, 1.
Phimosis, 36, 825; operation for, 36, 826.
Phlebitis, 40, 239; acute, 242; endosmosis in, 241; infective, 242; occlusion in, 241; process of repair in, 241; septicæmia, 241; spontaneous, 243; thrombus in, 240; traumatic, 242.
Phlebolites, 261, 264.
Phlegmon of fingers, 940; of hand, 940; of lip, 533; of the neck, 574; of the scrotum, 832.
Phlegmonous erysipelas, 39.
Phlyctenulæ, 493.
Phorometer, 513.
Phosphatic calculus, 764.
Phosphorus disease of jaws, 548.
Pigeon toe, 930.
Pigment of the skin, 265.
Pilcher. Fracture of radius, 373.
Piles, 721; capillary, 726; chronic, 722; external, 722; internal, 722, 723; ligation of, 724; nitric acid in, 726; treatment by the actual cautery, 726; Whitehead's operation for, 725.
Pin suture, 130.
Pinard. Symphyseotomy, 856.
Pinguecula, 490.
Pinkerton, S. H. Cases of hip-joint amputation, 228.
Pirogoff. Amputation at the ankle, 208; cases of aneurism, 282; etherization per rectum, 115; ligation of carotid for vascular tumor, 259.
Pitres. Cerebral localization of symptoms of motor paralysis, 467.
Pityriasis versicolor of anus, 704.
Planus talipes, 928.
Plaques, mucous, 58.
Plaster-of-Paris bandage, 156; in fracture of the humerus, 366; in fracture of the leg, 395; in fracture of the patella, 391; in synovitis, 443; in ununited fractures, 399; jacket, 891, 898.
Plastic operations for burns, 140.
Plastic surgery of the cheek, 541; of the lip, 534; of the mouth, 565; of the nose, 527; near the eye, 481.
Pleuritis following burns, 139; following wounds of the chest, 609.
Pleurothotonos in tetanus, 46.
Plexiform angeioma, 260.
Plug, vaginal, 858.
Plugging of the nares, 522.
Pneumonia, syphilitic, 62.
Pneumonitis following burns, 139.
Pneumothorax, 523.
Poisoned wounds, 132.
Polaillon. Cirsoid aneurism, 258.
Poland. Case of aneurism, 294.
Politzer. Tympanum perforator, 520.
Polydactylus, 929, 935.
Polypus, cystic, 718; fibrous, of nose, 523; fibrous, of rectum, 715; gelatinous, 523; of the larynx, 587; of the nose, 523; of the rectum, 715; villous, of rectum, 718.
Pope. Tarantula bite, 135.
Popliteal artery, aneurism of, 300; ligation of, 341.
Porro's operation, 867.
Porter. Case of aneurism, 294.
Port-wine mark, 263, 265; of head, 461.
Position of assistants during amputation, 174; of limb in gangrene, 153.
Posterior auricular artery, ligation of, 322; tibial artery, aneurism of, 300; ligation of, 342.

Posterior curvature of the spine, 892.
Posthitis, 36, 798.
Posture, in hæmorrhage, 119; in the treatment of aneurism, 274.
Potassium, citrate of, for chordee, 35; renal calculus, 731; permanganate of, in gonorrhœa, 34; for snake bite, 134; for chordee, 34; iodide, *vide* iodide.
Pott's disease of the spine, 893; diagnosis, 893; fracture, 893.
Poultices in carbuncle, 149; in furuncle, 148; in inflammation, 26.
Powers. Treatment of dislocations of the humerus, 403.
Preparation of antiseptic material, 79; of attendants, etc., for operation, 88, 93; of patients, for narcosis, 109; moral, 92; physical, 92.
Prepuce, adhesions of, 826, 828; amputation, 826; dilatation, 828; divulsion, 828; incision, 827; phimosis, 826.
Presbyopia, 512.
Pressure in hæmorrhage, 118; symptoms in aneurism, 266 *et seq.*
Primary amputation, 168, 169.
Probang for œsophagus, 590.
Probe, bullet, 100.
Productive ostitis, 5.
Profunda femoris artery, aneurism of, 299; ligation of, 341.
Projectiles, 135; varieties of, 136.
Prolapse of the rectum, 719; of the uterus, 880; Freund's operation for, 880.
Proliferation of cells in endarteritis, 247; in inflammation, 2.
Prostate body, 786; calculi of, 796; carcinoma, 795; concretions, 796; dilatations, 789; excision of hypertrophy of, 789; exploration, 790; hypertrophy, 787; neuralgia of, 796; sarcoma, 795; tuberculosis, 795.
Prostatic syringe, 794.
Prostatitis, 787.
Prostatorrhœa, 793.
Protection of field of operation, 92; of patients during operation, 93.
Protective, 85; for burns, 139; in amputation dressings, 177; on wounds, 128.
Protiodide in syphilis, 67.
Protozoa, 16; classification of, 17.
Pruritus of the anus, 703; of the vulva, 855.
Pryor. Amputation of cervix uteri, 864; hysterectomy forceps, 869; portable table, 89; vaginal section, 882.
Pseudo-gonococcus, 31.
Psoas abscess, 889, 896.
Psoriasis, syphilitic, 58.
Pterygium, 490.
Ptomaines, 27; cause of septicæmia, 27; in tetanus, 46.
Pubes, fracture of, 380.
Pubic dislocation of the hip joint, 414, 419.
Pudic, internal, artery, ligation of, 338.
Pulsation in aneurism, 268.
Pulse in tetanus, 46.
Puncture of the bladder, 753; multiple, of the testicle for epididymitis, 800, 842; for orchitis, 800, 843.
Punctured wounds, 124; of abdomen, 696.
Pure water for continuous irrigation in amputation, 182.
Pus, 5, 22; basin, 94; blue, 18, 22; corpuscles, 22; in the urine, 759, 760; serum, 5, 20, 22.
Pustular syphilide, 58.
Pustule, malignant, 43.
Putrefaction, in gangrene, 152.
Pyæmia, 28; after ligation of arteries, 246; metastatic abscess of, 28; emboli in, 28; thrombi in, 28; treatment of, 29.
Pyelitis, 728, 729.
Pyelonephritis, 728, 729.
Pylorectomy, 615.
Pyloroplasty, 615.
Pylorus, exsection of, 615; stricture of, 610.
Pyogenic membrane, 25; bacteria, 17.
Pyoktanin, 87.
Pyrogallic acid in lupus, 532.

Quadriceps extensor muscle, rupture of, 457.
Quill suture, 129.
Quinine in tonsillitis, 570.

Rabid animals, wounds by, 50.
Rabies, 50.
Racemose adenoma, 957.
Rachitis, 347; treatment of, by osteotomy, 347, 910, 915.
Radial artery, aneurism of, 295; ligation of, 332.
Radical cure of hernia, 652.
Radio-carpal dislocation, 412.
Radiograph of hand and arm, 350.
Radius, fractures of, 371; subluxation of head of, 409.
Radius and ulna, dislocations of, at elbow, 409.
Railway fracture, 392.
Ransohoff. Case of aneurism, 281.
Ranvier, *vide* Cornil.
Ranula, 569.
Rattlesnake bite, 133.
Razor and soap, 101.
Reaction in hæmorrhage, 118.
Rectal bougie, bulbous, 713; soft-rubber, 714.
Rectal urinary fistula, 818; rectal speculum, 705.
Rectocele, 859; treatment of, 859.
Rectotomy, 714.
Rectum, abscess of, 705; administration of ether by, 115; ascarides in, 704; atresia of, 701; carcinoma, 715; chancre, 709; chancroid, 709; dilatation, 714; epithelioma, 715; encepha-

loid, 715; exsection, 716; fistula, 705; foreign bodies in, 705; hæmorrhoids of, 721; lupoid ulcer, 709; neoplasms of, 715; neuralgia of, 719; papilloma of, 719; phagedenic ulcer of, 709; polypus, 718; prolapse, 719; treatment, 720; scirrhus, 715; speculum, 705; stricture, 641, 712; syphilis, 63; ulcerations, 709.
Redness in inflammation, 1.
Reef knot, 121.
Reeves. Operation for genu valgum, 914; shoe for talipes, 924; snap-finger, 938; suspensory cradle, 905; talipes valgus, 925.
Refraction of eye, 506.
Regional surgery, 460.
Reichert. Coagulation of blood, 241; serpent venom, 133.
Removal, *vide* excision, extirpation.
Renal calculus, 731; colic, 731; cysts, 732.
Repair of tissues in inflammation, 1, 2; in venous inflammation, 241; in wounds, 124; of bone, 12.
Resection, *vide* excision, exsection.
Resolution of tissue, 345.
Respiration, artificial, in ether narcosis, 113; Sylvester's method of, 113.
Rest in aneurism, 269; in inflammation, 23; in phlebitis, 243; in synovitis, 440, 443, 445, 446.
Restoration of eyelids, 481.
Resuscitation after ether and chloroform narcosis, 113.
Retention of urine, 752; from nerve lesions, 752; from paralysis, 752; from spasm, 752; from stricture of the urethra, 752.
Retina, 503; detachment of, 504.
Retinitis, 503, 517; pigmentosa, 504.
Retractors, 95; in amputations, 175.
Retroperitoneal abscess, 674, 896.
Retropharyngeal abscess, 574.
Retrosternal abscess, 607.
Reverdin. Method of skin grafting, 140.
Reverse in spiral bandage, 157.
Reynders. Apparatus for torticollis, 887; suspension apparatus, 898.
Rhabdomyoma of the kidney, 733.
Rheumatic arteritis, 256; myositis at hip, diagnosis of, 432.
Rheumatism a cause of arteritis, 256; gonorrhœal, 30.
Rhinolites, 522.
Rhinoplasty, 527; Hindoo method, 528; method of Linhart, 527; method of Malgaigne, 527; method of Szymanowsky, 528; partial, 528.
Riberi. Operation on Steno's duct, 545.
Ribs, dislocation of, 425; excision, 608; fractures, 375; ostitis, 607.
Rickets, 347.
Ricketts, M. Case of hip-joint amputation, 229.
Riegner. Case of ligation of common carotid, 312.
Rifle projectiles, 136.
Rigen. Case of aneurism, 279.
Rigors in inflammation, 28.
Ring finger, amputation of, 186.
Robert. Ligation of carotid for vascular tumor, 259.
Roberts. Operation on septum of nose, 524.
Robertson. Operation for ectropion, 481.
Robin. Myeloplaxes, 11.
Robinson, A. R. Carbuncle, 148; lupus erythematosus, 532.
Robinson, Byron. Operation for intestinal anastomosis, 614.
Rodent ulcer of rectum, 709.
Rodgers. Case of aneurism, 291; case of ligation of subclavian, 257.
Rodgers and Van Buren. Ligation of carotid for vascular tumor, 259.
Roentgen rays in fractures, 350.
Rokitansky. Diverticula of œsophagus, 595; multilocular cyst of ovary, 876.
Rongeur forceps, 98.
Room, operating, 77, 79.
Roser. Cheiloplasty, 541.
Rossi. Case of aneurism, 280.
Rotary lateral curvature of the spine, 888.
Round-celled epithelioma, 947; carcinoma, 955.
Rubber drains, 84; operating gown, 92; tissue, 85; tubing for application of cold in inflammation, 23.
Rupia, syphilitic, 60.
Rupture of abdominal muscles, 695; of abdominal organs, 696; of the bladder, 746; of the œsophagus, 588; of the perinæum, 849; operations for, 850, 853; primary, 850; secondary, 853; of the posterior commissure of, 849; of the vulva, 849; of the spleen, 694; of the tendon of the quadriceps extensor, 457.
Rushmore, T. B. Case of hip-joint amputation, 231.

Sacculated aneurism, 266.
Sacrum, fracture of, 380.
Saenger. Hysterectomy, 866.
Saline solutions for intravenous injection, 86.
Salivary calculus, 545; fistula, 545.
Salpingitis, 872.
Sands. Case of aneurism, 278; ligation of parotid, 317; œsophagotome, 592; treatment of external iliac aneurism, 297.
Santonin for Bilharzia hæmatobia, 762.
Saphrophytes, 17.
Sarcina, 16.
Sarcoblasts, 888.
Sarcoma, 950; diagnosis, 952; of antrum of Highmore, 549; of bladder, 756; of dura mater, 463; of intestine, 624, 641; of kidney, 733; of larynx, 587; of lower jaw, 556; of mammary gland, 600; of œsophagus, 594; of ovary, 878; of parotid gland, 546; of penis, 825; of prostate, 795; of testicle, 846; of thyroid gland,

576; of tonsil, 572; erysipelas in treatment of, 42, 953; special forms of, 955; varieties of, 950, 955.
Sattler. Case of intra-orbital aneurism, 284.
Saunders. Case of stab wound of the peritonæum, 699.
Saws, 96; use of, in amputations, 176.
Sayre. Apparatus for knock-knee, 913; artificial muscles for torticollis, 886; bandage for fracture of clavicle, 361; double hip splint, 438; exsection of hip, 446; hallux valgus, 930; jacket, plaster-of-Paris, 898; jury-mast, 901; osteotomy of femur, 910; periosteal elevator, 97, 109; splint for morbus coxæ, 438; talipes calcaneus, 919; talipes equinus, 916; talipes varus, 920.
Scalds, 139; treatment of, 139.
Scale for urethral instruments, 813.
Scaling syphilide, 58.
Scalp, abscess of, 461; cysts, 460; elephantiasis of, 461; fatty tumor of, 461; hæmatoma of, 461; pneumatocele of, 461; sarcoma of, 464; tuberculosis of, 461; wounds of, 464.
Scalpels, 94; method of holding, 93.
Scapula, 608; amputation of, 198; excision of, 198, 608; fractures, 363.
Scapular artery, posterior, ligation of, 325.
Scarpa. Ligation of arteries, 256; shoe for talipes varus, 923.
Schachner, A. Case of hip-joint amputation, 230.
Schleich's solutions, 106.
Schültz. Glanders, 44.
Schwann's nucleated sheath, 9; white substance, 9.
Sciatic artery, aneurism of, 297; ligation of, 337.
Scirrhus, 949; of the bladder, 756; of the mammary gland, 602; of the rectum, 715.
Scissors, 99; dressing, 100.
Scleritis, 495.
Sclerotica, 495.
Scoop, urethral, 816.
Scorpion venom, 135.
Scraping out for hospital gangrene, 42.
Scrofula, 52.
Scrotal clamp, 840.
Scrotum, 831; angeioma of, 833; contusion, 832; cysts, 832; eczema, 832; elephantiasis, 832; epithelioma, 833; erysipelas, 832; fistula, 833; gangrene, 832; hæmatoma, 833; œdema, 832; phlegmon, 832; wounds, 831.
Sebaceous cysts, 958; near the eye, 477; of head, 460.
Sebanijew-Frank. Operation of gastrostomy, 592.
Secondary amputations, 168.
Section, Cæsarean, 867; perineal, 812; trochanteric, of femur, 908.
Sedillot. Method of amputating leg, 213.
Selden. Case of fracture of neck of femur, 381.
Seminal vessels, 841.
Senile gangrene, 154.
Senn. Hydrogen gas for diagnosis of intestinal lesion, 697.
Separation of epiphysis of humerus, 368.
Septic fever, 26.
Septicæmia, 26; treatment of, 27; with metastases, 27, 28.
Septicæmic symptoms in hospital gangrene, 42.
Septico-pyæmia, 26.
Septum of nose, lateral deviation of, 524.
Sequestrum, 346; forceps, 98.
Serous cysts, 959.
Serpent bites, 132; venom, toxicity of, 133.
Serum therapy in diphtheria, 74.
Sexton. Ear hook, 519; forceps, 519; probe, 518; snare, 519.
Shaffer. Abduction splint, 434; spinal brace, 375, 892, 896, 902.
Shaffer-Taylor hip splint for hip-joint disease, 434.
Shells, 135.
Shock, 138; after gunshot wounds, 138; symptoms and treatment of, 138.
Shoulder cap in fracture of the humerus, 366.
Shoulder joint, amputation of, by Wyeth's method, 196; anchylosis, 933; disarticulation, 196; dislocation, 402; exsection, 453; suppuration of, 444; synovitis, 444.
Shropshire, L. L. Case of hip-joint amputation, 231.
Sichels. Iris knife, 491.
Silk, 79, 121; for sutures, 79, 129.
Silkworm gut, 79; for cleft-palate operations, 562.
Silver-fork deformity of wrist, 373.
Silver-wire suture, 79; in fracture of jaw, 359.
Simes. Phlebitis, 242.
Simple ulcer of penis, 828.
Sims, H. Marion. *Vide* Marion.
Sims's fork for silver sutures, 861; glass vaginal plug, 898; needle forceps, 131, 861; rectal speculum, 705; scissors, 100; speculum, 860; sutures in vesico-vaginal fistula, 861.
Sinus, frontal, abscess of, 462; of scrotum, 833.
Skin flap in amputation, 173.
Skin, inflammation of, 7.
Skin grafting, 142, 144; method of Girdner, 144; of Lusk, 142; of Reverdin, 140; of Thiersch, 141.
Skin transplantation, 144–146; Wyeth's method, 145.
Skull, carcinoma of, 464; depression of, 354; encephalocele, 463; exostosis, 463; fractures, 353; gunshot wounds, 465; meningocele, 463; net bandage for, 166; osteoma, 463; ostitis, 461; paracentesis of, 464; penetrating wounds, 465; periostitis, 461; pneumatocele, 461; sarcoma, 463; wounds, 464.
Sliding of skin for burns, 140; of palate, 562.

Smith. Hæmorrhoidal clamp, 726.
Smith, Stephen. Amputation at knee, 215; of leg, 212.
Smyth. Case of aneurism, 287, 298.
Snake bites, 132; treatment of, 134.
Snare, Sexton's, 519.
Snap-finger, 938.
Snellen. Entropion, 484; test types, 511.
Soap, 101.
Solid flaps in amputation, 173.
Solution, antiseptic, 86; bichloride-of-mercury, 86; boric-acid, 86; cocaine, 103, 106; hypodermic, 86, 106; normal salt, 87; oxalic-acid, 92; permanganate-of-potash, 92; Schleich's, 106.
Sore nipples, 597.
Sound, œsophageal, 590; steel urethral, 813.
South. Case of aneurism, 298.
Special amputations, 183.
Speculum, rectal, 705; urethral, 821; Sims, 860.
Spencer Wells's sac forceps, 878.
Spermatocele, 834.
Spermatorrhœa, 794.
Spheno-maxillary fossa, wounds of, 476.
Spherical aneurism, 266.
Sphincter ani, divulsion of, 709.
Spica bandage, 162.
Spina bifida, 905; treatment of, 905.
Spinal accessory nerve, resection of, 887.
Spinal column, deformities of, 885.
Spindle-celled sarcoma, 955.
Spine, abscess of, 896; anterior curvature, 892; bifid, 905; deformities of, 885; dislocations, 425; lateral curvature, 885; posterior curvature, 893; rotary lateral curvature, 888.
Spiral bandage, 156.
Spirilla, 15.
Spleen, 694; abscess of, 694; cyst, 694; excision, 694; hernia, 694; rupture, 694; syphilis, 63; wandering, 694.
Splenectomy, 379, 694.
Splenic abscess, 694; fever, 43.
Spondylitis, 893.
Sponge holders, 99.
Sponges, 82; disinfecting of, 83.
Spoons, sharp, 97.
Sporulation, 16.
Sprain of joint, 426.
Squibb. Ether, 107.
Stab wounds of abdominal viscera, 699.
Staff, 93.
Stalactites, 965; in fractures, 352.
Stalagmites, 965.
Staphylococcus pyogenes, 16, 19, 31.
Staphyloma of the cornea, 493.
Staphylorrhaphy, 562.
Starr. Localization of brain centers, 46.
Stasis in the blood current in inflammation, 5.
Statistics of amputations, 232; at hip, 227; of operations for aneurisms, 276, 279, 288.
Steel sounds, 813.
Stellate fracture of patella, 392.
Steno's duct, 545.
Sterilization, 79, 85, 92; of urine, 762.
Sterilized wax, 123.
Sterilizer, 81.
Sterno-mastoid muscle, neurectomy for spasm of, 887; tenotomy of, 886.
Sternum, exsection of, 607; fractures of, 375.
Steven's phorometer, 513.
Stewart, W. R. Case of hip-joint amputation, 230.
Stimson. Case of aneurism, 280; fracture of femur at neck, 381; through trochanters, 386.
Stimulation after gunshot wounds, 138; in gangrene, 154; in hospital gangrene, 42.
Sting of insects, 135.
Stokes. Case of aneurism, 298.
Stomach, affections of, 610; exsection of, 615; foreign bodies in, 610; syphilis of, 62.
Stone in the bladder, 763; in females, 785; lithotomy for, 771, 780; lithotrity for, 767.
Stool, operating, 88.
Strabismus, 505.
Strangulated hernia, 656, 661.
Strangulation of the intestine, 623.
Streptococcus pyogenes, 16, 19; erysipelatosis, 19, 37.
Stretching nerves in tetanus, 46.
Stricture of the intestine, 624; of the œsophagus, 590; of the pylorus, 611; of the rectum, 712; of the urethra, 34, 803; treatment of, 807, 810, 812; at the meatus, 806; of the vagina, 858.
Strock, D. Case of hip-joint amputation, 230.
Strychnine in tetanus, 47.
Stye, 479.
Stylet, 750.
Styptic cotton, 127.
Styptics, 122.
Subclavian artery, aneurism of, 281, 285; ligation of, 323; for aortic aneurism, 276, 303; for dislocation of humerus, 408; synopsis of cases of, 292.
Sublimate, for irrigating abscesses, 26; gunshot wounds, 137; wounds, 128; for poultices, 26; gauze, 85; for ulcers, 150; in amputations, 170, 174; in gangrene, 153.
Sublingual gland, swelling of, in epithelioma of lip, 531.
Subluxation of the head of the radius, 409.
Submaxillary glands, 548; extirpation of, 548; inflammation of, 548; swelling of, in epithelioma of lip, 531.
Subperiosteal operation on lower jaw, 556.
Subphrenic abscess, 689.
Subtrochanteric section of femur, 908.
Suction for cataract, 499; in snake bites, 134.
Sugar in the urine, 759.
Superior maxilla, *vide* jaw, 548.

Superior thyroid artery, ligation of, 318.
Supernumerary finger, 929; testicle, 847.
Suppression of urine, 727, 729; diagnosis, 755.
Suppuration, 14, 20; in inflammation, 14; of hip joint, 438; of knee, 440.
Suprapubic cystotomy, 771; statistics of, 778; for vesico-vaginal fistula, 771; in females, 771; puncture of the bladder, 860.
Supra-scapular artery, ligation of, 326.
Surgery of arteries, 234; of lymphatics, 234; of veins, 234.
Surgical dressings, 79; method of applying, 128, 140, 156.
Surgical pathology, 1.
Suspension apparatus, 898.
Suspensory carriage of Case, 903; cradle of Reeves, 905; handkerchief, 799.
Sutures, 129; antiseptic, 80 *et seq.*; continuous, 129; cross-, 130; Czerny's, 629; double-needle, 130; during operation, 93; in abdominal section, 632; in amputations, 177; interrupted, 129; intestinal, 629; in wounded intestine 630; in wounds, 128 *et seq.*; in wounds of the neck, 573; Lembert's, 629; mattress, 129; needles for, 131; of nerves, 60, 573; pins for, 130; quill, 129; silver-wire, 79, 130.
Swan, R. L. Case of hip-joint amputation, 229.
Swanzy. Cataract, 499; conjunctivitis, 488; ectropion, 484; eczema of lids, 485; herpes corneæ, 492.
Sway-back, 893.
Swelling, in gangrene, 151; in inflammation, 1.
Sylvester. Method of artificial respiration, 113; for foreign body, 113, 583.
Symblepharon, 479.
Syme. Amputation at the ankle, 206.
Symphyseotomy, 856.
Symptoms of inflammation, 1.
Synchisis, 503.
Syncope from hæmorrhage, 131; in ether narcosis, 114.
Syndactylus, 935.
Syndesmitis, 426.
Synechia, 493; anterior, 493.
Synovitis, 426; in dislocations, 400; of the ankle, 442; of the elbow, 445; of the hip, 428; of the knee, 439; of the shoulder, 444; of the wrist, 445; symptoms of, 426; syphilitic, 61.
Syphilides, 57.
Syphilis, 54; a cause of arteritis, 62; adenitis in, 57, 59, 237; acquired, 54; diagnosis of, 66; gummata in, 60; inherited, 54, 70; symptoms of, 57; iritis in, 59; lymphangitis in, 59; occlusion of basilar artery in, 253; of digestive system, 62; of jaw, 62; of larynx, 62; of mammary gland, 599; of nervous system, 60; of nose, 62; of rectum, 63; of tongue, 62; of vulva, 854; pathology of, 64; primary, 56; prognosis of, 67; stages of, 56; secondary, 57; synovitis in, 61; tertiary, 60; transmissibility of, 70; treatment of, 67.
Syphilitic adenitis, 57, 59, 237; arteritis, 62, 252; chancre, 56; phlebitis, 241; ulcers of the penis, 828.
Syringe, *débris*, 85, 783; for urethra, 681; prostatic, 794; sterilization of, 85.
Szymanowski. Cheiloplasty, 542; operation for urinary urethral fistula, 817.

Table, operating, 88, 89.
Tænia echinococcus, *vide* hydatid.
Talipes calcaneus, 919; cavus, 927; equinus, 916; planus, 928; valgus, 925; varus, 920.
Tamponade of nares, 522.
Tapping of ventricles of the brain, 464; in ascites, 685.
Tarantula venom, 135.
Tarsal bones, amputation of, 203; dislocation of, 424; excision, 451; fracture, 397.
Tarso-metatarsal joints, amputation at, 200; arthritis, 444.
Tarso-tibial amputation, 200.
Tarsotomy, 451, 924.
Tarsus, amputation through, 203.
Taxis on strangulated hernia, 656.
T-bandage, 167.
Teale. Method of amputation, 213; operation for symblepharon, 480.
Teeth, 559; extraction of, 559; control of hæmorrhage after, 560.
Telangiectasis, 260; of larynx, 587.
Temperature, bodily, in tetanus, 46.
Temporal artery, ligation of, 323.
Temporary packing in wounds, 119.
Tenaculum, 96.
Tendo Achillis, division of, 918, 923.
Tendon of kangaroo, 79; of deer, 79.
Tendon, inflammations of, 426; of paralyzed muscle grafted to healthy muscle, 459.
Tenesmus of the bladder, 749.
Teno-synovites, 426.
Tenotomy in club hand, 934; in talipes equino-varus, 923; in talipes equinus, 918; in torticollis, 886; of eye muscles, 505; graduated, 505; of peronei muscles, 925; of tendo Achillis, 918, 923.
Testicle, 842; abscess of, 842; adenoma, 845; carcinoma, 846; dislocation of, 847; enchondroma, 845; excision, 846; hernia of tubules of, 842; hydrocele of, 834, 837; incarcerated, 650; inflammation, 842; malposition, 847; removal, 846; retained, 650; sarcoma, 846; syphilis, 63; tuberculosis, 844; wounds, 842.
Testing vision for glasses, 508.
Tetanus, 46.
Tetragonus, 15.
Textor. Disarticulation at calcaneo-astragaloid joint, 204.
Thecitis, 426; diagnosis, 426.

Thermo-cautery, *vide* Paquelin cautery.
Thiersch's method of skin grafting, 141.
Thigh, bandage for, 160; amputation of, 217.
Thomas, J. D. Case of hip-joint amputation, 229.
Thomas's hip splint, 436; knee and ankle brace, 441.
Thompson. Evacuator, 770; lithotrite, 767.
Thomson. Color blindness, 504.
Thorax, abscess of wall of, 607; bandage, 162; foreign bodies, 582; gunshot wounds, 608; wounds, 608.
Thrombosis, arterial, 240; causes of, 240; in inflammation, 5; of basilar artery, 253.
Thrombus, in arteries, 240; in veins, 240.
Thumb, amputation of, 185; disarticulation, 185; at metacarpal joint, 186.
Thyroid, artery, ligation of, 318; axis, ligation of, 325; body, 576; aneurisms of, 576; bronchocele, 576; carcinoma of, 576; cysts of, 576; exophthalmic goitre, 579; hydatid cysts of, 576, 579; sarcoma of, 576.
Thyroidectomy, 580.
Thyrotomy, 580.
Tibia, dislocation of, at ankle, 424; at knee, 421; fractures, 392.
Tibial artery, aneurism of, 300; anterior, ligation of, 343; posterior, ligation of, 342.
Tibialis muscles, tenotomy of, 919.
Tibio-tarsal amputation, 206.
Tiemann. Aspirator, 754; tonsillotome, 571.
Tillanus. Case of aneurism, 279.
Tillaux. Cirsoid aneurism, 258.
Tissue changes after wounds, 124.
Tissues, normal resistance of, 14.
Tizzoni's antitoxine, 48.
Toad venom, 135.
Toes, amputation, 199; bandage for, 160; deformities, 928; syphilis, 64.
Tongue, 565; abscess of, 566; adhesion, 570; angeioma of, 566; atrophy, 566; bifid, 570; controlling hæmorrhage from, 565; cysts, 566; epithelioma of, 566; excision, 568; excision by Billroth's method, 568; excision by Gant's method, 568; excision by Kocher's method, 568; hypertrophy, 565; ranula under, 569; wounds, 565.
Tongue-tie, 570.
Tonsillitis, 570.
Tonsils, 570; abscess of, 570; carcinoma, 572; excision, 571; hypertrophy, 571; inflammation, 571; sarcoma, 572.
Torsion of arteries, 120.
Torticollis, 885; neurectomy for, 887; tenotomy in, 886.
Tourniquet, elastic, 99, 155; emergency, 126; Esmarch's, 155; for prolonging cocaine anæsthesia, 113; method of hæmostasis with, 118; Petit's, 126.
Toxæmia, intestinal, 24, 92.
Toxicity of serpent venom, 133.
Toxicophis, 133.
Trachea, foreign bodies in, 582; neoplasms of, 587.
Tracheotomy, 581; for foreign body, 582; for glossitis, 565; high operation of, 581; in ether narcosis, 113; in excision of the tongue, 568; low operation, 582.
Trachoma, 488.
Transfixion, for angeioma, 262; in forming flaps, 173.
Transfusion of blood, 86, 131, 171; apparatus for, 132; for syncope, 132; in ether narcosis, 113.
Transplantation of skin, *en masse*, 144, 146; for burns, 140; by sliding, 144; Wyeth's method, 145.
Transverse cervical artery, ligation of, 325.
Traumatic phlebitis, 242.
Trays for instruments, 89.
Treatment of inflammation, 23; wounds, 125.
Tremor in aneurism, 267.
Trendelenburg. T-shaped drainage-tube, modified, 777.
Trephine, 98.
Trephining in depressed fracture of skull, 353; in injuries of the head, 354; in ostitis, 346; instruments for, 98; of antrum maxillare, 549; of frontal sinus, 462; of mastoid cells, 520; technique of, 469.
Treves. Diverticula of intestine, 624; epithelioma of intestine, 624; intestinal obstruction, 622, 623; stricture of intestine, 625.
Trichiasis, 487.
Trigonocephalus, 133.
Trochanter of femur, fracture of, 386.
Trommer. Test for sugar in urine, 759.
True aneurism, 266.
Truss for hernia, 651.
Tubercular syphilide, 59.
Tuberculosis, 51; of ankle joint, 443; of bone, 346; of epididymis, 845; of head, 461; of hip joint, 428; of joints, 428; of knee joint, 440; of lymphatic glands of neck, 575; of mammary gland, 600; of peritonæum, 673; of prostate gland, 795; of spine, 893; of scalp, 461; of shoulder joint, 444; of testicle, 844; of thyroid gland, 577; of urethra, 821; of vesiculæ seminales, 841; of vulva, 855; of wrist joint, 446.
Tubular adenoma, 957; epithelioma, 947.
Tuberculous leprosy, 72.
Tufnell. Aneurism, 269.
Tumefaction in inflammation, 1.
Tumors, 943; malignancy and non-malignancy of, 943; cirsoid, 258; cutaneous arterial, 260; capillary, 260; venous, 260; cystic, of ovary, 875, *vide* cyst; erectile, 260; of antrum of Highmore, 549; of the bladder, 756; of frontal sinus, 462; of head, 461; of larynx, 587; of mammary gland, 598, 600; of neck, 575; of

nose, 523; of œsophagus, 594; of parotid gland, 546; of pharynx, 588; of the prostate, 795; of the scalp, 461; of urethra, 821; vascular, 258; excision of, 258, 262; ligation of carotid for, 259; venous, 260; venous cutaneous, 260.
Tunica funiculi, 837; intima, media, and externa, 239; vaginalis 789; affected in epididymitis, 841; hæmatoma, 834; hydrocele, 834.
Turbinated bones, 524.
Tuttle. Operation of resection of the rectum, 716.
Twisting of intestines, 120, 622.
Tympanitis in peritonitis, 672.
Types of phlegmon, 234.
Typhlitis, 675.
Typhoid bacillus, 20; sterilization of, 78.

Ulcer, 149; herpetic, 492; of the anus, 708; of the cornea, 492; of the leg, 264; of the lips, 530; of the penis, 828; of the tongue, 565; of the vulva, 854; phagedenic, 829; serpiginous, of cornea, 493; simple, 149; specific, 56; syphilitic, 56; tertiary, of the skin, 60; balsam and oil dressing in, 150.
Ullman. Ligation of carotid for vascular tumor, 259.
Ulna, dislocation of, at elbow, 409; fracture, 370.
Ulna and radius, dislocations of, 409.
Ulnar artery, aneurism of, 295; ligation of, 332; nerve, injury to, from dislocations, 410.
Umbilical hernia, 646, 662; diagnosis and treatment, 662.
Umbrella compress, 784; probang, 590.
Undescended testicle, 847.
Ununited fractures, 397.
Upper extremity, deformities of, 932.
Uræmia, 731.
Urea, 758; tests for, 758.
Ureteritis, 736.
Ureters, affections of, 735; catheterization of, 739, 741; operation on, 736, 737; stricture of, 736; Fenger's operation for, 736; wounds of, 737; Van Hook's operation on, 737.
Urethra, 798; carcinoma, 821; cocaine anæsthesia of, 106; fibroma, 821; fistula, 816; foreign bodies in, 815; malformations, 820; neoplasms, 821; papilloma, 821; stricture of, 803; stricture of membranous, 807; treatment of, 807, 810, 812.
Urethral forceps, 816; sounds, 813; speculum, 821; stricture, 803.
Urethritis, 30, 802; a cause of pyelitis, 728; chordee, 33; chronic, 802; chronic follicular, 803; non-specific, 36, 802; simple, 36, 802; specific, 30, 802; treatment, 34, 36, 803; Lyons's treatment of, 36.
Urethro-rectal fistula, 818.
Urethrotome, Otis's, 808.
Urethrotomy, 807; after-treatment of, 809; external, 807, 812; internal, 807; modified, 810; hæmorrhage after, 809, 811.
Uric-acid calculus, 764.
Urinal, 744, 755.
Urinalysis, 757.
Urinary fistula, 816; rectal, 818, 860.
Urine, 752; albumin in, 758; sugar in, 759; pus in, 759, 760; epithelia in, 759; sterilization of, 762; urea in, 758; examinations of, 757; incontinence of, 755; infiltration of, 745; physiology of, 757; retention of, 752; suppression of, 755, 762.
Uterine prolapse, 888.
Utero-vaginal asepsis, 882.
Uterus, Alexander's operation on, 880; anteflexion of, 879; asepsis of, 882; Cæsarean section, 867; carcinoma, 870, 872; cervix, amputation, 863; curettage of, 881; excision, 863; laceration, 861; excision, abdominal, 866; excision of pregnant, 867; vaginal, 868; extirpation, 866; prolapse, 880; prolapse, Freund's operation for, 880; retroflexion of, 879; retroversion of, 879; ventral fixation of, 880.
Uvula, affections of, 560; excision, 560.

Vagina, absence of, 858; atresia, 858; hernia into, 859; stricture, 858.
Vaginal asepsis, 882; hysterectomy, 868; plug, Sims, 858; section, 882; after-treatment of, 884.
Vaginismus, 857.
Vaginitis, 857.
Valgum, genu, 911.
Valgus, talipes, 925.
Valsalva. Treatment for aneurism, 269.
Van Arsdale. Balsam of Peru and oil dressing, 150; case of hip-joint amputation, 230; subluxation of the head of the radius, 409.
Van Buren. Curvature of steel sounds, 814; *débris* syringe, 783; hæmaturia, method of determining source of, 761; urethral scoop, 816.
Van Hook. Operation for wounds of ureter, 737.
Van Horn & Co., 79.
Vance. Corset, 891.
Varicocele, 838; diagnosis, 839; radical cure, 839; treatment, 839.
Varicose aneurism, 267; veins, 262; ulcers, 264.
Varicosities of lymphatic vessels, 239.
Varix, 258, 262; aneurismal, 267; arterial, 258; treatment, 258, 262.
Varum, genu, 915.
Varus, talipes, 920.
Vascular formation in wounds, 6; system, surgery of, 234; tumors, excision of, 258, 260, 262; ligation of carotid for, 259.
Vas deferens, 841.
Vaseline, 86.
Vegetations of heart, 247.

Vein, internal jugular, ligation of, 307; wounds of, in ligation of carotid, 309.
Veins, 234; hæmorrhage from, 118.
Velpeau. Bandage for dislocation of clavicle, 402; fracture of clavicle, 361, 402.
Venesection in aneurism, 269.
Venom, centipede, 135; scorpion, 135; snake, 133; tarantula, 135; toad, 135; albumen, 133; globulin, 133; peptone, 133.
Venous hæmorrhage, 118; occlusion in gangrene, 152; tumors, cutaneous, 260; varix, 262.
Ventral hernia, 646, 664, 695; treatment, 664, 695.
Ventral fixation of uterus, 880.
Verneuil. Case of aneurism, 294; tapping of echinococcus sac of liver, 687; varix, 263.
Vertebræ, dislocation of, 425; fractures, 375.
Vertebral artery, 325; aneurism of, 295; diagnosis, 295; ligation, 325.
Vesico-vaginal fistula, 860; operation for, 860.
Vesiculæ seminales, 841; inflammation of, 841; wounds of, 841.
Vesicular syphilide, 58.
Vibrion septique, 49.
Vichy water in cystitis, 750.
Villous polypus of rectum, 718; tumors of bladder, 756.
Vinke, H. H. Case of hip-joint amputation, 230.
Violin strings as ligatures, 79.
Vipera, 133.
Virchow. Phlebitis, 241; tumors, 943.
Visceral syphilis, 63.
Vision tests, 508, 511.
Vitreous humor, 423; foreign bodies in, 423.
Volkmann. Foot rest for fracture of femur, 385; operation for hydrocele, 837; scoop, 97.
Volvulus, 622.
Von Graefe. Case of aneurism, 259; excision of vascular tumor, 259; fixation forceps, 500; iridectomy, 494; linear knife, 500; operation for conical cornea, 494; speculum, 500; strabismus hook, 505.
Vulva, 848; abscess of, 848; affections of, 854; chancroids of, 854; contusions of, 848; cysts of, 855; epithelioma, 854; hæmatoma, 848; lupus, 854; papilloma, 854; pruritus, 855; syphilis, 854; tuberculosis, 854; ulcers, 854; wounds, 848.
Vulvitis, 855.
Vulvo-vaginal abscess, 855.

Walker, H. O. Cases of hip-joint amputation, 228.
Wardrop. Case of aneurism, 270, 272; operation for aneurism, 270, 272.
Wardwell. Calcification of arteries, 251.
Warren. Vascular tumors, 260; excision of, 260; ligation of carotid for, 259.
Wart, 58, 957; of head, 461.
Wasp sting, 135.
Waste, process of, 2.
Water, boiled, for irrigation of wounds, 128, 137; pure, for continuous irrigations in amputations, 183.
Watson. Case of aneurism, 298.
Wax, Cunningham's, 123.
Weber, O. Coagulation after arterial ligation, 256.
Web-finger, 936; operation for, 936; Didot's operation for, 936.
Webster. Hordeolum, 479; pannus, 492.
Web-toe, 929.
Weigert. Calcification of arteries, 252; coagulation necrosis, 252.
Weir. Case of aneurism, 280; method of raising ing sunken nose, 528; case of hip-joint amputation, 230.
Weitzer. Excision of vascular tumor, 260.
Wells. Fenestrated forceps, 878; sac forceps, 878.
Wens, 958; of scalp, 460.
Wharton Jones. Operation for ectropion, 482.
Whisky in anæsthesia, 116; for serpent venom, 134.
White. Phlebitis, 242.
White, C. A. Case of hip-joint amputation, 229.
Whitehead. Operation for hæmorrhoids, 725.
Whitman. Treatment of talipes valgus, 927; brace for talipes valgus, 927.
White lead for burns, 140.
Whitlow, 940; treatment of, 941.
Wire, *écraseur*, 523; in the treatment of aneurism, 273, 274; silver, 79, 130.
Wiring ununited fractures, 398; patella, 392.
Wolf bite, 50.
Wolff. Cradle, 890.
Wölfler. Gastro-enterostomy, 613.
Wolverton. Tooth forceps, 560.
Wood. Open method of treating amputations, 182.
Wounds, 124; contused, 124; dissection, 132; dressings, 79, 128; granulating process in, 125; gunshot, 124, 135, *vide* gunshot, healing of, 125; incised, 124; insect, 135; lacerated, 124; of ear, 518; of eye, 476; modes of dressing, 128; of the abdominal walls, 695; of the abdominal organs, 699; of the arteries, 268; of the bladder, 745; of the bowels, 698; of the chest, 608; of the cornea, 491; of the face, 476; of the heart, 609; of the kidney, 727; of the lips, 530; of the neck, 573; of the œsophagus, 588; of the penis, 822; of the scalp, 464; of the scrotum, 831; of the skull, 464; of the testicle, 842; of the tongue, 565; of wrist, 942; of the vesiculæ seminales, 841; of the vulva, 848; poisoned, 132; by dissection, 132; by glanders, 44; by insects, 135; by malignant pustule, 43; by rabid animals, 50;

by serpents, 133; punctured, 124; serpent, 133; sutures in, 128, 130; scalp, 464; treatment, 137, 138, 464.
Wright, T. R. Case of hip-joint amputation, 230.
Wrist, amputation at, 186, 189; dislocations, 412; exsection, 454; synovitis, 446; wounds of, 942.
Wry-neck, 885.
Wyeth. Amputation at hip joint, 218; amputation at shoulder joint, 196; bandage for foot, 160; bladder forceps, 774; cases of amputation at hip joint, 227; conclusions as to arterial occlusion after ligation, 256; drills, 450; experimental deligation of arteries, 246; needle holder, 100; operation for excision of lower jaw, 556; operation for harelip, 539; operation for removal of large tumors from antrum of Highmore, 549; pins in treatment of aneurism, 273.

Xanthic calculus, 764.
Xerosis, 491.
Xiphoid appendage, fracture of, 375.

Yeasts, 17.

Zoöglœa, 15, 76.
Zygomatic process, fracture of, 353.
Zymogenic bacteria, 17.

THE END.

TRAUMATIC INJURIES OF THE BRAIN AND ITS MEMBRANES.

With a Special Study of Pistol-Shot Wounds of the Head in their Medico-Legal and Surgical Relations.

By CHARLES PHELPS, M. D.,
Surgeon to Bellevue and St. Vincent's Hospitals.

8vo, 582 pages. With 49 Illustrations. Cloth, $5.00.

SOLD BY SUBSCRIPTION.

"This work is a concise and systematic treatise on that division of brain surgery arising from injuries of the brain through external violence, and has been based almost exclusively on the observation of five hundred consecutive cases of recent occurrence. Although the cases were so numerous, it seems they were incomplete only in the illustration of secondary pyogenic infection, which is naturally a tribute to the skill of the surgeons in charge of the cases, inasmuch as they were kept from infection. This clinical deficiency has been supplied by excerpts from Macewen's work on Inflammations of the Membranes of the Brain and Spinal Cord, with the permission of that gentleman. We have no hesitation in saying that it is the most complete work on this division of brain surgery which has yet appeared in America."—*Journal of the American Medical Association.*

"This book will prove of great service to both physician and surgeon; and to those interested in medical jurisprudence it will be of incalculable value. The author is not embarrassed by his great wealth of material; he studies it exhaustively, and arranges it clearly, concisely, and with great care and discrimination. The chapters on Pistol-Shot Injuries are particularly instructive, and the series of experiments on cadavers replete with interest. One of the strongest features of the book is the large number of photographic representations of cranial injury."—*National Medical Review.*

"We have here a new work highly creditable to American authorship and adding a material contribution to our present literature upon Brain Surgery. The first part of the work is devoted to the consideration of traumatic lesions of the cranium and its contents, embracing their pathology, symptomatology, diagnosis, prognosis, and treatment. Part II is an exceedingly interesting and original discussion of medico-legal and surgical relations and treatment of pistol-shot wounds of the head. Part III contains a condensed history of three hundred cases of intracranial traumatism verified by necropsy. A most interesting feature of the work is the introduction of a large number of full-page photographic illustrations of the effects of pistol-shot wounds produced by those of different calibers and at different distances. The work will at once be appreciated as one of original investigation, and especially by those who are particularly interested in brain surgery."—*North American Practitioner.*

D. APPLETON AND COMPANY, NEW YORK.

THE ANATOMY AND SURGICAL TREATMENT OF HERNIA.

By HENRY O. MARCY, A.M., M.D., LL.D.,

LATE PRESIDENT OF THE AMERICAN MEDICAL ASSOCIATION, ETC.

ILLUSTRATED

With Seventy full-page Heliotype and Lithographic Reproductions from Cooper, Scarpa, Cloquet, Camper, Darrach, Langenbeck, Cruveilhier, and others of the Old Masters,

AND THIRTY-FOUR WOODCUTS IN THE TEXT.

SOLD ONLY BY SUBSCRIPTION. HALF MOROCCO, $15.00.

THE author has reviewed, *in extenso*, the normal anatomy of the parts involved in Hernia, and the remote causes which tend to produce it. The pathological changes incident to the more marked condition are clearly defined, and the chapters devoted to the discussion of these subjects are very copiously illustrated. Instrumental supports are carefully discussed, and their better methods of application defined. All the various methods of modern operation are given in detail, and, as far as possible, a compilation of tne results obtained under modern antiseptic processes is made. The chapter devoted to the Animal Suture is worthy of especial consideration, since it clearly details one of the greatest innovations of modern surgery of universal value.

It is estimated that there are between three and four millions of people in the United States alone suffering from Hernia. Hundreds of thousands of trusses are manufactured annually. Every physician is aware that a hernia is a gradually increasing disability, and that it is very rarely cured except by operative measures. Serious complications and dangers are ever present to the individual suffering from Hernia, and statistical tables show that the resulting mortality is very large. No other surgical disability is so liable to come under the notice of the physician as Hernia, and the author holds that it is in the highest degree the duty of every practitioner to familiarize himself thoroughly with the subject. The opinion that professional obligations are discharged when the patient suffering from Hernia is relegated to the instrument-maker is erroneous. The belief, as taught by authors of the last generation, that operative measures should not be taken except as a last resort, because of the attendant dangers, has been controverted by the achievements of modern surgery, among which none are more noteworthy than the perfected operations for the cure of Hernia.

D. APPLETON AND COMPANY, NEW YORK.

NATIONAL LIBRARY OF MEDICINE

NLM 00555187 3