


DUNN (T.D.)

*Peliosis rheumatica*  
in a bleeder.







PELIOSIS RHEUMATICA IN A BLEEDER.

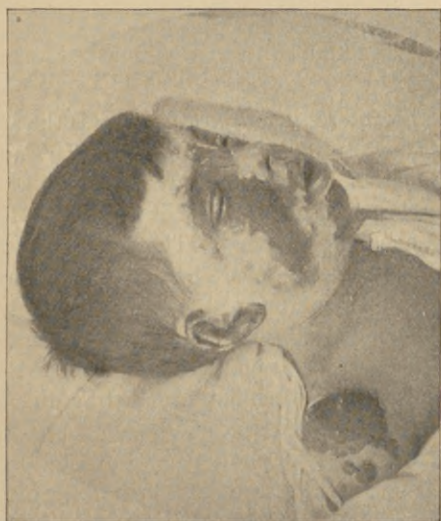By T. D. DUNN, M.D.,

PHYSICIAN TO THE CHESTER COUNTY HOSPITAL, WEST CHESTER, PA.

THROUGH the kindness of Dr. Okie, of Berwyn, I present the report of this interesting case of peliosis rheumatica. Dr. Okie has given me the following notes made of the case prior to consultation with me:

"I first saw Robert L., aged eight and a half years, January 5, 1893. Found slight congestion at base of both lungs. Carbonate of ammonium, counter-irritation, and cotton packing were prescribed.

"He was much better next day. I then noticed discoloration at top of right ear. As the weather was intensely cold, I supposed it had been



frost-bitten. January 7th, ear much worse, discolored and enlarged, with many spots appearing on face, neck, and thighs. Pain in knees and ankles. Was then told for the first time that the boy had complained of pain in knees several days before he was taken sick. Put patient on salicylic acid and soda,  $2\frac{1}{2}$  grains each, every two hours, and wrapped the joints in cotton; also gave tincture of chloride of iron, 20 drops, with acetate of potassium, 2 grains, every four hours. Temperature  $102\frac{2}{3}^{\circ}$ ; pulse 120."

*Condition, January 8th, when first seen by me:* Pain in joints improved but joints still tender and motion painful. Temperature  $102^{\circ}$ ; pulse 120 and feeble. Purpuric spots present on both ears, cheeks, neck,

shoulders, back, legs, and ankles, and some spots over trunk; also spots seen on gums, roof of mouth, and throat, which was sore. Swallowing painful and nourishment taken with difficulty. Ears, lips, eyelids, and chin greatly swollen and tender; conjunctivæ ecchymotic and œdematous; some vesicles formed on right ear and cheek, but no tendency to exudative erythema or urticaria. Slight bronchial cough, but no pulmonary congestion.

January 11. Slight increase of pain in joints, which quickly yielded on return to salicylic acid. The pain preceded the appearance of a few fresh purpuric spots. Temperature  $100^{\circ}$ ; pulse 108. On account of weakness he was given, by suppository, quinine, digitalis, and small dose of opium.

13th. Swelling of ear, chin, and eyelids diminished, and general condition much improved. The accompanying photograph was taken on the eighth day of the disease.

17th. Swelling of joints and tumefaction of face had entirely subsided. Temperature normal; pulse 100 and feeble. Liquid nourishment taken freely. No diarrhœa or mucous hemorrhages. Anæmia marked. Examination of blood showed 3,000,000 corpuscles to the cubic millimetre, in proportion of 1 white to 500 red; hæmoglobin 60 per cent.; numerous microcytes  $1\frac{1}{2}$  to 3 micro-millimetres in diameter. Under continuance of iron, general tonics, and a nutritious diet, the patient rapidly improved, and February 1st, notwithstanding marked anæmia, was able to walk about the house.

The subject of this interesting clinical picture is the sixth of a family of seven boys. They, as well as the father, suffer more or less from rheumatism in joints and muscles, but have no articular deformity. No tendency to hemorrhage has shown itself except in this little patient and an older brother, aged fifteen years. These have had frequent attacks of epistaxis from infancy and severe hemorrhages after trivial injuries. In 1888 I opened a large axillary abscess for Robert, which bled for some time. A profuse bleeding, lasting several days, followed the extraction of a tooth. An operation, which I performed on the father in 1890, for necrosis of sternum, was not attended by unusual hemorrhage. Neither father nor grandfather of the patient was a bleeder. The grandfather, however, came from a very remarkable bleeder family, which I reported in *THE AMERICAN JOURNAL OF THE MEDICAL SCIENCES*, January, 1883. Of his three brothers, Mordecai died of hemorrhage of the stomach at forty; George, from same cause, at twenty; and Davis, from hemorrhage following venesection, at twelve.

Professor Osler, in his *Practice of Medicine*, p. 318, states that "Schönlein's peliosis is thought by most writers to be of rheumatic origin; and certainly many of the cases have the characteristics of ordinary rheumatic fever, plus purpura. By many, however, it is regarded as a special affection of which the arthritis is a manifestation analogous to that which occurs in hæmophilia."

This case certainly supports the latter view—as does the fact that the disease sometimes appears in several members of the same family.





