MARCY (H. O.)

Compliments of the Author

THE SURGICAL TREATMENT OF UTERINE MYOMATA

presented by the author —

—MARCY

LIBRARY
SURGEON GENERAL'S OFFICE
OCT.-31-1898
620

The Surgical Treatment of Uterine Myomata.

BY HENRY O. MARCY, A.M., M.D., LL.D.
BOSTON, U. S. A.
Surgeon to the Cambridge Hospital for Women; late President of the American Medical Association; President of the Section on Gynæcology, Ninth International Medical Congress; late President of the American Academy of Medicine; Member of the British Medical Association; Member of the Massachusetts Medical Society; Member of the Boston Gynæcological Society; Corresponding Member of the Medico-Chirurgical Society of Bologna, Italy; late Surgeon U. S. A., etc.

REPRINTED FROM
THE JOURNAL OF THE AMERICAN MEDICAL ASSOCIATION,
SEPTEMBER 10, 1898.

LIBRARY
SURGEON GENERAL'S OFFICE
NOV.-4--1898
620.

CHICAGO:
AMERICAN MEDICAL ASSOCIATION PRESS.
1898.

THE SURGICAL TREATMENT OF UTERINE MYOMATA.

In the rapid progress of events, the timid steps earlier taken in a most careful way, in the devising of better surgical methods, are now naturally considered of little importance. However, historical studies are of interest and value: of interest, in that they show the thoughtful, reflective judgment of men who considered the gravity of the problems upon which a life is ever more or less dependent; of value, since they point out the way, open ever, but only, to the real student who seeks the ideal, regardless of self-interest; and especially in the fruitage of averted suffering and the saving of life beyond the hope of previous generations.

Based upon ample data, collected with painstaking care, a generation ago, military surgery was rewritten and stands today as the enduring monument of my early master, the late George A. Otis, Surgeon U. S. Army. The slowly developing interest in the surgical diseases of women was held in abeyance, as a seeming side issue of little importance at the close of our late war, and the few more courageous men who presumed to devote special study to this branch of surgery were looked down upon as men of doubtful importance, by the body politic, and unworthy the highest consideration of the public. The late Dr. Gilman Kimball of Lowell[1] appears to have been the first surgeon in the world who deliberately determined to attempt the removal of a large uterine myoma by abdominal section, which was followed by the recovery of the patient, and who planned step by step the procedures which he regarded essential to its accom-

[1] Boston Med. and Surg. Jour., May 3, 1855

plishment; and yet such was the criticism of his well meaning contemporaries that I was personally advised to avoid his acquaintance as detrimental to my professional repute.

Dr. W. Burnham of Lowell, in 1853, only a little time previous to Dr. Kimball's operation, removed a large fibroid tumor, followed by recovery of his patient. However, he began his operation in the belief that it was an ovarian cystoma. Dr. Burnham passed a strong ligature through the neck of the uterus and tied it on each side. Then to make doubly sure against hemorrhage, a ligature was placed round the whole neck. The ovaries were removed. The cervix was dropped and the ligatures were brought out at the lower angle of the wound. They came away during the fifth week. Dr. Kimball operated very much in the same manner, but, eight months later, he reported that the ligatures were still attached. Such was the heroic courage of Dr. Burnham, guided by the conviction that relief should be rendered this unfortunate class of sufferers, that he continued to operate from time to time until 1876, in all fifteen operations with only three recoveries. Heath and Charles Clay of Manchester, England, were doubtless the first who removed uterine fibroids by laparotomy, in 1843 and 1844, but both patients died.

The first Boston surgeon and the third in America to perform suprapubic hysterectomy was Dr. H. R. Storer, Sept. 23, 1865.[2] The criticism of his unwonted daring was almost universal and made so condemnatory that not one of his little circle of assistants was permitted to escape in sharing of it. The short cycle of a generation which has supervened since that period has worked most remarkable changes. In no other department of surgery have such striking victories been won as those now universally accredited to gynesic surgery. Every American surgeon points with pride to our McDowell, who, although described as a frontiersman of the West, profited by his careful

---

American Journal of Medical Science, June, 1866.

Edinburgh training, and in the freedom of his new surroundings dared to think for himself. This opened the way for abdominal surgery with its many present brilliant subdivisions, in which every abdominal organ has been a sharer. It would seem almost invid-

Fig. 1.—1, small uterine myoma. Singular resemblance to a fetal head. 2. uterine cavity. Specimen injected, vessels much enlarged.

ious to name any of the long series of most distinguished men who have labored to bring about, perhaps the greatest triumph of modern aseptic surgery; the present comparatively safe surgical removal of

uterine myomata. Indeed, it is not necessary, since to you the names of these leaders are not alone household words, but their personal influence has been felt and still governs a large share of those whom I have the honor of addressing.

Schroeder, in 1874, advocated the treatment of the pedicle of fibroid tumors by including it in the lower angle of the abdominal wound after the method of Koeberlé of Strasburg, or returning it into the cavity of the abdomen, after ligating or cauterizing it, much in the same way as advised for the treatment of ovarian tumors. In December 1879, he had operated eighteen times with eleven recoveries, and he then advocated the amputation of the uterus at the level of the os internum. The ovarian arteries were ligated on each side, and the cervix was tied in two portions, each including an uterine artery. The uterine stump was cut V-shaped, the muscular walls were closed with coarser, the peritoneal covering with finer, interrupted silk sutures.

In 1880, assisted by my distinguished teacher, Dr. Gilman Kimball of Lowell, I removed the uterus for the first time for a large multiple myoma, where I adopted a modification of Schroeder's method, embodying all that is at present considered essential. Commencing on one side, I sutured the broad ligament with a double continuous tendon suture, extended so as to include the cervix. The broad ligaments were divided, the peritoneum reflected from either side, the stump cut down conically, and this was covered over by an intrafolding of the peritoneum with a continuous sero-serous animal suture. The suture thus taken intrafolded the peritoneum evenly, while it was itself buried beneath it, leaving no line of infraction of the pelvic peritoneum. Thus the stump, while dropped within the abdomen, was itself *extra-peritoneal.* This method seemed to me so important an improvement upon that of Schroder that I reported it in a paper [3] read at the International Medical Congress,

[3] Trans. International Med. Congress, 1881, Vol. ii, pp. 233.

held in London, in 1881. I incorporated it in further detail in my address[4] upon "Fibroid Tumors of the Uterus," as President of the Section of Obstetrics and Diseases of Women, of the AMERICAN MEDICAL

Fig. 2.—Uterine myoma with multiple centers. Capsule formation well pronounced.

ASSOCIATION in 1882. In 1887,[5] I reported still further my experience with this method and emphasized

[4] Trans. Amer. Med. Asso., Vol. xxxiii, pp. 203, 204.
[5] Histology and Surgical Treatment of Uterine Myoma. President's address, Sect. of Gynecology, Ninth International Med. Congres, 1887. Vol. xi, pp. 835-845.

its value. I also pointed out the importance of dealing with the larger number of uterine myoma which develop in such a way as to have really no pedicle. My last special contribution upon this subject was a paper entitled, "The Surgical Treatment of Non-Pedunculated Tumors," read at the AMERICAN MEDICAL ASSOCIATION in May, 1890. Up to that period, in common with nearly every abdominal surgeon, I had considered hemorrhage as the greatest of all dangers, and in order to lessen this, I advocated and used the so-called rubber dam, a thin sheet of rubber with a central reinforced opening which was stretched over the tumor and crowded down as far as possible to its base, around which was placed a constricting rubber ligature. The suggestion of its use occurred to me from noting the admirable service rendered the dentist by the constricting rubber placed around the root of a carious tooth. It served the double purpose of controlling hemorrhage and keeping the abdominal cavity entirely free from surgical contact. This was applicable, however, only to movable tumors with a more or less distinct pedicle.

Dr. L. E. Stimson certainly made one of the most valuable contributions upon this subject by ligating the ovaries and uterine arteries preliminary to hysterectomy. He did this at first in order to perform a complete hysterectomy, but the teaching that hemorrhage might be controlled by the ligation of these arteries bore immediate fruitage in lessening the almost universal fear by the surgeon of the danger of hemorrhage. One has only to observe the enormous dilatation of the venous plexus, commonly accompanying large uterine myoma, to understand the reason of the fear and the real danger occurring from hemorrhage. It was on this account that I included the entire broad ligaments on either side by my method of double continuous en masse suturing.

In 1892, Dr. B. F. Baer made his valuable contribution to this subject, in which he modified the operation of Stimson by ligating the arteries indepen-

dently, while he left the cervical structures as a pedicle, quite in accordance with the method which I advocated. The adoption of new methods with the improvement of aseptic procedures has firmly established

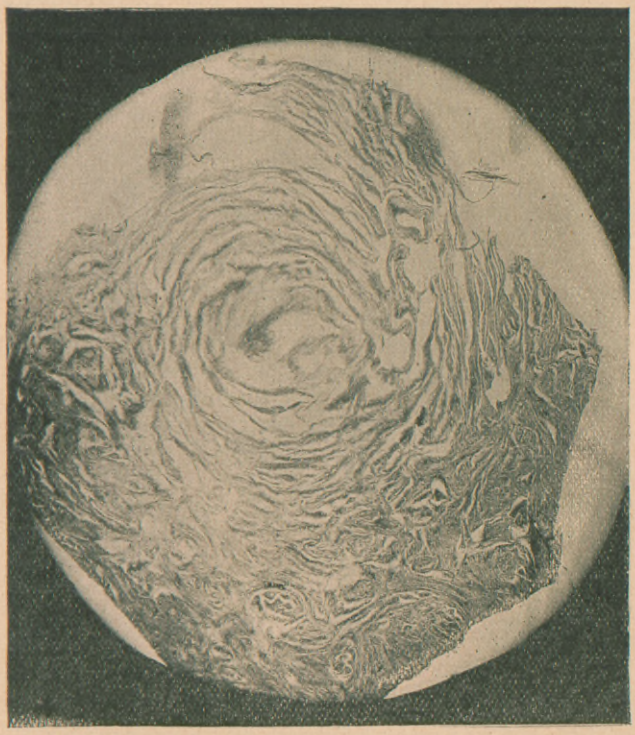

Fig. 3.—Section from just over a small myoma. The enlarging blood-vessels and capsular formation well shown.

hysterectomy as a well-advised and comparatively safe operation for the removal of large uterine myoma.

Dr. Joseph Eastman of Indianapolis has done valuable work in the removal of the uterus, including the cervix for fibroid tumors. He met with excep-

tional success in so doing, and has devised instruments of special type, which are valuable accessories for this purpose.

In an exceedingly interesting article, Dr. Charles P. Noble of Philadelphia, upon "The Development and the Present Status of Hysterectomy for Fibroid Myomata," gives Dr. Eastman the credit of first covering the pedicle with a double flap of peritoneum, which he states was similar to an operation of Dr. Emmett, performed in 1884. It will be noted, however, that I had deliberately effected this for the purpose of making the stump extraperitoneal in 1880, and published the same in 1881 and 1882.

The method of intraperitoneal fixation of the pedicle was of very slow adoption owing to the excessive fear of surgeons lest secondary hemorrhage might ensue. The fixation of the pedicle in the abdominal wall placed it where it could be kept under observation, but the mortality was so great that various ingenious modifications of this method were devised. One of the most interesting of these was by Dr. H. R. Storer of Boston, who sewed the pedicle, including also the ovarian tumors, into the lower angle of the abdominal wound for the purpose of shutting off the peritoneal cavity. This he called "pocketing the pedicle."[6] This operation was revived by Dr. H. A. Kelley of Baltimore, in 1888, with the addition of the use of a temporary elastic ligature.

The first operation for the removal of the uterus, including the cervix (total extirpation), for fibromata, is accredited to Dr. Mary Dixon Jones of Brooklyn, N. Y., who operated Feb. 16, 1888, whereas Dr. Eastman's first total extirpation bears date of August, 1889.

Dr. H. A. Kelley furnishes a valuable contribution with the title "Hysterectomy by Continuous Incision from Left to Right, or from Right to Left," November, 1895. It shortens the time of the operation by commencing at one side, securing the vessels,

---

[6] Journal of Gynecological Society Vol. *i*, p. 150, Sept. 23, 1867.

dividing the cervix, and under tension made upon the tumor, the uterine artery of the opposite side is easily exposed and seized with forceps. The division is continued until the ovarian artery is the last vessel secured. The vessels are ligated, the stump

Fig. 4.—Large surrounding vessels. Capsule well developed. Vessels greatly enlarged.

covered over by a continuous over-and-over-suture of catgut. Emphasis is made upon the importance of commencing the incision upon the side where the ovarian vessels and tube are most accessible.

There is an undoubted gain by this method in the saving of time, and the certitude of work accomplished, and very generally this is greatly facilitated by placing the patient in the Trendelenburg position. Although this paper is not intended to be an historical treatise upon the subject, and as a consequent, many of the most worthy workers in this field have not been mentioned, it seemed to me necessary to follow the line of thought the development of which has brought the present operation of hysterectomy to such greatly reduced rate of mortality, a danger not so very much greater than that attending the removal of an ovarian cystoma. It is very probable that further modifications of this operation will be adopted in the hope of giving still greater safety and satisfactory results. The greatest reason, however, why recent statistics show such marvelous improvement lies in the fact, just as pertains to the history of ovarian cystoma, of the greater confidence of the surgeon, who, as a consequent, advises early operation for comparatively small tumors, which, only a brief period ago, would have been let alone without discussion of operative measures.

The ovarian cystoma which has obtained any very considerable size is likely to have become adherent, and these complications render ovariotomy much more serious and dangerous than the treatment of the pedicle per se. On the contrary, the enlarging myomatous uterus is not likely to form adhesions until at a late period of its development, and its removal is attended with danger chiefly because of the basic structures which must be divided. A supravaginal hysterectomy, therefore, must necessarily involve much greater difficulty than the separation of the ovarian pedicle.

In a very large percentage of cases taken under advisement for operation the pelvic basin is filled with more or less of these growths, and the functions of the pelvic organs are so interfered with as to demand relief. Here adhesions are common, the rela-

tionship of the structures disarranged, the intestines and bladder not rarely involved, and the ureters are in dangerous proximity to the growth to be removed. Such cases will ever tax the most resourceful of operators, and the greater the experience the more will

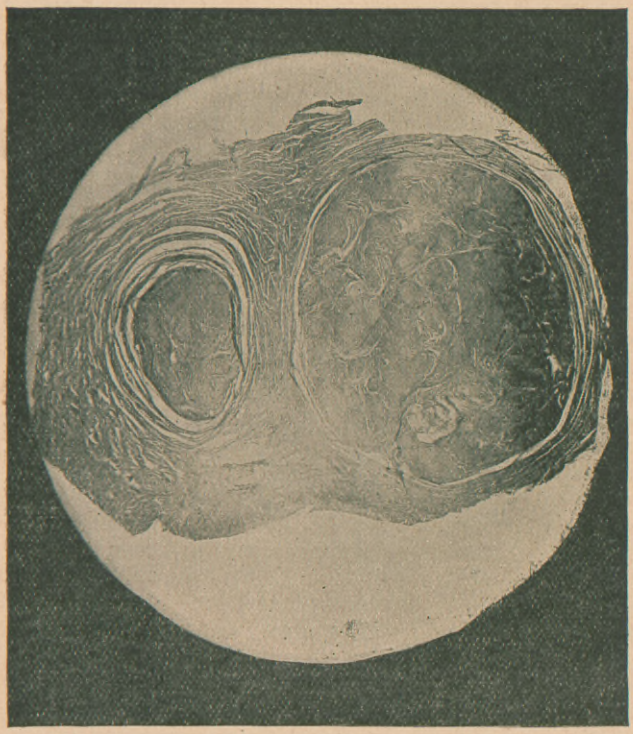

Fig. 5.—Double uterine myoma. Capsules well developed. Tumors slightly vascular.

the surgeon consider the responsibility of his duty. Oftentimes multiple masses are to be enucleated until at last the uterine arteries are seized upon well down in the cervical region. After the tumor has

been removed, the vessels ligated, not seldom a very important part of the operation consists in the reconstruction of the pelvic peritoneum. I exercise more and more care in this direction with each succeeding year.

Hemorrhage, the former greatest danger of the surgeon, is now practically eliminated from the problem, and septic infection, the peritonitis of the earlier day, is almost equally rare. In my last hundred hysterectomies I have not had a single death from hemorrhage or from septic infection. Almost the only cause of death has arisen from intestinal obstruction, induced by infractions upon the peritoneal surfaces, and it is in this I am exercising the greatest care. I recognize the value and importance of time to the patient in prolonged operations, but the rapid surgeon never hurries. "Well done is quick enough done," was the maxim of the elder Crosby. The surgeon should ever be assured of the integrity of the intestinal canal, and as far as possible avoid conditions which may induce obstruction. Adherent omentum not seldom leaves rents through which a loop of small intestine may easily slip. All adhesions of the peritoneum should be closed. This is easily effected by suturing in the same manner as that employed in covering the cervix with the intrafolded peritoneum. A fine tendon is selected and by a loop-stitch fastened in one end of the adhesion. The full-curved small Hagedorn needle is made to penetrate through the healthy peritoneum a few lines from the edge of the rent and parallel to its long axis. Each stitch is inserted directly opposite the emergence of the preceding one, in the same way on the opposite side of the peritoneal rent, and thus from side to side the suturing is continued until the rent is closed. When drawn upon, this sero-serous suture evenly intrafolds the peritoneum, while it is itself completely buried. An exposed ureter may be easily covered in this way, and when the pelvic peritoneum is much disorganized I have not seldom sutured the peritoneum of the entire

pelvic basin in even juxtaposition quite to the pelvic brim. I emphasize this method of closing the peritoneum, especially of the pelvis, since I am sure by it little harm can come from the future disarrange-

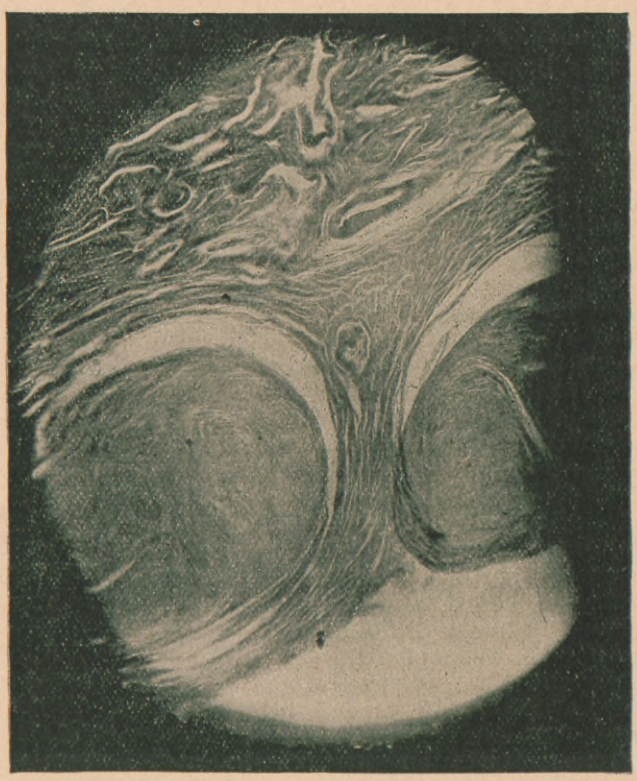

Fig. 6.—Triple uterine myoma. Adjacent vessels enormously ectasic. Taken from a uterus not greatly enlarged but studded with multiple growths.

ment of the organs; that it does not interfere with the rectum or bladder, and that it does materially lessen the really very great danger of adhesive proc-

esses so liable to induce obstruction of the intestines and subsequent functional discomfort, while it is now recognized as by far the most common cause of acute intestinal obstruction.

The variety of methods under discussion at the present time is limited chiefly to suprapubic hysterectomy as above described; to the removal of the uterus, including the cervix; to the saving of as much of the uterine tissue as possible when the myomata are small and not too numerous, and finally to the advantage of leaving the adnexa (the ovaries and tubes) when the conditions will permit. Each of these different methods have certain possible advantages. As I believe, for reasons already stated, the larger number of hysterectomies for uterine myoma should have a certain portion of the cervical tissue left. Generally the operation is less difficult and more rapid. The remaining structures furnish a means of support to both bladder and rectum, the vagina is uninjured and the relations of the pelvic organs are maintained in easy mobility, conditions having a value in marital life of great importance. The objections to this are the possibilities of infection of the wound through the cervical canal and lack of drainage, where conditions of the pelvic basin may render drainage an important factor. To my mind these criticisms are, at the most, of minor importance, since the cervical canal can easily be disinfected or the entire mucosa removed. Should drainage seem desirable, and each year this is considered of less importance, it can easily be provided for by an opening through the posterior fornix.

There are conditions in which it may be of decided advantage to remove the entire uterus. Doyen of France has modified the technic of complete hysterectomy, which, briefly, consists in making forcible tension upon the uterus and myoma by drawing it forward over the pubis through the abdominal opening and then incising the vagina posteriorly. This permits pulling the cervix upward into the abdomen,

which makes tension upon the broad ligaments. First one is divided and then the attachments of the uterus to the bladder are separated, and lastly the other broad ligament is divided. These are seized and held by assistants during the operation and until the

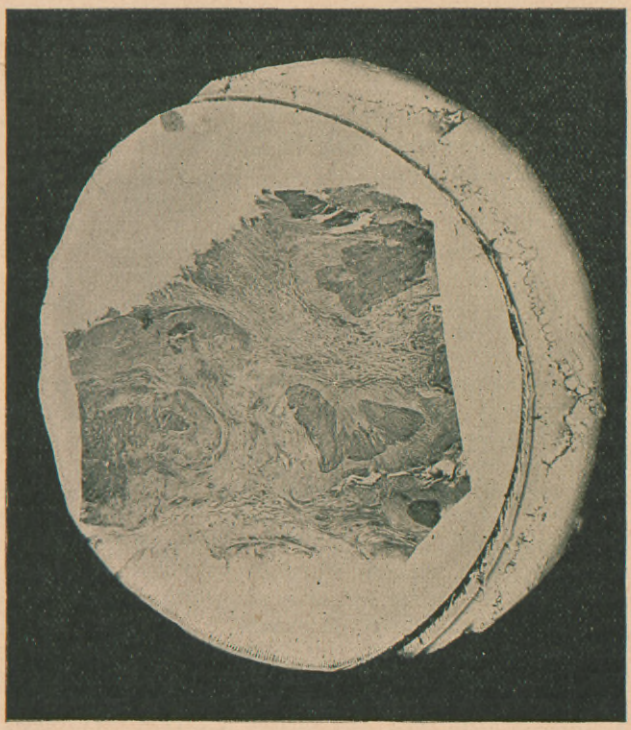

Fig. 7.—Calcified tumor. Infiltration by lime salts. Uterine myoma showing process of calcification. The dark spots mark the lime deposit.

arteries can be independently secured. It will be noted that by such a measure the operative field is brought clearly into vision, greater safety as well as celerity attained, since the relationship of the ureters,

intestines and bladder can be determined with much greater certitude. After hysterectomy has been thus performed, complete peritoneal closure of the pelvic basin may be made if considered advantageous. This leaves a wound open only from below, which may be lightly packed with iodoform gauze. Dr. W. P. Allen of Cleveland has contributed a valuable article upon complete hysterectomy, in which he advocates two modifications of Doyen's method, both preliminary to the abdominal section. The cervix is curetted and packed with antiseptic gauze, the vagina is carefully disinfected, the cervix seized with a strong pair of vulsellum forceps and drawn downward. With the cautery the vaginal tissue about the cervix is dissected. The advantages claimed are: "1. Asepsis is secured with more certainty than by any other method. 2. The division of the vaginal vault by the cautery is in most cases performed quickly and without hemorrhage. If the cervix be very short or difficult to reach, as is sometimes the case when the fibroid is developed in the lower part of the uterus, its separation by the cautery may be unusually difficult. It can, however, usually be accomplished." . . . "The abdominal cavity is not opened from below. A long pair of slender, curved forceps is now used to seize the tissue just behind the cervix at the point at which it is divided by the cautery. The object of this pair of forceps is that when the abdomen is opened, the forceps may be pushed upward into Douglas' cul-de-sac, and marking absolutely the vault of the vagina, enable the surgeon with certainty and rapidity to open downward into the vagina. With long vulsellum forceps the cervix is firmly seized and drawn upward and backward into the abdominal cavity." Dr. Allen thinks the operation of Dr. Doyen as thus modified greatly shortens the time consumed in the removal of the uterus, while the intestines, ureters and bladder are much more easily avoided, and he recommends it for favorable consideration.

By general consensus of opinion, little by little,

the cautery has been relegated to history, and at present, when asepsis makes a certitude of primary union, the use of any means which leaves of necessity necrosed structures should, if possible, be avoided. Dr. Eastman's hysterectomy staff easily fulfills every pur-

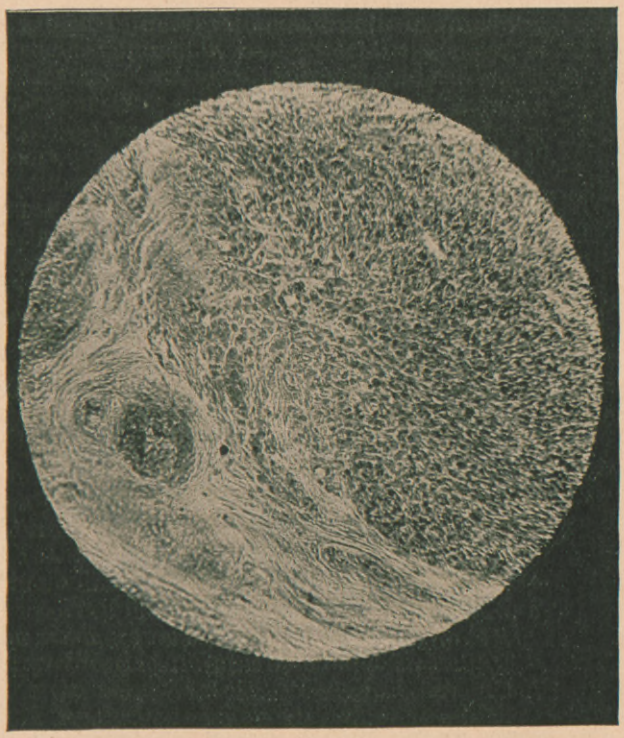

Fig. 8.—Section shows the cell disposition. In the larger portion the cells are cut transversely.

pose sought to be attained by Dr. Allen with his fixation forceps to mark the point of posterior vaginal section.

It not seldom happens that uterine myoma are

found which may be advantageously removed, leaving the uterus more or less damaged or deformed. Dr. A. Martin of Berlin was among the first and most earnest advocates of myomectomy. More than ten years ago this seemed to me the ideal method, and I examined all the cabinet specimens preserved in the Boston and New York museums for the purpose of determining its possibility. I also made a large series of sections of the smaller growths in order to establish the relation between the tumor and its parenchyma, the so-called capsule.

The accompanying photographs will show that this is developed from the deformed surrounding uterine muscular structure, and that the tumor itself usually receives its nutrition from it rather than by vessels directly penetrating its substance. In one instance, however, I succeeded in injecting the vessels of the tumor through the uterine arteries. Unfortunately, it happens that in the great majority of instances the myomata develop from a considerable number of independent centers, whatever may have been their cause and as a consequent the uterus can not be preserved intact, and the invading growths removed. In exceptional cases this may and should be done. In common with other operators I have not infrequently removed a considerable number of these growths, and do not recall a single case where convalescence did not easily follow. The constricting rubber-dam is often of much service in this operation, since it may make the operation bloodless. It is my habit to occlude the cavity with continuous tendon sutures and introflect the divided peritoneal surface over it. The pendulum of opinion upon this operation swings to both extremes. Dr. Noble above quoted, closes his paper as follows: "Myomectomy is the ideal operation for fibroid tumors. The next advance in the treatment of fibroid tumors will be the acceptance of early operation, with the definite purpose of substituting myomectomy for hysterectomy in women of child-bearing age in cases having a small number of fibroid nod-

ules." At the last meeting of the British Gynecological Society, Dr. W. Alexander of Liverpool urged the enucleation of multiple uterine myoma as a favorite alternative operation to hysterectomy, and that it being a non-mutilative operation it presented a marked advantage over total removal of the uterus. The society did not accept his views, but rather Mr. Bland-Sutton's terse summary, who claimed "that in most cases such tumors were developed after the child-bearing period, when the uterus was a non-important organ. He felt sure that a woman was much better off with ovaries and no uterus than with uterus and no ovaries." Dr. J. F. Baldwin of Columbus, Ohio, advocates in abdominal hysterectomy the fixation of the round ligament between the cervical flaps, which holds it *in situ* by buried animal sutures. He claims the advantage to be in the fixation of the parts and preventing prolapse of cervical stump in the vagina.

There can be no doubt but that the improved operations for the comparatively safe removal of large uterine myomata had not alone its inception, but its development to its present successful status in very much the larger degree with American surgeons, the credit of which should be given to American surgery. Within the last half decade, under the leadership of Doyen, Segmund, Richelot and others, vaginal hysterectomy has been successfully developed, especially for the removal of small uterine growths, quite beyond anything attemped in this country in this operation. Vaginal hysterectomy for cancer is more especially a German operation in its origin. Intrauterine myoma for a long period have been successfully removed per vagina by morcellement, even when of very considerable size. At an earlier period I removed a number such growths by this method, one weighing four pounds, where I am convinced I should now perform abdominal hysterectomy, and this because of our greater confidence in an improved technic for abdominal hysterectomy. The French school have advised spe-

cial methods for operating upon the pelvic structures through the vagina, here usually performed by the abdominal route. Their brilliant successes were at once accepted with approval by some surgeons in America and have at present their advocates. It is very probable, however, that this vaginal operation has been popular in France in a large degree owing to their comparative unfamiliarity with abdominal hysterectomy, which they are pleased to style "the American operation."

Blind surgery is bad surgery, and on this account vaginal operations upon the pelvis must ever be held to a certain degree in criticism. If, for instance, a small uterine myoma is to be removed, the choice of the vaginal route, under certain conditions, might advantageously be made. In a large degree this too is an American operation, first advocated and performed by our lamented fellow-countryman, Dr. Robert Battey of Georgia. In 1879 I first removed a fibroid tumor through Douglas' cul-de-sac (a myomectomy), saving the uterus. However, in much the larger class of cases, where it is judged wise to remove uterine myomata sufficiently small to accomplish the work through the vagina, it is undoubtedly better to operate by the abdominal route, since this is the class of cases most suitable for myomectomy.

Little further need be said in reference to the technic of the operation. It must be conducted as far as possible under strict aseptic conditions. An uninfected abdominal cavity, left in good condition, should be closed without drainage. The abdominal wall is reconstructed by independent lines of continuous buried tendon sutures. I consider the peritoneum and thick fascia can be much more satisfactorily reunited by the use of the double continuous tendon suture. A subcuticular, fine tendon suture is much to be preferred for holding in coaptation the edges of the skin. The final dressing consists in the application of contractile collodion, holding in solution iodoform, reinforced by a few fibers of absorb-

ent cotton. Unless the tumor is of exceptional size the patient is usually more comfortable without the application of an abdominal bandage. The advantage derived from suturing the abdominal wound in layers is so apparent that I find its adoption is becoming more and more common. I have thus sutured since my first advocacy of buried animal sutures quite twenty-five years ago, and for fifteen years with no other dressing than the collodion seal. Subsequent hernia does not occur, and in over eight hundred laparotomies I recall but one case of subsequent hernia, and this in a case where the abdominal wall had become excessively thin from a large fibroid tumor.

A final question for consideration is the ever recurrent one: When shall we operate? As in ovarian cystoma, so here the pendulum of opinion constantly varies. Without doubt the larger number of abdominal surgeons are operating on cases today, which they would have judged ill-advised four years ago. In young women, small growths which cause pain, excessive menstruation and interfere with the functions of the pelvic organs should be no longer subject to unsatisfactory medication, since operation in these cases gives the lowest rate of mortality, and not seldom by a myomectomy results in complete restoration of unmutilated organs with restored functions. There is a general consensus of opinion that the patient will profit less by the cessation of the menopause than was earlier believed.

Many of the more dangerous growths develop comparatively late in life, a considerable percentage of which go on to most extraordinary development regardless of menstruation. When the patient is still within the cycle of menstrual life and the ovaries comparatively healthy, it is probably wiser not to remove them. It is my own belief that in the future a wise conservatism will give an approval for operative measures upon a very considerable class of invalids, now usually permitted to drag out a more or less wretched life of suffering. I would, however, urge

the limitation of the operation to the practice of men who have equipped themselves in a special manner for this class of surgery, since it is not alone theoretic knowledge that he must master, but more especially a technic that shall make him at once an artisan and an artist.

BIBLIOGRAPHY.

1. Kimball, Gilman: Successful Case of Extirpation of the Uterus, Boston Med. and Surg. Jour., May 3, 1855, Vol. liii, p. 249.
2. Storer. H. R.: Suprapubic Hysterectomy for Fibroids, Sept. 23, 1865. Amer. Jour. of Med. Science, June, 1866.
3. Clay, Charles: A Successful Case of Entire Removal of the Uterus and its Appendages, Trans. London Obstet. Soc., 1863, Vol. v, p. 58.
4. Schroeder, C.: Weber Myomotomie, Zeitschrift f. Geb. und Gyn., 1882, Bd. viii, p. 141; 1883, Bd. ix, p. 204.
5. Marcy, Henry O.: Hysterectomy, Trans. International Med. Cong., 1881, Vol. ii, pp. 233-234. Fibroid Tumors of the Uterus, Trans. Amer. Med. Ass'n., Vol. xxxiii, pp. 175-208. Histology and Surgical Treatment of Uterine Myoma, President's Address, Secretary of Gynecology and Diseases of Women, Ninth International Med. Cong., 1887, Vol. ii, pp. 835-845.
6. Stinson, L. E.: Ligation of the Uterine Arteries in their Continuity as an Early Step in Total or Partial Abdominal Hysterectomy, New York Med. Jour., March 9, 1889, Vol. xlix, p. 277.
7. Baer, B. F.: Supravaginal Hysterectomy without Ligature of the Cervix in Operation for Uterine Fibroids, A New Method, Trans. Amer. Gyn. Soc., 1892, Vol. xvii, p. 235.
8. Eastman, Joseph: Work in Abdominal and Pelvic Surgery, Ind. Med. Jour., April, 1890, Vol. viii, p. 219 Total Extirpation der Gebärmutter Wegen Myoma, Zeitschrift f. rationelle praktische Aerzte, July 11, 1890, Vol. xxxiv, Jahrang 7, Heft, p. 389.
9. Noble, Charles P.: The Development and Present Status of Hysterectomy for Fibromyomata, reprint from Trans. Gyn. Soc., 1897, Vol. xxii.
10. Storer, H. R.: Pocketing Pedicle, Jour. of Gyn. Soc. of Boston, Vol. i, p. 150.
11, Jones, Mary A. Dixon: Two Cases of Uterine Myoma; one Suprapubic Hysterectomy, the other Complete Hysterectomy, New York Med. Jour., Aug. 25 and Sept. 1, 1888, Vol. xlviii, pp. 198 and 227.
12. Kelly, Howard A. Hysterectomy by Continued Incision from Left to Right, or from Right to Left, Johns Hopkins Hospital Bulletin, February and March, 1896, Vol. vii, Nos. 59 and 60, p. 27.
13. Allen, Dudley P.: Hysterectomy for Removal of Large Uterine Myomata by the Combined Vaginal and Abdominal Methods. Boston Med. and Surg. Jour., 1898, Vol. cxxxviii, No. 21, p. 485.
14. Battey, Robert: Oöphorectomy, Trans. International Med. Cong., 1881, Vol. iv, pp. 279-288.
15. Baldwin, J. F.: The Technique of Abdominal Hysterectomy, Jour. Amer. Med. Ass'n, Dec. 11, 1897, Vol. xxix, p. 1192.