French (Thos. R.)

THE

ACTION OF THE GLOTTIS IN SINGING

BY

THOMAS R. FRENCH, M. D.

CLINICAL PROFESSOR OF DISEASES OF THE THROAT AND NOSE IN THE LONG ISLAND COLLEGE HOSPITAL, BROOKLYN

SURGEON GEN'L'S OFFICE
410.
LIBRARY

REPRINTED FROM THE NEW YORK MEDICAL JOURNAL FOR JANUARY 31, 1891

NEW YORK
D. APPLETON AND COMPANY
1891

THE

ACTION OF THE GLOTTIS IN SINGING

BY

THOMAS R. FRENCH, M. D.

CLINICAL PROFESSOR OF DISEASES OF THE THROAT AND NOSE IN THE LONG ISLAND COLLEGE HOSPITAL, BROOKLYN

SURGEON GEN'L'S OFFICE
410.
LIBRARY

REPRINTED FROM THE NEW YORK MEDICAL JOURNAL FOR JANUARY 31, 1891

NEW YORK
D. APPLETON AND COMPANY
1891

Copyright, 1891,
BY D. APPLETON AND COMPANY.

THE ACTION OF THE GLOTTIS IN SINGING.*

THE diversity of opinion regarding the action of the glottis in singing which still exists among authorities on voice-production makes it imperative that some other means than that of the unaided eye in making direct observation must be employed if a satisfactory solution of this problem is to be reached. The photographic studies of the glottis in singing which I have made during the past four years have convinced me that through this, more than any other method, can we hope to reach a clear understanding of the mechanism of the vocal bands during the formation of the registers and in the changes in the pitch of the voice.

The movements of the glottis are often so rapid that the eye can not appreciate them, or are so numerous that the mind will not retain them in the order of their occurrence. It is estimated that the human eye can open and shut in the one tenth part of a second, but an impression formed upon the retina in that time lacks detail, while an image of the interior of the larynx, in all its detail, may be fully and clearly impressed upon the sensitive plate in the one hundredth part of a second. Those movements which the eye fails to appreciate may easily be defined by taking a series of photographs at different stages, which, being viewed consecutively, clearly show such movements in their entirety.

If the changes which occur in all larynges in singing were in all respects uniform, a clear exposition of their nature could readily be made; but, as such is not the case, the movements of the larynx in a large number of individuals must be studied by themselves and deductions made which will, perhaps, make clear the laws which govern such changes. Through instantaneous photography the actions of the bodies of men, animals, and birds, which were before known only in a general way, have been made quite clear in their detail; so also may the movements of the rapidly acting larynx, in the act of singing, be clearly defined. The practical application of photography to the study of the glottis in the act of singing is destined, I believe, to reveal the nature of most of the hidden movements of the parts in the production of tones. Photography will then supplant the unaided eye in the study of movements and changes which occur much too rapidly for accurate record upon the retina.

I have not yet permitted myself to formulate a theory of the action of the larynx in singing, for even now, after a large number of studies have been made, the camera is constantly revealing new surprises in the action of the vocal bands in every part of the scale. The movements of the larynx in a much larger number of subjects must be revealed, grouped, and recorded before definite conclusions can be drawn. It was with the belief that the camera would prove to be the key to the solution of a part, at least, of the problem, that I undertook the study, a portion of which has been made the subject of this paper.

There is but one class of subjects in which the study of the laryngeal image in singing can be satisfactorily made—namely, that in which the anterior insertions of the vocal bands are well shown during the emission of all the tones of the voice. If the ventricular bands make angular junctions with the anterior wall of the larynx, the anterior insertions of the vocal bands can not be seen. The extreme anterior limits of the vocal bands can only be seen when the outline of the tissues connecting the ventricular bands in front is semicircular in shape. This pair of photographs will enable me to make my meaning clear: *

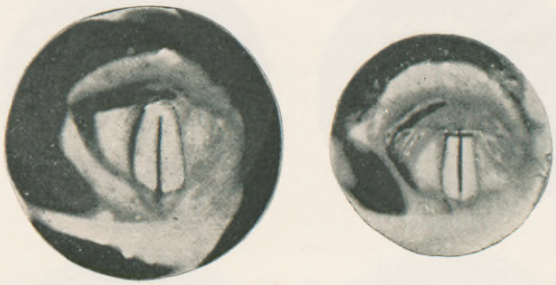

PAIR 1.

In the first photograph the anterior boundary is rounded, and permits a view of the insertions of the vocal bands into the thyreoid cartilage. In most larynges the condition shown in the second photograph is present during the production of all the notes in the compass of the voice. In this larynx the extreme ends of the vocal bands are concealed from view by the lower boundary of the anterior wall of the larynx. A portion of the bands is thus covered, to a small extent, of course, but enough to prevent accurate measurements being taken. In a large number of larynges the anterior wall projects backward. Its change in position reduces or enlarges the cavity of the larynx, and so, no doubt, affects the quality as well as the pitch of the voice. In this class of larynges it is impossible to determine whether the vocal bands are lengthened or shortened in the transition from one register to another, or in the variations in the pitch of the voice.

Occasionally the anterior insertions will show in only a portion of the scale. Such was the case in the subject of

* Read before the Laryngological Section of the Tenth International Medical Congress, Berlin, August 6, 1890.

* The illustrations used in this article are direct reproductions, by the "half-tone" photo-engraving process, of the photographs displayed upon the screen when this paper was read in Berlin. This method of reproduction, so far as laryngeal photographs are concerned, is in the nature of an experiment, and may not prove to be entirely satisfactory. A slight variation in the pressure of the plates upon the sheet may materially affect some of the lines about the glottis and so misrepresent the actual position of the parts. If the photo-engravings, especially those of larynges representing the higher tones, do not accord with the written description of them, it must be assumed that the fault is with the reproductions and not with the photographs.

whose larynx the second of the first pair was taken, as will be seen in this group of three photographs:

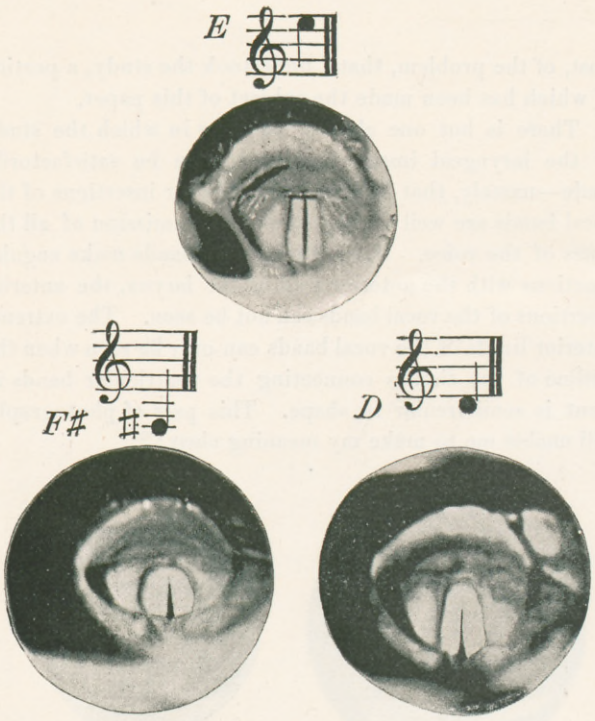

The group represents the larynx of this subject while singing the lowest, the highest, and a middle note of her voice. You may observe that in the lower and middle notes only are the anterior insertions exposed. In all the notes above they are covered by the lower boundary of the anterior wall of the larynx in the manner represented in the upper note.

The fact that there are relatively but few subjects in whose larynges the anterior insertions can be seen throughout the range adds greatly to the difficulties of this investigation. In order to find one satisfactory subject, a large number have to be examined, which necessarily takes much time and renders the progress of the study very slow.

In the short time allotted to me it will be impossible to do more than exhibit series of photographs taken of the larynges of four female subjects, which will show how the changes may be made in the action of the glottis from one register to another and in the variations in the pitch of the voice. These series were taken consecutively, and will, therefore, fairly represent the marked variations in the movements of the various structures which occur in different larynges.

The second pair of photographs is the first of a series which I will show of the larynx of a well-known professional contralto singer. The voice is of excellent quality. The first of the pair was taken while F sharp, treble clef, third line below staff was being sung, and the second while she was singing E above.* These are one of the lowest and the highest notes of her lower register. In the photograph representing the lowest note it can be seen that the vocal bands are quite short and wide, and that, with the exception of the anterior fourth, the ligamentous and a part of the cartilaginous glottis is open and the slit between the vocal

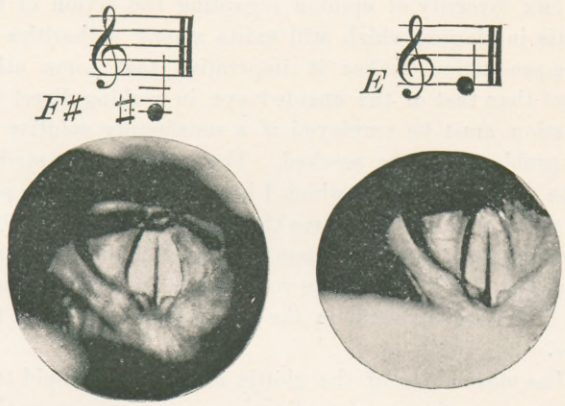

Pair 2.

bands is linear in shape. As the voice ascends the scale the vocal bands increase in length and decrease in width, until at the highest note of the register they can be seen to have become considerably longer. It can also be observed that the ligamentous portion of the glottis is still open to the same relative extent, and that the cartilaginous portion has opened to its full extent. In the photograph representing the lower note the anterior faces of the arytænoid cartilages can be seen. As the voice ascended, the capitula Santorini were tilted forward. This seems to be proved by the change in the position of these structures as seen in the photograph representing the upper note, as well as a similar change to be seen in nearly all the series showing the registers which I have taken. The epiglottis, though not well illuminated, seems to have risen as the voice ascended the scale.* The vocal bands have increased in length at least an eighth of an inch in seven notes. The compass of the voice of this subject is about two octaves and a half. Therefore at that rate of lengthening the vocal bands would increase nearly half an inch if their length

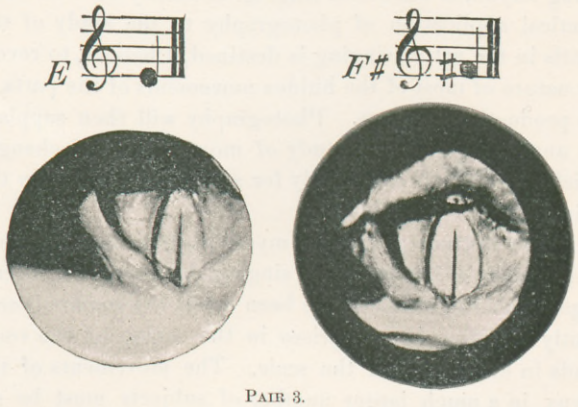

Pair 3.

was progressively increased while singing up the scale from the lowest to the highest note. This progressive increase

* All notes in this and the following series were sung in the key of A.

* The light upon the epiglottis is so weak that the structure does not appear at all in the photo-engraving.

in length does not, however, occur, and the reason will be apparent in the next pair of photographs (Pair 3), which show the changes which took place in the larynx at the lower break in the voice, which, in this subject, occurs at F sharp, treble clef, first space.

The changes which occur at this point are extremely interesting and instructive. In the transition from the lower to the middle register, from E to F sharp, in the voice of this subject, the vibratory portions of the vocal bands are shortened about a sixteenth of an inch. The anterior insertions of the vocal bands can be seen in both photographs; therefore the actual difference in the length of the bands can be appreciated. The vocal bands have not only become shorter, but they appear to be subjected to a much higher degree of tension. The cartilaginous glottis is closed and the aperture in the ligamentous portion has been much reduced in size. The laws which govern the pitch in both string and reed instruments will aid us in explaining this changes. Though the tone is higher and the degree of stretching less than in the note below, the tension is increased, and the aperture through which the air passes is much narrower. It seems to me that this clearly defined change in the mechanism of the vocal bands—which, so far as my investigations permit me to judge, are at this point in the scale the rule—will assist us to a clear understanding of the action of the laryngeal muscles in singing when we reach that part of the study.

In the first photograph, which was taken while the subject was singing the note immediately preceding that on which the break occurred, the vocal bands can be seen to be long and wide and the posterior three fourths of the chink of the glottis is open. By *open* I mean that the edges of the vocal bands are not in actual contact. The anterior fourth or fifth of the ligamentous portion of the glottis is closed. The space between the vocal bands is widest in the cartilaginous portion of the glottis. In the production of the next note higher, F sharp, the second of the pair, a marked change in the size of the larynx and in the length of the vocal bands is seen to have occurred. The cavity of the larynx has been suddenly reduced in size and the vocal bands have been shortened. The cartilaginous portion of the glottis is closed and the ligamentous portion is open in a linear slit from the posterior vocal process to within a short distance of the anterior insertions of the vocal bands. The decrease in the length of the vibratory portions of the vocal bands is due to the closure of the cartilaginous glottis, for the ligamentous glottis remains about the same as in the note before the break. The arytænoid cartilages have been brought much closer together and occupy a more posterior position. These pictures were taken one after the other in quick succession, the conditions in every respect, except the note sung, being the same. The antero-posterior and lateral dimensions of the cavity of the larynx are shown to have been considerably decreased when the voice broke into the register above. When the mechanism of the larynx was changed the voice acquired a very different quality, which continued, in gradual elevation of pitch, throughout the register. As marked a change as this in the mechanism of the vocal bands in females is, I believe, only found in the larynges of contralto singers.

It is believed by many writers on the voice that with the change in the mechanism of the vocal bands the epiglottis is raised higher than in the register below. I am of the opinion that it is usually depressed. The reason for this belief is that, with very few exceptions, I have found it lower in the photographs showing the change than in those representing the note preceding it. When the voice of this subject broke into the middle register it was with difficulty that I could get the epiglottis to rise as high as it is shown here, which, though high enough to show the anterior insertions, is not so high as it was before the break. There does not seem to be any difference in the width of the vocal bands, but in this particular the appearances vary, the variation being due to the position of the ventricular bands. The entire upper surfaces of the vocal bands are rarely exposed to view during the production of the middle and upper notes.

As this singer ascends the scale above the break at F sharp, the vocal bands are increased in length and the chink gradually enlarges, as shown in Pair 4. The first photo-

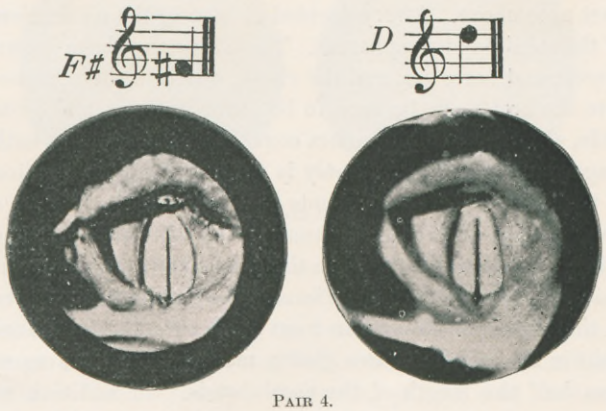

PAIR 4.

graph is of the larynx while singing F sharp, treble clef, first space, the note on which the lower break occurred, and the second while singing D, treble clef, fourth line, which is the highest note in the middle register of the voice of this singer. The difference in the length of the vocal bands and width of the chink of the glottis, as the voice mounts from the lowest to the highest note of the middle register, is clearly shown. Not only is it shown that the vocal bands increase in length as the voice ascends the scale, but the cartilaginous portion of the glottis—which, while producing the lowest note of this register, is seen to be tightly closed—has begun to open again, as shown by the small triangular opening which has appeared between the arytænoids in the second of this pair. Again, as the vocal bands increase in length in this register, their tension is apparently decreased. The capitula Santorini, which in the photograph representing the lowest note in the middle register are seen to be close together and occupy a position well backward in the laryngeal image, become more and more separated and are tilted more and more forward in the ascent of the scale.

Now the voice mounts one note higher—that is, to E

treble clef, fourth space—and as it does so a distinct change in the quality of the voice is heard and the second change in the mechanism of the vocal bands occurs. The changes which take place in the larynx at the upper break in the

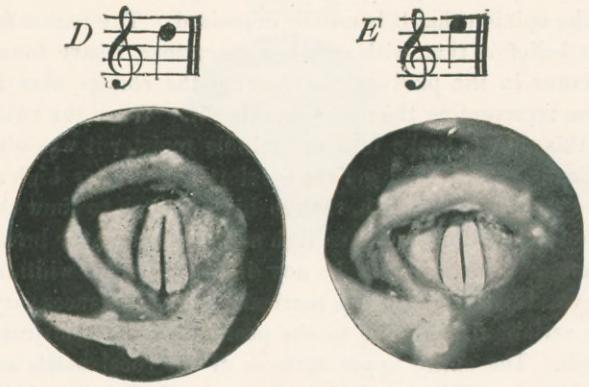

PAIR 5.

voice of this singer are shown in Pair 5. The first of the pair represents the larynx while singing D, treble clef, fourth line, the note immediately preceding the break, and the second shows the change which occurred while singing E, the next note above. A very decided change in the mechanism of the vocal bands is apparent. These ligaments have grown shorter and narrower, and the chink, which in the note before the break can be seen to be linear in shape and quite wide, after the break becomes considerably reduced in both length and width. Not only is the cartilaginous portion of the glottis closed in the note after the break, but also a small portion of the ligamentous glottis adjoining it. The chink appears to be closed to the same extent in front as it was while producing the note immediately preceding. There is, therefore, stop-closure in front and behind which leaves a slit in the middle of the glottis measuring a little more than half the length of the vocal bands. In addition to these changes it may be observed that the epiglottis is depressed and the arytænoid cartilages have again receded. As this is the highest note which this subject is capable of singing with ease, we can not study the action of the vocal bands in the production of tones in the upper register.

It may be remembered that in this larynx the vocal bands increased in length from the low F sharp to the E above. At the next note above they were suddenly shortened. At the next note higher they began to increase in length again, until D, above, was reached, and at E, the note next above, they were again suddenly shortened. It will be instructive to determine the degree to which the vocal bands were lengthened and at what point in the scale they were longest. We saw that in the lower register the vocal bands were longest in the production of the highest note, and in the middle register they were also longest while the highest note was being sung. By comparing the photographs representing these notes (Pair 6) it can be seen that the vocal bands were as long, if not the longest, while the highest note of the lower register was being sung. In this subject the vocal bands increase in length in each register, but they attain as great a length in the lower as in either of the registers above, if not greater. It is generally thought that the pitch is raised by the vocal bands increasing progressively in tension and length. In regard to length this is true in some cases, while in others it is only true as applied to a register, not to the whole of the voice.

The next series of photographs which I will exhibit are of the larynx of a professional singer who possesses a rich contralto voice of large range and good volume.* Though this singer has as large a range as she whose larynx we have just investigated, the pitch of her speaking voice is several tones higher. Here we shall find that the larynx acts in a very different way from that just examined. The first photograph of this pair was taken while F sharp, treble clef, third line below staff, was being sung; the second, while she was singing D, treble clef, first space below staff. The right arytænoid cartilage overlaps its fellow. In the production of the low note the anterior insertions are covered, and we can not, therefore, see how long the vocal bands really are. The ligamentous portion of the glottis is well open, the chink being much wider behind than in front. The cartilaginous glottis appears to be closed, but I do not think that it really is, but, because of the somewhat unusual setting of the arytænoid cartilages, the cleft between them can not be seen. As the voice ascends the scale, the epiglottis is raised, the vocal bands increase in length, and the chink of the glottis is gradually narrowed until at D, the highest note of the lower

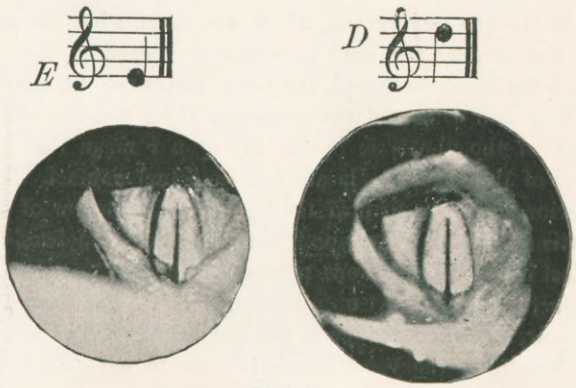

PAIR 6.

register, we find that the vocal bands appear to be considerably elongated, the chink considerably reduced in width, and the epiglottis raised considerably higher. The cartilaginous portion of the glottis still appears to be closed, and there is no evidence of a forward movement of the capitula Santorini. When the next note higher was sung, a very noticeable change in the quality of the voice was heard, and, by examining the photographs taken while that note was being sung with that representing the note below it, it will be seen that a slight change in the mechanism occurred. The epiglottis is depressed. The vocal bands are longer and narrower, their edges are straighter, and the chink of the glottis, which in the note before the break was closed in front, has opened from the anterior to the posterior commissure, and is considerably increased in size. The carti-

* The photographs of the larynx of this subject are clear and strong enough for satisfactory exhibition upon the screen, but are too weak for direct reproduction by the photo-engraving process.

laginous glottis still appears to be closed. The arytænoid cartilage on the right side occupies the same position as before the break, but the left has moved a little backward.

The voice now ascends the scale until D, treble clef, fourth line, is reached, when it can be seen that the epiglottis is slightly raised, the vocal bands appear to be increased in length and decreased in width, and the arytænoid cartilages are turned further forward and brought closer together. The chink of the glottis is still open from front to back, and is altogether larger than in the lower note of this register. The apparent increase in the length of the vocal bands is partly due to the fact that the cartilaginous portion of the glottis is now beginning to open. This note is as high as this subject can sing with ease.

In many particulars the action of this larynx is the reverse of that just examined. In this the cartilaginous glottis does not appear to begin to open until the highest notes are reached. In the lower register the chink of the glottis decreases instead of increases in size as the voice ascends. At the lower break the vocal bands are increased instead of decreased in length, and the chink of the glottis is increased instead of decreased in size. In the larynx before examined the chink of the glottis increased in size and the vocal bands increased in length as the voice ascended in each register, attaining their greatest length at the highest note of the middle register; but in this the vocal bands attained their greatest length at the highest note in the voice of this subject, which corresponds to about the highest note of the middle register.

The next series of photographs which I will show were taken of the larynx of a well-trained soprano singer who possesses the extraordinary range of four octaves. The voice is of excellent quality. The first of Pair 7 was taken

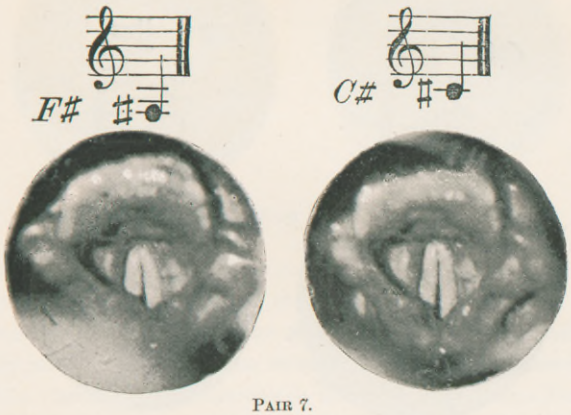

PAIR 7.

of the larynx while F sharp, treble clef, third line below staff, was being sung, and the second while singing C sharp, treble clef, first line below staff. They represent one of the lowest and the highest notes of the lower register of this woman's voice. As the voice mounts the scale, the vocal bands increase in length and the cartilaginous portion of the glottis, which in the lower note is seen to be partly open, increases in size. The arytænoid cartilages recede from the anterior wall of the larynx, and, as they do so, the capitula Santorini seem to pitch forward, leaving a deepening cleft between them. In the neighborhood of C sharp a change in the quality of the voice was heard, not only by myself, but also by a competent judge who listened to the singing of the tones while the photographs were being taken. The change in quality was not great, but was sufficiently distinct to be heard by a trained ear. I say that the change could be heard in the *neighborhood* of C sharp, for the note at which the break occurred varied considerably in this subject. In some of the runs it occurred at C sharp, in others at D or E. Not knowing exactly where it would occur, it was difficult to get a satisfactory idea of the nature of the change in the laryngoscopic mirror. I therefore took photographs while the subject sang each note from the A below to the A above. An examination of the negatives revealed the break at D, a photograph of the larynx while singing which is shown in Pair 8, together with one while singing the note immediately preceding it.

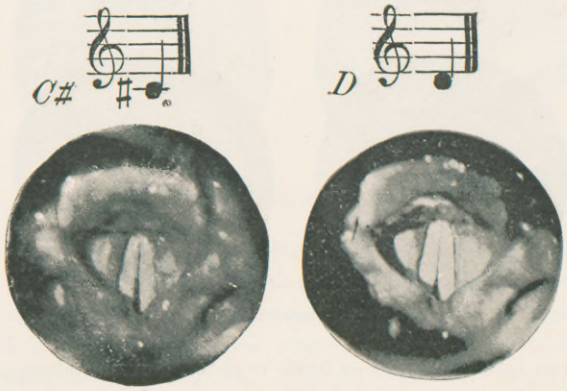

PAIR 8.

The change in the mechanism at the lower break of the voice of this subject consists of a marked decrease in the width of the slit between the vocal bands in the ligamentous glottis and slight tilting backward of the capitula Santorini, and consequently a shallowing of the cleft between them; but, unlike the contralto subject first examined, the cartilaginous glottis still remains open. This condition is, I believe, the exception, a partial or complete closure of the cartilaginous portion of the glottis the rule.

From this point the vocal bands are gradually increased in length and decreased in width as the voice mounts the scale in the middle register, as is seen in Pair 9.

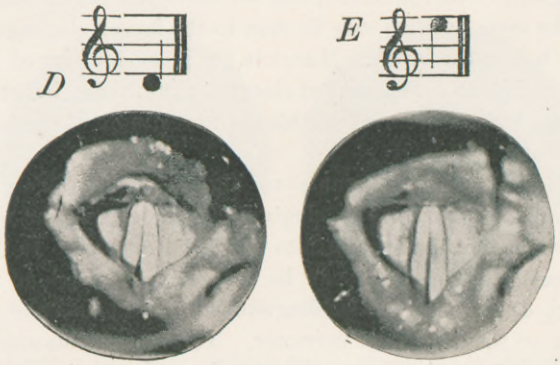

PAIR 9.

The first represents D, treble clef, first space below staff, the note after the lower break. The second, E, treble

clef, fourth space. These are the lowest and highest notes of the middle register of this subject. Besides the elongation of the vocal bands, which appears to be about an eighth of an inch, the arytænoid cartilages are again tilted forward and the cleft between them is deepened, thus exposing more of the cartilaginous portion of the glottis. The edges of the vocal bands have receded from each other as the voice mounted the scale. In all other respects the same remarks will apply here as were made upon the action of the larynx in the lower register.

At the next note higher—F sharp, treble clef, top line—another change in the quality of the voice occurred, and with it a change in the laryngeal mechanism, which is displayed in the next pair of photographs. The voice has

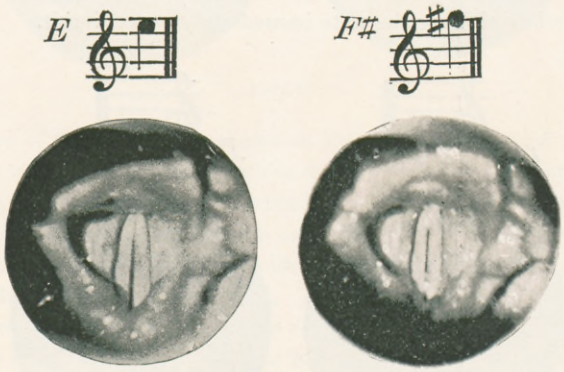

PAIR 10.

broken into the upper or head register, and the change in the mechanism is decided. The vocal bands are reduced in length and appear to be narrower. The edges of the vocal bands are closer together, only a narrow linear slit being left between them. The capitula Santorini are tilted backward, and the cartilaginous portion of the glottis is nearly or quite closed. The position of the epiglottis is about the same as when producing the note before the break. Indeed, its position is not changed at either of the breaks in the voice of this subject, which is, I believe, the exception to the rule. This marks the beginning of the upper register.

The opinion prevails that in the production of tones in the upper register, some portion of the edges of the vocal bands is in contact, or pressed tightly together. In other words, that stop-closure occurs. Here the anterior fourth of the glottic chink is closed, but the same amount of closure in the same position may be seen in the larynx singing the note before the break. Mucus in the posterior part of the chink gives an appearance of closure at that point, but stop-closure has not occurred in this the lowest note of the head register.

Now the voice mounts to high C sharp. Pair 11 shows the larynx while singing that note, and the note on which the voice broke into the head register. In that representing C sharp it can be seen that the whole of the cavity of the larynx is smaller and the vocal bands and the chink of the glottis are narrower. The vocal bands appear to be much shorter, but, as the anterior ends are covered by the cushion of the epiglottis, it is impossible to say how much shortened they really are. The arytænoid cartilages are closer together and are inclined farther forward in the high than in the low note of this register. The mucous membrane covering the lateral walls of the larynx is wrinkled, showing that during the production of this high

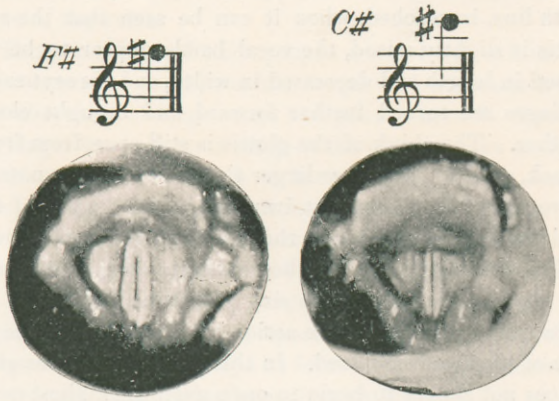

PAIR 11.

note it is not capable of contracting to a sufficient extent to present a smooth surface. In the high note even the contact between the vocal bands which can be seen in the lowest head note, and which we saw occurred in the production of notes in the middle register, has disappeared, and there is a clear linear space between the vocal bands the entire length of the glottis.

The next pair (Pair 12) represents high C sharp, and a still higher note in the voice of this subject—F sharp. In that representing F sharp we may observe that the cavity of the larynx is greatly contracted. The epiglottis not so high as when C sharp was being sung. In fact, the four walls of the larynx are crowded toward the center and the epiglottis is curled inward. The arytænoid cartilages are almost, if not quite, in contact. The vocal bands are very

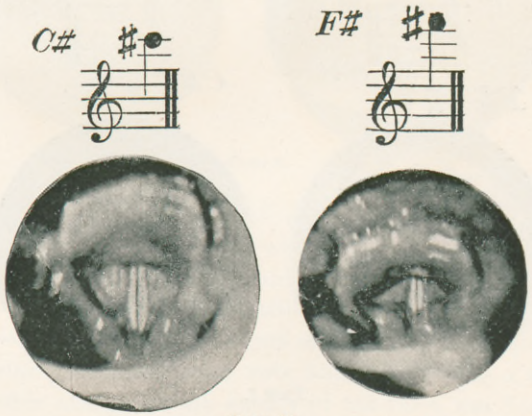

PAIR 12.

short and look like threads. The most surprising revelation made in this picture is that there is no stop-closure. It is possible that there was slight contact between the edges of the vocal bands in the posterior portion of the glottis, but it is my opinion that air was passing between the edges of the vocal bands the entire length of the glottis when this photograph was taken.

Here (Pair 13) is a photograph of another larynx, taken while high C sharp was being sung in the head register, coupled with the photograph of the same note which we

have just examined. Here, also, we find that there is no contact between the edges of the vocal bands.

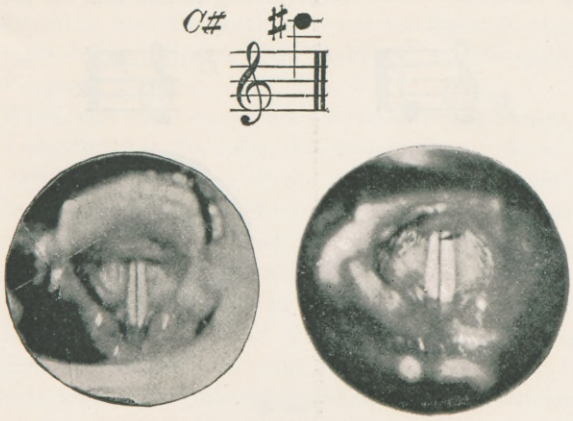

PAIR 13.

While the photographs represented in Pair 14 were being taken the subjects were, without question, singing pure head tones. I felt morally certain, while viewing the vocal bands in the laryngoscopic mirror attached to the camera at the instant the photographs were taken, that there was close contact between the posterior third of the vocal bands in the first subject, and a "jam" between the edges of the posterior half of the glottis in the second. The photographs, however, show that in the first subject

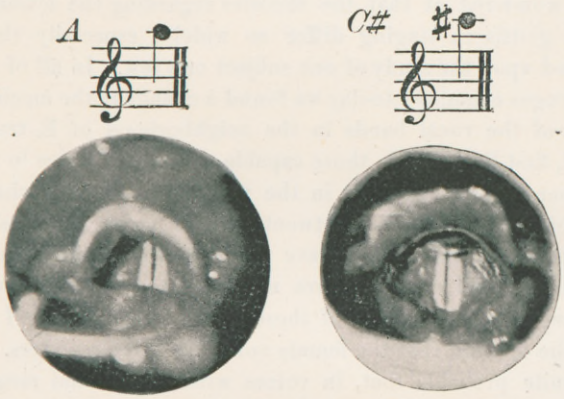

PAIR 14.

the vocal bands are closer together behind than in front, but there is no contact. In the second there is contact, but the edges are by no means as tightly pressed together as they seemed to be in the mirror. The eye was deceived while viewing the reflections in the mirror, and this deception has occurred not infrequently in my studies.

There is, perhaps, a greater uniformity in the opinions of writers in regard to the mechanism of the vocal bands in the production of tones in the upper, or head, register than upon any other action of the glottis in singing. Indeed, I am not aware that there is a writer of prominence who does not believe that stop-action occurs in all head tones. From the revelations made in the photographs of the glottis, taken while head tones were being sung, I would offer the opinion that contact of the vocal bands in the first five or six tones does not occur in half the cases.

Now, permit me to return to the series which we have just been studying to determine the point in the compass of this voice at which the vocal bands are found to be longest. The vocal bands increase in length as the voice ascends the gamut in each register, so that they are longest at the highest note of each register. Let us, therefore, compare the photographs representing the highest notes of the lower and middle registers. It is not necessary to apply the measuring line to prove that the bands are longest in the highest note of the middle register; the difference is evident to the eye.

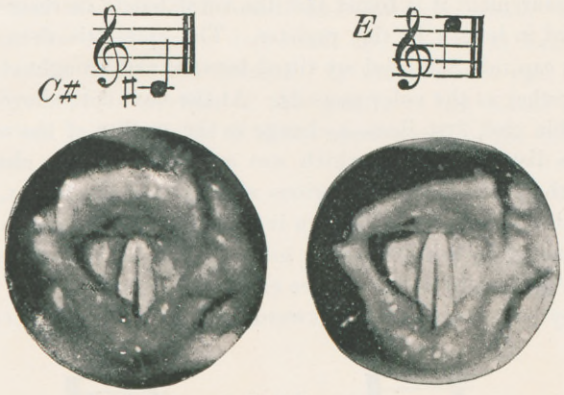

PAIR 15.

I have as yet been unable to determine that training of the voice affects the action of the glottis. The same conditions are occasionally seen to exist in the larynges of both trained and untrained singers while singing the same notes in the same register. The differences are as great in the action of the glottis in trained singers as between trained and untrained.

The next series of photographs were taken of the larynx of a soprano. The subject has a correct ear for music and has a good voice of small range. She knows nothing of the science of singing, never having received any kind of vocal instruction. She may therefore be called a natural singer. I took photographs of her larynx while singing from the lowest to the highest tones which she can sing with ease. Pair 16 shows the larynx while singing one of

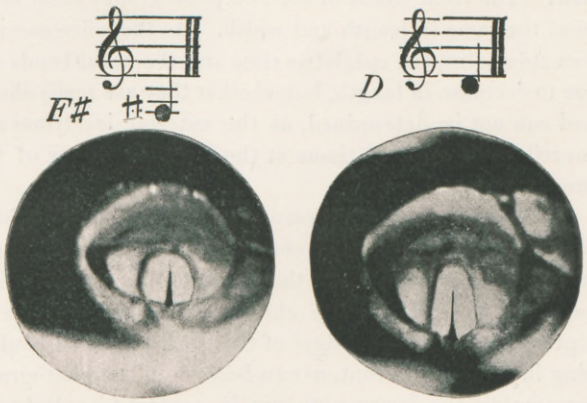

PAIR 16.

the lowest and the highest notes of her lower register—viz., F sharp, treble clef, third line below staff, and D, treble clef, first space below staff. The action of the larynx in this register is unlike either of those we have examined

to-day. In the first contralto and first soprano subjects both the ligamentous and cartilaginous portions of the glottis were open and the chink increased in size as the voice ascended. In the second contralto subject only the ligamentous portion of the glottis appeared to be open, and the chink decreased in size while the scale was ascended. Here the ligamentous and cartilaginous portions of the glottis are seen to be open, and there is a relative decrease in the size of the chink as the voice mounts upward. The anterior insertions show well in both photographs, and by measurement it is found that the vocal bands increase one third in length in this register. The epiglottis rises and the capitula Santorini are tilted forward and brought closer together as the voice ascends. At the next note above—E treble clef, first line—a change in the quality of the voice was distinctly heard, which was accompanied by a change in the position of the various structures of the larynx, the nature of which can be seen in Pair 17. The epiglottis has dropped to a considerable extent. The anterior faces of the arytænoid cartilages are exposed to view, showing that they have been tilted backward. They can also be seen to

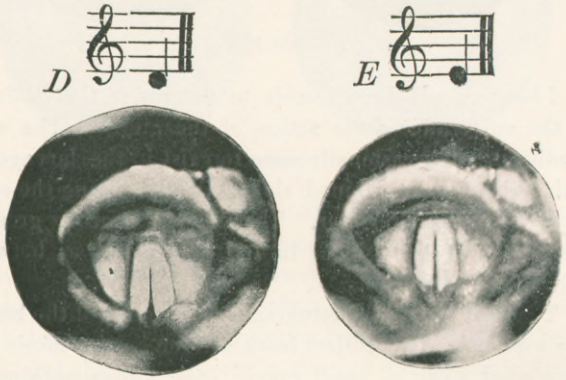

Pair 17.

be farther apart than in the note before the break, and yet the cartilaginous portion of the glottis, which was partly open in the note below, is now closed. The chink presents as a linear slit and the vocal bands appear to be much more tense. The vocal bands in the two photographs seem to be about the same in length and width. As the voice ascends from this point, the epiglottis rises and the vocal bands appear to decrease in length, but whether they are really shortened can not be determined, as the anterior insertions are covered by a fold of tissue at the lower boundary of the anterior wall.

In the photograph representing the highest note which this subject can sing with comfort—E, treble clef, fourth space—which is shown with that representing the note after the break in Pair 18, the chink can be seen to have an elliptical shape, and the edges of the vocal bands, instead of being in contact in front, as can be seen in the photograph representing the lower note, are in contact to a slight extent posteriorly. The arytænoid cartilages are seen to be closer together in the upper note and the mucous membrane between them has tightened up to a considerable extent. The epiglottis rose as the voice ascended the scale in this register. It is very certain that this woman was not singing a head tone at the time the last photograph was taken. She is incapable of singing in the head register. It is therefore somewhat surprising to find that the mech-

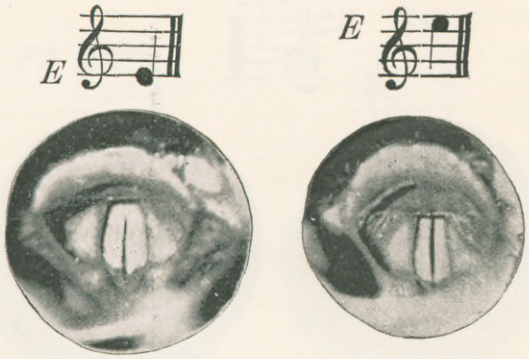

Pair 18.

anism used is that commonly believed to be characteristic of the upper register. It is also interesting to observe that the vocal bands are apparently shorter in the highest than in the lowest note of this register, and therefore shorter than while producing the highest note of the lower register.

The four series of photographs which have been shown to-day were not selected to prove any preconceived ideas. They simply represent the variations which will be met with in any four consecutive studies. It is therefore scarcely to be wondered at that the theories regarding the action of the glottis in singing differ so widely, especially those based upon the study of one subject or a few. In all of the larynges examined to-day we found a change in the mechanism of the vocal bands in the neighborhood of E, treble clef, first line, and in those capable of singing tones in the upper register, another in the neighborhood of F sharp, treble clef, top line. In twenty-five or more female subjects whose larynges I have investigated in the manner demonstrated to-day, I have not failed to find evidence of changes at one or both of these points in the scale. I am of the opinion that the female voice has three registers. It is quite probable that, in voices with exceptional ranges, there are four registers, but sufficient evidence has not yet been obtained to make this demonstrable.

Though the number of series of photographs which have been taken of the larynx in singing is quite large, I do not yet feel justified in drawing definite conclusions from them, regarding many of the movements of the glottis at different points in the scale, but, from the study made thus far, the following conclusions regarding the glottis of the female may, I think, be safely drawn:

1. The larynx may act in a variety of ways in the production of the same tones or registers in different individuals.

2. The rule—which, however, has many exceptions—is that the vocal bands are short and wide and the ligamentous and cartilaginous portions of the glottis are open in the production of the lower tones; that, as the voice ascends the scale, the vocal bands increase in length and decrease in width, the aperture between the posterior portions of the vocal bands increases in size, the capitula Santorini

are tilted more and more forward, and the epiglottis rises until a note in the neighborhood of E, treble clef, first line, is reached. The cartilaginous glottis is then closed. The glottic chink becomes much narrower and linear in shape, the capitula Santorini are tilted backward, and the epiglottis is depressed.

When the vocal bands are shortened in the change at the lower break in the voice, it is mainly due to closure of the cartilaginous portion of the glottis, the ligamentous portion not usually being affected. If, therefore, the cartilaginous glottis is not closed, there is usually no material change in the length of the vocal bands.

As the voice ascends from the lower break, the vocal bands increase in length and diminish in width, the posterior portion of the glottic chink opens more and more, the capitula Santorini are tilted forward, and the epiglottis rises until, in the neighborhood of E, treble clef, fourth space, another change occurs.

The glottic chink is then reduced to a very narrow slit, in some subjects extending the whole length of the glottis. In others, closing in front, or behind, or both. Not only is the cartilaginous glottis always closed, but the ligamentous glottis is, I believe, invariably shortened. The arytænoid cartilages are tilted backward and the epiglottis is depressed. As the voice ascends in the head register the cavity of the larynx is reduced in size, the arytænoid cartilages are tilted forward and brought closer together, the epiglottis is depressed, and the vocal bands decrease in length and breadth. If the posterior part of the ligamentous portion of the glottis is not closed in the lower, it is likely to be in the upper notes of the head register.

THE

NEW YORK MEDICAL JOURNAL,

Edited by FRANK P. FOSTER, M. D.

It is the *LEADING JOURNAL* of America, and contains more reading-matter than any other journal of its class.

It is the exponent of the most advanced scientific medical thought.

Its contributors are among the most learned medical men of this country.

Its "Original Articles" are the results of scientific observation and research, and are of infinite practical value to the general practitioner.

The "Reports on the Progress of Medicine," which are published from time to time, contain the most recent discoveries in the various departments of medicine, and are written by practitioners especially qualified for the purpose.

The Society Proceedings, of which each number contains one or more, are reports of the practical experience of prominent physicians who thus give to the profession the results of certain modes of treatment in given cases.

The Editorial Columns are controlled only by the desire to promote the welfare, honor, and advancement of the science of medicine, as viewed from a standpoint looking to the best interests of the profession.

Nothing is admitted to its columns that has not some bearing on medicine, or is not possessed of some practical value.

It is published solely in the interests of medicine, and for the upholding of the elevated position occupied by the profession of America.

The volumes begin with January and July of each year. Subscriptions must be arranged to expire with the volume.

SUBSCRIPTION PRICE, $5.00 PER ANNUM.

D. APPLETON & CO., Publishers,

New York, Boston, Chicago, Atlanta, San Francisco.