HEKTOEN (L.)

Reprinted from the JOURNAL OF NERVOUS AND MENTAL DISEASE, March 1895.

Amyotrophic Lateral Sclerosis with Bulbar Paralysis and Degeneration in Goll's Columns.

(*From Prof. Henschen's Clinic in Upsalia, Sweden.*)

LIBRARY
SURGEON GENERAL'S OFFICE
JUN - 8 1905
764

BY

BY LUDVIG HEKTOEN, M.D

Chicago.

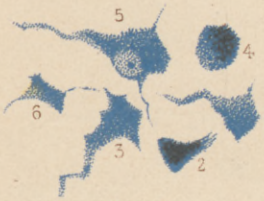

Fig. 1.

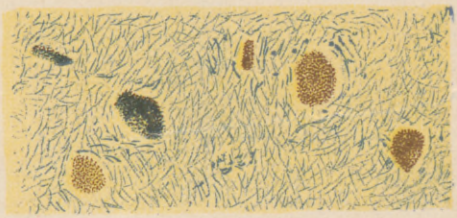

Fig. 2.

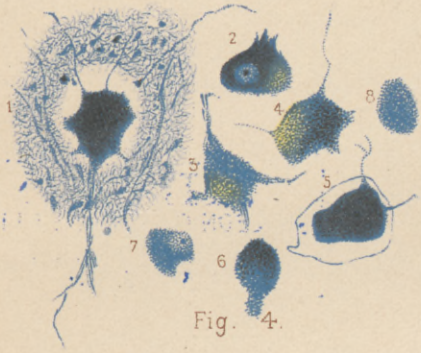

Fig. 4.

Fig. 3.

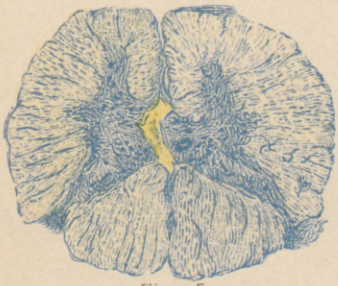

Fig. 5.

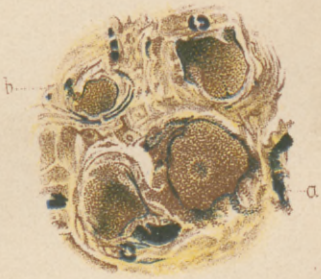

Fig. 6.

AMYOTROPHIC LATERAL SCLEROSIS WITH BULBAR PARALYSIS AND DEGENERATION IN GOLL'S COLUMNS: A CONTRIBUTION TO THE PATHOLOGY OF THE PRIMARY COMBINED SYSTEM DISEASES.[1]

(From Prof. Henschen's Clinic in Upsala, Sweden.)

By LUDVIG HEKTOEN, M.D.,

Chicago.

LIBRARY
SURGEON GENERAL'S OFFICE
JUN. 8. 1905
764

MODERN histologists teach the existence within the nervous system of innumerable anatomic, functional and nutritive units or "neurons,"[2] each being a ganglion cell with its axis cylinder which, becoming a nerve fibre, end in free dendritic ramifications. Two sets of motor "neurons" are recognized, namely, the indirect of Kölliker (Waldeyer's of the second order), which consists of ganglion cells in the brain cortex, their axis cylinders which pass down in the pyramidal tracts and end in free branches around the cells in the motor cranial nerve nuclei and in the anterior horns of the spinal cord; the ganglion cells just

[1] Presented to the Swedish Medical Society, Stockholm, November 27, 1894.

[2] Waldeyer and Kölliker prefer the word "neurodendren" for etymologic reasons. See latter's Handb. der Gewebelehre, Bd. ii., 1893, pp. 1 and 3.

mentioned, with their axis cylinders that form motor nerve fibres and end in the muscles, form the direct motor "neurons" of Kölliker (Waldeyer's of the first order).

The direct sensory "neurons" of Kölliker (Waldeyer's sensory neurons of the first order) are the large cells in the spinal ganglia whose T-shaped axis cylinders send one branch outward as a sensory nerve fibre and the other inward as an intra-medullary fibre. Full clearness has not yet been reached concerning all the higher, indirect sensory neurons, but it seems quite settled that Clarke's columns, the nucleus funiculi gracilis, and the thalamus are some of the centres for new systems (Kölliker, Waldeyer, Monakow, Henschen and others).

The ganglion cell is the trophic centre of the neuron, and, in the case of a direct motor neuron, of the muscle it supplies, but the condition of the cell is undeniably influenced by the degree of functional activity as well as by direct changes in the more peripheral parts of the neuron, the axis cylinder and its branches.[3]

This refinement in the minute anatomy of the nervous system is exceedingly important in connection with the various pathologic processes, and especially when it concerns the so-called primary system lesions of the brain and the spinal cord. These diseases are held by probably most writers as non-inflammatory, degenerative-atrophic processes in the physiologic tracts in which the motor and sensory neurons run in compact masses, *i. e.*, as primary diseases of the neurons, the nervous units.

The pathology of these primary system diseases may be truly said to be very obscure, although two etiologic conceptions have forced themselves forward into great prominence, namely, peculiar hereditary influences variously expressed, on the one hand, and certains forms of chronic intoxication on the other; most important among the latter is the post-syphilitic intoxication. Now it appears that either, or both together, of these factors, as well as other unknown causes, may seem to attack the neuron tracts in any part of their lengthy course, but as the integrity of the ganglion cell is so essential to the rest of the neuron, it follows that when this trophic centre is directly primarily involved, then the entire neuron quickly degenerates.

---

[3] Goldscheider, *Berliner kl. Wochenschrift*, Nos. 18 and 19, 1894.

The histologic character and the topographic distribution of the typical neuron tract diseases certainly point to some such pathogenesis as this, inasmuch as the degenerative atrophy of the nerve elements, the neurons, in definite paths (mapping out with precision the Wallerian tracts of secondary degeneration and Flechsig's developmental tracts) is undoubtedly primary and the insignificant real changes of the stroma secondary. Actual inflammatory and coarse vascular lesions, on the other hand, are always diffuse and pay no attention to the imaginary anatomic limits of the various physiologic systems within their reach.

Among the few typical primary system diseases, amyotrophic lateral sclerosis with bulbar paralysis may be mentioned as illustrating exactly the pathologic and the anatomic considerations hinted at. It is a primary, non-inflammatory disease of both the direct and the indirect motor neuron—the entire motor tract. Surely a more subtle agent is at work here than in inflammations for instance, as it selects with unerring precision the scattered ganglion cells of various individual motor neurons, and consequently this disease has been held as quite strictly *sui generis* ever since Charcot first described it.

While amyotrophic lateral sclerosis is a disease of the two separate motor systems, and consequently in one way a combined system disease, yet the so called combined system diseases proper are those in which there are primary changes of the same cause and kind in sensory as well as motor tracts. The instances of combined system diseases described heretofore have almost all been cases in which but one of the two motor neuron systems, together with the sensory tracts, have been involved at the same time, the combined system disease *par* preference being primary degeneration in the posterior and the lateral columns.

A hurried review of the literature will make this statement clear.

Since the researches of Friedreich, Westphal, Kahler and Pick, and Strümpell placed the combined system lesions upon a firm clinical and anatomic basis, a large number of instances have been described.

Ormerod,[4] in a critical digest on the combination of posterior and lateral sclerosis, considered twenty cases.

---

[4] *Brain*, April, 1885.

Grasset,[5] in 1886, grouped together thirty-three cases which, viewed mainly from the clinical side, he termed instances of tabes combinè or sclerose postero-laterale de la moëlle. Dana[6] collected forty-six cases under the name of progressive spastic paraplegia or combined fascicular sclerosis. The most recent discussion of the subject is by Lenmalm[7] in an article in which he studies about 100 cases with post-mortems from the literature and twelve personal instances (he includes in this number cases of so-called diffuse combined sclerosis as well).

Considering for a moment the topographic distribution of the combined system lesions, then the following combinations are represented in the literature: combined system disease of the posterior columns and the pyramidal tracts;[8] the posterior columns and the cerebellar tracts;[9] the posterior columns, pyramidal and cerebellar tracts;[10] the posterior columns and the anterior gray horns;[11] the pyramidal and the cerebellar tracts;[12] the pyramidal and cerebellar tracts, anterior horns and posterior columns;[13] the pyramidal tracts, anterior horns and the posterior columns.[14]

---

[5] *Arch. de Neurologie*, xi., 1886, p. 156.

[6] *Medical Record*, xxxii., 1887, p. 1.

[7] *Hygiea*, lvi., 1894.

[8] Strümpell, *Arch. f. Psych.*, 1880, xi.; Erlicki and Rybalkin, *Arch. f. Psych.*, 1886, xvii. Dana, *Medical Record*, ii. 1887, p. 10. Oppenheim, *Neurol. Centralblatt*, 1888, p. 617.

[9] Francotte, *Arch. f. Neurol.*, 1890, xix.

[10] Friedreich, *Virchows Archiv.*, Bd. 26, 27 and 70. Kahler and Pick, *Archiv. f. Psych.*, 1878, viii. Westphal, *Arch. f. Psych.*, 1878, viii. Strümpell, *loc. cit.* Smith, *Boston Med. and Surg. Jour.*, v. 113, 1885. Babinski and Charrin, 1886. Clarke, *Brain*, xiii., p. 356. Rutimeyer, *Virch. Archiv.*, Bd. 91 and Bd. 110. Lenmalm, *Hygiea*, lvi., 1894. p. 251. Schmaus, Neumann and Auscher are quoted by Lenmalm, *loc cit.*, as describing this combination in probable syphilitics. Dejerine and Schmaus, *Semaine Med.*, 1894, p. 321.

[11] Blocq and Londe, *Anat. Pathol. de la moëlle epinière*, and Charcot and Marie, *Rev. de Med.*, 1886. Leyden, *Rückenmarks pr.*, ii. Bd., ii Abth., p. 423. Marinesco, *Semaine Med.*, 1894. Dinkler, *Deutsche Zeitsch. f. Nervenheilk*, Bd. iv., 1893.

[12] Strümpell, *Arch. f. Psych.*, 1886, xvii. Münzer, *Wiener Kl. Wochenschrift*, 1892 (in this case Gower's tract was also involved). Minkowski, *Deutsche Arch. f. Kl. Medicin.*, 1884, p. 433.

[13] Mayer, *Lehr. die comb. system, Erkr. der Rückenmarksstränge, Wein. u Leipsig.*, 1894. Lenmalm, *Hygiea*, B. lvi., 1894, p. 256. Leyden, *loc cit.*, p. 441.

[14] Charcot and Marie, *Arch. de Neurologie*, x., 1885, p. 1. Leyden, *loc cit.* Moeli, *Arch f. Psych.*, x. 1880, p. 718. Rovighi and Melottie, *Riv. speriment di Fentria et di Med. Cg*, 1888, xiv., p. 315; Ext. in *Neur. Centralbl.*, viii., p. 177.

NOTE.—This list is not by any means complete as far as the number of cases are concerned. Furthermore, other combinations are also possibly described, but their title as primary systematic changes might be seriously questioned.

Looked at in this way the combined system diseases form a heterogeneous collection containing very likely myelitic and other cases that might seem to justify Leyden's[15] remarks that all so called combined system diseases are myelitic in their nature, except Friedreich's disease, because their symptoms are so indefinite and because their lesions do not respect the limits of the physiologic tracts. Lenmalm[16] shows, however, that these cases are, to a certain extent, susceptible of an etiologic division, while the clinical manifestations and the morbid anatomy might not allow any differentiation; in this way more order and clearness is reached.

Thus the evident hereditary nature of so many of the cases of lesions in the lateral and the posterior columns places these in classes of their own, as witness Friedreich's hereditary ataxia and Strümpell's[17] hereditary spastic spinal paralysis.

The distinct toxic etiology of the lateral and posterior tract degenerations shown by Juczek[18] to follow poisoning with decomposed corn (pellagra) makes another member in an etiologic division.

A very large number of the remaining cases appear to be anomalous forms of tabes dorsalis, the tabetic symptoms and lesions being the predominating, but accompanied with changes in the lateral columns, or in the anterior horns.[19] If the prevailing syphilitic toxine theory of locomotor ataxia be accepted then it follows that the tabic group of combined lesions also forms a separate one from an etiologic point of view.[20] In a few of the cases of combined system disease in syphilitics the localization in the motor tracts has been predominating,[21] and it seems that the syphilitic group of combined

---

[15] *Zeitschrift für Kl. Medicin*, xxi., 1892.

[16] *Loc. cit.*

[17] *Deutsche Zeitschrift für Nervenheilkunde*, Bd. iv., 1893, p. 173.

[18] *Klinisch und Anatomische Studien über die Pellagra*, Berlin, 1893.

[19] Dinkler quotes several such cases of changes in the anterior horns (*loc. cit*). Collins has a clinical case of tabes and progressive muscular atrophy in a syphilitic (JOURNAL OF NERVOUS AND MENTAL DISEASE, 1894, p 90)

[20] Should Obersteiner's demonstration (*Centralblatt für Path. u. Path. Anat*, B. v., 1894, p. 768) that the tabic spinal cord lesions are secondary and depend on a syphilitic meningitis, causing contraction of the pia, vascular sclerosis, and compression of the posterior roots, prove true in all cases, then it is likely that these cases of combined lesions would have to be explained in some other way than as primary degenerations.

[21] See as examples the cases of Leyden and Mayer (*loc. cit*).

lesions may include almost all the topographic combinations possible, although the preference of syphilitic primary disease for the posterior, sensory tracts will remain a peculiar feature. It is easily seen that in complicated individual instances of syphilitic degeneration it may become difficult to classify the changes whether as primary or secondary, diffuse or systematic, or as mixed.

Then there remain some cases without any known clue to an etiologic grouping. Nearly all such cases have been described as primary degenerations in the pyramidal tracts and in the posterior columns, the clinical picture being an easily recalled combination with elimination of varying degrees of the characteristic symptoms of lateral and posterior sclerosis; as examples may be mentioned the instances described by Pierret,[22] Strümpell,[23] Babinski,[24] Lenmalm,[25] and others, in all of which the microscopic examination showed system changes in the posterior columns, the pyramidal, and occasionally in the cerebellar tracts, including often Clarke's columns, the anterior horns being normal, while the cerebral motor ganglion cells have usually not been studied, and the symptoms during life corresponded with reasonable precision to the lesions demonstrated.

Finally is reached an insignificant number of instances in which the lesions involve both the motor neuron-system and the sensory tracts, and it is to this combination that special attention is directed at this time.

First may be mentioned a few instances of this comprehensive union of changes in undoubted or supposed syphilitics:

Leyden[26] found in a syphilitic with paralysis of the extremities, the tongue and the head, with some muscular atrophy, degenerations in the lateral, anterior and posterior (slight) columns, in the cells of the anterior horns, in the hypoglossus nuclei, and in the anterior nerve roots.

Mayer[27] has a case of tabes in a syphilitic plus spastic spinal paralysis and dysarthria; post-mortem he found

---

[22] *Arch. de Physiolog.*, iv., 1871-72, p. 367.
[23] *Arch. f. Psych.*, xl., 1881, p. 32 and p. 55.
[24] *Neurologische Centralblatt*, v., 1886, p. 140.
[25] *Loc. Cit.*, p. 251.
[26] *Klinik. der Rückenmarkskrankheiten*, Bd. ii., Abth. ii., 1876.
[27] *Loc. Cit.*

systematic lesions in the pyramidal, cerebellar and posterior columns, atrophy of the cells in the anterior horns, in Clarke's columns, in the hypoglossus, facial and sixth nuclei and of the posterior nerve roots.

Lennois and Lemoine[28] describe a case of atypic amyotrophic lateral sclerosis with optic atrophy and lancinating pains in a woman, 28 years old, without any history of syphilis. The changes were: Degeneration of the pyramidal and cerebellar tracts, of the posterior columns, of the cells in both anterior and posterior horns, and chronic changes in the medulla and pons.

Lenmalm[29] has an instance of tabes without any cerebral symptoms, combined with paralysis and some muscular atrophy. The changes were: Symmetric lesions of pyramidal, cerebellar and part of the posterior columns, with atrophy of the cells in the anterior horns and in Clarke's columns.

These instances may serve, then, as examples of a combination of system lesions in both the motor segments and the sensory paths with a more or less distinct syphilitic etiology. The resemblance of the clinical and antomical features in two of these cases to amyotrophic lateral sclerosis recalls the typical cases of this disease with optic atrophy observed clinically by Suckling[30] and Peltesohn[31] in syphilitics.

Then there are some instances of typical amyotrophic lateral sclerosis with system lesions in the posterior columns of slight extent, no symptoms pointing to their existence having been observed during life.

Charcot and Marie[32] found slight degeneration in Goll's columns in the two first cases of amyotrophic lateral sclerosis, in which degeneration was demonstrated in the ganglion cells of the cortex of the motor region, but sensory symptoms were not observed.

Maeli[33] has a case of symptomless degeneration in Burdach's columns in amyotrophic lateral sclerosis. Rovighi and Melotti[34] describe in extenso a typical case

---

[28] *Arch. de Med. Exp.*, 1894, p. 443.

[29] *Loc. Cit.*

[30] *British Med. Journal*, 1882, vol. ii., p. 1,152; quoted by Lenmalm, *Loc. Cit.*

[31] *Centralblatt für Krakt. Augenheilkunde*, 1886, p. 6; quoted by Lenmalm, *Loc. Cit.*

[32] *Arch. de Neurolg.*, x, 1885, p. 1.

[33] *Arch. für Psych.*, x., 1880, p. 718.

[34] *Riv. Speriment di Fenetria e di Medicina Legale*, 1888, xiv., p 315; Extr. in *Neur. Centrlbl.*, viii., p. 177.

of amyotrophic lateral sclerosis in a 27 year old man, the clinical course running from October, 1881, when atrophy and weakness in the hands and forearms appeared, bulbar symptoms coming on in November, 1882, the picture being complete in October, 1883, to January, 1886, without any disturbance of sensation or sphincter function. There was atrophy of the nuclei in the medulla, of the ganglion cells in the anterior horns, total degeneration of the crossed pyramidal tracts, with some degeneration in Goll's columns and atrophy of both anterior and posterior nerve roots, the cells in Clarke's columns being normal.

Oppenheim[35] has a case with sharp, systematic degeneration of Burdach's columns ceasing precisely at the septum intermedium, the cells in Clarke's columns being atrophic, and of this definite lesion he states positively there were no symptoms.

Marie,[36] in his description of the morbid anatomy of amyotrophic lateral sclerosis, states that the columns of Goll often show some slight degeneration, but that the characteristic "corps granuleux" are absent. No cause for this degeneration is known, but he hints at its possibly being due to lesion of the cells in the posterior horns.

Leyden[37] mentions a case of amyotrophic lateral sclerosis with slight prodromal symptoms of a tabic nature, to wit, anæsthesia of the plantar surfaces of the feet, and post-mortem slight degeneration in the posterior columns was found in addition to the usual motor tract lesions.

Oppenheim[38] has an instance of rapidly fatal amyotrophic lateral sclerosis. In addition to the typical symptoms there was hyperæsthesia in the left thoracic region and diminished pain and temperature sensibility in the right leg and foot. The characteristic lesions in the motor tract were demonstrated, and also a circumscribed lesion of the left posterior horn and the left posterior nerve root in the dorsal region corresponding to the origin of the second and third dorsal spinal nerves —a unique example of amyotrophic lateral sclerosis and and a diffuse sensory tract lesion.

Finally, Raymond's[39] case may be brought in. A

---

[35] *Arch. f. Psych.*, xxiv., p. 758; *Neur. Centrlbl.*, 1888, No. 6.
[36] *Traite de Medicine*, 1894, Tome vi., p. 340.
[37] Quoted by Omerod, *Loc. Cit.*
[38] *Arch. f. Psych.*, xxiv., p. 758.
[39] *Arch. de Phys.*, 1892, x.

woman, 78 years old, who had had pain in her legs since her fortieth year, suffered during the last years of her life with spastic paralysis, increased reflexes, wasting of many muscles without electric change, and post-mortem there was found in addition to arterio sclerosis rather irregular degeneration of the posterior columns, of the pyramidal and cerebellar tracts, with absence of many cells in the anterior horns and in Clarke's columns. This case is justly regarded by Lenmalm as an example of an arterio-sclerotic diffuse lesion, and is introduced in this manner simply for the sake of completeness and comparison.

These, then, are apparently all the cases from the long and complicated list of combined system lesions in the spinal cord that present at the same time primary changes in both motor neuron systems and in the sensory tracts. Much commentary is not necessary, because it will be observed that the syphilitic cases present a peculiar and varying mixture of the symptoms of tabes and of chronic spinal muscular atrophy, and the cases of amyotrophic lateral sclerosis accompanied with system changes in the posterior columns are disappointing in so far as corresponding sensory symptoms were absent (or not observed). In Leyden's single case only was there any disturbance of sensation—anæsthesia of the soles of the feet—and this was a prodromal symptom merely.

In other words, a typical case of amyotrophic lateral sclerosis, with bulbar paralysis and with the sensory symptoms of a genuine posterior sclerosis, does not seem as yet recorded. This condition is quite closely approached, however, by some of the instances of primary combined syphilitic lesions that have been mentioned.

Should this state of affairs be interpreted as meaning that the cause of amyotrophic lateral sclerosis and bulbar paralysis has such affinity for the motor neurons as to always leave the sensory uninvolved? In fact, the marked affinity of the syphilitic poison for the sensory neurons and the almost exclusive involvement of the indirect motor neurons in the hereditary forms of combined sclerosis point to some such explanation as suggested in the above question.

From this consideration it becomes plain that the following case of primary system disease of both motor neurons and of the direct sensory neurons presenting the clinical picture of amyotrophic lateral sclerosis with bulbar paralysis, in the course of which marked sensory

disturbances develop, becomes an important addition to the literature of the system diseases.

The case was observed clinically in Prof. Henschen's wards of the Upsala Academic Hospital; the organs of the nervous system were examined and studied by me under Prof. Henschen's supervision in his laboratory. I am deeply indebted to Prof. Henschen for placing the clinical records, the organs, and his laboratory at my disposition, and I thank him sincerely for his kindness, aid and advice.

THE CLINICAL HISTORY.

J. S., born 1825, farm laborer, admitted Aug. 7, 1890. His parents died fifty years ago of unknown causes; two sisters live and are well; one sister died two years ago. As far as he knows, no instance of a disease like his ever occurred in the family, which has always been regarded as strong and healthy. He is married and father of three sons, all of whom are soldiers (consequently well built, healthy men). He has always lived in the country, in good hygienic surroundings. He has had good health until this illness came on. He is ignorant of having had any of the diseases of childhood. While young he had chills and fever, and in 1857 an attack of small-pox; ten years ago his chest was crushed in and a rib was broken, but perfect health was soon regained. During the fifteen years after 1860 he was a bridge-tender, and was often subject to mental worry and sudden, momentary physical over-exertion; otherwise he has always been a farm laborer.

He has never used alcohol to excess, and denies all venereal diseases. In 1875 a brief attack of unconsciousness came over him, during which he fell to the floor; spasms, palsy or aphasia were not noticed; in a few days he was quite well again. Subsequently similar spells appeared from time to time; an attack in 1885 was characterized by twisting of the head down and to the right; the last attack occurred in 1887, and as it was ushered in by noises in the ears and flashes of light before the eyes, he had time to lie down before unconsciousness supervened. These attacks were all of very short duration, and, with the single exception of the one in 1885, consisted in momentary losses of consciousness, during which he would fall.

The actual commencement of his illness he traces

back to July, 1887; he can give no cause for the gradual weakness and increasing trouble in walking which then began. Soon after this time the left foot became stiff and painful, the pain extending into the thigh; he was treated in this hospital from January 20 to February 19, 1888, the diagnosis being chronic muscular rheumatism. The following is extracted from the records of this visit: "Muscular, healthy looking man; bodily functions normal; passive motion in the left foot is painful, and walking causes pain in the left calf, while the foot drags behind some, touching the floor very lightly. The left foot is a little swollen, but sensation is normal." Now (1890) the patient claims that some, though slight, weakness was present in his right leg during and even before this short visit to the hospital. In the spring of 1888 he gave up his work, principally on account of the trouble with walking; in the fall of the same year he had to use support in walking; at this time shooting pains came into the lower extremities, and the back was stiff and painful; the upper limbs also became weak; frequently they would "sleep;" this was noticed first in the left arm; the hands grew thin, the fingers stiff, so that he could not dress and undress himself unaided. Speech also became troubled; he could express himself if given time, and he did not forget the names of persons or objects, but it was hard to pronounce clearly, and he had to talk slowly. Nor was this all, for chewing and swallowing were also disturbed, and he could not prevent mucus from dribbling from his lips or trickling into the pharynx. Sensation, defecation and urination were unchanged. At New Years, 1889, he fell and hurt his chest some.

In March, 1889, he was readmitted to the hospital, remaining until June 8, the same year, the diagnosis now reading amyotrophic lateral sclerosis. The following is an extract from the records of this visit: "Shooting pains in the legs and in the back; it is hard for him to chew and to spit; there is no aphasia; vision good; smell and taste seem a little dulled; there is a slight paresis in the left facial nerve; the movements of the tongue are limited, the point deviating a little to the left; swallowing is labored, speech indistinct, the voice hoarse and monotonous. Sensibility everywhere normal. The hands are thin, and the movements of the fingers, hands and feet weak and slow; the left leg is weaker than the right; both feet drag behind when walking, and the legs

tremble much as soon as he tries to hurry. Reaction of degeneration is present in the adduct. digit min., abd. pollicis brev., peroneus long. dext., and in both the ext. com. long., while in the adduct. pollicis and abd. hallucis the excitability is lessened. The patellar reflexes are exaggerated.

Note May 29, 1889: "The forearms are flat and the interossei wasted, leaving depressions. The bulbar symptoms are prominent."

When he left the hospital (June 8, 1889) he walked by the aid of two canes. At the end of 1889 he could not move from chair to chair unaided. During this time he thinks that sensation also became lessened, first in the limbs of the right side, then in the left. In the early part of 1890 he often fell in trying to move from place to place; he became more and more helpless, and was brought back to the hospital August 7, 1890.

EXAMINATION, SEPTEMBER, 1890.

The patient is bedridden, and cannot unaided change his position.

Emaciation is marked, the hands especially being thin. No œdema, no decubitus. Sleep and appetite good; urine normal. Obstinate constipation. He cannot cough or spit out saliva, which accumulates in pharynx. No fever. Perception, judgment and memory seem normal. He is emotional, passing easily from smiles to tears. There is no aphasia, and, as he cannot write or read writing, he readily puts together words by means of loose letters.

The Cranial Nerves.

I.—No hallucinations. In the left nostril the smell seems a little lessened.

II. Vision good; no hemianopia.

III., IV. and VI.—The movements of the eyes are normal; the pupils equal and active; no ptosis, nystagmus or strabismus.

V.—Sensibility in all forms normal. Marked increase in the salivary secretion. Mastication is slow and feeble; the buccal mucous membrane often falls in between the teeth. He eats only soft bread and finely chopped food.

VII.—He wrinkles forehead well, perhaps a little livelier on the right side. The right eyelids are closed tighter than the left. The lips move stiffly, and often

allow food to fall out when he is eating. The left palatal arch hangs lower than the right; uvula does not deviate. Emotional movements in the face are active.

VIII.—Watch heard at 15 cm.; no hallucinations.

IX. (V.)—Taste is diminished; salt, sweet and sour are not definitely distinguished between along the left half of the tongue, particularly at the tip. He says he tastes his food less than formerly. No hallucinations. Deglutition is laborious, semi-solid articles giving less trouble than liquids, which run into larynx and cause cough.

X.—Respiration and pulse normal. Sensation in larynx normal.

XI.—Voice monotonous. Adduction of cords less prompt than normal. Movements in sterno-cleido-mastoid and trapezii muscles feeble.

XII.—The tongue is flat and thin; it can be put out only as far as the margin of the lips, and the tip points to the left; on the back and along the margins are fibrillary twitchings. It cannot be pressed firmly against the roof of the mouth. Efforts to pull it out are vigorously resisted.

Speech.—A monotonous sound is produced, in which there is but little accentuation. "Yes" and "no" (Swedish) are tolerably distinctly pronounced. Of the letters, "h" (Swedish) is best pronounced; the vowels come next; and of the consonants "f," "m," and "v" are clearest.

The Peripheral Nerves.

Sensation.—Examination on this point is somewhat difficult on account of the dysarthria. The following nearly completely anæsthetic districts are, however, easily demonstrable:

I.—The district supplied by the right ulnar and right internal cutaneous nerves. The included part of the hand and fingers and of the lower third of the forearm are about completely anæsthetic.

II.--The left little and ring fingers, the ulnar half of the hand and of the forearm up to 18 cm. above the styloid process.

III.—The right leg up to 7 cm. above the patella, inclusive of dorsum of foot.

IV.—The left leg up to 3 cm. above the patella, including the foot and the toes, except the plantar surfaces.

In these areas tactile sensation is lost. The sense of pain is dulled, but in the anæsthetic part of the right hand and forearm it is lost. Temperature sensibility is also diminished, and most in the right upper extremity. It is evident that the anæsthetic areas are daily becoming less in extent. Elsewhere sensation is normal, and the points of the æsthesiometer are felt as two at the usual distances, but on the legs and forearms (anæsthetic districts), only when 20 to 25 cm. apart.

Motility.—The head is moved freely. The trunk is stiff; bending it is impossible; cannot voluntarily change his position. The pectoral muscles are atrophic. In the shoulder joints motion is natural; at the elbow extension is limited, and requires much passive force; supination and pronation are restricted; motion in the fingers is diminished, and occurs slowly and fumblingly —cannot button his shirt. He cannot straighten all his fingers; passively all can be made straight. The muscles in the arms and forearms are thin and flaccid, except that there is some contraction in the biceps. The thenar and hypothenar eminences are flattened, and on the dorsum the intervals between the metacarpals are deep and marked.

The legs cannot be lifted from the bed. He can only partly flex hip and knee joints; ab- and adduction are also much restricted. The passive range of motion is normal. The feet are thin, and the leg muscles soft.

Electric Examination.—The reaction of degeneration is present in the interossei, thenar and hypothenar eminences, the right tibialis anticus, and peroneus longus, in the left gastrocnemius and adductor hallucis. There is diminished excitability in the left facialis district.

Reflexes.—No maxillary reflex. Biceps reflex increased. Triceps reflex absent on the right side, present on the left. Exaggeration of both patellar reflexes. Left ankle clonus. Plantar reflexes strong. Scrotal reflex normal. Abdominal reflex cannot be produced.

Mechanic irritability is increased in the muscles of both forearms, in triceps and biceps muscles, and in the anterior muscles of the left leg.

Trophic Changes.—In addition to the muscular atrophy there is nothing to remark.

Vegetative Organs.—Nothing abnormal to note, except bilateral mucous rales in lungs, posteriorly and laterally.

[From the records of subsequent complete examina-

tions only the very salient and new features are here introduced.]

October 17, 1890.—Anæsthetic areas gradually fading away; and October 24, 1890, are now absent in the legs. Right ankle clonus now present; bilateral triceps reflex.

November 11, 1890.—Anæsthetic areas now limited to little fingers; ankle clonus absent.

November 28, 1890.—Wind passes involuntarily. Anæsthesia has disappeared.

February, 1891.—Complains of pain in right forearm along ulnar nerve and thence into axilla. Efforts at coughing result simply in a prolonged expiration, with gurgling in the throat. Dysarthria aggravated.

Ophthalmoscopic examination negative. Æsthesiometer results are now like the normal everywhere.

May, 1891. Pain in right arm worse. Right vocal cord paretic. Contractures in biceps and forearm flexors. A light touch is not felt on the skin of the trunk and the extremities; neither can he distinguish definitely between head and point of a pin. Thermo-sensibility seems reduced inasmuch as he cannot distinguish any smaller differences in temperature than $+ 2^\circ$ c.

He is receiving massage with apparent benefit as far as the muscular wasting is concerned.

November, 1891. More and more helpless. Pain in the right arm persists, and there is now aching in the left ulnar district, in the right foot and in the back. He does not sleep well on this account.

Feces now pass involuntarily, but he is master of his bladder.

The visual fields are concentrically limited; eye-grounds normal; the movements of the eyes jerky and convergence limited. Cannot raise his head from the pillow. Left half of tongue atrophic.

Tactile sensation diminished in the hands, forearms and feet; and when pricked quite sharply with a pin he feels no pain; a test-tube filled with boiling water causes pain only after a few seconds. Ulnar districts show further loss of thermo-sensibility, otherwise this is as in May. Muscular sense good.

He cannot now lift his arms from the bed, and the interossei are completely absent; tremors are now and then visible in the forearms. Ankle clonus again present. Reaction of degeneration present in muscles of hands, legs and feet.

February, 1892. Emaciation and cachexia marked. Is fed with tube. Both urine and féces now pass involuntarily. The urine contains albumin. There is redness over all prominences. He understands what is said to him, but anarthria is extreme. Concentric limitation of visual fields; movements of eyes slow.

Temperature and pain sensibility in the face is diminished; does not recognize a difference of + 7 c. on forehead + 6 c. on cheeks.

The masseters are atrophic, a bite on the finger is hardly felt. The uvula deviates to the left. Cannot distinguish between sweet, sour and salt. Sterno-cleido-mastoids and trapezii atrophic.

Peripheral nerves; tactile sense as before; feels a pressure of 50 grams and distinguishes differences of 50 gr. Thermo-sensibility further diminished; with one thermometer constantly at + 28 c., a difference of + 9 to + 15 degrees is the first to be felt on hands and arms, + 14 c. on chest, + 9 + 12 on legs. On arms — 10° c. is pointed out as cold, on legs — 10 to 15, above — 5 is not recognized as cold anywhere. This shows sensibility to cold to be lessened also. Sensibility to pain is symmetrically diminished; with Björnström's algesiometer pain is indicated on arms at 7 to 8 kgm., chest 7, legs 8, 9. Pain is gradually and slowly produced by bringing the skin in contact with boiling water. An electric current from 60 elements does not cause pain. The points of the æsthesiometer are felt as two at a distance of 70–80 mm. on the arms; 60–65 on the volar surfaces, and 70 on the back of the hands; 70 on the chest, and 70–80 on the legs.

Contractures at right angles in the elbow joints. Main en griffe.

March 13, 1892. Alb. 4–6 per cent. in the urine. Extensive sacral decubitus. A firm pinch of the skin of the face is felt as a touch; on the right side after 1 second; on the left side after 1.5-2 seconds; as pain, right side, after 6–8 seconds; left side, 7–8 seconds.

Peripherally a firm pinch is recognized as a touch after 1–3 seconds, as pain after 3-8 seconds, the retardation most marked in the legs.

Temperature-sensibility as in February, but more diminished.

March 22, 1892. Moribund. Temperature, 38.5; pulse, 160; respiration, 40. Occasional trismus. Pupils react to light. Active patellar reflexes, do. plantar.

Died March 23, 1892.

THE MICROSCOPIC EXAMINATION.

Post Mortem.—This was limited to removing the brain, spinal cord, tongue, pharynx, larynx, and the cranial and a few peripheral nerves. To the naked eye the cerebral hemispheres and their coverings were normal; there was no atrophy of any convolutions visible, but the pyramids of the medulla were flatter than usual and the bulbar nerves noticeably thin and yellow.

The spinal dura was normal, but the pia seemed thickened some; the vessels did not show any macroscopic changes. The spinal cord was small, atrophic, but of uniform consistence and natural color and contour. On the cross sections the posterior part of the lateral columns presented bilaterally symmetric areas of gray color. There were no cavity formations or softenings.

The tongue seemed small, thin and flat; otherwise normal appearance in tongue, pharynx and larynx.

The above observations are corroborated by the appearances of the hardened specimens.

Technique.—Small pieces from the cortex of all parts of the central convolutions and segments from the various levels of the spinal cord were hardened in alcohol, imbedded in parafin. The sections fixed on the slide with oil of cloves-collodion, the parafin extracted with xylol, and the xylol with alcohol; staining in a 5 per cent. aqueous methylen blue solution was now done under gentle heat until steam arose, decolorization in alcohol-anilin oil, cleaning in origanum oil and mounting in benzine-colophonium (Nissl's method).

The brain and cord were otherwise hardened in Müller's fluid and Weigert preparations made from all parts of the cord, the right central ganglia and pyramidal radiation. The medulla and pons were cut in an uninterrupted series, and about every tenth section stained. Nuclear stains were also employed. The cranial and peripheral nerves were examined by means of teased arsenic acid preparations. The spinal nerves and ganglia were examined in Weigert and nuclear stains. The tongue and other muscles were studied in specimens made after the ordinary histologic plans. Specimens from the nervous system were also stained after the Stroebe* and Van Gieson* methods.

---

* *Centralblatt für Path. u. Path. Anat.*, 1893 and 1894.

The Brain.

1. Cortex of Central Convolutions.—Methyl blue sections show, in comparison with normal specimens made in the same way, a probable diminution in the number of large pyramidal cells. It is also noticeable that it is difficult to bring out the axis cylinders and protoplasmic processes, even though the cell body and nucleus may stain well and appear normal. There are no gross changes. Occasional pyramidal and ganglion cells are found which appear decidedly changed either in having lost their prolongation or nuclei, or in staining very diffusely and presenting very abnormal shapes. A few granular, rounded or irregular, masses are also found in the region of the large pyramidal cells. (Fig. 1.). As far as observed such changes are best marked in the central, then in the lower, and least often in the upper parts of the anterior and posterior central convolutions of the two sides.

In the Weigert preparations no changes are recognized and any atrophy of the fibriæ propriæ, or association fibres, cannot be demonstrated.

2. Pyramidal Radiation.—A large number of sections were made of the right pyramidal radiation, but degenerated fibres could not with certainty be made out.

3. Right Central Ganglia.—There is a distinct area of lighter color than elsewhere in the middle third of the internal capsule, *i. e.*, opposite the globus pallidus. This slight degeneration is uniform throughout this entire part of the capsule. Otherwise the right central ganglia are normal; the left was not examined. The optic tract is normal.

4. Crura Cerebri.—The only change observed is a rather faint but uniform degeneration in the part of the crusta occupied by the pyramidal tract.

5. Pons.—(*a*) Pyramidal Tracts: Distinct, uniform, though slight degeneration in the scattered bundles, but marked in smaller masses of fibres.

(*b*) Formatio reticularis, the fillet, the posterior longitudinal bundle, and the crura cerebelli ad pontem are all normal.

(*c*) Abducens, trochlearis, and oculo-motorius nuclei are also normal.

(*d*) Trigeminus.—The motor nucleus contains a few atrophic cells and there is some sclerosis of the ground substance. The motor roots contain some degenerated fibres. The sensory nucleus cannot be shown to contain

markedly changed cells, but the sensory nerve roots have degenerated fibres. Ascending and descending trigeminus roots seem unchanged.

6. Medulla.—(*a*) Pyramids: Uniform, moderate thinning of the fibres is presented in both these columns and is apparently more pronounced than in the pons or the internal capsule. There is no marked nucleus increase, a few large, round cells are present, and the vessel walls seem thick.

(*b*) Facial Nucleus.—Many excessively pigmented cells are found without prolongations; also, granular masses of pigment; many normal cells are present and the ground substance does not seem so sclerotic as in other nuclei. No changes are found in the knee, but the roots are very thin.

(*c*) Nucleus viii. and roots are normal.

(*d*) Spinal accessory, vagus, and glosso-pharyngeus nuclei.—These present a considerable degree of atrophy with evidently changed cells and sclerosis; the nerve roots are thin. The solitary fasciculus seems normal. Nucleus ambiguus atrophic.

(*e*) Hypoglossus Nucleus.—There is marked atrophy of the cells in the principal nucleus. Roller's small-celled nucleus seems unchanged. The nerve roots are very thin, but degenerated fibres are not seen. The healthy roots would correspond to a few normal cells still remaining. There is marked sclerosis and degeneration of the nerve network in the nucleus and the white matter surrounding the latter upon its ventricular borders has disappeared entirely. (Fig. 2).

(*f*) Funiculi Graciles.—There is slight uniform atrophy in the nerve fibres corresponding in degree to the change in the Goll's columns. The cells in the nucleus funic. gracil. appear quite normal.

(*g*) Funiculi cuneati, restiform bodies, olivary bodies, nuclei arciformes, formatio reticularis, and lemniscus are all normal.

(*h*) Central Gray Matter.—There is some accumulation of round cells about the central canal in the distal end of the medulla and the gray matter in the floor of the fourth ventricle is thicker than normal.

6. Cerebellum.—Methyl blue specimens from the cortex of both hemispheres present plainly normal conditions in all respects.

The Spinal Cord.

1. The Pia.—The vessels in the pia have thick walls,

the arteries especially. The thickening is uniform, involves particularly the media in which the number of nuclei is increased, but these are also endarteritic changes, although the intima is always smooth and presents no thrombotic deposits. The thickening extends along the entire course of the posterior and the anterior spinal arteries. In the small vessels in the posterior longitudinal septum the walls may have a homogeneous, glassy appearance, staining diffusely red with eosin and acid fuchsin. The walls of the veins are also quite thick and often homogeneous. There is no perivascular round cell infiltration.

The pial meshes seems somewhat denser in their fibrillation than usual; distinct inflammatory changes are absent.

2. Anomalous Vein.—At this time may be described a vascular peculiarity in the distal dorsal region of the cord. Here a rather large, fusiform, thin-walled, venous channel cuts across the central commissure from the bottom of the anterior to the posterior longitudinal fissures, passing between Clarke's column and the central canal. The bulging is greatest in the commissure, while the veins in the fissures do not seem at all enlarged. This venous channel has thin walls of connective tissue, filled with blood; the cord tissue on all sides is entirely unchanged. Serial sections including the entire extent of the dilatation were made and its vertical diameter would be about 5 mm.

It may be dismissed from further consideration as an anomaly without pathologic significance in this case. (Fig 5).

3. The Central Canal.—It is filled with small, round cells so that the lumen is often loosely occluded, the normal lining being entirely disarranged. This cell accumulation does not encroach upon the adjacent structures and shows no tendency to infiltration; it is largest in the dorsal region.

4. The White Matter.— The sections of the cord are considerably smaller in circumference than those of a normal cord from a man of the same age, prepared similarly.

The following changes in the cord substance have to be described: Systematic degeneration in the pyramidal tracts and in Goll's columns, atrophy of the ganglion cells in the anterior horns and in Clarke's columns.

(*a*) The Antero-lateral Columns.—Degeneration in the

lateral columns is present throughout the entire cord. In the lumbar region it has a triangular shape, the apex pointing medianwards, nearly touching the cornual junction ; the ventral limit is nearly on a line with the central canal, while the dorsal border touches the posterior horn, and the external border or base corresponds with the periphery of the cord. The degeneration is most intense in the central part of the area thus outlined, but a few normal fibres are present even here. In the dorsal region the degenerated area occupies relatively the same position ; it is, perhaps, more marked and does not reach the peripheral margin as a narrow strip of healthy substance intervenes—the direct cerebellar tract. In the mid and upper dorsal regions the degeneration is a little bit smaller in extent on the right side, and simultaneously with this disproportion between the two sides comes a crescent shaped district of degeneration in the left anterior column along the longitudinal fissure. Throughout the cervical region the changed district occupies the same relative position, and can be followed on both sides up to the decussation without any perceptible change in size or shape. (Fig. 3).

As one follows the changes upward the crescentic degenerated area in the anterior column becomes broader, and a very faint atrophy can be made out along the mesial border in the right anterior column, but the area of degeneration in the right lateral column remains noticeably smaller than in the left. (Fig. 3). Otherwise the antero-lateral column is normal.

(*b*) The Posterior Columns.—Already in the lumbar enlargement is observed a thinning in the medullated nerve fibres along the mesial borders of Goll's columns. In the dorsal region this degeneration becomes broader and involves to a limited but nearly equal degree all parts of both these tracts, the change being furthest advanced along the mesial border, and, becoming better and better marked, as it is followed in about this shape up to the nucleus of the funiculus gracilis in the medulla. (Fig. 3). Burdach's columns seem normal throughout.

(*c*) White Commissure.—In many sections, especially from the cervical enlargement, there is observed an irregularly distributed but distinct degeneration in the fibres of the anterior white commissure.

(*d*) Nerve Roots.—In the anterior nerve roots there is nearly without exception some degeneration, and in many instances this may be very intense. The posterior

nerve roots are also changed, but not so much as the anterior, and in the lumbar region many posterior roots show no marked atrophy.

5. The Gray Matter.—(*a*) The Anterior Horns: These are small but symmetric, retaining their normal shape. In the Weigert sections their color is more pronounced yellow than usual.

The following summarizing description of the ganglion cells is based mainly on the appearances observed in sections stained with methylene blue. In general it may be said that the changes consist in an exceedingly great diminution in the number of the ganglion cells due, so to speak, to a progressive degenerative atrophy or necrotic process. The changes in the stroma are very slight in degree.

The largest number of normal ganglion cells are found in the lumbar region; in the higher levels of the cord the wasting is so great that in the majority of the sections but few cells are present and many of these are greatly altered. In the cervical enlargement the mesial groups are almost entirely absent and the majority of the cells in the lateral groups are also more or less altered, so that frequently there are sections in which the normal ganglion cells are altogether absent, or at least the exception. Where the intermedio-lateral tract is distinct its cell are also more or less changed, but their number remains considerable.

The altered cells assume all sorts of forms. Any classification of the changes is hardly possible, inasmuch as there seems to be no other basis for division than the morphologic. In the examples of apparently early changes the cell body appears shrunken, usually without any distinct nucleus, and staining deeply and diffusely, while the processes may remain fairly well marked; often such cells are surrounded by a small empty space. (Fig. 4.) Then there are a large number of oval or rounded forms, often with an even outline, but frequently showing irregularities as though the processes had been broken of; in such cells it is surprising to often observe a quite typical looking nucleus. Here the cytoplasm also stains diffusely either wholly or partly, so that at portions of the periphery there may be light or deep-blue granules or particles scattered about. Cellular forms, usually rounded in outline, composed of colored and colorless granules, irregularly arranged, without indication of nucleus and with thin and

imperfect prolongation, are also found. In many abnormal cells one part of the cell body may contain light brownish, fine pigment granules, and the remainder may be diffusely and deeply stained—nucleus and processes being more or less disturbed or completely absent. (Fig. 4). Around changed cells of all forms may at times be found empty spaces on all sides or only part of their circumference. While the cells above indicated are all smaller than the normal ganglion cells, yet their dimensions are quite considerable, and there remains to mention that there are also many oval, rounded, angular and irregular forms of a comparatively smaller, but varying size, that stain either deeply and diffusedly, or present a granular appearance, the granules being scattered about either thickly or more thinly; these have no sign of nucleus, an even outline and no processes. Finally, there are loose granular masses of variable size and all possible forms, occasionally presenting small, pointed projections that probably are remnants of protoplasmic prolongations or axis cylinders, and also more minute nondescript clumps and masses; the smaller cellular remains usually lie imbedded in the stroma without any empty spaces about them. They stain deep red with eosin acid and fuchsin, etc. In the Weigert sections the changed cells present a yellow or brownish color with very frequent large pigment heaps of a deep brown color.

The ground substance is rather granular, and only seldom can it be said that any distinct fibrillation is present. There is no marked accumulation of round cells. The vessel walls are a little thickened, but there is no perivascular infiltration, and the lumina are patent. There are no recent hæmorrhages or tokens of ancient ones present. Only a few glia cells are demonstrable. There is considerable degeneration of the medullated network in the anterior horns, many atrophic fibres and also myelin detritus being present, but the change is not excessive or complete.

From the above summary it will be seen that it is possible to trace with reasonable ease the apparent changes in the ganglion cells from the earlier to the latter stages. Among the earlier changes may be mentioned a shrinking of the cell body, with a deep and diffuse stain of the cytoplasm, followed by gradual loss of prolongations, the formation of a more or less distinct vacuole around the cell, while the general appearance of

the nucleus may remain apparently unchanged, although in many cells it soon disappears. Then follows a gradual diminution in the size of the cell, marked changes in its forms, which generally has a tendency to become rounded, and at times the cytoplasm stains diffusely, and at other times colored and colorless granules are present. Finally, there remain irregular clumps and granular masses that evidently represent dead cells in the process of removal; these small remnants lie in the stroma, which surrounds them quite closely on all sides.

As to how much of the above-mentioned apparent changes may be artefacts cannot be stated, but certainly the gross changes in form and size are pathologic, and stages in the necrotic process that finally results in the complete disappearance of the cells.

Concerning the finer structure of the nucleus nothing can be said, because the tissues exaimed were not instantaneously killed and fixed; in general, the cells taken to be normal (lumbar region especially) corresponded fairly well to the histologically perfect specimens as they present the characteristic vesicular nucleus, the peculiar, colored granules and particles in the cell body, and well-developed prolongations.

(*b*) Posterior Horns.—Inthe posterior horns proper it was not possible to demonstrate any changes either in the cells, neuclei, or stroma, but in Clarke's columns the the number of cells seems diminished in some of the sections from the distal dorsal region. The majority of the cells are normal, but changed cells are present in small numbers in the shape of rounded shrunken forms, granular or homogenous, and of angular and irregular small masses. Any marked changes in the stroma and in the nerve fibres in or about the columns does not exist.

Spinal Nerves and Spinal Ganglia.—The changes in the spinal nerve roots have been mentioned in connection with the spinal cord.

In the Weigert sections across the cauda equina markedly degenerated bundles are observed.

The spinal nerves and the ganglia were studied by means of longitudinal and cross sections; in several instances a complete series of longitudinal sections were made through a short segment of the nerve, the ganglion and the roots.

In such longitudinal sections degenerated nerve fibres could be followed into the ganglion from the spinal

cord and among the nerves leaving the peripheral pole of the ganglion. Occasional degenerated fibres could be followed into the mixed spinal nerves.

In the spinal ganglia (Fig. 6) there is found, in addition to the moderate degree of degeneration of the nerve fibres, a number of changed ganglion cells; there are excessively pigmented cells, a few shrunken forms, thick, yellow, scale-like cells without nuclei, and also a few pale cells evidently in process of disintegration, the cytoplasms being finely granular and vacuolated, while the cell capsules seem enlarged. The cells regarded as excessively pigmented are filled so as to hide the nucleus (if it be present) with yellowish brown or quite black granular pigment (similar appearances in Weigert, Ehrlich, Biondi, and eosin-hematoxylin stains). The shrunken cells have no processes extending out to the walls of the capsules. There is no evident or marked increase in the nuclei of the ganglion cell capsules, and no striking change in the interstitial tissue, which is perhaps increased some.

Cranial and Peripheral Nerves.—Teased osmic preparations were made of all the cranial, the ulnar, median, and radial nerves; also of the cauda and of the left sympathetic nerve of the neck.

Typical pictures of degeneration, as shown by the breaking up of the myelin into characteristic, smooth, large and small, globular and oval lumps, were found, in varying degree, in the following nerves: A few degenerated fibres in the third pair, in the right fourth and the left sixth nerves; in the motor part of the fifth pair, and the sensory portion of the left fifth nerve; also in the seventh, ninth, tenth, eleventh and twelfth pair of cranial nerves, and of those especially in the ninth and right twelfth nerves; further, in the cauda, in both ulnar nerves to a marked extent, and, to a moderate degree, in the right radial and median nerves.

In many places the broken-up myelin had been taken away, as shown by the presence of droplets among granular detritus in sheaths that were empty between the heaps of such remains.

Apparently empty sheaths and thick as well as thin varicose threads were present also; granular myelin tubes, broken across at frequent intervals, were also seen; varicose threads and granular myelin sheaths were also found in those nerves that did not show any typical degeneration, but did not seem so frequent as in the degenerating nerve bundles.

The osmium preparations do not demonstrate any interstitial changes.

Left Cervical Sympathetic Nerve.—In this are found many myelinic fibres, the seat of typical degeneration.

Tongue, Laryngeal and Pharyngeal Muscles.—The mucosa of the upper and under surfaces of the tongue is normal, but the submucous connective tissue is increased some, and shows considerable round cell infiltration. The muscular fibres seem thin, the transverse striation indistinct, and the nuclei frequent; there are fibres which are narrower in one part of the longitudinal section than in others. Distinct fatty degeneration is not observed. The amount of connective tissue between the muscles and in the perimysium is increased, and in the deeper parts of the tongue much fat is present between the fibre bundles. The muscles of the larynx and pharynx show much atrophy; fibrous tissue replaces areas of muscular structure; small and narrow strands of muscle fibres are found here and there, and in such the transverse striation is indistinct.

CLINICAL SUMMARY.

A farm laborer, born in 1828, with negative family and personal history, has a few brief, sudden attacks of unconsciousness between 1875 and 1887; only one attack was marked by spasm (twisting of the head downward and to the right). In July, 1887, when he was sixty-two years old, weakness and trouble in walking appeared; pain, stiffness, and swelling in the left foot developed in addition, and was diagnosed as chronic muscular rheumatism in the early months of 1888. Soon the arms and hands became weak and thin; disturbance in deglutition, chewing and articulation also appear. In March, 1889, the diagnosis of amyotrophic lateral sclerosis is made, based upon spastic paresis in the extremities, with increased reflexes, muscular atrophy (hand muscles especially), and the reaction of degeneration, together with quite prominent bulbar symptoms, to wit: Dysarthria, difficult deglutition, paresis of the tongue and the muscles of mastication, etc. At the end of 1889 locomotion becomes impossible. General helplessness increases, so that by September, 1890, he is rendered permanently bedridden. The spinal and bulbar symptoms are now pronounced: The spastic-paralytic condition with muscular atrophy, increased reflexes, and reaction of degen-

eration in the extremities as well as in the trunk, prevents the voluntary change of position in bed. Mastication is feeble; there is facial paresis; diminished taste along the left half of the tongue towards the tip; marked dysarthria; vocal cord paresis; atrophy with paresis and contracture in the tongue. In addition to these exquisite symptoms of disease in the motor neurons there presents itself a nearly symmetric anæsthesia in the extremities (subjectively this was possibly noted already toward the end of 1889, but not demonstrated until in September, 1890), which is partial in the legs and feet as well as in the left ulnar district, but well nigh complete in the right ulnar area. This anæsthesia gradually fades away by the end of November, 1890; at this time partial loss of control of the sphincter ani is first noted; a little by little spontaneous, persistent pain develops first in the right, and, a few months later, in the left forearm along the ulnar nerves, and finally in the lower extremities also. In the May, 1891, there is found some loss of touch, pain, and temperature sensibility in the trunk and limbs; in November, 1891, the feces pass involuntarily; there is now concentric limitation of the visual fields and the eye-movements are jerky; there is further aggravation of the other symptoms detailed, both motor and sensory; there is slight delay of transmission of painful impulses. In February, 1892, cachexia has become marked; albuminuria and ordinary incontinence are now present, and temperature and pain sensibility is dulled in the face also; he cannot distinguish between sweet, sour, and salt; the sterno-cleido-mastoid and trapezii are also atrophic. In the trunk and limbs touch, pain, and temperature sensibility are further diminished. Contractures at the elbows and elsewhere are present. In March, shortly before death, there is double sensation and marked delay in transmission of impulses, both from face, trunk and limbs: a firm pinch being felt as a touch in 1–3 seconds and as pain in 6–8 seconds. Extreme anarthria, the mind remaining clear. Death, March 23, 1892, from exhaustion, four years and eight months after the appearance of the earliest distinct motor symptoms.

SUMMARY OF THE CHANGES.

The essential lesions may be summarized as follows:

Primary, chronic degeneration in the indirect motor neurons as shown by slight but distinct changes in the

cortex of the central convolutions and by degeneration in the pyramidal tracts from the internal capsule downward. Similar morbid changes in the direct motor neurons, namely, atrophy of marked extent in the bulbar nuclei and in the anterior horns of the spinal cord, degeneration in the bulbar nerves, in the anterior spinal nerve roots and in the mixed spinal nerves, in the cauda, the median and ulnar nerves, and also atrophy of the muscles of the tongue, larynx, and pharynx (other muscles not examined). Then there are quite identical lesions, though of less extent, in the direct sensory neurons: changes in the ganglion cells of the spinal ganglia, degeneration in the posterior spinal nerve roots and in Goll's columns; also, changes in the trigeminus sensory roots and the sensory part of the left trigeminus nerve (the Gasserian ganglia were not examined). In the indirect sensory neurons there are slight changes in the cells of Clarke's columns, but without degeneration in the direct cerebellar tracts.

There is also some thickening in the spinal pia and its vessels.

REMARKS.

The microscopic examination excludes all possible primary foci and diffuse lesions. Hence, the degenerations are not secondary. This observation is of interest in view of the attacks of unconsciousness mentioned in the clinical history as occurring for some years previous and up to the appearance of the early symptoms of the disease. These attacks are not explained by any of the microscopic findings.

Furthermore, the distribution of the lesions, as well as to a certain extent their histology, exclude the possibility of their dependence upon coarse arterio-sclerotic or syphilitic vascular changes; so that of whatsoever nature —certainly not syphilitic—the thickening in the vessels of the spinal pia may be, it cannot under any circumstances be regarded as playing any essential rôle in the production of the degenerations.

The degenerations are so systematic in extent and location that they correspond quite precisely with Flechsig's embryologic paths, as well as with the Wallerian tracts of secondary degeneration, both descending and ascending as far as the columns involved are concerned.

Consequently the degenerations in this case can be

defined as systematic and primary, depending in the main upon changes in the ganglion cells, in consequence of which the neurons became necrotic. In other words, the system lesions are the result of primary disease in both the motor and the direct sensory neurons.

The comparatively long duration of the sickness undoubtedly depended, to some extent, upon the absence of disturbances in the functions of the heart and of the lungs, which is rather remarkable in view of the degree of atrophy in the vagus nuclei. In connection with this the changes found in the left cervical sympathetic may be disposed of by saying that their relation to the other changes in the nervous system cannot be definitely specified, inasmuch as they form an exceptional condition without any corresponding known clinical manifestations.

As to the fundamental cause of the changes in the neurons, neither the clinical history nor the microscopic examination furnish any data. There are no indications of syphilis and no history of heredity. Malaria and small-pox are the only infectious diseases the patient ever had so far as known.

Should one believe with Strümpell, who has observed amyotrophic lateral sclerosis in two sisters,[39] that peculiar congenital and hereditary influences may play the same mystic rôle in individual instances of system diseases, even when no facts in the history point in that direction, as he regards them to do in his hereditary spastic spinal paralysis? The long duration of this man's disease would be one fact pointing in that direction.

Whatever the cause may have been, it had an apparently specific or selective effect upon the ganglion cells of both motor and sensory neurons. It was not coarse or intense enough to induce the ordinary phenomena of inflammation, and yet an extrinsic cause could reach the scattered cells only by way of the blood vessels. The only known form of chronic intoxication suggested by analogy is the syphilitic: the affinity of the syphilitic poison for the sensory neurons is generally accepted; its occasional appearance in an apparent etiologic relation to pure motor tract lesions not unknown, and, as already mentioned, there are quite a few cases of a somewhat similar combination of lesions as in this instance described in syphilitics (Leyden, Dinkler, Mayer, etc.). But further than the changes described in the sensory

[39] *Neurol. Centralbl.*, 1893, No. 19.

tracts, the present case lacks such evident ear-marks of syphilis as lesions of the nuclei of the motor nerves of the eye, opticus atrophy, etc. It is true that a few degenerated fibres were found in the third, fourth and sixth nerves, but evidently this degeneration did not depend upon marked nuclear lesions.

In so far as the case here recorded stands without any recognizable etiology, it corresponds with amyotrophic lateral sclerosis with bulbar paralysis, of whose etiology really nothing is known, and as a typical example of which the man's sickness seems to have started. After a period of about two years, during which the sickness had progressed from early indefinite symptoms to a quite typical clinical picture, sensory disturbances in the form of symmetric anæsthesia upon the extremities appear, to pass away again in a short time, when a general diminution in most forms of cutaneous sensibility develops and increases, together with lost sphincter control, but heightened reflexes, marked motor and bulbar symptoms, until death.

The motor and bulbar symptoms are quite readily accounted for by the extensive lesions described in the upper and lower motor segments, while the sensory disturbances find their explanation in the changes in the spinal ganglia, in the posterior nerve roots with probable degeneration in the sensory fibres, in the mixed spinal nerves, and in Goll's columns ; and, as to the face, in the degeneration in the trigeminus roots and in the sensory part of the left fifth nerve ; and these changes allow the inference that similar changes as in the spinal ganglia would have been found in the Gasserian had they been examined. The more or less isolated degenerated fibres from the spinal ganglia accumulate themselves in Goll's columns, in which the degeneration naturally is strongest in an ascending direction.

The absence of degeneration in other parts of the spinal cord, in which sensory paths go upward, point conclusively to the interpretation that the sensory symptoms were due to the changes in the direct sensory neurons, which possibly began in their more peripheral parts. The changes in some of the cells in Clarke's columns form an exception to part of the last statement, because these cells are regarded as the commencement of certain indirect sensory neurons, but there was no marked degeneration in the cerebellar tracts, although it is possible that a few scattered degenerated fibres

belonging to them might be running at the boundary between the cerebellar and the degenerated pyramidal columns.

Flechsig[39] has called attention to the fact that in amyotrophic lateral sclerosis there is frequently some change in the cerebellar tracts as well as in Gower's columns, and Marie[40] also emphasizes the indistinctness of the outlines and extent of the changes in and about the pyramidal columns in this disease. Charcot and Marie,[40] Collyns,[41] Dejerine and Hult,[42] v. Kahlden,[43] and others, all describe changes in Clarke's columns without corresponding degeneration in the cerebellar tracts and without sensory symptoms.

Any lengthy explanation of the peculiar and varying earlier manifestations of the sensory lesions—the temporary symmetric anæsthesia—the mechanism of the return of the sensibility, whether the underlying changes were first peripheral or first central, will not be attempted. Attention may be called, however, to this fact: that in accordance with the neuron doctrine parenchymatous changes due to various causes may locate themselves in any part of the neuron, most likely first where the influence of the ganglion cell is least felt. This must be quite true so long as the neuron is regarded as an anatomic and nutritive unit of which the ganglion cell is the essential centre. Hence, there may be partial neuron necrosis, and such partial neuron necrosis might very easily be mistaken for a genuine diffuse lesion—a neuritis, for instance, if the necrosis should be situated peripherally. The examples of "motor neuritis" in tabes dorsalis may be instances of partial motor neuron necrosis in connection with the changes in the sensory tracts. Joffroy and Archard[44] have a case of amyotrophic lateral sclerosis with a neuritis in the lower extremities, which they explain as due to a "spinal dystrophy." This case may very likely have been an instance of partial neuron necrosis. In the present instance a considerable number of the direct sensory neurons finally became totally necrotic.

This observation taken in conjunction with the instances of amyotrophic lateral sclerosis cited from

---

[39] Quoted by Goldscheider, *loc. cit.*
[40] *Loc. cit.*
[41] *St. Bartholomew Hosp. Rep.*, 1883.
[42] Virchow and Hirsch, *Jahresbericht*, 1886, Bd. ii.
[43] *Zeigler's Beitrage*, 1893, xiii.
[44] *Arch. de Med.*, exp. et d'anat. path., 1890, No. 3.

Charcot, Leyden, Maeli, Roveghi and Melotti as presenting system changes in the posterior columns, but without recognized sensory disturbances, would tend to show that this combination of changes in amyotrophic lateral sclerosis may not be so unusual as the name and the general idea of the disease may lead one to infer.

In addition to the unusual combination of system lesions presented by our case, the circumstances under which they are produced are also of interest: to the total necrosis in both motor neuron systems which appears as a typical amyotrophic lateral sclerosis—bulbar paralysis—a disease of definite entity, though unknown etiology, are added similar changes in the direct sensory neurons and, perhaps, in some of the indirect, so that finally there is presented a clinical picture in which both motor and sensory symptoms stand out clear and well defined, the motor predominating.

The unknown agent that first caused slow but progressive necrosis in the motor neurons was also capable of causing the same changes in the sensory in such a degree as to produce an exquisite example of combined system lesions.

The case consequently becomes a sort of connecting link between two groups of diseases in the nervous system that have usually been regarded as separate and distinct, namely, those in the motor segments, such as progressive spinal muscular atrophy and amyotrophic lateral sclerosis on one hand and tabes dorsalis, whose lesions involve the sensory neurons, on the other.

Finally, looked upon as a combined system disease, this case may be pointed out as illustrating a somewhat unusually complete combination of lesions. As shown in the introduction the vast majority of the combined diseases attack the posterior columns and pyramidal and cerebellar tracts—in a certain measure the indirect neurons—but in this case there is total neuron necrosis in both the motor and in the direct, as well as to a very slight degree the indirect sensory neurons.

EXPLANATION OF FIGURES.

FIG. 1. *Cell-forms from the layer of large pyramidal cells in the cortex of the central convolutions.*

1. Degenerated cell without nucleus and processes from the left arm centre.

2. Remnant of cell from left arm centre.

3. Atrophic cell without shrunken nucleus and corkscrew process from central part of the right ant. centr. convolution.

4, 5, 6. From lowest part of the centr. convolutions. 4, Granular mass. 5, Pyramidal cell in early atrophy. 6, Atrophic remnant.

Alcohol hardening, methylen blue staining. *Zeiss'* obj. 4 mm. apochrom. + ocul. 8.

FIG. 2. *From the hypoglossus nucleus* Pigmented atrophic cells. and slightly sclerotic stroma.

Weigert preparation. *Zeiss'* obj. 4 mm. apochrom. + ocul. 8.

FIG. 3 *Transverse section of the spinal cord at the fifth cervical segment.*

Degeneration in the lateral pyramidal, left anterior pyramidal and *Goll's* columns. Owing to incomplete decussation, the right pyramidal tract is a little smaller than the left. *Weigert* preparation, × 6 times.

FIG. 4. *Ganglion cells from the anterior horns of the spinal cord.*

1. From lumbar region: the nucleus absent, the body shrunken, the staining diffuse, some processes lost or changed.

2. Changed cell with demonstrable nucleus.

3 and 4. Pigmented granular forms from the cervical enlargement.

5. Dense and diffusely stained mass.

6, 7, 8. Smaller, round granular forms.

Alcohol hardened, stained in methylen blue, *Zeiss'* obj. 4 mm. apochrom. + ocular 8.

FIG. 5. *Transverse section of distal dorsal cord*, showing fusiform venous channel passing between the central canal and Clarke's column. Notice the very few ganglion cells in the anterior horns.

Alcohol hardened, stained in methylen blue, × 6.

FIG. 6. *First dorsal spinal ganglion.*

a, normal ganglion cell; *b*, shrunken cell.

Weigert preparation. *Zeiss'* obj. 4 mm. apochrom, + ocul. 8.

RAFF & CO.,
433 & 435 West 42d Street,
NEW YORK.