
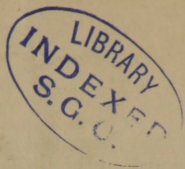


HUTCHISON (Jos. G.)



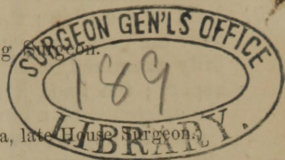


under the cases



## BROOKLYN CITY HOSPITAL.

✓  
DR. JOSEPH C. HUTCHISON, Attending Surgeon.



(Reported by ROBERT O. BUTLER, M.D., of Louisiana, late House Surgeon.)

*Case 1.—Abscess in the Tibia—Trephined—Recovery.*—John F.; æt. 21 years; hostler; native of Ireland; good constitution; sandy hair; dark blue eyes; temperate in his habits; healthy parentage; no hereditary taint; has never had syphilis.

His medical history is as follows:—In July, 1855, after being a good deal exposed in driving at night, he was attacked with stinging pains, apparently in the bone, just below the left knee joint, which always grew worse toward night. At the end of two months, he was compelled to quit work, and was treated by leeches and iodine locally, and iodide of potassium internally. Not having been materially benefited, he entered the Brooklyn City Hospital, in October, 1855, and was discharged in two weeks, with his limb feeling perfectly well, after the use of iodine as before, with rest. The pain returned about the middle of the succeeding February, and he entered the hospital a second time, March 5, 1856. The integuments over the upper part of the tibia were red, swollen, and exceedingly tender on pressure, and the pain in the part was very severe, especially at night. Under appropriate treatment relief was procured, and he was discharged April 11, believing himself to be perfectly well. At the end of a month, the pains again returned, and he entered the New York Hospital, July 21, 1856, with an abscess forming over the head of the tibia, which was opened the third day after admission. He remained in the house one month, and was discharged apparently well.

Five months subsequently the stinging and throbbing pain in the head of the tibia again returned, and he was admitted a third time into the Brooklyn City Hospital, February 1, 1857. Another abscess had formed in the soft parts over the seat of pain, which was opened, and about two ounces of thick, dark-colored pus discharged with considerable relief. The abscess got well, and the pain again began to increase on the 22nd February. Dr. Enos, who was then on duty, made a free incision on the inner aspect of the head of the tibia down to the bone, which afforded complete relief until March 6, at which time he was found suffering with



severe pain described as resembling the pain of toothache, increasing toward night, and situated at the point where the incision, which had not quite healed, was made. The integuments were red and swollen, and there was some febrile disturbance.

On the 8th of March the pain was most severe ; the redness of the integuments had extended around to the outer aspect of the head of the tibia ; there was very great tenderness on pressure over the part, and considerable fever. The head of the bone, carefully examined, was found somewhat enlarged, chiefly on its inner aspect ; the knee joint was healthy. Dr. Hutchison, suspecting the existence of a circumscribed abscess in the head of the tibia, (in which impression Dr. C. E. Isaacs, who was visiting the wards with him, concurred), had the patient etherized and exposed the bone by a crucial incision at the point to which the chief pain was referred, viz. : on the inner aspect of the head, one inch below its articular surface. The flaps were dissected back, a trephine of medium size applied, and, after penetrating the bone an inch, pus, of a peculiarly white and creamy appearance, oozed up by its side. A circle of eburnated bone was removed with an elevator and chisel, and at the bottom of the hole thus made, a portion of the cavity from which the pus flowed was observed extending upward toward the joint, beyond the circle made by the trephine. About half a drachm of pus was seen, and probably more escaped, mixed with blood so as not to be recognized. The periosteum was greatly thickened and disorganized. Copious hæmorrhage took place from the bone ; the cavity was filled with lint, the edges of the wound approximated by sutures and adhesive straps, and water dressing applied.

The pain in the limb subsided entirely after the operation, and the cavity in the bone gradually filled with a fibro-cartilaginous substance.

May 21.—A sinus, through which a small probe can be passed, leads to the bottom of the bony cavity, where denuded bone is detected. A small spicula of bone came away a few days since.

June 7.—Discharged cured.

Sept. 12.—Saw John F. to-day. He has no pain in his limb, works daily as a gardener, without the slightest inconvenience ; the bone has diminished in size ; his general health is excellent, and he expresses much gratitude for being relieved of his protracted suffering. Several small spiculæ of bone have come away since he left the hospital, and a sinus still exists leading to the bottom of the cavity made by the trephine through which a small probe can be passed, detecting a spot of denuded bone. This will probably exfoliate and permit the sinus to heal.

The above case is regarded as one of especial interest, on account of the infrequency of the disease (but three cases\* having

\* See case reported by Dr. McSHERRY, in *Am. Jour. Med. Sci.*, vol. xxii., N. S. p. 118.

do. do. Dr. STRONG, in same journal, vol. xxv., N. S., p. 81.

do. do. Dr. BLEEK, in *New York Jour. of Med.*, vol. xiv., N. S. p. 83.

been previously reported in this country so far as I can learn) ; on account of its resemblance, in some respects, to syphilitic disease, viz. : the exacerbations toward night, and the marked relief obtained at three different times by the use of iodine and rest ; and also from the satisfactory result of the treatment adopted.

*Case 2.—Fracture of the styloid process of the radius ; fracture at the junction of the lower and middle thirds of the same bone ; and laceration of the urethra from muscular contraction without effusion of urine.*—John F. ; æt. 14 years ; fell this day (March 22, 1857,) from a tree, which he had climbed for the purpose of getting his kite, which had become entangled in its branches, to the pavement below, a distance of about thirty feet, and was picked up in an insensible condition by a policeman and brought to the hospital. Soon after admission his consciousness returned. On examination, a fracture was detected, commencing at the base of the styloid process of the right radius, and extending down obliquely into the wrist joint, breaking off about one-fifth of the articular surface. The process was drawn up on the posterior surface of the radius, about one and a half inches by the supinator radii longus muscle. It was movable, but in consequence of the contusion and swelling of the part, it could not be returned to its place. There was also a fracture of the radius at the junction of its lower and middle thirds. The hand occupied the same position that it does in fracture of the lower end of the radius. He complained of pain over the right iliac bone, and tenderness on pressure over the three lower dorsal vertebræ. There was a bloody discharge from the urethra, *but no pain, contusion, or swelling, was observed then or subsequently about the perineum, scrotum, or penis.* His arm was placed on a pillow, an evaporating lotion applied, and an anodyne administered.

March 23.—Has discharged no urine, we learn, since the accident ; his bladder is distended, and there is a bloody discharge from the orifice of the urethra. A No. 5 catheter was introduced by Dr. Hutchison with some difficulty, and the urine drawn off.

March 24.—Suffering a good deal from retention of urine. My right hand being sore, Dr. Krackowitzer, who was visiting the medical wards before the arrival of Dr. Hutchison, attempted to introduce the catheter, when it glided into a false passage about two and a half inches from the orifice of the urethra, and passed backward to the right of the median line, until it could be felt by the finger introduced into the rectum so distinctly, as to satisfy him that there was nothing interposed between the finger and the instrument, except the walls of the bowel. After a second ineffectual effort to pass the catheter, the boy got up and discharged his urine spontaneously. Dr. Hutchison attempted to introduce an instrument on the same day, when it again entered the false passage, and was felt by the finger *immediately* in front of the rectum.



It finally entered the bladder by the natural passage. Rest, mucilaginous drinks, and cold water dressing to arm.

March 25.—Urine drawn off with catheter, its introduction caused great pain.

March 26.—Urine discharged spontaneously, with considerable smarting. There is a copious muco-purulent discharge from the urethra.

March 30.—The swelling and inflammation about the wrist-joint having sufficiently subsided, an ineffectual attempt was made to bring down the styloid process to its normal position, and, in order to prevent its farther displacement upward, a small pad of lint was placed above it, and retained in position by a strip of adhesive plaster, so arranged, as to exert a downward pressure. A pistol-shaped splint, extending from the elbow to the end of the fingers, and properly padded, was now applied to the outer side of the forearm, and a shorter straight splint to the inside.

April 20.—Splints removed; upper fracture pretty firmly united; the styloid process is immovably fixed in its abnormal position. It was thought best to keep the splints applied a few days longer.

May 10.—Splints taken off, and the fractures found firmly united. The skin over the projection of the styloid process is ulcerated, and the bone beneath exposed. The stream of urine is rather small, and is attended with smarting. The muco-purulent discharge has subsided, leaving behind only a small mucous discharge.

May 20.—Sound passed to-day with but little difficulty, after which the urine was discharged in a large stream.

May 28.—Sound introduced, and followed by the same benefit as before.

June 7.—The motions of pronation and supination of the injured forearm, and flexion and extension of the wrist-joint, are performed perfectly, and he has no trouble in passing his urine. Discharged.

Fracture of the styloid process of the radius, and laceration of the urethra without extravasation of urine, are accidents which invest the above case with an unusual degree of interest. The latter injury will be alluded to in connection with the next case. Prof. Hamilton, in his elaborate paper on fractures, published in the ninth volume of the *Transactions of the Am. Med. Association*, gives a plate of a dissecting-room specimen, somewhat analagous to the above case, found in the possession of Prof. H. H. Smith, of Philadelphia, in which there is an oblique fracture of the lower end of the radius, without displacement, commencing at the base of the styloid process, and extending into the wrist-joint, at the junction of the outer and middle thirds of the articular surface; there is also fracture of the styloid process of the ulna. The works of Sir A. Cooper, Malgaigne, Smith of Dublin, Chelius, Velpeau, Miller,

Ferguson, Erichsen, H. H. Smith, and many others which have been consulted, contain no account of fractures of the styloid process of the radius. The above case is therefore believed to be unique.

*Case 3.—Laceration of the urethra from muscular contraction, without extravasation of urine.*—W. P., seaman, æt. 26 years ; native of United States ; was admitted into the hospital, March 25, 1857, at three P.M. Twenty-three hours before admission, he was struck over the region of the left trochanter major by the end of a sugar hogshead, which was being lowered into the hold of a vessel. He was unable to walk after the injury, but could stand on both legs. On the following day, however, he was unable to stand, in consequence of the pain about the left hip-joint. Three or four hours after the accident, he attempted to evacuate his bladder, but could not do so, and he observed at this time, that the orifice of the urethra was closed with coagulated blood.

At the time of admission, he was suffering considerably from retention of urine, which had existed since the occurrence of the accident ; he also had a good deal of contusion and pain in the neighborhood of the left hip joint, which prevented him from turning in bed. Moving the joint increased the pain greatly. *There was no pain, contusion, or swelling then or subsequently about the perineum, scrotum, or penis.* The catheter, introduced by the House Physician, (my hand was still disabled), glided out of the urethra at the membranous portion to the left, and passed backward, with very slight pressure, so far that there was barely enough of the instrument outside of the meatus to hold between the thumb and fore-finger. On introducing the finger into the rectum, the instrument was felt immediately in front of the gut, nothing intervening apparently, but the coats of the bowel. The catheter was passed into the bladder after much difficulty, and the urine drawn off.

On the following morning (26th) he was suffering from retention of urine, and Dr. Krackowitzer, who was visiting the medical wards before the arrival of Dr. Hutchison, introduced the catheter. The instrument several times glided into the false passage, and was detected by the finger in the rectum, immediately in contact with the coats of the bowel. Dr. Hutchison passed an instrument on the same day, and also observed the false passage. No extravasation of urine occurred ; the catheter was retained in the bladder eight days without local pain, or constitutional disturbance. After its removal the urine was discharged spontaneously, and for three or four days without scalding, but it contained considerable mucus. He had now recovered from the effects of the contusion over the hip joint, walked about the ward and felt quite well ; his urine, however, could not be retained as long as usual, its discharge was attended with scalding, and it contained mucus in considerable quantity, which adhered to the bottom of the vessel when turned up. He used a copaiva mixture and mucilagi-



nous drinks, but no material change took place, and he passed into the hands of Dr. Minor, whose term of service commenced May 1.

The irritability of the bladder was now considerable ; he had to discharge his urine several times during the night, and was sometimes unable to sleep on account of pain in the bladder. The urine contained pus and mucus. *Pariera brava*, liquor *potassæ*, *copaiva*, etc., were used successively without benefit, and on June 13, an injection of one ounce of a solution containing 10 grs. nit. silver was thrown into the bladder. It produced considerable pain for a time, which was followed by a marked improvement. He did not get up to pass his urine for three or four nights, and the quantity of mucus and pus was greatly diminished.

Six days subsequently the injection was repeated, and was followed by the same benefit as before.

June 30.—Urine passes in pretty good stream, unattended with pain or scalding unless he walks about too much. The deposit of pus and mucus is one-half less than it was before the injections. Being anxious to visit his friends he left the hospital against advice, in July.

The prominent symptoms presented by the two preceding cases, viz., a discharge of blood from the urethra, retention of urine, great difficulty in introducing an instrument, and the existence of false passages, observed in each case immediately after an accident, evince, I think very satisfactorily the nature of the injury to the urethra. They are especially interesting in two particulars :  
1. For having been unattended by extravasation of urine, which must have been owing to the valvular nature of the laceration.  
2. The rupture was not caused in either case by direct external violence, but was probably produced, as suggested by Dr. Isaacs, by the violent contraction of the muscles of Guthrie and Wilson, and perhaps of the transversus perinei, which took place when the accidents occurred.

*Case 4.—Ligature of the dorsalis penis artery for hypertrophy of the prepuce.*—D. D. ; a native of Martinique ; æt. 30 years ; was admitted into the hospital in December, 1856 ; suffering with chancre, accompanied with considerable hypertrophy of the prepuce. The chancre healed under appropriate treatment, but the enlargement of the prepuce remained.

Being anxious to have the size of the organ reduced to its normal dimensions, Dr. Hutchison tied the dorsalis penis artery for the purpose of producing atrophy of the part by diminishing its vascular supply—that being the principal vessel through which the prepuce is supplied with blood. The ligature came away on the fourth day, and no untoward symptom occurred, except a want of action in the wound, which rendered stimulating dressings necessary. Pressure was applied to the prepuce by means of collodion, containing three grains of iodine to the ounce, which was



painted over its surface. He left the hospital June 7, the hypertrophy being somewhat diminished.

Although ligating the dorsalis penis artery in the above case was not followed by complete relief, the result indicated that the operation may in some cases prove valuable. The suggestion is therefore deemed worthy of being recorded. The arrest of abnormal developments about the face, erectile tumors of the orbit, etc., by diminishing their vascular supply is well known. I am not aware that the above operation has ever before been performed.

*Case 5.—Varicose veins treated by Vienna paste as an escharotic.—Cure.*  
—John C. ; æt. 55 years ; seaman ; native of Ireland ; was admitted into the hospital November 30, 1856, with an indolent ulcer on the left leg of twenty-five years duration, produced by the varicose condition of the left internal saphena vein below the knee. Under the use of opium, strapping, etc., the ulcer has healed from time to time, and again returned. On April 7, 1856, Dr. Hutchison applied eight pieces of adhesive plaster of three or four thicknesses, and half an inch square, with a hole in the centre of each as large as a split pea, over the prominent points of the veins. The openings in the plaster were filled with potassa cum calce made into a paste with alcohol. It was removed at the end of forty minutes, the parts washed with warm water, and a flaxseed poultice applied. The sloughs separated on the third day, and on the twenty-second day the issues were nearly healed, and the veins completely obliterated. He was discharged cured May 16. The skin over the seat of the recent ulceration had lost the bluish, flabby appearance it formerly presented.

