


Adami (G. G.)

Aneurism of the arch
of the aorta





ANEURISM OF THE ARCH OF THE AORTA.¹

By J. G. ADAMI, M.A., M.D.

Professor of Pathology, McGill University; Pathologist to the Royal Victoria Hospital.

The specimen about to be described, while possessing a certain amount of interest in itself, is more especially interesting inasmuch as the patient from whom it was obtained at the autopsy had been under observation for several years, and further, had formed the subject of a lecture delivered in the Montreal General Hospital by Dr. James Stewart, and published in the series of *International Clinics*.² Thus, apart from the fact that there is a very complete history of the case, the specimen is of value as demonstrating very clearly the explanation of the symptoms noticed during life and commented upon at some length by Dr. Stewart in the above-mentioned lecture. The clinical history of the case is contained in the case-books at the General Hospital, at the Royal Victoria Hospital and at the Longue Pointe Home for Incurables. I shall here give it very briefly, only referring to the special points in connection with the aneurism, for, superadded to this history of the aneurism, there is a long and interesting history of ataxic paraplegia. The patient, James L., first experienced pain in the chest in the early part of the summer of 1891. In the first week in August he began to complain of hoarseness; in the middle of October he entered the General Hospital, and a definite diagnosis of aneurism of the transverse aorta was made, the diagnosis being based upon the following points:³

1. Pain of a persistent character in a limited area of the chest (left infraclavicular region) relieved by change of posture.
2. Hoarseness, amounting at times to almost complete extinction of the voice. Upon laryngological examination Dr. G. W. Major found the left vocal cord paralyzed and standing in a mid position between extreme abduction and extreme adduction.
3. Cough of a brassy nature.
4. Pulsation synchronous with, but distinct from, that of the heart. The centre of the pulsatile area was situated at the junction of the second left rib with its cartilage.
5. Tracheal tugging.
6. Marked difference in the pulse at either wrist, the pulsation being far more voluminous on the right side than on the left.

¹ Read before the Montreal Medico-Chirurgical Society, March 8, 1895.

² *International Clinics*, Second Series, Vol. III., 1892, p. 49.

³ *Vide* Dr. Stewart's lecture, loc. cit.



7. The left pupil was found 2 mm. smaller than the right.

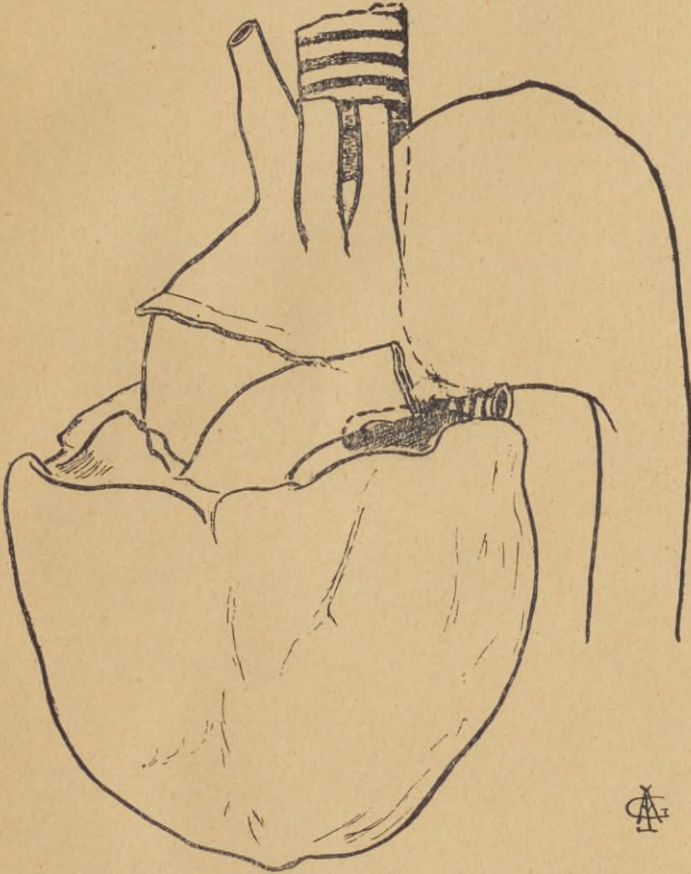
With rest and potassium iodide the pain, hoarseness, and cough disappeared, but even after five months' rest in the hospital there was no essential improvement of the fundamental state. Since 1892 the notes reveal no special addition to this list of symptoms; the ataxic condition, however, became more marked, and the patient's life has been spent mainly in the hospital.

The autopsy was performed at the Royal Victoria Hospital on February the 28th, 1895, the body having been brought from the Home at Longue Pointe on account of the more thorough post-mortem facilities. Upon opening the thorax there was no evidence of absorption of the sternum or ribs; the right lung was very large and full and presented a condition of acute bronchitis; the left lung was not half the size of the right and had a flabby collapsed feel; on section it had a dark collapsed appearance, with some œdema and bronchitis, as in the right lung. The main bronchus was pressed upon by the aortic aneurism, but did not show definite constriction or any sign of perforation.

The aortic arch was seen to be dilated and to have depressed the heart, so that the auricular ventricular groove, at a point just below the origin of the aorta, corresponded to a line joining the upper borders of the fourth chondrocostal articulations. The heart itself was very fatty, and the right ventricular muscle was profoundly infiltrated with fat; the left ventricle was somewhat dilated (as was also the right): the coronaries were dilated and showed patches of fatty degeneration, beginning 2 cm. and 1.5 cm. beyond the origin of the right and left respectively. Immediately above the valves the aorta was already larger than normal (9 cm. in circumference); it rapidly expanded into a general fusiform aneurism, with greatest giving way and some sacculation upwards and backwards beyond the origin of the innominate artery, so that the back wall of the main pouch was formed of the eroded left halves of the fourth, fifth and sixth dorsal vertebræ. The maximum depth of the aneurism at the autopsy was 11 cm. (about 4 inches), its breadth from before backwards was 15 cm. It ended in a line with the under margin of the transverse aorta, the descending aorta being of normal dimensions. Neither in the aneurism itself nor in the dorsal aorta could calcareous plaques be detected, although there were rare fatty patches of fair size. Above and behind, the cavity was filled with dense laminated clot.

Turning now to the more special features of the aneurism it may be pointed out that the aneurism pressed upon and flattened the trachea; the left bronchus, while passing outwards and forwards immediately

beneath the aneurism, appeared at the autopsy to be relatively little affected. Judging from the condition of the left lung the pressure of the aneurism upon this bronchus must have led to relative obstruction with consequent partial collapse of the lung. The left subclavian and left carotid appeared, from the development of the aneurismal sac upwards and backwards, to arise not from the apex of the arch, but from the front of the transverse portion. The innominate artery was the seat of a fusiform dilatation up as far as its bifurcation; the carotid and subclavian, while not aneurismal, were distinctly larger than normal.



The specimen, therefore, demonstrates most clearly the origin of the cardinal symptoms in aneurism of the transverse aorta. The great expansion of the tube upwards, backwards and downwards must of necessity have exerted great pressure upon the recurrent laryngeal and sympathetics of the left side; the position of the left bronchus

also, passing close beneath the aneurism from behind forwards, explains very clearly the production of the phenomenon of tracheal tugging.¹ In this position each expansion of the aneurism with the wave of blood propelled from the heart must have resulted in pushing the bronchus downwards, and it is this downward pull that is felt in these cases when the lower part of the larynx is held between the fingers.

The specimen also shows very clearly why the radial pulse was so much larger and fuller than the left; the innominate was placed in the direct line of the current and wave of blood propelled up the ascending portion of the aorta, whereas the left subclavian had, by the backward extension of the aneurism, been pushed forwards, so as to appear as though given off obliquely upwards from the front of the arch. In such a position, in consequence of the almost valvular orifice, both blood current and systolic wave could enter less easily.

¹ I have to confess that at the time of reading this paper before the Medico-Chirurgical Society I was unaware of how prominent a part had been played by our Montreal physicians in emphasizing the value of this sign in the diagnosis of aneurism of the transverse aorta. Practically, after Surgeon-Major W. S. Oliver (*Lancet*, II., 1878, p. 406) first noted the condition, the late Dr. George Ross, in his article on aneurism in *Wood's Reference Hand-Book of the Medical Sciences*, was the first to lay stress upon its value, and the late Dr. Richard L. MacDonnell was the first in an admirable article in the *Lancet* (I., 1891, pp. 535 and 650) to give a full explanation of its causation. He showed, as this specimen demonstrates so fully, that tracheal tugging is due to pressure by the aneurism either upon the last inch of the trachea or upon the left bronchus.

