

WOODWARD (J.H.)

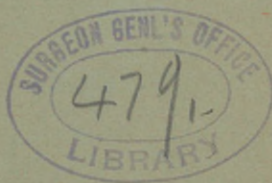GLAUCOMA, ITS NATURE AND
TREATMENT.

By J. H. WOODWARD, M.D.,


BURLINGTON, VT.

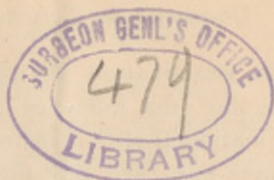Professor of Ophthalmology and Otology in the University of Vermont.

Reprint from The Ophthalmic Record, Nashville, Tenn.



NASHVILLE, TENN.:
A. R. GRAY & SON, BOOK AND JOB PRINTERS
1892.





*GLAUCOMA, ITS NATURE AND TREATMENT.

Written for the Ophthalmic Record by

J. H. WOODWARD, M.D.,

BURLINGTON, VT.

Prof. of Ophthalmology and Otology in the University of Vermont.

*Abstract of Remarks at the meeting of the Vermont State Medical
Society, October 16, 1891.*

Mr. President, Gentlemen of the Vermont State Medical Society:

When the invitation was given me to address you at this meeting, I experienced considerable satisfaction in the thought that an opportunity was afforded to say a few words to you upon the nature and treatment of Glaucoma, one of the most formidable diseases of the eye, the diagnosis and treatment of which must be early made and correctly applied to save the unfortunate patient from impending blindness. And I am all the more anxious to address you upon this subject because the recollection of some unhappy cases, which too clearly manifested the unfamiliarity of some of our colleagues with the nature of this trouble, is still fresh in my mind. Not many months ago I was consulted by a patient for defective vision. The sight had been almost entirely destroyed, and his physician, in order to

*Reprint from the *Ophthalmic Record*, Nashville, Tenn.

facilitate the examination at my office, had put the eyes thoroughly under the influence of atropine. An ophthalmoscopic examination at once revealed the fact that the patient had cataract in both eyes, and that this defect of the lens was due to a deeper seated trouble, that is to say, Glaucoma. The sight was already nearly destroyed and the atropine had only served to make the patient worse. On the same day I was consulted by a physician in regard to a case which had been diagnosed as cerebral hyperæmia, the symptoms being intense pain in the head, great intolerance of light, intense congestion of the eye-balls; and from which the patient recovered, but with both eyes absolutely blind. This was, I believe, although I did not see the patient, a case of acute irritative Glaucoma, and not one of hyperæmia of the brain. Not long after this I was consulted by a woman whose eye had been injured one year previously by a contusing blow of considerable force. Immediately following this injury the sight had been reduced to perception of light, and the patient had suffered nearly every day from pains in the eye-ball, and through the corresponding side of her head. This suffering had been so intense that she had been obliged to acquire the morphine habit, and only large doses of that narcotic would enable her to enjoy any comfort whatever. During the year the eye had become somewhat enlarged, and a tendency to hernia of the choroid was manifest at the time of her first visit to me. An ophthalmoscopic examination immediately showed that the lens had been dislocated backward into the vitreous, and that the patient had suffered all these months from the symptoms of secondary Glaucoma.

Glaucoma occurs both as a primary and as a secondary affection, and the symptoms of it are always due to an increase of pressure in the interior of the eye.

Primary Glaucoma is subdivided into three classes: Acute Irritative* Glaucoma, Chronic Irritative Glaucoma, and Glaucoma Simplex. Now, acute irritative and chronic irritative Glaucoma may be preceded by a *Prodromal Stage*. During this

* Most writers on Ophthalmology speak of *inflammatory* rather than *irritative* Glaucoma. It seems to me that there is much force in DeWecker's reasons for preferring to speak of the symptoms of Glaucoma as irritative.

stage the patient is troubled with cloudy vision. It seems to him that a veil or a mist is before his sight, and sometimes when looking at gas jets, or other luminous objects, he sees surrounding them a halo having the hues of the rainbow. This symptom of rainbow-vision is not necessarily significant of Glaucoma, for it occurs also in patients whose conjunctivæ secrete a rather viscid discharge. These patients also complain of difficulty in reading, especially in the evening, and many of them have been obliged to change their reading glasses frequently within a few months. If you were examining one of these eyes at such a time, you would observe that the pupil moves rather sluggishly under the influence of light, that it is rather larger than the other, and that the tension of the eye-ball is slightly above that of the healthy eye. An ophthalmoscopic examination of such an eye will show that the cornea is slightly cloudy, and that the optic nerve appears slightly redder than normal, and that the pulsation in the veins is more marked, and possibly there may be seen some pulsation in the retinal arteries. These prodromal symptoms in a patient predisposed to Glaucoma may be caused by overwork, and especially by strong emotion. They may last only for a few days, and disappear entirely as soon as the patient has recovered his normal bodily vigor. They will recur from time to time in response to the same influences which first produced them, until finally the patient may completely recover, or more likely he will develop the more marked symptoms of the acute irritative or of the chronic irritative variety of the disease. Other cases may, after a few days of these prodromal symptoms, pass at once, without any remission, into acute irritative glaucoma.

The *symptoms* of the *Acute Irritative variety* of *Glaucoma* come on suddenly, and often at night during sleep. The patient is awakened by severe pain in the eye. This pain radiates over the temple, down into the face and teeth, and back into the head; and its severity is sometimes almost unendurable. Associated with this are commonly nausea and vomiting, great prostration, sometimes delirium, and a rise of bodily temperature. The eye is red, the superficial vessels are engorged, the cornea is cloudy, the anterior chamber shallow, the pupil semi-dilated and immova-

ble to light, the eye-ball hard and tender to pressure, and the vision very much impaired. In a small number of cases the sight is permanently destroyed within twenty-four hours. More frequently, however, the course of the disease is longer, and after days or weeks of agony the eye becomes totally blind, the other symptoms gradually abate, and the patient recovers with the loss of sight in the affected eye. During the first days of the attack it is almost impossible to look deeply into the eye with the ophthalmoscope, owing to the cloudiness of the cornea; but after the cornea has again become clear, you can observe the optic nerve, and you find that it no longer presents a normal appearance. You find that it is deeply excavated, that the excavation extends clear around the nerve to the periphery of it, that the retinal vessels in their course from the bottom of the excavation to the retina are obscured for a certain distance by the overhanging edge of the excavation.

In the *Chronic Irritative variety* of *Glaucoma*, the symptoms may begin with a prodromal stage, such as has already been described, and the patient may go on suffering from irregular attacks of irritative symptoms which are like those of the acute irritative form, but are usually of less severity; and from each of these attacks the patient recovers with a still greater impairment of his acuteness of vision. During the intervals between these attacks we find that the intraocular pressure is above normal, that the optic nerve shows a progressing excavation, that occasionally the retinal arteries will show some pulsation, and that the retinal veins are somewhat congested. The optic nerve is no longer of normal color, but it acquires an increasing palor until by virtue of the death of the fibres of the nerve it has a bluish-white appearance. The field of vision is always contracted, and especially is this contraction of the field marked upon the nasal side. In the course of a few months the vision is permanently destroyed.

The symptoms observed in the course of *Glaucoma Simplex* resemble those already mentioned, but every sign of irritation is wanting. It is, therefore, the most insidious of the varieties of this disease, and it is not at all uncommon for ophthalmologists to see patients in whom *Glaucoma Simplex* has progressed

to an advanced stage, while the patients are utterly unconscious that they have any serious disease of the eye. Such patients have found that their glasses are becoming more and more unsatisfactory, and by the accident of testing the vision of each of the eyes alternately, they have discovered that the vision of the affected eye is very much less acute than it should be. A careful examination of such eyes would reveal a steadily increasing intra-ocular pressure. In other instances, however, although an increase of the intra-ocular pressure is undoubtedly present, the crude means at our disposal for measuring such changes are not delicate enough to detect it. The pupil is semi-dilated, and does not respond to light, or to accommodative efforts. The media are perfectly clear, and an ophthalmoscopic examination may be satisfactorily conducted. The peculiar glaucomatous excavation of the optic nerve is present, and an examination of the field of vision shows that it is contracted, and especially on the nasal side. The progress of this form of Glaucoma is comparatively slow. It ends in pressure-atrophy of the optic nerve, and consequent total blindness, and during the months preceeding the final destruction of sight, the lens may become cataractous.

As I have previously stated, the symptoms of Glaucoma are due to an increase in the intra-ocular tension. The pressure within the eyeball may be raised, by either an increase in the production of the fluids of the eyeball, while the outward current remains normal, or by the current outward being impeded, while the production of the intra-ocular fluids remains normal. It is now the general opinion of ophthalmologists that the cause of the increase in the intra-ocular pressure in Glaucoma is due to an impediment to the outward current, and this impediment is found to exist at the filtration angle where the iris and cornea meet. There are two channels by which the intraocular fluids escape from the eyeball: one is by way of the optic nerve, this is the minor current; the major current is formed from the vitreous through the zone of Zinn into the posterior chamber, through the pupil into the anterior chamber, out at the filtration angle through the spaces of Fontana. If this filtration angle be narrowed by any cause, then the intraocular fluids are backed

up. The consequence is that the iris bulges forward, and therefore the anterior chamber becomes shallower, the cornea is subjected to increased pressure, and therefore it becomes cloudy; the filament of the third nerve, which supplies the sphincter muscle of the iris is subjected to pressure, and therefore the pupil becomes semi-dilated, and does not respond to light; the nerve fibres supplying the ciliary muscle are likewise subjected to pressure, and therefore the accommodation is impaired; the delicate fibres of the optic nerve, as they emerge at the papilla, are likewise pressed upon and pushed backward towards the lamina cribrosa, and if this pressure be continued for a sufficient time, pressure atrophy must ensue, and the excavation at the disc become deeper and deeper. Pulsation in the retinal veins is also more marked as a consequence of pressure upon them, as they pass over the edge of the excavation, and so likewise is induced the pulsation sometimes observed in the retinal arteries. The contraction observed in the field of vision is due to anæsthesia of the retina produced by continuous pressure upon it.

Now, the *prognosis* of Glaucoma is always grave and depends to a considerable extent upon the early diagnosis, and the treatment adopted. It is the rule that both eyes are affected, but the second eye may not be attacked by the disease until many years later.

The *treatment* of the prodromal stage, when the symptoms are not very urgent, consists in restoring the general vigor of the body, absolute rest of the eyes, a moderate diet, and sufficient sleep. A one grain solution of sulphate of eserine may be instilled into the eye if necessary, in sufficient amount to produce contraction of the pupil. The treatment of the acute irritative and chronic irritative form of Glaucoma consists in the early performance of an iridectomy. This operation should be performed as early as possible after the diagnosis of the malady has been made; but if you do not feel competent to perform this operation yourselves, and if several hours must elapse before the services of an oculist can be secured, you may control the pain by opium, by hot applications to the eye, by abstracting blood from the temple, and especially by dropping into the eye a one or two grain solution of sulphate of eserine. Although

eserine may control the symptoms, it is, nevertheless, best to operate upon these eyes, because experience has shown that iridectomy, above all other varieties of treatment, is the most certain to save the sight of the patient. The results of the operation, if performed early, are oftentimes surprisingly good. I have performed iridectomy upon these patients by cocaine anæsthesia, but would not recommend such practice, where the object of the operation is not merely to stop pain, but to restore vision. For, in spite of the liberal use of cocaine, the operation is quite painful, and a nervous patient might cause dislocation of the lens or a prolapse of the vitreous, either of which would seriously complicate the case. Ether anæsthesia, as a routine practice, ought to be adopted for operations upon glaucomatous patients. Occasionally, Glaucoma is complicated by hemorrhagic retinitis, and such cases are often spoken of as hemorrhagic glaucoma. When this complication exists, and an iridectomy is performed, the retinal vessels may burst during the operation and the eye be destroyed in consequence. I have operated upon one patient suffering from hemorrhagic glaucoma. His left eye had been blinded by the disease, and his right eye had become affected some months before he consulted me. I attempted to control the disease by eserine drops, and succeeded in doing so for a few months, but at length the effect of the eserine became unsatisfactory. The patient was steadily losing his sight, and after considerable hesitation, I decided to operate upon him, after explaining to him the dangers of an operation in his case. I determined to make an iridectomy rather than a sclerotomy, for I did not think that a sclerotomy would be sufficient. I therefore operated upon him, under cocaine anæsthesia, he being a very cool and courageous patient. I made the corneal section very slowly with a Græfe knife, in order to lower the intraocular pressure as gently as possible. No hemorrhage occurring, the patient made a good recovery, the disease was checked by the operation, and after a few months all signs of retinitis had disappeared, and now, but for a rather high degree of corneal astigmatism, the patient's vision would be very acute.

The treatment of Glaucoma Simplex consists in iridectomy and eserine. When the diagnosis is correct; in other words, when we are dealing with a case of true glaucoma simplex, and not one of simple atrophy of the optic nerve, an iridectomy will be beneficial to the patient. But in these cases there is less need for haste than in the other varieties of this disease, and therefore some time may be devoted to an attempt to control the symptoms by means of eserine.

Time will not permit me to discuss more fully this important subject. I must pass over *Secondary Glaucoma* with the remark that it also depends upon an increase in the intraocular pressure for its symptomatology. Such cases are in general the consequence of traumatism or plastic inflammation of the iris, which gives rise to obstruction to the outward current in the intraocular fluids. And the treatment consists as a rule in the establishment of an artificial pupil or in removal of the eyeball.

In conclusion, let me warn you against the indiscriminate use of atropine drops in the treatment of diseased eyes. Atropine is a very useful medicinal agent in ocular therapeutics when administered to the proper cases. But in Glaucoma of any variety it is injurious: for its physiological effect is such that the intraocular tension is increased by it. I know that the authors of some works on *Materia Medica* make the opposite statement; they tell you that atropine *lowers* the tension within the eyeball. *This is a great mistake.* I have observed one interesting case in which atropine drops certainly increased the intraocular tension. My patient had been struck upon his closed eye by a piece of iron with such force that the crystalline lens was dislocated downward and backward. There was some irritation of the iris, and I instilled atropine drops into the eye. I am perfectly certain that there was no pulsation in the retinal arteries prior to that time. On the following day there was very marked pulsation in the retinal arteries of the atropinized eye. The drug was discontinued, and after a day or two the pulsations had entirely ceased; and, although I examined the eye many times afterward, I did not again detect any sign of pulsation in it.

