

Shakespeare (E. O.) &

de Schweinitz (G. E.)

An unusual case of ciliary
neuralgia &c

EXTRACTED FROM THE

TRANSACTIONS OF THE COLLEGE OF PHYSICIANS OF
PHILADELPHIA.

THIRD SERIES, VOLUME X.



AN UNUSUAL CASE
OF
CILIARY NEURALGIA WITH AN ERRATIC HISTORY;
A CLINICAL STUDY.

BY
E. O. SHAKESPEARE, M.D.,
OPHTHALMIC SURGEON AND PATHOLOGIST TO THE PHILADELPHIA HOSPITAL.
AND
G. E. DE SCHWEINITZ, M.D.,
OPHTHALMIC SURGEON TO THE PHILADELPHIA HOSPITAL AND TO THE
ORTHOPÆDIC HOSPITAL AND INFIRMARY FOR NERVOUS DISEASES;
PROSECTOR OF ANATOMY TO THE UNIVERSITY OF
PENNSYLVANIA.

[Read November 2, 1887.]

AGNES L., a widow, aged fifty-seven, born in Ireland, was admitted to the Philadelphia Hospital, August 21, 1880, complaining of pain in a scar situated upon the ninth rib in the mammary line. It occurred at varying intervals, sometimes being absent for several days, but usually returning every second day.

History.—The patient's father died at the age of sixty-two from meningitis following a sunstroke. She was an only child, her mother having perished when she was born. As a child she suffered from the ordinary exanthemata and, when a young girl, had an attack of typhoid fever. At the age of sixteen she was married and in her eighteenth year was delivered of her first child. She subsequently gave birth to five other

children, the last when she was thirty-six years of age. In 1861, or six months after the birth of her last baby, her husband and eldest child died suddenly of smallpox. The receipt of this news, which was rudely communicated to her, produced an illness which began with unconsciousness and continued in various periods of delirium and hallucinations. At the end of several weeks the mental equilibrium was restored and convalescence progressed to perfect recovery. The attending physician told her that her sickness had been an attack of "brain fever."

Through her entire married life her health had been exceptionally good, and there were no indications of uterine disease or history of syphilitic infection. In 1868 she had a fall and struck her left side against a projecting stone, producing a severe contusion. This subsided with the exception of one spot, then about the size of a pea, which, she says, "looked like a blood-blister." This spot became elevated and gradually enlarged, while its color faded. In three years it had reached a sufficiently large size to cause considerable annoyance and was, moreover, the seat of irregular, dragging pains, easily allayed by the application of hot fomentations. In 1871 the tumor was removed, but its exact nature is unknown. For several years subsequently she enjoyed good health, was able to work regularly and support her family. At the end of this time she had a severe attack of intermittent fever lasting six weeks. For one month after recovery from this illness her health appeared to be in its usual state.

In July, 1880, she began to have pain in the cicatrix which resulted from the removal of the tumor. This pain differed from anything she had previously experienced. It was intense, lancinating in character, and came upon alternate days at about ten o'clock in the morning. During each pain-period the scar flushed and took on an angry look. When the pain subsided the color faded. No remedial agency, except a hypodermic injection of morphia, gave relief. She endured this state of affairs for six weeks and then sought relief in the Philadelphia Hospital, where she was admitted August 21,

1880. She first entered the surgical wards, but after a month of fruitless treatment was transferred, September 21st, to the nervous wards. For several weeks internal remedies were tried in vain, when, by Dr. H. C. Wood's order, the painful cicatrix was removed. For six weeks there was an absolute cessation of pain, when, quite as suddenly as at its original onset, the pain returned with redoubled severity in the old situation. The attacks now usually occurred twice a day, at about ten in the morning and six in the evening, and were accompanied by the flushing of the tissues before described. No especial change, except quite temporary periods of relief, in the patient's state took place until the spring of 1881. Then, by the advice of Drs. Wood and Mills, under whose care she had been, active counter-irritation was performed. Dr. Pancoast made several pronounced applications of the actual cautery, over the posterior roots of the spinal nerves in the lower dorsal region. From the time of this application, for several months (probably two) she was entirely relieved of her sufferings. So radical did the cure appear to be that she was in the act of leaving the hospital when she was seized with pain in the left eye. As before, the pain was intense, lancinating in character, as if a sharp instrument was being thrust rapidly through and through the eyeball. The lids became congested and swollen, the conjunctiva reddened, the lachrymal secretion increased. For some time numerous and various remedies were tried without any but the most temporary results.

She was then transferred, May 20, 1882, to the eye ward, and became Dr. Shakespeare's patient. The pains were frequent, sometimes they occurred daily, sometimes twice a day, but occasionally were absent for a week, never, however, longer than for two weeks. A thorough and systematic anti-malarial treatment was ordered, even in so far as to use a decoction of lemon after the manner of Tommasi-Crudeli. As each successive remedy was tried the result and experience of the past were repeated. Temporary relief would be obtained, then the effect of the remedy would fail and finally the pains would

recur. A careful examination now revealed the following interesting facts. Preceding and during a pain-period marked tenderness over the middle cervical sympathetic ganglion of the same side was manifest. Moreover, pressure upon the eye produced pain in the region of the ganglion, and, *vice versâ*, pressure upon the ganglion caused pain in the eyeball. A similar tender area was found along the spine, directly between the shoulder-blades. This led to a return of counter-irritation as a means of treatment. Beginning with iodine and ending with the actual cautery, a succession of these agents was employed posteriorly on the left side of the neck and over the spine between the scapulæ. The actual cautery proved most efficacious and for several months the patient was free from her distressing affliction.

For the second time this unfortunate woman believed herself finally rid of her enemy and was in the act of gathering together her effects preparatory to leaving the hospital, when the pain recurred with all its former severity and attended with all its former symptoms. A seton was now introduced into the tissues at the back of the neck, and for a time, as with everything else, relief was experienced, hope returned, only to be displaced by a recurrence of the pain.

Examination of the interior of the eye never revealed any unusual features, as is evidenced by the following description: Round nerve, regular in outline, border distinct. Fundus not noteworthy beyond a peculiar curve of the lower vein. Inasmuch as the pain-periods were accompanied with great swelling of the conjunctiva the nutrition of the cornea was gradually impaired and a form of keratitis developed. This appeared as a curious opacity in the inferior half of the cornea, about midway between the centre and the lower limbus. This opacity, viewed by the ophthalmoscope, appeared to have dark processes like roots radiating from its upper edge. There was no connection between this and the iris or the anterior chamber. The pupil was normal, the anterior chamber of natural depth. There was never any increase of tension, and the field presented no distinct limitations.

In spite of a return to former lines of treatment and trials with all manner of general and special tonics, alteratives, and anti-rheumatic remedies, the pain continued and came with distressing frequency and severity. The keratitis increased, useful sight was obliterated, and the patient begged that the offending eye be removed. Although warned that the removal would in all probability only occasion a shifting of the seat of the affection, she was persistent in her entreaties, and her request was finally acceded to. In exactly three weeks after the enucleation was performed the pain appeared in the right eye in character precisely similar to that which had formerly had its seat in the left one, and accompanied by tenderness of the middle cervical sympathetic ganglion of the right side, just exactly as it had previously been present upon the left side.

Examination of the eye revealed the following features: Iris moved sluggishly to changes of light and shade. Mean size of pupil one-third the size of the cornea. Iris normal in appearance. Media clear. Outline of the optic nerve regularly oval, its long axes 75° . The color of papilla slightly brick-dust. The outer half somewhat paler than the inner, and the corresponding scleral ring more distinct. The vessels were normal in their course, the arteries probably a little lessened in their calibre. There was slight narrowing of the visual field on the nasal side and above and below. Tension of the eye normal.

To detail the symptoms and course of this case from this period up to the present year would simply be to repeat what has already been described, with the exception of one symptom, viz., the marked tenderness over the middle cervical sympathetic ganglion. This symptom was no longer a characteristic one in June of this year, when Dr. de Schweinitz took charge of the wards. Exactly when this curious tenderness began to subside cannot be definitely stated. Even now, during a pain-period, it is perfectly easy to demonstrate an area of distinct discomfort upon deep pressure over the gan-

gion, although there is no longer a sense of pain, nor does pressure on this region produce pain in the eye as it formerly did.

A careful reëxamination of the eye at this time showed the appearances before recorded to be unchanged. Moreover, a keratitis in all respects similar to the one which had developed in the left eye, had also appeared in the right one as the sequela of many pain-periods. The light projection was good in all parts of the field. A perimetric chart of the field of vision showed no defects other than those explained by the corneal opacity and a somewhat drooping upper eyelid. No increase of tension was observed at any time. The pains now occurred with great frequency, always once daily about 10 A. M., sometimes twice, when the second one would take place about 7 P.M., occasionally a third one in the middle of the night or early morning. The onset of a pain was as sudden as a lightning-stroke, was instantly followed by œdema and discoloration of the eyelids, reddening and swelling of the conjunctiva and excessive lachrymation. A brawny flush overspread the brow and face, the veins became turgid, the carotids throbbed visibly, the woman bent and trembled in her agony, and presented a picture of utter misery seldom witnessed. If an anodyne was withheld, in a few minutes a muco-purulent catarrh appeared and within the hour gray sloughs upon the conjunctiva, until the whole eye resembled, at the height, an attack of purulent ophthalmia. If morphia sufficient to stop the pain was given, and it was the only remedy of any avail, the appearances just described would subside as quickly as they had appeared. We have often observed an attack come on, reach its height, and disappear with scarcely a remaining trace within an hour or at most two hours. A careful retrial of former remedies was instituted. Quinine, arsenic, and oil of eucalyptus produced no results. Anti-rheumatic remedies, especially the salicylates and oil of gaultheria, gave, if any, the most temporary relief. No favorable response was given to antipyrin and antifebrin. The former was used not only by

the mouth but also hypodermatically after the manner of Germain Sée.¹

It was observed that the pain apparently started just below the tendo-oculi, and after its subsidence this spot remained tender. Partially inspired by this fact, and remembering the published successes of Badal² in the treatment of glaucoma and ciliary neuralgia by stretching and extirpation of the external nasal nerve, an operation of this kind was determined upon. Following the method described by Brailey (*British Med. Journal*, October 10, 1885), the supra-trochlear nerve was exposed, stretched until it broke, and then a piece one centimetre long excised. This operation was performed on June 21, 1887, the patient having had a pain shortly before the incision. Healing was perfectly normal. For one week there was absolute relief, but exactly seven days later, or on the 28th of June, the pain returned. At first this was less violent than formerly, but soon returned to all its severe and usual characters and also its tendency to appear about 10 in the morning and 7 in the evening.

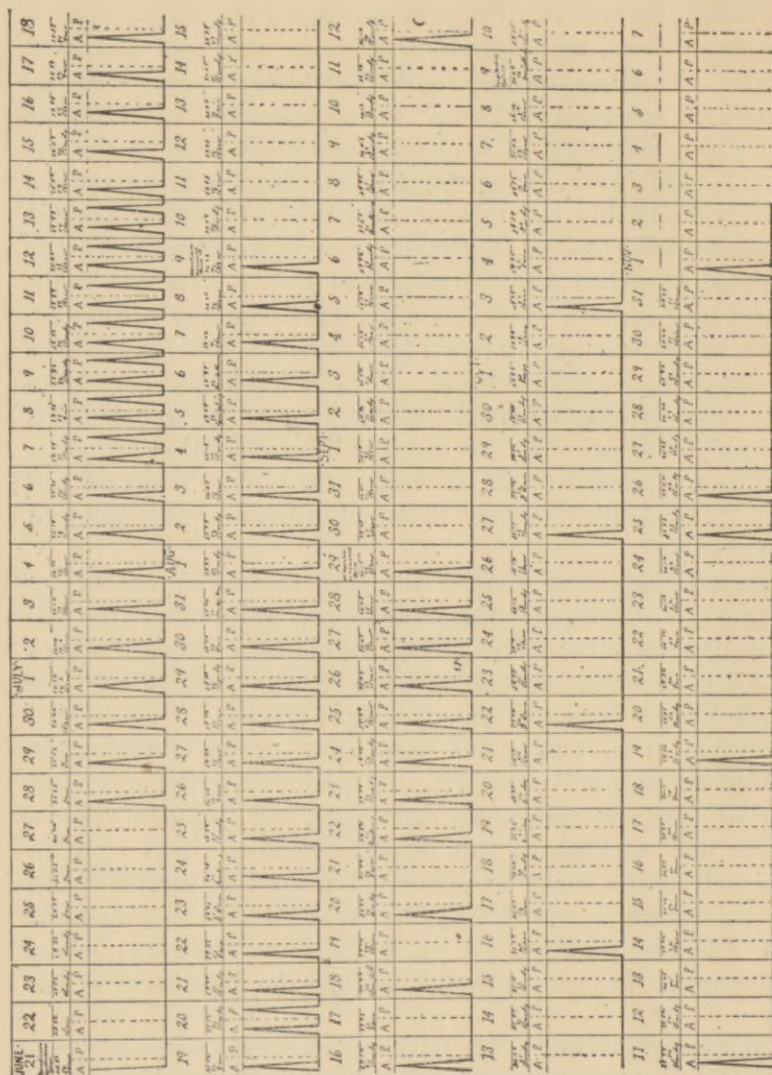
Experiments now elicited the fact that if at the beginning of an attack a hypodermatic of half grain of cocaine was injected along the course of the supraorbital nerve the pain would be distinctly allayed, although it would return after the effects of the drug had passed away. This led to the second operation of stretching and excising a portion of the supra-orbital nerve on August 9th. A period of relief again occurred, but precisely seven days later, viz., August 16th, a slight but still decided pain appeared, and two days later an intensely severe one. Disappointed at the very limited result of this operation, and also noting the small area of anæsthesia which had resulted (an oval patch just above the brow), it was thought that probably a branch and not the main stem of the

¹ It may be interesting to note that during the free administration of anti-pyrin the patient was seized with a sharp attack of dysentery, abdominal pain, tenesmus, and frequent bloody stools.

² Traitement de douleurs ciliaires par l'élongation du nerf nasal externe. *Ann. d'ocul.*, lxxxviii. 241-253, Brux., 1882.

nerve had been secured. Hence the incision was renewed and a careful dissection made down to the foramen, where the

Fig. 1.



Tracing representing pain-periods during 134 days. Each triangle represents a pain-period; the unbroken line the absence of pain. The condition of temperature, etc., is noted above each day. A=A.M., P=P.M.

nerve was seized, dragged forward and cut off, and then dissected up for two inches and excised. For two weeks there

was an entire absence of attacks, but on the fourteenth day a slight pain occurred, and four days later a severe one. Thus the tendency for these attacks to return on the seventh or multiple of a seventh day was again manifested. From this time on, however, this rule was not strictly adhered to and the type occasionally varied, as an examination of the accompanying chart, which represents the pain periods during the one hundred and thirty-four days, will show. It will be seen that pains appeared upon the fifth, sixth, and eighth days, as well as upon the seventh days.¹

The condition of the atmosphere and the changes of the weather have no influence in the production or absence of pain in this woman.

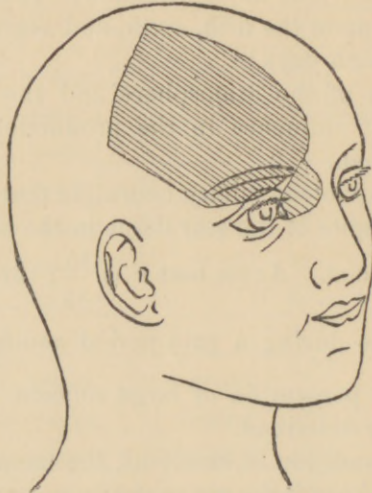
Even after the violent ciliary neuralgia that this patient has suffered, and in spite of the scar tissue in the cornea, the vision remains fairly good. At its best it is $\frac{15}{XL}$; three hours after an attack $\frac{15}{LXX}$, while during a pain-period acuity of sight is reduced to a mere perception of large objects. The field is as has already been described.

The mental condition is excellent, the memory entirely unimpaired. The knee-jerks are perfectly normal. There is no region of impaired muscular ability or unequal muscular energy. Hyperæsthesia and anæsthesia are absent, except the area of anæsthesia which followed the nerve section. The blood has been examined before, during, and after pain-periods in order to determine the presence or absence of the microorganisms peculiar to malaria. These examinations have been entirely negative. Dr. Osler and Dr. G. Dock kindly aided in this investigation. The blood had not only been taken in the usual manner from the finger, but recently we introduced a sterilized hypodermatic needle into the spleen, after the man-

¹ At the present time the type has been reëstablished and the pains occur weekly, just seven days almost to the hour elapsing between each pain.

ner described by Dr. Councilman,¹ without discovering any evidences of chronic malarial poisoning. Repeated examinations of the urine have yielded a specific gravity varying from 1.012 to 1.022; the entire absence of albumen and sugar; a sediment negative, except upon one occasion, when a few small hyaline casts were discovered.

FIG. 2.



Shaded portion represents the area of anæsthesia after excision of the supratrochlear and supraorbital nerves.

Our colleague, Dr. John H. Musser, has kindly examined the heart and splenic area and reports as follows: High tension, relative accentuation of the second sound, hypertrophy of the left ventricle and two systolic exocardial friction murmurs. Loud venous hum in the neck. Spleen not enlarged. A thorough inspection of the naso-pharynx by Dr. E. Martin revealed the parts in a fairly normal state; this is especially true of the left side. Upon the right side a small hypertrophy projects into the nasal cavity. The sense of smell is less acute

¹ Lecture to Path. Soc. of Philada., Oct. 17, 1887. Further Investigations with the Corpuscles of Laveran.

upon this side. The upper jaw contains no teeth except two fragments—the remains of canine teeth. In the lower jaw the incisors, canine, and two bicuspid remain, and are not carious. The gums are not tender in any place, and there are no appearances of such morbid processes as the late Prof. Gross has described to be a cause of neuralgia. The tongue is clean, the appetite good, the digestion unimpaired. There is no evidence of hepatic derangement.

Dr. B. C. Hirst has made a utero-vaginal examination and reports the condition perfectly normal for the patient's time of life; the uterus and broad ligaments are healthy, the ovaries unrecognizable. The temperature usually varies from 97° to 100.2° , and this variation has never conformed to any regular type. This character of temperature, occasionally slightly above the normal, and again below it, is, we think, always present. It has certainly always appeared whenever any thermometrical records have been made.

It has seemed to be the part of wisdom simply to present the report of this case without entering upon any theoretical considerations, for the good and sufficient reasons that seven years of theorizing and experiment have failed to achieve any very brilliant results. Quite naturally the malarial origin of this disorder has been discussed, but it certainly falls in the light of the failure of therapeutic tests and the examination of the blood.

The possibility that this is a form of rheumatic or gouty neuritis is deserving of respect. But inasmuch as there is an absence of any rheumatic history, of any symptom indicating a lithæmic diathesis, and, to a less degree, as there was no response to anti-rheumatic treatment, it seems an untenable position. Prosopalgia, of the most violent type, has certainly followed the pressure of growths upon the Gasserian ganglion, and in a case by Laveran a fibrous degeneration of the ganglion

itself was the cause of the pain. It is difficult, however, to accept this explanation in the face of the history of this disorder, beginning, as it did, in a cicatrix in a region under the supply of spinal nerves, necessitating, moreover, as it does, the belief that first the left and then the right ganglion were respectively the seats of disease.

The idea that these pains may be due to a disorder of the sympathetic nervous system and depend upon derangement of the vaso-motor tonus presents to us, we confess, many attractions. Dr. Wood has pertinently remarked, "These severer forms of prosopalgia are capable of being arranged in two groups—those in which a lesion can and those in which it cannot be demonstrated." This is certainly one of the forms in which, thus far, it has not been demonstrated.

