

STEWART (W. B.)

SPINDLE-CELL SARCOMA
AND EPITHELIOMA; A
REPORT OF CASES.

BY

W. BLAIR STEWART, A.M., M.D.,

Lecturer on Therapeutics; late Instructor in Practice of Medicine in the MEDICO-CHIRURGICAL COLLEGE, of Philadelphia.



REPRINT FROM

American Medico-Surgical Bulletin,
September 1, 1894.

TO CONTRIBUTORS.

Contributions of Original Thought and Experiences, on Medical and Surgical Topics, are desired by the AMERICAN MEDICO-SURGICAL BULLETIN on the following conditions:

1.—Authors of Scientific Papers or Clinical Reports accepted by us will receive—according to their own preference expressed *with each communication*, either:

a.—A number of REPRINTS of their article in neat pamphlet form (pocket size); or,

b.—Instead of the above, an Equivalent value therefor in CASH.

2.—All contributions are received only on the express understanding:

a.—That they have not been printed anywhere, nor communicated to any other journal.

b.—That, if they have been read anywhere to an audience, this fact be stated in full detail by a note on the manuscript.

Contributors will serve their own interest by heeding the following suggestions

Write Concisely and Clearly.

What we desire to print, and what professional men like to read, is information, not verbiage. An article will stand better chances of acceptance, and of being widely read and copied and discussed, the fewer its words are, in proportion to the facts or ideas it embodies. Of course, a thought too thinly clad must suffer. Use, therefore cheerfully, as many words as appear needed to convey your meaning,—but no more.

Aim at Fact.

It is not to be expected that every Medical or Surgical paper should be a mere array of statistical data, hospital records, tabulated figures, or graphic summaries; some room must be allowed to theory, or even conjecture, in its proper place; but the true aim of theory should never be left out of sight,—which is, to lead to fact; to a rule or result of practice.—And it should be likewise borne in mind that the Reader will attach little weight to mere generalizing statements (such as, that a certain remedy, procedure, or line of treatment has uniformly proved successful, etc.);—to be convinced, he wants to see positive evidence: recorded in clinical detail of cases: conditions found, courses pursued, and results achieved

Do Not Fear,

however, that a communication you may be inclined to make would be devoid of value because you have but little time to spend on writing it! If your thought be a good one to yourself and for your patients' benefit, it will be equally so to your colleagues and their practice, and will be worth communicating. It need not come in the garb of an elaborate Scientific treatise; a simple "Letter to the Editor" will often be just as acceptable.

Some Rules of Order we should like to have our esteemed Contributors comply with


Do *not* write on both sides of the sheet.

Write as legibly as you conveniently can (*names* especially so).

Leave a liberal margin on the sheet, or space between the lines. (*Close* writing is not conducive to correct typography; and what you save in writing material has to be expended a thousand-fold by us in eyesight labor, and expense for printer's corrections.)

Address:—P. O. Box, 2535,
New York City.

Editor American Medico-Surgical Bulletin.



SPINDLE-CELL SARCOMA
AND EPITHELIOMA; A
REPORT OF CASES.

BY




W. BLAIR STEWART, A.M., M.D.,

Lecturer on Therapeutics; late Instructor in Practice of Medi-
cine in the MEDICO-CHIRURGICAL COLLEGE, of Philadelphia.



REPRINT FROM

American Medico-Surgical Bulletin,
September 1, 1894.



SPINDLE-CELL SARCOMA AND EPITHELIOMA; A REPORT OF CASES.

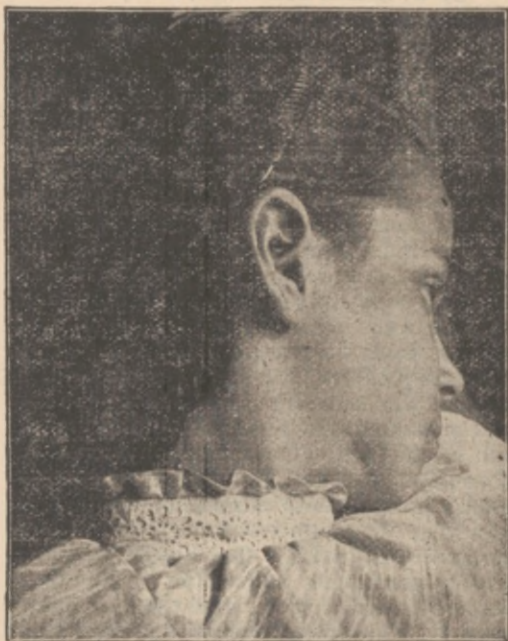By **W. BLAIR STEWART, A.M., M.D.,**

Lecturer on Therapeutics; late Instructor in Practice of Medicine in the MEDICO-CHIRURGICAL COLLEGE OF PHILADELPHIA.

IN the fall of 1893, Dr. E. HARLEY BUCKLAND, dentist, was consulted by a little girl of seven years for her teeth. At that time his attention was attracted by a small growth on her lower jaw, externally, and which presented the following very interesting history.

Mary Francis M., aged seven years, born of healthy parents and free from hereditary taint, suffered considerably with tooth-ache in her lower, right, temporary, second bicuspid, which was considerably decayed. In the spring of 1893, it grew worse and, as shown later, became abscessed at the root and presented itself as a swelling on the side of the face. The family physician was consulted, and he, thinking it was an ordinary boil, ordered a poultice applied externally. The lump softened and opened spontaneously with a free discharge of pus which continued some time. The tooth was afterward drawn, and the pus cavity closed. From that time on a small pimple developed and gradually increased in size until the time it was examined by Dr. BUCKLAND. He called me into his office and together we examined the growth. It was situated on the lower border of the inferior-maxilla, anterior to the facial artery about one-half inch. It was about the size of a

small cherry; dark in color and looked as if it were filled with venous blood; no pulsation; little or no soreness or pain; was itchy at times; the surrounding skin was slightly blushed; small waxy white scales surrounded the base; no apparent lymphatic involvement; physical signs on the inside



MARY F. M.—Photograph taken July 11, 1894.

of the mouth were negative; general health was fair but there was slight anæmia.

Immediate operation was advised, but not acted on. The growth gradually increased in size, and, under the advice of another physician, it was opened by him and several

small spiculæ of bone were removed. No improvement resulted; they consulted us again, and on November 11, 1893, at eleven A. M., Dr. BUCKLAND and myself, assisted by Dr. ANDREW LINDSAY, placed her under ether and operated for the removal of the growth. I made my first incision about one line anterior to the facial artery and carried it in an ellipse wide of the growth and dissected down to the bone where it was firmly adherent. A small sinus was detected in the inferior maxilla and around it considerable soft, spongy, dead bone. The periosteum was removed wide of the decayed area, and a section of the bone was removed with the dental engine and a good sharp bur and bone scraper. Wound was cleansed with bichloride; a drainage suture was placed in the bottom of the wound and the whole closed with black silk sutures and dressed with powdered aristol. Little or no discharge resulted, and on November 26 the little patient was declared cured. She was given syrup of hydriodic acid, in ten drop doses, three times daily for three months and made a speedy recovery. A decayed tooth was subsequently removed to prevent a possible involvement later.

At this time, August 1, 1894, the scar looks entirely healthy, and there is not the least indication of a return. The child is in perfect health. The specimen removed was given to Prof. E. B. SANGREE for examination, and he writes as follows: "The specimen you sent is a fibro-sarcoma of the spindle-cell variety. More toward the fibroma than the sarcoma type, however."

This case is one of unusual interest and is unique from the history and ætiology, and affords an important lesson in all tumors,

growths, and inflammations in the vicinity of the teeth. In all probability the growth would never have resulted had the tooth been extracted in the first instance. It also shows that a semi-malignant growth can develop in a perfectly healthy child without any hereditary predisposition.

Sarcoma is primarily a disease of young children and adults, and will spread rapidly according to type and anatomical location. It spreads through the circulatory system, and does not depend upon the lymphatics for its dissemination. The blood supply of every sarcoma is rather profuse, and the blood vessels tend to degenerate and break easily. In this case the bluish appearance of the growth was due both to ruptured vessels and a free venous supply. It is still a question in my own mind whether the growth involving the bone was simple in type or whether it was an osteo-sarcoma. No part of the bone was examined microscopically. It is altogether probable that the bone had not taken on any sarcomatous condition, or there would have been some manifestation of a secondary return by this time. It is extremely important in these cases to sacrifice plenty of sound tissue in order that every trace of the disease may be excised. The earlier the operation can be performed the greater the chances of recovery and its elimination. If the inferior maxilla were involved with sarcoma, nothing short of one-half or complete excision would be beneficial or permanent in its results. The vascularity of bone is such that in a short time it will be wholly infiltrated with the disease, and the only cure is its complete removal. It is a surgeon's duty to consider the subject of the scar, but, in an

osteo- or fibro-sarcoma or true cancer, life is of primary and the scar of secondary importance.

It is said that one never profits except by actual experience, and my next case illustrates what conservative surgery will do in a primary operation. May the same mistake never occur to me again!

Mrs. H. R. T., nearly eighty years of age, noticed a small itchy pimple on the back of her left hand which gave her but slight annoyance for some weeks. She used all sorts of home remedies which kind neighbors advised, but the pimple grew in size until she could not wear her glove. At times she experienced sharp pains. She consulted me on July 25, 1891, and the growth was diagnosed as an epithelioma, in its first stages, without lymphatic involvement. On August 26, the growth was removed under local anæsthesia with cocaine. The tendons on the back of the hand were not exposed during the operation and, unfortunately, the incision was carried rather near the growth. It healed rapidly but soon assumed a suspicious appearance, and another small growth developed in the center of the scar.

Dr. ERNEST LAPLACE saw it with me on September 20, and advised a second operation. On the twentieth of the same month, assisted by Dr. BUCKLAND, I removed the growth again under cocaine anæsthesia, but took especial pains to make my incision one-half inch beyond the supposed diseased area and dissected away all of the areolar tissue between the extensor tendons, and cauterized the bottom of the wound with nitric acid, introduced black silk sutures and dressed with aristol and iodoform. The

wound healed readily and little or no adhesion took place between the tendons and the skin. At this writing, three years later, there has not been the least indication of a return and I consider her cured. No secondary involvement is discoverable and the general health is very good. A close microscopical examination showed that the growth was a true epithelioma.

Here are two cases, both in their incipency,—one in a child and the other in an adult; both were of a malignant character; both were recognized early; were operated upon at once and were cured. There is never anything to be gained by waiting for growths to develop themselves, and it is rare that you are justified in cutting away one portion of a growth to determine its real character. There is often great danger in this from various points. It is possible that you may get a part of the growth which will not show the malignant elements; you may start up an active inflammation which would contra-indicate active operation in many cases; you will lose that much valuable time. When the removal of some internal organ such as the uterus is involved, such a course may be justifiable. All suspicious growths, independent of location, should receive immediate attention and be removed if practicable. Such cases as the ones detailed would rapidly assume a fatal type and infiltrate all surrounding tissues and lymphatics if not operated upon quite early.

ATLANTIC CITY, N. J.; N. Carolina and Pacific aves.

SEVENTH YEAR.

\$2.00 per year.

American Medico-Surgical Bulletin

A SEMI-MONTHLY JOURNAL OF PRACTICE AND SCIENCE.

Issued on the 1st and 15th of each month.

THE BULLETIN PUBLISHING COMPANY, 73 William Street, N. Y.

EDITORIAL STAFF.

WILLIAM HENRY PORTER, M.D.,

Chief Editor.

FREDERICK PETERSON, M.D.,

Associate Editor.

WILLIAM FANKHAUSER, M.D.,

Materia Medica and Therapeutics.

ADOLPH ZEH, M.D.,

Pathology and General Medicine.

WILLIAM C. GUTH, M.D.,

Pathology and General Medicine.

GEORGE G. VAN SCHAICK, M.D.,

Pathology and Clinical Medicine.

W. TRAVIS GIBB, M.D.,

Gynecology.

T. S. SOUTHWORTH, M.D.,

Pædiatrics.

WILLIAM OLIVER MOORE, M.D.,

Ophthalmology and Otolary.

ADOLPH BARON, M.D.,

Diseases of Children.

HENRY F. QUACKENBOS, M.D.,

General Medicine.

T. HALSTED MYERS, M.D.,

Orthopædic Surgery.

GEORGE THOMAS JACKSON, M.D.,

Dermatology.

WILLIAM R. COLEY, M.D.,

General Surgery.

JAMES E. NEWCOMB, M.D.,

Laryngology.

GEORGE K. SWINBURNE, M.D.,

Genito-Urinary Surgery.

SAMUEL LLOYD, M.D.,

Surgery.

I. RIDDLE GOFFE, M.D.,

Obstetrics, Gynecology, Pædiatrics.

HENRY T. BROOKS, M.D.,

Bacteriology.

JOHN WINTERS BRANNAN, M.D.,

Neurology and Psychiatry.

IRA VAN GIESON, M.D.,

Pathology of Nervous System.

LEWIS A. CONNER, M.D.,

Neurology.

ALBERT WARREN FERRIS, M.D.,

Neurology.

PEARCE BAILEY, M.D.,

Neurology.

MORTON R. PECK, M.D.,

Neurology.

LOUIS HEITZMANN, M.D.,

General Medicine and Pathology.

DANIEL R. HARDENBERGH, M.D.,

Obstetrics and Gynecology.

OTTO H. SCHULIZE, M.D.,

Obstetrics and Gynecology.

JOHN HOCH, M.D.,

General Medicine.

HOWELL T. PERSHING, M.D.,

Neurology.

THOMAS PECK PROUT, M.D.,

Psychiatry.

