

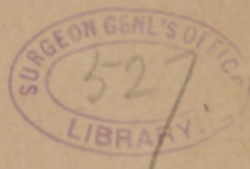Veasey (C. A.)

al

THE IMPORTANCE OF ACTIVE TREATMENT OF THE
NASO-PHARYNX,
IN THE
TREATMENT OF OBSTRUCTIVE DISEASE
OF THE
LACHRYMAL PASSAGES,

BY C. A. VEASEY, M. D.,

PHILADELPHIA, PA.



[Reprint from the OPTHALMIC RECORD March, 1895, Vol. IV, No. 2.]

UNIVERSITY PRESS, NASHVILLE, TENN.

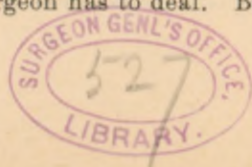
THE IMPORTANCE OF ACTIVE TREATMENT OF THE NASOPHARYNX IN THE TREATMENT OF OBSTRUCTIVE DISEASE OF THE LACHRYMAL PASSAGES.

By C. A. VEASEY, M.D.

Chief Clinical Assistant to the Ophthalmological Department of the Jefferson Medical College Hospital; Instructor in operative ophthalmology in the Philadelphia Polyclinic; Consulting Ophthalmic Surgeon to the Philadelphia Lying-In Charity Hospital and Nurse Training School.

That obstructive disease of the lachrymal passages are frequently caused by some intra-nasal lesion is generally conceded by the majority of ophthalmic surgeons. That, in a great many cases in which the intra-nasal affection, if there be such, is not the cause of the disease of the lachrymal passages, it is a potent factor in keeping up the inflammation in them, and in preventing the successful treatment, if such be directed against the lachrymal passages alone, is also generally understood. So it would seem almost superfluous for the author to add to the already large accumulation of literature on this subject were it not for the fact that he has in the past few years had the opportunity of treating a number of such cases of obstructive lachrymal disease where there were associated intra-nasal lesions, and in which, before coming under his observation, unsuccessful attempts had been made to cure the former without any attention to the latter, and in which as soon as the proper intra-nasal treatment was instituted the lachrymal affection was rapidly cured.

It is not claimed that all cases of obstructive disease of the lachrymal ducts are due to some trouble within the nose, nor that all cases can be rapidly cured; for, as is well-known, they are among the most difficult, and sometimes the most tedious, cases with which the ophthalmic surgeon has to deal. But it is



claimed that in a great many cases the cause is primarily within the nose, and that the treatment of the ducts alone in these cases will prove ineffectual; and, that when the origin of the trouble is not within the nose, nevertheless there being some co-existing intra-nasal disease, the most prompt and permanent eradication of the disease of the lachrymal passages that can be obtained, can be effected by directing treatment against the intra-nasal condition as well as against the disease of the passages themselves.

In the treatment of any disease of the lachrymal duct it is of course necessary, in addition to the treatment of the duct itself, to make a thorough examination of the nares and nasopharynx and if any disease be found to direct the treatment against it as well as against the former lesion. In many cases in which there is only a slight inflammation of the mucous membrane, having extended, perhaps, into the lower portion of the nasal duct, all that will be required is the spraying of the parts once or twice daily with a mild alkaline and astringent solution. The following will be found very useful, and can be employed by the patient at home with the use of a bulb-atomizer:

R

Acidi Borici,
Sodii Boratis,
Sodii Bicarbonat, $\overline{\text{aa}}$ grs. xii.
Glycerinæ ʒ ii.
Aquæ Destillatæ q. s. ʒ iii.

M. Use in Atomizer.

Should the mucous membrane be more severely inflamed and swollen, the treatment must be somewhat more elaborate. After cleaning the nares with the alkaline solution the author employs a spray of antipyrin (grs. xx— $\overline{3}$ i), preceding it with a spray of cocaine (3% solution) if necessary, which causes an immediate contraction of the swollen membrane, lasting for a

variable period, and then applies with a bit of absorbent cotton wrapped on a probe, or applicator, either the compound tincture of benzoin or the following, which is formula of Sajous:

R

Iodinii, $\bar{3}$ ss.

Acidi Tannici, $\bar{3}$ ss.

Aquæ, O ss.

Mix, filter and evaporate to $\bar{3}$ ii, and add

Glycerinæ, $\bar{3}$ iv.

Acidi Carbol. liq. ℥ ii.

Immediately afterward a spray of some bland oil, like albolene, to which has been added menthol (grs. x-xx to $\bar{3}$ i), will complete the nasal treatment, and give a most refreshing sensation to the patient.

Should there be any bony spurs, or polypi, or chronic hypertrophies, or any such severe lesion, and to these the appended list of cases more particularly refers, the patient should be referred to the rhinologist for the proper surgical interference. By attention to these intra-nasal affections it is frequently possible to cure a case of obstructive lachrymal disease in half the time it would take were they not attended to, and relapses are not nearly so frequent.

The following are a few of the cases that will serve to illustrate the points above referred to:

CASE I.—*Purulent dacryo-cystitis; hypertrophy of right lower turbinated bone.*—F. E., aged twenty-eight, consulted me, for lachrymal obstruction saying that for the past eight years he had been able at times to express some purulent material from the right lower canaliculus, and that the tears flowed over the right cheek almost constantly. Four years ago his canaliculus was opened and probes passed, but the obstruction, though being better for the time, always returned. His nares were examined, and the left side found to be normal; but the right lower turbinated bone was considerably enlarged causing some pressure on the swollen mucous membrane near the orifice of the duct. The hypertrophy was removed, the inflamed mucous membrane treated with sooth-

ing applications, probes were passed into the duct, and the latter washed out, daily at first, then less frequently, with antiseptic and astringent solutions, and in a few weeks the trouble entirely disappeared. Although one and a half years have elapsed, the patient reports that he has never had any return of the disease.

CASE II.—*Purulent dacryo-cystitis; hypertrophy of inferior turbinated bone on both sides with a spur of the septum on the right.*—A. S., age forty-four, married, presented herself for the treatment of obstructive inflammation of both lachrymal ducts characterized by a profuse discharge of pus from both upper and lower punctæ lachrymæ of each eye, with almost constant epiphora, these symptoms having been present for several years. Both lower canaliculi had been opened about two years before and the ducts washed, but the patient claimed that no fluids had ever passed into the nose. An attempt was made to pass probes, but it was impossible to get one through the duct on the right side, though with considerable difficulty one was introduced into the left duct, and fluid passed through into the nose.

An examination of the nares revealed a very much enlarged inferior turbinate on each side, and in addition a large spur of the septum on the right pressing on the hypertrophied turbinate. The hypertrophies and the spur were removed, the nares treated, and in a short time a probe was passed on the right side. The ducts were then treated in the usual manner with antiseptic and astringent washes and soon the purulent discharge and epiphora entirely ceased. The patient informed me by letter a few days since that there had been no relapse.

CASE III.—*Catarrhal dacryo-cystitis; hypertrophic rhinitis with deviation of the septum to the left.*—I. W., age forty-six, married woman, consulted me for a small abscess of lower lid of right eye. During the examination it was seen that the left lower canaliculus had been opened, and that considerable mucoïd discharge could still be expressed by pressure over the left lachrymal sac. Patient stated she had been treated three different times but had obtained only temporary relief. The intra-nasal examination showed a marked hypertrophic rhinitis on both sides, probably made much worse by a deviation of the septum towards the left. This condition was remedied by operation, and afterwards the duct was treated, the result being that the patient was cured of a chronic affection and has had no relapse seven months later.

CASE IV.—*Epiphora; polypus; hypertrophy of right inferior turbinate.*—C. H., aged thirty-eight, male, came to the eye dispensary of the Jefferson Medical College Hospital, service of Dr. de Schweinitz, for the treat-

ment of an extensive swelling of the lower lid and cheek of the right side of two days duration. Nothing could be expressed from the canaliculus but the parts were exceedingly painful, and there was marked epiphora which the patient said had existed for several months. Vision and accommodation were good. He was given Basham's mixture, told to employ hot compresses at frequent intervals, and sent to the throat department for the nasal examination. There was found a polypus with hypertrophy of the lower turbinate, both on the right side. The polypus was removed at once. In three days the inflammatory condition of the lid and face had subsided, and canaliculus was opened, probes passed and the duct washed out, the fluids readily passing into the nose. The mucous membrane of the duct was somewhat swollen but there were no strictures. In about ten days, however, the patient had a relapse, his lid and face being in as bad a condition as before. At this time the hypertrophy of the turbinate was removed and the duct treated as before. The patient is still being seen once a month but there has been no return of the swelling, and the epiphora has disappeared.

CASE V.—*Lachrymal abscess; syphilitic ulceration of septum; marks of former ulceration in pharynx.*—M. S., aged thirty-two, unmarried male, was sent to me for treatment of lachrymal abscess on right side of face. There were numerous scars on both sides over the region of the lachrymal sac, and the patient said he had had abscesses of the same kind, four times within the two years previous. Admitted contracting syphilis four years ago. The abscess was opened over the sac and treated with hot antiseptic compresses, and antiseptic irrigations, and he was given internally Basham's mixture. As soon as the acute inflammation had subsided the canaliculi were opened on both sides, there being some discharge from the left, with epiphora, probes were passed, and the nasal examination made when it was found that there was a large sharp cut ulcer which had eaten through the septum. There was chronic hypertropic rhinitis and the pharynx was also chronically inflamed, there being numerous scars indicating old ulcerations. He was placed on anti-syphilitic treatment, the nasal ducts and the nares were properly treated, and there has been no return of the disease except once, at which time he had neglected the internal medication for some weeks before. Upon resuming the remedies the relapse disappeared.

Many other cases could be added to the above, but these seem sufficient to emphasize the following points :

1. In beginning the treatment of any case of obstructive disease of the lachrymal passages, in addition to the passing of probes and the cleansing of the duct with solutions, it is essential that a thorough examination of the nares be made.

2. If a simple inflammation of the nares be found it should be treated by means of appropriate simple methods at the same time that the lachrymal duct is being treated from above.

3. If any more serious complications be observed such as require operative interference, this interference should be undertaken at once, as the disease of the lachrymal duct will get well much more quickly if this be done.

4. It should not be forgotten that many cases, to a very great extent, are due to constitutional disturbance, and that in such cases the proper internal remedies must be administered during the local treatment of the obstructive disease.

1720 ARCH STREET.



