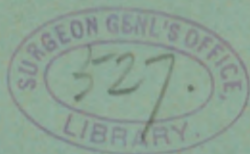


JAY (F. W.)

CYSTS OF THE MAXILLA CONNECTED WITH  
THE TEETH, WITH REPORT OF A CASE.

BY

FRANK W. JAY, M.D.,  
OF CHICAGO, ILL.



FROM

THE MEDICAL NEWS,

April 6, 1895.



*CYSTS OF THE MAXILLA CONNECTED WITH  
THE TEETH, WITH REPORT OF A CASE.*

BY FRANK W. JAY, M.D.,  
OF CHICAGO, ILL.

CYSTS of the maxilla, resulting from the proliferation in the substance of the bone of the epithelial cells composing a tooth-matrix which has not made its way to its normal situation in the alveolar process, but which has remained imbedded in the bone, are not a strange pathologic condition to the surgeon or the pathologist. Cyst-formation resulting from the displaced matrix of a tooth is of scientific interest because of its bearing upon Cohnheim's theory of tumor formation by cell-proliferation from a matrix of embryonal cells. In the case of a dentigerous cyst there is an inclusion in the mesoblastic bone of the epithelial cells of the tooth-matrix, which cells at some subsequent period undergo proliferation that may be typical or atypical, and become productive of a neoplasm that in almost every instance is a cyst. In the production of a dentigerous cyst, however, there is no necessity for the presence of the matrix of embryonal cells insisted upon by Cohnheim as being essential in the production of a true tumor. The cells composing the matrix may be typical in every respect, and are productive of a cyst because they are compelled to carry out



their life-history in an abnormal situation, with retention of fluid in the cavity produced during the attempt at tooth-formation. There is no progressive and atypical growth of the epithelial structure characteristic of a true cystoma. This variety must be classified as retention-cysts, but they differ materially from what are at the present time described as retention-cysts, *e. g.*, in which there is occlusion of the outlet of some otherwise normal secreting structure, with consequent retention, the most frequently met examples of which are the sebaceous cysts or wens. The retention-cysts due to inclusion of epithelial cells in the mesoblast should be called *retention-cysts from inclusion*, in contradistinction to the retention-cysts from occlusion.

Another variety of dentigerous cysts that must be differentiated pathologically from the retention-cysts just described is produced when the epithelial cells composing the imbedded tooth-matrix serve as a true tumor-matrix, and by exhibiting an atypical and lawless proliferation, perhaps without the slightest evidence of tooth-formation, become productive of a true proliferating cystoma, with the formation of numerous cyst-cavities. In the simple variety, *i. e.*, the retention-cyst, from an included tooth-matrix the progressive enlargement is due to tension, as the contents of the cyst increase, and, while there is the same influence of tension exerted in the true cystoma, there is what is more important and characteristic, *i. e.*, the increase in the epithelial neoplasm as the result of the unlimited cell-proliferation.

We therefore divide cysts of the maxilla result-

ing from displaced tooth-matrices into the following two varieties :

*Unilocular dentigerous cysts*, resulting from the matrix of a temporary or permanent tooth failing to find its way to the alveolar border of the jaw, and the cells of which matrix have subsequently undertaken the completion of their inherited capacity, viz., the formation of a perfect tooth, with the various pathologic conditions possible to result from even a typical cell-proliferation in this abnormal situation. Such a cyst is not necessarily a true tumor, but may be simply "a retention of fluid between the cuticular dentis and the crown of the tooth, distending the tooth-follicle into a cyst lined with epithelium, and containing in some part of its wall, or, more rarely, free in its cavity, a more or less completely developed tooth, or even teeth." (Hektoen.)

This variety is the cogener of a cyst resulting from retention of a Graafian follicle in the stroma of the ovary, with accumulation of fluid in the cavity by transudation and mucous degeneration of the epithelial cells lining the cyst-cavity, and which has an entirely different pathology from a multilocular or proliferating cystoma of the ovary, which also arises from the retention of a Graafian follicle, but which is an allied condition to the *second variety*, e. g., the *multilocular or proliferous dentigerous cysts*, which the imbedded epithelial cells constitute a true tumor-matrix, and by exhibiting unlimited proliferating capacity, give rise to a constant and progressive extension of the epithelial neoplasm in the substance of the jaw. This variety must be con-

sidered as a true cystoma. We have not included in this classification of dentigerous cysts those found in connection with the roots of the erupted teeth. According to Magitot, they are due to inflammatory processes, with retention of the product of such inflammation in the apical cavity.

Dentigerous cysts may, of course, become carcinomatous, as may an epithelial structure in any locality.

There are interesting points in the pathology of cysts resulting from the inclusion of epithelial cells in the mesoblast that will call for solution in the future. The simple dermoids and branchial cysts have as interesting a relation to Cohnheim's theory of tumor-formation as have the dentigerous cysts and the cysts of the ovary. We may well ask, for instance, which of the branchial cysts to call tumors and which simply retention-cysts. To be sure, the epithelial cells are displaced in every case; but being where they are they show no atypical tendencies when they exhibit a lawful proliferation and continue to line the cyst-cavity as its size increases from distention. As the lumen of a varicose vein increases, the endothelial cells still continue to cover its interior; it takes an increased number to do so, and new endothelial cells are produced, but this does not allow the pathologist to classify the new endothelial cells as a variety of endothelioma. At the present stage of our knowledge concerning the etiology of tumor-formation, these differences strike one as very theoretic, but the histology of the future will demonstrate them to be real.

The clinical differences are well drawn between

the retention-cysts from inclusion and the true proliferating cystomata. As an example, we may call attention to a branchial fistula, perhaps congenitally established. Here there is no retention, and consequently no development of a cyst, and if the fistula does not become occluded there will be no swelling unless infection occurs, because the proliferation of the epithelial cells lining the fistula does not give rise to a new-growth. This cannot be considered characteristic of a tumor. In the retention-cyst from inclusion the contents of the cyst do not represent the products of cell-proliferation. The fluid accumulates from transudation and perhaps secretion by the lining of the cyst; this is not characteristic of a true tumor.<sup>1</sup>

The case I desire to report is interesting and instructive from the fact that the cyst was the result of an imbedded supernumerary tooth-matrix, and the cyst-cavity was a considerable distance from the alveolar border of the jaw. In consequence of these conditions, the case illustrates some important facts regarding the diagnosis of the rarest form of cysts of the maxilla connected with the teeth, viz., dentigerous cysts arising from a displaced supernumerary tooth-matrix.

When the imbedded matrix is that of a permanent tooth eruption does not take place, and the examin-

---

<sup>1</sup> The etiology, pathology, and treatment of cysts of the maxilla connected with the teeth are thoroughly treated in the chapter in Holmes' "System of Surgery," devoted to *surgical diseases connected with the teeth*, which was written originally by S. James A. Salter, F.R.S. A paper containing a *résumé* of the literature was published by Hektoen in the Annual Report of Cook County Hospital of Chicago for the year ending 1890.

ation will show an absence of the tooth from its normal situation in the alveolar process, and the history will reveal to the surgeon that this tooth never made its appearance. A dentigerous cyst arising from the imbedded matrix of a temporary tooth will have the history of absence of a deciduous tooth and subsequent interference with the passage of the corresponding permanent tooth in its journey to the alveolar process of the jaw. Consequently the absence of a tooth from its normal location in the alveolar process is the guide-post pointing to the diagnosis of a dentigerous cyst. It is evident that this history and sign are absent when the imbedded matrix is that of a supernumerary tooth. The degree of displacement of the matrix and the location of the resulting cyst will have some influence on the diagnosis, especially when the teeth are normal in number. In the case here reported the cyst-cavity was situated in the palatine process of the superior maxilla, and had no apparent connection with the teeth. In such a condition the diagnosis will be difficult, and probably a simple conjecture. Cases have been reported in which the cyst was situated in the palate bone, and even in the orbit.

The imbedding and displacement of a tooth-matrix are due to one or more of the following causes: a perfect tooth may be prevented from reaching the alveolus by the retention of a temporary tooth; the tooth may develop too deeply in the bone; it may grow in a wrong direction; the development of the fang may become arrested, or there may be some diminution in the size of the space in the alveolar border. (Salter.)

A proper diagnosis is of considerable importance, as is illustrated by the numerous cases that have been subjected to resection of the affected bone under a diagnosis of sarcoma, and in fact, if the case is allowed to progress, especially in the proliferating cystomata, this treatment may be called for even under a correct diagnosis. If a simple dentigerous cyst opens externally through pressure atrophy exerted upon the surrounding bone, the relief of tension will put an end to the progressive enlargement of the bone. In the proliferating cystomata this is not the case, and progressive extension of the disease will still go on, unless the suppurative process has destroyed the entire tumor-matrix. In either variety we have the relief of tension and the addition of an infection with pus-microbes. In the simple unilocular variety the pathologic condition now consists of an infected cavity of the maxilla, which may or may not contain an infected, more or less perfectly developed tooth, and a sinus that remains open and discharging, or that closes and opens at varying intervals.

The case reported was one of a simple dentigerous cyst in the condition described, and in such cases a proper diagnosis is not required to lead the surgeon to institute the proper treatment, viz.: opening the cavity in the bone, removing the infected unabsorbable body, disinfecting the bone-cavity and treating it in one of the several ways, viz.: by packing with gauze, and allowing it to heal by granulation; or by endeavoring to secure a rapid definite healing; by packing with Senn's decalcified bone chips; or by allowing it to fill by Schede's blood-clot.

The difficulty of preventing post-operative wound-infection in the cavity of the mouth will make the packing of the cavity with gauze the only practical method to adopt.

The history and examination of the case revealed the following : The patient is a healthy farmer, aged forty-six years. Upon examination a sinus is found just to the right of the median line, at the reflection of the mucous membrane from the jaw to the upper lip, leading directly backward for an inch into a cavity situated in the palatine process of the superior maxilla and between the roof of the mouth and the floor of the right nasal fossa. An examination in these localities demonstrates convexities that correspond to the location of the cavity found in the bone with the probe. There is no enlargement on the anterior surface of the jaw, nor can craquement be elicited over the cavity. Discharge of pus is constant but slight. Injection of hydrogen dioxid into the sinus demonstrates the absence of any other opening into the cavity in the bone. The man's teeth are normal in number, location, and appearance, and are only remarkable for their perfection. The sinus is an inch and a-half directly above the first right incisor. The patient remembers that the eruption of his permanent teeth was devoid of abnormality, and his parents say that his milk-teeth made their appearance and gave way to the permanent teeth in an apparently normal manner. His permanent incisors appeared at seven years of age, and the other teeth appeared without incident. On August 18, 1867, he received a severe blow on the upper jaw, and to which he attributed an enlargement of the bone on the roof of the mouth that he discovered in 1870, and that corresponded to the swelling now present, and that has, according to the patient's state-

ment, remained without change in size since he first discovered it. The increase in size probably has been so gradual that it has not been apparent to him. I cannot imagine the sudden discovery of a swelling of the size found in the roof of the mouth at the present time.

In 1873, without any history of pain or discomfort, fluctuating swelling made its appearance beneath the mucous membrane covering the anterior surface of the upper jaw; the center of this swelling was a little below the situation of the present sinus. This swelling was incised by a physician, and the patient says a thimbleful of black, clotted blood escaped. The incision healed in a few days, and attention was not even attracted to this locality until 1881, when there was a recurrence of a similar fluctuating swelling that made its appearance in the same locality and in the same painless manner as in 1875. This was incised, healed in a few days, and there was no recurrence till 1884, when the same treatment was gone through, and this same cycle of painless swelling, incision, discharge of dark fluid, with subsequent rapid healing, was repeated a number of times between 1884 and 1892, the intervals gradually lessening. In 1892 the swelling was for the first time painful, and upon incision pus was evacuated. The physician in attendance made a larger incision than had been made at any other time and packed the cavity beneath the mucous membrane with gauze, but did not at that time express the opinion that there was a lesion of the bone. Since then the sinus has remained open and discharging, and the affection has been painless.

A diagnosis was not made further than to conclude that there was an infected cavity in the bone which should be opened, disinfected, and drained. An operation was, therefore, advised. Under ether

the anterior wall of the cavity was chiseled away, making an opening the size of a nickel five-cent piece. This cavity was the size of a hickory-nut, and the walls, which consisted of porous bone, were thoroughly curetted. During the curetting an imperfectly formed tooth of the size of a grain of corn was removed, which gave the appearance of the crown of an incisor covered on all but one of its surfaces with a slightly discolored dentine that was eroded in spots. The tooth was fixed in the wall of the cavity, but upon what aspect was not determined. The finding of this tooth made the diagnosis. However, it must be remarked that while the presence of a tooth in any stage of development in a cavity in the maxilla makes a diagnosis of some variety of dentigerous cyst imperative, the converse is not the case, for there may be the production of a most progressive cystoma from a tooth-matrix without the slightest exhibition of tooth-formation. In such a case the microscopic examination of the lining of the cavity would demonstrate the presence of epithelial cells, unless, as before mentioned, the cyst-cavity had become infected with pus microbes, and the epithelial structure had been destroyed by their action.

The cavity was packed with iodoform-gauze and healed rapidly. It was situated in the palatine process of the superior maxilla, and its size was compensated for by the convex projections found in the roof of the mouth and the floor of the right nasal fossa. The cavity was evidently produced by the interosseous tension resulting from the cyst-formation, and producing a bulging of the bone in the direction of least resistance.



*The Medical News.*

*Established in 1843.*

A WEEKLY MEDICAL NEWSPAPER.

*Subscription, \$4.00 per Annum.*

---

---

*The American Journal*  
OF THE  
*Medical Sciences.*

*Established in 1820.*

A MONTHLY MEDICAL MAGAZINE.

*Subscription, \$4.00 per Annum.*

---

---

COMMUTATION RATE, \$7.50 PER ANNUM.

LEA BROTHERS & CO.  
PHILADELPHIA.