

TIFFANY (L. McL.)

REPRINTED FROM

ANNALS OF SURGERY

A MONTHLY REVIEW OF SURGICAL SCIENCE AND PRACTICE

EDITED BY

L. S. FICHER, A.M., M.D., WILLIAM WHITE, M.D., FREDERICK TREVES, F.R.C.S., WILLIAM MACEWEN, M.D.

TABLE OF CONTENTS.

ORIGINAL MEMOIRS... TRANSACTIONS OF THE NEW YORK SURGICAL SOCIETY... INDEX... APPENDICES

UNIVERSITY OF PENNSYLVANIA PRESS, PHILADELPHIA, PA.


Great Britain: Cassell and Company, London.

Bound in Year in Advance... Single Copies, Two Shillings

MAY, 1895

REPORT OF ADDITIONAL CASES OF INTRACRANIAL NEURECTOMY.

By LOUIS McLANE TIFFANY, M.D., OF BALTIMORE, Professor of Surgery, University of Maryland.



REPORT OF ADDITIONAL CASES OF INTRA-
CRANIAL NEURECTOMY.

By LOUIS McLANE TIFFANY, M.D.,

OF BALTIMORE,

PROFESSOR OF SURGERY, UNIVERSITY OF MARYLAND.

IT was my fortune to be able to report four cases of intracranial neurectomy in the ANNALS OF SURGERY, January, 1894. Since that time I have operated upon three cases. The method pursued in the last three cases is essentially that mentioned in the article stated; and I have numbered them in sequence with those already reported. The sum total is seven cases, all recovering from the operation, and all with no recurrence of pain up to the present time, so far as I can learn.

The diagrams which accompany the cases now reported are of the same size as those reported a year ago, in order that comparison may be the more easily made. It is not possible at the present time to speak *ex cathedra* as to the expediency of the operation in question, or the probable outcome thereof,—the results are not at all similar, and sufficient time has not elapsed to show the ultimate result.

CASE V.—E. M., white, male, aged seventy-six years, a farmer, suffered from neuralgia in an area corresponding to the distribution of the second division of the left trigeminal nerve. In June, 1890, the left infra-orbital nerve was divided where it appears upon the face. Eighteen months of relief followed, and then gradually pain returned; now it is extremely severe and almost constant. Neither the first nor third divisions are affected. Morphia in large doses gives relief, but no other drug.

Operation March 22, 1894. Anæsthesia was induced by chloroform. I opened the head and removed the second division of the



left fifth nerve from the foramen rotundum to the Gasserian ganglion, which latter was exposed and carefully left intact. Oozing of blood from the upper part of the wound required gauze pressure, which was removed on the second day and the incision closed. All went well and the patient left hospital April 17, 1894.

Pain ceased from the time of operation. Anæsthesia exists over the upper lip, skin, and mucous surface, incompletely of nostril, skin, and mucous surface. The skin from the infra-orbital foramen to the angle of the mouth is anæsthetic. The mucous membrane lining the left cheek has diminished sensibility, but not entire abolition of the same. No loss of taste; thermic sense normal.



FIG. 1.—Showing areas of anæsthesia in Case V.

CASE VI.—L. M., white, widow, aged sixty-nine, years, the mother of several children, gave the following history:

Twelve years ago, without premonition, she experienced an acute sudden pain in the face over the right upper jaw, which lasted but a moment. She thought she had received a blow. No swelling, no discoloration of the skin, or other evidence of traumatism appeared. Several months later a similar pain was felt. In the course of the following year the paroxysms of pain became longer and more intense, the intervening periods of time more and more short, until the patient

was reduced to a condition of almost constant suffering. A paroxysm was induced by talking, swallowing, pressing the tongue to the roof of the mouth, etc.

Before coming into my hands nitro-glycerin, quinine, gelsemium, aconitia, salicylate of soda, and other drugs had been used without permanent relief; morphine was being taken in doses sufficient to abate pain; the patient, being aware of the unhappy results consequent upon the opium habit, had recourse to the drug as sparingly as possible.

Surgical relief had been sought. The upper jaw nerve (right) was divided below the orbit in September, 1889, and electricity used; ten months of relief from pain followed. In September, 1891, the lower jaw nerve (right) was divided, judging from the scar behind the upper part of the ramus; saliva is said to have flowed from the wound during several weeks. Relief from pain for sixteen months was obtained by this second operation.

The patient came under my care May 2, 1894. There was present the excruciating pain usual in cases of advanced trigeminal neuralgia; the territory affected was that supplied by the second and third branches of the fifth nerve (right). The tongue was not involved, but the act of swallowing was agonizing; talking induced a paroxysm, as did handling of the area mentioned; the patient had lost much flesh, yet no cause was found for the same except the voluntary starvation undergone by the patient as preferable to the pain induced by deglutition. The teeth in both upper and lower jaws (right side) had been extracted hoping to afford relief from suffering,—needlessly, it is scarcely necessary to add.

There seemed to be no reason for delay, so after a week of preparatory treatment (May 9, 1894) I operated. Anæsthesia was induced by chloroform. I again found that opening the dura allowed a free escape of cerebro-spinal fluid and permitted exposure of the organs sought. The intracranial portions of the second and third branches of the fifth nerve were removed together with the lower portion of the Gasserian ganglion, all in one piece. The upper portion of the ganglion was not touched.

The patient went to operation with pulse 84, respiration 24; left the operating table with pulse 100, respiration 28; during the evening the pulse remained 100, respiration falling to 24. All went well. Dressings were changed for the first time on the tenth day, the wound then was firmly healed and dry; stitches were

removed and a little absorbent cotton placed over the seat of operation to avoid a possible shock from blow, etc. The patient went home June 7.

Pain ceased from the moment of operation; swallowing, handling, etc., were absolutely painless; the patient gained flesh and spirits. The area of cutaneous anæsthesia is shown in the figure, which can with advantage be compared with those in the article alluded to. It is much larger than in any case yet coming under my observation, and may be due to a division of nerves passing on to the face from the neck, which had been severed by the incision made for



FIG. 2.—Showing area of anæsthesia in Case VI.

the purpose of exposing and cutting the lower jaw nerve. Just within the area of anæsthesia, along a line marked by crosses, cold was recognized as cold, while heat was recognized not as heat but as motion; the patient always said not “you are touching me with something warm,” but “you are scratching me.”

The mucous membrane of lips, cheek, soft palate, and upper pharynx (right side) was anæsthetic. The surface of the tongue as far back as the foramen cæcum was anæsthetic, perhaps farther, but of this I am uncertain. Taste on the tongue held outside the lips was

abolished; taste within the mouth seemed normal, the substance to be tasted being diffused, of course.

The right anterior half of the occipito-frontalis was paralyzed, also the corresponding corrugator supercilii.

The muscles of mastication supplied by the divided branches of the fifth were paralyzed.

CASE VII.—S. S., white, male, aged sixty-three years, married, several children, entered hospital December 11, 1894.

In 1890 he suffered from right facial neuralgia, and the infra-orbital nerve was excised. The relief which followed lasted nearly one year, when recurrence took place. At the present time pain very severe is felt in the right temporo-maxillary region, paroxysmal in character. The spot of greatest intensity is over the zygoma one inch in front of the ear, thence the pain radiates over the head, etc., but does not involve the territory tributary to the first division of the fifth nerve. The paroxysms vary in length from a few minutes to half an hour. Talking, swallowing, and handling the face induce pain, but changes of weather do not. All teeth on the right side, upper and lower jaws, have been extracted in the expectation of obtaining relief from pain. The patient had undergone treatment by drugs, so after a week of preparatory treatment, December 19, 1894, I resected the second and third divisions of the fifth nerve, together with the adjacent portion of the Gasserian ganglion. Anæsthesia was induced by chloroform.

The bone was chiselled through, and, not giving as much room as was desired, rongeur forceps were used and the opening made larger. The bone was not replaced. The dura was opened, cerebro-spinal fluid evacuated, the dura and brain raised, and the operation completed. The middle meningeal artery was not interfered with, nor was it in the way. To raise the dura from the bone I used a piece of absorbent cotton (sterile) held in bullet-forceps and wrapped around the ends of the forceps. I had less trouble than ever before, the cotton diminishing oozing as the separation occurred. Much venous blood came from the inner surface of the skull above the opening, I having torn a vessel passing between dura and diploë. I pressed into the cranium enough gauze to stop the bleeding, and closed the wound in the anterior half. A voluminous dressing was then applied. The patient came from the operation-table with good pulse and respiration. Thirty-six hours later I removed the gauze packing, and closed the wound by suture, save at the lower posterior angle, where I placed a

small shred of gauze. Two days later, December 22, the patient's temperature rose from normal in the morning to 103.4° F. at 2 P.M., and from this time until January 5 the temperature fluctuated from normal to 102° F., the pulse and respiration remaining normal. There was some pain in the head, and two or three times bleeding from the nose. High temperature with normal pulse and respiration suggests the administration of an antiperiodic, so the patient was given quin. sulph. gr. five every four hours, beginning December 23, and continuing until December 28 without result. Until January 4 no quinine. Commencing January 4, Warburg's tincture was given

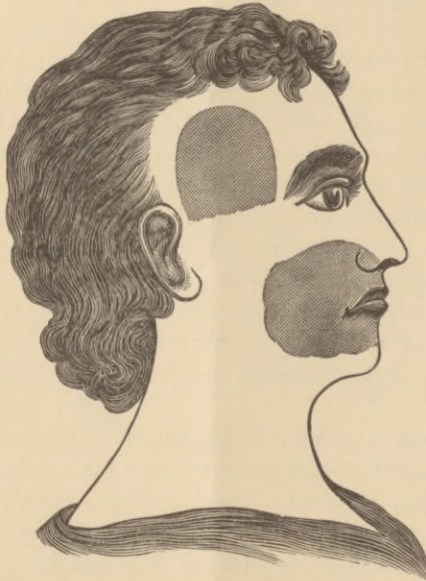


FIG. 3.—Showing areas of anæsthesia in Case VII.

in drachm doses every four hours, and there was no subsequent rise of temperature above normal. December 31, all stitches were removed, the wound being healed, and January 14 the patient returned home.

The area of cutaneous anæsthesia is shown in the diagram. The right half of the tongue and palate and inside of cheek are anæsthetic, the right side of forehead cannot be thrown into wrinkles, the right muscles of mastication supplied by the fifth are paralyzed, taste on the tongue held outside the mouth is not lost, the difference between heat and cold is not recognized upon the face and tongue in the anæsthetic area.

Comparing my seven cases, it would appear as if the middle meningeal artery is divided only when it passes through a foramen or very deep groove in the parietal bone ; it does not appear to be in the way or to interfere with access to the foramen ovale, notwithstanding the fact that Taylor's measurements may suggest such a condition of affairs. In no case have I found it in the way at its entrance to the skull, although running as a pulsating tube in the dura from the foramen spinosum. The opening of the dura and evacuation of cerebro-spinal fluid is a procedure followed by very great benefit ; the later steps of the operation become vastly more easy. It is to be noted that many operators have torn accidentally the dura, and so given exit to cerebro-spinal fluid by accident ; should this not have occurred, it is unquestionably right that the dura should be cut, and cerebro-spinal fluid allowed to escape. In my last four cases this I have done, and have not taken the trouble to sew up the dura afterwards, considering that the minute hole would take care of itself,—as has been the case.

The anæsthetic agent in all my cases has been chloroform ; the age of the patients, but, especially, the desire to avoid congestion of the face and head, so often seen with ether, has induced me to choose this anæsthetic.

In looking at the diagrams it will be seen that the face anæsthesia varies greatly, it not being so extensive as to cover the territory supplied by the fifth nerve,—its divided divisions. This is probably due to the presence of sensory nerves, which pass from the neck to the face. This is particularly noticeable in Case VI. The persistence of the anæsthesia is, of course, to be considered. This probably diminishes, both in extent and intensity, although I am not at present prepared to give the exact statistics in regard to my patients. I propose later to publish more accurate diagrams in regard to this.

Distinct from the anæsthesia, however, is to be considered the pain, because face anæsthesia and pain do not necessarily go together. In a certain number of cases, there is, I believe, no doubt about the fact that face sensation may remain or be present soon after the division of the nerve, yet pain be abso-

lutely wanting. One of Keen's cases shows this, and Dandridge's case shows it also. In a case of upper jaw neuralgia in which I did Carnochan's operation eleven years ago, in October, 1894, there is absolutely no pain, yet perfect face sensation. In no case have trophic changes been noted in the area of the fifth nerve after operation, the supraorbital region being in no wise different from the skin of the face, save what was normal, and in one of my cases, No. 3, the skin, from being harsh, returned to a healthy condition.

Taste deserves mention. Of the five cases in which the second and third divisions and adjacent ganglion were removed, three show persistence of taste, two absence of taste. Taste was tried with sugar and salt. In three of the same five cases the patients could recognize the difference between heat and cold in the anæsthetic area. In two cases the thermic sense appeared to be absent. Of the cases in which the thermic sense was wanting, one retained taste, the other did not. The temperature in Case VII was extremely erratic, without corresponding elevation of pulse or respiration,—was it due to trauma of a heat centre? Of my seven cases, in two the second division only was severed. Their progress will be watched with interest, and compared with the other five in whom a portion of the ganglion was removed, as it may offer a means of arriving at a knowledge as to whether the ganglion is in fault or not. It is to be remembered that Carnochan laid great stress in his operation upon the removal of Meckel's ganglion, considering that the *fons et origo* of neuralgia. It remains to be seen whether the Gasserian ganglion deserves to be elevated into a similar position or whether it may be neglected. In intracranial neurectomy for neuralgia I am inclined to the opinion that its removal is expedient. The length of time during which absence of pain is to be expected—in other words, whether the operation is curative or not—remains to be found out. My first case was operated upon twenty-nine months ago; it remains absolutely well. The second case of which I have information, No. 3, was operated upon nineteen months ago; she remains well; and so with subsequent ones down to my last, in December, 1894.

In regard to the preservation of the motor root of the third division, I thought that I recognized it in one case quite certainly, as published in the article referred to, but I have not tried to save it since, thinking that no special advantage would be gained thereby.

It is proper to mention that there has come to my knowledge a case operated upon successfully, the patient recovering and the neuralgia not recurring. Two other cases have come to my knowledge in which the operation has been followed by death. And two cases have come to my knowledge in which, while the patients recovered from the operation, recurrence of the neuralgia has taken place. These cases doubtless will be reported, and it is not necessary that I should speak more fully of them now.

The microscopic appearances presented by the removed portions of ganglion and nerves will form the subject of another communication, the pathologist to whom they were submitted not yet being prepared to report.

