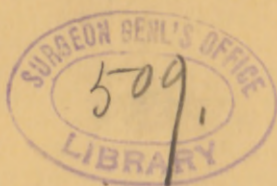


KING (E.H.)

An unusual accident
after Celiotomy.



[Reprinted from THE MEDICAL NEWS, April 14, 1894.]

AN UNUSUAL ACCIDENT AFTER CELIOTOMY.

BY E. H. KING, M.D.,
OF MUSCATINE, IOWA.

In a celiotomy performed during the past year, the abdominal stitches—silkworm-gut—were removed on the eighth day, primary adhesion of the wound having occurred without suppuration. There had been persistent ether-nausea from the time of the operation. No opiates had been used. The bowels had been freely opened on the third day by enemata and salines. There was no distention of the abdomen and but slightly elevated temperature.

On the evening of the ninth day violent nausea, retching, and straining occurred, when two-thirds of the extent—about three inches—of the wound were torn open, allowing a part of the colon and omentum and a mass of small intestines to escape. I found the patient in extreme mental and physical shock. The protruding viscera were covered and protected by a towel wrung out of hot water until an assistant could be obtained, when they were returned within the abdomen and the peritoneum secured by fine catgut, and the parietal tissues with silkworm-gut sutures, all without anesthesia. Drainage was provided for by a small roll of iodoform-gauze. At the conclusion of the operation the patient's pulse was too weak and rapid to be counted; she was in great pain, and very restless. Free use of morphin, atropin, and strychnin was made, and enemata of hot beef-juice and whiskey were given. This was kept up at regular intervals for forty-eight hours, without any perceptible



effect save to relieve pain, nausea, and restlessness; but after this the pulse began to increase in volume and decrease in frequency. The peritoneum united primarily and the parietal tissues secondarily, with but slight and superficial suppuration. The patient made a slow but good recovery. There is at present a small linear cicatrix, with no tendency to hernia.

It occurs to me, in view of the possibility of such an accident, that in clean celiotomies—that is, in operations in which the wound can be completely closed without the necessity of drainage—it would be a safeguard to fasten the omentum to the abdomen behind the incision, securing it by a stitch at the lower end of the wound, where by adhesion it would be interposed between the viscera and the weakened part of the abdominal wall, thereby reinforcing and strengthening it.

