COTTING. (B. E.)

Dr. SAYRE'S CASES
of
ARTIFICIAL HIP-JOINT.

Cotting (B. E.)

DR. SAYRE'S

CASES OF ARTIFICIAL HIP-JOINT

[EXTRACT FROM BOSTON MEDICAL AND SURGICAL JOURNAL]
Feb. 25, 1869.

A New Operation for Artificial Hip-joint in Bony Anchylosis, illustrated by two Cases. By LEWIS A. SAYRE, M.D., Surgeon to Bellevue Hospital, Professor of Orthopædic Surgery, &c. &c. Re-printed, &c. Pamphlet. 8vo. Pp. 39. New York: D. Appleton and Co. 1869.

THESE cases are re-published from the *New York Medical Journal* for January, 1869, where they are re-printed from the Transactions of the Medical Society of the State of New York, with Preface and Appendix, says Dr. Sayre, "to vindicate scientific truth, and my own reputation" from "false statements" with regard to them in a "work" recently published.

The vindication is thorough and complete—we need not tarry to rehearse the process—the "slander" henceforth can trouble only its inventor.

As these operations are remarkable, and "the first of their kind," the description, which is not long, is worthy of repetition.

"My object was to go above the trochanter minor so as to retain the insertion of the psoas magnus and the iliacus internus muscles attached to the lower fragment, for the purpose of flexion; and by cutting out a *semi-circular* piece, thus ⌒, with its convexity downward, and then rounding off the upper end of the lower section to more nearly imitate the natural joint, and give him a fair chance for motion at that point." The plan of the operation may be seen in the figure.

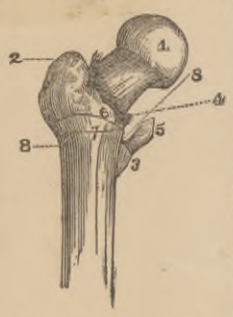

1, head of femur; 2, trochanter major; 3, trochanter minor; 4, line of insertion of capsular ligament (variable); 5, tendon of psoas magnus and iliacus internus muscle; 6, line of transverse section; 8, 8, dotted lines indicating the rounding off of lower fragment after removal of segment.

This operation, designed by Dr. Sayre "for the purpose of establishing a new joint," was first performed on a man at the Bellevue Hospital, June 11th, 1862. The details and history are given with sufficient fulness in the pamphlet. October 12th he "left the institution well, and with very good motion" in the new joint. Late in December he walked to Dr. Sayre's office, and could go up and down the steps without difficulty. April 11th, 1863, the patient wrote from Kentucky "I can now 'rough it' a little without apprehension of having to suffer from it afterward. I can bear my whole weight on the limb without inconvenience, and can walk very well without other assistance than a walking stick." (Page 13.) When last heard of, Jan. 9th, 1869, he was in Idaho, writing to New York for a two-wheeled velocipede!

On the 6th of Nov., 1862, assisted by Profs. Peaslee and Raphael, and in presence of other professional gentlemen, Dr. Sayre performed a similar operation on a Miss L.

This case went on well so far as the operation was concerned. Its subsequent fatality, however, became the source of the "slander," which Dr. Sayre has so triumphantly refuted. In its results, as displayed post mortem, this case is one of the most instructive ever recorded. Not only had a new joint, with synovial membrane, already formed, but it was furnished by an inter-articular ligament, answering in every respect to a new ligamentum teres.

The operation was performed Nov. 6th. On the 8th of Feb. following she got out of bed for the first time.

"February 20th (misprinted July) she begins to have more control over the movements of her limb by voluntary muscular contraction, and can bear nearly her whole weight upon it. The motions are nearly as perfect as those of the natural limb." p. 22. This patient, while progressing favorably and rapidly, "being able to bear her entire weight on the affected limb, with perfect freedom to passive mo-

tion, and gradual increase of control over the voluntary movements" so as to begin to walk around her room, was, early in April, 1863 (misprinted February), suddenly brought down by severe inflammation of the chest, caused by unwarrantable exposure. After a variety of complications and mishaps, the lungs gradually gave way to purulent degeneration and tubercular infiltration. She died May 12th, 1863, from these causes solely, as testified to by a dozen practitioners who attended the autopsy and examined the lungs, and who certify to the published account as "correct in every particular." (Prof. Raphael's letter on p. 37.)

The death of this patient, if it disappointed reasonable expectations from an operation in itself progressing well, brought to light through autopsy, what would never have been credited unseen, "how wonderful" (in the words of Dr. Bush who was present) "and how beautiful was Nature in this reproduction of even the ligamentum teres, in constructing the new hip-joint for the patient, imitating so well the anatomy of the normal articulation." p. 33.

"I made full examination," says Dr. Willard Parker, "of the limb operated upon, and the motion was *free* at the new joint. The parts were then laid open; the new joint consisted of a firm structure surrounding the point of operation, and made a capsular ligament. On opening this capsular ligament, the cavity was found to be lined by a synovial membrane, smooth and lubricated. Between the sawed surfaces of the bone an inter-articular ligament was found." Letter on p. 38.

That there might be no room for any one to think that the drawings were incorrect, says Dr. Doyle who prepared the specimen for preservation, the specimen was taken while fresh to photographers, and the engravings were made from photographs.

The formation of the inter-articular ligament, which makes this case so interesting, proves to be analogous to the formation of artificial joint in ununited fracture, as happily shown in a case published, in a note at p. 30, in connection with the results of this post-mortem examination.

We commend Dr. Sayre's pamphlet to all interested in such investigations, or in surgical progress. B. E. C.