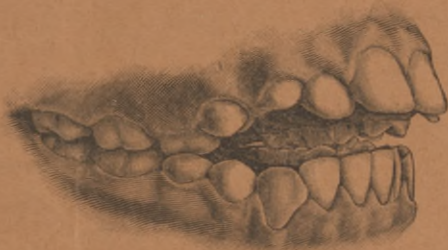


KINGSLEY (N.W.)

ADENOID GROWTHS,

Mouth-Breathing, and Thumb-Sucking,

IN THEIR RELATION TO



Deformities of the Jaws and Irregular Teeth.

BY NORMAN W. KINGSLEY, D.D.S.
115 MADISON AVENUE, NEW YORK, N. Y.

LIBRARY
SURGEON GENERAL'S OFFICE
DEC 23 1897
597

(Reprinted from the DENTAL COSMOS for January, February, May, and June, 1892.)

PHILADELPHIA :
THE S. S. WHITE DENTAL MFG. CO.
1892.



LIBRARY
SURGEON GENERAL'S OFFICE
DEC.-23-1897



Norman W. Kingsley M.D., D.D.S.

ADENOID GROWTHS, MOUTH-BREATHING, AND THUMB-SUCKING IN THEIR RELATION TO DEFORMITIES OF THE JAWS AND IRREGULAR TEETH.

BY NORMAN W. KINGSLEY, D.D.S., NEW YORK, N. Y.

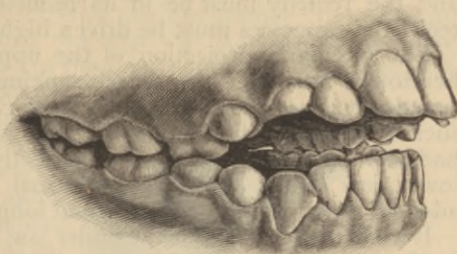
THE first case described and illustrated in this article is that of a young lady, who was between twelve and thirteen years of age when she came under my professional care. She is the daughter of refined and cultured parents.

Fig. 1 is an exact representation of her mouth, and face below the eyes at that time. The drawing is made from a plaster cast taken from life, but the upper part of the face has been varied purposely, to avoid the publication of a complete portrait.

FIG. 1.



FIG. 2.



This drawing shows the constant habit of the patient, with open mouth, because it was only with great effort that the lips could be brought in contact. The upper incisors are exposed and prominent; the lower incisors cannot be seen, being separated from the upper ones by a greater distance than the relaxed separation of the lips. This relation of the jaws to each other is more fully seen in Fig. 2, which represents the articulated models of the jaws.

The history of the case, as nearly as can be ascertained from the mother's recollection, is as follows: Through all the years of infancy the child was subject to asthma, and always breathed through the

mouth, asleep and awake. She shed the deciduous upper incisors prematurely,—between five and six years of age, as nearly as can be remembered. Up to that period there was no malocclusion of the teeth.

The permanent upper incisors made their appearance also prematurely, before seven years of age, and from that time the upper and lower incisors began to separate, the discrepancy continuing to increase until remedial treatment was resorted to.

From seven to eight years of age, adenoid growths were discovered behind the palate in the upper pharynx. The reduction of these growths was first attempted with the electric cautery without marked success; but subsequently, at about eight years of age, they were completely removed by surgical operation. Since that time the breathing through the nostrils has been free and natural. Nevertheless, the space between the upper and lower incisors continued to widen.

The impression made on my mind when I first saw the case was that the lower jaw alone was at fault.

I fancied that the lower jaw was bent down at the region of the bicuspid, and for the moment conceived the idea of bending it upward by mechanical means; but a study of the articulated models, as shown in Fig. 2 both separately and together, showed that the lower jaw was as perfect and well formed as any I ever saw. It was symmetrical in its arch, and regular in the plane of the occluding line.

The opening of the jaws in front was due slightly to the projection of the incisors, but principally to an excessive and abnormal development of the alveolar process in the molar and bicuspid region, and the remedy must be in its reduction; or, in other words, the teeth and processes must be driven higher up.

The pitch and projection of the upper incisors would have been heretofore attributed to thumb-sucking or its equivalent, but that practice had never been acquired; the child had never been a thumb-sucker. Still, we find a typical "thumb-sucking" case where there had been no thumb-sucking,—a perfectly developed and symmetrical lower jaw and a strangely abnormal upper one, coincident with adenoid growths of the pharynx and long-continued mouth-breathing.

It will be observed that the upper jaw in the region of the bicuspid is of normal width; the lower jaw is also normal in width and outline, and the back teeth of the upper jaw occlude or articulate properly with the lower ones; the opening of the mouth has not, therefore, caused a pressure of the muscles of the cheeks upon those teeth and narrowed the jaw.

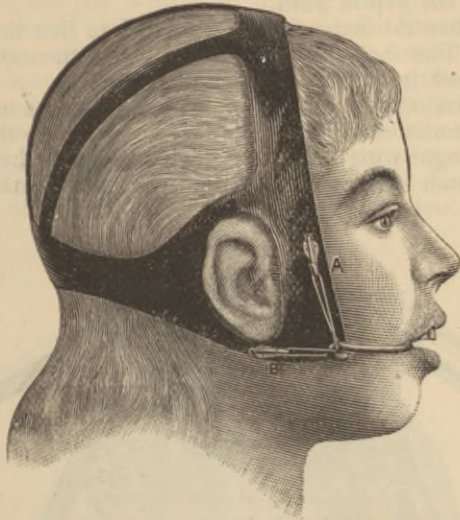As a proper correction of this deformity required the incisors to be carried backward somewhat, and as there appeared to be no spaces in the arch which would permit of its contraction, the first or sixth-year molar on each side was extracted.

These particular teeth were chosen for extraction in preference to the first bicuspid (which in many cases of protruding incisors would be proper), because they offered more resistance to correcting the malformation of that region than any other; and *that*, together with the apparent necessity for extracting one tooth on each side to provide for retraction, seemed ample justification for the removal of two per-

fectly sound molars.* At the same time a deciduous molar which was hiding the second bicuspid on the right side was also removed.

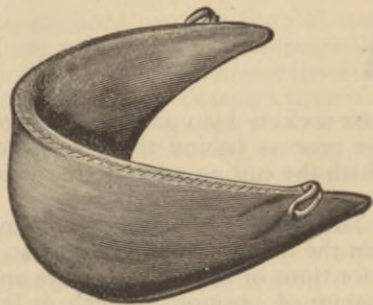
The first attempt at correction was made with a skeleton skull-cap, as seen in Fig. 3, a padded cap over the chin (shown in Fig. 4), and a

FIG. 3.



frame over the incisors, with arms projecting outside the cheeks, as shown in Fig. 5. The skull-cap was made of leather; the chin-cap of sheet copper (stiffened around the edge with non-elastic steel wire padded, and covered with leather. When these appliances were in use, an elastic strap cut from rubber tubing passed from the hook near the angle of the chin-cap to the hook marked *a* on the skull-cap (Fig. 3), and another similar strap passed from the button at the end of the incisor frame to the hook marked *b* in Fig. 3. The expectations from such an arrangement are obvious. The strain upon the incisors would carry them directly backward, and the hope was entertained that the pressure of the lower jaw upon the upper at the points of contact would diminish the undue prominence.

FIG. 4.



It is worth while here to query whether pressure, being equal upon

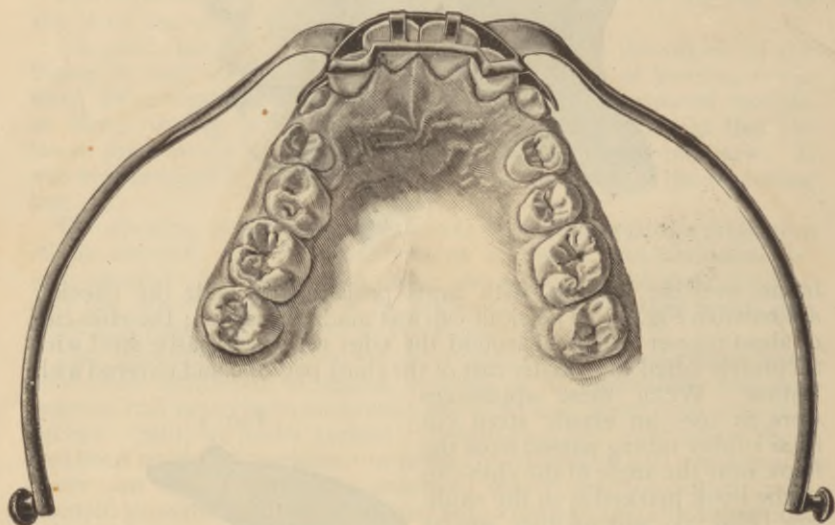
* I am convinced, by a study of the case since the correction was completed, that the extraction of those permanent teeth was unnecessary. I find now, to my surprise, that although there then appeared no room to carry the incisors back without extracting two teeth, there are now ample spaces among the teeth on each side to permit of another tooth.

the lower as well as the upper molars, might not, if it had ever accomplished anything, have done so at the expense of one jaw as much as the other. However that might have been, the fact was that although worn continuously night and day, except at meals, for about three weeks, the chin became so sore under the pressure that we feared an abscess, and it was abandoned. It is doubtful if it served any purpose in closing the gap in front.

The frame upon the incisors did accomplish in that time all that was desired of it. The incisors, without being lengthened, were altered in their pitch and the cutting-edges moved back.

The reason that this apparatus did not lengthen the incisors in their backward movement was because the strain put upon the crowns was not at a right angle with a line lengthwise through the center of the tooth. The strain was at such an angle that the teeth were held in

FIG. 5.



their sockets by a partially upward pressure while the absorption of the process behind them was going on. The distance backward which the cutting-edges were carried was ascertained to be eleven per cent.

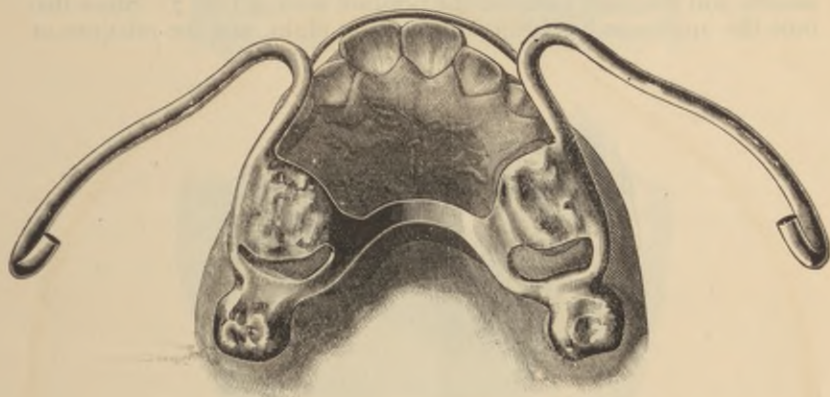
This method of stating the change may need explanation. To say that the incisors were retreated so many "lines" or "millimeters" or "fractions of an inch" conveys an imperfect idea of the reality. The change of position is much or little, great or small, relatively; two millimeters might be very much in one case and very little in another, therefore a statement of percentages is more definite.

In this case the amount of the movement was determined by measuring on a perfect plaster model from the external face of the incisors at their cutting-edges directly back along the median line, until this line intersected at right angles a line across the jaw from the posterior surfaces of the last molars. Such a line on the cast prior to any

movement represents one hundred per cent., and the same line after the movement in this case measured eleven per cent. shorter.

The second apparatus, which fully accomplished the work, I ought to have thought of in the beginning, as it is only an application of the principle involved in my interdental splints for the last twenty-five years. It is shown in Fig. 6: A frame covering the bicuspid and molars of the upper jaw, with arms coming out of the corners of the mouth and extending along the cheeks to a point exactly opposite the center of pressure required within the mouth; a small wire passed in front of the incisors to keep them from springing forward, and two elastic straps connected this frame with the skull-cap exactly as seen in Fig. 3. Both these elastics were required partly to prevent any tendency of the recently moved incisors from carrying the whole apparatus forward, but particularly to keep the proper balance of the skull-cap, the strain of either elastic alone having a tendency to pull it out of place.

FIG. 6.



The apparatus is made of one continuous piece of Stubbs' steel forged to follow the buccal faces of the teeth, then pass through the gap made by the extraction of the molars, and cross (without touching it) the vault of the palate to the other side. The bearings upon the teeth were made of silver plate swaged with accuracy to fit the *molars* to keep the frame from slipping about, but resting only on the cusps of the bicuspid, thus giving freedom for lateral movement of the bicuspid.

It was essential that the extremities of these arms should be adjusted with great nicety, so that the force exerted through them upon the offending teeth should be evenly distributed. If the bearing were forward of the center, the apparatus would be loose at the back, and *vice versa*. This apparatus was applied about the first of March, 1891, and worn almost uninterruptedly without inconvenience until June following, at which time the upper and lower incisors were in contact, the upper ones lapping normally. (See Fig. 7.)

An embarrassing feature of this case now presented itself: the second bicuspid, which had developed in place of the extracted deciduous molar, had grown down to the point of occlusion with the lower

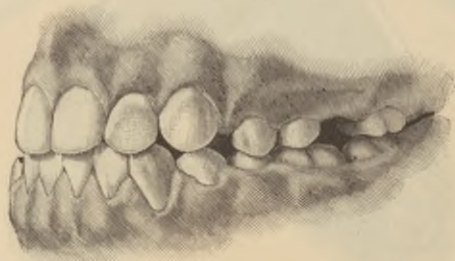teeth ; but it was pitched inward and articulated within the cusps of its antagonist, and the tendency was for it to be tipped still farther.

This was coincident with the removal of the family into the country for the summer, at such a distance that it was impracticable for the patient to visit me oftener than once a week.

Several futile attempts were made to force outwardly the malposed bicuspids without dispensing with the brace and skull-cap, until finally the apparatus had to be laid aside for a few days to admit of a jack-screw, and thus the bicuspids was driven into place. This jack-screw had its point resting in a pit upon a gold band around the malposed bicuspids, which band was cemented on with oxyphosphate : the opposite end of the jack-screw bore against a small plate, which covered two or three teeth and the gum of that vicinity, thus driving out one tooth without disturbing the teeth on the opposite side of the mouth ; but in doing so it opened the jaws again in front, and an entirely new apparatus similar to the other had to be made and adjusted.

This latter was worn constantly, with short interruptions, for a month, and the teeth assumed the position seen in Fig. 7. Since that time the appliance has been worn only at night, and the relations of

FIG. 7.



the teeth remain unchanged. The contact of the incisors is now so close that a thread can be bitten off by them.

A study of the models Figs. 2 and 7 shows that the articulation of the molars at the present time is precisely the same as before regulation commenced, and the great change in the front of the mouth is attributable principally to the driving upward of teeth in the molar region, the upward and forward movement of the lower jaw, and partly by the incisors being carried back without elongating.

I do not commit myself to, nor oppose, any of the theories of the relation of irregularities of the teeth to mouth-breathing, adenoid growths, or thumb-sucking, nor shall I here discuss the question of continuous or interrupted pressure.

The following described case is that of a boy between thirteen and fourteen years of age. The arrangement of the teeth in the upper jaw is shown in Fig. 8, that of the lower jaw in Fig. 9, and the articulation of both in Fig. 10.

In the upper jaw one of the cuspids is fully developed, while the other is just emerging from the gum.

The alveolar arch, as related to the size of the teeth, is narrow ; not narrow positively, because in a smaller face and with smaller teeth

FIG. 8.

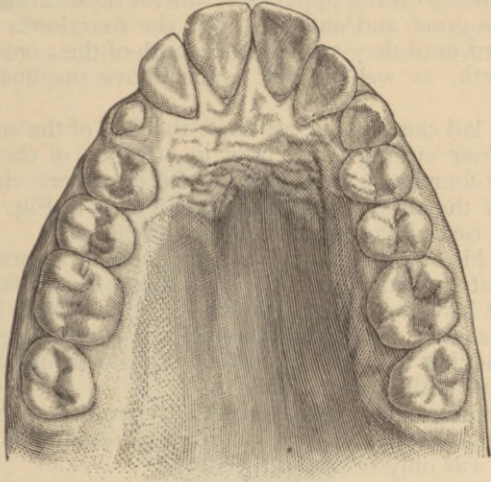


FIG. 9.

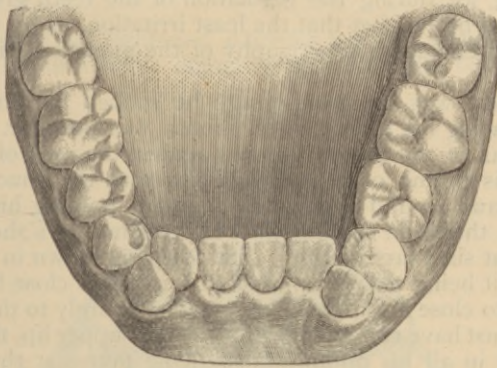
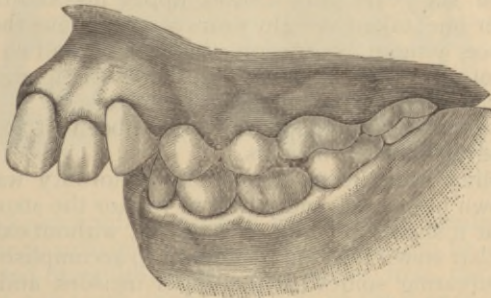


FIG. 10.



the width of this one would not be abnormal. The width of the lower jaw corresponds with the upper one, and for masticating purposes the articulation is good and sufficient, but the four lower incisors have grown upward until they are half the length of their crowns above the adjoining teeth, as well as that much above the line of a regular arch.

When the lad came under my care, the face of the superior central incisors at their cutting-edges was in advance of the inferior ones exactly three-fourths of an inch when the jaws were closed, and the expression of the mouth externally was as seen in Fig. 11, this being made from a cast of the face taken at the time.

The boy's history, as learned from the mother, shows several interesting associated particulars. He is, and was from infancy, a mouth-breather, but his father also is, and has been, a mouth-breather; and the father has good teeth, well arranged, and no suggestion of malformation; neither is there any tendency to deformity of the jaws or irregularity of teeth in the mother.

An examination shows an adenoid hypertrophy at the left side on the wall of the pharynx. How long this condition has existed is unknown, as it was only recently discovered.

There is also hypertrophy of the mucous membrane lining the nasal passage on the same side. A chronic tonsillitis is also observable; in fact, there is a distinct tendency toward hypertrophy of the mucous tissue, for during the regulation of the teeth great obstacles were presented by the fact that the least irritation, as by a ligature or a clasp, caused excessive hypertrophy of the gum-tissue in the neighborhood.

Until the boy was six years of age he sucked his thumb, but his method of placing his thumb in his mouth was peculiar. Instead of putting the ball of the thumb upward against the roof of the mouth, he hooked his thumb over the lower jaw with the knuckle up, and brought his hand around under the chin, thus holding his chin in his hand with his thumb in his mouth. His mother says she broke him of this habit at six years of age. The teeth, as shown in Fig. 11, are conspicuous, it being nearly impossible for him to close his lips; but this inability to close his lips could not be due entirely to the projecting incisors; it must have come partly from a short upper lip, this peculiarity appearing in all his photographs. One taken at the age of six months shows that the upper lip is so short that the upper gums are seen, though the mouth is at rest. Others taken at the ages of two, three, five, and six years show a short upper lip, and the teeth are seen. Another one, taken at eight years of age, shows the permanent incisors in place without protrusion; but one taken two years later, at ten years of age, shows perceptible protrusion, and the model exhibited (Fig. 11) shows the condition at thirteen.

The thumb-sucking habit appears to have been broken up before the eruption of the superior incisors.

The plan which I formed to correct this deformity was the result partly of my own judgment, and partly to humor the strong desire of the mother that it should be done, if possible, without extracting any teeth. With that view I decided to attempt to accomplish it by widening the jaw, retreating somewhat the upper incisors, and complete it by "jumping the bite."

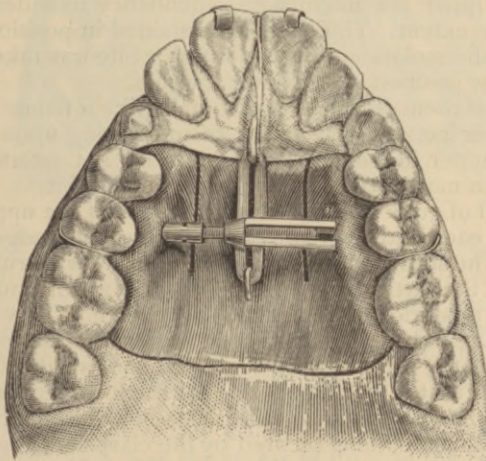
The apparatus for that purpose is shown in Fig. 12, and consists of a vulcanite plate and jack-screw for widening the arch, and, acting simultaneously with it, a T bearing on the face of the central incisors and connected by a rubber strap to a hook in the central part of the plate, as seen in Fig. 12.

FIG. 11.



The jack-screw was tightened daily for a couple of weeks, and the jaw widened about half the diameter of a bicuspid, but the incisors

FIG. 12.



had not moved perceptibly, nor had the widening made an enlargement of the circle sufficient to permit the incisors to be carried back.

I then realized more fully than I had before, first, the necessity for the removal of one tooth upon each side of the upper jaw ; second,

the exceedingly short upper lip ; and third, that if the incisors were moved back in the usual way they would become elongated.

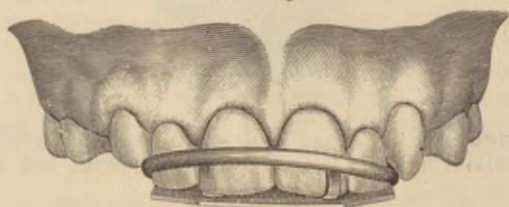
An experiment was made with a plaster model of the jaw, to determine approximately what that elongation would probably be.

The incisors were cut out of the model with roots, and reset on the model, keeping the extreme ends of the roots to their original position and moving the crowns to the place desired.

This experiment showed that in dropping the teeth from the angle occupied in the jaw to a perpendicular position, they would appear to be nearly half the length of their crowns longer than before. Taking the boy's short upper lip into consideration, such an elongation would have created a deformity worse than the first.

The first step in the second stage of treatment was the removal of the first bicuspid upon each side, and a plate was made of silver covering the roof of the mouth and the teeth. This was made of silver in preference to vulcanite because I wanted as little thickness as possible over the molars and bicuspid, and that thickness to be uniform, so that the interference with the lower teeth in mastication caused by

FIG. 13.



widening the upper jaw might have a tendency to widen the lower one to the same extent. This plate was retained in position by narrow clasps around the molars, and, when fitted, a bite was taken upon it in wax to show the position of the lower incisors.

The plate was then extended horizontally like a flange or apron in front of the lower incisors, on a level with and resting upon the cutting-edges of the upper incisors. This apron did not interfere with the lower incisors in masticating, as they closed behind it.

A stout band of gold was made to fit the face of the upper incisors, with a hook at each end, and hooks over the cutting-edges to keep it in position. The strain upon the teeth was made with rubber elastics reaching from the extremities of the bar backward, and caught on hooks near the posterior border of the silver plate. This apparatus is shown in Figs. 13 and 14. It needs no argument or description to show that while in use the incisors must be moved backward by the strain of the elastics, and that it was impossible for them to become elongated so long as the plate was kept in close contact with the molars and bicuspid, and this contact was secured by the clasps and by mastication upon it. This is exactly what it did accomplish. It was worn uninterruptedly except for cleansing, and was readily removable (almost too readily) by the patient. The only attention required at the office was to cut off the horizontal flange from time to time as the incisors were retreated.

There was no guessing at the movement of the incisors ; cutting

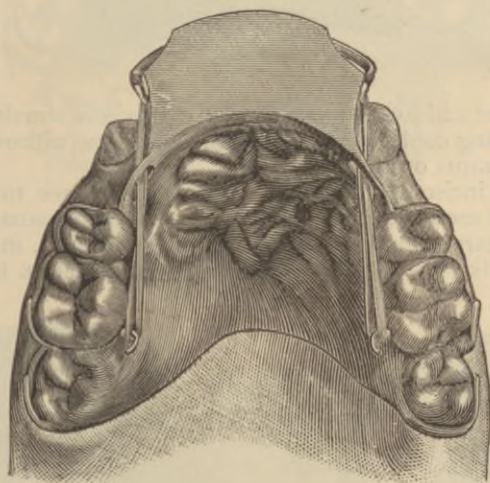
the flange even with their faces, the projection at the next visit would show the gain.

The plate represented in the drawing is the identical one which did the work, only that as the flange was cut off piecemeal during its use, a new one has taken its place for the purpose of this illustration.

The time required for the incisors to be moved backward into a perpendicular position was about two months, and, according to the experiment before described, they must have been driven up in their sockets nearly or quite half the length of their exposed crowns; nevertheless, the crown-exposure below the gums did not appear to be lessened. In this description and in the illustration, it will be seen that this apparatus bore only on the incisors.

The undeveloped cuspid upon the right side of the mouth was left to the forces of eruption to bring it into the place of the extracted bicuspid, and it was calculated that the secondary pressure upon the left cuspid would drive that also, but it did not, and it was soon observed that the incisors were falling in behind it, giving it the

FIG. 14.

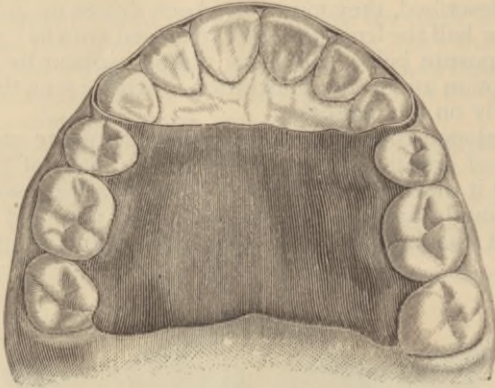


appearance of being forced outward instead of backward. As soon as this was discovered, a band with a hook upon it was cemented to the cuspid, and an elastic strapped to a hook at the end of one of the clasps on the face of a molar. This served to reduce it to the desired position as soon as the incisors had reached theirs. To retain these teeth in place, a vulcanite plate was made with a band of half-round gold wire in front of the incisors, as shown in Fig. 15, which also shows the circular form which the arch has assumed. The shortening of the arch from the center in front to the posterior border of the molars, measured as described before, is eighteen per cent. It is not likely that all this shortening of that line is due to the retreating of the incisors; it is probable that the molars and bicuspids yielded somewhat to the strain, and moved toward the front; nevertheless, a comparison of the articulated models before and after fails

to detect it, but this can be accounted for by the supposition that the lower jaw moved forward and accommodated itself to the upper one.

It was not until the regulation of the upper jaw was completed that any attention was given to the lower one. While in many cases regu-

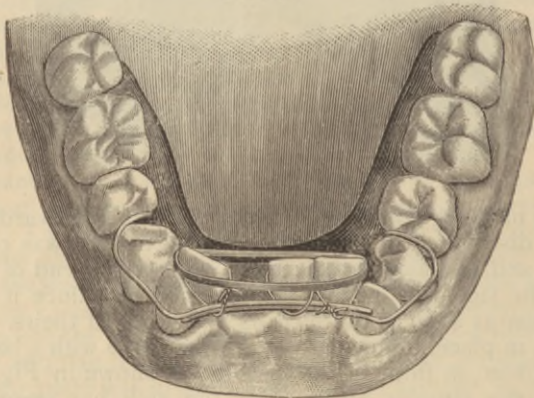
FIG. 15.



lation of upper and lower teeth can be carried on simultaneously, in this case nothing could be done with the lower jaw without interfering with the apparatus on the upper one.

The lower incisors, as will be seen by reference to Fig. 9, are elongated and crowded between the cuspids, or, as some might say, the cuspids were crowded out of place; and in fact, in some other case exactly like it,—without considering the relation to the upper

FIG. 16.



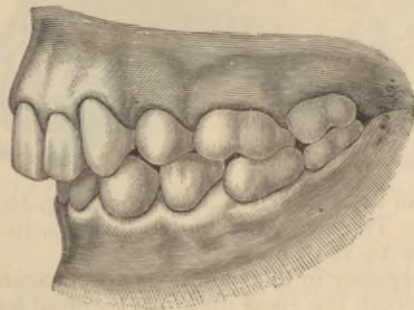jaw,—I should have so decided, and would have expanded the arch so as to have brought them all into line; but the upper arch had now been reduced so much in size by the extraction of the bicuspids and the retreated incisors, that some tooth in the lower jaw must be sacrificed.

The simplest and best way which I have advocated for many years

in similar cases is the removal of one of the incisors, particularly when the occlusion of the teeth behind the cuspids is fairly good.

In this case, as in most others, where one is to be extracted, I have chosen a central, the reason being that the inclination of the remaining teeth will appear better than when one of the laterals is extracted, and the three teeth remaining all lean that way in closing up the gap. One of these centrals was removed, and an appliance as shown in Fig. 16 was adjusted. It was a vulcanite plate with piano wires, one from each side, meeting and lapping in front, and in their relaxed position standing off for an eighth of an inch from the face of the teeth, but were sprung in and tied to the incisors with waxed ligatures. This vulcanite plate was made pretty stout, comparatively non-elastic, and impinged upon the lingual walls of the bicuspid and molars, for the purpose of assisting nature, which was widening the arch by occlusion with the upper one, and, as from time to time it loosened by those teeth yielding, the plate was warmed and readjusted. A small

FIG. 17.



ring from rubber tubing was also stretched over the three teeth, to assist in closing the gap.

In four weeks the space was closed, and an expert could not, with certainty, tell which tooth had been removed. The retaining fixture was exactly like the regulating plate without the piano-wire attachments. The final condition is shown in Fig. 17. The most singular result of the rearrangement of the lower incisors, and one for which at present I do not attempt to account, is that these teeth have gone down into their sockets not less than a quarter the length of their crowns; they are no longer higher than the natural plane of the lower arch.

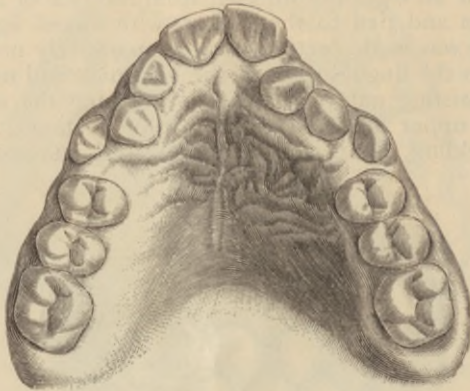
I say that these teeth appear to have been driven into their sockets, but no apparatus worn on either the upper or lower jaw could have had such a tendency; on the contrary, the strain upon them in moving forward would have been more likely to have elongated them than to have shortened them. If we cannot accept the idea that they sunk in their sockets, we are forced to the only other alternative, that all the other teeth, cuspids, bicuspid, and molars, simultaneously and uniformly rose from their sockets, for certainly now the plane is not abnormal.

My next illustration of abnormal protruding jaws is that of a little miss, twelve years of age.

In this case the lower jaw was perfectly developed in every particular, the teeth were all good, stood excellently well in their relations to one another, and the alveolar arch was well shaped.

The width of the upper jaw was normal, and the articulation of the molars and bicuspid of both jaws, while not quite in accordance with a standard which is considered the perfect type, was nevertheless good. The surface of every masticating tooth had a good occluding antag-

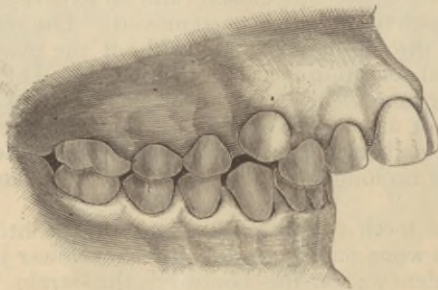
FIG. 18.



onist. The form of the upper arch is shown in Fig. 18, and the articulation in Fig. 19. The face of the upper incisors, in advance of the lower ones, is here 19-32 of an inch.

While the discrepancy in this case does not measure so much as in the last case described, the effect upon the external features was more disagreeable. The face in profile, as taken from life, is shown in Fig.

FIG. 19.

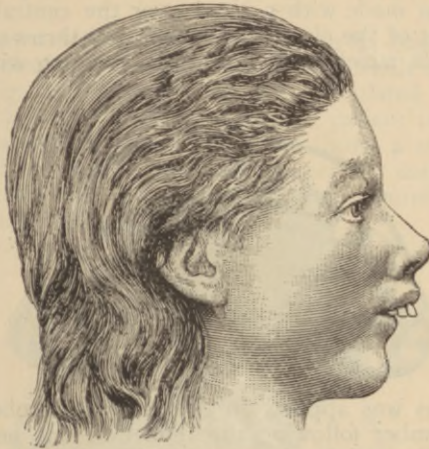

20, and it was said that she could not make her lips to meet. Perhaps this would not have been such a misfortune in a man, but in an otherwise pretty girl, approaching womanhood, her situation was deplorable.

The history of the case is principally made up of negations. There was no thumb-sucking, no catarrh, no adenoid growths, no enlarged tonsils, no mouth-breathing, no inordinately high vault. The teeth and jaws of the father are good; the upper jaw of the mother is

prominent, but less so than that of the daughter. The daughter's jaw would not be more prominent than the mother's but for an extra pair of laterals. These extra lateral incisors are a point of extreme interest. They are not what are usually termed supernumerary teeth, since they were antedated by similar teeth in the temporary set. In

FIG. 20.

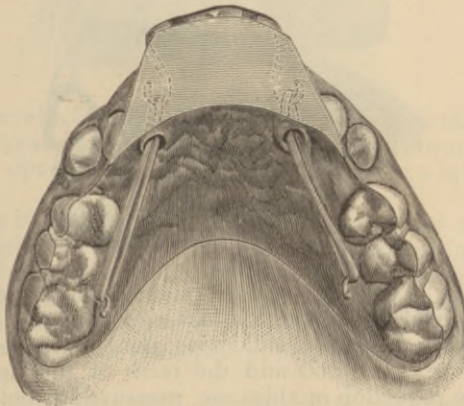


plain language, this child had four equally well-formed lateral incisors in the first set, and again in the second.

It was decided to remove the pair next the centrals. These, when extracted, showed well-formed and fully developed roots.

Owing to the pitch as well as projection of the incisors, the same

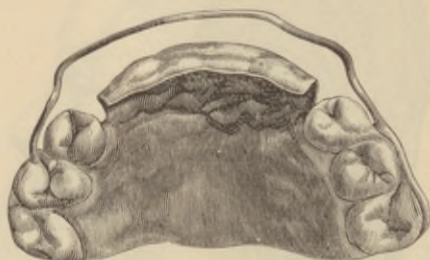FIG. 21.



difficulty confronted us as in the last-described case. If moved back without the cutting-edges being kept on the same plane, they would be likely to elongate enormously and give the child the appearance of a rodent. To meet this emergency the same plan was adopted as in the former case, although, as a matter of history, this ante-

dated the other. The apparatus is shown in Fig. 21. It was made of 18-carat gold plate, No. 29, and the principle of its action was identical with that of the silver plate before described. This plate was secured by little gold catches, passing outside between the bicuspids and between the second bicuspids and the molars on each side, and entering a short distance between these teeth at the margin of the gum. With these catches attached, the plate had to be sprung into place. The traction was made with a band over the centrals, and elastics. The arrangement of the elastics was such as to throw outward the two remaining laterals, which were, until then, standing within the arch.

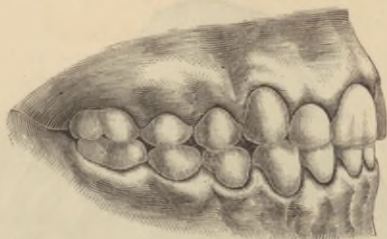FIG. 22.



This apparatus was applied on the 10th of October, and by the middle of December following the reduction was nearly complete. The main attention at the office which this required was cutting off the flange as the teeth retreated, and changing the form of the band in front, as needed from time to time.

The patient, living in a distant city, desired to spend the holidays at home, and this apparatus was removed and substituted by a gold plate, fastened in the same way, but with a small wire passing around the

FIG. 23.



incisors in front. The wire not only retained what had been accomplished, but served to even up the circle of the arch, and by a little bending, to reduce the front still more, until at the end of another month the circle was good and the teeth of the upper jaw close together. The reduction in this case, measured as before described, was twenty-three per cent. ; the actual retreat of the incisors measured in inches was less than in the former case, but the percentage, owing to the smaller jaw and smaller teeth, was greater, and the effect upon the external features more pronounced. There was, however, still a discrepancy between the upper and lower jaws, but the fault now was

with the lower one, which closed about one-third the diameter of a bicuspid too far back.

On February 1 a flange was built on this plate behind the incisors, to "jump the bite." This plate is shown in Fig. 22. In a few weeks the patient had acquired the habit of shutting the lower jaw in its new place, and the work was virtually complete, but the wearing of the plate was still continued until midsummer, more as a retainer than otherwise.

This apparatus was then discarded, and in its place a crib of light gold wire was substituted as a retainer. The result of the correction is shown in Fig. 23, representing the articulated models, and in Fig. 24, giving a profile of the face as the patient is at the present time. A comparison of this with Fig. 20 shows a striking contrast. The relation of the upper lip to the lower lip and chin has here reached the artist's ideal; the face is radically transformed, and the lips can fulfill their highest function.

FIG. 24.



The next case which I shall present in this series is that of a young lady, eighteen years of age. The projection of the upper jaw produced an effect upon the expression of the face that was almost repulsive.

This is shown in two views of the face, Figs. 25 and 26, and in the articulated models, Fig. 27. The front of the upper incisors here is in advance of the lower incisors 18-32 of an inch, and while this discrepancy is nearly the same as in the last case, it is relatively less, because these jaws are large and the teeth are large. There is but little in this case other than the discrepancy, and its striking effect upon the external features.

The form of the upper arch, considered in the abstract, is good; this is shown in Fig. 28. It is neither wide nor excessively narrow. The teeth are even and the circle is good, the vault of the palate is neither high nor low, and, apart from other considerations, the whole jaw, alveolar arch, and teeth come very near a perfect type, and would be quite in harmony with some skulls.

The occlusion of the teeth is good ; that is, every grinding-surface of the lower teeth has its antagonist upon the upper jaw, and for masticating purposes no apparatus could be better ; nevertheless, the articulation is not normal, as the lower jaw closes one tooth behind the proper place.

FIG. 25.



Looking for causes, we find principally only negations. She did not inherit this peculiarity from father or mother ; there were no enlarged tonsils ; there was no impediment of the nasal passages, no thumb-sucking. She was, however, a mouth-breather, in sleeping, and to some extent at other times ; but with the mouth closed there

FIG. 26.



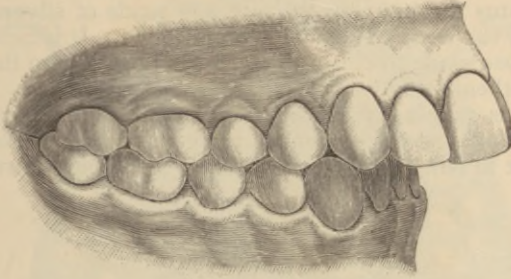
was free respiration through the nares, and when the correction of this deformity was completed, the mouth-breathing habit was broken up.

To correct this deformity, I believe that a majority of practitioners would have advised extracting a tooth from each side of the upper jaw, because it would be argued that the occlusion of the masticating

teeth was so excellent that there was no justification for breaking it up, when the six front teeth could be carried back without disturbing the articulation.

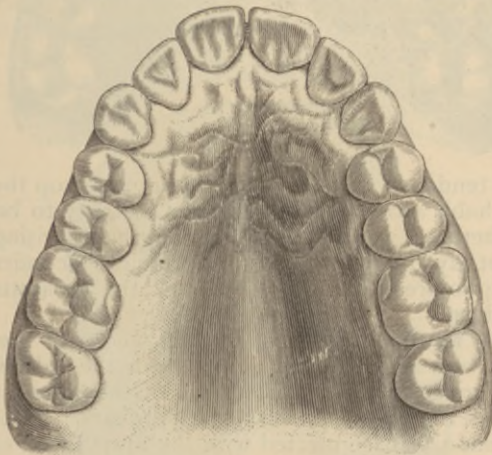
I did not pursue this course because the pitch and inclination of the incisors was already good; to have removed teeth from the upper jaw and reduced the prominence until such space was closed, or until the

FIG. 27.



relations of upper and lower incisors were more natural, would have pitched the cutting-edges of those teeth inwardly, to the point of disfigurement. The ideal to be attained in this case was to widen the jaw, flatten it in front, reducing it incidentally, jump the bite to a normal one, and, thus advancing the lower jaw and chin, restore the natural and inherited contour to the face.

FIG. 28.



The first apparatus for correction was almost identical with that illustrated in Fig. 12 (page 9),—a vulcanite plate, jack-screw, and reducing band on the central incisors with rubber straps. This apparatus, with its renewals of elastics, was worn for a month, and the arch was widened across from the first bicuspid three-fourths the diameter of one of those teeth (or, expressed in percentage, measuring from the

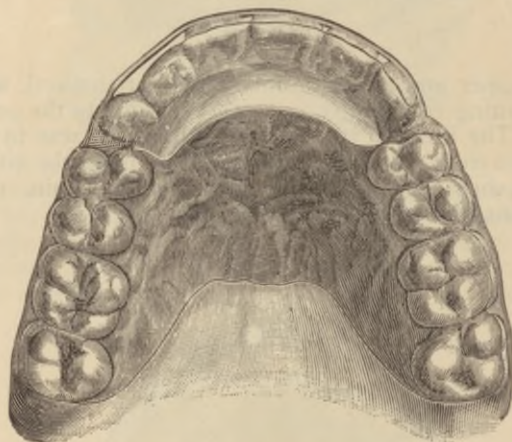
tip of the inner cusp of the first bicuspid across to the same eminence on the other side, the width was increased fourteen per cent.)

This plate was then substituted by one without the screw, but stiff enough to retain the width of the arch, and the pressure on the incisors was continued for two weeks longer, at the end of which time the arch was perceptibly flattened without apparently changing the pitch of the teeth. This flattening proved on measurement to be less than three per cent.

The apparatus for jumping the bite was made of silver plate, and was essentially the same as that shown in Fig. 22. It is here shown in Fig. 29, and was made to cover all the teeth posterior to the cuspids ; it thus bound them immovably to that form of arch.

It was at this time approaching the summer, and the patient was desirous of spending a few months in the country, but I was not quite willing to trust to her own volition to change the bite, particularly as

FIG. 29.



I discovered a tendency on her part to constantly drop the lower jaw. Whether this habit arose from her former inability to bring the lips together, or whether it was a mouth-breathing habit arising from other causes, I cannot say ; however, it seemed sufficiently confirmed to need extraneous help to break it up, and I devised the apparatus illustrated in Figs. 30 and 31.

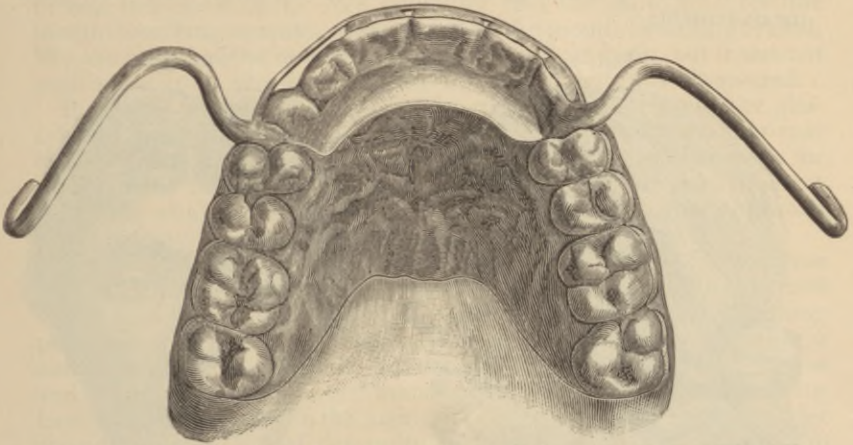
The appliance for the mouth, Fig. 30, was a copy of the silver plate already being worn, also made of silver, with the addition of arms attached to it projecting from the corners of the mouth and extending along the face a couple of inches toward the ears. A skeleton skull-cap was also made, and connected with the arms by an elastic strap, as seen in Fig. 31. This, as will be seen, was thus acting only upon the upper jaw, and was not originally intended to reduce that undue prominence, nevertheless it did prove of great value in that direction.

The primary object of this skull-cap and its connections with the plate in the mouth was to afford an attachment for an elastic band going under the chin, which should press with only sufficient force to overcome the natural inclination of the lower jaw to drop.

The patient had now two appliances for jumping the bite, and one or the other was worn constantly,—the skull-cap at night, and as much as convenience would permit during the day.

She was absent six months, and on her return the lower jaw seemed

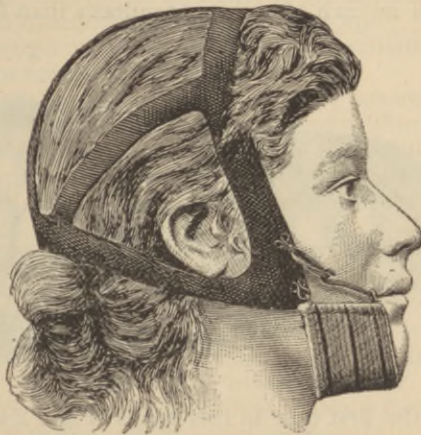FIG. 30.



to have found a resting-place permanently in its new and normal location.

And the woman was transformed; a face which six months before was almost repulsive had become handsome, and its expression winning. The relation of the upper to the lower lip in profile had very nearly, if not quite, reached the artistic ideal.

FIG. 31.



Two views of the transformed face are here given (Figs. 32 and 33).

I do not believe that the whole of this change was due to the advancement of the lower jaw. I believe it to have been a compromise effected partly by throwing the lower jaw forward, but the great ap-

parent change in the upper lip must have come from some yielding of the entire upper arch in obedience to the strain from the skull-cap.

The final occlusion of the teeth is shown in the articulated models, Fig. 34.

It is marvelous how great the effect is in the expression of the lips, which is made by a change so slight that it can hardly be expressed in measurements.

FIG. 32.

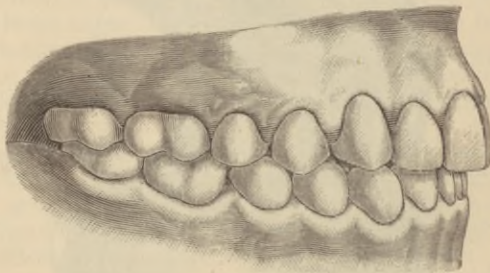

FIG. 33.



In this case a very careful and exact measurement, using the nose and forehead as fixed features, shows that the upper lip, where it joins the nose, remains unchanged, but the same lip has been lengthened by this process one-sixteenth of an inch, and its outer border is two-sixteenths of an inch only, less prominent than before.

FIG. 34.



I have given the first case in this series (Figs. 1 and 2, page 1) a great deal of thought in both the presence and absence of the patient for more than a year, and I am unable to come to any conclusion which will satisfy my own mind as to the real cause of the deformity.

In this case we have mouth-breathing, an adenoid pharyngeal growth, a prominence of the superior incisors, an excessive elongation of the

molars and bicuspid, with a normally broad palate and not a high vault.

It is easy enough to say that the deformity of the dental arch was due to the mouth-breathing and that the mouth-breathing was the result of the adenoid hypertrophy; but in the first place I know of no proof that the growth in the pharynx antedated the mouth-breathing or was the cause of it. We only infer that the growth caused the mouth-breathing because, when removed, the mouth-breathing ceased. We are told that the mouth-breathing dated from birth, but it was not until some years afterward that the adenoid growth was discovered.

It is most natural to suppose that with the two existing, the pharyngeal growth was the cause of the other; but in this particular case it is by no means proven, nor are we called upon here to account for the origin of the mouth-breathing. It is sufficient for us to discover if we can what possible relation there was between this abnormal respiration and the coincident abnormal arch.

None of the arguments which have ever been made, so far as I have read, to show the connection between mouth-breathing and a deformed dental arch, apply in this case. It has been said that mouth-breathing produces a narrowed arch and a high vault; but here was neither a narrow arch nor a high vault, and not even in those cases where narrow arches and high vaults were found coincident with mouth-breathing have I been satisfied with the logic of the arguments. In the case under consideration, the chief deformity lay in a bulging downward of the jaw and alveolar process immediately beneath the antrum, as if the cavity of the antrum had been enlarged in a downward direction, and yet I had no proof that such was the case any more than that the alveolar process had unduly thickened there with the growth of the permanent molars. In conclusion, I can see no possible reason for connecting that particular form of the jaw with a glandular growth in the pharynx, situated some distance from it and having no bearing upon it; and besides, the abnormality of the jaw continued to increase after the mouth-breathing habit was broken up.

It is easy enough to guess, and easy to speculate, but guesses and speculations are not bases for science.

It is also easy to dismiss the subject by saying that the above-described condition was due to an excessive or abnormal development of the jaw in the molar region, but such a statement, which may be entirely satisfactory to superficial thinkers, is only another form of stating the fact; it does not reach the origin of the deformity.

In the second case described (pages 8 and 9), the excessive protrusion is the main feature, and here we have thumb-sucking through early childhood, and an adenoid growth discovered later.

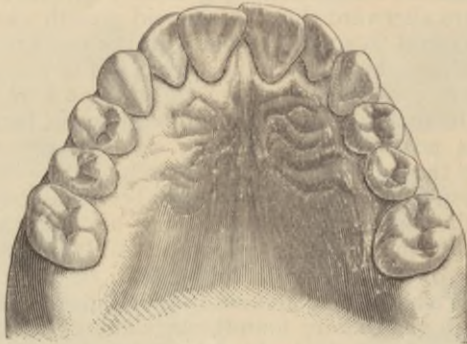
It is somewhat difficult to dispel the idea that the long continuance of the thumb-sucking in this case did produce an impression upon the deciduous dental arch which ultimately sent the incisors upon their forward slant. Here, again, is a mouth-breather, but the coincident dental deformity is so entirely different from the former case as to preclude the idea that one and the same cause could produce such entirely different results.

I should without hesitation eliminate mouth-breathing as a factor in this case, and the only tangible cause left is the thumb-sucking habit.

It has so long been held that thumb-sucking does produce deformi-

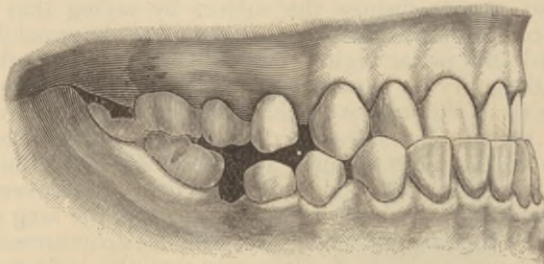ties like this, that the theory has been accepted without questioning its validity. I myself have fallen into that error (if it be an error) in the past, but I am becoming skeptical. I have seen so many cases of thumb-sucking or its equivalent where no deformity followed, and so many cases of protruding upper jaws where there had been no thumb-sucking, that I am beginning to doubt the relation. The following examples among others will illustrate. A child whom I was seeing

FIG. 35.



daily had been nursed from a bottle with a rubber nipple, and had formed the habit of going to sleep with the nipple in her mouth, and would cry for it until the nurse yielded and gave it to her. I was not aware of this until the child was about four years old, when I saw the four upper incisors protruding, the two centrals very markedly. The rubber nipple was taken away, but very soon the central incisors loosened and dropped out, with their roots absorbed as fully as in the natural course of events they would have been three years later. I was alarmed, and anticipated all the evil results coming from the common belief in the pernicious results of thumb-sucking; but the permanent incisors did not develop until the normal period arrived, and they and

FIG. 36.



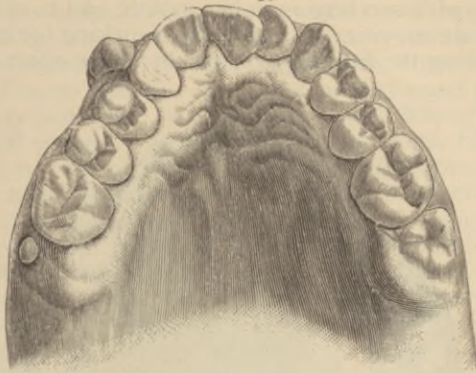all the other teeth in the jaw appeared in due time, in a perfectly regular dental arch. There is not and never has been the slightest protrusion.

Another example is that of a young man of seventeen. He had sucked his thumb until he was seven or eight years of age, and the habit was then broken up only after repeated applications of some offensive mixture upon the thumbs. The model of his upper jaw is shown in Fig. 35. Here is a regular dental arch, a well-formed palate,

and a natural pitch to the incisors. The curious part is the occlusion of the jaws; the upper one shuts inside the lower, as seen in the articulated models, Fig. 36.

I believe this prognathism to be a peculiarity inherited from the mother, but this is only an inference, as the mother has worn artificial

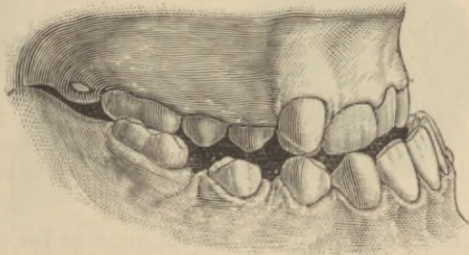
FIG. 37.



teeth so long that she has forgotten the relations of her natural ones. This lad was quite as persistent a thumb-sucker as the one described on page 8, but the habit does not seem to have exercised any influence upon the upper arch, where a forward movement would have been beneficial.

Another case of prognathous jaw, shown in Figs. 37 and 38, is that of a girl thirteen years of age. The mother tells me that the child was nursed from a bottle, and the habit of going to sleep with the rubber nipple in her mouth was not broken up until she was six years of age. In the upper jaw a cuspid has been crowded completely out of the arch, but a study of the case reveals no cause for this condition, particularly if the persistent use of the rubber nipple is accounted to have any effect in enlarging the anterior part of the dental arch. The lower jaw here not only shuts far in advance of the upper one, but

FIG. 38.

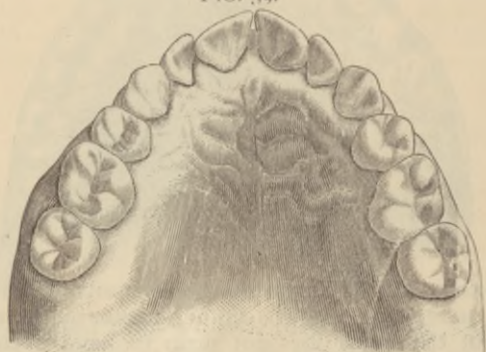


there are only two points where the teeth come in contact. It is not necessary to enlarge upon such an extraordinary condition as these two thumb-sucking cases show, which are the very reverse of all former theories.

Still another case is shown in Figs. 39 and 40,—a young lady of sixteen. In this case there was slight protrusion, V shape and lapping

of the central incisors of the upper jaw. But this peculiarity is unquestionably inherited, as the mother shows the same arrangement of incisors. Except for this slight V shape, the upper jaw is well formed, but the lower incisors are crowded and appear to have been forced back. There is a considerable gap between the upper and lower front teeth when the molars are in contact. She had the habit of going to sleep with two fingers in her mouth, and continued this habit until she was eleven years old. If thumb-sucking (or its equivalent in this case, sucking the fingers) ever produces the effect of altering the

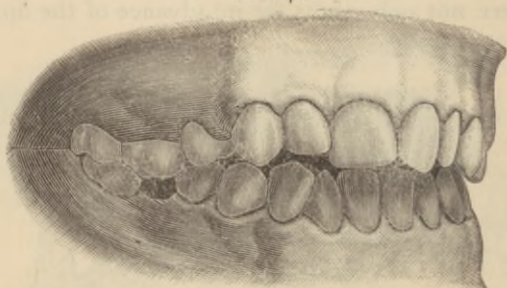FIG. 39.



shape of the dental arch, we may reasonably suppose that^o to be the cause of the crowded and retreated condition of these lower incisors.

The explanation of the condition seen in Figs. 18 and 19 is easier,—that is, if we can be satisfied with immediate causes. This child inherited an undue prominence of the upper jaw from her mother, and this inheritance was aggravated by the appearance of two additional lateral incisors. We can thus account for a portion of the deformity by the same law that transmits other peculiarities of form and feature; but

FIG. 40.



two things in this connection we cannot account for, viz: the origin of the deformity in the mother, and the appearance of the two extra laterals in the child. It will be of interest also to observe whether the child will transmit to her offspring the tendency to develop four laterals instead of two, should she ever become a mother. We may call this a freak of nature, but who shall say that an entire race may not have come from an initial which at that time was a freak of nature?

In the case described on page 17, Figs. 25 to 34, I have never

been able to formulate any explanation of its origin. There was no apparent inherited tendency, no thumb-sucking, and no adenoid growth; nevertheless the discrepancy between upper and lower jaws was enormous. I can only offer a theory: that it was the result of accidental causes occurring at the time of the eruption of the second set, beginning with some slight deviation of occlusion which may have affected the articulation at the condyles, and that in turn aggravating the malocclusion of the teeth. I am quite aware that such a theory will be scouted by Dr. Talbot (*vide* his paper before the New York State Dental Society, 1892), yet in that same paper he says, "I have never been able to 'jump the bite,' although I have tried in a number of cases. I do not believe anyone else has been able to accomplish it, nor do I believe that such a thing is possible."

This is the most extraordinary statement I have ever read from that fertile author, and it argues either that I attempt to impose falsehoods upon my colleagues, or that I *can* accomplish that which Dr. Talbot cannot, and which he believes *impossible* because *he* cannot. It has been done repeatedly by me for more than twenty years, and the great change in facial appearance in the case (Figs. 25 and 32) was due almost entirely to "jumping the bite." A moment's reflection will recall the knowledge to any dentist that the lower jaw can be moved forward on the same plane more than the diameter of a tooth, and this difficulty confronts everyone in making full sets of artificial teeth.

In strongly marked aberrations of development such as have been described in this series of cases, it is desirable to discover a tangible cause, the knowledge of which may be applied in the prevention of similar deformities; but to seek for the cause of the thousand trifling variations from our preconceived notions of the perfect type of the dental arch would be as useless as to go into the forest and try to explain why every limb took the particular turns and twists which distinguish it from every other limb.

Dr. Ottolengui says, "If it is true that thumb-sucking can cause a protrusion of the *secondary* set of teeth, why does it not produce a similar result with the *temporary* set? How can we suppose that a given amount of pressure can affect the more resistant bone, and not influence the younger mouth of the child with temporary teeth?"

"It seems to me that if it is ever true at all that thumb-sucking can cause a protrusion of the jaw, we have it within our means to determine when such a condition has so resulted. If a given case of protrusion is attributable to thumb-sucking, it must of necessity follow that had the child not practiced the habit, the jaw would not have protruded. If this be denied, and it be claimed that the jaw would have been prominent anyway, then it is plain that there must have been some other cause besides sucking of the thumb. Admitting this postulate then, that a thumb-sucker protrusion is where the protrusion has been caused by this, *and by no other cause*, we come to this, that the protrusion has occurred in one of two ways: First, the length of the arch, measured around the circle, has not been enlarged, but the projection has been produced by a flattening of the sides. The length being normal, but simply distorted, it must follow that *such a case could be restored without extracting any tooth*, or in plainer language that by widening the jaw, and reducing the forward

prominence, we may attain a normal mouth with all teeth in proper position. The second class of cases is where the length around the arch is increased, thus accounting for the anterior prominence. In such case the pressure would be supposed to have moved the teeth forward, new tissue forming the while. The result would be a normal occlusion from the bicuspid region backward, but a protrusion forward, *with distinct spacing between the teeth*. This, of course, would be another condition which could be corrected without loss of a tooth.

"From these statements I argue that if thumb-sucking ever causes a protruding jaw, *we may exclude from such etiological history all cases where it is absolutely necessary to extract a pair of teeth in order to reduce the arch to its proper proportions with the rest of the head*, not including the lower jaw. By this last I mean that there may be instances where the lower jaw is abnormally small, and a reduction of the upper to meet that would not be the operation which I am considering.

"What then are we to think of those cases of protruding jaws where the overhang is so great that it becomes absolutely necessary to remove a pair of bicuspids in order to reduce the arch to symmetrical dimensions? These are by far the most numerous of the protruding jaws, and therefore worthy of our consideration. Before proceeding, I wish to say that whereas etiology may seldom aid us in the correction of irregularities, I think that the theory of etiology which I am about to advance is one which, if thoroughly appreciated and understood, might help us very much, in that it would tell us at once when to extract, a procedure usually studied considerably before being decided upon.

"To begin at the end, let us suppose a case similar to the one of the boy shown in Dr. Kingsley's models (Fig. 11, page 9). Here we find that after removing the bicuspids the remaining teeth have been formed into a regular arch, and one which is well filled with teeth. From this it *is fair to argue that the size of his teeth was in excess of the normal capacity of the arch exactly equivalent to the width of the two teeth removed*.

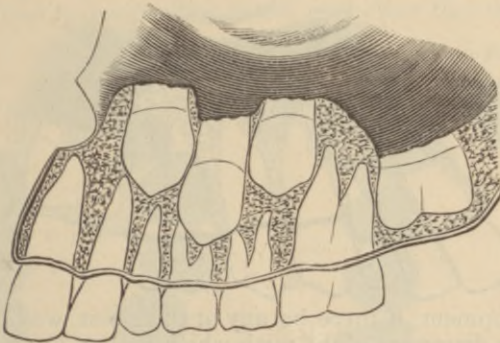
"My postulate, then, is that where a child by inheritance or from unknown causes develops a pair of jaws of a given size, and a second set of teeth too large to be received within the jaw, the result must be that the jaw is either increased to accommodate the teeth, or the teeth erupt in abnormal positions, or else, resisting such an impulse, they, or some of them, remain encysted and unerupted. Let us consider the direction in which this enlargement of the arch would occur.

"Fig. 41 shows a superior jaw, in which we find the incisors and molars of the second set in place, the cuspid and two molars of the first set still remaining, and we also see an approximate position occupied by the permanent bicuspids and cuspid. If we observe these three teeth a moment, we see first that each one is, from its shape, itself a wedge, while the three together form also a larger and more powerful wedge. We also observe that they are approaching an orifice which is smaller than the sum of their diameters. Of course these drawings are diagrammatical. They are manufactured, but this is fair, for I have simply produced for you the condition which must have prevailed in the mouth of the boy under discussion, *whose jaw at this age did not protrude in the least*. Moreover, his thumb-sucking habit had been abandoned some years previous.

"I have arranged this, then, as his was, viz : the space to be occupied would just accommodate the cuspid and the second bicuspid, but will not receive all three teeth.

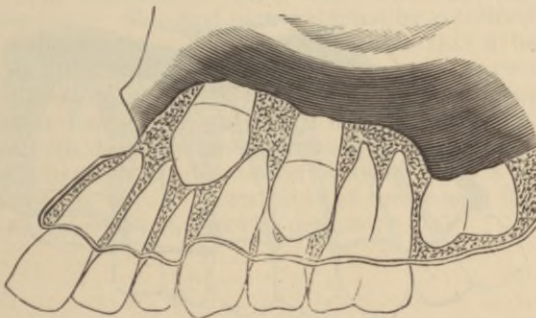
"In Fig. 42 we see the first bicuspid in place, and what is the result? In the diagram we observe that the forward part of the jaw has advanced. Is this what would occur in nature? What else? The advance of the wedge must increase the size of the arch, and no arch can be elongated at its abutments,—in this case the solid bone

FIG. 41.



in the region of the condyles. But supposing for a moment that it be asked, Why could not the sixth-year molar have been pushed backward rather than the incisors forward? The reply is evident : to push the incisors forward is to meet with no resistance equal to that offered by the two molars, one unerupted, but still existent. Secondly, the molars are locked by the occlusion with the lower jaw, which is not true in the incisive region. The result then would be that the anterior teeth

FIG. 42.



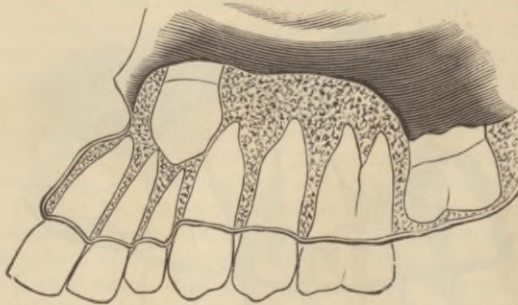
would be pressed forward. Here we come to a curious fact, which is that this forward movement of the incisors will not be appreciable till the first bicuspid has descended to a point where it bears upon the roots beside it. Then the action begins, the process yielding and the teeth moving forward, but their apices remaining almost stationary, so that the result is a tipping upward.

"Little if any change occurs with the presentation of the second bicuspid, because the temporary molar has probably occupied as much

space as it needs, as seen in Fig. 43. When the cuspid comes down, however, the forward movement is again initiated. In Fig. 44 we see the permanent teeth in position, and note the still greater protrusion of the jaw.

“That I may not be misapprehended, I will call attention to the fact that I claim this to occur only where the teeth are too large for the normal size of the jaw. With normal teeth, the space occupied by the cuspid and molars of the milk set, plus added length of the

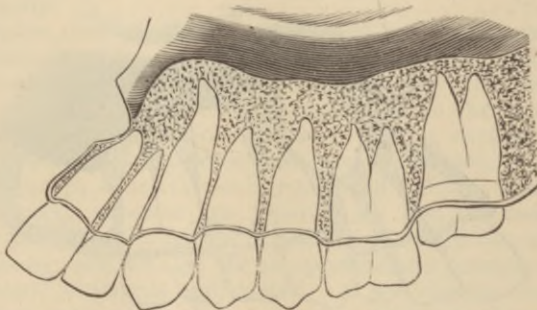
FIG. 43.



arch by development, if there be any at this point, would just equal the sum of the diameters of the teeth which replace them. But if we examine one of the bicuspid removed from the mouth of this lad, we note at once that it is as large as many molars. We have here tremendous teeth in a jaw not large enough to accommodate them, though proportionate to the boy's general frame.

“This, then, is one possible explanation of a protruding jaw which is otherwise symmetrical. We have other conditions, I think, which are dependent upon the same causes. In fact, the above-described action

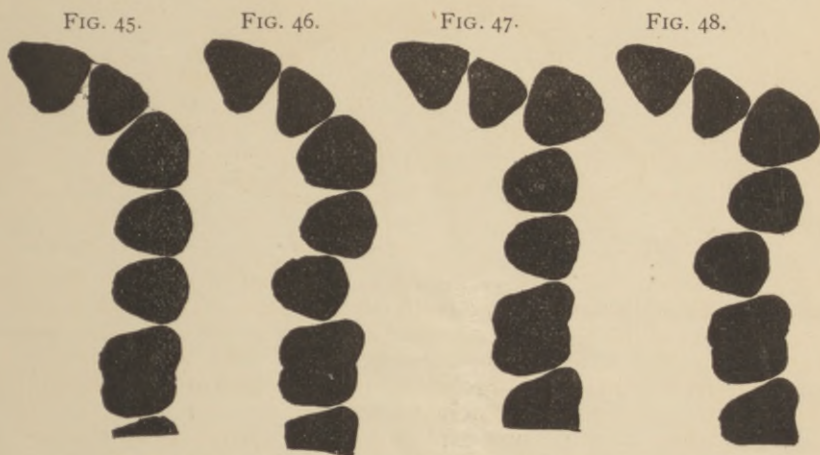FIG. 44.



would only occur when the bicuspid and cuspid occupied such position in relation to their central diameters that they together would operate as a single wedge. Such a position is shown in Fig. 45, where the sections of the teeth show that they bind one upon the other equivalently.

“In Fig. 46 is a suggestion of the production of an approximate saddle-shaped arch. Supposing that the first bicuspid is in place, if the second comes down relatively as placed in the diagram, it would fall within the arch.

"In Fig. 47 we find the most common result in a crowded jaw. The cuspid, from its peculiar shape, being a double wedge, longitudinally and laterally, if it miss an accurate contact with its neighbors would readily be crowded out of the arch, as seen. Thus the pressure which in the first place causes the forward movement of the teeth would be much less in this instance, if any at all existed. The two bicuspids would occupy the place of the three temporary teeth, the temporary cuspid being lost prematurely because of the absorption of its root by pressure of the first bicuspid. Then, of course, when the cuspid comes in as what is popularly termed a 'tush,' the wise dentist explains that its malposition is due to the fact that the temporary



cuspid was prematurely lost, whereas the converse is true, and the temporary cuspid was lost because of the position of the permanent successor. The correction of these cases is exactly similar to that of the prominent jaw. The first bicuspid must be sacrificed to allow the approach of the cuspid. This one fact shows that it belongs to the same class of cases, having a similar etiology, as I have suggested.

"Fig. 48 shows an arrangement by which protrusion is entirely avoided, whilst identical causes give us the typical saddle. The three teeth under consideration having missed contact which would keep them in place in the arch, the second bicuspid appears within and the cuspid without the curve. Extraction of the second bicuspid would usually be necessary to correct the deformity."



