

ALLIS (O. H.)

AN EXAMINATION

OF THE

USUAL SIGNS OF DISLOCATION OF THE HIP;

ALSO,

AN INQUIRY

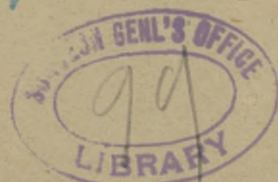INTO THE

PROPER MODE OF PROCEDURE WHEN DISLOCATION
OF THE HIP IS ACCOMPANIED WITH
FRACTURE OF THE FEMUR.

BY

OSCAR H. ALLIS, M.D.,

SURGEON TO THE PRESBYTERIAN HOSPITAL.



EXTRACTED FROM THE TRANSACTIONS OF THE MEDICAL SOCIETY OF THE STATE
OF PENNSYLVANIA FOR 1879.

PHILADELPHIA:
COLLINS, PRINTER, 705 JAYNE STREET
1879.

AN EXAMINATION

OF THE

USUAL SIGNS OF DISLOCATION OF THE HIP;

ALSO,

AN INQUIRY

INTO THE

PROPER MODE OF PROCEDURE WHEN DISLOCATION
OF THE HIP IS ACCOMPANIED WITH
FRACTURE OF THE FEMUR.

BY

OSCAR H. ALLIS, M.D.,
SURGEON TO THE PRESBYTERIAN HOSPITAL.



EXTRACTED FROM THE TRANSACTIONS OF THE MEDICAL SOCIETY OF THE STATE
OF PENNSYLVANIA FOR 1879.

PHILADELPHIA:
COLLINS, PRINTER, 705 JAYNE STREET.
1879.

AN INQUIRY

INTO THE CAUSES OF DISLOCATION OF THE HIP

BY

THEODORE SWANSON, M.D.,
OF THE HIP IS ACCOMPANIED WITH
FRACTURE OF THE FEMUR

BY

THE AUTHOR

NEW YORK

AN EXAMINATION OF THE USUAL SIGNS OF DISLOCATION OF THE HIP;

ALSO, AN INQUIRY INTO THE PROPER MODE OF PROCEDURE WHEN
DISLOCATION OF THE HIP IS ACCOMPANIED WITH
* FRACTURE OF THE FEMUR.

No one with limited experience can form an adequate idea of the embarrassment that may arise in this quarter. As the student takes the pelvis in his hand, notes its rugged outlines, its foramina, its spines and projections, and then places the head of the femur in the positions in which it is said to be most frequently dislocated, a wonder steals over him—a wonder that every one has felt—that any one should ever be at loss to determine a dislocation. And this feeling is greatly strengthened when the first few cases that come under his notice bear the unmistakable signs of the text-books. Such a one can hardly sympathize with the surgeon whose experienced eye has failed to detect a displaced hip. Fortunate, indeed, will it be, both for him and his patient, if a confidence strengthened by success shall not betray him into irretrievable error; fortunate, for no writer ever has been or ever will be able to present so vivid and comprehensive a view of this subject, as to awaken the interest and satisfy the inquiries that the subject in all its bearings demands. It is only by experience—purchased at the risk of a patient's weal and one's own reputation, an experience built up and elaborated by inextricable difficulties, by extended study, by experiments upon the cadaver, aided by the treasures of pathological cabinets—that one can rise to the full height of the subject, comprehend its difficulties, and confidently attempt its solution. Nothing short of such experience can reconcile one to the statement that the full hospital staff of one of the first and oldest hospitals in the United States met twice upon such a case, and then permitted it to go from their wards, an *undetected* dislocation of the hip.

Before entering upon an examination of the usual signs of dislocation, I shall relate a case that will serve the double purpose of introduction and example.

Peter J., æt. 42, colored, was injured Feb. 25, 1879, by earth (ship's ballast) caving in upon him. He thinks he was in the act of stooping when the earth fell, striking him upon the back, in the region of the loins and pelvis. He was buried to the waist and was extricated by his fellows in about twenty minutes, in a bent and helpless condition. He was conveyed to his home in a wagon, and for some reason received no further medical care than liniments procured at a charity. In the early part of May he managed to get to Howard Hospital, and was directed without examination to the department of nervous diseases. Dr. Livingston, then physician to that department, on examining the case, readily detected a dislocation of the right hip, and immediately referred him to Dr. Willard, as a surgical case. On Wednesday, May 14th, the man appeared before him for examination with the following symptoms: He cannot be said to walk; but by the aid of two crutches which he uses alternately he manages to creep slowly along. He is much bent. On stripping the limbs the right presents all the characteristics of a dislocation upon the dorsum ilii. There is shortening, adduction, and inversion; the knee and foot turn strongly in towards their fellow. Besides Dr. Willard and myself, there was present a surgeon who had made a special study of affections of the bones and joints. The case was examined, and the following Saturday, *i. e.*, May 17, just 81 days from the reception of the injury, was set for an attempt at reduction.

At the appointed hour we all met and, as soon as ether had been fully administered, Dr. Willard began by slow and careful circumduction and rotation to break up any adhesions that might exist. He then requested me to lift up upon the trochanter while he carried the limb through the motions so well known to favor reduction; and, to the gratification of all, the limb jumped *as* into its socket; the audible sound or thug was heard, and the limb assumed a natural position.

Dr. Willard and I both thought the dislocation restored, but to our surprise our friend expressed a doubt, since the right (restored) limb was still not the counterpart of the left. He pointed out a fulness at one place and a hollow at another, that was not to be found in the right thigh; and this together with the fact that the right limb was still an inch shorter than its fellow, convinced him that the head of the bone had only been shifted but not restored to its socket; *but it did not occur to him then nor to any surgeon or physician present that the left hip was also dislocated.*

To assure ourselves that the right hip was restored, it was redislocated and again carried into its socket, and the result so far satisfied us that we now took the right hip as our standard, and turned our attention to the left limb. It was an inch longer than its fellow; the knee was slightly elevated, though so little as hardly to attract attention. The two limbs lay parallel, but we noticed that when the left limb was adducted, it resisted; and when the adducting force was removed the limb sprang *gently* out again to a parallelism with its mate. It could not by any means be made to lie easily and naturally across its fellow. On looking at the thigh the great trochanter was less prominent than the right, and upon rotation and circumduction, a sense of crepitus was quite apparent. These signs were sufficient to suggest a dislocation to our minds, and so the man was sent to the Presbyterian Hospital (as there are no beds in the Howard Hospital), with a view of making a second examination on the following Monday. The case was now transferred to my own hands; Dr. Willard met me by appointment; we both suspected an obturator dislocation, and after a second careful examination under ether, we concluded that the head of the bone was in its socket, but that there had been a fracture of the pelvis or acetabulum.

I saw the case day-by-day in my hospital rounds, and as on each inspection the left limb was slightly *abducted*, still suggesting dislocation, I called a consultation of the staff. Drs. Reed and Porter only met me. The man was put thoroughly under the influence of ether, and after each had expressed his views Dr. Porter laughingly said, "we have three opinions and no two agree; Dr. Allis thinks there is a fracture of the acetabulum, but that the head of the bone is still in the socket; I think there is a fracture of the pelvis, but also a dislocation, and Dr. Reed thinks there is a dislocation, but no fracture." So great a discrepancy led to a more careful examination, and the result was that all agreed upon the dislocation; but it was not until some days later, when we attempted the reduction, that Dr. Porter and I were assured that there was no fracture.

Remarks.—1. Dr. Livingston, on his first examination of the case, detected the *dorsal* dislocation, but did not suspect a dislocation of the left hip. 2. Dr. Willard, myself, and a third surgeon, saw, stripped, and deliberately examined the case twice, standing and lying, without a suspicion of such an injury to the left hip. 3. Dr. Willard and myself examined the left hip twice under ether, even after suspecting dislocation, and decided against it. Lastly, Drs. Reed, Porter, and myself examined the case, and only after a long and searching investigation could we all agree upon the dislocation.

While the right hip remained dislocated, the deformity was so

marked, that it is not surprising that a kindred affection in the left passed unnoticed. But as soon as it was restored a new interest appears. Then it was that a surgeon standing by declared that the reduction was not complete, because the two limbs were not symmetrical, taking for his standard the left thigh, an *obturator dislocation*. Certainly it will be conceded, that had there been the usual deformity there could not have been a moment's hesitation in deciding between the now restored normal right hip and the dislocated left hip.

This case is, I think, a fair illustration of my subject, since it shows that a dislocation may be present, while the signs usually so characteristic of it, may be for the most part wanting or so modified and subdued as to be of little diagnostic value, and since their absence may be of most serious moment both to surgeons and patient, I have chosen as my subject—

AN EXAMINATION OF THE USUAL SIGNS OF DISLOCATION OF THE HIP.

I desire in the outset to say that I do not intend to enter upon a differential diagnosis; I shall confine myself to the points laid down in the text-books as diagnostic of dislocation, and try to show why these at times may be unreliable.

All the diagnostic signs of dislocation may be arranged under two heads, (1) loss of symmetry, (2) impaired function.

Loss of Symmetry.—In order to understand the nature of this asymmetry it will be necessary to turn to the anatomy of the joint, and examine the capsular ligament, since it is the untorn portion of this structure that contributes largely to the peculiar deformity under consideration. The capsular ligament may be said to pass from the brim of the socket to the neck of the femur. Behind it is thin and forms no strong attachment to the neck, but in front it is thick and strongly attached to the base of the neck. It is due to the retentive force of the anterior fibres of this ligament (the ilio-femoral lig., Fig. 1) that man is enabled to walk or stand erect; it is upon this portion that we rely for uniform symptoms in case of dislocation, while it is also upon the knowledge of its function that modern surgeons so much excel in restoring displacements. As an illustration of the great strength of this ilio-femoral ligament I may state that the severest test to which it can be exposed is when one falls a distance alighting upon the feet or knees; an accident that almost invariably results in a fracture of the thigh, thus showing the unequal contest between this ligament and the femur. It has been stated that dislocations are primarily downward, and that by consecutive

steps—*i. e.*, by a change in the limb, by its weight and average—the head of the femur is carried either upwards and backwards, or upwards, forwards, and inwards. If the head of the bone stops in the position in which it is first dislocated, the thigh will be advanced directly forwards; if it stops opposite the sciatic notch the thigh will be carried strongly over towards its fellow; while if the head of the bone rides up upon the dorsum ilii, Fig. 2, the thigh will be less

Fig. 1.

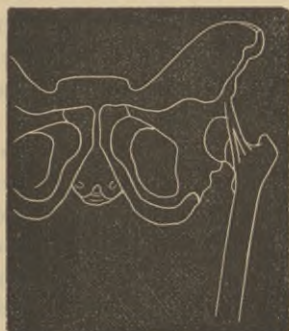
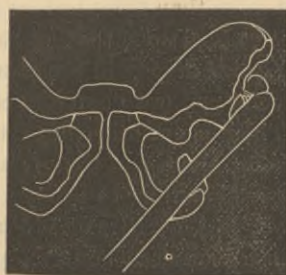
Fig. 2.



strongly adducted. Now in all of these positions the ilio-femoral ligament is put directly upon the stretch, and if it maintain its integrity there will always be uniform and characteristic deformity. But Bigelow has I think pointed out a valuable point under this head. He noticed that different parts of the ilio-femoral ligament were put upon the stretch in the various dislocations, and the thickening upon the borders of this (ilio-femoral) ligament led him to designate it by the term of (inverted) Y ligament. By reference to Fig. 1, this thickening will be understood. Now Prof. Bigelow noticed, when the dislocation occurred upon the sciatic and dorsal region, that the outer leg of the ligament was put upon the stretch, and that when the dislocation occurred upon the pubic or inner portion, the inner leg of the ligament was put upon the stretch. This led him to the solution of the variance in the degrees of deformity. Thus when the dislocating force was just sufficient to dislocate the bone, leaving the ilio-femoral ligament entire, the deformity would be great. If the dislocating force were unexpended after the dislocation, and carried the head of the bone still onward, exerting, as it could, great leverage by the weight and length of the thigh, then the tense portion of the ilio-femoral ligament would give way, and with it there would be a modification of the usual symptoms. Thus, instead of the thigh being always strongly adducted in dorsal dislocation, it may at times lie almost parallel with its fellow, and the foot, instead of being strongly

inverted, may not only look forwards but it has been known even in dorsal dislocation to turn outwards. When the dislocation is inward, upon the obturator foramen, the inner leg¹ of the ligament is put upon the stretch, and hence one symptom to be expected is the advancing of the knee. This will be well marked if there has been no additional rupture of the ligament beyond the dislocation, but if the tense portion of the ligament is ruptured, the knee will be too slightly advanced for this sign to prove of real diagnostic value. In the case of Peter J., already alluded to, the knee, as he lay upon the table, was not more than three or four inches above the line of its mate, and Dr. Reed relied upon the fact that he could feel the head of the bone slip under his fingers in the obturator region when the limb was circumducted, and not upon any characteristic deformity.

There is one other important point to bear in mind in reference to this ligament, and that is that the deformity will diminish by successive handling or use. I well remember in a case in which every effort had been made to restore a dislocation, that the surgeon, whose acuteness had first pointed out the deformity, was the only one to insist upon its reduction—because all the deformity had disappeared—*i. e.*, it was equal in measurement and gave the general appearance of symmetry. No other one present, however, felt that it was restored, and the fact that it is still unreduced proves his error. In this case the more the limb was subjected to restorative forces the less marked became the symptoms of dislocation.

One way of detecting deformity is to measure the lengths of the thighs. Upon this point I wish to state, that the information we gain must not be regarded as positive, but rather as a link in the chain of evidence; a link, too, that should be most rigidly tested before it is accepted. In measurements we must assume that one of the limbs at least is normal. Here was the error of all who saw P. J. before the reduction of the dorsal dislocation. When he stood upon his left limb there seemed to be at least four inches of shortening, and all who saw him attributed the shortening to the right thigh, but no one dreamed that, while the right one was shortened three inches, the left was actually lengthened one inch.

In a man who presented himself at the Presbyterian Hospital, it was noticed that the left limb was much shorter than the right, so that he walked along with a most decided limp; and yet upon measurement from the anterior superior spine of the ilium to the

¹ I have not found the inner and outer legs of this ligament invariably put on the stretch in inner and outer dislocations, but I have so far verified the observations as to state that different parts of the ligament are put upon the stretch under different circumstances.

inner side of the knee, I found that the left or apparently shorter limb was an inch longer than the long limb. This I measured several times, and my measurement was verified by Drs. Hodge, Neill, and Porter; but when at the suggestion of Dr. Hodge we measured from the symphysis pubis to the knees, we found the apparently shorter thigh to be an inch shorter than its fellow. I cannot explain this apparent discrepancy, and can only assert that we resorted to every means to avoid error. A similar result is recorded in *The Lancet*,¹ in which Mr. Adams (in a case of thyroid (obturator) dislocation) found a *shortening* of the dislocated thigh in measuring from the anterior superior spines to the knees, but when he measured from the roots of the penis to the knees he found a lengthening.

More than one instance has been recorded in which the two limbs being equal in length, no dislocation has been detected, the error being due to a previous fracture with shortening of the undislocated thigh. When measurements are taken, it is well to measure from the symphysis pubis, umbilicus, or ensiform cartilage, for under such circumstances one end of the tape will not require to be changed, and thus one avenue of discrepancy will be closed.

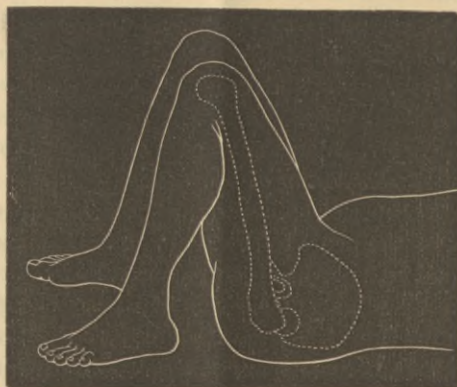Under this head I would mention that a change of posture may at times be of service, to bring out a feature that otherwise would not appear. I have noticed, when a thigh is dislocated upon the dorsum ilii, if the patient lies on his back and draws up both limbs to a right angle with the trunk, that the foot of the one that is dislocated will rest on the table while the foot of the thigh that is in its socket will be two or three inches higher, and cannot in this position be brought to the table. This will be readily understood by a reference to the cut, Fig. 3.

Impaired Function.—The range of motion enjoyed by the hip-joint is well understood; with this wide and perfect range of motion all the muscles and ligaments are in perfect accord, and hence one of the most evident signs of dislocation would be the want of harmony between the parts. Hence writers state that there will be a fixedness of the hip, and as the head no longer moves in a socket an unsteadiness and jerking sensation, due to the moving of the head, is imparted to the hand as the operator carries the limb through various motions. Stress is laid upon this fixedness of the thigh as a diagnostic contradistinction to fracture, and to make the test more striking and decisive, a crepitus is assumed in fracture, but declared to be absent in dislocations. To these evidences may be added the deprivation of the function of locomotion, the patient not

¹ 1850, vol. ii. p. 221.

being able to bear the least weight upon the limb, while pain more or less severe is always present.

Fig. 3.



In this figure it will be noticed that the head of the femur is just as far below its socket as the knee is below its fellow, and this permits the foot to rest on the table, a condition impossible for the sound limb.

All of these are valuable diagnostic points, but only valuable when rightly understood. Under impaired, or limited, or restricted motion one must not understand the patient to be meant. It is true that the patient cannot command the limb, neither can he in fracture or synovitis or rheumatism; the reference is directly to the sensations of restriction and resistance imparted to the surgeon's hand while manipulating the limb. Since the patient is usually placed under an anæsthetic, it is plain this resistance must be mainly due to the untorn capsular ligaments, and hence the constriction, resistance, limited motion *will vary with the extent of laceration of the capsular ligament*. In the case of P. J. I relied chiefly on two points for my decision that the head (left hip) was in place: first the easy steady motion of the hip, and second the wide and free area of motion through which I could carry the thigh. Over and over again I circumducted the limb to see if I could detect any unsteadiness, jerking, or resistance, and could elicit nothing to satisfy me that the head was not in its socket. It is true that the limb could not be adducted beyond a parallelism with its mate without *gently* springing back, and this *single* symptom spoke in favor of dislocation, but in obturator dislocations the knee is either markedly advanced, or abducted, while in this case the limb lay parallel with its mate and the knee only advanced about three or four inches.

Of all the points of diagnosis not one is harder to describe, not one is more thoroughly misunderstood than crepitus. The degrees

and qualities of the adventitious sounds and impressions we designate by dry and moist crepitus are quite as unteachable as the crepitant and subcrepitant of the physicians, the chief difference being that students plead ignorance of the latter, while no one doubts that he understands or may easily and fully comprehend the former.

The student is told that he can diagnosticate fracture of the neck from dislocation by the presence of crepitus in the former and its absence in the latter. I think I can say from an ample experience that crepitus is the least reliable sign in fracture of the neck, is seldom satisfactorily elicited, and when absent does not influence the opinion of the surgeon, while in cases of dislocation I have elicited a crepitus that could be heard distinctly by every one about the bed.

In a case brought to the Presbyterian Hospital, Dr. Porter shrewdly remarked: "I shall be satisfied that there is no fracture present if he makes a speedy recovery." The man began to draw up his limb in a week's time, and to walk about with crutches in a fortnight, and left with scarcely a limp in about three weeks; and yet in this case the head of the femur, when it rested on the pelvis, would permit of a crepitus as loud, harsh, and grating as that of any fracture. The fact is that bone is often denuded of its cartilage by the wrench that dislodges it, and the crepitus that follows is that of bone upon bone. Hence it is not true to say that in dislocation there will be an absence of crepitation, or if any be present it will be moist like that of cartilage rubbing against dense structures. One should be rather made to understand that crepitus may arise from various causes, and not simply from broken bone, and that nothing short of actual and extensive experience can make this symptom a reliable one.

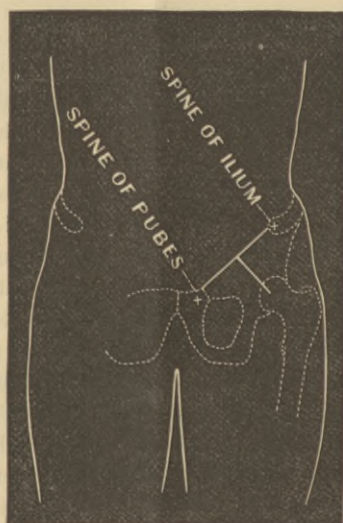The patient is usually rendered helpless. This is the rule, but there are notable exceptions to it, such as walking a hundred yards to one's home immediately after the injury, and when assured that there was nothing beyond a sprain, the patient walking three miles within a week.

It is always important in injuries of the hip to have the person stripped and stand erect. In the case of J. it was impossible after the right hip was restored to have him stand erect; and hence the free and unrestrained action of the left limb (dislocated into the obturator foramen) could not be made available.

In some varieties of dislocation the head of the femur can be felt, and presents also to the eye so manifest a tumor that the diagnosis hardly needs corroboration from other signs. The limb is shortened, the fascia lata rendered flaccid and comparatively little resistance is

offered to the fingers as they are made to mark out the head or grasp the great trochanter. But the prominence of the trochanter or head of the femur may be very slight when the dislocation is of the obturator variety. Here the head rests upon a muscular bed, and although the fingers may be pressed down deeply while an assistant circumducts and rotates the limb, yet I can speak from experience of the vague and unsatisfactory results of such impressions in this variety of injury; and even after Drs. Reed and Porter had assured me that they felt the head of the femur beneath their fingers, it was with great difficulty and much delay that I could give assent to their opinions.

Fig. 4.



This figure is introduced to illustrate a formula for finding the socket, or putting the finger over the position of the head of the femur when in its socket. *Draw a line from the spine of the ilium to the spine of the pubes. Bisect this and from this point draw a line at right angles to it equal in length to the halves of the first line.* The free end of the latter will lie over the socket.

Although in the foregoing remarks I have shown that the usual signs, as they appear under deformity and perverted action, may be greatly modified, yet I am happy to say that they are never so masked as to wholly deceive a careful observer. While the limb is dislocated there will be unmistakable evidence that there is something wrong. The danger lies not in regarding the hip as sound, but in attributing the symptoms to something else. It is a great misfortune when a hip remains out of its socket any length of time. A fracture of the acetabulum, a fracture of the neck, a synovitis, and kindred affections will be benefited by rest; but every day delayed

makes a dislocation more formidable. Hence, so long as there are symptoms unaccounted for, the patient should have the benefit of the doubt, and every advantage that anæsthetics can bring. To the use of the latter the patient and friends can have no valid objection, and when they oppose a barrier for insufficient reasons, there is but one course to pursue. The case is not to be angrily dismissed—since the objections come from friends and are often the fruits of ignorance—on the contrary, the surgeon or physician should acquaint them with the importance to the patient of an investigation, and the fearful responsibility of venturing in the case without positive knowledge, and then, if acquiescence is not gained, it is the duty of the medical attendant to take leave of the case. All will recognize the fact that the interests of the patient are always paramount to all other interests, but there are instances when the subordinate rights of the physician or surgeon assume a prominence that cannot wisely be disregarded.

I come now to the second part of my subject, viz.:

AN INQUIRY INTO THE PROPER COURSE TO PURSUE WHEN DISLOCATION
IS ACCOMPANIED WITH FRACTURE.

Before entering upon this subject, I desire to express publicly an appreciation of that manly sentiment that led Dr. Murdoch to brave unjust and narrow criticism, in publishing an error in diagnosis in the *Transactions* of this Society for 1878.

This complicated injury occurred twice in our State in very nearly a year. I am sure it is rare;¹ but I believe it is far more rare to find a surgeon *considerate* enough to acknowledge that he has overlooked the dislocation. Were all such cases published, physicians and surgeons would be more on the alert. As it is, the reported cases are so few that even our large monographs are almost silent on the subject.

CASE I.²—W. D., æt. 24, injured while coupling cars, Aug. 16, 1876. Losing his balance, he fell between the tracks, and two cars moving slowly passed over him. As there was not room enough for the car to pass over him in the clear, he was caught (as he thinks) by the brake rods. Three hours after the accident, Dr.

¹ I have references to at least fifteen parallel injuries in the shoulder-joint. This will, indeed, seem unaccountable from the shallowness and insecurity of that joint, and I think that very few will consider me extravagant when I say that upon anatomical principles this complicated injury ought to occur a half dozen times in the hip to once in the shoulder.

² History of a Case of Dislocation of the Hip, complicated with Fracture of the Femur, by J. B. Murdoch. Trans. of the Medical Society of the State of Pennsylvania, vol. xii. part i., where see full and excellent account.

Murdoch saw the case. There was then shortening of the right femur of one inch and a half, and a turning out of the limb; there was also a lacerated wound of the heel. Upon examination, the femur was found to have sustained a fracture in its upper third. The upper fragment, which was drawn upwards and inwards could be distinctly felt about two inches below Poupart's ligament. The direction of the fracture was from above downwards and from before backwards. It was noticed by Dr. Murdoch, at the time, that the upper fragment was drawn upward and inward to an unusual degree, but no suspicion arose in his mind of an injury beyond the fracture.

The thigh was dressed according to Buck's method, and every effort made with compresses and extension to bring the upper fragment into line with the lower. Failing in this, a Smith's anterior splint was applied about two weeks after the injury, and with a view of adapting the lower fragment to the upper, the apparatus was bent more at the knee than usual. This splint brought the fragments into better coaptation, and in this position it was retained for six additional weeks. It was two months after the injury, when on removing the splint, no union was found to have taken place. The limb was then encased in plaster of Paris—in this flexed position—and in this immovable dressing was retained for three more months. As the patient had been subjected to a recumbent posture for over five months, a sole-leather splint was contrived and the man permitted to go about on crutches.

Being of an active habit, he soon recovered sufficient strength to travel about, and for about eight months visited and consulted eminent surgeons, who advised him to submit to a resection as the only means of union. This he submitted to, at the hands of Dr. James McCann, a colleague of Dr. Murdoch—in the very hospital where he had been treated from the first and with the same hospital staff that had counselled Dr. Murdoch in his care of the man in his first injury. After full anæsthesia, an incision was made on the outer aspect of the thigh and over the point of the ununited bone. The fragments were found to be widely separated; the upper was drawn upwards and inwards—the lower backwards toward the tuberosity of the ischium—while between the fragments lay a thick band of muscular structure. As this band prevented the coaptation of the fragments it was cut, and then Dr. McCann was enabled to lift the lower or long fragment up to the upper one. This done the ends of the bone were freshened and wired, and the limb dressed upon a double inclined plane. The operation was skilfully performed, but death ensued in eight days. *Autopsy.* At the autopsy the most interesting feature of this case was revealed. For upon this occasion the head of the femur was found resting upon the tuber ischii, with

the upper fragment two or three inches long, pointing forwards and inwards.

CASE II.—Wm W., æt. 19, was struck while walking on a railroad track, by a car coming up behind him. He thinks he received the blow upon his shoulder and was knocked down, was conscious at the time, and remembers hearing some one say, "we have killed a man," but he soon lost consciousness and remained so for a few days. He was immediately taken to ——— Hospital, where besides other less serious injuries he was treated for fracture of the thigh. The fracture was at the junction of the lower with the middle third. He remained in the hospital seven weeks, at which time there was little if any difference in the lengths of the two limbs.

The man was discharged, and seven weeks later reappeared with the same limb about three inches shorter than when he left the hospital. This occurred from the fact that the head of the bone, dislocated upon the *dorsum ilii*, had remained during the cure about opposite the socket, but as soon as he began to place his weight upon the foot, the dislocated head gradually ascended until in seven weeks a shortening of three inches was most apparent.

Mr. W. then came to Philadelphia, and applied for aid at the Pennsylvania Hospital. Dr. Morton saw and examined the case under ether, but declined to attempt reduction. Through his kindness I saw the case.

Appearance.—Upon a superficial examination the dislocation is not apparent, there is no turning-in of the knee, and the leg and foot look natural, save the marked shortening. But, upon a more careful examination of the thigh, the dislocation is perfectly evident. The head of the bone is readily felt upon the *dorsum ilii*, and the direction of the upper fragment is characteristic of dislocation. There is at the knee a most notable thickening. This can be explained in the following manner, which the diagram (Fig. 6) will make more clear. The surgeon, unconscious of the dislocation, drew down, abducted, and rotated outward the lower fragment until the limbs should appear natural and of equal length. The upper fragment was, however, at the same time, obeying the laws of dislocation upon the *dorsum ilii*, and was shortened, adducted, and rotated inward. Hence nature was obliged to throw out a great excess of callus, otherwise this case would have shared the fate of Dr. Murdoch's case, and as a result non-union.

CASE III.—Henry S., æt. 9; while walking, his foot slipped into a hole and he fell with his legs separated, and on trying to rise he fell again on his left hip, his leg being still in the hole. He was removed within a few minutes to the Royal Free Hospital, where

Mr. Cooke noticed that the right limb was an inch and a quarter longer than the left, slightly abducted, with foot everted, and the head of the femur distinctly felt in the thyroid foramen. There was at the same time indistinct crepitus at the upper end of the shaft just below the trochanters, and at this point there was a projection which gave the impression that the head and upper part of the femur came off at right angles to the rest of the shaft.

Reduction.—This was accomplished by traction in a direction opposite to the displacement, while the head of the bone was manipulated and lifted into its socket by the fingers. The head went back with the usual snap, and was announced by a change in the limb, which became shortened and everted. As soon as reduction had been completed, the crepitus which had been very indistinct became readily apparent at the point of fracture.

Mr. Cooke felt that the ease of reduction was owing to its promptness, as scarcely ten minutes had elapsed from the reception of the injury. He thought the fracture, which in his opinion occurred at the second fall, was incomplete (greenstick) until after the reduction, when it became complete.

Treatment.—For the first fifteen days upon the double inclined plane, then upon the long splint.¹

Before entering upon the diagnosis and treatment of this injury I wish to offer the following propositions:—

1st. *These injuries, dislocation and fracture, cannot under any possible circumstances occur simultaneously in the same limb, but are always consecutive injuries, and are the result either of two separate and distinct forces, or of one continuous unspent force.*

A fracture may occur at almost any stage of existence. In old age there is the least toughness in bone, and the least capability to resist any great force; hence fractures are so frequent and dislocations so improbable late in life. In the prime of life, dislocations of the thigh are more frequent than at any other age, for at this age the femur has great strength, and is capable of breaking through its strong capsule, especially when the vulnerating force takes the capsule at a disadvantage. Thus, when the thigh is flexed, adducted, or abducted, a force acting at the knee, exerting a powerful leverage through the thigh, may effect dislodgment of the head. But let a dislocation occur by any means whatever, one thing may be said with precision; that dislocation would be impossible except in a strong, sound, and healthy femur, since a weak and brittle bone would fracture before the greater resistance in the capsule could be

¹ Lancet, 1864, i. 37.

overcome. Hence it is probable that before any secondary injury can take place, such as fracture, a dislocation of the head of the bone must have occurred. As soon as this is accomplished let us suppose the same or a continuous force to be still acting upon the femur. As soon as the head escaped from the socket, there was for the instant a suspension of all resistance, but the force continuing to act upon the thigh, the head of the bone must be carried away until it meets with a check or a resistance, and this may take place either in the bony irregularities or in the strong ilio-femoral ligament, or, as is most probable, in both combined. Here a new resistance to the force may arise. If the head can now slip away from the bony surface upon which it rests, or if the capsule can be torn, there will not likely be any further injury to the bone; but if the head of the bone is caught between the pelvis and the ligament the unspent force may fracture the bone since it has no means of escape.

There can be but little doubt that when the fracture occurs high up as in the upper third, the dislocation is always the first step, and the fracture the second in the morbid process, for it is hard to conceive of a force that could act upon so short a fragment and produce a dislocation. But this need not necessarily always be the case. It seems highly probable that even after a fracture has occurred in the lower third of the femur, that a peculiar force might exert sufficient leverage upon the long upper fragment to effect dislodgment.

2d. *The ilio-femoral ligament will always be found untorn, and the position of the head of the femur will be in close proximity to the socket.*

This proposition is the legitimate outgrowth of the first, and I give it prominence in order to add emphasis to a point in treatment hereafter to be mentioned. The ilio-femoral ligament is rarely if ever torn in any form of dislocation as the initial lesion. The head escapes from the socket, leaving this entire; and when the limb is unbroken it is possible for a sufficient force to be brought to bear upon this ligament after dislocation, to rupture a portion or the whole of it; but this presupposes an entire, an unbroken femur. When, however, this force is obliged to act upon a *fragment* of the femur it can hardly be supposed that the strong ligament will suffer in the least from any power acting at so great a disadvantage. Again, I may repeat that if the dislocated head of the bone could escape the new force, by slipping from its new position, or by a rupture of the ligament, it would do so; and the fact that a fracture resulted from this test shows that the ligament and its arrest upon the pelvis are more than a match for the femur. Hence I feel that it may be laid down with a reasonable degree of assurance that

the ilio-femoral ligament is untorn, and then follows of necessity the statement that *the head of the femur will lie in close proximity to the socket*. This must be true, first, from the length of the ilio-femoral ligament; and second, from the fact that the femur being broken, there is no sufficient weight in the limb to influence in any marked degree the position of the head. Whenever (in ordinary dislocations) the head of the bone is high up upon the dorsum ilii, and great shortening is present, it may be assumed that some portion of the ilio-femoral ligament has been ruptured.

3d. *The upper fragment will always be more under the control of the ilio-femoral ligament and the pelvic muscles than in uncomplicated dislocations, and will therefore always be more diverted from its axis than when the femur is unbroken.*

If the ilio-femoral ligament is answerable for the characteristic deformity of dislocations (as has been shown upon the cadaver) through its attachment to the anterior intertrochanteric line; if this ligament is strong enough to influence the movement of a strong and heavy limb, and that throughout all the years that a limb may remain unreduced, it is plain that when it has only a fragment of a femur to control and only a fraction of the weight of limb, the influence of this ligament should be at its maximum. This ligament is strong enough to advance the entire thigh when the dislocation is upon the tuber ischii. How much the weight of the limb might influence the ligament no one can say; but it is probable in all cases (and the case of Dr. Murdoch shows it to be possible in some) for the upper fragment to look almost directly forward, *i. e.*, to stand at a right angle to the axis of the trunk. (See Cases I. and III.)

Thus, whether the dislocation occurs primarily and a fracture follows, or the reverse, *the ilio-femoral ligament will be found entire, the head will lie in close proximity to the socket, and the upper fragment will be more under the control of the untorn portion of the capsule and pelvic muscles than in uncomplicated dislocations.*

Diagnosis.—In this compound injury the symptoms will partake both of fracture and dislocation. Those of fracture will always be present and unmistakable, and the danger is lest they overshadow the less apparent dislocation. When the fracture occurs in the middle or lower part of the thigh, the concomitant symptoms of dislocation will appear to best advantage, and the symptoms of dislocation will be less and less marked with the increasing length of the lower fragment.

Dr. Murdoch, who has given the subject a great deal of study, concludes that the fixed condition of the upper fragment, ought to give rise to the suspicion that a dislocation is present. In his article he ably reviews the various tests for dislocation, and finds

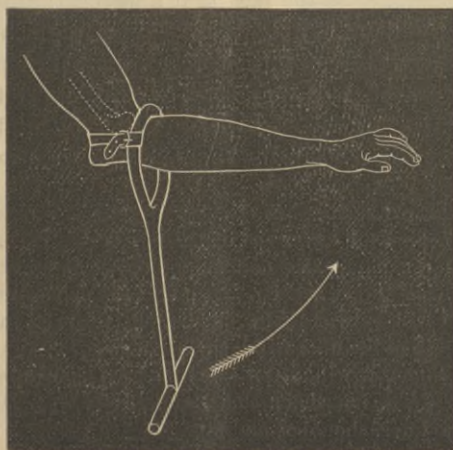
none that throw any light upon this complication. For my own part I cannot imagine a greater embarrassment than might arise from such an association of injuries, and feel that any surgeon would be justified in using an exploring needle to establish the fact of the presence or absence of the head of the bone from the socket. Under the previous article I have shown that simple dislocations may at times become most obscure, and if this is true when the femur is intact, how must it be increased by the presence of a fracture? Under such circumstances what gives assistance is the sense of touch. One must feel the head of the bone in its new position, and if the exploring needle and tactile sensation will not aid him he has no other resources.

Treatment (when dislocation is associated with fracture).—The first thing obviously to do is to reduce the dislocation. When the upper fragment is of sufficient length to be bound with the remainder of the limb to a long strong splint, the reduction may be attempted with every assurance of success; but when the upper fragment is short, then one must rely mainly upon his thumbs and fingers to push and lift the head into its place—since it is plain that extension under such circumstances would not avail anything.

There is no time so favorable for a reduction as immediately after the injury; and if the fragment was too small for grasping, and could not be conducted into its position by the thumb and fingers, I should not hesitate to employ a strong-pointed awl. This, or a gimlet or strong screw thrust into the great trochanter would be of great additional assistance, and might prove effectual.¹

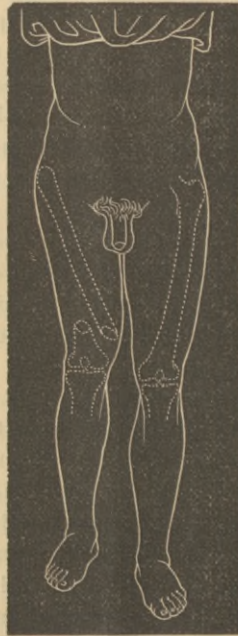¹ Although somewhat irrelevant, I desire here to introduce a most effective, simple, and ingenious contrivance of A. F. Edwards (*Lancet*, 1856, vol. i. p.

Fig. 5.



But when reduction cannot be immediately performed, when it must be deferred until after the union of the fragments, what course should be pursued?

Fig. 6.



There are two plans worthy of consideration, each of which presents a dilemma, and each should be examined carefully in order that an intelligent choice can be made. The first is to set the limb without any reference to the fact that a dislocation is also present. If we attach the pulley and weight to the lower fragment, Fig. 6, it will be drawn down agreeably to this new force, while if we place sand bags by the side of the limb it may be rotated outward to any desired degree. Now it should be remembered that no application to the lower fragment will influence the upper. The upper fragment, Fig. 6,

287) for reducing the upper end of the ulna that was separated from the shaft and dislocated behind the lower end of the humerus. It consists of an iron lever, made with a handle at one end and a loop at the other. The case was of three weeks' standing, when Dr. E. applied the apparatus. By reference to the diagram it will be seen that as the handle is carried in the direction of the arrow, the head of the ulna will be drawn forward by the strap, while the condyles of the humerus will, at the same time, be pushed back by the short arm of the lever. The instrument acted so perfectly, that Dr. E. has recommended it for the knee, shoulder, and hip.

if the dislocation is upon the dorsum ilii, will be *adducted* and *rotated inward*, and hence the extension and rotation outwards of the lower fragment will tend to separate the fragments. This separation of the fragments will vary according as the fracture is in the lower or upper portion of the femur. In Case I. the separation was so great that no union could be effected; in Case II. the limb was drawn down and rotated outward, and kept during the cure at a length corresponding to the other limb, and yet union took place, though the upper fragment was adducted and rotated inward.

Fig. 7.

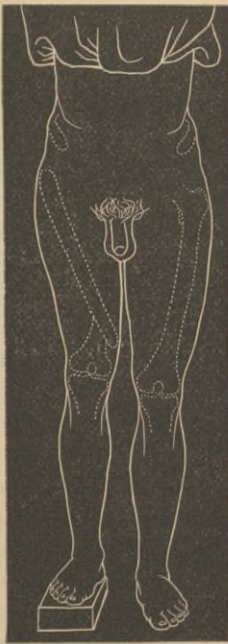
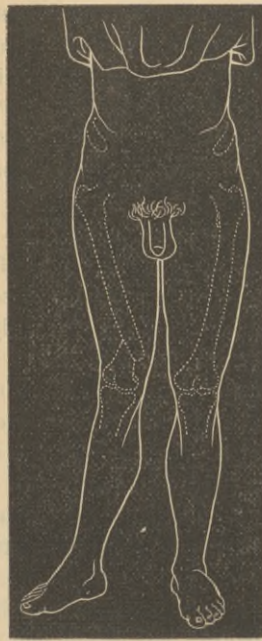
Fig. 8.



Dr. Murdoch suggests, in cases like his, where the fracture is high up, that the muscles should be permitted to draw the lower fragment to the upper, and that to apply extension in such cases is simply to defeat union.

After union has taken place, shall there be an attempt at reduction? This is an important point and worthy of careful consideration. It must be remembered that the limb has been set without any reference to the position of the upper fragment, that while the upper fragment was adducted and rotated inward (Fig. 7, taken from a photograph) the lower fragment was made to comport with the sound limb; *i. e.*, was rotated outward and extended. Thus when the

cure is effected the person presents but a slight deformity, Fig. 7, but if the poor fellow, unwilling to go through life with a dislocated femur, should have it luckily restored, a new deformity would arise, Fig. 8, since now the shafts of the femur become again symmetrical, and the angular deformity more manifest.

The only thing that could now be done, *i. e.*, to relieve the deformity brought about by the reduction, would be to refracture the bone, but the question arises, would it be safe to attempt a refracture immediately after the reduction—would it not endanger the recently restored head? Such would seem to be the case, and hence before an attempt at a refracture, the capsule should heal and another month at least be given to the fractured bone, and by this time the fracture would be so firm that to attempt it would be to endanger the bone at some other point, to say nothing of the risk one always incurs from a fracture of the thigh. *Hence when a dislocated and fractured femur is treated from the outset as if it were a simple fracture, it seems hardly justifiable to make any attempt at reduction after union of the fragments.*

The other course, and the one that seems to have far more in its favor, is to make the lower fragment assume the axis and direction of the upper fragment, and secure it in this position until union has taken place. This is the only course that secures coaptation of the fragments, and the only one that gives a rational promise of early and firm union. If the head lies upon the dorsum ilii, the upper fragment will be directed downward, inward, and a little forward, while at the same time it will be rotated inward, upon its axis. If the head is lodged in the region of the sciatic notch the lower fragment should be carried much in the same direction, only the knee should cross the sound limb about the middle of the shaft. When the head lies beneath the socket, *i. e.*, upon the tuber ischii, the end of the short fragment will point directly forward and upward, or forward and inward; but as the end could easily be felt, the lower fragment could easily be adapted to it. When the head lies in the obturator foramen, the direction will be downward, outward, and a little advanced. The position of the head of the bone and the obliquity of the upper fragment has been already alluded to, and should form the basis for the position of the remainder of the limb.

Having secured the limb now for about eight weeks, an attempt should be made at reduction; and this can be made with a reasonable hope of success. First, because the ilio-femoral ligament is entire and stands ready to aid the surgeon. Second, because the adhesions of the head of the bone are less to be considered than when the shaft is unbroken and the head with the entire weight of

the limb has been resting in its new bed. Adhesions form early and more effectively when the head of the bone presses firmly and continuously. Third, so many instances of reduction have occurred after two months, that few surgeons would refuse to give a man a chance under these circumstances, and then if a reduction were happily effected, there would be an end of the poor fellow's anxiety, and he could now be promised that in a few weeks he would be able to walk as well as ever.

But if reduction *cannot be* effected, then the best possible course will be to throw the head of the bone into the obturator foramen and let it form its new socket there. This will give the most serviceable limb, and most symmetrical figure. With an obturator dislocation a person can walk more naturally and with less inconvenience than with any other variety of dislocation. He can stoop, and flex the thigh to a right angle with the trunk; and the advantages of such a result will far exceed any other that can be obtained short of a complete reduction.

PHILADELPHIA, 1604 Spruce Street.

