

39

BIGELOW (H.J.)

Presented by
F. H. Brown M. D.

TURBINATED CORPORA CAVERNOSA.

By HENRY J. BIGELOW, M. D.

[REPRINTED FROM THE BOSTON MEDICAL AND SURGICAL JOURNAL, APRIL 29, 1875.]



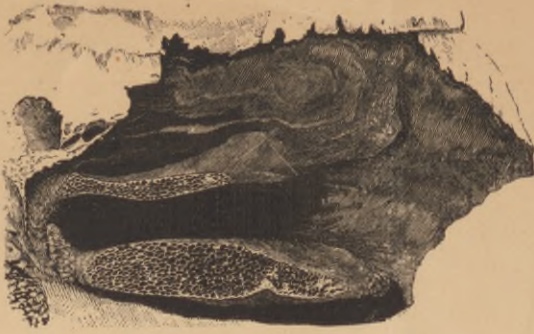

Fig. 1.

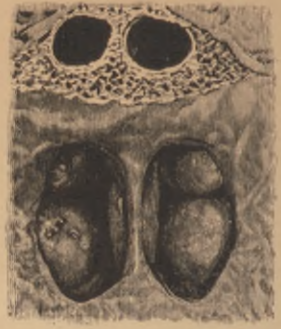

Fig. 3.

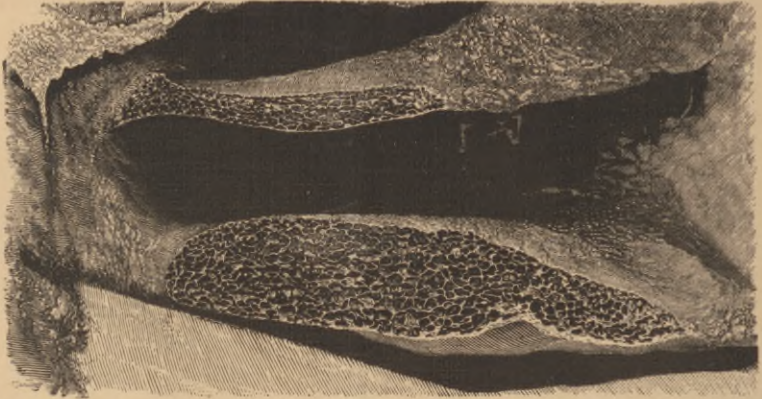

Fig. 2.

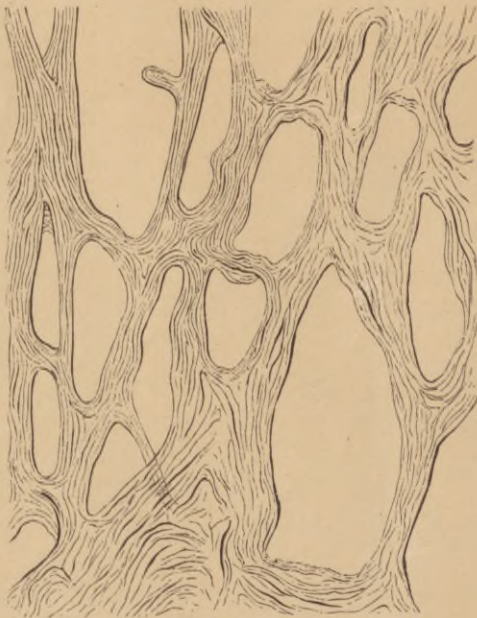


Fig. 4.

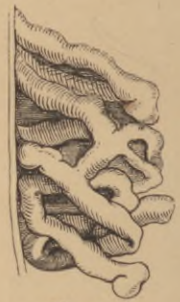

Fig. 5.

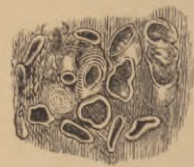

Fig. 6.

TURBINATED CORPORA CAVERNOSA.

BY HENRY J. BIGELOW, M. D.,

Surgeon of the Massachusetts General Hospital and Professor of Surgery in Harvard University.

THAT the turbinated bones are imbedded in erectile corpora cavernosa is a fact of interest to both surgeon and physician. But that this simple and satisfactory explanation of the every-day phenomena of a "cold in the head" has not yet passed into current science is sufficiently shown by the little attention given to the subject in most standard modern works of descriptive anatomy. Venous congestion, dilated veins, veins resembling sinuses, venous plexuses, etc., are sometimes briefly spoken of as explaining the singular tumefaction of the Schneiderian membrane during inflammation; but very commonly this membrane, as a locality of erectile tissue of any sort, is ignored altogether.¹

Many years ago, while examining for operation the cleft palate of a

¹ It is a little curious that Rouget, who has made an elaborate study of erectile organs, makes no mention of the Schneiderian mucous membrane. (*Du Tissu érectile*, etc., Paris, 1856; *Journal de la Physiologie de Brown-Séguard*, vol. i., 1858; *Comptes rendus de la Société de Biologie*, 1857; *Des Mouvements érectiles*, *Archives de Physiologie normale et pathologique*, 1868, page 671.)

Eugene Boeckel, in the *Nouveau Dictionnaire de Médecine et de Chirurgie pratiques*, Paris, 1870, t. xiii. pp. 721, 722, in an extended consideration of the subject, states, as the result of his own investigations and those of Kobelt, that erectile tissue is confined to the genital apparatus, male and female, internal and external; but that Rouget, who "considers as erectile every organ in which arterial or venous plexuses are submitted to the action of smooth muscular fibre," "finds erectile tissue" not only "in the wall of the vagina, the uterus, the substance of the broad ligaments, and in the wing (*aileron*) of the ovary," but also "in the iris." The Schneiderian membrane is omitted in these enumerations.

EXPLANATION OF FIGURES.

Fig. 1. Upper jaw showing sections of turbinated corpora cavernosa, inflated and dried.

Fig. 2. The same magnified two diameters.

Fig. 3. Turbinated corpora cavernosa injected with gelatine and seen from behind. The injected and thickened septum is also seen.

Fig. 4. Section of posterior extremity of a turbinated corpus cavernosum, hardened in alcohol, treated with iodine and glycerine, and magnified ninety diameters, showing cavities, walls, and trabeculae.

Fig. 5. (*From Kohlrusch.*) "Venous loops" injected.

Fig. 6. (*From Kohlrusch.*) Section of venous loops, showing the so called "cavernous venous tissue" and "cavernous cellular tissue" of Kohlrusch, consisting of "firm cellular tissue uniting vascular loops."

patient who happened to have a catarrh, I was attracted by the excessive turgescence of the mucous membrane on and about the inferior turbinated bone; but yet more, when it suddenly collapsed like the lung of a small animal. Remarking then to an assistant that this phenomenon was much more suggestive of the action of erectile tissue than of merely vascular congestion, I have since not unfrequently ventured to tell some suffering doctor that he would find upon the inferior turbinated bone an erectile tissue to elucidate, if it did not alleviate, his symptoms. Having, during the last year, examined the tissue in question, I have been able myself to identify a remarkable and well-formed cavernous structure, at least upon the inferior and middle turbinated bones.

The difference in the size of the distended and collapsed cavernous bodies is quite striking, and is best seen upon the inferior turbinated bone. Collapsed, the outline and dimensions are nearly those of its attenuated bony framework. Distended, it becomes an angry, turgid mass, of uneven surface and livid color, completely closing the lower nostril. A pouch-like process projects from the rear of the bone, increasing its length, and with the aid of a blowpipe readily showing on section, to the naked eye, the cavernous cells. It is this reticulated pouch that is seen with the mirror at the back of the nares.¹ Above it, is seen the middle turbinated mass, similarly distended; and if the injection of the whole membrane is considerable, the nasal septum also swells to the thickness of nearly one quarter of an inch, especially near its posterior edge. (Fig. 2.) With a little mucus in the interstices, the nostril is thus completely obstructed, the opposing surfaces doubtless producing by their firm contact the sense of weight and pressure sometimes experienced during the progress of a "cold." A depression in the bony septum sometimes corresponds to a protuberance of the cavernous tissue as if it had yielded to repeated pressure.

If inflated and dried, the cells project upon the surface. A section (Figs. 1 and 3) then gives further evidence of a cavernous structure, with closely juxtaposed cavities tolerably uniform in size and equally distributed; approaching quite nearly both the mucous surface and the bone. They communicate by irregular apertures, while minute bands and septa traverse and connect their common walls. A wet microscopic section (Fig. 4.) exhibits thin trabeculae and walls, composed mainly of connective tissue, presenting cavities of unequal dimensions, and closely resembling the cavernous structure of the penis;² although the smooth muscular element, as also the tunica albuginea, of the latter are some-

¹ For a description of some of its various appearances, see papers by Dr. Cutter in this journal, lxxiii. 397, etc.

² For the annexed section, near the cavernous pouch, I am indebted to Dr. A. N. Blodgett, and for the drawing to Dr. Quincy.

what more pronounced; as might be anticipated from the comparative erectile tension of this organ.

The opaque and bulbous termination of a "helicine artery," once supposed to be characteristic of erectile tissue, is considered by Stricker to be only an accidentally folded extremity of a "vascular loop." It is figured as a dilated loop in Todd and Bowman's *Anatomy and Physiology* (1856, page 6), and the drawing is taken from the olfactory membrane of the human fœtus. Observers differ about the dilatation.

Everybody is familiar with the firm and sudden impaction of the nose in acute catarrh; and has learned that a swallow of water, a pinch of snuff, a sudden start, mental or physical, as often clears the passage, to be again filled up. Medical men have usually taken for granted, as a satisfactory solution of these phenomena, the existence of a "congested mucous membrane;" and to explain this, an exceptional vascularity of this membrane, numerous and large veins, "venous plexuses," "cavernous venous plexuses," any or all of which would be, in fact, sufficient to distend a loose texture.

It is plain that either of the structures here enumerated might be artificially distended by the anatomist, with fluids or with air. But let it be remarked that if what is designated as a "venous plexus" resembles the choroid plexus, it consists of a bundle or skein of hollow loops or vessels, inside of which the blood circulates as usual, and is not a tissue of solid trabeculæ outside of which the blood collects in irregular cavities, as in the corpora cavernosa and spongiosa of the penis. In short, while the obstruction of the nasal fossæ is familiar, the explanation of its machinery has been neither uniform nor wholly satisfactory.

In the following quotations from the principal anatomists who have given attention to this subject, it will be found that the erectile action is attributed to the existence of a "venous plexus" or of a "cavernous venous tissue," in short, to enlarged vessels, rather than to well-developed "corpora cavernosa." Even Kohlrausch, the chief authority on this point, whose early investigations best cover the ground and are most quoted, figures only a section of distensible loops and veins traversing a dense structure in which they are separated from each other. (Figs. 5 and 6.) I have become acquainted with these various investigations for the first time, in looking up the subject since my own preparations here figured were made.

Hyrtl, to whom Kohlrausch refers, says, "The veins of the mucous membrane form plexuses which remind one of the relation of the veins in the cavernous bodies."¹

Kölliker affirms that "the thickness of the mucous membrane of these parts is not solely dependent upon the glands, but also, particu-

¹ Topographical Anatomy, i. 285.

larly on the edge and the posterior end of the lower turbinated bone, upon the abundant venous plexuses of almost cavernous character discovered by me in the interior of the same, so that a sort of erectile tissue exists here." ¹

Lastly, in Müller's Archiv (1853, page 149), is the communication from Kohlrausch before alluded to, from which the following is taken: "The simplest means of persuading one's self of the presence of this cavernous venous network, which is particularly developed upon the posterior portion of the turbinated bone, is by inflating it with air. By hardening such an inflated preparation in alcohol, we may get very good sections for observation. This cavernous venous tissue is beautifully injected at times, when the injection succeeds, by inserting a tube in one of the jugular veins. From such preparations are the drawings (Figs. 5 and 6) taken. The venous network, joined everywhere by abundant anastomoses, lies between the periosteum and the mucous membrane, and is everywhere, in a distended condition, $1\frac{1}{2}$ – $2'''$ thick. The venous loops, in their main direction, are vertical to the bone, showing in the injected condition a thickness of $\frac{1}{3}$ – $\frac{1}{2}'''$, and have tolerably firm and thick walls. A firm cellular tissue unites the vascular loops with one another, so that on section we see merely a cavernous cellular tissue; we can obtain such a specimen (Fig. 6) only by a careful and successful experiment."

It would seem from this description that Kohlrausch, observing that the turbinated tissue could be inflated with air, endeavored to throw into it a common injection, from the jugular vein. This injection failed to reach the cavernous cells. But it did distend veins and loops which were adopted and figured by Kohlrausch as the mechanism of erection. These veins and loops represented, as he erroneously supposed, the structure he had previously observed, on section, in the alcoholic preparations, and are offered by him as such.

It will be perhaps conceded that practitioners are not generally familiar with this anatomy, of which they will readily make a practical application; and lest injustice should be done to the investigations of twenty years ago, the text and figures of Kohlrausch are here carefully reproduced.

