

NEW YORK CLINICAL SOCIETY.

Meeting of January 27, 1888.

The President, Dr. ROBERT ABBE, in the Chair.

Alexander's Operation.—In a discussion on this subject the PRESIDENT said that he had had an experience with Alexander's operation which had developed in him some enthusiasm for it. He had performed it eight times, with, as far as could be judged at present, marked success. The earliest operation, however, dated back only a year and a half. In four cases the operation was done for extreme procidentia, in three for moderate procidentia, and in one for retroversion.

The case of retroversion was the first. The uterus was tilted completely backward on to the rectum, and gave the usual symptoms in great severity. The patient was practically disabled. The ligaments were very easily found, and the uterus was dragged up by pulling them out three inches and a half on one side and four inches on the other. Then one ligament was pulled through the subcutaneous cellular tissue over the pubes to the opposite side, and there tied in a knot with the opposite ligament so as to make it perfectly secure against retraction. The wounds healed primarily and the womb was held up against the pubes. The patient remained perfectly well five or six months, when pains developed in the pelvic cavity of a different character from those which had existed there formerly. It was found necessary to remove the ovaries, and during the operation he had an opportunity to examine the condition of the uterus. It was being held up in its normal position without the slightest retroversion. The round ligaments were firm, but not in a state of marked tension, showing that they were in the position that they had been placed in a year before. The uterus when



first replaced was in a state of hyperplasia; the fundus was large and heavy, and the cavity measured three inches and a half. At the time of the laparotomy the uterus was still

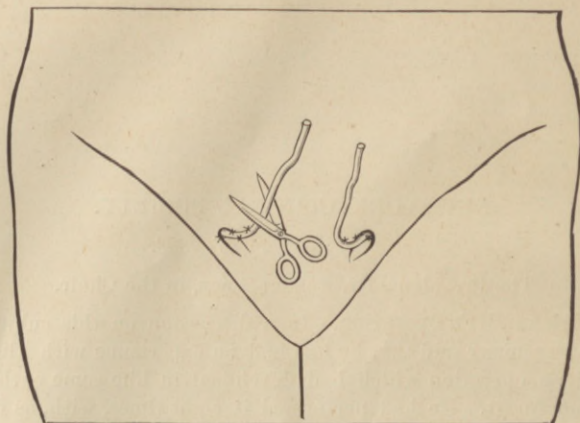


FIG. 1.—The usual method of securing the round ligament and cutting off the end.

large, yet it was being held in position. The removal of the ovaries led to marked atrophy of the womb.

The next case was one of procidentia uteri. While it was

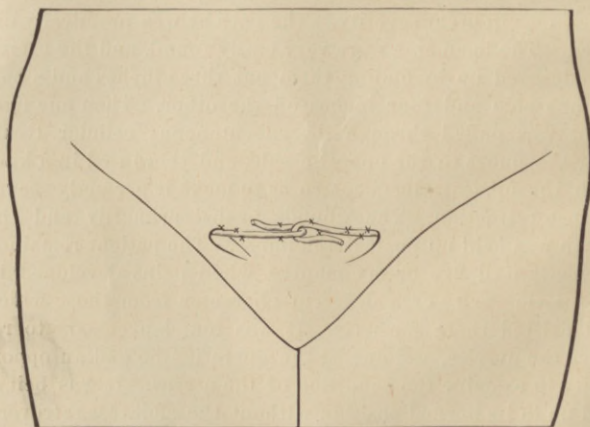


FIG. 2.—Subcutaneous looping and stitching of the ligaments together, a small incision being made.

not an extreme case, yet the womb was outside the body. Alexander's operation was performed in the same way as in

the first case, except that the ligaments were pulled out a distance of four inches on either side. A small incision was made over the symphysis, through which both ligaments were drawn, one from either side, when they were looped together and the two ends stitched to one another to retain them firmly in place. Primary union took place and the patient made a good recovery. The patient married a second husband soon after the operation, and there has not since been the slightest indication of recurrence of the procidentia. The operation was done eighteen months ago.

In another case the procidentia existed in the third degree, and cystocele was well marked. In this case he tied a knot in the round ligaments over one inguinal ring. Primary union occurred. The uterus was retained well up in position. This patient had had the womb outside of the vulva three or four years, and had suffered much in consequence.

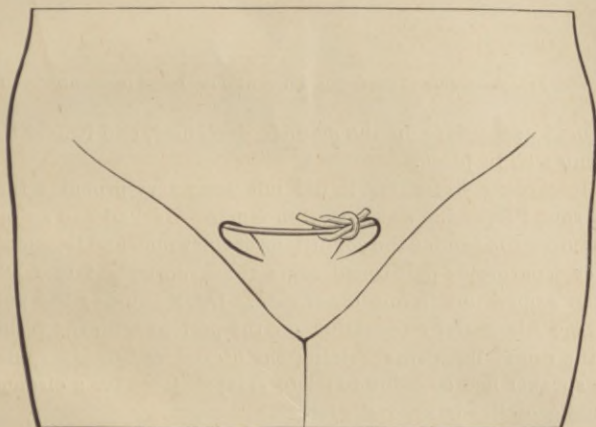


FIG. 3.—Knotting of the ligaments together subcutaneously.

In one other case he resorted to a different method, which he thought well illustrated the manner in which success was obtained in holding the uterus in position by the round ligaments. The ordinary method of cutting off the redundant portion of the ligaments after pulling them out, and stitching the remaining portion at the inguinal ring, it seemed to him, gave a chance for the ligament to slip back. He had practised three different methods in order to avoid this accident. The first consisted in looping the ligaments together, the second in tying them together in a knot, and the third in using them as a suture to close the wound made while searching for them. He had resorted to the latter method in three or four

cases. Primary union had followed, the ligament could not possibly slip back, and the result had been uniformly good. In one case he had been able to find but one ligament, which

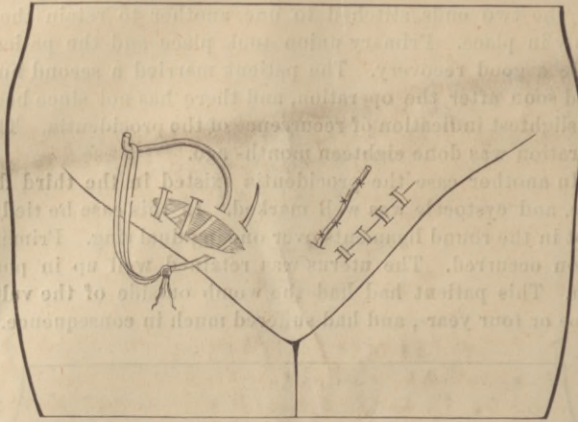


FIG. 4.—Suture of the inguinal ring with the round ligament.

he used as a suture in the manner described, and it held the womb well in place.

Regarding stretching, it did not seem very probable that the round ligament would stretch much. He had had an opportunity to examine the conditions of the womb and ligaments after laparotomy performed some time subsequent to Alexander's operation in one other case. Dr. McBurney had performed Alexander's operation on the patient with the result of the round ligaments holding the uterus well in place, and the speaker had occasion to perform laparotomy for a circum-rectal growth some months later.