

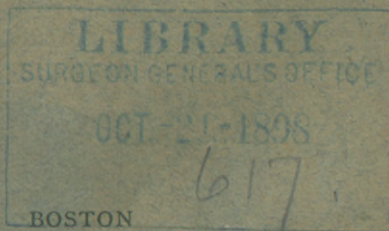
ABBE (R.)

Intradural Section of the Spinal Nerves
for Neuralgia

BY

ROBERT ABBE, M.D.
NEW YORK

*Reprinted from the Boston Medical and Surgical Journal of
October 1, 1896*



DAMRELL & UPHAM, PUBLISHERS
No. 283 WASHINGTON STREET
1896

S. J. PARKHILL & CO., PRINTERS
BOSTON

OCT.-21-1898

617.

INTRADURAL SECTION OF THE SPINAL
NERVES FOR NEURALGIA.

BY ROBERT ABBE, M.D., OF NEW YORK.

SYLLABUS.

(1) Brief report of three cases in which parts of the posterior roots of the brachial plexus were divided or resected at their origin from the cord (intradural) for neuralgia.

(2) Consideration of effect on sensation, theoretical and practical.

(3) Consideration of the class of cases of ascending neuritis to which such operation might apply, and of the difficulty of diagnosis from hysteria.

(4) The relative innocence and simplicity of intradural spinal surgery, if properly done.

NEARLY eight years ago I operated upon the first of three cases of intradural section of the posterior spinal roots which are presented for discussion this evening. Although two have been reported six years since, I repeat their histories in this connection as it is necessary for comparison in the group. They were included with a number of spinal operations I had done, and I then said, I "had no rose-tinted picture of startling achievements in spinal surgery."

To-day it may be said that spinal as well as brain surgery is quietly adding experience to experience, and we must pass by the *very few* brilliant results that have been obtained, to give our attention to more serious study of the cases which may yield fruit later, though not attaining wonders at first.

The unusual character of this operation and the fact that I have been able to keep the patients under observation and report the end results, after periods of from two to eight years, imposes a duty upon me of recording whatever may be of interest in them.

I am stimulated further to do this by questions occasionally received from correspondents, as to whether this operation would help certain neuralgic cases.

With equal implied questioning Mansell Moullin refers to the report of my first case, of which operation he says, "but whether with permanent benefit is not *yet* known."

The three cases I ask your attention to were all men in young middle life and in each the arm was the seat of trouble.

CASE I. Mr. I. R. T. is forty-four years of age, an iceman. He was referred to me by Dr. C. L. Dana, of New York, to see if I were willing to undertake an operation, conceived by him, to relieve the patient of one of the most intractable of neuralgias of the right brachial plexus, appearing in the arm and forearm. The essential features of the operation were carried out as planned from the first by Dr. Dana. The patient's history is as follows:

Prior to this trouble he had no disease — rheumatism, malaria or specific. During the war a small piece of an exploding shell buried itself in his left shoulder. This was extracted on the field, and left but a small flesh scar; never otherwise injured. One year ago last May, he spent a day putting in a zinc lining in a butcher's large refrigerator, and on the night following he first had a throbbing pain, localized in a single spot on the posterior surface of the right forearm, above the middle. The pain kept him from sleep. It was continuous at that site, but about one week later there was added a paroxysmal pain giving a peculiar twitching sensation in the thumb, index and middle finger of the same hand. He was treated by electricity, blisters, counter-irritants and internal medication, by excellent doctors, but his arm grew steadily worse. The pain was still localized over the forearm, and supplemented by the paroxysms of painful twisting sensation. There seems to have been distinct muscular spasm with the sensation of pain.

During the spring of last year there had ensued a

disablement of the hand. The fingers were not readily closed nor extended. The hand was kept in a stiff position, the fingers semiflexed. The forearm and hand were slightly emaciated. There was atrophy of muscle in the interosseous spaces. Dr. Dana and others then saw him, and a diagnosis of ascending neuritis was arrived at. At this time he came under the care of Dr. W. T. Bull, at the New York Hospital. After a week the patient begged an operation, and the doctor stretched the posterior interosseous and ulnar nerves. The pain was not improved. If anything, it was worse.

On July 16th, at the patient's earnest request, the arm was amputated by Dr. Bull above the humeral insertion of the deltoid, and above any site of local pain heretofore complained of. The wound healed by first intention. As far as the eye could judge, all nerves in the arm were in a normal condition. When the wound had healed it was found there was no abatement of pain. It still had a "drawing" character, and he could feel the fingers twist just as if they were on. He left the hospital August 1st, if anything, complaining of more pain than before. He then came under the care of Dr. William Kemp, of New York, who again sought Dr. Dana's counsel. The patient had now got in the habit of taking morphine, one-half grain every hour, to destroy the pain.

Of this interview Dr. Dana writes me thus :

"On September 25th I examined him again. The arm had been removed. The patient said he felt no better. There were twitchings and tonic contractions in the muscles of the stump. The patient had the Brauch-Romberg symptom, swayed in standing, and had a tendency to fall to the right when walking with eyes closed. Knee-jerks exaggerated and ankle clonus in right leg, all of which might be due to the morphine he was taking. There was much stiffness in the neck muscles. The patient could not rotate his head completely to the right, nor draw the head down to the right shoulder. The diagnosis so far had

been neuritis — and of this there could be no doubt. The question was whether it might be due to a tumor or inflammatory process, either extra-spinal or extra-dural. An exploratory operation was advised with the idea, if no tumor was found, of cutting the posterior roots of the nerves transmitting pain. If it were a tumor, *that* could be removed. If it were ascending neuritis, cutting or resecting the nerve might stop it; while cutting the posterior roots would cause an ascending degeneration and destroy the sensory tract, even into the spinal cord.”

At this juncture he went to Dr. Seguin for a month, and returning to Dr. Dana, was sent to me at St. Luke's Hospital. His condition then was as follows:

November 2d. Had grown thin, was careworn, and hollow under the eyes. Appetite fair, tongue coated. No fever. He gives evidence of sharp pain, every few minutes, in the stump of his right arm, and usually doubles over and grasps the stump with the other hand. When asked about it, says it jumps and the stump draws to his side when the pain shoots into the hands and fingers, as if they were still on, and he can feel them all drawn up. The pain seems to be genuine, and the recurrence every five or ten minutes. He says, also, that it keeps up all night. Muscular atrophy is beginning to be marked about the shoulder, either from disuse or degeneration. The deltoid, supra- and infra-spinati, and biceps are atrophied; while the latissimus dorsi and pectoralis major are short and thin, but still act strongly when called upon. A small, tender neuroma of the musculo-spiral nerve in the stump can be felt, and on pressure gives the same pain as is generally complained of.

November 7th. Dissected out the neuroma under cocaine.

November 24th. Not relieved by the removal of the neuroma. Urine 1.024, no albumin or sugar. Some oxalates.

December 31, 1888. Operated under ether, Dr. Bangs assisting, in the presence of a number of promi-

nent neurologists and surgeons. The usual surgical precautions were carried out. An incision was made along the ligamentum nuchæ, on the right side, from the third cervical spine to the first dorsal. The soft tissues were quickly separated from the spine, and the right half of all the laminæ well out on the articular processes. With rongeurs the laminæ were quickly gnawed away from the spine to articular processes — thus bringing into view the rather full pulsating dural membrane of the cord.

The seventh, sixth, fifth, and half the fourth vertebræ were thus treated. Severe venous bleeding from under the latter was only controlled by an aneurism-needle protected by cotton and hooked up beneath the bone. Over two inches of dura was exposed. It was soft and allowed the finger pressure to feel the cord. No tumor was thus detected, nor did a director passed up and down the canal feel anything like tumor. There was no inflammation or disease of the hard parts. With a heavy curved hook I then explored the intervertebral foramina, and drew back the sixth nerve by hooking under it and pulling gently, so that a short loop of it was raised on my hook outside its point of exit from the dura, but inside the vertebral canal. Upon this root, thus raised, I applied a small metal electrode, while the opposite pole (a sponge electrode) was held on the back. Dr. Dana noted the effect. The same was tried on the seventh nerve, with less effect. My own observations, as did those of Professor Markoe and others, coincided with Dr. Dana's. He writes: "on the day of the operation, a faradic battery of one cell, moderate current, was used. A sponge electrode on the back, a metal point electrode on the nerve. When applied to the sixth nerve, just external to the dura, it caused contraction of the supra- and infra-spinati, rhomboid, latissimus dorsi, pectoralis major, teres and deltoid. The results of electrizing the seventh nerve were not so satisfactory, it not

being certain that the point reached that nerve alone (on account of fluid that collected around the electrode). It was impossible to drag out the fifth nerve without exciting more hemorrhage from the venous sinus." The eighth nerve also was hidden below the bone, and it was thought enough had been done. The sixth and seventh were then again raised up from their beds and cut square across just outside the dura. Both motor and sensory roots lie together at this point, so that they must have been severed. The wound was packed, entirely open, with iodoform gauze covered by a voluminous gauze dressing. He bore the operation well, but soon found his old pain seemed much the same — still low down in the hand.

January 2d. Forty-eight hours after the operation I felt that I ought to divide at least one more branch (the eighth) if I could do so, in order to reach the lower arm pain. I therefore determined to proceed as follows: place the man prone, without ether, and open the dura, so as to get a clew to the sensations of the nerve-roots when handled. With the assistance again of Drs. Dana, W. T. Bull and others, I operated.

The patient was placed under a brilliant light, face downward, so as to maintain the operated part as the highest of the spinal axis. I carefully removed the packing, revealing a large, clean, dry wound, at the bottom of which lay the dura, throbbing and sound. Puncturing it with a knife, I slipped in a fine director and slowly let out the spinal fluid until it ceased to run. Then I slit up the dura for one and a half inch. The cord and membranes looked sound. The effect of evacuating two ounces of spinal fluid (carefully collected and measured) was practically *nihil*. The pulse did not change, and he experienced no sensations or pain. The dura was scarcely at all sensitive to cutting. I now picked up the roots of the eighth nerve within the dura at the level of the seventh nerve outside.

It looked normal, but I cut it close to the posterior columns of the cord, and then snipped off one-fourth of an inch for microscopical examination. Handling this nerve-root gave him the greatest pain of anything I had done, and of a kind exactly corresponding with that from which he constantly suffers. I had reason to hope, therefore, we had reached the offender. In addition I cut also the posterior roots of the seventh nerve, close to the columns of the cord.

In two operations, therefore, I had cut the sixth nerve, both roots, outside; the seventh, both roots outside, and also the posterior root inside; the eighth posterior roots only inside the dura. It was observed that the contact of even a blunt instrument to the posterior columns gave a sharp agonizing pain over the entire body, the patient crying out, "Ah! I *can't stand it.*"

We again tried the battery, and with regard to it Dr. Dana writes: "On the second trial, the patient being conscious, stimulation in the same way — of the peripheric end of the cut sixth nerve — caused contraction of the supra- and infra-spinati and rhomboid. Of the seventh nerve, contraction of the pectoral, latissimus dorsi, and adductors of the arm, with pains such as he usually suffers. Of the eighth nerve, similar contraction and intense 'drawing pains,' exactly such as are usually felt."

The slit in the dura was now sutured with fine cat-gut. A little cocaine had been injected subcutaneously along the skin half an hour before, and this allowed of painlessly suturing the entire length of the wound. Immediate union was obtained by second intention, and leaves a small linear scar. The patient had more or less pain in the arm in the next ten days, but it changed in character. It no longer went down into the fingers. It was a "drawing of the stump," as he expressed it. It ceased to go up on the shoulder as it once did. He was allowed enough morphine to

quiet pain for eleven days, when I deemed it best to let him sit up and stopped the drug entirely.

He missed it but quickly got used to it, and since has had even less pain than when he was getting his morphine to quiet it. He walked freely at the end of the third week, and soon went out in the open air.

His temperature was 101° F. on the second day, and 102° F. on the fourth, but declined from that to normal on the tenth. There is anesthesia of the skin of the entire outer side of the arm from the deltoid region downward, extending across the neck from the centre of the clavicle to the centre of the scapula. This area of the skin showed a short period of irritability, without sensation, from the fourth to the eighth day after the root section, as shown by getting quickly and persistently suffused when brushed over or handled; but when pinched retaining an extreme blanching at that point, which did not recover for two or three minutes. This entire area is now, however, normal in appearance.

The subsequent history of this patient is as follows: His morphine habit was in abeyance for a year or two, and he gained twenty pounds in weight. At the end of four years he complained that he still had some shooting pain in the stump and the drawing feeling in his fingers of the amputated arm. At the time he had again resorted to morphine, using a grain daily; and was seeking an increase in pension—for this reason, I discounted his complaints. His stump showed cutaneous anesthesia of the outer half extending up over the deltoid. Between seven and eight years after operation he still complains of the drawing pain in his amputated fingers for which he takes one and one-half grains of morphine daily. He is living in the suburbs of New York and maintains his health.

CASE II. Intractable brachial neuralgia: intradural division of the posterior roots of the sixth, seventh, and eighth cervical and first dorsal nerves.

Gabriel Z——, aged forty-five. Patient gives no history of rheumatism or syphilis, but has had malaria at one time.

In the latter part of 1886 he states that he exposed his arm at the window of a street-car while he was in a perspiration and he dates the beginning of his trouble from this time. A few days afterward he experienced sharp pain between his thumb and index finger. This grew steadily worse and at length became located on the outer side of his forearm and was accompanied by a feeling of drawing and twitching of the little and ring fingers as well. The pain extended up the forearm. It was intermittent, but of such severity as to cause him to cry out. After two months he grew weak and nervous, lost his appetite and suffered so much that he had to give up his business. The attacks were paroxysmal and the sensation described by the patient was that of a "drawing pain," the acute seizure leaving some continuous pain and soreness on the ulnar side of the hand and arm.

In August of the following year his ulnar nerve was stretched by Dr. L. A. Stimson. The pain grew steadily worse, the attacks coming on more frequently at intervals of half an hour. The pain spread over the forearm and hand, and in July, 1888, the ulnar nerve was excised by Dr. Fluhner. Following this the pain recurred in an exaggerated form, and the nerves of the brachial plexus were stretched in the axilla by Dr. Gerster. The paroxysms became even more severe, coming on every five minutes during the day and every half-hour in the night.

After the first operation the forefinger became drawn backward and the forearm wasted. The patient took to morphine in large quantity with only temporary relief.

On February 9, 1889, the patient came under my care. Examination showed him to be a rather intelligent man, of spare physique. He bears evidence of

long suffering and has a haggard expression. His attitude is peculiar; he sits with his head bent forward and his body bent so that his left elbow rests upon his knee, his right hand grasping his forearm, the elbow semiflexed. At intervals of a few minutes he is seized with violent paroxysms of pain which he describes as of a "drawing" character extending from the fingers up the forearm, as though his fingers were being drawn away from his hand and his hand from the forearm. He has a habit of shouting with these attacks of pain, which have made him a source of dread in the neighborhood of his residence. Grasping his arm he will walk the floor in agony for from three to five minutes until the pain subsides. The night attacks are similar to those of the daytime, although not so frequent. Sleep is, of course, only fragmentary. Urine showed specific gravity 1.009, no albumin. The flexor actions of the hand are very feeble. The intrinsic muscles of the hand are atrophied, the thumb and middle finger being constantly in a sweating condition. He can raise his hand to his head. The deltoid is atrophied. Triceps in good condition. Infraspinatus atrophied. He requires hypodermics of morphine about every two hours to render him at all comfortable — one-sixth of a grain.

On consultation it was thought possible to bring about sensory anesthesia by operation upon the sensory roots of the brachial plexus.

On the day following the operation the patient passed a very comfortable time, using less morphine.

On the second day he had but one hypodermic and slept two hours, taking his nourishment well.

The third day he complained of pain in the shoulder and arm, but had a fairly comfortable day and slept for four consecutive hours.

On the fifth day he had severe pain in his head and some mental excitement; took nourishment well. This day there was recurrence of his sharp attacks.

On the seventh day wound was dressed and he was more comfortable. He was allowed to get up, as it was found impossible to keep him quiet in bed.

On the eighth day he suffered less from pain.

From the ninth to the fifteenth day the old pain continued, though less severe.

At the end of four weeks the patient was discharged in a condition of moderate improvement in the matter of pain.

The morphine habit had been entirely checked.

Two months after the operation I visited him at his house. He was much improved in general condition and doing well. He still maintained the habit of leaning his head down and seemed to be in pain. He was, however, easily diverted, and if entertained seemed free from paroxysms for considerable intervals. His actions suggested those of a man craving attention and gave me the impression of one desirous of continuing the appearance of suffering. He had entirely stopped the morphine habit and had stopped crying out as formerly.

Examination showed the arm and shoulder appearing as before. The muscular power was unchanged. Anesthesia seemed complete on the left hand, front, and back up to an inch or two above the wrist, over the entire dorsum of forearm and side and dorsum of upper arm half-way above the elbow to the shoulder. Above the middle of the arm to the shoulder there was no anesthesia.

Dr. F. H. Strong, of Yonkers, under whose care this patient had long been, wrote me that he found him decidedly better, and that he thought the amount of physical suffering which he really felt was now comparatively insignificant.

Soon after this the patient had a severe attack of diarrhea, and lapsed into a low muttering delirium, showing no evidence of pain while in this condition. For one month he continued to have delusions. He

then improved rapidly and commenced having pains in the wrist, though not as before. Two months subsequently he began again to suffer pain and howled during the paroxysms. Three months after the operation his mind was perfectly sound, but he complained again of his pain and was despondent but did not scream out. The subsequent course of his trouble during the year has been a mild type of the same evidence of pain as before the operation. The pain does not now cause him to shout. The anesthesia remains the same.

Dr. Thacher's pathological report of the resected roots, says: "Inflammatory exudation quite marked at portions of the surface and less marked at a few points inside some of the roots. The changes are most marked in and around the root of the first dorsal."

At present the patient is in good general health and excellent mental condition. Under constant observation of a most intelligent physician, who reports that his subjective evidence of pain is relatively very slight. He has occasional paroxysms that make him call out; but unless some one is watching him to call his attention to the arm, he will play cards or talk with friends for hours at a time without sign of pain.

The physical condition of the hand is not different from that before my operation except as to anesthesia. He has diminished tactile sense for the ulnar and median distribution, and pain sense for the ulnar and median lost (analgesia). Above the elbow there is no apparent gross disturbance of senses.

The patient never requires anodynes, and his physician thinks much of what he still calls his pain is a memory sense.

CASE III. M. L. H., a florist, aged forty, came to me in May, 1890, with this history:

He had evidently had some form of infantile paralysis, which I judge to have been infantile hemiplegia,

resulting in athetoid paralysis of the right arm and hand and somewhat the same of the right leg, though not much, for he walks everywhere with a habit of turning his foot sidewise and stepping more on the fore part and outer side of his foot. His right arm had been so useless for years from constant and excessive athetoid movements with increasing neuralgia of the forearm that Dr. Charles Phelps, of New York, had some years before amputated the forearm. The pain, however, did not abate; another surgeon stretched his brachial plexus. The pain was not mitigated, and the incessant athetoid movements made it so unbearable that Dr. Weir amputated at the shoulder. The pain continued after this and seemed even worse.

He now came to me with a complaint of continued pain and movements. I found very bulbous nerve ends in the axilla, and dissected them out. No great improvement followed. Subjective pain continued, and the scapula and shoulder stump were incessantly in spasm being drawn up high on the neck.

Dr. Græmme Hammond tried his hand at the patient with electrical treatment and vesication. After one year of this, he referred him to me, with advice to stretch the cervical plexus. Instead of this, I did the intradural section of the posterior roots on June 4, 1894, at St. Luke's Hospital.

I exposed the cord beneath the arches of the fifth, sixth, seventh and eighth cervical and first dorsal vertebræ and made a full-length incision in the dura. After three ounces of cerebro-spinal fluid escaped I picked up the posterior roots and divided all that make the brachial plexus—the fifth, sixth, seventh and eighth cervical and first dorsal. From each of these I cut out a quarter of an inch piece.

On account of the unusual athetoid movements I thought it as well to divide the anterior or motor roots supplying the amputated arm. I picked up the

anterior root of the seventh and eighth cervical and divided them, which made the stump jump sharply; then the first dorsal, which did not call out muscular response, and the sixth cervical, which did not. This led me to fear that what I took for the sixth might have been the fifth, and that if I cut one more above for the fifth I might get the fourth, which would take some supply from the phrenic and disable the patient. I desisted, therefore, from cutting the higher motor root, satisfied with having resected thoroughly the posterior roots of the fifth, sixth, seventh and eighth cervical and first dorsal and cut the anterior of the sixth, seventh and eighth cervical and first dorsal.

The patient made a good convalescence, with primary union and a solid scar.

For two days he had a suggestion of meningeal and spinal irritation, talking erratically and had stiff neck and weakness of the left hand (which I attributed partly to attitude in lying). He had slight rise of temperature to 101° , followed by a nervous hysterical state for three or four days — and then rapid convalescence. The shoulder stump was somewhat insensitive on the axillary part of the deltoid flap which afterward became natural.

For the first week the patient said he still had pain in the part; but when he was discharged, four weeks later, every evidence was against it. His condition was greatly improved. The stump, which before operation was thrown into athetoid spasms with every subjective and objective evidence of pain, could now be handled without any such spasms or pain. At one point on the axillary side of the chest flap in the old scar there remained one sensitive point, probably from a thoracic nerve, but it was of not any moment. The original shoulder pains, which had been present and not dependent on handling, had largely abated, though not entirely gone; and he had none of the constant athetoid spasm which constantly jerked the

shoulder up on to the neck. He could, however, raise and lower the shoulder painlessly at will, and with one hand still resting on it drop it to a natural position — an action which had been impossible before operation. The operation may, therefore, be said to show a marked success in relieving athetoid spasms and pain.

The immediate result of section of the roots of the plexus as far as noting anesthesia and muscle paralysis is negative on account of the patient having previously had a shoulder amputation and lacking all the parts supplied by these: but the resection of the roots at the highest possible point was done with a view to prevent the constant play of reflexes from the stump to the spine.

The subsequent history of the patient is this: He had been for so many years an inmate of hospitals that, after a few weeks unavailing search for work, he drifted into one of the large charity hospitals and occasionally returned to see me. He has never had recurrence of pain and spasm as before. His own statement and action were corroborative. There was in his mind, however, such a lingering memory of former pain that what remnant of the real thing remained was exaggerated to him and led him to submit to treatment in the hospital for some months longer.

When I last saw him, a year and a half after my operation, there was none of the former athetoid spasm of the shoulder nor the objective evidence of suffering such as had formerly been present — though he says he still has pain. His general health was excellent, and the scar solid and painless.

About the same date of my first operation Mr. Bennett, of St. George's Hospital, London, operated for relief of sciatic neuralgia (evidently ascending neuritis of the lower extremity), with the same idea in view.¹ His case is most corroborative. I give an epitome here.

¹ *Med. Chir. Trans.*, 1889, p. 329.

CASE IV. The patient was a laborer, with acute persistent spasmodic pain of the left leg and recurring muscular spasms. His suffering was terrible; so that the family were obliged to move from their lodging on account of the crying out of the patient.

Amputation of the left leg at the knee. No improvement. Later, stretched the sciatic nerve. No improvement. Excised the sciatic nerve two inches. No result.

December 24, 1888. Incision in middle of back; divided lower four lumbar posterior roots, and one upper sacral.

Subsequently the temperature was 101° (next day). Pain shooting down both thighs, but disappeared when drainage-tube pressure was removed. Free leakage of cerebro-spinal fluid due to not suturing the dura. Pain entirely disappeared, but spasms of muscles occurred at intervals. The anesthesia of the thigh, as shown by diagrams, was absolute after the first day, for the cut nerve-roots. During the eight days following there was a progressive restoration of sensation of the anesthetic area.

The patient died suddenly of cerebral apoplexy, in the doctor's presence, on the twelfth day. The *post-mortem* verified this — as well as showing that no restoration of continuity of the divided nerve-roots had taken place.

Mr. Bennett says: "To whatever cause the return of function may be attributed, one very important contingency seems fairly certain in the case, namely, that, had the patient lived sufficiently long, the sensation over the whole of the affected part would have been regained; and, further, that no danger of a recurrence of the pain need have been apprehended with the return of sensation, seeing that the restoration was independent of union between the cut ends of the nerve-roots."

Victor Horsley contributes notes of two cases of

spinal intradural resection of the posterior roots in a tabulated list, but I can find no memorandum of the details.

(1) Localized spasms and pain in the right eighth and ninth dorsal posterior roots in a man aged thirty-three years. Exploration and division of these roots. Result: Primary union. Invasion of other roots.

(2) Localized severe pain, vaso-motor changes and wasting in distribution of roots from left half of lower third of cervical enlargement. Congenital origin. The patient was a boy of fifteen years. Exploration. Division of the left seventh and eighth cervical posterior roots. Result primary union. Escape of cerebro-spinal fluid for three weeks. Much relief.

McCosh did an intradural section of the posterior roots of the fifth and sixth dorsal for neuralgia, but had no anesthesia following. The patient survived, however, and died of tuberculosis a year or so later.

REVIEW OF CASES.

(1) Tilley. For nearly two years ascending neuritis, pain in the right arm, following violent work. Had had many operations, and finally amputation near the shoulder. Acquired morphine habit.

Final operation by me. Divided sixth and seventh cervical, both roots, outside the dura but inside the vertebral canal; seventh and eighth cervical posterior roots inside dura.

No evidence of permanent relief after eight years. Temporary cutaneous anesthesia. Has slowly recovered, though not entirely.

(2) Zabinski. Man aged forty-five years. Exposure of arm to cold. Ascending neuritis in left arm. Many operations on nerves—resection and stretching—with no relief during two and one-half years. Agonizing pain, paroxysmal and constant. Morphine hypodermically every two hours.

At the operation the posterior roots were divided

intradurally — sixth, seventh, eighth cervical and first dorsal. Immediate relief from pain. Some return of pain in second week. Entire stoppage of morphine.

Patient discharged in four weeks. Improved as to pain. Anesthesia up to middle of arm. Suffering comparatively insignificant. Six years later an inmate of an invalid home. Relatively slight evidences of pain. Many features of success from the operation.

(3) Hassett. Great improvement.

(4) Dr. Bennett. Sciatic neuralgia. May be classed as successful.

(5, 6) Horsley. Two cases. Insufficiently reported for criticism. One is recorded as having had much relief.

(7) Dr. McCosh. Of use only in showing the comparative innocence of the operative work.

In considering the effect on sensation, theoretical and practical, we have not only the foregoing cases but some more elaborate experimental work done by careful observers on monkeys and animals, which are of great value.

It had already been shown by Horsley and Gowers² that, to produce anesthesia of any area of the skin, division of three roots must be made.

Sherrington³ has given us some very instructive animal demonstrations of the peripheral distribution of the fibres of the posterior roots of some of the spinal nerves. Frogs, cats and monkeys were his patients.

To determine and map out the areas of each dorsal root, he removed the brain of a frog and severed the spinal cord above that root, to eliminate cerebral reflexes; then, cutting all roots but one close to the cord, he tested the skin sensation by dilute acid and mapped out sensitive areas for each, which, of course, would be the anesthetic area if that one alone had been severed.

² Med. Chir. Trans., 1889, vol. lxxii, p. 21.

³ Trans. Royal Society, London, 1894, vol. clxxxv, B, pp. 641, 763.

In monkeys he thus found that the zones of the posterior roots of dorsal nerves have a fairly regular course, extending from the median line behind to the median line in front, with a marked trend downward, the lower border more than the upper, so that the zones which were, roughly speaking, parallel lines, become broader as they pass forward.

These cutaneous zones do not correspond numerically with the course of the ribs, but are in general, much lower; for example, if the anesthesia begins at the level of the eleventh rib the lesion would be in the eighth or ninth root. The discrepancy becomes greater as we go farther down.

One important demonstration is that, while each spinal root contributes fibres to several peripheral sensory nerves, yet the territory covered by a single root is never a patchwork but a continuous area. Cutaneous territories of spinal nerves overlap each other to a great extent, so that most points on the skin receive their innervation from two or even three roots. Thus, for example, the nipple lies mainly in the territory of the fourth dorsal root but the third and fifth roots contribute fibres as well, and only after destruction of all these roots does the territory become anesthetic. Thus the whole of a posterior nerve-root may be destroyed and yet no distinct disturbance of sensation arise. On the other hand, if an area of absolute anesthesia is present, the highest root contributing to this area must be destroyed.

Later experiments by Sherrington and Mott⁴ are even more interesting. Whole series of sensory roots supplying a monkey's limb were divided. For the arm it was from the fourth cervical to the fourth dorsal. For the leg, it was the second to the tenth posterior dorsal. As soon as the animal came out of narcosis a diminished use of the hand and foot was noticed. Grasping motions were entirely absent. The

⁴ Royal Society, March 7, 1895.

monkey would take no nourishment with the affected limbs, and would not carry them to the mouth even when the other limb was tied. For the course of more than three months it remained unchanged.

To determine what influence the stopping of movements by cutting the sensory roots might have on the irritability of the cortex, Mott and Sherrington stimulated the cortex by electricity. In the motions of the limbs no difference was to be seen between the operated and the intact side. This showed that there is a considerable difference between the more delicate voluntary motions and those called forth experimentally by cortical stimulation. In a voluntary movement, not only the cortex, but the whole sensory tract from periphery to cortex is active. Where only a single sensory nerve-root was cut, even the largest, no complete anesthesia was produced, and no difference resulted in the motion and use of the limb. When any two adjacent roots were cut and a zone of anesthesia resulted, but slight effects of motility were observed except when the *palm* was made anesthetic. When sensation was cut off from the whole hand or foot then the disturbance of motion was found just as great as when all the sensory roots of the extremities had been cut. On the other hand, when all the posterior roots are cut except that which supplies the palm, to wit, the eighth cervical, the motility is almost completely retained. No trophic disturbances of the skin were seen to follow section of the sensory roots. Wounds which were inflicted on the affected extremities healed perfectly well.

CASES OF ASCENDING NEURITIS TO WHICH SUCH OPERATIONS MIGHT APPLY.

It seems probable that the field of this operation may remain a small one, though important. How much it may be widened, time will show. There is a class of cases of acute neuritis starting in a peripheral

nerve and ascending, classed as "neuritis migrans." Its gravity cannot be belittled. The sufferers from it express the agony they feel. It is horrible. Most of them ultimately resort to morphine. While minor degrees of multiple neuritis (alcoholic or toxic) are usually recovered from, the graver form is carried through life, and ends the usefulness of the patient.

Most surgeons have encountered these cases where nerve-stretching, resection and amputation have successively been done with no benefit.

It is not difficult for the neurologist to distinguish the real from the simulated or hysterical cases, by brief study and test of the electrical reactions.

The absence of faradic irritability characteristic of neuritis distinguishes the hysterical or simulated pain.

In illustration, I may mention the case of a lady whose hand was squeezed violently one night by her son. She thought nothing of it until next morning she was worried by a severe pain in it. She sent for a physician, who added to her alarm by exaggerating its importance and putting it up in snug bandages. The pain grew worse—at least in her mind—and he put it up in plaster-of-Paris. She felt her suffering worse in confinement, and he became so worried that he cut down upon and stretched the median nerve, with no relief. She was about to enter a hospital to have her hand amputated, when she consulted an eminent surgeon, who recognized her mental agony, and doubting a real neuritis, referred her to Dr. Dana. Dana found no electrical or other evidence of neuritis, nor of any defect except for operation. He told her she was not ill, and advised her to go home, take off her bandages, and have nothing done; and he has no reason to doubt she has recovered. The evidence of pain depends on individual resistance and the amount borne without showing it. One can usually tell how much distress really exists by watching keenly for a long

period. The resort to morphine quickly reduces the resisting power, so that after an operation the absence of morphine and lessening of signs of pain are conclusive proof of great improvement.

Hemiplegics with late peripheral neuritis ought to be suitable cases for operation, other things being equal. If pain has not been coincident with the primary motor defect it is probable that the peripheral inflammation is secondary to unrecognized traumatism.

Prolonged and intractable neuralgia from zoster or allied troubles would offer a typically perfect opportunity to test the operation, and I have confidence in its value.

Pain from cicatricial pressure after cancer operation would, if it were grave enough to justify the operation, be amenable to relief.

As to the gravity of the operation and its technique, we may judge by a large accumulation of evidence. The two dangers are shock from hemorrhage, and sepsis. All cases of root section thus far reported have made excellent recoveries — proof that it adds nothing to the risk of laminectomy to open the dura.

Opening the dura always allows the escape of two or three ounces of cerebro-spinal fluid if the patient is strictly horizontal. The treatment of the dural incision should always be by continuous suture with fine catgut. There is no difficulty whatever in doing this with a small curved eye needle. Leakage of cerebro-spinal fluid afterward is practically nothing; whereas, if no sutures are applied, leakage continues for weeks.

The approach to the cord is best done by a quick and simple method which I have devised and practised in many cases. A long skin incision is made over the spine by a rather large knife, which by one or two rapid strokes separates the muscle from one side of all the spinous processes to be operated on and touches the laminæ at their bases. The knife handle

is sufficient to scrape the muscle from the laminae. With a bayonet-shaped cutting pliers the bases of the processes are cut through in rapid succession, and with a curved periosteum elevator the series of spinous processes, with uncut interspinous ligament and muscles attached on one side, are pressed *en masse* to that side. The hemorrhage is very slight and entirely controlled by pressure, with perhaps two or three clamps to be taken off in a few moments. A properly curved rongeur (such as shown) now begins the destruction of the laminae. Beginning on the base of any process the dura is exposed at one point carefully, and then the rongeur proceeds up and down with rapidity.

Occasional points of venous bleeding may be met, but a narrow strip of iodoform gauze or MacEwen's sticky gauze pressed down upon them by some pointed instrument allows the work to go on rapidly. When the dura has been slit up as far as desired we can roll the cord from side to side without touching it, by lifting the cut edge of the dura. The roots must be picked up by a blunt hook and a quarter to a half inch cut out, without much handling, for microscopic observation. A half-dozen small bottles should be provided, as in my second case, to identify the roots and learn of their inflammatory invasion.

The dura ought always to be sutured by fine catgut, and the outer soft parts fall together easily because there is no perceptible loss of substance. Drainage of the vertebral groove should be done for one day by a small tube not going far in. No plaster jacket or support is ever needed, as the strength of the spine is in no way impaired.

CONCLUSIONS.

A comparatively new and interesting field of work is opened by these few cases.

Thus far, even in weak patients, the operation has been devoid of risk.

It is sound in theory, and has yielded enough results to show that it may become a meritorious operation.

It should be resorted to early in cases of ascending neuritis which have heretofore been subjected to successive nerve-stretching and resection and finally amputation, uniformly without benefit.

The experimental and practical evidence shows that two additional roots higher up than the apparent origin of pain should be included.

There ought to be no risk in severing the posterior roots of the third and fourth cervical, as well as those to the brachial plexus, simply because they supply the phrenic, inasmuch as that needs motor supply only, and at best it has the opposite phrenic in reserve.

— THE BOSTON —
MEDICAL AND SURGICAL JOURNAL.

A FIRST-CLASS WEEKLY MEDICAL NEWSPAPER. PUBLISHED EVERY THURSDAY.

Two Volumes yearly, beginning with the first Nos. in January and July. But Subscriptions may begin at any time.

This JOURNAL has been published for more than sixty years as a weekly journal under its present title. Still it is incumbent upon this JOURNAL, no less than upon others to assure its patrons from time to time, as the occasion arises, of its desire, ability, and determination to meet all the requirements of the most active medical journalism of the day, without sacrificing any of that enviable reputation which is an inheritance from the past.

It is under the editorial Management of Dr. George B. Shattuck, assisted by a large staff of competent coadjutors.

Communications from all quarters of the country are acceptable. Liberal arrangements are made for reprints of original articles, and for such illustrations as serve to increase their value or interest.

All editorial communications, and books for review, should be addressed to the Editor.

Subscriptions and advertisements received by the undersigned, to whom remittances should be sent by money-order, draft, or registered letter.

Terms of Subscription: In the United States, and to Canada and Mexico, \$5.00 a year in advance. To Foreign Countries embraced in the Universal Postal Union, \$1.50 a year additional. Single numbers, 10c. Ten consecutive numbers free by mail on receipt of \$1.00.

Sample copies sent free on application.

PUBLISHED BY DAMRELL & UPHAM,

283 Washington St., Boston.

