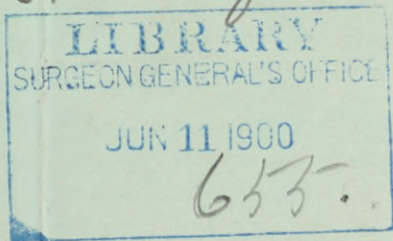


WAKEFIELD (W.F.B.)

The Radical Vaginal Operation for
Bilateral Disease of the Ovaries
and Tubes : : : : : :

BY
W. F. B. WAKEFIELD, M. D.
OAKLAND, CAL.

*The author's
compliments to
Dr Huntington*



(Read before the Alameda County Medical Society)

The Radical Vaginal Operation for Bilateral Disease of the Ovaries and Tubes.

BY W. F. B. WAKEFIELD, M. D.

OAKLAND, CAL.

LIBRARY

ALAMEDA COUNTY GENERAL'S OFFICE

JUN 11 1900

633-

Read before the Alameda County Medical Society.

When I speak of the radical vaginal operation for bilateral disease of the ovaries and tubes, I mean the removal of the uterus with the diseased adnexa *per vaginam*.

The purpose of this paper is two-fold. First, I desire to point out the advisability of always removing the uterus as well as the appendages in bilateral disease. Second, I wish to commend the vaginal route as being preferable to the abdominal whenever it is practicable, and the cases wherein the vaginal route is not practicable are very few.

In probably ninety-nine cases out of a hundred, the septic material that produces our cases of pyosalpinx, finds its way to the tubes through the uterus, and, with the possible exception of tubal disease resulting from direct traumatism, the uterus is always infected as well as the adnexa. To remove pus tubes and leave behind a septic uterus is equivalent to performing an incomplete

operation. The uterus deprived of its adnexa is functionless and useless, besides which its presence in the pelvic cavity is a positive menace to the patient's future health. How often do we find pelvic abscesses follow in the train of our most carefully performed oöphorectomies, and why? A septic focus—the infected uterus—has been left behind, and our patient's condition is very apt to be more deplorable than before our operation.

The following case will illustrate my position very clearly:

Miss W—— sent for me. I found her suffering from an acute pelvic inflammation. She gave a history of several similar attacks. When I had succeeded in overcoming the acute stage, I made an examination under chloroform and found a large conglomerate mass on the left side about the size of a man's fist, which I diagnosed as an old pus tube plus the agglutinations resulting from repeated inflammatory attacks. The right tube was somewhat enlarged and the right ovary enlarged and cystic. I recommended operation, and the operation verified, in every respect, my diagnosis. I removed the adherent inflammatory mass with considerable difficulty, but without rupturing it, and also removed the enlarged tube and cystic ovary on the opposite side, but did not remove the uterus. The operation was conducted under the strictest aseptic precautions; not a drop of pus was allowed to enter the pelvic cavity, the stumps were thoroughly cauterized, and I thought I had every reason to expect an uninterrupted recovery. I was doomed to disappointment, however, for, about two weeks after the operation, the patient developed a persistent fever, with high pulse and delirium. I could not feel anything in the pelvis to account for the trouble; nevertheless, to assure myself, the patient was anesthetized and I made an opening in

the posterior *cul-de-sac*, and thoroughly explored the pelvic cavity, with negative results. I then dilated the cervix, and curetted the uterus, removing a considerable quantity of foul-smelling muco-pus, and disinfected the cavity as well as I could. After this the temperature fell and the patient recovered, after a fashion, and passed out of my hands. Several months later her sister wrote me that a large abscess had formed in the pelvis, and had broken into the rectum, and that she had been in a wretched condition.

I am satisfied that had I removed the uterus with the adnexa at the primary operation, and drained thoroughly *per vaginam*, I would have saved the patient all the trouble she has since had. This case is exactly illustrative of the condition I had in mind when I commenced this paper, and I believe in all such cases we should remove the uterus as well as the diseased adnexa. I know we do not always have unfortunate results, even when we leave the uterus, but I can see no good reason for leaving a perfectly functionless organ in any case, and especially when we know that the mass of tissue remaining is almost certainly septic.

It is argued by some that we should leave the uterus, or at least the cervix, because of the support it affords, and thus lessen the danger of a vaginal hernia. I think this danger is a theoretical one, and in studying the record of nearly 200 cases, I cannot find that a vaginal hernia has ever occurred. In fact, if the case has been properly treated, I cannot see how such a thing could occur, for we well know that a broad, firm cicatrix forms at the posterior part of the vagina, which gives adequate support to the small intestines, and which, instead of becoming weaker as time goes on, becomes stronger and more resistant.

I now come to my second proposition, viz., that the vaginal route is, in nearly all cases, preferable to the abdominal. Montgomery, of Philadelphia, enumerates the advantages of the vaginal route as follows:

1. It permits us to explore, treat and preserve organs which would otherwise be sacrificed.
2. It promotes drainage from the most dependent portion of the pelvis, and enables the large peritoneum to be protected by plastic barriers.
3. It enables us to remove the uterus and appendages with less danger and more subsequent comfort than if the abdominal incision had been practiced.
4. The adhesions which nature has provided to protect the vital organs are undisturbed, and there is less likelihood of subsequent obstructive symptoms.
5. Convalescence is shorter, and the patient avoids such annoying sequelæ as abdominal sinus, painful cicatrix, weakened ventrum, and ventral hernia.

To these advantages may be added the facts that there is much less shock where the vaginal route is chosen, and also, that many patients will submit to an operation *per vaginam* who cannot be persuaded to have the abdomen opened from the outside.

I know that many good men will still express a preference for the abdominal route, but I cannot help feeling that their preference is due to their larger experience with it. Had they performed as many vaginal as abdominal operations, I believe their opinion would undergo a change.

But, questions some one, are not the space and light limited? I reply that the vagina is a very dilatable canal, and with a little patience the surgeon, with his

hand formed into a cone, can, in a few moments, dilate it sufficiently to admit the fist, and with this amount of dilatation the light, is ample. If, when you enter the pelvic cavity, you decide that you would like more room to manipulate the adnexa, it is an easy matter to clamp the broad ligaments close to the uterus and to remove that organ, after which plenty of room is afforded for all necessary manipulations. In most cases traction on the clamps which compress the broad ligaments will bring the adnexa into view, when they can be ligated or clamped off, according to the surgeon's preference.

But, asks another, have we command over hemorrhage in the vaginal method? We have all the control necessary. It must be remembered that during the operation an assistant is holding the bladder and ureters up out of the way by means of a lateral vaginal retractor, thus materially increasing the space. Other retractors can be used laterally, if desired to still further enlarge the field of vision, and with the space thus afforded, the parts can be sponged thoroughly and the bleeding point or points detected. I may mention that whenever there is troublesome hemorrhage we should carefully examine the posterior vaginal wall, as this is very frequently its source, being supplied by branches from the uterine artery which are not included in the clamps which secure the main vessel.

But, questions some very astute surgeon, I would like to ask what you can do *per vaginam* in those old cases of combined metritis, parametritis, and parenchymatous degeneration, where the whole pelvic cavity is filled with an adherent septic mass, in which neither uterus nor adnexa are distinguishable, the whole being immovable? I reply that when we get such a case as this, and on grasping the cervix with vulsellum forceps, we find

that we are unable to pull the uterus towards us even a quarter of an inch, we will wish that some other fellow had the case. I ask, however, what can you do with such a case in operating through an abdominal incision? Have we not seen the most distinguished laparotomists in such cases, open the abdomen, incise the septic mass, put in a drainage tube, and say they had had enough. Here there is only one thing that can be done: remove as much as possible of the septic mass and institute irrigation and drainage. Cannot this be done infinitely better through the vagina than through an abdominal incision.

Besides, are we not adding an increased risk to such patients by opening the abdominal cavity? We know that nature, in these cases, throws out limiting adhesions, completely shutting out the septic mass from the general abdominal cavity. When we open the abdominal wall, we must break down these safeguards in order to reach the mass. *Per vaginam* we open directly into it, cut away all we can, search out, open and flush thoroughly all the collections of pus, then pack with gauze, which controls oozing and establishes a natural osmotic drain, and we have a natural route through which we can practice daily antiseptic irrigation. It is not at all infrequent in these cases to see, at the end of forty-eight hours, our patient's temperature drop three or four degrees, while the pulse rate is reduced thirty or forty beats per minute. At the end of four or five days, the patient has developed a good appetite and goes on uninterruptedly to recovery, subsequently maintaining a fair condition of health.

What will we do with those cases in which the pus tubes are adherent in several places and matted to the coils of the small intestines? Shall we break up these

adhesions and run the risk of opening into the gut? In case the adhesions are extensive and cannot easily be broken up, it is better to remove all but the adherent portion of the mass and trust to future drainage and treatment for resolution. It is usually easy to pull the adherent gut down into view, and treat it as judgment dictates, just as one would if he were operating through an incision in the abdominal wall.

The time allotted to me will not permit a further discussion of the pros and cons of this great subject, but I trust that I have brought to my subject sufficient practical force to make my position in regard to it tenable.

554 Fourteenth street.

