

TRACY (E. O.)

LIST OF
SURGICAL SPLINTS EXHIBITED

AT THE
COLUMBIAN EXPOSITION, CHICAGO, 1893,

BY
EDWARD A. TRACY, M. D., BOSTON.

FELLOW OF THE MASSACHUSETTS MEDICAL SOCIETY.

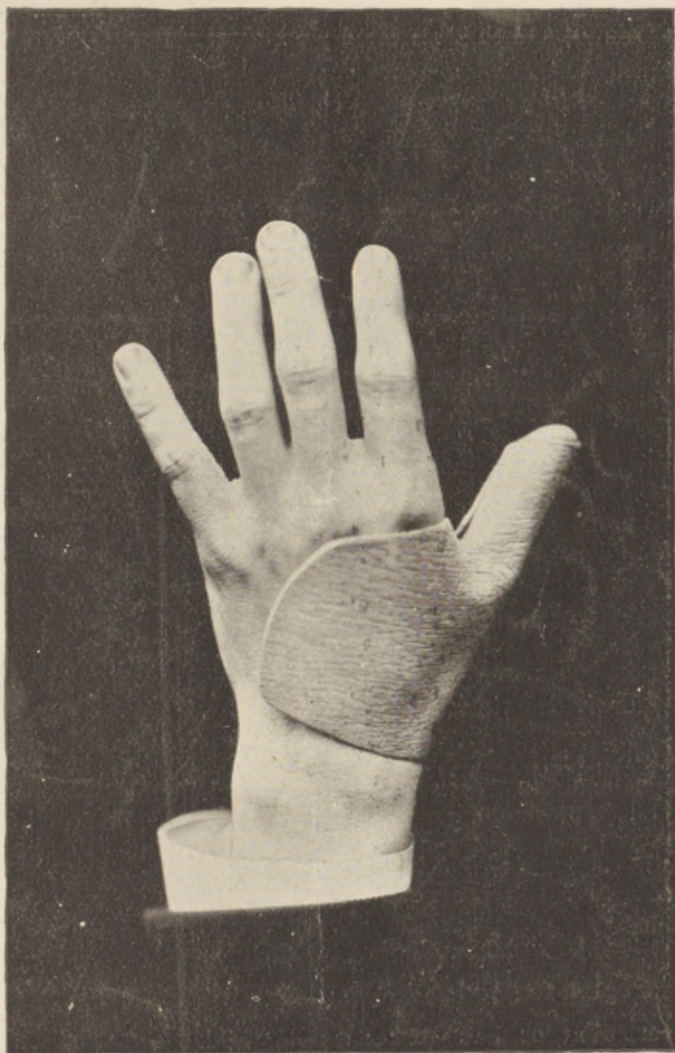

FIG. 1. A Splint for Fixation of the Thumb. See No. 1 in the List.

PRINTED FOR THE AUTHOR.
BOSTON: 1894.



PREFATORY.

All of the splints exhibited, including the Spinal Jackets, were made from the material devised by the author for Surgical Splints and Spinal Jackets. They were moulded by the exhibitor *on the living subject*, and for the greater part were devised to meet special indications. They serve to show the adaptability of the author's method to all possible splint conditions.

Several of the apparatus have been more fully described than in the list which follows, and the interested practitioner is referred to the following papers :

"A New Apparatus for the Treatment of Dislocation (upwards) of the Acromial end of the Clavicle."—*Boston Medical and Surgical Journal*, Vol. CXVIII, p. 186.

"A New Material for Surgical Splints and Jackets."—*Journal of the American Medical Association*, Aug. 26, 1893.

"A Brief Splint-Technology for Surgeons" to be published in the forthcoming Transactions of the First Pan-American Medical Congress, Washington, 1893. (An abstract of this paper was published in the *Medical News*, March 17, 1894.)

"Remarks on Surgical Splinting."—*Boston Medical and Surgical Journal*, April 12, 1894.

LIST OF SPLINTS.

- 1 A splint for the left thumb. See Fig. 1.

This splint is for fixation of the thumb, including its metacarpal bone. It embraces that portion of the hand shown in the engraving, and somewhat more than the thenar eminence of the palm, care being taken to keep below the cross palm lines that mark the region of the meta-carpo-phalangeal joints, so as not to hinder finger motions.

- 2 A splint for the right forefinger.
- 3 A palmar splint for the left forearm. Adult.
- 4 A palmer splint for the right forearm. Child.
- 5 A splint for the right forearm : moulded over the dorsal surface.
- 6 A splint for the right forearm : moulded over the palmar surface.
- 7 An anterior knee-splint. For fixation of the knee joint. See Fig. 2.

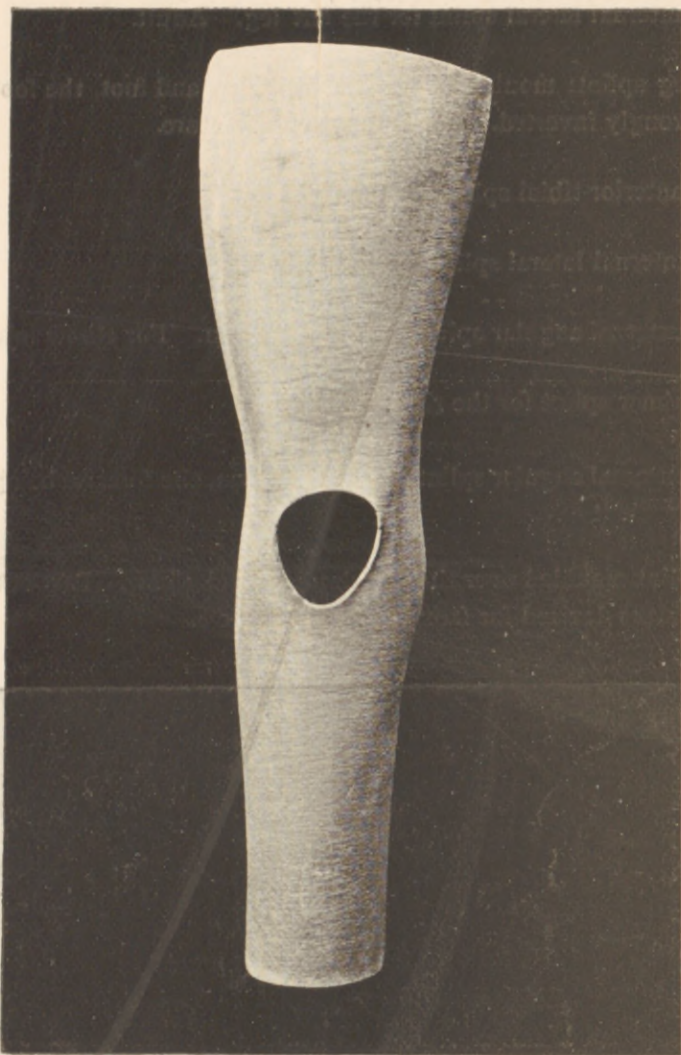


Fig. 2. An anterior knee-splint. See No. 7 in the List.

-
- 8 A latero-posterior knee-splint. For fixation of the knee joint.
 - 9 A thigh-splint: moulded over the outer aspect of the left thigh. Adult.
 - 10 A thigh-splint: moulded over the inner aspect of the left thigh. Adult.
 - 11 A long splint for the right arm; a modification of Hamilton's splint for fracture of the olecranon.
 - 12 A long arm splint: moulded over the inner surface, the forearm being semiprone.
 - 13 An external angular splint for the left arm: the forearm being semi-prone. For joint injuries, and particularly injuries of the internal condyle. See Fig. 3.

- 14 An internal lateral splint for the left leg. Adult.
- 15 A leg splint: moulded over the right leg and foot, the foot being strongly inverted. For Dupuytren's fracture.
- 16 An anterior-tibial splint for the right leg.
- 17 An internal lateral splint for the right leg.
- 18 An external angular splint for the right arm. For elbow injuries.
- 19 A palmar splint for the right forearm.
- 20 An external angular splint for the right arm, the forearm being semi-pronated.
- 21 A splint moulded over the left shoulder and elbow. Part of the apparatus devised for fracture of the clavicle.

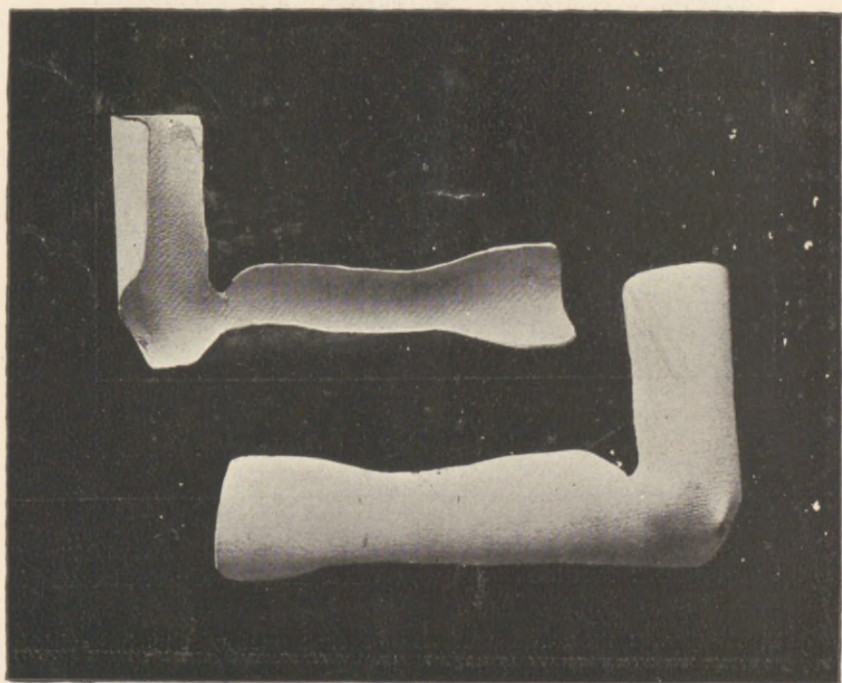


Fig. 3. An external angular splint for the left arm: for injuries to the internal condyle. (The upper view shows the inside of the splint, the under view the outside of the same splint.) See No. 13 in List.

22 A claviculo-scapular splint. See Fig. 4.

This splint is part of an apparatus devised for the treatment of dislocation (upwards) of the acromial end of the clavicle. The apparatus is fully described in the *Boston Medical and Surgical Journal*, Vol. CXXVII, p 186.

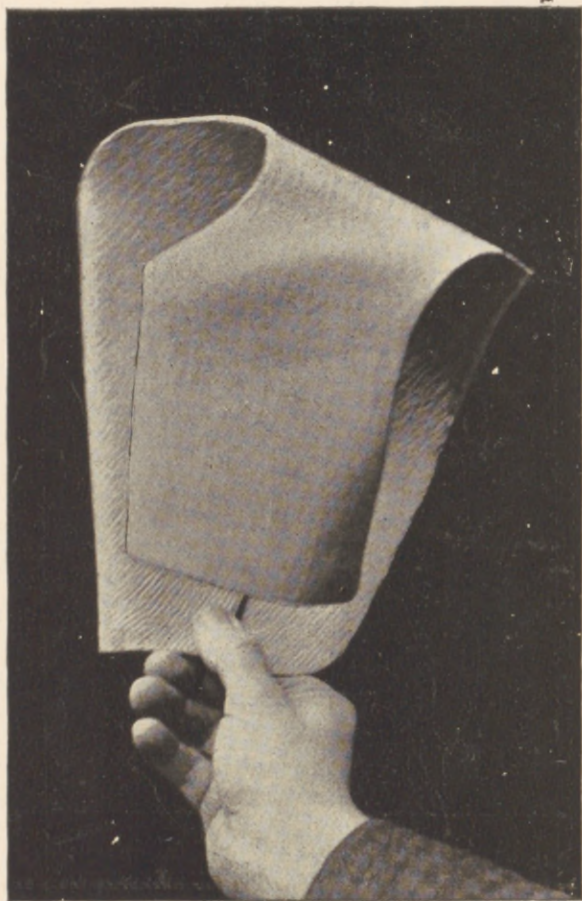


Fig. 4. A claviculo-scapular splint. See No. 22 in the list.

-
23. An internal angular splint for the right arm. For fixation of the elbow joint.
24. An internal angular splint: moulded over the inner surface of the arm and forearm, the forearm being semipronated.
25. An angular splint for the arm: moulded over the outer surface of the arm and the dorsal surface of the semiprone forearm

26 A spinal jacket, moulded upon an adult.

27 A spinal jacket. See Fig. 5.

Illustrates a spinal jacket moulded on and worn by a boy of six years. The binding and fasteners are made of chamois skin, glued by means of a cheap liquid glue directly to the jacket. The hinge joint is here omitted, the natural resiliency of the material sufficing for the removal and reapplication of the jacket. The jacket was made at the child's home in about forty minutes.

28 A pelvic splint. (For fixation of the pelvis, as after symphyseotomy.)

29 A splint for the nose.

30 A splint for under-jaw fractures. After Hamilton.

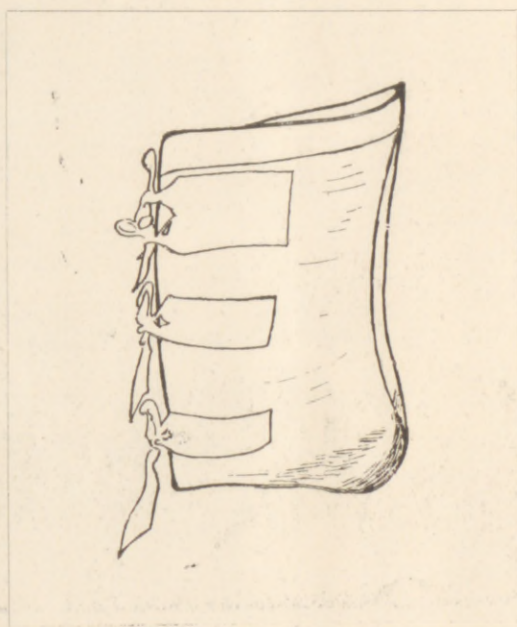

Fig. 5. A spinal jacket. See No. 27 in the List.

I trust that the publication of the Award granted for this exhibit will not be considered out of place here. Commendation from Ernest Hart; the editor of the *British Medical Journal*, is too gratifying for the author to pass unnoted.

[Copy.]

UNITED STATES. DEPT. L.—LIBERAL ARTS.

Exhibitor, EDWARD A. TRACY, M. D., Boston.

Exhibit, SURGICAL SPLINTS.

AWARD

For the extent and variety of the exhibit, excellence of manufacture, and efficiency.

(Signed) ERNEST HART, *Individual Judge*.

Approved: K. BUENZ, *President Departmental Committee*.

Approved: JOHN BOYD THATCHER, *Chairman Ex. Com. of Awards*.

Boston, September, 1894.

Notice to Practitioners, and in answer to many correspondents.

The material devised by me for Surgical Splints and Jackets, and described in a paper on Splint-Technology read at the First Pan-American Medical Congress, is manufactured by the American Wood-Pulp Co., **2169 Washington St.,** ~~Bronfield~~ Street, Boston, Mass.

Business communications should be addressed to them.

Questions from my fellow practitioners, concerning the surgical application of the material, shall receive my earliest attention.

EDWARD A. TRACY, M. D.

