

## SKIN GRAFTING FOR MALIGNANCY OF THE ORBIT.

By FLAVEL B. TIFFANY, M. D., KANSAS CITY, MO.

*Read before the North Texas Medical Association, at Sherman, Texas, June 20th, 1894, in the Section of Surgery, by J. T. Wilson, M. D.,  
Chairman of Section on Surgery.*

The following is an abstract from a report of a case wherein skin grafting was resorted to as a therapeutic agent in malignant growths, published in the *St. Louis Medical Journal*, September, 1882; with illustrations and other data.

It was as an effort to smother out malignant growths that continued in their persistency to spring up from the empty orbit after exenteration of the eye-ball which was enmassed by an epithelioma. The

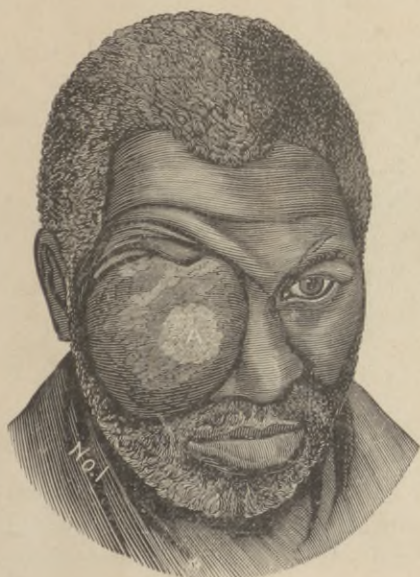
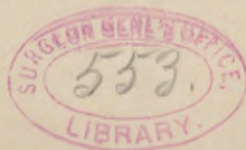

Fig. 1.



Fig. 2.

patient was a negro, Richard McGee of Galena, Kan., aged 58 years. The tumor originated at the margin of the inferior lid of the right eye, but when the patient visited me, February 7th, 1882, it had extended to the eye-ball, to the superior lid and to the cellular tissue of the orbit. The growth was about the size of an Osage orange and completely covered the globe. (Fig. 1.)



Upon removing the tumor the eye was found to be cataractuous. From this and the fact that the tumor had involved both lids and the surrounding tissue, it was thought advisable to remove the eye-ball. After sweeping away the tumor, lids and eye-ball with the soft tissues of the orbit, the parts were thoroughly cauterized with the thermo-cautery, completely cremating everything down to the periosteum. Hemorrhage was profuse and in order to check this the cavity was packed with lint saturated with sulphate of iron. This packing was left several days and after its removal the orbit was dressed by a carbolized wash; but in a short time several cauliflower growths sprang from the sides and near the apex of the orbit and grew with rapidity. These were removed by the scissors and the surface seared



Fig. 3.

or cremated with Paquelin thermo-cautery, but still the growths persisted and as fast as they were cut away or destroyed they would return, until I resorted to skin grafts taken from the chest of the patient. These grafts were large, measuring some more than one-half an inch in width and three-quarters of an inch in length. They were of the true skin and conveyed without handling to the raw and granular surface of the diseased orbit. There was no difficulty in getting the large grafts to live, excepting at one point, beneath the arch of the brow. (Fig. 2.) Over the site of the fungous growth the grafts grew with even greater avidity than elsewhere. The spot beneath the brow remained for a long time an open, indolent, raw surface, until finally the grafts were made to adhere. The grafts placed over the



site of the morbid growths were destroyed from time to time by the action of the zinc used, but new grafts, large though they were, successfully took root and grew, all the time recovering ground from the fungus growths until the bulk of the latter being removed the healthy cell life of such portions of the growth as escaped the scissors and zinc, converted as it were the malignant into the benign, smothering the morbid tendency and hastening the process of repair. After six




Fig. 4.

months treatment the wound was completely healed. (Fig. 3.) This patient was still living a year and a half ago when I received a letter from him written at Oklahoma City, and there had been no return of the tumor.

At the time I operated there had been no account of such large skin grafts used, and in no instance had they been employed for the purpose of subduing malignancy. This accidental use of the skin-graft

in malignant tumors with the results, showed that the potentiality for good in a few healthy living cells was even greater than that of an army of malignant ones for evil. It was like introducing a few good, law-abiding citizens into a gang of thieves and outlaws, where the few rule and peace and order is gained. Believing then as I had reason to, that I had made a discovery by which malignant cells could be controlled by a few healthy ones, I did not stop with this one case, but have repeatedly resorted to skin grafting in malignancy of the lids and orbits in cases which have since come to me. It has now been




Fig. 5.




Fig. 6.

about a year since I operated, assisted by my colleagues Drs. Bogie and Herrieford of Kansas City, upon a prominent physician in this city for malignant growth of the nose and lid near the inner canthus. Here I transplanted a circular piece of skin as large as a silver quarter from the arm of the patient. There was no sloughing of the graft, and to-day the parts are smooth and the scar is scarcely noticeable. Some two years and a half ago I operated upon a prominent citizen of Emporia, Kan., for cancer of the upper lid. (Fig. 4.) The growth was of several years standing and had involved almost the entire lid, so that I was compelled to remove nearly all of the integument of the lid. The plant taken from the forearm of the patient was cut at least one-third larger than the bed on which it was to lie. The man now



has a perfect lid with scarcely any scar, and there is no tendency of the tumor to return. (Fig. 5 was taken three days and Fig. 6 three weeks subsequent to the operation.)

In making these plastic operations the most scrupulous sanitation



Fig. 7.

is adhered to. I first see that the patient is in as good general health as possible and then with scrupulous cleanliness I transfer the grafts. I first scrub the surface of the malignant parts with soap and water. Afterwards with a solution of bi-chloride of mercury, 1 to 1000. The

parts from which the graft is to be taken are also subjected to a thorough cleansing with soap and water, and then bathed with antiseptic solution. The malignant growth is removed, its bed or seat measured and a corresponding measurement outlined upon the arm or chest



Fig. 8.

from whence the graft is to be taken, and then the graft is cut about one-third larger than the dimensions of the cavity to be filled. It is transferred without handling immediately to its new abode where it is fixed in position by a few stitches of delicate silk, which has been



passed through bi-chloride solution. In resorting to these grafts I frequently take very large plants. In my last case, where I operated for ectropion (Fig. 7), caused by a burn, I took a graft, one and a half inches wide by three inches in length. (Fig. 8 was taken three days



Fig. 9.

and Fig. 9 three weeks subsequent to the operation.) I excise the true skin down to the areolar tissue, taking care not to include any adipose or connective tissue. I am also careful to staunch all hemorrhage before transferring the plant. After attaching the graft by delicate

silk sutures I dust on dry calomel powder, cover with gauze and fasten with adhesive straps. I do not disturb the dressing for several days, not until it is time to remove the sutures. Circulation is usually established by the second day. At first the piece is cadaverous in appearance, but soon it grows red or takes on the color of the natural skin, occasionally it turns black but does not slough.

It frequently exfoliates, especially if it needs to be thinned, but nature takes care of that, moulding, shaping and coloring it to suit her need and taste. In none of the cases where I have resorted to skin grafting for cancer has there been any return of the malignancy.

When I first introduced this discovery, my professional brethren were disposed to make light of it, and treat it with incredulity. I recall one gentleman saying that he thought that placing the grafts in this mass of diseased tissue would be like throwing a sound, healthy apple into a barrel of rotten ones that the good ones would slump away with the rest. But not so, it is rather like grafting a healthy bud into a nearly sour apple tree and getting most excellent fruit; or, as I said before, it might be likened unto placing a few good law-abiding citizens among a gang of outlaws; by the few, law and order would soon be gained.