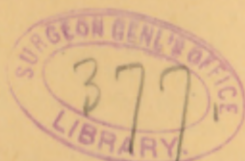



Kinloch (R.A.)

Two laparotomies on same
patient x x x x x x x





a
Kinlock, (R. A.)

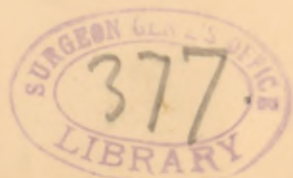TWO LAPAROTOMIES ON SAME PATIENT—REMOVAL
OF BOTH OVARIES FOR CYSTIC DISEASE, AND
ALSO A LARGE TUMOR OF THE MESENTERY
—SILK LIGATURE PASSES INTO THE
BLADDER AND SERVES AS THE NU-
CLEUS OF A CALCULUS.

BY R. A. KINLOCH, M. D., OF CHARLESTON, S. C.

On the seventh of January, 1886, I operated at the St. Francis Xavier Infirmary, upon Mrs. O'N., aged twenty-eight years, for the removal of a very large cystoma of the left ovary. She had been confined some three months before, at Port Royal, S. C., and had been ill with what was called puerperal fever, or peritonitis, following labor. Upon reaching this City she came under my care. I found the abdomen largely distended with fluid, the patient emaciated and enfeebled, and having fever of an asthenic type. After a few days' rest, careful regulation of diet, and a few doses of quinine and opium, her general condition improved. I now aspirated the abdomen, or rather the cyst as it proved to be, and drew off several gallons of fluid of a turbid, dirty straw-color. I supposed from the history that the fluid occupied the peritoneal cavity. After its withdrawal, I discovered by manipulation, that there existed a large movable tumor, and by further investigation, I made the diagnosis of ovarian cystoma. The tumor had likely been growing for more than a year, and had complicated the pregnancy.*

Her labor had been tedious and painful, but she had given birth to a healthy and well developed infant. Patient was, by diet and medication, with quinine and iron, prepared for operation. As before stated, the operation was done on the seventh of January, 1886. There were several extensive parietal and intestinal adhesions, and at one point, to the right side of the abdomen and above the umbilicus, a portion of the mesentery was attached to the tumor. This was resected after applying to the tissue several silk ligatures. A solution of Hyd. Bichl., 1-8000, was used in cleansing out the cavity. A glass drainage tube was inserted, and the external wound dressed with iodoform and cotton. I regarded the case as an unpromising one. To my surprise, the patient never had a serious symptom, and recovered so rapidly that in three weeks she was walking about her room. The only annoyance experienced was from the for-

*From the pressure of the uterus the tumor had been divided in such a way as to feel like a saddle-bag—full on each side and thin in the middle line.



mation of hard feculent masses in the colon and rectum, because of a too exclusive milk diet. In the early part of July, six months after this operation, patient called at my office and complained of symptoms of cystitis, or irritable bladder. I was about leaving the city for a summer vacation. I prescribed for her an alkaline mixture, and anodyne suppositories when necessary. Upon my return home in October, patient visited me and gave the following history: The remedies given for the cystitis had afforded very little relief, but about a month previous, while urinating, she experienced great difficulty and pain, and suddenly there fell into the chamber this foreign body (calculus exhibited), which she presented to me.

It is conical in shape, and at its apex can be seen the ends of the braided silk ligature which I used for tying the pedicle of the tumor at the time of the operation; curious enough it forms the nucleus of the phosphatic calculus. It most certainly passed from the abdominal cavity into the cavity of the bladder, how and by what means may be a matter for speculation.*

The history of this lady is further interesting. When presenting me with the calculus, she seemed to be in perfect health, but said she would like me to examine her abdomen, as there was a small depression or opening in the deep abdominal parietes, just where the drainage tube had been. A few days after this, I visited her at her residence, to examine the condition referred to. I found a deficiency in the deep abdominal structures, at the lower end of the cicatrix, into which I could put the end of my index finger. It was of no consequence; there was no hernial protrusion. But, to my surprise, I found the abdominal cavity occupied by another tumor, compact, semi-fluctuating and with diameters respectively of about eight and twelve inches. The patient had not been aware of its existence. She had attributed her enlargement to fat and improved health. On the twentieth of November, 1886, I operated for the removal of this second tumor, which I then presumed was a cystoma of the right ovary. Upon opening the abdomen, through the line of the old incision, I began my search for adhesions. I soon found a portion of the mesentery attached to the surface of the tumor, just about where I had ligated this structure at my previous operation. These supposed adhesions were spread out, fan-like, upon the outer cyst wall, and when traced backwards were resolvable into three very large veins, round and fully distended. I applied two silk ligatures, by transfixing the tissue, to each vein, and then encircled the three veins, together with the mesenteric tissue *en masse*, with the free ends of one of the proximal ligatures; the other ligatures

*Prof. T. G. Thomas, of New York, informs me that in one of his cases of ovariectomy, as he learned from the physician in charge, the ligature was discharged from the bladder.

were cut close to the loops. The vascular mesenteric structure was cut between the ligatures, and a portion left attached to the cyst walls. I next punctured the cystic growth with Emmet's large trocar, to try and reduce its size. This availed but little, as the interior cysts were small and their contents quite viscid. Patient was turned upon the side and the tumor freely cut into with a scalpel. This enabled me to begin its delivery through the abdominal wound, which was altogether below the umbilicus. As the tumor began to emerge, I passed my hand deep into the pelvic cavity to get at the supposed pedicle, still believing the growth to be a cystoma of the right ovary. Suddenly, and to my great surprise, the whole mass tumbled out on to the table. The tumor was of the mesentery, and the tissue, which I had in the beginning ligated and divided, constituted the sole attachment. The right ovary was now brought into view, and, as it presented evidences of beginning cystic disease, was removed. In bringing together the parietal wound with sutures of silk-worm gut, I thought it best to include the pedicle, which I have described as made up of enlarged veins and mesenteric structure, in the wound. I transfixed this with a large steel needle, wrapped the ends of the needle in iodoformed cotton, and dressed the wound with the same material. Patient progressed favorably, experiencing only slight rise of temperature for two or three days, attributable to a small parietal abscess. I adopted Tait's plan, and acted on the bowels on the third day with salines. In withdrawing the needle from the pedicle, which never presented any evidence of gangrene, the stump retreated towards the cavity, and was lost in the deep part of the parietal wound. I felt somewhat uneasy at this occurrence, but no trouble ensued. Patient was about in three weeks and was soon after this time discharged. My friend, Dr. John Guiteras, kindly examined the growth and reported as follows:

"It presented no evidence of malignity. The numerous cysts were lined with columnar epithelium, some of the cells being ciliated. The fibrous tissue stroma very vascular. There are innumerable minute cysts in the fibrous tissue walls. In all of these the columnar epithelium preserves its perfectly regular arrangement." At this date, April 8th, 1887, patient is in perfect health. There has been no menstruation since last operation.

