

EVALUATION OF I¹³¹-LABELLED DIODRAST RENOGRAMS WITH SUGGESTIONS ON IMPROVING THE TECHNIC*†

EDWARD D. FROHLICH, M.D.
FRANK J. FEDOR, M.D.
WILLIAM V. C. LEAHY, PH.D.
EDWARD D. FREIS, M.D.

Washington

INTRODUCTION

THERE IS A NEED for a simple, atraumatic screening test for estimating unilateral renal function. Until recently, the only such method available was the intravenous pyelogram. However, in 1956, a new technic, utilizing radioiodinated Diodrast was introduced by Taplin and his co-workers.^{1, 2} At approximately the same time there was a renewed interest by Howard and his co-workers³ and Poutasse and Dustan⁴ in unilateral renal disease as a cause for hypertension. Winter⁵ reported on 44 hypertensive patients in whom excellent correlation was shown between radioactive Diodrast "renograms" and conventional renal studies in 10 patients with unilateral renal disease.

In his initial report Taplin¹ attempted to estimate the vascularity, tubular cell function and patency of the upper urinary passages in each kidney separately. The purpose of this study is to evaluate this technic and to offer certain modifications which appear to increase its accuracy.

METHOD

One hundred and one patients, of whom 96 were males, were selected from the medical and

* From the Medical and Radioisotope Services, Mt. Alto Veterans Administration Hospital, Washington 7, D.C., and the Department of Medicine, Cardiovascular Research Laboratory, Georgetown University School of Medicine.

† This study was supported, in part, by the United States Public Health Service, grants H-2987 and H-1904 (National Heart Institute).

urologic wards of the Mt. Alto Veterans Administration Hospital, Washington, D. C., for study.

The patient was seated astraddle a high chair with his chest supported comfortably against the back of the chair (figure 1). Two scintilla-

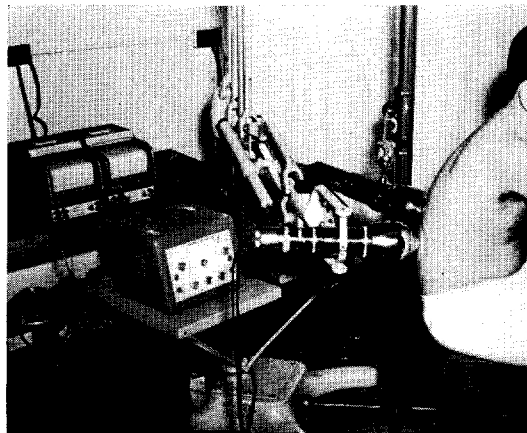


Fig. 1. The placement of scintillation probes and equipment.

tion probes with 20° flat field collimator inserts ("wide field" collimation) were attached to analytical rate meters and to their respective recorders and placed at right angles to the renal areas.‡ The range of the rate meters was set to

‡ Presented at the Regional Meeting of the American College of Physicians in Washington, D.C., November 1, 1958.

‡ DS-5 probes with 2-inch sodium iodide-thallium activated crystals, Nuclear Chicago. 1620 rate meters, Nuclear Chicago. Recti-Riters, Texas Instrument Company.

count radioactivity between zero and 3,000 counts per minute ("3K" setting) or between zero and 10,000 counts per minute ("10K" setting). The activity was sampled every 10 seconds, and the recorder chart speed was set at 6 inches per hour.

A preliminary test dose of approximately 3 to 5 microcuries of radioiodinated Diodrast was given intravenously and the probes moved about so as to locate the renal areas of highest activity. The probes were then fixed in position over those areas. One hundred and twenty-five milligrams of carrier, or nonradioactive Diodrast, was added to the preliminary dose in order to saturate some of the plasma albumin-binding sites and thus facilitate the clearance of the I¹³¹-labelled Diodrast, as advised by Block and Burrows.⁶ Following the "washout" of the initial dose, the baseline of each recorder was reset to compensate for the small somatic background. The full test dose of approximately 7 to 15 microcuries of I¹³¹ Diodrast was given intravenously and a record obtained over a period of 15 to 20 minutes.

RESULTS

Of the 101 patients tested, 30 had no known renal disease and served as normal controls (table 1). All of these patients exhibited normal

TABLE 1
Classification of Cases

| | NUMBER | RENOGRAMS | |
|--------------------|--------|-----------|----------|
| | | Normal | Abnormal |
| Normal..... | 30 | 30 | 0 |
| Renal disease..... | 29 | 0 | 29 |
| Hypertension..... | 42 | 24 | 18 |
| TOTAL..... | 101 | 54 | 47 |

renograms. There were 29 patients with suspected renal disease, and all had abnormal renograms. Finally, there were 42 patients with hypertension, 24 of whom exhibited normal and 18 abnormal renograms.

The renograms of 22 patients without hypertension, but with suspected renal disease, suggested unilateral renal disease (table 2).

TABLE 2
Renal Disease Patients

| | Renograms | Clinical Diagnosis |
|-----------------|-----------|--------------------|
| Unilateral..... | 22 | 20 |
| Right..... | 13 | 11 |
| Left..... | 9 | 9 |
| Bilateral..... | 7 | 9 |

Twenty of these patients had unilateral renal disease diagnosed and proven clinically, 14 by surgery and 6 by pyelography. The other 2 patients exhibited abnormal renograms on the right but were shown clinically to have bilateral renal disease. Of the 20 patients who had unilateral renal disease demonstrated clinically, the diseased kidney was correctly indicated by the renogram in each case. Of these, 13 were on the right and 9 on the left. Thus, all of the patients with abnormal renograms did, in fact, have abnormal underlying kidneys. Although bilateral disease was not detected in 2 instances, it should be pointed out that both of these patients were studied early in the investigation, prior to the use of the preliminary test dose for localization.

TABLE 3
Hypertensive Patients

| | Renogram | Impaired Function | Howard Test |
|-----------------|----------|-------------------|-------------|
| Bilateral..... | 13 | 13 | 1 |
| Unilateral..... | 5 | 2 | 0 |
| Right..... | 4 | 0 | 3 |
| Left..... | 1 | 0 | 1 |
| Normal..... | 24 | 1 | 0 |

Of the 42 hypertensive patients (table 3) 24 exhibited normal renograms and only 1 of these had impaired renal function (blood urea nitrogen 34 mg. per 100 ml.). All 13 hypertensives with bilaterally abnormal renograms also had impaired renal function by other clinical tests.

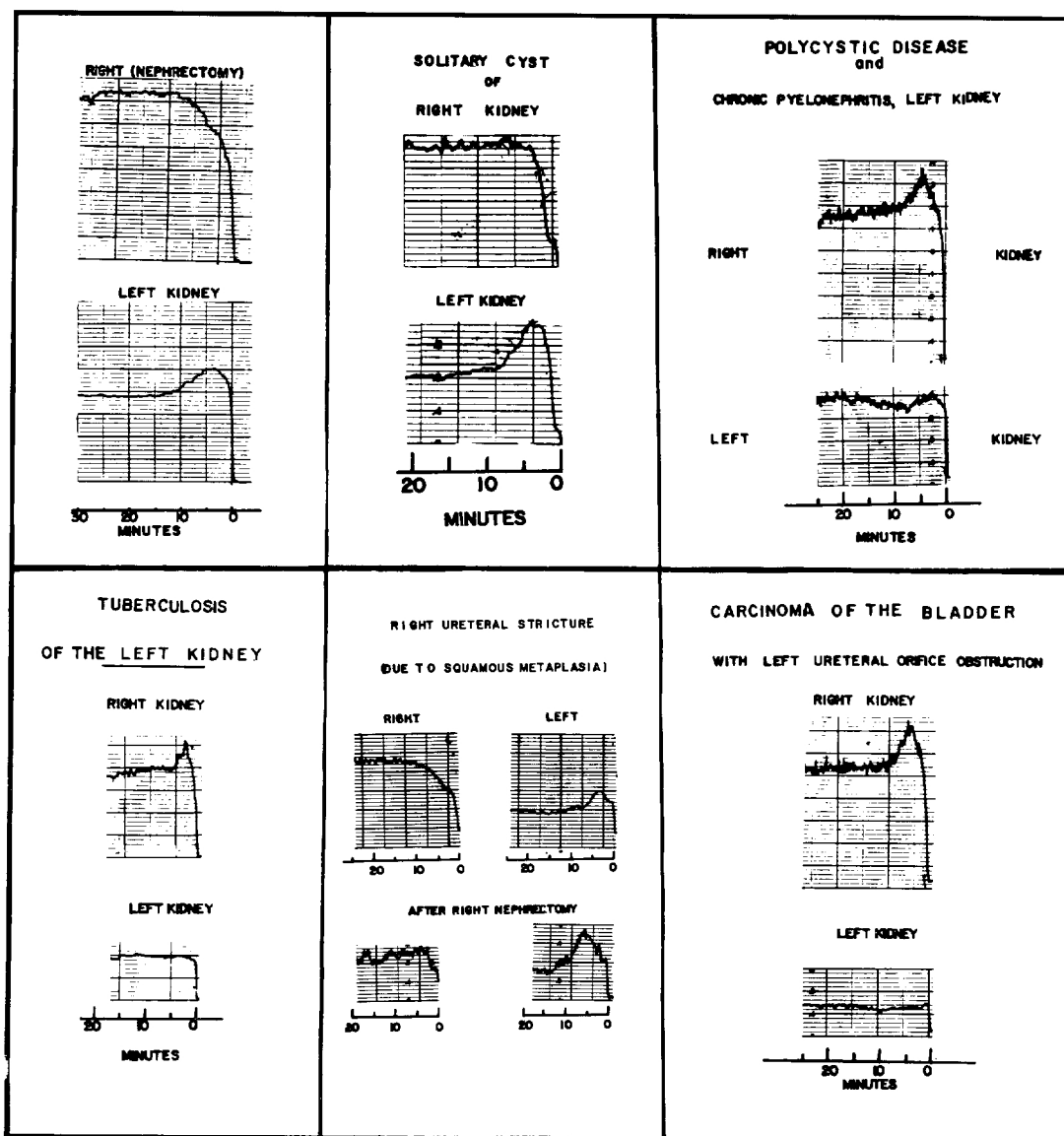


FIG. 2. Renograms of patients with various types of unilateral renal disorders.

Of the 5 hypertensive patients with unilateral abnormal renograms, all but 1 patient had normal renal function studies. This patient has a pyelectasis of the right renal pelvis proven by intravenous pyelography. Only 1 of the 4 patients having the Howard test had abnormal results confirming the abnormal renogram. This patient had an aortic aneurysm with involvement of his left renal artery. A second patient,

with a normal Howard test, on aortography showed a constriction of the right renal artery which confirmed the abnormality indicated by the "renogram." The remaining 3 patients have not yet had aortograms in an attempt to confirm or reject the renographic diagnosis of unilateral renal disease.

The renograms of a patient who had undergone right nephrectomy are shown in figure 2.

The curves are to be read from right to left. In the normal left kidney there is the characteristic peak of activity at approximately 5 minutes, followed by renal excretion or "washout." On the right side, the curve rises gradually to a plateau in 10 minutes without subsequent excretion, reflecting the hepatic and somatic background activity in the absence of a kidney.

It was important to determine whether the hepatic and somatic background could be screened out. Taplin indicated that the hepatic background could be kept to a minimum by X-ray localization of the kidneys and by caudal or inferior direction of the probe. In experimenting with different positionings of the probes, it was soon found that a higher peak and steeper washout of the curve were obtained by directing the probes at right angles to the back.

Further examination with different types of collimators demonstrated that a still more sharply defined peak and excretion could be obtained by using wide-field collimation on the right-angle-directed probes. Figure 3-A shows the renograms of a normal patient without the use of collimation. Since the field is more extensive, somatic and hepatic background was recorded, resulting in a poorly defined peak concentration. When the field was reduced by using a 9° straight-bore collimator insert ("narrow field" collimation) (figure 3-B), there was only a small amount of renal tissue open to the crystal. Consequently, it was necessary to decrease the range of activity on the rate meter and provide a shorter time-constant in order to obtain recordings. This change in the instrument settings resulted in fluctuating the distorted curves. Wide-field collimation provided the best compromise (figure 3-C), since it avoided the disadvantages of both of the previous methods, permitting a narrow enough field to effectively screen out somatic and hepatic background activity and, at the same time, a sufficiently wide field to obtain a representative cross-section of functioning renal tissue, without the necessity for high-sensitivity recording.

The importance of collimation is better depicted in figure 3-D, where the hepatic background is shown following the recording of the right renogram. At point "P.L." the probe was moved upward over the liver posteriorly, and at point "A.L." it was placed over the liver anteriorly. It is apparent that hepatic background needs to be carefully screened out posteriorly on the right side.

The most important factor, however, in localizing the renal area of highest activity was the use of the small preliminary dose of radioiodinated Diodrast. At the time the kidneys are taking up the material, the collimated probes are moved over the renal areas to find the locus of highest activity. Slight movement of the probe by as little as 1 inch resulted in appreciable differences in the peak height and downslope of the curves. This technic was particularly useful on the right side where the hepatic activity could be defined and the probe moved inferiorly just below this area of liver background. Following this, the probe could be moved from side to side in order to center on the site of greatest renal activity. This method was far more effective in our experience than attempting to use roentgenograms for localizing the placement of the probes.

By decreasing the range of the rate meters and by using the wide-field collimation a smaller dose of the I¹³¹ Diodrast could be administered. Although Taplin recommended a specific dosage proportional to body weight, we have not arrived at a single optimum dosage, and in general 7 to 15 microcuries was given as the test dose and 3 to 5 microcuries for the preliminary dose.

DISCUSSION

It was not possible to distinguish differences in the various phases of renal excretion of the I¹³¹-labelled Diodrast in normal and abnormal kidneys. The records are, in effect, a semi-quantitative renal function study in that the

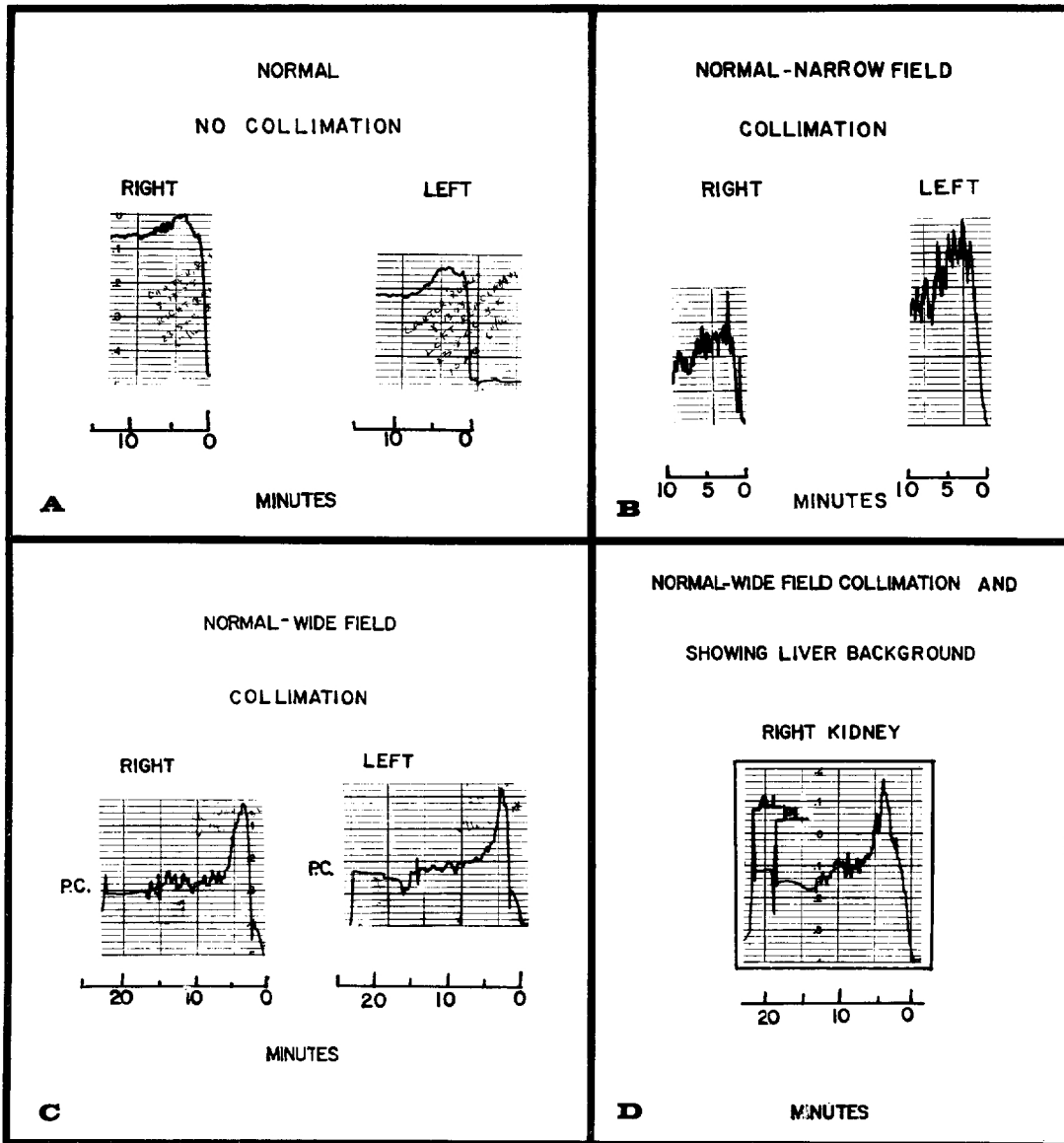


FIG. 3. Renograms showing (A) the type of records obtained with no collimation, (B) "narrow-field" (9° straight-bore insert) collimation, and (C) "wide-field" (20° flat-field insert) collimation. (D) The effect of positioning the probe over the liver posteriorly (P.L.) and anteriorly (A.L.). Time scale is from right to left. See text for further details.

renograms depict the uptake and excretion of the Diodrast of each kidney separately.

The only detectable abnormality was the delay in the excretion or "washout" of the Diodrast. This is illustrated in a variety of renal diseases in figure 2. Such results did not suggest that the renal lesion can be located with any anatomic precision to the vascular, glomerular

or tubular portions of the kidney. This point of disagreement with Taplin does not detract in any way from the utility of the procedure as a screening method for determining the presence of renal disease. It appears that the use of radioiodinated Diodrast is a useful technic in detecting unilateral renal disease. In none of the cases studied thus far was there an abnormal intrave-

nous pyelogram and normal renogram.

This new method may be especially useful in the routine screening of hypertensive patients for the presence of unilateral renal disease, a curable form of hypertension. Further work is still required to establish its accuracy and limitations. The evidence to date is encouraging and suggests that a negative test (normal renogram) may rule out the possibility of a unilateral renal abnormality.

Renograms may also be useful in corroborating abnormal intravenous pyelograms. They can be helpful to the physician who is following patients with a history of a urologic procedure. A further advantage is the small dose of radioiodinated Diodrast which exposes the patient to less total body radiation than that received from a roentgenogram of the chest. This dosage of radioactivity will deliver not more than 40 microcuries of total body radiation. Finally, it is suggested that this technic may be useful as a semi-quantitative method for serial follow-up evaluation of kidney function in patients with chronic renal disease.

SUMMARY AND CONCLUSIONS

One hundred and one patients with urologic complaints, hypertension or no renal disease were studied with I^{131} Diodrast renograms. Although the tracings were improved by (1) wide-field collimation, (2) directing the probes at right angles to the back, and (3) pretreatment with carrier Diodrast, the sharpest rendition

of renal uptake and excretion was obtained when the probes were positioned over the areas of highest activity following a small preliminary test of I^{131} Diodrast.

The technic reliably delineated the side of gross unilateral renal disease. Its application as an atraumatic screening procedure for unilateral circulatory abnormalities of the kidney in patients with chronic hypertension seems especially promising.

Acknowledgments: The authors acknowledge the technical assistance generously offered by Thomas F. McNickle and Joseph C. Fedor of the Radioisotope Laboratory at Mt. Alto Veterans Administration Hospital. The National Heart Institute, and particularly Dr. Eugene Braunwald, is acknowledged for obtaining aortography on 1 of these patients.

BIBLIOGRAPHY

1. TAPLIN, G. V., MEREDITH, O. M., JR., KADE, H., AND WINTER, C. C.: Radioisotope renogram: an external test for individual kidney function and upper urinary tract patency. *J. Lab. & Clin. Med.*, 1956, **48**, 886.
2. WINTER, C. C.: Clinical study of new renal function test: radioactive Diodrast renogram. *J. Urol.*, 1956, **76**, 182.
3. HOWARD, J. E., BERTHRONG, M., GOULD, D. M., AND YENDT, E. R.: Hypertension resulting from unilateral renal vascular disease and its relief by nephrectomy. *Bull. Johns Hopkins Hosp.*, 1954, **94**, 51.
4. POUTASSE, E. F., AND DUSTAN, H. P.: Urologic causes of hypertension; hypertension due to renal artery lesions. *Cleveland Clin. Quart.*, 1956, **23**, 3.
5. WINTER, C. C.: Unilateral renal disease and hypertension: use of radioactive Diodrast renogram as screening test. *J. Urol.*, 1957, **78**, 107.
6. BLOCK, J. B., AND BURROWS, B. A.: Renal clearance of I^{121} Diodrast at low plasma concentration. *Clin. Res.*, 1958, **6**, 284.