

CHAPTER III.

THE COLUMNS OF THE SPINAL CORD.

Having given a general sketch of the regions of the model and shown how its principal structures are related to the central fibre mass, each of the structures of the spinal cord may next be traced into the medulla oblongata. Starting with the central canal its entire course is not shown in any one plate, but it can be traced as follows:—In Plate v the canal is shown within the cord. In entering the medulla oblongata it curves dorsalward along the border of the medulla sheet until it opens out into the fourth ventricle as seen in Plate iii. The relation of the aquæductus cerebri to the third ventricle can be traced in Plate ii.

Structures in
the spinal cord
traced into the
Medulla.

A view of the lateral surface of the model gives the best idea of its relations to the spinal cord (Plate ii). The ventral funiculus is not seen, but the lateral and dorsal funiculi are plain.

On the distal edge of the model (Plate ii) is a shallow groove which divides the lateral funiculus into two parts. This groove corresponds to the line on Text-Fig. 1. The ventral portion is the fasciculus ventrolateralis, which, as the model will show, is subdivided in the medulla oblongata into four definite bundles and certain scattered fibres. The dorsal part, or funiculus lateralis, is divided into two parts, (1) the fasciculus cerebellospinalis, or direct cerebellar tract, which occupies the lateral surface at the distal end of the model, and (2) a mass of fibres concealed from the surface which enters into the formation of the formatio reticularis area of the medulla oblongata. The fasciculus cerebellospinalis lies near the surface and joins with a bundle belonging to the system of the dorsal funiculi to make the corpus restiforme (Plate ii).

The dorsal funiculi of the spinal cord are shown in Plates ii to vii (omitting vi).

In entering the medulla oblongata the fasciculi gracilis and cuneatus (Goll and Burdach) slant dorsalward and spread out into a nuclear capsule (Plate ii). This capsule is continuous with the corpus restiforme. The nuclei of the dorsal funiculi can be seen in Plates iv and vii.

The dorsal horn is visible in the surface view in the model, for the fasciculus of Lissauer has been removed. At the beginning of the medulla oblongata, the dorsal horn, swollen into a large substantia gelatinosa, becomes continuous with the nucleus of the tractus spinalis nervi trigemini (Plates II and IV). A full discussion of the gray matter of the cord in relation to the model is left for Chapters V and VI.

A.—VENTROLATERAL FUNICULI.

(a) *Pars Ventralis of the Ventrolateral Funiculi.*—The separate funiculi of the spinal cord will now be considered in detail, beginning with the ventrolateral fasciculus. This column includes all

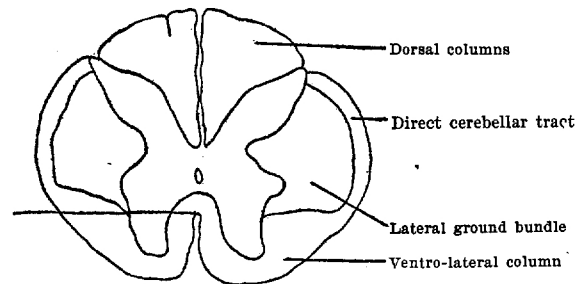


FIG. 1.—Transverse section of the Spinal Cord at the level of the distal end of the model.

of the white matter below the transverse line in Text-Fig. 1, for the pyramidal tracts are not yet medullated. It will be clear that the ventrolateral column as seen in Text-Fig. 1, is a cross-section of the trough at the distal end of the model (Plates V and VII). As has been said, the walls of the trough are divided in the medulla into four definite bundles, and certain scattered fibres.

The first group includes the most medial and ventral fibres (Plates V and VI). They have already been described as turning dorsalward along the border of the medulla sheet to make the fasciculus longitudinalis medialis.

In the transverse sections they are visible in Figs. 27 and 28, (F. v. l. of F. v. p.), both of which give a cross-section of the trough where it is opening out onto the medulla sheet. Fig. 20 shows these fibres in longitudinal sections. The trough is lettered F. 1.

The second bundle leaves the lateral funiculus a little farther cerebralward (Plate v, Fasciculus lateralis [2]). It passes obliquely toward the midline and is represented in the model as stopping abruptly against the root of the N. hypoglossus. In reality the fibres pass on between the root bundles of the nerve adjacent to the medial lemniscus (Fig. 19, F. 1.). In some of the sections it is possible to trace the fibres of this bundle through the parts of the medial accessory olive into the lemniscus medialis. Other fibres pass out into the proximal lobe of the nucleus olivaris inferior, the wall of which they do not appear to penetrate.

The shape of this second bundle in the model is peculiar, for the dorsal fibres do not appear to come from the lateral funiculus at all. They represent a little group of fibres which come from the formatio reticularis and pass with the bundle in question toward the area of the medial lemniscus. As the bundle is crossing from the lateral funiculus toward the middle line a small group of fibres becomes separated from the mesial surface of the main mass, passes parallel to it for a short distance and then joins with it again. It cannot be seen in the lateral views given in the plates, but it shows in Figs. 19 and 28. It is not labeled in either section but is a small bundle of fibres within the trough. (In Fig. 19 the line F. a. i. passes through it.) Its meaning I do not know. To return to the main bundle, the model shows the following points: (1) The bundle is connected with the lateral funiculus of the cord; (2) it does not decussate in the medulla oblongata; (3) it runs parallel to the medial lemniscus at the level of the inferior olive; (4) its fibres appear to join the lemniscus in part and in part to turn toward the olive, beyond which they cannot be traced in these preparations. If this bundle joins the lemniscus medialis it may represent a sensory path from the lateral funiculi which does not decussate in the medulla oblongata.

The two bundles just described receive the medial and ventral fibres of the fasciculus ventrolateralis (Text-Fig. 1). The lateral fibres pass onward to a point opposite the distal end of the inferior olive, where the bundle divides into two parts (Plates iv and v). This statement is made without regard to the direction of the axones of the fibres. The larger and medial of these two bundles extends between the lateral funiculus of the cord and the lemniscus lateralis (Plates iv and v). It does not join the lemniscus, but

Fibres to medial lemniscus.

Fibres from Deiter's nucleus to the spinal cord.

rather passes beyond the point of meeting; its fibres, however, could not be traced farther in the longitudinal series. The lateral lemniscus leaves the trapezoid body just dorsal to the nucleus olivaris superior which lies embedded within the trapezoid body. The bundle connected with the cord touches the lemniscus lateralis just dorsal to the medial border of the superior olive. The two bundles make a slight angle in which lies the nucleus of the facial nerve. The bundle will be traced spinalward inasmuch as this is the direction taken by at least a portion of the axones of its constituent fibres. Starting from the point where it touches the lemniscus, it passes at once ventralward, lateralward and spinalward. The bundle spreads out in its course and sweeps around the surface of the inferior olive to join the lateral funiculus of the cord (Plates iv and v).

This bundle must be studied carefully in both series of sections. In the longitudinal series, a considerable portion of the bundle can be seen in one section (Fig. 13, Tr. fr. Nu. D.). Its approach to the fasciculus lateralis of the spinal cord can be seen in Fig. 16. I wish to emphasize two points shown in Fig. 13: (1) that though the bundle adjoins the lateral lemniscus, its fibres are cut at a different angle, that is, more obliquely (compare Plate v), (2) that the bundle can be recognized from its relation to the nucleus of the facial nerve.

Turning to the transverse series the bundle is determined readily by this relation. In Fig. 38 the bundle corresponds with the tract described as passing from Deiters' nucleus to the spinal cord. It can be seen in Figs. 36 to 38, in which its fibres are passing dorsalward through the *formatio reticularis*. These sections include the area between the *pars prima* and *pars secunda* of the *N. facialis* (Plate v); hence the bundle scatters in its dorsal course so that it is not strange to lose it in the longitudinal sections, in which its fibres must be cut across. Even in the transverse series I cannot demonstrate the connection of the bundle with Deiters' nucleus.¹

Undetermined
bundle.

The last and smallest of the four bundles from the ventral part of the lateral funiculus maintains a lateral position throughout its course. It passes along the surface through the entire length of the medulla oblongata and joins the trapezoid body midway between its dorsal and ventral aspects (Plate v). In the trapezoid body it is wholly lost from view.

The bundle is horizontal, so its complete course can be seen in one section (Fig. 17). It can be followed as readily in the transverse series

¹ The position of the bundle corresponds with Ramón y Cajal's description. Ramón y Cajal, *S. Beitrag zur Studium der Medulla oblongata, des Kleinhirns und des Ursprung der Gehirnnerven*. Deutsche Uebersetz. von Bresler, Leipzig (1896), S. 71.

(Figs. 30 to 35) (F. 1.). This bundle is labeled the fasciculus anterior by Edinger.¹

It may correspond to v. Bechterew's² aberrant bundle. As regards Gowers' tract the section in Taf. IX of Hoche's article,³ shows the fibres of Gowers' tract just ventral to the tractus spinalis N. trigemini. The section is taken opposite the middle of the inferior olive proximal to the passage of the fasciculus cerebellospinalis into the corpus restiforme. In the series I have studied, a corresponding section has this area as a non-medullated space, while ventral to it lies the bundle shown in the model. A second section in my series, taken to correspond with Fig. 7, Taf. IX of Hoche's paper, will show still more clearly the non-medullation of the fibres of Gowers' bundle as described by Hoche (Fig. 38). At this level Gowers' tract cuts across the pars secunda of the facial nerve, just as it plunges into the corpus trapezoideum and this area in my series is non-medullated. At the level of Fig. 38, the fourth bundle of the model is no longer visible.

These four bundles in the medulla oblongata contain all of the fibres of the fasciculus ventrolateralis, medullated at this stage, with the exception of certain fibres of the formatio reticularis. These come from the mesial part of the lateral wall of the trough (Plate VII). They spread out in the medulla oblongata and constitute the ventral bundle of the formatio reticularis.⁴ This bundle is much smaller than the dorsal bundle of the formatio reticularis.

(b) *Pars Dorsalis of the Funiculus Lateralis.*—Turning now to the dorsal part of the lateral funiculus of the cord, the section in Text-Fig. 1, shows that it contains two fibre masses; one lateral, the fasciculus cerebellospinalis, or direct cerebellar tract, and one more medial, a part of the fasciculus lateralis proprius (Flechsigi), or the so-called lateral ground bundle.

Dorsal fibres of lateral column.

At the distal edge of the model the direct cerebellar tract forms a band or ribbon on the surface of the spinal cord (Plate II and Text-Fig. 1). In approaching the medulla oblongata the fibres converge to form a compact bundle (Fig. 28). In this bundle the fibres

Direct cerebellar tract.

¹ Edinger, L., Vorlesungen über den Bau der nervösen Centralorgane, Leipzig (1893), S. 186.

² Barker, L. F., op. cit.

³ Hoche, A., Ueber secundäre Degeneration, speciell des Gowers' . . . schen Bündels, nebst Bemerkungen über das Verhalten der Reflexe bei Compression des Rückenmarkes. Arch. f. Psychiat. u. Nervenkr., Berl., Bd. xxviii (1896), S. 510-543.

⁴ This is a part of the *vordere gemischte Seitenstrangzone* of Flechsig. Flechsig, P., Die Leitungsbahnen im Gehirn und Rückenmark, Leipzig (1876), S. 305.

pass on to a point opposite the distal end of the inferior olivary nucleus where the entire bundle turns dorsalward at almost a right angle (Plates II and V with Fig. 30). The lines in Plate II of the model showing this dorsal course are perhaps a little too abrupt. They should follow the course of the lines of the transverse sections shown on Fig. 52. The fibres extend dorsalward beyond the level of the tractus spinalis nervi trigemini; here they turn cerebralward again and join with the dorsal external arcuate fibres to enter the corpus restiforme. This arcuate bundle shows in the model as the direct continuation of the capsule of the nuclei of the dorsal funiculi (Plate II). The line in which the direct cerebellar tract meets this arcuate bundle forms an arch, beneath which the tractus spinalis nervi trigemini and its nucleus can be seen. The corpus restiforme passes cerebralward, and at the same time slightly lateralward, to a point opposite the level of the nucleus N. abducentis. Here it turns dorsalward to enter the cerebellum and hence is cut off in the model.

Lateral ground bundle. To return to the cross-section of the spinal cord shown in Text-Fig. 1, all of the medullated fibres of the lateral funiculus have been traced save the ground bundle, for at this stage the lateral pyramidal tract is non-medullated. The model shows that the ground bundle of the lateral funiculus has only to turn slightly dorsalward, in agreement with the cervical curve in order to enter the formatio reticularis of the medulla oblongata. (See the cross-section of the cord in Plate V.) This formatio reticularis region extends throughout the length of the medulla. It lies dorsal to the nucleus olivaris inferior and lateral to the medulla sheet.

B.—FUNICULUS DORSALIS.

Dorsal columns. The dorsal funiculi of the spinal cord form a wedge-shaped mass as seen in the cross-section (Text-Fig. 1). Each funiculus runs to the beginning of the medulla oblongata without change of form save that the groove between the fasciculus gracilis (Goll) and the fasciculus cuneatus (Burdach) deepens (Plates II and III). At about the junction of the spinal cord and medulla oblongata, the fasciculus gracilis becomes hollowed out to make a capsule for its nucleus and a little farther cerebralward the fasciculus cuneatus shows the same change. This capsule can be best understood after the nucleus has been described.

The nucleus of the dorsal funiculus of the cord is seen best after removing the fibre capsule (Plates IV and VII). It is an irregular mass of cells, which is divisible into three parts; moreover, this division, made from form alone is strengthened by the mode of distribution of the fibres. In general the distal portion of the nucleus has a long diameter in a dorsoventral plane (Plate VII) at right angles with the long axis of the proximal portion (Plate IV). The three divisions, as seen from a lateral view, are (1) a distal, (2) a middle and (3) a proximal part. The middle portion does not extend to the mesial surface of the nuclear mass and so may well be called the lateral portion. (Nucleus funiculi cuneati lateralis, Plate IV.)

Nuclei of the dorsal columns.

The distal part or nucleus funiculi gracilis consists of a column of cells placed in a dorsoventral direction. Its distal margin is straight but the dorsal margin is curved and raised above the rest of the nuclear mass (Plate IV). It is separated from the middle nucleus by a deep groove but its surface is smooth, thereby contrasting with the proximal portion. The rest of the mass has been called the nucleus funiculi cuneati, but Blumenau has shown that it consists of two distinct parts. The middle part, or nucleus of Blumenau is a mass of cells projecting from the lateral surface (Plate IV. Nucleus funiculi cuneati lateralis). It is separated from the distal nucleus by a deep groove but fades gradually into the proximal nucleus. Its distal border is about opposite the middle of the nucleus funiculi gracilis, while its proximal limit is opposite the lower part of the nucleus olivaris inferior, and the distal end of the radix descendens nervi vestibuli.

In the model, the nucleus cannot be traced as far cerebralward as Blumenau was able to trace it from histological details. Blumenau¹ places the proximal limit opposite the lowest plane of entrance of the fibres of the N. acusticus. The sections of both my series show small, scattered masses of cells in the corpus restiforme, and these can be traced even into the cerebellum itself. They are considered by Blumenau to be part of the nucleus which bears his name. As has been said, the nucleus of Blumenau does not reach the mesial surface of the nuclear mass. The thin mesial zone con-

¹ Blumenau, L., Ueber den äusseren Kern des Keilstranges im verlängerten Mark. Neurol. Centralbl., Leipz., Bd. x (1891), S. 229.

sists (1) of a small column of cells projecting parallel to the nucleus funiculi gracilis, and (2) a layer of cells associated with the proximal nucleus. This will be explained in connection with the course of the fibres from these cells.

The proximal portion of the mass is oblong in shape. It is characterized by the irregularity of its lateral surface which is broken by fibre bundles. One deep depression is to be seen near its ventral surface.

Internal arcuate
fibres and
decussatio
lemniscorum.

Further evidence of the division of this nucleus into three parts is seen in the course of the fibres from it. In Plate VII it will be noted that, while both the distal and proximal divisions give bundles of fibres that run toward the raphe, no such bundle comes from the lateral nucleus. These two bundles of internal arcuate fibres, distal and proximal, are wholly distinct from one another in the longitudinal series. In the transverse series, on the other hand, it can be made out that the thin medial border of the middle zone makes a transition between the distal and proximal bundles.

The distal bundle leads to the decussatio lemniscorum. It is a small, compact bundle, which comes (1) from the distal third of the nuclear mass, the nucleus funiculi gracilis, and (2) from the distal part of the thin middle zone of the mass, the nucleus funiculi cuneati. The bundle leaves the proximal border of the nucleus funiculi gracilis and hence appears in transverse section to arise wholly from the nucleus funiculi cuneati (Fig. 28). It is found in the distal part of the medulla oblongata, distal to the olive and opposite the proximal end of the decussatio pyramidum.¹ The bundle passes along the border of the central gray matter, to a point ventral to the central canal, where it decussates in mass between the medulla sheets of the two sides and joins the stratum interolivare lemnisci (Plate VII).

The proximal bundle of internal arcuate fibres, on the other hand, is different both in position and in form. It is related to the proximal part of the nuclear mass and forms a broad band which appears as a direct continuation of the entire proximal third of the nucleus into a fibre bundle (Plates IV and VII). This bundle sweeps across the medulla in a curve, dorsal to the olive, pierces the medulla sheet, turns ventralward to decussate in the raphe, and

¹ Ramón y Cajal, op. cit., S. 52.

joins the stratum interolivare lemnisci of the opposite side. This bundle contrasts with the distal arcuate bundle: (1) in position, for it lies opposite the middle of the nucleus olivaris inferior, while the latter is distal to it; (2) in course, for its fibres arise far lateralward and pass through the formatio reticularis instead of bordering upon the central canal; and (3) in the arrangement of its fibres into a broad band instead of a compact bundle (Figs. 28 and 31, F. a. i.). According to v. Bechterew¹ the fibres from the fasciculi of Goll and Burdach can be distinguished from each other throughout the pons. The mesial border of the middle zone gives off a few fine arcuate fibres which make a transition between the distal and proximal bundles. At first they lie near the central gray matter after the type of the distal bundle, but they gradually pass farther to the side until the proximal bundle is reached.

The model shows that the lateral nucleus of Blumenau² is in the exact position to send its fibres lateralward to the cerebellum rather than medialward to the medial lemniscus on its way to the cerebrum. This will appear clear by comparing Plates II, III and IV.

The capsule of the nuclei of the dorsal funiculi of the cord is continued directly into the corpus restiforme. This connection is made by means of dorsal external arcuate fibres. These arcuates come from two sources, (1) from the dorsal funiculi of the cord, (2) from the nucleus of Blumenau.³

¹ v. Bechterew, W., Ueber die Schleifenschicht auf Grund der Resultate von nach der entwicklungsgeschichtlichen Methode ausgeführten Untersuchungen. Arch. f. Anat. u. Phys., Anat. Abth., Leipz. (1895), S. 379-395.

² Blumenau, op. cit., S. 226.

³ In regard to the literature on this subject, Edinger, Flechsig, Hoche and v. Monakow say that fibres of the dorsal funiculi pass directly to the corpus restiforme. Vejas on the ground of experimental degeneration says that the dorsal funiculi and the corpus restiforme are connected only by mediation of a nucleus.

(1). von Monakow, C., Arch. f. Psychiat. u. Nervenkr., Berl., Bd. XIV (1883).

(2). Edinger, L., Neurol. Centralbl., Leipz., Bd. III (1885), S. 73-76.

(3). Flechsig, P., Neurol. Centralbl., Leipz. (1885), No. 5.

(4). Vejas, P., Arch. f. Psychiat. u. Nervenkr., Berl., Bd. XVI (1885), S. 200-214.

(5). Barker, L. F., Op. cit., p. 560 and p. 575.

Flechsig calls these fibres, "Fibræ transversales." Die Leitungsbahnen im Gehirn und Rückenmark des Menschen, Leipzig, 1876.

Dorsal columns
of cord and their
nuclei in sections.

The transverse series will be used first to illustrate the points of the model (Figs. 25 to 31). Fig. 25 shows that the nucleus funiculi gracilis is well developed at a level in which only the ventral part of the nucleus funiculi cuneati is visible. Fig. 28 shows both the nuclei of the fasciculi of Goll and Burdach, together with the nuclear capsules and the distal bundle of internal arcuate fibres. The capsule of the nuclei of Burdach's fasciculus is dense, while that of the nucleus of Goll's fasciculus is delicate. The characteristics of the distal internal arcuate bundle are evident in Fig. 28. The proximal bundle on the other hand is shown in Fig. 31, while the transition between the two is represented by Fig. 29. Figs. 29 and 30 show the lateral nucleus of Blumenau (Nu. f. c. l.). In the second section its close connection with the fibre capsule and the contrast of its cellular arrangement with that of the proximal nucleus is evident.

The relative positions of the three parts of the nuclear mass are more clearly made out in the longitudinal series (Figs. 5 to 17). The sections in Figs. 5 to 7 illustrate these relations. The nucleus funiculi gracilis and a small part of the nucleus funiculi cuneati form a common mass that gives rise to the distal internal arcuate bundle. The middle, lateral portion is the nucleus of Blumenau (Nu. f. c. l., Fig. 5). At the level of Fig. 7 it is separated from the proximal third by a band of fibres entering the nucleus from the capsule. All three sections pass through the corpus restiforme. The fibre bundle opposite the nucleus of Blumenau is much broken, due to the entrance and exit of the fibres of the capsule.

In passing ventralward the internal arcuate fibres can be traced to their decussations. On Fig. 9 the proximal third of the nucleus seems to have been transformed into fibres. These fibres can be traced through Figs. 12, 13 and 15. The distal bundle which lies farther ventral is seen first on Fig. 15 and is traced to the decussatio lemniscorum in Figs. 17 and 19.